Orthopedic surgery / by Sir Robert Jones and Robert W. Lovett.

Contributors

Jones, Robert, 1857-1933.
Lovett, Robert W. 1859-1924.

Publication/Creation

New York : William Wood, 1929.

Persistent URL

https://wellcomecollection.org/works/e6a6aecs

License and attribution

This work has been identified as being free of known restrictions under copyright law, including all related and neighbouring rights and is being made available under the Creative Commons, Public Domain Mark.

You can copy, modify, distribute and perform the work, even for commercial purposes, without asking permission.

Wellcome Collection
183 Euston Road
London NW1 2BE UK
T +44 (0)20 7611 8722
E library@wellcomecollection.org
https://wellcomecollection.org

DR. FRED G. HODGSON
362 PEACHTREE ST.
ATLANTA, GA.

22101751109

F. G. Hodgson.

Compliments of Author.

1929.

ORTHOPEDIC SURGERY

Digitized by the Internet Archive
in 2019 with funding from
Wellcome Library

https://archive.org/details/b31357568

ORTHOPEDIC SURGERY

BY

SIR ROBERT JONES, BART., K.B.E., C.B.

Ch.M. (Liverpool), F.R.C.S. (England, Ireland, and Edinburgh), F.A.C.S. (U.S.A.)

Emeritus President, British Orthopedic Association, Past President, Association of Surgeons of Great Britain and Ireland, Consulting Surgeon, Shropshire Orthopedic Hospital, Director of Orthopedic Surgery, St. Thomas's Hospital, London, Royal Liverpool Children's Hospital, and Royal Infirmary, Liverpool.

AND

ROBERT W. LOVETT, M.D., F.A.C.S.

Late John B. and Buckminster Brown Professor of Orthopedic Surgery in Harvard University, Member of the International Surgical Society, Member of British, Italian, French, and American Orthopedic Associations, Member of the Swedish Society of Physicians.

SECOND EDITION REVISED

With the Collaboration of **NATHANIEL ALLISON,** *M.D., F.A.C.S. Professor of Orthopedic Surgery, Harvard University;* **FRANK R. OBER,** *M.D., Instructor in Orthopedic Surgery, Harvard University; and* **HARRY PLATT,** *M.D., M.S., F.R.C.S. (Eng.), Clinical Lecturer in Orthopedic Surgery, University of Manchester.*

NEW YORK
WILLIAM WOOD AND COMPANY
MDCCCCXXIX

WELLCOME HISTORICAL MEDICAL LIBRARY

Copyright, 1929,
By WILLIAM WOOD & COMPANY

NBC

WELLCOME INSTITUTE LIBRARY
Coll. welMOmec
Call No. WE168 1929 J780

Printed in the United States of America

THE MAPLE PRESS COMPANY, YORK, PA.

PREFACE TO THE SECOND EDITION

I sadly miss the guiding hand of my distinguished and well beloved friend, Robert W. Lovett, in publishing the second edition of this book. His ripe experience and keen critical mind would have proved invaluable. Dr. Nathaniel Allison, now Professor of Orthopedic Surgery in Harvard University, has kindly consented to become American Editor-in-Chief assisted by Dr. Frank R. Ober, Assistant Dean Harvard Medical School and Associate Surgeon to Boston Children's Hospital, who gave valuable help to Professor Lovett in preparing the first edition. Mr. Harry Platt of Manchester, as representing the younger British School, has been chosen to assist me, and in this way I hope to retain the international character of the work.

Every chapter in the book has been carefully revised, and more particularly the sections on *Stiffness of Joints* (Chapter V); *Operative Treatment of Arthritis Deformans* (Chapter XI); *Developmental Affections of Bone* (Chapter XVI); *Affections of Adult Bone* (Chapter XVII); *Anterior Poliomyelitis* (Chapter XXI); *Obstetrical Paralysis* (Chapter XXXIII); *Lateral Curvature of the Spine* (Chapter XXXII). New illustrations have been introduced both as additional matter, and to replace a number of the originals. Chapter XVIII, which in the first edition dealt with malunited fractures, has been considerably extended, so as to present an epitome of the principles of the treatment of fractures at all stages. Entirely new chapters or sections have been inserted on (1) Affections of tendons, muscles and fasciae. (2) Peripheral nerve lesions. (3) Pyogenic affections of bone. (4) Vascular lesions of the extremities. (5) Amputations and artificial limbs.

The first edition published five years ago was based upon the wider definition of this branch of surgery as agreed to in the Great War. Surgery must be looked upon as a generic term comprising various branches, of which the group of affections dealt with in these pages is perhaps the most comprehensive. It will doubtless follow that in the near future the academic course of lectures on surgery will not be delivered by one, but by many surgeons, each expert in the subjects with which he deals. This division of responsibility and labor has to some extent been realised by the creation of Professorial Chairs in Orthopedic Surgery in many of the American Universities. So far no such chair exists in any British University, but this final recognition of the status to which orthopedic surgery has attained cannot be long delayed.

During the last few years great advances have been made in the care and welfare of cripples, both in America and in Great Britain. On this side, the State, represented by the Ministry of Health and the Board of Education, in combination with the Local Authorities, pay for the treatment and education of the crippled child of school age, and to a limited extent pay for the industrial education up to the age of sixteen. Open air hospitals have been started in most of the counties in England, and after care clinics are associated with each centre. Already this has materially reduced the number of bad deformities. A further scheme is on foot to bring vocational education within the reach of

every cripple, including adults, in order to increase his wage earning capacity and make him more self supporting. All schemes include instruction in preventive methods.

In the United States the orthopedic hospitals, so generously founded and endowed by numerous societies and individuals are rendering wonderful service. The past decade has witnessed a renaissance in the organization and treatment of fractures in the large hospitals based on the establishment of fracture clinics or departments with unity of surgical control. In this advance orthopedic surgeons in both America and the British Isles have taken the larger share.

I have again to thank my valued friend, Thurstan Holland, for the loan of many radiograms and for his advice in relation to the radiographic illustrations in general.

ROBERT JONES.

PREFACE TO THE FIRST EDITION

In the preparation of this book we have endeavored to give the practitioner and the medical student a plain and practical account of those pathological conditions which we believe may properly be classified under the unsatisfactory name of Orthopedic Surgery. We have felt that it was best to use this term, imperfect as it is, because we know of no other which adequately covers the ground. Regarding as we do, however, these affections as constituting only a special department of general surgery, we have avoided the use of the term orthopedic everywhere except in the title, because we believe that the principles governing the diagnosis and treatment of these conditions should be those, and only those, embodied in general surgery.

Any classification of the affections which we are considering would be criticized, as so-called Orthopedic Surgery has very ill-defined boundaries, and as the English definition of this form of special surgery has seemed to us the soundest, we have adopted this in our classification.

It has been difficult to apportion the space at our disposal and to decide how much should be allotted to each of the different subjects. In this matter we have been inclined to consider more fully those subjects which had not, in our opinion, received adequate consideration, and to emphasize those which seemed to us from their importance to require more thorough discussion. Any scale attempted would be open to criticism, and we have been obliged in this matter to use our best judgment. We have not attempted to make the work encyclopedic, and for that reason we have omitted methods which we consider obsolete or ineffectual, and throughout we have endeavored as far as possible to use our personal experience as the basis of our discussions.

We have not knowingly used the work of other men without making proper acknowledgment, but in spite of every care it is possible that there may have been omission of such credit in certain instances. If such omissions have occurred, we beg to express our regret.

It is impossible to acknowledge the help which has come to us from many quarters, always given willingly and accepted gratefully. Many of our colleagues have furnished us with illustrations, which we have acknowledged in reproducing them, and many others have given us permission to use illustrations already published.

We would make particular acknowledgment to Dr. Walter B. Cannon, Professor of Physiology at Harvard University; to Dr. S. B. Wolbach, Professor of Pathology at the same institution; to Dr. Milton J. Rosenau, Professor of Hygiene at Harvard University; to Dr. Thurstan Holland of Liverpool; to Dr. Bronson Crothers of Boston; to Dr. John J. Morton, Professor of Surgery, Rochester Medical School, and to Miss Wilhelmene G. Wright of Boston, expert in muscle training, for reading, revising, and furnishing material pertaining to their various departments.

We have borrowed largely from the clinical material of the Children's Hospital of Boston the Massachusetts Hospital School at Canton, the Warren

Museum of Harvard University, the British Military Orthopedic Hospitals, and the Liverpool Country Hospital; and from our colleagues and assistants we have had almost innumerable instances of willing and useful help.

We are indebted to Miss Esther G. Price for valuable aid in preparing the manuscript for the press, and to Dr. R. P. Schwartz for much assistance in securing illustrations.

Robert Jones.
Robert W. Lovett.

CONTENTS

CHAPTER I

Anatomy, Physiology, and General Pathology of Joints

	Page
General Considerations	1
Joint Reactions	2
Stiffness of Joints	4

CHAPTER II

Traumatic Affections of Joints

Acute Traumatic Synovitis	6
Traumatic Affections of the Hip-joint	7
Flattened Head of the Femur	11
Coxa Vara	14
Coxa Valga	20

CHAPTER III

Disabilities of the Knee-joint

Anatomy	22
Injuries of the Lateral Ligaments	24
Displacements of the Semilunar Cartilages	25
Slipping Patella	32
Rupture of the Quadriceps and Ligamentum Patellæ	34
Derangements of the Knee Due to Exostoses	35
Partial Separation of the Tubercle of the Tibia—Osgood's Disease, Apophysitis	35
Affections of the Infrapatellar Pad and Synovial Fringes	37
Rupture of the Crucial Ligaments and Fractures of the Spine of the Tibia	38
Loose Bodies in the Knee	41
Bursitis	47

CHAPTER IV

Traumatic Affections of the Ankle, Shoulder, Elbow, and Wrist

Ankle and Foot	48
Shoulder-joint	52
Habitual or Recurrent Dislocation of the Shoulder	59
Elbow-joint	62
Wrist-joint	66
Finger-joints	69

CHAPTER V

Stiffness of the Joints—Adhesions and Ankylosis

Adhesions	70
Stiffness Due to Prolonged Immobilization	76
Stiffness Due to Bony Blocks	77
Stiffness Due to the Contraction of Scar Tissue	79
Stiffness Due to Traumatic and Suppurative Processes in and about the Joints	81
Ankylosis	82

PAGE
Volkmann's Contracture . . . 91
Methods of Approach to the Hip-joint . . . 98
Reconstructive Excision of the Femoral Head . . . 100
Arthroplasty . . . 100
Extra-articular Pseudarthrosis . . . 101

CHAPTER VI

TUBERCULOSIS OF JOINTS

Etiology . . . 109
Prophylaxis . . . 110
Pathology . . . 113
Symptom . . . 115
Prognosis . . . 118
General Treatment . . . 119
Heliotherapy . . . 122
Local Treatment . . . 125

CHAPTER VII

TUBERCULOSIS OF THE HIP

Pathology . . . 129
Symptoms . . . 131
Diagnosis . . . 142
Differential Diagnosis . . . 142
Prognosis . . . 147
Treatment . . . 148
General Treatment . . . 148
Local Treatment . . . 149
Treatment during Convalescence . . . 158
Treatment of Complications . . . 160

CHAPTER VIII

TUBERCULOSIS OF THE KNEE-JOINT

Pathology . . . 161
Symptoms . . . 162
Diagnosis . . . 164
Differential Diagnosis . . . 166
Treatment . . . 168

CHAPTER IX

TUBERCULOSIS OF THE ANKLE, SHOULDER, ELBOW, WRIST, AND SACRO-ILIAC JOINTS

Ankle-joint . . . 177
Shoulder-joint . . . 183
Elbow-joint . . . 186
Wrist-joint . . . 189
Sacroiliac-joint . . . 190

CHAPTER X

TUBERCULOSIS OF THE SPINE

Etiology . . . 197
Pathology . . . 198
Symptoms . . . 202
Paralysis . . . 207
Examination . . . 210

Page
Diagnosis . . . 212
Differential Diagnosis . . . 214
Prognosis . . . 218
Treatment . . . 219
Treatment by Recumbency . . . 220
Ambulatory Treatment . . . 228
Treatment of Convalescence . . . 236
Operative Treatment . . . 236

CHAPTER XI

Arthritis Deformans

Synonyms . . . 242
Etiology . . . 242
Symptoms . . . 243
Traumatic Type . . . 247
Diagnosis . . . 247
Differential Diagnosis . . . 248
Prognosis . . . 249
Treatment . . . 251
Localization in the Hip-joint . . . 255
Knee-joint . . . 260
Shoulder-joint . . . 263
Ankle, Elbow, and Temporo-maxillary Joints . . . 264
Spine . . . 265
Tuberculous Rheumatism . . . 271

CHAPTER XII

The Pyogenic Infections of Joints

Pathology . . . 272
Etiology . . . 276
Symptoms . . . 277
Diagnosis . . . 277
Treatment . . . 277

CHAPTER XIII

Osteomyelitis

Hematogenous Osteomyelitis . . . 286
Circumscribed Form . . . 289
Acute Diffuse Form . . . 289
Treatment . . . 292
Topography . . . 293
Acute Epiphysitis . . . 294

CHAPTER XIV

Syphilis of the Bones and Joints

Syphilis of the Bones . . . 295
Syphilis of the Joints . . . 298

CHAPTER XV

Other Affections of the Joints

Hemophilia . . . 301
Intermittent Synovitis . . . 304
Neuropathic Joint Disease . . . 305
Gout . . . 306
Tumors of Joints . . . 308

CHAPTER XVI

Developmental Diseases of Bone

Page
Introduction . . . 309
Affections of Growing Bone . . . 310
Rickets . . . 311
Knock-knee . . . 322
Late Rickets . . . 328
Renal Rickets . . . 328
Achondroplasia . . . 329
Osteogenesis Imperfecta . . . 333
Generalized Osteosclerosis . . . 336
Localized Osteosclerosis . . . 337
Multiple Cartilaginous Exostoses . . . 337
Cretinism . . . 340

CHAPTER XVII

Affections of Adult Bone

Ostitis Deformans . . . 342
Ostitis Fibrosa Cystica . . . 349
Osteomalacia . . . 353
Leontiasis Ossea . . . 356
Secondary Hypertrophic Osteoarthropathy . . . 357
Actinomycosis . . . 359
Benign Tumors of Bone . . . 361
Giant Cell Tumor . . . 364
Primary Malignant Tumors . . . 366
Secondary Malignant Tumors . . . 374

CHAPTER XVIII

Fractures

Preliminary Considerations . . . 378
Malunion . . . 379
Nonunion . . . 380
Fractures of the Femur . . . 382
Fractures in the Neighborhood of the Knee-joint . . . 389
Fractures of the Patella . . . 392
Fractures of the Shafts of the Leg Bones . . . 392
Fractures of the Ankle . . . 393
Fractures of the Astragalus . . . 396
Fractures of the Os Calcis . . . 396
Fractures of the Clavicle . . . 397
Fractures of the Humerus . . . 398
Fractures of the Forearm . . . 400
Colles' Fracture . . . 401
Fractures of the Pelvis . . . 403

CHAPTER XIX

Disturbances of the Neuromuscular Mechanism

Nervous System . . . 406
Muscular Mechanism . . . 407

CHAPTER XX

Spastic Paralysis

Etiology and Pathology . . . 408
Symptoms . . . 409

PAGE
Diagnosis . . . 413
Differential Diagnosis . . . 413
Prognosis . . . 413
Treatment . . . 414
Non-operative Treatment . . . 415
Operative Treatment . . . 417
After-treatment . . . 421
Operations upon the Nervous System . . . 422

CHAPTER XXI

ANTERIOR POLIOMYELITIS

Pathology . . . 426
Symptoms . . . 427
Diagnosis . . . 429
Prognosis . . . 431
Treatment . . . 434
Treatment of Residual Paralysis . . . 438
Physical Therapeutics . . . 440
Apparatus . . . 442
Deformities of the Hip . . . 449
Deformities of the Knee . . . 455
Deformities of the Ankle . . . 459
Deformities of the Upper Extremity . . . 461
Tendon Transplantation . . . 466
Nerve Transplantation . . . 478
Neurotization of Muscles . . . 478
Asthrodesis . . . 478
Astragalectomy . . . 486
Lengthening the Short Leg . . . 487
Artificial Ligaments . . . 488
Tendon Fixation or Tenodesis . . . 488

CHAPTER XXII

MUSCLE TRAINING

Introduction . . . 492
Foot . . . 493
Knee . . . 494
Hip . . . 496
Wrist . . . 496
Forearm and Hand . . . 497
Elbow . . . 497
Shoulder . . . 497
Abdomen . . . 499

CHAPTER XXIII

INJURIES OF PERIPHERAL NERVES

Pathology . . . 500
Clinical Manifestations . . . 501
Treatment . . . 502
Conservative Treatment . . . 502
Operative Treatment . . . 503
Results of End-to-End Suture . . . 506
Results of Neurolysis . . . 507
Functional Contractions and Deformities . . . 507
Injuries of Individual Nerve Trunks, Facial . . . 511
Spinal Accessory Nerve . . . 511
Cervical Sympathetic . . . 514

PAGE
Cervical Plexus . . . 515
Brachial Plexus . . . 515
Musculospiral Nerve . . . 520
Posterior Interosseous Nerve . . . 522
Ulnar Nerve . . . 522
Median Nerve . . . 525
Musculocutaneous and Internal Cutaneous . . . 527
Lumbosacral Plexus . . . 527
Cauda Equina . . . 528
Great Sciatic Nerve . . . 529
External Popliteal Nerve . . . 529
Internal Popliteal Nerve . . . 530
Posterior Tibial Nerve . . . 531
Anterior Crural and Obturator Nerves . . . 531
Tumors of Nerve Trunks . . . 531

CHAPTER XXIV

Lesions Involving Locomotion

Progressive Muscular Atrophy . . . 533
Hereditary Muscular Atrophy of Peroneal Type . . . 533
Progressive Muscular Dystrophy . . . 534
Friedreich's Ataxia . . . 536

CHAPTER XXV

Affections of Muscles, Tendons, and Fasciæ

Rupture of Muscles . . . 537
Tumors of Muscles . . . 537
Myositis . . . 538
Ischemic Contracture . . . 538
Division of Tendons . . . 544
Rupture of Tendons . . . 547
Dislocation of Tendons . . . 550
Snapping Hip . . . 551
Tenosynovitis . . . 551
Ganglia of Tendon Sheaths . . . 554
New Growths of Tendon Sheaths . . . 555
Dupuytren's Contracture of the Fingers . . . 556

CHAPTER XXVI

Congenital Deformities

General Considerations . . . 560
Bony Defects or Anomalies . . . 561
Congenital Contractions . . . 567
Intrauterine (Spontaneous) Amputations . . . 568
Intrauterine Fractures . . . 569
Miscellaneous Deformities of the Hands and Feet . . . 570

CHAPTER XXVII

Torticollis—Congenital Elevation of the Scapula—Cervical Ribs

Congenital Torticollis . . . 573
Acquired Torticollis . . . 580
Dislocations of the Cervical Vertebræ . . . 581
Congenital Elevation of the Scapula . . . 582
Congenital Absence of the Scapula . . . 585
Cervical Ribs and Nerve Pressure on the First Rib . . . 585

CHAPTER XXVIII

Congenital Dislocation of the Hip and Other Joints

Page
Congenital Dislocation of the Hip . . . 591
Etiology . . . 591
Pathology . . . 592
Symptoms . . . 595
Diagnosis . . . 595
Prognosis . . . 598
Treatment . . . 598
Manipulative Reduction . . . 599
After Treatment . . . 604
Reduction after Open Incision . . . 609
Congenital Dislocation of Other Joints . . . 611

CHAPTER XXIX

Club-foot

Synonyms . . . 614
Etiology . . . 614
Pathological Anatomy . . . 615
Symptoms . . . 618
Diagnosis . . . 618
Differential Diagnosis . . . 618
Treatment . . . 620
After-care . . . 629
Talipes Varus . . . 632
Talipes Equinus . . . 633
Talipes Calcaneus . . . 633
Talipes Valgus . . . 633

CHAPTER XXX

Acquired Deformities of the Feet

Anatomical Considerations . . . 634
Static Disturbances of the Feet . . . 639
Symptoms . . . 642
Pressure Symptoms . . . 644
Diagnosis . . . 645
Prognosis . . . 645
Treatment of Foot Strain . . . 646
Treatment of Flat Foot . . . 647
Short Tendo Achillis . . . 652
Claw Foot . . . 654
Etiology . . . 654
Clinical Features . . . 655
Treatment . . . 656
Affections of the Heel . . . 658
Affections of the Metatarsus and Toes . . . 660
Hallux Rigidus . . . 662
Hallux Valgus . . . 662
Hammer Toe . . . 665
Vascular Lesions of the Extremities . . . 667
Organic or Obliterative Disturbances . . . 667

CHAPTER XXXI

Affections of the Bones and Joints of the Spine and Thorax

Anatomy of the Spine . . . 670
Spinal Injuries . . . 673

Page
Sprains . . . 673
Skeletal Injuries . . . 678
Compression Fractures . . . 679
Fracture Dislocations with Cord Involvement . . . 680
Dislocations of the Cervical Vertebræ . . . 684
Fractures of the Atlas and Axis . . . 685
Isolated Fractures of the Neural Arch and Transverse Processes . . . 687
Derangements of the Lumbosacral and Sacro-iliac Articulations . . . 689
Strains of the Sacro-iliac and Lumbosacral Articulations . . . 691
Treatment . . . 695
Round Shoulders and Adult Round Back . . . 696
Coccygodynia . . . 706
Spondylolisthesis . . . 707
Vertebral Osteochondritis . . . 711
Spina Bifida . . . 712
Deformities of the Thorax . . . 715

CHAPTER XXXII

Scoliosis

Occurrence . . . 718
Symptoms and Physical Signs . . . 719
Types of Lateral Curvature . . . 720
Examination . . . 727
Pathology . . . 731
Etiology . . . 736
Prognosis . . . 742
Treatment . . . 743
Turnbuckle Jacket . . . 757
Hinged Shell for Recumbency . . . 758
Operative Treatment . . . 763
Galeazzi's Method . . . 764

CHAPTER XXXIII

Obstetrical Paralysis

Introduction . . . 768
Etiology . . . 769
Symptomatology . . . 772
Diagnosis . . . 774
Prognosis . . . 774
Treatment . . . 775

CHAPTER XXXIV

Amputations and Artificial Limbs

Temporary or Emergency Amputations . . . 779
Amputations of Choice . . . 779
Amputation Technique . . . 779
Amputations in the Lower Limb . . . 780
Amputations of the Upper Limb . . . 781
Cinemoplastic Amputations . . . 782
Reamputations . . . 782
Artificial Limbs . . . 782
Permanent Prostheses . . . 783
Reeducation of the Amputated . . . 784

CHAPTER XXXV

Principles of Apparatus

Theory of Apparatus . . . 785
Plaster of Paris . . . 785
Celluloid and Leather Apparatus . . . 789

ORTHOPEDIC SURGERY

CHAPTER I

ANATOMY, PHYSIOLOGY AND GENERAL PATHOLOGY OF JOINTS

General Considerations.—Every joint of the body consists of two or more bones in contact with each other at their articular ends, which are usually broadened for the purpose and adapted in shape to move on each other. The end of each consists of a layer of cancellous bone known as the *articular plate*. The ends of the bones where they are in contact are covered by white hyaline cartilage, which presents a smooth, glistening surface, and the bones are held in contact by ligaments and muscles as well as by atmospheric pressure. At the junction of the bones they are surrounded and connected by a collar constituting the capsule on the outside, and continuous with this and forming the inside of the joint is a layer of synovial membrane. The capsule and ligaments are closely united or continuous.

The *synovial membrane* is the important structure of the joints, and the structure that mainly gives them their peculiar phenomena and reactions. It is a serous membrane, the internal surface of which is composed of modified endothelial cells, under which is a subendothelial layer merging into the fibrous capsule. The synovial membrane does *not* cover articular cartilages where they are in contact with each other in any part of the range of the motion of the joint, but thins down at the cartilaginous edges where it is firmly attached. Intra-articular cartilages are however covered by synovial membrane above and below.[1] The absorptive power of the synovial lining has been well demonstrated under experimental conditions after the introduction of inert particles (carbon) into the joint cavity. After reaching the deeper layers of the synovial membrane, most of such minute foreign bodies pass directly into the vascular system and are later deposited in the bone marrow. A certain amount of filtration also takes place via the synovial lymphatics into the neighboring glands (Key[2]). The close contact of the synovial cavity with the circulation is a matter of much significance in connection with joint affections. For this reason men of experience are exceedingly careful about opening joints under any except the best aseptic conditions.

The chief function of this membrane is to secrete a lubricating fluid for the joint. This fluid is the *synovia* and is clear, light yellow, and viscid to the touch, looking and feeling much like the white of an egg. It is secreted in part by the cells on the surface of the membrane, but especially by the synovial fringes or tufts where the membrane is folded on itself, and in which tufts or folds or fringes there are coils of blood vessels and a ready supply of blood.

[1] Gray's Anatomy, American Edition, 1913, 336.
[2] Jour. Bone & Joint Surg., 1926.

Allison,[1] Smith, et al. have shown by the study of synovial fluid recovered by tapping knee joints, that the fluid bears a direct relationship to the blood plasma, in fact it seems to be a transudate, and is analogous to spinal fluid. Its chemical composition, especially sugar determination, is of value in diagnosis.

A fluid, chemically much like synovia, can be produced by rubbing up epithelium in a weak aqueous solution of alkaline reaction. Its secretion is stimulated by motion of the joint and diminished by rest, a cardinal point to be remembered in the treatment of joint affections. The normal joints contain at all times a small amount of fluid for lubrication purposes, but attempts to substitute oil, vaseline, etc., in joints that have an abnormally small amount of this fluid are not successful, because not only is it very rapidly absorbed from the joints but it may cause considerable reaction.

Joints are moved by muscles, and upon the integrity and proper tone of muscles depends the proper function and resistance of the joint. This is best shown in the degree of rough use which the joints of the football player bear with impunity in every scrimmage, for many of the traumatisms received would disable an average man. The joints of young children are singularly immune to trauma, and sprains in them are rare in spite of their constant falls.

The nerve supply of joints is closely related to that of the muscles controlling them. A reflex muscular atrophy due to joint inflammation is closely limited to the muscles controlling that joint.

Intra-articular fibrocartilages, designed to divide or reinforce the joint, exist in the temporo-maxillary, sterno-clavicular, acromio-clavicular, wrist and knee joints, and where they exist, as in the knee joint, are covered in part on their articular surface by synovial membrane.

Joint Reactions.—Joints have a peculiarly limited range of reaction to unfavorable conditions, and this behavior is apparently conditioned by the fact that only two structures really exist inside the joint itself, namely, cartilage and synovial membrane. Cartilage is a comparatively inert non-vascular tissue, which reacts chiefly or wholly by fibrillation, and that only under considerable stress. We must look therefore to the synovial membrane for the other and important pathological conditions which interest us in all joint affections.

It is useful therefore to formulate just what joints can and cannot do in their reaction to unfavorable conditions. These unfavorable conditions are: (1) Trauma, (2) the absorption of toxins, (3) infection, and (4) disordered nerve impulses.

1. *Trauma* may be *acute* as after a contusion, a wrench, a forced movement beyond the normal range, or over use; or *chronic* as after a fracture where the joint surfaces have been brought into an improper relation to each other, or where a joint is subject to constant strain, as in the knee in certain cases of static errors in the foot.

2. *Toxins* may be absorbed from foci of pus in the body, most commonly from abscesses at the roots of the teeth, or from retained tonsillar secretions, and the reaction of joints to them is most familiar under the old name of "rheumatism." It is certain that chemical products absorbed from the digestive tract are often a source of joint effusion. In the cases due to toxins, bacteria are not found in the joint fluid.

3. *Infection.*—The pyogenic organisms enter the joint either from the outside as from a wound, or through the circulation, and suppuration may be

[1] Jour. Bone & Joint Surg., 1926.

a result. Bacteria may be found in the joint fluid in these cases. Infection much less active also exists in syphilis and tuberculosis where the organisms themselves may be present.

4. *Disordered Nerve Impulses.*—In certain cases of tabes dorsalis and occasionally in other forms of organic nervous disease a slow and comparatively inactive degree of joint degeneration is present. An attempt to explain this on the ground of repeated and unnoticed trauma in a patient whose sensation has been impaired or lost has not been altogether satisfactory, and one must assume the existence of some influence of the nervous system leading to degeneration.

From whichever of the detrimental factors just mentioned joint disturbance originated, the initial reaction in the synovial membrane is always the same. First there is hyperemia, then swelling, then usually increase in synovial fluid. Trauma, toxin, infection, and disordered nerve impulses all produce this manifestation.

Accompanying these, and not to be regarded as a complication, but as an essential condition of joint affection, is *muscular atrophy* in the muscles controlling the joint. This has been shown experimentally to begin within a few hours of the onset of the affection, and it is the last to be recovered from.[1] It has much significance in connection with athletics and is apparently a combination of a reflex phenomenon combined later with the atrophy of disuse.[2] It was described as early as 1776 by John Hunter, and subsequently by many others to whose contributions the references are given.[3] Microscopic changes in the muscles show a diminution in the number of muscle fibers,[4] and Klippel[5] found in the spinal cord of a woman with knee joint tuberculosis that the motor cells in the anterior cornua were smaller and the nuclei both less in number and diminished in size. This observation was also made by Orb, but other investigators did not find these changes, although they were obtained in eight experiments on dogs by Mally and Richon.

Changes in electrical reaction are also noted in this type of atrophy. Mally and Richon found in from one to three days an increased irritability to the galvanic current succeeded by a diminution of irritability to both galvanic and faradic currents; and in the severest cases of joint affections this remained permanently diminished. This type of muscle atrophy they found most often in the shoulder, knee and foot, and least often in the elbow and wrist.

The signs of "synovitis" may be formulated as follows: (*a*) Transient hyperemia, (*b*) swelling of synovial membrane, (*c*) increase of synovial fluid, (*d*) muscular atrophy, (*e*) increase of local temperature.

The diagnosis of synovitis naturally rests on these signs, but is often carelessly made on the presence of pain alone. Hyperemia is soon followed by synovial swelling, not easily to be detected in the deeper joints, and our main reliance in diagnosis must be based on the *presence of fluid*, muscular spasm and increased temperature.

Muscle spasm is a reflex tonic contraction of the muscles controlling the joint. The muscles hold the joint stiff or limit its arc of motion. It repre-

[1] "L'Atrophie Musc. dans les Mal. Artic," Emile Valtat, Paris.
[2] Lovett: Zeitsch. fur Orth. Chir., xxxii, 472 (with literature).
[3] Legg: Trans. Am. Orth. Ass'n., August, 1908.
Hoffa: Berliner klin. Wchsft., January, 1905.
Freiberg: Am. Jour. Med. Sci., May, 1908.
[4] Mally and Richon: Rev. de Chir., 1905, 383.
[5] Klippel: Bull. de la Soc. Anat., November, 1887; January, 1888.

sents nature's effort to splint the joint to prevent harmful motion. The term spasm does not mean that the muscles can be seen to be constantly jerking, but that when motion is attempted they become on guard and can be felt to tighten. It is not necessarily accompanied by pain although it generally is, and it disappears wholly under full anesthesia.

From this initial stage all joint disease must now pursue one of four courses:

1. *Complete or partial recovery.*
2. A *chronic* condition, in which the symptoms as described in the initial stage persist.
3. *Suppuration.*
4. *Degeneration* or *destruction.*

The further consideration of the terminal phases will be taken up in speaking of the separate affections.

Stiffness of Joints

Following a joint affection of classes (3) and (4), where suppuration, degeneration, or destruction has occurred in the joint, stiffness of varying degree is likely to result. This is due to one of the following causes:

1. *Reflex Muscular Spasm.*—Reflex muscular spasm is nature's attempt to inhibit motion in an injured or diseased joint or injured bone and should be respected. It should be met by measures to fix or make traction on the affected joint or the fractured limb which will control the spasm, quickly in the latter, and more slowly in the former. It should be regarded as a danger signal so far as manipulation is concerned and efforts to detect it should be of the gentlest kind, for the object of such handling is not to overcome it, but to ascertain whether it is present.

Therefore the unaffected member should be handled first and put through its range of motion in order to obtain a basis for comparison; then the affected limb should be lightly grasped and moved with the utmost gentleness,—when a firm check to motion is recognized, passive movements should stop. Such a check is generally accompanied by evidence of muscular resistance in the form of muscular contraction. A typical instance of this occurs in the hip where the adductor tendons can be felt by the finger to catch and tighten when the limit of safe motion is reached. In ankylosis and mechanical obstruction this does not occur. When muscular spasm is present it generally limits more than one motion. It disappears under anesthesia and is more evident during sleep because increased reflex activity prevails at that time.

It is sometimes difficult to distinguish this condition from the voluntary efforts of the patient to prevent movement of a joint. The latter varies with the patient's effort, is not uniform during a movement, and is lessened if the patient's attention is distracted. Real reflex spasm is constantly uniform and independent of the patient's attention.

The danger from a rough examination of an affected joint is really considerable and even repeated gentle examinations which involve moving the joint are undesirable. Indeed the examination should be so conducted that our information may be gained with but little if any interference with the disabled limb. If for instance, a tuberculous hip joint is fixed in extension by means of a splint and we desire to know whether any flexion deformity is present there is no need to interfere with the diseased limb, as all that we have to do is to flex the sound limb on the abdomen. If this can be done completely while the

back of the knee on the affected side rests on the table no flexion deformity is present in the affected limb. If it cannot be so done the angle formed between the thigh and abdomen on the sound side will represent the flexion deformity on the diseased side. In this way it is possible to gain the necessary information indirectly.

2. *Adaptive Muscular Shortening.*—The second cause of stiffness after joint affections of this type is muscular shortening.

The essential property of muscular tissue is contractibility, shown by an ever present tendency to shorten. "Every muscle in the body is in a condition of slightly continued contraction which keeps it tense . . . This tone is seen in the retraction undergone by muscles or tendons when they are divided in the living animal."[1] If a muscle is kept for any length of time in such a position that its ends are brought nearer each other it still remains in tone by shortening. This would happen to the biceps if the elbow were kept flexed. Even after a few hours of such a position the contracted muscles feel stiff and uncomfortable when they are stretched by voluntary effort. If such a position has been maintained for days or weeks a very real shortening occurs which will resist voluntary attempts to assume positions which extend the muscle to its full length. The longer the necessary fixation, the greater the adaptive muscular shortening. The fact that joint stiffness in these cases is not necessarily due to intra-articular lesions, but may be largely or wholly muscular, is an important one to remember.

The remaining causes of stiff joints,—adhesions, bony obstructions blocking movement, and ankylosis—will be dealt with elsewhere (Chapter V, p. 70).

Finally, before leaving the question of stiffened joints, a broad general statement may be made that *a joint in which any degree of limitation of motion in any direction exists is a mechanically imperfect joint* and often a source of trouble, and that, other things being equal, restoration of full mobility, where possible, is an essential factor in successful treatment.

Summary.—Schematically presented the preceding may be summarized as follows:

Reaction of joint to—

Trauma Toxin Infection Altered nerve impulse	is by	Hyperemia Swelling Increased fluid accompanied by muscular atrophy and perhaps muscular spasm.

The initial stage results in either one of the following:

1. Recovery—complete or partial, (2) chronic condition, (3) suppuration (4) degenerative or destructive process.

Ankylosis may be the end result and represents a cicatrix.

[1] STARLING: "Principles of Human Physiology," 3rd Edition, 1920, 333.

CHAPTER II

TRAUMATIC AFFECTIONS OF JOINTS

A comprehensive account of the traumatic affections of joints would involve a description of fractures and dislocations as a whole. The latter problems form an integral part of orthopaedic surgery, but as they are already dealt with in many special monographs, this chapter will be limited to a consideration of injuries and derangements of the joint structures proper.

Acute traumatism to joints may be induced by (1) overuse, (2) a wrench or twist, (3) forcible motion of the joint beyond its normal limit, (4) a blow or contusion, or (5) fractures near the joints.

Chronic traumatism may be the result of (1) continued overuse, or (2) use in a way that strains the joint from erroneous deflection of body weight causing improperly distributed pressure on the joint structures and strain of ligaments.

The most marked expression of trauma in both is in the synovial membrane, but ligaments and capsule are generally involved either primarily or secondarily, and tendons are also occasionally the seat of synovitis in these injuries. The course of synovitis has been described and the part taken by the ligaments in the injury is important; but the careless diagnosis of a "torn ligament" so often made, is not generally warranted, ligaments being more likely to tear off a piece of bone than to be ruptured themselves. Tenosynovitis is recognized by tenderness over the affected tendon, with perhaps soft crepitus on motion, and pain when the especial tendon is called into use by muscular contraction which is resisted by the surgeon.

Acute Traumatic Synovitis.—Acute traumatic synovitis, when not accompanied by fracture, as a rule runs a simple and uncomplicated course. Rest to the joint is physiologically indicated but increases the muscular atrophy and for this reason massage, when it can be obtained from skilful hands, should be employed from the outset. Measures to stimulate the local circulation, such as baking, hot douches and packs, are of value in the acute stage. Motion is generally painful and tends to excite the membrane to further secretion of synovial fluid and in the lower extremity weight-bearing motion is at first generally undesirable, but non-weight-bearing motion can be employed early.

In the progress of recovery the fluid disappears first, but some swelling may remain a little longer; and muscular atrophy disappears last. When the swelling is diminishing, the use of resistive non-weight-bearing muscular exercises is most important, for many hip, knee, and shoulder joints remain painful, irritable, and partially useless from muscular weakness alone, the joint itself having recovered. Unrestricted use cannot be prescribed in these cases, for such joints are too irritable, but increasing resistive exercises and massage, followed by regulated systematic use of the joint, aided by the voluntary contraction of the muscles without moving the joint, offer the best solution.

Chronic Synovitis.—In chronic cases the symptoms are of the same character as those of the acute stage, only less marked. Certain joints, notably the shoulder, knee, and ankle, are peculiarly liable to symptoms persisting after an acute synovitis for reasons which will be referred to again.

But chronic synovitis is not in general a final diagnosis, except in those cases where it is the direct outcome of the acute stage. This is shown for example in chronic synovitis of the knee following a strain of the internal lateral ligament, or in chronic synovitis which has been followed by tuberculous infection, or in cases where some antecedent pathological condition existed which had not been recognized before the injury, as in mild arthritis deformans or hemophilia.

The routine treatment for a case of chronic synovitis is compression over the joint itself, care being taken that the bandage is not carried high or low enough to interfere with the development of the muscles. To this should be added exercises for muscular development, the exercises being best performed with the compression bandage in position.

Importance of X-ray.—The surgeon who undertakes the responsibility of treating a joint injury without examining a *good* X-ray assumes a very great risk and it is often a safeguard to have an X-ray of the joint of the other side for purposes of comparison. In so-called sprains which have persisted, one finds a fair proportion of cases with fracture. In the hand, fractures of the phalanges and metacarpals are very common, and Colles' fracture and fractures of the carpal bones are constantly overlooked; in the shoulder one often finds an avulsion of the insertion of the supraspinatus. In the foot, fracture of the 5th metatarsal often escapes notice,[1] as well as the tearing off of the tip of the inner malleolus; and fracture of the os calcis is not always recognized. At the knee, avulsion of the tibial insertion of the crucial ligaments may be found. As for the hip, bending of the neck of the femur in children, especially, constantly escapes observation.

Patients are very intolerant of the omission of an X-ray under these conditions, however much they have objected to it at the time of injury, and the risk to the patient and to the surgeon's reputation from omitting X-rays in practically any case of joint injury is considerable.

TRAUMATIC AFFECTIONS OF THE HIP JOINT

Anatomy of the Hip Joint.—The hip joint is an essentially stable weight-bearing joint, the most deeply situated of any in the body and controlled by the heaviest of muscles and protected by the strongest of ligaments. Atmospheric pressure is also an element in its stability. For these reasons dislocation is rare, sprains less common than in other large joints, and fracture of the neck of the femur a common result of severe trauma. This is because the head of the femur is firmly held in the acetabulum, the shaft of the femur acts as the long arm of a lever and the offset of the neck makes that the weakest point in the mechanism. The motion of the joint is universal as in other ball and socket articulations, but as evident from its structure its range must be much less than in the shoulder.

Ligaments.—The most important ligament is the iliofemoral *ligament of Bigelow* which extends obliquely across the joint in front, being ultimately

[1] JONES, ROBERT: Trans. Liverpool Medical Institution, 1901, Dec. 19.

connected with the capsule. Above it is attached to the anterior inferior iliac spine from which it diverges into two bands which separate to be inserted, one into the lower part of the anterior intertrochanteric line while the other passes down and outward to be attached to the upper part of the same line and neck of the femur adjacent to it. It checks hyperextension of the joint and although flexion of the trunk on the lower extremity is free, this ligament prevents free hyperextension of the trunk on the legs. This fact is most important in the maintenance of the upright position.

This ligament is rarely torn, dominates the phenomena of dislocated positions, and is the surgeon's mainstay when reducing a dislocation as it affords a point of resistance. On account of the dominance and strength of this ligament the hip is strong anteriorly and comparatively weak posteriorly and this is confirmed by the frequency of posterior dislocations.

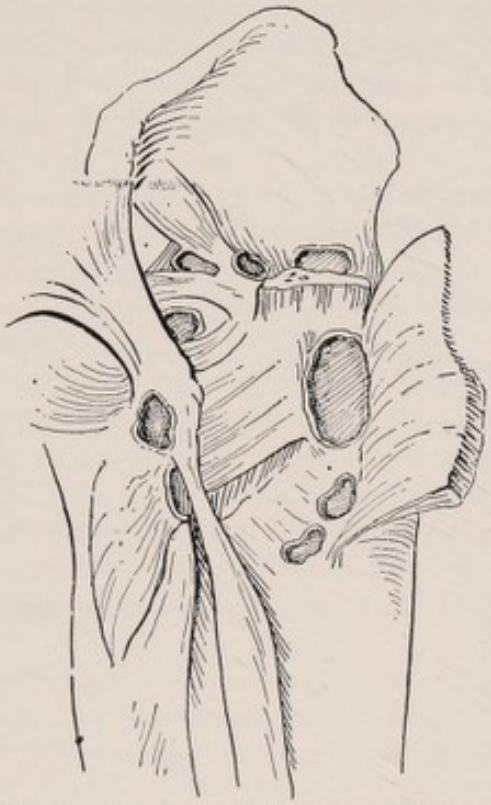

FIG. 1.—Bursæ about the hip. Posterior view.

The CAPSULAR ligament is a dense ligamentous collar embracing the circumference of the acetabulum above and surrounding the neck of the femur. Its longitudinal fibres in front are massed to form the iliofemoral ligament.

The LIGAMENTUM TERES is intra-articular, apparently concerned in strengthening the joint and "probably vestigial and practically useless." It has been conclusively shown that the few vessels present in early life supply a small zone of articular cartilage only. In the adult the ligament is an avascular structure (Walmsley[1]). The *cotyloid* ligament is a fibrocartilaginous rim attached to the edge of the acetabulum and deepening it whereby it adds to its stability. Where it bridges over the notch in the acetabulum it is called the *transverse ligament* of the acetabulum.

Synovial Membrane.—Beginning at the margin of the cartilaginous surface, which is at the limit of the smooth part of the head, it covers all that part of the neck contained in the joint, is reflected to the inner surface of the capsule, covers both the surface of the cotyloid ligament and the mass of fat contained in the depression at the base of the acetabulum ("Haversian Gland") and is prolonged as a tubular sheath surrounding the ligamentum teres. It sometimes communicates with the bursæ under the iliopsoas muscle.

Bursæ.—The most important are: (1) *Iliopectineal* between the iliopsoas tendon and joint, often communicating with the joint: (2) *Subtendinous iliac* between the same tendon and lesser trochanter: (3) *Ischiogluteal* between the gluteus maximus and ischial tuberosity (not constant): (4) *Bursa of the great trochanter* between it and gluteus maximus muscle: (5) *Subcutaneous trochanteric bursa* over the great trochanter: (6) *Obturator* between the sacrosciatic notch and the obturator internus tendon: (7) two or three *gluteofemoral*

[1] WALMSLEY: Journal of Anat. & Physiol., July, 1915.

bursæ. There are other less important bursæ where muscular action demands it as adventitious bursæ develop where needed.

The *nerves* are articular branches from the sacral plexus, great sciatic, obturator and accessory obturator and a filament from the anterior crural. The latter is of importance in explaining the knee pain, in arthritis of the hip.

The *arteries* supplying the joint are from the obturator, sciatic, internal circumflex and gluteal.

In connection with certain affections of the hip joint in children, notably flattened head of the femur,[1] the blood supply in the region of the epiphysis of the hip is important and has been worked out by Lexer[2] and Waldenström.[3] These researches seem to show that the main sources of supply are (1) a vessel entering the upper part of the neck just above the great trochanter and sending a branch to the upper epiphysis, (2) a vessel on the under side of the neck, (3) a small vessel at the internal side of the epiphysis of the head, and (4) a vessel in young children entering through the ligamentum teres, but the latter vessel apparently does not continue after very early childhood. Injections and sections show that the epiphyseal line is surrounded by a network of vessels, some of which apparently interlace across the epiphyseal line. Trauma or disease to the epiphyseal line is therefore likely to interfere with the circulation supplying nutrition to this region.



Fig. 2.—Circulation in the upper epiphysis of the femur (Lexer).

Motions.—Although motion in every direction is possible in a ball and socket joint like the hip, the motions of the hip are usually classified as follows:

(*a*) *Flexion* in the sagittal plane is allowed until the anterior surface of the thigh comes in contact with the abdomen and the amount varies with the fatness of the individual. It is less when the knee is straight during flexion on account of the checking influence of the hamstring muscles under tension. With the knee bent, passive flexion exists to about 50–60 degrees with the long axis of the body. One has, however, only to recall the feats of contortionists to recall that such limits of motion are exceedingly variable.

The chief muscles producing flexion are the *iliopsoas*, the *rectus femoris*, and the *sartorius*.

(*b*) *Extension* is checked by the iliofemoral ligament and anterior capsule. The motion exists to about 45 degrees beyond the long axis of the body.

The chief muscles producing extension are the *gluteus maximus* and *hamstrings*.

(*c*) *Abduction* in the frontal plane of the body is checked by the inner band of the iliofemoral ligament and pubofemoral band. It exists to about 50 degrees.

The chief muscles causing abduction are the *gluteus medius* and *minimus* and *tensor fasciæ femoris*.

[1] Legg: Surg., Gyn. and Obst., March, 1916.
[2] Lexer: Arch. fur klin. Chir., 1903, lxxi.
[3] Waldenström: From the Surg. Div. of the Children's Hospital of the Crown Princess of Stockholm.

(*d*) *Adduction:* When the patient lies on his back and the suspected leg is adducted, it is checked by the other leg. If the other leg is flexed to get it out of the way, adduction is found to exist to about 45 degrees.

(*e*) *Internal rotation* is checked by the ischio-capsular ligament and posterior capsule and is present to about 30 degrees.

(*f*) *External rotation* is checked by the outer band of the iliofemoral ligament and exists to about 60 degrees with patient recumbent. The chief muscles producing this motion are the posterior fibres of the gluteus medius and minimus, the lower fibres of the gluteus maximus, the gemelli, obturators and quadratus femoris.

Only the most important muscles have been mentioned in connection with function as there is general agreement among anatomists only with regard to these. In the minor accessory muscles there are many conflicting statements as to function.

Development.—(1) The head of the femur unites to the shaft by a separate epiphysis appearing late in the first year and uniting with the shaft at about the eighteenth. Prior to union, displacement of this epiphysis occurs at times but is not as common as one would expect from a consideration of the location, oblique line and conditions of leverage. The occurrence of hip dislocation in children is exceedingly rare as it is much easier to loosen the epiphysis than to throw out the head of the femur. This epiphysis is intracapsular. (2) The trochanter major unites as a separate epiphysis appearing about the fourth year and uniting about the eighteenth. (3) The lesser trochanter also unites by a separate epiphysis appearing about the thirteenth year and uniting at about the eighteenth. The two latter epiphyses appear not to be of great surgical significance, while that of the head is of primary importance.

Surface Anatomy.—The tip of the great trochanter is on a level with the center of the head of the femur and also with the spine of the pubis. The *Roser-Nélaton line* from the anterior superior spine of the ilium to the tuberosity of the ischium passes normally just across the tip of the great trochanter. To take this measurement the patient lies on the side with the thigh slightly flexed. Elevation of the trochanter above this line means either dislocation of the joint, a change in the neck of the femur, or a destructive or traumatic loss or fracture or condensation of bone between the trochanter and hip joint.

The joint is accessible to palpation in front where it is most superficial, between the outer edge of the sartorius and rectus and the inner edge of the tensor fasciæ femoris and gluteus medius on a level with the spine of the pubis and behind the femoral vessels.

Acute Synovitis.—In the hip joint the presence of fluid is not easily detected on account of the limited size of the capsule, and from the fact that it is deep and surrounded by large muscles. If fluid is present, it can only be detected as a deep, not wholly distinct fullness, lying just in front of the anterior border of the tensor fascia lata. When acute synovitis exists, it is generally decidedly painful and characterized by much muscular spasm, the limb usually being held in flexion and adduction or abduction deformity. The swelling must be differentiated from the enlarged bursæ we sometimes find underneath the psoas, by the limitations of motion, and by its anatomical position. Rest with fixation is the treatment.

Chronic traumatic synovitis of the hip, without affiliation with arthritis deformans or tuberculosis or other constitutional disease, is not an expression

of a grave lesion, and should not in the average case be a cause of anxiety, but should be treated by rest.

Epiphyseal Strain.—In young children, especially, and in some older ones, lameness, pain, and muscular limitation occur in the hip after a long walk, a slight fall, or even without recognizable cause.[1] The tenderness and pain as a rule are slight and the limitation of motion is confined chiefly to rotation, although slight flexion deformity often exists, atrophy is rarely present and the Pirquet skin test is negative. The affection usually lasts but a few weeks and is apparently due to an epiphyseal strain. X-ray appearances are as a rule negative, implying that the lesion is not a real displacement of the upper epiphysis of the femur, but probably only a trauma to the epiphyseal structures without loosening or displacement.

The prognosis is favorable for complete recovery when once the diagnosis is established and proper treatment instituted.

In the slighter cases the treatment consists of putting the child to bed and forbidding weight-bearing motion until at least a week after all limitation of motion has disappeared. Even after that time, full activity is not desirable for a week or two more, the surgeon being guided by the absence of the limitation of movement. Whenever a strain of the epiphysis is suspected the child should return for observation from time to time in order to be sure that no subsequent deformity of the nature of traumatic coxa vara develops.

FLATTENED HEAD OF THE FEMUR

(Legg's disease,[2] Perthes' disease,[3] pseudocoxalgia,[4] osteochondritis deformans juvenilis, "quiet hip disease," coxa plana[5]). This condition was first described by Legg in 1910 and later articles have added but little to our knowledge of the pathogenesis.

The clinical picture is one of mild hip disease in which recovery takes place.

Etiology.—The affection has acquired a most voluminous literature in which conflicting views as to its causation have been fully set forth. The *traumatic* theory, originally propounded by Legg has been accepted by the majority of writers, and for this reason coxa plana has been so classed in this chapter. Legg believed that a mild injury produces a disturbance in the circulatory balance between the epiphysis and the femoral neck. This consists in a diminished blood supply to the epiphysis and a compensatory hyperaemia in the neck. As a result the epiphysis atrophies and shows the characteristic flattening, whilst the neck becomes hypertrophied. One of the strongest arguments in favour of trauma as the primary etiological factor is the not infrequent occurrence of coxa plana following the reduction of a congenital dislocation of the hip. There are, however, many cogent objections to this hypothesis as applied to every case of coxa plana.

The *inflammatory* or *infective* theory has also received a considerable measure of support. The French school, following the lead of Froelich,[6] have grouped this condition with other analogous bone changes (tarsal

[1] Lovett and Morse: Boston Med. and Surg. Jour., Aug. 18, 1892.
[2] Legg, A. T.: Boston Med. and Surg. Jour., Feb. 17, 1910. Surg., Gyn. and Obst., March, 1916.
[3] Perthes: Arch. fur. klin. Chir., 1913, 779.
[4] Calvé: Rev. de Chir., July, 1910.
[5] Calot and Collen: Presse Méd., January, 1922, No. 4.
[6] Froelich: Revue d'Orthopédie, 1918, April.

scaphoiditis, apophysitis of the tibial tubercle, etc.) under the heading "osteochondrite de croissance." At one time the infective hypothesis appeared to be most convincing owing to the earlier histological and bacteriological findings of Perthes, Phemister,[1] Kidner,[2] and others. Legg himself had explored the femoral neck in one of his original cases and had been able to grow the *Staphylococcus aureus* from the material evacuated. This organism was also isolated by Kidner after a similar operation. Phemister's histological studies of a portion of the epiphysis had led him to consider that there was definite evidence of an old infective lesion. Both Phemister and Kidner[3] have since examined tissues removed from a typical case of coxa plana, and have failed to demonstrate any sign of an inflammatory lesion. It is to be realized that a true subacute infective epiphysitis may mimic the clinical and radiological picture of Legg's disease.

The most recent work on the etiology of coxa plana tends to suggest that the characteristic deformation changes may often develop in a hip joint which is already defective. Murk Jansen[4] has described two *congenital* stigmata—flattened socket and ischium varum, which in his view predispose to the subsequent onset of coxa plana.

Calot,[5] from radiological observations, believes that every coxa plana is an unrecognized congenital subluxation. These views have so far met with little support.

Radiological Appearances.—Changes occur in the epiphysis, in the femoral neck, and in the acetabulum. In the *epiphysis* there is a definite cycle; a phase of "destruction," followed by a phase of regeneration. In the early stages the epiphysis becomes flattened and thinned out. It may also show division into several pieces—"fragmentation." Later the fragments coalesce and uniform calcification is re-established. The *femoral neck* usually becomes broadened at its upper part and appears squat and foreshortened. In the subepiphyseal region areas of condensation and rarefaction are often demonstrable. *Acetabular* irregularities of various types are frequently seen, and in the later stages the hip socket changes its shape in conformity with the deformed head. The appearances then often suggest the presence of a subluxation. In rare instances the characteristic bony changes may be followed by a restituto ad integrum, but ordinarily a deformed and flattened femoral head persists through life.

Legg has described two types of change which occur in the femoral head. The "cap" type and the "mushroom" type. The epiphysis in the cap type is small and flattened; in the mushroom type the epiphysis is large and flattened. Associated with both types is marked thickening of the neck of the femur.

Symptoms.—Mild lameness and some limitation of motion, particularly in rotation and abduction, exist. There is slight atrophy and the joint is irritable, not especially painful, but subject to strain on much use, and some shortening may occur. It is an affection of the middle years of childhood and is usually unilateral but may be bilateral. The similarity between Legg's disease and Köhler's disease, vertebral epiphysitis, Osgood-Schlatter's disease Freiberg-Köhler's disease, and apophysitis of the knee is at times striking.

[1] Phemister: Archives of Surgery, 1921, March.
[2] Kidner: Amer. Jnl. Orthop. Surgery, 1916, June.
[3] Kidner: Jnl. Bone & Joint Surgery, 1926, Apr.
[4] Jansen: Jnl. Bone & Joint Surgery, 1923, April, V. 2.
[5] Calot: Bulletin de l'Academie de Médicine, 1924, Apr. 24.

Recently cases have been observed which have two or more of these lesions present.

The X-ray is the means by which the condition was recognized and is the source of practically all of our information with regard to it; the characteristic appearances have already been described.



FIG. 3.—Bilateral Legg's disease.

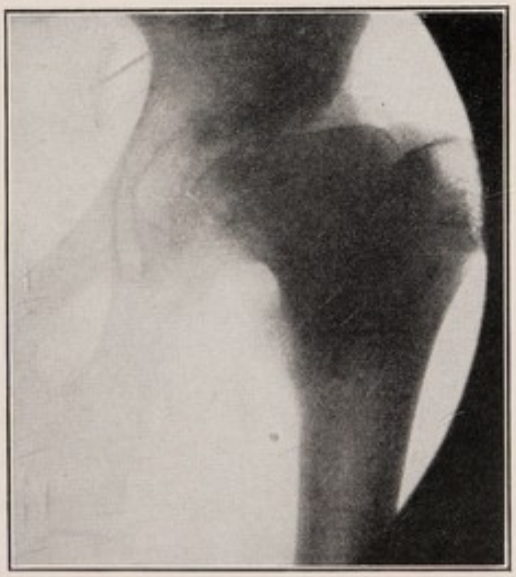

FIG. 4.—Same case as Fig. 3, showing the left hip nine years later.



FIG. 5.—Bilateral Legg's disease, more marked on one side than on the other.

The writers have reason to believe that certain cases of this disease subsequently develop chronic or degenerative arthritis with hypertrophic changes, and the changes that occur in the shape of the femoral head in this latter disease are very similar to those found in Legg's disease. Such cases often give a history of lameness in early life. There are other undoubted instances where

the radiogram shows a flattened head, and later destructive changes occur similar to tuberculosis if not actually tuberculous in character.

Prognosis—The condition has not been identified long enough to enable us to speak definitely with regard to the outcome in a given case. Under mild treatment, symptoms disappear, but the head of the femur remains flattened



FIG. 6.—Late Legg's disease in an adult female, thirty-five years old. Hip always troublesome. Other hip normal.

in most cases so far observed, although the irregularity becomes less marked. Certain cases in adult life, undoubtedly due to this condition in childhood, have been observed where irritability of the hip on overuse, and some limitation of motion and shortening had persisted. This amounted to an arthritis characterized by new bone formation evidently due to the traumatism of using a mechanically imperfect joint.

Treatment.—The treatment consists in some restriction of walking, protection from weight-bearing in cases which are hard to control, and, in exceptionally severe cases, fixation of the joint should be temporarily added to protection from weight-bearing.



FIG. 7.—Variation of angle of neck of femur within normal limits (Warren Museum, Harvard University).

COXA VARA

Coxa vara is a conventional name, used in general to describe a change in the normal relation of the neck of the femur and the shaft. This change consists in a depression of the neck, usually associated with some element of abnormal twisting of the neck in relation to the shaft. The condition is merely symptomatic and does not represent a pathological entity, being due to many different conditions. The name describes a mechanical defect, and is not a scientific term, but is used here because it is so universally accepted as descriptive.

In the normal adult, the neck of the femur forms an angle of from 125 degrees to 130 degrees with the shaft. The angle between the neck and shaft of the femur is greater in children, being approximately 160 degrees, and on account of the wider pelvis in the female the angle is somewhat less than it is in the male. The head and neck do not lie in the same transverse plane, as a line



FIG. 8.—Angle of torsion in a series of normal femora placed on a board with the condyles of the femur in contact with it (Warren Museum, Harvard University).

joining the condyles of the lower end of the femur and the neck of the femur runs slightly forward of this line, about 12 degrees. This angle, however, varies greatly and it was found at the Harvard Medical School that in a series of normal femora, taken at random and laid on a flat board on which rested the posterior surfaces of the condyles of the femur, the inclination of the neck

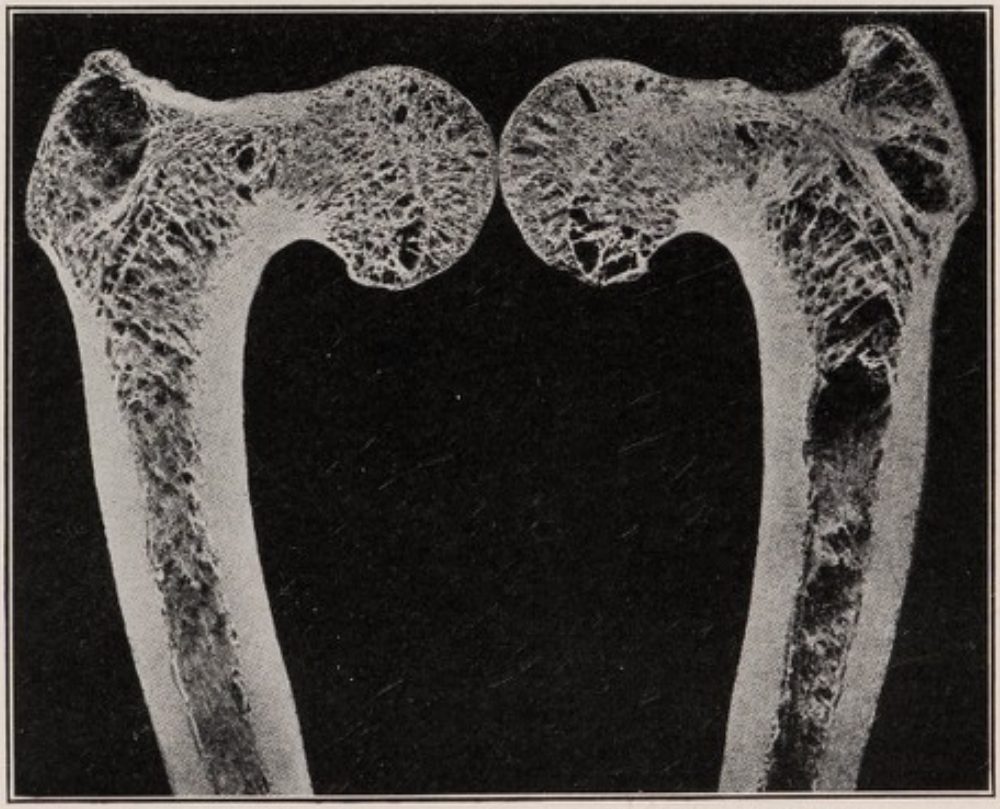

FIG. 9.—Section of the femur in a case of coxa vara (E. Albert).

varied very decidely. The neck of the femur faces upward, inward, and a little forward in its relation to the shaft.

With the lowering and twisting of the neck certain obvious mechanical changes occur: (1) The head of the femur is rotated in the acetabulum by the change in the angle of the neck, the normal contact of joint surfaces is disturbed, and the head of the femur not being a perfect hemisphere, the bearing surfaces of the joint no longer fit as they should normally. (2) With the

lowering of the neck the trochanter rises in relation to the pelvis and abduction is limited by the impingement of the tip of the trochanter against the pelvis in abduction. In severe cases this is very marked. (3) The twist in the neck disturbs the planes of motion in flexion, extension, and rotation, and (4) bony shortening of the limb occurs so that in walking abduction of this joint accompanies each step on the affected leg. The conditions are therefore mechanically bad and likely to cause irritation in the use of the joint.

Etiology.—Coxa vara may be (1) *congenital or* (2) *acquired.*

1. Congenital coxa vara[1] has not been sufficiently emphasized and is of importance as an entity. It may exist alone or in connection with other congenital defects, notably defective formation of the femur. Such cases, at least, belong clearly to the class of primary congenital deformities (p. 560). In other cases the deformity is apparently due to intrauterine affection of the bone, as in achondroplasia, while in a third group there seems reason to believe that intrauterine pressure may have been the cause.



Fig. 10.—X-ray of congenital coxa vara. (The mother of this patient shows a similar deformity.)

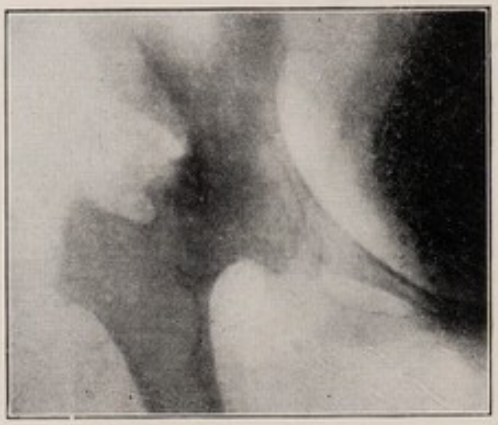

Fig. 11.—X-ray of coxa vara. (In the mother of the patient shown in Fig. 10.)

The symptoms are manifested when the children begin to walk and the gait and attitude resemble very closely those of congenital dislocation of the hips; walking is difficult and generally rather painful in these young children, but the symptoms, diagnosis and treatment do not differ essentially from those to be described later.

2. Acquired Coxa Vara.—This form is most often traumatic in origin,[2] but may be associated with pathological conditions in the neck of the bone, which, associated with weight-bearing, are apparently the cause of the deformity.

The common types of traumatic coxa vara are:

(*a*) Where the junction between the epiphysis and the upper end of the shaft of the femur yields under constant trauma or some disproportion between weight and bearing power, and slips downward without a complete fracture. This condition of course occurs only up to the time the epiphysis consolidates, and leads to a deformity of moderate grade. Very slight slipping of the epiphysis, as shown in the X-ray, may be the cause of symptoms.

(*b*) The epiphysis of the head is completely loosened from the upper end of the neck, the neck rides up and a considerable deformity is produced.

[1] Helbing: Zeitsch. fur. Orth. Chir., 1906, xv (with literature).
Hoffa: Orth. Chir., 1905, 618.

[2] Elmslie, R. C.: Lancet, Feb., 1907.

(*c*) A greenstick fracture of the neck of the femur may occur in young persons, as a result of which the shaft of the femur rides up in relation to the head by the yielding of the neck, and the neck is shortened and its upper border generally thickened, so that the head of the femur as a whole approaches the trochanter. This condition in itself causes only a moderate deformity, but if further slipping occurs as a result of the softening due to the fracture, severe deformity may arise. In this connection it may be mentioned that the condition existing after impacted fracture of the neck of the femur is mechanically, so far as the joint is concerned, a traumatic coxa vara.

A change in the relation of the head and shaft of the femur occurs in various abnormal conditions. In *rickets* during the stage of softening, the neck of the femur often yields to a considerable extent so that it may become horizontal. It is the least disabling of the forms of coxa vara, and spontaneous recovery is frequent.

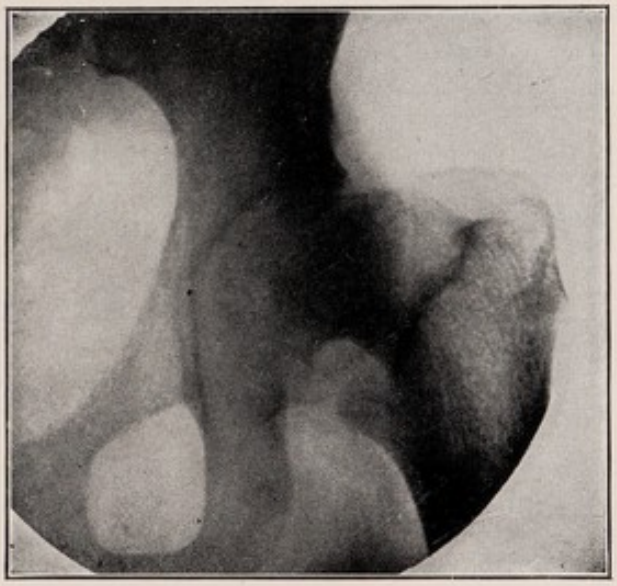

FIG. 12.—Adolescent coxa vara.

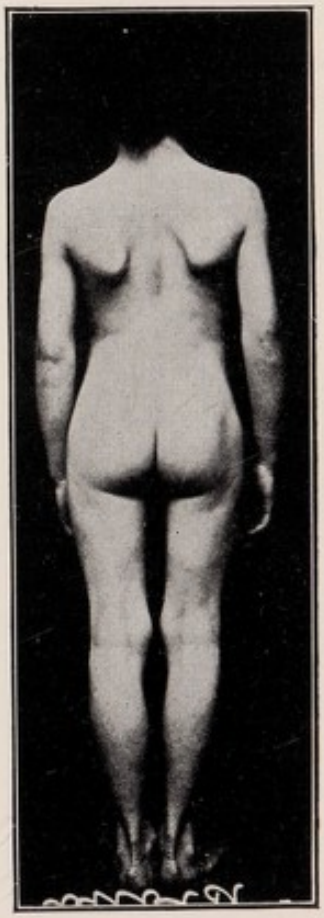

FIG. 13.—Double coxa vara, seen from the back.

In the condition known as *late rickets*, which will be discussed later (p. 328), yielding of the neck of the femur sometimes of an extreme character may occur. This condition, as has been said, is imperfectly identified, pathologically, and is often used to account for a degree of local bone softening that cannot otherwise be accounted for. In other words, in adolescence, local softening of the neck of the femur may occur, leading to severe coxa vara, which is often accounted for in this somewhat unsatisfactory way.

In *osteomalacia* yielding in any degree of the neck of the femur may occur from the absorption of lime in the neck of the femur and its plastic bending under weight.

As a result of disease, coxa vara may also occur in osteomyelitis, arthritis deformans, occasionally in tuberculosis of the hip, and in Legg's disease. It is also often found in congenital dislocation of the hip. These

conditions are discussed elsewhere; in them the patient shows the signs of coxa vara plus those of the especial disease.

In addition to the direct effects on the joint from the changed relation of the neck to the shaft, there is an effect on the neck itself which is of importance. The bone trabeculæ are arranged to protect the neck against weight-bearing more or less in the direction of its length, but when the neck becomes more horizontal a cross-strain falls upon it which by its structure it is ill calculated to sustain. As a result of this the bone may become congested and soft and yield further under the strain.

Symptoms.—The general clinical picture is as follows: A fall upon the hip is followed by symptoms mild or severe, varying from slight lameness to complete disability. The lameness results from limitation of abduction and inward rotation, plus tenderness in the joint during acute attacks. This condition



FIG. 14.—Very extreme coxa vara.



FIG. 15.—Coxa vara, due to separation of epiphysis from the neck of the femur.

if slight is rapidly recovered from, but in some cases irritability of the joint remains, with limited abduction and discomfort in overuse. A second accident is likely to occur resulting in an increase and aggravation of symptoms. As time goes on the symptoms become more severe, the leg begins to get shorter, is limited in internal rotation and abduction and the disability becomes so serious that the patient seeks advice. In other cases the disease begins in an adolescent, perhaps without known cause, perhaps after prolonged use, or after a slight fall which has escaped attention. One point to be remembered is that the symptoms may not become marked until some time after the accident.

Diagnosis.—The signs establishing the existence of the condition are the direct mechanical outcome of the deformity. *Synovitis* is present from time to time, perhaps constantly. *Shortening* of the leg results from the upward displacement of the shaft on the neck, and the trochanter is *always* above Nélaton's line. *Motion is mechanically limited in abduction* because the trochanter impinges on the ilium in that position, *inward rotation* of the hip joint is limited by the backward twist of the neck and *flexion* is somewhat restricted by the same malposition. These limitations are due to structural obstacles but muscular spasm may also be present in certain cases. In flexion

of the leg on the body the femur abducts and rotates out, and in walking the patient toes out. *Atrophy* is present.

In double coxa vara the trochanters are further apart than is normal, and for this reason the attitude and gait are very suggestive of a double congenital dislocation of the hip; in severe cases a further similarity to congenital dislocation of the hip is found in the existence of a Trendelenburg sign if there is much limitation of adduction. (See Congenital Dislocation of the Hip on p. 591.)

The X-ray defines the diagnosis and as a rule distinguishes between a real impaction of the neck of the femur, a partial or total displacement of the femoral epiphysis, or a yielding due to some pathological condition of the bone. Without the X-ray one must depend on the elevation of the trochanter and the characteristic limitations of motion described.

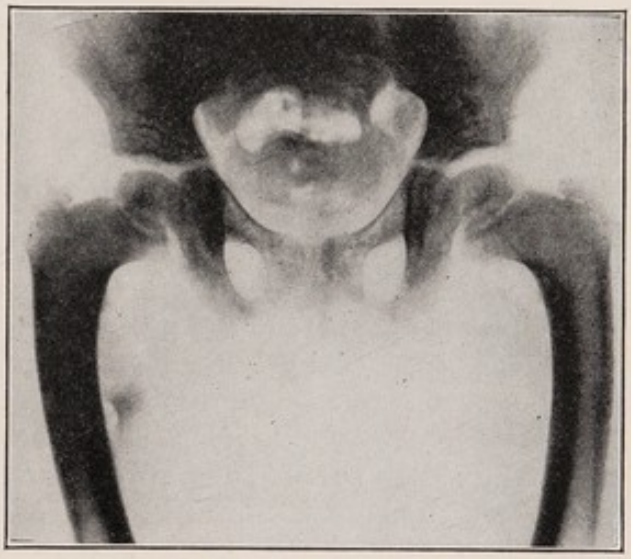

FIG. 16.—Rachitic coxa vara.

In acute cases and in cases during attacks of irritation, pain, muscular spasm and marked lameness are present in addition to the signs described.

Differential Diagnosis.—Coxa vara is most frequently mistaken for (1) *tuberculosis of the hip*, but in the former, joint symptoms are much less prominent, the X-ray is characteristic and the diagnostic signs of joint tuberculosis are absent; or (2) *congenital dislocation of the hip*, in young children, may in some cases be difficult even for the experienced surgeon to diagnose from coxa vara by manual manipulation. Two symptoms, however, are present in congenital dislocation which are absent in coxa vara. The head of the femur can be felt out of the acetabulum and telescoping is possible. Furthermore, lameness from birth is present in congenital dislocation. The X-ray however will settle the question. The diagnosis from other conditions should offer no difficulty.

Prognosis.—In the adolescent type of traumatic coxa vara, if the limb be moderately abducted shortly after the accident and retained in this position for a few weeks and if the epiphysis be protected by a Thomas caliper splint later, a certain amount of recovery takes place. There generally remains a certain limitation of movement, most marked in extension and rotation, but when the epiphysis becomes fully developed the range of mobility in the hip may again increase.

Treatment.—The treatment of coxa vara should be protective in the early stages and all weight-bearing avoided. As limited abduction is a normal sequence, the limb should be kept abducted. Gentle movements of a painless character are to be encouraged in order to avoid the stiffness which follows prolonged immobilization. This initial rest may considerably modify the course of the disease.

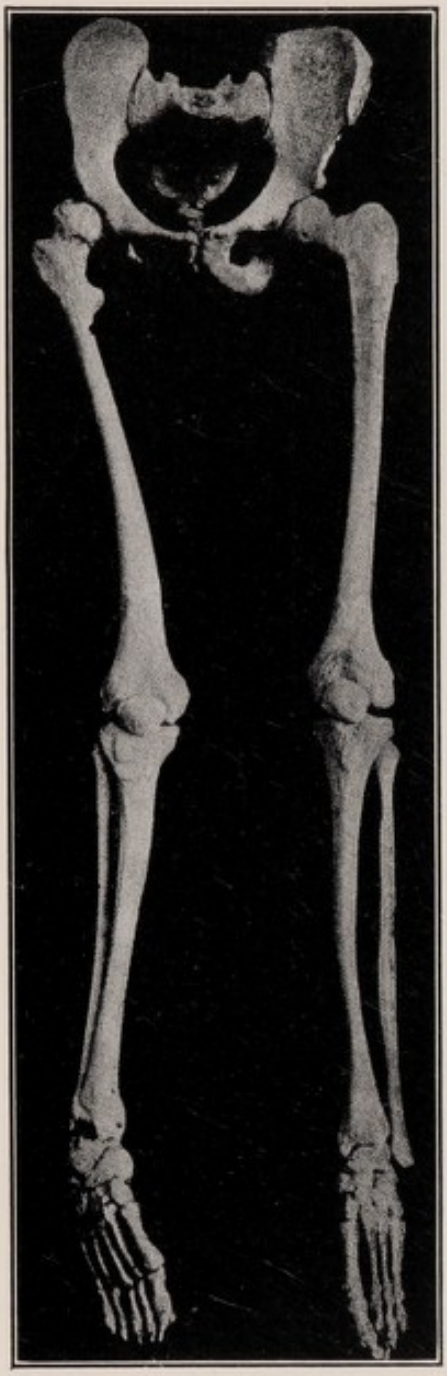

Fig. 17.—Coxa valga in the right hip resulting from paralysis of that leg and non-weight-bearing (E. Albert).

In the later stages accompanied by considerable stiffness and marked angulation of the neck, the limb may be gradually abducted and retained in abduction for weeks or months. Here it is especially important that periodically the limb should be gently adducted as cases are on record where ankylosis has occurred in very disabling abduction. This is more likely to occur from the traumatism of rapid correction of adduction, a method to be deprecated. Before weight-bearing is allowed, massage and movements in the recumbent position are to be practised. The subsequent ambulatory treatment should be graduated and in the unilateral cases a caliper splint will be found useful.

In fixed adduction an osteotomy just below the great trochanter should be performed. If only a slight degree of movement is present in the joint the limbs should be fixed midway between abduction and adduction; that is, each limb should form a right angle with the pelvis. Where the head of the bone rests upon the femur in the adult, and the lordosis is marked and the limbs are rotated inward and adducted, the head and neck of the femur should be excised and the limb abducted and hyperextended. Early movements should be encouraged.

In the traumatic coxa vara of adolescents the treatment should be similar to that of fracture of the neck of the femur, namely, abduction and internal rotation of the limb with a retention plaster.

Coxa Valga.—Coxa valga is the reverse deformity to coxa vara. In the acquired form it occurs in rickets and the reason for its occurrence is not clear in this condition, coxa vara being much more common. A form occurring in adolescents is described, but the commonest association is in cases where weight has not been borne on the leg, such as in congenital affections where walking is impossible; in hydrocephalus, myotonia congenita, and fetal amputations of the leg; in amputations in early childhood, after poliomyelitis; and in similar paralytic conditions.

The *diagnosis* is easily made, and the prognosis will depend upon whether the cause of the deformity can be eliminated.

The X-ray should be taken with the foot vertical and the patella pointing straight forward. If the picture is carelessly taken, by allowing rotation the neck is foreshortened, the angle of the neck of the femur disappears, and the case appears to be one of coxa valga, whereas if the picture were properly taken the angle might be found to be normal.

Treatment.—The condition is not serious enough to warrant extensive treatment as the symptoms are rarely troublesome, but if non-weight-bearing is suspected of being the cause, weight-bearing should be encouraged.

CHAPTER III

DISABILITIES OF THE KNEE JOINT

Anatomy

Sprains and fractures of the knee joint, as well as adhesions and ankylosis, have been dealt with elsewhere; and now will be considered the conditions, chiefly mechanical, which interfere with the function and stability of the joint.

The knee joint, which is the largest in the body, owes its great strength chiefly to the powerful ligaments that unite its two component bones. It derives no strength from the articular facets which consist merely of two rounded condyles articulating with two shallow depressions in the tibia, for in no position of the joint is there ever more than a small area of the femur in contact with the tibia.

The motions of the joint are antero-posterior gliding movements and rotation of the tibia upon the femur, for the ligaments allow no other movement. In no position of the knee is lateral movement normally allowed; but when in partial flexion, considerable rotatory movement can take place, and every time the knee is fully extended a certain degree of outward rotation normally occurs. The ligaments which prevent lateral movement during extension and during slight flexion are the laterals, and during the more acute flexions, the crucials. It is obvious, however, that in conditions of strain the muscles are valuable accessories; but they are quite inefficient as substitutes for either the crucial or lateral ligaments, should the latter be put out of action.

Experiments on the cadaver show that extension of the knee is limited: (1) By the anterior crucial ligament, (2) by the internal lateral ligament, and (3) by the external lateral ligament; and that an increased range of movement is obtained as each structure is divided in succession. External rotation of the leg is limited by the two lateral ligaments and is increased if either be ruptured or cut; and in external rotation, the tibia may slip forward slightly on the femur, but is stopped by the anterior crucial ligament. Internal rotation of the leg is limited by the internal lateral and anterior crucial ligaments. In internal rotation, the tibia may slip back a little, but is stopped by the posterior crucial ligament.

It may be stated briefly that flexion of the knee takes place between the semilunars and the femur, the discs moving with the tibia, and that rotation occurs between the tibia and the discs, the latter moving with the femur. Flexion of the joint is checked by the contact of the leg with the thigh. Flexion is produced by the hamstring muscles, assisted by the gracilis and sartorius, and indirectly by the gastrocnemius. Extension of the leg on the thigh is allowed until the thigh forms a straight line with the leg, and is produced by the quadriceps extensor.

Internal Lateral Ligament.—This is an exceedingly important structure and is a broad, flat membranous band, attached at its proximal end to the femur. It extends downward and is attached distally to the upper part of the inner border of the shaft of the tibia, and its deep fibres are intimately connected with the capsule of the joint and are firmly attached to the internal semilunar cartilage and the articular edge of the internal tuberosity. It plays a very important part in injuries of the joint. It has a superficial portion but its deep aspect is closely blended with the capsule of the joint and is firmly attached to the internal semilunar cartilage. These deep fibres of the ligament help to move the cartilage with the internal condyle of the femur.

External Lateral Ligament.—The external lateral ligament consists of two parts—a short posterior ligament and a long external lateral ligament, which, together with the tendon of the biceps, strengthens the outer aspect of the joint.

Posterior Ligament.—The posterior ligament is a strong fibrous band formed of fasciculi. The expansion from the tendon of the semimembranosus muscle is called the *posterior ligament of Winslow*. The posterior ligament forms the floor of the popliteal space and the popliteal artery rests on it.

Semilunar Cartilages.—Each cartilage assists the opposite lateral ligament in resisting lateral movements of the leg, for it acts as a wedge between the tibia and the femur and helps to make the crucial ligaments tense. The *external semilunar cartilage* is separated from the capsule at the point where it is crossed by the tendons of the popliteus, while at its posterior horn, a special slip of attachment runs up to be attached to the popliteal notch of the femur along with the posterior crucial ligament. On the other hand, the internal semilunar cartilage is attached to the capsule along the whole of its convex margin, and is firmly attached to the strong internal lateral ligament. The anterior cornu is always attenuated and its attachment to the tibia is never very strong and often very slender. It is easy to see that a sudden strain on the internal lateral ligament, especially if the femur is being rotated inward on the tibia, will tend either to detach the anterior cornu or split the cartilage longitudinally, or in rare cases cause a transverse rupture opposite the attachment to the internal lateral ligament.

A study of the anatomy shows us that there is a very close association between injuries to the lateral ligaments and displacements of the semilunar cartilages. An important point to remember is that from the closer approximation of its ends, the external cartilage is more movable than the internal, and this is made more pronounced by the laxity of the part of the capsule to which it is attached.

When the leg was forcibly abducted on the cadaver, Tenney found that the internal lateral ligament tore away from its femoral attachments. The femur then slipped over the posterior end of the cartilage and when replaced crumpled up the posterior half of the internal semilunar cartilage. Clinically it is the lower attachment of the ligament which usually gives away; the semilunar cartilage is then drawn back by the condyle, and its anterior end gets worn and pinched between the bones. We have seen that bending inward of the knee in the extended and semi-extended position is prevented by the internal lateral ligament. Bending inward of the knee during the fully flexed position is prevented by the crucial ligaments. These two anatomical facts should be remembered in their relation to displacement of the internal semilunar cartilage.

One can thus easily understand how it is that the internal lateral ligament so frequently suffers injury. It is subjected to strain whenever the foot is firmly planted and abducted, and the knee either slightly bent or kept extended. If, in addition to this, as in the "stroke to leg" in cricket, or the final act of the bowler, body weight with rotation of the femur is added, we have produced that stretching and strain which Griffiths has proved to be so harmful to the integrity of the ligament. Indeed, the strength of the knee joint can be well gauged by the resisting power of the internal lateral ligament.

Circumferentially, the internal cartilage is attached to the tibia by structures which allow it to be lifted fully a quarter of an inch—a point which is of importance. If the internal lateral ligament be torn above the level of the joint the cartilage remains upon the tibia; if torn below the level of the joint it follows the rotary movement of the femur. If the ligament be ruptured above and below the level of the cartilage it becomes a very simple matter to push it within the joint, a position in which we sometimes find it. It would appear therefore, as suggested by Griffiths, that displacement or fracture of the internal cartilage is accompanied by stretching or tearing of the internal lateral ligament.

This allows a separation of the joint surfaces and a slipping inward of the cartilage; as the separate bones snap back the cartilage is nipped, and the knee is fixed in a very painful manner. The pain and effusion can be ascribed to injury to the synovial membrane, with which, as has already stated, the cartilages are covered.

Crucial Ligaments.—These extend from the intercondylar notch of the femur to the upper surface of the tibia. They are about the thickness of a pencil and are intracapsular but extrasynovial. The anterior crucial is attached to the depression in front of the spine of the tibia, being blended with the anterior extremity of the external semilunar cartilage. It passes obliquely upward, backward and outward to be inserted into the inner and posterior part of the outer condyle of the femur. The posterior crucial ligament is the stronger of the two, but shorter. It is attached to the back part of the depression behind the spine of the tibia, to the popliteal notch, and to the posterior extremity of the external semilunar cartilage. It passes upward, forward and inward to be attached to the outer and fore part of the inner condyle of the femur. They are never very lax in any position of the joint, but the anterior is most tense in extension, and the posterior in flexion. The anterior prevents displacement forward, the posterior backward.

Synovial Membrane.—The synovial membrane is very extensive and complicated in arrangement. It bulges upward, following the capsule of the joint, into a large cul-de-sac

beneath the extensor tendon on the front of the femur, which reaches some distance beyond the articular surface of the bone. After investing the circumference of the lower end of the femur, it is reflected upon the fibrous envelope of the joint formed by the anterior, posterior and lateral ligaments. It passes over the greater portion of the crucial ligaments, but does not completely invest the posterior surface of the posterior ligament. It passes over both surfaces of the semilunar cartilages, and at the back of the articulation two pouches are prolonged beneath the muscles, one on each side, between the condyle of the femur and the origin of the gastrocnemius. Large processes of synovial membrane also project into the joint and, being filled with fat, serve as a padding to fill up spaces.

In the pyramid formed behind and above by the condyles of the femur, below by the tibia, and in front by the patella tendon, is lodged a pad of fat. This pad is extrasynovial but intracapsular and changes shape with every movement of the joint. The synovial membrane is reflected over this fat pad and a triangular fold passed upward and backward to be attached to the intercondyloid notch (ligamentum mucosum). The free edges of this fold diverge and enclose the lateral margins of the fat pad (ligamenta alaria).

Bursæ.—The bursæ which are more or less constantly present in the neighborhood of the knee joint are as follows: (1) The prepatellar bursa in the subcutaneous tissue between the skin and the patella, (2) the deep infrapatellar bursa above the upper part of the tubercle of the tibia and the ligamentum patellæ, and (3) superficial to the lower part of the tubercle of the tibia, the subcutaneous tibial bursa. The suprapatellar bursa would be considered as a part of the knee joint.

Nerves.—The knee joint is supplied from both the sacral and lumbar plexus. With the former, through both the external and internal popliteal branches of the sciatic nerve; with the latter, through the branches of the anterior crural and obturator nerves.

Arteries.—The arterial supply is from the femoral, popliteal, and anterior tibial vessels.

Surface Anatomy.—About midway between the tubercle of the tibia and patella on each side can be felt a groove which indicates the line of the joint and the location of the semilunar cartilages. The head of the fibula is opposite the level of the tibial tubercle on the outside, and running up from it is the tendon of the biceps. In front of the biceps can be seen and felt the ilio-tibial band. The joint on the outer side is about three-quarters of an inch above the head of the fibula.

From this consideration it will be seen that the knee joint is an exceedingly stable weight-bearing joint, subject to major displacements only from severe trauma; that the mechanism of the joint is exceedingly complicated, the extent of synovial membrane, very large and containing numerous pouches; and that the crucial ligaments and the semilunar cartilages add much to the complexity of the joint, and produce a symptom complex not existing in other joints. The popular feeling that an injury to the knee joint is a serious matter rests upon sound anatomical and clinical data.

Injuries of the Lateral Ligaments

The internal lateral ligament is frequently sprained, and the force which puts strain on this ligament is eversion of the foot and abduction of the leg in slight flexion. One must remember, as has been pointed out, that the deep fibres have a very short course from the condyle to the adjacent part of the inner tuberosity of the tibia and are intimately connected with the capsule; and it is these deep fibres which are usually injured in a "sprained knee," most often at their attachment to the margin of the tibia.

In connection with injuries to the internal lateral ligament it is not uncommon to meet with a *sprain fracture* which occurs most often when the ligament is torn from the femur carrying with it a small flake of bone. A similar fracture also occurs when the deep fibres are torn from the upper margin of the tibia.

The patient complains of pain at the inner side of the knee particularly when he twists his foot outward.

Pain is caused by passively stretching the ligament, and the tibia may be slightly separated from the femur in this movement. There is tenderness on pressure confined to the line of the ligament, most marked, as is also the pain,

at the tibial margin and not over the anterior end of the semilunar cartilage. If rupture is complete the joint is usually distended with fluid.

The external lateral ligament is much less frequently injured and the accident is produced either by direct injury, or by adduction and rotation inward of the knee. The anatomy explains how this ligament is allowed a greater play of motion than the internal and is not so liable to strain. Effusion into the joint only occasionally occurs, and tenderness is found near the head of the fibula.

Treatment.—Injuries to the internal lateral ligament are more serious than to the external for the latter is never complicated with a displacement of the meniscus. Too much importance cannot be laid upon the necessity of keeping ligaments at rest until tissues have consolidated. Rupture and stretching of the internal ligament is often the origin of cartilage displacements which may be traced to early passive and active movements.

The non-operative treatment for injury to the internal lateral ligament is the application of a splint to be worn for a fortnight, and the patient should deviate his body weight from the ligament by walking with his toe turned in. The inner side of the foot should also be raised a quarter of an inch to relieve the strain on the ligament. The treatment of the external ligament consists in fixation and deviation of the body weight in the opposite direction.

Operative Treatment.—If the measures mentioned fail to restore stability, the reconstruction of the injured ligament should be considered.

Displacements of the Semilunar Cartilages

In injuries of the knee joint the internal meniscus is far more commonly injured than the external, in the writers' experience the relationship being about nine to one.

Internal Semilunar Cartilage.—The internal cartilage is more firmly fixed and is not allowed the give-and-take movement vouchsafed the external, and in addition, it bears a greater strain during the normal movements of the joint, often becoming thinned and frayed along its inner margin. In the normal relation of femur to tibia the line of force is carried through the inner side of the knee, while the abducted position of the foot when exaggerated produces outward rotation of the leg. Moreover the shape of the internal articular surface of the tibia allows the inner condyle of the femur to glide backward, thereby making the range of internal rotation of the femur on the tibia greater than the external, which is a strain on the internal semilunar cartilage. The cause of the displacement is strain thrown on the internal lateral ligament while the knee is flexed and the femur rotated inward.

In view of the fact that displacement of the internal semilunar will at times give rise to symptoms on the outer side of the joint it is well to remember how rarely the external cartilage is displaced.

In practically all cases the cartilage is displaced inward, and in those rare cases where a protrusion has been felt from the outside it is due either to bruising and hemorrhage, or to a buckling of the cartilage which gives an irregular feel to the articular margin. Taking into consideration the wedge shape of the discs, a displacement outward could not possibly produce a locking of the joint, which can only occur when the displaced cartilage, acting as a foreign body, gets jammed between the bones. It is this internal displacement which gives rise to the acuteness and painfulness of the attack.

The external examination of a knee subject to recurrent attacks has been notoriously free from anything abnormal.

The most constant *symptom* is a sudden inability fully to extend the joint, most marked in first injury, less marked later. When this occurs it is the most trustworthy evidence of displacement, but out of about 2000 cases, operated upon by one of the writers, it was absent in about 30 per cent of the cases. Great force is generally necessary to cause an original injury, which is accompanied by great pain, and the victim, if an athlete, hobbles laboriously off the field with flexed knee. In the latter case he is afforded a certain degree of relief by his friends in the pavilion, who fully flex his limb and then extend it. When he reaches home the practitioner finds a distended knee, painful to manipulate. The strain which is most painful is that caused by stretching the structures on the inner side of the knee, and this is most acutely felt over the site of injury. In a certain proportion of cases, even with the knee fully extended, a gap between the bones on the inner side can be obtained by manipulation. Pain will be present for several days on pressure over the articular edge of the tibia opposite the ligament, and, generally speaking, some pain between the bones on pressure to the inner side of the patella. In a fortnight or three weeks, and after rest and massage, the patient is by common consent allowed liberty to walk. As will be pointed out later, this liberty is a mistake, and the outcome of very indifferent surgery. Days, weeks, or months may elapse, when again a train of symptoms, similar in character, but generally milder in effects, occurs. Many successive attacks, some grave and followed by effusion, some so trivial as me rely to incommode, mark retrogression. In nearly all cases there is a history of strain or injury, the initial displacement as arule being the most severe, while in the constantly recurring case any eversion of the foot may give rise to the displacement.



FIG. 18.—Position of knee predisposing to internal derangement.

Injury of the *internal semilunar cartilage* is diagnosed by the acuteness of its onset, by synovitis, by the persistence of pain on pressure over the detached or injured area, by tenderness less pronounced over the inner side of the patella, and by a locking of the joint. The patient usually refers the pain to the front of the joint until pressure helps him to localize it accurately. Irregularity is sometimes found along the articular margin, and often a sense of discomfort when the tibia is abducted and rotated outward, even when the toe lightly touches an obstacle. The tender points of pressure are over the internal lateral ligament and over the anterior horn of the internal semilunar. Any attempt to abduct the limb at the knee is acutely painful. Forced extension of the knee is painful over the site of displacement, and the history of the mode of production is helpful.

External Semilunar Cartilage.—Displacement of the external semilunar cartilage is not common, and the symptoms are not clear. The patient complains of something slipping in the knee and may state definitely that the sensation is on the outer side of the joint, but as has been said this may be due to dislocation of the internal semilunar cartilage, so that this is not diagnostic.

A condition occasionally encountered in this connection is where in acute flexion, or more commonly in complete extension, a back snap occurs when

extension is nearly complete. The clicking may be quite loud and is generally accompanied by some outward rotation of the tibia. The cause is generally ascribed to a disturbance of movement of the external semilunar cartilage and the clicking is rarely accompanied by pain or effusion. Of two cases operated on by one of the writers,[1] in one there was a cartilaginous body attached to the anterior portion of the internal cartilage which lay loose on the anterior side of the anterior crucial ligament. This was removed and the patient made a complete recovery. In the second one the anterior portion of the internal cartilage ended in a thickened anterior extremity which was attached by a cord-like band to the rest of the cartilage. In both cases the clicking disappeared. This condition is known as *trigger knee*, snapping knee, or clicking knee, but as shown in the following cases is not always caused by the external cartilage for in two other cases of the same writer the clicking was due to a slipping semimembranosus tendon over a small tibial exostosis. In a third case there was an exostosis just above the insertion of the biceps tendon.[2]

Differential Diagnosis.—Slipping of the cartilages is often hard to differentiate from the following:

Synovial Fringes.—The symptoms of the nipping of a synovial fringe are less acute in its primary occurrence than are those of a displaced cartilage, and the pain is strictly local and not participated in by the internal lateral ligament. Frequently a prominence may be found over the site of pain, and no matter how often the nipping occurs, effusion follows, creaking in the joint is a frequent accompaniment, and often an obvious swelling occurs on each side of the ligamentum patellæ, which is due to the chronic thickening of the infrapatellar pad.

Loose Bodies.—Loose bodies can usually be found and isolated by the patient. They often lock the knee, but only transitorily. The symptoms are sharp but not acute, and unless the bodies are pedunculated the pain may be referred to different places. Effusions in this condition are common.

Lipomata.—Lipomata will sometimes lock the joint, and there is often swelling about the lower part of the patella and painless effusion. Exercise rather than accident produces the symptoms, which are rarely acute, and pressure on the knee will produce no pain.

Osteomata.—Osteomata can be found by manipulation and by radiography. They sometimes lock the joint when a muscle or tendon becomes entangled.

Treatment.—This is (*a*) Mechanical, or (*b*) Operative.

It is difficult to give authoritative directions as to when a knee should be operated upon and when we should adopt mechanical measures. So large a proportion of cases make a good recovery under mechanical treatment that we should discourage operation when a patient is seen at once with a first displacement, nor should one urge operation where a recurrent trouble is painless and is not followed by effusion into the joint. The writers strongly advocate operation when the recurrence is sometimes followed by acute symptoms and in all cases where a strenuous athletic life is a means of livelihood or a physical necessity. Operation is essential in the case of men who work or stand in positions where a yielding knee may mean disaster. Age is not necessarily a contraindication. The writers have operated upon patients as young as thirteen and as old as sixty-five years. An argument in favor of operation is the undoubted fact that degenerative changes are apt to occur in joints as a result of these derangements.

[1] Jones: Annals of Surgery, December, 1909.
[2] Cotton: Jour., Boston Soc. Med. Sci., May, 1899.

(*a*) *Mechanical Treatment.*—If the case is seen immediately one may be called to reduce the displacement, and three things must be remembered: (1) Reduction must be absolute. (2) All movements of the cartilage must be checked until union of the torn structures is complete. (3) No lateral strain must be allowed until the internal lateral ligament has recovered its tone.

No reduction is complete until the knee can be voluntarily held in complete extension. In the majority of instances, reduction is easily effected and rarely in recent cases is there trouble, but in some old cases it may be extremely difficult. For an internal cartilage, acute flexion, lateral deviation, internal rotation, and full extension is the routine manipulation. If an anesthetic is not used, the patient must assist in the reduction. The surgeon first fully flexes



FIG. 19.—Cage splint uncovered.

the knee and rotates it inward on the femur and then at the count of three the patient is told to kick as powerfully as he can while the surgeon helps him by pressure downward on the thigh and upward on the leg, so that in this way the patient helps instead of obstructing. Under an anesthetic it is often possible to reduce a displacement of very many weeks standing.

When reduction is effected in a recent case the limb should be fixed for two or three weeks in order to allow the cartilage to become attached. If this be done in a recent first displacement, recurrence very rarely happens. If massage and movement however be used instead, it is the beginning of trouble. On resuming his activities the patient should be taught to save his internal lateral ligament from strain. He should walk with in-turned or parallel feet, aided by altered boots raised on the inside and changed as will be described in speaking of recurrent cases.

In cases where the cartilage becomes displaced at frequent intervals one should order an alteration in the heel and sole of the boots, the heel being elongated and raised one-quarter of an inch on its inner side, and the inner side

of the sole being fortified by a similar wedge of leather. When the patient stands in such a boot the foot is thrown onto the outer edge, and the lateral

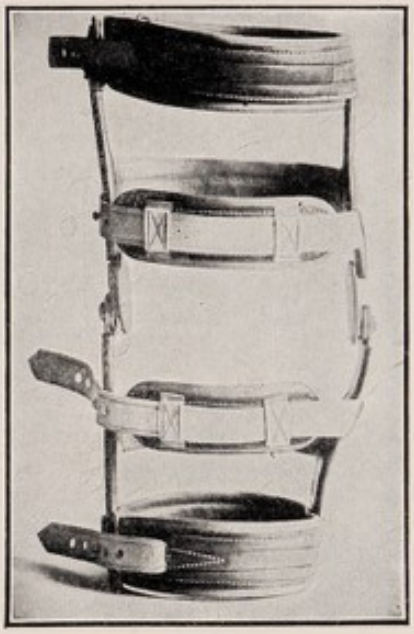

FIG. 20.—Cage support for knee.

strain which is needed to displace the cartilage is avoided. If, in addition to this, the young athlete be told to walk with an in-turned toe, and to run pigeon



FIG. 21.—Cage support for knee in case of chronic arthritis when full extension is not allowed.



FIG. 22.—Long cage to prevent rotation of the knee (Shaffer).

toed, strain is inevitably thrown upon the external lateral ligament, while the internal lateral ligament is protected. Although immunity from displacement

cannot be assured by this device, it materially lessens the tendency to its occurrence and becomes a valuable asset among our remedies. In addition, a *cage splint* must be employed. The cage support consists of two flat stems of steel 12″ to 13″ long for an adult, which are moulded to lie on each side of the knee joint with a joint in the center of each. These stems are connected at their upper and lower ends by a band of steel which fits exactly to the back of the thigh and calf. This whole frame work is covered with leather—the upper and lower steel bands being continued in leather to encircle the leg. Two intermediate leather bands support the limb, one above and one below the hinge and secure the cage to the leg. Joint movements can be controlled to any degree or excluded by a "stop" fitted to the joint. This type of brace is also applicable to certain elbow conditions when limitation of movement is necessary.

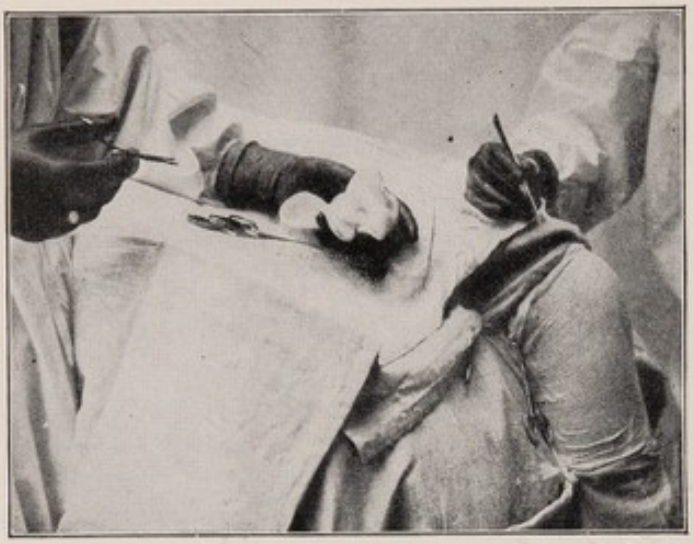

FIG. 23.—Field of operation on cartilage.



FIG. 24.—Operation on cartilage —line of incision into joint.

During the whole course of treatment the quadriceps and especially the vastus internus should be developed by active resistive exercises and massage.

Operative Treatment.—The surgeon must be as sure of his diagnosis as possible, for when he explores the joint, the cartilage may look normal and this is due to the frequency with which the posterior portion is involved, and can only be verified on opening the joint. There may be an involvement of the posterior end and the diagnosis can only be made sure when the cartilage is detached internally and drawn toward the center of the joint, and only then will the split become evident. He must therefore feel confident of his diagnosis.

The knee must be opened in such a position that no further flexion is needed during the operation. Unless this be assured the cloths get shifted, or air is introduced into the joint by movement. The simplest method is to allow the knee to hang over the table. The best view of the interior of the joint is obtained in the flexed position, and the cartilage can be well inspected. If the capsule plicates and hides the view it should be drawn outward with a skeleton retractor, which may be used to obtain a good view in any direction. In this position the final cleaning of the knee takes place while the joint is flexed and the skin tense. The most rigid aseptic technique is essential. The skin

incision should be made through sterile gauze squeezed out of an antiseptic solution. One of the writers (R. J.) uses 1–1000 biniodide of mercury, and the other author, the iodine preparation. The cut edges of the gauze are fixed to the edges of the wound, the knife which divided the skin is discarded, sutures should be handled by forceps and the finger should *never* be put into the joint, and neither wound nor skin should be touched by the fingers of the surgeon at any time during the operation. There is no margin for error in technique in operating on the knee joint. The length of incision which practically always suffices is three inches; the incision into the capsule is much smaller. Long skin incisions obviously add to the risks, and only very exceptionally are needed. The incision should be slightly curved and extend from an inch within the lower angle of the patella to half an inch below the tibial margin. curving more acutely at this point toward the lateral ligament. The interior of the joint is then inspected with the aid of carefully applied retractors.

A more extended experience has taught us the advisability of removing the whole cartilage if there is any doubt, for recurrence often follows a partial removal. The examination, which should be gentle, is facilitated by a blunt hook. Having removed the cartilage one should look for fringes, tabs, loose



FIG. 25. FIG. 26. FIG. 27.

FIG. 25.—Actual size drawing of coronal section through semilunar cartilage and cyst of Case 1. Defect in upper margin of drawing represents the principal cyst cavity which was opened to permit inspection of the cyst. Smaller cysts can be seen below. Remains of semilunar cartilage on extreme right.

FIG. 26.—Actual size drawing of coronal section through specimen removed in Case 2. Defect in extreme right represents the principal cyst cavity with numerous smaller cysts to the left. Remains of cartilage on the extreme left.

FIG. 27.—Actual size drawing of specimen from Case 3 showing the main cyst cavity. (Allison and O'Connor. Cysts of Semilunar Cartilage, Surgery, Gynecology and Obstetrics, Feb., 1926, pp. 259–262.)

bodies or other possible agencies which may cause trouble in the future, and remove them. If the cartilage is only slightly mobile, and the history characteristic, it should be removed.

The wound should be stitched layer by layer while the knee is over the table, and dressings should be placed over it before the knee is slowly extended. This prevents suction of air into the joint cavity.

After removal of the cartilage the knee is steadied by light traction applied to the leg and active motion is allowed; after seven to ten days the stitches are removed.

After this the patient is allowed to walk about with the knee still fixed on the splint at the same angle for a further period of ten days.

The back splint is then removed and a bandage is applied firmly round the knee joint up to but not extending above the upper border of the patella.

Massage of the thigh, particularly of the quadriceps is now freely employed and the patient is encouraged to use the knee freely.

No passive movements are at any time required.

Cysts of the Semilunar Cartilages.—Cystic degeneration of the semilunar cartilages has been described by many observers. In Germany by Ebner, Riedel and Schmidt; in England by Ollerenshaw, and in America by Phemister, Allison and O'Connor. This cyst formation occurs usually in the external semilunar, but two cases, that of Ollerenshaw, and of Allison and O'Connor have been found in the internal semilunar. The symptoms complained of may be similar to those of semilunar laceration, but locking is not present, and in each instance there has been an area of elastic tenderness over the cartilage. Removal of the entire cartilage is advisable, with the same operative technique and after-treatment, as is used in ordinary semilunar cartilage removal.

Slipping Patella

The patella may be displaced upward, outward, or inward from acquired or congenital causes, but the congenital variety is rare. The inward displacement is sometimes found in extreme neglected genu varum; the upward, in infantile hemiplegia and neglected rupture of the patellar ligament; but the common type of displacement is outward, and to this variety attention will be confined.

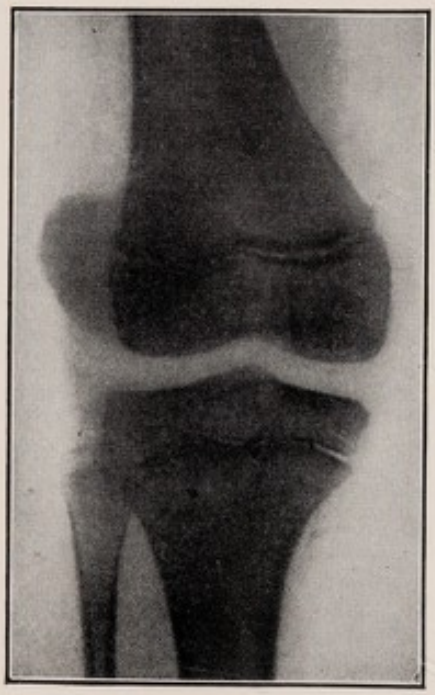

Fig. 28.—X-ray of slipping patella in girl of nine.

There are three types (1) The congenital; (2) the rachitic; and (3) the traumatic.

The *congenital* is accompanied by other abnormalities and is associated with irregular development of the femoral condyles, especially the external. In this type the patella cannot be completely reduced and lies to the outer side of the knee.

In *rickets* we frequently meet with a displacement of the patella in connection with extreme genu valgum and each time the knee is flexed a partial or complete dislocation occurs. If of long standing, secondary changes occur on the external condyle and the patella remains displaced even when the knees are fully extended.

The *traumatic type* may result from direct injury or from muscular action. It nearly always occurs in adolescent girls, or women, and is generally associated with a varying amount of knock knee, and sometimes with an elongated patellar tendon and a general laxity of the joint. Goldthwait[1] has pointed out that the quadriceps femoris in its line of pull forms an angle with the ligamentum patellæ to the inner side, so that when the quadriceps contracts, it draws the patella slightly toward the outer side and is checked by the external condyle of the femur and partly by ligaments. This can be demonstrated on any knee if it be fully extended and the quadriceps muscle be

[1] Goldthwait, J. E.: Slipping or Recurrent Dislocation of the Patella, Boston Med. and Surg. Jour., February, 1904.

alternately contracted and relaxed. Any condition, therefore, which emphasizes the outward pull of the quadriceps or diminishes the trochlear check will favor a displacement of the patella; for example, relaxation of the capsule from prolonged distension, knock knee, a diminished trochlear ridge, and a long weak quadriceps. Recurrent displacements of the patella are due to these mechanical factors. An isolated dislocation due to direct injury, if appropriately treated, does not tend to become habitual, but recurrences are apt to follow if treatment is not conducted on sound lines and predisposing causes are present.

Symptoms.—The symptoms vary considerably in intensity from a slight and temporary disability and a feeling of insecurity to a tense and painful effusion. In some cases the displacement is partial and the patella glides outward and back again. In others the dislocation is complete and help is required to replace it. In most cases the mental effect is disquieting and gives rise to nervousness and fear. If the displacement is frequent and occurs without much muscle tension, the symptoms of reaction are slight; but when the parts are less relaxed the symptoms are more pronounced and effusions often occur.

Treatment.—This may be mechanical or operative. The object of treatment in either case is to correct the faulty pull of the muscle so that it may be straight and not angular and to render the trochlear ridge of the femoral condyle more effective as a check.

The *mechanical treatment* is only effective in early cases before the displacement becomes habitual. If knock knee is present it may be corrected by mechanical means as in an early rachitic case. Walking with in-turned toes, elevation of the inner side of the heel and a cage or splint to prevent lateral deviation during walking are desirable. It is of importance to see that the quadriceps muscle, especially the vastus internus, is developed to its fullest extent and there is no better method than that of voluntary exercise of the muscle by alternative contraction and relaxation with the knee extended.



FIG. 29.—Goldthwait's operation for recurrent dislocation of the patella.

Operative Treatment.—In the common variety where but little knock knee exists, operation on the soft tissues generally suffices. The operation devised by Goldthwait has been practised with success by many surgeons.

GOLDTHWAIT OPERATION.—A longitudinal incision four or five inches long, starting at the lower end of the patella and curving convexly to the inner side ends about an inch below the tubercle of the tibia. The patellar tendon is exposed and split in halves in the anteroposterior plane through its entire length. The outer half is then removed from its insertion into the tubercle and passed under the inner half and attached to the periosteum together with the expansion of the tendon of the sartorius muscle at the inner side of the anterior surface of the tibia. If it is felt that the transplanted ligament should be shortened, the attachment can be made so that the patella is drawn down as much as possible; but in this

case, to lessen the risk of detachment, a hole must be drilled into the tibia to strengthen the attachment. Fixation for six weeks follows.

One of the writers has performed this operation on a large number of cases with but very few failures. In his later cases he invariably transplants half of the tubercle of the tibia well to the inner side and if the ligament is lax and apparently lengthened, he removes the whole of the tubercle with the ligament attached, prepares a bed on the inner side of the tibia at a lower level and transplants it, fixing it in position by a nail.

In a small proportion of cases it may be necessary to reconstruct the external condyle so that the trochlear edge is elevated. The articular surface is levered a sufficient height and left to fill up. In children the cavity is soon obliterated and the anterior wall does not collapse.

Where considerable knock knee is present it is advisable to operate in two stages. First of all the knock knee is corrected and in quite an appreciable number of cases a second operation will not be needed. Care should be taken, however, when the femur is divided, to rotate the lower fragments somewhat inward. In this way we increase the trochlear check, and if in addition we slightly overcorrect the knock knee when we operate upon both limbs, it strengthens the defence against the displacement of the patella.

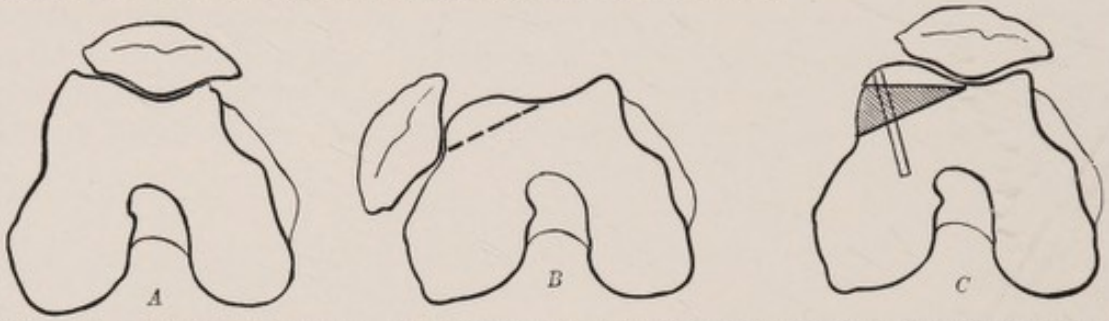

FIG. 30.—Albee's operation. *A* indicates the normal size and anterior prominence of the external femoral condyle. *B* indicates the flattened external condyle with a consequent luxation of the patella outward. *C* indicates anterior lifting of the condyle to block the recurrence of the luxation of the patella with the wedge graft (dark area) in position. The graft is usually held by a ligature of kangaroo tendon placed in drill holes in it and the split portions of femur anterior and posterior to it.

GALLIE'S OPERATION: LIVING SUTURE OF FASCIA LATA.—Perhaps the operation best designed to relieve slipping patella consists of using a strip of fascia lata as a stay to hold the patella in place. The strip of fascia lata is used as a suture, passed through a drill hole in the femoral condyle, and another in the margin of the patella, and pulled tight enough to prevent the slipping. *Soutter* has modified this by tying the patella to the tibial head, an improvement because the relationship of the patella to the tibial head remains constant, whereas that of patella to femoral condyle is constantly changed with motion at the joint.

ALBEE'S OPERATION.[1]—Albee reconstructs the external condyle by means of a bone graft. A semilunar incision is made at the outer border of the patella from above the external condyle to below the tibial tubercle (fig. 30).

The external condyle is penetrated with a thin chisel on its external surface for a width of one and a half inches, about half an inch below its anterior articular surface in a line with the long axis of the femur. The anterior surface of the condyle is elevated to a plane above the internal condyle by producing a greenstick fracture near the intercondyloid groove. The width of the gap is measured, and bone sufficient to fill it is removed from the crest of the tibia and placed there. The graft is drilled obliquely in order to admit dowel bone pins to fix it in position.

The writers are of the opinion that this operation is only exceptionally necessary and should not be looked upon as an operation of routine.

Rupture of the Quadriceps and Ligamentum Patellæ

The quadriceps muscle is often partially ruptured by the same force which generally results in fractures of the patella. Any part of the muscle may yield and complete rupture is extremely rare. When a rupture occurs just above the patella the joint may fill with blood.

[1] ALBEE: "Orthopedic and Reconstruction Surgery," Phila., 1919, 627.

Symptoms.—If the area of rupture is not infiltrated by blood a transverse hollow of varying depth will be easily felt at the site of the rupture, and while the muscle is at rest this will be the only objective symptom in these cases. Efforts to move the muscle result in the increase in the size of the tumor which becomes harder and moves toward the origin of the muscle. If the muscle is passively extended, the consistence of the injured muscle remains the same. With the muscle at rest, as the blood is absorbing, a soft tumor will be found, easily moved from side to side, but not up and down. Muscular function is impaired or lost, and it will not be possible to extend the knee.

Treatment.—Partial rupture occurring in the old or sedentary is best treated by rest. At any age if the rupture occurs just above the patella with hemarthrosis, operation is indicated. Unless the rupture is extensive, rest with relaxation of the muscles results in very fair function, but in young folk who wish to lead an athletic life, an operation is always advisable. If the decision is against operation, the muscle must be kept in its relaxed state and means must be taken to minimize active or involuntary contraction. This is best done by placing the patient on a Thomas bed splint and by fixing a pad above the rupture, applying sufficient pressure to prevent contraction of the muscle. This has been found of great value in these injuries and also in fractures of the patella. If the rupture is at all extensive, six weeks should elapse before voluntary contraction is allowed and then flexion and extension of the knee should be graduated by means of a cage splint.

The Operation of Myorrhaphy.—The sheath is exposed by a simple incision and freely opened and all blood clots removed. While the muscle is in a position of extreme relaxation the sutures which should be of thick catgut are introduced in layers, the needle taking a big bite in order to prevent the stitches from breaking through. A continuous suture is the best, aided by a few transverse ones to minimize the pull. If the joint is full of blood it should be evacuated by syringing with a sterile saline solution. The sheath should be carefully closed after all bleeding is stopped.

Derangements of the Knee Due to Exostoses

One of the writers has many times operated upon joints that became locked or obstructed by the slipping of muscle or tendon over exostoses.

An athlete was often stopped in running by a pain at the upper part of the popliteal space, accompanied by swelling. A pedunculated exostosis was found obstructing the vastus. In other cases a slipping may be felt at the back during active exercise and the knee locks. There is a continual sense of discomfort and slight slipping at the back of the knee. This may be due to a pedunculated exostosis which interferes with the biceps, the inner hamstrings, or even the outer head of the gastrocnemius.

The fact that osteomata are not associated with knee derangements is shown by the fact that they so often exist without giving rise to symptoms. The complete removal of these masses should be performed even in the growing epiphysis if they give rise to symptoms.

Partial Separation of the Tubercle of the Tibia—Osgood's Disease, Apophysitis

Complete avulsion of the tibial tubercle is rare, but a strain or partial separation is common and occurs chiefly in boys of about ten to fifteen.

It may be due to direct trauma, to sudden muscular effort, or to long continued exercise of the quadriceps, and may occur on one or both sides.

Symptoms.—In the partial separation described by Osgood[1] and later by Schlatter[2] the symptoms vary considerably. In one group of cases the symptoms come on insidiously and a history of strain or direct injury cannot be obtained. On examining the tubercle it is found tender to pressure, but all that is complained of is an aching after exercise, especially stair climbing, and a loss of speed in running. Both knees are usually affected and it is difficult by the X-ray to detect any abnormality in the tongue-like epiphysis, which is the center of active ossification. In some cases, however, where one knee alone is affected, the tongue-like epiphysis seems to be more separated from the shaft of the bone than is normal but this would hardly be detected in cases where both sides were involved.

In another group of cases, usually unilateral, the onset comes on with pain, local swelling, and sometimes even ecchymosis. The soft parts about the tubercle, including a bursa and subcutaneous tissue and even synovial membrane, are likely to be thickened and a source of discomfort. Increased pain and tenderness on pressure are suggestive of a yielding to strain. The diagnosis must be made according to the age of the patient, on the following signs: pain on full extension of the knee, located in the ligamentum patellæ; enlargement of the tubercle with tenderness; and X-ray appearances which may or may not be characteristic.



Fig. 31.—X-ray of Osgood's disease.

Prognosis.—The condition for some reason or other is not generally recognized by the surgeon and the patient is allowed to go about until pain, tenderness and swelling have reached a degree which is so severe that the diagnosis of osteomyelitis is occasionally made; but in a large number of cases seen by the writers, no case has failed to recover when the measures to be described have been adopted.

The clinical symptoms of recovery are more reliable than the X-ray. The tubercle forms by a separate tongue-like epiphysis and at this age, ten to fifteen, always appears partly attached. A comparison of X-rays of both knees may show an upward displacement of one side in which case one is justified in diagnosing displacement. In other cases symptoms may exist without obvious displacement.

Treatment.—A case, however acute, is usually amenable to treatment if the quadriceps muscle is thrown out of action and a back splint put on to fix the knee, thus removing from the injured structures the strain induced by activity. In very sensitive cases it is wise to insist on recumbency or the use of crutches for a few days. Bandages over the knee are generally not comfortable and the back splint is best fastened by strips of adhesive plaster, avoiding

[1] Osgood, R. B.: Lesions of the Tibial Tubercle, Boston Med. and Surg. Jour Jan. 29, 1903.
[2] Schlatter: Beitr. z. klin. Chir., 1908, lix.

the tender area. Under normal conditions the tenderness in the tubercle should begin to diminish in a few days and liberty may be allowed when the tenderness is decidedly diminished. Flexion of the knee, however, should not as a rule be allowed for at least five weeks and violent exercise should be postponed for about four months. Recurrences are likely to occur when liberty has been allowed too soon.

In the insidious chronic type it is sufficient to limit the degree of flexion. One effects this by applying a cage splint which allows only 30 degrees of flexion, and when there is freedom from pain during the limited exercises permitted by this apparatus, and tenderness from pressure on the tubercle has gone, the range of movement is gradually increased. In certain cases these cages may have to be worn for six months. In milder cases it is often enough to limit activity by avoiding stair climbing and active extension of the knee.

Occasionally we find a thickening of the tubercle very tender to pressure and most persistent, this occurs chiefly in adults. If it resists mechanical pressure it usually disappears if a chisel is introduced for about half an inch into the bone and a linear incision made over the length of the painful area.

Complete avulsion of the tubercle of the tibia is usually due to a violent contraction of the quadriceps. The symptoms are those of rupture of the ligamentum patellæ; the power of extension of the knee is almost completely lost, as the separation, if complete, will implicate the lateral expansion of the quadriceps tendon. If the ligament is ruptured, it should be sutured. If the tubercle of the tibia is torn away, it should be replaced and fixed in position.

Affections of Infra-patellar Pad and Synovial Fringes

The infra-patellar pad of fat, which is often found enlarged and is the cause of symptoms, has been described.

Alwyn Smith points out that when the knee joint is extended and the patella is elevated by means of a well contracting quadriceps, the fat pad becomes flattened in an antero-posterior direction and the alar ligaments are pulled from the neighborhood of the joint surfaces. If, however, an undue collection of fat is present in the fat pad, or if the quadriceps loses its tone the alar ligaments with their contained fat may become nipped between the femur and tibia in extension of the joint. As a result of frequent nipping this pad of fat becomes much hypertrophied and hard, often presenting a mass each side of the ligamentum patellæ about the size of a walnut. This enlargement is due to hemorrhage followed by fibrosis, directly due to successive traumata, and the condition is so closely associated with synovial fringes that clinically one must group them together.[1]

In the uncomplicated case of an enlarged pad one finds a rounded mass within the joint with unappreciable changes in the alar ligaments. In the simple type of synovial fringe we may encounter congested and elongated protrusions of synovial membrane with no appreciable enlargement of the pad, or often both conditions co-exist. A so-called lipoma arborescens may extend from the infra-patellar pad as a hernia into the joint.

The *symptoms* of these conditions are variable. In the uncomplicated thickening of the pad they are rarely acute, and give rise to a dull aching behind the patella and a stiffness after exercise. The knee tires when any extra strain is thrown upon the quadriceps such as going up stairs or hills, but there is barely

[1] Jones, R. J.: "Orthopedic Surgery of Injuries," i, 333.

any tenderness on pressure and the swelling which is harder than normal is easily seen and felt. Every now and again a stabbing sensation occurs which is caused by a slight pressure between the bones, not amounting to a real nipping, and this is immediately recovered from. In time the symptoms become more marked, effusions more common and there is more stiffness and there occurs a painful "giving way" of the knee, not of a very acute type. The pad is tender to deep pressure, and there is often a creaking which can be felt as a fine crepitation under the hand when the knee is extended.

At a later stage when the fringes become congested and tender, the symptoms are not unlike those of a partial displacement of the anterior horn of the internal semilunar cartilage, but the pain is usually sharp and transient and is not accompanied by the sickening feeling so often associated with the cartilage displacement. It will be seen from this description that the condition is traumatic and progressive. It can generally be differentiated from a general hypertrophy of the synovial villi because it is local and thickening of the synovial membrane is not present, nor is there limitation of movement in most cases.

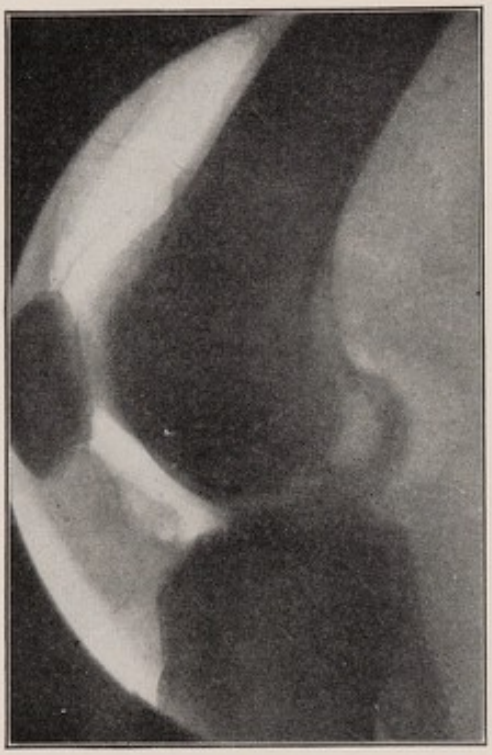

FIG. 32.—X-ray showing thickening of infrapatellar fat pads.

Treatment.—This is either (*a*) Mechanical or (*b*) Operative.

(*a*) *Mechanical.*—As the stabbing pain occurs when the knee is fully extended and is due to the trauma caused by the femur and tibia in this position, the treatment in the severer cases should consist in allowing the patient free movement of the joint, short of full extension. This can be effected by a knee cage splint which locks at 25 degrees from full extension but allows full flexion. In the milder cases, however, an addition of half an inch to the heel of the boot and a thick flannel bandage over the knee will suffice.

Complete recovery often occurs if these mechanical measures are employed.

(*b*) *Operative.*—When the symptoms are persistent and are not relieved by protective measures an operation should be performed. An incision is made on the inner side of the lower part of the patella and the pad exposed. It is best removed by a pair of curved scissors. In old cases numerous hemorrhages will be found when a section is made of the growth. If the fringes alone are affected, they should be freely removed. Removal of these masses is not followed by any functional defect. The quadriceps muscle must be exercised without weight-bearing in all cases, whether operated upon or not.

Rupture of the Crucial Ligaments and Fractures of the Spine of the Tibia[1]

These conditions are so often associated that they will be described together. Although the injuries are not uncommon, there is but little reference to them in our literature. The two conditions may be associated or either may exist alone.

[1] JONES, ROBERT, and SMITH, ALWYN: Brit. Jour. Surg., i.

If, after an injury of the knee, the tibia can be displaced backward or forward or rotated inward in the extended position, an injury of one or both crucial ligaments may be diagnosed. If in the extended position the tibia cannot be displaced forward, it may be assumed that the anterior crucial ligament is not torn across. If in full flexion the tibia cannot be displaced backward, the posterior crucial ligament is presumably not ruptured.

The history of an injury will help to exclude cases of abnormal mobility due to elongation or destruction of the ligaments, associated with long continued effusion into the joint, Charcot's disease, and locomotor ataxia. The diagnosis therefore of a ruptured crucial ligament should not be very difficult.

The most constant sign of fracture of the spine of the tibia is an obstruction to full extension, a block which feels like a definite bony obstruction, and is quite different from the locking which occurs when a dislocated semilunar cartilage is nipped.

Alwyn Smith and Robert Jones from a study of their cases divided these fractures into three groups:

1. Avulsion of the tibial spine or its internal tubercle.
2. Fracture of the external tubercle of the spine.
3. Injury to the spine combined with fracture of a tuberosity of the tibia.

1. *Avulsion of the tibial spine or its internal tubercle* is produced by violent tension on the anterior crucial ligament, a mechanism similar to that which produces rupture of the crucial ligaments.

To cause rupture of both crucial ligaments, extreme violence is necessary, and such violence indeed as would produce complete dislocation of the knee joint. Cases of this type are described by Battle, Mayo Robson and Pringle. One of the writers has seen a similar injury produced by forward displacement of the tibia in hyperextension, and also in cases where the tibia has been forcibly dislocated backward and upward. In all of these cases of severe injury the knee is flail-like, the tibia can be displaced forward and backward in full extension and the joint can be hyperextended, proving rupture of both ligaments.

Rupture of the posterior crucial ligament alone is a rare accident and Honigschmied was unable to produce it experimentally, but Pagenstecher caused it by flexing the knee fully and driving the upper end of the tibia backward. Rupture of the posterior crucial alone is very rare and when it occurs it is probably due to a force expended on the tibia when fully flexed on the knee. It may be diagnosed when the tibia can be pushed backward on the femur while the knee is flexed.

Rupture of the anterior crucial ligament was produced experimentally by Pringle by fixing the pelvis, flexing the knee, and at the same time abducting and rotating the leg inward. When the anterior crucial ligament is alone ruptured, the most common condition, the tibia can be brought forward on full extension. As the internal lateral ligament is usually involved, the leg can be deviated laterally in an outward direction. Unless the posterior crucial is involved the tibia cannot be pushed backward on the femur when the knee is flexed. In all cases the deep fibres of the internal lateral ligament were also torn, which is of interest in connection with the fact that the same fibres are always injured when an internal semilunar cartilage is displaced, as pointed out by one of the writers.

When the tibial spine is avulsed, it is displaced anteriorly and forms a block to complete extension.

2. *The mechanism of fracture of the external tubercle of the spine* is similar to that which produces a dislocation of the internal semilunar cartilage and can be produced on the cadaver by first dividing the internal lateral ligament when the inner margin of the external condyle can be made to impinge on the spine. The spine is displaced slightly to the inner side. The most constant *symptom*, apart from those associated with injuries to the other structures, is a block to complete extension of the knee.

3. *Injury to the spine combined with fracture of one of the tibial tuberosities* may be looked upon as a crush fracture. It is caused by direct injury such as a weight falling upon the thigh or knee when in a flexed position, causing forcible abduction or adduction of the knee. The injury is a grave one.

Treatment (a) of Rupture of the Crucial Ligaments; (b) of Fracture of the Tibial Spine.—(*a*) Rupture of the crucial ligaments is a very serious injury, but its ill effects can be much diminished if from the first it is treated by complete and prolonged immobilization of the knee, which is fundamental. Under no consideration whatever should active or passive movements be permitted in less than from two to four months. Even then it should be done most warily because we know that four or five weeks at least are essential to the repair of ligaments and that any elongation or laxity means functional disability. We know also that for the accurate repair of ligaments no strain should be thrown upon them during the period of healing. The fear of stiff joints has resulted in a policy of impatience but nothing but a temporary stiffness follows a few weeks' rest. Not until every flail element is eliminated should a jointed splint be applied to the knee, graduating the movement to 20 degrees at first and then increasing it.

One of the authors has published a series of cases with complete dislocation of the knee—which of course involved rupture of the crucial ligaments—which made good recoveries after prolonged fixation, some of them returning to hard manual work.

The management of old ruptures of the crucials which have not undergone adequate treatment requires consideration. A certain proportion of such cases will be very much improved by limiting strain on the injured internal ligament and quite a number of cases, so long as the internal lateral ligament has recovered, show remarkably little disability although one can push the tibia to and fro upon the femur. Such folk can even run and play games, and a patient of one of the writers carried on his work as a dock laborer.

Operation.—The writers have no hesitation in dissuading surgeons from operation upon recent cases of uncomplicated rupture of crucial ligaments. Apart from its being a difficult and grave procedure it is often impossible to bring about a suture, as the ligament is usually torn from the bone. Occasionally one must divide the anterior crucial ligament in order to remove a foreign body which lies behind it and in such a case suture is simple, but it is quite the reverse when avulsion has taken place.

In old flail knees with marked functional defect, recent attempts have been made to restore function by reconstructive operations. (Hey Groves[1] and Alwyn Smith.[2]) The writers have examined several of these cases without having seen a perfect result, but several have been much improved. The operations are unusually grave and require the highest craftmanship and the

[1] Hey Groves: British Journal Surgery, VII. 28.
[2] Alwyn Smith: British Journal Surgery, VI. 176.

strictest technique and should never be undertaken without a sense of grave responsibility.

(*b*) *Treatment of Fracture of the Tibial Spine.*—Unless a bony block exists which gives rise to functional disability, operative treatment is not called for. If it is advisable to remove the bony block it is best to approach the joint by splitting the patella longitudinally. The knee is flexed and the patella split as described and the joint inspected. Any obstructive mass is removed, the knee straightened, and the tissues sutured in layers.



FIG. 33.—Fractured spine of tibia and sprain fracture of internal lateral ligaments.

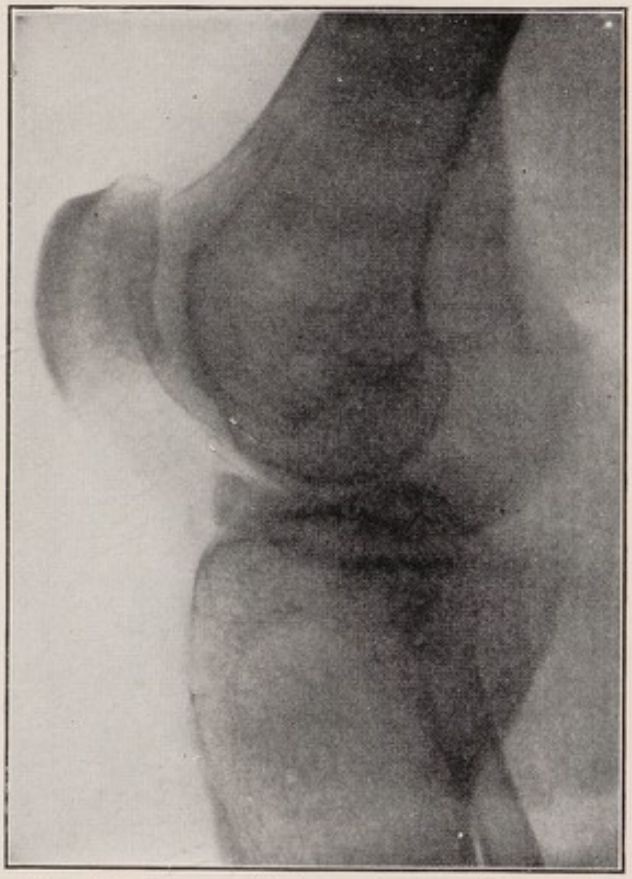

FIG. 34.—X-ray of fracture of spine of tibia with portion of tuberosity.

Loose Bodies in the Knee

Loose bodies of variable size, shape, and consistency are frequently found in the knee joint and are due to many causes. The condition was recognized and described by John Hunter in 1759, and has recently been studied by Timbrell Fisher,[1] whose classification and description are followed in this section. They are grouped by him as follows:

1. Loose bodies occurring in connection with some more or less general pathological process affecting the joints, such as (*a*) *osteoarthritis*, (*b*) *tabes*, (*c*) *tuberculosis, or* (*d*) *acute arthritis from infection.*

2. Loose bodies occurring in joints otherwise apparently normal—(*a*) *Bodies having a microscopic and often gross appearance of detached portions of articular cartilage*, (*b*) *bodies derived from intra-articular cartilages*, and (*c*) *bodies formed from detached epiphysis not forming portions of an articular area.*

3. *Synovial chondromata, laminated and non-laminated.* These may be—(*a*) single, (*b*) multiple, and (*c*) diffuse.

1. In (*a*) *osteoarthritis* are found: (1) synovial chondromata which will be described later; (2) loose bodies due to detached osteophytes, and a section through them shows that the periphery consists of well-developed fibro-cartilage with comparatively few cells. This

[1] Brit. Jour. Surg., 1921.

fibro-cartilage is invested with a zone of fibrous tissue with flattened cells as in perichondrium. In fibro-cartilage of this type there occur areas of hyaline cartilage, and the bone in the center consists of well-developed cancellous bone which is dead. At the junction of the osseous center and the surrounding cartilage there is a zone of calcified cartilage containing cartilage cells which are alive. Possessing such definite characteristics these can always be recognized and classified. It is unusual for more than two or three of these bodies to be found in the same joint, and often only one is found. In connection with them, however, may exist loose bodies of other types.

In (*b*) *tabes* the loose bodies, whether formed from synovial fringes or by detachment of osteophytes, are larger than usual and in some cases may be enormous. Moreover, the formation of bone involves the planes of connective tissue between the capsule and synovial membrane so that the joint may be surrounded eventually by bony masses, sometimes actively articulated.



FIG. 35.—Loose bodies in knee joint.

2. (*a*) *Loose Bodies Formed by Detachment of a Portion of the Articular Surface and Occurring in Otherwise Normal Joints.*—These occur more frequently in males than females and usually between the ages of fifteen and twenty-five. The classical type is usually circular or oval and about the size of an almond. The convex surface presents the characteristics of articular cartilage, while the flattened side is irregular with rounded border. Although usually single, two or three may be present in one joint, and they may be loose or incompletely detached, sometimes with a secondary adhesion to the synovial membrane. In other cases they are attached by a hinge of articular cartilage to the bed from which they are derived. Their continued presence in the joint may bring about secondary changes, such as chronic arthritis. In certain of them "the cartilage cells proliferate with such exuberance that veritable cartilaginous tumors are formed" by remarkable changes of a proliferating kind. The semilunar cartilage which is partially detached at its end may have a thick cartilaginous body, and as has been said elsewhere (p. 27) is sometimes the cause of "clicking knee." One of the writers has removed from the joint a rounded mass the size of a large bean, which was the only sign of a vanished internal semilunar cartilage which had a fibrous attachment to its internal origin.

Koenig[1] in 1888 described these separated pieces of the condyle as the result of an affection which he called osteochondritis dissecans, but in practical experience in cases where loose bodies of this type are excised a history of injury may be obtained. Brackett and

[1] KOENIG: Ueber frem. Körper in den Gelenken, Deutsch. Zeitsch. für. Chir., 1888, xxvii, 90.

Hill[1] have described an interesting case in which the early symptoms could be studied before the separation of the fragment. In cases operated on by the longitudinal division of the patella where the condyles are well exposed there is usually no evidence of disease except the depression already described from which the loose body originated. In the opinion of the writers loose bodies of this type have their origin in trauma and not in disease in a great majority of the cases. The area of detachment varies but is usually found near the condylar attachment of the posterior crucial ligament.

Recently Wolbach and Allison have described a case in which such a loose body resulted from a fibrous cyst in the internal condyle of the femur, which collapsing, the cartilage caved in over the area producing the defect. Osteochrondritis dissecans is usually seen in the knee, but may occur in the hips, elbow, wrist, or other joints.

(*b*) *Detached Articular Ecchondroses.*—Professor Shattuck first pointed out the bodies of the same essential nature as the periarticular ecchondroses growing from the articular margins might arise in the substance of the cartilage covering the normal bone. This takes place by local hyperplasia of the cartilage in which central ossification subsequently occurs. The epiarticular enchondroses are associated with the ordinary marginal outgrowths. These



FIG. 36.—Loose body in the knee-joint, probably resulting from synovial proliferation.



FIG. 37.—Loose body in the patella, probably arising from traumatism.

observations suggest that in certain cases the separation of such may lead to the production of loose bodies of a kind similar to those which are at times detached from the articular margins.

3. *Synovial Chondromata, Laminated and Non-laminated.*—It has already been said that these may be single, multiple, or diffuse, the latter being usually associated with free bodies in the joint cavity, and the two former being either pedunculated or free. They are true chondromata derived from cartilage cells of the villi and are attached to the synovial membrane. According to the degree of attachment and location of the loose bodies the symptoms may vary and one therefore finds three groups of symptoms:

(*a*) A portion of articular surface is completely detached; wanders freely about the joint; and after an interval becomes secondarily attached to the synovial membrane. An injury, direct or indirect, is followed almost immediately by classical symptoms and after an interval these disappear.

(*b*) The portion of articular cartilage is completely detached, and becomes almost immediately adherent to the synovial membrane but after an interval it is again detached. The clinical signs are: An injury, direct or indirect, is followed by freedom from classical symptoms, but after an interval classical symptoms appear.

(*c*) A portion of the articular surface is gradually detached, and at length it becomes freely movable or completely detached. Here the process of gradual detachment is accom-

[1] BRACKETT and HILL: Am. Jour. Orth. Surg., February, 1917.

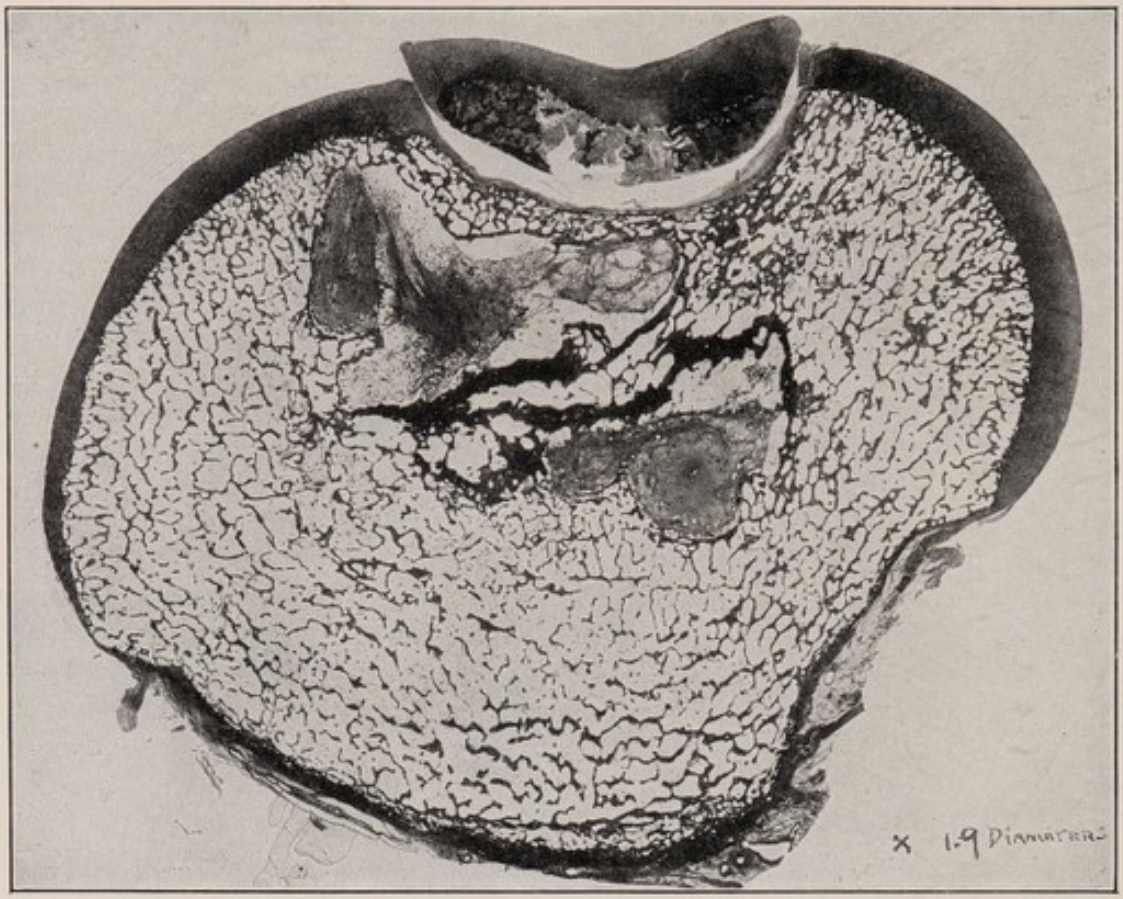

FIG. 38.—Osteochondritis dissecans (Wolbach and Allison). The defect produced by the separation of a portion of the articular cartilage with an underlying plaque of cancellous bone. In this instance the fibrous cysts are shown in the condyle, suggesting collapse with resulting rupture of the cartilage.

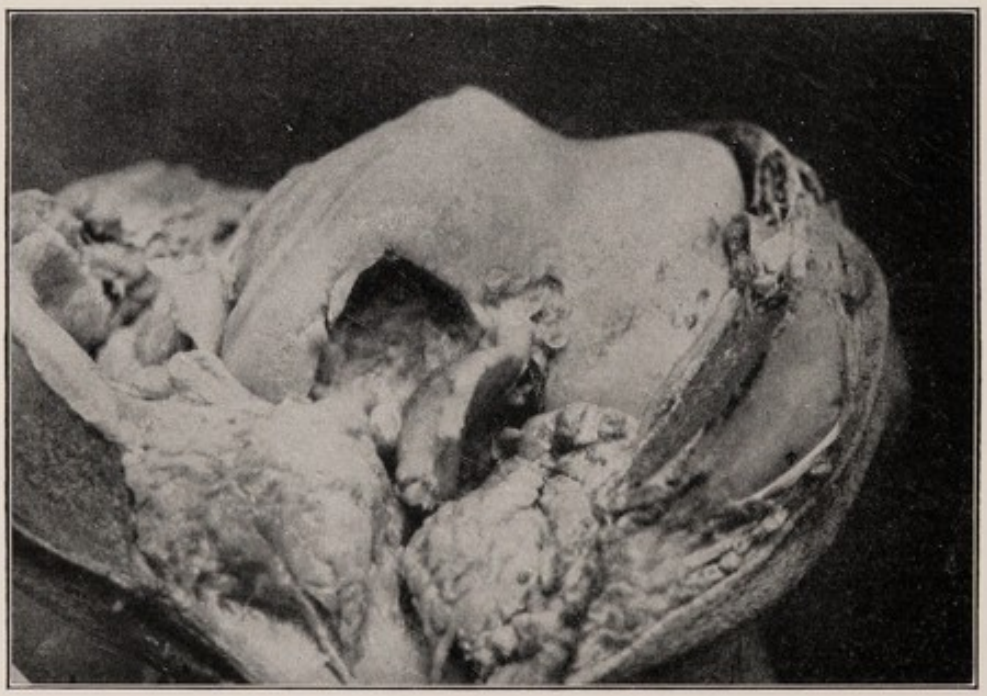

FIG. 39.—Loose body in the knee-joint. Osteochondritis dissecans. Gross appearance of specimen of which Fig. 38 is a section.

panied by attacks of pain and swelling, often increasing in severity and these are followed at last by the classical symptoms. These again may disappear when the body becomes secondarily attached to the synovial membrane.

Treatment.—If loose bodies give rise to symptoms they must be removed but before this is done a careful X-ray examination must be made, when we may find two or more bodies present. If the body is free it is very elusive and before an anesthetic is given the body should be localized and fixed. With gloved hands the assistant should steady it and if possible hold it against the bone. A small incision is then made through the skin and the body is transfixed. The capsule is then opened and the removal effected. It is a mistake to operate in the hope of manipulating it into position when the joint is incised. If the history is that of a pedunculated semi-detached body which always makes its appearance at one spot, there is no occasion for this precaution. The operation should be performed with the limb extended. If the body is large and confines its activities to the pouches, incision should be made along the inner or outer side of the patella. If there is a mass of bodies in front of the joint the operation of splitting the patella described by one of the writers (R. J.) should be practised.

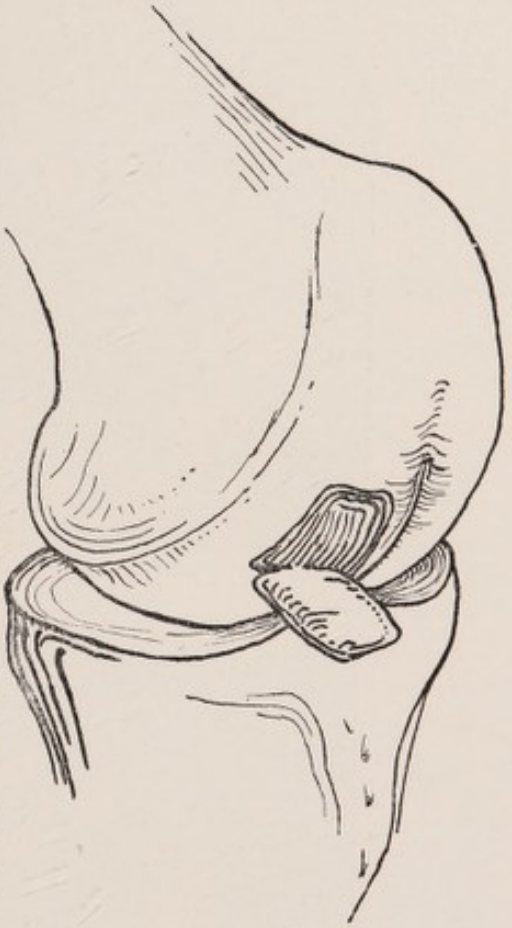

Fig. 40.—Osteochondritis dissecans. Loose body formation showing separation of loose body from internal condyle of femur.

If the bodies are located in the back of the joint and are too numerous or large to pass to the front, the popliteal incision described by Brackett and Osgood gives us the safest and best approach. In the latter case a linear incision ten centimeters long is made in the popliteal space centering over the joint line and slightly to the inside of the median line. In the upper part of the incision are seen the two diverging heads of the gastrocnemius muscle and the separation of these two discloses the vessels lying just below, crossing vertically over the space with a slight oblique direction from the inside above to the outside below. In the center of this space the structures lie nearly superimposed one upon the other in the order of internal popliteal nerve, vein, and artery. A few important muscular branches are given off by the nerve in this region and they are with one exception to the outside, and it is more practicable therefore to retract the vessels outward. With these at one side a blunt dissector will suffice to carry one down to the posterior ligament and a clear workable space may be opened up so that the body may be felt by palpation. The capsule is so tense when the knee is extended and the posterior joint space so circumscribed that there is little danger of displacing the body. When the incision is made the bodies usually present, owing to the tension of the capsule. This operation forms the best possible approach and when

difficulty is encountered, it is due to the fact that we are apt to find ourselves above the line of the joint, but a little care will avoid this. The body must be localized with accuracy as there is but little room for investigating, and

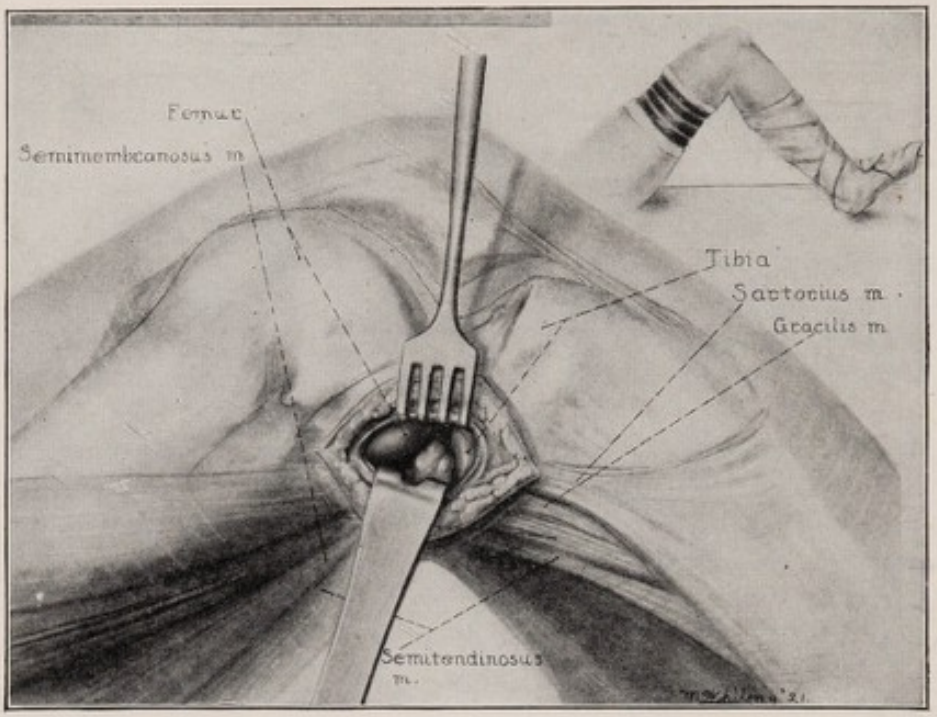

FIG. 41.—Posterior internal approach to knee (Henderson).

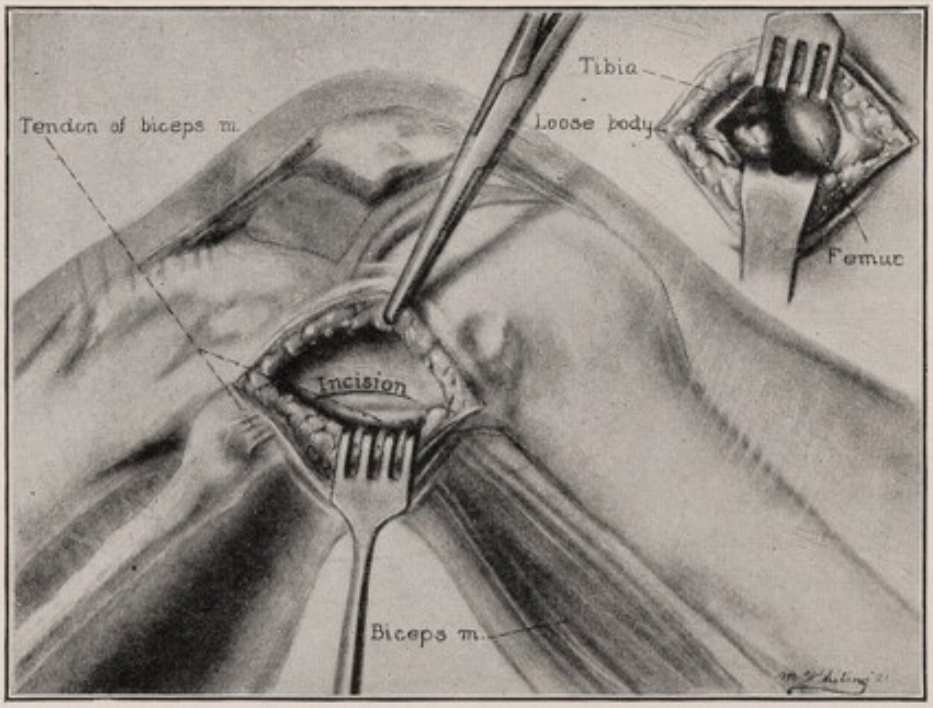

FIG. 42.—Posterior external approach to knee (Henderson).

this must be done with the knee slightly flexed. If the joint is to be entered laterally one may use the incisions recommended by Tenney.

External Posterior Lateral Incisions.—An incision is made along the anterior border of the biceps with extended knee down to the capsule. Flexing the

knee allows the biceps to pull back out of the way and the iliotibial band partially to cover the field. This can be nicked and drawn out of the way. The capsule is now lax and can be opened either above or below the popliteus tendon. Below the tendon the incision opens into the pocket under the popliteus, which in the ordinary bed position is the lowest portion of the joint cavity.

Internal Posterior Lateral Incision.—The incision follows the anterior border of the sartorius down to the capsule. The muscle draws back as the joint is flexed and the capsule may be opened behind the main part of the internal lateral ligament.

Henderson's approaches are somewhat similar to those of Tenney. On the outside he enters the joint in front of the tendon of the biceps and on the inside in front of the sartorius (Figs. 41 and 42).

Bursitis

Bursitis exists in three forms:

(1) of the prepatellar bursa, (2) of the deep pretibial bursa, (3) of the bursæ in the popliteal space.

1. *Prepatellar Bursitis.* Housemaid's Knee.—Following an injury, from excessive kneeling or without known cause, this bursa may become thickened and filled with fluid. A limited spherical swelling is evident at the front of the knee which is fluctuating and tender, and extreme flexion of the knee causes discomfort by tension, and kneeling is painful. The synovial membrane of the joint is not thickened and the patella does not float. The acute affection generally recovers in three or four weeks with care and limitation of the use of the knee, and a splint usually is not necessary. If from the patient's neglect or other causes the condition becomes chronic the bursa should be dissected out.

2. *Deep Pretibial Bursitis.*[1]—Under the patellar tendon directly over the tibia lies a triangular bursa about as wide as the tendon and not communicating with the knee joint. This bursa becomes occasionally inflamed which is shown by some local swelling and tenderness over the patellar tendon, and the tibial tubercle appears enlarged. Full active extension of the knee is painful. The cause of the affection is traumatic or of the toxic type formerly called rheumatic. Tuberculosis of this bursa has been observed by one of the writers. Under treatment by rest, and fixation if necessary, the affection generally subsides rapidly. Tuberculosis of the bursa should be operated on by the removal of the sac and surrounding diseased tissue.

3. *Bursitis in the Popliteal Region.*[2]—Inflammation of the bursæ in this region is shown by local fluctuating swelling at the site of the affected bursa, and motion is only painful from pressure or tension. Rest and fixation will generally effect a cure, but excision of the sac may be required in resistant cases.

In this region it should be remembered that, in connection with inflammation of the knee joint, synovial hernia into the popliteal space and in front of the knee may occur. This occasionally takes place in cases of chronic synovitis of the knee joint, especially when due to arthritis deformans or at times to tuberculosis. The condition of the knee joint and the X-ray appearances will generally clear up the diagnosis. It need only be remembered that opening one of these so called "cysts of the popliteal region"[3] is often opening the knee joint.

[1] Lovett: Med. and Surg. Reports, Boston City Hospital, 1897.
[2] Riedal: Deutsch. fur. Chir., 1915, cxxxiv, 144.
[3] Baker: St. Bartholomew Hospital Reports, xiii, 245, and xxi, 177.

CHAPTER IV

TRAUMATIC AFFECTIONS OF THE ANKLE, SHOULDER, ELBOW AND WRIST

Ankle and Foot

Anatomy.—The ankle joint proper is a hinge joint formed by the lower extremity of the tibia and its malleolus and the external malleolus of the fibula, which form a mortise to receive the upper convex surface of the astragalus and its two lateral facets. The capsule is thickened to form very strong ligamentous bands, known as the anterior, posterior and internal lateral or deltoid ligaments and the external lateral ligament.

The *anterior ligament* is a broad, thin membranous layer, in relation in front with the extensor tendons of the toes, and the tibialis anticus, and peroneus tertius muscles.

The *posterior ligament* is very thin as its place is largely taken in protecting the joint by the tendo Achillis.

The *internal lateral ligament* (deltoid ligament) is very important. It consists of a superficial and deep set of fibres. The superficial set constitutes a strong, flat, triangular band attached above to the internal malleolus, and the anterior fibres of this band pass forward and are inserted into the scaphoid bone and the inferior calcaneoscaphoid ligament. The middle fibres extend almost perpendicularly downward and are inserted into the sustentaculum tali of the calcaneus, while the posterior fibres pass backward and outward to be attached to the inner side of the astragalus. The deep fibres run from the notch of the internal malleolus to the inner side of the astragalus. In close relation to the ligament are the tendons of the tibialis posticus and flexor longus digitorum.

The *external lateral ligament* is divided into three portions, all originating from the external malleolus. The anterior passes forward and inward to the astragalus, the posterior runs horizontally to be inserted into the external tubercle and the posterior surface of the astragalus, and the middle fasciculus is a narrow, rounded cord running down the outer surface of the calcaneus. In close relation with this ligament are the tendons of the peroneus longus and brevis.

The synovial membrane lines the joint, invests the inner surface of the ligaments and sends a process upward between the lower extremities of the tibia and fibula and the astragalus. The arteries supplying the joint are derived from the malleolar branches of the anterior tibial and the peroneal arteries. The nerves are derived from the anterior and posterior tibial.

The joint is a weight-bearing joint, of course transmitting more weight than any other because there is more weight above it. Dislocation without fracture is unusual, but in connection with fracture quite common. The joint holds but little fluid, is very superficial and accessible to manual examination, and owes its stability, not only to the shape of its component bones, but to the strength of the external and internal lateral ligaments, the anterior and posterior being thin and insignificant.

It must be remembered that it is very difficult to separate the mobility of the ankle joint from that occurring in front of the astragalus, but it should be remembered that there is no lateral motion in the ankle joint proper except in extreme extension. From the nature of the joint it will be seen that injuries are likely to be participated in by synovial membrane, ligaments and tendons on account of their close relation, exposed position, and participation in all movements.

It must also be remembered that inasmuch as there are no muscles attached to the astragalus it is moved only by means of muscles attached elsewhere, the force of which is transmitted to the astragalus through some articulation external to it, and that a synovitis of the ankle joint produced by excess of flexion, extension, inversion, or eversion must be transmitted to the astragalo-tibial joint by means of some force acting outside of the astragalus.

Surface Anatomy.—The internal malleolus is large and flat, and the prominent tubercle of the scaphoid is one and one-half inches below and in front of the internal malleolus. The external malleolus is small and somewhat pointed and is a finger's breadth below the level of the internal malleolus. The transverse line of the joint is level with the upper limit of the convexity of the internal malleolus and about one inch above the tip of the external malleolus. About one inch below and a little in front of the external malleolus is the peroneal tubercle of the os calcis. The posterior tibial artery can be felt pulsating midway between the tendo Achillis and the internal tuberosity of the os calcis.

Motions of the Ankle Joint.—Dorsal flexion of the foot is produced chiefly by the tibialis anticus muscle, while the extensors of the toes and peroneus tertius take some part in this. This motion is stated in the books to exist to about 15 or 20 degrees beyond a right angle with the long axis of the leg, but the amount of it is greatly influenced by the position of the knee. If the knee is flexed the heads of the gastrocnemius are approximated to its insertion and more dorsal flexion allowed than when the knee is extended. The latter position is the one to be adopted as a standard, as weight-bearing on the ankle joint comes in connection with the extended knee. The degree of dorsal flexion varies greatly but in the majority of adults with the knee extended it will not exceed 10 or 15 degrees and often the foot can not be passively moved to a right angle with the tibia unless it is allowed to evert and abduct. This is most important in connection with the mechanics of the foot. Pure plantar flexion is produced chiefly by the gastrocnemius, tibialis posticus, and peroneus longus and brevis, aided by the flexors of the toes. Plantar flexion generally exists to a degree which allows the foot to be moved to a point 50 or 60 degrees beyond a right angle with the leg, that is, to form an angle of 140 or 150 degrees with the line of the tibia.

Sprains.—The structure of the ankle joint is such that involvement of ligaments and tendons, in addition to synovial membrane and capsule, is rather more common than in most joints. The term "sprain of the ankle" is often loosely used but conveys no accurate information to the mind of the surgeon. It is necessary to differentiate, with due regard to the anatomy of the articulation, what structures are involved in the injury.

If we eliminate fractures, the structures which are important in this connection are the ligaments, capsule, synovial membrane and muscles.

Ligamentous injury may be detected by the local pain, and by putting the ligament under strain, the findings being confirmed by local pressure on the part assumed to be affected. Effusion in the ankle joint is not so common after ligamentous injury as it is in the knee joint, although often present. Strain of the ligaments of the ankle nearly always is accompanied by localized swelling, which occurs underneath the malleoli, and when effusion in the ankle joint occurs, it denotes that the capsule itself is participating in the sprain. Local ecchymosis very often accompanies ligamentous injury.

The sprain is generally produced by twisting or over-extending the foot, which is most often also inverted, and the symptoms are, in such cases, most marked on the outer side of the dorsum of the foot; but a very painful sprain is also caused by catching the heel of the boot on the edge of a stair in going down stairs, or in stepping into a hole in walking, both causing excessive plantar flexion. The ankle immediately swells and becomes painful, especially in weight-bearing motion, and in a few hours or a day or two extensive ecchymosis occurs around the injured area.

In sprains of the ankle it is always necessary to take an X-ray photograph, as fracture may exist and in the stage of swelling is not always distinguishable by palpation. One fracture, likely to be overlooked, is that of the anterior portion of the lower edge of the tibia; it should always be treated with this in view as otherwise dorsal flexion of the ankle will be limited.

Treatment.—The immediate treatment of a sprained ankle of moderate or severe degree should consist of rest, avoidance of weight-bearing, and elevation

of the limb. By this means hemorrhage is diminished, excessive swelling avoided, and much comfort afforded to the patient. Severe sprains are made more comfortable by a pillow splint and ice bag. Convalescent treatment may be begun at once in slight sprains, but in the more severe cases convalescent treatment should only be begun when reaction has subsided and the joint is not painful to light pressure. Measures to promote the circulation are of value in the form of baking by the electric light or dry heat, soaking in hot water, and massage; moreover these methods help to preserve muscular tone.

Recovery from even a slight sprain of the ankle is as a rule a matter of at least two weeks, and severe sprains may continue over several weeks. In long continued cases the use of crutches to take some weight off of the foot is preferable to prolonged disuse. Much relief is afforded in these ankles by strapping. Inch wide strips of adhesive plaster from twelve to eighteen inches

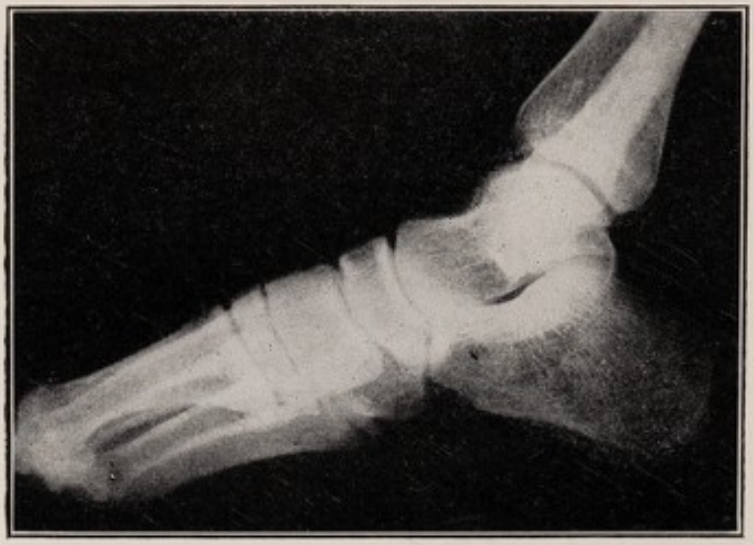

FIG. 43.—X-ray of fracture of the 5th metatarsal bone (Dr. A. W. George).

long, are applied to the inverted foot, which is held in this position during application. Each strip overlies the next, and all start at the outer border of the foot, pass under the sole and two-thirds of the way up the inner side of the leg. Circular straps around the ankle are often comforting, and in very sensitive cases a felt pad fitting into the arch of the foot, in addition to the strapping, increases the patient's comfort by preventing the downward sag of the arch. Strapping will generally enable the patient to bear weight without much discomfort, but excludes two measures of great value—massage and baking. Recovery from sprains is delayed by static error in the feet, such as pronation, a very highly arched foot, a loss of dorsal flexion, or a real flatfoot. Corrective shoeing to meet these indications is most important in promoting recovery.

Fractures of the astragalus, os calcis, and other bones of the tarsus may be overlooked. These sometimes produce serious disability and may require operative treatment. They cannot be dealt with in this work.

Fractures of the Metatarsal Bones.[1]—These deserve mention because they are so often overlooked and because the symptoms of the fracture are so slight. The common ones are *fracture of the base of the 5th metatarsal, and fracture of*

[1] New York Medical Journal, June 3, 1899.



FIG. 44.—X-ray of apophysitis of the heel.



FIG. 45.—The X-ray of the unaffected heel. Note that it is practically identical with that of the affected heel.

the shafts of the 2nd, 3rd, and 4th (pied forcé),[1] but any of the bones may be fractured by direct force. Following a sudden twist in standing or walking, or after excessively long walks, especially in soldiers carrying a pack in forced marches, local pain and swelling are noticed in the foot, which are generally attributed to a sprain. If the injury is neglected the foot becomes generally irritable and painful, and a prolonged disability may result from failure to recognize the condition. The X-ray clears up the *diagnosis*, and the *treatment* consists of fixation and protection from weight-bearing.

Fractures of the Toes.—This injury is often overlooked in sprains of the foot. Its existence is of course easily identified by the X-ray, or by manipulation. There is rarely malposition of importance and the patient may be allowed to walk if provided with a protecting shoe. A leather bar three-fourths of an inch high is nailed to the sole of the boot, and this bar passes across the sole just behind the metatarsophalangeal joint of the great toe and is bevelled at an angle of 45 degrees. By this means the overhanging forward part of the sole clears the ground in walking. The leather of the shoe must not compress the toes and it is necessary either to use a very large shoe or to cut away the leather from the front of the shoe and replace it by a loose piece of soft leather; this can be done by any shoemaker. It is important that good alignment should be obtained in order to prevent angular deformity which often produces a traumatic hammer toe.

Apophysitis of the Os Calcis.—The posterior part of the os calcis forms by a cap-like epiphysis which between the ages of eight and fourteen is the site of much formative activity. The Achilles tendon is attached to this epiphysis just as the patellar tendon is attached to the tubercle of the tibia and a condition similar to the apophysitis described in that connection (p. 38) exists at the heel.

The heel becomes enlarged and extremely tender at the back, and rising on the toe is painful. The X-ray, although often normal and alike on the two sides, most often but not necessarily shows changes which are very much like those seen in the femoral epiphysis in Legg's disease, there is thinning and fragmentation of the cap-like epiphysis, (Allison[2]), especially in the severe cases. The prognosis is always favorable. The treatment consists in restricting activity, raising the heel to take the strain off of the gastrocnemius, and in removing the stiff counter at the back of the shoe to avoid pressure.

Shoulder Joint

Anatomy.—The shoulder joint is the most unstable and poorly protected joint in the body and possesses certain features which make injury in this region peculiar and complicated. The socket is shallow and vertical, motion is of the universal type, and the joint surfaces are held in contact by muscles and ligaments. The latter, however, play only a secondary part in suspending the weight of the arm and are chiefly used in checking extremes of motion; if the muscles are divided or paralyzed, the humerus drops away from its proper position, not being sufficiently supported by the ligaments, which are necessarily lax in order to allow the requisite motion.

Moreover, the muscles have a very much more intimate relation to this joint than they have to any other, and this adds to the complexity of the situation. Certain muscles and their tendons pass across the capsule, in some cases blending with it, so that there is the closest relation between the muscles, the tendons, the capsule, and the ligaments. In close relation with the capsule and ligaments, and strengthening them, are the following tendinous structures: Above, the *supraspinatus*, below, the *long head of the triceps*, behind, the *infra-*

[1] Jones, R. J.: "Orthopedic Surgery of Injuries," i, 88.
[2] Allison: Bone & Joint Surgery, 1924.

spinatus and *teres minor*, and in front, the tendon of the *subscapularis*. There are three openings in the capsule: One anteriorly, below the coracoid process, establishes a communication between the synovial membrane of the joint and a bursa beneath the tendon of the subscapularis muscle; a second, at the posterior part, establishes a communication between the joint and a bursal sac belonging to the infraspinatus muscle; and a third, between the two tuberosities, transmits a sac-like prolongation of the synovial membrane for the passage of the long tendon of the biceps muscle. The deltoid, the biceps, and the triceps are the important muscles in holding the humerus up in place. The following muscles give security to the joint by holding the head of the humerus against the glenoid cavity: The subscapularis, the tendon of which covers the front of the joint and is inserted into and around the lesser tuberosity; the infraspinatus above and behind, and the teres minor behind, both inserted into the greater tuberosity of the humerus.

In addition to this intimate relation between the tendons and capsular ligament, there are several important *bursæ* in the immediate neighborhood of the joint. (1) The *subdeltoid* or *subacromial* bursa, between the under surface of the deltoid muscle and the outer surface of the capsule. This bursa consists of two parts: (*a*) The subacromial portion which is strictly subacromial, and its roof attached to the under side of the acromion and coraco-

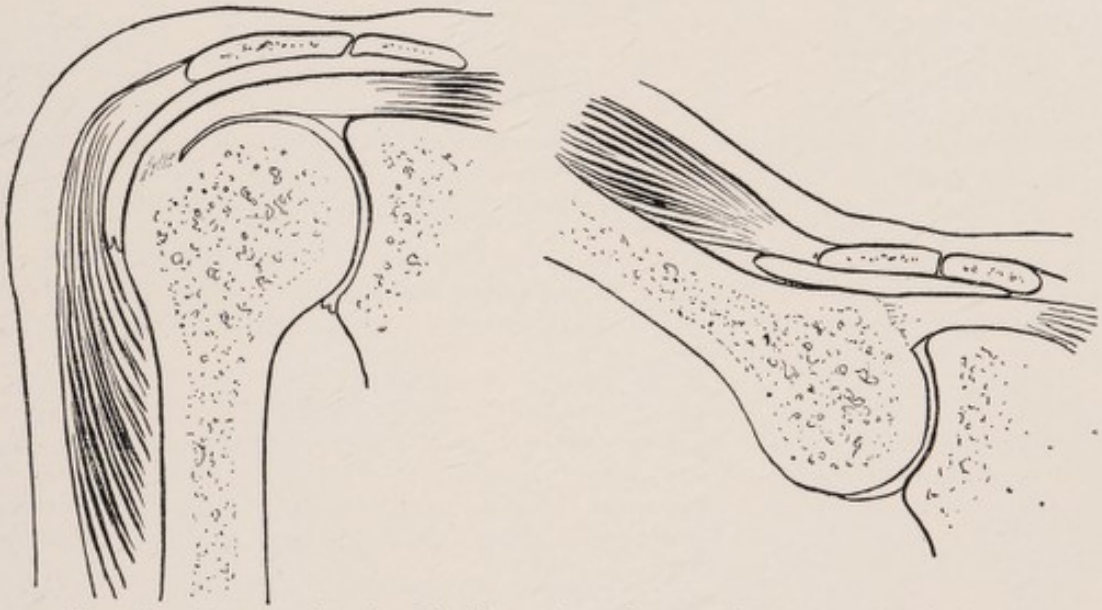

FIG. 46.—Bursæ under the deltoid muscle and supraspinatus muscle (Codman).

acromial ligament. The base of the bursa is attached to the top of the tuberosity of the humerus and the tendinous expansion of the supraspinatus, and (*b*) the subdeltoid portion of the bursa, which is movable in its periphery and by moving on itself allows the roof to slide on the base. In rare cases the two portions are separated by thin septa of serous membrane. The bursa is variable in size and somewhat over two inches in diameter.[1] (2) The *subscapularis* bursa, between the capsule and the tendon of the subscapularis muscle communicating with the shoulder joint. (3) The *infraspinatus* bursa, occasionally existing beneath the tendon of the infraspinatus muscle, and also communicating with the joint. In addition to this there are bursæ beneath the *coracobrachialis*, the *teres major*, and the *latissimus dorsi* muscles. There is a *subcutaneous* bursa over the summit of the acromion process, and a bursa between the *pectoralis major* and the long head of the biceps. Except for the main bursæ described one finds considerable variation in their number. Adventitious bursæ may form at any point where they are needed.

It is easy to see from this consideration that in such an anatomical arrangement, trauma is likely to affect some of these periarticular structures, and consequently a simple inflammation of the joint membrane is not likely to exist as an uncomplicated affair in injuries of the shoulder joint. Moreover, it makes the anatomical diagnosis of such injuries always difficult and often unsatisfactory. In addition to this it is evident that, after an injury, the weight of the arm will drag upon important structures, some of which must have been involved in the trauma.

[1] CODMAN: Trans. Mass. Med. Soc., June 9, 1908; Boston Med. and Surg. Jour., July 27, 1911.

Motions of the Shoulder Joint.—In determining the motions of the shoulder joint it is very important to have a definite standard for examination and the classification of Beevor[1] has been adopted.

Flexion of the humerus to the horizontal line and above the horizontal line is carrying the arm upward and forward from the side in the antero-posterior plane of the body. *Extension* of the humerus is bringing the arm down and forward from a vertical position at the side of the head to the plane of the body, and *hyperextension* is applied to carrying it back of the plane of the body. *Abduction* of the humerus to the horizontal line and above the horizontal line is carrying the arm away from the side in the frontal plane of the body to its uppermost limit. *Adduction* of the humerus is bringing the arm to the side. *Horizontal adduction* of the humerus is a movement in the horizontal plane bringing the arm forward toward the middle line of the body at the shoulder level. *Horizontal abduction* of the humerus is carrying the arm back at the shoulder level from the middle line of the body. *Internal rotation* and *external rotation* of the humerus apply to the motions of twisting the arm in or out.

As the scapula takes part in practically all movements the determination of the actual range of shoulder movements is very difficult and inaccurate, and as the mobility of the scapula is very variable all angular measurements of motions in and about the shoulder joint must necessarily be only approximate.

Flexion of the Humerus.—With the arm hanging at the side it can be raised above the head in the antero-posterior plane until it is practically vertical, the arm traveling through an arc of about 180 degrees.

Extension of the Humerus.—From a position with the arm above the head extension of the humerus is also through an arc of 180 degrees.

Hyperextension of the humerus, that is, when the arm is carried back of the long axis of the body, exists through about 45 degrees.

Abduction exists to about 90 degrees in the joint proper, at which it is stopped by the tension of the lower part of the capsule, and from then on the movement of the arm is carried out by the scapula until it is carried into a vertical position at the side of the head, thus covering in the combined motion an arc of 180 degrees.

Adduction of the humerus covers the same arc as abduction.

Horizontal Adduction and Abduction.—With the arm at right angles with the body the range of motion in the shoulder joint proper is about 90 degrees, but this is much extended by the scapular movement.

Rotation of the shoulder is greatest when the arm is partially abducted, and in a dissected joint the arc may approximate 135 degrees. At a right angle with the body under these circumstances it is about 90 degrees.

INJURIES OF THE SHOULDER JOINT

Acute Synovitis—Subacute Synovitis—Periarthritis—Strain of Muscles, Capsule or Tendons—Bursitis

The injuries to the shoulder joint consist of (1) *dislocation* or fracture, or both; or (2) may be confined to *injury* of the *bone* or joint, or the surrounding soft parts, without fracture or dislocation.

Fractures and dislocations are considered elewhere, and the one or two forms which it seems necessary to take up will be discussed after the second class of injuries mentioned above.

Injuries to the soft parts were formerly designated as *periarthritis,* which is perhaps still the best name to employ when an accurate anatomical diagnosis cannot be surely made. From the nature and relation of the structures an injury which in other joints would result in a simple affection of the joint membrane and perhaps of ligaments, in the shoulder joint is likely to be complicated by the involvement of bursæ and the tendons of supporting muscles, or the latter injuries may exist alone without perceptible involvement of the synovial membrane itself.

[1] Beevor: "Croonian Lectures on Muscular Movements." Adlard and Son, Bartholomew Close, London.

The *symptoms* of all these conditions are in general much the same, although they differ in details. After an injury to the shoulder joint there is generally marked pain of a dragging character aggravated by the dependent position of the arm. Movement is restricted by voluntary and involuntary muscular spasm, first in the direction of abduction and internal rotation; later, the other movements may also become restricted, often obliterating all movement in the joint. The latter becomes exceedingly irritable; pain extends down the arm chiefly on the outer side; and there is general tenderness, as a rule, most marked at special points which are of much significance. The patient's sleep is disturbed at night because lying on the affected shoulder is painful, and because he often awakes with a start, originating in pain in the joint. In the acute stage of the affection if the arm is not supported he is likely to hold the elbow by the hand of the other arm hugging it closely to his side and lifting it somewhat. Muscular atrophy generally occurs early and is marked, and, if the case is long continued, muscular atrophy becomes a serious complication. The atrophy of the deltoid, the triceps, and biceps does away with the protection which the support of these muscles should give in preventing the capsule from being stretched, and even after all inflammatory symptoms have disappeared, muscular atrophy may prove an obstinate element to the restoration of function.

An effort should be made to arrive at a definite anatomical diagnosis. This is not always possible as the injury is often too acute and diffuse. The term "sprain" therefore will be retained in describing certain acute injuries and "periarthritis" in referring to more chronic types. The following suggestions will be helpful.

Sprain.—A sprain may consist of stretching or tearing of the capsule, or ligaments, or of the extravasation of blood into the tendon sheaths or into any of the structures surrounding the joint, or injuries of the synovial membrane.

If the joint and muscles be allowed to remain too long quiescent, very firm intra-articular and extra-articular adhesions may result. Stiffness of the joint may also be the result of adaptive muscular shortening, physiological in character, or it may be due to loss of resilience in the sheaths surrounding muscles or intermuscular septa.

These sprains are rendered serious, usually from a want of appreciation of early and proper treatment, and by the formation of adhesions.

The *early treatment* of sprain should consist in not allowing the joint to remain too long at rest, nor in a position which interferes with its subsequent function. In the case of the shoulder, the grave after-effects are due to limitation of abduction and internal or external rotation. For this reason, and because the removal of the weight of the arm expedites recovery, and because the possibility of adhesions is minimized, the arm should be treated in the abducted position, and preferably externally rotated by means of an abduction or platform splint.

Muscular Strain.—The diagnostic signs of this injury are as follows: If a definite muscle suffers from strain it will be painful when it is actively moved and more painful still when resistance to its movement is offered or when it is passively stretched. Pain will be referred either to its origin or insertion, and if any muscular fibres have been ruptured there is sometimes acute pain on pressure at a special spot. After very slight rupture of fibres a varying amount of hemorrhage will occur, and sometimes the hemorrhage is very marked even

after a slight one. If many muscular fibres are torn the diagnosis in a superficial muscle is readily made, as a prominence will occur at the site of the rupture whenever the muscle is put into action. A familiar example of this is in the well known tumor which occurs after rupture of the biceps or quadriceps. When the muscle is not superficial the signs are deep and usually no tumefaction can be felt, nor can any change in outline be seen.

The muscles about the shoulder joint which are most commonly affected, are, in the order of frequency, the deltoid, the biceps, and the internal rotators, while the external rotators are rarely seriously strained.

The diagnosis in the injury of the deeper muscles is made evident by impairment of function, pain on effort to use the affected muscle, and pain on passive stretching. It must be recognized that in the involvement of the shoulder muscles passive motion in a certain direction may be painless, but that an attempt to perform this movement actively is painful. This is particularly noticeable in abduction movement of the arm where it may be passively lifted from the side to an angle of from 45 to 90 degrees without discomfort, but if the patient attempts to hold it there or attempts to perform the abduction movement himself, pain immediately occurs. In making the diagnosis certain facts must be borne in mind as to the function of the commonly affected muscles.

Deltoid and Supraspinatus.—The deltoid, assisted by the supraspinatus, raises the arm from the side. A consideration of the origin and insertion of the deltoid and supraspinatus will show that the first action of the deltoid in contracting must be to press the humerus up against the acromion and then to abduct, but that the supraspinatus muscle has only one function, that of abduction. Weakness in abduction, therefore, does not mean that it is necessarily caused by an affection of the deltoid, because soreness in the tendinous insertion of the supraspinatus will also limit abduction. Duchenne has reported a case of circumflex paralysis where the supraspinatus alone was sufficient to produce abduction of the arm and in poliomyelitis this condition occasionally is observed.

Biceps.—The function of the biceps muscle is to flex the forearm on the arm, to supinate the forearm, and to raise the whole arm forward from the shoulder. The movements best suited to bring out injury to the tendon of the biceps muscle are: (1) With the arm at the side, have the patient supinate the forearm, which will cause pain at the shoulder in case of involvement of the head of the biceps, and (2) flex the arm at the elbow against resistance, with the arm held at the side. Tenderness over the biceps tendon can be found in the bicipital groove in the humerus. This is identified if the arm is held at the side of the body with the palm facing forward, when at the inner side of the acromion process one finds a groove passing downward on a line with the middle of the arm, and if the forearm is flexed the tendon of the biceps can be felt to move. Swelling, tenderness, and soft crepitus in this region are suggestive of injury to the long head of the biceps.

Internal Rotators.—Internal rotation is produced chiefly by the action of the pectoralis major and the subscapularis muscles, aided somewhat by the teres major. The pectoralis major is accessible to palpation throughout its course, and its broad tendinous insertion can be followed into the outer bicipital ridge of the humerus. The subscapularis tendon is in part inserted into the capsular ligament of the shoulder joint, and in part into the lesser tuberosity of the

humerus and neck of the humerus. The tendon is thus in close contact with the anterior part of the capsule, and there is a bursa which separates them from the base of the coracoid process. A resisted attempt at internal rotation would thus result in pain not only from the involvement of the subscapularis, but also from injury involving the capsule in that region. When internal rotation is painful from injuries of the pectoralis major, this may be identified by palpation of the muscle. If this is negative it shows that tenderness in resisted active internal rotation is due to the involvement of structures connected with the subscapularis tendon, or to an affection of the anterior part of the capsule.

External Rotators.—External rotation is produced by the infraspinatus muscle, aided by the teres minor. The infraspinatus muscle is inserted by a tendon which glides over the external border of the spine of the scapula, passes behind the capsular ligament of the shoulder joint to be inserted into the middle facet of the greater tuberosity of the humerus. A synovial bursa sometimes separates the ligament from the capsule of the joint. This muscle is one of the important protections to the joint, guarding it from dislocation backward, but it is not one of the muscles commonly affected by muscular strain.

Any of the muscles however in the region of the shoulder joint may be strained, or injured by a direct blow, and the diagnosis in this region rests on the lines of applied anatomy.

The involvement of *tendons* presents practically the same signs as that of muscles and is to be detected by the same measures. It must be remembered that soft crepitus or creaking, especially in the acute stage, may be detected in tenosynovitis if the finger or a stethoscope is placed over the affected tendon.

Painful Arm Following Sprain.—In certain patients, particularly nervous and overworked women, symptoms wholly out of proportion to the cause follow slight injuries to the shoulder. These injuries are more often due to slight strains or excessive use of the muscles in persons whose shoulder muscles are poorly developed. Usually, immediately after the injury or overuse, an extremely painful condition arises involving the whole arm, and the diagnosis of neuritis is the usual one, but legitimate symptoms of neuritis are absent. There is no tenderness over the nerve trunk, no swelling of the hand, and no disturbance of sensation. The arm feels heavy, and wearing a heavy coat, or carrying a bag, gives rise to great pain. There is tenderness to pressure at the root of the neck on the affected side and the arm is habitually carried at the side and not moved unnecessarily. Massage, except of the gentlest kind, is irritating, and attempts to restore abduction are excessively painful. The treatment consists in supporting the weight of the arm, starting with a sling in a very painful case, and gradually inserting a cushion between the elbow and the side with a view of getting the arm into an abduction splint as soon as possible; after this, massage, stretching and developmental exercises should be given. On account of its extreme irritability the affection is usually long continued.

Acute Synovitis.—This occurs under the same conditions as in the other joints, but in its pure form is not so commonly met with here as in the knee or ankle.

On account of the laxity of the joint and the fact that the dependent arm is supported largely by muscles and capsule, synovitis in this joint is generally painful and often resistant. It may be confined to the joint membrane proper,

but is most often associated either primarily or secondarily with involvement of neighboring bursæ or tendons in addition to being associated with involvement of capsule and ligaments. It must be remembered that involvement of this joint membrane occurs also in connection with mild sepsis, formerly called "rheumatism," and in tuberculosis, and arthritis deformans. The two latter have been dealt with elsewhere. It must be remembered that tuberculosis of the shoulder is sometimes a mild affair in adults, and that arthritis deformans in this joint is not accompanied as a rule by the formation of demonstrable osteophytes. The existence of a mild sepsis complicated with trauma may lead to difficulty in diagnosis and, moreover, it should not be forgotten that the effect of trauma would be increased and intensified in this joint by the existence of such a condition before the injury.

Subacute Arthritis.—If the joint is involved by direct or indirect injury, the symptoms after a few days are those of a chronic arthritis elsewhere. There is a rigidity to each of its normal movements and the rotations are the first to be obviously limited, followed closely by abduction. The pain in the joint may be very slight unless active or passive movements are attempted. Pain on pressure is usually acute over the most superficial part of the joint just below and outside the coracoid. If the patient is asked to abduct the arm he will generally deflect the body to the opposite side and at once put the scapular muscles into action. The signs of recovery from this condition are the disappearance of pain when the patient lies on the shoulder and diminished tenderness on pressure over the anterior surface of the joint.

A symptom which now becomes prominent, is pain referred to the insertion of the deltoid muscle, especially on attempted motion. The natural course of this traumatic type of subacute arthritis is generally run in from eight to ten weeks and as soon as the pain is isolated to the insertion of the deltoid, movements may be begun.

In the painful and irritable stage, the *treatment* is as described for the other traumatic affections of the shoulder; fixation in the abducted position. Later a strip of adhesive plaster should be placed around the upper arm at the level of the insertion of the deltoid and the patient allowed to move his arm. When he can do this, and the range of motion is slowly increasing, massage and gentle passive motion may be practised. If, however, pain continues distributed over the deltoid muscle and the range of motion remains constant, neither decreasing nor increasing, an anesthetic may be given and periarticular adhesions may be broken down. The details of this manipulation are given elsewhere (p. 73).

Bursitis—Subdeltoid Bursitis.—This diagnosis at present is very frequently made, in America at least, on evidence which in many cases does not seem to justify it. There can be no doubt that inflammation of this bursa at times exists and that various types of degeneration may be associated with it; but the writers feel that the diagnosis is often made on insufficient evidence. The literature on this subject is now very extensive, but the symptoms ascribed as fundamental to the diagnosis are symptoms which can be associated with other and quite distinct conditions. After a careful search the writers have failed to find in the literature any symptoms essentially diagnostic of this condition, apart from those very clear cases where loose bodies are felt, or localized swelling and pain are confined to the region of the bursa. From personal observations they are inclined to believe that if the bursa is affected

this is generally secondary to other changes about the joint and that, therefore, it is unnecessary to enter into any detailed description of the condition.

The affection of other bursæ is as a rule connected with involvement of other joint structures and cannot in the deeper bursæ be differentiated; nor is it important that it should be, as it is better from the therapeutic point of view to regard the affection as one involving joint structures as a whole.

The *treatment* can be briefly summarized as follows: The arm should be fixed in a position of abduction and slight external rotation because unless this is done adaptive muscular shortening and articular and periarticular adhesions will cause stiffness in the adducted position of the arm. Radiant or other heat in the acute stage of the affection is desirable, and massage, while not suitable in the acute stage, is useful in the subacute stage. The restoration of abduction is accomplished by repeated passive stretching when the acute stage is over and pain limited largely to the insertion of the deltoid muscle. If this treatment proves ineffectual, and in long-standing cases, adhesions which are frequently present should be broken down at the outset by manipulation under anesthesia.

There can be no doubt that many cases described as subdeltoid bursitis are in point of fact periarthritis and rapidly recover when the adhesions are broken down. We have to differentiate carefully between the pain which accompanies a tender adhesion and that which is due to causes within the joint. The following facts will help: Traumatic adhesions usually form rapidly; they are not accompanied by any effusion into the joint and pain on pressure is usually elicited and is referred to the site of injury. The limitation of movement is confined to certain directions and occurs only when the adhesions are stretched. If, on the other hand, arthritis is present the symptoms follow injury after a varying interval and the limitation of movement is in every direction and is at first due to protective spasm. The patient is usually unable to lie upon the joint because of pain. One must not forget that both conditions may coexist.

Operative Treatment.—In cases not yielding to simpler measures, or in cases with severe and increasing pain with loss of function, which have been so serious that they have not yielded even to rest in bed with the arm abducted, the bursa should be dissected out as completely as possible. The incision is made through the fibres of the deltoid muscle, thus exposing the bursa. The operative removal of the bursa will rarely be needed in cases properly treated by conservative methods but a definite indication for such removal lies in the presence of a definite lime shadow in the X-ray existing in connection with marked symptoms. Many cases are reported where loose bodies are found in the bursa. These may be felt and are revealed by radiography. Their removal is always indicated.

HABITUAL OR RECURRENT DISLOCATION OF THE SHOULDER

In a small proportion of cases of dislocation of the shoulder there will be recurrences caused by less and less force. At first reduction necessitates the aid of a surgeon; later the patient is often able to reduce it himself. These recurrences may be frequent and occur every few weeks, or oftener, sometimes even in bed, or they may take place only once or twice a year. The more frequently they occur the less severe are the symptoms following them and

these may only represent a comparatively trivial disability. The possible danger from falls, and the uncertainty both as to the effect on occupational efficiency and indulgence in the activities of sport call for active treatment.

The *etiology* is not clear. Anomalies and injuries of the shoulder joint are responsible in some cases, especially fracture of the rim of the glenoid. In others, the secondary dislocation appears to have been uncomplicated and in no way dependent upon the inefficient primary treatment.

Symptoms.—A second dislocation, occurring on slight cause, should arouse our suspicions and suggest a more prolonged fixation than is usually needed. These dislocations are not particularly painful and, on examination of such a shoulder, it will be found that certain muscles are sometimes atrophied, namely the brachialis, triceps, deltoid, supraspinatus, infraspinatus, rhomboids, and latissimus dorsi. At other times, especially when the displacement is followed by no reaction, the appearance of the shoulder is normal. A curious frame of mind which is not due to suffering or disability, sometimes characterizes these patients, who in time acquire a morbid, exaggerated fear of a dislocation.

In a shoulder joint where a second or third dislocation has occurred, it is not likely that the condition will improve without treatment, but with treatment the outlook for recovery is good in the majority of cases.

Treatment.—The treatment should consist in the application of a small strap fixed around the arm or in fastening the sleeve of the coat to the side in order to limit abduction, which is the movement of danger. This will usually secure immunity from recurrence and is the treatment of election in the old, feeble, or nervous.

Operative Treatment.—Treatment by operation is in general to be advised when once the condition has become established.

The authors have found the Clairmont operation to be effective.

Clairmont's Operation.[1]—An incision five inches in length is made, extending from the coracoid process downward to the outer side of the anterior border of the deltoid. The fibres of the deltoid muscle are separated under this incision and after dissection the quadrilateral space is clearly defined. This space is now slightly enlarged by dividing the upper third of the tendon of the teres major muscle (Fig. 47). A second incision is then made parallel to and to the outer side of the posterior border of the deltoid muscle. Through this incision a flap of the muscle with part of the tendon is removed from the attachment to the humerus (Fig. 48).

With ordinary care the nerve supply to this flap is not injured for the nerve can be seen entering the muscle from below. The flap is passed from behind, forward, through the enlarged quadrilateral space and sutured to the split anterior portion of the deltoid muscle (Figs. 49 and 50).

In performing this operation it is necessary that the strip of deltoid which is to be passed from behind, forward, should comprise at least a fourth of the muscle and as there is a danger of the flap being short it should be made to contain a portion of the periosteum into which it is inserted. It is particularly important that the tunnel through the quadrilateral space should be sufficiently free for the muscle to pass through without strain.

This operation is the most reliable where recurrence is very frequent and the transposed deltoid not only acts as a sling but it also tightens by contraction when abduction is attempted.

Bankart[2] has attempted to repair the structural defect which in his view determines the recurrence of the displacement. He has found this to consist in a detachment of the fibrocartilaginous margin of the glenoid cavity on the anterior aspect of the joint. The restoration of a normal barrier by reattachment of the ligament has successfully prevented redislocation.

[1] Clairmont, P. and Ehrlich, H.: Arch. fur. klin. Chir., 1909, lxxxix, 798.
[2] Bankart, A. S. B.: Brit. Med. Jnl., Dec. 15, 1923.

Avulsion of the Tendon of the Supraspinatus Muscle.—After a serious wrench of the shoulder, as in a fall from a horse, the symptoms of a severe

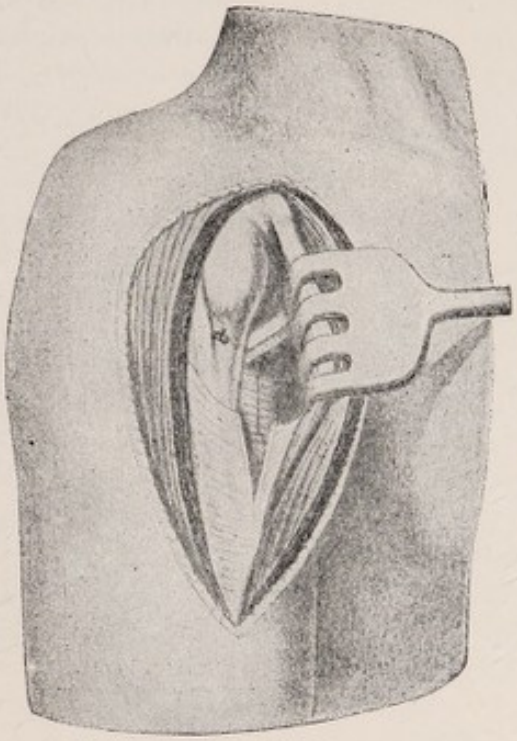

FIG. 47.

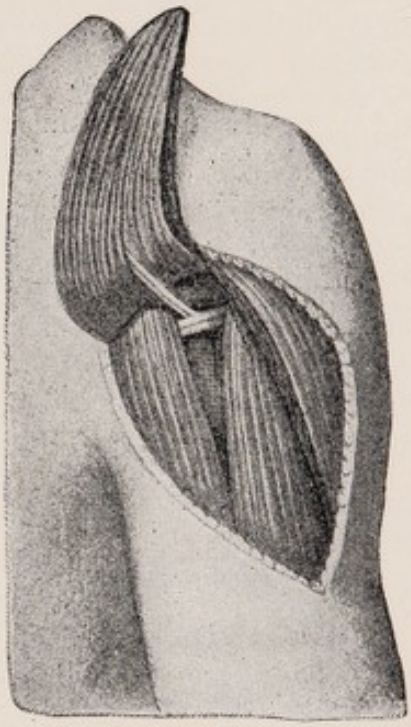

FIG. 48.

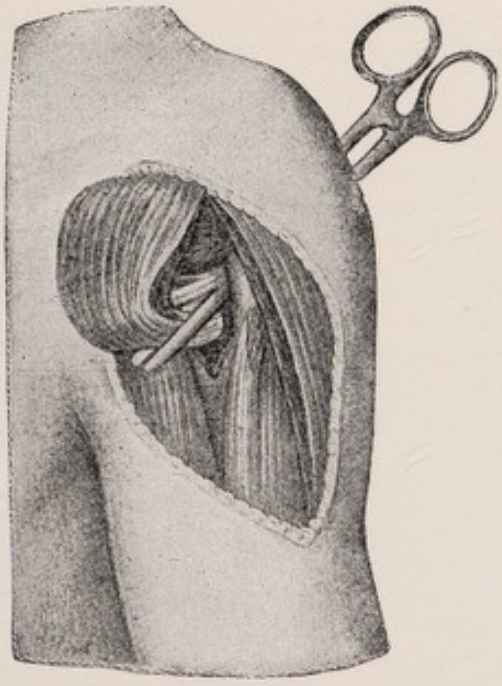

FIG. 49.

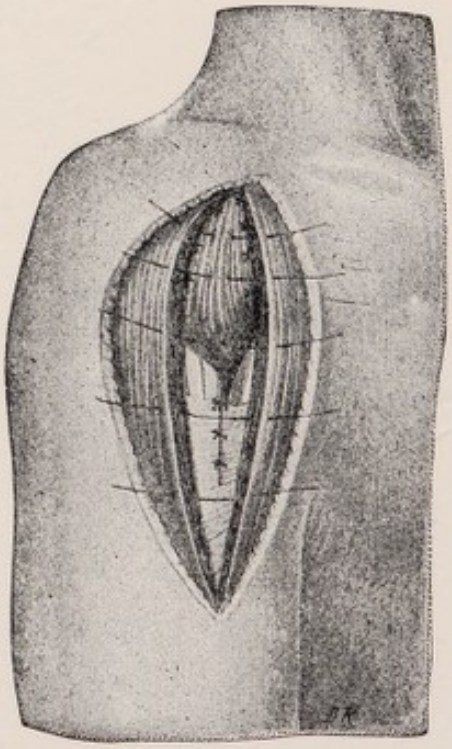

FIG. 50.

FIGS. 47–50.—Clairmont-Ehrlich operation.

sprain may be present with great pain in abducting the arm and local tenderness over the insertion of the supraspinatus muscle. In these cases the X-ray will most often show a fragment of bone detached from the superior one of

the three facets on the greater tuberosity of the humerus where the supraspinatus is inserted. The condition very often passes unrecognized and an irritable shoulder persists with particular discomfort in abducting the arm.

At the outset, when the condition is recognized, the arm should be placed on an abduction splint and an X-ray taken with the arm fully abducted. The X-ray may show the fragment in place and, if it is, the treatment should be continued with the arm in this position until time has been given for the fragment to unite. If it is not in satisfactory position, as will usually be the case, the displacement should be corrected by complete exposure of the fracture and pinning the fragment to the humerus.

The incision recommended for this is like the cut of a sabre straight across the shoulder, starting anteriorly, running back straight through the acromio-clavicular articulation, which is divided, and continuing posteriorly below the spine of the scapula at the origin of the acromion process. With a carrier a Gigli saw is passed beneath the root of the acromion and the process divided from the spine of the scapula. The deltoid is now turned outward and downward, thus making complete exposure of the floor of the bursa and the fragment is fixed in its proper position by a pin. The parts fall back easily into place and when the acromio-clavicular attachment is sutured there is scarcely need of a control suture of the acromion to the spine, since there is little likelihood of displacement when the arm is immobilized in abduction.[1]

Elbow

Anatomy.—The elbow joint is a hinge joint. The bones entering into its formation are the trochlea of the humerus, which is received into the greater sigmoid cavity of the ulna, while the capitellum articulates with the cup-shaped depression on the head of the radius. The circumference of the head of the radius articulates with the lesser sigmoid cavity of the ulna allowing rotation.

Ligaments.—The articular surfaces are connected by a capsular ligament of unequal thickness, the thickened bands being described as ligaments—anterior, posterior, and internal and external lateral ligaments. The orbicular ligament holding the head of the radius against the ulna should also be mentioned.

The anterior ligament is a broad and thin layer covering the anterior surface of the joint, in relation in front with the brachialis anticus muscle.

The posterior ligament is a thin and loose fold in relation with the tendon of the triceps and the anconeus muscle.

The internal lateral ligament is a thick triangular band consisting of an anterior and posterior portion. The former runs from the internal condyle of the humerus, to the coronoid process and the latter from the condyle to the inner margin of the olecranon.

The external lateral ligament is a short narrow fibrous band running from the external condyle to the orbicular ligament and the outer margin of the ulna. This ligament is intimately blended with the origin of the supinator (brevis) muscle.

Synovial Membrane.—This is very extensive, covers the margin of the articular surface of the humerus and lines the coronoid fossa. It reflects over the ligaments and forms a pouch between the lesser sigmoid cavity, the internal surface of the orbicular ligaments, and the circumference of the head of the radius. Between the capsular ligament and the synovial membrane are fat pads which are not of much surgical importance. The synovial membrane is most superficial at the sides of the olecranon process where swelling occurs first, to be followed later by effusion in the fold of the elbow.

The *arteries* supplying the joint are derived from the anastomosis between the superior profunda, inferior profunda, and anastomotica magna, branches of the brachial, with the anterior, posterior, and interosseous recurrent branches of the ulnar and the recurrent branch of the radial. The *nerves* are derived from the ulnar, musculocutaneous and median.

[1] Jones, Robert: "Injuries to Joints," 81.

Bursæ.—The olecranon bursa is superficial to the olecranon process A bursa exists between the tendon of the biceps and the tubercle of the radius, one between the triceps and olecranon process, another superficial to the external condyle, another superficial to the internal condyle, and one internal to the triceps at its insertion on the olecranon.

Surface Anatomy.—On the posterior aspect of the joint the ulnar nerve is the most important land mark. In the middle of the crease in the elbow is the biceps muscles, and the sharp upper edge of the bicipital fascia can be felt when the muscle contracts. On each side are two hollows known as bicipital furrows or grooves. The brachial artery lies to the inner side of the biceps tendon, and still further to the inner side, the median nerve.

Movements.—The joint between the ulna and humerus is a simple hinge joint and allows flexion and extension, but owing to the obliquity of the trochlear surface of the humerus this movement does not take place in a straight line. Flexion is produced by the biceps and brachialis anticus, assisted by the muscles arising from the internal condyle of the humerus and by the brachioradialis. Extension is produced by the triceps and anconeus, assisted by the extensors of the wrist and fingers. Extension is allowed to a straight line, and flexion allowed to about 150 degrees.

The joint between the radius and humerus is an arthrodial joint, and motion is allowed in all directions. Were it not for the orbicular ligament the head of the radius would be dislocated by the pull of the biceps as the radius articulates with the humerus by a very shallow surface. In complete extension of the head of the radius it glides so far back on the outer condyle that its edge can be felt at the back of the articulation. The strength of the joint depends not so much upon either ligaments or muscles as upon the coaptation of the bony surfaces, and the strength of the joint is very considerable, making dislocation of the elbow joint proper, without fracture rather unusual. Dislocation of the head of the radius is, however, very frequent in children.

Muscular Strains.—These are apparently the most characteristic injuries to the elbow and are to be identified anatomically when practicable, but this is not always possible as injury to one muscle is less common than injury to several.

The *diagnosis* is made by the following points: (1) By the patient's statement that only certain movements cause pain and sudden disability; (2) by localizing the tender spot by palpation at the origin or attachment of some muscle by active contraction of the muscle with or without resistance, and by passive stretching of the muscle; (3) by the exclusion of bone injury by an X-ray.

Strain of the insertion of the triceps may have to be distinguished from:

1. Bursitis of an adventitious bursa which is superficial to the tendon and should present no difficulty.

2. Fracture of the olecranon, often only an avulsion of the tip, but in other cases a fracture through to the sigmoid cavity. In the latter, the dense periosteum may prevent displacement, but the site of fracture can usually be recognized by feeling the crack in the bone. An X-ray decides the point.

3. Chronic strain of the triceps tendon may cause inflammation of the bursa situated between the tendon and capsule of the joint and gives rise to pain on pressure by the finger or on tension of the muscle.

The elbow is extended and a straight splint is applied along the front of the arm with a pad over the seat of injury and firm pressure to limit effusion. If the injury is a recent one, repair will be complete in a few days and movement will not cause pain. In cases in which repeated strains have occurred leaving the area of insertion tender, a firm pad applied over the seat of injury will suffice; but in acute cases, it will be necessary to apply a splint as well. To prevent strain on the triceps from being conveyed to the seat of injury a pad of adhesive plaster should be applied to the tendon of the triceps just above the olecranon and fixed with two firm turns of strapping around the arm.

Strain of Common Extensor of Flexor Origins.—It may be possible at times to localize the injury to one muscle, especially if it is only supination or pronation which causes pain, by carefully testing which muscular action is painful when one puts strain on the various muscles, and also be eliciting tenderness to pressure over the origin from the external or internal condyle.

If the injury is a recent one, the limb should be fixed with the injured muscle relaxed, and pressure applied to hasten absorption and prevent the effusion of fluid. In more chronic cases a pad should be applied by means of a strap round the top of the forearm, just below the flexure of the elbow and this pad of felt should leave a circular opening over the site of pain. To complete the recovery massage and graduated exercise are needed.

Brachialis Anticus.—Strain of this muscle at its insertion into the base of the coronoid process is easily localized. The muscle must be relaxed by flexing the elbow, while strain is to be relieved by fixing a strap just above the elbow.

Biceps.—The biceps is sometimes strained at its insertion into the radius and this is characterized by tenderness on pressure between the upper parts of the radius and ulna, but still more by the fact that passive resistance to attempted flexion and especially to supination is painful. Pain on supination distinguishes strain of the biceps from that of the brachialis anticus, for the biceps is a powerful supinator of the forearm as well as a flexor of the elbow, while the brachialis anticus is only a flexor of the forearm.

Sprains of ligaments about the elbow are generally fairly obvious by their localization and may exist alone or in connection with other injury to the joint. Sprains of the external lateral ligament represent the commonest form, and occur chiefly in tennis and golf players and baseball pitchers, especially if they pitch a curved ball, which necessitates a sharp snap in full extension of the arm. Resisted supination and extension are likely to be present and at the site of tenderness it may be painful passively to extend and supinate the elbow to its full limit. If the condition has existed for a long time it is likely to be troublesome, and even temporary fixation of the elbow may be necessary. Massage is of value followed by exercises to promote muscular development.

Bursitis.—In its chronic form, bursitis of the olecranon bursa, situated between the cutaneous tissue and olecranon process, is sometimes known as *Miner's elbow,* and is due to intermittent pressure upon the elbow in most cases, although a blow or some unusual pressure may be the cause. Motion is painless unless in full flexion when tension is made on the bursa. It is characterized by effusion in some cases and the treatment should consist of the application of a pad and bandage to the elbow. Pressure very soon disperses the fluid but in chronic cases dissection of the sac may be necessary.

Tennis Elbow. *Radiohumeral Bursitis—Epicondylitis—Epicondylalgia.*—This condition, which is well known, has been described and a complete survey of the literature given by Osgood.[1] Following tennis, or some continuous labor such as striking a blow with a hammer, discomfort amounting to acute pain is felt in the elbow. There is tenderness in the region of the external condyle of the humerus which the patient generally attributes to a slight strain and does not seek medical advice; but it is very persistent and continues constantly annoying. On lifting an object there is often a sense of weakness and pain running down the forearm, and the patient is likely to drop articles. The condition is often most intractable and may fail to respond to rest and the

[1] Osgood, R. B.: Arch. Surg., Mar., 1922, 420.

usual physiotherapeutic measures. One of the most effective forms of conservative treatment is the application of a small felt pad with a hole in the centre to accomodate the epicondyle, combined with modified use of the joint. In certain cases manipulation under anaesthesia often brings about a dramatic cure.

Examination shows little more than a definite area of tenderness with perhaps a feeling of increased elasticity and the X-ray examination is negative. Motions are free, and when passively carried out generally painless; but if a fist is made and the wrist palmar flexed, there is pain at the site of the lesion.

A study of the anatomy shows that there is often a small bursa beneath the conjoined tendon over the radiohumeral joint. In the cases reported by

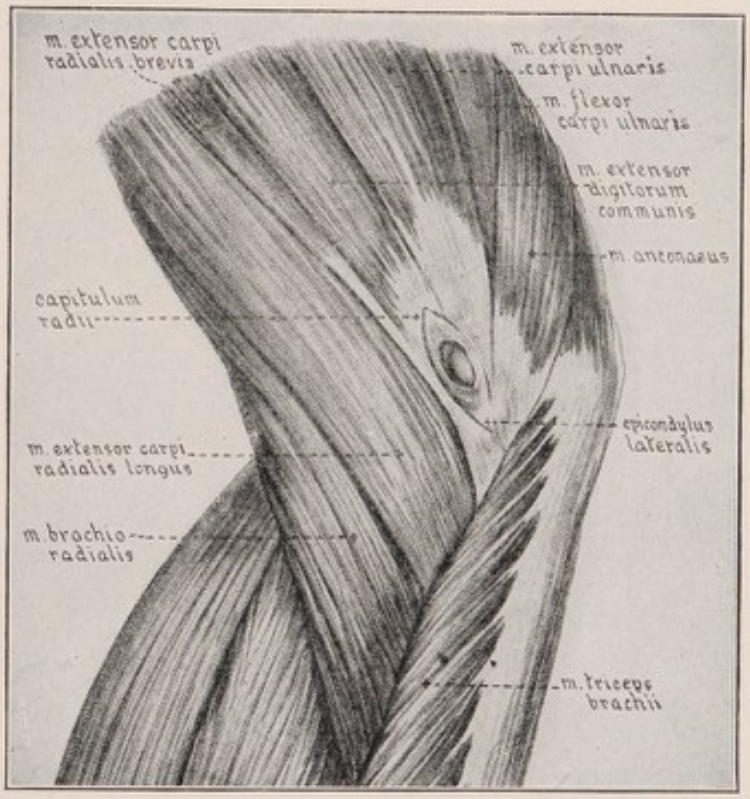

FIG. 51.—Muscular anatomy, showing location of radiohumeral bursa through split in conjoined tendon of extensor muscles (R. B. Osgood).

Osgood relief follows the removal of this bursa, and it seems fair to assume that in most cases the essential pathology is due to an inflammatory reaction in the connective tissue plane, located beneath the conjoined tendon of the extensor muscles between this tendon and the tip of the epicondyle, the origin of the supinator radii brevis and the radiohumeral joint. It is of course possible that this so-called "epicondylitis" may be due to lesions of more than one structure, but where a definite bursa exists, the operative removal of the latter seems to be the best *treatment.* An oblique incision is made, extending from the condyle downward in line with the radius, well over the radial head. Dissection is carried down through the fascia in this line and the fibres of the conjoined tendon split. The diseased tissues are removed and the wound closed (Figs. 51–52). A similar result may be sometimes obtained after the insertion of a hot cautery needle into the painful scar.

Fracture of the head of the radius in which a small portion is detached, requires careful treatment; otherwise considerable disability may arise. If the fractured portion cannot be placed in position by manipulation so that the radius will rotate easily and without crepitus, it should be removed by operation or fixed in position where feasible. Operation at a later stage is not nearly as effective from the point of view of function.

Strain of the orbicular ligament is not uncommon, and in this condition the elbow should be flexed to a right angle and the arm supinated.

Subluxation of the head of the radius occurs frequently in young children who are lifted by the hand in stepping onto a curbstone. Their joints are lax and the head of the radius is likely to slip forward. The luxation is easily reduced without anesthesia and speedily recovers. Reduction is effected by



FIG. 52.—Bony anatomy, showing location of small radiohumeral bursa (R. B. Osgood).

supinating the forearm, with the surgeon's thumb over the head of the radius and flexing; a click can always be heard in the act of reduction. In very exceptional cases this may become a recurrent condition and is best treated by exercises to strengthen the muscles.

WRIST JOINT[1]

Anatomy.—The wrist joint is an exceedingly complicated structure formed by the radius and triangular cartilage above, and the scaphoid, semilunar and cuneiform bones below. They are joined by anterior, posterior, internal and external lateral, and capsular ligaments. The two lateral ligaments are strong, well-defined bands, the anterior and posterior ligaments are weaker and are fused with the capsular ligament.

The strength of the joint is not derived from the joint surface in the radius or from the ligament and capsule, but rather from the tough fibrous tissues forming the sheaths of the large tendons passing over the front and the back of the joint, which are closely united with the bones.

It frequently escapes injury because of the gliding motion of the numerous bones which enter into the carpus, and because the two rows of joints in the carpus are available for taking up motion when the wrist joint proper is locked.

[1] JONES, SIR ROBERT: "Injuries to Joints," 104–105.

The joint is a condyloid joint, which means that it is a double hinge, having movement around two axes, one anteroposterior, and the other transverse. A combination of these movements results in circumduction, but rotation does not occur in this joint. The hand can be flexed to about 90 degrees with the forearm, but part of this motion takes place in the carpal bones. Extension in the same way reaches 65 degrees with the line of the forearm. Probably about 140 degrees of this combined motion occurs in the wrist joint proper. The wrist can be abducted and adducted about one-half as much as it can be flexed and extended; adduction, or bending to the ulnar side being much greater than to the radial side on account of the formation of the bones. It must be remembered that flexion and extension of the wrist is performed by the flexors and extensors of the carpus and also by the flexors and extensors of the thumb and fingers.

The extent of the movements in the wrist varies greatly in different individuals. The joint is particularly prone to sprains and injuries of the tendons, which are in close relation to the articular surfaces, and on account of the lax complicated articulation, relaxation of the joint is likely to follow serious injuries. The joint is accessible to examination in all parts and swelling may be manifested anywhere in its circumference, but as a rule occurs dorsally. The joint is particularly prone to injuries and tenosynovitis, but dislocation without fracture is not common in the wrist joint proper and when it does occur, is usually a dislocation of the semilunar, although fracture above the joint is very common and fracture of the carpal bones, particularly the scaphoid is of importance.

Muscular Strains.—Strains of some of the tendinous attachments about the carpus are not uncommon on account of their superficial situation and the anatomical diagnosis is generally easy. They are not generally severe enough to require more than the use of a firm strap around the wrist which affords relief. Fixation may occasionally be necessary.

Tenosynovitis (of the tendons) about the wrist occurs not uncommonly after a hard spell of some unaccustomed form of work such as rapid trench-digging, lifting weights or the prolonged use of scissors or pruning shears. Bricklayers, for instance, are prone to a synovitis of the sheath of the extensors of the left thumb (ext. ossis metacarpi and ext. primi internodii pollicis). It is almost invariably on the second day of work after a long period of rest that this condition shows itself. It is the repeated full abduction required in picking up and laying bricks that brings on this condition in muscles which are out of training for this especial demand.

For these simple but often disabling conditions the best treatment is a few days' rest with massage and firm bandaging, followed by gentle exercise. It must here again be remembered that the tendon may require rest and should be put in the relaxed position. If neglected in the first instance, the slight effusion and considerable tenderness may become chronic, with acute exacerbation, whenever the patient attempts to work or even to use the parts for complicated movements.

Sprains of the Wrist.—If an X-ray photograph is taken of every "sprained" wrist it will be found that a very large number of them are really cases of fracture of some bone of the carpus, or of a styloid process, and not merely the injury of a ligament.

Fracture of a carpal bone, if the patient is careless and uses the wrist roughly, may result in considerable permanent stiffness. The most common fracture of the carpals is that of the scaphoid, and accompanying this fracture there is often displacement. An attempt should be made to manipulate the prominent bones into position. The manipulation most usually successful is first to flex the wrist fully, and with the thumb placed on the prominent scaphoid, pressure is maintained as the wrist is brought into full dorsiflexion. Here it must be remembered that, unless at the completion of manipulation free

mobility results at the wrist, the removal of the obstructive portion of the bone should be considered. To produce a good functional result the operation should be done early, rather than at a later stage. *Dislocation of the semilunar* is not uncommon. There are two varieties—(a) semilunar-os-magnum displacement, and (b) semilunar os-magnum-radial displacement. In the latter the semilunar is extruded completely from the carpus towards the palmar aspect of the wrist, and there may compress the median nerve. In early cases reduction by manipulation is usually easily obtained. In long standing dislocations, the semilunar should be removed. Where operation is considered inadvisable the irritable wrist is often improved by a period of fixation on a short dorsiflexion splint.

Every injury about the wrist below the level of a Colles' fracture may be safely treated with the wrist *dorsiflexed*. Once the wrist has been put into

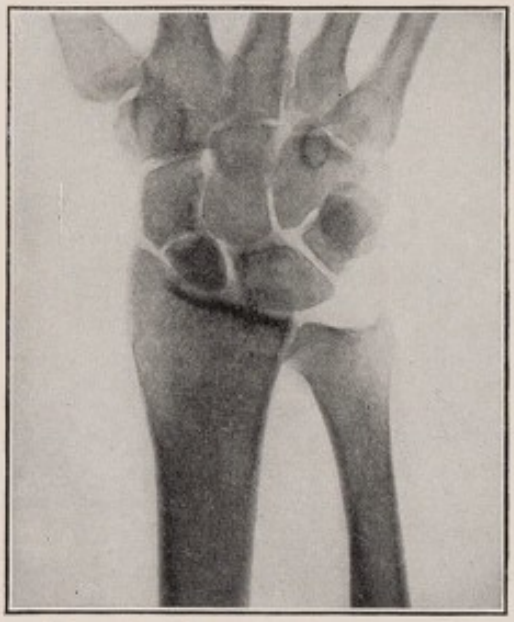

FIG. 53.—X-ray of fracture of the scaphoid.

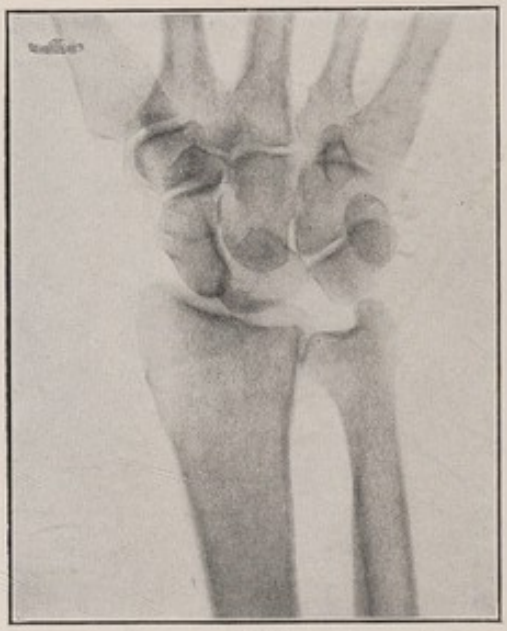

FIG. 54.—X-ray of dislocated semilunar bone in the wrist.

this position, and fixed on the splint, the patient may move his fingers after the first effects of the accident are past, without any fear of disturbing repair. If permanent stiffness should result after injury to the wrist joint, it is of great functional advantage that this stiffness should occur with the wrist in dorsiflexion. In this position the grasp of the hand is at its maximum, while stiffness or ankylosis in palmar flexion leaves the patient at a considerable mechanical disadvantage in the matter of useful function.

Madelung's Deformity[1] (Subluxation of the Wrist).—Following trauma and without known cause, there is occasionally noticed, especially in young persons, a laxity of the structures which give stability to the articulation between the radius and ulna. The lower end of the ulna is displaced upward in the direction of the dorsum of the hand and the lower end of the radius generally downward and often curved, and the bones can be moved on each other more than they normally should be. The wrist may appear enlarged and dorsal flexion of the hand is not freely performed, while pronation and supination may be affected in severe cases. The wrist feels to the patient loose,

[1] Arch. für. klin. Chir., xxiii.

insecure and irritable. The condition may be described as an occupational deformity following rotatory strain of the wrist and it consists of a subluxation at the radio-ulnar joint on the dorsal aspect and an inward and dorsal displacement of the ulna. It is often found in charwomen.

Dorsiflexion of the wrist maintained in a short dorsiflexion splint with a pressure pad over the prominence of the deformity offers the best prospect of relief. Care must be taken that the splint is so applied as to leave free range of movement in the metacarpophalangeal joints.

The prognosis as to function is generally favorable from treatment which consists in steadying the wrist as long as necessary and developing by manipulation and education the muscles most needed for use. In addition to restoration of function in the milder cases, there should be recovery from deformity.

The performance of radical bone operation, especially in adolescents, is not to be encouraged as the results are rarely satisfactory.

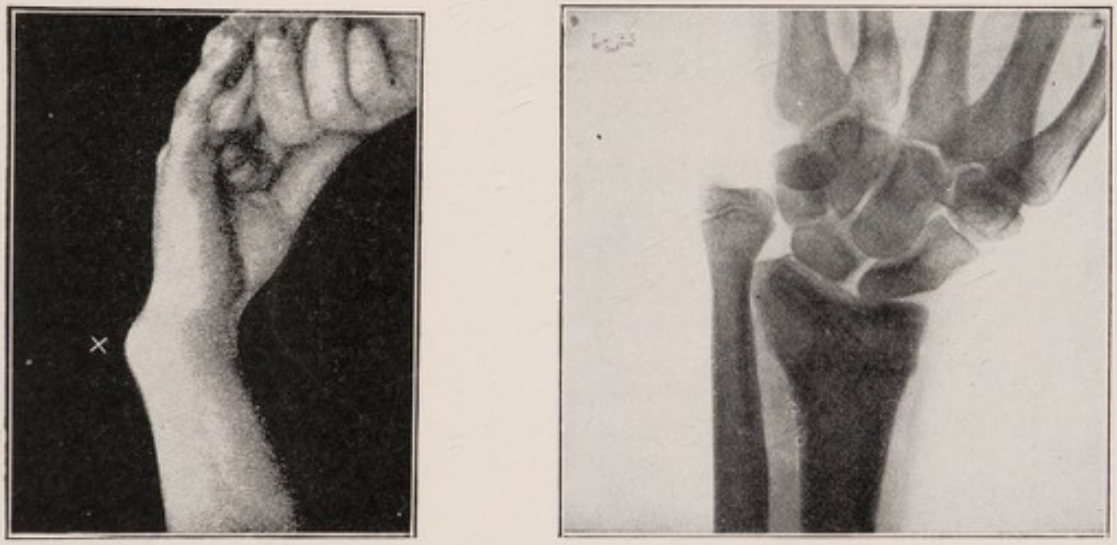

(*a*) (*b*)

FIG. 55.—Madelung's deformity. (*a*) Prominence of the ulna (Gaugele). (*b*) X-ray of the deformity

Finger Joints

Possessing almost wholly anteroposterior motion, the finger joints are very superficial and constantly exposed to trauma, and especially to sprain and fractures.

Sprains of these joints deserve mention because of their peculiar character. After a slight injury the joint is likely to become swollen, stiff, and very tender. The course of the injury is often extremely slow and obstinate. Fixation is advisable at first in combination with hot applications and this may be followed by massage and gentle manipulation to relieve the stiffness. If complicated by arthritis deformans of the hands, the case is even more troublesome.

CHAPTER V

STIFFNESS OF THE JOINTS—ADHESIONS AND ANKYLOSIS

Stiffness of the joints may be the result of (1) adhesions, (2) prolonged immobilization, (3) bony blocks, (4) scar tissue, (5) traumatic and suppurative processes about the joints, and (6) ankylosis. As the treatment of such widely diverse conditions must be based upon the pathological changes, and as it may entail operative procedures, it is important that we should formulate certain definite principles to help us decide when a joint should be moved, and when it should be kept at rest.

ADHESIONS

Adhesions are apt to follow—(*a*) sprains of joints, involving muscular attachments, capsule, and ligaments, (*b*) fractures through or in the neighborhood of joints, (*c*) dislocations, (*d*) contusion of joint cartilages (stub blows), (*e*) prolonged immobilization, and (*f*) periarticular inflammatory conditions.

Adhesions may be divided into two groups, which are—(1) intra-articular, and (2) extra-articular. (1) *Intra-articular* adhesions may be the result of rupture of the capsule, of hemorrhage, of plication with adhesion of the synovial membrane. (2) *Extra-articular* adhesions may originate in the capsule, the ligaments, the insertion or origin of muscles; or may follow extravasation into tendon sheaths.

Prevention of Adhesions.—The formation of adhesions suggests, but does not always imply, defective treatment. An accurate diagnosis is essential and the primary therapeutic aim should be directed toward subduing inflammatory reaction, and preventing strain on the damaged structure. As an example, one may take an ankle which has received an inversion twist. Pain is experienced upon pressure over the external lateral ligament, particularly over its bony attachment, and especially when an attempt is made to invert the foot. The essential principle of treatment is to keep the torn structures relaxed and this is done by fixing the foot in eversion. Fixation in the initial stage is of greater value than any type of physiotherapy which ignores this principle of relaxation, because it brings about immediate, rather than delayed, union of torn structures. The effusion of blood is obstructed by a firm bandage over cotton wool or absorbent cotton; massage and faradic stimulation may be started in a few days; and, later, movement of an active or passive type allowed, so conducted that no strain is brought upon the ruptured ligaments. When walking is allowed provision should be made to prevent the deflection of body weight to the injured part. The worst thing of all is to immobilize for weeks in plaster of Paris, which definitely perpetuates weakness and disability. A badly strained ankle, treated with deference to the anatomical lesion, should make a complete recovery in about fourteen days.

The indications, therefore, for the prevention of adhesions are:

1. To allay all inflammatory symptoms by rest and the removal of strain on the injured parts.
2. To obstruct local effusion of blood by pressure.
3. To massage the injured structures early.
4. To encourage active movements, early precautions being taken to avoid overstretching torn structures.
5. To encourage early active function.
6. To protect torn structures from the strain of body weight.

Diagnosis.—For all practical purposes it must be assumed that a painful joint which is rigid in all directions is the site of a present or past arthritis; on the contrary, a painful joint which is rigid only in certain directions with normal movements in other directions is free from arthritis (joint inflammation). This is more obvious in the joints which have a comprehensive range of movement such as the wrist, shoulder, hip, and spine, than in joints where the movements are practically in one plane, such as the elbow, ankle and knee. Examination for rigidity must be made without an anesthetic, because it is primarily due to protective muscular fixation if active disease is present. An illustration will perhaps help to make this clear—a girl complains of pain in the dorso-lumbar region of her spine. The surgeon asks her to flex, extend, rotate, and laterally move her spine, and if she can do this normally she has neither adhesions nor arthritis. If, however, she is unable to flex fully or bend to the side normally, but can hyperextend the spine, she can be considered free from arthritis but probably has adhesions. If she is unable to move in any direction the condition may be diagnosed as an active affection of the joints of the spine.

A joint whose range of motion increases with use is free from active arthritis; and in simple adhesions, the movement of a joint should not diminish with use, except very temporarily as the direct result of pain. The stiffness following arthritis is a slow and continuous process, while the stiffness due to adhesions may be pronounced as early as forty-eight hours after a direct injury—a condition commonly observed in the shoulder and knee. In adhesions, definite pain is experienced when they are put on strain, and the site can generally be definitely localized by pressure with the finger. In inflammation of the joint, pain is most marked when body weight is placed upon it, either in walking, standing, or lying. The temperature of the joint with arthritis is usually distinctly in excess of that felt where adhesions are present—indeed in the latter condition the joint is often colder than normal.

Treatment.—Adhesions may be treated by active or passive movements, or by manipulation under an anesthetic.

Active and Passive Movements.—These should be practically painless and should consist mainly in assisting the patient to move his own joint. If there has been no direct injury to the joint the proposition is a simple one, but care is needed in cases where fracture is present, and means should be adopted in the latter case to permit uninterrupted fixation. When a fracture is present near the joint, passive movements and the breaking down of adhesions by manipulation should be most carefully performed, and the fracture should be *adequately protected* from strain by closely applied splints. It is here that the ingenuity and training of the surgeon count.

In uncomplicated injuries to the joints, movement may be permitted immediately upon the cessation of acute symptoms, before which the joint

should have been immobilized. The clinical test of the cessation of acute symptoms is the elimination of swelling, tension pain and local tenderness. When these have abated the patient may be allowed to commence gentle, active movement because he will be careful to move the joint gently enough to avoid pain and damage. In the case of children gentle assisted movement may be started before active movement, and should be conducted progressively so that the joint is ultimately moved in each direction that its anatomy permits. In following this out, the full range should not be attempted at once, nor should there be more than one movement in each direction, and this should be limited to securing a free path for movements, in order to prevent the formation of adhesions. Roughness or haste in carrying this out is likely to lead to reaction and the formation of further adhesions. If the range of movement slowly and continuously increases with this form of treatment, there will be no reason to depart from the procedure. When pain following movement persists in spite of rest, harm is being done. If, however, pain is transitory, no ill effects will result from a continuance of movement.

Breaking Down Adhesions.—The indications for breaking down adhesions are:

1. When they do not yield to passive movements.
2. When passive movements are followed by reaction.
3. When the saving of time is important.

Light adhesions may be broken down under gas, or gas and oxygen; if strong and resistant, however, full anesthesia under ether is best, because complete muscular relaxation is rarely obtained by gas, and in consequence the surgeon is better able to gauge the force he should apply. An advantage of gas anesthesia, however, is that the movements may be voluntarily practised by the patient almost at once after manipulation, which is of considerable psychological advantage, as he realizes that the obstruction has been overcome. The earlier that movements are practised after manipulation, therefore, the better, and the pain is less acute while the results are more rapid and effective. The joints should be moved through their full anatomical range of motion unless the adhesions are very firm.

It must be remembered that the normal range of movement in a joint varies in different individuals, and at different ages, and it is advisable therefore, during the manipulation of a joint, to compare its range with that of the normal side. Unless this is done, it is easy to produce a reaction by forcing the joint beyond its normal range of motion.

After the adhesions have been broken down and while the patient is still anesthetized, the limb should be placed in the position of full correction until he recovers and is able to make a voluntary effort. If, on the other hand, the manipulation has been very severe and reaction is feared, it is advisable to fix the limb for a day or more in order to rest the traumatized joint, massage being substituted for movement. The limb should be fixed in the position opposite to that of the deformity as, for instance, if the deformity is in adduction, the limb should be fixed in abduction.

If, as a result of manipulation, the range of movement is diminished, it is fair to conclude that the manipulation has been ill-advised, or excessive or that the after-treatment has been defective. After the joint has been conducted once through its complete range of movement it is useless and often harmful to repeat the process. The "pump handle" method, as applied to the breaking

down of adhesions, or the practise of passive movements, is to be avoided. Voluntary movements, however, may be repeated with advantage as often as the patient can be persuaded to make them. If effusion should take place in a joint after manipulation it is strongly suggestive of the rupture of an intra-articular adhesion; but such effusion does not necessarily imply that the manipulation should not have been employed unless it is accompanied or followed by a diminution in the range of movement. If this occurs, the joint requires rest, but if, even in the presence of pain, the range of movement is increased by exercise, rest is contra-indicated. Again we emphasise that pain which is sharp and of short duration is negligible, but if pain continues for protracted periods it means a reaction likely to be followed by increased stiffness and calls for rest.

The rupture of the adhesions may be heard or felt under the hand. If no click is heard or felt, and resistance is overcome by a gradual stretching, the prognosis is not so good and the joint should be retained at rest for a few days in its new and corrected position, after which movement should be gently practised.

Forcible Manipulation as Applied to Individual Joints. *Shoulder.*—The normal range of motion of this joint is given on p. 54. The dangers to be avoided in forcible manipulation of the shoulder are fracture and dislocation. The patient should lie on his back while an assistant places his fist in the axilla to protect the head of the humerus from displacement or fracture. The surgeon should grasp the arm above the elbow with one hand and abduct it with the other, and he should control the shoulder girdle to fix the scapula. When the right angle is reached, the scapula is left free and the arm should be elevated to the normal limit of movement. When the arm is fully abducted the patient's hand should be placed behind his head and his elbow pressed backward until it assumes the position it occupies during a yawn. The shoulder should then be rotated inward and the hands placed behind the back until they overlap. The arm should next be brought to the side and very carefully rotated inward and outward, the extent of these rotations being checked by comparison with the movement of the sound arm. It should then be fully extended and supinated to free any adhesions which may have formed about the biceps tendon, and then circumducted, the palm of the hand finally being placed behind the occiput with the shoulder in external rotation. The patient should awake from his anesthetic in this position. Rotation must be very carefully performed to avoid fracture, but in the aged abduction is the movement most likely to produce it.

In addition to stiffness following sprains of the shoulder or adhesions in connection with bursæ, we may have to break down adhesions after fracture of the anatomical or surgical neck of the humerus, in reduced dislocation of the shoulder, in fracture of the outer end of the clavicle, separation of the tuberosities, and on recovery from the subacute arthritis which follows a fall on the shoulder or a fall on the palm of the outstretched hand. After fracture of the neck of the humerus great care is required to avoid refracture in manipulation of the shoulder, and it should never be attempted before two months after injury, as refracture of the arm has occurred on many occasions. In fracture of the greater tuberosity it is especially important that attention should be concentrated on restoring the rotary movements.

Elbow.—Manipulation of the elbow joint requires more care and judgment than does that of the shoulder and should always be gentle. If the adhesions

are light and there is no injury to the joint it is only necessary to flex and extend completely, with the arm first in complete pronation, and again in complete supination. In this way adhesions of the radio-ulnar articulation are simultaneously overcome. If adhesions, however, are firm and limitation of movement is marked, as is often the case in old fractures, the elbow should be gently extended in supination and then flexed to the point of safety and fixed in this position by a sling for a few days. It should then be extended and fixed in extension for no longer than two days. The arm should then be freed, and active and gentle passive movements practised, the fracture, if present, being protected from strain by splints. It may be necessary to repeat the movement in a few days.

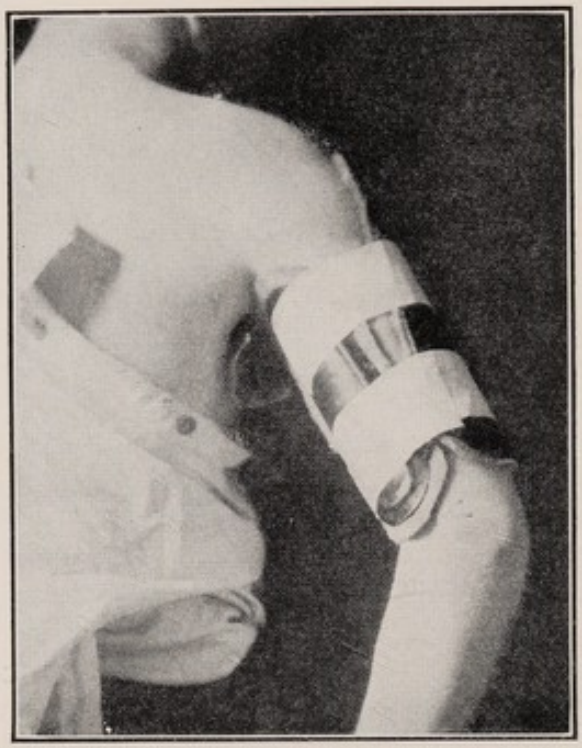

FIG. 56.—Fracture of the humerus protected by splints for shoulder manipulation.

The stiff elbow joint, especially in the case of children, often becomes mobile through active use when passive movements are followed by reaction, and it frequently happens that, when massage and passive movements have failed to make an impression and have been discontinued, the child appears a few months later with free motion in the joint. If the range of movement increases with use, even if very slowly, voluntary exercise should take the place of passive movement. If motion becomes restricted with exercise, rest is called for. If in the course of passive movement the joint becomes stiffer, traumatic myositis ossificans should be remembered as a possible factor. This condition is generally associated with fracture or dislocation and occurs very frequently in the region of the elbow.

Wrist.—The movements between the forearm and the carpus are condyloid, and therefore all movements except rotation are possible. The movements of the mid-carpal joint consist of flexion and extension, with slight rotation and a slight gliding movement; this is important to remember in manipulating the wrist. The metacarpal bones move upon the carpus with a slight gliding movement. The articulation between the thumb and the trapezium permits

flexion, extension, abduction, adduction, and circumduction. The metacarpophalangeal articulations permit of all movements, but the lateral movements are very slight.

In manipulating the wrist it should be dorsiflexed, palmar flexed, moved laterally, and finally circumducted. The head of the ulna should be moved to and fro on the fibrocartilage and carpus while the arm is supinated. If these movements have been restored without much force, active movement should be allowed immediately, but if dorsiflexion has been difficult the hand may be fixed for a day or two in the best position obtainable. If palmar flexion is limited and cannot be corrected without considerable force, the hand should be fixed in the corrected position for twenty-four hours to avoid reaction, after which active movements may be employed. Adhesions of carpal joints are met with chiefly in connection with Colles' fracture, sprains, and fracture or dislocation of the carpal bones, most frequently the scaphoid and semilunar. Free movements must be secured quite soon, when such fractures have occurred, as otherwise at a later date massage and manipulation will not secure free mobility of the wrist.

Fingers.—In manipulating the fingers extension should always be employed while adducting and abducting, and rotation should be practised while the fingers are slightly bent. The movements should be gentle, in order to prevent tearing of the ligaments, and all manipulations of the fingers should be practised with the wrist dorsiflexed.

Hip.—In manipulating the hip joint the patient lies on the back with both limbs fully extended; the affected hip is first rotated inward and outward, and the legs are then crossed in adduction, after which the knees are flexed to a right angle with the thighs abducted. Full flexion of the hips should be followed by abduction, rotation and circumduction and in the latter the foot should be conducted through a series of circles of increasing circumference.

It is well to perform these movements simultaneously on both sides so that the limits of normal movement may be noted. For complete extension the patient lies on his back with the pelvis supported at the end of the table and the limb is extended while the sound thigh is flexed on the abdomen.

Knee.—Before manipulating the knee the patella should always be examined to determine if it is movable, as it is *never* safe to forcibly bend a knee with a fixed patella. In breaking down adhesions the joint should be fully flexed while the tibia is constantly rotated upon the femur, and rotation should be continued as the limb is again brought into full extension. The manipulation for the reduction of dislocation of the semilunar cartilage is described elsewhere (p. 28). In breaking down adhesions the finger should be firmly pressed upon the painful spot, and the yielding can usually be felt under the finger. If adhesions of the knee are very firm the patient should be laid on his face with the front of the thigh resting on the table so that both hands can be used to flex and rotate the joint. In rupturing adhesions which follow fracture in the lower end of the femur, the thigh must be well protected by splints and flexion obtained by steady pressure.

Ankle.—Manipulation of the ankle joint should consist of flexion and extension, and it should be put through its full range of movement with the foot first inverted, and then everted. The calcaneo-astragaloid joint should then be put through its full range of movement, and similarly all the tarsal, metatarsal and phalangeal joints.

It should be clearly understood that the foregoing manipulations deal with a single form of periarticular adhesions or light intra-articular adhesions and not those accompanied by the destruction of joint surfaces, nor those where septic processes have involved the structures around the joints. These severe cases are not suitable for so-called forced manipulation, and should be approached in another way, which will be described.

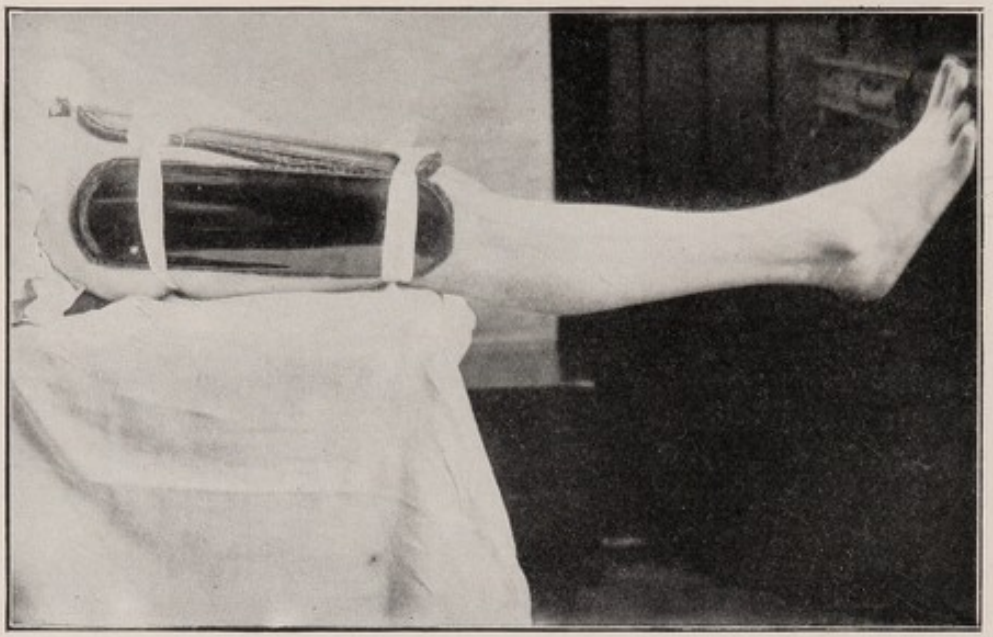

FIG. 57.—Fractured femur protected by splints before manipulation of knee.

STIFFNESS DUE TO PROLONGED IMMOBILIZATION

The prolonged immobilization of a healthy joint is usually avoidable, but when necessary it may be the cause of very considerable disability. If there be no direct injury, or no infection of the soft tissues in its neighborhood we may rest assured that, however long the immobilization has lasted, motion can easily be restored by simple means. This is particularly well exemplified in children. The most obstinate cases are found in connection with fractures near the joint where adhesions have formed about the fracture. In septic compound fractures near the joints, muscles and ligaments undergo secondary changes with great rapidity and if adhesions occur, very obstinate immobility may result.

Treatment.—Attempts at forcible manipulation as described for periarticular adhesions are in these cases often dangerous. So far as possible, fractures of the long bones should be treated with a view of immobilizing the fracture and mobilizing the joint, and in fractures close to the joint pressure likely to cause adhesion of muscle to bone must be avoided. If union of the bone is delayed, the muscles of the limb must be encouraged to relax and contract alternately without moving the joint. It may be repeated that an injured joint does not become truly ankylosed by rest, and that our preventive measures should be mainly addressed to the muscles that govern it.

If simple adhesions after fracture do not yield to movement they may be broken down as described in speaking of adhesions, either at once or in stages.

Stiffness due to prolonged immobilization is more intractable in old people than in children. That fixation in the latter is not a serious matter is evident from the treatment of congenital dislocation of the hip where, after reduction, immobilization is maintained for months.

STIFFNESS DUE TO BONY BLOCKS

The conditions giving rise to this are:

(*a*) Myositis ossificans.
(*b*) Excessive callus exudation.
(*c*) Unreduced dislocation.
(*d*) Malunited fracture through or about the joint.

The two latter are dealt with elsewhere.

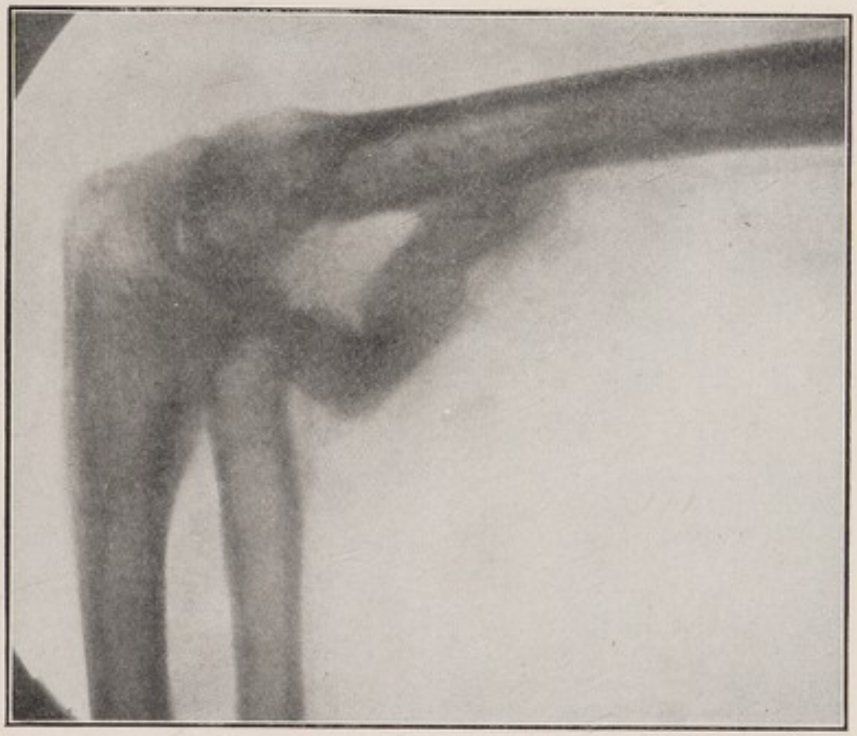

FIG. 58.—Traumatic myositis ossificans.

(*a*) *Traumatic Myositis Ossificans.*—Intra-muscular ossification may occur under the following conditions:

(i) As a widespread process—myositis ossificans progressiva, a disease which is rare and little understood.

(ii) Following chronic irritation or overuse (cumulative trauma) *e.g.*, in the adductor muscle (rider's bone).

(iii) Following a *single* injury. This is the common type, and when the bony mass develops in the neighborhood of a joint it is a serious menace to free movement.

Traumatic intra-muscular ossification is seen most frequently in the lower limb, the *quadriceps extensor* being the favorite muscle. In the upper limb the elbow region is the common site with the bony mass involving the *brachialis anticus*. The majority of the individuals affected are between the ages of 20 and 25, with the male sex predominant.

Antecedent Injury.—In the upper limb the usual primary injury is a posterior dislocation of the elbow joint, and less commonly an elbow fracture

(supracondylar) or even an uncomplicated strain. In the lower limb, ossification follows a direct contusion to the thigh.

Pathogenesis.—It is generally agreed that the bony tumor develops as a direct sequel of the invasion of injured muscle by bone cells. This necessarily implies a primary injury to the periosteum with a breach in its continuity.

The new bone exhibits all the stages of ordinary callus in which a cartilage phase may be demonstrated. Growth is rapid in the majority of instances and a swelling of hard consistency may be palpable a few days after the injury.



FIG. 59.—Myositis ossificans. Ossifying hematoma of periosteal origin.

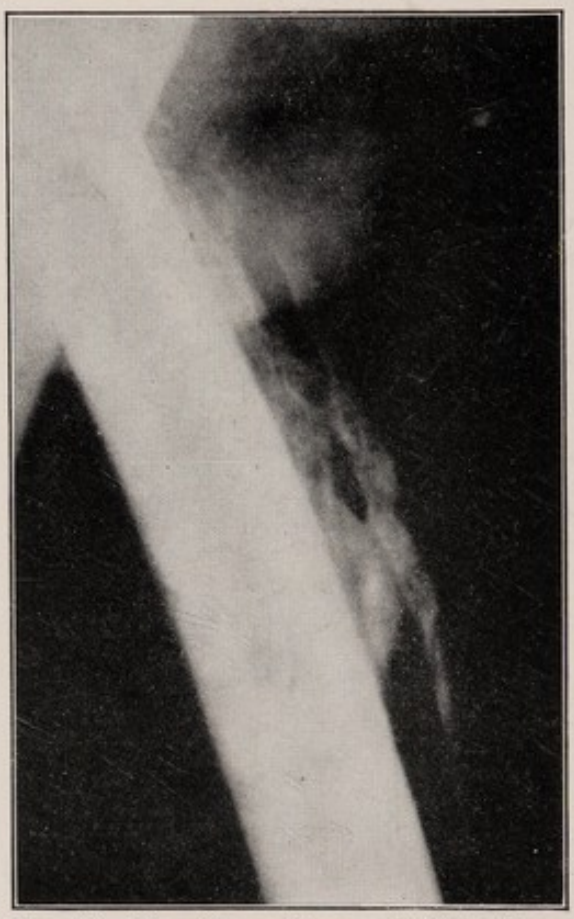

FIG. 60.—Myositis ossificans. Ossifying hematoma of periosteal origin.

Ordinarily a definite bony mass is not demonstrable until the third week. The tumor grows until it becomes "mature" and encapsulated; after this, it undergoes a steady diminution in size. Complete spontaneous disappearance is by no means uncommon.

The phases of growth and retrogression may be followed in a series of radiograms. In the stage of maturity the mass shows as a dense shadow lying in front of the lower end of the humerus or femur, to which it may be attached at one point. The diagnosis is usually a simple matter and the points of contrast between myositis ossificans and sarcoma are clear cut.

Treatment. (*a*) Preventive.—All forms of treatment which embody excessive stimulation and local irritation, after reduction of a dislocation of the elbow joint, favour the development of intra-muscular ossification—*e.g.*, energetic massage, repeated forced movement. The modern routine of *rest*

with the elbow slung in the position of acute flexion for a period of seven to fourteen days is rarely if ever associated with this complication.

(*b*) Treatment of the Actual Tumor.—It is well recognized that shrinkage of the tumor almost invariably occurs, and the residual mass does not usually cause serious disability. For this reason the joint should be rested and all physiotherapeutic treatment discontinued. Early operation is always to be condemned, as recurrence is bound to follow. Under certain conditions, operative removal of an unusually large mass causing great limitation of

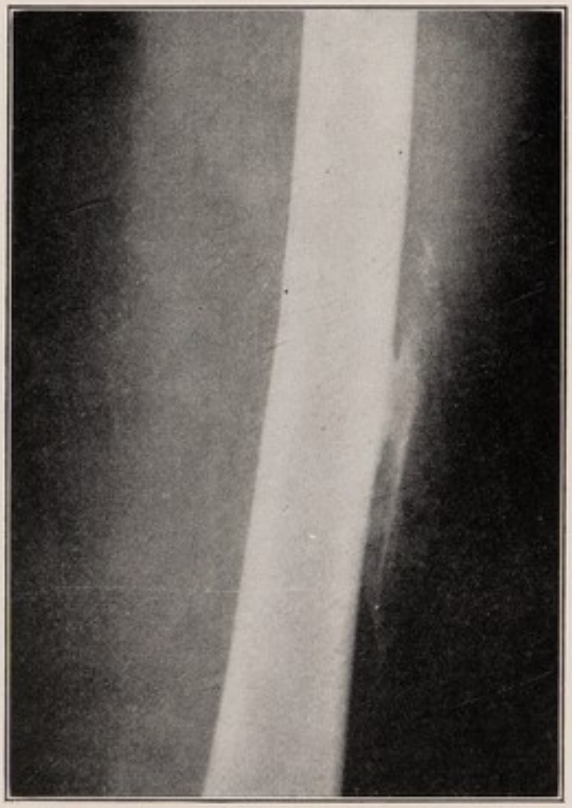

FIG. 61.—Myositis ossificans. Ossifying hematoma of periosteal origin.

mobility may be undertaken, but only after the tumor is fully mature, as proved by clinical and radiographic tests. With a policy of inactivity even large masses shrivel up, and mobility returns in surprising fashion. In rare instances the development of bone proceeds both above and below the joint until ankylosis is complete.

(*b*) *Excessive exudation of callus* is an occasional cause of bony block in fractures near or into the joint. Its development is often favored by premature attempts to secure motion.

STIFFNESS DUE TO THE CONTRACTION OF SCAR TISSUE

When a scar is situated in such places as the front of the wrist, back of the knee, flexure of the elbow, etc., its contraction may result in considerable deformity.

To Prevent Contraction in the Presence of Wounds in or Near the Joint.—The wound at the outset should be kept at rest and not roughly handled and torn tissues should be brought together. Fractures, if present should be placed

in the best position and free exit given to all discharges. The initial treatment of the wound is of importance, as excessive granulation tissue promotes contractile power in the scar. As the contractile power is greatest before the scar is fully matured, it is necessary to secure the limb in the correct position as soon as the condition of the wound will permit. This position is maintained until the scar is fully matured, as fully matured fibrous tissue has no contractile tendency.

The following rules should be observed:

1. If the muscles of the axillary fold are torn or if suppuration is present the arm should be kept abducted.
2. Wounds in the flexure of the elbow should be treated with the arm extended.
3. In burns and septic wounds on the front of the wrist the hand should be maintained in dorsiflexion.
4. Wounds in the flexure of the hip should be treated with the limb fully extended and abducted.
5. Wounds at the back of the thigh and the popliteal space should be treated with the knee extended.
6. Wounds at the front of the ankle should be treated with the foot plantar flexed.

Treatment.—This treatment may be (*a*) Mechanical, or (*b*) Operative.

(*a*) *Mechanical Treatment.*—When the scar is not too deep the limb can be stretched to obtain permanent correction of the deformity.

(*b*) *Operative treatment* may be necessary in (1) Painful scars. (2) Scars with deep attachments. (3) Firm scars involving the elbow or wrist.

1. *Painful Scars.*—Scars causing joint contraction are sometimes extremely hypersensitive. These should be completely excised and if possible the cut edges should be submitted to immediate suture. If this is impossible a plastic readjustment should be made, as healing by granulation tissue is detrimental.

2. *Scars with Deep Attachments.*—To insure success the most complete removal of cicatricial tissue possible is called for. In these cases the dissection may be quite extensive and it is necessary to proceed with caution, exposing nerve trunks to avoid accident. After operation the malposition of the joint should be overcome and the position maintained until the wound is healed.

3. *Firm Scars Involving the Elbow or Wrist.*—If these scars are of an extensive character, their removal may leave no available skin to cover the wound. The gap may be covered in either by a free skin graft or by a flap obtained from another part of the body. The best type of flap is the pedicled tube of skin used with striking success in recent years by Gillies.[1] This is most readily obtained from the abdominal wall. The operation takes place in stages. The flap is first fashioned by making two parallel incisions and uniting lightly the edges in the form of a tube. Some two or three weeks later one end of the tube is detached and its cut edge sutured to the margin of denuded surface of the injured limb. At a still later stage the remaining attachment to the trunk is divided, and the flap of skin is opened out and laid in contact with the denuded area. During the stage of transference the limb must be securely immobilized and approximated to the trunk by means of an appropriate splint or, better, by plaster of Paris.

[1] Gillies, H. D.: Plastic Surgery of the Face, London, 1920.

STIFFNESS DUE TO TRAUMATIC AND SUPPURATIVE PROCESSES IN AND ABOUT THE JOINTS

This type of joint stiffness which does not admit of forcible manipulation, requires much care and ingenuity in treatment. The stiffness results from—

(*a*) Prolonged immobilization during the treatment of compound fractures.
(*b*) Traumatic or slight septic arthritis without destruction of cartilage.
(*c*) Suppurations about the joint.

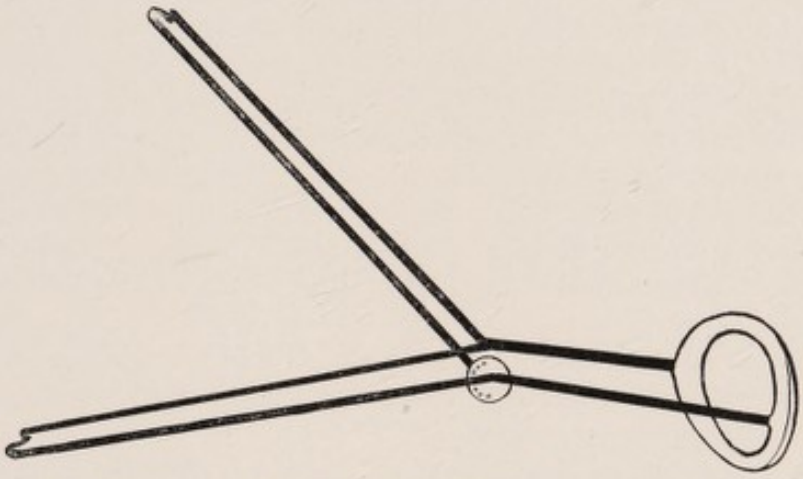

FIG. 62.—McMurray's modification of the Thomas knee splint for stretching knee.

Under such conditions marked fibrous infiltration develops in the joint capsule, and there may be adhesions between the periarticular structures and bone.

Treatment.—Attempts at forcible manipulation in this class of cases must be strongly condemned as various accidents may occur—*e.g.*, refracture of the

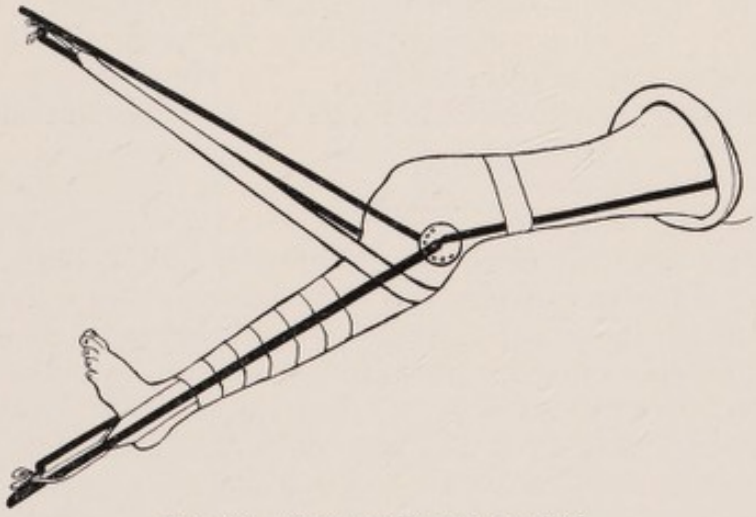

FIG. 63.—Same as Fig. 62, applied.

bone with a lighting up of septic foci; in the knee, fractures of the patella or rupture of the quadriceps or ligamentum patellae; or a violent traumatic arthritis.

Fractured bone takes much longer to consolidate than we were taught to believe, especially if sepsis has been present, where the callus often remains soft for several months; and if any unusual strain is permitted too early upon

such a fracture, it will often again yield. Even the gentlest sort of attempts to mobilize cases where stiffness has followed fracture near the joint must be safeguarded by support of the fracture by splints.

There are two ways in which we can safely attempt to bring about mobilization in this class of case: (*a*) By gradual flexion or extension on a splint in successive short stages; (*b*) by forcing, in successive stages, under anesthesia with rest in splints during the interval. The latter method of attack is suited to the stiffness of prolonged immobilization, traumatic arthritis, and cases where suppuration has occurred about the joint. For example, an elbow is stiff at an obtuse angle. The surgeon, after considerable effort, succeeds in gaining 20 degrees of flexion under anesthesia, but he then finds motion obstructed and desists, fearing fracture from further effort. The arm is then fixed by a sling in this position, that is to say, in the position of the greatest possible flexion, and in a few days the surgeon makes another effort. The second attempt under anesthesia brings about further flexion with but little effort, and a few days later another trial is made to secure the full extent of the flexion needed.

It should also be realized that joints which will not yield at all to manipulation under anesthesia often will do so when subject to the force applied by gravity, simply assisted by a bandage.

Operative Treatment of Attachment of Muscle to Bone.—This complication arises most often in the case of the quadriceps and triceps. In the case of the quadriceps, an incision is made over the front of the thigh, sufficiently large to allow a flap of fascia and fat to be inserted under the muscle after its separation from the femur. If the knee cannot be flexed from a structurally shortened quadriceps the muscle will require elongation by a "Z" incision. Bennett's[1] operation is one of the most useful of these procedures. The knee should then be slightly flexed and held in this position until the wound is healed. The triceps is dealt with in a similar manner. If the patella is adherent to the femur and cannot be loosened by manipulation it will be necessary to make two lateral incisions. The bone is then separated and a living flap of tissue is introduced between the cartilaginous surfaces.

ANKYLOSIS

There are two types of ankylosis—(1) fibrous, and (2) bony.

1. *Fibrous ankylosis* is understood to be the result of one of the various types of joint disease involving damage to joint structures. It may also result from acute or chronic infection, and from a fracture into the joint. H. O. Thomas, in discussing fibrous ankylosis, introduced a useful clinical classification into two varieties: Sound, and unsound. The term "sound ankylosis" denotes the absence of active disease and implies fully organized fibrous tissue in which the angle of deformity does not alter by use, while "unsound ankylosis" denotes active disease, which may be a very chronic or painless type. The deformity accompanying an unsound ankylosis can usually be corrected by mechanical means, and its treatment is absolute fixation until the inflammatory element has disappeared, when it becomes a sound ankylosis.

2. *Bony Ankylosis.*—When speaking of an ankylosis requiring operative treatment of the angle of deformity, for the sake of clinical simplicity the term

[1] Bennett, Geo.: Jour. Bone & Joint Surg., 1922.

"true ankylosis" will be used and not "bony ankylosis" which implies a synostosis.

Ankylosis in Good Position. *Prevention of Deformity.*—In cases where ankylosis may be expected, the limb is put in the position which insures the best possible function, so that a deformity requiring later correction is prevented.

Shoulder Joint.—In ankylosing shoulder joints, 75 degrees of abduction in children, and 50 degrees in adults is best. The elbow should be placed slightly in front of the lateral plane of the body and when at right angles, with the forearm supinated, the palm of the hand should be toward the face. The arm should be placed in this position while the scapula retains its normal position of rest as the hand can then easily be made to reach the mouth by bending the elbow. The arm should *never* be kept adducted if ankylosis is feared, for bad function will result.

Elbow Joint.—Consultation with the patient concerning his vocation and its requirements is important before fixing an elbow joint where ankylosis is likely to occur. Most men prefer ankylosis at about a right angle because this position enables the patient to move his hand to his mouth, button his clothes, brush his hair, and reach across the table.



FIG. 64.—Ankylosis of the elbow at 30° less than a right angle.



FIG. 65.—Ankylosis of the elbow 10° beyond a right angle.

Acute angles permit the hand to reach the mouth and head more easily, but limitation in other directions greatly counterbalances these advantages. If both elbows are ankylosed, one should be fixed at slightly less and the other at slightly more than a right angle so that the patient can fold his arms. Ankylosis at 130 degrees of extension, so commonly seen, is functionally bad.

Forearm.—If pronation and supination are both lost, the radius should be fixed midway between them, this being the position of election from every point of view, esthetic as well as practical.

Wrist Joint.—An axiom, not admitting of question, is that all wrist joint injuries should be fixed in moderate dorsiflexion, and this is equally true in cases where ankylosis or limitations of movement are expected, as in this position the finger grip is better, palmar flexion being a position of serious disability.

Hip Joint.—Very slight abduction and outward rotation with the hip fully extended is the position of choice for an ankylosed hip. Such a position gives free pelvic motion in walking and does away with lordosis and troublesome backaches; it avoids the unpleasant pelvic lift as the patient rises on his toes when walking; and walking is easier if the toes are not pointed straight forward. Some authorities favor slight flexion at the hip joint.

Knee Joint.—This joint should be fixed in an extended position. Good reasons may be given in favor of a position of slight flexion from the point of view of elegance in repose and ease in mounting stairs; but ankylosis is not always bony, and if unsound ankylosis is present, the tendency is for the angle to increase from exercise on account of the incidence of body weight on a slightly bent knee. Moreover, when the bone is forming, its complete

consolidation is slow, and if such a consolidating knee bears weight in a flexed position the flexion is likely to increase. The advantage of increased strength and stability outweighs all other considerations. In taking a wedge, however, from a flexed knee with bony ankylosis, where bony fixation is certain, the fixation in any position becomes easy, and it is an open question here whether slight flexion may not be indicated.

Ankle Joint.—Where ankylosis occurs at the tarsus or at the joints of the toes a few degrees of dorsiflexion is more useful than a right angle, because it enables the patient to walk with the minimum of strain on the front of the foot. The ankle should be fixed so that neither varus nor valgus exists.

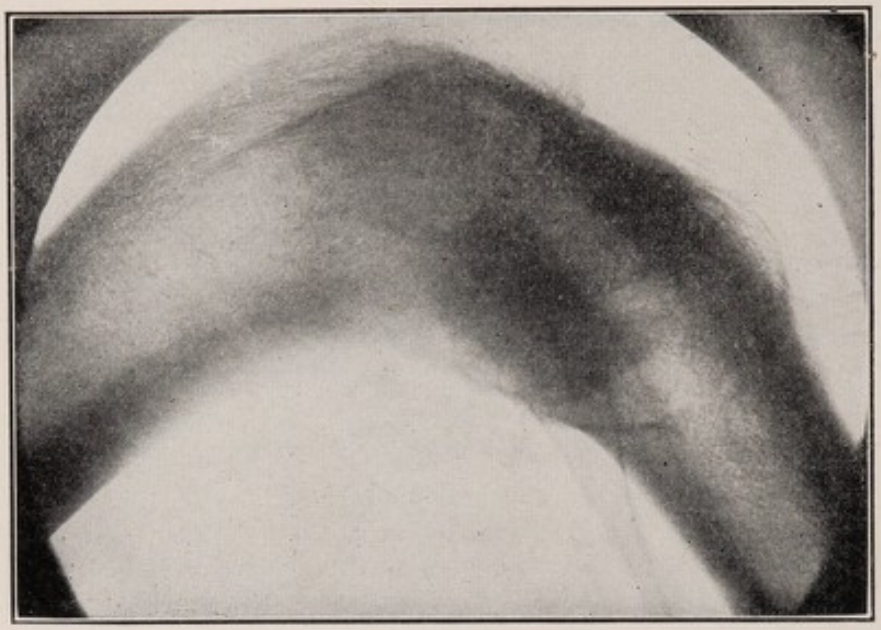

Fig. 66.—X-ray of bony ankylosis in knee joint.

Ankylosis in Faulty Position—*Treatment.*—If an ankylosis has occurred in a good position no other operation than that with a view to mobilizing the joint is to be considered. If ankylosis has occurred in a faulty position, operation must be considered as a means of securing the best function either to secure ankylosis in a better position or to secure some form of pseudarthrosis.

The operations which may be performed for this purpose are as follows: (*a*) Subcutaneous osteotomy, (*b*) open osteotomy, (*c*) removal of bone wedge, (*d*) partial or total excision of joint, (*e*) removal of bony outgrowth, or (*f*) pseudarthrosis of joint.

The correction of ankylosis in faulty positions will next be considered in connection with each of the important joints.

Shoulder.—In cases of stiffness of the shoulder in a bad position of a firm type, resulting from more or less severe injuries to ligaments and muscles, or extensive suppuration, the breaking down of tissues is to be condemned and the approach in such cases must be in the nature of a careful adventure. Under anesthesia, if necessary, the arm should be gradually brought up to the point of election and fixed there. When pain and tenderness have passed away the patient should be encouraged actively to lift his arm from the splint until it can be performed easily and without pain, after which the horizontal part of the splint may be lowered and a large range of exercises practiced until the splint can be discontinued. If the range of movement diminishes with use, according to the axiom presented above, freedom has been allowed at too early a date and rest is indicated.

For ankylosis in a bad position either *osteotomy* or *resection* should be performed, the former being more often demanded and is as satisfactory in improving function as that of the upper part of the femur. An incision is made through the anterior fibres of the deltoid and the bone divided by a chisel. The arm should be fixed for a few weeks in the position of election, not rotated too far outward, and a satisfactory range of scapular movement may be secured. This operation should not be performed unless the muscles

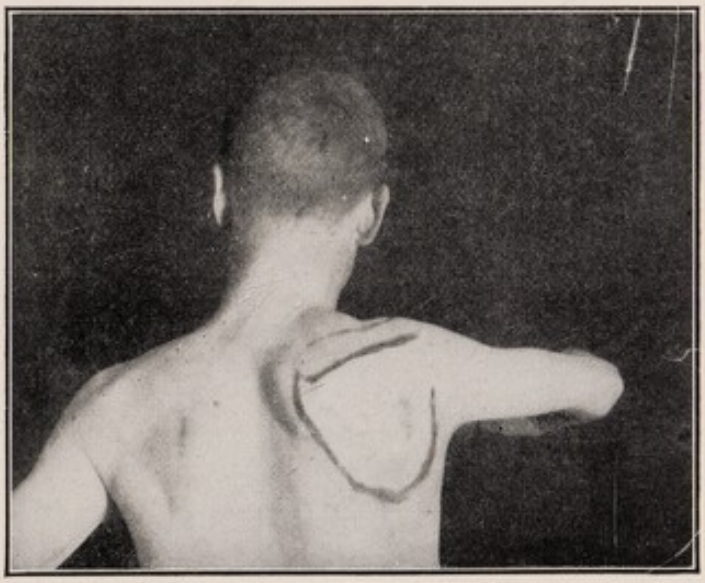

FIG. 67.—Result of arthrodesis of the shoulder.

moving the shoulder girdle are vigorous, nor where there is interference with the rotation of the scapula. Care should be taken to avoid overabduction.

Arthrodesis of the Shoulder.—An unsound ankylosis of the shoulder is often painful and it may be advisable to transform it to a sound ankylosis, thereby substituting a useful and painless arm for an irritable one. The joint is freely exposed—the base of the coracoid, the glenoid, and the under surface of the acromion are explored. The base of the coracoid is chiseled and the flaps of bone left attached. The acromion is denuded on its under surface and

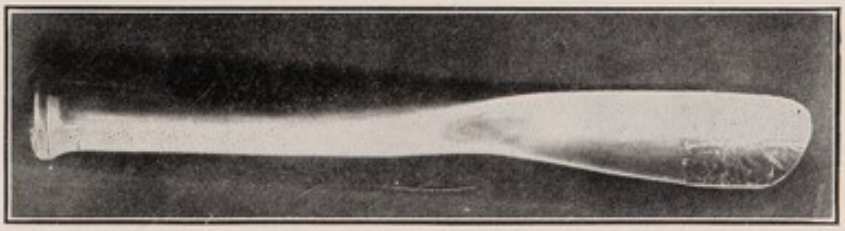

FIG. 68 —Curved chisel for arthrodesis.

one-half sawn through. The upper part of the humerus is freshened and flaps of bone left attached, the humerus is then pushed into the glenoid and lifted into a correct position after which the acromion is bent down and pushed into a groove prepared for it in the humerus. In this way one provides for a sufficiently extensive callus formation to secure ankylosis.

If the shoulder joint is already ankylosed in the correct position the mobilization of the scapula is such that the result is usually satisfactory and arthroplasty should be undertaken only under special circumstances.

Arthroplasty of the shoulder is not uniformly successful, often fails, and is only indicated where the scapula is immovable and a good deltoid present. It is contraindicated when there is a large mass of bone in the axilla.

The operation may result in a flail or weak joint or in painful fibrous ankylosis. It gives an arm of better mobility than strength and is inadvisable when the head of the humerus is obliterated.

Finally, the writers desire to call attention once more to two cardinal points: (1) An operation to produce ankylosis of the shoulder is never indicated where the muscles governing scapular movements do not act, or where an ankylosis in good position exists. (2) For a working man, ankylosis of the shoulder in good position, provides the surest functional success.

Elbow Joint. Fibrous Ankylosis.—This is due to one of the following conditions: (*a*) Extra-articular adhesions, (*b*) shortening of the capsule and adhesion of muscle to bone, (*c*) myositis ossificans, (*d*) old dislocations and fractures into the joint, (*e*) fixation due to extra-articular suppuration *and* (*f*) arthritis.

(*a*) *Extra-articular adhesions* have been dealt with.

(*b*) *Shortening of the Capsule.*—This may be either in front of, or behind, the elbow and in the ordinary cases the treatment does not differ from that of the adhesions already spoken of. The capsule is however sometimes so thickened and firm that no amount of force under anesthesia will stretch it, and if too much force is used, fracture of the arm or forearm is likely to occur. As suggested by Wheeler, in a limited number of instances division of the capsule may be performed to advantage.

(*c*) *Myositis Ossificans.*—Myositis ossificans has already been discussed in this chapter.

(*d*) *Old Dislocations and Fractures into the Joint.*—In old cases of unreduced dislocation of the elbow with very limited movement, the sham reduction of Thomas should be tried—a manipulation which has often proved of immense service. The manipulation necessary to produce an imitation reduction is as follows:

Under an anesthetic the forearm is pulled in the direction at which it lies in relation to the upper arm, the angle usually being about 125 degrees extension. The elbow is then steadily flexed, and if it is an old dislocation, it may not be possible on the first occasion to do more than flex it to a right angle. This angle is maintained for a few days, and an anesthetic is again given, and perhaps still again, until full flexion is obtained. This movement of flexion in stages succeeds when an attempt at one sitting would surely fail. The arm is slung in flexion and gradually dropped until it reaches the right angle. During the process of extension care must be taken that the patient can voluntarily flex the arm back to the angle from which it is dropped. This simple manoeuvre will often produce a most useful elbow—much more stable than could have been produced by excision.

Stiffness due to fractures into the joint should be treated by alternate flexion and extension, combined with fixation as already described in the discussion of shortened capsule. An obvious block by bone should be operated upon.

(*e*) *Fixation Due to Suppuration About the Joint.*—The elbow which has been surrounded by septic tissues must be approached in a very conservative manner. If painful, with only a few degrees of movement, one should anticipate ankylosis by placing the arm at rest in the position of election. If

painful and immobile, the elbow should be kept at rest. If painless and immobile, the angle may be changed from time to time by the use of a splint or collar and cuff. Any severe reaction should warn us of the danger of continuing movement.

(*f*) *Stiffness Due to Active Arthritis.*—In the presence of any degree of acute or subacute arthritis of any nature the elbow should be held in good position and if painful, let alone provided the angle of deformity does not change. When the process has quieted down and pain has disappeared, attempts at passive movement may be made at short intervals and may succeed in increasing the range of motion somewhat, but great care should be taken to avoid reaction. If the joint continues painful in spite of rest one must consider arthrodesis, pseudarthrosis, or excision.



FIG. 69.—X-ray of synostosis of superior radio-ulnar joint after operation.

Bony Ankylosis.—The treatment consists of—(*a*) changing of a bad position to a good one, (*b*) pseudarthrosis, (*c*) excision.

(*a*) *Changing a Bad Position to a Good One.*—If the elbow has become ankylosed in a position in which it is not useful, a question of importance arises. The joint may be corrected by a linear osteotomy which will give the desired angle, for after pseudarthrosis a perfect result is rarely seen, lateral mobility may exist and there is a loss of strength. If one were sure of securing free movement there could be no question of the superiority of the latter operation; but since this is not the case, one has often to choose between strength and mobility. Mobility is desirable when the angle of the elbow is fixed in a bad position, when a partial fibrous ankylosis exists with pain, when an ankylosis has occurred on both sides, and when ankylosis of the shoulder and wrist coexist. Fixation is preferable to an unsatisfactory operative result when the ankylosis is in good position, when the muscles moving the elbow are extensively damaged, when the ends of the bone are comminuted with much

exudate, when the joint is surrounded by scar tissue, or when the other arm has been amputated.

For the correction of position an open subperiosteal *osteotomy* is performed through a posterior incision. If there has been much new bone formation the osteotomy should be through the lower part of the humerus. In the absence of pronation and supination the head of the radius should be removed, but this operation should not be done at the same time as the operation on the elbow joint. Fixation may recur after the latter operation and this is minimized if the head of the radius is freely removed, and the end of the bone smoothed to lessen callus exudation, and Horsley's wax, as recommended by Stiles, rubbed into the cut end of the bone and periosteum stitched over the bone, or fascia wrapped around it.

(*b*) *and* (*c*) *Excision and Pseudarthrosis.*—Classical excision of the elbow is often followed by excellent results and the incision recommended here is the posterior one, which should be about four inches in length with its center opposite the tip of the olecranon. The insertion of the triceps and its expan-



Fig. 70.



Fig. 71.

Figs. 70 and 71.—Shaping of elbow joint for correction of ankylosis in faulty position. Radius and ulna from side, humerus from front.

sion into the fascia of the forearm should be preserved and also the lateral ligaments. The most useful line of section in the forearm should ensure the removal of the greater and lesser sigmoid with the olecranon, and the radius should be removed just above the insertion of the biceps. The humerus should be divided above the level of the epicondyle and the highest part of the epitrochlea on the inner side. This represents the minimum amount of bone that should be removed, and with the arm extended there should be an interval of one and one-half to two inches. When instability is feared, it is advisable to make the section through the bone a curved one. The arm is kept absolutely fixed under slight traction at a right angle until the stitches are removed and then very steadily flexed to an acute angle once a day for a fortnight. At the end of that time the wrist is slung to a right angle and lowered by degrees to an angle of 120 degrees, the patient being allowed active movement. At night it should be flexed to 60 degrees and released in the morning. This prevents strain of the brachialis anticus and biceps, and should be continued

for some weeks. This technique has given excellent results (Swan[1]). Neither excision nor pseudarthrosis should be performed in children.

Arthroplasty.—It is an open question whether this operation has sufficient advantage over excision to warrant one in pronouncing it the operation of election. It is more difficult and requires the highest grade of surgical technique and judgment. It provides a stronger joint with less lateral mobility than does excision, but recurrence of ankylosis is not infrequent and limited painful movement, similar to that of a chronic arthritis, sometimes results. Although often due to faulty technique, very experienced surgeons have encountered disappointment. The cases suitable for arthroplasty are those in which a mild arthritis or injury has produced bony fixation without grave distortion of the articular ends; and where there is an absence of scar tissue around the joint. In addition, the function of the upper arm musculature should be unimpaired.



FIG. 72.—Wrist in position of weak grasp.

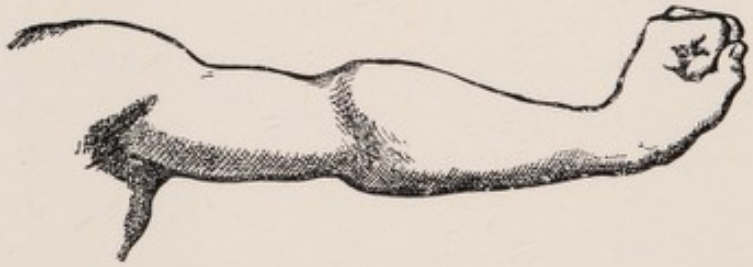

FIG. 73.—Wrist in position of strong grasp.

Excision is to be preferred in the following instances: (1) When the joint has been much obliterated, (2) when there is an abundance of scar tissue, (3) when sinuses exist, and (4) when bony masses occupy the bend of the elbow. The operation of choice will vary in response to the special type of case, but the operation to be described is satisfactory.

The joint may be exposed by posterior incision and all soft parts stripped from the posterior aspect, adhesions broken down, and the joint surfaces levered apart. If there has been much destruction, the operation must, to be satisfactory, leave a potential space between the bones. Therefore the roughened surfaces are trimmed to leave a space of about a quarter of an inch between the articulating bones. The same applies to radial and ulnar joints.

A flap of fascia lata, eight inches by four inches, is cut from the front of the thigh and, while it is still lying in its original place, a catgut suture is passed through the middle of the edge of each long side of the flap, tied, and one end of the suture cut short. The flap is raised by the sutures and forms a double curtain

[1] SWAN, R. J.: Lancet, London, 1917, i, 524–529; Brit. Med. Jour., 1917, ii, 704; 1918; 134.

of fascia. Straight cutting-needles are threaded with the sutures and passed into the back of the open joint and out in front, one near each side. By this suture the double fascia flap is pulled between the raw bone surfaces and the ends of the cat-gut tied in front of the joint. The flap is then carefully arranged to cover the raw bone surfaces, pains being taken to insert a portion between the radius and ulna. The triceps and its extension are next closed across the back of the joint and the skin wound sutured. The wrist is slung to the neck with the elbow joint in full flexion, and at the end of three weeks gradual relaxation from full flexion is allowed.

Fixation of the Radio-Humeral Joint.—When the elbow joint proper is ankylosed in good position, it may be advisable to mobilize the radio-humeral



FIG. 74.—Short hyperextension wrist splint.



FIG. 75.—Long hyperextension wrist splint.

joint alone. This is achieved by a free excision of the head and neck of the radius.

Wrist.—Stiffness or ankylosis of the wrist is most often due to—(*a*) prolonged immobilization in the presence of sepsis, (*b*) scar contracture, (*c*) bony block, (*d*) fracture and displacement of the carpal bones, (*e*) Ischemic palsy, (*f*) acute or chronic arthritis.

The stiff wrist, accompanied by stiffness of the fingers, is often the result of careless splinting, and ankylosis occurs most frequently in palmar flexion. After injury or in disease of the wrist, the hand should always be placed in a

splint in the position it assumes when it holds a big tumbler. This is the position of physiological rest. After correction, the standard correct position should be maintained by means of a splint, and if much force has been used in securing this position, the splint should be left in place for ten days or a



FIG. 76.—Skeleton hyperextension wrist splint.



FIG. 77.—Volkmann's ischemic paralysis.



FIG. 78.—Volkmann's ischemic paralysis. Finger splints applied.

fortnight, the fingers being gently moved and massaged. As active exercise is most important, the splint should be gradually discontinued until the deformity shows no tendency to recur. Stiffness of the wrist, due to *scar contraction*, requires the same treatment as that described above.

VOLKMANN'S CONTRACTURE

Volkmann, in 1875, described a severe contracture of the hand which he ascribed to tight bandaging in the treatment of fractures about the elbow, and he said that the deformity was due to a contracture myositis, and not to a primary nerve pressure palsy. He recognized that the condition was very grave and that amputation might be needed. In a classical article, which he published in 1881, he reaffirmed his belief in the ischemic origin of the affection, which he thought due to deprivation of arterial blood and to venous obstruction; consequently, the muscle perished from want of oxygen, and the phenomenon identical with that of rigor mortis set in. He called attention to the important fact that in this condition paralysis and contraction occurred simultaneously, whereas in primary nerve lesions contractions followed later. Volkmann submitted that similar contractions have been known to follow blood stasis due to compression with an Esmarch bandage, to injuries of large

vessels, and to exposure to extreme cold. He spoke of forcible extension of the fingers as likely to produce fracture of bones and tendons. The contributions of Volkmann and Lessa are very complete and have required but little revision or addition for fifty years.

The pathological changes found in the muscles have been described by several writers. The consensus of opinion is that the essential changes involve degeneration of the muscles and an increase of connective tissue in their substance. In many portions there is absence of sarcolemma nuclei, and but few individual muscle fibres. There is round-celled infiltration, showing the presence of inflammatory changes. Transverse striation is absent. Powers, describing the findings in his case, says: "All superficial muscles of the hand are markedly degenerated, pale, translucent, brownish-yellow. The muscle pieces removed from various areas show a varying amount of connective tissue which is fully developed, with few vessels, in every way corresponding to scar tissue. The muscle fibres are everywhere degenerated. The fibres are shrunken, of wavy outline, and for the most part are devoid of cross striation. They are frequently broken in coarse granules. In the area where the connective tissue is least advanced the muscle fibres are similarly more normal in striation, the cross striation being at times intact. The tissue taken from the ulnar side shows in general a more advanced degeneration."

Greenfield, reporting on a case of Bristow's, concludes: "The whole process seemed to be one of absorption and replacement of dead muscular tissue by fibrous tissue—the muscle acting as a non-septic, non-irritating foreign body, and being treated as such by the surrounding tissues."

Definitions and Symptoms.—Ischemic contraction is a deformity found mainly in children between 1 and 14 years, the majority between 6 and 11. It follows injury to the elbow, and is due to pressure from within or without, or both. It is usually, but not always, accompanied by fracture. In a typical case the wrist joint is palmar flexed, the carpometacarpal bones are dorsiflexed, the interphalangeals are flexed, the hand is often pronated, and the elbow-joint flexed. As a rule, sensation is normal in the milder case, and the electric reactions are unaltered; on flexing the wrist the fingers can be straightened. There is a lowered temperature in the hand and arm, the skin is blue and sometimes blistered, and scars are frequently present. The muscles rapidly waste, and become hard and ropy. If the nerves are sufficiently involved conduction may be lost, wholly or partially.

Symptoms may begin in the space of a few hours after injury. The fingers become numb and swollen, and possess little or no power of voluntary movement. The damage is very often completed in forty-eight hours, so that initial symptoms are very urgent. This point will be dealt with later. Muscular rigidity, and sometimes intense pain, come on early, and then the contracture. After some days the swelling disappears and the altered muscles become hard and resistant. The deformity, if untreated, increases, especially the flexion of the fingers due to the further contraction of the fibrous muscle, and also to the disproportional growth of bone.

Brooks, in a series of experiments on the etiology of ischemic palsy, found that after the obstruction of an artery for several hours, and the subsequent removal of the obstruction, the pulse might return in the artery and all the major branches, and yet the circulation might not be re-established in large areas of tissue. If the arterial obstruction lasted for many hours the muscle

might become wholly or in part necrosed, in spite of the resumption of pulsation in all the larger arteries. This pathological change in the muscles was accompanied by edema, hemorrhage, and by a slow inflammatory reaction, but there was not a rapidly developing fibrosis and contraction of the muscles. If the vein was obstructed, the artery being preserved, typical ischemic symptoms followed—hemorrhage, edema, degeneration, inflammation, fibrosis, and contracture.

These findings support the contention that the hematoma found within the limits of the antecubital fossa in supracondylar fractures is capable of producing a venous block, quite apart from bony displacement, special position of the elbow, or the application of a splint or bandage.

Jepson directed some interesting experiments upon dogs at the Mayo Clinic. In one series he attempted to produce ischemic contraction by the application of splints, casts, and bandages, but found it only possible to bring about a very temporary deformity.

In a second series of experiments a rubber bandage was applied above the knee of the right pelvic limb, and left on from half an hour to twenty-four hours. The animals which wore the constricting bandage for short periods developed a clawing deformity, but this lasted only from three to four hours. Where the constriction was maintained for twenty-four hours the deformity lasted for only three or four days.

In a final series Jepson operated upon dogs in pairs. In one animal a simple ligation of the femoral vein in Hunter's canal was performed. In the second an incision was made on the medial side of the right thigh, parallel to, and a few inches below, Poupart's ligament. The incision was carried down through the fascia to the muscle, encircling more than one-third of the thigh. The extremity operated upon became cold and bluish in a few minutes. There was no difference in the result of the two operations. The deformity simulated the contraction of Volkmann, and was maintained from six to nine days. When these two operations were combined the results were practically the same.

It was concluded that these experiments were insufficient—without other factors—to produce a true and persistent ischaemia. Accordingly, after the wounds had healed, an Esmarch was applied at the site of operation and maintained there from six to twenty-four hours. Even then the deformity did not persist in all the cases. The animal which wore the bandage longest had a contracted limb for eighteen months. The forefoot and distal phalanges were flexed, while the proximal phalanges were extended, the leg wasted and became board-like. Jepson, having succeeded in producing a persistent deformity, endeavoured to discover a way of minimizing the effects. A dog on which the incision and ligation had been performed was selected for the experiment. An Esmarch bandage was applied above the knee and left on for eight hours. At the end of this time there was considerable edema and disturbed circulation. Six hours later the wound was opened and the blood and serum evacuated. Rubber drainage tubes were placed in the intermuscular space and sutured. The swelling began to disappear, and four days later the dog was walking normally. The experiment was several times repeated, each time with controls, and the results demonstrated the important part played by intrinsic pressure on the causation of ischaemia. Their clinical bearing will be referred to later.

The work of Brooks and Jepson is a distinct contribution to the etiology of the subject. Volkmann's contractions are due to a combination of events, the most important of which are obstruction to venous flow, extravasation of blood and serum, and swelling of soft structures causing pressure on vessels and nerves.

The question of the frequency of peripheral nerve involvement is an important one. J. J. Thomas, in a careful survey of the literature up to 1909, found nerve involvement in 60 per cent of the series. Frank Dixon, in 1926, reports cases where conduction in the median and ulnar nerves was interfered with. Bristow reports a case of Volkmann where the median was completely divided by a sharp projecting end of the diaphysis—the nerve was sutured. Platt gives an instance of injury to the median at two levels. It was impaled on a sharp projecting end of the diaphysis in a supracondylar fracture, and also compressed by intramuscular fibrosis as it passed between the two heads of the pronator radii teres. Hamilton, in 1850, operated on a projecting fragment of bone and found the median stretched over the sharp end of the prominence, and obtained improvement after correction. Other writers have confirmed these experiences.

Although complete loss of conduction is rare, yet it is to be expected that there should be some pressure on nerves—disturbance of sensation in the hand can only occur in this way. The nerves become involved in scar tissue as elsewhere, and doubtless influence the course of the contractions.

The treatment of elbow fractures by flexion after reduction has so many advantages that it must continue to be the position of choice. Whatever happens, we must never subject fractures and displacements about the elbow to plaster-of-Paris, splints, or bandages. Prophylactic measures demand, therefore, that we should:

(*a*) Avoid circular compression.

(*b*) Reduce dislocations and displaced bones.

(*c*) Avoid all kinds of splints, more especially if there is much swelling.

(*d*) Use no force in flexing the elbow.

(*e*) Critically watch all cases of fracture about the elbow for the first few days. The warning symptoms are great pain (not always present); stiffening and swelling; cyanosis and lividity of the fingers. Ischemia may result without obliteration of the radial pulse, but this symptom is at least evidence of pressure. Loss of voluntary movements is a serious omen.

What Should Be Done if Ischemia Has Started.—The arm should be released from all restraint which involves compression, and should be elevated. Manipulation of every kind for the further reduction of displacement should be avoided. Murphy, in 1914, suggested that if cyanosis continued while the forearm was extended and elevated a subcutaneous division should be made on the antero-ulnar side of the forearm. The experiments of Jepson, which I have described, supply an argument in favor of Murphy's suggestion. In an editorial note to the thirty-first report of *Progress in Orthopaedic Surgery*, it is stated: "Some of us have encountered cases in which ischemic myositis was present when the patient was first seen, and before any dressing had been applied for the fracture. Contrary to the experimental evidence, which is in favour of venous congestion as the causative factor, the findings in these cases were absent radial pulsation, pallor, and coldness of the hand, together with inability to move the fingers. The first two developed typical ischemic

contractures. In the third case multiple incisions were made at the elbow and part of the subfascial hematoma evacuated with the result that the ischemia disappeared and the hand remained normal." Such a case is very encouraging and the method deserves further trial.

Prognosis.—The prognosis is most grave where:

(*a*) The nerve damage is excessive or complete.

(*b*) The obstruction to circulation in the fingers has remained pronounced.

(*c*) The wrist is fully flexed and the forearm is fixed in extreme pronation and there is very limited movement in the elbow-joint.

(*d*) Only *mass* movement occurs in the fingers.

The prognosis is more favourable:

(*a*) When the circulation is good, and nerve involvement is not too pronounced.

(*b*) When the forearm moves fairly freely on the humerus, and some supination is possible.

(*c*) When flexion of the wrist is not extreme, and some separate voluntary movements can be obtained in the fingers.

The prognosis is very favourable where only a slight contraction appears in the fingers when the wrist is dorsi-flexed. This is the unrecognized group where symptoms have been noticed only after the completion of treatment, and are even looked upon as mere stiffness.

Treatment.—The treatment should be as follows:

(*a*) The wrist is passively flexed by an assistant to allow the fingers to extend, and each finger is strapped to a little gutter splint to maintain extension.

(*b*) A day or two later, or even on the same occasion in mild cases, an attempt is made to extend the phalangeal and the metacarpal range by means of a flat metal splint, the wrist being allowed to remain flexed.

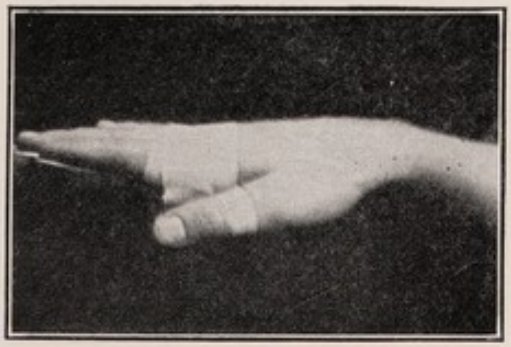

FIG. 79.—Volkmann's ischemic paralysis with finger and flat splints applied.



FIG. 80.—Volkmann's ischemic paralysis with finger and flat splints applied in hyperextension.

(*c*) The wrist is then from day to day extended a little further and held fixed in this position, and this is continued until it is dorsiflexed. Hyperextension of the wrist and fingers is maintained for some time in compliance with the rules already laid down. This procedure is decidely preferable to operations in which attempts are made to lengthen the tendons of the fibrosed muscles or shortened bones.

The above is a description of the measures to be taken during the acute stage—a stage which lasts for about a week. Usually the surgeon sees the case some weeks or months later, when the deformities are fully developed. He will then have to decide whether his attack should be a mechanical or an operative one, or a combination of both. Whatever method be adopted, the aim should be to keep the forearm supinated.

Surgeons and practitioners who meet with fractures about the elbow must insist upon obtaining an *x*-ray photograph. If the parents refuse, the refusal should be made in writing. The parents should be told that two serious conditions are apt to follow injuries to the elbow. One is the condition we are now discussing, which often comes in the first few hours, and the other is myositis ossificans, which is not likely to follow in less than three or four weeks.

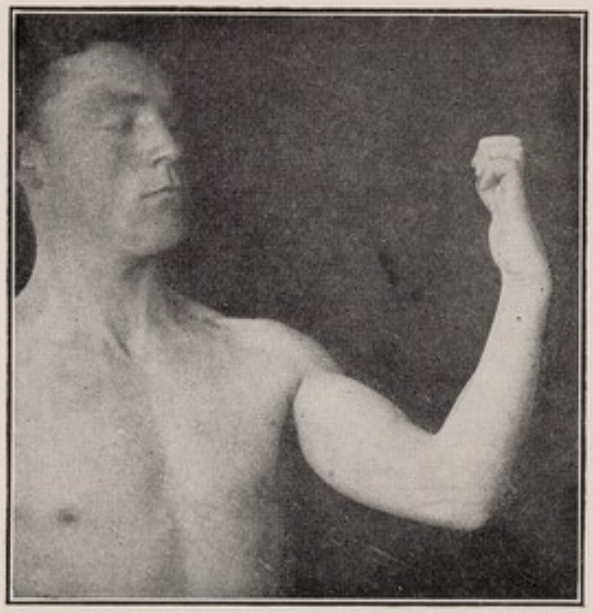

FIG. 81.—Stiff hand with flexed fingers, peripheral nerve injury, resembling Volkmann's ischemic paralysis.

Fracture and fracture dislocation of the *carpal bones* is often followed by stiffness. The treatment has already been considered.

Fingers.—Mild stiffness of the fingers is best overcome by ordinary massage and gentle active and passive movement, the principles laid down as covering the larger joints being applicable here; forcible movements are rarely called for.

The more rigid type presents unyielding fingers, often with hyperextension, atrophic changes, and smooth, glistening skin. The wrist may be flexed as well as the fingers, while the thumb is adducted. This type of rigid hand and fingers is most often due to: (1) Prolonged immobilization following compound fractures of the wrist and forearm, (2) direct injuries to the hand, (3) cellulitis of the hand, (4) injuries to peripheral nerves, (5) ischemia, (6) incorrect splinting.

Hyperextended fingers are the most difficult to treat and are usually the result of careless splinting. This will not be the case if all the joints of the fingers are slightly flexed in immobilization (Fig. 76). If stiffness of the wrist coexists with rigid fingers, the wrist should be dorsally flexed and the fingers then dealt with.

In the correction of stiff and contracted finger joints, continuous traction in the line of deformity while the joints are being extended is most helpful (Abbott, Baldwin and Danforth).

Hip Joint.—Ankylosis of the hip may be due to (1) prolonged immobilization of a septic fracture or suppuration in the neighborhood of the joint, (2) arthritis deformans accompanied by adhesions and limited movements, and (3) tuberculosis and other destructive processes resulting in bony ankylosis.

If the *ankylosis* is in a *bad position* this should be corrected by (*a*) transtrochanteric osteotomy, (*b*) subtrochanteric osteotomy, or (*c*) the removal of a wedge.

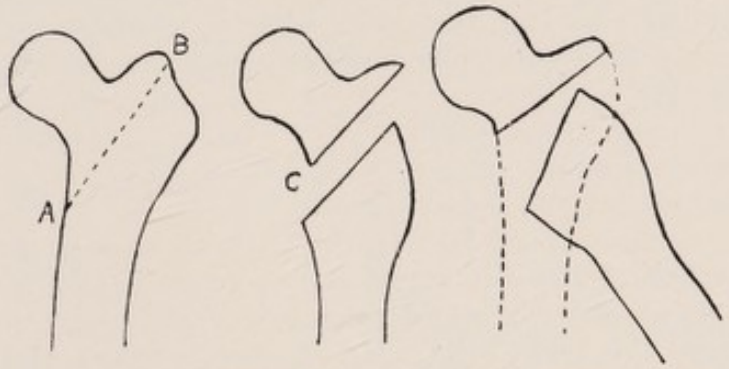

Fig. 82.—Transtrochanteric osteotomy: *A-B*, line of section through trochanter; *C*, lengthening after traction; *G*, position of fragments when limb is abducted.

(*a*) *Transtrochanteric Osteotomy.*—This operation, which gives the most accurate mechanical result, should be practised in all cases of ankylosis in malposition where the femoral neck is not absorbed and where there is no marked pathological displacement. It may be done subcutaneously with a saw or a chisel, or by an open osteotomy. A convenient and safe tool is an Adams saw with a knob at its end (Fig. 89). A very small incision is made directly down to the trochanter, the skin is drawn downward in order to form a valve when it slips up, and the blade of the knife is passed along the front of the bone in a line starting three-quarters of an inch below the tip of the great trochanter. With the knife in situ the blade of the saw is then passed below it, the knife withdrawn, and the bone sawed about four-fifths through, when it usually yields. The adductors are then divided if necessary and the limb is placed in abduction under extension.

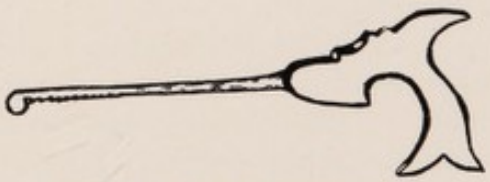

Fig. 83.—Saw for osteotomy.

(*b*) *Subtrochanteric osteotomy* is indicated when it seems desirable to avoid the old seat of the disease or where the fibrous ankylosis is in process of becoming solid. It is contraindicated in extreme flexion.

(*c*) *A wedge osteotomy* is indicated where the neck and head of the femur are absorbed, the trochanter raised, in pathological dislocations and in conditions where a mass of bone has to be penetrated. Here also the adductors must be divided. In fixing the patient after operation in an abduction frame or plaster splint, it may be necessary to apply traction on the limb to secure abduction, and the degree of abduction at which the limb is to be fixed depends upon the shortening.

Mobilization of Ankylosed Hips.—Apart from the exceptional cases where a patient insists that movement is more important to him than stability, mobilizing operations should be confined to cases of double ankylosis, and cases of unsound ankylosis with adduction. In the latter case the patient should understand that a sound ankylosis can be secured by operation with greater certainty than can a satisfactorily movable joint. In double ankylosis, operation is obviously imperative, and if the ankylosis is bony with the usual deformities, one hip should be submitted to osteotomy and the other to pseudarthrosis. The shorter limb should be the one to remain ankylosed as pseudarthrosis, or excision, is followed by some shortening.

The operations from which a choice may be made in attempting to obtain a movable joint are—

1. Excision of the femoral head.
2. Formal arthroplasty.
3. Pseudarthrosis below the joint level.

In general, *excision* should be practised where there is much new bone formation, distortion of the articular ends, or where pathological dislocation has occurred. *Arthroplasty* is more suitable for cases of ankylosis without gross distortion of the bone ends. *Pseudarthrosis* below the joint level is often the best type of operation where there is a large bony mass around the hip, or in elderly and fragile patients, and particularly in the bilateral ankylosis which is associated with spondylitis deformans.

METHODS OF APPROACH TO THE HIP JOINT

The hip joint is situated deeply, and after considerable retraction of important muscles, a limited area only is exposed. The greater part of the femoral neck and capsule is screened off by the trochanter and its attached muscles.

1. **Anterior (Classical).**—The patient lies on his back. The skin incision runs downwards and inwards from immediately below the anterior superior spine. The interval between the tensor fasciae femoris and sartorius is opened up, and more deeply the rectus femoris and gluteus medius are separated. A small twig of the circumflex artery lying in the precapsular fat, must be clamped and tied. The joint capsule is now exposed, and its division reveals the anterior aspect of the femoral neck, and affords just a glimpse of the femoral head.

This approach is inadequate for the more extensive operations on the hip joint, but may be used for

(*a*) Exploration and drainage in acute suppurative arthritis.

(*b*) Pertrochanteric osteotomy (Brackett).

(*c*) Fractures of the femoral neck (combined with an incision over the lateral aspect of the trochanter) where the fracture is to be fixed by "pegging."

(*d*) Reduction of a displaced femoral epiphysis.

2. *The Prolonged Anterior Approach* (Smith-Petersen; Sprengel).—The patient lies on his back, but the hip is thrust forward by means of a sand bag placed under the loin. The conventional anterior incision is prolonged upwards, skirting the anterior third of the upper border of the ilium. The aponeurosis, muscular fibres, and periosteum attached to the crest are divided to the bone, and the flap of soft tissues stripped downwards until the margin

of the acetabulum is reached. Brisk hemorrhage occurs in the posterior end of the wound from one or two points, which must be clamped. There is also a short period of oozing which is easily checked by packing. In the upper thigh, the deeper dissection proceeds down to the joint capsule as already described. The rectus femoris attachment to the anterior inferior spine is separated and the gluteal flap dissected off the capsule. The latter is now well displayed in its upper and anterior aspects and can be opened freely.

At the close of the operation, the divided aponeurosis and muscular fibres are reattached as accurately as possible to the ilium.

This approach is most suitable in children, and particularly for the various open procedures for congenital dislocation of the hip (open reduction, the creation of a new acetabular lip, etc.). In adults, it is less easy to restore the iliac crest attachments neatly.

3. *Postero-lateral Approach.*—(*a*) The patient is placed on his sound side, close to the edge of the table, steadied by sand bags in front and behind the loin, and with both hips and knees flexed.

A choice of skin incisions is offered. A convenient one is T-shaped (Brackett[1]) and runs downward from the anterior superior spine along the line of the interval between the tensor fasciae femoris in front, and gluteus medius behind. The incision reached the tip of the trochanter and is then continued down in the long axis of the femur for some 3 inches. From this a short additional cut is made at right angles, beginning just below the top of the trochanter. A U-shaped flap may also be used.

(*b*) The gluteus maximus aponeurosis is divided along the same line in T-fashion, the lower part of the incision exposing the subgluteal bursa and trochanter. In the upper part, the interval between the tensor fasciae femoris and gluteus medius is found, and the anterior edge of the latter muscle clearly defined.

(*c*) The next step is the separation of the great trochanter with its muscular insertions intact. A broad osteotome is driven obliquely through the base, flush with the upper surface of the femoral neck. The detached bone is turned upwards and held aside.

(*d*) The joint capsule is now visible on its upper aspect, and the margin of the acetabulum can be demonstrated. The capsule, often contracted, thickened and adherent, is opened up and the cavity inspected. It is now easy to dislocate the femoral head, or to trim off a deformed head in situ as in the operation of arthrodesis or excision.

(*e*) The intra-articular stage of the operation completed, the deeper part of the wound is closed. The trochanter is reattached by pegging or suture, either in its old position or at a lower level on a newly prepared surface. The gluteal aponeurosis is sutured accurately and the skin closed.

A more limited exposure of the hip joint can be obtained without detachment of the trochanter. The complete operation, however, is admirably suited for arthrodesis, arthroplasty, excision of the head of the femur, and indeed for all reconstructive procedures in adult patients.

4. *Posterior Approach.*—The patient is placed on the table as for the postero-lateral route.

The skin incision begins below the posterior superior spine, runs obliquely down to the trochanter, and then along the line of the femur. The fibres of

[1] Brackett, E. G.: Boston Med. & Surg. Jour., Feb. 15, 1912, Vol. clxvi, No. 7.

the gluteus maximus are split and the gap opened up. The joint capsule may be exposed at this stage, between the pyriformis and glutei. Additional room is afforded by peeling off the attachments of these muscles to the trochanter (Kocher[1]), or by cutting off the trochanter itself.

This approach, introduced by Kocher for excision of the hip joint in tuberculous arthritis, has been largely supplanted by the postero-lateral and Smith-Petersen routes.

RECONSTRUCTIVE EXCISION OF THE FEMORAL HEAD

This operation has achieved well deserved popularity during recent years, as applied to chronic painful affections of the hip joint. It is practised more especially in (a) osteoarthritis and (b) old fractures of the femoral neck with non-union (Whitman[2]).

(*a*) *Technique.*—The postero-lateral approach is the method of choice. The mushroomed femoral head is cut off, leaving a rounded stump to the now shortened neck. This stump is rendered smooth by filing and may be coated with a layer of wax. The trochanter is reattached at a lower level on the femur, in order to increase the length of the femoral neck, and provide a more efficient abduction leverage. The stump of the neck is brought deeply into the acetabulum by abducting the hip.

(*b*) *After Treatment.*—The limb is immobilized with the hip in abduction and negative rotation, and traction is applied, either by weight extension or with the patient on an abduction frame. At the end of three weeks the traction is discontinued, and gentle active movements begun. A weight bearing caliper splint is fitted by the eighth week and the patient allowed to get up. The caliper is worn for a few months, and during that time efforts to mobilize the joint by appropriate physio-therapeutic manoeuvres are continued.

The operation above described is ordinarily a safe procedure for comparatively elderly patients.

ARTHROPLASTY

The technique of this procedure was first perfected by Murphy[3] and later by Baer.[4]

The title *arthroplasty* is best limited to those reconstructive operations for true ankylosis in which the new joint is fashioned after resection of the area of fusion. In certain forms of arthritis this may be a dangerous experiment, as there is a risk of opening encysted areas of disease. The complete arthroplasty operation is often a severe test of the endurance of the patient, and although a stable joint may result, the range of movement is not always adequate. For these reasons, in many of the operations practised to reproduce mobility in an ankylosed hip, the pseudarthrosis has been wisely constructed some little distance from the old joint.

In bilateral ankylosis, where it is imperative to mobilize *one* hip, a very full range of motion must be obtained even at the expense of stability. For this purpose an extra articular pseudarthrosis is ideally suited.

[1] Stiles, Harold J.: Oxford Loose-leaf Surgery, 1919, ii, Chap. 10, 233–256.
[2] Whitman, Royal: Surg. Gyn. & Obst., June, 1921.
[3] Murphy, J. B.: Jour. Amer. Med. Assn., May 20–27, 1905, June 3, 1905.
[4] Baer, W. S.: Jour. Bone & Joint Surg., Vol. viii, No. 4, Oct., 1926.

The joint is exposed after detachment of the trochanter (postero-lateral route) and the line of fusion between femur and socket is cut through. The femoral head is remodelled and is then covered by a flap of fascia or Baer's membrane. The thickened adherent capsule should be freely excised. The

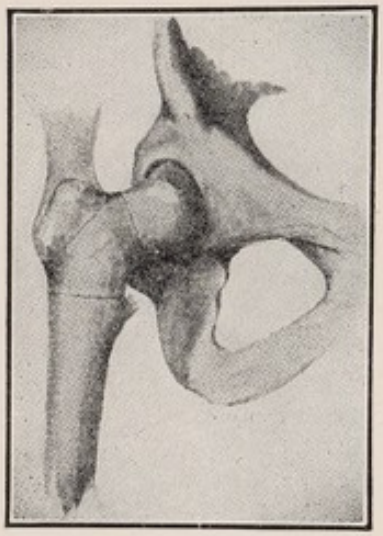

FIG. 84.—Jones' method for pseudarthrosis of the hip.

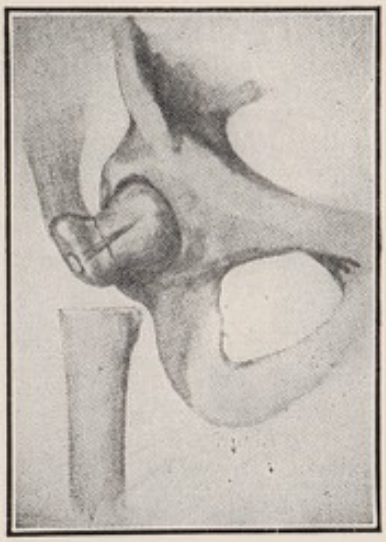

FIG. 85.—Jones' method for pseudarthrosis of the hip.

closure of the wound and the after treatment follow the same routine as for excision of the femoral head.

EXTRA-ARTICULAR PSEUDARTHROSIS

(below the joint level)

Amongst the methods practised with considerable success are the following:

(*a*) *Operation of Sir Robert Jones.*[1]—This was first introduced as a safe method of treating painful osteoarthritis in older and feeble individuals. The hip is approached from the lateral aspect, the trochanter detached, and a considerable segment of the femoral neck including its base is excised. The joint itself is left undisturbed. The trochanter is now pegged on to the distal raw surface of the neck. A very mobile but comfortable pseudarthrosis results. For some months after the operation a caliper is worn. (Figs. 84, 85, 86.)

(*b*) *Operation of Girdlestone.*[2]—The technique followed by Girdlestone also ensures a freely movable nearthrosis. The main features are:

(i) The complete femoral neck, with a portion of the shaft, is removed.

(ii) The raw surface of the head is covered by two fibro-periosteal flaps previously elevated from the neck.

(iii) The great trochanter is pegged or sutured to the raw upper end of the shaft.

(*c*) *Sub-trochanteric Nearthrosis.*—A useful pseudarthrosis may also be constructed below the trochanter, but the muscular control over such a "joint" is often less effective (Fig. 87). This operation is performed when there is a large mass of bone or cicatricial tissue around the head and neck of the femur.

[1] JONES, ROBT.: (from Binnie's Operative Surgery).

[2] GIRDLESTONE, G. R.: "Tuberculosis of the Hip," Oxford University Press, 1925.

Knee.—Stiffness of the knee joint from causes not resulting in ankylosis has been discussed above. Ankylosis in deformity as a result of disease or

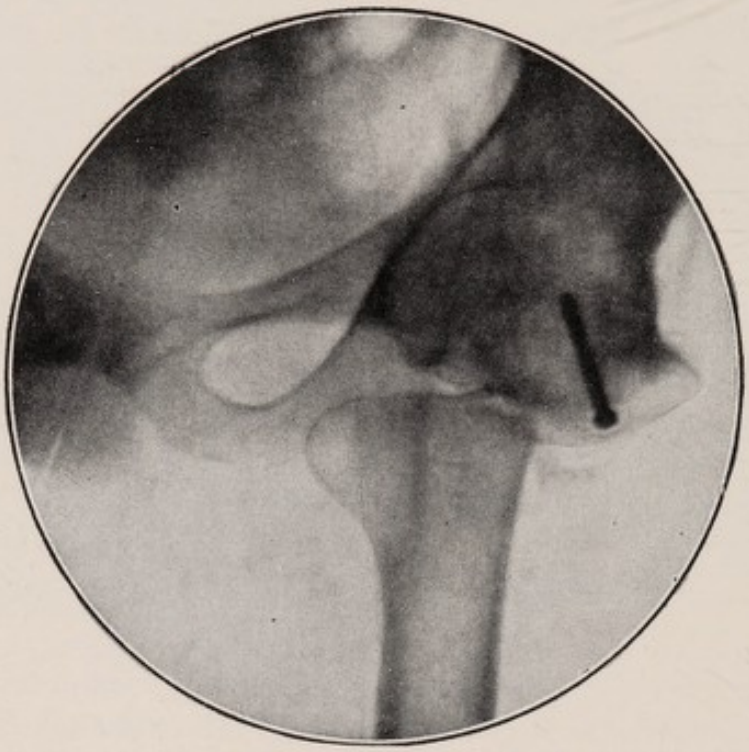

FIG. 86.—X-ray of Jones' method for pseudarthrosis of the hip.

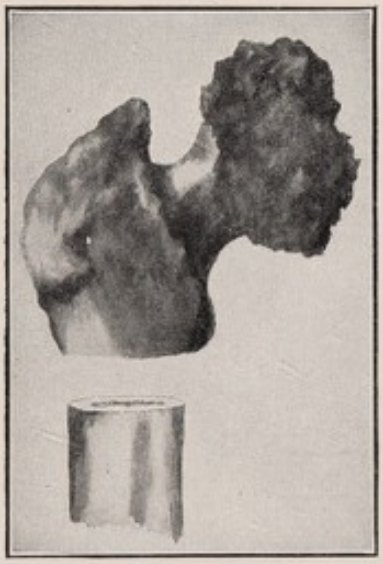

FIG. 87.—Removal of portion of femur to produce pseudarthrosis—muscle flap laid between.



FIG. 88.—Caliper splint for protection of knee joint.

trauma is usually in flexion. In children early treatment of the deformity is most important, especially as too long a delay is likely to cause recrudescence

of the disease whether tuberculous or septic. For the correction of deformity at the knee in children, the Thomas bed knee splint as described (Fig. 62, p. 81) or the wedging plaster may be used.

In adults the same measures are available, but operation to straighten the knee is often desirable either, the classical operation, or the operation devised by one of the authors.

Correction of Knee Ankylosis in Bad Position.

Excision of Wedge.—The most suitable operation for this consists in the excision of a wedge so constructed that when the knee is extended, the bones come into firm contact. Most of the wedge is derived from the femur and the bones remain in an excellent apposition, needing but little extraneous support.



Fig. 89.—Wedge arthrodesis of knee joint.

A "U" shaped incision is made over the joint, starting at the adductor tubercle and sweeping down over the upper margin of the tubercle of the tibia, and horizontally across the leg, then upward to the inner side. If one wishes to utilize the patella, the patellar tendon is divided and the whole flap turned up; if the patella is adherent, it must be chiseled away. A small wedge extending through four-fifths of the thickness of the femur is now removed. It is dangerous to divide the bone completely, for if the tibia is displaced backward, the popliteal vessels are in danger, an accident which has occurred to many careful surgeons. This can be avoided by making the apex of the sawn edges converge half an inch or more from the posterior surface of the bone. The joint is flexed and fractured, and the rough edges of bone trimmed by saw and chisel. It is best not to remove too much bone from the femur at the outset, but to take away thin slices with a saw in order to avoid hyperextension. If very much flexion existed before operation, it is advisable to keep the knee slightly flexed for a few days after operation to avoid strain on the popliteal vessels, as slight stretching may produce serious trophic disturbances. If the patella is utilized, a thin section of bone is removed from its articular surface, and the patella is inserted into a place prepared for it on the anterior surfaces of the femur and tibia (Figs. 89 and 90).

Osteotomy.—If there is some motion in the knee joint, but full extension is not allowed, femoral osteotomy is indicated so that the limb can be brought into the extended position through the movements already existing in the joint; it is also indicated in genu recurvatum, in genu valgum, and in genu varum. When the operation is performed for genu recurvatum the femur should be allowed to ankylose in slight flexion. Femoral osteotomy may be performed by open incision or subcutaneously with a chisel. Open incision is of advantage if the lower end of the femur is thickened or irregular from old inflammatory lesions.

Arthroplasty of the Knee.—The credit of placing arthroplasty of the knee upon a surgical basis is due to J. B. Murphy, who operated upon a number of cases with varying results. Many cases operated upon by various surgeons

have been examined by the authors, and in the larger proportion the joint would have been much more useful if it had been left alone. In a few the results were satisfactory, resulting in moderate stability—in others, the knee joint could be moved as in a ball and socket joint.

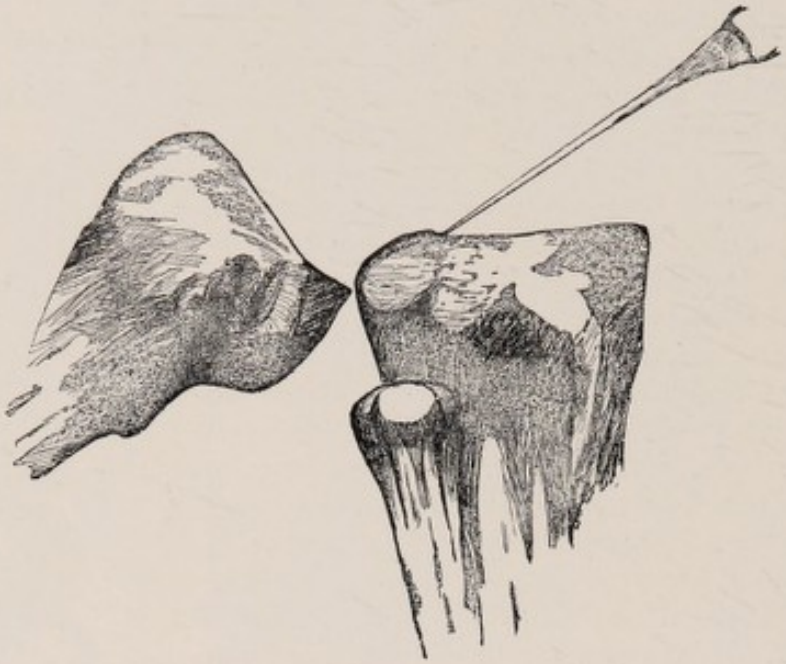

FIG. 90.—Wedge arthrodesis of knee joint.

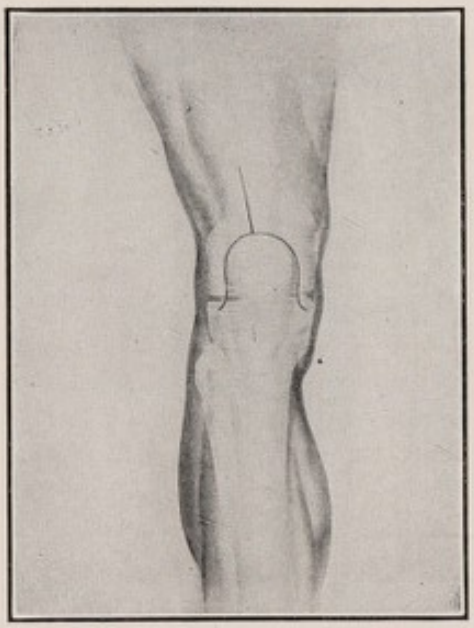

FIG. 91.—Putti's operation for arthroplasty—tracing and relation of the cutaneous incision (Putti).

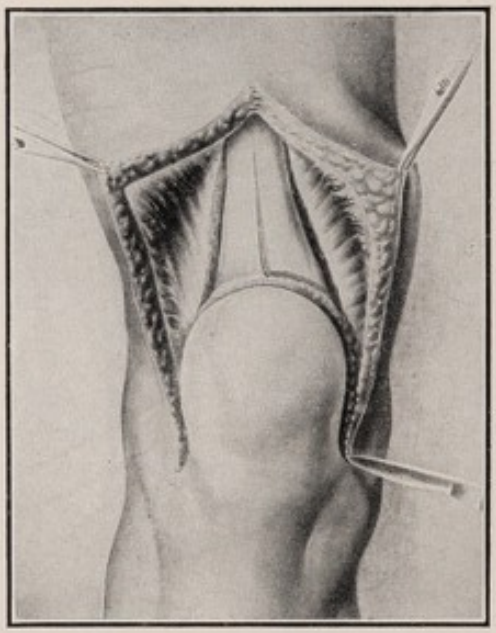

FIG. 92.—Isolation of the quadriceps tendon from the insertion of the two vasti. Z incision of the superficial layer of the quadriceps tendon (Putti).

PUTTI'S OPERATION.—In the last few years Putti, of Bologna, has much improved the technique and has thus placed the operation on a better footing. The best results have been obtained in ankylosis following gonorrheal arthritis, infective arthritis, or injuries,

when all traces of the primary disease have disappeared. It is agreed that old tuberculous joints should not be mobilized by operation.

Putti has shown that the patients should be carefully selected; only those who are willing to co-operate in the after treatment, which involves considerable discomfort, are suitable. The operation is contra-indicated in children or old people.

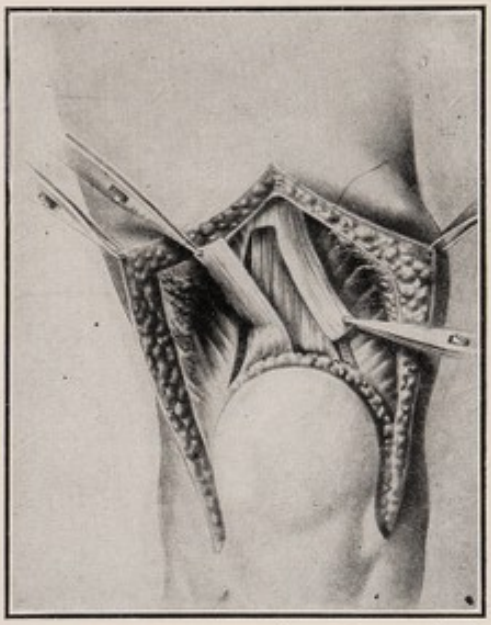

Fig. 93.—The superficial layer of the tendon has already been cut. Below it the deep layer, which is made up of the crural tendon, appears (Putti).

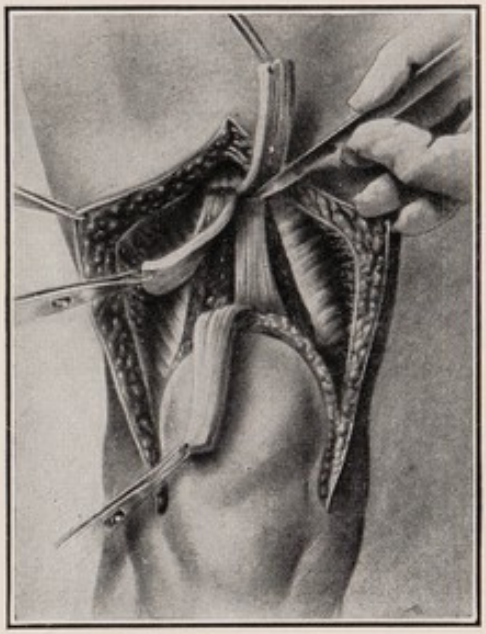

Fig. 94.—Z incision of the crural tendon. The separate incision of the two tendinous layers is superfluous in arthrotomy for ankylosis or resection; while it is indicated every time the opportunity offers, in the reconstruction of the joint, of putting the two tendinous layers in different degrees of tension (Putti).

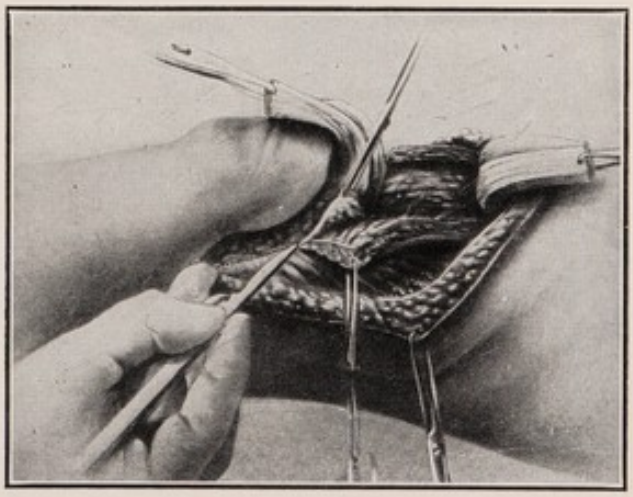

Fig. 95.—Incision of the lateral ligaments of the patella and of the arch-shaped fibres, without going beyond the line of separation of the joint.

The technique is shown in the illustrations (Figs. 91 to 99). A full arthrotomy, with displacement of the patella, is required. After cutting through the ankylosis, the bone ends are reshaped accurately and smoothed by filing. The femoral and tibial surfaces are covered by free flaps of fascia lata. The capsule is carefully sutured and the rectus femoris restored.

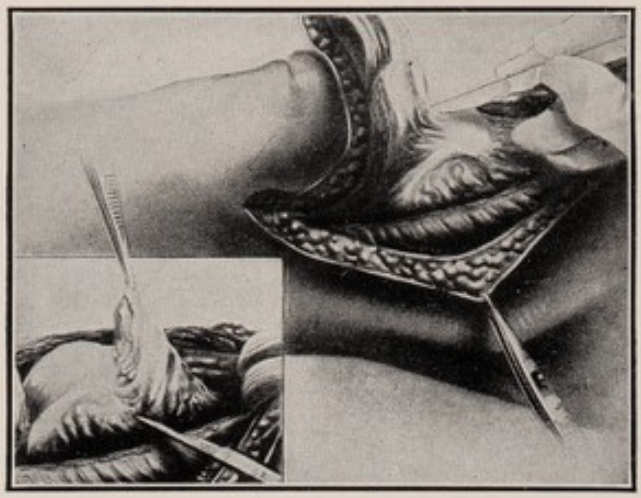

FIG. 96.—Separation of the connection between the femur and patella (Putti).



FIG. 97.—With the knee flexed, a complete view of the joint cavity (Putti).

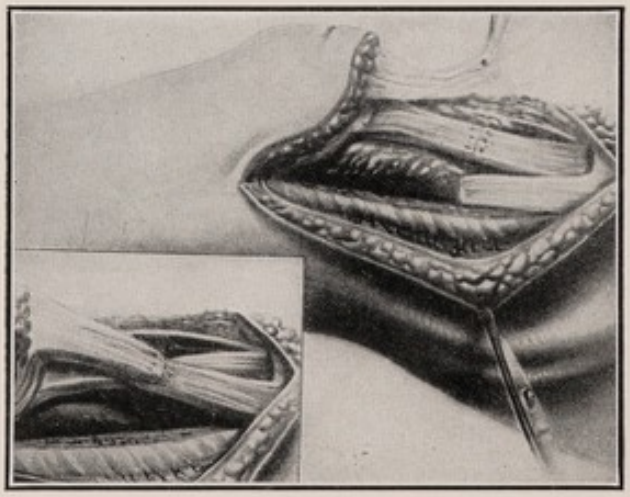

FIG. 98.—Reconstruction—separate suture of the two layers of the quadriceps tendon. The deep layer is sutured in less tension than the superficial (Putti).

From these descriptions it will be seen that the operation requires the greatest operative skill and a thorough knowledge of the principles governing after-care. It would be a tragedy if it were lightly undertaken or practised by surgeons of average experience.

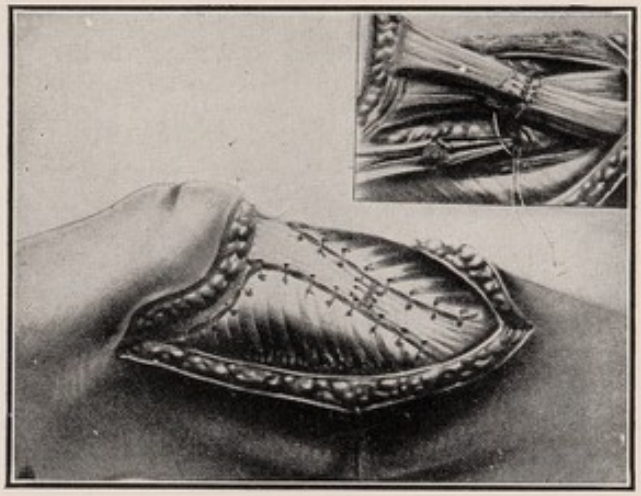

FIG. 99.—Suture of the bellies of the two vasti to the quadriceps tendon. In the drawing the suture is represented as an interrupted suture, while in practice, continuous suture is more convenient (Putti).

The authors are of the opinion that the operation of pseudarthrosis of the knee is still on trial, and that therefore, although good and even brilliant results may be attained in the hands of an expert craftsman, much further experience is needed before a successful issue can be predicted; hence it behoves surgeons to approach the problem with the greatest sense of responsibility, always bearing in mind that a sound, painless ankylosis is infinitely to be preferred to an unstable joint.

Ankle Joint. *Fibrous Ankylosis.*—This occurs as a result of injury, septic infection, tuberculosis, and other causes, and if painless and in a good position, should of course be let alone. Deformity is usually present in plantar flexion, and in certain cases, if the ankylosis is unsound the ankle may be forced into position by means of the Thomas wrench, followed by some weeks of fixation. A *bony ankylosis* gives a very useful foot if the position is correct.

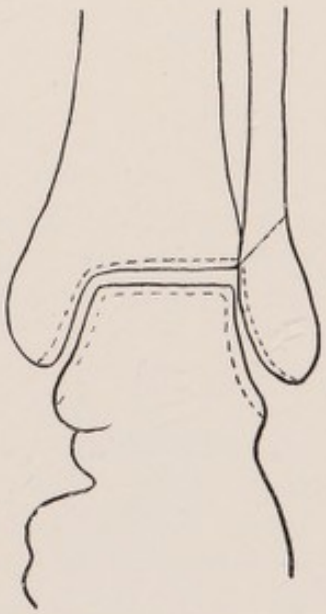

FIG. 100.—Goldthwait operation for arthrodesis of ankle.

For transforming a fibrous into a bony ankylosis, the joint is exposed by a longitudinal incision five or six inches long at the outer side of the tibialis anticus. The nerves and vessels are retracted outward and the tissues raised in order to give a good exposure of the joint. A broad arthrodesis gouge, following the articular surface, removes all cartilage and about one-quarter of an inch of bone. Both malleoli are bared where they articulate with the astragalus, this area also being denuded of cartilage, and the tendo Achillis should be elongated if necessary. To insure ankylosis, the suggestion of

Goldthwait should be followed and an oblique osteotomy of the lower part of the fibula performed, allowing the malleolus to be pushed against the astragalus, after which the foot should not bear pressure under six weeks.

In *true ankylosis* operation may be practised (1) to correct deformity, (2) to mobilize the joint.

1. *To correct deformity*, a wedge-shaped osteotomy through the front of the ankle joint is the operation of choice. It may be necessary to release the astragalus from the malleoli with a chisel in case they are adherent.

2. *Mobilization* may be achieved in the ankle by removing the astragalus. Pseudarthrosis may also be effected by narrowing the upper part of the astragalus and interposing fascia. These operations are very rarely advisable.

CHAPTER VI

TUBERCULOSIS OF JOINTS

Etiology. *Age.*—Joint tuberculosis is pre-eminently an affection of childhood. In something over 5000 cases of tuberculous disease treated at the Ruptured and Crippled Hospital[1] seven-eighths of the patients were less than 14 years of age.

In 1259 cases of spinal tuberculosis 85 per cent of the children were in the first decade, and 50 per cent were from 3 to 5 at the beginning of the disease. The figures for hip joint disease in 1000 cases were practically the same. In 1000 cases of knee joint disease three-quarters of the children were in the first decade, and 40 per cent from 3 to 5. In the ankle joint 70 per cent were in the first decade, and about one-third in the first 3 years of life, but the affection is rare before the age of 2. One of the chief reasons that this occurs so frequently in early middle childhood is that this is the active period of epiphyseal growth when the neighborhood of the epiphyses is largely supplied by blood.

Location.—The fact that the lower extremity is affected so much more often than the upper is very suggestive of the influence of weight-bearing and traumatism as a cause of the disease. A table published by Judson[2] is of much significance. In a series of cases taken from the Children's Hospital Orthopedic

TABLE[2]

Lower Extremity		Upper Extremity	
Hip	558	Shoulder	7
Knee	207	Elbow	16
Ankle	64	Wrist	3
Total	829	Total	26

Clinic there were 47.2 per cent affections of the lower extremity, and 1.3 per cent in the upper. In a series from the Vanderbilt Clinic and Hospital, treating both children and adults, the lower extremity was affected in 56.6 per cent of the cases, and the upper in 3.1 per cent.

Trauma.—The influence of trauma[3] has been much discussed. It has been shown experimentally that in animals rendered tuberculous, injured joints become the seats of tuberculous invasion in preference to normal joints. The preponderance of the involvement of the weight-bearing joints of the lower extremity in childhood favors the theory of frequent traumatic origin. Figures of investigators give widely varying percentages where a traumatic origin seemed established: Hildebrand and others, 16 per cent, Voss 7 per cent, and Ribera,[4] 49 per cent.

On the other hand, children are constantly falling and sustain mild and severe trauma almost hourly, so that it is nearly always possible to find a traumatic history by careful inquiry. And secondly, when the history is

[1] WHITMAN: Orth. Surg., 1917, 253.
[2] JUDSON: Growth and Deformity, 1905, 123.
[3] Literature of subject, Arch. für Orth. und Unfallch., 1906, iv, 4.
[4] KRAUSE and RIBERA: Presse Méd., May 13, 1910.

obtained from parents, they desire, often unconsciously, to avoid the onus of having the affection attributed to heredity, and much prefer a traumatic origin. The pathology, the experimental evidence, the more frequent affection of the lower extremities, and personal clinical experience make the writers feel that the influence of trauma in causing tuberculous localization in a special joint must be recognized, but that percentage figures are worthless.

Hereditary transmission deals with unit characters, which term means in the Mendelian sense that the unit character is transmitted through successive generations in accordance with definite laws. It is unthinkable in terms of heredity that a bacillus like the tubercle bacillus could be transferred in this sense, as, if in sperm or ovum it must be carried as a foreign body, and if from the placenta it takes the case out of the hereditary class and puts it into the congenital. Tuberculosis therefore cannot be transmitted by heredity, and this can be maintained dogmatically. Congenital transmission deals with any infection which occurs to the fetus from the moment of fetalization to birth. In this sense tuberculosis may be congenital, but this must be exceedingly rare. While tuberculous infection cannot be transmitted by heredity and the disease is very rarely congenital, a tendency to the disease in the way of increased susceptibility may be transmitted; but a family history of tuberculosis exists so often that too much importance must not be attached to it, and the disease must be looked upon as in any event due to an infection, except for the very rare congenital cases, which may be omitted from consideration. Moreover, it must be remembered that tuberculosis of joints does not arise unless tuberculous organisms exist in the body, and the writers feel that a most profitable line of effort to be adopted by those dealing with these affections is to *prevent* the *entrance* of these organisms into the body.

Prophylaxis of Bone Tuberculosis in Children.—No question is more important in connection with bone tuberculosis in children than a consideration of how it may be prevented or minimized. It must be remembered that bone and joint tuberculosis is a secondary manifestation, and generally secondary to infection of the lymphatic glands of the abdomen and mediastinum.

Of the three varieties of tubercle bacillus only two need to be considered in the present connection—the human and the bovine—the avian, which is found most frequently in chickens, as well as in pigeons, pheasants, and guinea fowl, may be omitted from this consideration. Bovine tuberculosis in man is usually a disease of the lymph nodes or bones, and the portal of entry is usually through the tonsils or small intestines.[1]

Bovine and Human Tuberculosis.—Valuable data have been collected establishing the ratio of bovine and human forms of the bacillus in surgical tuberculosis in the human being, and there are certain very suggestive figures. In Edinburgh in children under five, something more than one-half of the cases are reported as bovine, in children from five to sixteen about one-quarter, and in adults sixteen years or over about one-twentieth, the remainder being human.

	Bovine	Human	Total
Under 5	80 (78.4 per cent)	22 (21.6 per cent)	102
Between 5 and 16	45 (70.3 per cent)	19 (29.7 per cent)	64
Above 16	9 (7.8 per cent)	106 (92.2 per cent)	115

Children who were bottle fed on raw cow's milk were tested with tuberculin, and 37.5 per cent reacted. Children fed on boiled cow's milk gave only

[1] Rosenau: "Preventive Medicine and Hygiene," 4th Edition, 165.

15.4 per cent reaction. In 80 cases of tuberculous cervical lymph nodes in children under twelve, the bovine bacillus was present in 88 per cent, and the human bacillus in 12 per cent. These children had been fed on raw milk. The prevalence of bovine tuberculosis in cattle in France is called attention to by Moussu.[1] In 568 cases of pulmonary tuberculosis none showed the bovine bacillus. In cases under five years of age, however, with pulmonary tuberculosis, 15 per cent showed the bovine bacillus.

The most recent figures are those of Stanley Griffith,[2] compiled from an investigation of material from both England and Scotland. It is shown that in children under 10 years of age the *bovine* bacillus is responsible for the incidence of 36 per cent of cases of surgical tuberculosis. In cervical adenitis the bovine infection predominates, but in bone and joint tubercle the human bacillus accounts for the greater proportion. After the age of 10, the incidence of bovine infection is further diminished (17.3 per cent).

Milk.—The tubercle bacillus has been repeatedly demonstrated in the ordinary mixed milk supply of large cities in Europe and America (Rosenau). To the young child this is a most serious menace. The market milk of Chicago was examined, and in 10.3 per cent of 144 samples tubercle bacilli were present in sufficient numbers to infect guinea pigs. In 19 samples of pasteurized milk no bacilli were present. In New York City, in 107 samples, 16 per cent were found to contain them. In Washington, 223 samples showed 6 per cent to 7 per cent containing them, and in another series of tests made by the Bureau of Animal Industry 7.7 per cent. Delépine found in the milk sent by rail to Manchester from 272 farms tubercle bacilli in 9.5 per cent.

Tubercle bacilli are also found in butter. Of 498 samples examined by Swithingham and Newman,[3] 15.2 per cent contained tubercle bacilli. Schroeder and Cotton[4] found that living tubercle bacilli would retain their infective properties for at least 160 days in solid butter when kept without ice in a house cellar. Muller, Washburn, and Doane found that tubercle bacilli could live a year or more in cheese 220 days old.

Modes of Infection.—There are two great sources of human tuberculosis, one being man, and the other cattle. In man, sputum is the main source of human tuberculosis. Whether the human bacillus is usually transferred directly or indirectly, in moist or dry state, by ingestion or inhalation is a matter yet undetermined. It must be remembered that live tubercle bacilli are found in the rooms where tuberculous patients are careless with their sputum, and in one of Cornet's experiments forty-seven out of forty-eight guinea pigs exposed to the dust produced by sweeping a carpet became tuberculous. Crawling infants and playing children are exposed to a special danger of infection, as they are much on the floor and constantly putting their hands to their mouths. Another mode of infection of human bacilli is by the *droplet infection*. These droplets are carried only two or three feet, but under exceptional circumstances may be carried much more, and the frequency with which children are kissed is another mode of infection. Ingestion infection is the mode by which the bovine tubercle bacillus enters the organism, but one is not free from the risk of infection this way with the human organism. In 259 fatal cases in the Hospital for Sick Children in London, Still concluded

[1] Moussu: Bull. Acad. Méd., Paris, October, 1919.
[2] Jour. Path. & Bact. Vol. xxiii, Feb. 1920.
[3] "Bacteriology of Milk," 221.
[4] Bureau of Animal Industry, Cir. 153, 38.

that in 20.5 per cent of the cases the infection had occurred through the alimentary canal, and Shennon in 316 autopsies at the Royal Hospital in Edinburgh found this to be 28.1 per cent.

Rosenau says: "There is now sufficient proof to state definitely that tubercle bacilli, when taken in food or drink, may pierce the mucous membrane of the digestive tube and produce lesions in distant parts of the body."

Immunity.—The human body is capable of taking care of a certain amount of infection without the development of clinical tuberculosis. The dosage, its virulence, along with the resistance of the individual are the determining factors. "In man the balance between immunity and susceptibility is delicately adjusted. There is a very small factor of safety."[1] Decreased resistance to tuberculosis is a matter of which we have no definite knowledge, but experiments upon anaphylaxis in guinea pigs have shown that hypersusceptibility to a foreign protein, such as tuberculin, may be transmitted from mother to young.

The prevention depends upon two lines of effort—public measures, sanitary and administrative, and personal precautions. That tuberculosis is on the decrease in England, Wales, and in Massachusetts is established.[2] In the matter of prevention from human tuberculosis, contact with suspects and diseased persons, adults or children, is of the highest importance, and babies especially should be immediately separated from adults with this disease. The discharge from sinuses is likely to contain tuberculous organisms, indiscriminate kissing is to be discouraged, and children should be taught the importance of washing their hands before eating, and keeping their hands out of their mouths, as early as is practicable. The most important matter with regard to the prevention of tuberculosis in children centers around the question of obtaining proper, non-infected milk.

The proper inspection of cows, with segregation of doubtful cases is essential, and as cows develop tuberculosis in a short time, tests at regular intervals of three months are required. "Fake" tests are of two kinds—(1) plainly fraudulent, and (2) the immunization of infected cows before testing by doses of tuberculin given before the test. Infected cows should be slaughtered, and cleanliness in the collection of milk and its transport are obviously necessary. In Great Britain although infected meat is destroyed and tuberculous cows are not allowed to be used for food, the far greater evil of milk infection which remains can be avoided by the slaughter of the cow. A grave responsibility rests on a government which will permit the child to drink tuberculous milk.

Unless the child can be assured of pure milk it should not be allowed to drink it unless it is sterilized. Whatever the statutory requirements in these respects, the figures given show that the milk supply of large cities is infected in most cases, and safety to the individual results from pasteurization, which should be done in all cases. It is proper that mothers who refuse to nurse their own children should appreciate the risks to which they are exposing their children by changing them unnecessarily to cow's milk as a food, a risk which is not avoided by putting them upon the artificial substitutes in patent foods, which are so commonly a cause of malnutrition, rickets, and scurvy.

The public in general is ignorant of these facts, and in the opinion of the writers no more useful form of activity can be found than that of making these

[1] Rosenau, M. S.: Loc. cit., 177.
[2] Rosenau, Loc. cit., 182.

facts known and pleading for adequate regulations and laws. The experiments concluded by Fraser and Mitchell under the auspices of Sir Harold Stiles prove conclusively that both bovine and human tuberculosis could be stamped out in the young by insisting on effective control of the milk supply, and by separating a tuberculous parent from the offspring.

Pathology.—Tuberculous joint disease after the initial stage is essentially a low grade infection with a strongly destructive tendency and as a rule little formative bone activity. Of all forms of joint disease it is the most purely destructive. In the majority of cases, tuberculosis of joints arises, especially in children, in the articular end of the bone rather than in the synovial membrane. As a bone disease it is, moreover, always secondary to a focus elsewhere, most often in the bronchial or abdominal lymph nodes. The pathological lesion may be focal, but more often, by the time it gives rise to symptoms it is more or less general involving the cancellous bone as well as the synovial membrane. The original focus appears as a small tubercle or collection of tubercles made up of epitheloid cells with or without giant cells. These epitheloid cells are characteristic of tuberculosis and it is by their presence that tuberculosis is identified in the tissues. The process extends along the line of least resistance, which is generally toward the joint. Joint involvement occurs from contiguity and joint symptoms do not exist until the focus is near enough to the joint surface to cause reaction of the synovial membrane. At first the synovitis may be non-tuberculous, in which case it arises from irritation, and not from the specific organisms, but these soon enter the joint which speedily becomes tuberculous. The synovial membrane now becomes thickened, reddened, and tuberculous, and is soon covered with ulcerations, while a thickened layer of tuberculous synovial pannus creeps in over the cartilage, which under this covering growth becomes fibrillated, softened and destroyed, or the cartilage may become separated from the bone and flake off, leaving the tuberculous bone underneath exposed. The capsule thickens and the ligaments may also become involved, while periarticular swelling occurs. As a result of the muscular spasm, which will be spoken of, the softened ends of the bones are crowded together and worn away, and all the factors are at hand for complete destruction of the joint if the process is not checked. It may, however, be checked at any stage of the process. The broken down bone in the articular end of the shaft may melt down into purulent material, or it may become cheesy and inspissated, or in rare cases a sequestrum may form.

Repair.—Repair of tuberculous joints occurs when the resistance of the individual predominates over the infection. It originates in the granulation tissue which surrounds the tuberculous areas and encapsulates or absorbs it. The caseous contents of the joint may be largely absorbed, and the inspissated remainder replaced by fibrous tissue or encapsulated and surrounded by it. Where the joint surfaces are destroyed they may be bound together by fibrous tissue causing fibrous ankylosis, which later may be converted into cartilage or bone, causing cartilaginous or bony ankylosis.

Abscesses.—Tuberculous abscesses (cold abscesses) occur from an overproduction of broken down material, and are composed of serum, synovial fluid, caseous material and detritus derived from the coalescence and destruction of the tubercles, so that grossly the abscess contents consist of thin watery purulent material containing clots or thicker material indistinguishable from pus macroscopically. As a rule these abscesses originate from the bone rather

than primarily from breaking down of the other joint structures with perforation of the joint capsule. They are lined by a thick friable vascular tissue formerly known as pyogenic membrane, and do not originally contain pyogenic organisms, to which they become liable if very superficial or if present in an infecting neighborhood, as when near the rectum. The ordinary cold abscess is not accompanied as such by rise of general temperature or leucocytosis, and surface heat is absent. Tubercle bacilli are hard to find in the contents but inoculation from the abscess contents into a guinea pig demonstrates the nature of the process. Under favorable conditions many of these abscesses become absorbed.

It is frequently impossible to make a clinical distinction between two different types of these tuberculous collections. These types are either *residual*,

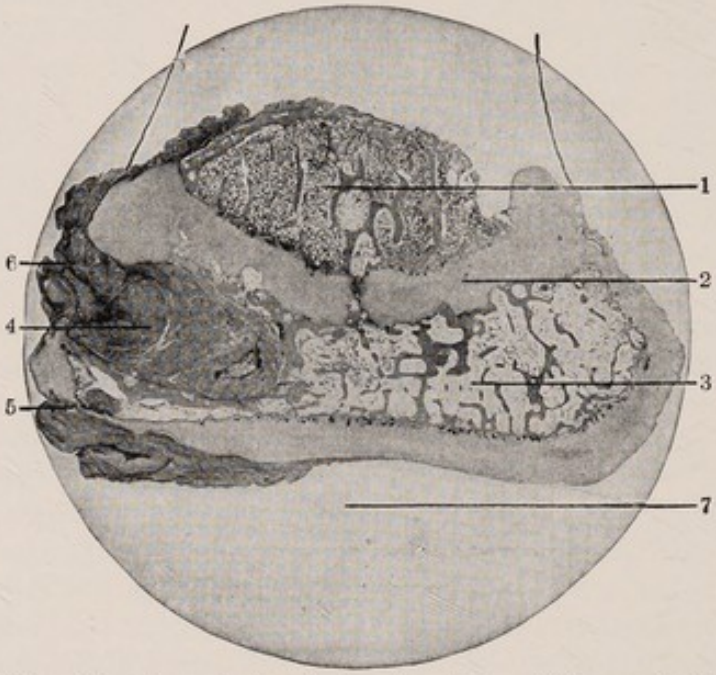

FIG. 101.—Vertical section through the diaphysis, epiphyseal line, and epiphysis of the upper end of the radius, from a case of tuberculosis of the radius. 1, Diaphysis, normal marrow and trabeculæ; 2, epiphyseal line; 3, epiphysis; 4, tuberculous focus in epiphysis; 5, perforation of joint cartilage from the side of the bone; 6, perforation of the epiphysis at the point of attachment of the capsule; 7, joint cavity. (Nichols.)

where they are the result of a burned out process, or they are *active*, being constantly fed from the focus of disease with which they are connected, a distinction of importance in making a prognosis and formulating treatment. An abscess, however, may occur during any stage of the disease and may arise without pain and persist for many months. A very large proportion of these collections spontaneously disappear by absorption and the writers would estimate that over fifty per cent disappear under the influence of rest.

The active collection of pus is likely to be associated with the acute stage of the process in the joint. The X-ray shadow shows imperfect repair, the disease is manifestly acute, and the fluctuation likely to be increasing. In these cases it is reasonable to suppose that the collection of pus is being actively fed from the joints with detritus and the purulent material which goes to make up its contents. These collections are the ones that are not likely to subside after being evacuated. The residual abscesses properly speaking,

where the active flow of purulent material has ceased or diminished in large part, occur later in the disease, are not apt to be associated with acute local symptoms, do not show a tendency to increase, but rather to diminish, and the X-ray picture of the joint should show indications of repair. A very interesting feature in connection with tuberculous abscess is that it frequently becomes cut off from the joint. This occurs very frequently but is especially uncommon when located in the upper outer thigh. Even after becoming isolated an abscess may increase in size.

Symptoms.—By means of this simple statement of the pathological process we are able to account for the clinical phenomena to be found in tuberculous joint disease, phenomena which are in no wise essentially different from those of joint inflammation of a very chronic type.

When once the synovial membrane is involved, synovitis occurs, the symptoms of which are—(1) swelling, including in addition to the synovial membrane both the capsule and periarticular structures, (2) effusion of a thick and gelatinous fluid giving rise to a semi-elastic fluctuation, (3) muscular atrophy which is always present and persists, and (4) muscular spasm which in the early stages is the most important and characteristic sign of all. It must be remembered that these symptoms may occur in non-tuberculous conditions as well, and that further data must be obtained before warranting the diagnosis of tuberculosis.

Swelling.—If disease has its first manifestations in the synovial membrane the swelling is such as may be found in simple chronic synovitis. Later changes take place in the membrane which may be felt and which give to the effusion a less superficial feel. This can best be exemplified by a superficial joint such as the knee. If the pouches be grasped in the hand they are felt to be thickened, and at a later stage masses may be clearly distinguished, especially behind the ligament of the patella.

The swelling which follows tuberculosis orginating in bone is more irregular. In the knee, *e.g.*, the patella loses its outline and becomes limited in motion. Fluctuation although present is less elastic and is limited to compartments. Adhesions form in the synovial membrane, early, so that the pouches lose their outline. Later the effusion disappears and the remaining swelling is tense and inelastic. Similar changes occur in the deep joints but cannot be so easily distinguished.

Spontaneous pain, and *pain on attempted motion* are frequent, but not pathognomonic. Although the disease in general, especially in the hip, is in most cases accompanied by pain and occasionally a great deal of pain, it must be remembered that in a good many cases no pain is present, and that in the spine for instance, the existence of a marked kyphos is frequently the first symptom noticed. Pain, therefore, is not a regular symptom, although it is often present, and the surgeon must not be misled by its absence.

Shortening of the limb on the affected side occurs from two causes—(*a*) retardation of growth, because bone as well as muscle atrophies in long continued disease, and (*b*) destruction of bone at the joint surfaces and at the epiphyses. In certain rapidly growing epiphyses, however, as in the knee, they are stimulated to abnormal growth by the continued hyperemia around the epiphyseal line, and lengthening of the limb may occur.

Deformity.—In the acute stage this is due most often to muscular spasm, the stronger muscles overcoming the weaker, but in the later stages it is also to be

attributed to muscular and ligamentous shortening, to bony destruction, or to ankylosis in faulty position. Protective spasm is at first occasional and sometimes even partially voluntary. It soon becomes constant and is very shortly accompanied by adaptive shortening. This is followed by contraction of all the structures which are kept shortened. A contracted muscle represents a muscle in temporary contraction; a muscle in contracture is shortened structurally and permanently. The conditions of "*contraction*" and "*contracture*" soon overlap and it will be found that in nearly all deformities of a fixed character an element of spasmodic contraction coexists. Great care and gentleness are required, especially in the case of children, to detect the degree of spasm. It can only be done by securing the confidence and cooperation of the patient.

Diagnosis.—The characteristics of tuberculous joint disease then, wherever situated are much the same, a chronic affection, destructive when long continued, with but slight bone formative tendencies. It is characterized by swelling, atrophy of muscle and bone, and especially muscular spasm, resulting at times in night cries, pain and sensitiveness, at others with scarcely any or no pain, and also in malposition of the limb. Abscess formation, the result of breaking down of tissue, is common, but tubercle bacilli are not always easily found in the fluid. Pyogenic organisms are absent except where there has been a mixed infection.

Blood examination is negative and leucocytosis is not present as a rule.

The *primary focus* elsewhere in the body may or may not be identified, but should be looked for, remembering that there is evidence that other foci most often exist in connection with surgical tuberculosis. In 216 cases of surgical tuberculosis Peterka[1] found evidence of infection during the first three years of life in 199; König,[2] in 67 autopsies on cases of tuberculosis of the bones and joints found only 14 in which he could identify no other forms of tuberculosis.

Proof of Tuberculosis.—The symptoms described, however, may exist in part or as a whole in other affections, and the only *real proof* that a given case is tuberculous rests on (*a*) identification of the organism of tuberculosis in abscess contents or in the walls of abscesses, (*b*) the histological identification of the disease in tissue removed at operation, and (*c*) positive results from the inoculation of guinea pigs with material from the wound or abscess.

Von Pirquet Skin Test.—A positive reaction to the Von Pirquet skin test in a child under twelve years who has no obviously enlarged lymph nodes in the neck, axillæ, groin or abdomen, or other signs of active tuberculosis, should make one suspicious in a doubtful case, but it is far less valuable than the negative test and only suggestive but never conclusive by itself, while a negative reaction is unusual in the presence of joint tuberculosis. This statement rests on about 1500 observations on children from the orthopedic service of the Children's Hospital in Boston, of which 250 have been reported.[3] Cases of all sorts were examined for tuberculosis in this way as a routine including consecutively, rickets, club foot, poliomyelitis, etc. In cases having clinical evidence of tuberculosis either in bone or soft parts only 3 per cent gave a negative skin reaction. About 14 per cent gave positive reactions when there was no clinical evidence of tuberculosis either in bones, cervical lymph nodes or any other accessible structure. The proportion of positive reactions in the

[1] Beitr. z. klin. Chir., 1912, viii.
[2] Deutsch. Chir., 1900, l, 28A, 157.
[3] Robertson: Boston Med. and Surg. Jour., Apr. 2, 1914.

apparently non-tuberculous cases under four years was 10 per cent; four to eight years, 14.5 per cent; eight to twelve years, 17.5 per cent. It was evident that enlarged cervical nodes generally gave a positive reaction and in other reactions it was assumed that bronchial or intestinal nodes were probably the cause. It must be remembered how frequent is the existence of unrecognized tuberculosis in children. Ganghofer in 2713 autopsies on children dying of infectious disease found tuberculous disease in 20 per cent, and in 769 autopsies on children at the Great Ormond Street Hospital, Still found tuberculous lesion in 269.[1] On the other hand in 460 cadavers studied by Reinhart, he found in the bodies under sixteen less than 30 per cent evidence of tuberculous infection as compared to 96 per cent in those of adult age. The Pirquet test does not distinguish between the tuberculosis of human or bovine origin, the reaction being practically always the same to inoculation from bovine and human tuberculin.

The *history* of the patient's illness as obtained from parents, is notoriously unreliable in children; in adults it is entitled to consideration. The diagnosis is best made from the physical signs.

Accompanying the local condition described there are certain *general signs and symptoms.*

Loss of weight and retardation of general growth are common in children preceding the outbreak of symptoms, but in some cases a child gains weight while disease is active, which is doubtless due to fresh air, feeding, etc. *Elevation of temperature* in the afternoon is almost universal in children and adults in the acute stage, except in the lightest cases.[2] Elevation of temperature in the afternoon was observed in about 250 consecutive observations on children undergoing ambulatory treatment or before treatment was begun at the Out Patient Department of the Children's Hospital, Boston. During the acute period of the disease the afternoon temperature ranged between 100° and 102°, and it was noted in early cases where the joint symptoms were comparatively slight that elevation of temperature was generally present. The observations were chiefly on tuberculosis of the spine and hip, and the existence of abscesses or sinuses was not necessary to cause elevation of temperature. Control observations were made on the brothers and sisters of the patients and were with one exception normal. When the children with elevation of temperature were put to bed in the wards of the hospital as a rule their temperatures fell to practically normal. The elevation of temperature in cases which had been for some time quiescent, in most instances proved to be a sign of unfavorable progress, and when the subacute stage was over the temperature as a rule became normal. Just as in pulmonary phthisis, activity during the period of temperature elevation is considered inadvisable, so in tuberculosis of the joints rest is indicated when the temperature is elevated.

X-ray Appearances.[3]—In the earliest stages the X-ray is generally negative. As a rule the first change noted is atrophy shown by increased radiability of the affected joint, and then appears a patch of diminished density in the bone, generally ragged, or an irregular notching out of part of the joint surface. With further progress, the bone becomes poor in lime, the joint outlines become soft and furred, and displacement of joint surface may be found. In the spine

[1] Brit. Med. Jour., Aug. 19, 1899.
[2] Lovett: Boston Med. and Surg. Jour., Apr. 17, 1890.
[3] Lovett, R. W., and Wolbach, S. B.: Surg., Gyn. and Obst., August, 1920, 111–131.

the erosion of the bodies is the first noticable change and should always be studied in an X-ray taken from the side.

So far as X-ray appearances go the process is destructive and atrophic with little reaction of bone about the focus, and with little or no formative bone activity in the acute stage; but tuberculosis of bone is sometimes formative and the appearances in such cases are extremely deceptive, so that in some cases the histological or bacteriological examination alone will establish the diagnosis. The fact that bone tuberculosis may cause a local destruction of tissue resembling the "Brodie's abscess" of pyogenic infection must be borne in mind (Figs. 102–106).

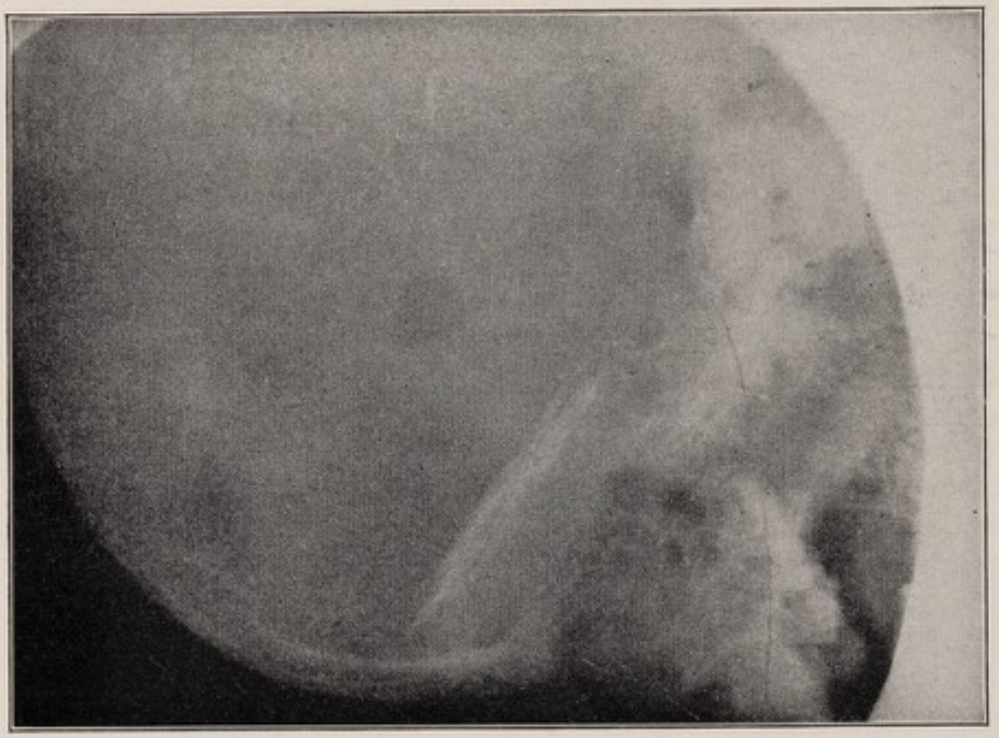

FIG. 102.—Tuberculosis of the skull, showing rare form characterized by round defect; diagnosis based on microscopic examination by Prof. S. B. Wolbach.

Prognosis.—The prognosis as to life depends on the resistance of the individual to the infection. Children resist better than adults and the prognosis in them is much more favorable. Hybrid races like mulattoes have in general poor resistance. The more acute the symptoms at the onset, the worse the prognosis; and high fever, much thickening, a poor lime content in the bone as shown in the X-ray, and great pain make the outlook less favorable. In the average child prognosis as to life is good, except in the acute cases described. The mortality rate for such cases cannot be stated, because with modern treatment the affection has become so much less formidable that the old statistics are no longer representative. In adults the prognosis as to life has also been improved, but it still remains worse than in children. The prognosis as to ultimate function in general depends upon the character and efficiency of the treatment, influenced by the acuteness of the disease, and the resistance of the patient. Nature's cures are almost uniformly poor as to function.

Death results as a rule from generalization of the tuberculosis in the form of tuberculous meningitis, pulmonary tuberculosis or general miliary tuberculosis.

Amyloid degeneration as a cause of death after prolonged suppuration is much less frequent of late years on account of the better understanding of the disease and the greater efficiency of treatment.

Treatment.—The object of treatment is to arrest the disease and to secure the best ultimate function. It is to be divided into general and local.

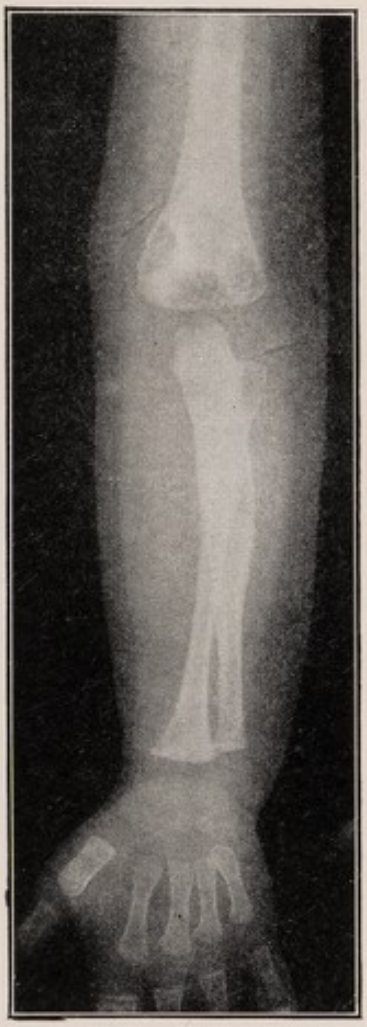

FIG. 103.—Tuberculosis of the lower end of the humerus—diagnosis based on microscopic examination by Wolbach.



FIG. 104.—Bone tuberculosis of the formative type; diagnosis based on microscopic examination by Wolbach.

GENERAL TREATMENT

Rest is desirable so long as the febrile stage continues just as in pulmonary tuberculosis. *Good food* and *hygienic surroundings* are of the utmost importance.

Outdoor Treatment.—Outdoor air has probably produced a greater change in our results than every other general measure put together. It has been possible for one of the writers to obtain certain data from a large school for crippled children at Canton near Boston, Massachusetts, where the outdoor treatment has been followed on a large scale for some years in a climate which in winter is severe and characterized by extremes of cold. In ninety-nine cases of joint tuberculosis, 78 per cent were under weight when admitted, and after an average residence of about thirty months they showed an average gain of two pounds more than the normal gain at that age. The same gain in

height did not pertain. In hemoglobin a gain was made from a minimum of 50 per cent and a maximum of 80 per cent at admission to a minimum of 75 per cent and a maximum of 90 per cent. The prevalence and spread of infectious diseases was low among the children living out of doors.

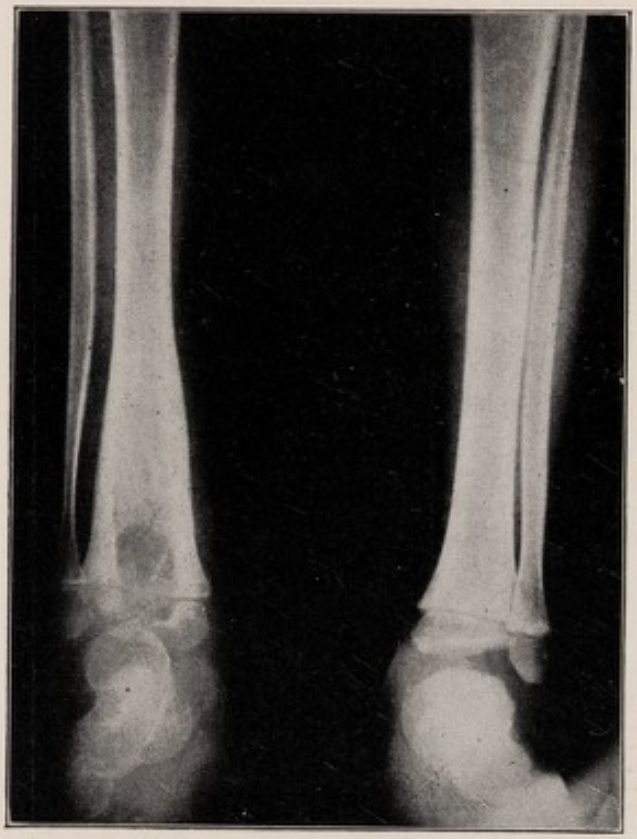

FIG. 105.—Tuberculosis of the lower end of the tibia; diagnosis based on microscopic examination by Wolbach.



FIG. 106.—Osteomyelitis of lower end of tibia; diagnosis based on microscopic examination (compare with Fig. 105).

The effect of the outdoor life on 172 children living at Canton as compared with the health of the children in a model residential boys' school of the best type in the same neighborhood is shown in the following table.[1]

		Boys' School		
Population.	Respiratory Affections.		Coryza.	Sore Throats.
220	Bronchitis.....	23	98 (44.5%)	
				Pharyngitis and tonsillitis.... 113 (51%)
	Catarrhal pneumonia....	7		
	Croupous pneumonia....	4		
220		34 (15%)	98 (44.5%)	113 (51%)

Total 220 boys. 245 illnesses (111.36%).

[1] LOVETT and FISH: Boston Med. and Surg. Jour., July, 31 1913.

CANTON (SCHOOL FOR CRIPPLES)

	Average Population.	Respiratory Affections.	Colds.	Sore Throats.
Infirmary	20	0	0 (0%)	0 (0%)
East Ward	70	0	0 (0%)	19 (23%)
West Ward	82	0	12 (14.6%)	7 (8.5%)
	172	0	12 (14.6%)	26 (22%)

Total 172 children. 3 illnesses (22%).

Children who came to Canton with distinct signs of tuberculous absorption, such as anemia, fever, and poor general condition improved rapidly and lost the symptoms.

The routine in this institution may be described as follows: The dormitories are practically outdoor pavilions, excepting that they are closed and heated for a short time during the evening when the children are put to bed, and in the morning when they are being dressed for the day. By careful regulation of the



FIG. 107.—Open air hospital, Heswall, England.

monitor windows and the direct supply of steam heat, it is possible to prevent the temperature in the wards from falling below 34 degrees Fahrenheit without at any time keeping all sections of the monitors completely closed. From October 15, 1911 to April 15, 1912, the maximum outside temperature was 62 degrees Fahrenheit and the minimum temperature 2 degrees below zero, the average being 31 degrees. Of the eight grades of the school, five were conducted out of doors, provisions being made for outside and inside rooms, the inside rooms being used in severe weather, the outside rooms being covered by an awning which is the only protection afforded. The chief difficulty in the outdoor school problem has been to find teachers who were willing to undertake to teach out of doors through the winter. The children have suffered no inconvenience.

At the Convalescent Home of the Children's Hospital at Wellesley, also near Boston, where the winter climate is severely cold, the outdoor treatment has been used for fifteen years. The children live in open shacks, partially heated at night, and in the entire time there have been but three cases of pneumonia, which occurred in the early years in children who had been operated on for empyema. There have been no frost bites or other complications to be attributed to exposure. When the method of treatment was adopted at the Convalescent Home of the Children's Hospital it is interesting to note that the provision bill immediately increased 30 per cent. The experience of the hospitals has been that children under two or three years old are not safely exposed as described above, being more liable to bronchial affections.

The first hospitals for the complete open air treatment of children were started in England. In 1902 the Baschurch Hospital in Shropshire was founded as a hospital where children were treated in the open air day and night through all weathers and seasons, the buildings being so constructed that there was no possibility of closing the children in. This was closely followed by the Liverpool Country Hospital at Heswall on the estuary of the Dee and by a hospital at Ruislip near London. In none of these hospitals is it possible to close the wards—they are structurally constructed to prevent it. The results of this innovation were anxiously awaited and have now passed the possibility of adverse criticism. Weak and anemic children improve surprisingly in the fresh air, putting on weight rapidly. Infectious disease, the bane of children's hospitals, failed to spread if it appeared. Wounds healed in a way not experienced before. Not a single pulmonary affection has resulted in spite of severe winters, indeed the cold weather has been the most favorable time for improvement. The increased appetite of the child is most marked in all the open air hospitals and must be met by very generous diet. No heating apparatus of any sort is used in the wards. The children have hot bottles to their feet in winter and woolen mittens on their hands. When their wounds are dressed they are taken to a side ward which is not an open one and the only other time they are removed to closed wards is for a few days before and after operations, for preparation and to recover thoroughly from the post-anesthetic stage. The difference in the well-being of these children as compared with those in city wards is quite conclusive, and the writers are convinced that in the future a children's hospital in a town will be looked upon with forebodings. There are now many most excellent hospitals for tuberculous children in Great Britain and the United States.

There are certain precautions to be taken. The patients should wear woolen jerseys, have blankets next the skin and a free supply of hot water bottles. The nurses should be exceptionally well fed and be suitably and warmly clad. They are instructed to dry their hands thoroughly in order to avoid chilblains. The floors of the wards should be made of wood.

Heliotherapy.—The sun treatment is an invaluable adjunct to outdoor air, and in all of these hospitals heliotherapy is an important aid to other methods of treatment, but great care is taken that in joint lesions no relaxation in regard to mechanical fixation is allowed. Rollier has done much to demonstrate the value of heliotherapy. At Leysin in Switzerland, high in the Alps, he maintains an institution which has proven beyond doubt that heliotherapy is of great value in the treatment of surgical tuberculosis. *La Cure du Soleil* by Rollier (1915) gives an admirable statement of the value of heliotherapy. In

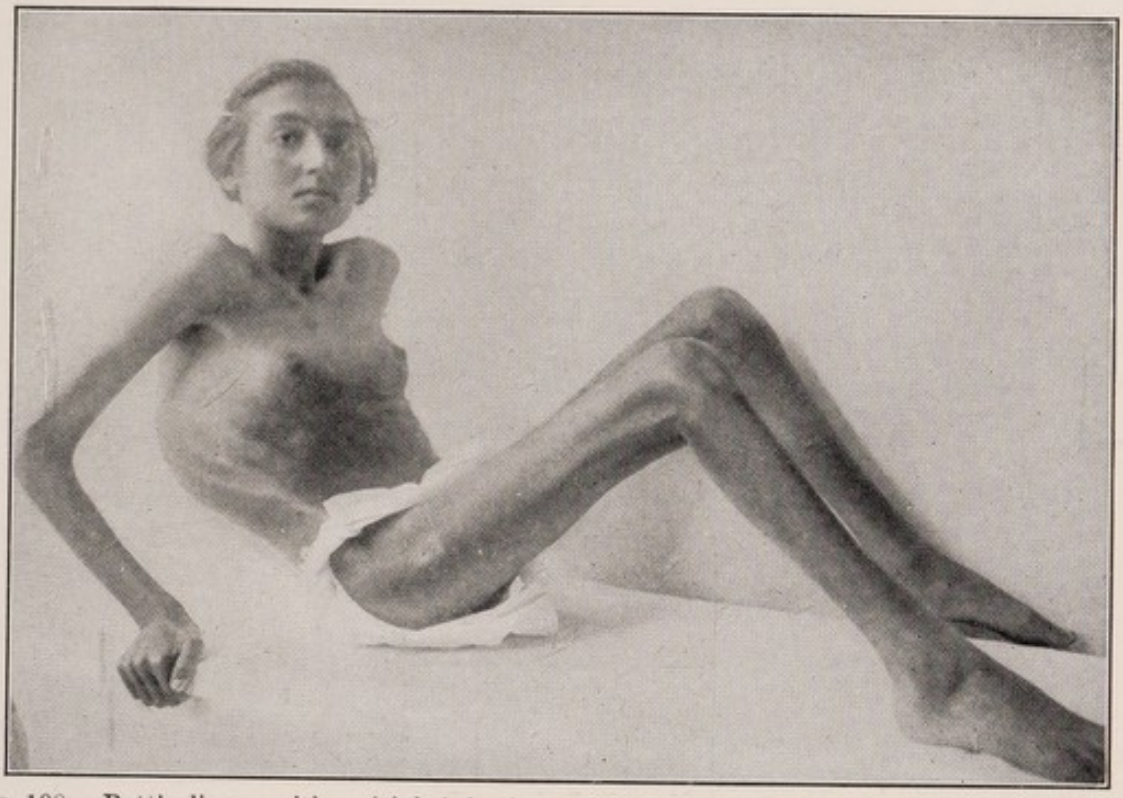

FIG. 108.—Pott's disease with multiple infection and discharging sinuses; also pulmonary tuberculosis (Rollier).

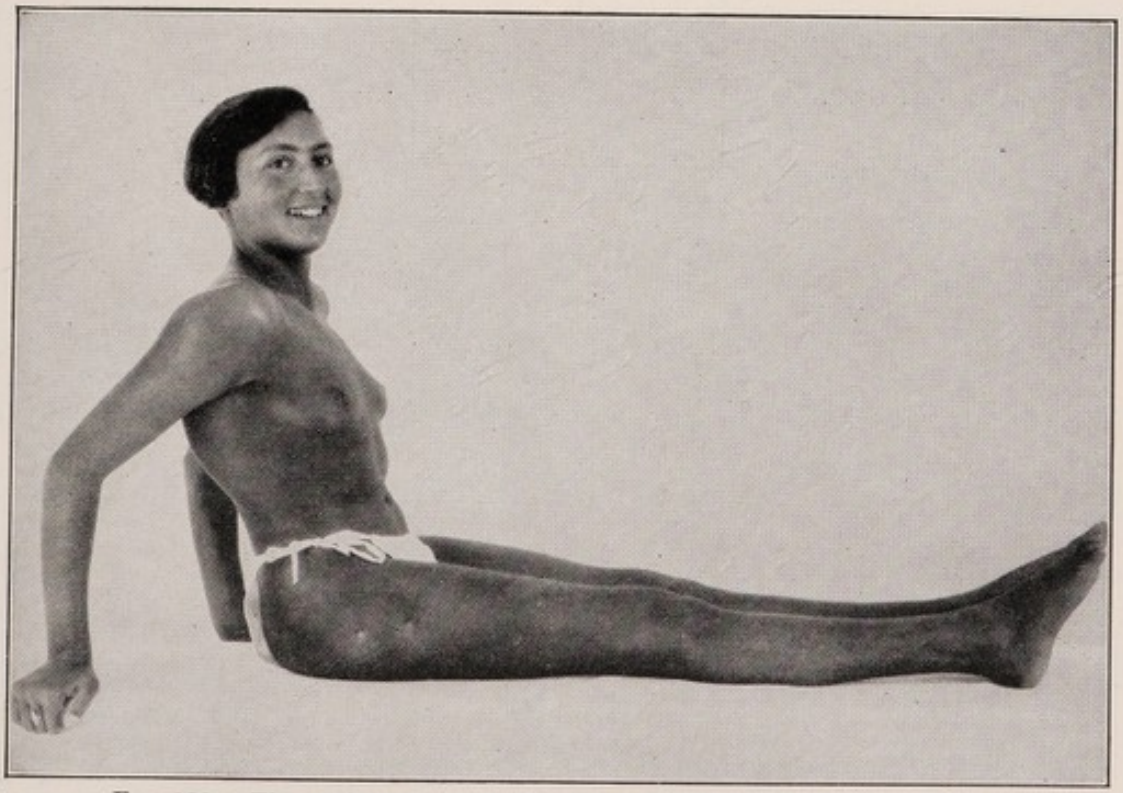

FIG. 109.—The patient shown in Fig. 108 after 18 months' sun cure (Rollier).

the latitude of Boston it has been possible to use this for nine years at the New England Peabody Home for Crippled Children, at the Convalescent Home of the Children's Hospital, and in other American institutions, with marked improvement over the results obtained by outdoor air alone. In England it is in general use in all the open air hospitals. In the Peabody Home the children are exposed naked during the warm part of sunny days from March to November. No pneumonia, no heat stroke, no illness traceable to this have as yet been recorded in the experience of the writers, but it must be used with great care, as sunburn is troublesome and may be dangerous. The skin tans, thickens, and becomes more vascular, and the child establishes an immunity to cold which is surprising. When the treatment ends for the season they become very intolerant of bed clothes and any degree of indoor heat. The following directions have been adopted for the use of heliotheraphy at the Children's Hospital Boston.

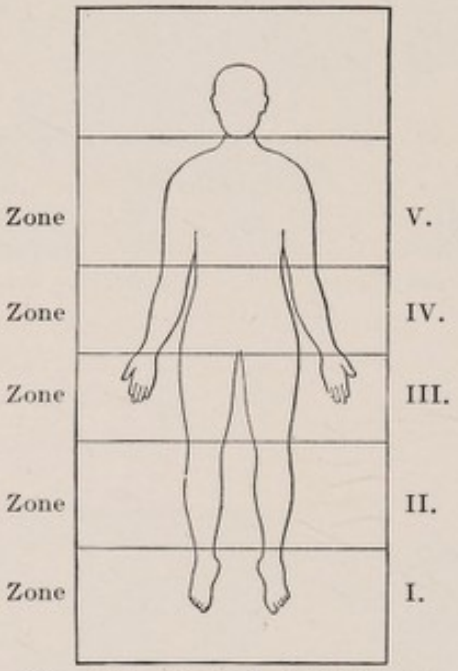

FIG. 110.—Zones for heliotherapy.

RULES FOR SUN TREATMENT

1. Preparation of Patients for Exposures.
   (*a*) Temperatures of all sun patients are to be taken at 11:30 A.M. and 2:00 P.M. Any abnormal increase of temperature shall cancel the next exposure and the House Officer in charge is to be notified.
   (*b*) *Eyes* and head are to be shaded during the exposure with a dark shade.
   (*c*) Loin cloth is to be worn at all times after exposure of Zone III is instituted.
   (*d*) Unexposed surfaces are to be covered.

II. Exposure of patients.
   (*a*) Zones are indicated in outline in the drawing shown (Fig. 110).
   (*b*) Time for exposure of the various zones is to be found in the following table unless changed by special order.

TABLE OF EXPOSURES

	Zone I	Zone II	Zone III	Zone IV	Zone V
Day 1	5 min.				
Day 2	10 min.	5 min.			
Day 3	15 min.	10 min.	5 min.		
Day 4	20 min.	15 min.	10 min.	5 min.	
Day 5	25 min.	20 min.	25 min.	10 min.	5 min.
Day 6	30 min.	25 min.	20 min.	15 min.	10 min.
Day 7	35 min.	30 min.	25 min.	20 min.	15 min.
Day 8	40 min.	35 min.	30 min.	25 min.	20 min.
Day 9	45 min.	40 min.	35 min.	30 min.	25 min.
Day 10	50 min.	45 min.	40 min.	35 min.	30 min.
Day 11	1 hr.	55 min.	50 min.	45 min.	40 min.
Day 12	70 min.	70 min.	60 min.	55 min.	50 min.
Day 13	80 min.	80 min.	70 min.	60 min.	60 min.
Day 14	2 hrs.	2 hrs.	90 min.	90 min.	90 min.
Day 15	2½ hrs.	2½ hrs.	2 hrs.	2 hrs.	2 hrs.

Special precautions should be taken with red headed children and lightly pigmented children—owing to increased susceptibility to burning, and at the slightest sign of sunburn in any child treatment should stop.

Artificial Heliotherapy.—Ultra violet emanations may be produced by means of electrical energy in lamps specially devised for therapeutic purposes. At the present time light therapy for diseases all and sundry is on the crest of the wave of extreme popularity. Its limitations and possible dangers are as yet imperfectly realized, and it is likely that its application will be much restricted in the near future.

Used as a form of treatment in certain types of surgical tuberculosis under inconstant climatic conditions its value is undoubted.

There are many forms of lamp available, the incandescence being produced through the medium of carbon, tungsten, or mercury vapor. The heat waves are cut out by the insertion of an appropriate filter. Careful dosage is necessary as in the use of the sun's rays.

It is now generally agreed that a department for light treatment is a necessary part of the armamentarium of a well equipped hospital dealing with surgical tuberculosis. The most useful installations include—

1 The Finsen lamp

2 The open carbon arc lamp

3 The mercury vapor lamp

Specific Treatment.—Various types of tuberculin have been tried but the results of this and other forms of specific therapy are, on the whole, unconvincing.

LOCAL TREATMENT

Whereas general measures are directed toward increasing the resistance of the individual, local measures are more concerned with the preservation of the joint structure in view of recovering the maximum ultimate function. They are *mechanical* and *operative*.

Mechanical.—There are three measures in general use—(1) fixation, (2) traction, and (3) protection, taking the body weight off the limb (in the lower limbs).

1. *Fixation.*—Fixation is indicated (*a*) by nature in her attempt to splint the joint by means of muscular fixation, and (*b*) by the fact that motion in tuberculous joint disease is dangerous pathologically, because it constantly interrupts the process of repair, which has been described, and because it is directly irritating to the joint. No one with any knowledge of surgery or pathology advocates motion during the acute stage of tuberculosis. The same is true with regard to breaking up joint adhesions in the subacute stage, for if one will reflect on the process of repair it will be seen that it rests upon the substitution of fibrous tissue for irritative tuberculous tissue, a process which obviously demands joint fixation until the tuberculous tissue has been absorbed.

2. *Traction.*—In certain joints, notably the hip, the strong muscles which control the joint are in a state of spasm and tend by their continued contraction to pull the head of the femur against the acetabulum, thus crowding together diseased or irritated surfaces, and if the bones forming the joint are softened they tend to wear away by pressure. Traction proves quieting in the acute stage in the case of the hip and in severe cases of knee joint tuberculosis. This may be maintained by weight and pulley (sliding traction) or by successive stages of fixed traction in a Thomas bed splint. The latter method is based on the theory that a continuous pull upon a limb is a traumatic act; the joint is rested after every act of extension needed for the correction of deformity and muscular spasm soon disappears if the limb is kept from moving.

3. *Protection.*—This measure applies only to the joint affections of the lower extremity. In the convalescent stage of tuberculous joint disease, tuberculous tissue has been replaced by newly formed granulation and fibrous tissue, but this replacement is gradual and included areas of tuberculous material may remain as such for a considerable time. The impact of weight-bearing has an irritating effect upon the diseased tissue or the newly repaired tissue, although it is not so harmful as to and fro movement which causes a stretching of the synovial and periarticular tissues. In the *acute stage* of the disease weight-bearing on the diseased tissue can never be anything but disastrous for the reason that the weight is transferred directly through the diseased structures and in consequence traumatizes these diseased structures.

Operative Treatment.—The views with regard to the place that operation should occupy in the treatment of tuberculous joint disease have varied from extreme radicalism to extreme conservatism. The latter is now the dominant view, although thirty years ago operation of a radical nature was advocated by many surgeons. The pendulum has swung to the opposite point of view until now the experienced surgeon rarely operates on tuberculous joints in children. The reasons for this are not hard to find. The tuberculous invasion is wide spread and extends beyond the limits shown by the X-ray picture, so that any operation which is not unjustifiably radical is incomplete and leaves behind it tuberculous tissue. Experience in the late war has shown that the devitalization of tissue by wounds, operative or otherwise, predisposes to bacterial activity in these tissues. On these two grounds one may explain the exceedingly unsatisfactory results from operative removal of tuberculous bone. Excision of the hip, for example, which formerly prevailed on a very

extensive scale, is now done in children only as a last resort by surgeons of experience. The removal of small foci in and about the hip joint advocated at one time has proved to be an effective way of stirring up joint symptoms, increasing the activity of the process, and generally delaying repair, and is at present little advocated. The fact of the matter is that the invasion of tuberculous bone by the knife, curette, and chisel stirs up the process and does not remove the disease. The excision of tuberculous joints in children has been largely and wisely abandoned. This change is due in part to the fact that we appreciate much more the benefits of general and local measures.

In adults, however, the question is entirely different. The disease is much more active, the pain is often a serious factor, and a treatment reaching over several years is not practicable for a wage earner, who is the head of a family. Under these conditions operation stands on an entirely different basis from that given above. An adult with tuberculosis of the knee joint, for example, in the ordinary case can be cured from four to five months by operation, whereas with fixation it would be a matter of three or four years, and at the best with a stiff joint. It will be noticed in the following chapters that a sharp distinction is made, in comparing the treatment employed in children and adults. This is based largely upon the knowledge that the disease is milder and more tractable in children, and that a type of treatment consisting of prolonged mechanical measures is possible in their case while it is not feasible in the adult. Furthermore in the case of children, growing epiphyses are in contact with all the joints, and the injury of some of them, as in the knee and shoulder, results in extreme deformity. In adults early operation is advocated on account of the destructive tendency of the disease.

Amputation is a legitimate surgical measure to be undertaken when life is threatened or when the joint is hopelessly disorganised.

Treatment of Cold Abscesses.—It must be appreciated that if the abscess is residual and the focus is no longer pouring material into it, it is much more likely to be cured by any procedure adopted than if it is continually receiving reinforcement from an active focus. The same conservatism that holds with regard to the operative treatment of tuberculosis is held in general with regard to the treatment of tuberculous abscesses, and measures for their relief are three—(1) *Expectancy*, (2) *Aspiration*, and (3) *Incision*.

1. Expectancy Under Effective Treatment.—In probably 50 per cent of cases abscesses are absorbed if let alone, and the absorption of such collections is not detrimental in any way to the patient, but is an indication of repair.

2. Aspiration should only be done to relieve excessive tension or where there is fear of spontaneous evacuation and contamination. When aspiration is performed the needle should be thrust not through the thin skin where the abscess is likely to evacuate, but through as sound skin as possible. Aspiration by itself is rarely successful. The abscess soon refills and it must be aspirated again and again, an experience which is not generally satisfactory. The injection of various substances has been advocated following the withdrawal of the fluid. Iodoform has been used in an emulsion with glycerine or oil, 10 c.c. of 10 per cent mixture being injected at intervals. Certain individuals are very susceptible to iodoform and several deaths from iodoform poisoning have been reported, but in general the procedure is safe. The injection of fluids

has been a good deal advocated,[1] but in the experience of the writers the abscesses practically always refill again and again.

3. Incision.—If the abscess fails to absorb after a proper time or threatens to burst, to do damage to surrounding tissues by spreading, or when first seen is so superficial as to discolor the skin, incision is desirable. The best results are to be obtained from a small incision one-half an inch long made over the thinnest part of the abscess cavity. The contents are evacuated and the abscess not squeezed or massaged. The gentlest manipulation of gauze and forceps is made to wipe off the excess of pyogenic membrane, and a thin wick or rubber drain may be inserted in the opening of the cavity for twenty-four hours, never longer, and then withdrawn and a dressing applied, which is disturbed as infrequently as possible. By this procedure many cavities heal which would stay open if the drain were left permanently.

To do the same kind of an operation that one would perform in opening a pyogenic abscess is to do unnecessary traumatism, as it opens up channels of absorption and produces a local disturbance which militates against healing, and in the end it must be remembered that the abscess is not the cause of the disease, but only a by-product to be dealt with in any event, and sometimes purely residual. It seems proper to deal with such cavities therefore in the way least detrimental to the patient.

Opening tuberculous collections of pus invites sepsis, and the wound should be opened and dressed with as much care as one would observe in opening the knee joint or abdomen. Frequent dressings are very hazardous and likely to lead to mixed infection and should be done with the same care and precaution that is observed in the dressing of any clean open wound. The surgeon who cannot provide this should let abscesses alone. There are worse calamities than a spontaneous rupture of an abscess, which in working to the surface creates a protective wall around it. Allowing that spontaneous rupture of abscesses today cannot be regarded as good surgery, it is, however, better than opening abscesses with any precautions short of the most careful asepsis and adequate after-care.

To sum up. Abscesses in the absence of pain and acute temperature should be left alone. If they rapidly enlarge they should be aspirated. If they threaten to rupture they should be aspirated through healthy skin or a very minute opening about one-quarter or one-half inch long is indicated. If the abscess is about to rupture an antiseptic dressing must be applied in anticipation.

[1] Calot: L'Orthopédie Indispensable, Paris, 1909, p. 157.

CHAPTER VII

TUBERCULOSIS OF THE HIP

(Hip Disease, Hip Joint Disease, Coxitis, Coxo-tuberculose)

Pathology.—The initial focus of disease occurs in the large majority of cases near the epiphyseal line of the femur, either above or below it. Primary involvement of the acetabulum is less frequent, but wherever the disease originates, both surfaces of the joint become affected if the process has extended through the synovial membrane.

The hip joint, it must be remembered, is controlled by the strongest muscles in the body, so that the element of intra-articular pressure is very pronounced. As a result of this, and especially under the influence of weight bearing, wearing away of the head of the femur becomes an early and constant feature of hip disease. When the acetabulum becomes involved, its upper edge is often eroded by the upward pressure of the femoral head. This results in the upward extension of the socket, the so-called "wandering acetabulum" (Fig. 112). It is usually not a true dislocation although this sometimes occurs, when the head is absorbed altogether. In the case of a focus in the neck of the femur, spontaneous fracture may result or there may be separation of the upper epiphysis from the shaft so that the head lies loose as a sequestrum in the joint cavity.



FIG. 111.—Head of tuberculous femur. Original focus in acetabulum. 1, Joint cartilage, which has been elevated from underlying bone and is perforated in various places—"pepper-pot" cartilage; 2, neck of femur (E. H. Nichols).

In long continued disease, where the resistance of the patient is poor, the pathological process may rarely extend down the shaft of the femur for a considerable distance. Periarticular thickening is present from the beginning in nearly all cases and in the severe cases constitutes a very dense, brawny infiltration.

Abscesses follow the line of least resistance when they occur, and the line followed is generally at the level of the trochanter, either in front of it or behind it, although they may appear in the groin or buttock, and abscesses of the hip occasionally discharge into the rectum. Although abscesses may at times pass around the femoral vessels, these are practically never perforated.

As a result of the perforation of the acetabulum there may form an intra-pelvic abscess which becomes surrounded by a dense and thickened fascia and

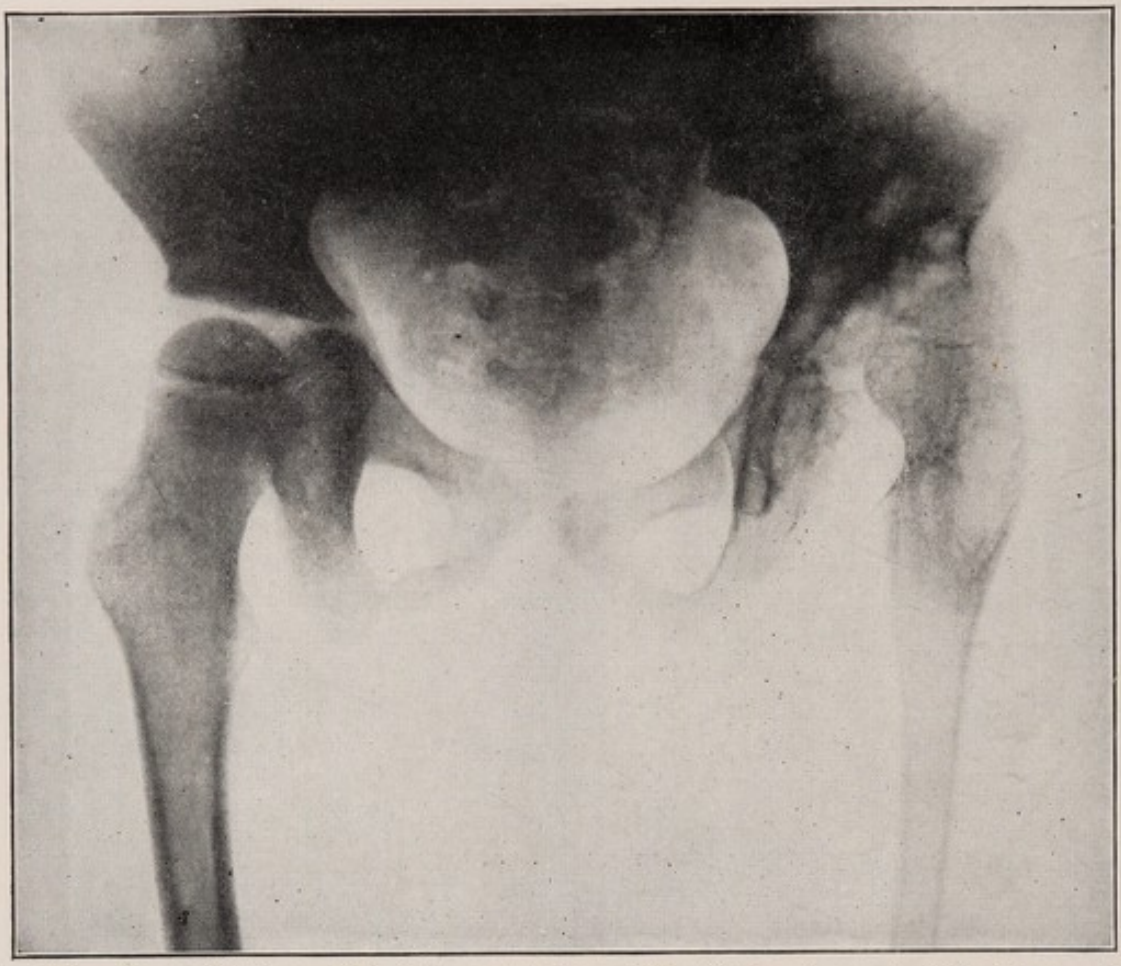

FIG. 112.—X-ray of tuberculosis of the acetabulum with slight involvement of the femur which is displaced upward. "Wandering acetabulum."



FIG. 113.—Specimen showing wearing away of head and erosion of acetabulum (Warren Museum, Harvard University).

can be felt through the rectum as a brawny or fluctuating elevation on the inner pelvic wall. Occasionally such abscesses may simulate psoas abscesses appearing either in the lower abdomen or around the upper part of the buttock.

Symptoms.—Tuberculosis of the hip presents characteristic appearances which may be briefly stated before considering special symptoms. In the case of a child, it may have been noticed that he was out of condition before the appearance of characteristic symptoms, but non-observant parents will not have noticed this. He is seen to limp especially in the morning and to grow better through the day. The lameness varies from day to day and intermissions occur. Night cries may appear early, sleep is disturbed and the

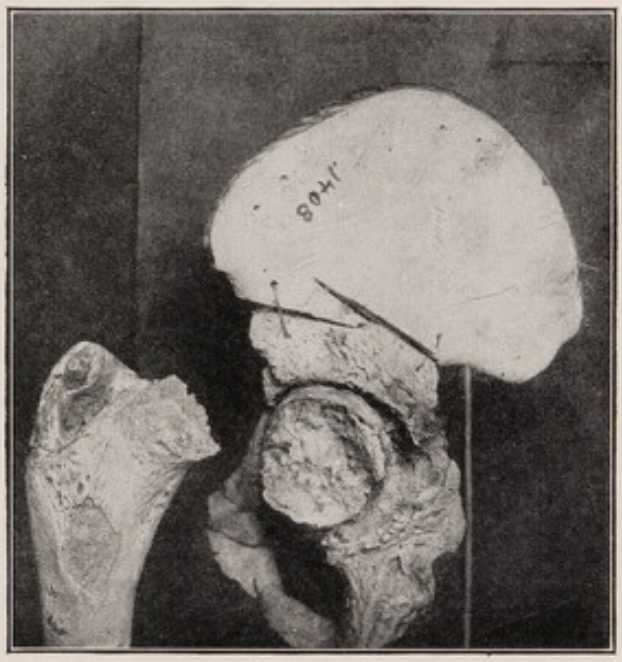

FIG. 114.—Separation of head of femur in tuberculous disease (Warren Museum, Harvard University).

general health is usually impaired. A seriously painful stage may supervene at any time or there may be little pain but increasing stiffness with deformity. As a rule walking becomes difficult or impossible and in painful cases abscesses are likely to appear after some weeks or months.

There are in the main three types: (1) A rapid and severe type, acute and painful from the beginning, rapidly destructive and characterized by much swelling, early abscess formation, marked general deterioration and much pain. (2) The average and commonest variety is accompanied by moderate pain and deformity, late abscesses if any, and not much marked general impairment. (3) A slowly progressive form with little pain, but with marked deformity and stiffness, going on without grave bone change for many years. This type causes little real destruction of bone but is very resistant to treatment.

In young adults the picture is somewhat different, for the symptoms are more acute and pain is likely to be the first symptom, whereas in the child lameness generally attracts attention first. As a whole the process is more acute, more rapid and more destructive in the adult but tuberculous coxitis after middle life (senile tuberculosis) may run a somewhat indolent course.

The symptoms of tuberculosis when manifested in the hip are modified in large measure by the anatomical considerations already presented (p. 7).

Swelling and Increase of Fluid.—These are not conspicuous in the hip on account of its inaccessibility to palpation, but can be identified by the trained finger as a deep circumscribed resistance over the anterior surface of the joint, which does not exist on the other side. There is apt to be some general periarticular thickening shown by pinching up a fold of skin over the trochanter on both sides.

Muscular Atrophy.—This is marked from the onset and is of much diagnostic value. It occurs in the muscles of the buttock, thigh and calf but is proportionately greater in the thigh.



FIG. 115.—Ankylosis of hip in flexion and adduction—the result of tuberculosis (Warren Museum, Harvard University).

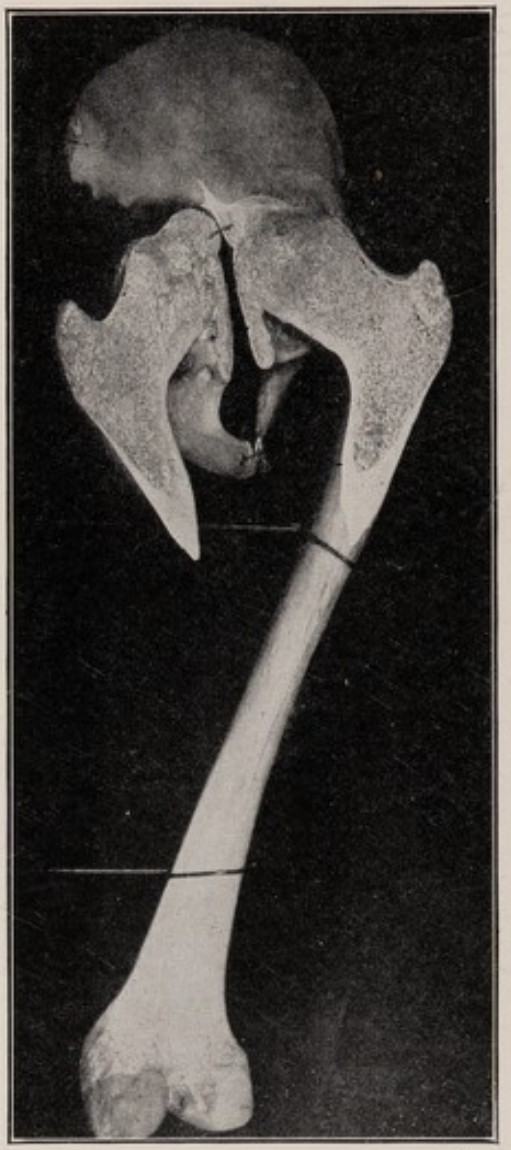

FIG. 116.—Ankylosis of the hip, showing the disappearance of all joint structure and continuity of bone (Warren Museum, Harvard University).

Muscular Spasm.—The hip joint, because of its universal mobility, exhibits more clearly than any other the phenomena of muscular spasm in the early stage of disease. The least involvement of the hip joint by tuberculosis results in limitation of motion in all directions. In the early stages the limitation of hyperextension, abduction, and rotation is most readily demonstrable.

During sleep the muscular spasm disappears but may return with full force if, by a movement of the limb, eroded joint surfaces are suddenly brought together. Under such conditions the patient awakes with a cry and severe pain is felt in the hip or knee. Night cries do not occur in the early stages of hip disease.

Pain.—Pain is a common symptom, but is not universal and many children experience little or no pain throughout the disease, although this is less likely to be the case in adults. Pain is most often felt down the anterior surface of the thigh or in the knee, and is a referred pain, in the distribution of the obturator and anterior crural nerves. Persistent pain under treatment is an indication that the disease is not progressing satisfactorily, or that treatment is not efficient. When severe pain occurs in children one should always suspect the formation of an abscess under tension.



FIG. 117.—Severe flexion and adduction deformity on left side in untreated case.

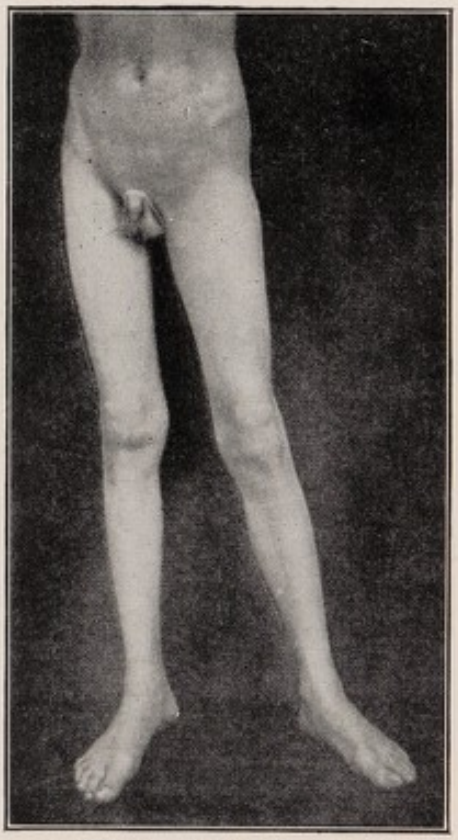

FIG. 118.—Ankylosis of left hip in abduction, from tuberculosis.

Sensitiveness.—Sensitiveness on manipulation varies from a degree where it is painful to jar the bed, to that which allows the hip to be manipulated with reasonable force without discomfort.

Lameness.—This is of five types: (1) *Pain in weight-bearing.* When the affected leg is put down, the patient flinches and hops quickly on to the other leg. (2) *Flexion limp.* In putting weight on the diseased leg the body bows forward from the hip as if someone pushed the shoulders forward. (3) In *adduction* the leg is practically shortened, and the lameness is most evident from the front in a lurch of the pelvis at each step. (4) *Abduction* causes practical lengthening and the leg is carried out from the middle of the body in walking, and some lurching of the pelvis is evident from the front. In both adduction and abduction it will be noted in walking that the angle between the leg and pelvis remains the same on the affected side at all parts of the walk. In the normal it changes throughout the step. (5) *Shortening.* The patient

drops the pelvis on the affected side and leans towards that side as he steps on the short leg. As a rule more than one deformity exists and the resultant gait is therefore modified by each element.

Temperature.—Observations on a series of cases have proved that there is generally a rise of temperature during the afternoon. If the rise is marked the presence of secondary infection may be suspected and should be searched for.

The phenomena which require special attention in connection with tuberculosis of the hip are shortening and deformity.



FIG. 119.—Old tuberculosis of the hip, showing sinuses and shortening of left leg.

Shortening.—This appears in nearly all cases of the disease, if long continued, even where there is no considerable bony destruction, and is due to the retardation of growth which apparently is a trophic change. In more serious cases the shortening is the result of epiphyseal involvement, the wearing away of the upper part of the femur and the upper edge of the acetabulum, destruction of the head and pathological dislocation (Fig. 113). If the disease is long continued and severe, the muscular pull causing an impact of the bones may erode the upper edge of the acetabulum and the diameter of the cavity is extended upward, which results in an elevation of the trochanter above Nélaton's line. After the disease has ended, the leg resumes a more normal rate of growth, but where the destruction has been extensive it does not grow as fast as the other. The amount of shortening depends in a measure upon the degree of involvement of the epiphysis, but we must remember that the upper epiphysis is not so important in relation to growth as the lower one. Excessive amounts of shortening are usual in neglected cases and are largely due to displacement upward.

The term "shortening" as applied to the lower extremity is used in two senses and much confusion often originates in the use of the two terms.

REAL SHORTENING.—(Actual shortening—bony shortening.) Real shortening is used to designate a diminution in the distance between the anterior-superior spine of the ilium and the ankle and is due either to arrested growth, bone destruction, or partial or complete displacement of the head from the socket. It is measured by a tape from the tip of the anterior-superior spine to the tip of the internal malleolus on the same side. In the normal individual the two legs when at the same angle to the pelvis should measure within one-eighth to one-quarter inch of each other. This small variation exists in the majority of normal individuals.[1] For measurement the patient should lie with the legs parallel or at the same angle to the pelvis, because the actual distance from the iliac spine to the malleolus is lengthened by adducting the leg, and shortened by abducting it.[2] The point of measurement is eccentric to the point of motion, and variation in length must occur, which would not be the case if the point of motion and of measurement were the same.

[1] MORTON: Phil. Med. Times, July 10, 1886.
[2] GARSON: Jour. Anat. and Phys., 1879, xiii, 502.

Apparent Shortening.—This is measured from the umbilicus to the internal malleolus of each side. If neither leg is adducted nor abducted, and there is no true shortening as shown by the measurement above described, there will be no apparent shortening. But if the right leg, for example, is fixed in an adducted position, the patient in standing or walking must get the legs parallel, which he can only do by raising the pelvis on the adducted side and lowering it on the other, employing the normal lateral mobility of the lumbar spine. A measurement from a point in the midline, such as the umbilicus, will show the adducted side shorter than the other, because that leg has of course been carried up with the right side of the pelvis and the left carried down. These changes are spoken of as "apparent" shortening, and "apparent" lengthening.

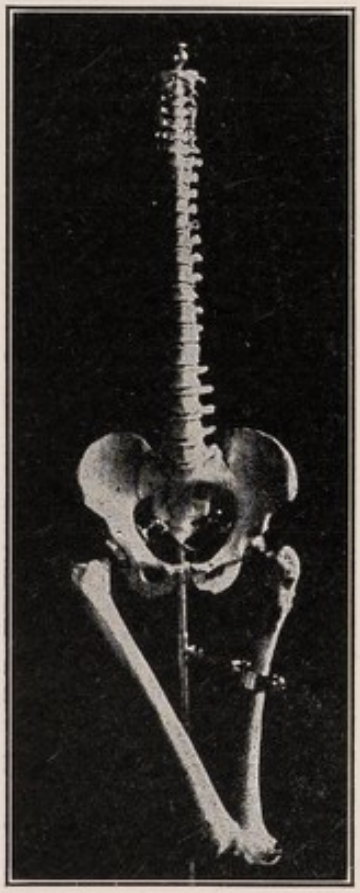

Fig. 120.—Adducted right hip (Wollenberg).

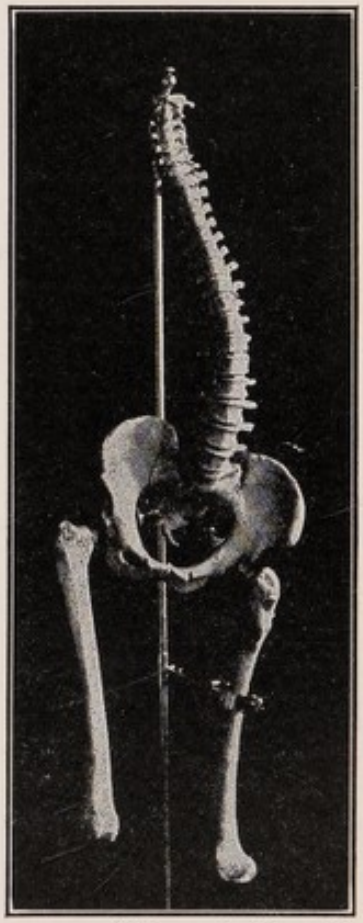

Fig. 121.—Adducted right hip with legs placed parallel and pelvis raised on right, causing apparent shortening of right side if measured from the middle line of the body (Wollenberg).

It may therefore be formulated that deformity in adduction causes "apparent" shortening, and deformity in abduction "apparent" lengthening. By a calculation based on trigonometry a table has been constructed enabling the amount of adduction or abduction to be stated in degrees.[1] In the use of this table the difference in inches between the real and apparent shortening is measured and recorded, and the distance in inches between the anterior-

[1] Lovett: Boston Med. and Surg. Jour., July 5, 1888.

TABLE I

Difference in inches between Real and Apparent Shorting.	Distance between anterior superior spines in inches																	
	3	3½	4	4½	5	5½	6	6½	7	7½	8	8½	9	9½	10	11	12	13
¼	5°	4°	4°	3°	3°	2°	2°	2°	2°	2°	2°	2°	2°	1°	1°	1°	1°	1°
½	10	8	7	6	5	5	4	4	4	4	4	4	4	3	3	3	3	2
¾	14	12	11	10	8	8	7	7	6	6	5	5	5	4	4	4	3	3
1	19	17	14	13	11	10	9	9	8	7	7	7	6	6	6	5	5	4
1¼	25	21	18	16	14	13	12	11	10	9	9	8	8	7	7	7	6	6
1½	30	25	22	19	17	15	14	13	12	12	11	10	10	9	9	8	7	7
1¾	36	30	26	23	20	18	17	15	14	13	13	12	11	10	10	9	8	8
2	42	35	30	26	23	21	19	18	16	15	14	14	13	12	12	10	10	9
2¼	..	40	34	30	26	24	21	20	19	17	16	15	14	14	13	12	11	10
2½	..	..	39	34	29	27	24	22	21	19	18	17	16	15	14	13	12	11
2¾	..	..	..	38	32	29	27	25	23	21	20	19	18	17	16	14	13	12
3	..	..	..	42	35	32	29	27	25	23	22	21	19	18	18	16	14	13
3¼	..	..	..	..	39	36	32	30	27	26	25	22	21	20	19	17	15	14
3½	..	..	..	..	..	40	35	33	30	28	26	24	23	22	21	19	17	16
3¾	..	..	..	..	..	..	38	35	32	30	28	26	25	23	22	20	18	17
4	..	..	..	..	..	..	42	38	35	32	30	28	26	25	23	21	19	18

If the apparent shortening is greater than the real shortening the diseased leg is adducted, if less than the real shortening it is abducted.

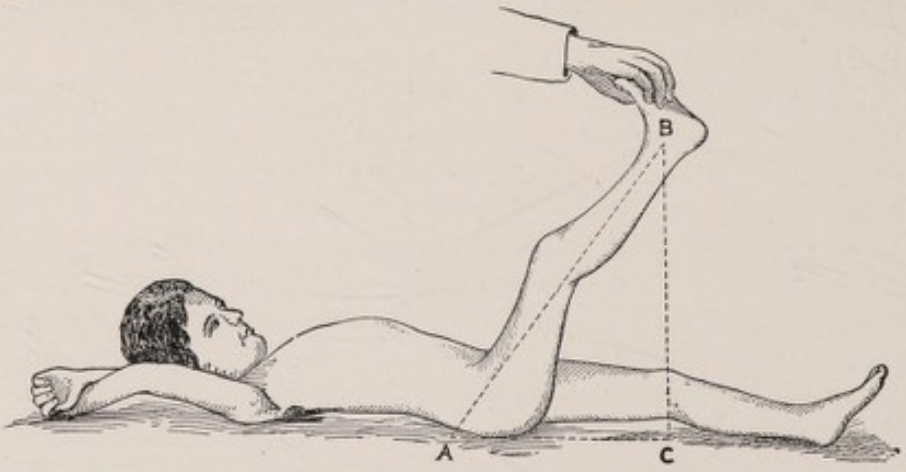

FIG. 122.—Estimation of flexion in tuberculosis of the hip (Bradford and Lovett).

superior spines of the ilia measured and recorded, and in the table, where the lines which contain the figuers obtained cross, the existing amount of adduction or abduction in degrees will be found.

For instance, if the length from the anterior-superior spine to the malleolus of the right leg is twenty-three inches and of the left leg is twenty-two and one-half inches and the length from the umbilicus to the malleolus in the right leg is twenty-five inches and in the left is twenty-three inches, the *difference* between the real and apparent shortening is one and one-half inches. To make the calculation of the angle of deformity a base line must be established, which base line consists of the distance between the two anterior-superior iliac spines. In the case given the distance between the anterior-superior spines



FIG. 123.—Slight flexion deformity of the left hip.

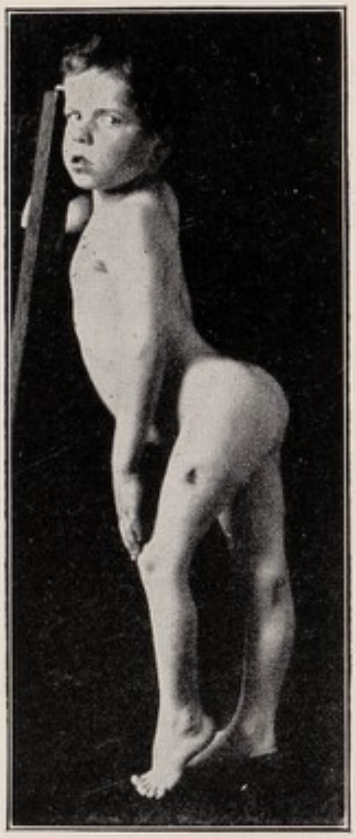

FIG. 124.—Severe flexion deformity of the left hip.

is seven inches. If we follow the line for one and one-half inches differences in the measurement of length until it intersects the line of the pelvis measurement of seven inches, we find 12 degrees to be the angle of deformity. As the apparent shortening is greater than the real, the leg is abducted and the reading shows that there are 12 degrees of adduction of the left leg.

In a similar way, *flexion deformity* may be estimated by a mathematical calculation[1] (Fig. 122). The patient lies upon a table flat on his back, and the surgeon flexes the diseased leg, raising it by the foot until the lumbar vertebræ touch the table, showing that the pelvis is in the correct position. The leg is then held for a minute at that angle, the knee being extended, while the surgeon measures off two feet on the outside of the leg with a tape measure, one end of which is held on the table (so that the tape measure follows the line of the leg (AB)). From this point on the leg (B) where two feet by the tape

[1] KINGSLEY, G. L.: Boston Med. and Surg. Jour., July 5, 1888.

measure reaches, one measures perpendicularly to the table, (BC), and the number of inches in the line (BC) can be read as degrees of flexion of the thigh, by consulting Table II. For instance, if the distance between the point on the leg and the table is twelve and one-half inches it represents 31 degrees of flexion deformity of the thigh.

TABLE II

In.	Deg.	In.	Deg.	In.	Deg.	In.	Deg.
0.5	1	6.5	16	12.5	31	18.5	50
1.0	2	7.0	17	13.0	33	19.0	52
1.5	3	7.5	19	13.5	34	19.5	54
2.0	4	8.0	20	14.0	36	20.0	56
2.5	6	8.5	21	14.5	37	20.5	58
3.0	7	9.0	22	15.0	39	21.0	60
3.5	9	9.5	24	15.5	40	21.5	63
4.0	10	10.0	25	16.0	42	22.0	67
4.5	11	10.5	27	16.5	43	22.5	70
5.0	12	11.0	28	17.0	45	23.0	75
5.5	14	11.5	29	17.5	47	23.5	80
6.0	15	12.0	39	18.0	48	24.0	90

If the leg is so short that it is impracticable to measure off twenty-four inches on the leg, one can measure twelve inches and ascertain the distance in a perpendicular line from this point to the surface on which the patient is lying; then by doubling this distance and looking in the table as before, the amount of flexion is found.

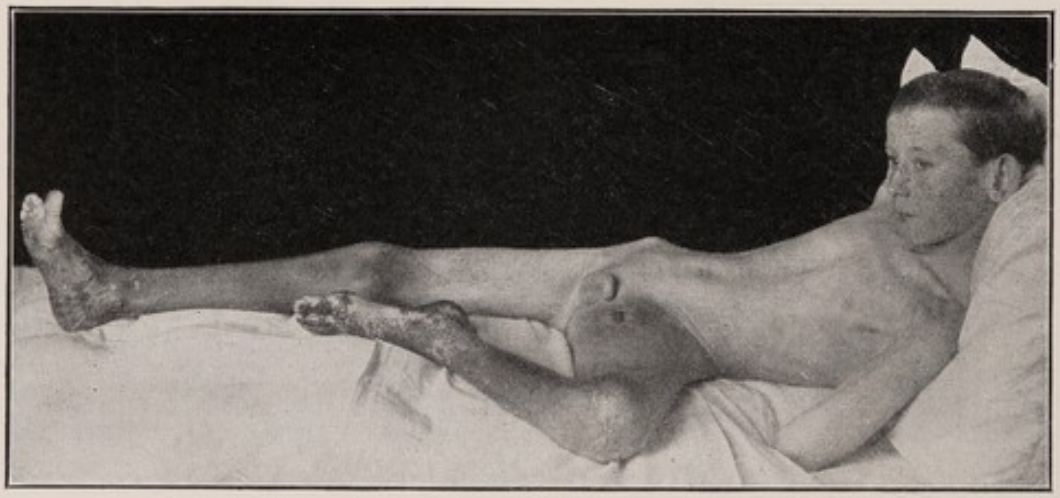

FIG. 125.—Severe abduction and flexion deformity of left hip.

Deformity.—Deformity is due, during the acute stage, to muscular spasm. When the muscles are all contracted by tonic muscular spasm, the position which the limb assumes is determined by the relative pull of these muscles. Flexion is the most common of the deformities, generally associated with some degree of abduction or adduction, and seems universal, whereas the deformity of adduction or abduction and of rotation is variable, although abduction is more frequent in the early stage. Muscular spasm varies in accordance with the acuteness of the disease and is to be interpreted as an index to the activity

of the latter at a given time; accompanying it the patellar reflex on the affected side is generally increased.

Examination to Determine Limitation of Motion and Deformity.—To determine the amount of motion present the patient is laid preferably on a table



FIG. 126.—Examination for flexion of right hip in tuberculosis.

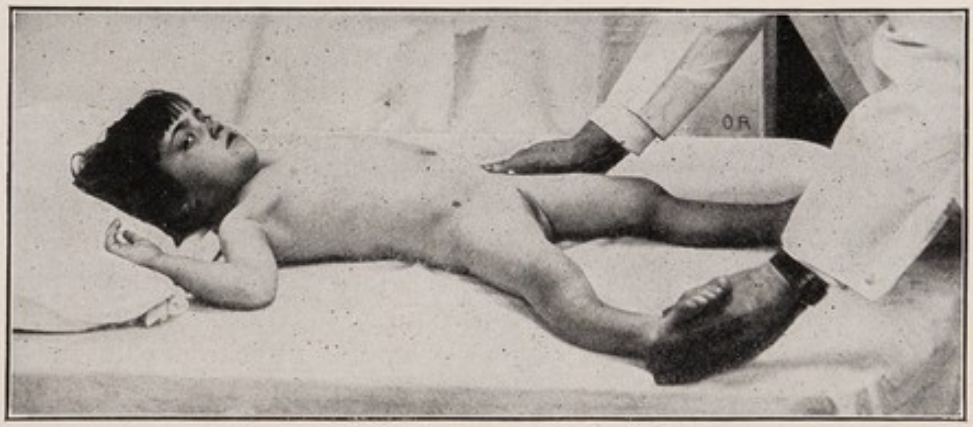

FIG. 127.—Examination for abduction in tuberculosis of the hip.

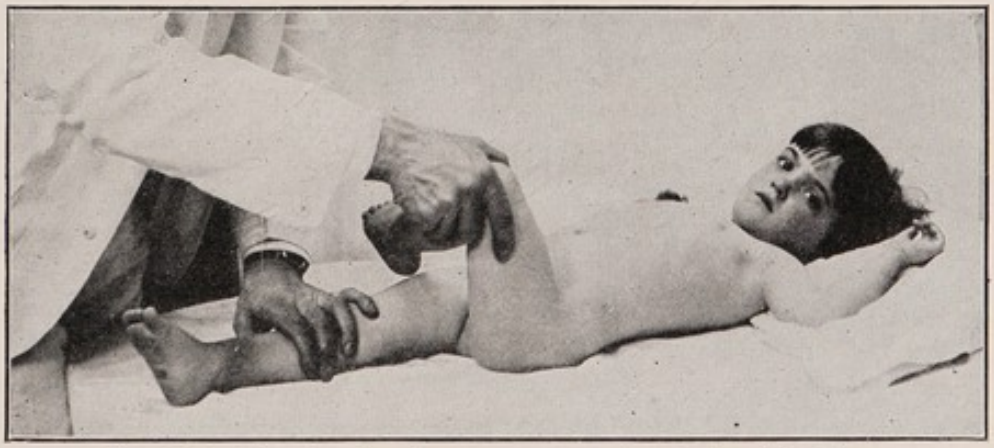

FIG. 128.—Examination for rotation in tuberculosis of the hip.

and the unaffected leg is examined first. In the examination the lower part of the leg just above the ankle should be held steadily and the normal movements of the joint tested in three planes—flexion and extension, abduction

and adduction, and rotation; first with the hip extended and then with the thigh flexed to a right angle with the body. Each movement should be performed once to its full extent, and then stopped, and the movements should never be mixed, but tried out separately and kept distinct. The other hand should be kept on the anterior superior spine to detect any movement of the pelvis. The suspected leg should then be grasped in the same way, and (1) steadily but very gently flexed until resistance of motion is encountered.



FIG. 129.—Correct method of flexing sound thigh on pelvis in Thomas test for flexion.

When this is felt before the full arc of joint motion is accomplished, limitation of motion is present in that direction. (2) Abduction is tested in the same way by abducting the leg in the plane of the body until resistance is encountered. (3) Adduction is tested by raising the sound leg to get it out of the way and adducting the affected leg in the plane of the body until motion is resisted. (4) To test rotation, the leg is flexed to a right angle if possible and internal and external rotation gently tested by rotating the leg while the femur is vertical. If flexion is not allowed, rotation should be tested with the leg extended as fully as possible. In young children, and in early stages of disease, great care is needed to determine loss of hyperextension and full degree of flexion of the hip. (Hyperextension is perhaps the earliest of all the hip motions to show signs of involvement.) The Thomas flexion test is founded upon our inability to extend a diseased hip without producing lordosis (Fig. 129). By lifting the knee of the sound limb until it touches the chest, the pelvis is fixed and the spine is straightened. If there is flexion deformity, the patient is unable to extend the thigh on the diseased side, and it remains at an angle. If disease is absent, the patient can voluntarily extend his limb. If we take any healthy subject, and lay him flat upon a table, we can easily pass our hand under the lumbar vertebræ; but if we ask the subject to touch the table with his back, he is able to obliterate the hollow without lifting his limb. This is a ready guide for the detection of deformity. In no case of hip disease is the patient able to straighten his spine when lying in this position, if flexion is present.



FIG. 130.—Faulty method of flexing sound thigh on the pelvis in Thomas test.

The application of the flexion test in the case of an infant requires considerable delicacy. A child two or three years old is brought for examination, a vague history of irritability may be alone complained of, or pain may be occasioned when the child is washed. The surgeon is to find out, in the first place, whether there is an inflamed joint, and, if so, on which side. The child is gently put upon the table, while the surgeon, without exciting alarm, holds a knee in either hand. The thighs are slowly flexed toward the chest, when

it is observed that one easily yields to full flexion, while the other becomes a little rigid. The stiff hip is then gently allowed to fall, while the sound one is fully flexed. It will then be perceived that the diseased limb remains at an angle and cannot voluntarily be fully extended. Stress must be laid upon the necessity of not startling the child, and of not using the slightest force; moreover care must be taken, first, not to flex the pelvis upon the spine, and secondly, to conduct the examination upon an even, flat surface. Although this test is not absolutely diagnostic; if the hip be complained of, and pelvic, vertebral, or sacroiliac disease be negatived, one can fairly infer the presence of coxitis.

A delicate test for the detection of limitation of motion is to perform the tests for abduction and rotation simultaneously on the two sides, and watch the respective behavior of the anterior-superior iliac spines.

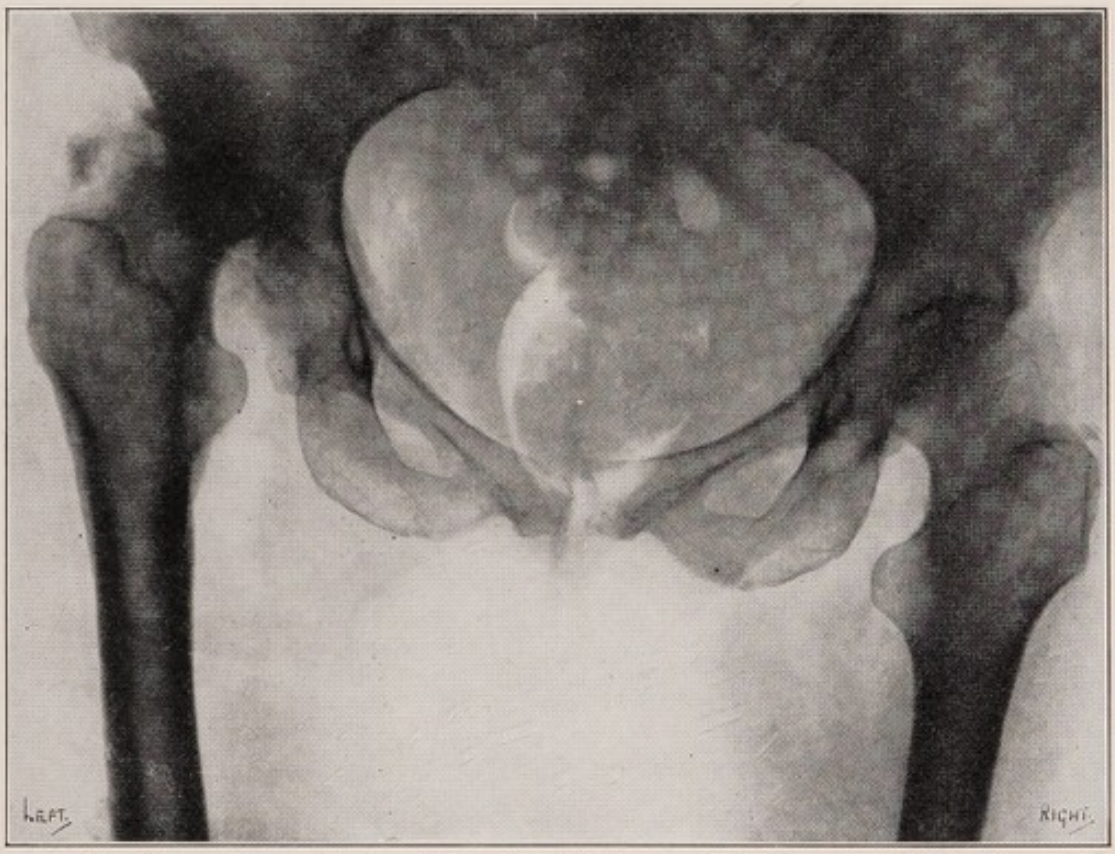

FIG. 131.—X-ray of tuberculosis of the hip in an adult (Thurstan-Holland).

Limitation of motion may vary from a restriction of a few degrees in the whole arc to an extent where no motion at all is present, and the leg is held stiffly, always in a position of some distortion, which is spoken of as deformity. The estimation of this by measurement has already been discussed in connection with adduction and flexion. To allow deformity to continue is to bid for ankylosis in faulty position—always a serious matter.

Gentleness of approach and delicacy of handling in examining a diseased hip are of primary importance. The fingers of the surgeon's hand should not squeeze the leg, motions should be gradual and gentle, and motion should *stop* when resistance is encountered. The object of examination is not to see if such resistance can be overcome, but if it exists. The danger of repeated and unnecessary examinations has been alluded to.

When a patient is in a splint it is often advisable to see if the flexion is quite reduced. This can be done without removing the splint. With the affected leg lying extended, the good one is flexed on to the abdomen. The angle formed by the good thigh and abdomen is roughly equivalent to the flexion deformity of the other leg.

Diagnosis.—In a child a painful hip characterized by stiffness, night cries, muscular atrophy, muscular spasm, and swelling, with perhaps deformity not immediately the result of an accident (especially when these symptoms are accompanied by a positive Pirquet test, and slight elevation of temperature) is presumably tuberculous. It should be treated as such, provided the surgeon recognizes that his diagnosis is not final without further evidence, remembering that positive proof can only be obtained by microscopical evidence or a positive guinea-pig test. Too often the continued progress of the disease and the appearance of focal destruction in the bone, as shown by the X-ray, make the diagnosis evident without such definite proof, which is rarely available. Many parents, however, have been caused undue mental anxiety by a diagnosis of tuberculosis of the hip made by the surgeon on no further evidence than a painful hip, without the characteristic signs mentioned above, and where recovery has occurred in a few days or weeks.

In adults a painful hip, with the symptoms described above is by no means as likely to be tuberculous as in children, and the diagnosis is not so easy. The Pirquet test is of little value, but the X-ray is much more helpful than in the case of children. In tuberculosis of the hip in adults, pain is often severe, swelling marked, stiffness and deformity occur early, and the whole picture is of a severe infection too often rapidly destructive. The same signs remain characteristic, but are all intensified.

X-ray Appearances.—In very early cases, especially in children, the X-ray does not help us in making a diagnosis. As the disease progresses, however, the bone shadow becomes a little less dense than in the other hip, and a density of the periarticular region is noted. An uneven and somewhat mottled shadow is next noted near the epiphysis, with later a disappearance or modification of bone structure in one or more places and perhaps the formation of definite spaces where the bone is not wholly destroyed but its density lessened. More evidence of destruction appears later, the joint outlines become less clear, the whole shadow is less distinct, and when real disintegration has occurred the joint outline is blurred and indistinct.

Formative bone action causing increased density is not often present in the acute stage, but is a sign of beginning repair when it occurs. It is a bad prognostic sign when the shadow of the bone becomes more indistinct.

Differential Diagnosis.—The affections which may be confused with tuberculous hip disease are:

Synovitis of the Hip.—If of traumatic, infectious, or other origin this is at times exceedingly difficult to differentiate from tuberculosis, especially in children. Simple synovitis usually runs a brief course but tuberculous synovitis is persistent and progressive.

Septic Arthritis or Osteomyelitis.—This is characterized by more threatening symptoms—the temperature is higher, leucocytosis is present, and although X-ray appearances are negative at first, proliferative changes in the bone speedily becomes evident. Pain, a serious systemic infection, a marked leucocytosis and high temperature are all presumptive evidence of this affection.

The occasional difficulty in diagnosis, however, is illustrated in a case where the picture seemed clear but where the microscopical examination after operation showed typical tuberculosis (Figs. 135 and 136).

Arthritis Deformans.—The same symptoms as those described in simple synovitis persist, and X-ray appearances are generally indicative of bone absorption and some marginal proliferation *without* focal destruction. Elevation of temperature does not occur as a rule; the affection is most often polyarticular, but a monarticular affection of this type in children is often

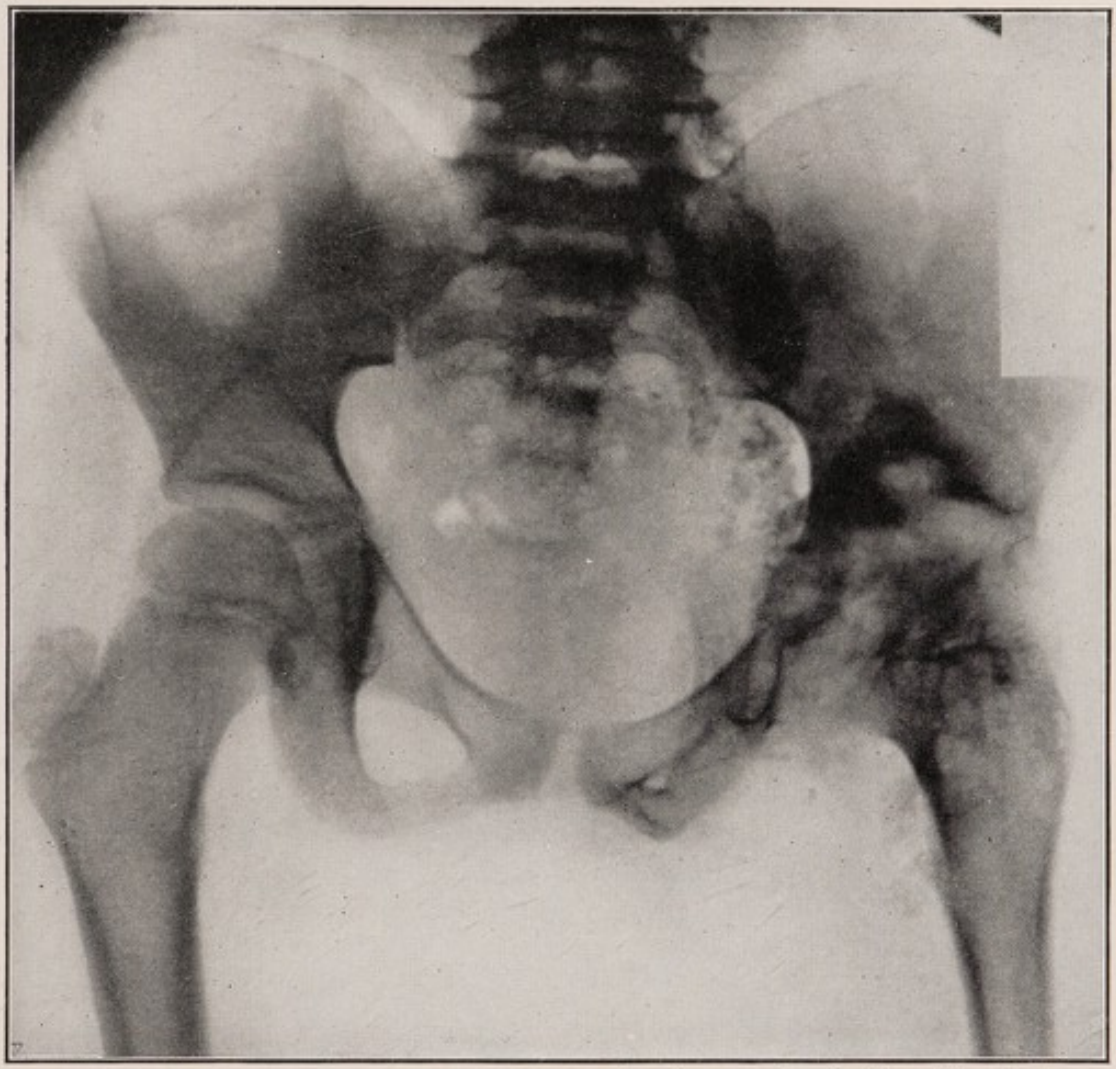

FIG. 132.—X-ray of severe tuberculosis of the hip, undergoing repair, as indicated by the increased lime shadow.

exceedingly difficult to diagnose. The chief reliance must be placed upon the temperature, Pirquet reaction, and the X-ray, although in children as a rule it may show but little. It is essentially a disease of middle and later life.

Flattening of the Head of the Femur.—Legg's Disease, Calve's or Perthes' Disease.—This disability of the hip is accompanied by mild limitation of motion. There is no rise of temperature, no deformity, and the physical disability is much slighter than the change in the head of the bone would lead the surgeon to expect. The X-ray is characteristic.

Lumbar Pott's disease, inflamed retroperitoneal lymph nodes, perinephritis, and appendicitis are occasionally accompanied by symptoms referred to the

hip joint, but limitation of motion is chiefly manifested in the loss of hyperextension, while rotation is free; the signs mentioned as characteristic are



FIG. 133.—Early tuberculous hip showing infiltration near epiphyseal line and elevation of periosteum at inner side of neck. Patient died of tuberculous meningitis.

absent, and the symptoms of spinal or abdominal trouble, present. If the onset is acute the difficulty of a differential diagnosis may be marked.



FIG. 134.—X-ray of the same case as Fig. 133.

Coxa Vara.—Coxa vara is at times mistaken for hip disease, especially in young children. In the quiet stages only abduction is limited but in the stage

of irritation, which frequently supervenes, muscle spasm restricts other motions. The X-ray will establish the diagnosis.

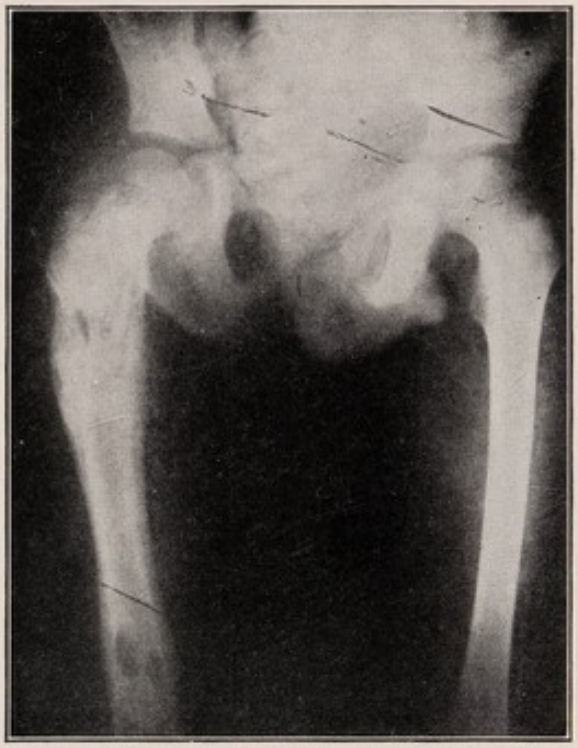

FIG. 135.—Tuberculosis of hip at left of picture, simulating osteomyelitis.



FIG. 136.—Microphotograph of case shown in Fig. 135 (S. B. Wolbach).

Traumatic Strain of the Neck of the Femur.—Traumatic strain of the neck of the femur resulting in a coxa vara in children may simulate tuberculosis of the

hip. In coxa vara, although there is shortening of the limb there is but slight limitation of movement which is not the case in tuberculous disease.

Congenital Dislocation of the Hip.—This is at times mistaken for tuberculosis of the joint, but only by persons ignorant of both affections. The X-ray is positive evidence, and none of the symptoms of tuberculosis of the hip are present. It should be mentioned in this connection that ankylosis of the hip in adduction leads to the position, when the patient stands on the affected side, which has been described as the Trendelenburg sign, in speaking of congenital dislocation of the hip (Figs. 137 and 138).

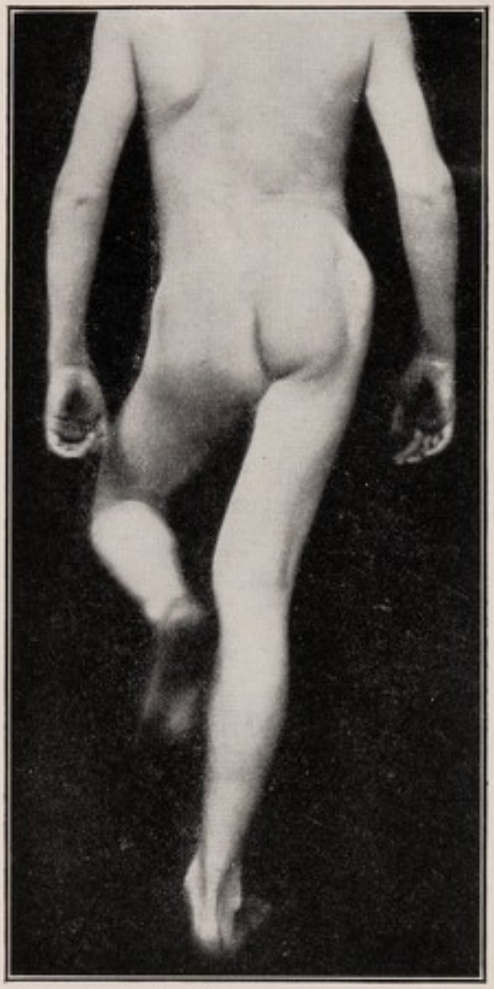

FIG. 137.—Patient with ankylosis of right hip in adduction stands on the right leg and the left side of the pelvis drops.



FIG. 138.—Patient stands on sound leg and the other side of the pelvis rises.

Scurvy and Rickets.—In the acute nutritive disturbances occurring in early childhood, called by these names, the epiphysis of the femur may become swollen and tender, and a painful condition of the joint results. The affection is generally polyarticular and the characteristic signs of these affections are present.

Hemophilia.—In bleeders a synovitis of the hip may occur, simulating tuberculosis. The history will give information of the previous existence of this diathesis, and in doubtful cases the rate of coagulation of the blood can be determined with a special apparatus designed for the purpose. Hemophilic blood coagulates more slowly than normal.

Functional affection of the hip may occur in children, especially about the age of puberty. Symptoms are exaggerated and contradictory, the muscle spasm variable and the usual associated loss of abduction, hyperextension and rotation is not typical. The X-ray and other signs are negative. There is no swelling about the joint. The diagnosis is a dangerous one to make without extended examination and observation.

Prognosis.—It must be remembered in this as in all bone tuberculosis that the final result depends upon the balance between the power of resistance of the individual, and the virulence and degree of the infection. It is like the invasion of a country by foreign troops; the outcome of the struggle will depend on the effectiveness and number of invaders balanced against the defences of the invaded territory and the effectiveness and strength of its defenders. There are no peculiar conditions in the hip joint to make the prognosis as to life different from that of tuberculous joint disease in general, except that apparently tuberculous meningitis is a more frequent complication of hip joint tuberculosis than in similar disease of other joints, excepting perhaps the spine. As in all tuberculous joints a high temperature, much swelling, great pain, and poor general condition are unfavorable prognostic signs and the prognosis in adults is much less favorable than in children, both as to life and function. Prognosis as to function is of course in the main dependent upon the degree of damage to articular tissue which in turn is influenced by the effectiveness of treatment. There is theoretically no reason why the process should not be checked at an early stage in exceptional cases with resultant restoration of motion, but it is difficult to be sure that such cases are really tuberculous, inasmuch as there will be no evidence of erosion of bone. It is therefore safe to say, in general, that damage sufficient to establish tuberculosis as the diagnosis will result in some impairment of motion, varying from complete stiffness to considerable restriction of the arc of motion.

Complete ankylosis in a good position leads to a useful joint which causes only a little limp and is troublesome chiefly in sitting. Ankylosis in flexion of more than 30 degrees or so leads to a rotation of the pelvis on a transverse axis at every step and a noticeable limp. Ankylosis in adduction results in practical shortening of the affected leg, and ankylosis in both flexion and adduction, which is the ordinary result in untreated cases, causes a complicated twisting of the hip at each step. Stiffness in slight abduction is less objectionable than the positions mentioned because there is, in ankylosed cases, generally some shortening from bony destruction, and the "apparent" lengthening from abduction is compensatory. The best position for an ankylosed hip is 20°–30° permanent flexion with neither abduction, adduction nor external or internal rotation. Ankylosis of the hip in a deformed position of any kind, existing in a patient with a stiff lumbar spine as from tuberculosis of the lumbar region, is a disabling deformity. Real bony shortening is less important from a functional point of view than a deformity where alignment is interfered with, as the former can be compensated for by a high heel. Combined with marked deformity it adds to the lameness.

A wholly ankylosed hip is a more useful joint than one with a few degrees of motion, especially if such motion is associated with marked or even moderate deformity, as such patients are liable to recurring periods of irritation and sometimes real relapses of the process. Motion remaining up to and beyond 45 degrees, when not associated with deformity of any degree, is an asset and such

cases are not so liable to periods of pain as where a small amount of motion exists. More motion than this is of value, but cases reported as having recovered with complete motion must be substantiated by a very definite proof that they were tuberculous in the beginning before the diagnosis can be accepted.

Where the disease is limited to the neck or trochanter, recovery may be accompanied by complete restoration of motion if the disease remains localized.

In a series of cases of tuberculosis of the hip from the New York Orthopedic Hospital and Dispensary from 1877 to 1882, 778 cases were treated, of which 50 had died during these five years from conditions associated with the disease. These causes of death were tuberculous meningitis 20, amyloid disease 5, phthisis 3, exhaustion 3, tuberculous peritonitis, septicemia and convulsions 1 each, cause unknown 16.

A series of these cases was investigated[1] as to shortening, which had been at least two years under treatment by traction, the patients having been discharged at least four years prior to the investigation. Fifty-one cases were available for this investigation, as to end results—4 had died, 2 of meningitis, and 2 of pneumonia. In these cases two showed no real shortening, and in the others with two exceptions it ranged from one half to one and one half inches. One case with dislocation showed six inches and one case, three inches. The presence or absence of abscess did not affect the amount of shortening, nor did it seem to have any influence upon the ultimate degree of motion. There was a tendency for the shortening to increase for a time after the disease was cured, but not indefinitely.

TREATMENT

General Treatment.—This has already been discussed in the general section. In the case of tuberculosis of the hip, it is too often regarded as a serious condition which must be treated within doors at home or in a hospital. The child in a tenement who is kept out on a balcony or in a perambulator on the sidewalks stands a better chance of recovery than a child undergoing similar treatment in the best equipped city hospital. The segregation of tuberculous children in a city hospital, except for the immediate correction of deformity, cannot be countenanced.

It may help us to understand the indication for the treatment if we trace a neglected case of coxitis from health to disease, and back again. We find that involuntary spasm of the flexors of the thigh becomes more and more pronounced, until at length the joint mobility has gone. The typical deformities appear, and the position of the limb is such that, when the patient attempts to walk, the bodyweight is carried on the diseased side for only a comparatively brief period at each step, and anything like prolonged weight-bearing while standing at rest is impossible. Later, the joint may become so painful that weight-bearing and even slight jarring are not tolerated, and the patient takes to bed. The leg assumes the position of greatest comfort, and muscular spasm protects and locks the joint. As the patient falls asleep the muscular spasm relaxes, motion takes place, injury is inflicted, the child screams, and the muscles are again on guard. Long continued malposition results in structural shortening of the tissues of the flexor side, and immobilization is maintained with but little muscular effort. When the joint has been free from motion and weight-bearing for a time, the tenderness passes off and

[1] Shaffer and Lovett: New York Med. Jour., May 21, 1887.

the patient is ultimately enabled to place full weight upon the affected side; nevertheless spasm and rigidity are maintained for a long time. When the disease has terminated, the spasm disappears but the structural shortening of the soft part remains and yields gradually to use during the subsequent months and years. The result of this cure by the natural process is an extremely deformed limb, with impaired movements. The defects appear to be due to the prolonged course of the disease, which hinders the growth of the limb and renders more rigid the shortened muscles, and to the position of deformity in which the leg rests while structural shortening takes place.

Local Treatment.—The means which art adopts, therefore, are (1) to protect from deformity, or, if deformity has appeared, to correct it, and thus to rob the muscular contraction of its power for evil; (2) to immobilize the joint and thus relieve the muscles from spasm, and then from contracture; and (3) to relieve pain and prevent the bone destruction due to both attrition and pressure, and also to relieve the joint from weight-bearing. *The all essential treatment therefore is rest.*

The requirements of the local treatment in tuberculosis of the hip are to meet the conditions which threaten the integrity of the joint and to bring about repair at the earliest possible stage. The anatomical characteristics of the joint have been commented on and muscular spasm must be recognized as a dominant factor to be reckoned with.

Acute Stage.—The four measures described as of use in tuberculosis of the joints in general are those which are most effective in meeting the indications in tuberculosis of the hip. They are (1) fixation, (2) fixed extension, (3) sliding traction, and (4) protection.

These measures are applicable both during recumbency and during ambulatory treatment. The writers are in accord as to the principles of treatment, but differ somewhat in the details of their application.

Treatment by recumbency as contrasted with ambulatory treatment is necessary (1) in all cases with considerable afternoon temperature, (2) in all painful and irritable cases, especially when night cries are present, (3) in all cases with deformity, abscess, or threatened abscess, and (4) when the general condition is poor. Recumbency should be continued until these conditions have been remedied and long enough to insure that they will not return on resumption of activity. The chief signs to rely on in deciding this are: absence of deformity and abscess, absence of tenderness on examination and manipulation, good general condition, and normal temperature.

1. *Fixation* of the hip is not easily obtained because of the difficulty of controlling the movement of the pelvis through the lumbar spine and this difficulty must be recognized at the outset. For this reason in the most acute stage, extension, fixation and traction applied during recumbency, in all cases constitute the best routine.

Traction with Fixation during Recumbency.—This combination which is the practice of the Boston school, is obtained by recumbency on a Bradford gas pipe frame (Fig. 139 p. 150) with traction on the leg by means of a weight and pulley made in the long axis of the body when deformity is not present, and in the line of deformity when it is present. The line of deformity may be defined as the line which the long axis of the affected leg assumes when a line connecting the anterior-superior iliac spines is parallel to the bottom of the bed, and when the pelvis is in such a position that the lumbar spine and sacrum are in contact

with the mattress on which the patient lies; in other words, when the pelvis constitutes a definite and standard base line. If the diseased leg is flexed and adducted, its axis should point up and inward as, if it is pulled straight, both flexors and adductors will be irritated by continued pull on these contracted muscles. This is demonstrated clinically by increase in pain when really effective amounts of traction are used in other than a correct line. In very painful cases, it may be wise to exaggerate somewhat the deformity in determining the line of traction, that is, too pull in a little more flexion, adduction or abduction than is strictly required. The patient is fixed to the frame and the leg placed at the desired angle by a leg piece attached to the frame, or by being held on a pile of folded sheets. As the spasm improves the leg may be pulled in a straighter line until it is in proper position. The patient must be turned

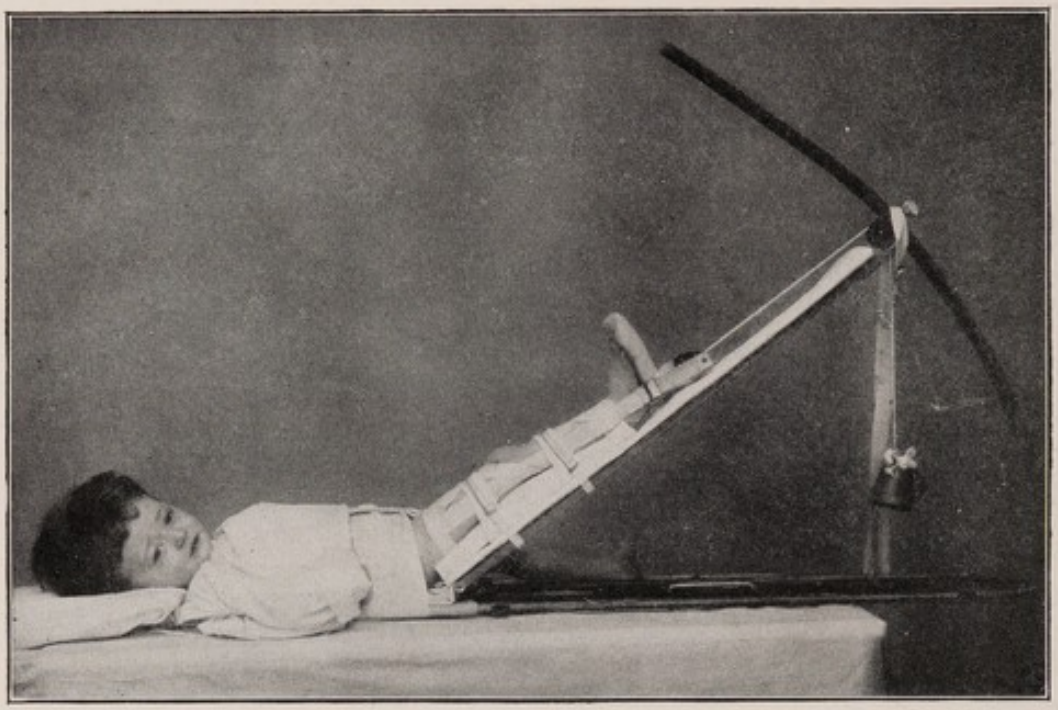

FIG. 139.—Bed traction in the line of deformity.

daily for the care of the back, and great caution should be exercised during this to avoid jarring of the hip. Perineal straps attached to the frame are of value. Traction should be increased to the point of tolerance, and in irritable cases slightly more than is used during the day is desirable at night. As a rule, about one pound of weight is required for each year of the child's age.

2. *Fixed Extension with Recumbency.*—Fixed extension is a phrase used to denote a complete fixation in extension which is never relaxed for a moment at any time during treatment. The counter extension is not the patient's body, but a fixed *point d'appui* on the tuber ischii. The lower end of the limb is attached to the splint so that the limb and splint become one.

When put on, the surgeon pulls the extension tapes tight and fixes them. Next day the muscles have come to rest with the extension tapes just slack. The muscles cannot pull by any spasm for the system is unyielding; there is no movable weight. When the surgeon has got the tension he requires he leaves the limb fixed in this condition.

In the practice of the Liverpool school continuous traction by weight and pulley is not employed either for the relief of muscular spasm or for the correction of deformity. Whatever relief of pain follows its use is due to the fixation which can be better secured by the method of fixed traction. It is by reflex nervous impulses induced by changes in the tension of muscle that spasm is induced. A patient lying in bed with a weight and pulley attached to his limb has as a counterpoise the weight of his body, and obviously, if he moves his body at all, even slightly, he alters the tension on his muscles and induces reflex spasm, because of a sudden change in tension. It is therefore logical to treat muscular spasm by correcting the deformity and com-



FIG. 140.—Jones abduction frame.



FIG. 141.—Jones abduction frame for tuberculous hip, applied.

pletely immobilizing the limb. Instead of continuous traction by weight and pulley, fixed extension, and that only to retain the limb from becoming adducted, is used. If there is no deformity, all that is needed is complete fixation. If considerable deformity is present it is practically corrected at one sitting. When the deformity is corrected the limb is kept in absolute rest on an abduction frame and is not troubled by muscular spasm. For this reason H. O. Thomas looked upon hip disease as painless excepting during the period of intracapsular tension. In early cases with but slight deformity an abduction splint secures immunity from flexion, adduction and pelvic obliquity. Deformities present in chronic cases even when extreme, are completely rectified, usually in a few days, and at most in fourteen days. Dissemination of tuberculosis or active local manifestation is extremely rare because the pull upon the joint is followed by complete immobilization.

It is a great advantage to have the splint self-contained without external attachments, as the patient can be safely carried without pain or discomfort from place to place and he need not be moved for any purpose whatever, such as cleaning, bed pan, etc.

As soon as a diagnosis of tuberculous disease is made it is essential to place the patient in a splint in recumbency. (*a*) If the disease is in a *very early stage* with no adduction he is placed in a double Thomas splint which secures simple fixation. (*b*) If there is present *slight adduction and flexion*, he is placed in Jones' modification of the Thomas double splint which is known as the "abduction frame." (*c*) If the *deformity is pronounced* and somewhat rigid, an anesthetic is given and the deformity is partially or wholly corrected and the patient is placed on an abduction frame in fixed extension.

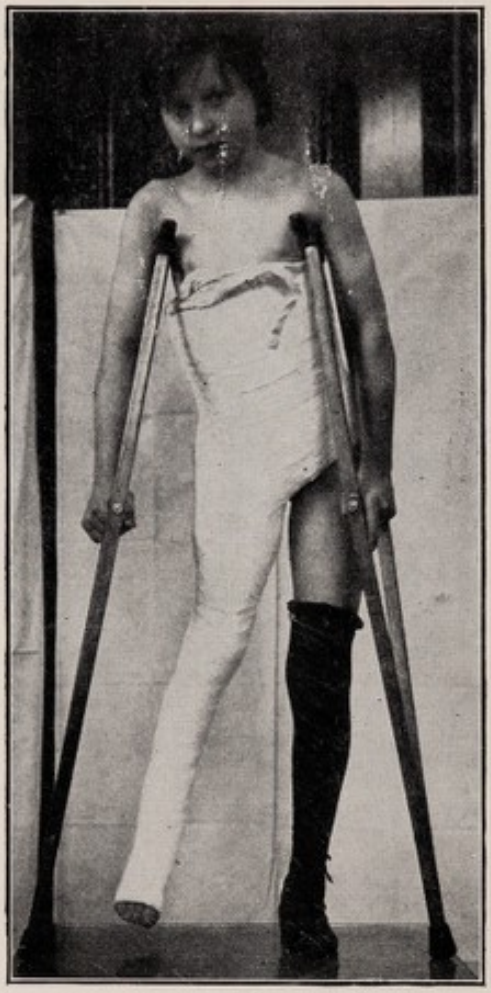

FIG. 142.—Long plaster spica for hip tuberculosis.

The double Thomas hip splint differs from the single splint simply in having an additional stem for the sound leg. The abduction splint differs from the double Thomas in that the leg stem on the diseased side is slightly abducted and both stems are arranged so that extension can be used.

Jones Hip Abduction Frame.—This frame consists of two bars of iron ($\frac{3}{4} \times \frac{3}{16}$ gauge for 20-inch frames), one perfectly straight and the other abducted at a level with the hip joint to an angle of 25 degrees up to 40 degrees. These bars are made of such a length as to extend from the scapulæ to 4 inches above the heels. The straight bar inclines outward at its lower end at an angle of 5 degrees up to 10 degrees. The abducted bar lies at a similar angle from the scapula to the hip joint where it becomes abducted. These stems are connected above the ankles by a cross rod ($\frac{1}{16}$ up to $\frac{3}{8}$ round) also at the top by a metal

band (¾ × ⅛ up to 1 × ⅛) which completely encirles the chest and is open in the front. A similar band (⅝ × ⅙ up to ¾ × ⅛) connects the stems just above the buttocks and extends as wings just long enough to grip the pelvis. A short iron grip is fixed to the end of each stem into which the ankles will be placed. To prevent any tendency to knock knee it is an advantage to add a bar between the two lower wings of the frame and at right angles to it, to which the knees can be bandaged. A long hairpin shaped loop of iron with a kink in its center is attached to each ankle grip. Two studs are fixed to the pelvic wing on the straight side at suitable points to which the groin strap is secured. This is a strap with holes at intervals at both ends, the center of which is thickly padded with graduated felt and covered with stretched leather. A firmly padded cushion (2 inches to 4 inches thick) the width of the trunk should reach from above the upper border of the frame and extend down each leg. A horse-shoe shaped piece is removed at the buttocks and extra thickening under the knees. This cushion is secured to the frame with tapes.

Treatment by Ambulatory Apparatus.—Ambulatory measures are adopted after a period of recumbency under certain definite indications. The change should be gradual and be confined to a part of each day. Treatment by recumbency was formerly inconsistent with outdoor life but in a modern open air hospital is easily maintained under ideal conditions. Prolonged recumbency after the immediate need for it has passed away is on general grounds uneconomical and undesirable if effective treatment can be continued.

The theoretical requirements of treatment while the disease is incompletely healed are unchanged from those originally stated above, except that the weight must not be borne on the affected leg. We have under these conditions three principles of treatment to discuss (1) fixation, (2) traction, (3) protection from weight-bearing.

(1) *Fixation.*—Two methods are available: (*a*) The single Thomas splint which is most useful in adults. Wearing this splint the patient must use crutches and have a patten on the shoe of the unaffected limb and (*b*) the plaster of

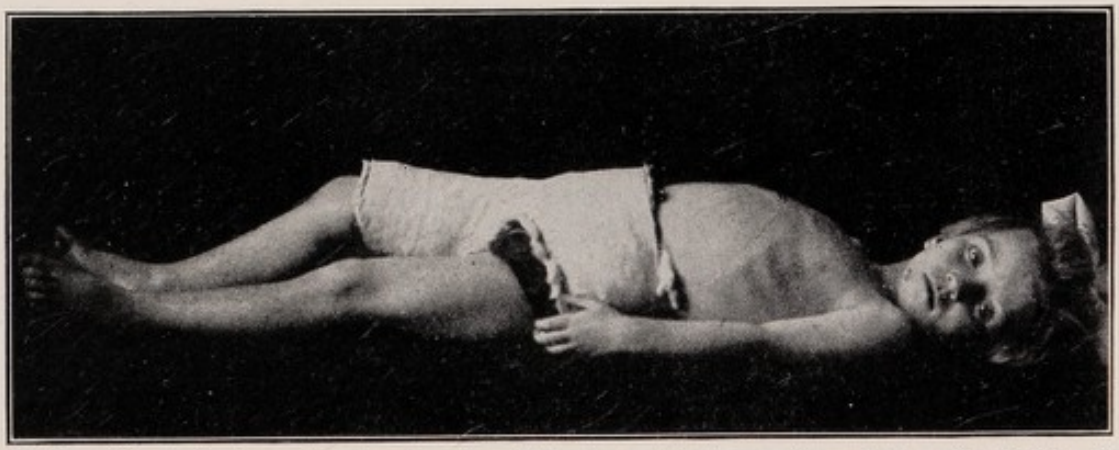

Fig. 143.—Short plaster spica bandage in which the patient was allowed to walk about. This bandage furnishes neither fixation nor protection against weight-bearing.

Paris spica. For the latter the bony prominences must be well padded, and over a layer of stockinet a snug fitting plaster cast should be applied with the patient lying on a spica board or standing. Such a bandage should include the lower thorax to fix the lumbar spine and should extend to just above the malleoli with the leg slightly abducted, but not flexed. The bandage must grip the pelvis laterally between the trochanters and iliac crests and between the sacrum and pubis. In very active children, or in those where sensitiveness has been unusually prominent, more efficient fixation is obtained

by carrying the plaster down on the well leg nearly to the knee, which affords practically complete fixation of the affected hip.

The Thomas Hip Splint.—The Thomas hip splint consists of a main stem, a chest band, a thigh band, and a calf band, and occasionally of an abduction or adduction wing passing around the flank. The splint is constructed of the softest and toughest iron. Annealed steel is not the material to be used, as sufficient rigidity cannot be obtained without rendering the parts too difficult to mould easily to the contour of the patient.

For an adult of medium height the upright should measure $1\frac{1}{4} \times \frac{3}{4}$ inch; in a boy of ten the upright should measure $\frac{3}{4} \times \frac{3}{16}$ inch; for a child of five the upright should measure $\frac{1}{2} \times \frac{1}{8}$ inch. In length it reaches from the lower angle of the scapula to the junction of the middle and lower third of the leg, passing down posteriorly to the hip joint. The upright stem is bent in two places, one opposite the fold of the buttock, the other just above



Fig. 144.—The Thomas hip splint.



Fig. 145.—The Thomas knee splint.

the joint, so that the leg portion and body portion follow parallel lines distant from each other from $\frac{1}{2}$ to 2 inches, this distance depending upon the size and stoutness of the patient.

The bends referred to should be rounded rather than angular, as may be seen in the illustration. The leg portion from the fold of buttock to the lower end is perfectly straight, as is the portion from the bend opposite the joint to the upper end. The stem is usually twisted somewhat in its longitudinal axis, so that the body portion lies directly posterior to the middle line of the leg. The chest band is also made of flat bar-iron, which varies in width and thickness in proportion to the size of the patient. It should be long enough to encircle the chest to within an inch or two, and is joined from 1 or 2 inches to one side of its middle so that one wing will be longer than the other. The longer wing encircles the chest opposite to the diseased side. There is no special advantage in having these wings end opposite each other, although it may perhaps make a somewhat neater looking apparatus. The upper end of the main stem is forged flat and bent over the chest band and the two are made fast by a single rivet. In each end of the chest-band a hole, $\frac{3}{4}$ of an inch in diameter, is forged for the fastening of the shoulder straps, or, what is less convenient, holes are drilled for the attachment of buckles, or bandage. The thigh-band is made of flat bar-iron, and being placed on the surface of the main stem next to the patient, is joined to it

by one rivet at a point about an inch below the lower bend. The calf-band is also made of flat bar-iron, and is joined to the lower end of the stem by a single rivet in the same manner and with the same relative lengths of wings as the thigh-band.

The wings or bands are bent approximately to fit the imaginary patient, and the surface of the entire splint next the patient is covered with felt, either harness maker's felt, or what is better, ordinary boiler felting of ¼ inch thickness. The whole is then covered with that kind of sheepskin known to the trade as basil leather or "tan sheep." This should be put on wet and snugly stitched into place, so that as it dries the shrinking will prevent any slipping upon the iron. The stitching of this leather is of course done on the surface of the splint away from the patient; it may be done with the so-called ball-stitch, or, what is more serviceable but less neat, the two edges of the leather may be drawn up together and sewed through after the manner of the harness-maker with a double waxed end; the redundant portion of the leather is then trimmed off.

The splint is then applied while the patient rests upon his back, the wings upon the side away from the deformity being opened out sufficiently to slide the splint under the patient from the affected side without unnecessary jar or movement. When the main stem rests in place, the leg portion will be directly behind the middle line of the thigh and leg, the part between the bends directly at the back of the hip joint, and the body portion somewhat to the outer side of this line, the whole lying flat against the chest, thigh and leg. This fitting may be done approximately by the hands, but better by wrenches. The wings to the inner side of leg and thigh and the wing of the chest-band on the same side, namely those on the side away from the diseased articulation, are drawn more closely than those on the affected side. The reason for this is that the splint tends somewhat to the affected side of the patient and to draw the leg into abduction.

When satisfactorily fitted a short piece of bandage is wrapped around the splint and leg at the lower extremity and pinned securely, and another wrapped around the thigh above the knee, or, what serves in some cases more satisfactorily, a single piece is wrapped around the knee in the figure-of-eight fashion and pinned with a large pin directly through the covering at the back of the splint, so that the bandage cannot slip upon the splint, and any tendency of the splint to slip downward is avoided.

(2) *Traction.*—There is a division of opinion in the surgical world as to the place which traction should hold in the treatment of tuberculosis of the hip. In England and France fixation alone after the active stage is the general custom, and in France, even in the acute stage, fixation alone is generally depended on. In America where the ambulatory traction splint was devised, traction is much more commonly used, at all stages of the disease. The authors believe that in the early acute stage both fixation and traction should be used and that ambulatory treatment should not be allowed while any considerable degree of muscular spasm exists. It is the American custom to allow ambulatory activity in a plaster spica bandage, provided with traction, when muscular spasm has diminished but is still present, and to continue traction until there is distinct evidence of repair in the X-ray and quiescence of irritative symptoms. The Liverpool school forbids ambulatory activity until all muscular spasm has disappeared. When all pain, tenderness, and muscular spasm have been quiescent for some weeks, and when no sign of fluctuation can be made out about the joint, the patient is allowed to get about on crutches, wearing the single Thomas splint, aided by a patten on the sound limb. The patten consists of an iron ring with two uprights, the ring resting on the ground and the uprights rising from the front and back, reaching to the shoe and fastened to the heel and sole. The height of the patten depends upon the size of the patient and should be from four to six inches, high enough to prevent the patient from reaching the ground with the toe of the affected side. This with the ordinary axillary crutches completes the walking outfit. A cork sole of the required height accomplishes the same purpose as the patten.

The fact would seem to be that fixation is undoubtedly necessary during this subacute period, and that the surgeon had better be guided as to the use of traction, also, by his own experience and his facility with the different types of apparatus. *If muscular spasm or irritability recurs during ambulatory treatment, fixation and traction in recumbency should be resumed.*

Traction may be applied by the Bradford abduction splint or the Taylor traction splint, both furnishing partial fixation and continued traction when properly applied. Both are used with a high shoe on the well foot, and crutches, as in the subacute stage, walking on the splint is almost sure to cause irritation or delayed progress because in any apparatus weight-bearing relaxes traction, while weight is borne on the affected leg in walking.

Bradford Abduction Splint.—The Bradford abduction splint is merely a modified Thomas knee splint with an open ring provided with an abduction horn. It consists of two steel rods longer than the affected limb connected below by a flat bar furnished with a windlass, and above by a ring of the Thomas type opened in front. Where the cut in the ring occurs the internal end is continued in a bent steel rod, which passes up on the diseased side above the symphysis pubis continuing transversely across and is bent down to pass under the perineum of the sound side, terminating posteriorly in an end long enough not to press into the buttock when the patient is seated. The ring and abduction horn are padded and covered with leather, and if properly shaped are not soiled by feces or urine. This brace possesses an advantage over the Taylor traction splint, in that it makes the traction against two rigid perineal bands, which cannot be loosened by children if so inclined, and it makes traction on the leg in the position of abduction, and if ankylosis is to occur, slight abduction is preferable to even a very small degree of adduction.

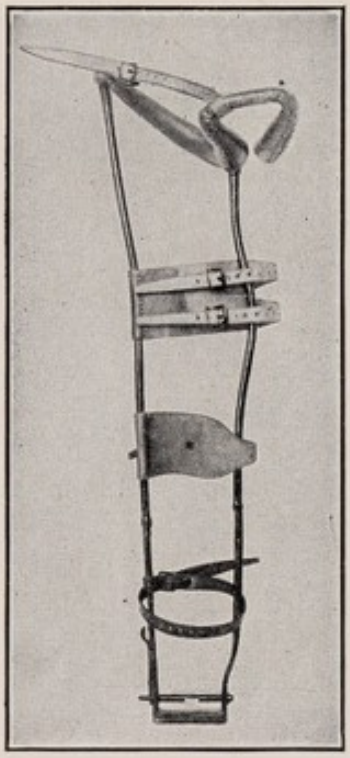

Fig. 146.—Bradford hip abduction splint.

When this form of splint has been used through the acute stage of the disease it can be used as a perineal crutch by an adaption similar to that described in speaking of the traction splint.

In the acute stage of the disease the splint is used purely as a traction apparatus and not for walking. A high sole, at least two or three inches in height, is put on the other shoe, so that the leg on the diseased side may clear the ground in walking with crutches.

Taylor Traction Splint.—In its simplest form this traction splint consists of (*a*) horizontal pelvic band, (*b*) an outside upright, and (*c*) two posterior bands, one behind the thigh and one behind the calf.

(*a*) The pelvic band is made of tire steel, No. 8 gauge, and 1 inch wide. The anterior half of this band extends from the anterior superior spine of the sound side around the diseased side just above the trochanter, around the back of the pelvis to a point about an inch further out than the anterior band. It is forged so that the anterior and posterior parts are parallel to each other in the vertical plane, and is fastened to the upright at an inclination of 20 degrees from the horizontal, the posterior part being the higher. The pelvic band in general forms a right angle to the upright. Buckles are placed on this band to which perineal straps are to be fastened. They are close together in front and at the back should be far enough separated so that the straps pass under the tuberosities of the ischium. A strap fastened to the posterior end of the pelvic band passes around the other side of the pelvis to a buckle at the end of the anterior band.

(*b*) The upright runs on the outside of the leg and is shaped to its contour extending 2½ inches below the bare heel, and the bottom of the upright is flattened from side to side and turned inward to form a right angle with the upright which constitutes the bottom piece of the splint, to which a windlass arrangement is attached. This consists of a spindle

turned by a key. The spindle is partially split in its middle for the insertion of webbing straps. The upright should be strong enough not to bend under weight.

(*c*) The two posterior bands of flat steel padded and furnished with straps are arranged to be adjustable on the upright, one behind the thigh and one behind the calf. The perineal bands are made of webbing straps, padded in their middle half by felt covered with canton flannel, or they are made of leather padded with felt and covered with moose hide. At the application of the splint the patient lies on the back, the diseased leg is raised and the pelvic band slipped on to the patient while the leg is placed in the two posterior bands of the splint. The perineal bands are fastened holding the pelvic piece at a level just below the anterior superior spine, the extension having been previously attached to the leg, webbing straps are united in the spindle at the bottom of the splint and tightened by means of turning the spindle with a clock key. This is controlled by a catch shown in the illustration which prevents it from loosening.



FIG. 147.—Taylor's traction hip splint for the right leg.

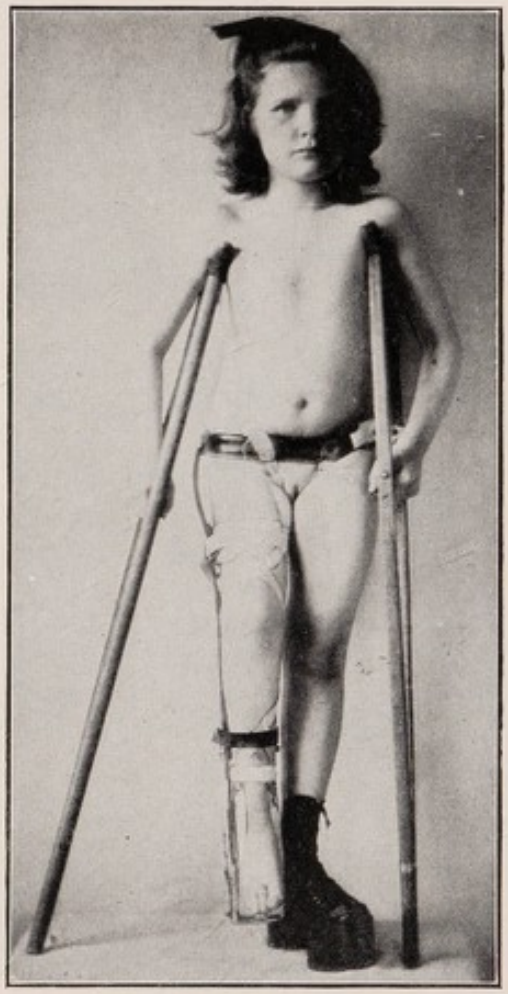

FIG. 148.—Traction hip splint applied.

If traction is used, it should be omitted as soon as the muscular spasm has wholly ceased, as its use after that is likely to pull on the joint capsule and weaken the joint. Fixation should be omitted only when the muscular spasm has entirely disappeared. The best test for this is a very gentle, sudden abduction of the leg with the finger on the adductor tendons—if muscular spasm is present they will immediately jerk to guard against the movement.

In the severest cases, excellent results are to be obtained by the combination of the two methods—*fixation and traction*. Fixation may be furnished by a plaster of Paris spica bandage as described, over which is applied the Taylor traction splint, which provides the continued traction by adhesive straps under the plaster. The practical objection to this method is that adhesive plaster straps should be renewed every three or four weeks to prevent excoriation of the skin, which means that the plaster bandage must be frequently

renewed. This may be obviated by substituting for the plaster bandage a moulded leather spica, laced in front, which may be renewed when necessary. The apparatus is necessarily cumbersome, and for this reason troublesome.

Protection from weight-bearing during the use of traction is secured by using a high sole of 2 or 3 inches on the boot of the normal leg and by the use of crutches.

Finally, a method of treatment a good deal in vogue must be mentioned only to be condemned. A *short plaster spica bandage*, ending above the knee, is applied and the patient allowed to walk without protection. This is done to obliterate the hip joint by causing an ankylosis due to the acute inflammation set up by weight-bearing. The surgeons who advocate it believe that an ankylosed hip joint is in general more useful and less vulnerable than one with motion. The use of a plaster bandage, *ending above the knee*, is very likely to cause lateral mobility or genu recurvatum because of the constant strain on the knee joint, especially on account of the atrophy of the thigh muscles incidental to the disease. *The hip joint should not be subjected to weight-bearing when the joint is tender and disease active.*

Summary of Treatment in Acute and Subacute Stages.—While muscular spasm is active, recumbency with fixation or traction, or a combination of both, in out-door air should be adopted, and the same measures employed where irritability, deformity, abscess, sepsis or bad general conditions prevail.

When the subacute stage has been reached and muscular spasm has disappeared, walking may be allowed with protection against or regulation of weight-bearing.

Treatment during Convalescence.—It is not easy to determine when the active process in the joint has sufficiently subsided to permit the beginning of convalescent treatment, and when fixation or traction or both may be abandoned and the use of the joint resumed. The general condition of the child is most important in deciding this. If he has gained flesh, is not anemic, sleeps and eats well, if his temperature is normal, and a sufficient period of time has elapsed for a cure, and his X-rays show signs of repair in the bone, this modification in treatment may be considered. Locally the joint should be free from tenderness and pain on manipulation, and muscular spasm long absent. If there is any suspicion that the angle of the joint is changing, that is *if the deformity increases, it suggests unsound ankylosis, and caution is necessary.* Repair of tuberculous bone is a slow process and local foci of the disease may be present after the general infection has healed, so that great conservatism at this stage is a sign of sound surgical judgment. Liberty should be very carefully approached. If the child has been hitherto fixed immovably in a splint, a light Plaster of Paris bandage reaching below the knee may be applied, allowing him to roll about and play in bed. If he has been walking, and signs of activity have been absent for some time, his splint may be removed an hour a day; the time to be extended if all goes well, and a firm spica bandage applied. The experiment should be made with great caution and under careful observation, and any return of symptoms, such as pain or increasing deformity, are important signs and demand immediate return to the original treatment.

If traction has been used while the patient has been going about, and there are no longer symptoms of joint irritation, the question of the use of a protection splint comes up for consideration.

Protection during Convalescence.—The perineal crutch is merely a modification of the Bradford abduction splint or the Taylor traction splint, extending below the sole of the foot to transfer the body weight to the perineum. If the Taylor hip splint is used for this, the pelvic band is shortened to a point in front, just above the adductor tendons, and at the back is shortened enough to provide that the perineal band passes under the tuberosity of the ischium but not far enough in to pass over the anus. The lower end of the upright terminates in a foot-piece to go inside the shoe, which is not quite as broad as the sole of the foot and ends at about the level of the metatarsal heads. It is curved sufficiently to lie smoothly in the shoe and is joined to the upright opposite the external malleolus. The brace is put on, the perineal band tightened with the heel of the foot about one-half inch away from the heel of the sole plate, and is best applied with the patient standing on the well leg. When the band has been fastened in place the patient should bear weight to see if the heel touches. If it does the perineal band should be tightened until the heel in weight-bearing clears the metal sole.



Fig. 149.—Perineal crutch.

In place of this apparatus a Thomas caliper knee splint may be used, or the Bradford hip splint with the lower ends turned in as in the caliper splint. In either case, the splint should be of such a length that the affected foot in weight-bearing does not touch the sole of the shoe.

Such an apparatus should be worn for at least one or two years, and discarded only after careful examination as to the presence of disease on the lines already indicated. Any increase in deformity or pain after use is a sign for a return to more protective measures. When the splint is removed, it should be for only a short period at first, say an hour a day, to be gradually lengthened if no adverse symptoms arise.

Double Hip Disease.—Disease involving both hips rarely, if ever begins in both at the same time. One type of deformity may exist in one leg and another deformity in the other, so that it is impossible to deal satisfactorily with so complicated a matter unless the patient is kept recumbent for a considerable period, when the problem is simplified.

This double involvement is generally of rather a quiet type, long continued and resistant, and very often, in the writers' experience, followed by very extensive or complete double ankylosis, not generally osseous. For this reason deformity must be dealt with promptly and effectively, so that the hips, if ankylosed, shall not be flexed or laterally deviated.

If ankylosis occurs with the legs parallel and not much flexed, the patient may get about without crutches with a distinctive gait. As the hips cannot rotate nor the thighs flex, the patient glides in a series of short steps governed by a rotatory action in the dorsal spine. If the ankylosis has occurred in childhood a remarkable degree of rapid movement is acquired later in life. Even in adults, provided deformities do not exist, the walk is astonishingly good. Sitting normally is practically impossible and usually the patient has to be helped to his feet. A double hip ankylosis is so serious that every effort should be made to prevent and correct deformity in children; this can be done

in the active stage of the disease by mechanical methods, and if ankylosis has occurred with deformity an osteotomy may be needed.

In the adult an *excision* or *extra-articular pseudarthrosis* is generally called for, because in double ankylosis an effort must be made to obtain one mobile hip. If excision is called for, the longer limb should be operated upon as the operation involves some shortening. Frequently an osteotomy is required on one side and a mobilizing operation on the other (see page 101).

Complications.—*Abscess* is to be treated on the principles indicated in the general section and offers no peculiarities requiring mention, excepting that abscesses in the groin in common with tuberculous hip are occasionally due to the breaking down of inguinal lymph nodes.

Deformity and Its Treatment.—Deformity and its treatment have been discussed in a measure in speaking of the active stage.

In the late history of the disease after muscular spasm has disappeared, deformity is caused by adhesions or ankylosis, and at this stage passive motion is dangerous, and particularly to be condemned is the daily meddlesome manipulation of the joint to increase motion, which is sometimes attempted. So-called brisement forcé, or forcible attempt to break up the adhesions under anesthesia, belongs to the surgery of the past, and in this text book is only mentioned in order to utter a note of warning against its use on account of its many dangers. It is safer to leave such cases alone until there is reason to believe that the process is entirely healed, when an osteotomy can be done with safety.

Some surgeons make a point of ignoring deformity during the active stage of the disease and wait until all symptoms have disappeared before correction is attempted. This involves fixation of the joint in the deformed position and later performing a corrective osteotomy. An osteotomy can always be avoided if mechanical treatment has been efficient in cases seen sufficiently early; but it may be a necessity if the patient has been allowed to recover in deformity.

Excision of the Hip.—This operation was formerly practised as an attempt to eradicate all diseased tissues. In children such attempts are now regarded with disfavor, as the results of conservative treatment have rendered this operation obsolete. Very rarely in extensive disease with secondary infection, excision may be advisable merely as a drainage operation.

In adults excision, or better arthrodesis, is a justifiable operation in the early stage of hip disease; and with prolonged and effective mechanical after treatment the results are encouraging.

Extra-articular Arthrodesis.—Early operative intervention has been advocated in recent years, based on the idea of hastening the natural ankylosis which so frequently accompanies the stage of "cure." In the technique used, the diseased area is left untouched; bony fixation being induced outside the joint between the trochanteric region and the pelvis (Albee, Hibbs[1]).

Amputation.—This is a life-saving measure, at times necessary in cases of hopeless disintegration of the joint where constitutional complications have arisen. This operation is often a severe test of the physical endurance of the patient.

[1] Albee, F. H.: Orthopaedic and Reconstructive Surgery. Phila., 1919.
Hibbs, R. A.: A Preliminary Report of Twenty Cases of Hip Joint Tuberculosis Treated by an Operation Devised to Eliminate Motion by Fusing the Joint. Jour. Bone & Joint. Surg. July, 1926, IIi, 3.

CHAPTER VIII

TUBERCULOSIS OF THE KNEE JOINT

(Tumor albus, "White swelling")

In addition to the general anatomical character of the knee joint referred to on page 21, the following points are of especial importance in connection with tuberculosis of the joint. (1) The very large area of synovial membrane extending well up above the patella, and (2) the fact that the lower epiphysis of the femur and the upper end of the tibia are the epiphyses in which the greater part of the growth of the leg occurs, for which reason the neighborhood of the knee joint is very vascular. A long continued inflammation caused by tuberculosis, or other chronic inflammatory affection at the knee joint, therefore, often results in increased growth of the leg on account of the congestion induced around the epiphysis.



FIG. 150.—Specimen showing thickened synovial membrane and eroded cartilage, especially noticeable in the patella (Warren Museum, Harvard University).

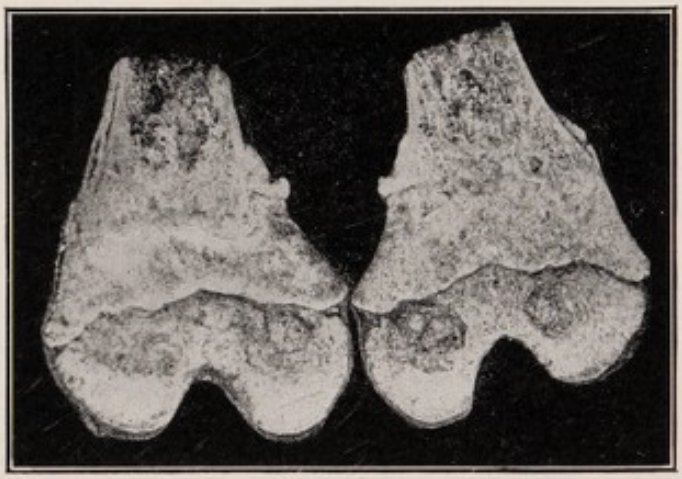

FIG. 151.—Foci in outer and inner condyles of the femur. Joint practically intact (Warren Museum, Harvard University).

For the same reason operative interference likely to damage the epiphysis of the knee in children is likely to result in very grave shortening of the limb.

Pathology.—The disease begins most often near the epiphysis of the femur or tibia, and less often in the patella. With the entrance of the organism into the joint a tuberculous synovitis begins. From data obtained at operation it would appear as if a primary tuberculosis of the synovial membrane occurs from time to time in the knee, especially in adults, but it must be remembered that no definite conclusions as to this can be drawn from operative findings, because nothing short of a complete series of sections of both bones warrants one in stating that a given case is of synovial origin.

Symptoms. *Swelling.*—The knee joint is accessible to direct examination at the sides of the patella, and the slightest degree of thickening of the synovial membrane can be easily detected so that the increase of fluid is to be found early by palpation. The direct examination of the joint therefore in the knee is of primary importance and significance. The swelling is semi-elastic, not clearly fluctuating, even and smooth in contour, and feels, as it looks when opened, like a mass of gelatin swollen by soaking in water.

Muscular Atrophy.—Marked early muscular atrophy in excess of that caused by desuetude occurs in both thigh and calf and measurement shows approximately the same difference between the two sides in both thigh and calf.

Muscular Spasm.—Muscular spasm is less important than in tuberculosis of the hip and when it does occur it is generally found at a comparatively late stage. Although in the hip, from the nature of the joint and the muscles one must depend on muscular spasm from the outset as a cardinal symptom, in the knee a very considerable degree of joint tuberculosis may exist for a long time with an inconsiderable amount of muscular spasm or with none at all.



FIG. 152.—Lower end of femur, showing erosion of cartilage and bone (Warren Museum, Harvard University).



FIG. 153.—Complete ankylosis of knee with ankylosis of patella (Warren Museum, Harvard University).

Deformity.—Flexion deformity is that which results from muscular spasm at the knee, and it is a most persistent and troublesome deformity. When once flexion has occurred it becomes very obstinate and after correction tends to recur again and again unless the joint is carefully protected in extension for a long period, and flexion deformity, if it recurs, is a sign of active disease or inefficient treatment. If it is long continued, the pull of the hamstring muscles displaces the flat articular surface of the tibia backward on the condyes of the femur and a so-called *subluxation* results which is often increased when the knee is straightened by force. In connection with long continued flexion deformity, there also occurs in most cases an outward rotation of the tibia on the femur due to the predominating pull of the biceps muscle. *Knock-knee* also occurs in cases where the deformity of flexion and outward rotation has been long

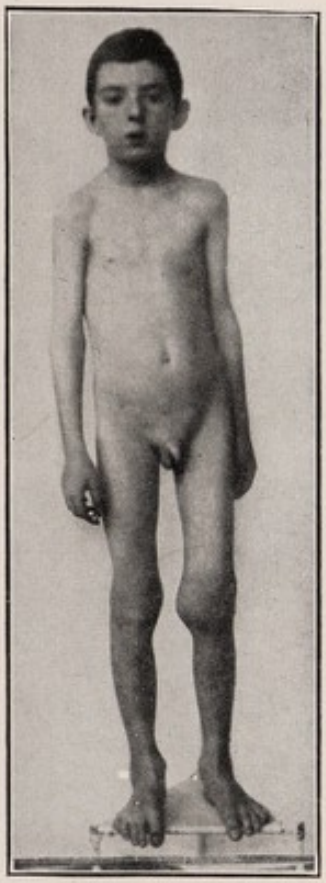

FIG. 154.—Tuberculosis of left knee, showing swelling of knee and atrophy above, but no flexion deformity.



FIG. 155.—Tuberculosis of left knee, with swelling and early flexion deformity.



FIG. 156.—Long continued tuberculosis of the right knee with multiple sinuses, right angle flexion and subluxation .



FIG. 157.—Excessive shortening due to excision of the knee in childhood with destruction of epiphyseal lines.

continued, and this is sometimes due to irregular growth of the limb during the distortion. The existence of subluxation, rotation and knock-knee must be borne in mind in formulating the prognosis after straightening such deformed knees. It should be borne in mind that these deformities can easily be prevented provided the mechanical treatment is correctly carried out.

Pain is frequently absent, generally moderate in amount, but occasionally in connection with flexion deformity in the acute stage may be very severe.

Shortening may occur from unusual retardation of growth in the limb, but principally from destruction of bone, and the shortening of bone, unless in very advanced destructive disease, is not more than about one-half inch. The prolonged congestion in the neighborhood of the joint, as has been pointed out, stimulates epiphyseal growth, and increased rather than retarded growth is common.

Lameness is the result of discomfort in weight-bearing on the affected limb because of the limitation in movement, and also on account of the shortening caused by a flexed position of the knee.

Lymph Nodes.—The lymphatics connected with the joint are tributary to the inguinal nodes and a noticeable enlargement of these on the affected side is often present.

Examination.—Both knees should be examined with the legs extended and the feet resting on the surgeon's knee while the patient is seated, or examined with the patient lying on a table or bed. The contours of the two knees should be compared, and it should be noticed if the hollows at the side of the patella are filled out. Palpation of the joint should be made in this position with reference to the amount of swelling over the condyles of the femur at the sides of the patella. Examination for fluid is made in this position with the thumb and middle finger of both hands encircling the front of the leg above and below the patella. With the tip of the forefinger of the right hand one presses down on the patella and if fluid is present, the bone can be felt to strike on the femur, but often on account of the gelatinous character of the joint effusion and some fixation of the patella distinctive "floating" is not present. Measurements of the knee joint are not of great value and a considerable amount of synovitis and synovial thickening may exist without showing in the circumference as taken by a measuring tape. The amount of wasting of the muscles above and below the knee joint should be noted, and any limitation of motion should be very gently investigated. At the slightest indication of resistance this attempted action should stop. It must be remembered that flexion deformity is one of the early manifestations of tuberculosis of the knee.

Diagnosis.—The diagnosis rests on the presence of a chronic, proliferative synovitis of indolent character, especially in the first decade of childhood. Limitation of movement and flexion deformity are early and important symptoms as in the case of other infected joints. These symptoms are absent in chronic effusions of traumatic varieties. Characteristic X-ray appearances of focal bone infection and destruction are much later in becoming evident in the knee than in most joints, even with the most modern X-ray technique. Flattening and squaring of the condyle of the femur is a suggestive change[1] which often occurs in children. The other symptoms in establishing the positive diagnosis in tuberculosis are those already described. In adults the

[1] Sever, James Warren, and Fiske, Eben W.: Jour. Am. Med. Ass'n., Apr. 24, 1915 and Am. Jour. Orth. Surg., April, 1915.

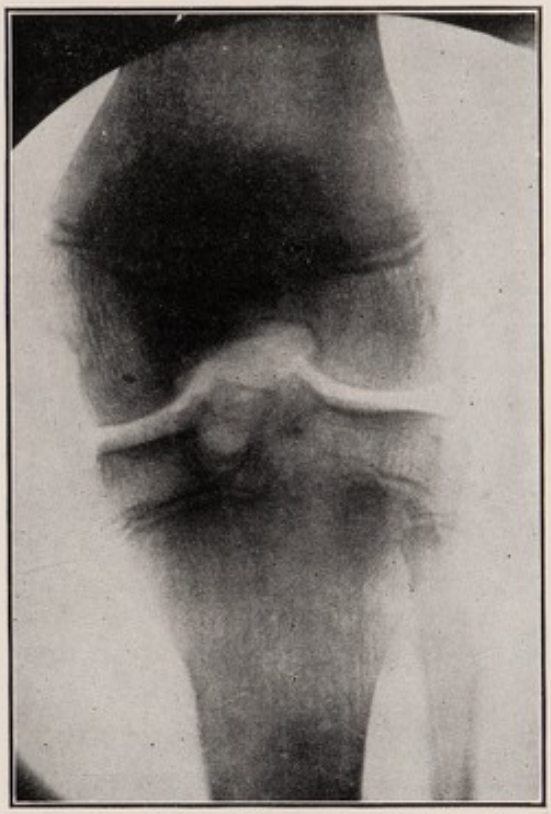

FIG. 158.—Front X-ray of tuberculosis of knee, showing focus in upper epiphysis of tibia.

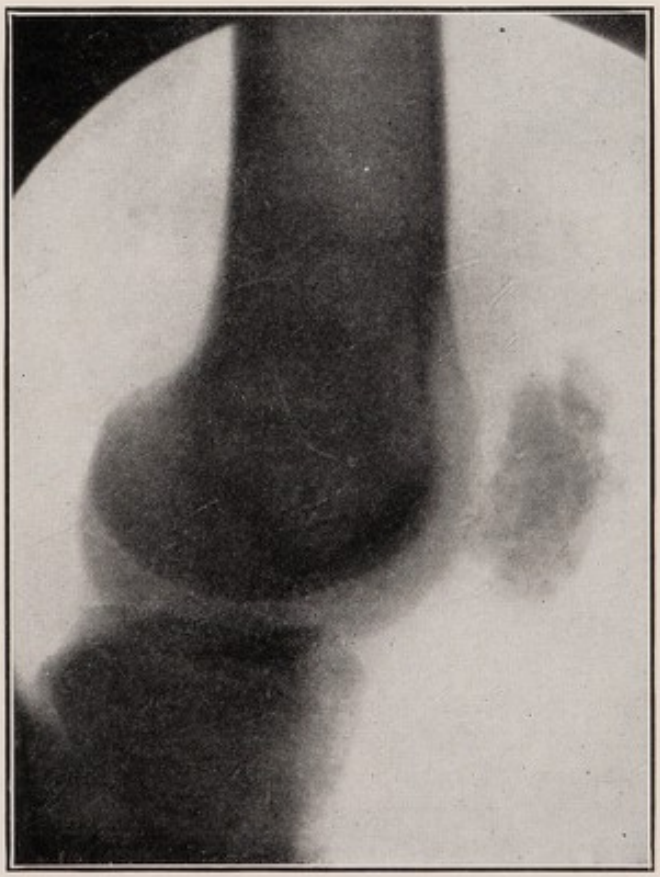

FIG. 159.—X-ray showing tuberculosis of patella in adult.

diagnosis is more difficult than in children. Bilateral knee joint tuberculosis is rare.

Differential Diagnosis. *Chronic Traumatic Synovitis.*—Following an injury, a painful long continued enlargement of the joint with considerable synovial thickening may persist. In children such cases are likely to be tuberculous, as it must be remembered that at times the traumatic swelling may pass directly into the tuberculous swelling. In adults, however, this is much less likely and the most careful investigation is sometimes necessary.

Infective synovitis of the knee joint, of which the gonorrheal form may be taken as the type, in mild and long continued cases may be difficult at first

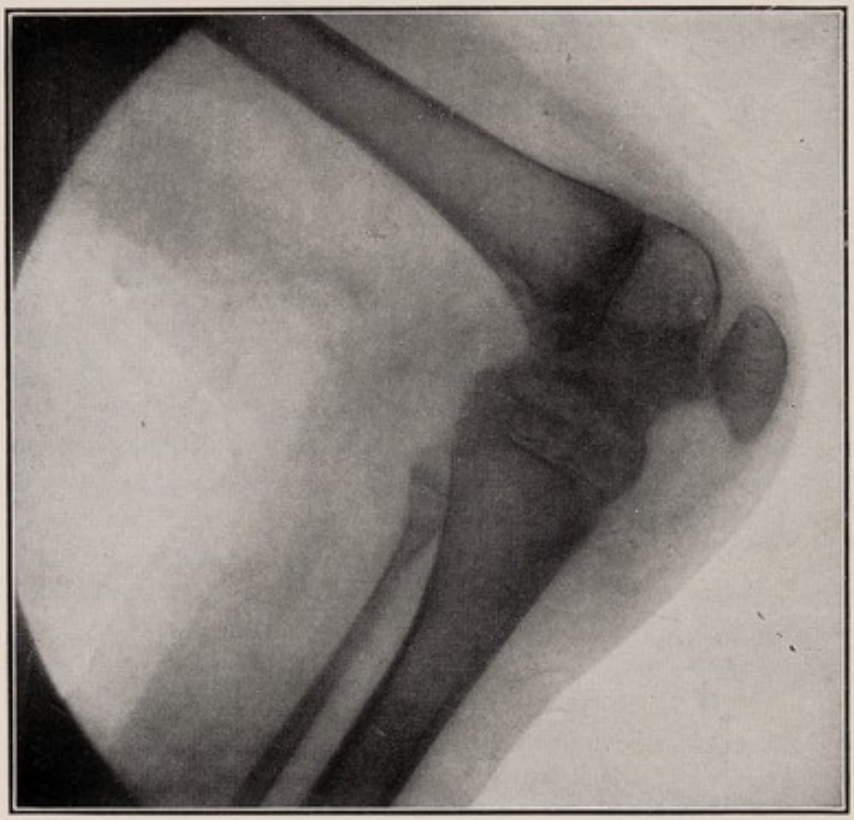

FIG. 160.—X-ray of tuberculosis of the knee joint with flexion deformity, showing beginning subluxation and beginning bone destruction.

to differentiate from tuberculosis. But the symptoms are more acute and painful, generally plastic thickening is marked and of a dense character; there is generally a history of antecedent gonorrhea, sore throat or "grippe;" fixation of the joint is marked, at first due to muscular spasm but early in the history often to a real and rapidly occurring ankylosis.

Arthritis Deformans.—In children monarticular non-tuberculous arthritis is for practical purposes non-existent. In the adult the differentiation between the two conditions may cause much difficulty, and the diagnosis can often be made only by prolonged study (page 116). In general this form of arthritis is more often polyarticular than monarticular even in adults. The X-ray changes are likely to be those of a formative character although simple atrophy may be the predominating appearance. Focal destruction is not found and a general mottling of the bone surface is the more usual appearance. Tuberculosis is more often focal than general, but may rarely be distinctly of an infiltrative character.

Syphilis.—One of the common manifestations of hereditary syphilis in children is a bilateral chronic synovitis of the knees. This may be accompanied by other stigmata of syphilis, and the X-ray appearances are of atrophied bone with no focal involvement or destruction of joint surfaces. Syphilitic osteochondritis in the child gives rise to swelling and sensitiveness of the knee, but the swelling and tenderness are most marked at the epiphyseal lines, and not at the joint.

Charcot's joint disease may show an indolent, painless, and destructive swelling of the knee joint but always exists in connection with organic disease of the nervous system. The swelling contains irregular masses, is dense and ovoid as a rule and laxity of the joint is present when the process has progressed.

Sarcoma of one of the bones of the knee joint may occur, as a spindle shaped swelling near the knee joint. Muscular spasm is not a prominent symptom, pain is slight, impairment of function is not prominent, and X-ray appearances are characteristic.

Hemophilia.—Hemophilia, fortunately uncommon, is a condition most likely to be mistaken for tuberculosis, by the well informed surgeon. The hemophilic knee is swollen, flexed and painful, and externally resembles tuberculosis very closely and in a suspected knee it is well to inquire as to the bleeder diathesis, in the individual and family, and to investigate the coagulation time of the blood. It should be remembered that the female sex is never affected. The hemophilic knee often shows traces of old bleedings; is usually limited in movement and old masses of unabsorbed blood clot may be felt. Adhesions are common, but close inquiry usually elicits the story of rapid effusion and painful onset with intermissions. An inquiry as to the history should always precede operation in all chronic knee joint affections.

Rickets.—Rickets in young infants and a nutritive disturbance of the knee joint epiphysis described as scurvy rickets are most often polyarticular but may affect one joint, particularly the knee. The affection is characterized by the general signs of scurvy or rickets, or both, and particular reliance may be based on the characteristic condition of the gums in children where teeth are present, and in the delayed ossification of the epiphyseal body where the element of rickets is marked. The symptoms are swelling, flexion and sensitiveness, but these are not localized in the joint primarily, but in the epiphyseal lines above and below.

Periarticular Disease.—Inflammation of the bursæ about the knee and lesion of the tubercle of the tibia are to be differentiated by the absence of effusion in the joint, the location of the swelling and the sensitiveness.

Functional Affections.—The neurotic knee is sometimes difficult to diagnose from early tuberculosis, especially in the child. Even in the well developed limb of a young woman it may closely simulate the early ostitic form. In these cases we have only the presence and exaggeration of subjective symptoms to aid in making the diagnosis. The patient walks with a limp, complains of pain, the leg is flexed, and the joint motions are restricted. There is tenderness to pressure, even heat about the joint, and only the trained hand of the surgeon accustomed and practised to appreciate the resistance of involuntary spasm, or the neurologist accustomed to investigate hysterical manifestations may be able to make the diagnosis. The hysterical knee is usually not accompanied by pronounced atrophy of thigh and calf, and we must always remember the possibility of such phenomena superimposed upon a slight organic basis.

Tuberculosis of the Deep Pretibial Bursa.—This should be remembered as occurring rarely. It is characterized by pain, local swelling, and discomfort in extending the knee. The X-ray from the side shows erosion of bone on the anterior surface of the tibia. The operative removal of the diseased structures is easy.

Prognosis.—Prognosis as to life in tuberculosis of the knee joint in children should be good. If, from an early stage of the disease, they receive effective, long continued treatment it is proper to look for the preservation in the end of a sufficient amount of mobility to be of use. A knee which can flex to a right angle is a useful knee and 45 degrees of motion enables the patient to walk well and sit comfortably. A perfectly stiff knee in the straight position is useful for walking but an annoyance at a theatre or in a street car as it cannot be put under the seat and people trip over it. In the adult, however, tuberculosis of the knee joint is a much more serious affair and much less amenable to treatment. In the working man it constitutes a serious menance and conservative treatment must be long continued to be effective, and even then in certain cases will fail. In this condition operative treatment adopted early may be the best procedure. The most that can as a rule be hoped for by mechanical treatment in adults is an ankylosis, and the shortest way to obtain this is by operation.

Treatment

In formulating the question of treatment of tuberculosis of the knee joint, one must remember that one is dealing with a weight-bearing joint, with a large extent of synovial membrane, the muscles controlling which are much less powerful than those controlling the hip. Consequently the jamming of the diseased surfaces together by muscular spasm is not nearly so important an affair as in the hip joint, and traction is therefore used only during the correction of deformity. The object of treatment must not be lost sight of, which is in these cases, as in other cases of tuberculosis of the joints, to secure arrest of the process in the best functional position.

Mechanical Treatment.—The two measures therefore that come up for consideration are: (1) *Fixation*, and (2) *protection against weight-bearing* too early.

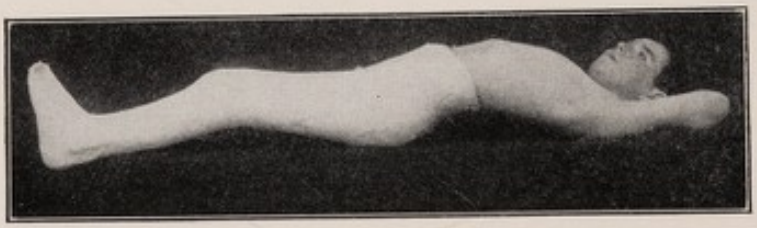

FIG. 161.—Correctly applied splint, embracing the pelvis, for tuberculosis of knee joint.

1. *Fixation.*—Fixation constitutes the main requirement of treatment. This is desirable at all stages of tuberculosis of the knee joint until convalescence is established, and is easily provided for by simple means.

For permanent fixation a *plaster of Paris bandage* is a simple measure available anywhere. This bandage is usually applied as a circular bandage, and to be effective as such must reach from the origin of the adductor tendons to the malleoli, for a short bandage is inefficient and deceptive as a means of fixation. One technical difficulty in the application of a circular plaster bandage for knee joint fixation lies in the tendency of the front of the upper

part of the cast to ride away from the leg, because in most instances the thigh is flexed during application. A better fitting bandage is applied if the patient is laid over the edge of the table and the affected leg hyperextended at the hip. As a rule it is better not to include the foot. Better fixation, however, is obtained if a *plaster spica bandage* is applied instead of a simple circular bandage ending at the top of the thigh, and this is to be recommended in all cases which are painful or particularly acute. It is important that the pelvic part of the spica should be snugly applied to the pelvis and scored in above and below the iliac crests.



FIG. 162.—Inefficient and vicious plaster bandage, loose fitting, too short, and applied with the knee flexed.



FIG. 163.—Schematic representation of Thomas caliper splint applied.

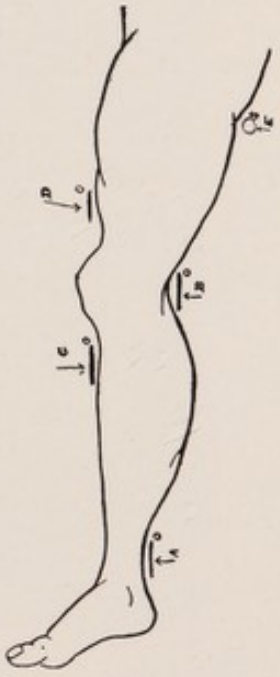

FIG. 164.—Diagram showing the direction of supports and pressure pads in Thomas caliper splint.

THOMAS KNEE SPLINT.—The best method of obtaining fixation and at the same time protection is by the use of the Thomas knee splint. It is commonly used in two forms: (1) The bed splint, and (2) the caliper splint. The original form of splint fitted with a patten at the bottom (Fig. 145), though little used by Thomas himself in later years, is most valuable where absolute relief from weight bearing is desirable.

1. The *bed splint* consists of a ring of round iron to which is welded a long loop of the same material, going some inches below the foot. The ring, in shape, is an irregular ovoid flattened in front, and drawn out at the posterior and inner outline of the thigh. As the inner rod of the loop is joined more anteriorly than the outer rod, the ring slopes from without inward and from before backward in such a way that the point upon which rests the tuberosity of the ischium is the lower part of the ring. The angle formed by the plane of the ring and the inner bar is about 135 degrees, and the anterior angle formed by the antero-posterior plane of the ring and the inner bar is about 145 degrees. The thickness of the iron depends upon the weight of the patient and is from three-sixteenths to three-eighths of an inch.

In making the ring the ends should be joined by welding, and the side bars of the long loop are joined to the ring in the same manner. The lower end of the long loop is dimpled somewhat to receive and retain the straps from the adhesive plasters. The ring is padded



FIG. 165.—The forces used in traction by the Thomas bed splint.



FIG. 166.—The Thomas bed splint applied.

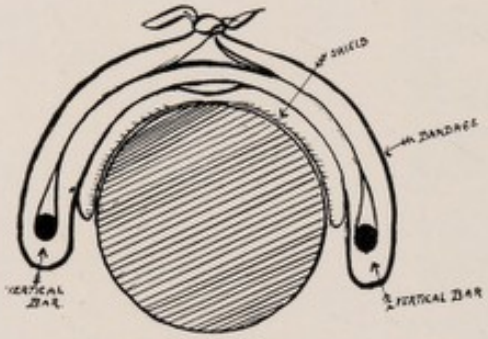

FIG. 167.—Section outline of splint and pressure pads.

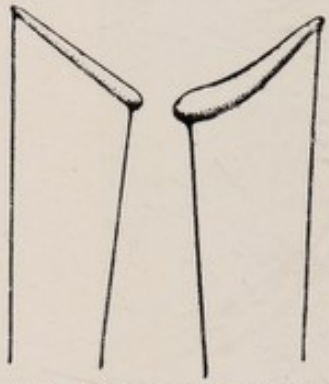

FIG. 168.—Front and back view of ring of Thomas caliper splint.

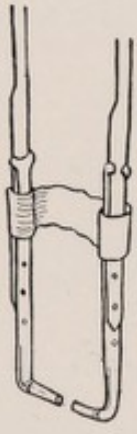

FIG. 169.—Sliding ends for caliper.



FIG. 170.—Dotted line shows tube in the heel in which are inserted sliding ends of caliper.



FIG. 171.—Showing the counter of the shoe cut away to prevent pressure to heel.

with boiler felting to the thickness of half an inch on its outer portion, and from one to one and a half inches in thickness at the inner posterior portion upon which the tuberosity of the ischium is to rest, and then covered with basil leather, or tan sheepskin, put on wet, and

sewed after the manner of the harness-maker along the lower and outer border of the ring, where the seam will not chafe the patient.[1]

A strip six inches wide of similar leather is sewn by one end to one side of the side bars, the other end being left free and of sufficient length to be drawn across to the opposite bar, and when sewn there to form a support for the back of the knee when the splint is applied. Another strip four inches wide is to be placed similarly at the back of the ankle.

The splint is applied by slipping the ring over the leg and pushing it well up against the tuberosity of the ischium. If fixative traction is to be used strips of strong adhesive plaster in width about one-third the circumference of the leg and in length equal to the distance from the knee to the ankle, to the lower ends of which pieces of strong tape, webbing, or muslin bandage have been sewn, are applied to the outer and inner surfaces of the leg. If these pieces of adhesive plaster are supplied with narrow, oblique, lateral strips for winding around the leg, they will remain much longer attached to the skin. The adhesive plasters applied are held in place by an ordinary roller bandage. The surgeon then grasps the patient's foot and pulls steadily downward, at the same time pushing the splint upward, and having straightened the limb as much as the patient will tolerate ties the tape terminations of the adhesive plasters at the dimple at the lower end of the splint. One may prefer to use a screw extension which saves the tying and untying of the tapes and so lessens labor. By this expedient all pressure on the ankle is avoided, and the tension is longer maintained.

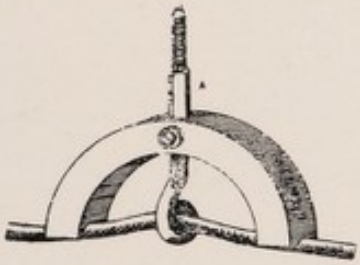

FIG. 172.—Tool used for bending bar of Thomas caliper splint.



FIG 173.—Thomas caliper splint with strap to correct knock-knee.

The lower leather cross strap is now placed at the back of the ankle, drawn snugly across, and sewed fast. The other leather strap is placed at the back of the knee, or at the back of some part of the thigh if the knee is too greatly flexed to rest upon it, drawn across to the opposite bar and sewed there. The knee is now pressed backward and straightened as much as the patient will tolerate, and is held there by a roller bandage carried to and fro across the front of the limb around first one side bar and then the other; or a thick pad may be placed across the lower end of the thigh, well down upon the patella, and backward pressure made by a strong strip of bandage passed across from side to side and somewhat downward and tied to each side bar by a half hitch, and then carried across the pad and tied. After this the traction tapes at the bottom are again tightened. The limb is left thus, if everything remains in place, for two or three days, when it can again be made straighter and the fastenings made tighter. In this way the limb is straightened.

2. The *caliper splint* is made from the bed splint by cutting off the lower end of the loop and bending an inch or more of side bar inward at right angles. The bed splint is at first applied and pushed well up on the straightened limb, a point is marked on each side bar half an inch below the sole and another an inch or an inch and one-half below this; the side bars are cut off at the second point, and the bend is made at the point first marked. Generally speaking it is better to order a caliper splint specially fitted with *sliding ends* so that the

[1] RIDLON and JONES: "Contributions to Orthopedic Surgery"

length can be increased as the patient grows. The shoe is cut at the heel, as shown in the Fig. 171, this mutilation of the shoe being often necessary to prevent abrasion of the heel in walking. A hole is next bored through the heel of the shoe at an angle and a tube inserted. Into the hole, or tube, the bent ends of the side bars are passed, the leather straps drawn fast and sewn, and the limb tied or bandaged in place. If the knee is so swollen that the inner bar presses against it, this bar is curved with wrenches, or the tool is employed as shown in Fig. 172.

The backward luxation of the tibia can be largely obviated by making the leather strip support the back of the head of the tibia, while extra backward pressure is made at the lower end of the femur. Instead of a bandage one may use two shields made of sheet iron and lined with felt. This is much more effective and far simpler than the employment of a bandage.

In the employment of this caliper splint in the case of children, surgeons should remember the necessity of making it sufficiently long so that the patient's heel is a good inch from the sole of the boot. In this way the ankle escapes a jar which, were the splint shorter, would surely be conveyed to the knee.

Treatment by Recumbency.—This is necessary in certain cases. These are (1) cases which are too acute to be treated elsewhere than in bed, (2)

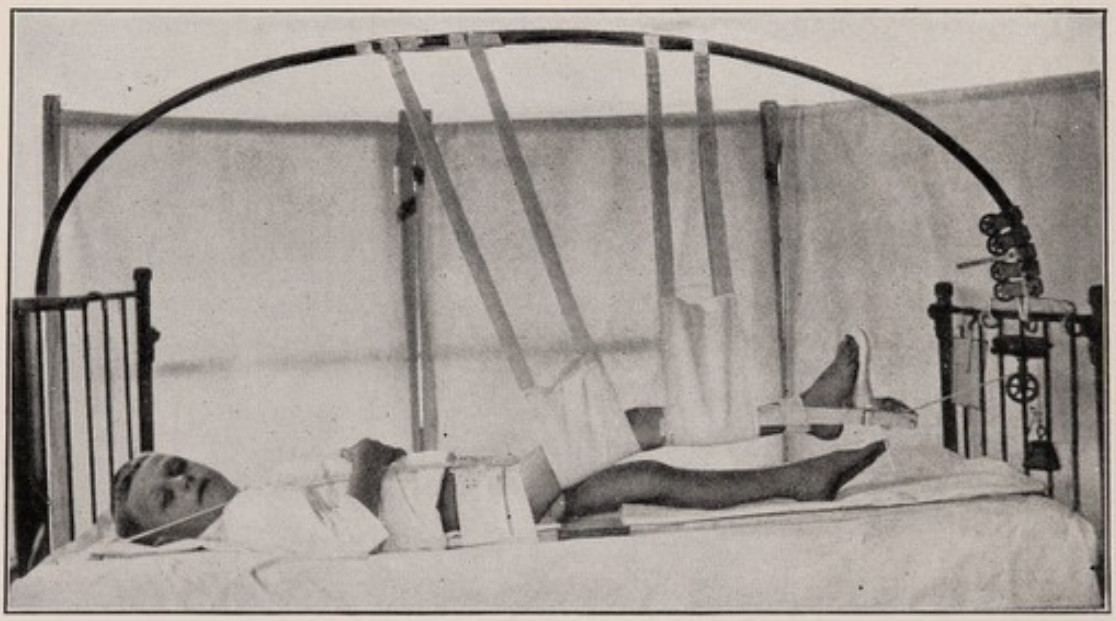

Fig. 174.—Traction on flexed knee joint in bed.

cases where abscess is threatening or beginning, (3) cases where the general condition is seriously threatened, and (4) cases with marked flexion deformity, which should *always* be corrected as soon as it appears.

1. In the cases which are too acute to be controlled by an efficient spica bandage while going about, recumbency with or without traction is necessary (Fig. 174). In these cases the Thomas bed splint should be used. Where such apparatus is not available, the following simple method of applying traction may be temporarily used. Adhesive straps with webbing at their ends are applied to the leg and thigh, running up and down from the knee. The leg and thigh are well padded with sheet wadding and a circular plaster of Paris bandage applied from groin to malleoli. If flexion is present, no

attempt should be made to straighten the limb in applying the plaster. In the outer and inner side of the plaster bandage, near its top and bottom edges, are incorporated buckles fastened to pieces of webbing. When the plaster has set, the projecting pieces of webbing are turned back over the upper and lower edges of the plaster and fastened into the buckles. In this way efficient traction may be made for a short time, but only for a short time, as such plaster straps must be changed every three or four weeks, or excoriations under the adhesive plaster will occur.

2. *Abscesses.*—Abscesses of the knee joint as a rule accompany acute and painful cases, and one of the methods of treatment by recumbency already described will probably have to be used on this account alone, apart from the existence of the abscess. If abscesses are threatening or present, the case should be treated as would be any acute and painful case. If necessary to open an abscess in the knee joint, a small incision under the most perfect asepsis is made when it threatens to burst. Aspiration may be attempted previously in the hope of preventing rupture. Early opening is to be deprecated as there is danger of infection.

3. *Poor General Condition.*—In cases of serious involvement of the general condition, as shown by elevation of temperature, anemia, etc., recumbency with the best mechanical treatment should be adopted in connection with outdoor treatment and heliotherapy. Heliotherapy is valuable, but should never be considered as other than accessory to the treatment according to the principles already laid down.

4. *Deformity.*—In cases where deformity is present it should be corrected at once since progress is retarded in the presence of a changing angle of flexion and recovery takes place much more quickly with the limb in extension. The deformity, as has been described, may be best corrected by continued leverage force accompanied by fixative traction. The bed splint is used to correct deformity, subluxation and genu valgum.

The Thomas knee splint is applicable to all stages, and has been dealt with above; but for *acute* cases where flexion is present with tenderness and irritability there are other methods also available to the surgeon, such as (*a*) *Plaster of Paris fixation*, and (*b*) the *Balkan frame.*

(*a*) A circular bandage from the malleoli to the groin is put on the knee in a position of flexion, the knee being put as straight as possible without causing pain to the patient. Under the rest afforded by this bandage the irritability of the joint diminishes, the muscular spasm relaxes, and if the plaster is removed in a few days it will be found that the knee can be straightened more than at the original application. A succession of such bandages will in these cases result in a correction of the deformity, in the later bandages the knee being put up with a little pull in the direction of straightening. (*b*) In the second method the lower leg is slung from an overhead support, such as a Balkan frame, in a sling. The posterior surface of the thigh is supported by another sling, running toward the top of the body. The knee is left at the natural angle of deformity and adhesive plaster straps are applied to the lower leg and run thence horizontally to a pulley at the bottom of the bed.

Flexion deformity which has become *chronic* and not accompanied by pain and tenderness is also easily straightened by wedging. A circular plaster of Paris bandage is applied to the leg in the position of deformity and made rather heavy over the knee. The back of this is then divided transversely

at the level of the popliteal space for three-quarters of its posterior circumference. Thin pieces of wood are then inserted into the cut part which is wedged open with the resultant straightening of the knee. The front of the knee must be heavily padded with felt, because it forms a fulcrum for pressure, and in the use of much force a slough would form if the knee were not carefully protected. By the use of this method it has generally proved that any knee which can be manually straightened under anesthesia can be straightened equally well by this method.

Flexion of the knee joint should be prevented by the application of the principles already described. If the knee is swollen, very tender, and the general condition of the patient shows toxic absorption or if abcess is threatened it is well to quiet down the acute irritation by fixation for a few days or by continuous traction.



FIG. 175.—Caliper splint for tuberculosis of the knee.

Convalescence.—Recumbency should be insisted upon until all tenderness has gone, swelling diminished and the general condition is good. These clinical signs are fortified if the X-ray shows reparative changes. The patient should then be allowed to walk in a carefully adjusted Thomas caliper. In the experience of the writers, harmful trauma is brought about by the motions of flexion and extension, but modified weight-bearing in the fully extended position during the convalescent stage is of slight practical harm compared with the advantages of locomotion. At the outset the splint is made of such a length that when the sliding pieces of the caliper are inserted into the holes in the heel of the boot, the heel does not touch the sole of the boot. The diagnosis of a cure of disease at the knee joint is the same as at any other joint, namely, absence of pain, swelling, tenderness, muscular spasm; no increased restriction in the range of movement in joints where there is motion, and no progressive tendency to deformity in joints where there is no motion.

Operative Treatment.—Correction of deformity under anesthesia saves time, is safe in skilful hands, but a very dangerous proceeding to use by those unfamiliar with tuberculous joints. Continuous traction is usually effective, but slow, and sometimes ineffective, so that one may after all resort to straightening under anesthesia, for the knee must under no circumstances be allowed to remain flexed unless this is necessitated by a very acute condition or some complication, but should be straightened as provided for in this chapter. Recovery in deformity is always unsatisfactory, a source of annoyance, and disabling. This can be appreciated by noticing the occasional man in the street with right angle deformity of the knee joint, walking on a peg leg with the foot sticking out behind. If slight deformity exists it should not be neglected

because it is slight, but should be immediately corrected by one of the methods described. The greater the deformity the more pains needed to correct it, but the correction of slight deformities is just as urgent as that of severe ones.

Correction of Deformity under Anesthesia.—If it is decided to correct the flexed knee under anesthesia it is done by straightening the knee against mild pressure not attempting to straighten it completely at one session unless it yields with the greatest ease, but to start the extension and continue with fixation and traction as described in speaking of the Thomas splint. Attempts to straighten flexed knees with much force are dangerous. When an anesthetic is used, the approach should be gentle, and when firm obstruction is encountered, further attempts should be abandoned and the procedure should be in gentle stages.

Subluxation of the tibia exists in long continued flexion deformity from the constant pull on the tibia of the hamstring muscles. When the knee joint is extended, as described above, the head of the tibia should be protected against posterior displacement by applying a forward pull upon it, or dividing the tendons of these muscles. Without these precautions, the result is too often a straight leg with the tibia in a plane posterior to the femur.

The use of a heavy degree of force in straightening a knee (brisement forcé) at any stage of the disease should never be undertaken, for the risk of lighting up the disease is great, the production of fracture or separation of the epiphysis is not unlikely, and for another reason the forcible extension of a knee under ether which has been considerably flexed for a long time is a hazardous procedure, for many legs have come to amputation through it. The sudden straightening of the knee lengthens the femoral artery and a rupture of the intima may occur; in any event a diminution of the lumen of the artery is likely to take place, just as a rubber tube is cut down very much in caliber when the two ends are pulled apart, and this diminution may be enough to cause gangrene without complete rupture of the artery, although the latter occurs at times.

If the limb is to be straightened at once, the patient being anesthetized, it is better to apply the caliper form of the splint as the one giving better fixed traction.

When a joint has been straightened under an anesthetic it should be left in the splint, without change of shoe, stocking, or bandages, until all pain and excessive tenderness have passed off. In a word, the joint has been more or less sprained by the manœuvre and must be treated with all the consideration which a sprain demands. The deformity corrected, the patient should be kept off of his feet until the muscular spasm has subsided, when he may be allowed to walk about. If for any reason the patient has to be up before this time he should use crutches or sticks and a thickened sole under the sound limb.

Operative Treatment in Children.—In children open operations except the evacuation of abscesses should be rarely called for, and never in the early stages of the disease. In acute angular flexion with external rotation and subluxation it may be necessary in adults to perform a wedge exsection removing the joint surfaces and correcting the alignment and displacement, but if this is done in young children there is danger of stopping or deviating the growth of the epiphyses and causing serious shortening. Erasion of the joint is no longer usually practised, but sometimes in very seriously disorganized

joints with secondary infection a mass of necrotic material forms in the joint resulting from extensive destruction, and this of itself constitutes a source of irritation. Therefore, in very severe cases of this type, filled with discharging sinuses, it is often helpful to open the joint and remove without trauma this necrotic material. Any attempt to remove all tuberculosis is futile, but sometimes the removal of this irritating débris promotes repair. The operation here is merely one of drainage.

Operative Treatment in Adults.—It has been stated that in most cases the best result that can be obtained from mechanical treatment is an ankylosis more or less firm, and that at the least three years of active treatment is necessary. A fusion of the knee means a considerable saving of time and freedom from other risks which surround such cases, and if a frank statement of the arguments is submitted to the patient he will generally elect to have the operation performed, and in the opinion of the writers this conclusion is a sound one. After fusion or a wedge osteotomy, immobilization will be needed for at least four months.

Jones' Operation.—A horse shoe incision is made over the anterior aspect of the knee joint, extending from four inches above the adductor tubercle, passing down to a point just above the tubercle of the tibia, and passing above the external condyle to the same level as on the inner side. The skin, fascia, and ligamentum patellæ divided by this incision are now reflected upward with the patella, great care being taken that all the synovial membrane, postpatellar fat and suprapatellar pouch are left in situ and not reflected with this superficial layer. The suprapatellar pouch is then completely removed in one portion from above downward, along with all the postpatellar and lateral fat which has been left in position. The knee is now completely flexed and, after division of both crucial ligaments, the remaining synovial membrane; both semilunar cartilages are also completely removed. A grooved arthrodesis chisel is used to remove the necessary thickness of bone and cartilage from the upper end of the tibia and femoral condyles.

The cartilage is entirely removed from the bone ends, and any area of necrosis excised. By retaining the shape of the condyles of the femur and deepening the tuberosities of the tibia, large bony areas are brought into contact in such a manner that the femur is locked in the tibia. This operation is most suitable for ankylosis of a firm fibrous type, such as accompanies a chronic arthritis with some destruction of joint surfaces. It is not suitable for the correction of a bony ankylosis in a flexed position.

In flexion of the knee following tuberculosis, bony ankylosis is the ideal result, and it is often necessary to transform a fibrous to a bony ankylosis, or correct a faulty bony one.

Amputation.—Amputation of the thigh is to be considered only as a life saving measure in children where the joint is hopelessly disintegrated, and in adults only when an excision has failed, or where the disease is too extensive to justify the performance of an excision.

CHAPTER IX

TUBERCULOSIS OF ANKLE, SHOULDER, ELBOW, WRIST AND SACRO-ILIAC JOINTS

Tuberculosis of the Ankle

Pathology.—The pathological characteristic of this disease, in and around the ankle, is the involvement of one or more of a series of weight-bearing joints, exceedingly complex in character, with a wide distribution and free communication of synovial membrane, making tuberculosis of these joints particularly resistant to treatment.

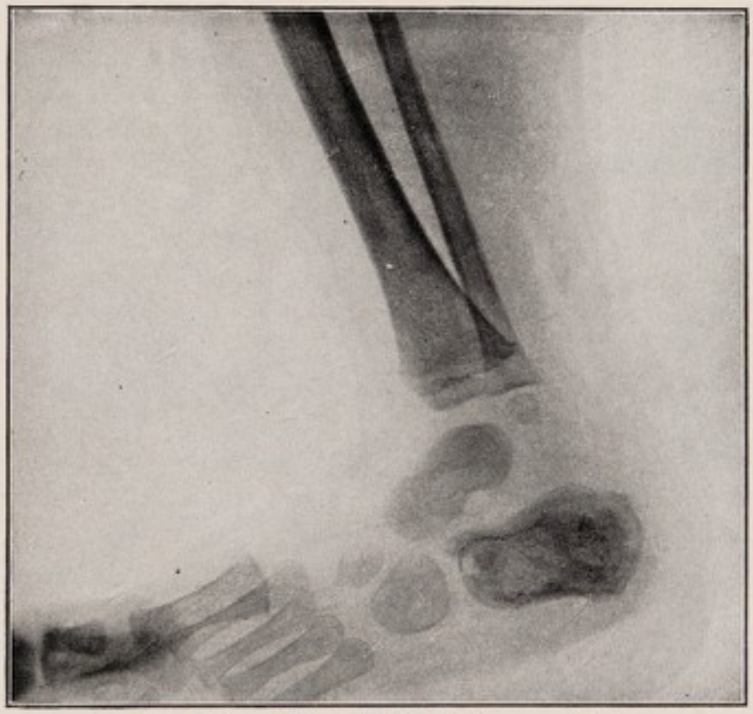

FIG. 176.—Tuberculosis of the os calcis.

There are several places in and around the ankle in which tuberculosis may occur. These are: (*a*) The astragalotibial articulation, (*b*) tarsal bones and joints, (*c*) metatarsophalangeal joints, (*d*) phalanges, (*e*) tendons.

In (*a*) *the ankle joint proper*, the disease resembles that of the hip and knee in the general pathology, and causes a similar destruction of joint surfaces.

(*b*) The *tarsal bones* are compact and small and the pathological changes are a little modified in certain instances. The form just described occurs where the destruction begins near the articular surface and erodes and destroys joint surfaces. In a second form a distinct cavity occurs in the bone, particularly the os calcis, and does not, at first at least, reach the articular surface. The cavity resembles a Brodie's abscess from pyogenic infection, and in some cases the two conditions cannot be differentiated, except by the microscope. In a

third form there is a condensation of the bone with some joint involvement, not accompanied by breaking down to any extent.

In (*c*) and (*d*) the process resembles tuberculous dactylitis in the fingers. Finally (*e*) tuberculous *tenosynovitis* occurs around the ankle eventuating perhaps in abscess with no clinical or X-ray evidence of involvement of the bones.

In an analysis by Sever of end results in 252 cases it was found that the astragalus was affected in 74 cases; the lower end of the tibia in 42; and the lower end of the fibula in 19; the os calcis in 45; the scaphoid and the cuboid, each 14; the three cuneiforms and then the metatarsals.[1]

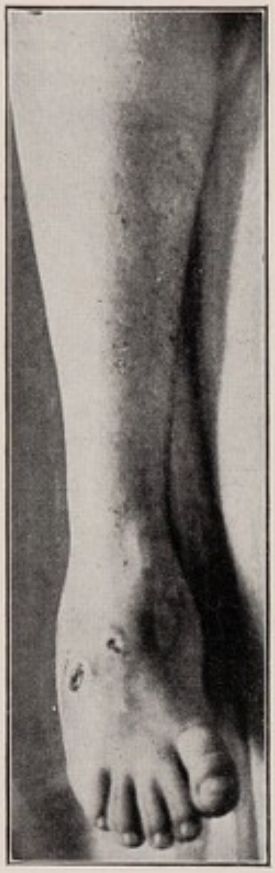

Fig. 177.—Tuberculosis of the ankle.

Symptoms.—There are two types of tuberculosis appearing at the ankle joint. One starts as a primary tuberculous synovitis—the other a primary ostitis. The synovial type is frequently associated with a sprain, and the first symptoms are restricted movements and pain. Swelling is often first of all found at the back of the joint in front of the tendo Achillis. This is followed by a fullness around the malleoli; the front of the joint, excepting where considerable effusion has occurred, is the last to become swollen. If untreated, the ankle first of all becomes plantar flexed and then slightly valgoid. Later the swelling is general, the malleoli becoming almost obliterated, and abscesses form.

In the ostitic form a limp is noted early and the pain is usually more acute, and all the movements may become obliterated before any marked swelling is to be noted. Sooner or later the synovial membrane becomes involved and the symptoms of a tuberculous synovitis appear. In other instances one or more localized semifluctuant points can be felt which do not seem to be connected with one another. Abscesses are very frequent unless the case is treated early.

Tarsal disease presents very similar symptoms to ostitic tuberculosis of the ankle joint. The differentiation between disease affecting the tarsus and ankle is assisted by noting the direction of restricted movement. Disease of the astragalo-tibial joint causes limitation of flexion and extension; disease just in front of the head of the astragalus generally causes little or no limitation of ankle joint motion, but of eversion and inversion. Disease involving joints further forward causes limitation of eversion and inversion. and also of adduction and abduction of the forefoot. In severe cases motion may be restricted in all joints of the foot.

Swelling and tenderness exist over the affected joint or bone, pain is not as a rule severe, but lameness exists for two reasons: (*a*) Pain in bearing weight and (*b*) loss of motion or deformity in the affected joint. Atrophy and muscular spasm occur when joint surfaces become involved, but not generally when the disease is confined to a local lesion in the center of one tarsal bone.

Deformity in plantar flexion is that commonly found, but inversion and eversion may be associated with this when tarsal joints are also implicated.

[1] Sever, J. W.: Jour. Am. Med. Ass'n., Dec. 17, 1910.

Diagnosis.—The general picture of such cases is of a chronic, semi-fluctuating swelling, accompanied by moderate pain and lameness. In tuberculosis of the ankle joint proper, the swelling first begins at the posterior part of the joint and is evident in front of the tendo Achillis; next, the outline of the internal malleolus is lost; then the outline of the external; and finally the swelling appears in front of the joint. In disease in the tarsus a tender swelling occurs over the focus. Limitation of motion is always present when the ankle joint is involved, and may or may not be striking when tarsal joints only are affected, as flexion and extension may remain free. A chronic, indolent swelling of this character in children is very strongly suspicious of tuberculosis. In adults such a swelling may occur from other causes.

In the diagnosis the X-ray is of great value, as the bones are small, not covered with thick soft parts, and show changes very early: extreme bone atrophy is often seen as a definite sign in the tarsal region.

Differential Diagnosis.—The following conditions often present difficulty in the matter of differential diagnosis from tuberculosis of the ankle, and much more commonly in adults than in children.

Chronic Sprain of the Ankle.—After an injury to the ankle joint, perhaps not effectively treated, perhaps thoroughly well treated, swelling, lameness, and tenderness persist, with often some stiffness. The joint is uncomfortable after use and becomes more puffy and congested, especially on hanging the foot down. The swelling in this condition is a general puffiness and not a local semi-elastic swelling. Tenderness is often local and usually over the internal lateral ligament, but this may be combined with a general hyperesthesia. Local heat is not present to any marked degree; stiffness, if present, is general; and the X-ray is negative.

Chronic Foot Strain.—A static error in the foot, as in flatfoot, at times leads to swelling, muscular spasm, acute pain and lameness, and is sometimes at first difficult to differentiate from tuberculosis. The same data that were given in connection with chronic sprain are applicable here.

Osteomyelitis.—In children osteomyelitis or local pyogenic infection of the localized type may appear both in the lower end of the tibia and fibula as well as in the bones of the tarsus. The symptoms are more acute at the onset than in tuberculosis, with some leucocytosis and elevation of temperature; but they may not be accompanied by the severe general reaction which one associates with osteomyelitis in general. In many cases a focus may exist for years in one of the tarsal bones giving rise only to slight lameness and occasional pain. The foci as shown in the X-ray are not always distinguishable from those caused by tuberculosis except by microscopic examination.

Chronic Arthritis Deformans.—This is not generally monarticular, but is most often seen in conjunction with general arthritis. When it occurs in such a joint as the ankle, it may for a time simulate tuberculosis. Bone changes are likely to be proliferative in character and a mottled or stippled X-ray shadow replaced the focal destruction seen in tuberculosis. The diagnosis is by no means always easy, but the general principles are the same as those laid down in the two previous sections.

Fracture.—The occurrence of an unrecognized or old fracture of the tarsus is not to be forgotten in considering tuberculosis about the ankle joint. Fracture of the *forward ends of the metatarsals*, described mostly by military surgeons as pied forcé, occurs in forced marches without noticed trauma. Fracture of

the *fifth metatarsal* without displacement, described by one of the writers, is frequently unrecognized and in this way may lead to pain and swelling on the outer border of the foot with local thickening and pain at the site of fracture.

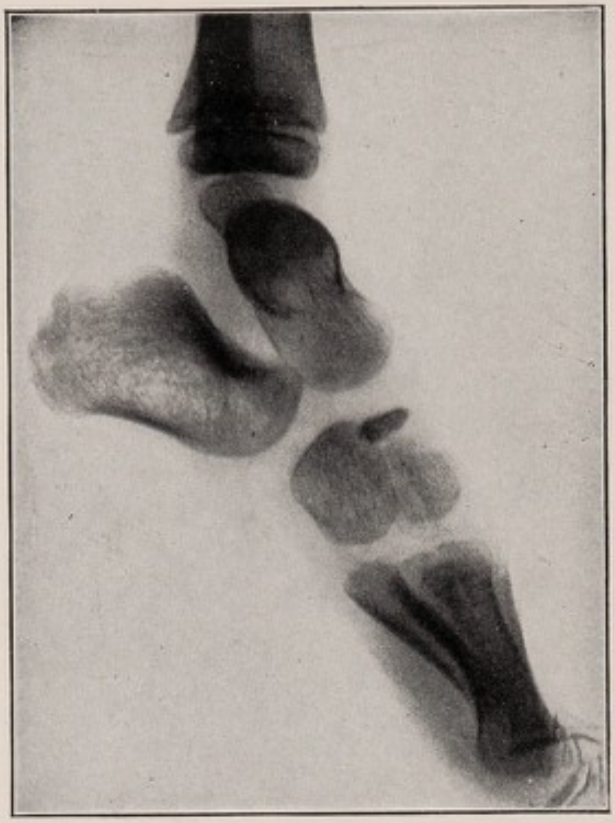

FIG. 178.—Köhler's disease. Child of three and a half years.



FIG. 179.—Same case over two years later.

Fracture of the *os calcis*, usually easily diagnosed, often escapes observation, until disability of the foot later on necessitates a close investigation. The

X-ray appearances render the diagnosis clear. The fracture occurs as the result of falls from a height, on to the heel. One finds swelling and thickening on both sides of the foot, beneath the malleoli. Flexion and extension of the ankle joint proper are not necessarily interfered with, and from the side there is often a deceptive appearance of a shortening of the heel. The sub-astragaloid joint is deranged with impairment or loss of adduction, or abduction.

Köhler's Disease.—An affection of unknown etiology occurs in children in the scaphoid bone which in the X-ray appears compressed in the long axis of the foot, but broadened in the lateral. It is most often symmetrical, sometimes attributed to trauma, causes lameness, and local tenderness is present. Patients make a good recovery if protected from trauma and weight-bearing.

Prognosis.—The prognosis of tuberculosis of the ankle joint and feet is on the whole good, and the affection is generally controllable because fixation is easily maintained.

Permanent limitation of motion at the ankle joint proper when it occurs is compensated by the mobility of the tarsal joints and even a stiff ankle is not disabling provided recovery has occurred without deformity. Sometimes prolonged suppuration with great enlargement of the soft parts exists and continues until the bones are largely disintegrated.

Treatment—*Mechanical.—Fixation* and *protection* from weight-bearing are our mainstays in local treatment, but traction is not applicable.

The treatment should consist in giving the joints absolute rest, in preventing deformity, and if deformity has occurred in correcting it.

The ankle should be fixed at right angles before the splint is applied and kept in this position until recovery has taken place. There are two methods which may be employed for this purpose.

(*a*) By a casing which surrounds the joint such as plaster, celluloid or a leather splint.

(*b*) By a skeleton splint which leaves the diseased area exposed.

(*a*) If no sinuses exist, a plaster of Paris bandage may be applied which should always extend to just below the knee. Its disadvantages are its weight, if used as an ambulatory appliance with crutches, and the difficulty in keeping the area of disease under observation, and also it does not allow of the advantages of heliotherapy, so useful in disease of the ankle. A celluloid splint is much lighter and both plaster and celluloid splints may be so split as to allow the removal of the anterior part so that the joint may be exposed for any accessory form of treatment.

(*b*) A simple fixation splint can be substituted for the plaster of Paris bandage. It consists of two uprights running up and down the outside of the leg to a point one inch below the tubercle of the tibia, and curved to fit the outline of the leg. The two may be made continuous with the uprights, or the uprights may be made out of one piece and the sole plate fastened to them. A posterior calf band connects the two uprights, which is padded with felt and covered with leather. Leather lacings are provided for both calf band and foot piece.

The splint recommended by the writers is what is known as the *crab splint.* It consists of a metal stem reaching from the junction of the upper and middle third of the tibia to the tread of the foot and is moulded to lie against the posterior aspect of the limb. A plate is fixed on the upper half of the stem to support the calf. Two strips of flat metal are fixed to the stem by their center

at the tread and at the heel to retain the foot in position on the stem. It leaves the ankle joint and tarsus fully exposed and allows of easy access to any sinuses which may have formed. It is made of malleable iron or duralumin.

Young children who can be kept off of their feet, and adults who can be trusted with axillary crutches require no further appliance, but in others the Thomas knee splint, made so as to extend three or four inches below the foot, and ending in a rounded ring, should be used, a patten or cork sole of similar hieght being placed under the sound foot.

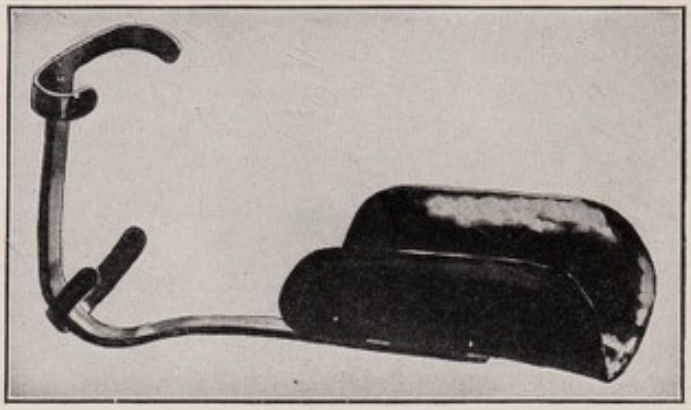

FIG. 180.—Crab splint for tuberculosis of ankle.

Operative Treatment.—On account of the very free intercommunication between the bones of the ankle, operative interference in these cases is singularly unsuccessful. It is wise to exhaust every resource of general and local mechanical treatment before proceeding to operative measures. Operative measures are applicable only where the disease is localized and complete removal is possible. In children non-operative treatment should be the rule. For adults as in bone and joint tuberculosis elsewhere, early operation planned on conservative lines is reasonable.

The mischievous curetting out of the diseased bone either in the ankle or tarsus, which has been so much in vogue, has been an ineffective proceeding, not based on sound pathology or good surgical judgment. Trauma devitalizes tissues and rough scraping with a curette furnishes a large cavity with devitalized walls in which the tubercle bacilli find ready growth. It must be remembered that the tuberculous invasion extends far beyond the area shown by the X-ray to be affected. Operations upon children suffering from tuberculous joints should be extremely rare. The conservative methods at our command are sufficient to effect a cure. In the adult, this is not so, and operation is frequently indicated to secure a rapid and effective result.

Operations for Tuberculosis of the Ankle in Adults.—(*a*) Arthrodesis, (*b*) Excision, (*c*) Astragalectomy, (*d*) Amputation.

In the adult one must decide whether to operate early or late. If early, an arthrodesis is generally sufficient. If the disease is more extensive and the bones composing the joint are more deeply involved, excision is indicated. In very advanced disease it may be necessary to perform an amputation.

Arthrodesis.—This operation gives a successful result if performed in the early stage of the disease. It materially shortens the course of events. The best that can be hoped for if the disease is allowed a prolonged treatment by fixation is a bony ankylosis. The operation expedites this end. Arthro-

desis of the ankle is a modified excision. It involves exposure of the joint and the removal of tuberculous tissue with the eroded cartilage. There are many ways of exposing the joint, but the best operative approach is from the lateral aspect (Kocher). The surfaces of the joint are removed by a grooved arthrodesis chisel, all possible tuberculous debris is taken out, the malleoli bared and an oblique osteotomy of the lower part of the fibula is performed as suggested by Goldthwait. The ankle should bear weight in about six weeks or two months.

Excision of the Ankle.—This operation involves a wider removal of tissues and may include removal of the astragalus if the bone is extensively diseased. The approach from the outer side is the most convenient. The external lateral ligament is divided and the astragalus forcibly rotated so as to bring into view the interior of the joint.

Astragalectomy.—If the disease has seriously involved the astragalus this bone may have to be removed. The method adopted by Whitman is described in another place (p. 486). A sound ankylosis is however preferable, especially where a spring can be obtained from the anterior part of the foot.

Amputation.—If disease is very extensive and the tibia and fibula not involved too high up, an amputation through the middle of the leg may be necessary.

Tuberculosis of the Shoulder

The disease is uncommon in childhood, and in both children and adults tuberculosis of the upper extremities is much less common than that of the lower. At the Boston Children's Hospital 7474 cases of tuberculosis of the spine and joints, only seventeen involvements of the shoulder joint were noted.[1]

Pathology.—Tuberculosis of this joint begins often in the head of the humerus and is generally not of synovial origin. It is often of the quiet type, suppuration is not common, and it was formerly described as "dry caries" (caries sicca), which is not considered a special affection by modern pathologists, but merely a quiet type of tuberculous disease. Destruction of the head of the bone as a rule occurs, which resembles a wearing away of the surface rather than a disintegration of the bone.

Symptoms.—The characteristic symptoms are dull, aching pain, stiffness of the shoulder, enlargement of the joint, and marked muscular atrophy. The discomfort is frequently increased by movements, especially rotation, and in complicated movements, going beyond the limit of motion allowed by the mobility of the scapula is very painful. The limitation of motion of the *arm* itself is much less marked than in other joints, on account of the mobility of the scapula upon the thorax. This limitation of motion in the joint, caused by muscular spasm or ankylosis will be evident if the scapula is first fixed. The arm exhibits the deformity of adduction.

The clinical picture shows a flattened outline of the shoulder, marked muscular atrophy, especially in the deltoid, but also in the other muscles, enlargement of the joint with perhaps heat and tenderness over the anterior surface, restriction of movement of the joint itself in all directions, first evident in rotation, but later becoming general. It is painful to lie on the shoulder at night, and some discomfort is often felt at the insertion of the deltoid. The X-ray shows a mottled and irregular shadow in the head of the humerus, with perhaps erosion of the normal spherical outline of the head of the bone.

[1] Sever: Boston Med. and Surg. Jour., Mar. 24, 1920.

Subluxation of the joint toward the coracoid process may occur. Abscesses appear anteriorly, escaping through the least protected part of the capsule, which is in front, between the anterior border of the deltoid and the clavicular portion of the pectoralis major. When an abscess occurs the tissues about the joint are swollen and infiltrated, and discharging sinuses may be persistent, involving in extensive cases the lymphatics of the axilla.

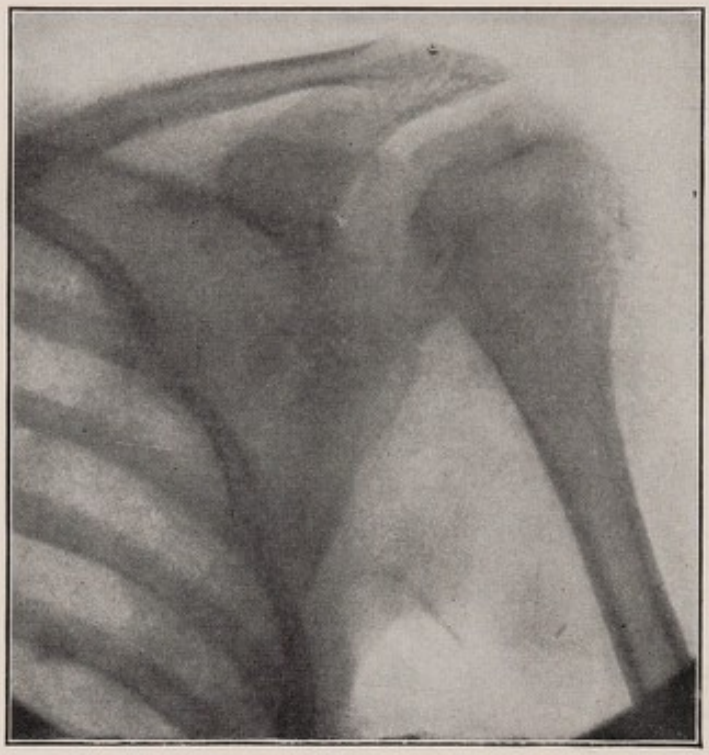

FIG. 181.—X-ray of shoulder joint tuberculosis.



FIG. 182.—Tuberculosis of right shoulder joint with attempted abduction of both arms.

Differential Diagnosis.—The diagnosis would be made by the signs given above and the differential diagnosis from the following conditions is often required.

Arthritis Deformans.—Tuberculosis is painful, generally monarticular, affects children more often than adults, and is slow and resistant to treatment; swelling is moderate, atrophy marked, and the X-ray picture will in time

generally show erosion of the joint surface. Even in the adult the process in the shoulder is less destructive than in most joints. Fixation is generally marked and persistent. Arthritis deformans is generally polyarticular, slower of onset, is most often preceded by creaking and stiffness, exists generally in other joints also, and only after existing for some time does it cause fixation and great pain of the shoulder. Formative changes are slight in this joint, but osteophytes are occasionally to be detected in the X-ray. In the acute stage of this affection the joint swelling, tenderness and pain are much the same as in acute stages of tuberculosis.

Syphilis.—This is rarely painful, often accompanied by periosteal proliferation and perhaps gummata, generally polyarticular, and the signs of syphilis are present.

Sarcoma occurs as a progressive swelling of the upper end of the humerus, not primarily involving the joint; it is comparatively painless, the swelling is dense and non-fluctuating, although this symptom may be closely simulated, and joint motion is not involved early. The X-ray shows no change in the joint surface, but changes characteristic of either type of sarcoma are evident high up in the shaft.

Bone cyst when high up in the humerus causes an enlargement of bone, but the joint is not involved, motion is but little restricted, and the X-ray is characteristic.

Prognosis.—The disease is notoriously slow and resistant to treatment, as a rule lasting from two to five years. Suppuration is unlikely and recovery generally occurs with a marked or complete stiffening of the joint, a stiffening which is less disabling than in almost any other joint. The disease rarely leads to a fatal issue. As the shoulder joint is in early life the important one in the growth of the limb, decided shortening of the arm may result from involvement of the epiphysis of this joint. In early operation the epiphysis may be interfered with.

Treatment.—Treatment should consist of fixation in some degree of abduction. The use of a sling may be temporarily comfortable, but favors ankylosis of the arm in an adducted position, whereas the position of abduction is most important and makes a great difference in the ultimate function of the arm. The reason for the use of the abducted position is, first, to take the weight of the arm off of the diseased joint structures, and thus save them from trauma and so hasten recovery; and second, if ankylosis should occur, to secure the angle of greatest usefulness. If the scapula is freely moveable, as it is in children and adolescents, its mobility allows the arm ankylosed in abduction to sink to the side and by scapular movements the arm can be used freely. But if the scapula is not freely movable (as is often the case in middle-aged people) abduction should be used to only a limited extent, as an abducted arm of this type is a surgical calamity. In children one can abduct to a right angle without fear. A permanent position of at least 45 degrees abduction, with the arm in front of the plane of the body, is the position to be aimed at. This position of abduction is best obtained by the use of a plaster of Paris or wire splint (Figs. 183–186).

When recovery is taking place the child is allowed to raise his arm from the splint and, if he can do this for some time without discomfort, another splint in less abduction can be used. By this gradual method we are enabled safely to conduct the shoulder through its convalescent period.

In the convalescent stages a leather or celluloid spica may prove more convenient. This also should hold the arm in an abducted position under the conditions described.

Excision of the joint is rarely necessary, and if performed, the arm should be left in a position of abduction and some flexion. Excision of the shoulder in children should not be performed.

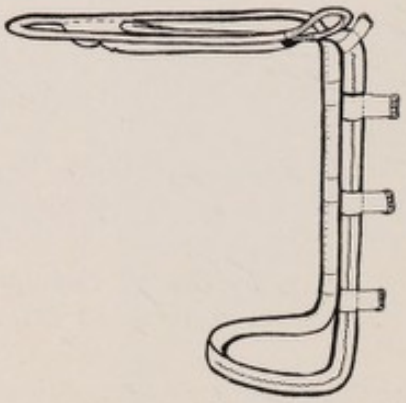

FIG. 183.—Shoulder abduction splint.



FIG. 184.—Shoulder abduction splint applied.



FIG. 185.—Abduction plaster in tuberculosis of the shoulder.



FIG. 186.—Abduction plaster in tuberculosis of the shoulder.

Tuberculosis of the Elbow

The elbow joint consists of three parts, (1) the joint between the ulna and the humerus, (2) the joint between the radius and the ulna and humerus, and (3) the superior radio-ulnar articulation. The involvement of the first two affects flexion and extension, and of the last, rotation; but one synovial cavity generally includes the three articulations.

Pathology.—The bone most frequently affected by tuberculosis of this joint is the ulna rather than the humerus. In the ulna the olecranon, and in the humerus the external condyle, are the points most often involved. Disease of the head of the radius is comparatively uncommon, the latter occurring in only 12 out of 119 cases reported by Ollier.[1] Tuberculosis of the elbow joint is

[1] KAREWSKI: Chir. krank. des Kindersalter, No. 268, 455.

fairly common in England, but somewhat rare in America. It is more common in adults than in children.

Symptoms.—The symptoms are those of joint tuberculosis in general, with no marked peculiarities. Swelling is noticed first at the back of the joint, at the sides of the olecranon process, and the elbow looks rounded and loses its bony contour. Anterior swelling comes on later, there is atrophy of the muscles of the arm and the forearm, and if the wasting is marked it accentuates the large, rounded swelling which involves all the tissues about the joint. The pain is localized at the elbow and there is sensitiveness to pressure, most marked over the site of the disease. The swelling is semi-elastic and not clearly fluctuating, and there is elevation of the local surface temperature, dependent upon the activity of the disease. Motion is restricted in all directions. The characteristic deformity assumed is a position midway between flexion and full extension,



FIG. 187.—Ankylosis after tuberculosis of elbow.



FIG. 188.—Tuberculosis of elbow joint with sinuses.

generally in a position midway between pronation and supination. Suppuration is not common if treatment is effectively conducted, and if an abscess appears it usually presents itself below and to the outer side of the external condyle.

Differential Diagnosis.—The diagnosis is as a rule easily made as the joint is superficial and accessible to examination.

Arthritis deformans presents no especial peculiarities in this location, and what has been said of the shoulder applies here.

Sarcoma may occur and cause a large, dense swelling, restricting motion, and in its early stages somewhat resembling tuberculosis. The appearances and X-ray characteristics are shown in chapter XVII.

Charcot's disease occasionally is found and the symptoms are those already described.

Prognosis.—The prognosis is favorable as to life, but the prognosis as to function is influenced by the care and precision of the treatment and in no joint is it more important, if ankylosis is imminent, to secure it in an absolutely

correct position in relation to function. The elbow should be kept throughout the treatment in a position of right angle flexion with the hand midway between pronation and supination. It must be remembered that a right angled ankylosis of the elbow with the hand in pronation prevents the patient from getting the palmar surface of his hand to his face, or carrying a cup to his mouth without spilling the contents.

Treatment.—A tuberculous elbow should be treated by rest and fixation and no attempt at extension made. The writers would recommend the method of H. O. Thomas, using no splint at all in most cases of tuberculosis of the elbow, but simply keeping the arm slung by what has been termed a "collar and cuff" (Fig. 189).

This in its simplicity consists of a piece of broad bandage sufficiently long to go round the wrist twice and round the neck once. It must be loose



FIG. 189.—Collar and cuff splint for tuberculosis of elbow.

enough not to constrict and yet sufficiently tight to prevent the patient taking his hand out of it. Near the neck the bandage is again knotted and then tied round the neck. To make the sling comfortable for many months the bandage around the wrist and neck is passed through a tube of leather. The position in which the elbow is first placed is that of almost acute flexion, a position in which the hand on the diseased side can rest on the shoulder of the opposite side. Complete rest is thus secured for the joint as the sling prevents extension and the contact of the hand with the neck prevents flexion. If ankylosis is threatened, there will be ample time in the later stages of the disease to drop the wrist to the most useful angle, which is generally found to be slightly more extended than a right angle. If an elbow is stiff at an obtuse angle, it may be necessary to manipulate it immediately into the best functional angle in semi-pronation and fix it there.

The test of recovery in this joint is very conveniently made and is founded on the principle which we have already laid down that, as the disease advances, motion becomes more restricted. When the patient feels his arm to be well and appears to be reckless about it, and all swelling is in abeyance, the experiment of testing is undertaken. The sling is lengthened two inches and the elbow is allowed to drop; if in a few days the arm can be voluntarily lifted to the point from which it was released recovery has taken place and the wrist may be allowed a further drop.

Splints in the case of the elbow should if possible be avoided, as they interfere with the blood supply of the upper arm, check reparative processes and are not comfortable. The elbow can also be fixed by plaster of Paris, celluloid, or by a rectangular splint made of duralumin, plaster of Paris or leather.

In the adult this disease should be closely watched and, if excision is performed, it is best performed early, before much bone is involved. Although amenable to conservative treatment, special care must be taken not to allow the disease to progress until an amputation becomes imperative. In children excision should be an operation of great rarity.

Tuberculosis of the Wrist

Out of 950 tuberculous joints classified by one of the writers 12 involved the wrist; but the involvement of the wrist is rare, however, in children. In 3105 cases of tuberculous disease of the joints treated at the Hospital for Ruptured and Crippled in New York, in only 4 was the wrist joint involved, and at the Children's Hospital in Boston this condition is very seldom seen.

Symptoms.—The symptoms of the disease located in this region are the classical ones of swelling, pain, deformity and limitation of motion. The swelling is noticeable early because the joint is so superficial, and becomes more marked as the disease goes on; and, as in the elbow, is made more prominent by the atrophy of the muscles above it. The characteristic deformity is with the hand in palmar flexion. Abscesses, when they occur, are superficial and not likely to be absorbed. The disease is resistant and troublesome on account of the free communication of the synovial membrane between the bones of the carpus; it spreads rapidly, and is apt to cover a large area for this reason.



FIG. 190.—Tuberculosis of wrist.

The clinical picture is typical of the condition. A large spindle-shaped swelling, generally riddled with sinuses, lies between an atrophied forearm and a wasted hand, with fingers extended. The swelling is doughy or semi-elastic, and the hand is held in some flexion.

Diagnosis.—The diagnosis should offer no difficulty, as the bones are superficial to manual examination and are clearly defined in the X-ray on account of the absence of overlying soft parts.

Prognosis.—The prognosis is not so good as to recovery as in the other joints; the disease is singularly resistant to treatment and is usually found in debilitated subjects who show a lack of general resistance.

Treatment.—The treatment should consist of fixation in a position of dorsiflexion of the wrist of about 35 degrees, which is a matter of much importance if ankylosis occurs.

It is essential that the mechanical treatment of tuberculosis of the wrist should be conducted while the joint is dorsiflexed. If it is treated in extension the fingers are deprived of much of their grasping power. The strong flexors overpower the extensors of the fingers and in consequence proper coordination of the finger movements is impaired.

If there are no sinuses, a short dorsiflexion splint is used, made of sheet iron, glazed and japanned. No lining is needed. The splint is designed to give full play to the metacarpophalangeal joints and to the intrinsic muscles of the hand. This last point is very important as we find stiffness of the hand a common accompaniment of arthritis of the wrist. If sinuses exist, a skeleton splint is used which is shown in the illustration.

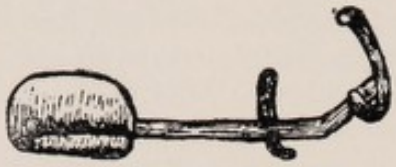

FIG. 191.—Splint for hyperextension of wrist.

Cases ankylosed in palmar flexion are corrected by manipulation, or operation, in order to be placed in dorsiflexion.

Abscesses should be opened if they become superficial, and bony masses of necrotic material removed. Curettage is generally mischievous and disappointing because it causes trauma and is not effective in removing all of the diseased tissue.

In the average adult case fixation of the wrist joint, including the fingers, in a position of dorsiflexion should be first tried; but if it proves resistant, *excision* should be done. If an excision is to be performed in the case of an adult, it should be in good time before the spread of disease jeopardizes the function of the hand. Amputation should be the last resort and every means should be taken to avoid it, as it is a serious reproach to all concerned. When operative measures are undertaken in this complex joint, they should be well planned, definite, and radical. Excision of the wrist should never be performed in children.

Tuberculosis of the Sacroiliac Joint

Anatomical Character.—The sacroiliac joint at every step bears the whole body weight, and transmits it through the pelvis to the leg. The joint is very large and very firm and held together by ligaments and not muscles, and possesses but little motion.

Symptoms.—The beginning of the disease may be very obscure. In certain cases an abscess may appear over the joint posteriorly without preceding pain or limitation of motion. More commonly, however, pain is felt in walking and in the lower back. There may be symptoms referred to the hip joint with some limitation of motion and with pain in the leg. It is generally aggravated by standing and walking, and in painful cases is increased by pressing the crests of the ilia together, or drawing them apart. The pain may be chiefly manifested along the course of the sciatic nerve, and a marked lateral curvature of the spine in which the body leans to one side when the attempt is made to stand is frequently present. In a well developed case of the disease the gait is characteristic and pathognomonic. The patient shuffles along with the knees close together, taking short steps and using the pelvis as little as possible. Both feet are kept on the floor, and when the weight is taken on one, the other one is kept on the ground to steady the body. There

is an entire absence of free stepping out, and the gait once seen is not easily mistaken for anything else.

Even before the gait becomes diagnostic, the patient usually finds himself fatigued on slight exertion and later stooping becomes difficult. In the early stages there is no flexion deformity of the thigh; this is a later symptom and may be accompanied by abduction, or adduction. Referred pain is usually located in the lower abdomen but may be felt along the front of the thigh and along the area of distribution of the sciatic nerve. The anterior ligament offers much less resistance to inflammatory thickening than the strong posterior ligament and for this reason it is more common to palpate a swelling by the rectum than to find it superficial.

Abscess.—The direction in which pus travels may be through the anterior ligament, keeping outside the pelvic fascia; following the course of the sacral nerves and pyriformis out through the great sacro-sciatic foramen and forming an abscess under the gluteus maximus; or following the curve of the sacrum behind the rectum to point on the sacroiliac fossa, causing inflammation and adhesion of the rectum and bursting into it; or coursing under the lumbosacral ligament into the psoas muscle and thence to the thigh; or into the iliacus muscle and into the groin; or through the back part of the joint into the multifidus spinæ muscle, creeping along this and pointing in the lumbar region, or directly over the joint itself.



Fig. 192.—Posture in sacroiliac disease.

Diagnosis.—The diagnosis is not easy. X-ray appearances may be slow in appearing, because the bone is thick and the contour of the joint in any event is irregular when seen from the front. In addition to the general signs which have been mentioned as of use in diagnosing tuberculosis of the joints, the diagnosis is often established by characteristic X-ray appearances, but the disease by this time is considerably advanced. Pressure of the iliac crests together is painful.

The disease may be confounded with arthritis of the hip, or with lumbar spondylitis. The diagnosis is rendered more difficult by spasm contraction and flexion. Motion at the hip joint may appear to be restricted in all directions, but if the manipulations are gently performed with the hip flexed in order not to disturb the sacroiliac joint, it will be found, as soon as the psoas is relaxed, that all the movements of the hip, except those due to contraction of the muscle, are present. In other words all movements are present excepting full extension and external rotation. In spondylitis also the restricted movements of the spine are those due to contractions of the psoas.

Prognosis.—The prognosis is definitely unfavorable, especially in the case of adults. Abscesses generally occur with secondary infection, and the disease is long continued and often intractable.

Treatment.—The best outlook is furnished by fixation and recumbency throughout the acute part of the disease, along with most stringent general measures. Efficient fixation may be obtained by the Thomas double frame with the main stems separated at such a distance as to pass to the outer side of the posterior superior spines of the ilia and the stems ending above the ankles.

A celluloid case, moulded on a plaster model from a cast, may be made extending from above the lumbar vertebræ around the pelvis and embrac-

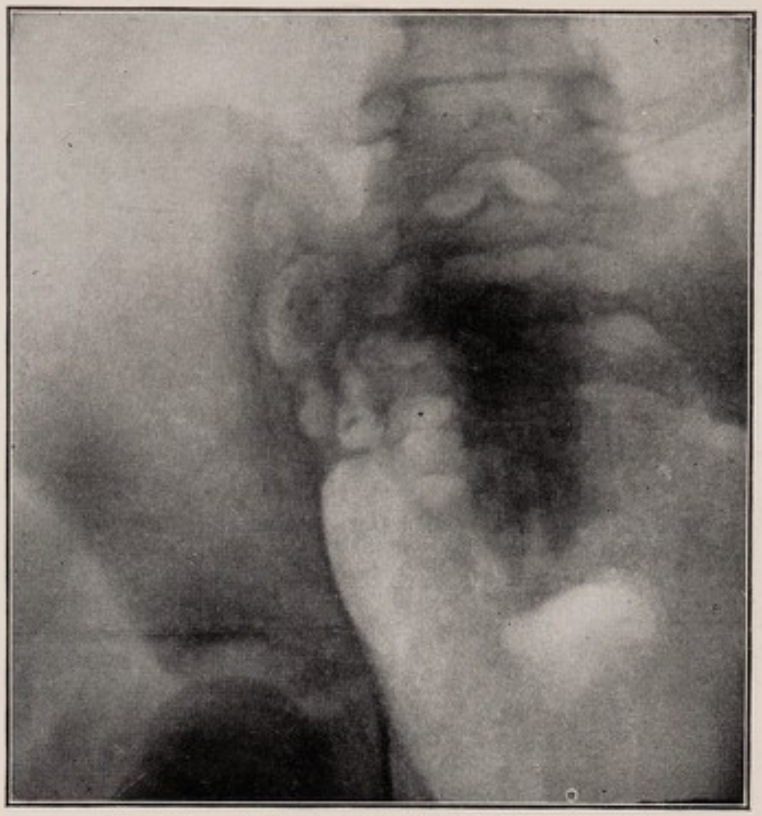

FIG. 193.—Tuberculosis of the sacroiliac joint.



FIG. 194.—Sacroiliac disease in a child of five. Recovery by prolonged recumbency.

ing the thigh on the diseased side; or a double plaster spica may be used extending high enough up to embrace the lower part of the thorax, including the well leg as far down as the knee, and on the diseased side including the foot. The immobilization should always prevent bending of the lower spine and the contraction of the psoas muscle. Pain is usually lessened by gently pressing the joint surfaces together by any form of pelvic girdle which steadies the joint.

Operative Treatment.—If a diagnosis of sacroiliac disease in the adult is fully justified, operation must be considered. In the adult, early operative treatment is indicated, provided the disease is local and there is no affection of the hip and spine. It is most fatal of all the joint affections and therefore an operative risk is justified. If undertaken, it should be thorough, for evacuation of abscess and curetting is not enough, and ineffective operations place the patient in serious jeopardy from infection without offering him any chance of recovery. The fact that an abscess is extra-pelvic does not imply that the disease is confined to the posterior part of the joint.

Two approaches to the joint will be described as they offer the best route for a radical operation.



FIG. 195.—Diagram of Picqué's operation from the side.

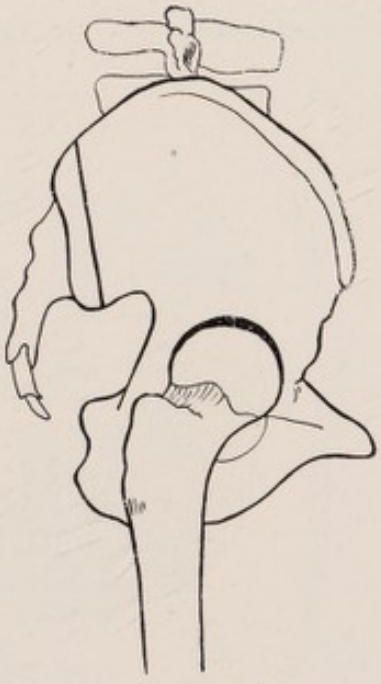

FIG. 196.—Diagram of Picqué's more complete resection.

(*a*) PICQUÉ'S OPERATION.—A curved incision is made reaching down to the bone, traversing the posterior third of the iliac crest along the border of the sacrum to the level of the third posterior external tubercle. The periosteum is elevated from the ilium and a portion of the ilium is then removed in order to give access to the joint. The bone is divided vertically with an osteotome from the crest to the upper and inner corner of the greater sciatic notch. The ilium, having been divided, is removed by elevating the fragment and dividing its ligamentous attachments. The iliac portion of the sacroiliac joint is next removed and the articular and adjacent portions of the sacrum well exposed. The chisel must now be freely used to remove all disease from the sacrum and it is important, as far as possible, to see the field of operation. By working systematically the nerve trunks may be isolated and no damage done. Picqué in certain cases makes a more partial removal of bone, leaving the upper border of the sciatic foramen in situ.

A few sutures are used but the greater part of the wound is plugged with gauze. The post-operative treatment should extend over a few months. Sixty-six per cent of recoveries are recorded in a series of twenty-two cases.

(*b*) SMITH-PETERSEN'S APPROACH.—Another good approach to the joint is that described by Smith-Petersen.[1] The steps of the operation are as follows:

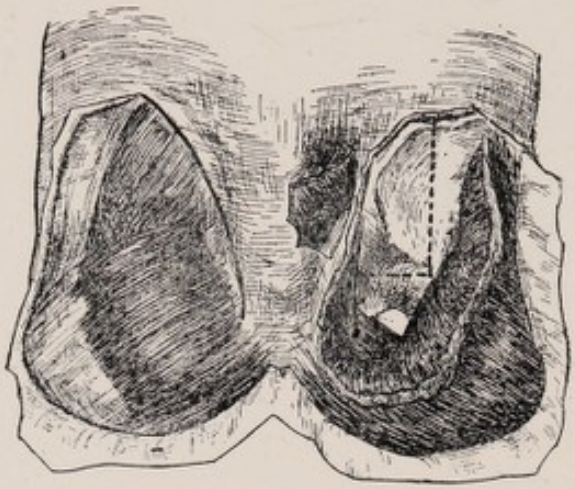

FIG. 197.—Sacroiliac resection. On the left cutaneous incision is shown; on the right the line of partial removal of ilium (Picqué).

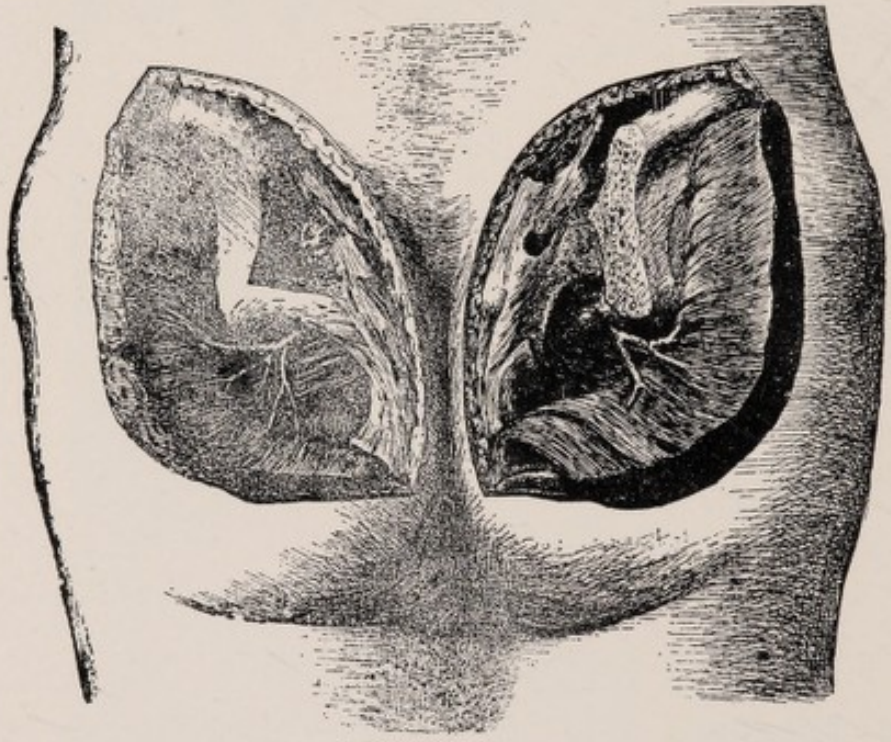

FIG. 198.—Sacroiliac resection. On the left, partial resection of the ilium; on the right, total resection (Picqué).

1. Curved incision from the posterior superior spine along the crest of the ilium, two-thirds of the distance to the anterior superior spine. This incision is carried down to the bone, and the reflection of the periosteum started.

2. Incision from the posterior superior spine in the direction of the fibres of the gluteus maximus for a distance of three to four inches. This incision is carried down through the subcutaneous fat and gluteal fascia, and the muscle fibres of the gluteus maximus separated

[1] SMITH-PETERSEN: Jour. Orth. Surg., August, 1921, 400–405.

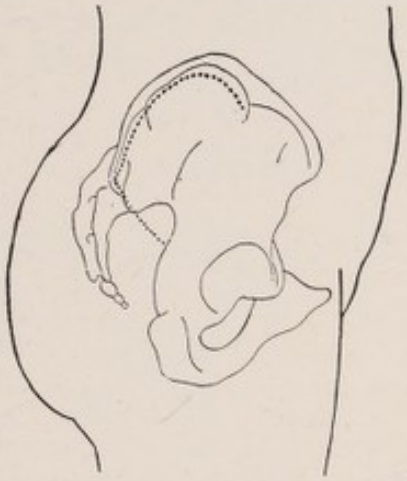

FIG. 199.—Smith-Petersen incision. Dotted line represents incision in its relation to the ilium; curved limb of the incision extends from the posterior superior spine two-thirds of the distance to the anterior superior spine. Straight limb from the posterior spine in the direction of the fibres of the gluteus maximus muscles for a distance of approximately three to four inches.



FIG. 200.—Flap reflected by subperiosteal dissection from lateral surface of the ilium. Dotted line shows sacroiliac joint projected on the lateral surface (Smith-Petersen).

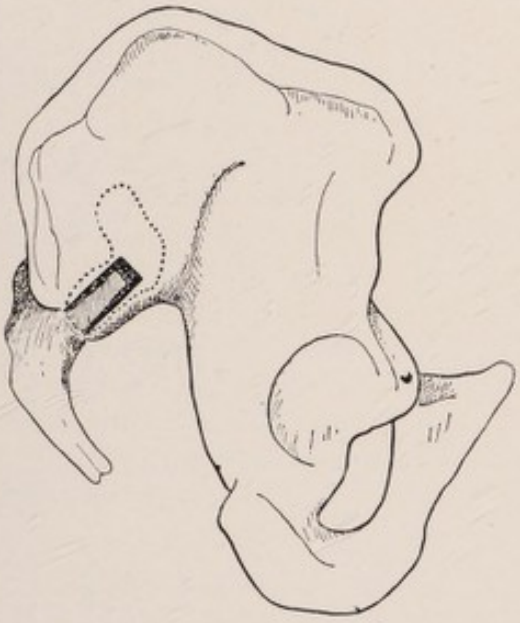

FIG. 201.—Dotted line represents sacroiliac joint projected on the lateral surface of the ilium. Window removed as described for cases of tuberculosis or of relaxation of the sacroiliac joint. Note that the window is well posterior to the median gluteal line and just above the sacro-sciatic notch (Smith-Petersen).

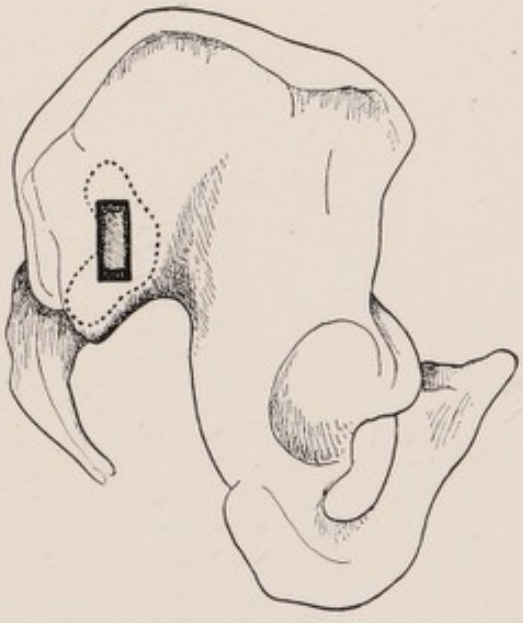

FIG. 202.—Dotted line represents sacroiliac joint projected on the lateral surface of the ilium. Window removed as described for cases of osteomyelitis from posterior border of the sacroiliac joint between posterior superior and posterior inferior spines. It runs anteriorly parallel with the sacro-sciatic notch (Smith-Petersen).

by blunt dissection until the junction of the ilium and sacrum between the posterior superior and posterior inferior spines is reached. In carrying out the dissection, one point should be kept in mind: The superior gluteal nerve and artery emerge at the anterior portion of the sacro-sciatic notch and give off posterior branches which are encountered by the straight limb of the incision, and sometimes cause considerable bleeding. They have to be sacrificed in order to get a satisfactory reflection.

3. The flap thus outlined is reflected subperiosteally, exposing the posterior portion of the lateral surface of the ilium.

4. If the sacroiliac joint is projected on the lateral surface of the ilium, it will be found that the inferior border corresponds with the sacro-sciatic notch, and the anterior border with the median gluteal line. The superior border is not of importance, because the two above landmarks determine the location of the joint sufficiently. A window is now cut through the ilium within the projected area of the joint. A window, rectangular in shape, has been used in the majority of cases. The thickness of the ilium just above the sacro-sciatic notch is considerable, sometimes as much as an inch, but if care is taken, the entire block of bone from the outer to the inner table of the ilium may be removed in one piece. The operator is rewarded for his labor when, upon removal of the window, the cartilaginous joint surface of the sacrum comes into view. The cartilage of the sacrum as well as its cortex is next removed bringing about a good exposure of cancellous bone. The above procedure results in a rectangular channel bordered on all sides by cancellous bone, extending from the ilium through the sacroiliac joint into the sacrum.

5. After removing the cartilage and cortex from the block of bone taken from the ilium, this is replaced in its original site and counter sunk, so that its cancellous surface will be in contact with the cancellous bone of the sacrum.

6. The flap is now returned to its place and periosteum and soft parts sutured in layers.

The position of the window should be varied according to the case encountered. In purulent infections of the joint, the window is cut in a direction parallel to the sacro-sciatic notch; this will give efficient drainage of the joint. In cases of tuberculosis, it is better to cut the window at an angle.

CHAPTER X

TUBERCULOSIS OF THE SPINE

(Synonyms—Pott's Disease, Angular Curvature of the Spine, Caries of Spine)

Tuberculosis of the spine is a pathological process, which does not differ in any essential way from tuberculosis of the joints as described, but the mechanical conditions existing in the spine modify very greatly its clinical manifestations. If it is regarded merely as a bone and joint tuberculosis occurring in a weight-bearing flexible rod, its special manifestations will be easily understood.

The spinal column is curved in the antero-posterior plane by the three physiological curves, forward in the cervical and lumbar regions, and backward in the dorsal. As tuberculosis of the spine usually affects the anterior part of the vertebral bodies, the curves of the spine determine the line in which weight comes upon the diseased bone, and the amount of damage which it will inflict. Disease of the dorsal region for this reason becomes a much more formidable affection than it is in the other two regions because it occurs on the concavity of a weight-bearing curve, whereas in the other regions it occurs on the convexity of the physiological curve, and superincumbent weight becomes much less detrimental.

Etiology.—Pott's disease is the commonest form of bone and joint tuberculosis, Whitman's[1] statistics showing 4299 cases as against 3329 of tuberculosis of the hip, and 3222 of all the other joints put together. The figures of the Children's Hospital, Boston, from 1869 to 1903 show 2867 cases of spinal tuberculosis and 3083 of all other joints. The most frequent location is in the dorsal region. Of 3026 cases from different authors[2] there were 247 cases of cervical disease, 1843 of dorsal, and 936 of lumbar. It must be remembered, however, that the length of the dorsal region constitutes approximately 50 per cent of the length of the entire spine. The lower dorsal region is affected much more often than the upper, so that of 321 cases only 71 were in the upper six dorsal vertebræ, and 250 in the lower six. The disease tends to occur in the region of greatest mobility (the dorso-lumbar) suggesting the influence of trauma in its localization.

In 1792 cases of spinal tuberculosis at the Children's Hospital[3] from May, 1883, to September, 1907, the distribution was as follows:

Cervical or cervicodorsal	247
Dorsal or dorsolumbar	1025
Lumbar	329
Insufficient data	191
	1792

[1] Whitman's Orthopedic Surgery, 1919, 20.

[2] Whitman's Orthopedic Surgery, 5th Edition, 23.
DOLLINGER: Die Bhdlg. der Tub. Wirbentz, Stuttgart, 1898.
HAYASHI and MATSUOKA: Zeitsch. fur. Orth. Chir., xxiv, 381.
HUMPHRIES and DURHAM: Jour. Am. Med. Ass'n., Jan. 27, 1917.

[3] LOVETT: La Cura della Tub. della Spina. Arch. di. Ort. xxv, 1, 1908.

Age.—About 50 per cent of the cases occur between the ages of three and five, and it is unusual before the age of two. From the records of the Children's Hospital, Boston, between 1883 and 1896, Thorndike[1] found only 115 cases occurring in children of two years or less. Seven of these were less than six months of age.

In 1792 cases at the Children's Hospital the ages were as follows.

Years	Females	Males
1	38	38
2	134	164
3	151	181
4	123	134
5	105	110
6	53	64
7	70	82
8	39	45
9	40	37
10	27	41
11	15	25
12	16	21
Over 12	18	21
	829	963

Pathology.—The essential pathological change is a tuberculous infiltration of the anterior part of the vertebral bodies involving later the intervertebral cartilages, but laminæ, spinous and transverse processes are rarely affected. Superficial infection of the anterior part of the column has been recognized and described.[2] The involvement of this weight-bearing structure, especially on the concavity of the dorsal curve, leads to a collapse of the softened part of the vertebræ and the column gives way backward, the spinous processes forming an angular projection posteriorly opposite the crushed area in front; but in the cervical and lumbar regions deformity is often incomplete because the physiological curve is forward. The superincumbent weight in the dorsal region constantly presses together the softened structures of the vertebræ and as the angulation increases it obtains a greater and greater leverage so that the tendency of the unchecked disease is to form a larger and larger backward projection (kyphos) which may reach an extreme degree, resulting in the unfortunate "humpback" so often seen in the streets.

As the deformity increases the upper part of the body falls forward, the trunk is shortened, a secondary deformity of the sternum occurs which is pushed forward by a disarrangement of the structures behind, and a most unsightly position of the body occurs, with the arms coming down very low, the trunk shortened, and the legs appearing proportionally abnormally long. The chest and abdominal organs are compressed, and ill health in adult life is not an infrequent result of the disease acquired in childhood, and is due in many instances to compression of the thorax and abdominal organs.

[1] Trans. Am. Orth. Ass'n., xi.
[2] Wieling: Langenbeck's Arch., lxxii, 2.

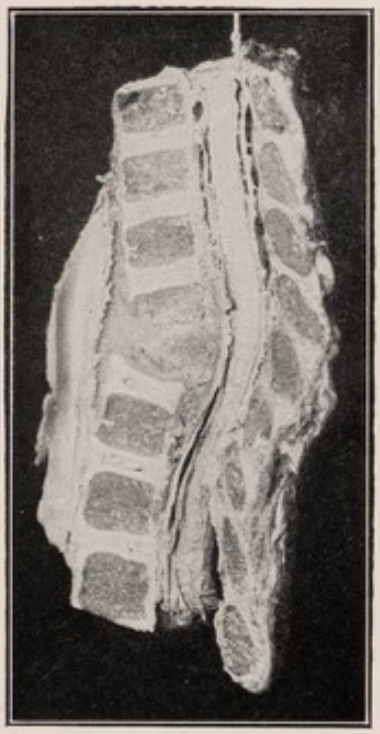

FIG. 203.—Median section of early tuberculosis of the spine, showing destruction of bodies and disappearance of intervertebral discs (Warren Museum, Harvard University).



FIG. 204.—Median section of tuberculosis of the spine of severer grade, showing destruction and involvement of several bodies (Warren Museum, Harvard University).



FIG. 205.—Skeleton, showing partial destruction of two bodies (Warren Museum, Harvard University).

Around the diseased part of the column there is practically always a perivertebral thickening, shown in the antero-posterior X-ray as a spindle shaped shadow of thickened soft parts extending well above and below the disease. Abscess formation will cast a similar shadow in the early stage.

Repair when it comes about is not by means of a callus, but by ankylosis between the diseased parts of the vertebræ, and a protective fusion of the

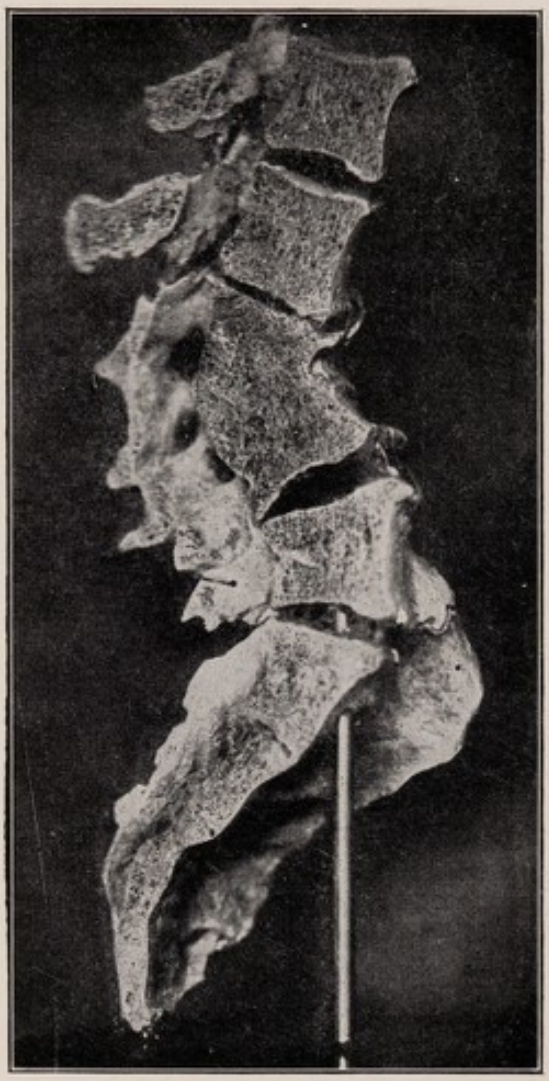

FIG. 206.—Healed lumbar tuberculosis of the spine, showing fusion of bodies with adaptive changes, most noticeable in the fifth where the anterior part of the body has apparently increased in height (Warren Museum, Harvard University).

laminæ over the diseased area, which, however, occurs late in the history. It should be particularly borne in mind that the process of repair, as indicated, is not in many instances adequate, later on, to hold the superincumbent weight of an adult head and thorax coming on an impaired column at an unfavorable angle. This is shown particularly in adults who have passed satisfactorily through the acute stage of the disease but recover with considerable deformity and comparatively complete healing of the column. Such people under the strain of over use or ill health are very apt to find that the deformity is increasing and possibly symptoms of discomfort begin in the back. That repair after tuberculosis of the spine is not mechanically adequate, must especially be

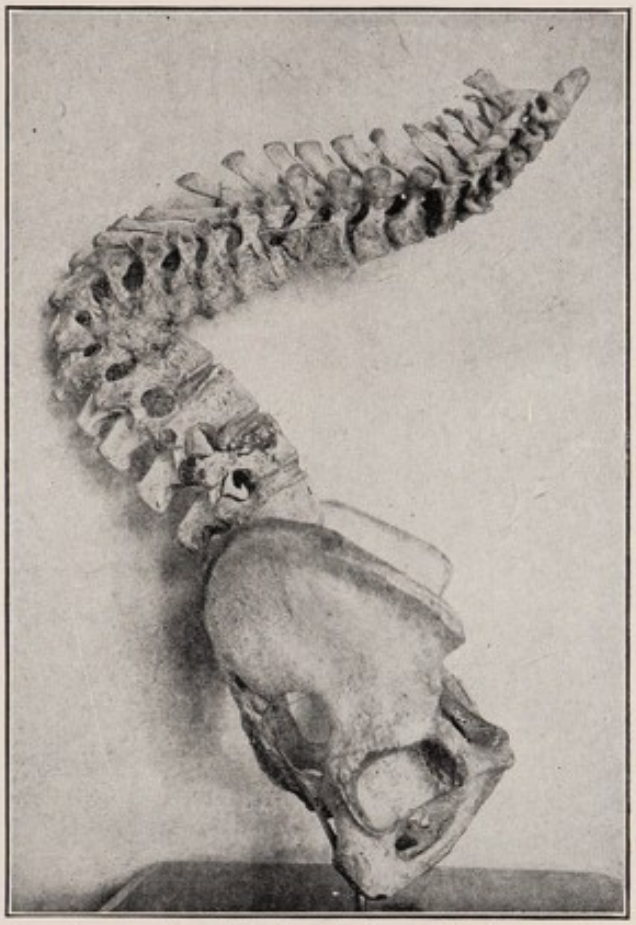

FIG. 207.—Severe dorsolumbar kyphos, showing fusion of bodies and great deformity (Warren Museum, Harvard University).

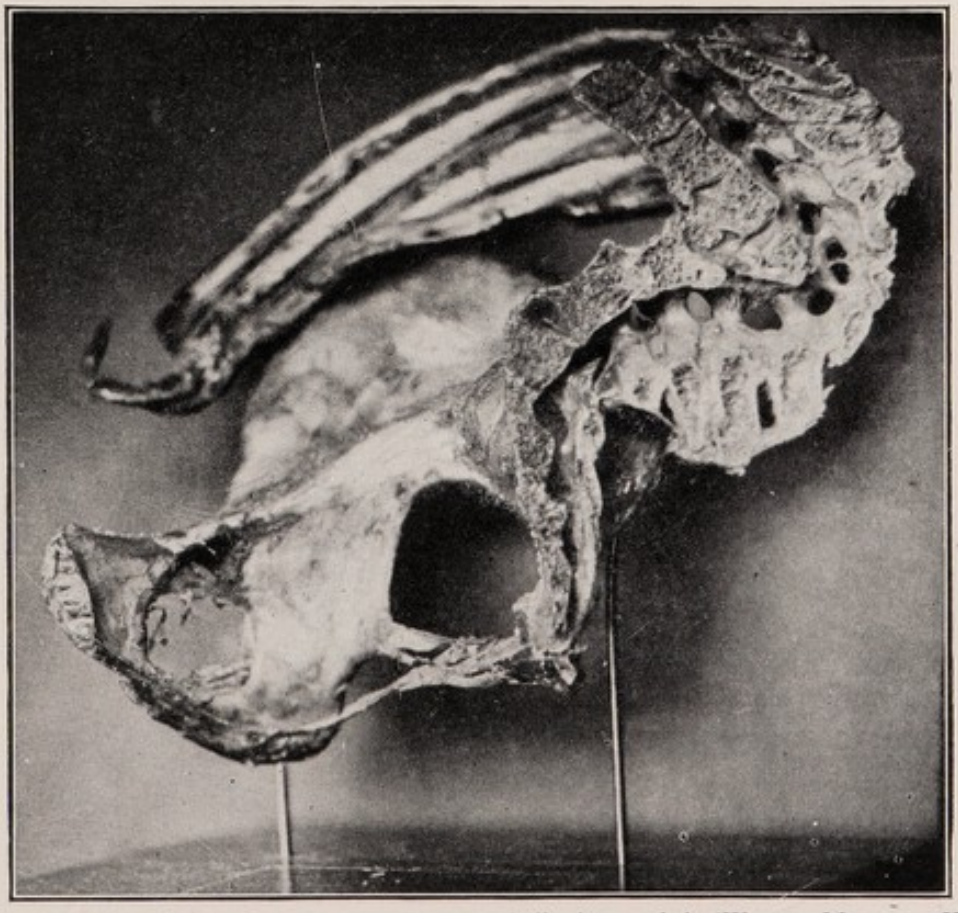

FIG. 208.—Excessive deformity, showing descent of ribs into pelvis (Warren Museum. Harvard University).

remembered in late convalescence when the newly formed bone is soft and easily yields to overstrain, and after repair has become complete it must be remembered that bone is always influenced by excessive pressure and may yield to it. It is almost impossible to say when the danger of further increase of the deformity is ended and when it is safe to leave off apparatus and to allow unlimited activity. These mechanical considerations have been presented at some length because they have been often overlooked and because a return of symptoms occurs late in so many cases of Pott's disease, which are due purely to the mechanical conditions described and not to a recrudescence.



FIG. 209.—X-ray of severe untreated tuberculosis of the spine, showing extent which deformity may reach.

A most important matter to be remembered in connection with spinal tuberculosis is that the nearness of the spinal cord to the site of the disease leads to its frequent involvement by contiguity, resulting in pressure symptoms and often a complete paralysis of the lower extremities.

Symptoms. *Premonitory Symptoms.*—Before the characteristic symptoms of the disease are manifested it is noticed, particularly in children, that they are often below the normal weight or have lost weight, that they tire easily and are in poor general condition. In adults these premonitory symptoms are less likely to be evident when the disease begins more acutely and is more painful at the outset.

Tuberculosis of the spine will be first dealt with along the same lines as those adopted in considering tuberculosis of the joints, after which the manifestations of the disease in the different regions of the spine will be taken up.

Swelling is not evident on account of the location of the disease. *Muscular atrophy* is not a symptom of importance, although it undoubtedly occurs in the intrinsic muscles of the spine.

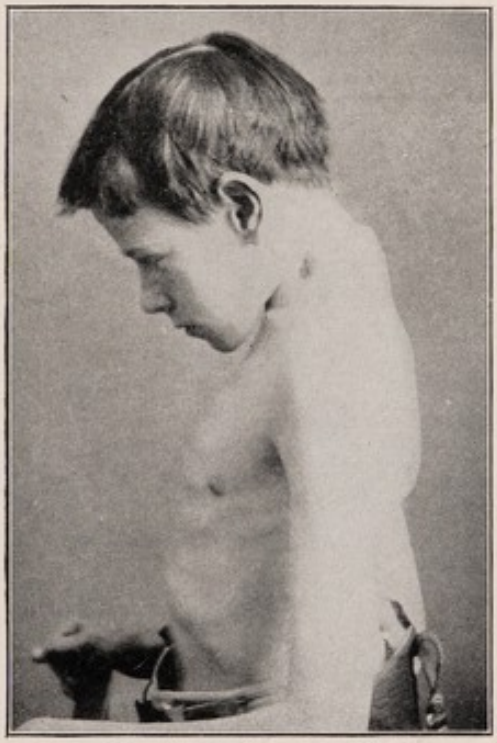

FIG. 210.—Cervical spine—head in forward position.



FIG. 211.—Characteristic attitude in high dorsal disease.

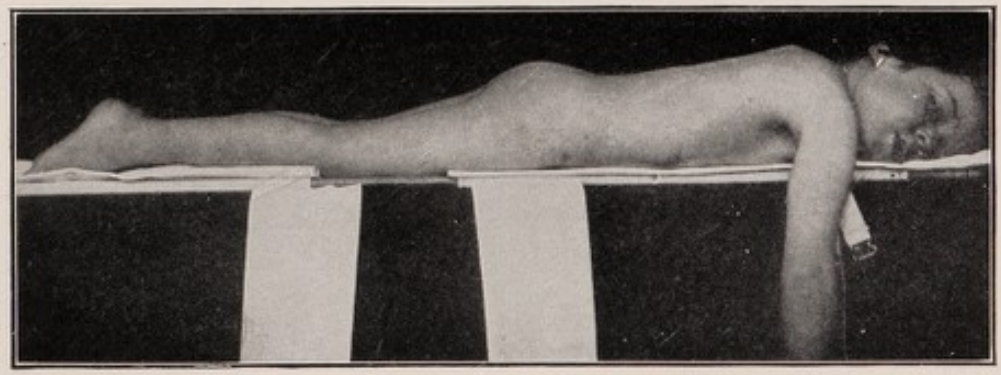

FIG. 212.—Beginning low dorsal deformity.

Muscular spasm is of the greatest importance and is our guide to early diagnosis, and is in part the explanation of the peculiar attitudes which will be described in speaking of the different regions. It is essential that the diagnosis should be made before deformity occurs, and this must be made

primarily by the recognition that certain or all of the movements of the spine are limited. In cases of high dorsal disease the lumbar movements may be practically free, especially to passive manipulation, and in lumbar disease cervical motion is not involved and *vice versa*.

Movements of the Spine.[1]—It becomes necessary to speak of the movements of the different regions of the spine, a knowledge of which is of the highest importance in connection with the diagnosis of early spinal tuberculosis.

The freest motion in the lower spine occurs at the dorsolumbar junction, which has been seen to be the most frequent location of the disease. The movements of the *lumbar spine* are primarily hyperextension, lateral bending, and, to a less extent, flexion. In forward bending the physiological curve of the lumbar region is rarely more than straightened. Rotation does not occur in the lumbar spine. The twelfth dorsal vertebra functionally is to be regarded as part of the lumbar region.

The movements of the *dorsal spine* are rotation, some lateral bending in the lower part, some flexion, and but little hyperextension. The *cervical region* is the most movable part of the spine in flexion and extension. Rotation and side bending occur in all parts. Rotation is most marked in the upper cervical vertebræ.

In examining the spine for limitation of motion these facts must be kept clearly in mind. For instance, the common test of having the patient bend forward to pick something up from the floor may not show disease of the mid-dorsal region. Rotation is not necessarily affected in disease of the lumbar region. Hyperextension may be possible when disease of the mid-dorsal region exists, and disease of the upper cervical region is especially manifested by the loss of rotation. It must be remembered, however, that muscular spasm is generally present well above and below the location of the disease so that it may affect the region above and below, especially as reflex muscular spasm is reinforced by the desire of the patient to protect himself against painful movements, for tuberculosis of the spine is at one stage or another painful. Lameness from psoas irritation may be the first symptom and in other cases all pain is absent until the disease is recognized by the occurrence of the deformity.

Pain.—Pain is generally present and often severe for two reasons: (1) The movements of the spine are distributed throughout, are very complex and are associated with almost every movement of the body, as in walking, for example, a slight lateral curve of the spine occurs at every step; and (2) the nearness of the nerves emerging from the spinal column to the site of the disease is another factor in making the affection a painful one. In the cervical region pain is manifested sometimes as a severe suboccipital neuralgia, and at other times is located in the neck. In the dorsal and lumbar regions the pain may be felt either in the back or, more frequently, referred forward to the terminal ends of the nerves, appearing as thoracic or abdominal pain. Night cries are less frequent than in tuberculosis of the hip, and pain is most often associated with movement and jars, resulting in the peculiar protective attitudes to be described. But pain may be wholly absent and the first sign of the disease may be the occurrence of a small kyphos, lameness from psoas contraction, or the occurrence of paralysis.

Shortening.—This is expressed by loss of body height, and is due to two causes: (1) The loss of height resulting from the backward curve in the spinal

[1] Lovett, R. W.: Boston Med. and Surg. Jour., June 4, 1900; Oct. 31, 1901; Mar. 17, 1904; Sept. 28, 1915.

column and the consequent forward bending of the upper part of the body, and (2) retardation of body growth, analogous to the retarded growth of the affected leg in tuberculosis of the hip.

Peculiarities of Gait and Attitude.—The gait in practically all cases of spinal tuberculosis is guarded and careful, and this is especially marked in disease of the dorsal region. The patient walks with short steps and often largely on the toes to avoid jar. He avoids such motions as jumping, and is careful in stepping from a curbstone. The body is held rigid, and in bending to pick up anything he most often bends the knees and holds the spine rigid. In turning he turns from the hips. Instinctive protection is more or less characteristic of tuberculosis, and in the cervical region the chin is frequently supported and steadied by the hand, or the child places the elbows on the table. In the dorsal region a favorite attitude of standing is with the body bent forward, and the hands supported on the knees. In certain cases of cervical disease the head is held in a



FIG. 213.—Dorsal spine disease, leaning on hands, standing.



FIG. 214.—Lumbar disease, causing lordosis.

marked hyperextended position with the chin up, while in other cases it may drop forward. In cervical disease, even without much deformity, the physiological curve is flatter, and the head appears to be carried forward. In cases of high dorsal disease the lumbar physiological curve becomes flattened to compensate and at first sight it would appear that a second focus of disease existed there, but rigidity is absent to passive manipulation and X-ray appearances are negative. It must be remembered, however, that two foci of disease in two different regions of the spine may exist. In disease of the upper dorsal region the shoulders are held high and squared, and the gait is especially guarded. In the lumbar region the body is thrown back from the hips to readjust the weight. A peculiar gait is induced by psoas spasm which occurs in connection with psoas abscesses, which will be described in speaking of that condition.

The attitudes in cervical disease are characteristic—the most frequent one is a torticollis due to muscular spasm, which can generally be distinguished

from congenital torticollis by the involvement of the muscles of both sides. Lateral curvature of the spine[1] is more or less constant in all cases below the cervical region and is a leaning of the body to one side or to the other rather than a true curve. It is caused either by unilateral destruction at the site of the disease or is due to a protective muscular spasm and in the latter case is analogous to the deformities of the hip in tuberculosis of that joint.



FIG. 215.—Marked dorsolumbar deformity.



FIG. 216.—Severe dorsolumbar deformity.

Deformity.—When destruction of the bodies of the vertebræ has really begun, a backward prominence of the vertebral spines becomes evident at the site of the damage. First one spine is noticed as projecting and it becomes more prominent and more spines are identified in the prominence. A sharp deformity in general means acute disease, while a more rounded one generally points to disease of long standing. As the line of the spine is changed in one place, a compensation occurs in another to maintain balance. An increase in the dorsal curve means an increase in the opposite lumbar curve and every change in spinal outline means a change elsewhere to maintain equilibrium. Deformity is most marked in the dorsal region, least in the cervical and generally moderate in the lumbar. In children the existence of *grunting respiration* in dorsal disease is frequent, and this symptom should always excite suspicion. In other cases a persistent *cough* may take the place of this.

Abscess.—The formation of abscesses in tuberculosis of the spine offers nothing peculiar in its pathology which is different from the ordinary tubercu-

[1] LOVETT, R. W.: Trans. Am. Orth. Ass'n., 1890.

lous abscess, except in its location and its relation to important internal structures.

Abscesses in the *cervical region* occur in two forms: (1) Retropharyngeal, where the collection of pus becomes evident at the back of the pharynx as a fluctuating swelling, frequently accompanied when it is large enough, by obstruction to respiration and (2) as deep cervical abscess, generally appearing at the side of the neck.

In the *upper dorsal region* the abscess is most often in the posterior mediastinum. It is unfortunately first made evident by disturbance of respiration, which occurs in the form of paroxysmal attacks of cyanosis and difficult breathing. Percussion will occasionally reveal its existence and it is evident in the X-ray as an abnormally broad shadow on one or both sides of the column at the diseased region.

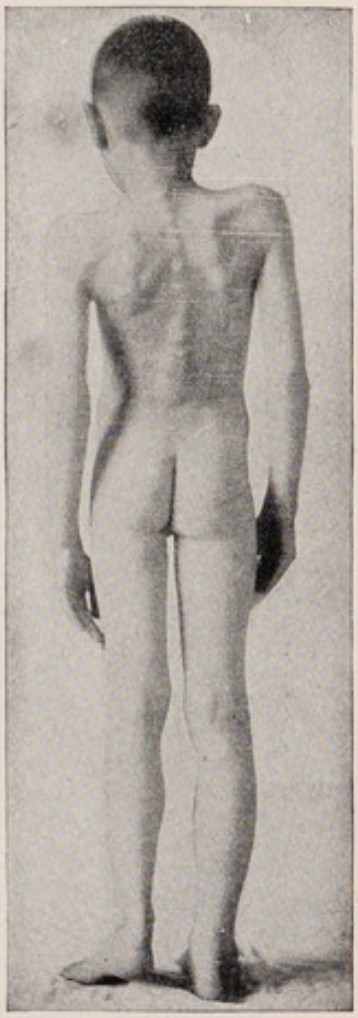

FIG. 217.—Lateral curvature from lower dorsal Pott's disease.

In the *lower dorsal and lumbar region* a collection of pus finds its way into the psoas muscle on one or both sides and follows down its course to a point in the groin or occasionally in the buttock, or it turns the edge of the quadratus lumborum muscle and appears as an abscess in the flank. In any event, extension of the leg is limited and this loss of full extension is particularly troublesome because on account of the rigidity of the lumbar spine resulting from the disease, the patient cannot compensate for the flexion in walking by a lordosis in the way that the patient with a fixed hip from other casues does. When the contraction reaches a considerable degree, he must walk on crutches with the spine straight and the leg flexed and off the ground. Walking with a very marked limp due to the loss of full extension of the thigh is possible in the slighter cases.

The possibility of the spontaneous rupture of these abscesses is not to be forgotten. Retropharyngeal abscesses may rupture into the mouth and suffocate the patient, or cervical abscesses may burst into the spinal cord. Lumbar abscesses may burst into the intestines or bladder, and there abscesses are so near the intestinal tract that they may become secondarily infected, although this does not often occur.

It is to be remembered that the occurrence of these abscesses is not necessarily accompanied by leucocytosis, nor by elevation of temperature more than what may be caused by the disease in general.

Paralysis.—Paralysis due to involvement of the spinal cord is a frequent complication of tuberculosis of the spine. This complication led to the recognition of the disease by Percival Pott, after whom the disease is named, in his original article where he described the disease under the title of: "Remarks on that kind of palsy of the lower limbs which is frequently found to accompany a curvature of the spine" (London 1779). Paralysis occurs most often in the disease of the upper and middle dorsal region of the spine, and this is due to one

of two causes: (1) The dorsal disease is more frequent, and (2) the spinal canal is smaller at this point than it is in the cervical region. Paralysis is usually bilateral; it may, however, be unilateral, and in some unusual instances it extends above the point of deformity.

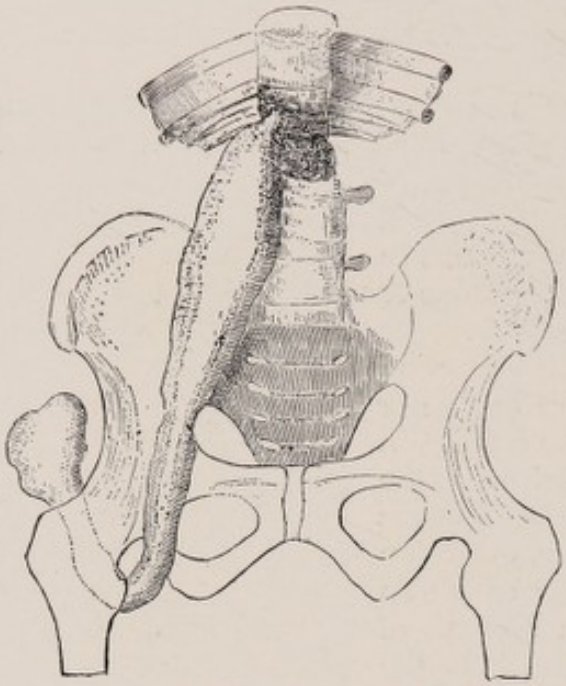

FIG. 218.—Dorsolumbar Pott's disease. Migrating abscess on the right side, coming down following the sheath of the psoas to the base of the thigh, turning around the neck of the femur and ending in the gluteal region (Ménard).

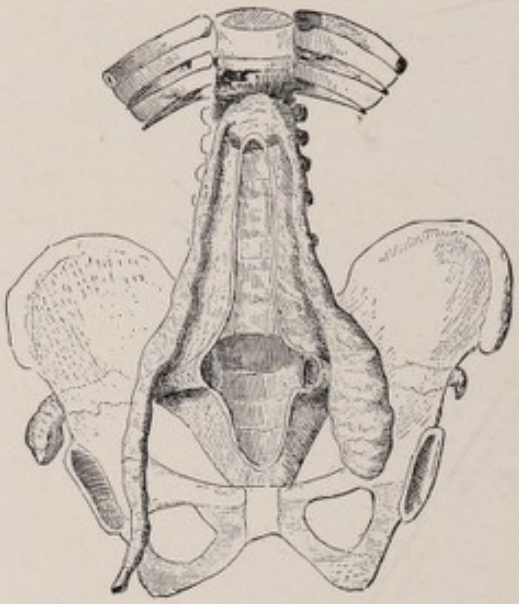

FIG. 219.—Dorsolumbar Pott's disease with secondary periosteal separation, descending in front of the last lumbar vertebra and the sacrum. Abscess from congestion: 1, In the right iliac fossa, following the sheath of the psoas (fistulous); 2, in the left iliac fossa, following the sheath of the psoas (not open); 3, in the gluteal region of each side (fistulous on the left; not open on the right) (Ménard).

Taylor and Lovett[1] found, in an examination of 59 cases of paralysis (out of 445 cases of Pott's disease), that the location of the disease was as follows 1 cervical, 7 cervico-dorsal, 37 dorsal, 7 dorsolumbar, 4 lumbar, 3 unclassified

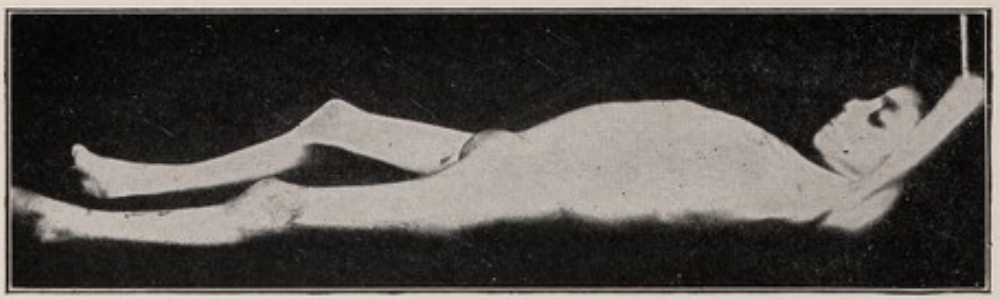

FIG. 220.—Psoas abscess.

The deformity was marked in 20, medium in 10, small in 7 (in 12 unclassified). The paralyzed cases presented no worse deformity than that seen in average cases. In 26 the outline was rounded and gradual; in 16 it was distinctly

[1] TAYLOR and LOVETT: Med. Record, June 19, 1886.

sharp. The duration of the paralysis was never, in the cases reported, over three years, except 1 case, when it persisted with but little improvement over a period of six years; in 2 cases it lasted three years; in 5 cases it lasted two years. There was recurrence in 6 cases, 4 cases having two attacks, 2 cases having three attacks.

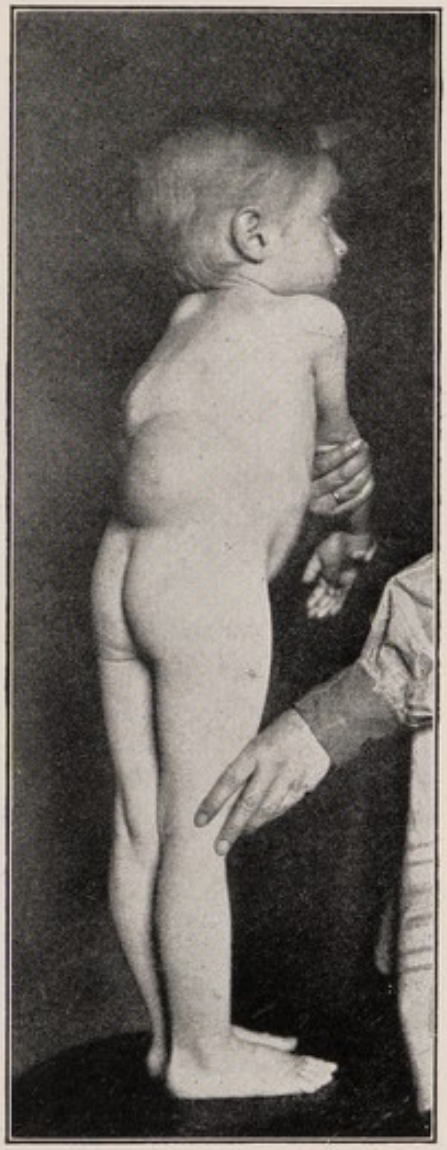

FIG. 221.—Lumbar abscess.



FIG. 222.—Position in psoas contraction.

In this series it was found in an examination of 55 cases of paralysis out of 449 cases of Pott's disease, treated by Charles Fayette Taylor, that the paralysis occurred on the average about two years after the beginning of the disease. Of the total number of cases analyzed 83 per cent recovered, but these were cases that came only for consultation, and were not necessarily under treatment. Where the paralysis came on under treatment the percentage of recovery was 100 and the average duration of cases was a little less than one year; and when the paralysis came on under treatment and the case was properly treated, the average duration was only seven months. The recurrence of the paralysis occurred in a few cases. Late recoveries were noted up to six years, several over four years' duration and one of ten years' duration

having occurred in the experience of the writers. The general outcome is that over 90 per cent of cases under treatment recover and the duration of paralysis under these conditions ought not to be much over six months, but recovery may occur after a much longer period.

The prognosis of paralysis therefore, is favorable under effective treatment, and although the complication often amounts to complete disability for the time being, under favorable conditions recovery may be expected.

Pathology of Paralysis.[1]—Bone compression of the cord is rare. This is clinically borne out by the fact that paralysis may occur with very slight angular flexion, while it may be absent in extreme deformity, and when present may recover while the kyphos increases. Pressure on the cord from a pachymeningitis is also unusual. The common cause of paraplegia is intraspina abscess.[2] In the early stages the cord changes are minimal and represent merely a state of vascular stasis. In long standing paraplegia true degeneration may occur. Dana[3] has called attention to the occasional existence of a myelitis of tuberculous origin.

Pressure symptoms are demonstrated, first, as a weakness in the legs as a result of which the patient becomes easily tired; and later by a progressive loss of power often going as far as complete paralysis. Spastic paraplegia of the extensor type is usual: the flexor type is very rare. Flaccid palsy is extremely rare. In lumbar Pott's disease the paralysis may be typical of a cauda equina lesion. Sensation shows little disturbance in the average case, although careful enquiry and testing may elicit the presence of such subjective signs as root pains, and of an actual zone of anesthesia or hypoaesthesia (Sorrel-Déjerine). Sphincter paralysis and trophic troubles may be seen when the compression is severe. Abscess paraplegia develops early in the course of the disease, usually at the end of the first year. The onset is often rapid: the spinal block is often complete, but there is always a tendency to spontaneous recovery.

Paralysis often disappears when the abscess travels. In children, paralysis is often the precursor of recovery as it insures rest in a manner that nothing else can. Hugh Owen Thomas used to say where paralysis occurred in the case of an unruly child, "Now we shall have a chance to get him well." Pachymeningitis paraplegia develops late in the course of the disease. The symptoms appear slowly and may remain indefinitely.

Examination.—Children should be examined naked and adults should be stripped to the hips. Young children if unruly are best examined lying on the mother's lap.

After a thorough general examination to detect the existence of any condition existing elsewhere than in the spine which might complicate or influence the prognosis or treatment, the patient's walk should be observed and any peculiarities of gait and attitude noticed. The most important thing to determine is whether or not the spine is limited in its motions. The presence of hyperextension is best ascertained while the patient lies on the face, for if tuberculosis be present, movement in every direction will be limited. In this position he should be gently lifted by taking hold of the legs at about the level of the ankles, and any limitation of passive hyperextension or lateral flexion observed. If the diseased area is below the lower dorsal region the lumbar

[1] Jones, Robert and Ridlon, John: "Chronic Joint Disease," 1890.
[2] Sorrel-Déjerine: Paris, 1925.
[3] Dana, C. L.: Med. News, Apr. 9, 1904.

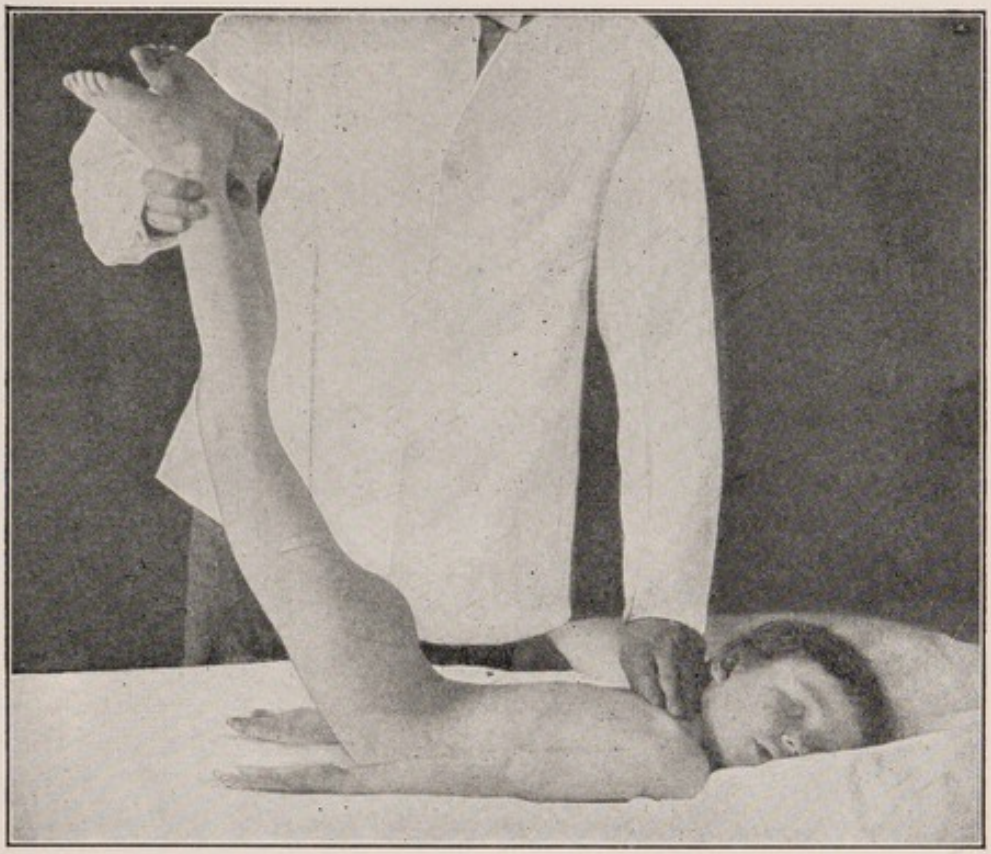

FIG. 223.—Normal flexibility of the spine (Children's Hospital Report, Bradford and Lovett).

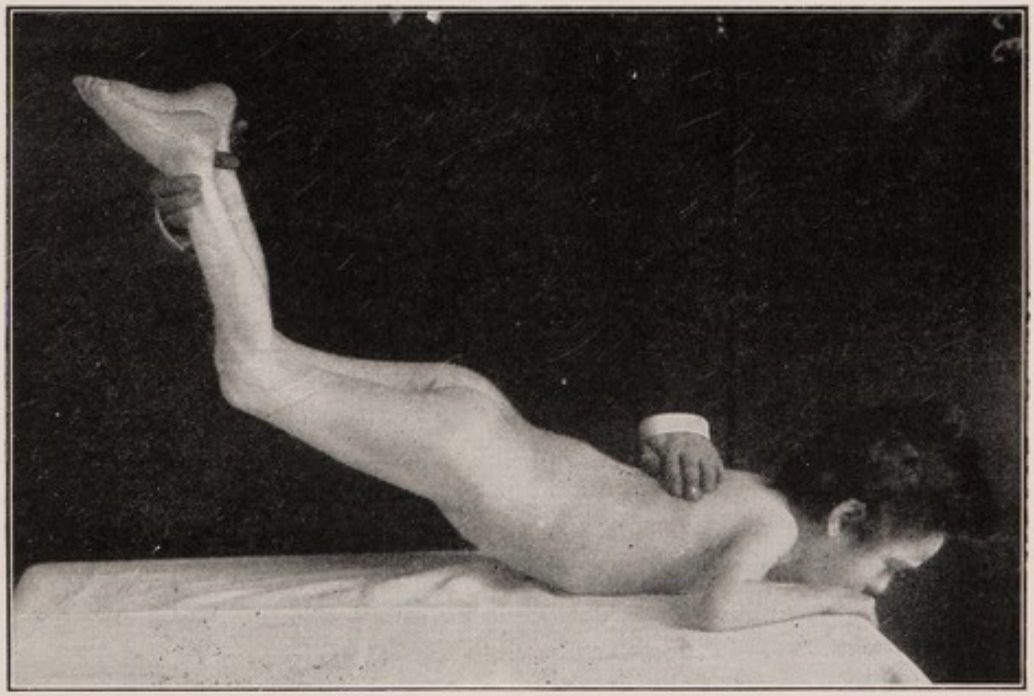

FIG. 224.—Examination of the spine, showing rigidity in spinal tuberculosis (Children's Hospital Report, Bradford and Lovett).

spine will not allow itself to be hyperextended but will be rigid when such an attempt is made. If no disease is present, hyperextension will be allowed to a marked degree in the lumbar region but ordinarily upper dorsal disease unless very acute does not cause much limitation in movement as there is very little hyperextension normally in these regions.

Older children and adults should then stand with the back to the surgeon, with the arms behind the head, and bend from side to side, and then with the pelvis held by the surgeon should rotate the trunk first to the right and then to the left. This is particularly important in determining disease of the middle and upper dorsal region, which might not be brought out by the hyperextension test.

Movements of the neck should then be examined. The motion between the atlas and occiput is largely flexion and extension, between the atlas and axis largely rotation. Disease in either one of these locations if sharply limited will cause restriction chiefly of this especial movement. As in the rest of this region motion is free in all directions, and as disease lower down is likely to check all movement, if rotation and flexion of the head remain free while the neck is stiff the upper two vertebræ are not involved. Most often there is limitation or loss of all head and neck movements.

The X-ray picture is essential and shows most from the side, as from the front the lower jaw obscures the shadow of the upper vertebræ. The front view of the upper vertebræ may however, be obtained if the mouth is opened wide and the X-ray picture taken in this way.

The abdomen should be thoroughly examined for masses of tuberculous glands, for psoas abscess, and for any other abdominal complication. The existence of cough or the slightest respiratory disturbance should at once lead to an investigation as to the existence of cervical or dorsal abscess or pulmonary tuberculosis. When the diagnosis has been made, examinations should cease and only be repeated at intervals of a few months as they are not necessary and are distinctly traumatic. Absolute and continuous rest is required.

Two special points in the examination should always form part of the first and all subsequent observations of the patient. These are:

1. Examination for psoas contraction indicative of threatening or beginning psoas abscess.
2. Examination for paralysis.

In examination for psoas contraction the patient lies prone on his face on a bed or table, and the left hand of the surgeon should hold down the pelvis while first the leg on the unaffected side and then the other should be hyperextended. The least limit of the hyperextension is suggestive of involvement of the psoas muscle, first contraction from irritation and then beginning infiltration. Following this restriction of motion a fluctuating tumor may appear in the iliac fossa on the affected side.

In *examining for paralysis* the knee jerks should be tested, and then the plantar reflex and ankle clonus. If these signs are present the question of disturbance of sensation should be investigated.

Diagnosis.—The very important fact must be repeated that the time to make the diagnosis of tuberculosis of the spine is *before* the deformity occurs. When once deformity has appeared, considerable damage has already occurred and the diagnosis is almost self evident. In the general examination, retarded

growth or loss of weight and the existence of an elevation of temperature in the afternoon are of considerable diagnostic value. In children under twelve the Pirquet reaction is of value in doubtful cases. In the presence of a destructive lesion of the spine obviously due to tuberculosis, the occurrence of two negative reactions should lead to make a very grave prognosis, for it means that the

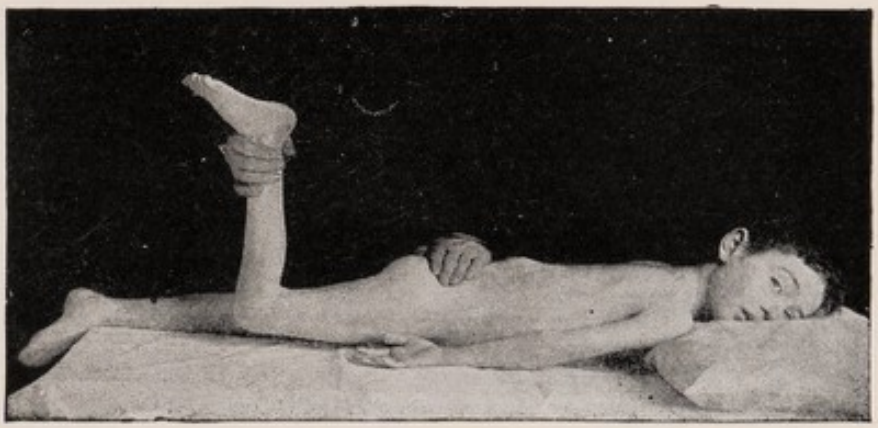

FIG. 225.—Examination for psoas contraction (Children's Hospital Report, Bradford and Lovett).

child is so toxic that it can no longer react. In the experience of the writers this combination has generally been followed by a fatal result within a few weeks. In a doubtful case, one negative Pirquet reaction should not be accepted as valid but the test should be repeated within ten days.

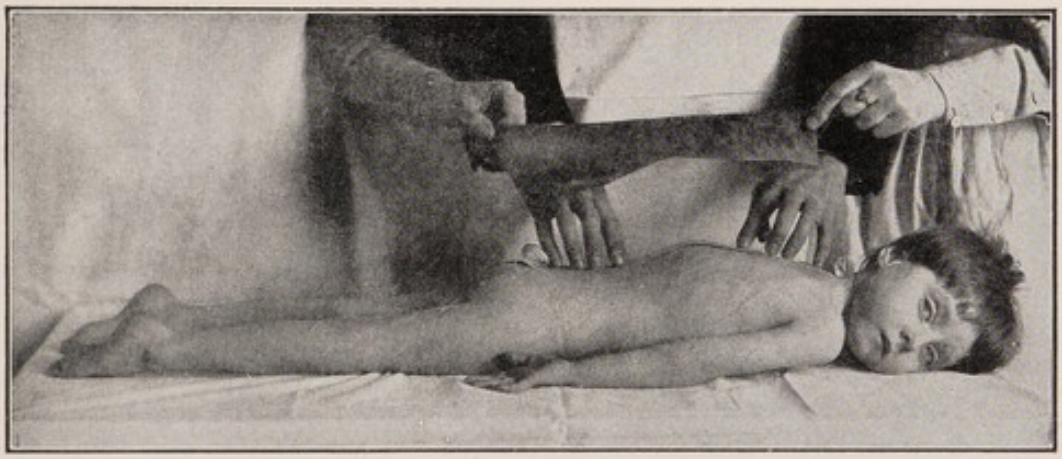

FIG. 226.—Recording of deformity in spinal tuberculosis, showing lead strip and card-board tracing (Children's Hospital Report, Bradford and Lovett).

The *radiographic evidence* for or against tuberculosis of the spine is of the highest value, and nowhere of more importance. The ordinary antero-posterior X-ray is far less valuable than the X-ray taken from the side. The latter shows almost from the outset any destructive focal change in the anterior part of the body long before it can be seen in the antero-posterior view. An irregularity of the anterior edge or corner of the vertebra is characteristic, then comes a wedging of one or two bodies with disappearance of the inter-vertebral space, and any "buckling" of the spine is evident early. In the cervical region the pictures are particularly clear and least clear in the lower

lumbar region. In the lateral X-ray of young children there is normally present a notching of the anterior surface of each vertebra occurring about the middle of the body which is incidental to the early development of the vertebræ.

The antero-posterior view is however also of much value later in the disease. The intervertebral space between the affected vertebræ disappears and when compression begins, the ribs are no longer parallel to each other at their posterior parts, but tend to radiate from the site of disease. In later stages the diseased vertebræ form a mass with no intervertebral discs showing. This mass generally throws a shadow of increased density. Of particular value is the perivertebral thickening which exists early in practically all cases as a spindle shaped and not very dense shadow clearly distinguishable from the heart shadow even when overlying it. This shadow persists well into convalescence; its shrinking is a favorable prognostic sign and its increase an unfavorable one.

In formulating the time when treatment may be modified, the lateral X-ray is of great value in showing something of the bone structure. An even, fairly dense shadow with no contained cavities is favorable; an uneven shadow poor in lime, and included areas with light shadows, is suggestive that repair is only partially completed.

The existence of a positive X-ray with a positive Pirquet reaction and muscular rigidity of the spine practically establishes the diagnosis. This evidence would be made stronger by the existence of the other signs mentioned. In the presence of a negative X-ray and a negative tuberculin reaction, even with the existence of muscular spasm, one is warranted in a child in believing that tuberculosis of the spine is not present. There is no other well defined destructive lesion affecting the anterior parts of the vertebral bodies of a slow and insidious nature which can be confused with tuberculosis of the spine.

These minimum diagnostic requirements should enable one to detect the disease at the time when detection is *most important.* When the deformity has occurred it of course confirms the X-ray and adds but little to the certainty of the diagnosis.

Differential Diagnosis. *Abdominal Conditions Simulating Tuberculosis of the Spine.*—The diagnosis of Pott's disease is beset by many difficulties, and one of the most troublesome and most urgent is to differentiate in practice between tuberculosis of the spine and acute abdominal conditions. Rigidity of the spine comes on quite often in connection with appendicitis, inflammation of the retroperitoneal lymph nodes, and in other inflammatory abdominal affections. And, although it would seem to be easy to distinguish between them, this is not always the case in practice, particularly in children. One will often find rigidity of the spine, a certain amount of abdominal pain, which also often occurs in connection with tuberculosis of the spine, possibly a positive Pirquet from tuberculosis elsewhere, as in tuberculosis of the posterior lymph nodes, and even if spinal in origin the case may be seen too early to show anything abnormal even in a lateral X-ray.

In late tuberculosis of the spine with great deformity the lower ribs sink into the pelvis and occasionally are the cause of severe paroxysmal pain simulating appendicitis.

Injury of the Spine.—After a fall or a blow a child very often presents all the clinical symptoms of early tuberculosis of the spine—pain, rigidity and

abnormal attitudes, but the X-ray is negative, the temperature should be normal, and the Pirquet test is here often of the greatest value. A short rest in bed will decide the diagnosis.

Chronic Arthritis Deformans of the Spine.—This offers but little difficulty in children, because as a rule it is a polyarticular affection and the spine is only affected with other joints, but in adults it is a source of much obscurity and many mistakes in diagnosis are made. In arthritis deformans whether acute or chronic, the spine is held very rigidly and there is much pain, at times referred to the abdomen and leg. Lateral deviation of the spine is often present here as in tuberculosis; movement is guarded and painful, the history may be indefinite and other joints, may not be involved. The X-ray is likely to show proliferative changes around the vertebræ, not always however, but in a lateral X-ray, focal destruction of the vertebral bodies is never present.



FIG. 227.—Typhoid spine, showing deformity.

Tuberculosis of the sacroiliac and lumbosacral joints is at times almost indistinguishable from disease of the lower lumbar region, and the chief reliance must be on the X-ray, but the matter is not of great importance as the treatment of the condition is practically the same as that of low lumbar disease.

In certain regions the diagnosis of the disease presents difficulty.

Torticollis which results from cervical Pott's disease is simulated by a similar position induced by "rheumatic" inflammation of the muscles or cervical joints, by inflamed cervical lymph nodes, by injury to the neck, and by congenital torticollis. In all of these the X-ray is negative, and in congenital wry neck the chin points away from the prominent sternomastoid muscle, movement is restricted in only one direction instead of in all as in tuberculosis, and the apprehensive look on the patient's face, when examinations by testing motion is done in tuberculosis, is absent in the congenital condition. In practice the diagnosis may occasionally prove difficult and a period of observation is sometimes required for the clearing up of the matter. This investigation should follow the general lines indicated, with chief reliance on the X-ray, the Pirquet reaction and the general picture to define the presence or absence of tuberculosis.

The *typhoid spine*[1] presents the symptoms of Pott's disease and sometimes deformity, but comes on only after typhoid fever, is osteomyelitic in character and the Widal test should be positive and deformity may be present.

[1] LOVETT and WITHINGTON: Boston Med. and Surg. Jour., Mar. 29, 1900.

Malignant disease of the spine in adults presents practically the same clinical symptoms as tuberculosis, but the X-ray picture most often shows formative activity around the growth, cord symptoms occur early and are pronounced and out of all proportion to the cord symptoms of tuberculosis. The affection is generally very painful. In certain cases here the diagnosis is not easy, and a long period of observation may be required. In a case where carcinoma is suspected, great care should be exercised in finding out whether cancer exists or has been operated on in any part of the body, remembering that carcinoma of bone is secondary.

Disease of the Hip Joint.—In the lumbar region the existence of a psoas abscess causes a flexion contraction of the hip, most often on one side, in which theoretically, passive rotation of the hip joint with the thigh flexed to a right angle should not be affected, but it sometimes is involved, and in certain cases all motions of the hip are lost. In such cases, even if the existence of tuberculosis of the spine is established, one cannot say whether or not the hip is also involved, and here again one must often wait before reaching a definite conclusion. The X-ray is of great value here. Conversely, an acute inflammation of the hip may cause considerable fixation of the lumbar spine in attempted passive manipulation. This is caused by the patient's voluntary attempt to guard against the pain of movement. Perinephritic abscess, appendicitis, and other inflammations of the abdomen and pelvis may cause a persistent flexion of the hip, which may mislead the untrained observer.

Lateral curvature of the spine is at times confused with spinal tuberculosis. In the latter some lateral deviation is often present, but it is rather a leaning of the whole body than a real curve. There is also in the latter a marked muscular spasm causing limitation of motion in a spinal region, and the X-ray shows focal destruction. In true scoliosis the curve is gradual, the stiffness affects only the curved position of the spine, and pain is not a part of the disease. But in practice the writers can recall cases of painful scoliosis where they were unable at the outset to make a definite diagnosis.

Spondylolisthesis is a partial dislocation of the fourth or fifth lumbar vertebra forward on the sacrum occurring mostly in adults. Shortening of the trunk results with a backward bony prominence of the upper part of the sacrum because of the slipping forward of the fourth or fifth lumbar so that the spine of the fourth lumbar vertebra is no longer on the line connecting the posterior superior iliac spines, but below it. The X-ray is characteristic and the diagnosis should offer little difficulty to one familiar with the characteristics of this somewhat rare condition.

Fracture of the Spine.—Since the investigation by the X-ray of spinal injuries it has become evident that compression fractures of the spine may occur without marked symptoms and are often unrecognized. The injury to the bone may result in its rarefaction and softening, and a kyphos later may result, a condition described by Kümmell under the name of "Spondylitis Traumatica."[1] Such fractures unrecognized may give rise to symptoms almost identical with tuberculosis of the spine and are mildly progressive in character. A careful X-ray study with an investigation of the history and of other data along the lines mentioned earlier will clear up the diagnosis.

Rickets.—In children in the active stage of rickets a backward prominence of the dorsolumbar region, which often occurs, resembles tuberculosis of the

[1] Kümmel: Deutch. Med. Wchsft., 1895.

spine very closely, but tuberculosis of the spine is uncommon at the age when rickets begins. The curve in rickets is rounded, often accompanied by lateral deviation, and in general is much less rigid than in tuberculosis, but definitely resistant to passive correction in long standing cases. The existence of demonstrable rickets aids in the diagnosis, and although this does not of course exclude tuberculosis, the coexistence of the two in a young child would be unusual. The X-ray is not of its usual value, as in young children there is so much cartilaginous structure still in the bodies of the vertebræ.

Tuberculous Lymph Nodes.—Tuberculous lymph nodes in the iliac fossa resemble psoas abscess very closely and may exist alone or in combination with tuberculosis of the spine. The diagnosis which must be made on the general lines indicated may be at first exceedingly difficult. Bronchitis, croup, pleurisy, empyema, and similar respiratory affections may resemble or complicate mediastinal or cervical abscess.

Rupture of the Spinal Ligaments.[1]—Occasionally after an accident causing severe spinal flexion, a traumatic kyphos appears in the spine which disappears on lying down and occurs again in the upright position. Although symptoms of nerve pressure may occur in many, there is no reason to suspect bony fracture. The treatment is prolonged protection from flexion by the use of a spinal brace, to which massage and exercises of the extensor muscles will later be added. The condition will easily be recognized when one is familiar with its possibility.

Functional Affections of the Spine.—The conditions described under the name of "railroad spine" "hysterical spine," etc., are often very painful and accompanied by rigidity, but the objective signs as described are absent. (See p. 204.)

Diagnosis of Paraplegia.—The signs of this lesion are generally those of muscular weakness, spasticity and later loss of muscular movement at a level corresponding to the site of the disease in the spine with disturbance of reflexes as described. Sensation generally escapes, but may be impaired or lost in the long standing cases. Paralysis is sometimes the first symptom noted and it must be remembered that paralysis may occur in connection with other lesions of the vertebral column. These are arthritis deformans of the spine, malignant disease, and fracture. *Primary spinal spastic paraplegia* resembles the spastic type of paralysis in spinal tuberculosis closely, but there is no lesion of the vertebral column. *Cerebral spastic paralysis* has the increased reflexes but not the loss of power. *Diphtheritic paralysis, poliomyelitis,* and *muscular dystrophy* must be mentioned as not uncommon motor affections in children, and at times coexisting with spinal tuberculosis.

Diagnosis of Abscess.—Abscess is recognized (1) as a fluctuating swelling in the regions described, the neck, the pharynx, the loin, the iliac fossa, and the hip—or (2) as the cause of difficult respiration when occurring in the cervical and upper dorsal regions, or (3) by flexion of the hip. Abscess is not accompanied by leucocytosis or elevation of temperature more than that common to the disease, and is not necessarily painful. In cases of doubt, aspiration will show a purulent or turbid serous fluid, not generally containing pyogenic organisms and showing few or no tubercle bacilli. Its inoculation into a guinea pig causes tuberculosis. In the X-ray, abscesses cast a cloudy, fairly well defined shadow with a smooth outline.

[1] Painter and Osgood: Boston Med. and Surg. Jour., Jan. 2, 1902 (with literature).

Prognosis.—Tuberculosis of the spine is always serious and so far as risk to life is concerned probably the gravest of the tuberculous joint and bone affections. Tuberculous meningitis apparently occurs less often than in connection with the hip, but frequently enough to be borne in mind and to be a source of anxiety. In these days when cases are treated earlier and more effectively on account of improved hospital facilities, amyloid degeneration is less frequently seen than twenty-five years ago, but still occurs in a certain number of cases and is generally followed by a fatal outcome.



FIG. 228.—Girl ten years old whose X-ray is shown in next figure, showing marked destruction of bodies of vertebræ, but no deformity. Treated by dorsal recumbency for three years, followed by the resumption of the upright position for part of the time.

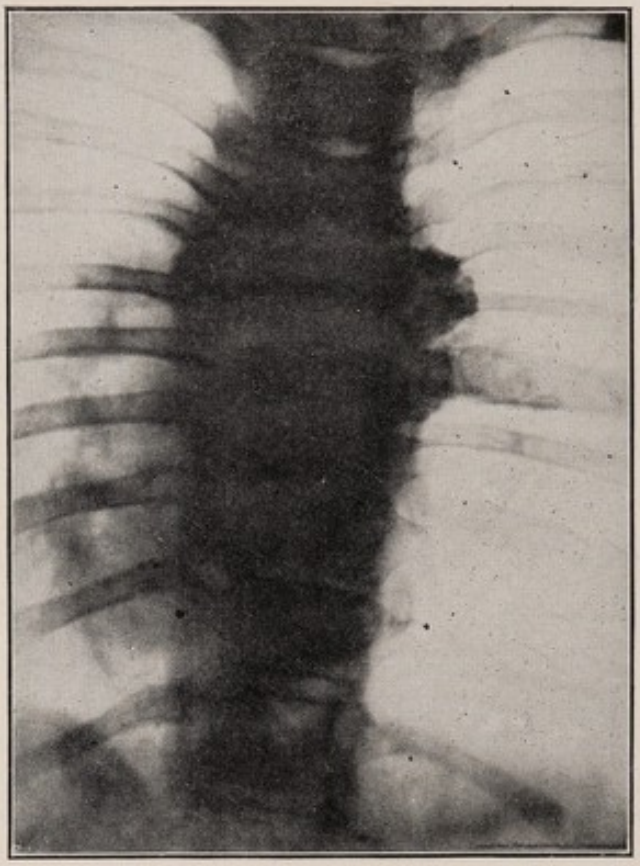

FIG. 229.—X-ray of case shown in Fig. 228, showing damage which has occurred in spine.

The outlook is most favorable in disease of the cervical region, and least favorable in the dorsal region. Cases which begin with great acuteness and depreciation of the general condition are not as favorable as those which begin slowly and are not so acute and painful.

In children the outlook for life is favorable, but there is a considerable mortality. A child with a beginning deformity should recover with no final deformity of importance *provided* it can receive adequate and long continued treatment. A child with a medium deformity under the same conditions should get well with a diminished deformity and perhaps with one reduced to a degree where it is unnoticeable. When a large deformity exists at the outset of treatment, the surgeon will do well if he prevents further increase, because the leverage of the superincumbent weight under these circumstances

is so great that it has a crushing effect on the site of disease. With anything but the best treatment the deformity will increase, perhaps to a distressing degree.

In adults the prognosis is very different, the danger to life is real, the mortality high, and the disease difficult to control by treatment. Adults bear prolonged confinement less well than children, and many of the patients are wage earners and unable to give the proper time to treatment. A large deformity is a handicap through life and most adults with deformity acquired in childhood are below the average in health and endurance, although certain of them remain apparently normal in this respect. Adults who have recovered from spinal tuberculosis with considerable deformity are most often of less than average resistance and more prone to pulmonary complications than the normal individual. Abdominal pressure is likely to cause indigestion and adults with such deformity are rarely able to undertake heavy manual labor, and if discharging sinuses persist, amyloid degeneration may occur, and in any event the patient with such sinuses is likely to be in poor health.

There are few figures dealing with the mortality which are of any special value. It has been estimated that 20 per cent to 50 per cent of all cases die as a result of the disease, but under more favorable conditions of treatment the mortality would probably be less than 10 per cent.

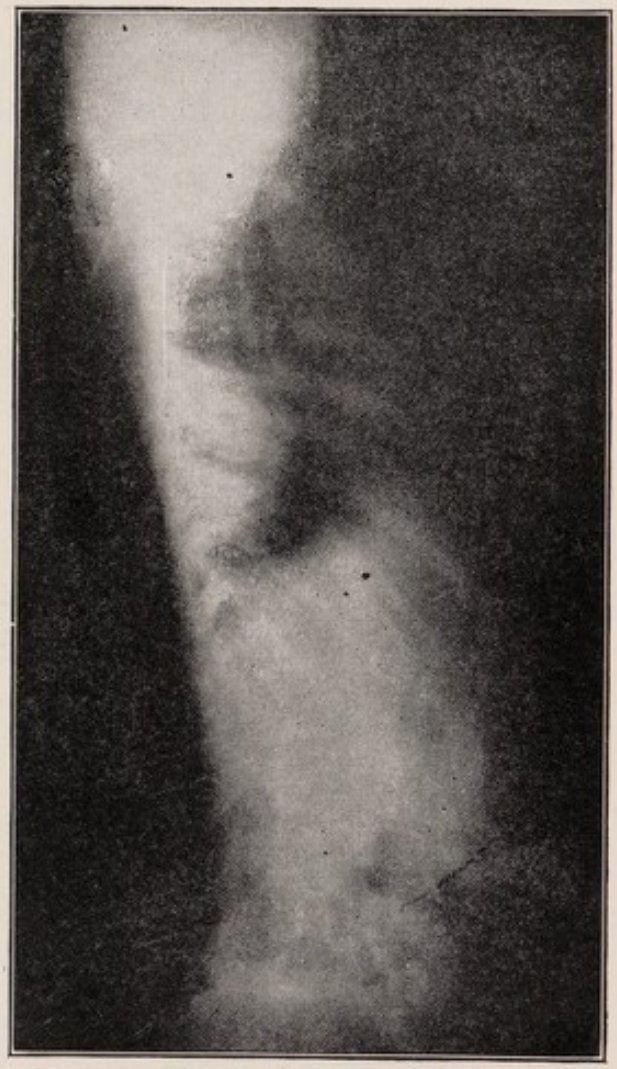

FIG. 230.—X-ray of a case of spinal tuberculosis treated five years by recumbency, with destruction of the bodies but no kyphos.

Treatment

The object of treatment in tuberculosis of the spine is to arrest the disease and to obtain healing in the most favorable position possible.

The *general treatment* of the patient is of the utmost importance, as the depreciation of the general condition is usually marked, and this is more often the case than in other forms of tuberculosis of the joints and bones.

The *local measures* to be adopted are also of the highest importance and the reason for them must be clearly understood if they are to be properly used. It should be borne in mind that the crushing effect of superincumbent weight upon the diseased bodies, and the irritating effect of motion at the site of

disease are factors detrimental to the healing process. It becomes evident, therefore, that the theory of local treatment resolves itself into meeting these conditions, and to meet three different requirements: (1) *The elimination of superincumbent weight*, (2) *fixation of the diseased part of the spine*, and (3) *fixation in a hyperextended position*, if good results are to be obtained.

Treatment by Recumbency.—Assuming that the disease affects the mid-dorsal region, in a child weighing approximately 50 pounds, half of this weight will be above the lesion, and in the upright position must be transmitted through the diseased part of the spinal column. Obviously, then, in the upright position the object of treatment must be to take the weight of this upper segment off the diseased vertebræ by leverage exerted by some form of apparatus, such as a brace or jacket. But to do this effectively means that the skin opposite the deformity will lie between the fulcrum of the lever and the brace and on this must be exerted a steady pressure of a degree that no skin could stand. In some experiments conducted by one of the writers[1] a model was constructed (Fig. 231) of two plaster cylinders, weighing 20 pounds each, which were supported by a series of blocks representing the vertebræ, and held apart by a Taylor back brace, as shown in the illustration (Fig. 254). It was demonstrated by this model that if the chest is firmly held, and the pelvis is held with equal firmness, the pressure coming upon the spine over the disease (*H*), in case the brace were used to modify intervertebral pressure, would be so great that no skin would be able to stand it. This was shown by placing the finger between the back brace and the wooden blocks in the model which represent the diseased column. It simply demonstrates the necessarily incomplete action of any support used in the upright position, for if it were possible for the pelvis and chest to be held as firmly to the brace in the living subject as in this model, the skin would not be able to stand the pressure.

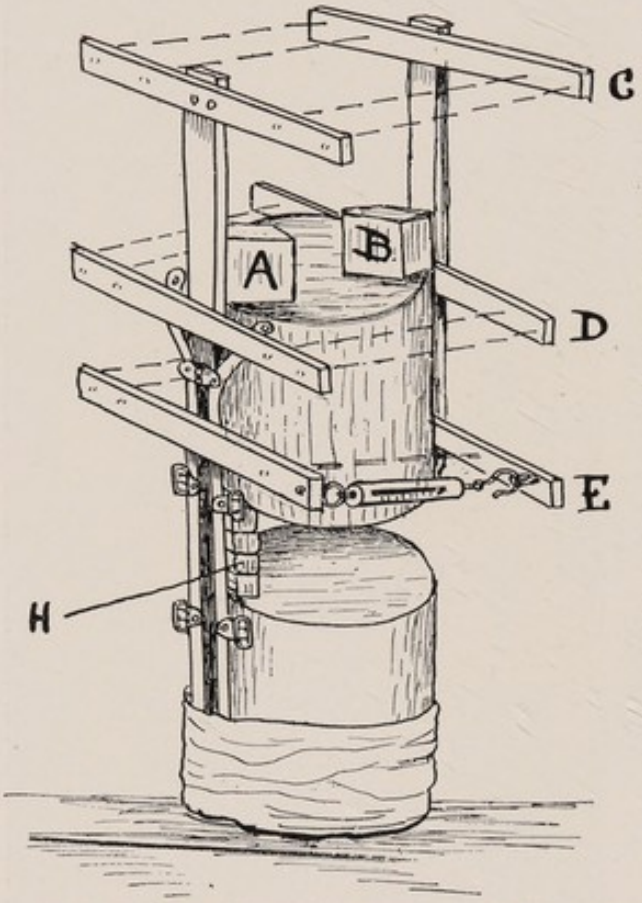

FIG. 231.—Model to show mechanics of anterior-posterior brace.

In considering the mechanics of any lever which will take the superincumbent weight off of the diseased vertebræ while the patient is in the upright position, one must estimate what mechanical hold it is possible to obtain on the upper segment of the body, because obviously if this is not accurately held, intervertebral pressure cannot be modified. Mechanically it is not possible to get an exact hold of the upper segment of the body by which the

[1] LOVETT: Med. News, Feb. 29, 1896.

lever may pull it definitely backward, because the backward pull must be exerted through the thoracic cage, which consists largely of ribs, movable at both ends, which run diagonally. If one then faces the condition squarely it must be recognized that any atteempt to separate the diseased vertebræ by leverage while the patient is upright is not practicable for two reasons: (1) That the skin would not stand it if it could be done, and (2) that the compressibility of the thorax is such that the pull cannot be made mechanically effective.

Recumbency is therefore imperative during the active stage of the disease. In making this statement it is definitely recognized that the circumstances of the patient in many cases of tuberculosis of the spine make ambulatory treatment necessary, but in adopting the latter method we should not deceive ourselves, but should recognize the fact that the patient is only receiving second best treatment.

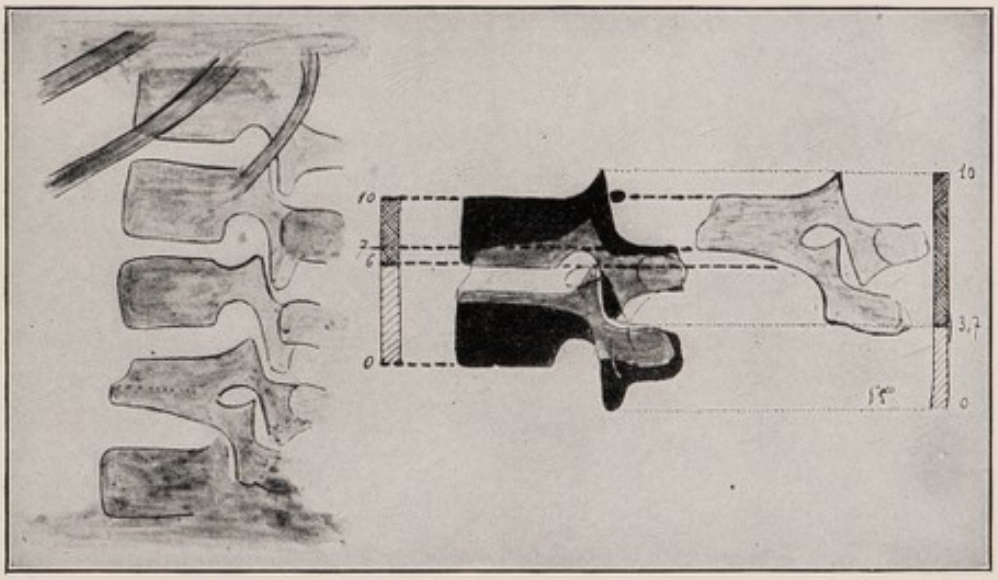

FIG. 232.—Cured and corrected Pott's disease, involving two lumbar vertebræ superimposed on two normal lumbar and their intervertebral disc. On the left note the osseous consolidation without new formation. In the figures on the right the black part shows the loss of osseous tissue (Calvé).

To come to the second requirement of treatment, namely *fixation*, it is evident that merely to put a patient with acute spinal deformity on a soft mattress allowing him to move at will, although it would remove the superincumbent weight, would allow movements which are most undesirable and irritating. Fixation, therefore, must be provided as in other forms of joint disease.

Fixation in recumbency involves the use of a suitable frame of which there are two outstanding types: (1) The Bradford gas pipe frame and (2) the double Thomas frame. As an alternative a plaster of Paris shell may be employed.

The third requirement of treatment is necessary if the surgeon is to obtain the best possible results: *The minimizing or prevention of deformity.* This is sometimes difficult to practise as it involves a prolonged recumbency, often extending to several years. The patient or parents should be made to understand clearly that time is but a secondary consideration.

The patient should lie through this time on a curved frame or in a jacket or a brace holding the spine in a position of the greatest possible *hyperextension*, at the site of the deformity. Not only antero-posterior motion, but lateral motion and rotation as well should be prevented. This treatment, as carried out at Berck sur Mer for many years has produced admirable results. The writers, however, consider that it is better not to use plaster jackets if the same results can be obtained by other means, and prefer frames which leave the chest free. The main thing is that the surgeon should appreciate the requirements of the local treatment, because the means of carrying it out are of comparatively little importance provided they are mechanically sound.

The explanation of why one can obtain a spine practically straight with a definite deficiency in the vertebral bodies, as shown in the illustrations is afforded by Calvé, who has demonstrated that there is an adaptation in the posterior part of the vertebræ, occurring as the result of an efficient correction over a sufficiently long time. This consists of a sinking down in the posterior structures, permitting the spine to come into line. The diagram gives a schematic representation of this change (Fig. 232).



Fig. 233.—Bradford frame for tuberculosis of spine.

The Bradford gas pipe frame is a little longer than the patient and is covered with stretched canvas.

This frame is useful in the surgical affections of children for securing a horizontal position, and is most often used for fixation. It possesses the advantage that children need not be removed for the use of the bed pan, which can be put under the opening in the frame, and the only time that they need be disturbed is to be turned twice a day on the face in order that the back may be rubbed in alcohol. It is impossible to keep the back in good condition without at least one turning a day.

In length the frame should be from four to six inches longer than the patient, and is a rectangular frame made of ordinary gas pipe. One-quarter inch pipe is sufficiently large for children, and three-eighths inch pipe for adults of moderate weight. One-half inch pipe should be used for heavy adults. Gas pipe is graded by the size of the hole, and not by the diameter of the pipe. Each piece is threaded at both ends for one inch, and these are attached to each other at the corners by four elbows, and the work can be done by any plumber. The width of the frame should be the width between the outside of the shoulders. The frame is covered with strong cotton cloth, generally doubled. The cover should be a little short of the full length of the frame, and one and three-quarters times as wide. It passes over the front of the frame, around its sides and is secured behind by webbings and

buckles. The cover should be smoothly stretched on the frame and lie without wrinkling. In the case of children who are inclined to soil the frame, and in adults, who should not be lifted for the use of the bed pan, the covering is made in two sections, one reaching from the top of the frame to just about the middle of the sacrum, and the other beginning at the top of the thighs and running to the bottom of the frame. In general it is more comfortable for adults to have the cover in one piece.

Treatment by Plaster Shell.—At the Boston Children's Hospital a posterior plaster shell is used for the purpose of obtaining hyperextension, which is increased more and more until there is reason to believe that the contact between the vertebræ is diminished but that they are not separated. The general method of making these shells is as follows:



FIG. 234.—Head traction in cervical tuberculosis.

A hammock of cotton cloth not as wide as the patient is stretched tightly between the two ends of a horizontal gas pipe frame (Fig. 235). The patient is protected by stockinet and placed face downward upon the hammock with his arms at right angles with the body. Plaster bandages are then passed around both patient and hammock, which is to secure temporary fixation and serves as a basis of the application of further plaster. This consists in carrying plaster bandages from right to left and back, and up and down the back, until ten or fifteen thicknesses have been applied, but not going completely around except at the end, when a series of final turns is made. The complete shell should reach from the top of the head to the knees and from the anterior axillary line on one side to that on the other. It is important that it should be well rubbed while being put on, and homogeneous when it sets. The encircling bandage is cut in front and the plaster shell removed. The shell is then cut through transversely at the level of the deformity before it hardens. The two segments are then bent on each other to secure greater hyperextension, the junction between them filled by plaster of Paris bandages crumpled up and the whole shell strengthened by plaster ropes running up the back, or by means of an iron hinge put in on each side of the cut. A connecting rod furnished with a screw and turn buckle connects the two segments, in which case any degree of hyperextension may be furnished. The shell is then padded with felt on each side of the deformity, a sheet of cotton is placed over the interior and the whole shell is covered with stockinet.

As patients in such shells must be turned often enough for the care of the back, it is absolutely essential that a lid or anterior shell should be provided of the same curve as the posterior shell, so that the hyperextension of the spine may never be disturbed. Such a lid

is laid over the child, filling in the opening in the shell—the two are strapped together, the child turned over onto the face, the posterior part of the shell removed and the child left still hyperextended, while the back is bathed. The process is repeated for turning the child back.

If hyperextension methods are used the patient must be watched with great care, for the skin is subject to much pressure and must be carefully guarded. Digestive symptons occasionally occur if extension is too extreme at the beginning. Vomiting and indigestion may become troublesome but are easily removed by a reduction of the hyperextension and generally avoided by caution at the beginning. Respiratory difficulty occasionally comes on in certain cases placed in marked hyperextension. This may be relieved by raising the head temporarily by means of a pillow. In a case of one of the writers the marked hyperextension with a dependent head caused an existing cervical abscess to cause some obstruction to respiration which was troublesome for a time but which was easily disposed of by diminishing the hyperextension. In general it is wise to begin gradually. That hyperextension is really effective at the site of the deformity is shown in the illustrations, and the result after three years of this treatment is shown in the X-ray (Figs. 228 and 229).



FIG. 235.—Cloth hammock for the application of plaster jackets and shells, placed horizontally for use. Tightness of hammock, regulated by windlass.

The objection to the method is that it is rather elaborate to be used except in well equipped hospitals; that it requires much care and constant changes as the patient grows. The advantages are that it is mechanically sound and is followed by most satisfactory results.

Treatment on the Double Thomas Frame.—Plaster is rarely used by the Liverpool school, as highly satisfactory results are obtained by the "long posterior support" so designed as to keep the spine hyperextended. The advantages are that it is easily applied, cleanly, cool, and leaves the chest quite unhampered. The child is easily nursed and carried about and there is no occasion to remove the splint for any purpose. Abscess can be watched and treated. The splint is a modification of the Thomas double frame, with a headpiece attached.

Long Posterior Support.—A Thomas double frame consists of two perfectly straight bars of iron ($\frac{3}{4} \times \frac{3}{16}$ gauge for 20-inch frames up to $1 \times \frac{1}{4}$ gauge for 40-inch frames) which are made of such a length as to extend from the scapulæ to 4 inches above the heels.

Both of these straight bars incline outward at their lower ends at an angle of 5 degrees up to 10 degrees. These stems are connected above the ankles by a cross rod ($\frac{1}{16}$ up to $\frac{3}{8}$ round) also at the top by a metal band ($\frac{3}{4} \times \frac{1}{8}$ up to $1 \times \frac{1}{8}$) which completely encircles the

chest and is open in the front. A similar band ($\frac{5}{8} \times \frac{1}{16}$ up to $\frac{3}{4} \times \frac{1}{8}$) connects the stems just above the buttocks and extends as wings just long enough to grip the pelvis. A short iron grip is fixed to the end of each stem into which the ankles will be placed. To prevent any tendency to knock-knee, it is an advantage to add a bar between the two lower wings of the frame and at right angles to them; to this the knees can be bandaged. A firmly padded cushion (2 inches to 4 inches thick) the width of the trunk should reach from above the upper border of the frame and extend down each leg. A horse shoe shaped piece is removed at the buttocks and extra thickening placed under the knees. This cushion is secured to the frame with tapes.

The patient is placed on the splint with the buttocks on either side of the horse shoe shaped gap in the back pad, which has been left for nursing purposes. The wings of the splint should then be moulded round the patient's chest and ribs, care being taken to turn them up acutely enough from the back pad to prevent side movements of the body. A 5-inch thick pad is placed under each knee to prevent genu recurvatum, and the ankle grips, which reach just above the malleoli, must be well padded. The knees are now bandaged firmly to the splint, and the head should rest snugly in the head piece.

At the Shropshire Open Air Orthopaedic Hospital when heliotherapy is desired, a plaster lid is used to supplement the double Thomas frame. Whenever the patient has to be turned, the lid is applied so that there is no interference with the rigidity of the spine and the patient can lie in the lid so that the spine may be exposed to the sun. The illustration describes this.

The patient should never be turned on the side for nursing purposes, or the spine and limbs will sag laterally. A block should be placed underneath the bar between the ankles to avoid pressure on the heels, increasing the height of the block when necessary to insert a flat bed pan beneath the splint. In this raised position all necessary washing of the buttocks can be done. The patient is never taken

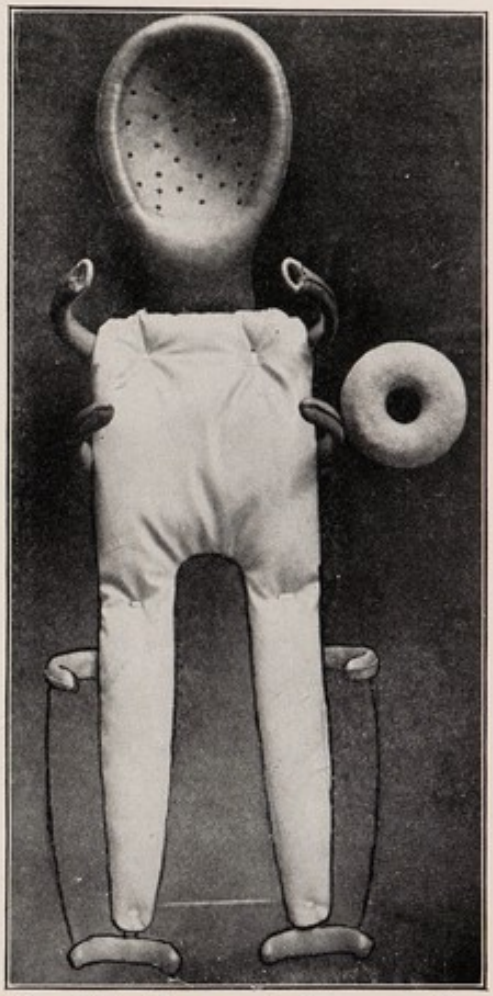

FIG. 236.—Long posterior support for spinal tuberculosis—seen from above.

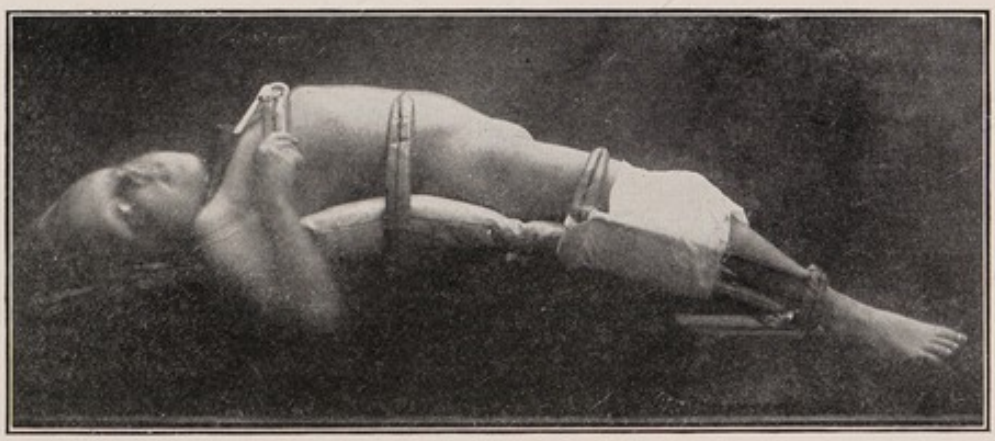

FIG. 237.—Patient on frame.

from the splint, nor are the bandages removed for any purpose, but only the exposed skin washed. The feet should be supported at right angles, and protected from the weight of the bedclothes.

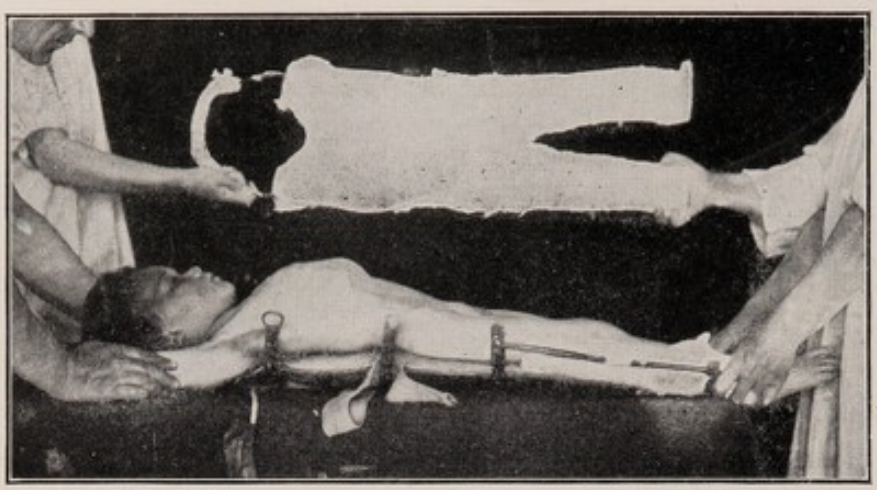

FIG. 238.—Patient in double Thomas splint, unbandaged ready for application of plaster; turning case shown in upper part of picture.



FIG. 239.—Application of shell.

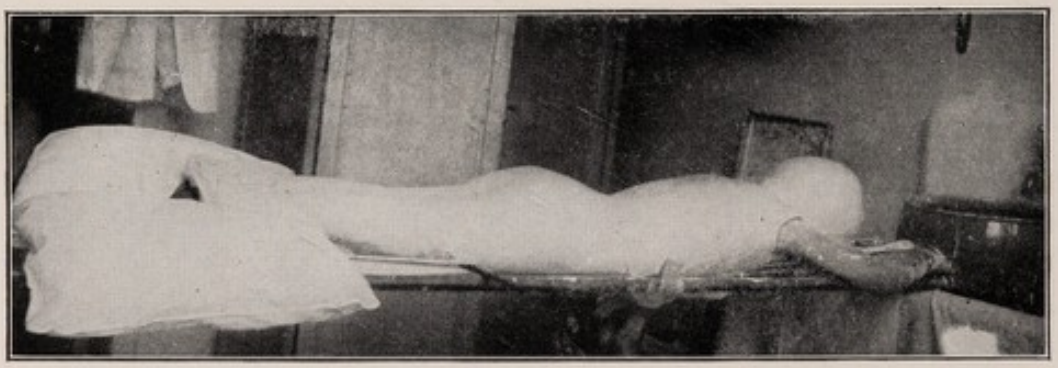

FIG. 240.—Completed shell.



FIG. 241.—Hyperextended shell with Schwartz adjustable saddle to make pressure on kyphos.

There can be no form of traumatism more harmful than allowing a patient to twist his tuberculous spine, or twisting it by careless turning. It is frequently followed by grave symptoms.

A most excellent apparatus invented by Mr. Pugh is in use at the Carshalton Hospital, of which illustrations are given. It is a form of carriage which allows of very easy nursing and is so constructed that exercise can be given to the knee joints without disturbing the spine. The patient can remain in this carriage night and day (Fig. 248).

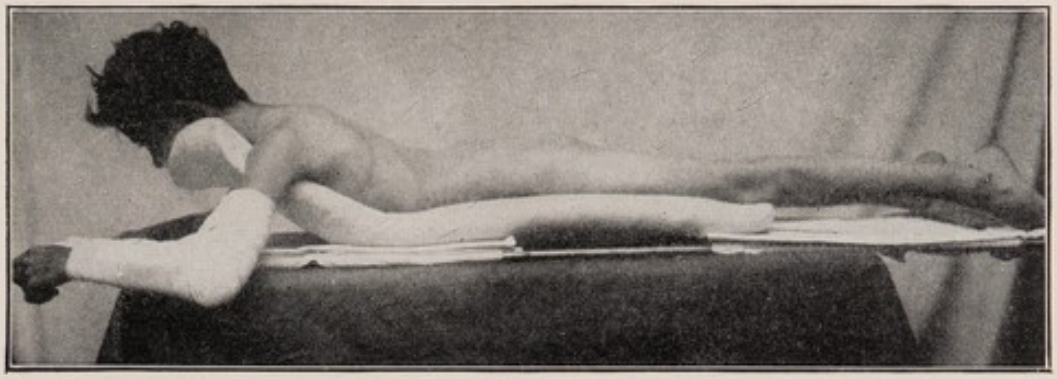

FIG. 242.—Anterior lid to maintain overcorrected position while turned.

To sum up the rational treatment of tuberculosis of the spine in the active stage. It is impossible to secure the removal of superincumbent weight and adequate fixation in the best position except by recumbency. This treatment should be continued for from eighteen months to two years in the average case. But in adults it is not always possible to carry this out.



FIG. 243.—Child on Pugh's frame and carriage for tuberculosis of the spine.

When recumbency is not pursued as the means of treatment, the surgeon should realize that he will probably not obtain as good an end result as he would have done, had the patient been recumbent over a sufficient time. If ambulatory treatment is adopted, recumbency becomes imperative in the presence of great pain, on the appearance of paralysis, failure of the general condition, the occurrence of abscesses or an increase in the deformity.

Ambulatory Treatment.—If ambulatory treatment, that is, treatment while the patient is going about, is to be adopted, the mechanical requirements mentioned at the beginning of this section will be best met by the use of (*a*) a plaster of Paris jacket, or (*b*) some form of brace. Either is fairly effective and the choice would rest on the individual surgical facility with either one.

Treatment by Plaster Jackets.—The jacket serves as a lever, must come low down and have a firm hold on the pelvis, and extend high enough up in front to give a real backward support to the upper segment. In disease above the middle of the dorsal region it is not effective unless combined with a head piece, a fact which is very often lost sight of. The effective jacket is carefully

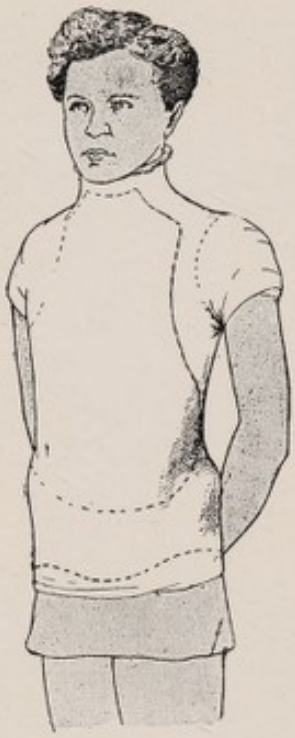

FIG. 244.—Military collar with plaster jacket. The dotted line shows the outline of the jacket and the window after trimming (Calot).



FIG. 245.—Application of back of jacket in one piece (Calot).

moulded in around the pelvis, it holds tightly between the symphysis and the sacrum, it is pressed in at the sides over the trochanter, and scored in above over the crests of the ilia. At the top in front it should press firmly against the top of the sternum, even when the patient is lying on the back. Unless these conditions are fulfilled the jacket will *not* exercise effective pressure forward on the deformity. The efficiency of the jacket can be estimated by the pressure marks existing at the site of the deformity when the jacket is removed for changing. No apparatus can serve as a lever without exercising pressure on the fulcrum.

Application of Jacket.—The plaster jacket as generally applied is often faulty in its mechanics, applied without a real knowledge of the requirements of

the situation, and its use under these conditions is naturally followed by many bad results. It may be, however, highly efficient and in France has reached a development and an exactness of application which has not in general been found elsewhere. It is there used in connection with recumbency and in this way is highly effective, being open only to the objection that it constricts the chest.

The application of the jacket is the same whether it is to be used in recumbency or ambulatory treatment, and the same description will answer for both.

In the application of the plaster jacket as described by Calot,[1] the patient is suspended by the head by a cotton sling, which may be incorporated in the jacket if a head piece is to be used. In this technique, a pattern is cut for the front of the jacket and one for the back, of



Fig. 246.



Fig. 247.

Figs. 246 and 247.—Plaster jacket applied, from side and from front. In this case some lateral deviation was present in the spine and was not corrected.

crinoline gauze of several thicknesses. These are impregnated with plaster cream which is rubbed in, and when the patient is suspended, the front piece is applied followed by the application of the back piece, and a few turns of bandage secure the two and hold them together. A collar is cut, if necessary by a separate pattern, from crinoline and impregnated with plaster in the same way. The technique of application in this way is somewhat difficult, and there is nothing that cannot be done equally well although less quickly by the ordinary plaster roller bandage. Particular attention is paid to the fit over the pelvis, all jackets go over the shoulders, and a head piece is applied for all disease above the mid-dorsal region.

When the jacket is dry, the front is cut out by removing a section from the top of the sternum to the symphysis pubis. A trap door is then cut out over the kyphos under which is placed a mass of compressed absorbent wool. The trap door is then returned to place and

[1] Calot, F.: L'orthopedie Indispensable, Paris, 1909, 7.

fastened down by plaster or strapping and the compression increased from time to time by adding more absorbent wool. The technique is not easy to follow without considerable practice.

A jacket of high efficiency may be applied during recumbency by the following method. The patient lies on the face on a gas pipe frame, the ends of which are connected by two webbing straps or a strip of cloth and a windlass is fastened to one end of the frame so that they may be tightened or loosened. An undervest is applied to the patient before laying him on these webbing straps, and two heavy pads of felt, at least an inch thick, are applied at the site of the kyphos running two inches above and below, the jacket is then applied as high as the middle of the kyphos and carefully moulded in over the pelvis as described above. It is allowed to set and the webbing straps are then loosened. As a result of this the spine is hyperextended against the posterior edge of the upper part of the jacket so far applied. The straps are loosened until the patient complains of slight discomfort, when further loosening is stopped and the rest of the jacket applied. This gives a jacket applied as high as the top of the axillæ and the patient turned on the back with head and shoulders projecting over the end of the table. Shoulder pieces are easily added with a collar if desired. The advantage of this method over the technique described by Calot is that the spine starts in a hyperextended position, after which the front of the jacket may be removed, the trap door cut, and pressure applied if it is required.



Fig. 248.—Plaster jacket with head piece—French model.

These two methods have been described at some length because they are both highly effective, and because the plaster jacket has been grossly misused and has been much underestimated. Plaster jackets are dirty, hot, and in poorer patients often infested by vermin. Grave objections, moreover, may be urged against plaster jackets *improperly* applied. They are seldom efficiently padded over the bony prominences, rarely carried high enough or sufficiently low; generally so loose that a hand can be readily passed under them, so that they are lacking in power to immobilize, as a result of all of which the patients give a history of a steady and progressive growth of the deformity. In fairly cleanly people the longer a plaster jacket is left on the better for the spine providing it is efficient, because the changing of the jacket is an undesirable traumatism, and jackets may be left on from six months to a year in many instances. When they are removed the skin will be found to be very dry and caked, and it is not a good practice to bathe such skin with water, or to attempt to soften the skin by oil or ointment, but to apply the new jacket over the skin without any extensive washing.

Jackets should be removed for persistent local pain, which may be caused by pressure; for an offensive smell, which may be caused by a slough under the jacket; and during the course of eruptive diseases. Ulcerations may form under the jacket if patients are not carefully nursed. When the jacket is changed the utmost care should be taken to avoid traumatism to the healing

spine. It is somewhat risky to apply jackets and allow the patients to go out of doors immediately in cold weather, as the plaster remains damp for at least twenty-four hours, and from its evaporation may cause a serious chilling of the body.

Braces.—A spinal brace acts as a lever pulling backward upon the shoulders, thorax, and pelvis, and exerts pressure on the kyphos which serves as the fulcrum. The mechanical objections to its use stated in an earlier section hold with regard to the acute stage, but in the convalescent stage one is dealing with a spine where healing has begun and the problem is different. The use of any brace must be regarded as an incomplete attempt to take all of the superincumbent weight off of the diseased vertebræ.

Posterior Support.—An effective support is the Thomas spinal brace used widely in Great Britain instead of a plaster jacket. The treatment by

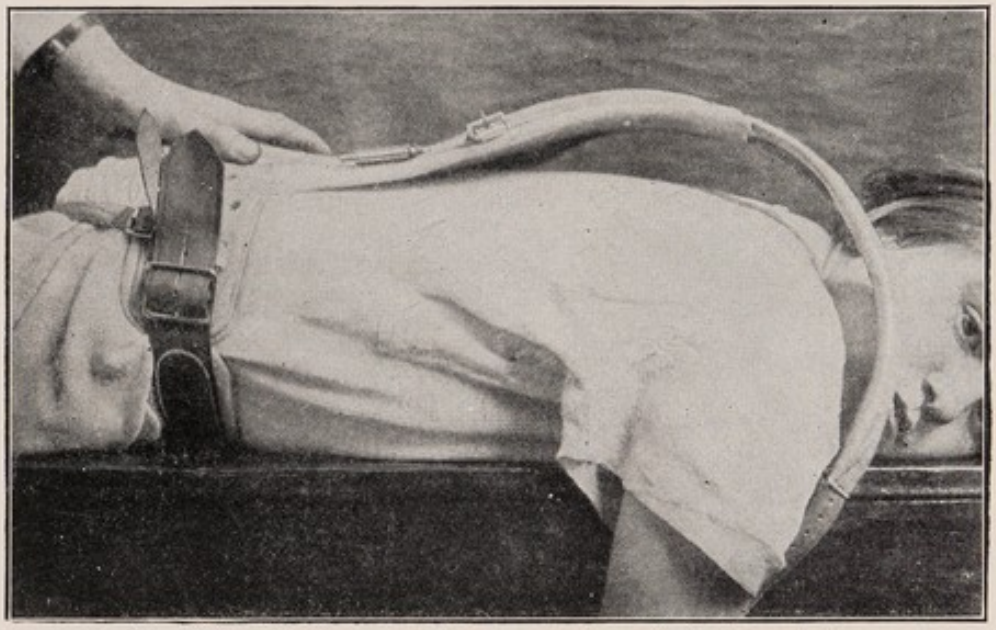

Fig. 249.—Fitting posterior support for spinal tuberculosis.

this appliance is based upon the principle of immediate and complete immobilization of the diseased area by an apparatus applied in most cases to fit the deformity which has been reduced to its minimum by recumbency, without any effort then, or at any other time to correct the deformity by suspension or posture and only very exceptionally by leverage. The principle logically obtains from the theory that a diseased joint recovers when subjected to immediate and complete immobilization and is injured and delayed in its ultimate recovery each time the surgeon succeeds in reducing the deformity. It has the advantage of fixing the spine without in any way hampering the expansion of the chest, a point of very considerable importance when dealing with a tuberculous child. For some years after the recovery from active disease a supporting brace will have to be used to prevent postural increase of deformity which is an additional reason for allowing full movement of the chest.

It consists of an irregular shaped frame of flat bar-iron forged into the required form, as shown in Fig. 250. At the bottom it reaches to the level of the great trochanter; that is to say, it extends as low as the sitting posture will allow. Laterally it extends from the space posterior to the great trochanter on each side, and from there curves upward passing to

the outer side of the posterior superior spines of the ilia; thence inward to the immediate neighborhood of the spinal column in the dorso-lumbar region, from there curving somewhat outward toward the posterior border of the axillæ, then upward and inward to the back of the shoulders, at such distance as not to interfere with the movements of the arms, till the root of the neck is reached, when the two sides join in a horizontal upper bar. The width and thickness of the bar-iron used will depend upon the size and weight of the patient. Thus for a child of four to eight years it should be three-quarters by three-sixteenths of an inch. In forging the frame it is made to lie flat with some accuracy upon the patient's back from pelvis to tip of kyphos. This frame being in one continuous piece and nowhere pierced with holes gives a great degree of rigidity for its weight. Under it is placed a piece of fairly rigid leather, cut to the same shape as the frame, but extending beyond its margins. Again under this is placed a sheet of saddler's felt extending a little beyond the borders of the leather piece. The felt and leather are sewed together, and to these are fastened the necessary straps and buckles. The whole is then covered with basil leather. From the bottom of the brace a broad leather strap, lined with felt, buckles across the front of the patient, and secures the brace to the pelvis. At the lower lateral curves of the frame, on each side a buckle faces downward to accommodate a perineal strap, which in front passes up to a buckle on the broad leather strap just mentioned. Above, at the junction of the neck and shoulder, a buckle looks forward and, at the lower border of the axilla, another looks laterally on each



Fig. 250.—Collar and posterior support for spinal tuberculosis.



Fig. 251.



Fig. 252.

Figs. 251 and 252.—Thomas collar, back and front.

side; these are for the shoulder straps. The shoulder and perineal straps are of leather padded with felt and covered with basil leather. From the middle of the brace on each side

a strap of webbing two inches wide passes over the patient's abdomen and buckles. The position of this strap is changed with the necessities of the case and at times a second strap is added.

Should the deformity be an extensive one and the angle formed by the spines of the diseased vertebræ be acute, one of two, or both procedures may be necessary. The leather between the frame and over the kyphos may have to be split, so that no pressure is exercised over sharp projecting bone. In exceptional cases, where the superincumbent spine falls considerably forward, traction is made by the shoulder straps toward the cuirass, which, in such cases, in order to allow of a pull, is not fitted accurately to the upper portion of the back.

The apparatus is comparatively cheap and cleanly. It can be removed at intervals while the back is cleansed, and a sheet of cotton wadding inserted between the support and skin. The special value of this support consists in the length of the spine which it controls. It reaches the seventh cervical vertebra above, and by its action on the shoulders partly governs the upper dorsal vertebræ, while below it extends to the trochanteric regions and is there assisted by groin straps. There is no undue pressure upon the chest or muscles, and with care, no danger of sores or excoriation. It is easily worn, and is never uncomfortable and in no way interferes with recumbency.

In order to measure for this support the patient should be placed on his face upon a level couch and the distance measured from the seventh cervical vertebra to the cleft in the buttock. The shape of the kyphos is taken and noted by means of a flexible metal tape.



FIG. 253.—Doll's collar of plaster for cervical tuberculosis.

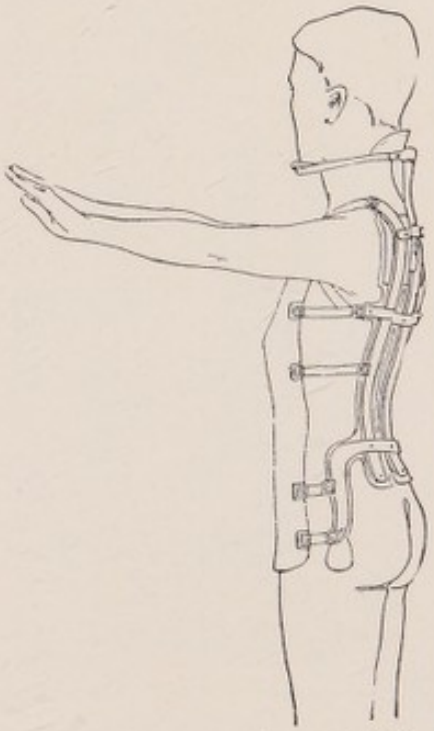

FIG. 254.—Taylor back brace with head support, side view, showing apron.

In disease high up where the collar is required it is well to cut out for the instrument maker a pattern in brown paper something like the old fashioned stock. Unless this be done it is very difficult to secure an accurate fit, as the position of the head and neck varies so much in different cases. Where there is any doubt on the part of the surgeon as to his being able to measure properly for a collar, it is well to order one filled with sawdust, which can be modified as to size and moulded as to shape to suit the particular case.

The absence of holes, screws and rivets renders the construction of this brace simpler than any of its modifications, and if the patient is obliged to lie down, it will be found more comfortable.

When about to wash the patient, the webbing waist belt is removed, and the patient lies on the face on a flat couch or table and all other straps are unfastened, after which the support can be turned off as a lid. A clean vest is put on, and the support reapplied. The groin straps can be removed daily for washing purposes, but once a week is quite often enough for the jacket.

The "Doll's collar" used in the Shropshire Open Air Hospital (Fig. 253) is very simple and effective. The patient is only partially suspended and the illustration describes its application. It must leave the shoulders free play.

Thomas Collar.—When disease is in the upper dorsal region a Thomas collar or other appropriate head rest or chin piece must be added to the posterior support. If the Thomas collar is used, as the illustration shows it prevents the chin from approximating the sternum and it should not put any pressure on the front of the neck.

Taylor's Antero-posterior Splint for Tuberculosis of the Spine.—This brace consists of (*a*) two uprights, (*b*) a bottom piece, (*c*) a top piece, and (*d*) a cross bar.

(*a*) The uprights reach from the seventh cervical vertebra to 1 inch below the posterior superior iliac spines, and run on each side of the spine over the transverse processes. They should be curved to fit a tracing of the spine made with the patient lying on the face, and taken over the transverse processes.

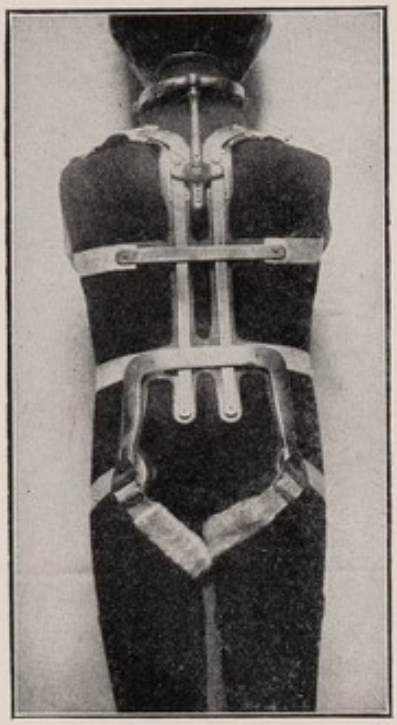

Fig. 255.—Taylor back brace with head support.

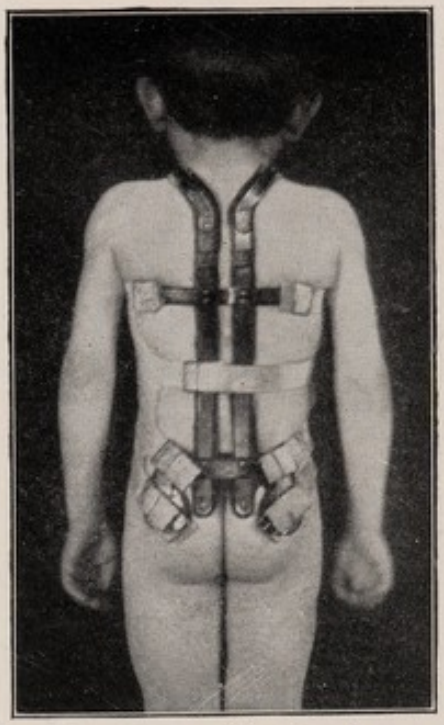

Fig. 256.—Same without head support.

(*b*) At the bottom the splint terminates in an inverted U. The transverse part of this bottom piece runs above the posterior superior iliac spines and is rounded to fit over the bony prominences. The ends of the bottom piece should terminate about 1 inch above the tuberosity of the ischium, as otherwise the patient will sit on the lower end of the brace. The bottom piece terminates below at its lower ends, in two circular plates 2 or 3 inches in diameter in the case of adults, less in children. The end pieces of the inverted U should lie in the post-trochanteric fossa.

(*c*) The shoulder piece is also a flattened U or two small angle irons curved on the flat and fastened on the top of each upright. They should be at an angle of about 45 degrees to the upright. They should run from the top of the upright to the forward edge of the trapezius, and they will show less if they lie in the supraspinous fossa of the scapula.

(*d*) The two uprights are connected by a flat bar at about the axillary line, projecting 1½ to 3 inches on each side of the upright.

The brace acts as a lever, using the deformity as a fulcrum, and where the bars come over the fulcrum they should be smoothly padded with felt and leather. The brace is fastened to the body by an apron of stout cloth fastened to the brace at several levels, extending above to the top of the sternum and below to the symphysis pubis. In width it should end at the anterior axillary lines in front. It should be shaped to the body by means of gores and gussets.

In cases where tuberculosis of the spine is above the sixth and eighth dorsal vertebræ, it is desirable that the head should be supported, and for this an oval ring is constructed, mounted in a post, which post is fastened by means of a box to a rather heavy piece of metal connecting the top of the two uprights. This apparatus consists of (*a*) an oval ring, (*b*) a spindle, and (*c*) a socket.

(*a*) The oval ring should extend from the occiput to the chin in front. In width it is slightly wider than the angle of the jaw. It is hinged at the angle of the jaw to open and should be made of spring steel about ¼ inch wide. There is a chin rest of hard rubber or moulded metal, shaped over a plaster cast of the chin, and occipital pad at the back, of thick leather fastened to the inside of the posterior part of the rim. A small block of steel is riveted to the middle of the back of the rim, which is pierced by a vertical hole, into which is inserted the top of the spindle which connects the ring with the top of the brace. It permits horizontal rotation.

(*b*) The steel spindle which connects the ring with the brace below fits into a socket, and the spindle should be bent in such an antero-posterior curve that the pitch of the ring holds the head in a natural position. The spindle is fastened to the brace and is adjusted by a set screw passing through the back part of the socket.

(*c*) The socket consists of a flat steel bar thick in the middle through which a hole is drilled.

In the hands of Dr. C. F. Taylor[1] this brace furnished excellent results, which have been published, but its use requires a very high grade of mechanical skill and constant watchfulness. After recumbency has been given up and the patient is allowed to go about, it forms an admirable support during convalescence.

Convalescent Brace.—A brace for use during convalescence is a lighter modification of the Taylor brace. This later apparatus is useful where some support to the spine in the sagittal plane is needed, but where the rigid antero-posterior spinal brace, as described, is not required. Like the brace described above it consists of (*a*) a horizontal pelvic band, (*b*) two uprights, made of 15 gauge steel, and (*c*) a cross bar curved to fit the contour of the shoulders and lying flat against the skin. The uprights should be generally a little further separated at the bottom than at the top and in their upper part should clear the posterior borders of the scapulæ. They are made of 16 gauge sheet steel about ½ inch or so wide and should follow the outline of the spine in general. They should be spring tempered.

The cross bar consists of a piece of steel about 2 inches short of the breadth of the body at the level where it is placed. The projecting edges should not rest on the scapulæ and it is often necessary to set them back. The padded axillary straps run from the top of the upright to buckles at the ends of the cross bars, and below is a cloth apron with buckles fastening it to the pelvic piece, and to the cross bar behind. In cases where there is much prominence of the abdomen, which it is necessary to support, it is desirable to use an anterior band from 4 to 6 inches in depth, in which case extra buckles will be needed on the uprights (Fig. 258).

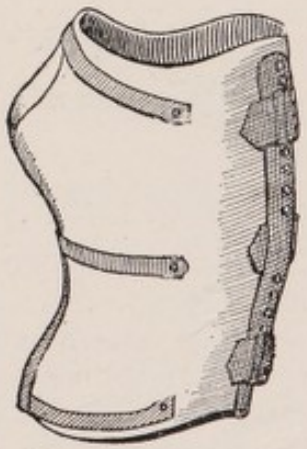

Fig. 257.—A worthless type of spinal support—poroplastic jacket.

In England the *poroplastic support* is a favorite appliance, and it is mentioned only to be condemned. It has no arrangement for relieving superincumbent weight, no shoulder attachments, no groin straps. It acts only as a ferrule which if too tightly applied, interferes with the play of the muscles and ribs, and if too lax has no power to support. The accompanying diagram represents a felt jacket removed from a patient. The position of the kyphos is easily seen and the reader will note that the felt hardly extends above it. This is equivalent to treating a fracture by splints confined to the lower fragment. One is not astonished, therefore, that failure so frequently accompanies the efforts at preventing deformity when fundamental, even if simple, mechanical principles are ignored.

[1]Taylor, C. F.: Trans. New York State Med. Soc., 1863.

Treatment of Convalescence.—Tuberculosis of the spine with destruction of the vertebræ, is slow in healing, and the beginning of convalescence is indicated by the absence of discomfort, the disappearance of muscular irritability in the spinal muscles, normal temperature, a good general condition, and at intervals of a few months a study of X-rays taken from the side without trauma. A satisfactory condition is indicated when the shadow is more or less even and not mottled, and when a normal lime shadow is cast by the diseased region. So long as the affected bone is poor in lime or shows cavities or mottling, the process is probably not ended. If convalescence is regarded as established the patient should be allowed to be more active, and walking increased. To avoid the return of deformity, a rigid brace, mechanically effective, should be worn for two or three years more, and replaced if need be by a light spring tempered brace later on. A case of tuberculosis of the spine should be watched for increase of deformity for at least ten years, especially if apparatus has been discontinued. A tracing should be taken by laying a lead strip on the back, shaping it to the back, tracing it on card board, cutting out the tracing and applying it to the back (Fig. 226). It is a very common occurrence in surgical practice to find young adults with an increasing deformity which they had not been warned against, and which had come on after a period of quiescence. This is not a relapse, but a yielding of softened bone under undue mechanical pressure. The mechanical treatment of tuberculosis of the spine has never received the credit that it deserves, because for the most part it has been incompletely used and carried out in a more or less haphazard way. It seems necessary to speak of this aspect of the question before proceeding to the discussion of the operative treatment, because any comparison between the two methods must be made with each method developed to its highest degree.

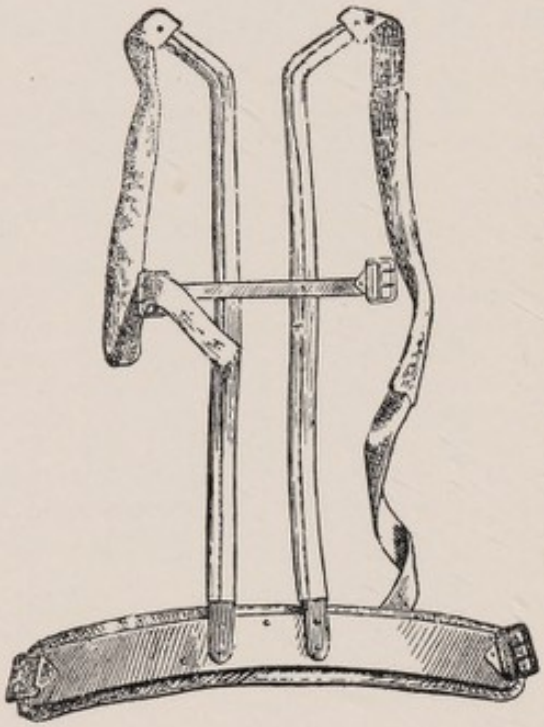

Fig. 258.—Convalescent back brace with tempered steel uprights (Bradford and Lovett).

Operative Treatment. *Operative Treatment of Complications.* Before coming to the operative treatment of the disease itself, some mention must be made of the operative treatment of complications.

Abscesses.—The principles of the treatment of abscesses in tuberculosis of the spine are not essentially different from that of tuberculous abscesses in general, but their location makes certain modifications necessary. Absorption may be expected in the large majority of cases, but in certain instances this does not occur. Evacuation of an abscess is demanded when the patient suffers from septic symptoms or when it threatens important structures.

Retropharyngeal Abscess.—A retropharyngeal abscess should be opened as soon as it is identified, on account of the danger of obstruction to respiration, and the very real risk that the abscess will burst and suffocate the

patient. An incision should be made at the posterior border of the sterno-mastoid muscle, care being taken to avoid the spinal accessory nerve. The structures are then drawn forward with a broad retractor when the transverse process of the vertebræ will be easily felt. It is a mistake to incise through the pharynx and even if the abscess presents there, it should be approached through the neck.

Mediastinal Abscesses.—A mediastinal abscess involves an operation of a very serious character as it is necessary to perform a costo-transversectomy: A transverse incision[1] exposes the spinal end of the rib at the level of the deformity. The corresponding transverse process is excised, the rib denuded of periosteum and cut off about two inches from its posterior end and the posterior fragment removed. It may be necessary to resect a second rib. The periosteal canal left by the removal of the rib generally leads to the tuberculous focus. The operation is frequently attended by a fatal result.

Psoas Abscess.—Psoas abscess should be let alone, as probably 70 per cent absorb under treatment by recumbency. Opening them should only be considered when they are on the point of rupture or when they increase so as to cause intra-abdominal pressure. In case the abscess is not absorbing it may be aspirated if the needle is introduced through healthy tissue. This may be repeated if the abscess refills, as a certain number of cases recover after such emptying. If the abscess is superficial and the skin thin and reddened, incision is desirable. The incision[2] should not be longer than half an inch; it should be made over the thinnest part of the distended sac, and the pus should be allowed to flow and no effort made by the surgeon to squeeze it out; no drainage tube should will be used.

If not infected by pus organisms abscesses will diminish in size and their content will calcify.

The abscess will in some instances close after a short time if it is a residual abscess. If, however, fresh material is still being poured into it from the focus, it cannot be expected to close and will continue as a sinus. A jacket or spinal support is applied immediately after operation, and the patient placed on a bed considerably elevated at the head or in a sitting position, in order that drainage may occur, for no psoas abscess can drain through an anterior incision with the child lying on the back. The child may be kept on the face all the time but the position is irksome. The fatal results from psoas abscesses occur as a rule from prolonged suppuration and amyloid degeneration, and no pains should be spared to promote drainage and healing. No results, in the series observed by one of the writers were so disastrous as those where a thorough surgical operation was done, the wound widely opened in front and at the back, wiped out by gauze and drained by tubes for a long time.

In a series of 54 cases of psoas abscess operated on at the Children's Hospital, Boston, it was possible to report on the final condition of 43 some years later. In cases where the temperature was high before operation the final mortality was 70 per cent, whereas in cases where the temperature was normal before operation it was only 33 per cent. Seventeen (35 per cent) were known to have died, 26 were alive some years later; and the results were not known in six. Of 20 cases operated on more than five years previous to the investigation 10, or 50 per cent, had died. Of 34 cases operated on within five years

[1] Ménard: Etude prat. sur le mal. de Pott, Paris, 1900.
[2] Lovett: Boston Med. and Surg. Jour., May 16, 1901.

of the investigation 26 per cent only had died. These cases were, however, reported twenty years ago, and under more modern conditions results should be more favorable. Death, when it occurred, in the majority of cases was a year or more after the operation and nephritis and tuberculous meningitis were two of the most frequent causes of death.

Lumbar abscesses should be regarded and treated in the same way, except that the patient may remain recumbent. The aspiration of these abscesses differs in no way from the question of tuberculous abscesses in general. Here as elsewhere we would emphasize that to open a tuberculous abscess is a dangerous proceeding unless every effort is made for the prevention of infection which has to be continued until the cavity has closed. It is a constant cause of tragedy.

Treatment of Paralysis.—There is no special treatment for the paralysis beyond that which is necessitated by the mechanical management of the disease. The question, however, often comes up as to the performance of laminectomy, but the operation is to be recommended only in exceptional cases where the paraplegia has long continued without improvement, and especially where sensory symptoms are present. Early statistics showed a heavy mortality. Of 132 operations reported by Menne[1] 56 per cent were reported as improved or cured, but it is impossible to judge from these figures as to the risk of an operation today. The whole sentiment has changed of late years with regard to laminectomy for this condition, and it is regarded as much less advisable than it was twenty years ago, in spite of the improvement in surgical technique. In abscess due to paraplegia operation is rarely necessary and in pachymeningitis paraplegia the operation is useless. Calvé[2] has recently treated abscess paraplegia by intraspinal puncture and aspiration using a special trocar and cannula which is introduced through an intravertebral foramen. The method is still on trial.

Operative Treatment of Pott's Disease. (Fusion Operations.)—In the last few years operations have been advocated and performed on a large scale for fixation of the spine in the treatment of Pott's disease. The technique followed is that of Hibbs[3] and Albee.[4] The Hibbs operation consists in fusion of the laminæ, spinous and articular processes by stripping them of periosteum and crushing them together. The operation of Albee consists in an implantation of a graft from the tibia, which is inserted in the row of spinous processes, which are split to receive it. The technique of these operations is described in the following paragraphs.

Albee's Operation.—A semilunar incision from six to eight inches in length beginning well above and below the diseased area swerves in a sweep to the side, the maximum curve being opposite the deformity. The flap is dissected up and reflected and the tips of the spinous processes, the supraspinous ligaments over the tip of the spinous processes, as well as the interspinous ligaments are directly exposed. With an osteotome the spinous processes are split in halves to a depth of one-third to two-thirds of an inch, and one-half of each spinous process, always on the same side, is fractured completely at its base and set over a distance varying according to the thickness of the graft which is to be implanted. A graft is then removed from the antero-internal surface of the tibia which includes the whole thickness of the cortex of the tibia. It may be necessary to mould the graft in cases of sharp deformity. The graft is transferred from the tibia to its spinous bed by clamps and is held in place by strong sutures of kangaroo tendon passed through one-half of the split supra-

[1] Menne: Ztschr. für Orth. Chir., 1912, iv.
[2] Calvé: Presse Médicale, March, 1922.
[3] Hibbs: New York Med. Jour., May 27, 1911.
[4] Albee: Annals of Surg., May, 1912.

spinous ligament over the graft and through the opposite half of the supraspinous ligament. The graft must be long enough in every instance to include the spines of two healthy vertebræ above and below the diseased area. Sharp corners of the graft should be removed before fixing in position. If a straight graft is to be bent transversely saw cuts should be made in it on its narrow surface two-thirds or three-quarters of its thickness to allow it to bend. The skin wound is closed in the usual way and sterile dressings applied.

Hibbs'[1] Operation.—An incision is made through skin and subcutaneous tissue from above downward, exposing the tips of the spinous processes of the vertebræ to be fused. The periosteum over the tips of these processes is split longitudinally and, with a periosteal elevator, pushed to either side, leaving them bare. The periosteum and interspinous ligament are still further split and pushed forward a short distance from each spinous process in turn as two lateral halves, gauze packs being inserted to prevent oozing. The dissection is carried further and further forward upon each vertebra in turn until the spinous processes the posterior surfaces of the laminæ and the base of the transverse processes are bared, thereby exposing the ligamentum subflava attached to the margins of the laminæ and the articulations of the lateral processes.

The ligament is removed from the laminæ with a curette, and the articulation of the lateral processes is destroyed in order to establish bone contact at this point. With a bone gouge a substantial piece of bone is elevated from the adjacent edges of each lamina, of half its thickness and of half its width. The free end of the piece from above is turned down to make contact with the lamina below and the free end of the piece from the lamina below is turned up to make contact with the lamina above.

Each spinous process is now partially divided with bone forceps and broken down, forcing the tip to come in contact with the bare bone of the vertebra below. The spinous process of the last vertebra below should be turned up to make contact with the next above. As the spinous processes of the lumbar region are wide, it is sometimes practicable to split them, turning one half up and the other half down. Thus is established contact of abundant cancellous bone at the articulations of the lateral processes, laminæ and spinous processes. The periosteum and ligament, which together have been pushed to either side and lie practically as an unbroken sheet, are brought together in the middle with sutures of ten day chromic catgut, interrupted. The subcutaneous tissue is then closed with a continuous suture of plain catgut, the skin wound closed by sutures of ten day chromic catgut, and sterile dressings and an immobilizing brace or plaster applied.

The dissection may be made in a practically dry field, without injury to the muscles, if it is subperiosteal, and if a free use is made of gauze packs. Only in an operative wound that is free from hemorrhage can the operator see to exercise the care necessary to thorough work. Not only may the baring of the bones be complete, but the periosteum may be separated from them in a practically unbroken sheet and without disturbance of its relation to the surrounding tissues and blood supply. The greatest care should be exercised in this dissection, since it is of primary importance, as the area of fusion is measured by its extent and thoroughness. After the bones are bared, they may be treated as indicated above, or in any manner which establishes their contact and stimulates bone formation. With the closure of the periosteum, what is practically a tube of periosteum is produced, with its abundant blood supply undisturbed, filled with healthy, living cancellous bone, lying in continuous contact. This situation is entirely consistent with the physiological laws of bone growth, and furnishes a great stimulus to their operation, and insures a fusion of the lateral processes, the laminæ and the spinous processes.

If surgeons perform any of the operations for spinal fixation they should at least exercise the greatest care in maintaining complete immobilization. Many failures are due without doubt to an inefficient attempt to immobilize after operation. Before the operation a plaster shell should be prepared upon the front of which the patient lies during his operation. A shell allows of safe handling of the patient with absolute security for the spine. This should be maintained for at least three months in the adult and six months in a child. These periods must be prolonged if the disease is so situated that it is difficult to control with a short support. For several months afterward a well fitting posterior brace should be worn by both adults and children. A carefully

[1] Hibbs: Jour. Am. Med. Ass'n., Jan. 30, 1915.

controlled régime which includes rest, fresh air, good food and sunlight is necessary.

A very high percentage of successful results have been reported by Hibbs, Albee and other surgeons. Farrell[1] reported 158 cases operated on by Hibbs of which approximately 90 per cent had an apparent arrest of disease. Albee[2] reported 198 personal cases with 92 per cent in which the disease was reported as being arrested. In a series of 642 operative cases reported by Walcott,[3] 83 per cent were benefited by the operation.

The operation has met with a very favorable reception in America and has been performed upon a large scale, but the final results as observed by the writers have not warranted the very optimistic view presented by these figures. In their opinion, the operation is an admirable one in tuberculosis of the spine in adults, which is a much more serious disease than in children and where prolonged treatment is generally impossible. But in a great many cases originally reported as successful are later to be classed as relapses.

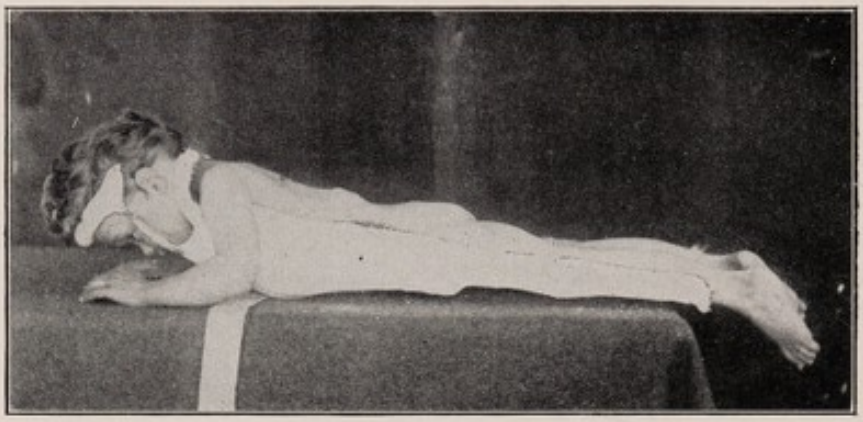

FIG. 259.—Patient turned in case used for giving anesthetic for Albee operation.

In a large number of cases of spinal tuberculosis observed at the Children's Hospital, at the Massachusetts Hospital School in Canton, at the New England Peabody Home for Crippled Children, and in hospitals in England, a great many relapses have been seen, not only in cases where the operation was performed by the writers personally, but also by other surgeons presumably competent. The very large proportion of ultimate failures in children has led the writers to feel that it is not an operation to be done as a routine and only to be performed where mechanical treatment is not possible, or where there is some especial reason which makes it justifiable. In young children especially, the operation is not free from fatalities, and relapses appear to be due to three causes: (1) Where the graft is not long enough to include normal vertebræ above and below the disease, (2) where the disease has apparently extended beyond the limits which have been protected by the graft, and (3) cases in which the graft has been broken or been absorbed.

That both operations cause fusion of the laminæ is not to be disputed. One of the authors has been obliged in two instances to cut down afterward upon cases where a fusion operation had been performed. After the Hibbs technique the fused laminæ formed a solid sheet of bone, and after the Albee

[1] FARRELL: Jour. Am. Med. Ass'n., 1915, lxiv, 398–400.
[2] HIBBS: Orth. and Reconst. Surg., New York, 1919, 119.
[3] WALCOTT: Jour. Am. Med. Ass'n., Jan. 8, 1916.

operation the bone of the graft was indistinguishable from the bone of the spinous processes to which it had adhered.

The opinion of the writers, therefore, after a very considerable experience in the operation and in the observation of its end results, is to the effect that osteoplastic operations should be done in children only when effective mechanical treatment cannot be carried out, but that in adolescent and adult life osteoplastic operations offer the best chance of a rapid and permanent cure.

The lumbar or dorsolumbar case in the adult is the best type for operation and the high dorsal the least favorable. The existence of unruptured abscesses does not contraindicate the operation but makes the prognosis less favorable and it is well to attempt to secure absorption of the abscess first where possible.

Summary of the Treatment of Tuberculosis of the Spine.—In children efficient mechanical treatment carried out over a sufficient length of time offers the best prospect of a useful spine with a minimum deformity. But treatment must be based on sound principles, and be effective and long continued, to effect a cure. In adolescents and adults osteoplastic operations are to be performed when possible. The treatment of paralysis consists in the treatment of the spinal tuberculosis. Abscesses should be let alone as long as there is any prospect of absorption, and if incision is necessary, it should be by means of a small opening, and traumatism to the walls of the abscess is to be avoided.

The convalescence of Pott's disease is a long process, and prolonged protection of the diseased spine is desirable. What appear to be relapses many years after the disease are often only the result of strain from insufficient protection. After recovery the kyphos has to be supported for a long time to obstruct the deforming tendencies of gravity and superincumbent weight.

CHAPTER XI

ARTHRITIS DEFORMANS

Synonyms.—Chronic non-tuberculous arthritis, rheumatic gout, osteo-arthritis, rheumatoid arthritis, chronic rheumatic arthritis, chronic rheumatism, hypertrophic and atrophic arthritis, and infectious or toxic arthritis.

The name given at the head of this chapter has been chosen to designate an imperfectly understood type of joint affection which in old days passed as "chronic rheumatism." Much confusion has been introduced into the subject by the introduction from time to time of a multiplicity of names implying an etiology, and as the views as to etiology have constantly changed, no one of these names has been universally adopted. Consequently in this chapter an endeavor will be made so far as possible to state only established facts under a title which does not imply any special etiology, and which has received perhaps the most general acceptance of any name.

Etiology.—The accepted etiological causes may be grouped as follows: (1) *Infectious*, where there is reason to believe that absorption is occurring from some focus of retained pus, (2) *toxic* (metabolic), where there appears to be some absorption of bacterial or chemical toxins, and (3) *traumatic*, where the joint is subject to constant or long continued strain or overuse. There is apparently but little relation between the etiological factor and the especial type of the disease which results from it; that is to say, a case of either one of the two types to be described may be due to any one of the three etiological factors. Finally, the fair-minded surgeon must confess in certain cases that he can find no cause to which he can reasonably attribute the disease.

Pathology.—From a pathological point of view this affection consists of a series of chronic degenerative joint changes which may be monarticular or polyarticular and, although more often a disease of middle life, it is not infrequently found in children where it is generally polyarticular. These changes are characterized in the main by atrophic or hypertrophic appearances and this has formed the basis of a classification, but as atrophy and hypertrophy occur in the same joint, such a classification is misleading. The pathological classification of Nichols and Richardson[1] will be followed in this section.

There are two groups, more or less pathologically distinct: (1) *Proliferative* (Rheumatoid Arthritis) and (2) *degenerative* (Osteo-arthritis).

Proliferative Arthritis.[1]—In this form, proliferations develop on the surface of the synovial membrane near the cartilage and in the perichondrium of the articular cavity, combined in many cases with synchronous proliferations of the connective tissue and of the endosteum in the epiphyseal marrow directly below the joint cartilage. As a result of these changes a pannus is formed which destroys the cartilage. In many instances a layer of connective tissue also grows from the part of the cartilage which is not covered by the pannus. Changes in the capsule and synovial membrane also take place, consisting of the development of granulation tissue with fibrous thickening. The joint may be gradually disorganized, the condition eventually perhaps terminating in ankylosis. Suppuration does not take place, and the process is not acute, although there may be acute stages. There may be long

[1] Nichols and Richardson: Jour. Med. Research, 1910.

remissions, the amount of the joint involved varies, and the process may be arrested at any stage. The periarticular tissues may be swollen, but without much heat or tenderness. Later the periarticular edema disappears in part and a shrunken condition of portions of the tissues may eventually result. As a rule there is an absence of peripheral exostoses.

The bones of the affected joint show an increased permeability to the X-ray, probably from an absorption of lime salts from nonuse, this occurring without other gross histological change of bone.

This form of arthritis attacks the middle-aged and the young, even the very young, but not often the aged. The affection generally involves a single joint at first, but gradually extends to other joints, as it is characteristically polyarticular. In the severe cases a pitiable condition of stiffening results, with ankylosis of all the important joints. The affection is extremely chronic.

Degenerative Arthritis.—In this group the primary change is the fibrillation and softening with erosion of a portion of the joint cartilage. The underlying bone may become exposed so that the joint surface articulates with bony and not cartilaginous contact, and with bone which becomes abnormally hard and eburnated. This terminal stage, however, exists only in exceptional cases. When it exists in its pure form the joints creak in motion like two polished surfaces of stone grinding together, and this stage is occasionally observed without great limitation of motion or much articular swelling. When, however, it is reached, joint motion is excessively painful. More commonly the changes are not uniform throughout the joint, but irregular growth of bone and cartilage takes place, often with erosion in one place and compensating overgrowth in another. There is increased perichondrial activity and new formation of cartilage and bone, with irregular increase circumferentially. The joint is irregularly enlarged; there is periarticular thickening; but, as a rule, the synovial membrane is at first comparatively normal, except at the periphery of the joint. As a rule, clinically, the formation of osteophytes reaches a marked or high degree before destruction of cartilage occurs, or often before any disabling affection of the synovial membrane exists. The presence of osteophytes as seen in the X-ray is often not as serious a prognostic factor as it would seem, and many joints, especially the knee, with a considerable formation of osteophytes can be made fairly useful, after eliminating any source of absorption of toxin, by protecting them against overuse and by the development of the controlling muscles.

There may form pedunculated growths of connective tissue, which may become edematous or infiltrated with fat, developing the so-called "lipoma arborescens." In these fibrous projections there may be found cartilage and bone, and the peduncular attachment may be torn, resulting in loose bodies, often partly ossified—the so-called joint mice.

The first, or *proliferative form*, is the one generally seen in children and is likely to be accompanied by much sensitiveness, while impairment of joint motion of a very serious character often occurs early. The *degenerative type*, on the other hand, occurs chiefly in the middle-aged and old, and is frequently associated with arteriosclerosis. In this type, the marginal bone proliferations are likely to impair motion mechanically and villous degeneration of the synovial membrane is one of the first symptoms to appear. Periarticular swelling exists to a large extent and increase of joint fluid may or may not be present. The disappearance of cartilage and contact of bare bony surfaces is a very late occurrence. Arrest may occur at any stage.

Symptoms.—Although these types are not always absolutely distinct, instances of each are seen more often than mixed types.

Proliferative Type.—The proliferative type is most often polyarticular; the swelling is slight and rather dense, and is much more prominent in children than in adults; increase of synovial fluid is not generally an important factor; muscular atrophy is rapid and severe; and muscular spasm exists from an early stage and is particularly troublesome and difficult to estimate because it is so apt to be associated with incipient ankylosis. Malpositions occur almost from the outset. Pain is almost constant and apt to be very severe, but shortening does not exist as a rule because there is no gross destruction of bone.

The clinical picture of this form is that of an acute, resistant, long continued joint affection, characterized by much sensitiveness and pain, marked muscular spasm, resistant malpositions of the joints, and early ankylosis. It

is the type most often associated with an infectious or toxic etiology and is rarely, if ever, to be attributed to trauma.

A spindle-shaped enlargement of the finger joints often occurs. It is roughly symmetrical and is most apt to affect the middle finger joints. It is not accompanied by malposition of the fingers as a rule, but remains a dense, tender swelling, fluctuating with the progress of the disease. There may be flexion contraction.

In children the affection presents a somewhat different type from that in adults, and the peculiarities of this form were first described by Still[1] and in children the affection is frequently called "*Still's Disease.*" It occurs as a rule in early or middle childhood, and is essentially polyarticular. Swelling is a prominent factor and the joints of the extremities are as a rule first involved. The disease is essentially painful, and accompanied by muscular spasm and joint malposition. Certain general symptoms occur in this type which are occasionally, but rarely, seen in adults. These are, enlargement of the lymphatic nodes, especially those in the groin and axilla, and, enlargement of the liver and spleen, even in infancy, a case of fifteen months having been reported. Spindle-shaped swelling of the fingers is common and the spine is generally involved. Emaciation is marked, and the general condition is poor. This type is exceptionally resistant to treatment, and the prognosis in general is poor, as it is too apt to terminate in ankylosis. The principles of treatment do not differ from those to be described later.

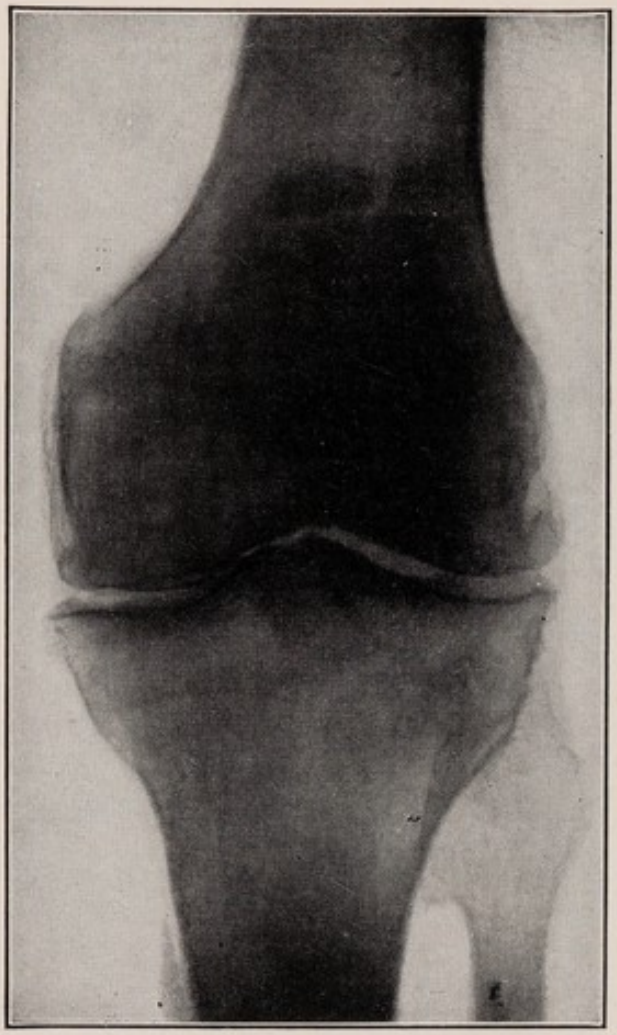

FIG. 260.—Front view of arthritis of knee showing diminished joint space and osteophytes.

X-RAY APPEARANCES.—In the proliferative type of the disease the X-ray picture shows a bone with a diminished lime shadow, generally not quite regular, but somewhat mottled and stippled. The space between the articular ends of the bone is narrowed indicating a thinner cartilage. Bony overgrowth is not present to any extent.

Degenerative Type.—This form is both monarticular and polyarticular. There are in general two varieties which may or may not be distinct. In one the peripheral joints are first involved, and this variety is more apt to be polyarticular, while in the other variety one or more of the larger joints, such as

[1] STILL: Trans. Medio-chir., 1897.

the hip, shoulder, or knee, are first affected. Of the two types, the latter is the more serious menace to ultimate function.



FIG. 261.—Arthritis of hip joint, showing wearing away of head with mushrooming, and broadening of acetabulum (Warren Museum, Harvard University).

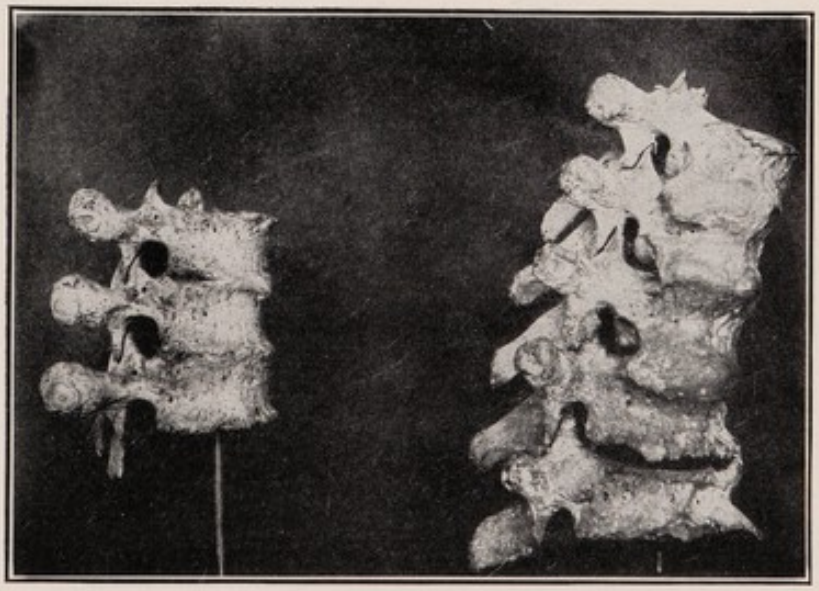

FIG. 262.—Arthritis of the spine, showing lipping and ankylosis of vertebræ (Warren Museum, Harvard University).

Swelling of the joint is marked and resistant, synovial fluid is generally increased, muscular atrophy is less severe than in the proliferative form and

muscular spasm may exist, often leading to deformity, but is less marked than in the other form. Pain is moderate, and shortening does not occur to any marked degree. The course of the degenerative type is a more or less slow and insidious affection of one or more joints, beginning as a chronic irritation accompanied by swelling, moderate pain, and impairment of function. The joints are likely to creak on motion, and to stiffen after periods of rest, but they loosen up under use. Periods of extreme pain and irritability are likely to occur from overuse or temporary increase of absorption of toxins.

Changes in the Fingers.—A characteristic involvement of the fingers and hands, which is of importance and of diagnostic value, is found in this type of the affection. One of the earliest changes in the generalized type of the proliferative form is the appearance of the so-called "*Heberden's nodes*" on the fingers. The terminal interphalangeal joint is most often affected and small bony enlargements are found at the sides of and in front of the joint. Accompanying this, the fingers are stiff in the morning and are inclined to be painful after use, especially in fine work such as knitting. If the general disease continues unchecked, these enlargements increase in size and become at times tender and painful, again relapsing into a quiet stage in the early phase of the affection. Following their appearance in the terminal interphalangeal joints they occur in the middle and proximal ones, affecting all of the fingers, and sometimes subluxation of the metacarpophalangeal joint occurs. In the terminal stage of this process, if it continues to progress, the hands become much distorted, the fingers are flexed, the metacarpus also often being flexed, and so much adducted to the ulnar side that, with the resulting stiffness, usefullness of the hand is much impaired.



Fig. 263.—Arthritis deformans of long standing—Heberden's nodes (Harvard Medical School).

A well recognized type of case is that in which Heberden's nodes appear, which do not reach a high degree, progress slowly if at all, and exist through life as a disfigurement rather than a disability. This type of the affection is particularly common among women at the time of the menopause, occurs less frequently in men, and when it does, generally at a later period.

This degenerative type of the affection is in general more controllable and more amenable to arrest at an early stage than the other. Even after the formation of osteophytes a useful joint can often be obtained by arrest of the process and by precautions to be spoken of under treatment. This type may be due to an infectious, toxic, or traumatic cause, but of these, as a rule, the infectious is the more severe and resistant to treatment; but it can be said by no clinical examination that the disease is necessarily either infectious or toxic. The influence of trauma is of much importance and not sufficiently recognized.

Traumatic Type.—The continued overuse or misuse of a joint, especially in people approaching middle age, is capable of producing low grade symptoms of the degenerative type. This is manifested as a chronic irritability and swelling of the joint, with perhaps some fluid, and this condition may go on to a stage when the structure and function of the joint are seriously impaired. This type of the affection is seen most frequently in the knees where there is some static disability of the feet, inducing constant strain on the knee. It is also seen where there is a very marked difference in the length of the two legs, and where the long leg is overworked, as after a fracture of the neck of the femur in a middle-aged person whose knee and ankle of the unaffected leg at times become affected by an arthritis characterized by the formation of osteophytes. Again, trauma is an element in localizing the affection in persons who are already affected by moderate or serious degrees of general arthritis deformans. A person falling and injuring the knee or hip is likely to develop a troublesome form of arthritis in the injured joint. For this reason joint injuries in arthritic persons are of unusual importance and deserve special care.

No chronic synovitis of the knee, especially of the type described, should be allowed to pass without a careful examination as to the condition of the *feet* from a static point of view, and a correction of any error of the sort which exists. The elimination of long continued trauma is always desirable, especially in middle aged persons. Erroneous deflection of body weight, especially in a person predisposed to arthritis, may result in an arthritis closely allied to or identical with this type of arthritis.

The *X-ray* shows a somewhat diminished lime content in the body of the bone; the shadow shows irregular trabeculæ with patches containing but little lime. Around the margins are seen hooks, or sharp or blunt projections, due to marginal osteophytes with a special tendency to extend into ligamentous and tendinous attachment. If cartilage is wearing away, the space between the bones is diminished.

In the X-ray of Heberden's nodes, broadening and wearing away of the articular ends of the phalanges is seen, with marked formation of marginal osteophytes.

Diagnosis.—To present definitely the diagnostic signs of the two types is not easy because, although fairly pure forms are the rule, not infrequently one finds mixed or border line forms. The affection is a chronic, mildly destructive process, at times distinctly formative, affecting one or many joints, with a tendency to loss of motion or ankylosis, not generally accompanied by fever or leucocytosis, and in children the Pirquet reaction should be negative. Impairment of function and swelling are almost constant, pain is generally present, suppuration does not occur, and muscular spasm is present in the acute stages. The existence of Heberden's nodes in the fingers is evidence of some degree of arthritis of the degenerative type, and this affection is most often roughly symmetrical. The X-ray appearance is as described. The disease is polyarticular or monarticular, the latter being rare in children, but common in adults.

The main characteristics of the two types are summarized in the following table:

	Rheumatoid Arthritis[3]	Osteo Arthritis
Age Incidence.	Infancy to middle life.	Middle life to old age.
Onset.	Acute to insidious.	Subacute to ignorance of presence.
Joint Manifestations.	Periarticular and articular swelling. Often free fluid. Early limitation of motion considerable. In hands mid-phalangeal and metacarpo-phalangeal joints usually involved first.	No periarticular and usually only localised articular swelling. Rarely free fluid. Little limitation of motion until late. In hands terminal joints usually involved first.
Symptoms.	General health usually less robust. Ptotic type. Pain and disability usually more marked.	General health usually robust. Well nourished type. Pain and disability usually less marked.
Early Roentgenogram.	No discoverable cartilage or bone changes. Shadows of excess of fluid and general increased density of soft parts.	Early slight "lipping" of articular margins. Shadows of localised synovial membrane proliferations may or may not be seen.
Late Roentgenogram.	Diminished density of bones. Usually absence of hyperostosis. Narrowed articular cartilage space. Ends of bones fairly regular in outline. Bony ankylosis common.	Except after long disuse no diminished density of bones. Presence of marked hyperostosis. "Joint mice." Narrowed articular cartilage space. Ends of bones irregular in outline. Bony ankylosis rare.
Temperature.	In early stages often slightly elevated, in late stage often sub-normal.	Normal.
Blood Pressure.	Usually lower than normal for age.	May be low, but usually normal or high for age.
Morbid Histology.	Early proliferation of synovial membrane. Pannus. Usually small round cell infiltration. Late atrophic changes in cartilage and bone. No cyst-like cavities in ends of bones. Fibrous or bony ankylosis common.	Early fibrillation of cartilage. Chondro-osseous hypertrophy at articular margins. Rarely small round cell infiltration. No general synovial membrane proliferation: separate villi. Late degeneration and loss of articular cartilage. Changes in shape of articular ends. Eburnation of articular ends. Cyst-like cavities in ends of bone. Bony ankylosis rare.

There are roughly two distributions of the disease, one beginning in the peripheral joints, hands, feet, etc., which is generally polyarticular, and the other, more often monarticular, beginning in the spine or in one or more the larger joints. The monarticular affection may occur anywhere, most often in the hip or knee, but even here, if a careful X-ray is taken of the opposite joint, changes may be seen in that also.

Differential Diagnosis.—There are two conditions which it is at times impossible to differentiate clearly from arthritis deformans because they are practically the same process in a little different form. The first of these is *gonorrheal arthritis*, which at first typically an infection, may degenerate later into a chronic arthritis of the type described as proliferative. The identifica-

[1] Osgood R. B.: Journal of Bone and Joint Surgery. Vol. viii. Jan. 1926.

tion of the gonococcus in the genito-urinary tract may be regarded as establishing the diagnosis. If it is absent and the history of a Neisser infection exists in the past, the question is open.

Secondly, an *acute pyogenic infection* of the joint not from external cause, after its acute manifestations, may subside into a condition indistinguishable from arthritis deformans of the proliferative type. Here again no hard and fast differentiation can be drawn.

Charcot's Joint Disease (Neuropathic Arthritis).—This is a third condition in which the pathological process has a certain similarity to the degenerative type. In Charcot's disease, however, the joint often becomes freely movable in all directions, large irregular pedunculated masses are found in the joint, synovitis coexists, and irregular creaking is a characteristic symptom. The Charcot knee is usually painless, a radiograph very easily clears up the diagnosis, and the fact that Charcot's disease is the result of an organic nerve lesion will of course establish the diagnosis.

Tuberculous Arthritis.—From tuberculosis of the joint a monarticular arthritis deformans is to be distinguished by the characteristics already mentioned in speaking of tuberculosis. In arthritis deformans, elevation of temperature is absent in most cases, and the Pirquet test should be negative in children. There is no focal destruction, pain is on the whole less prominent, and muscular spasm, although present, plays a minor rôle. At the same time, one not infrequently sees in adults cases with swelling, extreme sensitiveness and marked deformity in which the X-ray shows a mottling not inconsistent with a tuberculous infiltration of the end of the bone. In such cases the diagnosis may be obscure for a period. Arthritis deformans is on the whole less destructive than tuberculosis; but, on the other hand, tuberculosis in old people is as a rule only mildly destructive.

Prognosis.—In these days of more effective treatment, the prognosis is much more favorable than the older text books would lead one to believe. One matter should influence the prognosis very markedly in all types of the disease—if a focus of pyogenic absorption can be found, or if there is evidence of the disturbance of the digestive processes, or general condition, or if a traumatic element can be identified, the prognosis is better than if such causes cannot be clearly identified.

With regard to the traumatic type, this form of the affection is, as a rule, of low grade and does not tend to progress further if the source of the trauma is eliminated. The prognosis will depend upon the amount of damage that has already occurred to the joint.

The prognosis differs very markedly, according to which of the types of disease is present or predominant, and the stage at which treatment is undertaken. In the *proliferative* type of the disease the prognosis is always less good than in the other type, as the disease is acute and rapid and has a definite tendency to ankylosis. The best outlook in these cases when taken early, is to find and eliminate the source of infection, to quiet the process in the joint if this can be done, to encourage motion within the limits of pain and reaction in the affected joint, but at the same time to utilize the principle of rest and control of inflammation. Under these conditions certain cases can be arrested and mobility of the joint preserved. In other cases it must be recognized that they are so severe that they will pass slowly or rapidly to a partial or total loss of joint motion.

The prognosis should be exceedingly guarded in children where a focus cannot be found, or where no benefit has followed its removal; and the surgeon will be wise in all cases of polyarticular joint disease in children, especially if accompanied by glandular enlargement, to be exceedingly careful in his prognosis, as the majority of cases are most intractable to treatment.

In adults, cases in young people which begin as a polyarticular affection characterized by pain, early malposition of the joints, and a tendency to stiffness should be given a doubtful prognosis, which becomes graver if no obvious cause of the infection can be found. The difficulty in the prognosis of this type of the affection is the rapid destruction of joint tissue, and the very strong tendency toward ankylosis.



FIG. 264.—Patient with generalized arthritis with deformities of hips, knees, wrists, elbows, etc. (proliferative type).

When only one or two joints are affected in this type of the disease the prognosis for the individual joint is no better than in the general affection and must be formulated on the early history, the degree of acuteness at the onset, and the progress of the disease under treatment.

It is most important that it should be recognized that all cases of this type are serious, resistant to treatment, and most damaging to joint structures. When permanent stiffness of the joint has occurred it is too often the case that the ankylosis early becomes bony. The surgeon must be guided by the history and examination as to whether or not fibrous adhesions exist which can be stretched or broken, or whether he must proceed to a bone operation.

In the *degenerative type* the prognosis is very different and very much more favorable. In general the cases which begin in the periphery, as in the hands and feet, are milder than those which begin in the spine, shoulders, elbows, and hips, although at times all the joints are involved simultaneously in the process. A particularly mild type of the affection, which occurs often and has already been spoken of, is the development of Heberden's nodes in the fingers, which is often a source of apprehension to the patient, but if it begins mildly and progresses slowly without serious involvement of the other joints, it will probably, in the case of middle-aged women, in whom it most frequently appears, be no more than a local disfigurement and source of discomfort. In general it may be said with regard to Heberden's nodes, that they are likely to be permanent, and, although periarticular swelling makes them seem much larger when acute, the subsidence of this swelling gives the appearance of improvement.

If it begins in early adult life, the prognosis of this type is, however, definitely more serious as it is more likely to extend. The prognosis in general is more favorable in this type than in the proliferative one, because destruction to the joint is very much less rapid, and the changes are at first confined to the

synovial membrane and margins of the bone. The formation of marginal osteophytes as seen in the X-ray is not necessarily a serious matter by itself unless they obstruct motion, or are accompanied by a high degree of synovial involvement. Unfavorable elements in these cases are heat, dense swelling, pain and muscular spasm as they point to an acute process.

The prognosis from modern treatment has been very greatly changed by the insistence of searching for and removing if possible the cause.

One factor which makes people delay seeking advice is a diagnosis of "rheumatism" made by the patient or friends, and the assumption that there is very little to be done for rheumatism, and that the term rheumatism explains everything. Such patients, as has been said, are not likely to seek advice of a surgeon, but to follow the advice of their friends and neighbors, to use the joints and keep them from stiffening by constant overuse, to regard the pain and malposition as irremediable and allow themselves to drift into a condition where the outlook for treatment is very much less favorable than it would have been if they had started on remedial measures before pushing the joints to such a stage of acute irritation.

The larger joints with a moderate amount of swelling of a soft character and slight degrees of joint limitation, if pain and tenderness are not excessive and the progress is slow, can in the majority of cases, whether monarticular or polyarticular, be improved or even relieved of all their troublesome symptoms by adequate treatment. Cases which begin suddenly and acutely, in which the swelling is dense, hard and tender, the joint limitation early and marked, and where the X-ray shows evidence of cartilage injury by the diminution of the space between the bones, offer a less favorable prognosis. Joints with long standing malposition accompanied by shortening of the muscles and dense swelling about the joint have an unfavorable outlook for much restoration of function.

The prognosis should be somewhat influenced by the age at which the patient is seen. In early childhood and early adult life acute forms are likely to be seen. In women at and about the menopause a mild type often occurs.

Treatment. *General Treatment.*—In any form of arthritis deformans the first step should be to institute a thorough investigation as to the origin of the disease.

The question of infection should first be looked into. The *teeth* should be X-rayed. The existence of apical abscesses or of pyorrhea or Riggs's disease may be assumed to be an adequate cause of the disease. The type of dental treatment in these cases should rest with the dentist, but the surgeon is justified in insisting upon a removal of the focus or the efficient treatment of the pyorrhea.

In this connection it must be stated that the use of an autogenous vaccine, which should be made from the organism obtained at the time of the extraction of the tooth, or by a culture from under the gums in the case of pyorrhea, is of importance. In this, as in other forms of focal absorption, a considerable proportion of cases of arthritis deformans, where the focus is removed and an autogenous vaccine is administered, show an improvement in symptoms shortly after the time when the administration of the vaccine is begun.

With regard to the *tonsils* as a source of infection, the opinion of one skilled in the affections of the throat is necessary. The buried tonsil, which to superficial examination looks healthy, is often one of the most serious sources of infec-

tion, and in doubtful cases the modern laryngologist often applies suction to the tonsils to determine the character of the organisms. The non-hemolytic streptococcus viridans is the one most frequently found here and in the teeth.

It is also desirable to investigate the antrum and sinuses as the possible sources of retained pus. Retained pus in the abdomen may be found in the form of chronic appendicitis, chronic salpingitis, or pus retained in the intestines. In the male, the genito-urinary tract should be thoroughly investigated, especially the seminal vesicles and prostate as the possible locations of retained secretion following gonorrheal inflammation of these structures.[1] Chronic suppuration elsewhere in the body should be noted and investigated also. An obscure case of chronic arthritis was relieved by finding pus in the stools, which led to the identification of a chronic colitis with retained pus, the removal of which cleared up the arthritis.

A thorough medical examination is desirable with studies of the blood, urine, stools and general condition of the patient.

At the same time however that one is considering infection as a cause, it must be remembered that 46 per cent of Pemberton's series of cases in soldiers recovered in the presence of demonstrable foci. In a series of 100 cases studied especially carefully in this respect, 25 per cent improved in the presence of unremoved foci.

Syphilis should be excluded by means of the Wassermann test and other evidence, *organic nerve disease* excluded by a routine neurological examination and the condition of the endocrine glands looked into.

Anyone who sees many of these cases is impressed by the great gravity of the affection and the need of leaving no stone unturned to identify its cause. Local treatment, which prevailed alone up to a few years ago, was notoriously unsuccessful, and the modern improvement in the outlook appears to be due more to advance in general than in local measures.

Any surgeon undertaking the treatment of a case of arthritis deformans without an examination approximately as indicated above is likely to disappoint the patient, and to overlook the most important means of help which is at hand.

With regard to therapeutic measures, the use of *drugs* has been largely abandoned, although aspirin is still used on a large scale, but it is at times depressing and is not curative. It may be necessary, however, to administer it for relief of pain. If the Wassermann reaction is positive it is desirable to resort to anti-syphilitic treatment because it must be recognized that syphilis and arthritis deformans may exist in the same individual.

Hydrotherapy.—Hydrotherapy is of value in improving the general circulation and increasing elimination, and also because the patient generally has to go to a health resort and rest in order to obtain it. It cannot be regarded as a specific treatment of the disease.

Diet.—Every known type of diet has been recommended at one time or another in chronic arthritis. The reason for such wide variation has been due to the fact that we have no precise knowledge of the metabolic derangement that occurs in this disease, and as many theories have been offered, many forms of diet have been advised.

It is of fundamental importance, before advising any diet in arthritis, to know whether there is any functional or organic abnormality of the gastro-intestinal tract. Also one should

[1] Cunningham: Jour. of Urology, August, 1919.

know the condition of all the organs of the body, because if chronic nephritis, for example, was present, changes in the anticipated diet might be made on account of the nephritis. Symptoms referable to the gastro-intestinal tract are common in patients with arthritis. Abnormal bacteriological flora may be present as a result of abnormalities of the gastro-intestinal tract, but on the other hand, an abnormal flora perhaps may be their cause. In either event bacteria may lead to greater intestinal disturbances. When such conditions are recognized, diets suitable to them are indicated.

One of the common forms of intestinal abnormality seen in these patients, especially as evidenced by the stool examination, is chronic intestinal indigestion, particularly of the type dependent upon defective digestion of the carbohydrate foods. Where such is the case, a diet suitable for this condition should be given. This consists of just sufficient calories to meet the demands of the body, keeping the carbohydrates low, and particularly avoiding the more easily fermentable carbohydrate foods.

A modern scientific work on the relation of diet to arthritis has been done by Pemberton who has pointed out the harmful effects of carbohydrate food on arthritis. He cites many cases in which it has been possible to relieve patients of all or nearly all symptoms by a large curtailment of carbohydrates, coincidently with the ingestion of fat in such amounts to make up or exceed this caloric deficit. When protein is kept constant, some such patients actually gain weight. In cases rendered free from acute symptoms, Pemberton and others have shown that exacerbations may be caused by ingestion of pure carbohydrate, and upon its withdrawal the symptoms have again subsided.

The following is a sample of a diet advocated by Pemberton:[1]

The patient to whom this diet was given was suffering from acute symptoms from arthritis deformans and was found to be taking not less than 2000 calories, of which 17.5 per cent came from protein, about 40 per cent from fat, and about 43 per cent from carbohydrates. The following diet upon which she was placed gave her about 1700 calories distributed as follows: 10 per cent protein, 62 per cent fat, 28 per cent carbohydrate. After being on this diet for some days the pain, dependent upon the acute condition of her joints, subsided markedly. The diet was the following—

Breakfast—	1 orange	250 gm.
	2 eggs	100 "
	bread	30 "
	butter	15 "
	coffee	
	milk	60 cc.
Luncheon—	Bouillon	180 cc.
	lettuce	
	mayonnaise	1 tablespoon
	string beans	100 gm.
	1 apple	150 "
	bread	30 "
	butter	10 "
Supper—	Steak	50 gm.
	bread	30 "
	butter	15 "
	carrots	100 "
	lettuce	
	French dressing	2 tablespoons
	1 orange	250 gm.
	milk	60 cc.
	tea	
	bouillon	180 cc.
	Total calories	1694

It would appear that carbohydrate is not the only food factor that may directly aggravate the arthritis, because it has been shown that a total reduction of diet is also beneficial. In fact, in certain severe cases actual starvation periods may have a definite beneficial influence on the disease.

If the individual is overweight, as often occurs in this disease, the calories may be kept at a distinctly low level for a considerable period of time, because it is desirable to reduce the

[1] PEMBERTON: Arch. Internal Med., 1920, xxv; Am. Jour. Med. Sci., April, 1921.

weight of these patients to normal, provided this is done carefully.[1] This reduction is often easily accomplished by giving a diet low in calories, carbohydrates and fats; a diet which often will have a beneficial effect in causing a subsidence of the more acute symptoms of arthritis.

It must be recognized that though dietary measures alone may have an important influence on the disease, they should be combined with other measures, for attention to but one measure, with no attention to others, often results in failure. It is likewise to be noted that to accomplish results attributable to dietary measures, attention to detail, including detailed cooperation of the patient, is essential.

Local Treatment—Rest and Fixation.—Nowhere is a general knowledge of joint phenomena more useful than in this connection. Nine patients out of ten are overusing and abusing arthritic joints at the time they come to the surgeon. Pain is disregarded, and stiffness which comes on after sitting is regarded as a warning that sitting is harmful.

In an irritated joint where muscular spasm, joint swelling and pain are present, rest is the first requirement. In the acute attacks of the early stage of the disease in the weight-bearing joints, recovery is much hastened by the use of crutches, this being preferable to recumbency in most cases. In the acute attacks of the later history, rest in bed may be necessitated by suffering, and fixation and sometimes traction become necessary. The acute phase of any type of arthritis deformans should be treated by rest, for the time being. Thus fixation, protection from weight-bearing, and even traction in severe cases are indicated when muscular spasm and pain are present. There is, however, in this condition a tendency to early and rapid ankylosis. It is not safe to keep these joints fixed for too long a time, and for this reason the need of a compromise between rest and motion is one of the hardest problems of the disease. It may be definitely understood form the outset that motion to the degree of causing pain is harmful, and it may be equally assumed that motion within the limit set by nature is beneficial, but this does not refer to weight-bearing motion, which is of no more benefit than non-weight-bearing motion and is distinctly risky while the disease is painful.

Massage is not to be undertaken until the acute symptoms have subsided. It should then be given in *small doses,* above and below the joint, with a view of stimulating the local circulation and improving the lymphatic and venous flow. If it is pushed beyond the point mentioned, it is practically sure to make trouble and cause an increase of symptoms. Hard and long continued massage is distinctly traumatic and irritating, especially if given over the joint membrane. In connection with massage, as soon as it is possible, it is desirable for the patient to move the affected joint or have it moved as far as may be done without causing pain or encountering muscular resistance.

Other measures of use during the acute period in connection with those mentioned above are, local electric light baking and hot water applications, which apparently diminish congestion, although certain cases are too acute even for these measures, and one must wait until the symptoms have partially subsided.

Restoration of Motion.—Quiescent joints, where damage from arthritis has been done, often become stiff in malposition. The hip, for example,

[1] Palmer, W. W.: Nelson Loose Leaf Med., 1920, iii, 116.
Minot, G. R.: Med. Clin. North America, 1920, iii, 1001.

becomes adducted and flexed, and any improvement in this position adds to comfort and efficiency. It is possible in some such cases for a skilled person to restore by gentle stretching a certain amount of motion, which restoration is permanent. The method is not of course suitable where there is reason to suspect bony ankylosis, but in many cases such contractions are due to shortened ligaments, capsule, and periarticular tissues. Daily manipulation will often times be attended by increase of motion with resultant benefit. Manipulations should therefore be manually done without anesthesia and as a rule carried only to the degree of moderate pain. It is hardly necessary to call attention to the danger of this performance in rough or unskilful hands.

One class of cases requires special mention. These are cases with disappearing motion and marked destruction, in the hip, for example, with some distortion and considerable acuteness. In these cases the best policy is to fix the limb in the best available position and to do everything to promote ankylosis; for with the disappearance of motion, the disease is likely to quiet down, and in many instances the joint will cease to be a source of much trouble.

Exercises.—A weakened and irritable joint is necessarily vulnerable, but if muscular spasm is absent, exercises for the muscles controlling the joint constitute one of our most valuable remedial measures, as strong muscles protect and strengthen weak joints.

Such exercises should be given against manual resistance to the point of mild fatigue once or twice a day, and if the joint is upset by even this amount of non-weight-bearing exercise the muscles may be contracted and relaxed by the patient at intervals of a few seconds without moving the joint. For this manoeuvre stimulation by the faradic coil is most useful. This should be done from 50 to 100 times once or twice a day, or better still repeated a few times at very frequent intervals throughout the day.

Although arthritis deformans, wherever it is located, presents the general characteristics described above, in certain joints more or less characteristic peculiarities are present which should be mentioned.

Hip Joint

This joint is frequently affected by the disease, which is most often of the degenerative type, and in former times was spoken of as *malum coxæ senile.* In the great majority of cases it affects people at and after middle life and is not common in young adult life. It frequently follows trauma, which of course as a rule cannot be regarded as more than a localizing symptom.

Pathology.—The first change to be noted is a diminution of joint space, as seen in the X-ray, followed by a prolongation of the base of the head where it joins the neck. These osteophytes in time form a collar around the neck, the cartilage is worn away over the points of contact, and the edge of the acetabulum begins to proliferate. In more advanced cases the head appears to broaden, especially on its lower border, and in the X-ray the neck appears to have slid upward in its relation to the broadened head. A denser shadow is cast, not free from mottling as a rule, and the mottling extends down to the neck and even to the trochanter. The extension of the collar around the head makes the neck of the femur look shorter.

Symptoms.—On account of the nature of the joint, swelling of the joint and periarticular structures occupies an unimportant place, although peri-

articular thickening is generally present. The symptom which predominates in the picture is malposition induced by muscular spasm. In this affection of the hip, as in tuberculosis, muscular spasm occupies a prominent place. The characteristic deformity is adduction of the leg and flexion, and the adduction results in practical shortening. Lameness follows and is due to the fact that it is painful to bear weight on the joint, and that the leg for walking purposes is shorter than the other. Pain exists in and about the hip, may extend down the leg and is sometimes mistaken for sciatica. Muscular limitation is most marked in the directions mentioned, but also affects rotation and, later, flexion. When flexion is much limited, sitting in the normal position becomes uncomfortable and often impossible, because the thigh cannot be flexed to a right angle to the body. In such cases the patient sits leaning back with the body twisted, bearing his weight on the other buttock. The fact that the hip is in nearly all cases held in flexion and adduction at the earliest stage means strain of the hip joint in walking and a twist and wrench of the affected structures at each step. In walking the patient hurries off the affected leg, drops the pelvis a little on that side and the limp becomes constantly more conspicuous. The fact that the leg is adducted and practically shorter than the other, means that at every step the structures at the outer side of the joint are pulled upon.

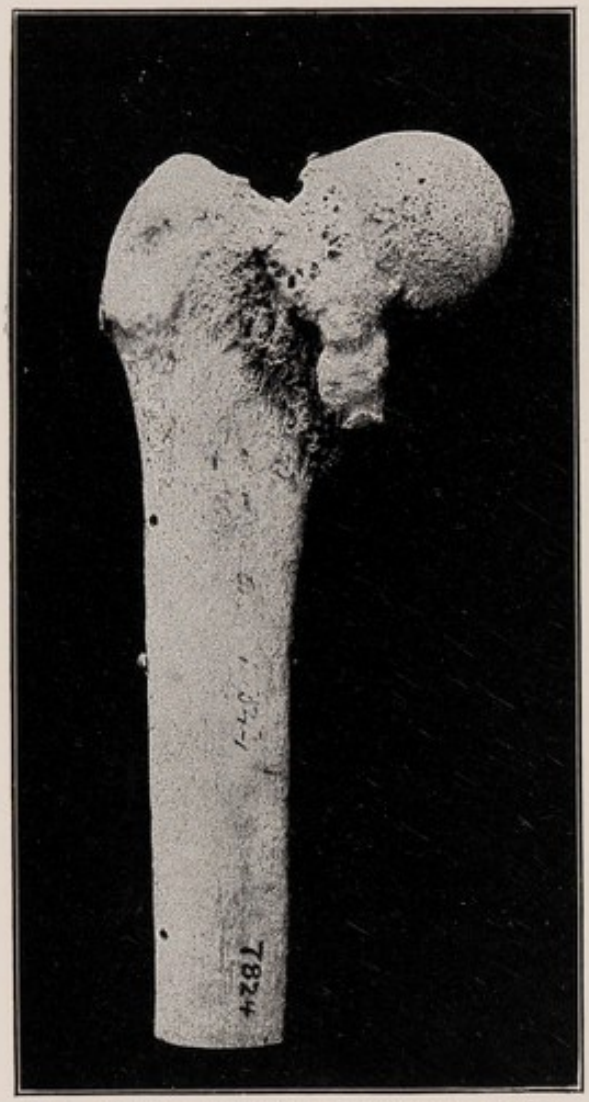

FIG. 265.—Arthritis deformans of hip (Warren Museum).

As the disease progresses, the deformities tend to increase and if any stiffness of the lumbar spine is present from coexisting arthritis the disability is greatly increased. Acute attacks of much severity, necessitating confinement to bed, intervene in certain cases.

Diagnosis.—This is made by a limitation of motion, by periarticular thickening in most instances, and a characteristic X-ray showing proliferative changes around the neck, and later the characteristic distortion of the head mentioned above. In the acute stage the affection resembles any severe involvement of the joint, and the symptoms do not differ from those of tuberculosis or an acute infection of the joint. The differential diagnosis has been dealt with above.

Prognosis.—The prognosis for complete restoration of function is not good when the affection has reached a degree where structural change is shown in the X-ray. In early cases the progress should be arrested under proper treatment,

and in the severest cases, where motion is entirely lost, the prognosis is not unfavorable for a painless joint, because when complete ankylosis has occurred the joint generally becomes symptomless, although stiff. The deformities caused by muscular spasm yield in large part to treatment, and the prognosis is greatly affected by the attention paid to the control of the malposition.

Marked benefit should result from treatment in practically all cases of the disease, but such treatment, to be effective, must always be long continued and more or less rigorous.



FIG. 266.—Arthritis of the hip, causing only moderate lameness.

Treatment.—The general measures have been described above.

Local Treatment.—In the early stages the continued traumatism of walking should be minimized and the deformity controlled. In the very earliest stages, massage, diminution of weight-bearing and correction of the apparent shortening by a high sole on the affected leg will often bring about a stationary condition of the disease. The wearing of a rubber buffer on the heel and a flannel spica bandage round the hip usually gives considerable relief. In addition the recognised forms of hyperaemia treatment should be tried, *e.g.* radiant heat or diathermy. In later cases where the affection is destructive, painful, and especially if there is any evidence in the X-ray of progressive destruction, weight-bearing should be eliminated by means of a Thomas

knee splint or perineal crutch and the same measures pursued. Throughout the treatment of this disease it must be borne in mind that weight-bearing on an adducted and flexed joint, which is diseased, is a serious and threatening trauma.

When the quiescent stage has been reached frequent manipulation by a highly skilful person to restore some of the motion by stretching adhesions is of great use, and it has been described in speaking of the treatment of the general affection.

In severe cases, and cases nearly ankylosed, fixation of the hip in a plaster of Paris spica bandage in the best position obtainable, with the use of anesthesia, if necessary, will bring about the desired ankylosis more quickly than any other means.

Operative Treatment.—As arthritis deformans is usually a disease of middle and late life, operative procedures should only be undertaken where pain and disability are marked. They should be designed with a full appreciation of the dangers of shock, and operations involving the disarticulation or removal of the femoral head should be used with due caution.

The following procedures may be discussed:

(*a*) *Manipulation under Anaesthesia.*—In the earlier stages of osteo-arthritis it is often possible to stretch the thickened capsule and break down adhesions between it and the femoral neck by a manipulation. This method is suitable for active and robust individuals in the prime of life, with a hip joint showing limitation of movement in one particular direction *e.g.* abduction. By means of a timely manipulation the arc of movement can be increased and the greater range thus obtained is generally followed by diminution of pain. In manipulating such a hip abduction is the most important to be secured. The stretching should be carried out with caution and no untoward reaction should follow. After the manipulation the patient is put on exercises, at first in the recumbent position, and later with graduated weight-bearing.

(*b*) *Excision of Bony Outgrowths.* (1) *Cheilotomy.*—Conservative operations which fall into this class are based on the operation of "cheilotomy" or removal of the osteophytic lip of the acetabulum (Brackett, Wheeler, Sampson Handley). This operation has a somewhat limited scope as the acetabular growths are not usually the chief cause of limitation of mobility but in selected cases good results have been observed and the improvement has lasted many years.

(2) *Remodelling the Femoral Head.*—An operation now on trial which promises well is simple and expeditious (Robert Jones). A Smith-Petersen approach is selected and the head and neck of the femur exposed; the capsule is circumferentially exposed and the head of the femur displaced by rotating the limb outwards. The circumference of the head of the femur is then reduced to that of the femoral neck, leaving cartilage if any exists, at the extreme end of the femoral head. Care must be taken not to interfere with the excrescences round the acetabular rim. The hip is then reduced by rotating the limb inwards. No muscular attachments are interfered with. The adductors are generally divided. No splint is needed provided flexion and adduction are corrected, but the limb should be kept in moderate abduction for 14 to 20 days when gradual movements may be started. This operation minimises friction at the joint which is the exciting cause of pain and deformity. Its special feature is the narrowing of the head of the femur and the retention of the acetabular excrescences, the removal of which must invite a callus exudation with possible ankylosis (Figs. 267, 268).

(*c*) *Arthrodesis.*—When the deformation changes are well advanced, the more drastic procedure of surgical fixation of the affected joint must be considered. Arthrodesis of the hip has now been practised long enough for its merits and drawbacks to be appreciated. It is quite certain that the majority of patients with well-marked osteo-arthritis are contented when the joint is completely ankylosed in a useful position and thereby becomes painless. The production of sound ankylosis is, however, by no means an easy matter. It is necessary to remove freely the eburnated bone-layers from both femoral and acetabular surfaces, an operation which may take a long time, and is often a fairly severe test of the endurance

of the patient. For robust patients of middle age arthrodesis may be regarded as a safe operation, and on the whole, the end results are satisfactory both to the patient and the surgeon.

After denudation of the joint surfaces, to expose cancellous bone, the hip is brought into a position of moderate abduction and 30 degrees flexion. This is maintained in a long plaster-of-Paris spica. Eight weeks later a short spica is applied and the patient is allowed to use crutches and in a few weeks may attempt partial weight-bearing in a Thomas caliper splint. When firm fixation has occurred—as judged by clinical and radiographic tests—



FIG. 267.—Remodelling of the femoral head in osteo-arthritis of the hip-joint, showing the line of trimming of the mushroomed femoral head.



FIG. 268.—The operation, outlined in Fig. 267, completed.



FIG. 269.—Shows line of section for (*a*) femoral head; (*b*) trochanter.



FIG. 270.—Shows the trochanter re-attached to the lower level.

the plaster or walking splint is discarded. In a certain number of cases true bony ankylosis fails to develop, but a degree of fixation something less than the ideal is often not unsatisfactory. A few patients complain of backache after arthrodesis of the hip-joint, a symptom which points to the undue strain now borne by the lumbar spine and sacro-iliac joints.

(*d*) *Pseudarthrosis below the Joint Level.*—See page 101.

(*e*) *Reconstructive Excision of the Femoral Head.*—For many patients, and particularly those who are past middle age, it is desirable to attempt to produce a painless hip-joint and at the same time to retain some degree of motion. The latter adds greatly to the com-

fort of the patient, not only in walking, but also in sitting. With this end in view, the reconstructive excision operation has been evolved (Whitman).[1] The femoral head is excised and the stump of the neck is thrust deeply into the acetabulum with the hip abducted. The trochanter, previously detached to allow free access to the joint, is now attached to the shaft of the femur at a considerably lower level. This reconstructs a longer femoral neck, and ensures to the hip joint the mechanical advantage of a better abductor leverage (Figs. 269, 270, 271).

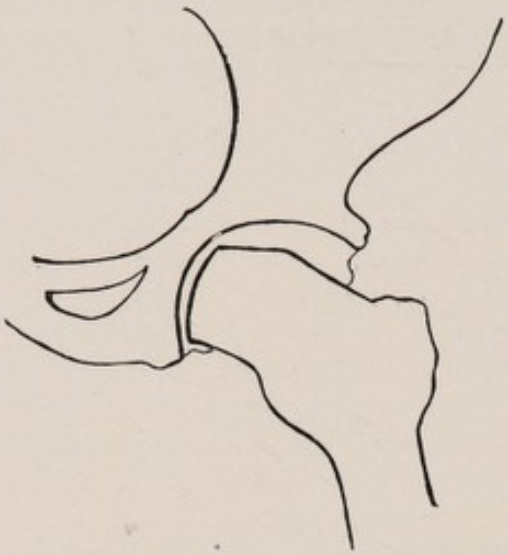

FIG. 271.—Shows operation completed with hip in abduction.

Traction is applied to the limb with the hip in the abducted position, the patient being nursed either on an abduction frame or a Pearson fracture bed. Active movements are begun at the end of a fortnight, and six weeks after the time of the operation a walking caliper splint is fitted.

In properly selected cases the results of this operation are gratifying. Pain is almost invariably abolished and often a limited though useful range of mobility persists. If there is any possibility of osteo-arthritic changes developing in the opposite hip-joint reconstructive excision must be preferred to arthrodesis in patients of all ages. It seems likely however that an equally good functional result will be obtained from the less severe operation of remodelling of the femoral head described above. This procedure has the great advantage of avoiding complete removal of the head and displacement of the trochanter.

Knee Joint

Symptoms.—The knee is the joint most frequently affected by arthritis deformans. The first symptoms noted are irritability of the knee, stiffness after sitting, some swelling, often a feeling of tightness at the back of the knee, and discomfort on use. The hollows at the side of the patella are lost, fluid may or may not be present and is not a marked symptom, but a more or less dense semifluctuant mass may occupy the whole joint sac, and the joint is rounded and spindle shaped. Flexion is the characteristic deformity and occurs fairly early. In severe and long continued cases subluxation of the tibia results from persistent flexion deformity. Acute attacks are likely to supervene in untreated and rapidly progressive cases, in which the knee may become excessively sensitive, and the patient be confined to bed.

The clinical picture of the early cases is perfectly characteristic. A middle-aged woman, who is overfed and under-exercised, has probably gained weight at the time of the menopause and finds that her knees are, as she calls it, stiffened. They creak on motion, are more or less swollen, and stiffen after sitting. Her friends have told her that they will probably become entirely stiff unless she uses them, and consequently she never sits still for any length of time, but constantly gets up and walks about because the knees feel a little better after use. Stair climbing in the same way she regards as a useful means of mobilizing the knees, and she takes long walks for the same purpose. In certain cases of this type the progress is extremely slow and the knees very tolerant. In other cases the prolonged misuse will precipitate an acute attack which compels the patient to seek advice. The X-ray will generally show in these cases early osteophytes.

[1] WHITMAN: Annals of Surgery, 1924, lxxx.

The knee is affected by both types of the affection, the proliferative and the degenerative, but the majority of cases in this joint belong to the latter class. The pathological changes have already been described.

The X-ray is of the greatest assistance in recognizing the disease in this joint. In the **proliferative** type the space between the bones diminishes, the bones become atrophied, there is no focal destruction and osteophytes are absent. In the **degenerative** type the mildest cases show at first a cloud involving the soft structures of the joint over the area of the joint membrane as seen from the side, and later osteophytes occur at the margins of the tibia, the posterior surface of the condyles as seen from the side, and in front at the junction of the anterior articular surface with the shaft. They occur also at the upper and lower anterior border of the patella, extending into the tendon. In severe cases osteophytes form on the tibial spines.



FIG. 272.—X-ray of arthritis of the knee joint in patient with generalized arthritis; loose bodies are forming.

Osteophytes are at first small and pointed, but become larger and more rounded and often break off to form loose bodies in the joints.

Etiology.—One point should be noted in connection with arthritis deformans of the knee—a traumatic element in its causation and prevalence is definitely suggested by the very frequent location of the affection in this joint, the fact that it is most often bilateral, at least in some degree, and the fact that so many cases of marked involvement of the knees occur without much involvement of other joints. When the symptoms have reached a fairly high degree in both knees, yet shoulders, elbows, hands, and hips are affected but slightly, if at all, one must look very carefully for some traumatic element, to be found especially in some malposition of the feet. Other causes are excessive weight, suddenly acquired, and prolonged walking or standing in persons not used to it. A very significant fact is that if one leg is longer than the other because of a fracture, or for other reasons, and arthritis of the knees is present, it will almost invariably be worse on the longer side.

Diagnosis.—The diagnosis presents little difficulty, and should be made on the general lines already indicated.

Prognosis.—The prognosis here is practically always favorable in early cases and is frequently favorable for restoration of complete function, while in other cases a perfectly useful, but somewhat vulnerable knee should be the result. The prognosis is obviously most favorable in the early monarticular cases of traumatic origin, where the source of trauma may be found and eliminated. The next most favorable cases are fairly early cases where osteophytes are found, but where the swelling is not marked and not dense. The existence of fairly marked osteophytes on the patella and the two large bones forming the joint is not an indication that warrants a grave prognosis, such knee joints most often becoming practically useful and fairly enduring if the general condition causing the arthritis has been found and the knee effectively treated at a comparatively *early* stage. Cases of longer duration with dense, brawny swelling, flexion deformity, and marked osteophytes can be made less painful, and with proper treatment it is possible to restore useful, though not complete, function. Persistent flexion, heat, dense, brawny swelling and much tenderness designate the severe and resistant type of case.

The prognosis of the proliferative form is poor, and the acute cases accompanied by heat and pain are likely to be permanently ankylosed, often in a position of deformity. In the slow and long continued cases, where a fair degree of motion exists and great tenderness is present, if the general factor causing the disease can be discovered and eliminated a fairly useful joint with some limitation of motion will be the result.

Treatment.—If there is reason to suspect a traumatic element in the origin, and by trauma is here meant overuse or misuse, this should be eliminated. Weight-bearing, especially in flexed knees, always in tender and painful knees, and in all knees where the affection shows signs of being progressive, should be eliminated or greatly minimized. Crutches may be used for the lightest cases, as their use will probably only be temporary, and in the severer cases a Thomas knee splint or perineal crutch should be worn during the acute stage.

It is of the utmost importance to control and do away with the flexion deformity, which can best be done in the Thomas splint by proper bandaging or by the wedging knee plaster (p. 173). In certain long standing cases, however, it is impossible to restore full extension to the leg without undue trauma. Fixation of the knees for any length of time is always to be avoided if possible as favoring ankylosis and the cardinal rule must always be remembered—that although motion in the limits set by nature is desirable, motion beyond those limits will increase muscular spasm, pain, and deformity.

In the chronic type of monarticular arthritis deformans it will be found that pain is felt most acutely when the knee is fully extended. Experience has proved that the act of full extension is a grave traumatic element and a nipping takes place which involves the structures posterior to the patella, and if this can be prevented by this means, ease is generally secured for the patient by prescribing a cage splint. This, while it does not prevent flexion is provided with a stop which prevents the knee from full extension, and unfavorable progress is often checked by its use. Flexion is incomparably less harmful than extension. In the matter of exercises it must be remembered that non-weight-bearing exercises within the limits described above are desirable, that weight-bearing exercises, particularly in the presence of deformity, lead to an abnormal deflection of body weight and are traumatic and irritative.

In the severest cases with a joint shown by the X-ray to be partly or largely disorganized in its articular surface, ankylosis in the straightest position obtainable should be induced by prolonged fixation.

In the proliferative form of the affection the utmost promptness in action is necessary and general remedial measures are of the highest importance, with a view to checking the process before it goes any further. During the acute stage when heat, pain, tenderness, and muscular spasm are present the measures must be soothing, and fixation will have to be used although it is undesirable for the reasons mentioned.

Attempted manipulation and correction of deformity in the acute stage are likely to prove exceedingly irritating and too often the acute stage ends leaving an exceedingly damaged and stiffened joint.

Operative Treatment.—Where the knee is flexed and painful, mechanical measures with a view to correcting deformity are often unsuccessful. The front of the joint is full of sensitive tissue and efforts at extension are resented. An operation in such cases is often of great value. The operative treatment consists of

(*a*) Removal of fibrous masses,
(*b*) Synovectomy,
(*c*) Arthrodesis or excision.

(*a*) In cases where there is great pain and the knee cannot be fully straightened and where in addition pulpy masses are felt in front of the joint, relief will often follow their removal. This is best effected by splitting the patella longitudinally by an incision starting four inches above the patella and reaching below the tubercle of the tibia. The two halves of the patella are widely separated and the knee is flexed. With curved scissors the thickened post-patellar pad and surrounding masses are freely removed. The knee is straightened and the aponeurosis covering the patella is stitched as well as the patellar ligament and bisected quadriceps. There is no occasion to fix the patella, which will lie in good position.

(*b*) Synovectomy consists of a more or less complete removal of the thickened synovial membrane. Through a mid-line vertical incision except that it passes to the inner side of the patella, the joint is opened, the patella turned over and the synovial membrane dissected out. Active movements should be attempted a few days after the operation and the range increased cautiously.[1] Any residual limitation of motion is best dealt with by manipulation under anaesthesia.

(*c*) *Arthrodesis.*—The joint is opened by a semicircular flap and the soft structures within the joint removed. With a curved gouge the cartilage is removed from the condyles of the femur and the intercondylar space. The cartilage is also removed from the tibia and the tuberosities gouged in order to receive the femoral condyles.

Excision.—If flexion is pronounced a wedge excision is performed, care being taken not to remove too much bone. The bones should lock on extension. The authors have performed this operation upon a very large number of cases with most gratifying results.

Shoulder Joint

Arthritis deformans of the shoulder joint is less frequent than is that of the knee and most often occurs in the monarticular form, although it may be part of a general joint involvement. It affects adults most often and is rare in children, except as part of a general arthritis. In this joint also when affected alone, the history of trauma, misuse or overuse is common. In the shoulder the affection is usually of the proliferative form and osteophytes are not so frequently seen as in the weight-bearing joints.

Diagnosis.—The affection most often begins insidiously, and consists of a lameness in the shoulder joint with difficulty and discomfort in abducting and rotating the arm. The arm feels heavy and there is pain in the shoulder

[1] Jones, Ellis: Journal Amer, Med. Ass., Nov. 10, 1923.

and down the arm. Attempts at movement, particularly complicated movement, are exceedingly painful. It hurts to lie on the shoulder at night, the muscles are wasted and there is moderate thickening over the joint. The use becomes more and more restricted, the arm is held constantly at the side, and attempts at passive motion are painful, particularly in the direction of abduction. The mobilization of the scapula allows a certain amount of motion, even when the shoulder joint has become entirely stiff, but even this may become painful and motion is avoided.

The X-ray picture shows generally atrophied bone shadow in the head of the humerus, often mottling of the bone structures around the edge of the glenoid cavity and base of the head of the humerus.

To distinguish this condition from periarthritis is always difficult and sometimes impossible, because the same symptoms exist in both, and traumatic affections of the shoulder joint are exceedingly chronic (p. 54). The X-ray and the feeling of the joint where it is most superficial just below the coracoid process are the most important factors in establishing the diagnosis of an arthritis deformans of the shoulder joint.

The prognosis is favorable for a restoration of comfort, and upon the degree which the process has reached and the acuteness of the symptoms will depend the prognosis. If the pathological process has really been destructive complete motion will not be restored, but in the majority of cases an arm with useful function will be the result of treatment.

Treatment.—The most serious obstacle to treatment which arises in practice is that the patient has generally worn a sling and the arm has been kept at the side until the inner side of the joint capsule and the adductor muscles have become adaptively shortened. This presents a serious symptom complex, and the arm must be held in an abducted position if this can be obtained by any reasonable means. A platform splint (p. 186) should be substituted for the sling and it should be remembered that the most desirable position for ankylosis, if it is going to occur, is in a position of slight abduction with the arm well in front of the body. Correction under anesthesia is always a possibility in this joint when one has given up the idea of restoring motion.

In the milder cases, rest, massage, and baking will help to quiet the joint to a degree after which the gentlest stretching in abduction will be allowed, and motion in abduction is so greatly preferable to fixation in an abducted position that correction under anesthesia should be the second rather than the first choice.

Ankle, Elbow and Temporo-maxillary Joints

The disease in these regions presents no especial difference from the disease in general. In the *ankle* as in the other weight-bearing joints, the proliferative form is the more common one; swelling and malposition of the foot are common accompaniments, and the trauma of weight-bearing is most undesirable. The ankle is not as frequently affected as the other joints of the lower extremities and a high degree of involvement of the hands may exist without any perceptible involvement of the ankle.

The *elbow* joint proper or radio-ulnar joint, or both may be involved. Swelling, limitation of motion, and the routine symptoms are present in these cases.

The *temporo-maxillary joint* is not infrequently involved, either alone or in connection with arthritis in the other joints. The affection may take the form of pain on chewing and opening the mouth wide, or may be a feeling of partially dislocating the joint when the mouth is opened. It is as a rule amenable to treatment, and the finger in the mouth will detect swelling and tenderness over the joint membrane. When this condition is present in an acute form the patient should be put on soft food and not allowed to yawn. Recovery is sometimes hastened by massage over the joint inside the mouth, the finger of the masseur being protected by a rubber cot.

Arthritis Deformans of the Spine

(Spondylitis Deformans, Spondylose Rhizomélique, Bechterew's Disease Marie-Strümpell Disease)

Pathology.—Arthritis deformans of the spine occurs (1) as part of a general arthritis, in which case it is most often proliferative, (2) in connection with involvement of the shoulders and hips, which form has been designated by Marie as spondylose rhizomélique, which is most frequently degenerative, and often spoken of as the Marie-Strümpell type of spondylitis deformans; and 3) as a primary affection without marked involvement of the other joints. This latter is rather more common than the other types and is ordinarily degenerative, but in certain cases is evidently of the proliferative type. With the exception of the Marie-Strümpell type, the pathological changes may be slight and easily controlled, but grade up through the scale to a point where the osteophytes and the process in the joints of the spine is so great that the spine is completely stiffened throughout. Naturally only the changes in the more severe types have figured in the pathology, and in speaking of this aspect it must be remembered that the pathological description is necessarily derived from this class.

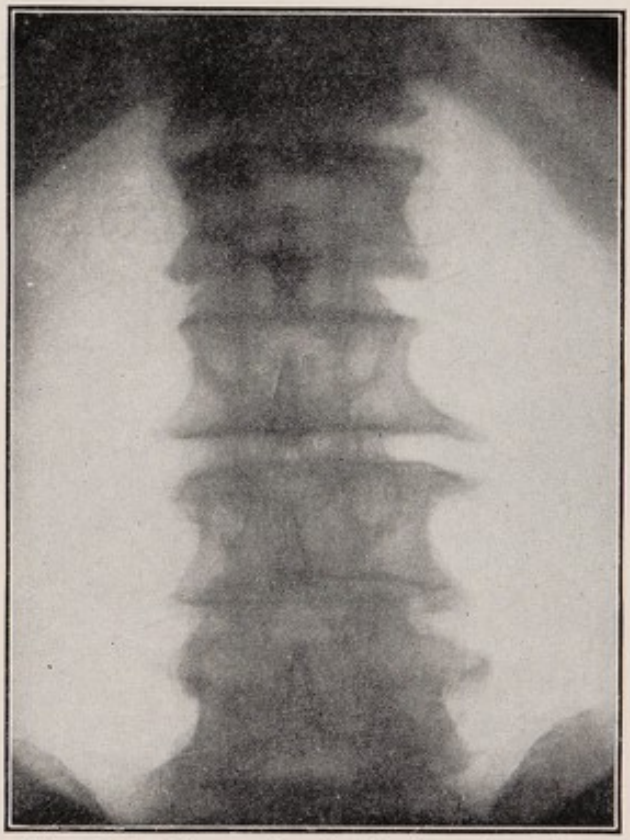

Fig. 273.—X-ray, showing lipping of vertebræ.

The intervertebral joints, and sometimes the joints between the articular and the costovertebral articulations become involved in the arthritic process and show changes similar to those described already, with synovitis, degeneration of cartilage, osteophytes, and resultant joint impairment. Fairly early in the affection in many cases, small pointed osteophytes appear in the X-ray picture as marginal exostoses, causing a prolongation of the upper and lower edges of the vertebræ, most evident in the lateral X-rays. Pathological

specimens show a row of marginal proliferations of the upper and lower surfaces of the affected vertebræ, and later in severe cases an ankylosing of several vertebræ together by irregular but continuous masses of bone, which looks as if a callus had been melted and allowed to run down the front of the vertebral column. Intervertebral discs disappear and the vertebræ are in contact by bony surfaces. resulting of course in ankylosis in the affected region.

Etiology.—The cause of arthritis of the spine does not differ materially from that described for other locations, except that gonorrhea is an antecedent in a large proportion of males when the affection is primarily in the spine and not part of a general arthritis. Trauma to the spine is often antecedent to the condition, and undoubtedly a localizing element in some.

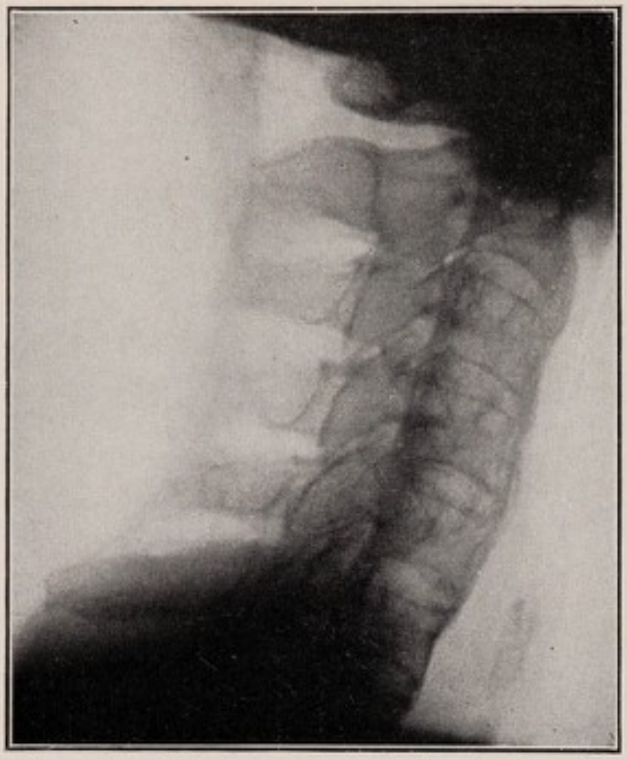

Fig. 274.—Side X-ray of cervical region, showing complete ankylosis of the cervical spine.

Symptoms.—The first signs noted are those described by patients as "lame back." The back is uncomfortable and it hurts to perform certain motions. The pain is generally in the spine, but at times is referred to the buttock or any part of the lower extremity. Attacks of "lumbago" may occur from time to time, sometimes the result of a sudden movement, as in twisting or bending, sometimes coming on slowly and without known cause. They last for a few days and then improve, but the patient does not get quite well, and after each attack he is likely to be less comfortable than he was before. It hurts him in the morning when he straightens up after bending over to wash his face, and likewise motoring over rough roads, horseback riding, and lifting are apt to be uncomfortable at the time, or to be followed by pain and stiffness. He notices next that the movements of the body are less free and that to get in and out of a bath or to lace up his boots is not as easy as formerly. Pain in the leg often becomes more prominent, and is especially likely to be called and treated as "sciatica." Coughing and sneezing may hurt, and in the acute attacks the patient may show marked lateral curvature of the body, which does not quite clear up in the interval. This state of affairs may continue for years but he is apt to be more or less conscious of his back and inclined to support it. Intervals of complete or almost complete remissions occur, but after an interval of months or sometimes years painful symptoms return. In other cases, especially where the hip and shoulder joints are also involved, the stiffness progresses and involves the entire spine.

Affection of the dorsolumbar region is the most frequent, but a primary cervical affection occurs occasionally, especially in elderly women, while in some cases the affection goes on to a complete ankylosis of the spine throughout;

in most, however, it affects but a limited portion, and is only slowly progressive. When complete ankylosis occurs, painful symptoms generally cease, and although the gait is clumsy and movements unsightly, these ankylosed cases later on often become active and comparatively little handicapped in pursuing an active life.

Any marked degree of this condition is as a rule attended during its acute stage by marked impairment of general health in the way of greatly diminished endurance and possible loss of weight. If chest expansion is lost, resistance to respiratory affections is diminished.

When the lumbar region is affected the movements of flexion, lateral bending and hyperextension are restricted. When the dorsal region becomes involved rotation is limited and in most cases chest expansion is diminished, while in severe cases it is cut down to one-half an inch or less. If the cervical region is affected motion of the head becomes painful, often this is the first sign of spinal arthritis, and in severe cases the chin drops down toward the sternum and the head is held flexed. The general attitude is different in early and in late cases. In early and slight cases, especially in the painful period, the lumbar curve is flattened temporarily and, as a result of this, the upper part of the spine is somewhat carried forward so that the patient appears to stand in an attitude not unlike round shoulders. Lateral deviation of the spine is apt to be present at this stage, but is not necessarily permanent and often only a temporary muscular distortion.

In the severest and ankylosed cases the lumbar spine is flat, the dorsal region abnormally convex backward, and the head carried forward. The gait of these cases with extensive ankylosis is peculiar as they have to swing the hips in walking to compensate for the lack of rotation in the spine. In attempting to look at anything at the side, the whole body is turned.

Nerve Symptoms.—Pain is often felt in one or both buttocks, radiating at times into the thigh, leg and foot, and is due to pressure on nerve cords as they emerge from the foramina. This spinal root pain may be present where no osteophytes are to be seen in the X-ray. In addition to pain, paraesthesia in the distribution of several nerve roots may be complained of. Motor symptoms are less common, but occasionally definite paresis is demonstrable. The symptoms may be bilateral but are rarely symmetrical. Lumbar spondylitis is a not uncommon cause of so-called idiopathic *sciatica*, and particularly when the changes are confined to the intervertebral articulations. In arthritis of these small joints, comparatively slight changes may involve the intervertebral foramina and may indirectly produce irritation of the nerve roots. Owing to their size the 4th and 5th lumbar roots are specially vulnerable. Putti has extended the work of Sicard on the pathogenesis of sciatica, and has shown that arthritis involving the foramina may be recognized in good stereoscopic radiograms.

In the clinical picture of an early case the patient moves most guardedly, gets up and down from the chair by holding on to the arms and with great caution, walks very carefully, and is often more comfortable sitting up than in bed. He sleeps badly, awakes whenever he turns over, and when he is enough improved to be examined it will be found that his limitation, particularly in movements involving the dorsolumbar and lumbar region is marked, that the erector spinæ muscles are on guard even when he is standing at ease, and that the patient is pretty apprehensive about being handled, preferring to help

himself rather than to be touched. In the more acute cases excessive, painful muscular cramps of the back occur on slight movement.

Types of Disease.—Two of the types of the affection have at times been classed as separate diseases, but the modern tendency is to class them together as phases of one affection. In one called the "Bechterew"[1] type, the spine alone is affected by the process. In the other type, the "Marie-Strümpell" type, the shoulder and hips are also involved, the latter deformity leading to flexion, and inasmuch as the lumbar spine is stiff and cannot compensate for the hip flexion by lordosis, the patient must walk bent forward from the hips with the trunk carried at an angle of about 45 degrees to the upright position. The gait is most unsightly, is familiar to everyone, and the use of one or two canes to preserve balance is generally necessary.

Diagnosis.—If arthritis deformans is present in other parts of the body, this makes it probable that the affection in the spine is also arthritic. The affection is progressive but intermittent, distinctly painful, characterized by pain and stiffness, with acute attacks of lumbago from time to time, and flattening of the lumbar spine with some lateral curvature. In the history, the absence of a severe accident involving the spine is important. Chest expansion is limited in any marked involvement of the dorsal region, and referred pains in the lower extremities with paresthesia occasionally occur.

The X-ray appearance when present is characteristic, but the absence of positive X-ray findings does not exclude arthritis, because, as in the other joints, the non-formative type may occasionally be present. A characteristic X-ray shows bone atrophy and an uneven shadow of the vertebræ after the early stage, and in the more advanced cases a mottling and stippling of the vertebral shadow is exceedingly suggestive. There is a loss of the intervertebral space and the occurrence of lipping and spur formation at the edges of the vertebræ is practically pathognomonic. This is better seen in the side X-ray than in the antero-posterior. In the absence of positive signs the diagnosis must be made largely by exclusion, and often a period of observation will be necessary before reaching a final conclusion.

Differential Diagnosis. *Tuberculosis of the Spine.*—This is a focal lesion with generally a perivertebral spindle-shaped shadow around the affected area in the antero-posterior X-ray. Kyphosis is always present except in the earliest stages and children are most often affected. Muscular spasm is present and paralysis may occur, generally symmetrical and accompanied by increased knee jerks and ankle clonus, except when the disease is very low in the spine. The X-ray shows bony destruction from the outset.

Fracture.—There is a history of trauma, the X-ray is characteristic, deformity is generally present and there is often local compression of the spinal cord and nerve roots.

Sprain.—Traumatic or postural sprain is often very difficult to diagnose from early arthritis of the spine and will be dealt with more in detail elsewhere, (p. 673). In this, history may be misleading, the symptoms are much the same, but of less degree in all respects. Paresthesia should be absent, atrophy of one limb is unlikely to occur, the X-ray is negative, and subjective symptoms may be present, suggesting a psychosis, particularly if litigation is pending. In sprains, rigidity is usually limited only in certain directions, while in arthritis it is limited in all directions involving the affected area.

[1] Berliner Klin. Wchsft., Nov. 20, 1897.

Malignant Disease.—A mottled, eroded appearance of bone is noticed in the X-ray and generally signs of a formative nature begin early. The pain is severe, nerve and cord symptoms of a pronounced character generally occur at an early stage, and the condition from the outset presents symptoms of grave character. Primary growths (sarcoma) are rare, but secondary deposits from carcinoma of the breast, thyroid, prostate or other deep-seated organs are comparatively familiar. The primary tumour may be latent or may have been removed some years before the onset of spinal symptoms.

Pelvic disease in women as a cause of backache may resemble arthritis deformans, especially in cases where the symptoms are exaggerated by a psychosis. In case of doubt the wisest course to pursue is to have a pelvic examination made by an expert. Nerve symptoms are as a rule absent, the X-ray is negative, and stiffness is not a prominent symptom.

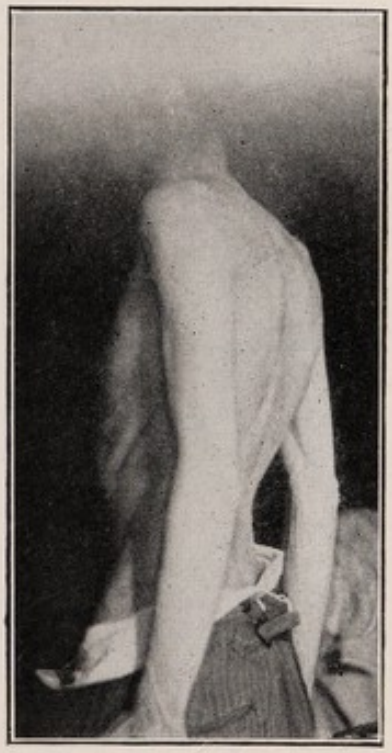

FIG. 275.



FIG. 276.

FIGS. 275 and 276.—Pictures of same patient with spondylitis deformans taken at an interval of twenty years. In the first, pain was acute and general condition poor. He was treated by a leather jacket and has been for many years free from pain, but his back is stiff and more rounded.

Sciatica.—Finally one of the commonest diagnoses made in this condition is sciatica. This is natural enough because a secondary irritation of the 4th and 5th lumbar roots may be present. In the experience of the writers primary sciatica is very rare and such a diagnosis should only be made after an elimination of any spinal cause.

Prognosis.—Under proper treatment the prognosis is good, so far as cessation and prevention of further stiffness are concerned. It may generally be predicted in early cases that unless the process is very marked, some or practically all of the stiffness will disappear, as this is in a measure due to secondary muscular spasm. Connected with generalized arthritis of a mild type, not markedly progressive, the prognosis for the spine is much the same as that for the general arthritis. In generalized arthritis of a severe or ankylos-

ing type the prognosis is of course poor, and the same outlook holds for the spine. In primary spinal arthritis in young men with antecedent gonorrhea, no matter how far back, if the disease is acute and extensive, the prognosis is not so good for restoration of motion. The disease is never fatal of itself, but extensive ankylosis of the spine and chest impairs the general health and predisposes to respiratory difficulty. Taking cases as they come in private practice, the great majority of them can be afforded permanent relief.

Light, early cases should be cured with a restoration of practical function if the osteophytes are small or absent, and the cause can be found and eliminated. Cases of moderate severity can be quieted down and it is a very rare experience to encounter a case where the pain cannot be stopped by proper treatment. Even the severest cases will become comfortable when complete ankylosis has occurred, while severe cases with deformity can be improved by measures to be discussed under treatment.

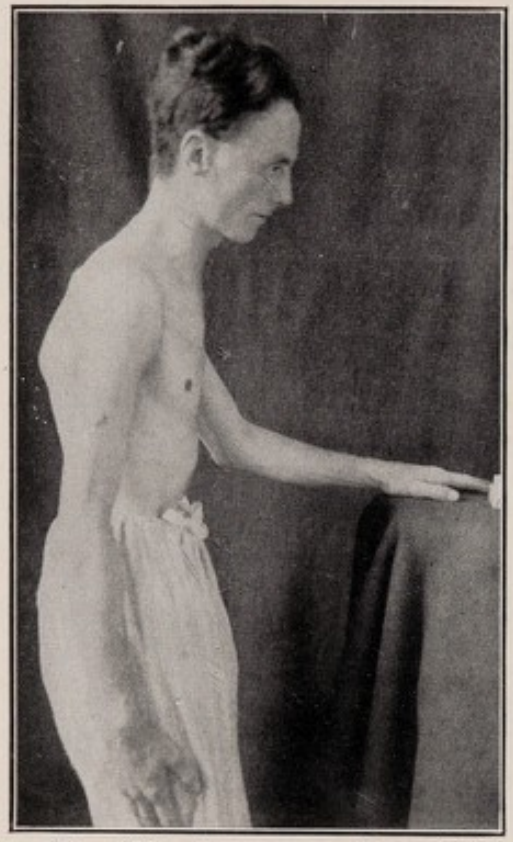

FIG. 277.—Severe case of spondylitis with deformity of flexion of head and spine. (See Fig. 278.)

Treatment.—The general treatment is the same as has been described under arthritis deformans. *Fixation* is of very great value. Rest in bed, on a frame if necessary, is required in the acute painful stage, but in mild cases, plaster strapping applied to the back affords relief for about three days at the end of which time it loosens and on account of skin irritation is very uncomfortable if worn for long.

At all stages the prevention of deformity and ankylosis must be the chief aim. When the acute symptoms are over gentle efforts to mobilise should be instituted. Radiant heat and diathermy are helpful as a preparation for the more active measures of physiotherapy.

The natural tendency towards the development of flexion deformity (kyphosis) should be remembered and for this reason it is wise to insist on the wearing of a light removable support. The ordinary plaster jacket does not fulfil the requirements of this stage. In the carefully supervised exercise treatment special attention should be paid to the development of chest expansion. By this means fixation of the costovertebral joints may be prevented or long delayed.

The patient is often presented for treatment when actual deformity has developed (Fig. 277). Correction should be attempted always by gradual methods and will be successful in so far as the contraction of the perispinal soft tissues are concerned. For fixed bony ankylosis nothing can be done, and the plight of the patient whose chin is approaching the sternum and whose field of vision is confined to the ground is tragic.

Gradual correction is begun with the patient recumbent on a frame with a head piece (Fig. 278), gravity being the main corrective force. For the cervical region a Thomas collar and graduated wedging by pads is used. The

dorsal spine at first propped by pillows is gradually lowered. In this way the contraction is slowly unfolded and the patient is allowed later to resume the upright posture wearing a posterior spinal support and collar. Once the deformity is corrected it cannot recur if the patient is adequately supervised.

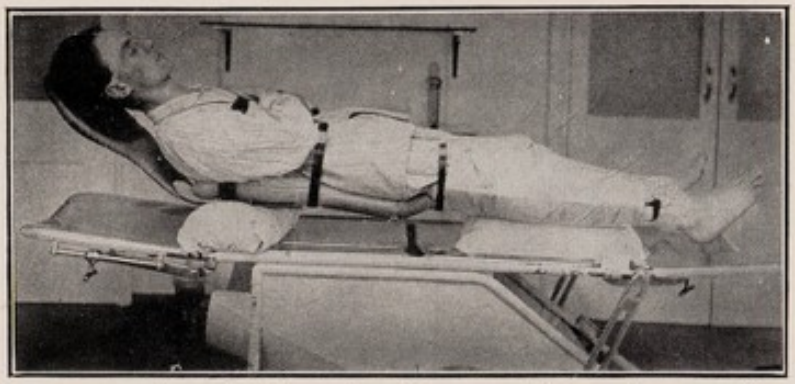

FIG. 278.—Severe case of spondylitis undergoing correction on frame. (See Fig. 277.)

Tuberculous Rheumatism

Tuberculous rheumatism (rhumatisme tuberculeux) has been described in French literature as an entity occurring in connection with tuberculosis. The description given covers a wide territory and includes the description of all types of arthritis deformans, classifying them as different types of tuberculous rheumatism. This hardly seems warranted from the evidence presented, but the practical point is that in connection with tuberculosis, either pulmonary or surgical, one sees at times cases of joint *effusion*, generally of a sub-acute type, which are polyarticular and are favorably affected by improvement in the tuberculosis. Those interested in the matter will find the whole subject discussed in detail in the book by Poncet and Leriche.[1]

[1] PONCET, A., et LERICHE, R.: *Le Rhumatisme Tuberculeux.*

CHAPTER XII

THE PYOGENIC INFECTIONS OF JOINTS

Pathology[1]

Route of Infection.—Infection of a joint with pyogenic organisms may take place by direct implantation into the joint cavity, as by a puncture wound, or by direct extension into the joint cavity, as along the intracapsular fissure lines of an infected fracture. Either of the above routes calls for a previous break in the joint lining. The other possibilities of pyogenic infection are by necrosis into the intact joint. This may take place through cartilage from an osteomyelitic bone focus, or through the capsule and synovial membrane from an infection of the soft parts.

The infecting agent may also be hematogenous and lodge in the capillaries of the capsule or synovia itself, only involving the joint proper when the intervening cells have been killed; or the channel may in a like manner be a lymphatic one. It is possible that bacteria may pass through the synovia without leaving any evidence of injury as a similar thing is presumed to occur in the intestinal mucosa.

Organisms.—There are a large number of pathogenic bacteria which possess the power of causing purulent, or modified purulent, inflammations in man. At some time or other nearly every known pyogenic organism has been described in association with a joint lesion, even to such rarities as finding a streptothrix as reported by Wolbach;[2] but by far the most common and important of these are the cocci, and especially staphylococci and streptococci of various kinds, *Diplococcus pneumoniæ*, *Diplococcus gonorrhœæ* and *Micrococcus intracellularis meningitidis*. More rarely joint inflammation may be caused by *Bacillus typhosus*, *Bacillus coli communis* and *Bacillus influenzæ*, but *Bacillus diphtheriæ* is very rarely a causative agent. In large open wounds Bacillus pyocyaneus may become a secondary invader.

Articular Pathology.—The reactions brought about in joints by pyogenic organisms may be classified into three groups: (1) The serous, (2) serofibrinous, and (3) purulent. These exudates depend on the relationship between the virulence of the bacteria and the resistance of the individual, and not so much on the specificity of the pathological process aroused by the infecting agent.

1. The *serous* effusion is probably the simplest demonstrable pathological change and consists in the outpouring of more or less fluid into the joint cavity and into the periarticular tissues. There is also at the same time a mild infiammatory congestion of the vessels of the synovial membrane and capsule, and the participation of a few of the cellular elements of the blood in the process of destroying the invaders. The effusion subsides without any sequelæ in most cases, although it may persist for a long time in some refractory individuals. This is the least common of the infectious types of acute arthritis.

2. Arthritis of the *serofibrinous* character is a much more serious affair. It is a true synovial disease from the outset and the earliest changes show this delicate membrane congested, reddened and covered by an exudate consisting mostly of fibrin, polymorphonuclear cells and a few red blood cells. The joint cavity contains a variable amount of cloudy fluid which has mainly polymorphic with a few large mononuclear cells as its cellular elements. The microorganisms may be present in the joint fluid early in the infection. The articular cartilages remain smooth and unaffected at the onset, but may have a few patches of fibrin-

[1] Poynton and Paine: Lancet, 1900, ii, 860–931. *Ibid.;* 1901, i, 1260. Practitioner, 1901, lxvi, 22. Trans. Path. Soc., 1901, li, 10, 248. Brit. Med. Jour., 1901, ii, 779. Practitioner, 1903, lxxi, 128.
Walker, Ainley: Practitioner, 1903, lxxi, 185.
Beaton and Walker: Brit. Med. Jour., 1903, i, 237.
Shaw: Jour. Path. and Bact., 1902, ix, 158.
Beattie: *Ibid.*, 1904, xi, 272.
Meyer: Berlin. Klin. Wchsft., 1902, xxxix to xl, 936.
Aronson: Berlin. Klin. Wchsft., 1902, xxxix to xlii, 979.
Schottmüller: Münch Med. Wchsft., 1903, l, No. 20.
Cole, R. J.: Jour. Inf. Dis., 1904, i, 714–737.

[2] Wolbach: Jour. Med. Research, 1917, xxxi, 3, p. 337.

ous exudate on their surfaces later. The exudate is also found in the recesses of the joint cavity, especially at the synovial articular junction and over the villous projections, while the villi are swollen and infiltrated with polymorphs. The periarticular tissues also take part in the inflammation. More or less scarring of the capsule will result from the organization of the exudate in the healing, and function will depend largely on the amount of scar formation and the number of adhesions as well as on the amount of atrophy and adaptive shortening in the surrounding structures.

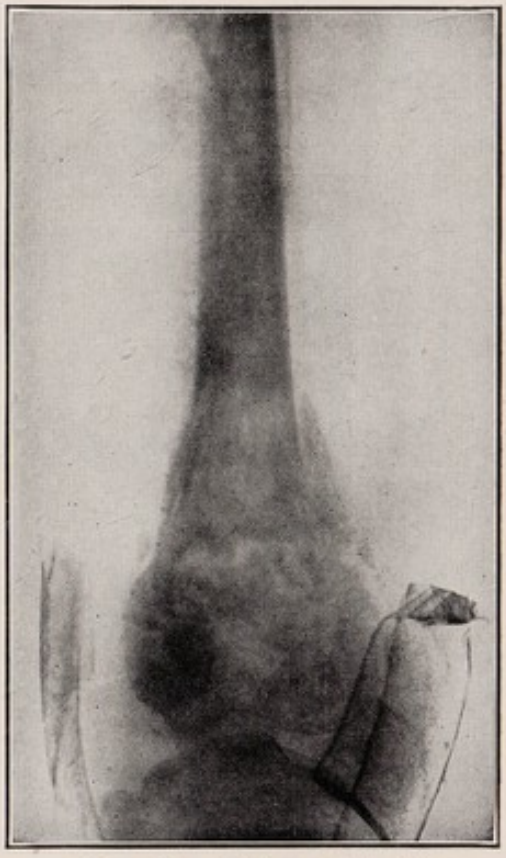

FIG. 279.—Diffuse periostitis.

3. *Purulent* arthritis is the most severe grade of joint infection. It is usually not a superficial disease and the invasive infiltrating character of the purulent exudate leads to early involvement of the whole joint structure and its surroundings. The infection may set in by any of the routes previously mentioned. The exudate is poured out into the joint cavity and contains large numbers of polymorphs and bacteria, as well as red blood cells and fibrin. The capsule and synovial membrane are infiltrated with leucocytes and thin capillaries, dilated and engorged with blood. Small areas of focal necrosis and fatty degeneration are found in the capsule and synovia. If the joint exudate be under considerable tension, erosion through the capsule may occur in one of these necrotic areas and the pus escapes into the surrounding tissues, burrowing deeply along fascial planes to form abscesses at a distance from the involved joint. These purulent infiltrations may also extend along the large vessel sheaths. The behavior of articular cartilage in the presence of purulent arthritis has been well described by Phemister.[1] Joint cartilage is dissolved in pus which contains polymorphonuclear leucocytes. This dissolution results from the proteolytic enzyme which is elaborated by the leucocytes The cartilage is dissolved first at points of pressure. In this way the bone becomes bared and a purulent ostitis develops in the bony substance rarefied by disuse. Sequestra may form if bone necrosis is marked. In very severe cases the intra-articular ligaments are entirely destroyed. The healing of such a joint may be of varied character.

If tension be relieved early and only slight cartilage erosion results, shortening of surrounding structures may be counteracted by early voluntary movements. Many such joints may recover almost perfect function (Willems' treatment), as the adhesions of a dense character may be prevented from forming by this means. In cases with a large amount of destruction, organization may lead to fibrous adhesions and partial ankylosis; and when bared bone ends are allowed to come into contact, various degrees of bony ankylosis result.

Acute purulent arthritis may further terminate by becoming a chronic process with periods of acute exacerbation.

Extra-articular Pathological Changes.—A very early change accompanying all three types of acute arthritis is the large amount of muscular atrophy, probably, in large part at least, of reflex origin.

Other complications accompanying acute arthritis of pyogenic origin are fatty and hyaline degeneration of the liver and kidneys in the more advanced infections. The development of amyloid disease requires suppurative conditions extending over a long period of time. Septicemia may occur, or lymphangitis with lymphadenitis and abscess formation, and the pocketing of pus, deep in the tissues, as described under the purulent type.

Specific Types.—The occurrence of pyogenic arthritis in the course of some infectious disease has been noted from very early time. Thus, it has been associated with scarlet fever, measles, dysentery, cerebrospinal meningitis, pneumonia, gonorrhea, typhoid fever etc. In most cases the process may follow closely one of the three types of arthritis described

[1] PHEMISTER, D. B.: Jour. B. & J. Surg., 1924.

above. In some cases, however, there may be slight variations, due to the specific reaction called out by the infecting organism. The joint usually is spared till somewhat late in the course of the disease; in fact there is some peculiarly interesting work pointing to the arthritic involvement following the establishment of a partial immunity. Bezancon and Griffon[1] were able to infect the joint with pneumococcus in partially immunized animals and a similar finding is reported by Hiss[2] for streptococcus. The joint seems to be one of the points of election in the septicemia occurring in these infections, but the exact reason has never been demonstrated. Trauma perhaps plays a slight role at times in causing a place of lowered resistance.

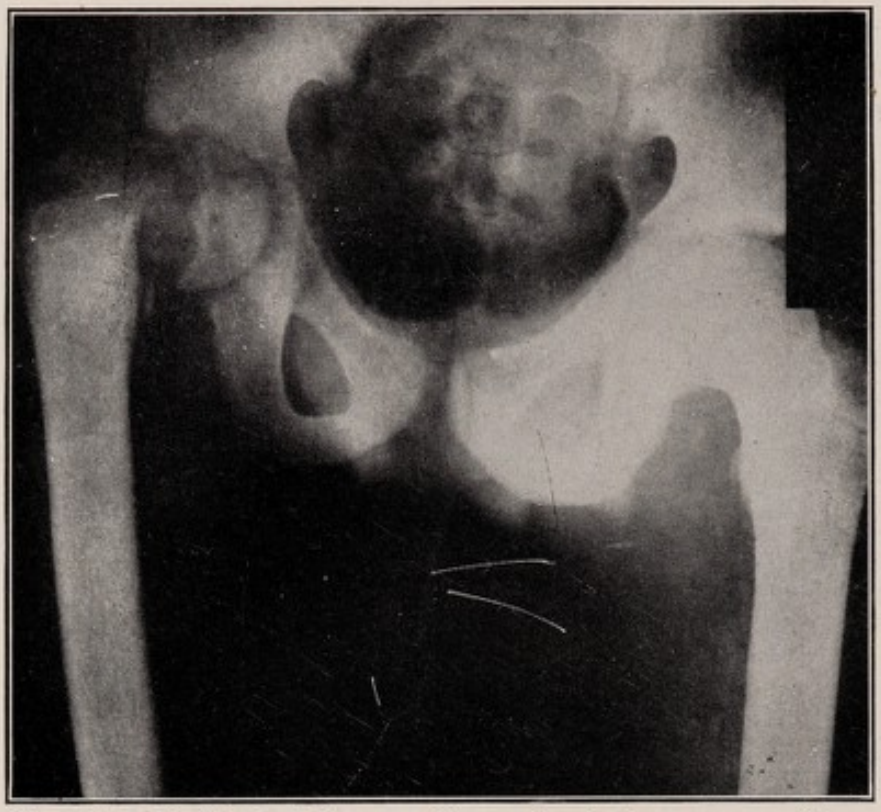

FIG. 280.—Pathological fracture of femoral neck from osteomyelitis.

1. **Staphylococcus and Streptococcus Pyogenes.**—These organisms may be taken up together because of the similarity in the pathological picture.

The experimental acute infection of joints received a marked stimulus in the reports of Poynton and Paine, Ainley Walker, Shaw, Beattie, Meyer, Aronson, and Schottmüller in 1900 to 1903. These writers claimed to have discovered a specific organism for acute rheumatism in the form of a streptococcus. R. J. Cole repeated the work, however, with intravenous injections of streptococci from many sources and was able to produce similar joint lesions with them all, thus discrediting the supposed etiological agent. The joint findings in his animals show that the infection started as a mild inflammation of the superficial layers of the inner surface of the capsule, *i.e.*, the synovial membrane, especially marked at the junction with the cartilage and just outside this line. There was a small amount of exudate on this surface. The exudate consisted mostly of polymorphs and a few red blood cells and fibrin, and the cartilage covering the head of the bone was smooth and unaffected. There was also a periarticular edema, a moderate increase in the joint fluid, which was turbid, sticky and tenacious, an injection of the capsule and slight infiltration of the villi with polymorphs. This was the milder form of reaction which subsided with few sequelæ.

In man we see in addition to the above type a much more severe purulent form.

2. **Diplococcus Gonorrhœæ** (Gonococcus).—The possibility of joint involvement during the acute stage of a Neisser infection has long been established not only for the urethral form of the disease but also following ophthalmia or vulvovaginitis. Arthritis usually occurs in the third or fourth week of the disease and is probably a localization of a septicemic

[1] BEZANCON and GRIFFON: Soc. de Biol., July 22, 1899.
[2] HISS: Jour. Med. Research, 1908, xix, 385.

embolus. The gonococcus has, at any rate, been cultivated from the blood by Ungar in a case of gonococcus arthritis, and Thayer and Blumer found it in the endocardium in an autopsied case which had joint involvement as well.

The arthritis may be single or multiple, in the latter case three or four joints as a rule being affected. The joint most commonly attacked is the knee, after which the ankle, hip, and wrist follow in the order of frequency. The most usual type of infection is a serous effusion and marked periarticular edema. The synovial membrane is boggy and slightly injected. The reaction is of a low inflammatory grade and the course is in consequence distressingly slow. There is very little cellular participation on the part of the blood. The diplococcus may be recovered from the joint contents during the first ten days, but very rarely at any later date.

The serofibrinous type of reaction is also occasionally seen, in which case there will be granulation tissue and healing with scar formation and thickening of the capsule. Fibrous adhesions of dense character may limit function to a marked degree in severe cases of this kind.

The occurrence of a purulent arthritis which is most rarely seen in a gonococcus infection is characterized by the slow course, the fibrillation of the cartilage and the formation of dense intra-articular adhesions giving serious joint disability on recovery.

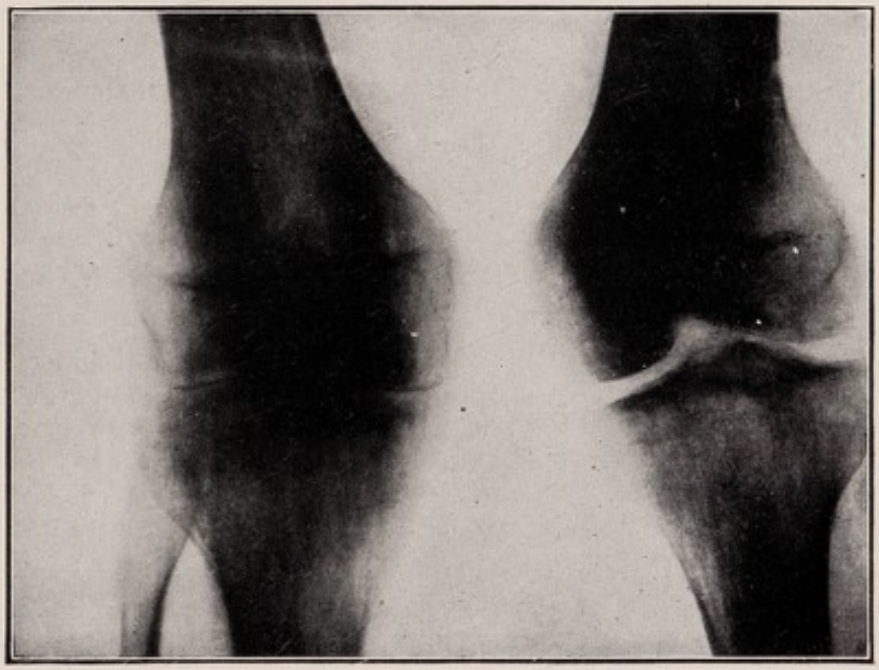

FIG. 281.—X-ray of septic arthritis of knee following typhoid.

3. **Diplococcus Pneumoniæ** (Pneumococcus).[1]—The earliest proved demonstration of the diplococcus pneumoniæ from a joint is that of Weichselbaum in 1888. The next ten years witnessed a very active search for bacteria in joint exudates and Leroux published a monograph on the cases in which pneumococci were found in 1899. In 1901 E. J. Cave reported the cases in England and reviewed the thirty-one proved pneumococcus infections at that time. The disease is most often monarticular and the large joints, *i.e.*, the hip, are more liable to be involved than the small ones. Polyarticular lesions occur about half as often as the monarticular. The simplest form of joint infection consists in an attack on the synovial membrane alone which loses its polish and the fringes become injected. Serous effusion takes place and the process subsides without leaving any evidence of injury. A much commoner finding, however, is suppuration. This was present in twenty-seven of a series of thirty-one cases observed.

[1] UNGAR: Deutch. Med. Woch., 1901, No. 51, 894.
THAYER and BLUMER: Johns Hopkins Hospital Bull., 1896, vii, 57.
ROGU: Jour. Am. Med. Ass'n., 1906, vi, 263.
WEICHSELBAUM: Wien Klin. Woch., 1888, Nos. 28, 32.
LEROUX: Les Arthrites a Pneumocoques, Paris, 1899.
CAVE, E. J.: Lancet, Jan. 12, 1901, 82–86.

The synovial membrane in these cases is as a rule thickened irregularly, and stained sections show two layers of about equal thickness, the deeper one, vascular and infiltrated with embryonal cells embedded in a meshwork of connective tissue, and the superficial one consisting of a network of fibrin arranged parallel to the free surface, and its true nature masked except for a thin layer on the surface itself. In this layer the pneumococci are at times demonstrable. The organisms are also to be found in the fluid of the joint exudate, either free or in the larger cellular elements. In many cases the cartilage is partially or completely eroded and the surface of the bone laid bare. In the cartilage the cells become swollen and edematous looking, while in some cells the degenerative changes are coincident with the disappearance of the nuclei although the ground substance remains unaffected for a long time, but eventually undergoes disintegration. In very virulent and in older cases, the changes are more destructive and in some of these the cartilages, articular ends of the bones and the ligaments are completely destroyed. These cases in nearly every instance have marked joint adhesions and partial or complete ankylosis when recovery takes place.

The pneumococcus is, next to the streptococcus, the most common organism affecting the joints of children according to F. E. Johnson.[1]

4. **Micrococcus Intracellularis Meningitidis** (Meningococcus).—An arthritis occurs in from 5 to 20 per cent of all cases of the true epidemic cerebro-spinal meningitis. As early as 1898 Still[2] reported a series of four cases of meningitis with joint involvement. He describes the affection as a rising in the neighborhood of the joints and consisting of an exudation just outside the capsule, usually surrounding one or more of the tendon sheaths. This occurs as a rule about one joint only. In these four cases the exudate was of a thick, adhesive character resembling that seen at the base of the brain, and the joints involved were the shoulder, ankle, wrist and metacarpophalangeal joint, respectively. In each case the joint remained healthy and the infection was strictly periarticular. The organism was recovered from the exudate in one of the cases.

Gwyn[3] recovered the micrococcus from the joint in a case in 1899. That this is not the only joint pathology, however, is shown by Herrick and Parkhurst[4] in 1919 who reviewed a series of 321 cases of meningococcus infection and found joint lesions of three types. The first was an acute polyarthritis which appeared during the first three days of the disease. Symmetrical joints were involved: Ankles, wrists, knees, elbows, and less often hips, shoulders and hands. Profuse hemorrhagic rashes occurred at the same time and the authors considered the joint lesions to be most probably hemorrhages into the articular and periarticular structures, especially the synovia. Pain and tenderness were marked and a moderate effusion of the joint was present, but rarely enough to aspirate.

The second type was monarticular. Twelve of their cases were of this type, which generally involved the knee, occasionally the ankle, hip, shoulder, wrist or elbow. Effusion was the prominent feature. The exudate was viscid, mucinous, semipurulent, sometimes hemorrhagic and contained pus cells, and rarely a thick, greenish pus was found. Micrococci were recovered in one-third of the cases and there were sixteen cases of this type. The duration was from one to four weeks and the recovery gradual and complete.

The third type of joint reaction is considered by the authors quoted to be a serum administration reaction. There were twelve cases of this.

That all the cases do not recover with complete functional use is evidenced by the reports of Sainton and Bosquet,[5] and that of Rogu[6] who cite cases with ankylosis of the knee, hip and shoulder, and also with rarefactions in the bone adjacent to the epiphyses. Herrick and Parkhurst have furthermore observed a case with necrosis of the head of the radius.

Etiology.—Most cases of acute synovitis of the joints are infectious in character when they arise in the absence of trauma. Adequate treatment in the earliest stages often results in complete recovery; but if the case is wrongly handled or neglected, the worst type of destructive arthritis may ensue. We cannot decide from clinical evidence the bacteriological nature of the infection, and in describing infected joints we will follow the clinical types based on the irritative reaction:

[1] Johnson, F. E.: Am. Jour. Dis. Child., 1920.
[2] Still, G. F.: Jour. Path. and Bact., 1898, 147–159.
[3] Gwyn: Johns Hopkins Hospital Bull., 1899, x, 112.
[4] Herrick and Parkhurst: Am. Jour. Med. Sci., 1919, N. S. 158, 473–481.
[5] Sainton and Bosquet: Soc. Méd. des. Hôp. de Paris, Mar. 17, 1916, 344.
[6] Rogu: Marseilles Méd., 1918, L. V., 505–516.

(*a*) Serous; (*b*) serofibrinous; (*c*) purulent; (*d*) suppurative.

The one reaction may pass on to the others, or may be checked by the resistance of the individual and the thoroughness of the treatment. Depending on the causation, acute suppuration may occur with great rapidity so that the preliminary stages seem to be absent.

Joints may be affected by direct traumatic infection, by extra-articular invasion, as in osteomyelitis, by auto-infection, similar to acute diffuse periostitis, by trauma in the presence of purulent infection elsewhere, or by the lodgment of a pyemic embolus. They also are sequelæ to fevers such as scarlatina and typhoid.

Symptoms and Diagnosis

(*a*) **Serous Type of Infection.**—This may be (1) acute, or (2) sub-acute.

1. *Acute*, infective synovitis is accompanied usually by a tense, painful swelling, obliterating all the bony outlines of a joint which is superficial, such as the knee. The joint feels hot and is usually maintained in its position of ease by muscular spasm. The knee, wrist, and hip are flexed; the shoulder, adducted; the elbow, slightly extended; the ankle, plantar flexed. In the superficial joints some hyperemia is present and any attempt at movement is accompanied by pain. Pyrexia is present and a high leucocyte count may exist. If the fluid is drawn at this stage it will be found clear, and the sugar content of the fluid will be lowered as compared to the blood sugar.

2. In the *sub-acute* variety of this type the joint is less painful, less distended, and can be gently moved without discomfort; and pyrexia is slight, or absent. Absorption of the fluid is slow, it is at first clear, but later becomes cloudy. It rarely becomes thickly purulent.

(*b*) **Sero-fibrinous Type.**—This is commonly a later stage of the serous type and is a much more serious condition. If acute, the joint may be exquisitely sensitive, the pyrexia is higher, and night pains occur, due to loss of muscular control.

(*c*) **Purulent Type of Synovitis.**—If the disease is limited to the synovial membrane and is unrelieved, it soon spreads to the cartilage and bone. The symptoms of the synovial type vary but little from those of acute infective serous synovitis. The patient is more apprehensive, suffers more pain, and feels ill. The limb rapidly wastes and his temperature is higher.

(*d*) **Suppurative Arthritis** (Panarthritis).—This is very grave, both with regard to life and limb. Unless immediately operated upon, the disease spreads, infecting ligaments, bones, and invading the muscular planes, separating muscle groups from their attachments. Pain is exquisite; fever, high; the leucocyte count, much raised; the joint is distended with pus and the surrounding soft tissues, become edematous. The patient is dangerously ill, and night pains are constant. The deformities increase and sinuses may form in one or many places, while exhaustion is rapid, rigors appear, and pyemia may result. The termination of such a case, inefficiently handled, is a prolonged chronic suppuration, and an ankylosis in a faulty position. During the acute stage death from exhaustion or pyemia may occur unless life is saved by the sacrifice of the limb.

Treatment

It is clear from the pathology and from the clinical course of these infections that treatment must be prompt and decisive. There is no margin for error,

and the surgeon must visualize the pathological changes which are at work.

(*a*) **Serous Type.**—In the *acute serous stage* aspiration should be done quite early. This may be repeated so long as the effusion returns, if it remains clear and the limb immobilized. If the effusion becomes even slightly cloudy, the joint should be opened and irrigated with a normal saline solution, or with an antiseptic, such as gentian violet or mercurochrome. To take the knee joint as a type: the knee is placed in an immobilizing splint with the joint exposed. The character of the fluid is ascertained by means of a hypodermic or larger syringe, or, if necessary to relieve tension, the joint is aspirated. If the fluid reappears aspiration is repeated, and a certain amount of circular pressure applied. So long as the fluid remains serous no further treatment is needed. If the secretion lessens, the limb may be very gently moved once a day to prevent the formation of adhesions, which are closely associated with septic infections. This should be performed by the patient himself. If one is late in beginning, and adhesions have already formed, it has been described elsewhere how they are to be attacked (p. 72), and one must learn how to distinguish clearly between a joint fixed by adhesions and one stiffened from arthritis. In the serous type the stiffening is due to plication and adhesions of synovial membrane. In the sero-fibrinous type they are due also to the organization of lymph with fibrocicatricial tissue, which often becomes vascularized.



FIG. 282.—Recovery from suppurative arthritis with right hip partly ankylosed and stiff in abduction. The illustration shows a method of reducing abduction deformity by a plaster of Paris spica on the well leg, to which the abducted leg is pulled over a strap.

In the *sero-fibrinous stage*, if the fluid is only slightly turbid, aspiration and irrigation may be tried. Two needles are made to enter the knee joint, one on each side of the patella. The aspirator is applied to one and the effusion is evacuated. When the joint is emptied by the aspirator, it is filled with saline solution, or with a dilution of gentian violet through the other needle, which hitherto has been plugged, and in this way it is thoroughly cleaned. The strictest aseptic precautions must be observed. If the fluid is again secreted, but only slowly, and is less turbid, no change in this procedure is needed; but, should the symptoms not abate and the fluid become more clouded, the joint should be opened by bilateral incisions and thoroughly irrigated. If infection is not far advanced the openings may be closed. Active movements should be started early.

(*c*) **Purulent Synovitis** (Empyema of Joint).—If the effusion should be free and thick, drainage of the joint may be considered.

Prolonged drainage of a joint has always been an unsatisfactory procedure. In the knee posterior drainage, lateral drainage, and even complete exposure of the joint surfaces by dividing the patella transversely, and acutely flexing the knee, have only occasionally rescued the joint from ankylosis. Drainage

tubes have to be condemned. In actual practice even in purulent arthritis, transitory drainage only of the joint cavity is required. But where the joint surfaces are severely damaged, as in gunshot injuries continued drainage is unavoidable.

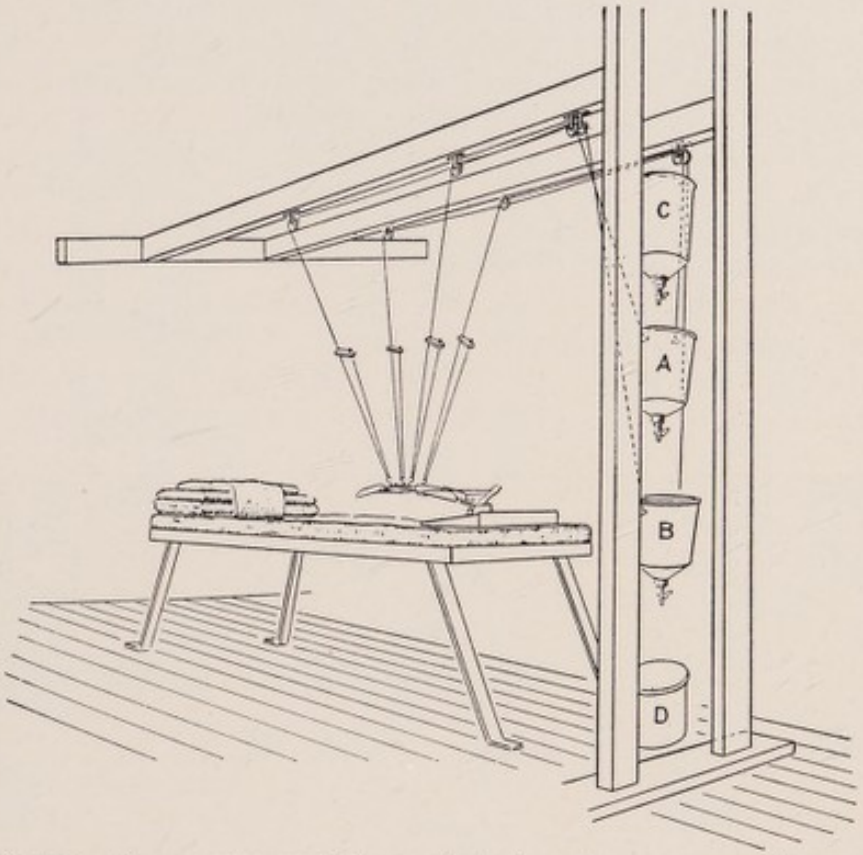

FIG. 283.—Diagram of apparatus used in graduated passive movement in pyogenic joints (Everidge.)

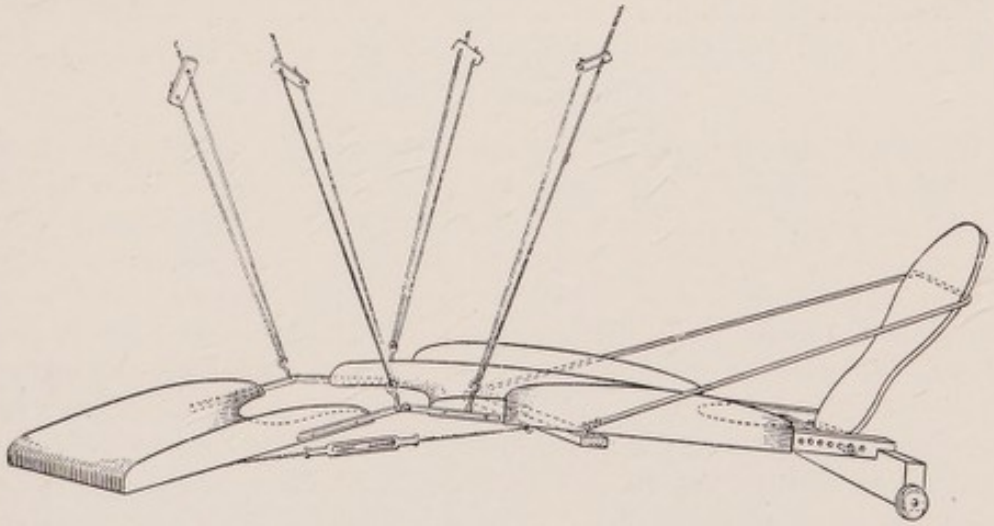

FIG. 284.—"Active" movement splint used in graduated movement. (Everidge.)

Willems' Treatment of Suppurating Joints.[1]—To Willems we owe a new procedure which, although described before the European war, hardly attracted the attention it deserved until opportunity arose to test it on a large scale.

[1] WILLEMS: Med. Record, 1919, xcv, 999.

Willems, recognizing the difficulty of securing adequate drainage, advocated free incision into the joint with immediate mobilization. He observed that movement was the most effective method of getting rid of the pus. Access to the joints is secured, in the knee, by very free incisions on either side of the patella which extend upward sufficiently to lay open the supra-patellar pouches; in the elbow, by incision on both sides of the olecranon; in the shoulder, by free incision along the bicipital groove; in the wrist, between the tendon sheaths, etc. Again taking the knee as an example: if the secretion is scanty the incision need not be bilateral; in such a case it should be made on the outer side of the joint. If any doubt exists the bilateral incisions are recommended and, from first to last, the wound should be kept open until the discharge becomes scanty. When treated by a wide incision and active mobilization, the wound behaves as in the case of an abscess cavity. The suppuration, profuse at first, diminishes and finally ends. The amount of secretion has a relationship to the irritative organism. In streptococcal infection the discharge is of moderate amount and the wound looks cleaner

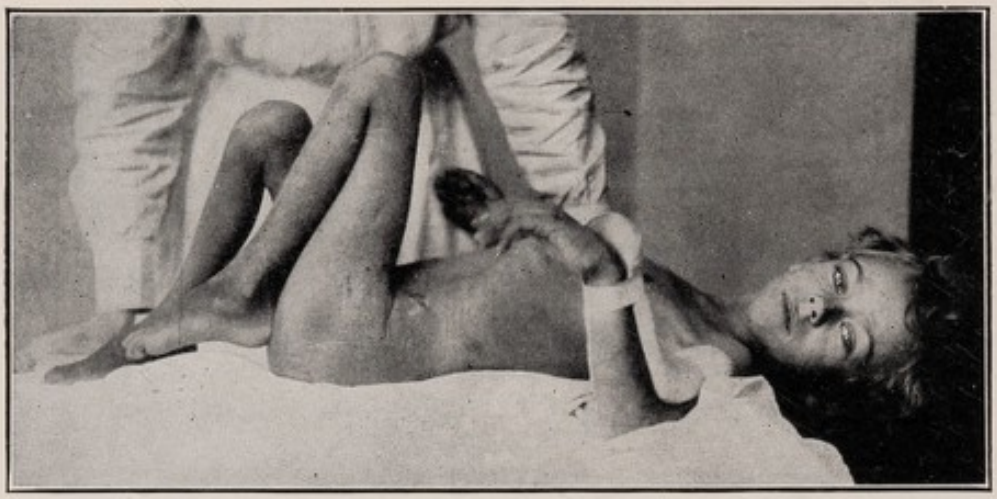

FIG. 285.—Septic arthritis at close of acute attack. Fibrous ankylosis of both hips at about 90 degrees.

and is characterized by a glassy surface; but it usually lasts longer than other bacteriological infections. If other bacteria are present, the pus is often thick and profuse. It is observed that cases which begin with the most abundant discharge are those which cease earliest. No drains of any kind are introduced and the movements are active and not passive, and should be continued both day and night, the patient being awakened if necessary every two hours. As soon as possible the patient is made to get up and walk. The appearance of these knees is somewhat alarming. They assume a globular outline, due largely to the tumefaction of the arthrotomy wounds, but the popliteal space maintains its normal outline. The wounds are puffy and the site of massive, exuberant granulations. The cartilaginous surfaces are, however, little altered, the infection seeming limited to the synovial sac. Spontaneous closure of the wounds is not encouraged and the incision which gives exit to the lesser amount of secretion is closed by secondary suture, but this only when the discharge is notably diminished. At a later stage the second wound is progressively closed in that portion which is not needed for discharge. This hastens recovery and diminishes the dangers of ankylosis.



FIG. 286.—Same case as FIG. 285 after a series of manipulations under anesthesia, lasting over many weeks. Manipulations were not begun until some months after cessation of acute process.



FIG. 287.—Spontaneous dislocation of the hip.

The presence of a periarticular abscess is evidence of insufficient drainage and if drainage is effective the pyrexia is slight, or even absent. The success of the treatment depends upon the will power of the patient who must, despite pain, keep up the movements. Willems places a light dressing over the wounds, which discharge freely during locomotion.



FIG. 288.—Dislocation of the hip on the left of picture, due to suppuration in early life, closely simulating congenital dislocation. Reduction was attempted, but on account of the cicatrical contraction, so much resistance was encountered that fracture of the femur occurred. Child of twenty months.

Everidge's Method.[1]—Basing his practice on the discovery of Willems, Everidge has devised a very ingenious apparatus to aid the patient's will power in moving the joint. In order to help in recognizing the clinical evolution of intra-articular inflammation he draws attention to three stages:

In the stage of a development the effusion consists of (1) synovial fluid discolored by altered blood; (2) albuminous fluid like coagulating white of egg; (3) sero-purulent fluid.

When suppuration is established one finds pus thick and creamy in staphylococcal infection, and thinner and less viscid in streptococcal infection.

In the stage of subsidence the joint contains (1) pus, with semi-solid curds; (2) curds floating in a clear liquid; (3) synovia clear and limpid.

In order to secure better healing with less danger of the formation of sinuses, the incision into the knee is made through the lines of cleavage; *i.e.* by transverse incisions. They are made from the inner and outer borders of the

[1] EVERIDGE, Major J.: A New Method of Treatment for Suppurative Arthritis of the Knee Joint. Brit. Jour. Surg., No. 24, 1919.

patella, commencing at the junction of the upper and middle thirds of the bone and continuing for a distance backward of an inch, or an inch and a half. These incisions do not interfere with the lateral ligaments. The cut edges of the synovial membrane are stitched to the cut edges of the skin by a series of suspension sutures, and a single layer of rubber tissue is inserted and left in situ for twenty-four hours, to prevent closure by adherent blood clot.

The apparatus devised to eliminate the obstructive action of gravity and so lessen the patient's effort to move his joint, consists of (1) a suitable splint with (2) an overhead counterpoise system.

1. This is a back splint with a foot piece, guttered to fit the shape of the leg; interrupted to give access to dressings, and a foot piece to steady the limb.

2. All that is essential for counterpoise is four pulleys, attached above the leg. These transmit four cords, two of which are attached just above, and two, just below the hinges of the splint. At their other end are affixed counterweights. These are not quite heavy enough to suspend the leg in the air and merely serve to overcome most of the force of gravity. With this device the patient can expend all that remains of his depleted energy in moving the knee without wasting it in attempting to lift the leg. This treatment is negatived by the presence of extensive bone injury and when suppuration has been allowed to reach the fulminating stage.

There is an element of the revolutionary in these methods of treating empyema of the joints, but we are well aware of the unsatisfactory results resulting from immobility. Fifty per cent of the cases treated by Everidge's method resulted in useful degrees of mobility. It was found that many of the patients became interested in carrying out the exercises, and they volunteered the remark that when the joint became painful they evacuated pus by flexing and extending the joint. The apparatus devised by Everidge renders the Willems method much more humane and practicable.

(*d*) **Suppurative arthritis** involving all the elements of the joint. (Panarthritis.) This condition is not suited to early mobilization, especially where bone destruction has taken place. The best to be hoped for is an ankylosis, and the treatment should consist of fixation, free drainage and the prevention of deformity. The question of excision must be considered if disease advances. In the hip joint, acutely infected, we must always bear in mind the possibility of so-called *spontaneous dislocation*. This occurs usually in the third or fourth week and is most common as a sequel to an infective fever such as typhoid or scarlatina. It occurs posteriorly and often quite suddenly. The limb should be immobilized and extended, and outwardly rotated. In many cases very little destruction of the head has occurred. As soon as inflammatory symptoms have subsided, an effort, often successful, should be made at a formal reduction.

Methods of Approach to Joints. (1) *Hip Joint.*—In suppurative arthritis a posterior approach offers many advantages. The technique practised by Ober[1] is simple and effective (Figs. 289, 290, and 291). A skin incision is made directly over and parallel to the central axis of the neck of the femur, extending to the tip of the sacrum, exposing the gluteal fascia, which is incised in the same line, defining the muscle fibres of the gluteus maximus which are parallel to it. These fibres then are separated with a blunt dissector, exposing the subgluteal fat, which is easily separated by blunt dissection. The great

[1] Ober, F. R.: Jour. A. M. A. Nov. 8, 1924.

sciatic nerve should be observed in the medial angle of the wound. The lower edge of the pyriformis, and the upper edge of the quadratus femoris, obturator externus, gemellus inferior, obturator internus, and gemellus superior are now seen, and divided by blunt dissection, separating the gemellus inferior from the tendon of the obturator internus, exposing the capsule, which is slit longitudinally throughout its entire length, exposing neck, head and acetabulum. The capsule is next divided vertically, giving a wide exposure to the joint structures. For drainage, two cigarette wicks may be sutured to diagonal corners of the divided capsule. These wicks drag down the capsule, affording

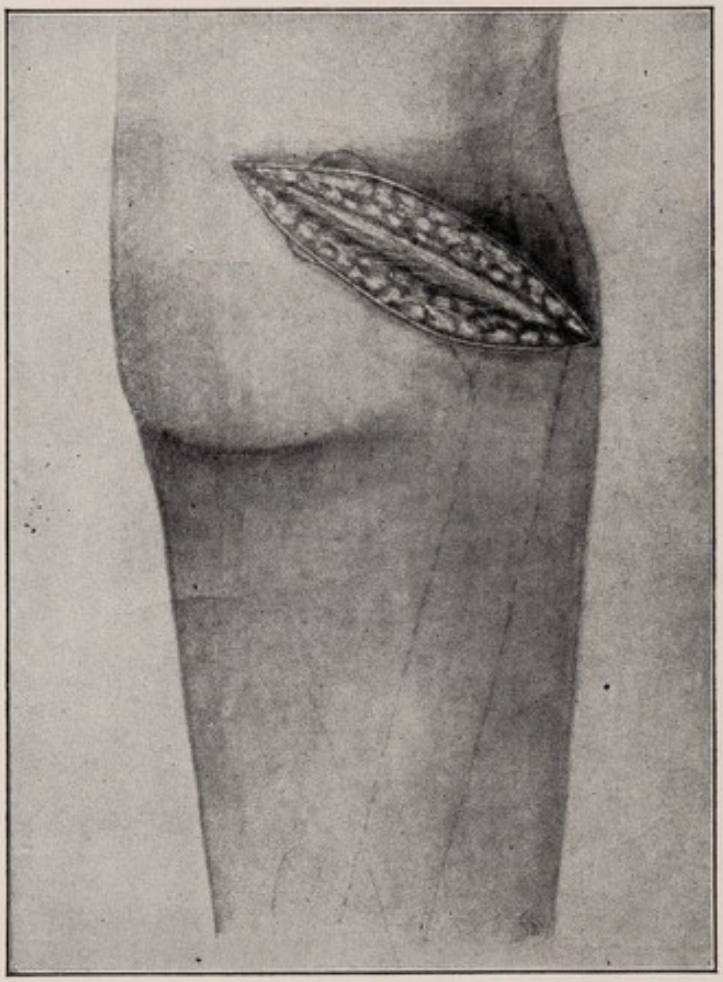

FIG. 289.—Skin incision parallel to the central axis of the neck of the femur, exposing the gluteal fascia (F. R. Ober).

rapid surgical drainage. If drainage is not needed, the capsule and wound may be closed. The operation offers rapid dependent drainage, and a minimum of injury to anatomical structures. There is practically no bleeding.

(2) *Knee Joint.*—The anterior compartments are opened on each side of the patella through short transverse incisions through the capsule. Except in the grossly infected joints of modern warfare, the capsular openings should be closed after evacuation of the effusion and irrigation. Strips of rubber tissue should be inserted down to the capsule, which serve to drain off the leakage of the first few days.

(3) *Ankle Joint.*—Effective "toilet" of the joint cavity is possible only after partial division of either the internal lateral or external lateral ligaments.

As in other joints an attempt should be made to close the capsular incisions and to rely on extra-articular drainage.

(4) The *shoulder joint* is best dealt with by the ordinary anterior approach; the *elbow* joint by incision of the radio-humeral capsule with a counter incision

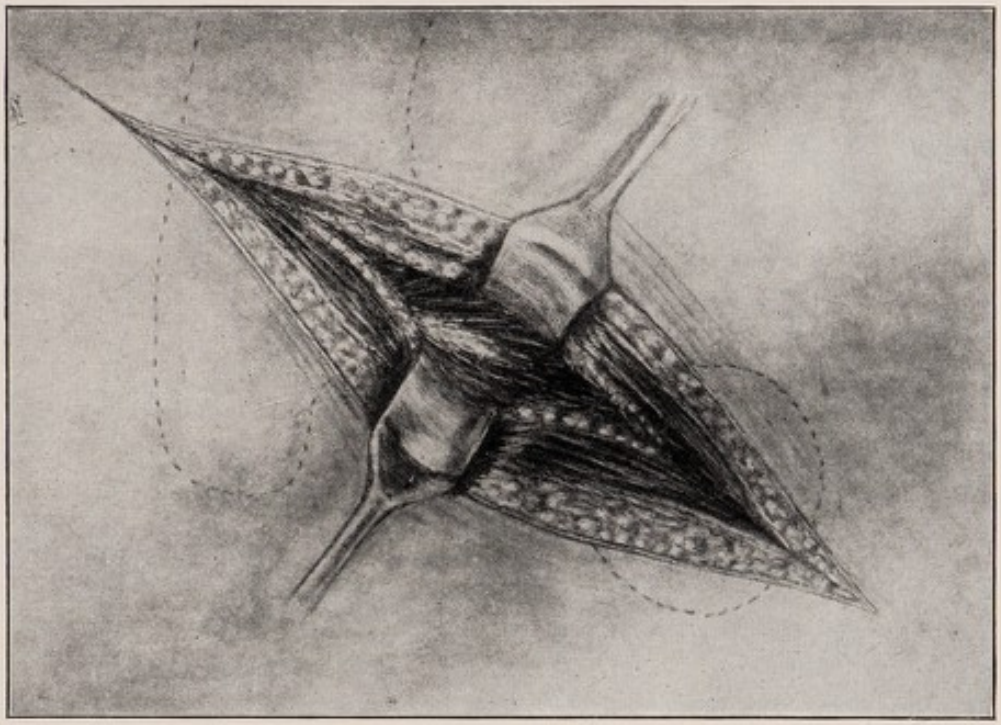

FIG. 290.—Fibres of gluteus maximus separated by blunt dissection, exposing the short rotators of the hip (F. R. Ober).

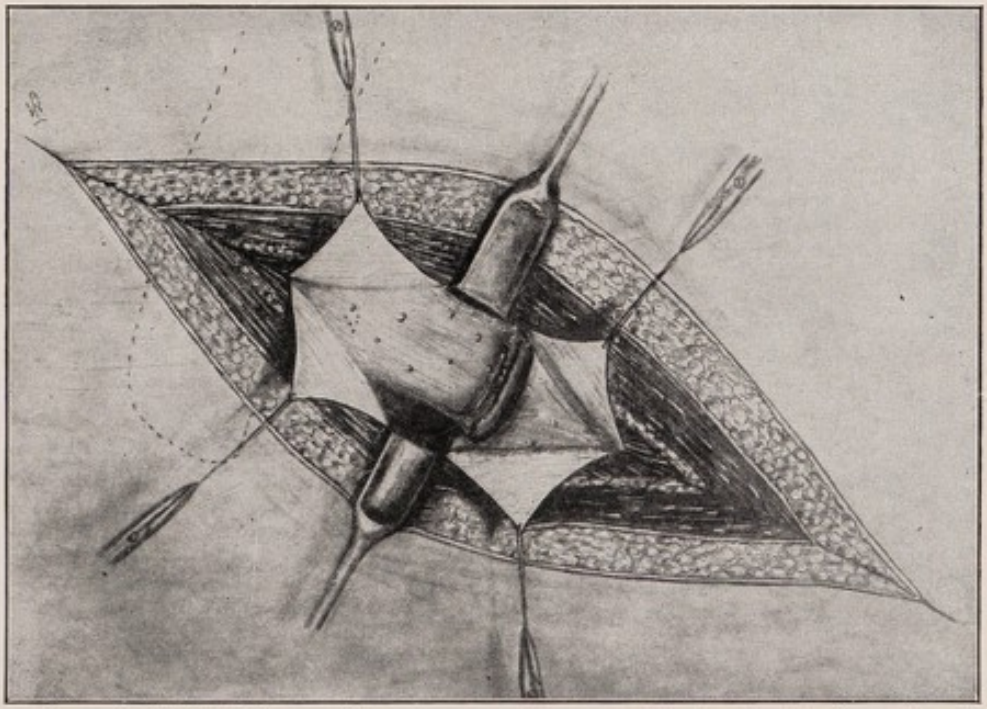

FIG 291.—Capsule divided in crucial manner and retracted, showing head and neck (F. R. Ober).

mesial to the olecranon if necessary. The *wrist* may be opened on the dorsum between the tendons of the extensor longus pollicis and the extensor indicis or between the extensor carpi ulnaris and the common extensor of the fingers.

CHAPTER XIII

OSTEOMYELITIS

Osteomyelitis is a collective term, covering all the various pyogenic infections of the bones. It includes the more definite diagnostic terms such as osteitis, periostitis, metaphysitis, and epiphysitis, and is used to signify an infectious process due to pus producing organisms in bone tissue. In case the process is sharply limited to a definite region of the bone the use of the above terms is justifiable. Ordinarily, osteomyelitis, acute or chronic, sufficiently covers the condition to be acceptable as a diagnostic term.

Osteomyelitis, or pyogenic bone infection, may be produced in one of several ways.

I. By direct infection from without as in compound fracture, or gun shot wounds, or penetrating stab wounds.

II. By direct extension from areas of infection situated near the bones.

III. By hematogenous infection, the organism being blood-borne, *i.e.* carried by the blood stream from a distant focus of infection and deposited in the bone tissue.

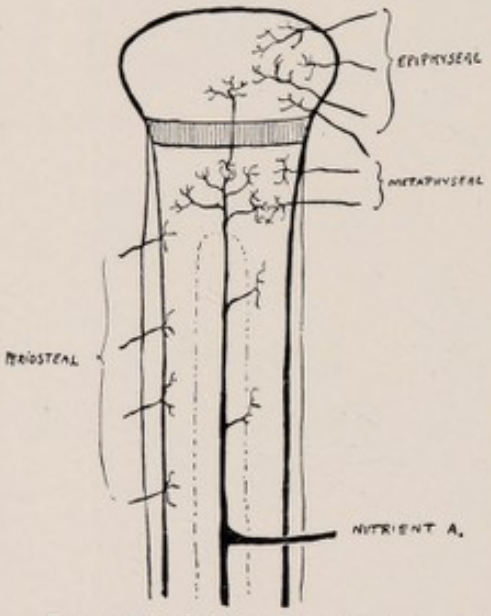

FIG. 292.—Schematic blood-supply of a long bone LEXER (Proc. Royal Soc. of Med., Vol. XXI, No. 5, June, 1928).

Hematogenous Osteomyelitis.—The most important group of cases are those which have their bone involvement due to the organism being carried in the blood and localized in the bone tissue. The response of the bones to invasion of bacteria is a series of reactions that on the whole are the same, regardless of the particular infectious agent. Such variations as do exist are those of difference in degree rather than in kind.

The spongy or cancellous bone is especially rich in blood supply, also the subperiosteal area, and the endosteum and marrow. Considering the compactness of bone as a substance and that the vessels carrying the blood must soon terminate and the rate of flow be much slowed,[1] it is not hard to visualize the advantages that exist in the bone for an infectious agency to gain a foothold, and having thus established itself, to multiply.

Bacterial Agencies.—A list of the bacteria which may invade the bones includes such well known organisms as the staphylococcus in its various varieties, the streptococci, the pneumococci, the typhoid bacillus (Winslow[2]), the

[1] LEXER, E.: Verzweigung der Knochenarterien und ihre Beziehungen zu Knochenenden, Deutsche Ges. f. Chir., 1903, Vol. 32, Part 1, p. 118–121; Further Studies on Osteomyelitis, Arch. f. klin. Chir., 1904, Vol. 43, pp. 481–491.

[2] WINSLOW, N.: Typhoidal Osteomyelitis, Ann, Surg. 77, 319, 1923.

tubercle bacillus, the pale spirochete of syphilis, and many others, including infections such as the echinococcus and the trichina spiralis. In fact, it may be said that any bacterial or parasitic agent may infect the bones.

It would seem unwarrantable to assume that each of these agents would have the privilege of starting an individual set of reactions in as simple a structure as bone tissue. The bone reacts to the invasion in its own way; any difference that we may observe in the reaction is only one of degree. Some of these bacteria cause acute, rapid and violent disturbances in the bone, accom-

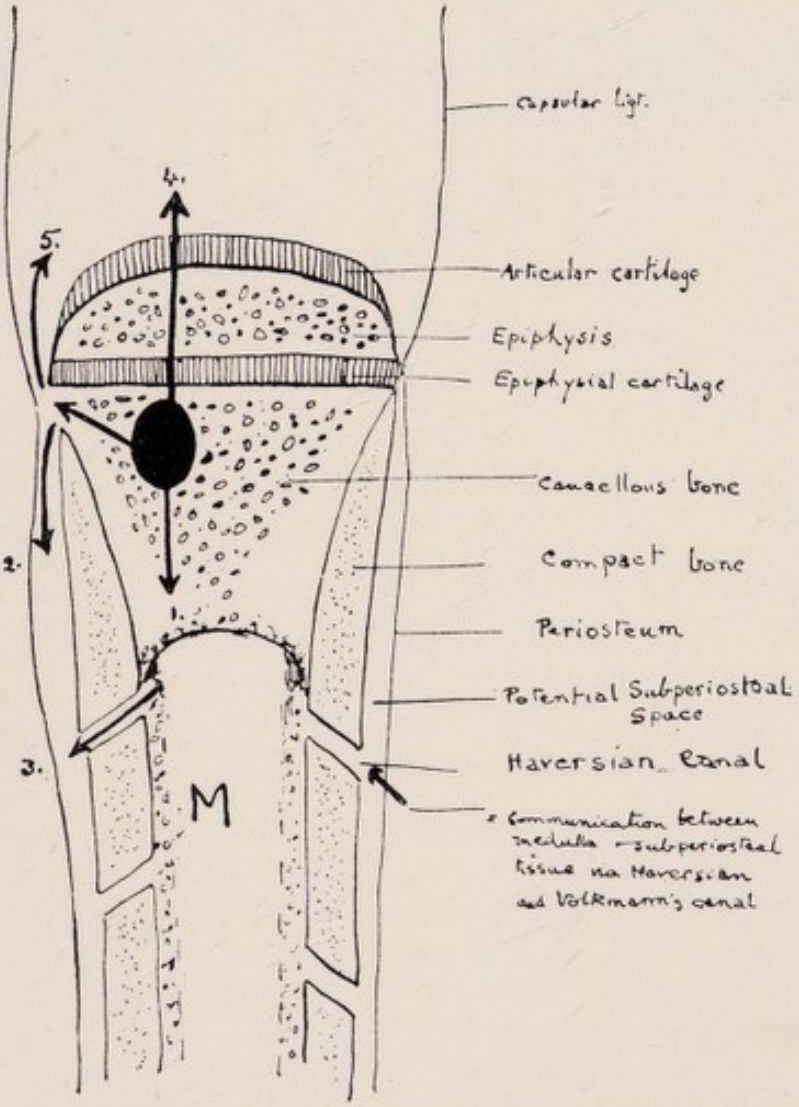

FIG. 293.—Schematic reproductation of a long bone, showing directions of possible spread of infection from the metaphysis (Proc. Royal Society of Med., Vol. XXI, No. 5, June, 1928).

panied by grave constitutional symptoms; while others cause slow, mild and localized reactions without much disturbance of the organism as a whole. In fact, the bones register the virulence and toxicity of an organism with a certain accuracy.

It is well to visualize the processes that follow infection with a clear knowledge of the parts of the bone that can best react to a stimulus, such as infection, and what that reaction will be and what it will mean in the battle the bone is waging to maintain its integrity. A long bone has two spongy ends; the shaft between these ends is incased in a periosteal tube; and the round hollow canal

inside the shaft is lined with endosteum and filled with marrow. The spongy bone at the ends is called cancellous bone, and the compact bone of the shaft is called cortical bone. These component parts of the bone have peculiar properties of their own. The periosteum, or limiting outside membrane of the shaft, includes in its deepest layers cells which possess a wonderful power of building bone,—osteogenetic or regenerative power. The endosteal cells have also this power to a less degree. The compact bone of the shaft, the cortical bone, is the finished product, actual bone substance, that on which we rely for support. This also contains osteogenic cells, though not as many as the periosteum and endosteum. The cancellous ends are best described as *spongy;* they are bearing ends so broadened out that they may articulate. They are made up of bone struts—the trabeculæ—with spaces between, filled with marrow. The architectural arrangement of these trabeculæ is beautifully planned to meet the stress of function. The cellular elements, the osteoblasts, the osteoclasts, and the bone cells are the units of bone tissue and substance.

Carried by the blood stream to the terminal vessels in the cancellous ends, the metaphysis, the bacterial invader enters this structure and finds there a healthful place to live and reproduce his kind. To the insult thus offered, the bone gathers its forces to resist and throw out the invader, and the battle is on. Portions of the bone and the defending leucocytes die in this fight and a bone abscess is formed. The osteoclasts, aided by the infiltration of leucocytes do their best to limit and wall off the invasion; the osteoblasts build up new bone. When the proliferating elements are present as they are in the deep layers of the periosteum, there may be large amounts of new bone built up. At the same time large areas may die and be walled off or sequestrated. Such *sequestra* are prone to form in the more severe acute forms of osteomyelitis and are often of large size. About them new bone is laid down, the *involucrum*. Where the proliferating elements are few in number and slow of action, as is the case in the cancellous bone of the ends, destruction is apt to gain the upper hand and repair is made with the recognition of defeat in the resulting bone effect.

Surgery must take a hand in the infectious diseases of bone (Phemister[1]), and the surgeon must know his surgical pathology well enough to be sure that his efforts are not on the side of the disease process. For instance, the protective reaction of the bone may be broken down by ill-advised surgical interference and healthy bone laid open to infection. The surgeon must aid the protective process by giving proper drainage at the right time and in the right place. He must aid the healing of the process by using proper means of bone sterilization. In the last war a great deal was learned about the proper method of handling infected bone tissue. Carrel taught us how to sterilize a wound chemically with Dakin's solution. There have been few greater contributions to surgery than this. The technique requires infinite pains on the surgeon's part.

Two main types of osteomyelitis are encountered, first, the circumscribed form and, second, the diffuse form (Willis and Willis[2]).

[1] Phemister, D. B.: The Recognition of Dead Bone Based on Pathological and X-Ray Studies, Ann. Surg. 72: 467, 1920.

Garre, C.: Types of Acute Infectious Osteomyelitis and Their Sequelæ, Beitr. z. klin. Chir. 10: 294, 1893; Etiology of Acute Suppurative Inflammations, Fortschr. d. Med. 3: 165, 1885.

[2] Willis and Willis: Osteomyelitis Acute in Children, New Orleans Med. and Surg. Journ. Nor. 75, p. 337, Jan. 1923.

Circumscribed Form

In the circumscribed form which occurs in both children and adults, either because the invasion is less overwhelming or the defense mechanism is more perfect, the infection becomes localized and surrounded by a wall of denser bone. Such a focus of disease is called a *Brodie's abscess* following the description by Sir Benjamin Brodie, in 1845, of a more or less circumscribed osteomyelitis of the lower end of the tibia. These sharply localized bone abscesses usually occur near the ends of the long bones, most commonly in the tibia.

Symptoms.—The symptoms which they cause are pain and frequently an effusion in the neighboring joint, which is often mistaken for the main lesion. There may be very little general constitutional reaction or elevation of temperature. The white blood count is usually higher than normal. The symptoms are often strangely intermittent and may continue for many years if undiagnosed and untreated, remaining localized with more and more dense bone formed around the abscess cavity and with frequently recurring symptoms.

Diagnosis.—The diagnosis is made from this train of symptoms and from the roentgenogram. A sharply localized area of greater radiability will be seen in the roentgenogram surrounded by a ring of bone which is more dense than the rest of the metaphysis. Sometimes in the center of this area of greater radiability will be seen the denser shadow of a sequestrum.

Treatment.—This type of circumscribed osteomyelitis is very amenable to surgical treatment, which provides drainage for the localized abscess in the bone. After the cavity has been carefully localized by roentgenograms in two planes, a small opening is made through the bone into the cavity. The approach is usually by the shortest route unless dense muscles or vital structures make a longer route more practical. Cultures from these bone abscesses will usually show the staphylococcus aureus or albus. The cavity is drained for a short time and no recurrence of the trouble may be expected.

Acute Diffuse Form

The type of osteomyelitis which is much more serious is the acute form in which the constitutional symptoms are often severe and the infection is less sharply circumscribed.

Incidence.—The statement that acute osteomyelitis is comparatively uncommon is well borne out by recent statistics. In the Registrar-General's report (England and Wales) for 1926, the deaths from acute osteomyelitis for the year were 417, as compared with 2,710 deaths from acute appendicitis. The mortality-rate has remained fairly constant during the six years, 1921–1926 inclusive, the average number of deaths per annum being 435. The highest mortality occurs during the age-period 10 to 15, and the male sex predominates in the proportion of 2 to 1.

Statistics from various hospital reports also form a useful commentary on the frequency of this disease in surgical practice. At St. Thomas's, during 1925, fourteen cases were treated; in 1924, seventeen cases; in 1923 there were seven operations, and in 1922, nine operations for acute osteomyelitis. At University College Hospital, in 1927, there were twelve cases; in 1926, three cases; and in 1925, nine cases. In one of Clarence Starr's most recent articles[1] there is a reference to a series of 207 cases treated at the Toronto Children's

[1] Starr, C. L., Lewis's Practice of Surgery, 1928.

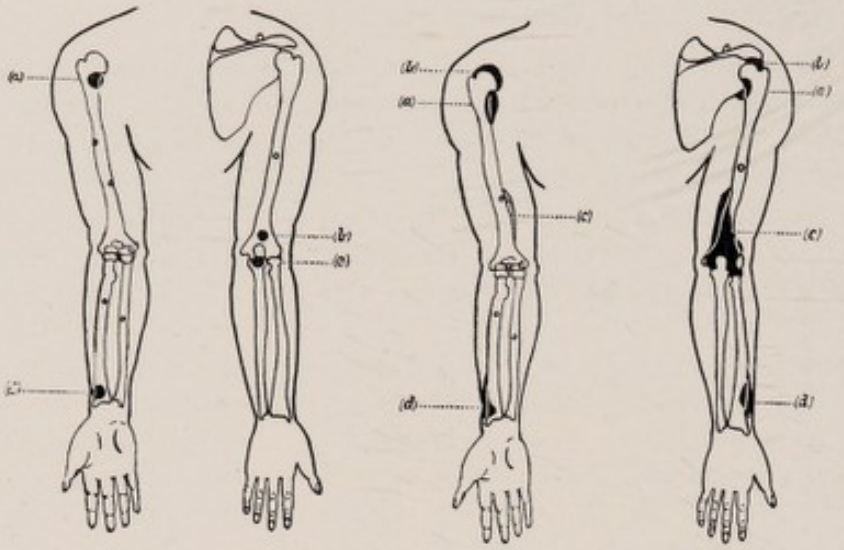

1 2 3 4

FIG. 1.—Maximal points of tenderness in early cases of osteomyelitis. Anterior aspect of upper extremity.

FIG. 2.—Maximal points of tenderness in early cases of osteomyelitis. Posterior aspect of upper extremity.

FIG. 3.—Sites of subperiosteal abscesses from osteomyelitis. Anterior aspect of upper extremity.

FIG. 4.—Sites of subperiosteal abscesses from osteomyelitis. Posterior aspect of upper extremity.

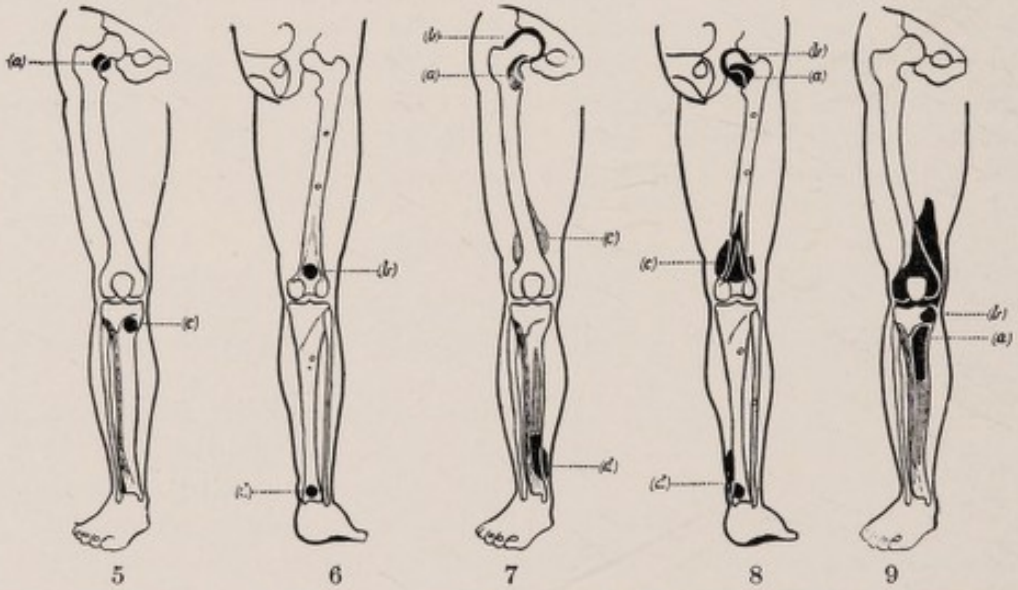

5 6 7 8 9

FIG. 5.—Maximal points of tenderness in early cases of osteomyelitis. Anterior aspect of lower extremity.

FIG. 6.—Maximal points of tenderness in early cases of osteomyelitis. Posterior aspect of lower extremity.

FIG. 7.—Sites of subperiosteal abscesses from osteomyelitis. Anterior aspect of lower extremity.

FIG. 8.—Sites of subperiosteal abscesses from osteomyelitis. Posterior aspect of lower extremity.

FIG. 9.—Sites of subperiosteal abscesses from focus at the upper end of the tibia.

FIG. 294.—Infective osteomyelitis (Robert Kennon, M.D. F.R.C.S.; Surgery, Gynecology and Obstetrics Vol. XLVII, No. 1. July, 1928).

Hospital in twelve years. The London Hospital, with its exceptional bed accommodation, and vast clinical population, is more fortunate. In 1926, thirty-five cases were dealt with, an average of seven to each surgical unit.

Acute diffuse osteomyelitis should more properly be called acute hematogenous osteomyelitis. Starr[1] has called attention to the fact that this disease of the bones is secondary to infection elsewhere in the organism. This infection is, in most cases, due to the staphylococcus aureus or to hæmolytic streptococci and its primary site in many cases is in a superficial skin lesion or a chronic infection of the tonsil or ear. It frequently follows a definite but not necessarily severe injury to a bone, but it rarely accompanies fractures. Acute osteomyelitis may be seen at any age, but it is most common in children between the ages of two and ten years. The primary bone focus is usually located in the metaphysis, involving the cancellous tissues near the cortex of the bone. After a few days the infection spreads and reaches the periosteum, raising it from the surface of the cortical bone. It may then spread backwards through the Haversian canals of the bone and invade the subcortical areas. The periosteum being raised on its under surface, new bone is formed and this new bone is known as the involucrum. The medullary canal of the bone may not be entered by the infection until after two or three weeks. Considerable bone tissue at the extremities of the long bone is usually involved before the medullary cavity is infected. The periosteum is attached to the extremities of the diaphysis and this attachment at either end of a long bone, together with the cartilage of the epiphyseal line in children, as a rule, safeguards the joints at either end from involvement and confines the infection to the shaft of the bone. The shaft of the bone or parts of it may become separated from the periosteum and the underlying new bone which forms the involucrum. As a consequence, the shaft may lose its circulation and die, forming a single large sequestrum or several smaller sequestra.

Symptoms.—There are marked constitutional symptoms incident to this infection. These are evident not later than six to eight hours after the invasion, and indeed they may appear earlier than this. These constitutional symptoms are very marked and consist of chills, nausea, vomiting, a very high temperature, and a high white blood count. The individual thus infected presents all the appearances of severe illness. The patient presents at times symptoms of extreme toxæmia similar to that seen in diphtheria or typhoid, and it is difficult with the sudden onset to explain his extreme prostration.

Acute osteomyelitis is of serious import. The outcome depends largely upon the speed with which diagnosis is made and treatment administered, the virulence of the invading organism, and the patient's resistance to the invasion.

It should be always remembered that this disease is a blood-borne infection.

Diagnosis.—Acute hematogenous osteomyelitis may be confused with cellulitis, with infectious arthritis, and with injury. The clinical picture presented by the disease ought to make the diagnosis a fairly simple matter.

In the early stages, perhaps even for two weeks when certain and accurate diagnosis is most needed, examination by means of the roentgen-ray offers no help and the shadow of the bone may appear quite normal. Later in the course

[1] Starr, C. L.: Acute Hæmatogenous Osteomyelitis, Arch. Surg. 4: 567, 1922.
Thompson, J. E.: Anatomical Methods of Approach in Operations on the Long Bones of the Extremities, Ann. Surg. 68: 309, 1918.

of the disease it becomes our most dependable index of the extent of repair or of the necessity for further intervention.

Perhaps the most certain symptom is pain in the limb of a deep boring character and worse at night. In young children the diagnosis must be based on the physical signs alone. In the presence of constitutional symptoms, *localized tenderness* near the diaphysis of a long bone[1] with or without marked swelling, redness and heat and with a high white cell count is usually enough evidence to warrant an exploration of the metaphysis.

Treatment.—A consideration of the mode of origin and spread of the osteomyelitic process in a long bone inevitably leads us to enunciate certain principles which should govern both the local and general treatment of the early lesion and its ravages.

1. It should be the aim of the surgeon to establish early and effective drainage, and to achieve early sterilization of the wound.

2. The operation must be so designed that: (*a*) further devascularization of both infected bone and uninfected bone is avoided; and (*b*) infection is not directly introduced into uninfected areas.

3. The systemic infection must be combated by appropriate general and specific treatment. In severe toxemia or septicemia, intravenous antiseptic medication and immuno-transfusion should be practised.

Operative Treatment.—In the surgical treatment of acute osteomyelitis three main types of drainage operation are commonly practised at the present time.

I. *Subperiosteal and Metaphyseal Drainage.*—It is obvious that in the earlier stages drainage of the infected area alone, implies: (*a*) drainage of the cancellous tissue of the metaphysis, combined with (*b*) drainage of the subperiosteal space in the area of spread. Although a subperiosteal collection of pus develops only when the infection has escaped through a definite hiatus in the bone, drainage of the subperiosteal space alone is insufficient, for the hiatus is always minute and often hidden on the deeper aspect of the bone. In patients who are desperately ill with a large extraperiosteal and subperiosteal collection of pus, and especially in osteomyelitis of the flat bones, it is occasionally necessary to be content with extra-osseous drainage alone as a temporary measure.

In the average case of acute osteomyelitis, however, it is sound practice to open freely into the metaphysis, either by multiple drill-holes, after the original technique of Starr, or by removal of a small trephine disc. All pus and infective débris should be sponged out lightly, but curettage of the interior should be avoided.

At this stage there cannot be the slightest justification for the common practice of extending the opening into the bone along the shaft, and exposing the medullary canal for a distance equivalent to the limits of the subperiosteal stripping (*the gutter operation*). We should unite to condemn this procedure and to explain its futility and dangers when the osteomyelitis is confined to the metaphysis.

Where the method of conservative drainage of the metaphysis has been consistently practised in acute osteomyelitis, the results have been most convincing. When carried out at the stage at which the periosteal stripping is minimal, or where the infection has not reached the surface, healing should be

[1] Kennon, R.: Surg. Gyn. & Obstet., XLVII, 1, July, 1928.

obtained without subsequent sequestration. In 207 operations at the Toronto Children's Hospital, twenty-six healed in this manner. In forty-one cases, (Ancoats Hospital[1]) subperiosteal and metaphyseal drainage was performed in twenty-two. Fourteen of these healed without sequestration; in the remainder, sequestra of various shapes and sizes were extruded spontaneously or were removed at a secondary operation.

II. *Diaphyseal Drainage (the Gutter).*—The gutter operation has its legitimate indications when the medullary canal with its lining of cancellous bone is infected widely. Such conditions are seen in osteomyelitis originating in the centre of the shaft, or in neglected cases or primary metaphyseal infection. Where the osteomyelitic process has travelled extensively in the cancellous tissue of the shaft of a pipe bone, it is difficult to establish drainage without imperilling the viability of the shaft as a whole. In such circumstances the gutter operation must tend to add to the amount of necrosis already determined by vascular obliteration and the chemical action of continued suppuration. In bones with a considerable subcutaneous area, *e.g.*, the tibia, the gutter has also the great disadvantage of leaving an avascular adherent scar.

III. *Subperiosteal Resection of the Diaphysis.*—Here we are on more debatable ground. If this operation is to be justified as a method of primary drainage, it must fulfil certain requirements. The arguments in its favour are: (*a*) That it allows a most effective drainage of the subperiosteal space; (*b*) that infected bone which would undergo massive sequestration at a later stage is removed at the outset, and thereby prolonged suppuration and secondary operations are avoided. In theory both arguments are sound. The obvious objection to the operation is that it is likely to be too radical as a method of simple drainage, and that complete or partial failure of regeneration of the shaft, with all its sequelæ, may be seen under certain conditions. For the earlier stages of acute osteomyelitis, where the results of conservative metaphyseal drainage are beyond criticism, diaphysectomy can have no justification; in the neglected case, where the whole shaft is riddled with infection, the operation is, however, in theory more rational than the gutter. But whenever performed in *acute* osteomyelitis, there must always be a definite risk of non-regeneration, owing to destruction of the periosteal tube in part or as a whole. In the less acute types failure of regeneration need not be feared, a fact which suggests that the operation is more suitable in the treatment of *subacute* osteomyelitis.

There is one final consideration in assessing the value of any operative procedure in acute osteomyelitis. It is customary to compare the respective mortalities of the various operations—a most illogical form of argument. In many cases of acute osteomyelitis, when first seen by the surgeon, there is a profound septicemia and the fate of the patient is not determined by operative treatment.

Topography.—The most frequent locations of acute osteomyelitis in the bones of the skeleton are the upper end of the tibia, the lower end of the tibia, the lower end of the femur, and the upper end of the humerus in the order mentioned. The upper end of the femur is frequently affected and so are the lower ends of the radius and ulna, the bones of the foot, and the scapula.

Conclusions.—1. A close study of the fleeting symptomatology of the prodromal phase of acute osteomyelitis will lead to earlier diagnosis.

[1] Platt, H.: Trans. Roy. Soc. Med. XXI, 5, June, 1928.

(*a*) Fixed pain at the end of a long bone, and (*b*) metaphyseal tenderness are the most significant early signs. In all doubtful cases exploratory puncture of the bone should be made.

2. With early diagnosis the operation of conservative drainage of the metaphysis becomes the correct routine. The gutter operation and diaphysectomy should be needed only in advanced and neglected cases.

Acute Epiphysitis

If an invading organism lodges at the epiphyseal line on in the osseous center of the epiphysis, we have the complication of joint infection. This occurs most commonly in very young children and is called acute epiphysitis. It is almost always a lesion of serious import causing a high temperature and great constitutional disturbance. In addition to the symptoms of an acute infection, we have great sensitiveness to joint motion and muscle spasm.

Treatment.—The joint should be at once freely opened, washed out thoroughly for fifteen minutes with hot saline or a non-irritating antiseptic solution and rubber tissue drainage instituted. Active (not passive) motion should be stimulated at the earliest possible moment (Speed[1]).

[1] SPEED: An Analysis of One Hundred and Sixty Cases of Osteomyelitis with End Results, Southern Medical Journ., Sept. 1922, p. 721.

CHAPTER XIV

SYPHILIS OF THE BONES AND JOINTS

Syphilis affecting these structures occurs in both the congenital and the acquired form.

Syphilis of the Bones

Congenital syphilis may appear at birth or first become evident during childhood or adolescence. Many syphilitic children die in utero, and in those who live the commonest osseous manifestations are osteochondritis and syphilitic periostitis and endostitis.

Osteochondritis.—In infants osteochondritis is the most frequent manifestation. It affects the epiphyseal regions above and below the joint, causes swelling of those regions, and tenderness and pain. Rarely do the epiphyses

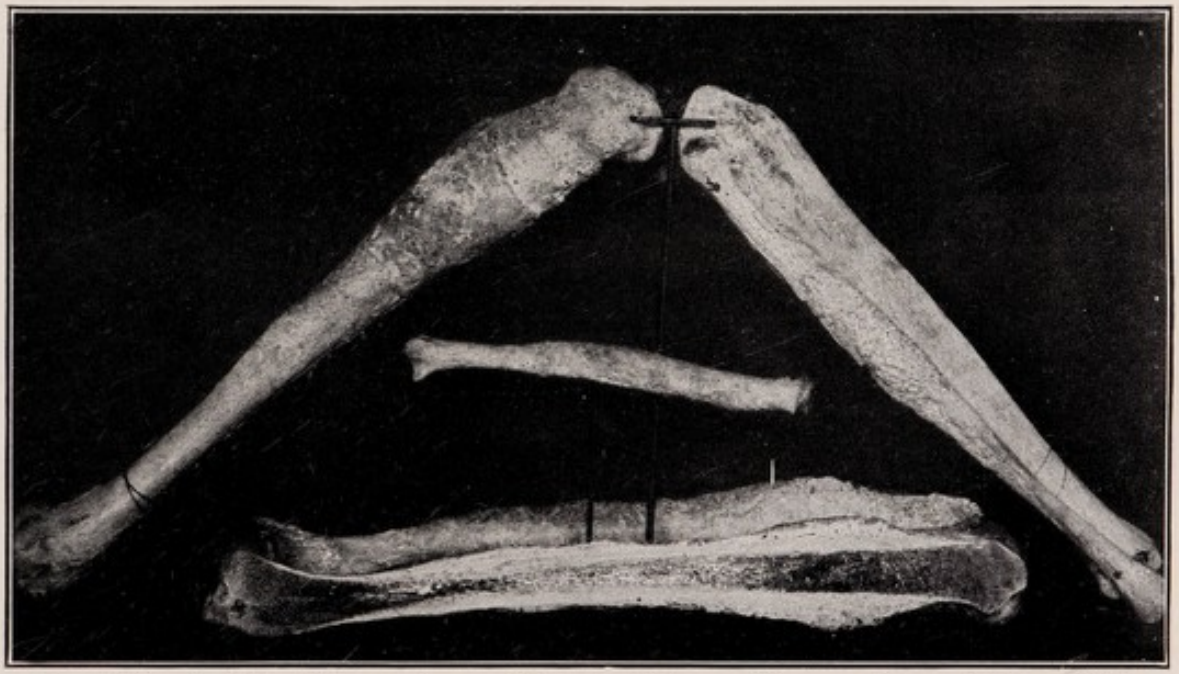

Fig. 295.—Syphilis of bones: femur, tibia, ulna (Warren Museum, Harvard University).

become loosened. Osteochondritis is most often symmetrical and affects the bones in the order named—lower end of femur; lower end of tibia and fibula, and forearm bones; upper end of tibia and fibula; is rarely seen in the upper epiphysis of the humerus; and very rarely in the upper end of the forearm bones. It leads to inability to use affected limbs, and is alluded to as *pseudo-paralysis.*

Pathologically one finds an irregular deposit of lime with irregularity also of marrow formation at the epiphyseal line. Here may be found a grayish yellow granulation tissue, which destroys the trabeculæ, and if sufficient softening occurs, it is the cause of the separation which sometimes takes place.

Clinically it resembles rickets or scurvy in its location and general character but the characteristic stigmata of syphilis are not present in the two last named

conditions, nor is there present in the X-ray of syphilis the characteristic appearance of the epiphyseal body seen in rickets. Syphilis and rickets may, however, coexist.

The prognosis in early cases properly treated is favorable, but in later or very marked cases it should be guarded. With complete separation of the

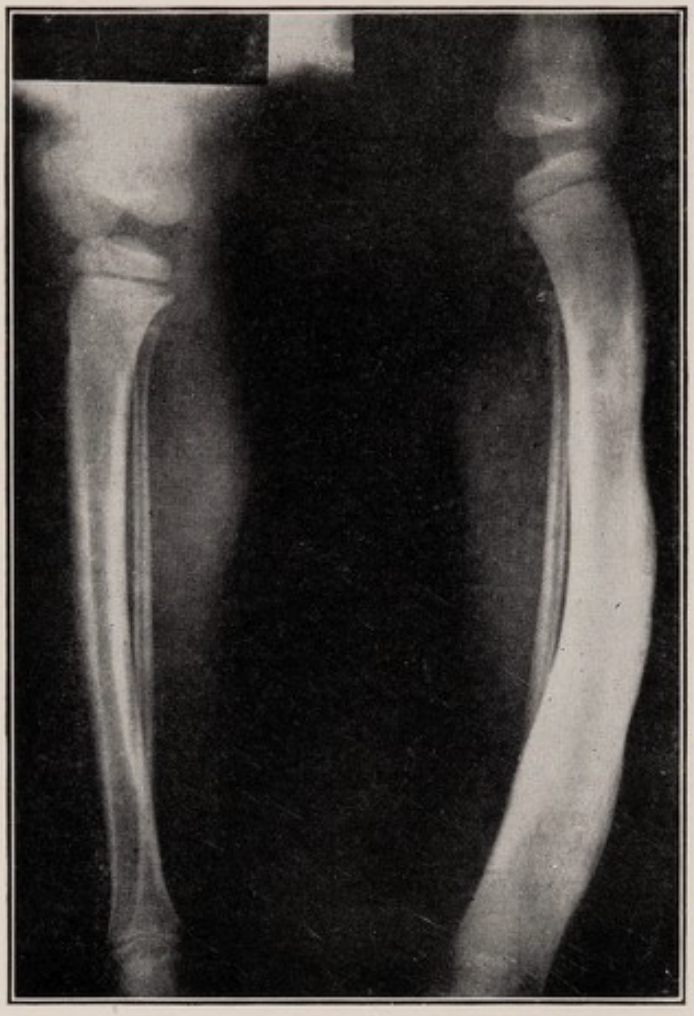

FIG. 296.—X-ray of old syphilis of tibia.

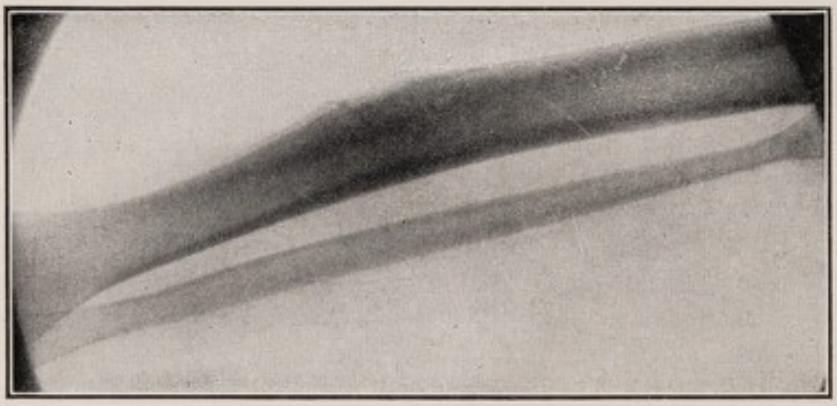

FIG. 297.—X-ray of sabre tibia.

epiphysis the ultimate function of the limb will be impaired by a variable degree of shortening. If there is an incomplete separation, an inequality of growth may subsequently result in a curvature at the joint, and the direction of the

bowing will be determined by that portion of the epiphysis which remains attached.

Syphilitic Periostitis.—Characteristic of the congenital form, this occurs also in the acquired. In the former it is called "periostitis ossificans" and there is but little destruction, and one or more of the long bones, usually the tibia, is surrounded by a layer of thickened subperiosteal tissue consisting of new formed bone surrounding the shaft. It is generally symmetrical, forms hard eburnated bone, and affects thigh, shin and forearms most often. Early signs of periostitis may exist in utero.

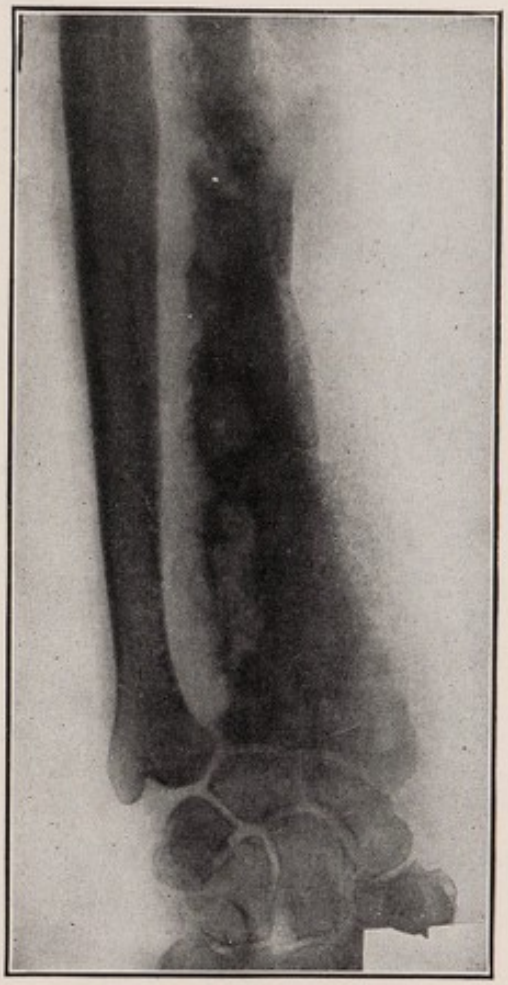

FIG. 298.—X-ray of syphilis of radius.

The "sabre tibia" is familiar to all and resembles closely the tibia of anterior bowlegs in rickets, but in syphilis the thickening is periosteal, and in rickets it is endosteal. As seen in the X-ray cortical thickening exists in both, but in rickets it is always on the concave side of the curve, while in syphilis it is generally on the convexity.

The epiphyses of the long bones may also be the seat of syphilitic periostitis.

Diffuse Periostitis.—Diffuse periostitis is more formative and less destructive and causes the bone to be greatly thickened by innumerable small hyperostoses, thickening the cortex.

Although these latter changes have been described as chiefly belonging to the acquired form, Franckel's Atlas of congenital syphilis shows similar changes so that one must remember that the process is much the same in tertiary and congenital syphilis. This is because *gummata* may accompany this periostitis in children and this is the characteristic feature of the periostitis of the acquired form of the disease in the tertiary stage. The typical form of this gummatous periostitis is found in a dactylitis.

A luetic periostitis may occur in the secondary stage of the acquired disease, but true gummatous periostitis belongs to the tertiary. Gummata may form in the deeper layers of the periosteum and cause more or less extensive destruction or necrosis of the bone surface, notably in the skull, or by deeper involvement of bone may cause a formative reaction not unlike the reaction to pyogenic organisms, as in acute pyogenic osteomyelitis, though of a much milder character.

In *gummatous osteomyelitis* there may develop in the marrow of the shaft or epiphysis a nut-sized destructive focus, the inside of which is a cavity from local bone destruction, and the periphery shows much formative activity. This process easily can lead to the formation of sequestra and fistulæ.

The radiographic appearances of syphilitic lesions of bone are on the whole characteristic, although they bear a superficial resemblance both to chronic pyogenic osteomyelitis and tuberculous disease of the long bones. As a rule in syphilis the formative reaction overshadows the destructive change, the lesions are multiple and tend to be comparatively painless.

Syphilis of the Joints

Syphilis of the joints proper is met more often in the earlier stages of the disease and therefore belongs in the main to the acquired form, but it occurs, as will be mentioned, also in the inherited, as a double hydrops of the knees.

The essential pathology of syphilis results from a chronic inflammation, produced by a periarterial invasion by the *Treponema pallidum*. A proliferation of fixed cells and an infiltration with small lymphoid cells and plasma cells most frequently involves the periarterial tissues and the walls of the nutrient arteries. The adventitia is the common initial focus of this lesion which develops into a small nodule, destroys the elastic tissue of the media, and produces proliferation of the intima with subsequent narrowing of the lumen. For this reason the blood supply is diminished and coalescence of adjacent granulomata favors degeneration and necrosis which result principally from occlusion and thrombosis in the capillaries and involvement of the vaso vasorum in the larger arteries.

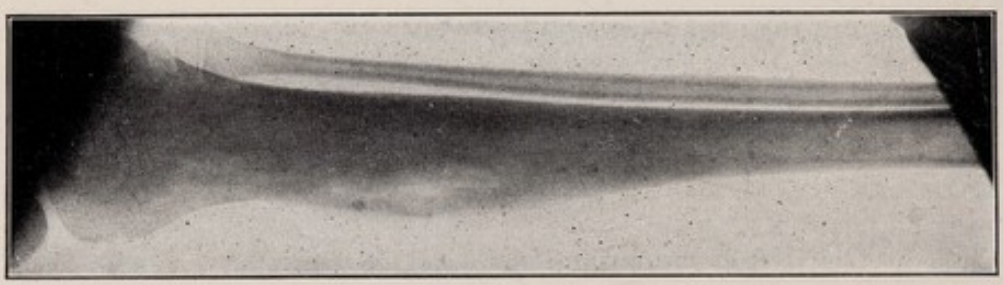

FIG. 299.—X-ray of syphilis of the tibia.

The commonest joint manifestation in acquired syphilis is a simple "*arthralgia.*" This usually accompanies the roseola, forming a part of the clinical picture in the secondary stage. Its course may be brief, but if protracted it usually progresses toward a more severe type of articular inflammation to be mentioned next. It usually affects one or more of the larger joints, which are painful and irritable when at rest, and therefore apparently worse at night. There is little if any muscular spasm and usually at this stage there is no local swelling, heat or tendency to deformity. The diagnosis is determined by the history and general phenomena, and a positive Wassermann reaction. The X-ray is of little or no value at this stage.

Acute, subacute, or chronic serous synovitis is not uncommon in the late secondary or early tertiary stage of syphilis and may succeed the arthralgia above described, and is due to a primary involvement of the synovial membrane.

The common manifestation begins by an acute onset which is succeeded by a somewhat protracted course, frequently ending in a chronic hydrops. The knee is the most frequent seat of this effusion, although any joint may be involved. The affection is most often symmetrical in distribution and usually shows marked variations in the amount of swelling. The bony prominences

are often obliterated by the swelling, the joint may be a little stiff and perhaps painful, local temperature is increased, there is slight muscular spasm, and function is impaired.

Gummatous Synovitis and Arthritis.—A more extensive involvement of a mildly destructive tendency usually occurs in the *tertiary stage*. The formation of such lesions occurs almost invariably in the perisynovial membrane, rarely in the hyaline cartilage of the joint surface, but may result from a primary gummatous lesion in the cancellous bone adjacent to the joint. The pathology described accounts for a clinical picture which is usually free from acute manifestations. If localized the lesion appears as a hard, painless nodule, of variable size, somewhat similar to a fibrous tumor, easily palpable and not adherent to the skin. The joint is seldom painful and its function is impaired



FIG. 300.—X-ray of destructive and formative syphilis of ulna in child.

principally by the sense of weakness. There is usually no increase in local temperature, and no muscular spasm, although there may be some swelling variable in degree. There is both local and general adenitis, a little tendency to permanent deformity, and the prognosis is favorable from the standpoint of the local condition, although the general health is somewhat compromised.

If gummata are spread diffusely throughout the perisynovial tissues and the synovial membrane, the clinical picture becomes more acute and the outlook less good. Chronic in its course, a moderate effusion spreads throughout the joint which is held firmly by muscular spasm, and there frequently form resistant masses made more or less permanent by the infiltration and thickening of the surrounding ligaments and subsequent cicatricial contractions.

Chronic Synovitis (Hereditary).—In middle childhood hereditary syphilis frequently manifests itself as a symmetrical chronic synovitis of the knees ("false tumor albus") exceedingly resistant in character. The joints are

moderately painful and generally slightly tender to pressure, there is some thickening of the synovial sac, muscular spasm is not prominent, and the affection only mildly disabling. The X-ray examination is negative, except for mild bone atrophy. The existence of the stigmata of syphilis generally aids greatly

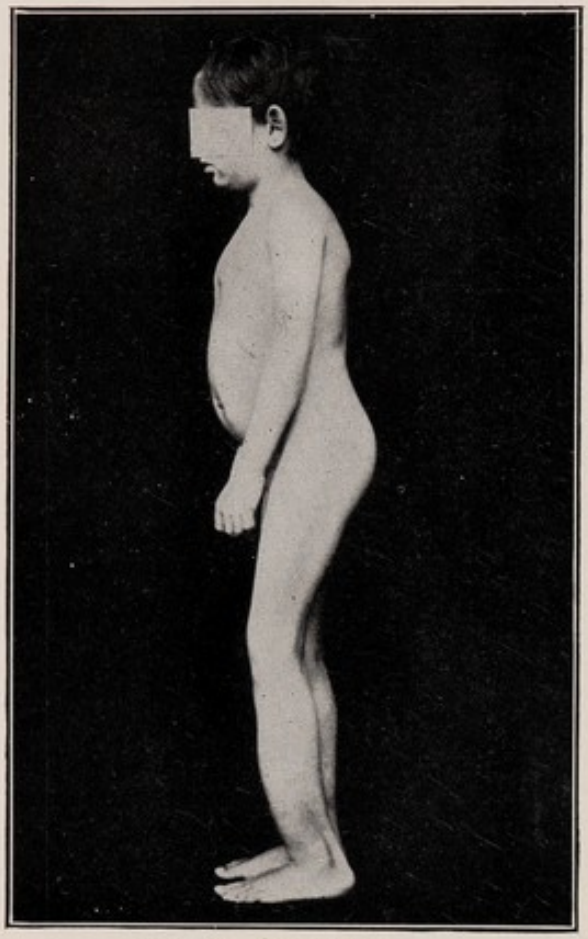

FIG. 301.—Sabre tibia.

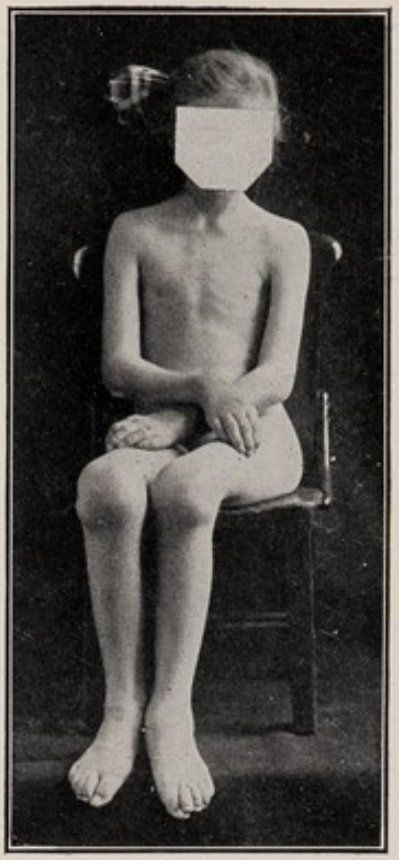

FIG. 302.—Syphilitic bilateral synovitis of knees.

in the diagnosis, and the majority of such cases show scars in the eye of a previous keratitis. The Wassermann reaction in the writers' experience runs parallel to the pathological and clinical findings in nearly all cases.

The prognosis in all syphilitic bone and joint affections is good under anti-specific treatment.

CHAPTER XV

OTHER AFFECTIONS OF THE JOINTS

Some joint affections do not fall into the classifications given in the previous chapters and must be considered separately.

Hemophilia[1]

In the case of "bleeders," a peculiar joint affection occurs, first appearing in middle childhood and affecting most often the knee joint, and is of importance, chiefly because of its close resemblance to tuberculosis, which resemblance is responsible for a considerable number of postoperative deaths from hemorrhage.

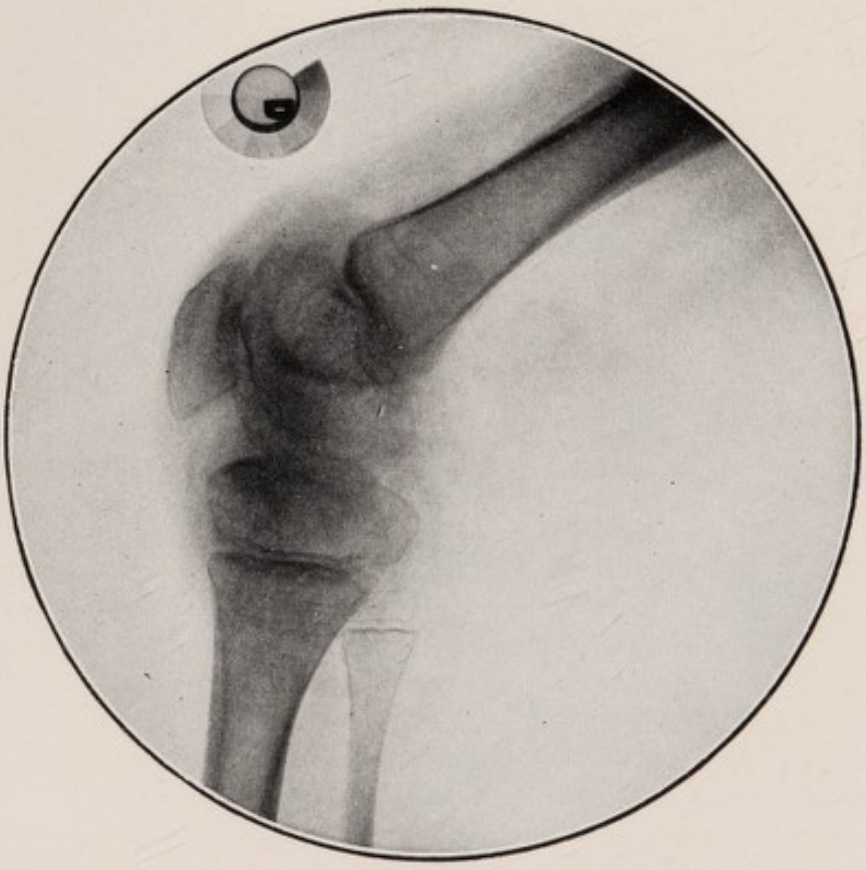

FIG. 303.—X-ray of bleeder's knee joint.

Pathology.[2]—The pathology of the joint affection is akin to that of arthritis deformans, and varies from a mild to a severe type. After repeated attacks of joint hemorrhage there is an overgrowth of brown synovial tufts, the cartilage may degenerate, and proliferation of the edges of the bones may occur at the joint margins. A brown staining of all the joint structures except the cartilage is more or less characteristic.

[1] CORLESS: Practitioner, 1903, lxx, 85.
[2] GOCHT: Münch. Med. Wchsft., 1899, 271.

Symptoms.—The knee which is by far the most commonly affected joint will serve as a type. Swelling, increase of synovial fluid and muscular atrophy are all present; muscular spasm is not prominent at first, but may occur later, pain is moderate, shortening is absent and lameness not severe. Ecchymosis of the skin and deeper structures may occur at times when joint hemorrhage takes place, or it may occur at intervals without known trauma. Overuse exaggerates symptoms, and remissions and exacerbations alternate with gradual increase of symptoms, and flexion deformity may occur from muscle spasm, with partial or complete stiffness. The affection may be monarticular or polyarticular.

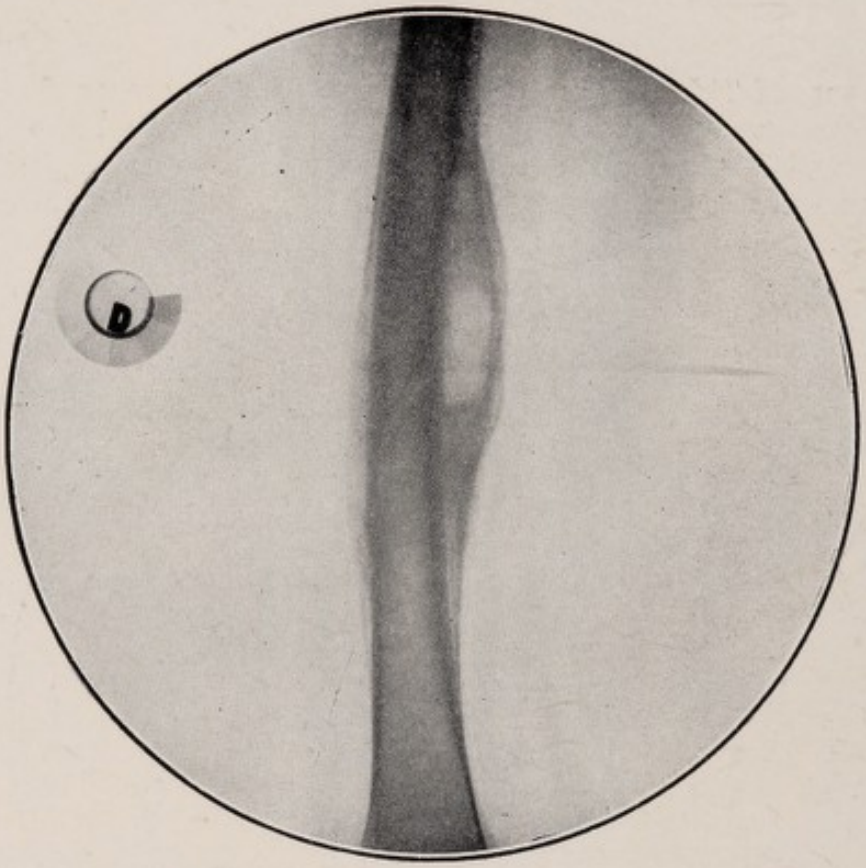

FIG. 304.—X-ray of same case as Fig. 303, showing appearance of fracture eight weeks after injury.

The clinical and X-ray appearance of the severer cases, where the patient has reached adult life, may be indistinguishable from chronic arthritis deformans with osteophyte formation.

Diagnosis.—The history is most important and before operation *every* case of supposed knee joint tuberculosis should be inquired into as to the existence of bleeders in the family. The characteristic cases of hemophilia are slow and indolent, and almost identical with a chronic tuberculosis. The X-ray is of little help, being so often negative in early knee tuberculosis as well as in early cases of this affection. Elevation of temperature and a positive Pirquet test should be absent, and hemorrhages into the joint are almost sure to be recognized sooner or later. Males are affected in all cases, no true female bleeder being on record.[1]

[1] BULLOCH and FYLDES: Haemophilia: Treasury of Human Inheritance, VI, London, 1910.

Blood Coagulation Time.—The most important matter in the diagnosis of hemophilia is the blood coagulation time.[1] The blood is obtained from a vein by puncture, quickly and with as little trauma as possible to avoid the admixture of air. The apparatus should be clean and the entrance of any foreign material carefully guarded against. One centimeter of blood is withdrawn and transferred to a test-tube eight millimeters in diameter, slightly dampened with normal salt solution. The tube should not be disturbed for five minutes and the clotting time is estimated when the tube can be inverted

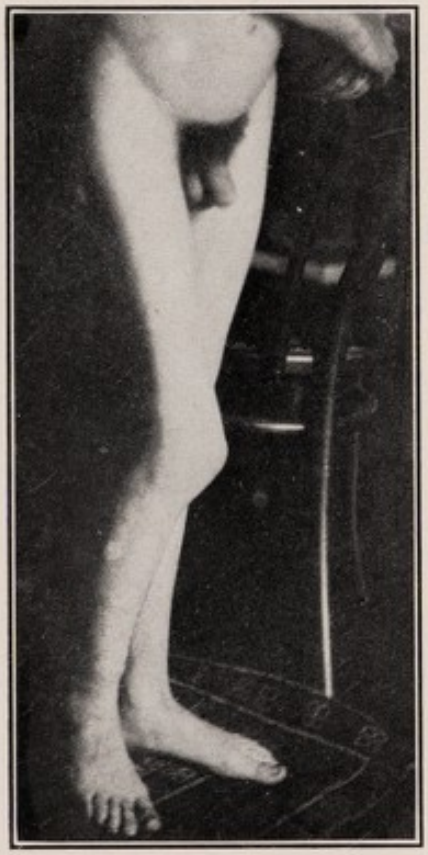

FIG. 305.—Hemophilia of right knee in an adolescent.

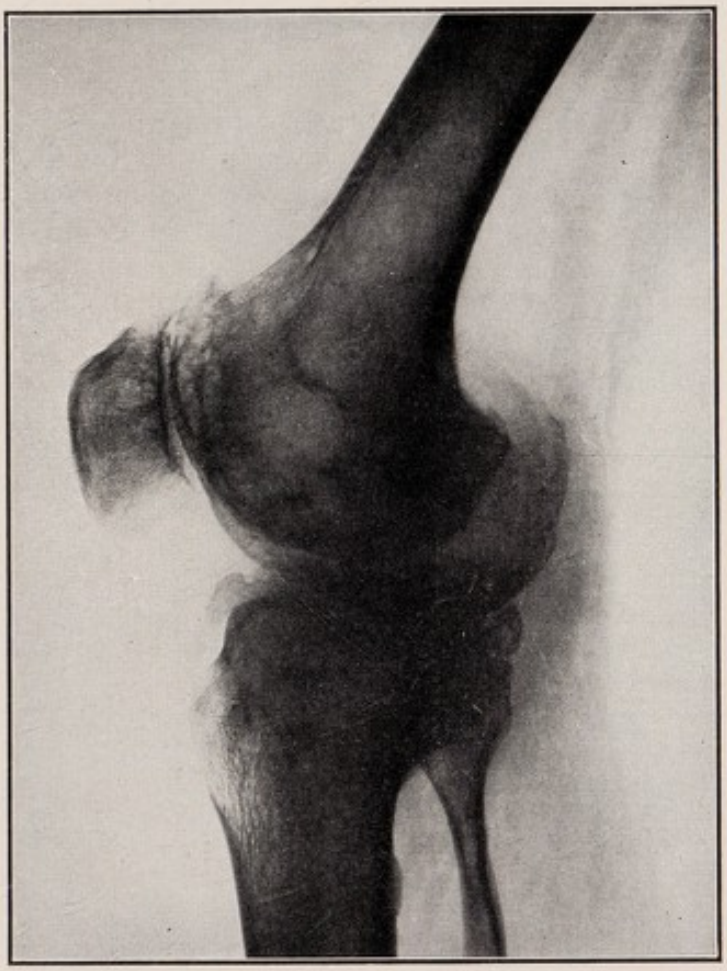

FIG. 306.—X-ray of bleeder's knee in middle aged man. Same case as Fig. 307.

without spilling the blood. Practically it is desirable to use four samples of one centimeter each, rather than one sample. The longest time that it takes the blood in any one tube to coagulate, or the average time, must be taken for the coagulation time. The admixture of air and foreign material hastens the time of clotting. Normally the tubes may be inverted without disturbing the blood in between six and twelve minutes. In hemophilia the clotting time is often an hour, sometimes several hours, and rarely as short as twenty minutes.

Tuberculosis of the knee is the chief affection to be differentiated in the early stages. After repeated attacks of intra-articular hemorrhage changes occur which simulate arthritis deformans. The real diagnosis need never be overlooked if care is used.

[1] MINOT, G. R., and LEE, R. I.: Hemorrhagic Diseases and Conditions, Nelson's Loose Leaf Medicine, 102.

Prognosis.—The outlook is for a steady increase of symptoms in those patients who survive the danger of fatal hemorrhage from incidental wounds, perhaps eventuating in a chronic arthritis moderately amenable to local measures of treatment. After operation on the knee under a mistaken diagnosis there have been numerous fatalities.

Treatment.—Fixation during the acute attacks, with protection against weight-bearing, constitutes the best treatment. In the quiescent periods the joint should be guarded by a suitable light walking splint *e.g.* a knee cage. In cases of severe hemorrhage, due to operation on a hemophilic joint, immediate transfusion with a large amount of blood offers the best remedy. The character of the individual's blood is so changed by this proceeding that the wound has a chance to heal before the blood of the patient returns to its hemophilic condition.

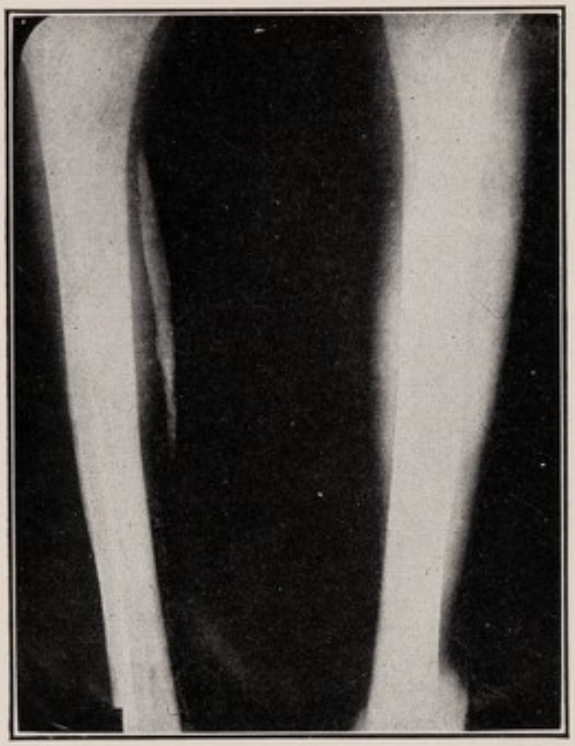

FIG. 307.—X-ray of bleeder's leg, showing incidentally new deposit of bone which was not a cause of symptoms.

Intermittent Synovitis

(Intermittent Hydrops, Quiet Effusion)

A curious type of painless synovitis occurs, most often in young adult females, in which at regular intervals from ten days to a month, one or both knee joints are rapidly distended, sometimes until they are very tense, by a collection of synovial fluid. This is not accompanied by fever, heat, pain, or tenderness. The distention causes a feeling of stiffness and discomfort, but apart from its mechanical effects there are no symptoms. When once established this affection occurs with striking regularity, and the occurrence of the effusion can be predicted with much accuracy. After one to three days the effusion rapidly subsides and disappears spontaneously, leaving behind it a joint, which from the outside feels somewhat boggy and thickened. In the interval the knees are fairly good but not quite normal, somewhat lacking in resistance, and perhaps showing lateral mobility. This is perhaps the result of continued distention and soaking of synovial fluid at frequent intervals.

The affection possesses no known pathology, the synovial membrane being normal, but rather boggy, in joints which have been explored. It has been regarded as connected with menstrual irregularity, as a trophic vasomotor neurosis,[1] as due to malaria, and as dependent on a deficiency of thyroid secretion.[2] In certain cases, however, the most detailed examination fails to show any explainable cause, for which reason no rational treatment can be formulated. Except for its very characteristic regularity it resembles in its behavior the transient angioneurotic edema occurring in other locations.

[1] KAMP: Deutsch. Med. Wchsft., Mar. 21, 1907.
[2] RIBIERRE: Bull. de la Soc. de Med. des Hôp. de Paris, 1910, xxvii.

The prognosis is not favorable for relief except in those rare cases where a definite etiological factor can be found. Fortunately the condition is not disabling. There is no known treatment of value, and routine fixation during the acute attack seems neither useful nor comfortable.

There is a type of recurring effusion of the knee joint which is due to an enlarged post-patellar pad. Apart from an occasional sharp pain, felt behind the patella, due to nipping of the mass, the joint gives rise merely to a feeling of stiffness accompanied by effusion. The condition is a very persistent one and may require operative interference. The effusion is kept up by successive traumata when walking or running, the pad being squeezed between the femur and tibia The treatment of this is discussed in Chapter III, on Disabilities of the Knee Joint (p. 38).

Neuropathic Joint Disease

A degenerative or destructive joint affection may occur in connection with locomotor ataxia, syringomyelia,[1] or other lesions of the central nervous system.

The affection, which is most often associated with tabes, is in many respects similar to arthritis deformans but is more destructive and less formative. The synovial membrane is thickened, the cartilage disintegrates, the ligaments become disorganized and luxation may occur. Osteophytes may be present.

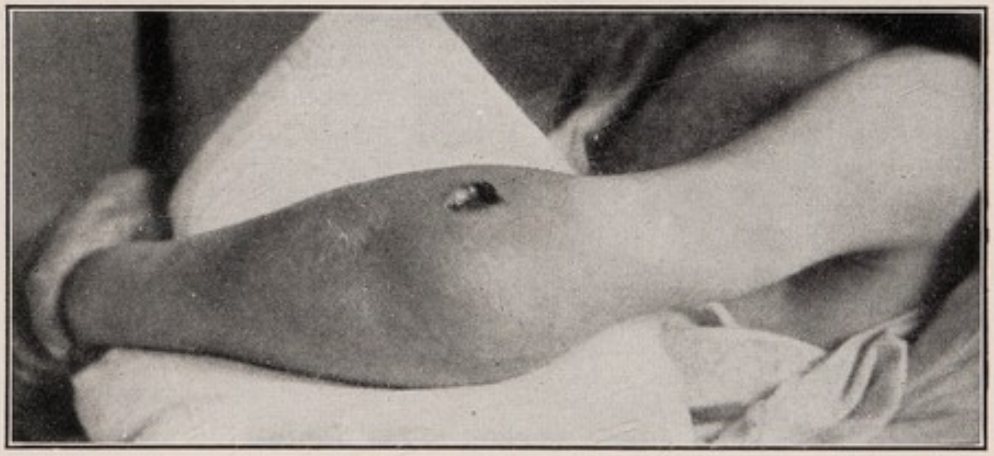

FIG. 308.—Charcot's joint disease of elbow—a piece of tissue had been removed, as a diagnosis of sarcoma had been made before the patient came to the hospital.

The most striking feature of the condition as shown by X-rays is the extensive destruction of the ends of the bones of the affected joints. This takes place without any atrophic bone changes, indeed frequently with an increased density of the bones. Additionally in many of the cases associated with the destructive changes, large irregular masses of new bone are thrown out around the remains of the joint. This disintegration occurs without much pain. All cases in which the X-ray shows a badly disorganized joint with hypertrophic and atrophic bone changes, and in which the condition is more or less painless and chronic, suggest a neuropathic arthritis.

The affection is more often monarticular and adults as a rule are affected. The knee, hip, shoulder, tarsus, elbow, ankle, and wrist are affected in the order named. In tabes the arthropathy commonly involves one of the joints of the

[1] SOKOLOFF: Deutsch. Zeitsch. für. Chir., 1892, 505.

lower limb (Charcot's joint); in *syringomyelia* the elbow or shoulder is usually affected.

Swelling and disability are the common symptoms and there is as a rule but little pain; spontaneous arrest may occur but the outlook in general is for a progressive destruction. Clinically one finds a dense swelling involving the joint, not uniform in character but containing harder masses, and the joint is apt to be abnormally loose. The diagnosis should rarely be in doubt. Treatment—in the majority of cases conservative measures must be adopted. The disorganized semi-flail joint should be controlled by a suitable apparatus. For the knee, a cage or a Thomas caliper splint is required, and for the hip a caliper or other weight-bearing splint.

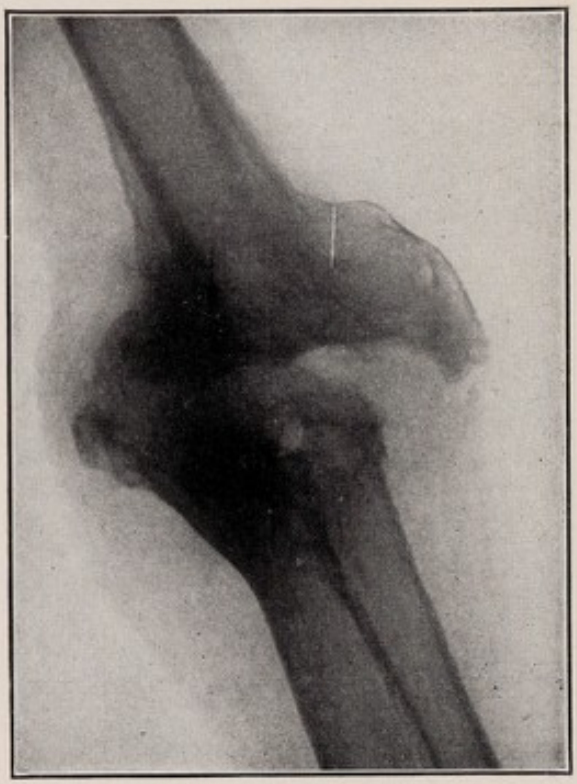

FIG. 309.—Charcot's disease of the elbow (case of Dr. W. J. Taylor of Philadelpia).

Operations for stabilizing neuropathic joints are occasionally practicable, but should not be lightly undertaken. Ankylosis, which is difficult to produce has been successfully obtained in the ankle, but rarely in the knee. Operations upon Charcot's joint have as a rule proved of little value.

Gout

This form of joint affection is more common in Great Britain than in America, although a careless diagnosis of gout is constantly made, not only by the patient but by the physician in cases of chronic arthritis. The pathology of the affection consists of the deposit of crystals of urate of sodium about the joints most often of the fingers, toes, ankles, and knees. In the acute attack the synovial membrane shows the appearances of acute inflammation with a thickening which becomes permanent in chronic cases. The cartilage shows a tendency to inflammatory degeneration and erosion, and in it as well as in the capsule and periarticular structures there occurs a deposit of urate of sodium crystals with local deposits known as "tophi."

The *symptoms* of gout are distinctive. It may attack any joint, but is usually associated with the metatarsophalangeal of the great toe or the metacarpophalangeal of the thumb. It is usually accompanied by effusion and is commonly characterized by a sudden onset and often develops in the middle of the night. The pain is often most intense, the skin itself being very tender and the affected joint almost at once assumes a red, shiny appearance. There is a certain amount of edema and the veins become prominent. Its disappearance is often as sudden as its onset, but at times on the cessation of the acute symptoms the joint remains swollen and sensitive. An attack of gout is very often induced by trauma.

The local *treatment* consists of rest to the part and hot fomentations. A bar across the boot, one-half inch thick, and placed well behind the metatarsophalangeal line often enables the victim to move about earlier.

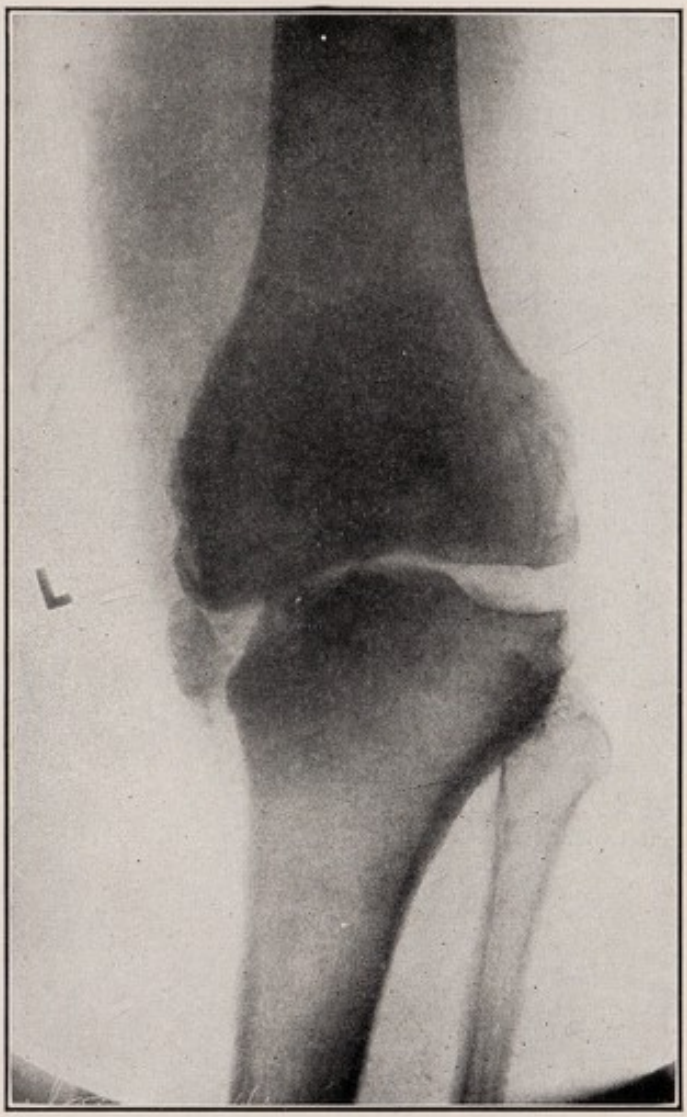

FIG. 310.—Chronic destructive disease occurring in the knee joint of a male patient, forty-five years old, with general paresis (Boston Psychopathic Hospital)



FIG. 311.—Knee joint with gout.

Tumors of Joints

Synovial membrane and capsular tumors are rare, but from time to time cases are seen which offer considerable difficulty in differential diagnosis. Of seventeen joint tumors analysed in 1922 by Hartman,[1] fifteen involved the knee, and two the ankle.

The *simple* tumors on record are chiefly angiomata, giant cell tumors (myeloid type), or myxomata, which may appear as localised pedunculated growths, or may invade the synovial membrane diffusely (Bolognesi).[2] Sarcoma of the connective tissue type is the only *malignant* tumor of importance, and may arise in the joint capsule in preference to the synovial membrane itself.

The *clinical picture* is variable. In the diffuse tumors the signs are those of a subacute synovitis, and the diagnosis of tuberculous arthritis may seem likely. Localised tumors in the knee may give rise to symptoms suggesting internal derangement of the joint, and a definite shadow may be demonstrable in a radiogram (Osgood).[3] In an angioma superficially placed, the characteristic shrinkage and expansion which occur on pressure may be demonstrable. The diagnosis of a joint tumor is usually settled by an exploratory operation. Excision of a pedunculated growth, complete synovectomy in the diffuse type, and amputation in sarcomata, are the recognised methods of treatment.

[1] Hartman, T. W.: Surg., Gyn., and Obstetrics, Vol. XXXIV, No. 2, February, 1922.
[2] Bolognesi, G.: La Chirurg. degli organi di Movimento, Vol. VI, No. 1, February, 1922.
[3] Osgood, R. B.: Surgical Clinics of N. America, Vol. 1, No. 3, June, 1921.

CHAPTER XVI

DEVELOPMENTAL DISEASES OF BONE

The bony framework of the body is a vital structure which may undergo great transformation in response to disease, malnutrition, the influence of hormones, trauma, infection, and variations in functional activity. In normal circumstances even adult bone is in a state of flux; throughout life there is a continual breaking down, rebuilding and remodelling. Growing bone is much more delicately balanced, and under the influence of the factors already quoted may show the most extreme changes either localised in one region, or widespread over the entire skeleton.

In the recognition and diagnosis of affections of bone, the radiographic appearances are of primary importance. But a blind reliance on radiographic signs alone will lead to serious error. The changes in bone demonstrable by this method of examination are those which concern bone as a *substance* and not as a *tissue*, for it is the inert framework of lime salts which alone is reproduced as an opaque shadow. But from the behaviour of this framework, an opinion may be formed on the underlying morbid change as it affects the vital cellular elements of bone. Three types of radiographic change present themselves for recognition and description. 1. *Diminution in lime content* (Atrophy, Osteoporosis). This consists chiefly in a diminution in density of the bone shadows. Cortical bone may be reduced to a thin white line, and the cancellous trabeculae may be attenuated almost to the point of disappearance. It must be remembered that atrophic bone does not change its inherent characteristics; its chemical composition, relative breaking strength, and power of repair, remain. Bone atrophy is an active process, but is not a specific change; it is fundamentally an index of the degree of use.

2. *Destruction.*—Limited or extensive. (*a*) *Limited* bone destruction is seen in small patches. There is usually an actual break in the line of cortex, or disappearance of cancellous tissue. The change is seen in inflammatory lesions, the malacias, cysts, and new growths.

(*b*) In *general* destruction a larger portion of the bone is disintegrated and disappears from the bone shadow. This most often occurs at the ends of the bone where all bone structure disappears, and its most characteristic form is seen in tuberculosis. It occurs also in pyogenic infections, although here it is joined to the process next to be described, and it at times occurs in syphilis.

3. *Formative Activity.*—The shadows in both cortical bone and cancellous bone show greater density, and there may be actual new bone superimposed on the original structure. On the whole, bone reacts in response to certain specific stimuli according to a definite pattern, but considerable variations occur. This inconstancy is well demonstrated in the inflammatory lesions. In the lesions due to pyogenic infection, destruction and formation are often combined. In the chronic stage the formative change dominates the picture. In tuberculous ostitis, destruction is usually uppermost, but in certain regions

new bone formation may be conspicuous. Syphilitic bone is characteristically formative with destructive changes in the background.

Diseases of bone fall into two broad groups:

(1) Affections attacking bone in the *growth* period, and

(2) Affections of *adult* bone.

A convenient classification of the generalised affections of the skeleton is given in the following table (Fairbank[1]):

General Affections Of The Skeleton

Congenital Developmental Errors—	
Osteogenesis imperfecta	Craniocleido dysostosis
Diaphyseal aclasis	Ateleiosis
Dyschondroplasia	Myositis ossificans idiopathica
Errors of Metabolism—	
Scurvy	Dwarfism associated with:—
Rickets	1. Coeliac disease
Renal dwarfism	2. Pancreatic disorder
	3. Hypertrophic cirrhosis of the liver
Endocrine Errors—	
Giantism	Osteomalacia
Acromegaly	Dwarfism and infantilism of various types.
Mollities ossium	
Affections of Unknown Origin—	
Fibrocystic disease	Osteitis deformans
Leontiasis ossea	Arachnodactyly
Multiple Neoplasms.	

AFFECTIONS OF GROWING BONE

In considering the developmental bone affections there are two classes of conditions: (1) Those where the affection is clearly of *congenital* origin, of which chondrodystrophia fœtalis is an example, and (2) those where the affection begins after birth; of the latter, rickets is the chief example. On account of its more practical aspect, rickets will be considered before the bone affections of congenital origin.

When the epiphyseal cartilage has ceased its function it unites with the shaft and growth in length stops. Growth in circumference, however, under pathological conditions my occur at any time, as in osteomyelitis and syphilis. Rapid epiphyseal growth is favored by prolonged hyperemia of the epiphyseal neighborhood, as in chronic disease of the joint, and is delayed (1) sometimes by general causes as in severe infectious illnesses in early childhood, causing a general retardation of body growth, and (2) by local causes, either developmental or infectious, which impair epiphyseal growth or destroy part of the epiphyseal cartilage. The destruction of part of an epiphyseal cartilage while the remainder is intact means angular deformity from the growth of one side, and the failure of growth on the other.

The first epiphysis to appear is the lower epiphysis of the femur, then the upper epiphysis of the tibia, while the other epiphyses at the ends of the long bones appear later and are variable in the time of their appearance.[2]

[1] Fairbank, H. A. T.: Brit. Jour. Surg. xv, 57, 1927.

[2] Rotch: "Roentgen Ray in Pediatrics," 13.

RICKETS

Rickets as a clinical entity was first accurately described by Glisson in 1650. It is a constitutional affection of infancy and childhood, and belongs

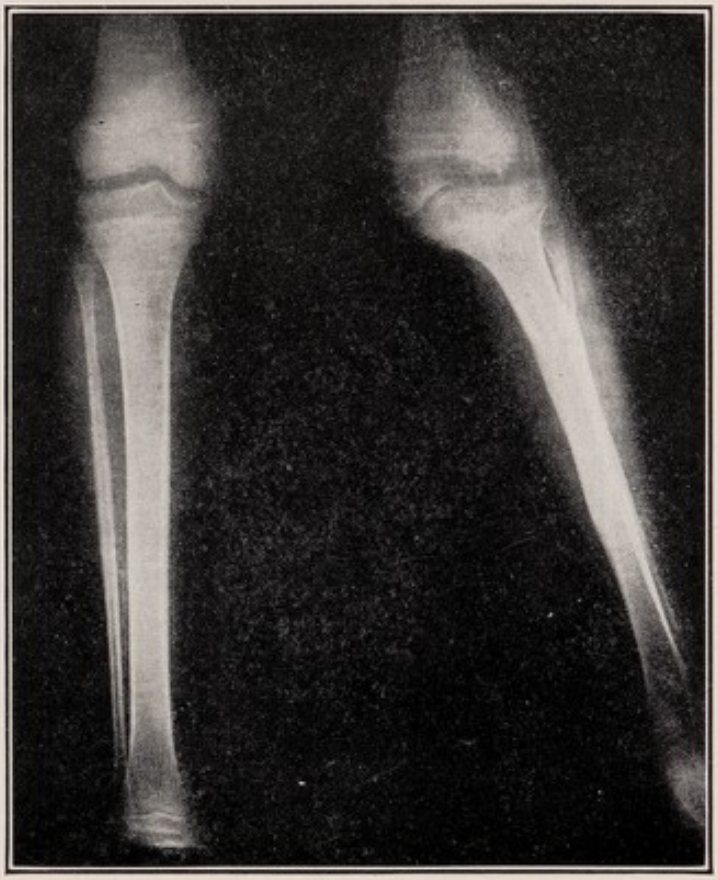

FIG. 312.—X-ray of dislocation of the lateral condyle of the femur on right of picture, causing knock-knee.

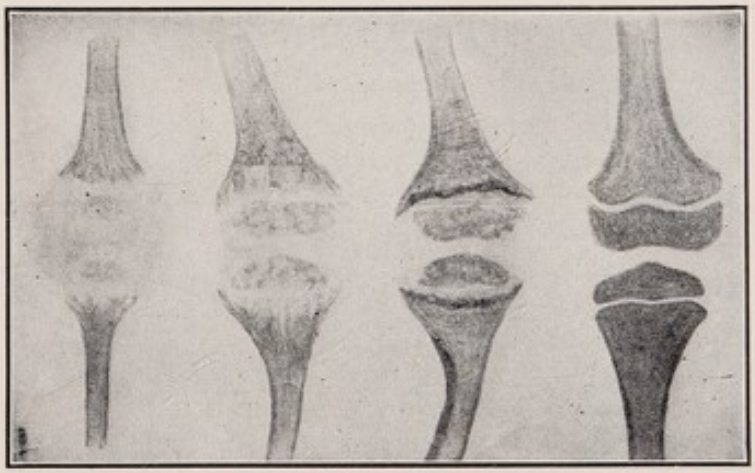

FIG. 313.—Diagram of rickets, showing the three stages as indicated in the X-ray—earliest stage on left of picture. Normal knee on right.

to the group of deficiency diseases. In recent years much information has come to light concerning its etiology. The disease is easily induced in young animals (*e.g.* rats or puppies), and just as easily cured by appropriate treatment (Mellanby, Shipley et al.).[1] In the child, rickets is primarily dependent

[1] MELLANBY, E.; SHIPLEY, et al.: British Medical Journal, 1924 and many other papers.

on the interaction of a number of factors which have been studied experimentally. These are (*a*) a diet deficient in the anti-rhachitic vitamins, (*b*) lack of exercise, and (*c*) lack of radiant energy (sunlight).

Pathology.—The characteristic changes in the bones are diminution of the earthy substances and an increase in osteoid tissue. The essential features of the process are an exaggeration of the processes preparatory to the development of true bone, but even this modification of the normal is irregular and erratic. If bone in the acute stage of rickets is cut across, it is noted that the periosteum is increased in thickness and adherent to the underlying softened and spongy tissue and that the medulla occupies more space than normal and is abnormally vascular. The most characteristic change however is in the

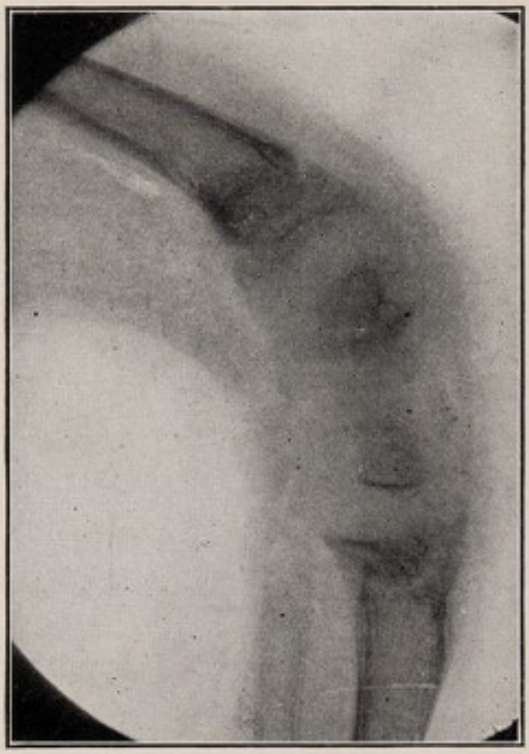

FIG. 314.—First stage of rickets.

epiphyseal cartilage, which is thickened and vascular; it is less translucent than normal and on microscopic examination of this region, marked irregularity in the size and shape of the columns of cartilage cells is noted, the same irregularity being noticed in the newly formed tissue in the medulla. The zone of calcification is lacking, or ill-defined, and the periosteum is definitely thickened along the shaft. The bone in certain of the early acute cases is brittle and prone to spontaneous fractures; this type is spoken of as the florid type.

As a result of this softening process of bone, due to imperfect deposition of lime, the deformities of rickets occur in response to mechanical causes. These mechanical causes are the abnormal deflection of body weight, muscular tonus, attitudes assumed by the child, atmospheric pressure on the chest, and similar causes which exercise the distorting pressure upon the softened bones. When the acute process is over, an abnormally rapid deposit of lime begins in the osteoid tissue and the bones become abnormally dense, being almost ivory-like in hardness; such bone is spoken of as eburnated.

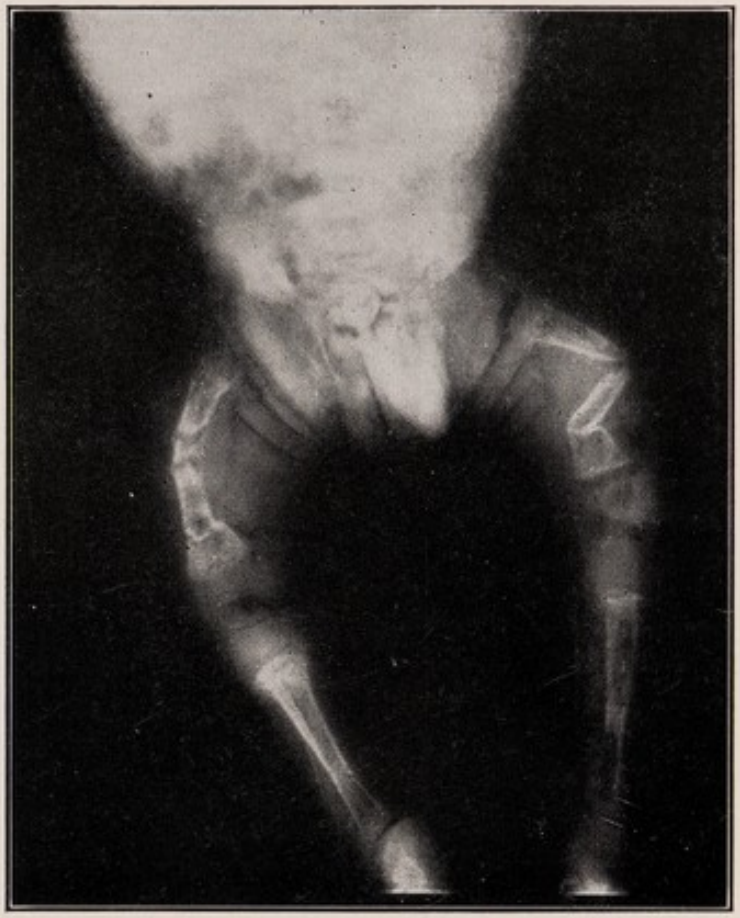

FIG. 315.—X-ray of multiple fracture in rickets, first stage.



FIG. 316.—X-ray of second stage of rickets.

X-ray.[1]—The X-ray changes are characteristic and important. In the *acute* stage the epiphysis does not present a definite rounded bone shadow as it should, but this is replaced by a cloudy area containing one or more vague centers of ossification. The end of the diaphysis is not sharp, but frayed out and deficient in lime shadow. In certain types of the acute stage, marked increase in the periosteal shadow occurs in the shaft showing a thickened, soft periosteum, and fractures in the long bones are frequently seen.

In the *second* stage, the epiphysis itself presents a mottled, irregular, ill-defined shadow with diminished lime content. The edge of the diaphysis remains ragged, but is broader than normal running out on the side where the pressure is greatest. This is apparently because the bone is of a poor quality and more of it is needed to perform function; *e.g.*, in bow-leg the supporting broadening of the diaphysis at the knee will be at the inner side of the femur and tibia. Periosteal thickening has disappeared, but if the curvature has occurred, the cortical part of the bone will be seen to be *thickened on the side of the concavity of the curve*, which is evidently a conservative measure to strengthen the part of the bone where the pressure is greatest, and this thickening is strictly endosteal (Fig. 316).



FIG. 317.—X-ray of third stage of rickets.

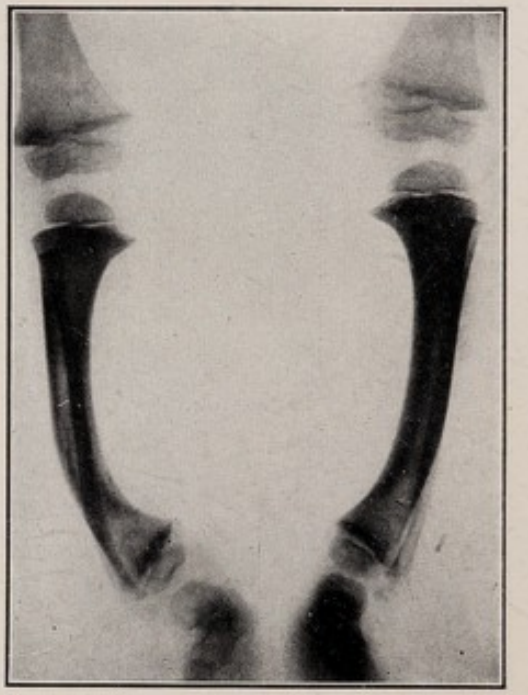

FIG. 318.—X-ray with process of rickets nearly completed.

In the *third* stage the lime shadow throughout the bone becomes stronger and at the end of the diaphysis a white line occurs which is due to the deposition of lime in the end of the bone, which is often spoken of as characteristic of scurvy but it occurs frequently in rickets (Figs. 344 and 345). The shadow of the epiphysis now becomes more clearly outlined, but is still not clean cut, and is inclined to be somewhat mottled. This is essentially the stage of repair. The most characteristic feature is the marked difference between the size of the end of the shaft and the epiphysis. In normal bone of the same age the lateral diameter of the latter is the same as the width of the end of the shaft. In rickets at this stage the end of the shaft is much wider than the epiphysis.

The finished process which might be spoken of as the fourth stage presents the characteristics of the third stage with a bone of unusual shadow showing increased deposit of lime.

Diagnosis.—As the recognition of rickets in its milder grades is important, something must be said of the diagnosis of rickets.

There is as a rule a history of a period of disturbed nutrition in the child's early life, which may or may not be recognized as associated with this process.

[1] LOVETT: Jour. Am. Med. Ass'n., Dec. 11, 1915.

The teeth are late in appearing, if rickets exists early, and any child who has not cut its first teeth at the age of twelve months is, in the great majority of cases rachitic. The epiphyses at the shoulder, elbow, wrist, knee and ankle are noticeably enlarged, and this is most easily detected at the wrist. The enlargement of the epiphyses at the anterior ends of the ribs results in a beaded chain on both sides of the chest, spoken of as the "rosary." The forehead is high and prow shaped, the abdomen is generally large, and in the lower part of the thorax is a transverse curve most marked in front, below which the ribs flare out, which is spoken of as Harrison's groove.

These diagnostic signs exist apart from the outspoken deformities which are characteristic of the affection, and are mentioned because many cases of mild deformity are associated, even in the better class of practice, with mild grades of rickets which have been entirely overlooked.



FIG. 319.—X-ray of healed rickets, showing white line.

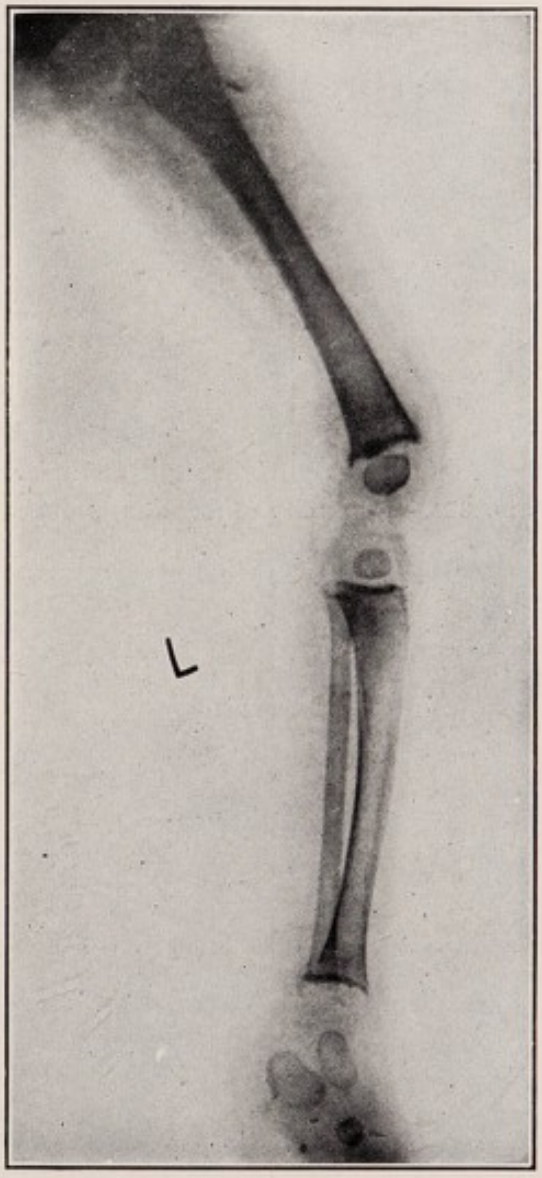

FIG. 320.—X-ray of white line of scurvy. Note that the epiphyses are perfectly formed.

Treatment.—The rachitic deformities with which the surgeon is chiefly concerned are bow-leg, knock-knee, lateral curvature of the spine, coxa vara, and deformities of the chest. Deformities of the arms, clavicles, spine, pelvis, and of practically all the long bones occur in the severer cases but are less common than deformities of the legs, are of varied character, and to be treated on general surgical principles. Although the treatment of bow-legs, knock-knee and coxa vara are of surgical interest, a very important matter lies in the prevention of deformity and its early treatment when it occurs in the acute stage of rickets. In a case of bad rickets in a child, recumbency in the open

air and sunlight, with an anti-rachitic regimen, should be carried out until the bones are hardened, which will often occur in from three to six months. This



FIG. 321.—Deformity of fore-arm, probably caused by the attitude or by lifting child by wrists.



FIG. 322.—Deformity of humeri, probably from attitude.

recumbency may be carried out on the Thomas or Bradford frame. If the bones are not hard, deformity will increase from abnormal deflection of body

weight and pressure, and, under the same conditions will return after operation if one operates too early. The X-ray is of the greatest value in determining the condition of the bones and one should warn against operation, especially cutting operations, before the lower epiphysis of the femur, which is a very good index, throws a fairly definite shadow.

The writers would insist on the following sequence in the prevention and treatment of rachitic deformity which holds true from the earliest to the latest stages.

The schedule of treatment should be as follows:

(*a*) Preventive during the acute stage. Anti-rachitic diet. Cod liver oil, sunlight, and mercury vapor lamp radiations.

(*b*) Recumbency in open air. Massage and sunlight.

(*c*) Deflection of body weight by boots, exercise, and avoidance of harmful attitudes.

(*d*) Manipulation and splints.

(*e*) Correction under anesthetic and plaster.

(*f*) Osteotomy.

BOW-LEG

Synonyms.—Genu varum—genou en dehors—ginocchio varo.

The term "bow-leg" is applied to an outward curve of the leg, involving either the tibia or the whole leg. A forward curve of the leg is spoken of as anterior bow-leg. It is a common deformity in children and is nearly twice as frequent as knock-knee. In 12,700 orthopedic outpatients applying at the Children's Hospital, Boston, there were 1000 cases of bow-leg with 750 of knock-knee. In 1887, Whitman noted among 2000 adult males observed in the streets of Boston, 400 cases of bow legs and 32 cases of knock-knee. It is more commonly double than single, and starts and occurs during the acute or subacute stage of rickets, so that it is essentially an affection of young children.

The deformity is due to a yielding of softened bone under body weight, or is a result of pressure exerted in some posture habitually assumed. The curve appears to be due more to a general yielding of the bone without fracture, although in certain cases the X-ray appearances indicate strongly that one or more greenstick fractures have occurred, generally at the point of greatest curvature. Bow-leg does not occur in healthy children as the result of walking too soon, and its existence is presumptive evidence of some degree of rickets.

Symptoms.—Bow-leg is evident from inspection, as the normal child can stand touching the knee and ankles together at the same time without effort. The curvature may be confined almost entirely to the tibia, or to both femur and tibia, or may be expressed by an outward yielding at the knee with the bones above and below fairly straight, or in rare cases may be most marked in the femur. In addition to the outward curve, there is always in bow-leg of any degree where the tibia is affected, an inward rotation of the lower end of the tibia in relation to the femur. This is because a three-cornered flexible rod, whether it be bone or rubber, cannot be bent laterally without rotating. As a result of the outward bend and the inward rotation, the child is likely to toe in, in walking, and to walk with the legs wide apart; the center of gravity is consequently disturbed so that when weight is borne upon one leg a noticeable waddle is present, often resembling the gait in double congenital dislocation of the hip. The other signs of rickets would of course be present.

Anterior bow-leg may exist alone or in conjunction with lateral bow-leg. The amount of deformity is rarely so great as in the lateral form, but it is much more resistant to treatment. In consequence of the abnormal deflection of body weight in this position the feet are almost invariably flattened.

Diagnosis.—The diagnosis of bow-legs should offer no difficulty, is made by inspection, and if necessary by identifying and defining the curvature and other characteristic signs in an X-ray and identifying the signs of general rickets. Young babies occasionally are brought to the attention of the surgeon because they lie in a position which gives to the inexperienced mother the suggestion of

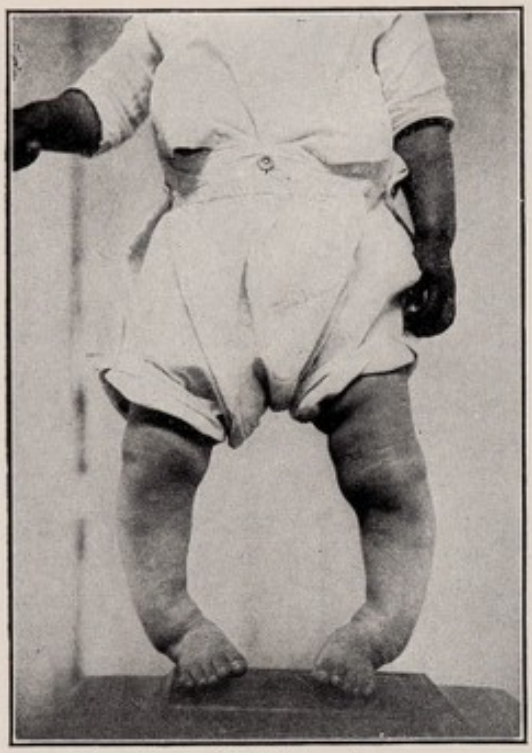

Fig. 323.—Tibial bow-leg.



Fig. 324.—Severe general bow-leg.

bow-legs, but a careful examination shows in most cases that the bones are straight, and that no deformity exists.

Osteomalacia rarely affects young children. It is not associated with the X-ray appearances of rickets. The epiphysis is normally rounded and clear from the beginning and the bone shadow is very clearly diminished.

The occurrence of multiple fractures in acute rickets is often mistaken for *osteogenesis imperfecta*, but in the latter condition the X-ray signs of rickets are not present. The epiphysis is round and clearly defined. There is no general periosteal proliferation as there always is in rickets and the whole bone is normal except that it may cast a somewhat lighter shadow than normal. *Traumatic bow-leg* with union at an angle will of course always be preceded by a history of injury and the signs of rickets should be absent. Bow-leg occurs in *ostitis deformans* and *ostitis fibrosa* which will be considered later.

In this connection one practical difficulty in diagnosis must be mentioned. Young men and young women, from seventeen to twenty, will often present themselves with a marked degree of bow-leg and the statement that it is increasing, a statement which is not confirmed by an inspection of their pictures

as children. These cases occur with such frequency in practice as to require mention.

Anterior bow-leg is closely simulated by the "sabre tibia" of *syphilis* and, aside from the stigmata of syphilis which will be present in the latter case, the syphilitic tibia also shows periosteal thickening almost always in the anterior border, whereas the thickening on anterior bow-leg is endosteal and on the concave side of the curve.

Prognosis.—Without treatment bow-leg in young children in cases of moderate degree may or may not be outgrown and in the early stage it is difficult or impossible to say which will be the case, except that the outlook for a spontaneous cure is better where the curve is general than where it is localized in the lower third of the tibia.

With treatment before the acute process is ended, bow-leg in children should practically always be cured by mechanical treatment or by repeated manipula-



FIG. 325.—Anterior bow-leg.

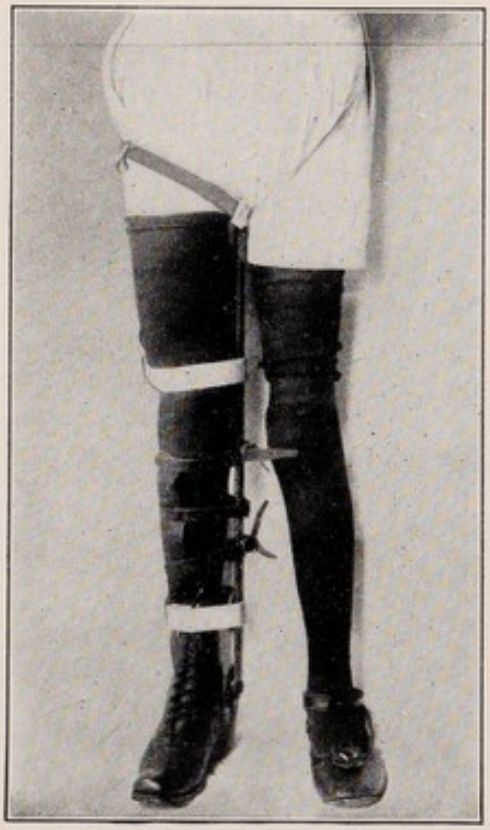

FIG. 326.—Bow-leg with brace applied (Bradford and Lovett).

tions, or in severe cases the leg can always be straightened by manipulation under anesthesia. Anterior bow-leg is much more resistant to treatment than lateral bow-leg. Much information with regard to prognosis can be obtained by a study of the X-ray when treatment is begun. The more acute the process, the better the outlook for treatment from the measures described, but when the process is finished and the bone is eburnated, little is to be expected from anything but operative treatment.

Treatment—*Expectant Treatment.*—Distorting attitudes and walking should be avoided and the legs should be manipulated several times a day by the mother in the direction of straightening them. In teaching such manipu-

lation, care should be taken that the legs are grasped in such a way that the epiphyses are not strained. In cases of bow-leg, the simplest manipulation is by pressing the legs together while the knees are straight and allowing the force to distribute itself. The curvature is recorded by means of tracing with the child sitting on a sheet of wrapping paper on a table with the toes pointing up and the inner malleoli touching. With the legs held as described, the tracing is made by a pencil held always vertical. Tracings should be taken once a month, and if the child shows a tendency to improve, the same treatment should be continued. This treatment is suitable to a large proportion of cases in young children.

If a child under these conditions fails to improve, if it is older and the process still moderately active, the application of a brace to straighten the leg is desirable. One type consists of an inside upright with a leather pad pulling to the upright over the outside of the tibia. The special type of brace to be used is not important.

Children's Hospital Bow-leg Brace.—It consists of (*a*) an upright running up the middle of the inner surface of the leg from opposite the malleolus to one inch below the origin of the adductor muscles. The top of the upright now curves around the front of the thigh in a line upward and outward to a point just posterior to the trochanter, and by bending it eversion and inversion of the limb can be secured. (*b*) The foot piece is similar in construction to that for knock-knee. A strap connects the two curved pieces at the top of the upright at the back, and a pad, furnished with two or three straps at the front and back, passes around the convexity and to the upright.

Operative Treatment.—So long as the X-ray shows evidence of incomplete ossification in the lower epiphysis of the femur, the ossification of the whole



Fig. 327.—Method of applying Rizzoli osteoclast (Bradford and Lovett).

bone is incomplete and the bone tissues unduly vascular, so that it is frequently possible during this stage to mould the bone into correct shape under anesthesia, but after correction it must be remembered that the bone is unduly soft and may yield again, and that retention by some apparatus will be necessary, and walking should be avoided.

Osteoclasis.—If the disease is arrested or finished, the deformity should be corrected at the point of greatest curvature. Although an exceptional surgeon

may be strong enough in his hands to break the bones at the deformity, the use of the osteoclast, of one of the recognized types, offers the best solution. If the bone is fractured and the position corrected, it must be remembered that the rectification of the inward rotation of the tibia is of the utmost importance and the foot should be rotated outward until it is in proper relation to the patella. The legs are retained in the corrected position for a period of from two to three months, and walking carefully regulated at first. Where it is possible the surgeon will find it expedient to take an X-ray of the bone after fracture, through the plaster of Paris bandage if that is used, or with a splint in place, in which X-ray there should be shown definite overcorrection of the deformity of a few degrees.

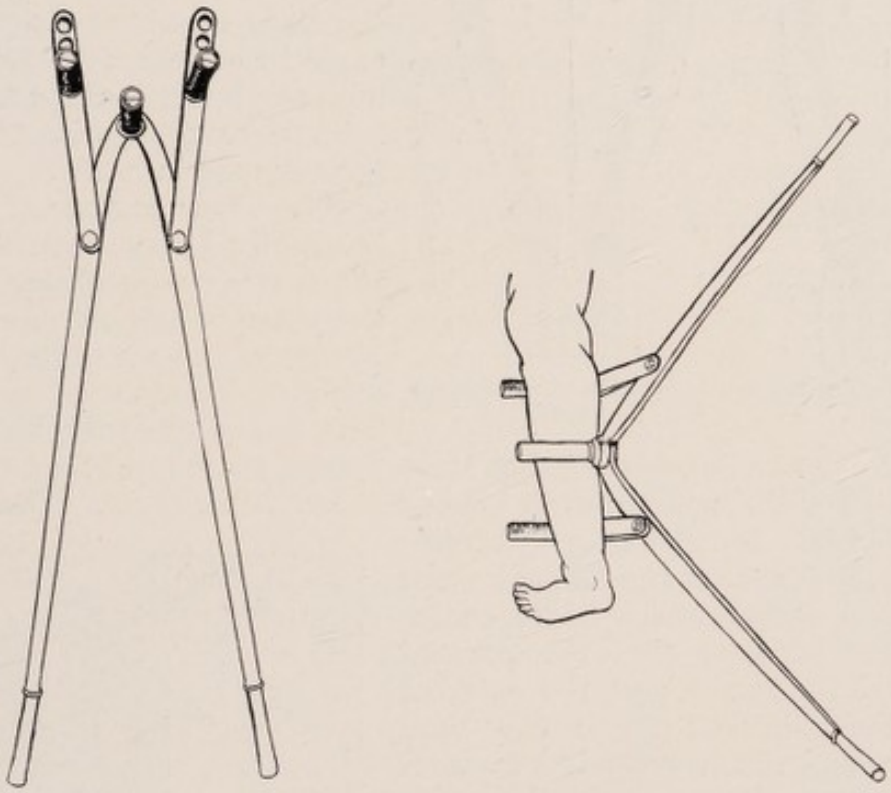

FIG. 328.—Thomas's Osteoclast.

OSTEOTOMY.—In cases of very sharp deformity, and in cases of anterior bow-leg, better results are obtained by osteotomy, or the division of the tibia by a saw or chisel than by fracture with the osteoclast because the fracture by the osteoclast often fails to localize exactly at the apex of the curve in sharp deformities, and in cases of a marked curve in anterior bow-leg, the removal of a wedge is desirable. In *genu varum* the osteotomy should be performed just below the knee; in bowing of the tibia the apex of the curve is usually in the lower third. In the latter situation the danger of delayed or non-union should be remembered. The surgeon who is uncertain just what size the base of the wedge should be has only to make a tracing of the leg laid on its side, cut out the paper tracings, and from the tracing, cut out a paper wedge of sufficient size to allow the tracing of the leg to be accurately straightened. The same period of fixation is desirable as after the fracture with the osteoclast.

The treatment of the bow-leg of rickets may then be summed up to the effect that when the process is acute the general measures are most important

and recumbency desirable; if subacute, expectant, manipulative or mechanical treatment should be used to improve the deformity, and only where there is evidence that the process is finished are operative measures in general advisable.

KNOCK-KNEE

Synonyms.—Genu valgum—genou en dedans—ginocchio valgo.

Mechanism.—The term "knock-knee" is used to describe an inward prominence of the knee, in which the lower leg deviates at an abnormal angle from the line of the femur, and in this condition the femur and tibia form an angle at the knee opening outward. This angle in normal individuals varies with the breadth of the pelvis, and is therefore more noticeable in adult females than in males.

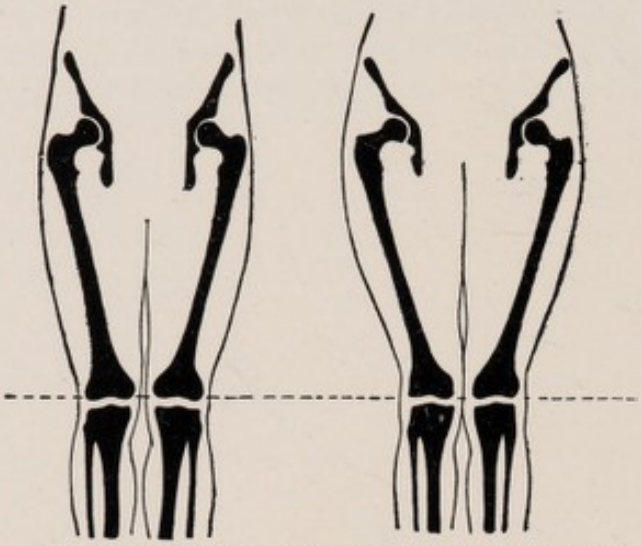

FIG. 329.—The normal inclination of the femora (Pfeiffer). Male on left; female on right.

The inner condyle of the knee is slightly longer than the outer, which is a compensation by which the plane of the knee joint is kept horizontal in spite of the somewhat oblique direction of the femur. This obliquity of the lower end of the femur must be borne in mind as an important anatomical condition which is associated with knock-knee in other diseases than rickets. These will be spoken of later. In rickets, the deformity is due to the fact that the line of weight in the femur comes outside of the center of the knee joint, so that the external condyle of the femur and the external facet of the tibia bear more weight than the inner, and if the bone is soft from rickets it is readily compressed on this side. In this way, the greater the angle that forms between the tibia and fibula, the greater the pressure upon the external condyle, and the more its atrophy. At the same time, the weight being diminished at the inner side of the knee, the internal condyle grows more rapidly than the outer. When the deformity has reached a moderate grade, the tibia begins to rotate outward on the femur, from the pulling of the external hamstring muscles, and very marked eversion with outward rotation of the tibia occurs. This is compensated for in standing and walking by the adduction of the front of the foot, which reaches in toward the median line to support the body, causing a varus position of the foot; but this is not always the case, however, as a marked flatfoot may exist in

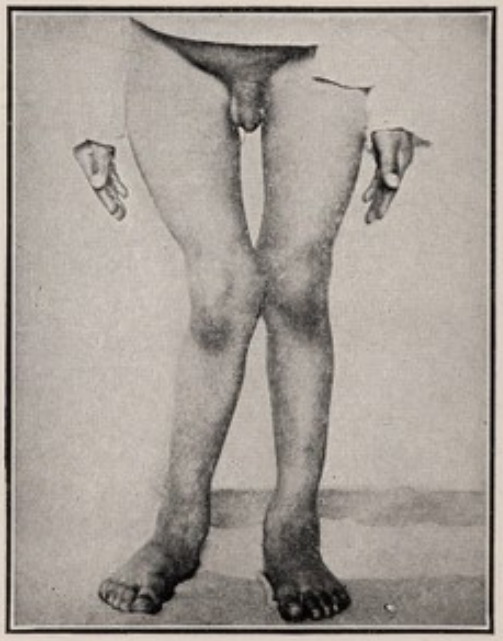

FIG. 330.—Attitude of standing in knock-knee, showing overlapping of knees.

connection with knock-knee and outward rotation of the tibia. In addition to the cases arising from the deformity at the knee joint, there are cases where the condition is largely due to a sharp curve of the femur above the knee joint, or below it, or both.

Bow-leg may be present in one leg and knock-knee in the other, or bow-leg and knock-knee may coexist in one or both legs, some bow-leg existing below the knee, and possibly above it, with a knock-knee deformity in the knee joint itself.

Symptoms and Diagnosis.—The analysis of the deformities occurring in the legs in rickets is an exceedingly complex matter. The cases differ greatly, and the only safety for the surgeon who approaches a case is to formulate it in the same way that he would estimate a malunited fracture, or a number of them in one leg, and to meet the indications for correction along sound surgical lines. A knock-knee is evident on inspection, but it is often very difficult to say, especially in children from three to four, whether the knock-knee has gone beyond the normal limits, or not. The average child of this age should be able to stand with the inner condyles of his femur and his inner malleoli approximately touching. Any marked deviation from this position technically constitutes knock-knee.

If knock-knee of any considerable degree exists, the gait is an unsightly one for two reasons: (1) If the child walks normally he is likely to knock his knees together, and to avoid this he is likely to toe in in walking, so that a flatter surface of the knees is presented when they pass each other. A degree of knock-knee is the most common cause of toeing in in young children. (2) The gait is abnormal because the line of gravity in standing on one leg in walking comes down too far to the outside of the knee joint, and the child has to throw his body over to get the center of gravity over the center of support. These two conditions made the patient walk with a lurching gait with exaggerated side sway of the body at each step for purpose of balance. In young children, stumbling and falls are frequent from knocking the knees together, and occasionally irritability and even synovitis of the knee may exist as a result of the cross strain on the joint.

Rachitic knock-knee always disappears on flexion of the knee because the deformity affects only the lower end of the condyles and does not distort their posterior surfaces. In complete flexion of the knee the lower end of the femur is of course uncovered and by fully flexing the knee and holding the femur vertical with the child lying on the back, one can sight across its contour and determine the relative length of the condyles and in this way estimate the amount of overgrowth of the internal condyle if such exists. In the normal child the internal condyle always projects farther down than the other, but in bad rachitic knock-knee the difference between the two is most striking when the lower end of the femur is looked at as described. In severe knock-knee the patient in standing has to overlap the knees, putting one behind the other, which is likely to result in hyperextension of the joint, which is carried habitually in position.

Of the conditions most likely to be confused with rachitic knock-knee, the most frequent is *loose knees* in children. Children from two to four years old, especially if very heavy, are likely to pronate their feet, and to have knee joints which are abnormally movable laterally, and generally hyperextended. If such children stand, the knee falls into a position of knock-knee, which is a

result of the lateral mobility and abnormal deflection of body weight from the pronated foot. If, however, such knees are sharply flexed while the child lies down and is examined as described, it will be found that the inner condyle of the femur when sighted across is not unduly long. The X-ray is of assistance in estimating the amount and location of bony deformities, in addition to which marked signs of rickets should be absent.

It must be remembered that rickets is not the only cause of knock-knee. The latter occurs in late *tuberculosis of the knee joint*, late in the history of bad *infantile paralysis* of the leg, and has been dealt with in speaking of these two

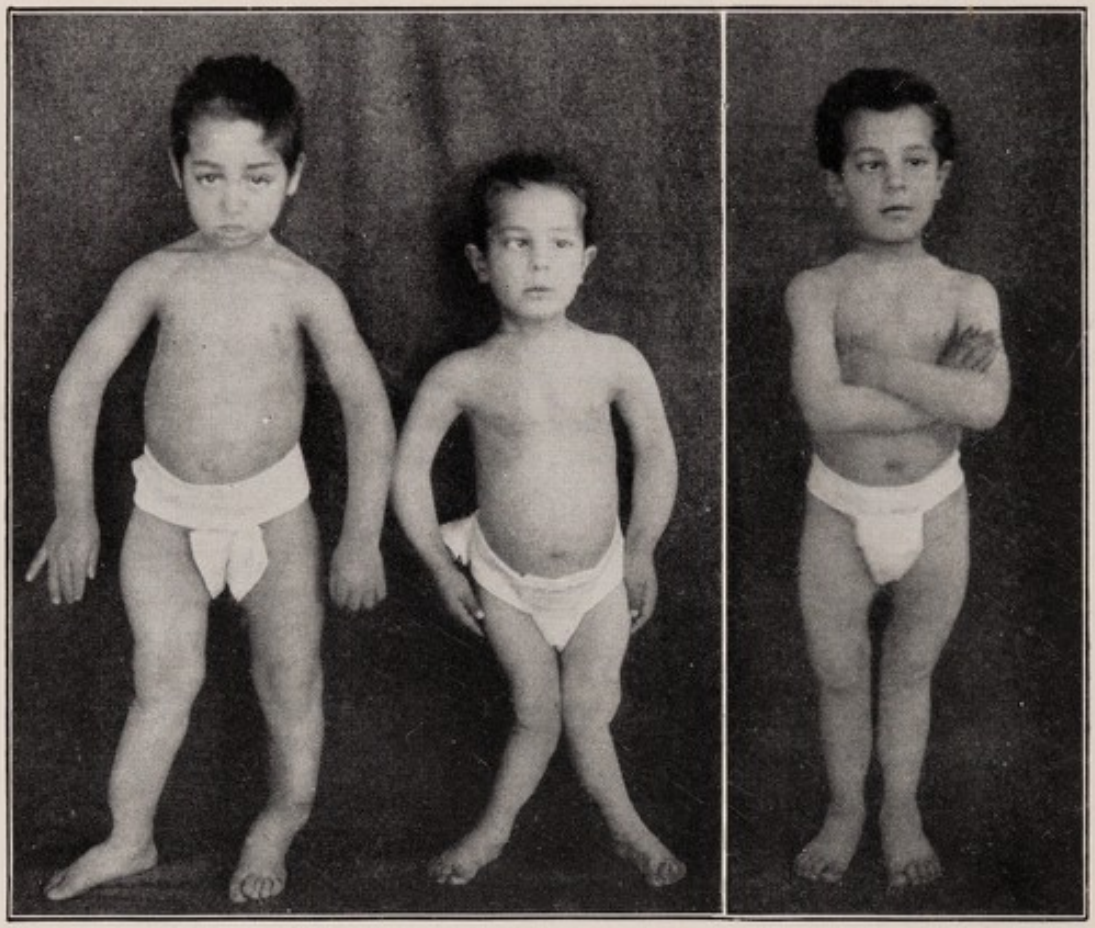

FIG. 331.—Knock-knee and bow-leg, existing in two brothers.

FIG. 332.—Smaller child shown in Fig. 331 after correction by osteotomy.

conditions. In these cases the diagnosis will offer no difficulty. It occurs also after *fracture* in the neighborhood of the knee joint with malposition, and after *epiphyseal injury* or *inflammation* destroying the outer part of the epiphyseal line at the lower end of the femur. This condition is progressive and particularly troublesome.

Prognosis.—Without treatment the prognosis in knock-knee of bony origin is not so good as in bow-leg, and although occasionally cases outgrow the deformity, any considerable degree of knock-knee in early childhood should be regarded as demanding treatment. With treatment by manipulation and braces, all moderate cases should be cured if treatment is begun before the age of three. The severe cases can be remedied by proper operation.

Treatment.—As in all bony deformities due to rickets the treatment of the general condition is most important, and an X-ray in this instance is of value in determining the stage of the process and in identifying the degree of bony deformity.

Manipulative Treatment.—When the process is still active or subacute, the best treatment in mild and average cases is as follows: Excessive walking is to be discouraged and the inner side of the heels should be raised at least a quarter of an inch to throw the line of weight farther in at the knee. The legs should be manipulated by the nurse or parents once or twice a day in such a way that the knee is straightened. The patient sits or lies with the knee extended, and in the case of the left leg the right hand grasps the lower leg just above the ankle, and the left hand is placed over the internal condyle of the left femur. By a succession of short movements, generally not severe enough to make the child cry, the position of the knee is temporarily rectified and held for a few seconds in the corrected position. This manipulation is intended to stretch the contracted external structures and to exert mild intermittent pressure upon the internal condyle. Tracings should be taken for comparison every month or two and if improvement occurs this treatment

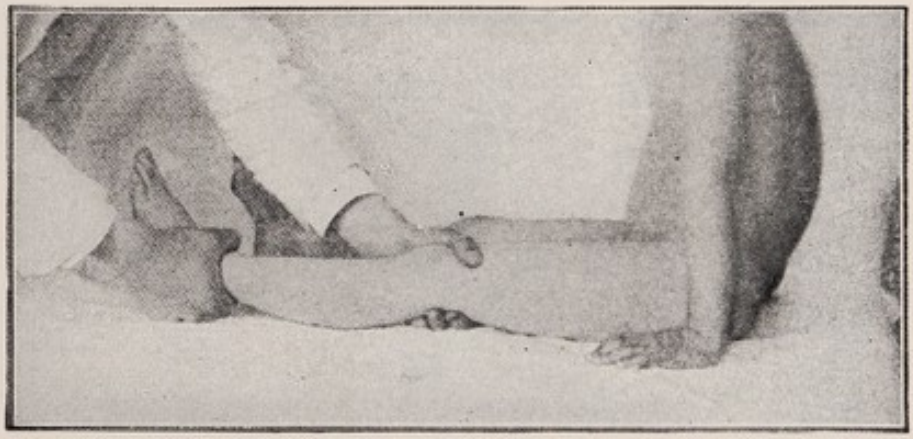

FIG. 333.—Manipulation in the treatment of knock-knee (Bradford and Lovett).

may be continued. At night time correction may be kept up by a long external splint towards which the knee is pulled by a simple bandage.

Mechanical Treatment.—In the severer cases in older children, in cases resistant to the treatment just described, and when the process has approached its close, mechanical treatment is to be substituted for that already noted by means of one of the forms of apparatus to be described.

BOSTON CHILDREN'S HOSPITAL KNOCK-KNEE BRACE.—This consists of (*a*) an upright (*b*) a foot piece, and (*c*) two posterior bands. (*a*) The upright is made of cast steel about five-eights of an inch wide for young children and runs on the outer surface of the leg from opposite the ankle joint to one-half an inch above the trochanter. The bottom part of the upright is flattened and enlarged to be jointed at the ankle to the foot piece. (*b*) The foot piece consists of a triangular piece of steel nearly as wide as the boot at its back about one and one-half inches long, terminating in an apex in front, fastened to the under side of the sole of the boot. (*c*) There should be two posterior semicircular bands made of sheet steel two inches wide curved to the thigh and calf and running around the lower third of the thigh and the upper third

of the calf. These bands are connected by a strip of steel running vertically at the back of the leg. There are two straps around the band of the thigh and calf to hold the leg in place, a pad runs from the upright around the inner side of the knee, a pad is placed over the external malleolus, and a strap runs from the posterior end of the upright around the body to be fastened in a buckle at the top of the upright in front, and by bending this arm the limb may be everted.

The reason for the posterior bands is to prevent the knee from flexing. It has been noted in speaking of knock-knee that it disappears on flexion, so that in an effective apparatus, flexion of the knee must be guarded against while corrective pressure is being made.

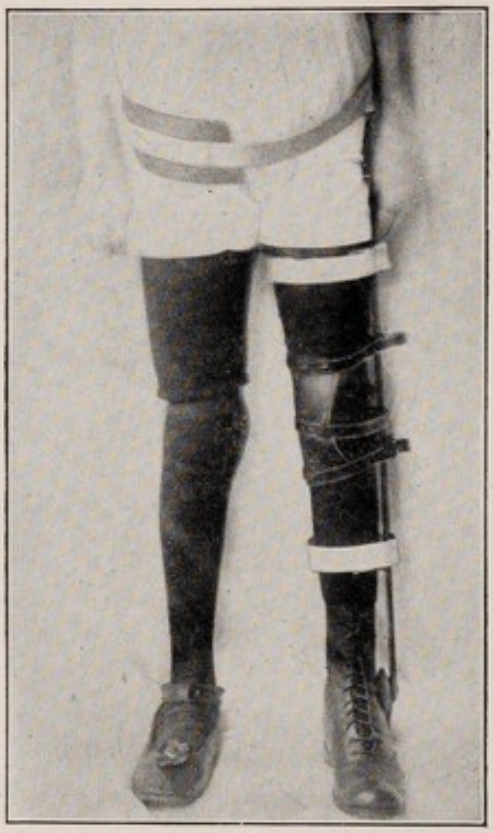

FIG. 334.—Children's Hospital knock-knee brace, applied (Bradford and Lovett).



FIG. 335.—Jones' walking knock-knee brace.

THOMAS KNOCK-KNEE BRACE.—This brace consists of a stem reaching from the great trochanter to the outer side of the boot heel. At its lower end it is turned in for one and one-half inches at right angles and fits into a tube which passes through the boot heel.

At this upper end it is hammered out flat and well padded to lie against the trochanter. A second stem reaches from the gluteal fold to the top of the boot. These stems are joined at the upper and lower extremities of the shorter one by a semicircle of flat metal covered with leather, the center of which is attached to the shorter stem. A pad is fixed behind the knee and a leather grip is attached to the outer bar and encircles the joint. A boot with the heel raised one-third of an inch in its inner border is worn with this brace.

Operative Treatment.—As long as the process continues active in any degree as shown by the X-ray, operative interference is very questionable, as in bow-leg, because the bone being still soft, the deformity is likely to recur. At the close of the active process, when the lower epiphysis of the femur has become thoroughly ossified, operation is the most satisfactory solution of the difficulty.

Manipulative Stretching Under Anesthesia.—This operation is done with a view of correcting the position and retaining the corrected position, leaving the joint to make the necessary adaptations in the matter of the shortening of the internal condyle and tightening of the lateral ligaments. If the limb is straightened under anesthesia it should be effected by a steady sustained effort, not by a sudden jerk. The surgeon grasps the extended knee on the inner side with one hand while with the other, holding the ankle on the outer side, he corrects the deviation. This pressure should be maintained until the rebound is rendered negligible. Plaster is applied which should extend from the pelvis enclosing the inverted foot. If the deformity is more pronounced the procedure may have to be repeated. This method of dealing with the deformity saves much time as compared with the use of splints.

Epiphyseolysis.[1]—A second method consists in a forcible manipulation to separate from the shaft the lower epiphysis of the femur. This is spoken of as epiphyseolysis. The patient is laid on the side with the inner condyle of the



Fig. 336.—Osteotomy for knock-knee.

affected knee resting downward on the padded edge of a table and the surgeon grasps the tibia and presses down sharply on it with the view of separating the epiphysis. In skilful hands the epiphysis separates easily and the end results show that no disturbance of epiphyseal growth has occurred. The operation has not been widely adopted. In unskilful hands it is definitely dangerous.

Osteotomy.—The femur may be divided in the supracondylar region, from either the outer or the inner side by means of the saw or osteotome. If the saw is used, the instrument should have a protected end, and be introduced through a short vertical incision one finger's breadth above the top of the

[1] Codivilla: I Kong. d. Deutsch. Ges. fur. Orth. Chir.
Reiner: Zeitsch. für Orth. Chir., xi.

external condyle. The periosteum is first elevated, the saw passed transversely across the bone, and the latter divided about three quarters through. The fracture is completed by manual force. In the Macewen method, the osteotome is used from the inner side. A small incision is made down to bone just in front of the adductor tubercle, and the osteotome inserted at right angles to the long axis of the shaft. With reasonable care the danger of injuring the vessels in the operation is negligible although occasionally the anastomotica magna artery is divided.

When the fracture has been completed the outward rotation of the lower leg should be corrected, and the leg put up in a position of mild bow-leg and maintained in this position for about three months. The retention may be effected by a plaster of Paris or a metal splint, running up the outside of the leg, to which the knee is pulled. If plaster of Paris is used, a splint ending at the groin is not always satisfactory as it obtains rather an inefficient hold on the upper part of the thigh and in young children, especially, a double plaster of Paris spica bandage is more secure. After removal of the plaster in doubtful cases the use of a knock-knee brace may be desirable for three or four months.

A cuneiform osteotomy is rarely necessary except in the severest cases. In older patients severe knock knee is occasionally best corrected by osteotomy in the upper part of the tibia.

LATE RICKETS

The condition known as late rickets is a somewhat doubtful clinical entity. The characteristic bony changes and deformities of rickets may be seen in older children or adolescents either as (*a*) a recrudescence of infantile rickets, or (*b*) as a condition arising de novo (true late rickets). It is often difficult to distinguish between the two forms. Progressive knock knee is the common deformity. The treatment is based on the principles which govern the treatment of rickets in younger children. A careful examination of the urine and a renal function test should be made in all cases where operative treatment is contemplated.

RENAL RICKETS

This condition has been much studied in recent years, but the combination of late rickets with albuminuria was first described in 1883 by Lucas.[1] The clinical picture is one of the onset towards puberty of the deformities of late rickets associated with profound muscular asthenia. There is usually marked stunting of growth (dwarfism), extreme pallor, a urine of low specific gravity containing albumin; and on testing, definite impairment of kidney function. The usual vascular signs of chronic renal disease are invariably absent. The radiographic changes resemble those of ordinary rickets, but there are certain specific features. The metaphyseal ends of the long bones usually show the most marked change, but there may be actual displacement of the epiphyses. The condition almost certainly begins in early life, and there is a stage before the development of deformities in which the following signs may be recognisable: Stunting of growth, muscular weakness and excessive thirst (Barber).[2] Towards puberty the bone deformities usually appear for the first time. In exceptional cases the complete clinical picture is seen in a younger child (Paterson).[3]

[1] Lucas, R. C.: Lancet 1883, 1, 993.
[2] Barber: Guy's Hospital Reports, July, 1926.
[3] Paterson: Proceedings of the Royal Society of Medicine (Diseases of Children Section), 1920, viii, 107.

The disease is uniformly fatal, death occurring from uraemia in the second stage. A few patients have been known to survive to the age at which the epiphyses have joined. Post-mortem examinations always reveal advanced interstitial nephritis in both kidneys. Fibrosis has also been discovered in the suprarenal glands (Ashcroft).[1] The histological changes in the metaphyseal regions differ from those of rickets. The red marrow is replaced by fat, and there is an advanced destruction of the cartilage cell columns (Brockman).[2] Operative correction of deformity is always to be condemned as many disastrous results have been recorded. Not only have the deformities recurred, but death from uraemia has been precipitated. There is little information available on the results of dietetic treatment. Ultra-violet radiation has been found to do harm in certain cases (Parsons).

Achondroplasia

(Chondrodystrophia Fœtalis,[3] Fetal Rickets)

Achondroplasia, which resembles in certain clinical respects rickets, was formerly supposed to be an intrauterine variety of it but modern investigation

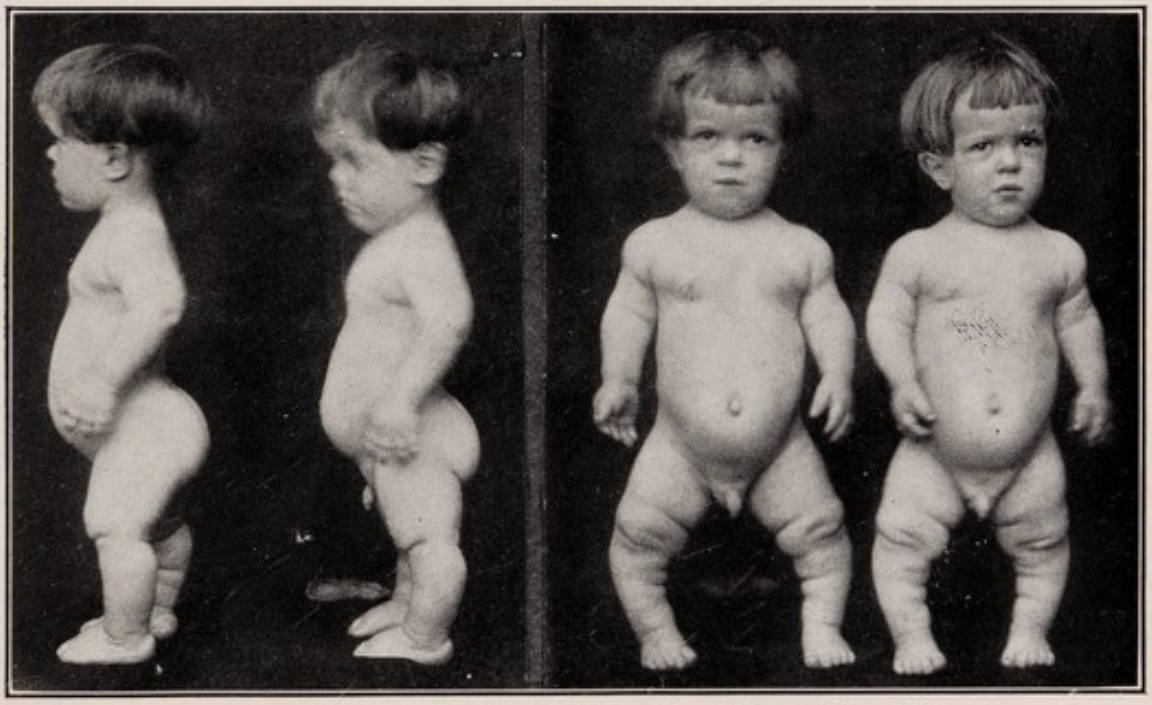

FIG. 337.—Case of achondroplasia in twins—side and front views.

has shown that it is not the result of a disturbance of nutrition, but is due to a congenital defect or interference with the development of the cartilaginous skeleton at different periods of intrauterine life.

Pathology.—The origin of the disease consists in a retardation of the growth of the bones in length, either through insufficient proliferation of the cartilage cells and early cessation of cartilaginous growth of the epiphyses (chondrodystrophia hypoplastica), or softening of the cartilage and irregular ossification (chondrodystrophia malacia) or marked proliferation of the cartilage cells and interrupted ossification.

[1] ASHCROFT: Journal of Bone and Joint Surgery, April, 1926.
[2] BROCKMAN: British Journal of Surgery, 1927, xiv, 56.
[3] KAUFMANN: Untersuch. u. die sog. fötale Rachitis, Diss. Berlin, 1892.

In the first named form there is a simple retardation of the growth in length since the epiphyseal cartilage ceases to grow, and this form resembles somewhat the similar disturbance of growth in length from cretinism. The three forms as described by Kaufmann[1] are not always distinct, but merge into one another, and changes of all three types may be present in one individual. The essential part of the process is a disturbance of ossification in those parts of the skeleton formed from cartilage, while periosteal bone formation goes on unhindered.

Etiology.—The condition is always congenital and sometimes inherited and the changes are evidently produced during the early weeks of intrauterine life and are attributed by some authors to smallness of the amnion (Jansen).[2]

Symptoms.—The condition, if not evident at birth, becomes obvious in growing children for the trunk grows much faster than the arms and legs, which



FIG. 338.—Characteristic hands in achondroplasia.

become stunted and definitely enlarged at the joints. Growth in stature is delayed as a result of the short legs, rather than of defective growth in the trunk. The head becomes brachycephalic, the vertical height is increased, and the circumference enlarged, but the intellect as a rule is unaffected. The nasal bridge is generally depressed, and the nose may be flattened. In the hands the metacarpals diverge more than is normal and the fingers do not group themselves about the middle finger, which condition is spoken of as "main en trident." Spinal malformations have not been generally discussed, but physiological curves are diminished, and in a case of one of the writers, studied by Wheeldon,[3] a definite kyphosis occurred at the dorso-lumbar junction, which resembled the deformity of tuberculosis of the spine as the vertebræ had become wedge-shaped (Fig. 339). Joint motion is restricted by the imperfect joints, and the overgrowth of bone in the region of the epiphyses. The

[1] KAUFMANN: Untersuch. über die sog. fötale Rachitis, Diss. Berlin, 1892.
[2] JANSEN, M.: Feebleness of growth, 1921.
[3] WHEELDON: Am. Jour. Dis. Child., January, 1920.

chondrodystrophic dwarf is familiar to everyone, and the Egyptian gods Bes and Ptah were evidently dwarfs of this type.

Diagnosis.—The essential clinical features are the short extremities. This difference does not become evident in the first year or two of life as growth

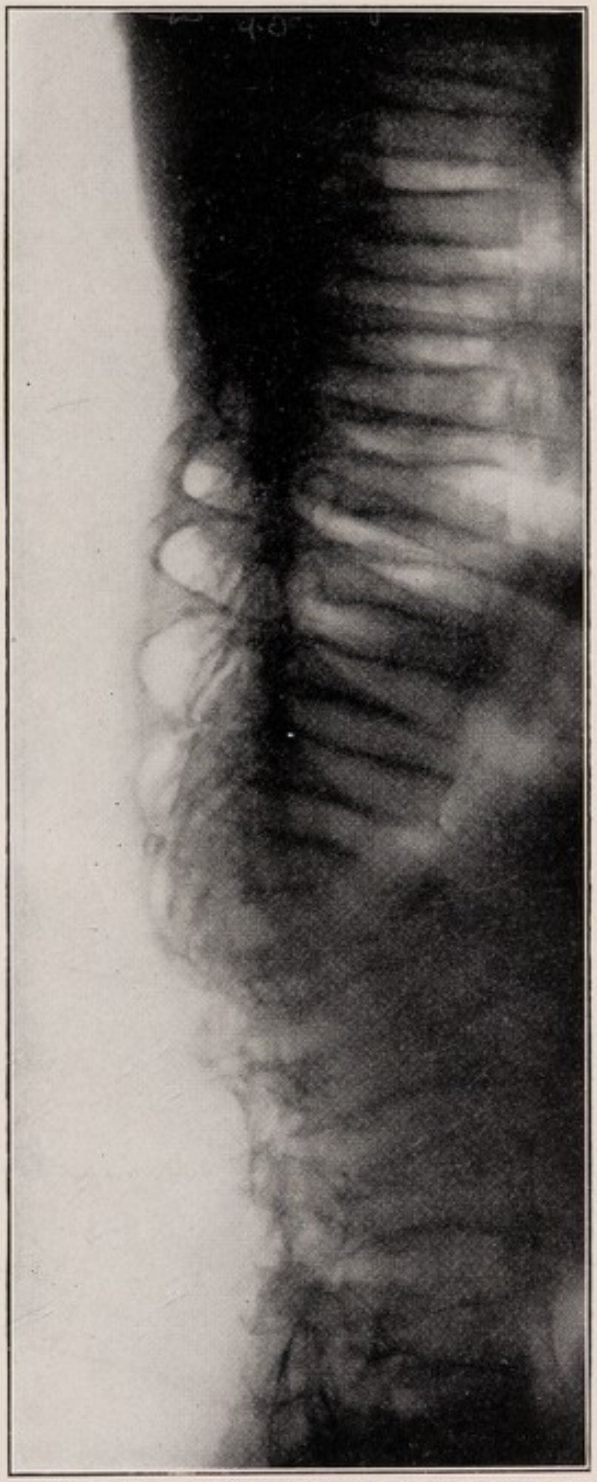

FIG. 339.—Radiogram of achondroplasic spine (C. Thurstan Holland).

has not progressed sufficiently, and at this time the condition may present a clinical resemblance to either rickets or cretinism. Later on, however, the clinical picture becomes so striking that a mistake is practically impossible.

The diagnosis from rickets in the early stages can be aided by the study of the X-ray, the two being entirely different; and in achondroplasia the epiphysis itself is clearly outlined and there is an excess rather than a diminution in early deposit of lime. The former is a premature, the latter, a delayed ossification. Cretinism is sometimes hard to distinguish from achondroplasia because the former is also a process of delayed growth due to imperfect and delayed ossification. The shape of the head is much the same, the arms and legs do not grow as they should normally and the clinical appearances may be confusing, but in cretinism there is generally a stupid look and mental deficiency, which does not exist in achondroplasia, and the X-ray appearances of the two are characteristic. In one, the epiphysis consolidates only in adolescence, and in the other in early childhood. In cretinism there is a characteristic appearance in the



Fig. 340.—Radiogram of achondroplasic hand (C. Thurstan Holland).

X-ray which is a transverse line of bone, very clearly marked, occurring just at the end of the diaphysis (Fig. 349). The chief thing to remember, however, is that in cretinism the epiphysis consolidates very late, in achondroplasia, very early.

Prognosis.—The prognosis will vary a good deal with the degree of the affection. No marked improvement is to be expected in the serious cases, and joint changes of an arthritic type occur in some cases later in life as a result of the imperfect function of the joints.

Treatment.—The ordinary achondroplasic dwarf leads an active life, and his conditions cannot in any way be altered by treatment. Occasionally a localised deformity of one limb may require attention.

Osteogenesis Imperfecta

(Brittle Bones, Idiopathic Osteopsathyrosis, Fragilitas Ossium)

This condition was separated from achondroplasia by Vrolik in 1849. The term osteopsathyrosis describes fragility of bones due to any cause and occurring at any age, and is divided into the so-called *symptomatic* cases, where fracture is due to some known pathology, as in osteomalacia, rickets, osteomyelitis, tumors, etc., and secondly into *idiopathic osteopsathyrosis*, which is the condition under description.

A considerable amount of literature on this subject has accumulated, most of which is a good many years old. In 1906 it was possible to find in literature allusions to a description of 123 cases.

Etiology.—A history of heredity is found in about 15 per cent of the cases, and the disease has been recorded as occurring in three or four generations. Apart from this nothing is known of the etiology.

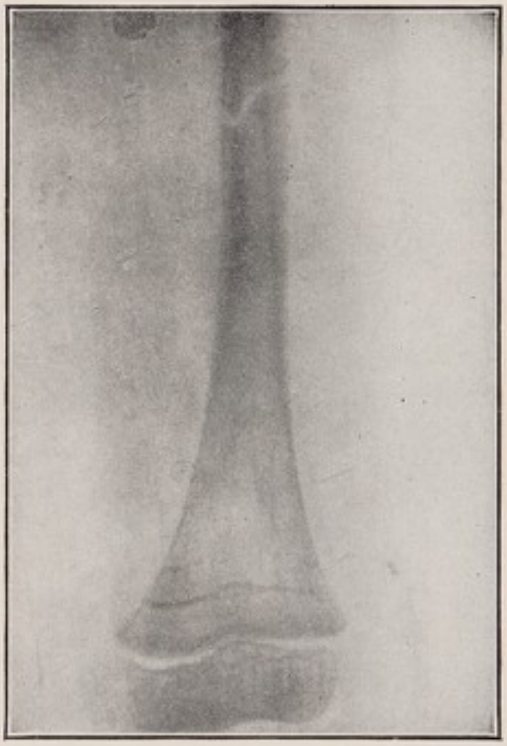

Fig. 341.—X-ray of real osteogenesis imperfecta, showing fracture at an early age with bone apparently of normal density.

Pathology.[1]—In a case studied by Lovett and Nichols it was found that, whereas in normal ossification the deposit of bone occurs in the matrix, in this case the trabeculæ were formed by direct metaplasia of persisting cartilage cells into bone. The further development of the bone trabeculæ formed in this abnormal way was as follows: The bone cells remained large and oval, showing little or no tendency to form canaliculæ and were much more numerous than normal and the trabeculæ also showed imperfect lamination. The fibrous layer of the periosteum was thicker than usual, and the deeper layer of bone-forming cells were more spindle-shaped than normal. Instead of the formation of a continuous layer of normal bone, the periosteum formed separate plates of non-laminated dense bone, in which were oval bone cells and no Haversian canals, in place of which were found marrow spaces. The trabeculæ in the medulla were much less numerous than normal, and were studded with flattened osteoblasts. The process of bone formation elsewhere was checked and of an abnormal kind.

We may recognise several clinical types, which are simply different phases of one and the same disease (Fairbank, *loc. cit.*). (1) The young infant born with multiple fractures (fetal type) affecting limbs which are markedly stunted as compared with the trunk. The long bones show enlargement of the whole of the shafts with one or more fractures. The fractures tend to unite readily with abundant callus. Such infants rarely survive for long. (2) The common type seen in older children, adolescents, and even in adults, where repeated fractures have occurred from time to time

[1] Lovett, R. W. and Nichols: Brit. Med. Jour., Oct. 13, 1906.

since infancy. In some cases the abnormal fragility of the skeleton seems to disappear, and towards adolescence the limbs become capable of bearing weight, and withstanding trauma. In others the condition becomes progressive, severe deformities result, and the patients die from intercurrent disease. The bones show a papery appearance, with a thinned out cortex, but no special alteration in internal texture. The changes may be confined to the limbs and pelvis. (3) In a third type, softened bones, with deformities or repeated multiple fractures are associated with blue sclerotics. The radiograms show marked honeycombing in the interior of the long bones. The vault of the skull is often flattened as if crushed by a superincumbent weight, giving a characteristic appearance to the head.

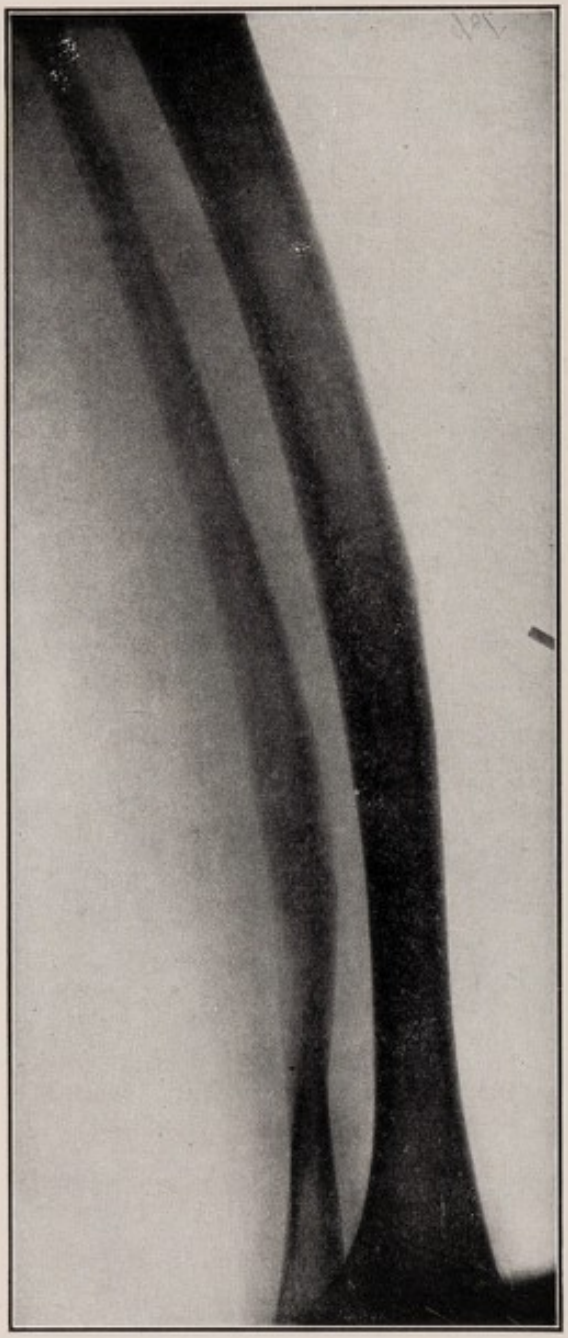

FIG. 342.—Osteogenesis imperfecta with fracture—X-ray. Same case as Fig. 341 at thirteen years of age with softened and atrophied bone.

Diagnosis.—The diagnosis in this disease is in most cases only too evident, but it is very often the case that other conditions are diagnosed as "brittle bones;" this has lead to a gread deal of confusion and an unjustifiably favorable view of the outlook in the real condition.

Differential Diagnosis. *Rickets.*—In the florid type of the early stage of rickets multiple fractures are common, and these cases outnumber enormously the cases of real osteogenesis imperfecta. When a child is found with from five to ten fractures existing in the first year, osteogenesis imperfecta is the common diagnosis made. But acute rickets accompanied by fracture is characterized by a perfectly definite X-ray picture,—there is periosteal proliferation, the ends of the diaphysis are ragged and contain little lime, and the epiphyseal body is irregular, cloudy, or absent, in addition to which the general signs of acute rickets are present. In true osteogenesis imperfecta the epiphyseal body forms normally, is clear and distinct, there is no general periosteal proliferation of bones, and the end of the diaphysis is properly formed. In acute rickets when repair has taken place fractures cease.

Osteomalacia.—Osteomalacia is in most cases a disease of formed bone, and only rarely attacks young children. The bone shadow resembles in its thinness

that of osteogenesis imperfecta, except that in the latter, fracture generally replaces bending. The process in osteomalacia is entirely different, being an absorption of lime from bone, presumably normal at the outset, while in osteogenesis imperfecta the bone was never normal. But in the experience of one of the writers two children with undoubted osteogenesis imperfecta with multiple fractures and bones casting a normal shadow at birth, in the course of eight and thirteen years respectively developed a condition not to be distinguished from osteomalacia accompanied by bending of the bones (Fig. 343).



FIG. 343.—This case started at birth with multiple fractures, but the bone cast a normal shadow in the X-ray. At eight years of age a condition resembling osteomalacia existed as shown in the picture.

Prognosis.—It is obvious from the consideration of the cause of this condition that the prognosis for recovery must be poor. Certain cases, however, apparently recover, and are little if any more liable to fractures in adult life than normal people. The tendency is, however, for fractures to continue rather less frequently as puberty and adult life are reached, but the constant fractures, the repeated confinement to bed, and the inactivity necessitated by this life, makes the outlook for a normal adult life poor. One would be influenced toward a better prognosis in cases where the number of fractures occurring before two years had been small, where there was a diminished tendency

toward them as the child grew older, and where the X-ray showed increasing bone shadow with increasing age.

Treatment.—The treatment of such children can only be conducted on general lines, with insistence on outdoor air and good muscular development as being of possible benefit. No drug or other procedure is likely to have any effect on the congenital disturbance of the deposition of lime. Fractures are treated on general principles, and in cases which have united in deformity, operative procedures may be undertaken as in a similar case in a healthy individual.

Generalised Osteosclerosis

Marble Bones (Albers-Schönberg Disease).—This is an extremely rare condition somewhat related to osteogenesis imperfecta. The outstanding

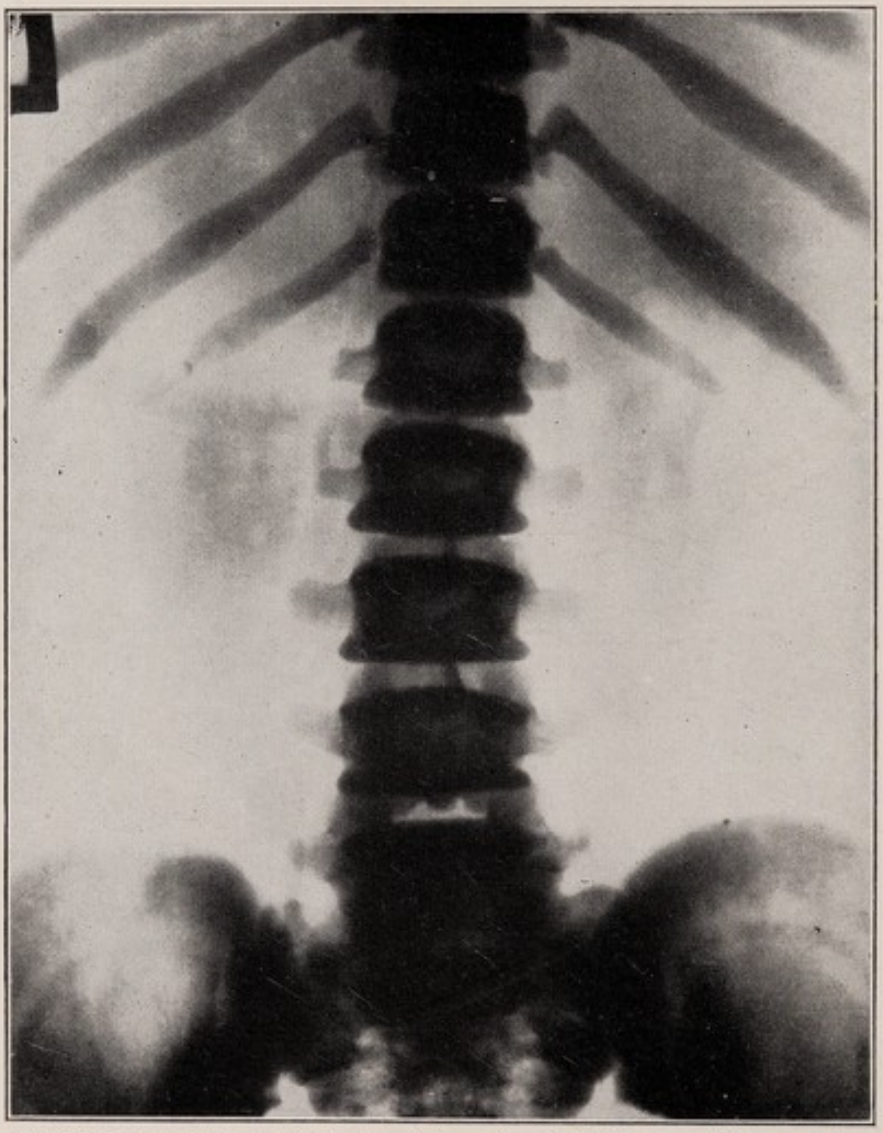

FIG. 344.—Marble bones (Albers-Schönberg disease). Girl, 7 years old; every bone affected.

feature is the gross excess of lime salts in all the bones, especially the diaphyseal ends. The affected bones show thickening of the cortex, and obliteration of the medullary canal. In radiograms the altered shadows stand out like dense plâques of metal (Fig. 344). Marked condensation occurs in the skull and face bones leading to encroachment on the nerve foramina. In spite of the sclerosis

multiple fractures may occur. There is often an enlargement of the spleen and liver, with a secondary anaemia. In the few cases on record the ages of the patients vary from three weeks to 43 years. Nothing is known of the etiology, and there is no treatment available. (Alexander,[1] Sear.[2])

Localised Osteosclerosis

Putti[3] has described two cases of an apparently new clinical entity in which there is an eburnation and sclerosis of a group of bones confined to one lower limb. Both patients were female children (aged 8 and 10 respectively). In one the condensing "ostitis" involved the ilium, pubis, femur, patella, tibia, astragalus, and certain other foot bones. In the other the change was restricted to the pelvis, femur, and one cuneiform. The radiographic appearances resemble marble bones. Léri and Johanny[4] have recorded a similar type of change in the upper limb of an adult (humerus, radius, index, medius bones). An interesting osteosclerosis limited to the forearm and hand bones, and occurring in the distribution of the ulnar nerve, has been carefully recorded by Lewin and Macleod.[5] It has been suggested that the underlying cause of localised osteosclerosis may be interference with the sympathetic nerve supply producing ischæmia (Putti).

Multiple Cartilaginous Exostoses

(Dyschondroplasia, Diaphyseal Aclasis)

This condition is a definite entity, congenital in origin, and occurring more often in males than in females. Formerly regarded as rare, in recent years many cases have been recognised and reported. (Ehrenfried.[6]) The several titles applied to this affection tend to obscure the underlying simplicity of its pathogenesis which has been so well illuminated by Keith.[7] In 1898 Ollier described a bone dystrophy characterised by dwarfing of the limbs combined with irregular ossification at the ends of the long bones, since known under the term *dyschondroplasia*. Dyschondroplasia is said to be usually unilateral, but the radiographic appearances of the affected bones are practically identical with those seen in multiple cartilaginous exostoses where symmetrically distributed over the skeleton. The two conditions are thus included under a common title. Although the existence of multiple tumors is often the outstanding clinical sign, the occurrence of such cartilaginous outgrowths is not the fundamental change. The exostoses are a secondary development. The condition shows a marked familial tendency; there are cases recorded affecting four generations.

Pathology.—The condition is essentially a growth disturbance in which the activity of both the cartilaginous and periosteal elements of the growth disc is checked. The changes occur where the two processes of membrane formation and cartilage formation come into juxtaposition, *i.e.*, at the diaphyseal ends of the long bones, and at the growing margins of the os innominatum and scapula. Purely membranous bones such as the face and vault of the skull

[1] Alexander, W. G.: American Journal of Radiology, April 1923.
[2] Sear, H. R.: British Journal of Surgery, April, 1927, xiv, 56.
[3] Putti, V.: La Chirurg: degli organ di Movimento, 1927.
[4] Léri and Johanny: Bull: et Mem: de la Soc.: Med.: Paris, 38, 3, No. 25.
[5] Lewin and Macleod: Journal of Bone and Joint Surgery, 1925, vii, 4, Oct.
[6] Ehrenfried: Jour. Am. Med. Assn., May 1915; Feb. 17, 1917.
[7] Keith, A.: Journal of Anatomy 1919–20. Vol. 54.

are never affected. This growth disturbance is most marked where growth in length is greatest; in the upper limb at the shoulder; in the lower limb, in the region of the knee. John Hunter long ago described the dual process by which bones grow in length. There is first of all the deposit of a cylinder of new bone in the diaphysis which undergoes remodelling before it is incorporated as part of the shaft. The remodelling is completed by the construction by the periosteum of a bony ferrule around the irregular cylinder. Arrest of this remodelling process occurs in dyschondroplasia and multiple cartilaginous exostoses. To this disturbance the general term diaphyseal aclasis has been applied by Keith. The absence of the periosteal ferrule is well shown in radiograms of this condition. The presence of a large mass of cartilage-formed bone at the growing ends no longer restrained by a periosteal ferrule,

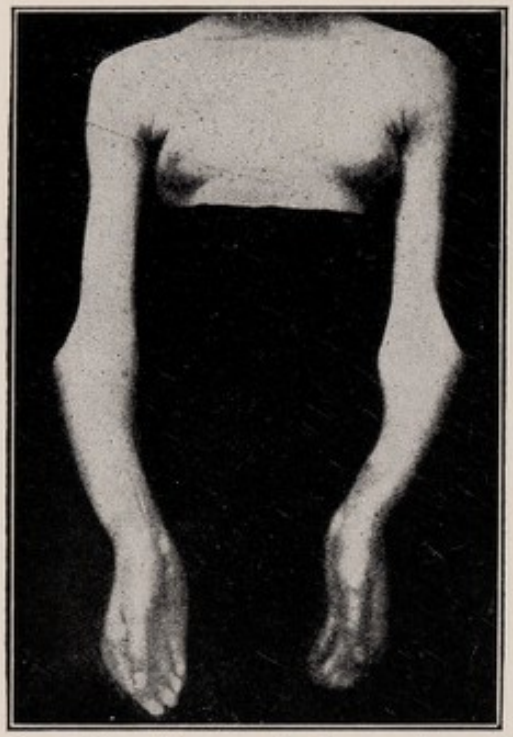

FIG. 345.—Photograph of arms of a girl, showing characteristic deformity. Note shortening and curvation of forearms, bulging in the region of lower epiphyses, and projection of head of radius (Ehrenfried).

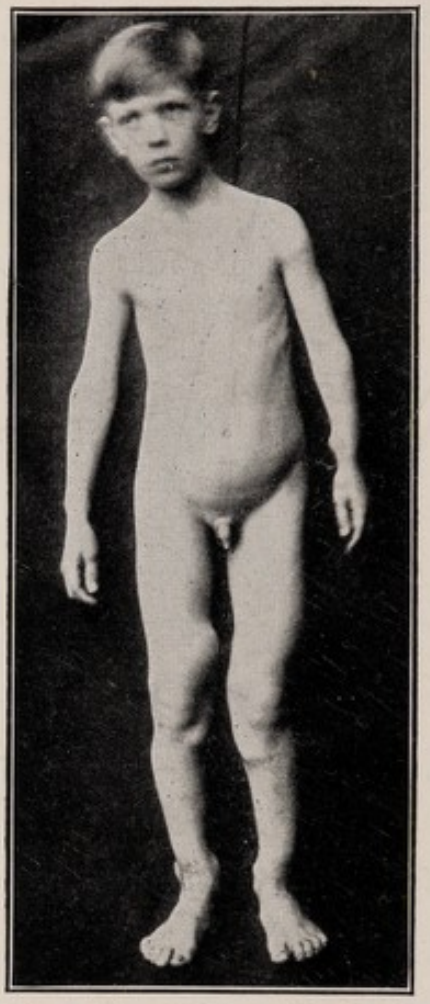

FIG. 346.—Patient with dyschondroplasia affecting practically all the joints (see Fig. 347 of same patient).

provides opportunity for the outgrowth of the multiple cartilaginous tumors. Many of the tumors remain latent until puberty. In addition to the arrest of diaphyseal remodelling, there is disordered activity in the growth disc itself evidenced by a definite stunting in the general stature. Histological examination of the diaphyseal end shows all the signs of irregular ossification. Masses of cartilage cells are intermingled with imperfectly calcified bone.

Clinical Picture.—The classical signs are—(1) The presence of hard painless swellings attached to the ends of the long bones, scapulæ, and pelvis. (2) The patients are below the average height, and the limbs are definitely stunted.

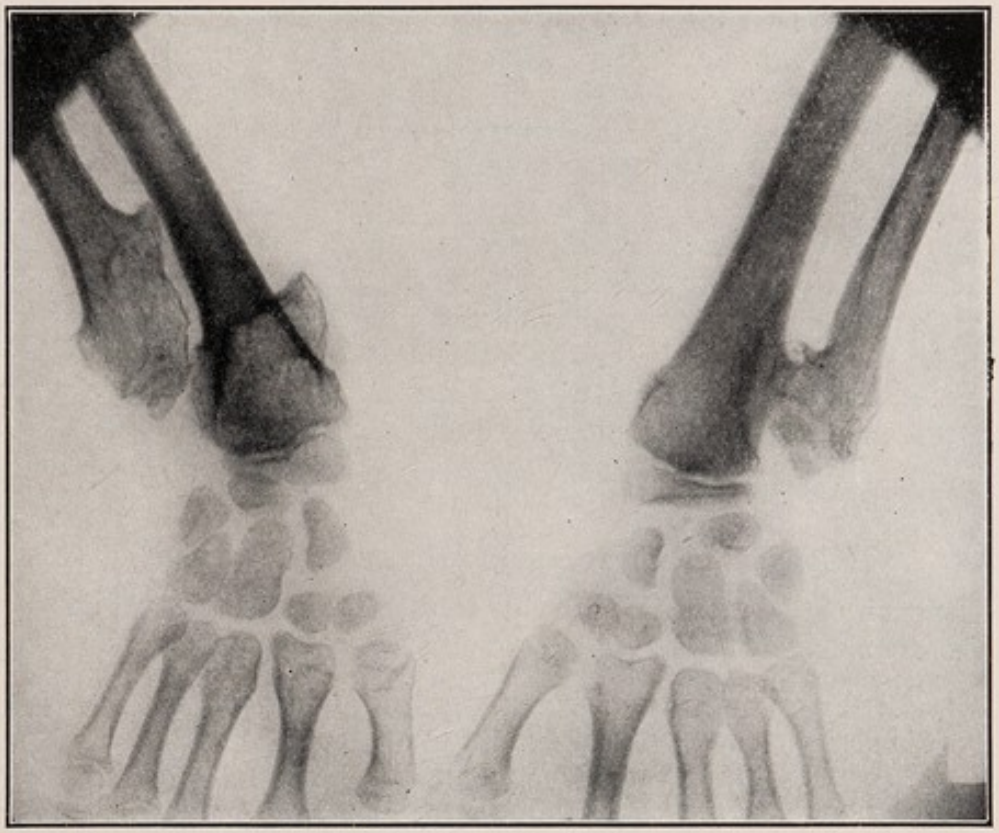

FIG. 347.—X-ray of dyschondroplasia showing appearances of wrists.

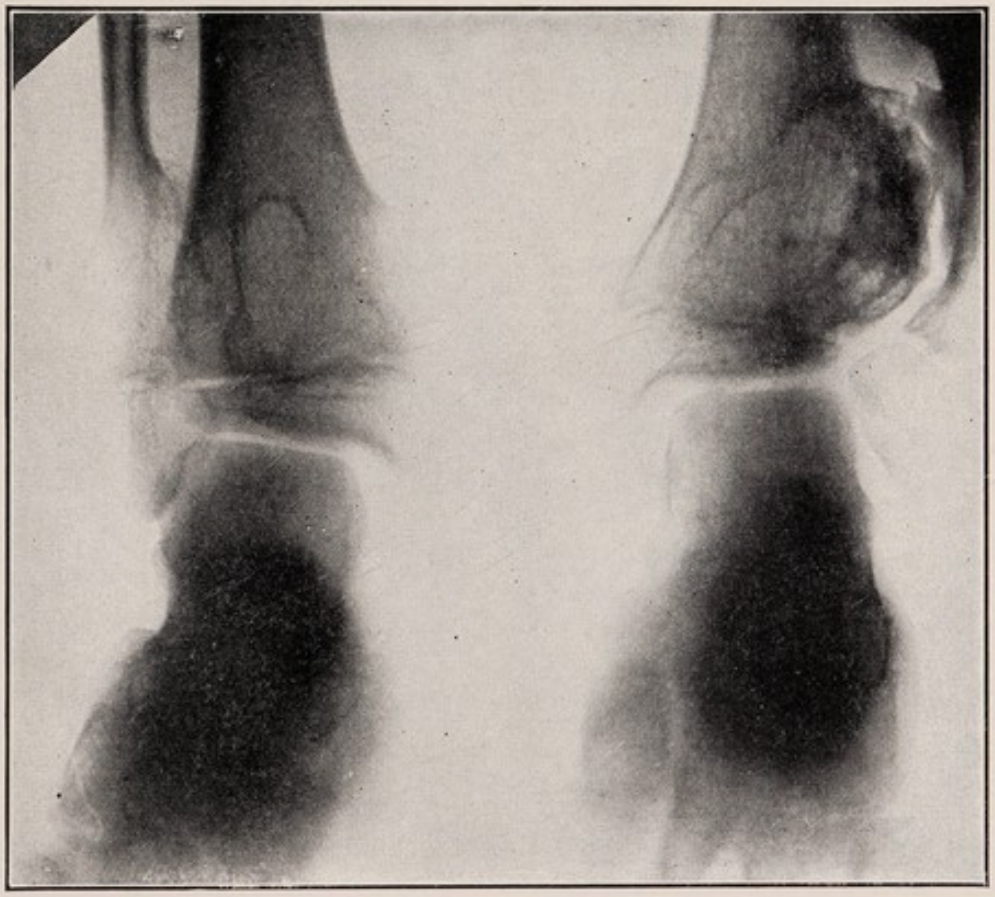

FIG. 348.—X-ray of dyschondroplasia of ankles.

(3) Secondary deformities are usually found in older patients, and are best marked in the forearm and ankle regions. Arrest of growth at the lower end of the ulna is commonly seen so that the radius becomes curved, and the upper end may be dislocated. The lower end of the tibia and fibula usually undergo fusion.

Radiographic Signs.—The appearances in diaphyseal aclasis are absolutely pathognomonic. The large irregularly expanded diaphyseal mass with an absence of cortex occurs in no other affection (Fig. 348).

Prognosis.—The condition is usually compatible with good health and an active life. Occasionally one of the multiple tumors may increase in size at the adolescent period. Malignant transformation is said to be a possibility, but the evidence in favour of such a sequela is scanty.

Cretinism

(Congenital Myxedema, Athyreosis Congenita)

Cretinism must be mentioned in this connection on account of its superficial resemblance to the disturbances of growth just mentioned. The appearances

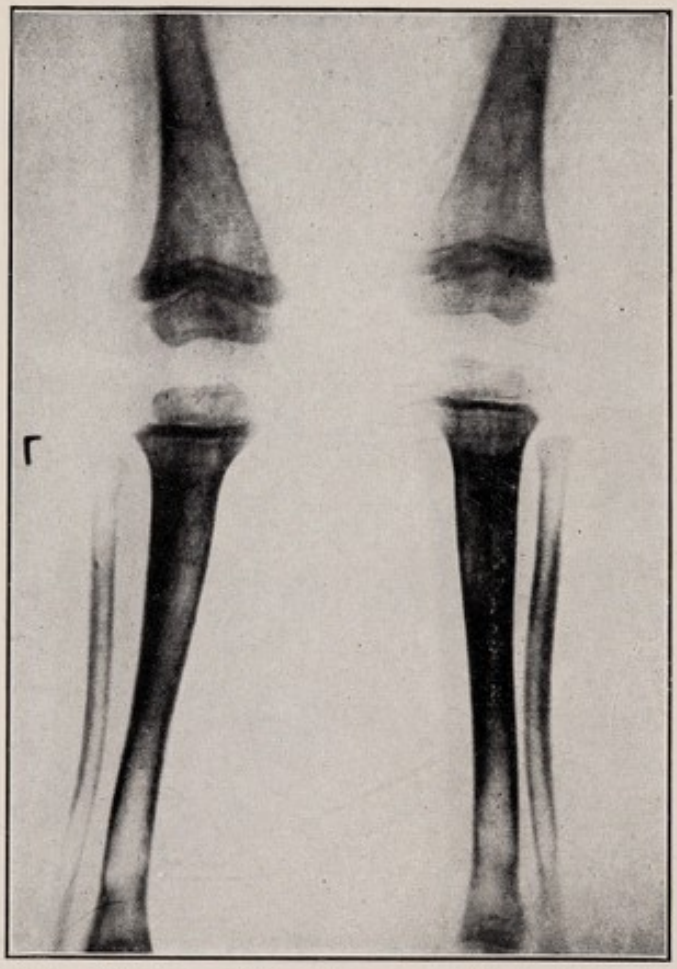

FIG. 349.—X-ray cretinism—the characteristic appearance is the dense band above the epiphyses.

develop soon after birth, the children have a stupid look, a large tongue which protrudes between thick lips, dry skin, the bridge of the nose is sunken in, and the nose is flat. The arms and legs do not grow as fast as the body, the anterior fontanelle closes late, the teeth are delayed, the children walk late and idiocy

often coexists. The epiphyseal cartilages do not ossify normally and may be found in an ununited condition twenty or thirty years after. The characteristic and pathognomonic change is seen in the X-ray as a broad transverse osseous shadow at the end of the diaphysis, particularly in the knee, and evidently formed by dense bone. This bony barrier is the cause of the retarded epiphyseal union and exists in no other condition. In addition to this, the shadows of the carpal bones are absent at birth and there is no bony shadow of the os calcis. The affection clinically resembles achondroplasia and rickets and the diagnosis has already been discussed. These patients as a rule do not attain a normal height.

CHAPTER XVII

AFFECTIONS OF ADULT BONE

Ostitis Deformans

(Paget's Disease)

This condition was first described by Sir James Paget[1] in 1876, and his description was so accurate that little has been added to our knowledge of the disease since that time. It occurs in middle life and is far more common than was formerly supposed.

Etiology.—Nothing definite is known as to the cause of this affection.[2] Heredity plays no part; no bacteria have ever been demonstrated; nor has any definite relationship to the endocrine glands been established in the autopsied cases. Attempts to assign a neuropathic origin have failed through lack of clinical and pathological evidence.

Pathology.—The fundamental changes consist in a general thickening and bowing of the shafts of the long bones, especially the tibiæ and femora, and a uniform enlargement of the whole skull, but practically every part of the skeleton may be involved in an extensive case. The distribution is most often symmetrical, but the disease may exist in a single bone.

The thickening of the bone is seen to be general, the whole bone appearing rough, and the surface uneven and deeply furrowed by the periosteal vessels. On section the normal structure is found to be completely disorganized; there appears to be a thickened subperiosteal layer, the cortex loses its dense character and sharp outline, and the marrow cavity is encroached upon and sometimes entirely filled with spongy, honeycombed tissue. The bone architecture is much modified, lamellæ run in every direction, and there is a marked increase in the vascularity of the bones, while areas of very hard, eburnated bone are found here and there, usually near the outer surface. Small, cystic spaces of one or two centimeters in diameter are occasionally found in the shafts, but never the larger cyst formation seen in certain other bone diseases. These cysts contain a reddish, or yellowish, gelatinous material. The process of resorption of the cortical bone leads to a certain amount of softening and results in the deformities to be described later. Microscopically, the bone marrow is found to have lost its blood-forming elements and to have undergone a replacement, or metaplasia into a fibrous vascular tissue. The fibrous tissue encroaches on the cortex, and considerable bone absorption takes place. This is the stage of softening when deformities arise. In the fibrous tissue, lamellæ of new bone are formed, which at first are osteoid, but later tend to become calcified, so that the shaft regains its old rigidity.

Symptoms.—The onset is as a rule in middle life, the majority of cases occurring from forty years on, but occasionally the first symptoms may be

[1] Paget, J.: Med. Chir. Trans. London, 1877, lx, 37; 1882, lxv, 225.

[2] DaCosta, J. C., Funk, E. H., Bergheim, O., and Hawk, P. B.: Proc. Am. Soc. Biol. Chem., Baltimore, 1914, xvii, No. 2, 30.

noted in young adult life. The sexes are about equally affected, but males predominate slightly.

Often patients suffering with this disease present themselves for some medical ailment, not related to the condition, the latter being discovered incidentally in the examination. When, however, they do report for the bone condition itself, it is usually with the complaint of rheumatic pains in the legs and knees, varying from mild to severe, aggravated by continued standing, or of fatigue, not constant in character. Other complaints are inability to get the legs comfortably placed, discomfort in the knees and legs, especially at night, clumsiness or stiffness in getting about, and sometimes backache. Usually the



FIG. 350.—Paget's disease; showing changes in the femora and pelvis (C. Thurstan Holland).

disease has been progressing for some time before it is noticed; but often patients come for advice because of increased bowing of the legs, decrease in height, and stooping of the shoulders.

Ostitis deformans is not infrequently complicated by fracture, which may result from a very trifling cause, but the callus usually forms well and union is generally rapid, as in normal bone, although sometimes it is much delayed. There may be associated with the disease some degree of arteriosclerosis and the X-ray may show calcified vessels. If a high degree of arteriosclerosis is present, complications in the cardiovascular apparatus may occur late in the disease, leading to decompensation of the heart or apoplexy as terminal events.

The tendency to malignancy was noted by Paget in his earliest communication and has been referred to by many other writers. Five per cent of all cases of osteogenic sarcoma included in the sarcoma Registry of the American College of Surgeons have arisen in Paget's disease (Kolodny[1]). It is probably

[1] KOLODNY, A.: Surg. Gyn. and Obstetrics, April 1927, vol. xliv, 4.A.

only the localization of malignant disease in a focus of chronic irritation, as the malignant change in reported cases has come on years after the ostitis deformans had been established.

Diagnosis.—In the majority of cases, the diagnosis is apparent from the deformities which are so characteristic. The age of onset, the chronic course, and the typical X-ray appearances make a picture which cannot be easily

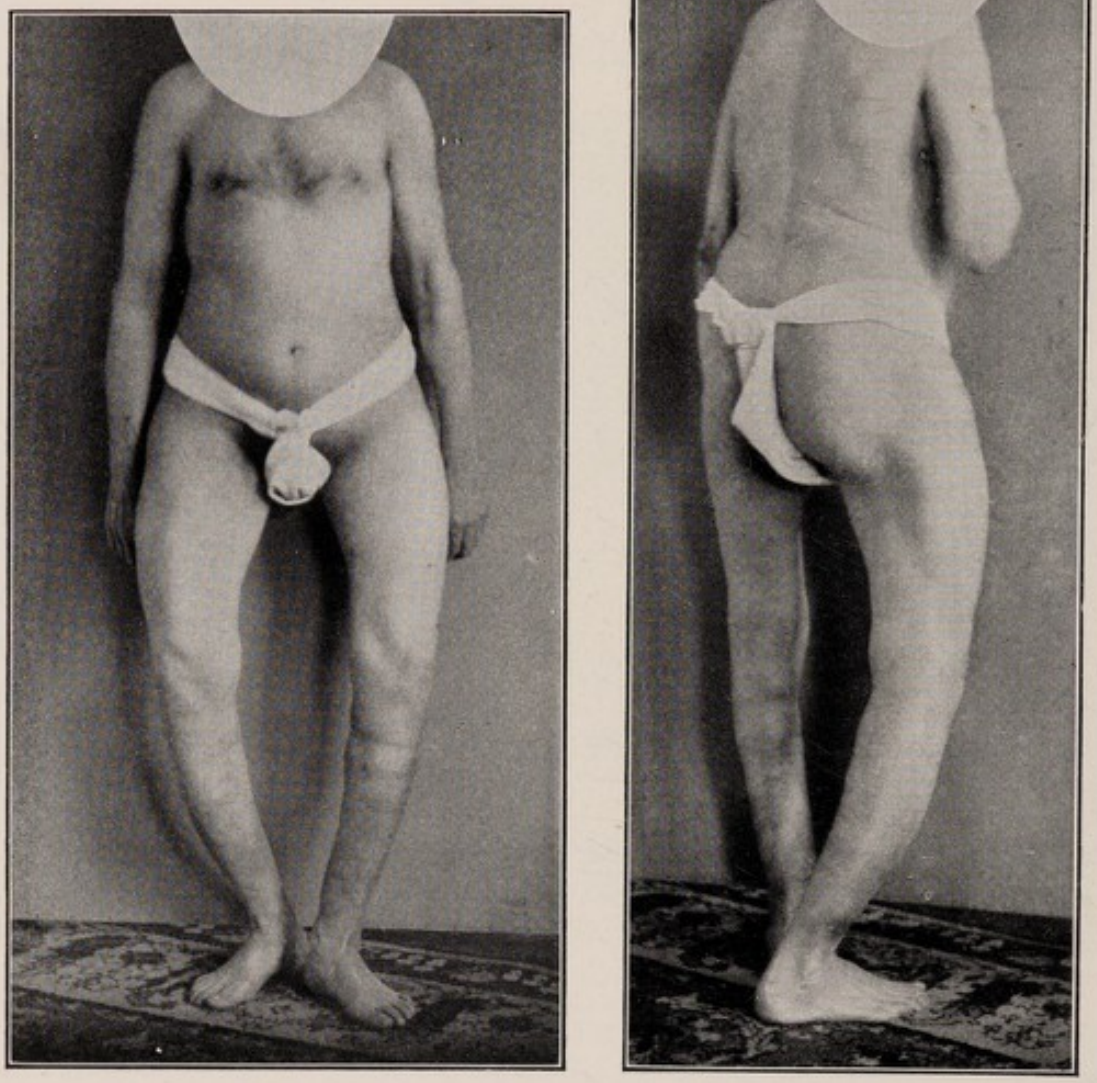

FIG. 351.—Ostitis deformans. Male, age fifty-four. First definite signs seven years before photograph (Bradford and Lovett).

mistaken for anything else. When the affection is well advanced, the clinical appearance is so characteristic that the diagnosis is apparent at a glance. The head appears very large and massive, but the face is seen to be of normal size and in decided contrast to the broad forehead. The head is carried forward; the neck seems short; the chest, compressed above and flared anteriorly at the costal margins; and the spine shows marked dorsal kyphosis. There is apt to be a deep transverse sulcus across the abdomen at the level of the navel, due to the flexion of the spine; the lower extremities are bowed outward and perhaps forward and at times the arms, especially the forearms, are bowed

outward and backward when the hand is in supination. Paget aptly compared the attitude to that of the anthropoid apes.

A form of the disease, confined to one bone, occurs and apparently remains stationary for very many years. Such cases have been noted by the writers. The bone affected is usually the tibia, which shows all the clinical and radiographic appearances of Paget's disease.

X-ray Appearances.—The roentgen picture is characterized by the irregular periosteum, the enormously thickened, furry looking cortex, the narrowed marrow space, and the patchy appearance of the bone structure. In addition, there is the deformity of the bone which consists in accentuation of its normal curves. Lines of cleavage through the thickened cortex are often visible, running at right angles to the long axis of the shaft. When the fracture occurs



Fig. 352.—Early changes in Paget's disease as seen in the os calcis (C. Thurstan Holland).

in Paget's disease the solution of continuity usually takes place along one of these pre-existing "cracks." Seen by themselves, the tibiæ could scarcely be distinguished from those of a marked case of syphilis. In *all* doubtful cases, a radiogram should be taken of the skull, for this presents a picture so totally different from any other condition that it is pathognomonic. The bones of the calvarium are thickened, sometimes to two or three times normal, and the calcification is so irregular that the shadow gives a cottony or smoky appearance.

One often sees a formation of osteophytes with patches of osteoporosis, and the articular ends of the bones as well as the diaphysis are involved in extensive cases.

Differential Diagnosis.—The condition is most often wrongly diagnosed as *syphilis,* and if one tibia only is examined by X-ray the differential diagnosis may be difficult. But with X-rays of the long bones, in the presence of a negative Wassermann reaction, and with the unique radiographic picture of the skull which is present in well marked cases, there should be no confusion between these two diseases.

From *ostitis fibrosa* (von Recklinghausen) the disease can be separated by the age of onset in a good proportion of the cases, the absence of thickening of the cortical bone in the X-ray picture, and the usual non-involvement of the skull. At the same time the early changes in the two diseases are practically the same as shown in the two illustrations presented (Figs. 352 and 360) where an early stage of each existed in the tibia, while elsewhere in the body were advanced changes, in one case of typical Paget's disease, in the other of ostitis fibrosa. Also the cysts and tumors of ostitis fibrosa give much larger clear



FIG. 353.—X-ray of Paget's disease of the tibia (E. A. Locke).

spaces than the small cysts of Paget's disease. The form of ostitis fibrosa which resembles osteomalacia more closely is very dissimilar to the disease under discussion.

Osteomalacia is marked by a rapid softening of the bones, especially those of the pelvis, leading to early fracture and angulation instead of the rounded curves of Paget's disease. It is often accompanied by emaciation and anemia. Atrophy of the bone, with great diminution of shadow, is the characteristic X-ray appearance. The cranial bones are but rarely involved, but may be thinned. One form of ostitis fibrosa is so similar to osteomalacia that it can only be distinguished by microscopic examination.

Acromegaly[1] may bear a slight degree of similarity to Paget's disease, but the features that cause its recognition should not be puzzling to anyone familiar with it. The enlargement of the skeleton is general and the texture of the bone

[1] Cushing, Harvey: The Pituitary Body and Its Disorders, Philadelphia, 1912.



FIG. 354.—Characteristic appearance of skull in Paget's disease.



FIG. 355.—Characteristic hand of acromegaly: note heaping up of tissues about nails. "Type en large" of Marie (Harvey Cushing, The Pituitary Body and Its Disorders, Lippincott Publ.).

is coarse and heavy. The terminal phalanges show clubbing and tufting that is important in the diagnosis, and exostoses of the phalanges are often found in later cases. The skull shows little change in thickness, though it usually presents prominent frontal sinuses and external occipital protuberances and a very large sella turcica associated with a large pituitary body. The bones of the face are markedly enlarged—an exact contrast to the case in Paget's disease. Aside from the kyphosis common to both conditions, there are no deformities in acromegaly that could be interpreted as similar to Paget's disease. The tendency to occasional glycosuria in acromegaly must not be forgotten.

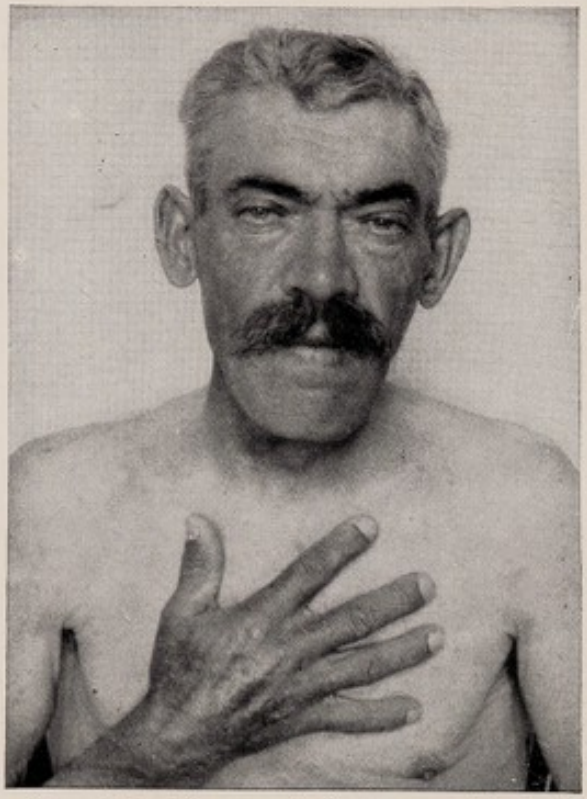

FIG. 356.—Characteristic acromegalic facies; square, deeply pigmented hand (The Pituitary Body and Its Disorders, Lippincott Publ.).



FIG. 357.—Stationary acromegalic gigantism. Height six feet one inch despite kyphosis. Weight 247 pounds (The Pituitary Body and Its Disorders, Lippincott Publ.).

Prognosis.—The course of Paget's disease is slow and steadily progressive, lasting over years without impairment of the general health or mental condition, and in certain cases the condition seems almost stationary; in other cases the changes do not extend to other parts of the body, but remain limited to one or both limbs for many years. The prognosis as to life is excellent as many of these patients live to a surprisingly old age. The tendency to deformity is an increasing one and many become more or less disabled in later years.

Treatment.—Nothing is known that will effectively check the progress of the affection. For the pain, the coal tar drugs give a considerable measure of relief and should be chosen over the opiates, because of the chronicity of the process and the probability of establishing a drug habit.

Pain in the enlarged tibia may be relieved by cutting into the marrow cavity. In the severe cases, sufficient bone to form a gutter should be removed. Correction of gross deformity by osteotomy is occasionally indicated; failure of consolidation need not be feared.

Ostitis Fibrosa Cystica

(Fibrocystic Disease; Metaplastic Malacia (Recklinghausen); Hæmorrhagic Osteomyelitis (Barrie))

In 1891 von Recklinghausen described three cases of a bone disease in young adults which differed in some respects from the ostitis deformans of Paget, and the osteomalacia of other writers. This new disease of bone was characterized by a softening of the osseous structure, the overgrowth of fibrous tissue in the bone, and the formation of cysts and tumors.

The condition has been well established as a clinical entity for some time, and under various titles which suggest the existence of widely divergent views on its pathogenesis. The changes may be localised to a single bone, or may involve a considerable part of the skeleton.



Fig. 358.—Ostitis fibrosa, showing bowing of femora.

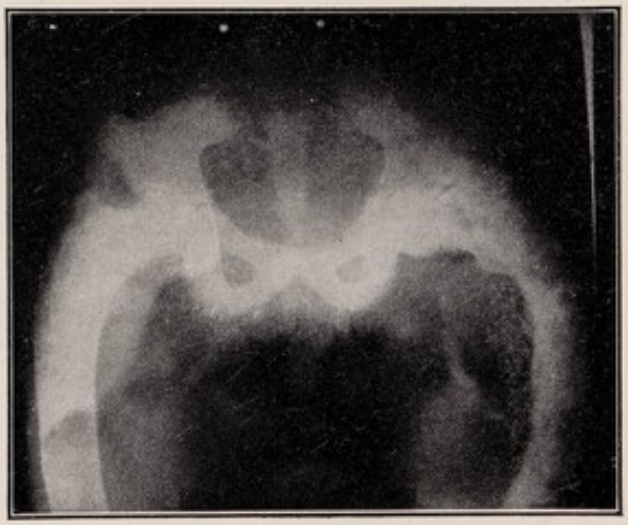

Fig. 359.—X-ray of ostitis fibrosa of pelvis and femora (same case as Fig. 358).

Pathology.—The essential lesion is the conversion of bone into a fibro-calcareous structure in which cysts, large or small, single or multiple, often develop.

Histology.—The earliest histological phase is a resorption of bone in the Haversian systems of the compact tissue, a process which is at first a simple decalcification, and later, an active erosion by osteoclasts. As the bone breaks down and is removed, it is replaced by a mass of invading fibrous tissue derived from the connective tissue elements of bone, and at a much later stage, of the bone marrow. In the newly formed tissue secondary changes are

usual. Where degeneration is uppermost, cysts may form, and hæmorrhages are frequently found. If proliferation dominates the picture, areas with the typical histology of the so called myeloid sarcoma (giant cell tumor) can often be discovered. The usual reaction of malacic bone follows in the appearance of lamellæ of osteoid bone in the connective tissue mass (Fig. 360). If healing occurs in a fibrocystic area the new bone undergoes a final architectural reconstruction. These various histological changes may be seen in different parts of the same bone, or in different bones, where the skeleton is widely affected.



Fig. 360.—Ostitis fibrosa, showing (*a*) fibrous hyperplasia of connective tissue; (*b*) erosion of bone; (*c*) ostoid bone formation.

Morbid Anatomy.—There are two types—(1) The solitary cyst, and (2) The fibrocystic change limited to a single bone, or affecting many bones.

1. The structure of a *solitary cyst* depends on the stage to which it has attained. The shell is composed of progressively thinning bone cortex, at first lined by patches of fibrous membrane. In the earlier stages the cyst often contains reddish brown tissue, not unlike new growth. Later the cyst is usually occupied by a small amount of fluid. Perforation of the shell may occur apart from actual fracture. The bone structure immediately above and below the cyst may show the early histological phases of ostitis fibrosa.

2. In a bone which is the seat of an extensive fibrocystic change, the shaft becomes transformed into a fibro-osteoid cylinder. The cortex is thinned out for the most part, but localised thickenings may be seen where the subperiosteal bone formation has attained a temporary mastery. The cancellous bone is replaced by a conglomeration of fibrous tissue, osteoid bone, and mature bone in the process of reconstruction; the marrow cavity may show disappearance of fat, and replacement by fibrous tissue. On naked eye inspection, small cysts may be recognisable, with here and there clumps of granulation like tissue which house the giant cell tumour areas. Bending or fracture occurs on slight provocation, so that considerable deformity may be present.

Etiology.—The exact cause of this bone affection is still obscure. Von Recklinghausen,[1] in his later work, classifies ostitis fibrosa as one of the metaplastic malacias closely allied both to ostitis deformans (Paget's disease), and myeloid sarcoma (giant cell tumour). Dawson and Struthers[2] believe that the train of changes is probably evoked by toxins from the alimentary canal, which after absorption, disturb the control of the bone cell over its local calcium metabolism. Normally this activity is believed to be regulated by the parathyroid hormone. Lawford Knaggs[3] also supports the toxic origin of ostitis fibrosa, and considers that both this disease, and ostitis deformans represent the same reaction of bone to toxic influences at different age periods.

[1] Von Recklinghausen: Untersüchungen uber Rachitis und Osteomalacia, 1910.
[2] Dawson and Struthers: Edinburgh Medical Journal, Oct., 1923, xxx, No. 10.
[3] Lawford Knaggs: British Journal of Surgery, October, 1925.

Clinical Manifestations.—The *solitary cyst* is most commonly found in young children; the upper end of the humerus, the neck of the femur, and ends of the tibia being the favourite sites. Occasional sites are the fibula, and the small pipe bones. The cyst appears insidiously, and rarely gives rise to discomfort. A localised swelling may occasionally be noticed, but in the majority of instances the condition goes undiagnosed until a spontaneous fracture occurs, and a radiogram is obtained. If fracture does not supervene, after some years the cystic area is pushed down the shaft as the bone grows in length.[1]



FIG. 361.—X-ray of bone cyst of upper femur on right of picture. (Microscopic diagnosis.)

When discovered at a later stage such a cyst may appear at first sight to have originated in the shaft itself. Although most cysts increase slowly in size until the bone shell is extremely attenuated, spontaneous healing may occur without the stimulus of fracture. Traces of healed cysts are not infrequently revealed in the long bones in radiograms taken for other purposes (Bloodgood[2]).

Diagnosis.—The age of the patient, long history, and the characteristic radiographic picture make the diagnosis comparatively easy.

X-ray Appearances.—The bone cyst shows as a symmetrical expansion in the sub-epiphyseal region. The cortical shell is thinned out, and the cavity often shows complete disappearance of bone. Trabeculation, when present, is usually fairly marked. The cystic area is sharply demarcated above and below from the rest of the bone (Fig. 361).

[1] ELMSLIE, R. C.: Brit. Jour. Surgery, ii, 1914.
[2] BLOODGOOD, J. C.: Journal of Bone and Joint Surgery, xviii, 8, July, 1926.

Differential Diagnosis.—Certain localised bone affections may be closely simulated by bone cysts, but the diagnosis should rarely be in doubt.

1. *Tuberculous Ostitis.*—In the indolent type located in the metaphyseal end of a long bone, there may be little swelling or pain in the early stage. There is, however, very little true bone expansion; if a definite cyst is present, it is irregular, and asymmetrical, and destructive changes are more marked.

2. *Pyogenic Ostitis.*—In a chronic bone abscess (Brodie's abscess) there is a dense thickening of the cortex; the cavity may be very small, and the radiogram often suggests the presence of a central sequestrum. Pain and swelling in the overlying soft parts may occur at intervals.

3. *Syphilitic Ostitis.*—A central gumma may produce localised bone expansion of an irregular type, but this is an extremely rare lesion in young children. Other characteristic appearances are likely to dominate the picture (Chapter XIV).

4. *Bone Tumors.*—Central bone tumors giving rise to cystic appearances may be—chondroma, benign giant cell tumor (myeloid sarcoma), multiple myeloma, metastatic growths, or sarcoma proper.

Prognosis.—The solitary cyst of ostitis fibrosa is a benign lesion which tends to heal spontaneously. Although this may take many years, healing is particularly favoured by the subperiosteal reaction which follows the occurrence of fracture through the cyst. A second fracture after an interval of a year or more is a not unfamiliar phenomenon.

Ostitis Fibrosa.—This clinical type is seen in older children, adolescents, or in young adults. The changes may remain latent for many years, so that occasionally the condition escapes diagnosis until middle life. A single bone, or many bones may be involved, the femur and the tibia being common sites. In the generalised form the skull and pelvis almost always show marked changes.

Bending or complete fracture from trivial violence may be the first clinical sign as in the solitary bone cyst of the young child. Such fractures unite in the ordinary way. In the adult the condition is to be distinguished from Paget's disease, osteomalacia, and multiple myelomata.

The prognosis in the localised type is almost as favourable as in the bone cyst. The outlook is not so good in the generalised type, where of necessity there is a very marked disturbance in the calcium metabolism of the body. In many cases the disease tends to extend from bone to bone, and gross deformities develop.

In the radiograms the affected bones are papery with a thin cortex, and loss of cancellous tissue extending over the whole shaft.

Small cysts, irregular in outline, may be present (Fig. 362).

Treatment.—1. *Solitary cysts* as a general rule may be expected to heal without any form of surgical intervention. Radiation is said to hasten the disappearance of a cyst, but little reliable information is available on this point. In view of the very slow rate of spontaneous healing, and the tendency to refracture, operation is often desirable. Curettage of the cyst, with crushing of its wall, or alternatively the insertion of an autogenous bone graft undoubtedly involves a rapid reconstruction of the diseased area. A useful method is to fill the cavity with cancellous bone. This operation is most conveniently done soon after the occurrence of fracture.

2. *Localised Ostitis Fibrosa.*—Curettage and bone grafting may also be used for the non-cystic type when confined to the shaft of a single bone. If

deformity is already present, an osteotomy—linear or cuneiform—is a safe procedure.

3. *Generalised Ostitis Fibrosa.*—A complete enquiry should be made into the possible source of toxins, (alimentary canal, etc.), and the patient treated on appropriate lines, as in other forms of malacia. The softened bone should be guarded against all deforming strains. Where there is evidence that the disease has become stationary, correction of gross deformities by operation is indicated.



FIG. 362.—Ostitis fibrosa in child of fifteen. Extreme coxa vara in the hip which has been operated on. Two fractures of the shaft of the femur from slight cause. The formation of cyst-like cavities is noted in the lower end of the femur (Dr. A. R. Lamb, New York City).

Osteomalacia

The term osteomalacia is a loose one and occupies a position analogous to that formerly held by epilepsy and really describes a symptom common to most of the diseases of formed bone. Von Recklinghausen, after an extensive pathological study, recognized this fact and made his classification of bone diseases on this basis. There is a clinical entity, however, which for lack of a better name might properly be termed idiopathic osteomalacia.

Idiopathic osteomalacia is a disease of bone, which most commonly arises in adult females during pregnancy or the puerperium, and runs a chronic course, being aggravated by succeeding pregnancies, especially if they follow each other closely. It is characterized by pain referred to the bones of the

pelvis, back or hips, and by a general muscular weakness; and in the later stages by extraordinary deformities of the skeleton due to bone softening and fracture. There is also a form not associated in any way with pregnancy or lactation, but otherwise similar in every respect.

The affection in a serious form occasionally occurs in children and is distinct from rickets in the absence of epiphyseal disturbances characteristic of the latter condition (p. 311). In the experience of one of the writers, severe osteomalacia in a child of seven was found superimposed on a patient with osteogenesis imperfecta, who from birth onward had experienced fractures diminishing in frequency with increasing age. In a second case of osteogenesis imperfecta the bone was normal to the X-ray at birth, although one fracture was present; but at thirteen, although fractures had been absent for two years, serious bowing of the leg bones had occurred. The cases are shown in the illustrations.



FIG. 363.—X-ray of osteomalacia.

The disease is by no means rare in portions of Central Europe and in the Far East, but in the English speaking countries is seldom found. Zesas[1] has reported a large number of European statistics and Scott[2] has collected a large group from India. McCrudden[3] was able to collect 360 cases in his report in 1910.

Pathology.—The essential pathology is a softening of the bones. The initial phase as in other forms of malacia is an absorption of lime by halisteresis. The cancellous bone disappears, the cortex becomes porous, and the marrow is replaced by a soft vascular cellular tissue which rarely becomes actually fibrous. In this there is a feeble deposit of osteoid bone. Marked deformity follows through bending and fracture of this weakened osseous tissue.

In gross, the bones are abnormally soft, pliable, and cut easily with a knife and their elasticity and flexibility are features which have attracted much attention. The periosteum may be thickened and hyperemic, much as in Paget's disease and in contrast to the unchanged periosteum in ostitis fibrosa. The bone structure is often much altered and the normal trabeculæ irregular and encroached upon by the enlarged marrow cavity, which contains a richly cellular-vascularized marrow with hemorrhagic areas. The joints and epiphyseal cartilages show no change.

Microscopically the trabeculæ show a central portion of calcified bone with osteoid margins. Osteoid tissue is also present about the Haversian canals which are wider and contain more blood vessels than is normal. Small numbers of osteoclasts are present in the osteoid tissue. No constant patho-

[1] ZESAS, D. G.: Central f. d. Grenzgeb. Med. Chir., Jena, 1907, x, No. 21, 801.
[2] SCOTT: Indian Jour. Med. Research, Calcutta, 1916–17, iv, 140.
Indian Jour. Med. Research, Calcutta, 1916–17, iv, 169.
[3] MCCRUDDEN, F. H.: Arch. Int. Med., 1910, v, 596.

logical findings are present in any of the internal organs. There is nothing remarkable about the skull as a rule, but it may be much thinned, especially in the non-puerperal form. Small cystic spaces are frequently present in the various affected bones. The non-puerperal form may involve any bone and does not differ essentially from the above.

The *deformities* are most commonly seen in the pelvis, hips and spine. In the pelvis, the sides are pressed in laterally, due to the body weight exerted through the femora, and the symphysis pubis protrudes in front, resulting in a so-called heart-shaped pelvic inlet. The vertebræ are compressed, the normal curves are modified and varying degrees of scoliotic change are seen; but the striking feature is the sinking together or "telescoping" of the trunk which is most obvious and makes the arms appear too long for the body. The femora are bowed irregularly and angulated in the line of their normal curves, according to the amount of disease; coxa vara is very common and the tibiæ often are convex forward or outward.

Etiology.—The etiology is unknown. It is obviously associated with pregnancy in some cases, but not in the others. An endocrine origin has been advanced, viz., that it originates in the thyroid, adrenals or ovaries, and each theory has had strong backing, but so far no evidence has been convincing. There seems to be a profound metabolic change which upsets the calcium balance in bone formation but we are as yet uncertain as to the nature of this process. No bacterial cause has been demonstrated.

Symptoms.—In the puerperal form, backache and pain in the extremities may be an early symptom, and deformity of various types occurs. Occasionally the spinal deformity is so great that compression of the cord has been described. In the non-puerperal form the deformity is the chief symptom with a tendency to fractures on slight cause.

Diagnosis.—In the puerperal form, diagnosis is made in a pregnant woman from pains in the pelvis and back, slowly increasing deformity, tenderness over the involved bones, and the typical X-ray appearance. In the non-puerperal form the diagnosis is difficult and made by the exclusion of the other bone diseases and by the X-ray picture.

The X-ray picture shows a skeleton which casts a very thin, indistinct shadow that appears almost translucent. There is very little contrast with the soft parts which at times offer about as much resistance to the rays as does the decalcified bone. The bones are irregular in outline, angular, and generally show poor callus formation in case of fracture. The cortex is regularly atrophied and the marrow cavity expanded.

Differential Diagnosis.—The diagnosis from Paget's disease has been discussed under that heading.

From *ostitis fibrosa*, osteomalacia is distinguished by the occasional occurrence in pregnancy, the involvement of several bones most often centering about the pelvis, the deformities and the characteristic X-ray appearance. From the multiple type of ostitis fibrosa it is practically indistinguishable, except on microscopic examination. The occurrence of giant cell tumor formation is sufficient to classify the disease as generalized ostitis fibrosa and many cases of this nature were first described as forms of osteomalacia.

Prognosis.—The prognosis from general or local treatment, as in all diseases where we do not understand the cause, is poor, and in general one must predict a chronic progression of the disease, often extending over many years.

The process seems to be accentuated by repeated pregnancies and many of the former "cures" by oophorectomy may represent arrest of the disease by prevention of conception. A few cases have been reported as recovering spontaneously, and acute and rapidly fatal types have also been described. In late stages the patient is likely to be bed-ridden, general systemic disturbance is marked and anemia and cachexia result.

Treatment.—An attempt should be made to find out a cause for the individual case, and for that purpose a comprehensive examination is of importance, especially with reference to the phosphorus and calcium content of the blood, and the total calcium metabolism. As a rule a low calcium excretion is found in these cases.

The environment should be the best possible, outdoor life, and heliotherapy may be of use, and the diet should be nutritious and theoretically contain a high calcium and phosphorus content, although calcium feeding has been on the whole unsatisfactory. Ductless gland therapy has not gone beyond the experimental stage, but the administration of phosphorus seems useful.

Deformity should be avoided and corrected so far as possible, and in the severest cases recumbency for a while will be necessary; but it must be remembered that non-use favors bone atrophy, and if walking must be stopped massage and exercises must be given. Oophorectomy is of doubtful use and much less advocated than a few years ago.

Leontiasis Ossea

This name has been given to two well defined bone conditions;—(1) one being caused by a very chronic periostitis which attacks the bones of the face and skull, and which spreads slowly, but irresistibly from bone to bone until the face takes on an appearance which has suggested the name; (2) The other is a diffuse ostitis of the same bones which may be general, circumscribed, or local, and in which the histological and pathological anatomy point to a condition resembling ostitis fibrosa. The periostitic form starts from the nasal fossæ or the accessory sinuses, and results in an enormous overgrowth of subperiosteal bone which shows its greatest development in the facial bones. It is presumed to be caused by some microorganism. The disease may start in childhood, and nothing is known which will arrest its progress. When fully developed, complications occur, such as nasal obstruction, interference with the lachrymal apparatus, proptosis, exophthalmos, and later blindness and mental and cerebral troubles. Death results in comparatively early life.

The *ostitis fibrosa* type is the result of an overgrowth of connective tissue in the interior of the bone, and there is no periosteal bone deposit. The affected bone (or bones) is enormously enlarged, but retains its form and outlines. At first the enlarged bone is soft and vascular, but as the disease progresses, as a result of bone formation, this thickened and enlarged bone becomes very dense to X-rays. It may result in a general diffuse ostitis of the whole cranium and the facial bones with a huge thickening of the whole skull. It may be restricted, and only attack in the same way, one cranial bone. Or it may attack one or both jaws only causing an enormous increase in size; in this form it is often accompanied by dental infection.

This form[1] differs in no way histologically from ostitis fibrosa attacking long bones, except that new bone formation overshadows the fibrous tissue, and very little of the latter remains. The disease frequently starts in early childhood, and in many cases at any rate its onset appears to be connected with injury.

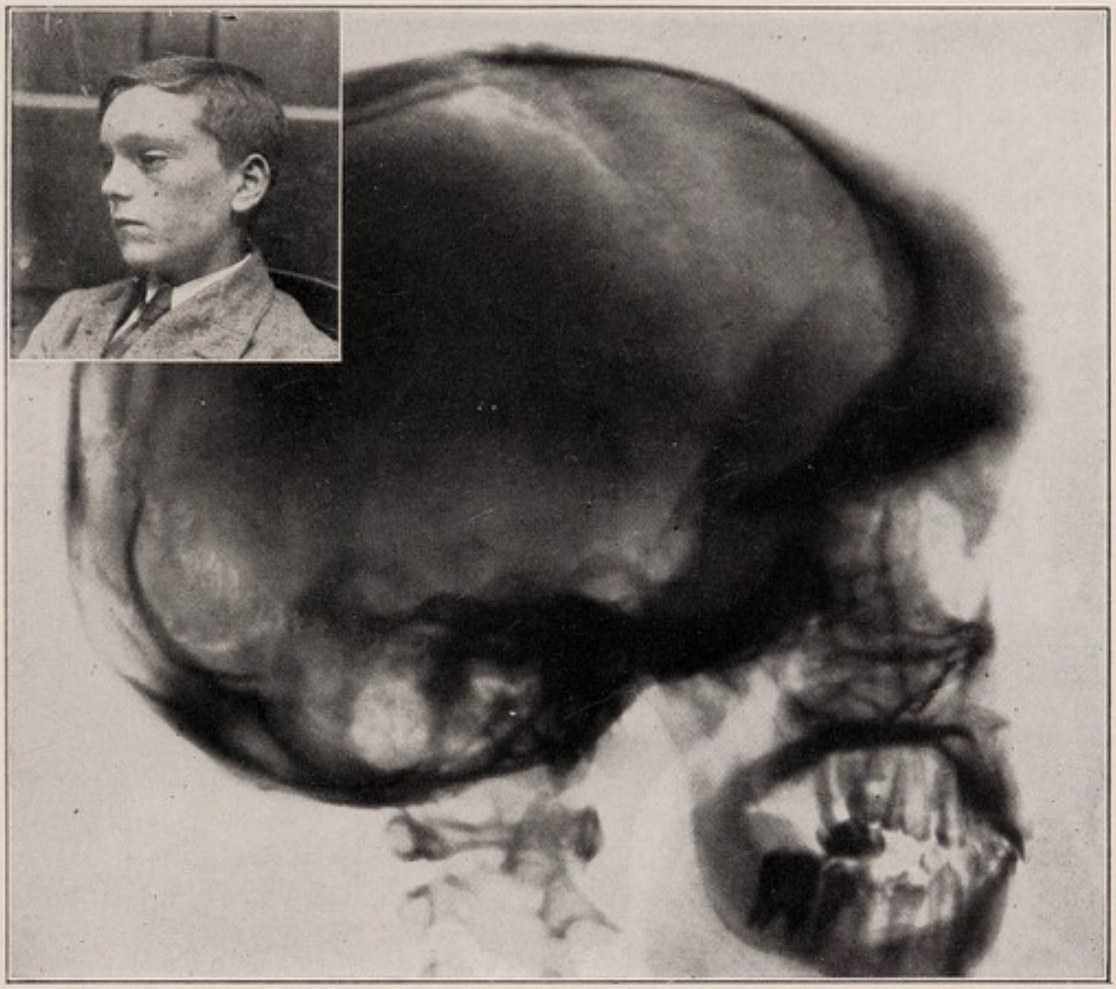

FIG. 364.—Leontiasis ossea, localized in the frontal bone (C. Thurstan Holland).

Secondary Hypertrophic Osteoarthropathy

(Clubbed Fingers, Hypertrophic Pulmonary Osteoarthropathy, Marie's Disease[2])

This name is given to a condition characterized by general and symmetrical clubbing of the fingers and toes, often associated with hypertrophy of the long bones of the hands and feet, and less frequently of the forearms and legs. This is secondary to some chronic disease, most often of the lungs. At first supposed to be an enlargement of the soft parts, Bamber in 1889 described bone changes, also classifying these as ossifying periostitis.

The most frequent causes are found in pulmonary disease, chronic intoxications and infections elsewhere, and cardiac disease and long continued surgical tuberculosis, as in Pott's disease.

[1] LAWFORD KNAGGS: The Inflammatory and Toxic Diseases of Bone, 1926.
[2] LOCKE, E. A. Arch. Int. Med., Chicago, 1915, xv, 659.

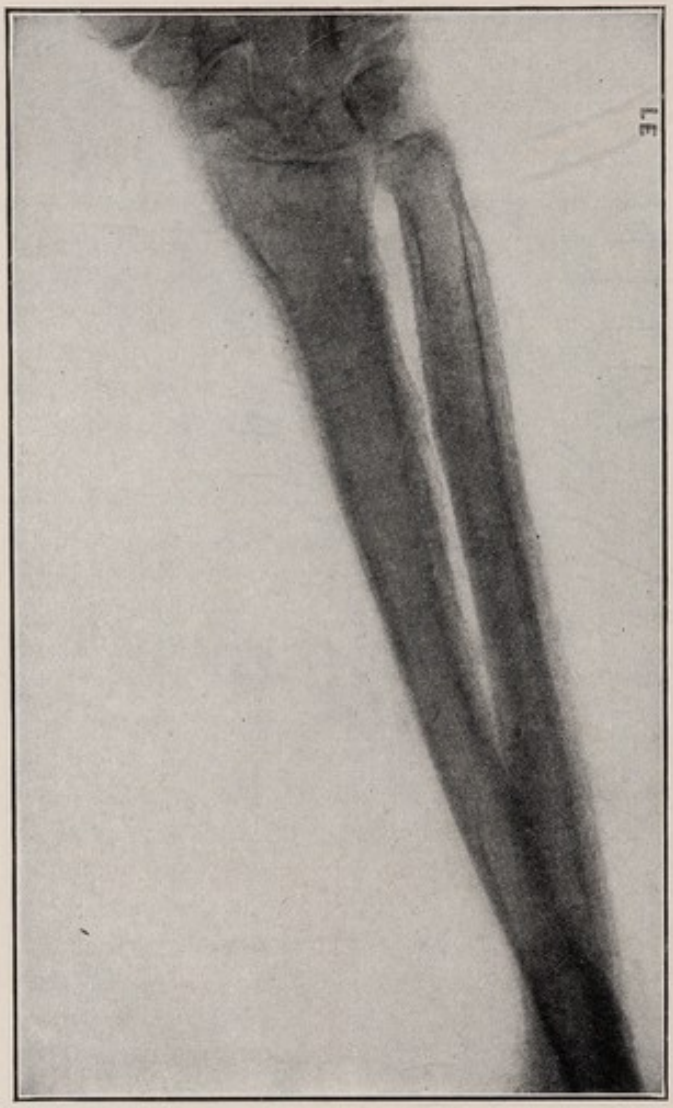

FIG 365.—Secondary hypertrophic osteo-arthropathy—adult male forearm, X-ray showing characteristic irregular subperiosteal layer of new bone, especially abundant about epiphyses (E. A. Locke).



FIG. 366.—Clubbing of fingers in secondary osteo-arthropathy (Bradford and Lovett).

When bony changes in the phalanges exist in addition to the enlargement of the soft tissues, they are seen as an irregular proliferation of the phalanges with occasional spurs. In the soft parts the nails are thickened, ridged, and curved, and the nail bed full, rounded and injected. The enlargement of the finger tips is due to proliferation of fat and connective tissue, and the name of "drum stick fingers" often used is descriptive.

When changes in the long bones also occur, ossifying periostitis of the shaft with a rarefying ostitis is often found. The joints participate in the process in severe cases and show enlargement and the presence of fluid in the joint cavity. Thickening of the capsule and erosion of cartilage have been described, but the evidence in these cases does not seem sufficient to exclude satisfactorily real arthritis deformans.

The description given above identifies the symptoms, and the only condition presenting even a superficial resemblance is acromegaly. No form of special therapy seems likely to be useful, and the treatment should be directed to the causative condition. If that is relieved the clubbing may improve or disappear or it may remain. If the general condition remains unchanged the fingers remain in the same condition with perhaps some progress.

Actinomycosis

Actinomycosis occasionally affects the bones, most frequently the jaw, from which it derives its popular name of "lumpy jaw," and at times the spine.



FIG. 367.—X-ray of case of actinomycosis of spine, side view.

Etiology.—The disease is an animal disease and the organism belongs to the streptothrix group of bacteria. Microscopical examination of a focus of the disease in the soft parts shows a central portion containing the fungus, with sometimes giant cells, and the cells may proliferate to such an extent that a definite tumor-like mass is produced. Suppuration sometimes occurs and fistulous tracts form discharging material containing the actinomycotic granules.

The ordinary locations of the disease are in the face, neck, thorax, abdomen, or skin. The spinal lesions present the chief interest in the present connection.

The skull may be attacked, but the form of disease affecting the intestinal tract is the one most often attacking the spine.

The disease is very often fatal in these locations, but it is now established that milder forms exist, and that spontaneous arrest of the process may occur. The disease attacks the forward part of the vertebra and especially the vertebral bodies, but it may spread to the other parts of the vertebræ and ribs.

The process is not essentially destructive in character, but rarefying and slightly formative. Osteophytes are found, with numerous small spaces in the body of the vertebra.

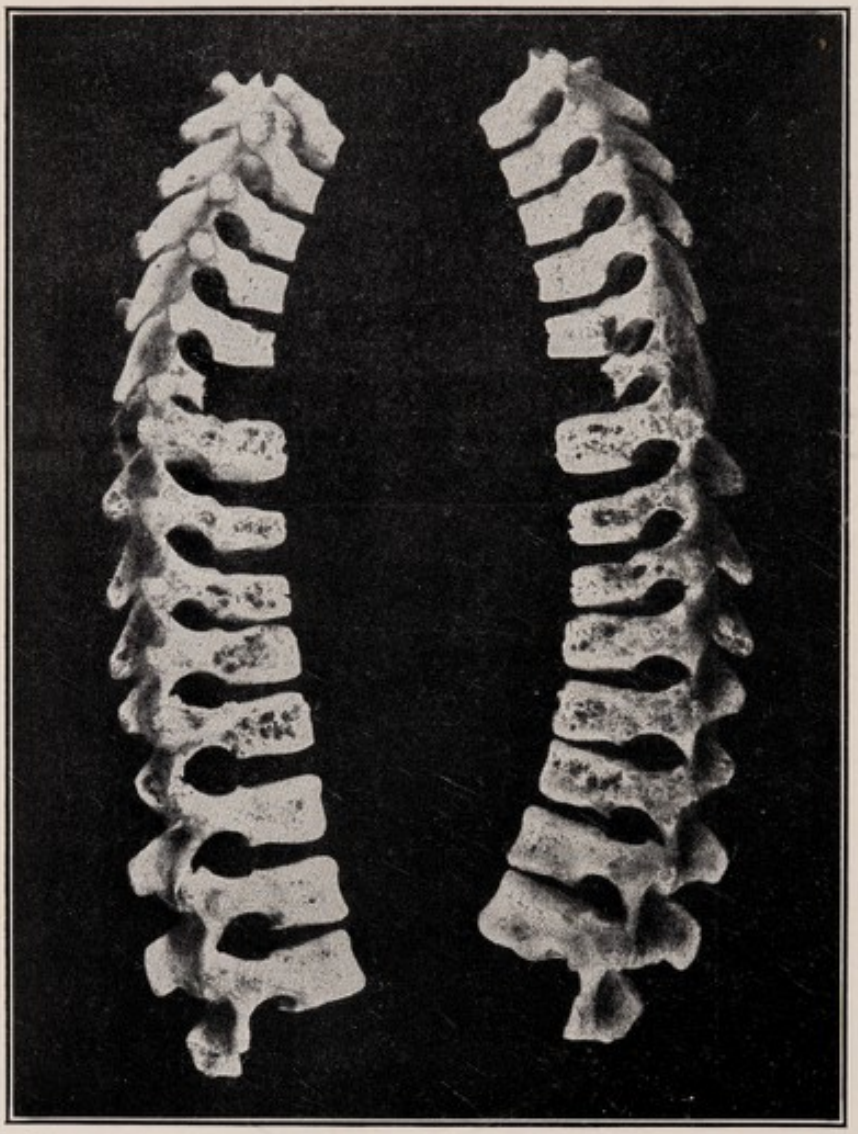

Fig. 368.—Specimen of actinomycosis of spine showing characteristic bone lesions (Boström).

Fig. 368 shows a case of spinal actinomycosis, and the X-ray of a case of one of the writers shows the X-ray appearance (Fig. 367). In this case a young man ten years prior to being seen had experienced a violent intestinal attack, accompanied by fever and diarrhea. It was long continued and convalescence was slow. There were no especial spinal symptoms, but the spine was slightly stiff and showed some lateral curvature. An X-ray was taken to clear up the cause of the lateral curvature, and the very unusual appearance in it was then investigated. As there were no symptoms, no treat-

ment was instituted. In cases where sinuses are present the actinomycotic bodies are found in the discharge. In general when it affects the cervical region a very dense and extensive infiltration is found, most often riddled by sinuses. This infiltration in a case seen by one of the writers reached from the occiput to the shoulder and was very extensive. This case was seen before the day of the modern X-ray.

Treatment.—In treatment[1] the use of iodide of potash is not a specific, but in the majority of cases helpful. The operative treatment consists in incision over the infected areas with extensive clearing out and packing.

Tumors of Bone

Bone tumors may be (1) benign or (2) malignant.

Benign Tumors

The common innocent growths are *osteomata*, *chondromata*, and the *giant cell tumors* (myeloid sarcoma). In the past, the latter have often been grouped with the malignant tumors, but are now admitted by the majority of authorities to be truly benign. Fibromata and lipomata connected with the periosteum have occasionally been described, but are of little practical interest.

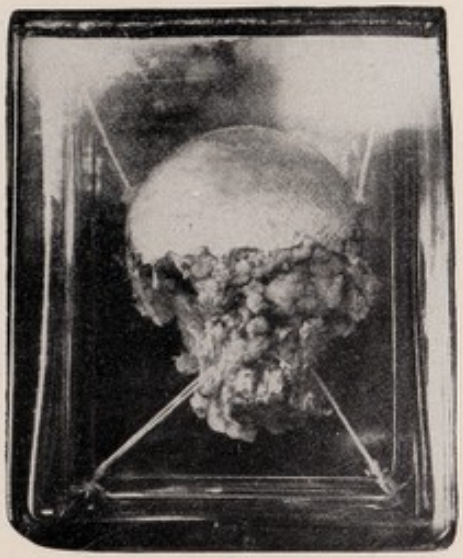

FIG. 369.—Chondroma of the neck of the femur, causing spontaneous fracture. Patient aged 51 years.

Osteoma (Exostosis).—This term is applied to a tumor composed of compact or cancellous bone. Osteomata are found on the surface of a bone; they grow slowly, and remain enclosed in a fibrous capsule. The usual sites are the ends of the long bones, or certain of the flat bones, most notably the skull and pelvis. The tumors may be solitary, or may be scattered widely over the skeleton (multiple exostoses). A favourite region is the lower end of the femur, or the upper end of the tibia, but examples have been encountered in almost every bone in the body.

The majority of osteomata originate in childhood, and often remain undiscovered until adult life. The solitary tumor, after years of slow growth may attain a considerable size, and ultimately lead to pressure symptoms. The clinical diagnosis is usually simple. The tumor presents itself as a painless

[1] WULLSTEIN: Die Wirbelentzündungen, Jena, 1907, 18.



FIG. 370.—Multiple enchondromata before removal of the external tumors.



FIG. 371.—Condition twelve years later. No recurrence of tumors and signs of spontaneous healing in interior of affected bones.



FIG. 372.—Chondroma of phalanx producing cyst (C. Thurstan Holland).

hard swelling, firmly attached to the underlying bone by a narrow stalk or broad base. The radiographic appearances are characteristic, and need not be described in detail.

Treatment consists in removal of the tumor if causing inconvenience.

Chondroma.—The chondroma is also a tumor of early life, and like the osteoma may escape diagnosis for many years. A single bone, or many bones may be affected. Three clinical types may conveniently be distinguished. (1) The *solitary chondroma* usually found attached to the growing end of one of the major long bones, *e.g.* the femur, humerus; or less commonly arising from the pelvis or scapula. The tumor is at first very small and inconspicuous, but if undetected until adult life, may grow to considerable dimensions. In the bigger tumors, ossification occurs in patches, but the greater part of the tumor retains its original primitive cartilaginous structure. Degenerative changes such as liquefaction and myxomatous transformation, are occasionally seen, but the tumor does not ordinarily perforate its capsule. The area of bone from which a chondroma arises may in time become weakened, but

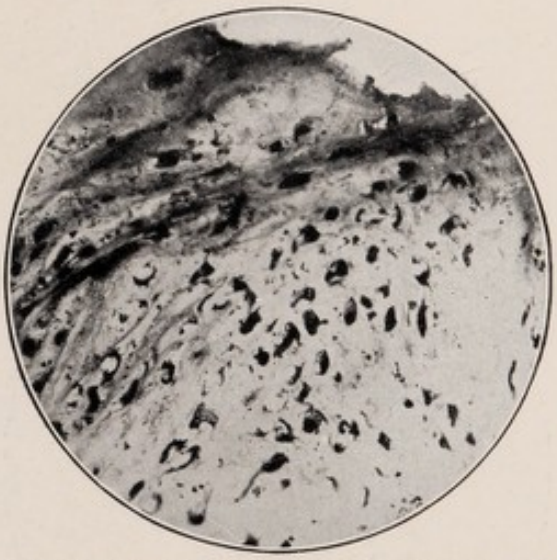

FIG. 373.—Myxomatous area in enchondroma of a phalanx. Note the stellate cells.

spontaneous fracture is a comparatively uncommon event. The clinical picture differs little or not at all from that of the solitary osteoma. The radiographic appearances are unmistakable, and in a long bone the origin of the chondroma from the interior of the growing end is generally well shown. The diaphyseal end of the affected bone may also show the changes typical of *diaphyseal aclasis* (Chapter XVI). *Removal* is indicated in a growing tumor which threatens to involve important structures. It is not sufficient to cut off the tumor flush with the surface of the bone; its roots within the cancellous tissue of the subepiphyseal zone must be curetted away, and the tumor bed treated with pure carbolic acid. Unless these precautions are taken recurrence is probable.

2. *Multiple Cartilaginous Exostoses.*—Diaphyseal Aclasis (p. 337).

3. *Multiple Enchondromata* not infrequently develop as multiple tumors involving a group of bones, the classical site being the small pipe bones of the hand. Such tumors may sometimes appear to be single, but radiograms almost invariably show chondromatous changes in adjoining bones. The enchondromata arise in the interior of a phalanx or metacarpal near its growing

end, but later tend to invade the remainder of the shaft. From such a beginning the enchondromatous change may proceed along one of three lines—(*a*) The pipe bone now transformed in its interior, may remain unaltered in shape or size, and after some years may undergo spontaneous reconstruction, the chondromatous area being replaced by mature bone; (*b*) solid cartilaginous tumors may push their way to the surface, forming multiple swellings easily appreciable on clinical examination; (*c*) liquefaction may occur with the production of a bone cyst, not easily distinguishable from the cyst of ostitis fibrosa (Fig. 362). The histological picture of the contents may simulate the rare pure myxoma. It is often possible to demonstrate all three phases in the different small pipe bones at the one time.

Operative treatment is often necessary as multiple tumors on the fingers soon tend to cause great inconvenience. The solid growths should be carefully resected, and their bases cauterised (pure carbolic acid). Where a bone cyst is present, curettage and cauterisation, or crushing, should be practised as in other types of cyst. Recurrence is probable unless a thorough technique is used.

Giant Cell Tumor

(Myeloid Sarcoma—Tumeurs à Myeloplaxes.)—The varied terminology applied to this tumor in the past has led to much confusion. By common

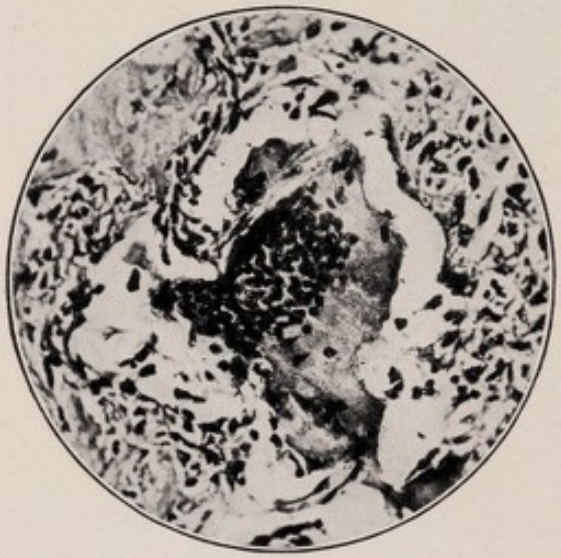

FIG. 374.—Giant cell tumor; typical giant cell.

consent the ordinary giant cell tumor is considered to be benign in its clinical course, but the occurrence of rare types in which pulmonary metastases have been identified cannot be disputed (Coley,[1] Finch and Gleave[2]).

Etiology and Morbid Anatomy.—The giant cell tumor is slightly more common in the female sex, and shows a predilection for the age period 15–30. A history of antecedent injury is usually forthcoming. In 80 per cent of cases the tumor involves one of the long bones and in the lower extremity twice as often as in the upper (Kolodny). The femur (lower end), tibia, and radius are the favourite sites. A similar histological type of tumor growing

[1] COLEY, W. B.: Am. Surg. Ass'n. 1919, vol. xxvii.
[2] FINCH and GLEAVE: Jour. of Path. & Bac., 1926, vol. xxix.

from the muco-periosteum of the lower jaw is well known under the title of *epulis*.

The typical giant cell tumor of a long bone begins as a central growth in the sub-epiphyseal region, and as it enlarges, induces a slow expansion of the cortex. The tumor tissue is composed of friable material, reddish brown in colour; certain areas often bear a close resemblance to red currant jelly, and there may be clumps of tissue which are stringy and fibrous. The white giant cell tumor is a rare but well recognised variation (Stewart[1]). The ordinary tumor is very vascular, and in the interior of the bone shell there may be liquid blood. In the solid tumor mass, cystic areas are often recognis-

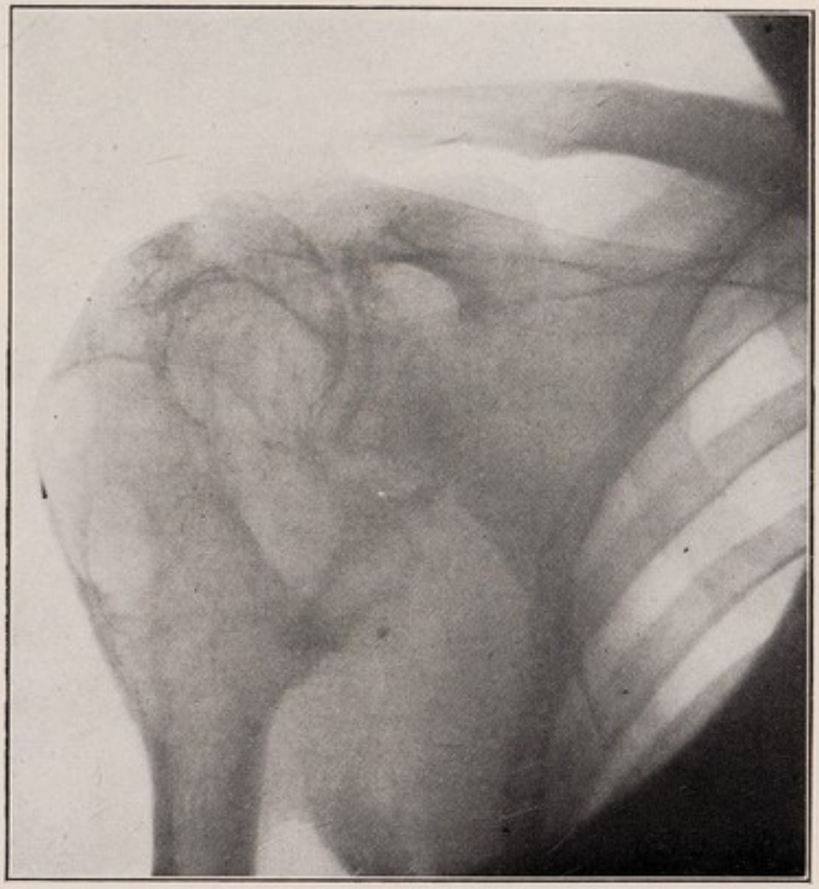

FIG. 375.—Benign giant cell tumor of the upper end of the humerus (Mather).

able. Bone expansion occurs in a somewhat symmetrical fashion, the shell remaining resistant until the later stages. Localised perforation may occur early in a tumor placed eccentrically. Certain giant cell tumors grow so slowly that the bone shell is intact at the end of many years. In this indolent type, changes occur which seem to represent an abortive effort to induce spontaneous healing.

Histology.—The tumor is composed of a cellular stroma in which large giant cells are scattered. The stroma is usually loosely packed, with cells of round or polygonal type. Thin walled blood spaces and hæmorrhages are familiar appearances. In addition, areas of fibrous tissue and osteoid bone may be discovered. The giant cells are absolutely specific, and are in striking

[1] STEWART, M. J.: Brit. Jour. of Surg., Jan., 1923, vol. x, No. 29.

contrast with the giant cells of sarcoma proper (Stewart[1]). The myeloid cell is large, contains many small nuclei (12 to 200) arranged in whorls, and in which mitoses are absent (Fig. 374). The histogenesis of the giant cell tumor is still the subject of much discussion and speculation. There are two main views.—(*a*) That the tumor is a true blastoma, both giant cells, and stroma cells being actual tumor elements; and (*b*) that the histological picture is simply the end result of an inflammatory process, the giant cells being of the foreign body type—the latter conception, originally, suggested by Barrie,[2] derives its chief support from the well established fact that giant cell tumor areas are found with unfailing regularity in ostitis fibro-cystica, a condition which is definitely known to be non neoplastic.

Diagnosis.—The clinical picture is that of localised expansion of bone, involving the end of one of the major long bones (femur, tibia, or radius). The swelling is generally painless; distended veins may be present, but the soft tissues show no signs of matting or infiltration. The classical sign of "egg shell crackling" is rarely demonstrable. In radiograms a giant cell tumor shows as a multicystic expansion of bone in the metaphyseal region. Coarse trabeculation is generally seen, and the bony shell is attenuated.

Prognosis.—As already stated, this tumor is a benign lesion. On the average its growth is exceedingly slow, and perforation of the shell occurs only after many years have elapsed. In the few authentic cases on record where visceral metastases have been observed, it is possible that malignant characteristics have been grafted on to a tumor originally innocent.

Treatment.—With the universal acceptance of this tumor as a benign lesion, conservative operations have been firmly established as the routine therapy. (*a*) Curettage with cauterisation has become the operation of choice, chiefly owing to the writings of Bloodgood. The bone shell is opened, the tumor contents evacuated, and finally the interior cauterized with pure carbolic acid, or by the thermo-cautery. Efficiently carried out, this operation is certain to be followed by complete and permanent cure. (*b*) Local *resection*, formerly recommended as a routine procedure, is occasionally necessary for mechanical reasons in extensive growths, or in cases of local recurrence.

Malignant Tumors

Malignant tumors of bone may be (*a*) primary or (*b*) secondary.

Primary Malignant Tumors

Many attempts have been made to evolve a comprehensive and useful classification of primary malignant bone tumors from the confused terminology which the vast literature on this subject affords. In recent years the foundation of the sarcoma Registry of the American College of Surgeons, at the suggestion of Codman, has done much to create order out of chaos. The many subdivisions of sarcoma, according to the type of cell, consistency of tissue, or site of origin, are difficult for the student to memorize. As in other intricate pathological fields, a simple broad grouping is most desirable. Kolodny[3]

[1] Stewart, M. J.: Lancet, November, 1914.
[2] Barrie: Annals of Surgery, 1913, vol. 57.
[3] Kolodny, A.: Surg. Gyn. Obs., April, 1927, Part II, No. 4, A.

in an elaborate monograph has suggested a classification which has considerable merits. In this four groups are recognised:

1. Osteogenic Sarcoma.
2. Endothelioma (Ewing's tumor).
3. Multiple Myeloma.
4. Unclassified { Extra periosteal fibrosarcoma / Angio-endothelioma / Myxoma

Osteogenic Sarcoma.—This title, originally introduced by Ewing, has been adopted widely in America in preference to the older and purely generic title, osteosarcoma. The choice of the term *osteogenic* was made with deliberation, in order to emphasise the view that the tumors to which it is applied, are derived from cells which are the ancestors of the specific bone cells (osteoblasts). The truth of this conception is very generally admitted, but has been challenged by certain French observers (Leriche and Policard) who regard the tumors as fibrous tissue sarcomata accidentally arising in the mature connective tissue matrix of the bone.

Osteogenic sarcoma is a comparatively rare tumor occuring most often in the male, and showing a predeliction for the second decade. The majority of the tumors involve the long bones, with a predominance of the lower limb—(Lower limb 90 per cent; upper limb 10 per cent). The incidence in the more important bones may be tabulated as follows:

	Percentage	Favourite Site
Femur	52 per cent	Lower end
Tibia	20 per cent	Upper end
Humerus	9 per cent	Upper end
Pelvis	5 per cent	Ilium

The fibula, forearm bones, scapula, and jaw, are less often affected, but sarcomata in these regions are by no means unfamiliar tumors. The smaller pipe bones are singularly immune. Osteogenic sarcoma occasionally develops in a bone already diseased—*e.g.* in Paget's disease, or very rarely, in multiple chondromata. A history of trauma is a very consistent feature, but the exact causal relation between injury and growth is difficult to define.

Morbid Anatomy.—It has long been the custom to distinguish between (*a*) periosteal, and (*b*) central sarcomata, but increasing knowledge has shown that there is no dividing line between the two conventional types. Bloodgood,[1] whose experience is unique, after a resurvey of a large mass of material, has emphasised the great rarity of central sarcoma, *i.e.* a sarcoma producing bone expansion after the fashion of the giant cell tumor or a simple cyst. The first nodule of growth may originate either under the periosteum, or in the cancellous tissue just beneath the cortex. There is no inherent difference between the two sites. Two routes of invasion are available for the early tumor, either towards the interior of the bone where the endosteal tissues put up a feeble defence, or along the surface of the cortex where the periosteal new bone formation provides a stout barrier at least for a time. The tumor tissue soon eats its way through the cortex, advancing in radiating lines, and pushing the sub-periosteal capsule before it. Perforation of the shell by

[1] Bloodgood, J. C.: Journal of Bone and Joint Surgery, 1926, vol. xxviii.

growth is ordinarily a later phase, but may result early when spontaneous fracture has occurred. Once the restraining action of the periosteal capsule has been eliminated, the growth extends rapidly into the soft tissues of the limb. The muscles are widely invaded, but the skin remains unbroken for a considerable time.

The naked eye appearances of the tumor tissue vary in accordance with its composite histology. Ordinary sarcoma tissue is reddish brown, and friable; this is modified by the presence of unusual vascularity, haemorrhages, myxomatous change, cartilage or bone. The histological picture is characteristic. The fundamental cell is a spindle cell, small or large. Giant cells may be

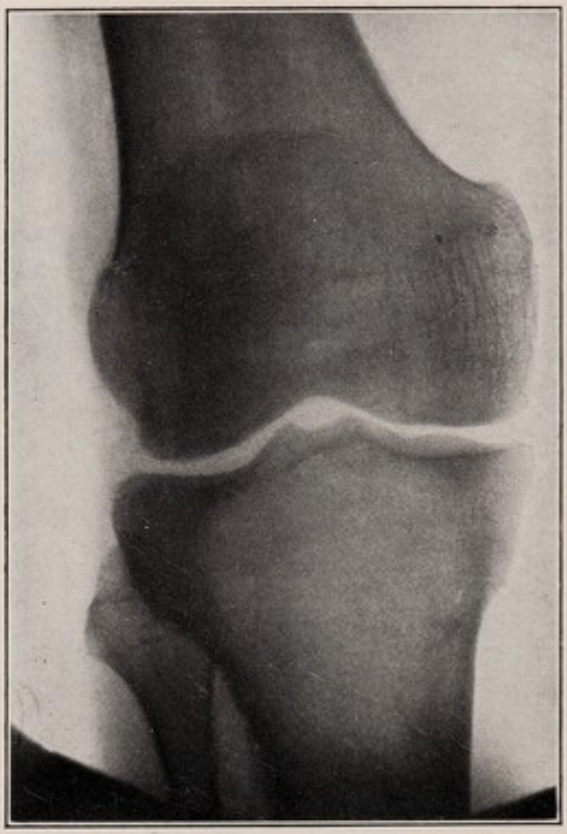

FIG. 376.—Central sarcoma of the upper end of the tibia. Death from lung metastases five years later. Patient aged 26 (C. Thurstan Holland).

scanty or plentiful; they are small in comparison with the myeloid giant cell, and contain one, or occasionally two or three nuclei. Mitoses of course are always recognisable. The matrix of the tumor shows many varieties of tissue derived from bone forming elements—hyaline, cartilage, myxomatous areas, osteoid bone, and mature bone. The blood vessels are invariably thin walled, and often contain clumps of tumor cells.

Clinical Picture.—(1) Pain in the affected bone is an early symptom, and is often complained of before the tumor becomes palpable. (2) The tumor exists as a swelling of the underlying bone, somewhat asymmetrically placed, and tender when handled. Matting of the soft tissues is usual, and the skin may be unnaturally pale, but nearly always shows considerable distention of the superficial veins. Pulsation and a bruit are occasionally

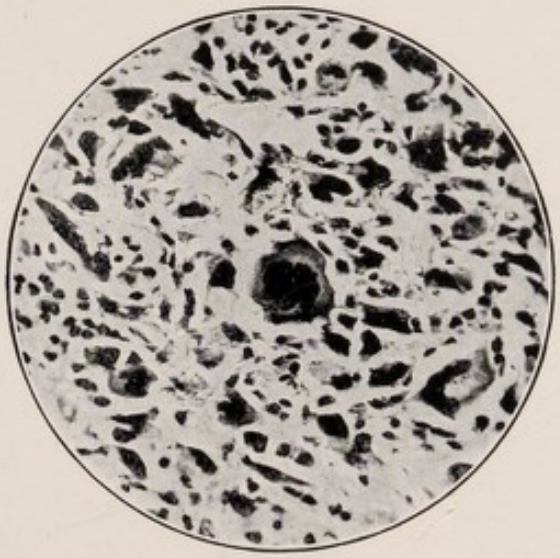

FIG. 377.—Osteogenic sarcoma showing giant cell in polymorphous stroma.



FIG. 378.—Osteogenic sarcoma of the upper end of the humerus. Patient aged 45 years. See radiogram, Fig. 379.

recognisable in vascular types of tumor. A mild effusion may appear in the neighbouring joint, but there is no limitation of mobility. (3) Spontaneous fracture may occur, and be the first sign to lead to a diagnosis. As sarcoma arises almost exclusively in the ends of the long bones, fracture is a less typical sequela than in metastatic growths which occupy the middle of the shafts. (4) In the early stages the patient's general health is generally unimpaired. (5) When dissemination of the tumor has taken place the patient goes down hill rapidly; metastases most often reach the lungs, and give rise to the symp-



FIG. 379.—Radiogram of osteogenic sarcoma of the upper end of the humerus. Same patient as shown in Fig. 378.

toms of cough, and blood stained expectoration. (6) X-ray appearances are often somewhat ill defined; there are certain changes suggestive but not actually diagnostic of sarcoma. These are, a spindle-shaped swelling with an indefinite outline, erosion of the cortex, and radiating lines of ossification at right angles to the shaft. (Figs. 379 and 380; 18 per cent cases only—Kolodny.) Undue emphasis has been laid on the latter sign, which occurs in inflammatory affections as well as in sarcoma.

Differential Diagnosis.—The extreme rarity of *central* sarcoma producing a localised expansion of the growing end of a long bone has already been stressed. When such a tumor occurs it may simulate a giant cell tumor, or a simple bone cyst. The latter gives a typical radiographic appearance, and will be encountered below the age of sixteen. Cysts which persist until

adult life are almost certain to have reached the middle of the shaft, a site where osteogenic sarcoma is practically unknown. The diagnosis between giant cell tumor, and central sarcoma is more difficult, and can be established only after exploration of the bone shell and a histological examination of the contained tissue.

Where there is a mass incorporated with the underlying bone, and where the radiogram shows not only destructive changes, but new bone formation on the surface, certain important lesions which may mimic sarcoma must be borne in mind. (*a*) Traumatic intramuscular ossification—although mistakes have been made in the past, there should be little difficulty in recognising this condition. There is a history of severe injury, followed by a considerable hæmatoma which does not subside. In the region of the hæmatoma a hard bony mass develops which is rarely painful, and which at first is often freely movable on the underlying shaft. In a radiogram the new bone is seen to be separated from the shaft by a clear zone, and the lamellæ are arranged parallel to its long axis; the bone cortex beneath the mass shows no signs of actual erosion. In the thigh, which is a common site for intramuscular ossification in the lower limb, the bony mass usually forms some distance above the lower end of the femur. (*b*) Sclerosing Ostitis — (Garré). In this affection there is an obvious thickening of the shaft of a long bone with subperiosteal new bone formation, and at certain stages, evidence of destruction. There is usually a long clinical history. The condition does not closely simulate osteogenic sarcoma, though it may be difficult to distinguish from the endothelioma (Ewing's tumor) which ordinarily involves the shaft of a long bone. (*c*) Syphilitic ostitis—the clinical and radiographic appearances of bone syphilis have already been described (Chapter XIV).

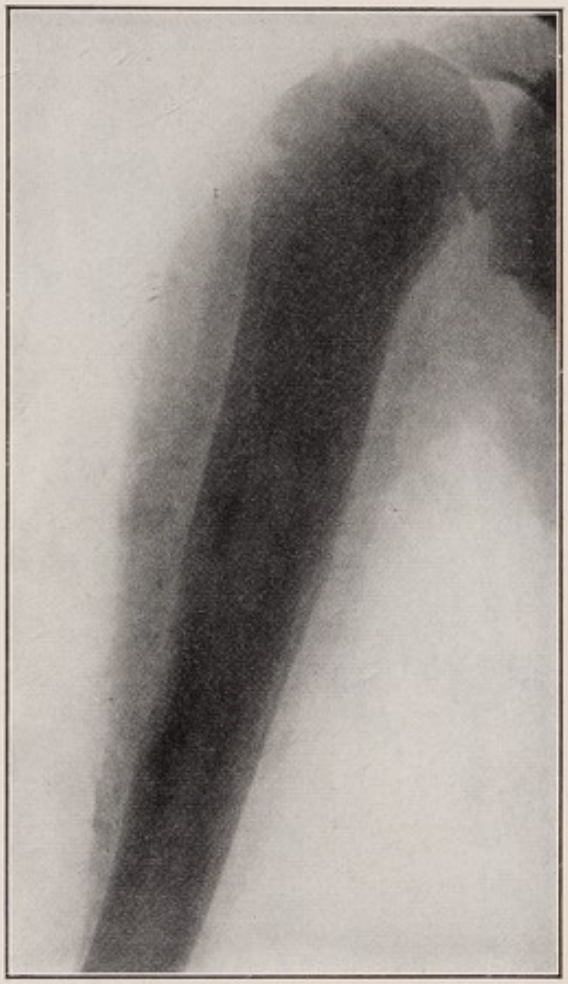

FIG. 380.—Periosteal sarcoma of humerus (C. Thurstan Holland).

Prognosis.—The outlook in osteogenic sarcoma, in spite of early diagnosis and treatment, is on the whole most gloomy.

Treatment.—Amputation is the method of choice where the absence of pulmonary metastases has been confirmed by clinical and radiographic examination. Disarticulation at the hip or shoulder is not necessary unless the tumor is situated in the upper part of the femur or humerus. The truth of this statement has been repeatedly confirmed. In the upper limb it may be possible to treat a small tumor by resection leaving a gap to be filled in later by

means of a bone graft. After the removal of the limb or tumor, the patient should be kept under observation, and treatment given in an endeavour to postpone the inevitable metastases. There are two forms of therapy well worth while; (*a*) regular injections of Coley's toxin, and (*b*) radiation. Coley's fluid, which consists of the toxins of the streptococcus and bacillus prodigiosus has been used for many years by Coley himself, both in inoperable cases, and following amputation or local resection. Although a scrutiny of many reported cures shows that the growths are of the giant cell tumor class, a few undoubted sarcomata have remained well after long periods. The toxin treatment, if given efficiently, causes great discomfort to the patient, but its importance should be urged. A weekly injection should be given, beginning with a small dose, and increasing it in stages. The patient should also be treated by means of deep X-ray emanations at intervals of three or four months with the hope that small pulmonary metastases may be killed. Intravenous injection of one of the lead compounds may also be tried (Blair Bell).

Few patients have been treated systematically following amputation for bone sarcomata, so that at the present time there are no statistics available. Experience has shown that after amputation, in the majority of sarcoma patients the symptoms of pulmonary metastases appear within three years. A few exceptional cases are said to have passed the five years' limit, but when this happens the diagnosis must be regarded with suspicion, and a careful re-study of the histological sections should be made. In inoperable sarcomata, Coley's fluid, and radium should always be given a trial.

Endothelioma (*Ewing's Sarcoma*).—This uncommon tumor appears to correspond to the *small round celled sarcoma* of the older classifications. In the opinion of Ewing and others, the tumor is both a pathological and a clinical entity, and should be separated from the osteogenic sarcoma group. Forty examples were recognised in 650 bone tumors collected in the American Sarcoma Registry up to 1927.

This tumor is found at the sarcoma age period, and shows preference for the long pipe bones, but tends to originate towards the *middle of the shaft.* The bones commonly affected are the tibia, fibula, ulna, and femur, in this order of frequency. Multiple tumors are by no means uncommon, and the metastases favour the skeleton and lymph glands rather than the thoracic or abdominal viscera.

The tumor cells invade the cancellous tissue widely, and on reaching the surface spread along the shaft for a considerable distance. There is usually a marked periosteal reaction, layers of bone being laid down in lines parallel to the shaft. The tumor tissue is greyish white, and friable. The dominant cells are small and polyhedral, arranged in clumps or groups, often in close relation to blood vessels. There are no giant cells, and no intercellular tissue. The concensus of opinion is that the tumor is an endothelioma, but its histogenesis is still sub judice.

The clinical course is unusually long. The tumor grows slowly, and ultimately forms a swelling which involves a considerable extent of the shaft of a long bone. Recurrent febrile attacks with exacerbations of pain and tenderness have been described. The radiographic signs closely resemble those of an inflammatory affection; there is no periosteal spindle as in the osteogenic sarcoma, and the new bone formed by the periosteum shows striations parallel with the shaft.

The diagnosis from pyogenic osteomyelitis and sclerosing osteomyelitis (Garré) is apt to be difficult until tissue is obtained for histological scrutiny. This type of primary malignant tumor is most responsive to radium and X-ray therapy. Complete disappearance of the tumor, with radiographic signs of healing have been recorded, but sooner or later recurrence is inevitable. The prognosis after amputation or radiation is, however, much better than in osteogenic sarcoma.

Multiple Myeloma.—This is a rare disease in which multiple tumors are found in the marrow of many bones at the same time. It was first described



FIG. 381.—Multiple myelomata of femur and pelvis. Patient aged 50 years (C. Thurstan Holland).

by McIntyre in 1850 under the term *mollities ossium.* The growths attack the long bones, vertebræ, skull, and other flat bones. The tumor tissue is composed of soft grayish red nodules which have a characteristic histology. The cells are of the plasma type, with variations, according to their origin from lymphoid, erythroblastic, or marrow progenitors. The tumors grow slowly, and remain within the cortex for some considerable time. Bone formation does not occur, and invasion of the soft tissues is a late event.

The affection is seen after middle life, and always terminates fatally. The bones soften and bend, or may fracture. Severe anæmia, and cachexia are usual in the later stages, and in one clinical type the lymphatic glands in many regions may be enlarged. Albumosuria (Bence-Jones' protein) is

discovered in about 50 per cent of all cases, but has not the diagnostic significance formerly attributed to it. When many bones are involved the clinical picture may resemble generalised ostitis fibrosa or multiple metastatic growths. The tumor areas appear in radiograms as localised zones of diminished density. In the earlier stages there is little or no sign or bone destruction. Myelomata of the *spine* may give rise to symptoms which closely mimic Pott's disease, and the patient may show temporary improvement when treated in recumbency by immobilisation (Osgood).[1] Treatment is usually of little avail, but fictitious improvement may be seen after radiation.

Atypical Sarcomata.—(1) *Angioendothelioma* is a very rare tumor considered to be a pathological entity, which behaves much as osteogenic sarcoma. (2) *Extra-periosteal sarcoma* is a term applied to a fibro-sarcoma arising in the outer layers of the periosteum. Such tumors do not invade bone; they remain



FIG. 382.—Extraperiosteal sarcoma of the left femur.



FIG. 383.—Specimen after disarticulation at the hip joint, from patient shown in Fig. 382.

encapsuled for a long time, and show little tendency to recur if effectively removed. (3) *Myxoma*—This tumor is considered by Bloodgood to be a definite entity, but by many authorities is regarded as a phase in the histology of either simple chondroma or osteogenic sarcoma. Bloodgood[2] has emphasised the tendency of the true myxoma to recur locally, and ultimately to produce metastases.

Secondary Malignant Tumors

Skeletal metastases are familiar in the later stages of carcinoma of the breast, prostate, thyroid, kidney, adrenal, and bronchus, and are occasionally seen in carcinoma of other internal organs. Such metastases may occur as part of a wide dissemination involving viscera and skin where the primary growth is known, and has been dealt with by operation; or not infrequently as

[1] OSGOOD, R. B.: Bos. Med. & Surgy. Jour., 188, 12, March 22, 1923.
[2] BLOODGOOD, J. C.: Annals of Surger, 1920, 70.

one or more isolated tumors with the primary growth remaining latent and undiagnosed. The shafts of the major long bones in the proximal parts of the limbs, the spine, pelvis, ribs, and skull are the common sites. The route by which the cancer cells reach the skeleton has been the subject of much controversy. Sampson Handley[1] has argued most ably in favour of the process of lymphatic permeation along the deep fascial planes. But Piney[2] has shown that no lymphatic channels exist in the bone marrow. The older view of

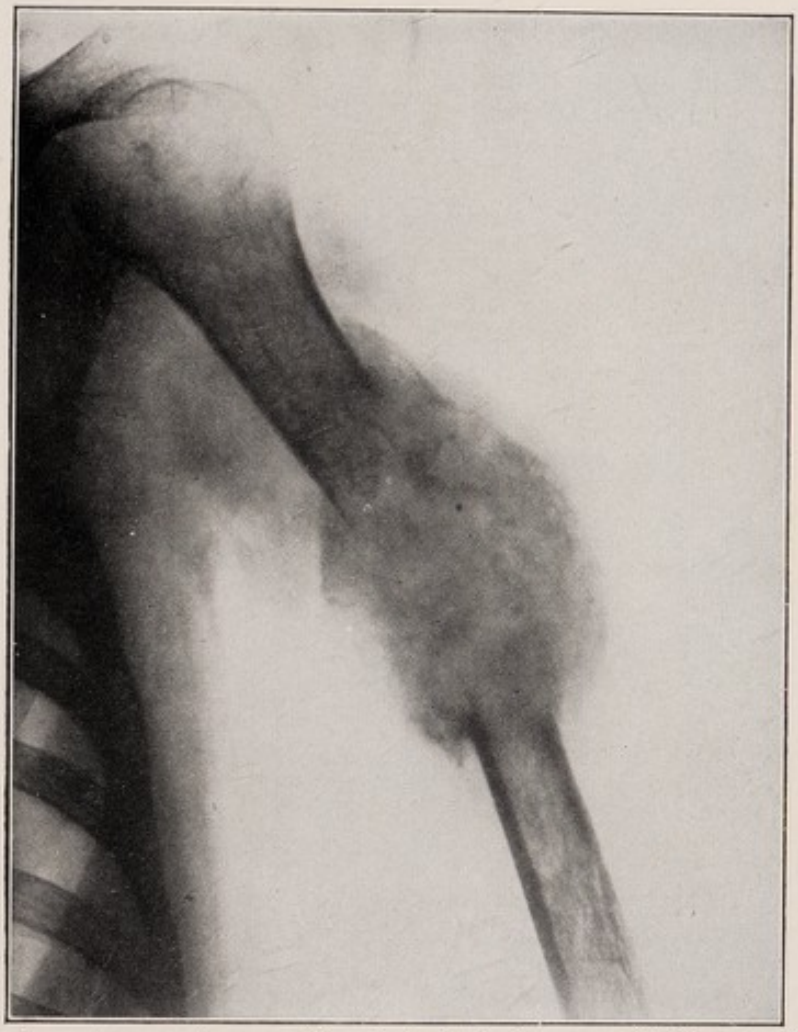

FIG. 384.—Secondary carcinoma of the shaft of the humerus (C. Thurstan Holland).

Von Recklinghausen that metastases result from the lodgement of malignant emboli in the capillaries of the bone marrow is generally accepted.

Secondary malignant bone tumors usually give rise to pain as one of the earliest symptoms; in the long bones spontaneous fracture may be the first sign to attract attention (Fig. 384). Spinal growths must be distinguished clinically from Pott's disease (Chapter X). Treatment of the growths per se is seldom indicated except when a single long bone is affected, and the primary tumor is latent. Resection or amputation may then be justifiable as a palliative measure. When operation is contraindicated, the patient should be treated by one of the appropriate forms of radiation, which often brings much comfort.

[1] SAMPSON HANDLEY: Carcinoma of the Breast (2nd. Ed.), London, 1922.
[2] PINEY: British Journal of Surgery, October, 1922.

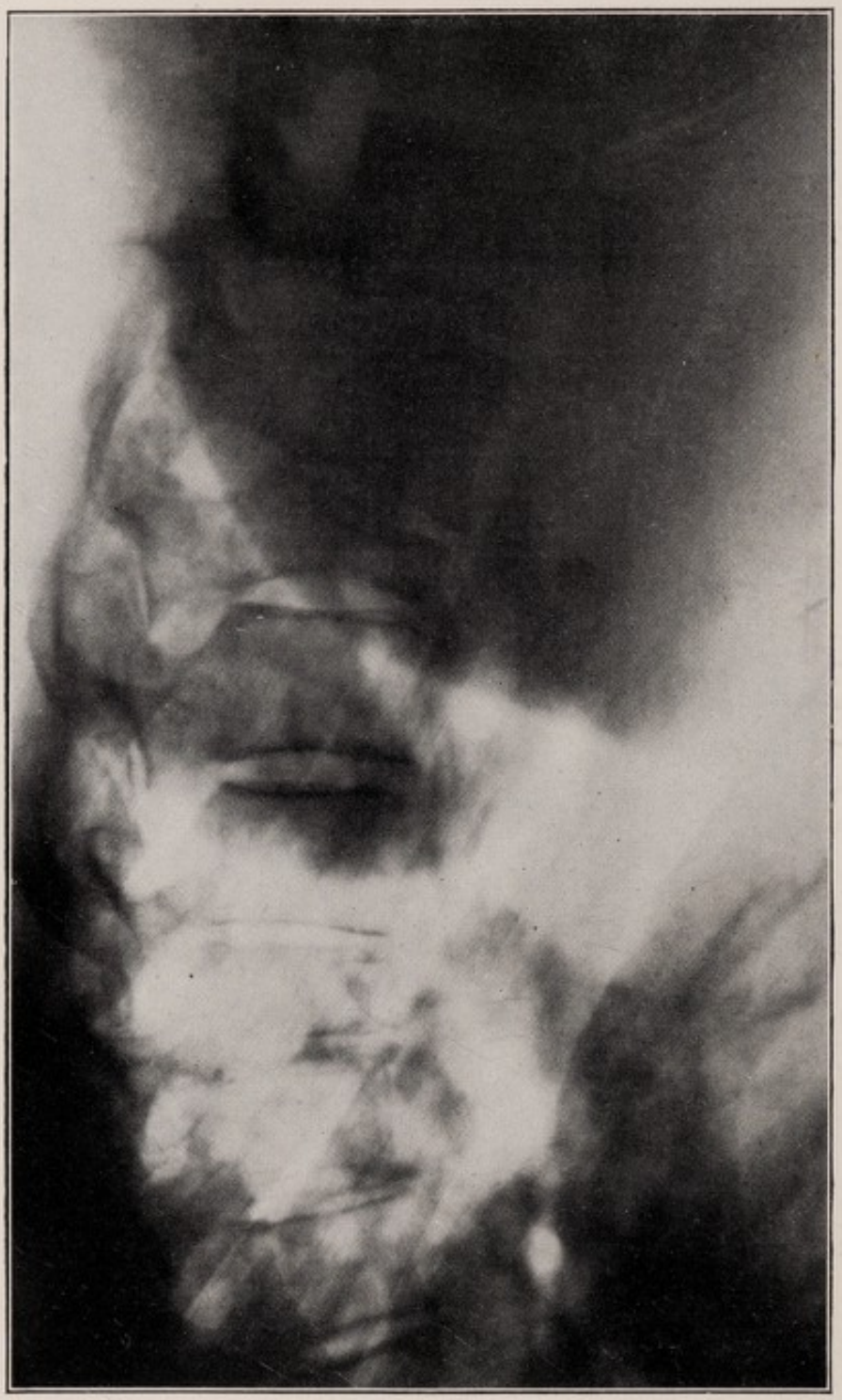

FIG. 385.—Secondary carcinoma of the spine (C. Thurstan Holland).



FIG. 386.—X-ray of osteoma of femur.



FIG 387.—Sarcoma of left femur (see Fig. 388).



FIG. 388.—X-ray of sarcoma of left femur (same case as Fig. 387).

CHAPTER XVIII

FRACTURES

Malunion—Delayed Union—Non-union

Preliminary Considerations.—Although the treatment of fractures, both recent and old, forms an integral part of orthopaedic surgery, it is impossible in a limited space to present this subject in the conventional manner.

The disabilities which result from fractures in the neighborhood of joints have already been discussed in Chapter V. The subject is now approached from a different angle, which involves a consideration of malunion, delayed union, and non-union.

We must remember that every fracture is a potential deformity and, if it becomes a deformity, will lead to impairment of function. The object of treatment is the restoration of complete function with the least risk and inconvenience to the patient. A clear idea is therefore needed of the disabilities and deformities most likely to occur after fractures in each particular region, and also of the special difficulties encountered in treatment.

The smooth working of a limb depends on the preservation of the true axis of movement of the joints, so that the stresses of muscular action may act across the joint in normal lines. Abnormal stresses will produce abnormal strains, for we are dealing with living bone in accordance with Wolff's law which is the physiological equivalent of that universal law, "Strain is proportional to stress."

In fractures of the shafts of long bones the first essential is to secure and maintain true anatomical alignment so that the axes of movement of the joints at the two ends of the bone may retain their correct relationship. The best result is obtained when the fragments at the seat of fracture are brought into correct reposition. Slight overlapping, however, provided the alignment is good, may result in perfect function, while so-called end to end apposition, if the alignment be faulty, may result in very imperfect function. A faulty alignment, whether there be end to end apposition or not, means erroneous deflection of body weight, a cross strain on the fracture, and a stretching of certain structures in the joints which lie above and below the fracture. This is especially exemplified in the knee and ankle.

In fractures near joints, or involving the articular ends of the bones the difficulties of treatment are greater. True alignment, especially of the axis of movement, is still of paramount importance, but there is the additional difficulty that small fragments of displaced bone, or an excess of callus which would be of little importance in a fracture of the shaft, may here get into the way and block movement. The ends of long bones consist, as we know, of cancellous bone containing red marrow. They are extremely vascular and are ready to undergo changes on very slight provocation, hence any conditions which maintain local irritation will tend to increase the amount of bone formation with consequent obstruction of movement (see Chapter V).

MALUNION

Malunion of a fractured bone is usually evidence of inefficient treatment. It is due to errors either in the initial setting, in the method of maintaining the fracture in position, or in after treatment.

DELAYED UNION

The difference between delayed union and true non-union is not always easily defined. We sometimes find that even after a delay of many months osteogenetic changes leading to consolidation ultimately take place. The period of consolidation of fractures shows much variation. There may be several weeks of apparent inactivity in callus formation, followed by rapid consolidation. Many cases of true non-union are directly due to nervous apprehension on the part of the surgeon who, being

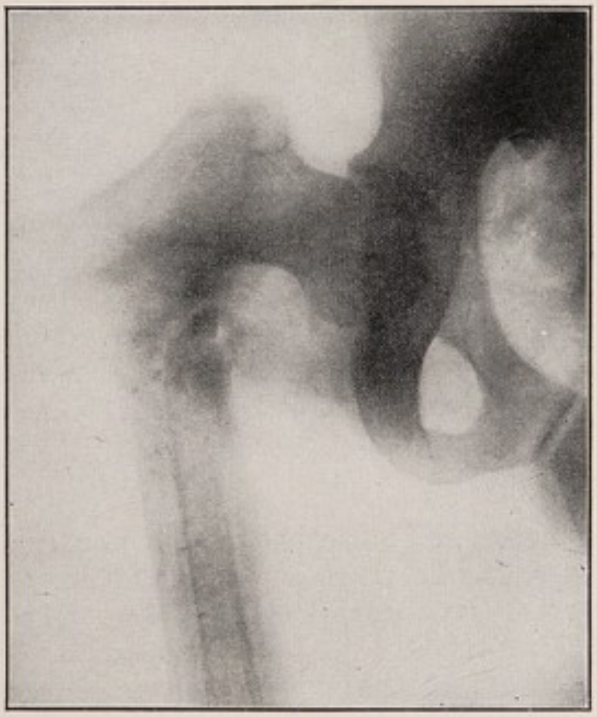

FIG. 389.—Malunion of upper end of femur—X-ray.

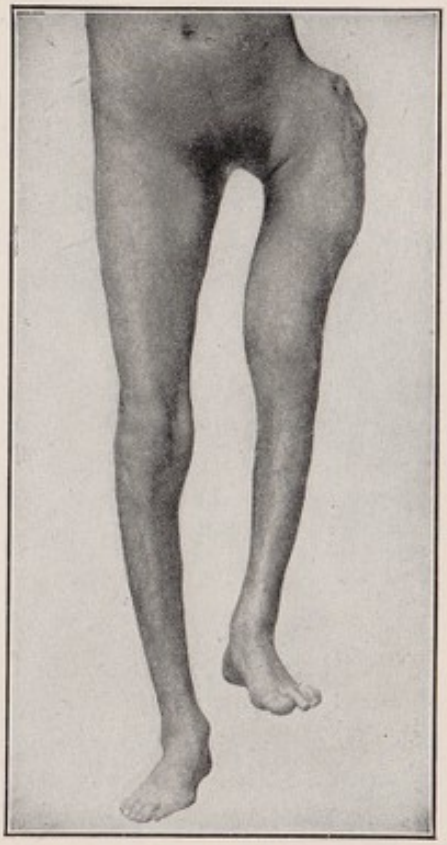

FIG. 390.—Malunion of upper end of femur—Position of patient.

alarmed at the delay, disturbs the bone ends by operation, thus transforming into a permanent disability a condition which merely demanded patience. Delayed union is most common in the middle third of the femur; in the humerus at the middle third, and in the tibia and fibula at their lower third.

The principal cause of delayed union is inefficient reduction. A fundamental principle is to secure and maintain good length and good alignment, and in attaining this, care should be taken that the circulation of the limb is not unduly hampered. If these precautions were universal we should hear very little of non-union. It is because plaster of Paris often fails to secure length and often hinders adequate blood supply that great care should be taken in its application. It is very rare to find muscular interposition in recent fractures except where marked overlapping exists or where a fragment has penetrated muscle. In

compound fractures the free removal of loose pieces of bone is often followed by failure of union. Over-extension may also inhibit union and in fractures of the humerus especially should be avoided. These are the chief local causes of delay. The influence of certain general factors must also be considered. Union is slow in patients of advanced age, or in individuals suffering from acute disease or syphilis. In cases of non-union where such special causes are not apparent, the calcium and phosphorus content of the serum have been found to be much diminished[1] (Petersen).

Prevention of Delayed Union.—To prevent delay in union therefore we must secure:

(*a*) satisfactory reduction, with correct alignment and length.

(*b*) satisfactory circulation to the limb,

(*c*) freedom from meddlesome interference,

(*d*) protection from the effect of body weight on soft callus,

(*e*) patience in transverse fractures in certain sites—such as the middle third of the femur, or the tibia and fibula at the junction of the middle and lower thirds.

Treatment of Delayed Union.—Stimulation of the bone ends and local congestion as practised by H. O. Thomas should be tried when delay occurs. Two pieces of indiarubber tubing are tied round the limb, one three or four inches above the fracture, and the other an equal distance below. They are kept on to begin with for about twenty minutes each day until they can be borne for several hours at a time. They should be sufficiently tight to produce considerable swelling and stasis between the tubes but not below. Occasional percussion of the fractured area will often expedite union. Under such treatment we can recall many cases where union has occurred even after long months of delay. If fractures were treated efficiently delay and non-union would be very rare indeed.

NON-UNION

When the bone ends become eburnated and absorbed and a gap exists between them, with or without an actual pseudarthrosis, non-union may be stated to exist. In the various stages of bone absorption and reconstruction radiograms should be consulted. Weak and delayed union may be diagnosed by the presence of tenderness on pressure over the site of the fracture and especially when this is accompanied by exuberant callus exudation. Such callus exudation and tenderness, especially when occurring in old people, has often given rise to a diagnosis of malignant disease of the affected bone.

Treatment of Non-union.—This may be (*a*) Mechanical or (*b*) Operative. The *mechanical* treatment consists of the wearing of a leather or celluloid sheath for the upper limb, and a weight-bearing apparatus for the lower limb. In a fracture of the femur, a splint of the caliper type running into the heel of the boot and supporting the heel of the boot and supporting the ischium is indicated. In fractures of the fibula a short brace is required which secures slight inversion of the foot. In non-union of the tibia a short caliper reaching from the heel of the boot to below the knee together with a leather case fulfils the need. Such measures are merely palliative and are adopted only where age or the condition of the limb renders operative attack inadvisable.

Operations for Non-union.—Whatever method of internal fixation of the fracture is adopted, it is essential to excise freely the fibrous tissue which

[1] Petersen: Journal of Bone & Joint Surgery, Oct. 1924.

surrounds and covers the bone ends, and to trim those ends until vascular bone is exposed. In non-union following compound fractures the scar excision is often best performed as a preliminary operation, in order to avoid the danger of a recrudescence of infection. If the wound heals without untoward reaction, the second stage operation of fixation may be attempted in some three to six weeks. Various methods of maintaining approximation and fixation of the refreshed ends are available.

(1) *Forcible Impaction.*—The distal fragment may be forced into the enlarged medullary canal of the proximal fragment. This is occasionally practicable in fractures of the middle of the humerus.

(2) *Stepcut Operation.*—Where additional shortening is of little moment, as in the upper limb, fixation by the stepcut is an excellent method. The bone ends are split vertically for some 1½″ to 2″ along a line which divides the shaft into two flanges, one thick, the other thin. The thinner flange is cut away from each fragment, thus creating a "step" which allows a close apposition of the remaining flanges. Fixation may be obtained by means of transfixion pegs or pins, or by a Lane steel plate.

(3) *Intramedullary Pegging.*—Where it has been possible to obtain suitable bone surfaces the fragments may be controlled by means of a peg introduced into the medullary canal. The peg may consist of ivory or "beef" bone.

(4) *Bone Grafting.*—This is the most certain method of treating non-union, for it involves the introduction into an area of defective osteogenesis of a strut composed of living bone. On the exact physiological rôle played by an autogenous graft there is considerable diversity of opinion. The histological changes which follow its insertion have given rise to conflicting interpretations. It is certain that many of the bone cells in the graft die, while others survive and are able to initiate osteogenesis in the graft itself. But union of the graft seems to be primarily dependent on the initial osteogenetic reaction in the host at the points of contact. From here the process extends into the graft itself. Thus the bone graft should be valued firstly as a strut, and secondly as a conducting bridge. Too much reliance should not be placed on its own somewhat fickle productive powers.

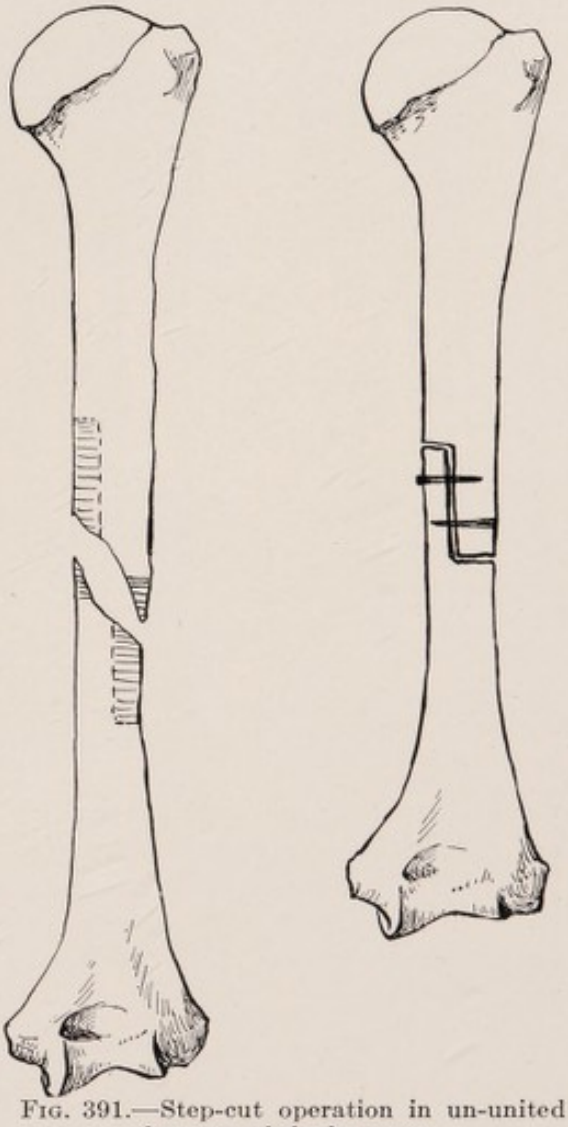

FIG. 391.—Step-cut operation in un-united fracture of the humerus.

Autogenous grafts are most commonly taken from the *shaft of the tibia*, and the graft may be inserted by the inlay method or may be used as an intra-

medullary peg. Other sources may be used as occasion demands, *e.g.* fibula, crest of ilium.

Technique of the Inlay Bone Graft.—A motor-driven saw and drills are an essential part of the surgeon's armamentarium.

(*a*) The graft bed—After the bone ends have been prepared and brought together in correct alignment a gutter is cut for some 2½ to 3 inches in both fragments. Drill holes are now made in both walls of the gutter through which are carried stout sutures, each with a loop which is to pass over the graft. (Fig. 392). The size of the gutter is ascertained by calipers and the wound packed pending the arrival of the graft.

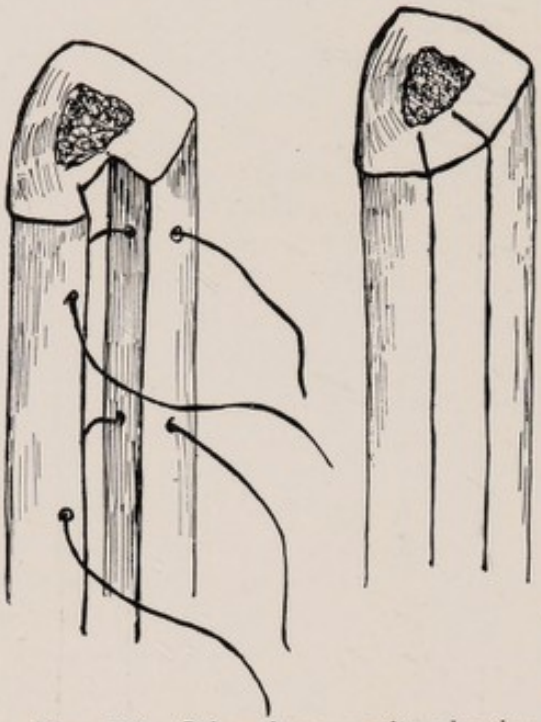

FIG. 392.—Inlay bone graft; showing construction of gutter and method of inserting sutures.

(*b*) The graft—The subcutaneous surface of the tibia is exposed, and the dimensions of the graft marked out by notching the periosteum. The graft may include the crest of the bone if extra strength is desirable. The graft should be cut slightly wider than the gutter in the host bone. A periosteal covering should be retained, and it is also an advantage to include with it a flap of the sheath of the tibialis anticus. (Hey Groves.)

(*c*) The graft is wedged into the gutter and fixation is finally assured by tying the sutures.

The operation is not always as simple as would appear and variations in technique must sometimes be adopted. Thus one end of the graft may be fixed by the inlay method and the other impacted into the medullary canal as a peg. Where it is impossible to cut a symmetrical gutter in a misshapen or fragile bone, the cancellous surface of the graft may be simply apposed and fixed to the host bone by suture or pegs.

Careful fixation of the grafted fracture is an essential feature of the post-operative treatment and the progress of the union should be followed in radiograms.

Fractures of the Femur

(*a*) **The Neck and Upper Third.**—Fracture of the neck of the femur, occurring in patients from the age of twelve to seventeen is sometimes overlooked because it is apt to be an incomplete fracture. It is a rare injury in adolescence, and is confused with separation of the upper femoral epiphysis. *Separation of the upper epiphysis* of the femur may follow a slight injury, etc. the patient being up and about, or it may be mistaken for an early affection of the hip joint. Shortening is present; there is limitation of movement, chiefly of abduction and rotation, so that, if a further strain occurs, complete disability of the hip is likely to result. In these cases the X-ray shows a coxa vara of the epiphyseal type with partial or complete separation of the epiphysis from the neck of the femur. The existence of this condition is suggested by

(1) a single strain of an adolescent hip, followed by disability and pain on abduction; (2) a slight injury, followed by pain on abduction, with shortening;

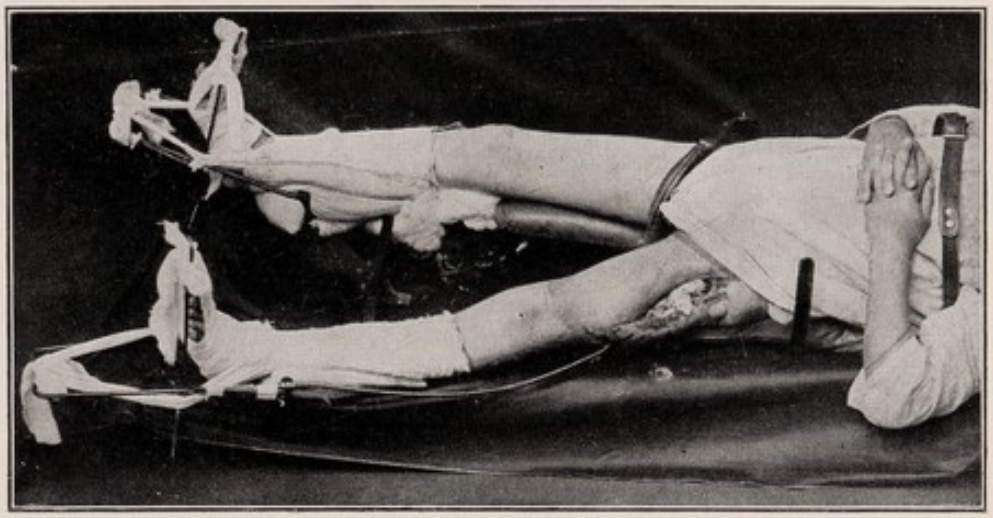

FIG. 393.—Case shown in Fig. 390 under treatment in an abduction frame after osteotomy.

(3) a strain followed by complete disability and elevation of the trochanter. This usually indicates complete separation of the epiphysis, and if such cases are neglected they develop into well-marked cases of coxa vara, with the hip rigid in adduction and slight flexion.

A recent case should be immediately fixed with extension, internal rotation, and abduction to anatomical limits. By this means the sliding head or fractured neck is placed in its proper relation to the shaft. If all deformity is corrected, fixation in a plaster of Paris spica or abduction frame should be continued for about three months, *i.e.*, until consolidation has occurred.

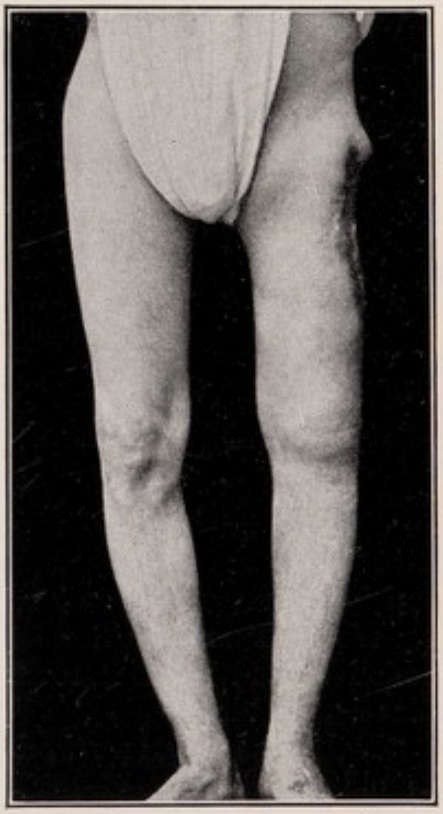

FIG. 394.—Result in case shown in Figs. 390 and 393.

If the case is not a recent one, the treatment is the same, but traction may be required to bring the neck into position and such a case should be held in fixation for three months. If the deformity cannot be corrected by *manipulation* and abduction with traction, open operation may be tried. Through a Smith-Petersen exposure the hip-joint is opened, and the displaced epiphysis replaced on the neck. Wilson, P. D.[1] and Key J. A.,[2] have each reported excellent results from this method of treatment. The after-treatment is the same as that given when replacement of the epiphysis is accomplished by manipulation *i.e.* abduction in plaster spica for twelve weeks. On getting about, protection of the neck of the femur from weight-bearing is necessary and may be secured by means of a caliper splint or the protection splint described on page 154.

[1] WILSON, P. D.: Jour. A. M. A., 1925.
[2] KEY, J. A.: Journ. Bone & Joint Surg., July, 25.

Fracture of the Neck of the Femur in Adults.—Although this is the traditional fracture of old people, the injury is often sustained by individuals in the prime of life. Two anatomical types are recognised—(*a*) basal, and (*b*) subcapital—a classification which has replaced the old distinction between the so-called extra-capsular and intra-capsular fracture. True impaction may be present, but most commonly the fragments merely interlock. The injured limb is often capable of bearing weight immediately following the accident and for this reason the fracture is sometimes overlooked until a later date. The characteristic deformity is eversion of the limb. Shortening and elevation of the trochanter may be barely appreciable, but limitation of the range of abduction and internal rotation is usually present. The fracture should always be suspected in an elderly patient who has fallen on to the hip or sustained a forcible eversion twist of the lower limb. The results of treatment of fracture of the neck of the femur leave much to be desired, as a laissez-faire attitude is still popular. Royal Whitman[1] of New York has done much to put the treatment of this injury on a rational basis and has shown that correct mechanical treatment is applicable to patients of all ages with very few exceptions. The deformity should be corrected under anaesthesia without delay. After disengaging the fragments strong traction should be exerted and the limb brought into full abduction at the hip with the thigh internally rotated.

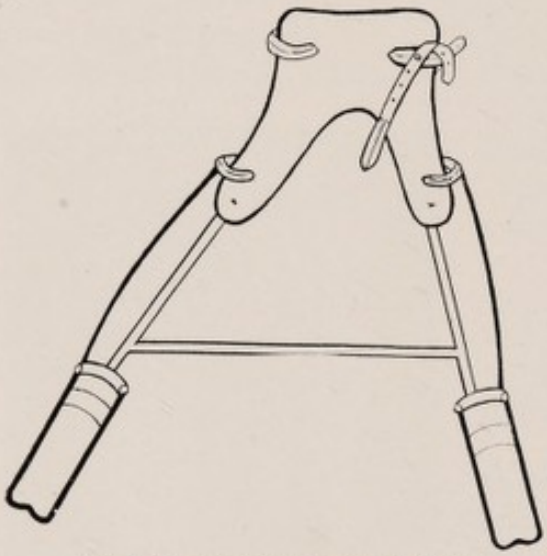

Fig. 395.—Short abduction frame.

Adequate fixation should now be provided. Whitman's own method is to apply a long plaster of Paris spica which facilitates subsequent nursing. In elderly patients the head of the bed is elevated and in exceptional circumstances the patient may be placed in a chair at the end of a few days. Alternatively, the patient may be treated on an abduction splint modified so that the body wings do not extend beyond the lower chest. (Fig. 395.)

The period of recumbency usually lasts for three months. On removal of the plaster, particular attention should be directed towards restoring mobility of the knee by appropriate physiotherapeutic measures. If the patient has been nursed on a frame, light massage can be employed at an earlier stage.

Weight bearing is first attempted in a caliper or Bradford abduction splint which should be discarded when consolidation of the fracture has taken place.

If the abduction method is properly applied bony union should result even in old people. Waldenström[2] has obtained bony union in 50 per cent of patients over seventy years of age, and Willis Campbell[3] in a considerable series has reported bony union in 89 per cent. These results bear out the claims which Whitman has made for many years.

[1] Whitman: Annals of Surgery, January, 1925.
[2] Waldenström: Journal de Chirurgie. Aug., 1924.
[3] Campbell: Journal American Medical Association Oct., 1923.

In late years the operative treatment of recent fractures of the femoral neck in patients of suitable age and physique has been advocated by Delbet and others. The technique used most frequently has been the introduction of a peg or metal screw through the trochanter and across the line of fracture into the femoral head. Excellent results have been obtained by this method, but in the practice of the majority of surgeons open operations are reserved for the treatment of the disabilities which follow the old neglected fractures.

Treatment of Old Fractures.—It should again be emphasized that the disablement which follows a fracture of the femoral neck is all too often



FIG. 396.—Brackett reconstruction operation.

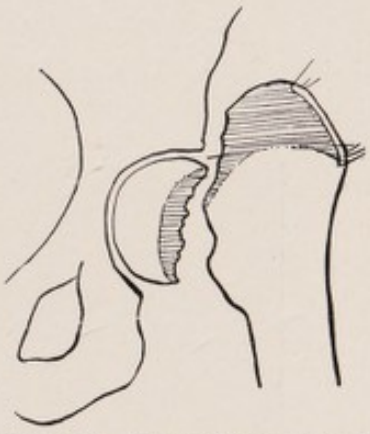

FIG. 397.—Brackett reconstruction operation.

evidence of neglect. Malunion and non-union are still familiar sequelae of this injury. Occasionally, when sound union in fair position has been obtained, a painful hip with a limited range of movement is found. These symptoms may indicate the presence of traumatic arthritis, or adhesions in and around the joint capsule. Traumatic arthritis will usually respond to a period of rest and protection from full weight-bearing. Limitation and pain due to adhesions is best dealt with by judicious manipulation under anaesthesia (see Chapter V).

Malunion is represented by shortening, eversion, and adduction. It is often wiser to ignore a moderate deformity and to treat the painful adhesions and traumatic arthritis which contribute so much to the disablement. If the deformity is extreme an osteotomy may be performed.

Where *non-union* has resulted, the patient is usually unable to bear the slightest weight on the limb and must face the lifelong wearing of a supporting splint (*e.g.* a caliper with bucket top) or some form of operation. In the old and feeble, conservative treatment only is to be advised.



FIG. 398.—Brackett reconstruction operation.

Of the operations which have been designed for the relief of this disability the following may be considered:

1. *Bone Grafting.*—This procedure is suitable only in younger individuals and where absorption of the femoral neck has not taken place. The fractured surfaces are exposed and refreshed through the ordinary anterior approach to

the hip. Through a separate incision over the lateral aspect of the trochanter, the neck is drilled and a tibial bone graft driven from without inwards to engage in the cancellous tissue of the femoral head. The hip is then fixed in abduction.

2. *Brackett*[1] *Reconstruction Operation.*—The tip of the trochanter is detached, and the raw surface now exposed, including the refreshed fractured surface of the base of the neck, is brought into apposition with the hollowed out under surface of the femoral head. A stable hip should result. (Figs. 396–398.)

3. *Whitman Reconstruction Operation.*—(See p. 260, Chap. XI.)

Separation of the Lesser Trochanter

This injury is usually a traction fracture and occurs in adolescents. The process is torn off either by an active contraction of the iliopsoas or by sudden

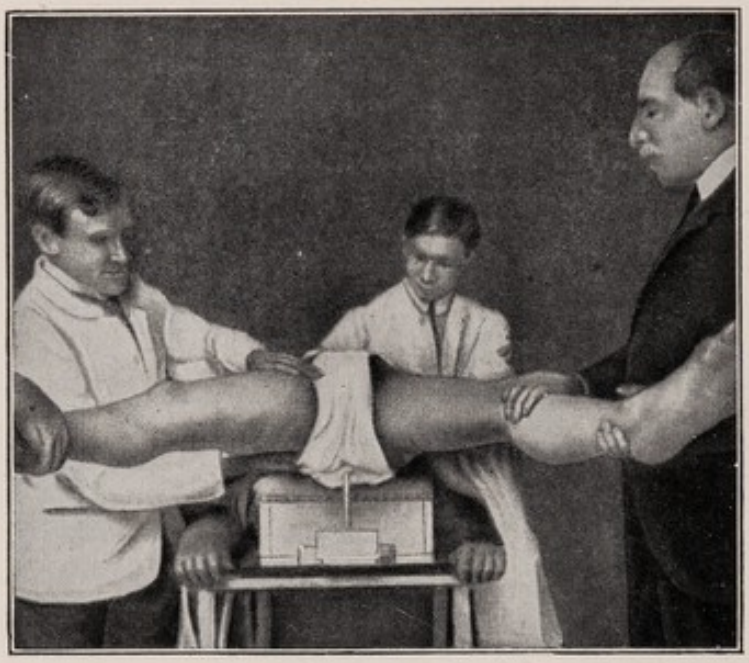

FIG. 399.—The abduction treatment of fracture of the neck of the right femur, illustrating the reduction of the deformity by direct traction and abduction. The operator supports the joint. The left limb is abducted to indicate the normal range, which varies in different subjects, and to prevent tilting of the pelvis. The perineal bar is not shown (Whitman).

overstretching of this muscle. The symptoms are often trivial; a characteristic sign is inability to flex the hip in the sitting posture (Ludloff). The detachment is usually well shown in a radiogram. Perfect functional recovery is the rule if the hip is fixed for a fortnight in moderate flexion and slight internal motion.

Fracture of the Shaft of the Femur. *Recent Fractures.*—Malunion occurs more frequently in the shaft of the femur than in any other bone of the body, and is due either to incomplete reduction of the initial displacement, inadequate control of the fragments during the stage of healing, or to the influence of weight bearing without protection before consolidation is complete.

In fractures of the upper third the proximal fragment is short and tends to be flexed and abducted. In the middle third, overlap with sagging which obliterates the normal anterior convexity of the thigh must be combated. In the lower third the distal fragment is usually tilted backwards.

[1] BRACKETT: Boston Med. & Surg. Journal. June 4, 1925.

In the first aid treatment of fractures of the femur it is now the custom to fix the limb before removing the patient from the scene of the injury, using the Thomas splint with direct traction on the boot, after the method employed in the latter part of the European War (1914–1918). On admission to hospital the fracture should be definitively splinted under anaesthesia, correct alignment and length being obtained at the outset. From this stage onwards the potential deformities should be ever present in the mind of the surgeon.

Angulation is prevented by lateral pressure; posterior sagging by the proper adjustment of the "master" sling behind the fracture. *Overlap* is impossible if efficient traction is maintained. In compound injuries with laceration of the soft parts it may be necessary to use direct skeletal traction,



FIG. 400.—Ununited fracture of neck of femur.

either by the ice-tong caliper or by a transfixion pin through the crest of the tibia. The period of fixation and traction on the Thomas splint extends over some six to eight weeks and at regular intervals the position of the fragments is checked by radiograms. A carefully fitted caliper splint is supplied and weight-bearing attempted after the tenth week. Mobilization of the knee joint demands assiduous care. Operative fixation in recent fractures must be comtemplated occasionally, but cannot be advocated as a routine method. Transverse fractures may be pegged and oblique fractures controlled by a Lane plate.

Treatment of Malunion.—If deformity has occurred during the early weeks before consolidation is complete, it is usually possible to obtain correction by simple mechanical means.

Angulation and overlapping can often be overcome by lateral pressure and strong extension. It may be necessary to assist by a preliminary *manipulation* under an anaesthetic. When consolidation is present, operation is called for. If there has been recent sepsis, correction of the deformity by open operation should be postponed until the condition of the limb suggests that



FIG. 401.—Correction of angulation by osteotomy



FIG. 402.—Correction of overlapping and angulation by osteotomy.

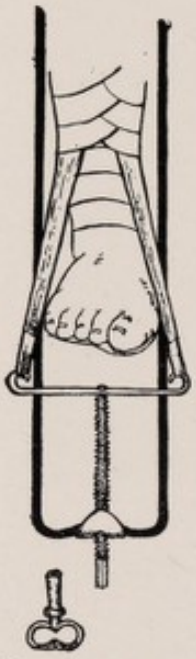

FIG. 403.—Screw extension for use with Thomas knee splint.



FIG. 404.—Traction applied by means of Thomas splint.

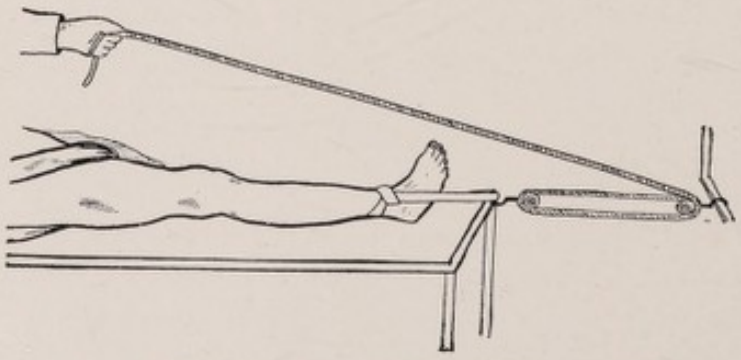

FIG. 405.—Traction to reduce fracture of femur.

the risk of producing a "flare up" is minimal. In a badly nourished limb with much scar tissue the operative correction of malunion should be approached with a serious sense of responsibility. If possible stiff joints should be mobilized before refracture is attempted.

For angulation or rotation an osteotomy is usually sufficient to restore alignment. Where union with overlapping has followed a simple fracture, after the bone ends have been refreshed, an attempt should be made to bring them into correct relationship. If there has been much suppuration and scar tissue abounds, it may be wise to ignore the overlap and to correct the angulation alone. In the choice of operation the surgeon will be guided by radiograms. Ordinarily, the line of bone section should traverse the angle of deformity.



FIG. 406.—Genu varum, following fracture of lower end of femur two and one half years before—X-ray.

After refracture, whether by manipulation or operation, correct alignment and the length of the limb should be restored by strong traction applied by means of pulleys (Fig. 405). The fractured ends should be moved freely in all directions to disengage the restraining fibrous tissue. If full length cannot be obtained at one sitting, the limb is placed on the Thomas splint and a few days later a further application of the pulley is carried out. By such means lengthening of three or four inches may be secured.

A malunion fracture of the femur cannot be cured by operation alone. The operation merely provides the surgeon with a recent fracture which demands adequate mechanical control until sound union has occurred.

Fractures in the Neighbourhood of the Knee Joint

Supracondylar Fracture of the Femur.—In this injury the backward tilting of the distal fragment is the most important mechanical consideration. Under steady traction combined with a pressure pad, the displacement can

always be prevented or rectified. If union takes place with the displacement uncorrected a Genu recurvatum results. This is not only unsightly but is often a considerable disability. Correct alignment should be restored by means of an osteotomy.

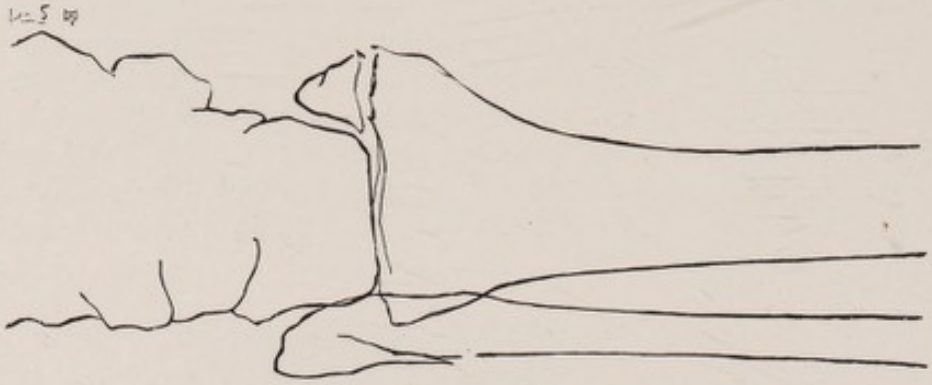

Fig. 407.—External rotation fracture, antero-posterior view.

Separation of the Lower Epiphysis of the Femur.—This injury is apt to be compound and gross displacement may be seen. Usually the lower end of the diaphysis protrudes backwards and may compress or tear the popliteal vessels or nerves. Reduction is ordinarily possible by manipulation, but



Fig. 408.—External rotation fracture—lateral view.

where there has been delay in treatment an open operation is sometimes demanded. When reduced the fragment is best retained by placing the knee in flexion as in comparable injuries about the elbow joint. This position should be maintained for some three to four weeks. Extension should be restored by gradual stages.

Fracture of the Femoral Condyles.—These may occur as isolated injuries or as part of a T-shaped fracture. The line of fracture enters the knee joint

and considerable interference with function is likely to result. If displacement is unreduced characteristic deformities may develop. Fracture of the *inner condyle* may be followed by genu-varum, fracture of the *outer condyle* by genu-valgum, deformities which may necessitate osteotomy at a later date. Prompt



Fig. 409.—Abduction fracture with diastasis at inferior tibio-fibular joint.

reduction by manipulation followed by traction with the knee extended should be tried. If the fragment does not remain in accurate position it should be pegged or nailed.

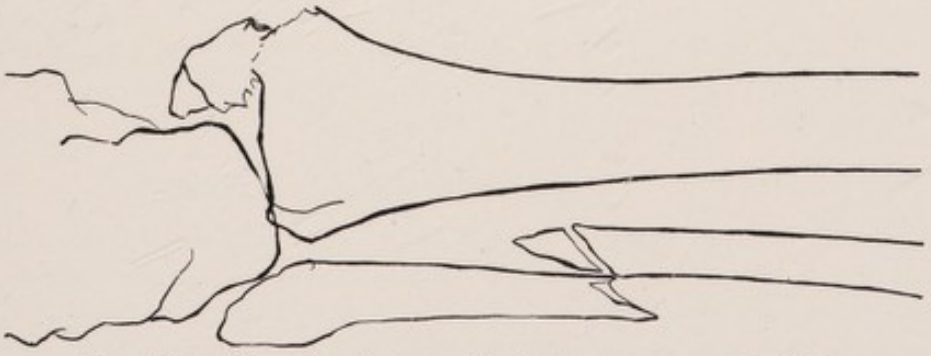

Fig. 410.—Abduction fracture: fibular fracture unusually high.

Fracture of the Tibial Tuberosities.—Disturbance of the articular surface of the tibia and late deformity are seen where displacement persists. If it is impossible to restore correct alignment by pressure and traction, the displaced fragment should be fixed by peg or nail.

Fractures of the Patella

These fractures are treated by open operation almost as a routine. Absorbable suture material should be used whenever possible. Stiffness and adhesions may follow where sound union has taken place, but such results are usually preventable. Their treatment has already been discussed in Chapter V. Non-union, or more correctly fibrous union with a gap, is occasionally seen in neglected injuries. In such cases the inability to extend the knee is a very great handicap. As time goes on the fibrous bond of union tends to stretch and adaptative shortening of the quadriceps takes place. In vigorous patients, operation should be advised. The bone ends are refreshed and drawn together after preliminary lengthening of the quadriceps. This is accomplished by

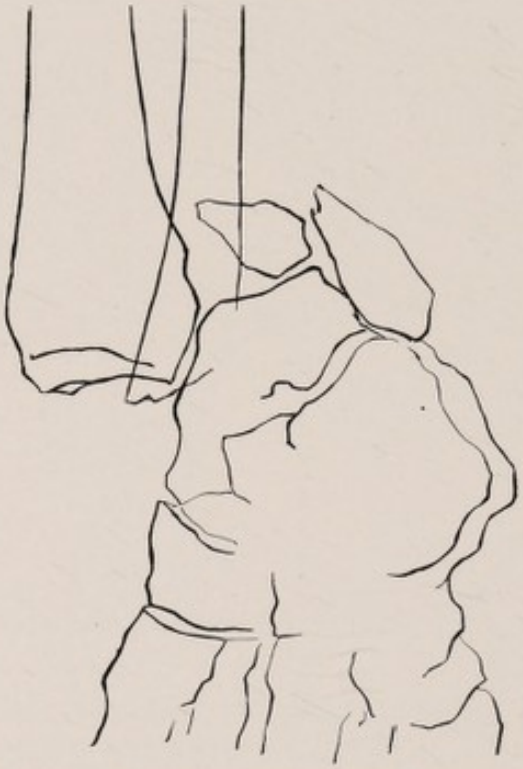

FIG. 411.—Pott's fracture with gross displacement.

completely separating the rectus femoris from its fusion with the vasti, and if necessary splitting it in the coronal plane. In cases of complete non-union in elderly patients a walking appliance is the only alternative.

Fractures of the Shafts of the Leg Bones

Recent Fractures.—In combined injuries of the tibia and fibula, the site of fracture is most commonly at the junction of the lower and middle thirds. The displacement is variable, but overlapping, external rotation of the lower fragment, and forward projection of the upper fragment, are often seen. Transverse fractures are usually easily controlled, but spiral fractures are more difficult to treat by conservative methods. In correct alignment of the lower leg the normal outward bowing must be preserved. A common error is to "set" the fracture in a straight line. Early reduction is most important in healthy muscular adults. With a delay of two or three days the displacement and shortening increase rapidly, and the infiltration of the relatively

non-extensile fascial compartments of the leg by haemorrhage adds to the obstacles to reduction.

In fractures with little initial displacement, fixation in a bivalved plaster of Paris cast is a most useful method. Where there is overlap or other deformity, traction on the Thomas splint should be utilised. By means of pads and side splints of the gutter type the normal bowing is secured. For compound injuries or certain obstinate simple fractures, skeletal traction may be necessary —a pin through the posterior part of the os-calcis is the method open to the least objection. Union is rarely secured before the eighth week, after which weight-bearing should be tried with caution.

Operative reduction is not infrequently required in spiral fractures, which are best controlled by a Lane plate adjusted to the natural curve of the tibia. In transverse fractures, for which operation is not often required, the intramedullary peg is an effective mode of ensuring fixation.

Malunion.—Where there is bad alignment with much shortening, operation is indicated. The line of the fracture should be cut through, the bone ends freshened and brought into correct apposition. Traction by means of the pulley may be used to stretch the soft tissues. Internal fixation of the bone is not always necessary. If there is difficulty in maintaining the correct position a sliding bone graft, a Lane plate, or intramedullary peg may be used. Angulation is corrected by a wedge osteotomy, and great care should be taken to maintain correct alignment without rotation and to avoid the natural tendency to posterior sagging.

Delayed Union and Non-union.—Union is often slow in fractures of the lower third of the leg, but patience should be exercised and early operative intervention prohibited. For true non-union bone grafting is the only feasible treatment.

Ankle Fractures

Fractures of the Leg Bones

In 50% of these fractures a combined injury of both bones is present. The terms "Pott's fracture" and "Pott-Dupuytren fracture," are used as generic titles to embrace those fractures of the lower end of the fibula and tibia which lead to a disturbance of the mechanics of the ankle joint. These injuries are produced by one of three types of forced movement of the foot on the leg: external rotation (61%), abduction (21%) or adduction (13%) (Ashhurst).[1] The fibular fracture is the pivotal injury. The tibial injury consists in a fracture of the internal malleolus, or its equivalent, a rupture of the internal lateral ligament. In 20% of the cases a third fracture is present produced by the upward compression thrust of the astragalus. This is the posterior marginal fracture of the tibia, which involves the separation of a triangular fragment in the neighbourhood of the inferior tibiofibular joint. The fragment remains attached to the fibula and is displaced with it in company with the astragalus. Gross displacement occurs in some 25% of ankle fractures. The characteristic deformity is eversion, with or without backward displacement of the foot. The latter deformity cannot occur unless there is either a posterior marginal fracture or a complete diastasis at the inferior tibiofibular articulation.

[1] Ashhurst, A. P. C.: Archives of Surgery, Jan., 1922.

Treatment of Recent Fractures.—Reduction should be attempted under anaesthesia without waiting for the subsidence of swelling. The knee is flexed and held by an assistant. The surgeon grasps the back of the heel

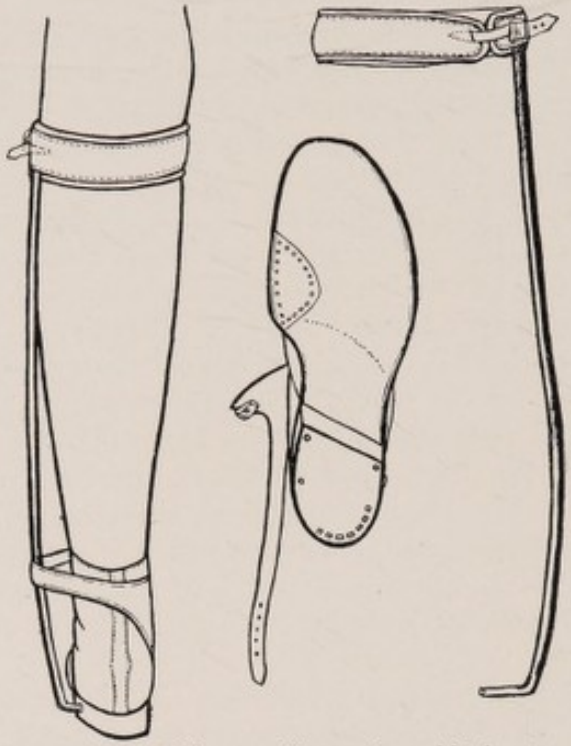

Fig. 412.—Walking appliance for ankle fractures.

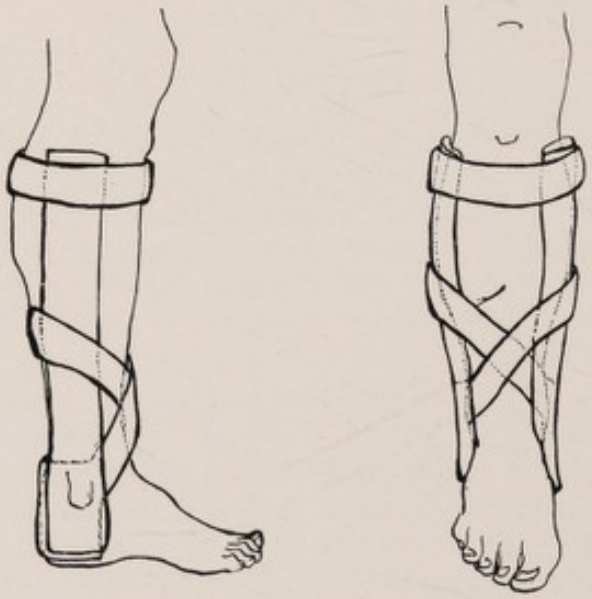

Fig. 413.—Delbet ambulatory plaster.

with one hand, the dorsum of the foot with the other, and then inverts the ankle. The heel is now pulled forward and the tibia pushed backward. When the manipulation is completed there should be no block to dorsiflexion. The foot is fixed in inversion and dorsiflexion for a period of two to three weeks, prefer-

ably in a carefully applied plaster of Paris cast. The cast is later bivalved and light massage and active movements of the toe and ankle are begun. Weight bearing is allowed, some time after the sixth week, but only with a walking appliance which will prevent strain on the fractured fibula. This is best obtained by a "T strap" and outside steel, combined with a raised inner border of the sole and heel of the boot (Fig. 412). The Delbet ambulatory plaster is a useful substitute in fractures with little or no initial displacement. (Fig. 413.) Given accurate reduction and careful after treatment late deformity should never be seen.

Treatment of Old Fractures.—Malunion is common in fractures of the Pott-Dupuytren type, for the primary displacement is not infrequently overlooked. In other cases the fracture sags under too early and non-protected weight bearing. The foot is usually everted and may also show some backward displacement. The ankle joint may allow a surprising degree of mobility, but occasionally dorsiflexion is much obstructed. In patients of suitable age and physique, operative correction of the malunion should be undertaken. The choice of operation will be based on the pathological anatomy of the fracture in each individual case.

(1) *Deformity of Few Weeks Standing.*—If the fibula is firmly united, osteotomy in the line of the fracture and the use of a wrench may restore alignment. An osteotomy of the internal malleolus may be required in addition if the foot is not easily inverted. Where backward displacement persists it is necessary to expose the posterior marginal fragment of the tibia through a second incision skirting the internal malleolus. This fragment is replaced in its old position and fixed by peg or screw.

(2) *Deformity of Long Standing.*—The choice lies between a complete anatomical *reconstruction* of the ankle joint, or an *arthrodesis*.

(*a*) *Reconstruction.*—The fibula is approached through an incision running behind and below the external malleolus, and the old line of fracture divided. Where shortening of the bone has occurred re-alignment tends to produce a gap which may require bridging by an autogenous graft. (Trethowan.[9]) The posterior marginal fracture and inner malleolus are next approached through an incision running below and behind the malleolus. The posterior fragment is exposed in the interval between the posterior tibial vessels and the flexor longus hallucis, replaced in correct position, and secured by peg or nail (Fig. 414).



FIG. 414.—Reconstruction of malunited Pott's fracture (Trethowan).

(*b*) *Arthrodesis.*—In many malunited ankle fractures a disabling mechanical arthritis results. For the relief of this, arthrodesis of the ankle joint is the most suitable procedure. A stable painless foot is obtained which enables many patients to return to arduous work.

[9] TRETHOWAN, W. H.: Lancet., Jan. 9, 1926.

Fractures of the Astragalus

These are less common injuries. Where displacement occurs, gross interference with the function of the ankle, mid-tarsal, or subastragaloid joints may result. Correction should be attempted by manipulation. If a bony block develops, operative attack may be necessary, which will involve either the removal of the obstacle, or partial astragalectomy. Total removal of the astragalus should rarely be practised. In old cases with deformity and pain, arthrodesis of the affected joint may be demanded.

Fractures of the Os Calcis

This injury is notoriously prone to leave a permanent disability for walking or climbing. The ordinary fracture is of the compression type and the bone

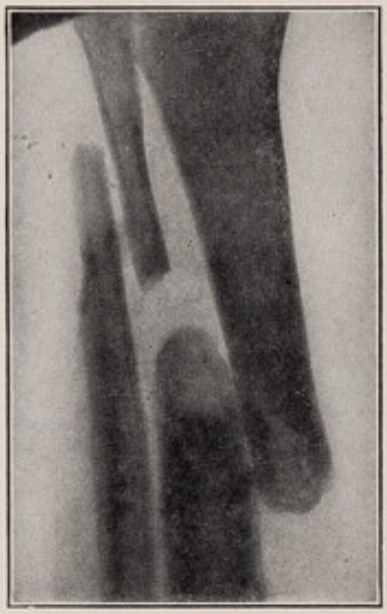

FIG. 415.—X-ray of fracture of both bones of the leg with marked overlapping of the tibia.



FIG. 416.—Normal convexity of tibia.

shows multiple cracks or is severely pulped. Lateral expanison occurs and the bone is severely distorted in its longitudinal axis. The heel is swollen and tender and there is a bulge beneath both malleoli. There may be a bony projection in the sole. In addition to the deformity which so commonly results, the involvement of the subastragaloid joint is of serious import.

In *recent* fractures all displacement should be corrected and the crushed bone remoulded. For *old* fractures a manipulation may suffice to correct eversion at the subastragaloid joint, but where painful bony masses exist

operation should be undertaken. Bony projections below the malleoli and in the sole should be freely excised. Arthrodesis of the subastragaloid has been found most useful in old os calcis fractures where pain and deformity are due to incomplete fixation of this articulation. Recently the scope of this operation has been extended to include recent fractures (Allison and Wilson).

The rare *avulsion* fracture of the posterior end of the os-calcis may necessitate open operation if in the position of extreme plantar flexion the fragment cannot be retained by splinting.



FIG. 417. FIG. 418..

FIG. 417.—Pott's fracture—front view.

FIG. 418.—Side view of Pott's fracture, showing posterior displacement.

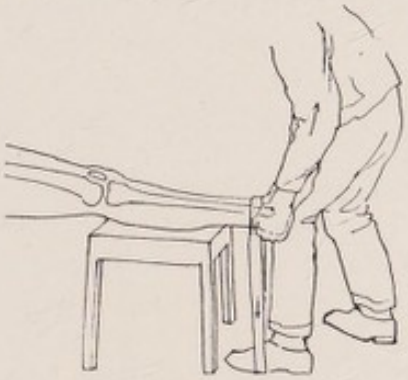

FIG. 419.—Reduction of Pott's fracture.



FIG. 420.—Pott's fracture, showing position of pads to restore curve of fibula and balance of ankle.



FIG. 421.—X-ray of fracture of the neck of the scapula.

Fractures of the Upper Extremity

The influence of the body weight being eliminated, errors of alignment in the upper limb do not, as a rule, give rise to disabilities equivalent to those which accompany malunion in the lower limb.

Fractures of the Clavicle.—This is a familiar injury at all ages, and is rarely followed by permanent disability. The bone usually breaks in the middle third, the outer fragment being carried downward and forward in company with the shoulder. Treated by ambulatory methods, which is the custom for the majority of patients, union often occurs with slight overlap,

which is of little moment. In elderly patients some degree of limitation of motion at the shoulder joint occasionally persists.

Fractures of the Scapula.—Fractures of the *body* are produced by direct violence and there is little or no displacement of the fragments. If early mobilisation of the shoulder is begun, complete restoration of function is the rule.

Fractures of the scapular *neck* are rare; if displacement occurs, the shoulder drops downwards and forwards. Fractures through the *glenoid cavity* are not uncommon, but often there is a mere crack without disturbance of the fragments. A sling and large axillary pad should be applied so as to keep the shoulder well supported. The keynote of after treatment is early mobilisation of the shoulder, by active movements carried out under the supervision of an experienced masseuse.

In neglected cases, the patient appears with a shoulder fixed by adhesions. Under these circumstances a judicious manipulation is indicated. A method used long ago by H. O. Thomas and described by him is as follows:

"If three or four weeks elapse before the surgeon has an opportunity of reducing the deformity he ought to perform an imitation of the operation of reducing a shoulder (this in Thomas' case meant horizontal traction of the arm from the side). The imitation consists in subjecting the structures connecting the upper extremity to the scapula, clavicle and trunk to a force sufficient to strain them, and then for several days maintaining further moderate force by leverage with a moderate sized axillary pad. The parts will gradually accommodate themselves so as to permit the upper extremity to lie close to the chest so that the most obvious deformity, abduction, is not perceptible and a position is gained for the extremity which enables it to come more under the patient's will and thereby acquire a power and usefulness it otherwise could not have gained. The initial act of reducing the deformity will be followed by only slight amendment. It will be during the exercise of unremitted and moderate leverage with the axillary pad that the major part of abduction will be corrected."

Fractures of the Upper End of the Humerus.—In fractures of the *surgical neck* or *anatomical neck* of the humerus, the importance of perfect alignment is overshadowed by the problem of early restoration of the full range of mobility in the shoulder joint. Many fractures are impacted and unless the deformity is gross, the impaction is best left undisturbed. A sling and axillary pad are applied and gentle movements of the shoulder begun at the end of a week, the fracture being always carefully supported. Any residual limitation of movement can be later overcome by a timely manipulation under anaesthesia. Operation for malunion is rarely necessary.

A more serious injury is *fracture-dislocation* of the shoulder, an accident by no means rare (Fig. 422). The most usual combination is dislocation of the head with a fracture through the surgical neck. Other complicating fractures occasionally seen are—fractures of the anatomical neck, of the scapular neck, or glenoid. Separation of the greater tuberosity can be demonstrated in a considerable proportion of ordinary dislocations if routine radiograms are taken. Reduction may sometimes be very difficult or even impossible. A method which has proved most successful is vertical traction on the arm combined with upward pressure on the displaced head. If reduction is successful, the after-treatment is the same as in an uncomplicated fracture

or dislocation. If all efforts at reduction fail an open operation should be performed. The shoulder is exposed through the classical anterior approach. The disturbed head is easily found and an attempt should be made to replace it in correct apposition with the glenoid.

In old neglected cases excision of the head is usually demanded. The stump of the neck should then be apposed to the glenoid in abduction. After a period of fixation and support a very useful pseudarthrosis may result.

Fractures of the Shaft of the Humerus.—Fractures at this level present little difficulty in treatment. Malunion is unlikely to be seen except after grossly inefficient treatment, but non-union in fractures of the middle third is a recognized disability. It is rare in simple fractures but common in the compound injuries of warfare. Union may take place after long delay without operative intervention. If operation is undertaken fixation of the fragments by the stepcut method or bone grafting are the most effective procedures. Involvement of the musculo-spiral nerve is an occasional complication but in simple fractures spontaneous recovery often occurs. A complete nerve lesion demands operative repair.



FIG. 422.—Fracture of the humerus and dislocation of the head—X-ray.

Fractures in the Region of the Elbow Joint.—Deformity and disability are often seen as a result of fractures in this region, which have received inadequate treatment in the early stages. The widespread practice of treating all such injuries (except fracture of the olecranon) with the elbow in full flexion, has improved the general standard of functional results.

Fractures of the Lower End of the Humerus.—Of the fractures of the lower end of the humerus the *supracondylar* type often presents special difficulties in treatment. In the average fracture with moderate displacement perfect adjustment is possible by manipulation.

Where there is wide separation between the fragments, the lower end of the diaphysis usually projects forwards into the antecubital fossa. The distal fragment is often a mere shell and is not always easily replaced and maintained in accurate position by manipulation. Reduction by open operation is needed for exceptional cases, the fracture being approached through an incision which splits the triceps in the middle line. A lever is introduced between the bone ends and the diaphysis brought backwards and apposed to the lower fragment. In full flexion of the elbow there is little or no tendency to recurrence of the displacement. Uncorrected displacement often results in the development of a bony block to movement, for which late operation

may be necessary. Other complications of supracondylar fractures *viz.:* ischemic contracture and myositis ossificans, have already been described, (Chapter V, pp. 77 and 91). Involvement of the median or musculo-spiral nerve is an occasional accompaniment. A mild degree of *cubitus valgus, i.e.* an increase in the "carrying angle," may result, but in itself rarely requires treatment. The deformity may be prevented in the early weeks following the fracture by the application of a lateral gutter splint to the arm. The reverse deformity—*cubitus varus*—is rare. It has little functional importance, but when the cosmetic appearance is most unpleasing, correction by means of an osteotomy of the lower end of the humerus may be desirable.

Fractures of the *external condyle* are prone to give rise to both early and late deformity. The line of fracture runs obliquely into the joint, cutting off a large fragment which includes the capitellum. Owing to the initial displacement and the pull of the extensor group the fragment often "turns turtle," and cannot be reduced accurately by manipulation. Left alone the displacement seems to increase, and on the outer side of the elbow, the fragment projects immediately under the tightly stretched skin. Under such circumstances reduction by open operation is advisable; if the fragment cannot be replaced it should be removed. This type of fracture rarely undergoes complete bony union. Cubitus valgus deformity of an extreme type is a common sequel, and many years later ulnar nerve involvement may occur. (See Chapter XXIII.) Separation of the *internal condyle* is common in older children and is sometimes accompanied by a transitory ulnar lesion. *Olecranon* fractures may undergo bony union under conservative treatment if a sufficiently prolonged period of fixation with the elbow extended is maintained. Short fibrous union may give a functional result of equivalent value. Open operation is the only certain method of producing bony union in a short time, and is recommended as the routine method.

Fractures of the Head and Neck of the Radius.—Fractures of the head and neck of the radius are not infrequently overlooked. Localised tenderness, crepitation on rotation, and pain when supination is forced are signs which should be borne in mind. The chief disability in old injuries is limitation of rotation of the forearm and extension of the elbow. Conservative treatment is successful in most cases. The elbow is fixed in full flexion with the forearm supinated. Early operation is called for where there is a separation of a large single fragment which cannot be replaced by manipulation. Late operation is indicated where, after six weeks' treatment, rotatory movements are at a standstill. At this stage all displaced fragments together with the head and neck should be completely excised.

Fractures of the Forearm.—In *combined* injuries of the radius and ulna the chief disability to be feared is inability to carry out full rotatory movements, and especially the range of supination. The whole length of the ulna is subcutaneous and practically straight, and on this bone the curved radius rotates in "bucket handle" fashion. In the treatment of forearm fractures two points are of outstanding importance: (1) the ulna must be kept straight and (2) nothing should be allowed to disturb the natural curve of the radius; there must be no pressure of bandage or splint on the middle of the shaft. The forearm bones can only be adequately controlled in gutter shaped metal splints (or plaster of Paris) adapted to the contour of the limb. The routine position in treatment should be full supination. Union is often slow and

secondary bowing at the site of fracture is apt to occur if fixation is discarded too early. The dangers of cross union are exaggerated. Where there is gross overlap and angulation, open operation may be necessary in patients of suitable type. The forearm bones are best fixed by means of intramedullary pegs. A single dorsal skin incision with two separate intermuscular approaches should be used.

Chauffeur's or *back-fire fractures* form an interesting clinical group in which the common injuries are—

(1) Fracture of the styloid process of the radius.
(2) Colles' fracture.
(3) Fracture of the radial shaft in the lower fourth.
(4) Fracture of the radial shaft in the lower third.

Except in the Colles' type, the displacement is usually slight and no special difficulty is experienced in treatment.



FIG. 423.—Fracture of the anatomical neck of the humerus—X-ray.

Colles' Fracture.—Under this heading are included all complete fractures of the radius within an inch from the articular surface. The fracture is often comminuted and impaction without gross displacement is common. Separation of the ulnar styloid is the usual accompaniment. The classical dinner fork deformity is the exception rather than the rule. Displacement occurs in in three planes—the lower fragment is forced upwards and backwards en masse, is displaced radialwards, and is rotated backwards on a transverse axis. If early and complete reduction is ensured, a Colles' fracture should be followed by perfect restoration of function in patients of all ages. The lower end of the anterior aspect of the radius is concave with a marked curve towards the prominent anterior edge of the lower articular surface. This curve must be preserved or joint alignment will be altered. Rotation of the lower fragment throws the joint out of true relation to the normal action of muscles; furthermore the tendons which run in the radial grooves may be

disturbed. Where imperfect reduction has been obtained, undue prominence of the lower end of the ulna is seen and there may be actual separation of the two bones at the inferior radio-ulnar joint.



FIG. 424.—Splint for the extension of the humerus.



FIG. 425.—Colles' fracture—antero-posterior and lateral—X-ray.

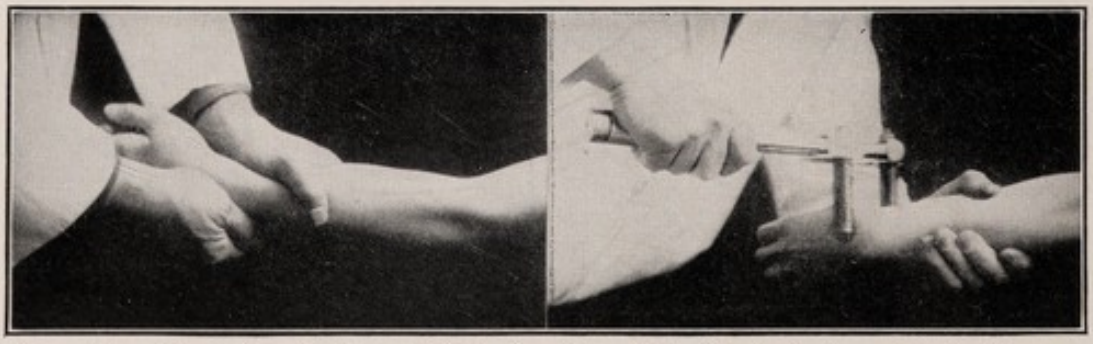

FIG. 426.—Manual reduction of Colles' fracture.

FIG. 427.—Manipulation of Colles' fracture with a Thomas wrench.

The traditional method of *reduction* by taking a grip of the hand as if shaking hands is still employed. It is quite inefficient in any stubborn case

for it is the application of indirect force instead of direct. The grip which is best is shown in Fig. 426. To reduce a left Colles' fracture the surgeon takes the patient's arm in the left hand with his own scaphoid tubercle against the projecting lower end of the shaft. He then places his right hand on the dorsum of the patient's wrist with his own scaphoid on the projecting lower fragment. A firm grip with a slight traction and twist of the wrist completely reduces the deformity. The fragments can be retained in position by slight pressure of the finger and thumb, one on the upper fragment just above the seat of fracture, and the other on the dorsum of the wrist joint. The tendency for the deformity to recur is not great if the reduction is complete, therefore the fracture is put up by placing a pad of wool on each of these two points, and retaining the pads in place with splints. In cases of longer standing it may be necessary to use the Thomas club foot wrench to secure reduction as shown in the illustration (Fig. 427).

The splints the writers use are made of thin sheet metal. If the material is duralumin radiograms can be obtained without removal of the splints. A slight twist is put on these to make them wrap spirally round the limb,

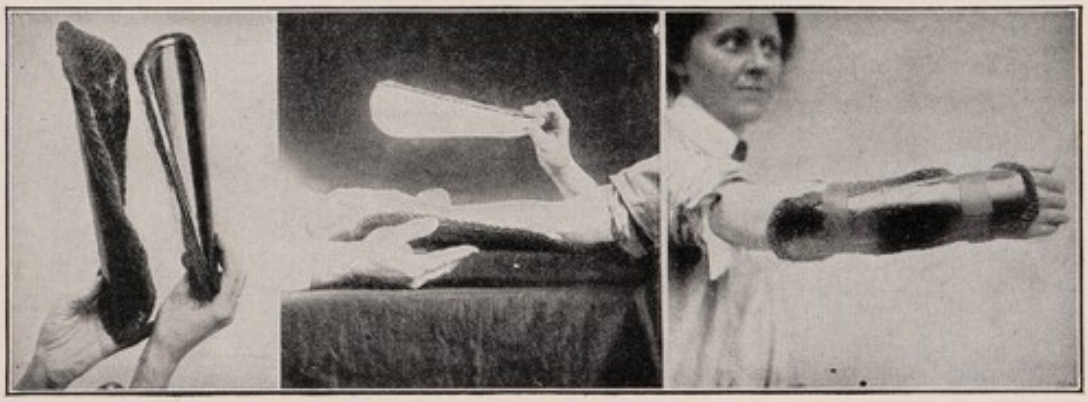

FIG. 428.—Metal splints for forearm fractures.

keeping the wrist pronated. The posterior splint extends from the external condyle of the humerus to about the middle of the metacarpals, and runs spirally from the ulnar side at the elbow to the radial side below. The anterior splint on the palmar aspect of the forearm has the twist in the opposite direction, and must stop short of the thenar eminence (Fig. 428).

A firm band of strapping holds these together at the carpus, keeping the wool pads in place, another at the upper end of the forearm holds the splints on. The spiral twist of the posterior splint is against the direction of rotatory deformity. The fingers are left free; the play of the finger tendons over the seat of the fracture cannot do any harm when reduction has been complete. The forearm is slung at a right angle. A Colles' fracture properly reduced never gives trouble.

Synostosis between the bones is treated elsewhere. (See Ankylosis, p. 82.)

Carpal Injuries.—(See Chapter IV, p. 66).

Fractures of the Pelvis.—Pelvic fractures are usually produced by severe crushing forces. Three main types are distinguished:—(1) Fractures of the pelvic ring (whole pelvis), which are of special importance owing to the occasional involvement of intra-pelvic organs: (2) fractures of the separate pelvic bones (isolated fractures), and (3) fractures of the acetabulum.

Fractures of the Pelvic Ring.—The solution of continuity in the pelvic ring occurs along the line of the oblique diameter. Posteriorly, the fracture involves the ilium close to the sacro-iliac joint; in front, the break traverses the pubic and ischial rami, or separation may occur at the symphysis itself. An upward displacement of one half of the pelvis may then result. The asymmetry is well shown in radiograms but may be barely demonstrable on clinical examination. The diagnosis is suggested by the type of violence, the distribution of the bruising (*e.g.* along the line of Poupart's ligament) and the pain elicited by compression of the iliac crests. The possibility of visceral injury should always be borne in mind, and as a routine, a catheter should be passed and a rectal examination made.

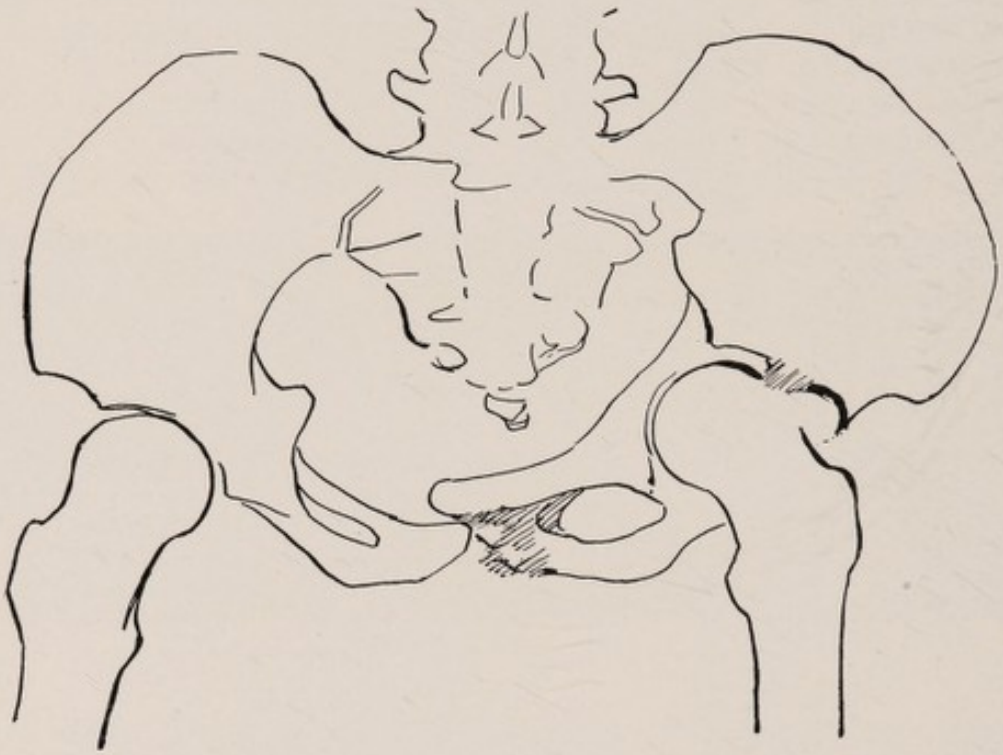

FIG. 429.—Fracture of the pelvis showing dislocation of the head of the femur.

In uncomplicated cases the treatment consists in keeping the patient recumbent with fixation of the pelvis by a swathe and sandbags, or alternatively in a Thomas frame. A period of four to six weeks' recumbency is necessary. Where there is considerable unilateral displacement traction on the lower limb may be used, or an attempt made to remedy the displacement under anaesthesia. Usually, however, gross deformity cannot be overcome.

When the patient is allowed to get up, a well-fitting pelvic belt should be worn for some months. Any residual stiffness of the lower back should be treated by systematic exercises. In spite of persisting displacement, the functional results of uncomplicated fractures of the pelvic ring are surprisingly good. Many individuals return to full duty in strenuous work or sport. Pelvic asymmetry resulting from fractures in females in early life is of course important in relation to potential child-bearing.

Complicated pelvic fractures are fortunately not very common. The most familiar associated injury is rupture of the urethra. Rupture of the bladder, and laceration of the rectum are seen more rarely. Incomplete ruptures

of the urethra often heal satisfactorily without operative intervention, but for complete ruptures and for other visceral complications, prompt exploration is essential. Contusion or stretching of the lumbo-sacral cord on one side is a rare complication. The signs are those of an external popliteal palsy.

Isolated Fractures.—Isolated fractures of the ilium, pubis, or ischium, rarely show gross displacement, and may be undiagnosable except with the aid of radiograms. A short period of recumbency is all that is needed and complete functional recovery is the rule. Fracture of the anterior superior spine due to traction is occasionally met with.

Fractures of the Acetabulum.—These vary from a simple crack across the hip socket, to a displacement of the acetabular floor towards the pelvic cavity (central dislocation of the femoral head). In the latter injury, grave interference with the function of the hip joint may result, but complete ankylosis is by no means inevitable. The displacement should be promptly corrected under anaesthesia and traction applied. After three or four weeks efforts to mobilise the joint should be made. Residual limitation of movement may be overcome by manipulation when all irritation of the joint has subsided. Later on, when complete ankylosis supervenes, a pseudarthrosis operation must be contemplated.

Fractures of the Spine (see Chapter XXXI).

CHAPTER XIX

DISTURBANCES OF THE NEUROMUSCULAR MECHANISM

In approaching those disturbances of the neuromuscular mechanism which require surgical treatment, the surgeon must be reminded of certain very elementary facts which he learned in his early years in the medical school, which are essential to the proper handling of such cases. Although parts of one mechanism, the nervous and muscular elements may be separated for such consideration.

Nervous System.—From the point of view of *motor impulses* the nervous system is organized into two levels of nerve cells—the upper and lower motor neurons. The cell bodies of the upper neurons are in the motor area of the cerebral cortex; the axon processes, or conducting parts, are distributed to the motor cells in the anterior cornua along the length of the spinal cord. These cells are the cell bodies of lower neurons; their axons pass out of the cord at regular intervals as the motor roots. The motor and sensory roots join inside of the spinal canal. From this point on, the combined neurons are spoken of as "spinal nerves." All the spinal nerve trunks contain sensory as well as motor and vasomotor fibres.

Each *voluntary motor impulse* is transmitted first from the cells of the cortex to the upper neurons, passes along them to their junction with the lower neurons, which are called the synapses. Here it is distributed to the different muscles which are to be innervated for the motion. The distributed impulses to contract a certain muscular group go by way of the lower neurons out through the anterior root, through the plexus in most instances, and then down the peripheral nerves to the terminal muscle plates where they cause muscular contraction.

The impulse to movement affects the upper neurons, the performance of the movements is the immediate result of action of the lower.

Localization.—Loss of motion, not accompanied by loss of sensation, must have occurred above the junction of the roots and is either a lesion of the anterior root alone or of the motor cells in the anterior cornua of the cord. If the lesion occurs below this point of junction of the roots, a loss of sensation must be present.

Lesions of peripheral nerves, distal to any plexus, will affect the muscles supplied by those nerves and will be limited in their distribution to the muscles supplied by those nerves. Lesions in the plexus will have a more scattered distribution and cannot be anatomically predicted as limited to certain definite muscles. Lesions of the nerve roots will be still more scattered and indefinite in their distribution.

The upper neurons are supposed to have an inhibitory effect upon the lower neurons and restrain their automatic mechanism which is spoken of as a "reflex" mechanism. In sleep and under deep anesthesia inhibition by the upper neurons is diminished.

A *reflex* consists of an afferent impulse from the periphery, travelling up to the center of motion in the spinal cord for that part, and reflected back down the efferent tracts to cause muscular contraction, so that a normal reflex implies intact afferent fibres, and an intact reflex center in the cord, and also intact efferent fibres. A lesion or division of any one of these diminishes or abolishes the reflex. If cerebral inhibition is diminished, the reflex is increased.

In the spinal cord the motor cells are situated in the anterior cornua in groups and consist of large multipolar nerve cells. Each terminates in an axon which leaves the cord by the anterior or motor root and passes by way of the peripheral nerve to the muscle fibre which it innervates. The supply for a given muscle is not confined to a single segment of the cord, but the cells supplying such a muscle extend in a longitudinal group up and down the cord over a region of two or three or more segments—each group communicating with more than one muscle and each muscle with more than one group. Moreover it seems that there are cells and communicating paths not in daily use, that is, the cells and paths are not working to full capacity under ordinary conditions, but there is a "reserve" not usually called upon. These matters are of great importance in connection with muscle reeducation.

When a destructive lesion has occurred in the peripheral motor neuron the *reaction of degeneration* to electrical currents occurs in about ten days. If the reaction is incomplete, it may be assumed that the lesion is incomplete, but the full reaction does not necessarily imply entire division or destruction.

Muscular Mechanism.—Striped muscles are essentially contractile tissues, of which an essential attribute is muscular tone—a state of persistent tension so long as the muscle receives impulses from the central nervous system. If divided, the cut ends retract even under full anesthesia.

Muscles do not tolerate prolonged or excessive stretching and they deteriorate under these conditions. They are easily fatigued and work best at a temperature only a few degrees short of that which would cause injury to the muscular tissue. If allowed to remain shortened, by having their ends approximated, for example, as in the biceps in flexion of the arm in a splint for some weeks, a process known as "adaptive muscular shortening" occurs and if long continued will lead to fibrous muscular degeneration. If rough forcible stretching is applied to such contracted muscles great pain is caused and the muscle is injured and perhaps partially ruptured. Adaptive shortening is apparently the result of continued unopposed muscular tone. This has much practical importance in the treatment of lengthened and weakened muscles. Stretched muscles also deteriorate and lose their tone, so that an excessive or prolonged stretching may cause a great depreciation of power which may be permanent, or even a loss of all contractile power if neglected. Power can be best restored by removing all strain, keeping the muscle relaxed, and making use of all adaptive shortening. A blow on a muscle causes it to contract and massage and vibration increase muscular tone.

CHAPTER XX

SPASTIC PARALYSIS

(Cerebral Paralysis of Children, Little's Disease)

Definition.—This affection, classified as a paralysis, is a lesion of the upper neuron due to disease or injury of the cerebral motor centers controlling the extremities. As a result of the removal of cerebral inhibition, muscular tonus is greatly exaggerated, reflexes become hyperactive, and a condition of hypertonicity prevails in the affected parts. The affection is therefore not strictly a paralysis, but rather a hypertonicity which varies from a slight muscular irritability to a condition of spastic rigidity, which renders the limbs useless, not from loss of muscle power (although this is often present), but from excess of muscular contraction. The disease in its physiology is not essentially different from the hemiplegia of adults, although greatly modified in its symptoms by the fact that it has its origin at an early period of life.

Distribution.—According to the region affected, different names are applied to the condition. If only one extremity is involved, it is called monoplegia; if one-half the body, hemiplegia; if both lower extremities, paraplegia; if involving both arms and legs, diplegia or quadriplegia. In 451 cases analyzed by Peterson,[1] 332 were hemiplegia, 73 diplegia, 46 paraplegia. In 121 cases reported by Whitman,[2] 58 were hemiplegia, and 68 paraplegia or diplegia; and in 60 cases reported by one of the writers,[3] 26 cases were hemiplegia, and the rest of them were of general distribution.

Etiology and Pathology.—Spastic conditions may be the result of (1) Antenatal, (2) Natal, (3) Post-natal influences on the central nervous system.

1. *Ante-natal.*—This variety is due to failures or errors in development, resulting in cerebral defects and defective pyramidal tracts. They represent the gravest class of cases, but are not always to be distinguished later in life from those where the injury occurred at birth. Syphilis must be taken into account as an occasional factor.

2. *Natal.*—This variety includes the majority of cases. The injury caused by difficult and prolonged labour to the brain or to the spinal cord is the cause. Bronson Crothers[4] has done admirable work in the last five years on clearing up the difficulties which were encountered in establishing the etiological factor in spasticity. He has conclusively shown that many cases of what was formerly believed to be cerebral paralysis, are recognizable as spinal cord injuries. He calls especial attention to the dangers of traction on the child at the time of delivery. The imposition of unphysiological force upon the various structures of which the most fragile, the least elastic, and the most important are the nervous system and its membranes, by traction for example, has resulted in spasticity. The most common cause of intracranial haemor-

[1] Peterson: "American Text Book of Diseases of Children."
[2] Whitman: "Orthopedic Surgery," 6th Edition.
[3] Lovett: Boston Med. and Surg. Jour., June 28, 1888.
[4] Crothers, Bronson. (*a*) Surg. Gyn. & Obs., Dec., 1923. (*b*) Amer. Jour. Med. Sciences, Jan., 1923. (*c*) Medicine, Feb., 1927.

rhage is trauma to the child's head during prolonged labor, forceps delivery, or prolonged asphyxia at birth. The regions of the brain usually involved are the cerebral cortex, the corpus striatum and the basal ganglia. The spinal cord and its membranes may be, and frequently are, the seat of the injury. As a result of this one finds chronic meningeal encephalitis, sclerosis, cysts, atrophies, and porencephaly.

3. *Post-natal* varieties of spastic paralysis include those due to haemorrhage into the brain or cord, nervous thrombosis, chronic meningitis, encephalitis, and the rare form of polio-encephalitis.

The pathology of the condition in brief is a lesion of the motor area of the brain, with consequent atrophy, retarded development, sclerosis or softening of the affected portion, and a degeneration of the pyramidal tracts and lateral columns of the cord.



FIG. 430.—Spastic diplegia with athetosis.

Symptoms

About two-thirds of the cases of acquired paralysis occur in the first three years of life. In about one-fifth of these the affection of the brain is to be attributed to infectious disease. The onset in other cases is generally febrile in character and is apt to be sudden rather than slow. The signs are what one would expect from the pathology: a hypertonic condition of affected muscles, which results in a varying degree of tonic spasm of the muscles of the affected extremity.

Motor Symptoms.—The motor symptoms consist in a stiff and irritable condition of the muscles resulting in imperfect use, particularly on effort, which increases the spasm. Standing and walking and all movements are imperfectly and uncertainly executed. If a special movement of the foot, for example, is attempted, all the muscles of the lower extremity become spastic and contracted. If this occurs, the foot, for example, will be held in the position determined by the relative strength of the opposing groups of muscles. The foot will be carried in a position of plantar flexion, as at the age of five, for example, the gastrocnemius possesses a resisting power of about 50 pounds to pressure, and the dorsal flexors about 20 pounds. If all muscles are in tonic spasm therefore, the foot must be held in a position of equinus.

Gait and Deformities.—The gait of the hemiplegic child represents exactly the gait of adult hemiplegia. In paraplegia the legs may be crossed in attempted walking as a result of adductor spasm. The spastic contractions of the muscles may be so great that *luxations* of the hip are occasionally found. Although equinus, with often an element of varus, is the common deformity noted in the foot, it is frequently the case that when walking begins, the

deformity is transformed into a severe valgus. This apparently is due to the fact that the spastic condition of the gastrocnemius muscle holds the os calcis firmly, so that weight in walking comes on the tarsal joints and flattens and abducts the foot on the arch.

The deformities are perfectly well formulated. In the lower extremity, the hip is somewhat flexed and internally rotated and adducted, the knee adducted and flexed and the foot plantar flexed. If both limbs are involved, and in cases with any degree of adductor spasm, the patient will cross one leg

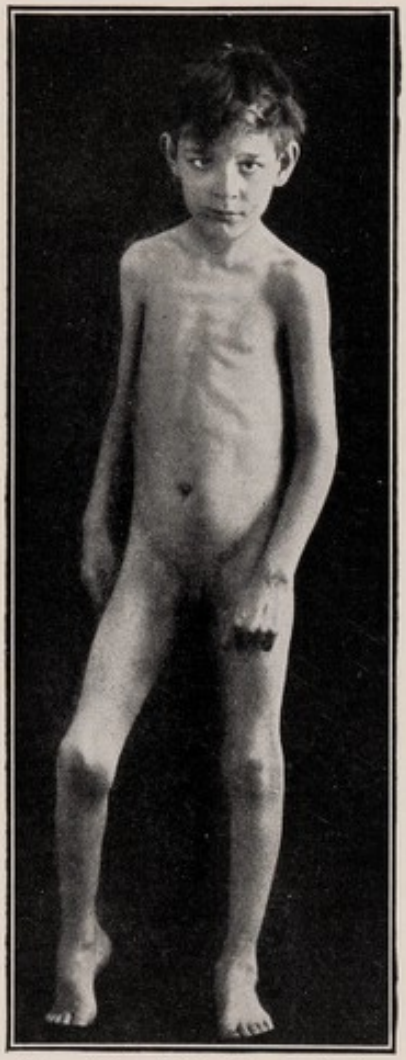

FIG. 431.—Right hemiplegia.



FIG. 432.—Cross-legged progression due to adductor spasm.

over the other when an attempt is made to walk. (Cross-legged progression, scissors gait.) In the arm, the shoulder is held internally rotated and adducted, the elbow flexed, the forearm pronated, and the fingers flexed. Resistance to correction of these deformities is at first less than it is later after adaptive muscular shortening has occurred. Hemiplegia never prevents walking, but in paraplegia of a severe grade, unaided walking is impossible.

Ankle clonus is at times present, especially in the more marked cases, knee jerks are increased, as well as the radial and triceps reflexes, and the Babinski and Oppenheim signs are present. It must be noted, however, that in very mild cases all these phenomena, except the knee jerk reflexes, may be incon-

spicuous; again in very severe cases it must be remembered that if all the muscles are in extreme spasm, it may be difficult to obtain reflexes, because the maximum muscular reaction is already present.

Facial paralysis is common, but disturbance of sensation is not to be detected. Trophic disturbance exists in the paralyzed limbs in hemiplegia, and muscular atrophy and retardation of growth may occur. *Ataxia* exists to a certain degree and is manifested by poor balance and inability to use the available muscular power.

Athetosis.—Choreic or athetoid movements occur from some months to two years after the paralytic onset in a proportion of the cases, estimated at about one-half; it has been estimated by Peterson that in 20 per cent of all cases athetoid movements occur. These movements are limited to the paralyzed part and occur both in hemiplegic and diplegic cases and are more troublesome in the arms than elsewhere. They consist of constant, irregular, arrhythmical movements of great range, and if the legs are involved in paraplegic cases, lead to great unsteadiness in gait. The pitiable condition of patients with general athetosis is familiar to everyone, and any degree of athetosis adds much to the gravity of the prognosis. If severe, it renders the arms useless, and the patient constantly makes purposeless and sometimes harmful movements, which are not under his control. The movements are exaggerated by voluntary effort or emotional disturbance, and sometimes do not disappear during sleep; more commonly they exist only during waking hours. The existence of athetosis and the disturbance of associated movements, shown by incoordination, are to be attributed to lesions of the basal ganglia and particularly of the lenticular nucleus.



FIG. 433.—Severe Little's disease with characteristic facies.

We shall get a better picture of spastic paralysis if we do not regard it solely as a hypertonicity of muscles, but remember the disturbance of associated movements and the arrhythmical movements which form a very serious part of many cases. This point of view is helpful in enabling us to separate these two factors in determining the results of surgical treatment which in the main is directed only to the relief of the element of spasticity.

Mental Development.—In the majority of cases some degree of mental impairment exists, although in a fair number of cases it is hardly noticeable and the children are quite as bright as the average; yet even these cases, especially when they come to adult life, are likely to show some impairment of mental stability. This of course is in part due to their environment; but just as in adult hemiplegia, mental balance as a rule is impaired by the lesion, so in children, the cerebral lesion added to the limitations of life imposed by the affection is likely to be manifested in some degree of mental peculiarity

at least. This matter is of great importance to the surgeon, because it is unwise to operate on children who are very defective, for reasons which will be explained in speaking of treatment.

From mild mental disability the condition varies to a mental state which must be classed as practically idiotic. The patient has strabismus, is unable to sit erect, has a stupid expression, and sits with mouth open, from which the saliva drips; and such patients are often uncleanly in their habits. The prognosis in such cases is exceedingly unfavorable, and such children are not proper subjects for surgical treatment. It is estimated by Sachs[1] that 50 per cent of the hemiplegic cases are feeble-minded, and about 13 per cent idiotic, while in the paraplegic and diplegic forms about 70 per cent are feeble-minded, and 40 per cent or 50 per cent idiotic. Epilepsy occurs later in life in about 40 per cent of all forms of cerebral paralysis, and should be borne in mind in formulating the prognosis.



FIG. 434.—Extreme spastic club foot.

Cerebral Spastic Paralysis of Poliomyelitic Origin.—That cases of cerebral paralysis occur in connection with large epidemics of poliomyelitis has been noted, but they have been found to be exceedingly rare, and have not been clearly formulated. Strümpell in 1884 described a condition called polioencephalitis and expressed the opinion that polyneuritis and acute infantile encephalitis might be regarded as different manifestations of a specific disease or were closely related. This of course occurred long before our modern knowledge of the pathology and the widespread character of poliomyelitis.

A few isolated cases were reported, but Médin[2] definitely placed the type as occurring in epidemics. The work of Wickman[3] definitely identified this as one of the six types of poliomyelitis described by him, although in 1000 cases in Sweden in the epidemic of 1905 he did not see an instance. None were reported in the New York epidemic of 1907, where there were 2000 cases. Cases of hemiplegia with flaccid and spastic paralyses coexisting have been reported as occurring in the midst of epidemics of poliomyelitis by Müller[4] (two cases), Zappert[5] (three cases), Williams,[6] Neurath,[7] Calabrese,[8] Oppenheim,[9] Pierre Marie,[10] and Wickman.[11] Cases of cerebral paralysis occurring in the midst of poliomyelitis epidemics, often in the same family with typical

[1] SACHS: "Nervous Diseases of Children."
[2] MÉDIN: Arch. de Med. des Enfants, May, June, 1891, 257.
[3] WICKMAN: Die akute Poliomyelitis, Berlin, 1911, 58.
[4] MÜLLER: Munch. med. Wchsft., 1909.
[5] ZAPPERT: Vers. d. ges. deutsche Naturforsch and Aerzte, Konigsberg, 1910.
[6] WILLIAMS: Lancet, 1899.
[7] NEURATH: Wien. med. Wchsft., 1909.
[8] CALABRESE: Riforma med., 1903.
[9] OPPENHEIM: Berliner klin. Wchsft., 1899.
[10] PIERRE MARIE: Bull. et Mem. Soc. Med. des Hop., 1902.
[11] WICKMAN: Die Akute Poliomyelitis, Berlin 1911.

cases, are reported by Moebius, Médin, Buccelli, Hoffmann, Schlesinger, Nonne and Krause.

The characteristic of the affection is that it is a mild hemiplegia presenting no different appearances from any other hemiplegia in its general spastic character—the position of the limbs, the awkwardness of gait, and the increase of reflexes—but it is mild and the characteristic point is, that along with the spastic muscles one finds flaccid muscles irregularly distributed. In this way the type becomes a little irregular and unusual. In the cases observed there has been no mental deterioration, and the progress of these cases under treatment by muscle training has been very much more rapid and much more satisfactory than in routine cerebral spastic paralysis.

Diagnosis.—The diagnosis of spastic paralysis results directly from the facts elaborated with regard to the pathology. Mental enfeeblement occurs in many patients. In the well established case there is no doubt of the diagnosis, but in the very mild cases there may be difficulty on account of the mildness of the affection; however, unilateral increase of reflexes is very significant. The determination of syphilis as a possible cause is most important, and should of course be investigated by means of a spinal fiuid Wassermann test.

Differential Diagnosis. *Poliomyelitis.*—Suspicious cases are the cerebral paralyses which occur during an epidemic of poliomyelitis with the characteristic onset followed by hemiplegia. When the paralysis is established, increased reflexes of the affected part should excite suspicion of the existence of cerebral involvement. The existence of flaccid muscles in connection with spastic muscles is presumptive evidence of a poliomyelitic origin and of a spinal as well as a cerebral lesion.

Idiocy.—The diagnosis from idiocy is not always easy. Any degree of spasticity or increased reflexes in a feeble-minded child would establish the condition as belonging to the spastic class. In many cases of idiocy, however, the limbs are flaccid with very imperfect motor power, and such cases obviously do not belong to the spastic group. In amaurotic family idiocy, the children become weak, lethargic and stupid; at the age of a few months blindness develops, and one finds degenerative changes in the gray matter of the entire cerebrospinal axis, and even in the root ganglia.[1] In other cases the cause of the idiocy appears to be cerebral agenesis.

Tumor of the Brain.—Tumor of the brain must be distinguished by the focal or localizing symptoms, the frequency of choked disc, the prevalence of headache, and the perfectly definite localization of symptoms.

Hydrocephalus.—Hydrocephalus may be associated with spasticity, apparently in a causative way. Some flaccid paralysis is likely to be associated with spasticity, which is often of hemiplegic origin. The diagnosis of hydrocephalus is evident.

In *spastic paralysis of spinal origin*, pain is a prominent symptom as a rule at some stage of the process. The affection is bilateral, sensation is affected, and trophic disturbance is marked. It is essentially an affection of adult life.

Prognosis.—In ordinary cerebral spastic paralysis the outlook for much improvement without treatment is not very favorable. As the children get older, the intelligence usually improves and they generally obtain somewhat better control. They usually learn to walk in some fashion or other; if they

[1] Sachs: Jour. of Nervous and Mental Diseases, January, 1903.

are not greatly enfeebled mentally they can talk; but they sit up later than other children. In these cases, walking and talking are delayed.

Treatment offers the prospect of a practical cure in very mild cases. In less mild cases, great improvement is to be expected from treatment, but not complete recovery, as some degree of stiffness and incoordination will probably remain. The existence of athetosis and disturbance of associated movements is an unfavorable prognostic element, and although it is favorably affected by operative treatment directed to the spastic muscles, it will probably always persist to some extent. The frequency of mental enfeeblement must be borne in mind and dwelt on, and the frequency with which epilepsy occurs in later life should not be forgotten in formulating the outlook.

Mental enfeeblement is a deterrent to operation when it reaches any considerable degree, and a practical test consists in determining whether or not the child is able to obey orders promptly, because if not, the use of muscle training after operation will prove impossible. This does not mean that gross deformities should not be prevented, or even corrected, as the defective child is spared much suffering thereby. Furthermore, there can be no doubt that the mental condition often improves when the contractions are removed. It is wise in doubtful cases, if an expert is at hand, to have a psychological examination made with a view of rating the child as to his intellectual capacity.

The upper extremity always improves more slowly than the lower one and rarely makes a wholly satisfactory recovery.

Children with spastic paralysis are more liable than the ordinary child to attacks of acidosis after operation, and are often quite sick in the post-operative period. On the other hand, in the experience of the writers, in carefully performed operations for the relief of contractions, a fatal result is exceedingly rare.

The prognosis in spastic paralysis caused by poliomyelitis is much more favorable than that of the other variety.

Treatment

The theory of treatment is perfectly plain but not always clearly formulated. For this reason the following scheme may be of assistance:

General: Out door life, discipline—hygienic regular life—freedom from excitement and stress.

Local:

1. *Non-operative treatment.*
   - (*A*) Muscle re-education.
     - (*a*) To develop by exercise, weakened muscles.
     - (*b*) To direct motor impulses into legitimate channels.
     - (*c*) To cultivate rhythm.
     - (*d*) To improve balance.
2. *Operative treatment.*
   - (*A*) Operation on the muscles or tendons.
     - (*a*) Tenotomy (Tendon lengthening).
     - (*b*) Myotomy.
     - (*c*) Muscle transplantation.

(*B*) Operations upon the nervous system.
(*a*) Alcohol infiltration of nerves.
(*b*) Division of the posterior nerve roots (Förster's operation).
(*c*) Division of muscular branches of motor nerves (Stoffel's operation).
(*d*) Ramisection.

It is obvious that the *general treatment* of these children is important. Hygienic surroundings should be good, mental discipline is important, excitement is as a rule badly borne, and drugs, so far as known, are of no use, except that bromides are apt to be useful in periods of excitement and especially after operation. If syphilis is present, rigorous antisyphilitic treatment is essential. In all country orthopaedic hospitals experience has shown that outdoor life, free range in play, walking and farm life almost invariably of themselves improve the condition in spastic cases, both mentally and physically.

Muscular reeducation and similar non-operative procedures will first be dealt with, and then the operations addressed to weakening or improving the function of the spastic muscles after which will be discussed the operative procedures upon the nervous system itself.

Non-operative Treatment

Muscle Re-education. *Development of Weaker Muscles.*—To teach the patient to use the weaker muscles one aims in the leg to cultivate the extensors, abductors and outward rotators, and in the arm to develop the extensors, external rotators and supinators. This is best accomplished by aiding the movement gently with the hand until the maximum of voluntary movement has been reached, then to carry it a little beyond this by means of a very gentle stretch, and then to replace the limb passively in the flexed position and again to repeat the exercise. It will be found that at each voluntary extension the power and range increase slightly. The exercise should not be pushed to the point of fatigue. Non-weight-bearing exercises are preferable to weight-bearing ones.

To Direct the Erratic Motor Impulses into Legitimate Channels.—If a patient with spastic paralysis attempts to flex the elbow, he is likely to set in action the muscles in the whole upper extremity. If he attempts to flex the knee, an equal amount of motion is likely to occur at the hip and ankle; and if he attempts to perform a movement with the fingers the entire arm takes part. This, except in the severest cases, is dealt with by aiding the patient first to contract the biceps, for example, leaving the other muscles lax. When this is learned the patient should be taught to abduct the shoulder without contracting the other muscles. Having thus learned to perform the coarser movements in this way, he may then be carried on to the finer movements in the fingers, and be aided in separating these also. This method of procedure is most important and must be assiduously followed to obtain the best results.

To Cultivate Rhythm.—If a patient with spastic paralysis, even of a mild degree, is told to tap rapidly on the floor with the toes of his unaffected foot while his heels rest on the ground he will do so rapidly and in rhythm. If the affected foot is tested in the same way the taps will be exceedingly slow and somewhat irregular. This pertains with regard to all movements of the affected limbs, and a drill in rhythm is most important. This may be accom-

plished in three ways: (1) By performing movements synchronously with those of the other side, (2) by performing movements to the beat of a metronome, and (3) by marching to music, or by getting accustomed to the sound of the footsteps when walking on a hardwood floor, and learning to make the sounds alike on both sides.

To Improve Equilibrium.—In the affection of the lower extremities the balance in these children is invariably poor and they are heavy on their feet and clumsy. Gymnastic exercises for balance, and particularly dancing lessons, are effective.

This treatment to be effective must be carried on for a long time and must be done with the utmost care, or it will be unsatisfactory. In the muscular education it is important that the person in charge should have the entire attention of the patient, that the words of command should be given promptly and sharply, and instantly obeyed, that the commands should be separated by an equal interval, and be so far as possible rhythmical, and that the patient should not be pushed to the point of muscular fatigue or mental inattention.

Reeducation treatment alone in the majority of cases of spastic paralysis is not enough, and is applicable only to the very mildest cases. The treatment thus described is regarded by the writers as basic and as applying chiefly to postoperative cases. It is placed first on account of its extreme importance and the fact that a minority of the cases can be handled by it alone; but in those cases where marked muscular resistance is encountered in performing the exercises, operative measures are desirable if the intelligence of the patient is such that postoperative muscle reeducation seems practicable.

No one should expect more of operative treatment in spastic paralysis than to correct deformity and prepare the way for teaching muscular coordination.

A treatment too frequently followed in these cases is *massage* and *intermittent muscular stretching*, both of which are calculated to do injury. *Massage* is given in general to increase muscular tone, and, except in its mildest form for the purpose of a quieting effect, is manifestly contraindicated in a condition of muscular hypertonicity. *Intermittent stretching* of the contracted muscles, if forcibly done, is invariably injurious. One must remember that the stronger muscles are the ones that contract, and the ones which should be stretched if any are to be attacked by this method. To stretch a contracted muscle and pull against its contraction is a form of exercise recognized in the gymnastic systems as eccentric. The intermittent stretching of a muscle is an exercise which tends to make it stronger than it was before. A faithful carrying out of this procedure therefore will have the effect of making the muscular balance worse than it was originally. On the other hand, it is very desirable for the contracted muscles to be subject to *continuous stretching:* in the wrist, for example, on a dorsiflexion cock-up splint bent to the degree of tolerance. In this position the muscles at the back of the forearm are shortened, and the flexor muscles are under continuous tension, which must not be increased beyond the position of easy tolerance or it will increase the tonic spasm.

Certain measures of importance in the treatment of cases of spastic paralysis, especially after the removal of splints, are as follows: in walking the patient should be taught not to look at the ground, but to stand erect, and walk with the legs apart forming a wide pedestal of support; the toes should be turned out if possible and the walking done rhythmically and slowly, as many of the patients have a tendency to walk extremely fast on account of poor

balance. They will be much helped in walking if they are also taught when possible to stand on one foot with the other knee raised.

In walking the erect position is often helped by parallel ropes placed at the level of the head on which the hands can be carried, and in feeble cases there should be somebody present in front of and behind the child to catch him in case of falling. This is especially necessary at the beginning of the training. The pushing of a carriage ahead of him is undesirable, as it encourages flexion of the thighs, a position which is always to be avoided.

Systematic exercises should be given every day. Braces to hold the knees extended should be worn at the back of the knees day and night, if necessary, to avoid flexion of the knees. Right angled splints should be worn both day and night, if necessary to prevent equinus from occurring. The limbs should be also well abducted at night time in mild cases of adduction.

Operative Treatment

Regarding, as the writers do, the essential treatment of spastic paralysis to be muscular reeducation, and the operative treatment to be merely preliminary to this, it is well to remember that children should not be operated

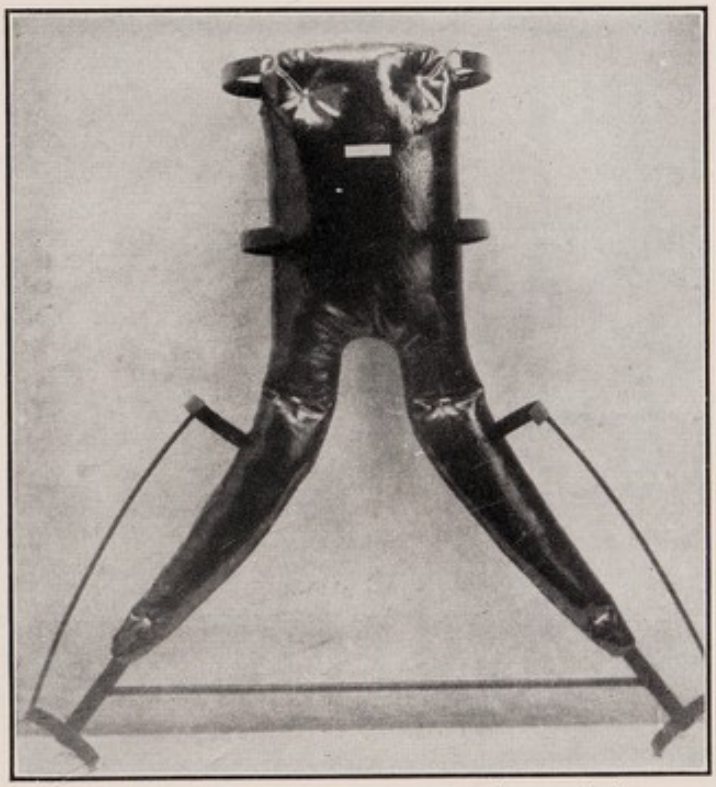

FIG. 435.—Double frame for spastic paralysis.

on at too early an age, as it is important that the muscular reeducation should follow soon upon the operative treatment. Children under four or five are not as a rule old enough to obey orders promptly and accurately, and therefore unless deformity is very severe and causing bony distortion it is generally wise to wait until the age of five or six before operating. This is of course not a fixed rule and we must be guided by the mental condition. In formulating operations it must be remembered, as said before, that these children

are poor operative risks as they have less than the average resistance. It cannot be too strongly insisted that to operate on a child with a marked degree of mental enfeeblement will only bring discredit on the surgeon, but it must be remembered at the same time that *operations to diminish spasticity and to improve function are in most cases attended by a marked improvement in mental condition and a diminution of nervous symptoms.* Athetosis, for example, is almost invariably diminished by tenoplasty of the tendo Achillis and similar operations, but the operations will not transform a child who is decidedly deficient mentally into a child with average mentality, and postoperative mental improvement is to be counted on in children only where a mild mental deficiency exists. Operations are designed to correct deformity, to equalize opposing groups of muscles, and to lessen the athetotic spasms. In the lesser degrees of spasm operations may not be needed, for mechanical measures will often suffice. They should consist in placing the patient at rest for some weeks in a position opposed to the deformity. In the upper limb the pronated forearm should be kept supinated, the hand dorsiflexed with the thumb abducted and slightly palmar flexed. The lower limb should be rotated outward, abducted with the knees fully extended and the feet dorsiflexed. Stretching movements should be avoided as they tend to increase the spasm; active movements, when the period of rest is ended, should be rigorously practised. This obtains also if preliminary operations have been performed.

Tenotomy and Myotomy.—In the lower extremity the operation is intended to make the patient walk more normally by lengthening the contracted muscles. Plastic division of the spastic muscles (tendons) also eliminates for a time all irritant afferent impulses from that particular group. The determination of what operation is necessary should be made in the standing position as well as when the patient is lying down, or sitting with extended knees.

For equinus position of the foot the tendo Achillis should be lengthened by plastic tenotomy through an open incision on account of the great importance of getting exactly the right correction. After the operation the foot should be put up exactly at a right angle, and under no circumstances overcorrected, and the plaster should extend above the knee. The indiscriminate cutting of the tendo Achillis by subcutaneous tenotomy in spastic paralysis cannot be too strongly condemned. One has only to see in their later stages cases where this operation has been performed to appreciate what a really serious harm has been done by converting an equinus, into a very serious calcaneus. In slight and moderate cases operation may very rarely be avoided by properly planned exercises which tend to lengthen gradually the contracted muscle. Let us repeat that the classical transverse division of the tendo Achillis has no place in spastic paralysis, and when performed often produces very unfortunate results.

For knee flexion of a persistent character interfering with walking, which has resisted attempts at correction by muscle training and stretching, the two hamstrings may be divided by a short incision above their insertion, in which operation it is well to leave the biceps alone except in very severe cases. The surgeon need hardly be warned that the external popliteal nerve at this level runs in close contact with the biceps muscle The operation of dividing the hamstrings is to be done only very exceptionally, as the relief of the tendo

Achillis contraction very often enables the leg to be put straight on the ground after it is divided, and tendon transplantation has largely superseded it.

For adduction contraction a subcutaneous tenotomy generally suffices, although the surgeon may prefer to operate through an incision. The tenotomy knife is introduced about an inch below the origin of the adductor longus muscle, which is divided, and while the leg is abducted, all resistant muscles should be similarly cut, generally including the adductor magnus and brevis and sometimes the gracilis. In very severe cases, especially in the adult, it may be of advantage to remove a portion of the muscles, but as a rule the operation described suffices. After division, the leg should be put up in a position of as much abduction as can be obtained, combined with outward rotation.

Fixation in abduction is used for two reasons: (1) To lengthen the adductors and allay spasm, and (2) to prevent the painful contractions that are sometimes present.

If an abduction frame is applied to allay painful spasm it should be retained in position until the tendency to irritable spasm has disappeared. If the splint be taken off and on, the recovery from spasm will be delayed. The same is true with regard to fixation in plaster of Paris.

The division of the adductors may suffice to correct *inward rotation*, but if the latter persists the gluteus medius should be exposed by an incision running parallel to the crest of the ilium and ending at the anterior superior spine. The muscular origins of the gluteus medius and of the tensor fasciæ femoris are then detached and stripped off the bone from the anterior superior iliac spine backward for a distance of two inches or more and peeled off the bone for one and one-half inches or more from the crest and detached from the notch below the anterior superior spine as far as the anterior inferior spine. When they are reattached they unite at a much lower level and the muscle is permanently lengthened; or the gluteus medius tendon may be detached with a chisel or knife from its insertion into the great trochanter.

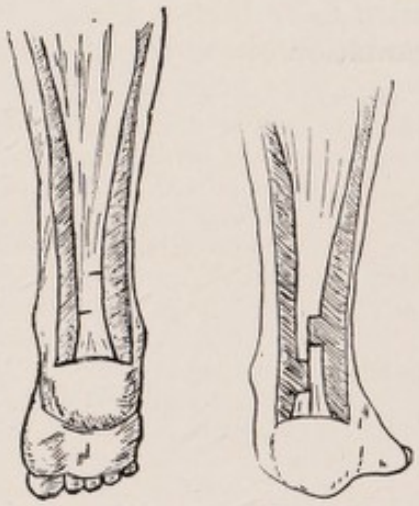

FIG. 436. FIG. 437.

FIG. 436.—Plastic tenotomy of tendo Achillis. The diagram shows the two incisions through half of the tendon at different levels.

FIG. 437.—The foot has been dorsally flexed and the tendon stretched and elongated but not separated across.

The legs should then be put up in a plaster of Paris spica bandage, or an abducted Thomas double hip splint with extensions in a position of as much abduction and outward rotation as can easily be obtained, with the knees extended and with the feet at right angles to the legs. This position should be maintained for about six weeks. The advantage of the abduction splint over the plaster of Paris is that bandages can be temporarily slackened, and reapplied after voluntary efforts directed to the exercise of the quadriceps.

The decision of how much operating to do in a given case is often perplexing and must be settled on general principles. From an equinus position, constantly maintained, one must expect resultant knee and hip flexion in standing, but not necessarily adduction or internal rotation. If such contractions at

knee and hip are evident when the patient lies down, it is fair to assume that real contraction exists there also. If contraction exists, it should be relieved.

With regard to tenotomy and myotomy, it is wise for the surgeon to call the attention of the parents to the fact that a recurrence of the deformity may occur in spite of a properly performed operation in hip, knee, or ankle, and after proper after-treatment, but this fear should not influence the surgeon to overcorrect the foot after plastic tenotomy of the tendo Achillis, a practice which is invariably bad.

Muscle Transplantation.—In the *ankle* this is not to be recommended.

At the *knee* the forward transplantation of two hamstrings to the patella is to be reserved for only the very severe cases. It is not always attended by satisfactory function, and often gives rise to genu recurvatum. The transplantation of the biceps alone into the patella is the better operation.

Operation of Transplanting the Biceps to the Patella.—An incision eight to twelve inches in length is made along the course of the biceps, extending upward from its fibular attachment, the muscle being clearly defined.

The tendon is now divided at its insertion into the head of the fibula and completely freed from its fascial attachments.

The lower half of the fibres of the short head of the muscle are now divided from the femur, and the tendon is then passed, without torsion, through a loose, fatty tunnel on the outer side of the thigh into a small incision made over the upper border of the patella.

The end of the divided tendon is now firmly fixed into a groove made on the anterior border of the patella.

If the semitendinosus is also used, the incision through which it is divided and transplanted is similar in relation to this tendon as that over the biceps, and the insertion of the tendon into the patella is carried out in a similar manner (Figs. 500 and 501).

In the *hip* no definite muscle transplantation seems available.

In very severe inward rotation at *the shoulder*, due to contraction of the pectoralis major tendons, the latter should be divided by open incision. In very severe contractions of the shoulder in adduction and inward rotation, it may be necessary to divide the tendon of the pectoralis major and subscapularis muscles, either alone or in connection with operations lower down. Tendon transfer in this region is not of value.

Operations for deformity and improved function in the upper extremity are as follows:

(*a*) *Correction of Spasmodic Pronation.*—This may be achieved by changing the point of insertion of the pronator radii teres in order that it may supinate the forearm.

Jones' Operation.—This consists in detaching the pronator radii teres and inserting it into the extensor carpi radialis longior et brevior. A straight incision is made over the insertion of the pronator radii teres. The supinator longus is situated immediately over the tendon of the pronator radii teres and is moved to one side in order to expose the tendons of extensors of the wrist. The pronator radii teres is now detached at its insertion, which is a wide one. This division is made easier by passing a flat instrument between the muscle and the bone. Great care must be taken to remove the whole of the tendon from the bone, for if any part of it is left behind, the operation is of no avail. A part of the periosteum may be removed with the tendon, and is passed through two small slits in the extensor carpi radialis longior et brevior, and may be sewed in position. During this part of the operation the hand should be kept dorsiflexed in order that the transplanted tendon may be attached as low down as possible. The hand should be kept for three or four weeks dorsiflexed and completely supinated. By this operation the dorsiflexion of the hand is strengthened and the pronation weakened.

Operation for Adduction and Flexion Deformity of the Hand.—One troublesome deformity consists of flexion of the wrist joint with hyperextension of

the fingers at the metacarpophalangeal line, ulnar adduction of the hand, and marked adduction of the thumb. The thumb is held flexed across the palm, so that attempts to make a fist are prevented by the fingers closing down on the thumb rather than inside it. Voluntary efforts to open the hand result in further hyperextension of the fingers, very slight change in the flexion deformity of the wrist and no appreciable alteration in the adduction of the hand, or in the position of the thumb.

One of the chief mechanical obstructions to the powerful use of the fingers is the adduction of the hand because the flexor tendons are not working in a straight line but rather at an angle. This adduction angle is maintained by the flexor carpi ulnaris and the extensor carpi ulnaris, and of these two the latter has the greater influence in producing the deformity as it is situated near the bony prominence of the lower end of the ulna over which it is frequently displaced. Its deforming influence is thereby increased. Electrical stimulation of this muscle in hemiplegia produces very slight dorsiflexion of the wrist and a very marked increase in the ulnar adduction.

The operation consists in transplanting the tendon of the extensor carpi ulnaris into the three extensor tendons acting on the thumb. This is performed through a vertical incision about four inches long made over the posterior aspect of the wrist about one-half inch to the outer side of the extensor carpi ulnaris tendon and extending upward from its insertion. Through this incision the tendon is divided close to its insertion and freed throughout the whole length of the incision. The tendons acting on the thumb are now defined as they pass obliquely downward and outward, and the divided lower end of the ulnar carpal extensor is inserted through small slots made in their substance while the thumb is held in the position of full abduction.

Postoperative fixation of the thumb in this position, with the wrist dorsiflexed, is maintained for four weeks before active movements are instituted.

The Correction of Severe Palmar Flexion.—The writers have found that by transplanting the tendon of the flexor carpi ulnaris into the extensor carpi ulnaris, in addition to inserting the pronator radii teres into the extensors on the radial side, dorsiflexion is considerably strengthened.

After-treatment.—In the after-treatment of all these operations it must be remembered that spastic muscles bear stretching very badly, and it is a severe ordeal to anesthetize, abduct the legs forcibly, and put them up in a position of extreme abduction, for example, without dividing the adductors. Very marked general disturbance, great nervousness, and even convulsions may result from this, and it is never wise to put up limbs in a more corrected position than the operative treatment easily permits.

With regard to the operative risk involved in this class of cases, there is a general impression that it is bad. In this connection the experience of the writers is of interest. In 1700 cases of spastic paralysis operated on in Liverpool there were only five fatal results, four from shock and one from acidosis. It must be said, however, that the cases as a rule are a good deal upset by operation and they often take anesthetics rather badly. In a case of one of the writers spasm of the adductor muscles of the larynx was present, and it proved impossible to carry on the operation under ether; but under gas and oxygen anesthesia multiple tenotomies were performed.

The use of bromides after operation is often desirable in small doses, and twitching of the face and convulsive movements of the extremities are to be regarded as indicating that perhaps too much discomfort is being exerted by the postoperative position.

Operations upon the Nervous System—(*a*) *Alcohol Infiltration and Nerve Pinching.*[1]—The injection of alcohol into motor nerves paralyzes for some weeks the muscles supplied by them, the nerves being exposed by dissection; or better than alcohol injection is a pinching of the nerve. This is done by exposure and grasping the nerve for five or six seconds in a blunt artery forceps. This procedure paralyzes the muscles involved for from three to four months. During this period of inactivity their opponents may be intensively exercised and developed. Four locations seem especially adapted to these operations—(1) the obturator nerve at its exit from the pelvis to paralyze the adductors; (2) infiltration of the branches of the sciatic nerve which supply the hamstrings; (3) the branches of the popliteal nerve which supply the soleus and gastrocnemius in the popliteal space; and (4) the anterior tibial nerve to paralyze the group of muscles supplied by it.

The spasticity ultimately will return in part and no gain will be secured unless it is borne in mind that the proceeding is only useful to secure a quiet period for intensive development of opposing muscles. Physiologically this method amounts to abolishing, for the time being, both motion and sensation in the blocked off area.

The measures to be described next are addressed, one, to sensory and the other, to motor blocking.

(*b*) *Section of the Posterior Nerve Roots.* Förster's Operation.—This procedure, first proposed by Mizzanini in 1900 for relief of the crises in tabes dorsalis, and advocated and carried out in 1907 by Förster[2] was the intraspinal section of the posterior nerve roots dorsal to their ganglia.

This procedure is based on the supposition that afferent impulses of a reflex character are constantly streaming in from the periphery to the reflex center in the cord from which they are reflected as efferent impulses to the muscles and cause muscular contractions. These impulses are normally regulated, controlled and inhibited by certain fibres in the pyramidal tracts which distribute and control inhibitory impulses; but when these inhibitory fibres are impaired, or injured, or powerless, the irritating efferent impulses flow uncontrolled to be expressed as hypertonicity, and irregular and uncontrolled movements of the muscles. Förster proposed to break the reflex arc on the sensory side, and during the period before sensory restoration begins to exercise and develop the muscles which are for the time being free from spasm.

The operation as formerly practised involved (*a*) section of the 3rd, 4th, 5th lumbar, 1st and 2nd sacral roots, to eliminate lower limb spasm and (*b*) section of the lower four cervical and 1st dorsal roots to abolish upper limb spasm. Although a number of encouraging results were reported, the operation has fallen into disuse for a combination of reasons. In the first place the shock of a laminectomy in spastic children is apt to be severe, and there are simpler methods of eliminating or minimising spasm. Then again post-operative re-education of paralysis is rendered easier if the sensory arc is intact.

(*c*) *Division of Motor Nerves.* Stoffel's[3] Operation.—The operation now to be considered interrupts the reflex arc on the motor side. Motor fibres to individual muscles and muscle groups leave the main nerves at different points and the position and function of these motor branches are more or less constant.

The motor branches are exposed, identified by an electric needle, and resected. Immediate relaxation of spasm in the affected muscles comes on, and during this period exercises are begun.

The advocates of this operation lay special stress upon the necessity of preliminary care and after-care. Deformities should be, as far as possible, corrected and maintained in the corrected position for some weeks. The operation consists in an excision of those nerve fibres which supply the strong contracting muscles. In this way an effort is made to restore the muscular balance.

The technique of the operation, as described very lucidly by Bruce Gill,[4] is as follows:

Technique of the Operation.—First, the *median nerve.* It has not been found necessary to operate for flexion contracture at the elbow. But it is possible in certain cases that a portion of the nerve supply to the biceps muscle might require resection. The median nerve is exposed in the bend of the elbow and the incision need not be more than two inches in

[1] Harris: Boston Med. and Surg. Jour., July 17, 1913.
Allison and Schwab: Trans. Amer. Orth. Asso., 1910–1911.

[2] Förster: Surgical Section Jour. Royal Soc. Med., 1911. Ergeb. d. Chir. and Orth., Berlin, 1911; Zeitsch. fur physikal therapie, June, 1913.

[3] The Treatment of Spastic Contractions, Am. Jour. Orth. Surg., 1911.

[4] Gill, Bruce: Stoffel's Operation with a Report of Thirty-two Cases, Jour. Orth. Surg., 1921.

length. The nerve is freed from surrounding tissue, and partially retracted out of the wound, and supported on a grooved director or a hemostat placed transversely. On the anterior aspect of the median nerve adjacent to the biceps muscle is to be seen a nerve tract or cord. A portion of this separates itself from the median nerve and goes directly to the superficial head of the pronator radii teres. This is the first branch to leave the median nerve in the flexure of the elbow and this branch should be entirely resected for a distance of several inches. It can be cut off below near the point where it enters the muscle, and can be dissected up from the median nerve the desired distance. The remainder of the tract already described consists of the nerves to the flexor carpi radialis, the palmaris longus, and the deep head of the pronator radii teres. These bundles of nerves are to be freed from the remainder of the median nerve and from one another and to be tested by the electrode, and in severe cases of pronation and flexion contracture all of these nerves should be excised. In less severe contracture one may split the nerve to each muscle and may resect approximately one-half to three-fourths of it. The nerve to the pronator quadratus is to be found in the dorsal portion of the median nerve. Usually it should be left intact, but in very severe cases it may be resected. In none of the cases has this resection been found necessary.

The median nerve is now further separated into its constituent bundles. It will be found that the nerve supply to the flexors of the fingers is on the dorsal and ulnar aspect. These bundles should be freed from the remainder of the median nerve, separated from each other and tested by the electric current. Such portion of them may be removed as is demanded by the severity of the contracture. The remainder of the median nerve consists of the sensory tracts, and of the motor nerves for certain intrinsic muscles of the hand. It is thus found that the median nerve consists of a definite number of nerve bundles or funiculi, which, like cables, are bound together. The tracts to the various muscles always occupy the same relative position in the nerve; in other words, the nerve has a definite topography or internal structure which is always the same. The surgeon will soon learn by observation the position of these various bundles, and may in time learn to dispense with the use of the electrode; but in his earlier cases it is advised that he always test each bundle after it has been isolated to determine which muscle it supplies. One may use the ordinary brain electrode, or one may have made a special electrode for this purpose. It will be found that very slight stimulation is necessary to secure response in the muscle. If a strong current is used there is danger of its spreading from one bundle to another, thereby confusing the surgeon as to which bundle of nerves he has isolated. The least strength of current necessary to produce muscular contraction should be employed. It is found that these spastic muscles respond to slighter stimulation than do normal ones.

The surgeon has now produced a certain amount of paralysis of the muscles of pronation and of the flexors of the wrist and fingers. He has left, of course, untouched the ulnar nerve, which also supplies a portion of the flexors of the wrist and fingers. It may be attacked in a similar manner at a later operation if necessary.

Second, the *obturator nerve*. The anterior branch of the obturator supplies the gracilis, the adductor longus and all or a portion of the adductor brevis. The posterior branch supplies the obturator externus, the adductor magnus, and at times the adductor brevis. Certain other muscles aid in the adduction of the thigh, notably the pectineus, which is supplied by a branch from the anterior crural, and the hamstring muscles which are supplied by branches of the sciatic. The dorsal portion of the adductor magnus frequently receives nerve supply through the great sciatic nerve. The adductor magnus is frequently divided into two distinct portions. The upper part of the anterior portion is usually quite separated from the rest of the muscle and has been termed the adductor minimus. It is therefore clear that if the anterior branch of the obturator nerve be excised a considerable degree of adduction remains in the muscles supplied by the posterior branch and by the other nerves just mentioned. If the posterior branch be excised in addition to the anterior, the patient still possesses power of adduction through the pectineus, the dorsal portion of the adductor magnus, and through the hamstrings in certain positions of the thigh. Therefore in moderate degrees of spasticity, the entire anterior branch of the obturator nerve should be excised and in severe degrees both branches are excised. It has been found necessary only on one occasion to excise the posterior branch as well as the anterior.

An incision two or three inches in length is made from the pubic spine downward along the tendon of the adductor longus. This tendon is identified, and a blunt dissection is made by the handle of the scalpel or with the fingers along its inner margin. Dissection should never be made through muscle substance but always in the cleavage planes between the muscles. The tendon of the adductor longus is then retracted outward and the anterior

branch of the obturator nerve is clearly seen running in the intermuscular fascia. If one division only of the anterior branch is observed it may be lifted upon a small hook and the blunt dissection carried proximally until the main stem of the nerve is isolated. The main stem is found to divide usually into three branches. The dissection is carried up to the obturator foramen. The posterior branch of the obturator can then be seen issuing from the foramen, or running backward behind the anterior fibres of the obturator externus, and behind the adductor brevis. If the anterior branch alone is to be resected, the main stem is clamped by a hemostat, and is divided above the hemostat. The various branches are then divided several inches lower as they are seen entering their respective muscles. If the posterior branch is to be resected also, it is removed in a similar manner. One or two sutures are placed in the deep fascia and the skin wound is closed.

Intra-pelvic Section of the Obturator Nerves.—The main obturator trunk is easily exposed in the pelvis by the extra-peritoneal route. A median supra-pubic skin incision is made and the recti muscles separated. The bladder is held to one side and the interior of the pelvis inspected. The nerve can then be seen and felt as a white cord running along the lateral pelvic wall to disappear through the obturator foramen. Closely attached to its sheath is a leash of veins which must be carefully separated before the nerve is hooked up on an aneurism needle. The neurotomy is now carried out, a length of ½" being resected consisting of four-fifths of the total cross-section or even more. The wound should be completely closed in layers. One of the advantages of this method of exposing the obturator nerve is that the wound is placed well away from the perineum and is thus less liable to soiling in children whose habits are untrained.

Third, the *sciatic nerve.* This is attacked to overcome contracture of the hamstring muscles. The nerve is exposed without difficulty by an incision begun at the gluteal fold, and running downward for four or five inches, and placed about midway between the tuberosity of the ischium and the great trochanter. After the deep fascia has been incised, the long head of the biceps muscle is identified. This muscle is then retracted inward and the dissection continued along its edge until the sciatic is encountered. On the median aspect of the nerve is found the cord which supplies the long head of the biceps, the semimembranosus, and the semitendinosus. This tract or cord is separated from the main trunk of the sciatic nerve, is lifted by a hook or an elevator, and is then dissected into its component parts. These three nerves are identified by means of the electric needle. In moderate degrees of spastic contracture the nerve to the biceps and the nerve to the semimembranosus are excised completely. In severe cases of contracture the nerve to the semitendinosus is split and about one-third of it is resected. The surgeon therefore in the first instance leaves intact the short head of the biceps and all of the semitendinosus, and in the latter instance the short head of the biceps and on the median side the greater part of the semitendinosus. These two muscles are sufficient to secure active flexion of the knee, but their united power is not sufficient to overcome the extensor muscles of the thigh.

Fourth, the *internal popliteal.* This operation is done to correct pes equinus or pes equinovarus. This nerve is exposed in the center of the popliteal space, where it is superficial and is easily approached as the blood vessels and other structures lie deeper. The nerve is lifted from the wound and placed across a grooved director. It is well freed upward and downward from surrounding tissue. The first branch seen to be coming from the nerve, leaves on the internal and posterior aspect and immediately pursues a superficial course. This is the sensory branch called the nervus cutaneus suræ medialis or the tibialis communicans. The next two nerves to leave the main trunk are the nerves to the outer and inner heads of the gastrocnemius muscle. Running beside these two nerves is the nerve to the dorsal portion of the soleus, and the nerve to the plantaris. The common tract containing these nerves lies on the dorsal or superficial aspect of the internal popliteal nerve. The ventral portion of the soleus muscle is supplied by a special tract which lies on the antero-external aspect of the nerve. The nerve to the tibialis posticus will be found on the posterior or the postero-external aspect. That for the flexor longus digitorum on the postero-median aspect. In moderate cases of pes equinus the two nerves to the heads of the gastrocnemius alone are resected. In slightly more severe cases a portion approximately one-half of the nerve tract to the dorsal portion of the soleus is also excised. In still more severe cases this entire tract is excised. If it is found in the severe cases that the flexor longus digitorum is materially aiding in producing the deformity, a portion of its supply must also be resected. If the tendency to pes varus is marked, a portion of the supply to the tibialis posticus must be taken. After the nerves have been resected the remainder of the internal popliteal nerve

is dropped back into its position where it lies embedded in fat. The deep fascia is brought together by a few sutures and the skin wound is closed.

When the patient is under the full influence of the anesthetic it is usually found that all contractures which were present before operation have disappeared. In other words, the contractures were spastic contractures and not atrophic, such as occur in infantile paralysis. If it is found at the time of operation that contracture of the tendons still is present then we know that real shortening has occurred, and tendon lengthening should be done in addition to the nerve resection. However, this tendon lengthening should be performed only in case the surgeon is unable by manipulation to stretch the tendon.

The authors have had the opportunity of examining several cases after operation which have been very encouraging, especially with regard to the equinus deformity, and they feel that with further experience even better results may be expected. At the same time equally good results are noted from procedures which do not involve the risk of faulty technique.

As an alternative to section of the motor branches, crushing may be employed, a procedure less permanent in its effects. The authors have performed this operation on the obturator nerve with success, and Naughton Dunn has published a series of cases where the operation of compression of the nerve to the peronei has cured the spasm sometimes attending flatfoot.

(*d*) *Sympathetic Ramisection.*—Royle[1] of Sydney, Australia, has addressed attack upon the sympathetic nervous system in certain types of spasticity of the arms and legs. He has called attention to the mechanism of the reflex response to stimulation, demonstrating the condition which he calls "*Plastic tone*" or retained response of the muscles. This protracted tonus is relieved by ramisection, an operation consisting of exposure of the sympathetic ganglion and section of the grey rami communicates. The rationale of this procedure has met with considerable criticism and many failures have been experienced by other surgeons. That in certain cases a diminution in hypertonus follows the operation as designed by Royle cannot be denied. This work is too recent to allow of proper estimate of the value.

Summary.—On the whole the division or plastic lengthening of muscles and certain of the neurotomy operations (*e.g.* on the obturator), followed by reeducation, give satisfactory results in the spastic paralyses of children and adults. Posterior rhizotomy is now obsolete, and the newer operations on the sympathetic are still sub-judice. It must be remembered that spastic paralysis is not so simple a neurological problem as these operations on the nerve centers would make it appear. Diffuse, excessive and irregular impulses go to the muscles and cause hypertonicity of all of the muscles, lack of coordination, disturbance of balance in sitting and standing, loss of proper rhythm and often athetosis. A muscular contraction moreover has three characteristics: (1) force, (2) extent, and (3) rhythm, all of which are disturbed in spastic paralysis. That this complex problem may be solved by breaking the reflex arc does not seem probable and the representative surgeons of today are turning more and more to the simple direct tenotomy, tenoplasty, myotomy and muscle transplantation combined with muscle reeducation as the direct surgical attack upon disordered function of a very complex nature, so complex that the needs of every case must be met by individual modification of the surgical requirements.

Finally, operation should be regarded not as treatment itself, but as removing an obstacle to the real treatment by muscle reeducation.

[1] Royle, N. D.: Surg. Gyn. and Obst., 1924. Med. Jour of Australia Jan. 26, 1924.

CHAPTER XXI

ANTERIOR POLIOMYELITIS

(Infantile Paralysis, Anterior Poliomyelo-encephalitis)

Definition.—Poliomyelitis is an acute infectious disease, accompanied in many, perhaps most cases, by paralysis. The *paralysis is incidental and not essential*, and when it occurs, is a weakening or total loss of power in certain muscles, with no gross disturbance of sensation. Its distribution is widely scattered, very erratic, and not necessarily symmetrical, and the lower extremities are very much more frequently affected than the upper. The paralysis is flaccid in type and the reflexes are lowered, except in those very rare cases affecting the upper neuron, a lesion which has been discussed (p. 412).

Pathology[1]

Infantile paralysis is a general infection, the results of which are most marked in the nervous system, in which at autopsy the meninges are found to be edematous and injected, a slight increase in the amount of cerebrospinal fluid also being evident. The brain and cord are edematous, and minute hemorrhages can generally be distinguished.

The first stage in the pathological process is an acute interstitial meningitis, usually most marked on the anterior surface of the spinal cord. In the cord itself there occurs a hyperemia, and a collection of small round cells in the lymph spaces surrounding the vessels (perivascular infiltration) as a result of which in many places the cells are so numerous that they press on the lumen of the vessel and obstruct the circulation. Minute or extensive hemorrhages occur, and there is extensive edema. The lumbar enlargement of the cord is most often affected, and the anterior horns, more often than the posterior or the white matter, as in the former the blood supply is more abundant. Although the process by which the vascular lesions affect the nerve cells is in large measure a mechanical one, it is impossible to exclude the fact that the virus may exert some directly toxic action on these cells. The damaging effects therefore, are to be attributed (1) to direct pressure on the nerve cells by hemorrhages, edema and exudate, (2) to the anemia following the constriction of the blood vessels, which is probably the most general and important change, and (3) perhaps to a direct toxic action of the virus itself on the nerve cells. On account of this pressure and anemia, the nerve cells may degenerate, yet if the exudate or hemorrhage, or both, are absorbed soon enough the cells may recover function; on the other hand, if the unfavorable conditions have been over-prolonged or are excessive, the changes in the nerve cells may go on to complete degeneration. In addition to changes in the spinal cord it is very important to note that the same sequence of changes are found to a less degree in the brain, medulla, and pons. The posterior root ganglia are practically

[1] Peabody, Draper and Dochez: Rockefeller Institute, New York, 1912.
Flexner and Amoss: Jour. of Exp. Med., 1914, No. 2.
Draper, George: "Acute Poliomyelitis," Blakiston, Philadelphia, 1917

always involved by lesions similar to those in the cord itself, and in experimental pathology this is the first step in the process. The terminal stage in the pathological changes is represented by the replacement of the motor cells by focal glioses (focal scleroses), due to increase of neuroglia tissue, which are analogous to areas of scar tissue in other organs. The destruction of spinal cells in any center naturally represents a loss of function of those cells, but the inter-communications between the bundles of motor cells and the connections between muscles and the motor centers are so free and so manifold that, unless the destruction has been very extensive, the possibility remains of establishing function through the "overlap." This fact serves as a basis for muscle training.

The changes which are found in other organs in severe infantile paralysis are less striking than those in the nervous system, but are practically as constant, and constitute an extensive involvement of the lymphoid tissue and of parenchymatous organs. In the latter, cloudy swellings are usually met with, not unlike those of typhoid fever.

In short, it must be remembered that poliomyelitis is a general toxemic process which affects organs throughout the body, but which apparently acts mildly; on the other hand, it is characterized by lesions in the spinal cord which occasionally prove fatal by involvement of the nerve cells controlling respiration or these changes may lead to greater or lesser impairment of *motor* function in certain of the cells controlling muscular action, most often in the legs. The great tendency toward spontaneous repair in this disease is explained by the pathology, which also shows why partial paralysis is so much more common than total.

Symptoms

There is, in the great majority of cases, nothing characteristic about the acute onset, for the symptoms are, in general, those of an acute infection. In many instances gastro-intestinal symptoms predominate, while in others those referable to the respiratory tract are the most marked. *Stiffness of the neck*, sweating, marked nervous irritability, and general hyperesthesia are present in many instances before the onset of the paralysis, but they are not at all constant. In some cases in adults, where a clear history can be obtained, one finds that pain, paresthesia, or a feeling of numbness of the affected part has preceded the paralysis.

The great majority of cases are of the familiar and long recognized type, mentioned first in the following classification; but there are variations in the disease, described by Wickman[1] as types, in which the symptoms are not of the usual kind, and this description has aided us in recognizing the multiform character of the disease.

Wickman's classification is as follows:

1. Ordinary spinal paralysis—anterior poliomyelitis.
2. Progressive paralysis, usually ascending, less often descending—Landry's paralysis.
3. Bulbar paralysis—polio-encephalitis of pons.
4. Acute encephalitis—giving spastic monoplegia or hemiplegia.
5. Ataxic type.
6. Meningitic type.

[1] WICKMAN: Die akute Poliomyelitis, etc., Berlin, 1911.

7. Polyneuritic (multiple neuritis) type.
8. Abortive type.

The fact is, that a diffuse and variable process, by affecting different parts of the nervous system, causes different symptoms, and that no one classification will satisfactorily cover all cases. The references[1] are to unusual variations in the symptoms. One attack apparently confers immunity, although one or two instances have been reported where a second attack seems to have occurred.

There are three divisions which should be made in the clinical history, which are as follows:

1. *The Stage of Onset.*—Pathologically it is an acute hemorrhagic myelitis and meningitis, and clinically the child is suffering from that, combined with an infection more or less severe. It covers the period from the beginning of the illness until the disappearance of the tenderness, because tenderness must be accepted as evidence of an active process still existent in the cord. In those exceptional cases where tenderness is absent, this stage may be assumed as lasting from four to six weeks.



FIG. 438.—Facial paralysis due to poliomyelitis.

2. *The Stage of Convalescence.*—Pathologically, the products of the hemorrhage are being absorbed, edema and perivascular infiltration are diminishing and, physiologically, the motor area of the brain is trying to send impulses to the affected muscles only to find certain paths partly or wholly blocked. Clinically, the child is more active and is trying to use the affected parts; tenderness has gone, but the power to execute certain movements may be impaired or lost. Notwithstanding this, there is a continuous gain, under all conditions of treatment or neglect. So-called "trophic" disturbances begin to appear now or later, circulation is impaired, affected members are atrophied and do not grow as they should, and deformities begin to develop. This stage begins with the disappearance of tenderness and lasts for about two years.

3. *The Chronic Stage.*—Pathologically, edema and perivascular infiltration have long since disappeared, the meningitis has healed, and in place of the destroyed areas in the cord are found focal glioses. Clinically the case is apparently stationary, or retrograding. Spontaneous improvement is much less noticeable than in the previous stage, and in most cases seems to have stopped and so-called trophic changes are present. Deformities from muscular contractions and gravity have occurred in many cases, and further improvement without treatment is not to be hoped for. This stage apparently begins about two years from the onset and continues through life.

[1] PEARSON: Birmingham Med. Rev., April, 1910, 148.
MÜLLER: Münch. Med. Wchsft., Jan. 23, 1912.
COLLIVER: Jour. Am. Med. Ass'n., Mar. 15, 1913.
WACHENHEIM: New York Med. Jour., Nov. 8, 1912.
FRISSELL: Jour. Am. Med. Ass'n., lvi, No. 9.
KOPLIK: Amer. Jour. Med. Sc., June, 1911.
BATTEN: Jour. Am. Med. Ass'n., lxii, No. 15, 1200.

Distribution.—The distribution of the paralysis is as follows in cases analyzed and contrasted from the New York and Massachusetts figures:

TABLE.—PERCENTAGE DISTRIBUTION OF PARALYSIS AT FIRST EXAMINATION
1. 166 Cases New York—1916 epidemic. 621 cases Massachusetts.

Distribution of paralysis	Per cent of cases	
	Massachusetts	New York
Both legs	40.0	29.0
One leg	21.0	25.9
Two legs and two arms	12.5	10.9
Two legs and one arm	5.2	8.7
One leg and one arm (same side)	1.3	3.2
One leg and one arm (opposite side)	1.3	2.5
Both arms	1.9	2.8
One arm	5.7	7.1
Two arms and one leg	1.4	1.7
Miscellaneous (distributed in other parts)	9.7	8.2
All cases	100.0	100.0

Tenderness.—This symptom may vary from slight tenderness on pressure to a condition of exquisite sensitiveness to touch, jar or movement. It is located either in the affected muscles or is widespread over the whole of the affected region. In an analysis made in the New York cases it was found that in 57 cases, in which tenderness existed at the time when the patients were seen at the clinic, the longest duration of tenderness had been sixteen weeks. The average duration is about six weeks, but tenderness can be prolonged almost indefinitely by massage, active movements given too early, osteopathy, chiropractic treatment, and other forms of manipulation, and a persistence of this condition over three months is in most cases likely to be explained in this way. This exceedingly important symptom has received too little attention, but exists in nearly all cases and is one of the most important guides to diagnosis and treatment.

Paralysis of the bladder occurs occasionally in the acute attack in connection with involvement of the abdominal and hip muscles, rarely, otherwise. Its duration is from a few days to a few weeks and the prognosis is favorable for complete recovery. Catheterization, under every aseptic precaution, may be necessary.

Diagnosis

Although the diagnosis of the disease in the acute stage does not belong exclusively to the surgeon's domain, many disputed cases will be brought to him later on; therefore, he should be able to estimate the significance of the history and symptoms in the *stage of onset.*

The appearance of symptoms suggesting an acute infection, in a young child in late summer, especially in a community where the disease prevails, is

always suspicious. Particularly is this the case if accompanied by sweating, nervous irritability, and especially hyperesthesia and neck stiffness. In the epidemic prevalence of the disease an immediate lumbar puncture is advisable in all cases and forms our chief diagnostic support at this time. This is for six reasons: (1) During the occurrence of an epidemic many abortive cases occur, which are a source of danger to the family and the community as foci of infection. (2) A positive diagnosis in the pre-paralytic stage allows the isolation of these cases, (3) it indicates the institution of complete rest before the onset of the paralysis, (4) it makes the surgeon careful about overlooking slight paralysis in such cases, which often escape attention, (5) it prevents carelessness in treatment based on the assumption that the child has only a fever attack or indigestion, and (6) it gives information of much comfort to the family that the child is immune from a future attack. In sporadic cases the proceeding would not be so often desirable, but in a region where poliomyelitis is so unfortunately prevalent as in the United States and Canada, the number of incorrect diagnoses in the acute attack is a serious matter not only to the patient, but to many practitioners as well as to the general public.

The characteristics of the spinal fluid in this disease are as follows in the acute stage: The fluid as a rule is clear and colorless and does not show great increase of pressure. In the first few days after the onset of symptoms it shows changes in the number of cells present, or in the globulin content, or in both. The increase in cells is highest during the first week as a rule, and in the case of Fraser's[1] reached the figure of 1221 per cubic millimeter. The number of cells diminishes rapidly, and in Fraser's cases was above normal in only 32 per cent in the third week. The globulin reaction, however, is usually most marked during the third week, persisting as a rule into the fourth week, and it may be present for a longer period. The increase in cells is due almost invariably to mononuclear cells of various types, of which the lymphocytic is the most common, and the fluid usually reduces Fehling's solution. In the early stages the blood count shows a mild leucocytosis with a decided increase in the lymphocytes and a decrease in the polymorphonuclear leucocytes.[2] The appearance of tenderness often masks the condition and leads to incorrect diagnosis, and it must be remembered that *tenderness is a routine symptom* in the majority of cases.

In the paralytic stage the paralysis is purely *a motor affection*, of scattered distribution, because it involves the anterior horn cells at various levels. Weakening is more common than total paralysis. It is accompanied by muscular atrophy, and because the reflex arc is broken, the reflexes in the affected area are diminished or lost. The reaction of degeneration to the galvanic current may be present, but its diagnostic value is limited. The greatest difficulty in diagnosis occurs when the disease is complicated with some other affection, as in the following personal cases:

1. A boy with a fractured elbow, while the arm was in the splint, was seized with an attack of fever, and had increased pain in the elbow. When the splint was removed, the arm was found entirely paralyzed from the shoulder down, and on examination was found to be a typical case of infantile paralysis. (2) A boy, with a congenital talipes equinus, came to the clinic with a history of having always been lame, but after a feverish attack being more lame.

[1] Fraser: Study of the Cerebrospinal Fluid in Acute Poliomyelitis, Jour. of Exp. Med., 1913, 242.
[2] Skoog: Treatment of Acute Anterior Poliomyelitis, Jour. Am. Med. Ass'n., Nov. 19, 1910.

Analysis of the case showed a combination of congenital deformity, and recent infantile paralysis. (3) Two cases were seen at the Children's Hospital, Boston, one child with a congenital dislocation of the hip in one leg and infantile paralysis in the other, and the second a child with an obstetrical paralysis of the arm on the right side, and a subsequent infantile paralysis of the leg on the same side. Infantile paralysis has been observed by the writers supervening on a former cerebral paralysis, and also added to muscular dystrophy. The history is often misleading and the origin of the paralysis is at times attributed to trauma by the parents.

The identity of poliomyelitis must be established alone or in connection with other nervous affections on the following data:

1. Early diagnosis from lumbar puncture.
2. Generally an acute attack.
3. Tenderness in the acute stage almost always exists.
4. The paralysis is (*a*) scattered, (*b*) flaccid, (*c*) reflexes in affected members are diminished or lost.

Anatomically it may be seen that no other *purely motor* paralysis or weakening of this scattered character can occur except from the lesion described (or theoretically also from the division of the anterior nerve roots of the cord). Hematomyelia, peripheral nerve lesions, transverse spinal cord lesion, etc., are all attended by change of sensation.

Cerebral Location of Lesion.—One definite obscurity arises when, as occasionally happens, the cerebral motor cells are attacked as well as the spinal. In this case there results a hemiplegia of unusual type, not very severe, but with spastic and flaccid muscles combined, while reflexes are increased and the gait is like that of an ordinary cerebral hemiplegia.

Amyotonia Congenita (Oppenheim).—This condition can simulate a severe grade of infantile paralysis quite closely, especially when accompanied by hip and knee flexion contractures. It is to be differentiated by the history of onset which is usually insidious and very early, generally being present at birth, although not as a rule immediately detected. It is essentially a lowered muscular tone (hypotonus) and the distribution is symmetrical, most often affecting the proximal rather than the distal parts of the limbs. It is characterized by flaccidity, without local atrophy, and may affect any part of the body, especially the trunk and arms. The changes in the muscles are essentially those of the myopathic group. The deep reflexes are lost and it is not essentially a paralysis, but a weakening of wide distribution.

Prognosis

The mortality rate is shown in the table on the following page.

Prognosis as to Life.—In general, large epidemics produce a more serious type of case than occurs sporadically, and at the beginning of the epidemic the mortality is higher than toward the close. High mortality is associated in most cases with the location of the paralysis in the trunk and arms, as death occurs almost always from respiratory involvement. This is a serious matter as to prognosis from the beginning and continues serious for a good many months, for not only does the patient often die in the first days of respiratory failure, but subsequent fatal pneumonias often occur after some weeks. The prognosis as to life is worse in adolescents and adults than in children.

Comparison of Foreign and American Death-rates

	Year	Cases	Death	Mortality, per cent
Caverly, Vermont	1894	132	18	14.5
Wickman, Sweden	1905	868	145	16.7
Leegaard, Norway	1905	577	84	14.5
Zappert, Austria	1908	266	29	10.8
Linder and Mally, Austria	1908	71	16	22.5
Furntrat, Steiermark	1908	433	57	13.1
Krause, Germany	1909	633	78	12.3
Müller, Germany	1909	100	16	16.0
Peiper, Germany	1909	51	6	11.7
Eichelberg, Germany	1909	34	7	20.6
Massachusetts, U. S. A.	1907–1910	1,599	125	7.9
Vermont	1914	235	50	17.0
New York City and State	1916	13,223	3,329	25.2

Table Showing Higher Mortality in the More Advanced Ages

	Age	Mortality, per cent
Wickman	12 to 32	27.6
Leegaard	15 to 30	25.8
Furntrat	Over 15	25.5
Lindner and Mally	Over 11	50.0
Massachusetts, 1910	Over 10	20.0

Prognosis as to Function.—Unfavorable elements in prognosis of ultimate paralysis connected with the attack seem to be (1) a slow attack with exacerbations and involvement of new muscles lasting over several days, (2) excessive and persistent tenderness lasting for many weeks under proper treatment. A scattered paralysis seems on the whole to have a more favorable prognosis than a complete loss of power below a certain level. In muscles which remain totally paralyzed for six months, the outlook is not good.

Spontaneous Improvement.—This begins in most cases in a few weeks. It does not progress rapidly during the existence of acute tenderness and parents should be warned not to expect too much during the tender stage. It is most rapid for the first six months, but continues to be well marked for at least two years, and under favorable conditions probably goes on longer.

Complete Recovery.—Complete recovery occurs in a certain number of cases and there are no definite criteria by which one may establish at the outset which cases will recover. In a group of New York cases ninety-two had completely recovered in a few months, and the analysis of the early distribution in these cases was practically like that of the other cases in the series. A series of 212 cases investigated in Massachusetts by B. E. Wood in 1911,[1]

[1] Wood, B. E.: Boston Med. and Surg. Jour., Oct. 5, 1911.

showed 27 per cent of complete or practical recovery in three or four years, but here again an analysis of the early distribution showed nothing to attract attention.

In general, the residual paralysis, if of scattered distribution and light degree, following a mild attack, without excessive tenderness, offers the best prospect of complete recovery, but recovery from complete paralysis of both lower extremities in the early days may be sometimes expected. The surgeon will be wise to avoid definite prognostications as to ultimate function in the early days, and will do well to confine himself to a statement that the patient is sure to improve when tenderness has gone, that the improvement will go on indefinitely under proper conditions, and that ultimate function will be influenced and perhaps determined by the soundness, persistence and care with which the treatment is formulated and carried out.

Prognosis without Treatment.—Without treatment, spontaneous improvement will occur in nearly all cases at first, after which functional deterioration from fatigue, muscle stretching, and deformity will eventually take place. Many muscles partly paralyzed in the beginning will become totally paralyzed in moderate cases. Finally, a period of stability, generally with some deformity, will be reached, which may not alter except under the influence of increase of weight, illness, gross overuse, or middle age.

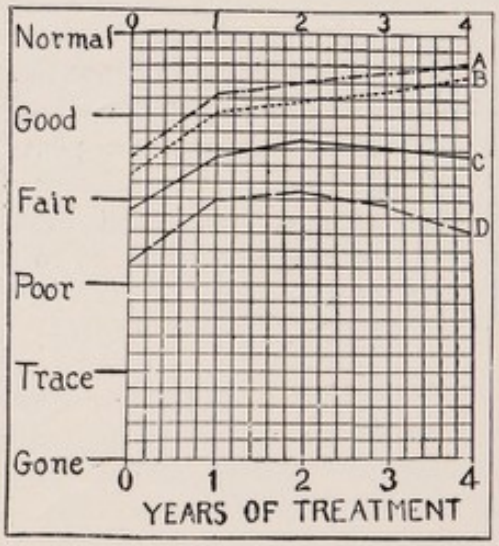

FIG. 439.—Progress of the average affected muscles of the arms and legs in four years: *A*, lower arm; *B*, upper arm; *C*, upper leg; *D*, lower leg.

Prognosis with Treatment.—The outlook for favorable progress under treatment is best in the first six months, next best in the following six, fair in the second year, and limited after the second year. There seems, however, to be no time limit to the benefit to be derived from treatment; a case of one of the writers of twenty-five years' standing, who had never walked with the feet on the ground, being most satisfactorily treated by braces which enabled her to walk with a cane; and in another case of thirty-six years' duration, in a few weeks the gluteus medius muscle more than doubled its contractile strength by careful muscle training and restriction of activity.

The following table gives an analysis of two groups of cases from the Vermont series, one treated by rest and muscle training, and the other not treated at all. This analysis covers a period of eighteen months and begins six months after the attack. These cases all appeared at the clinics and were apparently average cases. The same directions were given for treatment to both groups, but the parents of one set followed instructions, while the parents of the other set did not. All were clinic cases under home treatment, and all subject to the same conditions, except in the matter of treatment. Estimates of "clinical improvement" were made from the clinic records confirmed by the statements of the parents.

Table

Treated Cases—97	Per Cent	Untreated Cases—60	Per Cent
Unable to walk at first clinic	30	Unable to walk at first clinic	13
Able to walk at second clinic	90	Able to walk at second clinic	15
Unable to walk at second clinic	10	Unable to walk at second clinic	85
Recoveries between First and Second Clinic			
13 recoveries	13.4	2 recoveries	3.3
Improvement between First and Second Clinic			
Improved (clinically) 97	100	Improved (clinically) 16	27
Unimproved	0	Unimproved 44	73

Prognosis as to Shortening.—It must be remembered that the amount of leg shortening, except from paralytic dislocation of the hip, is not often great, and an ultimate shortening of more than two inches is unusual. The amount of shortening is not necessarily proportionate to the degree of the paralysis, slight cases often being accompanied by much shortening and severe cases by moderate shortening. Shortening is due to lack of growth and non-use.

There is nothing to show that the use of a brace promotes shortening.

Summary of Prognosis.—Early care probably limits the residual paralysis. Most deformities can be prevented. The great majority of muscles are weakened rather than wholly paralyzed. Skilful muscle training and the proper care of weakened muscles prevents stretching and overuse. We should no longer be content to put on a brace and let the child get about as best he can.

Treatment

Treatment of the Acute Phase.—This lasts from the onset of the disease till the disappearance of the tenderness. Treatment should consist of rest and absence of irritation, and the avoidance of meddlesome therapeutics. Fixation of the neck, trunk and limbs in some confortable appliance such as a well padded plaster of Paris bed is desirable in the most acute cases. There is no evidence that drugs are of any use, nor is anything to be expected from counter-irritation, externally applied applications of heat or cold, or from electricity. There is evidence to show that hexamethylenamin prevents or delays the infection in monkeys, but no evidence to show that it is of use after the infection has occurred.

Immersion in a warm saline bath is agreeable and apparently beneficial toward the end of the tender stage and may be comfortably carried out by immersing the patient on a sheet. It is not physiological to irritate and stimulate the peripheral ends of nerves connected with affected and hemorrhagic nerve centers by massage and muscular exercise while the acute process, as evidenced by tenderness, exists. Joints will not become ankylosed, muscles will not hopelessly atrophy, and the patient will not become bed-ridden because he is kept quiet for as long a time as need be, to enable the damaged cord to repair without interference. This policy of doing nothing is trying to the parents who have heard of the wonders of massage and electricity and are anxious that no time should be lost, and trying also even to the experienced surgeon when the tenderness is of unduly long duration.

Prevention of Deformity.—The prevention of deformity is of primary importance at this as at every stage of the disease. Evidence will be presented

later showing that deformity is accompanied by loss of muscle power in both stretched and shortened muscles. Aside from deformity, muscle stretching is detrimental at all stages and the unsupported paralyzed foot in the acute stage, even if it does not become deformed, will surely lose power in the stretched muscles. In addition to the contraction of the feet in plantar flexion, the following deformities are important to expect and avoid, if it can be done without too much discomfort to the patient, flexion deformity of the knees, flexion deformity of the hips, adduction contraction of the shoulder, and lateral curvature of the spine.

In occasional cases in this tender phase it is unwise to cause too much discomfort in overcoming contraction because it is almost sure to increase the tenderness sometimes to an intolerable degree so that the effort must be abandoned. In these exceptional cases it is wiser to cease aggravating the patients by attempts at correcting deformity if they are very painful, and to allow the tenderness to disappear while the limb is supported as accurately as practicable and then to remove the contractions by stretching as will be mentioned later.

Summary.—The treatment of the acute stage consists in (1) the avoidance of meddlesome therapeutics, (2) rest, and (3) the prevention of deformities.

Convalescent Phase.—The acute stage of the process in the cord may be assumed to be at an end with the disappearance of tenderness, and the time to be at hand when one may make an estimate of the damage done and plan the campaign of treatment. This stage may be assumed as beginning with the cessation of tenderness and ending when spontaneous improvement has *largely* ceased.

We are facing in this stage a definite surgical problem. Certain parts of the neuromuscular mechanism have been so affected that some muscles have lost all power while others have so depreciated that their power is reduced to 20 to 50 per cent of normal. These depreciated muscles can be improved by certain precautions and are almost sure to be damaged by certain factors unless precautions are adopted.

The factors which depreciate them are: (1) *Stretching*, impaired muscles must at all times be supported in a position of relaxation. The deltoid muscle is rapidly damaged by the unsupported weight of the arm, and the anterior muscles of the lower leg depreciated or their contractile power lost by failure to support the foot at a right angle. This principle has been recognized for years, but is by no means carefully observed. (2) *Fatigue* is a detrimental factor of the highest degree. It has been demonstrated[1] that partial paralysis can be changed to total by overuse, and when one reflects that a patient ten or twelve years old has certain muscles in the leg which may be no stronger than those of a normal child of three, it can easily be seen how gross is the misuse of these in ordinary walking.

A patient some months after the attack was being kept absolutely off of his feet, and was receiving daily muscle training with steady improvement. He was allowed to walk once a day into the bath room, which was adjoining. Within a week his gain had stopped, but began again when this exercise was stopped. An adult patient, with mild involvement of one leg, one year after his attack was allowed moderate walking, and was quantitatively tested[2] for

[1] Lovett, R. W.: Jour. Am. Med. Ass'n., July 21, 1917.
[2] Lovett and Martin: Am. Jour. Orth. Surg., July, 1916.

muscular strength once a month by the spring balance test, and his improvement rate was known. His house burned down and he was on his feet for hours. It took him three months, with very restricted exercise to regain the power that he had before the fire. This point is insisted on because of the frequent direction of the surgeon to use the muscles as much as possible to strengthen them. In stretching and overusing muscles we forget our physiological teaching, to the effect that a muscle may be paralyzed by one serious over-stretching, and that fatigue diminishes muscular power.

3. *The occurrence of deformity* diminishes muscular power in both lengthened and shortened muscles. An analysis[1] of 180 consecutive cases showed that deterioration of muscular power under treatment occurred in the third year in 49 per cent of affections of the lower leg, and that in about two-thirds of these the loss of power was associated with the development of deformity. In the remaining third the examination was vitiated by the fact that operation had been recently performed. The only other considerable loss was overuse. The table (Fig. 439) shows that loss occurs more often in the lower than in the upper extremity.



Fig. 440.—Abdominal paralysis.

4. *Disregard of Muscular Balance.*—If a child is allowed to walk on a paralyzed leg, or to do exercises of an indefinite character he will use the strong muscles and not the weak ones which we wish him to use, and the balance between the two groups will become steadily worse on account of the development of the stronger ones from their use. Much discredit comes at times to muscle reeducation because the exercises are formulated carelessly, or by poorly trained people who encourage movements in all directions, whereas movements should be directed only to the weakened muscles.

Treatment, therefore, primarily should consist in the avoidance of these detrimental factors, stretching, fatigue, deformity, and disregard of muscular balance, and all measures recommended, whether physical therapy, apparatus, or operation, must be governed by and subservient to these principles.

Having laid down these general principles governing all treatment at this stage, we come next to the discussion of how the individual patient should be managed when the acute stage is ended. Recumbency is no longer necessary for the whole day and the upright position may be gradually assumed.

5. *Sitting.*—Sitting in many cases is at first impossible on account of weakness of the spinal and abdominal muscles, but in cases with any respiratory involvement the patient may be propped up in a chair surrounded with pillows on all sides to prevent malposition as soon as the tenderness has nearly gone, with a view of avoiding the pulmonary dangers of prolonged recumbency. This is because of the danger of hypostatic pneumonia, a danger which exists for many weeks in these cases, and if such pneumonia occurs, the result is too often fatal.

[1] Lovett, R. W.: Jour. Am. Med. Ass'n., Dec. 17, 1921.

Abdominal weakness or paralysis (Fig. 440), very common in both lateral and anterior groups, is often overlooked, but demands serious attention, as the improvement rate in abdominal muscles is exceedingly low even under proper precautions. In all cases of abdominal weakness or paralysis an abdominal support should be furnished immediately and constantly worn in the sitting position to prevent muscular stretching. This may be done by means of an accurately fitted cloth corset. In many cases recovery will occur under these conditions which probably would not have occurred had the muscles remained unsupported and continually stretched, and scoliosis may be prevented or minimized. If the back is involved either alone or in connection with abdominal weakness a back brace should also be used if necessary to prevent backward bending of the spine. The period of sitting up may be gradually increased but at all times when sitting, malposition of the spine and stretching of the abdominal muscles must be prevented.

Walking.—The patient at this stage may or may not be able to walk without apparatus. Before deciding whether or not an individual patient should be allowed to walk, the surgeon must consider certain data obtained from an analysis by one of the writers of 1836 cases,[1] which showed that walking to any extent in the first year after infantile paralysis is apparently attended with risk, because it is followed in many instances by a change from partial to total paralysis in the muscles of the lower extremities, whereas in other parts of the body this deterioration does not occur. Evidence from these figures is also definitely to the effect that the right hand recovers much more effectively than the left, but that the recovery rate is the same in both legs, which may be interpreted as showing that the use of non-weight-bearing exercise is beneficial. The weight-bearing use of muscles with or without braces, in the first year or so following infantile paralysis involving one or both legs, is risky and detrimental if practised to any considerable extent. By the avoidance of this and by the use of non-weight-bearing therapeutic muscular exercises conjoined with little or no walking in cases affecting the leg, it is possible, if the general principles already alluded to are followed out, to secure a class of results with which in the past we have been wholly unfamiliar.

On general principles unrestricted ambulatory activity at this time is only to be allowed (1) when complete recovery has occurred or (2) when there is reason to believe that the hope of complete recovery or further substantial gain must be abandoned.

A weakened muscle can be given all the use that is desirable by means of therapeutic exercises without weight-bearing, and moreover one must be exceedingly careful not to overdo this therapeutic exercise as this constitutes fatigue. No prescription is harder to carry out than to keep children from walking, and in nothing is it more difficult to secure the cooperation of the parents. The less the degree of paralysis the harder it is to induce the people to keep the children still, yet it is in these cases that the hope of final complete recovery is the greatest. It can only be said that the number of cases in which brilliant results and even complete recovery is to be obtained in infantile paralysis is very greatly extended by keeping the patient from much walking during the first few months at least. In hospital practice it is often impossible to carry out this method on account of the parents' circumstances, but if walking must be permitted, it should be as limited in amount as possible and only after the parents have been informed of its disadvantages.

[1] LOVETT, R. W.: Jour. Am. Med. Ass'n., June 21, 1917.

Other forms of activity during this stage must be analyzed in the light of the principles given at the head of this section, particularly having regard to the question of muscular balance. *Creeping* is an exercise for the hip flexors, but favors foot drop. *Swimming* is in general desirable, as much of the weight of the members is taken off by the water. It exercises chiefly the gluteus maximus and medius, the quadriceps and the gastrocnemius, and is especially desirable in cases where these are weak, but under water all motions are somewhat resisted by the water, and of all loosely controlled exercises it is the least objectionable. It is of course often necessary that the paralyzed patient should be carried into and out of the water. *Bicycling* calls most on the gluteus maximus and the hamstrings, and, if the toes are placed on the pedals, on the gastrocnemius. If suited to the individual case, a stationary bicycle gives mild and graded exercise, or a tricycle may be used where more exercise is desired.

From this point the discussion of the treatment of the *convalescent* and *chronic* or stationary stages will be merged, as there is no sharp distinction between them. The chief difference is in the amount of walking which may be allowed without detriment, and the fact that late deformities are more difficult to deal with than early ones.

Treatment of the Residual Paralysis

In undertaking the responsibility of treating a case of poliomyelitis the surgeon owes the patient a thorough general and local examination.

General Examination.—The general condition of the patient is important. After a sharp attack he is likely to be weak, anemic, irritable, and to possess very poor resistance. Cardiac examination will frequently reveal some organic lesion, not necessarily connected with the disease; the pulmonary examination is most important as to rales and chest expansion and the inability to cough audibly is a sign of importance. The urine should be examined in all cases and with especial thoroughness in cases having had paralysis of the bladder in the acute attack. The per cent of hemoglobin in suspected anemia should be estimated and any loss of weight taken into account.

Muscular Examination.—A thorough examination of the grade of voluntary power in all available muscles in both legs, both arms, back, abdomen, and neck is essential to an anatomical diagnosis, which in turn must be at the foundation of any modern effective treatment, non-operative or operative. The technique of this examination is given in connection with the subject of muscle training which seemed of sufficient importance to be considered in a separate chapter (Chapter XXII). Each case must be approached as a definite anatomical problem.

Examination of Gait.—Moreover, every patient is also a social and economic problem, and the surgeon should from the outset formulate the plan which will bring the patient to adult life with the highest possible degree of function and consequent efficiency. As the disease affects the legs in most cases, the practical surgical problem will generally be to make those patients walk who cannot do so, and to make those who can walk, walk better. For this latter purpose a careful study of the patient's gait should form the first stage of the modern examination, being equally important with the examination in recumbency, because the disability of a patient cannot be estimated by an examination made only in the sitting or lying position, especially in bilateral cases, for the com-

pensation and the combination of muscular weakness on the two sides can be estimated only during weight-bearing and progression. We should bear definitely in mind the fact that deformity only causes part of the lameness, and that muscular weakness works with balance and deformity to establish the special gait and degree of lameness and disability.



FIG. 441(*a*).—Gait in paralysis of gluteus medius of right side.



FIG. 441(*b*).—Gait in paralysis of hip flexors.

The *examination* for gait, that is for ambulatory disability, may either precede or follow the examination of the individual muscles. Walking should be done unclothed, especially when the hips and lower back are involved. A T-bandage should be used for adults as the only covering. If the patient has already been prescribed braces, and they are required to enable him to stand, he should walk in them for his examination of gait. In this examination of gait the lameness should be analyzed and the reasons for the abnormal gait formulated. The difficulty may be in the abdomen, the hips, the thighs, or the lower leg and foot, or it may be any combination of these, or even in all of them. Without a careful estimate in this way of the salient features of the muscular weakness, the desired functional aim cannot be formulated. In this connection it becomes necessary to call attention to characteristic features of certain paralyses of the hips and abdominal region as there are several of these which demand especial consideration.



FIG. 442.—Gait in quadriceps paralysis.

1. The *gluteus medius* is a muscle very frequently affected. Its function is to abduct the limb and when weight is borne upon the limb to raise the other side of the pelvis. The gait associated with weakness or paralysis of this muscle is perfectly characteristic. When the patient bears weight in walking on the affected side he lurches over to that side in an attempt to balance, and the lameness is often indistinguishable from that caused by marked shortening of the leg on that side. The limp cannot be covered by apparatus, and lameness caused by paralysis of the gluteus medius muscle is one of the most difficult, if not the most difficult, form of limp to compensate for, and all apparatus so far tried has been wholly unsuccessful. Building up the sole of the foot on the short side makes the patient limp more because it throws more strain on the affected muscle. The gluteus medius limp can be practically eliminated during the examination by giving the patient a weight of five to fifteen pounds to carry in the hand of the affected side, which changes the center of gravity and compensates for the weakness of this muscle. In this way a complex limp may be split up and more accurately analyzed.

2. *Gluteus Maximus.*—When weight is borne on the affected side the body is thrown back with a sudden lurch and the patient hurries with the other leg. The gait is like that of a patient with an amputation of the thigh wearing an artificial leg.

3. *Adductors of the Hip.*—Weakness of the adductors does not cause a real limp, but it can be detected by asking the patient to place one foot directly ahead of the other in walking. With weak adductors this can be done only by swinging the body.

4. *Hip Flexors.*—The patient brings the affected limb forward by a forward twist of the pelvis on that side (Fig. 441*b*).

5. *Quadriceps.*—With a weakened or paralyzed quadriceps muscle the patient may be able to walk unaided in the following ways:

1. The patient keeps the knee from flexing as he walks by pressing the thigh back with one hand.
2. As the affected foot touches the ground the patient hyperextends the knee, thereby locking the joint (Fig. 442).
3. The patient walks with the leg rotated outward.
4. With talipes equinus the foot when placed on the ground locks the knee back because it cannot dorsally flex, and thus the knee is held extended and able to bear weight.
5. With strong hamstrings the patient can lock the knee without hyperextending or even fully extending it, simply by bending the whole body forward, thus carrying the center of gravity forward.



Fig. 443.—Gait in paralysis of dorsal flexors of foot.

6. *Gastrocnemius.*—The walk is heavy, the heel is brought down first and there is no spring when the next step is taken. If one side alone is affected, the gait is arrhythmic, the patient pausing longer on the good foot. When both sides are affected the gait is waddling, with the feet turned upward.

7. *Dorsal Flexors of Foot.*—The patient lifts the knee of the weak side high in order to clear the front of the paralyzed foot, which drops when lifted from the ground on account of the loss of dorsiflexion power (Fig. 443).

8. *Equinus Deformity of the Foot.*—This is a deformity which if existing to a marked degree in both legs makes walking practically impossible, and if in one foot causes a marked limp.

9. *Abdominal Muscles.*—With weak abdominal muscles the patient stands and walks sway-backed, with the hips flexed, the lumbar spine in strong lordosis and the abdomen prominent. Unilateral paralysis of the abdominal muscles, and especially of the quadratus lumborum, causes the patient to drop the pelvis on the weak side in taking the weight on the good leg. The position is like that taken by a patient with congenital dislocation of the hip when standing on the affected leg (Trendelenburg sign) (Figs. 444–445).

10. *Spinal Muscles.*—Seriously weakened back muscles make it impossible for the patient to hold the spine erect if unsupported, in sitting, standing or walking.

Physical Therapeutics

Having in mind the governing central fact that all treatment must aim at securing the best ultimate function and remembering that muscular stretching, fatigue, deformity and improper muscular balance are detrimental factors of the highest degree, we come to a consideration of those physical therapeutic measures which we may use to carry out the indications just mentioned. They are as follows:

(*a*) *Massage.*—The favorable action of massage on parts affected by infantile paralysis is undoubted, but it must be recognized that it has distinct limitations and that too much must not be expected of it. The proper stroking, kneading, and manipulation of an affected limb, placed in a position where affected muscles are relaxed, stimulates the flow of venous blood toward the heart and increases the flow of arterial blood to the limb. It also facilitates the flow of lymph toward the center of the body by mechanical emptying of the lymphatics, and direct manipulation of the muscles must also in a measure empty them of waste products.[1] Thus massage may be expected to retard and antagonize muscular atrophy by inducing better nutrition locally. On the other hand, the overuse of massage by too long or too rough manipu-

[1] Kleen, A. G., and Elmslie, R. C.: Massage and Medical Gymnastics, New York, 1921.

lation causes muscular fatigue, increases muscular atrophy, diminishes muscular tone, and may do damage to the fragile muscle fibres.

Massage will not restore muscular power, and it has no direct effect on the disease, nor on the transmission of nerve impulses from brain to muscle.

(*b*) *Heat.*—If a partly paralyzed limb is heated it is capable of performing better muscular function than before, because muscles work better at a high temperature. Moreover, the heating of the limb apparently adds to the effectiveness of massage because, if the massage is given directly after the heat-



FIG. 444.



FIG. 445.

FIGS. 444 and 445.—Weakness of left lateral abdominal muscles. In standing on the left leg (FIG. 444) the right side of the pelvis is raised; in standing on the right leg, the left side of the pelvis drops (FIG. 445). (Compare figs. 614 and 615.)

ing, while the superficial capillaries are full of blood, a greater volume of blood is driven toward the center of the body to be replaced by a similarly large volume returning to the limb. Heat may be applied as radiant heat or non-radiant heat. Hot water is not desirable as a form of heat, as it makes the skin tender and cannot be borne at so high a temperature as can dry heat. In view of the fact that muscles function better when warm, the paralyzed limbs should always be warmly clothed, for chilling of the affected parts is always bad and superficial necrosis of the skin is easily produced by chilling the feet and legs.

(*c*) *Electrical Stimulation of Muscles.*—There is a general impression that the electrical current has some mysterious bodily virtue not clearly definable. For this reason electrical treatment is often prescribed and carried out in poliomyelitis in a manner calculated to do harm rather than good. The rationale of electro-therapy may be stated quite simply. A muscle can be made to contract by the direct application of an electrode over its motor point. The normal muscle responds both to the faradic and galvanic type of stimulus. A paralysed muscle almost invariably loses its response to faradism, but retains its response to galvanism with certain qualitative and quantitative modifications. (R. D.)

One of the most effective methods of preserving nutrition in a paralysed muscle is to induce a series of contractions at regular intervals. Interrupted galvanic stimulation of the affected muscles is thus a logical and sound method of treatment in poliomyelitis after the acute stage is over.

This procedure should be used only in combination with heat and light massage, and always with the limb or part supported in the position of physiological relaxation. Each muscle is picked out in turn by the electrode and a series of twitches produced.

In a recovering muscle the faradic response reappears once more, so that at this stage interrupted faradic stimulation may be used instead of the galvanic current. At a still later stage when voluntary power has returned in a muscle formerly completely paralysed the movement evoked by appropriate electrical stimulation is a useful form of exercise. Much discretion is necessary on the part of the masseuse entrusted with the electrical stimulation of paralysed and recovering muscles. Fatigue from over stimulation must be avoided by careful dosage. In very young children electrical stimulation has a comparatively limited application, but in older children and adults it forms a natural introduction to the stage of active muscle training.

(*d*) *Muscle Training.*—This subject is of such importance that it is discussed in a chapter by itself (see p. 492).

Apparatus.—Splints, braces and corsets are used (1) to enable patients to walk who cannot walk, (2) to enable patients who can walk to walk better, (3) to prevent malposition, and (4) to correct deformity. Apparatus is indicated if the patient cannot walk without such aid, or if he can only walk or stand in a position of deformity. It is essential that apparatus should be mechanically sound, light and properly fitted, for no where is nicety of adjustment so important in its direct effect on gait as in this disease.

When the braces are fitted the question arises whether the patient will walk better in balance or by the use of crutches. The former is of course preferable if it can be done without too much effort by the hip muscles. Over fatigue has been noted as a detrimental factor, and the conservation of the hip muscles is most important. If therefore a patient fitted with braces labors seriously in trying to walk without crutches, as in a case of double abductor hip weakness, and distorts himself in order to progress, the use of crutches is preferable. The use of crutches for progression, without walking exercises, retards the restoration of balance and muscular development, but one must be careful not to overwork the hip muscles. The use of sticks and of the arm crutch in which the elbow lies should be encouraged in place of crutches.

Braces, however, are obviously undesirable, excepting as the lesser of evils. If anyone with a normal leg were to put on a brace constricting the muscles

and preventing motion at the knee, and were to walk about in it all day, he would have to walk unnaturally and would tire his hip muscles. In the same way the use of a brace, especially a heavy one, in the case of a leg weakened by infantile paralysis must in the long run be detrimental to muscular welfare. Constricting bands and lacings are notoriously undesirable and harmful; and although we might argue that activity was desirable in a given case, we should not regard a brace as being in itself of use to the muscles. Braces bear about the same relation to treatment of anterior poliomyelitis that crutches bear to the treatment of a fracture of the leg; they both enable the patient to get about, while the local process is repairing. To speak of the "brace treatment" of poliomyelitis would from this point of view be inaccurate except in so far as it assists nutrition, for we generally observe a marked improvement in the appearance, nutrition and "vitality" of the limb under ambulatory activity.

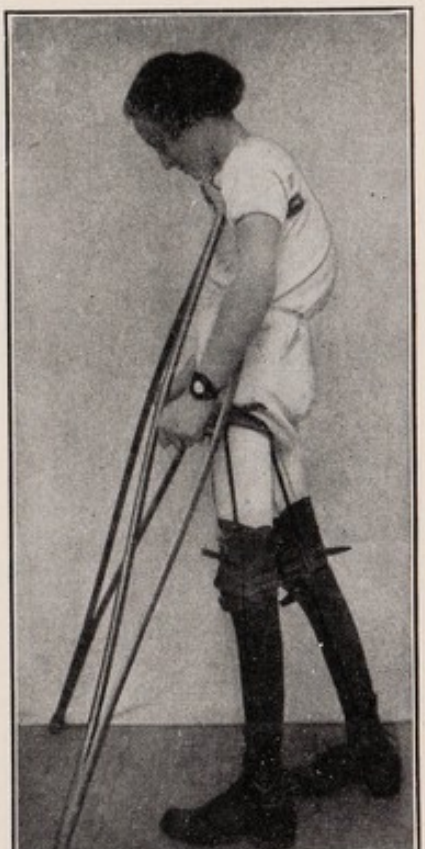

FIG. 446.—Tripod walking in case of nearly complete paralysis in the lower half of the body.

In certain cases much improvement in the gait with or without crutches may be obtained by connecting the upper part of the brace with a belt or corset by means of heavy elastic straps such as are used in artificial limbs. A strap running down the front, aids a defective hip flexor, down the outside it supplements the hip abductor, down the buttock the gluteus maximus.

But granted that apparatus is undesirable, the conditions which it is put on to prevent are still more undesirable. These are (1) *inability to walk*, and (2) *the acquirement of malposition and permanent deformity, and* (3) *the stretching of paralyzed muscles.*

1. *Ability to Walk.*—It may be formulated in advance that any patient of average intelligence with flaccid paralysis of the lower extremities, abdomen and back, without contraction deformities, can be made to walk in some form or other provided he has one arm good enough to hold a crutch. Practically all of these patients can be taught to get up and down from a chair, and most of them can learn to go up and down stairs in some fashion or other. If deformities are present which prevent the assumption of the upright position, they must be removed, and the only cases that need be dismissed as hopeless are those with flaccid paralysis of both arms, combined with flaccid paralysis, with or without deformities, of both legs.

Patients with complete paralysis below the axillæ can walk if the knees are kept from flexing by simple splints, the loss of the gluteus maximus being compensated for by a peculiar method of using the crutches for what may be called "*tripod walking.*" If the crutches are placed apart and slanted well forward at their lower ends, they form the two anterior points of a tripod, while the third and posterior part of the tripod is formed by the body of the patient inclined forward at its upper part, with the feet well behind. A paralyzed patient with no power below the waist can stand unsupported easily

in this position provided there are no contraction deformities in hip, knee, or ankle. This is a point which should be remembered by surgeons called upon to treat a fractured spine. When a patient with severe or complete leg paralysis has sufficiently acquired the sense of balance to have self-confidence, he should begin to walk in this tripod fashion. This is accomplished by hitching one crutch a few inches forward, then the other crutch, and then in cases of complete flaccid paralysis, jerking the feet forward together a few inches by a body movement, bearing down with the hands on the crutch bars and sliding



FIG. 447.—Caliper splint unapplied.



FIG. 448.—Form of caliper splint.

the feet over the floor, and later, most patients, even without power in the hip flexors, are able to accomplish this advancing of one foot at a time by twisting of the body.

Getting up and down out of a chair can be taught to any patient of this type. From the sitting position he turns on one hip, then wholly over by holding onto the chair, by means of the arms of the chair he then extends his trunk and reaches for his crutches.

For holding the knees extended one uses a caliper splint, the simplest, lightest and best of all such apparatus.

CALIPER SPLINT.—This may be used in the original form as described under the Thomas caliper splint (Figs. 447, 448, and 449) or a modified caliper. The latter splint is very useful as a routine splint in poliomyelitis, and is used to keep the knee extended and not to take weight. For this reason the ring at the top consists of only a half circle, which is

made of flat curved steel at the same angle as the Thomas ring, and fastened at the top of both uprights. At the inside of the leg the splint should terminate at least one inch below the adductor origin, and the top edge of the band should come below the transverse fold at the bottom of the buttock, as otherwise chafing is likely to result. The uprights are carried down, preferably shaped to the leg, turned at a right angle when they reach the level of the sole of the foot, and fitted into a tube running through the heel.

In poliomyelitis it will generally be desirable to check either dorsal or plantar flexion of the foot, which can be done by the small flanges running up vertically about one inch from the tube, and these flanges are placed posterior to the uprights to check plantar flexion, and anterior to check dorsal flexion of the foot. In older children and in the higher grade of practice it is desirable to furnish such splints with a joint at the knee, which is furnished with a simple drop catch, and in the older patients a self locking spring catch. In walking, the knee must be locked and the joint is only for convenience in sitting down. It matters not whether the uprights are made of round steel,as in the Thomas splint, or flat, but the latter is generally desirable in older cases, and especially where the splint is to be jointed. The principle of thesplint remains the same, and it consists of three points of pressure which hold the knee straight: (1) The posterior band at the top, (2) the boot at the bottom, and (3) backward pressure on the knee, which is exerted by means of a fenestrated knee cap. Leather straps above and below the knee are desirable. The splint is light, mechanically sound, and of almost universal use in poliomyelitis.



Fig. 449.—Modified caliper splint —front.

If much abdominal weakness is present, a cloth corset or back brace is advisable to support the abdomen and give greater steadiness.

2. *Apparatus for Foot Deformity.*—Having analyzed the limp and omitting for the moment the question of deformity, apparatus is of use in improving walking in the following conditions:

(*a*) Foot Drop.—If a caliper brace is required by the existence of other paralysis above, the foot may be kept from plantar flexion by two flanges of iron fastened to the sole of the shoe, just posterior to the uprights. If no brace is required above the knee a short caliper brace may be used.

Light Foot Drop Splint.—A very satisfactory brace, which is equally efficient and less unsightly, but at the same time less durable, is used by one of the writers (R. W. L.), and has the advantage of being very inconspicuous. It consists of two strips of steel about one-half inch wide, gauge No. 14. These are run from the top of a high laced boot to the junction of the heel and the sole of the shoe The bottom ends are curved at a right angle to pass between the anterior half of the heel and sole of the boot, and project under the heel for at least one inch on each side. From this point they run up the leg being fitted absolutely to the curve of the surface that they lie over. They are curved on the flat somewhat posteriorly to pass behind the malleoli and they are connected at the top of the boot by a thin curved band of steel. After the steels are made they are passed between the layers of the leather of the boot, the uprights where they are turned in are riveted through both sole and heel, and if properly constructed the apparatus practically does not show at all. This is a consideration of a good deal of importance in young women with paralytic foot drop but a good knee. No joint is necessary at the ankle, because the flexibility of the sole of the boot allows adequate dorsal flexion, and the brace, which is practically a light iron quadrilateral, at the back of the leg checks foot drop. The objection to the brace is that the fastening

in the sole is insecure, and after some months is apt to loosen. To tighten them is an easy matter, they are easily constructed, easily readjusted, and their manufacture within the range of any carriage blacksmith.

(*b*) Calcaneus (Walking on the Heel).—In cases of weakness of the gastrocnemius even of the slightest grade it is desirable to raise the heels of the shoes and to stiffen the tongue of the boot in order to prevent the weight of the body from coming upon and stretching the muscle in walking. The heels of the boots of young children should be ½ or ¾ inches high, and of older children 1 to 1½ inches. The weight of the body should not be allowed at any time to come upon the foot without the boot, that is, barefoot walking even in undress-



Fig. 450. Fig. 451.

Fig. 450.—Inconspicuous brace for foot-drop, seen from the back. The uprights can be seen just under the leather.

Fig. 451.—Same as (Fig. 450) seen from the side.

ing, tennis shoes, etc., should be absolutely forbidden. In this way stretching of the muscle is prevented, its recovery or improvement favored, and permanent talipes calcaneus avoided in many cases. In cases when the deformity exists and operation is to be deferred, flanges similar to those described for foot drop, but reversed, may be used in connection with the long or short caliper.

(*c*) Lateral Deformity.—If the foot rolls to the inner or outer side and operation is to be deferred, the Taylor club foot shoe (p. 632) or the three-point pressure brace is to be used also to prevent the development of bony deformity, or a single splint fitting into the heel of the boot with a strap around the ankle outside or inside.

Such apparatus cannot be regarded as corrective of marked fixed deformity and does not replace proper operative or manipulative measures. But in

poliomyelitis such apparatus is often necessary and to be mechanically effective must embody the principle of leverage. This necessitates furnishing three points of pressure, one to serve as a fulcrum and one for the end of each arm of the lever.

Three-point Pressure Braces.—For example: in a case of varus it is desired to throw the foot into eversion. This is most simply accomplished by a padded ring over the external malleolus which is the fulcrum with two points of pressure, one on the inner border of the foot and one on the inner surface of the leg. For valgus the description is reversed. A simple apparatus provides that (1) a flat sole plate is turned up on the inner side of the foot to form a surface about one inch high, to furnish a point of resistance and the foot is fastened to the sole plate by straps, (2) an upright runs two-thirds of the way up the leg on the outer side, over the external malleolus is a circular piece of sheet steel about two inches in diameter padded as a ring to allow the point of the malleolus to escape pressure from the upright, (3) a flat curved piece of steel at the top of the upright embracing the inner half of the circumference of the leg (Fig. 453).

In valgus the apparatus is the same only for "outside" read "inside" and *vice versa*.

Practically all portative apparatus for the correction of varus and valgus deformity rests on this leverage principle, but straps and springs are used in most of them. By simplifying the mechanical problem as described above a simple and exceedingly powerful apparatus may be obtained.

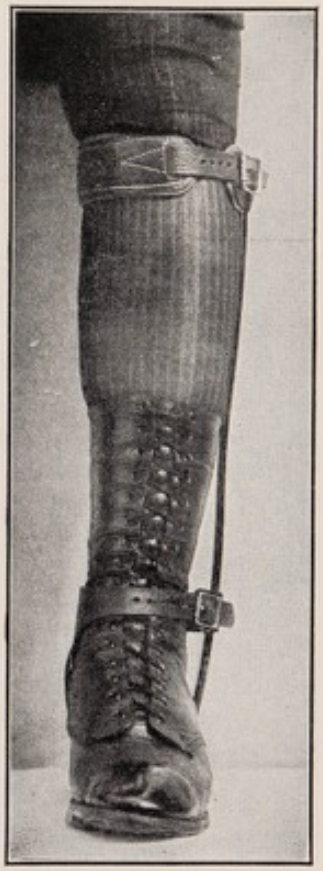

Fig. 452.—Crook long heel with outside iron for valgus.

Stages of Deformity.—There are three stages in the development of deformity in infantile paralysis which are as follows:

1. *Postural malposition*, in which the limb can still be replaced in the normal position without the use of force.

2. *Adaptive changes in the soft parts*, consisting of lengthening on the stretched side of the joint, and shortening on the other, which occur in most cases which are subject to prolonged malposition. In some cases, however, this does not occur and the joint remains flail.

3. *Permanent Bony Deformity.*—This must occur if the malposition remains permanent during the years of growth in accordance with Wolff's law.

Types of Deformity.—Deformity in general is of two types: (*a*) That due to *gravity or weight-bearing* in wholly paralyzed or flaccid limbs. If a leg is wholly paralyzed it hangs in a position of slight knee flexion and plantar flexion at the ankle, just as the leg of an anesthetized patient would hang under the same conditions. If a leg is paralyzed or partly paralyzed below the knee, and the patient is able to bear weight on it, the unsupported foot rolls into a position of valgus and the stretched soft parts become lengthened and shortened ones contracted, making a fixed deformity. In the arm a similar condition is to be seen when paralysis of the arm and shoulder has occurred and the head of the humerus, no longer supported by muscles, is dragged down and away from the glenoid cavity by the weight of the arm. Under anesthesia if the upper limb is allowed to hang, the position is rotation inward of the humerus, pronation and incomplete extension of the forearm, and some flexion of the fingers.

(*b*) *Malposition Due to the Overcoming of Paralyzed Muscles by Their Unaffected Opponents.*—If the anterior muscles of the leg, or most of them, are affected, and the posterior escape injury, the non-antagonized healthy muscles will by virtue of their tonicity draw the foot into a position of equinus and hold it there, and shortened muscles will in time become permanently contracted and lengthened ones permanently stretched so that a fixed deformity will result. It can be predicted in advance, in most instances, what a definite muscular paralysis will produce in the way of deformity. From the study of 635 cases in the Children's Hospital, Boston, the following table of deformities of the foot was formulated:[1]



1 2 3

FIG. 453.—Three point pressure brace, 1 and 3 outside and 2 inside.

DEFORMITY	RESULTING FROM PARALYSIS OF
Varus	Peronei.
Valgus	Anterior tibial.
	Posterior tibial.
	Both tibials.
	Flexor longus hallucis.
	Whole leg (weakened).
	Complete paralysis.
Equinus	Anterior muscles, paralyzed or weak.
	Complete paralysis (from dangling).
Equino-varus	Anterior muscles (with persistence of flexor longus hallucis).
	Anterior and external group.
	Paralysis apparently complete (toe flexors remaining).
Equino-valgus	Anterior and internal muscles.
	Anterior muscles and weight-bearing
Calcaneus	Posterior muscles.
Calcaneo-valgus	Posterior muscles and one or both tibials.

Other instances of this type of deformity are flexion at the knee and flexion at the hip. In the former the hamstrings are active and the quadriceps weakened, in the latter the hip flexors predominate over the weakened glutei.

Of the contractions that occur, those of the hip and shoulder are the most difficult to deal with, the ones most frequently overlooked, and the most diffi-

[1] LOVETT and LUCAS: Jour. Am. Med. Ass'n., Nov. 14, 1908.

cult to prevent. The attention of most men is directed to prevention of foot drop, often leading them to overlook these other serious deformities.

Contractions of the shoulder arise where the deltoid muscle is involved and the pectoralis major and latissimus dorsi retain some power.

Deformities of the Hip—Dislocation.—This begins as a subluxation which may become a true dislocation. It seems to be due practically in all cases to paralysis of the gluteus maximus with persistence of the hip flexors and resulting flexion contracture. It does not prevent walking, but causes much lameness and occasionally much irritability of the joint. In old cases the head of the femur atrophies and may entirely disappear.



FIG. 454.—X-ray of a paralytic dislocation of the left hip.

Its correction should be by operation. A successful procedure which may be applied in these cases is to relieve contracture by a fasciotomy (Figs. 457 and 458): reduce the hip and make an incision over the posterior part of the capsule of the hip joint, which is pleated, and then to put the leg up in a position and over-extension for a period of six months. In performing this operation of abduction the principle of strap and buckle should be practised—a broad strip of the capsule used as a flap and passed through a button hole slip in the lower part of the capsule. The strength of the restraining portion of the capsule is thus doubled (Figs. 457–458). Other operative procedures of value may be employed for slipping hips following poliomyelitis. Ober has transplanted a strip of fascia lata from the thigh to the erector spinae muscle (Figs. 504–505). A bony shelf may be constructed at the acetabular margin, by turning down a portion of the ilium.

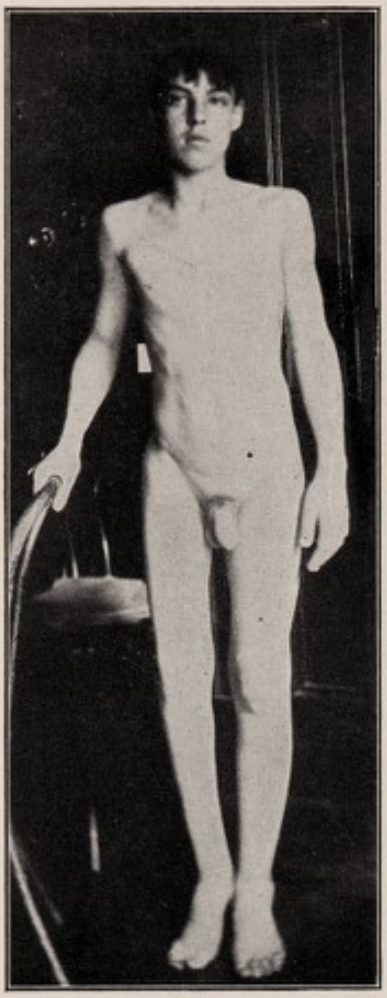

FIG. 455.—Dislocation of right hip of many years' standing from poliomyelitis.



FIG. 456.—Same case as FIG. 455. X-ray of the dislocated hip many years after its occurrence, showing absorption of the head and neck. Early X-rays were normal.



FIG. 457.—Jones' operation for paralytic dislocation of the hip, shortening and duplicating capsule. The forceps hold the flap, which has to be drawn through upper opening.

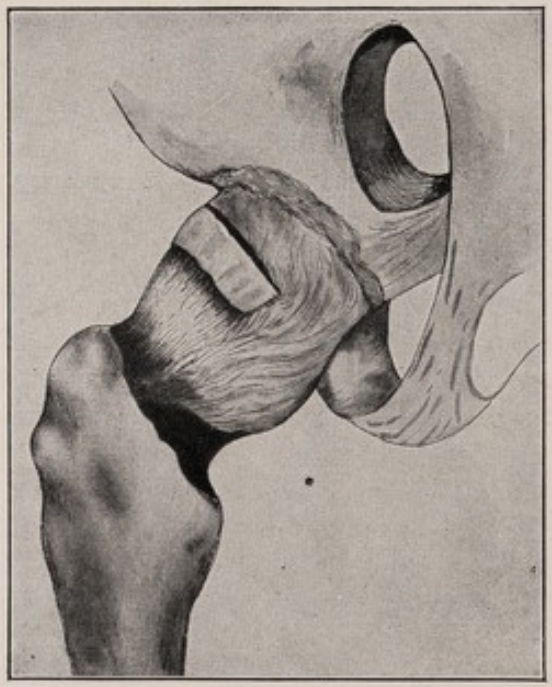

FIG. 458.—Jones' operation for shortening and duplicating capsule in paralytic dislocation of the hip. The flap has been drawn through the slit and is to be sutured.

Hip Flexion Contraction.—Contraction of the hip in flexion and abduction is most likely to occur in cases where the hip flexors retain some degree of

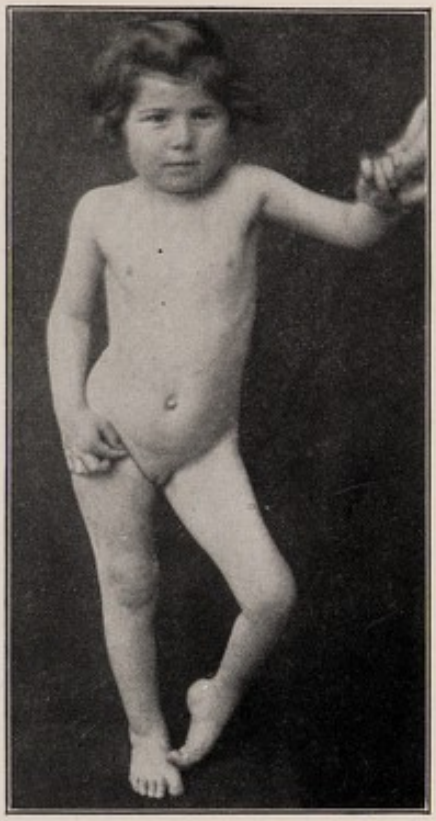

FIG. 459.—Unilateral hip flexion on left leg, combined with knee flexion and equinus.



FIG. 460.—Quadruped progression, due to hip flexion contraction.

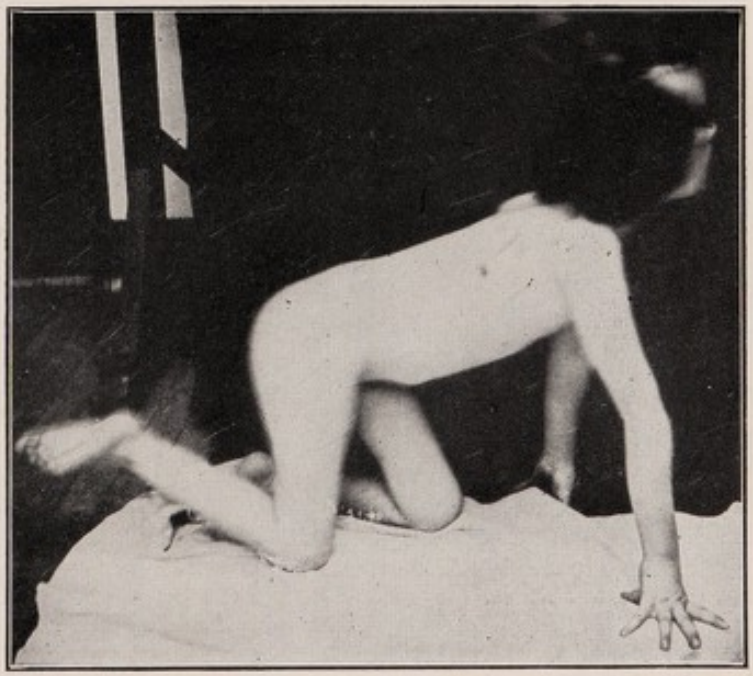

FIG. 461.—Quadruped progression.

power, and the gluteus maximus is weak. The contraction is so often overlooked that the surgeon may be reminded that it is easily detected, and its

degree estimated by the use of Thomas' test for hip flexion, described under tuberculosis of the hip (p. 140). In performing this test the femur of the affected leg must *not* be allowed to abduct or rotate out, which will vitiate the

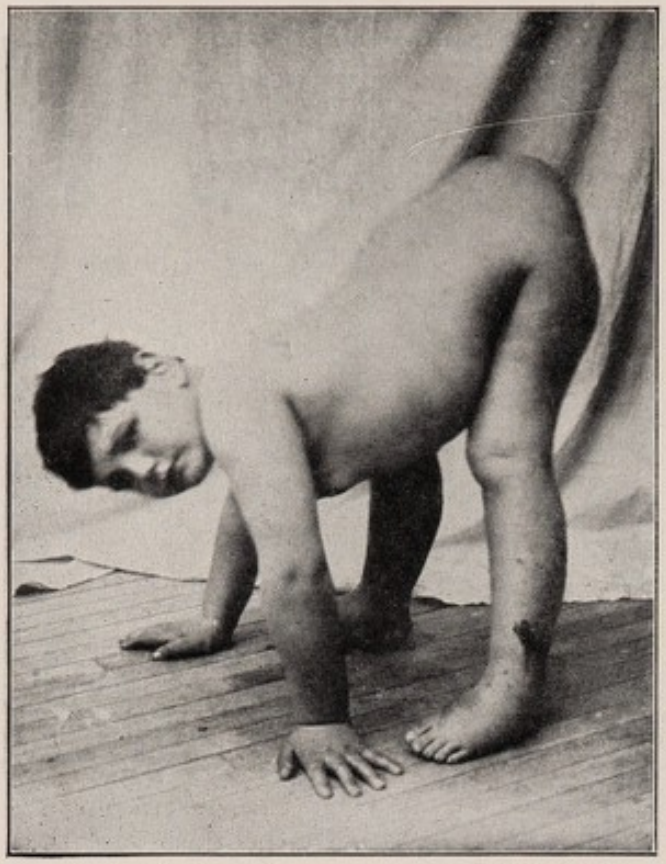

FIG. 462.—Quadruped progression due to hip flexion.



FIG. 463.—Same case as FIG. 464 after treatment.



FIG. 464.—Examination for hip flexion with the leg not allowed to abduct.



FIG. 465.—Same examination as in FIG. 464, but the leg has been allowed to abduct and the examination is therefore vitiated.

observation by diminishing the amount of flexion. Or it may be detected by laying the patient on the face with the legs hanging over the edge of the table and hyperextending each leg in turn while the pelvis is held. It is favored by creeping and by the sedentary position and is also likely to occur

in young children, with loss of power in the hip, who lie for a long time in the frog position.

Unilateral hip flexion contraction when the foot and knee are stable causes a lameness much like that of ankylosis of the hip in flexion, a pulling forward of the body when the affected leg is placed on the ground. When the knee is steadied by a brace the same lameness is evident. When double it prevents walking even in braces and thus is not remedied by the pelvic band attached to many leg splints.

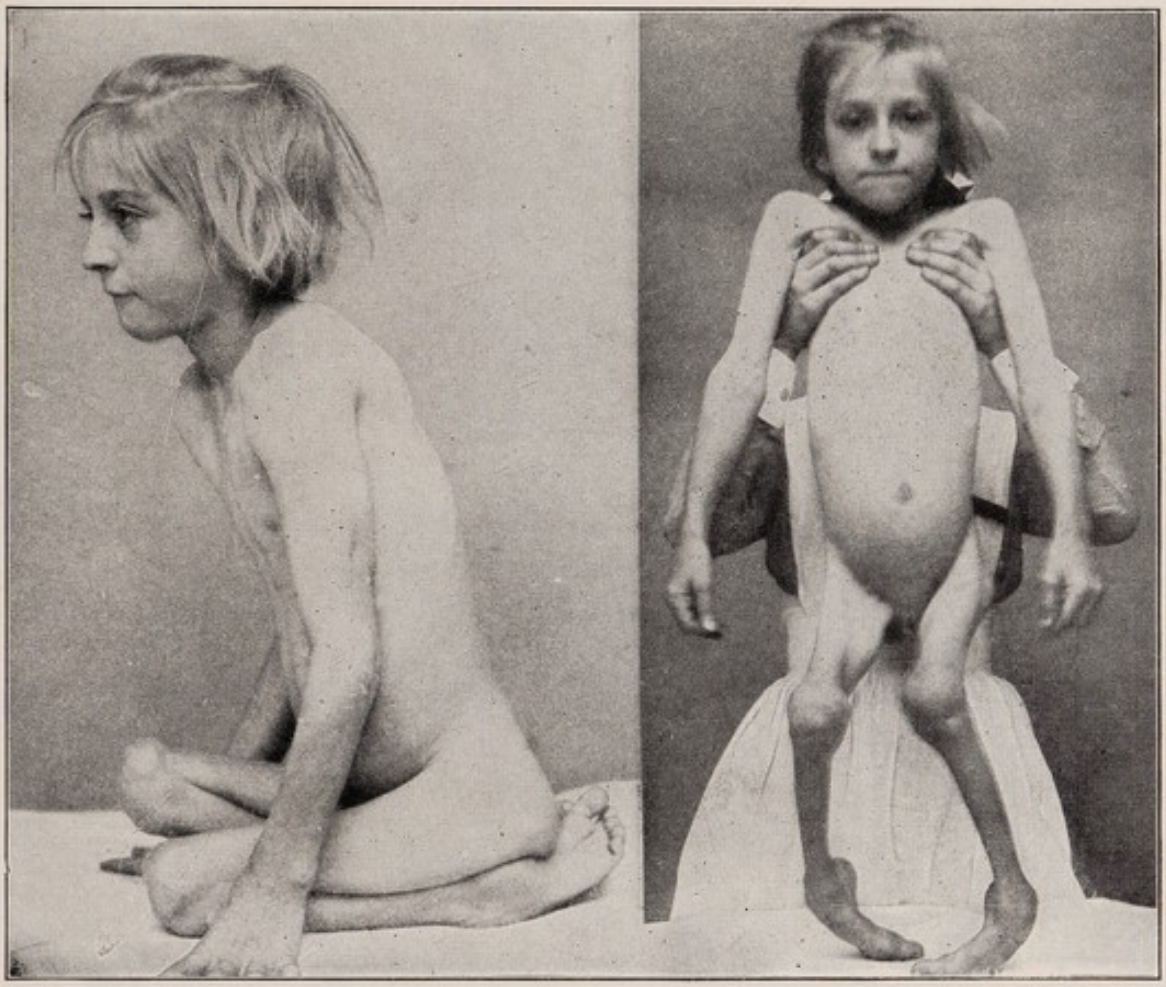

FIG. 466.—Quadruped progression necessitated by hip flexion, knee flexion and equinus.

FIG. 467.—Same case as Fig. 466. Suspended to show deformities.

As to the *prevention* of this deformity—when cases predisposed to it are sitting most of the time—it is desirable that they should spend some hours each day lying on the face with the legs hyperextended and the knees together. It has been possible in many cases, where the contraction had begun, to dispose of it by this means. Young children who lie in the frog position should have the knees tied together. The obstacle to stretching of the contraction lies in the fact that lordosis occurs when the limbs are laid flat on the bed because the back arches up from the pull of the contracted structures.

The best way to correct the deformity is by means of a double Thomas hip splint with extensions, fixing this splint to the foot of the bed and raising the foot of the bed two or three feet. Marked contractions can in this way be

corrected. The thighs should be in-turned in order that the greatest force may be added to the pull.

In mild cases a subcutaneous or open division of the fascia may be performed followed by stretching on an elevated gas pipe bed-frame with the affected leg or legs hanging over the edge of the covering, not allowed to bend at the knee and not allowed to abduct.

Soutter Fasciotomy.—When the contraction can be felt to be deep seated and resistant on extension of the thigh, when it has reached a considerable degree (45–90 degrees), or when it has proved resistant to stretching, the condition is best relieved by the Soutter fasciotomy.[1] The operation consists in a longitudinal incision three or four inches long, an inch or so outside of the anterior superior spine, which comes about opposite the middle of the incision. The fascia lata is exposed, cleaned of fat, and divided from the trochanter major nearly to the anterior superior spine. The anterior superior spine is then loosened by an osteotome and the attachments of the soft parts are stripped subperiosteally from the crest of the ilium outside and inside for at least one and one-half inches back. The soft parts are then detached from the anterior surface of the ilium down to the anterior inferior spine. The thigh is then gently extended, the soft parts give way, and it is apparently never necessary to divide the psoas muscle. The denuded part of the anterior portion of the ilium sticks out under the skin, and it is well to cut this off with a pair of bone forceps. The wounds are closed and the patient is put to bed on a frame without a plaster for ten days or so, after which the position of hyperextension, which must be free from any element of abduction of the leg, should be obtained by the use of a double Thomas splint as described above, or the patient stretched over the edge of a suspended frame, or a double plaster spica bandage put on in two sections—one for the legs and one for the trunk—and stretched for a few days by the use of one of the frames shown in the figures (474, 475) and then connected. The position obtained by any one of these methods should be maintained for about six weeks, after which for some weeks it is desirable for the patient to lie for two or three hours a day in a position of hyperextension and slight adduction. A markedly hyperextended position of one leg immediately after operation is dangerous as it stretches and therefore narrows the lumen of the femoral artery and circulation becomes impaired, and with or without operation over-extension of both legs in young or old may give rise to abdominal symptoms. The flexion contraction may also be corrected by dividing the ilio tibial bone transversely above the patella (Yount[2]).



Fig. 468.—Same patient as in Figs. 466 and 467. After operation, wearing braces and corset.

[1] Soutter: Boston Med. and Surg. Jour., Mar. 12, 1914.
[2] Yount: Jour. Bone and Joint Surgery, Jan., 1926, Vol. viii, No. 1.

Deformities of the Knee.—There are four deformities found at the knee in infantile paralysis—(1) flexion deformity, (2) knock-knee, (3) hyperextension of the knee, and (4) backward subluxation of the tibia on the femur with outward rotation of the tibia.

1. *Flexion Deformity.*—This is due to the predominance of the flexors over the extensor muscles, which results in flexion of the knee. It may occur early in the disease, being acquired during the tender stage, or it may appear later

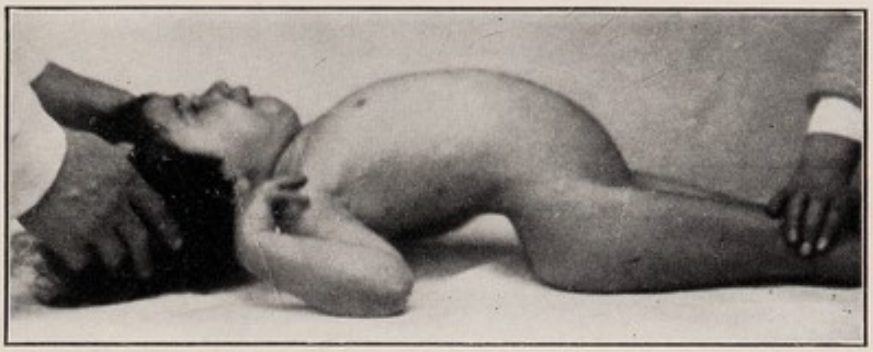

FIG. 469.—Lordosis caused by double hip flexion contraction when the thighs are extended.

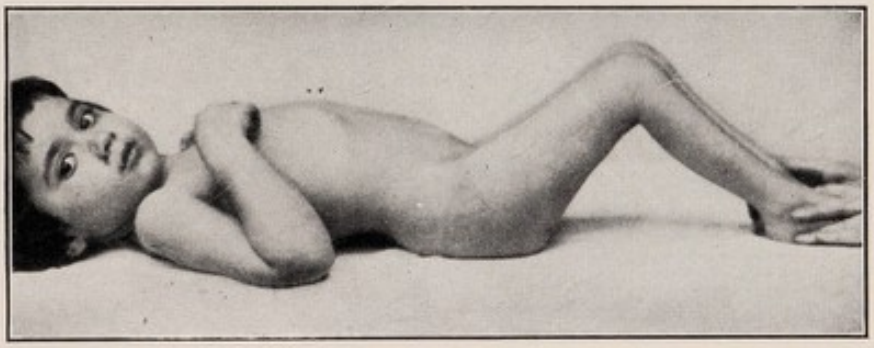

FIG. 470.—Double hip flexion deformity with legs flexed on body and lordosis diminished (same case as FIGS. 469 and 471).

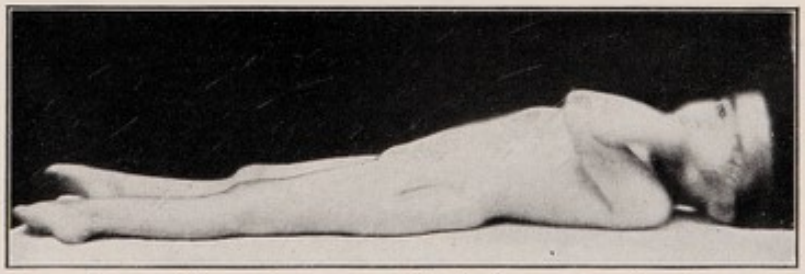

FIG. 471.—Post-operative position after severe hip flexion contraction (same case as FIGS. 469 and 470).

as a result of the predominance of the posterior muscles and walking may become impossible, and correction is necessary. The use of a Thomas knee splint will almost invariably correct this condition. The splint is applied by slipping the ring on over the leg and pushing it against the tuberosity of the ischium. Fixative traction is secured by strong adhesive plaster applied to the sides of the leg and maintained in position by a roller bandage. The surgeon grasps the patient's foot and pulls steadily downward, at the same time pushing the splint upward; after having straightened the limb as far as feasible,

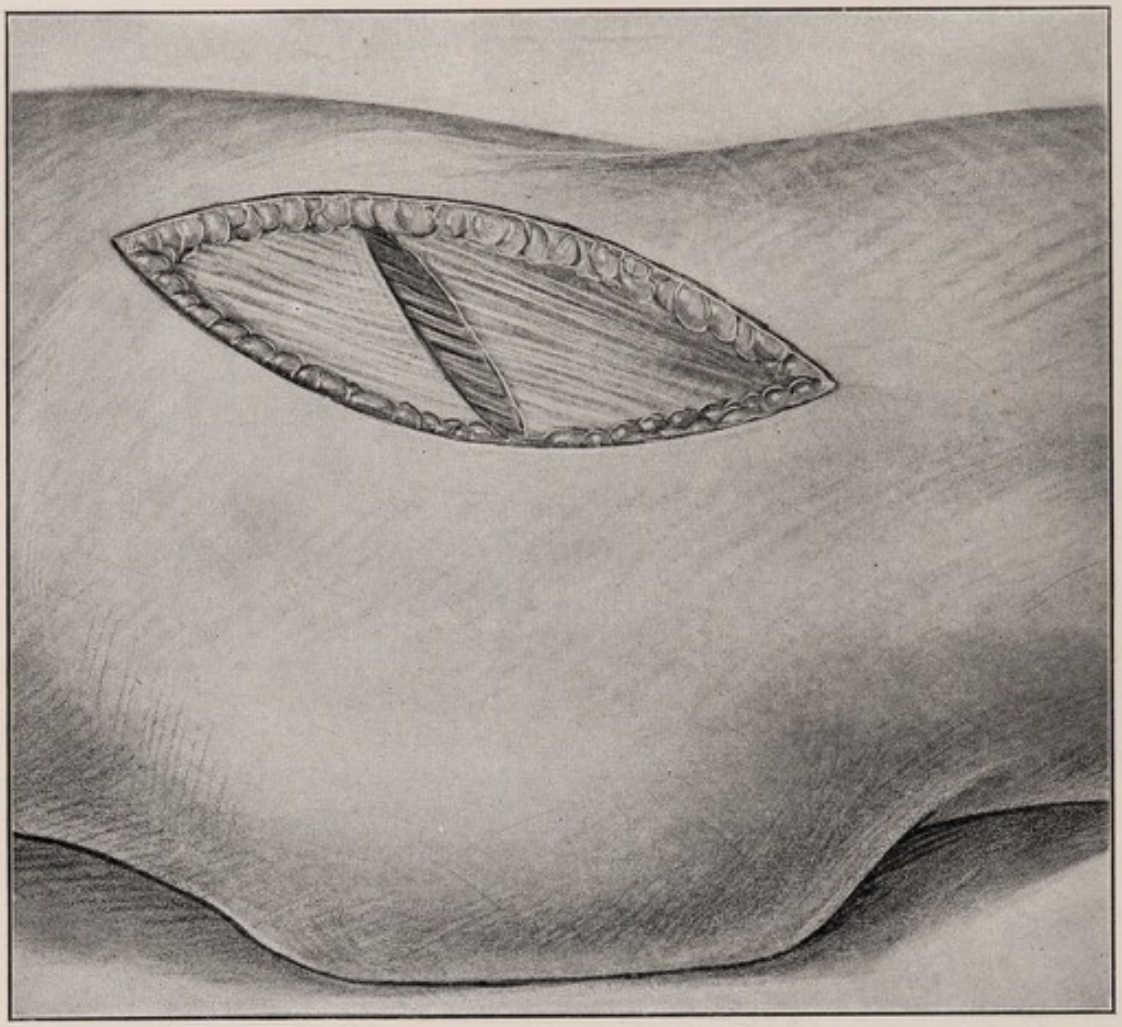

FIG. 472.—Soutter fasciotomy right hip, showing skin incision and incision of fascia lata.

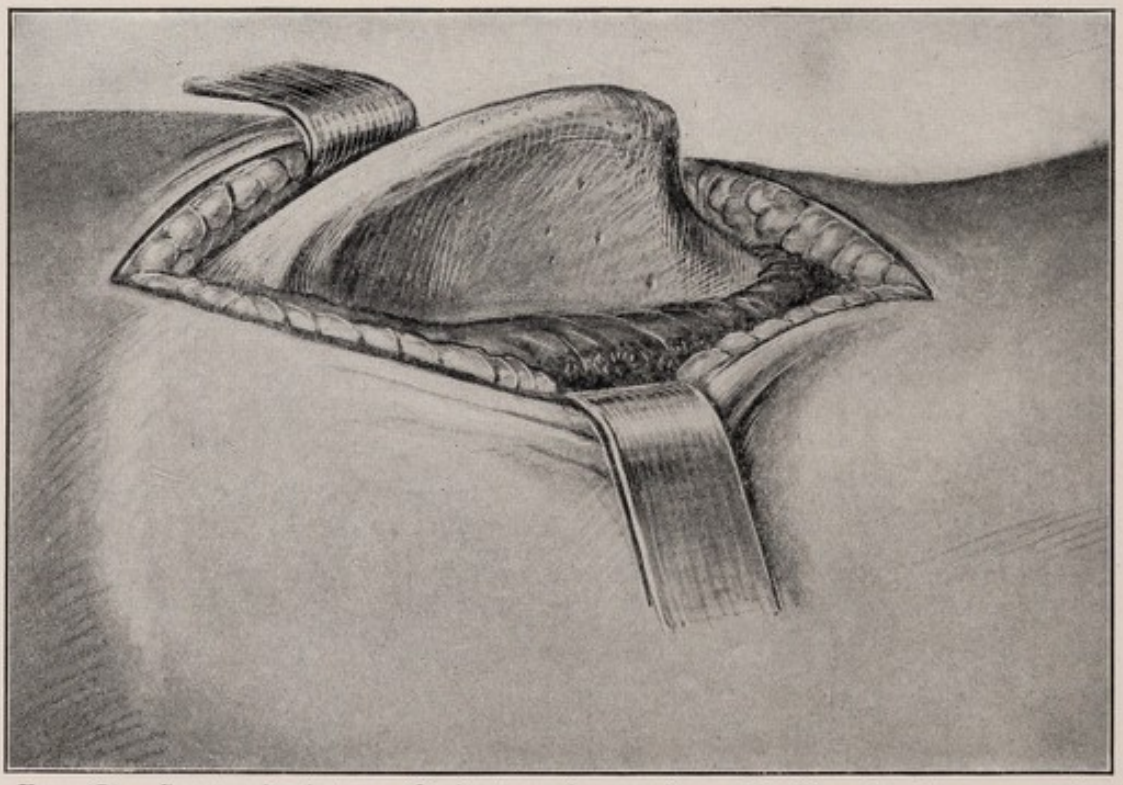

FIG. 473.—Soutter fasciotomy, final stage of operation. The ilium has been exposed subperiosteally, as far down as the anterior inferior spine of the ilium, and far enough back to allow the tissues to slip. Later the projecting spine is cut off with bone forceps.

the tape terminations of the adhesive plaster are tied to the bottom of the splint. These are tightened from day to day. Pad pressure is employed above and below the knee as illustrated (Fig. 165).

To those unfamiliar with its use a very simple adaption of the ordinary leg plaster is surprisingly effective. The reduction is accomplished by putting a

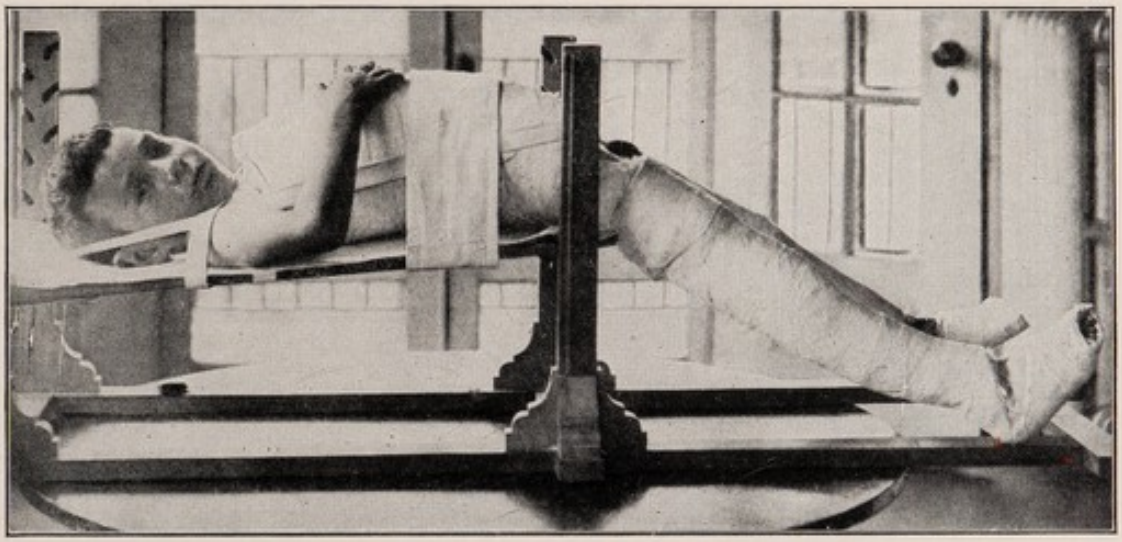

FIG. 474.—Steward frame for stretching after operation for hip flexion contraction.

circular plaster on the leg from the toes to the groin in the position of deformity, allowing it to harden for twenty-four hours, and then making a transverse slit through the posterior two-thirds of the plaster at the level of the popliteal space. Thin pieces of wood are then put in the slit to force it open, and the conditions of leverage are so favorable that the knee straightens rapidly.

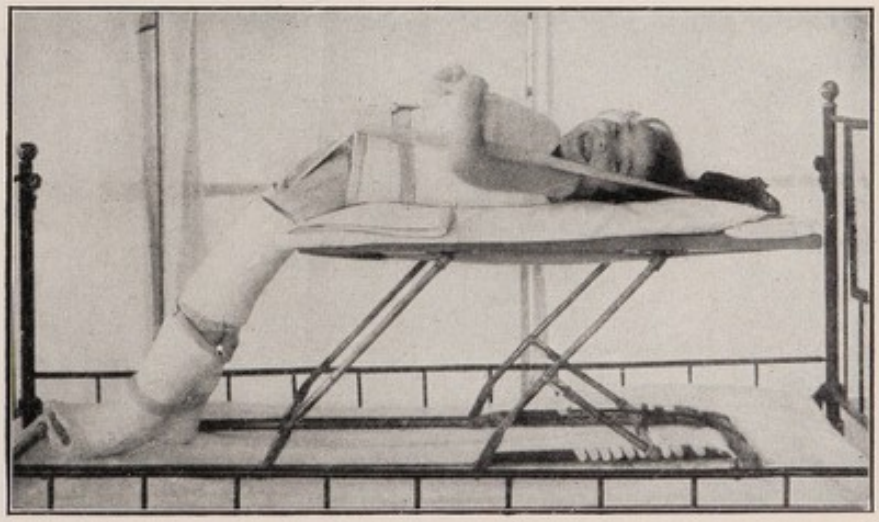

FIG. 475.—Schwartz frame for stretching hip flexion contraction after operation.

In cases, which for any reason, cannot be handled by either of these methods reduction under anesthesia, preferably with division of the hamstring tendons, and the ilio tibial band, may be performed, followed by fixation. It is never wise to cause pain by straightening knees in the acute stage of the disease as it is sure to delay the progress and the deformity is never formidable in the first months after the attack. The objection to sudden reduction of a severe knee

flexion under anesthesia is that subluxation is apt to persist and to appear as an unsightly deformity after the leg is straight. This has been noticed several times in cases reduced under ether without the division of the hamstring tendons. It is a better procedure even after division of the hamstrings to correct the deformity slowly.

2. *Knock-knee.*—Children with extensive infantile paralysis of the legs, especially if associated with flexion deformity, are likely to acquire a knock-

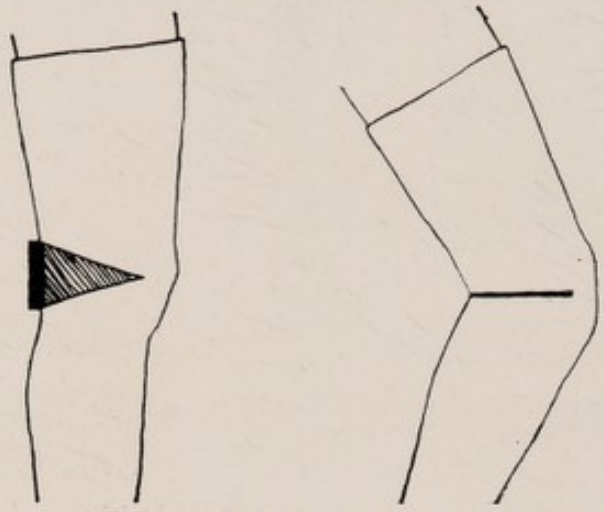

FIG. 476.—Method of wedging knee for flexion contraction.

knee (the mechanism of which has never been quite clear) due to walking on a valgoid foot, to postural malposition in connection with knee flexion deformity, and to overaction of the biceps. This knock-knee does not in its end result differ essentially from the knock-knee of rickets, except in its etiology. It is not only unsightly, but if it becomes very severe is likely to make the use of

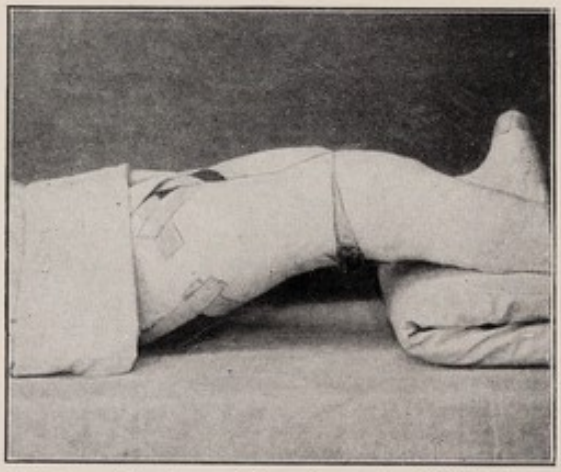

FIG. 477.—Plasters to stretch knee flexion. The plaster is divided transversely, leaving a hinge in front and pieces of wood are inserted.

splints difficult on account of the internal prominence of the knee. In younger children this can be controlled and perhaps cured in the milder cases by the use of a splint pressing outward upon the inner condyle of the knee. In cases of longer standing, where it becomes a serious disability, osteotomy may be done by means of a saw or chisel just as in rachitic knock-knee. This consists in partial division of the lower end of the femur from the inner side

just above the inner condyle of the femur and by means of reasonable force fracturing the femur to correct the alignment, or of introducing a saw from the outer side through a small opening and sawing three-quarters through the bone, and then fracturing.

3. *Hyperextension* (Genu Recurvatum).—The over-extended knee most often is a result of weakness or paralysis of the hamstring muscles. If the gastrocnemius is also affected the deformity is still more likely to occur. It occurs occasionally when the hamstrings are perfectly normal but the gastrocnemius decidedly weak. A common cause of hyperextension is a contracted tendo Achillis, especially if the hamstrings or gastrocnemius are weak

As the knee is hyperextended its continued stretching makes it loose so that it moves laterally in the extended as well as the hyperextended position. The deformity is a serious one, as it is most detrimental to function, and the surgeon should be prepared for it in cases with weakness of the posterior muscles and guard against it by checking the hyperextended position of the knee at all times. This may be done by the use of a caliper splint provided with a cross strap running behind the knee.

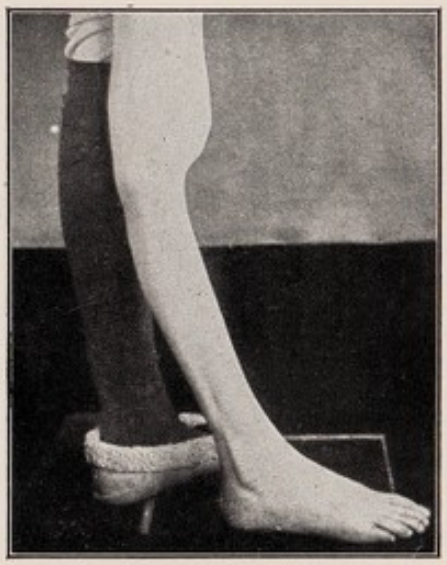

Fig. 478.—Subluxation of right knee following reduction under anesthesia.

4. *Backward Subluxation of the Tibia on the Femur with Outward Rotation of the Former.*—This occurs from overaction of the flexors of the knee when the quadriceps is weakened; from a general relaxation of the joint; and where a flexion deformity is corrected too rapidly and in the wrong way.

Deformities of the Ankle—*Equinus.*—The deformity of equinus is caused most often by the persistence of the gastrocnemius and weakness of the anterior muscles, but the flexors of the toes must not be forgotten as a positive factor when all other muscles are paralyzed. Severe equinus deformity in both feet makes walking practically impossible, and if in one foot, it causes a marked limp.

The division of the tendo Achillis has been the customary method of removing this deformity, but it is an operation to be done with care. There are two definite reasons for this: first, if the anterior muscles of the ankle are also paralyzed, a flail foot results after operation and in the absence of anterior muscles the operation should not as a rule be done without some attempt to check the foot drop by tenodesis, or the insertion of an artificial ligament.

A foot in the position of equinus is often a useful weight-bearing member especially where the limb is short, but once converted to a flail foot it may become insecure and troublesome. Tenotomy of the tendo Achillis, therefore, should not be done in cases where the anterior muscles are paralyzed unless at the same time some means is adopted to prevent a perfectly flail foot.

Second, the objection to the indiscriminate division of the tendo Achillis to correct equinus is that if the quadriceps on that side is paralyzed or weak, and the hamstrings are good enough to prevent hyperextension of the knee, the existence of some equinus is a valuable asset and enables the patient to walk without a brace, whereas, if the equinus is removed and the normal amount

of dorsal flexion is allowed, a brace becomes necessary. A foot with a moderate equinus deformity when placed on the ground in weight-bearing, locks the knee in extension, and the patient walks perfectly well without a brace, the only disability being that in a crowd, if anyone hits the knee from behind the patient is likely to fall.

As a matter of fact, the division of the tendo Achillis is generally not necessary in poliomyelitis to correct equinus

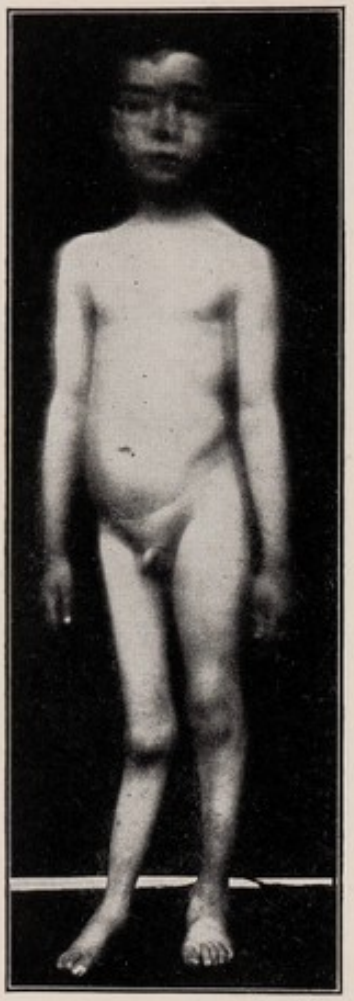

FIG. 479.—Knock-knee in infantile paralysis of right leg.



FIG. 480.—Hyperextension of both knees.

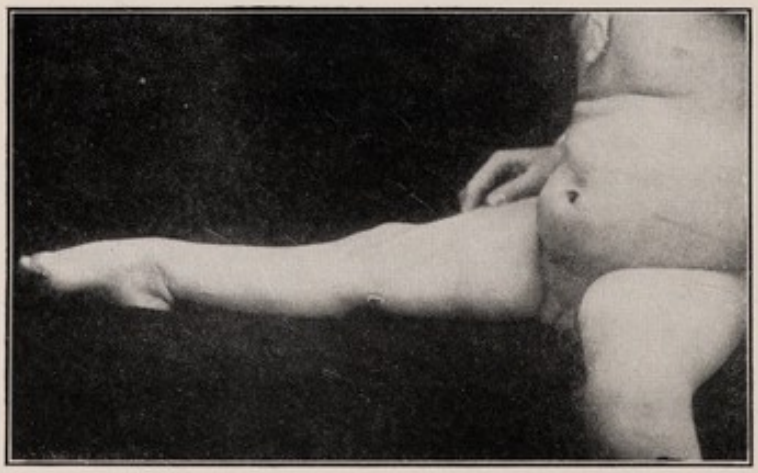

FIG. 481.—Extreme equinus of right foot.

because most cases yield to a method of gradual stretching similar to that which is described for the knee. A plaster is applied from the toes to just below the

knee, with the foot in position of deformity, and an elliptical piece of the plaster is then removed from the anterior three-quarters of the bandage just over the fold of the ankle. A strap is put around the front and around the top of the plaster, and these two straps are connected by another webbing strap and buckle, and in most cases in from ten days to four weeks the foot can be brought to or beyond a right angle, or if it is desirable to save time, the foot can be stretched under gas; but it must be remembered that after stretching by either means, if the posterior muscles still predominate the deformity will tend to recur.

Lengthening of the tendo Achillis should *not* be performed in infantile paralysis by the subcutaneous complete division of the tendon, but by plastic tenotomy done either subcutaneously, which is preferable, or by an open incision, in which the tendon is half cut through on one side at one level, and the other half is divided at another level, and the two transverse cuts connected by a vertical cut. The foot is then flexed when the divided parts will glide apart to the desired extent without a complete separation of the tendon occurring. It is quite possible to do the operation subcutaneously, but it requires experience, and surgeons unfamiliar with this operation will be wise in making an incision exposing the tendon before cutting it. The old operation of complete subcutaneous division at one level is in a certain number of cases followed by failure to repair with disappearance of the tendon resulting in distressing deformity and very often the bond of union is imperfect and yields.



FIG. 482.—Equinus of right foot.



FIG. 483.—Tenotomy knives.

If the foot is held in *varus*, *valgus*, *cavus* or *calcaneus*, it is generally due to the predominance of one set of muscles over their affected antagonists and must be corrected, as otherwise permanent bony deformity will occur in accordance with the laws of growing bone, and a fixed malposition will result. These deformities have been tabulated earlier in the chapter (p. 448).

If fixed deformity exists, it must be first removed before mechanical or operative treatment is undertaken. This is done by stretching, manipulating under anesthetics, tenotomy, fasciotomy, myotomy, osteotomy, or removal of bone.

Deformities of the Upper Extremity.—*Shoulder Contraction.*—This is one of the seriously troublesome deformities of infantile paralysis and is wholly

unnecessary. Contractions of the shoulder in adduction and internal rotation arise where the deltoid muscle is involved and the pectoralis major and latissimus dorsi retain some power. The protracted use of a sling, which should never be allowed in these cases, results in the continuous position of the arm at the side and thus favors this contraction, which comes on rapidly, and is a serious hindrance to the development of deltoid activity. The deltoid is unable to work properly until this contraction has been removed. It is frequently overlooked, but as a preliminary to the treatment of the shoulder, the contraction must be entirely overcome. This is done by stretching, in all instances a painful matter. The scapula must be fixed and the arm abducted and rotated out while the scapula is held. The contraction cannot be considered relieved until the patient can lie on the back and have the arm extended above the head and close to it, without raising the chest from the table. After each stretching the arm should be fixed on an abduction splint, then stretched again and fixed and so on. Daily stretching in stages is to be preferred to immediate correction under anesthesia.



Fig. 484.

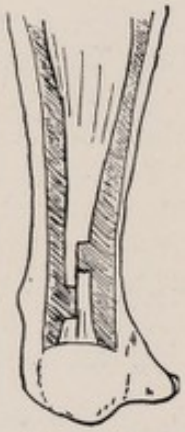

Fig. 485.

Fig. 484.—Plastic tenotomy of tendo Achillis. The diagram shows the two incisions through half of the tendon at different levels.

Fig. 485.—The foot has been dorsally flexed and the tendon stretched and elongated but not separated across.

All cases of deltoid paralysis should be treated from the outset with a platform splint of wire (abduction splint), which not only tends to prevent the contraction but which has yielded a proportion of recovery in deltoid paralysis previously unknown (Fig. 491).

The aeroplane or *platform splint* is made from one-fourth-inch steel wire covered with light duck or black cambric to which are fastened buckles and straps by which the splint is attached to the chest and the arm of the splint to the arm. The wire is bent so that the whole arm is supported from the tips of the finger to the axilla, with the elbow flexed at a right angle. The body portion extends from the axilla to just above the trochanter, the pelvic portion being expanded laterally and curved so that a good grip is obtained on the pelvis to avoid tilting. Other forms of shoulder abduction splints used are shown in figures 183–184 (p. 186).

Dropping of the Shoulder.—The humerus may drop away from the glenoid cavity in severe paralysis of the shoulder. This is not a true dislocation but simply a stretching of the joint capsule and is a grave deformity. It does not as a rule exist unless the deltoid, biceps, and triceps are all seriously involved, as they are concerned in keeping the humerus in contact with the glenoid cavity. If they are affected even in moderate degree it is easy to see how they must be stretched by the weight of the arm. It may be repeated here that from the time tenderness disappears the arm should be kept abducted from the side, and the weight of the arm should *never* drag on the shoulder structures.

Deformities of the Arm and Hand.—Deformities of the elbow, wrist and fingers are of no one type and occur in response to the influence of gravity and unbalanced muscular contractions.

Scoliosis.—*Lateral curvature of the spine* is a late complication of infantile paralysis, and may result apparently from paralysis of the back muscles, paralysis of the shoulder, and shortening of one leg, but the most commonly associated condition with severe scoliosis is *unilateral abdominal paralysis or weakening.*



FIG. 486.—Pes cavus of right foot.

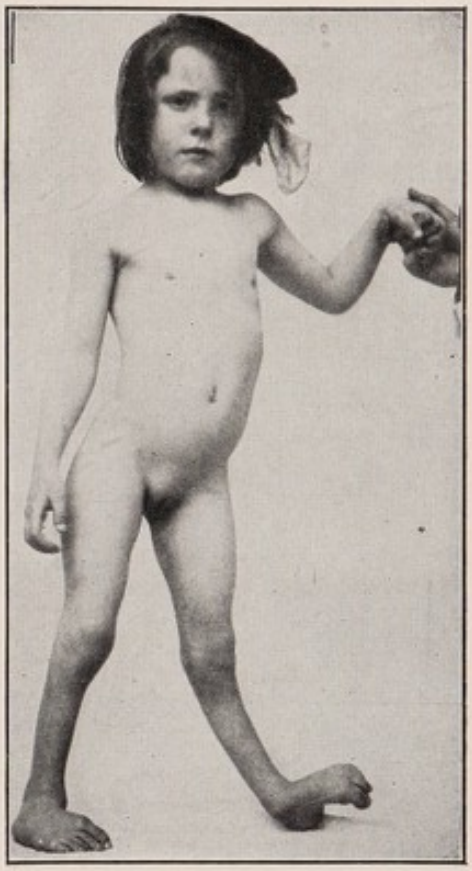

FIG. 487.—Talipes calcaneus of left foot with element of cavus.



FIG. 488.—Severe calcaneo valgus of right foot.



FIG. 489.—Varus of right foot.

Every patient in the New York State series was examined for abdominal paralysis or weakening.[1] In recent cases involvement of the abdomen and

[1] LOVETT: Jour. Am. Med. Ass'n., July 21, 1917.

back occurred in 57 per cent, so that weakness of the abdomen in the early stage, especially if unilateral, should make one watchful for scoliosis at any stage. This deformity may occur while the patient is still recumbent and is often evident when the patient first sits up. All cases of infantile paralysis should be examined for scoliosis.

In contrasting recent and old cases of poliomyelitis, scoliosis proved relatively four times as common in old as in recent cases and is therefore a late complication.

Of all the deformities, scoliosis is probably the one most frequently overlooked. Naturally the conditions of unilateral muscular paralysis which caused it in the first place are going to persist in a measure, and it is not likely to recover or to improve spontaneously. To attempt to cure the deformity by exercises seems



FIG. 490.—Contraction of right shoulder and deltoid paralysis with inability to abduct right arm.



FIG. 491.—Platform splint.

irrational, because the basis of the condition lies in the weakness of the muscles of one side; and although it may be well to attempt to strengthen these muscles by exercise, it is doubtful in the marked cases if they would ever recover power sufficiently to hold the spine straight against an oblique superincumbent weight. It is definitely desirable in every case of lateral curvature due to infantile paralysis to support the spine as soon as the deformity is discovered, even before the children are able to walk. Bone is an adaptive structure and grows in the line of least resistance, and to allow a growing child to sit, lie or stand in an habitually distorted position is to bid for permanent bony deformity. This has been established experimentally by Wullstein[1] and Arndt.[2] Moreover, the stretching of affected muscles by the deformity is a hindrance to their improvement.

Remembering the frequent abdominal source of the affection, in *every* case of abdominal weakness in the early stages the use of a canvas corset reinforced by steels is desirable, even in small children, to prevent the distorted position of the spine. This is a mild remedy, and improves the sitting position, and in

[1] WULLSTEIN: Zeitsch. fur Orth. Chir., x, No. 2.
[2] ARNDT: Arch. fur. Orth. Chir., i, No. 1, 2.

certain cases cures mild deformity, which was threatening. The deformity of lateral curvature in infantile paralysis when untreated reaches a very severe and gravely disabling degree. It is useless to wait for this to occur and it is better to attack the deformity vigorously and on sound mechanical principles.

The mechanical treatment of severer cases differs in no way from the treatment of any scoliosis of the same grade, due to other causes (p. 743) except that deformity in the paralytic cases yields much more readily to correction, although the correction is more difficult to maintain. Moderate cases of scoliosis may be treated by recumbency or corrective jackets or apparatus; severe cases in children, when possible, by recumbency on a double Thomas hip splint or on a plaster of Paris bed in a hyperextended position. The corrective force is thus distributed through the spine, the bad influence of gravity removed and the improvement is often surprising. When this is not practicable a forcible plaster jacket followed by another one of the same sort is very effective in restoring flexibility, after which a corrective jacket must be worn. It is probable that in most moderate and severe cases, apparatus will have to be worn throughout early life and probably some form of support permanently.



FIG. 492.—Dropping of right humerus and complete paralysis of right arm.

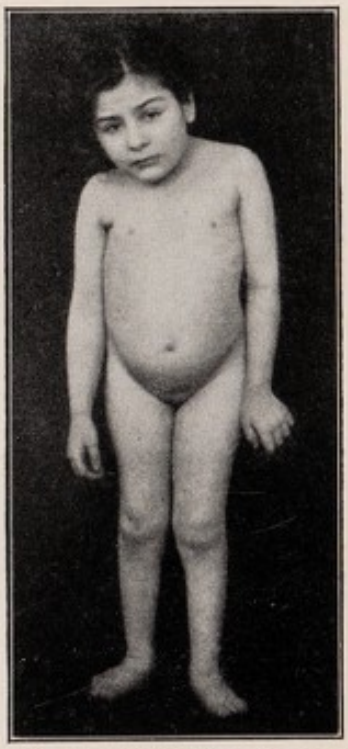

FIG. 493.—High left lateral curve with distortion of position of the head.

Finally, the most distressing form of paralytic scoliosis must be mentioned where the curve is too high to be held by a jacket and reaches into the high dorsal or even cervical region. The head is carried to one side, the root of the neck very prominent on one side, and the shoulder very high on the same side. The weight of the head rapidly increases the upper curve, the neck shortens, and the deformity becomes very distressing.

In growing children with this deformity, prolonged recumbency as described, with the addition of head traction offers the best hope of avoiding a very distressing deformity, and this should be continued as *long as possible*, as

no other treatment will compare with it. It is often not possible, however, to continue this as long as one would wish, and the only ambulatory apparatus which is in any way effective is a plaster or celluloid jacket to the back of which is added an oval head ring set on an upright which can be raised or lowered on the jacket by means of a key. The oval ring can turn on the post on which it is set to allow the head to rotate, and the head piece is swung at the middle on a fork, which allows flexion and extension of the head as otherwise children cannot wear it to study or read. The apparatus is unsightly, clumsy, and complicated, but if the head can be kept from sinking down between the shoulders during the period of rapid growth much time will be saved, and improvement may be secured.



FIG. 494.—Unilateral abdominal paralysis and scoliosis shown by the bulging of the right abdomen in crying.



FIG. 495.—Right dorsolumbar scoliosis due to infantile paralysis.

TENDON TRANSPLANTATION

The object of this operation is to improve or restore muscular balance, and it is not justified unless it is likely to improve function, for there is little satisfaction to the patient if the transplanted muscle merely responds to faradism, or even makes a feeble movement in response to voluntary impulse. The transplanted muscle is to become a substitute for the muscle it supplies and must therefore possess useful function. Transplantation is directed (*a*) to restore the balance between opposing groups of muscles by helping to redistribute the power, or (*b*) to prevent or correct deformity, or (*c*) it may be used to improve stability in conjunction with operations such as astragalectomy, arthrodesis, tendon fixation or the use of artificial ligaments.

The most important factor in obtaining success from a functional point of view is careful study of the individual case and sound judgment on the part of

the operator, who should definitely realize what he wants to do and the means at his disposal, and should judge not only of the action and power of the muscle he is transplanting, but also of the disability which he may create at the part from which the tendon is removed, for there is no sense in substituting one deformity for another. Transplantations are more successful when the paralysis is limited, and when reinforcement can be introduced from the immediate neighborhood.

The operation should not be undertaken until every effort has been made to restore the paralyzed muscle by other means, as described earlier. It is not so much a question of how long the paralysis has existed, but rather of what kind of treatment has been carried out. If nothing has been attempted with a view to securing the shortening of stretched muscles, this should be attended to before any transplantation is discussed. If the paralysis has lasted twelve months and appropriate treatment applied and there is still no response, operation may be considered. If we wait too long, bony deformity is apt to occur or increase. It is not as a rule desirable to perform the operation before the age of five, and better results will be as a rule obtained in children older than this, but it is often forced on one by rapidly increasing deformity. The objections to operating on young children are (1) the technical difficulty in handling and fixing minute tendons, (2) the long period of growth ahead of the child, and (3) because the after-treatment is so important in these cases that the child must be depended upon to assist the development of the transplanted tendon by voluntary muscular contractions.

Tendon transplantation is in practice the most generally useful and satisfactory of the operative measures at our command, intended to improve function. It makes no difference to a muscle where it is inserted, for it pays but little attention to a change of its distal end. Every case represents a separate anatomical problem and it must be remembered that a tendon transplantation cannot be done unless there are at hand fairly normal muscles to transplant. The question does not arise in a wholly paralyzed region.

Originally the transplanted tendon was sewed to the tendon for which it was substituted,[1] but this method has been on the whole abandoned. The insertion of the tendon into the periosteum, as advocated by Lange,[2] followed it, but better than this and more like nature's attachment is the insertion of the tendon directly into the bone, stitching it to both bone and periosteum. Another distinct modification of the operation was brought about by the discovery that when a muscle is too short to reach its destined point of attachment it can be prolonged by silk or fascia which is sewed into the tendon and carried on to be inserted into the bone just as the tendon would have been had it been long enough. Carefully planned operations have made this proceeding rarely necessary in the foot.

Technique of Tendon Transplantation.—(1) Rigid asepsis and careful handling of the tendon, which should not be bruised.

2. The tendon may be passed through subcutaneous fat, or along the sheath of the paralyzed tendon as recommended by Biesalski and Mayer[3] and by Steindler.[4]

[1] Vulpius: Behand d. Spin. Kinderlahmung, Leipzig, 1910.
[2] Lange: Ergeb. d. Chir. u. Orth., Berlin, 1911. Zeitsch. fur Orth. Chir., xvii, 266; xxx.
[3] Mayer: Die phys. Sehnenverpflanzung, Berlin, 1916.
[4] Steindler: Jour. Iowa State Med. Soc., 1919, lx, 75–78.

3. The tendon should form a straight line from its origin to its insertion. Any sharp deflection jeopardizes the result.

4. If the tendon has to perforate fascia it should be supplied with ample room as otherwise adhesions will occur.

5. Tendons should be attached in moderate tension: if too tight, atrophy may occur; if too slack, function will be delayed.

6. The insertion is best made into bone and, where possible, the tendon should be passed through a tunnel in the bone or under a bridge of bone periosteum and stitched to the bone. If this is not possible, an osteoperiosteal flap may be made and stitched over the end of the tendon which is sutured into periosteum.

7. Chromicized gut or carefully sterilized silk should be employed to fix the tendon in position.

8. No transplantation should be done before the deformity is corrected.

9. The greatest care should be exercised in the selection of the proper case and the proper operation. It is of doubtful utility to transplant a very weak muscle in the place of a powerful muscle which has become paralyzed, although it must be remembered that a transplanted muscle is capable of considerable development. Generally speaking, it is not wise to change flexors for extensors as well coordinated function is more difficult to attain, but in certain transplantations, such as in musculo-spiral paralysis, they result in admirable function.

There is no definite rule to be laid down as to which are and which are not available operations. In the earlier operations there was a tendency toward great complexity, splitting of tendons, doing many things at once on a generally intricate plan. The later operative tendency among the most experienced surgeons is toward simpler operations, attempting to do fewer things at a time, and things that are obviously of anatomical benefit and are mechanically sound. The most frequently performed and the most available operations are the following:

Foot

Varus.—In cases of varus where the peroneal muscles are paralyzed, the anterior tibial muscle if active should be transplanted.

The tibialis anticus tendon is divided at its insertion into the tarsus and metatarsus close to the bone, through a small incision.

Another incision is now made about three inches in length along the course of the tendon with its center at least four inches above the upper border of the ligament. Through this incision the deep fascia is freely divided and the severed lower end of the tendon is pulled into this upper incision. A third incision is made transversely close above and parallel to the base of the fifth metatarsal. The lower divided end of the tibialis anticus tendon is now passed under the annular ligament through this outer incision.

A gutter is now chiselled on the outer border of the foot at the base of the fourth or fifth metatarsal in which the end of the tendon can be firmly fixed, or a hole may be bored through the bone for the reception of the tendon, or with a curved osteotome a broad slit may be made in the bone making an osteoperiosteal bridge through which the tendon is passed. Fascia and skin are now separately sutured and the foot held in slight eversion and dorsiflexion.

In mild cases if the insertion of the tendon is made too far out the foot may become overcorrected and a valgus position results.

Valgus.—In a mild talipes valgus, where the anterior tibial is merely weakened, the extensor proprius hallucis should be divided well toward its insertion and passed through a

hole drilled near the distal end of the first metatarsal bone. It is important to fasten to the extensor brevis digitorum the distal end of the tendon where it has been cut, as toe drop sometimes occurs after the operation if this is not done. The extensor longus hallucis is an exceedingly useful muscle and can also be used for the correction of *varus* by transferring it



FIG. 496.—Transplantation of the tibialis anticus tendon to the outer side of the tarsus for varus due to paralysis of the peroneal muscles. The muscle is inserted, in this case, under an osteoperiosteal bridge and the foot maintained in abduction. The transplanted muscle is shaded darker than the others.



FIG. 497.—Transplantation of the extensor propius hallucis to the outer side of the tarsus to correct mild varus deformity. The proximal end of the divided tendon is sutured to prevent flexion of the toe, and the distal end is inserted into an osteoperiosteal bridge at the outer side of the tarsus. Transplanted muscle shaded darker than the others.

to the outer side of the dorsum of the foot. This muscle is not sufficiently strong to be used where all the other muscles are paralyzed, but is exceedingly useful as an accessory to them, in the way of correcting valgus and varus, as has been stated, and it sometimes will reinforce weak dorsal flexors of the foot if its action in flexing the toe is eliminated by dividing it as described, and inserting it somewhere in the middle of the metatarsus.

In cases of marked talipes valgus resulting from paralysis of the anterior tibial, if the peronei are good, the peroneus longus may be transplanted to support the inner side of the foot. It is dangerous to transplant both peronei on account of possible overcorrec-

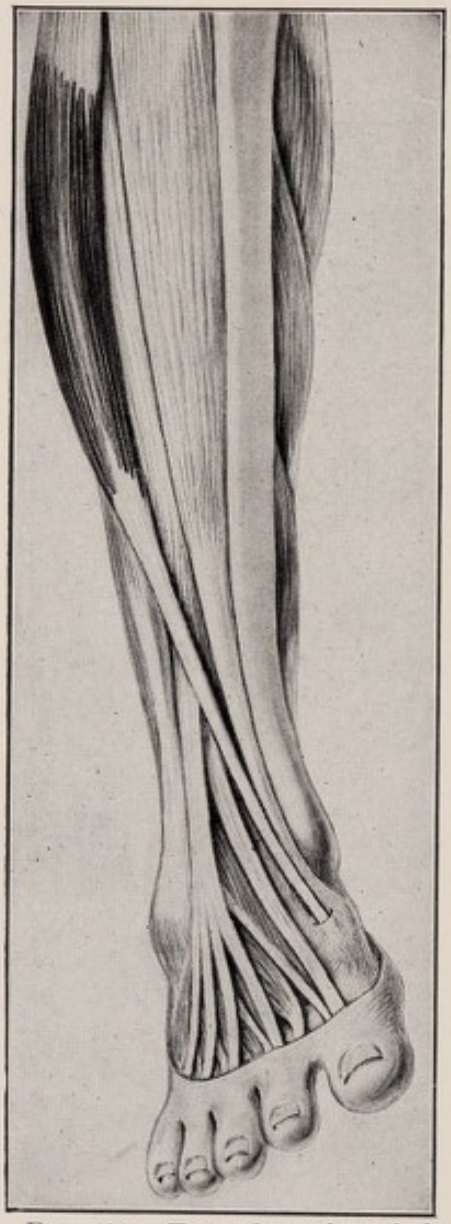

FIG. 498.—Transplantation of the peroneus longus to the inner side of the foot to correct valgus deformity due to the paralysis of muscles at the inner side of the leg. The tendon is attached to the bone, being in this case passed under an osteoperiosteal bridge. Transplanted muscle shaded darker than the others.

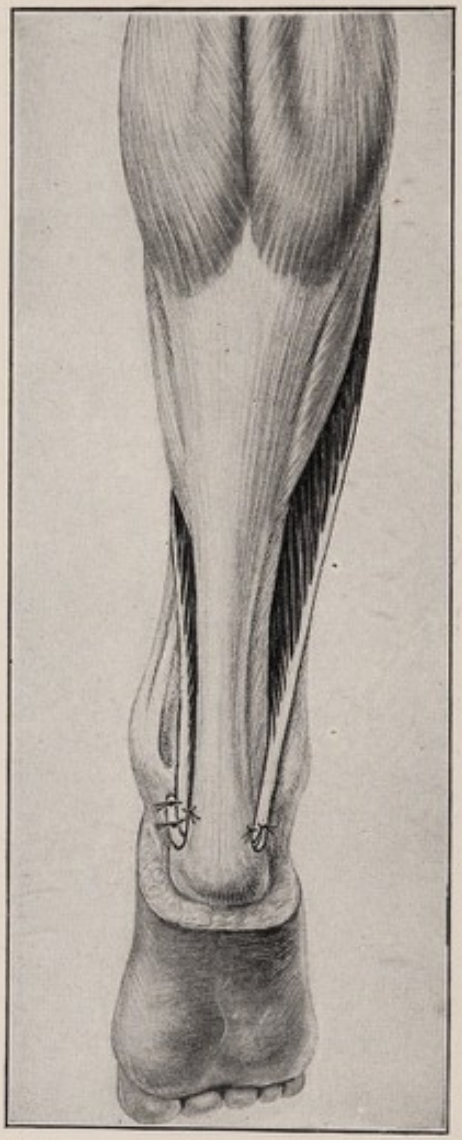

FIG. 499.—Paralysis of gastrocnemius muscle. Transplantation of the tibialis posticus and the peroneus longus into the os calcis. The tendons are passed into a hole in the bone and stitched to each other. The peroneus longus passes through the bone, and up on the inside. The tibialis posticus is not long enough to reach to the outer side of the foot, and is attached to the other muscle by a quilted suture inserted in the tendon before it was pulled down. The transplanted muscles are shaded darker than the others.

tion. An incision 1½ inches long is made in the long axis of the foot along the outer border of the tarsus, just in front of the external malleolus where the tendon passes under the foot. The first tendon reached will often be the peroneus brevis, which runs more or less on the line of the incision, and just below and a little deeper running more transversely to the foot

will be found the tendon of the peroneus longus. The foot is adducted, plantar flexed, and the tendon cut off as near its insertion as possible by a tenotome. An incision of 3 or 4 inches is then made at the junction of the lower and middle third of the fibula, the tendon is indentified and is the first one reached by the incision. It is pulled out through this opening and the fascia separating the peronei and the anterior tibial group is widely perforated and the tendon of the peroneus longus is passed down through the anterior tibial compartment and sutured in the medial side of the base of the 1st metatarsal. This method is more anotomical and physiological (Biesalski and Mayer[1]). A tenotomy of the tendo Achillis in connection with this operation is often necessary if equinus exists, but should be performed *with great reserve* because a calcaneus may follow such a procedure if a free division of the tendo Achillis is done. The foot should be held in varus (Fig. 498).



FIG. 500.



FIG. 501.

FIG. 500.—Hamstring transplantation, showing division of tendons of the semitendinosus and biceps close to their insertion, prior to transplantation.

FIG. 501.—Hamstring transplantation, showing semitendinosus and biceps inserted into patella.

Talipes Calcaneus.—In cases with some gastrocnemius power remaining and a good posterior tibial and good peronei excellent functional results may be obtained by attaching these tendons to the back of the os calcis. When the flexor communis digitor is good the function will be markedly improved if that tendon is also implanted in the top of the os calcis. Prolonged protection against the strain of weight-bearing is most important as the transferred muscles are not fit for this until they are developed by muscle training. This operation is especially desirable because with a weak or paralyzed gastrocnemius the posterior tibial and peroneal muscles tend to produce a pes cavus if the gastrocnemius is not working; they act as flexors of the mid foot and by their attachments to the os calcis this is prevented (Fig. 499).

Knee

Hamstring Transplantation.—Care must be taken to overcome all flexion of the knee before operation is undertaken, as otherwise there will be too much strain upon the tendons after transplantation. If the biceps alone be transplanted an incision is made over the muscle starting half-way up the thigh, and extending 1 inch below the head of the fibula.

[1] Surg. Gyn. Obstet., Feb., Mar., April, 1916.

The tensor fasciae latae may be transplanted along with the biceps femoris. The iliotibial band must be separated near the head of the fibula and a strip of fascia one inch wide including the band is dissected up to the upper extremity of the wound exposing the biceps femoris. A second incision is now made over the lower part of the belly of the tensor fasciae latae, and the fascial flap is drawn up through the upper wound, and the muscle belly is freed all around from fasciae. The biceps tendon is cut close to the head of the fibula, and that muscle is cleared up to the upper extremity of the lower wound. Both the tendon and the iliotibial band are passed beneath the fascia lata and firmly sutured under an osteoperiosteal bone flap in the patella and are also sutured to the tendon of the quadriceps femoris. Care must be taken not to wound the external popliteal nerve. An oblique incision is then made,

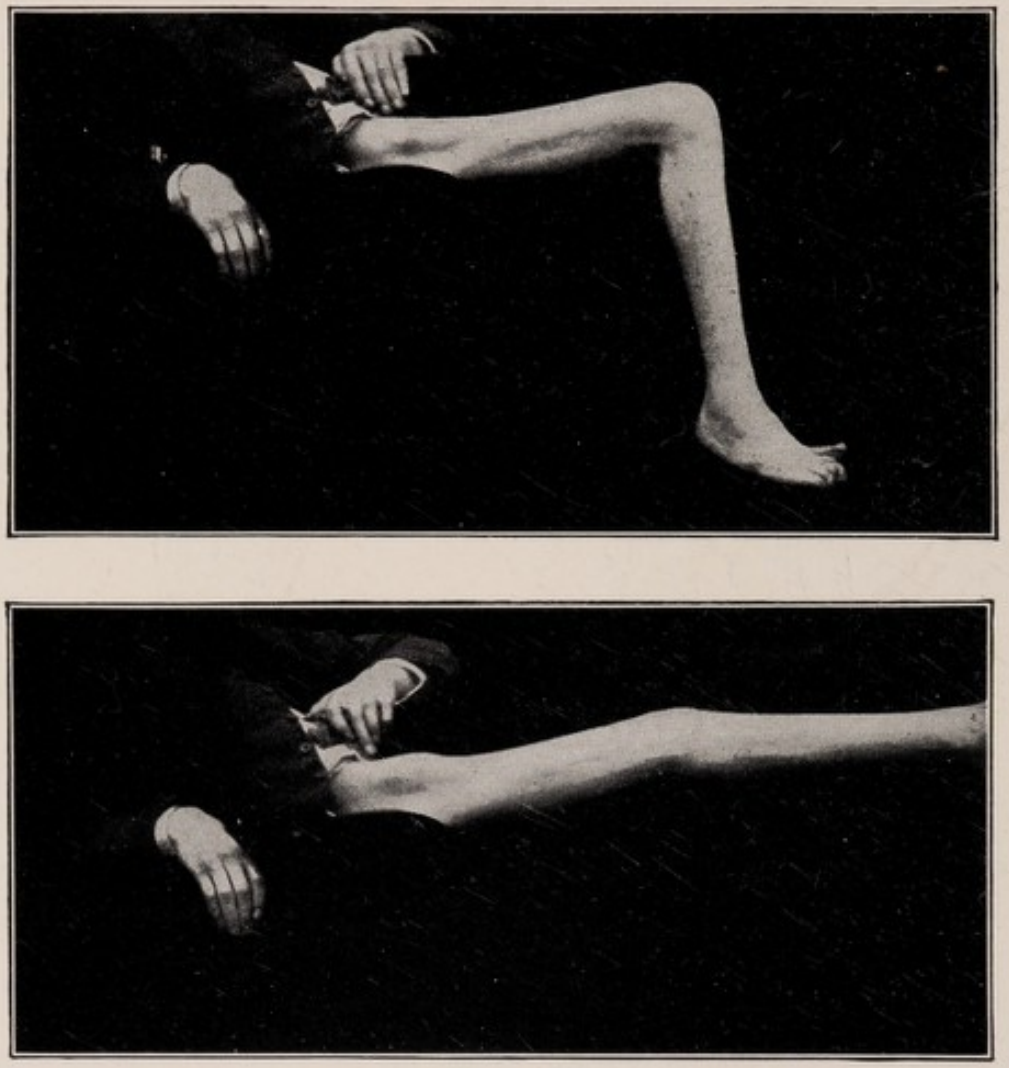

FIGS. 502 and 503.—Showing hypertrophy of the tensor fasciæ femoris and its action as an extensor of the knee-joint after its transplantation to the patella (Naughton Dunn and F. Wilson Stuart, British Journal of Surgery, XI, 43, 1924).

starting from the middle of the patella and continuing for 3 inches in the line which the muscle will take when transplanted. More power of flexion is gained if in addition to the transplantation of the biceps the inner hamstrings are also used which are exposed by incisions corresponding to the one described by the biceps.

Transplantation at the Hip

Ober's[1] operation for the relief of paralysis of the gluteus maximus muscle is fairly satisfactory in relieving the limp of gluteus maximus paralysis. An incision is made over the lumbosacral region at about the level of the second lumbar vertebra extending

[1] OBER, F. R.: Jour. of the A. M. A., April 2, 1927, Vol. 88, pp. 1063 and 1064.

down the posterior superior iliac spine, exposing the deep lumbar fascia and the erector spinae group of muscles. The lumbar fascia is divided about one half inch lateral to the spinous processes extending well down on to the sacrum. The muscle belly of this group is separated from its lateral attachment by blunt dissection up to the large dorsal nerves, care being taken not to divide these nerves. The fascia is separated from the crest of the ilium well down on to the sacrum and the muscles are divided in the medial aspect of the wound by blunt dissection until one gets down to the transverse processes. A large mass of muscle tissue can now be lifted up. Another incision is made over the lateral aspect of the thigh exposing the fascia lata down to the upper level of the patella,

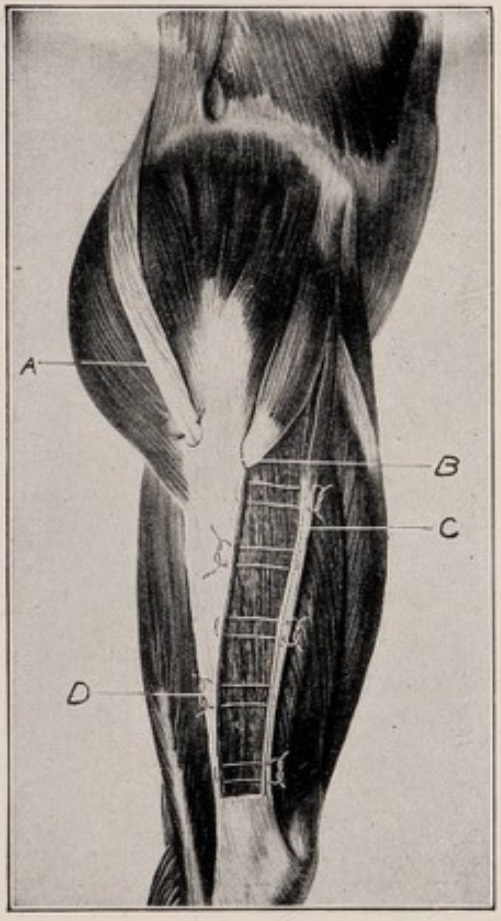

FIG. 504.

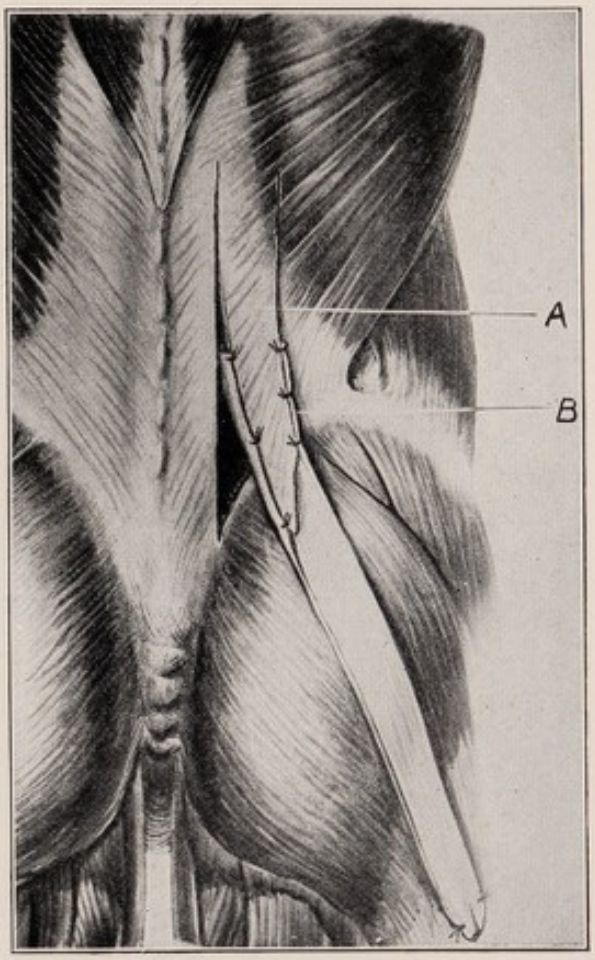

FIG. 505.

FIG. 504.—Ober's operation. Long flap of tensor fasciæ, 1¼ inches wide, dissected free from the thigh up to and including some muscle fibers of the tensor fasciæ latæ. *A*, flap of fascia extending up to spinal muscles; *B*, hole drilled through femur at level of insertion of gluteus maximus tendon; *C*, edge of fascia space closed with mattress sutures (Frank R. Ober, Journal Am. Med. Ass'n, April 2, 1927).

FIG. 505.—Ober's operation. *A*, outer half of erector spinæ group, split off and dissected free from its attachment: *B*, method of entering fascia lata to inferior surface of freed spinal muscles (Frank R. Ober, Journal Am. Med. Ass'n, April 2, 1927).

extending from just below the trochanter to the upper level of the patella. Two incisions may be used with an isthmus between. The tensor fasciae is divided at the level of the lower extremity of the wound across the iliotibial band and a flap of fascia is dissected up to the tensor fasciae latae, the iliotibial band being the tendon of this muscle. The fascia is freed at the lower end. The tensor fasciae is pulled out of the upper wound and through a hole drilled previously in the femur opposite the insertion of the gluteus maximus tendon, or an incision may be made through the deep fascia and the free fascial flap either put through the hole in the femur or underneath the transverse incision in the fascial flap. The free fascial flap is next passed up over the gluteus maximus muscle and sutured to the free end of the muscles dissected up from the spine, under moderate tension. The fascial flap should be

placed next to the bone, and there is an overlap of about two or three inches where the lumbosacral muscular fascia is united to the end of the fasciae latae.

This operation is indicated in gluteus maximus paralysis, flexion deformities of the hip, and dislocation of the head of the femur. If there is no flexion deformity of the hip it is not necessary to apply a plaster cast, and exercises may be started two weeks after the operation.

Transplantation of the Tensor Fascia into the Femur for Weakness of the Gluteus Medius. LEGG'S OPERATION.—This operation was devised for cases where the gluteus medius was paralyzed with impairment or loss of abduction of the leg. The incision is made starting at the anterior superior spine, extending backward and downward over the great trochanter, then downward along the course of the femur for about 3 inches. The skin with the subcutaneous fat is reflected forward, exposing the fascia lata. Anteriorly, running downward from the anterior superior spine, the fascia lata is seen to become thin before extending over Scarpa's triangle. Along this line the fascia is incised downward

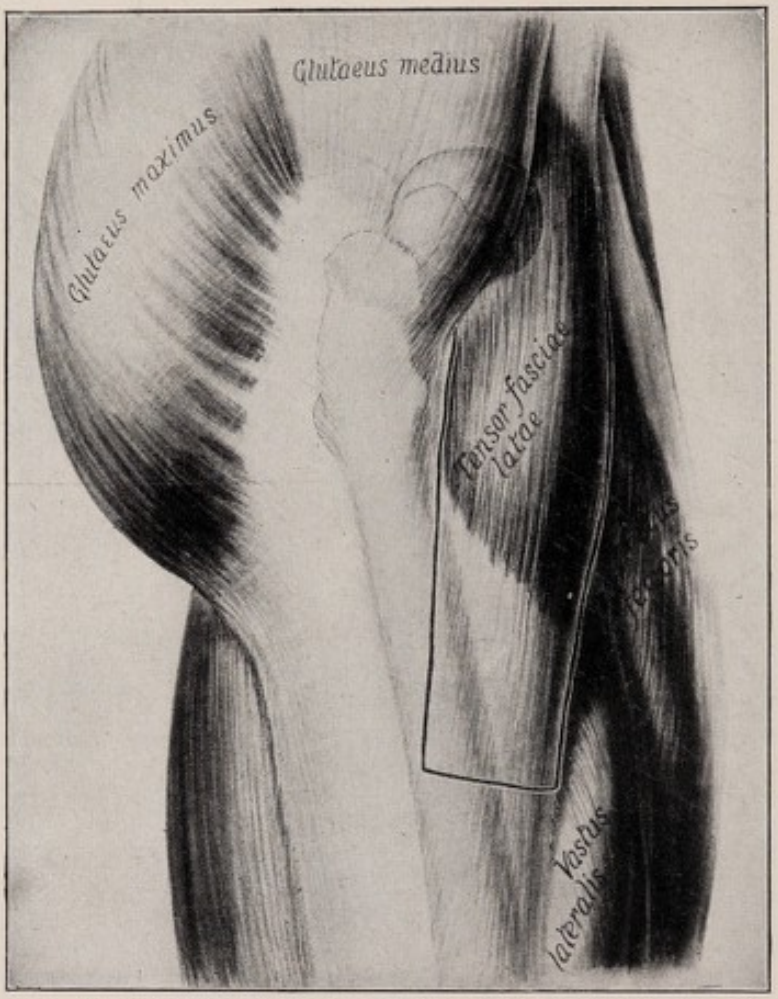

FIG. 506.—Legg's operation for transplantation of the tensor fasciæ latæ.

from the anterior superior spine to 3 inches below the great trochanter where it is divided transversely backward for about 1½ inches. At about 1½ inches below the great trochanter the fibres of the tensor fascia femoris may be seen becoming inserted into the fascia lata. The outer surface of the femur is next exposed, about 2½ inches below the trochanter, by dividing the fibres of the vastus externus. A periosteal flap is turned downward at this point and a groove, going into the marrow, is made about 1 inch long and ½ inch wide.

The free end of the fascia lata is now sutured with number eighteen twisted silk and inserted into the groove by carrying the silk ends through holes drilled through the femur to the groove. The knot is tied over the fascia in the groove and the periosteal flap is turned and sutured over the groove containing the fascia.

Before completing the suture of the silk the thigh is abducted about 20 degrees and the fascia is seen to have moderate tension. The skin with the subcutaneous fat is now turned

back and sutured by layers to its original situation, and a plaster spica is applied from the waist to the angle with the leg in 20 degrees abduction (Figs. 506–507). General superficial massage should be started two weeks after operation, and muscle training four weeks after.

Upper Limb

Deltoid Paralysis.—The trapezius has been transplanted into the humerus to secure abduction of the arm,[1] and the origin of the pectoralis major has been detached from the thorax, swung over the shoulder and sewed into the spine of the scapula for the same purpose, the arm being held in a platform splint for some weeks and exercised without weight-carrying. Sometimes there is definite improvement in abduction, but although highly successful cases have been reported and pictured, they are unusual.

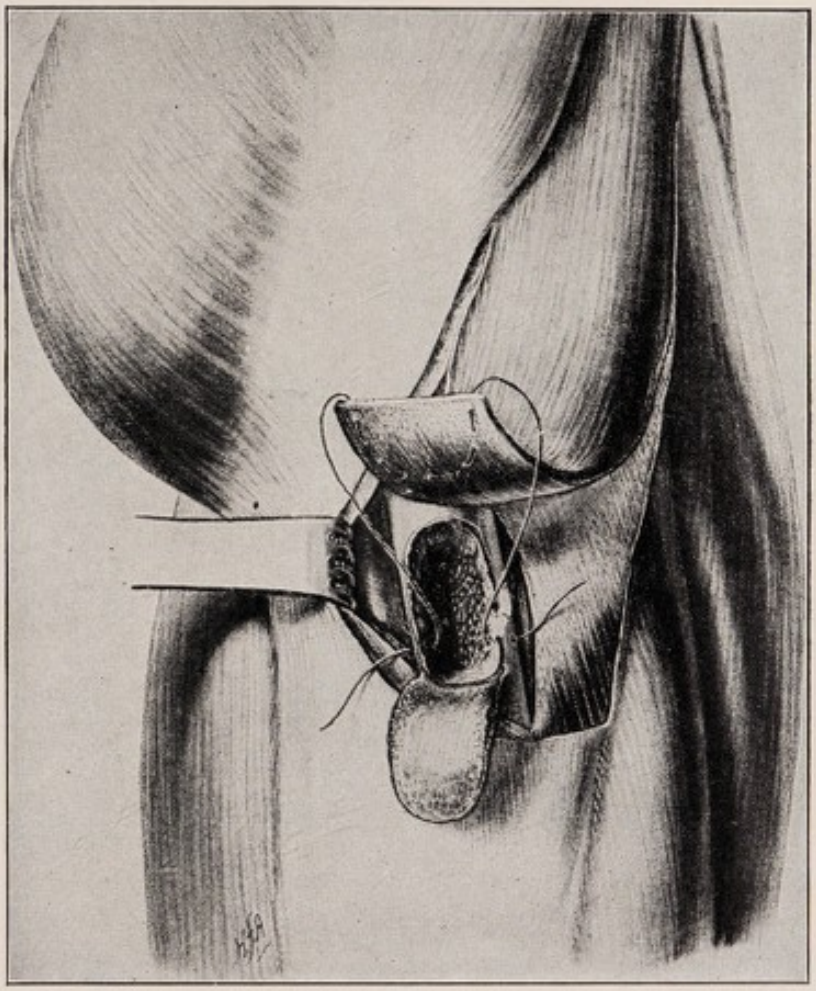

FIG. 507.—Legg's operation for transplantation of the tensor fasciæ latæ.

In *paralysis of the hand*, no definite rules can be laid down for the performance of operation, and each case must be worked out on anatomical lines to see if function can be improved. As a rule, in poliomyelitis, tendon transplantation is not satisfactory; but in injuries of the peripheral nerves, the operation is often indicated.

A tendon transplant for intrinsic hand muscle paralysis as described by Ney[2] gives very satisfactory results. An incision is made over the lateral

[1] LANGE: Orth. Chir., 391.
SPITZY: Zeitsch. fur Orth. Chir., xxx, Beilage Heft, 221.
LEWIS: Jour. Am. Med. Ass'n., Dec. 14, 1910.
Jour. Bone & Jour. Surgery, July 1927.

[2] NEY, K. W.: Surgery, Gynecology and Obstetrics, October, 1921, pages 342–348.

aspect of the radiocarpal articulation exposing the extensor brevis pollicis muscle and tendon. This incision may be carried down to the base of the first phalanx, or a second incision may be made over the base of the first phalanx exposing the insertion of the above tendon. An incision is now made over the palmaris longus exposing it down to its attachment into the palmar

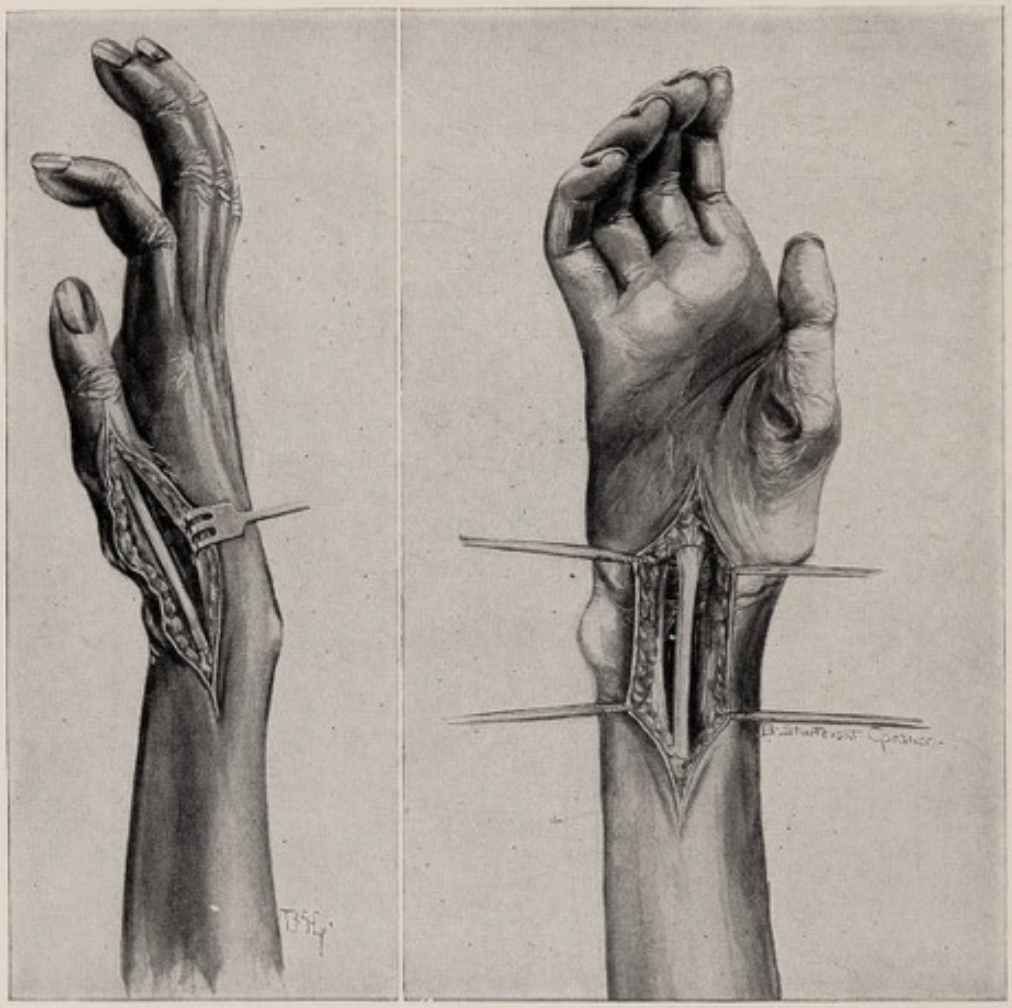

1 2

FIG. 508.

fascia. The palmaris longus tendon is severed low down. The extensor brevis pollicis is divided in the upper portion of the first wound and withdrawn through the second wound at the base of the first phalanx, and then by means of a tendon director it is passed across the thumb and out in the carpal region, and sutured under moderate tension to the palmaris longus.

After-treatment of Tendon Transplantation.—It is difficult to exaggerate the importance of the after-treatment of tendon transplantation, for if the best functional results are to be obtained, proper after-treatment is *absolutely necessary*. The failure to correct deformity at or before operation and to hold it corrected after operation are the two most fertile sources of disappointment after tendon transplantation. If deformity remains in any degree, or if weight

is thrown too early on the transferred muscle it is likely to destroy its power and make the operation a failure.

The foot should be retained after operation in an overcorrected position and the patient is better off in bed for at least two weeks; after that he may be carried or wheeled about. In the second week the plaster should be bivalved and the upper half removed, or the retaining splint loosened and the foot

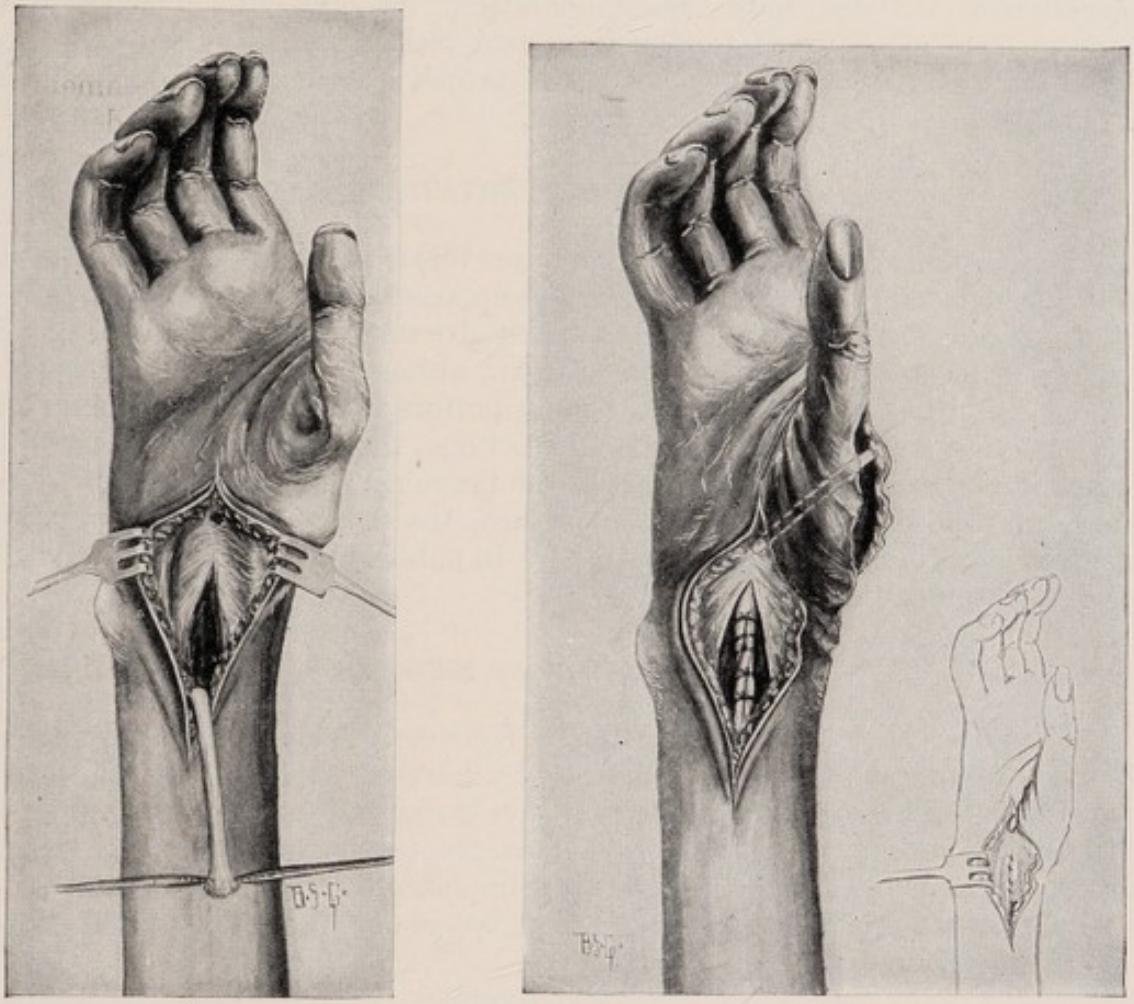

3 4

FIG. 509.

FIGS 508 and 509.—Tendon transplant for intrinsic hand paralysis. 1. First stage of operation—dorsal incision extending from metacarpophalangeal joint to 3 centimeters above attachment of the extensor ossis metocarpi follicis, exposing the short extensor of the thumb, also showing its relation to the extensor ossis metacarpi follicis. 2. Exposure of the palmaris longus tendon, as it passes above the annular ligament. 3. Palmaris longus tendon sectioned; the passage under the anterior annular ligament and the opening in the palmar fascia. 4. Shows the transplanted short extensor of the thumb passed subcutaneously over the thenar eminence, under the annular ligament, and anastomosed to the palmaris longus (K. Winfield Ney, Surgery, Gynecology, and Obstetrics, October, 1921).

gently massaged, an attempt being made by the patient to voluntarily contract the transferred muscles. In the fifth week apparatus should be removed temporarily and the whole foot massaged and the desired movements passively made with the patient aiding. In the seventh or eighth week an apparatus is applied to hold the foot in an overcorrected position, and activity on crutches

is allowed. Weight-bearing may be begun as soon as the muscle seems strong enough to warrant it, but aided by the corrective apparatus which must be worn for some months while muscle exercise is given every day. Apparatus is diminished and discontinued when the weight can be borne and held in the correct line, and is always removed gradually.

Failures in tendon transplantations occur from the following causes: (1) Improper selection of cases. (2) A badly planned operation. (3) Insufficient correction of the deformity before operation. (4) Insecure attachment of tendon. (5) Adhesions of tendon from bad technique. (6) Over-deflection of the transplanted tendon. (7) Lack of proper asepsis. (8) Too early use of the muscle. (9) Insufficient after-care.

NERVE TRANSPLANTATION

The anastomosis or transplantation of nerves, whereby an unaffected nerve is attached to one whose function has disappeared, is a proceeding which is physiologically sound and which can be demonstrated experimentally in animals as efficient, but in the case of man, although successes are reported, the operation has not as yet been widely performed. The sound peripheral nerve may be transplanted into the affected one, the insertion may be central or peripheral, and the whole or part of the nerve may be used. If successful, power may be expected to begin to return, the return of voluntary action generally preceding that of the electrical. In poliomyelitis the results reported have not been encouraging.

NEUROTIZATION OF MUSCLES

It has been shown experimentally by Heineke,[1] Erlacher,[2] and Steindler,[3] that if a muscle is artificially paralyzed by nerve section and the peripheral end of a healthy nerve is implanted into the paralyzed muscle, in a few weeks electrical nerve impulses may be sent down the transplanted nerve and cause a contraction of the muscle in which it is implanted. This method at present is wholly in the experimental stage and is not ready for clinical application.

ARTHRODESIS

An artificial ankylosis thus named, produced by the removal of the articular cartilage, has been in extensive use, particularly at the tarsal joints.

Arthrodesis of the Ankle.—With the better development of the operative side of this aspect of surgery, the operation of arthrodesis at the ankle is less often performed than was formerly the case because better functional results are to be obtained by other operations.

The ankle joint is opened, preferably by an anterior incision, the cartilage removed by a chisel or osteotome from the top of the astragalus and the lower surface of the tibia. The foot being placed carefully at a right angle to the leg with no eversion or inversion, a plaster is applied and the ankle joint is fixed for a period of some three months at least, in order to secure firm ankylosis.

[1] Heineke: Zent. fur. Orth. Chir., 1914, xli; Arch. fur klin. Chir., 1914, cv.
[2] Erlacher: Zeitsch. fur Orth. Chir., xxxiv; Am. Jour. Orth. Surg., July, 1915.
[3] Steindler: Am. Jour. Orth. Surg., July, 1915, and December, 1916.

Many operators also stiffen the mediotarsal joints by removing the cartilage from them also to prevent a drop of the forefoot which often happens, and if one performs arthrodesis of the ankle, it is desirable to stiffen both joints.

There are definite objections to the operation. (1) It causes a stiff ankle which is a handicap in walking and causes some limp, because it does not allow dorsal flexion of the foot; (2) if young children are operated on in a certain number of cases the late result will be a distorted foot, generally twisted into the position of varus, and (3) at times failure to obtain a firm ankylosis occurs. The greatest safeguard against these consists in waiting until the bones are sufficiently ossified to allow bony surfaces to be exposed and then after a sufficiently radical operation to place in accurate position raw bony surfaces.

In the writers' opinion arthrodesis of the ankle is an operation yielding at the best an imperfect functional result, and although perhaps at times desirable in adults, it is contraindicated in young children, and less desirable in older children than the measures to be described.

Arthrodesis of the knee should not be performed in children, because to shave off enough cartilage to secure ankylosis may change or injure the epiphyseal lines and very seriously interfere with the growth of the leg which takes place largely at the knee epiphyses. At best, even in adults it furnishes a stiff knee which cannot be bent, and a stiff knee is an awkward handicap, so that most people prefer to wear a brace. This operation at the knee, therefore, in the opinion of the writers should be discouraged.

Arthrodesis of the hip is not a very satisfactory operation, because often one fails to secure bony ankylosis, and still more important, if weight-bearing is desired the functional result is better with an ischial bearing brace. When the operation is performed nothing short of a complete denuding of the head of the femur and of the acetabulum is likely to succeed, and not then unless the bones are thoroughly ossified.

Arthrodesis of the Shoulder.—When the patient possesses enough power in the muscles controlling the scapula strongly to shrug his shoulder the case is a suitable one for arthrodesis, and this operation in properly selected cases holds out a prospect of fair ultimate function of the arm. The operation should not be done under the age of eight. It is not advisable in early childhood because there is so large an amount of cartilage in the articulation, and because so much of the growth of the arm occurs at the shoulder joint. Failure of union at this age is the rule, and fibrous ankylosis is not satisfactory. The operation should never be performed in adults without explaining the disadvantage. In youth the scapula can be made very mobile and can take upon itself the function of rotation, but later this is not so. In a case of one of the writers a technically successful operation on the shoulder of an adult was not satisfactory to the patient, because previously she could do her hair and fasten the back of her dress by placing the paralyzed arm in position with the other, whereas, after the arthrodesis the inability to mobilize the scapula in adult life prevented the extremes of motion required in these two movements. As a preliminary to arthrodesis intensive exercises for the elevators of the scapula are needed. Unless the patient can shrug the shoulder with considerable power arthrodesis is harmful. But in an arm paralyzed at both shoulder and elbow, arthrodesis of the shoulder would be useless from the point of view of function unless

the elbow could be fixed at a right angle. The same is true if the shoulder is active, but the patient unable to flex the elbow. If arthrodesis of the elbow should be performed the hand should be fixed midway between pronation and supination.

In performing an arthrodesis of the shoulder the deltoid can be turned up as a flap, or cut across its upper part. The glenoid, the base of the coracoid and the acromion are bared. The acromion is partially divided by a chisel and broken and placed in a groove prepared for it in the humerus. Good apposition should be secured and the head of the bone should be fixed to the acromion, glenoid and base of the coracoid by kangaroo tendon. Care should be taken to fix the shoulder in a good functional position.

An arthrodesis of the wrist with the hand in a cock up position where the finger flexors remain gives a very useful wrist. If there be no wrist flexors arthrodesis of the first metacarpal articulation may be done to keep the thumb in a partially opposed position so that the thumb and forefinger may be opposed.

Arthrodesis of the Smaller Joints of the Foot.—The deformity known as paralytic pes calcaneo-cavus is one of the most intractable to treat successfully. It may be associated with complete or only partial paralysis of the calf muscles, and be accompanied by paralysis of some or all the other muscle groups. The heel is depressed and often continues the line of the tibia, so that the posterior aspect of the os calcis may become the inferior. As the toe drops sometimes below the level of the heel, the inexperienced surgeon often commits the serious blunder of dividing the tendo Achillis and so cuts an important ally adrift.

Jones' Operation for Calcaneo-cavus (Figs. 510–513).—The operation described by one of the writers[1] for calcaneo-cavus with complete paralysis should not be performed in children below the age of eight. It is as follows:

(*a*) *Where the paralysis is complete and the foot quite flail* the operation is to be done in two stages—two weeks intervening. In the *first stage* the plantar fascia is divided if contracted, and stretched with hand or wrench. An incision is made down to bone about three inches long on the inner side of the foot, the center opposite the angle of convexity. With a periosteum elevator the soft structures are separated from the tarsus above, and below from the inner to the outer side. A transtarsal V-shaped section of bone is removed, and if there is valgoid deformity the section is wider on the inner side than the outer side. The wound is sutured, and the cavus deformity obliterated by extending the foot which is now bandaged to the tibia, the calcaneus deformity being apparently much increased.

The *second stage* consists of a longitudinal incision made at the back of the heel, the center being opposite the ankle joint. The ankle and astragalo-calcanean joints are exposed and arthrodesed, the foot being fixed in slight plantar flexion. If the calf muscles are acting, the astragalo-calcanean joint is alone arthrodesed and the posterior muscles, as in Dunn's operation, may be used to reinforce the calf muscles. If the calf muscles do not act but the peronei and sole muscles do, they may be inserted into a tunnel bored through the os calcis and the tendo Achillis may be divided and the lower end, longitudinally slit, may be passed through a tunnel bored into the tibia or fibula or both. In this way a very firm short ligament is secured which materially aids the transplantation.

Dunn's Operation for Calcaneo-cavus.—A distinct advance in the treatment both of calcaneo-cavus and other types of flail joints has been made by Naughton Dunn. In a case with complete paralysis of the calf muscles but where the other posterior muscles are acting, the steps of the operation are as follows: The plantar fascia is divided and the deformity corrected as far as possible. A four-inch incision is made over the outer part of the dorsum of the foot, between the extensor longus digitorum and peroneus tertius. A wedge is removed from this point, involving the scaphoid and calcaneo-cuboid joints, allow-

[1] Jones: Am. Jour. Orth. Surg., April, 1908.

ing correction of the cavus deformity. The patient is turned on his face and a wine-glass incision made over the ankle, the tendo Achillis retracted and the peroneals exposed and divided as far forward as possible. A bone wedge with the base backward should be removed and should allow easy correction of the calcaneus as well as any associated valgus or varus. The tendo Achillis is split into an anterior and posterior layer in its lower two inches and a groove in the os calcis made between the layers. The peroneal tendons, the long flexors of the great toe and other toes are placed in the groove in the os calcis and also stitched to the tendo Achillis.



FIG. 510.—Jones' operation for talipes calcaneo-cavus—stage 1.

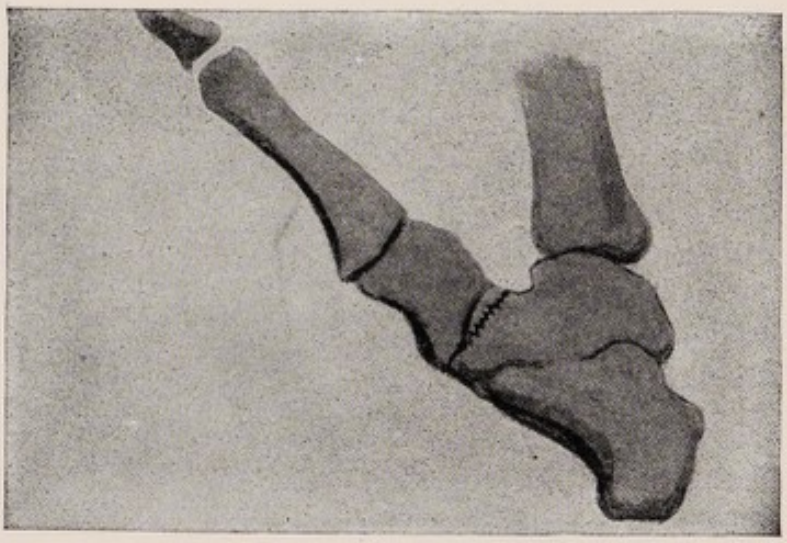

FIG. 511.—Jones' operation for talipes calcaneo-cavus—stage 1.

The foot is done up and put in plaster of Paris in full equinus with flattened sole for two or three months. If there is complete loss of power in the posterior muscles, arthrodesis of the ankle joint is done in addition.

One of the authors has examined over a hundred cases in which this operation has been performed and was much impressed by the excellent function obtained.

DUNN'S OPERATION TO SHORTEN THE FOOT.—An incision is made from over the external malleolus to the base of the fifth metatarsal. The extensor brevis digitorum muscle is exposed along its outer border and its origin divided. By its reflection with the anterior tibial to the inner side of the foot, the dorsal surfaces of the tarsal bones are exposed.

If equinus exists, as shown by the position of the astragalus, plastic tenotomy of the tendo Achillis should be done to allow normal movement at the ankle. A portion of bone,

including the articular surfaces of the os calcis and cuboid, is removed by an osteotome and the head of the astragalus divided behind its articular cartilage along with the proximal cartilage of the cuneiform bones, and the entire scaphoid taken out. A cup-shaped depression is cut on the dorsal surface of the cuneiform bones to receive the under surface of the head of the astragalus. The interosseous ligament between the astragalus and os calcis is divided and the bones pried apart by means of a gouge. The foot is displaced at the subastragaloid joint, allowing the head of the astragalus to rest on the cuneiforms while the raw surfaces of the cuboid and os calcis come in apposition. The extensor brevis muscle is replaced and the wound closed. Plaster of Paris is applied to the foot (Figs. 514–516).



FIG. 512.—Jones' operation for talipes calcaneo-cavus—stage 2.

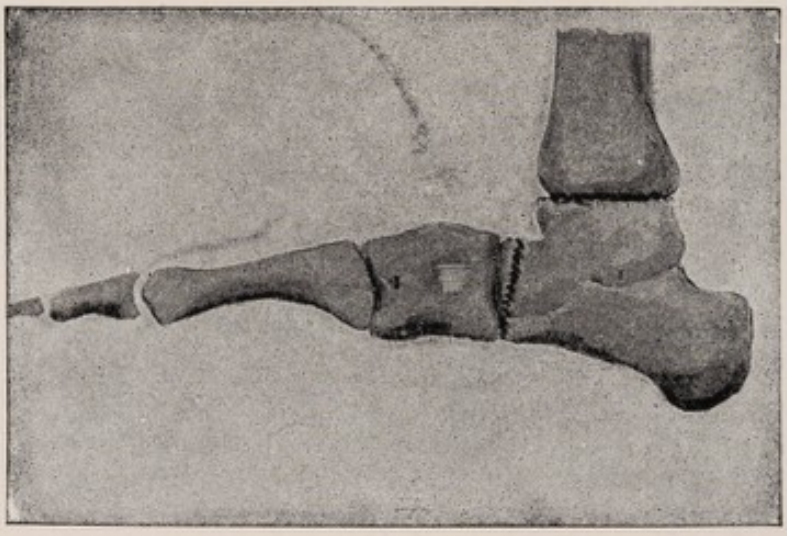

FIG. 513.—Jones' operation for talipes calcaneo-cavus—stage 2.

GWILYM DAVIS' OPERATION consists of an incision two inches long on the outer side of the tarsus from the tip of the malleolus forward. The peronei if required for transplantation into the os calcis are cut. With a periosteal elevator the periosteum is cleared in front and behind. A section is then made with a chisel in the line of the incision passing entirely through the tarsus from the junction of the os calcis and astragalus behind and emerging in front on the anterior surface of the cuneiform. In this way the tarsus is completely divided into an upper and lower part. The incision passes through the subastragaloid joint cutting off parts of the upper surface of the os calcis and lower portion of the astragalus. Another incision is now made on the inner side about an inch long over the sustentaculum tali. The tibialis posticus is held out of the way and the soft parts loosened before and

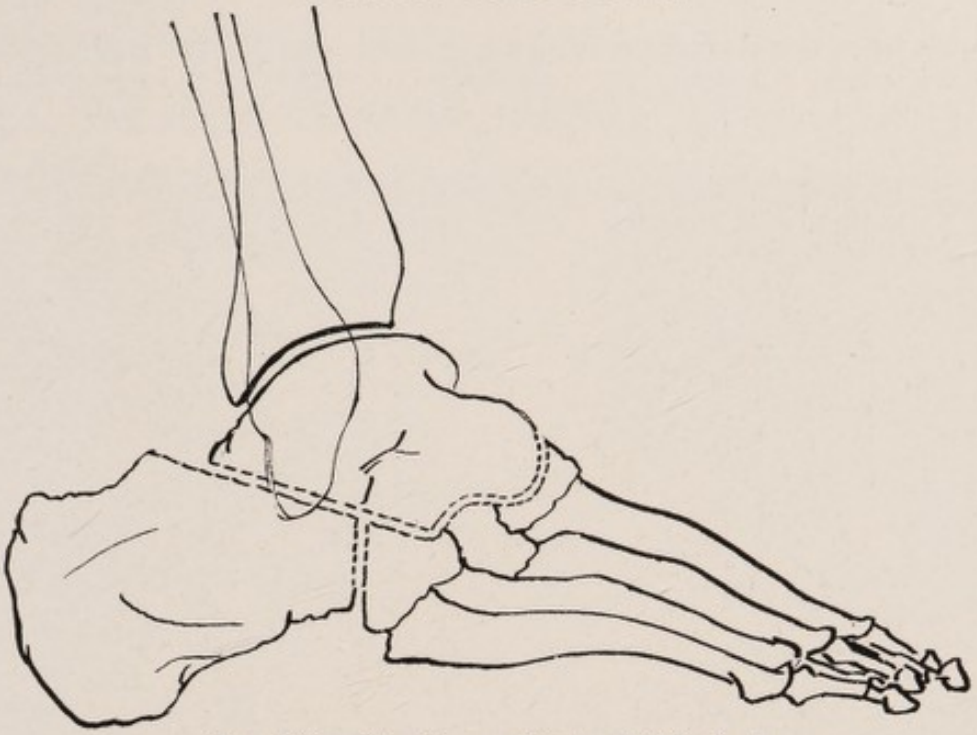

FIG. 514.—Dunn's operation to stabilize foot.

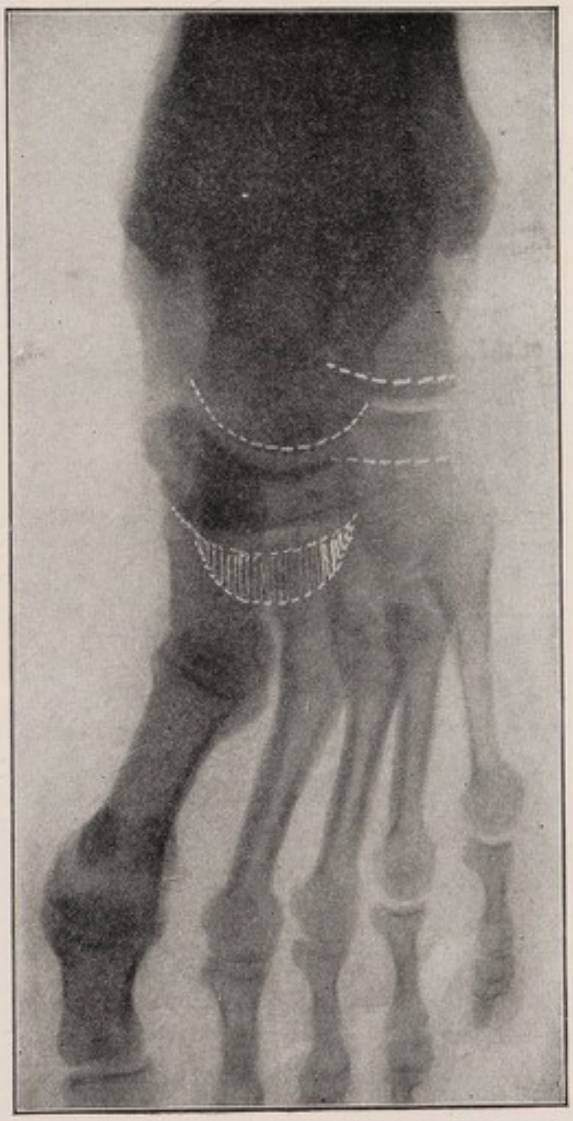

FIG. 515.—Dunn's operation to stabilize foot.

behind when the section through the bones can be completed. The foot is now pushed back and the leg forward. A posterior incision can be made if required and the posterior tendons implanted into the os calcis. The foot is put up in a position of slight equinus and varus.

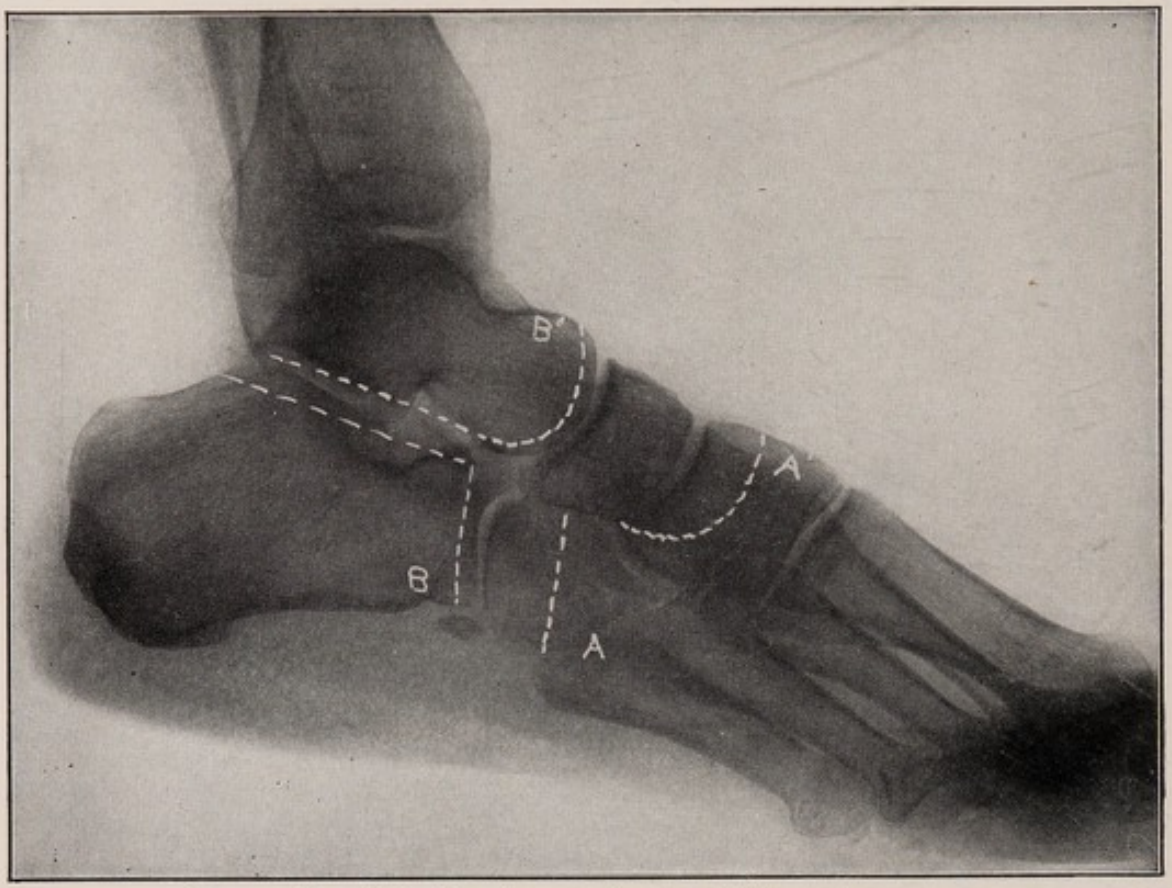

FIG. 516.—Dunn's operation to stabilize foot.

HOKE'S OPERATION.[1]—This operation is designed to stabilize the paralytic foot. An incision is made over the lateral aspect of the ankle joint bisecting the joint obliquely. This incision is carried through the fat and capsule exposing the astragalo-calcaneal, the astragaloscaphoid, and the calcaneocuboid articulations. The tissue in the calcaneo-astragalar fascia is dissected out. The cartilage is removed from the superior surface of the os calcis and from the inferior surface of the astragalus in a parallel manner, bearing in mind that some wedge shape may be necessary in case of valgus or varus. The neck of the astragalus is now divided and its head removed. The assistant removes the cartilage from the head of the astragalus. The cartilage is gouged away from the proximal surface of the scaphoid, and the cartilage is removed from the articular surfaces of the cuboid and calcaneus. The head and the neck of the astragalus are reshaped so as to take care of a valgus or varus position of the foot when it is replaced in its old position. Great care should be used in approximating all bare bony surfaces, and in putting the foot in a slightly over-corrected position. The wounds are all closed and a plaster cast is carefully applied holding the bones snugly. In from two to four weeks the position of the foot should be revised and altered if necessary. In many cases of paralytic valgus or varus there is a marked tibial torsion, and this should be corrected before the foot operation is done. It consists in shortening the neck of the astragalus, arthrodesing it with the scaphoid and ankylosing the astragalo-calcaneal joint.

Equino Valgus.—In old cases of equino valgus in adults the bony changes may be so pronounced that the foot cannot be manipulated or wrenched into position. A wedge exsection may be employed and the anterior portion of the foot arthrodesed in order to correct deformity and secure stability.

[1] HOKE, M.: Am. Jour. of Orth. Surg., October, 1921, Vol. III, No. 10, pp. 494–507.
Am. Jour. of Orth. Surg., October, 1921, Vol. III. No. pp. 494–512.

Campbell's[1] Operation for the Correction of "Drop-foot."—An arthrodesis is done at the calcaneocuboid, the astragaloscaphoid, and the calcaneo-astragalar articulations, thus forming a triple arthrodesis. The particles of bone removed are saved. The raw bony surfaces are approximated and the wounds all closed in the routine way. The cartilage and fibrous tissue are removed from the particles of bone.

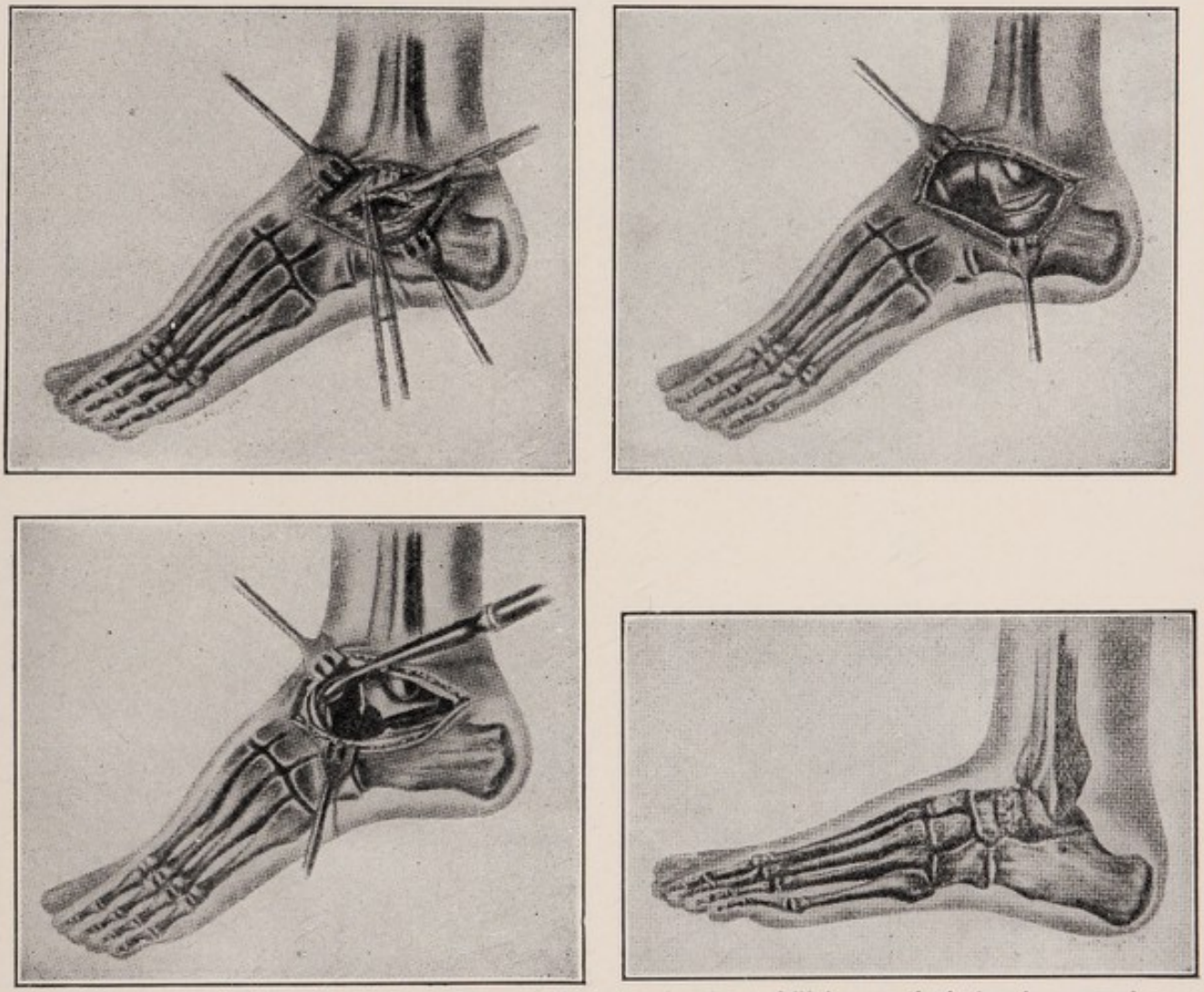

FIG. 517.—Hoke's operation. Steps in the operation for stabilizing paralytic feet in cases of drop-foot from infantile paralysis (Michael Hoke, Am. Jour. of Orthopedic Surgery, iii, 10, October, 1921).

A second incision is now made exposing the posterior aspect of the tibio-astragalar articulation and a groove is chiseled into the calcaneus across to the astragalus and tibia. The posterior surface of the tibia, the ankle joint, and the superior surface of the os calcis are cleared to the bone. The posterior extremity of the astragalus is removed, and a wedged shaped cavity is made in the os calcis below the posterior extremity of the astragalus, into which the scaphoid is inserted, and all the loose particles of spongy bone placed in a pyramidal mass, and sutured snugly. The foot is put up in plaster in the usual way. (Figs. 518 and 519.)

A similar operation has been envolved by Putti.

[1] CAMPBELL, W. C.: Jour. Bone & Joint Surg., October, 1923, Vol. V, No. 4, pp. 815–825.

Astragalectomy.[1]—The technique of the operation is not difficult. An external incision is made from above and behind the external malleolus sweeping down and extending forward nearly to the middle point of the foot. The peroneal tendons are identified and pulled out of the way or divided. The ex-

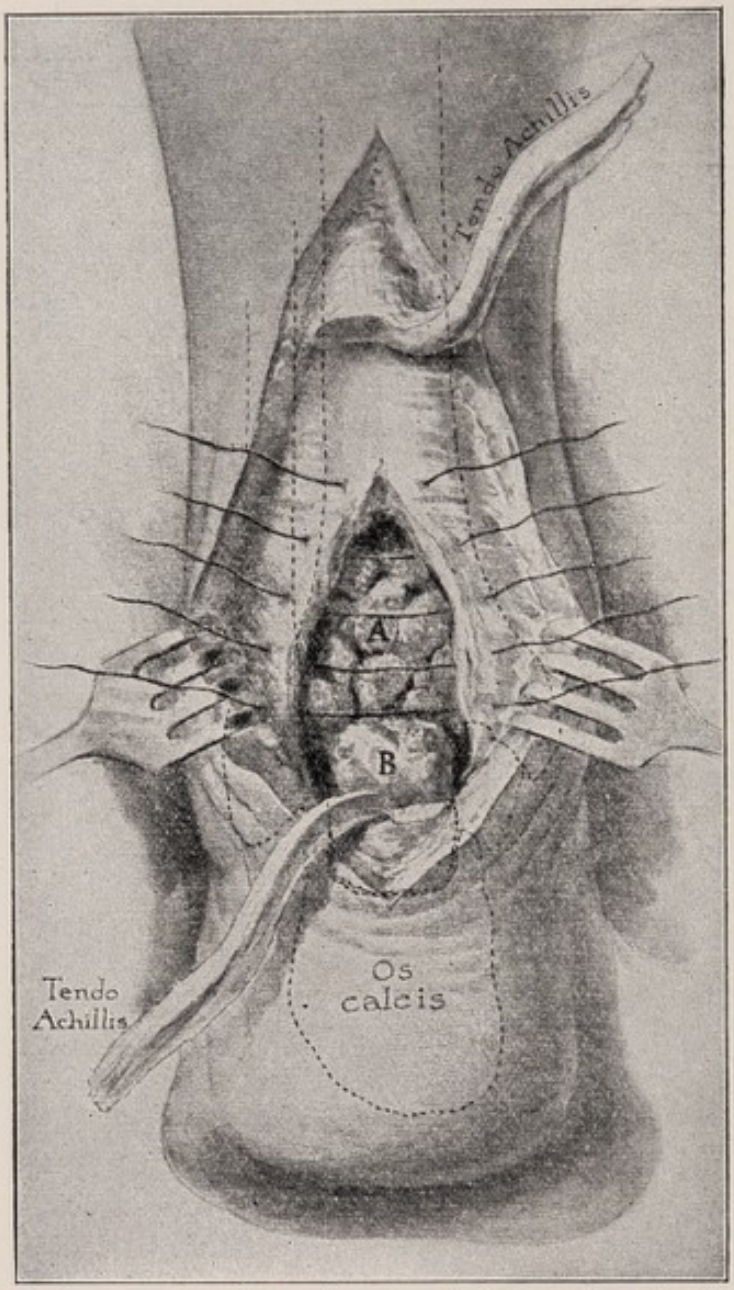

FIG. 518.—Campbell's operation, illustrating steps of the operation, showing *A*, small particles of bone making a pyramidal mass, and *B*, the scaphoid (Willis C. Campbell, Journal of Bone and Joint Surgery, V. 4, October, 1923).

ternal lateral ligament of the ankle is cut, the foot is faced in, and the ligaments of the astragalus freed. The astragalus is removed without difficulty, and it is then necessary with an osteotome to free the soft parts from the lower end of the tibia for one-half inch to an inch from the tip and also from the inner malleolus in order that the foot may be displaced backward without difficulty. As a rule it is necessary to gouge away a piece from the outside of the adjoining os calcis and cuboid bone in order that the external malleolus

[1] WHITMAN: Am. Jour. Med. Sci., November, 1901; Annals of Surgery, February, 1908; Am. Jour. Orth. Surg., August, 1910; Med. Record, January, 1914.

may be securely bedded. The foot should be put up in a position of slight equinus and slight valgus, as this gives the best ultimate position. The backward displacement of the foot on the tibia is most important. A plaster or other form of retention splint should be worn holding the foot in the desired position for eight or ten weeks, after which walking is to be permitted in a shoe with a high heel. The postoperative progress of the case will be better if unnecessary traumatism to the foot is avoided during operation.

If the operation is performed on young children there is a long period of growth ahead and distortion of the foot is likely to appear later. This distortion takes the form of an inward rotation of the foot most marked in the forward part. The operation was primarily intended to correct calcaneus

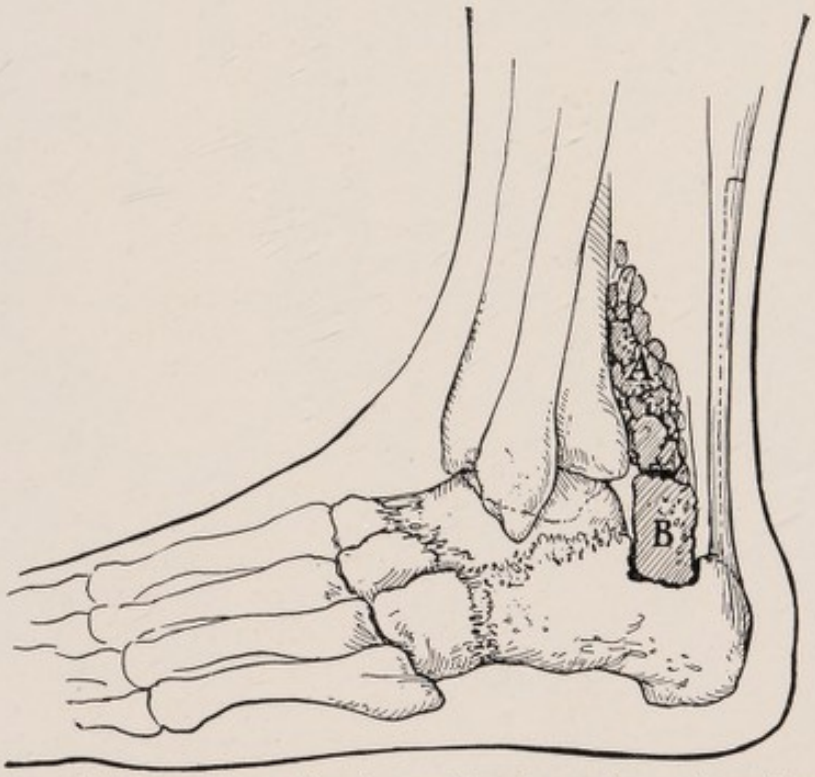

FIG. 519.—Campbell's operation. Showing results of operation. *A*, small particles of bone from the tarsal region; *B*, scaphoid bone grafted into the os calcis, making a stop-joint (Willis C. Campbell, Journal Am. Med. Assn., Dec. 19, 1925).

for which it is admirable, but in America it is often performed as a routine operation to correct all varieties of paralytic deformity at the ankle. The surgeon should reserve astragalectomy for calcaneo-cavus and for deformity in feet too paralyzed to allow of transplantation.

Operations for Lengthening the Short Leg.—One of the authors has succeeded in lengthening femora three inches. An external incision is made of sufficient length to obtain a good exposure of bone. The femur is then incised in the same direction through its middle, and through its entire substance. The bone is then divided above and below at the extremities of the longitudinal incision. Silver wire or kangaroo tendon is passed not too tightly around the femur and the limb is extended. The loop around the bone prevents a lateral displacement of the fragments and yet allows of continuous traction. (Fig. 520). The limb is treated as a simple fracture in a Thomas knee bed splint.

Putti has described an operation which could quite well be applied to the shortening of the limb in infantile paralysis, although he has confined the

operation to old malunited fractures. He has devised an ingenious apparatus which secures continuous traction by means of a spring. The apparatus consists of two parts:

(*a*) A couple of large metal pins to penetrate respectively the proximal and distal fragments of the fracture.

(*b*) A telescoping tube in which is contained a spring governed by a screw. He calls this instrument an osteotome and it is supplied with two metal sockets into which the two pins run. The pins are left in the bone for thirty days when they are removed and the limb is encased in plaster. He has operated upon ten cases and union, which is always delayed, was secured (Figs. 521–522).

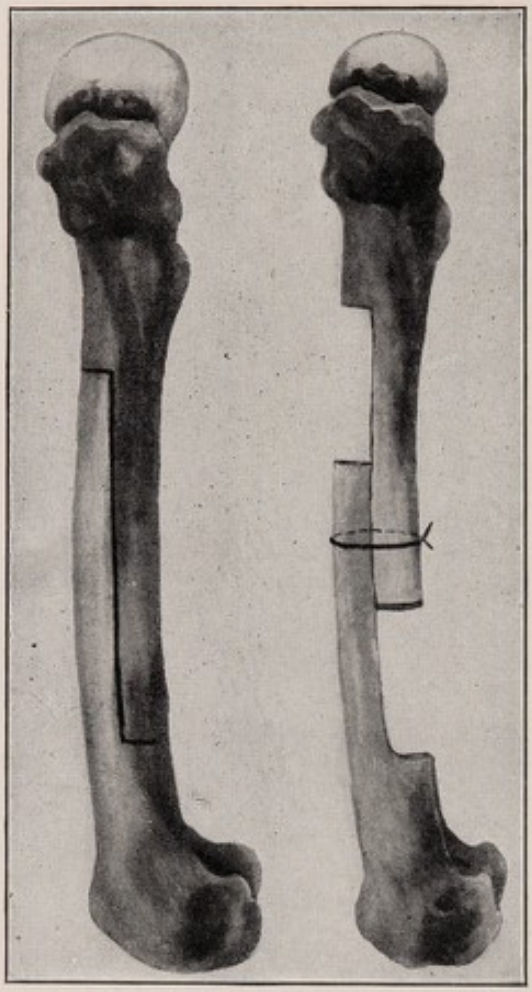

FIG. 520.—Jones' sliding bone graft for lengthening the femur.

Artificial Ligaments. *Silk Ligaments.* The creation of artificial ligaments[1] by inserting strands of silk between the articular ends of the bones to check undesirable motion (as between the anterior surface of the tibia and the tarsus in foot drop) has been tried on rather a large scale. The silk is coated by fibrous tissue just as are the silk extensions of tendons and a fair sized ligament forms, but the end results of these cases have not as a whole been sufficiently satisfactory to justify the long fixation required. Apparently the silk may break or pull out, or the ligament stretch, or the knot cut through the skin, and although in a fair proportion of cases investigated by one of the writers[2] the results were excellent, the proportion was not large enough to justify recommending the operation.

Tendon Fixation or Tenodesis.—The conversion of the tendons of the muscles passing over the ankle joint into ligaments has been described by various writers,[3] the latest extensive work being by Gallie.[4]

The method consists in exposing and isolating one or more of the paralyzed tendons whose support is desired. The tendon is drawn taut to correct the deformity—varus, valgus, equinus or whatever it may be, and is buried in a groove in the bone located in such way as to counteract the deformity. The tendon after being scarified is sewed in place by kangaroo tendon, or silk sutures passing through the tendon, the bone, and the periosteum or cartilage at the sides of the groove. The skin wound is closed and the foot held by plaster in the corrected position for six weeks, after which walking is allowed.

[1] LANGE: Münch. Med. Wchsft., 1907.
[2] LOVETT: Am. Jour. Orth. Surg., January, 1915.
[3] TILANUS: Ned. Tijdschrift Voor Geneskunde, 1898, ii, 23; Am. Jour. Orth. Surg., August, 1911, 65; Revista di Orthopedia, 1901, No. 1; Zeitsch. fur. Orth. Chir., 1903, 2; Lancet, May 30, 1914.
[4] GALLIE: Annals of Surgery, March, 1913; October, 1915; Am. Jour. Orth. Surg., January, 1916.

The operation is on the whole useful, but tendons serving as ligaments in this way often stretch, especially if too long a piece of tendon is used. The best results are obtained when anchorage is very near the articular end of the

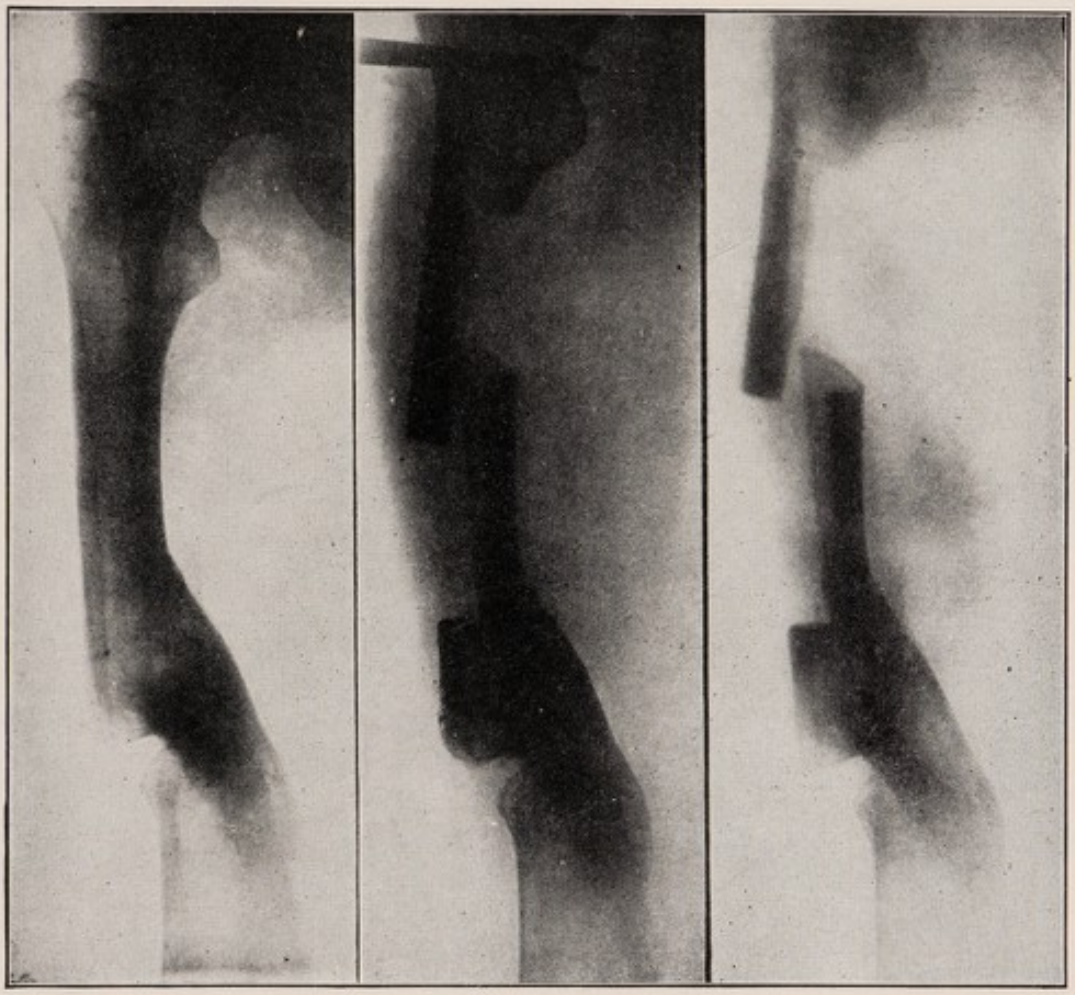

FIG. 521.—X-ray of bone graft to lengthen leg—war fracture—osteotomy outside of the callus lengthening obtained four inches. Perfect consolidation after six months (Putti).



FIG. 522.—Putti's apparatus for bone lengthening.

bone on both sides of the joint, so that a very short piece of tendon should be used. During the War many operations of tendon fixation were performed especially in irrecoverable injuries of the sciatic nerve where the peronei and tibialis anticus were utilized. Although the tendons were fixed into bone in such a way that they could not be torn out they invariably stretched to a

greater or less extent. Better results were obtained when one divided the peronei and tibialis anticus as high up as possible; bored holes through the tibia and fibula, passed the divided tibialis anticus through the tibia, the

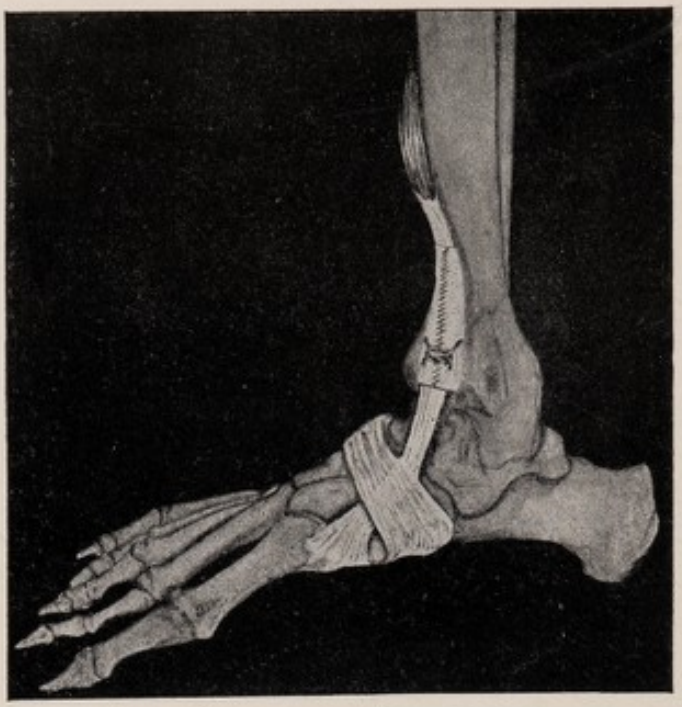

FIG. 523.—All the structures have been removed from the skeleton except the tibialis anticus muscle and tendon which has been buried in the tibia to prevent foot-drop (Gallie).



FIG. 524.—Tendon of peroneus longus has been fixed in anterior border of external malleolus and tendon of peroneus brevis is ready to be laid in trough prepared for it behind the malleolus (Gallie).

peronei through the fibula, and then fixed the end of the tendons into the astragalus. In this way one procured additional short ligaments attaching the

astragalus to both tibia and fibula. Similarly in forming a posterior ligament, the tendo Achillis was divided high up, split longitudinally and one half brought through the tibia and the other through the fibula and attached to the insertion of the tendon. This supplied a very firm unresisting ligament preventing dorsiflexion. It must be remembered that tenodesis should never be



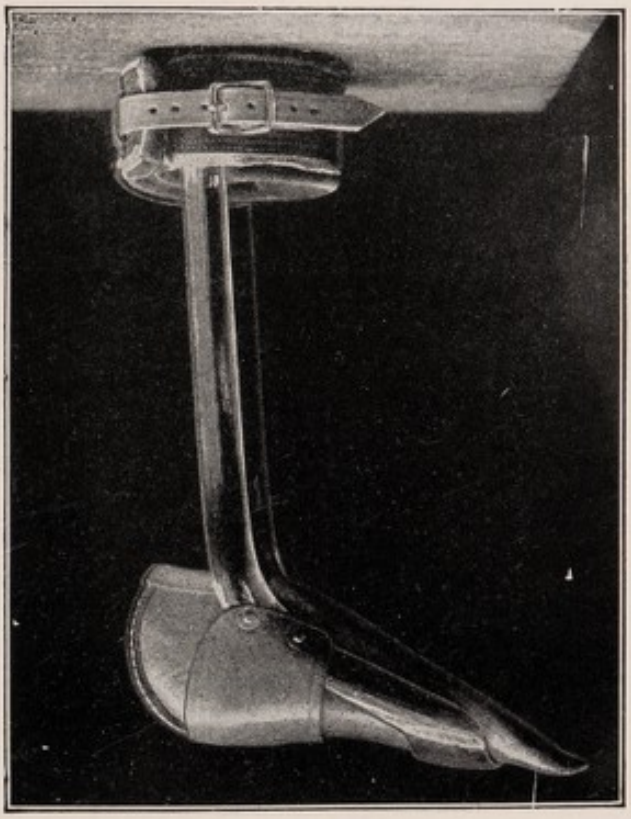

Fig. 525. Fig. 526.

Fig. 525.—The tendo Achillis is fixed in the posterior surface of the tibia to prevent calcaneus and the peroneal tendons have been transplanted into the os calcis (Gallie).

Fig. 526.—Whitman's brace for calcaneus and lateral distortions of the foot. It consists of two light lateral steel bars joined in front above by a padded band of steel which crosses the upper third of the tibia, and below expanded to a narrow anterior sole plate, supplemented by a leather support for the sole. The brace is made on a plaster cast in the attitude of slight plantar flexion. The shoe is adjusted to the inclination of the brace by a cork wedge in the heel (Whitman).

performed on tendons whose muscle retains any power, as the operation permanently puts active function of that muscle out of the question (Figs. 523–525).

Free Fascia Transplants.—Ligaments may also be constructed out of tough fascia removed most often from the fascia lata and rolled up into cords, which are inserted into holes in the bone near the articular ends where ligamentous attachment is desired. The space in the fascia lata should always be sewed up to prevent muscle hernia. The operation is too recent for one to speak of final results, but it is simple, non-mutilating and promising.

CHAPTER XXII

MUSCLE TRAINING

Muscle training is fundamentally an attempt to restore a cerebral motor impulse to a muscle, an impulse which has been either impaired or lost during the acute stage of poliomyelitis. The method of muscle training aims at two things: first, at establishing a better co-ordination between the remaining nerve fibres supplying the affected muscle; and second, at securing contraction of the desired muscle, however feeble, which is of course the best possible treatment of the muscle itself. These two objects rest upon a sound anatomical and physiological basis. In muscles which have lost every motor nerve cell there can be no



FIG. 527.—Photograph of a patient with double infantile paralysis of the legs. Patient had walked for many years on the hands, and the muscular development shows the effect of the reversed position and the unusual development of the muscles which is the reverse of that occurring in ordinary use. Note for example the small biceps and the very highly developed triceps.

hope of recovery of power through exercise or by any other means; but in the partially paralyzed muscle there is probably much apparent weakening due to failure of the remaining nerve fibres and their respective muscle fibres to co-operate in producing movement in the absence of the destroyed nerve cells which formerly acted with them. At all events it has been proved by experience that the partially paralyzed muscle gains a larger percentage of power through exercise than the normal muscle does. So far as the second aim, muscular development *per se*, is concerned, it is a matter of common knowledge that muscular exercise in proper amounts strengthens muscles. The athletic trainer does not turn primarily to massage or electricity to strengthen weak muscles, but to muscular exercise, which consists of active contractions. The muscles partially paralyzed in poliomyelitis are simply weakened muscles requiring an extremely small dose of exercise.

If a muscle is apparently without any power, the patient should concentrate his attention on the attempt to accomplish the movement while it is performed passively. It often happens that weak muscles may be able to carry the limb through only a part of its normal arc of motion. In such a case the limb should be carried by the surgeon passively through the remaining arc of motion normal to the joint, and there should be no pause after the muscle has ceased acting, but the assistance should come in time to make one smooth move-

ment throughout the whole arc, in order that there may be no interruption in the patient's mental effort. Not until muscles are capable of performing a movement through the whole arc should any additional resistance be given, and not until they are capable of performing the movement next in order of strength throughout the whole arc, should that movement be given in place of the easier one.

When resistance is applied, it should be graduated from weak at the beginning of the movement to strong in the middle, and to weak again at the end of the movement, in accordance with the change in leverage that takes place during the movement. The resistance at every point should be just a little less than would stop the movement.

It is usually enough to let the patient go through all his exercises once a day, six days in the week, as the one day of rest prevents him from becoming stale. Each exercise may be performed ten or twelve times in succession in slow enough rhythm to allow for complete recovery between efforts. Unless it is done as well the second time as the first, and the tenth as well as the second, it is being done too fast or being continued too long and the patient should be given a rest at once. A few seconds are usually enough for recovery between successive attempts.

If possible the patient should never be left to do his exercises alone, even when he is old enough to understand his own case. The response of muscle and nerve is dependent on the strength of the stimulus and the volition of the patient is greatly aided by the outside stimulus of a word of command.

If the patient is a child the schemes for exciting interest and concentrating the attention on the effort to be made have to be varied day by day, but there should not be any sacrifice of precision in the performance of the exercises. If the child is too young to make any intelligent effort at formal exercises, the ingenuity of the mother will usually discover a means of bringing the affected muscles into play if she is made to understand what is required.

Accuracy and precision are of the utmost importance in obtaining a proper result. Carelessly performed exercises are of little value, and loosely prescribed exercises harmful because if some of the muscles are weaker than others, unless the exercises are carefully limited, the tendency of the patient is to use the stronger rather than the weaker muscles and thus to increase the disparity between the two. To encourage general all around activity in these cases, without control, is most undesirable. In all exercise periods the whole attention of the patient should be required.

The practical application of muscle training is discussed in the following paragraphs in which typical exercises are described and this also covers the question of muscle examination, the exercises given being practically equivalent to the examination of the same muscles. For the detection of slight degrees of power the exercise last named should be used and for fairly strong muscles a stronger exercise which is given earlier. *The exercises are named in the order of their difficulty, the strongest being given first.*

The Foot

Toes. *Flexion.*—The patient lies on the back or sits and bends the toes toward the sole of the foot, to "make a fist" with the foot (*a*) with resistance and foot steadied; (*b*) without resistance from the surgeon, who places one finger across underneath the toes and pushes up against them.

Extension.—The patient sits or lies on the back and bends the toes toward the dorsum of the foot (*a*) with resistance and foot steadied; (*b*) without resistance. The surgeon may resist the movement with one finger placed on the dorsal surface of the toes.

Ankle. *Dorsal Flexion.*—The patient stands on the foot to be tested and raises the front of the foot from the ground until he is balanced on the heel (Fig. 528).

The patient sits with the feet hanging free and tries to raise the foot against resistance on the dorsum, the leg being steadied (*a*) with resistance; (*b*) without resistance (Fig. 529).

The patient lies on the affected side with the affected leg held firmly down on the table and with the foot in plantar flexion and attempts to bring it into dorsal flexion.

The patient lies on the face with the knee flexed at a right angle and the lower leg directed vertically upward and dorsally flexes (*a*) with surgeon's finger on the dorsum of the foot, resisting the movement; (*b*) with gravity assisting the movement.

Plantar Flexion.—The patient stands on the affected side with the sound knee bent and, steadied by holding the surgeon's hands with his own, and rises on the ball of the affected foot.

The patient walks on tip toe.

The patient lies on the face with the knee flexed to a right angle and the lower leg directed vertically upward and plantar flexes the foot (*a*) without assistance on the dorsum of the foot; (*b*) with assistance.

The patient lies on the face with the feet projecting over the end of the table and attempts plantar flexion against the resistance of the surgeon's hand (Fig. 530).

The patient lies on the affected side with the leg held and attempts plantar flexion at the ankle (*a*) with resistance; (*b*) without resistance on the sole of the foot.

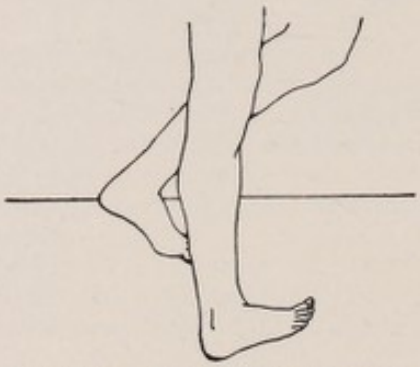

FIG. 528.—Examination and exercise for dorsal flexion.

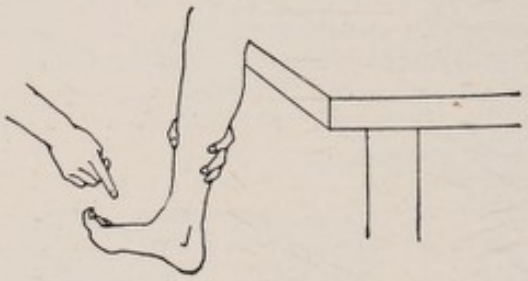

FIG. 529.—Examination for dorsal flexion.

Inversion of the Foot.—The patient lies on the affected side and while the leg is held firmly down on the table lifts the outer border of the foot away from the table (*a*) with resistance on the inner border of the foot; (*b*) with help at the end of the movement (Fig. 531).

The patient sits on the edge of the table with the legs hanging down and the leg steadied by the surgeon. He then attempts to turn the front of the foot inward and upward (for

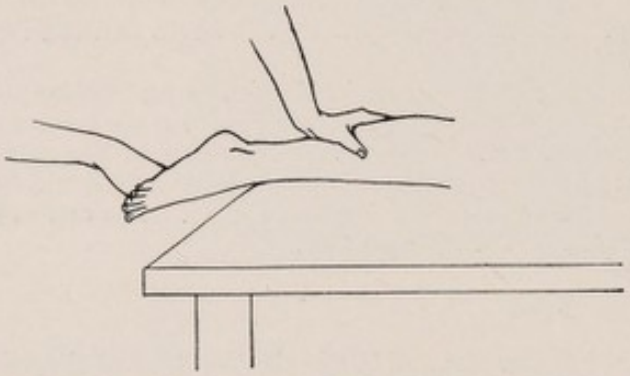

FIG. 530.—Examination and exercise for plantar flexion.

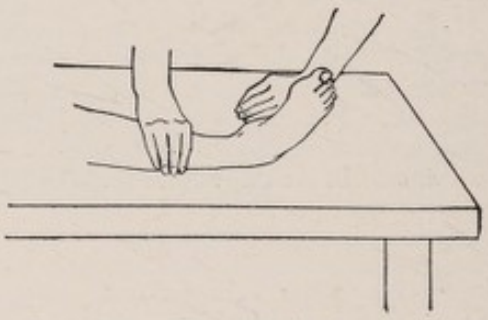

FIG. 531.—Exercise for inversion of the foot.

the tibialis anticus) toward the ankle (*a*) with resistance against the inner border of the foot; (*b*) with the resistance of gravity alone. For the tibialis posticus the motion should be inward and downward.

The patient lies on his back, the surgeon holding the affected leg above the ankle to steady it, and turns the foot inward toward the other ankle (*a*) without help; (*b*) with help.

Eversion of the Foot.—The patient sits with the foot hanging free, and the lower leg steadied by the hand and everts the foot (*a*) against manual resistance; (*d*) with the resistance of gravity alone (Fig. 532).

The patient lies on his back with the affected leg held and turns the sole of the affected foot outward away from the other foot.

The Knee

Flexion.—The patient lies face downward and flexes the knee from the straight position until the heel touches the buttock (*a*) with resistance at the back of the ankle; (*b*) with the resistance of gravity (Fig. 533).

The patient lies on the affected side with the hip flexed and the knee extended while the thigh is held firmly, and attempts to flex the knee (*a*) with resistance on the back of the ankle; (*b*) unaided muscular contraction; (*c*) with assistance on the front of the ankle (Fig. 534).

The patient lies on the back while the surgeon holds up the affected leg, steadying the thigh in the vertical position and offering resistance on the back of the leg as the patient flexes the knee.

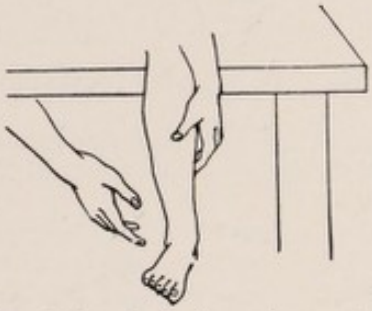

FIG. 532.—Exercise and examination for eversion of the foot.

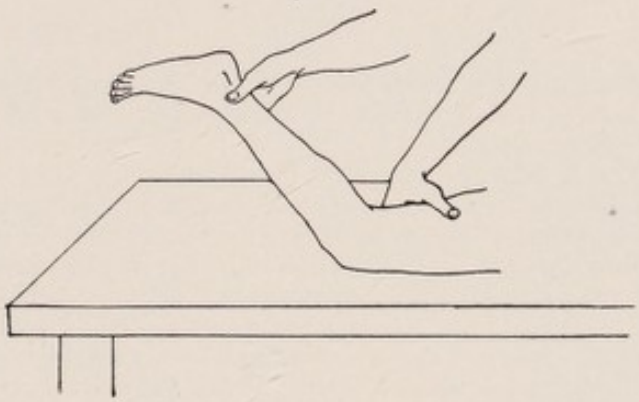

FIG. 533.—Exercise for knee flexors.

Extension.—The patient sits on a table with the knee flexed and the legs hanging over the table and attempts to extend the knee (*a*) against resistance on the front of the ankle; (*b*)with the resistance of gravity alone; (*c*) with assistance.

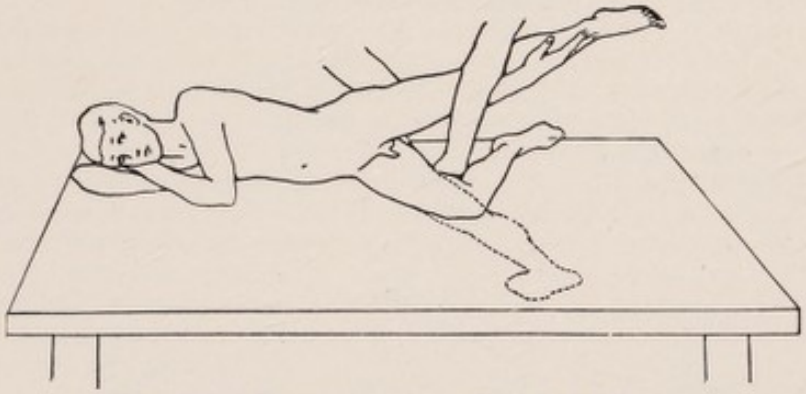

FIG. 534.—Exercise for knee flexors of right leg.

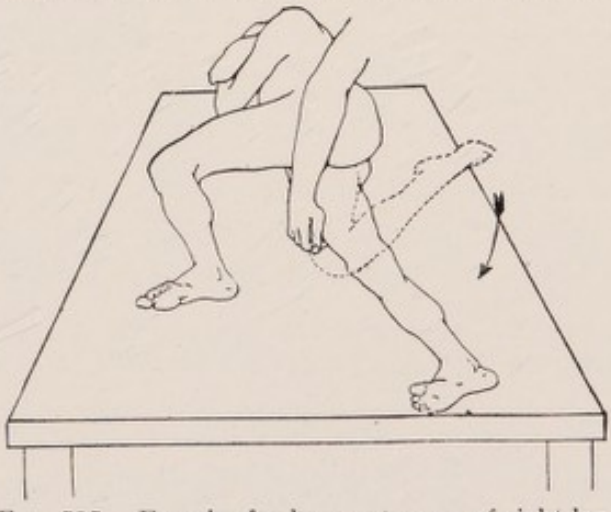

FIG. 535.—Exercise for knee extensors of right leg.

The patient lies on the affected side with the hip fully extended, the knee flexed and thigh firmly held and attempts to straighten the knee (*a*) with resistance on the front of the ankle; (*b*) unaided; (*c*) with assistance (Fig. 535).

The patient lies on the face with the knee flexed to a right angle and extends the knee against resistance.

The patient lies face down on a table with the hips flexed and legs hanging over the edge of the table. The surgeon steadies the affected thigh with his hand and with his other hand flexes the knee and holds it in front of the ankle while the patient attempts to extend the knee with the help of gravity.

The Hip

Flexion.—The patient sits with the lower legs hanging over the edge of a table and raises the knee to the chest (*a*) with resistance (at the front of the thigh just above the knee); (*b*) without resistance.

The patient lies on his back and brings his knee up to his chest (*a*) with resistance; (*b*) without other resistance than the weight of the leg.

The patient lies on the affected side, the surgeon supporting the other leg, and attempts to draw the knee up to the chest (*a*) with resistance against the front of the thigh; (*b*) without resistance; (*c*) with assistance.

The patient lies face down on a table with the legs hanging over the edge, being flexed at the hip joints. The affected leg is then raised to the horizontal by the surgeon and from this position the patient flexes the hip with the surgeon supporting as much of the weight of the leg as may be required.

Extension.—The patient lies on the face and hyperextends the hip with the knee straight, raising the leg from the table (*a*) with resistance; (*b*) without resistance—without twisting the body.

The patient lies face downward on a table with the hips flexed over the edge and the legs hanging down. In this position he raises the leg to horizontal or above (*a*) with resistance on the back of the thigh; (*b*) with the resistance of gravity alone.

The patient lies on the affected side with the hip fully flexed and moves the thigh back into the line of the body (*a*) with resistance; (*b*) unaided; (*c*) with assistance.

The patient lies on the back, and the affected leg, with the knee straight, is lifted as high as possible by the surgeon; the patient then brings the leg back to the table with the surgeon offering as much resistance as can be overcome.

Abduction.—The patient lies on the sound side and raises the affected leg with the knee straight and in line with the body (*a*) with resistance; (*b*) without resistance.

The patient lies on the back with the pelvis held and abducts the affected leg without outward rotation. In case of very weak muscles, friction of the heel on the table should be eliminated by slinging the leg by a bandage, the upper end of which is held by the surgeon.

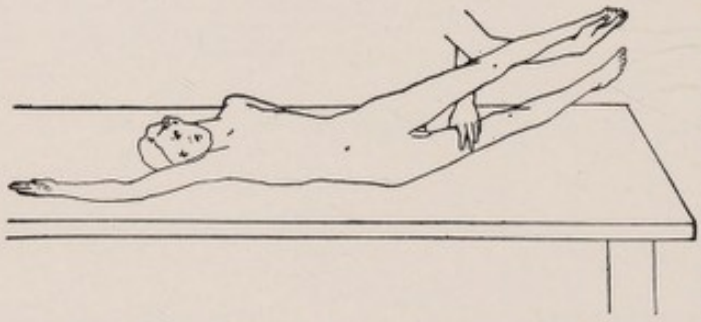

FIG. 536.—Exercise for adductors of right hip.

Adduction.—The patient lies on the affected side with the sound leg held up by the surgeon in a position of abduction and raises the affected leg with the knee straight and without rotation (*a*) with resistance; (*b*) without resistance.

The patient lies on the back with knees and hips flexed, the feet together, and the soles resting on the table and, with the knees apart, attempts to bring the knees together (*a*) with resistance; (*b*) without resistance.

The patient lies on the back with the pelvis held and the affected leg in a position of abduction and adducts the leg (*a*) with resistance; (*b*) without resistance; (*c*) suspended in a sling.

The Wrist

Flexion.—The forearm should be laid on the table with the palm up, the hand extending over the edge and the wrist flexed against the surgeon's resistance.

The forearm and hand are supported on the under side with the wrist hyperextended and an attempt is made to flex the wrist (*a*) with resistance; (*b*) without resistance.

Extension.—Exercises for the extension of the wrist are the reverse of those described for flexion.

Forearm and Hand

Pronation.—The patient sits with the forearm resting on the table with the palm upward and pronates the forearm (*a*) with the surgeon grasping the hand and resisting pronation; (*b*) without resistance (Fig. 537).

Supination.—The exercises for supination of the forearm and hand are the reverse of those described for pronation.



FIG. 537.—Test or exercise for supinators and pronators.

Elbow

Flexion.—The patient sits with the arm extended and, with the upper arm held, bends the elbow until the hand touches the shoulder (*a*) with resistance; (*b*) without resistance. The movement should be first done with the hand in complete pronation and then in complete supination; to exercise the biceps, the latter position must be used. The exercise is performed (*a*) with resistance; (*b*) without resistance.

The patient lies on the affected side with the arm straight and flexes the elbow until the hand touches the shoulder (*a*) with resistance; (*b*) unaided; (*c*) with assistance. The patient lies on his back on a table, the upper arm supported vertically and the elbow extended and flexes the elbow while the surgeon resists the movement.

Extension.—The patient lies on his back with the upper arm vertical and the elbow flexed and attempts to extend the elbow (*a*) with resistance; (*b*) without resistance.

The patient sits with the arm at the side, the elbow fully flexed, the forearm being held by the surgeon, and attempts to extend the elbow, the surgeon making such resistance at the wrist as may be necessary to neutralize the weight of the forearm, but offers weak resistance if it can be overcome.

Shoulder

In analyzing the extremely complicated movements of the shoulder Beevor's[1] very complete study of this region will be followed and his terminology of movements will be adopted with the explanation in brackets. This has proved the most satisfactory scheme of analysis.

Abduction of the Humerus to and above the Horizontal Line. (Raising the Arm From the Side).—If the deltoid is paralyzed, the trapezius and serratus begin to act at once when the patient attempts to raise the arm sidewise, and the arm will not be carried to more than 45 degrees from the side by the scapular movement. The action of these muscles will be eliminated if the surgeon fixes the shoulder gradually by pressing downward on the shoulder which, in the normal, limits the movement to abduction to the horizontal. In no exercise is a knowledge of anatomy more necessary or precision in the exercise given more essential.

The patient sits erect with the arm at the side and raises the arm, with the palm directed downward, as high as possible. If this precaution is not observed, the biceps acts as an abductor of the arm. The shoulder girdle is fixed and the movement is performed, (*a*) with resistance; (*b*) without resistance.

The patient lies on the back or the face on the table, the palm of the hand faces the body throughout the movement, and the patient abducts the arm (*a*) with resistance; (*b*) without resistance; (*c*) with the assistance of a sling.

Adduction of the Humerus (Bringing the Arm to the Side).—The patient sits or stands with the arm abducted and pulls it down to the side against resistance under the elbow.

The patient lies on the face or back and draws the arm to the side. For exercise of the pectoralis major, the position on the back is to be preferred, and that on the face for the latissimus dorsi. The exercises may be given (*a*) with resistance; (*b*) without resistance; (*c*) with the aid of a sling.

[1] BEEVOR, C. E.: "The Croonian Lectures on Muscular Movements and Their Representation in the Central Nervous System," London, Adlard and Son, 1904.

Advancing or Flexion of the Humerus to the Horizontal Line or Above (Raising the Arm Forward).—The patient lies on the face with the arms extended forward above the head and raises the arms from the table without raising the body. It should be possible with normal muscles to raise the arm a certain distance from the table.

The patient stands or sits and raises the arm forward and upward (*a*) with resistance; (*b*) without resistance on the front of the elbow. If the shoulder is held down during this motion, the serratus magnus and trapezius are thrown out of action and only those muscles are exercised which advance the shoulder to the horizontal (Fig. 538).

Extension of the Humerus (Bringing the Arm Downward and Forward).—The patient lies on the face with the arm at the side and raises it backward with resistance (Fig. 539).

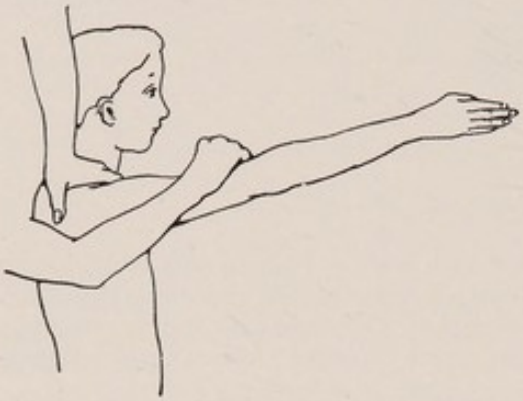

FIG. 538.—Advancing or flexing of the humerus.

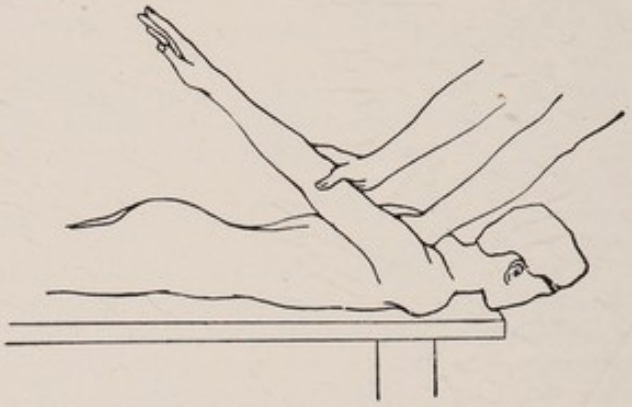

FIG. 539.—Hyperextension of humerus.

The patient stands or sits with the arm hanging at the side and raises it backward as far as possible.

The patient stands or sits with the arm vertical above the head and brings it downward and forward in line with the body.

Horizontal Abduction (Carrying the Arm Back at Shoulder Level).—The patient lies on the face with the arm stretched sidewise at right angles from the body and raises the arm straight up from the table (*a*) with resistance; (*b*) without resistance (Fig. 540).

The patient sits facing the table, with the arm resting on it, in a position of extreme adduction, that is, crossing over to the other side, and tries to abduct the arm (*a*) with resistance; (*b*) unaided; (*c*) supported in a sling.

Horizontal Adduction (Bringing the Arm Toward the Middle Line of the Body at Shoulder Level).—The patient lies on the back with the arm stretched out at right angles to the body at shoulder height, with the elbow straight and the palm upward, and raises the arm toward the mid-line of the body until it is vertical (*a*) with resistance; (*b*) without resistance.

The patient sits with the affected side next to the table upon which the arm is supported at shoulder height, as far back as possible, and slides the arm forward along the table toward the mid-line (*a*) with resistance; (*b*) unaided; (*c*) with a sling.

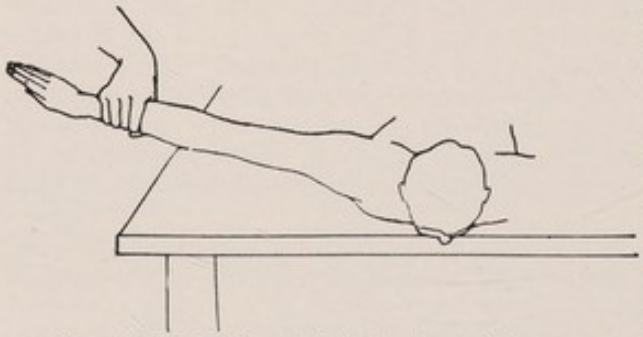

FIG. 540.—Horizontal abduction of humerus.

Internal Rotation of the Humerus (Twisting the Arm In) **and Outward Rotation of the Humerus** (Twisting the Arm Out).—The patient lies on the face with the arm stretched out at shoulder height, the elbow bent over the edge of the table and the forearm and hand hanging vertically. The surgeon steadies the upper arm and offers resistance against either the ulnar or radial side of the wrist while the patient attempts inward or outward rotation as may be required.

The patient lies on the back with the arm close to the side and the forearm resting across the body. By turning the arm outward and pivoting it on the elbow which is kept at a right angle, outward rotators are exercised and by starting with the arm outward, rotating and bending the hand toward the median line, inward rotators are exercised.

Elevation of the shoulder is produced by the levator anguli scapulæ, rhomboids and clavicular and acromial parts of the trapezius which occasionally need to be exercised. If this is required the patient sits and shrugs the shoulder while the surgeon offers resistance by pressing downward on it.

Certain other exercises should be mentioned as being at times particularly needed.

Flexion of the Head.—If the sternomastoid muscles are weakened or paralyzed, apparently the other flexor muscles of the neck are not strong enough to raise the head from the table with the patient lying on his back. The exercise consists in having the patient lie in this position with the shoulders held down; the patient then attempts to raise the head from the table (*a*) with resistance; (*b*) without resistance; (*c*) with aid from the surgeon's hand.

Abdomen.—The frequency of occurrence of abdominal paralysis makes it necessary to define this matter clearly. With normal abdominal muscles, with the patient lying on the back and making an attempt to sit up with the arms folded on the chest, the ensiform cartilage is drawn toward the symphysis pubis by the recti, assisted by the other abdominal muscles, and this flexes the lumbar spine. Then the psoas and iliacus and other hip flexors flex the pelvis on the thighs.

If the hip flexors are paralyzed and the abdominal muscles normal, the patient cannot rise to a sitting position but the abdominal muscles can be felt to contract in the attempted movement. If, on the other hand, the recti are paralyzed and hip flexors normal, the patient will first fix the lumbar spine by contracting the erector spinæ and then flexes the pelvis on the thighs with the back hollowed and the abdomen soft and prominent.

Exercises.—The patient sits in a semi-reclining position with the back supported and arms folded on the chest and knees held down and tries to assume an erect sitting position. The strength of the exercises is increased or diminished by lowering or raising the support.

The patient lies on the back and flexes the knees onto the chest, if necessary with assistance under the knees.

The patient lies on the side, with the arms folded on the chest and the pelvis held, and flexes the spine by bending the body forward, resistance being afforded by the friction of the body on the table. The exercise should be done with the patient lying first on one side and then on the other.

CHAPTER XXIII

INJURIES OF PERIPHERAL NERVES

Peripheral nerve injuries may be divided into—(1) Open, or compound injuries accompanied by an accidental wound; and (2) Closed, or subcutaneous injuries due to (*a*) contusion or laceration; (*b*) friction or compression; or (*c*) traction.

The lesions produced by the various forms of injury present three main naked eye types:—

(*a*) Complete division with a gap; (*b*) Complete division without a gap (pseudo-continuity); (*c*) An intact nerve trunk showing a localised alteration in contour, size or consistency—*e.g.* a nerve spindle (fusiform neuroma) (Fig. 541).

In a histological sense such lesions are usually composite, and illustrate the destructive effects of the primary injury, the influence of wound infection, and the attempts on the part of the nerve at spontaneous repair.

PATHOLOGY

Healing of Injured Nerves. (*a*) *After Complete Division.*—When a nerve trunk is divided completely, retraction of the cut ends occurs within a short time. On the proximal end a bulb rapidly develops, composed of proliferating connective tissue and budding nerve fibres. The distal stump may become atrophic and pointed, or may acquire a fibrous cap (Fig. 541). Under such conditions spontaneous regeneration on a large scale is impossible, although a few axons may occasionally bridge the gap, and reach the distal trunk.

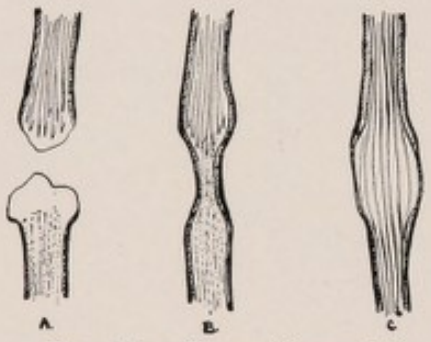

Fig. 541.—Types of nerve lesion. (*a*) Complete division with gap; (*b*) pseudo-continuity; (*c*) nerve-spindle.

Where the nerve trunk has been severely lacerated with a considerable loss of substance, the size of the gap and the connective tissue reaction in and around the area of the lesion constitute insuperable obstacles to regeneration.

The fibrous tissue reaction is most abundant in a wound in which the organisms of suppuration have been introduced. The inimical influence of sepsis is best illustrated in the peripheral nerve lesions of modern warfare where the nerve trunk lacerated or divided by a missile, undergoes further destruction as the early acute suppuration sets in. When the inflammatory reaction has subsided, scar tissue extending widely and undergoing steady contraction, contributes further to the local obliteration of the nerve trunk. This scar, when fully matured, presents an impenetrable barrier which the young axon cannot possibly traverse.

Such are the grosser and purely local effects of wound infection; but there is further damage to be reckoned with. The nerve trunk absorbs toxins or bacteria into its interior, which may ascend for a considerable distance above

the level of the original lesion. In the proximal nerve trunk a neuritis thus develops, the end result of which is a wide-spread fibrosis in the connective tissue framework. The changes of ascending neuritis have been repeatedly demonstrated in injured nerves many inches above the primary lesion.

(*b*) *Lesions without Loss of Continuity.*—In the nerve injuries produced by contusion, friction, or traction, where there is no loss of anatomical continuity, the phases of degeneration and attempted regeneration proceed inside an intact nerve sheath. Here again the amount of connective tissue reaction usually determines the success or failure of the regenerative efforts. When the lesion extends over a considerable length of nerve, as in many traction injuries, few axis cylinders are able to find a way through the formidable intraneural scar.

Changes in Other Tissues.—Certain changes in structure are also found in the tissues to which the terminal nerve fibres are distributed. These changes may be due either (*a*) to the *disuse* which is an inevitable sequela of nerve block, or (*b*) the repeated *irritation* of sympathetic and sensory axons which remain intact. The disuse changes consist in muscular atrophy, and retarded growth in the skin, hair, and nails. The changes dependent on irritation are usually described under the title "trophic," and are characterised by a progressive fibrosis in the muscle bellies, tendon sheaths, and joint capsules, combined with degenerative changes in the superficial tissues.

Clinical Manifestations

A nerve injury is recognised either by the signs of loss of conduction (nerve block), or by the signs of disordered function. The symptomatology varies in accordance with the extent of the lesion and the interval which has elapsed since the date of the injury. For clinical and diagnostic purposes certain distinctive syndromes are conventionally recognised.

I. **Syndrome of Complete Interruption.**—A complete nerve block may be present at some stage in every type of lesion.

(*a*) *Motor Signs.*—The muscle groups supplied by the injured nerve show a complete paralysis of the lower neuron type; flaccidity, wasting, loss of deep reflexes, and certain alterations in the electrical responses (R.D.).

(*b*) *Sensory Signs.*—Sensation is lost in an area representing the exclusive supply of the nerve. It is customary to record sensory loss in terms of three types of stimulus: (1) Epicritic loss, embracing the absence of response to the lightest touch, inability to recognise finer variations in temperature, and failure to localise accurately the point of stimulus. (2) Protopathic loss (analgesia), over a less extensive, and often ill defined zone where painful stimuli and the extremes of temperature are unrecognised. (3) Deep loss, which includes those afferent impulses from fasciae, muscles, tendons, and joints, which determine the recognition and localization of pressure touch and pressure pain. The area of deep anaesthesia is usually much smaller than the area of analgesia.

(*c*) *Vasomotor, Secretory, and Trophic Signs.*—These are inconspicuous in the syndrome of complete block. The skin may be cold, pale, or dusky, and slight retraction of muscles and fibrous changes in the joint capsules may be seen.

(*d*) The injured nerve trunk is usually painless on direct palpation.

II. **Syndrome of Incomplete Interruption.**—Considerable variations are found owing to the presence of intact nerve fibres. A characteristic picture

is often seen in the earlier stages of compression or friction lesions. (Stopford.[1]) This consists of (*a*) increasing paralysis and muscular atrophy; (*b*) dissociated sensory loss with the analgesia (protopathic area) greater than the area of tactile (epicritic) anaesthesia. The injured nerve may be thickened and tender.

III. **Syndrome of Irritation.** (Traumatic Neuritis.)—Trophic and sensory signs now predominate—viz., pain, hyperaesthesia, tenderness of the nerve trunk, cyanosis, glossy skin, brittle and stunted nails. The most severe form of the irritation syndrome known as *causalgia* is seen more especially in gunshot injuries of the median or sciatic nerves. Sensory and trophic phenomena of extreme severity are combined with the signs of partial nerve block. Pain of a bursting or burning type is felt in the hand or foot, and is enhanced by all forms of emotional or physical stimuli.

IV. **Syndrome of Recovery.**—Tone appears in the wasted muscles which also become tender. Later there is a return of voluntary power, accompanied or preceded by the return of faradic excitability. Sensation reappears in two distinct stages. (1) The protopathic phase, and (2) the epicritic phase. In the earlier stage referred tingling evoked by tapping the nerve may be a striking sign (Tinel).[2] Complete return of sensation is seen in a minority of nerve injuries only, and then only after an interval of some eighteen months to three years.

Treatment

When a diagnosis of injury to an important nerve trunk is made, a further problem at once arises. It is necessary to decide whether spontaneous recovery will occur, or whether the lesion will demand operative repair. In nerve injuries accompanied by an open wound the damaged nerve is sometimes available for direct inspection during an emergency operation. But in subcutaneous injuries the extent of the lesion must usually be assessed on clinical evidence alone. In doubtful lesions it is reasonable to explore the nerve early and to deal with it in accordance with the findings. In a certain number of injuries explored for diagnostic purposes, it will be found unnecessary to carry out any form of nerve repair. In competent hands no harm will result. Before and after operation the nutrition of the limb should be maintained and improved by appropriate physiotherapeutic measures.

Conservative Treatment

Physiotherapeutic treatment has no direct influence on the regenerative process, but the quality of recovery obviously depends on the condition of the tissues supplied by the injured nerve. Paralysed muscles continually overstretched cannot regain power even after regeneration has taken place, and recovering muscles cannot function adequately if opposed by contractures and fixation of joints. It is thus essential to keep a paralysed muscle or group of muscles, constantly in a stage of moderate relaxation (the position of physiological rest). This is achieved by suitable light splints, worn day and night. At this stage the limb should be treated regularly by warmth, massage, electrical stimulation of the paralysed muscles, and gentle movements of the finer joints. At a later date when recovery has set in, muscle re-education, exercises, and curative occupations play an important part.

[1] Stopford, J. S. B.: British Medical Journal, 19th June, 1926.
[2] Tinel: Nerve Wounds, London, 1917.

Operative Treatment

It is customary to distinguish between the primary and secondary exploration of an injured nerve.

Primary exploration is rarely practised except where a nerve injury is accompanied by an external wound. In civil injuries which are commonly produced by the penetration of sharp instruments, fragments of glass, and the like, the wound may be surgically "clean." Under such conditions the immediate repair of a divided nerve is likely to be followed by uninterrupted regeneration. But where the wound is infected from the outset, recovery after primary nerve suture is problematical, for sepsis is always inimical to regeneration. In highly infected wounds it is often sound policy to repair less vulnerable structures (*e.g.* divided tendons), and to postpone the nerve repair to a later stage. Meanwhile the cut ends should be approximated by sheath sutures, and the trunk shut off from contact with the injured and infected area. When the wound is soundly healed, the nerve trunk should be re-explored and repair completed. These considerations apply with particular force to gunshot wounds where gross contamination is the rule.

Secondary explorations are undertaken—(*a*) after healing of an accidental wound; or (*b*) in "closed" (subcutaneous) nerve injuries produced by contusion, compression, or traction.

In the former some three to six weeks should be allowed after final healing, in order to minimize the risk of a recrudescence of wound infection. During this probationary period skin scars should be softened and loosened, and stiffened joints mobilized. Such obstacles to free mobility not only add to the difficulty of exposing the nerve, but may render the lesion irreparable.

Operation difficulties will also be lessened if attention be paid to the following details: (*a*) A wide skin area including the whole limb, and often part of the trunk, should be sterilized; (*b*) suitable splints should be assembled, which have already been fitted to the limb in the position to be adopted when the operation is completed; (*c*) the correct position of the patient or limb on the operation table should be tested before the sterile sheets are in place. Where a change in position is necessary in the closing stages of the operation, the readjustment should be made with the minimum disturbance. The success of the operation and the comfort of the surgeon often depend upon careful pre-operative rehearsal.

Exploration Technique.—The exploration of an injured nerve comprises the following steps:

I. The skin incision made either over the course of the nerve or in the form of a flap.

II. Exposure of the Nerve Trunk.—The nerve should be displayed in a suitable intermuscular interval, and sought for first above, and then below the level of the lesion. The trunk should be freed from its bed by gentle dissection, care being taken to avoid injury to the sheath.

III. Electrical Stimulation.—The response of the nerve to direct excitation is now noted. A suitable sterilised electrode (bipolar, or unipolar) with long cords connected to a faradic coil is used for this purpose. In a nerve injury of more than two weeks' standing, a reaction to the faradic current indicates continuity of nerve fibres through the lesion. In a nerve trunk explored many months beyond the normal limits of the spontaneous regeneration period, a lack of response suggests an *insuperable* block to regeneration. Not infrequently a positive response may be demonstrated at operation, when pre-operative electrical tests have failed to evoke a faradic reaction in the affected muscular group.

IV. Exposure of the Lesion.—At this stage the operation difficulties usually arise, owing to the obliteration of landmarks by scar tissue. It is wise to assume at first that in an

unpromising block of scar tissue intact nerve bundles are hidden. A nerve trunk much distorted and thickened, but capable of future conduction may often be disentangled from a complicated scar. In freeing, all incisions should be made in the long axis of the nerve trunk. Further dissection may of course show that pseudo-continuity only is present.

V. Treatment of the Lesion.—The method to be adopted will depend on the extent of the injury and its effect on conductivity. (1) For a complete solution of continuity, the operation of *end to end* suture only will suffice. (2) Where the nerve trunk shows insignificant macroscopical changes, as in many of the subcutaneous injuries (*e.g.* compression lesions), freeing of the nerve, removal of the compressing agent, or displacement of the nerve to a new bed, is the appropriate measure—the operation of *neurolysis*. (3) In many of the graver lesions with apparent naked eye continuity, a choice has to be made between resection followed by suture, and the conservative operation of neurolysis. No hard and fast rules can be laid down. The surgeon must attempt to estimate the relative amounts of scar and intact nerve bundles. Useful information may be obtained by opening the nerve sheath carefully and inspecting the interior. When the cicatrical tissue predominates, regeneration on a large scale is hardly possible after neurolysis. In long standing injuries of this type, resection is generally indicated. A cautious attitude should be adopted towards more recent injuries, in which neurolysis should often be given a trial. If recovery does not follow a neurolysis, re-exploration should be carried out without delay, and the lesion resected. (4) Where the clinical signs point to partial interruption of conductivity, the choice between resection and neurolysis is often determined by the relative importance of the motor and sensory functions subserved by the injured nerve. Thus in the *median nerve* it is reasonable to sacrifice intact *motor* bundles when the obstacles to the regeneration of sensory fibres are admittedly insuperable. In the *ulnar nerve* the conditions are reversed; the sensory supply is of little value compared with the function of the intrinsic muscles of the hand. (5) So far the treatment of the nerve lesion has been considered merely in relation to the interruption of conductivity. But in certain injuries the clinical signs of nerve block are overshadowed by the sensory and sympathetic phenomena of irritation. Many of the milder types of traumatic neuritis respond to conservative treatment, but occasionally neurolysis is required. In the severe forms of the irritation syndrome, and particularly in *causalgia*, conduction must be completely abolished. This may be attained (*a*) by the intraneural injection of alcohol (60 per cent). A fine hypodermic needle is thrust into the nerve trunk above the level of the lesion, and the complete cross section infiltrated. The nerve becomes distended in the region of the injection, and assumes a dead white appearance; or (*b*) by resection and end to end suture.

Operation of End to End Suture. *Difficulties.*—Where considerable loss of substance has occurred, it is by no means easy to close the gap. Certain manoeuvres are available which facilitate end to end apposition. (*a*) The nerve trunk should be exposed and mobilised as widely as possible, and should be fully relaxed by an appropriate change in the posture of the limb. (*b*) Motor branches which anchor the nerve trunk should be stripped up from within the nerve sheath and thus elongated. If done with extreme delicacy the small twigs suffer no permanent injury. (*c*) Displacement of the nerve to a new bed in order to shorten its course—*e.g.* transposition of the ulnar nerve to the front of the elbow. If in spite of such efforts, end to end apposition is still unattainable, there remain two alternatives:

(*d*) The Two Stage Operation.—At the first stage the nerve stumps (untrimmed) are approximated as closely as possible and anchored with a stout suture with the limb in the position which affords the maximum relaxation. The wound is then closed. A few days later gradual stretching of the flexed joint is begun, and is completed by the end of a fortnight. The steady traction tends to elongate the nerve trunk and so diminish the gap. The second stage is now undertaken. The wound is reopened and an attempt made to complete the suture.

(*e*) Bone Shortening.—This procedure is justifiable only to facilitate repair of the musculo-spiral nerve when accompanied by an ununited fracture of the humerus.

Suture Technique. (Fig. 542.) (*a*) *Trimming the Nerve Ends.*—The aim is to bring normal bundles in the proximal stump into apposition with normal bundles in the distal stump. This necessitates a preliminary trimming of the nerve ends in a complete anatomical lesion, or resection of the injured segment where pseudo-continuity is present. On the trimmed surfaces there should be no macroscopic areas of scar tissue. In grave injuries a considerable length of nerve may require resection, and the resulting gap may bring the lesion almost to the irreparable class. This risk should be ever present in the mind of the surgeon.

(*b*) *Coaptation of the Surfaces.*—The nerve ends should be apposed without disturbing the intraneural "pattern." Rotation of either the proximal or distal stumps is best avoided by inserting guide sutures into the nerve sheath at corresponding points above and below the level of the resection or trimming, before the latter is completed. The cut surfaces are now brought into contact under slight tension, without undue crowding or eversion of the bundles. The actual suture consists in closing the nerve sheath by means of some half dozen interrupted stitches. Every suture produces a connective tissue reaction along its track, so that the material should be non-irritating and of very fine calibre. (Sargent and Greenfield).[1] Fine linen thread (160) or plain catgut (00000), mounted on slender round bodied needles should be prepared for routine use in operations on peripheral nerves. Catgut impregnated with formalin or chromic acid is not admissible for this purpose.

(*c*) *The Nerve Bed.*—The repaired nerve should be replaced in a bed from which all scar has been removed. When possible this should consist of healthy muscle, and if need be the nerve should be displaced from its course in order to attain ideal surroundings. In certain regions where a suitable bed is unavailable or not readily constructed, a sheet of fascia may be interposed between the nerve and such dangerous areas as denuded bone or tendon. Complete investment of the repaired nerve by "sleeves" of fat, fascia, or animal membrane, is not to be recommended.

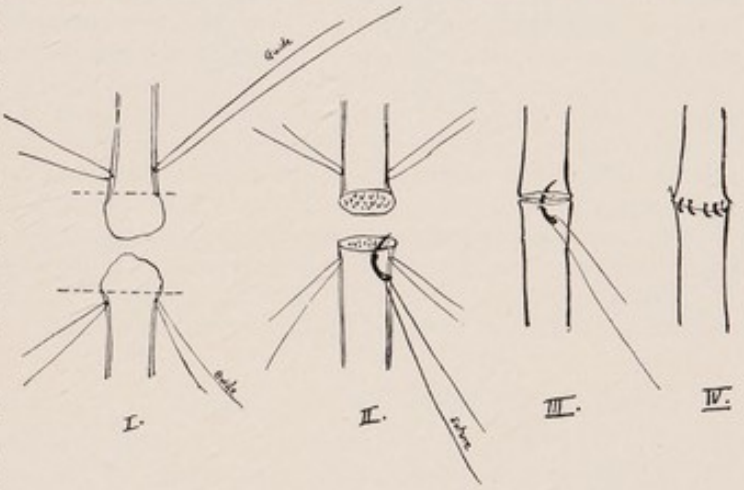

FIG. 542.—Technique of nerve suture.

Operation of Neurolysis.—In its limited sense the term *Neurolysis* implies the simple release of a nerve trunk from the restraining or constricting effects of scar or other abnormal structures. This procedure is thus an essential part of every operation for nerve repair.

Special technical details are also included under the heading of neurolysis. Thus, in dealing with an adherent "nerve spindle," it is often advisable to dissect off the superficial layers of thickened capsule (capsulectomyneurolysis). Removal of scar tissue from the interior of a nerve trunk, (endo-neurolysis) has often been attempted, but is a procedure liable to do more harm than good. After the nerve trunk has been freed, and the compressing agent removed, the nerve bed should be reconstructed, or a new bed provided.

Operations for Irreparable Nerve Lesions.—Irreparable nerve lesions are rare except in gunshot injuries. If the two stage operation fails, the surgeon is faced with the prospect of (*a*) attempting some form of "bridge" operation; or (*b*) abandoning nerve repair and adopting one of the recognised alternative operations on tendons, bones, or joints.

Bridge Operations.—The term is used to describe the various methods of filling in extensive gaps. Many operations practised to attain this end are now of purely historical interest, *e.g.* neuroplasty (flaps), fascial tubulisation.

There remain two procedures which have a certain limited value. (1) Nerve grafts. It has been well established by experiment that regenerating nerve fibres are able to cross a *short* gap by utilising the channels afforded by a nerve graft, whether autogenous, homogeneous, or heterogenous in origin. In the earlier nerve grafting operations, it was the custom to use an unimportant sensory nerve, *e.g.* the radial in the forearm. Later it was realised that unless the graft was equal in calibre to the lost segment, the number of axis cylinders conveyed were too few to restore adequate function.

The great majority of nerve grafting operations for injuries have been failures, but partial recovery has been recorded in a few cases by competent observers. The operation should be practised only where no alternative procedure of equivalent value such as tendon transplantation is available, and little or no restoration of function should be predicted. (2) Nerve crossing (nerve anastomosis; lateral implantation). Various types of nerve crossing have been tested both in experimental work and in the repair of injuries. In the earlier

[1] SARGENT and GREENFIELD: Brit. Med. Journ., 1920, Sept. 25.

operations the distal end of the injured nerve was implanted into a transverse or median slit in a neighbouring sound nerve, or occasionally sutured to its central end after complete section. More recently the results of double lateral implantation have been carefully investigated by Ballance[1] and his co-workers. In this procedure, the central and distal ends of the injured nerve are implanted some little distance apart into the receiving nerve, which provides as it were a living bridge. The opportunities for the legitimate use of nerve crossing are few and are practically confined to injuries of the facial nerve and of the brachial plexus. As applied to the upper limb nerves, the procedure is open to serious objections.

Alternative Operations.—These consist of (1) procedures designed to compensate for lost motor function, or (2) as a final resort, the elimination of a useless, dangerous, or painful limb.

(i) Tendon transplantation is applicable in certain irreparable nerve injuries. In *musculo-spiral* or *posterior interosseous* lesions, transplantation of the pronator radii teres into the radial extensors of the wrist, the flexor carpi radialis into the short thumb extensors, and the flexor carpi ulnaris into the extensors of the fingers and the long thumb extensor, gives most striking results. A strong hand is obtained, capable of being used in many arduous occupations. In *median* and *ulnar* lesions tendon transplantation has a more limited field, except for paralysis of the thenar muscles where the power of opposition of the thumb may be restored by the operations introduced by Ney and Bunnell (Chapter XXI).

(ii) Tendon Fixation (Tenodesis) has been used chiefly for the foot drop of irreparable sciatic or external popliteal injuries as an alternative to the life long wearing of a walking appliance.

(iii) Arthrodesis may occasionally be contemplated for a flail shoulder joint, but this operation should be practised with great reservation in the adult.

(iv) Amputation is chiefly used in old sciatic injuries where intolerable pain and trophic ulceration in the foot prohibit weight bearing.

Results of Operations for the Repair of Nerve Injuries.[2] *Methods of Estimation.*—In judging the late results of operations for nerve injuries it is necessary to distinguish between two standards of assessment—the physiological (or neurological), and the functional (or economic). The former simply represents the amount of conductivity restored to the nerve as measured by clinical and electrical tests. The latter, as the term would indicate, denotes the capacity which the limb or part exhibits, apparently as the result of the operation. The two standards do not necessarily run on parallel lines. A good functional result may be seen in the presence of a poor neurological result; and, on the other hand, with a satisfactory or almost perfect neurological result, there may be little improvement in the function of the limb. The reasons for such discrepancies are not far to seek. It is to be recalled that a complete lesion of a peripheral nerve may produce little practical disablement in certain individuals. Thus, the elimination of the *ulnar* intrinsic muscles of the hand is of paramount importance only to those whose occupation demands the finer hand movements. In lesions of the *median nerve*, the anesthesia of the index finger is a far more serious disability, and impairs the capacity of the hand for most types of work.

Again the loss of conduction and function due to a nerve injury may be overshadowed by the disabling effects of the changes in other tissues. The successful repair of the nerve, even if restoration of function and conduction go hand in hand, may then be of little practical value to the patient. Finally, in the absence of mechanical obstacles, delayed recovery may be due to psychical causes.

Results of End to End Suture. (1) *Primary Sutures.*—Perfect recovery of both motor and sensory functions may follow the repair of a clean cut division

[1] Ballance, Colledge and Bailey: Brit. Jnl. Surgery, XIII, 51, Jan., 1926.
[2] Platt, H. and Bristow, W. R.: British Journal of Surgery, Vol. XI, No. 43, 1924.

of a nerve where aseptic wound healing has occurred. Such results are exceptional in surgical practice.

(2) *Secondary Sutures.*—The results on the whole tend to be unsatisfactory, and more especially in the gunshot wounds of modern warfare. Of the factors which determine the standards of recovery the following are the most important:

(*a*) *Wound Infection.*—The influence of infection is well demonstrated in the changes which occur in the nerve trunk itself. Above the level of the suture an interstitial neuritis may extend for many inches. At the site of suture cicatrical shrinkage may result in the obliteration of nerve fibres which have re-established communication with their end organs. Below the level of the suture the axis cylinders often remain imperfectly myelinated. The sum of such changes means that reinnervation has occurred in a most scanty fashion.

(*b*) *The Time Factor, i.e.*, the Delay between the Injury and the Repair. After a certain optimum period, arbitrarily estimated at three years, recovery tends to be less certain and less complete. The harmful effects of long delay depend on the occurrence of degenerative changes in the muscles and other peripheral tissues, and retrogressive changes in the central nerve cells.

(*c*) *Topographical Confusion.*—Inaccuracies of regeneration due to the "shunting" of motor nerve fibres along sensory channels and vice versa, occur after most nerve sutures. In lesions in which extensive resection is necessary, a considerable disturbance of the intraneural pattern results. Such regenerative errors are undoubtedly reproduced in the imperfections of the neurological and functional results after nerve suture.

(*d*) *Anatomical Situation of the Suture.*—Sutures in the proximal part of the limb show a higher percentage of recovery than sutures situated in the distal part.

(*e*) *Age.*—In early life recovery is more rapid and perfect.

Results of Neurolysis.—It is often difficult to define how far a neurolysis has brought about the recovery which has been observed after the operation. In many pure compression lesions, removal of the compressing agent is rapidly followed by the reappearance of both conductivity and function. This means that the nerve block has not been due to actual degeneration of axis cylinders. The effect of a neurolysis under these conditions is to eradicate the trauma caused by the repeated stretching or friction of the anchored nerve during the natural movements of the part. Where a compression lesion has been in existence for some time, and degeneration has occurred on a considerable scale, formidable obstacles to the full attainment of spontaneous regeneration are now situated in the interior of the nerve trunk—*i.e.* interstitial fibrosis. Thus, the elimination of the cause of the trauma in the late stages does not necessarily determine the complete restoration of function. This sequence of events is shown quite clearly in the results of the treatment of brachial neuritis produced by the various types of supernumerary cervical rib. (See Chapter XXVII.)

Functional Contractions and Deformities

Functional deformities present themselves to the surgeon in so many different forms, and with such variations in the history of their onset that the differential diagnosis between them and true organic affections is frequently a matter of the greatest difficulty and one which can only be accomplished

after the most careful investigation into all the signs and symptoms presented. Each sex is liable to these deformities and they may occur at any age.

Symptoms.—In war injuries and those resulting from industrial accidents the symptoms are very variable and are largely dependent upon the nature of the exciting organic lesion if present. If the joint is affected, the symptoms are out of all proportion to the objective signs. The pain is superficial and excessive; it varies in its site from time to time and may be in the wrong spot, and the painful area may become anesthetic or hyperesthetic. If there is rigidity, it is quite different from that which accompanies an arthritis, and the surgeon will experience a muscular resistance. Although the limb may present advanced circulatory change of a congestive type, no marked alteration in the contour of the joint is to be expected, there is no redness and the joint is not hot. Although real disease is simulated, the symptoms do not coincide in character; tenderness, while in excess of that which is observed in arthritis, is not accompanied by the classical signs; and pain may be complained of with the slightest movement, yet there are no night cries, nor "starting" of the limb. In regard to pain, it will be observed that it rarely affects the patient's sleep or general health. He often moves freely in bed. If attention is diverted the joint may bear firm pressure. Wasting may be very slight and the walk unusual for a true joint affection.

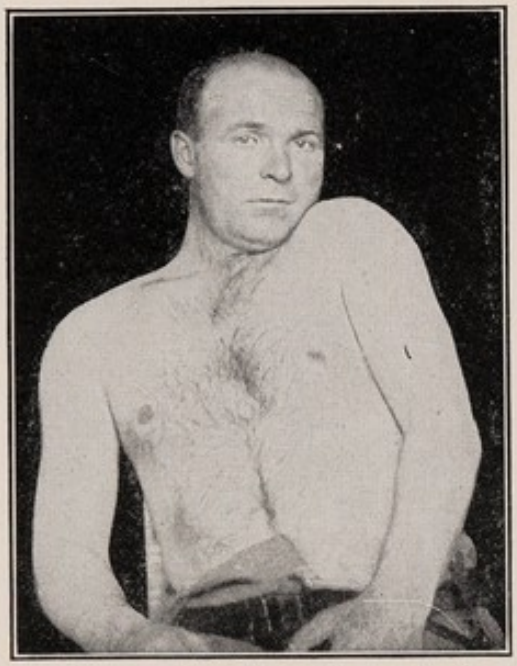

Fig. 543.—Functional affection of the shoulder.

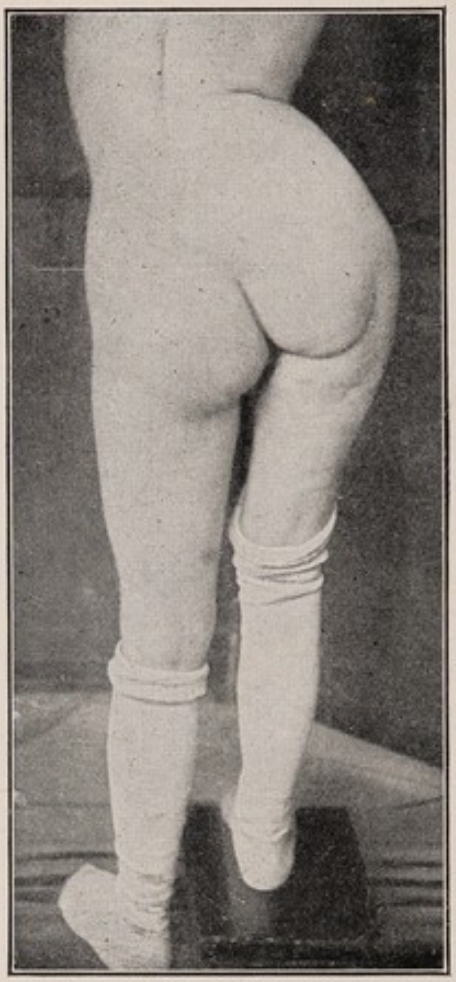

Fig. 544.—Hysterical hip.

In cases of flaccid paralysis, pain is often a feature and is usually of a burning character, but the muscles react to electrical stimulation. Anesthesia will reveal much. When an anesthetic is employed for diagnostic purposes, the paralyzed limb may move before unconsciousness takes place and also before full consciousness returns, and this is also true in cases of spastic contraction. If the arm remains adducted from spasm and the ribs are

stimulated before unconsciousness takes place, the patient may move it energetically. However severe and prolonged the muscular contractions, no displacement of bone occurs.

Swelling is usually absent and this is an important diagnostic sign although it is occasionally to be found in nervous mimicry, in which case it is usually outside the joint, irregular and puffy in character, and confined to the areolar tissue. The skin may be bluish from errors of circulation and may at one part of the day be flushed and hot, at another, cold and clammy. A cold knee may suddenly become warm when an attempt is made to move it; but the mere fact that at times it is cold is sufficient proof of the absence of an inflammatory lesion.

Stiffness of the joint, when present, is very suggestive and produces an exaggerated deformity and does not assume the position of greatest ease, but may be rigidly flexed, or rigidly extended in a way not characteristic of true joint affections. If the hip is affected, there may be adduction one day, abduction the next, and it may be accompanied by simulated talipes. If the mimicry has lasted a long time, a certain degree of rigidity may be maintained during sleep. Moreover, the joint is far less moveable than it would be in early disease of the joint.

It must always be borne in mind that in a large proportion of cases, neurotic symptoms are associated with organic lesions and only careful examination can help us to a correct diagnosis. In the case of a joint, particular stress must be laid upon rapid wasting, night cries, and intra-articular swelling as signs of organic lesions in spite of the presence of marked neurotic symptoms. An anesthetic may be given, if necessary, and an X-ray photograph should be taken if there is any doubt as to the diagnosis.

In a very large group of injuries met with in the late war, the so-called *neurotic contractions* were often a maintenance of the deformities which accompanied the original injuries. These may have been originally due to the assumption of the position of ease, or to transient affection of the peripheral nerves. An injury to the ankle joint accompanied by pain on movement may result in loss of will power, so that movement remains restricted. Such cases are often deceptive because of the wasting which results from the original lesion, and the circulatory disturbance due to the nervous element. Hurst[1] has pointed out that changes occur in the tissues which are secondarily due to deficient circulation. The deficiency is largely due to the lack of active movements, "the efferent nerve fibres from the muscles probably giving rise to localized reflex vaso-dilatation." If the limb is not moved in cold weather the nutrition and movement, say of the hand, are impaired and it becomes blue and painful; but under treatment these vasomotor symptoms may disappear at once.

Stiffness of the joints, so extreme as to be perfectly rigid, especially in the hands, will occur in long standing cases, as Hurst points out, without any spasmodic contractions. This is due to changes in the physiological properties of paralyzed muscles, even if the paralysis is entirely hysterical. When these joints are moved under an anesthetic, actual tearing may be experienced and effusion appears around the joint, often ascribed to the yielding of adhesions. As Hurst says—"as the stiffness is due to circulatory disturbance and not to any muscular spasm, whether hysterical in origin or not, it naturally persists

[1] HURST: War Contractures, Brit. Jour. Surg., 1909.

under an anesthetic and, when the joint is forcibly moved the surrounding structures which are torn are not abnormal fibrous tissue, but simply the normal periarticular tissue which is temporarily in an abnormal condition, owing to the deficient circulation." The importance of this is that the apparent tearing of adhesions and production of inflammatory reaction does not prove the presence of an organic lesion. This is borne out by the damage often done by ruthless manipulation. The deficiency in circulation, long continued in character, leads to very pronounced atrophy, sometimes resulting in loss of the nails.

Diagnosis.—These affections may occur in subjects of obviously neurotic type, but they are also found among the phlegmatic and robust. They often exist without any discoverable exciting cause. Many cases, however, exhibit signs of physiological or pathological strain and stress, such as disturbance of the menstrual function, shock, injury or any illness which causes marked disturbance of tissue metabolism, which may alter the balance of the neuro-muscular mechanism. Functional deformities may be suspected if they bear no relationship to the injury upon which they are supposed to depend.

The purely neuro-mimetic cases are distinguished by the fact that, although they present symptoms closely simulating, or identical with those which arise from structural or organic lesions, they are not associated with any alteration or defect of structure. This is particularly noticeable in the so-called "hysterical" joints of children and of the paralysis of arms and legs where the defect

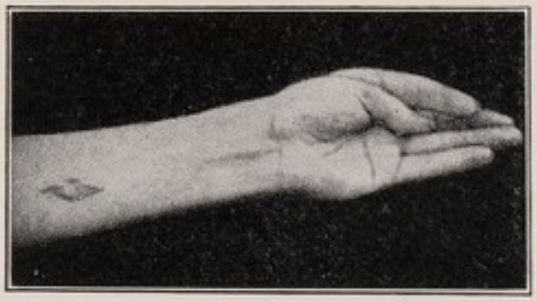

FIG. 545.—Hysterical main d'accoucheur following wound of forearm (Hurst).

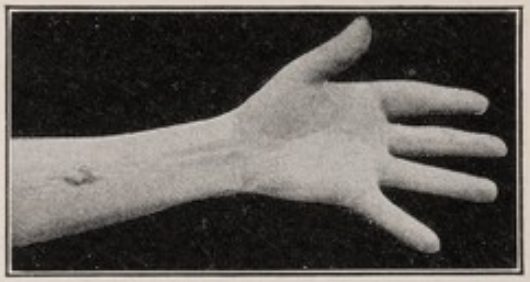

FIG 546.—Same hand as that shown in Fig. 545, cured in two and one-half hours after lasting eighteen months (Hurst)

is merely one of volition. Such cases are often robust and healthy minded, brisk and energetic, but the will fails to control muscles which may be either spasmodic or flaccid.

Very little help is gained in making a diagnosis from the history which is often vague and variable, the imagination playing a considerable part. Sometimes there is a definite history of sudden mental strain, or shock, and this is followed by deformity which bears no relation to it. On the other hand, there may have been a severe or trivial injury to one of the limbs, which leads to a deformity, persisting after the cure of the injury. This is the type which became so common during the war and which so often exposed the patient to a charge of malingering. The work conducted by Hurst, Mott, Burrow, and Morton emphasized the fact that the malingerer was extremely rare.

A common origin of a functional deformity is a sprain of a joint and long after it is recovered from, the deformity which followed the accident is main-

tained. One has to distinguish very carefully between a reflex deformity due to painful afferent stimuli which are the result of a lesion, and a purely functional affair.

During the war great advances were made in the study of functional deformities, owing to the fact of the immense numbers which were seen following injuries. These injuries which might be regarded only as the exciting cause of the deformity, varied from extensive loss of tissue to a mere scratch, and frequently were not of the nature of tissue wounds but rather of the type of general shock, usually due to shell bursts, burying etc.

The division, or irritation, of one of the main peripheral nerves is followed by a deformity, and this deformity may be said to be pathognomonic. Cure of the nerve lesion should naturally lead to a disappearance of the deformity; and if this does not occur, the persistence is due to a secondary contraction of the soft tissues, which prevents the restoration of the normal shape of the limb, or to a superimposed functional element.

There are certain deformities of a functional nature which frequently occur in the hand, and these have been classified by Hurst into three distinct groups:

1. With fingers extended and adducted, and flexion at the metacarpophalangeal range (main d'accoucheur).
2. Fingers firmly flexed into the palm.
3. Intermediate position or position of rest.

These three typical deformities are by no means the only ones which occur, but they may be said to represent the three large groups, while the occasional occurrence of other forms only serves to emphasize the rule.

Treatment.—In the mapping out of a line of treatment, it is essential that the diagnosis of the condition should be made with the greatest care, because on this depends the particular form of therapy which must be adopted. When every physical cause for the deformity has been excluded, the patient's interest in his own cure must be excited, and from the very first he must be encouraged to give help. The essential point is the building up of his confidence and interest. Explanation of the deformity, its method of production, and the object of the surgeon, must be made to him in language easily understood. If he is convinced that a group of muscles are paralyzed, then he must be assured that this is not so, either by an electrical stimulation of this group, which will illustrate to him the fact that power is present in them, or by persuasion to use these muscles at an advantageous angle. Muscles which have been stretched for a long time and have not been given any active use become weak, and if a voluntary stimulus is sent to the muscles to perform some movement which requires considerable power, they may fail, and the patient is then more strongly convinced than ever that the muscles are paralyzed and that recovery is impossible. If, however, these muscles are so placed that they act at a better mechanical advantage, then, frequently, the action which they are called upon to perform is easily possible, and the patient's confidence is thereby completely restored.

As an illustration of this point one may take the case of a shoulder, in which there is a functional paralysis of the shoulder girdle muscles with adduction of the arm. The treatment which is, unfortunately, too often adopted here is massage and electrical stimulation of the shoulder girdle in the deformed position, which usually leads to little or no improvement, and only convinces the patient of the extreme seriousness of his condition, since any effort he

makes at abduction results in failure because the muscles, weak from being stretched, fail to respond to the strongest voluntary effort of lifting the weight of the arm. They are placed under great mechanical disadvantage in attempting to act against the influence of gravity as in the upright position. If the patient be placed on a smooth table in a horizontal position the voluntary effort which previously failed will succeed and the arm will be abducted as it is not asked to struggle against the force of gravity.

Massage and electrical treatment of themselves serve to improve the tone of muscle and increase the circulation of the affected part, but they do not restore to the patient the confidence in his ability to use the muscles which are being treated. This improvement in mental outlook, in regard to the deformity, can only be attained by demonstrating to him his power to perform some small movement which he considered to be impossible. When this feeling of confidence and hope has been implanted, then progress is usually very rapid, and a complete cure may safely be expected.

Passive correction, or overcorrection of the deformity, which previously was universally adopted, may lead to a retardation of the rate of cure and, indeed, the pain caused by these forced movements may entirely inhibit any voluntary efforts on the part of the patient, and so cause a complete recurrence of the original deformity. The theory under which forced passive correction of the deformity was used as a means of treatment during the war relied on the fact that by this means the resisting muscles were gradually fatigued until they did not respond to voluntary stimuli, and so offered no bar to complete restoration of the deformity; but unless the patient can thereby be convinced of his own ability to produce this same correction by voluntary effort, this form of treatment must fail.

After the patient's confidence has been secured, gentle passive movements to rectify the deformity, without producing pain, undoubtedly help to hasten the correction, but only as a subsidiary aid to the essential factor, which is to convince the patient of his own power to correct the deformity, a stimulus to endeavor.

One of the great lessons taught by the War experience was the rapidity with which long standing contractures and paresis could be cured, and the rapid disappearance of trophic disturbances. These experiences are of great value in treating the after-effects of industrial accidents. Hypnotism proves of very little advantage and often produces other symptoms, difficult to get over.

The treatment of neurotic joints in young women and children is often difficult and no universal law can be formulated. Re-education is very important, but every effort should be made to convince the patient that the condition is curable. If the arm cannot be lifted, one may explain loudly to a colleague the conditions under which the arm can be lifted. She hears the surgeon say "Now this patient cannot lift the arm but if I place my finger on this spot and press it she can hold it in this position." The arm is then lifted by the surgeon against the weight of gravity and she voluntarily holds it there. This is the text upon which her re-education is based. Every art must be exercised and whether or not an immediate recovery can be brought about depends largely on the surgeon's sympathy and resourcefulness. The patient must never suspect that the surgeon thinks her complaints imaginary; he must assure her that he knows what she suffers from and can cure it. All

functional cases should be prescribed regular work in order to exercise the affected limb and prevent an introspective mind.

Finally, the patient must be instructed in the voluntary preservation of the normal position of the limb, so that the tendency to the reappearance of the deformity is prevented; and usually an ordinary occupation, which gives scope to muscular activity of the necessary type, will entirely prevent the tendency to recur.

INJURIES OF INDIVIDUAL NERVE TRUNKS

FACIAL NERVE (7TH CRANIAL)

Facial palsy may also be produced by causes other than pure injury. The nerve trunk may sustain damage (*a*) inside the cranium, (*b*) as it passes through the temporal bone, or (*c*) after it has reached the neck. In the first situation the lesion is usually combined with other intracranial injuries.

In the temporal bone the nerve is occasionally involved in a fracture of the middle fossa or following an operation on the middle ear. In the neck, injury usually results from a penetrating wound or from the pressure of obstetrical forceps.

Many of the injuries of the facial nerve are incomplete, and spontaneous regeneration occurs with partial or full recovery of function.

Symptomatology (*Extra Cranial Injuries*). (*a*) *After Exit from the Stylo-mastoid Foramen.*—If the nerve lesion be complete, a classical Bell's palsy is seen. The affected side of the face is mask-like, and all emotional and voluntary movements are lost. The eye remains open during the day, but the upper lid often droops at night time. The palsy is best demonstrated when the patient attempts to smile or whistle. In long standing cases of facial palsy, where there has been partial regeneration, contracture of the muscles is seen, and the facial asymmetry becomes much less conspicuous.

(*b*) *In the Fallopian Aqueduct.*—When the lesion is below the geniculate ganglion, in addition to facial palsy there is a loss of taste over the anterior two-thirds of the tongue; paralysis of the stapedius muscle may also occur and is recognised by the resulting hyperacusis. If the nerve is injured in the region of the geniculate ganglion, the auditory nerve is often involved, and the clinical syndrome may be that of an intracranial lesion.

Treatment.—Conservative treatment on accepted lines should be tried for some months. Direct repair of the nerve injury is rarely possible, so that in lesions which do not recover spontaneously, some form of alternative operation is required. Nerve crossing has achieved its best results in facial palsy, the hypoglossal or the glossopharyngeal being the reinforcing nerves of choice. Muscle transplantations, using strips of the temporal or masseter to replace the paralysed sphincters of the eye and mouth have also been used with a certain measure of success.

SPINAL ACCESSORY NERVE (11TH CRANIAL)

This nerve is usually injured by accidental penetrating wounds (*e.g.* gunshot) or during operations in the neck involving deep dissection. If divided in the anterior triangle the resulting paralysis includes the sterno-mastoid and the upper fibres of the trapezius. When the nerve is injured in the posterior triangle, the motor branches from the 3rd and 4th cervical rarely escape so that the whole trapezius muscle is affected.

Sternomastoid paralysis produces little or no alteration in the contour of the neck when at rest. But when the wasted muscle is passively stretched or the head is actively tilted towards the opposite shoulder—a movement still carried out with undiminished power—the asymmetry becomes noticeable.

Trapezius palsy, when complete, constitutes a more serious defect, and the cosmetic result is always striking. The upper limb is weakened; at first the patient may be unable to raise the arm above the head, but this movement is soon reacquired owing to the combined action of the deltoid, pectoralis major, and serratus magnus. The contour of the neck is quite characteristic. The upper trapezius fibres are absent and the levator anguli scapulae muscle shows up in bold relief (Fig. 547). Lower down, the outlines of the upper rhomboid muscle are visible. The scapula is dropped slightly and its lower angle is deviated towards the line of the spinous processes. *Winging* is evident when the arm is elevated but is often by no means a conspicuous feature.



FIG. 547.—Patient showing complete paralysis of the trapezius. Note the prominence of the levator anguli scapulae, winging of the scapula, and the disability.

Treatment.—The spinal accessory nerve is easily exposed, but in actual practice, lesions of the nerve and of the accompanying cervical branches are usually irreparable. Many different operations have been devised for the correction of a winged scapula. Most of them consist in attempts to anchor the scapula to the chest wall. (Nové-Josserand,[1] Henry.[2])

CERVICAL SYMPATHETIC

The sympathetic cord lies deeply in the neck, but may be injured by gunshot wounds or by operative dissection. The resulting syndrome may denote either a complete division of the cord or irritation. In the sympathetic cord run (*a*) the oculo-pupillary fibres, which supply the dilator of the pupil, the unstriped muscle in the levator of the upper lid and the small orbital muscle of Müller; and (*b*) vasomotor and secretory fibres, a most important group being distributed to the sweat glands of the head and neck. The dilator pupillae fibres leave the spinal cord in the 1st and 2nd dorsal anterior roots and reach the inferior cervical sympathetic ganglion via the white rami communicantes. Conduction in these fibres may therefore be abolished by lesions in different situations, viz., in the cervical cord or in the 1st and 2nd dorsal nerves or their anterior roots.

1. The signs of *paralysis* of the sympathetic are obvious on inspection. They are (*a*) drooping of the upper eyelid (pseudo-ptosis); (*b*) narrowing of the palpebral fissure (enophthalmos); and (*c*) contraction of the pupil (myosis). The normal reaction to light and accommodation is retained, but the pupil fails to dilate on pinching the skin of the neck (ciliospinal reflex) or after instillation

[1] NOVÉ-JOSSERAND and RENDU: Revue d'Orthopedie, XIII, No. 5, Sept., 1926.
[2] HENRY, A. K.: Brit. Jnl. Surgery, XV, 57, 1927.

of cocaine or adrenalin into the conjunctival sac; (*d*) absence of sweating in the whole of the upper limb, upper part of the chest, neck, and one half of the face, the area being accurately bounded by the middle line.

2. *Irritation* of the cervical sympathetic produces symptoms which are the exact reverse of those already described. Thus there is a dilatation of the pupil, and widening of the palpebral fissure (exophthalmos), a syndrome more familiar in Graves' disease. Repair of a sympathetic cord lesion is in theory possible, but few successful cases are on record.

CERVICAL PLEXUS

Injuries of the trunks of the cervical plexus are extremely rare, but in extensive operations on the neck the sensory branches may be accidentally or unavoidably divided. The resulting anaesthesia is ordinarily slight and passes unnoticed unless a careful examination is made. Of the *motor branches* of the plexus (1) the phrenic, and (2) the branches of supply to the sternomastoid and trapezius muscles are occasionally injured.

1. **The Phrenic Nerve.**—Division in the neck produces a paralysis of one half of the diaphragm which is often incomplete owing to the existence of an accessory nerve supply. In a healthy individual with a complete unilateral diaphragmatic paralysis, the subjective and objective symptoms are slight and the disability negligible. The palsy is best demonstrated by a radiographic examination.

2. **Branches to the Sternomastoid and Trapezius.**—(*a*) The sternomastoid is partly supplied from the 2nd and 3rd cervical nerves which may be injured in conjunction with the spinal accessory during operations for the removal of lymph glands from the anterior triangle of the neck. As already stated, complete sternomastoid palsy is a negligible quantity. This lesion is necessarily accompanied by a paralysis of the upper fibres of the trapezius. (*b*) The *trapezius* supply from the 3rd and 4th cervical nerves is usually confined to its middle portion. Isolated injury of these branches is almost unknown, the spinal accessory nerve being always implicated. The treatment of trapezius palsy has already been considered.

BRACHIAL PLEXUS

Injuries of the brachial plexus may affect the nerve roots proper, their anterior primary divisions, the primary plexus trunks, the secondary trunks, or the branches of distribution, either separately or in combination. Each level has its distinctive syndrome, but in multiple injuries at different levels the resulting clinical picture often presents a somewhat difficult problem in applied anatomy.

Types of Injury

Plexus injuries are commonly grouped into *supraclavicular* and *infraclavicular* lesions. In the former the nerve roots, primary trunks, or their small branches of distribution are involved; in the latter the secondary trunks and their branches; but an absolutely hard and fast line cannot be drawn.

Supraclavicular Injuries. (i) *Traction Lesions.*—When the head is laterally flexed, with the opposite shoulder fixed, or the shoulder forcibly depressed when the head is fixed, the plexus trunks are rendered taut. If considerable force is used one or more trunks may tear or rupture. Such violence may

occur in falls on to the shoulder, or more commonly in the infant during a difficult birth. (ii) Penetrating wounds of the supraclavicular region are liable to be fatal, but even in gunshot injuries the great vessels occasionally escape damage. (iii) Friction or Compression Lesions Associated with Rudimentary Ribs. (Chapter XXVII.)

Infraclavicular Injuries.—(I) *Contusion* or *compression* injuries may be associated with dislocations of the shoulder joint, fractures of the upper end of the humerus, or of the glenoid fossa. Certain chronological distinctions must be recognised; (*a*) the nerve injury may be produced by the violence which at the same moment produces the fracture or dislocation; (*b*) the nerve trunk may be contused or stretched by a displaced bony fragment; or (*c*) more rarely, the nerve lesion may be the unavoidable result of manipulation on the part of the surgeon in his attempts to reduce the displacement. All the infraclavicular trunks may be implicated or, what is more common, the lesion may be confined to the *inner cord* or to the *circumflex nerve.*

(II) *Penetrating* injuries from accidental or gunshot wounds are usually complicated by lesions of the axillary or brachial vessels. If the patient survives the initial haemorrhage, one of the various types of aneurism may later develop.

Symptomatology

Injuries of the plexus present certain broad clinical types, each with a characteristic syndrome.

1. The root syndrome.
2. The complete plexus syndrome.
3. The upper arm syndrome.
4. The lower arm syndrome.
5. The cervical rib syndrome.
6. Miscellaneous syndromes.

I. **The Root Syndrome.**—Isolated injuries of the cervical roots proper are extremely rare. Such lesions either form part of a complicated traction injury of the supraclavicular plexus, or may result from gunshot wounds in which the missile passes along the plane of the intervertebral foramina.

Two clinical groups may be demonstrated. (Stopford.[1])

(*a*) Root lesions without cord involvement (extraspinal injuries). In these there is a segmental type of paralysis and sensory loss, with a distribution in accordance with the particular root or combination of roots implicated. In actual practice it is often impossible to distinguish between root lesions and plexus injuries at a lower level. In pure root injuries there is likely to be a greater dissociation between the sensory and motor symptoms, but these finer differences may not always be appreciable. In defining the level of a plexus lesion, the origin of the motor nerves to the rhomboids (from the 5th cervical anterior primary division), and to the serratus magnus (from the 5th, 6th and 7th anterior primary divisions) should be borne in mind, for in injuries of the upper and middle trunks, these muscles are usually spared. Such minutiae relating to diagnosis, are of practical value when the question of surgical exploration arises, for root injuries and most injuries of the anterior primary divisions are irreparable.

[1] Stopford, J. S. B.: Lancet, March 1st, 1919.

(*b*) Root lesions with cord involvement (intraspinal injuries). A comcomitant cord and root injury usually implies damage to the spinal membranes. In severe lacerations of the cord, root symptoms are likely to be overshadowed, but in the lesions under consideration the cord symptoms are entirely subordinate, and may date from the time of the injury, or may arise later. If the former, the symptoms may be due to (i) spinal concussion, or (ii) a definite haematomyelia.

The late development of cord signs is usually due to the formation of adhesions inside the spinal theca. Where the symptoms suggest either a true root lesion or a plexus lesion high up, it is essential to examine the motor and sensory functions of the lower limbs.

In many cases the signs of cord involvement are trivial, and merely consist in an increase in the deep reflexes accompanied by a plantar response of the extensor type (Babinski reflex). If due to spinal concussion the symptoms tend to clear up in toto. Where there has been a haematomyelia, although improvement may be seen, there is often a residual disability, *e.g.* spasticity of one or both lower limbs, the Brown-Séquard syndrome, or mild but persistent ataxia.

II. **Complete Plexus Syndrome.**—In the majority of cases this is due to a supraclavicular lesion, but in gunshot injuries of the infraclavicular region, or more rarely in a dislocation of the shoulder a most extensive palsy may be seen.

The syndrome may be transitory, with partial recovery, leaving a residual palsy of a more limited degree.

(*a*) *Motor Signs.*—There is complete paralysis of all the muscles of the hand, forearm, and upper arm. The rhomboids and serratus magnus remain intact unless the injury to the 5th, 6th, and 7th roots is practically flush with the cervical transverse processes. When the nerve damage is extensive, rapid and profound wasting occurs in the useless limb and contractures develop.

(*b*) *Sensory Signs.*—There is a wide zone of insensibility which includes the hand, forearm, and part of the upper arm (the lateral aspect in the lower two-thirds). The *epicritic* and *protopathic* loss extends over the whole of this area, but the *deep loss* is usually limited to the hand and forearm.

(*c*) *Vasomotor and Trophic Signs.*—If the lesions be anatomically complete—which is unusual—the symptoms are slight. More commonly, owing to the axon irritation by scar tissue, gross fibrosis and degenerative changes are present in the tissues of the hand.

(*d*) *Sympathetic Signs.*—When the 8th cervical and 1st dorsal nerves are injured close to the intervertebral foramina, the oculo-pupillary and other sympathetic fibres are often implicated.

III. **Upper Arm Syndrome.** (Erb-Duchenne.)—This familiar and more limited syndrome is usually assumed to be diagnostic of a combined lesion of the 5th and 6th cervical nerves, either before their junction or at Erb's point. Operative findings have shown that an injury confined to the 5th nerve alone may occasionally produce an identical palsy. (Sherren.)

IV. **Lower Arm Syndrome.** (Klumpke.)—This is generally associated with the name of Klumpke, and denotes a lesion of the lower two plexus roots; the 8th cervical and 1st dorsal, or lowest trunk. As an isolated syndrome in traction injuries it is uncommon, although well recognised.

(*a*) *Motor Signs.*—There is a paralysis of all the intrinsic muscles of the hand, and where the atrophy of the thenar, hypothenar, and interossei groups is well marked, and a contraction of the long flexors of the fingers has developed, the typical *claw hand* deformity may be present.

(*b*) *Sensory Signs.*—The zone of anaesthesia includes the postaxial area of the forearm and hand, and a narrow strip in the upper arm. The loss of sensation is of the root type, the area of protopathic loss being more extensive than the epicritic loss.

(*c*) *Sympathetic Signs.*—Oculo-pupillary symptoms are often characteristic features.

V. **Cervical Rib Syndrome.** (See Chapter XXVII.)

VI. **Miscellaneous Types.**—Miscellaneous syndromes are seen in injuries involving the secondary nerve trunks in the axilla and their branches, for which it is convenient to adopt an anatomical classification.

(*a*) *The inner cord syndrome* is encountered most frequently in subcoracoid dislocations of the shoulder joint. The *paralysis* embraces the complete ulnar supply and the median intrinsic muscles of the hand. The area of *insensibility* is the ulnar zone of the hand, together with the postaxial surface of the forearm. The bulk of the disability thus falls on the hand.

(*b*) *The outer cord syndrome* is more rare. The motor signs consist in paralysis of the biceps, coracobrachialis, and proximal median muscles; with anaesthesia confined to the preaxial surface of the forearm.

(*c*) *The posterior cord syndrome* may also follow a dislocation of the shoulder joint. The syndrome covers a combined lesion of the musculo-spiral and circumflex nerves.

(*d*) *Circumflex Nerve.*—This nerve occupies a hazardous position as it passes backwards beneath the subscapularis and lower part of the shoulder joint capsule. Its course is very short, and it is closely fixed to the sheath of the subscapularis muscle.

The nerve may be compressed by an axillary crutch, but the common lesion is produced by the thrust of the displaced head in a subcoracoid dislocation of the shoulder joint. At the same moment the branch to the infraspinatus muscle from the suprascapular nerve may be stretched or torn. Although the circumflex nerve is in intimate relation to the neck of the humerus it is rare to find it involved in fractures of this region. The most important clinical sign is paralysis of the *deltoid*, with atrophy and loss of the normal contour of the shoulder; as a result the head of the humerus may be subluxated downwards and the joint becomes semi-flail. At first the power of true abduction is lost, but after a time the patient may develop a trick movement simulating abduction in which the pectoralis major plays the chief rôle. The paralysis of the teres minor adds little or nothing to the clinical picture. If the infraspinatus supply is also injured, wasting of this muscle will be evident.

The *cutaneous* supply of the circumflex covers a fair sized area on the lateral aspect of the shoulder and upper arm, in which epicritic and protopathic anaesthesia may be demonstrated. It is important to distinguish between the deltoid palsy of a circumflex lesion, and a paralysis of the same muscle due to a supraclavicular lesion of the plexus. Both may follow an injury to the region of the shoulder. In the former there is a definite area of anaesthesia; in the latter there is no sensory loss, and other muscles of the deltoid group are also involved.

Nerve Injuries Complicating Dislocations of the Shoulder Joint

Owing to their surgical importance it is convenient to summarise here the nerve complications of dislocations of the shoulder. These fall into two distinct groups: (1) Traction injuries of the plexus (supraclavicular lesions), absolutely independent of the luxation, but produced at the same time and by the same force (11 out of 36 cases—Delbet and Cauchoix[1]). (2) Infraclavicular nerve trunk lesions, which are almost always the direct result of the displacement of the humerus. (25 out of 36 cases—Delbet and Cauchoix).

In the latter group the *circumflex nerve* alone is most frequently injured. Less commonly there is a combined *circumflex* and *musculospiral* injury, or an injury of the *inner* cord. Other distributions may occur, but are atypical.

(*e*) *Serratus Magnus Palsy.*—Lesions of the long thoracic nerve (nerve of Bell) which originates from the fusion of three small branches derived from the 5th, 6th, and 7th cervical nerve, fall into three classes—(i) accidental division during operations for the removal of diseased cervical glands; (ii) pressure lesions induced by the constant carrying of heavy articles on the shoulder. In the latter the long thoracic nerve is involved in company with the descending *cutaneous* branches of the cervical plexus (3rd and 4th cervical) the motor branches to the trapezius, and occasionally the nerve to the rhomboids. (iii) Infective or toxic neuritis. The clinical signs of isolated serratus magnus palsy are (*a*) inability to raise the arm above the shoulder level in front of the body, (*b*) loss of forward pushing movements of the shoulder, and (*c*) slight winging of the scapula, which is rotated so that its lower angle is nearer to the middle line. But in the combined syndrome, the disability and deformity are much more conspicuous. The winging of the scapula is marked even when the arm is at rest and there is a complete loss of ability to carry out forward pushing movements of the upper limb.

In addition to the paralysis, pain radiating from the neck downwards over the clavicle is often complained of.

Treatment

The treatment of traction injuries in the new born infant, and compression neuritis due to cervical rib are described in Chapters XX and XXVII.

Supraclavicular traction injuries due to falls on to the shoulder region offer the same problems as the commoner obstetrical lesions. But in the adult the policy of early exploration has much to commend it. In the graver lesions operated on at a later stage, considerable difficulty is invariably experienced in both the exposure and the identification of nerve trunks which are usually incorporated in a mass of scar containing the remains of the scalene muscles. Division of the clavicle is often necessary before the distal trunks can be exposed and mobilised adequately. By patient dissection it may be possible to disentangle nerve trunks which contain a certain number of intact fibres running through the block of scar tissue. The choice between neurolysis and resection is then no easy matter, but it is wise to err on the side of conservatism in long standing injuries where a generous resection may leave a gap which cannot be bridged. The more limited lesions are easily dealt with, and the results of suture at the level of Erb's point are generally most satisfactory. The prognosis in suture of the lowest trunk is usually poor.

In *infraclavicular* injuries accompanying subcoracoid dislocations of the shoulder, spontaneous recovery is the rule. But in an unreduced dislocation of some weeks standing the palsy may increase owing to the continued pressure of

[1] Delbet and Cauchoix: Revue de Chirurgie, 1910, 41.

the displaced head, and the formation of scar tissue. Reduction by open operation, or excision of the head is usually followed by recovery of the nerve lesion.

Infraclavicular lesions due to penetrating wounds are often combined with thrombosis or aneurism of the axillary artery to which the nerve trunks are closely adherent. In the operation of neurolysis, the remains of the artery should be removed entire.

MUSCULOSPIRAL NERVE

Etiology.—(1) In the axilla the nerve is liable to be compressed from the prolonged use of a crutch, but such lesions are always transitory. (2) In the upper arm the intimate relation of the nerve to the humerus explains the frequent occurrence of dual lesions. Involvement of the musculospiral nerve in fractures of the shaft of the humerus may be primary or secondary. Primary lesions are generally due to the impact of one of the fractured surfaces, and may be produced by clumsy manipulation. Secondary lesions are popularly ascribed to enclosure of the nerve trunk in callus, a description which bears little relation to actual fact. In such cases the nerve is usually adherent to a sharp bony projection, or anchored in the distorted musculospiral groove. In old lesions a large nerve spindle may form on the proximal end connected to the distal end by a fibrous cord. (Fig. 548.) (3) In the region of the elbow the nerve is occasionally implicated in supracondylar fracture where lateral displacement of the lower fragment has left a bony "spike" or ridge.

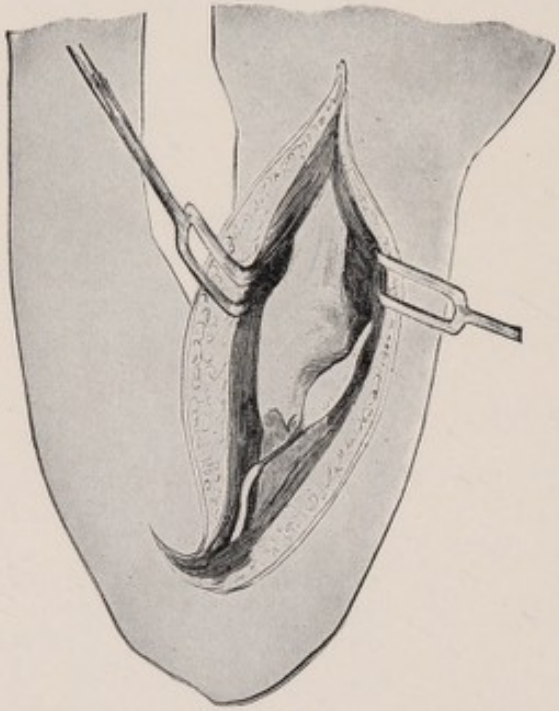

Fig. 548.—Old fractured humerus. Musculospiral nerve involvement. Shows a neuroma on the proximal end of the nerve trunk, connected with the distal trunk by a slender fibrous cord (Jr. Bone and Jt. Surg., July, 1928).

The nerve trunk may also be lacerated or divided at any level by penetrating injuries. Gunshot lesions of this nerve are familiar in modern warfare, and are usually combined with fractures of the humerus which show a predilection for non-union.

Symptomatology.—(1) The *motor* signs are at once apparent owing to the existence of "wrist drop." The paralysis affects the extensor group of muscles —the supinator longus the radial and ulnar wrist extensors, and the extensors of the thumb and fingers.

Paralysis of the triceps muscle is almost unknown in lesions of this nerve, as the branches to the constituent heads (four in number) arise between the lower part of the axilla and the upper limit of the musculospiral groove. An individual with a complete devision of the musculospiral nerve may sometimes exhibit a spurious extension of the wrist, one of the best known of the "trick movements" which patients with nerve injuries are able to acquire.

(2) The *sensory* signs are trivial. When the lesion is in *the upper third* of the arm there is a small, ill-defined triangular zone of anaesthesia on the dorsum of the hand on its radial border, and extending on to the thumb. In lesions below the origin of the lowest external cutaneous branch, there is no sensory loss.

The diagnosis of a musculospiral nerve injury is rarely in doubt. The wrist drop of *lead neuritis* is usually bilateral, and the palsy is incomplete, the supinator longus remaining unaffected. The paralysis is combined with the general signs of lead poisoning and the blue line on the gums.

Treatment.—The treatment of crutch palsy does not call for special comment. In the majority of nerve lesions accompanying simple fractures of the shaft of the humerus, spontaneous recovery is seen, but the primary lesions are occasionally grave, and require operative repair. Sharp spiking of the humerus in the area of the groove, or in a supracondylar fracture as shown in radiograms, may suggest a probable severe laceration or complete division. (Fig. 549.)

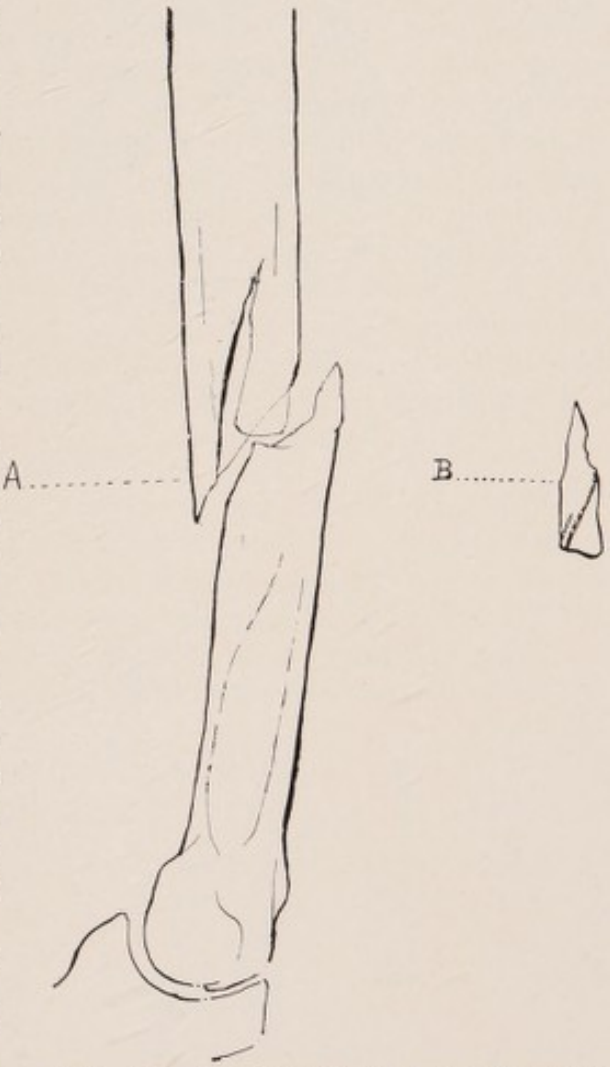

FIG. 549.—(*a*) Fracture of the shaft of the humerus, middle third, with musculospiral nerve involvement. (*b*) Small comminuted fragment, adherent, and slightly puncturing the nerve sheath (Jour. Bone and Joint Surg., July, 1928.)

In secondary lesions spontaneous recovery may usually be predicted, voluntary power appearing in the supinator longus in twelve to sixteen weeks after injury. Gunshot injuries for the most part demand operation, and their treatment is often complicated by the difficulty of obtaining union in the fractured humerus.

The conservative treatment of musculospiral palsy consists in relaxation of the paralysed extensor group of muscles by means of a cock-up splint, and the usual regular nutritional measures. Stiffness at the metacarpophalangeal range is liable to develop if an ill-fitting splint is used. The operative repair of a musculospiral lesion is rarely a matter of great difficulty. End to end suture is often possible even where a considerable length of nerve has been resected. In the more extensive gaps transposition of the nerve to the front of the arm results in a gain of one inch (Danforth and Stiles). In dual injuries with persistent non-union, fixation of the fracture by the stepcut or bone grafting operation (Chapter XVIII) should precede the nerve suture. After repair of any lesion the nerve trunk should be protected from contact with the humerus. In recent injuries a sufficient muscular flap is usually available, but in long standing injuries with destruction of muscular tissue, a sheet of fascia lata should be interposed.

The results of suture of the musculospiral nerve are most satisfactory, even after long periods of delay. Almost perfect restoration of function may be expected in a considerable proportion of the operations. For the few irreparable lesions an ideal tendon transplantation operation is available. (See p. 466.)

POSTERIOR INTEROSSEOUS NERVE

This short nerve trunk is occasionally divided by the penetration of a sharp tool or glass fragment, and may be injured in complicated gunshot wounds of the elbow. In simple fractures of the upper end of the radius, involvement of the nerve is almost unknown. The clinical signs consist in paralysis of the extensor carpi ulnaris and extensors of the fingers and thumb. The power of wrist extension is not appreciably diminished, but the disability is important in many manual occupations. Repair by operation is practicable only in a clean cut division, and the prognosis is poor in cases of suture performed just above the origin of the fan-like leash of branches. In irreparable lesions a modification of the tendon transplantation used in musculospiral palsy will give almost perfect function.

ULNAR NERVE

Etiology.—The more important classes of injury are (1) Penetrating wounds; more especially in the lower third of the forearm, and complicated by division of neighbouring tendons. (2) Gunshot wounds at various levels. (3) Traumatic neuritis in the post-condylar groove.

Symptomatology.—I. Lesions in the upper arm. The *paralysis* affects the flexor carpi ulnaris, and inner half of the flexor profundus digitorum (proximal muscles); the hypothenar, interossei, inner two lumbricales, adductors of the thumb, and the deep head of the flexor brevis pollicis (distal muscles). The flattening of the hypothenar eminence, the hollowed out interosseous spaces and the claw hand deformity which tends to develop, are characteristic signs. In the early stage the contracture is easily corrected, but as time goes on becomes fixed. Palsy of the ulnar intrinsic muscles is sometimes masked by "trick" or substitute movements. Adduction of the thumb may be simulated by the combined action of the opponens and flexor longus pollicis. Interosseous action (spreading of the fingers) should be tested with the hand lying palm downwards on a flat surface. If the fingers are allowed to flex, a spurious abduction and adduction may be produced by the extensors. *Sensation* is lost in the "one and a half finger area"—the ulnar border of the hand, the entire little finger and the ulnar half of the ring finger on both aspects. The protopathic and deep losses are usually confined to the little finger (Fig. 550).

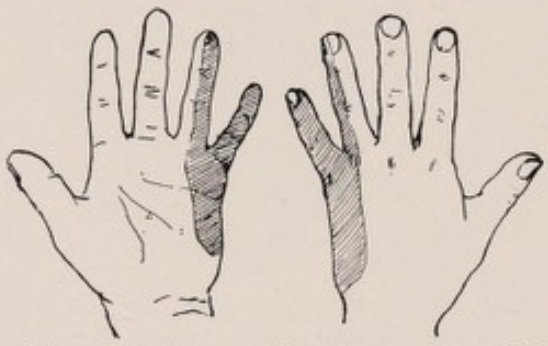

Fig. 550.—Sensory loss in complete division of the ulnar nerve.

II. **Lesions in the Forearm.**—The proximal muscles are unaffected, the wasted claw hand alone representing the palsy. This disability may be accompanied by the loss of flexion of one or more digits owing to adherence of the long flexor tendons. If the nerve has been divided below the origin of the large

dorsal cutaneous branch, sensation is retained on the dorsum of the hand, and the area of analgesia is much diminished.

III. **Lesions in the Post-condylar Groove.**—In the post-condylar groove the ulnar nerve occupies a somewhat hazardous position. During each movement of flexion the nerve is slightly stretched, but its normal elasticity and mobility allow it to respond to changes in tension without incurring damage. This compensatory mechanism is easily upset if either the nerve trunk itself or the bed in which it lies be injured. Under such conditions a traction or friction neuritis may be induced by unforced movements of the elbow. A neuritis is even more readily evoked in a nerve which has become anchored, if forced movements of the joint are used at certain stages in the treatment of the elbow injury. The nerve trunk may also be affected adversely if the joint is hypermobile, an anomaly which exists in a certain proportion of individuals. If the hypermobility reaches the stage of complete dislocation, and the displacement occurs with each movement of flexion, a friction neuritis is almost inevitable. There are certain ulnar nerve lesions in which a disturbance between the normal relation of the nerve and its bed is of considerable etiological importance. These conditions fall into three clinical groups and as the lesions are mainly incomplete may be classified under the title *traumatic neuritis*.



Fig. 551.—Separation of the internal epicondyle, with ulnar nerve involvement (Jr. Bone and Jt. Surg , July, 1928).

1. Primary neuritis—(*a*) Simple contusion.
   (*b*) Complicating—(*a*) Internal epicondyle fractures.
   (*b*) Supracondylar fractures.
   (*c*) Dislocations of the elbow.
2. Secondary neuritis complicating (*a*) Fractures of the lower end of the humerus.
   (*b*) Dislocations of the elbow joint.
3. Delayed neuritis—(*a*) Late ulnar palsy.
   (*b*) Recurrent dislocation of the nerve.

Primary Neuritis.—The most familiar primary lesion is the contusion which accompanies a separation of the internal epicondyle in children over twelve years of age. The signs of nerve block are usually slight and transitory, but a persistent neuritis may occasionally be seen under conditions which favour the onset of a secondary neuritis.

Secondary Neuritis.—Secondary lesions usually develop about the third or fourth week after the initial trauma. The underlying cause is a disturbance of the normal relation between the nerve and its bed. In the treatment of all fractures of the lower end of the humerus there is a critical stage at which the ulnar nerve may be damaged by the repeated stretching which accompanies the natural movements of the elbow joint. This is a rare sequel in supracondylar fractures promptly and efficiently reduced, where the elbow has been rested in flexion for some two weeks, and where mobilisation of the joint has been

carried out by the patient's unassisted efforts. But where the nerve has been slightly contused or where the nerve bed has been disturbed as a result of the fracture, a mild friction neuritis is sometimes induced by ordinary movements of the elbow. If there is a considerable disturbance of the nerve bed as in uncorrected lateral displacement of the lower fragment (Fig. 552); or if in contravention of all the principles of correct treatment, *forced* movements are used, a severe neuritis is almost certain to develop. The influence of these different factors, either singly or in combination, can be traced in the ulnar lesions which are encountered from time to time as complications of fractures of the lower end of the humerus. It should be emphasised that so-called callus compression plays no part in the pathogenesis of these lesions.

Delayed Neuritis.—(1) *Late ulnar palsy* is a well known sequela of external condyle fractures (Mouchet[1]). The clinical picture embraces three phases:



Fig. 552.—Supracondylar fracture with lateral displacement of the lower fragment; ulnar nerve involvement (Jr. Bone and Jt. Surg., July, 1928).



Fig. 553.—Old fracture of the external condyle with non-union. Late ulnar palsy (Robert Jones Birthday Volume, Oxford University Press, 1928).

(*a*) the fracture in early childhood (very rarely in adult life); (*b*) a latent period rarely less than ten years; and (*c*) the onset of ulnar neuritis. The nerve injury is a traction lesion predetermined by the cubitus valgus deformity resulting from the fracture. (Fig. 553.) The nerve trunk being compelled to take a longer course becomes stretched like a bow-string in the post-condylar groove. The onset of symptoms often coincides with a period of strenuous use of the limb in work or sport in which repeated flexion movements of the elbow are carried out. The lesion usually takes the form of a nerve spindle.

(2) *Recurrent dislocation of the ulnar nerve* may develop insidiously in a hyper-mobile nerve or may follow a primary dislocation due to a single severe trauma. The condition may be unsuspected for a considerable period. The onset of neuritis may be long delayed, there being a silent period as in late ulnar palsy after fracture (Platt[2]). The neuritis is a typical friction lesion with the ultimate formation of a nerve spindle.

[1] Mouchet, A.: Journal de Chirurg., 1914, No. 12, 457.
[2] Platt, H.: Brit. Journ. Surgery, XIII, 51, 1926.

Treatment.—In the majority of lesions due to penetrating injuries operative exploration is demanded. In a clean-cut division where the wound is uncontaminated, primary suture is always feasible. Fot gunshot injuries after sound healing of the wound, secondary suture or neurolysis will be practised according to the type of the lesion.

Where an extensive gap is present, displacement of the nerve to the front of the elbow gives additional relaxation, and is a routine step in all difficult sutures. In the milder forms of neuritis in the post-condylar groove, a period of rest for the elbow is usually sufficient. For all types of severe or progressive ulnar neuritis, the operation of anterior transposition should be employed.

The results of secondary suture are physiologically most imperfect. Signs of recovery in the intrinsic muscles may appear after long delay, but complete restoration of function in this group is for practical purposes unknown. The average sensory result involves the reappearance of protopathic sensibility alone. Musicians, artists, and fine manual workers remain seriously handicapped, but many individuals with complete ulnar palsy have been known to follow laborious activities such as dock labouring. The operation of anterior transposition when practised for traumatic ulnar neuritis at the elbow gives most admirable results.

MEDIAN NERVE

Etiology.—The chief types of injury result from (1) penetrating wounds especially in the region of the wrist; (2) gunshot injuries; (3) contusion or laceration in fractures of the lower end of the humerus (supracondylar injuries).

Symptomatology.—**I. Lesions in the Upper Arm.**—The *paralysis* is most extensive and includes (1) the proximal muscles—pronator radii teres, flexor sublimis digitorum, flexor carpi radialis, palmaris longus, flexor profundus



FIG. 554.—Sensory loss in complete division of the median nerve.

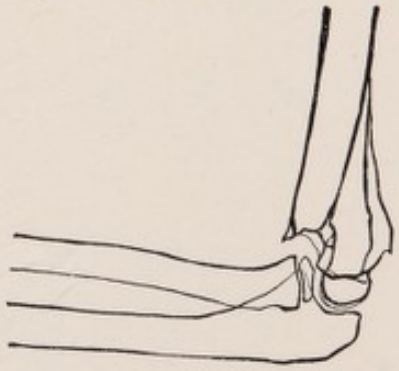

FIG. 555.—Supracondylar fracture of the humerus, with forward displacement of the shaft; median nerve involvement (Jr. Bone and Jt. Surg., July, 1928).

digitorum (outer half), flexor longus pollicis, and pronator quadratus; and (2) the distal muscles—the abductor-opponens group of the thumb and the outer two lumbricales.

Flattening of the thenar eminence is a prominent sign. Elimination of the proximal muscles does not constitute a very serious disability, as flexion of the wrist and fingers is still possible through the ulnar and musculospiral supply. Flexion of the terminal phalanx of the thumb against resistance cannot be mimicked by any form of trick, so that the absence of this movement is always an important diagnostic sign. False abduction and opposition of the

thumb may be produced by the combined efforts of the thumb extensors, the flexor brevis pollicis, and the adductors of the thumb, but a careful scrutiny should demonstrate that the thenar group is out of action.

Sensation is lost in the "three and a half finger" area (Fig. 554). The epicritic zone is clear cut, but the protopathic zone is much smaller, and is inconstant. Deep loss is confined to the middle and terminal phalanges of the index and medius. The complete anesthesia of the index finger renders this digit and the hand as a whole singularly helpless, quite apart from the accompanying paralysis. Irritative lesions are common in gunshot injuries with all

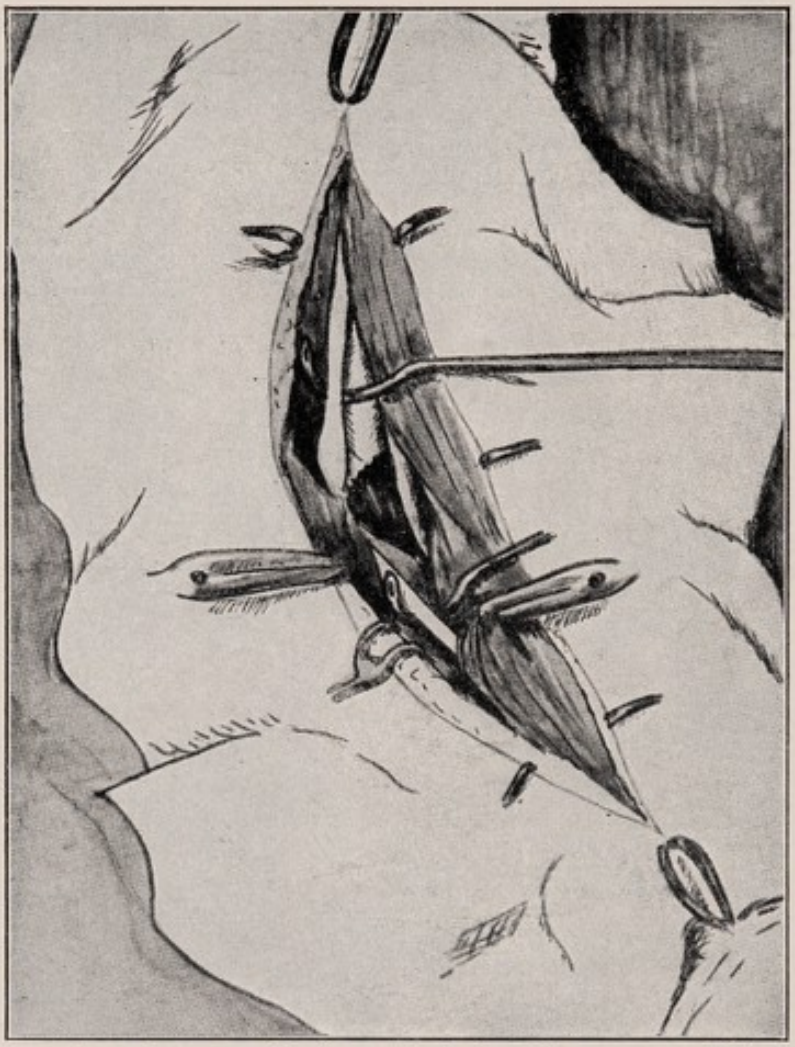

FIG. 556.—Supracondylar fracture. Median nerve lesion after exposure (Robert Jones Birthday Volume, Oxford University Press, 1928).

the usual trophic and sensory symptoms. In causalgia the symptoms are of dramatic intensity, and the degenerative changes in the tissues of the hand are profound.

II. **Lesions at the Elbow.**—Involvement of the median nerve is an occasional complication in supracondylar fractures where complete backward displacement of the lower fragment has occurred and the point or jagged end of the shaft has perforated the brachialis anticus (Fig. 555). The nerve is either contused or torn at the moment of displacement (primary lesion) or later becomes adherent to the projecting spike (secondary lesion) (Platt.[1]) (Fig.

[1] PLATT, H.: Journal of Bone & Joint Surgery, Vol. X, July, 1928.

556.) Clumsy manipulation of the fracture, or forced movements of the elbow at a later stage may add to the gravity of the lesion. The clinical picture may be that of an incomplete or complete nerve block, with the palsy including the proximal as well as the distal muscles.

III. **Lesions in the Lower Arm.**—In lesions at the wrist, owing to the limited muscular palsy, and the small area of complete anesthesia, the nerve lesion is apt to be overlooked, especially if overshadowed by the effects of coexisting tendon injury.

Treatment.—In penetrating lesions the problems are similar to those which arise in connection with the ulnar nerve. Early operation is usually required when the syndrome of irritation is present. Neurolysis may relieve the milder forms of neuritis, but in causalgia the complete block produced by resection or alcohol injection is essential. Operation is usually advisable in the lesions accompanying supracondylar fractures. The nerve trunk should be released, or repaired by suture, and after removal of the projecting bony spike, the bed should be lined by a fascia lata flap. The results of secondary suture of the median are unsatisfactory owing to the inadequate return of sensibility; recovery in the thenar muscles is also most inconstant.

During the recovery stage there may be a return of the syndrome of irritation. In irreparable lesions there is little scope for alternative operations except the tendon transplantation for thenar palsy which has already been described.

MUSCULO-CUTANEOUS AND INTERNAL CUTANEOUS

Injuries to these trunks are very rare and usually result from penetrating wounds. Division of the *musculo-cutaneous* produces a palsy of the biceps, coracobrachialis, and brachialis anticus, with anaesthesia in the preaxial half of the forearm. Flexion of the elbow is still possible owing to the combined action of the supinator longus and the pronator radii teres. The internal *cutaneous* nerve supplies the postaxial surface of the forearm. When divided the anaesthesia is usually confined to the epicritis type of stimulus.

LUMBOSACRAL PLEXUS

The lumbosacral plexus trunks may be injured in the pelvis under diverse conditions—*e.g.* by penetrating wounds, fractures, inflammatory disease or new growths of the pelvic wall or pelvic viscera, or even by compression of the foetal head. The majority of such lesions are entirely fortuitous, and do not warrant description as definite entities.

Maternal Obstetrical Palsy.—This is a special type of lumbosacral plexus injury which occasionally follows a difficult labour. The mechanism of its production is by no means settled. A logical suggestion is that the lesion is a traction injury, the fourth and fifth lumbar nerves being overstretched by the rotation of the sacrum which occurs during the first stage of labour. This view is supported by experiments on the cadaver, in which it has been shown that extreme rotation at the sacroiliac joints puts the roots of the lumbosacral cord under considerable tension (Lambrinudi[1]).

Symptoms occasionally arise before the actual labour begins, and usually consist in pain referred along the sciatic distribution. After delivery, a palsy is noted affecting the external and internal popliteal supply, chiefly the former,

[1] Lambrinudi, C., British Journal of Surgery, Vol. XII, 1925.

and accompanied by a varying amount of anaesthesia. Usually the nerve block though severe, is incomplete, and recovery sets in rapidly. Paresis of the external popliteal muscles with foot drop may persist for many months, and a certain degree of residual weakness may remain indefinitely. Treatment should be given along the accepted conservative lines,—viz., splintage, regular physiotherapeutic measures, and a walking appliance worn to correct foot drop.

A traction injury of the lumbosacral roots or plexus trunks may very rarely be seen in the new born *infant* after difficult delivery. Such exceptional lesions form the counterpart of the more familiar brachial plexus birth palsy.

CAUDA EQUINA

Etiology.—The lumbosacral and coccygeal nerve roots which occupy the lower part of the spinal theca may be injured (1) by penetrating wounds *e.g.*, gunshot injuries, (2) in fractures of the lumbar spine or sacrum, or (3) without actual bony injury from falls on to the buttock. Injury to the tapering end of the spinal cord (conus medullaris) may also occur at the same time, and add confusion to the clinical picture.

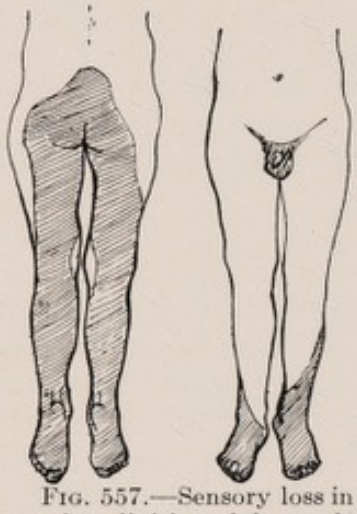

FIG. 557.—Sensory loss in complete division of the cauda equina.

Symptomatology.—It is necessary to distinguish between the cauda equina syndrome proper, and the conus medullaris syndrome.

I. **Cauda Syndrome.**—The symptoms are those of true root lesions, and are determined by the level and extent of the injury.

(*a*) *Motor Symptoms.*—In a total bilateral lesion both lower limbs show a complete flaccid palsy. Paralysis of the sphincters of the anus and bladder, and of the perineal muscles is also present. In less extensive injuries there is a tendency for the upper roots to be spared; in lesions below the second sacral roots the lower limbs are unaffected.

(*b*) *Sensory Symptoms.*—The anaesthesia is of the root type with a protopathic loss greater in extent than the epicritic loss. In complete lesions the area included consists of the lower limbs, perineum, and the saddle shaped area, (second, third, and fourth sacral segments) (Fig. 557). In incomplete lesions pain and hyperaesthesia may be important symptoms.

II. **Conus Syndrome.**—The conus contains the spinal segments below the third sacral. The paralysis is confined to the sphincters, and sensation is abolished in the saddle shaped area. The anaesthesia may show a dissociation of the cord type, *i.e.*, loss of pain and heat with preservation of the tactile sense.

Cauda lesions tend to develop slowly, and the distribution of the palsy and anaesthesia is often asymmetrical, whereas conus lesions appear abruptly and the signs of block are symmetrical.

Treatment.—Treatment of the resulting paralysis by conservative measures is usually the only form of therapy available. Conus lesions are of course irreparable. In exceptional cases of incomplete injury of cauda roots due to bony displacement, removal of the compression may be possible. Actual suture of cauda roots, or even anastomosis has been attempted, but such operations are largely theoretical.

GREAT SCIATIC NERVE

Sciatic injuries are familiar results of gunshot wounds of the lower extremities, but are uncommon in civil surgical practice. The nerve trunk may very rarely be damaged in fractures of the pelvis or femur, or dislocations of the hip joint. A traction lesion may be produced by the manipulative efforts to reduce a congenital dislocation of the hip in an older child. (Chapter XXVIII).

Symptomatology.—In a complete lesion high up there is a total paralysis of all muscles below the knee. The hamstrings are almost invariably spared, owing to the separate origin within the pelvis of their leash of motor branches. In partial injuries it is usual to find that the external popliteal group is chiefly affected. The outstanding sign of sciatic palsy is **foot drop.** Sensation of all types is lost in the foot in an area covered by the ordinary slipper. In the leg there is a loss of protopathic and epicritic sensibility except in a strip of skin on the mesial surface supplied by the long saphenous. (Fig. 558.) Traumatic, ulceration is often seen in the sole particularly under the head of the fifth metatarsal, or in the terminal phalanx of the great toe. The ulcers tend to be most intractable, and infection may extend deeply and produce necrosis of bone. Partial lesions often present the irritation syndrome, and in gunshot injuries causalgia is common.



FIG. 558.—Sensory loss in complete division of the great sciatic nerve.

Treatment.—The choice between conservative and operative treatment must be made on general principles. The foot drop should be corrected by the wearing of a night splint, and an appropriate walking appliance with a "stop" or uplifting spring. Contracture of the tendo Achillis develops rapidly if such precautions are neglected. The operative repair of extensive lesions is often a most tedious procedure. The fullest relaxation of the nerve is obtained when the knee is flexed and the hip hyperextended. The latter is a difficult position to maintain during the operation and afterwards. By the careful adjustment of the patient on the table by means of sand bags, the difficulty is minimised, and post-operative relaxation is best preserved by constructing a plaster of Paris shell beforehand fitted to the limb in the correct position. The neurological and economic results of secondary sutures are poor. Sensory recovery is always most imperfect, and constitutes a source of danger to the patient. For persistent ulceration and trophic phenomena, amputation is not infrequently necessary.

EXTERNAL POPLITEAL NERVE

The nerve trunk lies in an exposed situation behind the neck of the fibula, and is liable to injury from external pressure (strapping extension), contusion, or penetrating wounds. Traction injuries are occasionally seen combined with detachment of the fibular styloid process (Fig. 559). A similar lesion may occur in complete dislocation of the knee joint.

Symptomatology.—The motor signs are those of paralysis of the anterior tibial and peroneal groups with resulting foot drop. Sensation is lost in an

area on the lateral aspect of the leg and dorsum of the foot which also corresponds to the sensory distribution of the 5th lumbar segment. (Fig. 560.) The protopathic loss is almost as extensive as the epicritic loss unless the nerve is injured below the level of the origin of the lateral cutaneous branch.

Treatment.—Penetrating injuries should be dealt with by accepted methods. Mild contusions will undergo spontaneous recovery. The rare traction injuries are usually grave, and should be explored at an early stage, for in cases of suture after long delay the prognosis is bad. At the time of the operation the displaced fibular styloid process should be reattached, or if this is impossible should be excised. (Platt.[1])



FIG. 559.—Traction fracture of the upper end of the fibula with external popliteal nerve involvement (Jr. Bone and Jt. Surg., July, 1928).



FIG. 560.—Sensory loss in complete division of the external popliteal nerve.

A considerable portion of failures have been observed after suture of the external popliteal nerve for penetrating injuries; but after early intervention in traction lesions complete restoration of function has been observed.

INTERNAL POPLITEAL NERVE

Isolated injuries are uncommon. The nerve is usually damaged by penetrating wounds in conjunction with the external popliteal nerve and the popliteal vessels. If an aneurism develops the internal popliteal nerve trunk is always incorporated in the walls. Incomplete lesions are the rule, with the sensory and trophic syndrome of irritation. The paralysis affects the superficial and deep calf group of muscles and the intrinsic muscles of the foot.

[1] PLATT, H.: Journal of Bone & Joint Surgery, Vol. X, July, 1928.

Sensation is lost in the sole and dorsal surface of the outer four toes. (Fig. 561.)

Treatment is based on the usual principles. Early operation is indicated in irritative lesions or where the nerve is involved in an aneurismal sac. Neurolysis, or resection and suture will be required according to the local conditions.

POSTERIOR TIBIAL NERVE

Injuries of the nerve are rare, and occur only from penetrating wounds. The irritation syndrome is usually present, and overshadows the loss of function of the intrinsic muscles of the foot. As in lesions of the internal popliteal nerve early operation is advisable.



Fig. 561.—Sensory loss in complete division of the internal popliteal nerve.

ANTERIOR CRURAL AND OBTURATOR NERVES

Uncomplicated lesions of these trunks are practically unknown. Two cases of anterior crural palsy following child birth have been recorded by Cary.[1] Complete division of the anterior crural in the thigh is followed by paralysis of the quadriceps, a disability which can hardly escape notice. The sensory loss includes an ill-defined zone on the antero-lateral aspect of the thigh, and a narrow strip in the lower third of the leg on the mesial surface. Operative repair of the nerve lesion is out of the question. The quadriceps function may be restored by transplantation of the hamstrings or of the tensor fasciae femoris to the patella (Chapter XXI).

In a lesion of the obturator nerve, the adductor longus, adductor brevis, gracilis, and part of the adductor magnus are paralysed, but there is no sensory loss. Suture of a clean cut division is a feasible procedure, but opportunities for practising the operation will rarely arise.

TUMORS OF NERVE TRUNKS

The title *neuroma* is given to tumors which arise in the connective tissue framework of a nerve trunk. The true neuroma is a pathological curiosity. False neuromata may be single or localised, circumscribed or diffuse, affecting one or many nerve trunks.

(1) *Solitary Tumors.*—The benign tumors are usually slow growing *fibromata* or *fibro-myxomata* found on one of the larger nerves—sciatic, median, ulnar—in individuals between the ages of twenty and forty. A swelling, hard or cystic, occupies the line of the nerve to which it is fixed in the longitudinal direction only. Signs of nerve block or irritation are very rarely seen. The *malignant* tumors are *sarcomata* which grow rapidly in all directions, become fixed to surrounding structures, produce early interference with nerve conduction, and metastases. Operative treatment is always indicated. A benign tumor may usually be shelled out without injury to the nerve bundles. If liquefaction has occurred in a tumor arising in the centre of a nerve trunk,

[1] Cary, N. A.: Jnl. of Bone & Joint Surgery, Vol. VII, No. 2, April, 1925.

puncture and partial removal of the sac is often sufficient. A malignant tumor in the earlier stage demands complete resection, including a length of nerve trunk; if seen later, amputation of the limb is the only rational procedure.

(2) *Diffuse or Generalised Tumors.*—These tumors occur in many different forms, and should not really be included in the group of true neoplasms, because they represent a non-inflammatory overgrowth of the intraneural connective tissue—a lesion described as *neuro-fibromatosis* (Alexis Thomson).[1]

The main clinical features consist in (*a*) multiple tumors along the course of one or several nerve trunks; (*b*) pigmentation of the skin in definite localised areas; (*c*) palpable thickening of the nerve trunks; (*d*) very slight interference with nerve conduction; (*e*) a progressive course with a tendency to wide dissemination of the growths, and ultimately a fatal issue.

In many cases the tumors are inaccessible, but in the localised superficial types of neuro-fibromatosis, excision may be feasible, or in certain conditions amputation may be required.

[1] Thomson, Alexis: Neuroma and Neurofibromatosis, Edinburgh, 1900.

CHAPTER XXIV

LESIONS INVOLVING LOCOMOTION

The peripheral motor neurons of the spinal cord and the muscles form a trophic unit and degenerative disease may attack either end or any part of this physiological mechanism.

When the anterior horn cells are attacked the name *progressive muscular atrophy* is used. When the disorder first attacks the muscle tissue it is called *a muscular dystrophy.*

Progressive Muscular Atrophy

(Chronic Anterior Poliomyelitis)

The disease is due to a progressive sclerosis of the anterior cornual cells. The characteristic signs are muscular wasting in one or both upper extremities unaccompanied by loss of sensation. In its usual form it is not hereditary and affects adults from twenty-five to forty-five.

The *symptoms* first appear in the intrinsic muscles of one hand, especially in the thenar eminence and interossei muscles. The atrophy increases and extends and is accompanied by weakness and later paralysis. It extends gradually upward and involves the wrist flexors and extensors and a claw-like position of the hand results. The other arm is likely to be affected in a few months. If, as is usual, the disease continues to progress, it extends to the shoulder girdle, the deep muscles of the back, and then downward to the hips and thighs, but the legs generally escape. In a few cases, the atrophy begins in the shoulder and arm muscles, biceps, deltoid, and triceps and extends downward to the hands (upper arm type).

Very rarely it begins in the leg and ascends. Weakness and paralysis follow and are the result of the atrophy, deep reflexes may disappear or remain active or increase, and the muscles are flaccid.

The complete reaction of degeneration is rarely seen. The disease is slowly progressive and the prognosis is bad. Where the sclerosis extends into the pyramidal tract fibres, spasticity of the lower limbs with exaggerated knee jerks and a Babinski reflex, are added to the clinical picture. This type is known as *amyotrophic lateral sclerosis.*

There is no real remedy for the disease. Temporary assistance is afforded by the development of weakened muscles by massage and exercises.

Hereditary Muscular Atrophy of Peroneal Type

(Charcot-Marie-Tooth Type)

This form of the affection is hereditary or familial in character, begins in childhood and usually attacks the muscles of the leg first, especially the peronei muscles, the result of which is an equino-varus. The hands and forearms are occasionally involved in a similar process. Walking becomes difficult

on account of the malposition of the foot and the diagnosis is not easy, because children without this disease occasionally develop a **pes cavus** running into a mild equino-varus without known cause. Cramps may occur in the muscles and fibrillation is not infrequent. The tendon reflexes are usually lost but sensation is not greatly disturbed although feelings of numbness may be noticed by the patient.

The deformity of equino-varus due to muscular atrophy of this type is well marked, the muscles are rather rigid and the legs are small. Early claw foot combined with claw hand in young people, is an almost certain diagnostic sign of this uncommon affection.

Plastic tenotomy of the tendo Achillis is desirable and followed by improved walking for some years. Muscular development of the atrophied muscles should be attempted by exercises, and is often useful. Prevention of the deformity should be attempted by supporting the feet at right angles to the legs to minimize the drag on the anterior muscles.

Progressive Muscular Dystrophy

(Primary Myopathy—Pseudo-hypertrophic Muscular Paralysis)

This condition begins in early or middle childhood, affects boys oftener than girls and is due to a symmetrical progressive atrophy of the muscles associated with an apparent hypertrophy due to a deposit of fat in the muscles, which is most evident in the calves. These appear to be unusually well developed while the thighs are relatively small. The element of heredity is present in about three-fifths of the cases.

The first *symptom* usually noted is weakness in the legs and the child is easily fatigued. Going up stairs is noticed to be difficult and falls are frequent. The gait later becomes peculiar as the patient leans back from the hips, sways a little and balances carefully in walking. The calves later appear larger and denser than normal and a weakness of the extensor muscles of the legs, thighs, hips and trunk develops. This dominates the symptoms, makes rising from the floor difficult and the patient climbs up on his own thighs by placing his hand there, but a patient with weakness of the gluteals and knee extensors from poliomyelitis or any other cause gets up in the same way. The fact to remember as dominating the early and middle stage of the disease is weakness of the extensor muscles.

As a result of this, talipes equinus is a frequent accompaniment of the disease. Later on hip and knee flexion occur from prolonged sitting and marked bowing of the back occurs also in the cases of the later stages.

Accompanying this apparent hypertrophy of the calves there is noted an atrophy of the scapulo-humeral muscles with slight hypertrophic changes, but the latter are often absent or at least inconspicuous. The deltoid and all the muscles moving the scapula on the thorax are flaccid, weak and more or less impaired in function and when the child is lifted by the axillæ the scapulæ slip upward to an astonishing degree.

The reaction of degeneration is not present, sensation is not disturbed and the condition of the tendon reflexes varies with the degree of muscular atrophy, disappearing when atrophy becomes very marked.

"The *pathological changes* are first hypertrophy of muscle fibre and increase of muscle nuclei, swelling and rounding of fibres and splitting of same; then

increase of connective tissue with corresponding atrophy of muscle and deposit of fat. The process is a primary degeneration due to an inherent nutritional weakness of muscle."[1]

The *diagnosis* in all cases is not as easy as the text-books would lead one to suppose. In early cases, certain heavy children learn to walk late, they tire easily, are clumsy and their calves are large and yet they have no disease. At this stage it is of much assistance to see if any scapulo-humeral atrophy and weakness exist. The inability to go up stairs without assistance at even an

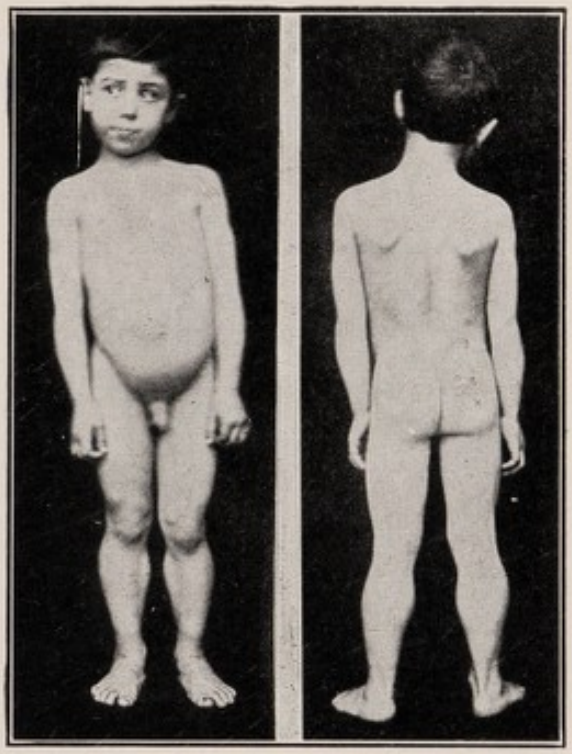

FIG. 562.—Muscular dystrophy—early stage.



FIG. 563.—Muscular dystrophy with equinus.

early stage is a very helpful diagnostic sign and inability to get off the floor without climbing up the thighs is characteristic of extensor and not general weakness, for weak children do not go through this proceeding.

The family history may clear up matters but sometimes a period of observation will be required before giving a definite opinion.

The foot deformity may be more marked on one side than on the other and may present difficulty in diagnosis.

A boy of six was sent to the clinic with a diagnosis of infantile paralysis and was slightly lame on account of an equinus on one side. But there was no *local* muscular weakness or paralysis anywhere else in the body and his gait was a little peculiar and balanced. Scapulo-humeral weakness of a slight grade was present, both calves were rather large and he went up stairs with difficulty. After study of several days the diagnosis seemed clear, but it could hardly have been made off hand.

[1] DANA: "Text-book of Nervous Diseases," 9th Edition, 317.

The *prognosis* is of course bad and some cases progress rapidly to a condition of helplessness, while in others progress is exceedingly slow and almost stationary. The later stages are characterized by a distressing degree of helplessness.

Treatment can of course be only palliative. If equinus deformity exists, a plastic tenotomy should be performed which will enable the patient to stand squarely and walk better and it often is several years after operation before the patient becomes as helpless as before operation.

Exercises for the extensor muscles aid muscular balance and improve the gait and usually a supporting corset makes walking easier.

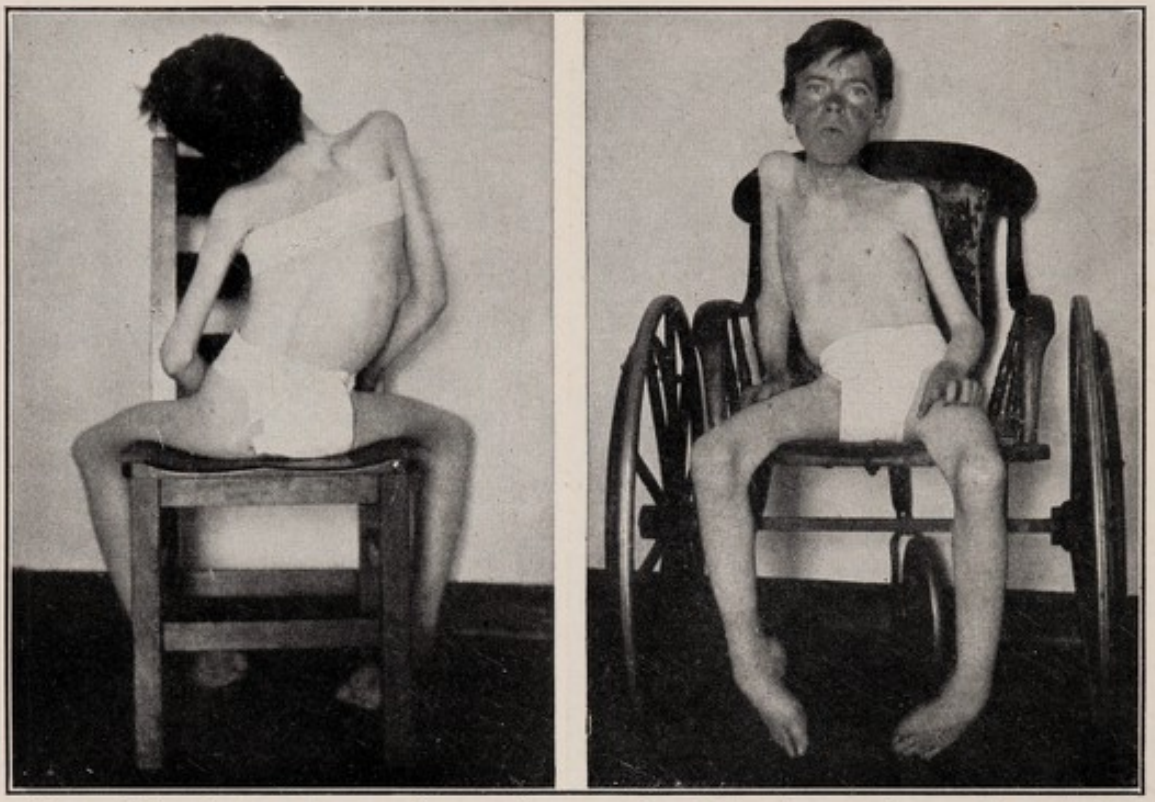

FIG. 564.—Later stages of muscular dystrophy with deformity and complete helplessness.

FIG. 565.—Same patient as Fig. 564, showing severe equinus.

Friedreich's Ataxia.—This is a developmental disease in which a progressive degeneration occurs in the postero-lateral columns of the cord. The symptoms usually appear at adolescence and consist in increasing awkwardness of gait, ataxia, clumsy speech, nystagmus, scoliosis and pes cavus. The deep reflexes are absent but the plantar reflexes are extensor in type. In the later stages there is a profound loss of joint and vibration sense in the lower limbs. The claw foot deformity may develop early before the characteristic ataxia. For this reason a careful neurological examination should be made in all adolescent cases of claw foot before operative correction is undertaken. Nothing can be done to stay the onward progress of the disease. For a time physiotherapeutic treatment may help to minimise the disability in locomotion.

CHAPTER XXV

AFFECTIONS OF MUSCLES, TENDONS AND FASCIAE

RUPTURE OF MUSCLES

Rupture of a muscle may occur from sudden overstretching, or during a powerful active contraction. The site of the rupture may be either in the muscle belly itself, or at the musculo-tendinous junction. All grades of injury may be seen, from a tearing of a few fibers to a complete solution of continuity. Partial ruptures are familiar accidents in various forms of sport and games. The muscles most frequently affected are (*a*) in the upper limb, the *biceps* and *triceps;* (*b*) in the lower limb, the *quadriceps, adductors, biceps cruris* (*short head*), and *gastrocnemius;* (*c*) in the trunk, the *abdominal*, and the *posterior spinal* muscles.

The symptoms consist in a sudden pain, sharp and stabbing, as if from a direct blow; a sensation of something giving way, and an immediate disability. Soon the swelling of a deep hematoma appears which may mask a gap in the line of the torn muscle. At a later stage the muscle belly when brought into action may be unduly prominent above the level of the rupture.

Treatment.—In *partial* ruptures where no gap can be demonstrated, the muscle should be kept relaxed, and the swelling controlled by strapping or by a firm bandage applied over cotton wool. After a few days graduated movements should be allowed. The most effective method of inducing contraction in an injured muscle without overstretching, is by faradic stimulation (Bristow[1]). In minor injuries treated promptly, full recovery of function should occur, but, if neglected, considerable disability may persist. This is often due to painful adhesions in the scar which forms at the site of the hematoma. In such circumstances a judicious manipulation under anesthesia will often be required. (See Chapter V.) For *complete* ruptures, which are rare, repair of the injury by open operation is usually indicated in patients of suitable age and physique. This is especially necessary where the rupture has occurred at a musculo-tendinous junction as in the gastrocnemius or rectus femoris. (See tendon ruptures.)

TUMORS OF MUSCLES

New growths of muscle are comparatively rare. Of the *simple* tumors, lipomata and angiomata are the most familiar. A *lipoma* forms a soft swelling in the substance of a muscle, and may simulate a muscular hernia. The diagnosis is usually confirmed by exploration. *Angiomata* have been observed chiefly in the triceps or forearm muscles. Such tumors tend to spread into the neighboring tissues, and free excision with or without some form of cauterisation is usually demanded.

Of the *malignant* tumors, *sarcoma* arising in the interstitial tissue, is the most important. Various histological types have been described, the slow

[1] Bristow, W. R.: The treatment of muscle and joint injuries, London, 1917.

growing fibro-sarcoma (Paget's recurrent fibroid) being the best known. The majority of the patients are under thirty, and a favourite site is the scapular region. The tumor grows slowly, is well encapsuled for a time, and is of firm consistency. Local recurrence is apt to occur even after an apparently complete removal, but visceral metastasis is often long delayed.

Treatment consists in excision of the tumor, with a wide margin of the surrounding muscle and fascial tissues, followed by the insertion of radium tubes.

MYOSITIS

(Infective; Specific; Parasitic)

A muscle may become infected directly from a wound or a neighbouring disease process; or indirectly through the blood stream. The bacterial agencies are of the usual variety, and the pathological process is that of simple abscess formation with destruction of muscle tissue.

Haematogenous infection by *pyogenic* organisms is rare.

Tuberculosis has very rarely been found in the larger muscles, but such lesions are difficult to produce experimentally.

Syphilitic myositis (gumma), actinomycosis, hydatid cyst, and trichiniasis may also be encountered.

The symptoms of localised myositis are pain, local tenderness, and a tumor.

Trichiniasis is not as infrequent as may be supposed. The embryos of the trichina spiralis, which flourish in uncooked meat, reach the muscle by the blood stream, become coiled up in fibrous capsules, and later calcify, leaving minute hard nodules. When present in great numbers they may cause severe pain, and even death. The symptoms are those of fever, muscular pain, stiffness, and swelling. The patient loses weight, and may be prostrated.

A positive diagnosis of the type of myositis is usually made by microscopical examination of the affected muscle tissue. Treatment with purgatives to clean out the intestinal tract when the affection is of parasitic origin is indicated. Tuberculosis and syphilis require constitutional and specific treatment. Infective myositis with suppuration requires surgical drainage, and the ordinary treatment of an abscess.

INTRA-MUSCULAR OSSIFICATION (See Chapter V, p. 77)

ISCHEMIC CONTRACTURE[1]

(Volkmann's Ischemic Contracture) (See also Chap. V)

In 1875 Volkmann first described a contracture of the fingers and wrist which he attributed to tight bandaging in the treatment of fractures about the elbow. In a later and classical article in 1882 he reaffirmed his belief in the ischemic origin of the contracture as opposed to a primary nerve palsy. Leser[2] in 1884 came to the same conclusion, and gave the first complete description of the histological changes in the affected muscles. These consisted in (*a*) a degeneration and disappearance of muscle fibres; and (*b*) a hyperplasia of the intermuscular connective tissue, preceded in the early stage by a most intense round-celled infiltration. The contributions of

[1] Jones, Robt., Sir: Brit. Med. Journ., 1928, Oct. 13.
[2] Leser: Saml. Klin. Vortr., 3208, 1884.

Volkmann and Leser have required but little revision or addition for nearly fifty years.

Clinical Picture

The condition is seen mainly in children between the ages of 6 and 11, and usually follows injury to the elbow (*supra-condylar fractures*), or more rarely, fractures of the forearm. The symptoms may begin in the space of a few hours; the hand is extremely painful, the fingers become swollen and discoloured, there is a feeling of numbness, and voluntary power disappears. At this stage there is usually marked swelling of the whole elbow region and particularly in the antecubital fossa. The fingers and wrist rapidly become contracted, and after some days, the muscle bellies in the upper third of the forearm are definitely hard and resistant. The skin may show blistering or localised sloughs, whether splints have been used or not.

The deformity increases until the fibrous tissue which has replaced the muscle, attains its maximum contracture. When the deformity is fully established, the appearance of the limb is characteristic. The wrist joint is palmar flexed, the fingers are slightly extended at the metacarpo-phalangeal range, and flexed at the interphalangeal joints. The forearm is often pronated, and the elbow joint fixed in flexion. It is usually possible to straighten the fingers with the wrist fully flexed. The general nutrition of the limb is also impaired; the hand is cold, bluish, and may show trophic ulceration. A feeble twitch may be present in the flexors of the fingers and thumb, or there may be complete loss of flexor power in all digits.

Various clinical types may be distinguished:

(*a*) The severe contracture already described; (*b*) Mild or transitory contractures. These are by no means uncommon; they often escape diagnosis and are recognised years after the fracture as a slight residual limitation of the range of extension of the fingers. (*c*) Ischaemic contracture complicated by nerve involvement. Involvement of the median or ulnar nerve is by no means rare, and many examples of such complications have been recorded in the literature (J. J. Thomas,[1] Dickson[2]). Nerve involvement adds much to the already severe crippling of the hand, and for this reason careful testing of motor and sensory functions should always be carried out in cases of ischaemic contracture. The *median* nerve may be implicated, either as a direct result of the elbow fracture, *e.g.*, when "spiked" or divided by the forwardly projecting diaphysis in a supracondylar fracture (Bristow[3]), or at a lower level may be compressed as it passes between the two heads of the shrunken and fibrous pronator radii teres. It is important to realise that this nerve trunk may occasionally be injured at both levels (Platt[4]). The *ulnar nerve* is less exposed to harm, but may suffer owing to shrinkage of the muscular and fibrous tissues around it. The clinical signs of nerve involvement are usually those of an incomplete lesion with partial anaesthesia and loss of function in the intrinsic muscles of the hand. On the whole there is a tendency to spontaneous recovery.

[1] Thomas, J. J.: Annals of Surg., March, 1909.
[2] Dickson, F. D.: Southern Med. Journ., xix, 1, Jan., 1926.
[3] Bristow, W. R.: Brit. Journ. Surg., x, 40, 1923.
[4] Platt, H.: The Robert Jones Birthday Volume, 1928. Oxford Medical Publications.

Pathogenesis

I. **Experimental Ischemia.**—In recent years much light has been thrown on the etiology of Volkmann's Contracture as a result of a study of experimental ischemia by Brooks and Jepson. Brooks[1] investigated the changes in muscle when deprived separately of its arterial and venous supply. It was found that after complete occlusion of the arterial supply, a massive necrosis of the muscular tissue occurred, which was not followed by fibrous tissue replacement on a large scale and contracture. But when the *venous* return only was blocked, a cycle of changes immediately followed, which formed the exact counterpart of the histology of ischemic contracture as described long ago by Leser in the human subject. First of all there was a wide-spread degeneration of muscular fibres, and a rapid invasion of the whole muscle by round cells so intense as to suggest an inflammatory lesion. This phase was immediately succeeded by the formation of fibrous tissue which helped to obliterate the remaining muscular fibres, and which showed a progressive contracture. Figs. 567, 568, 569.

Jepson[2] attempted to reproduce in dogs the conditions of prolonged external constriction of the limb by tightly applied splints, bandages, or plaster casts, but was unable to cause true and persistent ischemic contracture in the foot, except where the *femoral vein* had been previously ligated. The effect of the early relief of subfascial tension was also tested by reopening the wound and evacuating serum and clot after some hours, and it was conclusively shown that by this manoeuvre the onset of ischemic contracture could be prevented.

These experiments have proved what had already been surmised from clinical experience, that ischemic contracture is due to an acute venous obstruction, and does not occur where the obstruction is gradual.

II. **Anatomical and Clinical Factors.**—(1) Since the first recognition of this condition by Volkmann, many cases have been observed in which an external constriction of the limb by bandaging, splints, or plaster of Paris has been maintained during the first 48 hours. But from time to time undoubted true examples of severe ischemic contracture have occurred when no form of external constriction has been employed. The experimental work already quoted supports the view that a circulatory block may occur from within, due to the pressure of edema and hemorrhage. In most fractures of the lower end of the humerus a considerable hematoma forms in the antecubital fossa which is a somewhat circumscribed fascial compartment with unyielding boundaries. At this level the venous return from the internal epicondylar group of muscles (pronator radii teres, flexor carpi radialis, flexor sublimis digitorum, flexor profundus digitorum, flexor longus pollicis) converges to one main vein, which is readily compressible (Middleton, Fig. 566). The rapid occlusion of this nodal point will obviously produce the type of venous block which has been proved in experiments to initiate the degenerative and fibrotic changes of ischaemic contracture.

(2) There are, however, certain other factors of etiological importance in relation to ischaemic contracture as a complication of supracondylar fractures. It has become the routine to treat all such injuries with the elbow in full flexion, a position which when employed intelligently should be the method of

[1] Brooks, B.: Archives of Surg., v, 1, July, 1922.
[2] Jepson, P. N.: Annals of Surg., 84, Dec., 1926.

choice. By full flexion is meant suspending the wrist below the chin with the hand resting on the opposite shoulder.

Unfortunately the misleading term "acute flexion" has crept into general use, and the position has been interpreted by many, as close contact of the forearm to the upper arm, with the hand on the shoulder of the same side. It must be emphasised that *hyper-flexion* is both unnatural and dangerous, even where excessive swelling of the elbow is absent, for in this position venous compression, and indeed arterial compression, is almost unavoidable.

(3) Delay in reduction, or failure to correct the forward displacement of the shaft in supracondylar fractures may also determine ischemic contracture. It is well known that the sharp projecting fragment occasionally compresses the median nerve, and it is easy to see how venous kinking and obstruction may also be produced. Full flexion of the elbow in an unreduced fracture is bound to be disastrous, for it requires force which should never be applied in the treatment of such an injury. If the elbow does not flex easily it is always suggestive of blocking due to bony displacement.

Prophylaxis

Prophylactic measures demand therefore that we should (*a*) avoid circular compression; (*b*) reduce all bony displacement whether a fracture or dislocation; (*c*) avoid all splints and more especially if there is much swelling; (*d*) use no force in flexing the elbow; (*e*) critically watch all fractures about the elbow for the first two days. The warning symptoms are great pain, stiffening and swelling, cyanosis and lividity of the fingers. Ischaemia may result without obliteration of the radial pulse, but this symptom is at least evidence of circulatory pressure.

Prognosis

In many cases the prognosis is unfavorable, although the function of the hand can generally be much improved by appropriate treatment. The prognosis is most grave where (*a*) the nerve damage is severe or complete; (*b*) the obstruction to circulation in the fingers has remained pronounced; (*c*) the wrist is fully flexed and the forearm is fixed in extreme pronation with limited movement in the elbow joint; (*d*) only mass movement occurs in the fingers. The prognosis is more favourable (*a*) when the circulation is good and nerve involvement is slight; (*b*) when the forearm moves freely on the upper arm, and some supination is possible; (*c*) when flexion of the wrist is not extreme and some separate voluntary movement can be obtained in the fingers. In the slighter degrees of contracture noticed only after the completion of treatment, the prognosis is always favourable.

Treatment

(1) **When the Ischemia Has Started.**—The arm should be released from all restraint, and should be elevated. Manipulation of every kind should be avoided. The experiments of Jepson suggest the advisability of dividing the fascia over the antecubital fossa, in order to relieve tension, and indeed this procedure was advocated by J. B. Murphy in 1914. There are but few cases on record in which this operation has been carried out, but the method deserves further trial.

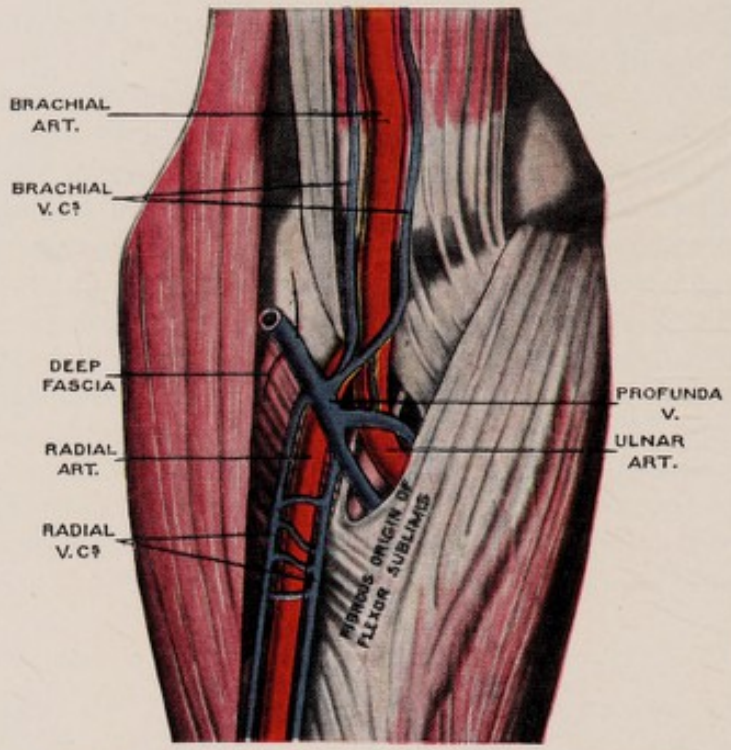

FIG. 566.—Venous anatomy at the elbow (Middleton).



FIG. 567.—*Transverse Section of Muscle*, showing (*a*) many oval fibres which do not fit in so well together as normally, (*b*) no sarcolemma nuclei, (*c*) a slight thickening of fibrous tissue and absorption by cells of connective tissue working in from the edge, (*d*) the very slight, if any, diminution in width of fibre. (The cells from the connective tissue have absorbed the muscle fibre and laid down connective tissue in its place. There is some muscle detritus left at the edge.) (Bristow, British Journal of Surgery, April, 1923.)



FIG. 568.—*Longitudinal Section of Muscle.* Passing from left to right across the section the following points are noticed: (*a*) dead muscle bundles in which cross-striation is very marked—actual fragmentation of the fibre in some sections at the cross-striation, (*b*) a few nuclei of cells spreading along the outside of the muscle fibres, breaking the muscle up into fragments, and absorbing the remains, (*c*) the fibrous tissue is laid down in regular bundles, replacing muscle bundles which have been removed by the phagocytic cells. (Bristow, Brit. J. Surg., April, 1923.)



FIG. 569.—*Degeneration of Muscle* (after division of a peripheral nerve). Transverse section showing (*a*) the muscle fibres shrunk, (*b*) the nuclei of the sarcolemma multiplied and, in some cases, passing into the fibre, (*c*) the thickening of connective-tissue septa. (In longitudinal section this muscle shows no cross-striation. This muscle is capable of recovery.) (Bristow, British Journal of Surgery, April, 1923.)

(2) **Treatment of the Contracture.** (*a*) *Mechanical Treatment.*—The method advocated in 1908[1] of unfolding the contracture by gradual splintage has been fully described in Chapter V, page 95. As the contracture yields, the hand improves greatly in function; the circulation is better, and the fingers often show a return of voluntary power. If the ischaemia has caused complete obliteration of muscular fibres, it is obvious that good function cannot be secured, but patients are most grateful to be relieved of the claw deformity which is so conspicuous. The splinting should be combined with physiotherapeutic treatment, consisting of radiant heat, contrast bathing, gentle massage, and electrical stimulation of the muscles.

(*b*) *Operative Correction.*—Many of the operations formerly practised for the relief of severe contractures are not to be recommended. Amongst these are (*a*) tenoplasty, in which the individual tendons were lengthened at the wrist and (*b*) shortening the radius and ulna by resection of a sufficient length of bone. A more logical procedure where there is slight residual deformity which refuses to yield to further splintage, is the detachment of the origins of the affected flexor muscles from the internal epicondyle and upper end of the radius and ulna. (Muscle-sliding—Page.[2]) Where a severe contracture is accompanied by fixation of the forearm in pronation and marked limitation of the elbow joint, an excision of the joint may be indicated. It should be emphasised that before resorting to any form of open operation as much correction as possible should be obtained by gradual stretching.

(3) **Treatment of the Nerve Complications.**—Where the signs of nerve block are marked, and particularly when there is persistent displacement of the shaft in a supracondylar fracture, exploration of the median or ulnar nerve is advisable. The median nerve should be freed from its adherence to the bony spike and should be relieved from compression as it passes through the fibrous mass formed by the pronator radii teres. This operation may be usefully combined with the detachment of the origin of the ischaemic muscles at the inner side of the elbow.

INJURIES TO TENDONS

A tendon may be divided by the penetration of a sharp object, or may undergo subcutaneous rupture.

Division of Tendons

Penetrating injuries are usually due to the introduction of foreign bodies, such as fragments of glass or sharp tools, the common sites being the lower third of the forearm, the palm, and fingers. At the wrist, tendon section may be complicated by injury to the median or ulnar nerves. Most of the wounds encountered in industrial surgical practice are infected, and in the subsequent inflammatory reaction, considerable sloughing of the injured tissues may result.

In a complete division the proximal end quickly retracts, and a considerable gap may be present almost immediately. This is best marked in the flexor tendons of the digits. If the tendon sheath itself remains intact, and the gap is small, a fibrous bond of union may form which leaves the tendon permanently elongated. The healing of a divided tendon is almost always followed by the formation of adhesions which may bind the tendon down and effectively put it

[1] Jones, Robert Amer. Journ. Orth. Surg., v, 1908.
[2] Page, C. M.: Proc. Roy. Soc. Med., 1922–3, xvi, Sect. Orthop., 43.

out of action. This may occur after either complete or partial division. Where the wound infection has run its course unchecked, the scar tissue is correspondingly marked.

The diagnosis of tendon division is often made, or at least confirmed, during the course of an exploratory first aid operation. But even in the presence of an external wound, tendon injuries are frequently overlooked. It should be the rule to test each individual tendon action in all penetrating wounds of the hand and forearm before the patient is anaesthetised. At the same time careful testing of nerve conduction should be carried out. Digital tendons are not infrequently divided through a mere puncture which heals rapidly leaving an inconspicuous scar. The disability is thus apt to be recognised only at a later date. A useful clinical sign in division of one of the flexor tendons of a finger is the undue laxity of the segment controlled by the injured tendon. It must be remembered that flexion of the terminal phalanx is produced by the profundus tendon alone, and this movement cannot be mimicked effectively by any form of trick action. If the sublimis tendon has been divided, the continued action of the profundus will tend to flex the middle phalanx as well as the terminal phalanx. When both the sublimis and profundus have been divided, flexion at the metacarpo-phalangeal range is still possible owing to the action of the interossei and lumbricals. Division of the extensors of the digits is usually more easily recognised owing to the superficial position of the tendons.

It is not always easy to distinguish between loss of tendon function due to adhesions, and complete division. An exact diagnosis may be impossible until the injured area has been exposed at operation.

Treatment

I. **Recent Injuries.**—The wound is treated on conventional lines, which may include the excision of devitalised tissues. The ends of the divided tendon should be accurately apposed by fine sutures of absorbable material. In multiple tendon injuries the repaired tendons should not be allowed to come into close contact. If end to end approximation cannot be obtained without extending the dissection into non-infected areas, primary tendon repair should be abandoned and efforts concentrated on the sterilisation of the wound. At a later date when healing is completed, the tendon should be re-explored.

The functional result of a primary tendon repair in the presence of an accidental wound will depend entirely on the type of healing. If infection runs riot, suture lines are almost certain to break down, and sloughing and extensive scar formation will follow. If such a sequela is happily avoided, early movement should be allowed. After a few days, faradic stimulation of the muscle belly should be used, and voluntary movements of the digit encouraged.

The prognosis in suture of the digital extensor tendons is usually much better than in suture of the flexors.

II. **Old Injuries.**—Considerable success may follow carefully planned reconstructive operations for old tendon injuries. The tendon should be exposed through a generous incision, and a free exsection of scar tissue carried out. The operation may consist in the simple freeing of an adherent tendon (tendolysis) or suture after the local resection of a fibrous band of union or of

a considerable length of altered tendon. The technique of suture is illustrated in Fig. 570. The size of the resulting gap may necessitate the insertion of a graft composed of either free tendon or fascia lata. If grafting be considered impracticable, the distal end of the tendon may be attached to a neighbouring sound tendon.

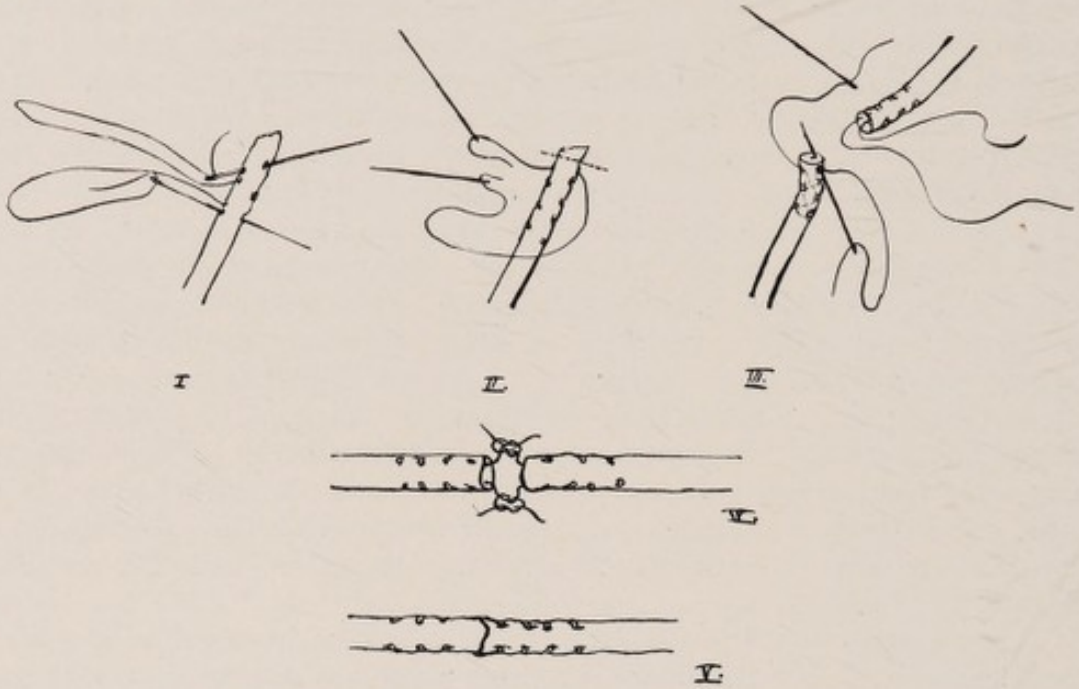

FIG. 570.—Technique of tendon suture (Bunnell).

The majority of such reconstructive operations must necessarily be carried out on the hand, where success is dependent on meticulous attention to technical detail. In this region the skin incisions should not cross transverse creases in the palm or fingers at right angles, and needless division of the digital nerves should be avoided.

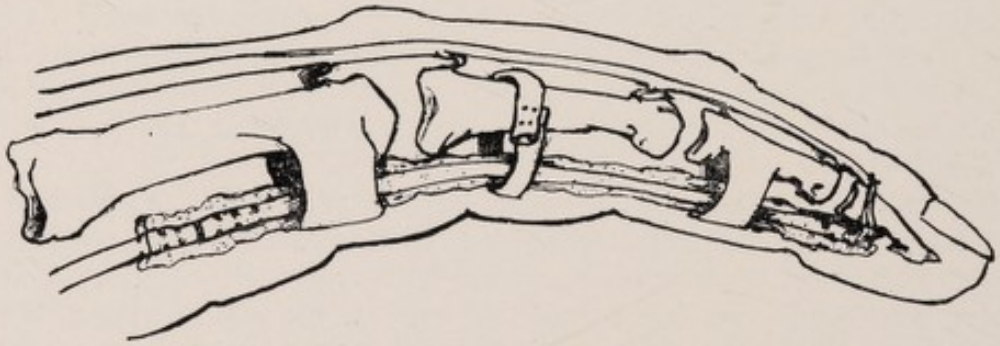

FIG. 571.—Tendon grafting for gap in flexor tendon with reconstruction of pulley and gliding mechanism (Bunnell).

Where a tendon has been freed from scar, or reunited by suture or graft, the gliding mechanism should be restored. A simple method is to surround the repaired tendon with a graft of paratenon fat taken from the superficial surface of the fascia lata or triceps aponeurosis. Tendon grafts should be removed with the paratenon intact. Such tendons are available in the long extensors of the toes or palmaris longus. In the reconstruction of the flexor tendons of the fingers, the pulley mechanism should also be restored. Where

necessary a simple pulley may be fashioned from a free tendon graft which is carried round both the bone and tendon (Fig. 571).

In resecting a damaged area it is sound practice to excise a considerable length of tendon in order that the graft may be sutured distally in the region of the terminal phalanx, and proximally as high up in the palm as possible. Suture lines placed in tendons in the region of the proximal and middle phalanges tend to contract considerable adhesions (Bunnell[1]).

After Treatment.—After a tendolysis, movement should be started the day following the operation. After repair by suture or grafting, the tendon should be maintained in relaxation by an appropriate splint, and active movement allowed after about a week.

Rupture of Tendons

Rupture of a tendon often occurs from sudden overstretching as an alternative to rupture of the muscle belly at a higher level. In tendons which pass along an osseous groove a more insidious type of rupture is occasionally seen. This is due to a preliminary adherence of the tendon, which later becomes frayed out, and finally snaps in response to a trivial force (*spontaneous rupture*). A tendon may also be torn from its point of insertion with or without an accompanying separation of a flake of bone (*disinsertion*).

The common tendon ruptures may be tabulated as follows:

Upper limb	Lower limb
Supraspinatus (see Chapter IV)	Rectus femoris
Biceps—long head	Ligamentum patellae
Extensor longus pollicis	Tendo Achillis
Extensors of the fingers (disinsertion)	Plantaris

Biceps

Of the two proximal biceps tendons, the *long head* is the usual site of rupture. The tendon may give way in the bicipital groove, or may be detached close to the margin of the glenoid cavity. In the groove the rupture may follow a known severe violence, or on the other hand may occur spontaneously where the tendon is adherent in a bed distorted by chronic arthritic changes. Disinsertion from the glenoid margin is invariably due to definite injury. The immediate symptoms are identical with those of rupture of the muscle belly itself. Considerable weakness of the arm often results, and in old ruptures the flabby muscle, with the bulge nearer the elbow than normal, is the outstanding diagnostic sign. Rupture of the tendon of *insertion* is a rare injury.

The disability should be treated by open operation in the early stage. In rupture near the insertion, reattachment to the glenoid is usually impracticable, but the free end of the tendon may be passed through the short head, and fixed to the coracoid (Gilcreest[2]). In rupture in the lower part of the groove direct suture may be possible.

[1] Bunnell: Journal of Bone and Joint Surgery, Vol. 1, No. 10, 1928.
[2] Gilcreest, E. L.: Journ. Amer. Med. Assoc., Vol. 84, June 13, 1925.

Extensor Longus Pollicis

Rupture of the long extensor of the thumb is the most typical example of spontaneous or delayed tendon rupture. This injury may be seen: (*a*) as an isolated lesion, or (*b*) in association with a fracture of the lower end of the radius. The former type has been observed many times in kettle-drum players (Levy[1]), and may also occur in certain manual occupations. It is probable that the rupture is preceded by a mild teno-synovitis. After fracture of the lower end of the radius (Colles', or backfire fractures) the extensor longus pollicis is liable to become adherent in the lower part of the radial groove. Ordinarily the effects of such adhesions are transitory, but occasionally the tendon becomes anchored, and at its point of fixation becomes frayed out. Complete rupture usually takes place some weeks after the fracture, and when the patient is beginning to use the hand freely. The disability may pass unnoticed unless a definite "snap" is felt at the time.

The signs of rupture of the extensor longus pollicis are (*a*) complete inability to extend the terminal phalanx of the thumb against resistance, and (*b*) the absence of the subcutaneous "bowstring" in the line of the tendon when the thumb is actively extended.

Operation gives the only chance of a reasonable functional result. In *recent* injuries, end to end suture is usually possible, but the ruptured tendon should not be replaced in the original groove. If considered desirable the normal oblique course may be restored by passing the tendon through a small pulley constructed from a free tendon graft. In *old* ruptures, it may be necessary to close a gap by tendon graft, or as a last resort, to affix the distal end of the long tendon to the short tendons. After any form of operative repair early mobilisation should be allowed, with due precautions to prevent overstretching.

Extensors of the Fingers

Disinsertion of one of the long extensors of the fingers usually results from a blow on the tip of a digit, producing a forced flexion at the terminal interphalangeal joint. The accident is a common one, and is often sustained in cricket or baseball. The tendon gives way close to its attachment, and a tiny flake of bone may also be avulsed. Considerable swelling develops in the soft tissues within a few hours, and for a time may conceal the dropping of the terminal phalanx, which later is a conspicuous sign (mallet finger). In neglected cases, a painful finger with contraction of the terminal inter-phalangeal joint may be seen. Excellent results follow prompt conservative treatment. In recent injuries, the finger should be fixed on a small malleable splint with the terminal phalanx hyper-extended, for not less than four weeks. Immobilisation for a shorter period does not ensure sound union and a restoration of the power of extension. Even in a "mallet finger" of some weeks' standing a sufficiently prolonged period of fixation will often restore the function of extension, and such a course should always be tried before any form of operation is contemplated. Reattachment of the tendon by suture is a difficult technical procedure, and the results of operations for this disability are on the whole disappointing.

[1] Levy, W.: Zentralblatt f. Chirurg., 89, Jan. 7, 1922.

Rectus Femoris

The strong rectus femoris tendon may be torn across by a powerful contraction, as in the equivalent injury, fracture of the patella. The tendon fibres of insertion may be avulsed close to the bone, or rupture may occur through the tendon mass a little higher up. If the quadriceps pouch is torn a haemarthrosis is usually seen. In spite of the integrity of the vastus externus and vastus internus, extension of the knee is quite impossible.

Repair of a complete rupture by operation is always indicated except in feeble or aged patients. After suture the band of union should be strong enough in three weeks to allow cautious graduated mobilisation of the knee joint. Where operation is contraindicated the knee should be kept in full extension preferably by a caliper splint. A pad should be placed above the level of the rupture to prevent undue retraction.

Ligamentum Patellae

Rupture of this ligament is rare. In an early case, repair by suture is usually feasible. In long standing and neglected ruptures where the ligament has been replaced by an attenuated fibrous band, the construction of a new ligament is indicated. This may be supplied by a free tendon graft, or a fascia lata sling passed through the tibia in the region of the tuberosity, and above through the lower angle of the patella. Strong active extension has been restored to the knee after such reconstructive procedures.

Tendo Achillis

Rupture of the tendo Achillis is usually seen in individuals over the age of 40. The accident is not unfamiliar in tennis or badminton players and in many cases occurs as the individual is stepping backwards. The tendon may give way about ½″ above its insertion, or a little higher at its narrowest point, or still higher at the musculo-tendinous junction. The rupture may be either a simple transverse break, or the tendon bundles may be dragged apart in the coronal plane. The sheath may remain intact, or a definite hiatus may be found. In such a powerful group of muscles rapid retraction of the proximal end is inevitable. Experience gained from the operative repair of Achilles-tendon ruptures has shown that the plantaris does not usually give way.

The diagnosis of complete rupture of the tendo Achillis is not always a simple matter. The interior of the sheath rapidly fills with blood, and the walls of the sheath become infiltrated with oedema. This gives the impression of continuity of tendon fibres on each side, even where a definite gap is palpable in the middle line. As in other muscle and tendon ruptures the gap may be fully obscured by the haematoma after twenty-four hours. The diagnostic signs of complete rupture of the tendo Achillis are: (*a*) a palpable gap increased by dorsiflexing the ankle; (*b*) the absence of the true gastrocnemius and soleus action in plantar flexion of the foot—a very fair plantar flexion can of course be carried out by the combined action of the tibialis posticus, peroneus longus and flexors of the toes; (*c*) high retraction of the calf belly; (*d*) an abnormal range of passive dorsiflexion now possible in the foot. This latter sign is most useful in differentiating between complete and partial rupture.

Treatment.—(1) *Recent complete* ruptures should be repaired by operation without delay. Difficulty is sometimes experienced in the actual suture, and more especially in the sliding tears where the ends consist of ragged tendon bundles in which sutures do not easily hold. Under such circumstances the site of union may be usefully reinforced by a living suture of fascia lata transversing the tendon well above and below the point of section. Adequate contact of the ruptured ends is only possible with the foot in the full equinus position. The sheath should be restored as carefully as possible. After completion of the operation the leg should be fixed in plaster of Paris with the foot in full equinus and the knee flexed. After three weeks the foot should be gently brought up to the right angle position, and a walking plaster applied for a further three weeks. Walking is later allowed with an elevated heel or a thickened boot tongue to prevent overstretching of the band of union. *Partial ruptures* may be treated by this method from the beginning. The return of full function in the calf group is expedited by faradic stimulation and exercises.

(2) In *old* ruptures which have escaped diagnosis, operative reconstruction should be attempted. Owing to the great retraction, end to end suture may be difficult, but with the knee flexed strong traction on the proximal end may allow the gap to be closed by direct suture. The repaired area should be reinforced by a living fascial suture. In an extensive gap bridging may be obtained by turning down flaps from the proximal end, or free tendons grafts may be inserted. Where it is feared that the bond of union will be slender, the action of the calf muscle may be reinforced by transplanting the tibialis posticus and peroneus longus to the os calcis.

Plantaris.—A diagnosis of rupture of the plantaris tendon is often made, but it is doubtful whether such a lesion is an actual entity. The fact that this tendon is almost invariably intact in complete Achilles ruptures is most significant. It is probable that the majority of so called ruptures of the plantaris are minor tears in the belly of the gastrocnemius in the neighbourhood of the musculo-tendinous junction. The disability responds well to conservative treatment which consists in strapping the leg from the ankle to the knee, with a pad over the painful area. Walking may be allowed at once after elevating the heel of the shoe.

DISLOCATIONS OF TENDONS

Peroneal Tendons

Luxation of the peroneal tendons from the groove behind the external malleolus is by no means rare and unless efficiently treated is very apt to recur. Both peronei may undergo luxation or the peroneus longus alone may be affected. The condition is usually seen in older children or adolescents and may escape notice for some time. The tendon slips forward during each dorsiflexion of the foot, especially when this movement is combined with eversion. A definite snap is experienced; when the reverse movement is carried out the tendon returns to the groove. In paralytic calcaneo-cavus a similar displacement is occasionally seen.

The initial cause of the displacement is not always evident, but it is often the effect of indirect trauma. It occurs during running or jumping, when the foot is sprained by inversion and flexion. The external annular ligament is usually torn. The symptoms are pronounced and definite. They consist of

pain, swelling, ecchymosis, and a feeling of something having given way. The tendon or tendons can be felt lying over the malleolus.

Shallowness of the groove, abnormal laxity of the tendon mesentery, and shortening of the tendons, have been suggested as possible factors in recurring luxation. The repeated slipping may cause little disability in some individuals, but not infrequently gives rise to pain, local swelling, and lameness.

Treatment.—If seen at once treatment should consist in reducing the displacement and retaining the tendons in position. This can usually be done by applying a pad of sticky felt under pressure just over and behind the malleolus. If the ankle is kept at rest for four weeks recurrent displacement is rendered unlikely. If operation is needed in a recent case, the ruptured structures, sheath, annular ligament, etc., should be reattached. In the recurrent stage many different procedures have been practised to hold the tendon in place. The sheath should be reefed and used as an anchorage to the periosteum. A periosteal flap from the malleolus with adjoining soft tissue should be reflected over the tendon and attached to the astragalus. It is better to bring about replacement without bone grafts if possible. The results of operation are favourable if the tendon is kept out of action by maintaining the foot in eversion and plantar flexion for fourteen days.

Snapping Hip

The condition known as *snapping hip* is a somewhat analogous type of disability. A snap is heard and felt when, with the knee flexed, the hip is rotated inward; a tight band may be seen to slip to and fro over the great trochanter. The snapping rarely occurs when the hip is moved passively. An anatomical explanation has been put forward by Wood-Jones[1] who has described a well defined tendinous band on the deep surface of the gluteus maximus in these cases. The power of snapping once acquired may become an ingrained habit and a source of considerable discomfort in highly-strung individuals. Others learn to inhibit the snap and especially under reeducation treatment. Where actual operative treatment is considered necessary, simple division of the accessory tendon is usually sufficient to produce complete cure. We have operated on such a case under spinal anesthesia, the action of the tendon being well demonstrated. When divided the patient could not reproduce the snap. To prevent recurrence after operation the divided band should be sutured behind the trochanter.

TENOSYNOVITIS (Tenovaginitis)

Tendons and their sheaths may be affected by various types of inflammation due to mechanical, toxic, or bacterial agencies.

Acute Infective Tenosynovitis

Etiology.—A tendon sheath may become infected through a puncture wound; by spread from a neighbouring focus, *e.g.*, cellulitis; or more rarely through the blood stream. The commonest site of suppurative tenosynovitis is in the hand, and very considerable crippling may result in neglected cases. The tendon sheath becomes distended with pus and the tendon infiltrated and later destroyed. Pus may burst through the sheath and track widely in fascial

[1] Wood-Jones, F. W.: Journal Orthop. Surgery, Vol. XVIII, 1920.

planes. After the acute inflammation has subsided scar tissue formation causing obliteration of both tendon and sheath, is seen.

Symptomatology.—The *onset* is often abrupt with rapid development of the ordinary signs of a localised infection of the soft parts—pain, swelling, redness of the affected finger and adjacent regions. The maximum oedema and redness are often best marked on the dorsum of the hand, a misleading sign. Fever and the symptoms of toxic absorption may be slight or severe. The special signs which are diagnostic of tenosynovitis proper as opposed to suppuration in the neighbourhood of tendon sheaths are: (*a*) tenderness along the line of the tendon sheath only and best marked at the proximal end of the digit; (*b*) rigid flexion of the finger, and (*c*) pain when extension is attempted. These signs are most easily demonstrated in tenosynovitis of the ring, middle, and index fingers. (Kanavel.[1])

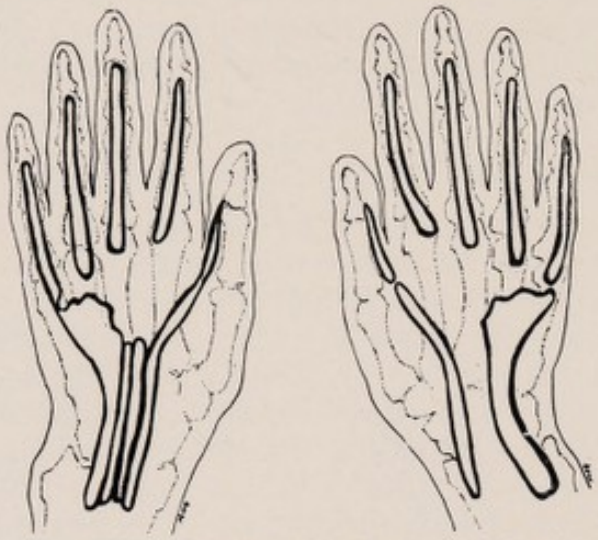

FIG. 572.—Flexor tendon sheaths of the fingers showing the two common anatomical types of arrangement.



FIG. 573.—Incision for draining the flexor tendon sheaths in the fingers, in the palm, and of the wrist (Kanavel).

Extension of the Infection.—(1) Suppuration in the flexor sheath of the little finger and thumb, may extend to the ulnar and radial bursae at the wrist (see Fig. 572). This gives rise to localised tenderness and swelling in the lower part of the forearm in the region of the upper border of the annular ligament.

(2) Secondary spread may also occur to the connective tissue spaces in the palm following rupture of the infected tendon sheaths. Rupture of the ulnar or radial bursa allows infection to track deeply in the forearm between the deep flexors and the pronator quadratus.

(3) In the later stages and particularly in neglected cases, involvement of the carpal bones or of the wrist joint may be seen, resulting in the gravest disorganisation of the hand.

Treatment.—The treatment consists in prompt drainage, rest, and early mobilisation of the affected digit. The operation may be conducted with advantage under a tourniquet.

[1] KANAVEL, A. B.: Infections of the Hand, London, 1925.

(1) For the digital *sheaths* the incisions should be placed at the side of the digit and over the middle or proximal phalanges (Fig. 573). When the tendon sheath is exposed, if there is any doubt about the diagnosis, a preliminary aspiration should be carried out using a fine needle. In the thumb the sheath should be first opened over the proximal phalanx and the incision extended cautiously in the plane between the two heads of the flexor brevis pollicis. Care should be taken to avoid injury to the motor branch from the median nerve to the thenar muscles.

(2) The ulnar and radial *bursae* are best entered through incisions on the lateral and mesial borders of the forearm in the lower fourth. The common tendon sheaths are exposed on their deeper aspect and thus division of the anterior annular ligament is avoided.

(3) The palmar *fascial spaces* may be drained through incisions accurately placed (see Fig. 574).

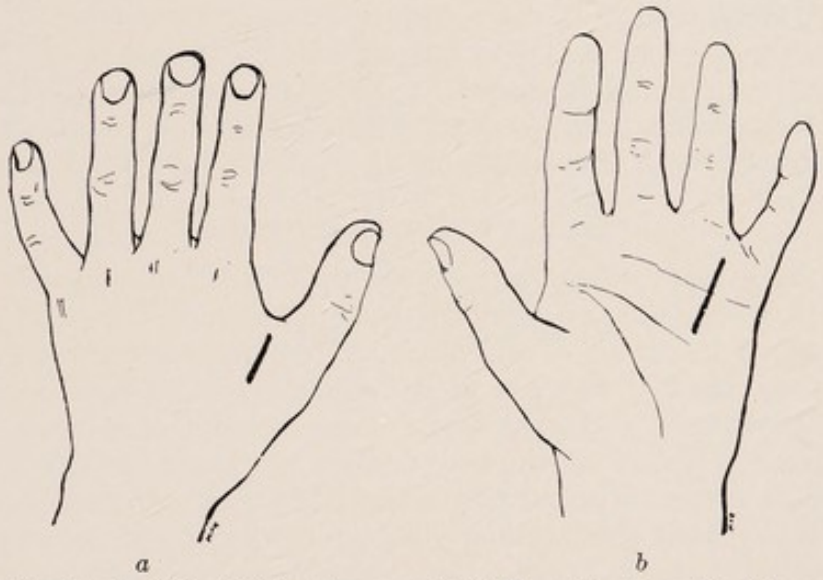

FIG. 574.—Incision for draining (*a*) the thenar and (*b*) the mid-palmar fascial spaces (Kanavel).

After evacuation of the pus from a tendon sheath or fascial space, the drainage material should consist of a strip of vaseline gauze or rubber tissue. The hand is then fixed on a sterile metal cock-up splint with the wrist in dorsiflexion. The affected finger may be separately splinted in the position of slight flexion at all joints. Needless dressings should be avoided and all drainage material should be removed after forty-eight hours if possible. Prolonged fomentations and constant soaking should be prohibited. Early active movements should be commenced once the danger of spread of the infection is at an end. Movements are best carried out with the hand maintained in the corrected position in an antiseptic bath. In the healing stage the splintage should be intermittent and active movements should be combined with gentle stretching and faradic stimulation of the muscle bellies.

Simple Tenosynovitis

Subacute or chronic teno-synovitis is a common type of disability. A mild inflammatory reaction is seen with distension of the sheath, which may clear up entirely or may leave a variable amount of thickening and adhesions. Repeated attacks may lead to an actual narrowing of the sheath, a condition described by De Quervain in 1895 as tendovaginitis stenosans.

Simple teno-synovitis may be produced by (*a*) trauma—more especially if repeated (occupational strain, or overuse); or (*b*) a mild toxic or infective agent—rheumatism, gout, fibrositis and similar conditions. The tendon sheaths most frequently involved are the extensors of the thumb, radial extensors of the wrist, flexors of the fingers, long head of the biceps, tibialis anticus and posticus, and peroneal tendons. The symptoms are pain on movement (often a constant ache), local swelling in the line of the tendon sheath, and silky crepitus. Considerable disability may be present in the more chronic cases, and especially where the tendons of the thumb are affected. One form of "trigger" or snapping finger is due to the stenosing type of teno-vaginitis involving the flexor tendon.

The treatment in the early stages consists in rest, compression by strapping and the elimination of any focal sepsis such as apical tooth infection. In neglected or untreated cases the question of operative exploration must occasionally be considered. In tendo-vaginitis stenosans of the thumb tendons, considerable success has followed simple division of the shrunken sheath. (Larroyenne and Bouysset.[1]) In trigger finger a similar operation is usually effective, but occasionally a definite nodule is found on the tendon itself. This should be exsected without actually dividing the tendon.

Ganglia of Tendon Sheaths

Ganglia are cystic swellings connected either with tendon sheaths or with smaller joints, and are found chiefly on the dorsum of the hand or wrist, on the fingers, or on the front of the ankle. The swellings are usually painless and may be fluctuant or so tense as to feel solid. The pathology of ganglia has been much debated. It has often been assumed that they originate as hernial protrusions from a tendon sheath or carpal joint, but operative findings often fail to demonstrate any direct communication. A more logical suggestion is that they result from colloid changes in the capsule or tendon sheath. The cysts which form in the external semilunar cartilage in the knee are analogous conditions.

The small tumors rarely cause actual disability; when they develop in a region subjected to overuse or strain the individual may complain of weakness. If necessary a ganglion may be treated by dispersion or by aspiration followed by the application of pressure by means of a small adhesive pad. If such simple measures are unsuccessful, careful removal by dissection is necessary.

Tuberculous Tenosynovitis

Tuberculous disease of tendon sheaths is seen in younger adults of both sexes and often in individuals who are otherwise in good health. Compared with other forms of surgical tuberculosis the incidence is low. The most common site is the sheath of the flexors of the fingers, on the front of the wrist and in the palm. Two main pathological types are seen: (*a*) a chronic fibroserous tenosynovitis with "melon seed body" formation, and (*b*) a fungating type. In the latter the changes are more advanced; the sheath is widely infiltrated with typical granulation tissue, and abscess or caseation may occur.

Symptomatology.—A doughy swelling appears in the line of the affected sheath; fluctuation may be demonstrated and the existence of melon seed

[1] Larroyenne and Bouysset: Archives Franco-Belge de Chirurg., 30, No. 2, Feb., 1927.

bodies diagnosed by a peculiar fine crepitation. In tuberculous teno-synovitis of the common flexor sheath there is a swelling above the wrist and one in the palm, and fluctuation may be demonstrated from one swelling to the other (compound palmar ganglion). This is best displayed by asking the patient to flex and extend the fingers. In the early stages the fingers are freely mobile, but later become slightly flexed and contracted. Spontaneous healing with little residual disability may occur or the tuberculous process may extend widely. If secondary infection follows, intractable sinuses may develop. Extension of the disease to the carpus or wrist joint is ordinarily a very late phenomenon and occurs in neglected cases only.

Treatment.—Conservative measures should be used as a routine. The wrist should be immobilised on a cock-up splint and the patient treated under open-air conditions with all the accessory forms of therapy used in tuberculous disease of bones and joints. Aspiration of a large effusion or of a cold abscess may be necessary. Success has been reported from the injection of various forms of modifying fluids. Operative attack in tuberculous teno-synovitis is rarely justifiable, for the diseased areas cannot be completely eradicated without jeopardising the function of the contained tendons.

If, however, pain is persistent, a small incision may be made into the sheath in the palm and another above the wrist. The cavity can be well syringed with a sterile saline solution, the melon seed bodies squeezed out, and a silk-worm drain passed through. The drain should be kept in for a few days.

Syphilitic Tenosynovitis

In the *secondary stage* of syphilis a mild tenosynovitis has been described in the extensor sheaths of the hand or foot; it is usually bilateral, symmetrical, and painless. In the *tertiary stage*, gummatous infiltration of the larger tendon sheaths may be seen. The clinical signs are in no way distinctive, but the Wassermann test will aid in differential diagnosis. Both conditions rapidly subside under antispecific treatment.

NEW GROWTHS OF TENDON SHEATHS

Primary tumors of tendons proper are almost unknown. Tumor of tendon sheaths are well recognised though rare, and may be classified as follows:

I. Benign Tumors—Lipoma.
Myeloid tumor (giant cell type).
Xanthoma.
Fibroma.
Chondroma.

II. Malignant Tumors—Sarcoma.

Benign Tumors.—(1) *Lipomata* are rare and may occur in two forms, either as solitary tumors, or as lipoma arborescens, a condition which is also seen in the knee and other joints. These tumors are usually found in the tendon sheaths in the palm or region of the ankle. The clinical signs resemble those of chronic teno-synovitis, and a final diagnosis is likely to be made only as a result of operative exploration. If causing disability, excision of the fatty mass and part of the tendon sheath is indicated.

(2) *Myeloid Tumor* (Giant Cell Tumor).—This is the commonest simple tumor affecting tendon sheaths, and is usually found in the palm in a flexor sheath about the level of the metacarpo-phalangeal joint. The tumor is

small, of soft consistency, grows very slowly, and interferes little with the function of the tendon. This histological picture resembles the giant cell tumor of bone. Diagnosis is usually somewhat difficult. There is often a history of injury. The chief signs are those of a mild chronic teno-synovitis only, until a definite localised swelling becomes palpable. Free excision is necessary as the tumor shows a tendency to recur locally.

(3) *Xanthomata* are tumors of the giant cell type affecting the tendon sheaths of the fingers and hands, and presenting a special histological picture. This consists of the presence of pigment and xanthoma cells. (Broders[1]); Mason and Woolston.[2])

(4) Fibroma and chondroma are rare tumors of which a few examples are on record (Buxton.[3])

Malignant Tumors.—Sarcoma has been observed in the palm, forearm, peronei sheath, and the tendo Achillis. The tumor is rapidly growing and dissemination occurs as in other forms of connective tissue sarcomata. A polymorphous histological picture with secondary changes is usually presented. If diagnosed in the early stage, wide local excision may be feasible, but amputation of the limb is often necessary.

DUPUYTREN'S CONTRACTURE OF THE FINGERS

Contracture of the palmar fascia was first described by Dupuytren in the early part of the nineteenth century in a course of clinical lectures delivered at the Hotel Dieu in Paris. (1832).[4] Quoting from his lecture

"M. Dupuytren, who had watched the patient for a long time, was informed of his death, and, happily, this remarkable case was not lost to the science of medicine. As soon as the arm was at his disposal, he procured an exact drawing of the parts, and then proceeded to the dissection. The whole of the skin was removed from the palm of the hand, and from the palmar face of the fingers; the folds and the wrinkles which it had represented hitherto, entirely disappeared; it was then evident that this appearance during the disease was not natural, but was communicated to it; but in what manner, and by what cause? The dissection was continued; the professor laid bare the palmar aponeurosis, and was astonished to perceive that it was tense, contracted and shortened; from its lower portion proceeded, as it were, cords which extended to the sides of the diseased finger. In attempting to extend the fingers M. Dupuytren saw clearly, that the aponeurosis experienced a kind of tension or crisping: it was a beam of light: he therefore conjectured that this aponeurosis was connected in some measure with the effects of the disease. But it still remained to find the part affected: he cut the prolongations sent by it to the sides of the fingers: the contraction ceased immediately: the least exertion extended the phalanges perfectly. The tendons were entire: the sheaths had not been opened: what then was the change? To remove all doubts, and conquer every objection, Dupuytren exposed the tendons; they were of the usual size, and as movable as common, and their surfaces were smooth: he carried the examination still farther; and articulations were in their normal state; the bones were neither swelled nor uneven; they were not in the least affected, either externally or internally; there was no perceptible change in the inclination of the articular surfaces, no alteration in the external ligaments, nor ankylosis: the synovial sheaths, the cartilages, the synovia, were perfectly unchanged. Hence it was natural to conclude, that the commencement of the disease was in the unusual tension of the palmar aponeurosis, and that this tension arose from a contusion of the aponeurosis, in consequence of the too violent or too long continued action of a hard body upon the palm of the hand."

[1] Broders, A. C.: Annals of Surgery, 70, 574, 1919.
[2] Mason and Woolston, Archives of Surgery, 15, 4, Oct., 1927.
[3] Buxton, St. J. D.: Brit. Journl. Surgery, x, 40, April, 1923.
[4] Clinical Lectures on Surgery, Hotel Dieu, Paris, 1832, by Baron Dupuytren. (Translated by A. S. Doane, Boston, 1833. Carter Hendee & Co., Pub.)

This deformity was described as early as 1610 by Plater and by other writers after him, but it remained for Dupuytren to determine the exact nature of the contracture.

Pathology.—In Dupuytren's contracture there is a hyperplastic inflammation of the palmar fascia affecting its longitudinal bands which begins locally, usually opposite the metacarpophalangeal joint (Fig. 575). On microscopic examination the fascia shows a diminution in vascularity and an infiltration by scar tissue. The skin of the palm, the tendons and their sheaths

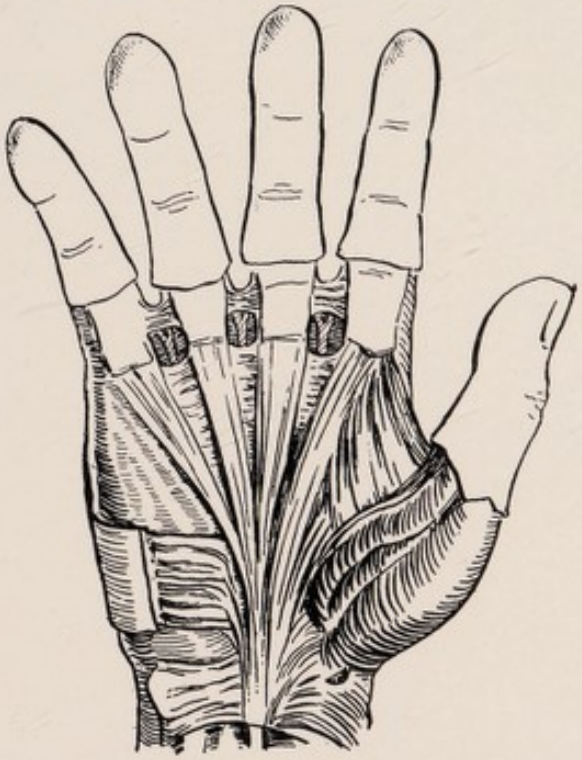

Fig. 575.—The palmar fascia with its prolongations.

are not involved unless the contracture is of very long standing. Only in the most severe and long standing cases are the digital joints at all disturbed.

Etiology.—In a series collected by Keen and Nichols, 180 out of 227 cases were in men, and heredity was shown to be a factor in 50 out of 198 cases. The right hand was involved 70 times in 223 cases singly, the left hand 38 times, and both hands 125 times.

The ring finger was the first finger to contract in 249 out of 572 cases. Occupation was believed to play an important role in this contracture by Dupuytren. Statistics, however, do not bear out the contention that occupation is the sole determining cause. In 72 cases analysed by Keen, 18 patients only used their hands in manual labour. Many other etiological factors have been cited; trauma, gout, rheumatism, arthritis deformans, arteriosclerosis, syphilis, organic nerve disease, and bacterial agencies. It seems reasonable to assume that the contracture may arise from more than one cause, and that trauma only serves as an excitant in the first stage of the condition.

Symptoms.—The first sign of on-coming Dupuytren's contracture is the appearance of small hard nodules in the palm of the hand, with inability to extend fully the ring finger and the little finger. Later one or more strong bands form which run toward the fingers. The latter gradually become

flexed at the metacarpo-phalangeal joints. The terminal interphalangeal joints remain extended because the fascial prolongations do not reach so far (Figs. 576 and 577).



FIG. 576.—Dupuytren's contracture; the outer three fingers are involved, showing the dense fibrous bands in the palmar sponeurosis.



FIG. 577.—Dupuytren's contracture; the ring finger is chiefly involved.



FIG. 578.—Dupuytren's contracture. The early stage, showing the nodules in the palm. Incision for Keen's operation for removal of the palmar fascia is indicated.

Diagnosis.—Diagnosis is based on the hard nodules in the palm, the freedom of the tendons, and the inability to extend the first phalanges.

Treatment.—In the very early stages exercises designed to hyperextend the fingers should be prescribed. The patient should be instructed to stretch the contracture regularly. Operative methods are required when the deformity is more marked. The most effective procedures are:

(1) *Subcutaneous division* of the tight bands by multiple punctures. Carefully performed, this operation is most successful. The punctures should not be made through the creases in the palm of the hand because of the danger of tearing the skin when the fingers are straightened. A sufficient number of sections should be made with a fine tenotome to allow easy correction of the deformity, and a splint should be applied for a few hours daily. The after treatment consists in early active movements and regular stretching. Prolonged splintage will defeat the objects of this simple operation.

(2) *Open dissection* and removal of the contracted bands. Dissection operations require the greatest care, and should not lightly be undertaken. The method was practised successfully by Dupuytren himself. A useful skin incision is in the form of a V, sutured as a Y when the finger is straightened. Flap incisions (Fig. 578) also give excellent access (Keen), but should be used with great caution for if there is any delay in healing the contracture is likely to recur leaving a hand more crippled than before the operation. The more radical procedure of excision of the skin of the palm, subcutaneous tissue and palmar fascia followed by whole-thickness skin grafting, occasionally practised, is a method in our judgment not to be recommended.

CHAPTER XXVI

CONGENITAL DEFORMITIES

General Considerations.—When one comes to the practical consideration of the subject of congenital deformities of the bones, joints, and muscles, it becomes evident that apart from a few to be mentioned, they are on the whole infrequent and many are of purely academic interest. A consideration of them in detail would fill a book of considerable size, and be on the whole simply an assembling of facts already known.

The writers will consider at such length as seems required the following congenital deformities, which are in their opinion of the highest importance.

1. Congenital dislocation of the hip and other congenital dislocations.
2. Club foot.
3. Torticollis.
4. Congenital elevation of the scapula.

In the matter of other and less important congenital deformities, a list of the more usual ones will be presented later with brief comments and references to the literature dealing with them.

One fact must be remembered: our knowledge of congenital deformities comes largely from a literature antedating the X-ray, and pathological reports for the most part are not modern. With the study of these cases by the X-ray the frequency of real bony defects becomes evident, which must place many of the cases in the class of primary congenital defects and diminish the importance of the influence of amniotic bands so much alluded to in the older literature. The views of Mall[1] should be given due weight with regard to the exaggerated influence of this cause. The tendency of the writers therefore is to attribute a larger proportion of these cases to the class of primary congenital defects than has been done by most of their predecessors. The difference between primary and secondary congenital deformities will be explained in the following section.

Primary and Secondary Congenital Deformities.[2]—Congenital deformities are divided into two classes—(*a*) primary or idiopathic, and (*b*) secondary.

Primary congenital deformities are inherent defects in the fertilized ovum which influence the development of the embryo spontaneously without outside cause. If such a deformity exists in a family where it already has occurred, it is spoken of as hereditary, and this element apparently exists in about 25 per cent of the congenital cases. Inherited deformities may come from the father or mother, or both, or from more remote forefathers, and may exist in a succession of children. Inherited deformities come only where the deformities in the antecedents were themselves congenital, for acquired deformities cannot be inherited. Instances of primary congenital deformities are club hand

[1] Mall: Jour. Morphol., 1908.

[2] Hoffa: Lehrb. d. Orth. Chir., 5th Edition, Stüttgart, 1905.
Joachimstal: Hdbch. d. Orth. Chir., i, 1.
Lange: Lehrb. d. Orth. Chir., Jena, 1914, 8.

with bony defect, malformations of the spinal column, certain forms of club foot, polydactylism, deficiency of the tibia, etc.

Secondary congenital deformities are those where the foetus is at first normally formed, but through some extraneous cause, deformity arises at a later stage. It was formerly the custom to attribute such deformities to one or more of the following factors:

1. Trauma to the pregnant mother.

2. Pathological conditions of the amnion, especially amniotic bands, or variations in the amniotic fluid.

Streeter has recently shown that bands are not to be regarded as important. No one has ever found amputated extremities in the uterus. He believes that these anomalies are due to fundamental changes in the growth of the embryonic cell.

Terminology.—The following terms are used: one or more extremities may be absent except for a rudimentary stump, *amelus* or *ectromelus*. *Abrachius* designates the absence of an upper extremity, *apus* that of a lower extremity. *Phocomelus* is the name applied to the condition where the bones of the upper or lower extremity are absent, or rudimentary, and a more or less well formed foot or hand articulates directly with the trunk. *Peromelus* designates shortening, and *micromelus* diminished size of the extremities. As alternatives to the latter, *microbrachius* is sometimes used for this condition in the upper, and *micropus* in the lower, extremities. *Perodactylism* is applied to shortening or diminution in size of the fingers or toes, which is often combined with *syndactylism* or fusion of them, and frequently associated with defective development of the long bones of the extremities. *Brachydactylism* implies shortening of the whole hand and *brachyphalangism* shortening of one or more fingers. *Ectrodactylism* means the absence of one finger, and *adactylism* the absence of all fingers.

These names are given because they are often used in literature, especially in the older books, and because the enumeration of them defines the conditions and describes some of them sufficiently for the present purpose. Certain of them are important enough to require further consideration.

Bony Defects or Anomalies

Defects of the Humerus.—Isolated defect of this bone is extremely rare. The humerus and bones of the forearm are of course wholly lacking when the upper extremity is absent or where the hand articulates directly with the trunk.

Defects of the Radius.—This condition was more often single than double in 114 cases reported by Antonelli[1] in 1905. The defect is generally not a total absence of the bone, although superficially that may appear to be the case. Total absence was described by Kümmel[2] as present in the majority of cases, but the development of the X-ray since that study makes the more recent data of Antonelli more reliable. When cases are carefully investigated, persistence of the proximal with absence of the distal end is most often found, but absence of the middle portion may occur.

There are often present anomalies or absence of the bones of the thumb and fingers, and perhaps muscular anomalies, and the radial artery may be

[1] Zeitsch. fur Orth. Chir., 1905, xiv.

[2] Die Missbild, der ext., etc., Cassel, 1895, 33 (literature).
Michelson: Zeitsch. fur Orth. Chir., xii, 445 (with literature).

absent. Club hand is present in nearly all cases, with deformity to the radial side of the arm. Function may be fairly good or seriously impaired. Treatment will be discussed in connection with club hand.

Defects of the Ulna.—This is much rarer than the similar condition in the radius. In 1911 Hoffmann reported only thirty-two cases from the literature. Kümmell[1] in thirteen cases, reported in 1895, found three types, which were as follows: (*a*) Ulna wholly absent, radius normal or bent, little finger absent, (*b*) ankylosis of the radius and humerus, or radius and proximal fragment of ulna, and (*c*) luxation of radius upward. Any part of the ulna may be absent, and the hand is displaced to the ulnar side, constituting ulnar club hand.

Club Hand.[2]—This deformity is either of the primary or secondary type, and the name is used to describe a permanent deviation of the hand in relation to the forearm. The main groups are (1) deviation to the radial side (radial



FIG. 579.—Club hand in child of patient shown in Figs. 581 and 582.

club hand—manus vara), (2) to the ulnar side (ulnar club hand), (3) the wrist may also be flexed (palmar variety) or (4) it may be rarely hyperextended (dorsal variety). One therefore speaks of radio-palmar, radio-dorsal club hand, etc. The deformity may exist with (1) normal bones, (2) curved bones, or (3) defective bones. It may at times be associated with club foot and other defects, and certain of the nerves, vessels and muscles in the affected arm may be wanting or abnormal. The symptoms vary with the type and variety of the deformity, and one of the most serious defects is the retarded development of the arm. A young woman, who was a bookkeeper, applied for relief to one of the writers, not because a severe club hand was not useful in her work, but because of its unsightliness and shortening which led her always to conceal it in public. Another patient was brought to one of the writers by a mother who had a similar deformity (Fig. 581), and whose one wish in the

[1] KÜMMELL: Biblioteca. Med., 1895, Abt. e. Haft. 3.

[2] HAUDEK: Zeitsch. fur Orth. Chir., xvi.
HOLMANN: Zeitsch. fur Orth. Chir., xix.
STÖFFEL and STEMPEL: Anat. Studien uber die Klumphand, Stüttgart, 1909; Zeitsch. fur Orth. Chir., xxiii, 1.

treatment was that dorsal flexion be restored, because in her own its absence had proved the serious defect.



FIG. 580.—Club hand with absence of radius in infant.

The *treatment* depends upon the cause of the deformity. If bones, muscles, and nerves are fairly normal, either manipulation or gradual stretching, perhaps aided by tenotomy, may be sufficient to lessen deformity. Curved bones may require linear or wedge shaped osteotomies, and in radial club hand with absence of the radius, the lower end of the ulna may be inserted into the carpus, from which some of the small bones have been removed to make a socket,[1] or the lower end of the ulna split and the proximal end of the carpus inserted into it.[2]



FIG. 581.—Club hand in adult (mother of child shown in Figs. 579 and 580).

A successful bone graft in a patient with absence of the radius with radial club hand is reported by Albee,[3] where a tibial graft was mortised into the ulna at about its middle, and the lower end inserted into properly prepared orifices in the carpus.

Synostosis of the Bones of the Forearm.[4]—Synostosis between the bones of the forearm is closely related to defects, as shown by the figures of Blodgett, who found seventeen instances of radio-ulnar synostosis in fifty-one cases of luxation of the radius. The upper end of the radius may be fused with the ulna or united by a bridge of bone, in which case growth of the bones is apt to be somewhat retarded, and in these cases there is likely to exist at the distal ends of these bones a fibrous union which after remedy of the synostosis may check rotation.[5] There may be also union between the humerus and both

[1] SAYRE: Trans. Am. Orth. Ass'n., vi.
[2] BARDENHEUER: Verhdlg. d. Deutsch. g. fur. Chir., 1894.
[3] ALBEE: "Orthopedic and Reconstruction Surgery," 1919, 904.
[4] LIEBLEIN: Zeitsch. fur Orth. Chir., 1909, xxiv.
[5] LANGE and SPITZY: Chir. and Orth. in Kindesalter, Leipzig, 1910.

forearm bones. In dislocation of the head of the radius from multiple cartilaginous exostoses, and in true congenital dislocation of the radius, restriction of rotation is usual.

Favorable cases should be operated on by cutting down on the synostosis, freeing the bones and either putting up the arm in such a position that the divided surfaces are no longer in contact, or inserting between them a layer of fascia, muscle or fat. It must, however, be stated that operative procedure is much less successful in these cases than in similar ones following trauma.

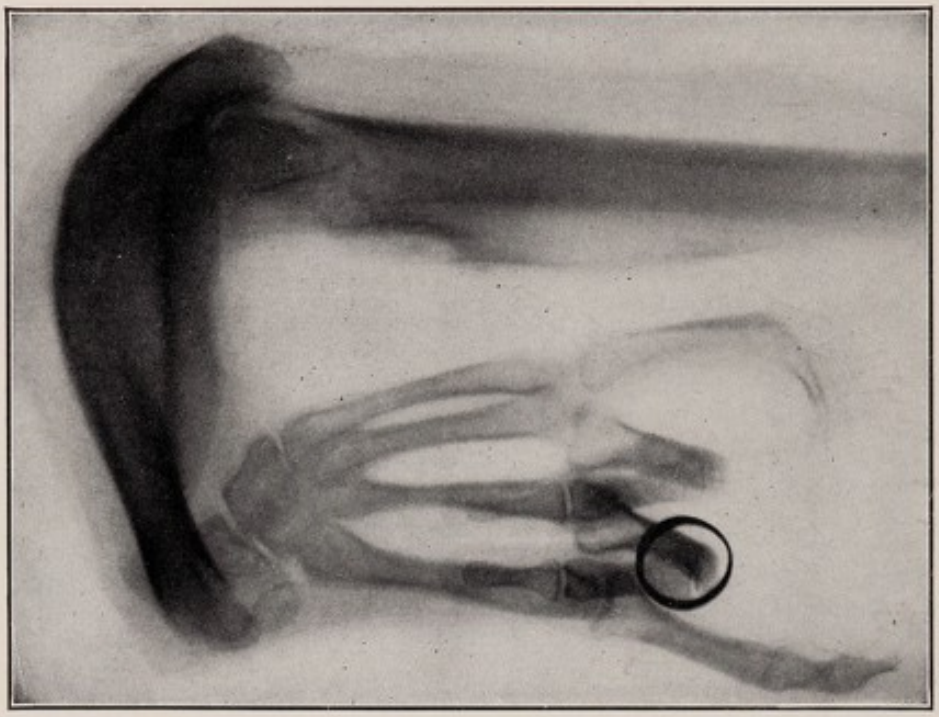

FIG. 582.—Club hand in adult—X-ray (mother of child shown in 579 and 580).

Defects of the Femur.—Complete absence of the femur is less common than partial. When partial defect occurs, the patella is generally absent[1] as well as the fibula, and flexion contracture of the knee and outward rotation of the tibia may coexist. The defect is often double.

Reiner[2] identifies five varieties: (*a*) Shortening and delayed development with coxa vara, (*b*) the femur consists of an upper and a lower end, and the middle section is absent, (*c*) the lower end of the femur is alone present and is united with the tibia, (*d*) the upper end of the femur is not differentiated as to head and neck and is curved and sometimes luxated, (*e*) the hip and knee joints are well developed, but the shaft is greatly shortened. In a case of this variety seen by one of the writers six inches of shortening existed in a girl of fourteen.

The child should be supplied with a simple walking appliance; the most suitable type being a Thomas's knee splint, with a ring at the bottom. When growth is completed, operation may be considered in suitable cases. Bone lengthening of the affected femur has been practiced, but this, and other procedures have a limited field of application.

[1] THORNDIKE: Trans. Am. Orth. Ass'n., xi, 206.
[2] SPITZY: Zeitsch. fur Orth. Chir., xviii, 70.
SPITZY: Zeitsch. fur Orth. Chir., 1901, ix.
BLENKE: Zeitsch. fur Orth. Chir., 1901, ix.
PURCHAUER: Zeitsch. fur Orth. Chir., xxiii, 368.

Defects of the Tibia.—Of this deformity, Bade[1] reported, in 1906, fifty-four cases. Unilateral cases are more frequent than bilateral. The patella is often absent, but other bony defects are unusual except in the leg of the affected side.

The thigh is rotated out and adducted, the knee is flexed, and the upper end of the fibula dislocated out and back, so that the function of the knee joint is seriously interfered with. The external malleolus is very prominent and the foot is dislocated into marked varus, with curving and thickening of the fibula.

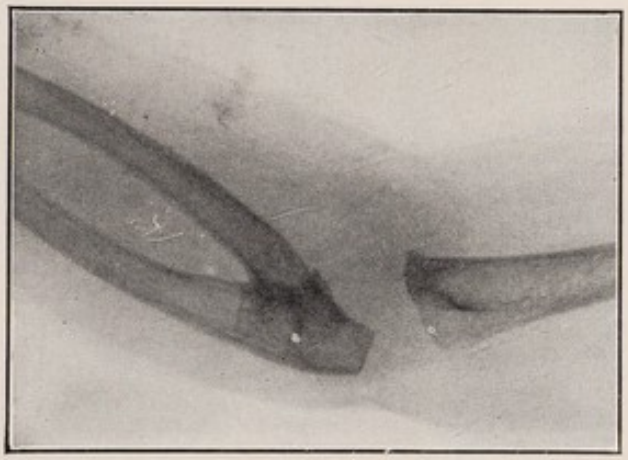

FIG. 583.—Congenital fusion of radius and ulna—male, eleven months old.



FIG. 584.—Defect of right femur.

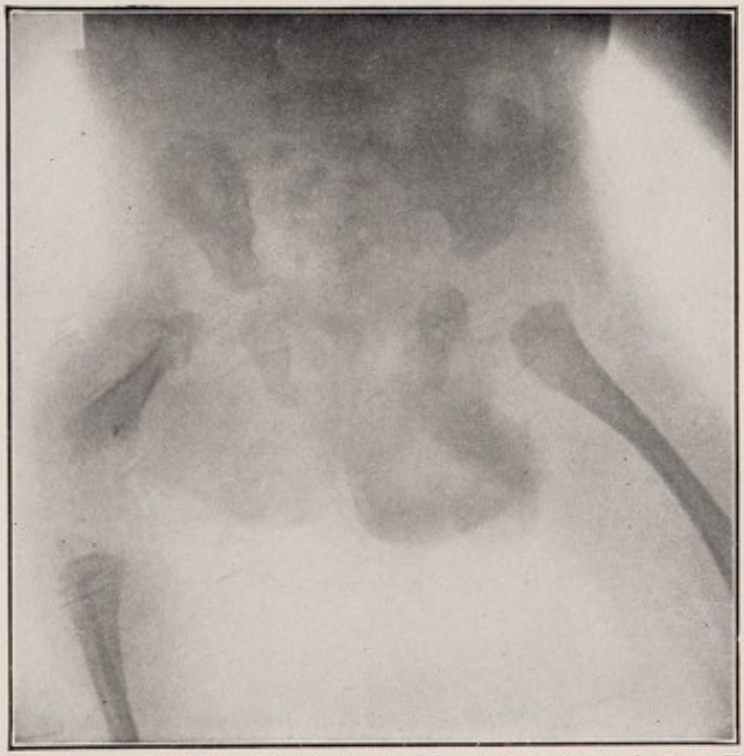

FIG. 585.—X-ray of congenital defect of femur; same patient as Fig. 584.

[1] MYERS: Trans. Am. Orth. Ass'n., 1905, 72.
BADE: Zeitsch. fur Orth. Chir., xvi, 150.
STEELE: Trans. Am. Orth. Ass'n., xv, 94.

The surgical remedy of the condition is difficult, although the implantation of the fibula into the femur has been performed several times, the deform-



FIG. 586.—Congenital absence of tibia.

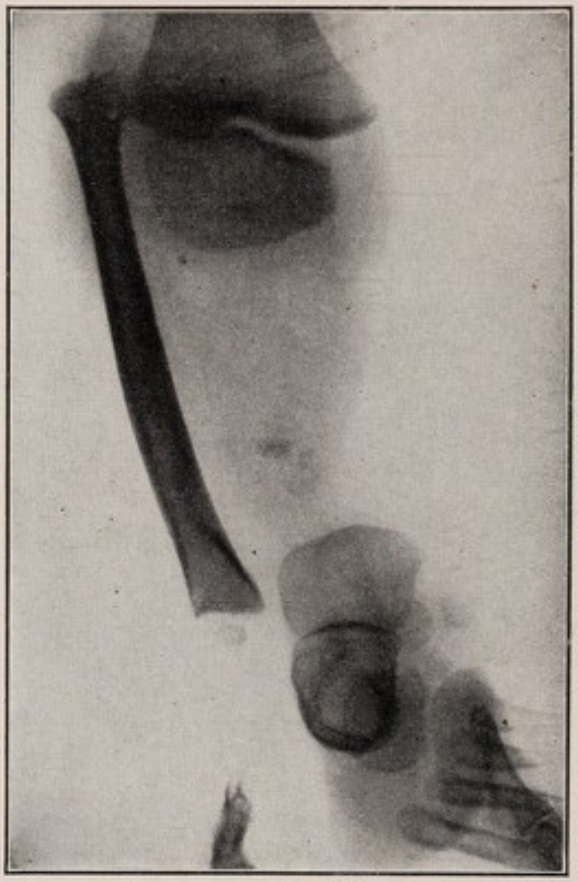

FIG. 587.—Antero-posterior X-ray of congenital absence of tibia—same patient as Fig. 586.

ity having been corrected so far as possible beforehand by corrective plasters. In certain cases the disability becomes so great that amputation becomes



FIG. 588.—Lateral X-ray of congenital absence of tibia—same patient as Fig. 586.

necessary, as in an adult case of one of the writers. Some form of prosthetic appliance will as a rule have to be worn.

Defects of the Fibula.—This is more often single than double, and is apparently more frequent than the similar defect of the tibia. Total absence is somewhat more common than partial (65 cases of total defect to 30 of partial in Haudek's series). Franke[1] in 1905 was able to collect 118 cases. The tibia is shortened and curved anteriorly as a rule, with often a dimple over the apex of the curve. The foot is most often in a position of equino-valgus, and the outer toes may be missing and the limb is usually shortened.

The bone deformity should be corrected by osteotomy after rectification of the position of the soft parts. Many other types of operation are performed, especially the implantation of the lower rudiment into the tibia.

Congenital Contractions

When the contractions occur at the ankle or wrist they are classed as club foot or club hand. In the hip, knee, shoulder, elbow, or fingers, they are classed as congenital contractions. They occur either with or without bony

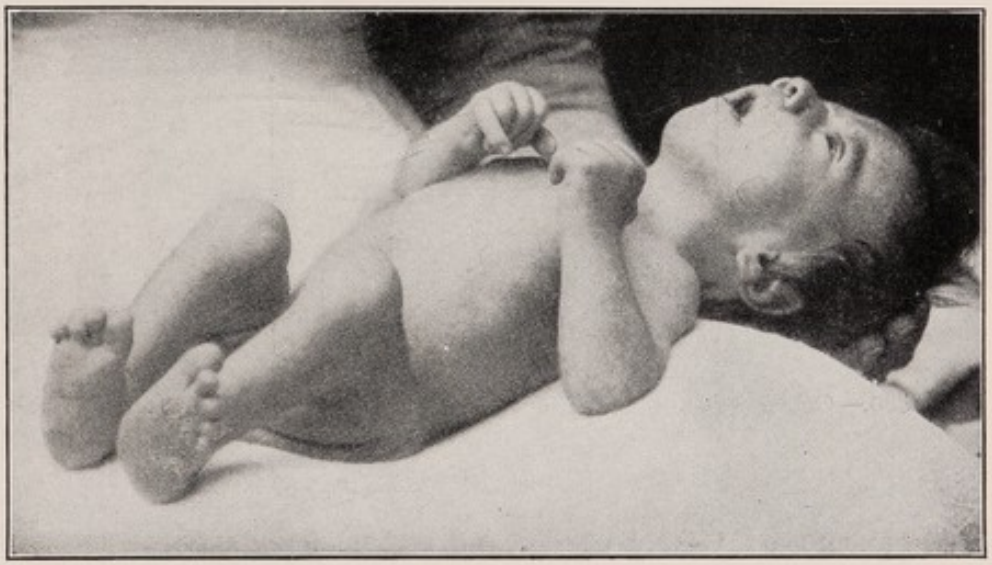

FIG. 589.—Congenital contraction of hips, knees, elbows, etc.

abnormalities. Occurring without other malformations they represent a rarity, but are occasionally seen in a large children's surgical clinic. In the upper extremity they constitute about 0.006 per cent of all surgical affections (Rosenkranz).[2] Their origin is no clearer than that of club-foot, club-hand, torticollis, or the deformities with which they may be associated, nor do they present any different pathological changes. They are attributed to different causes—many would attribute them to nervous origin, the cause perhaps being intrauterine nervous disease or primary defects of the brain or cord. Another cause assigned is a defect of the germ cell, classing the condition with other primary deformities, while a third group of writers class the deformity as due to intrauterine pressure and amniotic bands.

In the *fingers* the contraction is in flexion with a tendency to adduction of the thumb, and side deviation of the phalanges has also been recorded. It affects most often the *little finger* and is *bilateral*. At the *elbow*, in which con-

[1] KREBSER: Zeitsch. fur Orth. Chir., xxiii, 167.
FRANKE: Zeitsch. fur Orth. Chir., xvi, 200 (with literature).
SCHARFF: Zeitsch. fur Orth. Chir., xxiii, 391 (with literature).
[2] ROSENKRANZ: Zeitsch. fur Orth. Chir., xiv, 53 (literature).

traction apparently does not exist without also contraction in the wrist, the flexed position is the usual one in the writers' experience, although contraction in the extended position is recorded. The contraction may be in the supinated or pronated position. In the *shoulder* there is a general limitation of motion, particularly resistant in abduction. In the *hip* the thighs are flexed and cannot be fully extended, and in the *knee* the deformity is also one of flexion. In certain cases a web of skin may be found more or less filling the normal angle. (Fig. 590.)

The treatment consists in gradual extension by apparatus, manipulation under anesthesia, or division of the soft parts where necessary.

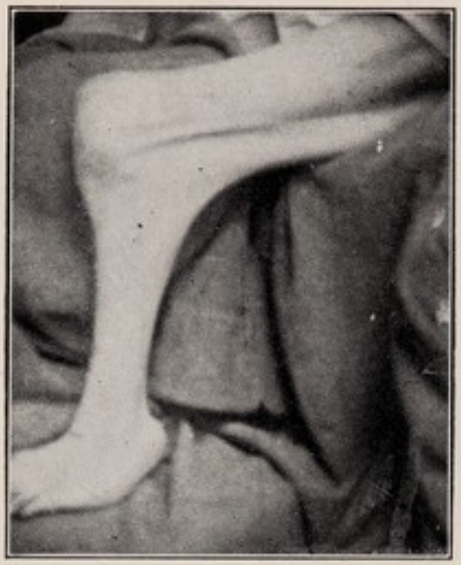

FIG. 590.—Congenital contraction of knee with web (G. R. Girdlestone's case).

Intrauterine (Spontaneous) Amputations

Spontaneous amputations were formerly regarded as secondary congenital deformities, and were attributed to:

1. Constriction by the umbilical cord.
2. Amniotic bands.
3. Intrauterine fracture.
4. Inflammatory conditions affecting the limbs of the fetus.

The work of Mall throws considerable doubt on the occurrence of such extraneous trauma.

Cases of true spontaneous amputation do not show remains of a foot or hand at the end of the stump. In the arm and thigh the amputation is as a rule high up; in the forearm amputation occurs most often at the upper third, and in the lower leg at the lower third. Where there is no actual complete amputation, a deep circular constriction is sometimes found on the limb (Fig. 592). Some of these constrictions are so severe as to cause marked enlargement of the distal parts. Constrictions will require plastic operations. The operation which the authors advise is making a circular incision above and below the sulcus, carefully dissecting away all the skin involved in the constriction, and uniting the edges.

In these amputations the question of treatment resolves itself into the fitting of a prosthetic appliance.

Intrauterine Fractures

Our modern knowledge of these dates from the work of Gurlt, who in 1862 collected in his work on fractures thirty-three cases. In nine, the fractures were multiple, in three two bones were broken, and in the remainder only one bone. Fractures of the thigh and leg constituted 70 per cent of the cases,[1] and the latter is the most frequent of all, and has attracted most attention.

These fractures are usually attributed to:

1. Primary congenital defects,[2] malformations of other parts being frequently associated.

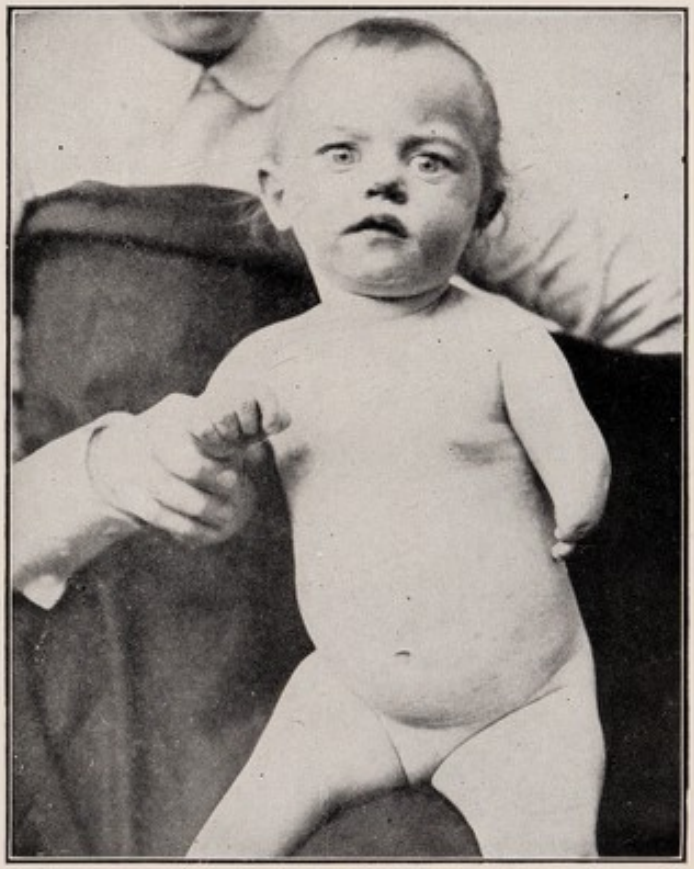

FIG. 591.—Intrauterine amputation.

2. Secondary congenital causes—(*a*) amniotic adhesions, (*b*) amniotic bands, (*c*) intrauterine pressure.

3. The history of trauma to the mother is frequent, and undoubtedly the cause of some; forty-two cases apparently of this origin have been collected by Smith.[3]

4. Intrauterine disease of bone.[4]

The fractures at birth are healed or ununited; in the former case some deformity is generally present, and over the apex of the deformity there is generally a dimple or scar-like mark. Small granulating wounds have been recorded over the apex of the fracture at birth (Klein and Guersaut).[5]

[1] ITHCH: Intraut. un tersch. burche, Inaug. Diss. Einsiedten, 1805.
[2] MALL: Jour. of Morphol., 1908.
[3] SMITH: R. R.: Surg., Gyn. and Obst., September, 1913, 346 (with recent literature).
[4] NATHAN: Am. Jour. Med. Sci., cxix, 1.
[5] GUY'S Hosp., 1855, 472.

These marks were at one time supposed to be scars due to compound fractures and puncture of the skin by the bone, but they are always small, at the apex of the curve, and more uniform than would be expected if that were always the cause. On examination they do not show true scar tissue, but rather pressure effects of a chronic inflammatory character.[1] The scar is very similar to that found in congenital defect of the fibula which also used to be ascribed to compound fracture, but in the scar all the elements of skin are found. It would seem more reasonable therefore to attribute them to amniotic adhesions and bands.

In so-called intrauterine fractures of the lower extremity, the fibula is absent in many cases, but whether it is present or not, the tibia presents an angular deformity often reaching 90 degrees, with a prominence forward. This deformity occurs at the junction of the middle and lower third of the bone, and in most cases union has taken place with a dimple over the scar. Fracture of the tibia is the most frequent and most important of the intrauterine fractures, and its association in so many instances with congenital absence of the fibula is not explained and is simply another instance of our lack of real knowledge of these conditions and their causes.

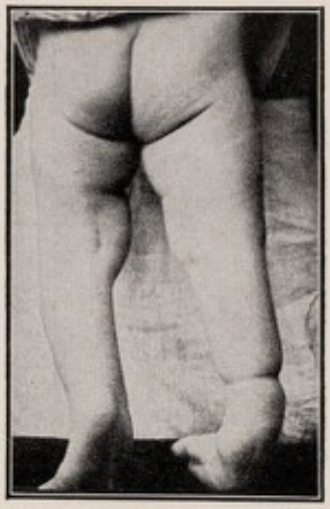

Fig. 592.—Congenital constriction around the leg.



Fig. 593.—Intrauterine fracture.

In the fractures of the tibia with and without defect in the fibula, a *pseudarthrosis* is found at times at the lower third of the bone.[2] These cases are extremely resistant to surgical treatment, such as resection and refreshing of the ends, periosteal flaps, and bone grafts.

Miscellaneous Deformities of the Hands and Feet

Syndactylism (Webbed Finger).—In this deformity two or more digits are fused. The bond of union may consist of skin only, skin and connective

[1] Haudek: Zeitsch. fur Orth. Chir., 1896, iv.

[2] Hoffa: Lehrb. d. Orth. Chir.
Reichel: Vergdlg. d. Deutsch. Ges. fur Chir., 1903, 32.
Auffret: Rev. d'Orth., 1899.

tissue, or soft parts and bone. The fingers affected are usually those on the ulnar half of the hand. Other defects such as polydactylism may also be present. The functional capacity of the hand is often unimpaired. The fingers can be readily separated by a suitable plastic operation where the fusion involves the soft tissues only. A wide range of operations have been described. The one difficulty is to prevent reformation of the web at the base of the cleft. In order to avoid this sequela, it is sound practice to operate in two stages.[1]

(1) *First Stage.*—A skin lining should be established in the base of the cleft. A simple and convenient method is to reflect a flap from the dorsum, divide the subcutaneous tissue of the web in the middle line well up into the intermetacarpal region, and suture the flap in position. (Fig. 594.) The raw

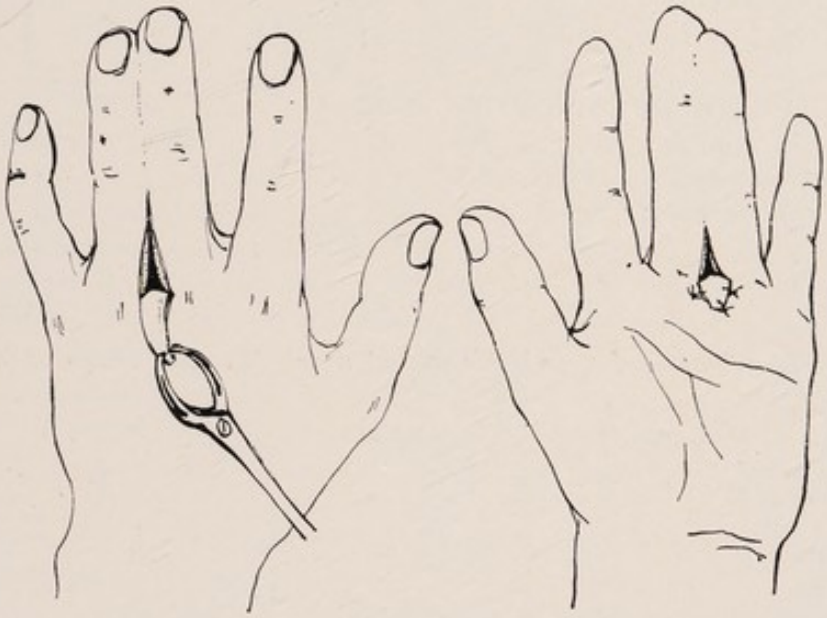

FIG. 594.—Operation for syndactylism. 1st stage—The formation of a skin-lined cleft at the base of the web and intermetacarpal region. Dorsal flap forms the floor of the cleft.

surfaces on each side can now be covered by free skin grafts held in place by a plâque of dental composition sterilised and moulded accurately to the shape of the hiatus. For a partial web no further procedure may be required.

(2) *Second Stage.*—The distal part of a complete web may be conveniently used as part of a flap as in the well known Didot's operation. (Figs. 595 and 596.) Small islands which remain uncovered may be treated later by free skin grafts.

Cleft Hand and Cleft Foot.—A defect may exist in either hand or foot consisting of more or less extensive bifurcation, due to an absence of the middle digits or even metacarpals. It is spoken of in English as the "lobster claw hand," and in French as "main fourché." The defect may be hereditary, is more often double than single, and is often associated with polydactylism. Plastic operations on bone and soft parts may be indicated in some cases, but will depend upon the degree of function present. Each case must be judged on its merits.

Polydactylism.—This condition is either symmetrical or asymmetrical and implies the existence of extra fingers or parts of them. It exists in every

[1] DORRANCE and BRANSFIELD: Annals of Surgery, October, 1923.

variety and is often combined with syndactylism, or other deformity. The treatment consists in the removal of the extra finger.

Macrodactylism—(Giantism).—Congenital hypertrophy of one or more digits is by no means rare. The large finger may be more or less inconspicuous

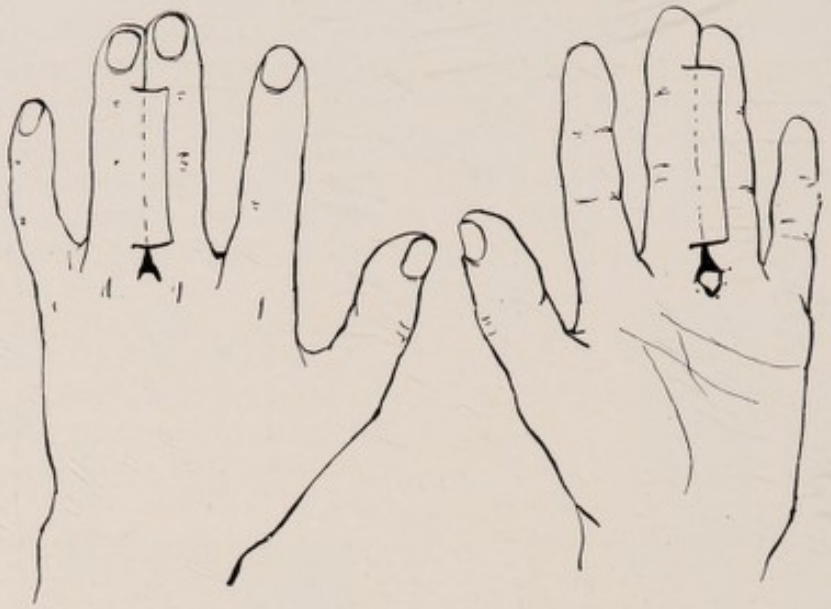

FIG. 595.—Operation for syndactylism 2nd stage The Didot flaps outlined.

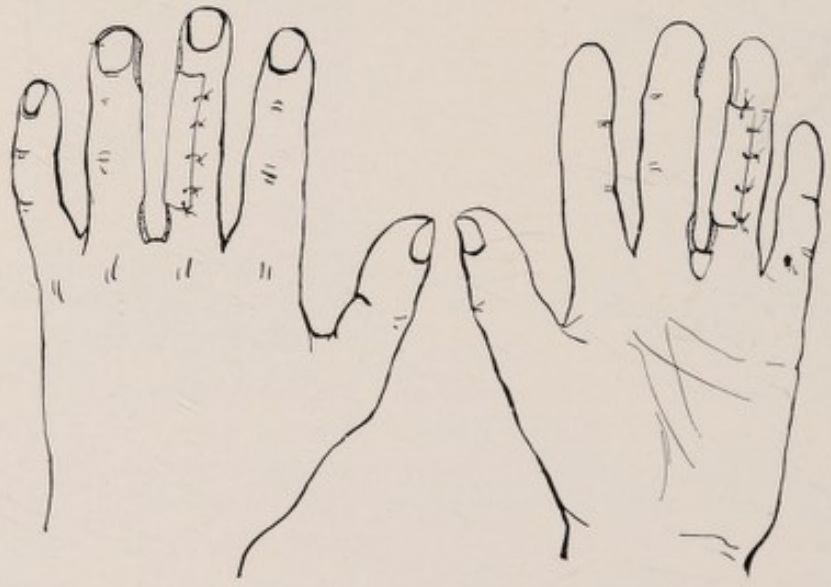

FIG. 596.—Operation for syndactylism. Completed with the Didot flaps in situ. The remaining areas are covered by free grafts.

at birth, but later grows apace, and becomes most unsightly. The hypertrophy which affects all the tissues, soft and bony, may be accompanied by a definite nevoid condition of the digit or limb as a whole. Amputation of the giant finger or toe is generally demanded by the parents.

CHAPTER XXVII

TORTICOLLIS—CONGENITAL ELEVATION OF THE SCAPULA—CERVICAL RIBS

TORTICOLLIS

Torticollis is divided into two distinct varieties—the *congenital* and the *acquired*.

Congenital Torticollis

Cases occurring strictly in intrauterine life and antedating birth are of two types: The first (*a*) is a *primary congenital deformity* due to some defect of the embryo. This form is at times associated with congenital defects elsewhere, such as abnormality of the bones in the extremities, and similar conditions, obviously to be identified as primary defects. One form of this type is due to an anomaly of the *cervical vertebræ*[1] obviously belonging to the primary class, in which the distortion of the head is due to the bony defect rather than to shortening of the soft parts as in the ordinary case. Anomalies causing this are as follows: (1) Fusion of the atlas and occiput, (2) synostosis of the atlas and axis, (3) malformation of the cervical vertebræ, of which one variety is an extra wedge-shaped cervical vertebra, and (4) cervical ribs. This type of wry neck is sometimes inherited.

The second form (*b*) which antedates birth, is usually classed as a secondary congenital deformity, but the cause is purely speculative. Abnormal position of the head in utero has often been suggested as a reasonable explanation, but without any definite evidence in favour of its actual occurrence.

Cases Occurring during Delivery.—There has been much discussion as to the rôle played by hematoma of the sternomastoid muscle occurring during birth as a cause of wry neck. Various writers have observed hematoma of the sternomastoid muscle which has not been followed by wry neck. Others, including the writers, have seen cases where a tumor of the sternomastoid has been followed by wry neck. In one case alluded to, the child was seen in the first few days of life with a definite tumor in the muscle following a difficult labor and two years later typical wry neck existed. That partial rupture of the sternomastoid muscle is the cause of all cases is out of the question; that it occasionally is associated with wry neck is not to be questioned. In the latter case it must be remembered that the proof is not quite complete, because it may be that the wry neck antedated birth, and during forcible delivery the shortened muscle became ruptured. The matter is by no means clear, but partial rupture of the sternomastoid muscle or effusion of blood into its sheath during delivery must be regarded as one of the causes of wry neck, for purposes of classification here described as congenital.

Pathology.—In congenital torticollis due to the shortening of the sternomastoid muscle, the substance of the affected muscle is smaller in amount and

[1] Drehman: Verhdl. d. Deutsch. Ges. fur Orth. Chir., 5th cong., 1906.
Eckstein: Zeitsch. fur Orth. Chir., 1908, xx, 177

contains when compared to the contractile tissue an abnormal amount of fibrous tissue. Patches of scar-like fibrous tissue may be distributed throughout the substance, or in severe cases the muscular tissue may be largely replaced by this. In addition, the other soft parts of the neck are of course adaptively shortened. These changes in the muscle would seem to indicate a fibrous myositis and perimyositis, which have been demonstrated to exist in certain cases.

Secondary changes from position occur in long continued torticollis. There is a marked asymmetry of the face and skull and a slight diminution in the size of the cerebral hemisphere on the affected side. This asymmetry of the face is not an especial attribute of wry neck, but is a static deformity, and occurs in other conditions which cause a long continued one-sided position of the head during the growing period. It has been observed by the writers in a very striking degree in a twisted position maintained over many years as a result of tuberculosis of the cervical spine, and it occurs in acquired wry neck in children if it is sufficiently long continued. The carotid artery of the affected side in certain cases has been found smaller.

Symptoms.—The chin is rotated away from the side of the shortened muscle, and the head tilted to the affected side. In addition to this, the whole head is displaced to the same side of the median line. A normal position cannot be obtained by passive manipulation, and on corrective manipulation the shortened sternomastoid muscle will stand out as a cord and be found to offer a resistance to reposition. Other movements of the head, such as flexion and extension, which are not restrained by this shortened muscle, are free. The deformity is free from pain and does not impair the general health.

The *lateral curvature* which is associated with it must not be overlooked, and always will be found present in some degree as a secondary change. The lateral curvature does not reach a high degree and if it is recognized is curable after the position of the head is corrected, by appropriate exercise.

Facial Asymmetry.—The vertical length of the face is shortened on the side of the affected muscle and the eye is lower on that side. The facial asymmetry, which is very marked in some cases, is less conspicuous in the deformed position than when the head is straightened, and this is to be remembered in formulating the prognosis of operation in older children, especially girls, as a corrected position of the head brings out a facial asymmetry very markedly, which the parents may not have noticed before. The facial asymmetry is most easily detected and estimated by placing the head vertical and shutting off the rest of the body from the surgeon's view by holding a pillow across under the chin covering the rest of the body.

It must be remembered that the hemiatrophy develops as long as the torticollis remains untreated, but tends to diminish or wholly disappear when the position of the head is rectified and the blood stream becomes normal. The writers can recall instances when after persisting for years the facial deformity has become normal after operation.

Double Torticollis.—The affection is occasionally double, in which case a very curious position results. The neck is short, the shoulders are high, the chin somewhat elevated, and both muscles are found to be contracted.

Diagnosis.—Theoretically the diagnosis should offer no difficulty, but in practice there are many cases which are obscure even to the experienced surgeon. The characteristic features have been described in speaking of

symptoms. These are a rotated, tilted, and displaced head, with facial asymmetry, a shortened sternomastoid muscle, and lateral curvature of the spine. The conditions which will offer any practical difficulty will be discussed under differential diagnosis. It is most important to be sure of the diagnosis before proceeding to operation. For this reason an X-ray of the cervical vertebræ should be taken in all cases to see if any anomaly exists there which would prevent a correction of the deformity. A certain number of cases have been operated upon without such precaution, and no improvement has resulted, because the shortening of the sternomastoid muscle was secondary to a malformation of the cervical vertebræ.



FIG. 597.—Wry neck, due to contraction of the right sternomastoid muscle.

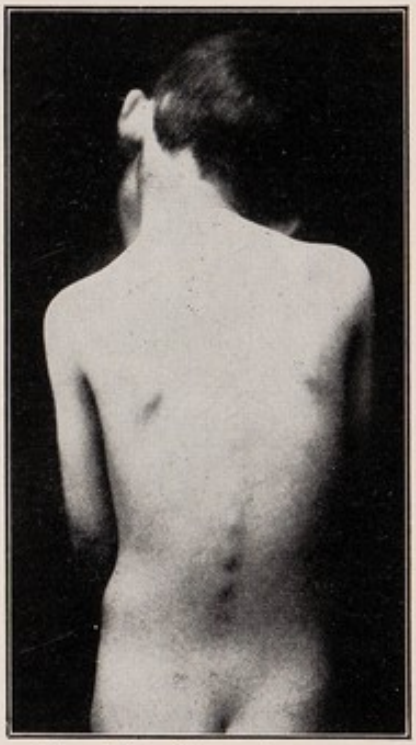

FIG. 598.—Lateral curvature, due to wry neck, the right sternomastoid muscle being contracted.

Differential Diagnosis.—Of the conditions simulating wry neck, the most troublesome to differentiate in practice is *tuberculosis of the cervical spine.* In these cases pain should be present, all the muscles should be in spasm, the X-ray should be characteristic, and the other signs described in speaking of that affection should be present. The chin points away from the prominent sternomastoid muscle in torticollis, and points toward the prominent muscle in tuberculosis of the cervical spine. In the latter the movements are restricted in all directions, and in torticollis only in one direction—that which places the shortened muscle on the stretch. Occasionally, however, an early mild case of cervical tuberculosis may offer much trouble, and it may be difficult to say whether one is dealing with a congenital wry neck which has become irritated by some accidental reason, or with tuberculosis. The X-ray, especially if taken from the side, is of the greatest value in clearing up these cases. The resemblance between the two conditions as a rule is only superficial.

Traumatic, and Inflammatory Wry Neck.—After a fall on the head, or a severe wrenching of the neck, a painful stiffness of the neck may occur with the head held in a position of torticollis. The condition simulates early tuberculosis of the cervical spine very closely, but the X-rays are negative and the condition clears up fairly soon.

Inflamed cervical lymph nodes in children, whose response to reflex stimuli is very active, is at times a cause of wry neck, the character of which will generally be recognized by finding enlarged and tender cervical lymph nodes on one side of the neck.

In *arthritis deformans* a position of wry neck is occasionally assumed, and in children at times an acute inflammation of the structures of the neck, which in former days would have been called rheumatic, gives a stiffness and painful wry neck.

Reflex Irritation.—In children wry neck is at times due to reflex cause, and may result from suppurative otitis, irritation from abnormal teeth, and occurs in the course of certain general diseases, such as scarlet fever, diphtheria, mumps and measles. One hundred and eighty-one cases of this sort were analyzed by Whitman. This class of wry neck especially effects children, on account of their greater reflex excitability.

Ocular torticollis[1] exists in a certain number of children where it is due to an error in vision. It is important in all cases of torticollis of doubtful origin to have the eyes examined by an expert.

Cicatricial contractions from burns and similar conditions may cause a unilateral malposition of the head, and are evident on inspection.

It occasionally happens that a very mild degree of wry neck causes a noticeable scoliosis, and the *scoliosis* is recognized while the wry neck is overlooked. In doubtful cases of obscure scoliosis it is desirable to see if any shortening of either sternomastoid muscle exists.

Paralytic wry neck may occur in poliomyelitis from involvement of one sternomastoid muscle. The affection is almost sure to be identified by the involvement of the other muscles elsewhere in the body, and by the fact that when the patient lies on the back and attempts to raise the head from the pillow one sternomastoid muscle acts very much more powerfully than the other. Wry neck sometimes follows the removal of cervical glands when the spinal accessory nerve is injured or destroyed.

Prognosis.—In congenital wry neck there is no hope of improvement or cure without treatment. Proper operative treatment in early childhood will give a practically complete correction. In adolescence and in early adult life it is wise to give very careful consideration to the question whether it is worth while in moderate cases to correct the position of the head, perhaps incompletely, at the expense of the very great apparent increase in the facial asymmetry. It must be remembered, however, that the asymmetry will diminish steadily after correction. An X-ray, moreover, will give valuable information in adult cases as to how much correction is to be expected. If the bony deformity of the cervical vertebræ has become very marked from growth in an abnormal position it is unlikely in any event that full correction will be obtained, and it is simply to be stated that one should not rush into the operation in the older class of case without very careful consideration of what will be the final outcome.

[1] Lovett: Trans. Am. Orth. Ass'n., 230.

Treatment (Non-operative).—Mild cases are amenable to the following measures: (*a*) Manipulation and exercises, (*b*) manipulation and fixation; a very considerable degree of wry neck may be corrected by manipulation and mechanical means.

(*a*) Slight cases can be corrected by a combination of manipulation and exercises, great care being taken not to use too much force. The head is held over the end of a low couch and resting on the knees of the surgeon, and the contracted sternomastoid is slowly stretched or the deformity is corrected in the sitting position. This is best effected by moving the head in a direction opposite to the deformity. The manipulation should be followed by massage



FIG. 599.—Manipulation for correction of wry neck.

of the healthy sternomastoid, and by active exercise of this muscle. The manipulation should be practised every day.

If the deformity is more extreme and less yielding (*b*) *manipulation and fixation* should be tried. Correction may be done on one occasion or in stages. Immediate correction is suitable for the less extreme cases. An anesthetic is given and the surgeon overcorrects the deformity, taking plenty of time over the act. A plaster bandage is applied and the head is kept in an overcorrected position for three or four weeks when massage and exercises are prescribed. In the less mobile cases the deformity is partially corrected and placed in plaster, and this is repeated in fourteen days, and yet again if necessary.

This point is emphasised because many parents refuse an open operation. Exercises to correct the position without previous manipulation are of little use and braces without previous manipulation are futile. In general, except for these cases already spoken of, a cutting operation is to be advised.

Operation.—The operation consists in the division of the sternomastoid muscle, and the overcorrection of the deformity. (1) The preference of the writers is for the operation at the *lower end* of the muscle. Subcutaneous division of the sternal head is easy and safe, but where there is an advanced contracture of the clavicular fibres, full correction by this method is impossible.

In the *open* operation all tight structures can be effectively divided through a small incision which leaves an almost invisible scar. The skin of the neck is pulled up so that the cutaneous scar will come as low down as possible, the incision made over the lower part of the muscle, and the muscle exposed and divided on a director. In many cases it appears before operation as if the sternal part of the muscle alone were contracted, but on dividing this, the clavicular part will in nearly all instances be found to be involved in the contraction also, and its division will be necessary. It is a very unusual case where the division of the sternal end alone is a satisfactory operation. The surgeon should be reminded that the outer edge of the clavicular part of the muscle lies directly in contact with the internal jugular vein, which should be seen at the bottom of the wound after dividing the muscle in any complete operation. In approaching this region, tissue should not be picked up with the forceps, but divided on a director. That this caution is not theoretical is shown by the fact that the internal jugular vein has not infrequently been opened by taking up loose tissue with the forceps in dividing the deeper layers of tissue. A most important part of the operation is the complete division of the sheath of the sternomastoid muscle which can only be accomplished by a thorough division of all resisting bands. The position of the head is overcorrected and the wound closed with great care in the apposition of the skin edges to make an inconspicuous scar.

2. *Division of the Upper End of the Muscle.*—It has been claimed that the pathological change which exists in the muscle in cases of long standing causes adhesions between the sheath and body of the muscle, so that after correction by division of the lower end the reposition of the head is not as complete as it would be if the upper end of the muscle were cut. It is claimed further for this operation that the scar can be covered by the hair. This is perfectly true, but the division of the lower end of the muscle is followed by perfectly satisfactory results if proper after-treatment is carried out, and the operation is further removed from structures which may make trouble. In the operation for division of the upper end of the muscle originally described by Tillaux and elaborated by Lange, a vertical incision is made about an inch and a half long, the middle of which comes opposite the middle of the mastoid process. The fascia and platysma are separated, the sterno-cleido-mastoid muscle exposed on an elevator, and divided. The head is easily overcorrected, and a degree of overcorrection is possible which is not safe to maintain. The position of the spinal accessory nerve and external jugular vein must be remembered.

3. A third operation consists in a plastic lengthening of the sternomastoid muscle at its middle. A coronal elongation is performed, the head is overcorrected, the two halves slide by each other and are connected by suture. The operation should be chosen only in exceptional cases.

After any one of these operations the head should be placed in an overcorrected position for twenty-four hours, which may be done by putting the patient on the back in bed with sand bags or straps of adhesive plaster on the head which make traction over the side of the bed to maintain the overcorrected position. The disadvantage of putting on plaster of Paris immediately after the operation is that if post anesthetic vomiting occurs the plaster is likely to become soiled and offensive. At the end of twenty-four hours a plaster cuirass is applied holding the head in marked overcorrection, attention being paid to the elements of the deformity in the correction of the rotation of

the head, the tilting, and the position of the chin. Inexperienced surgeons in putting on this plaster will sometimes be confused as to the proper position of the head, and a safeguard against this is easily provided by taking a picture of the patient beforehand and reversing the position, exaggerating the elevation of the chin.

The head is maintained in an overcorrected position for at least six weeks, after which the fixation apparatus is removed and passive overcorrection of the head should be done once or twice a day, followed by the active overcorrection of the head by the patient himself. In a case of left torticollis, the left mastoid process would be approximated to the sternum, the head tipped

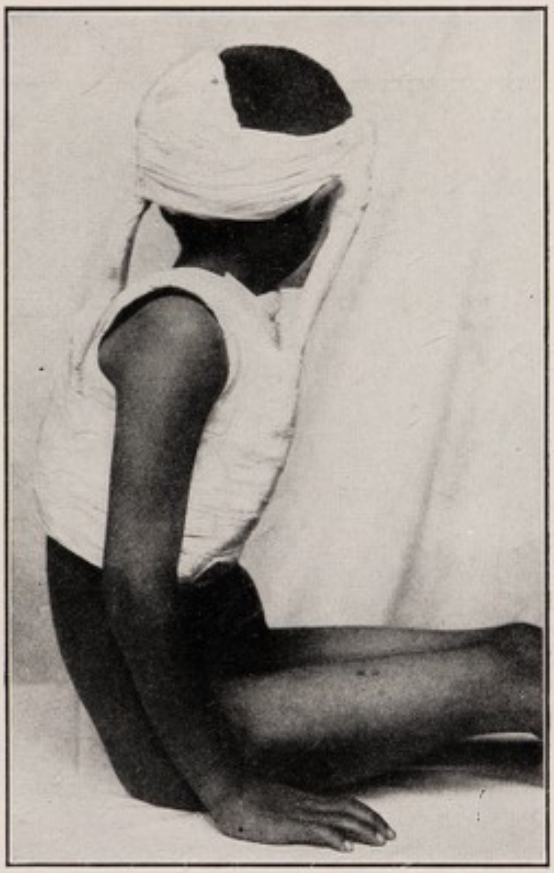

FIG. 600.—Plaster cuirass maintaining overcorrection after operation for wry neck.



FIG. 601.—Buckminster Brown brace for maintaining overcorrection after operation for wry neck.

to the left and rotated to the right. Corrective exercises should consist in tipping the head to the right, rotating the face to the left while the shoulders are held, in addition to flexion and extension of the head to restore complete mobility. In older children, standing in front of a mirror, in the middle of which is hung a plumb line, and bringing the middle of the mouth and the middle of the forehead under this plumb line is a useful exercise after operation. Exercises should be repeated at first two or three times a day, and manipulation given at least twice a day. Later active voluntary correction should entirely replace passive overcorrection. Supervision should be continued for about six months. In the case of ignorant and careless parents some form of retention apparatus may be necessary (Figs. 600, 601). It should be insisted upon here as in the somewhat similar proceeding for the correction of club foot that success

will depend upon a thorough stretching or division of the muscles at the time of operation, the maintenance of an overcorrected position for a suitable time, followed by the development of muscles to maintain the correct position.

ACQUIRED TORTICOLLIS

Acquired torticollis is an affection more common than the congenital form, and at least 80 per cent of the cases begin in the first ten years of life. At the Hospital for the Ruptured and Crippled in New York, of 507 consecutive cases 420 were acquired. The position does not differ from that of the congenital variety, and the common manifestations of the acquired forms have been already described in speaking of differential diagnosis under the congenital form, and they do not need further mention in this place.

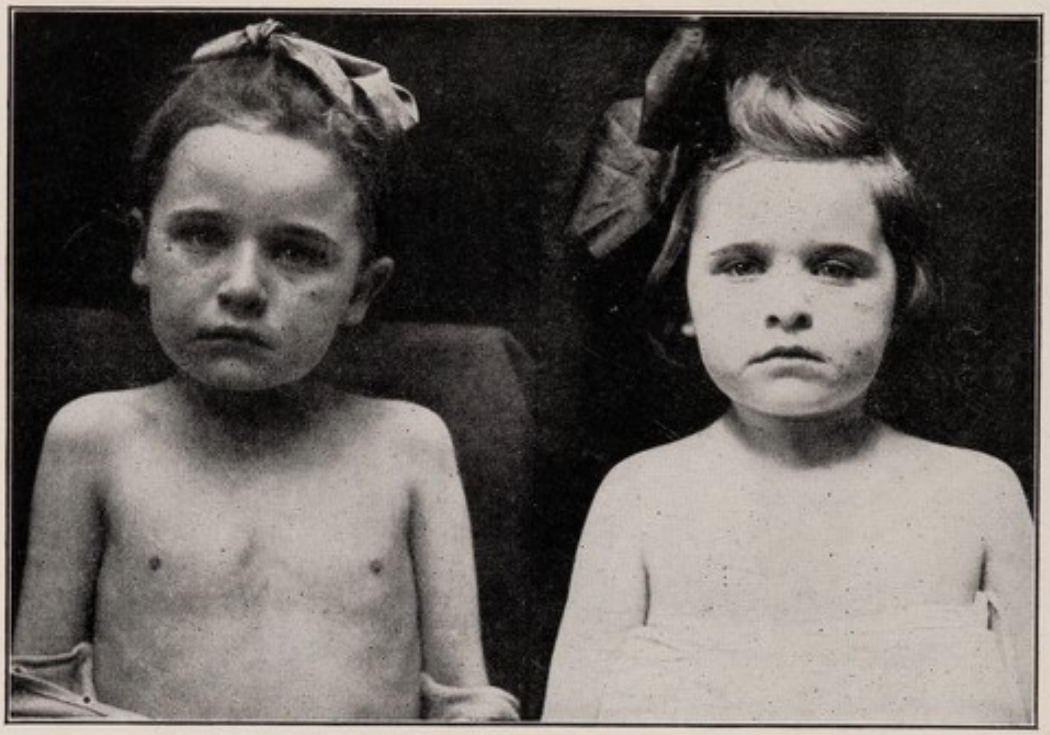

FIG. 602.—Torticollis before and after treatment.

Spasmodic Torticollis.[1]—One variety of acquired torticollis differs essentially from any other form and is of much importance. It is essentially an affection of *adult* life, and like the other varieties affects the right and left sides with about the same frequency and is about equally divided between the two sexes. The manifestation of the affection does not occur as a permanent muscular shortening or continued tonic spasm as in the other varieties of torticollis, but is a clonic contraction which involves not only the sternomastoid on one side, but the posterior muscles on the other side which work with it. At intervals a clonic spasm occurs in all these muscles pulling the head around into the same position as that assumed in congenital wry neck, either with a jerk and considerable force, in which case the affection is inclined to be painful, or with a slow smooth forcible movement either in regular or irregular rhythm, which movement is checked only when the limit of motion has been reached. The affection comes on insidiously with a little drawing of the head to one side at first, or by a feeling of stiffness and tightening of the

[1] Traité des Torticolis Spasmodiques. Cruchet, Paris, 1909 (with full description and literature).

affected side. This increase in force and extent, and as the case progresses the tonic element becomes more marked and the head is held some of the time in the distorted position. The affection is not often particularly painful, but extremely distressing, and is often determined by some movement or occupation. For instance, a high-grade employee in a watch factory, whose business it was to adjust the movements of fine watches, with a very short focus lens, found that the use of this lens was at first occasionally, and then invariably, attended by a spasm of the muscles, drawing his head around. Other patients find that shaving or attempts to fix the head in a certain position are attended by spasm of the muscles. At first, the power of voluntary correction is generally present; later it disappears, but after it disappears the head can often be pushed around by the hand; but in the severer cases attempts to correct the deformity excite spasm and malposition which cannot be overcome until the muscles relax.

The affection is a functional nerve disorder occurring chiefly in people of neurotic temperament, and in normal persons under great strain from mental anxiety or overwork.

The *prognosis* of the affection is on the whole unfavorable and when well established the affection is often hopeless and always resistant to treatment, and the prognosis should be extremely guarded, as the majority of cases will not be cured by any treatment, although occasional cases can be helped and even cured.

Treatment.[1]—The general condition of the patient must be taken carefully into consideration, and any source of reflex irritation removed. A thorough examination of the eyes is of the greatest importance, and other sources of possible reflex irritation from the throat, the teeth, etc., must be looked into. Occupational cause of the condition must be investigated, and if necessary eliminated, and the mental element in the causation must not be overlooked.

In the matter of local treatment, one has to face a record of failure in the majority of cases. The development of the muscles antagonizing the spasmodic ones, by gymnastic methods, is perhaps the best aid in early cases, and active attempts at correction are preferable to passive ones attempting to overcome the malposition by force which too often excites spasm. Occasionally an apparatus retaining the head in a position of correction or overcorrection has been thought to be of service, but in the really bad cases this retention may become painful and at times intolerable. Some cases reported as cured by this method have afterward proved to be failures; it is, however, worthy of a trial. The simplest apparatus for this use is the Thomas collar (p. 232) worn continuously.

Of the *operative* measures, a large number have been suggested, with a record of failure nearly equal to that of the other treatments. The spinal accessory nerve has been divided, also of the posterior nerve roots of the cervical plexus, and a division of practically all of the neck muscles has been performed, all with a large proportion of failure and the return of symptoms sooner or later.

Dislocations of the Cervical Vertebræ.—Complete or incomplete dislocation may occur in the cervical vertebræ below the axis, which causes a distortion of the head simulating torticollis. Shortening of the sternomastoid muscle, loss of motion, and radiating pain down the arm are likely to be symptoms of

[1] KEEN: Operative Treatment of Wry Neck, Annals of Surgery, January, 1891.

nerve root pressure on the side of the injury. As this pressure comes from the roots of the cervical plexus, the distribution of the symptoms is not limited to individual nerves, but to zones.

Dislocations with fracture may present the same picture as the dislocations alone. In these cases cord lesions are also likely to be present. Incomplete dislocations, especially in children, are likely to cure themselves. If reduction is attempted it is preferably done under an anesthetic. The patient lies on the back with the head and neck over the edge of the table. The head is grasped under the occiput and chin by the operator, with slight traction. The head is swung away from the side of the injury and rotated forward on this side; then rotated back while the position is maintained.[1]

CONGENITAL ELEVATION OF THE SCAPULA

(Sprengel's Deformity,[2] Angeborene Hochstand der Schulter)

This deformity was described by Eulenberg in 1863. Willett and Walsham in England reported two cases in 1880 and 1883. In 1888 McBurney and

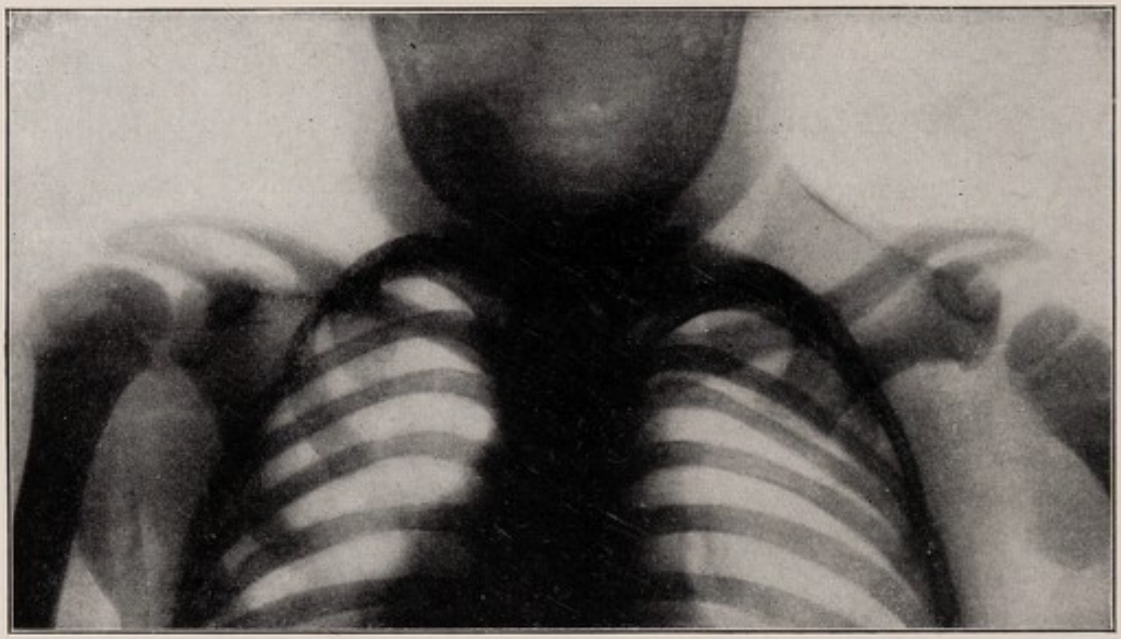

FIG. 603.—X-ray of Sprengel's deformity.

Sands in America reported cases, and in 1891 Sprengel described four cases and gave an account of the condition, which was of sufficient interest to have the deformity often called by his name. Bergel[3] found the deformity in approximately one in three thousand military recruits between the ages of twenty and twenty-two.

The congenital deformity described by this name consists in an upward elevation of the scapula in relation to its normal position. There is in most instances a rotation of the scapula, its lower angle brought nearer to the vertebral column. The deformity exists more often on one side, but cases affecting both sides occasionally occur. Combinations with other deformities are frequent, such as club foot, spina bifida, and other primary congenital deformities, especially malformations of the upper vertebræ and ribs.

[1] COTTON: F. J.: "Fractures and Dislocations," 76.
[2] SPRENGEL: Arch. klin. Chir., 1891, XLII.
[3] BERGEL: Zeitsch. für Orth. Chir., xxvi, 148.

The deformity is to be classed as a primary congenital defect. The primitive upper limb takes origin as a cervical appendage, and later there is a descent of the shoulder girdle from the neck to the thorax. This may be arrested at various stages.

Pathology.—The pathological changes are (1) a shortening of the scapula so that the transverse diameter is greater than the vertical, (2) a hooking over of the upper part forward, (3) the presence of bony, cartilaginous or fibrous connections of the scapula with the vertebræ, as a rule between the fourth and the seventh cervical, and (4) coexisting defects of ribs, vertebræ, and muscles.

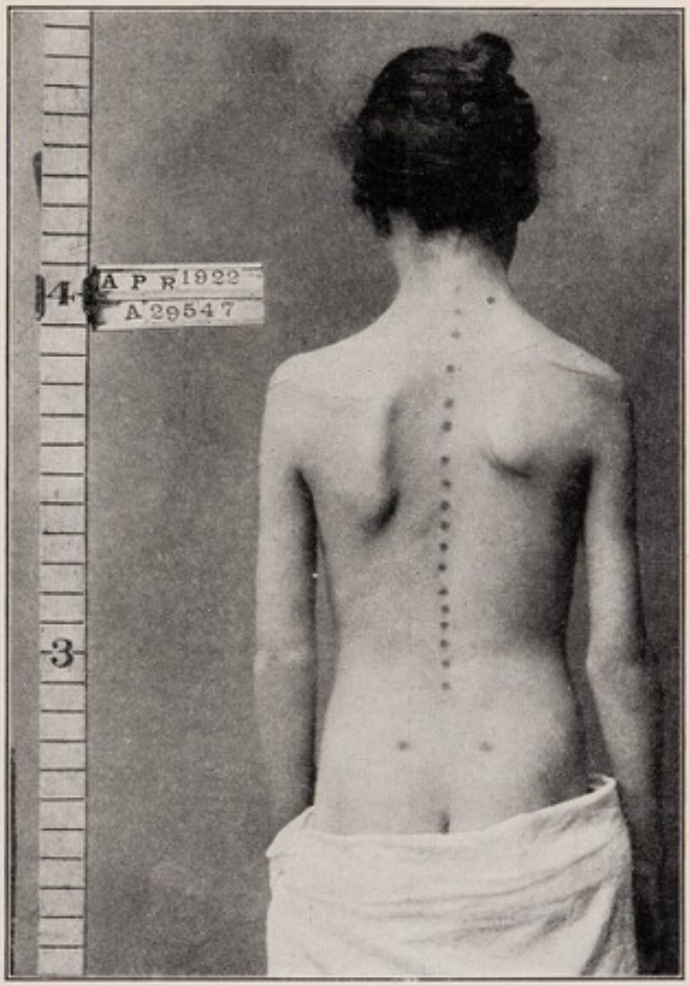

FIG. 604.—Congenital elevation of the scapula.

Symptoms.—The scapula is elevated from one to four inches and rotated somewhat forward so that the whole shoulder seems displaced forward, and the movement of the arm is restricted in abduction in about one-half of the cases, which restriction is obviously mechanical. Torticollis is present in about 10 per cent of the cases.

Scoliosis was reported in 48 per cent of Horwitz's cases, but it is probable that it existed in a much larger number, as it is difficult to see how it can be absent any more than in torticollis. The curve may be either away from or toward the deformity, and is most frequently the latter.

Twenty-five per cent of the cases show attachments between the scapula and the vertebral column, the majority of which are bony. This attachment

runs from the superior median angle or upper third of the median border of the scapula to the transverse process of one of the lower three cervical vertebræ, and the union is usually by means of a triangular shaped bone with the base at the scapula, but it may be united at one or both ends by cartilage or direct bony growth. Ligamentous union has been reported. In another type of case a long piece of bone projects upward from the upper border of the scapula, only does not articulate with the spine.

Horwitz[1] in 1902 reported and analyzed 136 cases, and 99 cases had been previously collected by Zésas.[2]

Diagnosis.—The X-ray appearances are characteristic, showing the bending of the upper half of the bone, and the elevation of the whole scapula.



FIG. 605.—Approximation of shoulders in congenital absence of clavicle (S. T. Irwin's case).

Congenital defects in the neighborhood if present are shown also in connection with this.

Prognosis.—The prognosis is obviously unfavorable without operation, and only fairly satisfactory with it.

Treatment.—In the minor degrees of this deformity no treatment is necessary. Much can be done to increase the range of abduction and elevation of the limb in young children by judicious exercises. Operative measures have a certain limited value.

The scapula should be exposed by an incision running parallel to the spine of the scapula and a little above it. Muscles in the suprascapular fossa are then subperiosteally removed, the upper border identified, and the muscles removed from the under side, also subperiosteally. The upper part of the scapula is then cut off with bone forceps and the rest of the scapula pushed down as far as possible. The difficulty is that after operation the scapula is likely to ride up again, and this can be antagonized by passing a suture

[1] HORWITZ: Am. Jour. Orth. Surg., vi, 260.
[2] ZÉSAS: Zeitsch fur Orth. Chir., xv, 11.

through the tip of the scapula and around one of the ribs to hold it in place. Certain cases of brachial paralysis have occurred from this, but they have not been permanent. The operative treatment is not very successful.

Congenital Deficiency of the Clavicle (*Cleido-Cranial Dysostosis*).—Partial absence of the clavicle is a rare malformation which gives rise to little or no disability. This condition, which is accompanied by certain other defects relating to the cranial bones, is hereditary, and may affect several children in one family. One or both clavicles may be affected; usually the middle portion is absent with the sternal and clavicular ends intact. On cursory inspection the deficiency is barely perceptible, but is at once demonstrable by approximating the shoulders in front of the body (Fig. 605). The frontal bones are imperfectly developed, the fontanelles remaining unclosed until late. The base of the skull and face appear narrowed from side to side. The palatal arch is abnormally high, and usually the teeth are irregular, delayed, or absent. Murk Jansen[1] has drawn attention to two other constant signs: (*a*) a stunting of the middle and terminal phalanges of the toes, and (*b*) bilateral narrowing of the chest. All the phenomena of cleido-cranial dysostosis are in Jansen's view evidence of a general stunting of growth produced at the eighth week of embryonic life by abnormal infolding of the amnion.

CERVICAL RIBS AND NERVE PRESSURE ON THE FIRST RIB

Cervical ribs were first described by Hainault in an account published in 1742, and subsequently Gruber in 1869, and Pelling in 1892 contributed to our knowledge of them; but it is only in comparatively recent times that it has been realized that these abnormal bone growths might be the cause of certain types of neuralgia and of muscular paralysis in the upper limbs, usually in young adults. In the year 1893, Lewis Jones, and nine years later, Farquhar Buzzard described certain cases showing paralysis and atrophy associated with this anomaly.

The suggestion that the cause of a lesion of the first dorsal root might be due to pressure also of the first rib, on account of the very close relation which the first dorsal nerve has to the sharp inner border of the first rib, was made by Edwin Bramwell in 1903. In 1904 Thorburn read a paper before the Medical and Chirurgical Society of London describing two cases, in which the presence of cervical ribs had been demonstrated by X-ray, which was one of the first occasions on which Roentgen rays had been used for the diagnosis of this abnormality.

Anatomical Considerations.—Much valuable work has been done by Wood Jones and Wingate Todd on the relation of costal anomalies to the constitution of the brachial plexus. Two types of plexus are recognised; (*a*) the *pre-fixed* plexus which receives a considerable part of the 4th cervical root, but has a small contribution from the 1st dorsal, and (*b*) the post-fixed plexus which has the 5th cervical as its upper limit, a large 1st dorsal contribution, and a reinforcement from the 2nd dorsal. In the latter run the sympathetic (vascular) fibres for the upper limb. With a pre-fixed plexus the costal process of the 7th cervical vertebra tends to be unusually well developed, and with the post-fixed plexus the 1st rib may be rudimentary. The relation, however of such costal anomalies to the plexus variations is by no means constant.

[1] Murk Jansen: Feebleness of Growth and Congenital Dwarfism, Oxford, 1921.

Types of Supernumerary Rib.—The extra rib is usually present on both sides, and corresponds to one of the following types. (*a*) An exaggeration of the costal element of the 7th cervical vertebra. From the tip of the enlarged transverse process a *fibrous band* runs down to the first rib. This is by far the commonest variation.

(*b*) An incomplete rib of variable length articulating behind with the 7th cervical vertebra, but continued down as a fibrous band to the first rib.

(*c*) A complete rib, jointed behind, and fused below to the first rib.

Topographical Relations of Cervical Rib.—(*a*) Plexus roots—In the incomplete type of rib the 7th cervical root often lies on the bony part, with the 8th cervical or lowest trunk crossing the fibrous prolongation.

(*b*) Subclavian vessels—The *artery* usually lies in front of the rib which at a higher level is crossed by the suprascapular and transversalis colli vessels. An apparent localised dilatation of the subclavian artery has been described many times in association with cervical ribs, but true aneurism is unknown. The arterial pulsation in the neck is often more noticeable in such individuals, owing to the exaggerated droop of the shoulders. The subclavian *vein* at a lower level, is in no direct relation to the rib.

Causes of Symptoms.—It is well known that large cervical ribs may exist without giving rise to the signs of nerve irritation. When symptoms appear they are rarely seen until adult life, the average age of onset being about thirty. During childhood and adolescence there is a progressive descent of the shoulder girdle which attains its final position in adult life. In many individuals a further droop may occur as an asquired postural deformity. Where a cervical rib is present, a persistence of this deformity brings the plexus trunks under conditions of slight abnormal tension. During each inspiration the middle and lower brachial trunks become increasingly taut, and tend to be bowstrung over the bridge formed by the extra rib or its fibrous prolongation. In virtue of their elasticity the nerve trunks are able to bear the slight repeated friction without sustaining damage, but the margin of safety is small, and a *friction neuritis* is easily initiated. The gradual onset of symptoms is often determined by active and strenuous use of the upper limb, a factor which finally turns the scale. More rarely a severe strain may usher in the neuritic signs abruptly. The sex incidence is striking as the clinical syndrome is eight times as frequent in females as in males.

Bilateral symptoms are uncommon (8 in 62 cases—Sargent[1]).

Symptomatology.—In the cervical rib syndrome, sensory, motor, and sympathetic manifestations are seen variously combined in accordance with the type of rib and composition of the plexus.

(*a*) *Motor Signs.*—In the early stages there is a steadily increasing weakness in the hand, with inability to carry out the finer movements. Later the intrinsic muscles show definite wasting, and actual palsy. The long flexors of the fingers may also be involved.

In a number of cases an interesting dissociated paralysis may be found in the *thenar* group, the flexor brevis pollicis remaining intact (Wilson[2]). This feature is believed to be peculiar to the cervical rib syndrome. In 32 cervical rib patients showing muscular atrophy, operated on by Sargent (*loc. cit.*), the groups affected were as follows:—

[1] Sargent, P.: Brain, Pt. 2, Vol. 44, 1921.
[2] Wilson, S. K.: Proc. Royal Soc. of Medicine, Clinical Section, 1913. Pt. 6.

(i) Intrinsic muscles alone—14
(ii) Abductor-opponens group alone—12
(iii) Intrinsic muscles plus long flexors of the fingers—12

(*b*) *Sensory Signs.*—Pain and paræsthesia are experienced in various root areas—most frequently the 1st dorsal; the 8th, 7th, and 6th cervical areas are less commonly included. The 8th cervical area is often missed, as in the prefixed plexus the 1st dorsal fibres are incorporated in the 8th nerve. (Sargent).

The objective sensory signs are less obtrusive. Hypoesthesia and hypoalgesia may be detected by careful testing, which will often demonstrate the characteristic sensory dissociation of a compression lesion.

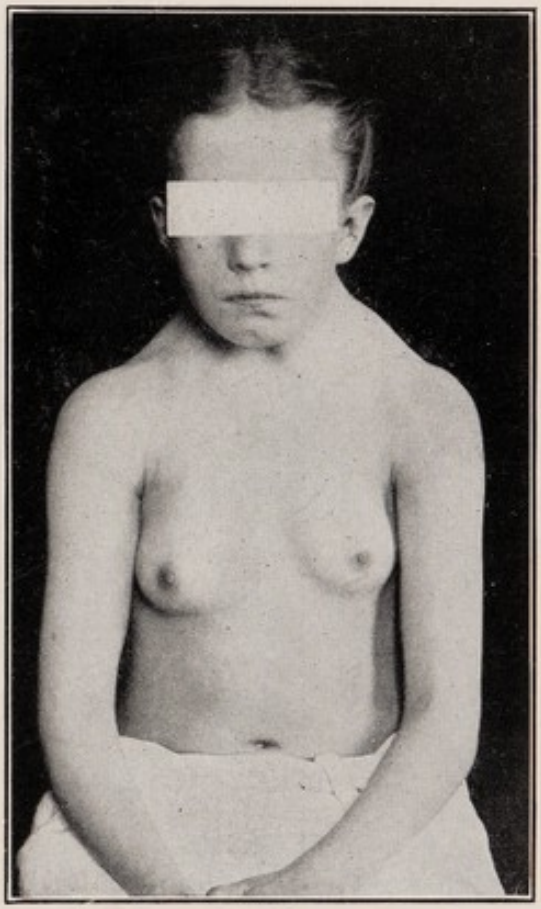

Fig. 606.—Double cervical rib.

(*c*) *Sympathetic Signs.*—The vasomotor fibres in the 8th cervical and 1st dorsal roots are irritated by the repeated friction exerted by the rib. Among the resulting symptoms are paræsthesia, pallor, coldness or cyanosis in the fingers. The *radial* pulse is often diminished in volume, and may be delayed in time. Spontaneous ulceration or dry gangrene in the ulnar area of the hand may be seen. Complete obliteration of the lumen of the radial artery by a progressive endarteritis has also been described. (Todd.)

It must be emphasised that the vascular symptoms dependent on a cervical rib are not due to any mechanical compression of the subclavian artery.

Other Signs.—The extra rib may, or may not, be easily palpable in the supraclavicular region. If a definite rib be present its existence is at once revealed in a radiogram. But as already stated, the syndrome may be seen where the costal element of the 7th cervical vertebra is merely exaggerated. The shadow of the fibrous band may occasionally be demonstrable in the radiogram. It is the presence of the latter which most probably accounts for the neuritis formerly attributed to the 1st dorsal rib alone.

Diagnosis.—Because of the inconclusive value of the radiographic signs, the motor symptoms of cervical rib compression have often to be distinguished from certain spinal diseases such as *syringomyelia* and *progressive muscular atrophy*, and also from lesions of the ulnar nerve. The claw hand with wasting of the intrinsic muscles, is a sign common to all. There are, however, finer distinctions. In syringomyelia the thenar eminence may remain unaffected for some time, whilst in progressive muscular atrophy this group is usually first to show wasting.

The dissociated palsy of the thenar muscles in the cervical rib syndrome has already been mentioned. In ulnar palsy the median muscles are, of course, absolutely intact.

Treatment.—In many cases all that is required is to raise the shoulder girdle upward and backward either by a sling or by the development of the trapezius and levator anguli scapulæ muscles, so that the constant strain is not placed on the lower roots over the abnormal rib. This is frequently necessary after an injury to the affected shoulder, or after a debilitating disease in which the muscle tone is diminished and a slight deformity thereby increased. In other cases, a change of occupation to one which does not throw so great a strain on the affected arm may be all that is required to promote a cure.

There are, however, certain cases in which *operation* is the only course which holds out hope of a cure, and these cases should be treated in this way as soon as it has been shown that the less radical forms of treatment cannot promote

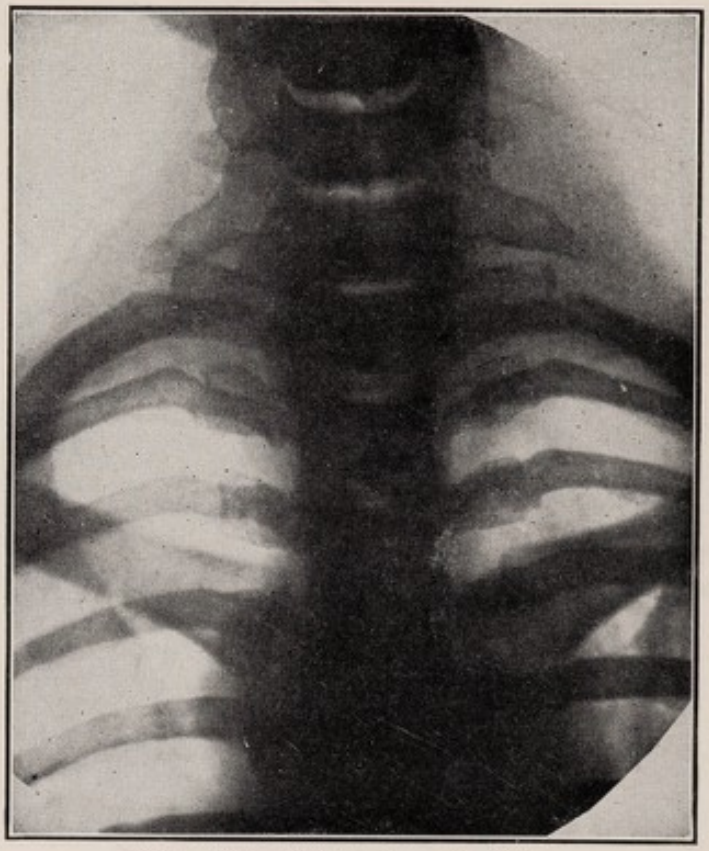

FIG. 607.—Bilateral cervical ribs.

a cure. The operation which is performed is one designed to remove the abnormal rib, and the ligamentous band, if present. But before any operation is attempted the differential diagnosis must of course be clearly made, and such general complaints as toxic neuritis, progressive muscular atrophy, syringomyelia, etc., must be eliminated from the field of possibilities. We are indebted to Sir Harold Stiles for the following description of the steps of the operations for the removal of (1) a cervical rib, and (2) a portion of the first rib.

Operation for the Removal of a Cervical Rib.—The patient should be placed on the operating table with the shoulders slightly elevated and the head turned well over to the opposite side. The clavicle should be pulled downward by traction applied to the wrist by a bandage secured to it by means of a clove-hitch knot. An L-shaped incision is made, the vertical limb being along the anterior border of the lower third of the cervical portion of the trapezius, and the horizontal limb a little above the middle third of the clavicle. The middle branch of the descending superficial cervical nerve is resected; the posterior branch is isolated

and retracted backward along with the trapezius and the spinal accessory nerve. The posterior belly of the omohyoid muscle is freed from the cervical fascia so that it may be retracted upward or downward as required. The lower part of the external jugular vein and the posterior border of the sternomastoid are freed and retracted downward and inward. The transversalis colli artery is divided between forceps as it crosses the brachial plexus. The plexus itself is then exposed as it lies upon the anterior surface of the scalenus medius muscle between the lateral border of the scalenus anticus and the clavicle. The lower part of the scalenus medius muscle is reached by mobilizing the plexus and retracting it downward and inward. In doing this, the suprascapular nerve is found arising from the lateral border of the upper trunk of the plexus (formed by the fifth and sixth anterior roots). In freeing the plexus from the scalenus medius care must be taken not to injure the roots of the long thoracic nerve, which lies behind the lateral portion of the plexus between it and the muscle. The two upper roots pierce the muscle, the lowest crosses in front of it, and the trunk of the nerve, after crossing the first digitation of the serratus magnus, descends behind the clavicle to reach the axilla; the latter muscle, which occupies the floor of the outer angle of the wound, is recognized by the transverse direction of its fibers. If the cervical rib is not well developed, it will be discovered by dividing the fibers of the scalenus medius above the first thoracic rib. Stretching between the two ribs is a thin sheet of muscular fibres, the homologues of the thoracic intercostal muscles; they are divided close to the cervical rib so as not to injure the pleura, and what corresponds to Sibson's fascia is carefully divided along its inner border. Before this can be done, the lowest trunk of the plexus, which arches over the cervical rib, must be freed and retracted downward and inward. Before freeing the rib carefully from the cervical pleura it is divided at its junction with the tip of the transverse process of the seventh cervical vertebra.

Not infrequently the anterior extremity of the cervical rib is found to extend farther forward, and to join the first rib opposite the scalene tubercle, the scalenus anticus being inserted into both structures. In these cases the subclavian artery lies immediately in front of the articulation. In dealing with this condition the third part of the axillary artery must be exposed at the lower and inner angle of the wound, freed from its fascial sheath and retracted downward and inward. This allows of the detachment of the insertion of the scalenus anticus from the tip of the cervical rib and also of the removal of the outgrowth of bone which is sometimes thrown out to meet the cervical rib.

When the cervical rib is rudimentary it is completely imbedded in the substance of the scalenus medius, and in these cases a fibrous band frequently extends downward and forward like a bow-string to be attached to the first rib at or distal to the scalene tubercle. As the first dorsal nerve arches over this band on its way to join the eighth cervical nerve, it is important to remove it along with the rudimentary rib. The best access to it is obtained by opening up the interval between the upper and middle trunks of the plexus by means of small goitre retractors.

The operation is completed by suturing the cervical fascia with catgut and the skin with fine silkworm-gut. Drainage is unnecessary, but as the wound is a deep one carefully adjusted pressure must be applied by means of a liberal dressing and a bandage which should include the head and neck and fix the upper extremity to the chest.

Operation for Removal of a Portion of the First Rib.—When there is no cervical rib, and when the symptoms are due to pressure of the inner border of the first rib upon the first dorsal nerve, it is necessary to remove the portion of the bone extending from the tip of the transverse process of the first dorsal vertebra to the scalene tubercle. As the scalenus medius is attached to the piece of rib which has to be removed, the insertion of this muscle furnishes the most important guide to the operation, the earlier steps of which are practically the same as for the removal of a cervical rib, except that the vertical part of the incision need not extend quite so high. Again the brachial plexus is freed from the scalenus medius muscle and retracted downward and inward, care being taken not to injure the long thoracic nerve or any of its roots. The insertion of the muscle is then detached from the upper surface of the first rib, the intercostals and the upper digitation of the serratus from its outer border, and Sibson's fascia from its inner border. A Doyen's periosteum separator is then passed from within outward between the rib and the pleura, and by a to-and-fro movement the rib is freed. A Shoemaker's rib cutter is then substituted for the Doyen's separator and the rib is divided posteriorly immediately in front of the tip of the transverse process of the first dorsal vertebra. The rib is divided anteriorly by a pair of ordinary angular bone forceps. The inner angle of the proximal stump is nipped away with gouge forceps. At the bottom of the deep wound is the cervical pleura, now freely exposed, and

lying flaccid and somewhat tortuous upon it is the lowest trunk of the plexus. By tracing this backward behind the pleura the eighth cervical and the first thoracic roots may be exposed; the latter almost equalling the former in its size, thus supporting the view that the post-fixed plexus is probably the predisposing factor in the etiology of brachial neuritis due to pressure or a normal first rib. The small nerve which is seen running forward behind the pleura just below the gap which was occupied by the segment of rib removed is the first intercostal nerve. The superior intercostal artery and the first thoracic ganglion of the sympathetic are not exposed; they lie, in relation to the neck of the rib, posterior and medial to the proximal stump of the divided rib.

As the wound is still deeper than that which is left after the removal of a cervical rib, it is very important to prevent, as far as possible, the formation of a dead space. This is best done by suturing the divided insertion of the scalenus medius to the upper digitation of the serratus anterior. Before suturing the skin, a second layer of deep sutures should be introduced to bring together the cervical fascia. If hemostasis be carefully attended to, and if the wound be closed as above described, there is no necessity for drainage, and no harm would result if a small opening should have been accidentally made in the pleura.

In dressing the wound, plenty of gauze and wool are employed so as to keep up steady pressure. The head as well as the upper extremity should be included in the dressing, and the bandage should be applied so as to fix the arm to the side, and at the same time support the elbow.

CHAPTER XXVIII

CONGENITAL DISLOCATION OF THE HIP AND OTHER JOINTS

CONGENITAL DISLOCATION OF THE HIP

Congenital dislocation of the hip is a fairly common deformity of much importance. It has been recognized since the time of Hippocrates and was known to Galen and Paré. The first attempt at reduction seems to have been made by Verduc in 1700 on the cadaver, and the first one on the living was done by Humbert about 1830. In 1888 Agostino Paci[1] advocated the reduction of the hip by manipulation and demonstrated that it could be done, but this method was made practical and effective by Lorenz,[2] who appreciated the importance of retention over a long period. In 1888 Poggi reduced the head by operation, but Hoffa[3] was the first systematically to describe the open operation. Today the manipulative operation has practically displaced the open in the hands of experienced surgeons, except in cases where reduction has proved impossible, where relapse has occurred, and in cases too old to offer a prospect of successful reduction without incision. In the earlier experience of the writers congenital dislocation of the hip was regarded as an incurable and hopeless affection, and the change from that point of view to the very favorable prognosis which can now be given in suitable cases is one of the striking achievements of modern surgery.

Etiology.—Congenital dislocation of the hip exists at birth and it is a question whether it should be classed as a primary or a secondary deformity, or as both. With regard to the first, it exists at times in connection with other congenital deformities, obviously primary, and in such cases it is fair to assume that it is also a primary congenital deformity, except in those cases of spina bifida where the legs are paralyzed and the hips also dislocated, in which it is a question whether the displacement of the hips is not of paralytic origin. With regard to its identity as a secondary deformity, it would seem that excessive flexion and adduction of the thigh in utero would lead to a stretching of the capsule and favor displacement of the head. Also favoring this view is the fact that very often children with such displacement hold their legs for a good while after birth in a position of accentuated flexion. A second reason to believe that the deformity is at times to be classed as secondary is the fact that it may coexist with club foot, evidently of secondary origin. It therefore seems reasonable to assume that, like club foot, the deformity may be classed either as primary or secondary. This is not a matter of much practical importance and does not affect the question of diagnosis or treatment.

In 3767 cases reported by Hoffa, the Milan Polyclinic, the Vienna Institute, the Hospital for the Ruptured and Crippled, New York, and the Children's

[1] Paci: Arch. di Orth., 1892, ix, 1893, x.

[2] Lorenz: Ueber die unblutige chirurgische Behandlung der angeborenen Hüftverrenkung mittels der fnuktionellen Belastungsmethode, Zentralbl. für Chir., Leipzig, 1895.

[3] Hoffa: Die Endresultate der Operationen der angeborenen Hüftgelenksverrenkungen, Verh. d. Deutsch. Ges. für Chir., Berlin, 1895, xxiv.

Hospital, Boston, the affection occurred in females in about 85 per cent of the cases. The affection is about twice as frequently single as double, and the children affected, as a rule, are of average physique, except in those cases where other congenital malformations exist.

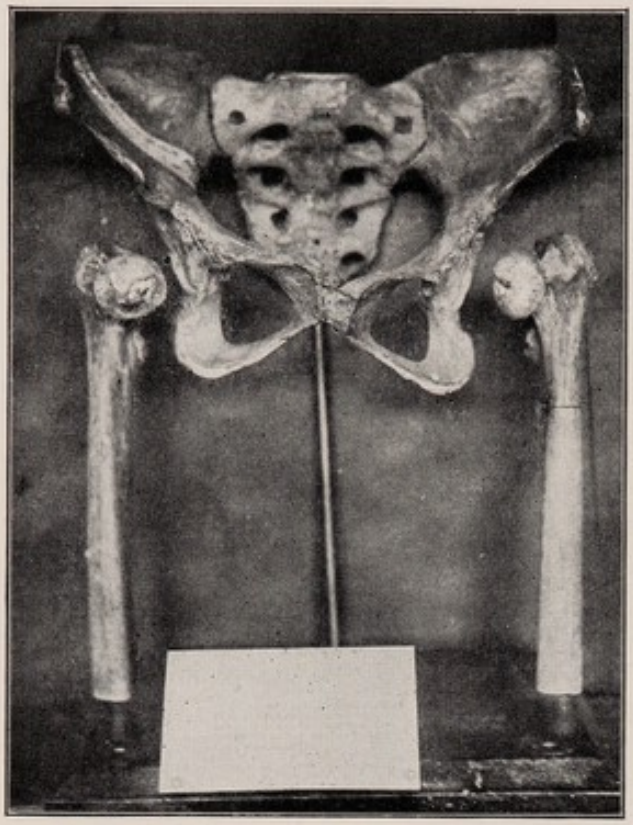

FIG. 608.—Specimen of double congenital dislocation of the hip (Warren Museum, Harvard University).

Pathology.—The pathological changes were first demonstrated by Dupuytren in 1826, but the modern knowledge of the condition dates practically from 1890, when the open operation was first done. In general, the changes consist in a backward and upward displacement of the head of the femur, which is connected with the acetabulum by the stretched capsule. This change exists in new-born children, but the condition is not noticed as a rule before weight-bearing occurs.

With growth two changes occur —(1) abnormal development of the head and neck of the femur, owing to the fact that there is no apposition with the acetabulum; and (2) after walking begins, secondary changes in the displaced joint structures, and an alteration in the figure and gait due to weight-bearing in the abnormal position. In a child old enough to walk, the following changes are found: The acetabulum is always present and in its normal situation, it is shallow, generally triangular in shape, and the base of it more or less filled with fat and fibrous tissue. The head of the femur lies above and generally behind the acetabulum although at times anterior dislocation is present. The neck of the femur is twisted, pointing forward, and the ligamentum teres may be present or absent. The upper epiphysis of the femur fails to ossify as it should and is often in an abnormal relation to the long axis of the neck. In comparing the X-rays of both sides in a case of unilateral dislocation in a child of one and one-half or two years, ossification of the epiphysis of the affected side may be definitely behind that of the sound side. At this age the neck of the femur will be found to be definitely twisted and a stereoscopic X-ray will show that the twist consists of anteversion.

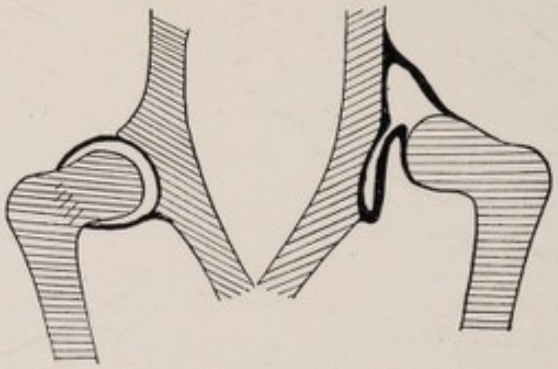

FIG. 609.—Diagram of section of capsule in normal and in congenitally dislocated hip (Bradford and Lovett).

The changes in the capsule are significant and important. After weight-bearing begins, it acts as a suspensory ligament and becomes thickened and

stretched. Where it stretches across the acetabulum it is likely to become adherent to the rim and to a portion of the ilium, thus contributing to the apparent obliteration of the acetabulum. Between the acetabulum and the head of the femur there is found an hour-glass constriction in the lumen of the capsule, which may be smaller than the head of the femur, thus constituting a serious obstacle to reduction. Finally, the changes of the other soft parts are of much importance. Muscles and ligaments are adaptively shortened and stretched. The contraction of the adductor muscles is most marked and has a definite bearing on reduction.



FIG. 610.—X-ray of double congenital dislocation of the hip some years after reduction.

Where the head of the femur is displaced upward two or three inches, as it often is in older children, it must be remembered that the sciatic nerve and the femoral artery are also shortened. This has a definite bearing on the question of reduction in cases with great shortening.

Another important matter is the twist of the lower extremity in relation to the axis of the neck. If the anteversion of the neck is greatly in excess of normal and the foot still points forward, it is obvious that an inward twist in the whole lower extremity must have occurred, enabling the foot to face forward while the neck of the femur is anteverted. This twist must be reckoned with in the matter of reduction.[1]

X-ray Appearances.—In an X-ray of a congenital dislocation of the hip the epiphyseal shadow of the upper end of the femur will be smaller than normal on the affected side and generally displaced somewhat outward in relation to the neck. The neck is foreshortened and may be twisted, but the X-ray is merely

[1] HIBBS: Jour. Am. Med. Ass'n., Nov. 20, 1915.

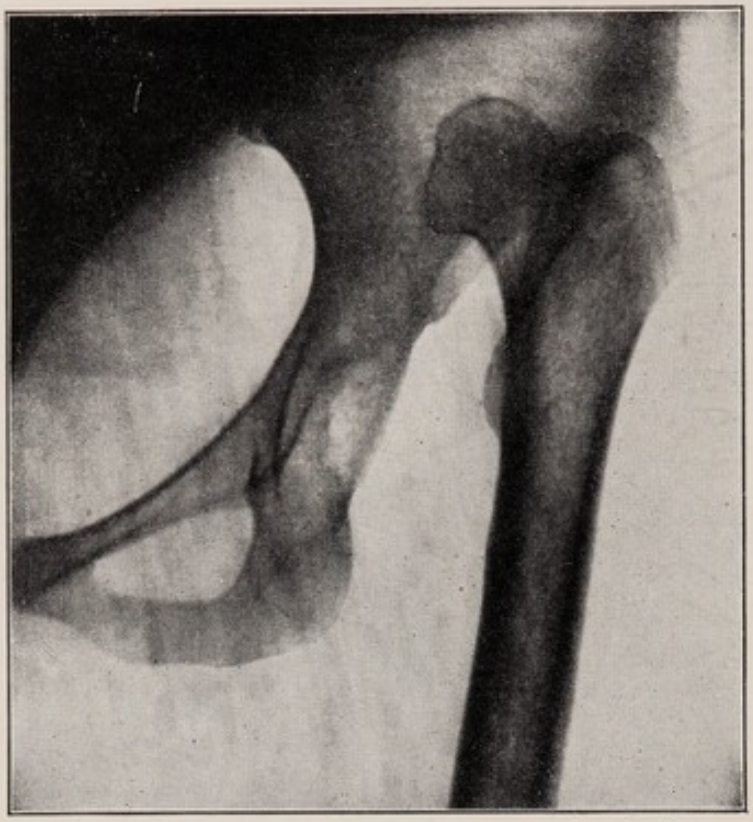

FIG. 611.—Congenital dislocation of the hip, never reduced. Patient twenty years old.

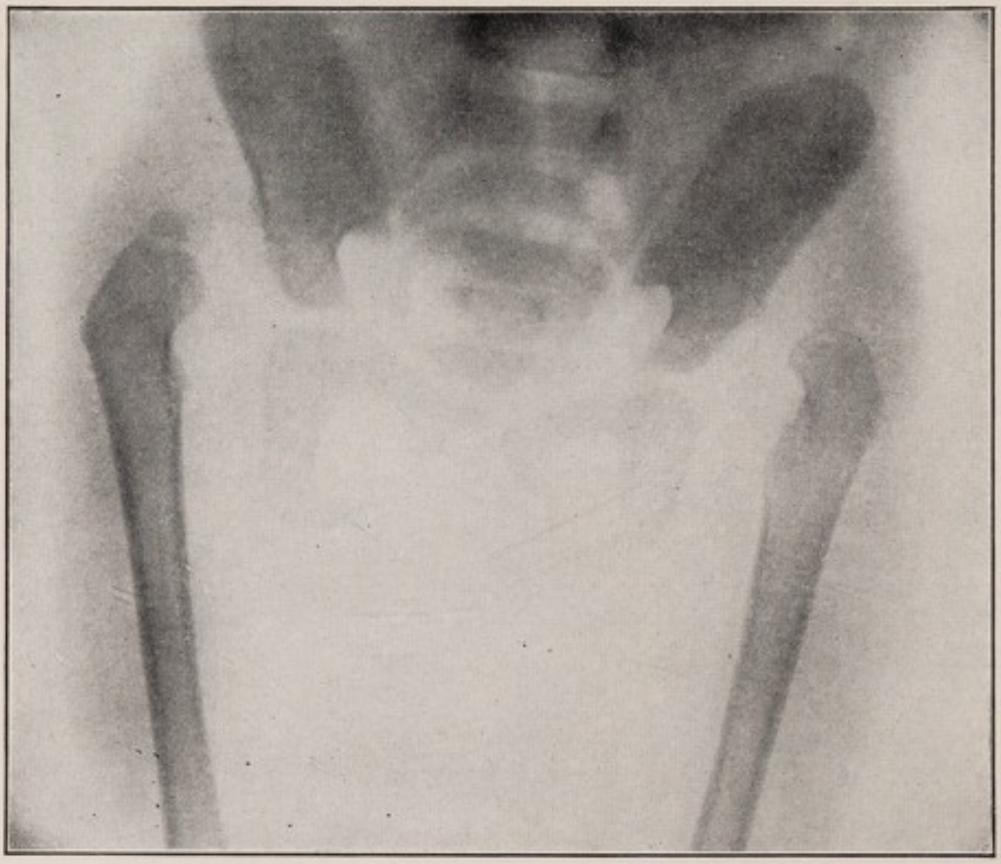

FIG. 612.—X-ray of double congenital dislocation of the hips.

a shadow and it requires stereoscopic plates to say whether the twist is forwards or backwards. The acetabulum appears less indented than normal, but it is difficult to judge of its real character from X-rays, and too much importance must not be attached to this appearance. It is exceedingly important in older cases to estimate the amount of upward displacement of the femur in its relation to the position of the acetabulum as this is of much value in formulating treatment.

Symptoms.—Congenital dislocation of the hip is rarely recognized before a child begins to walk. As a rule, children with double dislocation learn to walk later than usual and the gait is characterized by marked waddling. In the unilateral cases there is a marked limp with lurching to the side, and shortening exists. The trochanter is always displaced above Nélaton's line, the hip is unusually movable and on being pushed upward is found not to be firmly implanted in the acetabulum. A click is sometimes felt in manipulation, the head can generally be identified under the soft parts, and manipulation is not painful under normal conditions.

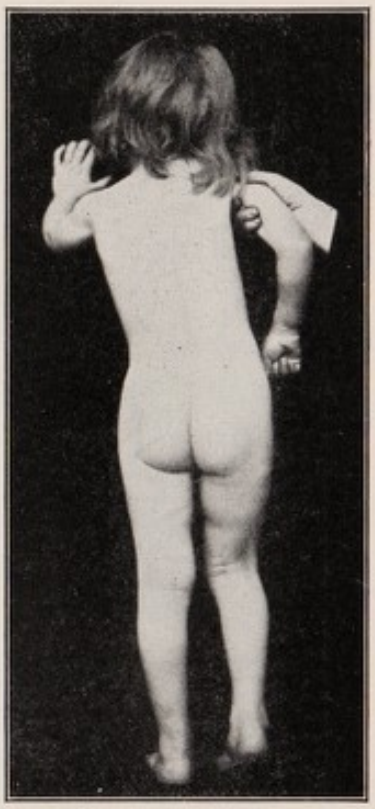

FIG. 613.—Single dislocation of right hip with shortening.

In the routine backward dislocation, the point of suspension of the femur is behind and above its normal position. As a result of gravity the pelvis rotates forward, there is marked lordosis, the trochanters are prominent under the superficial tissues of the buttocks, and the perineum is broadened. These changes later may result in much fatigue in walking, a good deal of backache, and often irritability of the hips.

Probably the most important sign is the so-called *Trendelenburg sign*, which is very characteristic and explains a good deal of the curious gait (Figs. 614 and 615). This sign is demonstrated as follows: If a normal child stands on one leg and flexes the other thigh on the abdomen, to maintain balance, he will raise the side of the pelvis on which the knee is flexed. This is done in order to maintain gravity, and to get the center of gravity over the center of support. If the hip on which he stands is dislocated, and he flexes the other knee, there is no firm point on which to make an adjustment as there is when the head of the femur is in the acetabulum, and the pelvis becomes lowered on the side on which the knee is flexed. The gait is a repetition at each step of the procedure described in standing on one leg. In anterior dislocation the implantation of the head of the femur is firmer and all symptoms less marked.

Diagnosis.—The diagnosis is almost positively made by the X-ray, but temporarily the surgeon will at times have to rely on other signs.

It would seem as if mistakes in diagnosis would not occur in this condition, but the fact remains that it is frequently overlooked or wrongly diagnosed. The clinical picture is, however, characteristic. In a case of single dislocation, the child *limps* as soon as he begins to walk, *shortening* exists on the affected side from ½ to 1½ inches in young children, the *trochanter* is above Nélaton's

line, in standing on the affected leg and flexing the other knee the side of the pelvis is lowered on the unaffected side, the hip is generally painless and the motion is limited in *abduction* but is abnormally free in other ranges. The head of the bone is felt to be out of place, the leg if pressed upward can be felt to slip up (telescoping) and there is a depression in front over the joint.

In double congenital dislocation, the child walks later than normal, a *waddling* gait is present from the outset, *lordosis* is more noticeable than in

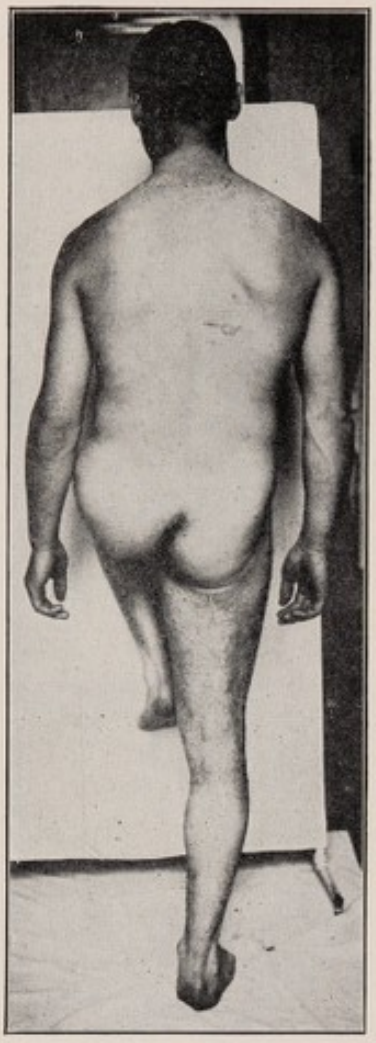

Fig. 614.



Fig. 615.

Figs. 614 and 615.—Trendelenburg sign in congenital dislocation of the left hip.

single cases, the *trochanters* are unduly prominent at the lateral aspect of the buttocks, the *perineum* is broadened, the *trochanters* are above Nélaton's line, and motions in the hips are free and generally painless.

Taking the diagnostic symptoms one by one in their bearing on the diagnosis, the *elevation of the trochanter* above Nélaton's line occurs also in coxa vara, fracture of the neck of the femur, and destructive disease of the neck or shaft. In coxa vara there is always limited abduction as also in congenital dislocation; impacted fracture of the neck of the femur is only a traumatic coxa vara; while disease in the neighborhood of the neck of the femur, serious enough to cause destruction, is almost sure to result in limited motion in the hip. In congenital dislocation, hip motion is abnormally free (except in abduction).

With regard to the *Trendelenburg sign*, there are at least three other conditions which may cause it besides congenital dislocation of the hip. These are not generally recognized, and are: (1) Ankylosis of the hip joint in adduction, and in this it is obvious in standing on the diseased leg that the other side of the pelvis cannot be raised; (2) coxa vara severe enough to prevent abduction beyond the line of the body, and (3) infantile paralysis involving the lateral abdominal muscles on one or both sides will generally cause a marked Trendelenburg sign, not different from that shown by congenital dislocation.



FIG. 616.—Lordosis in double congenital dislocation of the hip.

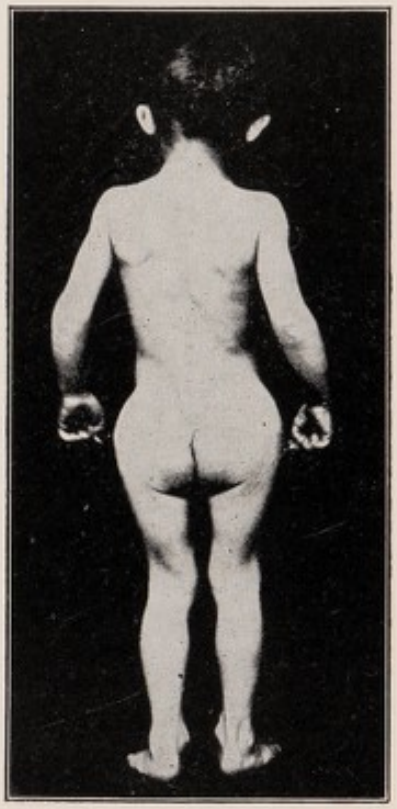

FIG. 617.—Broadening of the perineum with prominence of the trochanters in double congenital dislocation.

The *gait* is very suggestive, and the experienced surgeon will recognize that when the weight is borne upon the affected leg the other side of the pelvis drops; yet even an experienced surgeon may at times be deceived by the waddling gait of double coxa vara. *Manipulation* to the skilled fingers will reveal the displacement, but in certain cases of coxa vara in young children much care may be required in excluding a dislocation. *Lordosis*, which is a very marked symptom of double dislocation, is due to the altered position of the suspension of the pelvis, which is posterior to the acetabulum, so that an increased inclination of the pelvis occurs and thus causes the forward curve of the lumbar spine. Older persons with a congenital dislocation, unilateral or bilateral, are subject to sprains and irritation about the joint, which may suggest some form of joint affection.

In the presence of a good X-ray, difficulty in diagnosis will occur in only one point, and this is the differential diagnosis between *congenital dislocation* and

dislocation from *destructive disease* of the joint. It has recently been the experience of the writers to see cases which were really congenital reported as cases of dislocation due to suppuration. Shortly after birth a superficial suppuration may appear over the hip, which is opened, and when the child is old enough to walk it is found that the hip is dislocated. In such cases the epiphysis of the affected side will be smaller than normal and in an improper relation to the neck of the femur, and the neck is twisted; these cases have every appearance of congenital dislocation, which has been proved to be the case by subsequent operation. The existence of suppuration in the region of the hip may be purely a coincidence and therefore does not establish by itself the existence of dislocation of the hip by a destructive suppuration. When these cases are seen months or years after the suppurative damage has occurred they will closely resemble similar cases of dislocation of congenital origin and are described by the French as *pseudarthroses flottantes*. All the clinical signs described for congenital dislocation are present, but the dislocated joint is generally less mobile, being tied up by scar tissue.

Prognosis.—Without treatment, hips which are unstable and loose in early or middle childhood, characterized by a bad limp and much laxity on manipulation, are likely to prove troublesome in adult life. They are subject to sprain, they are frequently a source of much discomfort, and in double dislocation may be severely disabling. This is most likely to arise between twenty and thirty. Cases which are stable early in life, not particularly lax in manipulation, and walk without much lurching, frequently go through life without serious disability, and only moderate discomfort. Adults with obvious double dislocation of the hips can be seen in the streets of any large city walking in a perfectly characteristic way, apparently going about their daily work. The prognosis with treatment will be discussed under treatment.

Treatment.—The object of treatment is obviously to place the head of the femur in the acetabulum, and to retain it there for a sufficient time. It is equally obvious that treatment by braces and corsets has no place except in adolescent or adult cases when operation is not allowed or indicated, in which cases apparatus may be used to minimize limp and pain.

The obstacles to successful and permanent reduction are:

1. The imperfect shallow acetabulum, more or less filled up by fatty and fibrous tissue.
2. The imperfectly developed head of the femur.
3. The anteversion of the neck.
4. The stretched and thickened capsule constricted in the middle.
5. The shortened muscles.

These obstacles become increasingly formidable as the child grows older. Reduction is naturally easier in infants, but retention is not always a simple matter, as at this age it is difficult to prevent repeated soiling of the plaster-of-Paris cast. In spite of such nursing difficulties delay in reduction should not be countenanced. The young child should be given a few weeks' training in habits in hospital before reduction is attempted.

In theory any dislocated hip could be reduced if force enough were used, but to stretch the sciatic nerve three inches at one sitting is to bid for paralysis, to stretch the femoral artery as much as this is to narrow the lumen or possibly to rupture the artery, and the damage to the soft parts in general must be very great. Paralysis, temporary or permanent (144 instances being reported

by Bade[1]), fracture of the pelvis, rupture of the artery, gangrene of the whole lower extremity and a high death rate attributed to "anesthesia" have been recorded in older cases up to nineteen years of age. The most frequent postoperative paralysis is complete sciatic, the peroneal alone comes second, and the anterior crural third. Aside from these accidents the end results in older cases are not functionally satisfactory as a rule, much limitation of joint motion usually resulting.

The problem resolves itself to a plain question of surgical judgment in these older cases. There is no surgical triumph in the reduction of a case sixteen years old if irreparable damage is done, or if life is hazarded by shock. The triumph comes in knowing how much force is justifiable and when to stop, and nothing is more difficult to decide than this last question.

Manipulative Reduction

("Bloodless" Method, Lorenz Method and Its Modifications)

Except in very unusual circumstances reposition by manipulation should first be attempted in all cases under ten, and in certain cases older than this. As has been said, the most favorable age for reduction is before five, when real difficulty will rarely be encountered by the experienced surgeon. From five to ten, reduction is definitely more difficult and should only be attempted by the surgeon with large experience. After ten years the obstacles to successful manipulative reduction are likely to be insurmountable and recourse to the open operation must be contemplated. In exceptional cases great difficulty may be experienced, even in young children.

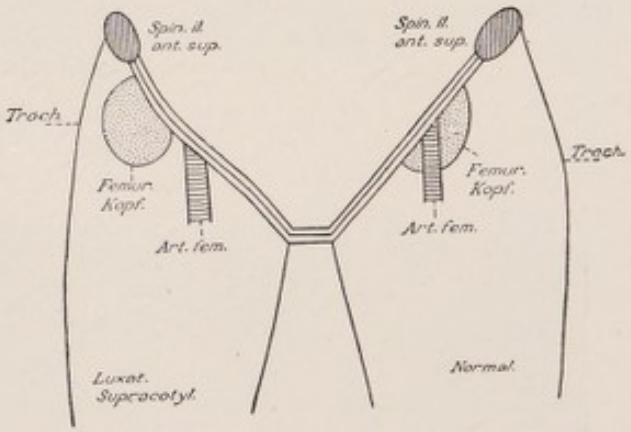

FIG. 618.—Schematic representation of the position of Poupart's ligament, the femoral arteries and the head of the femur. On the right of the picture a normal angle; on the left a supracotyloid luxation (Lange).

No definite rule can be laid down other than to suggest that sound surgical judgment and experience are the only criteria for deciding when sufficient traumatism has been produced.

Manual Reduction.—The statistics as to this operation vary so widely that they fail to inspire confidence. The reported percentages of approximately 100 per cent of permanent cures cannot be accepted by the writers as really representing end results, and the low percentages reported by others would suggest a possible defect in technique. From their experience, the writers are of the opinion that with good after-care, almost perfect anatomical and functional results should be obtained in from 50 to 75 per cent of unilateral cases up to the age of eight, and of bilateral cases up to the age of five. This estimate is based on the assumption that the operator has had experience and is using a technique of reduction with which he is familiar, no matter which it is, that the retention apparatus is put on by him and not by inexperienced assistants, that the after-care is also under his supervision and is adequate, and that the

[1] Verhdg. d. Ges. für Orth. Chir., 1909.

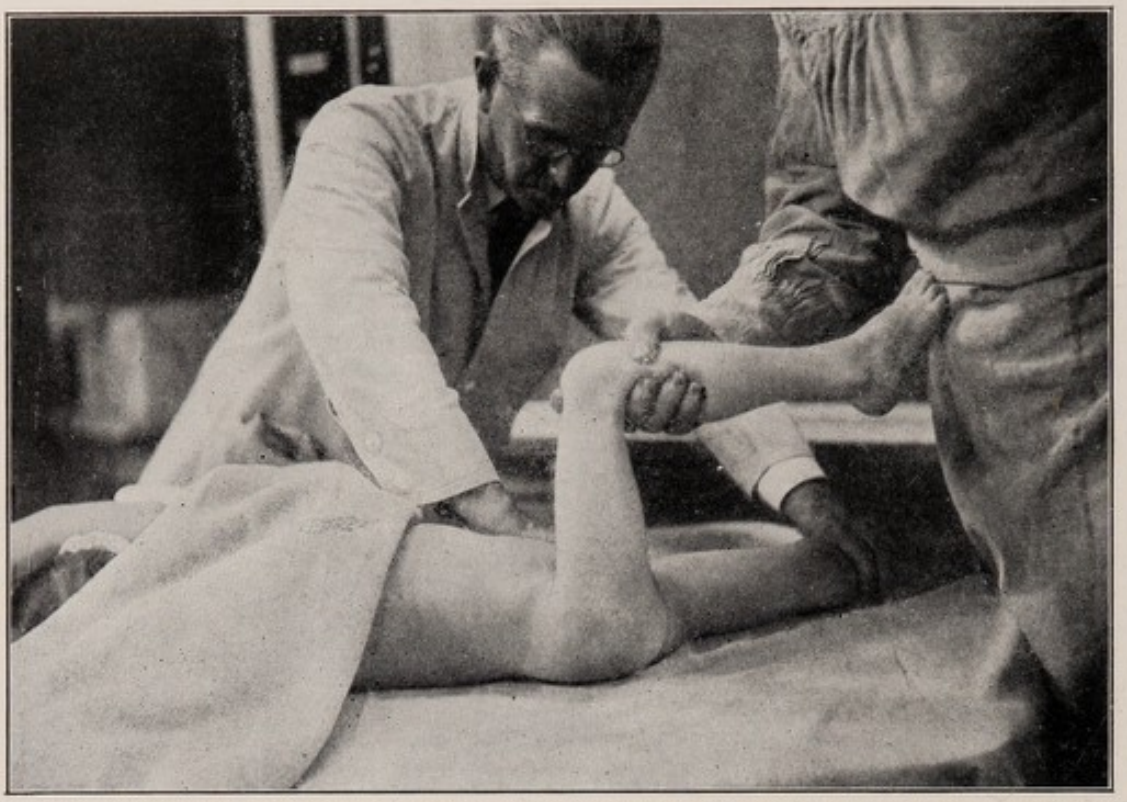

FIG. 619.—Method of manipulation used most often by the writers for reducing congenital dislocation of the (right) hip—first step.



FIG. 620.—Second step of manipulation.

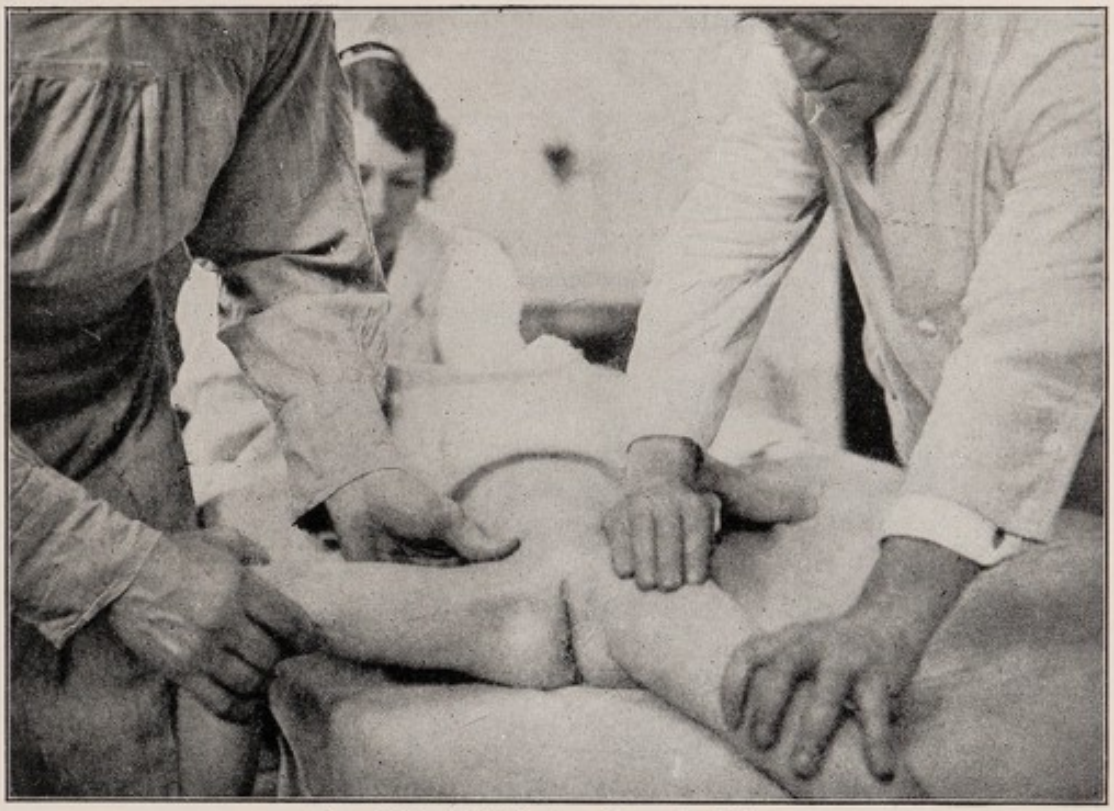

FIG. 621.—Third step of manipulation.

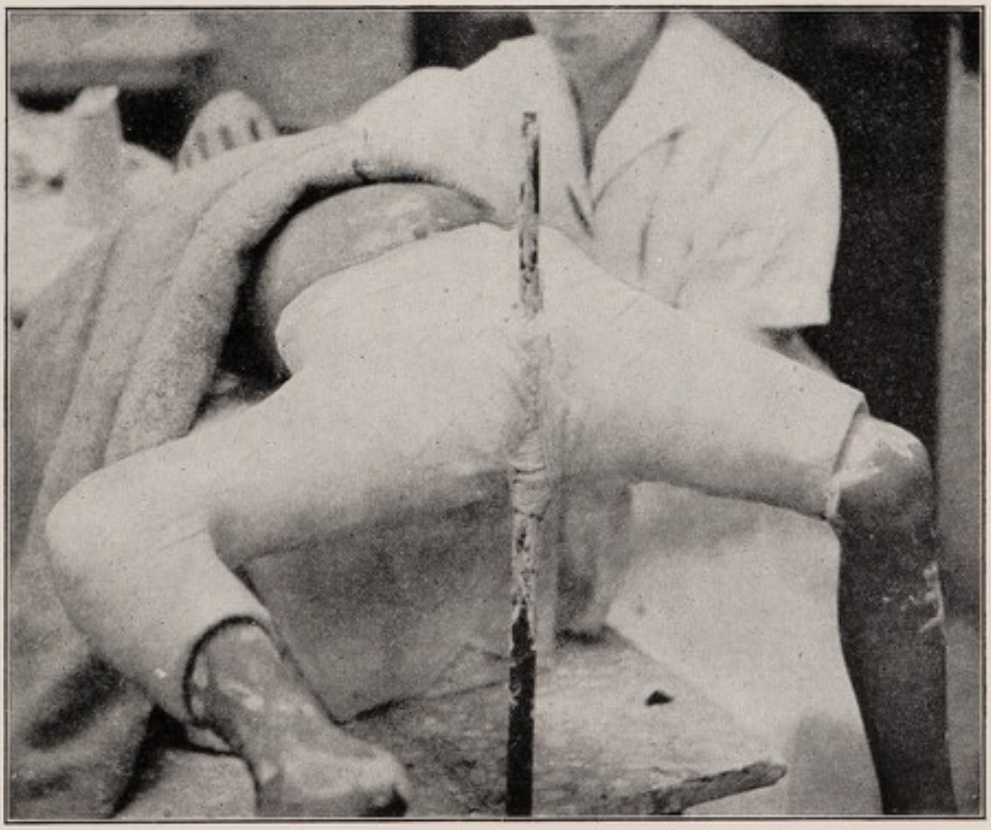

FIG. 622.—Finished plaster with patella pointing outward.

head of the bone is shown to be in place by a post-operative X-ray taken through the plaster before the patient leaves the hospital. It is the belief of the writers that these are the points which are important rather than the especial technique employed, because a reduction is a reduction, however obtained.[1]

The technique of Lorenz was at first universally used, but of late years there have been adopted many modifications replacing it.

In cases which are apparently going to present difficulties of reduction, especially cases with high degrees of shortening, preliminary traction during recumbency of two or three weeks before the attempted manipulation is often of value.

In the reduction, as in all manipulations, care should be taken to grip the thigh above the knee or fracture of the femur may occur.

Manipulative Technique.—There are minor differences between the methods practised by such authorities as Lorenz, Hoffa, Ridlon, Denucé and others.

In the original Lorenz procedure, a forcible preliminary stretching of the adductors and hamstrings was carried out before the actual reduction was attempted. This stage is omitted by the majority of surgeons at the present time, as it is generally felt that just enough stretching to allow reduction should be produced, but no more. The importance of gentleness in reduction has been especially emphasized by Denucé, whose results in a large series of cases have been exceptionally good.

The actual method of reduction as used by the writers is as follows:—(Figs. 619–622). With the child lying on its back, the pelvis and opposite thigh are fixed by an assistant. The affected thigh is flexed to a right angle, rotated in, and then abducted without losing the flexion and rotation. Counter-pressure is used under the trochanter and the head brought forwards. Reduction may take place with an audible snap as the head slips over the acetabular rim, but sometimes the sense of resistance is barely appreciable. After reduction, the soft tissues on the front of the hip are gently stretched so as to bring the knee into the same plane as the body. Stability is now tested by relinquishing control of the limb and observing the angle at which the hip redislocates. Various modifications of this method may be tried if diffculty is encountered. Thus, reduction may be begun with the thigh flexed fully on the trunk and the knee directed towards the opposite axilla (Denucé).[2] Before abducting the hip it is often a useful step to exert a downward thrust on the knee and to bring the thigh into full internal rotation (Ridlon).[3] Instead of the supporting hand, a padded wedge may be used as a fulcrum behind the trochanter. The method introduced by Gwilym Davis differs considerably from the conventional technique. The child is placed on its face with a sand-bag under the pelvis and the affected leg hanging over the edge of the table. An assistant grasps the knee with one hand and the shaft of the femur beneath with the other and flexes and slightly abducts the limb, steadying and supporting it against his body. The surgeon meantime presses down upon the head and neck of the femur. The abduction is continued by repeated manipulation of this kind until the head of the femur slips forward into the socket. In difficult cases flexion should be increased.

[1] Fairbank, H. A. T.: Late results of treatment of congenital dislocation of the hip. Brit. Jour., Surg., x, 37, 1922.

[2] Papin, Ed.: University of Bordeaux Thesis, 1919.

[3] Surgical Clinics of Chicago, 1917–276.

Instrumental Aids.—Traction force as a preliminary to reduction has been advocated by Humbert, Schede, Biesalski, Lange and others. The machine perfected by Bradford has been used with considerable success in Boston. On the whole, instrumental aids have attained little popularity, and except in the hands of experienced surgeons, are fraught with considerable danger.

In *conclusion,* with regard to manual manipulation with or without the use of traction, the writers are of the opinion that it should be attempted in all cases of congenital dislocation of the hip which offer a chance of reduction. The following general considerations must be mentioned. Age, as has been said, is generally an index of difficulty of reduction, but occasionally a young



FIG. 623.—Apparatus for reduction of congenital dislocation of the hip (Bradford and Lovett).

case is encountered which presents decided difficulty and, on the contrary, an older case will sometimes be reduced with surprising ease. Cases at or beyond puberty have been and often can be reduced, but the question is whether the functional results justify the use of high degrees of force in these cases. There are two considerations of prognostic value.

In general, cases with a limp suggesting a loose capsule, and cases where the head of the femur can be pushed up and down (telescoped) with ease while the patient is lying relaxed, are easier to reduce at any stage than cases where the hip appears firm in walking, and where there is little telescoping to be accomplished by manipulation. This factor will be found of assistance in deciding what to do in borderline cases. Excessive shortening, that is, from two and one-half to four inches, is a real though not insuperable menace to successful reduction, on account of the danger to vessels and nerves. These two considerations should have weight with the surgeon in deciding what to

do with a given case which apparently presents more than average difficulty. In such cases, extension in a Thomas knee splint is advisable before reduction is attempted.

Anterior Reposition.—In cases of dislocation of the hip which it is found to be impossible to reduce, the surgeon should consider the possibility of transforming the posterior into an anterior dislocation with a view to securing better function, as anterior dislocations on the whole possess comparatively good function. This manipulation is best performed by gradually working forward the head of the femur toward the anterior aspect of the joint and the anterior part of the capsule.

Anteversion of the Neck of the Femur.—In the cases where under proper conditions of reduction and after-treatment the head of the femur has slipped out, the question should be considered whether or not the difficulty may lie in an extreme degree of anteversion of the neck of the femur, which makes it impossible for the head of the femur to engage when the foot is pointed straight ahead. In this connection one must remember the proposition of late advocated and practised by Reiner,[1] Lorenz, von Aberle, Spitzy, and Hibbs,[2] the performance of an osteotomy of the shaft of the femur and rotating the lower fragment out through an angle of 90 degrees, as a pre-operative measure.

Fractures should be treated on general principles and disturbances of circulation should not be minimized, but receive prompt attention.

After-treatment

It is universally admitted that after-treatment of some form is necessary, and it is generally agreed that this fixation should continue over some months in a position of marked abduction and flexion, but beyond this there can hardly be said to be agreement.

After reduction of the hip, whether by manipulation or the use of traction and manipulation, the joint should be stretched until the femur can be abducted to a right angle with the body and until the anterior surface of the knee lies to the back of the plane connecting the anterior superior spines of the ilium. Preferably the position should be a little in excess of this described, which must be regarded as the minimum. The leg is then put up in the old frog position, or in the position with the patella forward, or in any position between the two, or sometimes in an exaggeration of either, according to the position in which the head of the femur is most stable; but in the final position, whatever amount of rotation is adopted, the amount of abduction must be extreme, pushing the head of the femur forward into the anterior part of the capsule.

The patient is then placed upon some contrivance for the application of a spica bandage, consisting essentially of an upright post with a small metal pad to support the sacrum. The extremities and pelvis are protected by stockinet or sheet wadding bandages; the sacrum and back of the pelvis, the anterior superior spines, and the knee are protected by felt pads; and a most important thing at this stage is that the surgeon should assure himself that the head of the femur is actually in reposition before proceeding to the application of the bandage. Throughout this whole process it cannot be too strongly insisted upon that the application of the bandage is almost as important a part in

[1] LANGE: Lehrb. d. Orth. Chir., 297.
[2] Jour. Am. Med. Ass'n., Nov. 20, 1915.

obtaining a successful result as the reduction itself. The surgeon having assured himself that the hip is in place and that the femur is actually in reposition, the leg

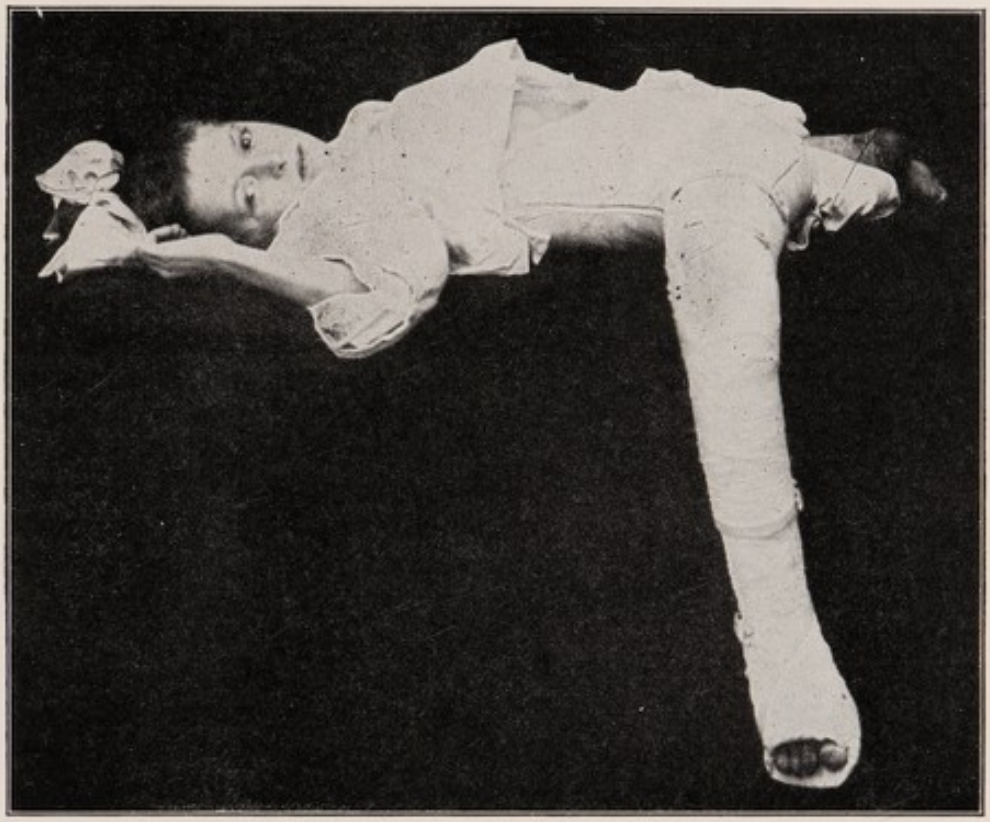

FIG. 624.—Finished plaster, bivalved, patella pointing forward.

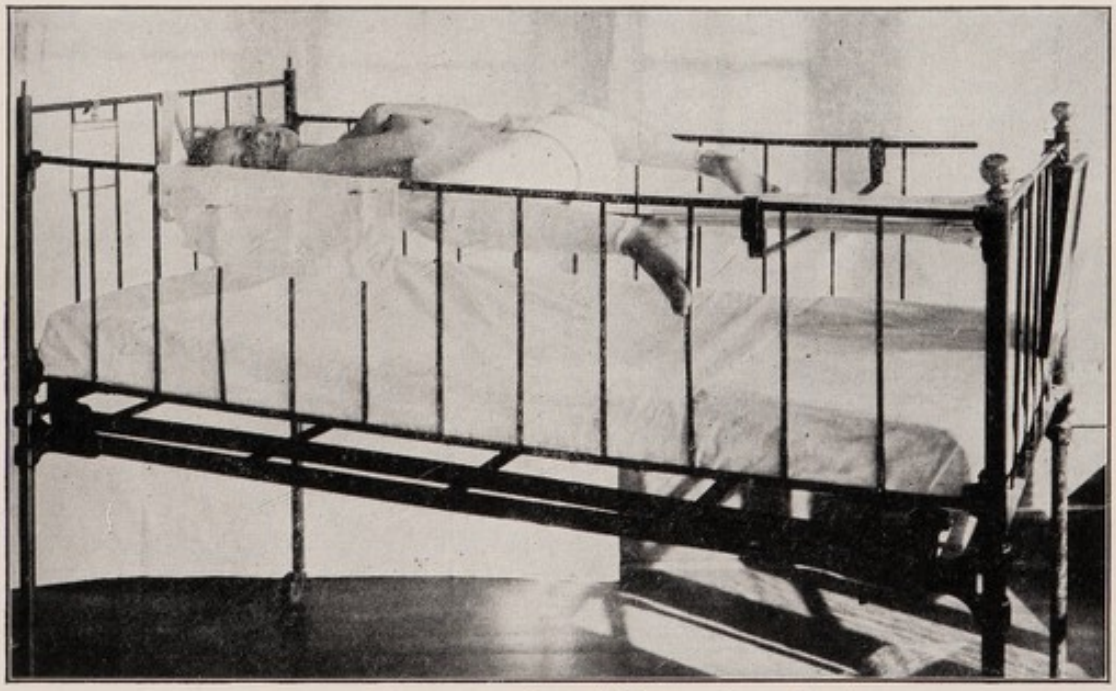

FIG. 625.—Patient on elevated frame after reduction.

is flexed to a right angle and abducted to a position where the anterior part of the knee is posterior to a plane connecting the two anterior superior spines, when a

plaster of Paris spica bandage is applied. The replaced femur should be held either by the surgeon or by a very experienced assistant during this application. It is very easy to allow the knee to come forward without noticing it, and the maximum of abduction obtained must be maintained during the application of the plaster. It is most important that the plaster should be pushed in at the back to hold the trochanter forward and it should be made particularly solid in this place as here lies the greatest danger of slipping out. It should embrace the whole leg on the reduced side, including the foot, should extend well above the crests of the ilia on both sides and include the well leg down to

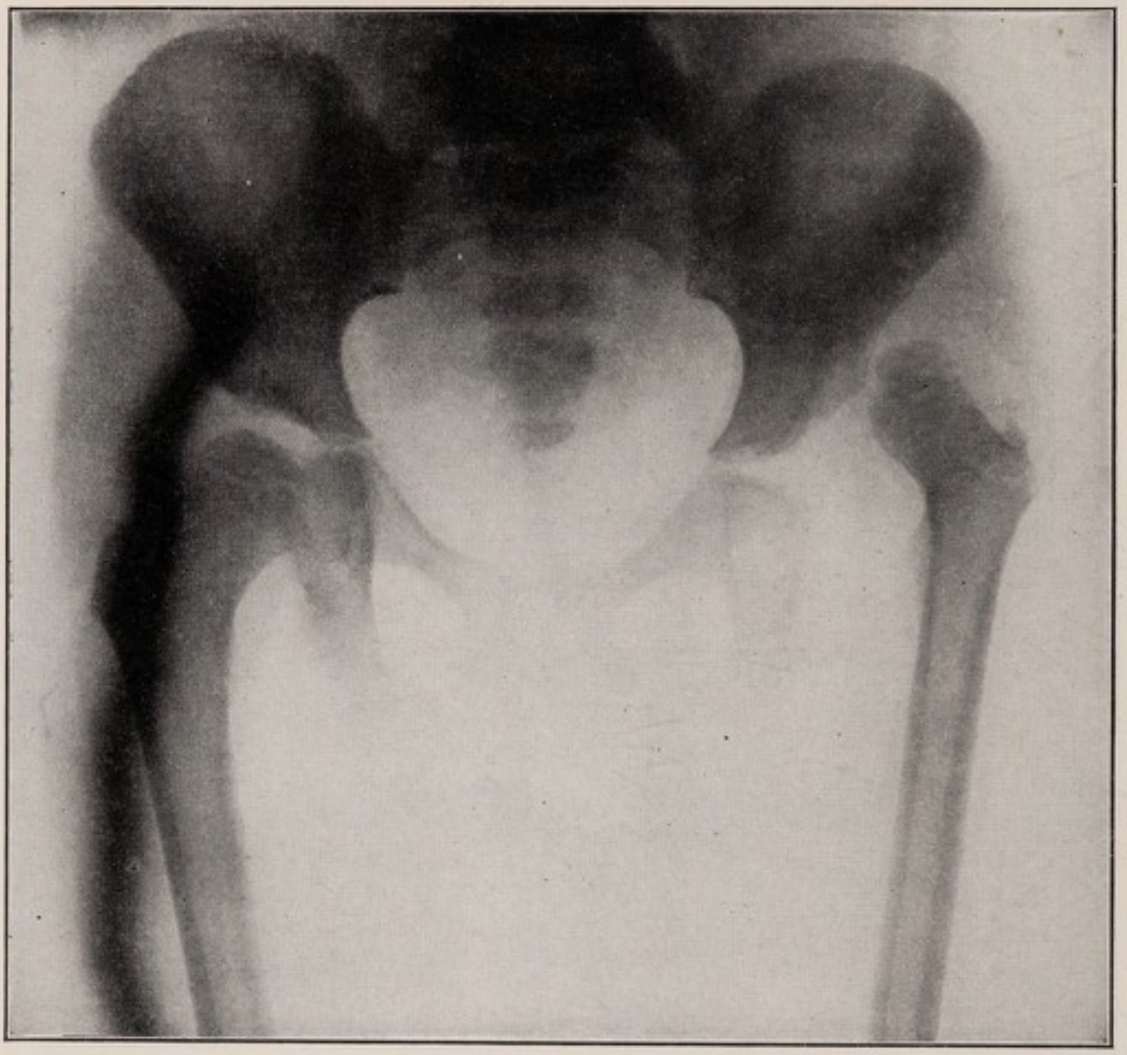

FIG. 626.—X-ray of hip before second reduction. A year previously an unsuccessful attempt at reduction had been made elsewhere. See Fig. 627.

a short distance above the knee. It should be well cut away in front and behind to avoid soiling. Following the reduction the patient should be put to bed, preferably on an elevated gas pipe frame which enables the nurse to keep the plaster cleaner, and is also more comfortable for the patient than to lie on the face and with the leg hanging off the edge of the bed, as is necessary in certain positions of the leg, notably when the leg is done up with the patella rotated forward. The opening of the plaster necessary for the use of the bed pan should be faced with oil silk.

In the earlier reductions there was much swelling and ecchymosis around the genitals, but in the modern operation there is much less. In some of the more difficult cases there is tearing of the skin which should be treated antiseptically; but on the whole, cases today suffer little discomfort after the operation and very often no morphine is required, for although the position would suggest extreme discomfort, this apparently does not occur. Too much importance cannot be placed here, as in similar reductions, on a thorough stretching in the manipulation and the use of retentive plaster *only* to hold

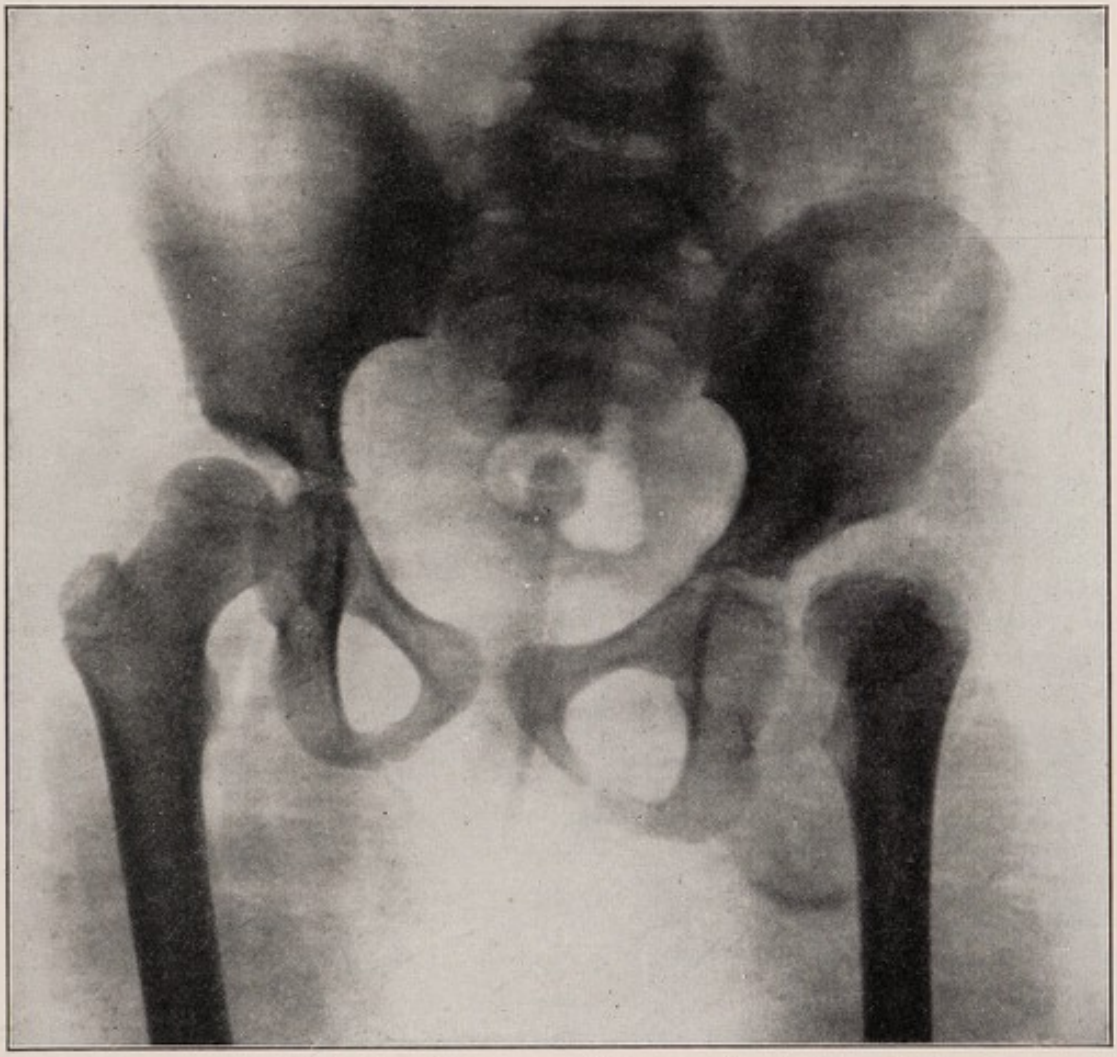

FIG. 627.—Same case as Fig. 626. Two years after second reduction which was successful.

the position already obtained. To depend upon the plaster to accomplish more stretching is to bid for discomfort and trouble.

The patient should be kept in bed and quiet for a week or two, the position of the head of the femur should be verified by an X-ray taken through the plaster at the end of forty-eight hours, and if it proves that the head is not in place one of two courses may be pursued. If the displacement is slight and the head seems to be nearly in the acetabulum it is possible at once to give anesthesia again to see if by a little further manipulation and by putting the limb up in a differently rotated position complete reposition can be secured. If, however, the case was a difficult one, and reduction has absolutely failed, it is

wise to remove the plaster and allow the child to lie in bed until the soreness has disappeared. It is surprising how quickly the hip recovers after a really severe manipulation, and traction to the leg is almost never necessary to quiet postoperative discomfort in these cases. If the plaster has been removed after being on some time, an immediate attempt at a second reduction is dangerous and likely to be attended by fracture, as any bone can be made brittle by being kept in plaster sufficiently long. By avoiding operations on cases just out of plaster the number of fractures can be greatly reduced.

If the case is shown by the X-ray to have been satisfactorily reduced, at the end of one or two weeks the child may be allowed to get up and be carried about in any way that does not cause discomfort (Figs. 626–627).

The treatment from this stage onwards varies considerably in the practice of different clinics. A well established method is to bring the hip down into a weight-bearing position, in two successive stages following the actual reduction. The first plaster is kept on for about three months. On removal, if the hip is stable the angle of flexion and abduction is lessened, and the thigh is rotated inwards. The second plaster is now applied and retained for two months. In the third and concluding stage the hip is brought down still further. Occasionally a fourth plaster is required. The total period of fixation lasts from six to nine months.

An alternative method is to retain the primary position of 90° flexion and abduction throughout. At the end of two months, the plaster is cut away from the unaffected leg and from the affected leg below the knee. A high sole is worn on the reduced side and the child is encouraged to walk about. Plaster fixation lasts from six to ten months.

Whatever routine is followed, after discarding all fixation, attempts should be directed towards restoring motion in the hip. At this stage the joint is often very stiff and remains fixed in the abducted position. Stiffness is especially marked in older children and may persist for many months, but tends to pass off spontaneously. It is important to prohibit all forced efforts to mobilise hips which are painful. Heat and heliotherapy should be used to allay joint irritation, and the gentlest active exercises only allowed. These are most effective when performed in hot brine baths (Denucé). Re-education in walking is the final stage of all, and in successful cases all trace of limp and lordosis disappears. Very occasionally a residual degree of stiffness may last for a year or more, and the advisability of eliminating this by cautious manipulation under anæsthesia must be discussed.

Summary of Manipulative Reduction.—In summing up the whole question of reduction by manipulation, some men have more facility with one method, and some with another. The surgeon will be wise to use the method or methods with which he is most familiar, with perhaps another method held in reserve for unusual cases, bearing in mind that the object is to put the head of the femur into the acetabulum without doing damage to the growing head of the femur, to vessels or nerves, and without endangering the life of the patient or usefulness of the limb by prolonged and violent manipulation. Long continued operations are dangerous to life and symptoms of shock should be constantly watched for and guarded against.

The young surgeon should perform his earlier operations under the guidance of an expert, so that he may learn the degree of leverage which it is safe to put upon the femur in his final manipulation.

In the case of double dislocations, the surgeon may find it expedient to reduce only one hip at a time as, in difficult cases, attempting a second manipulation at the same sitting may be attended by real risk to life.

REDUCTION AFTER OPEN INCISION

In 1888 Poggi was the first to undertake to place the dislocated head unchanged in the acetabulum, which was deepened for the purpose. Hoffa developed the open operation, and after him Lorenz. The earlier operation consists in exposing the head of the femur and the acetabulum, freeing obstacles to reduction in the way of the capsule and shortened ligaments, deepening the acetabulum, if need be remodeling the head of the femur, and sliding the head into the acetabulum by means of a deep retractor shaped like a shoe horn. In the Hoffa-Lorenz operation the joint was opened through an anterior incision running along the outer border of the tensor fasciæ femoris which exposed the joint capsule. A posterior route was occasionally followed through the Kocher incision five to eight inches in length.[1]

The treatment of this affection has progressed in cycles. First came the manipulative reduction without cutting, then Hoffa advocated the operation by cutting. Next ensued a wave when the reduction without cutting prevailed, and at present there is a tendency on the part of some surgeons to advocate reduction by cutting, in some cases on a very large scale.

A distinction must be drawn between the deliberate use of the open operation in young children for dislocations which are reducible by manipulation, and the more limited application of the operation to older children, adolescents, or even adults, where manipulative reduction has failed or is impracticable.

Galloway[2] is a leading exponent of the open operation as the method of choice. In 1920 he gave his results in 37 patients—50 hips were dealt with in all, 38 of which were available for final review. Of these 12 were described as cured; 14 as good results; 6 as doubtful and 6 as failures. The good results included one case in which neither hip was in the acetabulum and a few in which ankylosis had occurred. Further experience with the open operation has convinced Galloway[3] that this method will give a higher percentage of success than manipulative reduction. At the present time there is an increasing dissatisfaction with the late results of manipulative treatment, even when practised by experienced surgeons. (Farrell, von Lackum et al.[4]) But in the Italian clinics, most notably Bologna and Milan, where congenital hip dislocations are treated in exceptionally large numbers and where the children are brought for treatment at an early age, manipulative methods continue to hold sway.

In the modern open operation as practised by Galloway and others in young children, the hip is reduced with extreme gentleness after division of the contracted capsule. The remodeling of the head and gouging of the acetabulum of the old Hoffa-Lorenz procedure is no longer considered desirable. In skilled hands the shock of an open operation is minimal, but in the younger children the operation is always a fairly severe test of the patient's endurance.

[1] Ludloff: Zeitsch. fur Orth. Chir., 22.
[2] Galloway: H. P. H.; Journal of Orthopaedic Surgery, 1920, 390.
[3] Galloway, H. P. H.: Journal of Bone & Joint Surgery, July, 1926.
[4] Farrell, von Lackum and Smith: Journal of Bone & Joint Surgery, July, 1926.

A good many years must pass before the final results are available on a scale which allows true comparison with the results of manipulative reduction.

Where redislocation has occurred after successful manipulative reduction or in irreducible cases, the open operation has a well-established rôle.

Redislocation is sometimes seen in comparatively young children where the acetabulum is unusually shallow. For such cases the operation of *reconstruction of the acetabular shelf* has been used with considerable success (Fairbank[1]).

The hip joint capsule is exposed using the Smith-Petersen approach, but with preservation of the periosteum on the ilium during the stripping down of the gluteal muscles. The hip is reduced without opening the joint capsule. Along the upper and posterior border of the socket a groove is made by turning down a flap of the periosteum and attached bone, which is now stitched to the capsule. A bone graft suitably curved is cut from the iliac crest and wedged into the groove. Secure fixation of the graft is obtained by one or more bone pegs. The growth in size of the buttress thus constructed is followed in radiograms. Open reduction must be contemplated in most cases after the age of ten years, and given a free exposure of the joint after division of the capsular isthmus, the head is usually replaced in its acetabulum without undue trauma.

In difficult cases the operation may be carried out in two stages. In the first, the capsule and the shortened muscles are divided and skeletal traction applied to the limb. The second stage, carried out some weeks later, comprises the replacement of the head in the socket. Allison[2] has succeeded in reducing adult dislocations by the open method after skeletal traction.

Palliative Operations.—When manipulative reduction is impossible, certain procedures are available as alternatives to open reduction in older children or adolescents:

(1) Osteotomy.—Correction of the adduction and lordosis by an osteotomy in the sub-trochanteric region was first introduced by Kirmisson. The operation is often followed by a great improvement both from a cosmetic and functional point of view.

More recently, the "bifurcation" osteotomy, described by Lorenz[3] and Bayer independently, has been used in a large series of cases. In this operation the femur is divided obliquely and the upper end of the distal fragment abducted and thrust inwards until it engages the pelvis at the level of the acetabulum. The cosmetic results are sometimes most gratifying, but the method is still sub-judice.

(2) Stabilisation.—In joints which are markedly unstable, function may be improved by constructing a bony *shelf* above the dislocated head (Dickson[4]).

(3) Arthrodesis.—In the adult when arthritic changes have occurred, and pain is a prominent symptom, fixation of the hip by an *arthrodesis* may be advisable.

Summary of Treatment.—The manipulative reduction of congenital hips should be attempted in children under ten years, except under unusual circumstances. The most favorable time for manipulation is below the age of five. From five to ten it is difficult to accomplish without a certain amount of stretching and trauma, but rarely impossible. The method by which the

[1] Fairbank, H. A. T.: British Journal of Surgery, x, 37, 1922.
[2] Allison, N.: Journal of Bone & Joint Surgery, Oct., 1924.
[3] Lorenz, A.: Wiener Klin. Woch., 1919 on 41.
[4] Dickson, F.: Journal of Bone & Joint Surgery, April, 1924.

hip is reduced is not of importance, providing it is firmly placed in the acetabulum. The use of mechanical force to loosen up the contracted structures about the hip often makes reduction possible when it would not be otherwise and preliminary traction is often valuable. The reduced hip should be retained at a right angle to the leg with the knee in the frontal plane of the body in the degree of rotation in which the hip is most stable. An X-ray of the hip should be taken through plaster within three or four days after the operation. If the hip redislocates two or more times without known cause, or if reduction proves impossible in the hands of an experienced surgeon, operation by open incision is to be considered as justifiable.

Palliative Treatment.—In adults where a unilateral dislocation of the hip is a source of pain and lameness, sufficient to cause marked discomfort and joint irritability, it is possible at times to alleviate or relieve this by the application of a tight fitting leather pelvic corset with a pad above the trochanter which checks the upward excursion of the latter.

CONGENITAL DISLOCATION OF THE OTHER JOINTS

Congenital dislocation of the joints other than the hip is distinctly rare and of much less practical interest. These dislocations, however, are definitely recognized and should be mentioned.

Congenital Dislocation of the Knee.—This is one of the more common of the dislocations of the other joints, and is usually a forward displacement of the



FIG. 628.—Congenital dislocation of the knee with club-foot.

tibia on the femur. There are two forms of this which should be identified separately.

1. What appears to be a secondary congenital deformity due to intrauterine pressure, and this consists merely in a hyperextension of the knee rather than a true dislocation. It may be spoken of as a subluxation, but there is no marked displacement of the tibia on the femur, and it is simply an exaggeration of normal extension.

2. There is, however, a true dislocation which outwardly resembles this, but in which the condyles of the femur are displaced backward in their relation to the tibia. In this variety the condyles of the femur are felt in the popliteal space. Drehman[1] has reported 127 cases, of which 54 were unilateral, and 44 were bilateral.

[1] DREHMAN: Zeitsch. fur Orth. Chir., vii, 22.

The clinical appearances are simply those of a hyperextension of the knee of greater or lesser extent. Flexion may be painful, and lateral mobility may be present. The skin at the forward part of the knee is slack and wrinkled and the patella generally smaller than normal, and sometimes displaced or even wanting. In the severest cases the anterior surfaces of the thigh and lower leg may be in contact. In these cases there is more or less hindrance of normal movement in accordance with the deformity. The diagnosis offers no difficulty.

The *treatment* consists in manipulation into the straight position, and the application of a splint. This is continued until the knee can be brought into a position of flexion and normal mobility induced, with retention in the improved position. It may be possible to accomplish this by gradual means; but if the deformity is severe, manipulation under anesthesia is desirable with a view to replacing the tibia in its proper relation with the femur, followed by retention in the proper position. After a successful reduction it will be necessary to apply some form of splint to check hyperextension of the knee.[1]

Various operative procedures have been tried in cases where manipulative correction has proved impossible.

It is always necessary to lengthen the quadriceps by tenotomy or by open excision. This usually allows the displaced hamstrings to be slipped back behind the femoral condyles. In more long-standing dislocations division of the ilio-tibial band is required in addition to lengthening of the rectus femoris.

Congenital Dislocation of the Patella.—This is extremely rare, is about as common single as double, and the outward variety is the more common.[2] In connection with outward dislocation may be associated knock-knee, with perhaps flattening of the external condyle. The operative treatment does not differ essentially from that of slipping patella, and similar acquired malpositions.

Absence of the Patella.—The bone may be imperfect in development, late in forming or absent, and the deformity may be unilateral or bilateral. Of the congenital deformities accompanying this condition, club foot occurred in 24 cases out of 51 reported by Thorndike,[3] other forms of talipes in 5, congenital dislocation of the hip in 5, and other primary congenital deformities several times, especially congenital dislocation of the knee. As a rule the absence of the patella is not a very serious matter and such a knee in adults is not apt to be a source of much disability, although lacking somewhat in power and motion. No definite treatment has been formulated beyond meeting the mechanical indications existing in the individual case.

Congenital Dislocation of the Ankle.—Inward and outward dislocations of the ankle have been reported in connection with defective development of the tibia and fibula. A deformity of the ankle has been described by Volkmann,[4] known as Volkmann's congenital dislocation of the ankle, which consists of a defective development in the bones of the leg with a normal foot, but with an oblique ankle joint holding the foot most often in a position of valgus, but in one reported case in a position of varus. The condition is to be treated by osteotomy above the ankle.[5]

[1] Lange: Lehrbuch der Orth., 1914.
[2] Potel: Etude sur les mal. congén. du Genou, Lille, 1897.
Zésas: Rev. de Chir., 1902, iii, 4.
[3] Thorndike: Orth. Trans., xi.
[4] Volkmann: Deutsch. Zeit. Chir., xxviii, 2.
[5] Burkhardt: Jahrbch. fur Kinderheilkunde, xxxi.

Congenital Dislocation of the Shoulder.—True dislocation of this joint is extremely rare, very many of the reported cases being paralytic or traumatic at birth. The head may be displaced in any direction and is sometimes associated, as in a case of Smith's, with congenital malformation of the joint. Reposition of the joint may be attempted, but the diagnosis of dislocation should be made with great caution, the majority of such cases being attributable to other causes. Reposition or arthrodesis at a suitable age when the matter proves to be irremediable would constitute the treatment.[1]

Congenital Dislocation of the Elbow.—These are so rare that they possess little practical importance. When dislocation exists, it is generally only partial luxation of the radius, and severer forms are frequently associated with malformations of the bones; fifty-one cases have been reported by Blodgett,[2] but not all of them are to be accepted as true dislocations. The backward luxation is the most frequent, forward displacement is nearly as common, but outward luxation is unusual. Mobility is more or less restricted, especially in the direction of supination and extension, but may be free, but in backward luxation, flexion is the motion restricted. Elongation of the upper end of the radius is reported in about three-quarters of the cases, but care must be taken not to confuse this with the backward dislocation of the radius occurring in connection with multiple cartilaginous exostoses (dyschondroplasia, p. 337), which resembles very closely congenital backward luxation of the head of the radius. Associated deformities are likely to be bone fusion of the radius and ulna or partial deficiency of one of these bones. The deformity in most cases apparently belongs to the class of primary congenital deformities as shown by associated deformities of the primary class. Resection of the head of the radius is indicated in cases where it seems responsible for impaired function.

Congenital Dislocation of the Wrist.—True congenital dislocation of the wrist is exceedingly rare, apart from club hand, described elsewhere (p. 562). Double dislocations have been reported with the hands flexed at a right angle to the forearm, and also with the arm hyperextended.

Madelung's Deformity.—(See p. 68.)

[1] PORTER: Trans. Am. Orth. Ass'n., xiii, 89.

[2] BLODGETT: Trans. Am. Orth. Ass'n., 1905, 253 (with literature).

CHAPTER XXIX

CLUB-FOOT

Synonyms.—Talipes equino-varus, pied bot, piede equino-varo congenito, Klumpfuss.

The Latin word *talipes* originally described only the deformity known as *club-foot*, but later became a generic name to designate four other varieties of foot deformity which are as follows:

Talipes equinus, the plantar flexed foot.
Talipes calcaneus, the dorsally flexed foot.
Talipes varus, the inverted and adducted foot.
Talipes valgus, the everted and abducted foot.

In addition to these, the name *pes cavus* has been applied to the hollow foot and *pes planus* or *pes valgus* to the flat-foot. Both of which are more often acquired than congenital and will be described in speaking of static affections of the foot (p. 639).

Talipes equino-varus may be either congenital or acquired, but the congenital form is the one here chiefly considered. Equino-varus constitutes about 77 per cent of all forms of congenital talipes, valgus comes next with about 5 per cent, and varus, calcaneo-valgus, equinus, calcaneus, and equino-valgus come in the order named with diminishing percentages.[1] Equino-varus occurs about once in every one thousand births, and males are affected in about 65 per cent of all cases against 35 per cent of females. It is unilateral in about 57 per cent of all cases and bilateral in about 43 per cent. The deformity shows no preference for the right or left foot.

Etiology.—In 4 per cent of 735 cases tabulated by Waller other congenital deformities were also present. Such associated deformities are apt to be combined with the less common types of talipes than with the ordinary equino-varus (Ehrenfried[2]).

Heredity.—Heredity is a factor in some cases. Little traced it in four generations, Adams recorded the case of a man with club-foot who had five children, one nephew, and one grandchild with similar club-foot, and Ehrenfried and Ketch[3] both found 5 per cent with a history of heredity in their separate series. Apparently it occurs relatively more often in multiple than in single pregnancies, and in the Ehrenfried series, 30 per cent of the patients were first born, and in 78 per cent the labor was described as normal.

The deformity apparently may belong to the class of either primary or secondary congenital deformities (p. 560). If in the former, other congenital deformities may be associated, such as hare lip, spina bifida, etc., or there may be present congenital anomalies of the bones of the foot or elsewhere. We know very little regarding the real cause of congenital deformities in general, and we know no more with regard to club foot.

[1] Townsend: Trans. New York State Med. Soc., 1890.
[2] Ehrenfried: Jour. Am. Med. Ass'n., Nov. 20, 1912.
[3] Ketch: Trans. Am. Orth. Ass'n., 1892, v, 159.

It is obvious that cases with other primary congenital defects are also primary. Other cases may be due to developmental causes as described by Mall,[1] such as faulty implantation of the ovum, as in endometritis and similar diseased conditions of the uterus, and in tubal pregnancy. That club-foot is often due to purely mechanical causes is generally accepted, and this theory dates from the time of Hippocrates. It was claimed that the deformity was the persistence of a position normal to the three months old embryo,[2] but the work of Bessel Hagen[3] and Scudder[4] has shown that this is not apparently the case. It seems probable that the abnormal position is produced by pressure or constraint, as in the case of twins, deficient amniotic fluid, fibroid tumors in the pelvis, interlocking of the feet, entanglement in the umbilical cord, etc., and pressure marks and thinning of the skin over the outer side of the dorsum of the foot are not infrequently found in these cases. The distinction between the two classes is not always clear, it is, however, important to know whether spina bifida is present, as it will frequently be associated with ulceration of the feet seriously interfering with operative treatment.

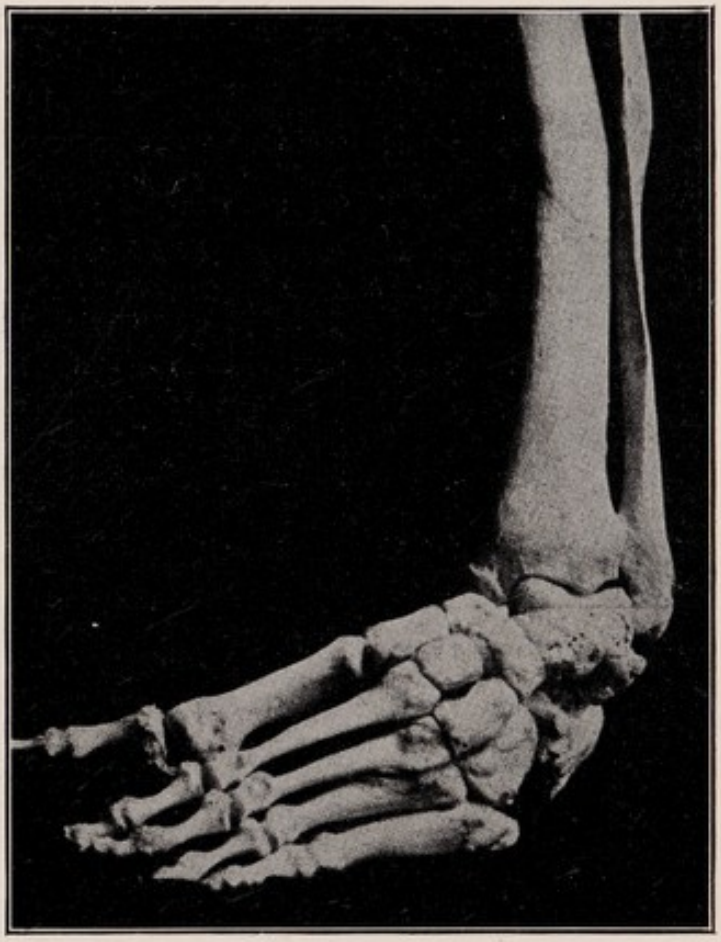

Fig. 629.—Left-sided club-foot in an adult seen from the front. From the Path. Anat. Institute of the University of Innsbruck (Lange).

That maternal impressions have any influence is not likely, a long series of cases having been observed by the writers where the mother was asked if there had been anticipation of the kind before the birth of the child, and in nearly all cases was denied. Similar series of cases have been collected by others.

A very great deal of theorizing has been done upon this subject, as to whether the muscular contraction or the bone deformity was primary, and as to the effect of retarded rotation of the foot, etc., but what has been stated is a fair resumé of our present knowledge.

Pathological Anatomy.—The deformity consists of inversion of the whole foot, adduction of the forefoot, and plantar flexion. As the child grows, adaptive changes in bones and soft parts occur as a result of the malposition in

[1] Mall: "The Causes Underlying the Origin of Human Monsters."
[2] Eschricht: Deutsch. Klin., 1852, 4.
Berg: Arch. Med., New York, December, 1882.
[3] Bessel Hagen: Die Path. and Ther. des Klumpfusses, Heidelberg, 1899.
[4] Scudder: Boston Med. and Surg. Jour., Oct. 27, 1887.

accordance with Wolff's law. The changes in the bones are secondary and adaptive, except where real malformation of them is present, and are what one could predict from the maintenance of such a distortion during rapid bone growth. The deformity is generally distributed through the foot affecting all structures a most important matter in formulating treatment. The analysis of the deformity is as follows:



FIG. 630.—Cast of club-foot, showing fan-shaped spreading of the metatarsals (Warren Museum. Harvard University).

The *astragalus* is plantar flexed so that a large part of its superior surface escapes from between the malleoli, and is prominent on the dorsum of the foot. This free part becomes somewhat broadened on account of its freedom from constriction between the malleoli, and having become broader, may offer an obstacle to passive dorsal flexion of the foot in severe cases when the soft structures have been loosened up. The neck of the astragalus is somewhat longer than normal, inclined downward and twisted inward. The head points inward as well as forward, carrying the scaphoid and forefoot with it.

The *os calcis* is plantar flexed, and is tilted so that its inner tuberosity approaches the internal malleolus, which is spoken of as the varus position of the os calcis. The forward extremity is deflected inward following the direction of the neck of the astragalus, and the os calcis tends to lie directly under the astragalus instead of to its outer side.



FIG. 631.—X-ray of extreme club-foot.

The *scaphoid* is carried in with the head of the astragalus and approaches the internal malleolus. The *cuboid* follows the scaphoid and is displaced inward.

The *phalanges* are likely to be plantar flexed, the *tibia* may be rotated inward on the long axis of the femur or twisted inward on its own long axis, and the other bones are changed in position and the metatarsals are spread like the leaves of a fan (Fig. 630).

The soft parts adapt themselves to the new position, and ligaments on one side are shortened and on the other stretched. The internal lateral (deltoid) ligament of the ankle and the plantar fascia are especially important obstacles to reduction. The posterior fasciculus of the deltoid does not usually participate in the deformity. The middle fasciculus produces some inversion of the os calcis while the anterior portion is the principal agent by blending with the internal and inferior calcaneo-scaphoid ligament, forming a strong mass between the internal malleolus, sustentaculum tali and tubercle of the scaphoid. This is one of the chief sources of obstruction to reduction, and was called by Parker "the astragalo-scaphoid capsule." This mass is sometimes three-quarters to one inch in thickness. Muscles and tendons being adaptively shortened and stretched, the course of the tendons is deflected, and anatomical landmarks are confused.



FIG. 632.—Severe club-foot.

We would wish to point out what is so often forgotten, that in equino-varus the Achilles tendon becomes an active invertor of the foot, and is to be found deflected to the inner side.

These changes are less marked in the infant and increase in severity as the child grows, reaching their maximum in the adult. The muscles of the leg atrophy from disuse, and in cases of unilateral club-foot of long standing, the bones of the leg and foot are shorter than the bones on the other side.



FIG. 633.—Extreme club-foot.

Knock-knee and laxity of the ligaments of the knee generally exist in severe cases of long standing; the cause of this may be most often ascribed to faulty technique in treatment. No club-foot should be manipulated in the direction of eversion without protecting the internal lateral ligament of the knee from strain. The deformity should be corrected with the knee held in flexion, as the constant strain of this ligament which takes place almost as a routine when

surgeons twist the foot, is invariably the reason for the existence of knock-knee in the so-called cured or uncured case. Knock-knee is also intensified by the instinctive effort of the patient to place the soles of the feet on the ground in standing, as in this way deflection of body weight tends to strain the internal lateral ligament of the knee and to exert undue pressure upon the external structures of the joint.

The pathological anatomy of *acquired talipes equino-varus* is of the same character as of the congenital variety, but changes are less marked, and much less resistant to immediate correction. Poliomyelitis, however, being the most frequent cause of acquired talipes equino-varus, it must be remembered that although immediate correction is easy, the deformity will relapse on account of the paralyzed condition of the muscles which have remained stretched during the presence of deformity.

Symptoms.—The foot in congenital equino-varus is plantar flexed, inverted and adducted, perhaps very little, perhaps so severely that the sole faces almost upward. The heel is small and elevated, the forefoot broad and twisted, the dorsum of the foot curved and prominent, and in severer cases the outer border and even the dorsum of the foot bear the weight in walking. The foot cannot be overcorrected by the examining hand and from infancy on the deformity will increase in the untreated cases. A very important factor which has to be dealt with quite early is an inward twisting of the tibia and fibula, and this increases if the patient is allowed to walk long untreated. It is one of the serious drawbacks to subsequent function, as in these cases even when the foot has been well corrected the patient will walk with inturned toes. In other instances the twist occurs at the ankle joint, and is due to the altered shape of the astragalus. This factor may be looked upon as quite apart from the obvious turning-in deformity of the foot itself.

If the patient reaches adult life with an untreated club-foot of moderate grade, he will walk on the outside of the foot and a bursa will form over the cuboid. There is no elasticity in the gait and he will be unsteady on his feet, the forefoot will point inward and he will have to lift one foot over the other in walking and the calves of the legs will be shrunken. Although the gait is most unsightly, such patients frequently are active wage earners, but always have more or less discomfort from callosities on the outer borders of the feet.

Diagnosis.—The diagnosis is evident on inspection and manipulation, and a resistant deformity, even of slight grade, with the foot in a position of inversion, adduction, and plantar flexion is equino-varus. The most frequent need of making a differential diagnosis is in young babies of inexperienced mothers, who are alarmed by the inverted position of the feet so often assumed by young infants. The existence of a deformity is excluded in such cases by finding that the foot can be easily overcorrected by the gentlest manipulation.

Differential Diagnosis.—There is very occasionally a difficulty in determining whether an existing equino-varus is of congenital or acquired origin. This does not occur in babies, but the difficulty most often arises in middle childhood in families where the parents are so ignorant that they are liable to overlook either an early existing deformity, or the occurrence of an attack of mild *poliomyelitis* involving the anterior and outer muscles of the foot, as a result of which the foot has been pulled by the stronger muscles into a position of equino-varus.

In the latter case it is most unlikely that the two groups of muscles affected will have been affected alone without involving to some degree other muscles, particularly of the same leg, and a careful muscular examination as described under poliomyelitis (p. 429) will reveal in most cases the existence of localized muscular weakness of the other muscles, particularly of some of those of the affected leg. In poliomyelitis mild trophic disturbances are likely to be present, but the reflexes of the affected side are not necessarily diminished if the quadriceps muscle is intact. The history of a febrile attack preceding the deformity is of value, but it must be remembered that poliomyelitis occasionally begins without a perceptible attack of this sort. In general the congenital form is more marked and more severe, but a long continued case of poliomyelitis of the variety described may result in a condition closely resembling a mild congenital club-foot. Although an occasional case arises in which the differentiation is extremely difficult, in nearly all cases the proceeding described will clear up the diagnosis.



FIG. 634.

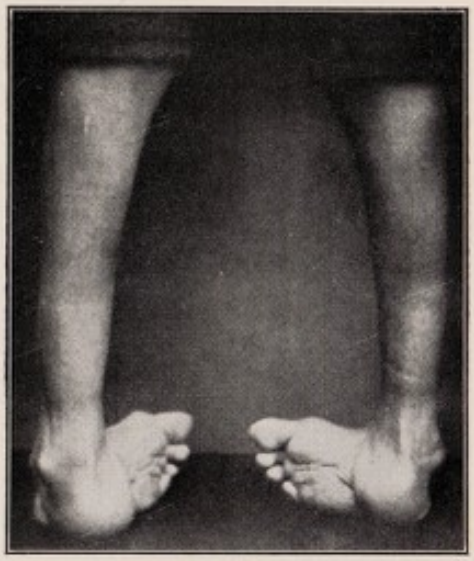

FIG. 635.

FIGS. 634 and 635.—Club-foot before treatment seen from front and back. For result see Figs. 636 and 637.

Acquired equino-varus may also result from other conditions of which the following are the most frequent:

The *peroneal type of muscular dystrophy* is generally associated with a moderate or severe degree of equino-varus, and certain other organic nervous diseases are at times associated with this deformity (see p. 408).

Early *tuberculosis of the tarsus* with a deformity of this type may present a superficial resemblance to congenital club-foot, but local swelling will be present with muscular spasm and generally pain, and the resemblance should not be misleading.

Epiphyseal injuries, or *disease of the epiphyses*, which involve the inner part of the epiphysis at the lower end of the tibia may cause an inverted position of the foot from the cessation of growth on the outer side, and its continuance on the inner side. This condition will be recognized by an antero-posterior X-ray of the lower part of the leg.

Fracture of the ankle with union in a position of inversion would not of course easily be mistaken for congenital equino-varus and needs only to be mentioned.

Prognosis.—Without treatment club-foot will steadily increase, and in an adult the gait is most unsightly and the foot sure to be a source of discomfort on account of calluses and ulcerations. In former days this entailed so much suffering that amputation was not infrequently requested.

With *effective and continued* treatment all cases of club-foot in young children, and up to middle childhood, should be cured and a useful and properly shaped foot obtained. In older children the prognosis for complete restoration of function is not so good, as the foot will be shortened and somewhat misshapen from continued growth in the abnormal position, and some shortening of the leg may occur from retarded growth. Normal function should, however, be obtained by proper treatment up to adolescence. In adolescents and adults the foot will again show the effect of abnormal growth and the problem of restoring function is more difficult and requires severe manipulation. The prognosis for a useful foot is always good under proper treatment, and in nearly all cases for good function, proper endurance, and inconspicuous deformity.

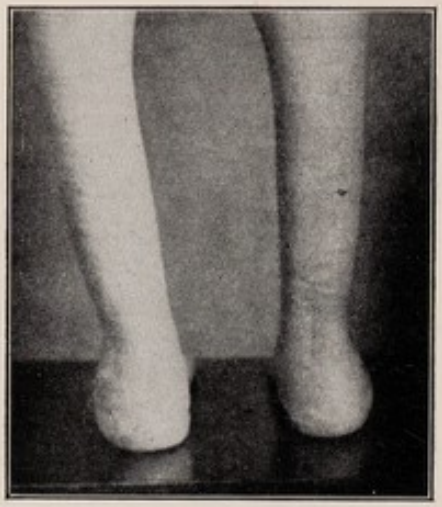

FIG. 636.



FIG. 637.

FIGS. 636 and 637.—Club-foot showing result after using Thomas wrench (same patient as shown in Figs. 634 and 635). In Fig. 636 notice reposition of heel.

Treatment

The problem of treatment is simple; the foot should be overcorrected by the mildest effective means, and kept in an overcorrected line until the bones have been reshaped, the soft parts have adapted themselves, and the muscles have acquired sufficient strength to maintain the foot in the overcorrected position. Added to this, in the case of children old enough to walk, the foot must be able to evert sufficiently in the standing and walking positions to enable the body weight to be corrective.

Overcorrection means a position of (1) marked dorsal flexion and (2) marked eversion, and (3) marked abduction. When treatment fails, it is because one or all of these elements have not been thoroughly obtained at the time that the attempt was made, or because following the attempt the foot has not been kept in a proper position.

Choice of Treatment.—In the opinion of the writers, the treatment of congenital club-foot should always be manipulative or operative. Apparatus may be of use in retaining overcorrection, but should be limited to that, and the more effective the correction, the shorter time will retaining apparatus be needed. The immense literature that has arisen on the subject and the many mutilating operations advised are evidence that the treatment is by no means universally successful, and that the essentials of it are not generally understood.

In formulating the treatment of club-foot it must be remembered that the earlier in life one starts on the treatment, the milder the measures required to obtain overcorrection, and the later in life, the more severe. One fundamental consideration is that club-foot is a deformity distributed through the whole tarsus, and that measures which will distribute themselves through the foot and become effective on all parts are much more mechanically sound than any measures effective only upon one part of the foot. For this reason manipulative treatment which distributes itself through the foot is much more effective than local cutting operations, which will relieve tension chiefly in one place. It cannot be too strongly emphasized that an open operation should only be performed when the surgeon feels that it is the one method by which he can get the foot straight. The fact, however, remains that the experienced surgeon can succeed in cases which to others would seem impossible, and that without any danger from traumatism.

Let it be here emphatically urged that no operation involving the removal of bone be performed upon a foot without first obtaining by manipulation, or the Thomas wrench, the maximum of preliminary correction. Too often one finds a club-foot brought to the operating table without any preliminary attempt at correction and this may mean a needless and wholly unjustifiable removal of bone.

In a series of 200 consecutive cases[1] admitted to the Children's Hospital, Boston, between 1907 and 1913, all observed at least three years after the beginning of treatment, it was found that in cases operated by cutting, the results were good or fair in 55 per cent, poor or bad in 45 per cent; and in the cases which were treated by manipulation without operation, the results were good or fair in 95 per cent, and poor or bad in 5 per cent. These were hospital cases often irregular in their postoperative attendance at the clinic.

Relapse.—The causes of relapse are: (*a*) Insufficient correction at the time of operation, a failure to obtain full overcorrection in the three directions of dorsal flexion, abduction, and eversion, (*b*) inability of the overstretched anterior and external muscles to function sufficiently to pull the foot actively into an overcorrected position, and (*c*) the erroneous deflection of body weight in walking so that superincumbent weight does not act as a corrective force but emphasises the deformity.

It must be definitely recognized that even if one corrects a foot so effectively at operation that it can be overcorrected by the light pressure of the surgeon's little finger, this is not maintained unless the patient can *actively* move the foot into this overcorrected position by voluntary muscular action. If the patient is not able to do this, it is obvious that the same physiological conditions exist as in poliomyelitis where the muscular balance is such that the pull of the internal and posterior muscles is continuously effective on account of the inability of the anterior and external muscles to function, and that under

[1] Fiske, E. W.: Jour. Am. Med. Ass'n., 1915, lxv, 375–380.
Am. Jour. Orth. Surg., 1916, xiv, 693–707; Jour. Orth. Surg., 1921, iii, 668–677.

these conditions deformity must recur. The tendency to relapse is always present and every foot will relapse unless the operation is effective and the precautions just mentioned are observed in after-treatment. What has been said above applies to the treatment of club-foot in the hands of the fairly experienced, but another cause of relapse arises when a surgeon, not familiar with the natural history of club-foot, performs tenotomies, overcorrects the foot for two or three weeks, and assumes that the trouble is ended. It would seem that this latter condition would not be met, but unfortunately experience proves the contrary. Relapsed club feet are always more difficult to treat than those which have not been treated.



FIG. 638.—Manipulation of club-foot.

Treatment in Infants.—In very young children, it is probable that every case can be cured without operation, with the exception of a possible tenotomy of the tendo Achillis in the final stage, by constantly repeated *manipulation by the parents*, carefully taught by the surgeon. The foot is manipulated by the mother into a position of dorsal flexion, abduction, and eversion and it will loosen up with surprising readiness, and at the end of a few weeks will be capable of being placed in the overcorrected position without encountering resistance. Having reached this point it is only necessary to see that the contraction does not return through the use of less frequent manipulations.

In manipulating the foot it is well to have an order of procedure. If we are dealing with the right foot, the left hand should grasp the lower part of the tibia to protect the epiphysis from strain, while the knee is flexed or held by an assistant to avoid strain. The ball of the surgeon's left thumb will rest to the outer side of the foot at the forward part of the os calcis and should act as a lever for the correction of the adduction at the midtarsal joint, the right hand grasping the forefoot. When this has been effectively done, the epiphysis should still be held by the hand while the sole of the foot is flattened and everted and the tendo Achillis stretched by the right hand. This should be done by one sweeping action and should give rise to very little pain. Combined with this should be passive manipulation to correct the varus position of the os calcis, the bone being tilted so that its outer surface approaches



FIG. 639.—Manipulation to correct rotation of tibia and fibula.

the external malleolus. It should be pointed out that the stretching of the tendo Achillis is most effectively and easily done in the infantile stage. Later, considerable contraction occurs in the posterior capsule and ligaments of the ankle joint, which adds to the difficulty of correcting plantar flexion. In infants the elements of the existing deformity most difficult to correct are the equinus and the inverted heel. If much force is incorrectly applied in manipulation under anesthesia there may occur in infants an incomplete fracture of the anterior part of the tibia just above the ankle, or a separation of the lower epiphysis of the tibia.

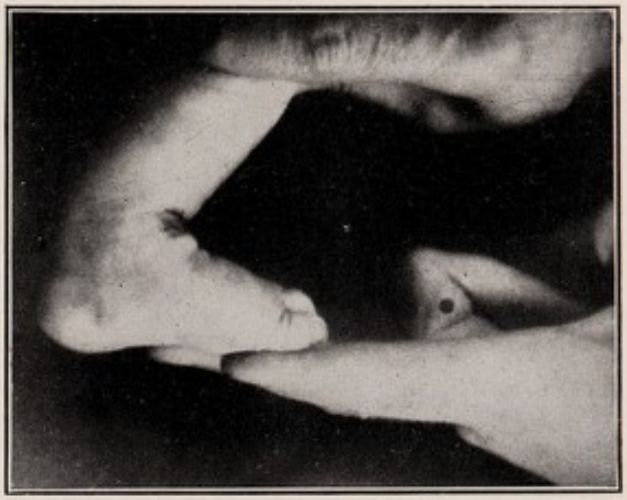

FIG. 640.—Showing dorsiflexion after manipulation of club-foot.

For the first few days the manipulation should be done several times a day, the surgeon instructing the nurse or mother against the danger of straining the epiphysis or internal lateral ligament of the knee. An inward rotation often occurs in the tibia and fibula rotating the foot inward. This should be corrected day by day and is best done by placing one hand below the knee and the other hand above the ankle epiphysis, and rotating the lower tibia and fibula outward on the upper end by the same movement that a washwoman uses in wringing out a cloth. *All manipulations should be practised with the knee flexed.*



FIG. 641.—Method of applying adhesive plaster for correction of club-foot.

Adhesive Plaster Strapping.—When the foot has become thus movable, recovery can be hastened by retaining the foot in the overcorrected position by the use of adhesive plaster. The foot may be retained in a position of eversion with slight dorsiflexion by means of a strip of adhesive plaster one to one and one-half inches wide. This is applied round the fore part of the foot beginning on the outer border of the tread, taken across the dorsum round the sole and fixed to the starting place, but not torn off. The foot is then held in extreme eversion and slight dorsiflexion while the strapping is drawn very tightly, parallel with the leg and applied to and around the back of it just below the knee joint. Further eversion is obtained by applying a second shorter strip of adhesive plaster around the ankle and the first strap which lies beside it. If this proves uncomfortable it must be omitted.

In the case of unintelligent parents the manipulation may have to be done by the surgeon. In such cases it is well to retain the foot in the overcorrected position either by adhesive plaster or by a *plaster of Paris bandage* applied every few days. The bandage should always go above the knee, which should be flexed during application, as otherwise the plaster will roll on the leg and the abduction of the foot not be maintained. The method without plaster of Paris, however, is to be preferred.

Tenotomies in infants and young children are undesirable and should not be performed if they can be avoided, as they produce cicatricial tissue and are more effective locally than generally—they are not to be regarded as routine procedures.

It is well to give the surgeon some guide in order that he may know which type of infantile club-foot is likely to present difficulty in correction. A baby may be born with very marked inversion deformity, with a fairly long heel and very little adduction at the mid-tarsal joint. This type of foot is invariably easy to correct. A child with short heel and adduction deformity, even though there may be no marked inversion of the foot, may present considerable difficulty.

Treatment in Young Children.—In young children with club foot of any degree the attempt at reduction by manipulation should always be made, and division of tissues only resorted to after this has failed. It will rarely fail in competent hands. Such manipulation may be done effectively without anesthesia in the milder cases, should be frequently repeated, and the foot held in overcorrection.

In the severe and moderate cases the manipulation should be done under anesthesia. In young children in all but the severest cases the correction should be performed by the hand, aided when necessary by the Thomas wrench.

The Manual Rectification of Club-foot.—The deformities are corrected in the following order: (*a*) Adduction, (*b*) Inversion, (*c*) Plantar flexion—but all at the first sitting.

During the correction the greatest care must be taken to avoid straining the epiphyses of the tibia and fibula which during the manipulation of the foot should be grasped by the surgeon's hand. Care should also be taken that the internal lateral ligament of the knee is not stretched, for it has been already mentioned that neglect of this precaution is a prolific cause of knock-knee. We would repeat, therefore, that the knees should be kept flexed during the manipulation.

No matter how severe the deformity in the very young and in older children with moderate deformity, correction should be as complete as possible on the first occasion and the foot retained for several weeks in plaster of Paris in the overcorrected position, *viz.*, everted, abducted at the mid-tarsal joint, and fully dorsiflexed. Very rarely are more than two or three wrenchings required even in older cases with considerable deformity. The manipulator's technique where tendons and ligaments are divided is similar to that where no operation is performed.

Adduction.—The outer portion of the dorsum of the foot is placed upon a covered block or hard rolled bandage. An assistant grips the front and back of the foot. With both hands the surgeon obliterates the adduction angle and flattens the sole. This should be thoroughly done no matter how long it takes. It may be, and often is, necessary for the surgeon to stand above the foot and

invoke his body weight to add to his power. He should not be satisfied until he has secured a certain degree of abduction at the mid-tarsal joint. The persistence of this deformity is fatal to success.

Inversion.—If it is the right foot the epiphysis is grasped from below with the left hand. With a twisting movement in which the surgeon's body participates, the foot is twisted into eversion. To give power to the operator his right arm should be closely adducted to the chest and in this way his hip muscles will be requisitioned. *Particular care must be taken to overcome the inversion of the os calcis.* The only remaining deformity should now be equinus.

Plantar Flexion.—The left hand should grasp the epiphysis from below, the right arm should rest on the surgeon's chest and with the foot everted the whole of the body weight can, if needed, be applied to the manipulative act. The foot should be dorsiflexed well above a right angle.



Fig. 642.—Manipulative correction to secure abduction at mid-tarsus, using wedge.

In simple cases the extraneous aid of the body is not needed and no tendon need be divided. In more pronounced deformity in older children less harm may be done by dividing the tendo Achillis if the obstruction is great.

The Use of the Thomas Wrench.—The surgeon experienced in the use of the Thomas wrench will save himself needless effort by using it in all cases of even moderate deformity. Unfortunately the use of this wrench is very imperfectly understood both in Great Britain and in the United States, and an attempt will be made to describe its use in some detail. Each of the three deflections which constitute the deformity should be fully corrected before the other is attacked and failure is often due to a want of concentration upon each act.

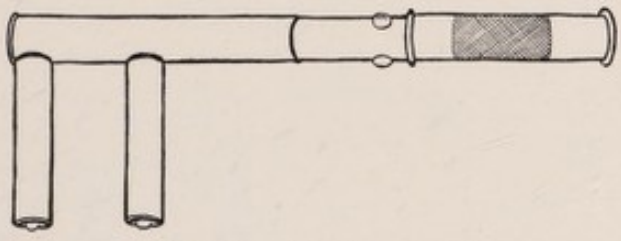

Fig. 643.—Thomas wrench.

The Thomas wrench is made on the principle of a monkey wrench. Instead of the jaws two pins are substituted covered with thick rubber. By twisting the handle of the wrench these two pins approach or separate from each other. The club-foot is gripped by these covered pins.

The accompanying illustrations will describe the way to apply the wrench (Figs. 644–646). In cases of moderate severity the hands alone are used. Where greater force is needed the surgeon's hip muscles are brought into play, the hands being free in order to gauge the tension of the tissues (Fig. 647). The twisting and bending is done forcibly and quickly. The foot should be gripped very firmly by the wrench to avoid slipping and consequent trauma, but holding the foot too long in the bite of the wrench may result in a pressure sore. The pins of the wrench can be applied to each side of the os calcis to correct eversion (Fig. 645). The wrenching should be carried far

enough to destroy temporarily the resiliency of the soft parts so that the foot lies limp in the hands of the operator. It is then placed in plaster of Paris or in a retention brace. If a further wrenching is required in a few days, a retention brace is used meantime.

Treatment in Older Children.—In older children the manipulative method is again to be preferred to the open operation, but the amount of force necessary to produce overcorrection is often too great to be effectively exerted by the hand alone and some form of lever is necessary, notably the Thomas wrench. Whatever method of retention is used sloughs may occur if certain principles are ignored.

When a foot is manipulated or wrenched into a good position it should be held by the retaining apparatus in a position only *just short of the overcorrection* which has been obtained by the manipulation. To force the foot into a more overcorrected position than that obtained by the manipulation is to run the risk of obstruction to the circulation, sloughs, and often much unnecessary discomfort.

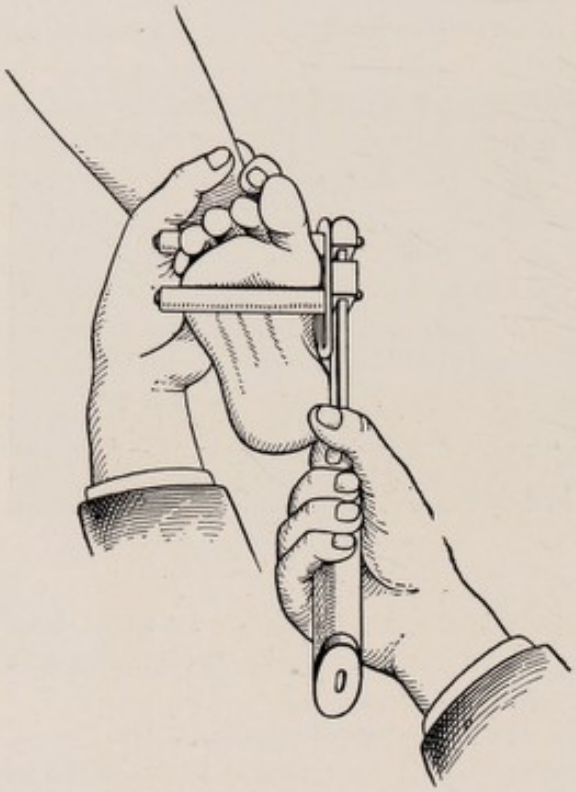

FIG. 644.—Correction of equinus and inversion by Thomas wrench.

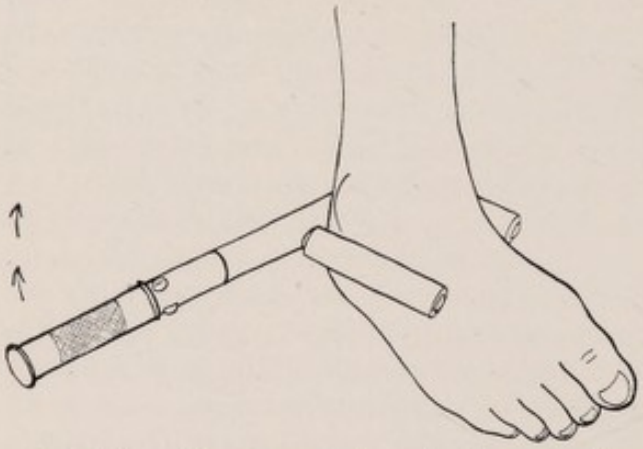

FIG. 645.—Thomas wrench applied for correction of club-foot.

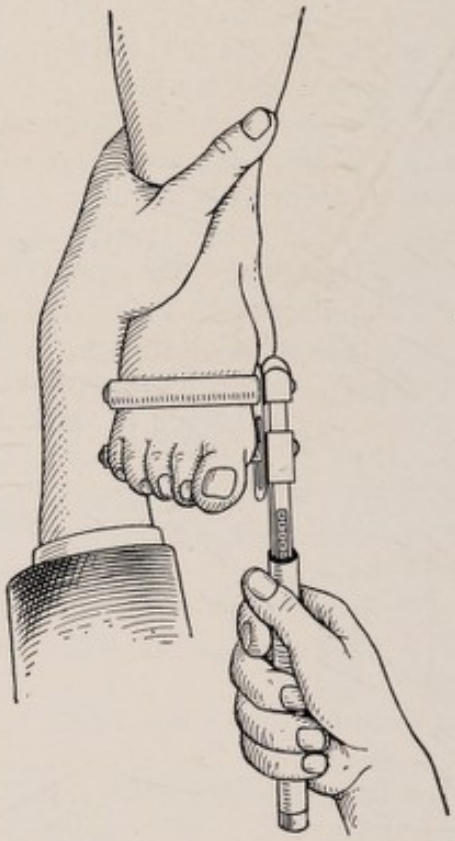

FIG. 646.—Correction of plantar flexion by Thomas wrench.

Subsequently manipulation should be carried on by the parents, and voluntary exercises of the stretched muscles should be given while the foot should be kept under observation for a period of many months in order to detect any tendency toward relapse.

Operative Procedures. TENOTOMY.—Tenotomy is most often required for the lengthening of the *tendo Achillis*, and in young children may be performed subcutaneously; in older children preferably by the open plastic operation as described (p. 419). It should be borne in mind that tenotomy of the tendo Achillis should be performed at the close rather than at the beginning of any series of operative procedures, as it is desirable that the os calcis should serve as a fixed point for the reduction of the deformity in the subastragaloid and medio-tarsal articulation. If the tendo Achillis is divided first, this point of resistance is done away with and the operation made less effective. In cases of moderate deformity in the experience of the writers it is rarely necessary to divide more than the tendo Achillis. The simple operation of subcutaneous

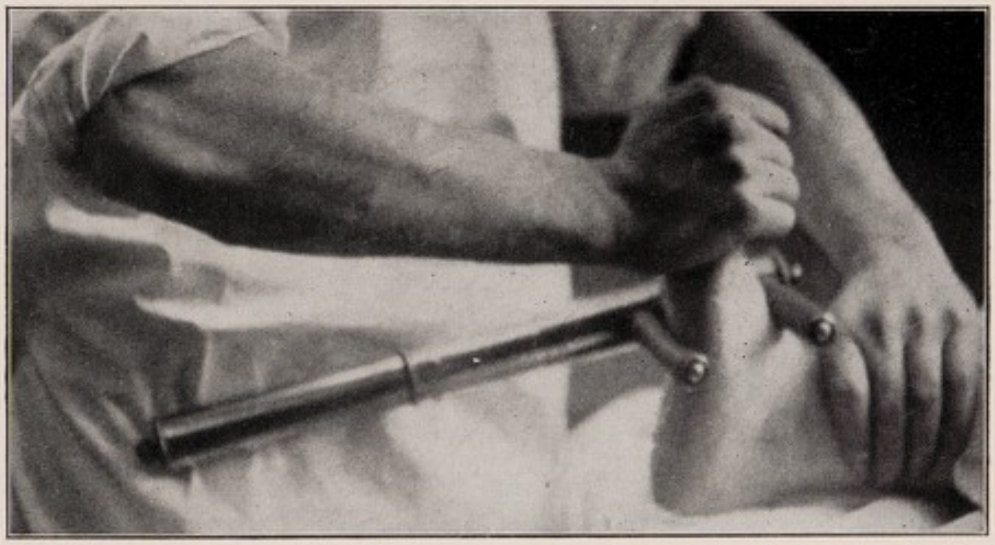

FIG. 647.—Thomas wrench applied, showing how to use it with the hip, leaving the hands free.

tenotomy in fat children is often very badly performed for surgeons are apt to forget that the tendon lies more internally than in the normal foot. The child should be placed upon its face with the sound leg held out of the way. The tendon is first made tense and with the handle of the tenotome a depression is made either to the inner or outer side of it. The tendon is then relaxed and the tenotome introduced through the depression and carried behind the tendon which is divided by a sawing movement as the foot is dorsiflexed. After the tendon is divided the equinus can be fully corrected. There is apparently no danger of non-union so long as a pressure pad is not placed over the gap in the tendon.

In certain cases the *anterior* and *posterior tibial* muscles will be found to constitute a real obstacle to correction, but this obstacle must be differentiated from resistance of the ligaments at the inner and under side of the tarsus. If the tendons constitute a real obstacle they will be found to stand out strongly under the skin when overcorrection is attempted by the hand so that it is obvious that their division is necessary, but the necessity of dividing these tendons is very unusual.

If it is necessary to divide the tendon of the tibialis posticus it should be cut where it is prominent under the skin and not after it becomes spread out into a thin sheet for insertion. It should be remembered that the posterior tibial artery lies directly behind and to the inner side of the tibialis posticus tendon separated from it by the tendon of the flexor longus digitorum. After the division of the tendon the foot is placed and held in a position of overcorrection.

In the majority of cases which resist correction by manipulation, the obstacle to reduction lies rather in the deformed shape of the bones, aided by the resistance of ligaments and fasciæ, than in the tendons.

Division of Ligaments.—The best possible position having been secured by manipulation and wrenching, attention must be paid to the shortening of ligaments, which can be divided subcutaneously if necessary. A tenotome is introduced in front of the internal malleolus midway toward the tibialis anticus. Through this puncture the anterior and middle fasciculi of the internal lateral ligament are divided and if it is necessary the tibialis posticus and anticus can be divided through the same opening. The tenotome is then directed toward the inferior calcaneoscaphoid and the short calcaneocuboid ligaments which are to be divided. On rarer occasions the plantar fascia is cut. With ordinary care the internal plantar vessels and nerve can be avoided. Occasionally, after dividing the tendo Achillis, the posterior capsule is very tight, and can usually be ruptured if a wrench is used. It may require incision and this is best done by the open method.

The division of tendons and ligaments is best done subcutaneously however in order that the wrench may be the more safely and effectively used. The illustration shows the type of tenotome which it is best to employ.

When tendons, ligaments and all obstructing bands have been divided the foot must be manipulated with sufficient vigor to obtain the necessary overcorrection.

Treatment of Severe Cases.—In the severest class of cases, especially relapsed cases and those in late childhood, the proceeding just described in connection with manipulation will not prove adequate, especially in inexperienced hands, because just so far as the surgeon is skilled in manipulative procedure the fewer cutting operations will he find necessary. At the same time it must be repeated again that overcorrection is the object of all treatment and must be obtained. In case correction cannot be obtained by the measures described, which sometimes happens in the severe types of the deformity, more radical operative measures will be required. With regard to more radical operative procedures, the removal of bone is always to be avoided if possible, especially in younger patients. A careful exposure should be made of all ligamentous tissues on the inner aspect of the foot. The well known Phelps' operation, long since discarded, was one of the earliest attempts to accomplish correction by extensive division of the shortened ligamentous structures. The technique of an efficient open operation has been carefully worked out by Ober[1] and Elmslie[2] in recent years.

The essentials in such a procedure are to mobilize the foot at the mid-tarsal and subastragaloid joints, each element of the deformity being dealt with in turn. The adduction of the forefoot and the cavus are eliminated by detaching the plantar structures from the posterior margin of the os calcis

[1] Ober, F. R.: Jour. Am. Med. Ass'n., Aug. 14, 1915.
[2] Elmslie: Jour. Orth. Surg., December, 1920.

(Steindler technique). Division of the astragalo-scaphoid capsule at its insertion, the calcano-astragalo-scaphoid ligaments, and the deltoid ligament of the ankle, allow both the forefoot and heel to be everted. The tibialis posticus insertion to the scaphoid should be preserved, otherwise this bone becomes completely isolated, and tends to become dislocated (Trethowan).

Where the equinus is still resistant, the posterior capsule of the ankle joint must also be divided. The complete dissection is easily performed through a curved incision skirting the internal malleolus. After suture of the skin wound the foot should be bandaged on a splint in bare correction, avoiding undue tension on the inner side. After a few days the position of full over-correction should be obtained, and a close fitting plaster applied.

Removal of Bone in Adult Club-foot.—A much more serious problem confronts the surgeon who is called upon to treat a neglected adolescent or adult club-foot. Even here no bone should be removed, until all improvement possible has been secured by wrench, tenotomies and division of ligaments prior to or at the time of operation. The removal of the bone is at times advisable but comparatively little mutilation is needed if the surgeon is experienced in the use of the wrench. If bone has to be removed, every effort should be made to save the joints in order not to destroy the mobility of the foot. Particularly necessary is it to obtain by manipulative effort the maximum of dorsiflexion.

Bone Wedge Operation.—In suitable cases correction may be obtained without interfering with the subsequent mobility of the foot. A wedge of bone is first removed from the os calcis behind the mid-tarsal joint with its base outward.

A similar wedge is taken from the cuboid in front of the joint. Finally a curved wedge is removed from the head and neck of the astragalus with its base upward and outward. It is usually necessary to divide in addition the astragalo-scaphoid capsule and deltoid ligament. Sufficient bone must be removed to bring the foot into the corrected position without force. The operation is performed through a curved lateral incision.

Stabilization.—In neglected relapsed club feet (where previous operations have been carried out unsuccessfully) permanent correction is often best achieved by stabilising the mid-tarsal and subastragaloid joints, leaving the ankle free, as in certain forms of flail foot. The technique of Hoke or Naughton Dunn may be followed.

Suitable bone wedges are removed from the mid-tarsal and subastragaloid regions, which include the articular surfaces. The foot should be "set" in a good weight-bearing position.

Although *removal of the astragalus* has been advocated by experienced surgeons, the authors do not recommend it. Relapses occur often and the joint left will not compare with that which has been sacrificed. If the operation is performed the advice of Whitman should be followed and the foot displaced backward.

The worst type of foot to be corrected is one that has relapsed after the removal of bone, and therefore the surgeon is under a grave responsibility to make the operation an effective one, or to leave it alone.

After-care.—The question of manipulation and the immediate after-care of corrected club-foot has been the only phase of the question so far discussed, but

an equally important part of the treatment, if ultimate function is to be obtained, is the later after-treatment of operated cases.

The mere obtaining of overcorrection and maintaining it for a few weeks is of no value unless it is followed up by the other two elements of successful treatment. These are measures (*a*) *to enable the overstretched anterior and outer muscles to function*, and (*b*) *the deflection of body weight in such a way that it will become corrective.* Unless adequate overcorrection of the foot is secured at the time of operation failure is inevitable.

(*a*) The ability to use the overstretched and weakened anterior and external muscles must be restored by muscular re-education. In the case of babies or infants and very young children this of course is often impracticable, and in these cases retention in the overcorrected position must be continued until they are old enough to help themselves in this matter. In children old enough to obey orders, the patient should be taught to dorsally flex and evert the foot. This motion depends largely upon the action of the extensor longus digitorum and of the peroneal muscles. The child should first be taught to move the foot into this position, the motion being guided by the hand until he learns to do it actively, after which it should be performed against slight resistance. Of all the measures connected with the after-treatment of club foot this is the most often neglected, and it may be again insisted, that unless this measure is carried out the foot is mechanically little better than are those feet where after poliomyelitis the anterior and external muscles remain paralyzed or weakened.

(*b*) The second measure which is of equal importance is the deflection of body weight in such a way that the center of gravity falls inside the center of support. In other words, in weight bearing the foot must be so balanced that it tends to roll onto its inner instead of onto its outer border. This measure cannot be employed in the case of children too young to walk, but in children who are able to get their weight on their feet, the shoes should be raised from one-quarter inch to one-half inch on the outer side to throw the weight on to the inner border. In some cases a better balance will be obtained if only the front of the boot is raised and the heel left square. This induces a twist in the mediotarsal joint which is of itself corrective.

Retentive Apparatus.—If full overcorrection has been obtained at the time of operation, if this retention has been adequately maintained for three or four weeks after operation, if functional power is restored to the stretched anterior and external muscles, *no form of retentive apparatus* should be required in children *who are old enough to walk.*

It should be the surgeon's aim so to correct deformity that ambulatory splints are not needed. This should be possible not only in the mild early case, but also in the older and more deformed.

The stages should be, (*a*) over correction; (*b*) retention in the overcorrected position in which the education and development of the dorsiflexors and evertors proceeds; (*c*) walking barefooted when body weight can be correctly deflected; (*d*) shoes without heels and the outer borders raised should be worn when walking commences; (*e*) no side supports or any form of apparatus should be allowed. For a considerable period splints should be used at night to keep the tendo Achillis and anterior tibials stretched. This is the ideal way of treating club feet, and should with few exceptions be possible.

Some form of night retention shoe is desirable for a while if during the night the feet at first tend to fall back into a position of deformity. The simplest

form of apparatus is a splint holding the foot at right angles and somewhat everted, consisting of a sole plate and two uprights.

The splint used to retain the club-foot in a position of overcorrection consists of a stem of metal down the center back of the calf and sole of the foot. This stem is moulded well away from the heel to avoid pressure. Two malleable plates are fixed to the stem. The upper one, which is wider on its inner side, moulds to the calf; the lower one supports the sole of the foot and has a flange on its inner border to retain the foot in position on the plate. The foot piece is everted and slightly dorsiflexed on its outer border by means of a twist in the stem between the plates (Fig. 648).



Fig. 648.—Metal club-foot splint.

In the case of infants and young children the overcorrected position may be temporarily maintained by the use of the adhesive plaster straps.

In the severest cases the surgeon has the choice of using a high degree of force and obtaining complete correction on one occasion, or performing the operation on two or more occasions, using a milder degree of force each time. These events should be separated by short intervals and the foot maintained in the overcorrected position by adhesive plaster, plaster of Paris, or a retention splint in the manner described, unless the surgeon has considerable experience in which case he may prefer to wrench at intervals.

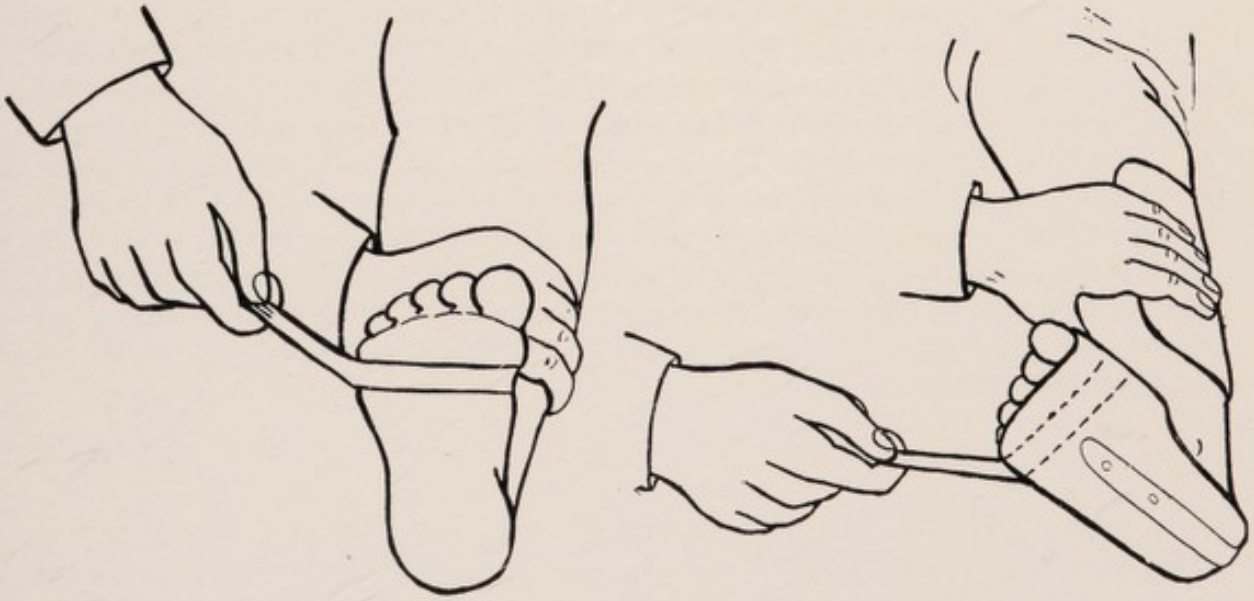

Fig. 649. Fig. 650.

Figs. 649 and 650.—Method of applying Jones' club-foot shoe.

A retention brace is put on as illustrated in the diagram (Figs. 649 and 650). A strip of adhesive plaster is placed around the dorsum of the foot starting from the sole and passing from without in. The foot is held everted and dorsiflexed by the adhesive plaster until the splint is applied.

In a certain class of hospital patients, and occasionally in private practice when the parents are indifferent and careless, some form of retention apparatus

will be necessary to safeguard the child against this indifference of the parents. It must be remembered, however, that this method of proceeding is less efficient and decidedly inferior to the measures which have been described.

An apparatus of this sort is described under infantile paralysis (p. 491) and seems adequately to fulfill the requirements.

There are many types of retentive splints of which the Taylor club foot shoe is a good example. It consists of three parts—(*a*) a sole plate, (*b*) an upright, and (*c*) a calf band. (*a*) The sole plate consists of a bottom part which is turned up on the inside to form a flange and is made of No. 16 gauge sheet steel. It extends from the posterior border of the heel to the heads of the metatarsals. In front the plate is as wide as the spread of the ball of the foot, and behind as wide as the os calcis. (*b*) The upright extends up the inner side of the leg and is jointed opposite the internal malleolus. It ends above in (*c*) a curved flat band of steel encircling the posterior half of the leg and projecting in front of the upright about one inch and is fastened in place by a strap and buckle. The foot is held to the apparatus by means of straps. By tilting the foot piece at an angle to the upright some degree of valgus may be produced. The apparatus is only useful in maintaining correction obtained by other means and is not to be advocated as a treatment for club-foot, but merely as a means of holding the foot in a partially overcorrected position. With the better appreciation of the need of overcorrection of the deformity at the time of operation it will be less and less used.

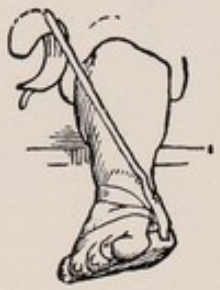

FIG. 651.—Taylor brace in process of adjustment. The sole plate applied and the foot strapped to the sole plate. The upright is then brought into place and fastened (Bradford and Lovett).

Summary.—The chief difficulty in obtaining successful results in club-foot lies in the neglect of the measures stated in this section as essential to success, and the most serious of these difficulties is a failure of the surgeon at the time of operation to obtain adequate overcorrection. If this is not done relapse is sure to occur, and no apparatus and no procedure can overcome this obstacle to successful function. It is too much the custom to depend upon apparatus to supplement inadequate operation. This is never successful because the corrective power of apparatus in club-foot is negligible and if apparatus is used it is to be regarded only as a means of retaining correction already obtained by other measures.

Talipes Varus

This form is both congenital and acquired. The *congenital* form is generally an incomplete form of equino-varus, but may exist occasionally as a pure type. The treatment does not differ from that of equino-varus, except that the tendo Achillis does not require division, and if the foot in addition to being inverted should be markedly adducted at the mid-tarsal joint, both elements of deformity should be corrected and retained for some weeks.

Acquired talipes varus is discussed under poliomyelitis which is its most frequent cause.

The cases are much easier to treat than is congenital equino-varus and a few months are sufficient to effect a cure. One must be careful not to classify as cases of pure varus those of equino-varus with only a slight deformity

in plantar flexion. In cases of pure varus the foot can be passively fully dorsiflexed.

Metatarsal Varus.—This is usually congenital and consists of an adduction of the phalanges on the metatarsal heads. It is sometimes acquired and found in connection with knock-knee and is then usually compensatory. Bankart[1] has drawn attention to the fact that the scaphoid is often absent in the congenital variety.



FIG. 652.—Outside crook long heel and outside flapper.

Talipes Equinus

Talipes equinus may be congenital or acquired. As a *congenital* variety it is distinctly rare and is generally slight. If very resistant it should be dealt with by stretching, or if an old case by plastic elongation of the tendo Achillis. The *acquired* forms of the variety are discussed in connection with the affections which cause them (see Chapter XXX).

Talipes Calcaneus

This affection in the *congenital* form is comparatively rare. The foot is habitually dorsally flexed and the top of the foot can be brought into contact with the front of the tibia. The sole of the foot is generally flat and there is no element of cavus. Associated with it may be hyperextension of the knee. In young children the treatment consists in manipulation of the foot toward plantar flexion at short intervals during the day, and by the use of a splint maintaining the foot in plantar flexion. Tenotomy of the anterior muscles is very rarely needed and should be confined to the tibialis anticus. The *acquired* form of the deformity is practically always associated with infantile paralysis or some nerve lesion, as in spina bifida, and is discussed elsewhere.

Talipes Valgus

When *congenital* this is often combined with some degree of calcaneus or equinus. It is important that the position of the foot should be corrected early in life, as if neglected it will lead to a severe form of rigid flat-foot. The foot should be thoroughly loosened up by manipulation under anesthesia and held in a position of adduction and inversion. The *acquired* form is described in the following chapter.

[1] BANKART, A. S. B.: Brit. Med. Jour., 1921, ii, 685.

CHAPTER XXX

ACQUIRED DEFORMITIES OF THE FEET

The subject of static disabilities of the feet has been much obscured by the enormous literature which has accumulated dealing with classification, causes, and treatment. An attempt will be made here to present these affections as a whole and to simplify the classification which has been very much obscured by the indiscriminate use of the term "flat-foot" to designate all phases of foot strain. The term is greatly abused, and "flat-foot" in the minds of the public implies the use of foot plates, which are sold in shoe stores, advertised in the popular press, and used on an appalling scale. This is based on the assumption that every case of foot strain is caused by a broken down arch which requires support. Much harm is being done by this indiscriminate use of plates, the majority of which are ill-fitting. It seems more reasonable to use "foot strain" as a term covering these disabilities, and to point out that this foot strain is confined to no one definite type of foot, but may occur in the foot with the high arch as well as the foot that is flattened. In the hope, therefore, of making the matter clearer, the term "flat-foot" will be confined to those cases where the arch of the foot either touches the ground, or where it is so much lowered that it nearly touches. The situation is summed up very well by Aitken[1] as follows: "People with flat feet seldom or never suffer from 'flat-foot' as a pathological condition." In other words, people with flat feet need not necessarily suffer from their feet. In view of this situation the terms "weak foot," "pronated foot," "fallen arches," "broken arches," and similar terms will be omitted from this chapter.

Anatomical Considerations

Mechanically the foot is an elastic arched structure, bearing the body weight, and it articulates with the bones of the leg at about the posterior third of the foot. The functions of the foot are (1) *weight bearing*, and (2) *propulsion*. It must be remembered that in standing as well as walking or running, the entire weight of the body is transmitted to the ground by way of the astragalus, which is the only foot bone in contact with the leg bones. Thence the weight passes to the ground through the other bones of the foot, and it is obvious that no other bone in the body is subject to so much superincumbent weight.

The Arch of the Foot.—The hind part of the foot, consisting of the astragalus and os calcis, articulates in front with the fore part of the foot at the mid-tarsal joint which is in two portions—an inner part, the astragalo-scaphoid, and the outer part, the calcaneo-cuboid. The instep or arch of each foot forms a half dome, and when the two feet are placed close to each other they form a dome, not circular, but elliptical in shape.[1] The dome formed by the two feet rests on the ground all around the edge from the heel of one foot round the outer border of the foot along the treads and back along the outer border of the other foot to the heel. Considering one foot by itself, the weight of the body rests upon a half dome touching the ground on its outer border. It is stable if the body weight is so balanced that it rests on its outer edge, but if the body weight falls too near the inner side of the half dome there is a tendency for it to capsize inward. The mid-tarsal joint running across the foot is so constructed that it works properly only when the foot is in proper balance; if it capsizes inward, the joint is twisted, ligaments are unduly stretched, and sometimes bones are unduly compressed against each other, producing localized pain and tenderness.

[1] AITKEN: Jones, "Orthopedic Surgery of Injuries," 1921. Vol. 1, p. 371.

The two component parts of the arch of the foot, the outer and the inner, must be considered separately, and this matter is of much importance.

The outer component consists of the os calcis behind, the cuboid in the middle, and the fourth and fifth metatarsal bones in front, and is supported on the heel behind and the heads of the fourth and fifth metatarsals in front. The surfaces between the os calcis and cuboid are saddle-shaped, and allow a limited degree of motion in flexion, extension, abduction, and adduction. Between the cuboid and the bases of the metatarsals only a slight gliding movement is allowed. The outer component of the longitudinal arch, therefore, is a low, flat arch with fairly stable joint mechanism, and under a heavy load flattens until practically the whole outer arch is on the ground. One would therefore not look to this to be the site of painful symptoms in capsizing of the arch on account of the stability of these structures.

The inner component of the arch comprises more joints than the outer, and the mobility of these joints is greater. This part of the arch rests on the heel behind, rises steeply forward to the neck of the astragalus, the scaphoid, and the three cuneiform bones to the three inner metatarsals, resting in front mainly on the head of the first metatarsal. The mid-tarsal joint between the astragalus and scaphoid is a ball and socket joint with motions in all directions, including rotation. The remaining joints in front of this have nearly flat joint sur-

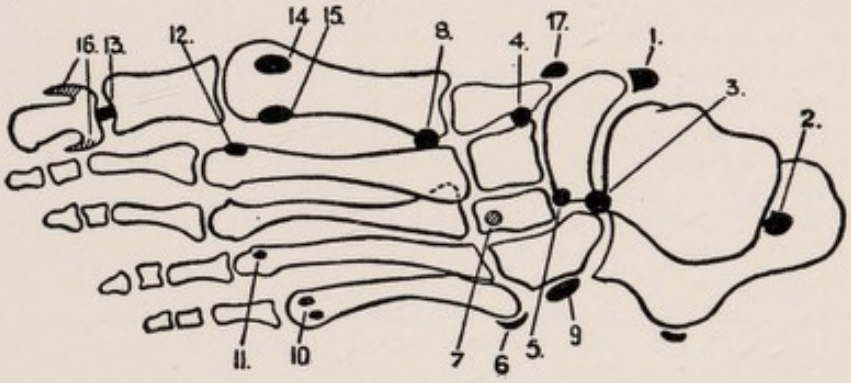

FIG. 653.—Diagram of the position of the important accessory bones in the foot (C. Thurstan Holland).

1. Tibiale externum.
2. Trigonum.
3. Secondary os calcis.
4. Intercuneiform.
5. Secondary cuboid.
6. Epiphyseal vesalian bone.
7. Uncinatum.
8. Intermetatarsum.
9. Peroneal sesamoid.
10. Fifth toe sesamoid.
11. Fourth toe sesamoid.
12. Second toe sesamoid.
13. Interphalangeal big toe sesamoid.
14. Internal flexor hallucis brevis sesamoid.
15. External flexor hallucis brevis sesamoid.
16. Spurs on terminal phalanx.
17. Paracuneiform.

faces, with gliding motions and movements limited by strong ligaments. In addition to what has been said it must be remembered that the astragalus, which acts with the leg bones in flexion and extension, is part of the inner component of the longitudinal arch and not of the outer, and that any yielding is much more likely to occur in the inner than in the outer component of the arch; that abnormal deflection of weight-bearing is naturally more effective on the inner than on the outer; and that at the inner side of the foot will occur the yielding which leads to the capsizing of the foot. In addition to this fact it must be remembered that the astragalus rests on the inner side of the os calcis, so that in addition to what has been said about the comparative weakness of the inside of the arch the line of thrust is also to the inner side.

In addition to the longitudinal arch of the foot, there is a *transverse arch*. This is formed posteriorly by the cuboid and cuneiform bones. Its convexity is directed upward and outward and this arch should be regarded as not separate from the longitudinal arch; both are integral parts of one structure and an affection of the longitudinal arch is associated with a disturbance of the transverse arch. The heads of the metatarsal bones do not lie in a line transversely across the front of the foot, but the second projects ¼ inch in front of the first, the third ¼ inch behind the second, the fourth ¼ inch behind the third, and the fifth ⅜ inch behind the fourth. Moreover, the heads of the five metatarsals form an arch with a dorsal convexity in order to give greater strength and elasticity to the forefoot.

Movements of the Foot.—The primary movements of the foot are four in number. The most important motions are *flexion* and *extension*, but as these terms introduce confusion, because the names of the muscles are diametrically opposed to the names of the movements, it is better to use *dorsal flexion* for the movement which approximates the dorsum of the

foot to the front of the leg, and *plantar flexion* for the reverse movement, and these names will be used in this connection. The two other movements of the foot which are of importance are *inversion*, in which the whole foot is turned on an antero-posterior axis, so that the sole points toward the other foot, and *eversion*, a movement of the whole foot on a longitudinal axis, so that the sole of the foot turns away from the other foot. *Abduction* and *adduction* of the foot are applied to the movements of the forefoot on the hind foot, occurring on a vertical axis. In adduction the forefoot approaches the middle line of the body, and in abduction moves away from it, but the situation is not quite as simple as this, for with non-weight-bearing plantar flexion of the foot is associated some adduction and inversion, and with dorsal flexion some abduction and eversion. This is because the ankle joint is protected against lateral movement of the astragalus between the malleoli, and the movement is in general a hinge motion upon a transverse axis, in which there is a twist, owing to the fact that the axis of the astragalus is slightly oblique to the leg, and that the outer side of the astragalus moves more freely on the external malleous than the internal side does on the inner malleolus.

These two most important factors in the mechanics of the foot must be thoroughly understood and may safely bear repetition. (1) Plantar flexion is essentially a movement of the astragalus upon a transverse axis, but this transverse axis is oblique and there occurs with the plantar flexion an adduction and inversion of the foot, which is due in the main to a slight obliquity in the action of the astragalus in relation to the bones of the leg, and (2) the fact that more movement occurs between the outer malleolus and the bone than at the inner side.

Pronation and Supination of the Foot.—Pronation and supination are two names applied to two motions of the foot which are also applied to positions, especially in weight-bearing, where there is a normal difference between the fully weighted and the non-weighted foot. Pronation is a combination of eversion and abduction, and supination a combination of inversion and adduction.

The movements may be tabulated as follows:

1. *Plantar flexion*, which combines some inversion and adduction.
2. *Dorsal flexion*, which combines some eversion and abduction.
3. *Eversion* occurring in tarsus anterior to and below astragalus.
4. *Inversion* occurring in tarsus anterior to and below astragalus.
5. *Adduction* occurring in front of astragalus and os calcis and also in joints in front of them.
6. *Abduction* occurring in front of astragalus and os calcis and also in joints in front of them.

Active or passive pronation consists of abduction and eversion; and active or passive supination, of adduction and inversion.

Range of Motion.—At the ankle joint, dorsal flexion—it is said by the anatomists—should normally be from 10 degrees to 20 degrees less than a right angle, and plantar flexion 50 degrees to 60 degrees more than a right angle. With the knee extended and passive dorsal flexion attempted, the limit of 20 degrees will be found to exist in the minority of cases; and in very many perhaps the majority of cases, the foot will not go appreciably above a right angle unless it is allowed to evert and abduct. The other motions of the foot, with the exception of plantar flexion, cannot be accurately estimated but exist to only a few degrees.

Function of the Muscles of the Foot.—The function of the muscles of the foot is as follows:

Toes—Flexion.—Flexion of the toes is produced by the following muscles: The *flexor longus digitorum* acts on the distal interphalangeal joints of the toes, and the *flexor* brevis on the proximal interphalangeal joints. The *lumbricales* act on the metatarsophalangeal joints flexing and drawing medially the second, third, fourth, and fifth toes, while the *interossei* act on four toes, and abduct or adduct. In walking they normally stabilize the toes on the rounded and slippery heads of the metatarsals at the moment when the flexors of the toes press upon the ground backward after the heel has been raised and just before the forefoot leaves the ground. It should be borne in mind that just as in the case of the flexors of the toes all retromalleolar muscles cooperate in raising the back part of the weight-bearing foot in normal walking until the moment the leg swings forward. It is of practical importance to note that in the act of walking the insertions of the muscles attached to the toes become the fixed points.

Extension.—Extension is produced by the following muscles at the metatarsophalangeal joints: *Extensor longus digitorum*, *extensor brevis digitorum*, and *extensor proprius hallucis*.

Ankle—Dorsal Flexion.—Dorsal flexion of the foot is produced by: *Tibialis anticus, extensor longus digitorum, extensor proprius hallucis,* and *peroneus tertius. Plantar flexion*—this is produced by: *Gastrocnemius, plantaris, soleus, tibialis posticus, peroneus longus* and *brevis, flexor longus digitorum, flexor longus hallucis. Inversion*—by the *tibialis anticus, tibialis posticus, peroneus tertius* (acting with the preceding). When the anterior tibial is paralyzed the *extensor longus hallucis* acts with some slight force to invert the foot, but its action depends upon the position of the foot. *Eversion*—the muscles concerned with eversion are: *Peroneus longus, peroneus brevis, peroneus tertius* (acting with the preceding), and the *extensor longus digitorum.*

A very important muscle in maintaining the arch of the foot is the *tibialis posticus,* the tendon of which passes through a groove behind the inner malleolus, beneath the inferior calcaneoscaphoid ligament, the sustentaculum tali, and the tubercle of the scaphoid and is inserted by a broad fan-like attachment to all the bones of the tarsus, except the astragalus, and to all the metatarsals except the first and fifth. Another muscle, important in maintaining the arch of the foot, is the *flexor longus digitorum,* which also passes behind the inner malleolus and is inserted with the *flexor accessorius* in the bases of the last phalanges of the four lesser toes. When the toes are flexed in the weight-bearing position they become a fixed point from which the flexors act. The *flexor brevis digitorum* has also a very strong arch-raising motion, especially from its insertion into the second phalanges of the toes and its short course from the os calcis to its insertion, so that with the toes acting as the fixed point, its force is expended directly on elevating the arch. The transverse arch at the mid-tarsal joint is supported by the *tibialis posticus* and *peroneus longus,* and the arch formed by the metatarsal heads is supported by the *transversus pedis.*

Ligaments of the Foot.—The ligaments of the ankle joint consist of the anterior and posterior, and external lateral and internal lateral ligament, the latter called the deltoid ligament. The articulations of the tarsus are maintained by strong ligaments binding the bones together, the inferior and internal being generally the more powerful as they protect the foot against an inward and downward thrust. The most important ligament in maintaining the arch of the foot is the inferior calcaneoscaphoid, which is broadened and thick, the fibres of which pass forward from the anterior margin of the sustentaculum tali to the under

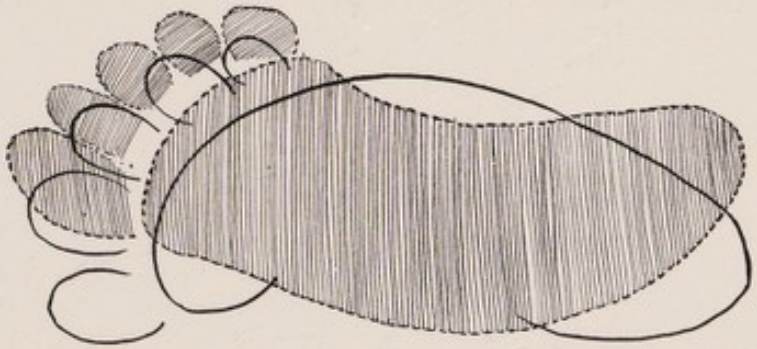

FIG. 654.—Schematic vertical projection of normal foot and flatfoot in standing. It represents the change flexible flatfoot undergoes each time it bears weight.

surface of the scaphoid bone. This ligament supports the head of the astragalus forming part of the articular cavity. If it yields, the head of the astragalus is pressed downward, inward and forward. This ligament contains a certain amount of yellow elastic tissue, due to the fact that the insertion of part of the tibialis posticus going to the scaphoid is blended with the inferior calcaneoscaphoid. The anterior portion of the deltoid ligament blends with the inferior and internal calcaneoscaphoid and has been called the astragaloscaphoid capsule, as it forms the capsule of the inner part of the mid-tarsal joint.

Plantar Fascia (Aponeurosis Plantaris).—The plantar fascia with the digitations between the muscles forming the first layer in the sole of the foot is part of the origin of these muscles—hence its strength. It runs longitudinally and consists of a central portion and two lateral portions. The central portion is narrower behind and originates from the inner tubercle of the os calcis. It becomes broader and thinner in front, and near the heads of the metatarsal bones is divided into five processes. The superficial part of the fascia in front is inserted just behind the toes into the skin, and deeper stratum divides into slips which blend with the sheaths of the tendons and laterally with the transverse metatarsal ligaments. The deep surface of the fascia gives attachment behind to the short flexor of the toes. Of all the structures in the foot it most nearly corresponds to the "binding rod" of the arch.

Transverse Metatarsal Ligament.—The transverse metatarsal ligament is a narrow, fibrous band which passes transversely across and connects the anterior extremities of all the metatarsal bones. Anteriorly it blends with the plantar ligament of each metatarsophalangeal articulation. It is probably not of great assistance in maintaining the arching up of the

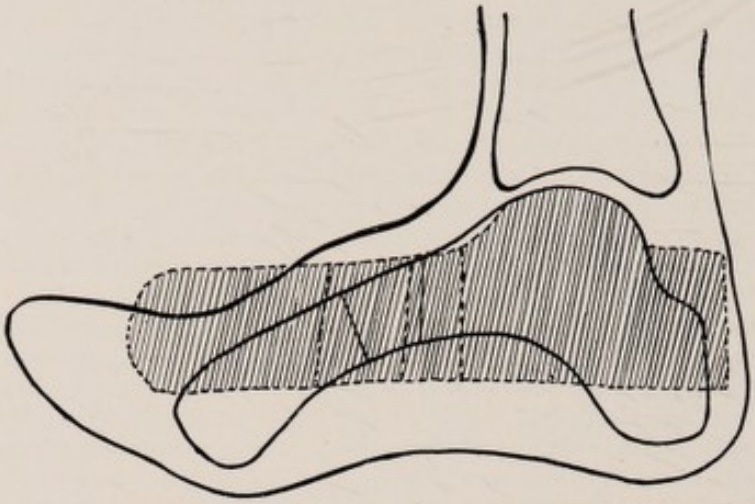

FIG. 655.—Schematic lateral projection of bones of normal foot and flat foot.

anterior ends of the metatarsals, as the heads of the metatarsals are very mobile, and the arch is maintained chiefly by small muscles.

The Weight-bearing Position in Standing.—The weight-bearing foot is somewhat modified over the non-weight-bearing foot by a movement which occurs in front of the astragalus. This movement is a combination of eversion and abduction, and is often spoken of as pronation. The heel and forefoot, which are in contact with the ground, remain stationary while the bones of the leg rotate with the astragalus slightly inward on a vertical axis. Analyzed by X-ray photographs the movement of pronation consists of the following elements:[1]

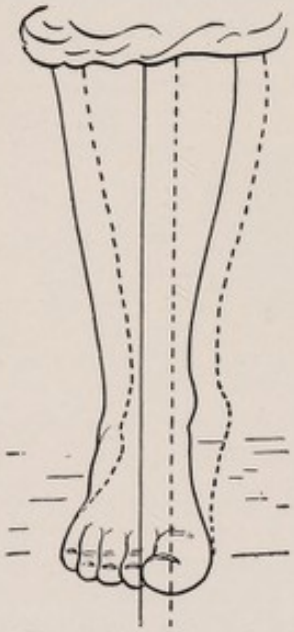

FIG. 656.—Normal and pronated position of the foot, the latter in dotted outline.

(*a*) In changing from supination to pronation in the standing position the foot rotates as a whole beneath the astragalus and the os calcis, at the same time moving laterally. (*b*) The astragalus so rotates in pronation that its head moves inward and backward, and its body outward and forward, (*c*) there is some movement of the cuboid on the os calcis, (*d*) the fore-foot is displaced outward on the astragalus, (*e*) there is very little motion between the bones in front of the scaphoid. This rotation of the leg bones analyzed by composite photographs shows that the inner malleolus moves inward, downward, and backward, and the outer one in the reverse direction. This simply indicates a movement of the whole lower extremity. In the standing position the foot broadens and lengthens.

The Imprint of the Foot in Standing.—The smoked tracing of the foot as well as the wet tracing is unreliable for purposes of study, because in imprint tracings the non-weight-bearing tracing is indelibly recorded before the weight-bearing position is reached. To secure an accurate idea of the weight-bearing position of the foot a method of observation and record adopted by one of the writers[2] is more accurate for study. The patient stands on a piece of plate glass, under which, and facing the light, is a mirror set at an angle of 45 degrees to the floor. In this mirror may be seen with great clearness the reflection of the bottom of the feet, bearing weight. The weight-bearing surfaces appear as dead-white areas, while the lines of contact can be seen easily. Tracings made on the glass demonstrate that there is one tracing for the foot when not bearing weight, and another when it does bear weight, and that the ordinary wet imprint tracing is a composite of the two.

[1] LOVETT and COTTON: Boston Med. and Surg. Jour., Aug. 4, 1898.
[2] LOVETT: New York Med. Jour., June 20, 1896.

Static Disturbances of the Feet

In view of the anatomy as presented it is evident that the weight of the body comes down in the line of gravity through the astragalus to an elastic, weight-bearing arch, and is distributed through it to the ground; that the line of gravity comes somewhat to the inside of the center of support, and comes upon an arch weaker in its inner component than in its outer, so that the whole tendency of superincumbent weight is to thrust the arch inward. Against this tendency it is protected by muscles and ligaments. An excess of superincumbent weight and diminution of muscular power are to be considered as the causes of foot strain. Foot strain becomes effective in causing pain, discomfort and disability from two causes—(*a*) strain of muscles, joint, and ligaments, and (*b*) wrongly distributed pressure.

Causes Predisposing to Foot Strain. *The Shoe.*—One universal cause in civilized races is found in the use of the shoe. From early childhood the foot is encased in a more or less unyielding leather shoe, which is not the shape of the human foot, but almost invariably narrowed and somewhat pointed in its

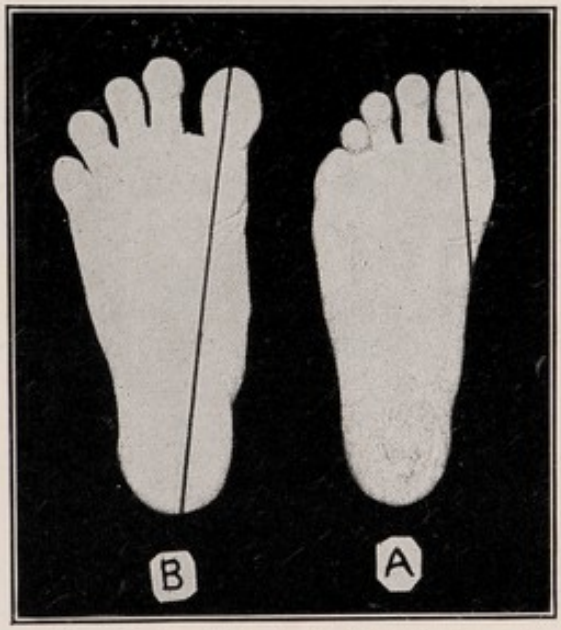

FIG. 657.—*A*, Foot of a Bagobo boy who had worn shoes only a few months contrasted with *B*, foot of an adult Bagobo who had never worn shoes (P. Hoffmann).

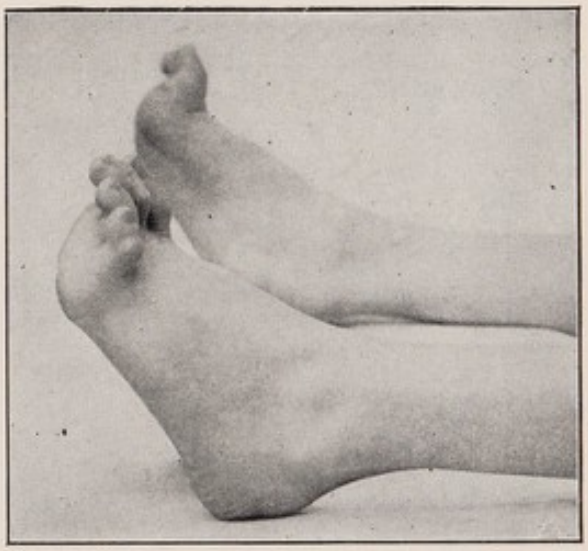

FIG. 658.—Clawed toes at times associated with short tendo Achillis and a high arch and often due to improper shoes.

forward part, so that the great toe is necessarily displaced outward. It must be remembered that normally the great toe forms the buttress of the anterior part of the inner arch as it broadens the weight-bearing area and thus stabilizes the foot. If displaced outward, the great toe cannot grip the ground as it should and furnish a fixed point from which the muscle may serve in maintaining the arch. In addition to this the sole of the shoe is more or less unyielding, as a rule stiffened in the shank, so that the foot is laced down to a more or less stiff sole, a proceeding which tends to pull down the dorsum of the foot at the end of each step when the weight is borne on the front of the foot. The modern shoe causes crumpling and distortion of the toes, and diminishes the power of the toes to spread, the muscles of the foot atrophy, and a condition is brought about which is opposed to the maintenance of the arch without strain. In a

foot which has not been thus cramped and distorted a very striking difference is found, which distinguishes it from the average foot. In a case of one of the writer's, a girl of fifteen who had lost the use of both arms as a result of double obstetrical paralysis, had been shod from early childhood with the greatest care, and had been encouraged to use the foot instead of the hand for such purposes as writing, drawing, knitting, etc. Her foot in the standing position has but little arch, which is due to the great development of the muscles in the sole of the foot. The flexor brevis digitorum forms a heavy muscular band, flexion and extension of the toes exist to an extent which is surprising, spreading of the toes appears extreme, and the prehensile power of the toes is so developed that objects such as pencils, etc., can be picked up from the floor and held between the toes. In another case of an athletic young woman, who has always worn a shoe the shape of the foot, all of these characteristics exist to a less degree, the motion of adduction and inversion is very strong, but the most striking characteristic in both instances is the marked body of muscle existing in the sole of the foot.

Aside from the modern shoe, the main causes of foot strain are:

1. *Diminution in Muscular and Ligamentous Support.*—This occurs during convalescence from illnesses and especially during the convalescence from child-birth, to a certain extent during menstruation, in rapid growth, and in acute illnesses, and it is noticeable following severe trauma to the leg, which results in muscular atrophy and loss of muscular tone.

2. *Excessive Weight.*—This arises in two ways (*a*) from excessive body weight, or (*b*) from the habitual lifting or carrying of heavy loads. A typical case of this sort is to be found in the middle-aged woman who has become less active, who has accumulated from fifteen to thirty pounds of weight in a short time, and whose muscles which were adequate to maintain the foot against strain in the first condition, are unable to do so in the second.

3. *Overuse of Feet.*—Overuse of the feet in standing or walking is a frequent cause of foot strain. Typical instances of this are as follows: An active young woman, accustomed to being on her feet and athletic, under war conditions would stand for hours in a canteen, often fatigued, and would find after six weeks, or perhaps earlier, that the feet became painful and progressively worse. The same condition occurs in hospital nurses and house officers from standing or walking for hours on hardwood floors. The latter is so well-known a source of trouble that in most hospitals it has led to a general reduction of the shift from twelve to eight hours of duty, resulting in an enormous diminution in the amount of trouble encountered. Another form of overuse occurs in prolonged use of the feet in active exercise. A young man, after graduating from the university where he has been engaged in active exercise, engages in some sedentary occupation, which he follows through the week, and on Saturday and Sunday takes long tramps in the country, or on his holidays goes on a walking tour. In such cases, especially if the man is overworked, the foot is likely to become painful and develop symptoms of strain.

The same symptoms arise in excessive exercise after prolonged rest and can only be avoided by carefully training the weakened muscles under these conditions. Another form of overuse occurs in the violent use of the foot, and is found in high jumping or in the running broad jump, where the repeated jar of landing is frequently followed by painful symptoms in the feet, on which the entire body weight rests at the end of the jump. The same condition is seen

in naturally athletic young men and women, who, due to their occupation, have acquired sedentary habits, but who play squash or rackets on hardwood or cement floors once or twice a week in soft soled shoes.

It should be mentioned that these three classes are not mutually exclusive of each other, but to a certain extent interact. Excessive weight is more harmful if the muscles are weak, and the same may be said of overuse.

Types of Foot.—There is no one type of foot which is to be classed as normal, any more than there is one type of features which can be classed as such. In general there are three main types of weight-bearing surface, as determined by inspection of the weight-bearing position.



FIG. 659.—Tracing of foot resting on two islands. No symptoms, foot useful.



FIG. 660.—Type of tracing described as normal, with outer border touching ground.

1. *The high arch*, where the foot touches the ground only in a round area under the heel, and in an elliptical area under the forefoot. In many cases there are pointed projections on both of these at the outer side showing that the front and back of the outer border touch (Fig. 659).

2. The type generally described as "*normal*," and so figured in the books, shows a straight bearing line for the outer border, narrowest opposite the head of the base of the fifth metatarsal, and from there running obliquely or transversely inward, forward, and back to join the pressure area of the forefoot and the heel. In general the bearing area corresponds to the shape of the foot with a deep indented bay running out more or less transversely from the great toe joint to the outer border with an indentation forward in the middle of the foot, and then from the outer border running obliquely backward, outward, and inward to the area of heel pressure (Fig. 660).



FIG. 661.—Tracing of flatfoot. No symptoms, foot useful.

3. A type to be described as *flat-foot*, where the whole sole of the foot touches the ground, and in the severest cases of this type the breadth of the bearing area is greatest opposite the scaphoid bone. Every possible gradation between these types is seen, but in general there will be no difficulty in classifying correct impressions of the weight-bearing area of the foot as belonging in the main to one of the three classes (Fig. 661).

Of the three, the flat-foot type is the least numerous in normal individuals, and the high arch, and the so-called "normal" arch are about evenly divided. With regard to the height of the arch, the following conclusions were drawn by

Hoffman,[1] who analyzed the height of the arch in 330 barefooted individuals at the World's Fair in St. Louis, none of whom had symptoms; in 100 negroes wearing shoes, but symptomless; in 200 Caucasians, shoe wearers but without symptoms, and in 500 Caucasians, shoe wearers who were under treatment for static troubles in the feet, and reached the following conclusions:

1. That there is no normal type of arch.
2. That the height and shape of the arch are of no value in estimating the strength or usefulness of the foot.
3. That normal feet present high, medium and low arches in nearly the same proportion as do feet with weakened arches.

Limited Dorsal Flexion.—One further type of foot must be mentioned, which has an important influence on the mechanics of the foot. If the gastrocnemius is short, as it frequently is, in the standing and walking position, dorsal flexion

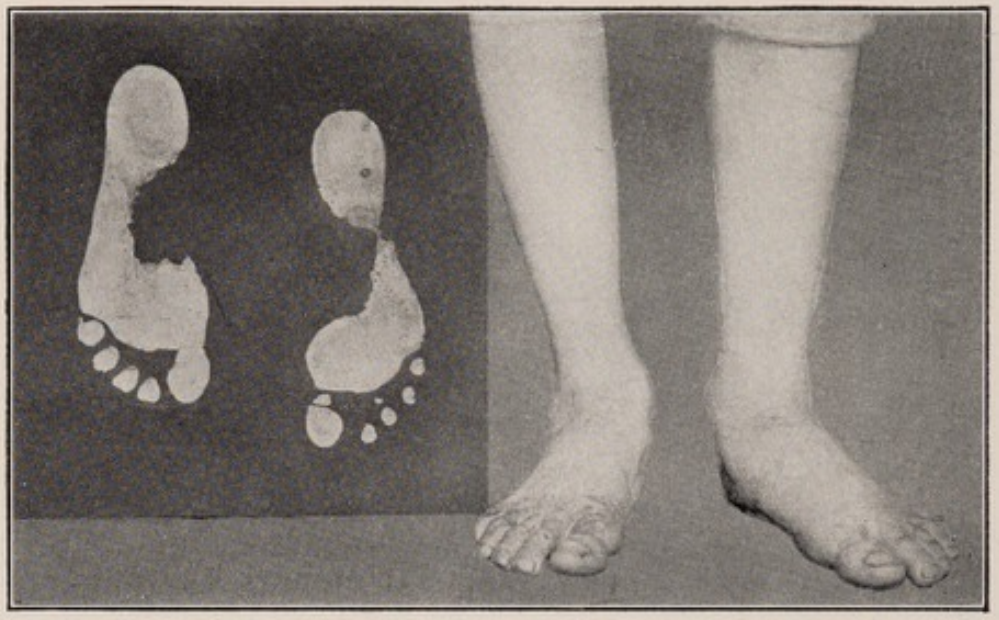

FIG. 662.—Weakened foot without breaking down of arch (Bradford and Lovett).

is checked at the ankle joint when the gastrocnemius has reached its limit of extensibility. Further dorsal flexion must now occur in the joints in front of the astragalus; and in finishing the step, and to a certain extent in standing, undue pressure will come on the fore foot, and undue strain will come on the ligaments on the under side of each one of the tarsal joints.

Symptoms.—The symptoms resulting from the abnormal relations of superincumbent weight to the foot in forms of strain and pressure will next be considered. It is probable that certain types of foot are more resistant to strain than are others, but this matter is not entirely clear, and the statement may be made that in our present state of knowledge no one type of foot can be picked out as one necessarily vulnerable, but that the foot with the high arch for mechanical reasons should prove most liable to trouble. In general the abducted and everted foot, and the foot with a notably short tendo Achillis are probably more liable to painful strain under unfavorable conditions than are the other types.

The unfavorable symptoms will first be presented as a whole, and then modifications of them as induced by different varieties of foot will be discussed

[1] American Medicine, August, 1907.

under separate headings. The first symptoms of foot strain generally noticed are that the feet become hot and uncomfortable, burn after use, and perspire more than before. General and local stiffness and lameness come next, the feet stiffen on sitting, and are most uncomfortable on getting up in the morning, and at the close of the day. Such patients are generally more comfortable after a day of rest, and least comfortable after an active day. The circulation becomes disturbed, and the return of blood is slow when pressed out of the skin, local or general swelling appears, the feet feel tight in the boot, and the gait becomes inelastic and clumsy with a tendency to walk with the feet everted and not to rise on the toes.

Pain and *tenderness* are generally present under the tubercle of the scaphoid, due chiefly to the stretching of the inferior calcaneoscaphoid ligament. Pain and tenderness are also found, particularly in everted feet, below the internal malleolus and along the ridge of the astragalocalcanean joint, and running down on to the inner side of the os calcis, and in certain cases at the tip of the external malleolus and on the outer side of the os calcis. Pain on the top of the foot over the tarsus is also often noted. A very common symptom, especially in everted feet, is a dragging sensation in the arch and along the course of the tibialis posticus, and tenosynovitis of this muscle, accompanied by silky crepitus, at times occurs. In acute cases the whole foot becomes tender, swollen and painful, and in the severer cases this reaches such a degree that the patient cannot endure the pain of walking; walking if it is possible is done by a shuffling gait without muscular action in the feet.



FIG. 663.—Real breaking down of arch with swelling of ankle.

It should be borne in mind that the *normal gait* is characterized by gentle undulation described by the center of gravity. The supporting leg in remaining behind lengthens as the body goes forward by raising of the heel and thus prevents the center of gravity from falling low. In flat-foot the raising of the heel is avoided in fear of stress being thrust upon the tarso-metatarsal ligaments. The whole of the foot remains in contact with the floor as the body moves forward. Thus the leg is not lengthened and the *center of gravity* describes a curve, the center of which lies about the axis of the astragaloscaphoid joint, the whole length of the leg being the radius. In order to thrust the center of gravity forward so as to bring it well over the heel of the other foot, the knee has to be flexed and then forcibly extended. The flat-footed patient very carefully manages to lift ball and heel of the foot at the same time in order to prevent stress on plantar ligaments. He lengthens the weight-bearing leg, which is to become the swinging leg, by forcibly straightening the knee which for that purpose had to be previously bent. Outward rotation of the feet and legs is moreover a favorite device in this mode of

walking. It lessens the danger of antero-posterior stress on the plantar ligaments, the foot being turned more or less over the inner border instead of over the ball of the foot at the end of the step.

Synovitis may occur in the knees at times in connection with static disability of the feet, most often due to flat-foot, excessive eversion, or to short tendo Achillis. *Backache*, especially manifested by sacral pain in the buttocks and back of the legs, is often caused by shortness of the calf muscles. The trunk of the flatfooted tends to stoop, because of the strain placed upon the sacro-lumbar muscles. Pain or irritability in one or both *hips* is sometimes associated with everted and flat-foot,[1] and the left foot is often more severely affected than the right. Diminished resistance to fatigue and impaired nervous resistance in people of a neurasthenic type are at times associated with static affections of the feet. *Cramps* in certain cases occur in the soles of the feet, and in the calves of the leg, the latter particularly in the cases of patients with short calf muscles. In long continued cases of foot strain a fluctuating swelling, not necessarily painful, develops just in front of and below the external malleolus just to the outerside of the tendon of the extensor longus digitorum, and at times a swelling anterior to the tendo Achillis. Of all the symptoms the most constant is the tenderness and pain below the scaphoid. These symptoms are common to all types of foot described.

Stiffness and Muscular Spasm.—This type of foot generally resists passive correction in the line of adduction and inversion, particularly the former. This is in part apparently due to adhesions which have formed from joint irritation and the maintenance of the foot in this position which calls for the least muscular effort in use. *Peroneal spasm* accompanies as a rule the more severe cases. The peroneal tendons will be found contracted and standing out under the skin, the foot is abducted and everted, and attempted correction is painful along the course of the peroneal muscles. Besides the peroneal muscles, all other muscles of the foot and lower leg may reach a spastic condition and thus complicate the picture of foot strain. Spasm of the extensor digitorum is sometimes found in addition to that of the peronei. The gastrocnemius and soleus muscles are also sometimes in spasm, and progressive deformity of the foot ensues, the os calcis at the back, the metatarsals and toes in front, and the lateral border of the foot all being lifted up more and more, so that the lowest part of the foot is formed by the navicular bone. An isolated spasm of the flexor digitorum longus is very frequent and produces characteristic callosities just below the nails at the tips of the toes. According to Murk Jansen spasm of the interossei gives rise to "march foot," the characteristic swelling of the mid-foot which often marks metatarsal fractures. Spasm of the short flexor of the big toe is often secondary to rigid toe and lipping of the head of the first metatarsal.

Pressure Symptoms.—Symptoms of abnormal distribution of pressure are noticed in the everted foot whenever part of the sole of the foot is made to bear more weight than normal, and are found especially at the inner side of the heel and under the great toe joint. The inside of the sole of the boot wears correspondingly and the impress of the callosities may be found on its inner aspects. The order of sequence is the development of callosities under the second and third metatarsal heads, which, as the condition gets worse, extend medially, sometimes forming a callus ridge along the heel and inner border of the foot.

[1] DANE: Trans. Am. Orth. Ass'n., 1897.

The skin is thickened and calloused, perhaps in ridges or in circular patches, and in acute cases these become painful, and there is definite thickening of the subcutaneous tissue underlying.

Tender Heel.[1]—This symptom is in the majority of cases found in patients with a high arch where the posterior bearing surface is limited. A tender area forms over the lower surface of the posterior part of the os calcis under the external and internal tubercles. This may become so tender as to prevent walking and is frequently attributed to a periostitis of the under surface of the os calcis in certain cases, and to bursitis. This condition is frequently spoken of as "policeman's heel," and in many instances osteophytes are found running forward from the tubercle of the os calcis. If one looks at the sole of the boot it is obvious that it is flat and not concave to conform to the convex surface of the heel and that the pointed bony processes on the under surface of the os calcis bear on this hard, flat surface with a resulting contusion of the soft parts at every step.

Pressure Symptoms of the Forefoot.—Apart from anterior metatarsalgia, which will be described by itself, symptoms arise from pressure under the forefoot which are especially common where there is a high arch or short calf muscle. The skin becomes thickened with callosities already described, which may be an inch in diameter surrounded by hyperemic skin with thickened subcutaneous tissue. In the severer cases the whole forefoot becomes affected and walking becomes impossible. In other cases exceedingly painful corns form in the weight-bearing area at the front of the foot, and these in turn may make walking impossible. If such corns are removed, they return in due time, and if the patient goes to bed with a long continued illness they disappear during the enforced rest to return on the resumption of activity. Calluses and corns form under the distal heads of the metatarsals where they press the soft parts against the unyielding sole of the boot, because the ends of the second and third metatarsals have to sustain too much of the body weight in those weak feet, and this is often the cause of callosities under these heads in the slighter cases of weak feet. In the most pronounced cases the inner side of the heel also wears off sooner than the outer. An edged callosity then develops on the inner side of the foot.

The lateral displacement of the forefoot in flat-foot often brings the little toe into too intimate contact with the leather of the boot and causes a callosity on its most prominent part, and the toes are compressed laterally even when the boot is not too narrow. The nail of the big toe shows a tendency to grow into the flesh.

Diagnosis.—The diagnosis of static error in the foot is not an easy one. The first question to be determined by the surgeon is whether the pain and symptoms are due to a static error or some other cause, and secondly, if static error exists, to determine its type. The data for determining this have been given in the previous pages.

Prognosis.—The prognosis falls under two heads: (1) The relief of pain, and (2) the correction of existing deformity, for the two are not necessarily associated. With regard to the relief of pain and the restoration of function, the prognosis is best in people before middle life, without the existence of organic disease, where painful symptoms are comparatively recent and can be directly attributed to some obvious factor, such as overuse, bad shoeing, or

[1] STEINHARDT, L.: New York Med. Jour., Mar. 27, 1909.

temporary ill health. The prognosis for the relief of pain is not so good in neurasthenic and overworked women obliged to be on their feet for long hours, such as clerks and boarding house keepers, and the general condition of the patient particularly with regard to general muscular tone and nervous stability is of importance. The prognosis is poorest in a small foot, which is giving trouble, where the weight is excessive. A certain type of over-fed, under-exercised woman, with flabby muscles and large abdomen, is not a favorable type of case for complete relief. Remembering that the problem is one of the weight to be borne, and the machine for bearing it, it can easily be seen that the problem is to a certain extent one in which we must not lose sight of the general conditions.

Speaking in general terms the prognosis for the improvement of pain is practically always favorable, for permanent improvement of function it is influenced by the general and local conditions mentioned above. There are, however, many factors to be taken into consideration in the circumstances of the patient. The waiter, the clerk, the hair dresser, the overworked housewife, and people who are obliged to earn their living by being continually on their feet are not such good subjects as those who are at liberty to spare themselves somewhat, especially as it is the former class of patients who have as a rule acquired pretty severe disability before they seek relief.

In normal children properly treated, the prognosis as to the correction of deformity is favorable. If the children are undergoing a period of rapid growth or are over-sized, heavy, or of lax fibre, the prognosis is still favorable but progress will be slower. If the condition is due to rickets and the foot is rigid the outlook for complete correction of the deformity is not so good.

Treatment of Foot Strain. *General Principles.*—The object of treatment may be formulated as (1) to correct the abnormal thrust of the line of gravity on the foot so that the weight of the body falls on the foot in a proper relation, and (2) to remove pressure symptoms.

It should be definitely stated at the outset that pain and impaired function are indications for treating these cases. The flat-foot, even rigid flat-foot, the low arch, the everted foot, and the foot with the short tendo Achillis should not be interfered with or treated mechanically in adults unless they are a source of trouble and discomfort. Many people with perfectly rigid feet have served under war conditions without the slightest discomfort. This has an important bearing on the examination of recruits for army service, in indicating that the characteristics of the foot do not necessarily disqualify the man from rendering active service. In this consideration it is definitely understood that the treatment prescribed is only intended for cases with feet which are a source of trouble, with the proviso that certain people are so anxious for cosmetic reasons to minimize the deformity that there may be an occasional exception to the rule just stated.

Treatment in general is required for three types: (1) *Acute, painful feet,* in which the arch has or has not collapsed, (2) *rigid flat-foot,* in which the arch has collapsed and has become rigid, which may be a sequel to acute flat-foot, and (3) *mobile feet,* which are tender when strained, but where muscular correction is possible. The object is to convert the first two types into the third and then follow general principles. It should be stipulated here that all treatment should aim at the restoration of function and not merely at correcting deformity. The measures will be notified somewhat according to the type of foot affected,

and further discussion of treatment will be given in connection with the various types of static deformity. It must, however, be definitely borne in mind that deformity is not corrected until normal active and passive adduction and inversion are secured, for complete mobility is essential.

Treatment of Acute Painful Foot.—This type of foot trouble was formerly often seen in nurses undergoing hospital training. Under present day conditions the average hospital nurse rarely suffers from acute foot strain. The disability may occur in other workers who spend long hours on their feet, and it often follows a debilitating illness.

Treatment.—Rest in the recumbent position is the *first requisite*, as such cases are practically sure to increase if the feet are overused, no matter what treatment is followed. Contrast foot baths should be used in the acute stages, and in convalescence massage and baking as soon as the foot can be handled. As soon as the very acute stage is passed the foot may be splinted and moulded into correct position, or adhesive plaster strapping may be used, which is perhaps less inclined to cause atrophy of the leg muscles. For this the foot is inverted and adducted, and adhesive plaster straps about one inch wide are applied one overlapping the other. These start at the outer border of the foot, pass under the arch and up the leg half-way to the knee. In very acute cases it is well to apply under the strapping a pad of felt filling the arch of the foot. Weight-bearing exercises as a therapeutic measure are not to be advised until the acute stage is over, but active non-weight-bearing exercises may be begun as soon as they can be given without pain. In either type the exercises are to be given to cultivate adduction and inversion of the foot.

Treatment of Flat-foot.—The symptoms in feet where the arch is really flat and nearly or quite touches the ground do not differ essentially from those described, and again it must be repeated that the foot which is flat is not necessarily a painful foot, but one of course unsightly and clumsy, and the gait of such patients is necessarily inelastic, the feet are everted, and in walking the body sways somewhat from side to side.

Real flat-foot is either *congenital*, or *acquired;* the congenital form is of a severe type and not so likely to be painful in later life as is the acquired. Congenital cases are brought for advice largely on account of the extreme unsightliness of the deformity, and the gait characteristic of the affection.

Acquired flatfoot is of two types, *flexible* and *rigid*.

Flexible Flat-foot.—In flexible flat-foot the arch can be largely or wholly restored by manipulation in the non-weight-bearing position, but in standing the arch falls, accompanied necessarily by *abduction* and *eversion*. Adults with flexible flat-foot seek advice either for the unsightly appearance or for pain and discomfort. The symptoms do not differ essentially from those described above. When reposition of the foot becomes impossible, the case must be classified as rigid flat-foot.

The flexible flattened foot in children should be permanently cured and in young adults the outlook is also favorable. In adults after middle life the arch of the foot can be held up and the deformity counteracted by support, but unaided restoration of function and correction of deformity without assistance may not be brought about. There are certain obvious *general considerations* which should be borne in mind in treating these cases if treatment is required on account of pain or unsightliness. These are as follows and are in general directed to removing the cause of strain:

(*a*) If excessive weight is present the weight should be reduced if possible. (*b*) If the general condition is poor and the muscles consequently lax, the condition should be improved. (*c*) If overuse preceded the strain, such overuse should be avoided as far as possible. (*d*) If the patients are children, and are suffering from overwork and rapid growth a remedy of these conditions and a cutting down of activity are indicated. (*e*) If due to unusually bad shoes, better shoes should be worn. (*f*) Mechanical defects of the feet should be sought for, identified if present, and so far as possible compensated.

Tilted Heels.—In general the simplest treatment of cases of this type is to raise the heel of the boot by a wedge one-fourth to one-third of an inch on the inner side, sloping to zero at the outer side, and if necessary place a small wedge on the sole just behind the head of the first metatarsal. This tilts the foot on to the outer border and makes the patient turn the toes in when walking so that the weight comes upon the foot in its position of strength. Cases with strained arches should *never* stand barefooted, or in stocking feet, because every time that weight comes upon the foot, when relaxed in the improper position, stretching of the irritated structures occurs and progress is delayed. Any walking without shoes, as in going to the bath, should be done on tiptoe as then the muscles take the strain, and ligaments are kept relaxed.



FIG. 664.—Side view of flat-foot (right).

Patients should learn to walk with parallel feet, as in this position the muscles which support the arch are active and it is associated with adduction and inversion of the foot which is the position of strength and muscular support. The heel and toe walk which is again the walk of muscular strength should be cultivated. If it is followed, the feet being held parallel and finishing the step from the toes instead of rolling the foot over from the inner side, the position is used in which the arch of the foot is supported against strain by muscular effort. In standing, the weight should be borne on the outer side of the foot, and not with the foot slumped and relaxed. When the stage of irritability has not been present or is passed, contrast baths of the feet in hot and cold water night and morning improve the tone of the muscles and tend to stimulate the circulation in the foot. A strap of adhesive plaster around the scaphoid is often sufficient support to control pain when it exists in walking.

All exercises should be practised in the corrected shoes, because if standing on the bare foot such exercises are apt to end in a slumped position and this is a cause of stretching of the structures on the inner side of the foot which we are trying to strengthen. The exercises which are of the greatest value are those which the patient is easily taught, and are as follows: With the feet parallel he should rise on tiptoe and sink on to the outer side of the foot, he

should walk along a straight line, and be taught to keep his feet parallel when walking, and he should be taught to hold his foot with the arch up and the forefoot adducted and inverted. He should walk in this position as an exercise. Exercises, however, must be used cautiously and, as has been said, not in the condition of acute strain. If the muscles are already tired and irritated from overuse, to exercise them is to irritate them still more, and when the foot muscles have become thoroughly stirred up, the use of therapeutic exercises is to be avoided until they have quieted down.

Foot Plates.—The use of *flat-foot plates* must be discussed. In most countries heavy metal plates are in very general use, with large flanges coming up outside and inside with a view of throwing the foot on to the outer side into a position of adduction and inversion. These plates are too frequently used without attempting to change the balance of the body by building up the shoe, and the question of muscular development is neglected. They chafe and cause calluses in many cases at the inside of the foot, they cause atrophy of the muscles in the sole, and they are not calculated to produce a permanent cure of the condition. Another type of plate that is used is a small arch either of rigid metal, or leather sometimes containing a metal spring; and these are sold by the thousand to people who make their own diagnosis and prescribe their own treatment. It is an unusual thing in private practice to see a patient with foot strain who is not wearing some form of plate or support. The writers are of the opinion that plates are often harmful, although it may be that in very exceptional cases the rigid high plate with two flanges may be necessary. They would feel, however, that with a more liberal use of mobilization under anesthesia, in cases severely enough distorted to require this, the use of such plates would be reduced to a minimum. In heavy adults after middle life with foot strain associated with arthritis of the smaller joints, a carefully moulded light duralumin plate is often most useful.



FIG. 665.—Plate for flat-foot.

Where patients are compelled to use a ready made shoe, sufficient support to the irritable foot is often lacking. In addition to the wedging up of the sole and heel along the inner border, the shank may be reinforced by the insertion of a curved steel strip.

Mobilization.—The writers wish to lay special stress on the complete mobilization under an anesthetic of certain types of painful feet, generally treated as flat-foot. They are by no means uncommon and if not diagnosed and treated are very persistent. They may be static or traumatic in origin. They may be accompanied by limitation of movement or may be apparently quite mobile. They resist every sort of treatment usually applied to flat feet. The feet may be flat but this is not the cause of disability. Two typical cases will identify the type. A middle-aged woman complains that her foot has broken down. She has always had flat feet. There has been no injury but her symptoms began after exceptionally long hours of standing and have lasted over twelve months in spite of an endless variety of treatment. The foot

though flat does not seem abnormal and there are no varicose veins. The pain is chiefly over the dorsum of the foot, along the plantar fascia, and along the front part of the deltoid ligament. The foot is painful on manipulation, especially when it is twisted and she refers it to the dorsum. Again, a young man states that a horse trod on his foot eight months ago, but no bones were fractured. Ever since he complained of pain which at times was very acute. No treatment helped him. His pain was mainly in the dorsum of the foot which at times swelled. Both of these patients were given an anesthetic and the foot, joint by joint, was manipulated and adhesions were felt to give. The manipulation was followed by active exercise in normal boots, the patients being told to walk in spite of pain, and in a few days they were quite recovered.

In all cases of persistent pain of the foot, accompanied at times by a little swelling and resistance to treatment, adhesions should be suspected.

Treatment of Rigid Flat-foot.—This is a serious condition in which the flattened, abducted, and everted foot cannot be corrected either by elevation of the arch or by correction of the other two elements of the deformity. It may rarely be a congenital deformity, it may be a result of overstrain in its acuter stages whether the overstrain is due to unaccustomed exertion in walking, to injury, or to weakness of the ligaments accompanied by mild infection. This emphasizes the need of proper treatment of acute foot strain already alluded to, as, if this important routine is neglected, recovery of the ligaments may occur in a flat-footed position with stiffness in all the joints.



FIG. 666.—Severe flat-foot with abduction. Pressure sores on feet.

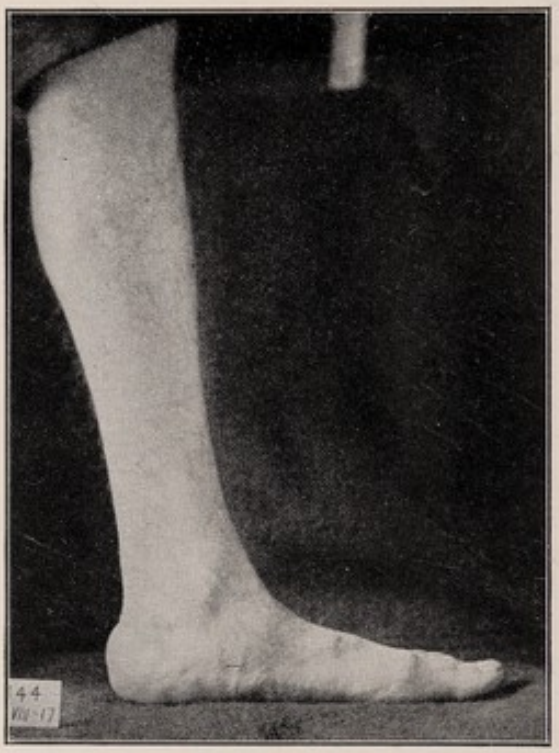

FIG. 667.—Rigid flat-foot.

If accompanied by peroneal spasm the condition is very disabling. The rigid flatfoot without peroneal spasm is not necessarily painful; in fact when the arch is completely on the ground, the pain is likely to be less than when the collapse is partial, as it then gets support along the whole lower surface. Arthritic changes in the way of osteophytes and joint involvement in the mediotarsal joints are frequently observed in the flattened feet of adults, and in these cases the symptoms are particularly persistent. The rigid flat-foot, if accom-

panied by arthritic changes, can be mobilized to a certain extent, but complete unaided function with the disappearance of deformity can be secured only in exceptional cases. In rigid flat-foot without arthritic changes in young persons the deformity can be corrected, and in older persons it can be improved by correction of faulty alignment.

Spasm of the Peroneal Muscles.—This condition was described by one of the authors[1] many years ago, and is by no means uncommon. It occurs usually after puberty and early adolescence, and is common among all classes, but is not particularly associated with a neurotic temperament. The patient walks with rigid everted foot and there is tenderness over the peronei along the outer border of the foot. Pain is marked when the foot is manually inverted, and the peronei immediately firmly contract and strongly resist the effort. If the patient is taken off his guard and his foot sharply inverted—a very painful act—the foot becomes quite relaxed and all rigidity is overcome, to return immediately the foot is released.

For this condition mechanical measures are of little avail. The patient must be anesthetized to relax all spasm, and the peronei should be tenotomised. The foot must then be fixed for about fourteen days, well inverted and adducted at the mid-tarsal joint, and later the ordinary treatment for flat-foot is begun. An alternative method of eliminating the spasm is to crush the musculo-cutaneous nerve (Dunn).

Manipulation.—In painful cases of rigid flat-foot the patient should be anesthetized and the foot made supple by wrenching with the hands or Thomas wrench until it is thoroughly flexible in all directions. It should then be put up in layers of sheet wadding and fixed in a plaster of Paris bandage with the arch well moulded, the foot at right angles to the leg, and the forefoot well *adducted and inverted* for inversion of the foot alone does not accomplish the same object without adduction. That is to say, the foot should not merely be twisted over on to its outer border, but the forefoot should be pushed inward in relation to the hind foot. Unless the reduction by wrenching is complete the foot is likely to be very painful after being put in the plaster on account of unbroken adhesions or incompletely stretched ligaments. If the manipulation is thorough and the foot thoroughly loosened up in all directions this painful tension will be avoided and very little discomfort occur.

By this process the foot is converted into an acute traumatic foot and must undergo the course of treatment described as being of use in that condition (p. 640). The body weight must be deviated from the inner to the outer side of the tarsus, for which purpose an outside iron is often of great assistance in maintaining the correct position of the foot, the heel of the boot being raised on the inner side.

Cases of extreme rigid flatfoot too resistant for stretching, or cases in which arthritic changes in the tarsus render force inadvisable, may require remoulding by operation. This is also applicable to certain cases of congenital flat-foot where the bony changes are extensive. The operation will usually consist in the removal of a suitable wedge combined with the stabilization of the mid-tarsal and subastragaloid joints.

Flat-foot in Young Children.—In young children flat-foot is generally associated with knock-knee or relaxed knees, and the children tread over on the inner side of the boot and are insecure on their feet. In older children

[1] JONES, ROBERT: Med. Chir. Jour., Liverpool, 1905

the deformity presents the same characteristics, but eversion is a more prominent symptom than the complete flattening which occurs in younger children. What is generally noticed by the parents is that the internal malleoli become prominent. In children from eight to twelve the condition sometimes becomes exceedingly painful, but is most often noticed as a deformity rather than as a condition causing disability.

These children may be too young to aid by therapeutic exercises, and although the whole foot is tipped to the outside by the use of the crooked heel, it is occasionally desirable to add some support to the arch. This is provided by a leather sole with a soft felt pad forming one-half of an ellipse, the straight side being the highest, and at the inner side of the foot, running from the base of the first metatarsal to the front of the os calcis, and domed up to raise the arch and hold the foot in adduction and inversion. It is usually sufficient to trust entirely to the crooked heel to deviate body weight from the inner to the outer side of the tarsus and thus leave the sole muscles free from pressure. If knock-knee is pronounced it is necessary to mould the knees into position by manipulation and fix them for some time before allowing the patient to walk.

When the child is old enough to cooperate he should be taught to walk with the feet parallel, never to stand on the bare foot or in tennis shoes, or rubber soled shoes, which have not been properly corrected. The corrected shoe should always be worn even during the exercises.

Short Tendo Achillis

Short Tendo Achillis.—A short gastrocnemius muscle exists in a very large number of people, and in general is not a source of discomfort, but in those cases where it is a source of discomfort it must not be overlooked, but be treated as a condition predisposing to foot strain, as in most cases it entails a flat or everted foot in standing. In the adult, shortening of the tendo Achillis may exist as a structural shortening, or it may be part reflex. In the former case it is apparently an hereditary type of foot, a foot which is better suited for quick action, such as tennis and sprinting, than for long distance running, snow-shoeing and skating. In the reflex variety it apparently occurs as a muscular irritation and shortening due to disturbance in the mechanics of the foot, just as peroneal spasm occurs in other cases. It is, however, less acute than the latter.

The two varieties of this condition are sometimes difficult to distinguish from each other, but the reflex variety is generally manifested by pain on dorsiflexing the foot with the knee extended, cramps in the legs, and muscular tenderness on pressure over the calf muscles. The object of treatment in the reflex cases is to relieve the irritation and so quiet the reflex; and in the structural cases, when they are troublesome, to lengthen the tendon by mechanical means whenever possible.

Reflex irritation is caused by the continual pull on the calf muscles at the end of the step. To relieve this strain the heels of the boots may be raised temporarily, and where necessary other mechanical errors in the foot corrected.

Structural Shortening.—In the other class of cases where the shortening is structural the tendon should be stretched. The mildest form of stretching consists in lowering the heel of the boot or removing it entirely, and sometimes a bar across the front of the sole may be added to increase the pull on the

tendon. This method at first is painful and may have to be abandoned if the pain continues indefinitely, or becomes intolerable. Much trouble will be avoided if the lowering of the heel is done gradually and not suddenly.

In *stretching by manipulation* the leg is extended and the surgeon with his hand on the forefoot and the other hand grasping the ankle, dorsally flexes the foot in the line of the tibia, not allowing it to evert or abduct. When the maximum position has been obtained, the foot should be held there for a few seconds, and the manipulation should be repeated two or three times and will be accompanied by a certain amount of discomfort in the calf and behind the knee. The patients are a good deal relieved by manipulation. At each stretching, a greater amount of dorsal flexion is obtained and increasing comfort is felt which lasts for an indefinite period.

Stretching in Plaster.—A plaster is applied to the foot with the knee in acute flexion. The plaster ends below the knee, the foot is dorsiflexed to the maximum in this position which relaxes the heads of the gastrocnemius, and as the knee is extended, tension comes on the gastrocnemius and it is stretched. If the foot, in spite of this position, remains beyond a right angle with the leg it is wise to follow the course advised on page 642, by removing an elliptical piece from the front of the plaster and pulling up the foot by a strap.



FIG. 668.—Method of testing for normal dorsal flexion of the foot. It is important that the knee should be extended.

A very excellent method of stretching the tendo Achillis in the adult has been devised by Aitken.[1]

Manipulation under Anesthesia.—Manipulation under anesthesia followed by fixation, applied as described, will be necessary in only the minority of cases. After convalescence the patient should be made to walk with a stiffened knee for a while in order to deviate the whole body weight to dorsiflex the foot.

Division of the tendo Achillis by subcutaneous tenotomy or plastic tenotomy is to be discouraged as in most cases it results in a weakened foot, and sometimes the patient may be permanently unable to stand on his toes. It upsets the balance of the foot, and in certain cases the patients walk for a long time after operation with a shuffling gait and an entire absence of spring showing no dependence on the action of the weakened tendon. This operation is particularly harmful and undesirable when performed on young people where the condition is reflex, as this condition will disappear in nearly all instances under the treatment described above.

Where plantar flexion, due to a short gastrocnemius, persists in spite of all measures at relief as already described, and especially where it is associated with a formation of a painful corn or callus under the forefoot, a plastic tenotomy is proper; but these cases are exceedingly few, and the indiscriminate performance of tenotomy for every case of shortened tendo Achillis is to be strongly condemned.

[1] JONES: Orthopaedic Surgery of Injuries, 1921.

There is one abuse to which women subject their feet to which the surgeon's attention should be called. The woman with a deformed foot, the result of years of bad shoeing, has naturally a weak arch, which may not be able to support her weight without pain. But if she puts on a pointed shoe and a high heel the toes are held by the front of the shoe and the foot slides forward on itself, the strain thus being taken off of the muscles supporting the arch, and the arch staying in place without muscular support by having its ends crowded toward each other. If women with weak deformed feet are suddenly put into shoes with low heels and room in front for the foot to spread, it may precipitate a case of acute foot strain. Changes in the shoes in this class of patients should be very gradual and accompanied by strengthening exercises.

The Foot with the High Arch

The foot with a high arch, which is not sufficiently pronounced to be classed as a *claw foot*, is not relieved as is the everted foot by the crooked heel, because the sag is more directly downward upon the structures in the soles of the feet. In these cases raising the arch as described, taking out the piece of steel already in the sole and putting in one which fits the foot, is generally sufficient to afford relief. It must be repeated again that boots are made on the assumption that all feet are alike, and that all feet have a low arch. This expedient just described is intended only to make the boot fit the foot.

CLAW FOOT

The term claw foot is applied to a deformity in which clawing of the toes is combined with cavus and a shortened tendo Achillis. The condition was clearly described by Duchenne[1] in 1863, as one of four types of acquired pes cavus, and was likened by him to the main-en-griffe. The mechanism of the deformity was most carefully studied by Shaffer[2] in 1885 under the title "Non-deforming Club Foot."

Etiology

The exact cause of claw foot is in many cases most obscure, and discussion has centered around the possibility of the deformity arising in the absence of a lesion of the central or peripheral nervous system. For convenience we may describe the following groups:

(1) *Claw Foot in Infantile Paralysis.*—Where there is a definite history of a former attack of acute poliomyelitis, and the limb shows atrophy, paralysis, and shortening, the origin of the deformity is obvious. Marked cavus combined with valgus or calcaneus, but without clawing of the toes, is common in severe residual paralysis of the calf group. But the true claw foot is more frequently seen where paresis is almost negligible, and in fact is often a characteristic deformity in the so-called sound leg. Many explanations of the mechanics of paralytic claw foot have been offered. Duchenne regarded paralysis of the intrinsic muscles and other short muscles of the sole, with over-action and contracture of the long flexors and extensors, as the underlying cause. The ordinary paralytic claw foot tends to reach a certain stage, and then remains stationary.

(2) *Claw Foot in Progressive Lesions of the Central Nervous System,* such as Friedreich's ataxia, peroneal type of muscular atrophy, and other rare affec-

[1] Duchenne: Mem. Soc. de Chir. de Par., 1863, Vol. V, p. 63.
[2] Shaffer, N. M.: Med. Record N. Y., 1885, Vol. XXIV, p. 261.

tions, is a well known clinical phenomenon. The deformity is most frequently bilateral.

(3) *Claw Foot Following Inflammatory Affections.*—A deformity reproducing the various components of a claw foot may occasionally be due to inflammatory contracture of fasciae, ligaments, or joint capsules following cellulitis, fibrositis, or polyarthritis in the adult.

(4) *Idiopathic* (essential) claw foot is an unsatisfactory title applied to the common deformity seen in older children or adolescents where definite poliomyelitis or lesions of the central nervous system can be ruled out. The deformity which tends to be progressive, may be unilateral or bilateral. It has been claimed that this type of claw foot may be produced by mechanical causes alone, such as the prolonged wearing of too short shoes. Whilst it is obvious that improper shoeing may act as a contributory factor, there is little evidence in favour of the existence of a pure mechanical claw foot. In recent years the association of spina bifida occulta with claw foot has attracted much attention (Lance & Rendu, and others[1]). Systematic radiological examination of the lower part of the spine in cases of claw foot has revealed the frequency of such congenital anomalies as bifid laminae of the 5th lumbar and 1st sacral, or sacralisation. In some cases these anatomical variations are accompanied by definite clinical manifestations of spina bifida occulta; *e.g.* troubles with micturition, and sensory disturbances in the lower limbs. It has been suggested that an actual malformation of the cord exists, or that there is some form of pressure on the lower spinal roots due to intra-thecal fibrous bands. The claw foot which accompanies spina bifida occulta is thus of neurological origin.

Clinical Features

Considered as a deformity *per se* claw foot presents five degrees or stages. The deformity may progress from one degree to another but in some cases it is arrested at an early stage. (Jones.[2])

First Degree Claw Foot.—The first degree is seen in childhood and is often overlooked. A complaint is made that the child is clumsy when running and that he frequently stumbles or slips without obvious cause. On examination the foot appears almost normal but it will be found that dorsiflexion beyond a right-angle is impossible and that there is a commencing contraction of the structures in the sole and of the Achilles tendon.

Second Degree Claw Foot.—At this stage there is a more definite contraction of the plantar fascia and the deformity is obvious on inspection. The forepart of the foot is dropped at the mid-tarsal joint, the great toe is dorsiflexed at the metatarso-phalangeal joint, and the tendon of the extensor proprius hallucis stands out prominently. The other toes do not show a similar deformity. It is possible to correct the depression of the ball of the great toe by pressure of the finger. (Fig. 669.) A child may not complain of pain or disability, but in an older patient the foot may give trouble after prolonged walking. Slight distortion of the shoe is often noticed after a short period of wearing.

[1] Lance & Rendu: "Le pied creux," Gaz. des. Hop., 1923, Vol. 96, p. 1377.
Mutuel, M.: Pied Creux Essential et spina bifida occulta, Rev.d 'Orthop., Vol. VII, p. 13.
Josfph, B.: "A Study of Merorachischisis," Amer. Jr. Dis. Childr., April, 1913, Vol. V, p. 285.
[2] Jones, Sir Robt.: Notes on Military Orthopaedics, London, Cassell & Co., 1918.

Third Degree Claw Foot.—In the third degree the characteristic cavus deformity is much more conspicuous, and it is no longer possible with the finger to lift the head of the first metatarsal into normal line. The plantar structures are further shortened. All toes are now dorsiflexed at the metatarso-phalangeal range, flexed at the interphalangeal joints, and are becoming rigid in the position of deformity. (Fig. 670.) Corns and callosities form across the ball of the foot owing to the unequal pressure of body-weight, for at this stage the patient can hardly get his heel to the ground. The Achilles tendon is still more contracted.



FIG. 669.—Second degree, claw-foot.



FIG. 670.—Third degree, claw-foot.



FIG. 671.—Fourth degree, claw-foot.

Fourth Degree Claw Foot.—In the fourth stage, in addition to the deformities already described, the foot usually acquires a well marked varus at the midtarsal joint. (Fig. 671.) Callosities are even more tender and walking is increasingly painful and difficult.

Fifth Degree Claw Foot.—The last stage finds the patient in a most disabled condition. The toes are blue and contracted and the callosities exquisitely tender. A rigid equino-varus deformity is present.

Treatment

First Degree.—In the early stage the plantar structures and Achilles tendon may be stretched by simple manipulation, after which the boot should have a bar half an inch thick placed transversely on the sole under the tread (metatarsal bar).

Second Degree.—Operative correction consists in dividing and stretching the plantar fascia, and then transplanting the extensor of the great toe through the neck of the first metatarsal bone. (Fig. 672.) After completion of the operation the foot should be firmly bandaged to a metal sole plate with a thick roll of wool placed transversely just behind the heads of the metatarsals so as to flatten the arch as much as possible. The foot is now fixed in a rectangular foot splint or in plaster of Paris. The latter is retained for three to six weeks and walking may be allowed. On resuming shoes a metatarsal bar should be used for some months.

Third Degree.—The operative measures are now more drastic. First of all the plantar structures must be divided subcutaneously or detached posteriorly from their insertion to the os calcis (Steindler) (Fig. 673) and the foot wrenched so as to obliterate the cavus. The flexor and extensor tendons of the toes are now attacked and should be tenotomised in turn. This step is often neglected and leads to relapse of the deformity. If full correction is not obtained, a half to one inch of the shaft of the first, second, third, and fourth metatarsals should be removed through separate incisions on the dorsum of the foot. At a later stage a plastic elongation of the Achilles tendon may be needed to complete the correction. It should be emphasized that the tendo-Achillis should never be lengthened in claw foot until the maximum correction of deformity has been obtained by division of the plantar structures and toe tendons. The after-treatment and alteration in shoes follow the lines already described.

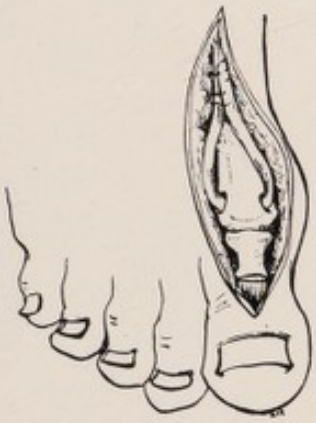

FIG. 672.—Transplantation of the extensor proprius hallucis through the neck of the first metatarsal bone.

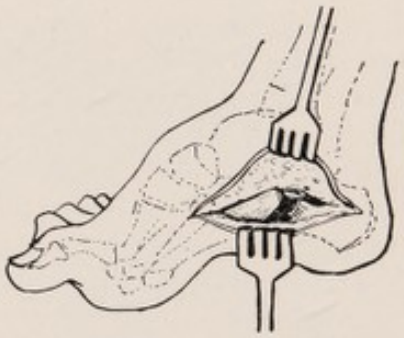

FIG. 673.—Detachment of the plantar structures from the under surface of the os calcis (Steindler).

Fourth Degree.—In addition to free division of the soft parts and wrenching, it will be necessary to remove the head of the astragalus or to arthrodese the mid-tarsal joint after exsection of a bony wedge. In a very rigid foot with bony deformation, a combined midtarsal and subastragaloid correction with shortening of the foot may be advisable. (Dunn.)

Fifth Degree.—The patient often demands amputation but this should be avoided, as an excellent foot may be obtained by the following procedure. The astragalus is first removed and then a flap incision made along the sole. A flap is also raised from the dorsum of the foot and the metatarso-phalangeal range exposed. All toes and the heads of the metatarsal bones are now removed, and the stump covered in by suture of the dorsal and plantar flaps. The scar lies on the dorsal aspect of the foot. The operations above described should be practised only where claw foot is the source of real disability, is progressive, or causes early distortion of all new shoes. The paralytic claw foot which does not ordinarily reach a very advanced stage shows little tendency to relapse after efficient operative correction. In idiopathic claw foot, relapse is seen more frequently but is usually due to partial correction. The question of attempting operative correction in the claw foot of Friedreich's disease or other central nervous system lesions, is a debatable one. In selected cases such a procedure is legitimate.

Affections of the Heel

The painful conditions about the heel most commonly met with may generally be traced to one of three causes:

1. Injuries or strain about the insertion of the tendo Achillis.
2. Spurs of bone and adventitious bursæ under the os calcis. Ostitis and periostitis from direct injury to the os calcis.
3. Traumatic arthritis of the subastragalus joint (see Chapter XVIII).

1. Injuries and Strains about the Insertion of the Tendo Achillis.—These are marked by pain about the back of the heel which is aggravated by walking and relieved by rest, but the pain recurs if the patient is tempted to take exercise too soon. The condition may be divided into three types.

(*a*) *Tenosynovitis*, in which there is swelling due to effusion about the tendon accompanied often by a silky crepitus. This swelling extends some distance up the tendon, and is both palpable and visible. The treatment during the acute stage should consist of rest, which will hasten recovery, but if it is necessary for the patient to go about he can be taught to walk with his leg rotated outward and not to rise on his heel in finishing the step. This method of walking about to a very limited extent can be done without much detriment if the heel is raised temporarily one-half to three-fourths of an inch, and a band of adhesive plaster placed around the tendo Achillis above the malleoli, although the progress will be rather better where a few days of rest can be taken. This condition sometimes becomes chronic in which case the measures described should be persisted in with the addition of massage, contrast baths, and sharp counter-irritation by liniment or cautery. If the pressure of the back of the boot is painful it should be split.

(*b*) *Bursitis* of the bursa under the insertion of the tendon into the os calcis. This is diagnosed by localizing the tenderness at the site of the bursa and by detecting a small area of fluctuation.

The tendon should be relaxed by raising the heel three-fourths of an inch and a strapping applied around the leg above the malleoli to act like the wristlet worn by workmen who have strained a tendon at the wrist. The stiff leather counter of the heel should be removed and the patient should be instructed to walk only a little every day. This condition may become chronic, and the walls of the bursa thickened so that removal is required.

(*c*) *Periostitis* at the site of insertion of the tendon due to strain of the insertion. It must be remembered that in growing children this symptom may be attributed to apophysitis. The diagnosis is made by localizing the tenderness on pressure a little lower down than in the case of bursitis, and by the absence of deep fluctuation in the bursa beneath the tendon. Treatment by rest is the same as for the preceding condition. Both these last mentioned conditions may be present simultaneously and become chronic, and it may be necessary to relieve tension by an osteotomy one-fourth of an inch into the bone. This should never be done during childhood.

Irregular fibrous masses are sometimes noted in the Achilles tendon. These are usually the result of partial ruptures, and if large and persistently painful they should be removed. The tendon should be split longitudinally, the thickened tissue removed and the edges accurately sutured.

2. Spurs, Bursitis, Ostitis, and Periostitis under the Os Calcis.—Spurs of bone running forward into the plantar fascia or short muscles of the sole are frequently seen in skiagrams. They often cause no symptoms, but, on

the other hand, if the patient accidentally jumps on to a stone and bruises the periosteum over one of these spurs, it may become enlarged, or an adventitious bursa may develop over it. In this condition the patient feels pain every time he puts his heel on the ground.

Ostitis and periostitis of the os calcis often arise from bruising of the bone by a jump or fall from a height, or by direct injury from a missile. There may be no gross fracture, but only some crumpling of the lamellæ, which may be seen in a good skiagram. When a fracture occurs, the disability is often due to bone irregularities on the under surface of the bone.

Treatment of Spurs and Ostitis.—The discomfort and often great soreness caused by these conditions is generally relieved by a soft pad under the heel with a hole cut in it over the tender area, or by a metal sole plate, well cupped under the heel. Such a plate must come up into the arch of the foot and take the weight forward in order to relieve the tenderness at the heel.

The existence of osteophytes, as shown by the X-ray, is not necessarily an indication for operation, as in a large number of cases observed, with marked osteophytes and an extremely tender heel, the condition has been relieved by the

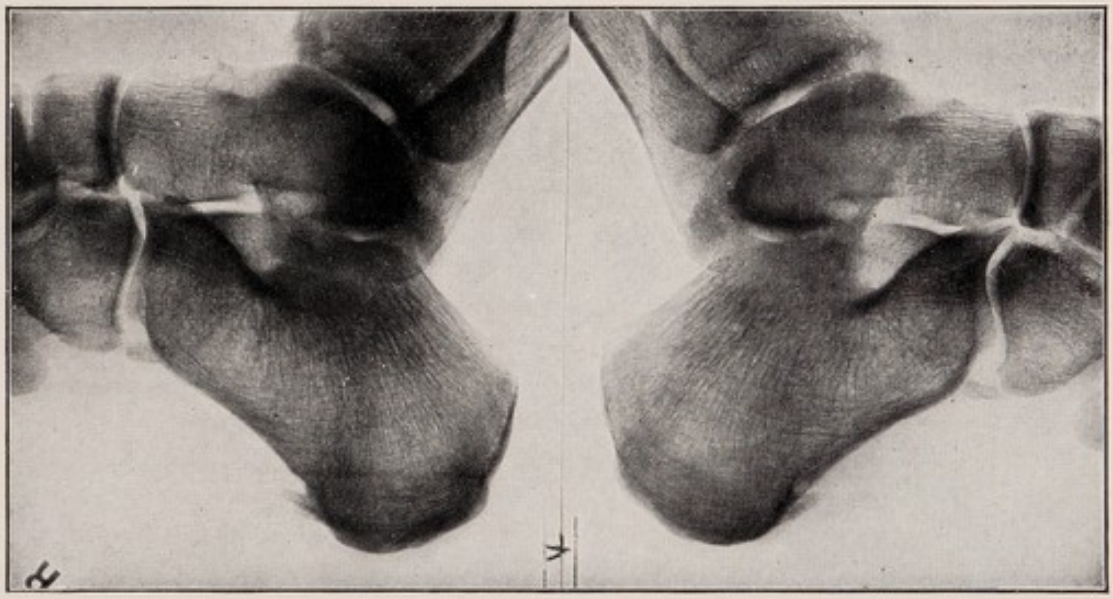

Fig. 674.—Spur under os calcis on both feet; very painful on right; on left no pain.

temporary use of a spongy rubber buffer or cupped plate, after which the patients have been able to wear an ordinary boot. Patients suffering from a painful heel in certain instances are found to have a marked spur under the os calcis on one foot, and also on the other foot one of equally large size which does not give rise to any discomfort. An instance of this is shown in the illustration (Fig. 674).

The operative treatment consists of the removal of the spur. The X-ray appearance of the spur does not give a correct idea of its extent because only the contour is seen in the X-ray. Very often the base covers one inch or one and one-fourth inches transversely across the os calcis. No operation is complete which falls short of the complete removal of the osteophyte and with it some of the bone from which it springs. It can be approached by one of two incisions: (*a*) A semilunar one, which runs posteriorly just below the insertion of the tendo Achillis. The flap is dissected down, the spur exposed at the

origin of the plantar fascia, and the spur with underlying bone is removed by means of a gouge or chisel. The cancellous tissue is then pressed and burnished by means of a smooth instrument to lessen the amount of callus exudation. (*b*) If the spur is not extensive a lateral incision on the outer side of the heel will suffice.

Affections of the Metatarsus and Toes

Metatarsalgia (Anterior Metatarsalgia).—Metatarsal neuralgia, or Morton's disease, was described by Morton in 1876, as neuralgia due to compression of digital nerves between the heads of metatarsals. One of the writers[1] in 1892 investigated the condition independently and found that the sudden severe neuralgic pain characteristic of the condition was due to a compressing of the nerve twigs by the metatarsal heads, which had fallen down out of their proper position in the transverse arch and nipped the nerves between the head of the metatarsal bone and the ground. The anatomy of the forefoot has already been discussed (p. 634).



Fig. 675.—Frozen transverse section of forefoot.

The symptoms are characteristic and definite. The patient experiences a burning, cramping pain in the front of the foot, generally under the fourth metatarsal head, often under the third, and less commonly under the second.

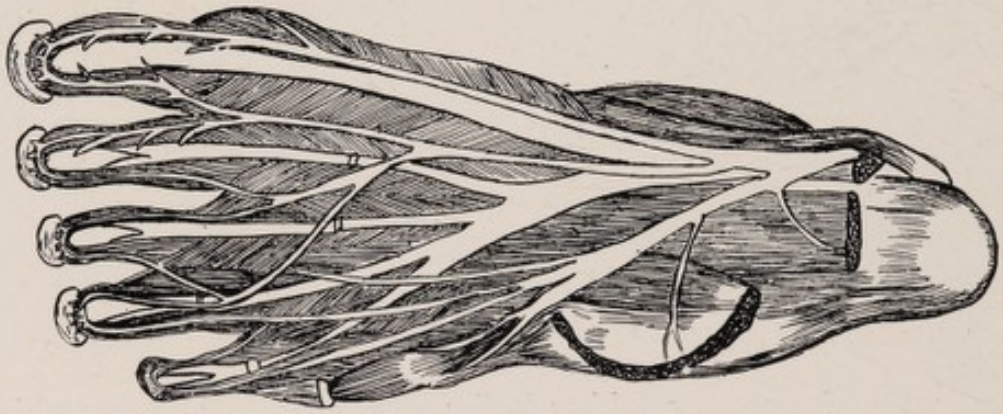

Fig. 676.—Drawing of nerves in sole of foot.

The pain is sometimes preceded by a sensation of slipping. It occurs usually in walking, sometimes in standing, and very rarely in bed. The pain is very intense, and the patient almost immediately learns to relieve it by removing the boot, flexing the toes, and rubbing the front of the foot and squeezing the metatarsals together, while other patients place the bare foot on a cold surface to obtain relief. In the severe cases the suffering is so great that if the patient is seized in the street he will go into a doorway and remove the boot, in order to get relief. The symptom of pain, it must be remembered, is due to a neuritis of the plantar nerve and varies according to the condition of the nerve, sometimes disappearing entirely and again recurring when it receives a fresh injury.

[1] Jones: Med. Chir. Jour., Liverpool, 1897.

Following the acute attack the foot remains tender and painful around the affected area for two or three days. The painful attack is sometimes followed by a numbness in the toe, or a feeling as if a string were tied around the toe. The affection varies from slight discomfort occurring at intervals for which the patient does not seek advice, to frequently repeated and exceedingly painful attacks, which occur as a rule at shortening intervals and become almost disabling. The affection generally exists in one foot, but often slight symptoms are present in the other. A fully developed case in both feet is unusual.

Etiology.—The condition rarely exists without it being possible to find some definite mechanical cause of the flattening of the anterior arch. These causes are in the order of frequency—(1) an everted and abducted foot which causes a disturbance of the forward ends of the metatarsals on account of the twist and abnormal line of weight-bearing in the whole foot, (2) a short tendo Achillis with signs of undue pressure coming on the front of the foot, (3) and the highly arched foot with clawed toes which is rather more prone to the condition than the foot with the low arch.

Treatment.—In the treatment of metatarsalgia a careful diagnosis of the faulty mechanics of the foot should be made to see what defects if any are disturbing its relations so as to cause pressure on the plantar nerve by the heads of the metatarsals. It is most important, whatever measures are adopted for the relief of the pressure of the metatarsals on the nerves, that the main mechanical error of the foot should be taken into account as dealt with in the preceding pages. In order to relieve pain, a bar of leather may be placed across the foot under the tread well behind the head of the metatarsals. This is the simplest method and generally relieves but may not cure. An accurately fitted metal plate shaped to fit the curve of the arch and running forward to a point just behind the heads of the metatarsals should be domed up in front to press into the hollow of the foot behind the heads of the metatarsals. In the majority of cases this will be found to give relief but it must be fitted with extreme accuracy and much adjustment is necessary. The demonstration of its efficiency is made by the disappearance of the pain. A strapping around the forefoot restoring the transverse arch with a pad behind the painful area should be first tried, which will throw light on the possibilities of conservative treatment. In resistant cases the head of the second, third, or fourth metatarsal bone may be removed through a dorsal incision, but even after this procedure continuance of pain sometimes occurs. This operation should be reserved for severe and prolonged cases.



FIG. 677.—Crook long heel and bar behind tread.

When the metatarsal head is removed the surgeon must be careful to see that no spicule of bone is left and that the extensor tendon of that toe is divided and possibly transplanted into the distal end of the metatarsal bone; and when the foot is put up after operation a splint should be placed on the sole of the foot, shaped so as to restore the transverse arch and allow plantar flexion of the metatarsophalangeal joints. The removal of two metatarsal

heads is to be deprecated as it weakens the foot and places too much strain on the rest of the transverse arch. Patients should be kept from walking for three weeks, and when beginning to walk a bar should be placed on the boot as described and a band of adhesive plaster should be placed around the front of the foot to preserve the transverse arch.

Hallux-Rigidus.—The line of gravity normally passes through the second or third metatarsal head in walking. In flat-foot the line of gravity comes nearer to the first metatarsal head, and thus it is made to bear excessive weight. The joint cartilage becomes thin, the head and phalangeal bases are flattened out, lipping manifests itself; in short all signs of osteoarthritis, or joint wear accompanied by stiffness of the great toe joint are present. This is especially



FIG. 678.—Hallux valgus—extreme.



FIG. 679.—Hallux valgus—great toe underneath.

the case in the adolescent and adult who have outgrown their strength. Besides the callous ridge on the inner side of the ball of the foot and heel there is a rigid toe. The pain which is evoked when the tip of the toe is made to bear weight induces the patient to contract his flexor brevis hallucis, which may soon become over fatigued and thus develop spasm, producture of hammer toe or Hallux malleus.

Hallux valgus is in so far related to hallux rigidus that it is often combined with it, yet it is a separate condition. Hallux valgus is a deformity of the first metatarsophalangeal joint, the essential feature of which is that the great toe is deflected outward, and in extreme cases may lie over or under the second toe. Too narrow or pointed shoes, or both, are the mechanical cause, yet only a percentage of those wearing such shoes acquire hallux valgus of a troublesome degree, so that some force has to be assumed besides the injurious effect of the shoes. One cannot but think that extra effort on the part of the

flexor muscles is this deciding factor. The toe being turned out by the boot will be held in that position when forcible contraction of the flexor hallucis longus at each step produces lateral displacement of its tendon. When this occurs it is the beginning of the second stage, that is to say, the stage of the progression of the deformity.

One consequence of this position of deformity is that the head of the metatarsal and the base of the proximal phalanx form an undue angular prominence on the inner border of the foot. As a result of chafing and pressure by the boot, a bursa, or *bunion*, forms over the thinned inner part of the capsule of the joint which may communicate with the synovial cavity. The continued pressure and friction cause the skin over the bursa to become indurated and horny, which greatly adds to the pain and discomfort suffered by the patient. Frequently suppurative inflammation occurs in the bursa (*septic bursitis*) which may be followed by septic cellulitis with inflammatory thickening of the tissues around the joint, or, in cases in which the bursa communicates with the joint cavity, it may lead directly to septic arthritis. It has been a surprise to many surgeons that soldiers have been able to go through their training and even to serve in war with pronounced hallux valgus deformity. The reason is that the disability is not due merely to the visible deformity but to the addition of the following three conditions, of which the first is the most frequent.

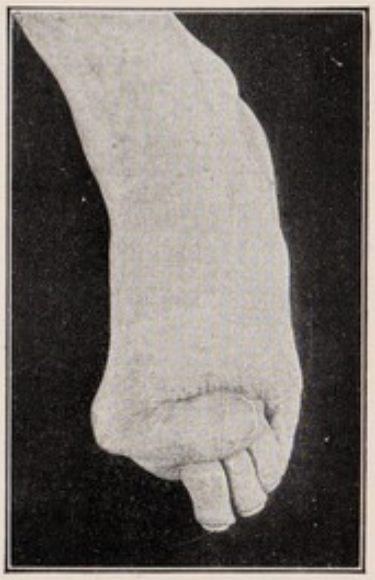

FIG. 680.—Hallux valgus—great toe over (Bradford and Lovett).

1. Inflammation of the bursa (bunion).
2. Traumatic arthritis, of the same type as the arthritis in cases of hallux rigidus.
3. Tenderness due to pressure on digital nerves in every respect similar to the tenderness in a classical case of metatarsalgia or Morton's disease.

Arthritis is more rare, and is usually of the subacute type common in cases of hallux rigidus without the valgoid deformity. It is diagnosed by tenderness and pain on any movement of the joint, even gentle attempts at passive rotation of the toe, and is most acute on lateral pressure.

The third variety, comparable to Morton's disease, is marked by acute pain on oblique pressure on the joint between the finger and thumb, and is due to excessive sensitiveness of the digital nerves and adjacent tissues outside the joint. It is not, as a rule, characterized by any objective signs other than the valgoid deformity, and in cases of hallux rigidus of this variety there is no visible deformity—only tenderness on pressure on the joint. It is difficult to make a sharp division between hallux rigidus and hallux valgus. The same types of pain and disability occur in both. It may, however, be said that with a distinct valgoid deformity it is less common to find rigidity, but that in cases of painful great toe without valgoid deformity—that is, in cases classed as hallux rigidus—arthritis and the resulting rigidity are much more common. Hence the difference in descriptive terminology—but to understand the conditions properly they should be taken together.

Treatment.—Palliative measures may suffice in mild cases. First, the weight of the body should be taken off the joint by putting a bar—like a foot-

ball bar—across the sole of the boot behind the head of the metatarsal; if the boots are specially made, this is worked into the thickness of the sole with a hollow in the sole for the great toe joint or a light metal support to transfer the weight temporarily to the arch. The bar on the shoe will, however, keep a man on his feet who would otherwise be disabled by pain in the great toe joint. The boot should, of course, be straight on the inner side, and the leather of the upper must be full enough vertically and laterally to clear the joint, leaving room for the large head of the first metatarsal. In acute cases of bunion a hole may be cut in the leather of the shoe over the bunion, which can be filled in, by a skilful shoe maker, with a cemented leather patch giving plenty of room, which is not unsightly. Such measures, however, are curative only in the milder cases, and are not applicable to the more severe types.

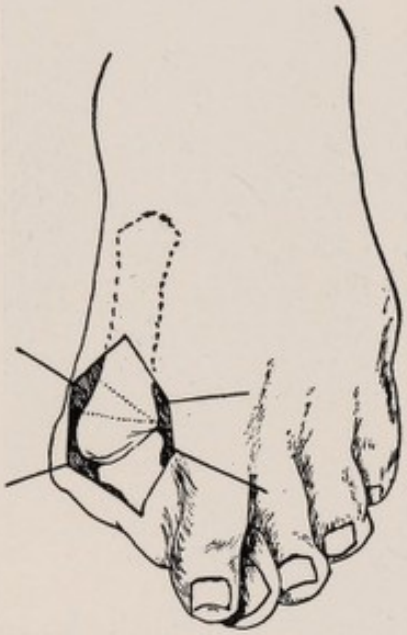

FIG. 681.—Osteotomy of the metatarsal neck.

The aims of operative treatment should be correction of deformity, restoration of movement, and when possible, preservation of the weightbearing portion of the foot. These principles apply equally to *hallux valgus* and *hallux rigidus*. Certain procedures which have often been practised must be condemned at the outset. (*a*) Any reconstruction operation performed when the bursa is actively inflamed, (*b*) complete excision of the joint, (*c*) excision of the bursa without reference to the underlying prominence on the metatarsal head, and (*d*) transplantation of the extensor proprius hallucis to the inner side of the metatarsal head or base of the phalanx.

Four types of operation are worthy of consideration:

1. Removal of the exostosis and bursa.
2. Osteotomy of the neck of the metatarsal.
3. Resection of the metatarsal head.
4. Removal of the base of the first phalanx.

The choice of operation will be determined by the special circumstances of the case. A careful enquiry into the exact cause of the pain and disability should be made. Pain may be due either to persistent bursitis, arthritis of a hypertrophic type, or a combination of both.

I. Removal of Exostosis.—When the deformity is mild and there is no evidence of arthritis, removal of the lateral exostosis and overlying bursa combined with division of the extensor proprius hallucis and joint capsule, is often sufficient to give complete relief. If the displacement can be rectified with little force, a deep suture passed through the structures on the inside of the neck and base of the phalanx acts as a most effective internal splint.

II. Osteotomy of the Neck of the Metatarsal.—This operation is applicable where the deformity is more extreme, but arthritic changes are still undeveloped. The bursa and exostosis are first removed, and then the metatarsal is divided by a linear or cuneiform osteotomy (Fig. 681).

III. Resection of the Metatarsal Head.—This is the operation par excellence for middle aged patients where arthritic and periarthritic changes are well marked. The joint is opened through an incision on the dorso-mesial aspect. A flap from the deep tissues is reflected for interposition at a later

stage (Fig. 683). The shortened capsule on the inner side and the extensor longus hallucis should be divided. The metatarsal head is now cleared and the line of section decided upon.

In young athletic people it is always desirable to preserve the weight-bearing surface of the neck. In the osteo-arthritic joints of later life a freer resection of the head is essential. The stump should be rounded off and smoothed by filling. The sesamoid bones form an excellent buffer between the skin and metatarsal head and should rarely if ever be removed.

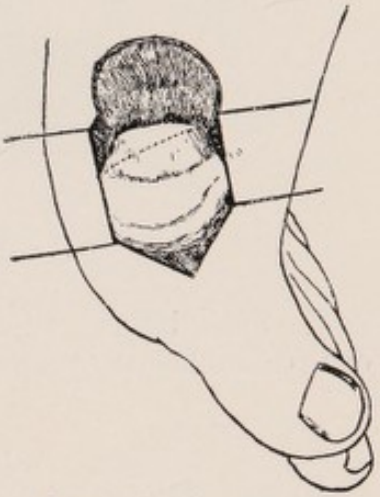

Fig. 682.—Operation for hallux valgus—removal of metatarsal head and interposition of flap.

Occasionally the intersesamoid pad when much hypertrophied may be snipped away. The operation should produce a considerable gap between the stump of the neck and the base of the phalanx. After closure of the wound the toe should be fixed in the position of moderate over-correction by splint or bandage and strapping.

After-treatment.—This is all important. Active movements of the nearthrosis should be encouraged at the end of the second week. Weight-bearing may be allowed after the third week in a wedged shoe with metatarsal bar affixed, and with the metatarsal arch supported by appropriate strapping. The intrinsic muscles of the foot should be stimulated by the faradic current and later graduated exercises given. Carefully performed, the operation of excision of the metatarsal head gives most satisfactory results.[1]

IV. Removal of the Base of the First Phalanx. This operation was suggested long ago by Davis Colley and in recent times has been practised and advocated by Keller.[2] It is eminently suitable for hallux rigidus in younger individuals where the joint surfaces are comparatively unchanged. The operation is simple and consists in the resection of about one third of the phalanx. Its chief merit is the preservation of the integrity of the transverse metatarsal arch.

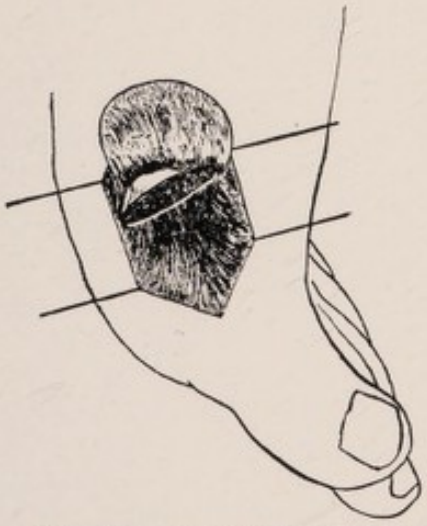

Fig. 683.—Operation for hallux valgus—interposition of flap.

Hammer-toe.—Hammer-toe is a deformity which usually affects the second toe, though it is common to find slighter degrees of the condition in other toes. It consists of flexion of the proximal interphalangeal joint and dorsiflexion of the metatarsophalangeal joint. The prominent knuckle of the proximal interphalangeal joint chafes on the upper of the boot, while the tip of the toe is pressed on the sole. Painful corns naturally develop at these points of pressure, making walking difficult or impossible. The causes are numerous. Sometimes the deformity is congenital, but the commonest cause is the crowding of the toes in ill-fitting,

[1] Perkins, G.: Lancet March 12th, 1927.
[2] Keller: New York Medical Journal, 1912, xcv, No. 14.

badly designed boots. Hence it is common to find hammer-toe associated with hallux valgus.

Treatment.—In the adult, operative procedure is indicated if we are to produce a quick and lasting recovery. Amputation of the second toe should



FIG. 684.—Hallux valgus splint.

not be done, because its absence often increases the tendency to the production of extreme hallux valgus, and leads to a second disability much more serious than the original hammer-toe.



FIG. 685. Hammer toe.

Operation.—The operation found most uniformly satisfactory is a wedge shaped excision removing the articular cartilage on both sides of the joint, so as definitely to ankylose the joint in extension. An oval piece of skin, including the corn, is excised over the prominent knuckle. A wedge, base upward, including the joint, is then excised, of sufficient size to allow the toe to be straightened. The flexor tendon is divided by tenotomy. The skin incision is then stitched so as to leave a transverse linear scar. The toe is fixed down to a toe-splint and the patient walks about, still wearing the splint inside his boot for some weeks, to make sure that solid ankylosis occurs without any return of the deformity.

Some surgeons, when operating to correct the deformity, leave the articular cartilage on one side of the joint in order to obtain a new joint. Experience shows that this is followed by recurrence so frequently that the operation should be condemned as uncertain in result.

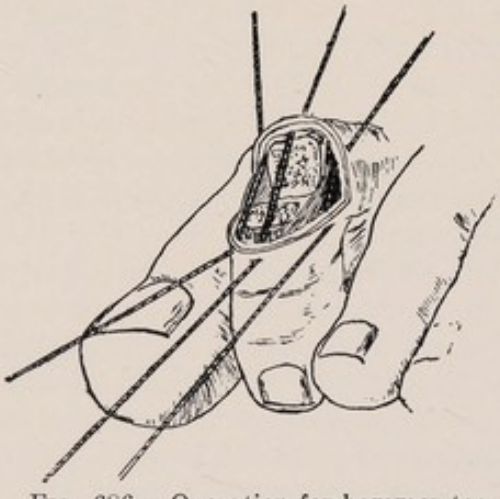

FIG. 686.—Operation for hammer toe.



FIG. 687.—Hallux valgus from amputation of second toe.

Displacement of the Little Toe.—A displacement of the little toe, similar in nature to hallux valgus, frequently occurs, usually as the result of wearing boots which are too tight and too pointed. Occasionally the condition is congenital. The toe is displaced inward either over the dorsal or under the palmar aspect of the fourth toe. In either position it is subjected to undue

pressure in an ordinary boot, and therefore becomes painful. This condition is very troublesome and may be a source of great discomfort.

Treatment.—In children and young people an attempt should be made to correct the deformity by the use of manipulation to straighten the toe, the use of a boot which is sufficiently wide in front, and the application of a small metal splint, to which the toe is strapped. Tenotomy of the dorsal tendons may be of assistance, but amputation of the toe is so simple and effective in most cases that it is generally advisable. In amputating it is advisable to make an ample flap to obviate the result of subsequent contractures and to secure a lax fleshy covering for the bone. If a callosity has formed, no pressure should be allowed upon that area until by rest and treatment it has become soft and normal. If the head of the bone is arthritic and the condition is complicated by exostoses or irregularities, these should be removed. Only in very exceptional circumstances should the head of the metatarsal be removed, for, as pointed out in a previous chapter, this forms one of the points of support on which walking depends.

Vascular Lesions of the Extremities

In the absence of definite skeletal or joint disease, pain, local fatigue, and other subjective phenomena referred to the lower extremities are commonly ascribed to minor static disturbances. In many patients this is a correct interpretation, but in others a careful examination will show that the syndrome is dependent on a circulatory disturbance which at a later stage becomes apparent owing to the development of trophic signs, or gangrene.

The vascular affections which fall into this category may be divided into two main classes (Brown and Henderson[1]):—

1. Functional, or vasomotor disturbances,
2. Organic, or obliterative disturbances.

Functional or Vasomotor Disturbances.—In the functional affections the main arteries remain open, and show adequate pulsation, the colour changes in the skin react well to heat, and the symptoms are frequently seen in all four extremities. The vasomotor disturbances may be dominated either by vascular spasm or dilatation.

I. In the *vasospastic* group, *Raynaud's disease* is the best known affection, and is characterized by a two phase or three phase colour reaction—pallor, cyanosis, rubor—; pain, and trophic disturbances. Gangrene may occur in the later stages, but is by no means a common sequela. Mild or abortive types are recognizable with vasospasm localized to a small area such as a single digit. The majority of the patients are females, and under the age of thirty-five.

II. *Erythromelalgia*, first described by Weir Mitchell, is the most typical *vasodilator* affection. The symptoms are intermittent, and consist in attacks of redness, increased surface heat, and pain and intense burning usually referred to the feet. Abortive types also may be encountered.

Organic or Obliterative Disturbances

Thrombo-angiitis Obliterans.—Though recognized as long ago as 1879, the first accurate pathological and clinical description of this affection was given by

[1] Brown, G. E., and Henderson, M. S.: Journal of Bone and Joint Surgery, ix, No. 4, p. 613, October, 1927.

Buerger in 1908.[1] The disease consists in a progressive obliteration of the large vessels of the lower limbs—both arteries and veins. In some 30 per cent of cases the upper limbs are mildly affected, and involvement of the intra-abdominal vessels has been recorded. In the early stage the affected vessel shows an inflammatory reaction in its walls which is later followed by thrombosis. The occluded artery and adjoining vein may become bound together in a mass of cicatrical tissue. After some time an extensive collateral circulation tends to develop. (Dean Lewis.[2])

The disease is not exclusively limited to the Jewish Race or to excessive tobacco smokers as was formerly claimed. It is found in males over the age of thirty; few female cases have been observed. The chief symptoms in order of onset are:

(1) Claudication—spasm, pain and cramps in the feet brought on by exercise, and relieved by rest; (2) Colour changes in the feet—a reddish cyanosis when the feet are in the dependent position; (3) Trophic changes—localized superficial thrombosis or ulcers; (4) Gangrene.

In the later stages the pain usually becomes intolerable, and is unrelieved by rest.

Arteriosclerosis.—Gradual vaso-occlusion due to arteriosclerosis occurring in elderly patients may give rise to symptoms which bear a somewhat superficial resemblance to those of thrombo-angiitis. Mild claudication, pain on exercise, increasing coldness of the feet, and colour changes are seen in the pre-gangrene stage. Gangrene of the toes in a *diabetic* patient is usually due to arteriosclerosis.

Differential Diagnosis.—Confusion in diagnosis may arise owing to the presence of vasomotor symptoms in the obliterative lesions, but a careful survey of the history, symptomatology, and the results of simple vascular tests should enable the clinician to distinguish between the various types. The main points of resemblance and distinction are well summarized in the following table (Brown and Henderson, *loc cit.*):—

Early diagnosis in vascular lesions of the extremities is of the greatest practical importance, for by timely advice and treatment the onset of gangrene may be long delayed, or even prevented entirely. The possibility of an early vascular lesion should be ever present in the mind of the surgeon when a diagnosis of static disturbance in the lower limbs is contemplated.

Treatment. *Vaso-motor Affections.*—In the mild or localized vaso-spastic lesions treatment is rarely necessary, but the patient should be advised to avoid exposure of the part to severe cold. For fully developed Raynaud's disease little can be accomplished, though in the lower extremities excision of the lumbar sympathetic ganglia has been followed by striking results (Adson). This procedure in common with other operations on the sympathetic system must still be regarded as sub judice.

The treatment of the vaso-dilator affections is on the whole unsatisfactory. During the height of the attack, in erythromelalgia, immersion of the feet in cold water is often a most useful remedy.

Occlusive Affections.—1. In the pre-gangrene stage every effort should be made to stimulate the collateral circulation by means of active exercises, heat, and contrast baths. The patient should be instructed in the care and pro-

[1] Buerger, Leo: Thrombo Angiitis Obliterans: A Study of the Vascular Lesions Leading to Presenile Spontaneous Gangrene, Am. J. Med. Sc., cxxxvi, 567, 1908.

[2] Lewis, Dean: Archives of Surgery, xv, No. 4, October, 1927.

DIFFERENTIAL DIAGNOSIS OF VASCULAR DISEASE AFFECTING THE EXTREMITIES

	Thrombo-angiitis obliterans	Arterio-sclerotic disease	Raynaud's disease and similar conditions	Primary erythrome-lalgia
Pulsation of arteries	Pulseless 50 per cent Diminished 45 per cent Normal 5 per cent	Pulseless 50 per cent Diminished 45 per cent Normal 5 per cent	Normal	Normal
Excessive rubor with dependency	Present	Present	Absent	Absent
Excessive pallor with elevation	Present	Present	Absent	Absent
Claudication	Usually present	Usually present	Absent	Absent
Gangrene	Common	Common	Rare	Never
Rest pain	Usually very severe	Usually mild	Usually absent	Usually mild
Type of rest pain	Sharp, stinging	Aching	Absent	Burning
Appearance of gangrenous ulcers	Moist, inflamed; discharging	Usually dry	Small punched-out areas	None
Superficial phlebitis	30 per cent of cases	Absent	Absent	Absent
Age	Mostly between 25 and 45 years	Mostly between 55 and 85 years	Mostly between 17 and 35 years	Mostly between 30 and 50 years
Sex	Males 99 per cent	Males 90 per cent	Females 95 per cent	Females 70 per cent
Race	Hebrews 50 per cent	Any	Any	Any
Roentgenogram of arteries	Usually negative for sclerosis	Usually positive for sclerosis	Negative	Negative
Colour changes following exposure to cold	30 per cent	15–20 per cent	Always	Never
Temperature of extremities	Low	Low	Low	High
Odema	Frequent	Infrequent	Absent	Absent

tection of the feet, and the dangers of rough and ready nail trimming, corn cutting, and other forms of trauma should be emphasised. Gangrene commonly arises in a small area which has been subjected to injury.

2. In the later stages when trophic ulcers or gangrene are present the problem is more urgent. In *thrombo-angiitis* the severe pain calls for treatment in itself, and often does not respond to the ordinary hypnotics. Complete remission of the subjective symptoms has been observed after the injection of a non-specific protein (*e.g.*, typhoid vaccine),[1] a method of treatment which offers considerable promise. If conservative measures fail, amputation of the painful gangrenous extremity must be considered. Careful pre-operative and post-operative treatment has made it possible for the surgeon to amputate below the knee (Allen and Meyerding). Excision of the lumbar sympathetic ganglia has also been tried in this affection, and in nine cases out of eleven operated on by Adson, pain was completely relieved, and large trophic ulcers were seen to heal.

In *arteriosclerotic* gangrene pain is usually a less arresting symptom. In this disease experience has shown that amputation below the knee is rarely, if ever, practicable. In a diabetic patient under insulin therapy, the mortality and the local results of amputation do not differ from those obtained in the non-diabetic. In a series of five cases recorded by Brooke[2] a low amputation was successful after a preliminary ligature of the femoral vein combined with a periarterial sympathectomy. Sampson Handley[3] and others have also reported excellent results from the last named procedure.

[1] ALLEN A. and SMITHWICK: Trans. Sect. on Gen. and Abdem. Surgery, A.M.A., Minneapolis Meeting, June 11–15, 1928.

[2] BROOKE, R.: British Journal of Surgery, xv, No. 58, 1927.

[3] HANDLEY, W. S.: Lancet, 1922, ii, p. 173.

CHAPTER XXXI

AFFECTIONS OF THE BONES AND JOINTS OF THE SPINE AND THORAX

Anatomy of the Spine

In considering affections of the spine, certain fundamental factors have a definite bearing on the interpretation and treatment of the affections of the vertebral column. Attention will be called to some of the practical points.

Physiological Curves.—These are three in number, (*a*) cervical (forward), (*b*) dorsal (backward) and (*c*) lumbar (forward). The *dorsal* curve is the first to become evident, is present in the quadruped skeleton of most mammals and was found present in 86 per cent of normal children over a year old.[1] In children under six months of age the backward dorsal convex curve includes the lumbar region, but after this age in the majority of cases the *lumbar* curve begins to form at the expense of the dorsal curve. After two years, it is present in a very large majority of cases, but in children who walk late it is late in manifesting itself. Through childhood it remains less marked than in the adult, and in most children between the ages of nine and thirteen the curve is obliterated in the sitting position. It is much less essentially an integral part of the spine than is the dorsal curve, which is shown by the fact that it becomes well manifested only after walking is attempted and is not fixed during childhood. The *cervical* curve is well marked in children at fourteen months in the standing position and persists throughout life. It is formed principally by the intervertebral discs and may be straightened by suspension. The dorsal curve is due chiefly to the shape of the bodies of the vertebræ which are thicker in front than at the back, while the lumbar curve like the cervical is dependent largely on the greater anterior height of the intervertebral discs.

A slight *lateral* curve convex to the right in the dorsal region has long been recognized as occurring in many, if not in most individuals. It extends from the fifth dorsal to the second and third lumbar vertebræ and its cause is not clearly established. It has been attributed to the pressure of the aorta on the vertebral bodies, to right-handedness, and to the greater use of the right side of the body in certain occupations. Its almost constant occurrence suggests a constant cause which is most likely to be aortic pressure.



Fig. 688.—Curves of the vertebral column. *A*, with intervertebral discs; *B*, without intervertebral discs (Fick).

Intervertebral Discs.—These are thicker anteriorly in the cervical and lumbar curves, and posteriorly in the dorsal region. The influence of the discs in the formation of the physiological curves of the spine is shown by the two curves in the diagram (Fig. 688). Curve *A* is formed by the bodies and discs together, and curve *B* is the result obtained by placing the bodies one upon the other, without discs, which forms a long curve with convexity backward, while the lumbar and cervical physiological curves almost completely disappear and the spine forms one backward curve, greatest in the lower dorsal region. This is the reason for the bowed back of old age, and explains why many people who have had round shoulders throughout life, or a moderate scoliosis, begin to have pain and discomfort in the spine in late middle life when the intervertebral discs atrophy, and the bodies of the vertebræ, as a result of the abnormal alignment of early adult life, come more closely in contact, particularly in the dorsal region.

Muscles of the Spine and Thorax.—The spine lies toward the back of a more or less cylindrical muscular tube, of which the abdominal muscles form the front wall. The maintenance of the spine in the upright position by the muscles has been compared to the way

[1] Lovett Davis, and Montgomery: Arch. di. Orth., 1906, v and vi, 372.

in which a flagstaff is held upright by stays reaching from the top of the staff to the ground. Although there is no one muscle reaching from the skull to the pelvis, there is a continuous sheet of muscles each supplementing the action of the others. For example, anteriorly, the sternomastoid runs from the skull to the front of the top of the thorax, the sternum forms a rigid anterior piece and the lower thorax is connected to the pelvis by the rectus abdominis muscle. In the back the continuity of muscular action is shown by the fact that before the top insertion of the longissimus dorsi has been reached, the complexus and transversalis cervicis have begun. The whole conception of muscular action in its relation to spinal movements, body balance, and gymnastic exercises is simplified by remembering the continuity of the muscular tube from the head to the pelvis.

Spinal Nerves.—The points of emergence of spinal nerves through the intervertebral foramina are shown in the diagram and are self explanatory (Fig. 689).

Joints and Ligaments.—The extreme complexity of the structure of the vertebral column itself need only be alluded to.

The vertebræ articulate with each other by ball and socket joints made by the intervertebral discs, in addition to which they articulate with each other and also with the ribs by means of articular processes. The anterior and posterior common ligaments are most important in holding the column together, and the posterior ligament is reinforced in its action by the supraspinous and interspinous ligaments. There are capsular ligaments for each articulation and intertransverse ligaments and ligaments between the laminæ. Every spinal movement will therefore be checked, not by one, but by several ligaments, and the posterior ligaments are much more extensive and effective than the anterior. This is important with regard to spinal injuries.

In addition to this a most important matter in connection with spinal injuries is the intricate and multiple character of the articular surfaces. Taking a thoracic vertebra, for example, at the top and at the bottom of the body is the articulation with the neighboring vertebra. At the top posteriorly are two articular facets, one on each side, for the articular processes. At the side of the vertebra at the top are two demi facets for articulation with the head of the rib, and two facets for the inferior articular process. These articulations are all separate synovial cavities, except that in the intervertebral articulations no true synovial cavity exists, ball and socket movement being accomplished by the compressibility of the discs and especially the *nucleus pulposus* in the centre of each disc. Each thoracic vertebra therefore has approximately ten synovial cavities concerned in its movement, in addition to the intervertebral discs above and below. There are 134 joints between the base of the occiput and the sacrum. This fact is not always remembered in accounting for the complexity and resistant character of spinal injuries. Finally, the importance of the relation of the spinal cord to bony structures surrounding it and of the nerves emerging through the foramina is too obvious to require comment in this place.

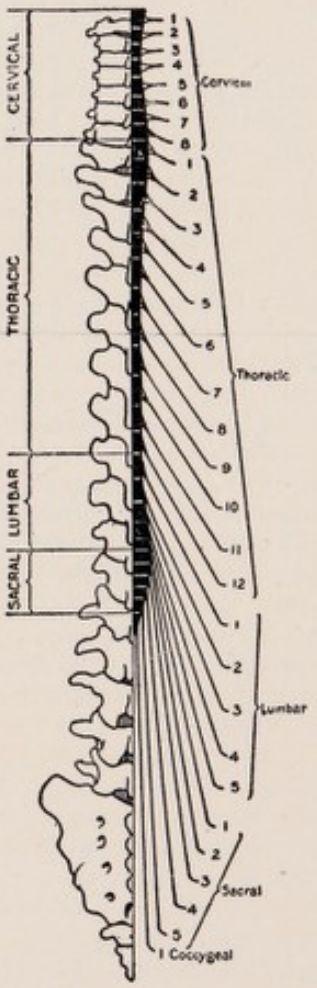

FIG. 689.—Showing the relation of the cord and nerve origins to the levels at which the nerves emerge through the intervertebral foramina—diagrammatic (Gray).

Pelvic Inclination.—The position of the pelvis in the horizontal plane in the erect position would be of importance in connection with scoliosis and faulty attitude if it could be estimated with any degree of accuracy in the living subject. If the front part of the pelvis is lowered and the back correspondingly tilted up it is spoken of as "increased inclination" of the pelvis, and the position is associated with an increase of the lumbar physiological curve. If the front of the pelvis is raised and the back part lowered it is called "diminished inclination", and the lumbar curve is flattened. Changes in pelvic inclination form an important part in the faulty attitude spoken of as round shoulders. The results obtained from measurements of pelvic inclination in the living and from measurements on the cadaver vary from 44 degrees to 60 degrees in men, and in women from 41 degrees to 65 degrees. Some writers make the variation much larger.

In a research on this point,[1] in which one of the writers was concerned the utmost care was taken to establish the variations of pelvic inclination under varying static conditions, but after months of effort with various methods the conclusion was reached that it is impossible to measure the inclination of the pelvis in the living individual with sufficient accuracy to be of any practical value. It would be a fair statement to say that in general the normal inclination was not far from 50 to 60 degrees to the horizontal.

The Movements of the Spine.—The human spine is not an extremely flexible structure taken by itself; much of its apparent flexibility is due to accessory movements between the spine and the head, and between the pelvis and hips. An extreme forward flexion, in the living model or the intact cadaver, with the flexed head, the drooping shoulders, and the rotated pelvis, implies a greater mobility than the spine itself possesses. In comparison to this amount, it is surprising to see in the cadaver how little actual mobility is possessed by the three regions of the spine considered separately, or by the whole spine. The application of this is obvious. If active or passive exercises are given which are intended to take effect upon the spine alone and to be effective there, the pelvis must be fixed. If this is not done, part of the muscular force is used in displacing the pelvis to the opposite side to balance the body, and the movement becomes a general and not a spinal one.

The movements of the human spine are three in number: (1) Flexion, (2) extension, and (3) a compound movement: Side-bending-rotation.

The statement that there are four movements—flexion, extension, rotation, and side-bending—is wholly incorrect, as neither side-bending nor rotation exists in a pure form, as may be demonstrated on any normal child. The statement that such movements exist as pure movements necessarily leads to a false basis for gymnastic exercises and obscures the whole mechanism of scoliosis.

1. *Flexion* (*Forward Bending*).—Flexion is a pure antero-posterior movement. It is the most evenly distributed of all spinal movements, and in extreme flexion in the standing position the outline of the tops of the spinous processes forms a curve approaching the arc of a circle slightly flattened at the top. The movement is most marked in the lumbar region, which in extreme flexion loses most of its forward convexity. The backward curve of the dorsal region is somewhat increased in extreme flexion. In flexion the distance between the seventh cervical vertebra and the sacrum measured along the spinous processes is increased over the same measurement taken in standing or lying. This movement tends to straighten an existing lateral curve.

2. *Hyperextension* (*Backward Bending*).—This movement occurs almost wholly in the lumbar and two lower dorsal vertebræ. In extreme hyperextension a tracing taken over the spinous processes resembles a hockey stick. The dorsal region is but little affected, the physiological curve being only slightly straightened by hyperextension. In this position the distance between the seventh cervical vertebra and the sacrum measured over the spinous processes and following the curve is decreased over the same movement taken in the erect position.

3. *Side-bending-rotation* (*a*) (*Side-bending Element*).—Lateral bending does not exist as a pure movement but is always associated with some element of rotation. In the erect position, side-bending occurs most markedly below the tenth dorsal vertebra, and the dorsal region takes but very slight part in it. In the flexed spine, side-bending occurs higher than in the erect position and in the hyperextended position it occurs lower. In side-bending a rotation of the spine occurs, shown by a twist of the shoulders in relation to the pelvis. This matter is extremely intricate and will not be further dealt with here, except by giving a reference to articles on the subject.[2]

(*b*) (*Rotation Element*).—The rotation part of this combined movement is performed in the dorsal and cervical region, but practically not at all in the lumbar region. Rotation in the lumbar region, however, becomes possible if strong longitudinal traction is applied to the cervical region. Rotation in the flexed position occurs higher than in the upright position and in the hyperextended position lower. The effect of rotation, as well as of side-bending in manipulation and gymnastic exercises may thus be moved up and down the spine according to whether the spine is flexed, erect, or hyperextended. This matter is of much importance in exercises for the treatment of lateral curvature.

[1] Reynolds and Lovett: Jour. A. M. A., March 26, 1910.

[2] Lovett, R. W.: Boston Med. and Surg. Jour., June 4, 1900 to Oct. 31, 1901, Mar. 17, 1904 to Sept. 28, 1905.

Am. Jour. Anat., ii, 4, 457.

Deutsch. Zeitsch. fur. Orth. Chir., xiv.

The following rules may be formulated as practical matters in spinal manipulations and gymnastics:

1. In the lumbar region the flexed position diminishes mobility in the direction of side-bending and rotation, and extreme flexion seems to lock the lumbar spine against side-bending.

2. In the dorsal region the hyperextended position diminishes mobility in the direction of side-bending and rotation. Extreme hyperextension seems to lock the dorsal spine against these movements.

3. In flexion of the whole spine, side-bending is accompanied by rotation of the vertebral bodies to the convexity of the lateral curve, the characteristic of the dorsal region.

4. In the erect position and in hyperextension, side-bending of the whole spine is accompanied by rotation of the vertebral bodies to the concavity of the lateral curve, the characteristic of the lumbar region.

5. The dorsal region rotates more easily than it bends to the side, whereas the lumbar region bends to the side more easily than it rotates.

6. Active rotation movement in the dorsal region is accompanied by a lateral curve, the convexity of which is opposite to the side to which the face turns.

These conclusions are true of the normal spine, but they do not necessarily apply to the deformed portions of a scoliotic spine. The nearer a scoliotic spine approaches the normal, the more likely are they to apply without modification.

Surface Anatomy of the Spine.—If a person stands with the back exposed, a median furrow is seen extending from the occiput to the sacrum. The lower end of the furrow corresponds to the interval between the fifth lumbar vertebra and the sacrum. At the bottom of the furrow the tips of some of the spinous processes can be felt. In the cervical region the furrow lies between the trapezius and complexus muscles, and lower down between the erector spinæ. It is usually most marked in the lower third of the spine.

It is important to identify the spinous processes in many cases. The spine of the *second cervical* vertebra can only be reached by deep pressure in a relaxed neck. The spinous process of the *seventh cervical* is usually quite prominent, but it is not a reliable guide as the spine below it may be more marked. The root of the spine of the scapula is opposite the spinous process of the *third dorsal*, the lower angle of the scapula is opposite the upper border of the *eighth rib* and on a level with the *seventh dorsal* vertebra. The spine of the *fourth lumbar* is on a level with a line connecting the highest point of the iliac crests. The *third sacral* is identified by a line connecting the posterior superior spines of the ilia. It should be remembered, however, that in the dorsal region the tip of the spinous process of one vertebra on account of its obliquity is opposite the body of the vertebra next below it, whereas the tips of the lumbar spinous processes are opposite the corresponding bodies.

The spinal cord in adults ends at the lower border of the *first lumbar* vertebra, but in children at the lower border of the *third lumbar* vertebra.

The curve caused by the forward inclination of the sacrum merges so into the lumbar curve of the spine that the inclination is, on a casual inspection of the back, to assume that the spinal column itself is longer than it really is. If the spines are identified and a mark placed on the skin just below the spinous process of the fifth lumbar it will be found that the spine really ends higher than most people would assume, and this fact must be borne in mind in formulating the antero-posterior attitude. Lordosis is often assumed to exist because one carries in his mind the lumbar curve down at the sacrum. That this matter is of practical importance is shown by the fact that at least three advanced medical students out of four will place the end of the vertebral column proper well down on the sacrum.

SPINAL INJURIES

Spinal injuries fall naturally into two main classes: (*a*) Sprains (ligamentous or muscular), and (*b*) skeletal lesions.

Sprains

Simple sprains of the spine are common and vary in their symptoms in accordance with their site and severity. The symptoms may be immediate, or remote; at times they are those of injury to muscles, or groups of muscles, and no grave consequences follow them. They are produced by external

violence, sudden muscular strain, or a stretching of muscle due to overstretching of the spinal column. They are most common in the more flexible regions, namely, the cervical and the lumbar. They are frequently, however, associated with ligamentous strain and even rupture. If the muscle is alone affected, the symptoms are intensified when the muscle or group of muscles is put into action; it is also increased when the injured muscle is placed under strain by stretching. The onset of pain here is similar to that in other regions. It is sudden and is often described as that following a blow; is increased by

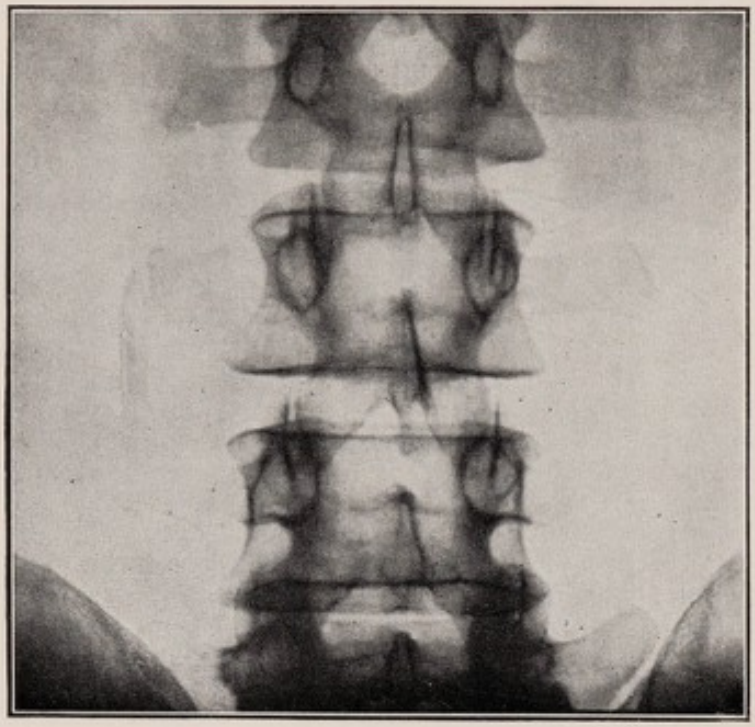

FIG. 690.—Fracture of transverse process of third lumbar vertebra.



FIG. 691.—Method of tripod walking used by cases of fractured spine with paralysis.

certain movements and relieved by rest, but is constantly felt. One can often detect bruising, and sometimes swelling, and pain is elicited by passive flexion and by active extension; passive backward flexion is painless. In lesions which are unilateral, their involvement can be detected by movements which produce stretching on one side. In most cases standing is irksome and often very painful. Severe blows on the head will sometimes cause rupture of the inter-transverse ligaments, producing rigidity and symptoms very like subluxation. In the lower back, muscular and ligamentous strains are often associated with lifting.

Where there is stiffness in motion in injuries of the lumbar region, it is most marked in side-bending and hyperextension, and in the dorsal region in rotation. Some lateral deviation of the spine may be temporarily present. There may be discomfort in coughing and sneezing, and it is painful to ride over rough roads and to experience sudden jars. Pains radiating down the buttocks, thighs and even the calves occasionally occur on one or both sides. In some cases the affection is severe enough to resemble a real sciatica, but the distribution of the pain is rarely that of the peripheral nerves, but rather that of the nerve cords or roots. X-ray appearances are negative.

An accurate diagnosis between a lesion in muscle and that in ligament is often not possible. When a muscle is sprained, it usually means that certain fibres are ruptured and if the pain is long continued it is commonly the result of many additional, but slight, strains before the scar has had time to heal. This means a constant accumulation of fibrous tissue. Pain in ligaments is referred to as a deep-seated pain and it can be elicited both by movement of the spine and pressure with the finger. It is more apt to increase after a delay, and unlike muscle injuries, active movements and passive movements in the same direction give pain. The differential diagnosis is of no great clinical importance as the treatment of both conditions is similar unless a serious rupture of ligaments occurs. If serious rupture of ligaments occurs, cord symptoms may accompany them and this is especially the case where the ligamenta subflava are involved. Injuries of the back, if the symptoms are long continued, are very apt to be complicated with mild septic attacks and, in that case, the pain becomes more diffuse and covers a large area.

The treatment of injuries to the back is similar to that of other joints—at first complete and uninterrupted rest until the acute symptoms have disappeared; later, gentle massage. In muscular lesions the rest should not be encouraged for more than three weeks. In bad ligamentous strain recumbency may be necessary for six weeks and this stage must be followed by a support during walking. In all injuries of the back the intestines should be well cleansed and the diet supervised, both as to quantity and quality.

In another class of cases, however, the symptoms remain unimproved or get worse, the pain takes on a wider distribution, and unconscious exaggeration of the symptoms plays a part.

Functional Spine (Railway Spine)—Traumatic Neurosis of Spine.—With regard to back injuries in general, there is one cardinal point to be remembered. An injury of the back may be attended by more serious, widespread, and demoralizing symptoms than occur in the injury of any other joint. A trauma to the knee is followed by moderate pain, effusion, and localized discomfort. A similar injury to the back is often followed by great pain, rapidly appearing stiffness, and a condition wholly out of proportion to what one would expect from a simple joint injury. The reason for this is probably to be found in the nearness of the spinal cord to the site of the injury; the imperfect fixation after spinal injury; and the participation of the spinal joints in every movement of the trunk, thorax, legs, and arms; and in addition, to a strong psychological element which is apt to be present.

Spinal symptoms, sometimes of a very intractable kind, are apt to follow accidents such as railway collisions, or, as in the late war, burial under earth, of proximity to a bursting shell. It often happens without an ascertainable organic lesion in the spine itself, but usually there are other injuries elsewhere. From the nature of the accident we cannot exclude some shock to the brain and spinal column. Indeed the patient's first complaint is usually of pain in his back. It is, however, certain that in the majority of cases there is an absence of an intraspinal lesion.[1] The condition is best described as a traumatic neurosis which is a simulation of an organic change in the nervous constituents of the cord. In many cases there are distinct early evidences of injuries to the ligaments and muscles of the spinal column, resulting in rigidity and pain. The mental shock, however, causes much depression and this is

[1] PAGE: Concussion of the Spine, Treves' Surgery, ii.

more evident if the spinal pains increase some time after the accident. The pain is usually not especially localized, and is often of a radiating character. It may be accompanied by a partial rigidity, or the spine may be completely fixed. Sometimes the patient may complain of one or more spots which are tender to the touch and, at other times, large patches of hyperesthesia are present. His legs may become weak, and fecal and urinary incontinence may appear. All this inspires the lay mind with fear of impending paralysis.

During the development of these symptoms the surgeon will have an opportunity in various ways to note lapses of rigidity in the movements of the spine. This affection is often accompanied by neurasthenia. The patient aches in every part; the extremities are cold and clammy; he is weak, depressed, and often complains of a heavy and constant pain at the back of his head. He usually takes to his bed; sleep forsakes him; he is oppressed and depressed, irritable and hopeless; and he loses all power of concentration. Faults of digestion lead to malnutrition, which again affects the nervous system harmfully. Added to this condition at times is found a state of traumatic hysteria, carrying in its train functional paresis, illusions and semi-unconsciousness.

In a class of cases less severe, if litigation is pending, or if the patient is neurasthenic, the subjective symptoms are likely to be marked. Pain is often complained of as intolerable and its distribution is erratic. The symptom complex is often obscure and will tax the skill and steadiness of the most experienced surgeon. These cases figure largely in law suits and one has only to listen to the medical testimony given in regard to them to realize how little this condition is understood by the average expert.

A minor, but sometimes a very persistent, form of traumatic backache must be mentioned here. This is the so-called *post-operative backache* where, after the performance of a major operation the patient experiences a great deal of pain and discomfort, especially in the lumbar region. Most normal individuals who are put to bed and compelled to lie on their backs because of some accident or illness, on the second or third day experience a dragging lumbar backache, which is relieved in a measure by supporting the lumbar spine and flexing the knees. It is apparently due to the tendency of the body weight to drag upon and irritate the posterior structures in the region of the lumbar curve. Post-operative backache is apparently an exaggeration of this condition in that the patient is relaxed by anesthesia and laid on a hard table without support to the lumbar spine. A pad under the lumbar spine is the best means of combating this disagreeable complication, and such support of the lumbar spine when the patient is first put to bed, and especially while under the influence of anesthesia, should be borne in mind. Massage and change of position, when possible, are also of assistance.

The *diagnosis* of traumatic backache is often beset by difficulties. Fracture is detected only by an X-ray of the highest grade, a poor picture being worse than useless. Arthritis deformans is a possibility in the future and, if it existed in the past, it will have been evident. If arthritis of the formative type is present, the osteophytes will show in the spine, but the elimination of this condition is one of the minor difficulties.

One of the principal difficulties is to separate the *organic* from the *functional* element of the condition. In the case of two patients who receive similar injuries with apparently similar lesions, one may recover in a few weeks, while the other becomes a bedridden invalid. This has been spoken of above.

The latter type is familiar to all practitioners as the "spinal invalid." A typical case in the experience of one of the writers is as follows: A woman in the country had been in bed two and one-half years. No lesion could be detected, and the X-ray was negative. The treatment finally adopted consisted of massage for a fortnight, followed by a gentle endeavor to break adhesions under anesthesia. This was in addition to psychic treatment, and the patient was walking well in three weeks.

Spinal neurosis can be diagnosed from an organic lesion by the usual signs. With cold limbs and sluggish circulation, nutrition is barely affected. The deep reflexes are never absent; the complete paraplegia is often dissociated from bowel or bladder, and the loss of sensation does not follow an anatomical nerve distribution. Not infrequently the same train of symptoms is observed following a shock where no injury to any part of the body has occurred.

Yet in making a diagnosis we should guard against the fallacy of assuming that, because we can find no organic lesion, it is absent. The so-called "functional" or "neurasthenic" spine has most often some structural basis.

The clinical picture of a case of the milder type of functional and neurasthenic type will be found in an under-nourished and nervous woman who has generally received some injury to the back, although this is not necessarily the case. The pain in the spine is complained of as intolerable, and sometimes accompanies the slightest movements. It is often not in evidence until some hours after such movements have taken place. Some stiffness of the spine is present and, as a rule, the standing attitude is guarded and the lumbar spine flattened somewhat. Spasm of the erector spinæ muscles may or may not be present in attempted motion. There is an attitude of extreme apprehension, and introspection and self-pity are prominent, often under the guise of great repression. A useful keynote in detecting the functional element in these cases is found in the contradictory character of the symptoms. The degree of pain complained of is often extreme, but if the attention of such patients is diverted, they can perform movements which they will not do when asked. It is a mistake to regard this exaggeration of symptoms as conscious and wilful, although this element may be present; but in the majority of cases the patient is convinced that she is the victim of horrible suffering, that the outlook is practically hopeless; the case, unique; and her family and friends, unsympathetic.

The *prognosis* as to recovery in simple back strain should be as good as in that of other joints if we bear in mind two conditions. (1) If the patient is muscularly weak, round-shouldered, and stands in a bad attitude, recovery is likely to be slower than in a normally balanced individual, on account of the fact that in a bad attitude the back is more vulnerable than when the attitude is good, and (2) any degree of neurasthenia, or tendency to exaggerate on the part of the patient is a very unfavorable matter in formulating the prognosis. If the symptoms are contradictory and confusing, and the picture is not a consistent one, the chances are very strong that there is a definite neurasthenic element.

Treatment of Sprains.—Immediate recumbency is required for the most severe cases and strapping of the spine with adhesive plaster is the best immediate treatment, but if movement is very painful, recumbency on a bed frame with pads under the lumbar region is advisable. Later, motion should be restricted by means of a fixation corset of cloth, or if the pain is in the upper part of the spine, a cloth corset and light steel back brace. In the later stage

of the case, measures to restore circulation, such as massage and passive movements, under anesthesia if necessary, to break adhesions and restore spinal motion, are essential. As soon as possible, movement must be encouraged and bed forbidden. Our experience of similar conditions occurring during the war will be very helpful here. Optimism, explanation, and re-education are the essential factors. A traumatic neurosis is usually considerably affected by apprehension in regard to the future and many cases improve considerably, or recover, after the worry of litigation is over. This is what we should expect from the nature of things and is no proof of a malingering element.

The Breaking Down of Adhesions.—If chronic backache persists, in the absence of spinal arthritis, the symptoms of which have been described, we must suspect the presence of adhesions. In these the sites of pain are usually about the seventh cervical vertebra, the dorsolumbar junction and also over the fifth lumbar vertebra and sacrum, often over one of the posterior iliac spines.

These adhesions could be prevented if, after the abeyance of active symptoms in trauma of the back, graduated exercises and movements were practised. Surgeons are apt to regard the back which is very painful on certain movements to be the seat of an actual inflammatory lesion, but the test available elsewhere holds good here.

The painful area having been marked, the patient is placed upon his back with the knees and thighs flexed, the pelvis is lifted and rolled forward rounding the spine to the full extent of its movement. From the first position the spine is bilaterally deviated to its full range. It is next rotated by means of the leverage exercised by the flexed limbs and pelvis. The first movement is hyperextension. If an assistant places his hand over the painful spots he will often feel and sometimes hear the adhesions giving. The manipulations should be followed by very active exercises.

Skeletal Injuries

Injuries of the bony skeleton of the spine may be divided into three groups: (1) fractures, (2) dislocations, and (3) fracture-dislocations.

General Mechanism

The great majority of spinal fractures occur as the result of force applied at some distance from the level of the injury (indirect violence). On analysis this violence may be resolved into two component forces: (*a*) compression of the vertebral column in its longitudinal axis, and (*b*) hyper-flexion of the spine. Fractures due to direct violence are comparatively uncommon, except under warfare conditions, and are usually confined to localised injuries of the spinous processes or neural arches.

The spine is composed of two bony columns differing in structure and function. The anterior column consisting of spongy vertebral bodies and elastic intervertebral discs, is more compressible than the posterior column formed by the intervertebral articulations and neural arches. The brunt of the compression-flexion force falls on the vertebral body, which collapses under the stress. If the force is expended at this stage, a crush fracture without actual displacement results. If, however, the force continues to act, the intervertebral disc is torn, the pedicles give way, and the forward dis-

placement characteristic of a fracture-dislocation occurs. In many cases the displacement is momentary, and is followed by recoil. The great majority of spinal fractures occur at two main levels: (1) in the lower cervical region; and (2) in the dorso-lumbar region.

In the *cervical region* spinal fractures are usually caused by violence applied to the head, the most important injuries being (*a*) fracture-dislocations or compression fractures at the level of the fifth or sixth cervical vertebra; and (*b*) fractures of the atlas and axis.

In the *dorso-lumbar* region, fractures result from force applied to the upper part of the spine and shoulders. Compression fractures of the body are much more common than the complete fracture-dislocation, and constitute at least 40 per cent of all spinal fractures.

Fractures of the sacrum are occasionally seen after falls on the buttocks.

Compression Fractures

The majority of these injuries occur in adults in the active period of life, and are sustained in sport, road accidents, or certain industries (coal mining). A few examples are on record of compression fractures in children. Falls from a height and blows on the upper part of the spine are the usual causes. In the great proportion of cases one vertebral body only is crushed, and in 50 to 60 per cent, this body is the *twelfth dorsal* or *first lumbar*. Uncomplicated compression fractures are rare above the level of the fifth dorsal.

Clinical Picture.—The *early* symptoms may be masked by those of general shock or of more painful accompanying injuries of the soft parts, or fractures elsewhere. Pain in the back in the region of the lesion, localised tenderness, and limitation of motion are fairly constant, and careful inspection may reveal a small localised knuckle or kyphus. This combination of signs occurring after an injury in which there has been a forced hyperflexion of the spine, should always give rise to the suspicion of compression fracture. The final diagnosis will depend on radiographic evidence and particularly the appearances seen in lateral skiagrams. The affected body will show a localised irregularity or indentation, or may be definitely wedge-shaped (Fig. 692). Kümmell,[1] Fosdick Jones,[2] and others believe that in some cases collapse of the vertebral body does not occur at the time of the injury, but develops gradually after an interval of some months. In compression fractures which have escaped recognition and treatment in the early stage, the *late* onset of symptoms is well recognised. Before the advent of radiology this clinical syndrome was described by Kümmell under the title spondylitis traumatica.[3] The symptoms, which consist in backache, spinal rigidity, and a localised kyphus, may not be conspicuous until months or years after the original accident. In lateral radiograms at this stage the wedge-shaped body is always a conspicuous sign, and there may be traces of a bony bridge connecting the injured vertebra to the body above and below. The differential diagnosis from Pott's disease, spondylitis, or vertebral tumors is usually simple.

Treatment. 1. *Early Stage.*—When the diagnosis is established, the patient should be treated in recumbency for a period of eight weeks, with the spine hyperextended. The upright position should be assumed gradually, and a supporting brace worn for a further three to six months. Under such

[1] Kümmell: Arch. f. Klin. Chirurg., 118, 876, 1921.
[2] Jones, Fosdick: Jnl. Amer. Med. Assoc., 81, Dec. 1, 1923.
[3] Kümmell: Deutsche med. Wchnschr., 1895, No. 2.

conditions a restoration of full activity and wage earning capacity can be predicted. The large series of end results reported by Wallace,[1] Thorndike,[2] Rogers,[3] Osgood,[4] and others, has proved quite conclusively that after conservative treatment alone, patients are able to return to heavy labouring occupations such as coal mining.

2. *Later Stages.*—In patients with painful weak backs and a definite kyphosis, a period of recumbency with fixation may often bring about considerable relief of the symptoms. This should be followed by the use of a spinal brace on return to work. In many patients a more rapid method of treatment is often demanded, and for these the operation of spinal fusion as in the treatment of Pott's disease, has given most gratifying results.

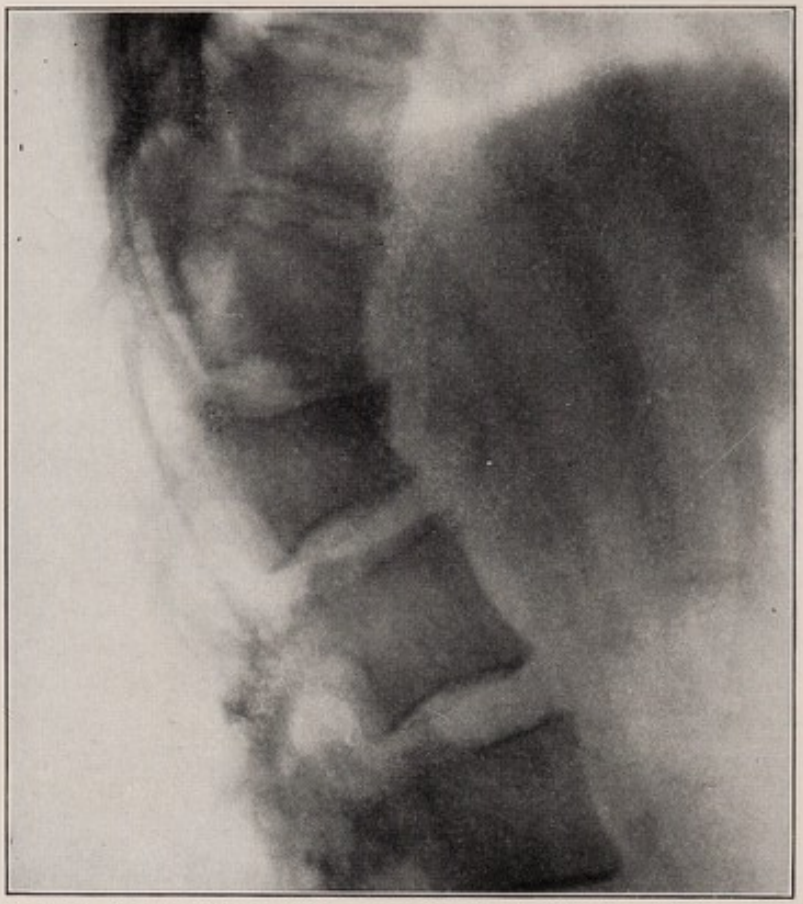

FIG. 692.—Compression fracture of the second lumbar vertebra (C. Thurstan Holland).

Fracture-dislocations with Cord Involvement

Fracture-dislocations occur most frequently in the lower cervical and dorso-lumbar regions. At the former level, forward displacement of the vertebral body tends to persist (Fig. 693), but in the lower part of the spine immediate recoil is the rule. The injury to the nervous structures may involve (*a*) the cord proper, or (*b*) the nerve roots. Injury to the spinal cord is usually the result of actual bony displacement, and is coincident with the bony injury. The cord may be contused, torn, or, more rarely, completely

[1] WALLACE: Jnl. Bone & Joint Surg., v, 28, Jan. 1923.
[2] THORNDIKE: Acta. Chir. Scand., lvii, 339, 1924.
[3] ROGERS: Boston M. & S. Jnl., 193, 494, Sept. 10, 1925.
[4] OSGOOD: Jnl. American Med. Assoc., 89, Nov. 5, 1927.

transected. In the milder lesions there may be a transitory oedema, or haemorrhages of varying size may occur in the cord itself (haematomyelia), or in the spinal theca. Destruction of nerve tissue and consequent degeneration of nerve tracts is seen in the more serious lesions. At a later stage meningeal thickening and adhesions (meningitis circumscripta serosa) may develop.

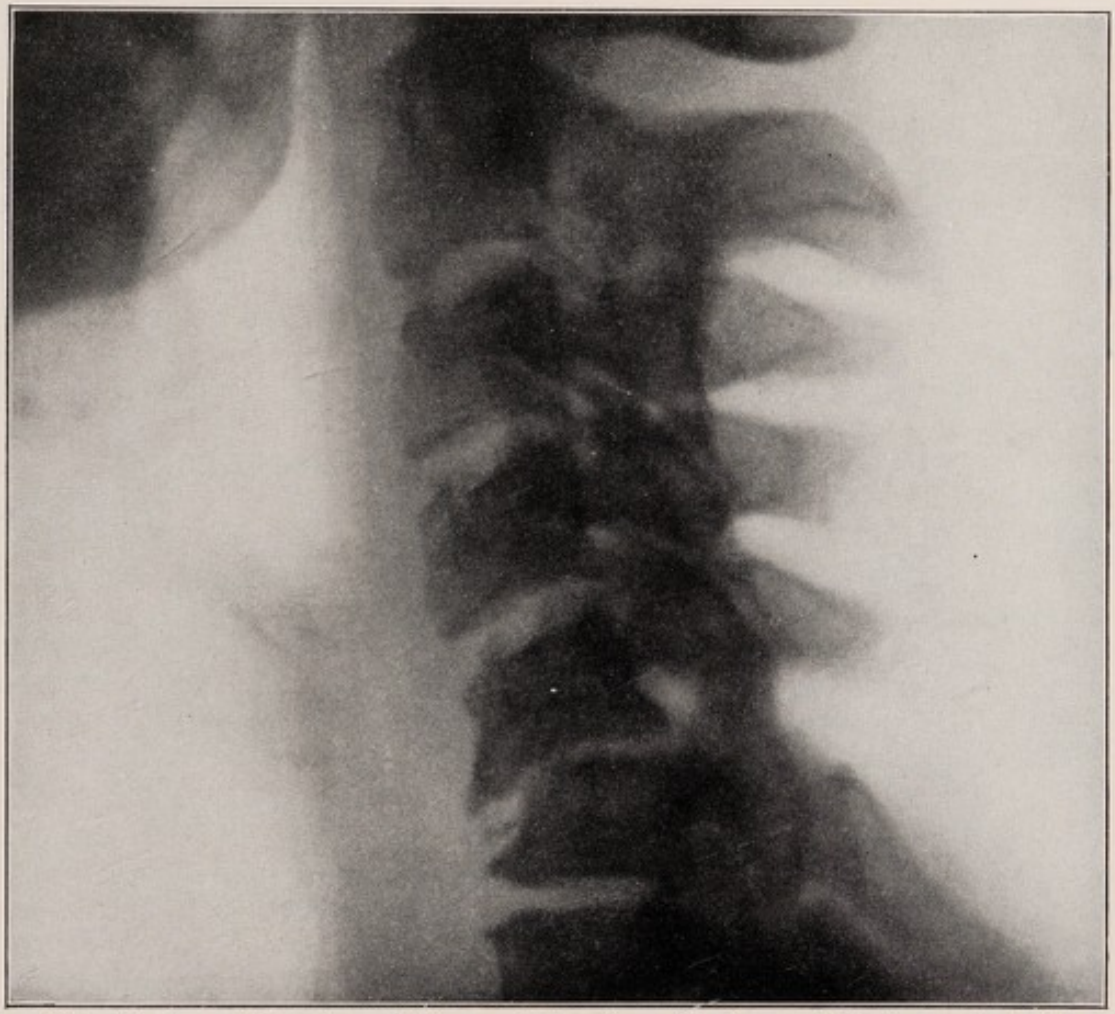

FIG. 693.—Fracture dislocation of the cervical spine, with forward displacement of the fifth cervical body on the sixth (C. Thurstan Holland).

Symptomatology.—The patient exhibits the ordinary localising signs of spinal fracture, viz., pain, tenderness, and deformity. Owing to the conditions under which the accident takes place, coexisting injuries of the limbs and trunk are not uncommon, and severe shock is likely to be present. The neurological picture varies in accordance with the level and extent of the cord injury. Several clinical types may be distinguished:

1. *Severe Paraplegia.*—Three stages are recognised (Head and Riddoch[1]):

(*a*) The stage of *spinal shock* in which the symptoms are those of complete spinal block—flaccid palsy, loss of sensation below the level of the lesion, and retention of urine and faeces. Reflex action is almost entirely suppressed; in the lower limbs the knee jerks are absent, but the plantar reflex is often retained, and may show either a flexor or an extensor response. There is also a complete loss of sweating in the paralysed area. This stage lasts from two to

[1] HEAD and RIDDOCH: Brain, 1917, Vol. xl.

six weeks, and does not necessarily indicate that the cord has been completely divided.

(*b*) The stage of *reflex activity*. As the effects of the spinal shock pass off, reflex function returns. The deep reflexes reappear, and with them involuntary spasm of the limbs. There is also a gradual development of automatic micturition and reflex defaecation. At this stage the "mass reflex" may often be elicited, a flexor spasm of the lower limbs, accompanied by reflex emptying of the bladder, excited by pinching or tickling the skin of the legs. The reflex stage may remain unchanged for years in patients who are carefully nursed.

(*c*) The stage of *failure of reflex activity*. If complications develop, whether pulmonary, urinary, or bed sores, the reflex function of the cord is liable to disappear, and the stage of complete spinal block is reproduced.

2. *Incomplete Paraplegia.*—In less severe cord injuries the stage of spinal shock may be absent, short, or incomplete. Spasticity of the limbs of the extensor type is sometimes seen, with the hypertonus affecting chiefly the glutei, quadriceps, and extensors of the foot. Return of power and sensation occurs to a variable extent, and control of the sphincters is often reestablished.

3. *The Brown-Séquard syndrome* may be demonstrated in the early stage in some of the slighter injuries, either as a transitory phenomenon, or as a permanent feature where a marked haematomyelia has occurred.

4. *Nerve root involvement* is often overshadowed by the signs of cord injury in the early stage, but in the cervical region is more easily recognised by the anaesthesia and palsy of the lower neuron type affecting the upper limbs.

5. *Cauda Equina and Conus Medullaris Involvement.*—The syndromes of these conditions require investigation of the sensory and motor fields.

Diagnosis.—In the absence of definite clinical and radiographic evidence, the exact level of the fracture may be in some doubt. The site of the cord lesion will then be determined on neurological grounds. The spinal cord ends opposite the lower border of the first lumbar vertebra, so that the segmental levels of the cord do not correspond numerically with the vertebral spines. A simple but rough method of ascertaining corresponding levels introduced long ago by Chipault is in common use, and may be conveniently tabulated here.

Cervical region	Vertebral spine plus 1 = cord segment	*e.g.* 4th spine opposite 5th segment
Upper dorsal region (1–6)	Vertebral spine plus 2 = cord segment	3rd dorsal spine opposite 5th dorsal segment
Lower dorsal region (6–12)	Vertebral spine plus 3 = cord segment	6th dorsal spine opposite 9th dorsal segment
Lower three lumbar segments (3, 4, 5) are opposite—11th dorsal spine		
Sacral segments are opposite—12th dorsal spine		

The segmental level of the cord lesion is defined by careful charting of the upper limit, not of complete analgesia, but of sensory impairment, and the distribution of the flaccid paralysis. Pain and hyperaesthesia of root distribution, if present, give most valuable assistance. Such sensory and motor

phenomena are more easily demonstrated in the limbs than in the trunk. In spinal injuries as a whole certain syndromes are well recognized:

(*a*) *Lesions of the Cervical Enlargement.*—In a complete cord injury above the *third cervical* segment, death results almost immediately from respiratory paralysis. In cases of survival when the third and fourth segments are damaged, paralysis of the sterno-mastoid, trapezius, and diaphragm may be demonstrated. In injuries of the *fifth cervical* segment respiration is carried on by the diaphragm alone, all four limbs are paralysed, the upper limit of analgesia is at the level of the second costal cartilage, and signs of interference with the oculo-pupillary fibres are present. With the lesion at a lower level, when the fifth and sixth segments are intact, a characteristic position of the upper limbs is assumed: the arms are abducted and rotated out at the shoulders, the elbows flexed, and the forearms supinated (Thorburn[1]).

(*b*) *Lesions of the Lumbar Enlargement.*—When the twelfth dorsal and first lumbar segments are involved, the lower parts of the abdominal muscles are paralysed, and the lower abdominal reflex is lost. If the first lumbar segment is intact, the upper limit of sensory impairment runs just below and parallel to Poupart's ligament. In lesions of the lower part of the lumbar enlargement, with the fifth lumbar segment as the upper limit, the line of demarcation between normal and abnormal sensory areas is easily demonstrated.

Prognosis.—The mortality in spinal fractures with cord involvement is necessarily high, for a considerable number of patients die within the first few days from shock or from the effects of accompanying injuries. Of those who survive the initial stage, some die during the first few weeks from complications—pneumonia, bed sores, or infection of the urinary tract. Patients who reach the stage of recovery of reflex function may last for many years with a complete transection of the cord. In the less severe cord lesions the prognosis is favourable as regards duration of life, and useful function may develop in the paralysed limbs.

Treatment. (*a*) *Immediate.*—The patient should be placed on a firm stretcher, and transported from the scene of the accident with the greatest care. On arrival in hospital he should be put on a firm mattress, and the initial shock treated on the usual lines.

In injuries of the *cervical* region, where the radiogram shows a persisting forward displacement, reduction should be attempted by manipulation. The method used by A. S. Taylor[2] of New York with considerable success is as follows: The patient is carefully placed on a fracture table (*e.g.* Hawley table) and an ordinary suspension halter applied to the head. A stout line is attached to the side rings of the halter and is passed round the waist of the surgeon. Traction on the head is exerted by the backward thrust of the operator's body, whilst the neck is firmly controlled by his hands. Counter traction is maintained by fixing the lower limbs in the usual way. Traction is first made with slight flexion of the spine so as to unlock the articular processes, and when the neck is felt to elongate, the head and upper part of the spine are allowed to drop gently downwards. When reduction is confirmed by clinical tests and by immediate radiography, a plaster of Paris jacket is applied holding the head and neck securely. In this the patient is nursed in recumbency for six weeks or longer, and a light removable brace with collar is substituted later.

[1] Thorburn, W.: Surgery of the Spinal Cord, 1889.
[2] Taylor, A. S., Archiv. of Neurol. and Psych., Dec., 1924.

In fractures in the dorso-lumbar region, such manipulative efforts are rarely necessary.

(*b*) *Nursing.*—A careful régime for the care of the skin should be instituted. In some patients the bladder may be emptied regularly by pressure, but more often catheterisation with a meticulous aseptic ritual is indicated. Suprapubic cystostomy with drainage has been advocated as a method of preventing the onset of cystitis, but has not found favour with the majority of surgeons. The bowels should be emptied by a regular mild aperient, and if there is any tendency to ileus, physostigmine or pituitrin should be given.

(*c*) *The Rôle of Operation.*—Experience has shown the futility of exploratory operations in the early stages of fractured spine with cord involvement. It must be realised that the cord injury occurs at the same moment as the fracture, and that such damage is irreparable. At a later stage, however, in patients who have shown recovery, but who develop signs of root pressure or symptoms due to meningitis circumscripta, laminectomy is sometimes a reasonable undertaking.

(*d*) *Recovery Stage.*—In patients who show recovery of cord function, a spinal brace should be fitted at the end of three months. Re-education as used in other forms of spastic paraplegia should be given a prolonged trial, and every effort made to prevent the development of contractures by appropriate splinting. Many patients may be taught to walk with the aid of crutches even where severe spasticity of the lower limbs remains (Fig. 691). For others a "wheel chair" existence is the best that can be offered.

Dislocations of the Cervical Vertebrae

In the cervical spine, *dislocations* may occur owing to the configuration of the interarticular processes which allow unlocking without actual fracture. This type of spinal injury is most usually seen at the level of the *fifth* or *sixth* cervical, and is produced by forced flexion combined with rotation. In some of the minor displacements the actual violence may be comparatively trivial. The various dislocations, which may be classified according to the direction of the displacement, are tabulated as follows:

Forward	Unilateral { incomplete / complete }
	Bilateral
Rotatory	Double complete
Backward	{ Unilateral / Bilateral }

Clinical Picture. 1. (*a*) *Unilateral Forward Dislocation.*—In the *incomplete* form the head is tilted and the face rotated to the side opposite the dislocation. In the early stages all motions of the cervical spine may be restricted by muscular spasm. In some cases there may be local signs of injury, such as deep tenderness, but these are inconspicuous. The symptoms of cord or nerve root involvement are invariably absent. In the *complete* type, where the interarticular process has slipped into the underlying intervertebral notch, the head is tilted and rotated as in congenital torticollis, and the neck is quite immobile. Nerve root pressure signs may be present.

(*b*) *Bilateral forward dislocations* are rare, and are almost invariably fatal. In patients who survive, the whole head and upper cervical spine are displaced forwards, and there is a projection in the neck at the level of the dislocation.

2. *Bilateral rotary luxations* have been observed in which the articular process slips forward on one side and backward on the other. The clinical picture resembles the unilateral complete forward dislocation, with the deformity rather more exaggerated.

3. *Unilateral backward dislocation* is very rare, and is usually complete. *Bilateral backward dislocation*, also very rare, may be recognised by the following signs: (*a*) Backward displacement of the head, (*b*) Shortening and immobility of the neck, (*c*) A hollow in the nape of the neck, and (*d*) Signs of cord or root pressure.

Treatment.—An attempt should be made to reduce all cervical spine dislocations, whether pressure signs are present or not. Cases are on record where incomplete unilateral displacements have undergone spontaneous reduction. In the manipulative technique, the most important manoeuvres are *tilting* and rotating of the head in order to unlock the entangled inter-articular processes. As pointed out long ago by Walton, traction pure and simple tends to defeat the objects of the manipulation. The test of successful reduction is the restoration of the range of movement formerly blocked. In early cases correction is possible with the employment of very little force, and after reduction, the neck should be fixed in a plaster of Paris collar. This should be worn for three or four weeks, and a light removable collar substituted for a further short period. The return of full mobility will be favoured by judicious exercises.

Fractures of the Atlas and Axis

Atlas.—Fractures of the first cervical vertebra are by no means rare, and as they are quite often unaccompanied by cord injury, they tend to be overlooked. The fracture results from the squeezing of the atlas between the occiput above and the axis below, a condition of affairs which occurs in falls on to the head (Jefferson[1]). The line of fracture usually runs across the slender part of the *posterior arch*, where it is grooved by the vertebral artery. Whether the fracture be unilateral or bilateral, there is little or no displacement, so that the cord or medulla escapes damage. Coincident fracture of the odontoid process is a not uncommon accompanying injury. Fractures of the *anterior arch* or *lateral mass* of the atlas have also been observed, but are much more rare.

In *recent injuries* the symptoms may consist merely of slight stiffness of the neck. Nodding movements are somewhat limited, but the range of the lower cervical spine is unimpaired. Pain in the upper part of the neck or radiating along the distribution of the great occipital nerve may also be present (Sicard and Roger[2]). The diagnosis usually depends on radiography, the line of fracture being clearly shown in a lateral view (Fig. 694).

In *old injuries* where the fracture has been overlooked, persistent stiffness of the neck and occipital neuralgia are most suggestive symptoms. Careful testing may show a zone of anaesthesia in the scalp in the distribution of the great occipital nerve.

[1] Jefferson, G.: Brit. Med. Jnl., 1927, July 30.
[2] Sicard and Roger: Paris Médicale, 1917, Vol. 7.

The *treatment* consists in immobilising the head and neck in a plaster of Paris collar as soon as the diagnosis is made. This is worn for some four to six weeks, and a light removable collar used for a further period.

Axis.—Fractures of the axis involve the *odontoid* process, which usually breaks across at its base. The accident is liable to occur when the vertebra is compressed vertically and the head at the same time forcibly extended. The transverse ligament remains intact, and indeed rupture of this structure, contrary to common belief, is one of the rarest events in a healthy cervical spine (Jefferson). Odontoid fracture may occur as an isolated lesion, or may

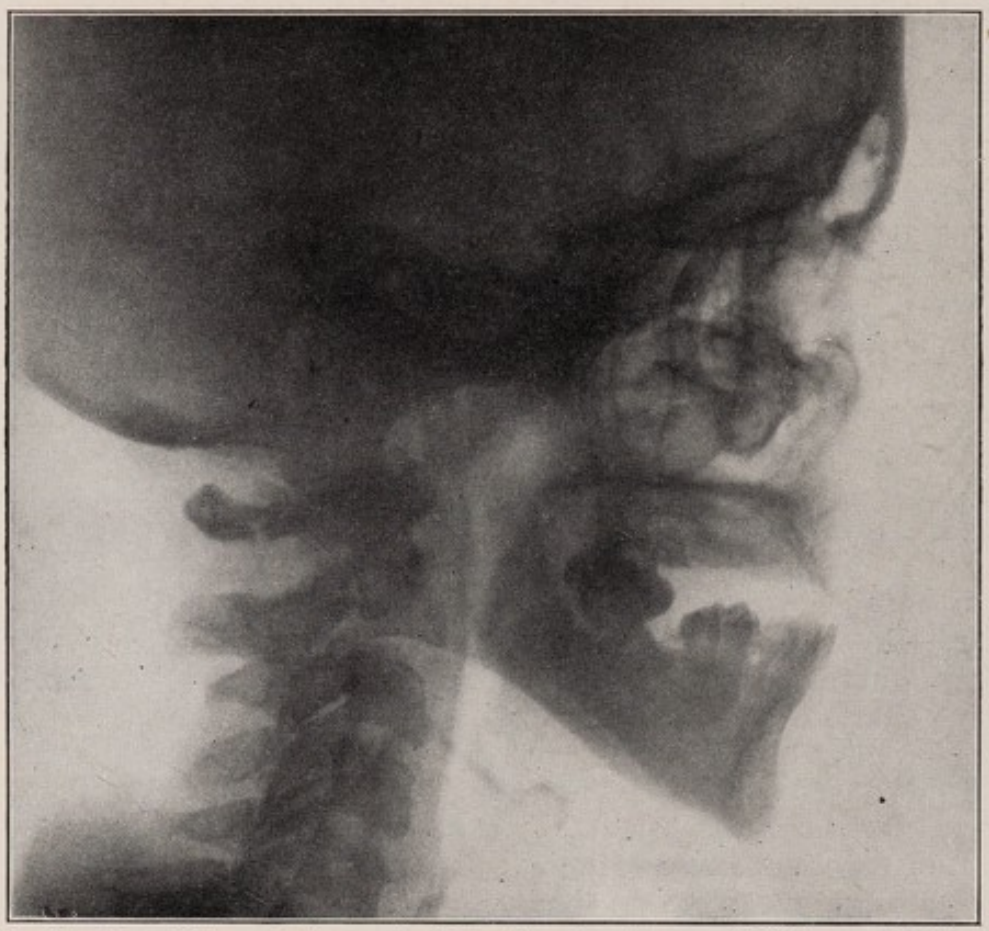

FIG. 694.—Fracture of the posterior arch of the atlas; also shows a slight forward displacement of the axis on the third cervical vertebra (Ancoats Hospital).

accompany a fracture of the posterior arch of the atlas. A fatal result may be seen, but not necessarily immediately following the accident. Cases are on record where cord injury has occurred some days later after a further strain, such as in coughing or sneezing. On the other hand, as in uncomplicated atlas fractures, the injury is liable to escape diagnosis, and in such patients it is probable that firm union, fibrous or bony, ultimately takes place.

The chief symptoms bear a close resemblance to those which occur in atlas fractures, viz., pain and stiffness in the head and neck, anaesthesia or hyperaesthesia in the distribution of the great occipital nerve. In addition difficulty in swallowing is often complained of during the first few days. Where there is a rotatory or forward displacement of the atlas, a definite projection may be made out behind the posterior pharyngeal wall.

The fracture is generally clearly shown in a lateral radiogram (Fig. 695) or in an antero-posterior radiogram taken through the widely opened mouth.

Odontoid fractures should be treated promptly by adequate immobilisation of the head and upper spine in a plaster of Paris cuirasse. The period of fixation should last three months, and should be followed by the use of a removable collar for some little time. With such precautions bony union is likely to occur, and the danger of secondary displacement will be avoided. Where there is an accompanying displacement of the atlas, reduction should be

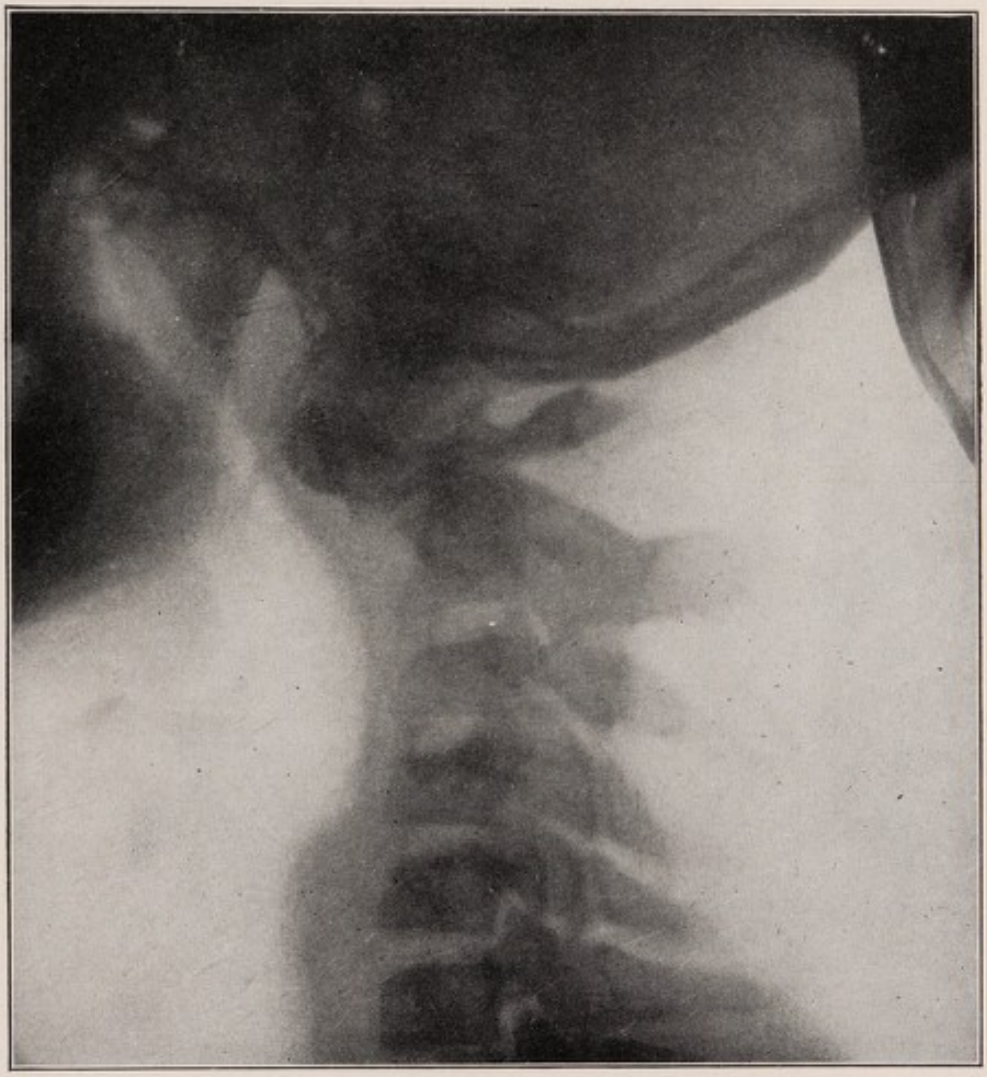

FIG. 695.—Fracture of the odontoid process, with forward displacement of the atlas (C. Thurstan Holland).

attempted by careful manipulation. Open operation may be required when the late signs of cord pressure appear. In such cases anchorage of the posterior arch of the atlas to the spine of the axis may be indicated (Osgood and Lund[1]).

Isolated Fractures of the Neural Arch and Transverse Processes

Fractures of the *spinous processes* or *laminae* are usually due to direct violence, and may involve one or more vertebrae. Displacement is ordinarily slight, but in rare cases part of the neural arch may be driven into the cord.

[1] OSGOOD, R. B., & LUND, C. C.: New Eng. Journ. Med., 198, 2, March 1, 1928.

The signs are those of a localised spinal injury with some disturbance of the alignment in the spinous processes. Crepitus may be demonstrable. Fractures of the spinous processes may be safely treated by ambulatory methods, a light plaster of Paris jacket being worn for several weeks. In fractures of the laminae, a period of recumbency is desirable. In the rare cases with pressure signs, immediate operation should be carried out, and the depressed fragment restored to its original position and fixed.

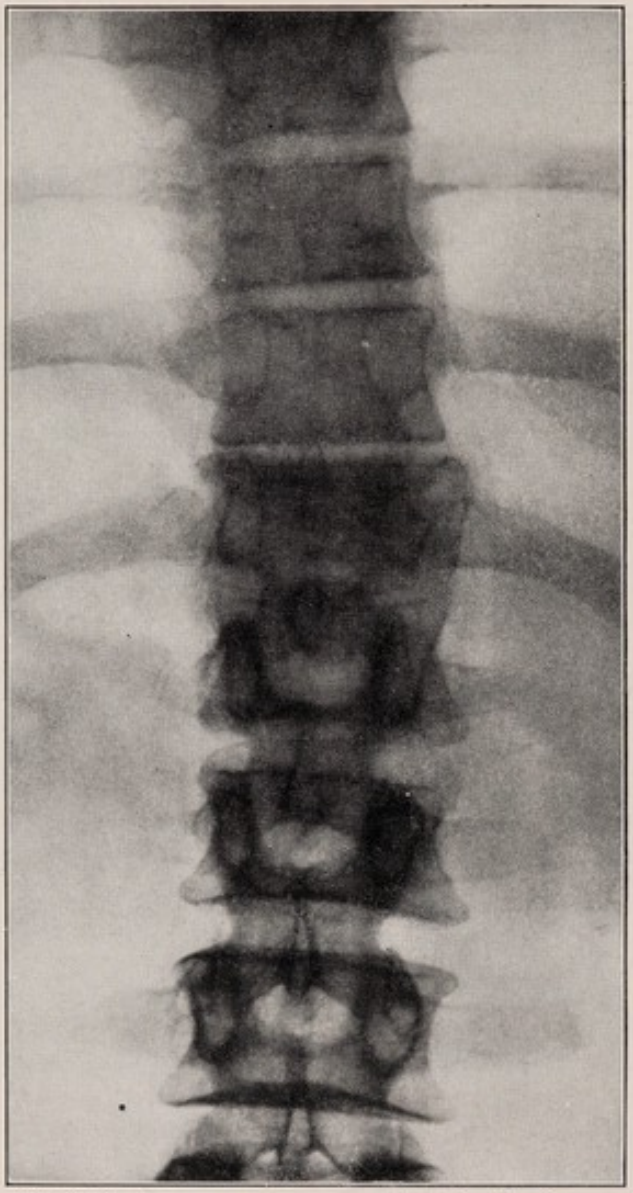

FIG. 696.—Congenital cleft in the transverse process of the first lumbar vertebra (J. H. Mather).

Fractures of the *transverse processes* (Fig. 690) are seen almost exclusively in the lumbar region, and are usually produced by violent torsion, sometimes combined with direct violence. The symptoms are local pain and tenderness and limitation of motion, and differ little from the ordinary symptoms of a ligamentous or muscular strain. The radiographic appearances must be interpreted with caution, as a solution in continuity in the lumbar transverse processes may be present in certain congenital anomalies, *e.g.*, rudimentary

ribs or non-union of the epiphyses. In true fractures the clefts are usually irregular, several processes are involved, and considerable displacement of the detached fragments is often present. The treatment used in ligamentous and muscular strains is appropriate.

DERANGEMENTS OF THE LUMBO-SACRAL AND SACRO-ILIAC ARTICULATIONS

Anatomical Considerations

Lumbo-sacral Joint.—At the lumbo-sacral junction the spinal column is balanced on an inclined plane, the upper surface of the sacrum forming an angle of about 30 degrees with the horizontal. The instability which such an arrangement suggests is neutralised by the close interlocking of the inter-articular processes, and the binding action of strong ligaments. The articulation is not only stable, but allows a considerable range of movement in the antero-posterior plane. Resilience is also favoured by the intervertebral disc, which is unusually thick at this level, and which acts as a competent buffer.

The lumbo-sacral region is especially liable to strain, due either to definite injury or to mechanical causes, which are conventionally described as static or postural. In this region also, congenital variations occur with such frequency that it is not easy to define the normal. In the genesis of those symptoms which are attributed to strains of the lumbo-sacral joint, and of which low backache is the most prominent, trauma, static errors, and congenital variations may act singly or in combination. The whole problem of lumbo-sacral strains is also intimately related to similar derangements of the sacro-iliac joint.

Sacro-iliac Joint.—The peculiar form of the human pelvis has resulted from the assumption of the erect attitude. In the lower mammals the plane of the sacro-iliac joints is almost horizontal, and the articular surface of the ilium is in contact with the first and part of the second segments only of the sacrum. The human pelvis has been dragged down posteriorly by the pull of the hamstrings and glutei, with the sacrum rotating on a transverse axis, and the whole pelvis rotating at the hips. As a result the two components of the sacro-iliac joint have been brought into more intimate connection. In the male, rotation has proceeded to a greater degree than in the female.

The *female* pelvis tends to preserve the more primitive form of the lower mammal: the sacrum is more horizontal, the plane of the brim forms a greater angle with the horizon, and the articular facet extends on to the second sacral segment.

In the *male*, the sacral articular surface has come into still greater relation with the ilium, and usually extends over three sacral segments and a part of the fourth. In addition the joint surfaces differ markedly in the two sexes. The auricular facet of the ilium in the female forms a rounded condyloid area, which fits into a correspondingly hollowed-out surface on the sacrum. The male auricular surface shows irregular projections and ridges, which interlock with corresponding pits and grooves. The edge of the articular surface is also lipped on its anterior surface, so as to overlap the adjacent margin of the sacral facet.

In early life the sacro-iliac joints are freely moveable in both sexes, but after puberty the male joint shows a relative loss of motion, compensated for by definite gain in strength. The free mobility of the female sacro-iliac joint obtains until advanced life, but in the male fixation often occurs at this period owing to the intervention of osteoarthritic changes. Thus, in both sexes the normal sacro-iliac joints are diarthrodial in type, and show a definite synovial lining on the deep surface of the capsule. According to Derry[1] the female joint is a condyl-arthrosis, and in its excursion is comparable to the wrist joint.

The special characteristics of the female pelvis and sacro-iliac joints are evidence of a mechanical adaptation to the function of child bearing. During pregnancy there is a gradual increase in the range and mobility in all the pelvic joints. At full term the sacro-iliac joint may attain a range of motion which is two and a half times the normal. (Brooke.[2]) After child-birth the hyper-mobility disappears gradually.

Congenital Variations and Anomalies at the Lumbo-sacral Joint

These may involve the transverse processes, the interarticular processes, or the neural arches of the 5th lumbar and 1st sacral vertebrae.

1. **Fifth Lumbar Transverse Processes.**—The processes may be long and slender or short and squat. They may be in contact with the ala of the sacrum or wing of the ilium, with a pseudarthrosis at the point of contact. Actual fusion of one or both processes to the upper part of the sacrum, the so-called sacralization, is by no means uncommon (Fig. 698). In 75 per cent of individuals the processes are asymmetrical so that the "enlarged" process which impinges on the ilium or sacrum is usually a unilateral anomaly.

2. **Articular Processes.**—The close interlocking between the fifth lumbar and first sacral vertebrae is dependent on the shape and orientation of the articular processes. Normally these are vertical, with facets which lie in the sagittal plane, but on one or both sides the processes may show the characteristics of the dorsal region, *i.e.*, the facets face forwards and backwards, an anomaly which predisposes to unlocking in extreme forward flexion of the spine.

3. **Neural Arches.**—There are two principal anomalies: (*a*) Lack of fusion in the middle line in either the fifth lumbar or first sacral—a common variation—which forms the basis of spina bifida occulta. (*b*) In some 5 per cent of subjects a hiatus exists between the body and neural arch of the fifth lumbar. Under such conditions there is little to prevent a forward slipping of the fifth lumbar body on the sloping sacral base, and the development of the deformity known as spondylolisthesis.

Clinical Significance.—The relation of lumbo-sacral anatomical variations to symptoms referred to the lower back or lower limbs, has aroused much discussion and produced a literature of formidable proportions. Scrutiny of radiograms on a large scale has shown conclusively that such anomalies are present in a considerable number of individuals, who would otherwise be quite unaware of their existence. It is believed, however, that asymmetrical variations may occasionally act as either a contributory or a direct cause of

[1] Derry, D. E.: Jnl. Anat. Phys., Jan., 1911, April, 1911.
[2] Brooke: Jnl. Anatomy, 58, July, 1924.

symptoms. (1) In the first place, as taught originally by Goldthwait,[1] asymmetry of the transverse processes or inter-articular joints is liable to produce a cross strain on the lumbo-sacral joint as a whole. When this factor is combined with others, such as injury or an habitual bad posture, its influence in perpetuating a chronic strain can readily be appreciated.

(2) Considerable attention has also been paid to the occurrence of *sciatica* in association with unilateral "enlargement" of the fifth lumbar transverse process. The close proximity of the lumbo-sacral cord to the transverse process suggests that direct irritation might easily occur.[2] The clinical picture in such patients is usually that of *sciatic scoliosis* and in the hands of a number of surgeons relief of symptoms has followed the removal of an enlarged transverse process (Baumann and others). Convincing proof, however, is lacking of a direct causal relation between this anomaly and unilateral sciatica, and the operation, which is both difficult and hazardous, should rarely be necessary. The recent work of Putti[3] has shown that intervertebral arthritis is a not uncommon cause of sciatic scoliosis, and that this condition is recognisable only in stereoscopic radiograms of the highest technical excellence. In another group of cases, the sciatica has been proved to be due to hypertrophic changes at the margins of the fifth lumbar vertebra producing encroachment on the intervertebral canal from which the fifth lumbar nerve emerges (Danforth and Wilson[4]).

(3) Inflammatory swelling in the bursa which forms the pseudarthrosis between the impinging type of transverse process and the ilium, is also said to occur. Such a lesion may be responsible for transitory attacks of sciatic pain amenable to treatment by conservative measures.

(4) It is generally agreed that sacralisation of the fifth lumbar vertebra, whether unilateral or bilateral, has no clinical significance whatsoever.

Strains of the Sacro-iliac and Lumbo-sacral Articulations

Under the generic term "strain," are included derangements which fall into two main classes: (*a*) Traumatic strains, and (*b*) Postural or Static strains.

Although this etiological distinction is useful, it must be realised that strains which follow a definite injury may be perpetuated by postural influences.

Traumatic Strains

Sacro-iliac.—*Acute* strains of this joint usually result from violence applied to the lower limbs, and are met with in both sexes. As in strains of other joints, the exact lesion may vary from a simple stretching or tearing of the strong extra-articular ligaments or joint capsule, to an actual injury of the articular surfaces. A true "slip" or minor displacement may even occur, and such lesions, though of debatable frequency, are probably more common in the male sex. The chief symptom is localised pain and tenderness in the region of the posterior sacro-iliac ligaments. Immediately after the accident the pain may be agonising, and the patient unable to move without extreme dis-

[1] Goldthwait, J. E.: Amer. Jnl. Orthop. Surg., Feb. 1, 1913.
[2] Baumann, G.: Jnl. Bone & Joint Surgery, 5, 579–589.
[3] Putti, V.: Lancet, July 9, 1927.
[4] Danforth and Wilson: Jnl. Bone & Joint Surgery, vii, 1, Jan., 1925.

tress. In the early stages all movements of the lumbar spine may be temporarily inhibited by intense muscular spasm, but in the milder strains it is usual to find that forward bending and unilateral side bending only show restriction. The patient sometimes holds the knee flexed on the affected side, walks with a limp, and drags one leg. The spine may show a deviation as a whole to one side. All movements which tend to rock the ilium on the sacrum are painful and evoke muscular spasm, such as forced abduction and external rotation of the hip, and more especially flexion of the hip with the knee extended. The latter movement—the so-called *straight leg raising* test—usually shows considerable limitation, and efforts to reproduce the full range cause an increase in all the painful symptoms.

Sub-acute or *chronic* strains are often induced by minor degrees of violence repeated at intervals. As already stated the strain may attain chronicity owing to the intervention of certain postural or static factors. In this group may be included some of the painful sacro-iliac joints which follow child-birth and which have been familiar to the obstetrician for many generations. In these patients trauma is merely one of a number of etiological factors, for the influence of subinvolution and mild infection cannot always be discounted. It is in these cases also that true relaxation of the sacro-iliac joints may occasionally be demonstrated.

Lumbo-sacral Joint.—*Acute* strains are produced by leverage from above when the spine is in flexion. The symptoms bear a superficial resemblance to those which characterise the sacro-iliac strain. The pain and tenderness are however located to the lumbo-sacral junction, and the lumbar spine movements are restricted in all directions. The straight leg raising test may show slight limitation in the extremes, but this is present equally on both sides.

Subacute or *chronic* strains due to injury present a clinical picture identical with the chronic postural strain.

The *treatment* of acute strains of the sacro-iliac or lumbo-sacral joints consists in a period of rest in the recumbent position with compression over the painful area, either by strapping or a firm bandage. As the pain and tenderness subside, light massage and other local analgesic measures may be used. When walking is resumed the joint should be protected from violent stretching, but graduated mobilisation should be encouraged in order to counteract the formation of painful adhesions. In a sacro-iliac strain where the acute symptoms do not subside rapidly under the influence of rest, a true "slip" of the joint may be suspected. This uncommon lesion, which is not demonstrable in ordinary radiograms, usually responds to gentle manipulation under an anaesthetic. In neglected cases the symptoms do not clear up entirely, and the clinical picture of the chronic strain becomes established. The treatment of chronic traumatic strains will be considered with the postural strains.

Postural Strains of the Sacro-iliac and Lumbo-sacral Joints

The individuals who comprise this group form a considerable proportion of patients suffering from chronic backache, in whom pelvic visceral disease, lesions of the spinal column and pelvis, lesions of the central nervous system, and renal affections have been excluded.

The clinical picture is covered by what may be termed the sacro-iliac syndrome, in which may be distinguished certain features which allow a

differential diagnosis to be made between sacro-iliac and lumbo-sacral lesions. Postural strains as a whole are more common in the female sex, and are especially seen at certain age periods—most notably, 15 to 25, and from 35 to 50 (Lovett[1]). In all such patients a careful examination of the body as a whole will reveal a postural defect. This may be either a lateral deviation of the spine, or, more frequently, an alteration in the antero-posterior plane. A history of injury may be forthcoming, but as a rule the symptoms arise insidiously without any obvious and dramatic cause.

Symptomatology

1. **Sacro-iliac Strain.**—The condition is common in the slender visceroptotic type of individual (Goldthwait). The patient is often a young or middle aged woman in whom the symptoms originated during pregnancy or after the birth of a child. The most important symptom is low back-ache, usually a dull gnawing pain, which radiates to the thighs. There may be tenderness over the sacro-iliac joint, either posteriorly, or anteriorly as demonstrated by abdominal palpation. Lateral compression of the pelvis may sometimes elicit pain. Forward bending in the lumbar region is usually painful and limited in the extremes, but when tested with the patient in the sitting position the restriction disappears. As in acute traumatic strains, the straight leg raising test on the affected side shows distinct limitation and evokes pain in the joint. In many of the younger patients there may be a lateral deviation of the spine without fixed deformity. It is believed by a number of authorities that the symptom-complex just described may indicate a true relaxation of the sacro-iliac joint, and that this condition is demonstrable in radiograms as an alteration in alignment at the symphysis pubis (Smith-Petersen[2]). This is a most debatable subject, and at the present time the consensus of opinion is that sacro-iliac relaxation is a rare phenomenon.

2. **Lumbo-sacral Strain.**—The type most liable is the heavy stout individual with a protruding abdomen. At the lumbo-sacral junction there is a sharp angulation, and this postural deviation has usually existed for many years. The backache is often vaguely localised, and is combined with referred pain in the sciatic distribution. Deep tenderness may be demonstrated over the lumbo-sacral junction and along the line of the ilio-lumbar ligaments. All movements of the lumbar spine are restricted, in the standing, sitting, and lying position. The hip joint range is free on both sides, with straight leg raising occasionally limited in the last few degrees only. In a certain number of these patients radiograms of the lumbo-sacral region reveal one or more of the congenital anomalies to which reference has already been made.

Diagnosis

1. **Differential Diagnosis between Sacro-iliac and Lumbo-sacral Strains.**—The outstanding clinical distinctions between sacro-iliac and lumbo-sacral lesions may be conveniently summarised in tabular form, based on the writings of Smith-Petersen.[3]

[1] Lovett, R. W.: Jnl. Amer. Med. Assn., July 23, 1914.
[2] Smith-Petersen, M. S.: Amer. Jnl. Roent. & Rad. Therap., xii, 6, Dec., 1924.
[3] Smith-Petersen: Jnl. Bone & Joint Surgery, vi, 4, Oct., 1924.

	Lumbo-sacral	Sacro-iliac
History—trauma.....	Leverage from above with spine in flexion	Leverage—unilateral via lower limb
Pain—referred—distribution.	5th lumbar, 1st sacral } areas: outer side leg—dorsum foot—sole of foot	4th & 5th lumbar, 1st & 2nd sacral } areas: especially posterior aspect of thigh, adductor region
Points of tenderness.....	The ilio-lumbar ligaments, spinous processes of 4th & 5th lumbar, and 1st sacral	Inferior sacro-iliac ligaments Sacro-sciatic notch
Movements of spine: (Fig. 697)		
(*a*) Standing.....	All lumbo-sacral motion is restricted	All free except { unilateral side bending, forward bending in extremes
(*b*) Sitting.....	All restricted as in standing position	Forward bending free with hamstrings relaxed
(*c*) Lying.....	All restricted	Free
Special tests:		
(*a*) Straight leg raising.	Limited in extremes on both sides equally	Unilateral limitation at small range
(*b*) Compression of pelvis.	Nil	Occasional pain in sacro-iliac joint

2. **Differential Diagnosis of Sacro-iliac Disease.**—Sacro-iliac strain must also be distinguished from inflammatory conditions of this joint in the early stage, *e.g.*, infective arthritis and tuberculosis. Much will depend on the radiographic evidence, and where the appearances are indeterminate, the diagnosis may be in some doubt for a time.

3. **Differential Diagnosis of Backache.**—The conditions in which backache is a prominent symptom may be arbitrarily divided into a number of clinical groups. It is sufficient here to enumerate them, as the symptomatology of many of the different groups has been dealt with elsewhere in this work.

(1) Arthritis of the spine.

(2) Traumatic lesions of the spine.

(3) Static derangements of the lumbo-sacral and sacro-iliac joints (static backache).

(4) Chronic bony lesions of the spine: Pott's disease, Syphilis, Neoplasms, Charcot's disease.

(5) Inflammatory conditions of muscles and fasciae (Fibromyositis).

(6) Congenital anomalies and variations of the spine.

(7) Affections of the nervous system.

(8) Pelvic visceral disease.

(9) Renal affections.

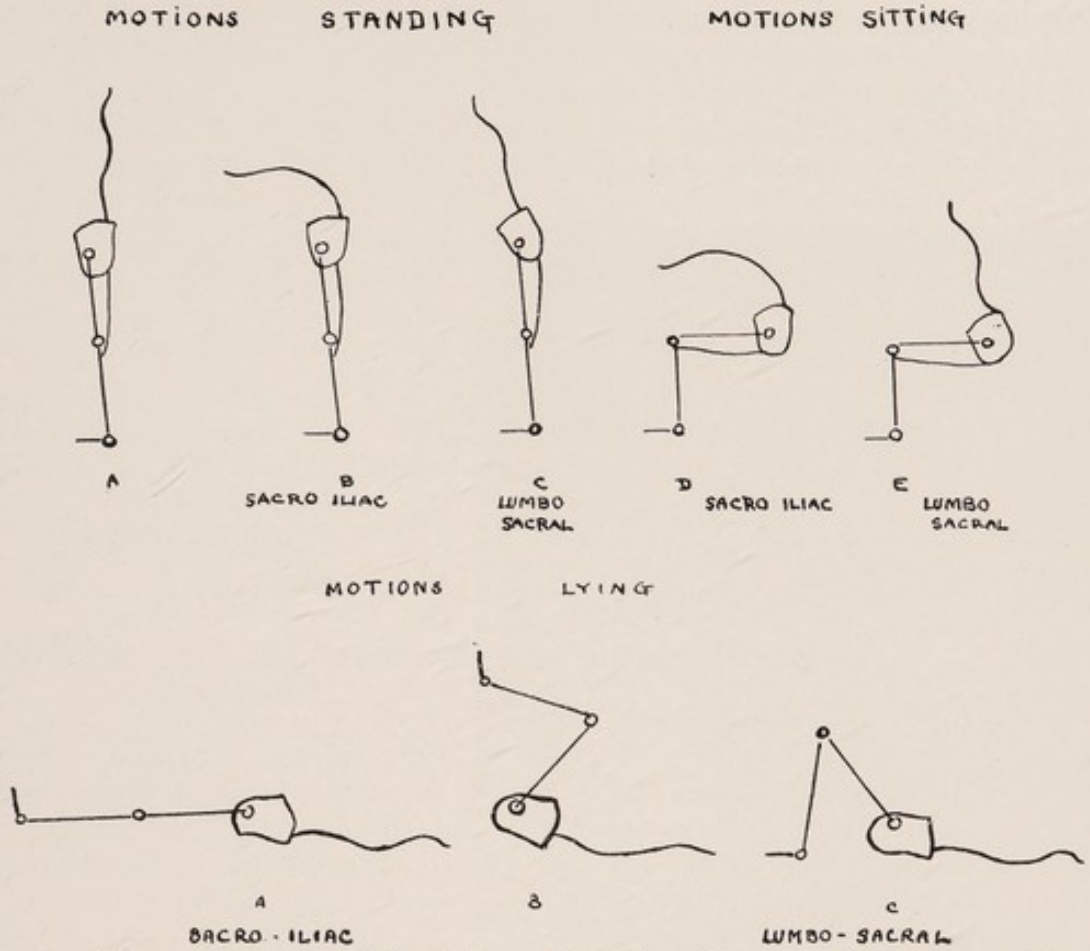

FIG. 697.—Diagrammatic illustration of forward bending of the spine in various positions, in sacro-iliac and lumbo-sacral strains (Smith-Petersen).

Treatment

1. **Symptomatic and Reëducational.**—All postural errors in both the spine and lower extremities should be systematically treated. A period of rest is often a useful preliminary to any intensive scheme of postural training, and is especially valuable where backache is severe. During this stage, massage, radiant heat, and other local pain-relieving measures may be used. Comfort may also be obtained by strapping the pelvis as in an acute strain.

In *lumbo-sacral* strains with an exaggerated lordosis, the patient must be taught to flatten the lumbar spine, first in the lying position and later when standing, by active contraction of his abdominal and gluteal muscles. With this is combined reëducation in diaphragmatic breathing. (Goldthwait.) A light spring back brace, with or without corset, should be worn for some months and discarded only when a correct posture has become habitual.

In *sacro-iliac* strains a sacro-iliac belt with a pad over the painful joint is the most useful type of support during the stage of reëducation. In a patient with a lateral deviation of the spine due to shortness of one leg, the pelvis should be levelled by appropriate addition to the shoe. This simple measure has often cured mild cases of back-ache.

2. **Manipulation.**—In long-standing postural strains, adhesions develop in the joint capsules at the lumbo-sacral junction and sacro-iliac region, and considerable shortening occurs in the hamstrings. In such patients a judicious

stretching under an anaesthetic is the appropriate treatment. This is followed by the wearing of a light support and a period of postural reeducation with special attention to mobility exercises.

3. **Operation.**—Where prolonged conservative treatment has failed, the question of fusion of the painful articulation may be considered. Such operations should rarely be needed, but in intractable postural strains due originally to trauma, fixation may be justifiable. The technique of arthrodesis of the sacro-iliac joint has been described in Chapter IX. In the operation of fusion of the lumbo-sacral junction, either the Hibbs or Albee method may be employed.

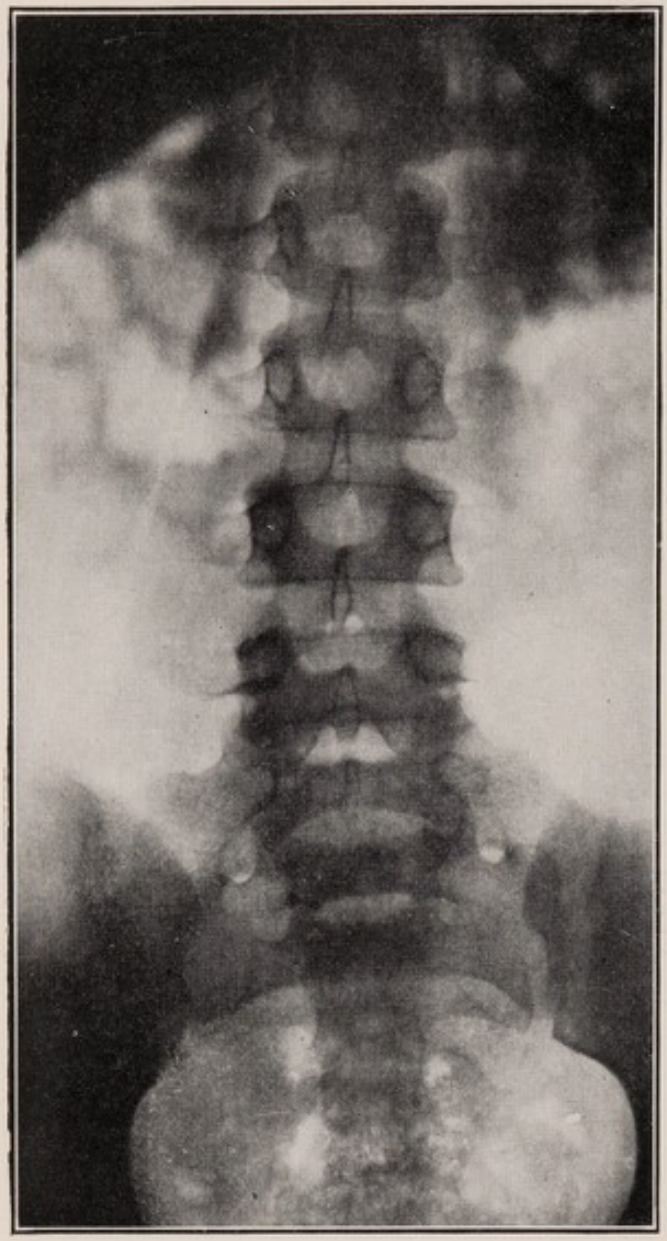

FIG. 698.—Six lumbar vertebræ and double sacralization of the last lumbar vertebræ—no symptoms.

Round Shoulders and Adult Round Back

(Faulty Attitude, Stooped Shoulders, Round Back, Round Hollow Back, Kyphosis.)

In addition to lateral curves of the spinal column which are considered under scoliosis, there are modifications of the normal physiological curves in the antero-posterior plane of the body which demand consideration. These are (1) purely mechanical in origin and are seen in growing children or adults with lax muscles; or (2) of a graver nature, associated with more or less structural change; the latter form occurs mostly in adults and accompanies various diseases. Class (1) is generally designated as "round shoulders."

Mechanics of the Upright Attitude.—Some simple, fundamental considerations with regard to the upright attitude must be mentioned. In the standing position the body is in unstable equilibrium and the conditions for maintaining the upright position are, that the center of gravity must lie over the base of support; and that the line of gravity, which is a perpendicular dropped from the center of gravity, must therefore fall within the base of support, which in the human figure consists of a trapezoid formed by the outer borders of the feet and lines connecting the back of the heels and the front of the toes. For this reason, children and persons with a poor equilibrium spread their feet to gain a larger base of support. From a mechanical point of view, all the weight of the body is to be regarded as concentrated in the center of gravity, and the center of gravity must be kept over the

center of support by such adjustment as may be necessary; as this supporting structure is itself adjustable in the antero-posterior plane, it is obvious that a change in antero-posterior relations in any part of the body must be met by a compensating change in some other part. Hence an increase in the dorsal curve implies an adjustment from the ground upward. This has not been sufficiently taken into account in analyzing this attitude of round shoulders, and many of the figures representing faulty attitude, based on theoretical lines, are absolutely misleading. When the standing position is analyzed in relation to the line of gravity by the method given in the reference, faulty attitude is found to be an exceedingly complex affair, and our present knowledge of it from a really scientific point of view is most crude and unsatisfactory. This explains much of the confusion in the literature concerning it; and, in the absence of a normal standard, statements made about variations from the normal attitude must be accepted with great reservation.

One final consideration with regard to the mechanics must be mentioned—the human skeleton is of course merely the quadruped skeleton in the upright position without radical modifications, and two or three serious defects consequently exist. (1) The quadruped vertebral column served as a central structure from which the viscera were supported at right angles to its length. In the human skeleton this structure is vertical and the viscera hang from it in the line of its length. (2) The anterior limbs, which in the quadruped served as a support to the vertebral column at one end, now hang from it at its length and, instead of supporting, have to be supported. (3) In inspiration, the ribs in the quadruped were assisted by gravity, while in man, they have to be lifted against gravity, in expansion. (4) The backward curve of the dorsal spine which exists in most quadrupeds is the first physiological curve to develop in the human spine and the only inherited, physiological curve.

The normal attitude is best defined by the erect, well-balanced attitude assumed by a muscular adolescent or adult. It is the attitude of balance and ease, and the attitude of muscular efficiency and vigor. The variations from this attitude will next be considered, always with the proviso that data in general have been derived from no exact or reliable method of measurement.

Round Shoulders

It is comparatively easy to determine whether or not lateral curvature exists by the methods of examination advocated in describing this type of curve, but it is not always easy to determine, by looking at a patient from the side, whether what appears to be round shoulders should be considered abnormal or not. In marked cases there is no question, but in young children a certain degree of round shoulders is more or less normal, and we suffer from the fact that we have no accepted standard for normal. The normals described by a long series of writers differ considerably among themselves because of lack of a uniform or satisfactory system of measurement, and because attitude is influenced by sex, race, age, and occupation. The literature on the subject is given in the references.[1]

Types of Round Shoulders.—Grouped under the name of round shoulders are various types of faulty attitude, which shade into each other and are characterized by a disposition to economize muscular force in maintaining the erect position. The affection is not wholly one of the spine, but implies a disturbance of relations from the feet upward because in the upright position the dorsal spine cannot become more convex without a compensating lumbar curve forward, or a forward displacement of the pelvis and legs if the lumbar spine is involved in the backward dorsal curve. The condition, therefore, is not to be considered or treated as an affair exclusively concerning the dorsal spine and shoulders. On closer analysis these cases will be found to fall into four not very well-defined groups. Transition cases of all grades are seen, and

[1] Lovett: Boston Med. and Surg. Jour., Nov. 6, 1902.
Lovett: "Lateral Curvature of the Spine and Round Shoulders," 1916.
Reynolds and Lovett: Am. Jour. Phys., xxiv, May 1, 1909, No. 2.

the division is mentioned simply to aid in the study of the cases and their treatment. The groups are as follows:

1. *Round Back.*—The dorsal and lumbar spine form one convexity backward, which is physiologically a persistence of the infantile position. A lordosis is often apparently present, but on identifying the spinal landmarks, what appears to be the forward curve in the lumbar region will be found to be merely the upward and forward slope of the sacrum and the lumbar spine does not share in it.

2. *Round Hollow Back.*—The dorsal spine is bowed backward, but the lumbar spine is curved forward. The appearance of round shoulders is present; the abdomen is prominent; and the gross appearance is much the same as in round back.



Fig. 699.—Round shoulders with prominent abdomen.

3. *Round Upper Back.*—In certain cases the dorsal backward curve occurs in the upper part of the spine and gives an especially noticeable forward thrust to the head and a prominence between the scapulæ. The lumbar physiological curve is not necessarily abnormal. Spinal movement is somewhat restricted in the curved portion and children with a deformity of this type as a rule possess less than normal general mobility of the spine. Chest expansion is likely to be diminished.

4. *Flat Back.*—In certain cases the vertebral column is flat and has apparently nearly lost its dorsal and lumbar physiological curves. The pelvic inclination is obviously diminished and a frequent association with this attitude is a resistant forward position of the shoulders.[1]

For purposes of discussion these four types will be spoken of as "round shoulders," bearing in mind the fact that this condition is merely one expression of faulty antero-posterior attitude, which involves the whole body from the base of support to the head.

Symptoms and Signs.—In general the attitude is familiar. The head is carried forward and is somewhat flexed; the physiological curve in the dorsal region is increased and the dorsal region unduly prominent backward, in which backward curve the lumbar region may share, or there may also be an increased lumbar curve forward. The shoulders are drooping and the chest, narrow and flat, while the scapulæ are prominent behind on their posterior borders and the inferior angles may stick out prominently. The abdomen is prominent, especially in its lower part, and is not so much distended as relaxed. The abdominal walls have evidently lost tone and the suggestion from inspection is that the viscera occupy the lower, rather than the upper, part of the abdomen. Flatfoot, or pronated foot, frequently coexists. The antero-posterior diameter of the chest at the top seems diminished and the lower part of the thorax,

[1] Bradford: Orth. Trans., x, 162.
Goldthwait: Am. Jour. Orth. Surg., 1, 64.

seen from the front, seems to flare somewhat over the relaxed and enlarged abdomen.

Children with round shoulders are, as a rule, below the average in muscular development and lack vigor; they are generally clumsy in their movements and walk heavily. In some cases the deformity can be removed by a muscular effort on the part of the patient or by gentle pressure with the hands; but in most cases of even average severity the deformity cannot be wholly corrected by gentle passive force as the maintenance of the malposition has led to adaptive shortening of the soft parts concerned, chiefly the pectoralis major and minor muscles. The cases must, therefore, be classed as (1) flexible or (2) resistant, an important distinction in treatment.

Great injustice is done to children with resistant round shoulders by the continual commands to "sit straight," a position which it is impossible for them to assume. If such a child is told to put the arms up in the air in the standing position, it is done by making the back hollow in the lower part and protruding the abdomen because the soft parts between the chest and arms have become contracted and do not permit a free movement. In the same way if such a child lies on its back on a table and the arms are carried from the sides up to the side of the head they cannot be brought flat to the table in the long axis of the body.



Fig. 700.—Round back in a growing child, showing wedged deformity of vertebræ at apex of curve.

Etiology.—The shape of the figure is as characteristic of the individual as the form of the features and some children inherit straighter spines than others. A certain amount of importance must therefore be attached to the type of spine with which the child starts. Further evidence than this of a congenital origin of round shoulders (except in gross congenital lesions of the spine) is on the whole wanting.

In general the causes of round shoulders are to be sought in—(*a*) conditions causing muscular weakness; (*b*) conditions causing a flexed position of the spine for long periods; (*c*) overweighting of the shoulders by improperly arranged clothing (Fig. 747); (*d*) rickets. (*e*) Developmental changes in the epiphyseal plates causing wedged vertebræ—the so called vertebral epiphysitis of Buchman. Some German writers incline toward the view that a weakness of the will is a more important cause than weakness of the muscles.

Kyphosis adolescentium
Scheuermann

(*a*) Conditions causing muscular weakness are found in rapid growth, overwork and bad air at school, improper school furniture, acute illness, bad hygiene at home, insufficient food, and similar conditions.

(*b*) Prolonged flexion of the spine is induced by vicious school furniture, by errors in vision which necessitate stooping over the books in reading, and in careless attitudes of reading and sitting, permitted at school and at home. The child with normal eyes should not have to hold the book nearer than twelve to fourteen inches.

(*c*) The customary method of supporting a child's clothes in America consists in the use of a waist, loose around the abdomen, to which drawers and skirts or trousers are buttoned.[1] To this waist are also attached side elastic stocking supporters which are kept tight to prevent the stockings from wrinkling. This waist is supported above by two shoulder-straps, passing over the shoulders near their tips, and the whole weight of the clothes and the added pull of stout elastics is thus transferred to the child's movable shoulders, of all parts of the body the least suited to hold against a steady downward pull. This pull is in a measure transferred to the spine by the muscles, clavicles, and thorax, and tends to produce spinal flexion as well as forward and downward displacement of the shoulders.

The remedy of this condition consists in supporting as much as possible of the clothing from a belt, using circular garters, or in cases with markedly prominent abdomens the use of the corset waist which will be described.

In examinations of school children observers find antero-posterior curves less frequent than lateral, but as before explained it is often impossible to say what is an antero-posterior curve and what is normal. At Stockholm, Haglund found, in 1599 children, 280 scolioses and 170 antero-posterior curves (90 boys and 80 girls). The Lausanne series of 2314 children showed 571 scolioses (24.6 per cent) and 135 antero-posterior curves (5.8 per cent), with 47 combined cases included in the above. Gronberg found 715 antero-posterior curves in 8250 Finnish children. They were divided as follows according to his classification:

Kyphosis (round back), 478 (66.9 per cent).

Kypho-lordosis (round hollow back), 149 (20.8 per cent).

Lordosis (hollow back), 88 (12.3 per cent).

The age of occurrence of round shoulders covers the period of childhood from shortly after the time that walking begins to adolescence; most cases are seen by the surgeon in middle childhood and about puberty, when, in girls, especial attention is paid to the figure and carriage.

Effects on General Health.—The attitude described, with round back, flat chest and relaxed abdomen, is beyond all question most undesirable from the point of view of appearance, efficiency and good health. It means diminished inspiratory capacity, and involves more muscular effort than normal in standing and walking, and it would seem as if it would predispose to ptosis; its relation to ptosis has received particular emphasis.

It would seem as if this attitude of round shoulders would lead to a degree of ptosis which would be sufficient to cause symptoms, but in eighty-three normal children investigated by Sever[2] by means of bismuth X-rays taken in the upright position it was found that in these children the position of the stomach was much lower than is generally recognized, and it was not at all

[1] Bradford: Orth. Trans., x, 162.

[2] Sever: New York Med. Jour., Sept. 20, 1913.

unusual to find the stomach at or below the crest of the ilium; yet only one of these children had any symptoms which could be attributed to ptosis, chronic constipation existing in this case.

It cannot, therefore, be assumed in view of this evidence that ptosis giving rise to symptoms is caused by the attitude of round shoulders, inasmuch as the majority of normal children showed a position of the stomach which anatomically, would have to be called ptosis, but which did not affect the health. The outcome is that one would have to be careful in regarding a lowered position of the stomach in children as shown by this method as seriously abnormal, and the need of further investigation along these lines is evident.



FIG. 701.—Prominent abdomen in a weak individual with ptosis.

That adult ptosis is a frequent accompaniment of arthritis, auto-intoxication, low vitality, poor general resistance, pulmonary tuberculosis, impaired digestion, loss of flesh, constipation, abdominal pain, and similar conditions is not to be disputed.[1] That faulty attitude in children is undesirable is recognized, but that faulty attitude in children is accompanied by an unusual degree of ptosis over the normal for that age, is not established. Marked faulty attitude with a prominent abdomen in adults is likely to indicate ptosis, and is not only unsightly, but detrimental, and should be remedied; however, it must not be forgotten that in both children and adults the faulty, slack standing position is at times the result rather than the cause of the ill health. We are sometimes inclined to confuse cause and effect in this connection.

Diagnosis.—The diagnosis of round shoulders, when it is present in any marked degree, as a rule, presents no difficulty; but at times it is not easily distinguished from more serious affections which cause a backward bowing of the spine. When antero-posterior and lateral variations from the normal coexist, as frequently happens, the lateral variation is usually considered the more important one, and the case is classed as scoliosis. Variations from the normal in the antero-posterior plane are called "round shoulders" because an increased convexity of the dorsal spine is the most obvious characteristic. The means of distinguishing between the different varieties of round shoulders have been sufficiently indicated in the description of them. The important point is to distinguish a static bowing of the spine from one caused by disease. In the former there is no marked stiffness of the spine, pain is absent, the bowing is gradual, and X-ray appearances are normal.

[1] GOLDTHWAIT and BROWN: Am. Jour. Orth. Surg., Nov., 1911.
BROWN, L. T.: Boston Med. and Surg. Jour., June 24, 1920.
BROWN, L. T.: Am. Jour. Med. Sci., Nov., 1920.
BROWN, L. T.: Am. Jour. Orth. Surg., Nov., 1917.
GOLDTHWAIT, J.: Surg., Gyn. and Obst., 1913, xvii, 587.
REYNOLDS and LOVETT: Jour. Med. Ass'n., Mar. 26, 1910.

Tuberculosis of the spine has been described (Chap. X). When located in the dorsal region at certain stages it may resemble the attitude of round shoulders, but it is characterized by a focal lesion of the vertebræ, shown in the X-ray; pain, rigidity of the spine in the affected region; and characteristic attitudes and gaits.

Prognosis.—The attitude of round shoulders is not to be regarded as one which will be spontaneously outgrown, and it must be remembered that if children are allowed to grow with a flexed spine, adaptive changes will occur in accordance with Woolf's law, which will in time become irremediable. This condition, therefore, requires treatment; but with adequate treatment and proper hygiene the prognosis for recovery is good in young children. In older children and adolescents improvement with a possibility of cure may be obtained. Even in young adults an improved position of the shoulders and a better expansion of the chest are to be secured by adequate treatment.

If the attitude of round shoulders is allowed to persist into adult life there are certain respects in which it may unfavorably affect the health of the individual as indicated in speaking of the effect of the faulty attitude upon general health.

Treatment.—The treatment of round shoulders must be clearly divided into two parts—(1) the treatment of flexible round shoulders, and (2) the treatment of resistant round shoulders. The same principle must be observed here that has been discussed in the treatment of other deformities such as scoliosis,

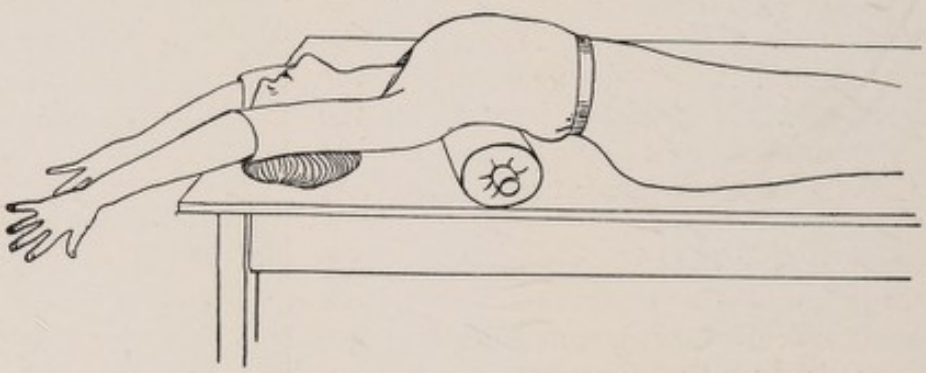

Fig. 702.—Stretching round shoulders over padded roll.

flat foot, etc., namely, that *if a degree of resistance exists which makes it impossible by active effort or passive manipulation to place the parts in their normal anatomical relation to each other, flexibility must be restored before proceeding to other treatment, either gymnastic or mechanical.* Nowhere is this matter more important than in the treatment of round shoulders. Furthermore no gymnastic treatment for a case of round shoulders should be undertaken in a patient where pain, rigidity or stiffness of the back is present without a very careful preliminary period of observation and a careful elimination of the possibility of tuberculosis of the spine.

1. *Treatment of Flexible Round Shoulders.*—If the rounded dorsal spine can be fairly well straightened by active effort or passive manipulation, and if the scapulæ can in the same way be brought back to nearly their normal relation with the vertebral column, the case is suitable for treatment by exercises and mild stretching; but normal flexibility must exist if satisfactory results are to be obtained from gymnastic treatment. This treatment should be

carried out at first daily by actively stretching the contracted parts, and by exercises under supervision, akin to the setting up drill of the army recruit.

Improper clothing should be immediately given up, and the skirts or trousers supported from a belt or corset, or a union suit substituted for the waist, and round garters should be worn instead of side elastics.

Such children will generally be found to be either overworked, overstimulated, or underfed. It is desirable to shorten the day by seeing that they do not get up too early, and that they lie down for a while in the middle of the day. General hygiene should be regulated; school attendance, especially in badly ventilated rooms, watched; and incorrect attitudes minimized at home as far as possible, as soon as flexibility has been restored. Proper food, regulation of bowels and general hygienic measures should be instituted.

Corrective Exercises for Flexible Round Shoulders.—In addition to exercises for the spinal muscles corrective exercises must also be directed to the

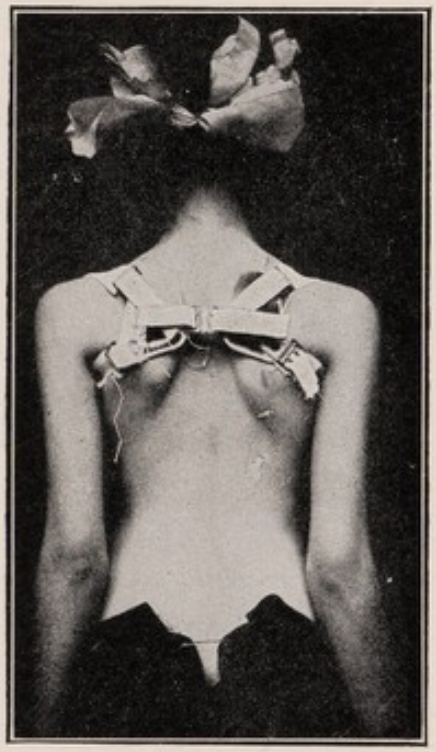

Fig. 703.

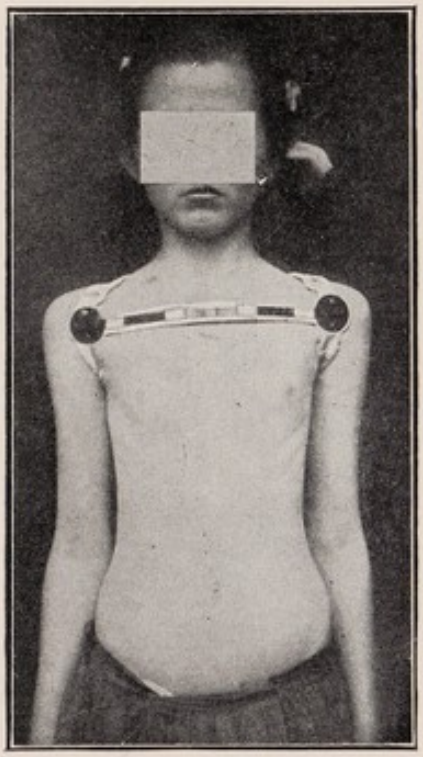

Fig. 704.

Figs 703–704.—Apparatus for holding improved attitude in forward shoulders.

abdominal muscles and to the muscles which hold the scapulæ back toward the vertebral column. If the scapulæ are allowed to continue in a forward position, satisfactory results will not be obtained. Two types of exercises are given for this condition: (*a*) back; (*b*) abdominal.

(*a*) The patient stands and bends the body forward at the hips and flings the arms forward and upward with the elbows straight. A deep breath is taken as the arms are flung forward and it is important that the back be kept straight as the bending position is assumed.

(*b*) The patient lies on his back and comes up to a sitting position, with the hands behind the neck.

2. *Treatment of Resistant Round Shoulders.*—The loosening up of the resistance is as a rule best accomplished by a skilful gymnastic assistant, and should

consist in diminishing the backward dorsal convexity by stretching while the patient lies on the back with the arms over the head and with the most curved part of the dorsal spine resting upon a padded roll; and in stretching of the scapulæ back to remove the contraction of the anterior structures, notably the pectoralis minor and major, and the other soft parts.

Corrective Exercises for Stiff Round Shoulders.—The same developmental exercises are used as for flexible round shoulders, and in addition the following exercises to mobilize the spine:

1. The patient kneeling on the table, arms stretched in front, and elbows straight, tries to touch the chest to the table, at the same time raising the head. This stretches the dorsal region and does not exaggerate the lumbar curve.

2. The patient lies on his back with a pillow rolled up under the shoulder blades. The lower ribs being held down by the operator, the patient attempts to bring both arms over the head and down to the table.

When the lumbar spine is stiff in lordosis, it is of no use to mobilize the dorsal region unless the lumbar curve is also corrected, which may be accomplished by means of the following exercise:

3. Sitting, with the legs extended, the patient attempts to put the head on the knees.

Stretching in a head sling is also desirable to straighten the cervical and upper dorsal spine; and forced inspiratory exercises are given to increase the thoracic capacity, which has the effect of making the maintenance of the proper attitude easier, after the mechanical obstacles to it have been diminished.

Apparatus.—The use of so-called "braces" to cure round shoulders should be condemned. A form of modified suspender is sold in the shops which is only detrimental, and the parents of such patients must clearly understand that the cure in the end must depend upon the restoration of mobility and the development of the muscles.

The use of a corset or brace in flexible cases may be permissible to hold the gain secured by gymnastics and, of the two, a light abdominal corset is much to be preferred. It will be found that if a light abdominal corset is applied to young children whose abdominal muscles are stretched and atonic, a better attitude will immediately be assumed by the child, and that the results in general will be more rapid and more satisfactory than after the use of a brace. The parents are almost invariably of the opinion that the corset will have a tendency to weaken the abdominal muscles, but they may be reminded that nothing weakens abdominal muscles more than stretching, and that the use of such a corset is only a temporary matter and protects the muscles against stretching while they are being cultivated by the proper gymnastic exercises.

In other cases, in which there is a distinct tendency of the spine to sag, a brace, consisting of a pelvic band and light posterior uprights, may be of assistance in maintaining the correct position.

The operative relief of the anterior contractions, which has been attempted from time to time, has never been satisfactory and is not to be advised.

Adult Round Back

The second type of round back, or kyphosis, is associated with, or the result of, some general condition, and is often associated with a change in the general condition.

Etiology. *Occupational Kyphosis.*—It is doubtful in what class the bowed back of the laboring man, accustomed to hard work, should be placed, occurring, as it does, as an adaptive change due to occupation, and becoming fixed in time.

Old Age.—The bowed back of old age is almost physiological, being due to the atrophy of the intervertebral discs, which increases the dorsal curve. This condition is frequent and troublesome, and begins to manifest itself in middle life, sometimes reaching a serious degree. Beginning with late middle life, the intervetebral discs become atrophied and shrink. As a result of this the vertebræ themselves come into closer contact and the modifying effect of the shapes of the discs is lost, and as the formation of the cervical and lumbar physiological curves is greatly influenced by the shape of the intervertebral discs, an atrophy of the discs changes the curve of a very considerable portion of the spine.



FIG. 705.—Round back and prominent abdomen of old age.

For this reason the single curve of the spine in old age replaces the three physiological curves of earlier life, the spine being bowed more or less backward with great diminution of the anterior cervical and lumbar curves. The kyphosis of old age makes itself manifest by a change in figure, loss of height, and, in many cases, a forward position of the head, often with pain at the back of the neck, and at times with an increase in a pre-existing lateral curvature.

The Result of Disease.—Aside from the bowed back due to spinal tuberculosis, kyphosis occurs in ostitis deformans, acromegaly, after spinal fracture and rupture of the interspinous ligaments, sometimes in poliomyelitis, in the last stages of the muscular dystrophies, in spondylitis deformans, scoliosis, osteomalacia, and rickets.

Treatment of Adult Round Back.—In the treatment of adult round back, the problem is entirely different from that of round shoulders in children, since the bones have assumed their final shape, and because the majority of the pathologic conditions mentioned above occur in later life. The round back occurring in connection with the general diseases mentioned is, in adults, exceedingly difficult to remedy.

If it is due to the persistence of the condition of round shoulders in children, the same measures as those advised for treatment of this condition are in general available, except that they must be more gentle and the outlook for improvement is considerably diminished. In the adult round back, Paget's disease, arthritis deformans and similar degenerative conditions, and in the stoop of old age, little or no improvement is to be expected in the curve; but a brace or chin support like a Thomas collar, for example, will often relieve the spine from the constant drag of the weight of the head. The treatment of a fractured spine, in which a deformity is increasing, does not differ from that

described in speaking of tuberculosis of the spine, the mechanical problem being the same; that is, protecting the softening bone from superincumbent body weight. Rupture of the interspinous ligaments is treated by the use of a posterior back brace.

Coccygodynia

A painful and sometimes disabling condition in the region of the coccyx occurs from time to time and in nearly all cases occurs in young adults, generally of a neurotic temperament.

The *clinical picture* is that of a youug rather highly strung female who has had an accident perhaps slight or severe, in which she sat down hard on the side walk or in rare instances fell astride of a chair or rail, but in some cases no traumatic history is obtainable. Much pain and soreness has followed the accident, which for a while improved, but later perhaps under nervous stress or being on her feet a good deal, pain steadily increased, and reached a degree which is described as intolerable. Going up and down stairs is uncomfortable and the patient is unable to sit, especially in a soft chair on account of the local pressure at the end of the spine, but may be able to sit in a wooden chair because the buttocks then may keep the coccyx from touching. The patient is very apt to sit twisted, resting only on one buttock. In the severer cases standing and walking are painful and particularly going up and down stairs. Defecation is accompanied by great discomfort in the severest cases, especially if constipation is present. The patient learns to sit on a rubber cushion with a hole in it, which she carries around everywhere, and is only too apt in many cases to relapse into a condition of invalidism. There is extreme local sensitiveness over the region of the coccyx and the condition is closely allied to what has been described in speaking of backache as the "spinal invalid."

A well marked type of case begins somewhat insidiously, is not connected with trauma, and passes on to a high degree by gradual but intermittent progress. In this particular class, in addition to the local examination a careful investigation into the static conditions of the erect position should be gone into, as many of these cases are apparently caused by abnormal deflection of body weight. The most common abnormalities in the balance are the existence of a short leg, flat feet or other disturbances of the feet, together with an abnormal antero-posterior position. In short, the same class of cause which would produce chronic backache is likely in certain cases to be expressed as coccygodynia, and just as careful an examination is necessary. The attachment of the gluteus maximus muscle to the coccyx should not be forgotten in connection with the static cause of the difficulty.

Other cases are due to pelvic cause, such as uterine displacement and pelvic inflammation. The normal, healthy subject after a fall, strain, or even fracture of the coccyx usually experiences great discomfort for a few days, is decidedly uncomfortable for some weeks, but should recover just as she would after any other fracture or similar injury provided it is properly treated.

Diagnosis.—The coccyx is easily reached through the rectum and any displacement or break can be readily determined by examination with the finger in the rectum. Local tenderness and swelling can in this way be also found. Sprains of the coccyx are manifested by tenderness over the articulation involved and over the sacrococcygeal ligaments, anterior, posterior, or lateral, and the great and small sacro-sciatic ligaments. It must be remem-

bered that muscular attachments may also be strained, four sets of muscles being connected with the bone—the coccygeus at the sides, the gluteus maximus behind, and the extensor coccygis (when present); at the apex the sphincter ani, and in front the levator ani. It must also be remembered that the coccyx is composed of four small bones, the various segments becoming united from below upward, the union between the first and second being frequently delayed until after the age of twenty-five or thirty. Late in life, especially in women, the coccyx often becomes ankylosed at its junction with the sacrum.

The X-ray may or may not be reliable in this region, and the antero-posterior view of course shows only lateral displacement. To obtain satisfactory definition in a side X-ray of course is difficult but often possible with a highly perfected technique.

A definite diagnosis is important whether the case is seen soon after the accident or later. The majority of such cases completely recover, but the prognosis must be greatly influenced by the patient's temperament. The main point to note in the diagnosis and prognosis is whether or not trauma was present and, if present, its degree, and the local findings are of less importance in formulating the future than is the temperament of the individual. Some of the worst cases arise without trauma, and severe trauma if properly treated is usually recovered from, provided the individual is normal.

Treatment—Acute Stage.—After a serious fall attended by pain at the end of the spine, an examination as described should be immediately made and the diagnosis determined. If displacement exists it should be corrected. In case of minor severity great comfort is derived from a hot hip bath taken two or three times a day. In the severest cases a strap of adhesive plaster around the pelvis low down gives comfort. Rest in the recumbent position is desirable if walking is painful. The use of a tight band or swathe around the pelvis will add to comfort and hasten recovery. Deep massage is of value in the convalescent stages.

Chronic Stage.—In this stage or when no accident has occurred a most careful search for a cause should be made. Errors in balance should be sought for and corrected, a supporting corset of the type suggested in backache should be worn particularly tight around the pelvis; irritating exercise should be avoided, and massage and electric light baking given locally. The general condition is important and should be looked after. The prolonged use of a rubber ring for sitting is undesirable as by pressure it causes congestion around the coccyx; its use should therefore be discontinued as early as possible.

Operation.—The operation of removal of the coccyx is too frequently performed and it is obvious that it will not necessarily cure the affection if it is due to static causes. The frequent persistence of pain after this operation should make one cautious in undertaking it and it should be performed only when every other resource has been exhausted.

It is essential to protect the strained coccyx from all pressure while it is in a painful condition. Clothing must be quite loose over that area and a long three inch thick pad in the shape of a horse shoe may be worn secured to the underclothing to prevent pressure when sitting.

SPONDYLOLISTHESIS

The term spondylolisthesis is applied to a forward displacement of the body of the fifth lumbar vertebra on the sacrum, or more rarely of the fourth

lumbar body on the fifth. Lumbo-sacral spondylolisthesis is by no means an uncommon deformity, and long ago attracted the attention of obstetricians to whom much of the earlier literature on the subject is due. (Neugebauer.[1]) It is now realised that the deformity occurs in both sexes equally, and in recent years has been recognised with increasing frequency in young subjects.

Etiology.—I. In true spondylolisthesis the fifth lumbar body alone is displaced, but the neural arch remains in situ. This is possible only where there is a solution of continuity in the pedicles. Such a hiatus might conceivably result from a definite fracture or destructive disease, and spondylolisthesis



FIG. 706.—Spondylolisthesis. Lateral view of spine, showing complete forward dislocation of the fifth lumbar body (C. Thurstan Holland).

arising under such conditions is occasionally seen. But in the majority of cases of spondylolisthesis, the clinical signs are first noted in adolescence or early adult life, and in patients in whom there is no evidence of pre-existing spinal disease or fracture.

We have already stated that anatomical studies have shown that *congenital* non-union between the body and neural arch of the fifth lumbar occurs in some 5 per cent of individuals. In this observation lies the true explanation of the ordinary form of spondylolisthesis. Where such a malformation exists, the fibrous bond between the centrum and neural arch may be sufficiently strong to hold the vertebra in place. But either as a result of a definite severe injury, or from gradual strain, the pseudarthrosis may undergo elongation, and

[1] NEUGEBAUER: Annals de Gynecol., xxii, 362, 1884 (and many other papers).

allow the vertebral body to slide downward and forward toward the interior of the pelvis. All degrees of displacement may be seen, and in the most extreme type the fifth lumbar body is rotated through an angle of 90 degrees on its transverse axis.

II. Under most exceptional circumstances the fifth lumbar vertebra may undergo displacement as a whole, after unlocking of the inter-articular processes has occurred, on either one or both sides. (Goldthwait.[1]) When the

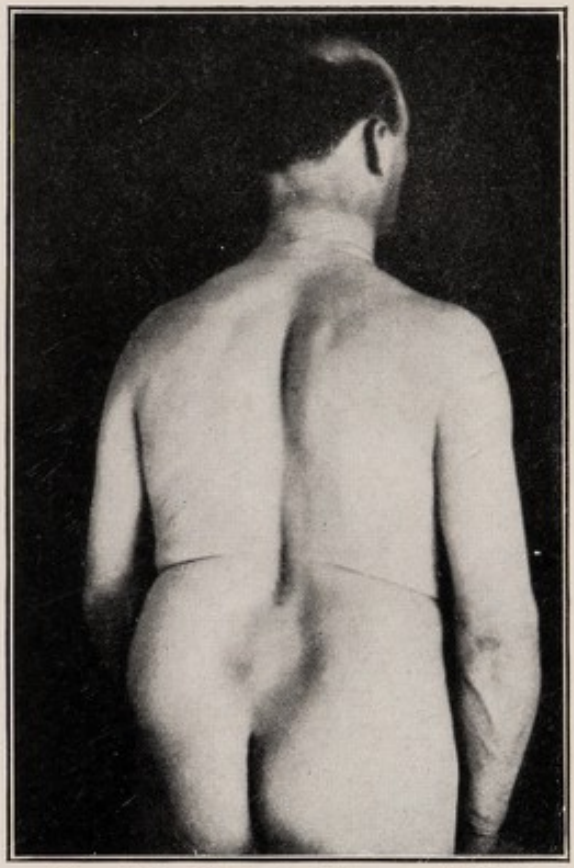

FIG. 707.—Patient with spondylolisthesis, showing characteristic hollow above the prominent sacrum.

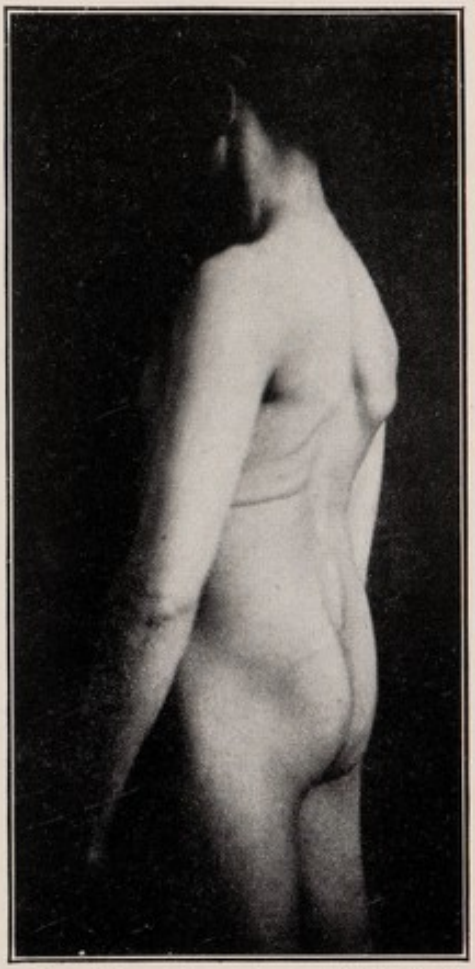

FIG. 708.—Case of spondylolisthesis seen from the side.

neural arch accompanies the body, pressure on the cauda equina roots is almost inevitable.

Clinical Picture.—The patient may complain of low backache, stiffness of the spine, and pain in the lower extremities, but in the majority of the younger individuals subjective symptoms are entirely absent. When attention is drawn to the spine, certain characteristic signs are readily demonstrable.

1. The profile of the trunk is most striking. The spine as a whole appears foreshortened as if telescoped into the pelvis, and there is a corresponding deep furrow encircling the body at the level of the loin. (Figs. 707 and 708.)

2. Just above the sacrum there is a hollow which gives the appearance of a localised and sharply defined lordosis. In the hollow, the fifth lumbar

[1] GOLDTHWAIT, J. E.: Boston Med. & Surg. Jnl., 164, 11, March 16, 1911.



FIG. 709.—Spondylolisthesis—characteristic appearance of X-ray.



FIG. 710.—Brace used for spondylolisthesis. Same patient as Fig. 707.

spinous process is deeply buried and just below it the upper angle of the sacrum is unusually prominent.

3. At the dorso-lumbar junction there is often a slight local kyphosis. (Turner and Tchirkin.[1])

4. The inclination of the pelvis is altered, and the long axis of the sacrum is more vertical than usual. The buttocks appear broadened and prominent, and the patient may walk with a waddling gait.

5. The range of motion in the lumbar spine often shows some limitation in the direction of forward bending.

6. The prominent vertebral body may sometimes be palpated through the abdominal wall, and is still more easily defined by rectal examination.

The diagnosis is confirmed by radiographic demonstration of the displacement. In the antero-posterior view of the pelvis the shadow of the complete lumbar body and transverse processes is seen to be superimposed on the upper part of the sacrum, (Fig. 709),—an appearance which is absolutely pathognomonic. In the lateral view the exact degree of forward dislocation and rotation of the vertebra may be estimated (Fig. 706).

Treatment.—Where the deformity is accidentally discovered in a child or adolescent there is no indication for immediate treatment. If symptoms arise later, the choice lies between conservative treatment, which should include a period of rest followed by the wearing of a well fitting spinal brace (Fig. 710) or fusion of the lumbo-sacral region by operation. Considerable success has followed the operation of *spinal fusion* in the hands of Ryerson,[2] Albee,[3] and others. Owing to the depth of the lower lumbar spinous processes, an angular bone graft suitably shaped must be used if the Albee technique is followed.

In the rare cases with cauda equina pressure, laminectomy should be performed without delay.

VERTEBRAL OSTEOCHONDRITIS

The above term is applied to a localised lesion of the spinal column in children simulating the clinical picture of Pott's disease, and first described by Calvé[4] in 1925. The condition is apparently rare and little is known concerning its etiology. Tubercle and syphilis have been definitely excluded in all cases recorded up to date—(nine cases, 1928, Calvé[5]). Trauma, infection, and endocrine disturbance have all been cited as possible factors.

Symptomatology.—In a child between the ages of five and ten, a localised angular kyphus appears in the lower dorsal or dorso-lumbar region. This may be accompanied by pain and muscular spasm. The radiographic appearances are absolutely characteristic. The changes are confined to a single vertebral body, which in the early stage shows a flattening of its central osseous nucleus, with a marked increase in density. (Fig. 711.) The intervertebral discs above and below the deformed body are unaffected. Later the vertebra undergoes reconstruction, but as far as is known does not return to its original shape. The clinical symptoms tend to last for a short time only.

Diagnosis.—The clinical picture is identical with uncomplicated Pott's disease in the earlier stage. The vertebral deformation as seen in radiograms

[1] Turner and Tchirkin: Jnl. Bone & Joint Surgery, vii, 4, October, 1925.
[2] Ryerson, E. W.: Journ. Amer. Med. Assoc., lxiv, 24, 1915.
[3] Albee, F. H.: Jnl. Bone & Joint Surgery, ix, 3, July, 1927.
[4] Calvé: Jnl. Bone & Joint Surgery, vii, 41, 1925.
[5] Calvé: The Robert Jones Birthday Volume, Oxford University Press, 1928.

must be distinguished from—(*a*) Congenital flattening (Putti[1] and Lance[2]); and (*b*) Pott's disease.

In the latter, wedge deformation is the rule, and two bodies are involved; but occasionally a lamellar flattening may be seen which closely resembles osteochondritis. On careful inspection the deformed body is found to correspond to two pedicles.

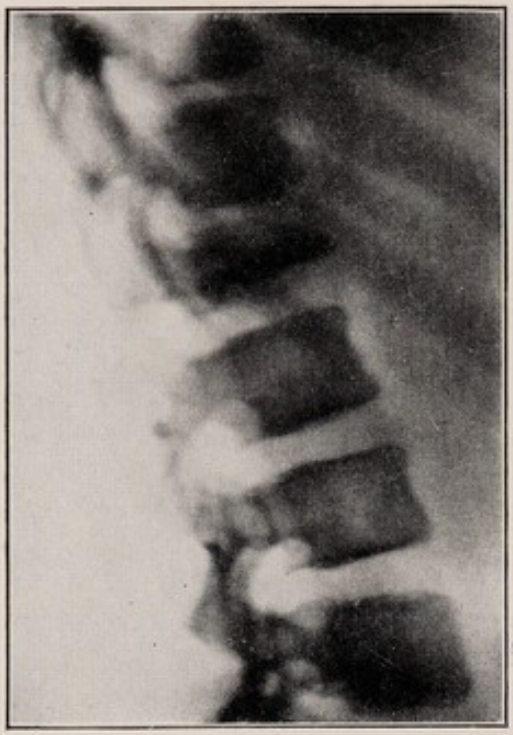

FIG. 711.—Osteochondritis of the first lumbar vertebra (Ancoats Hospital).

Treatment.—During the stage of pain and muscular spasm a period of rest in recumbency with the spine hyperextended is advisable, but in the light of our present knowledge treatment per se has little influence on the ultimate progress of the affection.

SPINA BIFIDA

The term Spina Bifida is applied to a congenital gap in the vertebral column, through which a sac protrudes. In the majority of cases the hiatus involves the neural arches (posterior spina bifida). More rarely the vertebral bodies are defective with the sac projecting into the pelvis, abdomen, or thorax (anterior spina bifida). The deformity is said to occur once in every thousand births, and affects both sexes equally. The cause is enshrouded in mystery. Many infants do not survive birth and others die in the early months of life.

Morbid Anatomy

Five varieties of spina bifida are usually recognised: (Fig. 712).

1. **Meningocele.**—The hernial protrusion consists in a pedunculated sac derived from the dura mater and connected to it by a narrow neck. The sac contains cerebro-spinal fluid but no nerve tissue.

[1] PUTTI: Fortschritte auf dem Gebiete der Rontgenstrahlen, 1900, 14 and 15.
[2] LANCE: Bull. et Mém. de la Soc. Nat. de Chirg., 4, Feb., 1927.

2. **Myelo-meningocele.**—The sac is usually sessile, and projects through a large gap in the laminae of three or four vertebrae. It contains both spinal fluid and nerve tissue which varies according to the level of the tumor. The spinal cord or its terminal filament may enter the sac and blend with a vascular area in its lining. In other cases nerve roots only are demonstrable.

3. **Syringo-myelocele.**—In this type, the spinal cord itself forms an actual lining to the sac and is thinned out as a cyst by distention of its central canal.

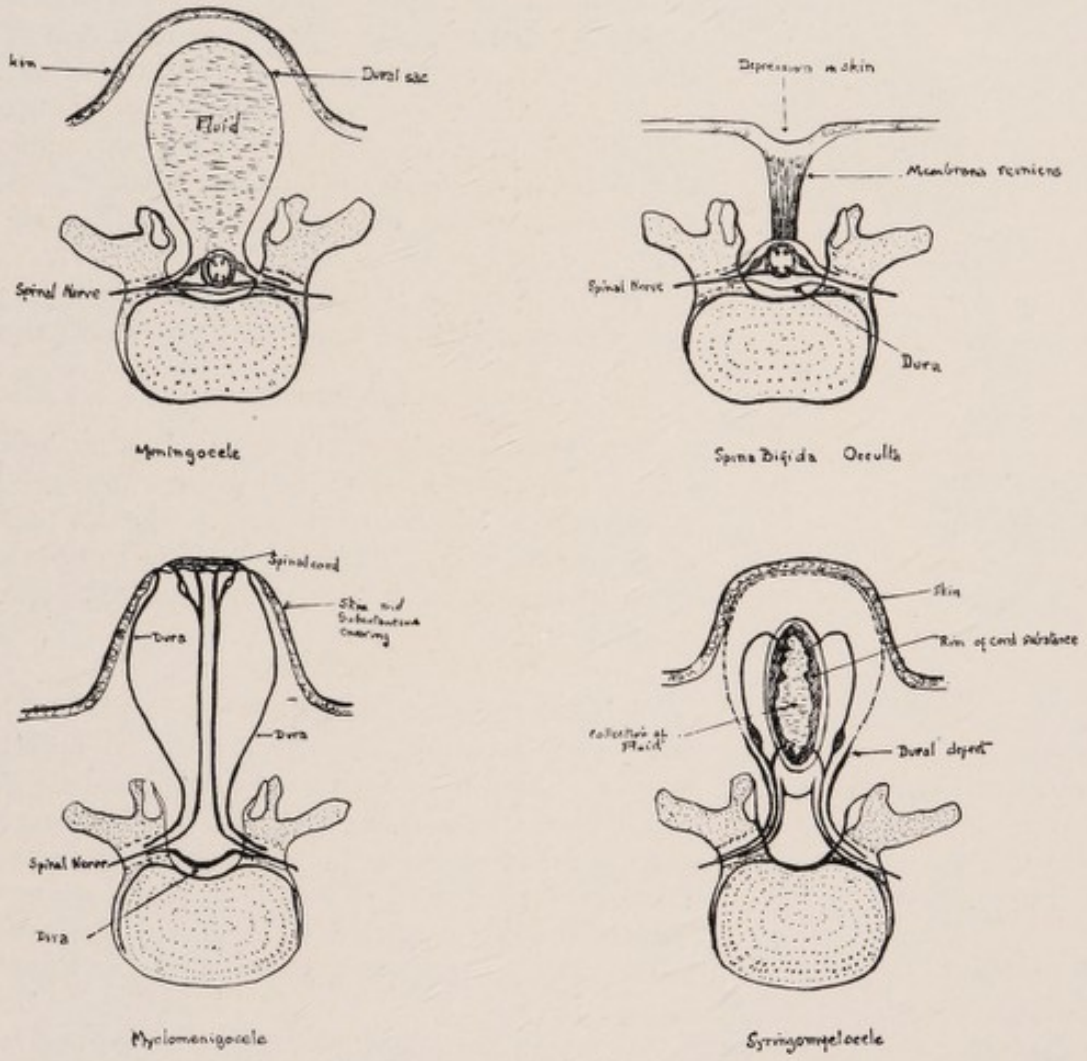

FIG. 712.—Types of spina bifida (after Frazier).

4. **Myelocele.**—This grave defect which is usually seen only in the lumbar region, consists of a cleft leading down from the skin surface to the interior of the spinal cord. Infants born with this type of spinal deformity rarely survive more than a few days.

5. **Spina Bifida Occulta.**—In this type a skeletal defect exists without protrusion of the contents of the spinal canal. The dura is often connected to the skin by a fibrous band, which passes through the bony hiatus. Occasionally a tumor may be present, either outside or inside the vertebral canal. Such tumors are usually lipomata or angiomata, and may remain latent for a considerable period before taking on growth. The skin overlying a spina bifida occulta generally shows a dimple and a localised overgrowth of hair. Claw foot is a not uncommon associated deformity (Chapter XXX).

Clinical Picture

1. **The Tumor.**—The tumor is situated in the middle line and is most frequently found in the lumbar or lumbo-sacral region (Fig. 713). It is fluctuant, sometimes transparent, and shows variations in size during coughing or crying. The hiatus in the spinal column is demonstrable in a radiogram.

2. **Nervous Signs.**—When present these vary from a slight localised palsy, to severe motor, sensory, and trophic phenomena in the lower limbs. In spina bifida occulta, signs of nerve involvement do not usually appear until about the age of puberty, and are then due to the pressure of the fibrous band already described.



FIG. 713.—Spina bifida; myelomeningocele type.

3. **Associated Deformities.**—In many cases of spina bifida other deformities are present, affecting either the spine itself or the lower limbs (talipes, contracted knees, congenital dislocation of the hip).

Hydrocephalus is also seen in a certain proportion of cases, and is an important prognostic sign.

Diagnosis

In the diagnosis of the type of spina bifida a radiogram taken after the injection of oxygen into the sac gives most valuable help. By this method of examination the distribution of the nerve structures in the sac may be clearly demonstrated.

Treatment

1. **Conservative Treatment.**—In an infant born with a spina bifida the sac should be protected from the first by a clean wool pad enclosed in a small frame, and the skin should be sterilised each day by ether or alcohol. If the tension increases rapidly, repeated aspiration of small quantities of fluid should be carried out. If such precautions are omitted, infection of the skin, ulcers, and the leaking of spinal fluid will occur, and lead to meningitis and death.

2. **Operative Treatment.**—Operation may be undertaken with good prospect of success in most meningoceles after the third month, but in the myelomeningocele and the syringo-myelocele the outlook is unpromising. The myelocele is of course not suitable for any form of operative repair. No operation should be attempted in the presence of a leaking sac, extensive paralysis of both lower limbs, or associated hydrocephalus.

The aim is to excise the sac, reduce or remove the contents, and to close the hiatus in the spinal column. The skin incision should be made encircling the base of the tumor, and the meningeal sac freed down to the gap in the laminae. The sac is then opened, the interior inspected, and the contents dealt with in accordance with the type and distribution of the nervous structures. In a pure *meningocele* the sac should be completely excised and the neck closed by suture. In a *myelomeningocele* the vascular area which contains nerve cells and from which nerve roots may take origin, should

always be preserved. The termination of the cord and the nerve roots should be freed from their adherence to the sac and returned to the vertebral canal. In a *syringo-myelocele* the whole cyst should be replaced after tapping it to reduce it in size. Closure of the vertebral gap may be achieved by various methods, the simplest being the approximation of muscular flaps with or without division of the laminae at their bases so as to allow bony contact in the middle line. In *spina bifida occulta* operation is indicated only if signs of pressure develop in later childhood. The operation consists in the removal of the fibrous band which connects the dura to the skin, or the extradural lipoma if such a tumor be present.

THE THORAX

Anatomy.—The thorax consists of a bony framework joined together front and back by articulations and covered by soft parts. The anterior median wall is composed of the sternum to which are attached by short cartilages the upper six ribs. The anterior end of the sixth rib is about on a level with the lower end of the sternum. The seventh, eighth, ninth and tenth ribs are below the lower end of the sternum and are united to it by a series of cartilage which form an angle—the subcostal angle. The eleventh and twelfth ribs are not connected with the sternum. The upper margin of the sternum in the adult female is on a level with the lower part of the body of the third thoracic vertebra, and in the male with the same part of the second thoracic vertebra.

The adult thorax is conical in shape with the apex of the cone upward, longer behind, and flattened in the antero-posterior diameter. The anterior surface is inclined forward from above downward. In inspiration the ribs become more horizontal and the chest is deepened in its antero-posterior diameter and its circumference increased. It is important that in man muscular effort has to overcome gravity to lift the ribs in order to fill the chest, while in the quadruped, gravity aids inspiration because of the different slant of the ribs.

In the fetus the antero-posterior diameter is greater than the transverse, reverting to the shape of the thorax in the quadruped. In infancy the two diameters are nearly equal, from which we get the rounded chest of the child, and about the second year the chest becomes oval on its way to the adult shape, in which the transverse diameter is one-quarter greater than the antero-posterior. Hutchinson[1] has worked out an index showing the relative depth of the chest at different stages. This index is found by dividing the antero posterior diameter at the nipples by the transverse diameter at the same level. The lower the index the flatter the chest.

TABLE OF INDICES

Embryo	105–115
At birth	101
Under two years	94
Three to seven years	85
Fourteen to eighteen years	80
Adult	72

Deformities of the Thorax

Rachitic Deformities.—In rickets the thorax is compressed from side to side, most markedly in the middle region, the back of the thorax is flattened and the sternum unduly prominent in front, that is, the antero-posterior deformity of the chest is increased at the expense of the lateral. Enlargements are found at the junction of the ribs and costal cartilages, "the rosary," and in marked case of rickets there is a transverse constriction of the chest known as *Harrison's groove*, which is most evident just below the nipples and below this groove the lower part of the thorax flares out. These changes are apparently largely due to atmospheric pressure working upon a softened thorax. It is most important that they should be clearly identified and cor-

[1] Jour. Am. Med. Ass'n., Sept. 11, 1897, and May 2, 1903.

rected after the softening of rickets is over. They are amenable to treatment by gymnastic exercises, and by changing erroneous deflection of body weight where it exists.

Pigeon Breast (Pectus Carinatum).—This deformity, more or less common in children, is characterized by an increase in the antero-posterior diameter of the chest with a diminution in the lateral which carries forward the sternum and cartilages of the ribs. The deformity is in nearly all cases acquired, is frequently associated with rickets, and is aggravated and apparently also caused by obstruction of respiration due to enlarged tonsils and to adenoids. It is also a secondary effect of tuberculosis of the spine in the upper thoracic region which thrusts the sternum downward and forward. The deformity, although generally most marked in the median line, in some cases, especially when lateral curvature of the spine exists, is most marked on one side of the sternum, due to a buckling forward of the costal cartilages on that side. This unilateral deformity is often more unsightly and more difficult to deal with than the median prominence.

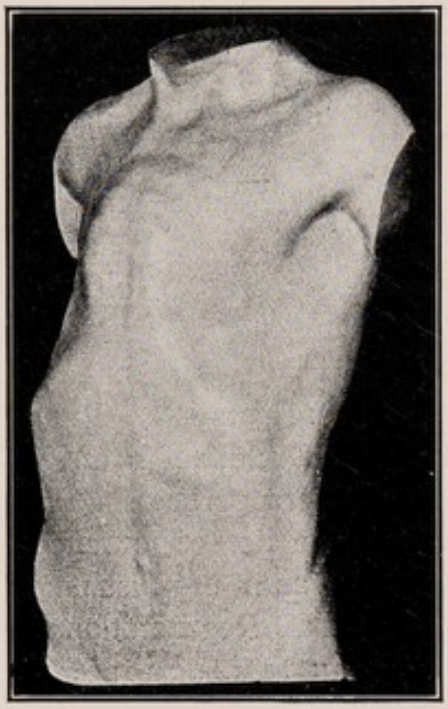

FIG. 714.—Pigeon breast (Wollenberg).

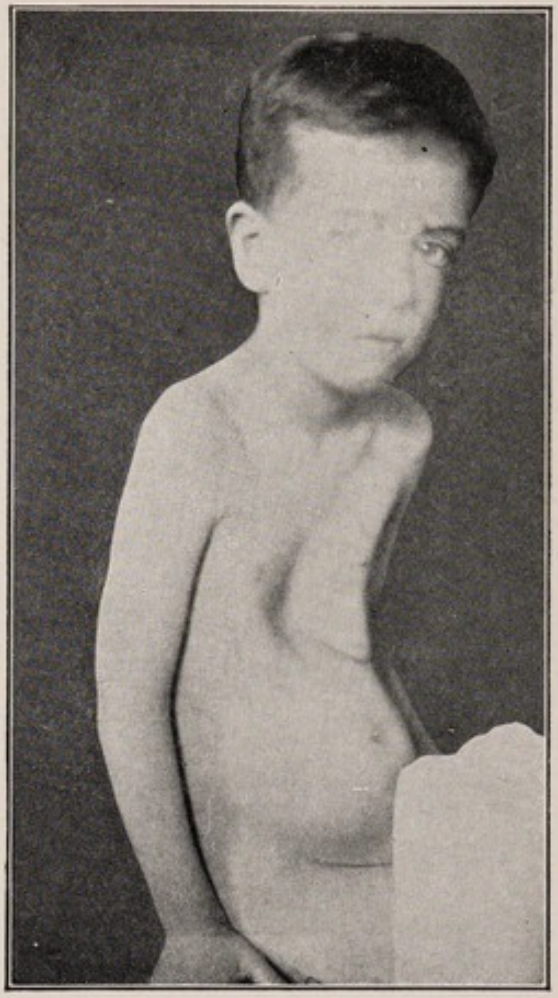

FIG. 715.—Funnel chest (Bradford & Lovett).

The treatment consists in gymnastic exercises and sometimes pressure on the unilateral prominence by means of a spring brace, like a truss for hernia, pressing by means of a spring on the prominence in front and obtaining a hold on the back of the thorax. A most useful exercise for both median and unilateral deformities is for the patient to lie on his back and take deep forced inspiration while manual pressure is made downward on the anterior prominence. This compels inflation of the lateral parts of the chest. In addition

to this, forced inspiration with the arms above the head, and general exercises of a type suitable for chest development are the best means of treatment at our disposal.

Funnel Chest (Pectus Excavatum).—This name is applied to a deformity in which the sternum is depressed below its normal level carrying with it the costal cartilage attached to it. The lateral diameter of the thorax is correspondingly increased and the antero-posterior diminished. It is often evidently of congenital origin and its severest forms can only be accounted for in this way, but the slighter cases are probably associated with respiratory obstruction. The causation of the deformity has, however, never been satisfactorily explained.

The deformity is unsightly but moderate cases in boys are of little consequence. In girls, however, a moderate persistence of the deformity into adult life will make the wearing of an evening dress impossible. In the severest cases the sternum is sunken so low that it seems as if between it and the vertebræ there could be very little space.

For the severest forms the best that can be hoped will be an amelioration of the deformity by gymnastics, depending chiefly upon expiratory movements such as blowing a wind instrument, by gymnastics to pull out the sternum, for which the pectoralis major must be chiefly depended upon. Inspiratory gymnastics must be strictly avoided. No operative treatment is of value. A very doubtful prognosis should be given as to any marked improvement in severe cases.

Flat Chest.—The flattened chest has been described under the heading of round shoulders.

Cicatricial Deformities.—Attention should be called to the cicatricial deformity following various affections of the pleural sac so often resulting in severe scoliosis as the chief deformity of the thorax. When such curvature occurs it is convex toward the sound side of the chest, but the most important aspect of the matter is for the surgeon to bear in mind the frequency with which scoliosis occurs late in these cases, particularly after empyema.

Congenital Deformities of the Chest.—Congenital deformities of the chest arise from cervical ribs, congenital malformation of the vertebræ, and malformation of the ribs. The subject is not of great practical importance, the condition is rare and is easily identified by the X-ray, and will not be dealt with here. The matter is discussed somewhat in connection with congenital scoliosis (p. 739).

CHAPTER XXXII

SCOLIOSIS

Lateral Curvature of the Spine

Synonyms.—English: Scoliosis, rotary lateral curvature of the spine Kyphoscoliosis. French: Scoliose, déviation latérale de la taille. Italian: Scoliose. German: Skoliose, seitliche Rückgratsverkrümmung. Kyphoskoliose.

Scoliosis, or lateral curvature of the spine, is the name applied to a condition in which any series of vertebral spinous processes shows a constant deviation from the median line of the body, a deviation always accompanied by an element of twisting; in certain cases the twisting may be the predominant appearance. Deviation of a single vertebra from the median line does not constitute scoliosis.

Occurrence.—Scoliosis in animals[1] other than man has been observed, but is rare. Among domestic fowls scoliosis is not uncommon in hens, ducks and geese. In fowls and quadrupeds it is due to vertebral defects and unilateral numerical variation of the vertebræ, and vertebral anomalies, inflammation of bones, and rickets. It occurs also in fishes and snakes. Experimentally scoliosis has been produced in animals by Wullstein,[2] Arndt,[3] and Ribbert.

Figures with regard to the frequency with which scoliosis is found in the population as a whole are lacking, except for some figures brought forward by Schanz.[4] In five years, of 189,000 recruits available for the German army 7.2 per thousand were disqualified for spinal curves of all kinds; that is, less than 1 per cent. Figures with regard to the percentage of scoliotics in hospital practice show nothing because the clientele of various hospitals varies so largely. It is evident, moreover, that the percentage of scoliotics among numbers of persons examined will vary with the point of view and standard of the observer. The very careful and modern investigations of Combe, Scholder and Weith, Gronberg,[5] Haglund,[6] and Lubinus[7] seem to form the safest basis for conclusions. According to these, the frequency in girls of the school age varies from 10 to 23 per cent, and of boys from 16.4 to 26 per cent. It is generally the opinion that in adults women show a greater number of scoliotics than men, although published statistics confirming this fact do not exist. Records of the relative frequency of scoliosis in adolescents and children made in orthopedic institutions where patients apply for treatment show a very much larger percentage of scoliosis among girls than boys.

The difference between the sexes is less where large numbers of school children are investigated, such figures showing in general a slightly higher percentage in girls than in boys. To explain this difference we must either

[1] Hartel: Deutsch. Zeitsch. für Orth. Chir., lxlviii, 277.
[2] Wullstein: Zeitsch. für Orth. Chir., x, 2.
[3] Arndt: Arch. für Orth. Chir., i, 1, 2.
[4] Schanz: Verhdl. d. Deutsch. Ges. für Orth. Chir., 1910, 454.
[5] Zeitsch. für Orth. Chir., xxiii, 130.
[6] Zeitsch. für Orth. Chir., xxv, 649.
[7] Verhdl. d. Deutsch. Ges. für Orth. Chir., 1910, 469.

assume that boys outgrow scoliosis, or that they do not come to the institutions for treatment until the curves become severe or until complications arise.

Scoliosis is an affection of the years of growth in a large majority of cases, but in individual cases it is often extremely difficult to form an accurate idea of the age at which the deformity begins to be evident. Scoliosis due to rickets, infantile paralysis, and congenital causes may become evident up to the fifth year. In general, however, the inaccurate observations of parents furnish no foundation upon which to base theories or statistics concerning the time of the beginning of the scoliosis observed in older children.

Symptoms and Physical Signs

Lateral curvature of the spine is necessarily accompanied by some distortion of the symmetry of the body. It is not generally recognized by the laity as a spinal distortion, but the patient is brought for surgical advice because of "a high shoulder," "a prominent hip," or "a projecting shoulder-blade." Very often the dressmaker is the first to recognize the affection, because she finds that she must make the skirt longer on one side than on the other, or because the distance from the armhole to the waistband is longer on one side than on the other. The condition is essentially a distortion and symptoms other than the deformity are rather unusual in average cases. Occasionally the patient complains of feeling "one-sided," but this is rare.

Pain is generally not complained of, but in neurasthenic young women, especially with functional curves, backache may be felt more or less on standing. In the severest cases, pain may be caused by the descent of the ribs to the level of the crest of the ilium against which the lower ribs may rub, and severe local pain may be felt. In other severe cases, in older people, nerve-root pressure may result from the distortion and be referred to the peripheral ends of the spinal nerves.

The shortening of the trunk and the diminished capacity and immobility of the thorax may lead to impairment of the function of thoracic and abdominal organs, especially in severe cases; and shortness of breath is common in such on account of diminished respiratory capacity. Displacement of the heart and phthisis frequently occur in severe cases during adult life. Disturbances of digestion are also frequent from displacement of the stomach and liver. The adult with a severe deformity may show considerable impairment of vigor, but during childhood there is often little deterioration of the general health.

It is not uncommon for patients to go through life with curves of moderate degree which have given rise to little or no trouble; but at or after middle life, when atrophy of the intervertebral discs occurs, such curves may increase and give rise to a sense of asymmetry or to pain in the back or at nerve terminations. It can generally be predicted that a curve of moderate severity will be more troublesome in later adult life.

Terminology.—The terms used in describing lateral curvature must be defined. Curves are named "right" or "left" according to their convexities—curves convex to the right being called right curves, and *vice versa*. In addition to the terms right or left, the curves are named also according to the anatomical region involved, with the qualifying adjective right or left preceding the anatomical name. If a curve involves more than one region, it is classed as "cervicodorsal" or "dorsolumbar." If two curves exist, the upper curve is

spoken of first and the lower follows, *e.g.*, right cervicodorsal, left dorsolumbar; or right dorsal, left lumbar.

It is important that the anatomical region affected by the curve be designated accurately and not loosely. For this purpose the seventh cervical and last lumbar vertebral spines are marked on the skin and connected by a string representing the long axis of the spine. Parts of the spine lying to the right of this line are classified as right curves, parts to the left as left curves. Such curves must be assumed to begin and end where they pass under the string. This, therefore, provides a simple rule for the naming of every curve, insisting on the fact that the location of the upper end of the column has nothing to do with the naming of the curve.

The classification of curves into primary and secondary, or compensatory, is not of great importance, nor is it sound, as one cannot always say which curve was really primary. Often it is obvious that one curve is predominant and evidently the one to be attacked in treatment. In other cases this cannot be done, as the curves are of equal degree and importance so far as can be seen. It is, however, of importance to recognize the predominant curve where possible. For example, in a marked and predominant right dorsal curve it matters but little, practically, whether a slight lumbar curve exists or not; for purposes of treatment the case is a dorsal curve. In general, rational treatment must eliminate unimportant factors and deal with the salient ones. The former division of lateral curvature into stages has no rational basis.



FIG. 716.—Boy with left total scoliosis photographed from overhead, showing the carrying back of the shoulder girdle on the right. The front edge of the board on the floor marks the lateral plane of the pelvis.

Types of Lateral Curvature

Lateral curvature is a progressive affection passing over only one sharp line, the transition from postural or functional curves to structural or organic ones. This classification of "postural" and "structural" will, therefore, be adopted here.

Postural Scoliosis (Total or False Scoliosis).—The term "total scoliosis," is applied to cases where the spine forms one gradual curve to one side without compensatory curves. In 90 per cent of such cases the curve is to the *left.*

The deviation at the greatest curve is not often over one and one-half inches from the median line of the body. There is no obvious compensatory curve, and the untrained eye is likely to find slight cases normal. There is, however, a perceptible displacement of the trunk to the left, especially as seen from the front, and a plumb line suspended in the median line of the body, as defined by the vertical fold between the buttocks, will detect a decided deviation of the spinous processes from the median plane. Postural curves disappear on sus-

pension or recumbency, and side flexibility is but little limited, bending to the left occasionally being somewhat restricted. In cases of right curves the description is reversed.

The typical characteristics of a left total scoliosis are as follows:

1. A general curve, convex to the left.
2. The left shoulder is elevated.
3. The right side of the shoulder-girdle is carried back and the left side forward.
4. When the patient bends forward the right side of the back may be slightly higher than the left (Fig. 718).

The position in a typical postural total curve is merely the physiological one necessitated in every normal spine when for any reason it is made convex to the left; and such a curve can be produced experimentally by putting a book under the right foot, which raises the right side of the pelvis and necessitates for balance a left convex curve of the spine. A spine making any bend convex to the left in the erect position must rotate at its upper end to the right, in accordance with mechanical laws.[1] The thorax and shoulders will be twisted backward on the right, and when the patient bends forward, this twisted position of the shoulders may be carried over into the position of forward bending, if the case has been of long standing, and the right side of the back will be higher in this position. This "reverse rotation," "concave torsion," "retrotorsion," as it has been called, has been much discussed[2] as an accompaniment of total

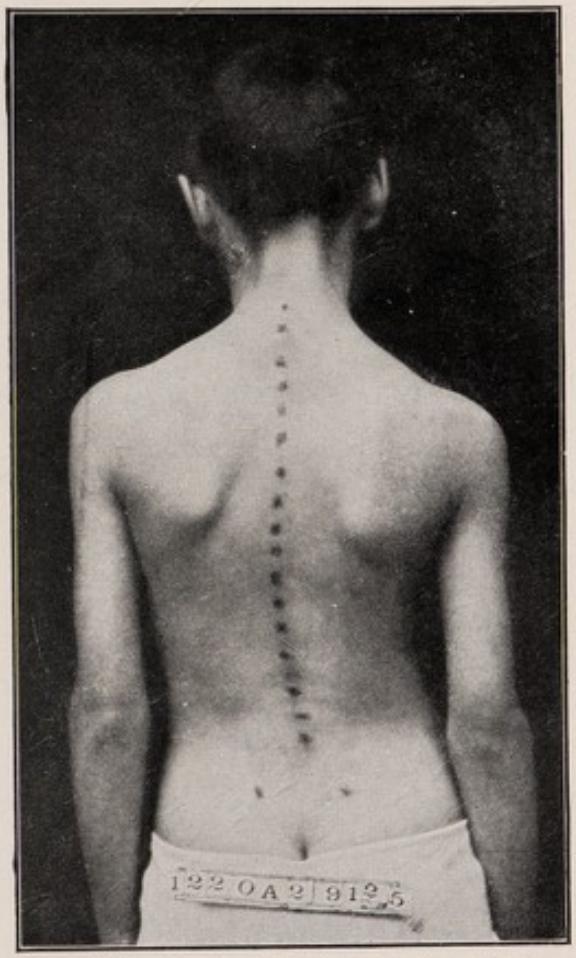

Fig. 717.—Moderate left postural scoliosis.



Fig. 718.—Same case as Fig. 717, bent forward, showing slight elevation of right side of back; sometimes called "retrotorsion" or "reverse rotation."

[1] Lovett, R. W.: Boston Med. and Surg. Jour., June 4, 1900; Oct. 31, 1901; Mar. 17, 1904; Sept. 28, 1905.
[2] Schulthess: Zeitsch. für Orth. Chir., x, 489.

scoliosis, but is a physiological matter easily understood by studying the mechanics of the normal spine.

Structural Scoliosis (Organic, Fixed, or True Scoliosis).—This term is applied to those cases in which there is reason to believe that a structural change has occurred in the vertebræ. It cannot be reproduced experimentally in the model, cadaver, or child, and is not within the physiological limits of the spine. It must, therefore, be classed as *structural* or *organic lateral curvature.* The characteristic feature is a local backward prominence of the ribs or

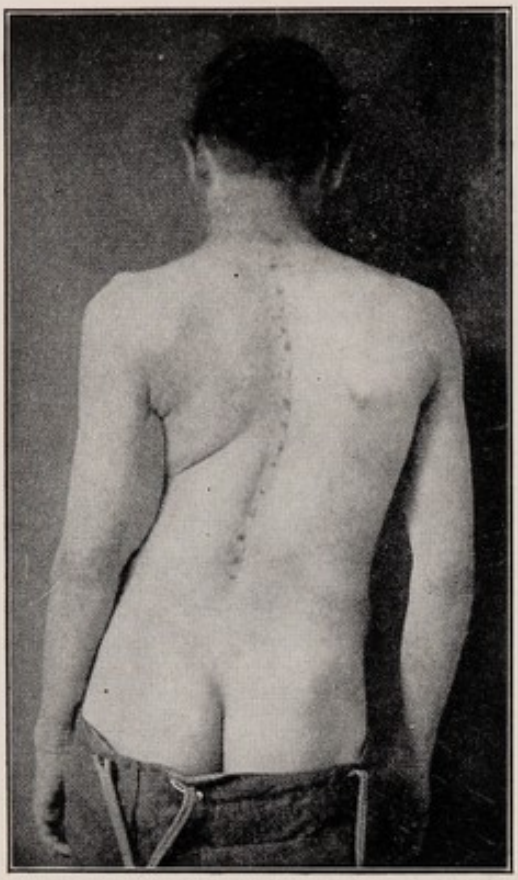

Fig. 719.—Right dorsal, left lumbar curve.



Fig. 720.—Forward bent position, showing right dorsal, left lumbar rotation (same patient as Fig. 719).

lumbar transverse processes in the curved region, which is called "bony rotation."

The reason that *bony rotation* or twisting of the vertebral bodies always accompanies organic lateral curvature, is because the vertebral column is a flexible weight-bearing rod curved in the antero-posterior plane. A plastic weight-bearing column already curved in one plane cannot yield in another plane (*i.e.*, to the side) without twisting, and in this twist the vertebræ can turn in only one way, namely, away from the greatest weight and pressure, which is, of course, on the concave side of the lateral curve, so that they must turn toward the convex side. The plastic bones yield to unequal strains, and the deformity becomes perpetuated by secondary changes.

Structural curves are simple or compound—simple, when the deviation is single and accompanied by no compensating curves, *e.g.*, left lumbar scoliosis. The scoliosis is compound when more than one curve is present, *e.g.*, right dorsal, left lumbar scoliosis. The simple curves have sometimes been spoken of as

"C curves" and the double ones as "S curves." Triple curves at times exist. When compound curves are present, they alternate to the right and left.

Lateral Curvature as Influenced by Location. *Lumbar Curves.*—Lumbar scoliosis exists as a simple curve, but more often is only one component of a compound curve, the dorsal curve being, of course, in the opposite direction.

The trunk is displaced to the side of the convexity of the curve, so that the line of the waist is flattened on the convex side, while the waist on the concave side of the curve is sunken, and folds may form in the skin of the flank. This is expressed by an apparent prominence and greater size of the hip on the concave side, and it is popularly said that one hip has "grown out," or one

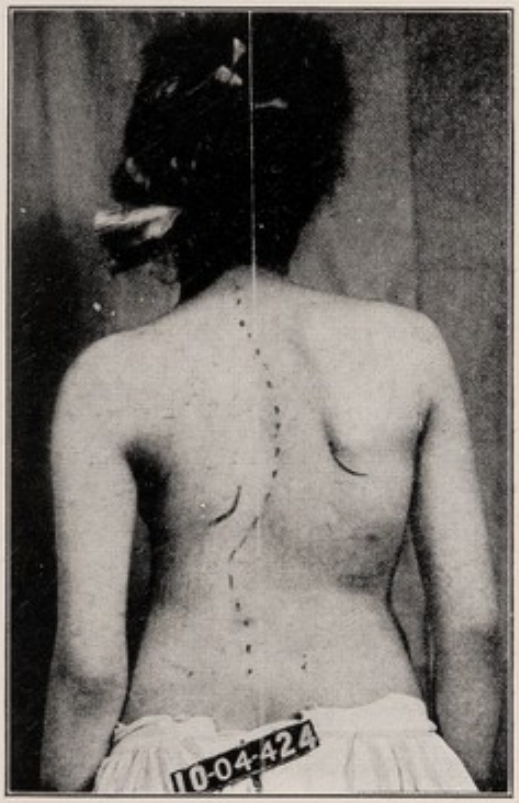

FIG. 721.—Triple curve—left cervico-dorsal, right dorsal, left lumbar.

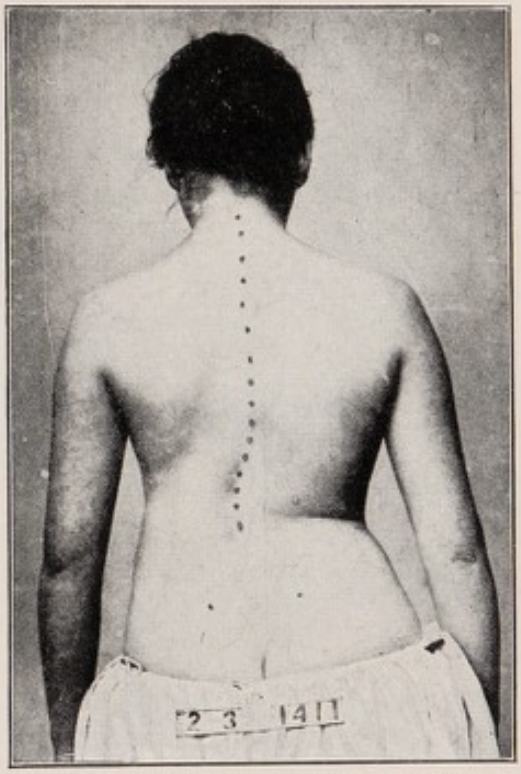

FIG. 722.—Left lumbar curve, showing indentation at waist on right.

hip is "higher" than the other, meaning in anatomical terms that the crest of one ilium is more prominent than the other. This inequality of the hips and waist-line is the most striking feature of lumbar curves, and unless corrected, forms an unsightly deformity in women with prominent hips, and makes it necessary to make the skirt longer on one side than on the other.

As the patient stands, there is noticed in marked cases on the convex side of the curve a fullness of the back, caused by the rotation of the vertebræ, which carry the heavy transverse processes around and make prominent the overlying structures. In the position of extreme forward bending, the side of the back on the convexity of the lateral curve is prominent upward, but lumbar rotation is always less prominent than dorsal, and to the untrained eye even in the severer cases seems slight. In side bending, mobility is greater toward the side which makes the curve worse than to the side which improves it (Figs. 723–724).

Dorsal Curves.—A single dorsal curve is more frequent than the single lumbar type, but dorsal curves are, more often than not, accompanied by reverse or compensating curves above or below.



FIG. 723.—Left dorsolumbar curve; the patient is shown bending to the right, which is easily accomplished and increases the lateral curve.



FIG. 724.—Same patient bending to the left, which straightens the curve and is obviously restricted.

In a marked right dorsal curve, as seen from behind, the thorax is displaced to the right, and the right arm hangs farther from the side than the left. The right costo-humeral angle is less than the left; the right shoulder is raised and the waist-line on the right is less concave, and much flattened in the severer

cases, the ribs coming close to the crest of the ilium and obliterating the natural waist indentation. The rotation is made evident by a prominence in the back of the right side of the thorax, which may be seen as the patient stands erect. Unlike the rotation in lumbar cases, the rotation element in dorsal cases is a very marked feature of the deformity. The left side of the



FIG. 725.—Left dorsal curve.

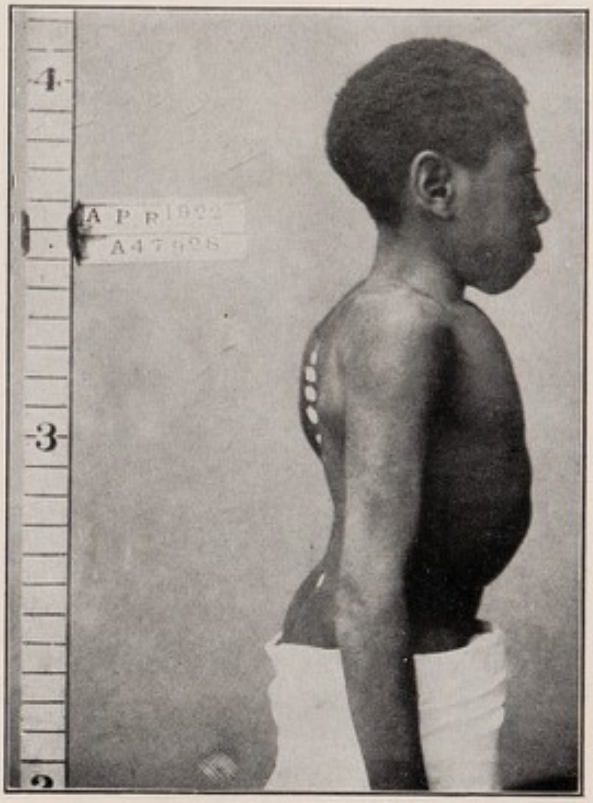

FIG. 726.—Kyphoscoliosis.

thorax as seen from behind is flat or concave, and when the patient bends forward until the trunk is horizontal, the rotated ribs are very prominent upward on the right, and a long arch of rib angles is seen which is much more marked than in the standing position. In a right dorsal curve the right shoulder will inevitably be higher than the other unless a left compensating cervico-dorsal curve exists above it. As seen from the front, the deformity is even more evident. This description is, of course, to be reversed for left dorsal curves.

In a left dorsal curve the thorax is displaced to the left, the left shoulder is higher than the right, and the right side of the thorax more prominent in front than the left. The contour of the chest is changed, and the longest horizontal thoracic diameter is the oblique antero-posterior line from the point rotated backward on the right, to the point rotated forward on the left—in this case from the right scapula to the left nipple.

The dorsal physiological curve is most often increased, making the rounded and distorted back spoken of as *kyphoscoliosis*. It may, however, be flattened, and even slightly concave forward in the dorsal region. Loss of height and shortening of the trunk are evident in the severer cases.

Dorsolumbar Curves.—Dorsolumbar scoliosis is a form seen as a single curve with considerable frequency (20 per cent), much more common than

single lumbar, and about as frequent as single dorsal scoliosis. It naturally partakes of the character of the two forms just described. The seat of the greatest curve is generally at the dorsolumbar junction, and the trunk and lower thorax are displaced toward the side of the convexity of the curve and overhanging the pelvis, and the waist-line on that side is flattened or obliterated, while on the concave side the waist outline cuts in sharply above the pelvis, frequently forming folds in the skin. The attitude is more like that of an exaggerated total scoliosis than like either the dorsal or lumbar form.

Cervicodorsal Curves.—Cervicodorsal scoliosis, existing by itself, is a comparatively rare form of the deformity. The head is carried forward and tipped to the concave side of the curve. The neck is obviously shortened, and the outline from the base of the skull to the shoulder is fuller and less crescentic on the convex side of the curve than on the other. The shoulder on the convex side of the curve is raised and the other lowered, and the scapula of the raised side is conspicuously higher. The arm of the convex side hangs farther from the side than the other. The rotation appearances are marked, and the sharp angles of the upper ribs are prominent in the lower part of the curve, while above, the rotation is less evident because there are only the transverse processes of the cervical vertebræ to make a projection.

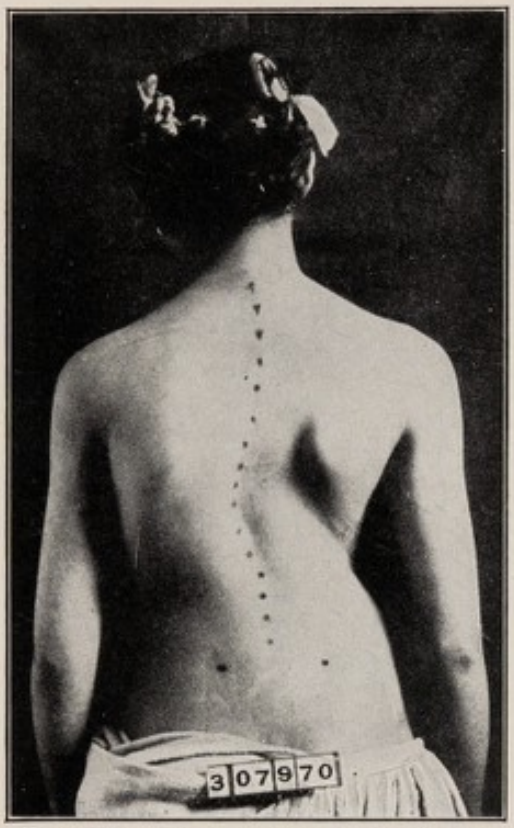

FIG. 727.—Left dorsolumbar scoliosis.



FIG. 728.—Left cervical curve involving the dorsal regions.

Compound Structural Curves.—The pictures of compound curves cannot, of course, be as simple or uniform as those of the single types. A right dorsal

left lumbar curve, for example, will present a combination of the appearances described in both dorsal and lumbar curves; a right cervicodorsal left dorsolumbar, the sum of the two pictures. If the dorsal element predominates, the appearance will be more dorsal than lumbar, as is usually the case, and every grade of variation is to be seen, the predominant curve setting its stamp on the clinical appearance.

Examination

Following a general examination which is of much importance in these cases, especially in the matter of physical fitness and also with regard to etiological causes, the surgeon should proceed to the examination of the spine. A patient with suspected lateral curvature should always be examined with back wholly bare. The clothes should be firmly pinned or fastened by a strap around the hips at a level low enough to show the top of the cleft between the buttocks and to show the outline of the pelvis. Children should be stripped to this level; in adolescent and adult women the chest should be covered by an apron hanging over the front of the thorax, the strings of which are fastened around the neck.

The patient should stand, back to the surgeon, squarely on both feet with the arms hanging at the sides. It is desirable to allow the patient to stand quietly for a minute or two before beginning the examination in order to secure the fatigued or relaxed position which is the characteristic one. The patient should not be handled or touched during the first inspection, as the contact of the hand frequently stimulates the muscles and negatives for the time being the relaxed position.

Inspection of the natural standing position forms the first step in the examination. The surgeon notes:

1. The body outline, whether symmetrical or not, comparing on both sides the outline from the axilla to the crest of the ilium, whether one is flatter or more curved than the other. It is obvious that if any part of the spine is laterally curved, it must carry with it a segment of the body to the right or left. This *displacement* will be accompanied by a change of body outline, and difference in body outline on the two sides is presumptive evidence of a lateral curve. The outline of the body and displacement of the trunk to one side may always be seen more plainly from the front than the back, as the outline is sharper. In children this method should follow the one described.

2. The surgeon next notices the level of the shoulders, whether one is higher than the other, and whether this is a constant position. The elevation of one shoulder is generally a sign of lateral curvature, but may exist rarely with no perceptible curve.

3. The position of the scapulæ should then be noted and the two sides compared. It is not of primary importance, but it is desirable to note their relative distance from the spine, whether one or both of the scapulæ are displaced forward, and whether any rotation of the bone has taken place.

4. The habitual position of the head should be noted, whether tipped to one side or held constantly rotated.

5. The antero-posterior physiological curves should be investigated and any increase or diminution of the dorsal or lumbar curves noted.

Estimation of the Spinal Curve.—Over the middle of each spinous process a mark is then made on the skin by a flesh pencil or by ink while the patient still

stands as described. The skin must not be drawn to one side or the other in making these marks, or distortion may be caused by the movements of the skin over the bony points. This line of marks is accepted as representing the spinal curve, although it does not accurately represent the position of the bodies of the vertebræ (see Pathology). If a curve is present, the line of marks will be evident as a curved instead of a straight line.

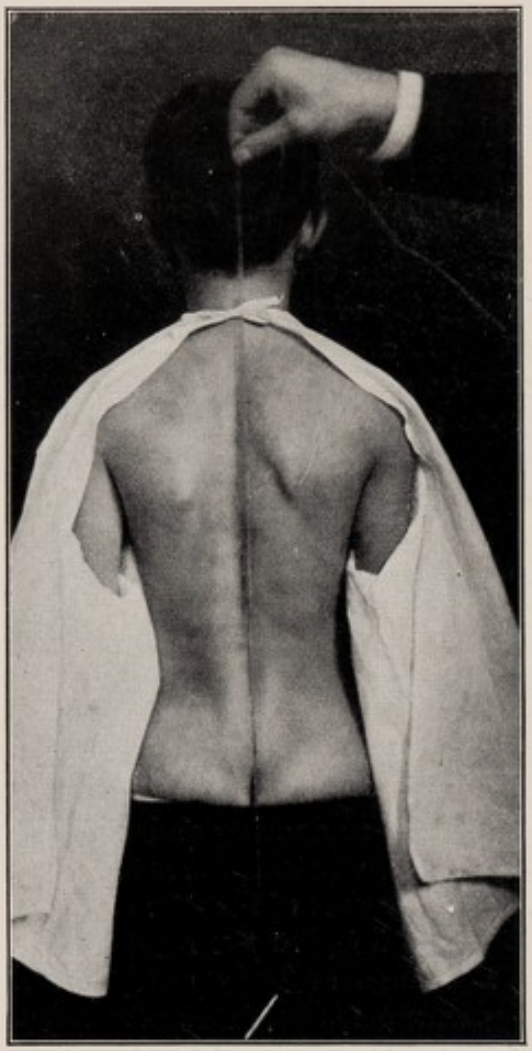

Fig. 729.—Method of holding the plumb line in the cleft between the buttocks to determine the median plane of the body.

There are now two questions to be answered: (1) Is lateral curvature present? (2) If present, what sort of a curve is it?

The median plane of the body in which the spinous processes normally lie is readily determined by holding a plumb-line behind the patient, the lower part of which passes through the cleft between the buttocks. In the normal spine each mark will lie under this plumb-line. The deviation of any number of spinous processes from this line represents a lateral curve. This method of erecting a perpendicular from below is preferable to the method of dropping a plumb-line from the top of the column (the Beely-Kirchoff method).

If a curve exists, as shown by the plumb-line, the second question arises as to what sort of a curve it is, whether postural or structural.

Postural curves have four definite attributes which should be looked for, and in the absence of any one of them the diagnosis of a postural curve cannot as a rule be made: Under these conditions the case is, therefore, by exclusion, structural.

Cervical curves must be roughly estimated by the eye, for on account of inaccessibility of the cervical spinous processes and the instability of the head, they cannot be definitely measured.

Estimation of Rotation or Twist.—The surgeon, having thus recognized any bodily asymmetry and having identified and defined the curve, is in a position to investigate the element of rotation or twist which is essential in every case. The surgeon, standing close behind the patient, looks down on her shoulder-girdle from above to estimate whether it is in the same lateral plane as the pelvis, or whether twisted forward on one side and back on the other which is of significance chiefly in postural cases. Evidence of rotation of the ribs or lumbar transverse processes backward on the convex side of the lateral curve, which accompanies structural cases, will in severe cases be evident in the standing position, but it is generally examined for and estimated in a position of forward flexion of the trunk, sometimes spoken of as Adams' position. The patient bends forward until the trunk is horizontal, with the arms hanging down

and the knees not flexed. In this position the patient remains while the surgeon glances along the back from behind, or in front, with his head on a level with the spine, noting whether either side of the trunk is more prominent upward in the lumbar, dorsal, or cervical region. Any such upward prominence represents rotation or twist and is a most important matter.

If it occurs on the *concave* side of the lateral curve and involves the curved region, it will be slight and evenly distributed through the spine, and designates a postural curve. That is, in a left total postural curve the right side of the back will probably be more prominent upward in the forward bent position.

If it occurs as a well-defined local upward prominence occupying the curved region, it designates a structural curve at that location, the curve being *convex* to the side on which the prominence occurs and occupying the same anatomical area. That is, a right dorsolumbar upward prominence in the forward bent position, designates a right dorsolumbar structural curve.

Estimation of Spinal Flexibility.—The patient should now lie on the face; in postural curves the spine will become straight in recumbency, while structural curves will be perceptibly straighter than when the patient is erect. The patient should next stand facing a table, close to the edge of it, and bend forward so that the trunk lies face down on the table while the legs are on the floor; a stool is now placed under the knees, which are bent so that the patient may relax. This removes superincumbent weight, and the position of the patient in this attitude represents the maximum that may be expected from treatment in that individual case until further flexibility is restored by treatment directed to that end. The restoration of complete, or almost complete, symmetry in this attitude points to an early case and one amenable to treatment, for one of the early changes in structural curves is a stiffening of the curved region of the spine which causes the persistence of the deformity. The patient should then bend forward to determine normal flexibility forward. The average child can touch the floor with the fingers while the knees are straight, while in adult life less flexibility is obtained. The patient then stands with the elbows out and the hands clasped behind the neck, and bends to one side and to the other. Patients with curves can, as a rule, bend more easily to the side that makes the curve worse than to the side that improves it. (See Figs. 723–724.)

Rational treatment cannot be undertaken without clear formulation of the character of the deformity, and experience shows that in the loose use of terms and in slipshod examinations certain failures to obtain proper results from treatment have their origin.

X-ray.—The X-ray is of use in showing: (1) The existence of bony defects, numerical variation, or other anomalies or diseases of the spine; (2) the degree of distortion of the individual vertebræ; and (3) the degree and character of the curve. The results of the X-ray do not as a rule agree with the clinical appearances, the amount of curve in the X-ray being generally more than is indicated by the marks over the spinous processes, because the X-ray gives the shadow of the bodies while the skin marks record only the position of the spinous processes. The amount of rotation is indicated in the X-ray by the position of the shadow of the spinous processes in relation to the shadows of the bodies, normally the spinous process appearing in the middle of the body. The element of necessary distortion in X-rays must be remembered; a patient

will be twisted by lying on the back, if rotation is present, and any deviation of the tube from the middle line of the body is expressed as distortion of the vertebræ; yet X-rays today, taken under proper conditions, afford the best

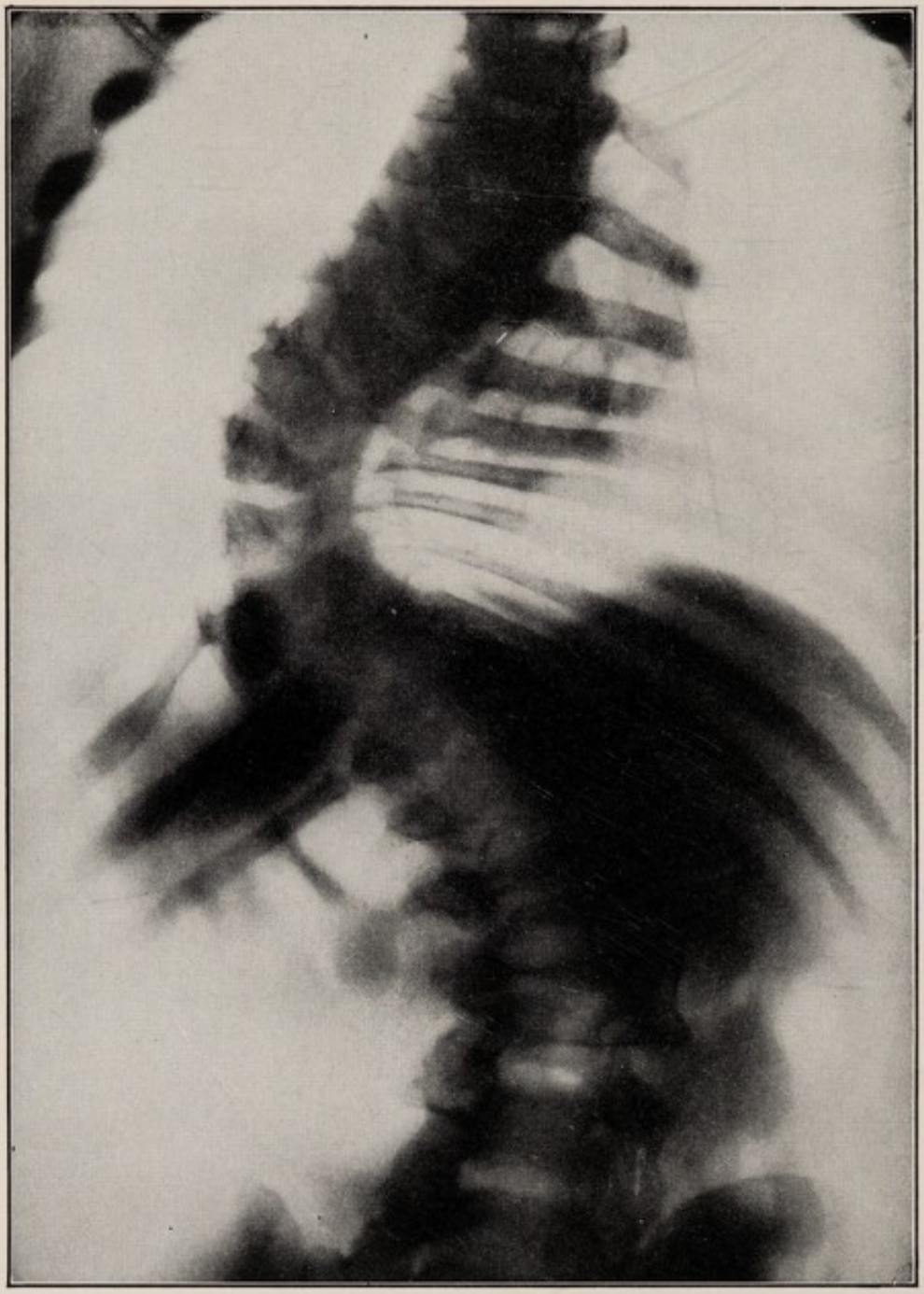

FIG. 730.—X-ray of severe left dorsal, right lumbar scoliosis, showing the rotation of the vertebræ in the right lumbar region, which are so distorted that they are apparently seen from the side. The rotation to the left is also shown in the dorsal region.

and most reliable index of the degree of the curve and of progress under treatment.

Record.—An accurate and simple method of recording scoliosis would be of great value to the general practitioner and to the specialist, but no such method exists today, although many have been described and advocated. The X-ray has been spoken of. *Photography* is an easy means of record, but does not

fairly represent the position of the spine and simply gives the body outlines. We must remember the limitations of photography, but it constitutes a fair rough method for the recording of bodily asymmetry caused by scoliosis.[1]

Pathology

The pathological changes in the vertebral column to be described as existing in scoliosis consist of modifications in shape and structure of the bones and soft parts. In addition to these there are found at times congenital anomalies of the vertebræ, changes due to rickets, the pathological results of empyema and infantile paralysis, all of which are to be regarded as primary, and causative of the changes to be described.

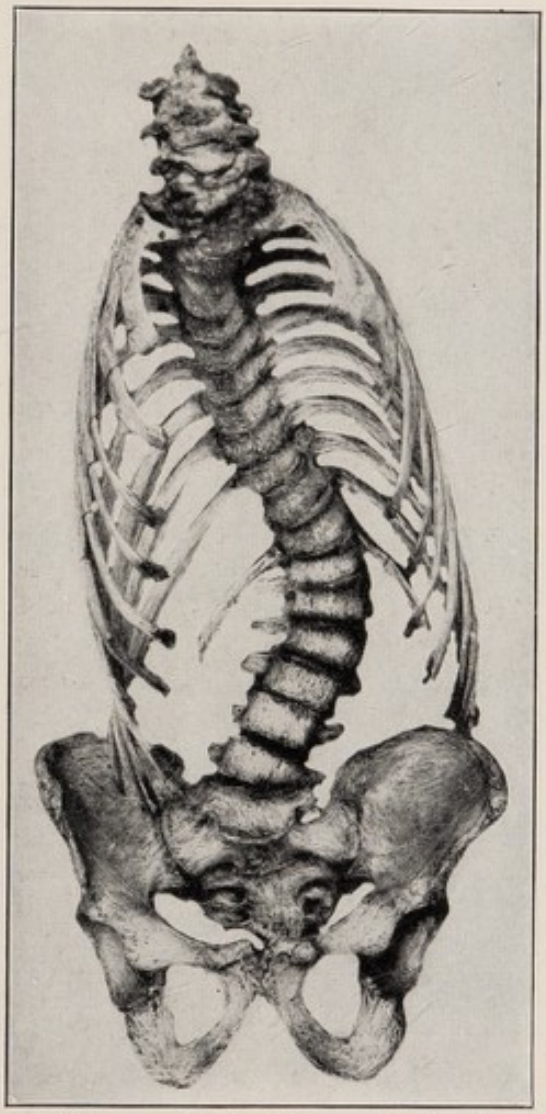

FIG. 731.—Congenital scoliosis associated with numerical variation of the vertebræ. Wedge-shaped vertebræ are shown clearly in the lumbar region. There is fusion with irregularity of the ribs (Warren Museum, Harvard University).

The pathological changes occurring in scoliosis may vary from moderate asymmetry to extreme distortion; the curves are formed by the deviation of the vertebræ from the median sagittal plane of the body and are more marked in the column of bodies than in the column of arches. The lateral curve may be a general sweep to one side, or it may be sharp and in the severer cases angular; and in the severer cases it exists not alone in the presacral vertebræ, but may also involve the sacrum and coccyx. In addition to the lateral deviation, the curved region is rotated or twisted on a vertical axis, the bodies of the vertebræ always turning toward the convex side of the lateral curve.

[1] HOVORKA: Ueber die messmethoden des Rückens, Wien, 1914, xii, 77.
FINLEY: Am. Jour. Orth. Surg., 1904.

Changes in the Vertebræ.—The vertebræ at the apex of the lateral curve and just above and below it, from one to five in number, are called the *wedge or apex vertebræ*, and are compressed on one side and consequently wedge-shaped. The thinnest part of a wedge vertebra is found on the side of the concavity of the lateral curve and generally toward the posterior aspect of the body. The side of the body toward the concavity is broadened and lipped in severe cases, and synostosis between two vertebral bodies may occur in this location. The apex vertebræ are rotated, as a whole, toward the convexity of the lateral curve.

Lozenge-shaped Vertebræ (Torsion or Oblique Vertebræ).—The vertebræ above and below the region of maximum curvature also show a characteristic distortion. In outline they are

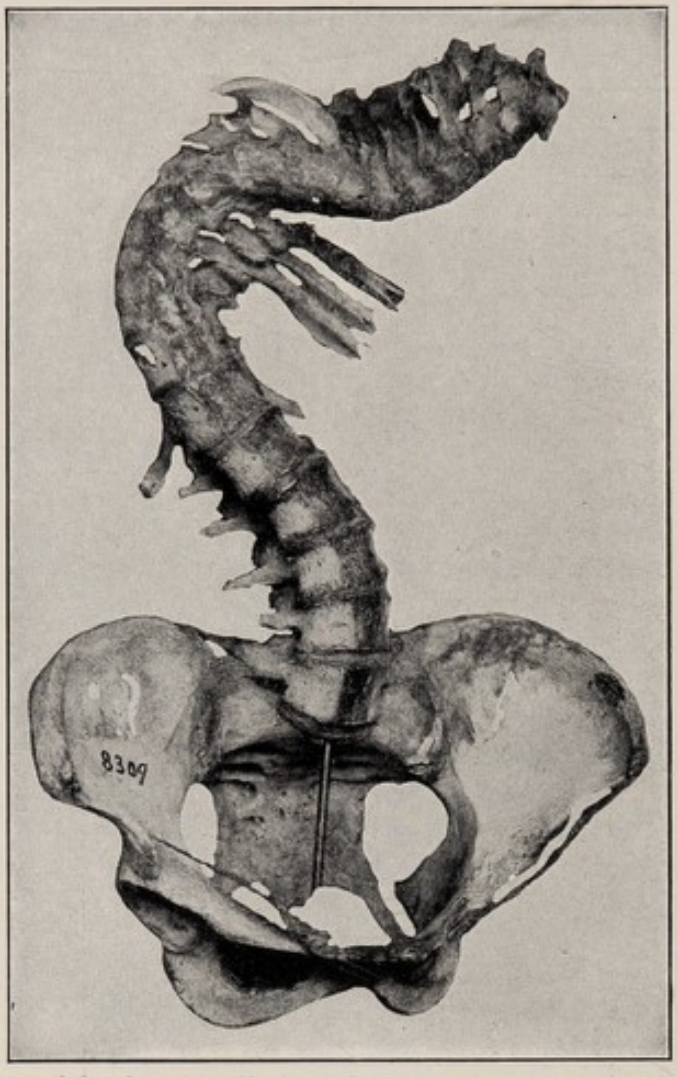

FIG. 732.—Extreme right dorsal scoliosis with fusion of the vertebræ and marked rotation. The wedge-shaped vertebræ are shown in the lumbar region (Warren Museum, Harvard University).

lozenge-shaped, and are twisted on a vertical axis in varying degrees. This is called *longitudinal torsion.*

Pedicles, articular processes and transverse processes all share in the distortion of the vertebræ with which they are connected.

The spinous processes are deflected toward the convexity of the lateral curve in the dorsal region, and in the lumbar in severe cases the spinous processes are diverted toward the concavity. This behavior of the spinous processes tends to make their line different from the line of the column shown in the X-ray, which gives chiefly the outline of the bodies. The individual vertebræ are thus seriously deformed in the vertical and the horizontal planes, a matter not to be forgotten in formulating the prognosis of treatment.

The *intervertebral discs* show the earliest changes, and at the points of greatest curve are compressed and project beyond the edges of the vertebral bodies as if the bodies had grown into them; on the convex side they are thicker than on the other.

Ligaments.—On the side of the concavity the anterior common ligament is dense and thick, while on the convex side of the curve it is thinned and shows no definite lateral border; moreover, the ligaments connecting the heads of the ribs and the spine are long and atrophied on the convex side and short and tense on the concave side.

Where *muscles* are thrown out of use they atrophy and may undergo fatty or fibrous degeneration. When increased demands are made upon them they may hypertrophy. Nutritive or adaptive shortening occurs when the ends of the muscles are approximated. All these changes are to be found in cases of severe scoliosis. In addition to this, the stiffness of the column, which sets in fairly early in moderate and severe grades of scoliosis, tends to cause atrophy of the muscles of the back in general, the atrophy of disuse, or desuetude.

The diaphragm assumes an oblique position and is lower on the side of the convexity of the dorsal curve.

In lumbar scoliosis the changes in the *thorax* are slight, but some rotation of the structure as a whole is noted in relation to the frontal plane of the pelvis.



Fig. 733.—A "wedge" vertebra (Schulthess). Second lumbar seen from the front; left lumbar curve.

In dorsal scoliosis the thorax is not only displaced as a whole toward the convexity of the curve, but its structure is distorted. The thorax as a whole tends to regain its normal position with regard to the frontal plane of the body more closely than does the spine, which, as it were, rotates in the thorax. It thus undergoes a twist in the opposite direction from that of the spine. This results in a change in its horizontal diagonal diameters already mentioned. As a result of this, in right dorsal scoliosis the internal surfaces of the shafts of the right ribs are brought nearer to the front of the vertebral bodies, and the right side of the thorax is seriously diminished in capacity.

The *ribs* on the convex side of the lateral curve show a backward increase of their angularity, forming on the side of the back of the thorax a more or less sharp and prominent ridge, spoken

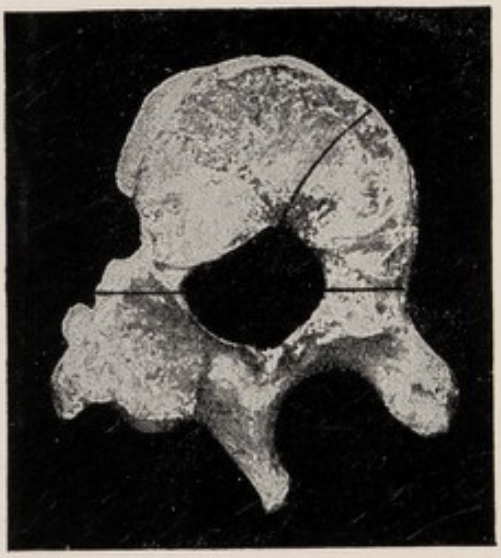

Fig. 734.—Distorted antero-posterior plane of a scoliotic vertebra (Riedinger).



Fig. 735.—An "oblique" vertebra (Schulthess). Fourth lumbar seen from the front; left lumbar curve.

of technically as the rotation. In compound curves of the dorsal region these phenomena accompany each curve. From the angle forward to the sternum the ribs of the convex side show a loss of their normal curve, the ribs on the side of the concavity of the lateral curve show a straightening of their angles and an increased outward bowing of their shafts. The costal cartilages of the concave side in front show an increased curvature forward and form on the front of the chest a prominence at the side of the sternum. The ribs on the side of the convexity are spread apart and have a more oblique direction; on the side of the concavity they are closer together and tend to a more horizontal course. These phenomena are dependent upon the degree of inclination of the part of the spine to which the ribs are attached.

The *sternum* as a rule deviates but little from its normal position and direction except in a very severe scoliosis.[1] The marked deformity of the thorax cannot be without influence on the form of the *clavicles* and *scapulæ*.

Pelvis.—In low curves, the sacrum may be affected in a way analogous to that of the other vertebræ, but modified in extent by its fixed position. There is to be seen at times a slight indication of a lateral curve of the sacrum, reaching its apex at or below the middle of the bone, in which the coccyx may share. The pelvis is somewhat changed in diameter and shape in severe low lumbar curves in which the sacrum shows distortion.

In long-continued scoliosis, especially of the upper part of the column, asymmetry of the face and *skull* may exist.

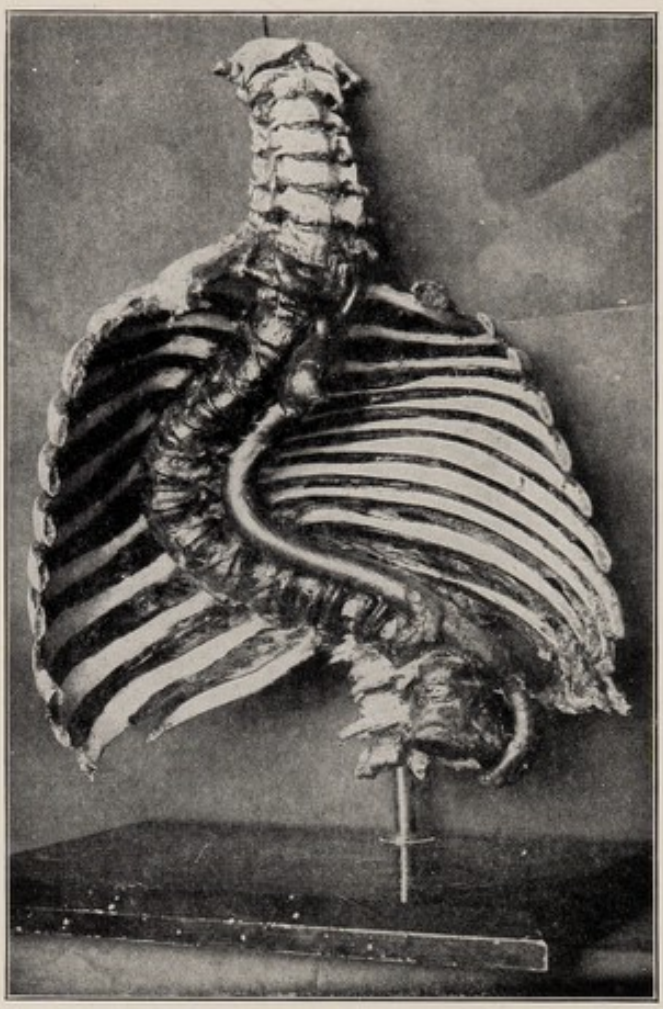

Fig. 736.—Extreme right dorsal scoliosis, showing distortion of the aorta, flattening of the ribs at the back of the left thorax, and increased angulation of the ribs on the right (Warren Museum, Harvard University).

In scoliosis, especially in moderate and severe forms, a shortening of the trunk is apparent, which prevents the normal development and function of the *internal organs*. By the lateral displacement of the trunk and rotation of the thorax the pleural and abdominal cavities become distorted. The patients become anemic and show a certain disposition to tuberculous pulmonary diseases; and affections of the pleura, leading to total obliteration of the pleura and atelectasis, are frequently found.

Undoubtedly the lungs of scoliotic patients, especially in cases of kyphoscoliosis, are predisposed toward a greater number of diseases than the lungs of normal individuals.

The same narrowing of thoracic space affects the *heart*, which is frequently found pushed upward and pressed against the anterior chest wall, and it is at the same time, according to the direction and the extent of the curvature, more or less displaced laterally. Hyper-

[1] Fauconnet: Zeitsch. für Orth. Chir., xvii, 201.

trophy and dilatation of the cavities of the heart are frequent, especially of the right heart in severe scoliosis.

The aorta in general follows the curvature of the spine, particularly in right curves. The large veins show less typical changes.

In general the *esophagus* has a tendency to deviate in the direction of the concavity of the curve, although frequently its form and course are but little changed.

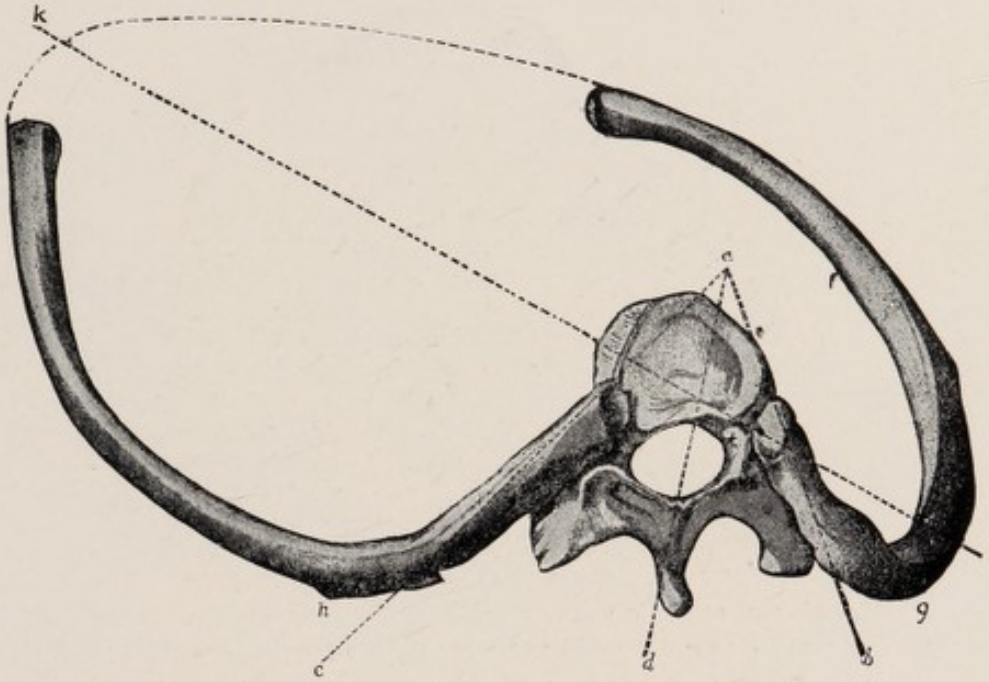

FIG. 737.—Thoracic ring in a right dorsal scoliosis, seen from above (Lorenz).

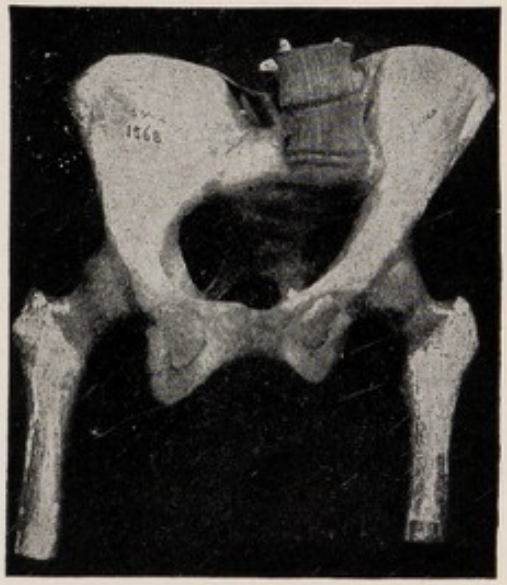

FIG. 738.—Oblique pelvis accompanying scoliosis (Warren Museum; cast from a specimen in Musée Dupuytren, Paris).

Stomach and Intestines.—The abdominal contents are, in consequence of restricted space, pressed downward and forward, and added to this is the influence of the approximation of the chest to the pelvis and the side displacement of the vertebral column. The downward pressure results in crowding the intestines into the true pelvis. *The liver and kidneys* are displaced in severe cases.

Cystic degeneration and floating kidney are common. Bachmann enumerates, among 180 observations, 14 cystic kidneys, 31 cases of granular atrophy, 18 cases of simple atrophy, and 6 cases of hydronephrosis.

Etiology

The subject of the etiology of scoliosis easily lends itself to elaboration and it is difficult in discussing it to preserve simplicity. It will clear matters very much to remember that there are two types of scoliosis: One, the postural,

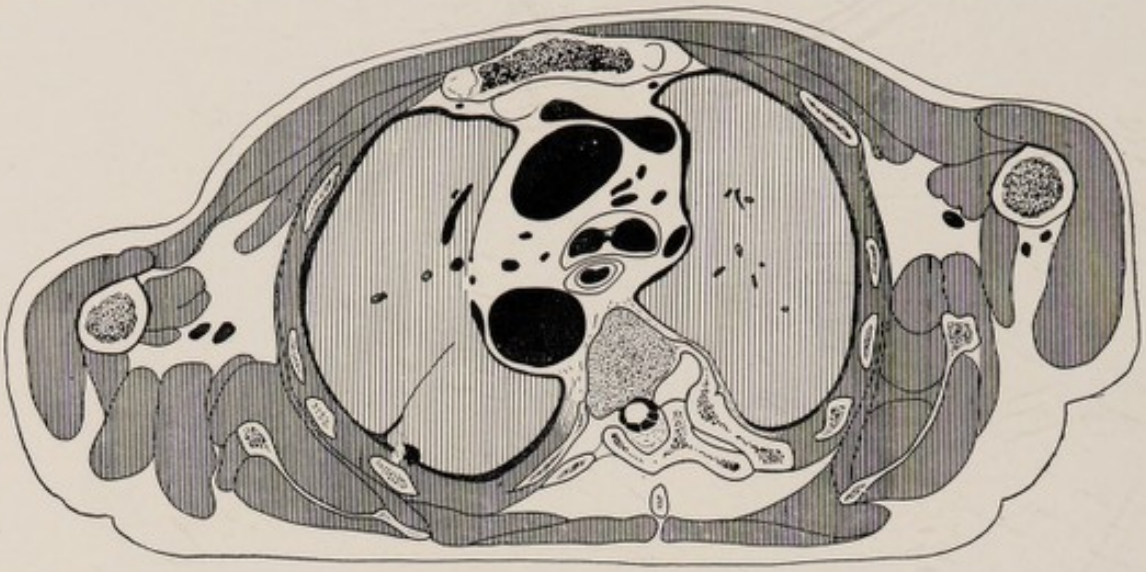

Fig. 739.—Cross section of scoliotic cadaver in the upper dorsal region, showing distortion of vertebræ and asymmetry of the body at this level (Anatomical Dept., Harvard University).

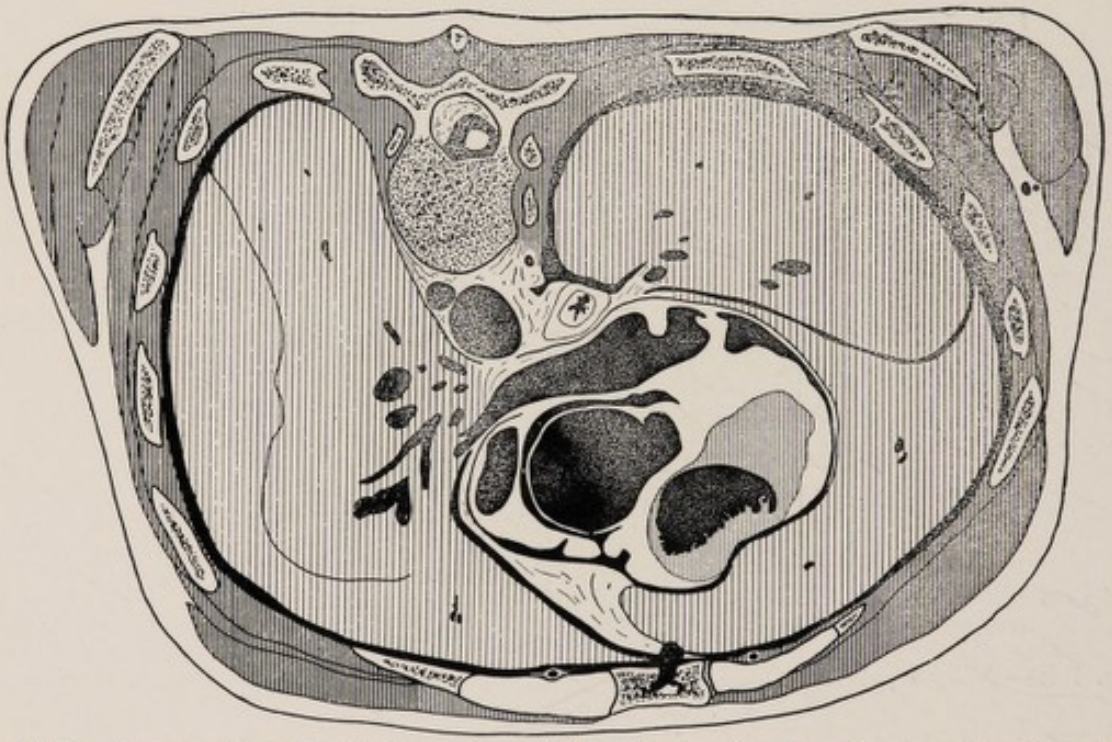

Fig. 740.—Cross section of scoliotic cadaver in the mid-dorsal region, showing distortion of the vertebræ and asymmetry of the thorax (Anatomical Dept., Harvard University).

better spoken of as *false scoliosis*, which is really only faulty attitude and has its own causes; the other, the structural or *true scoliosis* where there is pathological change in the vertebræ, and where a different set of causes must be looked into. False scoliosis passes into true scoliosis at times, but not all true scoliosis originates in false scoliosis.

In true scoliosis there are met many cases so severe that they cannot be accounted for by the assumption that they are the natural result of the maintenance of a normal spinal column growing in a malposition over a period of years, and one must look for an additional cause. These causes are as a rule to be found in (*a*) *congenital anomalies of the spine and its appendages;* (*b*) *rickets;* (*c*) *empyema;* (*d*) *infantile paralysis*, and (*e*) cases where the deformity of the

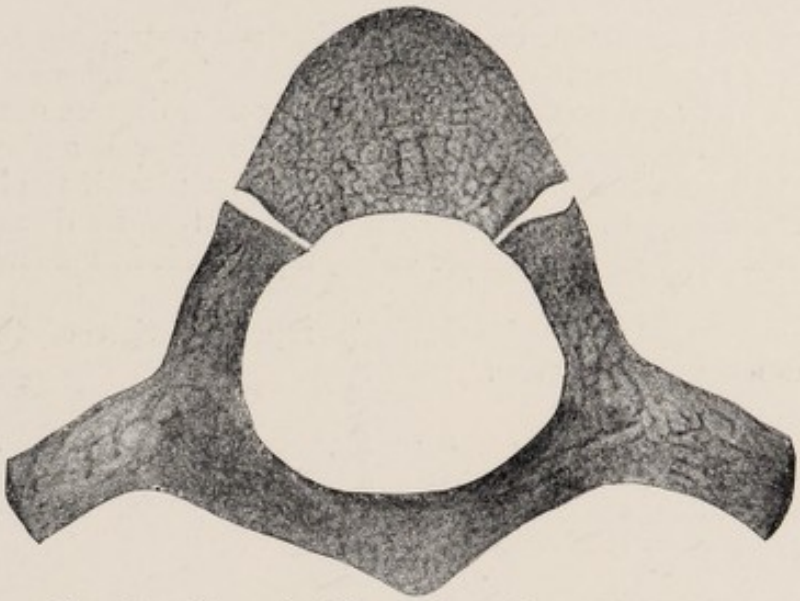

FIG. 741.—Normal epiphyses of vertebræ (Engelmann).

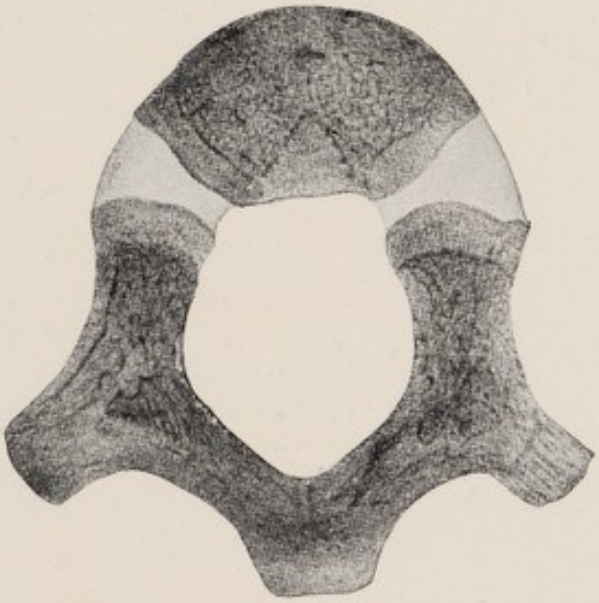

FIG. 742.—Epiphyses broadened by rachitic changes (Engelmann).

bones is so great that one must assume the existence of *diminished individual resistance of bone.* In the last class of cases many writers would assume, in all instances, the existence of rickets as explaining the softness of the bones; but as in many of the cases evidences of rickets are not to be found, it seems fairer to meet the situation by the statement that there is apparently a diminished resistance of bones in such cases of unknown origin, but that no demonstrable evidences of rickets are present.

But later views[1] are to the effect that mild rickets, by affecting the epiphyses between the laminæ and bodies of the vertebræ, or the bodies themselves, may bring about distortion of the vertebræ which is the cause of scoliosis, and that grades of rickets which are not severe enough to cause general deformities may thus be a factor in causing scoliosis (Figs. 691–692). The matter is not yet sufficiently established to enable one to give clear directions as to the X-ray diagnosis of such cases.

As a practical illustration of the foregoing one may assume that a short leg, *e.g.*, will cause asymmetry and faulty attitude, *i.e.*, a false scoliosis, and in certain cases may be apparently accountable for mild degrees of real scoliosis, but that it is not competent to cause a moderate or severe scoliosis in a child whose bones possess a normal resistance to pressure; but if the bones do not possess this resistance, because of rickets or causes that we do not at present recognize, a short leg, or any similar cause, may result in moderate or severe scoliosis.

The following conventional schematic representation of the causes of scoliosis formulates the question:

(*A*) Congenital scoliosis.
1. Malformation of the spine.
2. Malformation of the scapula.
3. Malformation of the thorax.
4. Deforming intrauterine pressure.
5. Paralysis of intrauterine origin.

(*B*) Acquired scoliosis.
1. Anatomical, physiological, or other asymmetries elsewhere than in the spine.
   (*a*) Torticollis (wry neck).
   (*b*) Pelvic asymmetry.
   (*c*) Pelvic obliquity (short leg).
   (*d*) Unequal vision.
   (*e*) Unequal hearing.
2. Pathological affections of the vertebræ.
   (*a*) Rickets.
   (*b*) Osteomalacia
   (*c*) Tuberculosis.
   (*d*) Dislocation.
   (*e*) Fracture.
   (*f*) Arthritis deformans.
   (*g*) Tumors, etc.
3. Pathological affections of the bones and joints of the extremities, causing asymmetrical position.
   (*a*) Diseases of bones and joints of the leg.
   (*b*) Diseases of bones and joints of the arm.
4. Distorting conditions due to disease of the soft parts.
   (*a*) Infantile paralysis.
   (*b*) Spastic paralysis.
   (*c*) Nervous diseases (hemiplegia, syringomyelia, Fredrick's ataxia etc.).
   (*d*) Empyema.
   (*e*) Organic heart disease.
   (*f*) Scars.
   (*g*) Throat, abdominal or pulmonary disease.
   (*h*) Acute or chronic inflammation of the spine and its soft parts.
5. Habit or occupation.

[1] Engelmann: Zeitsch. fur Orth. Chir., 1915–16, xxxv, 256.
Herg: Thorakoplastik und Skol. Beilagehaft der Zeitsch. fur Orth. Chir., xlii, Stüttgart, 1921.
Bohm: Vorhdlg. d. Deutsch. Ges. fur Orth. Chir., 1921, xvi.

(*A*) *Scoliosis of Congenital Origin.*—In former years practically all cases were regarded as acquired and the congenital form considered as a rarity, but this condition is coming to be recognized as by no means infrequent, and every year an increasing number of the moderate and severe types are being transferred from the acquired to the congenital class. This is due largely to

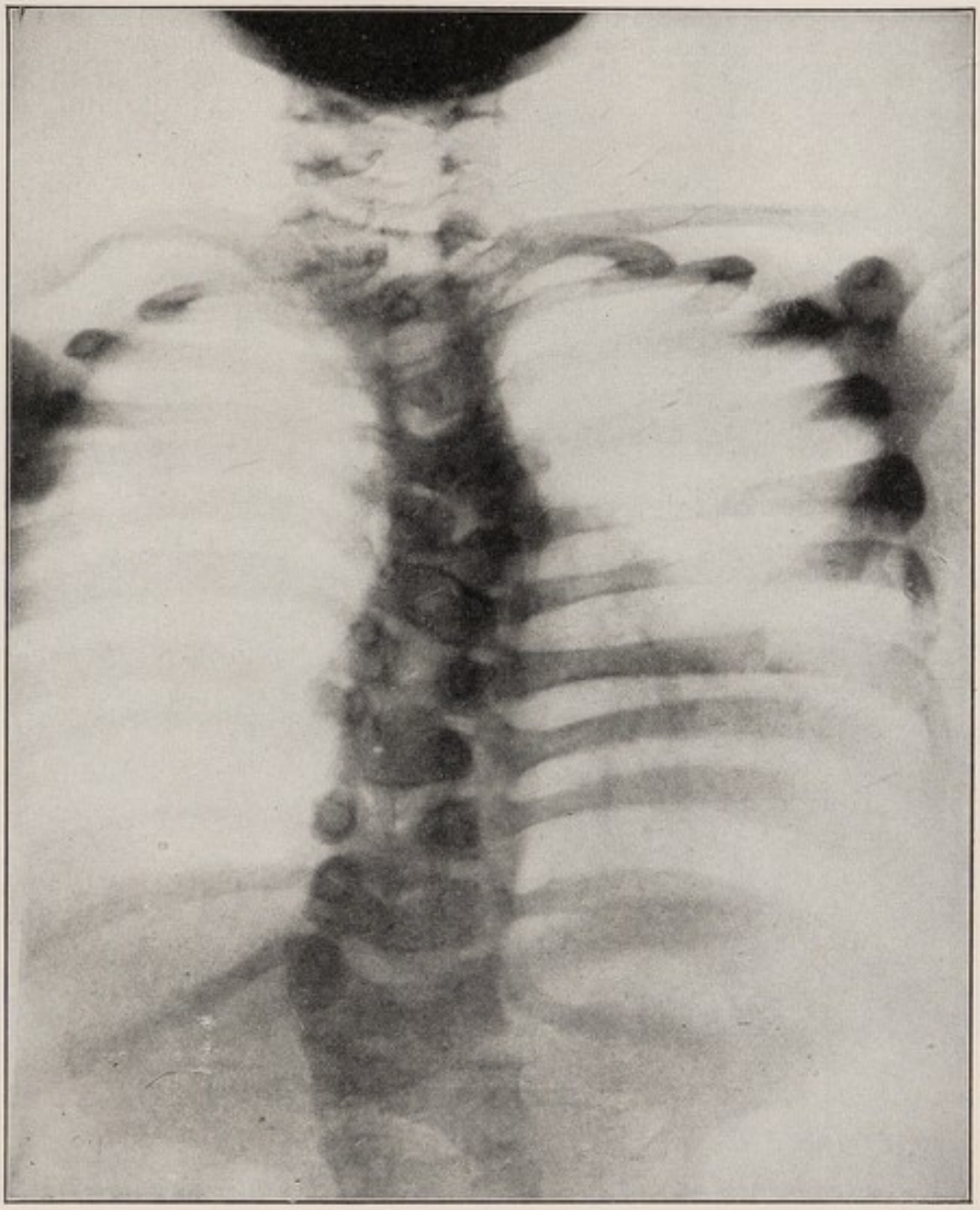

FIG. 743.—Widely distributed congenital defects of the spine.

the development of the X-ray and the study of the living spine thus made possible.

In certain congenital cases of marked scoliosis where a careful study of the spine is possible, no additional congenital anomaly is to be found.

Scoliosis may occur as a congenital condition in connection with severe malformations, such as rachischisis and the like.[1] It occurs also as the result of less severe spinal defects, such as cervical ribs, spina bifida, and abnormal formation of the last lumbar vertebra. Congenital scoliosis may be evident—

[1] SCHMIDT: Allg. Path. und path. Anat. d. Wirbelsäule.
LUBERSCH: Ergeb. zur allg. Path., Jahrg., 1897, iv.

(1) immediately after birth, as in the case of the severest malformations, or (2) only when the child begins to walk. In these latter cases the curvature appears as the result of the superincumbent weight coming upon the defective spine or as the result of asymmetrical growth due to the malformation. Congenital elevation of the scapula (Sprengel's deformity) will cause a scoliosis which is usually a high cervicodorsal curve with compensating dorsolumbar curve. Occasionally great irregularity characterizes the ribs of one or both sides. Some may be bifurcated, others are united by a bridge of bone, while in still other cases certain ribs are missing. Such irregularities are not the actual cause of scoliosis.

Heredity must also be considered, as it is known that scoliosis is apparently inherited in some families.

(*B*) *Acquired Scoliosis.*—Scoliosis is to be classed as acquired when the deformity comes on after birth from some cause apparently not congenital, and this type includes, so far as we know now, the greater number of cases. The experimental production of scoliosis in animals has been demonstrated.

The causes of acquired scoliosis have been tabulated above and are largely self-explanatory except for habit or occupation scoliosis—the modern view of which must be dwelt on.

That the continued maintenance of an asymmetrical position of the spine through the period of growth may result in some degree of bony deformity of the growing spine is a self-evident proposition, dependent on the fact that growing bone is plastic and follows the line of least resistance. But that such conditions are likely to result in moderate or severe scoliosis in normal children is not, in the opinion of the writers, likely. That they may result "in false scoliosis" or slight scoliosis is apparently reasonable to expect. The commonest causes of "*occupational*" *scoliosis* are to be found in the assumption of faulty attitudes by children at school and at home, in violin playing, the use of a side saddle in riding, carrying heavy weights asymmetrically, etc.

The relation that *school conditions* bear to scoliosis is one of the most important questions in formulating the cause of scoliosis and has been much discussed of late.

It may be assumed as reasonable (1) that bad air, fatigue and school life under poor general conditions, (2) improper school furniture, and (3) twisted writing positions favor bad attitude, and that the more constantly they are in operation the more effective will be their result in producing bad attitude. In the same way unfavorable home conditions in the way of bad food, overwork, and unsanitary surroundings depreciate muscular strength and favor bad attitudes.

It is therefore likely on general principles that unfavorable school conditions are a competent cause of faulty attitude (false scoliosis) and of slight grades of true scoliosis, but that they are the cause of moderate and severe scoliosis is not, in the writer's opinion, likely. This view is in accord with that of the best modern authorities,[1] but not in accord with former views.[2]

Apparently if one takes into account all grades of scolisois, postural and structural (false and true), there is a tendency to increase during the years constituting school age, but there apparently is no good evidence that moderate and severe structural scoliosis during school life or are directly caused by it.

[1] Schulthess, Schanz, Mayer, Spitzy, Böhm, Muskat, Lubinus and others: Verhdlungen d. Deutsch. Ges. fur Orth. Chir., 1910, 443–514.

[2] Smith: Lateral Curvature of the Spine and Flatfoot, New York, 1911, 28.

Diagnosis

Scoliosis is an affection in most cases appearing before the tenth year. It is not a disease of the spine, but the result of mechanical forces acting upon a spine which in other than slight cases must be assumed to be abnormally formed or to possess less than normal resistance. Scoliosis is not, as a rule, accompanied by any degree of pain. Stiffness, if it is present, is an accompaniment of late cases and the result of long-continued structural changes.

In the diagnosis of the affection the first question that arises is whether or not scoliosis is present. If scoliosis is present the question is, is it postural or structural, and what is the curve?

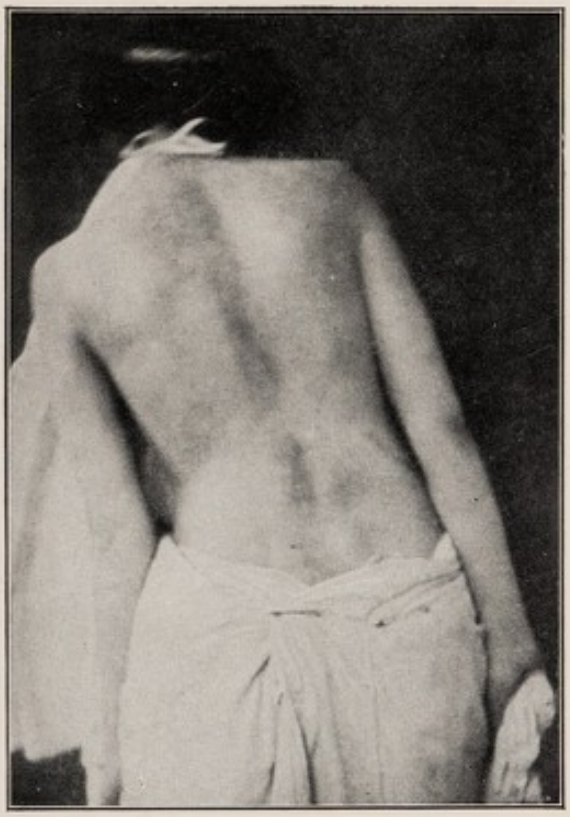

FIG. 744.—Hysterical scoliosis.

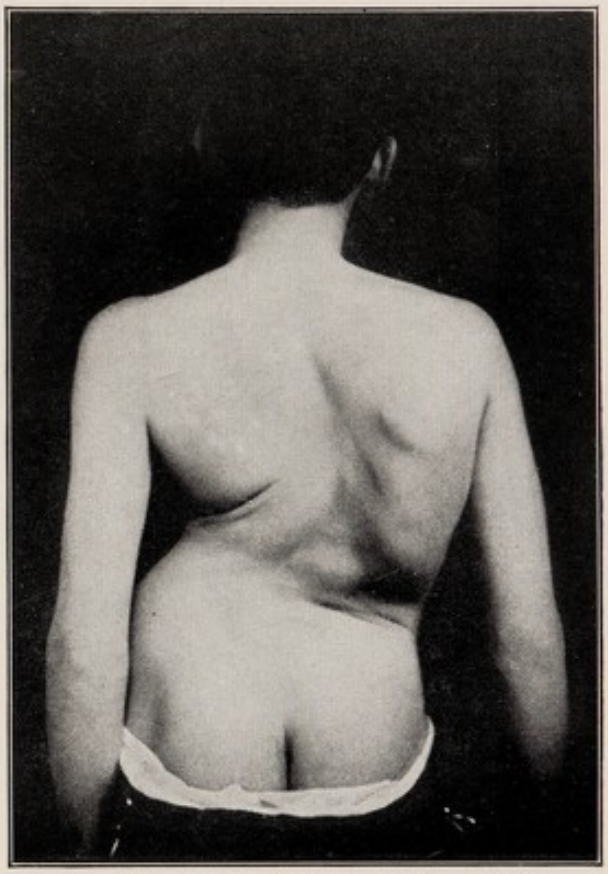

FIG. 745.—Scoliosis due to poliomyelitis.

If the curve is *postural*, it is desirable if possible to identify its cause in a short leg, unequal vision, etc.

If the curve is *structural*, it is important, if possible, to assign it to its proper etiological division.

On account of the possible existence of pathological conditions accompanied by lateral curvature as a symptom, cases of lateral curvature accompanied by pain, especially if this is exaggerated by motion, should not be given exercises, but be kept under careful observation until a perfectly definite diagnosis has been made. The same applies to slight curves accompanied by stiffness of the spine. Doubtful cases may often be cleared up by the use of the X-ray.

Tuberculosis of the Spine.—The symptoms of this affection are: stiffness of gait and loss of mobility in the spine, pain on motion or jar, and spontaneous pain in the chest and abdomen, elevation of temperature, and impairment of

the general health. As the disease progresses a sharp backward prominence of the spinous processes occurs at some part of the spine. Lateral deviation of the spine occurs in the acute stage of practically all cases, but it is a leaning of the body to one side rather than a true gradual curve; there is no rotation of note, and the deviation, disappears after a period of recumbency in bed when controlled by efficient treatment. The danger of mistaking Pott's disease for scoliosis lies in the early cases before the knuckle, or backward deformity, has occurred.

A form of lateral deviation accompanies *arthritis deformans* of the spine. This is essentially an effection of adult life, but not unknown in children. The

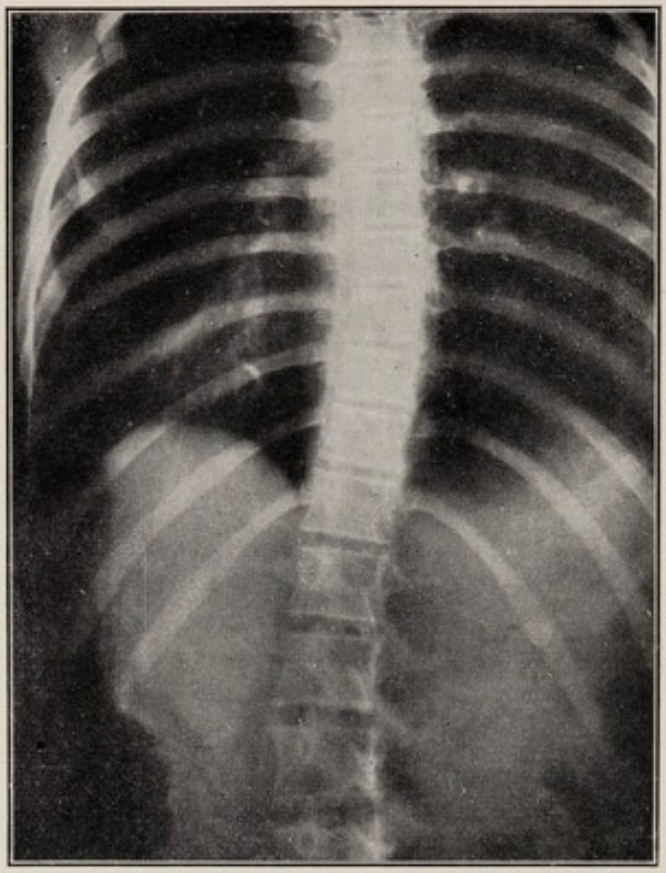

FIG. 746.—X-ray of slight right dorsal, left lumbar curve, showing dense shadow on concave side of curve.

spine is stiff and painful, the lumbar convexity is diminished or lost, and the curve a gradual one with slight or no rotation.

The lateral curves accompanying tumors of the spine, old fractures and dislocation of the vertebræ, etc., would hardly be mistaken for real scoliosis, the usual signs of those affections being present.

Prognosis

Without Treatment.—Total postural curves may remain through life, probably increasing somewhat. They may change to *structural* curves; or they may be cured by proper treatment, but they are *not* likely to disappear spontaneously. So long as they remain purely postural curves, they will probably not influence the general health unfavorably, or produce any unpleasant result further than slight asymmetry. In women they are frequently accompanied by backache.

Structural curves, whether simple or compound, in young children should be regarded as serious if of moderate or severe degree, as almost sure to increase, with the possibility of rapid increase. They will surely lead to some deformity, and perhaps to grave deformity. They are likely to affect the general health and may shorten life by favouring the development of phthisis or other serious diseases.

Slight or moderate structural curves in older children and adolescents which have not progressed rapidly through childhood are likely after puberty to increase but slowly, if at all, until late middle life, when the atrophy of the intervertebral discs is likely to make them more evident and troublesome. Severe structural scoliosis at any period of life is to be regarded as likely to induce ill health and to shorten the patient's life. The rapid increase of a postural or structural curve is a threatening symptom demanding attention.

With Treatment.—Postural scoliosis should be entirely and permanently cured by adequate treatment.

Structural scoliosis of moderate degree in *young children* is curable by adequate and long continued treatment; severe deformity cannot be entirely abolished, but can be much improved.

In older children and adolescents the prognosis is less favourable; complete correction is rarely possible even in moderate structural cases, but under appropriate treatment the deformity should be lessened.

When growth has been completed, only improvement and not complete cure is to be hoped for from treatment in true scoliosis of any but the mildest grade. In adults with severe scoliosis the general condition of the patient may be greatly benefited by an improved position of the spine. In late adult life support of the spine in the best obtainable position is the only outlook from treatment, again often attended by improvement of the general health.

Scoliosis due to severe congenital defects of the vertebræ, scapulæ, or thorax, or to empyema cannot be cured if a curve of moderate or severe grade has occurred, but can be improved. Rickets contributes a class of cases on the whole resistant to treatment, and in severe cases, even in young children, a complete cure is not obtainable. The curves caused by poliomyelitis are the most amenable to correction of any scoliosis of the same grade but as a rule cannot be held in the corrected position without long-continued and too often permanent wearing of supporting apparatus. The existence of organic heart disease or phthisis makes the prospect of obtaining improvement from treatment unfavorable.

Treatment

The treatment of scoliosis can be most clearly considered if one separates for purposes of discussion the two types already described—(1) the postural or functional, and (2) the organic or structural.

Postural Scoliosis (Functional Scoliosis, False Scoliosis).—Regarding the condition as an habitual inability to stand correctly, as a postural malposition without marked structural change, it is evident that the treatment should consist in the substitution of a correct attitude for a faulty one. This is obviously to be preceded by eliminating conditions unfavorable to the maintenance of a correct upright position. The conditions requiring investigation and possible correction in every case as a preliminary to beginning treatment are (1) seats and desks at school; (2) the manner of clothing the child; (3)

the condition of the eyes and ears; (4) the existence of a short leg; (5) overwork or too long hours, leading to persistent fatigue; (6) excessive recent growth with consequent impairment of resistance. These matters are also of importance in structural lateral curvature.

Having placed the patient under the most favorable general conditions obtainable, and having corrected so far as possible the defects above mentioned, the patient should work on the exercises to be prescribed (p. 745) for from half an hour to two hours a day for a period of some weeks, which exercises should not be pushed beyond the limit of fatigue.

The length of treatment, the period of the exercises, and the extent to which they can be pushed will depend on the vigor of the child; half-way

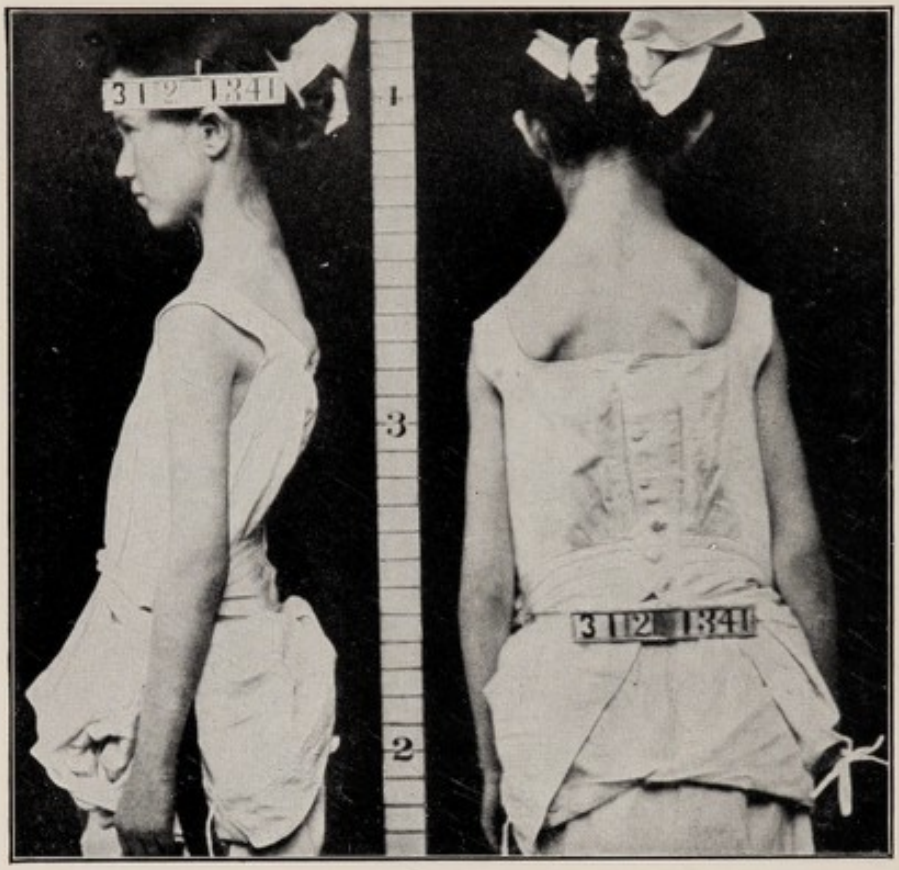

FIG. 747.—Vicious waist to which elastic garters are fixed, making a pull on the scapulæ and adding to the superincumbent weight coming upon the spine.

measures are not likely to be successful, and exercises done at home under the supervision of careless parents are less efficient than those given by persons trained in gymnastics. The treatment lies within the range of any good teacher of gymnastics who will carry out the instructions of the surgeon. The causes of failure are to be found in the fact that such children are generally in poor muscular condition, overworked at school, under unfavorable conditions at home, or that the exercises are given too seldom and are not sufficiently vigorous.

If flexibility to one side is limited, *e.g.*, if the child can bend farther to the right than to the left in a left total curve, the flexibility of the spine must be made equal. Having restored the flexibility of the spine or if flexibility to the two sides is alike, a treatment differing but little from the "setting-up

drill" of the army recruit is to be instituted and continued until the correct attitude is constantly maintained, after which some form of exercises should continue for one or two years.

Treatment of Structural Scoliosis (Organic Scoliosis, Habitual Scoliosis, Fixed Scoliosis, True Scoliosis).—The treatment of structural lateral curvature presents a much more serious and much less encouraging problem than the treatment of postural cases, and measures must be vigorous, adequate and *mechanically* sound to produce a permanently satisfactory result. The causes of failure of efficient treatment lie in the unwillingness of the parents or the patient to submit to sufficiently long-continued supervision for a condition which is necessarily difficult and resistant.

It is evident, where the pathological changes have reached a moderate degree, that considerable and continuous force would on general principles be necessary to force the column into a position approximately normal and also that on the forcing into and retaining of such a position depends our sole hope of any considerable degree of favorable progress.

Scheme of Treatment.—The following scheme presents the matter in the form of a table.

1. Gymnastics alone { (*a*) in apparatus. (*b*) without apparatus.
2. Gynmastics and corsets.
3. Gymnastics and stretching.
4. Gymnastics and corsets and stretching.
5. Forcible correction.

(*a*) *Gymnastics Given in Apparatus.*—By means of apparatus, gymnastic exercises can be more correctly localized, and the work of loosening the spine and of strengthening the desired muscles can go hand in hand. This method, which is in general use on the continent, never found a foothold in England and America on account of the complicated and expensive apparatus.

(*b*) *Gymnastic Exercises Given Without Apparatus.*—This method of treatment is the one in most general use in England and America.

Gymnastics have a two-fold object—first, to loosen up the curved portion of the spine to make an improved position possible; and second, to aid in retaining the improved position by strengthening certain groups of muscles. Most exercises tend in a measure to accomplish both of these, so that a sharp division into mobilizing and retentive exercises is not possible, and one can only point out that a certain exercise is especially valuable for one or the other purpose.

In *mild* structural scoliosis efficient gymnastics should constitute the sole treatment, and may be continued as the sole treatment so long as the improvement from one exercise period until the next one. If such improvement is not held between exercises it must be assumed: (1) That the exercises are not good ones; (2) that they are not properly carried out; (3) that the amount of treatment is insufficient, or (4) that the case is too severe for purely gymnastic treatment.

Gymnastic Exercises.—The exercises are of two kinds, symmetrical and asymmetrical, and only the latter can be depended upon to loosen up a really marked case of scoliosis. However, unless a skilled gymnast is going to give the exercises at home, it will be safer to

prescribe only symmetrical exercises. These are safe if they are given in the best corrected position possible for the spine to assume while the exercises are performed. They are mildly corrective and do not constitute the highest grade of treatment for structural scoliosis. As instances of such exercises, the following may be given as samples:

1. Patient stands erect with the knees extended, the hands on the hips, the back straight, the head erect, and with the scapulæ close to each other, and presses down with both hands on the hips, stretching the whole spine upward, inspiring during the stretching, and breathing out as the position is relaxed. This exercise should be repeated in regular rhythm, and calls upon the muscles which maintain the proper erect position, notably the spinal extensors. It is applicable to any case of scoliosis, but is of course especially effective in the postural class.

2. While the spine is stretched, with the hands still on the hips, the patient bends forward, maintaining the stretch of the spine. In addition to the essentials of Ex. 1, the weight of the trunk is also thrown upon the extensor muscle of the back and the gluteus maximus muscles. It is especially suitable to cases with a tendency to exaggeration of the lumbar curve. If in taking this exercise the hands are placed behind the neck with the elbows squared back as far as possible, the exercise becomes more difficult, as the center of gravity is raised by the position of the arms.

3. Trunk Hyperextension with Side-bending—Lying on the Face —The patient lies face downward on a table or on the floor and the feet are held or fastened down. The trunk is raised from the table as far as possible by hyperextending the spine and from this position the trunk is bent to the side toward which the lumbar curve is convex. The first position is resumed and then the prone lying position is resumed and the exercise repeated as often as ordered.

This exercise is an active lateral flexion of the spine in the position of hyperextension. As hyperextension locks the dorsal region against side flexion, the movement is almost wholly confined to the lumbar region. If there is a right dorsal curve in connection with a left lumbar curve, bending to the left, while it corrects the lumbar curve, does not at the same time greatly increase the dorsal curve, as that part of the spine is locked against side-bending. The exercise is, therefore, suited not only to lumbar curves, but especially to compound curves in both dorsal and lumbar regions.

The exercise may be done passively when the object is to loosen up a stiff spine. In this case the surgeon instructor stands on the side of the convexity of the lumbar curve, with one arm under both the patient's arms which are stretched forward; his other hand on the convexity of the curve. He then lifts the patient up from the table as high as possible and swings him over forcibly toward the side of the convexity as far as the patient will allow. This passive exercise accomplishes much more forcible stretching of the spine—loosening up of the curve—than the preceding active form of exercise.

4. Drawing up the Hip—Lying on the Face.—The patient lies prone on a table, holding the end with both hands, the arms extended and the spine and legs in a straight line. The surgeon instructor grasps the ankle on the side of the lumbar convexity and resists while the the patient draws the hip up as far as he is able, the knee being kept straight.

The approximation of the side of the pelvis and the thorax on the side to which the lumbar curve is convex is brought about by an active contraction of the muscles on the convex side of the lumbar curve which it is desirable to develop. The amount of work thrown on these is determined by the amount of traction made on the ankle. The exercise is suited to cases of lumbar curves or to the lumbar element of compound dorsal and lumbar curves. If a dorsal curve is also present, it should be fixed by pressure to prevent its increasing, while the patient draws up the hip on the side of the lumbar convexity.

5. One exercise which takes effect on the rotation as well as on the lateral deviation is a passive forcible one. The patient stands on a table on all fours, with the feet strapped down, and the surgeon instructor stands on the side of the concavity of the curve and puts both his arms under the patient's body, far enough around so that his fingers grasp the convexity of the curve, and then pulls down on the convexity with a turning motion so as to correct the rotation, and at the same time with his arms he pulls the patient's whole body toward him. While pulling, the surgeon instructor places his shoulders against the side of the patient next to him, placing one shoulder at a point above the curve, and the other just below it. In this way he furnishes counter-pressure against the top and bottom of the lateral curve, while he pulls the apex toward himself.

This exercise is suitable for a dorsal or lumbar curve, and is forcible and capable of exerting great pressure. It is intended wholly for mobilizing and not for development.

6. The patient stands back to a table and lies down against the edge of the table, so that this edge comes just below the shoulder blades, while his knees are extended and his legs stretched out. He then grasps the table on both sides with his hands to keep the upper part of his body firm, moves his legs toward the side of the lumbar convexity as far as possible, keeping both knees straight, feet together and pointing straight ahead, and sliding them along the floor sideways. It should be a direct side-bending in the hyperextended position, and care should be taken to keep the legs in the same plane with no twisting. The patient remains in the corrected position as long as he can, maintaining all the stretch possible.

This exercise gives the same stretching as where the surgeon raises the body and turns it over, a thing which can seldom be done by the mother. The only danger is that the patient might twist the spine instead of getting a direct side-bending. This exercise gives a very effective lumbar stretch, but is only good for a lumbar curve. It is a very effective exercise and needs no help from the surgeon instructor so that the patient can do it at home.

Each of these exercises should be repeated 10 or 15 times according to the patient's vigor, and done forcibly, carefully, and rhythmically.

Progressive improvement must be assumed as the criterion of efficient gymnastic treatment for it is impossible to draw a general line either theoretically or in practice at the outset between cases of structural scoliosis which should be treated by gymnastics alone and those which should not. The line comes somewhere between the mild and the moderate cases, and doubtful cases should be tried on the purely gymnastic treatment and kept on it *only* so long as the deformity improves, or is at least controlled. In other words, mild cases are generally suitable for gymnastic treatment. Cases of moderate deformity with slight rotation and not much lateral curve should also be started on gymnastic treatment for trial. Where there is marked rotation, and in all advanced curves, gymnastic treatment alone is ineffective. If moderate and severe cases are loosened up by effective gymnastic treatment and not supported by braces or jackets at the outset, as they become flexible the deformity will increase. The surgeon who undertakes the responsibility of a severe case of scoliosis will do well to avoid all treatment unless he can furnish effective support to hold what is gained by gymnastics.

Exercises given by a competent gymnast, should occupy a period of from one to three hours a day, according to the vigor of the patient, and must be continued under personal supervision for a period of some weeks or months to obtain satisfactory results. After this, exercises at home can be substituted for part of the work under supervision.

As a preliminary to gymnastic work the heart of the patient should have been, of course, examined. Afterward the weight should be taken each week as, in children, persistent loss of weight from exercises may be an indication for moderating or discontinuing temporarily the exercises, providing that the patient is not being overworked at school, in which case the school conditions should first be remedied. During menstruation, gymnastic exercise should be modified. Persistent fatigue, anemia, loss of appetite, nervousness, and frequent or profuse menstruation should cause a careful investigation of the patient's environment, as they may arise from that or from excess of gymnastic work.

Plaster Jackets, Braces and Corsets.—Braces and corsets have little or no corrective value in the treatment of lateral curvature, and are only to be regarded as a means of retaining the gain secured by other methods.

The practice amongst some instrument-makers of fitting corsets and braces to such patients and allowing the parents to hope for any considerable benefit is therefore to be condemned.

The complicated braces in former use have been largely displaced by the plaster jacket or corset and may be found described in the older literature.[1]

In the writers' experience better retention is secured by removable plaster jackets than by braces. Under the conditions specified the choice between a removable jacket, a corset, or a brace will be determined by the facility of the surgeon with each.

Passive Stretching of the Spine.—It is at times desirable to increase flexibility of the spine more rapidly than can be done by free standing gymnastics alone, and the patient may be stretched by (*a*) suspension, or (*b*) while recumbent.



FIG. 748.—Quadrilateral back brace applied to an ordinary corset with a leather pressure pad on the right side to correct a low curve.

(*a*) *Passive Stretching by Suspension.*—The patient stands or sits erect,



FIG. 749.—Side view of same apparatus, showing the quadrilateral iron brace.

and the head is pulled vertically upward by means of a Sayre head sling, which embraces the chin and occiput. Traction should be made by a compound pulley, and the patient or the surgeon may hold the rope. Suspension is mildest: (1) When the feet are not made to leave the floor; next in grade comes (2) the position of tiptoe induced by the traction, and (3) a greater pull is secured by lifting the whole body until the feet swing free. In this case the traction force equals the body weight. The maximum traction can be secured (4) by strapping the thighs down to a seat on which the patient sits. An upward pull greater than the body weight can now be exerted on the head.

(*b*) *Stretching in Recumbency.*—Correction of the lateral curve of the spine is, however, to be obtained more economically by having the patient lie prone, and the corrective force should be divided into two elements: The

[1] HOFFA: Lehrb. d. Orth. Chir., 4th Edition, 1905, 429.
REDARD: Chir. Orth., Paris, 1892. 382.
BRADFORD and LOVETT: Orthopedic Surgery, 1st Edition, 1890, 168.

force to correct the rotation, and the force to correct the side deviation. A simple apparatus for this is as follows:

The patient lies face downward, with the knees flexed, on a board three feet wide by four feet long. Assuming the case to be that of a right dorsal curve, a broad canvas strap is passed around the left thorax, over and under the patient and fastened to a cleat on the right side of the board. This furnishes a point of pressure to the left against the upper thorax at the level of the axilla. A broad canvas strap is then passed around the pelvis of the patient above and below, and is fastened to a cleat at the right side of the board. This furnishes a point of pressure to the left at the level of the pelvis. A broad canvas strap is then passed around the thorax at the level of the greatest point of curve; it passes above and below the thorax and its upper end is fastened to a cleat at the left side of the board. Its lower end is fastened by means of a rope into a compound pulley attached to a cleat at the left side of the board. By means of this pulley any reasonable degree of force may be exerted against the right side of the thorax, pulling it to the left, and at the same time that it pulls, it tends to reduce the rotation from the fact that its upper end is fastened and its lower end moving toward the pulley (Figs. 751 and 752).

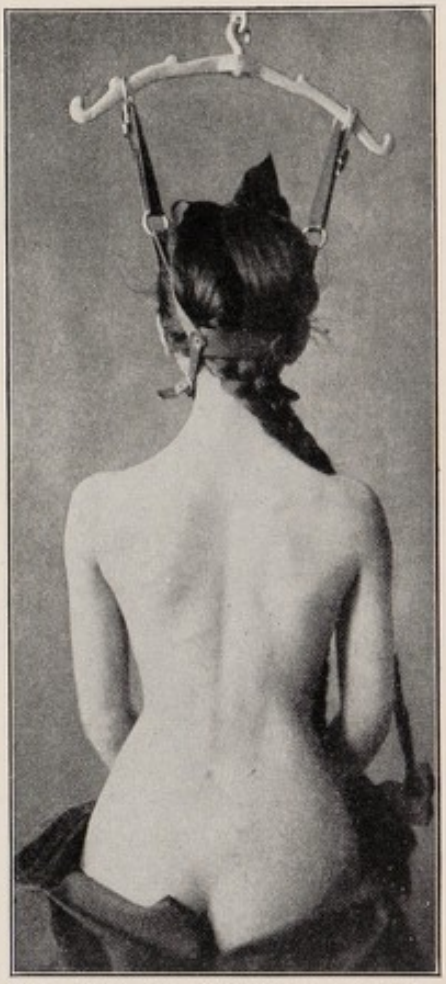

FIG. 750.—Stretching by suspension on Sayre head sling.

Forcible Correction.—In marked moderate and in severe structural lateral curvature no means of treatment is, in the opinion of the writers, so efficient as continuous stretching by means of plaster jackets applied under force. This method is spoken of as "forcible correction." Such jackets are applied with the purpose of stretching the contracted structures and of inducing an improvement in the curve, or a readjustment of curves.

The object of the corrective jacket being to force the spine into the best obtainable position, and in that position to apply a retentive plaster jacket, it becomes pertinent to inquire in what position and by what technique the best correction may be obtained.

Such jackets may be applied in (*a*) suspension or (*b*) recumbency.

(*a*) *Application in Suspension.*—Sayre's jackets were applied with the patient suspended by the head with the heels lifted from the ground.

Wullstein's[1] method was also a suspension method, but he used 250 pounds of traction, and to secure this, the patient was strapped by the thighs to a revolving and tilting stool and lateral pressure was secured by pads running in from an upright frame on horizontal rods. These pads were incorporated in the jacket.

[1] Zeitsch. für Orth. Chir. x, No. 2, 238.

The use of strong traction in the length of the spine tends to straighten the lateral curves and to diminish the rotation, but without added lateral pressure sufficient correction is not obtained.

However, the upright position is the one in which the patients will wear the jacket; the technique of application is in this position the simplest; access to

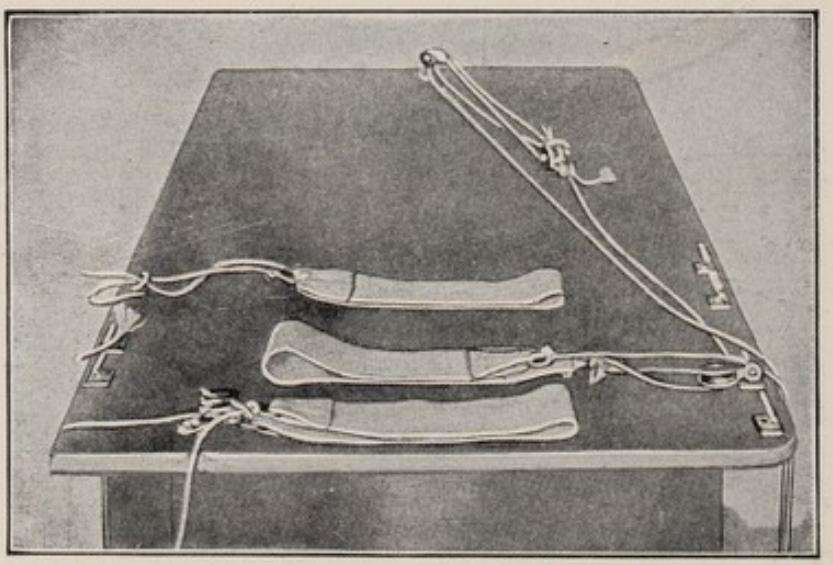

FIG. 751.—Stretching board with loops, ready for application (Jour. Am. Med. Assn.).

the shoulders and neck is easy, and the lower part of the jacket can be accurately fitted to the pelvis. A close-fitting and presentable jacket can be most easily applied by this method, but it does not exert as much force as the following method and is suitable only for mild cases, or cases that have been made flexible.



FIG. 752.—Stretching board with loops applied to a patient. Position of straps is the reverse of that shown in Fig. 751 (Jour. Am. Med. Assn.).

(*b*) *Application in Recumbency.*—In this technique head traction is not used and lateral pressure is wholly depended on. The patient may lie on the face with the hips flexed, or on the back. The latter position seems to allow a little more lateral flexibility of the spine under pressure.

A simple application of this method is to be found by having the patient lie in a rectangular gas-pipe frame on two straps of webbing running from end

to end, or on transverse cross straps of webbing. If the patient lies on the face the thighs and knees should be flexed. By means of webbing straps attached to the side of the frame, in a right dorsal curve, one going around the left side of the pelvis and another around the left upper thorax, while a third pulls on the right side of the thorax against these as points of resistance, great force may be exerted on the spine, much more force than can be safely used. With the patient lying on the webbing strips which are padded, the pelvic and axillary straps are adjusted to the proper tension and tied around the side of the frame. A heavy pad of felt is then applied over the rotated and curved portion and a

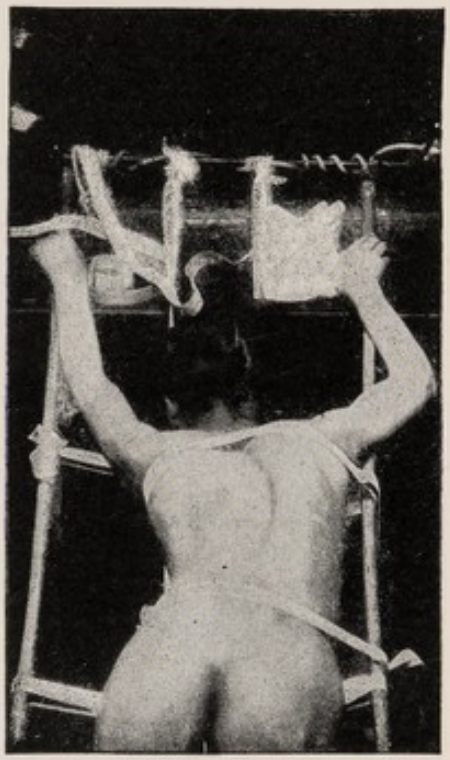

FIG. 753.—Patient lying in corrective frame, showing the improvement gained by the horizontal position. (Photographed from above.)



FIG. 754.—Patient in corrective frame with side pressure applied by strap. Showing additional correction to that in Fig. 753.

webbing strap attached to the side of the frame and tied at one end. This strap is then passed over the rotation, under the patient and back to the frame. By pulling on this end of the strap (the upper end of which has already been tied) the curved portion of the spine is pulled to the side and the rotation acted on by the twisting action of the strap. When sufficient tension has been obtained the end of the strap is fastened to the frame. The jacket is then applied with the side webbing straps in place, the bandages being worked around the straps. When the plaster is sufficiently hard these side straps are cut off where they emerge from the jacket and a finishing bandage is applied. The patient then stands up; the longitudinal straps are pulled out, the jacket is cut out under the arms and by plaster bandages the jacket should be extended to include the shoulders, which is always desirable, but not always tolerated.

When it comes to the application of corrective force it must be remembered that there are two elements in the deformity, namely, side deviation and rotation.

Attempts to diminish the lateral curve by pure lateral pressure, not carefully antagonized, will result, in fixed curves, in an increase of the rotation. The solution lies in dealing separately with the rotation and with the lateral deviation. Having corrected the lateral deviation first, this correction is held, as will be described, while the rotation is corrected, or *vice versa*. In this way one element is not improved at the expense of the other.

The patient should preferably be stretched once or twice daily for two or three days preliminary to the correction, but this is not essential. Anesthesia is never necessary, as all endurable correction may be obtained without much pain. A seamless under-vest is put on and the iliac crests padded with heavy felt; a pad should also be placed over the sacrum. Under the side straps heavy felt or cotton pads are required. The correction is pushed to the point of causing mild discomfort, and difficulty in breathing is a sign of too much correction. The amount to be obtained in any case is better decided by the patient's sensations than by any theoretical standard. The danger lies on the side of obtaining too much rather than too little correction, for the jacket will be much more uncomfortable when the erect position is assumed.

After correction the patient should *remain under the surgeon's direct observation, preferably in a nursing home or a hospital* under close supervision for at least twenty-four hours. Some shock is not infrequently experienced and in a case of one of the writers very serious collapse and cyanosis followed the correction of a severe curve due to infantile paralysis in a child of six. Wullstein has recorded the occurrence of somewhat serious symptoms following correction.

For the application of corrective jackets the writers favor the recumbent position, preferably on the back.

The *Abbott*[1] *method* of applying corrective jackets advocated by the originator as "a simple, rapid and complete reduction of deformity, in fixed lateral curvature of the spine" consists of placing the patient on the back in a specially devised frame with the legs flexed and suspended to a bar above the frame. The patient lies in a hammock and side pressure and rotating force is exerted by means of webbing straps running from the sides and top of the frame. Large windows are cut in the jacket and subsequently additional pads inserted to press on the convexities.

Jackets applied by this method are most unsightly and very uncomfortable and, in the experience of the writers, less efficient than those applied by the simple recumbent method advocated. In this matter their experience is confirmed by others.[2]

Treatment Subsequent to Application of Jacket.—Following the application of the corrective jacket two methods of treatment are available: (1) The original jacket may be left on, or (2) after one or more corrective jackets have been applied a removable jacket or corset or brace may be used.

1. Permanent Corrective Jackets.—When the jacket is hardened, it is left solid over the parts that are made prominent by the rotation behind and in front; that is, in a right dorsal curve the right back and left front are not touched, but large windows are cut over the depressed side of the chest behind (and perhaps the corresponding portion diagonally opposite in front), so that

[1] New York Med. Jour., June 24, 1911, Apr. 27, 1912.

[2] Lance: Le traitement des scolioses graves par la Méthode d'Abbott, Paris, 1914.
Kleinberg: Am. Jour. Orth. Surg., June, 1914; New York Med. Jour., Apr. 27, 1912; New York Med. Jour., June 24, 1911.

in a right dorsal curve the left side would be cut out behind from the middle line of the back to the anterior axillary line in front. This makes it possible for the depressed parts of the chest to be expanded by respiration, while the prominent parts are compressed. Pads of felt are now inserted between the prominent part of the chest on the right and the jacket (and perhaps in the corresponding region in the front on the left), thus making the jacket more corrective, and thicker pads are substituted each week without changing the jacket, these being drawn through without difficulty by means of a bandage. In this way,



FIG. 755.—Permanent corrective jacket applied.



FIG. 756.—Removable jacket for right dorsal curve with left side cut out, applied to patient. The jacket is reinforced by steel around the edges of the window to prevent breaking.

a continual diagonal side pressure is kept up on the curved portion of the spine and is steadily increased. When these pads have become so thick that the jacket is pushed away from the patient and no longer fits, it will be found that it is advisable to apply a new jacket, to cut it out in the same way and to begin on the progressive padding. The use of such a permanent jacket may be continued as long as it seems possible to gain further correction, but two are generally sufficient, being changed at intervals of a few days; and at the end of this time a removable jacket is substituted for the permanent one and gymnastic treatment is begun. The removable jacket is then gradually discontinued while the patient's muscular condition is being improved by gymnastic exercises.

2. REMOVABLE TURNBUCKLE JACKET.—The turnbuckle jacket for correction of structural lateral curvature was first used in November 1923. In

searching the literature the following references were found Hanansek[1] described a jacket cut circularly in two sections controlled by two long wooden rods which he used temporarily for twisting laterally curved spines. Hibbs[2] only refers to a turnbuckle jacket but no further description can be found. The use of a turnbuckle in the forcible treatment of Pott's disease is described in numerous articles, particularly by the German authors.

Construction: Given a patient with a right dorsolumbar curve, with the apex of the curve at the twelfth dorsal vertebra, the patient is suspended in a Sayre head sling until his toes are just touching the floor. He holds on to the bars above his head with his hands. The position hyper-extends the spine and elevates the scapulæ as well as making them prominent laterally. Both of these points are important in the construction of the jacket. A plaster jacket is then applied from high up in the axillæ down over the greater trochanters taking particular care to mark out the anterior superior spines and inguinal regions. This is immediately removed by a front midline incision and a few more plasters wound around to hold it in shape. A wooden box is then obtained and a hole is made through its center. A steel rod is passed through this hole in the box—the rod in position is perpendicular to the floor. The jacket is then so placed on the box that the steel rod passes directly through its center and is then filled with plaster mud and allowed to set. The jacket is then removed and the torso is ready for hewing.

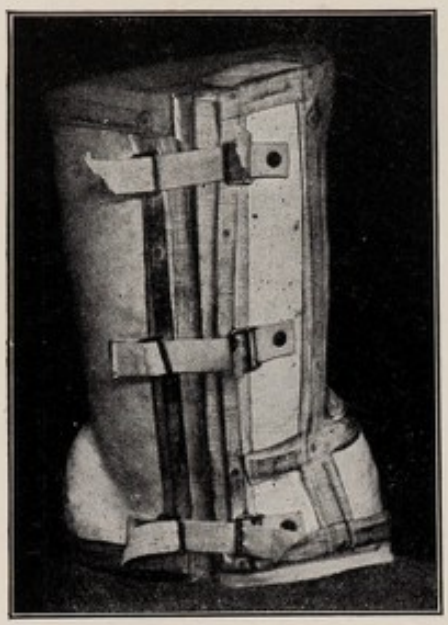

Fig. 757.—Front of jacket shown in Fig. 756.

The steel is placed in a vice and the torso is hewed. The prominences on the torso caused by the elevated scapulæ are cut away and about an inch is also hewed from the top of the torso posteriorly. The torso is then considered squared (Fig. 758). This hewing is necessary to prevent the finished jacket from being too large at the top. The next step is to mark out the inguinal regions and shave off the abdominal prominence. It is most important not to lower or change the contour of the iliac crest, because such a change makes the final jacket very uncomfortable from pressure on these bones, particularly the anterior superior spines (Fig. 759).

With the squaring of the torso finished, as well as the abdominal prominence shaved away and the inguinal regions marked out, correction of the torso is begun. If the curve is a right dorsal, left lumbar the right prominence is shaved with a draw knife as much as from experience it is evident the patient can stand. The left hip is then lowered, and the part of the torso at the top, left posterior, is hewed away. This decreases the left concave side of the body making it approach a straight line. By the above procedure, it is readily seen that pressure is exerted at points A, B, and C, as shown in Fig. 760. This is the same principle on which most forcible jackets work—only in a less efficient manner—B representing the place where the pads are forced in, A and

[1] Hanansek: Rev. d'Orthop., March 1922, p. 130.
[2] Hibbs, R. A.: J. Bone and Joint Surg.: 6: 3, Jan., 1924.



FIG. 758.—The turnbuckle jacket. The squared torso of plaster of Paris ready for shaping. Back.



FIG. 759.—Same as Fig. 758, front.

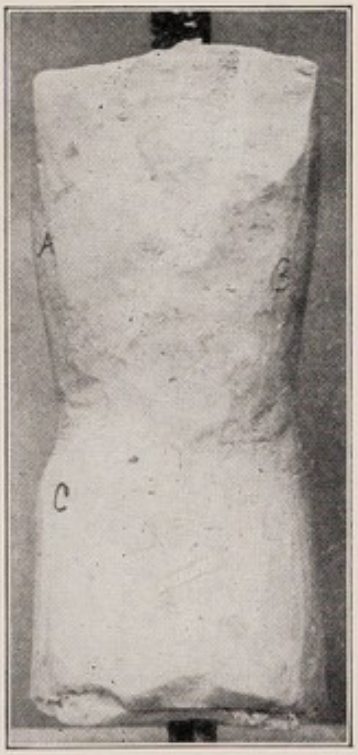

FIG. 760.—The turnbuckle jacket. The plaster torso finished and ready for application of jacket. Back.



FIG. 761.—Same as Fig. 760. Front.

C the top and bottom of the jacket. A triangular area of about an inch deep at the top, and tapering off at the apex, is then cut out. This is done so the jacket will fit skin tight between the scapulæ, and also prevents the clothes being pushed out in the back—a point patients appreciate.

After the torso is cut as above described, a new plaster jacket is put on and immediately cut off by a front line incision. This jacket ought not to be more than three-eighths of an inch thick and should be the same thickness everywhere. The thickness of seven plasters will as a rule be just about three-eighths of an inch.

Application.—After the jacket is dry about four or five inches are cut off at the top in order that it may be comfortable with the arms hanging at the

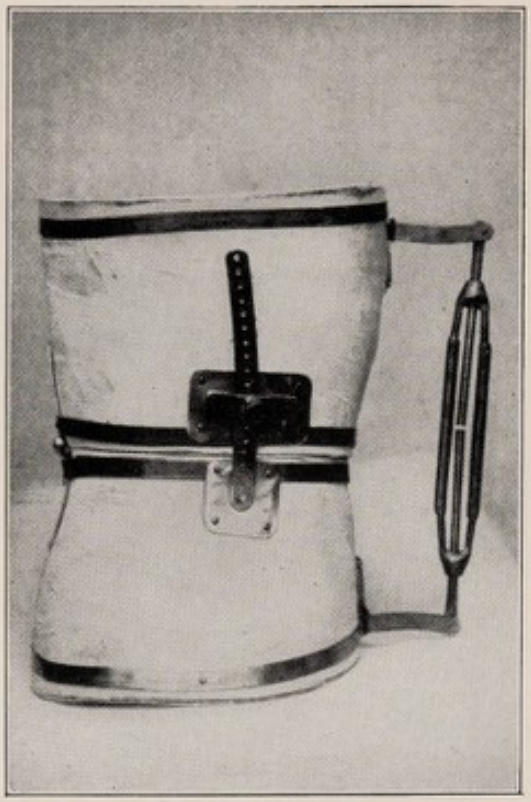

FIG. 762.—The turnbuckle jacket. Back view, turnbuckle in place, closed.

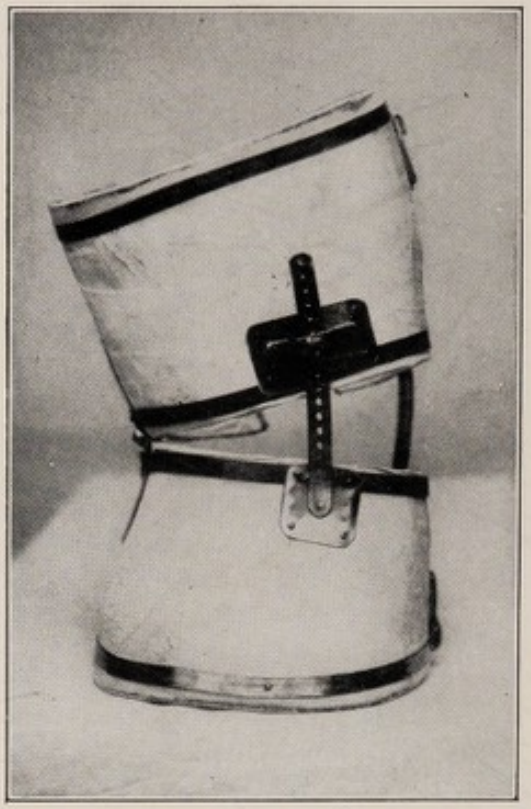

FIG. 763.—Turnbuckle jacket, back view, opened, locked, turnbuckle removed.

sides. It is necessary to remove enough at the top so the circulation will not be impaired. At the bottom, the jacket is cut off about one inch below the anterior superior spines tapering downward posteriorly. This allows the patient to sit comfortably (Figs. 762 and 763).

The jacket is put on, the patient reclines on a table and an assistant holds the patients arms while the jacket is pulled well down. The temporary straps are tightened while the patient is on the table. If the jacket fits correctly, he is unable by putting his hands on his hips and pushing his body up to get out of the jacket. The jacket is worn for a day or so to be sure that it exerts pressure over the rotation being attacked. This is shown by a slight redness of the skin. The jacket must be comfortable.

The general principle of the construction and application of the jacket up to this point was described by R. W. Lovett and J. W. Sever.[1]

Method of Splitting a Turnbuckle Jacket. Applying the Turnbuckle

Given a right dorsolumbar curve with the apex of the curve at the twelfth dorsal vertebra, a string is tied around the patient at the level of the twelfth dorsal vertebra. The jacket made from the corrected torso—which gives pressure at the desired points and has proven to be comfortable, is applied. At a point in front, at the level of the string, the jacket is marked. This point is higher than the level of the twelfth dorsal vertebra because in putting on the jacket in the recumbent position the skin is pulled up more than the spine



FIG. 764.—Back view of turnbuckle jacket with turnbuckle in place.

is extended. A line is then drawn around the jacket about one half-inch below the above described front mark (Fig. 764). A cross is put in the left mid-axillary line at the level of the circular mark to indicate where the hinge is to be placed. On the right side on the mid-axillary line at the top and bottom, crosses are made indicating the position of the boxings for the removable turnbuckle. Lines are drawn around the jacket indicating where it is to be steeled. In front, marks are made indicating where the boxes for the top and bottom stays are to be placed. The jacket is then sent to the appliance shop and the hinge, boxings and steels above described are all put on before the circular incision separating the jacket into two parts is made. This is necessary in order to keep the exact relations of the two parts. The position of the front and back locking device has to be determined by the mechanic and adjusted so it will work easily when the jacket is turned up or down. The buckles and straps for fastening are routine and always occupy the same position.

[1] LOVETT, R. W. and SEVER, J. W.: The Treatment of Lateral Curvature of the Spine. J.A.M.A., 57; 786, September, 1911. See also LOVETT, R. W. and BREWSTER, A. H.: J.A.M.A., Vol. 82. pp. 1115–18, April 5, 1924; and Jour. Bu. & J. Sur., Oct., 1924.

Construction of Hinged Shell for Recumbency

Given a left dorsolumbar curve centering at the twelfth dorsal vertebra, the patient is placed on an ordinary Bradford frame, face down and in a straight position. Straps are run lengthwise of the frame to hold the patient. A plaster shell is applied including the head and all the body down to the middle of the lower legs. Care is taken to mould the shell to fit the body and to shape it well up over the chest and hips anteriorly. While the patient is still in the shell the place for the hinge is marked (Figs. 765 and 766). To get the exact

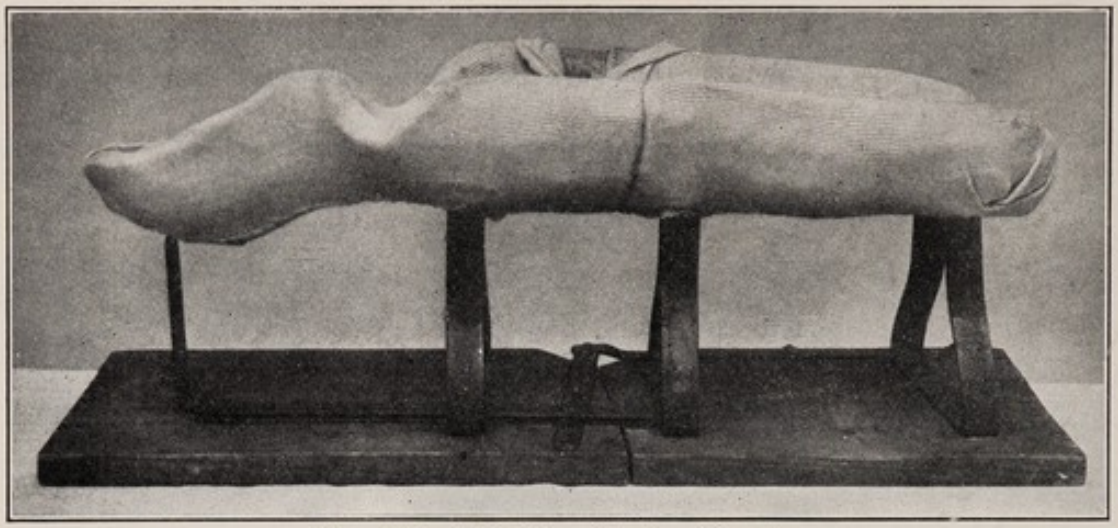

Fig. 765.—The hinged shell. Closed.



Fig. 766.—The hinged shell. Open. The patient lies in dorsal recumbency.

position of the hinge, a string is tied around the body at the desired level and a mark is made indicating the position. This is done before putting the patient in the shell. The shell is removed and cut evenly around the edges and trimmed off at the bottom just at the bend of the knees. The mechanic then applies the hinge where indicated by the mark and mounts the shell on a plank by means of steel supports. A second hinge is placed on the plank so that its center of action is the same as that of the one on the shell, but at a lower level, like the hinge of a door. The shell and board are then cut at the same level. The locking device is placed on the opposite side of the board from its hinge and is simply a slotted steel rod working on a small steel upright which is threaded to take a

thumb screw. The shell is well padded and covered with stockinette. The construction of the shell, excepting the hinges and split board, was described by R. Plato Schwartz[1] for treatment of tuberculosis of the spine.

Mechanical Principles of Turnbuckle and Shell

The mechanical principles of the turnbuckle and shell are exactly the same. The simplicity of their mechanics is their virtue.

A laterally curved spine represents one or more arcs. The problem is to straighten the spine, and to do so we must employ a method which entails no harm to the patient and correctly obeys mechanical laws. To break an arc, three forces are necessary: (1) A resisting force on the convex side of the keystone at its center, (2–3) An active force at each end exerting pressure on the concave side. Such forces if strong enough will snap the arc. To straighten an arc are also needed three forces, but differently employed: (1) A resisting force evenly distributed over all the convex side of the keystone; (2–3) An evenly distributed force working on the entire concave side of each limb of the arc. The turnbuckle jacket and shell furnish the forces used to straighten an arc. Another mechanical principle of the turnbuckle jacket and shell is that they are eccentric. The hinge on either does not correspond to the center of motion in the spine and when they are opened they are elongated, which produces a distraction of the spine above and below the part opposite the hinge.

Choice of Cases for Treatment.—The turnbuckle jacket is of little avail in old ankylosed cases with marked rotation. It is not efficient in a curve whose apex is above the eighth dorsal vertebra. The turnbuckle shell is effective in cases of babies with congenital scoliosis who are too small to walk and for curves whose apices are higher than the eighth dorsal vertebra.

Treatment by Turnbuckle and Shell.—The fact must not be lost sight of that the gymnasium with trained physiotherapists is a valuable asset in any method of forcible correction of lateral structural curvature of the spine. The back and abdominal muscles must be kept in good tone by regular visits to the gymnasium for exercises and massage.

At first the patient wears the jacket for a week in the turned down position. Then it is turned up just as far as it is comfortably borne; it is locked in this position, and worn night and day. The patient should never bear weight without his jacket on. Some patients can have the jacket turned up almost to the maximum on the first day, but this is probably a little dangerous. Once a week it should be turned up one or two notches until the desired correction is obtained.

If the turnbuckle is correctly made the patients do not object to the pressure it exerts and in all the cases treated a pressure sore has never been experienced.

Experience in the use of this method of treatment of structural scoliosis, permits the following conclusions:

1. It affects mobilisation of the spine by stretching all the tissues on the concave side and allows the stretched tissues on the convex side to regain some of their lost tone.

2. The force applied spreads the ends of the arch and does not disregard the mechanical law that the keystone is the strongest part of the arc.

3. It permits gradual correction.

[1] R. Plato Schwartz: The Journal of Bone and Joint Surgery, October, 1922.

4. It will produce an immediate correction of certain moderate curves.
5. It tends to decrease rotation, as seen clinically, and in the roentgenograms.
6. It secures the means of obtaining an adjustable over-corrective retention jacket.
7. It increases the height.
8. It is not uncomfortable and is not noticeable when the clothes are on.

Mechanical Objections to All Corrective Jackets.—In applying force to correct the lateral curve and rotation of the scoliotic spine we cannot apply such force directly to the spine, but we must apply the corrective pressure to the ribs. The ribs are loosely attached to the spine, and are, moreover, rather easily distorted themselves by pressure. We therefore must do without that direct application of force to the affected structure which we possess in the treatment of most deformities.

Secondly, to exert effective side pressure one must be able to press laterally not only against the apex of the lateral curve, but to exert counter-pressure in the other direction at the top and bottom of the curve,[1] and this we cannot do by pressure against the thorax in high dorsal curves because we cannot reach as high as the top of the curve. To attempt to secure a higher level of side counter-pressure against the root of the neck is to pull against soft structures overlying a nerve plexus, where strong pressure is not tolerated, nor can side pressure be exerted on the lumbar spine; consequently corrective jackets are not satisfactory in lumbar curves nor in curves whose apex is as high as the upper dorsal region. In lower dorsal and dorsolumbar curves they find their best application.



FIG. 767.—Swinging head piece for high dorsal scoliosis.



FIG. 768.—Back view of swinging head piece attached to jacket.

Thirdly, forcible jackets by fixation and pressure cause atrophy of the muscles of the trunk and spine, and this fact has been much insisted on by the opponents of the method. But when the time has come to begin the after-treatment, such atrophy is quickly recovered from by the use of gymnastics and massage, and by the gradual rather than the sudden discontinuance of the support when the proper time comes.

[1] LANGE, F.: Zentrlblt. fur Chir. Mech. Orth., Bd. v, Hft. 12.

That such jackets will prove detrimental to the general health is a fear which is not supported by facts, for the improved posture and the restoration of the viscera to a more normal position are more than enough to counterbalance the discomfort and the handicap of the jacket, in the great majority of cases. A gain in flesh and improvement in the general condition may, as a rule, be predicted from the application of a proper jacket.

Finally, the danger to life from the application of jackets may practically be disregarded. Alarming symptoms have arisen and in a few instances deaths have occurred as a result, but in these cases the use of force has been too great. With the use of judgment and moderate force no real danger can be incurred in normal individuals.

In cases of *high dorsal curves* no jacket can be effective because it is impossible to exert counter-pressure on the upper end. Effective side pressure by a

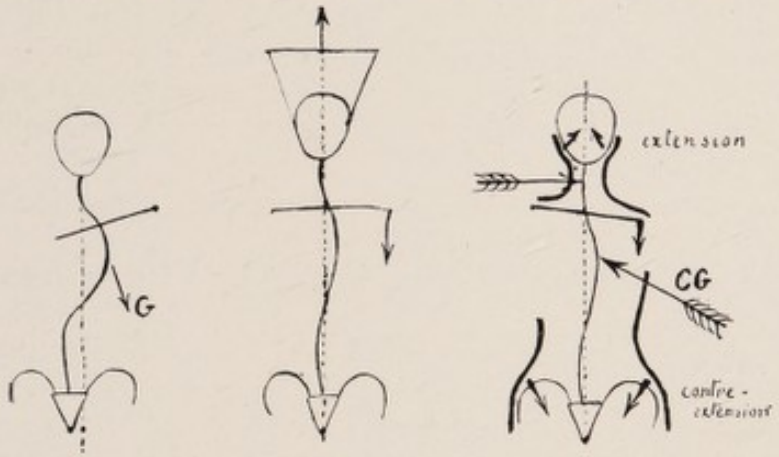

FIG. 769.—Diagram showing the principle of applying the Minerva jacket in high dorsal scoliosis (Calvé).

jacket cannot be effectively made above the fourth or fifth rib. As a result of this, although in such curves it may be possible to press on the apex without counter-pressure at the upper end of the curve, corrective pressure cannot be obtained. Consequently one must abandon the idea of controlling this class of cases by a simple plaster jacket without a head-piece. An exception can be made here if the patient is treated in recumbency, then the turnbuckle shell above described is efficient throughout the length of the spine.

Upward traction in high curve is often useful. A suspension jacket is put on just as in the lower curves and is carried as high as it will comfortably go. A Taylor head-piece, similar to that used in Pott's disease, is then made from a cast, embracing the chin and occiput. This cast is taken with plaster of Paris bandages, which are wound circularly around the head and occiput, then removed and filled.

The head-piece is fastened at the back to a piece of steel through which an upright hole has been bored, and this upright hole sets down on a post which fastens to the jacket by means of two boxes attached to steel uprights on the back of the jacket. The post is raised and lowered by a rachet and pinion action, a set of teeth being cut in the posterior part of the post. It is raised and lowered by a key and a band slips down when the proper position has been reached, holding the position by means of a spring with a projection on the front which fits into the space between the teeth. The post is attached to a yoke running half way forward on both sides of the base of the skull and the yoke is joined to the head-piece just under the ear, allowing antero-posterior motion. This does not diminish the efficiency of the apparatus and allows flexion and extension of the head as well as rotation (Figs. 767 and 768).

This apparatus is used in connection with exercise treatment by being mounted on a removable jacket and being kept at a constant height, making traction on the neck and two or three times a day by winding it up as far as the patient can stand it and leaving it there for a minute or so, making a real traction on the curve. With the use of this apparatus a very different grade of result has been obtained from that which was previously possible.

The same principle is followed by Calvé, who uses a Minerva type of plaster jacket, cut away on the hollow side, supporting the head. (Fig. 769.)

Curves due to congenital defects, rickets, and empyema are available for forcible correction, but are resistant; while those from infantile paralysis are often easy to improve by correction but must be held by apparatus, often permanently.

Permanence of Results.—Successful permanent results can be obtained in hospital practice only in selected cases, the average patient being unable to appreciate the importance of following out the treatment sufficiently long. The criticism that such correction is not likely to be permanent at once presents itself. The grounds that lead one to suppose that retention of the growing spine in a corrected position over a sufficient period will lead to a change in the shape of the bones of the vertebral column and to a permanently improved position are as follows:

1. The bones of the feet of Chinese women of rank are seriously misshapen by retention in an unnatural position.[1]

2. Wullstein produced bony changes in dogs by a few months of abnormal position of the spine.

3. Arbuthnot Lane[2] has demonstrated that the habitual carrying of heavy loads by laborers will produce changes in the bony skeleton.

4. The fact that bone under pressure changes shape after growth has been reached is shown in the fact that scar tissue pressing on bone will cause a change in shape,[3] *e.g.*, on the chin.

5. Pressure of tumors or aneurysm will cause absorption of bone.

These facts all point to the conclusion that bone alters its shape under changed conditions of pressure, and that although this change would be more marked during growth, the phenomenon is not unknown in adult life.

It seems reasonable to hope that the maintenance of improved position may be expected in time to produce a change in the shape of the vertebræ. It is obvious that such a corrected position must be maintained over a long period to secure permanent results. Schanz[4] has provided clinical evidence that his results have been permanent in the time during which they were observed.

Choice of Methods.—The choice between the use of fixed or removable corrective jackets must be determined by the circumstances of the patient, the temperament of the child, and similar considerations. Careless hospital patients will do better in a fixed jacket for a year or two, while nervous girls in private practice will do better in split jackets.

Gymnastics Following Forcible Correction.—As soon as the final corrective jacket has been removed and replaced by a removable one, gymnastic treatment should be begun. Such treatment to accomplish results must be given from one to four hours a day for a period of a least six months from the removal of the final corrective jacket, after which less frequent and vigorous exercises

[1] Brown, P.: Jour. Med. Research, December, 1903.
[2] Arbuthnot Lane: Guy's Hosp. Rep., xxviii.
[3] Zeigler: "Pathology," English Edition, 1896, xi, 146.
[4] Schanz: Verhdlg. d. Deutsch. Ges. fur Orth. Chir., 1908, 57.

may be sufficient. Exercises must be continued until the corrected position is maintained without apparatus from month to month, and the supporting apparatus discontinued at first for short periods, gradually increasing in length. The length of time that active treatment must be continued will depend on the age of the child, the severity of the case, the efficiency of the treatment, and similar factors; but any case of scoliosis severe enough to require forcible correction will not, as a rule, occupy less than two years, and often a longer period.

The present discredit of gymnastic retentive treatment is due to its use in too small dosage and to a failure to appreciate that a problem so grave as the permanent maintenance of the corrected position in a spine, which has suffered some degree of bony distortion, is only to be obtained by a long continuance of sound mechanical treatment.

Operation.[1]—Resection of the ribs on the convex side of the curve as proposed by Volkmann and Shaffer and carried out by Casse and Hoffa, and an operative correction by Hoke, who also lengthened the ribs on the concave side, and somewhat similar operations by Jaboulay and Bade have not been satisfactory. This type of operative relief of scoliosis has been for the present abandoned.

The question of stiffening the spine in the region of the curve has of late been much discussed and is being practised on a large scale in certain clinics. The operations are the same as those advocated for tuberculosis of the spine.[2] In the Hibbs operation the spine is cut down on, the laminæ and spinous processes are exposed, the periosteum is stripped in a tube from the laminæ out as far as the transverse processes; the spinous processes are then cut part way through and broken down and the edges are cut through and broken down while the edges of the laminæ are refreshed. The tube of periosteum is then brought together and closed in the middle line and the skin sutured. The spine is pressed into the best possible position and the jacket applied.

There is no question that the above described operation will produce ankylosis of the posterior part of the spine. One of the chief objections is that it fuses only the posterior part of the spine. The authors believe that this operation has a field in the treatment of lateral structural curvature of the spine, but it seems best to make a very careful selection of patients. Except in very unusual cases it is a safe rule to follow, not to fuse any spine until the patient has reached adult life. In the infantile group of cases that have reached adult life and seem to be doomed to jackets or some form of heavy apparatus all their life, fusion of the spine is recommended. Fusion of the spine in children is very often followed by an increase in the curve, and an increase in the deformity; for this reason surgical interference in the period of bone growth seems unwarranted.

[1] Volkmann: Berliner klin. Wochnschr., 1889, 50.
Casse: Bull. de l'Acad. Royal de Med. de Belg., Dec. 30, 1893; Jan. 27, 1894.
Hoffa: Zeitsch. fur Orth. Chir., 1896, 401.
Shaffer: Am. Surg. Bull., Jan. 1, 1894.
Hoke: Am. Jour. Orth. Surg., i, 2.
Jaboulay: Prog. Med., November, 1893.
Bade: Klin. Mittheil. in Centralbl. fur Chir., 1903, xxxviii, 1045.

[2] Albee: Bone Graft Surgery.
Humphries: Jour. A. M. A., 1921.
A. McKenzie Forbes: Jour. Orth. Surg., 1920.
Whitman: Jour. Orth. Surg., March, 1916.
Whitman: Jour. Orth. Surg., July, 1921.

Galeazzi[1] of Milan has practised with considerable success a method of correction first demonstrated by him in 1913.

The patient is given a preliminary course of mobilisation of the spine by stretching and exercises. The actual correction of the deformity is then undertaken, using a special machine (Fig. 770), in which, after separate fixation of the pelvis and shoulder girdles, the spine may be laterally flexed and rotated as desired. The patient is placed in position standing on the platform (Fig. 771), and the apex of each curve defined (Fig. 772). At this level a linen counter traction band is passed round the body, and held taut by an assistant (Fig. 773). The apex of the lumbar spine is centred over a nut on the floor of the machine,



FIG. 770.—Galeazzi machine for the correction of scoliosis.

about which the whole pelvic portion swings, and the apex of the dorsal curve over a corresponding nut, about which the shoulder portion of the machine swings.

The pelvis is now enclosed in plaster as far as the lumbar spine, and the shoulders also enclosed in plaster as far as the junction of the dorsal and lumbar curves. The actual correction is attempted first on the more mobile of the two curves. In a right dorsal left lumbar fixed scoliosis, the lumbar curve is corrected by rotating the pelvis counter clockwise, and swinging it to the left (Fig. 774). Counter traction is maintained by the linen band. The pelvic plaster is now extended to enclose the lumbar spine and lower ribs. It is cut away above until the apex of the dorsal curve becomes the centre of the hiatus. The dorsal curve is next attacked by rotating the shoulder portion of the machine clockwise and swinging it to the right until the line of the body

[1] (Personal communication.) The Authors are indebted to Professor R. Galeazzi for the description and illustrations of his method of correction.

is straight. The jacket is now completed. The windows are placed on the left of the dorsal spine, and the right of the lumbar spine. After the application of the corrective jacket the patient is kept in bed for seven days, and then

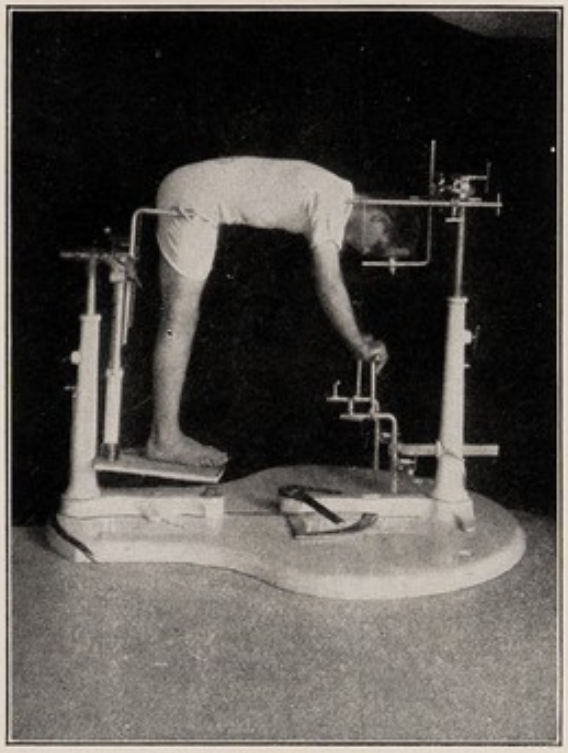

FIG. 771.—Patient in position.

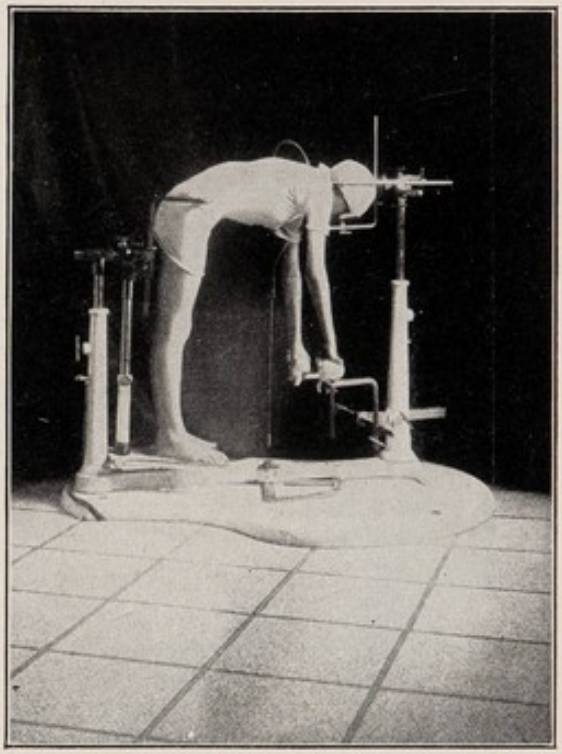

FIG. 772.—Method of ascertaining the centre of rotation.

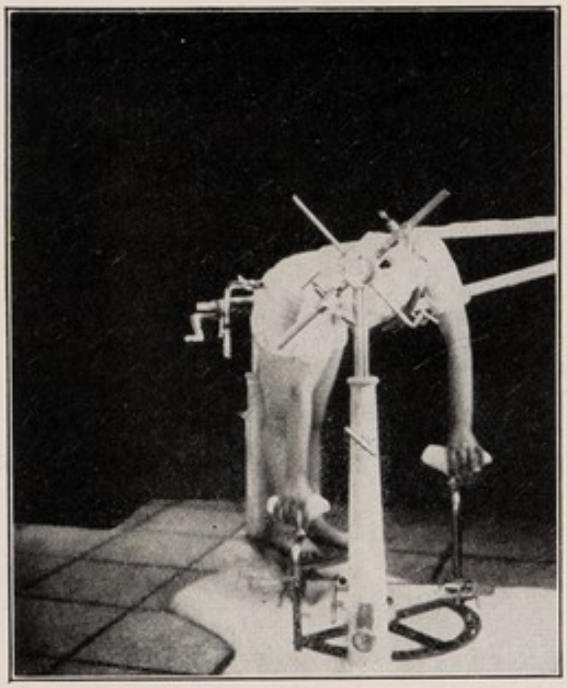

FIG. 773.—Linen traction band in position.

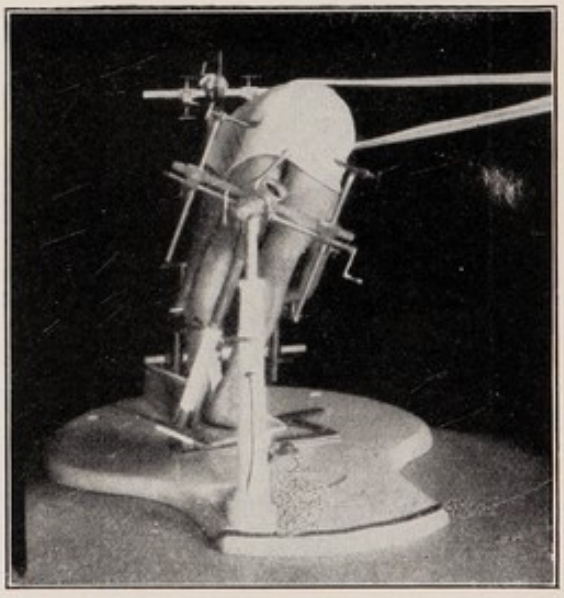

FIG. 774.—Position of correction before application of plaster of Paris.

allowed to leave hospital. A second corrective jacket is applied after two months, and successive jackets used until the maximum correction or over correction has been obtained (Figs. 775 and 776). A removable celluloid jacket is worn for two or three years, or until growth has ceased.

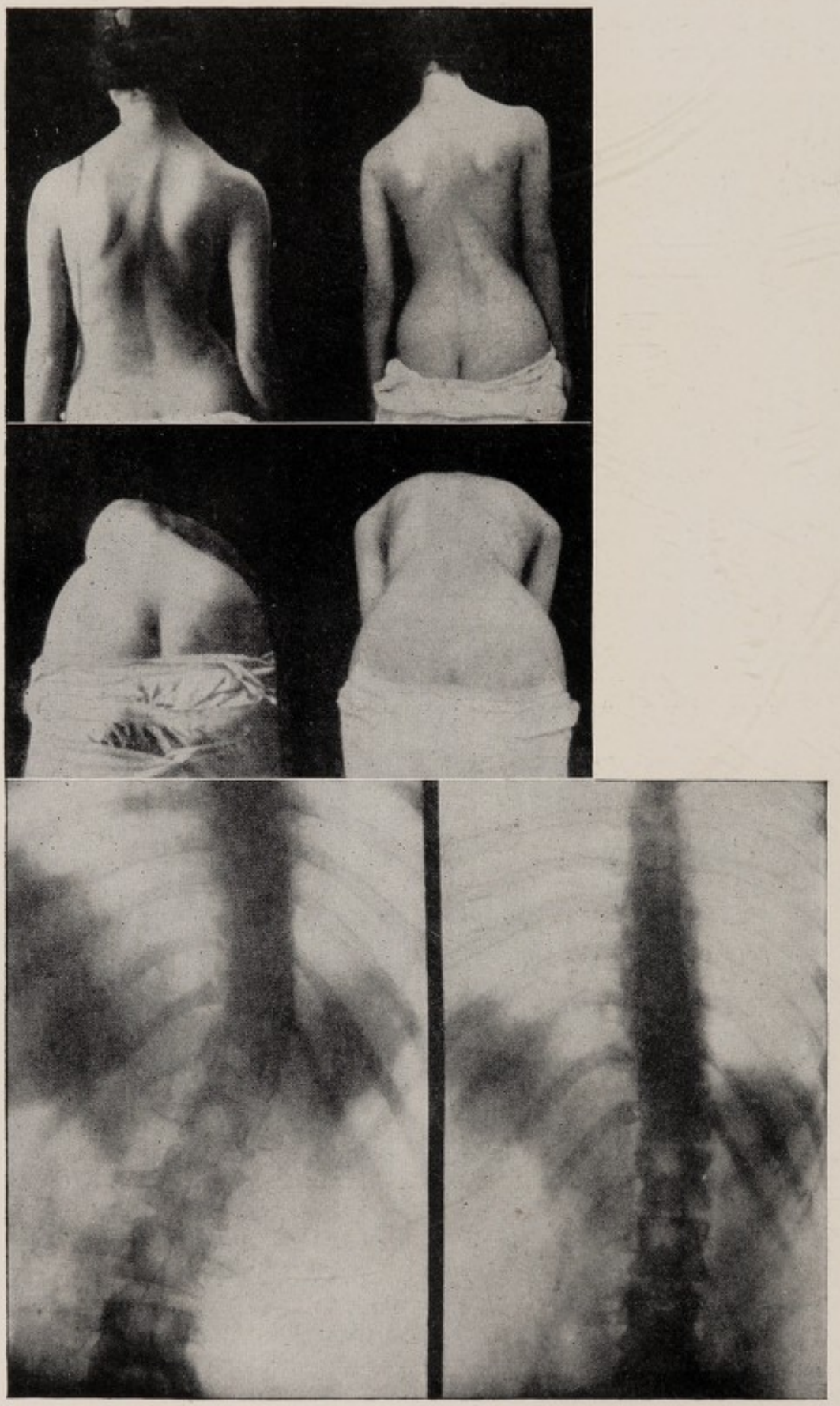

FIG. 775.—Patient before and after correction of the deformity, with radiograms.

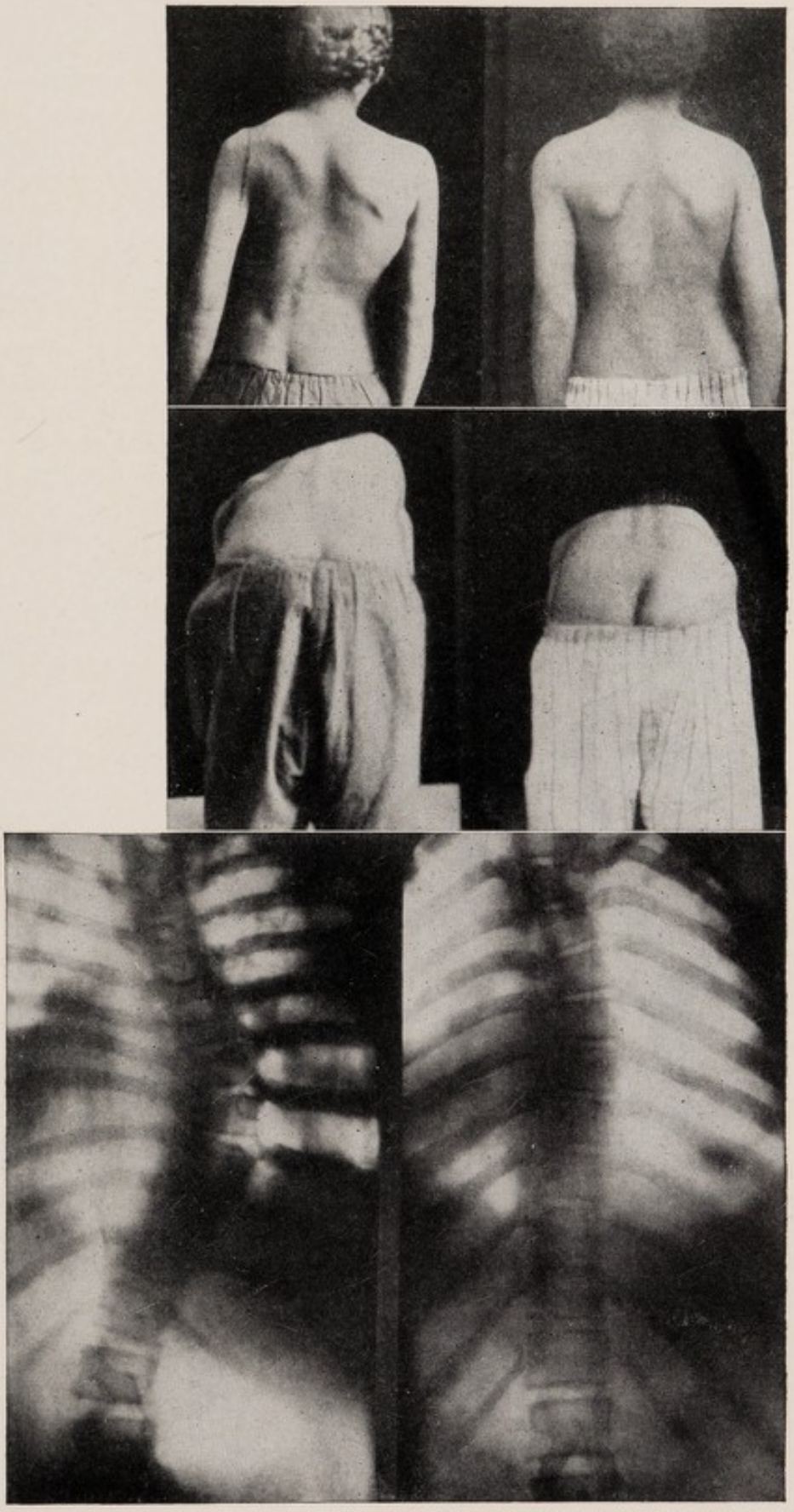

FIG. 776.—Patient before and after correction of the deformity with radiograms.

CHAPTER XXXIII

OBSTETRICAL PARALYSIS

This lesion which is produced during birth is due to an injury of the trunks of the brachial plexus, and results in paralysis of the arm, affecting the upper arm, the lower arm, or the whole arm.

The condition has long been familiar to obstetricians, one of the earliest available descriptions being that of Smellie (1768). Duchenne[1] in 1872, from an investigation of the electrical reactions of the upper arm muscles in four infants with this form of birth injury, concluded that he was dealing with a true paralysis. Two years later, Erb,[2] suggested that the paralysis was due to a lesion of the upper part of the brachial plexus, at or about the junction of the anterior primary divisions of the 5th and 6th cervical roots. It was assumed at first that the plexus was injured by direct pressure, but after the experimental work on the cadaver of Clarke, Taylor, and Prout,[3] the view that the nerve trunks were stretched or torn when the head was forcibly thrust away from the shoulder, was universally adopted. Operations on the plexus in the hands of Kennedy,[4] and later Taylor,[5] and Sharpe,[6] have confirmed the experimental findings as regards both the localisation and the type of the actual nerve injury. Until recent years, the view that in birth palsy there is always a supraclavicular plexus injury was accepted without comment. But the comparatively transitory paralysis in many cases, and the well recognised tendency to the development of contractures in the limb, are facts amongst others which have been responsible for the enunciation of newer theories of pathogenesis. In 1910, Turner Thomas[7] and almost immediately after him, Lange[8] of Münich, put forward the view that the early clinical signs of birth palsy, and the mechanical sequelæ, were indicative of an injury to the shoulder joint capsule. In this conception, the accompanying paralysis was believed to be due to a secondary inclusion of nerve trunks in the region of the shoulder joint. Further contributions to this controversy have been made by Vulpius[9] who revived the old theory of Kustner (1889) of displacement of the upper humeral epiphysis as the underlying lesion. The shoulder joint theory has also been vigorously supported by Ashhurst.[10] As a compromise, the view that under the clinical picture of birth palsy are to be included at least *two* distinct types of lesion, producing in the later stages identical mechanical disabilities, has been advanced by a number of observers—(Van Neck,[11] Peltesohn,[12]

[1] Duchenne: L'Electrisation, 1872.
[2] Erb: Naturhistorisch, Med. Heidelberg, 1874.
[3] Clarke, Taylor and Prout: American Journal Med. Sc., October, 1906.
[4] Kennedy: British Medical Journal, February 7, 1903; October 22, 1904.
[5] Taylor: Journal of American Med. Ass'n., 1913.
[6] Sharpe: Journal American Med. Ass'n., 1916, lxvi.
[7] T. Thomas: Annals of Surgery, Feb., 1914.
[8] Lange: Muench. med. Woch, 1912, No. xxvi.
[9] Vulpius: Deutsch. Med. Woch, May, 1914.
[10] Ashhurst, A. P. C.: Annals of Surgery, Jan., 1918.
[11] Van Neck: Journal de Brux, 1912, xvii, 117.
[12] Peltesohn: Berlin Klin. Woch, 1914.

Biesalski[1]). But there is only one recorded case of obstetrical palsy in which a nerve injury in the axilla has been demonstrated at operation (Lange).

In spite of such conflicting views, it cannot be denied that all clinical, experimental, and operative evidence is in favour of the view that in birth palsy there is always a supraclavicular lesion of the brachial plexus.

Etiology.—The majority of cases of birth palsy are seen in infants born after a difficult and prolonged labour where there has been a disproportion between the size of the child and the maternal pelvis. In the available statistics vertex presentations outnumber breech presentations. These and other points of etiological importance are well illustrated in the exceptional series of cases collected by Sever.[2]

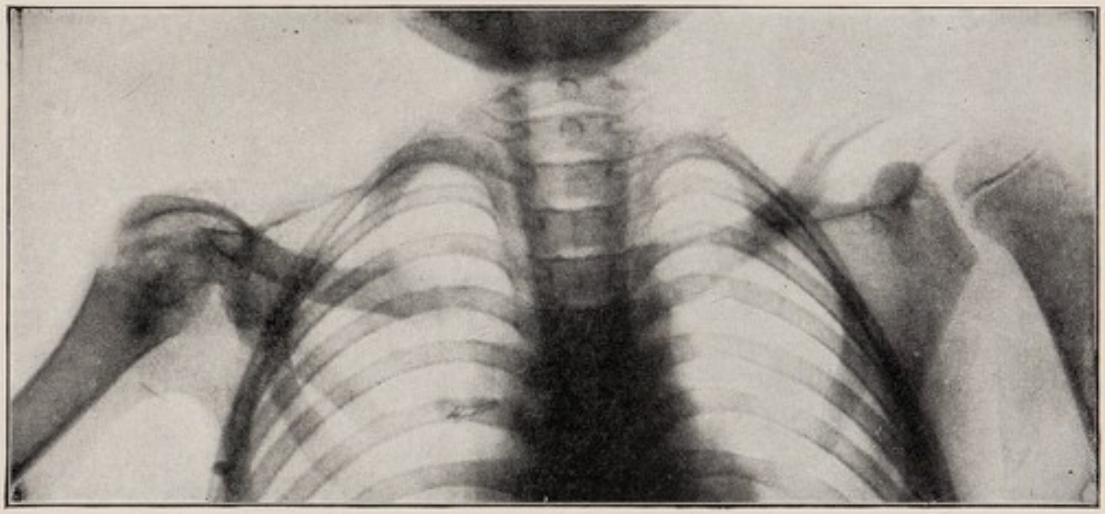

FIG. 777.—X-ray of right shoulder, showing lipping of the acromion. The dark, curved line on this side is due to the overlapping of the acromion and clavicle and defines the lower edge of the acromion, showing in contrast to the other side how the tip is curved down.

OBSTETRICAL PARALYSIS IN ELEVEN HUNDRED CASES (SEVER)

Boys	551
Girls	549
Right arm affected	670
Left arm affected	430
Both arms affected, upper arm type	35
Both arms affected, whole arm type	22
Both arms affected, type not recorded	6
Upper arm type	829
Whole arm type	208
Difficult labour	584
Ether used	502
Normal labour	57
Head presentation, including face	443
Breech presentation, including foot and version	142
Presentation not known	458

Mechanism.—Occasionally other associated injuries are discovered—*e.g.*, sterno-mastoid hematoma, fractures of the humerus or clavicle. Experiments on the cadaver have allowed the exact mechanism of the nerve injury to be analysed. The *upper plexus trunks* are put on the stretch when the head is forcibly separated from the shoulder, but actual tearing is most easily

[1] BIESALSKI: Lehrbuch der Orthopaedie Lange, 1914.
[2] SEVER, J. W.: Journal American Medical Association, Dec., 1925.



FIG. 778.—Obstetrical paralysis of the left arm, showing characteristic method of raising arm from side.



FIG. 779.—Double obstetrical paralysis—whole arm type.

produced when the head is also *rotated* away from the arm upon which traction is made (Platt,[1] McFadden[2]). Such risks are encountered in the delivery of an infant where there has been failure of rotation of the shoulder in a vertex presentation. In the management of a breech, the same dangerous combination of rotation and traction is often employed in the delivery of the after coming head. When the arm is dragged on vertically by the side of the head, the *lower plexus trunks* take the strain.

Morbid Anatomy.—Every degree of lesion may occur from a simple rupture of the perineural sheath without actual tearing of the contained nerve fibres,



FIG. 780.—Same patient as Fig. 779, writing with the foot.

to complete severance of one or more nerve trunks. In exceptional cases the nerve roots proper are avulsed from the spinal cord. Following the initial injury, whether of the sheath alone, or combined with fraying or rupture of nerve fibres, there is considerable local hæmorrhage and oedema. The scar tissue which forms later, extends around and into the nerve trunks and not only constitutes an insuperable obstacle to regeneration, but also induces irritation in axons which are intact. In the root injuries inside the spinal theca, the meninges become thickened and adherent, and the scar may invade the cord.

1. In at least 75 per cent of all cases, the brunt of the damage falls on the upper plexus trunks at the level of Erb's point (Fig. 781). Characteristic

[1] PLATT, H.: Americal Journal of Orthopaedic Surgery, 1920.
[2] MCFADDEN, G.: Unpublished Observations.

lesions are (*a*) fraying out or avulsion of the supra-scapular nerve alone (McFadden); (*b*) partial or total rupture of the 5th and 6th cervical trunks at their point of junction; (*c*) tearing of the 5th and 6th roots in the intervertebral foramina; or (*d*) avulsion of the upper roots within the spinal theca.

2. In the graver injuries the *whole plexus* participates, but the stretching usually affects the nerve trunks at different levels.

3. Occasionally the *lower trunks* (8th cervical and 1st dorsal) are damaged without any involvement of the upper trunks.

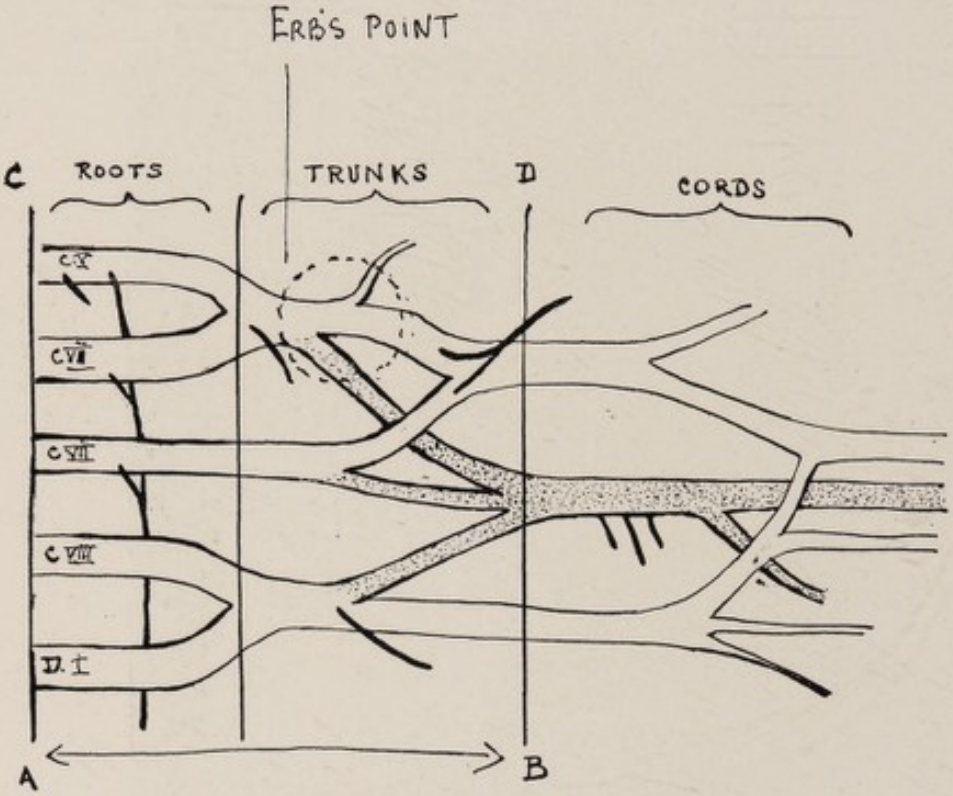

FIG. 781.—Brachial plexus and its subdivisions (Linell).

Brachial Plexus Motor Root Supply

5th cervical—Deltoid, spinati, brachialis anticus, biceps, supinator longus.

6th cervical—Serratus magnus, latissimus dorsi, triceps, pectoralis major, teres major and minor.

7th cervical—Extensors of wrist and fingers, pectoralis major.

8th cervical—Flexors of wrist and fingers.

1st dorsal—Intrinsic muscles of the hand.

Symptomatology. *Early Stages.*—In the new born infant the clinical picture of obstetrical palsy is familiar to all. The arm hangs limply by the side, rotated in at the shoulder, with the elbow extended, and the palm of the hand facing backwards. Swelling and tenderness in the supraclavicular region may be demonstrable, and the infant may resist all efforts to handle the affected limb. Such local signs of trauma are, however, usually short lived. It is customary to distinguish three clinical types according to the distribution of the paralysis. (1) Upper arm palsy; (2) whole arm palsy; and (3) lower arm palsy. In the *upper arm* type (Erb-Duchenne), the muscles supplied by the 5th and 6th cervical nerves are silent *i.e.*—the deltoid group. Combined with this, the extensors of the wrist, fingers, and thumb, may be weak or

completely paralysed. In the *whole arm* type the limb is absolutely flaccid and immobile. The sensory loss of a complete plexus lesion may be present, but is rarely demonstrable at this stage. The *lower arm* type (Klumpke palsy) gives a characteristic syndrome. In addition to paralysis of the intrinsic muscles of the hand, and the long flexors of the digits, there are certain oculo-pupillary signs of extreme diagnostic importance—viz., drooping of the upper lid, narrowing of the palpebral fissure, and contraction of the pupil. These are due to involvement of the sympathetic fibres included in the first dorsal root. Anaesthesia in the postaxial area of the hand and forearm may also be present, but in the young child accurate testing is of course impossible.

Later Stages.—I. In the majority of cases *spontaneous recovery* of varying degree is seen in the first few months. The infant soon begins to use some part

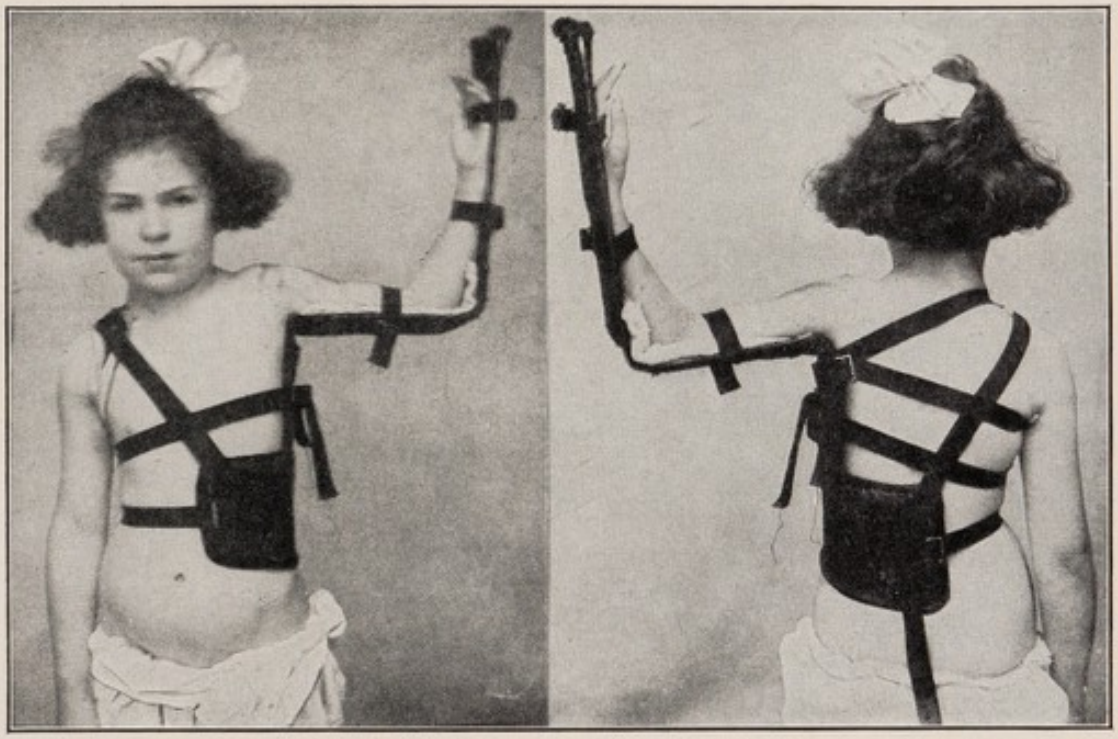

FIG. 782.—Platform splint—front view.

FIG. 783.—Platform splint—back view.

of the affected limb. In a few cases the recovery is rapid, and voluntary power returns in all muscle groups. But it is more usual to see an imperfect recovery. The whole arm type may change to the upper arm type, or there may be recovery in the deltoid group leaving a residual paralysis of the extensors of the forearm. It is rare to see complete disappearance of intrinsic muscle palsy, or the oculo-pupillary signs, for these phenomena are almost pathognomonic of a severe lesion of the lower roots close to the spinal cord. Whether spontaneous recovery be slow or rapid, complete or incomplete, there is always a tendency towards the development of contractures in the limb. In untreated cases the contractures may appear early, as in other irritative lesions of peripheral nerves. The deformity in birth palsy consists in an internal twist of the whole limb, best marked at the shoulder joint. The occurrence of the shoulder contracture is favoured by early recovery in the deltoid uncombined with recovery in the external rotators. The loss of the latter allows the subscapularis to act unchecked. It would appear that the deltoid alone is a most

ineffective abductor (Walmsley[1]). The contracture is perpetuated by progressive shortening of the subscapularis, pectoralis major, and pronator muscles of the forearm. With the internal rotation twist, it is usual to find the head of the humerus displaced posteriorly. As the child grows, the contracture becomes more pronounced, and the under-development of the limb and shoulder girdle is most conspicuous. The general contour of the miniature limb, however, is usually preserved, the absence of localised muscular atrophy being always striking. The contracture and the shoulder joint subluxation, are accompanied by secondary changes in the joint structures, characteristic signs being hooking down of the tip of the acromion, and elongation of the coracoid. Subluxation of the head of the radius occasionally appears at a later stage. These growth changes are readily appreciable in radiograms in older children. In spite of the obvious return of voluntary power in the affected muscle groups, the function of the limb nearly always shows some

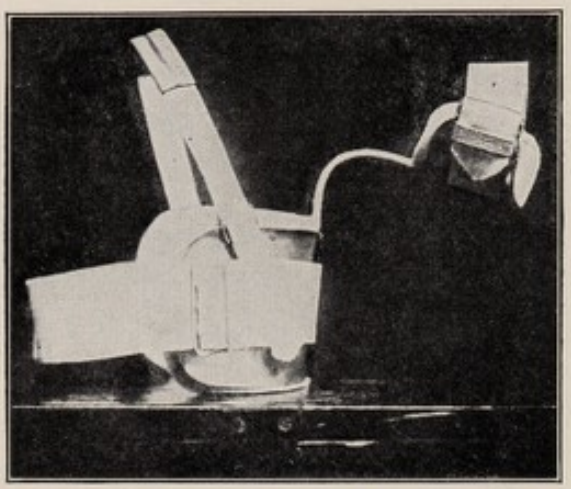

FIG. 784.—Shoulder abduction splint for obstetrical paralysis.

impairment. This is due in the first place to the incomplete re-innervation of the recovered muscles; and secondly to the presence of contractures. The hand is carried awkwardly to the mouth, and the range of elevation of the limb is deficient. It must be emphasised that the internal twist of the arm usually dominates the clinical picture of birth palsy where considerable muscular recovery has occurred.

II. In a minority of cases, the initial palsy remains almost unchanged, and all the familiar sequelæ of an irreparable lower neuron lesion may be seen—profound muscle atrophy, with a flail and poorly nourished limb, comparable to the paralysis of anterior poliomyelitis. In the lower arm type without recovery, a *claw hand* deformity usually develops.

Diagnosis.—At birth the diagnosis is not always easy. A powerless arm in a new-born infant may be caused by separation of the epiphysis of the head of the humerus, by a fracture of the humerus, or a fractured clavicle. Dislocation of the humerus has been mentioned as occurring, but the writers have not personally observed the condition occurring at birth. True congenital dislocation of the shoulder is extremely rare, and the diagnosis should be made with great reservation.

Prognosis.—In all subcutaneous peripheral nerve injuries it is impossible in the first few weeks to state dogmatically how much, if any, spontaneous

[1] WALMSLEY, T.: Unpublished Observations.

recovery is likely to occur. The gravity of the lesion can usually be estimated only after a period of observation. From accumulated clinical experience it is possible, however, to hazard an opinion as to the future behaviour of the different clinical types of obstetrical paralysis. Thus in the *whole arm palsy* complete and perfect recovery should not be expected. In the average *upper arm* palsy some return of voluntary power should be awaited with confidence. In the *lower arm* palsy, the prognosis is generally unfavourable. Where early treatment is conducted along conservative lines—which should be the rule—it is useful after the third month to test the electrical reactions under an anaesthetic. The readings thus obtained, combined with the clinical picture, often help the surgeon to assess the severity of the nerve block. But the

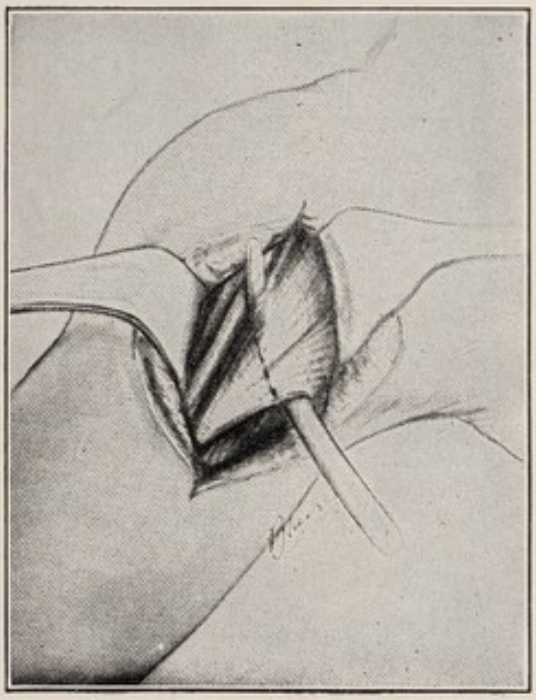

FIG. 785.—Skin incision and isolation of pectoralis major. Cephalic vein at outer edge of pectoral. Arm abducted and rotated out (J. W. Sever).



FIG. 786.—Sound under subscapular tendon. The pectoralis major has been divided. The joint capsule shows at bottom of cavity (J. W. Sever).

mere demonstration of the reaction of degeneration in any given group of muscles, has little significance apart from clinical observations.

Treatment. *I. Postural Treatment.*—In a new-born child the arm should be placed as comfortably as possible in a position opposed to the deformity. This is easily accomplished by applying a light abduction splint of wire, tin, or duralumin with the shoulder rotated outward, the forearm supinated, and the wrist dorsiflexed. The arm should be retained in the splint for a prolonged period as a fairly large number of cases recover if this is done. Massage and gentle stretching to prevent contractures, should be instituted from the beginning. The arm should be retained in the "birth palsy" position during all treatment. Special attention should be directed towards maintaining the full range of external rotation at the shoulder and supination of the forearm. The cases where an early contracture is likely to develop are those in which fairly rapid return of voluntary power occurs, *i.e.*, where the actual destruction of nerve fibres has been minimal, but the fibrous tissue ingrowth exerts an

irritant effect on the intact axons. With the first appearance of true voluntary power, simple re-education should be attempted. As the child increases in intelligence, effective muscle training is best devised by the use of toys. Great patience and enthusiasm are necessary on the part of the masseuse at this stage. The splint should be discarded in the daytime as soon as adequate power is present, but is best retained at night for some months, to help to prevent the onset of contracture. Supervision is essential for some years even where almost full voluntary power has returned. The cooperation of the parents must be enlisted in a constant endeavour to make the child utilise the limb to the fullest extent in his daily pursuits.

II. Surgical Repair of the Nerve Lesion.—It is a fundamental principle in the treatment of all peripheral nerve injuries, that when it seems probable that insuperable obstacles to spontaneous regeneration exist, and the nerve lesion is capable of being exposed, operative exploration should not be delayed.



Fig. 787.—Obstetrical paralysis of the right arm with inability to carry back or supinate.

Past experience has shown that in obstetrical palsy (*a*) it is safe and proper to use conservative measures as a routine in the early stages because of the considerable number in which adequate spontaneous regeneration occurs; and (*b*) in a certain proportion of lesions the nerve injury is inaccessible to direct surgical attack. This latter consideration applies to many examples of the *lower arm* type of palsy, and to a great many of the *whole arm* type. But in spite of such knowledge the exact limits of the lesion cannot always be defined from clinical evidence alone. After some three or four months splinting and physio-therapeutic treatment, if the signs of nerve block remain stationary, the question of the advisability of exploring the plexus should be seriously discussed. It must be emphasised that no harm can result from an exploratory operation in experienced hands. On exposure of the plexus the surgeon must be prepared to find that it is sometimes unnecessary to carry out any actual nerve repair, or alternatively must not be surprised to discover an irreparable lesion. Excellent results have been recorded by Kennedy and others after the repair of the more limited lesions (*e.g.* confined to Erb's point). In more recent years, Sharpe, and Taylor of New York, have urged the advisability of exploring as a routine at the early age of one to three months, and have reported independently, a large series of operations. This teaching has failed to convince the majority of surgeons, for it is generally held that the

plexus lesions in which actual repair is necessary or practicable, form a small proportion of the total number of cases treated in well equipped clinics. But on the other hand this conclusion does not negative the essential soundness of exploring the plexus in lesions where operative repair gives the only chance of recovery.

Operation.—The exposure of the plexus is described elsewhere (Chapter XXVII). Considerable difficulty may be experienced in recognising and disentangling the various trunks which are usually matted together by cicatricial tissue. According to the findings the actual operation may consist in a simple *neurolysis*, or may involve resection of the remains of one or more trunks followed by *end-to-end suture*. Care must be taken to avoid resecting nerve trunks which at first sight look completely fibrosed but in which run many intact bundles of nerve fibres. After resection of a lesion limited to Erb's point, the 5th and 6th cervical trunks must be sutured to three trunks below *viz.*, the suprascapular nerve, the branch to the outer cord and the branch to the posterior cord (Fig. 781).



FIG. 788.—Same case as shown in Fig. 787 after operation.

Results.—Accurate statistics are still unavailable. The effect of a pure neurolysis is always difficult to estimate. The best prognosis is obviously afforded when suture is limited to Erb's point. In the rare complete plexus repairs, recovery may be anticipated in the upper trunks but should never be predicted in the lower trunks.

III. Treatment of the Contracture.—In the infant or young child it is often possible to correct an early subluxation and twist of the shoulder by a single manipulation, or a series of manipulations under anaesthesia (Whitman). After the manipulation a period of fixation in plaster or on an abduction splint is essential. But this should be combined with daily stretching to counteract the stiffness to which these shoulders seem to be prone. In children after one year, correction by manipulation is often difficult, and above the age of two often fails completely. In such cases an open operation should be adopted. Correction of the internal rotation by osteotomy of the humerus (Hoffa) is rarely practised today. Division of the contracted soft structures, according to the technique originally described by Fairbank,[1] and later modified by Sever,[2] is the procedure of choice.

[1] FAIRBANK, H. A. T.: Lancet, May 3, 1913.
[2] SEVER, J. W.: American Journal of Orthopaedic Surgery, August, 1916.

Operation.—The shoulder joint is approached through the usual anterior incision between the pectoralis major and the deltoid. The subscapularis tendon is fully exposed after partial division of the pectoral tendon. Fairbank divides the subscapularis at its insertion, and in addition cuts all tight capsular bands—*e.g.*, the coraco-humeral ligament. Sever divides the subscapularis just before it blends with the joint capsule. If the acromion is much hooked, and appears as an obstacle, it should be cut through; and where there is a considerable flexion contracture of the elbow, the tip of the coracoid with its attached muscles may be lowered. In very advanced contractures, the teres major and latissimus dorsi insertions may be stripped subperiosteally, but if the humerus is freed too much the limb may prove to be less powerful than before. After the operation the arm should be splinted in the position of correction; full elevation combined with external rotation is advisable. Active movements and gentle stretching should be practised within a few days, and all fixation discarded at the earliest possible date. The functional result will depend largely on the after treatment. The operation adds nothing to the power of the arm, but is almost always followed by considerable cosmetic improvement as the child is able to use his limb in a less ungainly fashion.

IV. Treatment of Residual Palsy.—Recovery in the upper arm group is occasionally associated with a persistent residual palsy of the extensors of the wrist and digits. For this disability in an older child the operation of tendon transplantation (p. 466), as practised for irreparable lesions of the musculo-spiral nerve (Chapter XXIII), is admirably suitable.

CHAPTER XXXIV

AMPUTATIONS AND ARTIFICIAL LIMBS

AMPUTATIONS

Amputation is called for when a limb, or part of a limb, has become dangerous or useless owing to disease or injury. The level of the amputation is primarily determined by the local conditions, but the operation should also be designed to provide a stump suitable for the attachment and use of an artificial limb. The vast experience gained in recent years has led to a revision of many of the accepted views on the utility of certain types of amputation.

Temporary or Emergency Amputations

In the advanced operating stations (Casualty Clearing Stations and Field Hospitals) of the World War (1914–1918) it was found expedient occasionally to amputate speedily by a method which was known as the *guillotine*. The soft tissues were cut through by a circular incision down to the bone, which was then sawn at the same level. Even in time of war this method was too frequently adopted, and gave rise to much suffering in the after treatment. Should it be necessary to perform this operation it must be remembered that considerable retraction of the soft parts occurs, and this must be checked by a strapping extension attached below to a short Thomas bed splint. An alternative rapid emergency amputation is to use the modified circular flap, which takes only a little more time, and obviates a second amputation.

Amputations of Choice

An ideal stump should possess a good covering for the bone, should be painless, and freely moveable. The best covering consists of healthy skin, subcutaneous tissue, and fascia. The operation scar should be placed to avoid the pressure of the artificial limb socket, and the skin should be mobile.

Amputation Technique

(1) *The Flaps.*—The complicated flaps of many of the conventional amputations are no longer used. The modification of the classical *circular* method in which a skin cuff is dissected up, and the muscles divided transversely at a higher level, is eminently suitable in many regions. Elsewhere a *single flap*, not greater than the diameter of the limb may be used. A thin covering of muscle, provided it becomes adherent to the bone is not objectionable, but bulky masses of muscle tissue should not be included in any flap.

(2) *Bone Section.*—The bone should be sawn transversely, leaving a plane surface; any prominent ridge or margin should be smoothed off. The periosteum should be stripped up for about a quarter of an inch before the bone is divided. The methods of covering the bone by periosteal or osteoperiosteal flaps have never achieved popularity.

(3) *Haemostasis.*—The main vessels should be tied securely by double ligatures of absorbable material.

(4) *Nerve Section.*—In order to prevent the formation of adherent nerve bulbs, the main nerve trunks should be pulled down, divided high up, the ends crushed, and injected with absolute alcohol.

(5) *Closure of the Wound.*—The skin edges should be approximated by interrupted sutures, and at each end of the wound a small rubber tissue drain should be inserted.

After Treatment.—During the healing of the wound the stump should be kept at rest on a splint in a position which does not favour the development of a contracture. Active movements judiciously supervised should be encouraged when the wound is sound, and shrinkage of the stump promoted by bandaging and massage. After some four weeks a temporary artificial limb should be fitted which serves to familiarize the patient with the wearing of a prosthesis, and helps to hasten shrinkage of the stump.

Full details of the technique of individual amputations will be found in the ordinary manuals of operative surgery; here the essential principles only will be emphasised in those amputations which are suitable for future limb fitting.

Amputations in the Lower Limb

An amputation stump in the lower limb is not only required to act as a lever but must also be capable of bearing weight. The stump may bear weight directly on its extremity (end bearing), or weight may be concentrated at a higher level (tibial or ischial bearing). Complete end bearing is an ideal often attempted, but seldom attained in practice.

Disarticulation at the Hip Joint.—The operation may be accompanied by considerable shock, but risks are minimised by the accurate control of haemor-

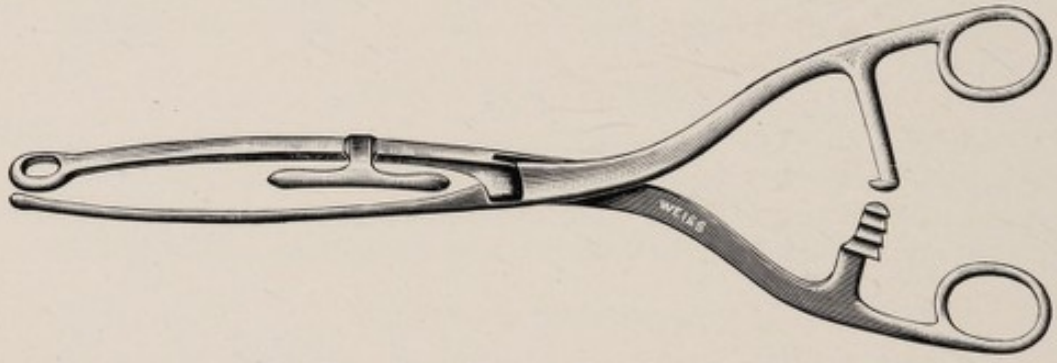

Fig. 789.—Lynn-Thomas Tourniquet forceps.

rhage, and the administration of continuous saline infusion during the operation. The classical incisions known as the Furneaux-Jordan and anterior racket, are both unsatisfactory from the limb-fitting point of view. A pendulous skin covering containing a mass of muscle should always be avoided. The most suitable flap is one reflected posteriorly from the gluteal region containing no muscle, and sutured in front just below the line of Poupart's ligament (Huggins). The femoral vessels are exposed and tied in the early stages of the operation, or may be temporarily controlled by the Lynn Thomas tourniquet forceps (Fig. 789). The femoral head may be disarticulated, or the neck sawn through, leaving the head in the socket.

Thigh Amputations.—A stump with not less than six inches of femur should be provided; shorter stumps are not easily fitted. The *middle third* and *lower third* are both suitable levels, and the modified circular technique or single anterior flap may be used. A thin muscular covering to the bone end is advantageous. Spur formation at the site of the linea aspera is sometimes seen, and is best avoided by smoothing off the projecting ridge. In addition to the great sciatic, the internal saphenous nerve should be dissected out. If the latter is overlooked it may form a tiny painful nerve bulb in the inner part of the stump. In amputating through the lower third of the thigh, the femur should be divided well above the condylar region.

Transcondylar amputations are still practised. Of these, the Stokes-Gritti operation, in which the patella is preserved, and fixed on to the lower end of the femoral shaft, has survived the test of modern experience. The advantages of such end-bearing stumps are somewhat neutralised by the undue length of femur, which complicates the fitting of a strong knee joint.

Disarticulation at the Knee Joint.—The well known operation of Stephen Smith with lateral flaps also gives a broad end-bearing stump, but is not ideal on prosthetic grounds.

Below Knee Amputations.—The *middle third* of the leg is the site of election with a stump containing seven inches of tibia. The scar should be placed posteriorly to avoid pressure of the upper end of the bucket in front. This is best accomplished by using an anterior flap. The fibula should always be divided at a higher level than the tibia, or even resected entirely. If a shorter stump is inevitable, the popliteal nerves should be resected in the popliteal space itself. Amputations of the lower third of the leg are as a rule to be condemned, as they leave a conical, ill nourished, and cyanotic stump.

Foot Amputations.—*Symes' amputation* through the tibia and fibula just above the ankle with a flap from the heel, gives a perfect end-bearing stump, easily fitted with a prosthesis.

Amputation through the tarso-metatarsal and mid-tarsal joints (*Lisfranc* and *Chopart*) are now of historical interest, although combined with an elongation of the tendo Achillis, the patient could often walk in an ordinary boot. In deciding the site of amputation for a patient who can be provided with an adequate prosthesis, the Symes' amputation should be chosen.

Amputations of the *toes* present no special features.

Amputations of the Upper Limb

The function of the upper limb stump is leverage only. As there is less objection to a terminal scar, a variety of flaps is available. Great care should be taken to divide each large nerve trunk as high up as possible.

Forequarter Amputation.—Removal of the upper limb and scapula is usually required for malignant disease of the upper end of the humerus. The modification of the well known Berger operation described by Littlewood[1] is strongly to be recommended. The dissection is made from the back; the brachial plexus trunks are divided in the early stage of the operation and the subclavian vessels secured later.

Disarticulation at the shoulder may be performed through an antero-lateral or lateral racket incision.

[1] Littlewood: British Medical Journal, Vol. I, p. 381, 11th March, 1922.

Upper Arm Amputations.—The short stump of an upper third amputation is unsuitable for limb fitting. The *lower third* is the level of choice, and the modified circular flap is simple and efficient.

Disarticulation at the Elbow.—From a prosthetic point of view this is not a method to be practised.

Forearm Amputations.—The stump of an upper third amputation is too short for practical use. Amputation in the middle third is more satisfactory; in the lower third the skin covering is often poorly nourished, and it is difficult to prevent fusion of the lower ends of the forearm bones, and thus a loss of the power of rotation.

Disarticulation at the Wrist.—This operation is rarely practicable and is open to the objection common to all disarticulations.

Hand and Digit Amputations.—The preservation of part of the carpus as a stump moving at the wrist joint is always desirable. In mutilated hands every effort should be made to conserve the thumb, and at least one other digit.

Cineplastic Amputations

In 1898 Vanghetti suggested that an amputation stump might be refashioned so that its muscles could be harnessed to a prosthesis. Few opportunities were available for testing this idea until the European War, when the method was practised by Putti, Bosch Arana, Sauerbruch, Krukenberg, Bastos Ansart, FitzMaurice Kelly, and others. For obvious reasons the majority of operations were carried out in the upper limb.

In the cinematised stump two kinds of motor were fashioned by plastic procedures; (*a*) A "club" consisting of a group of tendons contained in a sleeve of skin, and (*b*) a "loop" in which the muscles or tendons were pierced by a skin-lined tunnel. The artificial arm was activated by cords attached either to a ring clamped to the neck of the club, or passed through the loop tunnel. A special type of working prosthesis is necessary for a stump which has been cinematised. The difficulty of providing a suitable prosthesis has discouraged efforts to use the cineplastic amputation on a large scale.

Reamputations

Bad amputation stumps are all too familiar, and are usually due to the presence of sinuses, annular sequestra, spurs, adherent ill nourished scars, painful nerve bulbs, or contracture of the proximal joint. The technique of reamputation is thus important, for it should be the surgeon's aim to reconstruct the stump without material sacrifice in length. Flexion deformity of a femoral stump is often seen, preventing the proper fitting and function of a prosthesis. An artificial leg applied to a flexed stump throws a strain on the pelvis which is conveyed to the back, and gives rise to pain. A flexed femoral stump may be very difficult to correct, and must be subjected to one of the many methods which a surgeon may employ. If mechanical means fail—and this should rarely happen—operative methods should be tried. Division of the psoas muscle should rarely if ever be performed.

ARTIFICIAL LIMBS[1]

Provisional Prostheses.—Reference has already been made to the value of temporary prostheses in lower limb amputations. Temporary artificial limbs

[1] Little, E. Muirhead: Artificial Limbs & Amputation Stumps, H. K. Lewis & Co., London, 1922.

should be simple in construction and comparatively cheap. Many different patterns have been evolved in different countries. Types which have proved efficient are (1) a plaster of Paris bucket fastened on to crutch sticks; (2) the cone fibre pylon; (3) for children, a Thomas's knee splint with a "peg" end. Simple provisional arms are easily designed to which may be attached a pencil, spoon, or fork.

Permanent Prostheses.—*Upper Limb.*—There are two classes of artificial arm—(*a*) the ornamental, and (*b*) the working arm. The ornamental arm is provided merely to mask the mutilation, but some form of elbow control, and a hand with a simple gripping mechanism are usually included. Special hands capable of elaborate and fine manoeuvres, such as the well known Carnes' hand, have been used with great success by trained patients.



Fig. 790.—A working arm.

The working arm is designed without regard for appearances. In its simplest form it consists of a socket strengthened by steels to which various appliances can be attached. Many of the most effective working arms and their tool attachments have been designed by amputés. (Fig. 790.)

Lower Limb.—Buckets are chiefly made of willow wood, leather, celluloid, or light steel (duralumin). At one time the "all metal" limb seemed likely to oust other types, but efficient light limbs are now made in which metal and other materials are combined. Extension of the knee is effected either by an anterior spring of elastic webbing—the older method—or by a central knee control activated by cords passing over the shoulders. There are many types of foot in general use, either with or without a moveable ankle. Hip joint amputations are fitted with what is known as a "tilting table," the socket of which embraces the pelvis with the limb proper articulating by a hip joint

locked by means of a ring catch. For a moderately short thigh stump a pelvic band is usually necessary. In a recent type of socket, an air valve is attached which allows the creation of a vacuum, the firm suction hold on the limb obviating the need for a pelvic band.[1]

In certain below knee amputations, weight bearing pads may be introduced into the bucket.

Re-education of the Amputated

It is not sufficient merely to provide a patient with an artificial limb; he must be educated in its use. Properly trained the amputé is often capable of competing with able bodied men in many forms of occupation or sport.

[1] Little, E. M.: British Medical Journal, Nov. 14th, 1925.

CHAPTER XXXV

PRINCIPLES OF APPARATUS

Theory of Apparatus.—Apparatus is applied to meet one or more of four definite indications in surgical cases. These are:

1. *Fixation.*
2. *Traction.*
3. *Protection or stilting* (in the case of the lower extremity).
4. *Prevention or correction of deformity.*

If apparatus is approached from this point of view instead of by selection from the catalogue of the instrument maker, it becomes much less mysterious and much simpler. It must be remembered that plaster of Paris, crutches and wooden splints are apparatus and used freely by surgeons who hesitate to adopt apparatus of iron to fulfill the same needs. For example, the ordinary axillary crutches are used to provide protection of the lower extremity from weight-bearing by transferring the weight to the axillæ, but the Thomas knee splint does the same thing by transferring the weight to the tuberosity of the ischium and is in one of its functions a perineal crutch.

With a view therefore of making it possible for surgeons who are not in the large centers to have routine apparatus constructed under their own supervision the descriptions of apparatus have been given somewhat in detail, as most of the apparatus may be made by the ordinary carriage blacksmith if the surgeon understands the theory of apparatus and has at hand a technical description of its construction.

Plaster of Paris

Plaster of Paris is a native sulphate of lime, and is really crushed gypsum which is ground and calcined in ovens at a temperature between three and four hundred degrees Fahrenheit, at which temperature gypsum parts about 93 per cent of the original water of crystallization and is converted into an amorphous anhydride, which possesses the power of recombining with water to form crystals. When mixed with water a chemical union takes place which is called recrystallizing or "setting." In "setting" it expands a very slight amount, calculated at one-five-hundredths of its volume. This is most important as it demonstrates that plaster bandages cannot shrink about the leg in drying. Sores under the plaster bandages are almost invariably due to improper application, to the lack of cleanliness on the part of the patient, to foreign bodies getting under the plaster or to obstruction of circulation under the plaster.

The change in "setting" is accelerated by the addition of salt, which cuts the time nearly in half if added to an amount not exceeding 3 per cent. Other less common chemicals like sulphate of potash, borax, and sulphate of zinc all hasten "setting." Common alum hastens the "setting," but is objectionable because the common plaster fills with bubbles. Glycerin, molasses, and certain other substances retard "setting," and glue, which enters into sizing the ordi-

nary crinolin, is another of the substances which delays it, and this is of much practical importance. Dental plaster is a finer, quicker setting grade than ordinary plaster. It is much used by dentists, and is of two kinds, either a plaster mixed with potassium sulphate as an accelerator, or pure finely ground plaster of high grade.

It may be formulated in the use of plaster that anything which accelerates "setting" tends to diminish the durability of plaster bandages. Pure plaster should set in seven minutes and possesses a tensile strength of about 400 pounds to the square inch.[1]

Portland cement when mixed with plaster of Paris in amounts varying from 10 to 20 per cent increases the durability of the cast but delays its "setting" somewhat and adds to its weight.

The bandage material to be impregnated with plaster is a book-muslin sized with starch and not with glue. The meshes should not be finer than twenty to twenty-five threads to the inch.

Preparation of Plaster Bandages.—The gauze should be torn into lengths of about 4 yards for the ordinary bandage, and 3 yards for bandages for small children, in widths of 3, 4 or 6 inches according to the use. For club-foot in young children a 2-inch bandage is sufficiently wide. When the muslin has been torn into bandages, these should be folded on each other and the loose threads removed from the edges by a pin. Many forms of machines for rolling bandages have been described, but on the whole the general practice is to have them rolled by hand.

The muslin bandage is laid flat on the table with a heap of plaster near it. A handful of the plaster is then laid on the bandage and with a flat piece of splint wood or with the hand this plaster is pushed along over the bandage and any excess of plaster thus removed. The bandage is then pulled, filled with plaster and rolled. Bandages should be rolled loosely, for if they are rolled tightly the center of the bandage will not become saturated. They should be kept in a tin box and in a dry place, for if exposed to moisture they will deteriorate and if kept for a very long time under any circumstances they will prove unsatisfactory.

For use a pail is filled about 6 inches deep with warm water, and if quick "setting" is desired a teaspoonful of salt is added. The bandages are then set on end in the water and let alone until the bubbles cease to rise. They are then squeezed dry by holding them with one hand over each end of the bandage to prevent the escape of plaster. If they are left in the water too long before use they will "set" in the water and be of no value. For this reason it is wise to keep only one or two bandages in the water ahead of the surgeon.

Plaster bandages when applied contain a large amount of water and should be left uncovered. If they are covered by bed clothes or clothing the water will not evaporate, proper chemical change will not take place, and the bandage may be ruined. If X-rays are to be taken through plaster no attempt should be made for forty-eight hours after application, as apparently up to this time the bandages contain too much water. A bandage 4 or 5 inches wide and 4 yards long into which the plaster has been rubbed should weigh about 6 or 8 ounces.

Application of Bandages. *Protection of the Skin.*—The protection of the patient's skin is of the utmost importance. It is not desirable to put a plaster

[1] Stern: Trans. Am. Orth. Ass'n; iv, 354.
Meisenbach: Trans. Am. Orth. Ass'n, iv, 1.

on skin with an eruption, especially scabies, and in this connection it should be mentioned that the occurrence of one of the eruptive skin diseases, even chicken-pox, may cause serious ulcerations under the plaster. Plaster should not be applied directly to the skin. In the application of plaster jackets a layer of stockinette should be put on, and the bony prominences padded with felt. In the extremities, however, it is generally better to use sheet wadding, torn into bandages 4 inches wide, and of this at least two or three layers should be applied. It is particularly important to provide for thick padding over bony prominences, such as the hip, the malleoli, and the knee. Cases of foot drop occasionally originate from pressure on the external nerve outside the fibula.

The bandage should be applied by straight circular turns, or by a figure of eight. In applying such turns, in the leg, for instance, the lower edge of the bandage will hang loose while the upper edge is tight. This should be remedied by taking a pleat in the lower edge which will make it lie smoothly. Plaster bandages should never be "reversed," and only be put on with enough tension to keep them from sagging, and should *never* be pulled tightly at any part of the application. They will "set" better if smoothed by the hand with each application, the smoothing following the line of the bandage.

"Reversed" turns, or tension, or correction of the position of the limb after the plaster has begun to set, will result in folds in the deeper aspect of the bandage, which become sharp ridges, which may cause sloughs and irritation. From six to ten layers of a properly applied bandage are enough to give proper strength.

For a workman-like finish the sheet wadding should project somewhat above the top and bottom of the plaster, and just before the bandage is finished it should be turned down and one or two turns of the bandage made to hold it, leaving the sheet wadding exposed for about half an inch at the top and bottom of the bandage. Care should be taken in application that the assistants do not make finger marks on the bandage in holding the limb, because if they do, these will result in prominences on the inside; and while the plaster is drying care must be taken to see that the heel does not rest upon a flat surface, which would press in the plaster, and that indentations are not made by any other means.

After the application of a plaster bandage the circulation should be tested by seeing if the return of blood in the ends of the toes and fingers is of normal rate, and the parents or patients, especially in hospital outpatient practice, should be cautioned about watching for any disturbance of circulation in the toes and fingers, and instructed in splitting the plaster if anything of the sort occurs.

Plaster bandages may be strengthened if desired by the use of plaster "ropes" or ribs of plaster, which are made by twisting and folding the bandage until they form a rope of the desired length of about one inch in diameter. This is then laid on where extra strength is desired and incorporated in place by the subsequent bandages. In doing this it is particularly desirable not to pull these bandages tight as otherwise a dead space will be created at the sides of the "rope." Plaster "ropes" are particularly useful in the application of a plaster spica at the hip, and in plaster jackets. They are occasionally very useful in the ordinary circular leg plaster where one or two ropes at the back enable one to put on a much lighter plaster than would otherwise be possible.

The use of wire gauze, pieces of metal, thin strips of wood, etc., has not in the experience of the writers proved necessary or desirable.

Splitting the Bandage.—When plaster of Paris bandages have been used in fractures, or after operations on the limbs, it is desirable in most cases to split them as soon as they are dry as it adds very much to the comfort of the patient without diminishing the efficiency of the bandage. A plaster bandage forms a very rigid encircling ring, and in the presence of even slight swelling it may become painful or dangerous.



FIG. 791.—Plaster cutters.

Bivalving may be performed when the plaster is dry by the use of one of the regular plaster cutters. These are of various patterns, but the one shown in the illustration is the form that the writers find most useful. The line in which the plaster is cut should be about the middle on both sides so that reentrant angles are not formed. If the anterior part embraces one-third of the circumference it will be difficult to get the arm or leg out of the posterior shell. The two halves of the plaster should then be fastened in place by webbing straps and buckles, or in case these are not available, by adhesive plaster. The plaster cutters do not work satisfactorily on wet plaster and if it is desired to bivalve the plaster immediately it may be done by using a knife shown in the illustration, known as a shoe knife, which has a sharp concave point. If the strokes are made parallel to the surface of the plaster, there is little or no danger of cutting the patient as he is protected by a layer of sheet wadding and stockinette underneath. The use



FIG. 792.—Knife for cutting plaster.

of metal strips pushed under the plaster to guard against the use of the knife is unnecessary and the use of saws in general is much less satisfactory than that of the cutters or knife.

Dangers of Plaster Bandages.—Plaster bandages should not be uncomfortable, and *continued local pain,* especially in a child, is an indication for a removal and investigation. A foul smell coming from the plaster is generally an indication of a slough underneath, and such sloughs are generally produced by some foreign body dropped inside the bandage by the child, by an improperly applied bandage with pressure over the bony landmarks, by pressure, ridges or marks left on the inside from careless application, by vermin, by uncleanly

habits on the part of the child, which result in the plaster becoming urine soaked, by the occurrence of the eruptive diseases, or by increasing deformity, as in the knee joint for example, or in the spine, where in an increasing deformity the skin may be pressed so hard against the unyielding plaster that a slough results. Sloughs may occur, however, without any painful symptoms.

Disturbances of the circulation are of the highest importance, and every plaster, where there is any definite slowing of the return of blood in the fingers or toes, or any considerable swelling of the fingers or toes, should be *immediately* bivalved, the lid removed, and all constricting soft bandages cut through. The latter point is most important.

Changing Plaster Bandages.—Plaster bandages may be kept on as long as may be desirable and six months is not an excessive time. If the bandage is kept on for this length of time the skin will be found dry and in brown horny flakes, but this is not objectionable and far preferable to the traumatism of reapplication, which is so often detrimental. It must be remembered, however, that atrophy of muscle and bone occurs in plaster of Paris bandages and therefore that on general principles they should be kept on as short a time as possible.

Celluloid and Leather Apparatus

Plaster bandages which must be worn continually may serve as the model for the construction of light, cleanly, and more durable appliances of the same type. In a case where it is desirable to reproduce a circular leg plaster or a plaster of Paris jacket, the cast which has been completed for removal by one vertical cut is fastened together by a plaster bandage and filled with plaster of Paris and water mixed to the consistency of porridge and allowed to dry. The mold is then removed and the cast dried, smoothed, and shellacked.

For the application of a *celluloid* splint the cast is covered by stockinet or cheese cloth bandages, into which is painted a celluloid paste, made by dissolving celluloid chips in acetone or wood alcohol. This paste should be as thick as ordinary mucilage, and after each coat, which is allowed to dry, a new layer of cloth is applied and a new layer of celluloid painted. From six to ten layers of stockinet are as a rule sufficient for jackets or leg bandages. When it is finished it is most important to leave the bandage or jacket on the cast until it is thoroughly dry, otherwise it will warp when taken off. When thoroughly dry it is cut and removed, the inside finished and smoothed with a fresh painting of celluloid, the edges trimmed and bound with leather, the splint perforated by holes throughout, and leather lacings or straps one inch wide containing studs or lacings from one to two inches apart sewed to the jacket an inch or more from each side of the cut and extending its entire length. If straps or buckles are preferred they may be substituted.

Molded *leather* splints and jackets are made from oak-tanned English leather, which should not be "stuffed" or "filled." The leather is cut of the desired pattern and softened by soaking in water. When thoroughly flexible it is stretched over the plaster cast and made to conform to all its curves. This is accomplished by fastening one side with tacks, pulling it tight and hammering or pressing it in to fit the hollows, and fastening it by tacks to the other edge, or it may be wound to the cast by means of a rope encircling it in closely applied turns, but the latter method leaves marks on the leather and is no better. When dry it will retain the shape which it assumed when wet, but this is

rarely sufficient to serve the purpose, and for this reason it is desirable in most cases to stiffen the leather. This is done by painting the molded leather splint when dry with hot bayberry wax until it ceases to absorb it, and it is then allowed to dry. The wax discolors the leather somewhat, and when it is thoroughly dry it is better to paint it inside and out with a solution of shellac, applying several coats, and allowing each to dry thoroughly. If only moderate support is required a soft leather jacket may be reinforced by steels fastened on the outside and riveted to the jacket. These should be covered with kid sewed over them.

INDEX

Abbott method of treating scoliosis, 752
Abdomen, affection in the, simulating Pott's disease, 214
  exercises for muscle-training of the, 499
Abdominal organs, displacement of, in scoliosis, 735
Abrachius, 561
Abscess, cold, 113, 206
    treatment of, 127, 236
  in Pott's disease, 206, 236
    diagnosis, 217
  in sacro-iliac tuberculosis, 191
  mediastinal, in Pott's disease, 237
  psoas, 207, 237
  retropharyngeal, in Pott's disease, 236
  tuberculous, 113, 206
    treatment, 127, 236
Acetabulum, fracture of the, 405
Achilles tendon, see *Tendo Achillis*
Achondroplasia, 329
  diagnosis, 331
  etiology, 330
  pathology, 329
  prognosis, 332
  symptoms, 330
  treatment, 332
Aclasis, diaphyseal, 337
Actinomycosis, 359
Adactylism, 561
Adhesions, articular, 70
    breaking down, 72
    diagnosis, 71
    prevention, 70
    treatment, 71
  extra-articular, 70
  intra-articular, 70
  of the ankle-joint, breaking down, 75
    elbow-joint, breaking down, 73
    finger-joints, breaking down, 75
    hip-joint, breaking down, 75
    knee-joint, breaking down, 75
    shoulder-joint, breaking down, 73
    wrist-joint, breaking down, 74
Albee's operation for Pott's disease, 238
  for slipping patella, 34
Albers-Schönberg disease, 336
Amelus, 561
Amputation, 779
  after-treatment, 780
  artificial limb after, 784
  cineplastic, 782
  emergency, 779
  intrauterine, 568
Amputation of choice, 779
  of the elbow, 782
    foot, 781
    forearm, 782
    forequarter, 781
    hip, 780
    knee, 781
    leg, 781
    lower limb, 789
    shoulder, 781
    thigh, 781
    upper arm, 782
    upper limb, 781
    wrist, 782
  secondary, 782
  technique, 779
  transcondylar, 781
Angioendothelioma, 374
Ankle-joint, adhesions in, breaking down, 75
  anatomy of the, 48
    surface, 49
  ankylosis of, 107
    best position for, 84
  arthritis deformans of the, 264
    diagnosis, 179
  arthrodesis of, in poliomyelitis, 478
  congenital dislocation of the, 612
  deformities of, in poliomyelitis, 459
  dislocation of, congenital, 612
  exercise for muscle-training of the, 493
  fracture, diagnosis, 179
  ligaments of the, 48
  motions of the, 49
  operative approach to the, 285
  sprains of the, 49
    diagnosis, 179
  tuberculosis of, 177
    deformity in, 178
    diagnosis, 179
    differential diagnosis, 179
    pathology, 177
    prognosis, 181
    symptoms, 178
    treatment, 181
      mechanical, 181
      operative, 182
Ankylosis, bony, 82
  fibrous, 70, 82
    breaking down, 72
  of the ankle-joint, 107
    elbow-joint, 86
    hip-joints, 97
    mobilization of, 98

Ankylosis of the hip-joint, mobilization of, pseudarthrosis in, 101
of the knee, 102
radiohumeral joint, mobilization of, 90
wrist, 90
prevention of deforming, 83
treatment of faulty position, 84
Apophysitis of the os calcis, 52
of the tibia, 35
Apparatus, 785
celluloid, 789
leather, 789
plaster of Paris, 785
principles of, 785
theory of, 785
uses of, 785
Apus, 561
"Arches, broken," see *Flat-foot*
Arm, deformities of the, in poliomyelitis, 462
fracture of the, 398
painful, following sprain of the shoulder, 57
Arteries of the hip-joint, 9
of the knee-joint, 24
Arteriosclerosis of the extremities, 667
differential diagnosis, 668, 669
treatment, 668
Arthritis, chronic nontuberculous. 242; see *Arthritis deformans*
deformans, 242
cervical, 576
degenerative type, 244
diagnosis, 247
differential diagnosis, 248
etiology, 242
Heberden's nodes, 246
of the ankle, 264
diagnosis, 179
of the elbow, 264
fingers, 246
hip, 255
diagnosis, 143
treatment, 257
knee, 260
diagnosis, 166
shoulder, 263
diagnosis, 184
spine, 265
diagnosis, 215
scoliosis in, 742
treatment, 270
temporomaxillary joint, 265
pathology, 242
prognosis, 249
of the degenerative type, 250
of the proliferative type, 249
scoliosis due to, 742
symptoms, 243
degenerative type, 244
osteoarthritis, 248
rheumatoid arthritis, 248
traumatic type, 247
Arthritis deformans, synonyms, 242
traumatic type, 247
treatment, 251
diet, 252
exercises, 255
fixation, 254
general, 251
hydrotherapy, 252
local, 254
massage, 254
mobilization, 254
rest, 254
degenerative, 243
gummatous, 299
proliferative, 242
rheumatoid, 242; see *Arthritis deformans*
suppurative, 277
syphilitic, 298
tuberculous, 109
Arthrodesis for equino-valgus in poliomyelitis, 485
in poliomyelitis, 478
of the ankle for malunited fracture, 395
for tuberculosis, 182
of the hip in arthritis deformans, 258
in poliomyelitis, 479
of the knee for ankylosis, 103
of the shoulder, for ankylosis in faulty position, 85
in poliomyelitis, 479
wedge, of the knee, 103
Arthroplasty of the elbow for ankylosis, 89
of the hip for ankylosis, 100
of the knee for ankylosis, 103
of the shoulder, 100
Artificial limbs, 782
Astragalectomy in poliomyelitis, 486
in tuberculosis, 183
Astragalus, fracture of, 396
Asymmetry, facial, 574
Ataxia, Freidreich's, 536
Athetosis in spastic paralysis, 411
Athyreosis congenita, 340
Atlas, fracture of the, 685
Atrophy, hereditary muscular, of peroneal type, 533
muscular, accompanying joint disease, 3
in hip-joint disease, 132
in knee-joint tuberculosis, 162
progressive muscular, 533
Attitude, faulty, 696
mechanics of the upright, 696
Axis, fracture of the, 686

Back, flat, 698
round, 698
Backache, differential diagnosis of, 694
in foot-strain, 644
in sprains of the spine, 676
traumatic, 676
Bandages, plaster, 785

Bandages, plaster, dangers of, 788
Bechterew's disease, 265
Birth palsy, 768; see *Paralysis, obstetrical*
Bone, actinomycosis of, 359
  affections of adult, 342
    of growing, 310
  brittle, 333; see *Osteogenesis imperfecta*
  cancer of, 366
    secondary, 374
  developmental diseases of, 309
  diminished resistance of, in scoliosis, 737
  endothelioma of, 372
  fractures of, 378; *see Fractures*
  lime content diminished in, 309, 353
  marble, 336
  myeloma of, 373
  myxoma of, 374
  pyogenic infection of, 286; see *Osteomyelitis*
  radiographic appearances of diseased, 309
  sarcoma of, 367, 374
  syphilis of, 295
  tumors of, 361
    benign, 361
    giant cell, 364
    malignant, 366
      secondary, 374
Bone-grafting in the treatment of non-union of fractures, 381
Boston Children's Hospital knock-knee brace, 325
Bow-leg, 317
  diagnosis, 318
  osteoclasis for, 320
  osteotomy for, 321
  prognosis, 319
  symptoms, 317
  treatment, 319
    expectant, 319
    operative, 320
Brachial plexus, injuries of the, 515
    symptomatology, 516
    treatment, 519
    types of, 515
  motor-root supply, 772
Brachydactylism, 561
Brachyphalangism, 561
Bradford abduction splint for hip-disease, 156
  gas-pipe frame in Pott's disease, 222
Buckminster Brown brace for wry-neck, 579
Bunion, 663
Bursæ of the elbow-joint, 63
  hip-joint, 8
  knee-joint, 24
  shoulder, 53
Bursitis in heel, 658
  of the elbow, 64
  popliteal, 47
  prepatellar, 47
  pretibial, 47
  subdeltoid, 58
Butter, transmission of tuberculosis by, 111

Calcaneum, affections of the, 658
  apophysitis of the, 52
  fracture of the, 396
Calcaneus, see *Talipes calcaneus*
Caliper splint for the knee, 174
Campbell's operation for correction of drop-foot, 485
Cancer of bone, 366
    secondary, 374
  of the spine, diagnosis, 216
  of tendon sheaths, 556
Carcinoma of bone, 366, 374
Cauda equina, injuries of the, 528
Cauda-syndrome, 528
Celluloid splints, 789
Cervicallymphnodes, inflamed, diagnosis, 576
  ribs, 585
Charcot's joint disease, 305
    of the knee, diagnosis, 167
Charcot-Marie-Tooth type of muscular atrophy, 533
Chest, changes in, in scoliosis, 733
  deformities of the, 715
  flat, 717
Chondrodystrophia fœtalis, 329; see *Achondroplasia*
Chondroma, 363
Clairmont's operation for habitual dislocation of the shoulder, 60
Clavicle, congenital deficiency of the, 585
  fracture of, 397
Claw-foot, 654
  clinical features, 655
  degrees of, 655
  etiology, 654
  treatment, 656
Cleft foot, 571
  hand, 571
Club-foot, 614
  acquired, 619
  after-treatment, 629
  diagnosis, 618
  differential diagnosis, 618
  etiology, 614
  pathological anatomy, 615
  prognosis, 620
  relapse after treatment, 621
  symptoms, 618
  treatment, 620
    after-care, 629
    in children, 624, 626
    in infants, 622
    manipulative, 622, 624
    of severe cases, 628
    operative, 627
    removal of bone, 629
    retentive apparatus, 630
    tenotomy, 627
    Thomas wrench, 625

Club-hand, 562
Coccygodynia, 706
Colles's fracture, 401
Contractions, congenital, 567
  functional, following nerve injuries, 507
  neuromimetic, 507
Contracture, Dupuytren's, 556
  Volkmann's, 91, 538
Conus syndrome, 528
Cord, spinal, injuries of the, 680
Coxa plana, 11
  valga, 20
  vara, 14
    acquired, 16
    congenital, 16
    diagnosis, 18, 144
    prognosis, 19
    symptoms, 18
    traumatic, 16
    treatment, 20
    Trendelenburg sign in, 19, 597
Coxitis, 129; see *Hip-disease*
Coxotuberculosis, 129; see *Hip-disease*
Cretinism, 340
Crural nerve, anterior, injuries of the, 531
Crutch-palsy, 520

Davis' (Gwilym) operation to stabilize the foot in poliomyelitis, 482
Deltoid paralysis, tendon transplantation for, 475
Deformities, acquired, of the feet, 634
  congenital, 560
    bony defects or anomalies, 561
    cleft hand and cleft foot, 571
    club-foot, 614
    club-hand, 562
    contractions, 567
    deficiency of the clavicle, 585
    dislocation, 591
    elevation of the scapula, 582
    intrauterine amputations, 568
    intrauterine fractures, 569
    macrodactylism, 572
    of the chest, 717
    of the feet, 618
    of the femur, 563
    of the fibula, 567
    of the hands and feet, 570
    of the humerus, 561
    of the patella, absence, 612
      dislocation, 612
    of the radius, 561
    of the tibia, 565
    of the ulna, 562
    primary, 560
    polydactylism, 571
    secondary, 561
    syndactylism, 561, 570
    synostosis of the bones of the forearm, 563
    terminology, 561
Deformities, congenital, torticollis, 573
    webbed fingers, 570
  functional, from nerve injuries, 507
    diagnosis, 510
    symptoms, 508
    treatment, 511
  in poliomyelitis, 447
  in spastic paralysis, 409
  in tuberculosis of the ankle, 178
  thoracic, 715
Dislocation, congenital, 591
    ankle, 612
    elbow, 613
    hip, 591
    knee, 611
    patella, 612
    shoulder, 613
    wrist, 613
  of the ankle, congenital, 612
    cervical vertebræ, 581
    elbow, congenital, 613
    hip, congenital, 591; see *Hip, congenital dislocation of the*
      in poliomyelitis, 449
    knee, congenital, 611
    patella, congenital, 612
    shoulder, congenital, 613
      habitual or recurrent, 59
      nerve-injuries complicating, 519
    spine, 680, 684
    wrist, congenital, 613
Doll's collar in Pott's disease, 233, 234
Drop-foot, Campbell's operation for, 485
Dunn's operation for calcaneo-cavus, 480
    to shorten the foot, 481
Dupuytren's contracture, 556
    diagnosis, 558
    etiology, 557
    pathology, 557
    symptoms, 557
    treatment, 559
Dyschondroplasia, 337
Dystrophy, progressive muscular, 534
Dwarfs, achondroplasic, 329
  cretinous, 340

Ectrodactylism, 561
Ectromelus, 561
Elbow, adhesions in, breaking down, 73
  anatomy 62
    surface, 63
  ankylosis of, 86
    best position for, 83
  arthritis deformans of the, 264
  arthroplasty of, for ankylosis, 89
  bursæ of the, 63
  congenital dislocation of the, 613
  disarticulation at the, 782
  epicondylitis of the, 64
  excision of, for ankylosis, 88, 89
  exercises for muscle-training of the, 497

Elbow, ligaments of the, 62
miner's, 64
movements of the, 63
muscular strains of the, 63
operative approach to the, 285
sprains of the, 64
synovial membrane, 62
tennis, 64
tuberculosis of the, 186
differential diagnosis, 187
pathology, 186
prognosis, 187
symptoms, 187
treatment, 188
Empyema, articular, 272; see *Joints, pyogenic infection of*
Endothelioma of bone, 372
Epicondylitis of the elbow, 64
Epiphyscolysis for knock-knee, 327
Epiphysitis, acute, 294
Erb's joint, 772
Erb-Duchenne syndrome, 517
Erythromelalgia, 667
differential diagnosis, 668, 669
treatment, 668
Everidge's treatment of suppurating joints, 282
Ewing's sarcoma, 372
Excision of the elbow, for ankylosis, 88, 89
hip-joint for ankylosis, 98
Exostoses, 361
multiple cartilaginous, 337

Facial asymmetry, 574
palsy, traumatic, 513
Fascia transplantation, 491
Fasciotomy for contraction of the hip in poliomyelitis, 454
Feet, see *Foot*
Femur, congenital defects of the, 564
excision of the head of the, in arthritis deformans, 260
flattened head of the, 11
diagnosis, 143
etiology, 11
prognosis, 14
radiological appearances, 12
symptoms, 12
treatment, 14
fractures of the, 382
neck of the, traumatic strain of the, 145
remodelling of the head of the, in arthritis deformans, 258
Fibrocystic disease, 349; see *Ostitis fibrosa cystica*
Fibula, congenital defects of the, 567
fracture of, 392, 393
Fingers, adhesions in the joints of, breaking down, 75
clubbed, 357
Fingers, drum-stick, 359
sprains of the, 69
stiffness of, treatment, 96
webbed, 570
Flat-foot in young children, 651
flexible, 647
mobilization of, 649
plates for, 649
rigid, 650
treatment, 647
Foot or feet, acquired deformities of the, 634
anatomy of the, 634
arch-supports, 649
arthrodesis of joints of, in poliomyelitis, 480
congenital deformity of the, 614
exercises for muscle-training of the, 493
flat 647; see *Flat-foot*
high arch, 641, 654
ligaments of the, 637
low arch, 641
movements of the, 635
muscles of the, 636
painful, mobilization of, 649
static disturbances of the, 639
types of, 641
weight-bearing position of the, 638
Foot-drop, apparatus for, 445
Foot-strain, causes of, 639
diagnosis, 639
pressure symptoms in, 644
prognosis, 645
symptoms, 642
treatment, 646
Forearm, exercises for muscle-training of the, 497
fracture of, 408
synostosis of the bones of the, 563
Förster's operation for spastic paralysis, 422
Fractures, 378
chauffeur's, 401
Colles', 401
compound, mobilization of stiffened joints following treatment of, 82
delayed union, 379
intrauterine, 569
malunion, 379
non-union, 380
bone grafting for, 381
forcible impaction for, 381
inlay bone-graft for, 382
operation for, 380
stepcut operation for, 381
treatment, 380
of the acetabulum, 405
ankle, 393
diagnosis, 179
astragalus, 396
atlas, 685
axis, 686
calcaneum, 396

Fractures of the clavicle, 397
femur, 382
condyles, 390
neck, 382
separation of lower epiphysis, 390
separation of trochanter, 386
shaft, 386
supracondylar, 389
forearm, 400
hip, 382, 405
humerus, 398
leg, 393
metatarsal bone, 50
os calcis, 396
patella, 392
pelvis, 403
radial head, 66
radius, 400
scapula, 398
spine, 679, 685
diagnosis, 216
tibia, shaft, 392
tuberosities, 391
toes, 52
wrist, 67
Pott's, 393
Fragilitas ossium, 333
Friedreich's ataxia, 536
Funnel chest, 717

Gait in congenital dislocation of the hip, 596
in infantile paralysis, 438
in spastic paralysis, 409
normal, 643
Galeazzi's method of treating scoliosis, 764
Gallie's operation for slipping patella, 34
Ganglia of tendon sheaths, 554
Genu recurvatum in poliomyelitis, 459
valgum, 322; see *Knock-knee*
varum, 317; see *Bow-leg*
Giant-cell tumor of bone, 364
Girdlestone's pseudarthrosis operation for ankylosis of the hip, 101
Goldthwait's operation for arthrodesis of the ankle, 107
for slipping patella, 33
Gout, 306
rheumatic, 240; see *Arthritis deformans*
Gwilym Davis' operation to stabilize the foot in poliomyelitis, 482
Gymnastics in the treatment of scoliosis, 745, 762

Hallux rigidus, 662
valgus, 662
operative treatment, 664
palliative treatment, 663
Hammer-toe, 665
Hand, deformities of the, 570
Hand, exercises for muscle-training of the, 497
trident, in achondroplasia, 330
Heart displacement of the, in scoliosis, 734
Heberden's nodes, 246
Heel, affections of the, 658
painful, 658
tender, 645, 658
Heliotherapy, 122
artificial, 125
of joint tuberculosis, 122
Hemophilia, joint affection in, 301
blood coagulation time, 303
diagnosis, 146, 167, 302
differential diagnosis, 303
pathology, 301
prognosis, 304
symptoms, 302
treatment, 304
Heredosyphilis of the bones, 295
of the joints, 299
Heredity, influence of, in joint tuberculosis, 110
Hibbs' operation for Pott's disease, 239
Hip, adhesions in, breaking down, 75
anatomy of the, 7
ankylosis of, 97
best position for, 83
mobilization of, 98
Trendelenburg sign in, 597
arthritis of the, diagnosis, 142
arthritis deformans of the, 255
diagnosis, 143, 256
pathology, 255
prognosis, 256
symptoms, 255
treatment, 257
arthrodesis of, in arthritis deformans, 258
in poliomyelitis, 479
arthroplasty in ankylosis of, 100
blood-supply of, 9
bursæ of, 8
congenital dislocation of the, 591
after-treatment in manipulative reduction, 604
anterior reposition, 604
"bloodless" method of reduction, 599
diagnosis, 146, 595
etiology, 591
instrumental reduction, 603
Jones and Lovett method of reduction, 602
Lorenz method of reduction, 599
manual reduction, 599
operative treatment, 609
pathology, 592
prognosis, 598
symptoms, 595
treatment, 598
manipulative, 599
operative, 609
palliative, 610, 611

Hip, congenital dislocation of, Trendelenburg's sign in, 595
x-ray appearance, of 593
deformities of, in poliomyelitis, 449
development of, 10
disarticulation of the, 780
dislocation of, congenital, 591
in poliomyelitis, 449
epiphyseal strain of, 11
excision of, for ankylosis, 98
exercises for muscle training of the, 496
flexion-contraction of, in poliomyelitis, 451
fracture of the, 382, 405
functional affection of the, diagnosis, 147
hemophiliac affection of the, diagnosis, 146
hysterical, 508
ligaments, 7
motions of the, 9
muscles of the, 9
nerves of the, 9
operative approach to the, 98, 284
osteomyelitis of the, diagnosis, 142
pseudarthrosis for ankylosis of the, 101
snapping, 551
synovial membrane of the, 8
synovitis of, acute, 10
chronic traumatic, 10
diagnosis, 142
tuberculosis of the, 129; see *Hip-disease*
Hip-disease, 129
amputation for, 160
complications, 160
deformity in, 138
treatment, 160
diagnosis, 142, 216
differential diagnosis, 142
double, 159
excision in, 160
flexion test, 140
limitation of motion in, 139
muscular spasm in, 138
pathology, 129
prognosis, 147
quiet, 11
shortening of limb, 134
apparent, 135
symptoms, 131
treatment, 148
ambulatory apparatus, 153
fixation, 149
general, 148
in convalescence, 158
local, 149
open-air, 119
operative, 160
of deformity, 160
recumbency, 149
traction, 149, 155
types of, 131
Hokes' operation to stabilize the foot, in poliomyelitis, 484
Housemaid's knee, 47
Humerus, congenital defects of the, 561
fracture of, 398
Hydrops, intermittent, of joints, 304

Immobilization, stiffness of joints due to, 76
Infantile paralysis, 426; see *Poliomyelitis anterior*
Ischemic muscular contraction, 91, 539; see *Volkmann's contracture*

Jackets, leather, 789
plaster of Paris, 785
in the treatment of Pott's disease, 228
in the treatment of scoliosis, 749
Jaw, lumpy, 359
Joints, adaptive muscular shortening in disease of, 5
anatomy and physiology of, 1
ankylosis of, 82
contraction of, congenital, 567
neuromimetic, 507
diagnosis, 510
symptoms, 508
treatment, 511
empyema of, 272; see *Joints, pyogenic infection of*
hemophiliac, 301; see *Hemophilia*
intermittent hydrops of, 304
methods of operative approach to, 98, 284
muscular atrophy accompanying disease of, 3
spasm, accompanying disease of, 3, 4
neuropathic disease of, 305
pyogenic infection of, 272
diagnosis, 277
etiology, 276
pathogenic agents, 274
Diplococcus gonorrhœæ, 274
Diplococcus pneumoniæ, 275
Gonococcus 274
Meningococcus, 276
Micrococcus intracellularis meningitidis, 276
Pneumococcus, 275
Staphylococcus pyogenes, 274
Streptococcus pyogenes, 274
pathology, 272
serous type, 277
specific types, 273
symptoms, 277
treatment, 277
Everidge's, 282
methods of operative approach, 98, 284
serofibrinous type, 277
serous type, 278
purulent synovitis, 278
Willems', 279
types of, 277
quiet effusion into, 304

Joints, reaction of, to disordered nerve impulses, 3
to infection, 2
to toxins, 2
to trauma, 2
to unfavorable conditions, 2
stiffness of, 4, 70
due to bony blocks, 77
contraction of scar tissue, 79
excessive callus formation, 79
immobilization, 76
myositis ossificans, 77
suppurative processes in and about the joints, 81
following traumatism, 81
following treatment of compound fractures, 81
syphilis of, 298
traumatic affections of, 6
tuberculosis of, 109; see *Tuberculosis of joints*
tumors of, 308
Jones' abduction frame for tuberculous hip, 151, 152
knock-knee brace, 326
operation for calcaneo-cavus, 480,
spastic paralysis, 420
tuberculosis of the knee-joint, 176
pseudarthrosis operation for ankylosis of the hip, 101
Jones and Lovett method of treatment of congenital dislocation of the hip, 602

Kahler's disease, 181
Kidneys, disturbances of, in scoliosis, 735
Klumpke syndrome, 517
Knee, adhesions in the, breaking down, 75
affection of the infrapatellar pad, 37
synovial fringes, 37
anatomy, 22
surface, 24
ankylosis of, 102
best position for, 83
arteries of the, 24
arthritis deformans of the, 260
diagnosis, 166, 261
etiology, 261
prognosis, 262
symptoms, 260
treatment, 262
arthrodesis of, in poliomyelitis, 479
bursæ of the, 24
bursitis of the, 47
clicking, 27
congenital dislocation of the, 611
cysts of the semilunar cartilages, 32
deformities of the, in poliomyelitis, 455
derangements of, due to exostoses, 35
disabilities of the, 22
disarticulation of the, 781
Knee, displacements of the semilunar cartilages, 25
diagnosis, 27
treatment, 27
mechanical, 28
operative, 30
exercises for muscle-training of the, 494
functional affection of the, diagnosis, 167
hemophiliac affection of the, diagnosis, 167
hyperextension of, in poliomyelitis, 459
injuries of the lateral ligaments, 24
internal derangement, 25
ligaments of the, 22
lipomata in the, 27
loose bodies in the, 27, 41
treatment, 45
nerves of the, 24
nipping of synovial fringes, 27
operative approach to the, 285
osteomata in the, 27
rupture of the crucial ligaments, 38
treatment, 40
rupture of the quadriceps and ligamentum patellæ, 34
semilunar cartilages, 23
slipping patella, 32
snapping, 27
synovial membrane of the, 23
synovitis of, diagnosis, 166
syphilis of, diagnosis, 167
tuberculosis of the, 161
deformity in, 162
correction of, 173, 175
diagnosis, 164
differential diagnosis, 166
examination, 164
pathology, 161
prognosis, 168
symptoms, 162
treatment, 168
fixation, 168
in convalescence, 174
mechanical, 168
operative, 174
recumbency, 172
Knock-knee, 322
from infantile paralysis, 458
braces for, 325
diagnosis, 323
epiphyseolysis for, 327
osteotomy for, 327
prognosis, 324
symptoms, 323
treatment, 325
manipulative, 325, 327
operative, 327
Kyphoscoliosis, 718; see *Scoliosis*
Kyphosis in Pott's disease, 206
non-inflammatory, 696, 704

Kyphosis, non-inflammatory, etiology, 705
treatment, 705

Lateral curvature of the spine, 718; see *Scoliosis*
sclerosis, amyotrophic, 533
Leather jackets or splints, 789
Leg, fracture of the, 393
short, operations for lengthening, 487
Legg's disease, 11
operation for weakness of the gluteus medius muscle, 474
Leontiasis ossea, 356
Ligaments, artificial, to check undesirable motion, 488
of the ankle, 48
of the elbow-joint, 62
of the hip-joint, 7
of the knee-joint, 22
Ligamentum patellæ, rupture of, 34, 549
Limbs, artificial, 782
Lipoma arborescens, 243
Little's disease, 408; see *Spastic paralysis*
Locomotion, lesions involving, 533
Lorenz method in the treatment of congenital dislocation of the hip, 599
Lumbosacral joint, 689
congenital anomalies of the, 690
strains of the, 692
diagnosis, 693
symptomatology, 693
treatment, 695
Lumpy jaw, 359
Lymph nodes, tuberculosis of the, diagnosis, 217

Macrodactylism, 572
Madelung's deformity, 68
Malacia, metaplastic, 349; see *Ostitis fibrosa cystica*
of bone, 353; see *Osteomalacia*
Manus vara, 562
March-foot, 644
Marie's disease, 357
Marie-Strümpell disease, 265
Median nerve, injuries of the, 525
Meningocele, 712
Mental impairment in spastic paralysis, 411, 414
Metatarsal bones, fractures of the, 50
Metatarsalgia, anterior, 660
Microbrachius, 561
Micromelus, 561
Micropus, 561
Milk, transmission of tuberculosis by, 111
Miner's elbow, 64
Mobilization of stiffened joints, 82
Morton's disease, 660
Movements, active, in the treatment of articular adhesions, 71
passive, in the treatment of articular adhesions, 71
Muscles, adaptive shortening of, accompanying joint diseases, 5
affections of, 537
atrophy of, accompanying joint disease, 3
inflammation of, 538
ischemic contracture of, 91, 538; see *Volkmann's contracture*
neurotization of, 478
of locomotion, lesions involving, 533
of the hip-joint, 9
rupture of, 537
spasm of, accompanying joint disease, 3, 4
tumors of, 537
Muscle-sliding, 544
Muscle-training, 492
Muscular system, disturbances of the, 407
Musculospiral nerve, injuries of the, 520
Myelocele, 713
Myeloma, multiple, 373
Myelomeningocele, 713
Myopathy, primary, 534
Myositis, 538
ossificans, traumatic, joint stiffness due to, 77
Myotomy for spastic paralysis, 418
for torticollis, 577
Myxedema, congenital, 340
Myxoma of bone, 374

Neck, exercises for muscle-training of the, 499
Nélaton's line, elevation of the trochanter above, in congenital dislocation of the hip, 596
Nerves, healing of injured, 500
injuries of, 500
anterior crural, 531
brachial plexus, 515
cauda equina, 528
cervical plexus, 515
cervical sympathetic, 514
clinical manifestations, 501
external popliteal, 529
facial, 513
functional contraction and deformities following, 507
great sciatic, 529
healing after, 500
in Volkmann's contracture, 92, 544
internal cutaneous, 527
internal popliteal, 530
lumbrosacral plexus, 527
median, 525
musculo-cutaneous, 527
musculo-spiral, 520
obturator, 531
pathology, 500
phrenic, 515
popliteal, 529
posterior interosseous, 522
posterior tibial, 531

Nerves, injuries of, sciatic, 529
spinal accessory, 513
symptoms, 501
syndrome of complete interruption, 501
incomplete interruption, 501
imitation, 502
recovery, 502
treatment, 502
bridge operations, 505
conservative, 502
neurolysis, 505
operative, 503
suture, 504, 506
ulnar, 522
of the hip-joint, 9
of the knee-joint, 24
peripheral, injuries of, 500
suture of, 504, 506
transplantation of, in poliomyelitis, 478
tumors of, 531
Nervous system, disturbances of the, 406
Neuralgia, metatarsal, 660
Neuritis, traumatic, 502
ulnar, traumatic, 522
Neurolysis, 505, 507
results of, 507
Neuromuscular mechanism, disturbances of the, 406
Neurosis, spinal, 675

Obstetrical paralysis, 768; see *Paralysis, obstetrical*
Obturater nerve, injuries of the, 531
Os calcis, affections of the, 658
apophysitis of the, 52
fracture of, 396
Osgood's disease, 35
Osteoarthritis, 242; see *Arthritis deformans*
Ossification, intramuscular, joint stiffness due to, 77
Osteoarthropathy, hypertrophic pulmonary, 357
secondary hypertrophic, 357
Osteochondritis deformans juvenilis, 11
vertebral, 711
Osteoclasis for bow-leg, 320
Osteogenesis imperfecta, 333
diagnosis, 334
differential diagnosis, 334
etiology, 333
pathology, 333
prognosis, 335
treatment, 336
Osteoma, 361
Osteomalacia, 353
diagnosis, 334, 346, 355
differential diagnosis, 355
etiology, 355
pathology, 354
prognosis, 355
symptoms, 355
Osteomalacia, treatment, 356
Osteomyelitis, 286
acute diffuse, 289
diagnosis, 291
drainage operation, 292
gutter operation, 292, 293
symptoms, 291
incidence, 289
subperiosteal resection of the diaphysis, 293
topography, 293
treatment, 292
acute hematogenous, 291
bacterial agencies, 286
circumscribed, 289
gummatous, 297
hematogenous, 286
hemorrhagic, 349; see *Ostitis fibrosa cystica*
of ankle, diagnosis, 179
Osteoporosis, 309
Osteopsathyrosis, idiopathic, 333; see *Osteogenesis imperfecta*
Osteosclerosis, generalized, 336
localized, 337
Osteotomy for bow-leg, 321
for ankylosis of the hip, 97
of the knee, 103
for knock-knee, 327
Ostitis deformans, 342
diagnosis, 344
differential diagnosis, 345
etiology, 342
pathology, 342
prognosis, 348
symptoms, 342
treatment, 348
x-ray appearance, 345
fibrosa cystica, 349
diagnosis, 351
differential diagnosis, 346, 352
etiology, 350
pathology, 349
treatment, 352

Paget's disease of bone, 342; see *Ostitis deformans*
Palmar fascia, contraction of, 556; see *Dupuytren's contracture*
Palsy, birth, 768; see *Paralysis, obstetrical*
crutch, 520
facial, traumatic, 513
serratus magnus, traumatic, 519
Panarthritis, 277
Paralysis, cerebral, of children, 408; see *Spastic paralysis*
in fracture-dislocation of the spine, 682
in Pott's disease, 207
infantile, 426; see *Poliomyelitis anterior*
obstetrical, 768
diagnosis, 774

Paralysis, obstetrical, etiology, 769
location, 769
maternal, 527
mechanism of production, 769
morbid anatomy, 771
prognosis, 774
symptomatology, 762
treatment, 775
of the contracture, 777
of the residual palsy, 778
postural, 775
surgical, 776
Pott's, 207; see *Pott's paralysis*
pseudo-hypertrophic muscular, 534
spastic, 408; see *Spastic paralysis*
Volkmann's ischemic, 91, 538; see *Volkmann's contracture*
Patella, absence of the, 612
fracture of the, 392
congenital dislocation of the, 612
slipping, 32
Albee's operation for, 34
Gallie's operation for, 34
Goldthwait's operation for, 33
treatment, 33
Pectus carinatum, 716
excavatum, 717
Pelvis, distortion of, in scoliosis, 734
fractures of the, 403
inclination of the, 671
Periostitis, syphilitic, 297
Perodactylism, 561
Peromelus, 561
Perthes' disease, 11
Phocomelus, 561
Picque's operation for sacroiliac tuberculosis, 193
Pigeon breast, 716
Pirquet skin test for tuberculosis, 116
Plaster of Paris apparatus, 785
jacket in Pott's disease, 228
in scoliosis, 740
shell in Pott's disease, 223
in scoliosis, 758
Plaster-cutters, 788
Poliomyelitis anterior, 426
arthrodesis in, 478
astragalectomy in, 486
caliper splint for, 444
cerebral spastic paralysis in, 412
chronic, 428, 533
convalescent stage, 428
deformities in, 447
ankle, 459
arm, 462
claw-foot, 654
foot-drop, 445
hand, 462
hip, 449
knee, 455
knock-knee, 458
Poliomyelitis anterior, deformities in, prevention of, 434
shoulder, 461
treatment of, 447
diagnosis, 429
fascia transplantation in, 491
gait in, 438
nerve transplantation, 478
neurotization of muscles, 478
onset, 428
paralysis in, 429
pathology, 426
prognosis, 431
recovery from, 432
scoliosis in, 463
shoulder contraction, 461
drop, 462
spinal fluid in, 430
stages of, 428
symptoms, 427
tendon fixation (tenodesis) for, 488
treatment, 434
by apparatus, 442
by electricity, 442
by heat, 441
by massage, 440
by muscle training, 442
examination prior to, 438
in acute phase, 434
in convalescent phase, 435
of deformities, 447
ankle, 459
club-foot, 445, 459
hip, 449
knee, 455
shoulder, 461
talipes, 445, 459
of residual paralysis, 438
physical, 440
results of, 433
tendon transplantation, 466
Trendelenburg's sign in, 597
Poliomyelitis, chronic anterior, 428, 533
Poliomyelo-encephalitis anterior, 426; see *Poliomyelitis anterior*
Polydactylism, 571
Popliteal nerves, injuries of the, 529
Pott's disease, 197
abscesses in, 207
diagnosis, 217
treatment of, 236
Albee's operation, 238
attitude in, 205
Bradford frame for, 222
cervical, diagnosis, 575
convalescent brace, 235
deformity in, 206
diagnosis, 202–212
differential diagnosis, 214
Doll's collar in, 233, 234
etiology, 197

Pott's disease, examination for, 208
gait in, 205
Hibbs' operation for, 239
lumbar, diagnosis, 143
muscular spasm in, 203
pain in, 204
paralysis in, 207
diagnosis, 217
treatment, 238
pathology, 198
plaster jacket for, 228
plaster shell for, 223
prognosis, 218
shortening in, 204
symptoms, 202, 741
Thomas collar in, 232
Thomas frame for, 224
treatment, 219
ambulatory, 228
braces, 231
fusion operations, 238
in convalescence, 236
operative, 236, 238
plaster jacket, 228
plaster shell, 223
poroplastic support, 235
recumbency, 220
summary of, 241
x-ray picture of, 212, 213
Pott's fracture, 393
Pott's paralysis, 207
diagnosis, 217
treatment, 238
Prostheses, permanent, 783
provisional, 782
Pseudarthrosis of the elbow for ankylosis, 88
Pseudocoxalgia, 11; see *Femur, flattened head of the*
Pseudohypertrophic muscular paralysis, 534
Putti's arthroplastic operation for ankylosis of the knee, 104
Pyogenic infection of bones, 286; see *Osteomyelitis*
joints, 272; see *Joints, pyogenic infection of*

Quadriceps muscle, rupture of, 34

Rachitis, 311; see *Rickets*
Radiohumeral joint, mobilization in ankylosis of, 90
Radius, congenital defects of the, 561
fracture of, 400
of the head of the, 66
subluxation of the head of the, 66
Railway spine, 675
Raynaud's disease, 667
differential diagnosis, 668, 669
treatment, 668
Reamputations, 782
Reflexes, diagnostic significance of, 407
Rheumatism, tuberculous, 271
Rib, cervical, 585
anatomical considerations, 585
diagnosis, 587
motor signs, 586
operative treatment, 588
sensory signs, 587
sympathetic signs, 587
symptoms, 586
treatment, 588
first, removal of a portion of the, 589
supernumerary, types of, 586
Rickets, 311
diagnosis, 314, 334
fetal, 329; see *Achondroplasia*
late, 328
pathology, 312
renal, 328
spinal, diagnosis, 216
treatment, 315
x-ray appearance in, 314
Round shoulders, 696, 697
adult, 704
etiology, 705
treatment, 705
apparatus for correction of, 704
corrective exercises for, 704
diagnosis, 701
effects of, on general health, 700
etiology, 699
prognosis, 702
symptoms and signs, 698
treatment, 702
types of, 697

Sabre tibia, 297
Sacro-iliac joint, 689
strain of the, 691
diagnosis, 693
symptomatology, 693
treatment, 695
tuberculosis of the, 190
abscess in, 191
anatomical character, 190
diagnosis, 191, 215
differential diagnosis, 694
Picque's operation for, 193
prognosis, 191
Smith-Petersen operation, 194
symptoms, 190
treatment, 191
operative, 193
Sarcoma, Ewing's, 372
extraperiosteal, 374
myeloid, 364
of the shoulder, diagnosis, 185
osteogenic, 367
clinical picture, 368
differential diagnosis, 370
morbid anatomy, 367
prognosis, 371
treatment, 371

Scapula, congenital elevation of the, 582
fracture of, 398
Sciatic nerve, injuries of the great, 529
Sclerosis, amyotrophic lateral, 533
of bone, 336
Scoliosis, 718
abdominal organs displaced in, 735
acquired, 740
age in relation to, 719
arthritis deformans causing, 742
C curves, 723
cervicodorsal curves, 726
classification of curves, 720
compound curves, 722
compound structural, 726
concave torsion, 721
congenital, 739
definition, 718
diagnosis, 216, 741
dorsal curves, 724
dorsolumbar curves, 725
estimation of rotation, 728
of spinal curve, 727
of spinal flexibility, 729
etiology, 736
examination, 727
false, 720
prognosis, 742
treatment, 743
fixed, 722
flexibility of spine in, 729
functional, 720
prognosis, 742
treatment, 743
Galeazzi's method of treatment, 764
gymnastics in the treatment of, 745, 762
heart displaced in, 734
in animals, 718
influence of location, 723
intervertebral discs in, 732
jackets in the treatment of, 749, 761
mechanical objections to, 760
kidney troubles in, 735
left total, 721
ligaments of the spine in, 733
location of curves, 723
lumbar curves, 723
Minerva jacket in the treatment of, 761
occurrence, 718
organic, 722
pain in, 719
paralytic, 463
pathology, 731
pelvic changes in, 734
physical signs, 719
plaster jackets in, 749
poliomyelitic, 463
postural, 720
prognosis, 742
treatment, 743
prognosis, 742
Scoliosis, record of findings in, 730
retrotorsion, 721
reverse rotation, 721
rotation in, 728
S curves, 723
sex frequency of, 718
simple curves, 722
spinous process deflection in, 732
structural, 722
suspension in the treatment of, 748
symptoms, 719
thoracic changes in, 733
terminology, 719
total, 720
treatment, 743
Abbott's method, 752
apparatus, 747
choice of methods, 762
forcible correction, 749
Galeazzi's method, 764
gymnastics, 745, 762
hinged shell for recumbency, 758, 759
operative, 763
permanent corrective jackets, 752
passive stretching of the spine, 748
plaster jackets, 749
removable jackets, 753
scheme of, 745
stretching the spine by suspension, 748
in recumbency, 748
suspension, 748
turnbuckle jacket, 753, 759
true, 722
types of, 720
vertebral changes, 732
x-ray examination, 729
Shell, plaster, in the treatment of scoliosis, 758
mechanical principles of, 759
in the treatment of Pott's disease, 223
Shoulder-joint, adhesions in, breaking down, 73
anatomy of the, 52
ankylosis of, best position for, 83
treatment of, 84
arthritis deformans of the, diagnosis, 184, 263
arthrodesis of, in poliomyelitis, 479
for unsound ankylosis, 85
avulsion of the tendon of the supraspinatus muscle, 61
bursæ of the, 53
bursitis of the, 58
congenital dislocation of the, 613
deformities of, in poliomyelitis, 461
disarticulation at the, 781
dislocation of the, congenital, 613
habitual or recurrent, 59
nerve injuries complicating, 519
treatment, 60
exercises for muscle-training of the, 497

Shoulder-joint, fracture-dislocation of the, 399
injuries of the, 54
motions of the, 54
muscular sprain of the, 55
operative approach to the, 285
sarcoma of the, diagnosis, 185
sprain of the, 55
subacute arthritis, 58
synovitis, 57
syphilis of the, diagnosis, 185
tuberculosis of the, 183
differential diagnosis, 184
pathology, 183
prognosis, 185
symptoms, 183
treatment, 185
Skeleton, general affections of the, 310
spinal, injuries of the, 678
Smith-Petersen operation for sacroiliac tuberculosis, 194
Soutter fasciotomy for hip contraction, 454
Spasm, muscular, in foot-strain, 644, 651
in hip-joint disease, 132, 138
in knee-joint tuberculosis, 162
in Pott's disease, 203
Spastic paralysis, 408
after-treatment, 421
alcohol infiltration, 422
ante-natal causes, 408
athetosis in, 411
definition, 408
deformities in, 409
diagnosis, 413
differential diagnosis, 413
equilibrium improvement in, 416
etiology, 408
fixation in abduction frame, 419
Förster's operation in, 422
gait in, 409
Jones' operation to correct spasmodic pronation, 420
massage contraindicated in, 416
mental development in, 411
motor symptoms, 409
muscle re-education in, 415
stretching, intermittent, injurious in, 416
transplantation in, 420
myotomy in, 418
natal causes, 408
nerve pinching for, 422
nerve section for, 422, 425
pathology, 408
poliomyelitic origin of, 412
post-natal causes, 409
prognosis, 413
rhythm cultivation in, 415
section of motor nerves, 422
of posterior nerve roots, 422
Stoffel's operation in, 422
sympathetic ramisection in, 425
Spastic paralysis, symptoms, 409
tenotomy in, 418
treatment, 414
non-operative, 415
operative, 417
Spina bifida, 712
clinical picture, 714
diagnosis, 714
morbid anatomy, 712
occulta, 713
treatment, 714
varieties, 712
Spinal cord, localization of lesions of the, 406
invalid, 677
Spine, actinomycosis of the, 359
adhesions in the, 678
affections of the, 670; see also *Pott's disease* and *Scoliosis*
anatomy of the, 670
angular curvature of the, 197; see *Pott's disease*
arthritis deformans of the, 265
diagnosis, 215, 268
differential diagnosis, 268
etiology, 266
pathology, 265
prognosis, 269
symptoms, 266
treatment, 270
caries of the, 197; see *Pott's disease*
compression-fracture of the, 679
curves of the, 670
dislocation of the, 680
cervical vertebræ, 684
flexion of the, 672
fracture of the, 679
diagnosis, 216, 682
prognosis, 681
symptomatology, 681
treatment, 679, 683
fracture-dislocation of the, 680
functional, 675
hyperextension of the, 672
injuries of the, 673
bony, 678
diagnosis, 214
intervertebral discs, 670
joints of the, 671
lateral curvature of, 718; see *Scoliosis*
ligaments of the, 671
lumbosacral joint, 689
malignant disease of the, diagnosis, 216
movements of the, 672
muscles of the, 670
neurosis of the, 675
physiological curves of the, 670
railway, 675
rotary lateral curvature of the, 718; see *Scoliosis*
rotation of the, 672
rupture of ligaments of the, diagnosis, 217

Spine, sacro-iliac joint, 689
side bending of the, 672
skeletal injuries of the, 678
sprain of the, 673
treatment, 677
surface anatomy of the, 673
traumatic neurosis of the, 675
tuberculosis of the, 197; see *Pott's disease*
typhoid, diagnosis, 215
vertebral osteochondritis, 711
Splints, celluloid, 789
leather, 789
Spondylitis deformans, 265
Spondylolisthesis, 707
clinical picture, 709
diagnosis, 216
etiology, 708
treatment, 711
Spondylose rhizomélique, 265
Sprains of the ankle, 49
elbow, 64, 66
finger joints, 69
shoulder-joint, 55
spine, 673
wrist, 67
Sprengel's deformity, 581
Stiffness of joints, 70; see *Joints, stiffness of*
Stoffel's operation for spastic paralysis, 422
Stooped shoulders, 696
Strains, muscular, of the elbow, 63
of the shoulder, 55
of the wrist, 67
of the lumbosacral and sacro-iliac joints, 691
Supraspinatus muscle, avulsion of the tendon of the, 61
Sympathetic ramisection for spastic paralysis, 425
Syndactylism, 561, 570
Synovial membrane of the elbow-joint, 62
of the hip-joint, 8
Synovitis, acute traumatic, 6
chronic traumatic, 7
gummatous, 299
heredosyphilitic, 299
intermittent, 304
purulent type of, 277
treatment, 278
syphilitic, 298
Syringomyelia, joint affections in, 305
Syringomyelocele, 713
Syphilis of bones, 295
of joints, 298
of the knee, diagnosis, 167
of the shoulder, diagnosis, 185
of tendon sheaths, 555

Tabes, neuropathic joint affection in, 305
Talipes calcaneus, 633
apparatus for, 446
tendon transplantation in, 471
Talipes equino-varus, 614; see *Club-foot*
poliomyelitic, treatment of, 445, 459
valgus, 633
tendon transplantation in, 468
varus, 632
metatarsal, 633
tendon transplantation in, 468
Tarsal disease, 178
Taylor's traction splint for hip-disease, 157
Temporomaxillary-joint, arthritis deformans of the, 265
Tendo Achillis, short, division of, 652
rupture of, 549
Tendolysis, 545
Tendons, dislocation of, 550
peroneal, 550
division of, 544
treatment, 545
injuries to, 544
rupture of, 547
biceps, 547
extensor longus pollicis, 548
extensors of fingers, 548
ligamentum patellæ, 549
plantaris, 550
rectus femoris, 549
tendo Achillis, 549
treatment, 550
Tendon-sheaths, cancer of, 556
chondromata of, 556
fibromata of, 556
ganglia of, 554
inflammation of, 551; see *Tenosynovitis*
lipomata of, 555
myeloid tumors of, 555
syphilis of, 555
tumors of, 555
xanthomata of, 556
Tendon-suture, 545
Tendon-fixation for paralysis, 488
Tendon-transplantation, 466
after-treatment of, 476
at the knee, 472
at the hip, 472
at the shoulder, 475
for deltoid paralysis, 475
in talipes calcaneus, 471
in talipes valgus, 468
in talipes varus, 468
hamstring, 471
in the hand, 471
technique, 467
Tennis elbow, 64
Tenodesis for paralysis, 488
Tenosynovitis, 551
acute infective, 551
in heel, 658
of the wrist, 67
simple, 553
syphilitic, 555

Tenosynovitis, tuberculous, 554
Tenotomy for club-foot, 627
for spastic paralysis, 418
Tenovaginitis, 551
Tensor fascia, transplantation of the, for weakness of the gluteus medius muscle, 474
Thomas collar in Pott's disease, 232, 234
frame in Pott's disease, 224
knock-knee brace, 326
splint for tuberculosis of joints, 154, 169
double, 152
wrench in the treatment of club-foot, 625
Thorax, anatomy of the, 715
changes in, in scoliosis, 733
muscles of the, 670
rachitic deformities, 715
Thrombo-angiitis obliterans, 667
differential diagnosis, 668, 669
treatment, 668
Tibia, apophysitis of the, 35
congenital defects of the, 565
fractures of, 391, 392
of the spine of the, 38
treatment, 41
partial separation of the tubercle of the, 35
sabre, 297
Tibial nerve, posterior, injuries of the, 531
Toe, displacement of the great, 662; see *Hallux valgus*
of the little, 666
fractures of the, 52
Torticollis, 573
acquired, 580
Buckminster Brown brace in, 579
congenital, 573
diagnosis, 215, 574
differential diagnosis, 575
operative treatment, 576
pathology, 573
prognosis, 576
symptoms, 574
treatment, 576
double 574
ocular, 576
paralytic, 576
spasmodic, 580
Trauma, influence of, in joint tuberculosis, 109
Trendelenburg's sign in congenital dislocation of the hip, 595
in conditions other than congenital dislocation of the hip, 597
Trigger-knee, 27
Tuberculosis, bovine and human, relative infectivity of, in man, 110
droplet infection, 111
immunity to, 112
of the ankle, 177; see *Ankle, tuberculosis of*
of the elbow, 186; see *Elbow, tuberculosis of*
of the hip, 129, see *Hip-disease*
of joints, 109
Tuberculosis of joints, diagnosis, 116
etiology, 109
heliotherapy, 122
hereditary transmission, 110
immunity to, 112
modes of infection, 111
pathology, 113
Pirquet skin test for, 116
prognosis, 118
prophylaxis of, in children, 110
repair of, 113
sun-cure, 122
symptoms, 115
trauma in the etiology of, 109
treatment, 119
general, 119
local, 125
mechanical, 126
operative, 126
outdoor, 119
solar, 122
x-ray appearances, 117
of the knee, 161, see *Knee, tuberculosis of the*
of the lymph nodes, diagnosis, 217
of the pretibial bursa, diagnosis, 168
of the sacroiliac joint, 190
of the shoulder, 183; see *Shoulder, tuberculosis of*
of the spine, 197; see *Pott's disease*
of tendon sheaths, 554
of the wrist, 189
rheumatic, 271
Pirquet skin test, 116
prevention of, 112
in children, 110
Tumor albus, 161; see *Knee-joint, tuberculosis of the*
false, 299
Tumors of joints, 308
of muscles, 537
of nerve trunks, 531
of tendon sheaths, 555
Turnbuckle jacket in the treatment of scoliosis, 753
mechanical principle of, 759
method of splitting and applying, 757
Typhoid spine, diagnosis, 215

Ulna, congenital defects of the, 562
Ulnar nerve, injuries of the, 522

Vascular lesions of the extremities, 667
differential diagnosis, 668, 669
treatment, 668
Vertebræ, cervical, dislocation of, 581, 684
changes in, in scoliosis, 732
fracture of the, 687; see also *Spine, fracture of the*
osteochondritis of the, 711

Volkmann's contracture, 91, 538
clinical picture, 539
etiology, 92, 540
pathogenesis, 540
pathology, 92
prognosis, 95, 541
prophylaxis, 94, 541
symptoms, 92, 539
treatment, 95, 541
early, 541
mechanical, 544
operative, 544

Walking, tripod, 443
Webbed fingers, 570
Weight, loss of, in joint tuberculosis, 117
White swelling, 161; see *Knee-joint, tuberculosis of the*
Willems' treatment of suppurating joints, 279
Wrist-joint, adhesions in, breaking down, 74
anatomy of the, 66
ankylosis of, 90
best position for, 83
congenital dislocation of the, 613
disarticulation at the, 782
exercises for muscle-training of the, 496
fracture of a bone of the, 67
movements of the, 67
muscular sprains about the, 67
operative approach to the, 285
sprains of the, 67
subluxation of the, 68
tuberculosis of the, 189
Wry-neck, 573; see *Torticollis*

WELLCOME LIBRARY INSTITUTE