The practice of surgery / by James Gregory Mumford.

Contributors

Mumford, James Gregory, 1863-1914.

Publication/Creation

Philadelphia ; London : W.B. Saunders, 1914.

Persistent URL

https://wellcomecollection.org/works/anp89spb

License and attribution

This work has been identified as being free of known restrictions under copyright law, including all related and neighbouring rights and is being made available under the Creative Commons, Public Domain Mark.

You can copy, modify, distribute and perform the work, even for commercial purposes, without asking permission.

wellcome collection

Wellcome Collection
183 Euston Road
London NW1 2BE UK
T +44 (0)20 7611 8722
E library@wellcomecollection.org
https://wellcomecollection.org


22900108417

Digitized by the Internet Archive
in 2019 with funding from
Wellcome Library

https://archive.org/details/b31355997

BOOKS

BY

JAMES G. MUMFORD, M. D.

A Narrative of Medicine in America. 1903

Clinical Talks on Minor Surgery. 1903

Surgical Aspects of Digestive Disorders. 1905 and 1907

Surgical Memoirs and Other Essays. 1908

The Practice of Surgery. *New (2d) Edition.* 1914

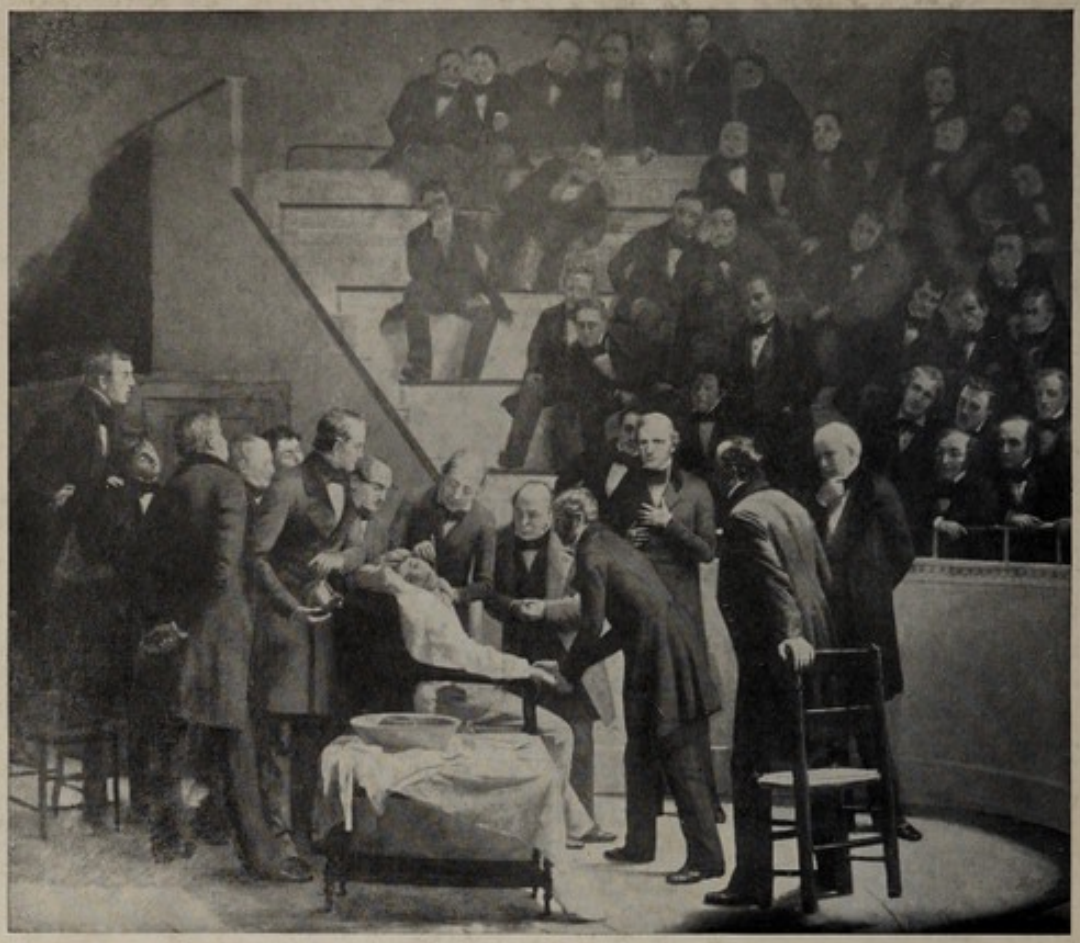

FIG. 1.—AN OLD-TIME OPERATING ROOM.

The dome-amphitheater, Massachusetts General Hospital. The first public demonstration of ether anesthesia, October 16, 1846. (After the well-known painting, in the Boston Medical Library, by Hobert Hinckley.)

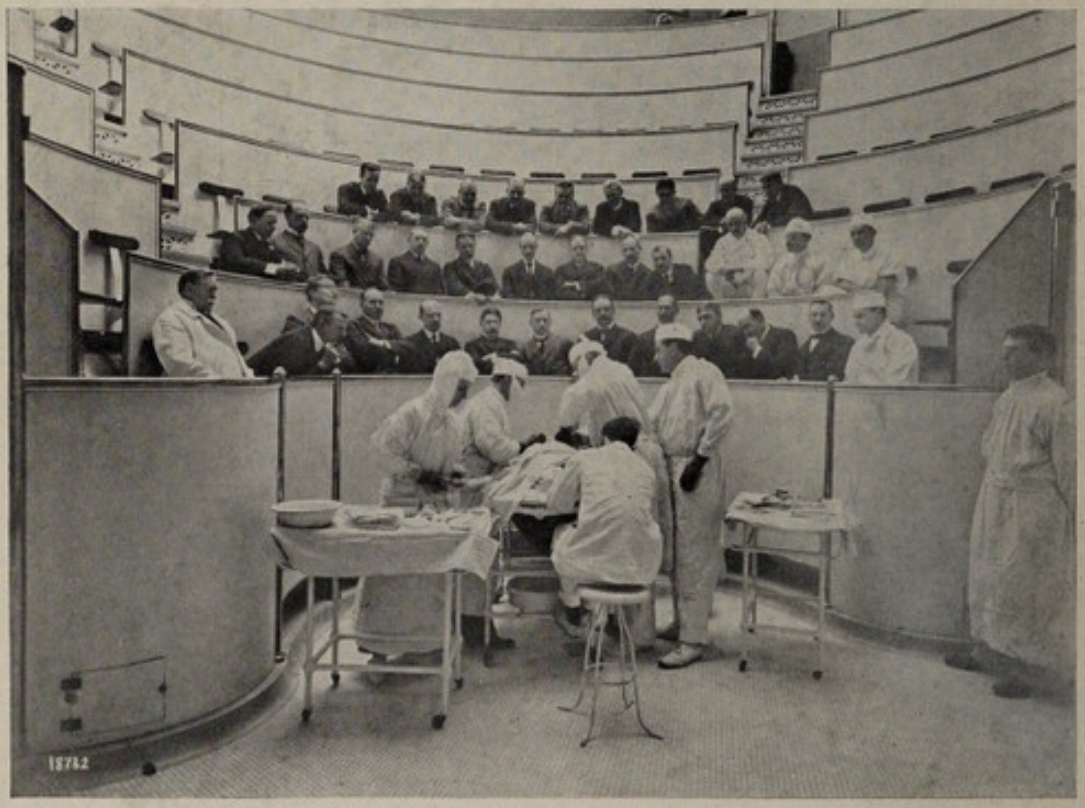

FIG. 2.—A MODERN OPERATING ROOM.

The Bigelow amphitheater, Massachusetts General Hospital. A meeting of the Society of Clinical Surgery, May 1, 1908.

VIII. 14
4 $7.00 net.
30/- net.

THE PRACTICE OF SURGERY

LIBRARY OF THE
PRESENTED
BRITISH MEDICAL ASSOCIATION
CANCELLED

BY

JAMES GREGORY MUMFORD, M. D.

LECTURER ON SURGERY IN HARVARD UNIVERSITY; SURGEON TO THE CLIFTON SPRINGS (N. Y.) HOSPITAL; FELLOW OF THE AMERICAN SURGICAL ASSOCIATION; RECENTLY VISITING SURGEON TO THE MASSACHUSETTS GENERAL HOSPITAL, ETC.

WITH 683 ILLUSTRATIONS
SECOND EDITION, THOROUGHLY REVISED

PHILADELPHIA AND LONDON
W. B. SAUNDERS COMPANY
1914

WITH
THE PUBLISHER'S
COMPLIMENTS.

14803101

Copyright, 1910, by W. B. Saunders Company. Reprinted October, 1911.
Revised, reprinted, and recopyrighted June, 1914

Copyright, 1914, by W. B. Saunders Company

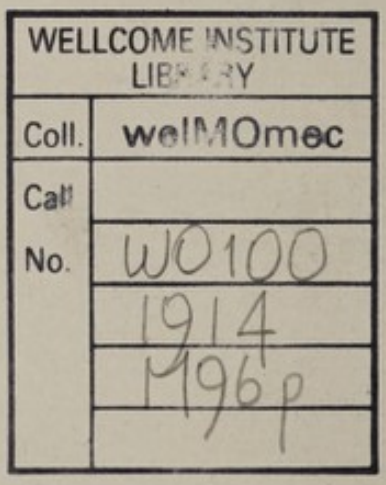

PRINTED IN AMERICA

PRESS OF
W. B. SAUNDERS COMPANY
PHILADELPHIA

To my friends and associates
in the
Society of Clinical Surgery

The Wisdom of God receives small honour from those vulgar Heads that rudely stare about, and with a gross rusticity admire His works: those highly magnifie Him, whose judicious inquiry into His Acts, and deliberate research into His Creatures, return the duty of a devout and learned admiration.

Religio Medici.

PREFACE TO THE SECOND EDITION

I HAVE gone carefully through the text of this book, and have revised it so far as seemed necessary to keep it abreast of progress.

To my friends, the book reviewers, I am grateful for their kind reception of the first edition. I am myself a member of the brotherhood; for I have been a reviewer for many years. I have read seventy reviews of this book, and feel that it has found favor beyond its deserts. The reviewers do not always agree with me; but, then, they do not agree with each other. Nevertheless, most of them have read my first preface, have understood my purpose, and have dealt with the volume in courtesy and frankness.

J. G. M.

CLIFTON SPRINGS, NEW YORK,
June, 1914.

PREFACE

In this writing I present a short treatise on the Practice of Surgery. Perhaps the title "Clinical Surgery" would equally describe the work. I omit consideration of the *principles* of surgery, except incidentally and when the course of the argument seems to call for such consideration. Within youthful memory even the field of surgery has broadened so enormously; so many new subjects have come within its embrace; knowledge of its manifold expression has become so extensive; its study is now found to expand into so many branches, and its roots to penetrate so deeply, that a sound, comprehensive knowledge of all its parts is no longer possible to a single individual, or to be condensed as I wish to condense this work.

When men of my generation were young their studies in surgery were regarded as reasonably complete when they had grounded themselves in gross and surgical anatomy, in general pathology, in such simple bacteriology as was then taught, and in operative technic. To-day studies in surgery embrace an immensely wider field. Surgical pathology has grown until that branch alone has become the object of a teacher's undivided efforts. Special inquiry into particular diseases, processes, and lesions absorbs individual investigators. Studies in bacteriology, in questions of immunity, in serum and opsonic therapy, in the blood, in tumors, in neurologic surgery, in gastro-intestinal surgery, in diseases of the eye, the ear, the throat; in surgical physiology and numberless kindred topics, have become so far reaching and diffuse that no one mind can master their infinite variety.

The situation is different from what we knew when a single teacher could instruct his classes in all there was to know of surgery; when a general surgeon was thought competent to practice in every field.

To-day the practitioner, as well as the student, must acquire knowledge in special laboratories, under special teachers, and from special books, before he is thought competent to take up his clinical work; while clinical work and teaching alone, with such a background of study as I have described, must be the task of specially qualified persons, whose function it is to follow the *practice* of surgery. Every surgical clinician may have his particular interest, his skill in some branch of knowledge or research, but he cannot be a sound exponent of all surgical knowledge.

And so it must be with a *treatise* on the Practice of Surgery. As a general surgeon, I may not attempt to deal comprehensively, accurately, and scholarly with all branches of surgery. Writers of

text-books on Medical Practice have learned something of this. They no longer fill their pages with elaborate essays on theory as well as on practice.

In this book, accordingly, I give to the reader an account of the practice of surgery—of surgery as he will see it at the bedside, in the accident ward, and in the operating-room. The writing is elaborated from many years of active hospital and private surgical practice, from clinical teachings, from class-room discussions, and lectures. With proper modesty may I hope that the student will find here a comprehensive description of all such general surgical ailments as may fall to him for treatment and advice.

Moreover, the reader will find the plan of this book somewhat unconventional in other respects. I purpose taking up surgical diseases in their order of interest, importance, and frequency, so far as one may with due regard to a proper sequence; and I endeavor also to lay stress on those subjects which nature herself has accentuated. By such a plan one should be able to present the various subjects in their true perspective. Appendicitis concerns us far more than does inflammation of Meckel's diverticulum; meningitis, than cirsoid aneurysm; and felon, than Dupuytren's contraction. The student should learn to look for, to recognize, and to treat the common and grave ailments which practice furnishes. Curiosities of surgery should be known, but their infrequency will limit their familiar study by the average practitioner. For this reason their exhaustive exposition must be left to writers of especial monographs. Frequently one finds essayists complaining that their own immediate topics are slighted by the writers of text-books. In the nature of text-book composition such slighting is inevitable. A text-book of surgery cannot be an encyclopedic treatise on all surgical knowledge.

In this book, therefore, I assume the reader's preliminary training, and endeavor to present to him the Practice of Surgery as surgeons see it—as a subject of unending variety and importance, as a pursuit of the deepest human interest.

I thank cordially my friends who have assisted me by their criticism in the final revision of the manuscript: Dr. Malcolm Storer, Dr. Thomas F. Harrington, Dr. E. W. Taylor, Dr. R. B. Greenough, Dr. Lincoln Davis, Dr. Samuel Robinson, and Dr. John B. Hartwell.

The original illustrations are by Miss Ruth O. Huestis, an indefatigable artist.

J. G. M.

29 Commonwealth Ave.,
Boston, Mass.

CONTENTS

PART I—THE ABDOMEN

CHAPTER I

PAGE

Appendicitis 17
Forms of Appendicitis 23
Symptoms of Appendicitis 26
Diagnosis of Appendicitis 30
Treatment of Appendicitis 31

CHAPTER II

The Small Intestine and Colon 42
Symptoms 46
Intestinal Obstruction 47
Injuries 54
Foreign Bodies 56
Meckel's Diverticulum 57
Enteroptosis 60
Colitis 63
Typhoid Perforation 64
Tuberculosis of the Intestines 67
Actinomycosis of the Intestines 69
Embolism and Thrombosis of the Mesenteric Vessels 71
Intussusception 73
Volvulus 75
Internal Herniæ 76
Idiopathic Dilatation of the Colon 76
Tumors of the Intestine 76
Fecal Fistula and Artificial Anus 82
The Mesentery and Omentum 87

CHAPTER III

The Rectum and Anus 89
Hypertrophy of the Rectal Valves 90
Imperforate Anus 90
Inflammations 92
Fissure of the Anus 94
Ischiorectal Abscess 95
Fistula in Ano 97
Hemorrhoids 100
Prolapse of the Anus and Rectum 103
Stricture of the Rectum 104
Tumors of the Anus and Rectum 105

CHAPTER IV

The Esophagus, Stomach, and Duodenum 113
The Esophagus 114
Stricture of the Esophagus 115
Cardiospasm 120
Diverticulum of the Esophagus 122
Foreign Bodies in the Esophagus 123
Tumors of the Esophagus 125
Injuries of the Esophagus 126
Inflammations of the Esophagus 127

THE ESOPHAGUS, STOMACH, AND DUODENUM (CONTINUED). PAGE
The Stomach ... 127
Peptic Ulcer ... 129
Pyloric Obstruction ... 141
Hemorrhage ... 143
Perforation ... 144
Distortion of the Stomach ... 144
Gastric Adhesions ... 145
Gastric Tetany ... 146
Gastric Cirrhosis ... 146
Spasm of the Pylorus ... 146
Gastroptosis ... 146
Stenosis of the Pylorus ... 147
Foreign Bodies ... 147
Cancer ... 147
Sarcoma ... 156
Wounds ... 156

CHAPTER V

THE LIVER AND BILE-PASSAGES ... 158
The Liver ... 158
Abscess of the Liver ... 159
Cysts of the Liver ... 160
Injuries of the Liver ... 161
Tumors of the Liver ... 162
Cirrhosis of the Liver ... 166
Hepatoptosis ... 168
The Bile-passages ... 170

CHAPTER VI

THE PANCREAS AND SPLEEN ... 184
The Pancreas ... 184
Inflammations—Pancreatitis ... 184
Tumors ... 188
Traumatic Injuries ... 190
The Spleen ... 190
Injuries ... 191
Abscess and Tuberculosis ... 192
Cysts ... 192
Neoplasms ... 193
Splenic Enlargement ... 193
Ptosis ... 194

CHAPTER VII

ABDOMINAL HERNIA ... 196
Inguinal Hernia ... 203
Femoral Hernia ... 217
Umbilical Hernia ... 219
Ventral Hernia ... 223
Diaphragmatic Hernia ... 224
Obturator Hernia ... 225
Retroperitoneal Hernia ... 225

CHAPTER VIII

PERITONEUM AND RETROPERITONEAL SPACE ... 227
Acute Peritonitis ... 227
Diffuse Peritonitis ... 229
Chronic Peritonitis ... 238
The Retroperitoneal Space ... 242

CHAPTER IX

PTOSIS OF THE ABDOMINAL ORGANS—THE ABDOMINAL WALL ... 247
Abdominal Ptosis ... 247
The Abdominal Wall ... 260

PART II—FEMALE ORGANS OF GENERATION

CHAPTER X

PAGE

The Uterus 265
Anatomy 265
Inflammation 271
Lacerations 282
Wounds 284
Displacements 285
Tumors 302
Myoma 302
Cancer 315
Endothelioma 327
Sarcoma 327
Deciduoma Malignum 328

CHAPTER XI

Fallopian Tubes and Ovaries 329
The Fallopian Tubes 329
Salpingitis 329
Tumors 339
The Broad Ligaments 340
The Ovaries 341
Ovaritis 341
Tumors 343
Tubal Pregnancy 350
Pelvic Hematocele 354

CHAPTER XII

Perineum and Vagina 355
Perineal Lacerations 355
Urethral Caruncle 362
The Vulva 362
The Vagina 363
Vaginal Fistulæ 363
Inflammation 367
Vaginal Cysts 367
Atresia of the Vagina 367

PART III—GENITO-URINARY ORGANS

CHAPTER XIII

Kidneys and Ureters 368
Anatomic Relations 368
Diagnosis in Renal Disease 370
Injuries of the Kidney 376
Stone in the Kidney 379
Hydronephrosis 384
Pyelitis 385
Tuberculosis of the Kidney 390
Tumors of the Kidney and Suprarenal Gland 392
Lumbar Fistula 396
Chronic Nephritis 396

CHAPTER XIV

Bladder and Prostate 398
The Bladder 398
Exstrophy of the Bladder 398

Bladder and Prostate (Continued). PAGE
Absence of the Bladder, Double Bladder ... 399
Retention of Urine ... 400
Cystitis ... 404
Stone in the Bladder ... 408
Ulcer of the Bladder ... 414
Tumors of the Bladder ... 415
Sacculation of the Bladder ... 418
Bladder Injuries ... 419
The Prostate ... 421
Anatomy of the Prostate ... 421
Inflammation of the Prostate ... 422
Prostatic Calculi ... 424
Hypertrophy of the Prostate ... 425
Cancer of the Prostate ... 438

CHAPTER XV

Penis, Urethra, and Testes ... 443
The Penis and Urethra ... 443
Gonorrhea ... 444
The Genital Lesions of Syphilis ... 454
Injuries of the Penis ... 457
Genital Herpes ... 458
Venereal Warts ... 458
Circumcision ... 458
Cancer of the Penis ... 460
Foreign Bodies in the Urethra ... 461
Para-urethral Abscess ... 462
Stricture of the Urethra ... 462
Urethral Fistula ... 468
Urethroscopy ... 468
Hypospadias and Epispadias ... 469
The Testicles ... 474
Undescended Testicle ... 474
Wounds and Contusions ... 478
Inflammation ... 478
Hydrocele ... 480
Varicocele ... 484
Tumors ... 485
Twisted Cord ... 487
Castration ... 487

PART IV—THE CHEST

CHAPTER XVI

The Bronchi and Lungs ... 488
Foreign Bodies in the Bronchi ... 489
Bronchiectasis ... 490
General Technic of Operating upon the Lungs ... 491

CHAPTER XVII

The Pleura ... 497
Inflammatory Disease ... 497
Pyothorax ... 499

CHAPTER XVIII

The Heart and Pericardium ... 506
Pericardial Effusions ... 507
Operations upon the Pericardium ... 507
Wounds of the Heart ... 509

CHAPTER XIX

PAGE
THE CHEST-WALL—THE BREAST ... 512
The Chest-wall ... 512
Contusions of the Chest ... 512
Inflammations ... 513
Neuritis of the Intercostal Nerves ... 514
Tumors of the Chest-wall ... 514
The Breast ... 515
Anatomy ... 515
Cancer ... 517
Other Breast Tumors ... 534
Mastitis ... 539
Retention Cysts ... 542
Supernumerary Breasts and Nipples ... 542

PART V—THE FACE AND NECK

CHAPTER XX

HARELIP AND CLEFT-PALATE ... 543
Harelip ... 544
Cleft-palate ... 550
PLASTIC OPERATIONS ON THE FACE ... 555
SALIVARY FISTULA ... 556
SALIVARY STONES ... 558
RANULA ... 558
THYROLINGUAL OR THYROGLOSSAL CYSTS AND SINUSES ... 559
CANCER OF THE LIP ... 559
RODENT ULCER ... 565
INJURIES OF THE FACE ... 566
TUMORS OF THE FACE ... 567

CHAPTER XXI

JAWS, TONGUE, LARYNX, AND PHARYNX ... 569
The Jaws ... 569
Infections ... 570
Tumors ... 572
The Tongue ... 580
Inflammation ... 581
Cancer ... 582
Sarcoma ... 585
The Salivary Glands ... 585
The Pharynx and Nasopharynx ... 587
Diseases of the Larynx ... 589

CHAPTER XXII

THE NECK ... 597
Cicatricial Contractions ... 597
Torticollis ... 597
Cervical Adenitis ... 600
Wounds of the Thoracic Duct ... 604
Deep Cervical Abscess ... 605
Pediculi Capitis ... 605
Lymphatic Cysts ... 605
The Carotid Gland ... 606
Cervical Rib ... 608
Disease of the Thyroid Gland ... 608
Goiter ... 613
Epithelial Diseases of the Thyroid ... 621

PART VI—THE HEAD AND SPINE

CHAPTER XXIII

PAGE
The Scalp 624
Contusions of the Scalp 625
Tumors of the Scalp 627

CHAPTER XXIV

The Skull, Brain, and Meninges 630
Fractures of the Skull 631
The Meninges 653
Developmental Anomalies 654
Hydrocephalus 655
Cerebrospinal Rhinorrhea 657
Sinus Thrombosis 657
Meningitis 658
Meningeal Tumors 661
The Cranium 662
Tumors of the Cranial Bones 662
The Brain 663
Encephalitis 663
Cerebral Abscess 664
Tumors of the Brain 665
Results of Injuries and Diseases of the Brain 670
Intracranial Operations 675

CHAPTER XXV

The Spine and the Peripheral Nerves 681
The Spine 681
Anatomy and Physiology of the Cord 682
Concussion and Contusion 686
Wounds of the Cord 687
Dislocations and Fractures of the Vertebræ 688
Spinal Meningitis 692
Spina Bifida 693
Tumors of the Spine 697
The Peripheral Nerves 706
Neuritis 707
Neuralgia 709
Operations upon the Nerves 719

PART VII—MINOR SURGERY. DISEASES OF STRUCTURE

CHAPTER XXVI

Minor Surgery 731
The Examination and Study of Cases; Wounds; Fractures; Local Infections; Massage 731
Incised Wounds 736
Simple (Closed) Fractures 741
Lacerated Wounds 744
Compound (Open) Fractures 748
Granulating Wounds and Varicose Ulcers 752
Felon; Whitlow; Paronychia; Palmar Abscess 757
Boils; Carbuncles 764
Bunions; Ingrowing Nails; Corns; Warts 769
Massage 774

CHAPTER XXVII

PAGE

SHOCK; BLOOD-VESSELS; LYMPHATICS; MUSCLES; TENDONS; BURSÆ; SKIN ... 779
Shock and Collapse ... 779
Surgery of the Blood-vessels ... 787
Phlebitis ... 788
Angioma ... 791
The Arteries ... 791
Ligation of the Arteries ... 791
Aneurysm ... 798
Suture of the Blood-vessels ... 807
Surgery of the Lymphatic System ... 807
Lymphangitis ... 809
Lymphangioma, Lymph Varices, Lymphangiectasis, and Lymphadenocele ... 811
Lymphadenitis ... 813
Hodgkin's Disease ... 814
Surgery of the Muscles, Tendons, and Bursæ ... 816
Muscles ... 816
Tendons ... 818
Bursæ ... 823
Surgery of the Skin ... 827

CHAPTER XXVIII

TUMORS ... 834
Classification ... 835
Causation ... 835
Cysts ... 836
Dermoids and Teratomata ... 840
Tumors of the Connective-tissue Type ... 842
Epithelial Tumors ... 854
Cancer ... 858

CHAPTER XXIX

FRACTURES AND DISLOCATIONS ... 865
Fractures ... 865
General Considerations ... 866
Simple Fractures ... 870
Compound Fractures ... 874
Special Fractures and their Treatment ... 875
Ribs ... 875
Sternum ... 877
Pelvis ... 878
Clavicle ... 879
Scapula ... 883
Humerus ... 884
Elbow ... 893
Forearm ... 900
Colles' Fracture ... 902
Carpus ... 907
Metacarpal Bones ... 908
Phalanges ... 911
Femur ... 911
Patella ... 920
Leg ... 923
Foot ... 932
Face ... 933
Pathologic Fractures ... 940
Dislocations ... 940
Special Dislocations ... 942

CHAPTER XXX

PAGE
Bones and Joints (Orthopedic Surgery) 959
The Bones 959
The Joints 970

CHAPTER XXXI

Amputations 990
Special Amputations 997

Index 1009

THE PRACTICE OF SURGERY

PART I

THE ABDOMEN

CHAPTER I

APPENDICITIS

APPENDICITIS, more than any other acute disease, interests all classes of the community. It is everywhere present; it is serious and alarming; it appears under many guises and passes through many phases; it calls for heroic treatment; its study has been developed and formulated in our own generation, and so has become a favorite theme of modern surgeons; about it have centered some of the most stimulating and vital medical discussions of our time, and in the great majority of cases it can be cured.

The **history** of appendicitis is recent, because so lately as 1886 only was its nature properly demonstrated,[1] but for generations there were knowledge and fear of attacks of pain and inflammation, often fatal, in the right lower portion of the abdomen. Sporadic accounts of cases appear far back in medical literature, and are recorded by French, Italian, and English reporters of the last three centuries. In the nineteenth century, and with the development of abdominal surgery, following Lister's teaching, our attack upon this disease became more concentrated and effective. The Englishman Hancock, and the New York surgeons Willard Parker and Gurdon Buck, opened abscesses in the right iliac fossa fifty years ago. In 1886 R. H. Fitz, of Boston, explained the nature of the process, while J. Homans, C. McBurney, C. B. Porter, M. H. Richardson, J. B. Deaver, and many recent operators have developed and perfected a technic for dealing with the disease in both its acute and quiescent stages.

The **anatomy** of the vermiform appendix is important. The little organ lies in the right iliac and hypogastric regions, in its typical position hanging down over the brim of the pelvis; but it may swing in any direction, from its base as an axis. Occasionally it lies entirely behind

[1] R. H. Fitz, Perforating Inflammation of the Vermiform Appendix, Trans. Assoc. Amer. Physicians, June, 1886.

the cecum. Its most common length is between 2 and 3.2 inches; rarely, one sees removed a great appendix, 5, 9, and even 10 inches long. The lumen is from 0.1 to 0.2 inch in diameter. At its entrance into the cecum is a fold of mucous membrane known as the valve of Gerlach.

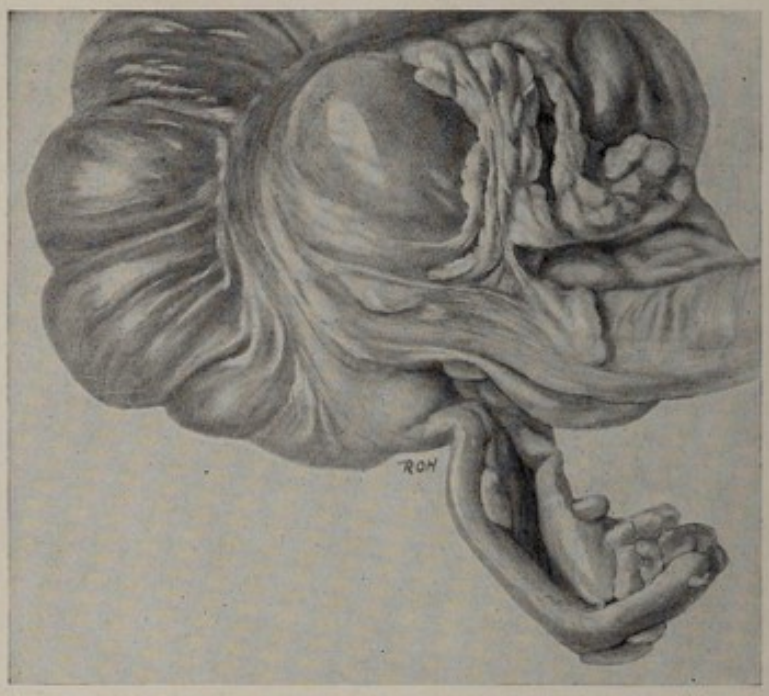

Fig. 3.—Normal vermiform appendix.

In a few reported cases no appendix has been found. Let me remind the student that in the development of the fetus the cecum and appendix descend from high up under the liver, in which position the appendix is

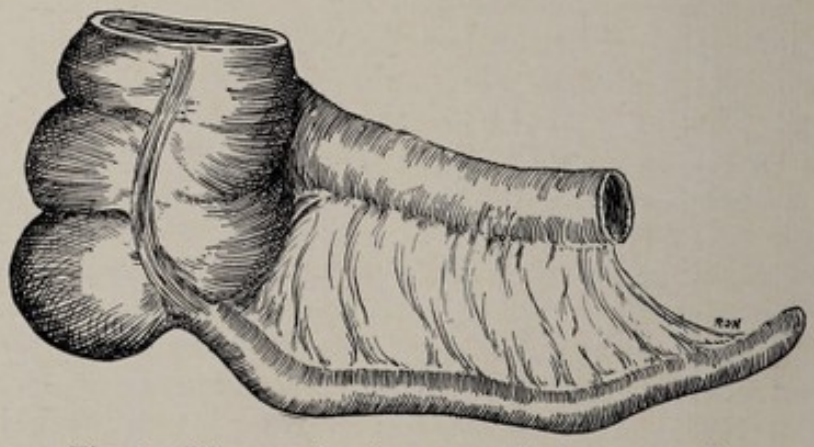

Fig. 4.—Diagram showing unusually long appendix.

an organ of considerable size.[1] At the fourth month of intra-uterine life the size of the appendix is to the cecum as about 1 is to 5. At birth it approximates to the adult size and form, its proportion to the cecum

[1] In herbivora no true appendix is found, but a large, useful, and dilatable second cecal pouch. In carnivora this pouch has shrunk to the apparently useless appendix or has disappeared.

being about 1 to 15. As infancy and youth advance, this disproportion becomes more and more marked, until the cecum has overgrown and crowded the appendix to such an extent that the latter has been pushed upward, backward, and usually inward, so as to appear as a mere spiral

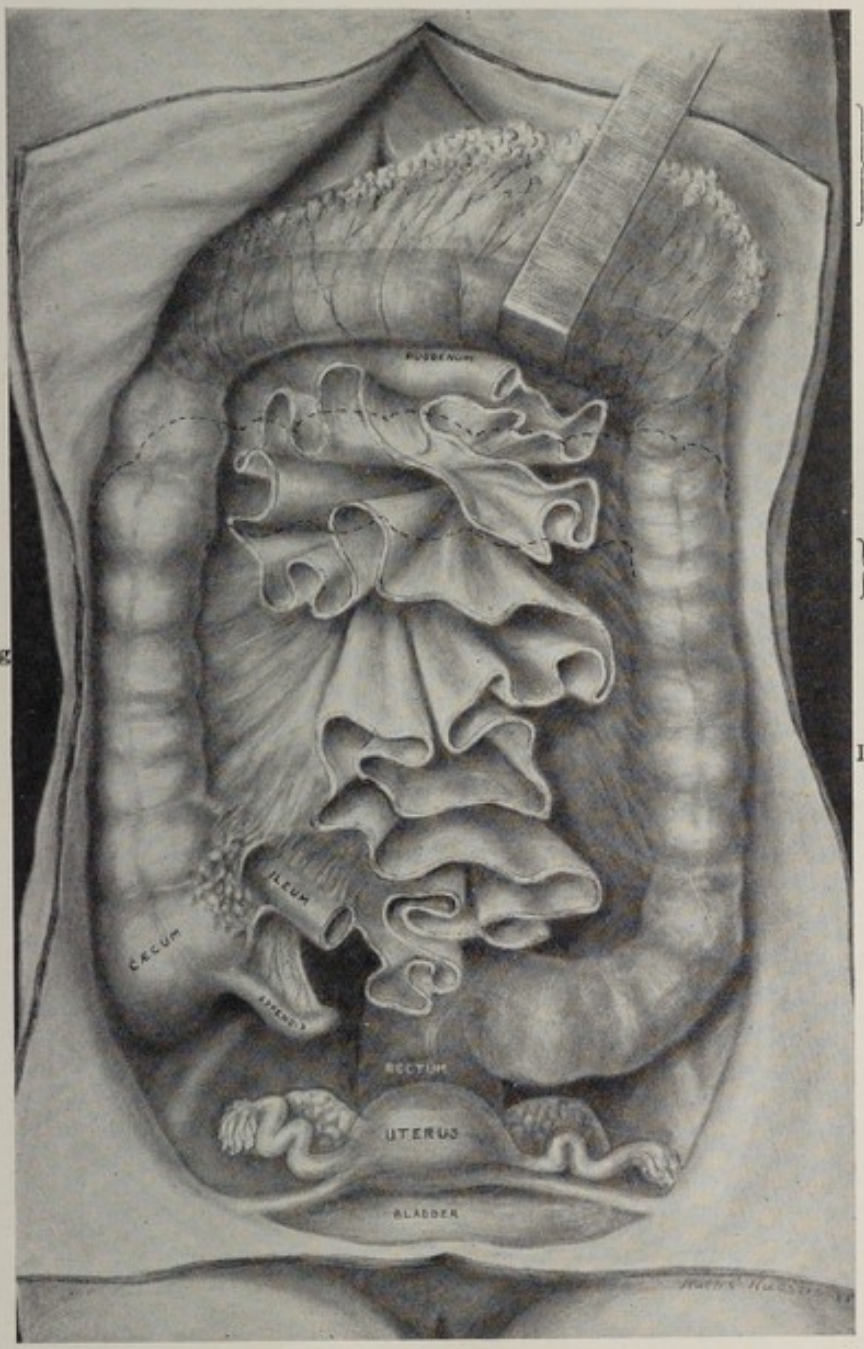

Fig. 5.—Normal position of appendix and cecum, with transverse colon raised; dotted line showing natural position of transverse colon.

projection from the posterior aspect of the cecum. This position it reaches about the fifth year. Commonly, one finds the appendix swinging loosely in a fold of peritoneum, which forms its mesentery,—the meso-appendix,—and carries its blood-supply, nerves, and lymph-vessels.

The *artery* of the appendix[1] springs from the superior mesenteric, and feeds the organ through a number of branches. The *nerve* distribution is shared with the small intestine and the stomach; the *muscular* mechanism runs to the cecum.[2] The significance of this divergent arrangement will be seen when we consider the etiology of appendicitis. While the wall of the appendix resembles that of the cecum, its mucous membrane is far richer in lymph-glands, which are intimately concerned with its inflammatory processes. The organ practically is always covered with peritoneum, but its freedom of movement and its variable position have an important bearing on the extent and severity of inflammation originating in it. When free in the general peritoneal cavity, it is obviously a source of more serious danger than when tucked away behind the cecum.[3]

The **function,** or lack of function, of the vermiform appendix is the subject of an interesting chapter, and the question is closely allied to the rather intricate anatomy at which we have glanced. The process of shrinking of the appendix by no means stops with the fifth year.[4] Obliteration continues. From the fifteenth year on a small but increasing proportion of appendices are found to be cut off from the gut, through changes in their mucous lining. By the thirty-fifth year this proportion is said to have reached 25 per cent., and so on until, by the sixty-fifth year, it has reached nearly 70 per cent. This corresponds to the lessened liability to appendicitis with advancing years. On the other hand, the appendix, or cecoappendix, as the complete cecum-plus-appendix has been called, appears to have a distinct function in secreting a fluid which aids in digestion and absorption and in controlling materially the action of the bacteria always present there in great numbers.[5]

In the **etiology** of appendicitis we find that the various factors already mentioned have an immediate bearing upon the process. It is obvious that appendicitis is of bacterial origin, and the question is, How do the bacteria gain a lodgment in the tissues and produce disturbance? Pus-cocci and the Bacterium coli commune are the most common offenders. We know that bacteria, when they are retained under pressure, may enter into the tissues. A congestion of the cecal mucous membrane may obstruct the valve of Gerlach; the appendix then becomes distended with mucus loaded with bacteria; localized

[1] A secondary blood-supply in women is sometimes described as reaching the appendix through the appendiculo-ovarian or, more properly, the suspensory ligament. Such a blood-supply, as well as a lymphatic supply by the same route, is problematic, though it has occasionally been described. Embryologically, it is a paradox (*vide* D. H. Craig, Clinical Experiences with the Appendiculo-ovarian Ligament, Amer. Jour. Obstet. and Dis. of Women, 1904, vol. l, No. 3.

[2] McEwen, Function of Cecum and Appendix, Lancet, October 8, 1904.

[3] W. A. Brooks, Jr., Boston Med. and Surg. Jour., 1905, vol. cliii, p. 358, refers to a "subject of a sixteen-year-old girl at the Harvard Medical School. . . The ascending colon is completely unattached to the posterior abdominal wall, except by the root of its mesentery. The appendix may be placed at almost any point in the abdominal cavity."

[4] Woods Hutchinson, Appendicitis as an Incident in Development, Amer. Med., August 1, 1903.

[5] McEwen, *ibid.*

necrosis follows; the bacteria enter the tissues, and the mischief is done.[1]

McEwen[2] makes the observation that since the appendix shares in the nerve distribution of the small intestine and stomach, therefore, under normal conditions of health, food high up in the gut stimulates the appendix, which proceeds to pour out its secretion long before the chyle reaches it. Conversely, irritating substances in the stomach or small intestine will disturb the nerve mechanism of the appendix, so that its secretion is checked, and the cecum remains dry; consequently bacteria multiply and act viciously, especially if there be temporary obstruction to the outlet of the appendix. Such irritation and obstruction will prove a still more serious matter if the appendix be adherent or kinked from a previous inflammation, or if the normal process of

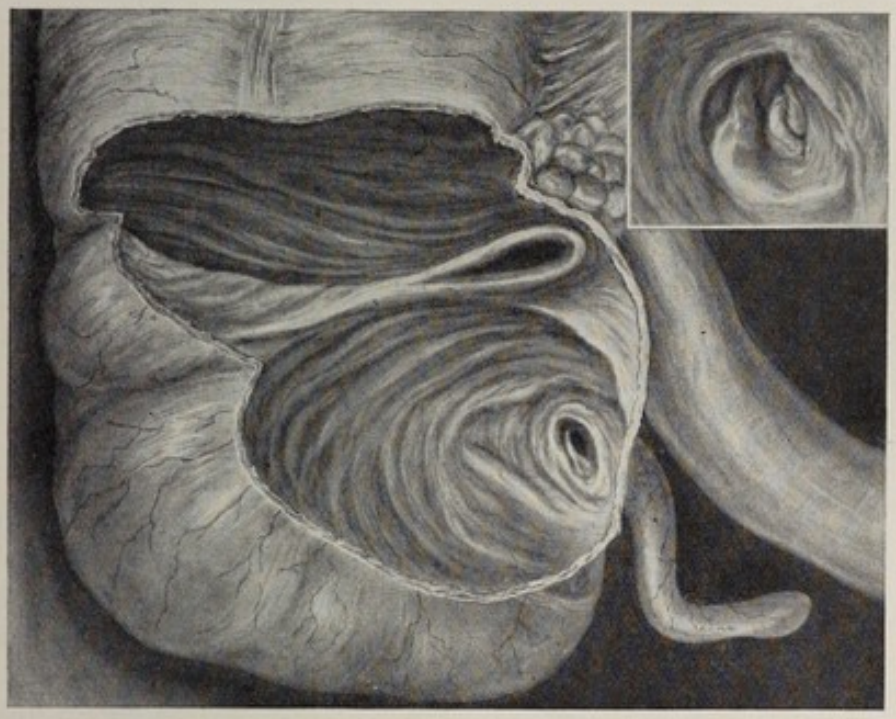

Fig. 6.—Valves of the ileum and appendix (open and closed).

obliteration has caused stenosis of the appendix outlet.[3] The ancient impression that these appendix inflammations are due to foreign bodies or even to fecal concretions lodged in the appendix is seldom true, though it is conceivable that such a body might close the valve of Gerlach[4] or even cause mechanical erosions, with a consequent train of destructive changes.

Alterations in the blood-supply of the appendix were at one time regarded as the cause of appendicitis, but although such arterial changes

[1] C. Van Zwalenburg, Jour. Amer. Med. Assoc., March 26, 1904, under the caption, Obstruction and Consequent Distention the Cause of Appendicitis, records some interesting observations bearing on this point.

[2] *Ibid.*

[3] Ribbert and Zuckerkandl found a partial or complete closure of the appendix in about 25 per cent. of the cases examined.

[4] The existence of which is questioned by George Woolsey and other sound writers.

are found, it is likely that they are usually secondary and not primary. Exposure to cold, influenza, and rheumatism have been mentioned as causes of appendicitis, through their producing swelling of the mucosa and obstruction of the lumen. There is little evidence that such causes are frequent.

Pathologic Anatomy.—Any surgeon of experience will tell you that he learns something new from every case of appendicitis, because cases differ so constantly in detail, and because, frequently, the symptoms and signs fail as guides to the conditions actually present. The terms *appendiceal colic, catarrh of the appendix, hydrops of the appendix, acute appendicitis, gangrenous appendicitis, relapsing appendicitis, chronic appendicitis,* etc., are common. Let us study the conditions which may justify these terms. Bearing in mind the *normal* obliterative process which is seen in great numbers of appendices, we must conclude that this process of obliteration may enter at times into the problem of *abnormal* pathologic conditions. It does not seem probable that "appendiceal colic" is a term which should be applied to any clearly recognized process. At any rate, if there be such a condition, it is not demonstrable. But there may be, and unquestionably are, colicky pains due to temporary obstruction of the appendix lumen, with consequent distention, which subsides, leaving no trace behind. As a general thing, however, some form of inflammation is associated with pain in this region, and such inflammations may vary in degree within the widest bounds. We may have a simple catarrh of the mucous membrane, with a reddened and swollen mucosa and an abundant secretion. With this there will be found an infiltration of small round-cells into both the mucosa and the submucosa, with swelling of the follicles. An appendix so affected appears thicker and stiffer than normal. There is probably almost always some obstruction to the outlet from this cause, so that the appendix becomes distended with mucus and fecal matter. These are the cases which subside and recur without marked and permanent damage to structure, though there may be erosions and consequent cicatrices if the process is frequently repeated. Obviously, such cicatrices encourage subsequent attacks, while one occasional result of such attacks is a cicatrix, which, by its contraction, produces a complete stenosis. In such cases the appendix is transformed into a retention cyst. The contained fluid may be sterile apparently, and the cyst may remain for a long period, without other result than pain and occasional functional disturbance. On the other hand, the retained fluid may become septic—a more usual result, so that you will find a purulent fluid within the appendix associated with thinning and destructive changes in the walls. Such a condition may be likened to empyema of the gall-bladder. Rarely, the cystic tumor may grow to a considerable size, even as large as the closed fist. Such are the conditions known as "catarrhal appendicitis" and "suppurative appendicitis"; but we are coming to believe that they are less common than was supposed at one time, or more properly that they do not often remain innocent, but develop into more alarming forms of the disease.

FORMS OF APPENDICITIS

Acute appendicitis, often perforative, is the grave and urgent condition which is commonly meant when we speak of appendicitis. It may come on suddenly, without previous warning, or it may develop out of a previous and more chronic condition. There are the swelling and obstruction precedent; the mucosa and the deeper tissues become infiltrated; slight hemorrhages and erosions occur; bacteria find their way into the tissues; the appendix becomes enlarged and stiffened; active ulceration of the mucosa may supervene, and perforation may quickly follow at any point from the tip to the base. If this were all, the condition would be found uniform, and the symptoms in various cases not dissimilar, but the student must remember that the appendix is a movable organ, covered with peritoneum, and placed variously in its relations to the cecum and other abdominal viscera. The rate of progress of the infection is also a variable quantity. If the process be delayed and the organisms few and not markedly virulent, the case may run a subacute and prolonged course. As the inflammation extends through the coats of the organ an injection of the serosa takes place; indeed, that is a frequent and early event, and fibrous adhesions quickly are set up. In the great majority of cases such adhesions are formed—this is nature's protective process. The appendix becomes glued to the surrounding tissues and organs. Frequently one finds it wrapped up in the omentum, which presents a strong barrier to the progress of a dangerous infection. Along with the inflammation of the wall of the appendix there is a progressive suppurative thrombosis of the appendix vessels, with destruction of tissue, thus establishing a vicious circle, the progress of the primary inflammation affecting the vessels, the affected vessels in their turn failing to nourish the tissues, and consequently a rapidly spreading necrosis or gangrene. It is not necessary that the perforation be macroscopic or even microscopic in order to act upon the serosa, for infecting material may reach the surface without actually breaking down in necrosis the intervening tissues. However that may be, with involvement of serosa and neighboring structures the progress of the disease may go on in a variety of ways. The infection of the adhesions about the appendix may spread, involving organs more and more remote, until a great "cake" or matted mass of viscera results. In such cases suppuration usually supervenes, and pus collects in pockets about the appendix, the omentum, and among the coils of intestines. The destructive process in the appendix may not cease with the escape of infecting contents into the surrounding tissues, but the necrosis may continue until the organ is destroyed or sloughed off, leaving a mere hole or stump in the cecum to mark its site. Sometimes several sections of the appendix are found scattered about and adherent through the mesentery and omentum.

If unchecked, the extension of suppuration may be remarkable. Great lakes and wells of pus interspersed among matted intestines may fill the lower part of the abdomen and pelvis; sometimes the intestines

themselves are involved in necrotic changes. In a recent case of two weeks' standing I found 4 feet of ileum detached from its necrotic mesentery and floating loosely in a lake of pus. In this case the appendix had disappeared and was represented only by a great hole in the cecum, from which poured a stream of feces.

In the case of infections of the appendix, whether or not there be pus present,—and there is always a purulent-looking fluid,—one hopes that the process will remain limited and will not invade the general peritoneal cavity. That chance of such an invasion and the consequent great danger to life are possible; but so long as diffuse peritonitis has not occurred, the chance of cure is considerable. Let us consider for a moment what may be the outcome of a perforating appendicitis if left to nature. There can be no doubt that in a considerable proportion of cases the acute process begins to subside after the fourth or fifth day. The abundant lymphatic connections of the peritoneum take up and carry off the infecting agents. For a while adhesions become more dense and

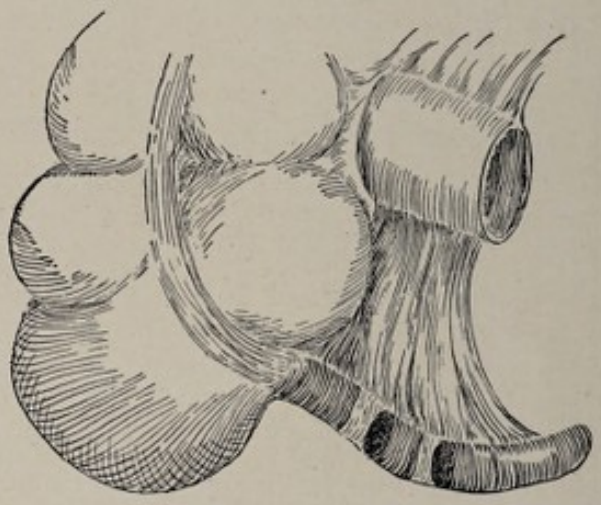

Fig. 7.—Diagram showing segmented appendix.

incarcerate the disease. Resolution takes place, reparative processes follow, and in the course of a few weeks nothing is left to mark the seat of trouble save a few adhesions and a crippled, distorted appendix. Even when pus is present, it may be strongly confined; small amounts may be absorbed, and large amounts may find exit either by rupture into the intestines, bladder, or vagina, or may work their way through to the skin and "point" externally. This tendency of pus from appendicitis to burrow in sundry directions following the line of least resistance has given rise to diverse and puzzling symptoms and signs. We see abscesses pointing in either inguinal region, burrowing under the cecum, liver, and diaphragm, and breaking into the lungs and bronchi, followed by the expectoration of pus. Pus from the appendix has been vomited and has been passed by urethra and rectum. I have seen an appendix abscess pointing in the prevesical space, and it is not uncommon to have the abscess open in the lumbar region.

Such abscesses and burrowings of pus as I have described are due to

the course of the disease being limited and directed by fibrinous adhesions, or to the appendix itself being placed in unusual positions—behind the cecum, under the liver, adherent to the bladder, etc.

The conditions which we have been considering are the more common and are those least likely to become lethal, but there is a development of acute appendicitis which is far more grave—that form which involves the free peritoneal cavity, which spreads rapidly, and usually ends in death from peritonitis. Such a peritonitis may be due directly to a rapidly perforating appendicitis, which progresses without the formation of adhesions, or it may be due to the breaking-down of adhesions and to the invasion of the general peritoneal cavity by infective material from an abscess. We shall study general peritonitis in a subsequent chapter.

There are other forms of appendicitis and other causes than those which I have mentioned. Appendicitis may be due to tuberculosis of the appendix, in which case it is usually associated with a general intestinal tuberculosis. Writers have reported appendicitis due to irritation by intestinal parasites. Moreover, one sees occasionally diseases simulating appendicitis, and the conditions may be confused with fecal impactions, gall-stone colics, renal colics, actinomycosis, and symptoms dependent upon visceral ptosis. Some years ago I reported a curious case in which all the symptoms of appendicitis appeared to be present; but upon opening the abdomen, I found the appendix normal, while a mass of dry and dense orange-pulp was discovered packing the *caput cæci*.

Age has a decided bearing upon the liability to appendicitis, as one would expect from what we have heard of the developmental and obliterative changes in the appendix. The disease is most common between the ages of fifteen and thirty, and decreases in frequency after that time. Nevertheless, we are finding that appendicitis in children is frequent, and numerous writers have reported cases from the age of one year and upward.[1]

Sex, too, has been regarded as having a bearing upon liability to these inflammations, and probably men are affected more frequently than women; but the great series of statistics now at our disposal show that women are not infrequently affected, and some reporters have recorded more women than men in their lists. Sometimes it appears that there is a family predilection for appendicitis.

We use the terms **relapsing appendicitis** and **chronic appendicitis**—terms indicating conditions which merit serious study. From our discussion of the natural history of the disease it appears that attacks of acute appendicitis may subside and may recur. If the obliterative process does not destroy the organ, it leaves it in a condition favorable for subsequent attacks, and experience teaches that subsequent attacks are common—indeed, that is the usual history of our cases. The surgeon, on being called to see a case of acute appendicitis, frequently learns that this is not the first attack, but however that may be, the

[1] See McCosh, Appendicitis in Children, Jour. Amer. Med. Assoc., September 24, 1904; and Beth Vincent, Boston Med. and Surg. Jour., October 1, 1908.

condition found does not vary from those acute attacks already described.

The propriety of the term *chronic appendicitis* has been questioned, and surgeons have asserted that such a disease does not exist, but that *recurring* or *relapsing* appendicitis is the proper term. On the contrary, it appears that the term chronic appendicitis is a proper one, because definite chronic trains of symptoms are found in many cases, and such symptoms are associated with definite pathologic changes in and about the appendix. One finds injection and thickening of the whole organ, cicatrices, kinks, and adhesions, which, though unassociated with an active inflammatory process, do, by their constant presence, set up annoying or grave symptoms, while at any time these symptoms may be aggravated or rendered alarming by a supervening acute attack.

An important practical reason for using the term *chronic appendicitis* is for the education of the community, and I urge students and practitioners, when discussing appendicitis with patients and their friends, to insist constantly upon the clinical distinction between acute appendicitis and chronic appendicitis. The community appreciates in a general way that operations for chronic appendicitis, or "between attacks," are far less grave than operations for acute appendicitis; nevertheless, the word "appendicitis" and the word "operation" are sounds of dread. The whole subject is terrifying, and often needlessly so.

SYMPTOMS OF APPENDICITIS

As for the *symptoms* of appendicitis, it is well to divide the subject into several headings: 1. Symptoms of acute appendicitis when the inflammation is still confined to the appendix. 2. Symptoms of acute appendicitis which has perforated and involved neighboring structures—periappendicular tumor and abscess formation. 3. Appendicitis causing diffuse peritonitis and other complications. 4. Symptoms of chronic appendicitis.

The first, most important, and omnipresent symptom of acute appendicitis is **pain**—often agonizing pain. In his important review of 2000 cases Murphy states that "pain is a constant and uniform symptom, and was not absent as an initial symptom in this series of 2000 cases."[1] This initial pain rarely is definitely localized. It may be general over the abdomen. Frequently it is referred to the epigastrium. Often the patient holds himself rigid and dreads palpation. Such disseminated pain is reflex, for we recall that the nervous mechanism of the appendix is shared with the stomach and small intestine. The initial pain is due to obstruction and distention of the lumen of the appendix. While the pain is present, one may feel confident that the disease is still strictly within the appendix. This severe pain is usually transient, and reaches its height in about four hours from its onset; by that time it becomes localized in the right iliac fossa; after this it subsides gradually, if all goes well, for the exudate is absorbed, or

[1] John B. Murphy, Amer. Jour. Med. Sci., August, 1904.

slowly released into the cecum, and by the end of thirty-six hours the pain may have subsided entirely, in which case one may regard the attack as over and may look for convalescence. Probably 75 per cent. of the attacks of appendicitis are of this nature and run this course to spontaneous recovery. However, if within thirty-six hours pain is relieved *suddenly*—that is a danger-signal. It may mean escape into the cecum of an obstructing body, but more often it means perforation—rupture of the appendix or complete gangrene of that organ.

Nausea and *vomiting* follow pain in acute appendicitis. If they precede pain, one questions the diagnosis of appendicitis and looks for some such condition as acute gastritis. The nausea and vomiting in acute appendicitis are reflex also. The primary nausea usually subsides shortly.

Tenderness in the region of the appendix practically always is present in acute attacks. Usually it is somewhat diffuse, but often it is located at a definite point—sometimes at the umbilicus, but more commonly at what is known as McBurney's point—in a line drawn between the anterior-superior spine of the ilium and the umbilicus, about 1½ inches from the anterior spine.[1]

Other symptoms and signs are a flushed and anxious face; slight general distention of the abdomen; the right thigh held flexed so as to relax the iliopsoas muscle, which underlies the appendix; a moderate elevation of temperature, sometimes preceded by a chill, and a variable pulse, ranging between 80 and 100. The condition of the bowels is not particularly significant: usually there is constipation. During this acute attack careful palpation will elicit not only tenderness, but often the enlarged appendix, which may be easily palpable in thin subjects. It is my habit, if the patient is seen early and the condition is obscure, gently to pass my hands, previously wet in warm water, over the whole abdomen. The greater part of this surface may be handled with comparative freedom, but upon approaching the right iliac fossa resistance and discomfort pointing to a local trouble are experienced by the patient. Another useful maneuver is slightly to irritate the skin by gently pinching the surface of the abdomen, when the skin in the appendix region is found more sensitive than that elsewhere.

An important feature of the examination, never to be neglected, is exploration of the rectum. Very often the patient, when thus examined, will experience a sensation of sharp localized pain high in the rectum, even though the finger discover nothing abnormal. You must satisfy yourself that the expression of pain is not due to alarm or to the discomfort of a stretched sphincter.

In the early stages of appendicitis the range of pulse and temperature is of little significance, though a mounting pulse means more than does a high temperature. At this early time also the leukocyte count has little bearing on the situation. It is usually slightly elevated—10,000, 12,000, or even 15,000 "whites"; but it is significant only when

[1] For an interesting discussion of McBurney's and (Robert T.) Morris's points see Jour. Amer. Med. Assoc., January 25, 1908, p. 278.

mounting steadily and associated with other symptoms and signs. A sudden drop of the temperature to normal, especially when associated with a rise of pulse, means trouble, and indicates probable perforation of the appendix, with a temporary cessation of septic absorption. If all goes well and the inflammation subsides, convalescence may be short and the patient may regard himself as sound again in the course of a few days or of a week at the most; but the physician must bear in mind the probability of a subsequent attack, and must take his measures and warn his patient accordingly.

Appendicitis with Periappendicular Involvement.—In a considerable number of cases, and these are the ones which try the nerves and call for the best surgical judgment, appendicitis does not subside quickly, but progresses to the involvement of other structures. After the initial disturbance which I have described the pain may decrease in a measure, tenderness may be somewhat less acute, nausea may cease, and pulse and temperature may show a slight drop; but convalescence does not proceed. Pain remains localized in the right iliac fossa; slight nausea may persist, as well as abdominal distention; obstinate constipation ensues. Gradually the temperature may rise in a somewhat typhoidal fashion. The pulse mounts to 100, 110, 120, and higher. Leukocytosis increases. Frequently, vomiting may supervene. A mass may become evident in the appendix region—at first obscure and perhaps covered by distended bowel; later, more clearly diffused, generally resistant, rarely fluctuant, definitely outlined, exquisitely tender. The finger in the rectum may encounter boggy tissues or distinct fluctuation. The right side of the abdomen is held rigid, and it may be almost board-like, while on slightly irritating the skin a characteristic spasm of the right rectus is seen; localized edema of the skin appears. Sometimes the tenderness reaches into the flank, and, if the appendix be retrocecal, acute tenderness and fullness even may be found in the lumbar region.

These signs and symptoms indicate a progressive infection, an involvement of the peritoneum with a serous, a serofibrinous, or fibrinopurulent exudate. Happily, adhesions are forming, a matting of intestines and omentum is taking place, and pus is collecting in the interstices. In such cases again one may not foretell the outcome; but the conditions present have already been described sufficiently in our consideration of the pathologic anatomy.

Termination in Diffuse Peritonitis and Other Complications.—If resolution does not take place, the clinical picture becomes more and more alarming; the patient's face continues flushed and anxious; frequent persistent vomiting ensues, with straining and retching; there is absolute constipation; the temperature continues high, with slight, if any, remissions; the pulse is full and rapid; the leukocyte count may drop at first, and later may rise to 30,000, 40,000, or more; the whole abdomen becomes rigid; its distention increases; it is everywhere tender, especially in the appendix region; the normal ballooning of the rectum may become obliterated; the urine is high colored, often loaded with albumin and

casts, and is passed in small amounts; the normal sounds of peristalsis cannot be heard with the stethoscope; Peters, a Canadian writer, has called attention to the "telephonic properties of the inflamed abdomen in peritonitis"—the distended coils of intestine pressing against the diaphragm transmit the heart-sounds, so that they may often be heard low down in the abdomen.[1] I have often found this sign striking and significant. The vomit, at first bile-stained, becomes more and more offensive as intestinal contents are returned into the stomach.[2] Such is the picture of an intense diffuse peritonitis resulting from appendicitis.

Even though peritonitis does not supervene, other grave complications may ensue, resulting in pyemia. Abscesses may make their way in various directions, as has been pointed out, and there are those rare cases of the rupture of an abscess into a vein, producing suppurative thrombosis. Sometimes an abscess may become surrounded by a mass of cicatricial tissue, so that the condition suggests actinomycosis; but the general condition of such patients rapidly deteriorates, and the symptoms are more grave than commonly is seen in a localized actinomycosis.

The nature of the infecting organisms in acute appendicitis seems to have a bearing upon the progress of the disease and upon the clinical picture. If staphylococci be the offenders, the resulting exudate checks immediate systemic absorption of poison, and protects the patient against an overdose of the septic products. When the exudate loosens, rapid absorption and sudden collapse, with diarrhea and an anxious expression, soon followed by death, are apt to occur. If we are dealing with streptococci and their invasion of the peritoneum, there ensue rapid blistering of that membrane, a high pulse, and active delirium; and, on the other hand, the colon bacillus may produce but slight local irritation and a moderate fever. The progress of the coli commune infection is slow, generally. In infection by staphylococci there is little pus in the peritoneal cavity usually, but when there is a large amount, it is of the seropurulent type. In the case of streptococci there is little if any free pus, but the peritoneum has a peculiar dry, granulated, blistered appearance. Colon bacilli produce a copious, offensive pus, thick and creamy.

The profound collapse which is seen in the cases of diffuse peritonitis does not mean recent perforation, but indicates advancing septic absorption, and occurs late in the course of the disease.

The symptoms of what is called **chronic appendicitis** are more elusive than are those of acute appendicitis, but we are coming to recognize the condition as far more common than was supposed at one time. You must note the distinction between chronic appendicitis and relapsing appendicitis, in the sense in which we are coming to use the terms. Relapsing appendicitis signifies a series of acute attacks of appendicitis following one another at varying intervals, while each

[1] Canadian Jour. Med. and Surg., December, 1902, p. 420.

[2] So-called "fecal vomitus" is usually the secretion of the small intestine mixed with altered blood.

attack may be grave. The liability to recurrence in acute appendicitis has long been recognized, and writers estimate variously that liability, Fitz placing it at 44 per cent. of all cases; Hawkins, at 23.6 per cent., and other writers as high even as 60 per cent. By *chronic appendicitis* I mean a condition which is not necessarily associated with acute attacks. A case from my list will illustrate what is meant. Some years ago there came under my care a college student, twenty-one years of age. He was a robust, well-developed, athletic young fellow, a foot-ball player, of excellent habits and wholesome mode of life. Three years before I saw him he was supposed by his physician to have contracted malaria. Every six or eight weeks he had, for four or five days, attacks of malaise, with headache, slight pyrexia, occasional nausea, and general abdominal discomfort. Between these attacks he regarded himself as well, but he confessed to a delicacy of digestion—hearty meals distressed him—and an irregularity of the bowels, with alternating periods of constipation and diarrhea. These conditions had continued without special change. The young man had sought various advice; had traveled in search of health, and had lived in sundry places. Finally, during one of his remissions he happened to consult me, when, on making a careful abdominal examination, I made out repeatedly a sensitive, not painful, point in the right iliac fossa. Convinced that his appendix was at fault, even if it was not the source of the trouble, I removed it. The patient's recovery of health was prompt and permanent.

Such an example is not typical of all cases of chronic appendicitis, but it suggests the sort of cases we are discussing. In general terms patients with chronic appendicitis complain of more or less dyspepsia and general poor health, without very definite symptoms except that the disturbance is abdominal. Rarely do they give a history of an acute attack of appendicitis. Acute attacks are more likely to be followed by acute attacks. The chronic condition is found frequently in children, as well as in adults, and accumulating experience has convinced us that the group chronic appendicitis is far larger than most physicians and the writers of text-books are disposed to think.

DIAGNOSIS OF APPENDICITIS

In the *diagnosis* sundry conditions simulating appendicitis must be borne in mind. Whenever confronted with a case of abdominal disease, try first to rule out appendicitis. A common and serious error is the confounding a perforating duodenal or gastric ulcer with appendicitis. A duodenal ulcer breaks through into the abdominal cavity, pouring out intestinal contents into the right flank, over the kidney, and down into the appendix region. Symptoms suggestive of appendicitis may arise immediately. Whichever condition is present, however, prompt operation is indicated, so that in the hands of an intelligent surgeon no time is lost. Typhoid fever has been mistaken for appendicitis, and often the differentiation is difficult. In many cases of appendicitis one must bear in mind the symptoms of typhoid, especially the

character of the temperature and stools, the prodromata, the gradual onset, the enlarged spleen, the rose spots, and the reaction to Widal's test. Rarely, a typhoid ulcer may be located in the appendix, and writers estimate that about 5 per cent. of all typhoid perforations are appendiceal. Then there are actinomycosis and tuberculosis—chronic processes, but sometimes impossible to determine before operation. Other diseases—inflammation of the gall-bladder and ducts, renal calculus, mesenteric thrombosis, inflammation of a Meckel's diverticulum, cancer, inguinal adenitis, intestinal obstruction from fecal impaction—all must be remembered, and usually are easily distinguished, with the exception of mesenteric thrombosis and disease of Meckel's diverticulum. In women, too, we must think of diseases of the right ovary and tube.

When we see a patient who gives the history of sudden, prostrating abdominal pain, nausea and vomiting, with constipation, with distention, with right-sided rigidity, with high rectal tenderness, spasm of the right rectus, tenderness in the right iliac fossa, a rising temperature and pulse, and a leukocytosis of 10,000 and upward, we are safe in concluding that here is a case of acute appendicitis, though we must remember always that all these symptoms are not constantly present in that disease. Above all things, never forget that an obscure, obstinate, and acute abdominal distemper, suggestive of sundry diverse diseases, is appendicitis on the chances, and in a great majority of cases.

A discussion of the **prognosis** of appendicitis is profitless, because of the varying types of the disease, and because, more than any other surgical lesion, appendicitis lends itself to surgical treatment. We have seen that a majority of acute cases recover spontaneously, though a large proportion of them are subject to relapses, and no man may say which will relapse and which will remain well.

TREATMENT OF APPENDICITIS

The **treatment of acute appendicitis** has been made a subject of infinite variety. It should be almost a matter of routine. Like the offending eye in the parable, the inflamed appendix should be cut out and cast away. Yet so various are the symptoms of appendicitis, so confusing often are they, and so manifold are men's points of view, that it seems as though this discussion of treatment may be prolonged through the ages. In many cases patients recover spontaneously. That is the hub of the situation; and because many cases recover spontaneously, therefore certain men say, "any case may recover spontaneously, so let us wait." In contradistinction to this opinion, which recognizes an immediate mortality of at least 20 per cent., it is well to balance the fact that if we operate upon all cases of appendicitis, we shall have a mortality of 5 per cent.[1] Divergence of opinion on this matter is more accentuated now than it was twenty years ago. Twenty years ago a

[1] John B. Deaver, Factors in the Mortality of Appendicitis, Jour. Amer. Med. Assoc., September 24, 1904.

large majority of physicians and surgeons believed that we should delay operation, should wait until an abscess was "ripe," and should then open it under the most favorable conditions. This was called the conservative method, and physicians were wont to watch the case until, in their opinion, it was time for operation, when they called the surgeon. Gradually, the scales have been reversed. No sane practitioner now regards appendicitis as a "medical disease" to which a surgeon occasionally may be called. It is a surgical disease as much as is a broken leg, and the surgeon should be called as soon as appendicitis is suspected. The practitioner must not wait to make the diagnosis. He must call the surgeon to do that. He must call the surgeon to determine the cause of every acute abdominal pain such as I have described in this chapter.

As a knowledge of appendicitis developed we came to see that operative measures must be applied early and thoroughly; but there has always been a certain number of men who opposed this view. Numerous modes of treatment have found favor, among the advocates of delay, such methods as the use of opium and ice, on the one hand, of saline purges and poultices, on the other. Happily, such treatment is now relegated by the best practice to the limbo of a contemptuous oblivion; but in spite of strenuous years of missionary work, we find bad practices still pursued in many communities. Setting aside a consideration of antiquated and improper procedures, we find that there is still a division of opinion among competent surgeons as to the wisdom of operating always and in early stages of acute appendicitis. There is still debate upon the question whether or not to operate at once in the second stage of appendicitis—in that stage when periappendiceal tissues are beginning to be involved, and when adhesions of strength sufficient to confine the process have not yet been formed. In the vast majority of cases, however, all competent surgeons are agreed that immediate operation is necessary. Let us now consider briefly the early operation.

We have seen how appendicitis usually starts; how, commonly, the process is at first confined to the appendix, and we know that no man may say at the outset what the course of the disease will be. Therefore, at the outset, open the abdomen and remove the appendix—and we understand by *outset*, within the first twenty-four or thirty-six hours.

Early Appendectomy.—There are two excellent methods, among others, of reaching the appendix—the McBurney method and the retromuscular, sometimes called Battle's method. The McBurney method was devised by that surgeon some sixteen years ago.[1] Its purpose is a muscle-splitting, not a cutting, operation, so that practically structures are not damaged, and, especially, nerves and aponeuroses remain intact.[2] The skin is incised obliquely for 3 or 4 inches, over the usual seat of the appendix. The aponeurosis of the external

[1] Ann. Surg., 1894, vol. xx, p. 38.

[2] When possible, employ the McBurney method below, or on a level with, the anterior iliac spine. The lower the opening, the wider and freer can it be made. This low opening, "the low McBurney," is my operation of choice in all appendix operations.

oblique is reached and split longitudinally. The parts are drawn aside with narrow retractors, exposing the internal oblique, running at an angle with the previous incision. In its turn this is split, and the underlying transversalis is treated in the same fashion. Then the peritoneum is opened, the finger is introduced, and the cecum is drawn to the surface. In

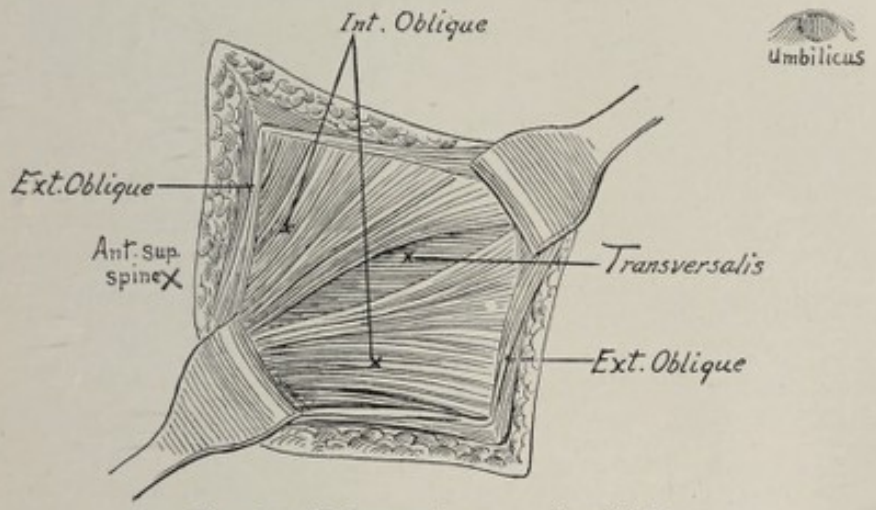

Fig. 8.—McBurney's operation (high).

Battle's method the abdomen is opened through the sheath of the rectus. The uncut rectus is drawn inward, and the peritoneum behind it is incised. In closing the wound the muscle falls back into place without stitching. The peritoneum and anterior sheath alone are sutured. These maneuvers are facilitated by tipping the patient into the Trendel-

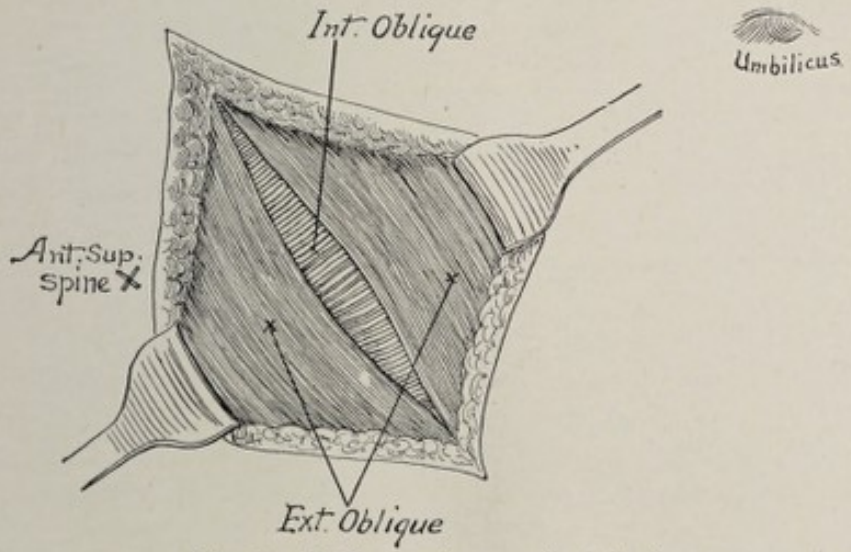

Fig. 9.—McBurney's operation (low).

enburg position—that is, inverting the body so that the pelvis lies at an angle of from 30 to 45 degrees above the shoulders. The cecum is drawn outside the wound, and the appendix is delivered. Usually it is easy at this stage to find the appendix, for it is swollen and readily

palpable and pops out at once. If it is not quickly discovered, the best guides to it are the longitudinal bands of the cecum, which converge at the appendix immediately below and behind the ileocecal valve.[1] Remove the appendix by clamp, ligature, and cautery or knife, as follows: Compress the organ close to the cecum with a stout pair of hemostats, then remove the hemostats and apply firmly a stout catgut ligature in the crushed line. Clean away toward the tip of the appendix the contained fluid for a short distance from the ligature, and again grasp the appendix with hemostat about $\frac{1}{3}$ inch from the ligature. Cut away with the actual cautery or knife the appendix, between the ligature and the hemostat.[2] Drop back into the abdomen the cecum with the appendix stump, and follow it down with a gauze wick, which must be left in place as a drain. Do not leave the stump undrained, and do not sew up the wound tightly. I believe sewing up to be a dangerous procedure;

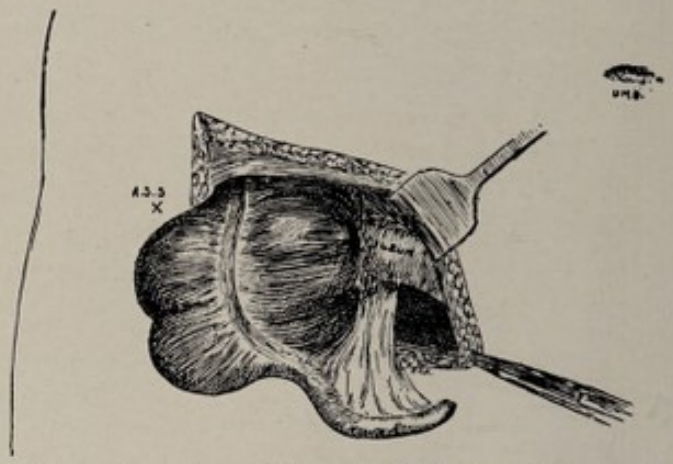

Fig. 10.—Diagram showing delivery of cecum.

nothing is gained in time or strength of scar by so doing, and no man may say that a nidus of infection does not remain, which, if left undrained, will lead to disastrous results. If all goes well with the drained case, the wick may be removed at the end of forty-eight hours,[3] the tissues will fall together, the external oblique aponeurosis and the skin may be stitched if one chooses, and convalescence will progress without disturbance and without resulting hernia.

In the *after-treatment* of these early cases three factors are to be observed: rest, feeding, care of the bowels. The patient should be kept in bed, preferably on a bed-rest or "Gatch bed" from the first for at least seven days; he should then begin to sit up a little every day,

[1] Note Hough's peritoneal band, running from the anterior iliac spine to the cecum at the base of the appendix.

[2] I shall mention later the debated question of treatment of the appendix stump.

[3] I have been criticised for advising that the wound be left open. In fact I do frequently close the wound as in the "interval operation." But for the novice and for the general practitioner without wide operative experience the above method is the safer. A great experience only will teach the expert when he may safely close the wound.

and by the end of three weeks he should be walking about. He should wear a stout abdominal binder for a month after the operation. This relieves occasional discomfort and provides support to facilitate the firm healing of the scar. In most cases, after two months, patients may turn to active exercise. For the first twenty-four hours after the operation the patient should be starved, and allowed water only. For the second twenty-four hours he may have clear soups and broths. After that a gradually increasing diet, until, at the end of five days, he is eating regularly. The care of the bowels is a debated question. They might be left alone, waiting upon nature's prompting, except for a tendency to meteorism, sometimes associated with severe pain. One should remember, however, that most of these patients are emergency cases and come to the operating table with bowels more or less loaded. My practice, therefore, is to give the patient a high glycerin enema twenty-four hours after the operation, and at the end of thirty-six hours to clean out the bowels from above with calomel and salines.[1] This practice is not invariable. In many cases it must be altered; when distention and pain are marked, high enemata and the rectal tube may be used soon after the recovery from ether. Furthermore, it is sometimes advisable to employ calomel immediately on the subsidence of ether nausea.

The reader will see that such dealing with acute appendicitis in the early stage does not differ materially from our treatment of the appendix "in the interval," as I shall explain later.

Discussion rages about the question of operating upon cases in which the inflammation has spread *beyond* the appendix. The weight of authority directs that we operate at once even in this stage. Objections to such operating have been urged by certain well-known writers, dealing with certain stages of periappendicular inflammations, and their sentiments found able voice through A. J. Ochsner at the Saratoga meeting of the American Medical Association in 1904.[2] He pointed out that the mortality in appendicitis results from the extension of infection from the appendix to the peritoneum, or from metastatic infection from the same source; that the distribution of the infection is accomplished by the peristaltic actions of the small intestines, and that it is *also* accomplished by *operation* after the infectious material has extended beyond the appendix, and *before* it has become circumscribed. Accordingly, in certain of these cases it is advised that operation be delayed until strong adhesions are formed, and in general terms the time limit for such delay is from thirty-six hours from the onset of the disease until about the fifth day or later, if the process is obviously subsiding. To accomplish rest and to give nature an opportunity to wall off the disease it is directed that every form of nourishment and cathartics by mouth be prohibited, and that gastric lavage be employed in order to remove

[1] Calomel, ½ grain every hour for four doses; a Seidlitz powder one-half hour after the last dose of calomel, and a low suds enema when the desire for a movement is felt.

[2] Ochsner made a first detailed statement at the meeting of the American Medical Association in 1903. See Jour. Amer. Med. Assoc.

any food or mucus from the stomach. Nutrition is to be maintained by low enemata. Large and high enemata must not be given. It is claimed, and apparently is proved by a great array of figures, that in this way cases of acute appendicitis may be changed into relatively harmless cases of chronic appendicitis, and that the mortality may be greatly reduced. In spite of vigorous criticism by a majority of surgeons, and skepticism as to such results, there is no doubt that the treatment above described, which has come to be known as the "Ochsner treatment," has been remarkably successful in the hands of its author. Surgeons claim, however,—and with this view I am in hearty sympathy,—that this let-alone treatment is dangerous in the hands of the general practitioner who attempts to carry it out without consulting a surgeon. The disease is so insidious, its changes, progress, and recessions are so rapid, complicated, and puzzling, that it is far safer to consign all cases immediately to the hands of an experienced operator. If his experience shall prompt him to delay, it will also prompt him to operate, should prolonged delay appear dangerous. Though the Ochsner figures show a low mortality and a brilliant series of results, so, too, do the figures of competent surgeons who operate at once in practically all cases. J. B. Deaver is a strenuous advocate of immediate operation,[1] and his statistics, showing a mortality of 5 per cent. only, can hardly be improved upon. If the operation be properly done, if the spreading infection be walled off, if prolonged effort be not made by the surgeon when searching for the appendix, if pockets of pus be sought out and drained, the results will be favorable in a vast majority of cases.

There are, however, certain conditions under which all men are agreed that operation should not be attempted; it may be impossible to secure a competent surgeon for the given case, or there may be some serious underlying disease, such as advanced nephritis, heart disease, diabetes, or tuberculosis. Operation is ill advised also in those cases of diffuse peritonitis in which the abdomen is distended, the temperature high, the pulse rapid and of high tension, the patient's expression anxious and indicative of serious intra-abdominal infection, the bowels constipated and unable to cause the expulsion of flatus, and in which vomiting is continuous and tenderness is diffuse over the entire abdominal wall. Then the tongue is dry and brown, the skin is dry, and the frequent delirium is shortly followed by coma and death.

"In another class of cases the features are pinched, the skin cold and clammy, the temperature is normal or subnormal, the pulse rapid and thready, the leukocytes are below normal in number, and the abdomen hard and rigid throughout, without much distention."[2]

Such conditions as the above are desperate. Diffuse and rapidly spreading peritonitis is present, and the patient is on the brink of dissolution. Operation, then, is practically always followed by death.

[1] J. B. Deaver, Factors in the Mortality of Appendicitis, Jour. Amer. Med. Assoc., September 24, 1904.

[2] Deaver, ibid.

If it does seem best to operate, however, in order to relieve distention or in the hope possibly of draining septic products, one should be satisfied with making an incision and inserting a large drainage-tube without irrigation and without sponging or manipulation of the tissues.

One sees from the above statements that it is often impossible clinically to determine the time at which operation is wise or unwise in an advancing infection. Practically, the answer to the question amounts to this, that so long as the patient's general condition is fair and the toxemia is not extreme, some form of operation is indicated, whereas in the face of a profound toxemia, operation must be futile except for the relief of distention. If the stage favorable for operation has not yet been passed, one should remove the appendix, if accessible, as well as institute drainage.

Observe that in discussing the advance of periappendicular inflammations I have not drawn a sharp line of distinction between the early progress of the disease and advanced diffuse peritonitis. I have not drawn this line because frequently it is impossible to differentiate, and because one may find within the abdomen unexpected conditions, quite different from those anticipated—sometimes a limited inflammation, when a diffuse peritonitis was anticipated, sometimes an unexpected spreading peritonitis. Under all circumstances the surgeon must be guided by his estimate of the patient's general condition and capacity for resisting infection.

Happily, it occurs that in the great majority of cases adhesions do form, so that the progress of the disease is checked or retarded, and a localized inflammation surrounded by sound viscera is presented to the operator.

The *method* of dealing with a **localized process**—inflammatory adhesions, exudate, pus-pockets, and necrosis—is as follows: Open the abdomen through a free incision somewhere to the inner side of the inflamed mass—a low McBurney incision is recommended; the cut should be long enough—five, six, or more inches—to admit of free manipulation within the abdomen;[1] recognize by gentle intra-abdominal palpation the limits of the mass, and wall it off with gauze wicks before proceeding (Fig. 11). Such gauze wicks carefully and deftly introduced into the pelvis, to the inner side of the mass and above it, limit the possible damage from escaping septic material. My experience does not teach me that such walling off favors the subsequent formation of extensive adhesions. Having walled off the intestines, one may proceed at leisure. Break up adhesions to the outer side of the mass, explore and evacuate pus-pockets, seek and remove the appendix, employing catgut ligature and cautery; wipe out the wound carefully with gauze, and complete the operation by appropriate drainage—one wick to the appendix stump, and if con-

[1] John G. Sheldon, A Posterior Incision in Certain Appendix Operations, Ann. Surg., September, 1904, p. 376. Sheldon has approached the disease by a lumbar incision, through the triangle of Petit. Sheldon has operated thus on about 60 cases, and claims for his method the advantage of perfect drainage and no chance of hernia.

ditions indicate it, two, three, or more wicks for walling-off purposes and for the drainage of separate pus-pockets. If the appendix has sloughed off and the cecum is open, drain by a tube the cecum at once, as in the operation of enterostomy, thus establishing a temporary fecal fistula and guiding intestinal contents away from the deep tissues. The tube (Fig. 12) may be withdrawn in a few days, after which the fistula usually will close spontaneously. In the after-treatment of these wide appendicitis wounds far more care and attention to detail are demanded than after the simple *early operation*. In the compli-

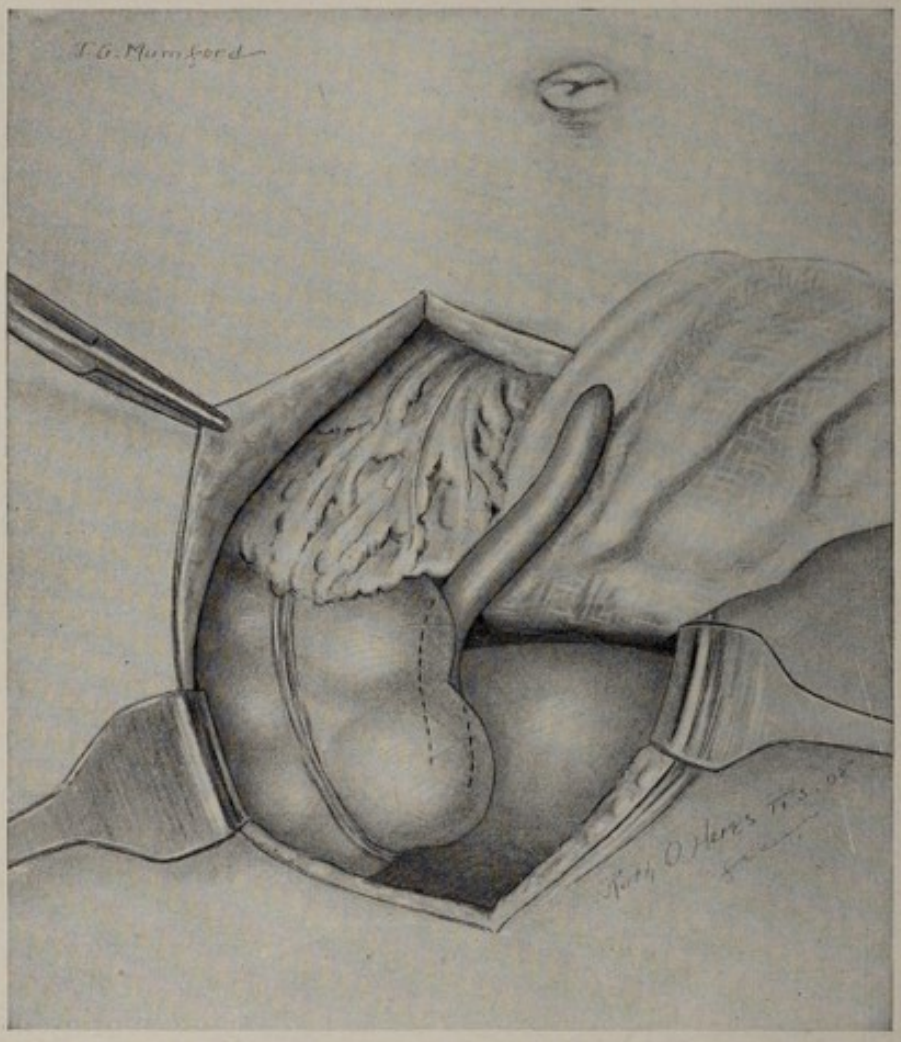

Fig. 11.—Appendix under cecum; pregnant uterus. Note walling off with gauze.

cated cases the abdominal wall must not be stitched up closely, though two or three through-and-through stitches at the ends of the wound are allowable; a large opening must be left for free drainage. For the first day or two exudate escapes copiously; gradually the amount diminishes, and gradually the wicks loosen. By the end of five days or a week the wicks may be withdrawn easily, and shorter, fresh ones substituted. Do not draw the wicks out roughly so long as they remain adherent to the viscera. Commonly, the wicks are all out and the wound granulating superficially at the end of three or four weeks. A weak scar results,

sometimes subject to hernia, of which the patient must be warned; and sometimes a subsequent operation for hernia is necessary. The regulation of the bowels and of the diet does not differ materially from that already described; but in these cases, with large wounds, convalescence is slow, many weeks often are necessary for recuperation, and the use of an abdominal belt for five or six months may be important.

So far as concerns operating in cases of diffuse and spreading peritonitis from appendicitis, I do not recommend the multiple incisions, the wiping and long-continued washing sometimes advocated. Open the

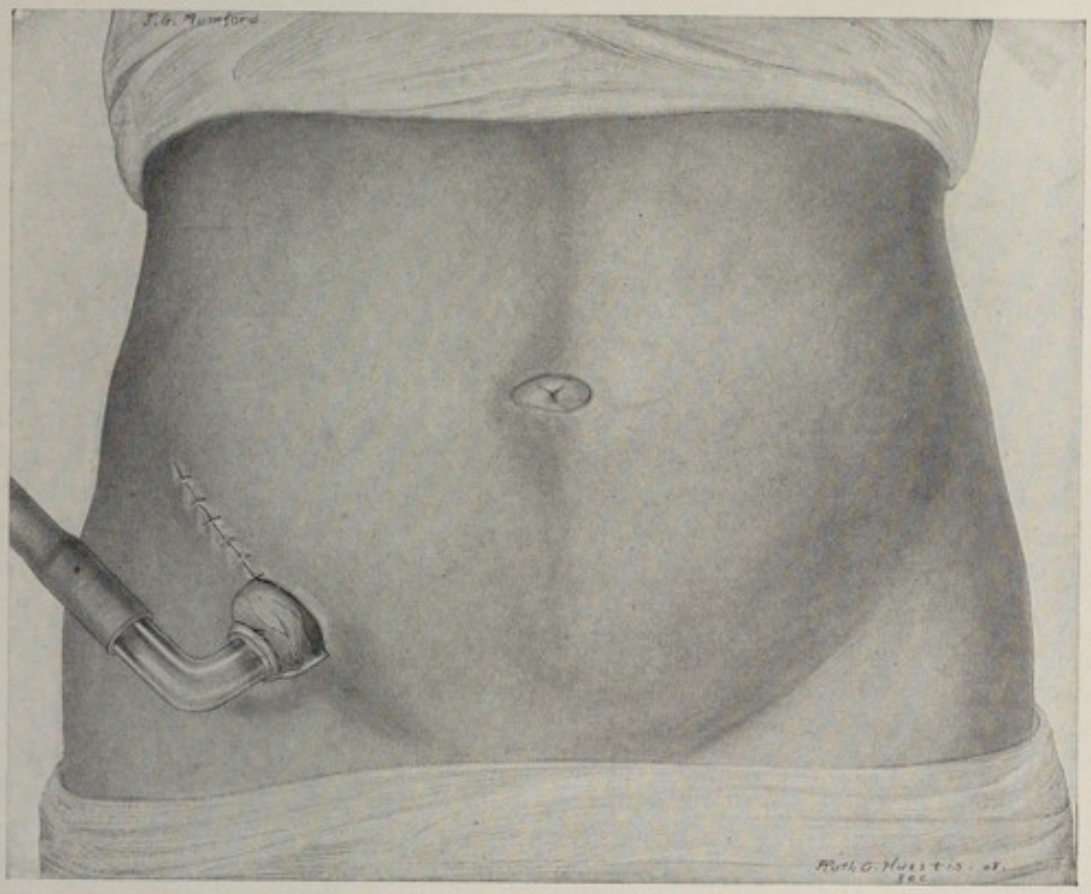

Fig. 12.—Mixter tube in cecum.

abdomen by a free incision on the right, as already described, secure the appendix if it is easily accessible only, introduce into the pelvis a large fenestrated cigaret drain or split rubber tube, and provide for further tube-drainage through a stab-wound above the left inguinal ring.[1] To relieve excessive and paralyzing intestinal distention puncture the bowel in several places with a trocar or knife, and draw off gas and liquid contents. I have seen no benefit from introducing concentrated epsom salts through the trocar, as is sometimes advised.

The after-treatment is important, and the practitioner will do well to follow for a day or two the so-called Ochsner method—no food or drink

[1] See an interesting discussion of this question by Lucius W. Hotchkiss in Med. News, July 2, 1904.

by mouth, gastric lavage if vomiting persists, nutrient enemata, and the use of copious saline injections, preferably by the "seeping method" introduced by J. B. Murphy.[1] In both diffuse peritonitis and in the simpler circumscribed cases the semi-upright posture of Fowler is essential for promoting drainage and limiting the spread of infection.

There are numerous other nice and complicated questions which arise in the discussion of appendicitis; but their consideration finds no place here except for two important points: (1) In the case of appendicitis occurring in pregnant women, one must disregard the pregnancy and operate. Miscarriage sometimes follows, but that is an inevitable risk. (2) When operating within the abdomen for some other lesion, always investigate the appendix, and remove it if it is involved, or if there is cause to suspect that it may become involved through the spread of a peritoneal inflammation and the formation about it of adhesions. Says C. A. Williams:[2] "The main argument against removal of the appendix when the abdomen is opened for other conditions is that it will increase the mortality. This is not sustained in the 212 operations (reported) in which the appendices were removed in association with other primary procedures. The only fatal case was one in which there was an intense suppurative colitis (autopsy); cecostomy was performed in addition. The appendectomy had nothing to do with the fatal issue."

Operation for Relapsing and Chronic Appendicitis.—Kocher says that this operation has been treasured as the jewel of operative surgery. So easy is it, and so far reaching are its benefits, that the question often has been raised, should not the appendix be removed whenever the abdomen is opened for any purpose; and when one remembers that a majority of mankind, first and last, suffer in some degree from trouble in the appendix, this proposition does not sound unreasonable. After removal of the crippled, but quiescent, appendix, 94 per cent. of patients make a prompt and complete recovery, and the remaining 6 per cent., though occasionally troubled by painful adhesions and irritation about the wound, are freed entirely from the dread of a subsequent appendicitis. The mortality in these operations is practically nil.

The technic of removing the quiescent appendix is essentially that of removing the appendix in the first hours of inflammation, though in the case of the quiescent appendix the skin incision may be very small—from one to two inches in length. Of recent years, however, most surgeons have abandoned the very short incision as eccentric and freakish. Moreover, through it one cannot properly overhaul the ileum and cecum in the routine search for "kinks" and "veils." The approach

[1] The method of allowing saline solution to seep into the rectum is widely applicable in these cases, which demand a large supply of water for the exhausted tissues. A common vaginal nozzle attached to a fountain syringe is introduced within the sphincter ani. The reservoir is placed about 8 inches above the buttocks, and the solution, constantly kept warm, is allowed to drift through the tube. Many pints daily may thus be introduced without especial discomfort.

[2] Ann. Surg., June, 1910.

may be made by either the high or low McBurney or the retromuscular (Battle's) route. I prefer the "low McBurney" because thus the opening may be enlarged without damage to structures. Having clamped and removed the appendix, the question of the treatment of the stump has agitated surgeons,[1] but experience shows that sundry methods are safe and applicable. Some operators cut off the unclamped appendix close to the cecum and invert and stitch up the resulting hole; some operators ligate and cut off the appendix and bury the stump by sutures in the wall of the cecum. For some years I have followed the practice of crushing and ligating the stump with catgut, cauterizing the exposed end, burying it in the stump of the meso-appendix, and dropping it back without further treatment. This method has been satisfactory in many hundreds of cases.[2]

The wound in the abdominal wall may be secured with buried catgut stitches or with through-and-through sutures. It makes little difference so long as the severed aponeuroses are accurately repaired. The after-treatment differs in no essential from the after-treatment employed in the case of operations for early acute appendicitis. The patient sits up at the end of a week, is out of bed in ten days, and is about his business in from two to three weeks. No abdominal belt is worn, and no hernia results. The patient may indulge in violent exercise two months after the operation if all goes well.

Appendicitis has been chosen as the subject of this first chapter because appendicitis is the most conspicuous example of acute abdominal disease. In the next chapter we shall advance upon a broader field, and consider the important surgical diseases of the intestines as a whole.

[1] H. A. Kelly in Amer. Med., December 31, 1904, describes what he calls "the ideal method."

[2] The rationale of this method has been admirably explained in a careful paper by M. G. Seelig, Ann. Surg., November, 1904, p. 710; and by H. Lilienthal in Med. News, November 28, 1903. Seelig's paper is so conclusive, and the large series of cases thus treated is so successful, that I unhesitatingly recommend this simplest of all methods.

CHAPTER II

THE SMALL INTESTINE AND COLON

One of the most remarkable chapters in the history of medicine is that which tells of the development of our knowledge of diseases and injuries of the intestines. We are wont to think that the days of ancient surgery, which ended with Lister's explanation of the causes of wound infection, were hopeless days for intra-abdominal surgery, and especially for intestinal surgery. From our viewpoint they were hopeless days so far as regards intelligent understanding of conditions and proper technic, but the old surgeons did not think them hopeless. The old surgeons often dealt boldly with intestines accidentally wounded, though they themselves rarely opened the belly to search for inward troubles. The draining and stitching up of intestinal wounds was not uncommon, and ancient literature is full of the discussion of such matters of technic. Here are two illuminating notes: In 1826 Denans[1] introduced silver rings into the lumen of the severed intestine, and clamped them together with springs, in a fashion suggesting the Murphy button, while Lembert, in the same year, described the extramucosa stitch, which still goes by his name.[2] Lembert's and Denans' principles survive, and though we have improved on their measures during the past thirty years, it is interesting and humbling to reflect upon what they might have done had Lister lived before them.

We must recognize the impossibility of distinguishing always disease of the intestines from associated disease of other organs, as well as from other accompanying and complicating diseases of the intestines themselves. We see ptosis of the bowels combined with volvulus; hernia, with appendicitis; foreign bodies, with actinomycosis; and peritonitis, with them all. At the same time there are broader associations—calculi may perforate from the gall-bladder into the colon; appendicitis may be the remote cause of perigastric adhesions and distortions of the stomach, while malignant disease of any part may create its first inconvenience through metastases in a distant organ.

In recent years writers have been insisting upon the association, with each other, of various lesions in the *upper* portion of the abdomen; but such associations are not limited to the region above the umbilicus. All the abdominal organs, and organs beyond the abdomen even, frequently are closely and curiously associated in disease processes; for example, we sometimes see affections of the abdomen reflected in affections of the chest.

[1] Recueil de la Société Royale de Médecine de Marseilles, 1826, l'an No. 1.

[2] In South's edition of Chelius' Surgery, vol. i, p. 465; see an interesting account of Shipton's success in repairing wounds in the intestines of dogs in 1702.

It is not proper, therefore, for the practitioner to study lesions as isolated entities—the method commonly employed. He must approach his patient with unbiased mind, and with a generous understanding of the delusion as well as of the significance of local symptoms—an understanding favored and informed by experience of the operating-room and the postmortem table. Regarding misleading or obscure symptoms, as I have said in another writing,[1] the patient who complains of morning headache, of occasional eructations, of some palpitation, and of constipation may be the victim of gastric cicatrices and beginning pyloric stenosis. The man who tells you that he is troubled with distress several hours after taking food and with occasional stomach-ache may be suffering from duodenal ulcer or gall-stones. The child with a poor appetite, pallor, lassitude, and constipation alternating with diarrhea may have a chronic appendicitis. The rather frail, neurasthenic young girl, or the tired mother of many children, the sufferer from dysmenorrhea, or the elderly widow with heartburn, may be afflicted with displacements of the stomach, the colon, the kidneys, or the uterus.

With some appreciation, then, of the complicated mechanism with which we deal in approaching all disease, and particularly abdominal disease, let us study in detail the lesions of the intestines in particular.

Regarding the **anatomy** of the bowels, we make one or two notes of importance: The duodenum is but partly covered by peritoneum; the jejunum and ileum are covered completely; and a portion only of the large intestine is covered completely—the sigmoid, the transverse colon, and sometimes the cecum. Portions of bowel but partly covered are bound down and fixed; portions completely covered by peritoneum swing at anchor, as it were; they are not grounded.

The position of the cecum varies considerably: it may be high or low; it may or may not be covered by peritoneum, and it may have a considerable mesentery. The position of the splenic flexure of the colon must not be forgotten. It is often much higher than the hepatic flexure, and has so sharp an angle that often it seems kinked almost, and as though contents would pass with difficulty. The transverse colon swings loosely below the stomach, and rises and falls with the movements of that organ.

In operating through a small parietal opening upon the intestines, when a short loop of bowel is in view, one is constantly faced by the important question, With what portion of the gut are we dealing, and what is the direction of flow of its contents? Monks has contributed some valuable information on these points.[2] There is no normal length for the small intestine in the adult. It is from 15 to 30 feet long. The upper 6 feet of intestine lie deeply in the left hypochondrium; the middle portions usually occupy the center of the abdomen, while the lower portions generally are in the pelvis or in the right iliac fossa. The upper part of the gut is thicker than any other part, and normally is bright pink or red, the color gradually fading as we go down, and the vascularity becoming less marked. In the upper portion the *valvulæ*

[1] Surgical Aspects of Digestive Disorders, 1905, p. xi.
[2] George H. Monks, Intestinal Localization, Ann. Surg., October, 1903.

conniventes are large and numerous, and can be felt always, or can be seen as pinkish or whitish rings. They diminish gradually in number, but especially in size as we pass downward, until about the middle portion, beyond which they can seldom be seen. The mesenteric vessels, opposite the upper portion of the bowel, below the duodenum, are dis-

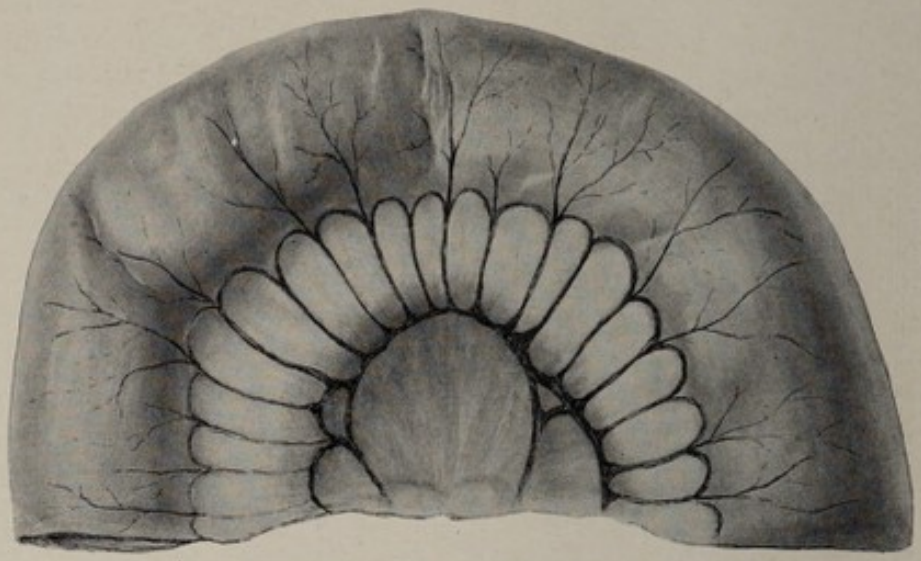

Fig. 13.—Intestinal localization (Monks).

tinctly larger than elsewhere in the mesentery; gradually they diminish as we pass downward until the lower third is reached, after which they retain the same size. Most interesting are the loops of the mesenteric vessels; opposite the upper portion there are primary loops only, with an occasional secondary loop. As a rule, secondary loops become

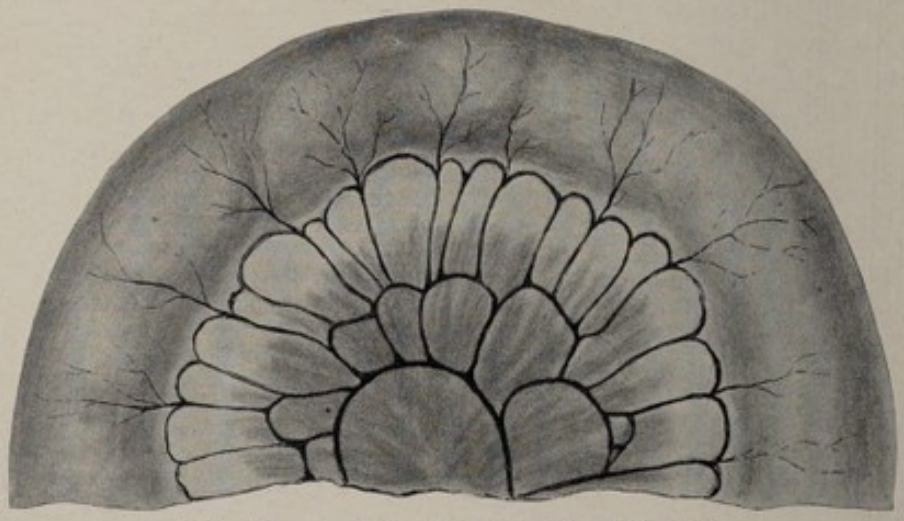

Fig. 14.—Intestinal localization (Monks).

prominent at about the fourth foot from the duodenum. Going down further, secondary loops, and possibly tertiary loops, become more numerous and the primary loops smaller, the loops all the time approaching nearer and nearer to the gut. In the lower part of the mesentery the loops lose their characteristic appearance and are represented by a

complicated network. The *vasa recta* are larger and better defined in the upper than in the lower portion of the bowel. The thickness of the mesentery varies with different subjects according to the deposition of fat; but, as a rule, it is thinnest in the upper portion of the track, and becomes thicker as we descend. In the upper portion there may be

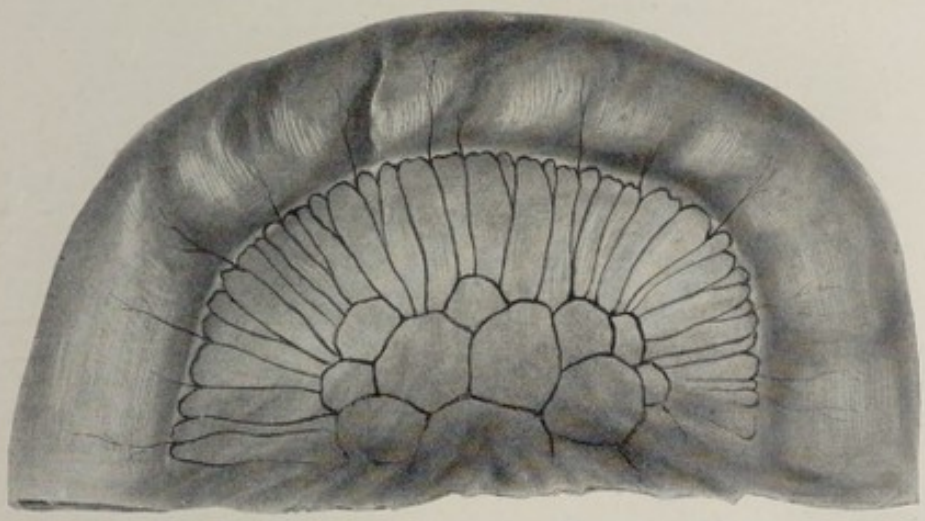

Fig. 15.—Intestinal localization (Monks).

found small, translucent spots between the vasa recta. Monks calls these "lunettes," and finds that gradually they grow smaller, become streaked with fat, and disappear at about the eighth foot from the duodenum. To determine the direction of the fecal stream, observation of peristalsis is unreliable, because retroperistalsis may be present; but

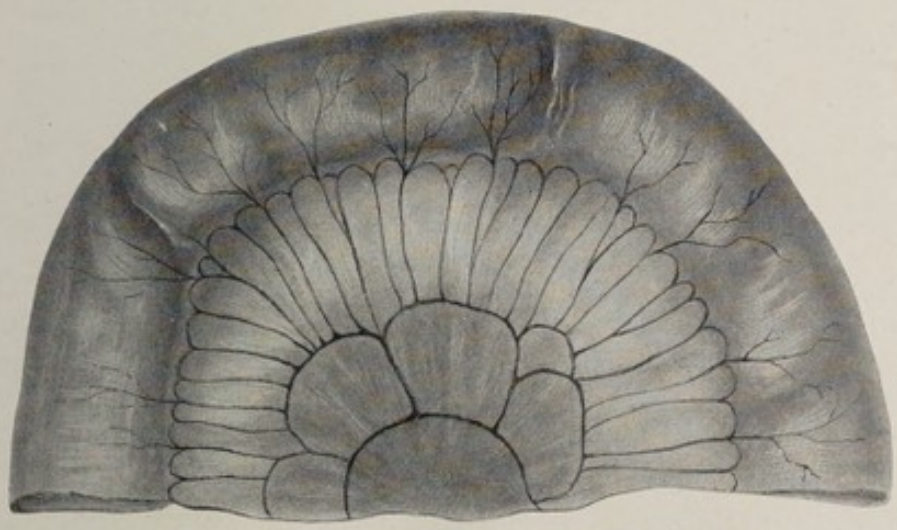

Fig. 16.—Intestinal localization (Monks).

by passing the fingers down the side of the mesentery and its attachment, and by correcting any twist that may be present, then with a finger on either side the direction of the bowel may be observed. These studies of Monks' form one of the most valuable of such contributions to the surgery of the intestines.

In studying intestinal surgery bear in mind that there are three im-

portant divisions of the subject: (*a*) The surgery of injuries; (*b*) of inflammations; (*c*) of new-growths; while at the same time one must

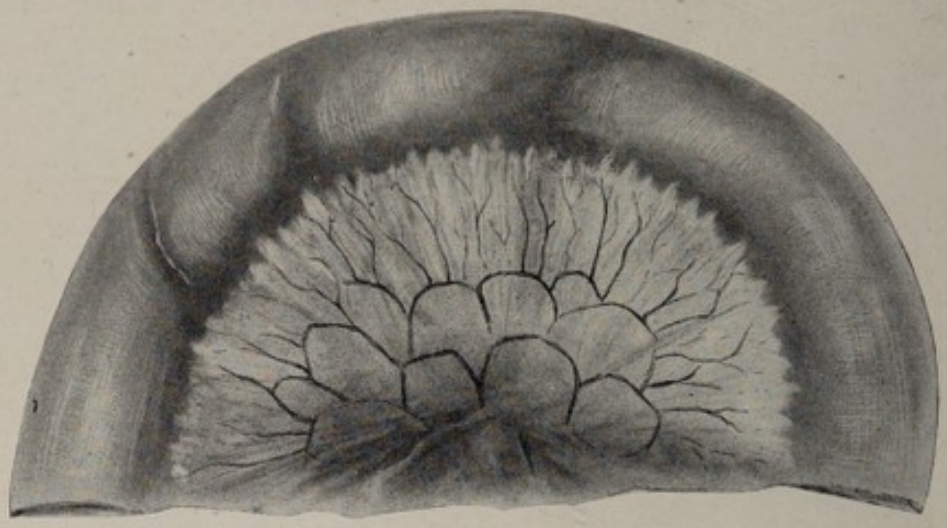

Fig. 17.—Intestinal localization (Monks).

remember constantly that lesions of the intestines often are secondary and complicate far-reaching constitutional disturbances. In consider-

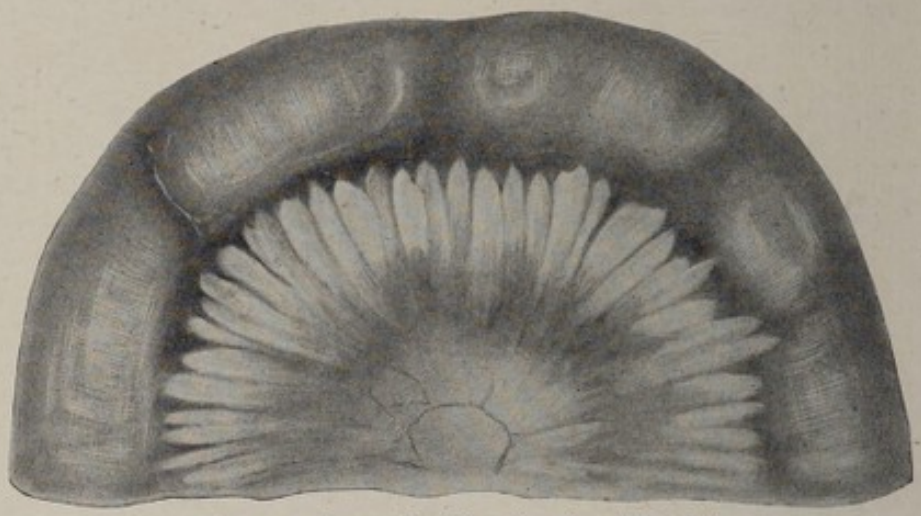

Fig. 18.—Intestinal localization (Monks).

ing these three types of disease, remember that they all cause death in much the same way—through interference with metabolism, and in the end through peritonitis and toxemia.

SYMPTOMS[1]

The examination for intestinal lesions is a difficult matter frequently, because the intestines are not always accessible by the methods employed in the examination of the more fixed abdominal organs. The patient's *symptoms* are an important guide: Pain suggests the location of trouble, but pain may be reflex or referred. The character of the discharge from the bowels is of value—frequent, loose, watery, bloody, lumpy, slimy movements must be investigated, while the microscope and

[1] A further discussion of intestinal examinations will be found in the chapter on Ptosis. The bismuth *x*-ray method is especially important.

chemical tests may throw further light on the problem. Constipation or complete obstipation suggests an obstruction somewhere; but we know that such conditions may mean merely the derangement of organs outside of and involving the intestines.

In studying the **signs,** *inspection* is of value often. In a distended abdomen waves of peristalsis or retroperistalsis may be seen, and swellings or tumors occasionally may show themselves. Inspection of the rectum with sigmoidoscope or proctoscope is imperative when we are dealing with intestinal lesions, for obstructions and sources of hemorrhage may be discovered there low down, while it is well, at the same time, to distend the sigmoid and colon with air or water, and then to determine their exact position when inflated, as well as their topographic relations to suspected disease. *Palpation* is the most important of our resources. *Palpation* elicits tenderness, detects resistance, and discovers tumors, masses, or fluctuating areas. *Percussion* discloses tympany, indicating a distended bowel; dulness or flatness shows impaction, obstruction, collections of fluid, or tumors. With a change of position of the patient shifting fluid, free in the abdominal cavity, is discovered by percussion. *Auscultation* is of value in determining the presence or absence of peristalsis, and in connection with transmitted heart-sounds (see p. 29) it may indicate a bowel paralyzed and distended with gas. A good bismuth *x*-ray picture shows narrowings, displacements, obstructions, and sometimes ulceration.

INTESTINAL OBSTRUCTION

The first and most conspicuous intestinal lesion with which the surgeon has to deal is obstruction of the intestines. This may be complete or partial. It may be acute or chronic, and it may be due to a variety of causes, many of which we shall consider later in detail, under their appropriate headings, such as volvulus, cancer, etc. Writers discuss sundry degrees of obstruction: *stenosis*, or narrowing; *occlusion*, or complete closure; *stricture*, due to disease of the wall of the intestine; *constriction*, due to pressure from without; *strangulation*, in which a strong irritation of the nerves in the intestinal wall occurs, and at the same time the circulation in the intestinal wall and mesentery is so affected that severe venous hyperemia, ending in gangrene many times, ensues. For our purpose it is not necessary now to consider elaborately all these forms, for we shall deal with them more or less in the discussion of special lesions.

Generally, and in a broad sense, subject to certain exceptions, intestinal obstructions are associated with acute *peritoneal* inflammations, on the one hand, or are free from immediate peritoneal involvement, on the other hand. And be it observed that the peritoneal involvements commonly are due to *acute* obstructions, while non-involvement of the peritoneum usually indicates *chronic* obstruction. A conspicuous example of the first is the acute intestinal obstruction seen in strangulated hernia, causing "stoppage," with violent symptoms. An example of the second is seen in the case of cancer, slowly encroaching upon the lumen of the cecum, and shutting off gradually the fecal stream.

Acute Intestinal Obstruction

Ileus is an ancient term which is now used to indicate not a special pathologic condition, but a group of symptoms, among which four are specially present: stoppage of the fecal stream; abdominal pain; vomiting of material containing bile and feces, and distention by gas. This symptom-complex is serious, because it indicates an obstruction which may quickly terminate in death.

Dynamic ileus is a special form of ileus, and is due to paralysis of some portion of the intestine, and the effect may be transitory. Such paralyses are reflex, and may be seen after incarceration of a testicle in the inguinal canal, contusion of the abdomen, and operations upon hemorrhoids. It appears that distention of the intestines with gas may produce paralysis, and that sometimes the action of bacteria may produce it, even though there be no evidence of peritonitis. Any inflammation of the peritoneum may cause an intestinal paralysis and stoppage. Nothnagel says that this paralysis is reflex; that, at first, subacute peritonitis may stimulate increased peristalsis, but that, later, the absorption of gas from the intestines is checked by the peritonitis, and that, consequently, the gut becomes overdistended, with a resulting paralysis.

Treatment.—The cases of dynamic ileus usually are acute, and frequently subside spontaneously. Treatment consists in absolute rest, in abstinence from food, and in the cautious use of morphin hypodermically to relieve pain. Favorable results have been obtained from the use of physostigmin to stimulate intestinal action. If an operation is done, its purpose must be to remedy the primary cause, to set right the organ or organs whose damage is giving rise to the reflex phenomena. If proper nutrition seem to be failing during the continuance of the obstruction, nutrient enemata should be employed. If the obstruction persists, however, and the patient's symptoms become grave, while the true cause of the obstruction is still obscure, one should open the abdomen, and seek, through draining the bowel, to relieve the difficulty. As a rule, the reason for dynamic ileus is obvious, and the surgeon may content himself with palliative measures only.

Mechanical ileus, far the more serious form of ileus, is commonly meant when we speak of intestinal obstruction, and the varieties and nature of such obstructions have been already suggested. Although we use the terms "acute obstruction" and "chronic obstruction," we must bear constantly in mind that such terms are relative, and that the condition is shifting, for acute obstruction may be but a phase of chronic obstruction, and chronic obstruction may supervene upon a subsiding acute obstruction. In a valuable analysis of 1000 cases of intestinal obstruction, Gibson enumerates the following diseases:[1] Hernia, 354 cases; intussusception, 187; bands, 186; volvulus, 121; Meckel's diverticulum, 42; gall-stones, 40; openings, 34; foreign bodies, 16; miscellaneous, 20. These were cases operated upon, and the death-rate was

[1] C. L. Gibson, A Study of One Thousand Operations for Acute Intestinal Obstruction and Gangrenous Hernia, Ann. Surg., October, 1900.

43.2 per cent., showing the serious nature of the condition and suggesting the frightful mortality in the cases left to nature. The reader will notice that Gibson's cases are practically all of the acute type.

We shall consider later these special lesions, but let us note here the *symptoms* common to them all. In many respects the symptoms are such as we have discussed already when considering appendicitis. There are always pain, nausea, and vomiting. There are obstipation, abdominal distention, a soft, rising pulse, a variable temperature, sometimes subnormal, a flushed and anxious face; late in the disease a bounding pulse frequently; tenderness localized or diffused over the abdomen, and, toward the last, there are the familiar symptoms of collapse, due to an intense and lethal toxemia. We shall have occasion to observe these symptoms over and over again in discussing abdominal diseases, and the student cannot fix too vividly in mind the alarming and characteristic picture.

Pathology of Acute Obstructions.—In practically all these acute obstructions the peritoneum quickly becomes involved, the intestines become paralyzed, and the affected portion, as well as the gut above the obstruction, becomes distended with gas. Sharp kinks throughout the distended coils occur, frequently limiting their contents and checking both upflow and downflow of contained material. In *acute circumscribed* peritonitis the paralysis and dilatation do not reach their maximum, so that slight peristaltic motions sometimes may be observed in the affected coils. Acute *diffuse* peritonitis, on the other hand, results in a complete intestinal paralysis.

When a coil of intestine with its mesentery is *strangulated*, there ensues not alone an obstruction, but an acute swelling of the affected portion. Since the loop of intestine is fixed mechanically at a point of constriction, it cannot move, and all peristaltic motion is stopped by the alterations in the circulation and innervation. There is a discharge of serous fluid into the peritoneal cavity from the strangulated intestine, and in the course of twelve hours this may be so considerable as to be determined by percussion. The bowel below the strangluation becomes empty and contracted. Above the strangulation it is distended. It is a noteworthy fact, however, that the more complete the strangulation and the greater the shock, so much the more slowly does the bowel distend. In such extreme cases death frequently results so soon that great distention of the afferent portion of the bowel may not occur.

Conversely, if the strangulation be incomplete and perhaps a small loop only be affected, the afferent loops of intestine may become enormously distended, because the process of the disease is slow and death is not imminent. Several days may elapse. It is always a suspicious symptom if one can feel the outlines of individual portions of the intestine, indicating localized and extreme distention. Of course, if peritonitis supervene, there will result intestinal paralysis with checking of peristalsis and disappearance of the contour of single dilated coils, but as long as peritonitis is absent, peristalsis continues even in the distended intestine, though such peristalsis is of varying intensity.

From such observations the reader will see that a sharp distinction must be made between obstruction associated with strangulation and obstruction not so associated. Obstruction from strangulation is immediately grave. There is no anastomosis between the terminal mesenteric vessels supplying the intestine, so that occlusion of any of the mĕsenteric arteries results promptly in necrosis of the corresponding gut. Therefore, when pronounced symptoms are present, associated with obstruction, we fear strangulation. When the symptoms are of a milder grade, we may conclude an obstruction without strangulation, and take our measures accordingly.

Diagnosis of Acute Intestinal Obstruction.—A suggestion of the general condition of acute obstruction has already been given in the discussion of symptoms. One sees at a glance, from the Hippocratic face, the expression of distress, the shortened respiration, the dorsal decubitus, the flexed thighs, the tender, distended abdomen, the story of constipation, pain, and vomiting, and the rapid, compressible pulse, that a serious intra-abdominal disease is present. Sometimes palpation will reveal the seat of mischief; often the distention masks the lesion. The possible absence of tympany, combined with the other signs, may suggest an obstruction high in the small intestine. In this case the vomiting is not stercoraceous. Obstructions lower down, especially in the colon, give opportunity for more and more pronounced distention. Examination of the rectum may disclose the cause of the obstruction, or injection of the colon with air or water may demonstrate the seat of trouble. The adult colon, normally, should contain 6 quarts of fluid; if one can introduce less than 4 quarts, there is probably obstruction of the large intestine. The age of the patient may have an important bearing on the diagnosis.

The history of hernia, or the discovery of a hernia present, will settle the diagnosis. The fact of internal concealed hernia cannot definitely be ascertained. Obstruction in a young child, especially if there be a recent history of colicky pains and bloody, mucous stools, with the occasional presence of a rounded or sausage-shaped tumor, suggests intussusception. The history of a previous abdominal section may indicate strangulation by a band, by adhesions, or the possible presence of a lost sponge or instrument. The onset of sudden pain, with collapse, tumor, and bloody stools, may indicate volvulus. An obstruction due to Meckel's diverticulum is almost impossible of diagnosis, so closely are its symptoms simulated by an acute appendicitis. Gall-stones may obstruct. In such a case one expects to find a history of disease of the bile-passages, and probably of a previous passage of gall-stones. The presence of other foreign bodies frequently may be assumed from the history.

In spite of these apparently definite suggestions, it is not by any means possible to make a positive diagnosis in all cases of acute intestinal obstruction. In a large hospital experience, embracing dozens of these cases annually, given the above symptoms, one sees made commonly the diagnosis of appendicitis, intussusception, peritonitis

from sundry visceral perforations, and strangulated hernia. Then one operates for appendicitis, perhaps, but finds thrombosis of the mesenteric vessels or a Meckel's diverticulum. So the most experienced surgeon may make mistakes. Instead of the suspected diverticulum, there may be a volvulus, an internal strangulated hernia, or an obstructing band from an old operation. Moreover, there are the occasional cases of kinks and obstructions due to ancient and extensive peritonitis of unexplained origin. A small ovarian tumor with twisted pedicle may cause acute symptoms simulating closely the symptoms of intestinal obstruction.

Writers will tell you that a differentiation may be made between obstructions with strangulation and obstructions without strangulation, but clinical experience does not bear out this assertion. Classic descriptions appear clean-cut and final; the bedside visit fails to confirm classic descriptions. There are, however, four rules for the diagnosis of obstruction without strangulation, by the application of which we are sometimes enabled to rule out strangulation. In *simple* obstruction there are: (1) Less intense and continuous initial pain; (2) no symptoms of collapse; (3) clearly marked dilated loops of intestine to be made out, showing more or less peristaltic action; (4) the frequent history of indefinite abdominal disturbance, especially of intestinal colic, and of intestinal colic with constipation, possibly alternating with diarrhea. By the application of these four rules frequently we may eliminate not only strangulation, but peritonitis also.

Treatment of Acute Obstruction.—When brought face to face with a case of intestinal obstruction, the first question the surgeon asks himself is, Shall I operate or not? Coupled with this question and suggesting the answer is the secondary query, Are we dealing with strangulation or are we not? If one is fortunate enough to be able definitely to answer the latter question and assure one's-self that strangulation is not present, tentative measures are sometimes justifiable. Hernias and intussusceptions may be reduced; gall-stones and foreign bodies may pass; and rest, opium, and intestinal dilatation by enemata gradually may solve the difficulty. If such measures are attempted, the surgeon must stand by, ready to operate if improvement does not follow within a few hours. Operations in these emergency cases are by no means so simple as when one deals with properly prepared patients, because in the emergency cases the patient's stomach and bowels frequently are loaded, and because the disease has lowered his resisting powers. It is well to wash out the patient's stomach at once. The preparation of the skin should be made with the patient on the operating table, and his strength should be reënforced by strychnin and warm bottles. Careful bandaging of the legs and arms, or the use of Crile's pneumatic suit, are advantageous. The incision is made over the suspicious region, or in the median line, if the diagnosis is in doubt. The conditions found must be dealt with as I shall indicate later, when speaking of special lesions.

If *strangulation* be present, or if its presence be suspected only,

immediate operation is imperative. Delay of a few hours will involve gangrene of the intestine, rapid toxemia, and death. Open the abdomen by a long, free incision. Find the trouble, and remove it at once. If intussusception, volvulus, Meckel's diverticulum, or hernia is found, the deranged mechanism sometimes may be restored without impairment of organs; but if it appears that necrosis already is present, the dead tissue must be removed. By leaving it and attempting drainage, a focus of infection will remain and toxemia will persist.

Often the surgeon is tempted to do a partial operation, which will relieve the symptoms, but will not remove the cause. Such a partial operation is justifiable only in case the disease be limited by peritoneal adhesions or in case gangrene be not found. For instance, if there are extensive bands and cicatrices obstructing the intestine, but not causing strangulation, and if the patient's condition be such as to render dangerous a radical operation, in such case simple drainage of the bowel by enterostomy[1] is permissible. This drainage gives exit to the fecal stream; it favors a subsidence of the acute symptoms; it allows a reëstablishment of normal functions; and, later, should the patient's strength be good, a secondary operation may be performed to remove the primary cause and restore normal conditions. Another palliative operation is entero-anastomosis. For example: should obstruction be found high in the ileum or jejunum, it is inadvisable to establish there an artificial anus by enterostomy, because the drained-away chyle will leave the patient undernourished, and there will be established a form of fistula extremely irritating to the skin and difficult to care for. In these cases of high obstruction, therefore, the surgeon should side-track the disease by carrying the fecal stream around it, through anastomosis of afferent with efferent intestine.

The after-treatment of the operative cases must be followed carefully. The surgeon must endeavor to support the patient's strength, but must limit himself to mild measures. Nutrient enemata should be used for the first four days, especially if intestinal sutures have been employed. In the case of an artificial anus having been made, feeding by the mouth may be instituted on the second day and pushed rapidly. Through the early days of convalescence one must be prepared for secondary shock, which, in contradistinction to primary shock, may be met with alcoholics, atropin, and digitalis, in addition to strychnin.

Gastromesenteric ileus is a special form of obstruction which has recently been observed. We believe it to be more common than at first was thought. Gastromesenteric ileus is characterized by a partial or complete obstruction of the duodenum, resulting in a sudden acute dilatation of the stomach. The cause of the gastric dilatation is still somewhat debated, though there seems to be little doubt that the obstruction of the duodenum is due to pressure upon that viscus by the superior mesenteric artery near its origin. It appears that a long mesentery supporting a coil of intestine may so drag upon the mesenteric

[1] Note the distinction between enterostomy, which establishes fecal fistula, and artificial anus, which sets a limit to the further progress of the fecal stream.

artery as to compress beneath that vessel the underlying duodenum. The upright or supine positions seem to accentuate the drag on the mesentery and the obstruction. Conversely, the knee-chest or the prone position even will relieve the drag and do away with the obstruction. This form of obstruction, the exact nature of which was long unrecognized, frequently has been referred to as "acute gastric dilatation." The acute gastric dilatation is, indeed, a fact, but it is secondary to the duodenal obstruction, and must not be confounded with the acute gastric dilatation associated with the pyloric spasm of gastric tetany.

The *symptoms* and *signs* of acute gastromesenteric ileus already have been suggested: pain; collapse; frequent vomiting, often of large amounts, with an abundance of bile; and the usual evidence of absolute obstipation, together with the striking fact that the stomach, by percussion, is found to be enormously distended.

The *treatment* of gastromesenteric ileus must be prompt, and must be intelligent. Rarely, washing out of the stomach will relieve the condition. Frequently the obstruction disappears when the patient is put in the knee-chest position or prone on the belly. If these measures fail, the surgeon may be forced as a last resort to perform gastroenterostomy—artifically connecting the stomach with the intestine below the obstruction.

Occasionally, it happens that gastromesenteric ileus follows an abdominal operation for some other cause. These cases are particularly distressing, and are most difficult of management.

Chronic Intestinal Obstruction

Chronic intestinal obstruction is a condition found about as commonly as is acute intestinal obstruction, and the causes are almost as various. We have noted, moreover, that chronic obstruction may pass into acute obstruction. We are wont to think of it as due to malignant disease, and occurring after middle life, but this is by no means the case. Most of the conditions which cause acute obstruction may cause chronic obstruction; indeed, almost any circumstance which gives rise to a localized peritonitis, with its associated adhesions and bands, may bring about a narrowing of the intestinal lumen, in spite of which the patient may go about for years. Among such causes are incarcerated hernia, chronic intussusception, limiting bands, gall-stones, foreign bodies, fecal accumulations, and locomotor ataxia. There are, however, two other conditions which are the conspicuous causes of chronic obstruction: (1) malignant disease of the intestine and (2) the presence of tumors outside of the intestine. Another cause giving rise to symptoms which may simulate malignant disease is narrowing of the intestinal tube through cicatricial stenosis and atony of the intestine.

Symptoms of chronic obstruction may extend over months or even years. There is a gradual failure of health, or a condition maintained below the normal. Sundry dyspeptic disturbances are common, such

as one may see associated with chronic appendicitis. There are occasional attacks of pain, sometimes nausea and vomiting, chronic constipation alternating with diarrhea, and periods of obstipation, relieved after a time, but associated with intestinal disturbance. These attacks are wont to occur with increasing frequency, and if unrelieved by treatment, end eventually in slow exhaustion and death, or in a complete and alarming obstruction for which operation is imperative.

The **treatment** of chronic obstruction forms an intricate and important chapter in abdominal surgery; briefly, it amounts to this, that if we are dealing with a patient giving a long history of dyspepsia, occasional pain in the lower part of the abdomen, with nausea, vomiting, and constipation, recurring at intervals and with gradual loss of flesh and strength, we must operate to discover the cause and remove it if possible. Bands, adhesions, and external tumors must be removed. Damage to the intestine itself must be repaired by section of the bowel and excision of the diseased portion, or, if the patient's condition is

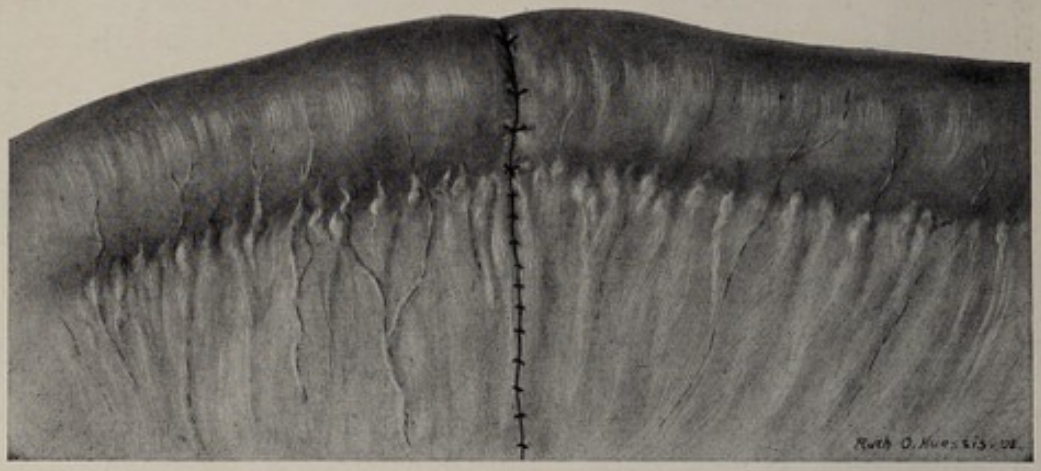

Fig. 19.—End-to-end anastomosis.

serious, we must content ourselves with the palliative operations of making an artificial anus or performing anastomosis.

So much for a general consideration of intestinal obstruction, acute and chronic. Let us now make a brief study of the *special* intestinal lesions with which the surgeon is concerned.

INJURIES

Injuries to the intestines commonly are of three sorts: (1) Those from sudden blows; (2) those from crushes; (3) those from penetrating wounds; and in all three types of injury the damage to the intestine may be out of all proportion to the apparent violence. I do not include here foreign bodies which may cause trouble within the bowel. Rarely, the intestines may be ruptured by increased tension from within. **Blows** and **crushes** may injure the viscera without greatly contusing the skin. In such cases one finds ecchymoses of the gut and of the mesentery; tears of both; free blood or blood mixed with feces and gas in the peritoneal cavity. Not long ago I was called to

attend a child of three years, who was said to have been knocked down, but not run over, by a dray. There was little or no collapse, the child was wailing, but not dull or lethargic, the skin was moist and warm; the temperature was normal; the pulse was 100; there was a slight external bruise, rigidity of the left lower portion of the abdominal wall, and tenderness across the abdomen below the navel. The case was obscure, but after watching it for a short time it was evident to me that some form of visceral lesion was present—the evidence was a rising pulse, with increasing pallor, restlessness, and some clamminess of the skin. I opened the abdomen hastily, and found three feet of intestine torn loose from the mesentery, in which were two spouting arteries; there was also a small rent in the intestine, with escape of its contents. Such cases are not uncommon, and the obscurity of the symptoms in this particular instance suggests the difficulty often of accurate diagnosis.

In the case of **penetrating wounds** of the abdomen, which are usually due to gunshots or knife-thrusts, the immediate symptoms frequently are deceptive also and their severity is dependent more or less upon whether or not the intestines be loaded. A bullet usually inflicts more than one wound on the gut, for it may penetrate several superimposed coils. Usually fecal contents and gas escape into the peritoneal cavity, and there may be extensive hemorrhage from laceration of the mesentery. A knife-thrust is less dangerous, for a knife may push aside the bowel it encounters. Penetrating wounds of the thin small intestine are more fatal than wounds of the thicker stomach and colon.

The *diagnosis* of *traumatic intestinal perforation* is extremely difficult. We look for the cardinal signs of collapse—constant pain and tenderness, clammy skin, rapid and thready pulse, and a subnormal temperature; rigidity, shifting dulness on percussion, but with an increasing tympanites. Frequently there is vomiting, at first bloody, later stercoraceous, and there may be bloody stools, but usually the bowels do not move. Often these signs fail us. In the great majority of cases, however, if there has been a wound of the intestines, we may be certain that death will ensue unless there be active surgical intervention.

The *treatment* in all such cases, even though the extent of the damage be doubtful, is exploration by opening the abdomen. Combat shock by small doses of morphin and by bandaging the extremities. Have the patient upon a hot-water table or surrounded by heaters. Open quickly in the median line; wipe out blood and extravasated material; do not employ extensive irrigation; find the source of hemorrhage and check it; overhaul the intestines and repair rents; excise badly torn bowel and mesentery; drain with gauze strands or a cigaret wick, carry one wick at least to the bottom of the pelvis, and sew up quickly with through-and-through stitches. Place the patient in bed in the semi-upright (Fowler's) position; keep him warm; keep him quiet with morphin; and for thirty-six hours withhold all food, water, and drugs by mouth or rectum. For the thirst, inject saline solution under

the skin of the breast or into a vein. For secondary shock employ strychnin carefully. In case there is evidence of spreading peritonitis, endeavor to combat it by slow, continuous saline irrigation—the method of J. B. Murphy, which I describe in detail in Chapter VIII. If convalescence progresses, feed by nutrient enemata for five days after the second day; then water and nourishing liquids, without milk, gradually may be given by mouth. At the end of ten days, if all goes well, we may regard the convalescence as established, and may treat the patient as in the convalescence from appendicitis.

The *prognosis* is grave in all these cases. Although surgeons report brilliant results, the practitioner must not count upon a low death-rate. Brilliant results may be ascribed to superior technic or to good luck; but in the routine of a large accident service, or in the experience of a busy practitioner, injuries to the intestines always must be regarded as grave.

FOREIGN BODIES

Foreign bodies may cause injury to the intestines. They usually come down through the stomach; sometimes they enter from outside; sometimes they enter through the anus. When inside the intestine, they work damage through obstructing the canal, setting up perforating ulcers, or themselves penetrating the intestinal wall, and we must note that such perforating and penetrating lesions may heal afterward, so that the adhesions even are absorbed. A man may survive the experience of having bodies in the peritoneal cavity work through into the intestines. One writer found that 10 out of 28 pieces of gauze left by accident in the abdominal cavity passed per anum; while 1 of 4 drainage-tubes, and 3 of 17 artery forceps, so left, also passed per anum.

Foreign bodies introduced into the rectum do not work their way upward beyond the ileocecal valve. Obstructing bodies may form within the intestines, such as enteroliths, fecal calculi, or fecal tumors. The fibers of plants, the seeds and fibers of fruit, or pin-worms may be matted together to form the nucleus of an obstructing ball. As a usual thing, however, any object which passes through the narrow pylorus will seldom find difficulty in passing the length of the intestines, even through the ileocecal valve. When such bodies do lodge, they will be found at the ileocecal valve, at the flexures of the colon and duodenum, and most commonly at the sphincter ani.

The small size of obstructing bodies is surprising often, and this is true especially of biliary calculi. Such calculi, larger than 1.2 inches in diameter, rarely pass through the intestines without causing trouble. Sharp-pointed bodies, such as open safety-pins, may stick in the lining of the gut.

Symptoms and Diagnosis.—Often there is the history of a foreign body swallowed or otherwise introduced. Sometimes foreign bodies may be felt through the abdominal wall. There may be a history of gall-stones passed, or the fact of a recent abdominal section may suggest the retention of a sponge or instrument. The symptoms are

those of intestinal obstruction: pain increasing, localized tenderness, nausea and vomiting, constipation, a rise of temperature and pulse, frequently a rising leukocytosis; abdominal distention, tympany, rigidity. Sometimes intestinal perforation or penetration by a sharp object may be walled off, with a resulting localized abscess. Needles or splinters of bone or wood may penetrate the wall. Recently, in the hands of a colleague, I saw a case which had simulated malignant disease of the abdominal wall. Exploration disclosed actinomycosis introduced by means of a sharp fish-bone, which was found to have worked its way outward from within the intestine.

Fecal tumors simulate neoplasms and may remain side-tracked and obstinately present while the fecal stream flows by, and the patient has regular movements of the bowels. Such fecal tumors are found in the cecum, the sigmoid, and the flexures of the colon. They are doughy, and pit on pressure. There is little evidence that fecal masses of this nature cause ulceration and perforation, as do fecal calculi and other hard bodies.

Treatment.—Gradually, foreign bodies will pass through the intestines and reach the anus if time be allowed. Fecal masses may be dislodged by abundant doses of oil and by saline purges. When a foreign body is suspected, however, especially in the case of children, the patient must be kept under observation until the object is recovered in the stools.

If serious obstructive symptoms arise, such as I have described, we must operate promptly. Should the foreign body be found within the undamaged intestine, a simple enterotomy, removal of the body, and sewing up will suffice; drainage is needless. Should the intestine be found damaged, however, with involvement of the peritoneum and underlying structures, the surgeon must remove the offending material and wipe out and drain as though dealing with an inflamed appendix. The after-treatment is like that following operation for acute appendicitis.

MECKEL'S DIVERTICULUM

The existence of this diverticulum has been recognized for two hundred years, but only recently have we known it as a source of danger, and with accumulating experience we see that it is increasingly important. About 2 per cent. of mankind carry a Meckel's diverticulum, and its disease is thrice as common in men as in women. In 6 per cent. of all obstruction cases this diverticulum is said to be at fault.[1] When present, it is a danger to life in more ways than is the appendix. It is a menacing and little appreciated organ.

The diverticulum of Meckel is a fetal remnant of the intestinal tract, an incomplete obliteration of the vitello-intestinal duct. Normally, it disappears long before birth, but it may remain as an open duct connecting the bowel with the outer world by way of the navel. Part of it may atrophy, leaving a blind pouch out of the bowel, and strung

[1] A. E. Halstead, Ann. Surg., 1902, vol. xxxv, p. 471.

by its tip to the navel; or it may be a mere blind pouch, similar to the appendix. Generally, it springs from the ileum, from 15 to 30 inches above the ileocecal valve, but it may arise from any part of the intestine, and usually from the side opposite the mesenteric attachment. When you operate for supposed appendicitis and find the appendix normal, search for a Meckel's diverticulum. Its blood- and nerve-supply are those of the intestines, as its musculature is from the intestines.

Sometimes, through persistent granulation at the navel, there is external evidence of a diverticulum; and, when patulous throughout, it may form the sac of an umbilical hernia.

This brief sketch of the anatomy shows that a Meckel's diverticulum may cause trouble in two ways—by becoming diseased itself, like the



Fig. 20.—Meckel's diverticulum (Warren Museum, Harvard, Specimen No. 7915).

appendix, or by obstructing, entangling, and strangulating the gut in some fashion.

Inflammation, or *diverticulitis*, as it has been called, has occurred in about 13 per cent. of the reported cases of diseased diverticula,[1] and among these are a few from typhoid and tuberculous ulcers. Far more commonly it acts by strangulating the bowel as by a band—59 per cent.; while there are many cases of intussusception, or telescoping of the diverticulum (10 per cent.), of hernia (10 per cent.), and several cases of volvulus or twist about the diverticulum.

It appears that when the diverticulum forms a mere cord from gut to navel, strangulation of the intestine is probably never produced.

[1] Miles F. Porter, Jour. Amer. Med. Assoc., September 23, 1905, discusses 184 reported cases in a valable paper, "Abdominal Crises Caused by Meckel's Diverticulum."

It is the free diverticulum secondarily fixed to portions of the viscera which makes trouble. Again, the free end may become club-shaped through ampullary dilatation, and twist and knot itself about the intestines. Sundry other rare forms of interference with the bowel are described. Unfortunately, the exact condition cannot be determined at the bedside; the results only are seen, and these are nearly always ascribed to acute appendicitis. The clinical pictures of the two are similar. Meckel's diverticulum is diseased most commonly in young men, averaging twenty-one years of age.

The **symptoms,** then, in most cases, are those of a peritonitis, or of an obstruction with or without strangulation, pointing to a disturbance localized below the navel, and generally to its right.

The **diagnosis** cannot accurately be made, therefore, but with the symptoms of pain, tenderness, nausea and vomiting, constipation, distention, sometimes a tender mass below the umbilicus, fever, rapid pulse, and late collapse, indicating profound toxemia, one must conclude that there is present a serious intestinal derangement, obstructive and infective, and must operate for its relief.

Treatment.—When the abdomen is opened and the suspected appendix is found uninvolved, search must be made for a diverticulum. If that be discovered, the condition present must be treated appropriately. The diverticulum should be excised, and the stump turned in with sutures; further than that, a localized or general peritoneal infection must be treated on the lines laid down in the chapter on Peritonitis; bands must be removed, twists and intussusceptions reduced, necrotic gut excised, and the abdomen drained. The after-treatment does not differ from that for appendicitis. Fowler's position is a valuable aid in securing drainage.

When, in the course of any abdominal operation, a diverticulum is found, it should be removed.

The mortality from diseased Meckel's diverticulum untreated is about 60 per cent. In cases promptly operated upon the mortality is about 10 per cent.[1]

Diverticula of the sigmoid are almust always acquired, as distinguished from Meckel's diverticula, which are congenital. The acquired diverticula may occur elsewhere than in the sigmoid flexure, but they are extremely rare in other portions of the intestinal tract. Frequently, they lead to disease. These acquired diverticula may be true or false—that is to say, there may be a pouching at some point of all the coats of the intestinal wall, or there may be a hernia of the mucosa through a rent in the muscularis. This last is a false diverticulum, and is far the most common. Disease of these diverticula may arise to simulate appendicitis. Indeed, at one time surgeons were inclined to look for a transposition of viscera when they had to deal with acute inflammatory processes in the left iliac region.

Constipation is regarded as an important factor in the production

[1] Leon Cahier, L'inflammation des diverticules intestineaux ou diverticulite, Revue de chir., September, 1906.

of diverticulitis. Hardened fecal masses are commonly found in the sigmoid, and may lead ultimately to inflammation, which accounts for the fact that sigmoid diverticula are more commonly inflamed than are vermiform appendices. Most of the cases of diverticulitis occur in persons of middle age. The attacks may be acute or may be chronic, and the clinical course in either case closely resembles analogous disease of the vermiform appendix.

The *treatment* is generally quite like that employed for appendicitis, though W. J. Mayo advises resections of the gut in certain cases. His admirable summary of the treatment is as follows: "The surgical treatment of diverticulitis of the colon depends upon the condition present. First, localized suppurative cases must be treated by free drainage. If, in conjunction with the infective process, acute obstruction of the bowels develops, as in the cases reported, a temporary artificial anus should be made, and, if necessary, after the infection has subsided, the involved colon may be resected. Second, if a considerable tumor is present and the symptoms do not show a tendency to disappear, it is better to make a primary resection of the affected part of the bowel, before abscess and fistula supervene to render patients prolonged invalids." This advice of Mayo seems to suggest extremely radical treatment; as a fact, the larger number of cases of diverticulitis recover promptly with the opening and draining of the abscess.[1]

ENTEROPTOSIS

Enteroptosis—displacement or prolapse of the intestines—is another common condition of serious importance. It leads to multiplied and distressing symptoms, and is a cause of serious chronic ill health. Some notion of visceral ptosis has long been held—Virchow had words to say about it nearly fifty years ago, but it remained for Glénard, in 1885, to accentuate its importance. He described especially a prolapse of the small intestine, transverse colon, stomach, and right kidney. He named this combination "enteroptosis," though that name should apply properly to descent of the intestines only. The affection is sometimes called "Glénard's disease."[2]

Etiology.—The condition is most common in women and may be due to both congenital and acquired peculiarities. Owing to structural development, to flabby abdominal muscles weakened by severe illness, to improper clothing, or to pregnancies, the normal abdominal tension is diminished; the transverse colon is loosened, usually at the hepatic flexure, and sags downward, and it crowds the coils of the small intestine so that they in turn press upon the pelvic organs, which become displaced in turn. The stomach follows the intestines, and the right kidney frequently sinks loosely below its normal position.

[1] G. E. Brewer, Amer. Jour. Med. Sci., October, 1907, and Jour. Amer. Med. Assoc., August 15, 1908. W. J. Mayo, Surg., Gyn., and Obstet., July, 1907. Edwin Beer, Amer. Jour. Med. Sci., July, 1904.

[2] For a fairly comprehensive account of abdominal ptosis the reader is referred to Chap. IX of this volume. The subject is assuming great importance.

There results a train of **symptoms** so complex, obstinate, and puzzling that it is impossible often to determine what organs are at fault, and frequently symptoms are assigned to derangements of the stomach, kidney, or uterus, when the true condition is one of prolapse of the intestines and stomach, which must be dealt with together. Gastric dilatation frequently is associated with gastric ptosis. As a result of these combined ptoses, we see a condition often assigned to neurasthenia—the symptom-complex insomnia, irritability, headache, malaise, anorexia, abdominal pain, especially after meals, obstinate constipa-

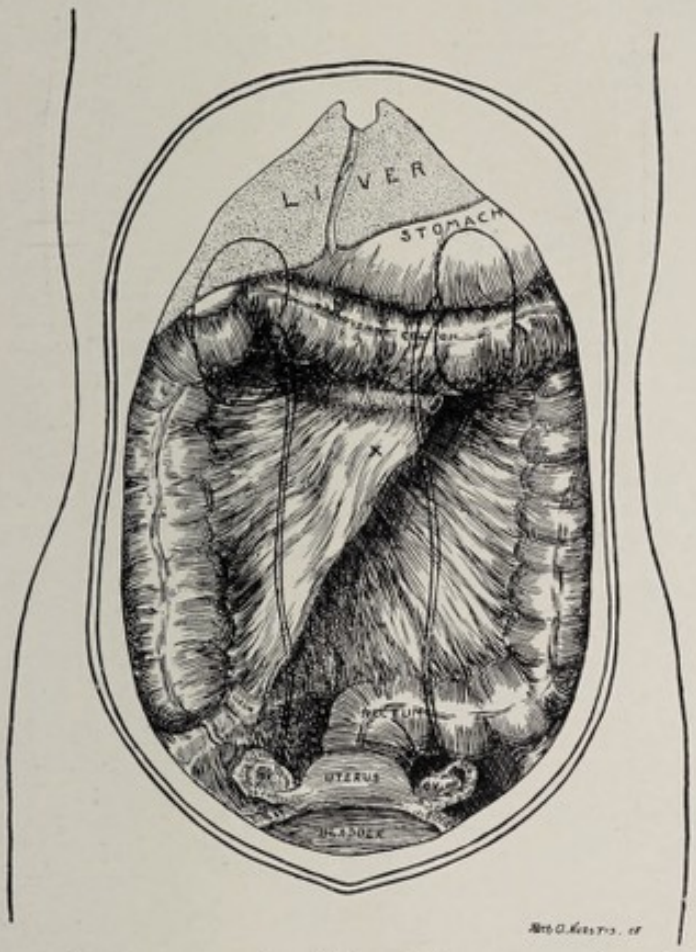

Fig. 21.—Diagram showing normal position of liver, stomach, colon, and kidneys. Kidneys and ureters indicated by heavy black line.

tion, "dyspepsia." The patient is long waisted, emaciated, with a dry skin and flabby, pendulous abdomen. Rectal examination may discover displaced pelvic organs, while the rectum, normally ballooned, is collapsed and admits the finger with some difficulty. These patients are in a condition of continual wretchedness; they are subject to occasional crises of pain and to a constant sensation of "falling to pieces." Of course, there are lesser degrees of the malady, especially in young women who have not borne children, in whom neuralgias and obscure symptoms of discomfort alone suggest that the cause may be intestinal ptosis.

Treatment.—We shall discuss later the extensive and grave ptoses of special abdominal organs, and the operations which have been recommended for their relief. As to the treatment of intestinal ptosis—that is rarely operative. Rest,—especially in the open air,—a carefully regulated diet, gentle, regular exercises directed mainly to strengthening the abdominal muscles, mild laxatives, high cold enemata, the wet-pack, and massage usually will improve or rectify the evil. Especially valuable is the wearing of well-fitting straight-front corsets, loose at the top and tight at the bottom, so as to raise the viscera. We hear

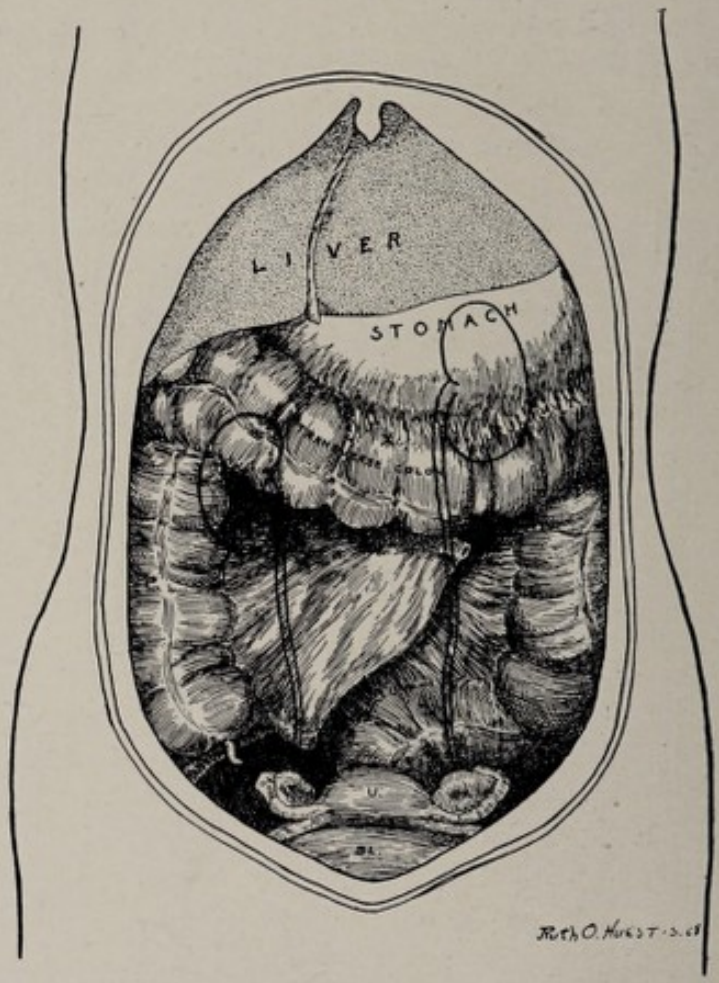

Fig. 22.—Diagram showing ptosis of liver, stomach, colon, and right kidney. Kidneys and ureters indicated by heavy lines.

talk of carefully applied abdominal belts. Abdominal belts are hard to fit, but when properly fitted by an expert are extremely effective, and are often curative. To apply it, the patient should lie down with the pelvis raised on a pillow, and a roller bandage, 6 inches wide, should be carefully put on, caught first about the thigh and then carried smoothly and firmly about the abdomen from pubes to xiphoid—tighter at the bottom than at the top.

Such should be a routine treatment for intestinal ptosis of whatever severity. Sometimes a sagging and collapsed transverse colon must

be stitched up to the abdominal wall; sometimes a sigmoid, twisted and dilated and causing chronic obstruction, must be reduced; but, as a rule, the simpler, non-operative measures will give relief.

COLITIS

Certain inflammations originating in the interior of the bowel may become subject to surgical treatment. Among these affections are diffuse or localized catarrhs and their sequelæ, sometimes running a limited course, sometimes becoming chronic. Owing to the nature of the contents of the *small* intestine and the presence of active chemical agents there, it is rarely permissible to operate for inflammation within this portion of the intestinal tract. We may treat the *colon*, however, through an artificial fistula. In certain cases of protracted colitis such treatment is valuable.

Mucous colitis, known by various other names, such as mucous colic, membranous enteritis, and tubular diarrhea, is an obstinate and peculiar affection. It is confined to the colon, and is characterized by the production of a tenacious mucus, which may be passed in small or large quantities, in lumps, in strings, or in the appearance of a membrane. It is commonly seen as a result of visceral ptosis and in neurasthenic women; more rarely in men. Osler describes the disease as a secretion neurosis of the colon. There are two clinical types: (1) The neurotic and hysteric, in men and women; (2) cases due to local, uterine, tubal, and ovarian troubles.

Symptoms.—The disease is known and characterized by paroxysms of abdominal pain, with tenderness, occasional tenesmus, and such passages of mucus as I have described. Commonly one sees it associated with visceral ptosis. The abdominal walls are flabby and relaxed, while the stomach, right kidney, and especially the transverse colon are fallen out of place. Not infrequently, after a long continuance of the disease, the appendix becomes affected, so that the wretched patient may have a chronic appendicitis or even an acute appendicitis, superimposed upon the already existing conditions. It has been thought that mucous colitis is at times a sequel of chronic appendicitis, but such a supposition reverses cause and effect. Sometimes the patients have bloody stools and sometimes they have other associated distressing dyspeptic symptoms. These persons are easily affected by all sorts of fanciful or actual worriments, which may give rise to acute crises of pain. They may be victims of morphin and other drug habits also.

The **diagnosis** is not difficult, for the discharges are characteristic, but the associated lesions, especially the ptosis, must be carefully investigated.

Treatment[1] is becoming more and more satisfactory, and besides general tonic and hygienic methods, consists in exercises, massage, and, most important, proper mechanical abdominal and skeletal supports. Such treatment can best be carried out in a well-equipped hospital or sanatorium.

[1] See Chapter IX.

In a good many cases, also, cures are effected by the medium of irrigation, through cecostomy, and, if other methods have failed and the patient is not too much exhausted to bear the slight shock of this operation, it should be employed more frequently than in the past. The abdomen is opened through a low McBurney incision on the right, the colon is drawn out of the wound, and a soft catheter is inserted into it, as in the case of a Witzel's gastrostomy. (See p. 154.) The colon should be caught up by four stitches to the parietal peritoneum, and then allowed to sink back into the abdominal cavity, which should be closed about the protruding catheter. Through the catheter irrigation may be introduced daily and in copious quantities. At the end of a week the catheter may be withdrawn, but should be reinserted daily for the regular washings. When it is not in place, the valve-like opening in the wall of the cecum closes, and prevents the escape of intestinal contents. Weir has suggested utilizing the appendix as a passage for irrigation, rather than opening the cecum, and his method has met with favor. [1]

I have employed Weir's appendicostomy with the highest satisfaction.

TYPHOID PERFORATION

Far more important than simple *inflammations* of the mucosa are *perforations* of the gut which originate in such inflammations as we have been discussing; and the most important of these perforations is that of typhoid. In recent years valuable contributions to the literature of this subject have been furnished us by Cushing, Briggs, Harte, and Ashhurst.[2]

When it occurs, this formidable complication of typhoid fever is seen commonly in the third week of the disease. So frequent is it that its recognition and treatment must be regarded as important items in the study of typhoid—a disease with which surgeons should be conversant. Probably more than 30 per cent. of the deaths from typhoid are due to perforation, so that in the United States alone, in the year 1896, 16,660 deaths were due to this cause; and it seems fair to state that at least 5000 of these deaths might have been prevented by an early recognition of the perforations, followed by proper operations.

About 75 per cent. of the perforations occur in the lower portion of the ileum, mostly within 12 inches of the ileocecal valve. Rarely the colon itself is perforated; still more rarely, the appendix, a Meckel's diverticulum, or the rectum even. There are exceptions to these statements. Last year, in the Massachusetts General Hospital, I operated upon a case in which 5 perforations were discovered in the jejunum. In view of such facts and of the frequent obscurity of

[1] The term appendicostomy is used. When the healing of the diseased colon is complete, the appendix is removed.

[2] Harvey Cushing, Johns Hopkins Hosp. Bull., November, 1898; C. E. Briggs, Amer. Jour. Med. Sci., May, 1903; Harte and Ashhurst, Ann. Surg., January, 1904. R. H. Harte, Jour. Amer. Med. Assoc., October 28, 1905.

diagnosis, it would seem proper, as Osler has recommended, that all cases of typhoid fever should be subject to regular surgical observation when possible.

Etiology.—Though the majority of cases occur in the third week, perforations have been known as early as the fifth day after the disease had declared itself; indeed, perforation may be the first evidence of typhoid. At the other extreme, there have been cases of perforation after convalescence was thought to be securely established. The severity of the disease seems to have little bearing on the possibility of perforation, so that this calamity is seen in the mildest, as well as in the most severe, cases. It is most frequent in young adults, and is more common in men than in women. Intestinal hemorrhage has no relation to intestinal perforation, except in so far as the symptoms of hemorrhage may mask those of perforation.

The **symptoms** of perforation must be clearly distinguished from the symptoms of peritonitis from typhoid, because the two phenomena do not coincide in time. Moreover, evidence of peritonitis must not be mistaken for evidence of perforation. Peritonitis may supervene without perforation. It is improbable that perforation occurs without peritonitis. The intensity of the symptoms of perforation is dependent more or less upon the patient's mental condition, for his apathy may fail to be stirred by this alarming catastrophe. The most important symptom is *pain*—sometimes sudden and overwhelming, sometimes of gradual onset. In the case I referred to above there had been slight increasing pain in the epigastrium for three days, suggesting a localized peritonitis; but the perforations, when found, appeared to be recent. Commonly, however, pain develops suddenly, when the patient has been comparatively comfortable; it is sharp, often agonizing, circumscribed, usually located below the navel, and somewhat to the right of the median line. If this pain persists for an hour or more, even if it subsides later, it is almost conclusive evidence of perforation. Spreading pain indicates spreading peritonitis. *Sensitiveness* usually accompanies the pain, but, like the sensitiveness of appendicitis, it is quite closely limited to the area of the lesion. The patient's *sensations* are unreliable. Frequently he feels suddenly exhausted and prostrated; but this is not always the case. Frequently also he suffers from dyspnea due to the collapse, and the difficulty of diaphragmatic breathing.

The **signs** of perforation are similar to those of perforation of the appendix. There are the local signs and the general signs. There are muscular resistance and spasm, intestinal distention, and delayed or abolished peristalsis. Sometimes there is evidence of gas free in the abdominal cavity, shown by tympany in the right hypochondrium, diminishing the liver dulness, though such diminished dulness may also be due to gas within the bowel. Nausea and vomiting are of little diagnostic importance, since they may occur in typhoid without perforation. A rapid respiration is an important sign, though it is by no means pathognomonic of perforation. The temperature may drop to normal or may rise, though a marked drop is less frequent probably

than generally has been supposed. It is suggestive of hemorrhage rather. In perforation such a drop commonly is succeeded by a rise, as peritonitis spreads. An initial chill is infrequent. The character of the pulse is important. Often it rises suddenly,—perhaps 20 or 30 beats to the minute,—and it becomes easily compressible. The sudden rise is unlike the rise in hemorrhage, which is slow and gradual. Usually there is a gradually increasing leukocytosis. Briggs remarks that in perforation there is no such change in the amount of hemoglobin and in the number of red blood-corpuscles, as is seen in hemorrhage.

The **diagnosis,** therefore, must be based merely upon pain, sensitiveness, muscular rigidity, altered respiration, change in rate and quality of the pulse, and evidence of shock. In the differential diagnosis we bear in mind the possibility of pleurisy, pneumonia, mesenteric and iliac thrombosis, appendicitis, peritonitis from any cause, intestinal obstruction, adenitis, and cholecystitis.

Before going on to the important subject of treatment there are two or three points in the **pathology** which every practitioner should appreciate. The nature of the peritoneal infection varies greatly, for the infection depends upon the character of the organisms which have escaped from the bowel. These organisms in the ileum are multifold. Generally, however, we find in the abdominal cavity the Bacillus coli communis and the Bacillus mucosus capsulatus, mixed occasionally with sundry cocci. Briggs recalls the fact that infection of the peritoneal cavity may occur through the base of an ulcer without its perforation, and quotes Ioison.[1] Such cases are unusual. Adhesions occur more or less extensively in nearly all cases. It is wise and of considerable assistance in making the prognosis to take cultures from several places in the abdomen; deep and superficial, when an operation is done. It is surprising often to find a sterile culture at the surface and virulent organisms lower down.

Treatment is by operation. There is no satisfactory evidence that patients can be saved by any other means. Operation is imperative always when the diagnosis of perforation is made. In case of doubt, when intestinal perforation is suspected only, an exploratory operation generally is wise, though this must depend, of course, on the patient's condition. These typhoid patients often endure abdominal section surprisingly well, and even if no perforation be found, the better chance has been taken through exploratory incision. With proper care in dressing the wound afterward, a return to routine cold bathing can be made in the course of a few hours.

There has been debate as to how soon after perforation abdominal section should be done. It should be done as soon as the patient has rallied from the initial shock; but if there be no rally, as rarely happens, operation should be done in any case.

There has been debate also as to the choice of an anesthetic. As a rule, we should use general anesthesia, preferably ether, and should intrust it to an experienced anesthetist. Local cocain anesthesia is

[1] Revue de chir., February 10, 1901, No. 2.

permissible in operating upon a patient in profound shock. As a rule, however, the operation demands considerable exploration and thoroughness, which are difficult or impossible under local anesthesia.

The incision should be made through the right rectus muscle, below the navel, for we know that most perforations occur in the ileum, which lies in the right lower quadrant of the abdomen and in the pelvis. The incision should be long enough to permit comfortable manipulation within the abdomen, and be it remembered that these operations should never be consigned to the surgical tyro. The cecum should be sought at once as the guide to the ileum; then the last two or three feet of the ileum should be carefully overhauled, after which one should explore the cecum, the appendix, the sigmoid, and perhaps a Meckel's diverticulum. It is unlikely that perforations exist elsewhere. If they do, local evidence before operation will probably have suggested an incision other than in the right lower quadrant. Multiple perforations are not commonly found, but multiple areas of thinning may often be detected in careful palpation. The repair of lesions in the gut is a simple matter, and should be made with two rows of Lembert stitches. Thin patches not yet perforated should be turned in also. Do not excise the ulcer. Rarely, if repair involves dangerous narrowing of the lumen, the surgeon must excise portions of the intestine. Abdominal irrigation is of great importance, and the stream should wash thoroughly the cavity from diaphragm to pelvis. Close the abdominal wound with drainage, using a split rubber tube in the pelvis and wicks at the site of perforation. If the patient's heart will permit, he should be put to bed in Fowler's position, and he should be carefully stimulated. The after-treatment is not remarkable, and except for the care of the abdominal incision, the routine typhoid treatment should be continued. In giving baths, cold sponging and fan baths must suffice for a few days, the wound being guarded by cotton, rubber protective, and collodion.

The possibility of subsequent perforations is always present, and should they occur, the need of a second operation is as imperative as before the first.

Prognosis.—Without operation all these patients die. The mortality with operation is falling as physicians and surgeons are learning their business. The mortality depends, of course, on the general condition of the patient, the progress of the disease, the time elapsed since perforation, and the skill of the surgeon; but successive statistics are showing constant improvement, and such observers as Keen, Osler, Harte, Cushing, and Briggs are optimistic enough to look forward to 30, 50, 60, and even 70 per cent. of recoveries.

TUBERCULOSIS OF THE INTESTINES

Tuberculosis of the intestines presents to the surgeon a form of lesion frequently seen. Experience varies, but probably this disease comes to operation as often as does a perforating typhoid ulcer, and

the surgeon should always bear tuberculosis in mind when he is confronted with an obscure abdominal lesion.

We may name 3 groups of tuberculous intestinal lesions: (1) The disseminated form of tuberculosis of the mucosa without tendency to recovery; (2) solitary or multiple ulcers with tendency to recovery; (3) tuberculosis of the ileocecal region, with the formation of a tumor.

The first form need not concern the surgeon, because it is associated with a general tuberculosis, and involves the intestines so widely as to render operation futile.

Individual or associated multiple tuberculous ulcers, which tend to heal, rarely concern the surgeon during their activity. They, too, are generally part of an acute tuberculosis, often pulmonary. They do concern every practitioner, however, in so far as they present a possible source of farther infection, and because they may be cured through

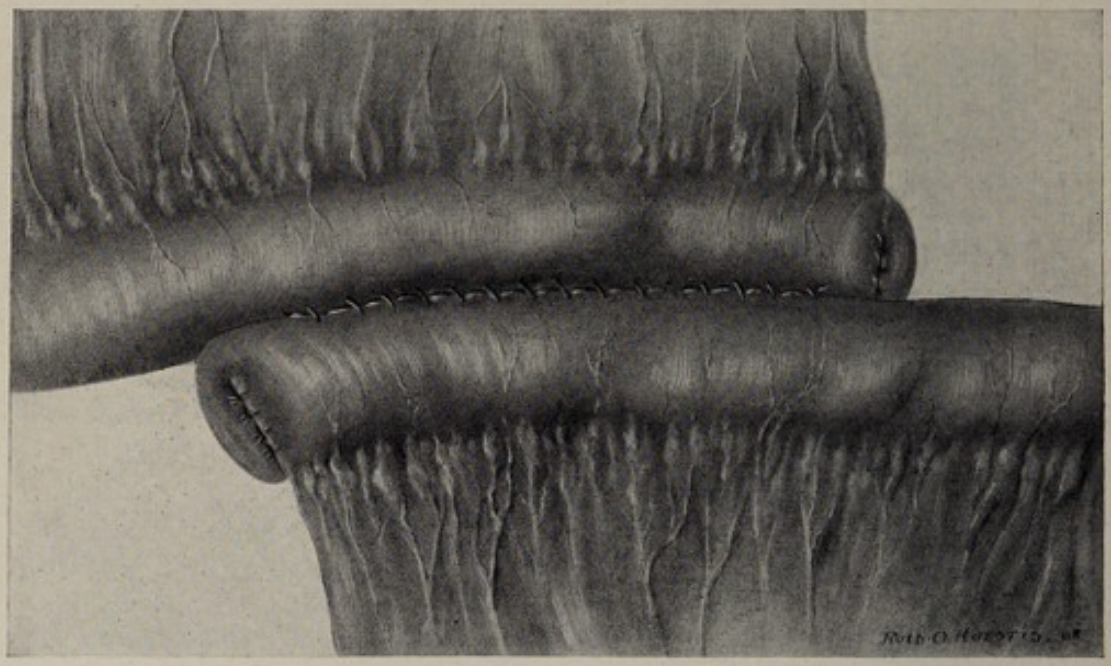

Fig. 23.—Lateral anastomosis.

proper measures. Such patients should have the out-of-doors life prescribed for them, and should be dieted with care, eating, in forced fashion, non-irritating but fat-producing foods.

The sequelæ of these healed ulcers are of great surgical importance, because the sequelæ are stenoses of varying degree, leading up even to complete obstruction. Writers have estimated that 25 per cent. of healed tuberculous ulcers produce stenoses.

The **symptoms** of such stenoses are the ordinary symptoms of chronic intestinal obstruction, and the proper diagnosis is often difficult. It will be founded upon a general consideration of the patient's condition. A young man in poor health, with evidence of pulmonary or other tuberculosis, hectic, running a low, irregular fever, with disturbance of nutrition, with constipation alternating with diarrhea, or with signs of total obstruction, belongs to the type we are considering.

The **treatment** is by operation. Open the abdomen in the median line, find the constriction, which may be in either the large or the small intestine; release adhesions, and excise the affected area. If the constriction is in the small intestine or the transverse colon, end-to-end suture is permissible to complete the repair. Do not use the Murphy button in the large intestine, because irregularities in the thickness of the bowel, troublesome epiploic appendages, the solid character of the contents of the colon, and a blood-supply less abundant than in the small intestine render the button-union uncertain. An effective method of joining any portions of the bowel is side-to-side anastomosis, after closing completely the cut-off bowel-ends (Fig. 23). The after-treatment is of the same painstaking sort I have described when speaking of intestinal obstruction.

Ileocecal tuberculosis is the most common variety seen in surgical practice. It is associated with the development of a tumor in the appendix region, and may be confused with appendicitis, with actinomycosis, or with cancer of the cecum. Like the other forms of intestinal tuberculosis, it is usually secondary. The disease may or may not encroach upon the lumen of the bowel, but the bowel-wall is greatly thickened, often by chronic inflammation, and the neighboring lymph-nodes frequently are affected. Progress of the disease is slow.

The **symptoms** are those of chronic intestinal stenosis—constipation rather than diarrhea, or the alternation of the two, is the rule—with colic, rumbling, occasional vomiting, and sometimes visible peristalsis. There may be blood in the stools, due to ulceration of the mucosa, but there is rarely a complete obstruction. When the tumor develops, it is usually in the line of the colon, and is hard, nodular, and frequently visible. It is not very tender, and does not move with respiration, though it may be shifted by handling and gives a dull, tympanitic note on percussion. The disease may last for years, and under the best of conditions may disappear spontaneously. On the whole, however, the patient's condition gradually becomes worse, and he dies eventually of wasting general tuberculosis or from the intestinal obstruction.

The **treatment** of this form of tuberculosis is operative, our purpose being to side-track the disease by intestinal anastomosis if the conditions are desperate and the obstruction serious; or, in milder cases, to remove the disease, should it be susceptible of such radical treatment; and be it remembered that total extirpation gives the only reliable chance of restoring health. I shall discuss the method of removing this portion of the bowel when I speak of the removal of cancer of the large intestine.

ACTINOMYCOSIS OF THE INTESTINE

Wright, in his valuable monograph, states that in his opinion "the term actinomycosis should be restricted in its meaning to a suppurative process combined with a granulation-tissue formation, the pus of which contains the characteristic granules or 'Drüsen,' composed of dense

aggregates of branched filamentous micro-organisms, and of their transformation or degenerative products." [1] Frequently writers have confused with actinomycosis sundry other conditions, such as pseudo-tuberculosis, streptothrix, or cladothrix, from which actinomycosis should be sharply distinguished.

The presence of actinomycosis within the abdominal cavity, and especially within the intestine, is now recognized as of not infrequent occurrence. It is mistaken for tuberculosis by the student. The disease is a chronic inflammatory process, associated with abundant production of new tissue, as well as with active tissue destruction. It may come to a standstill or be recovered from; or it may continue active. It is more common in the colon than in the stomach and small intestine. It has been found in the appendix, the cecum, and the

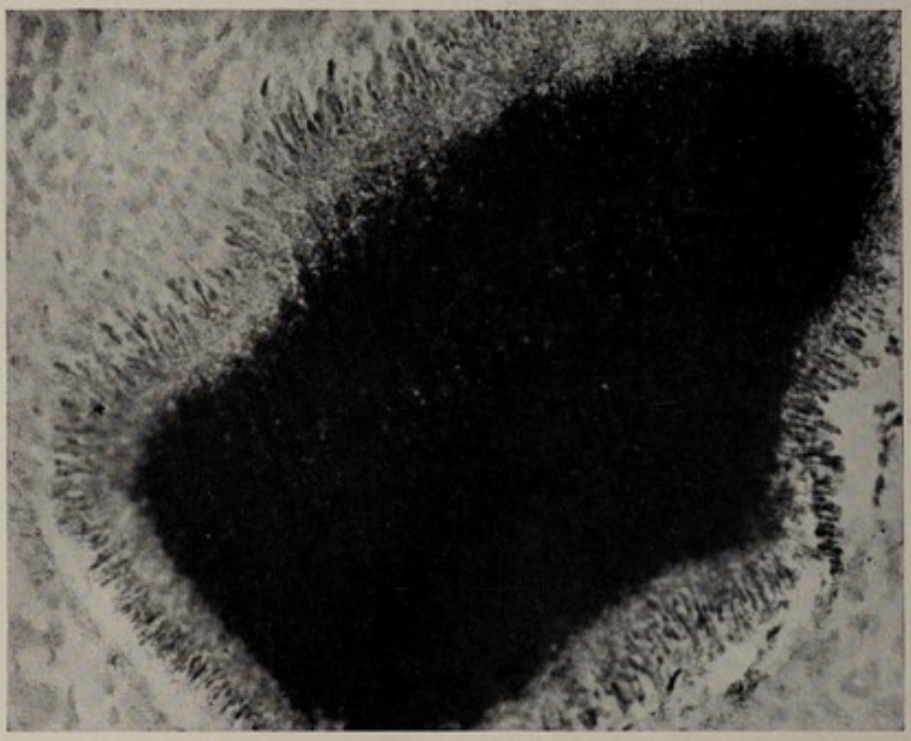

Fig. 24.—Actinomycosis, showing clubs.

rectum. It involves the whole thickness of the bowel, causes adhesions to the neighboring viscera, attacks all tissues in its path, and finds exit usually through the abdominal wall. It presents a brawny appearance on the body-surface, with peculiarly bright-red granulations cropping through and bleeding easily. It becomes undermined, suppurates, and discharges pus from sundry openings. The pus is usually thin, less often stringy, and frequently contains the characteristic granules. The parasites may spread throughout the body by the blood-vessels, as well as by continuity. They do not seem to enter the lymphatics; therefore the associated lymph-nodes are probably enlarged through a mixed infection.

[1] James Homer Wright, Publications of the Massachusetts General Hospital, 1905, vol. i, No. 1.

Symptoms.—The clinical course is slow. There are 3 periods: an initial latent period, a period of tumor formation, and a period of suppuration and fistula. The patient suffers at first with a varying intestinal catarrh. After some weeks or months a tumor is felt, usually in the ileocecal region. It may or may not be movable. Frequently it is attached to and infiltrates the abdominal wall. Generally there is little pain or tenderness. At this stage it simulates chronic appendicitis, an abscess, or sarcoma. With the formation of sinuses and outcropping granulations fecal fistula may be established. Intestinal obstruction is rare.

Patients frequently suffer from malnutrition and exhibit a fluctuating fever. There is a late amyloid degeneration of other organs, and there may be a low percentage of hemoglobin. Actinomycotic invasion of the peritoneal cavity with diffuse peritonitis is seldom seen.

The **diagnosis** cannot certainly be made until the disease breaks through the skin or until the organism is obtained in some other fashion. The surgeon should suspect the disease, however, in every case of chronic tumor of the ileocecal region associated with fever and malnutrition.

The **prognosis** is bad if the disease be left to itself.

The **treatment** is surgical. The mass of disease must be cleared away with the knife and curet so far as possible. By this means granulation tissue and pus-pockets are removed and drained, and air is admitted, which seems to limit the growth of the parasite. There is no distinct advantage in extensive operations upon the intestine, for it is difficult to secure an aseptic field, and, moreover, as the gut is patent, there is no call for anastomosis to relieve obstruction.

Potassium iodid has been relied upon in the after-treatment, and frequently has seemed to act favorably on those portions of the disease which could not be removed by operation. A. D. Bevan advises copper sulphate in the treatment of this disease, and thinks it valuable, taken internally and used as a wash.[1]

EMBOLISM AND THROMBOSIS OF THE MESENTERIC VESSELS

It is difficult to condense into a few lines this important subject—important for its high mortality rather than for its frequency. Happily, it is not common. The diagnosis is obscure and difficult, but the operative treatment is as urgent as is that for typhoid perforation. In 1904 Jackson, Porter, and Quinby summed up for us the knowledge of the subject.[2]

The cases are acute and chronic. The acute cases are far the more numerous, and are due to plugging, either of the arteries or veins, fol-

[1] Bevan uses a 1 per cent. solution of copper sulphate injected into the sinuses and applied liberally about the wound. He gives the drug internally in doses of ¼ to ½ grain, three times daily (communication to the Society of Clinical Surgery, October 5, 1905).

[2] J. M. Jackson, C. A. Porter, and W. C. Quinby, Mesenteric Embolism and Thrombosis, a Study of 214 Cases, Jour. Amer. Med. Assoc., June 4, July 2, 9, and 16, 1904.

lowed by infarction, with usually a bloody exudate into the bowel corresponding to the site of plugging. The size and relative importance of the vessels occluded determine the extent of the infarction and the amount of the exudate. If a small vessel only be obstructed, and if collateral circulation through the mesenteric loops remain, there may be no bloody exudate, and the symptoms may be slight; but such mild cases are rare. About 10 per cent. of the cases are chronic—that is, running over two months. 90 per cent. are acute. Acute cases are due to quickly developing thrombosis or embolism overwhelming the nutrition of the parts. Chronic cases appear to be due to a thrombosis which makes progress from time to time, with the accompanying and intervening establishment of a collateral circulation. There are a few rare cases in which partial healing has taken place through collateral circulation.

The **pathologic** appearances are various, running from a simple hyperemia to gangrene, perforation, and peritonitis. In about three-fifths of the cases the infarcted area shows a line of demarcation. We find ulcerations of the mucosa, a mesentery thickened and edematous, sometimes containing extravasated blood forming a palpable tumor. In a small percentage of the cases the infarction may involve the whole small intestine, the ascending colon, and part of the transverse colon. This indicates closure of the superior mesenteric artery. Closure of the inferior mesenteric causes corresponding damage to the large intestine only. There may be small areas of involvement of the ileum alone. Subserous hemorrhages are not uncommon; the mesenteric lymph-nodes frequently are swollen. Involvement of the large intestine is due usually to arterial embolism, not to venous embolism.

The disease occurs in men twice as often as in women, and is seen at all periods of life, but more especially from middle age onward.

Symptoms.—The few chronic cases need not detain us. They are impossible of diagnosis generally, and have as characteristics occasional attacks of pain, rumbling, diarrhea or constipation, and dyspepsia. Frequently they progress until they exhibit evidences of an acute abdominal disease. In rare cases they cease spontaneously.

Symptoms of acute embolism or *thrombosis* are violent, but not characteristic. *Pain* is always present. Generally it is felt throughout the abdomen; rarely it may be localized in the epigastrium, about the umbilicus, or possibly in some unusual portion of the abdomen. Sometimes it is of sudden onset, sometimes it is gradual, but in any case it usually becomes intense and wearing. Tenderness is present in about three cases out of four, and corresponds to the location of the pain. *Nausea and vomiting* generally are present, especially when the attack of pain is acute. The vomiting may be considerable, and in the end may become stercoraceous or contain clear blood. There may be diarrhea or constipation. There is no rule, but the action of the bowels and the character of their discharges depends upon the extent of the lesion. Most commonly there are bloody movements, but if the area of the disease is extreme, there will result obstruction, with obstipation.

If the area be small, there may result normal movements. There is almost always a leukocytosis and an iodophilia. The temperature falls at first, and rises later, with the onset of peritonitis. The pulse becomes soft, rapid, and compressible. Sometimes the skin shows purpuric spots.

The **diagnosis** rarely is made with any certainty. Commonly the condition is mistaken for appendicitis, intussusception, or volvulus. Jackson, Porter, and Quinby quote Gerhardt,[1] who makes the following diagnostic postulates:

1. There must be present a source of the embolus.
2. There are copious intestinal hemorrhages unexplainable by diseases of the gut-wall or by hindrance to the portal circulation.
3. There is quick and marked fall of body temperature.
4. Colicky abdominal pains, which may be very severe.
5. Later, distention of the abdomen and free fluid occurs.
6. Emboli of other parts may have been present before, or may occur simultaneously with, closure of the mesenteric vessels.
7. There occurs sometimes a large, palpable blood tumor between the layers of the mesentery.

Clinically, it is rare to find all these points established. It is impossible to differentiate clinically between the closure of arteries and veins.

The **prognosis** is bad. About 94 per cent. of the patients die if untreated. According to the statistics at command, about 92 per cent. die when treated.

The **treatment** is by operation, and this implies resection of the affected intestine. The mortality is due to profound shock and septic infection, and, in a large number of cases, doubtless, to faulty technic in not removing all the bowel involved. Accurately to remove all the disease is rendered difficult because frequently there is no sharp line of demarcation, with the result that after the intestinal joint has been made, spreading gangrene may persist. In view of these facts it is advisable to bring the involved bowel well outside of the wound, leaving a liberal margin at either end. Cut away the disease, and fix the intestinal stumps, carefully protected by gauze, in the abdominal incision. A further spreading of the gangrene may thus be watched and treated. If the patient survive, a secondary operation is necessary. In all cases a thorough flushing of the abdominal cavity is recommended. After the operation the patient's strength must be carefully supported with stimulants, heat, and rectal feeding.

INTUSSUSCEPTION

Intussusception or invagination may produce obstruction and even strangulation. The process is a displacement of a portion of the intestine, by which the upper part is telescoped into the lower. In some cases this relation is reversed. Most cases of intestinal obstruction in children are due to intussusception. Four varieties of the disease

[1] Würzburg. med. Zeit., 1863, vol. iv, p. 141.

are recognized: The *ileocolic,* in which the ileum prolapses through the ileocecal valve; the *ileocecal,* in which the ileum and the ileocecal valve prolapse into the cecum and colon; the *ileal,* in which the ileum alone is involved; and the *colic,* in which the colon alone is involved. The intussuscipiens drags with it its mesentery into the intussusceptum, and the symptoms vary according to the tightness of the invagination and the constriction of the mesenteric vessels. With slight pressure the parts become hyperemic and edematous; with long-continued pressure, necrosis and hemorrhage take place, as when the mesenteric vessels are thrombosed. Accordingly, the cases are acute and chronic. Rarely, spontaneous healing takes place through automatic resection of the invaginated bowel, with sloughing and discharge. The danger of this acute condition is great. In the chronic cases, with obstruction, but without strangulation, death results from malnutrition. In the acute cases of strangulation we anticipate perforation and peritonitis. Even in those cases which recover spontaneously, through automatic resection, there is danger of subsequent intestinal stricture, with permanent obstruction.

The **symptoms** of intussusception are similar to those of sundry other forms of intestinal obstruction. There are pain, meteorism, and vomiting, with obstipation if the obstruction is complete. Frequently there are bloody stools, or free blood may be passed by the rectum. The picture is similar to that presented by mesenteric thrombosis. Sometimes a sausage-shaped tumor may be felt.

The **diagnosis** in children is not especially difficult. In adults it is obscure. Given a young child with abdominal pains, vomiting, distention, and bloody stools, one will conclude that intussusception probably is present. The much-talked-of sausage-shaped tumor is not always felt.

The **treatment** generally is operative, if permanent success is looked for, though palliative measures sometimes are justifiable. Palliation consists in the injection of water high into the bowel, using low pressure, the reservoir being not more than 3 feet above the buttocks, which are elevated somewhat above the shoulders. Occasionally, this measure has reduced the intussusception, but it must be applied early—within twelve hours—and must be used with caution. Even a low head of water has caused intestinal perforation.

Operation consists in opening the abdomen in the median line, finding the obstruction, and reducing it, if possible, by pushing back the intussusceptum rather than by pulling out the invaginated portion. As in all cases of operation upon strangulated bowel, the surgeon must assure himself that the released gut is viable. In case of doubt, resection must be made with the Murphy button, end-to-end suture, or lateral joining, according to the situation of the disease. In the case of the common invagination of ileum into cecum a lateral joining is to be preferred.

Intussusception, owing to the small area of bowel involved and the gradual nature of the process, has a much lower mortality than mesenteric thrombosis. Prompt surgical intervention saves a large propor-

tion of the cases—the earlier the operation is undertaken, the less extensive are the tissue changes found, and the more probable is recovery.

VOLVULUS

Volvulus is a twist of the intestine upon its axis, usually causing strangulation. Rokitansky describes three forms:

1. A coil of intestine may twist through a half-circle or a whole circle, around its own long axis.

2. The mesentery, or a portion of it, may twist with the attached intestine.

3. A portion of the intestine, together with its mesentery, may twist around another loop of intestine.

If more than 370 degrees of twist are present, symptoms will arise. The sigmoid flexure is the part commonly affected, though the small intestine may be the seat of trouble, in which case the result is more dangerous than is a sigmoid volvulus. The causes of volvulus are not clear, though generally a long mesentery is a prerequisite. Traumatism and a previous peritonitis causing adhesions seem to be etiologic factors.

The **pathologic** appearance depends on the extent of the volvulus, and may vary all the way from a mere hyperemia with edema to complete obstruction, with strangulation and gangrene.

The **symptoms** vary also. There is generally pain, sometimes intermittent, sometimes acute and constant. There are vomiting and obstipation. Rarely, there is a little blood from the rectum.

In many of the cases the exact **diagnosis** can be made. The condition is seen most often in patients advanced in life. There are the symptoms of obstruction. The case may or may not appear alarming, but the characteristic feature is the enormous localized early distention. The involved bowel balloons a portion of the abdomen; the distention is not uniform. The great coils frequently can be distinguished. If vomiting occurs, it is not often excessive, and usually comes on late.

The **prognosis** depends upon the extent and severity of the strangulation. Volvulus of the small intestine kills 70 per cent. of its victims,[1] as contrasted with 46 per cent. in the case of the large intestine.

The **treatment** is operative only, and does not differ in principle from that for intussusception. Gibson records 121 cases. For these the following procedures were employed: Untwisting, 79; died, 31—mortality, 29 per cent. Resection, 16; died, 13—mortality, 81 per cent. Resection and artificial anus, 5; died, 4—mortality, 80 per cent. Artificial anus, 15; died, 12—mortality, 80 per cent.

Such figures demonstrate in another fashion what I have said already, namely, that early cases, in which the volvulus may be untwisted, have a fair chance of recovery, while later cases, complicated with tissue destruction and requiring severe and extensive operations, are far more fatal.

[1] C. L. Gibson, ibid.

INTERNAL HERNIÆ

Internal, retroperitoneal, or intra-abdominal herniæ occasionally are found causing obstruction and even strangulation. Clinically, these herniæ cannot be differentiated from obstructions due to bands, and are rarely made out before operation. Such herniæ are found in the foramen of Winslow, in the retroduodenal fossæ, the retrocecal fossæ, and the intersigmoid fossa. As with other conditions causing obstruction, the treatment is by operation.

IDIOPATHIC DILATATION OF THE COLON

Idiopathic dilatation of the colon is rare. It gives rise to a train of puzzling symptoms, is a cause of so-called phantom tumor, and runs a chronic course.[1]

Dilatation of the colon usually begins in childhood, and is marked by obstinate constipation, occasional distention low within the abdomen, and malnutrition. As time passes the distention becomes pronounced, often being present for months, at times diminishing or totally subsiding, to recur later. An ether examination in certain cases causes an abundant discharge of flatus and disappearance of the tumor. Treves[2] states that "in young children (the conditions) are due to congenital defects in the terminal part of the bowel, that there is in these cases an actual mechanical obstruction, and that this dilatation of the bowel is not idiopathic." It is probable that such permanent obstruction is sometimes the cause of the dilatation.

The **treatment** of these cases of dilatation must be palliative at first by washings out through the rectal tube and by saline purges. If the dilatation persists, however, and becomes grave, as is sometimes the case, an operation is demanded. In cases not too far advanced, opening the abdomen, draining off the contents of the sigmoid, and fixing it to the abdominal wall, in case of torsion, may suffice for a cure. Commonly, however, in the old persistent cases more radical measures are necessary, and the treatment must be by excision of the affected coil. This should be done in two steps. An artificial anus should be made above the distention, *first*, by drawing out the sound gut and performing colostomy, the gut being left fixed outside of the abdomen. *Later*, when convalescence is established and the patient's general condition is improved, the distended bowel must be excised and an anastomosis made between sound intestine and rectum, or the lower portion of the sigmoid.

TUMORS OF THE INTESTINE

By far the most important and serious obstructions to the intestines in advanced life are those obstructions due to tumors of the intestine

[1] R. H. Fitz, The Relation of Idiopathic Dilatation of the Colon to Phantom Tumor, and the Appropriate Treatment of Suitable Cases of These Affections by Resection of the Sigmoid Flexure, Amer. Jour. Med. Sci., August, 1899.

[2] Lancet, 1898, i, 276.

itself, and the most common of these is cancer.[1] Most cancers of the intestine are found in the large bowel, but before taking up this important subject, let us turn for a moment to benign tumors and tumors of the small intestine.

Benign tumors of the intestine are adenoma, lipoma, fibroma, myoma, myxoma, angioma, teratoma, and such combinations of benign and malignant neoplasms as myosarcoma, fibrosarcoma, etc.

Most of these benign tumors may be found in almost any portion of the intestine and at any age, though they are commonest in youth. Sometimes they are polypoid, sometimes they are large, diffuse, and fixed. They may hang down and obstruct intestinal flexures and valves. Sometimes they are found to be the cause of invaginations. They develop from tissues in the intestine corresponding to their own structure. They may exist for many years without giving rise to serious symptoms. When they do cause obstruction or even chronic ill health, they should be removed—an undertaking usually easy and little dangerous.

Sarcoma of the intestines is a rare affection. Its relation to cancer is as 1 is to 20. It may involve any portion of the bowel, and may occur at any age, but most commonly between thirty and forty. Most of the cases reported have been in women. The tumor may reach a considerable size and involve a great extent of bowel. It is likely to involve neighboring structures, especially the mesentery and omentum. Metastases are found in the liver, kidney, spleen, and retroperitoneal glands. Sarcoma produces stenosis less often than does cancer.

The *symptoms* of sarcoma are variable. There are the characteristic wasting, much more rapid than in the slow-growing cancer. A movable tumor sometimes may be felt, though later the tumor becomes fixed. Ascites and metastases are common. There may be bloody stools, and, rarely, there may be obstruction. Life seldom is prolonged beyond a year.

The *diagnosis* is difficult on account of the rarity of the disease and the similarity of its symptoms to those of cancer, the only striking difference being the more rapid progress of sarcoma.

Treatment.—In any case, when a diagnosis suggesting malignant disease is made, and a possibility of radical removal exists, some operation for excision should be attempted. On opening the abdomen, if excision appears impracticable, especially if symptoms of obstruction are present, the surgeon should perform entero-anastomosis if the disease be high up, or colostomy if the disease be low in the large intestine. The recorded operative mortality of intestinal sarcoma is high, because hitherto these cases have come to the surgeon too late for successful radical treatment.

[1] Obstruction due to tumors from without pressing upon the bowel must be dealt with according to the indications of the case. Generally, an operation is indicated for removal of the obstructing mass. When this is impossible, the surgeon must perform enterostomy should the obstruction persist.

Cancer of the Intestine.—Cancer is far more common in the large intestine than in the small intestine, and it is most common of all in the rectum. Von Mikulicz and Kausch give the following interesting figures: "One hundred cases situated above the rectum; in 5 instances the tumor was in the small intestine; in 19, in the cecum; in 39 in the colon above the sigmoid flexure; in 31 in the sigmoid flexure itself, while in 6 cases the seat of the trouble was not exactly stated." It appears further that of all cases of cancer of the alimentary tract, below the stomach, one-half are in the rectum. The proportion of men to women affected is as 3 is to 1. It is a disease of middle life. Almost invariably it is primary and solitary.

Different forms of cancer of the bowel occur in the following order: cylindric carcinoma with a glandular structure, medullary, gelatinous, scirrhous. Cancer of the intestines leads early to ulceration, associated sometimes with slight hemorrhage and rarely with perforation into the peritoneal cavity, into some hollow viscus, or externally. Cancer tends to incircle the gut, and thus to produce stenosis, often very early, with consequent hypertrophy and dilatation of the intestine above it. There may be **acute** obstruction. There may be invagination. The disease may extend by continuity, by the blood-vessels, by the lymph-vessels, and by the peritoneum; but early metastases are infrequent. It progresses slowly, and may run a course of several years without alarming symptoms. Sometimes there are no pronounced symptoms whatever until the alarming terminal symptoms. In its course cancer of the colon appears to be far less malignant than cancer of the rectum.

The characteristic *symptoms* of intestinal cancer are indefinite for long. There is at first a certain amount of dyspepsia, and constipation alternating with diarrhea. Such attacks occur and subside, but return with increasing frequency. After a while the earlier symptoms become associated with abdominal distention, which is a suspicious sign. There are occasional attacks of colicky pain. Later in the disease periods of obstruction become absolute, with great distention and vomiting. Even the most pronounced obstruction may subside, however, perhaps through ulcerations rendering patent the obstructing mass. Finally, such symptoms of ileus occur as have been described in the early pages of this chapter. There may be a sudden attack of peritonitis, or symptoms of involvement of other organs—the bladder, uterus, or liver. A tumor is not always felt. It may not be found until late in the disease, or it may be discovered early, for its detection depends upon the site of the growth. If the cancer originates in the posterior wall of the bowel, it may grow to a considerable size, and give rise to serious symptoms before it becomes palpable. On the other hand, a small cancer, situated on the anterior surface of the cecum, may be detected before the *symptoms* of its presence are conspicuous. These tumors feel hard and nodular, and may or may not be tender; they may give rise to characteristic stools containing pus and blood, and the discharges will have a foul, gangrenous odor, and carry necrotic fragments if there is an extensive ulceration. The growth is not painful in itself, but such pain as there is, which may be excessive, is due to obstruction,

adhesions, inflammations, or spreading ulcerations. With low-lying cancer there may be distressing rectal tenesmus. Ascites develops after the growth has involved the serosa.

The *diagnosis* of cancer of the intestines is founded on the age of the patient, wasting, dyspepsia, and symptoms of obstruction with periods of distention. The recognition of blood in the stools is highly important, and the most minute traces of blood should be searched for repeatedly through careful chemical tests. The detection of a tumor is confirmatory usually. It is not always possible to ascertain the site of the disease, unless a tumor be made out or the location of the obstruction be apparent. Artificial distention of the bowel with air or water is an important aid, for, as I have said on a previous page, the unobstructed large intestine of an adult should contain six quarts of fluid. Pelvic examination sometimes helps. It is not always easy to distinguish cancer of the transverse colon and its flexures from malignant disease of other organs above the navel. In making the diagnosis one observes the extent of the distention, the nature of the vomiting, and the amount of fluid which may be injected into the bowel. In making a *prognosis* one recalls that the disease runs a chronic course—sometimes as long as two to four years, if involvement of other organs does not take place, and especially if relief be afforded by an artificial anus. The lower down in the bowel the disease is found, so much the longer proportionately will be its course, if we except cancer of the rectum.

The *treatment* of cancer of the intestines is operative, even though the operation be but palliative.[1] In these cases, however, as in nearly all cases of internal cancer, one should inform the patient or his friends of the extreme liability to recurrence in case of excision, and of the dangers residing in all radical procedures. Cases of intestinal cancer are bad "surgical risks." The patient's condition is poor; his metabolism and nutrition are defective; his vitality is greatly diminished; he is prone to cardiac collapse, and is especially subject to toxemia. Except in the case of patients seen early, and in the robust, radical procedures generally are futile and merely hasten the inevitable end. Perhaps wisely the majority of patients afflicted with intestinal cancer choose the euthanasia which morphin provides.

From the preceding statements one sees that there are three types of contraindications to operating:

1. A condition of the patient so bad that he cannot withstand the shock of operation.

2. A certainty that radical operation is impossible on account of metastases; an unfavorable position of the tumor; or extensive adhesions.

3. Wide-spread metastases and ascites, rendering useless a palliative operation even.

When it is possible, a radical operation should be done, and not a palliative operation, because the late appearance of metastases and

[1] Incurable cancer of the intestines often may be greatly relieved by a long course of compound solution of iodin, administered in increasing doses from five drops upward. (See foot-note, p. 864.)

the frequent mobility of the tumor render its safe and complete removal possible in the early stages. The method of resecting a tumor of the small intestine needs no comment. The operation is simple and direct, such as I have described earlier in this chapter, when discussing resection of the gut. Removal of a tumor of the large intestine is a more difficult matter, as the union of the cut edges is less ready there, owing to the inferior blood-supply, the presence of epiploic appendages, and a short or absent mesentery, with a gut only partially covered by peritoneum. Says W. J. Mayo: "Generally speaking, malignant disease in any part of the large intestine proximal to the middle of the transverse colon is treated best by removal of all the large intestine up to and including the growth, doing lateral ileocolostomy. Beyond this point resection of the colon in one or two stages is preferred." So it has come about that surgeons prefer to do certain of these radical excisions in two or three separate steps. Von Mikulicz has taught an admirable procedure, applicable especially to resections of the sigmoid. To quote again the words of W. J. Mayo:[1] "It consists in drawing the affected part out of the abdomen, and, after separating its mesentery and suturing the two limbs together, attach it to the abdominal incision, with the diseased part projecting beyond the skin. After waiting as long as the condition of the patient will permit for adhesions to protect the wound, the obstruction is relieved by a small opening in the distended loop. In from two to four days the entire projecting area is cut away, leaving the two ends of the colon flush with the skin, side by side, like a double-barreled gun. At the end of two weeks a clamp is introduced, one blade in each opening, and made to grasp the opposed walls of the intestine, where they are held by the sutures for a distance of not less than three and a half inches. The clamps are gradually tightened until they cut their way through, which takes from four to six days. This reëstablishes the communication. The fistula gradually contracts, and will either close itself, or can readily be closed by secondary plastic operation."

McGraw has recommended that the new lumen be completed by the insertion of an elastic ligature which will cut through in four or five days and establish an anastomosis between the two limbs within the abdominal cavity. Von Mikulicz's *second* step is taken ten days or two weeks after the first. By that time the patient has recovered from the previous operation, the inflammatory reaction has subsided, the peritoneal cavity is shut off, and the intestine has been thoroughly drained.

Cancer of the ileocecal region may be removed with less difficulty than cancer of the sigmoid, for the blood-vessels of the ileocecal region are terminal. Moreover, the contents of the ileum and caput are fluid, so that the mechanical problem of resection is simpler than in the large intestine, where solid fecal masses endanger the security of the suture line. Furthermore, the arrangement of the lymphatics of the large intestine favors resection. The nodes are infrequent, and are invaded late in the disease. More than one-half of the patients with

[1] W. J. Mayo, Resection for the Relief of Intestinal Obstruction, Jour. Amer. Med. Assoc., September 14, 1907.

cancer of the colon die from obstruction of the intestine before glandular metastasis has taken place.

Resection of the ileocecal portion should be made to include the whole of the ascending colon; and, conversely, resection of the ascending colon should be made to include the cecum. After removing the ileocecal portion or the ascending colon, which should be done as a primary operation, the surgeon should proceed at once to a reëstablishment of the intestinal canal, and this is best accomplished by lateral anastomosis, the ends of the cut-off bowel being previously crushed, tied off with catgut, and turned in with a purse-string suture. Do not use the Murphy button.

The transverse colon may be resected in much the same way, but the surgeon should not forget, when resecting the transverse colon, that in four-fifths of the cases the middle colic artery is its only source of blood-supply. This artery, with its branches, should be preserved so far as possible. In restoring the canal one may employ end-to-end anastomosis, as in the case of the small intestine, because the transverse colon is completely surrounded with peritoneum, and is enveloped in the folds of the omentum. Do not use the Murphy button, because there may be occasionally large obstructing fecal masses deposited in this portion of the large intestine.

The after-treatment of cases of intestinal resection is of no little importance. The patient should be held in the semi-upright position, in order that any septic products may gravitate to the pelvis. Fig. 130 in Chapter VIII shows an admirable apparatus by which the patient may be held comfortably in Fowler's position. In this position also the continuous rectal infusion of salines is most satisfactorily given. Furthermore, if there be tendency to prolonged nausea or vomiting, the patient's stomach should be repeatedly emptied, and irrigated with hot water.

Palliative operations are justifiable when radical excision is impossible. They are done to relieve progressive stenosis, which may render intolerable the life of the patient. We are assuming, of course, that the patient is in condition to bear a palliative operation, and we recognize three such operations: The *first* is the most serious of all: the *elimination* of the intestine, by which we close off the affected portion of the bowel, leaving the tumor in place, and then bring together by anastomosis sound gut, above and below the mass. The *second* palliative operation is *entero-anastomosis*, which merely side-tracks the infected intestine, but does not close it off; and the *third* method is the establishment of an artificial anus—that is, drawing out of the abdomen the bowel above the tumor, and fastening it in place, so that the fecal stream shall be discharged externally at this point.

These palliative operations themselves are not devoid of danger, and the mortality risks are in the order of the operations named. Of course, statistics of such risks are relative, and depend upon the ability of the reporting surgeon; the general condition of the patient; and the extent of the disease. Wölfler's statistics in 1896 showed a mortality of 40 per cent. from resections; von Mikulicz's statistics have given a

mortality of 12.4 per cent. The mortality from palliative operations varies also, and, among others, de Bovis has reported for the elimination of the intestine a mortality of 33 per cent.; for entero-anastomosis, 28 per cent.; for enterostomy, 39 per cent.

Cancer of the intestine can be cured, for von Mikulicz, Körte, and Mayo have recorded the cases of patients living more than four years after extirpation of the growth; and palliative operations must be regarded as justifiable, since we see patients living two, three, and even four years after colostomy. The average length of life after colostomy is twenty-one months; after entero-anastomosis, eight and a half months.

The after-treatment in case of all these operations does not differ materially from that described previously in the discussion of section of the bowel for other causes—absolute rest, stimulants, abstinence from food for at least a week, except in the case of colostomy, and nutrient enemata given with special care when the operative field lies low in the bowel. These patients demand abundance of water, which may be given at first in a vein or under the breast, but after the first day may be allowed freely by mouth.

FECAL FISTULA AND ARTIFICIAL ANUS[1]

Fecal fistula is a subject of ancient interest to physicians. Descriptions of this condition are found throughout our literature, and the topic must be regarded from the points of view of both detriment and ad-

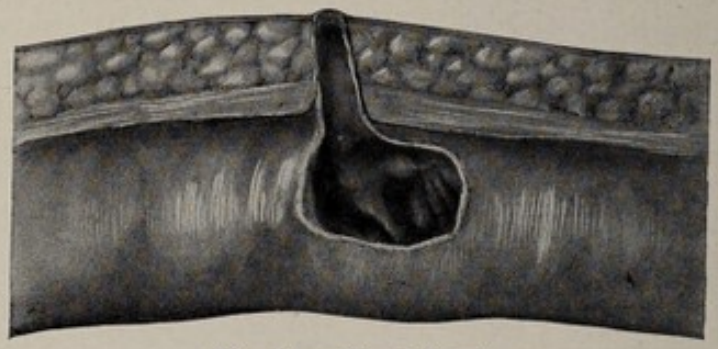

Fig. 25.—Fecal fistula.

vantage. These fistulæ occur as the result of disease or operation, on the one hand, or, on the other, they are purposely and artificially created by the surgeon to relieve disease.

Fecal fistulæ may form between the bowel and an adjacent hollow organ, or they may form between the bowel and the abdominal wall and perforate the skin. Sometimes the former, or internal fistulæ, give no symptoms of inconvenience; for instance, when the anastomosis is between the gall-bladder and the bowel, or between the stomach and the small intestine; at other times serious inconvenience results, as when the anastomosis is between the bowel and the urinary bladder. The troublesome internal fistulæ must be dealt with by separating the adherent viscera and sewing up the rents.

[1] Fistula in ano is not included in this section.

The **diagnosis** of all these internal fistulæ must depend on finding fecal discharge from the organ secondarily affected, as from the uterus, the vagina, the bladder, etc.

The spontaneous external fistulæ, however, are commonly meant when we speak of fecal fistula. They may be due—(1) To penetrating wounds injuring the intestine, with a resulting adhesive inflammation and an opening left between the interior of the bowel and the outer world; (2) to an incarcerated hernia, which has become gangrenous and has perforated externally, leaving a permanent fistula; (3) or internal fistulæ may follow ulceration of the bowel from tuberculosis, cancer, actinomycosis, or appendicitis; (4) disease of organs or of the abdominal wall may involve the intestines and result in a permanent fistula; (5) perhaps, most common of all, fecal fistulæ may follow surgical operations undertaken for appendicitis, cancer, salpingitis, or any disease involving the bowel-wall, and necessitating opening or resecting the intestine.

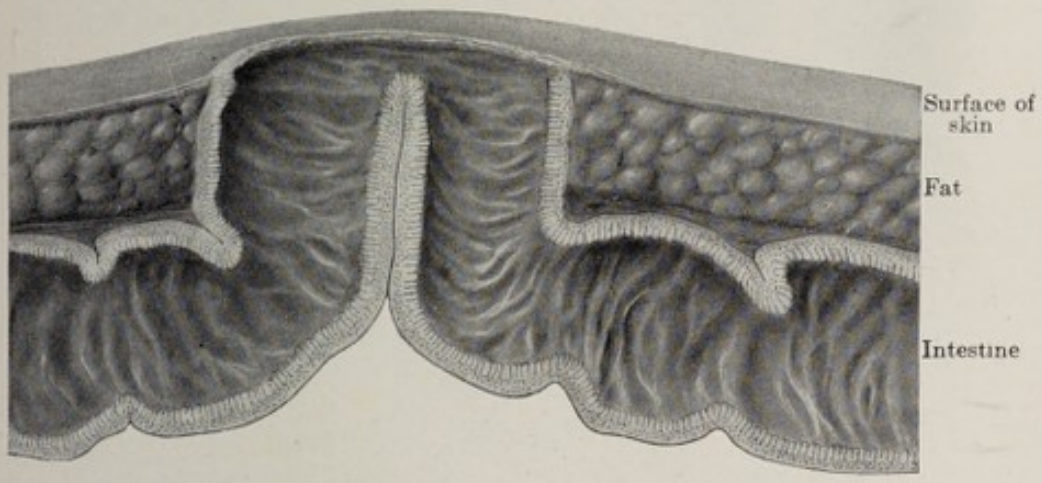

Fig. 26.—Artificial anus.

Spontaneous fistulæ, formed as I have described, may heal spontaneously, or they may remain indefinitely. The commonly permanent fistulæ are those due to disease. Fistulæ due to traumatism or operations often heal, even after months. If they have not closed in three months, and if the patient's strength permit, an operation for their closure should be undertaken.

We recognize anatomically two forms of fecal fistula: First, those which communicate with the outside world through a tortuous track, involved in adhesions and newly formed connective tissue; second, those in which the bowel is immediately adherent to the abdominal wall, while through the opening the interior of the intestine may be seen. The second variety of fistula is lined often with mucosa continuous with the skin and intestinal mucosa—a mucous fistula, which does not heal spontaneously. The first variety rather than the second is likely to heal if let alone.

The **symptoms and signs** of fecal fistula are a discharge of a part or all of the intestinal contents through the opening, and more or less

malnutrition, which depends upon the site of the bowel perforation. If the upper part of the ileum or the jejunum be tapped by a fistula, and any considerable portion of the bowel contents escape, the patient may suffer seriously from wasting, and the acrid discharge will set up a troublesome dermatitis. Fecal fistula from the colon does not interfere seriously with the body's nutrition, but it is gravely annoying, owing to the constant discomfort of an offensive discharge.

Artificial anus must be distinguished from fecal fistula. Artificial anus usually is formed purposely by the surgeon, though in rare cases it may arise spontaneously. It is an anus—a terminal vent of the intestinal canal, where the bowel comes to the surface and discharges

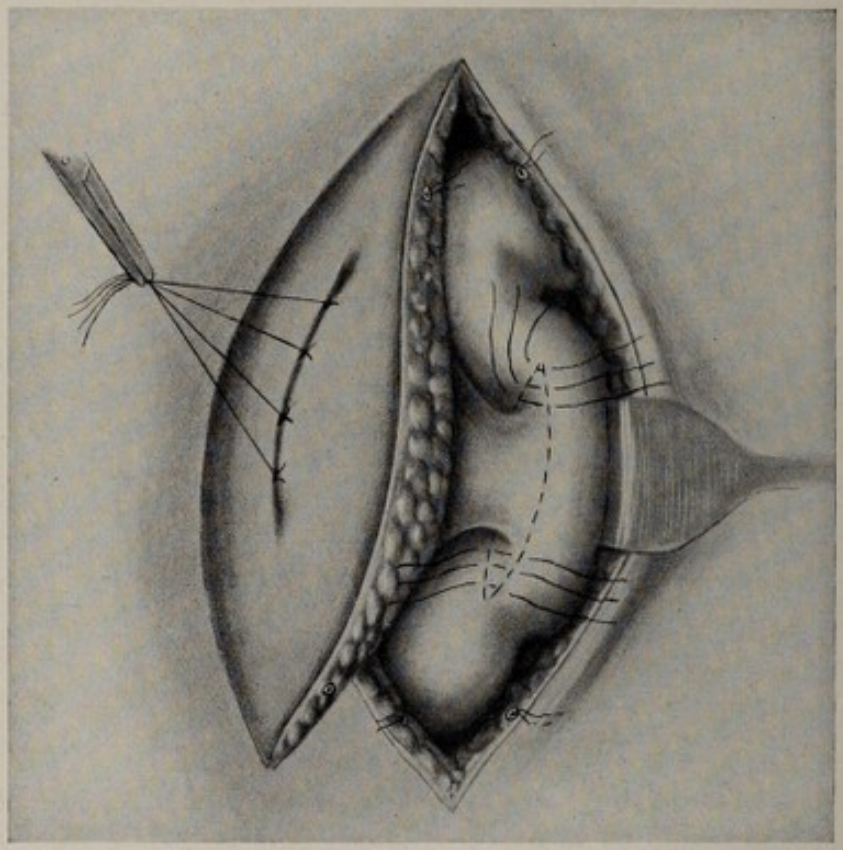

Fig. 27.—Operation for fecal fistula or artificial anus (after Bickham).

all its contents. It leaves collapsed the portion of intestine below. Commonly, the surgeon forms it for the purpose of shunting off permanently the fecal stream above an old obstructing cancer. In a subsequent paragraph I shall describe the method of constructing it.

The **treatment** of fecal fistula is to close it by operation. To do this successfully and rationally one must open the abdomen, and make a lozenge-shaped incision surrounding and cutting out the fistula. The fistula, with its attendant loop of bowel, is then drawn outside the abdominal cavity, and a portion of bowel corresponding somewhat to the excised skin is removed, leaving a longitudinal slit. Close this slit in the bowel with a double row of Lembert stitches, and return the gut to the peritoneal cavity. The abdominal wound is sewed up,

leaving a small drain down to the injured intestine. The drain may be removed in forty-eight hours.

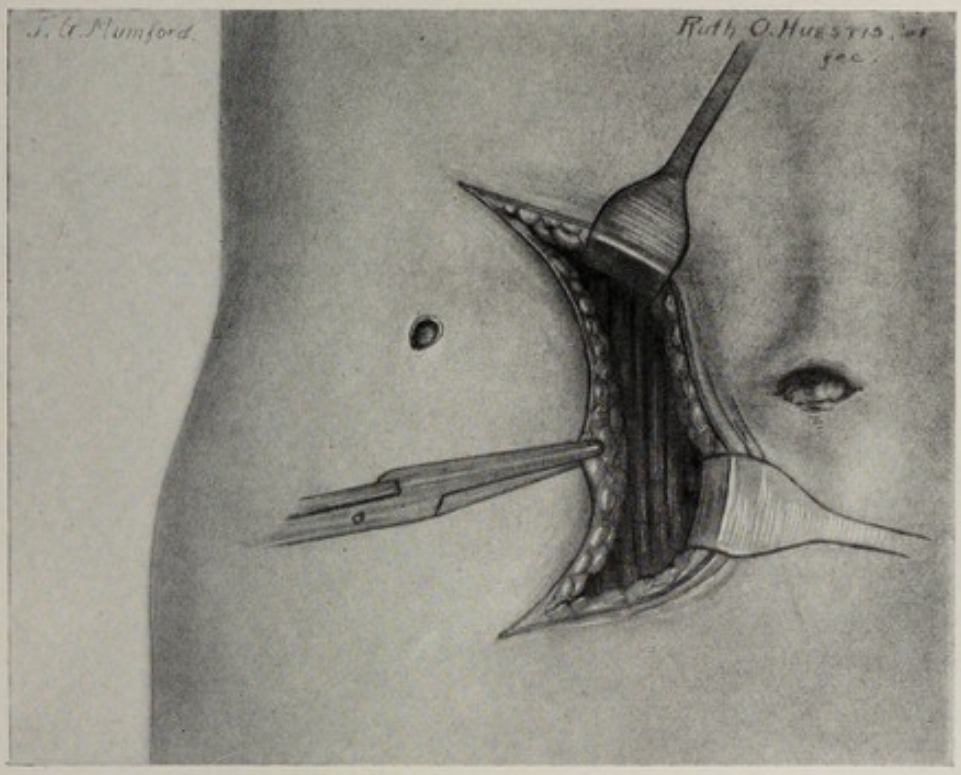

Fig. 28.—Operation for remote fecal fistula. Step 1: showing wide skin dissection.

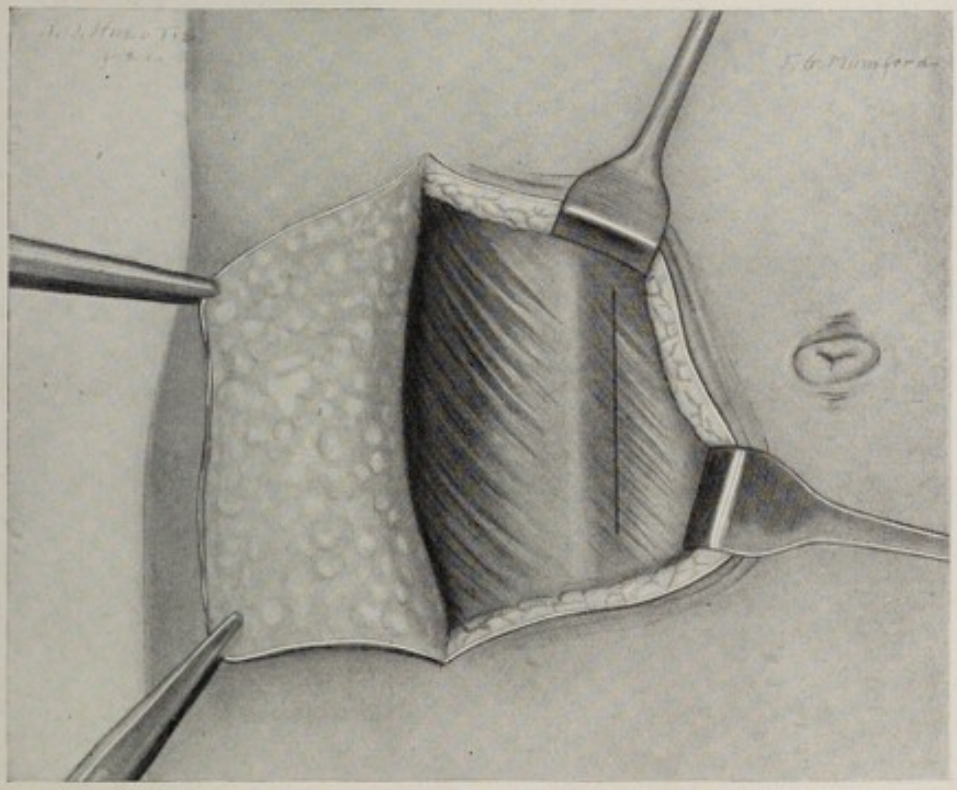

Fig. 29.—Step 2: Skin-flap retracted, line of incision in muscle.

All fistulæ may not be dealt with so easily, owing to a tortuous channel adhering to and involving various structures. In such case

the surgeon may open the abdomen at a point outside of the area immediately affected, may search for the afferent and efferent limbs leading to and from the fistula, may resect them, and unite their cut ends to each other, or may treat them by entero-anastomosis. In either case the side-tracked intestine must be closed up lest it serve as a pouch for fecal accumulations which will keep the fistula open. The after-treatment of these cases does not differ from that given to any case of enterectomy.

The formation of artificial anus may be accomplished by sundry methods, but in all the surgeon's effort must be to provide for complete evacuation of the intestine through the artificial anus. Owing to the



Fig. 30.—Kocher's method. Artificial anus.

frequency of malignant obstruction in the rectum and sigmoid flexure, the descending colon or upper portion of the sigmoid is the portion of bowel commonly selected for artificial anus.

Various attempts have been made to provide a sphincter for the new anus by utilizing the abdominal and thigh muscles, but no method has proved entirely satisfactory. I recommend Kocher's method: Make a cut on the left side, about four inches long, through skin and fascia, two finger-breadths above, and parallel to, Poupart's ligament. Splint the fibers of the internal oblique and transversalis muscles, as in the McBurney incision. Retract and divide the fascia transversalis.

Open the parietal peritoneum and draw its edges well outside the wound, so that they form a funnel. Through the funnel draw out a loop of the bowel selected, and stitch it to the edges of the open peritoneum outside of the abdominal wall. Close the skin-wound about the protruding intestine. It is well not to open the bowel at once, but to leave it for from two to four days, to form adhesions in its new position. Then open the afferent portion, preferably with the cautery. The abdominal muscles will form a sphincter for the control of feces, and, with a supplementary dressing and padded truss, will provide the patient with a fairly satisfactory anus.

THE MESENTERY AND OMENTUM

Injuries and diseases of the mesentery and omentum deserve a word of notice. Incidentally, I have spoken of traumatism of the mesentery, and we have considered at some length mesenteric thrombosis. There are, moreover, sundry tumors of the mesentery occasionally to be found—malignant tumors and benign tumors, as well as cysts. The tumors may remain latent for years, or they may give rise to symptoms due to pressure upon organs or to obstruction in the intestinal circulation.

The **diagnosis** rarely can be made, but one should operate for tumor or obstruction and be governed by what he finds. The question of vital importance in all operations upon the mesentery is that of possible damage to the intestinal circulation. If the removal of a mesenteric tumor is inevitable and involves destruction of vessels, the corresponding portion of the intestine must be resected.

The *omentum*, being covered with peritoneum, is subject to those diseases which involve the peritoneum. It shares frequently also in diseases of the organs which it overlies. One finds in the omentum cancer spreading from the intestine, tuberculosis, actinomycosis. It becomes inflamed and gangrenous. It may be involved in herniæ, and be constricted and necrotic. It may contain within itself tumors of great size. It may become twisted and strangulated.

These varying conditions give rise to varying **symptoms**, which rarely may be diagnosticated with certainty. The only possible treatment is by operation and removal of the affected omentum. Tumors must be excised; gangrenous and strangulated portions must be removed. Operations for removal of portions of the omentum are extremely common, but there is one point of importance in the technic. The affected omentum must not be tied off *en masse*, but a series of ligatures overlapping each other must be passed through the portion of healthy omentum above the disease, and secured separately, in order to insure perfect hemostasis—a difficult matter often in the slippery and elusive substance of the fatty omentum.

So much for the intestines and their appendages. It is difficult for the student, or for the experienced practitioner, to separate the diseases we have been considering from diseases of other abdominal organs, of

which the lesions may complicate or simulate diseases of the intestines. Constantly the reader must be bearing in mind the fact that few of these intestinal disease processes appear as distinctive entities. Varieties of symptoms overlap and interlace. Varieties of signs mislead and confuse. Anatomic relations are indefinite, shifting, puzzling. Gradually, as he studies, the reader will perceive that the conglomerate mass of abdominal organs, whether normal or diseased, begin to arrange themselves in their logical relations and positions. Sometimes he may see special organs and special diseases standing apart from their fellows. In this chapter we have dealt with such independent diseases.

CHAPTER III

THE RECTUM AND ANUS

After the reader has gained a general acquaintance with diseases of the intestines, his curiosity will lead him to inquire about the terminal portion of the gut—the rectum and the anus. A knowledge of these parts is essential to an understanding of intestinal disease, for anatomic and functional disturbances of the terminal portion of the canal are closely associated with, and simulate or mask, diseases of the intestines proper. For example, constipation and diarrhea are conditions, the

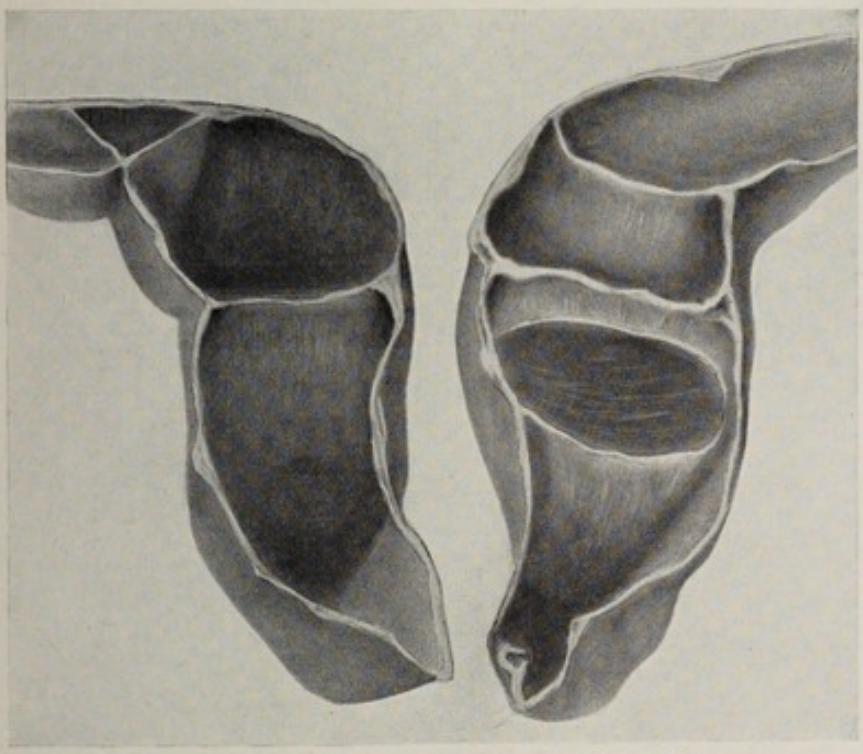

Figs. 31 and 32.—Rectal valves (Martin).

cause for which must be sought in all portions from gullet to anus. Obstructions may be high in the duodenum or low in the rectum, and peritoneal infection may arise from lesions in any part of the alimentary tract.

Inflammations and new-growths are causes of rectal disturbance as commonly as they are causes of intestinal disturbance, but the rectum is subject to *two* special conditions which are seldom found in the upper reaches of the gut with the exception of the esophagus—disturbances of circulation, leading to venous engorgement and hemorrhoids; and congenital malformations, extending sometimes to complete occlusion.

Surgery of the rectum in patients of all ages, from birth to advanced years, concerns the student, and the first condition of interest is that of—

HYPERTROPHY OF THE RECTAL VALVES

These valves, normally three in number, are commonly called Houston's valves, and their proper function is to control the descent of fecal masses into the rectum. Hypertrophy of these valves may be so extensive as to interfere seriously with the movements of the bowels, or as to cause an almost complete obstruction even. A great many cases of hypertrophy of Houston's valves—when the hypertrophy is an inflammatory or congestive process—may be relieved by touching the injected mucosa through the proctoscope with a 5 per cent. solution of silver nitrate, taking care to cover an area no larger than a ten-cent piece, to wash out the rectum at once with a normal saline solution, and to leave the affected area well powdered with sodium bicarbonate. If this simple treatment fails to relieve the disorder, the surgeon may cut down the edge of the valves.

IMPERFORATE ANUS

It is the duty of the practitioner to examine carefully a new-born child after delivery, in order to ascertain congenital defects. In a certain proportion of cases he will find that there is no anal opening,

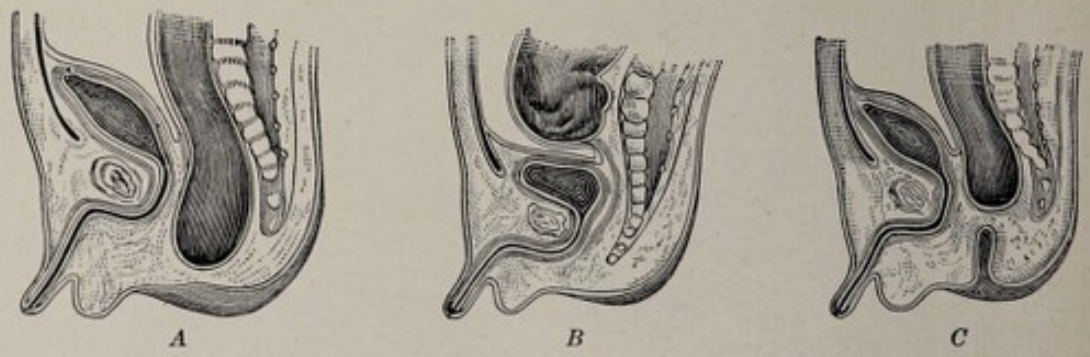

Fig. 33.—Imperforate anus: *A*, Thick layer of tissue intervening between the rectum and the site of the anus; *B*, occlusion of the rectum; *C*, imperforate rectum (Esmarch).

or that the anal canal ends shortly in a blind pouch. The sphincter and levator ani muscles are properly developed, but the rectum does not communicate with the anus.

There are three types of imperforate anus and rectum: (1) That simple type in which the bowel comes down to the sphincter and is separated from the skin by a thin membrane only; (2) the form in which the anal dimple is seen, but is separated by an appreciable distance, measured in inches, from the end of the gut; (3) the form in which the bowel empties through a fistula into the genito-urinary tract, bladder, urethra, vagina.

Imperforate anus is due to failure of proper fetal development, and the **symptoms,** after birth, are striking and almost immediate,

varying with the nature of the abnormality. If the rectal obstruction be complete, there will result a failure to pass meconium; with this there are associated abdominal distention, colic, lack of appetite, vomiting, malnutrition, and death. If the bowel open into the genito-urinary tract, feces will be passed by the urethra or vagina, and the symptoms of intestinal obstruction will be slight or entirely absent. Under these circumstances the child may survive to maturity even, but in addition to the intense discomfort of the unnatural condition and its disgusting evidences, there is always present the danger of septic infection of the kidneys and genital organs. Most of these fistula cases die in a few months, however, unless relieved by operation.

The only **treatment** is by operation. The procedures are interesting and various. The first and simplest form of imperforate anus is easily remedied; but, unfortunately, the simplest condition is not the common condition. When a diaphragm of thin membrane only separates the

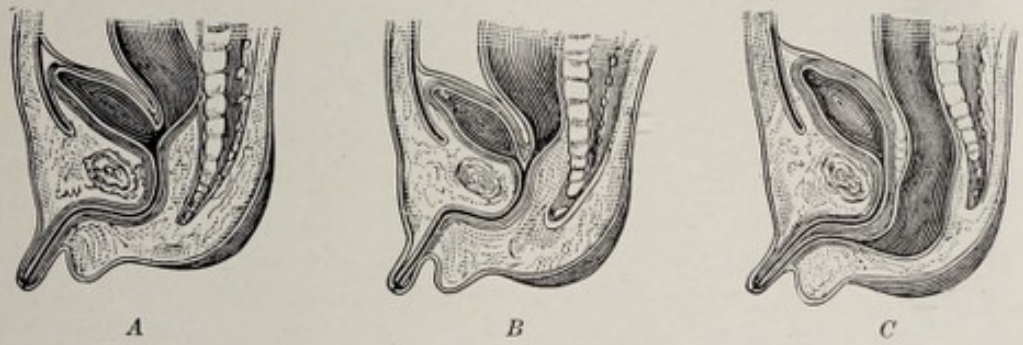

A *B* *C*

Fig. 34.—Imperforate anus with different cloacal openings (male): *A*, Terminating in bladder; *B*, terminating in the urethra; *C*, terminating at the meatus (Esmarch).

bowel from the skin, meconium may be seen through it, or an impulse may be felt when the child cries. In such case rupture with the finger or aspiration of the bowel through the anus, and drainage for a few days with catheter or gauze, will establish a cure, care being taken that the opening is kept patent by daily stretching.[1]

The second type of imperforate anus is far more difficult of treatment, and the mortality is far higher. If bulging outward can be seen, the surgeon should make a median anteroposterior incision from the scrotum or vulva to the coccyx. The incision must be exactly in the middle line, so as to divide the external sphincter at the raphé. Thus the bowel may be entered, after which it is carefully washed out and the mucous membrane stitched to the skin.

A high closure of the rectum presents a still more difficult problem. If no bulging at the anus can be seen, the surgeon has no knowledge as to the location of the rectal pouch, and his operation, if done as described in the last paragraph, must be done blindly. Curling and Anders state that by the perineal operation surgeons have failed to find the bowel in 30 per cent. of these cases. For this reason it is good

[1] E. H. Small, in an interesting paper read before the American Medical Association, 1905, describes a difficult case of this type, showing how, after aspiration, the bowel will itself gradually descend and unite with the anal skin.

practice, in the case of such complete rectal occlusion, to open the abdomen above the pubes, to establish an artificial anus in the groin, and later, perhaps after many months, when the child is well-nourished and vigorous, to make a secondary operation by the combined method,—working from above and below,—in order to bring down the rectal pouch. This is the intelligent and proper surgical method. Blind groping from below is dangerous; especially to be condemned is blind aspiration from below, because thus one is almost certain to open the peritoneal cavity and is likely to smear it with meconium.

Rectal occlusion combined with fistula into the other organs presents another problem difficult of treatment. Fortunately, the condition is rare. The operation begins like that for uncomplicated occlusion. When the bowel is low down, it should be reached by the perineal route. Then the bladder or urethra must be separated,—a difficult matter,—and it is well, as a preliminary, to pass a small sound through the urethra or bladder into the rectum, and so to locate the lowest point of the latter organ. Often the point of the sound, when it is directed toward the anus, may be felt in the anal cleft. Deep dissection of the perineum will then develop the fistula, which must be clamped, cut off, and the bowel and vesical openings turned in and sutured. If the fistula is placed high, so as not easily to be reached, the abdomen should be opened, an artificial anus established, and later a secondary operation done to close the rectovesical fistula. In all these operations abundant provision for drainage must be made, and every pains must be taken to prevent soiling the peritoneum with meconium and feces.

At the best, these operations show a high mortality, and Anders publishes the following table:

	Cases.	Mortality.
Proctoplasty	44	29 per cent.
Incision	27	33 " "
Colostomy	21	52 " "
Puncture	4	50 " "

INFLAMMATIONS

Inflammations about the rectum and anus are manifold, and lead to a great variety of results, depending upon the origin of the infection. They may give rise to hemorrhage or to intestinal obstruction through peritonitis. Owing to the extremely septic condition of the normal rectal mucosa, these inflammations are frequently acute and sometimes fatal. Septicemia, pyemia, general peritonitis, and gangrene may result, and must be treated appropriately when they are discerned. Such alarming conditions call for extensive drainage and excision of the necrotic portions. Foreign bodies, such as fish-bones, safety-pins, and gall-stones, may lodge in the rectum, and great fecal masses may become inspissated and plug the outlet. Many years ago I saw, at the Massachusetts General Hospital, a curious case in the service of M. H. Richardson. The patient, a man with perverted instincts, had introduced through the anus a large catsup-bottle, of quart size, neck first, until it slipped from his fingers and passed into the bowel. Such

large bodies can be secured only by splitting the sphincter backward to the coccyx so as to allow of their free exit. Small bodies, like fish-bones, can be seen through the proctoscope, and may be secured with the fingers or forceps. Fecal masses may be dissolved and washed out with lime-water enemata, or may be broken up and removed piecemeal with a spoon or the finger.

I have seen serious damage to the rectum inflicted by the patient himself roughly introducing the hard nozzle of a Davidson syringe, which lacerated the mucosa and gave rise to a wide-reaching periproctitis; the resulting inflammation was so extensive that the mass encroached upon the rectum, and for some time was mistaken for a malignant growth.

Inflammations about the rectum and anus arise commonly from external causes, or from ulcerations of the mucosa extending to and involving the surrounding tissues. *Pruritus ani* is one of the commonest and most distressing of conditions. It is a symptom, not a disease. It may be due to a variety of causes, from syphilis or gonorrhea to a simple eczema, to pin-worms, or to filthy habits.

Treatment must be directed to removing the underlying cause, and especially the frequent constipation, while for the local conditions the surgeon must prescribe careful soap-and-water bathing several times daily, and the application of an oxid of zinc ointment, or a wash composed of phenol, 1 part; alcohol, 3 parts; chloral hydrate, 10 parts; water, 86 parts. J. R. Pennington[1] reports excellent results from the *x*-ray treatment of pruritus, and his experience corresponds with my own.

Simple **proctitis** and **ulcers of the rectum** may be due to mechanical irritation, such as the pressure of a tied-down uterus, to the use of strong laxatives, exposure to cold, foreign bodies, fecal impactions, traumatisms from hard syringe nozzles, and to hemorrhoids, rectal prolapse, on anal fissure. The course of the inflammation may be acute or chronic, and the actual condition invariably must be ascertained by the use of the proctoscope and by digital examination. The *symptoms* are fever, tenesmus with straining, fluctuating pains, and bloody or mucous stools. The *treatment* consists in removing the cause, if possible, rest in bed, a carefully regulated diet,—mainly of broth,—and mild daily irrigations of normal saline solutions, or 2 per cent. solution of argyrol. Sometimes ulcers may be treated by touching them with caustic (silver nitrate) or the actual cautery, and, above all things, it is essential that a tight sphincter should be thoroughly dilated; indeed, a great many of these local infections are due to chronic spasm of the sphincter.

Gonorrheal inflammation of the rectum is not uncommon, especially in women, in whom the infection occurs by direct extension from the vulva. The *treatment* is similar to that described in the previous paragraph.

Syphilitic affections of the anus and rectum must be treated on general principles, with topical applications of iodoform, by irrigation,

[1] N. Y. Med. Jour., February 20, 1904.

and by the internal administration of mercury and the iodids, according to the progress of the disease.

Tuberculosis of the anus and rectum shows itself in ulcerations, abscesses, and fistulæ. Ulcerations must be treated locally, and abscesses must be opened, but far more important is hygienic treatment directed to the general tuberculous condition. This treatment embraces a constant life in the open air, whether in city or country, and such tonics as iron, malt, and cod-liver oil. An out-of-doors life often suffices to relieve, or to effect a cure, in these cases.

FISSURE OF THE ANUS

Fissure of the anus, improperly so called, is a trifling but very distressing affection. Properly, anal fissure is a small ulcer at the muco-

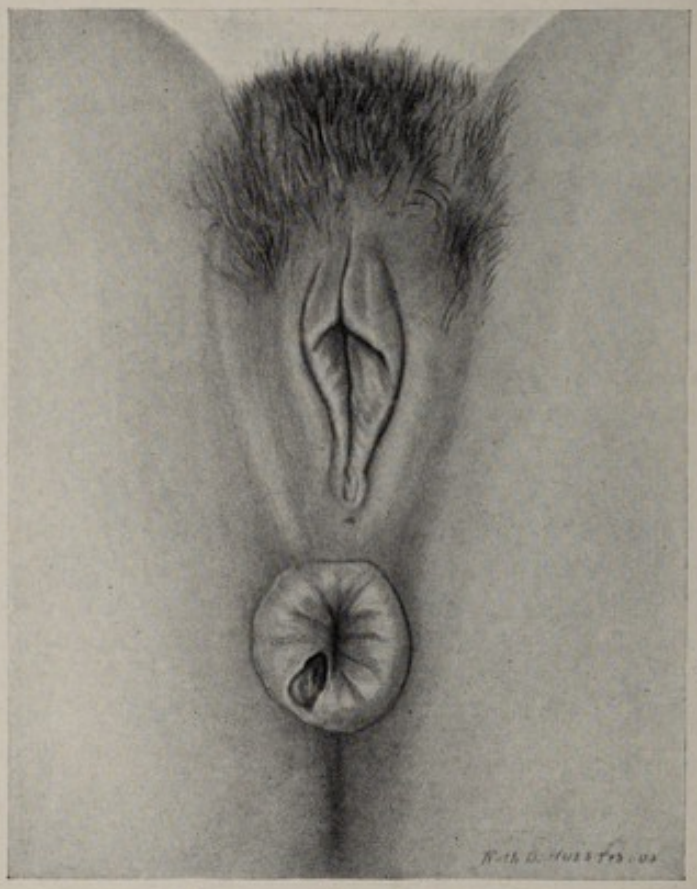

Fig. 35.—Fissure of anus.

cutaneous margin. It may be due, among other causes, to fecal irritation, piles, or scratching. With the patient in the lithotomy position, the anal folds may be stretched apart and the ulcer revealed. *Treatment* is either palliative or radical, and the radical treatment generally is the better. Palliative treatment involves constant visits to the surgeon, who applies cleansing applications, drying powders, and caustics, with directions for a limited diet and careful regulation of the bowels. By such means the ulcer may heal after weeks or months, but the activity of the sphincter and the frequent passage of feces over the ulcer render its healing through these measures a tedious

process. The radical treatment—which is usually to be recommended—consists in a slight operation, quickly recovered from: the bowels are thoroughly evacuated, the patient anesthetized, and the sphincter paralyzed by stretching. A simple index of proper stretching is the passing of the surgeon's four fingers, up to the metacarpal joints, into the rectum, until they slide easily in and out. The sphincter remains paralyzed for a few days, and the quiescent ulcer has a chance to heal, while fecal movements are prevented by the use of a broth diet. On the fifth day the bowels are moved by cascara, oil, and an oil enema. After this the patient may resume his regular habits as to diet, and may go about his business.

ISCHIORECTAL ABSCESS

Ischiorectal abscess is a general term applied to abscesses in the periproctal connective tissue. A glance at the accompanying figure (Fig. 36) shows how numerous may be the sites and directions of burrowing of such abscesses. Ischiorectal abscess is common, and examples of it may be found frequently in every surgical ward. It occurs in persons of all ages and in all degrees of health. It may be acute or chronic; it may be localized or diffused. The commonest form of abscess in this region starts in the neighborhood of the sphincter ani is due to infection from the gut, inflamed piles, and is localized in the fat tissues about the anus, outside of the deep pelvic fascia. Again, it may extend beyond the fascia and involve the soft parts, between the ischium and the levator ani muscle, or it may pass beneath the internal sphincter, burrow up indefinitely along the rectum, and invade the peritoneum. The extent and location of these abscesses are in the order I have named, but the superficial acute abscess is far the most common.

These periproctal abscesses are due usually to some irritation within the rectum or anus, such as abrasion by hard fecal masses, small ulcers, ulcerating piles, or wounds by foreign bodies. Sometimes a fissure is the source. Frequently the patient will tell you that he noticed his first pain after a difficult movement of the bowels. The pain is sharp and throbbing. Sitting down is very distressing. The sufferer must stand or recline. Movements of the bowels are agonizing often. The patient is feverish, distressed, loses his appetite, and will tell you that he is a very sick man. The severity of the symptoms seems out of all proportion to the apparent extent of the lesion, but the severity of the symptoms is no trifle, because septic absorption from this lesion is rapid and continuous.

Diagnosis.—The surgeon cannot thoroughly examine the patient without an anesthetic, but generally, in spite of the sufferer's extreme sensitiveness, the surgeon may pass his forefinger within the sphincter, where he will detect a smooth, rounded induration, which may be grasped between the thumb and finger, and feels like a thickened sphincter. Sometimes there is bleeding from distended and eroded hemorrhoids. In some cases the surgeon may be unable to distinguish between a mass of hemorrhoids and a beginning ischiorectal abscess; indeed, the two may be associated; but the patient's account of throb-

bing, boring pain and extreme distress on sitting down, with fever and rapid pulse, confirms the diagnosis of abscess.

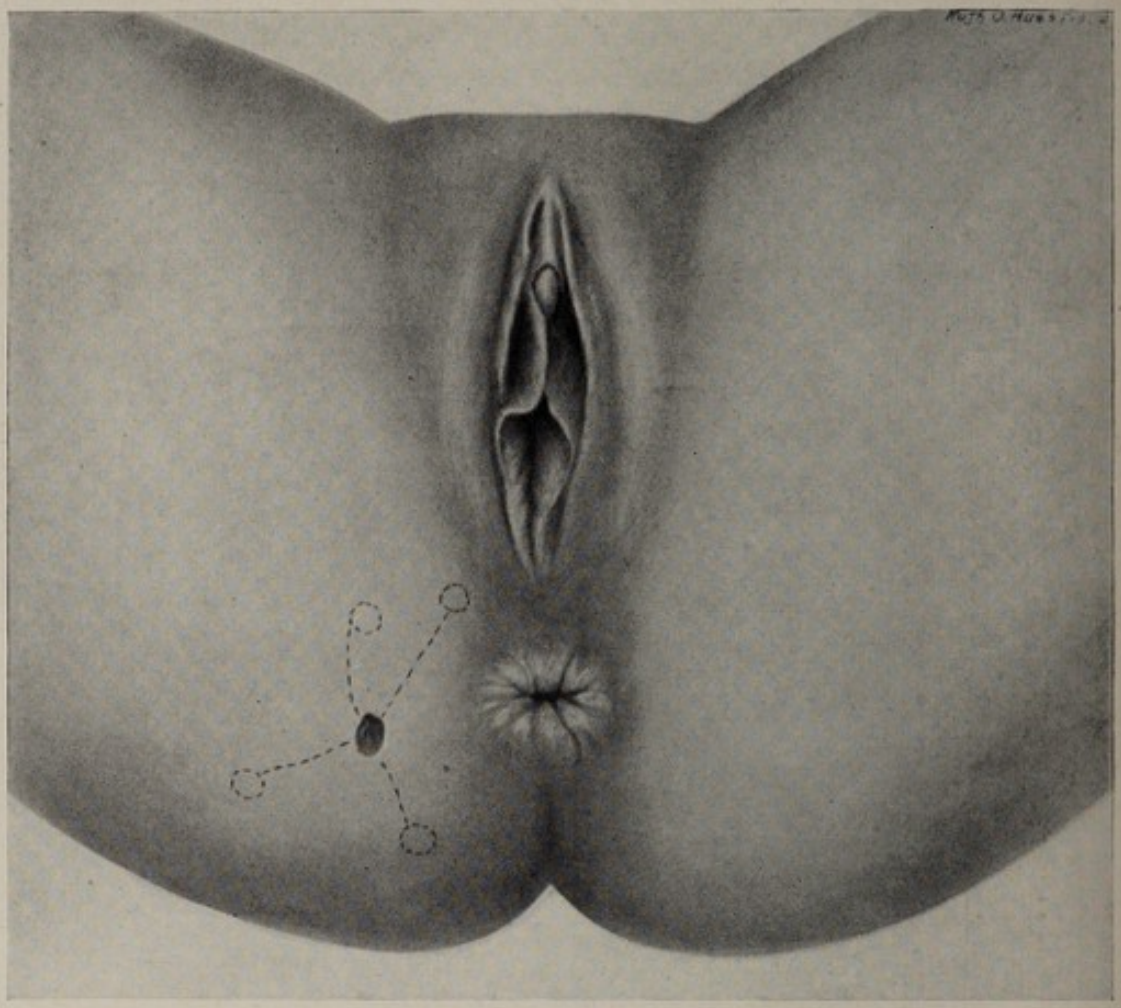

Fig. 36.—Ischiorectal abscess. Dotted lines indicate burrowing fistulæ.

More deeply seated abscesses are characterized by an exaggeration of the symptoms I have described. The constitutional disturbance is graver. Pulse and temperature may run high, and the patient's condition may be alarming. Generally, obstipation is complete, and there is a high leukocytosis. In advanced cases there may be present the signs of a local or general peritonitis. Examination of these cases may be difficult, but a glance at the buttocks usually is enough to convince the surgeon that a serious inflammation is present. In acute cases one sees a deep purplish injection of the skin, with fullness about the anus and edema of the parts. The finger introduced into the rectum lights upon the more or less elastic or doughy, constricted canal.

The **treatment** of all these cases of acute abscess is operative, for palliation seldom does good even to the mildest cases. Writers will tell you that cold applications, cold sitz-baths, warm saline irrigation, and sundry much-vaunted remedies may abort the disease. Do not be misled. Rarely with a superficial abscess at the outset you may succeed by applications in checking its progress, but do not procrastinate more than twenty-four hours.

The operation for all forms of periproctal abscess is free incision

and drainage. Open by a cut parallel to the fibers of the external sphincter—either through it or outside of it. Usually you may avoid opening the rectum. Scoop out thoroughly all pus and sloughs. Irrigate and pack lightly with iodoform gauze. Generally, reaction begins at once, and in a few days comparative health is restored; but the patient must be kept in bed so long as the wound requires deep packing, and he must appreciate, from the outset, that the convalescence will be slow. As usual, when the rectum is operated upon, the bowels must be kept quiet by the use of a liquid diet without milk for a few days, and after regular movements are established the wound should carefully be kept cleaned by irrigation after every defecation.

Chronic abscess about the rectum and anus is not commonly a sequel of acute abscess, but is due most often to tuberculosis, and it starts either inside the rectum or about the anus. Such chronic abscesses develop slowly and with little discomfort to the patient. He discovers them finally by the sense of touch or by observing some slight obstruction to defecation, with possibly pus or blood in the stools. These abscesses must be opened, drained thoroughly, and made to heal from the bottom by daily packing with sterile gauze or iodoform gauze. The course is very slow and is dependent upon the patient's general condition, which must be supervised, as I stated in discussing tuberculosis of the rectum.

FISTULA IN ANO

Fistula in ano is a frequent result of inflammation about the rectum, and is a direct outcome of ischiorectal abscess from infected hemorrhoids. Such a fistula represents the track or site of an abscess incompletely healed, and not treated by thorough drainage from the bottom. It is a common lesion and is seen more frequently in men than in women. From my description of ischiorectal abscess the reader will conclude correctly that the fistula may or may not be tuberculous. When tuberculous, it is chronic and obstinate, and may not heal under the the best of care even. We recognize three forms of fistula in ano: (1) Blind internal fistula, which represents an abscess that has opened into the rectum; (2) blind external fistula, which represents an abscess that has opened externally, and (3) complete fistula, representing an abscess which has opened internally and externally. The internal opening may be above or below the external sphincter. These fistulæ may be numerous and complicated, and may have many tracks burrowing in all directions into the buttocks.

The symptoms of fistula are annoying, but are not often painful. The blind internal fistula may become a receptacle for feces and so one may see a secondary abscess and extension of the process. The blind external fistula appears to the patient as a trifling running sore generally, which may itch and throb occasionally. The complete fistula forms a false channel for the passage of feces and flatus, and is the most annoying form of this disease.

The **diagnosis** must be made by careful inspection of the parts and by probing to ascertain the situation and extent of the fistula.

The only rational **treatment** is by operation, though sundry practitioners still attempt a cure by the ancient methods of irritant injections and by setons. As Elting[1] writes: "Two cardinal principles should underly the treatment of fistula in ano; first, the separation of the fistulous tract or tracts from the communication with the bowel, and secondly, the adequate closure of that communication with the removal of all the diseased tissues in the rectum." Before the radical operation the patient must have his bowels thoroughly cleared out and the parts shaved and cleansed with soap and water. He must be anesthetized, but a preliminary stretching of the sphincter, as sometimes is proposed, is not necessary. The usual operation consists in passing a probe or

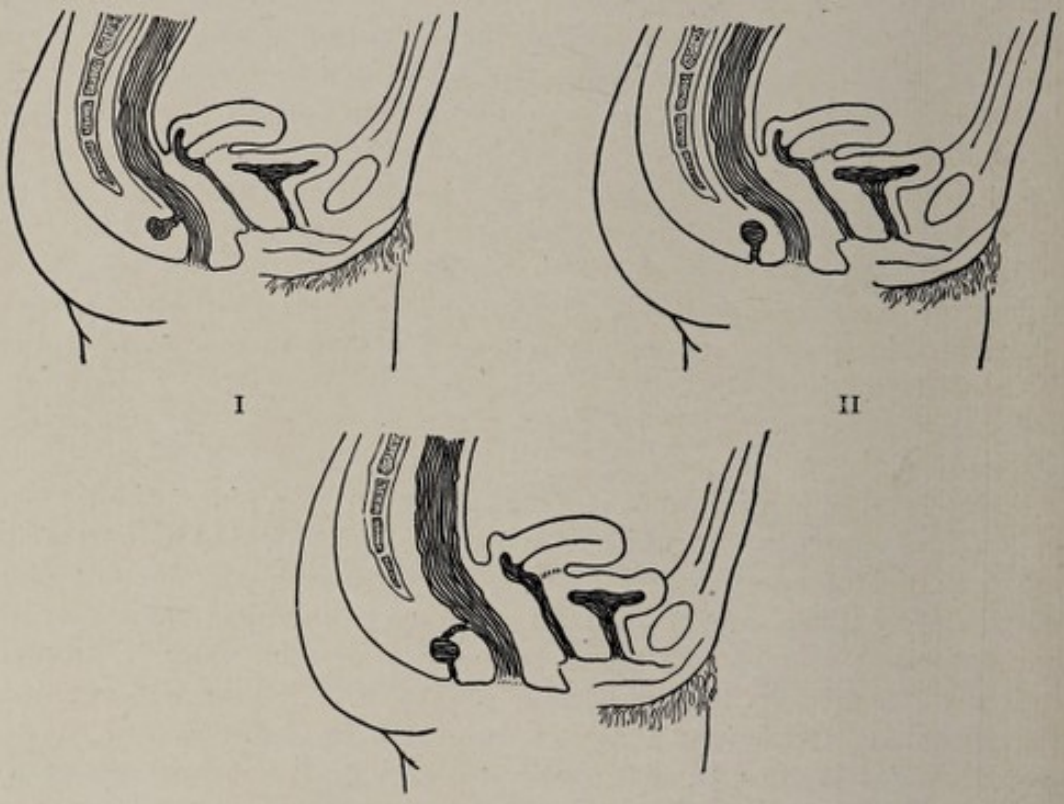

Fig. 37.—Forms of fistulæ (schematic).

director into the depths of the fistula, or through it, if it is complete, and a thorough laying open of the tract, followed by curetting or cauterizing and packing with iodoform gauze. It is sometimes difficult to discover the opening of a blind internal fistula. One may have to dilate the sphincter with the fingers or pass the proctoscope. Insert a bent probe into the fistulous opening, and pass it to the bottom of the fistula; then lay open the tract with a knife. A majority of all fistulæ leave the external sphincter uninvolved, but if this muscle is penetrated or involved by the fistula, it must be cut across. The cut sphincter recovers its normal function (almost always), especially if it be cleanly divided in one place only, and if that place be at the raphé. Elting operates as follows on patients in whom the fistula communicates with the rectal canal: "A thorough dilatation of the rectal sphincters, *laterally*. With

[1] A. W. Elting, Ann. Surg., November, 1912.

a probe the general course of the sinuses is located, and the communication with the bowel is determined, if one be demonstrable. A circular incision at the junction of the skin and mucosa is then made and the bowel dissected away from the external and, if necessary, the internal sphincters, which are carefully pushed upward and away from all possibility of injury." He dissects above the internal fistulous opening. So he separates the fistulous tracts from all communication with the bowel. All fistulæ are curetted from without. Then the lower end of the rectum is amputated above the internal fistulous opening, and the raw gut edge is stitched to the skin margin, the interrupted silk sutures being placed so as to obliterate dead spaces. The external fistulæ are packed and heal rapidly.

In operating upon fistulæ which do not penetrate or involve the rectal canal the surgeon may sometimes practise a careful dissecting out of the tract. Pass a stout probe or grooved director through the fistula, and dissect around it, cutting out the probe with its sheath of fistula exactly as though it were a vermiform tumor. This procedure leaves behind a clean, fresh, superficial wound, which may be sewed up by encircling stitches, carefully inserted so as to take up and obliterate the gap. Frequently one succeeds in securing a primary union by this method, but when employing it, one must pay the closest attention to aseptic technic. After all operations upon fistulæ I recommend keeping the bowels quiet for five days at least, or a week if the patient can

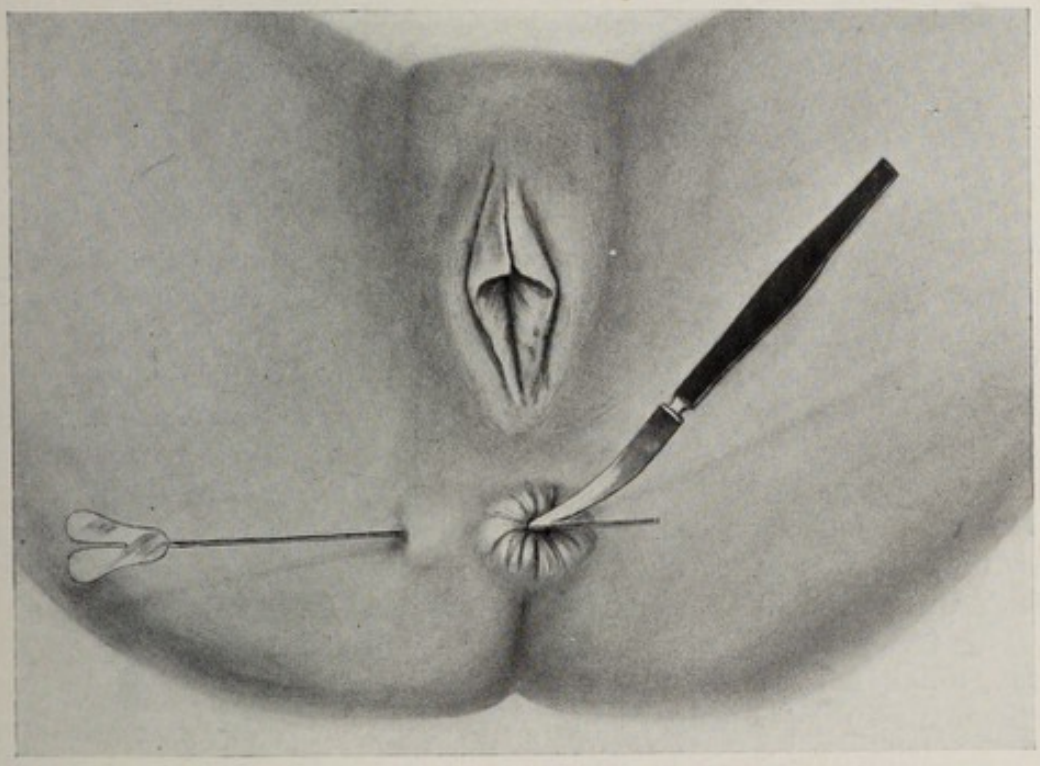

Fig. 38.—Operation for fistula in ano.

be made comfortable. The outside dressing after these operations, as after all operations upon the anus and rectum, is a rather scant pad of gauze and cotton held in place by a T-bandage.

HEMORRHOIDS

Hemorrhoids are common to all mankind.[1] First and last, few persons escape them. Hemorrhoids are usually regarded as distended, tortuous veins—varices of the rectum. Reinbach thinks the essential part of the process to be a new formation of capillary vessels. Therefore he speaks of hemorrhoids as angiomata. Gunkel agrees with him, but has found the veins to be varicose in a few cases of pregnancy and pelvic tumor.

We distinguish three varieties of hemorrhoids: *Internal* hemorrhoids, found within the external sphincter, and developed in the superior hemorrhoidal plexus of veins; *external* hemorrhoids, developed about the anus, in the branches of the inferior hemorrhoidal plexus, the blood from which passes into the pubic veins; and *mixed* hemorrhoids, which are a combination of the other two.

Internal hemorrhoids are the most difficult to determine; they vary much in size, according to the nature and caliber of vessels involved, and they may or may not bleed easily. They extend from just above the anal margin upward for an inch or two. Arteries are not involved. Piles are due to any cause which induces venous congestion of the rectum—pregnancy, tumors, habitual constipation, portal obstruction, certain heart and pulmonary diseases, sedentary occupation, and stricture of the urethra. Probably constipation is the most common cause. Conversely, piles are a cause of constipation. Constantly one sees neurotic persons, especially neurasthenic women, who suffer from constipation and have a consequent development of piles. Remove the piles and you will cure the constipation, which in turn has been aggravated by the piles. The patient with piles dreads the act of defecation, and so a vicious circle is established.

The most common symptom of internal hemorrhoids is bleeding—usually a few drops, a mere streaking—occasionally a considerable gush of bright blood. Observe that the blood from hemorrhoids is bright and fresh in contrast with the tarry, partly digested blood which comes from high up in the intestines. Sometimes piles cause a sense of weight, oppression, and aching. Finally they protrude when the bowels move, and must be replaced if subsequent pain is to be avoided. Truly painful piles are those which protrude, are caught down by the sphincter, and become engorged and strangulated. Such strangulated piles may swell to a considerable size—as large as a child's fist even, and, if unrelieved, become necrotic, gangrenous, and may slough off.

The **treatment of internal piles** varies with the gravity of the case. Small masses, which bleed seldom and do not protrude, may be kept in subjection by palliative measures, such as a restricted diet and the avoidance of alcohol, highly spiced foods, and slothful habits. Prescribe regular exercise, a course of Carlsbad salts, and nightly doses of cascara sagrada. After each movement of the bowels, and night and morning, direct the patient to apply a cold sponge to the anus for five minutes. The cold douche, directed against the parts,

[1] The common term *piles* is from the Latin *pila*, a ball or rounded mass.

is still better. Slight bleeding may be relieved and controlled by astringent injections, and of these, an excellent remedy is fluidextract of hamamelis, of which one-half ounce is injected morning and night into the rectum, and retained. Sundry ointments and suppositories are recommended, one of the best of which is Allingham's ointment, which should be rubbed in thoroughly after the use of the cold water.[1] G. W. Gay, of Boston, a surgeon of the widest experience, writes to me: "Internal piles may generally be much relieved, not cured, by injecting one or two drops of the following mixture: Phenol (95 per cent.), 1 part; glycerin and water, each, 5 parts. Two piles may be injected at once. No repetition for at least one week. The patient has no pain to speak of, keeps at his work, and nine times out of ten gets so much relief that he refuses more radical treatment." In a published article he sums up his treatment as follows:

"1. Inject only *internal* piles. 2. The solution of carbolic acid should not exceed 10 per cent. 3. Do not repeat the operation under

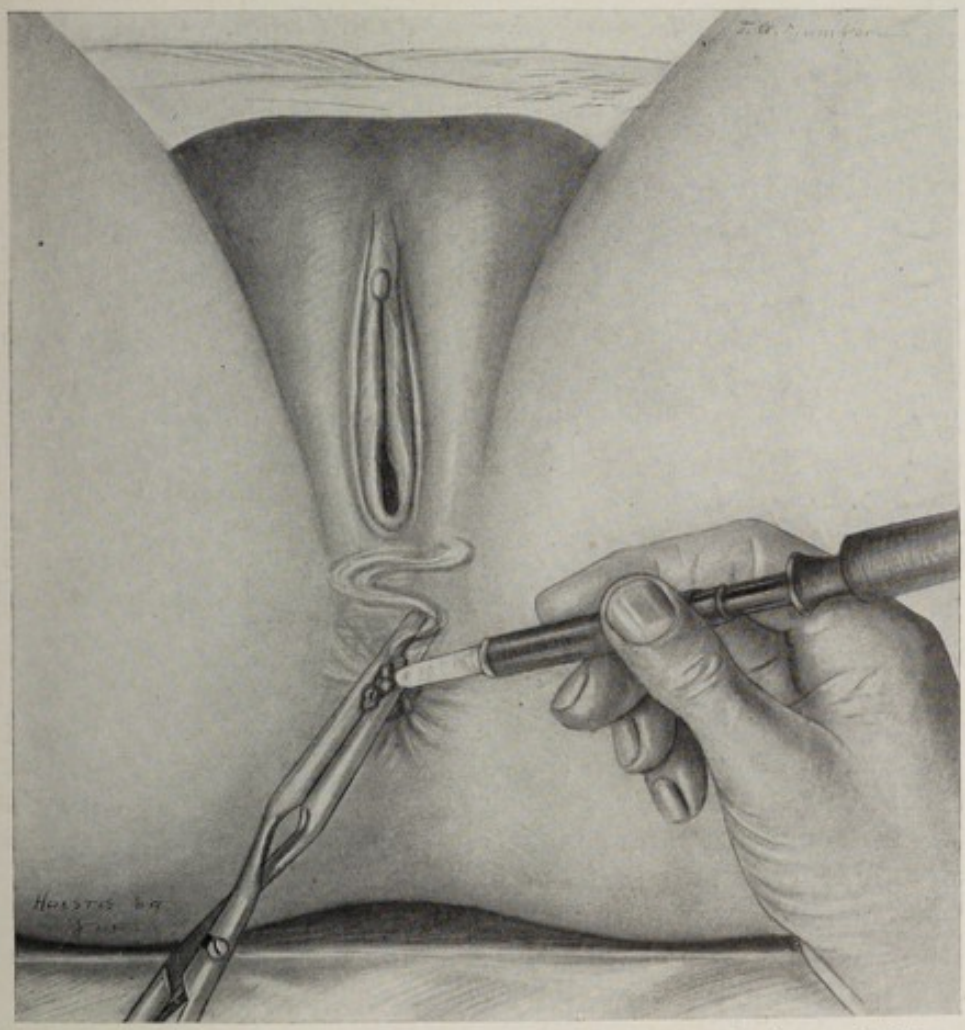

Fig. 39.—Clamp and cautery applied in operation for hemorrhoids.

a week. 4. Inject only one or two minims into each tumor. 5. Inject not more than two piles at any one time. 6. Promise relief only, and

[1] Allingham's ointment: Extract of conium and extract of hyoscyamus, of each, 2 drams; extract of belladonna, 1 dram; petrolatum, 1 ounce.

not a radical or a permanent cure." If the piles protrude and cannot be reduced, the patient should be put to bed and an operation undertaken; meantime, if you choose, relief, or reduction even, may be brought about by the sedative action of opium and hot poultices.

There are two operations especially to be recommended for extensive hemorrhoids—their removal by clamp and cautery and their resection —commonly known as Whitehead's operation.

Clamp and Cautery.—The bowels should be thoroughly evacuated by castor oil and enemata, and the patient should be kept on a liquid diet for twenty-four hours before the operation. When operating, have the patient on a table in a strong light and in the lithotomy position. Thoroughly clean and shave the external parts, and stretch the sphincter with the fingers. This evacuates any remnants of the enema and allows the piles to drop down within easy reach. When operating by clamp and cautery, it is not necessary to remove all the masses,—three are enough,—as too thorough removal results sometimes in stricture of the rectum. Grasp the bunch of piles with the forceps and squeeze it tight in a strong clamp, taking great pains not to include skin, and see to it that the clamp is placed parallel to the course of the rectum and not across it. Crush the piles thoroughly. Some surgeons regard this as sufficient and end the operation here. I prefer to employ the cautery also. With the crushed hemorrhoid protruding from the clamp cut away the redundant tissue and sear thoroughly the stump outside of the clamp. Caution: The clamp may become very hot and burn or blister the buttocks; therefore, protect the skin carefully with an asbestos shield or wet sponges. Having removed two or three bunches of piles and observed that hemorrhage is checked, allow the parts to sink back. Insert a $\frac{1}{4}$ grain morphin suppository, or, better still, dust the lacerated parts within the sphincter thoroughly with sodium bicarbonate, leaving 4 or 5 drams within the bowel. This usually suffices to relieve pain.

Whitehead's operation, so called, is practised and advised by many experienced surgeons, and I recommend it highly. It is applicable to low-lying hemorrhoids only. If employed high in the rectum it may give rise to stricture. The operation consists in stretching the sphincter, turning out the hemorrhoids, excising them with a knife, and sewing the severed mucous membrane to the skin.

External hemorrhoids are classified by Tuttle as thrombotic, varicose, inflammatory, and connective-tissue hemorrhoids. The terms are self-explanatory and indicate various stages of the same process. These hemorrhoids are multiple generally. If the veins are filled with clots, they may be opened with the knife and washed out. If they are varicose, they may be treated by either of the methods already described—clamp and cautery or excision; and the same statement applies to inflammatory hemorrhoids. The symptoms of all these conditions are pain and itching, with occasional slight hemorrhage. Connective-tissue hemorrhoids or skin tabs are due to hypertrophy of the mucocutaneous tissue at the margin of the anus. They are to be treated by excision with the knife or scissors.

PROLAPSE OF THE ANUS AND RECTUM

Prolapse of the anus and rectum is closely allied to hemorrhoids, which are a frequent cause of prolapse, as well as a complication of that condition. By prolapse of the anus we mean a protrusion of the mucous membrane only. By prolapse of the rectum we mean a protrusion of the whole thickness of the gut. The causes of these protrusions are numerous, and include, besides hemorrhoids, tumors, long-standing diarrhea and constipation, proctitis, congenital rectal stenosis, worms, phimosis, stone in the bladder, whooping-cough, and sundry exhausting constitutional disturbances which weaken the rectal supports, rendering them unable to withstand straining at stool. Prolapse is not uncommon in children, and is seen in persons of all ages, especially in women who have suffered from extensive lacerations in childbed.

The *symptoms* are protrusion of the gut or its lining, mucous or bloody discharges, and pain. If the prolapsed bowel is not reduced, it may become engorged up to the point of strangulation and gangrene, but the last condition is uncommon. The rule is, chronic prolapse easily reduced.

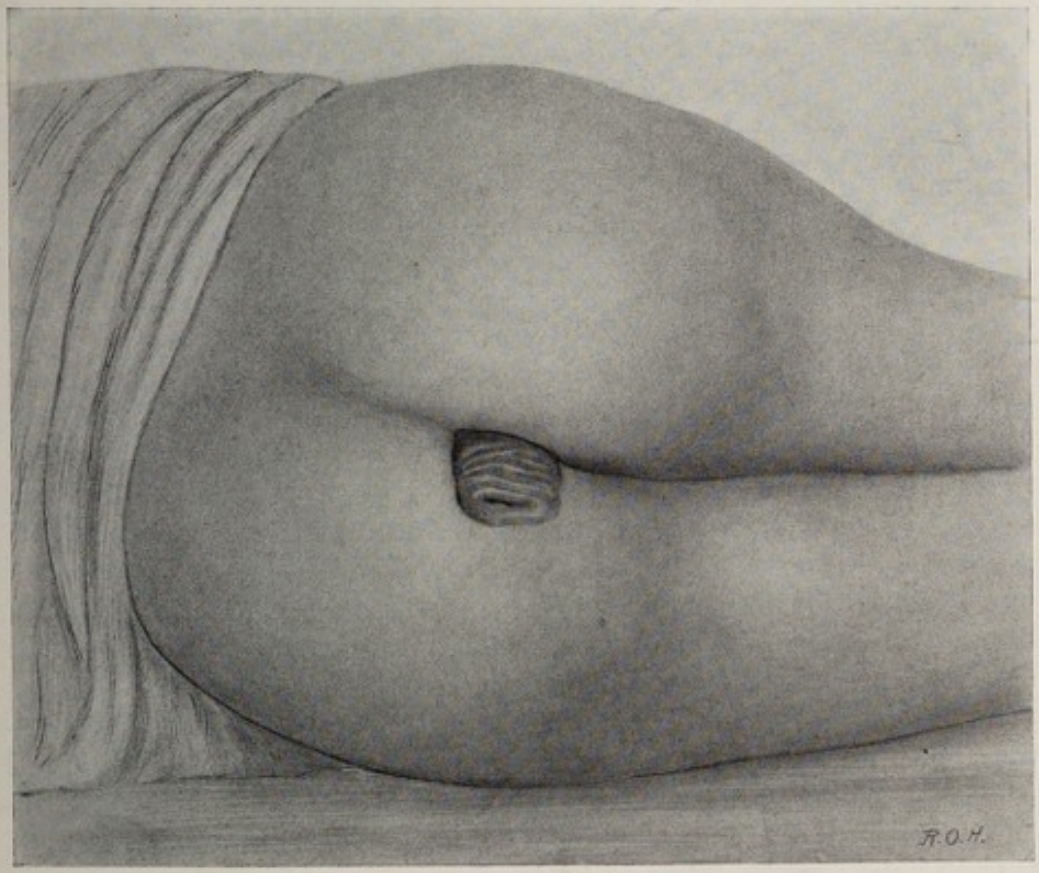

Fig. 40.—Prolapse of the rectum.

The **treatment** is either palliative or operative. *Palliative* measures include as most important: defecation in the recumbent position, a carefully regulated diet, the use of laxatives and enemata, and daily flushing of the bowel with cool water. Moreover, the primary cause must be removed—such causes as phimosis and stone in the bladder.

A rectal support by truss or napkin constantly must be worn. By such means many cases of prolapse in children may be cured.

Operative treatment varies according to the extent and chronicity of the disease. If the mucosa alone protrudes and the condition is recent, longitudinal searing with the Paquelin cautery may suffice. An effective method of operating is to take a wedge-shaped excision, made posteriorly, its base at the anal margin. The wound is closed at once with deep catgut sutures, combined with a superficial suturing of the mucosa and of the skin. When the prolapse is of long standing, especially when it is complicated with ulceration, chronic inflammation, or new-growths, the protruding portion must be amputated in the following manner: The prolapse is grasped with clamp forceps above the diseased area, carefully cleansed and disinfected, and surrounded with gauze. A small incision is made into the mucosa, and then into the wall of the rectum, until the fold is reached which separates the two walls of the prolapse. When this space has been opened, a suture is introduced, and as the surgeon proceeds with the dissection above the forceps, interrupted sutures are applied at once to shut off the peritoneal cavity. When the separation is completed, the final step consists in uniting with a continuous suture the contiguous lines of mucosa. *Rectopexy* and *sigmoidopexy* are sometimes satisfactory operations and are done as follows: The abdomen is opened, and the prolapsed gut is drawn up and fixed along a considerable length by two rows of continuous Lembert stitches to the peritoneum of the iliac fossa.

STRICTURE OF THE RECTUM

Stricture of the rectum may be congenital or acquired, and the acquired forms are due to new-growths and inflammatory processes. The characteristics of congenital forms and of tumor or neoplastic forms are obvious. *Inflammatory stricture* arises from extensive damage to the mucosa, resulting in scar-tissue formation and contraction.

The *symptoms* of inflammation of the rectum and their appropriate treatment have been described. The symptoms of organic obstruction, however, are of gradual onset. With organic obstruction there are increasing constipation, pain, and streaks of blood in the stools. Later, liquid movements only are passed. If the stricture is low down, but of caliber sufficient to admit formed feces, the masses may pass thin or ribbon-shaped. Such deformed masses are not seen when the stricture is above the ampulla. The motions are then normal in appearance. Sometimes, with the accumulation of fecal masses, there may result intestinal obstruction, more or less complete, with such constitutional changes as loss of weight, anemia, indigestion, stercoremia, and sundry nervous phenomena.

The **diagnosis** must be made by digital examination or by the use of the proctoscope.

The **treatment** for rectal stricture is various, depending on the cause of the obstruction and its location. Acute inflammation must be subdued, careful dieting and rest in bed must be prescribed, and if an

active syphilis or tuberculosis be present, it must be treated; but be it observed that old cicatrices, due to healed syphilitic ulcers, are not affected by potassium iodid. The caliber of the gut must be maintained by the careful use of bougies. Lothrop describes the operative treatment of rectal stricture as *dilatation, proctotomy, excision, entero-anastomosis, colostomy,* and *proctoplasty.* Gradual *dilatation* is safe and generally satisfactory. Rapid divulsion is dangerous. *Proctotomy* consists in incising the stricture either from without or from within—when from without, the disease is reached through the vagina or through the coccyx and sacrum. Dilatation is necessary as part of the after-treatment, and the method is unsatisfactory, except as a palliative measure. *Excision* of the stricture is performed in a fashion similar to excision of other lesions of the rectum, and will be described later in this chapter. *Entero-anastomosis* is applicable only in case of high stricture of the rectum, when a loop of the sigmoid flexure may be brought down and joined to the rectum below the stricture. *Colostomy* is employed in the case of inoperable malignant disease, or in the case of benign stricture, when immediate relief is necessary to save life. *Proctoplasty* is a useful measure, and is applicable often to the strictures found in the last 3 inches of the rectum. Lothrop describes an interesting method of proctoplasty.[1] He reports the case of a woman who was afflicted with a close stricture of the rectum 2 inches above the anal opening. The operator approached the stricture from the front, splitting the septum between the rectum and vagina by the so-called Tait method. A No. 18 French sound was then passed through the anus and stricture, and its tip was made to impinge upon the anterior wall of the rectum, pressing it up into the wound. Upon the sound, as a guide, the rectum was opened, longitudinally, a sufficient distance, and was held open by retractors. This cut split the stricture. The posterior wall of the rectum was then incised in a similar fashion, the knife being introduced through the anterior incision. The cuts anterior and posterior were then closed by approximating their upper to their lower ends, following the well-known Heineke-Mikulicz method of pyloroplasty. This operation resulted in securing a competent lumen for the rectum, which at the time of writing had performed its function satisfactorily for more than a year. In the case of a man the same operation may be done by approaching the rectum from behind, with or without resection of the coccyx and sacrum. After an operation for widening the caliber of the rectum it is generally necessary to follow up the treatment for a long time, even for life, by occasionally dilating with bougies.

TUMORS OF THE ANUS AND RECTUM

Tumors, and malignant tumors especially, offer the most perplexing problems of the various diseases of the rectum and anus. As with tumors elsewhere, a cure depends on extirpation; but extirpation of the lower bowel is one of the most difficult of surgical procedures,

[1] Howard A. Lothrop, Stricture of the Rectum: A Plastic Operation for the Relief of Certain Varieties, Boston Med. and Surg. Jour., April 27, 1905.

because complete eradication means a long and trying dissection, because the restoration of a complete anal outlet rarely is possible, and because asepsis can be attained by the most careful and painstaking work only.

A word about tumors of the anus: they may be benign and they may be malignant. About the anus are found condylomata, especially in women, and these condylomata are due to irritation from gonorrheal discharges. Considerable tumor masses form, which may be mistaken for cancer, but the masses do not infiltrate the skin. Histologically, they appear as papillomata. These condylomata may be excised safely and satisfactorily.

Cancer of the anus is found in rare cases. Cancer here begins a good deal as does cancer of the lip. But cancer of the anus grows rapidly, involving the skin rather than the mucosa, often completely surrounding the anus. The inguinal glands and the glands about the ischiatic nerve are affected early.



Fig. 41.—Benign tumors of the rectum (after von Bergmann).

The only effective treatment is a wide and thorough excision, such as will be described in dealing with cancer of the rectum.

Coming to **tumors of the rectum** proper, we find that *benign growths* are not especially uncommon, and that these may be grouped in two classes—a connective-tissue group and an epithelial group. The former group is seen to develop in the muscular tissue of the rectum —fatty tumors, myomata, and fibromata. Angiomata have been reported, and one finds rarely echinococcus and dermoid cysts.

All these tumors give rise to pain and constipation and may readily be discovered by digital or visual investigation. Frequently they may be removed without opening the rectal canal.

Of the epithelial *benign* tumors, adenoids or mucous polypi are the most common. They develop in the lower third of the rectum, and may be harmless or may give rise to a troublesome catarrh associated with tenesmus and hemorrhage. They are seen generally in children, but are often overlooked.

They may be snipped off or carefully excised, and the pedicle or resulting wound ligated or stitched. Unfortunately, these growths tend to recur and multiply, so that their removal results in temporary relief only. They are not common.

There is a rare form of papilloma of the rectum seen in adults; it

resembles a mucous polyp, but may be mistaken for cancer. It has a broad base, but does not infiltrate the mucosa.

Treatment is by excision and cautery.

Cancer of the Rectum.—Some competent surgeons still seem to feel that cancer of the rectum is always an incurable disease, and is susceptible of palliative treatment only. They justify this view by the fact that a large majority of patients suffering from cancer of the rectum consult a physician only *after* the time during which radical measures are practicable. At the best, a radical operation is often difficult and dangerous, and to insure success should be undertaken early in the disease. A few recent statistics are encouraging, if one may trust statistics. W. P. Petersen,[1] of Heidelberg, reports operations upon 248 cases of rectal cancer, with a mortality of 13 per cent.; permanent cure, 18 to 20 per cent.—that means, patients living over ten years. John A. Hartwell[2] reports 46 cases with an operative mortality of 26 per cent. Hupp[3] analyzes 881 cases with a mortality of 9.4 per cent. But reports vary in their estimates, some finding the mortality from operation to be as high as 70 per cent.

Cancer of the rectum is composed of cylindric cells like the epithelium from which it grows. Adenoma develops from the lining of the crypts of Lieberkühn. Early the adenomata may appear benign, but soon they take on malignant characteristics.



Fig. 42.—Scirrhus cancer of the rectum (von Bergmann).

We may divide true cancer of the rectum into three groups histologically: (1) Carcinoma of the rectal wall in the ampulla, the commonest cancer of the rectum, making up about 65 per cent. of all the cases. This is adenocarcinoma, and is generally found on the anterior wall, just above the anus. (2) Fibrous tumors, high above the pouch of Douglas, from 2 to 3½ inches above the anus. These tumors are hard, and vary in size from a walnut to an egg. These are the tumors which encircle the bowel early and produce stenosis. This group comprises about 23 per cent. of the whole, and one remembers of them that these high-seated tumors form a ring of stenosis. (3) The third group is the most malignant, but the least common—from 12 to 15 per cent. of all. These growths are of a mucoid nature; they develop in and envelop the lower portion of the rectum; they spread superficially and infiltrate the deeper tissues. Necrosis of these masses is seen commonly; and on inspection there appears a bloody, gangrenous tube, substituted for the normal rectum.

[1] Proceedings German Surgical Congress, 1903; Ann. Surg., December, 1903.
[2] Ann. Surg., September, 1905.
[3] Med. News, September 28, 1901.

The lymphatic connections of rectal cancer are of vital importance to the surgeon, because upon a knowledge of lymphatic extension depends the feasibility of successful excision. There are 4 lymphatic connections: (1) Those draining the anal skin; (2) the intermediate zone of the anal portion; (3) the columnar zone of the anal portion; (4) the group draining the rectum proper. Evidence of involvement of group 1 may be found in the inguinal nodes. The other three groups drain upward into the nodes in the sacral hollow and along the superior hemorrhoidal artery. Remember this important fact, however, that all 4 of these groups have a liberal anastomosis, so that disease of any portion of the rectum may result in the involvement of other portions and in the enlargement of any one of these lymphatic groups.

Here are a few interesting statistics to be noted in passing: Cancer of the rectum causes about 0.3 per cent. of all deaths; it is twice as common in men as in women. It is seen most frequently after forty, but cases as young as twenty-three are reported. Indeed, it is a remarkable fact that rectal cancer has been known in children below ten years of age.

Symptoms.—The early symptoms of cancer of the rectum are so indefinite that we cannot wonder at delay in establishing a diagnosis. The early symptoms are slight pain and bleeding and are not characteristic; often they are so indefinite as to cause a patient no special inconvenience; often they simulate the symptoms of other lesions; most commonly they suggest hemorrhoids. Later, there may be a sense of fulness and increasing constipation. Later still, when the disease is well advanced, there are fairly constant pain, hemorrhage, a foul discharge with gangrenous odor, and the evidence of more or less complete intestinal obstruction. Constitutional disturbance is not a marked feature early; indeed, in the 46 cases reported by Hartwell cachexia was present in only one-third at the time of the operation. So it is evident that the diagnosis rarely can be made early—seldom in less than nine months from the onset of symptoms; often as late as two years. These cancer cases emphasize again the extreme importance of making a careful examination of every patient who complains of constant rectal disturbance. Age signifies little, as cancer of the rectum may occur in youth. Pain and occasional hemorrhage always should be investigated, and the diagnosis confirmed by digital exploration or by inspection with the proctoscope.

Treatment of Rectal Cancer.—Obviously, no mild measures will avail in cancer of the rectum unless, indeed, the patient and his friends prefer that he content himself with the euthanasia produced by opium—perhaps the preferable method in a majority of cases. The question of methods of operation is one which has occasioned wide and rather hot discussion, its answer depending probably upon the notions and personal experiences of individual operators. The surgeon has to regard 3 factors in the problem: he must remove the cancer entire; he must combat sepsis; he must supply a satisfactory artificial anus.

The first point rarely is met. Cancer usually returns. As for the second, sepsis is common after all operations upon the rectum, and as for the third, a satisfactory artificial anus rarely is secured.

Let us consider briefly a few of the measures employed in attempting to attain these desired results. It has come about that there are three main routes by which cancer of the rectum is approached: (1) Through the perineal or anal region; (2) through the sacral region; (3) by abdominal section.

Approach to the cancer through the anal region gives no surety of complete and successful removal of the tumor, though in a certain number of cases success is attained. By this route the involved lymphatics cannot always be reached, and the employment of this method is no more rational than is resection of the cancerous breast, leaving the lymphatic connections undisturbed.

Resection of the rectum through the sacrum, that is, by removing a portion of the sacrum, as recommended by Kraske and others, is a fairly satisfactory method. Low-lying cancer may thus be removed and involved lymphatics traced. But an incompetent anus, situated in an inaccessible region, nearly always results.

The method to be preferred in a majority of cases is extirpation through the combined abdominal and sacral or anal routes. It is needless here to discuss at length the various arguments advanced by advocates of various methods. Suffice it to suggest that the abdominal route makes possible a cleaner dissection, with less chance of sepsis, and establishes a fairly controllable artificial anus in an accessible region; but, most important of all, it provides an aseptic field, and renders possible a complete removal of the growth and a comparatively easy reaching of the lymphatic channels. Bear in mind this important point also, that inasmuch as all the rectal lymphatics anastomose with more or less freedom, therefore cancer situated in any portion of the rectum, from anus to sigmoid, may give rise to cancerous lymph-nodes in any of the 4 lymphatic drainage channels which I have described. Above all things, the practitioner must remember that the presence of metastasis in other organs, notably, the liver, positively forbids excision of the rectum. Through abdominal section only can such metastases be found.

All operations for cancer of the rectum are difficult—not lightly to be undertaken. The surgeon must have an exact knowledge of the anatomy of the parts and an intelligent comprehension of his patient's general condition. At the best, both surgeon and patient are embarking upon a forlorn hope.

The patient must be carefully prepared, whatever the operation employed, and a daily treatment of the bowels, for from one to two weeks, is in order, that the passage may be completely cleared. Every morning before breakfast half an ounce of castor oil should be given, followed by an enema. The diet should consist of meat, eggs, and strong soups. For two days before operation the patient should be limited to a liquid diet, and should be given opium. The last enema should be given not later than six hours before the operation.

The Anal Resection.—With the patient on his back and his knees drawn up, exaggerated lithotomy position, the sphincter is dilated or divided posteriorly from anus to coccyx (Kocher removes the coccyx), and the new-growth is seized and excised with knife, scissors, or Paquelin cautery. Bleeding is controlled, the gap is sutured, the posterior cut being drained with gauze, while a tube is left in the rectum.

A more complete method is approach through the perineum. The incision is made from the middle of the perineum to or through the coccyx, encircling the anus. The anus and lower portion of the rectum are then carefully separated from surrounding tissues, when the bowel with the new-growth is drawn downward, bringing with it the branches of the middle hemorrhoidal artery, which must be tied. By proceeding carefully in this manner, which usually involves opening the peritoneal cavity, the rectum may be brought well down and cut off above the growth. The final step consists in suturing the stump of bowel, without too much tension, into the wound, and packing around it with gauze to control hemorrhage. This method with various modifications is still frequently employed, but the danger from sepsis is great, and there is no possibility of removing thoroughly infected lymph-nodes.

The Sacral or Dorsal Method.—Various operators, from Kocher, in 1874, have advised dorsal methods of approaching disease of the rectum; but to-day the most commonly accepted course is that advised by Kraske in 1885. The patient lies upon his right side, with his thighs sharply flexed, and an incision is made in the middle line, from the anus to the sacrum, and from there along the left border of the sacrum to the posterior iliac spine. The gluteus maximus is divided, and hemorrhage is checked. Then the sacrosciatic ligaments are divided close to the sacrum, nearly to the sacro-iliac synchondrosis. The lateral sacral arteries are secured, but the pubic nerve and vessels must not be injured. The coccyx is then cleared or removed, and the rectum exposed. Various operators remove varying portions of the sacrum. The presacral tissues as high up as the second vertebra are pushed away from the bone, saving the sacral nerves only. In this way one includes all the lymphatic nodes and vessels which are apt to be involved. Search must then be made for the superior hemorrhoidal artery, which lies in a fold of peritoneum behind the upper portion of the rectum. After ligating this artery the gut is freed posteriorly and laterally and the peritoneum is opened. Then, beginning well above the growth, the rectum, with its associated nodes, is removed from above downward, intestinal clamps having been placed upon it at the point of section. The whole of the rectum below the point of section, and including the anus, should be excised; then the proximal portion of bowel is brought out and fastened in the sacral wound, provision being made at the same time for ample gauze drainage of the surrounding parts.

So much for two of the methods commonly employed.

Combined Method of Resection.—A method of operating in two stages, and approaching the growth from above and from below, is growing in favor and promises to improve our statistics as regards both operative risk and permanent cure.

The question of operation by the combined method involves also a discussion of *palliative measures*. Such measures are employed when total resection of the tumor is impossible, when obstruction is nearly or entirely complete, and when pain is constant. Palliation consists in establishing an artificial anus by colostomy. It used to be known as Littré's operation, and has been in use for generations. The combined method of excision of the rectum is by two stages, and takes advantage of a preliminary colostomy. By this preliminary measure the bowel is efficiently drained, and the patient's general health is improved, because a sufficient nutritious diet may be administered up to the time of the final operation, while, owing to the previous colostomy, septic absorption is diminished or eliminated when the rectum is removed. In addition to Kocher's method of forming an artificial anus, already described, another satisfactory method is to bring out the sigmoid in the left groin, to cut it off, leaving a voluminous pouch of bowel above, to draw the proximal end beneath the anterior sheath of the rectus muscle, and to establish the new anal opening above the pubes in the median line. After this first operation the patient generally mends in surprising fashion, and he often declares himself to feel entirely relieved.

If it is now determined to proceed to more radical measures, the second step is taken after an interval of from two to three weeks. This second step may be entered upon variously. The abdomen may be opened from above at the same time that the sacral route is followed from below, and so a complete and thorough dissection of the pelvis may be accomplished. If the abdomen is opened, the superior hemorrhoidal artery must be tied at once, and in all cases the ureters must be identified and isolated. Section of the ureters is a grave calamity, which has happened in many cases.

The best position for the patient, for approach by the sacral route, is in the exaggerated knee-chest posture, which controls remarkably the venous oozing. Many operators prefer to work entirely along the sacral route, and not to open the abdomen from above at the time of this second operation. Probably this method involves less risk of sepsis. The method then is quite similar in technic to that of Kraske. The rectum may be drawn down after the superior hemorrhoidal artery is ligated, until the blind end, which was tied off at the preliminary operation, has been delivered. This elimination of the whole lower bowel, leaving no blind pouch behind, is probably the best method of operation. Thus the entire mass is completely excised, and the entire rectum is removed, with its attached glands and lymphatics, down to and including the anus. The peritoneum is then closed, and the superficial wound sutured about a small drain, which must be left.

There is always considerable shock following these operations, so that the patient must be carefully watched afterward and symptoms must be met as they arise. Feeding may be done through the artificial anus until the stomach is ready to take care of nourishment.

Numerous modifications of the combined method of excision have

been devised. Powers[1] recommended operating on women by working from above and through the vagina, instead of through the sacrum; the entire rectum is thus readily removed. This method is essentially that which has been popularized by J. B. Murphy. The student of the literature should also familiarize himself with W. J. Mayo's[2] modification of Maunsell's method, as well as with the operation of Weir.[3]

All these operations are difficult and dangerous at the best. The immediate mortality is high, and recurrence is common; but accumulating statistics seem to show that in the hands of competent surgeons, and of competent surgeons only, excision of the rectum, especially by the combined method, holds out promise of a radical cure, or at least of relief from pain, and a prolonged remission of symptoms.

[1] C. A. Powers (Denver), Boston Med. and Surg. Jour., January 21, 1904.
[2] W. J. Mayo, Ann. Surg., June, 1910.
[3] Med. News, July 27, 1901.

CHAPTER IV

THE ESOPHAGUS, STOMACH, AND DUODENUM

We have made some study of the intestines and rectum, and have been able to arrive at a general understanding of such of their diseases as concern the surgeon; and we have observed this supremely important fact, that the digestive tract is continually subjected to the presence of foreign substances—food and the products of digestion. These substances are there, indeed, to meet physiologic demands, but their



Fig. 43.—*a*, Bougies or sounds; *b*, bulbous sounds; *c*, English rubber sound with funnel and openings at the tip; *d*, Trousseau's olive-tipped bougie (Keen's Surgery).

mere presence is at times an irritation to the organs, and always they carry with them malign organisms. The non-functionating gut of a fetus is practically sterile; the active gut of an infant or of an adult is loaded with bacteria, capable of setting up the most severe infections.

Let us turn now to the upper portions of the alimentary tube,—the esophagus, stomach, and duodenum,—and note the diseases which

occur in them, observing that in spite of minor differences in function all parts from pharynx to anus are of a generally similar structure, are subject to much the same influences, and develop similar disease processes. As we have seen that *inflammations*, *obstructions*, and *new-growths* are the important lesions of the intestines, and as we shall see later that *ulcer* and *new-growths* are the important lesions of the stomach, so we must now observe that *obstructions*, *new-growths*, and *malformations* are the important lesions of the gullet; but we observe at the same time that all such lesions are common to all portions of the alimentary tract.

The Esophagus

When you pass a tube or bougie into the stomach of an adult, remember that the average distance from incisor teeth to cardia is 16 inches. Moreover, as the trend of the esophagus is gradually from median line to the left of the spinal column, the operator must observe

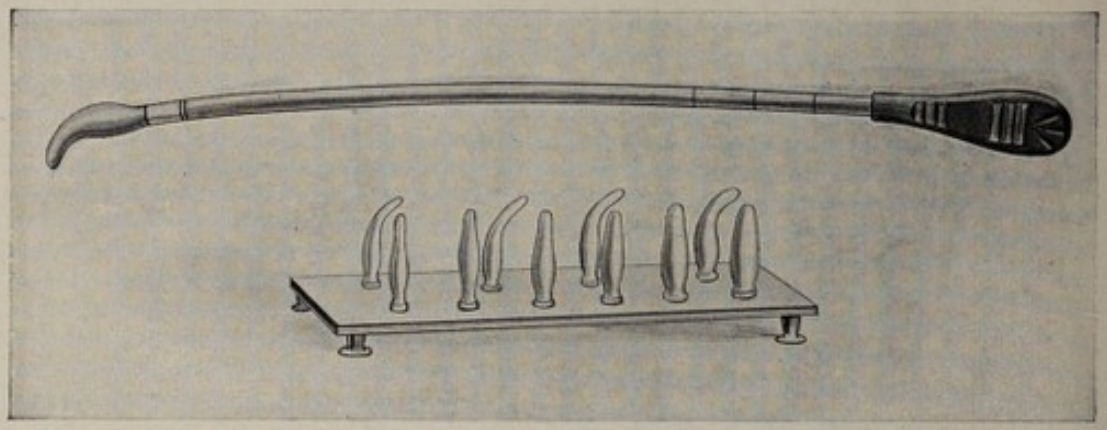

Fig. 44.—Starck's diverticulum sound (Keen's Surgery).

that right to left direction in passing an instrument or the esophagoscope, and he must cut upon the left side of the neck in the operation of esophagotomy. The commonly employed instruments for examining the esophagus are bougies and olive-tipped probangs of graduated sizes. By their use strictures, pockets, and diverticula may be dis-

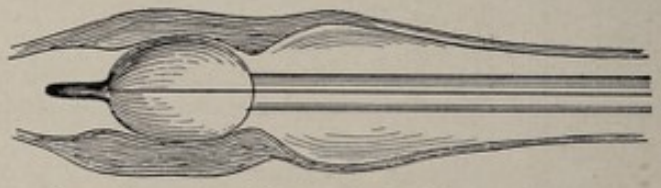

Fig. 45.—Esophageal stricture. Shows Schreiber's dilating sound in position (Keen's Surgery).

covered, and foreign bodies may be detected. Various forms of endoscopes are used for the inspection of the gullet, but the most satisfactory is some form of straight instrument, as recommended by von Mikulicz. By any of these instruments it is possible to make out also the rare malformations, congenital occlusions, and fistulæ.

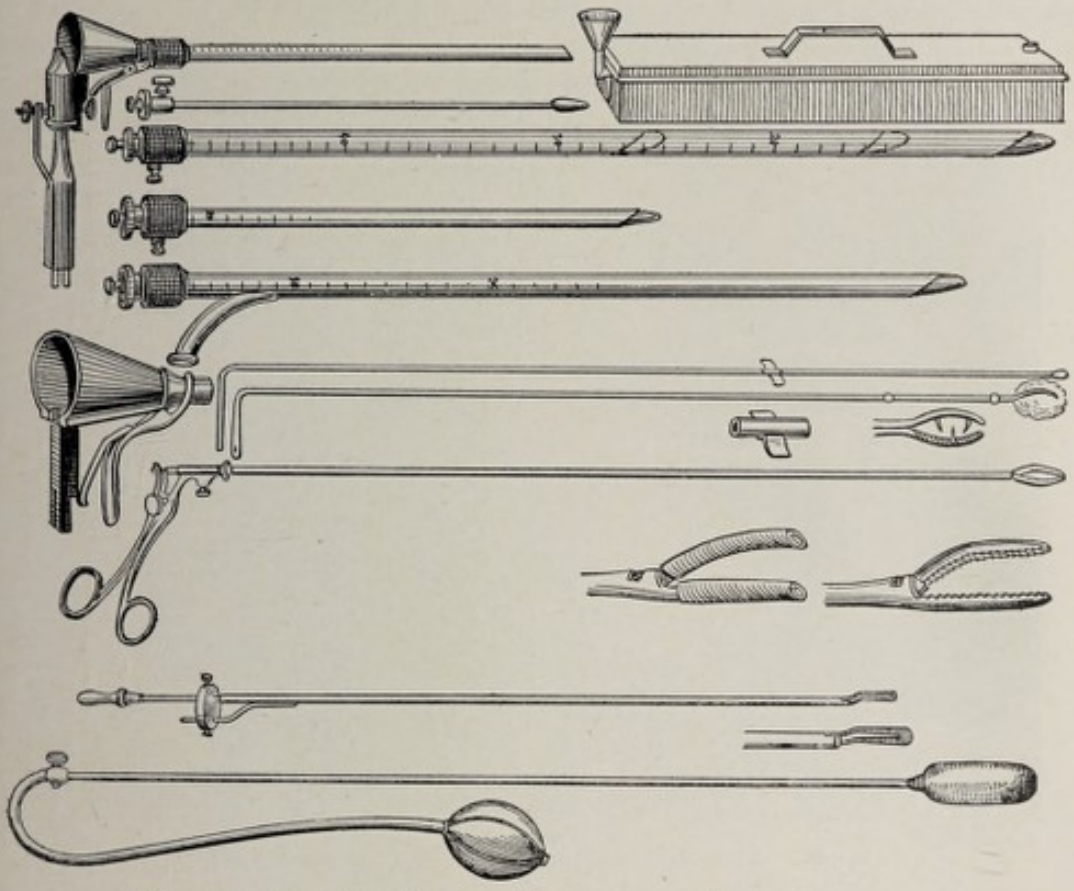

Fig. 46.—Von Mikulicz set of instruments for esophagoscopy.

STRICTURE OF ESOPHAGUS

Stricture is far the most common lesion of the esophagus with which the surgeon has to deal, and in exploring for stricture the beginner must remember that there are 4 normal narrowings in every esophagus—at its beginning, behind the cricoid cartilage, opposite the tracheal



Fig. 47.—Permanent cannula (after von Leyden-Renvers).

bifurcation, and at the cardia. Moreover, there are two important varieties of stricture—malignant and cicatricial—the latter usually caused by some corrosive poison. In more general terms these strictures are due to the healing of an ulcer—from any traumatism, chronic inflammation, typhoid ulceration, syphilis, tuberculosis, prolonged vomiting, small-pox, or gout. A common seat of stricture is at one of the normal esophageal narrowings. The stricture may be single

or multiple, depending on the cause. Pressure from without, as by a tumor, may cause constriction, but this is not properly stricture; nor must the surgeon forget that form of dysphagia, or difficulty in swallowing, known as spasmodic stricture, commonly of a hysteric nature, and frequently relieved by the passage of a bougie.

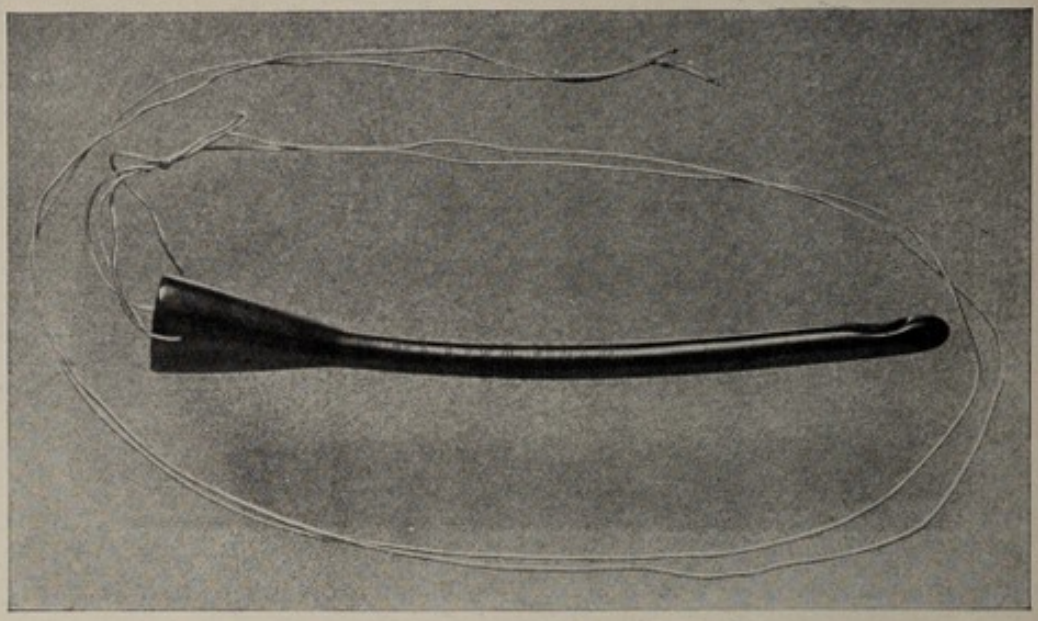

Fig. 48.—Symond's esophageal tube (Keen's Surgery).

We need not consider in detail the pathology of the cicatricial strictures. Suffice it to remind the student that the initial injury is followed by an inflammatory reaction which gradually subsides, with healing by granulation and the production of a firm fibrous cicatrix, whose breadth and depth depend on the extent of the original injury.

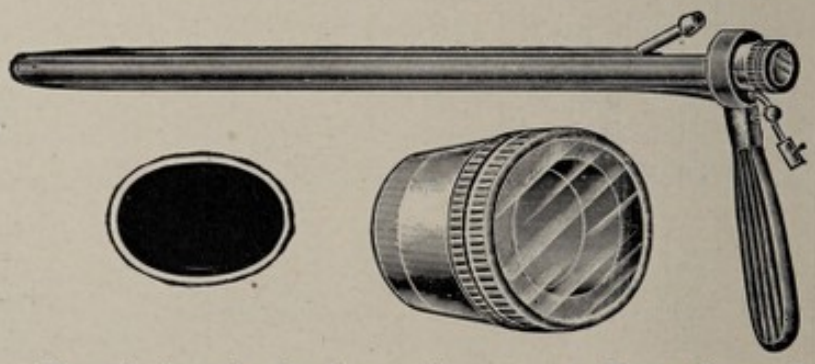

Fig. 49.—The window-plug for the esophagoscope. Upper figure, the esophagoscope, made air-tight by the window-plug. Lower figure, the window-plug, exact size, and a cross-section of the esophagoscope, actual size. The plug is taken out and inserted at will.[1]

The **symptoms** will vary with the progress of the disease. Early there are pain, distress, and a sense of burning, which pass in a few days. Then, as the gullet lumen contracts, there comes difficulty in swallowing,

[1] "This is the tube which I prefer. It should be called the Einhorn-Jackson-Mosher tube. The window-plug is mine. This tube for adults should be of two lengths—10 inches and 18 inches."—Statement by H. P. Mosher.

which may increase until liquids even fail to pass; but the tube distends above the stricture, as occurs in the case of strictures elsewhere.

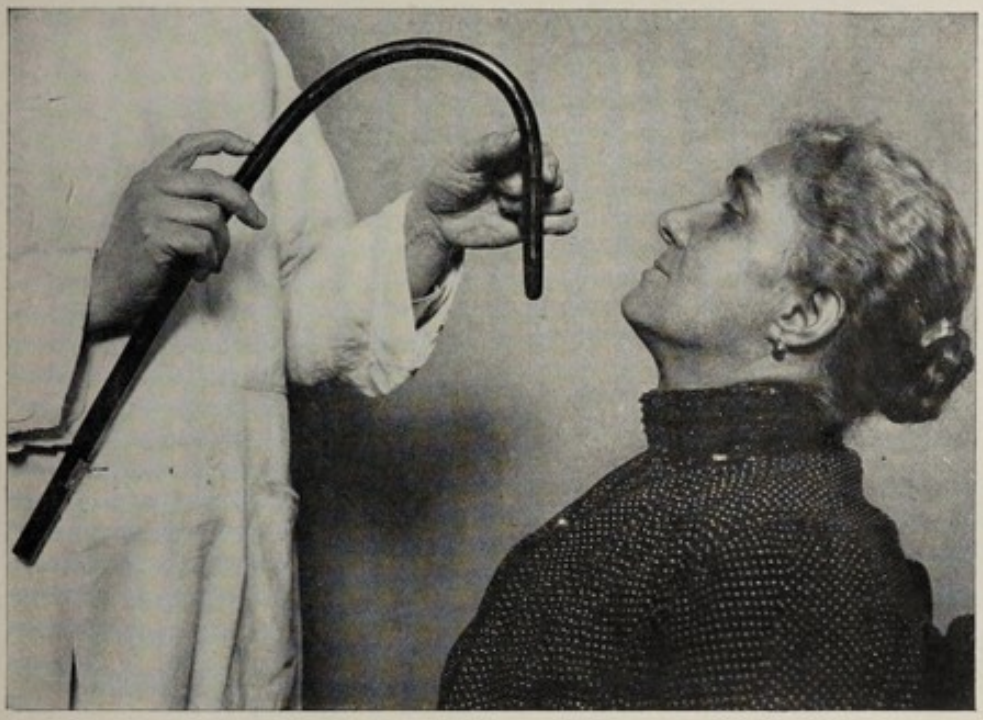

Fig. 50.—Method of introducing esophageal bougie. The bougie is bent before it is introduced (Keen's Surgery).

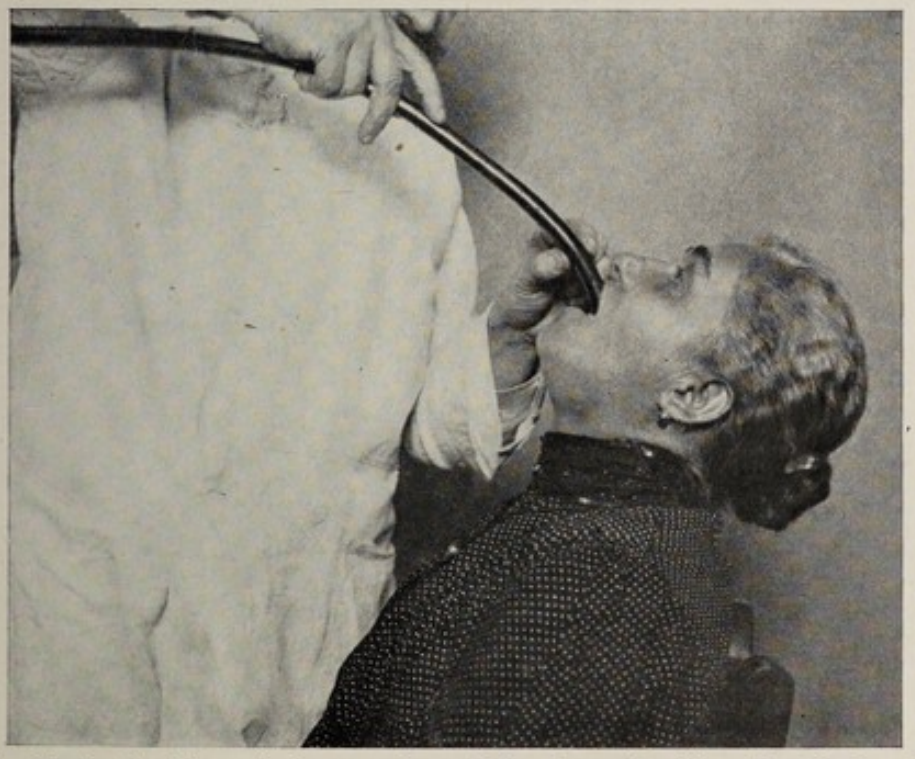

Fig. 51.—Method of introducing esophageal bougie. Position I: The head in extension until the bougie reaches the esophageal entrance (Keen's Surgery).

Thus the esophagus becomes sacculated and the sacculation gradually attains a considerable caliber, so that quantities of food lodge there. From time to time the patient vomits this accumulated material.

Sometimes the vomitus is bloody; sometimes it is composed of saliva and mucus. The patient becomes feeble and emaciated. He suffers from hunger and thirst. There may be pain or a sense of discomfort in the region of the stricture, or over the epigastrium and in the back.



Fig. 52.—Method of introducing esophageal bougie. Position II: The chin brought down almost to the chest; the bougie glides into the esophagus (Keen's Surgery).

Such a history points to the **diagnosis** of esophageal stricture, of which the presence is confirmed by exploring the gullet with bougies.

The first step in **treating** these strictures is to ascertain their size. We use for this purpose olive-tipped bone probangs, taking care not to damage the wall of the gullet, for one hears dreary tales of incautious

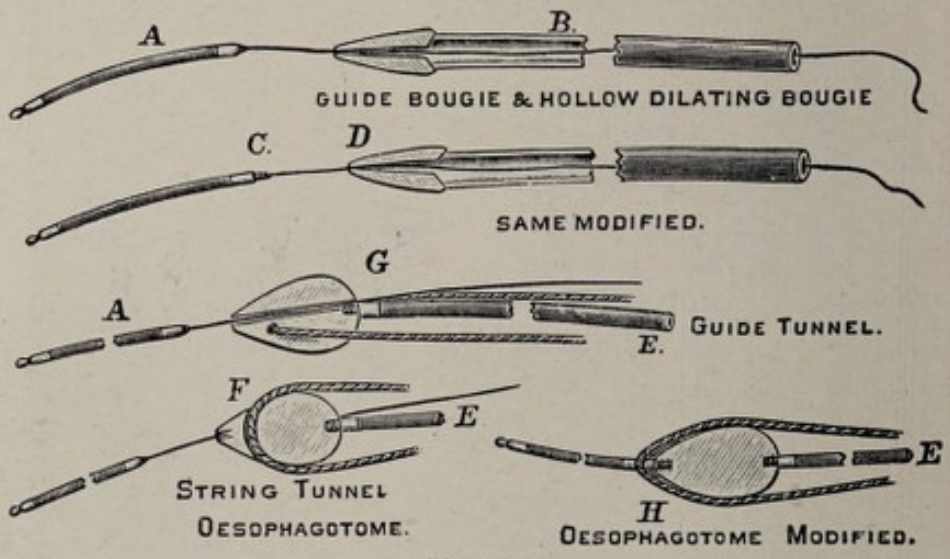

Fig. 53.

operators who have passed instruments through the wall of the esophagus into the trachea, the mediastinum, and even into the aorta. If the stricture will admit a probang, one may proceed to dilate the narrow opening with flexible bougies in the manner illustrated by the figures. In this way most strictures may be dilated readily, and when

stretched to a comfortable size, may be kept open by the occasional passage of an instrument. You must warn the patient that the stricture is liable to recur unless it be watched and treated occasionally.

Then there is that class of tight strictures on which Abbe and Mixter have experimented, and for which Dunham and Plummer have devised their ingenious instruments.[1] The appended cuts (Figs. 53, 54, 55) show graphically the technic of Dunham's method, which, in common with many other surgeons, I have used with satisfaction. There are two distinct sets of apparatus, but the principle of both is the same: the stricture is sawed through with a thread. The first apparatus is used for strictures through which a guide may be passed. An olive tip follows and engages in the stricture. Over the olive there plays a stout thread, which is pulled back and forth against the stricture until it cuts a way for the instrument, which is then pushed on into the stomach. Anesthesia is not needed.

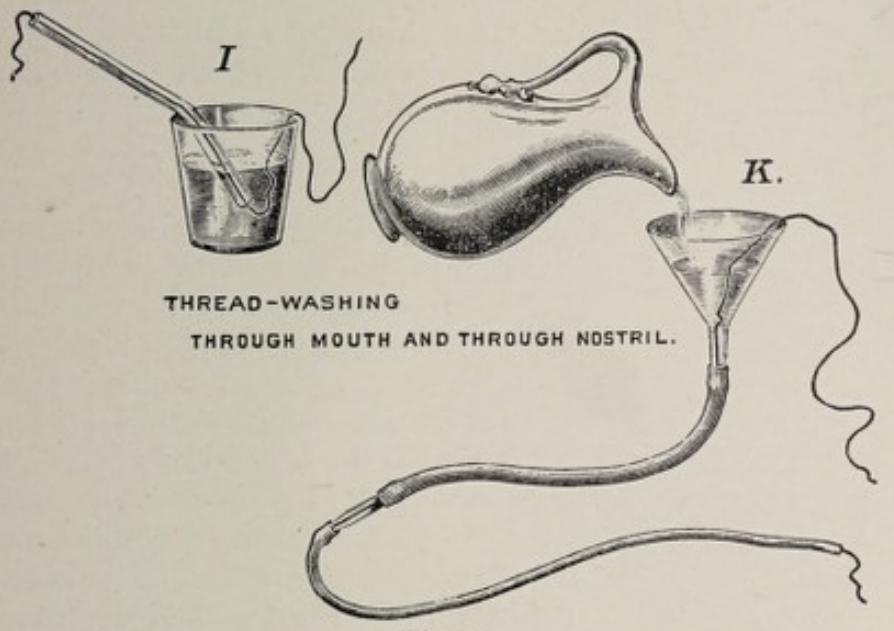

Fig. 54.

Dunham's second apparatus is for tight strictures which will not take a guide. For such, a preliminary gastrostomy is necessary, and this artificial opening must be kept open until after the secondary operation. A thread is then washed down from mouth to stomach, one end being retained above. The thread end in the stomach is then hooked out, and a stout *double* linen thread is drawn through the gullet. There are now two threads in the esophagus. By one a "wire-and-spindle bougie" is drawn up against the stricture from below. The other thread plays over and alongside of this bougie, and so cuts out a path for the larger instrument.

Dunham's method of passing the first thread down into the stomach is curiously ingenious: The thread of silk, several feet long, is fed through a funnel and drinking tube into the mouth of the patient, who swallows water slowly poured into the funnel. The descending stream

[1] Theodore Dunham, New Instruments for the Treatment of Esophageal Stricture, Ann. Surg., 1903, vol. xxxvii, p. 350.

quickly carries the thread through the closest and most tortuous strictures into the stomach.

When a stricture has been sufficiently dilated by this method, the gastrostomy opening is closed, and a patent esophagus is maintained by passing a bougie occasionally—perhaps two or three times a year.

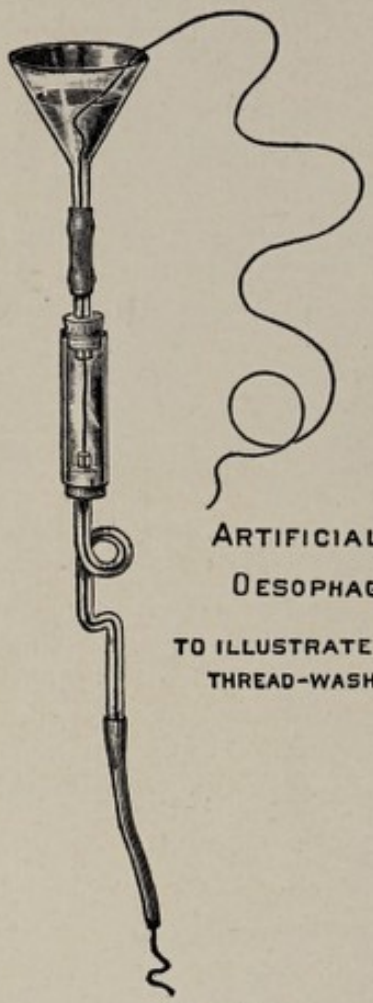

Fig. 55.

Dunham's method is applicable to all strictures through which a stream of water can pass. In the case of impermeable strictures, a permanent gastrostomy is required to avert starvation. Mixter, at the Massachusetts General Hospital, had a remarkable case in which the destructive agent had obliterated not only the lumen of the esophagus, but that of the stomach also. The patient is now comfortably nourished through jejunostomy, and he thrives after six years, his only complaint being that he can swallow no better than before the operation!

CARDIOSPASM[1]

The term cardiospasm has been applied in recent years to a stricture of the cardiac end of the esophagus, associated with dilatation of that tube. It is probable that the term is still used to embrace a greater variety of esophageal changes than should be indicated by a single word. We know, for example, that a sudden acute spasmodic closure of the cardia may take place, exactly resembling a spasmodic closure of the pylorus. This sudden closure of the cardia is called *acute cardiospasm*. Furthermore, there is *chronic cardiospasm*, for which various causes are assigned—kinking of the esophagus, esophagitis, atony, degeneration of the fibers of the pneumogastric, and primary long-continued spasm. The last two causes, assigned by von Mikulicz and Kraus, may very well coexist, and are probably the most common. In other words, we see that cardiospasm, so called, may be acute or chronic, may be primary or secondary.

These cases usually go unrecognized for a long time. At first the patients are thought to have a disease of the stomach. Again, the diagnosis of cancer of the esophagus frequently is made.

The **symptoms** are those of pressure in the epigastrium, and fulness, which is relieved by vomiting, while the vomitus is always undigested food containing no hydrochloric acid, pepsin, or rennet. There may

[1] See admirable essay on Cardiospasm, by H. S. Plummer, in The Journal of the Minnesota State Medical Association, and Northwestern Lancet, October 1, 1906. Also H. S. Plummer, Transactions of the Section on Surgery, Am. Med. Assoc., 1910.

be dyspnea and hoarseness. We ascertain the exact condition by passing bougies or stomach-tubes, which may or may not engage in the stricture and pass it with difficulty. The Roentgen-ray picture is characteristic if the suspected pouch be filled first with a mixture of potato and bismuth porridge. Best of all, the esophagoscope gives an excellent picture of the condition.

That form of the disease with which surgeons are most specially concerned is the chronic form. Chronic cardiospasm lasts many years. The constriction becomes gradually tighter and tighter; the dilatation of the esophagus greater and greater, the patient's nutrition more and more disturbed, until, finally, death from starvation results. Von Mikulicz believed also that cardiospasm predisposes to cancer.

The **treatment** is symptomatic and is direct. The symptomatic treatment means a careful dieting, abstinence from all stimulants, and daily lavage with astringents. The local application of cocain has been found useful. In the case of acute attacks with complete obstruction, rectal feeding may be necessary, or gastrostomy even. Various ingenious devices for dilating the stricture have been employed, and are undoubtedly serviceable, but at the best they seem to be palliative merely. Assuming the disease to be primary, von Mikulicz cured a few chronic cases by opening the stomach and forcibly stretching the stricture. The disease is coming to be regarded as more common than was thought a few years ago. Certainly the complex of conditions is extremely interesting, and is still in process of elucidation.

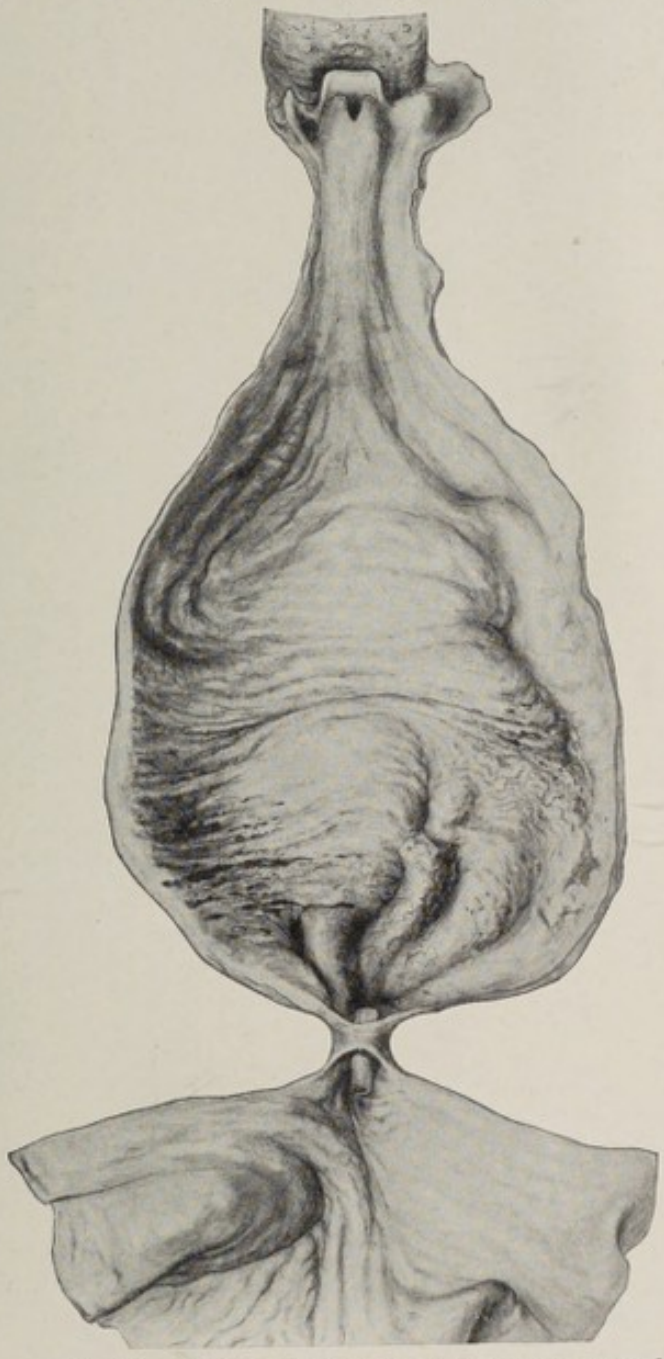

Fig. 56.—Anatomic preparation from a case of cardiospasm with saccular dilatation of the esophagus. A drainage-tube is seen in the cardiac segment (Keen's Surgery).

DIVERTICULUM OF THE ESOPHAGUS

Diverticulum of the esophagus is a condition clinically allied to stricture at times. That is to say, its symptoms may simulate those of stricture. Moreover, we are coming to believe that it is a rather common condition. M. H. Richardson, writing eleven years ago, stated that a search through the literature disclosed but 56 cases of esophageal diverticulum; on the other hand, Riebold [1] says that such diverticula have been found in 3.5 per cent. of all autopsies in adults, but that they have never been seen in children under fifteen years. Be all that as it may, no one surgeon can point to a great list of these cases.

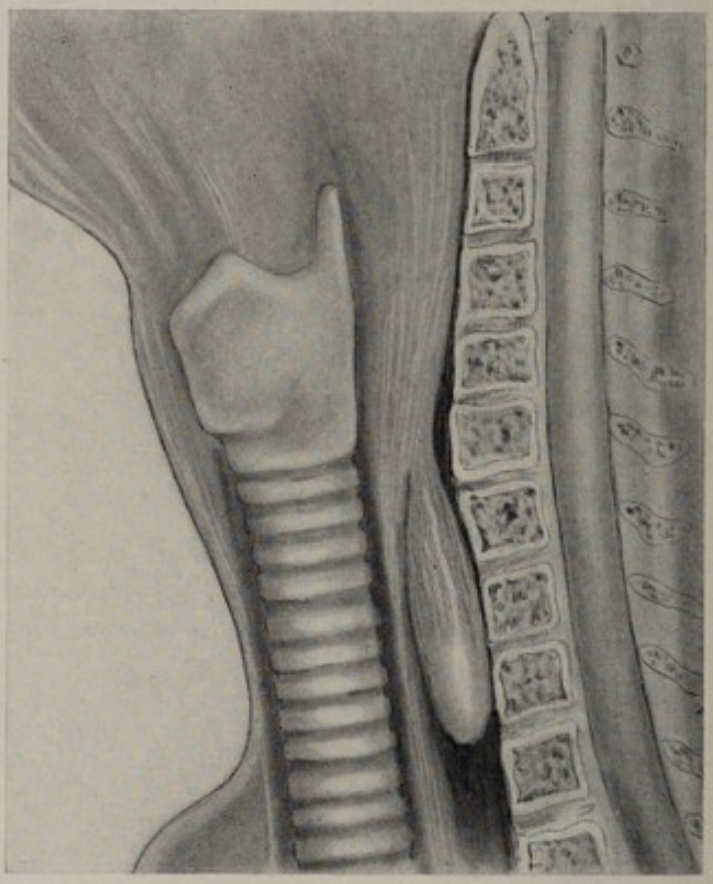

Fig. 57.—Diverticulum of esophagus (after Richardson).

Diverticula are pouches, varying in size, springing from some portion of the esophagus, and somewhat resembling a gall-bladder in shape. A true diverticulum is lined with mucous membrane. There are three varieties—traction diverticula, due to the adhesions and pulling of scars external to the esophagus; pressure diverticula (sometimes called pulsion diverticula), due to pressure from within; and traction-pressure diverticula. These diverticula are variously placed, but most commonly are found at the junction of the pharynx and esophagus. Rarely they are as low as the mediastinum. Generally, they lie behind the esophagus, between it and the spinal column.

Diverticula may or may not give rise to **symptoms,** which will

[1] Virchow's Arch., vol. clxxiii, No. 3.

depend on the site of the opening, the size of the diverticulum, and its capacity for incommoding by pressure. Symptoms may vary all the way from a sense of thickness in the throat and a tendency to clear away mucus, to dysphagia, nausea, vomiting, and sundry pains due to pressure by the distended pouch. Sometimes a tumor is seen in the side of the neck, and the swelling may be obliterated by pressure; sometimes there is no tumor apparent. Sometimes the diverticulum fills with food before food will pass to the stomach. Frequently a bougie will not pass into the stomach unless the pouch is full of food. Erroneously, this has been asserted to be an invariable sign. The stethoscope may detect fluids passing into the pouch. Mix food with bismuth subnitrate and allow the patient to swallow it into the diverticulum, when a satisfactory skiagraph of the pouch may be taken.

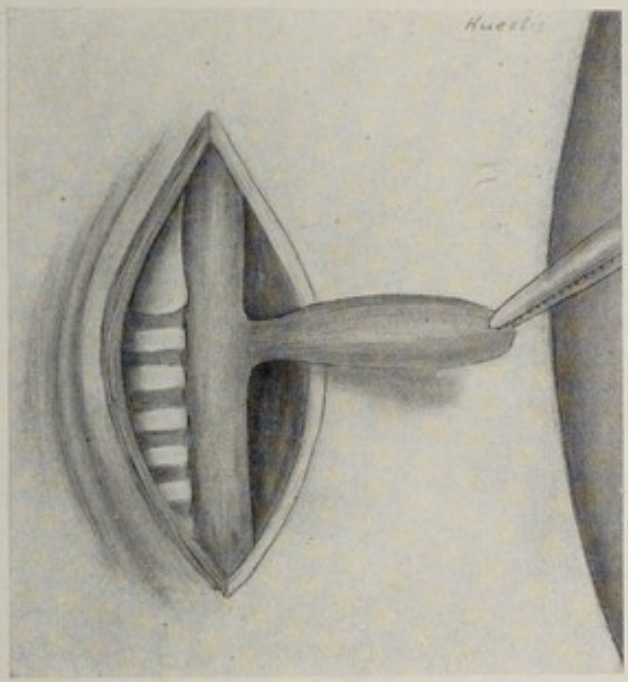

Fig. 58.—Diverticulum of esophagus (after Richardson).

Treatment.—The only radically satisfactory treatment of diverticulum is by excision, when the sac is within surgical reach. Cut down on the left side of the neck, directly over the sac; cut off the sac, cauterize the stump, turn it in, and complete the operation with a row of Lembert stitches in the esophageal wall. A small diverticulum, without being opened, may be inverted into the esophagus. Avoid always the recurrent laryngeal nerve. Sew up the wound with drainage. Dress the wound with an extra large absorbent dressing, and fix the head for five days in a Thomas collar. For the first three days after operation give no food by mouth.

FOREIGN BODIES IN THE ESOPHAGUS

Regarding foreign bodies in the esophagus, an abundance has been written. Yet the subject is simple. It has attracted a multitude

of writers, because foreign bodies in the esophagus are a commonplace of practice. All sorts of objects, from coins and fish-bones to open safety-pins and plates of false teeth, have lodged in the esophagus. When they lodge and stick, they make trouble. D. W. Cheever, one of the first of American surgeons to perform esophagotomy, delivered a famous lecture on this topic. Foreign bodies make trouble because they obstruct the passage of food, primarily, and because they damage seriously the esophagus, secondarily. They damage the esophagus either by wounding it sharply, rarely by passing through it, or by setting up an ulcerative process, leading, if unrelieved, to extensive and alarming inflammation. The student must remember that most foreign bodies lodge commonly at one of the points of physiologic constriction,

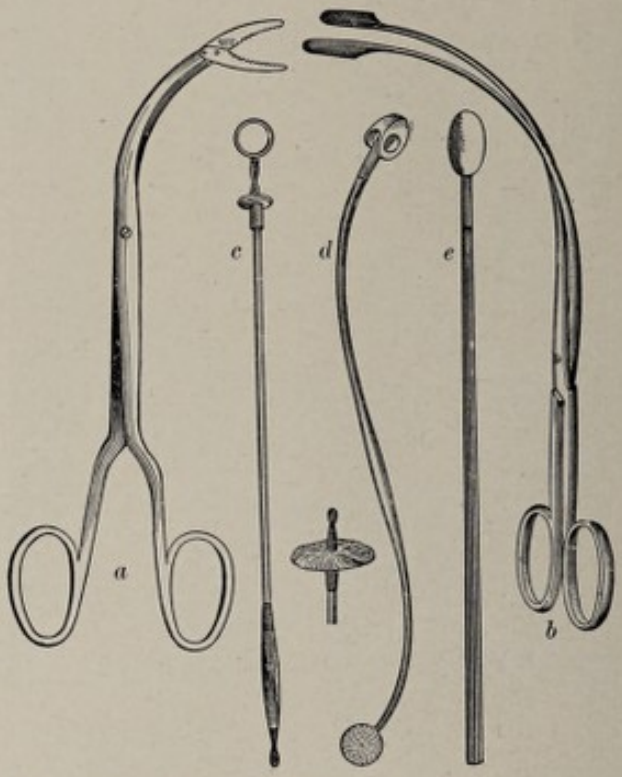

Fig. 59.—Esophageal instruments: *a*, *b*, Forceps; *c*, horsehair probang; *d*, coin-catcher; *e*, esophageal bougie.

but small sharp articles, like fish-bones, catch in the tonsils usually. In any case foreign bodies should be removed as soon as possible.

As to **treatment,** there are obviously three methods of extracting foreign bodies: through the mouth, through the stomach, and through the neck by esophagotomy. A great many substances may be pulled up or pushed down by proper instruments introduced through the mouth—bougies, coin-catchers, the umbrella probang; though one must remember that these measures are not altogether devoid of danger, as coin-catchers have been known to stick or break off in the gullet. For this reason it is well, if possible, to obtain a sight of the foreign body with the esophagoscope or the *x*-ray. M. H. Richardson, in 1886, was the first to demonstrate the feasibility of removing foreign

bodies through the stomach. He drew out and opened the stomach, passed in a forceps, and removed a plate of false teeth lodged just above the cardia. Bodies may also be removed from the esophagus by passing down a large-sized endoscope, such as is used in the urethra, and grasping the offending object with pliers introduced through the endoscope. Failing other means, one may employ esophagotomy, which consists in opening the esophagus on the left side of the neck in the region of the anterior belly of the omohyoid muscle. Through such an opening the esophagus may be explored with the finger or with instruments, and any foreign body, except the most low lying and firmly impacted, may thus be removed. Esophagotomy is followed commonly by slow healing and an infected wound. The esophagus may be stitched up with catgut, and the external wound drained. Various other ingenious devices have been employed in special cases, but the main principles are those already laid down.

TUMORS OF THE ESOPHAGUS

Tumors of the esophagus are common; next to benign stricture and foreign bodies, they constitute the most important and interesting group of lesions of the esophagus with which the surgeon has to deal. Benign tumors are not common, but cancer is a frequent affection, as one would expect when dealing with an organ so subject to traumatism as is the esophagus.

Of the benign tumors, one should remember that *cysts*, *papillomata*, *myomata*, and *polypi* are occasionally found, and may prove troublesome. Klebs points out the interesting analogy between diseases of the esophagus and those of the external skin. These various benign tumors may cause slight or marked symptoms. The important evidence of their presence is difficulty in swallowing; but one can establish a positive diagnosis by the esophagoscope only. Obviously, these tumors can be removed by surgical measures alone—by snaring, by excision, or by the cautery, when they are within reach; or they may be approached through esophagotomy.

Sarcoma of the esophagus rarely occurs. It runs a rather rapid course and is uniformly fatal. Any attempt at treatment must be along the lines to be suggested for cancer of the esophagus.

Cancer of the esophagus[1] is one of the most grievous and fatal diseases known. We see it in daily practice and in every surgical ward. Its site is generally at one of the normal esophageal narrowings, especially behind the cricoid and just above the cardia. It, too, causes dysphagia as a first symptom—dysphagia which may steadily increase from the beginning until there is complete occlusion, or rarely may appear late in the disease only. That depends on the anatomic arrangement of the cancer, whether it encircle the gullet or grow to a considerable size without encroaching specially upon the lumen. Gnawing,

[1] For an admirable recent bibliography on cancer of the esophagus see the article by M. G. Seelig, Ann. Surg., December, 1907, p. 809. Also H. S. Plummer, in Northwestern Lancet, January 15, 1912.

continuous pain often is present—sometimes over the seat of the disease, sometimes in the epigastrium or between the shoulder-blades. Of course, one observes also the rapid cachexia, more pronounced than cachexia of cancer elsewhere, because starvation is added to the toxic process. In other respects encircling or occluding cancer causes symptoms similar to those of benign stricture—the spitting up of undigested food and occasionally bloody or foul expectoration. The patient's breath is noticeably offensive. Moreover, when cancer of the esophagus is low lying, it may involve the fundus of the stomach and give rise to a train of symptoms resembling those of gastric cancer.

From the history of cachexia, emaciation, pain, and obstruction a diagnosis of cancer can be made almost with certainty. Of course, a positive diagnosis is of great importance, and to establish this, the esophagoscope is useful sometimes; or bits of tissue may be removed with the sharp spoon or the tip of an esophageal instrument.

Treatment is by palliation. I have rarely seen a cancer of the esophagus which lent itself to an attempt at radical removal. Palliative measures include morphin, the passage of bougies, and in a few cases the insertion of a hollow tube to be worn permanently. If there be complete obstruction and if the patient's strength permit, one may stave off starvation by establishing a permanent feeding-opening in the stomach—gastrostomy. The old routine in all cases of esophageal stricture of doubtful origin is to give a course of potassium iodid, with syphilis in mind. Sometimes this does no harm, but the treatment should not be continued longer than two weeks if no benefit results. Today a positive Wassermann demonstration, followed by salvarsan, is preferable. Several operators have performed radical removal of the growth, but no case of permanent cure is recorded. Recent experiments have shown that it is feasible to enter the mediastinum from behind and to resect the esophagus in its lower portion, the Sauerbruch cabinet or some similar device being employed at the same time to favor expansion of the lung. At the present writing there is no satisfactory evidence that such procedures promise benefit to these unfortunate patients.

INJURIES OF THE ESOPHAGUS

In addition to the diseases of the esophagus already discussed, there are certain other conditions with which the surgeon occasionally may concern himself. There are *injuries*, which the writers are wont to treat under various headings, though, in fact, I have already referred to this subject in dealing with foreign bodies and with stricture. Injuries due to foreign bodies explain themselves. I have seen the esophagus ruptured by a fall upon the head, and writers report cases of rupture of the esophagus due to vomiting. These patients almost always die from sepsis, but the effort of the surgeon must be to provide proper drainage and to nourish the patient without irritating the wounded tissues.

INFLAMMATIONS OF THE ESOPHAGUS

Inflammations of the esophagus occur at times and may interest the surgeon. They may assume various forms, such as acute or chronic catarrhs, and necrotic or diphtheric inflammations. These inflammations may be ascertained by the use of the esophagoscope. *Treatment* is rather uncertain. If the disease is mild, relief and cure follow the administration of a cool liquid diet and the use of general tonics. If the disease is more severe, it may be necessary to make local applications with such solutions as silver nitrate (1:4000) or a 5 or 10 per cent. solution of argyrol.

Ulcers of the esophagus occur also—gangrenous ulcers caused by pressure from within or from without; syphilitic ulcers in the upper portion; rarely tuberculous ulcers; and actinomycosis of the esophagus has been described. It appears also that peptic ulcer of the esophagus[1] may be found as well as the curiously uncommon typhoid ulcer.

All these latter lesions are curiosities of surgery. They can be ascertained by the use of the esophagoscope, and by the recognition of associated general disease, while their treatment, with the exception of that for actinomycosis, must be along general systemic lines.

THE STOMACH

The stomach has become an organ of supreme interest to surgeons in these days. Within the past twelve years the literature of gastric surgery has grown to enormous dimensions; and advances in accuracy of diagnosis, in confidence of treatment, and in operative technic have been in proportion. We have seen how the appendix with its various manifestations of disease dwarfs the importance of most other abdominal organs, and how its disturbances have a special bearing on digestive disorders. In like manner the stomach, ulcerated, catarrhal, or the seat of malignant disease, looms up as an organ continually subject to surgical observation and treatment.

Gastric surgery is more than thirty years old, but for the first fifteen years its progress was halting and unsatisfactory. So long ago as 1880 von Mikulicz sutured a perforation on the lesser curvature of the stomach, but the patient died, and in the year previous Péan attempted a pylorectomy,—unsuccessfully,—to be followed by Rydygier in 1880. Billroth improved the operation and saved his first patient in 1881, while Rydygier excised successfully an ulcer in 1881, and in the same year Wölfler performed the first gastro-enterostomy.

Up to that time, and until much later, indeed, lesions of the stomach were regarded as belonging to the domain of the internist acting alone, but of recent years we have come to see that many disorders of digestion are due to anatomic changes which disturb the stomach's mechanism and demand mechanical interference for their relief. For instance,

[1] Peptic ulcer of the esophagus is well recognized and may lead to stricture. Considerable literature on this subject is summed up by Wilder Tileston, Peptic Ulcer of the Esophagus, Amer. Jour. Med. Sci., August, 1906.

a narrowed pylorus will always obstruct the onward passage of food until the opening has been enlarged by the surgeon.

Observe, too, the vital importance of associated diseases of sundry abdominal organs. Such association, accompanied with misleading symptoms, renders extremely difficult the physician's task, if, on the evidence of symptoms alone, he attempt to name a particular organ as the one at fault. Gastric ulcer, duodenal ulcer, cholangitis, pancreatitis, and perigastritis may give rise to identical trains of symptoms. The recognition of such facts has led to the conviction that diseases of these various abdominal organs must be studied together, for these diseases form a complex but interdependent group.

Another important point in considering diseases of these organs, which we group under the name *digestive organs*, is that they all bear a definite relation to the duodenum. The duodenum is their central

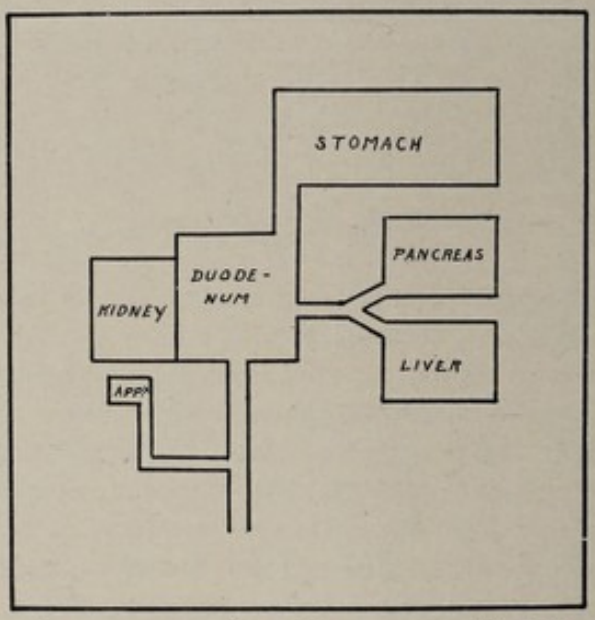

Fig. 60.—Diagrammatic representation of the organs which lie near or are drained through the duodenum.

chamber or clearing-house. The stomach, the common bile-duct, and the pancreatic ducts empty into it, and in it there take place the most important digestive changes. Moreover, through an interesting arrangement of the intestinal innervation, disease of the vermiform appendix causes reflex irritation of the stomach; while ptosis of any of the abdominal organs may set up a great variety of distressing "dyspeptic" symptoms.

Bearing in mind then the close anatomic, physiologic, and pathologic relations of the abdominal digestive organs, let us take up in detail a brief consideration of stomach and duodenal diseases, so far as they concern surgeons.

Ulcer and *cancer* are at the bottom of most operable gastric disorders, but we must name also the complications of ulcer—pyloric obstruction; gastrectasia, or dilatation of the stomach; hemorrhage;

distortion of the stomach (hour-glass stomach); adhesions; tetany. Then there is that curious condition, spasm of the pylorus; stenosis of the pylorus in infants; cirrhosis and gastroptosis.

PEPTIC ULCER

It is probable that 5 per cent. or more of all mankind suffer from gastric or duodenal ulcer, first and last. The precise frequency of such ulcers seems impossible to determine, however, and the fact that scars of old ulcers are often found at operations and postmortem, when the patient gave no history of symptoms pointing to ulcer, suggests that peptic ulcer is more common than has been supposed.

The **cause** of peptic ulcer is still a matter of dispute, though the actual condition present seems to be a localized necrosis acted upon persistently by the digestive fluids. Women are afflicted, compared

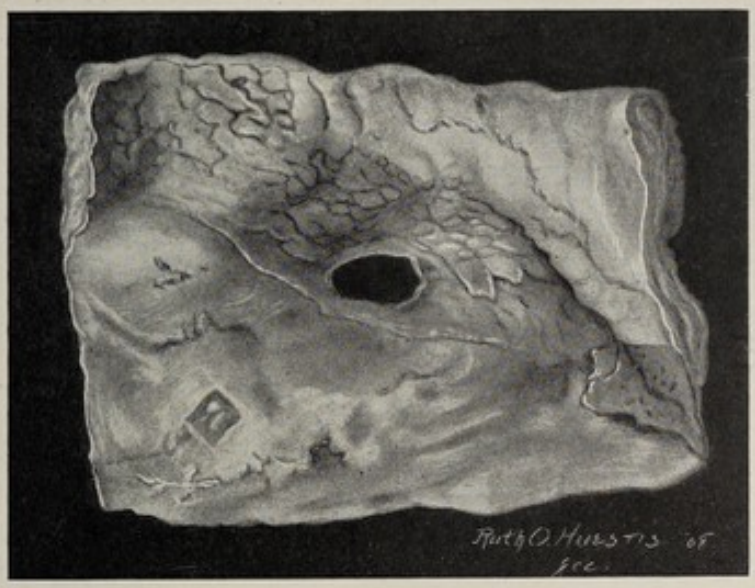

Fig. 61.—Acute round ulcer with perforation (Warren Museum, Harvard, 8476).

with men, in the proportion of 2.5 to 7.4.[1] *Age* has an extremely important bearing on the subject, for peptic ulcer in the young is a more acute and remediable disease than is peptic ulcer in the middle-aged. Bear in mind always this interesting fact that in young women of the chlorotic type (more rarely men) one expects *acute* ulcer. In men (more rarely women) between thirty and fifty one expects *chronic* ulcer. The acute ulcers are curable by simple measures, as a rule. The chronic ulcers call often for surgical intervention, though both of these statements are subject to exceptions.

A majority of peptic ulcers are found in the pyloric portion of the stomach and the first three inches of the duodenum; and such locations have an important bearing upon the complications which may ensue, as well as upon the nature of surgical treatment.

Three varieties of peptic ulcer are described: (1) The acute round ulcer, punched out, as it were; (2) the irregular burrowing, chronic

[1] W. J. Mayo, Long Island Med. Jour., February, 1911.

ulcer, which may involve large areas of the stomach; (3) erosions of the mucosa.

The *acute* round ulcer may run into the chronic form, or it may progress rapidly to perforation. Most commonly it heals spontaneously. It may give rise to *hemorrhage* or it may be associated with little or no hemorrhage. Often it causes boring, localized *pain* and tenderness; occasionally there is no pain. In more than 90 per cent. of the cases it causes *vomiting*. In nearly 80 per cent. of the cases the vomitus is bloody.

Chronic ulcer rarely is developed out of acute ulcer; its course may run over years. If it has attacked the muscularis, it may never heal. It causes *pain* in nearly 95 per cent. of cases, and it causes *vomiting* more often even. The *bloody* vomiting of chronic ulcer is as common as that from acute ulcer, and tenderness in the epigastrium beneath the left shoulder-blade, or about the tenth left rib, is a frequent symptom.

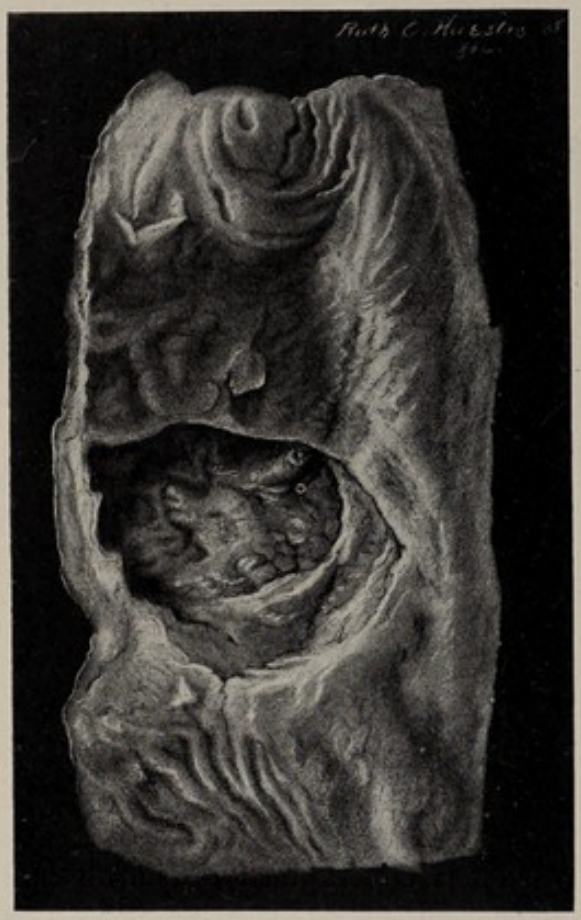

Fig. 62.—Chronic gastric ulcer (Warren Museum, Harvard, 2199).

Erosions are often impossible to distinguish *postmortem*. They are slight abrasions of the mucosa, and may be single or numerous. Such is the condition described as "simple erosions" by Dieulafoy. He also described a form to which he applied the term "ex ulceratio simplex," which is more extensive than the simple erosion, and may expose small arterioles, giving rise to excessive—even to fatal—*hemorrhages*. Erosions are found in all parts of the stomach.

Peptic ulcers may be single or multiple, and it is likely that they are multiple more often than generally is supposed. A common estimate is that 19 per cent. of all cases show multiple ulcers.[1] Ulcer of the duodenum may be associated with gastric ulcer—the presence of the one does not rule out the other.

The **course** of peptic ulcer is as various as its form. Both the acute and chronic varieties may *perforate;* both may set up extensive perigastric inflammation; both may cause adhesions to neighboring organs. The chronic ulcer leads to far more extensive and crippling inflammation, perforation, adhesions, and malformation than does the acute. Ulcer

[1] Multiple acute ulcers are common; multiple chronic ulcers are far more rare. (W. J. Mayo, *ibid.*)

on the posterior surface of the stomach is not likely to cause so alarming a form of perforation as is anterior ulcer, for adhesions do not form so readily on the anterior surface. Perforation may give rise to immediate outpouring of gastric contents and to a diffuse peritonitis; or through adhesions and localized abscess a more chronic form of disease may be established, with pockets of pus, forming most commonly behind the stomach in the lesser cavity of the peritoneum, causing subdiaphragmatic abscess, or, in rare cases, subphrenic pyopneumothorax. Rarely fistulæ form, which may connect the stomach with the gall-bladder or the intestines, or may penetrate through the skin.

Hemorrhage from peptic ulcer is extremely variable. Four varieties of hemorrhage are described:

(1) Frequent slight hemorrhage,—venous or capillary oozing,—sapping vitality, leading to profound anemia, often long undetected—a serious matter.

(2) Intermittent hemorrhage of considerable quantity, probably from a small eroded artery. This rarely ends with fatal bleeding, but the patient becomes profoundly depressed.

(3) Acute and profuse hemorrhage, frequently repeated. It may kill the patient.

(4) An overwhelming, quickly fatal hemorrhage, due to the erosion of a large artery.

The reader will see then that the *progress* of peptic ulcer may lead to two alarming conditions,—perforation and hemorrhage,—while the *healing*, or attempted healing, of an ulcer may lead to serious mechanical distortion or crippling, through cicatrization. The important varieties of mechanical crippling are pyloric stenosis and hour-glass stomach.

Pyloric stenosis is an affair of gradual onset. Generally, it does not at once interfere with gastric function and plug back or delay the chyme, because the gastric muscularis undergoes compensatory hypertrophy and succeeds for a time in overcoming the pyloric obstruction. In the course of time, however, the muscular activity of the stomach fails to respond satisfactorily, so that the gastric tonus is lost, when a thinning and dilatation of the stomach-wall ensue. These pyloric cicatrices may form bunches of considerable size. They may appear as mere slight encircling bands, or as indurated masses as large as a hen's egg, and palpable through the abdominal wall.

Distortion of the stomach, or *hour-glass stomach*, as it is commonly called, is due to contracting cicatrices, furrowing the wall of the stomach, and throwing that organ into a series of two or more pouches.

Ulceration of the duodenum is somewhat more common than gastric ulcer; but being situated in a thin-walled organ, as contrasted with the stomach, it is more serious in its consequences, though its progress is not always obvious to the patient. In proportion to its frequency, duodenal ulcer perforates more often than does gastric ulcer. Hemorrhage from duodenal ulcer occurs in the same fashion as hemorrhage from gastric ulcer, but the bleeding is somewhat more wont to be abundant and long continued. Duodenal blood generally is

passed off through the bowel; rarely it enters the stomach. Gastric blood is usually vomited; sometimes it is passed off by the bowel.

Symptoms.—The symptoms of peptic ulcer will suggest themselves to the student who is familiar with the morbid anatomy, and the symptoms will be found to vary with every case studied. A few years ago students were taught that a definite train of symptoms was necessary for the diagnosis, or for the consideration even, of peptic ulcer—pain, tenderness, "dyspepsia," and coffee-ground vomitus, or melena. Recent experiences of surgeons convince us that ulcer may exist for years without causing such classic symptoms. For example: I was recently consulted by a physician who told of persistent anorexia, with occasional voimiting, for ten years. There was no pain; there was no hemorrhage; he was not prostrated. Occasionally he was troubled by a sense of soreness and tenderness on pressure below the tip of the xiphoid. Convinced that he was the victim of a chronic inflammatory process which might lead to malignant disease in later life, he asked me to do an exploratory operation. I found an hour-glass stomach, surrounded by numerous and dense adhesions. No active ulcer was present. Gastroplasty after Finney's method completely relieved his symptoms.

What, then, are the symptoms of peptic ulcer with its sequelæ, or how shall we make a diagnosis? That is one of the most difficult problems of abdominal surgery. If the classic symptoms—pain, vomiting, and hemorrhage—be present, the problem is easy; but I believe that in many cases of "dyspepsia" gastric ulcer or its complications is present without many or all the classic symptoms. Carefully conducted laboratory tests help us to a diagnosis. In the presence of peptic ulcer hydrochloric acid is increased generally. Slight traces of blood in the stomach may be detected by the guaiac test.[1] These investigations may be made by the use of the stomach-tube, and the gastric contents must be expressed. Vomited gastric contents give a much less satisfactory test. We have to deal with a symptom-complex. Pain, preceding and relieved by vomiting, at a varying period after meals,—one to three hours,—associated with excess of free hydrochloric acid and blood in the stomach, makes the diagnosis of ulcer reasonably sure.

Tenderness on pressure in the epigastrium is a frequent symptom.

In the case of an old ulcer with a thickened base the mass may sometimes be felt in the pyloric region.

[1] *Guaiac test:* Fresh alcoholic solution of guaiac should be made by scraping with a knife a few grains of gum guaiac into a test-tube containing about 5 cc. of alcohol, in which the guaiac quickly dissolves. It is better to select that portion of the gum guaiac appearing as yellow nuggets on the surface. A few drops of hydrogen dioxid are added. The stomach-contents or the watery mixture of feces to be examined are mixed in a test-tube with one-third their volume of glacial acetic acid, and the whole shaken with an equal volume of ether. On standing, the ethereal extract containing the hemoglobin, if present, will separate and occupy the upper portion of the mixture in the tube. A few drops of this ethereal extract are next added to the alcoholic guaiac solution, and if blood was present in the original material, a blue-violet color should appear in the mixture. So delicate is this test that meat in the stomach-contents will give the blue color.

The general symptoms—loss of weight and anemia, with diminished total amount of urine excreted, and chronic constipation—are also suggestive.

The symptomatology of *duodenal ulcer* is more obscure than that of gastric ulcer, and the two are often indistinguishable. In duodenal ulcer, however, the pain may be more to the right of the middle line, and blood must be looked for carefully in the stools, rather than in the vomitus. There may be no vomiting. The blood passed by the stools may be in minute traces only, or it may appear in large, tarry masses. Late pain, or discomfort, two or three hours after eating; and epigastric pain ("hunger pains"), relieved by eating, must be regarded as characteristic of duodenal ulcer. This double symptom may persist for years, and commonly and erroneously is called "acid dyspepsia."

Perforation occurs in about 6.5 per cent. of all cases of peptic ulcer. The *symptoms* of acute perforation are overwhelming pain in the epigastrium, followed by a general or localized peritonitis. The acute pain signifies acute perforation, and is far more serious than the chronic, slowly progressing perforations, which become limited by adhesions to surrounding organs.

Diagnosis.—The diagnosis of *peptic ulcer* has been indicated in the foregoing paragraphs. One looks for a long train of dyspeptic symptoms, gastralgic attacks, and hemorrhage. One must differentiate these ulcers from disease of the bile-passages, from pancreatitis, from gastritis, perigastritis, gastralgia, and appendicitis, with all of which conditions peptic ulcer may be associated, and from which it cannot always be distinguished. In diseases of the bile-passages pain is more constant and acute, is longer continued, and is not likely to be associated with vomiting on the ingestion of food. The same statement is true of pancreatic disease. In gastritis pain is less constant; it does not come on at such regular periods, nor is it so commonly associated with and relieved by vomiting. Gastralgia is relieved by ingested food. A chronic appendicitis may cause obscure gastric symptoms suggesting ulcer—symptoms of "dyspepsia," belching of gas, and distaste for food; but the characteristic pain and vomiting rarely are present. Acute perforating duodenal ulcer pours out chyme into the right flank and appendix region, setting up an acute peritonitis throughout that area. It is a common error to mistake perforating duodenal ulcer for acute appendicitis.

Prognosis.—The prognosis of *acute* ulcer is good, generally, if rest and dieting be observed. The prognosis of *erosions* is good also, with the same proviso; but the prognosis of *chronic* ulcer is not so favorable, and the statistics of the Massachusetts General Hospital show that about 50 per cent. of chronic ulcers are either not cured by medical treatment or that, if symptomatically cured, they recur.

Treatment of Peptic Ulcer.—When you have to deal with a patient the subject of an obscure chronic "dyspepsia" which has withstood intelligent medical treatment for a year or longer, you are fairly safe in assuming that the trouble is one of mechanical damage, and that a

surgical operation on one or more of five organs will bring relief—on the stomach, bile-passages, pancreas, kidney, or appendix.

Every case of peptic ulcer should have the benefit of an expert internist's opinion and proper intelligent medical treatment, which, in general terms, consists of rest and cleanliness for the organs concerned. Rest is obtained by the use of light liquid diet or rectal feeding. Cleanliness is maintained through abstinence from food and by gastric lavage.

The surgeon also in his treatment aims at rest and cleanliness, and attains these by supplying the laboring organs with additional and competent drainage—drainage into the intestines at a point below the pylorus. Such drainage is secured through the operation of gastro-enterostomy or through Finney's pyloroplasty.

Methods of gastro-enterostomy are various. Suffice it here to say that two general methods are in common use—anterior gastro-enter-

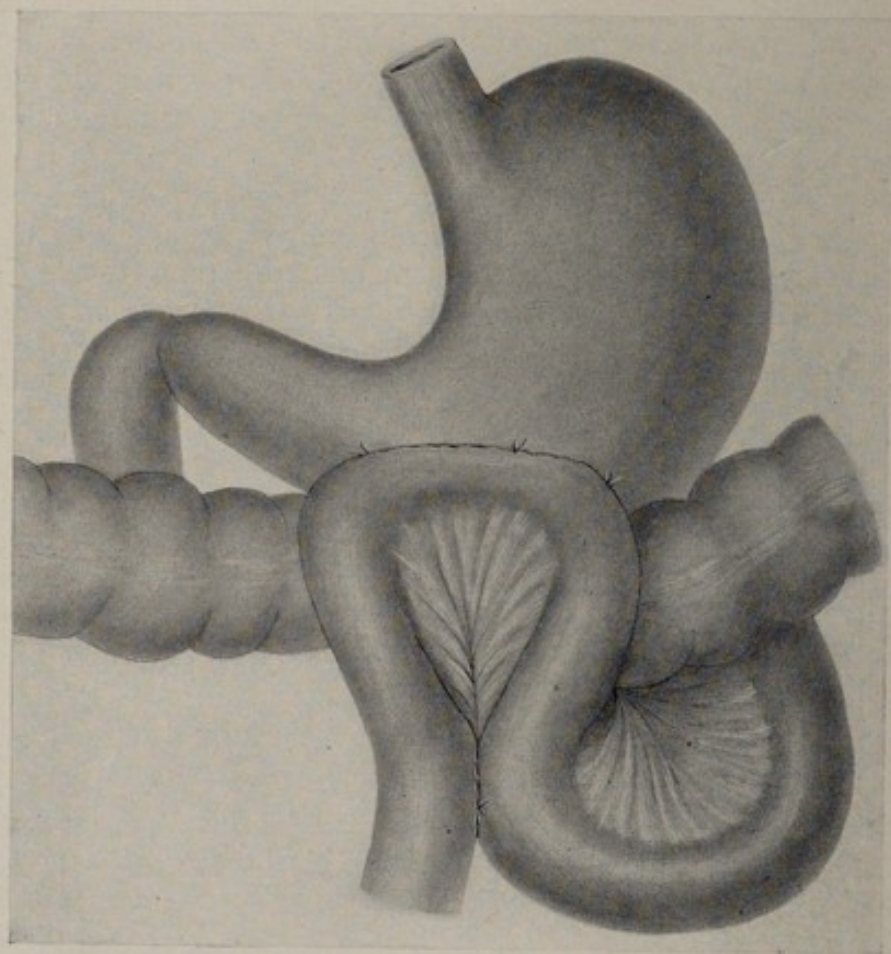

Fig. 63.—Diagram illustrating anterior gastro-enterostomy. Jejunojejunostomy between proximal and distal coils (Gould).

ostomy and posterior gastro-enterostomy. Anterior gastro-enterostomy is secured by bringing up a loop of the jejunum in front of the omentum and forming an anastomosis between it and the stomach at the lowest point available in the latter organ—generally near the

pyloric area. Posterior gastro-enterostomy is preferable. I need not here go into a discussion of the long-loop and no-loop operations, and of entero-enterostomy with or without division of the afferent loop. Excellent present-day opinion favors the no-loop operation of Mayo, by which an anastomosis is made between the lowest portion of the

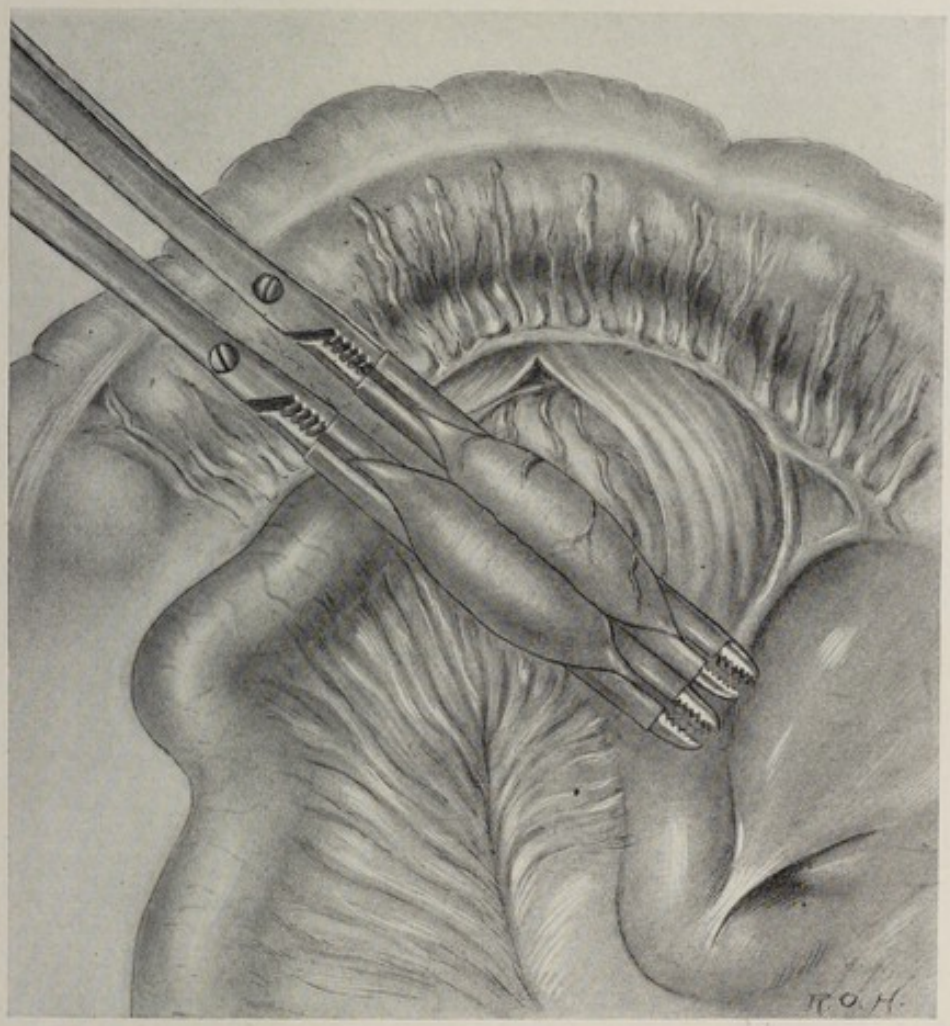

Fig. 64.—Posterior gastro-enterostomy. The clamps have been applied about 3 inches distal to the duodenojejunal flexure. The blades of the stomach clamp have been placed obliquely (Moynihan), while the handles point to the patient's right shoulder (Mayo, Munro) (from Gould, drawn according to the suggestions from W. J. Mayo).

stomach and the jejunum, where it lies behind the stomach, three or four inches from the end of the duodenum or ligament of Treitz.[1]

Finney's operation is often applicable to gastric ulcer when it can be done without opening into the ulcerated area. It gives admirable physiologic drainage.

The after-treatment of these cases is extremely simple. Generally, convalescence begins at once. With the cessation of ether vomiting patients may be given water by the mouth; albumin-water and thin

[1] I refer the reader to the text-books on operative surgery for details of these elaborate stomach operations, especially Moynihan's Abdominal Operations, and Surgical Aspects of Digestive Disorders, by J. G. Mumford.

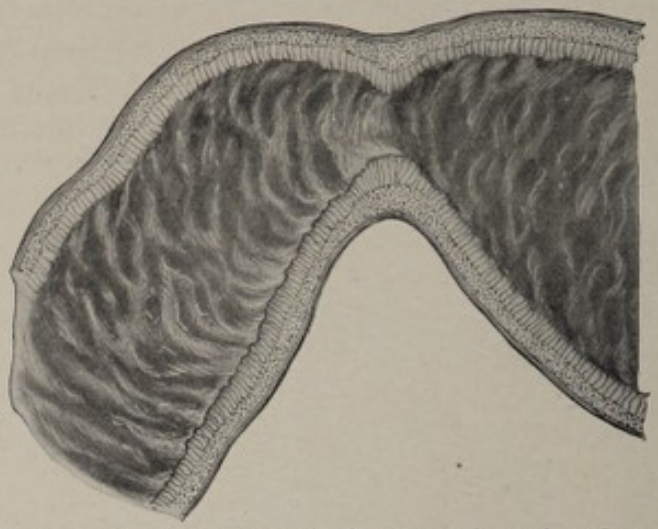

Fig. 65.—Finney's gastroduodenostomy. Cross-section of pylorus and duodenum before operation, for comparison with Fig. 70 (Gould).



Fig. 66.—Mobilization of the second portion of the duodenum (Finney). Note vertical peritoneal incision parallel to and to the right of the second portion of the duodenum. The duodenum is being shelled out with the finger. Also note the dotted line on the edge of the lesser omentum. A superficial cut through the omentum at this point allows the pylorus to drop down, thus assisting in the mobilization of the duodenum (Gould).

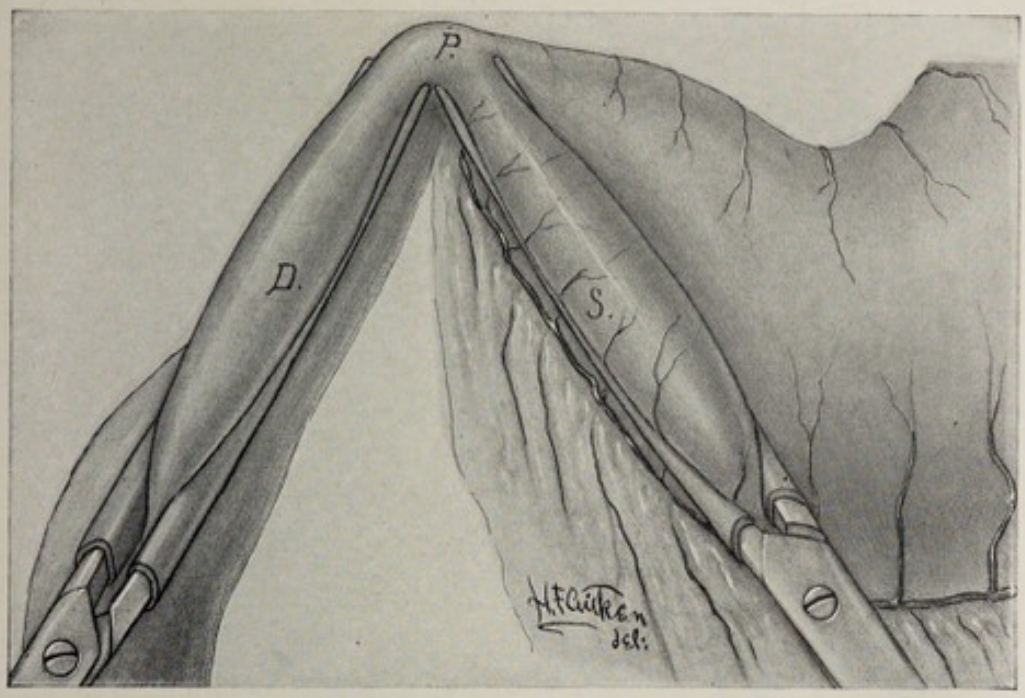

Fig. 67.—Gould's modification of Finney's operation. Note application of clamps. On the stomach they are placed parallel with the greater curvature, thus controlling the hemorrhage from the vessels which are seen crossing line of future incision. Inner jaws of both clamps touch at the pyloric angle. When the handles are brought together, the pyloric angle (*P*) is put on the stretch. It can be seen that the use of guides is unnecessary to make the folds lie side by side (Gould).

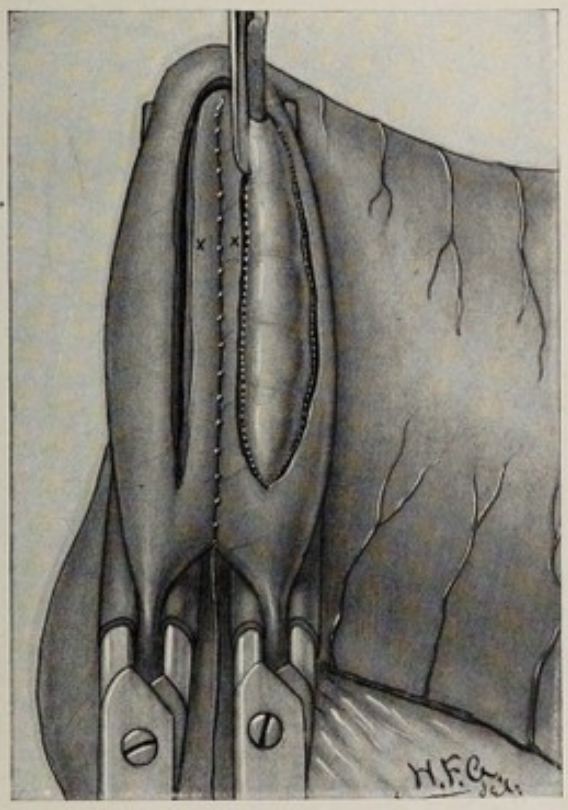

Fig. 68.—Gould's modification of Finney's operation. Clamps now side by side. Folds approximated by a continuous seromuscular stitch. Stomach incision to mucous membrane; duodenum then opened freely to pyloric angle. Scissors now cutting out redundant mucous membrane at dotted line. The next step is to sew x to x, beginning at the pyloric end of the tongue (Gould).

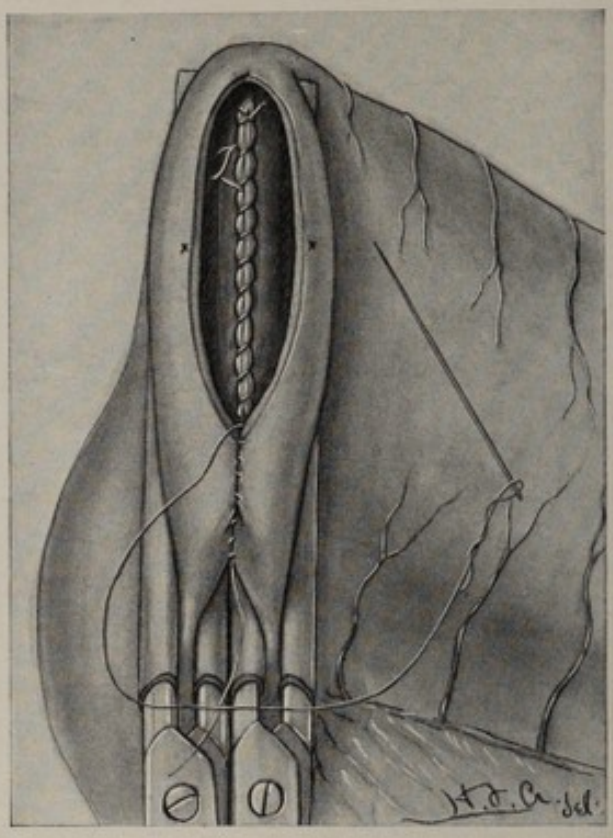

Fig. 69.—Gould's modification of Finney's operation. Tongue now closed over by continuous stitch which has turned corner to finish front of suture, bringing x to x; (*T*) sewed over tongue. The line of suture is finally buried by a seromuscular stitch (Gould).

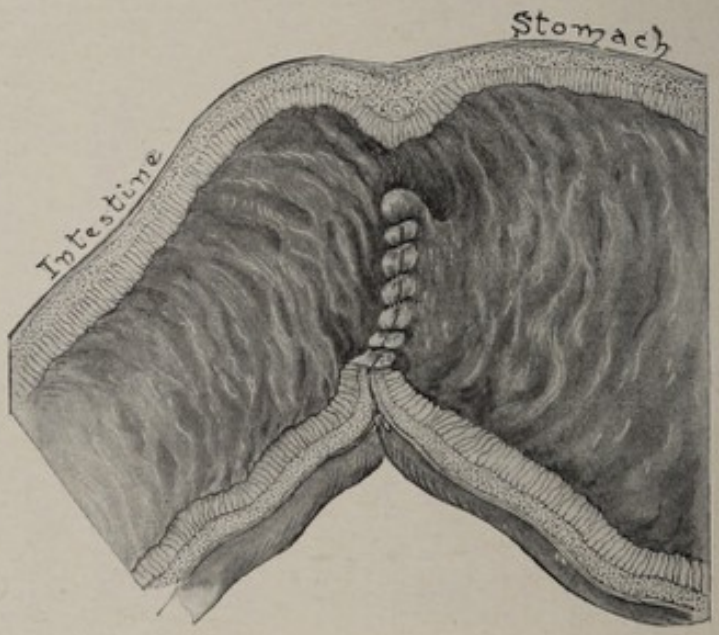

Fig. 70.—Finney's gastroduodenostomy. Cross-section after operation, showing increase in caliber of pylorus; caliber increased over Fig. 69 by length of sewed edges (Gould).

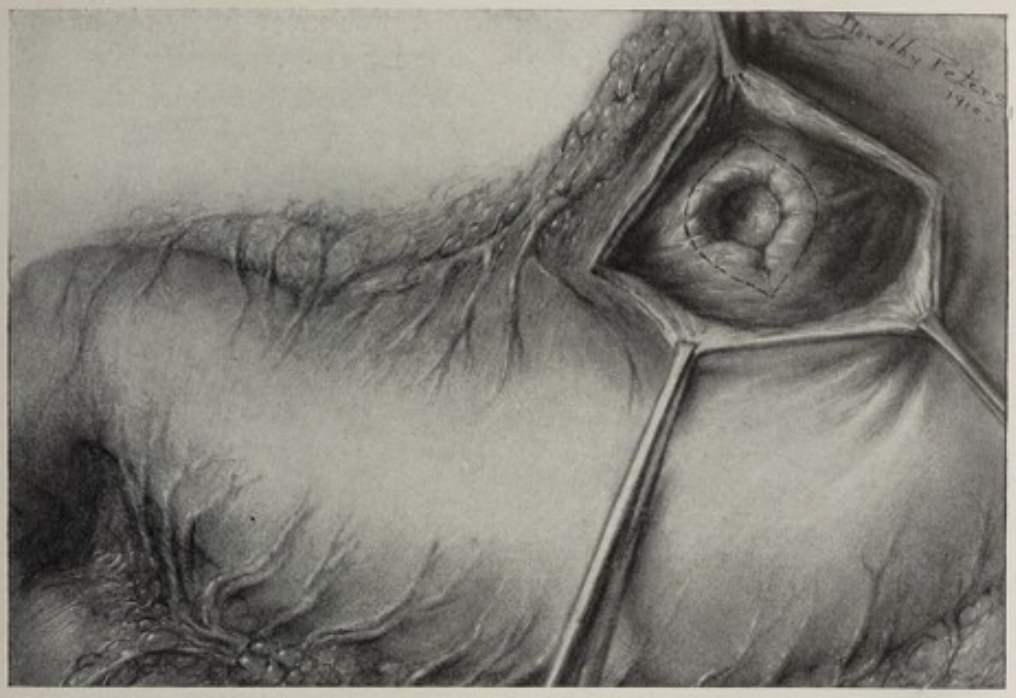

Fig. 70*a*.—Transgastric excision of calloused ulcer of the posterior wall of the body of the stomach, showing anterior wall of the stomach open and the ulcer exposed. The dotted lines show proposed site of excision (W. J. Mayo).



Fig. 70*b*.—Ulcer excised, and the through-and-through mucous suture partially completed (W. J. Mayo).

soup after twenty-four hours, a full liquid diet after forty-eight hours, and a carefully prescribed full solid diet by the seventh day. Convalescence is quick, and patients may be up and about in the second week.

The *modus operandi* of the cure of ulcer by these operations is an interesting problem, the probability being that the additional drainage relieves the diseased area of a constant irritation and allows healing to take place rapidly.

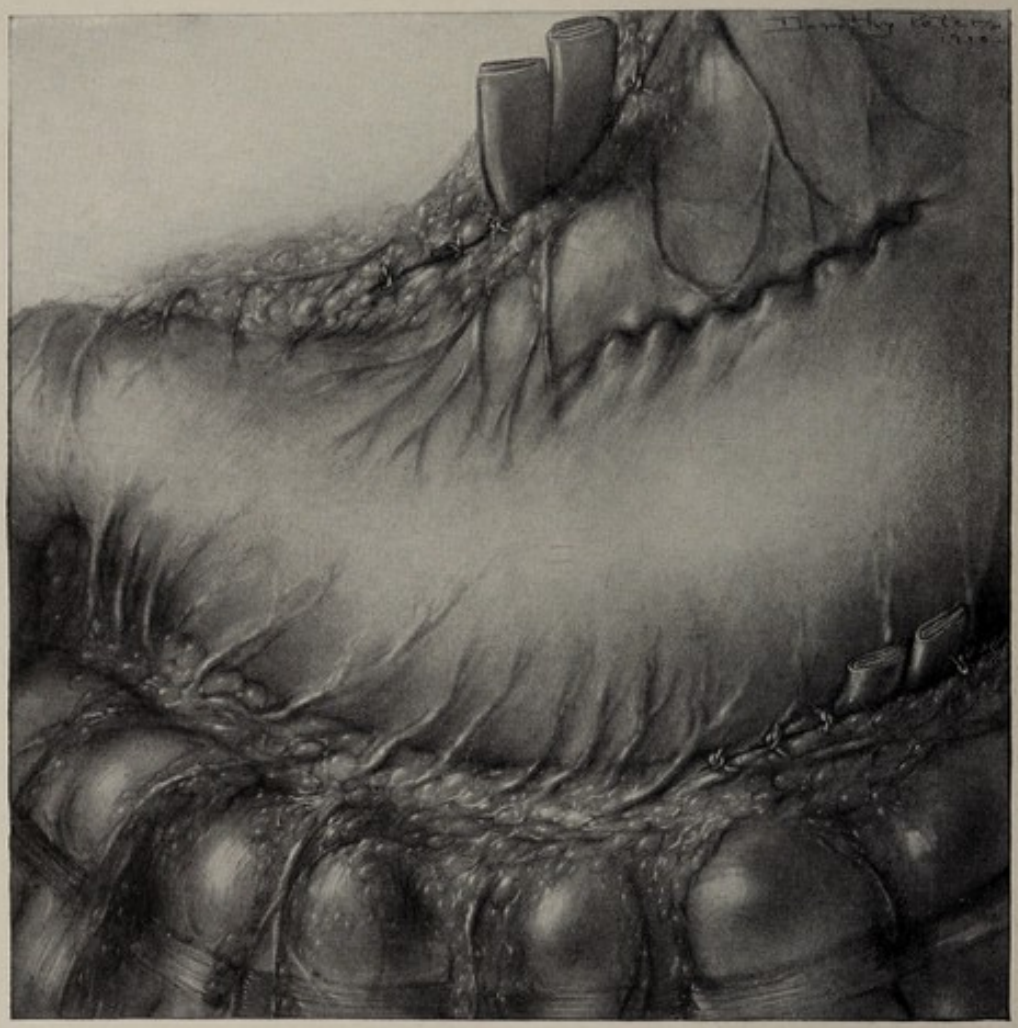

Fig. 70c.—Anterior wall of the stomach sutured. Rubber-tissue drains in place (W. J. Mayo).

The experience of the past three years is conclusive that proper gastro-enterostomy alone is curative in cases of *duodenal* ulcer. This however, is not true of all chronic *gastric* ulcers. They should be excised, as a supplement to the gastro-enterostomy; for they do not always heal when left; they may be malignant already, or later malignant disease may develop in them.[1]

[1] See W. J. Mayo, Ann. Surg., December, 1910, p. 797.

PYLORIC OBSTRUCTION

Pyloric obstruction is one of the most important complications of ulcer. It is due commonly to cicatricial contraction of ulcer of the pyloric portion, as I have explained already, and the obstruction may be very slight or complete; but even when slight, its effect upon the stomach and the stomach's mechanism is marked and disastrous in the long run. There are other causes of pyloric stenosis, such as neoplasms—benign and malignant—pressure from without, crippling extensive adhesions, and the dragging of a prolapsed stomach, causing a kink at the pylorus. Whatever the cause, the stomach will eventually become thinned and distended. If it contains comfortably more than 40 ounces of water, it may be regarded as a dilated stomach.

The interesting and not infrequent pyloric obstruction of infancy is congenital. The vomiting of the small patient and the alarming emaciation are striking symptoms.

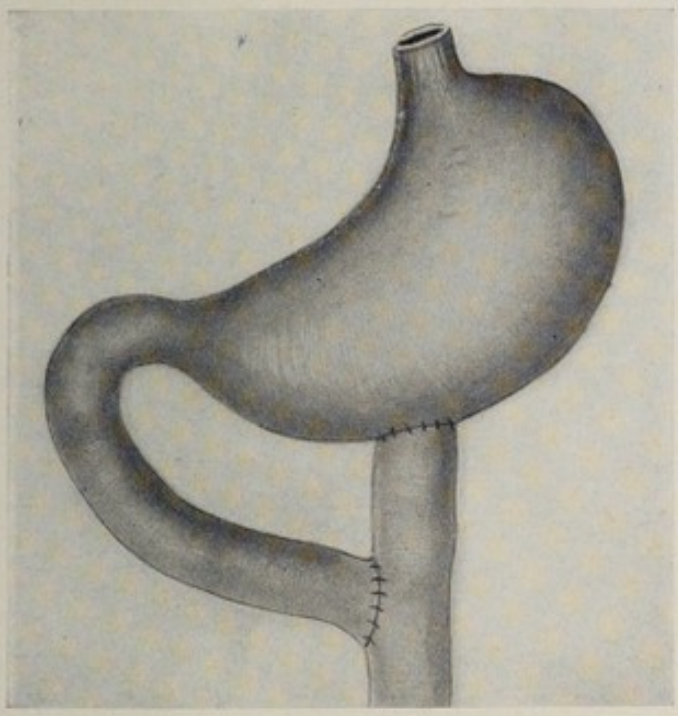

Fig. 71.—Operation of Roux completed (schematic).

The **symptoms** of pyloric obstruction are properly those of gastric dilatation. An uncomplicated obstruction rarely gives rise to symptoms. Obstruction with dilatation quickly becomes associated with gastric stasis—that is to say, ingested food remains in the stomach longer than normal. If one removes with the stomach-tube the stomach-contents eight hours after the patient has taken a full meal, one should find no trace of food if the stomach be normal. Food found after eight hours signifies delayed motility or stasis, and the symptoms are due to this stasis. The picture is a complicated and distressing one. The patient becomes emaciated, is troubled with pain coming on three or four hours after eating, has more or less vomiting, the vomitus varying in amount according to its frequency, and at times—perhaps

once in three or four days or perhaps very rarely—he vomits enormous quantities of food. He is troubled with thirst, constipation, heartburn, and headache. An important sign is visible peristalsis. Often a distinct splashing is heard if the examiner shakes the abdomen with his hand. The urine is scanty, the tongue dry and parched, and the urgency of the condition may vary all the way from a state of mild "dyspepsia" up to impending death from starvation.

The **treatment** of pyloric obstruction should be operative in the case of persons able to submit to operation and desirous of regaining permanent health. On the other hand, palliative treatment only may be permissible, and palliative treatment often relieves and seems at times to cure. Palliative treatment consists in lavage of the stomach, careful feeding, and the prescribing of tonics and laxatives. Un-

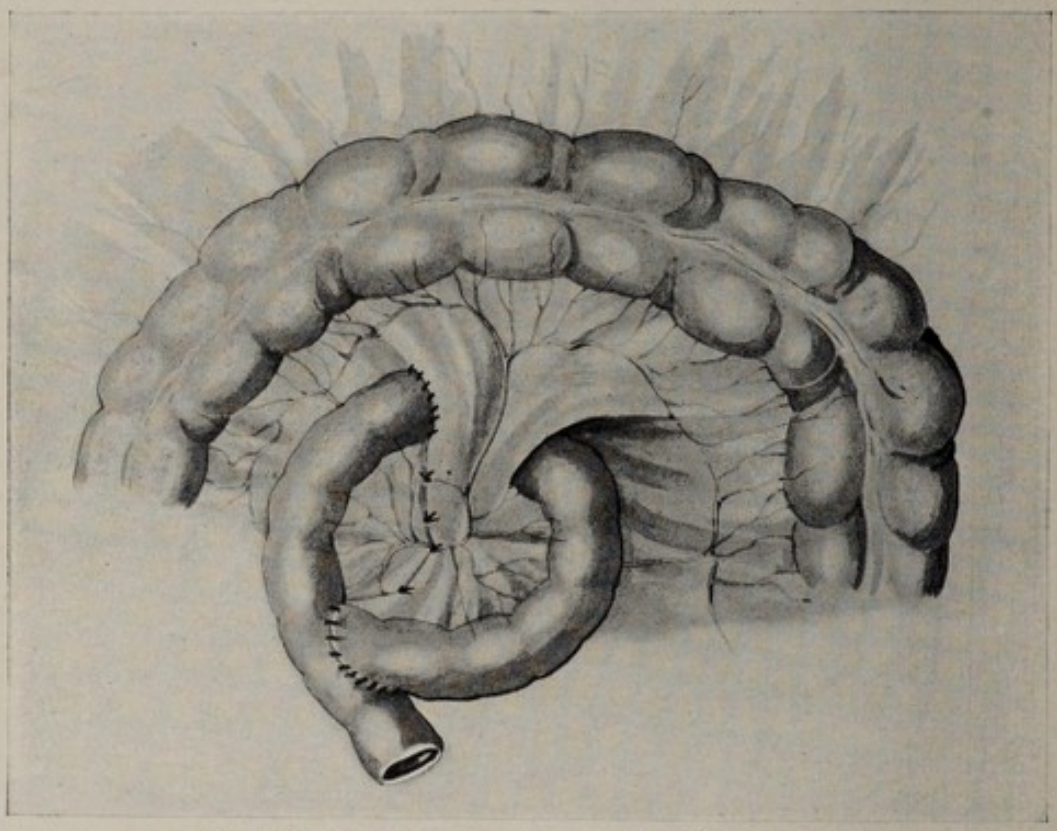

Fig. 72.—Roux's operation complete (Moynihan).

fortunately for the outlook of patients who depend on palliative treatment, we cannot prevent the frequent implantation of cancer upon the site of an old ulcer, whether healed or unhealed. My recent studies in the after-history of these cases at the Massachusetts General Hospital has shown that a majority of persons with stomach dilatation, when untreated, die within a few years; that a small percentage are relieved, and that a still smaller percentage (12 per cent.) recover.

Surgical treatment of pyloric stenosis is by gastro-enterostomy, by Finney's pyloroplasty, or by pylorectomy. Gastro-enterostomy is best performed by the no-loop method, and is generally satisfactory. However, in the case of a greatly dilated stomach the new stoma may be dragged upon as the stomach retracts, so that one may sometimes

prefer to do the operation of Chaput or that of Roux, as shown in the accompanying cuts. If the stomach and duodenum are not too much tied down and buried in adhesions, Finney's operation is extremely satisfactory. In any case of doubt as to the nature of the obstruction, especially when a considerable indurated mass is felt, one should suspect malignant disease and should perform pylorectomy. For congenital or infantile pyloric stenosis gastro-enterostomy is the only cure.[1]

The after-history of these obstruction cases, when treated by appropriate operation, is exceedingly satisfactory, but I cannot too earnestly caution the student and practitioner against indiscriminate and routine operating. Every case should be treated on its own merits and according to the nature of the mechanical derangement, otherwise the practitioner may be distressed to find that his patient is not benefited and that the old symptoms return after a short time. In no class of cases more than in stomach disorders is a careful and thorough study of conditions demanded, and no man should presume to take up this line of work unless he has attended the surgical clinic of an expert and has practised the operations upon the cadaver or upon living animals.

HEMORRHAGE

Hemorrhage from peptic ulcers may be demonstrated by finding stomach blood—vomited or expressed—or blood in the stools. There are numerous causes for gastric hemorrhage besides gastric disease; among such causes are diseases creating venous stasis, such as cardiac, renal, and hepatic disorders, as well as rare cases of angioneurotic edema and aneurysm. But it is gastric disease with which we are now dealing—with gastric ulcer and gastric cancer. I have spoken of the varieties of bleeding from gastric ulcer. There is the bleeding from acute ulcer and from chronic ulcer. Hemorrhage from acute ulcer rarely is persistent or extremely grave, though there are exceptions to this rule. Hemorrhage from chronic ulcer may be slight or overwhelming. The phrase "acute bleeding ulcer" is used, but it is a misleading phrase, since it seems to imply active hemorrhage from an acute ulcer, whereas the condition is more frequently found to be an active hemorrhage from a chronic ulcer. When the first evidence of ulcer is a sudden hemorrhage, however, the chances are that the ulcer is acute. The Massachusetts General Hospital records show a total mortality from stomach hemorrhage of 3.7 per cent.—males, 17 per cent., females, 1.27 per cent. Moreover, it appears that lethal hemorrhage is much less common in the young than in the middle aged, and less fatal in acute ulcer than in chronic ulcer. This 3.7 per cent. is a low mortality from hemorrhage. Other statistics give the death-rate as 8 per cent.

The **treatment** of hemorrhage is an intricate and interesting question. In general terms it is fair to assume that acute ulcer hemor-

[1] C. L. Scudder, Boston Med. and Surg. Jour., 1907, vol. clvii, p. 321; and 1909, vol. clx, p. 273. George Thompson, Surg., Gyn., and Obs., 1906, vol. iii, p. 521. F. E. Bunts, Surg., Gyn., and Obs., 1908, vol. vi, p. 663.

rhage may be subdued by rest and rectal feeding, while chronic ulcer hemorrhage, though it may be allayed for a time, is likely to recur after such internal treatment, and, therefore, requires a surgical operation for its permanent cure. Moreover, in those rare cases of hemorrhage which is persistent and brings the patient to a low ebb, an operation must be done immediately to save life.

The surgical treatment of hemorrhage from gastric ulcer is gastro-enterostomy. Other methods have been tried, but rarely have proved successful. Excision of the ulcer or ligation of the bleeding point is not to be recommended as routine. Time is lost by such measures, and the bleeding vessel is not always found. Gastro-enterostomy, by one of the methods already described, is quick and reasonably safe. The ulcer is put at rest, the bleeding ceases shortly, and convalescence generally is assured. Some care in feeding is required afterward, and if the patient's strength will permit, nutrient enemata will be employed for five or six days. The same rules apply to bleeding duodenal ulcer.

PERFORATION

Perforating peptic ulcer, whether acute or chronic, must be treated surgically. Though spontaneous cures are recorded, they are too rare to be anticipated in any given case.

The **symptoms** of acute perforation are: sudden pain, acute localized tenderness, a falling and, later, a rising temperature, a rapid and compressible pulse, peritoneal facies, and vomiting generally. In other words, the symptoms are quite similar to those of perforative appendicitis, except that the pain and tenderness are commonly located in another region. These cases, if untreated, go on to a diffuse peritonitis which kills the patient.

The **treatment** is by early operation. Recoveries are rare after eight hours have passed without such treatment. Open the abdomen through the right rectus muscle, above the umbilicus. Find the perforation, and sew it up with Lembert stitches. Wash out thoroughly the abdomen with salt solution, and drain the wound with gauze. The ulcer will heal usually if death from peritonitis does not supervene. In the after-treatment the semirecumbent position aids drainage, which should be supplemented further by a proper wick passed into the pelvis through a suprapubic stab-wound.

DISTORTION OF THE STOMACH

Distortion of the stomach (hour-glass stomach) may be regarded as an analogue of pyloric stenosis. In other words, the conditions which cause pyloric stenosis may exist elsewhere in the stomach and may narrow its lumen. There may be one or more constricting cicatrices, so that the stomach is thrown into two or more pouches.

Until recently it was believed that many cases of hour-glass stomach are congenital. Further study convinces us that congenital hour-glass stomach is rare, if, indeed, it exists at all. Most of the cases

investigated show that the deformity is due to cicatrices following an ulcerative process.

The **symptoms** are prolonged "dyspepsia," pain and tenderness, pain relieved by vomiting and malnutrition, frequently associated with pronounced nervous symptoms.

The **diagnosis** is difficult. Sundry maneuvers are advocated for demonstrating and making prominent the various pouches. Wash out the stomach until the water returns clear. If a gush of foul fluid follows later, it comes from a probable second pouch. Another test advocated by Moynihan is to map out the stomach resonance and then give a Seidlitz powder in two portions; after twenty or thirty seconds an enormous increase of resonance will be found in the upper pouch of the stomach. Later, the lower pouch will become distended. In spite of such ingenious tests, hour-glass stomach is often overlooked until it is revealed by operation or at autopsy.

The **treatment** for hour-glass stomach, like the treatment of pyloric stenosis, is palliative or operative. We need not consider palliation here. Operation generally cures. There are two excellent methods. If the cicatricial tissue be not too abundant, a gastrogastrostomy may be done by Finney's method, or by overlapping and forming an anastomosis between pouches. In other cases, where the distortion and surrounding adhesions are extensive, gastro-enterostomy may be necessary, and in such case the surgeon must form an anastomosis between the jejunum and each stomach pouch.

GASTRIC ADHESIONS

Gastric adhesions are a frequent complication of gastric ulcer. They are present in nearly 40 per cent. of all ulcer cases, and are a common cause of distressing symptoms. They distort the stomach; they fix it in abnormal positions; they delay its motility, and they interfere with the action of neighboring organs. Frequently they are accompanied by suppuration and burrowing fistulæ.

They are due to the extension of inflammation from gastric ulcer,—the most serious forms of adhesions,—or to a peritonitis spreading to the epigastrium from elsewhere in the abdomen—perhaps from the appendix or Fallopian tube. An inflamed gall-bladder may become adherent to the stomach and a gastrocystic fistula form. In like manner fistulæ may connect the stomach with the transverse colon, the duodenum, or the pancreas.

The **symptoms** of gastric adhesions, or perigastritis, are as manifold as are the pathologic conditions, and the symptoms are extremely puzzling. Nearly always there are "dyspepsia," indefinite pain, and occasional vomiting. The chemic output of the stomach may be interfered with, and digestion may be long delayed. Sometimes bile is vomited; sometimes there are recurring attacks of intense colic.

The surgical treatment of gastric adhesions, granted the patient comes to surgery, is often difficult. If the adhesions are light and easily broken down, permanent relief may follow their separation.

On the other hand, if heavy bands, with fistulæ and involvement of other organs, exist, the best treatment is gastro-enterostomy to facilitate stomach drainage.

GASTRIC TETANY

Gastric tetany is occasionally seen, but is more often overlooked. In every case of tetany one should think of the possibility of pyloric obstruction. Gastric irritation is a common cause of convulsions in children; it may cause convulsions in adults, and such tetany is sometimes associated with pyloric stenosis. The spasms are due probably to the absorption of some poison from the dilated stomach, with an associated painful contraction of the pylorus.

The **treatment** is directed at first toward relief of the stomach by lavage or induced vomiting. Often lavage is difficult or impossible because the attempt to pass a stomach-tube excites renewed spasms. Permanent cure may be obtained by Finney's operation or by gastro-enterostomy.

GASTRIC CIRRHOSIS

Gastric cirrhosis deserves mention, though it is a rare condition. The disease is chronic, and does not appear to be associated with ulcer or cancer. The stomach-wall is found thickened, often seared and stenosed, and the symptoms resemble those of long-standing ulcer, except that the vomiting is small in amount. Patients die of the disease unless relieved by operation. Gastro-enterostomy has improved the condition, though the reason for such improvement is not immediately apparent. At least one operation of total gastrectomy for this disease has been reported.[1]

SPASM OF THE PYLORUS

Spasm of the pylorus (Reichmann's disease) is a rare condition when unassociated with obvious pathologic changes. It is said to be due to gastric hyperchlorhydria. Often it will be relieved by lavage and dieting. Should these fail, Finney's operation is a rational method of cure.

GASTROPTOSIS

Gastroptosis, or dislocation downward of the stomach, is commonly associated with dislocation of the colon and right kidney. The prolapsed stomach is often dilated also, since dragging on the fixed pylorus kinks and narrows the gastric outlet. The greater curvature may be found on a level with the navel, or as low as the pubes even, and the diagnosis of ptosis is confirmed by dilating the stomach with air or water, and finding its upper border low in the epigastrium. In such case the pulsation of the aorta may be felt easily in the epigastrium.

In addition to such general treatment as I shall describe when dealing with visceral ptosis as a whole one may practise a variety of surgi-

[1] B. G. A. Moynihan, Lancet, August 12, 1911.

cal procedures for the prolapsed stomach. I have been satisfied in two cases with Beyea's operation of reefing the gastrohepatic omentum, while an independent or supplementary gastro-enterostomy is of value also. In two other cases of gastroptosis with dilatation I have found Finney's pyloroplasty to relieve the symptoms.

STENOSIS OF THE PYLORUS

Hypertrophic stenosis of the pylorus is a condition occasionally seen at autopsy and upon the operating table. It is associated with gastrectasis, but there is no connective-tissue development. Microscopically, the condition is found to be hypertrophy of the muscularis and submucosa of the pylorus. It has been suggested that some of these cases may be congenital, as the same condition is found also in infants.

Treatment is by Finney's operation or by gastro-enterostomy.

FOREIGN BODIES

Foreign bodies may pass through the esophagus and lodge in the stomach, though commonly, if they pass the cardia, they escape through the pylorus. The victims of this accident are generally children, insane persons, or drunkards. One sees lodged in the stomach such articles as pins, safety-pins, shot, coins, plates of false teeth, hat-pins, pebbles, masses of hair, nails, screws, pieces of broken glass, etc. In the case of a juggler, I have seen incredible numbers of metallic objects removed from the stomach. Dr. T. F. Harrington, of Boston, tells me that he saw a soldier, returned from the Spanish War, who was treated for sundry wasting diseases without avail; at the end, in a fatal and only hemorrhage, the man vomited a lizard. If the foreign bodies do not pass, they may remain indefinitely in the stomach or may give rise to pain, vomiting, and other "dyspeptic" symptoms. They may cause ulcer; they may perforate the stomach. Most of these objects may be encouraged to pass on with the fecal stream, but cathartics should *never* be employed. Our endeavor is to incrust the foreign body with some non-irritating food, so as to prevent its perforating the viscera or doing other damage. Give a diet of bread and milk or Indian-meal mush, or mashed potatoes, for several days, and follow this with a mild laxative. In rare cases, when there has been long-standing retention of the foreign body or evidence of perforation, one must operate. Not long ago I saw a colleague cut down upon a stomach from which an eight-inch hat-pin protruded and penetrated the liver. The head of the hat-pin prevented the pin's complete exit from the stomach.

CANCER

Cancer, next to ulcer, is the disease of the stomach which interests us most. Gastric cancer is extremely common. According to the figures of von Mikulicz and Mayo, one-third of all cancers are found in the stomach. We were formerly told that it is a disease of sudden

onset, coming on often in persons of previously good health and strong digestion. On the contrary, we believe to-day that cancer frequently develops at the end of a long course of "dyspepsia," being implanted upon ulcer or the sequelæ of ulcer. Competent writers go so far as to say that about 70 per cent.[1] of all cases of gastric carcinoma may be traced to pre-existing ulcer. Cancer of the stomach is nearly always primary, those gastric ulcers which are secondary being traceable usually to primary esophageal cancer. Metastases from gastric cancer are found in the lymph-nodes, along the lesser curvature, in the liver, in the pancreas,

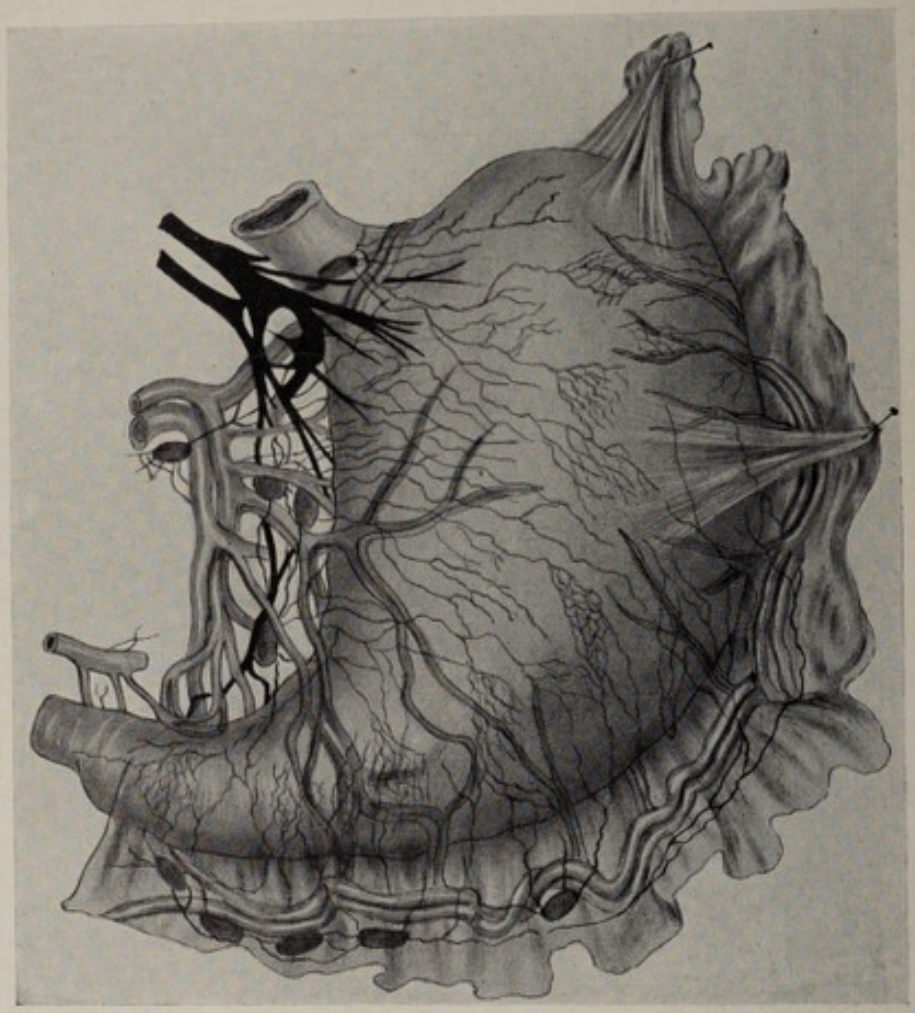

Fig. 73.—Lymphatics of the stomach.

and in other more distant organs. Bear in mind that enlarged nodes along the greater curvature suggest pyloric ulcer, while enlarged nodes along the lesser curvature suggest pyloric cancer. The location of cancer in the stomach is in the pyloric region in about 70 per cent. of the cases; on the posterior surface in about 4 per cent.; cardia, 9 per cent.; greater curvature, 4 per cent.; anterior surface, 3 per cent.; fundus, 10 per cent. The ratio of men to women is about as 7 is to 5.

The common varieties of gastric cancer are the cylindric-celled adenocarcinoma and the encephaloid or medullary carcinoma; next in frequency is scirrhus, and then colloid cancer.

[1] W. C. MacCarty, Surg., Gyn., and Obst., May, 1910, p. 449, etc.

Marked gastric changes take place in the presence of cancer, depending upon the location of the disease. When the cancer is at the pylorus, it causes a thickening of the stomach-wall in the pyloric region and a gradual closing of the outlet, associated first with hypertrophy of the fundus and then with its dilatation. When the cancer is not at the pylorus, it may involve considerable areas of the gastric wall and cause marked deformity and crippling of the organ, with frequent adhesions to the neighboring structures and direct extension of the disease to those structures. Perforation into the peritoneal cavity, followed by a diffuse peritonitis, is a not infrequent occurrence.

In regard to metastases, remember that in from 4 to 10 per cent. of the cases no metastasis has been found, the enlarged nodes present being shown to be hyperplastic merely; that the fundus is rarely the seat of carcinoma, and that its lymphatic nodes seldom are involved.

The **symptoms** of gastric cancer are either latent or pronounced. In a great many cases we hear a story of long-continued "dyspepsia" merely, with a certain amount of heartburn, distaste for food, especially for meat, and sometimes a craving for highly spiced food. Such symptoms may exist for many months without exciting the patient's suspicions. There is generally an associated loss of weight and strength, with anemia, and possibly an irregular temperature, with occasional chills. In a certain proportion of cases free hydrochloric acid is decreased or lacking in the stomach-contents, while lactic acid and putrefactive organisms are found; blood in abundance or in mere traces may be present, and late in the disease the Oppler-Boas bacillus (a club-shaped organism). Indican is often increased in the urine, and in about one-third of the cases there is albuminuria with casts. Frequently there is edema of the feet and legs and of the abdominal wall even. The bowels are nearly always constipated.

In marked cases pain, hemorrhage, and vomiting are the important symptoms, though all these symptoms may be absent throughout the disease.

The **diagnosis** of cancer of the stomach is extremely difficult in its early stages. But, given a patient of middle age, with prolonged "dyspepsia," distaste for food, occasional attacks of epigastric pain, and wasting, one should suspect cancer. If to these symptoms bloody vomiting be added, and if a mass can be felt in the epigastrium, the diagnosis of cancer is almost assured. But we must not wait for these late manifestations in order to confirm the diagnosis. If we are in doubt, and if the patient's strength will permit, a rapid exploration should be undertaken early to ascertain the exact condition.

Treatment.—Cancer of the stomach is a surgical disease, as is cancer elsewhere. No so-called medical treatment avails for a cure. It may well be that the patient and his friends prefer mild measures and a waiting for death. That is at their own discretion. There can be no doubt that cases of advanced cancer are incurable by surgery, and the kinder course is palliation, but accumulating experience shows that in the early stages of gastric cancer, extirpation of the disease, by

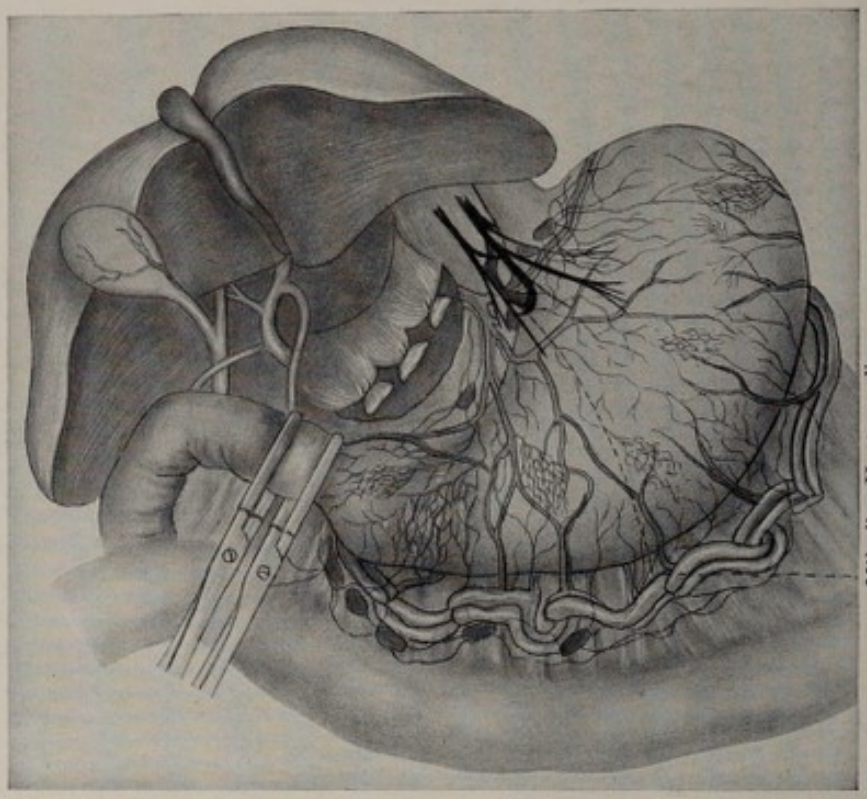

Fig. 74.—Showing ligation of gastrohepatic omentum and superior vessels in such manner as to leave all the lymph-nodes attached to the part of the stomach to be excised; also lines of division of duodenum and stomach (after W. J. Mayo, Ann. Surg.).

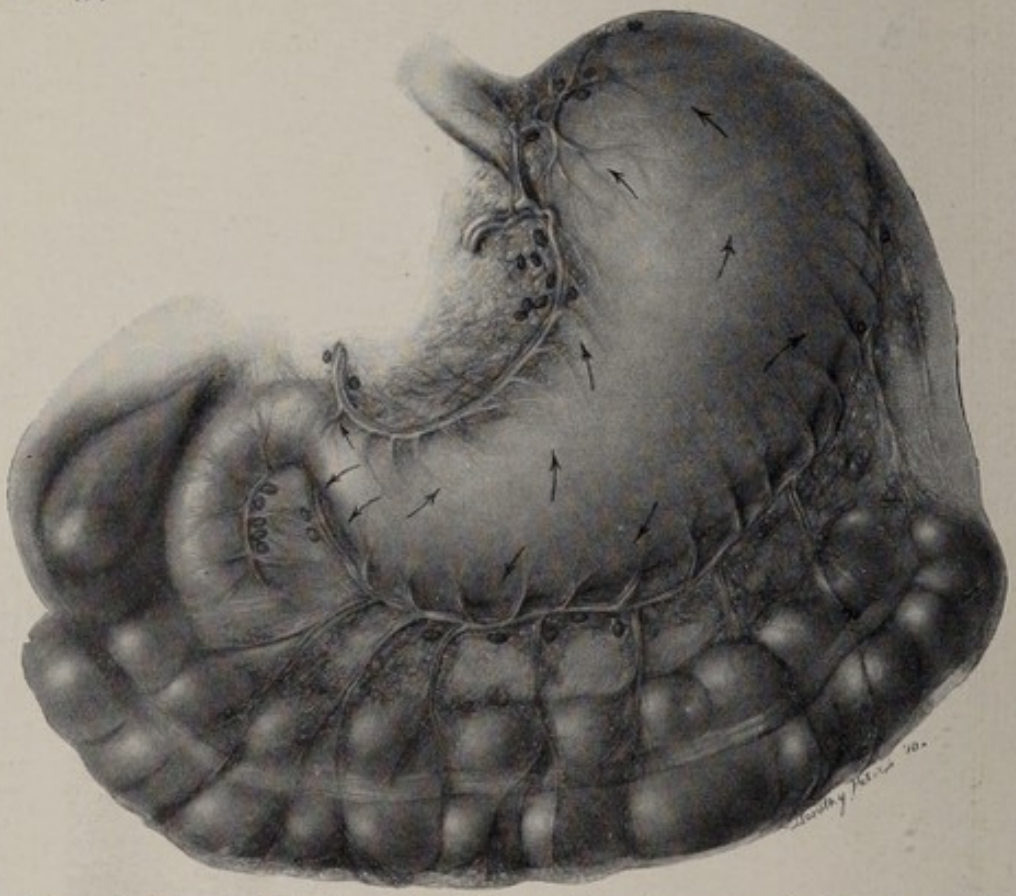

Fig. 74*a*.—Anatomy of the stomach with especial reference to the blood-vessels and lymphatics. The arrows indicate the direction of the lymphatic flow (W. J. Mayo).

a competent surgeon, will cure a goodly proportion of patients, or, more often, will postpone for years the inevitable end. It was formerly said that the finding of a tumor contraindicated gastrectomy. On the contrary, the finding of a tumor may be cause for hope from gastrectomy. A small tumor of the anterior pyloric region may be felt and excised and the patient recover, while a large and extensive growth on the posterior wall of the stomach may run its course, without detection, to a fatal termination.

Should the patient elect to have no operation done, we must strive to make him comfortable with gastric lavage; with small and frequent feedings of easily digested food, especially milk; with gradually ascend-

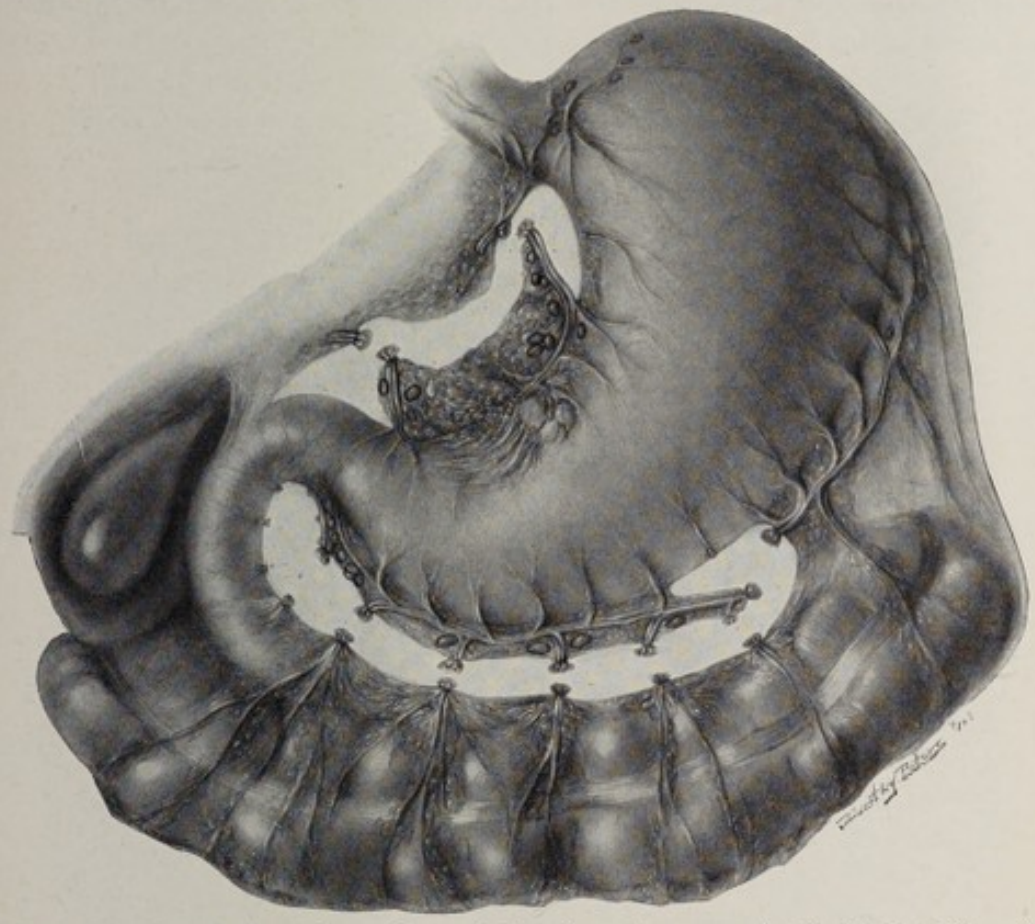

Fig. 75.—Vessels ligated and lymphatic dissection completed (W. J. Mayo).

ing doses of the compound tincture of iodin (beginning with 5 minims); with morphin for pain; and with other remedies to meet the conditions which arise. The symptoms vary with the location of the disease. Cancer of the fundus may cause no symptoms other than anorexia, wasting, and debility; cancer of the pylorus may cause the most distressing symptoms—intolerable pain, vomiting, and constitutional exhaustion leading to early death. In such cases the physician is driven to the constant use of morphin.

There are operations other than gastrectomy for cancer of the stomach. There are radical operations and palliative operations, and the choice depends upon the site and extent of the disease. We excise

cancer of the stomach when the growth is small, the lymphatic connections but slightly involved, and when no metastasis exists. We perform palliative operations to relieve impending starvation, and for pain and vomiting. The radical operations are pylorectomy, partial gastrectomy, and total gastrectomy; and the difficulties of these operations are in the same order. Practically, however, a mere pylorectomy is of little service in cancer, because it is not radical enough. Partial gastrectomy is the more common and satisfactory operation. The mortality varies between 8 and 50 per cent., but as we are getting these cancer cases earlier, we are securing a lower operative mortality and an increasing number of permanent cures. The accompanying cuts (Figs. 74–77) illustrate the operation which I have been using. It is the operation described and advocated by W. J. Mayo in 1904.

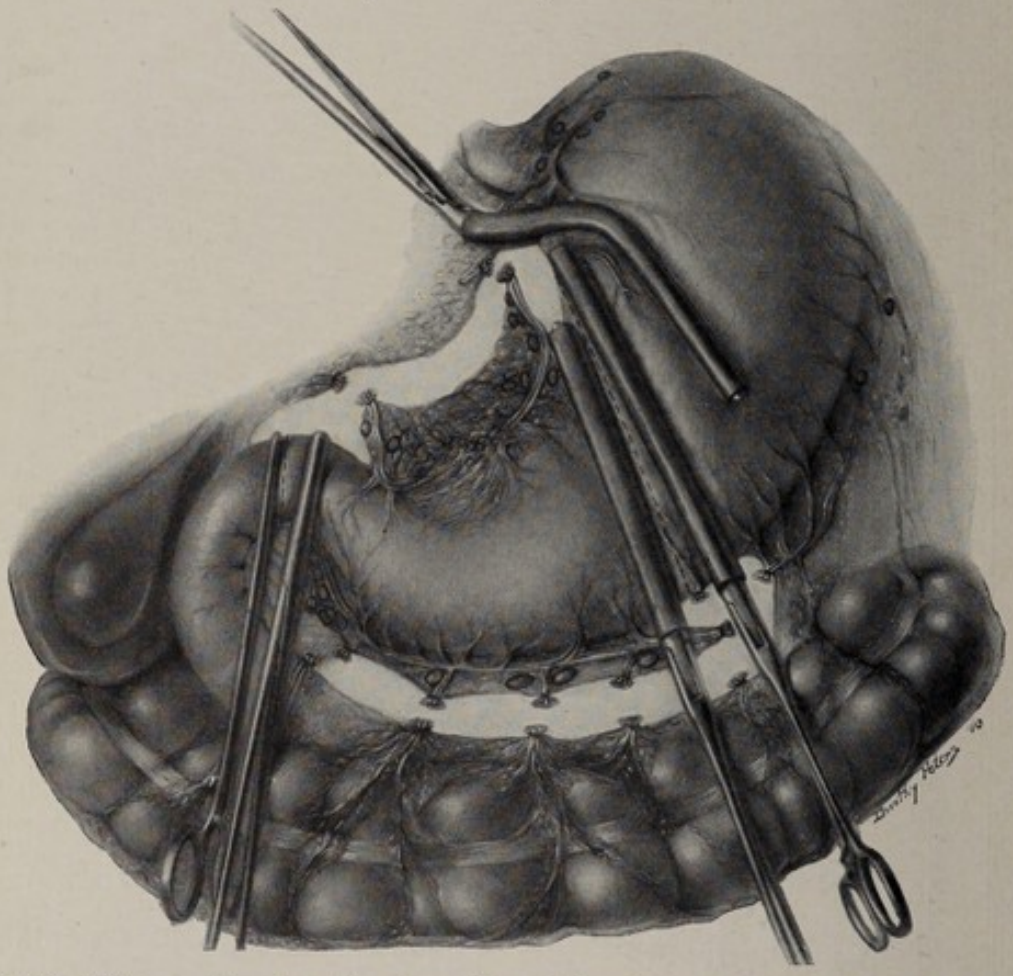

Fig. 76.—Clamps placed on the stomach and duodenum, isolating the pyloric end and lesser curvature (W. J. Mayo).

Open the abdomen through the right rectus muscle, and turn out the stomach and omentum. Tie off the gastrohepatic omentum close to the liver, thus opening widely the lesser omental cavity and mobilizing the pylorus. Pack off with gauze the entire area exposed. Then tie the four important arteries, two above the stomach and two below it. The gastric artery is best secured at once by double ligature where it joins the lesser curvature, about an inch below the cardia. The superior

pyloric artery, a branch of the hepatic, is tied just above the pylorus. To get at the two lower vessels, pass the left hand into the lesser cavity behind the pylorus, find the gastrocolic omentum, and raise it from the transverse mesocolon; then isolate and secure from the front the right gastro-epiploic artery. Next tie the left gastro-epiploic artery at a suitable point on the greater curvature, and tie in sections and cut away the gastrocolic omentum, taking great care not to interfere with the middle colic artery, which runs in the transverse mesocolon.

It is a simple matter now to remove a portion of the stomach: double clamp the duodenum, and divide it with the cautery between the clamps. Then turn in the distal stump of duodenum. Cut off the superior portion of the stomach in much the same fashion, thus: grasp the viscus with a rubber-guarded holding clamp, and about half an inch below it place a strong biting-clamp, to prevent leakage. Then cut off with the cautery the stomach between the two clamps and turn

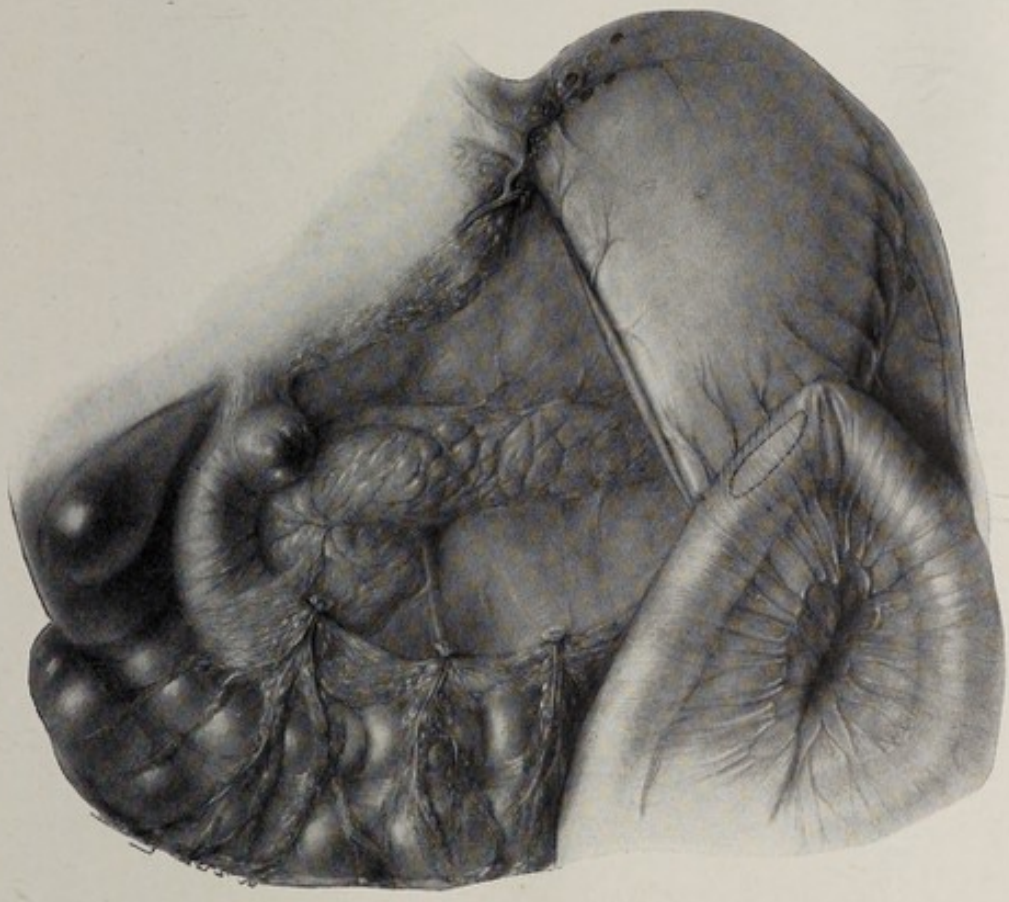

Fig. 77.—Restoration of gastro-intestinal continuity by an anterior gastro-enterostomy, which may be used in place of the posterior operation when the remaining stomach pouch is very small (W. J. Mayo).

in the gastric stump. We have now an isolated stomach pouch and an isolated intestine to be connected. Various methods of making this connection have been devised. The so-called Billroth's first method consists in uniting the stump of duodenum with the lower angle of the gastric stump, but this method forms an insecure joint and is now little used. Kocher inserts the duodenal stump into the posterior wall of

the stomach—an excellent procedure. Billroth's second method—the method employed by Mayo—consists in performing gastrojejunostomy.

With a little practice, and in case the stomach is freely movable, one may perform the whole operation of gastrectomy rapidly, and the shock is less than one might expect. In fairly vigorous patients reaction from the operation is rapid. After three days of rectal feeding careful liquid nourishment may be given by mouth, and by the end of two weeks a fairly full diet with caution may be prescribed. These

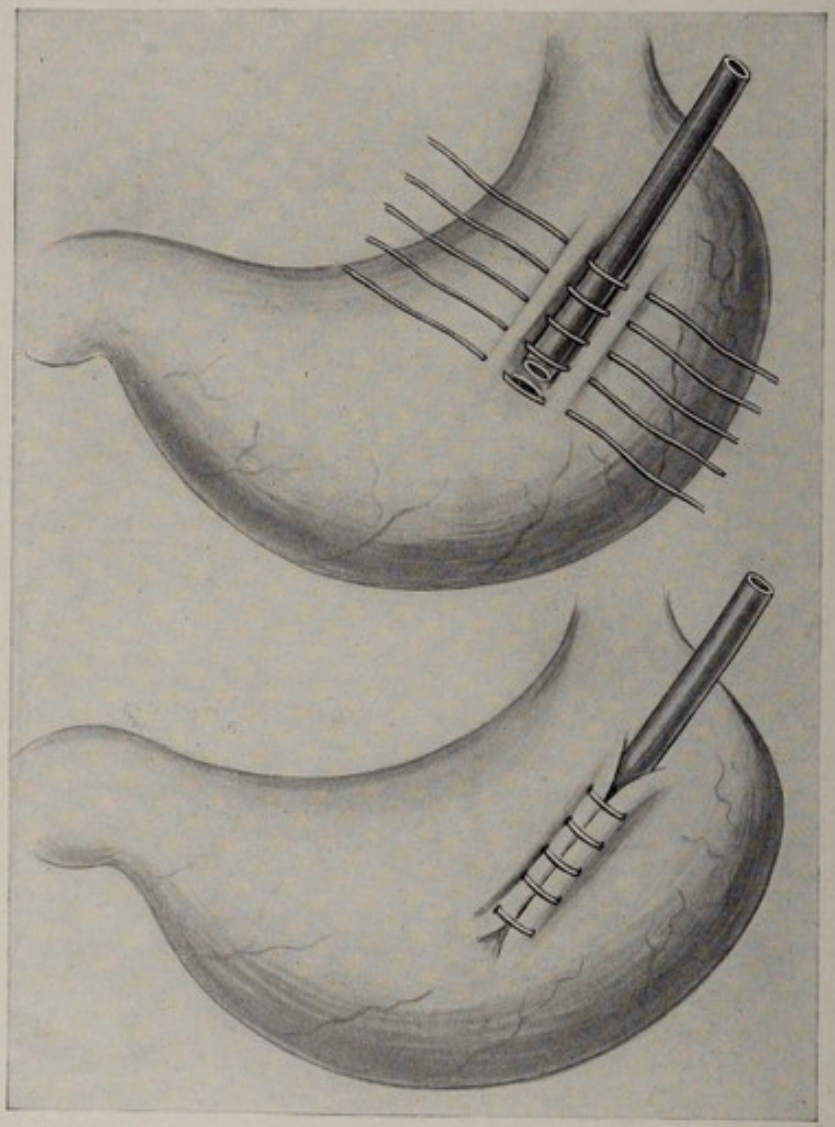

Fig. 78.—Gastrostomy—Witzel's method (Keen's Surgery).

patients should be instructed, however, that they must never indulge fully their vigorous appetites, and should always follow a careful dietary.

Removal of the whole stomach, with a mortality of about 39 per cent., has been performed some 60 times. So far as the latest statistics go, it appears that about 15 per cent. of the cases have been cured for four or more years. W. J. Mayo writes of this operation in his own clinic: "The mortality has been high, and I do not know of any record

of a patient remaining well five years." The patients, if they survive the operation, show a surprising increase in weight and strength, and get along in a fairly satisfactory manner so far as their digestions are concerned.

There are two commonly recognized palliative operations for cancer of the stomach—*gastro-enterostomy* and *gastrostomy*. The mortality from gastro-enterostomy for malignant disease is higher than the mortality from gastrectomy even—not that gastrectomy is a less severe

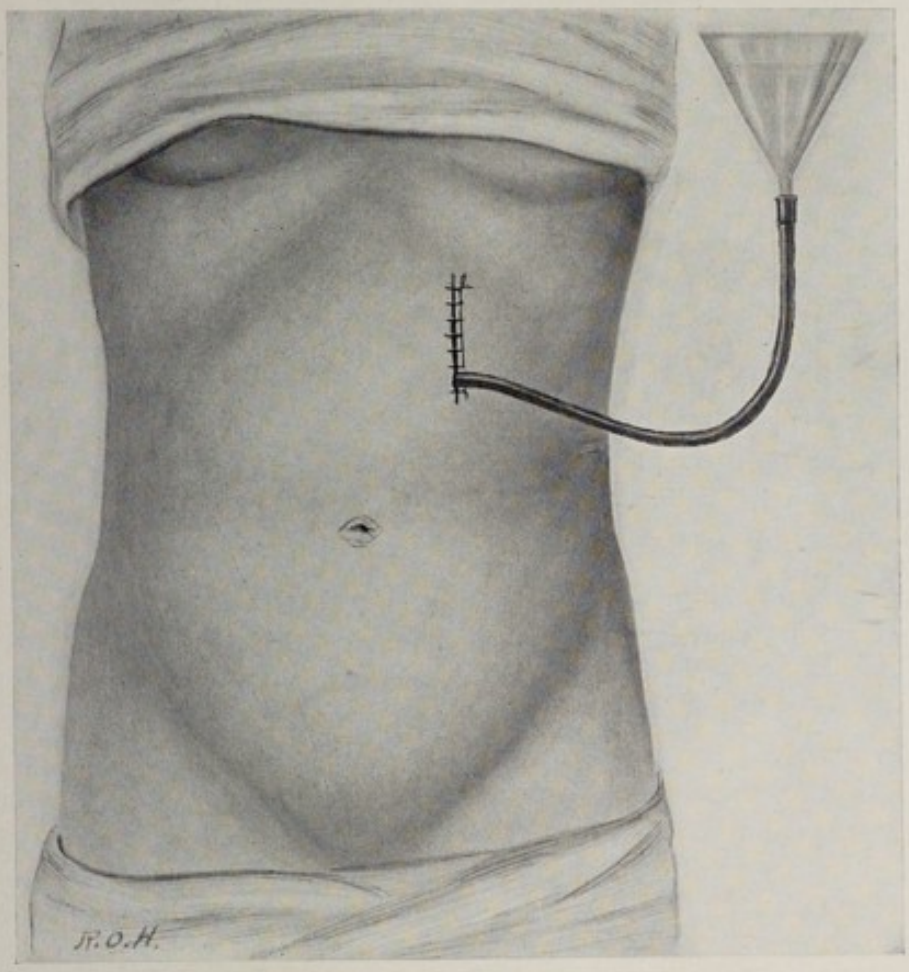

Fig. 79.—Feeding by gastrostomy.

operation, but because gastro-enterostomy is performed in the more grave and hopeless cases, on persons greatly reduced and with low resisting powers. Gastro-enterostomy is applicable to patients suffering from pyloric obstruction, and to these only. When the cancer is in the fundus of the stomach and the pylorus is not involved, gastro-enterostomy is useless. Gastro-enterostomy is a makeshift at the best. Frequently, after submitting to it, patients improve for a time and are greatly more comfortable than before. They gain in strength, flesh, and vigor, and may get about their work. The average length of life after gastro-enterostomy for cancer of the stomach is fourteen months. In advanced cancer cases, with their extensive and crippling adhesions, *posterior* gastro-enterostomy rarely is applicable. The routine operation is *anterior* gastro-enterostomy, performed by suture.

Gastrostomy, or sometimes jejunostomy, is used in the case of extensive cancer of the fundus of the stomach, or when the cardia is obstructed by disease. The purpose of the operation is palliation merely, in order to ward off starvation. It has no effect on pain or vomiting except in so far as it removes irritating food from the immediate neighborhood of the growth.

The viscus to be opened is drawn up to the surface, and a rubber tube or catheter is inserted, after the manner of Kader or Witzel. The viscus is then attached to the abdominal wall, and the tube is left protruding. Through the tube food is introduced at will. After two weeks the tube may be removed permanently. A fistulous tract is left through which a tube may be reinserted and food poured in at any time. The nature of the operation, if performed correctly, is such that a valve-like obstruction exists in the fistula, and the stomach-contents are retained by the closed valve between feedings. By means of this operation a patient's life may be prolonged many months.

Besides cancer, the stomach is occasionally the seat of other tumors, both malignant and benign. Benign tumors make little trouble unless they obstruct the pyloric outlet, and they need not concern us further. They are rare. Of the other malignant tumors, the only one of importance is sarcoma of the stomach.

SARCOMA OF THE STOMACH

This disease has all the clinical characteristics of cancer of the stomach, and cannot with certainty be differentiated from it. Anatomically, it is found at the pylorus less frequently than is cancer—that is to say, about one-fourth of the sarcomata are pyloric. Generally, sarcoma involves the posterior wall and the greater curvature, arising in the submucous coat. Whereas cancer is more common in men than in women, sarcoma is equally common in both. It grows to a large size often before killing the patient, and the tumor may be seen actually distending the abdominal wall. Hemorrhage is not common; pyloric stenosis is not common; metastases are rare. The disease is rapid, and usually kills in from ten to eleven months.

The only **treatment** is by operation, as in the case of cancer—gastrectomy or gastro-enterostomy.

WOUNDS OF THE STOMACH

Wounds of the stomach have been considered already in part under the captions Wounds of the Intestines and Foreign Bodies in the Stomach. The history of the injury often gives little indication of the extent of the visceral lesion. Damage is inflicted by blows, crushes, and penetrating missiles or stab-wounds. The stomach is rarely *ruptured* by blows or crushes. The commonest injuries are bullet-wounds and stab-wounds. The stomach differs from the intestines in being a thicker-walled organ, with muscular layers so arranged that they are

less liable to allow the escape of gastric contents than is the intestinal wall to allow the feces to escape.

The **symptoms** of wounds of the stomach are: acute localized pain, vomiting,—sometimes bloody,—and collapse, with rapid pulse and a falling, followed by a rising, temperature. Later the symptoms of peritonitis supervene. The **diagnosis** is often difficult, for a penetrating wound of the stomach may exist without obvious striking symptoms.

The **treatment** is immediate exploration and repair of the damaged organ. In all cases of doubt it is the surgeon's duty to explore. The stomach must be sewed up with two rows of Lembert stitches, the abdomen thoroughly flushed with warm salt solution, and drainage established at the site of injury and above the pubes. If convalescence proceeds, the patient should be nourished by nutrient enemata for five days at least.

In addition to the diseases and lesions of the stomach already discussed, there are numerous rare conditions and borderland diseases with which the surgeon may occasionally have to deal. Such are sundry forms of inflammation, curious tumors, tuberculosis, and syphilis. The writers on internal medicine deal with these matters. I refer the reader to such treatises as those of Nothnagel, Osler, Wood, Fitz, and the larger systems of surgery.

CHAPTER V

THE LIVER AND BILE-PASSAGES

The Liver

In general terms it is convenient for the surgeon to regard the liver as an accessory digestive organ—accessory to the stomach and intestines. Moreover, it is interesting to reflect that by far the most important portion, surgically, of the liver apparatus is the system of ducts connecting the liver with the bowel. Not that the liver in itself is devoid of surgical interest, but such interest is infrequent compared with interest in the bile-passages. Though diseases of the liver are common in the experience of the internist, it is an unfortunate fact

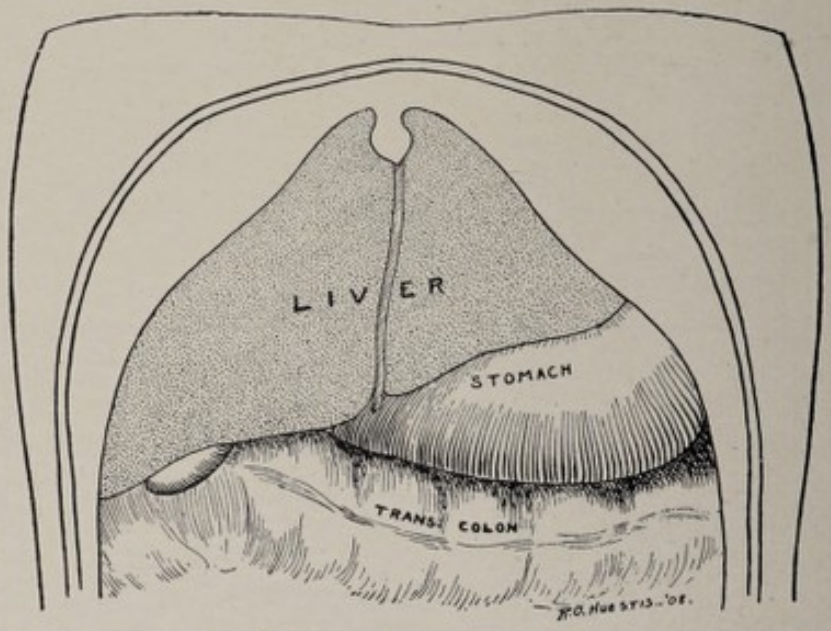

Fig. 80.—Relations of liver.

that, as yet, surgical therapeutics has found small place in the great field of the liver proper.

There are certain liver lesions which have always belonged to the surgeon, and lately two or three other diseases of that organ have been added to this list. Abscesses, traumatic injuries, cysts, and tumors are the most important of the lesions of the liver, long recognized as surgical. Lately, the surgeon has treated cirrhosis and ptosis.

Remember how the right lobe makes up the bulk of the liver; how the left lobe stretches out to the left across the epigastrium; how the broad suspensory ligament, with its round ligament coming up from

the navel, lies between the lobes; how the lower posterior portion of the right lobe is uncovered of peritoneum; how the small quadrate lobe appears in the midst on the under surface, with the gall-bladder lying between it and the right lobe, while at its base lie the ducts, the portal vein, and the hepatic artery. Normally, the liver is quite movable. It may be tipped up with the costal cartilages. Nick the suspensory ligament with the round ligament, and you may pull the liver down.

ABSCESS OF THE LIVER

Abscess of the liver has gained interest for American surgeons within the past fifteen years, because such abscesses are common among white men in the tropics. Our military surgeons are treating tropical abscess in the Islands, and frequent cases find their way to the States. These tropical abscesses are usually *single*. They vary in size, but may involve a whole lobe. Organisms from the intestines enter the portal circulation, and dysentery is the primary disease. Many observers have found the ameba of dysentery in the pus of these liver abscesses. Hepatic abscess sometimes follows malaria, influenza, yellow fever, and typhoid. Henry Jackson, in a résumé of 17 cases at the Boston City Hospital, found that 10 of his list were due directly to a concurrent appendicitis—an important observation of many other writers also. Therefore, staphylococci and streptococci are found in the pus, while, among other agents, are coccidia, the ray-fungi of actinomycosis, and rarely tubercle bacilli. A syphilitic gumma may suppurate, and secondary abscesses due to echinococcus and cholangitis occasionally are found. Moreover, these abscesses may be metastatic and occur in the course of a pyemia.

The course of hepatic abscess varies with the nature of the infection. Tropical abscess grows slowly; infections from the appendix progress rapidly. In general, the pyogenic organisms produce much more acute inflammations than do the other and more uncommon forms.

The **symptoms** of liver abscess vary also with the nature of the infection. The disease may run its course without symptoms. Characteristic fever, pain, tumor, and enlarged liver rarely are present. The patient becomes sallow and emaciated, and lies in a doubled-up position. There is seldom any jaundice of moment. If the abscess is near the liver surface, it may cause protrusion of the skin. If it is in the center of the liver, it remains inconspicuous. Of course, rupture into the peritoneal cavity or into adjoining organs will set up additional symptoms of greater or less gravity, depending on the locality thus invaded. None of the classic signs of abscess are to be looked for or relied upon. Fever and a high-tension, rapid pulse may or may not be present. I have found the leukocytosis varying from 7000 to 40,000. Tenderness is generally absent.

The **diagnosis** is, therefore, extremely difficult often. The condition may simulate manifold disorders, such as pleurisy, subphrenic abscess, disease of the bile-passages, gastric ulcer, pyonephrosis, pan-

creatitis, or any other of the complex conditions seen in the associated neighboring organs. Aspiration may fail to detect pus which is present, but do not aspirate for diagnosis. It is a risky and inconclusive maneuver. As with cancer of the stomach, an exploratory incision is justifiable and generally advisable in these obscure cases of suspected hepatic abscess. Operate to make the diagnosis, and complete the operation to establish proper treatment.

Accordingly, the **treatment** of abscess of the liver is operative except in the early stages of a suppurative hepatitis. Two methods of operation have been recommended: complete operation at one sitting and operation in two stages—I prefer the former. Open down upon the suspected region, wall off the liver with gauze, open, wash out, and drain the abscess. If the liver has become adherent to the abdominal wall, the operation is by so much the easier. Operation in two stages consists, first, in exposing the suspected area and stitching the parietal peritoneum to the liver about the lesion. Then, after ten days, adhesions will have formed, when the abscess may be opened. Under the conditions of modern technic this cumbersome procedure is seldom necessary.

In the case of actinomycosis, as with actinomycosis elsewhere, follow the operation with medication by copper sulphate or potassium iodid.

CYSTS OF THE LIVER

Cysts of the liver are variously described by writers, but you will find in practice that the echinococcus cyst alone is important. It is due to the Tænia echinococcus, a tape-worm of 4 joints, measuring about 0.2 inch. This parasite is found in the duodenum of dogs and a few

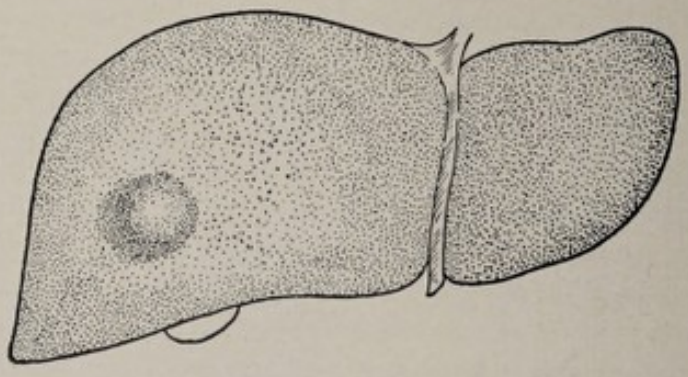

Fig. 81.—Diagram of cyst of liver.

other domestic animals. The embryo finds its way into the human liver and develops slowly. It is found surrounded by a capsule of connective tissue, within which is the cuticle of the cyst, lined with parenchyma, from the cells of which develop the scolices or heads of the tape-worms. These scolices have suckers surrounded by hooklets. The fully developed scolices are detached from the membrane and float free in the cavity of the cyst, which contains a clear fluid, nearly colorless. These cysts may exist undiscovered for years. They grow slowly,

and may never cause symptoms, unless, from their size, they distend the liver, press upon neighboring organs, and rupture or become infected.

So the **symptoms** vary as much as do the symptoms of liver abscess. When the tumor is small and deep, it is unrecognized. When it is recognized, it appears connected with the liver, rounded, smooth, and elastic. Sometimes it causes pain; it moves with respiration. If it suppurate, it will have the characteristics, or lack of characteristics, of hepatic abscess. On such indefinite evidence the diagnosis must be made.

The **treatment** is like that for abscess, and exploratory operation often is needed both to confirm the diagnosis and to relieve the condition. The conservative method is to evacuate the fluid and other contents, to break up supplementary or "daughter cysts," which are frequently found, and to pack the wound, leaving it to heal by granulation—a slow process, requiring weeks or months. A more radical, bloody, and somewhat dangerous method is to enucleate the cyst with curet or cautery. If successful, this method is followed by healing in three or four weeks. One might discuss at length methods of opening down upon these liver cysts. Generally, they may be approached through an abdominal incision. Sometimes one must remove the lower costal cartilages and ribs, pack off the pleural cavity, and enter through the diaphragm.

In all cases the after-treatment must be pursued energetically with local irrigations and packing and by general sustaining treatment.

INJURIES TO THE LIVER

Injuries to the liver are common in military and railway surgery. Ruptures and penetrating wounds frequently are seen. The right lobe most often is ruptured, and the tear may be slight or extensive. Lacerations of this gland are often wide, because it is inelastic. These cases are dangerous, and the mortality is nearly 50 per cent. under the most favoring circumstances. Most of the patients who die perish within twenty-four hours from hemorrhage. Among those who live longer, peritonitis and ptomain poisoning may supervene.

The **symptoms** are the symptoms of acute intra-abdominal hemorrhage, plus pain, while the shock is often out of proportion to the bleeding. Severe and continuous pain in the abdomen—pain both local and general—persists. It does not intermit. It may radiate toward the navel and the right shoulder. Sometimes there is late jaundice. Bile may appear in the urine.

The **treatment** must be heroic; rarely is delay permissible. With evidence before him of severe injury, pain, abdominal hemorrhage, and profound shock, the surgeon must open the abdomen at once through a long incision in the right semilunar line, or through a sweeping incision parallel to the margin of the ribs. Thus he will discover blood and clots. If one fails to find at once the rent in the liver, or if it is

evident that the organ is wounded on the convexity of the right lobe, up under the diaphragm, one may employ Lannelongue's plan to reach the seat of injury—that is, through a curved incision two inches above and parallel to the border of the ribs; and by resecting the eighth, ninth, tenth, and eleventh costal cartilages. When the rent in the liver is found, it must be treated with deep sutures, threaded on a blunt needle, by the cautery, or by tampon. I prefer to use heavy, buried catgut stitches, carefully opposing the torn capsule. The abdominal cavity must be mopped out, and the external wound must be closed with drainage. Gun-shot and stab-wounds must be treated in

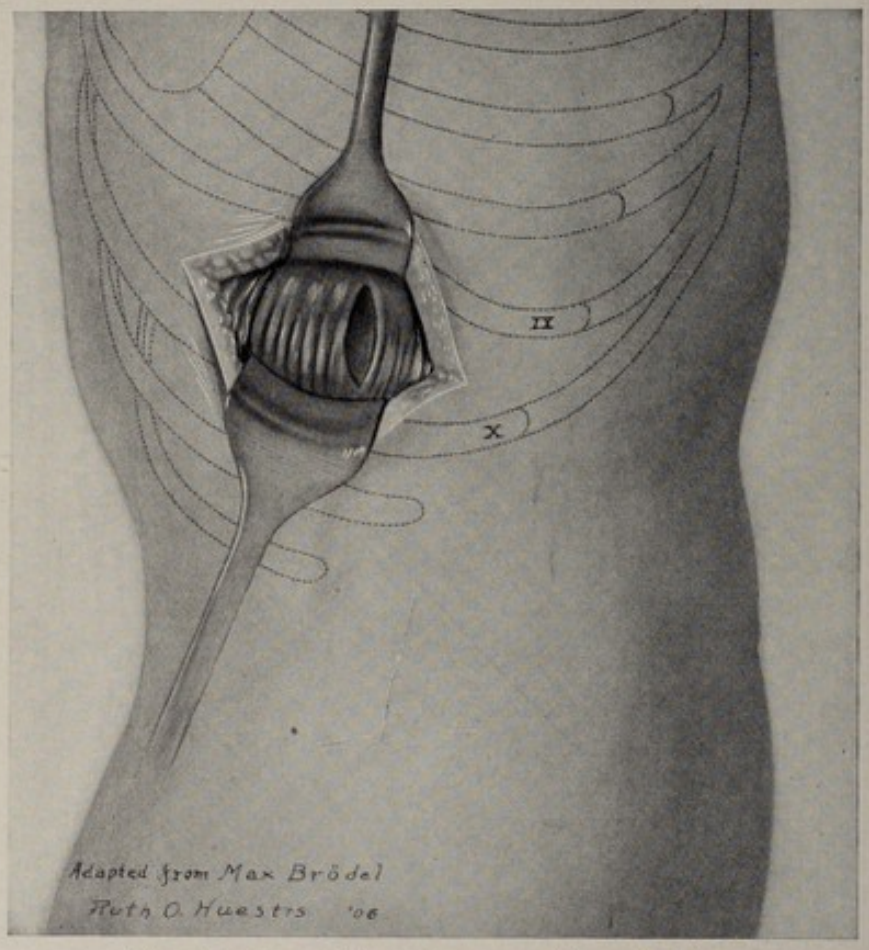

Fig. 82.—Transthoracic approach to the liver.

much the same fashion, except that in such cases the cautery and tampon are often better than stitches. If ribs or cartilages have been resected, the surgeon, in closing the wound, must see to it that sharp, bony edges do not lacerate the exposed liver. Convalescence from these injuries is surprisingly rapid often.

TUMORS OF THE LIVER

Solid tumors of the liver focus the subject of hepatic surgery, a subject of growing interest. We have seen how wounds of the liver were regarded for long as extremely fatal, because it is hard to control

hepatic hemorrhage. On account of hemorrhage it has been thought difficult or impossible also to cut down into the liver safely in order to remove a tumor. Thanks to the endeavors of recent experimenters, we are now coming to feel that we can cut into the liver with reasonable confidence. But we do not yet attempt extensive explorations of that organ, nor try to remove its multiple tumors—and, unfortunately,

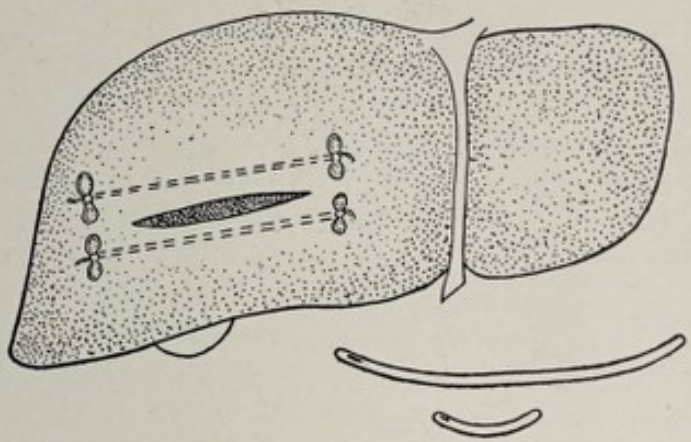

Fig. 83.—Knott's method of suturing the liver. The sunken catgut strands in the tissue parallel to the wound to be sutured.

multiple tumors of the liver are more frequent than are solitary tumors. Of the liver tumors, **syphilomata** are common. They occur in two forms: as circumscribed gummata and as syphilitic lobulation. A gumma is usually single, and may grow to the size of a hen's egg, being situated near the suspensory ligament usually or near the entrance of the portal vein. Lobulation results from cicatricial contraction following the absorption of syphilitic nodules.

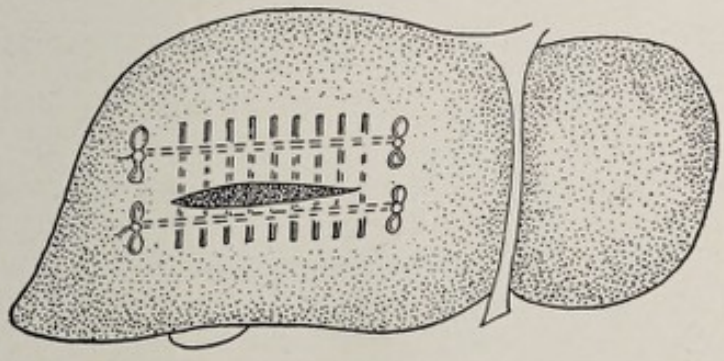

Fig. 84.—Knott's method of suturing the liver. The transverse interrupted sutures introduced.

The *symptoms* of syphilitic liver are indefinite and somewhat various. The first evidence is often a movable lobe suggesting floating kidney, or there may be ascites, due to pressure on the portal vein; jaundice is rare. These tumors cannot always with certainty be differentiated from cancer, even when the abdomen is opened. It is seldom wise to attempt a removal of a syphilitic nodule, because specific treatment will frequently suffice to subdue the symptoms. If a partially detached

lobe protrudes, however, and makes trouble, it may be removed with the cautery, and the hemorrhage may be controlled by such deep stitching as I shall describe presently. Some six years ago I removed such a lobe from the liver of a woman who had complained for several years of constant abdominal pain. The result was entirely satisfactory. In her case, before operation, the tumor was supposed to be a floating kidney.

There are sundry **benign tumors of the liver**—fibromata, fibromyomata, angiomata, and adenomata. These are important when they obstruct the circulation or press upon neighboring organs. They may be removed with the knife or cautery.

Cancer of the liver is common, and is generally secondary to cancer elsewhere—in the stomach, the bile-passages, or some portion of the intestinal canal. Secondary cancer of the liver develops about many foci, or is multiple, as we say. One should never attempt its removal. Primary cancer of the liver rarely may be multiple or infiltrating. In the case of solitary primary cancer, excision sometimes conceivably is permissible. Unfortunately, primary cancer of the liver rarely is detected until it is too large for removal.

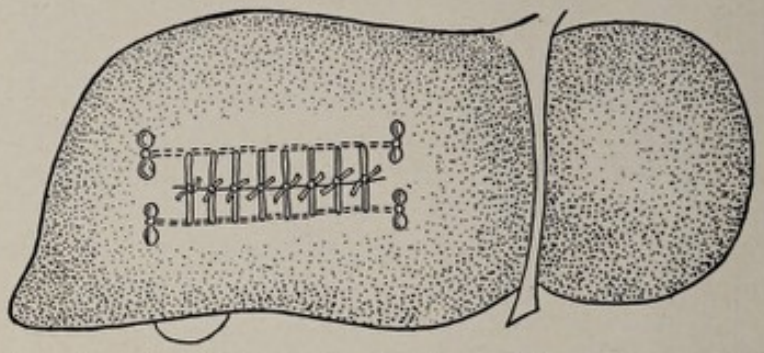

Fig. 85.—Knott's method of suturing the liver. The transverse sutures tied.

The *symptoms* of primary hepatic cancer are the general symptoms of cancer with certain special late manifestations. The patient becomes cachectic and loses his appetite, especially for fatty foods and meat; and there may be vomiting of blood, due to passive congestion of the gastric mucosa. The liver becomes slightly enlarged; rarely, a tumor may be felt; there may be ascites, and there may be late jaundice, but if ascites and jaundice are present, the disease is too far advanced for radical treatment.

Primary sarcoma of the liver is still rarer than carcinoma, and the symptoms of the two cannot be distinguished from each other.

Treatment of Liver Tumors.—Excision of liver tumors is the only radical treatment possible, and of late such operations have multiplied. They all depend upon hemostasis for their success. The mere cutting out of a tumor of this organ is as easy as cutting cheese, but the control of hemorrhage is the problem. Tumors of the *left* lobe are the most easy to remove, because the left lobe itself can be amputated. Indeed, it was long ago proved by numerous experimenters that large portions

of the liver may be removed without danger to life. Unfortunately, primary cancer usually is found in the *right* lobe. The literature of operations on the liver is now considerable, and advertises the names of

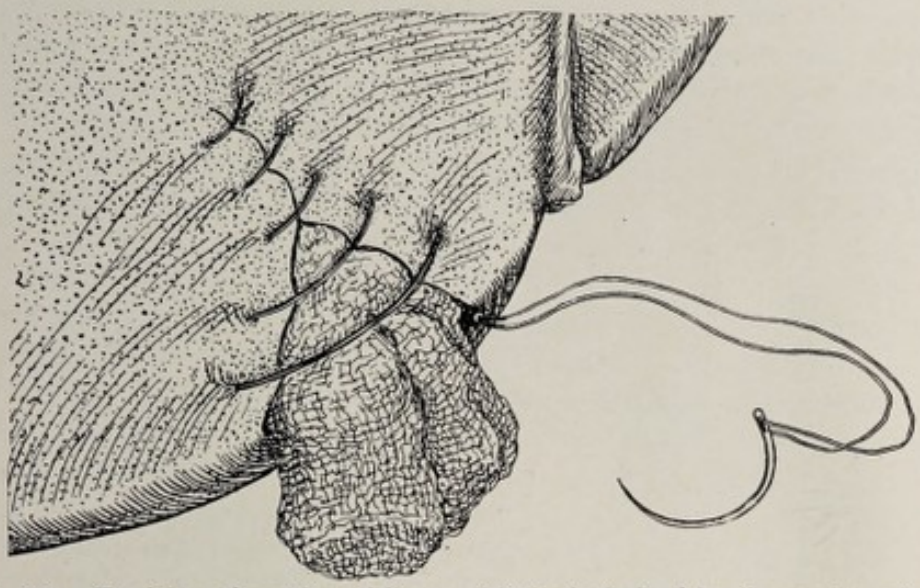

Fig. 86.—Excision of section of liver. Method of checking hemorrhage by combined catgut suturing and gauze. Compression seen from above (Mayo, in Keen's Surgery).

Holm (1867), Tillmanns (1879), Escher (1886), Burkhardt (1887)—the first to insist upon abdominal section to control hepatic hemorrhage; Glück (1890), who demonstrated that one-third of the liver may be

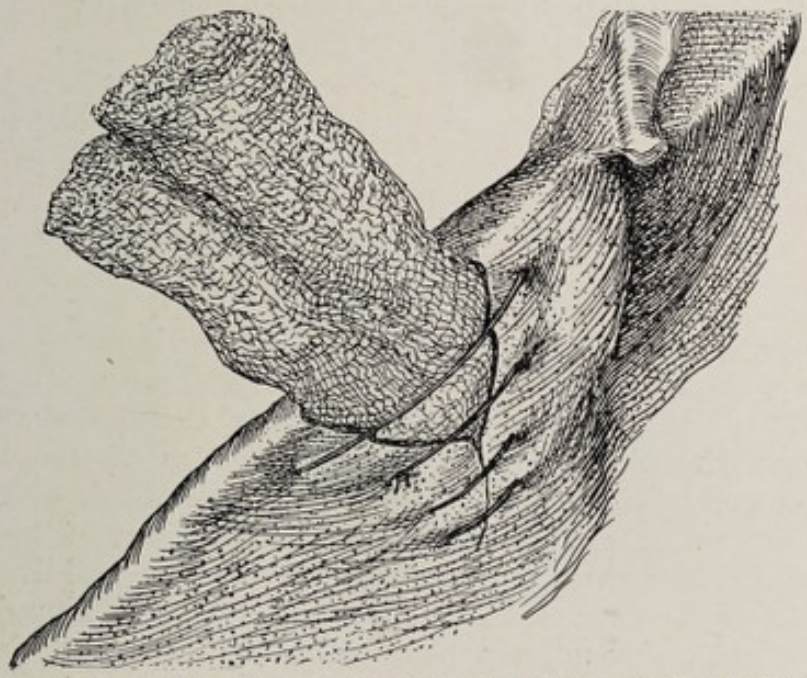

Fig. 87 —Same as Fig. 86, seen from beneath (Mayo, in Keen's Surgery).

removed safely; and Ponfick (1895). The experiments of these investigators encouraged many surgeons to operate upon and report cases of liver tumor, all their work being directed toward improving

the methods of controlling hemorrhage. Kousnetzoff and Penski, in 1894, devised an ingenious method of constricting with mattress sutures the operation field in the liver, and their method or its modifications still maintain. A more important detail of their plan is the use of blunt needles, which may be carried readily through liver tissue without wounding vessels. A series of these sutures is passed as illustrated in the cuts; the liver tissue is thus constricted, and the tumor with a V-shaped section of the organ itself is removed. The wide wound is then sewed up tight, the liver capsule repaired, and the abdominal wound closed without drainage. Jacob Frank, in 1905, developed a method of suturing the liver which is described briefly as follows: After excising a wedge-shaped portion of the liver, "the two broad raw surfaces left by the removal of the wedge-shaped piece are now converted into troughs. This is accomplished by the excision of wedge-shaped pieces, the troughs thus formed each having two flaps. When the operation is completed, the raw surfaces of the original V left are transformed into smooth, continuous liver tissue, assuming the form of liver borders, and the V space left persisting as a notch. This method of incising the liver facilitates easy suturing." Keen, in 1899, reported an interesting case of removal of the left lobe with the cautery; while Kocher has advocated the use of heavy compression forceps to seize and crush the bleeding points. He leaves the forceps in place for twenty-four hours, a disadvantage necessitating their removal later through an open abdominal wound.

Such is the status of the excision of liver tumors. In spite of the enthusiasm of surgeons and the promise of widening the field for such work, the unfortunate fact remains that few of these tumors are single and susceptible of removal.

Within recent years more or less successful attempts have been made to operate upon two other forms of liver disease—*cirrhosis* and *ptosis;* but, unfortunately, the results of these operations are proving less promising than at first was hoped.

CIRRHOSIS OF THE LIVER

Cirrhosis of the liver in all its manifestations is not susceptible of operative treatment. R. B. Greenough [1] summed up the facts in 1902, and little of value has been added to what he then wrote. The familiar operation for cirrhosis is credited to Talma, of Utrecht, though Greenough points out that Morrison and Drummond, of Newcastle, were the first to make it practicable. Talma's theory of the operation was based upon his observations at autopsy that cases of liver cirrhosis which showed the least ascites were those in which abundant anastomoses existed, through the preëxisting channels, and through *accidental* adhesions between the vessels of the portal system and those of the systemic circulation. By multiplying the adhesions he hoped to multiply the anastomoses, and thus diminish the portal congestion.

[1] R. B. Greenough, Amer. Jour. Med. Sci., December, 1902.

It is obvious that even if abundant collateral anastomoses are thus established, so that the liver circulation is relieved, still little improvement in the disease process within the liver can be anticipated. Moreover, considerable experience has now shown that Talma's operation is applicable in cases of hypertrophic cirrhosis only, and not to cases of atrophic cirrhosis—certainly not to cases of acute yellow atrophy.[1] Quite another operation, devised by Terrier, of Paris, is performed for that condition known as *biliary cirrhosis*—the "Hanot's cirrhosis" of the French. The presumption is that biliary cirrhosis is due to an infection of the liver through the bile-passages. Terrier, and later Dela-

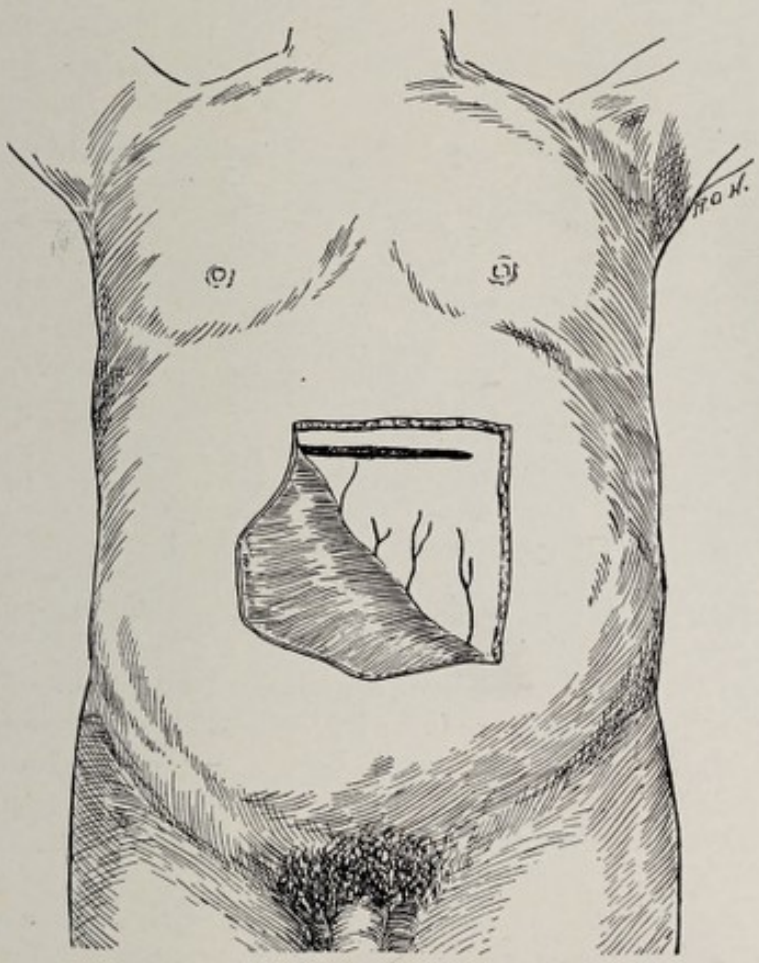

Fig. 88.—Schiassi's modification of Talma's operation.

genière, undertook to side-track the infecting bile, and so to relieve the liver, by draining the gall-ducts through the gall-bladder—cholecystostomy. In certain cases this operation has been beneficial. M. L. Harris, in an admirable essay in 1903, pointed out that the two forms of cirrhosis susceptible of surgical treatment sometimes may coexist, and he advocated a combination of Talma's operation with gall-bladder drainage in suitable cases. Gall-bladder drainage is indicated when there is evidence of hepatic infection—localized pain over the

[1] See account of case reported by Wilder Tileston, in Boston Med. and Surg. Jour., 1908, vol. clviii, p. 509.

bile-ducts, tenderness, fever, chills, enlarged liver, occasional jaundice, but no ascites.

Talma's method of establishing a collateral anastomosis around the liver is known as *omentopexy*—fastening the omentum to the parietal peritoneum. The omentum carries veins to the portal system, and these veins, through omental adhesions to the abdominal wall, may be made to connect with radicles of the parietal veins. Sundry modifications of Talma's method have been advocated, such as laying the omentum between the abdominal muscles, or the more radical procedure of Schiassi [1]—omentopexy plus splenopexy. Abdominal drain-



Fig. 89.—Schiassi's operation.

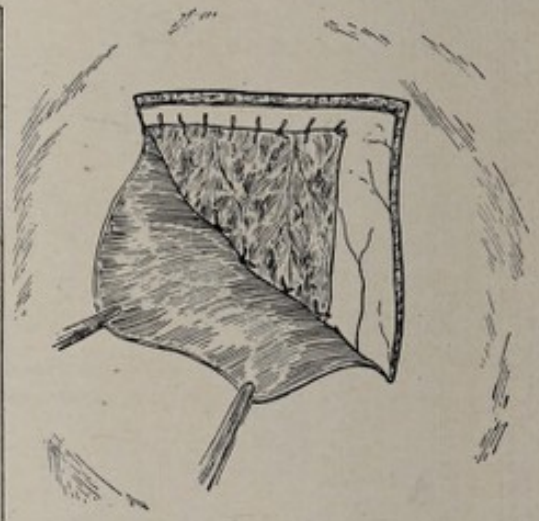

Fig. 90.—Schiassi's operation.

age should not be used after these operations, but occasional tappings may be employed until the sought-for collateral anastomosis is established. These operations are not to be used in cases of ascites due to causes other than cirrhosis of the liver; and the selection of cases suitable for operation demands careful judgment.

HEPATOPTOSIS

Hepatoptosis, or dislocation of the liver, is another subject which has exercised surgeons of late. It is important not alone for the immediate symptoms it causes, but because usually it is associated with derangements of other organs. It is associated with other ptoses. Moreover, it may give rise directly to disease of the bile-ducts, stomach, pancreas, duodenum, kidney, and appendix.

Writers talk about *partial* and *complete* hepatoptosis. There is no such thing as partial hepatoptosis. They mean by the term a partial cutting off and dropping of a piece of the right lobe. Tight lacing is the common cause. The deformity is found among women, mostly. As a result of this partial cutting off of the right lobe there are *symptoms*

[1] Semaine Méd., May 27, 1903.

of pain and dragging. The blood-supply to the constricted part may become obstructed, with strangulation and peritoneal involvement. In mild cases there are commonly associated nervous phenomena and digestive disturbances—anorexia, flatulence, constipation, pain, nausea, and vomiting.

The **diagnosis** of this lesion of the right lobe is always obscure, for the separated portion must be felt to be identified, and even when felt, it simulates a movable kidney, a liver tumor, or a distended gall-bladder. It stretches down into the right inguinal region or the right loin, and, rarely, may reach the pubes.

The **treatment** is palliative and radical. You may support the hanging mass and relieve symptoms by bandaging (see Chapter IX), or you may amputate the offending portion, using the cautery and through-and-through mattress stitches to control hemorrhage. Sometimes the isthmus consists of little more than fibrous tissue, with a small amount

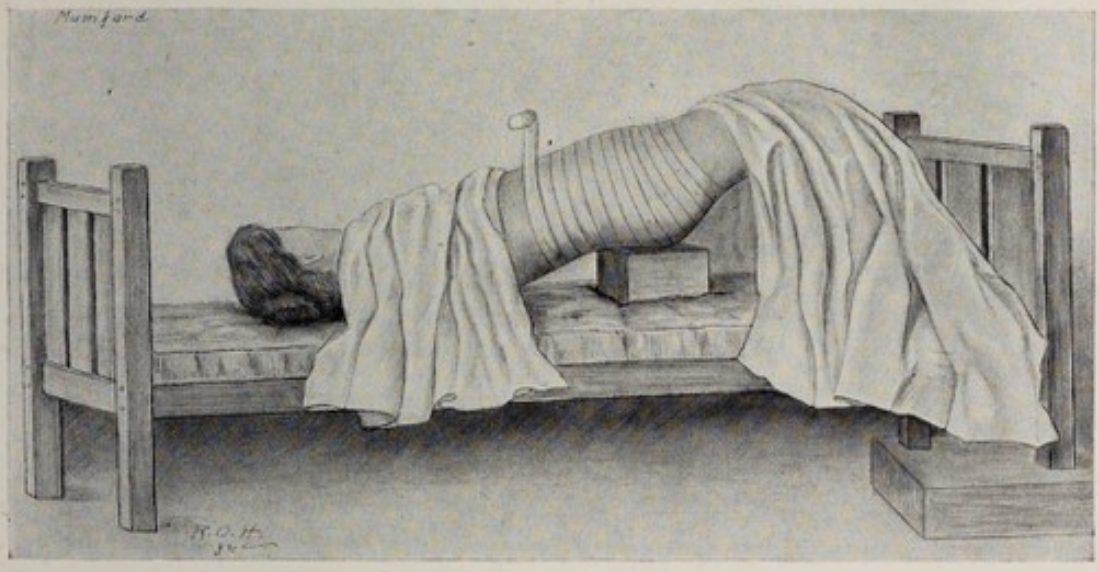

Fig. 91.—Application of bandage for abdominal ptosis.

of liver substance. As a rule, the operation is not dangerous in skilled hands, and the relief to the patient is often remarkable.

Total hepatoptosis is becoming recognized as a somewhat frequent condition, and sundry surgeons, notably Ellsworth Eliot, Jr., have devised operations for its relief. The liver descends *en masse*, and partially rotates on itself. Generally its displacement is but slight; rarely it sinks deep in the abdomen. As with "partial" hepatoptosis, the *symptoms* are due mostly to pressure on other organs. There is pain, which may become agonizing and come on in crises. Often the pylorus is dragged upon, so that it becomes kinked, with a resulting gastrectasis. There is frequently an associated bile-duct disease with jaundice; sometimes portal obstruction with ascites. Indeed, there are manifold and puzzling symptoms of recurring or persistent severe digestive disorders. The *diagnosis* is made by finding a great solid, movable abdominal tumor and noting the absence of the liver from its proper site.

The *treatment* of liver ptosis is one of the most difficult of surgical problems. Floating liver is so commonly associated with other floating organs that one may be at a loss where to begin treatment and what organ to attack. For this reason it is well, primarily, to undertake general measures applied to all the abdominal organs: tonics, laxatives (nux vomica, iron, Carlsbad salts), massage, exercises designed to strengthen the abdominal muscles, cold baths, open-air life, and, most important of all, the wearing of a carefully applied bandage or binder. Then there are various operations, all of which are still on trial. The liver may be pushed up into place and held there by stitching the round ligament and the spread-out falciform ligament high on the abdominal wall (Eliot). Surgeons have fastened the liver to the costal cartilages. The lower edge of the liver may be pocketed high behind the parietal peritoneum (after Rydygier's splenopexy), and the distressing ascites may be treated by Talma's operation.

Notable benefit has resulted from some of these operations, and we are encouraged to persevere on such lines for the solution of the problem.[1]

"**Riedel's lobe**" is a downward projection from the right lobe of the liver, immediately to the right of the gall-bladder. Riedel's lobe is usually associated with gall-stone disease. Cholecystostomy will bring often a disappearance of this abnormal projection, though its amputation may be necessary at times.

Aneurysm of the hepatic artery, a very rare disease, has never been operated upon. The symptoms resemble those of bile-passage disease. If the true condition be ascertained, it is proper to tie or excise the vessel.

The Bile-passages

The passages which drain bile from the liver into the intestines are of more surgical interest than is the liver itself, and the problems of bile-passage disease are intricate and puzzling. Yet these problems are made needlessly obscure often by the use of a multiplication of names and terms, and the confounding of cause with effect. Students hear of *gall-stone disease*, *cholangitis*, and *cholecystitis*, and are wont to conclude that these are definite entities, to be studied separately. Then, at autopsy or operation, they see two or more of these entities present at once, and so their puzzlement grows.

We had best discard terms, or use them with their relative significance. We are discussing *disease of the bile-passages*—of a system of passages. The gall-bladder is but a part of the system; cholangitis and cholecystitis are but special manifestations of a progressive bile-passage disease. We have to deal with infection, inflammation, stone-formation, suppuration, ulceration, cicatrization, stenosis, perforation, fistula formation, adhesions, peritonitis, local or general, malignant changes, and the involvement of other organs.

The underlying cause of all this is an *infection*, conveyed upward

[1] B. G. A. Moynihan (Abdominal Operations, 1905, p. 108) makes some interesting suggestions.

along the common duct generally, to the cystic duct, the gall-bladder, and the hepatic duct. Perhaps the infection may come at times through the blood-stream. At any rate, there is an invasion of organisms—pyogenic cocci, colon bacilli, the Bacillus typhosus, the pneumococcus. Then there result the same conditions as are always found when mucous membranes are attacked by such organisms, plus special conditions due to the presence of bile—swelling of the mucosa in the ducts, obstruction and stagnation of bile, and a precipitation of cholesterin from the irritated epithelial cells—stones are formed from such a precipitate. The stones in their turn may irritate the mucosa, causing abrasions and ulcerations; more organisms find lodgment here, and the process may go on developing indefinitely, or the process may become quiescent, sometimes leaving stones harmlessly lodged in the gall-bladder and passages, sometimes with the escape of stones and the restoration of a normal condition. Or a persistent inflammation may become established, leading to the extensive complications and cripplings which I have named. All these phenomena are part of a *chronic* process.

There are *acute* inflammations also—acute from the outset, or implanted upon the chronic process. Stones are a result of chronic inflammation, not of acute inflammation. Acute inflammations are urgently serious affairs; they go on rapidly to suppuration, ulceration, and gangrene even.

Chronic indolent catarrh is the important factor in the etiology of calculi. But chronic catarrh may exist for a long time and cause distressing symptoms, without leading to stone formation. The symptoms may suggest the presence of stones, and operations to relieve the symptoms may properly be done. Stones actually present are not the *sine qua non* of bile-passage disease.

Cholangitis means an inflammation of the passages—such inflammation, acute or chronic, as I have described, and the reader will note that a certain degree of cholangitis is a prerequisite to stone-formation. Cholangitis may subside and stones be left.

Cholecystitis is merely a cholangitis confined to the gall-bladder, and catarrh of the gall-bladder is apt to be a more indolent disease than catarrh elsewhere in the bile-passages. So it is in the gall-bladder that stones are wont commonly to form. Stones may form in the gall-bladder and then pass into the ducts, or they may form primarily in any part of the bile-passages. Stones give rise to a variety of symptoms according to their size, number, mobility, and location.

The **anatomic relation of the bile-ducts** to the pancreas, duodenum, and stomach is important. In some 90 per cent. of cases a small section of the common duct lies within the substance of the head of the pancreas, in close relation with the pancreatic duct (duct of Wirsung). A section of the common duct lies also against the posterior wall of the duodenum, while toward its end the common duct traverses the wall of the duodenum, ending, together with the duct of Wirsung, in the ampulla of Vater. The gall-bladder also lies close to the duodenum,

to which it may become adherent; and just below the gall-bladder runs the transverse colon. So observe that numerous structures—the gall-bladder, the ducts, the head of the pancreas, the portal vein, the duodenum, the transverse colon, and the right kidney—all lie packed together in an area which may be covered by a child's palm. It is this close anatomic arrangement which leads often to a confusion of symptoms and to a confounding of disease of one organ with disease of another. It is owing to this anatomic relationship also that diseases of adjacent organs frequently coexist; gastric and duodenal ulcer with cholangitis, and cholangitis with pancreatitis. When one takes this broad general view of so-called gall-stone disease, one sees that the symptoms, the prognosis, and the treatment indicated must change with the progress of the disease. Therefore, let us take up briefly a study

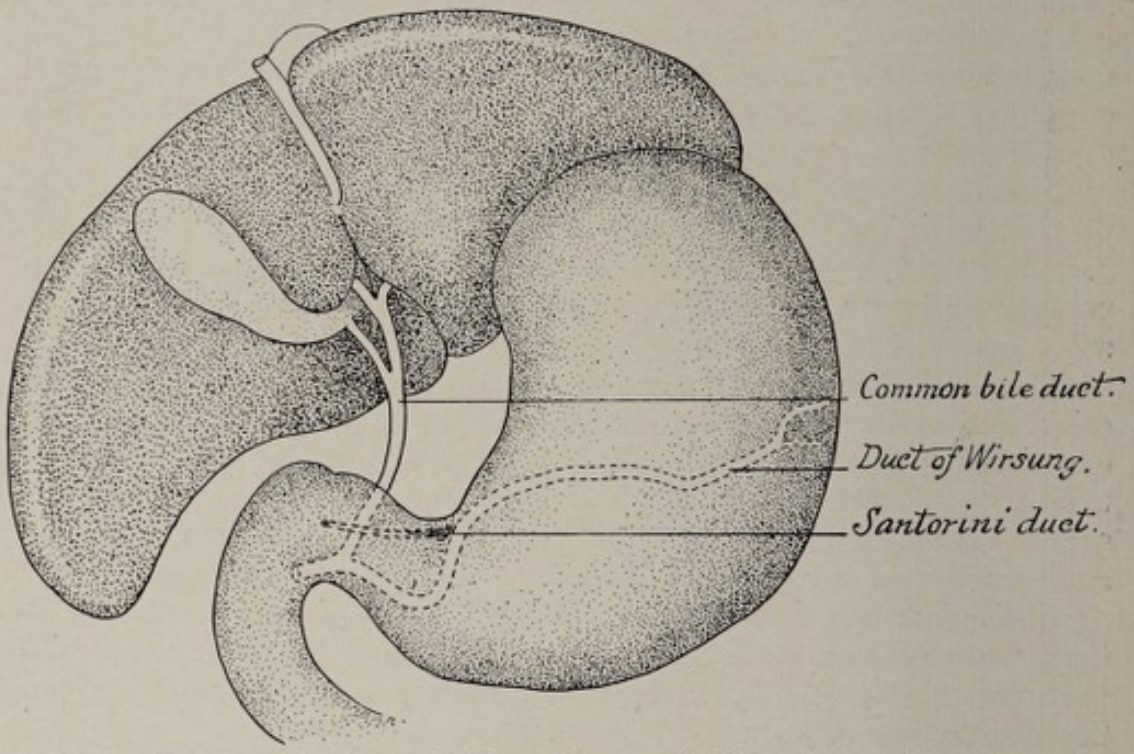

Fig. 92.—Relations of bile and pancreatic ducts (schematic).

of symptoms and the corresponding pathologic changes, with the appropriate treatment.

Symptoms.—Writers assert, and you will be told, that of all persons with gall-stones, 5 per cent. only know it or are troubled by symptoms. This is misleading, and depends upon the personal equation of patients. The fact is that there may be and often is a long train of uncomfortable sensations leading up to the formation of actual gall-stones. One must be suspicious on hearing of such symptoms as discomfort, "all-goneness," distress, anorexia, nausea, headache, flatulence, constipation, malaise, malnutrition, continuous or repeated and running over any considerable period of time. Such symptoms may mean many things, but often they mean trouble in the bile-passages. Often there is an associated *tenderness* in the right hypochondrium over the ducts, or at "Robson's

point," midway between the right costal margin and the navel. Sometimes pressure with the finger at a point one inch to the right of the navel will elicit pain, as pointed out by Robert Morris.

All these signs and symptoms may subside and recur, and may be associated further with distress after food, indefinite but sharp occasional pains in the upper part of the abdomen, a bad taste in the mouth, furred tongue, frequent headaches, diminished diaphoresis, high-colored urine, and frequent blurring of vision. Such patients will tell you that they are "bilious."

When you have to deal with a "bilious" patient, remember that the true condition may be one of beginning infection of the bile-passages, and may be the precursor of stone-formation, with the classic pain and icterus. It is impossible to say just what is the pathologic condition present in each case. There may be a slight catarrh only of the passages; there may be a chronic thickening of the ducts; there is almost always a diminished passage of bile; there may be stones formed already in the gall-bladder.

The **treatment** of patients with these mild indefinite symptoms is not operative, as a rule. These are the patients who are "cured" by Carlsbad treatment, change of air and scene, recreation, a carefully regulated life, a restricted diet, exercise, massage, proper bathing, and the abundant drinking of saline waters, the effect of all of which is obvious enough. The patient's general condition is improved, the systemic circulation is stimulated, and the affected parts are flushed. Passive hyperemia is diminished, catarrh is relieved, local swelling subsides, and normal drainage of the ducts is reëstablished. In a few weeks the sufferer is well, and he may continue well indefinitely. Perhaps he had gall-stones in addition to the inflammation, but if so, the stones were in the gall-bladder, and they are there still. They are not removed by medication. They may or may not cause subsequent trouble. But the patient is cured of his symptoms, and that is what he cares most about. It is as well, perhaps, to leave without operation these cases of apparent cure. They may remain well for a life-time, and if they relapse, then is the time for operation. There are cogent arguments, however, against this let-alone course, one argument being that long-continued gall-stone irritation may lead to malignant changes in the tissues affected. I shall discuss that question later.

Persistent and severe disease of the bile-passages may develop out of the mild cases, though, be it remembered always, that severe disease is the exception. Few of the "bilious" become victims of advanced bile-passage disease. Another class of cases in which operation may be avoided is that in which an attack of gall-stone colic passes and does not return, but leaves dyspeptic symptoms behind. In such cases internal treatment is indicated.

Again, in the case of acute symptoms with pain, icterus, and obvious closure by a stone of the common duct, it is best to delay operation, waiting for the severity of the attack to subside. Then there is a goodly number of cases of bile-duct inflammation—cholangitis and cholecysti-

tis—which should be let alone. They, too, subside, generally without surgical treatment, though the persistent symptoms and their increasing severity rarely may lead to the need of an operation.

Besides the great class of cases which are treated by internal measures, there is *a small class which demands operation inevitably*. Writers have divided this class into "calculus diseases" and "inflammatory diseases." You cannot so divide them, for you cannot possibly always tell the inflammatory diseases from those which produce calculi; and we have seen, moreover, that all are inflammatory, strictly speaking. The small class of operative cases is the class in which the disease is advanced, in which a persistent inflammatory action goes on, with or without the presence of irritating stones.

The *symptoms* of pronounced disease of the bile-passages are, first and most important, recurring attacks of **pain**—pain of a cutting, excruciating character—probably the most severe form of pain known, coming on unexpectedly, often in the night, quickly working up to an intense agony, persisting for hours, subsiding gradually or suddenly, the manner of subsidence depending upon whether a stone retreats into the ducts or escapes from them into the intestine. The pain of hepatic colic is located in the right hypochondrium or epigastrium. It may radiate to the right shoulder-blade or into the back. Pain is associated with tenderness, often exquisite, at the ninth costal margin on the right, or along the course of the passages. Sometimes tenderness is greatest at Robson's point. Sometimes pressure one inch to the right of the navel will elicit pain, indicating adhesions about the bile-passages.

Jaundice is a classic symptom of bile-duct disease. When present, it is characteristic, but it is not often present. Jaundice indicates some obstruction in the common duct or hepatic duct—obstruction backing up the bile into the liver. Such obstruction may be due to inflammatory closure of the ducts, to the presence of calculi in the common or hepatic duct, to a neoplasm pressing upon the passages and occluding them, or to the pressure from without the passages of some mass.

You must look for sundry other symptoms indicative of disturbance in the bile-passages—fever, suggesting an acute inflammation; an abnormally rapid or abnormally slow pulse; bile-stained urine, clay-colored stools, and, on examining the blood, a slow coagulation time. Such is the description of an acute attack of hepatic colic for which large doses of morphin or a general anesthetic even may be necessary. These attacks may come at varying intervals through a long course of years (recurrent attacks). Between the attacks the patient may feel comparatively well, but as time goes on he is more and more likely to become the victim of such uncomfortable chronic dyspeptic symptoms as I described when dealing with the subject of mild disease of the bile-passages.

Acute inflammations of the bile-passages may come on without previous warning or may complicate the chronic process. Acute inflammations take the form of cholangitis or cholecystitis, and, according to their location, produce various symptoms and are called by

various names. By *acute cholangitis* we usually understand a severe infection involving the common duct, the hepatic duct with its radicles, and often the cystic duct and gall-bladder. The patient becomes extremely ill in a few days; his temperature is high, his pulse rapid; he appears dusky, with anxious face; there is complete loss of appetite; sometimes there are nausea and vomiting; the tongue is red and cracked. There are dull pain and extreme tenderness over the bile-passages; the liver may be slightly enlarged, and there may be icterus. The picture is one of an acute systemic infection, with a localized inflammatory process in the right upper abdominal quadrant.

Acute cholecystitis presents many of the features of acute cholangitis, except that commonly the symptoms are less severe and icterus is

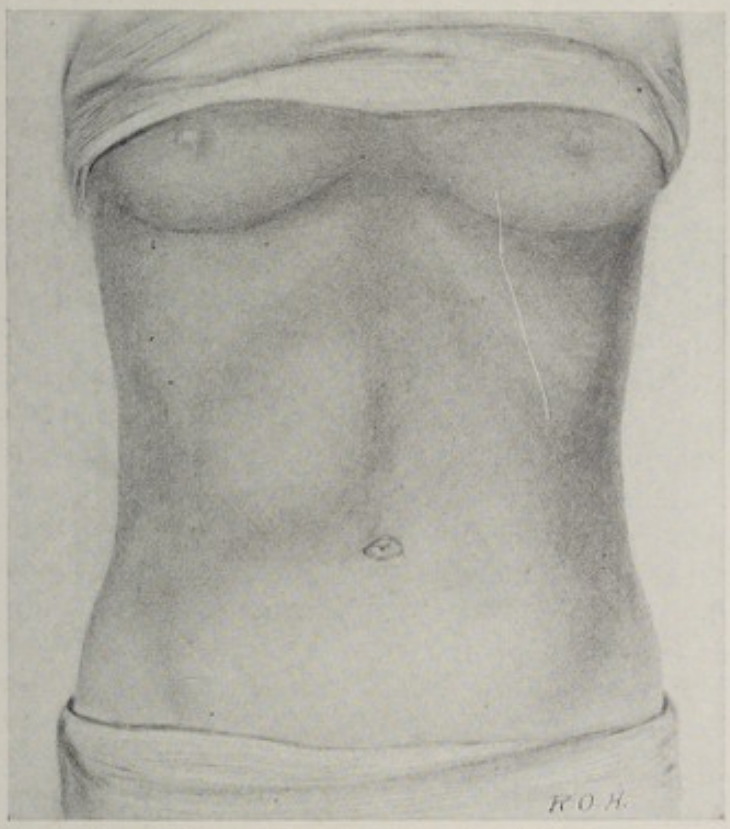

Fig. 93.—Outline of enlarged gall-bladder.

absent. A special feature of cholecystitis is an enlargement of the gall-bladder, due to inflammatory obstruction of the cystic duct. The gall-bladder becomes palpable, and, assuming a pear-shaped outline, may extend downward as far as the navel even. It is distended with bile-stained mucus or mucopus.

There is no need of going into the various complicating conditions associated with these bile-duct diseases. The complications are similar to the late complications of extensive gastric ulcer, and are due to the spread of inflammation from the bile-passages so as to involve adjacent organs. The ducts may become stenosed, thickened, and crippled. They may become distended above cicatricial strictures. The gall-bladder may become thickened and contracted almost to obliteration;

fistulous openings may connect it with neighboring organs; extensive localized peritonitis with numerous complicated adhesions may result, and the functions of all the organs implicated may become seriously deranged. Always, in considering disease of the bile-passages, the surgeon must remember that close similarity of the symptoms of such disease with the symptoms of duodenal ulcer. Furthermore, when operating for bile-passage disease, always examine the duodenum.

Operative Treatment.—There are three reasons for operating on the bile-passages: *First*, for frequent and recurring biliary colic without jaundice, with or without enlargement of the gall-bladder. That is the condition for which we most commonly operate, and we expect to find stones in the gall-bladder. If the attack is associated with jaundice, we operate and expect to find stones in the common duct as well.

In a *second* operative class is a group of cases in which the *inflammatory* symptoms are the more apparent; that is to say, when there is enlargement of the gall-bladder without jaundice, and with or without pain; with fever, tenderness, and general constitutional disturbance. This situation probably is due to some obstruction of the cystic duct, and a resulting backing up of bile-stained mucus or pus into the gall-bladder. When we suspect a phlegmonous cholecystitis or gangrene, a rupture of the gall-bladder, or an infective or suppurative process, we must operate.

The *third* reason for operating is that we suspect an involvement of other organs or of the tissues outside of the bile-passages—peritonitis, painful adhesions, abscess, and fistulæ. We must operate also for traumatic lesions of the bile-passages, stabs, shot-wounds, and for primary tumors of the gall-bladder, provided there be no metastasis.

Cancer of the bile-passages is not uncommon. It may be primary or secondary. When secondary, it is practically outside the field of operative measures, but primary cancer sometimes may be removed, and, even when it is not removable, the patient's symptoms may be relieved by some palliative operation. The cause of cancer of the bile-passages and its relation to gall-stones is highly interesting. You will find gall-stones present in nearly all cases of primary cancer of the bile-passages, whereas they are infrequently present in secondary cancer, so that we have come to believe that there is a distinct relation between gall-stones and primary cancer; that the long-continued irritating presence of gall-stones is the important causative factor in the production of primary cancer. For this reason, if for no other, as I stated before, it is wise always to remove well-established and persistent gall-stones.

It is not easy to make a *diagnosis* of cancer of the bile-passages. In its early stages cancer simulates inflammatory disease. It causes more or less pain; it may cause jaundice, and it is associated with various dyspeptic symptoms. Its presence becomes obvious when a tumor can be felt. Courvoisier's law is sometimes of value in determining the presence of cancer, and that law amounts to this: if you feel a distended gall-bladder, assume that the distention is due to stones in

the duct or to cancerous obstruction of the duct. The distention from stones is transient; the distention from cancer is *persistent*. Occasionally I have found this law valuable, but observe that it does not account for gall-bladder distention due to swelling of the mucosa of the ducts or to cicatricial obstruction of the ducts.

Technic.—There is a mass of writing, luminous and confusing, in regard to methods of operating for disease of the bile-passages, but I believe the reader will gain a fairly clear perception of how he should operate if he will observe *three laws*. These laws are founded upon the analogy between bile-passage disease and inflammation elsewhere. If you are dealing with a palmar abscess, you open it, remove disorganized tissue, and drain it. So in operating upon the bile-passages:

1. Remove stones.
2. Remove, so far as possible, all disorganized, degenerated, and permanently crippled tissue.
3. Drain.

In special cases the emergency of the condition and the intelligence of the operator will cause him to amend or to depart from these rules, but they are applicable in the great majority of cases.

The special problem which commonly confronts the surgeon is, whether to perform cholecystostomy (gall-bladder drainage) or cholecystectomy (removal of the gall-bladder), and men have advocated one measure or the other according to their convictions regarding the mortality and permanence of cure with one or the other maneuver.

It is needless here to discuss again this much-debated question, because the indications for either cholecystostomy or cholecystectomy are reasonably clear if you observe our three cardinal rules. For example: perform *cholecystostomy*—

(*a*) When the gall-bladder and ducts, though containing stones, are not crippled by inflammation—that is, when they are not markedly stenosed, thickened, twisted, or contracted.

(*b*) When *acute* inflammation exists, with or without the presence of stones. *Acute inflammation* demands thorough drainage.

(*c*) When the common duct is obstructed by unremovable malignant disease.

Class (*a*) is the largest of all. Class (*b*) furnishes a great variety of cases suitable for cholecystostomy. It is a complicated class, and, if you choose, you may call it the inflammatory class and may include in it empyema of the gall-bladder; chronic catarrh of the gall-bladder and ducts; obstruction by hydatids; hydrops of the gall-bladder (not due to stricture of the cystic duct); and certain cases of phlegmonous cholecystitis accompanied by great prostration.

As for class (*c*), it must be obvious that with an obstructive jaundice, due to tumor occluding the ducts, a cholecystostomy is essential for permanent drainage.

Cholecystectomy is probably no more dangerous than cholecystostomy if it be performed for such simple conditions as are demonstrated in class (*a*); but, as a matter of fact, cholecystectomy is employed in more

serious conditions. There are two important indications for cholecystectomy:

(*d*) Disease crippling the cystic duct.

(*e*) Disease crippling the gall-bladder.

These two—(*d*) and (*e*)—often are interdependent, and are frequently present together. We perform cholecystectomy when the cystic duct is crippled, because cholecystostomy, in that case, would not drain properly the ducts, and would leave a gall-bladder subject to subsequent disease. For much the same reason we remove a gall-bladder when it is crippled, because leaving it would mean leaving a nidus for future trouble.

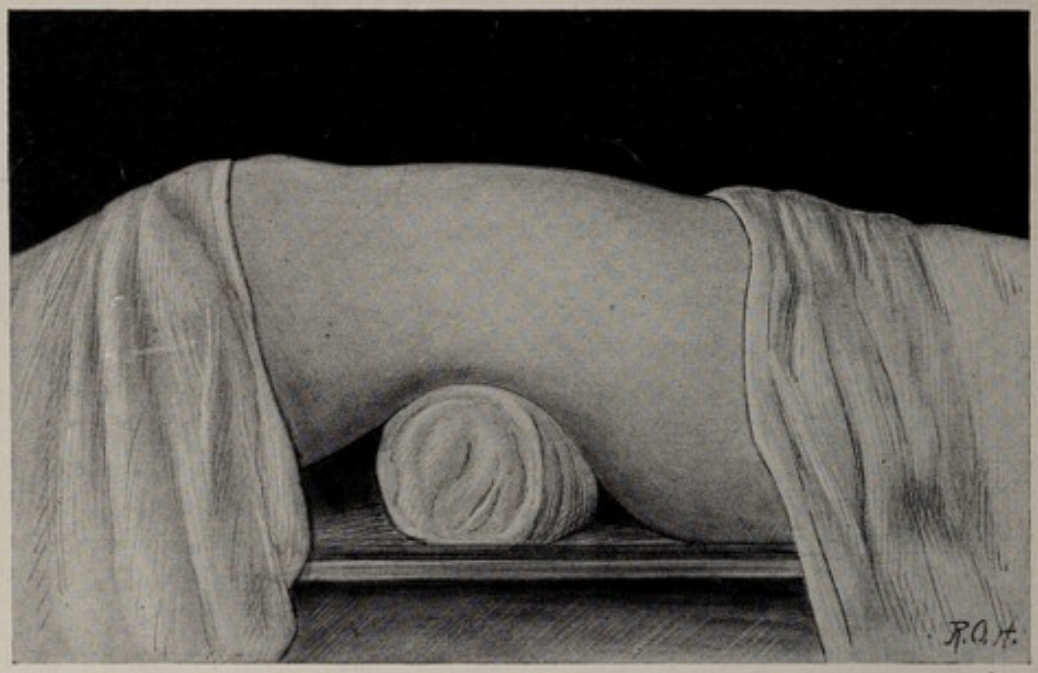

Fig. 94.—Position of patient for operation on liver and bile-passages.

Classes (*d*) and (*e*) are wont to be concerned with further advanced and complicating disease, such as fistulæ and adhesions involving other organs.

Here are certain words which demand definition. *Cholecystendysis* is an antiquated procedure. It means opening the gall-bladder, removing its stones, and sewing it up again. This is dangerous and uncertain, for leakage may occur. *Choledochotomy* and *choledocholithotomy* mean opening the common duct and removing stones. *Cholecystenterostomy* means forming an anastomosis between the gall-bladder and the bowel. I have found this last operation useful in the case of permanent obstruction of the common duct or cicatricial stenosis by malignant disease, pancreatic disease, or cicatricial obstruction. It should not be done if the obstruction can be removed, or in malignant disease of the pancreas with gall-bladder distention when the patient is extremely reduced. In such a case perform cholecystostomy. Nor should cholecystenterostomy be performed when the gall-bladder is contracted and disorganized, or when the cystic duct is crippled or

occluded. *Choledochenterostomy* is a substitute for cholecystenterostomy, and means uniting by anastomosis the common duct with the intestine. When doing either of these two last operations, in the case of malignant disease of the bile-passages, the anastomosis had best be made with the transverse colon.

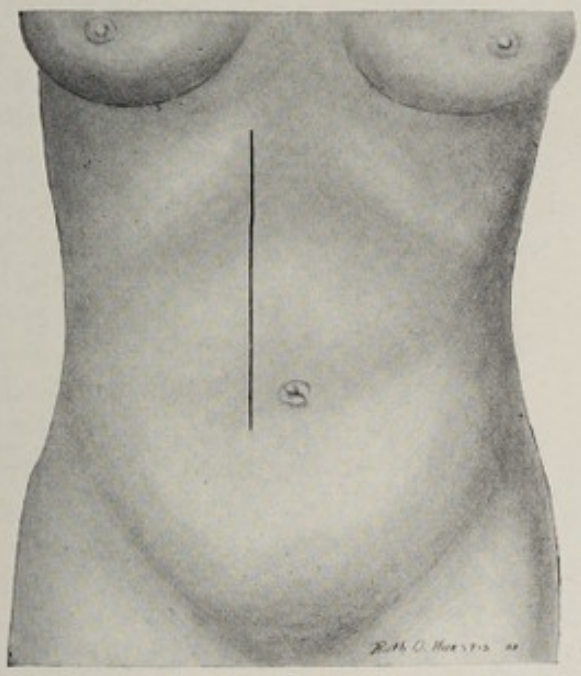

a

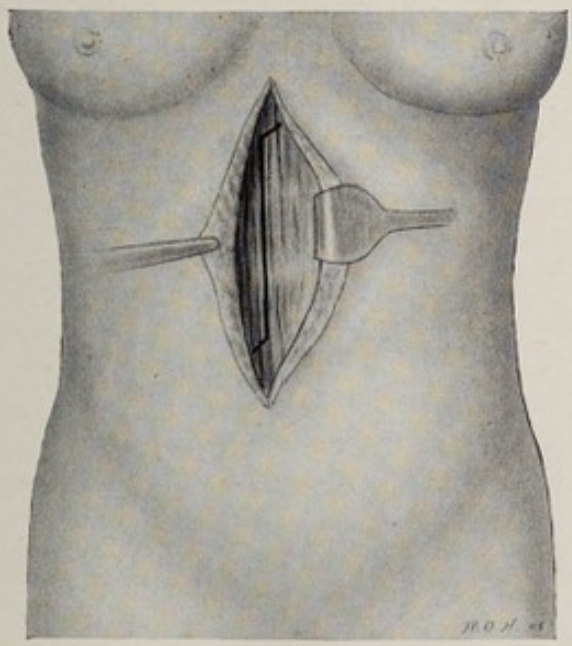

b

Fig. 95.—Incision for operation on the liver and bile-passages.

The detailed *technic* of operating upon the bile-passages need not detain us here.[1] Do not operate hastily on patients with long-standing

[1] I have described the technic in "Surgical Aspects of Digestive Disorders," and also refer the reader to the books of Jacobson, Binnie, Bryant, Bickham, Moynihan, Kocher, and the large systems of surgery.

jaundice, for their blood-coagulation time is slow. This may be remedied, however, by giving large doses of calcium chlorid—30 grains three times daily for three days before operation and afterward 60 grains by the rectum three times daily. These jaundiced patients sometimes bleed, by persistent oozing, after the operation, and may die of such hemorrhage unless the coagulation time be shortened. A hard pillow or movable support, such as Lilienthal describes, should be put under the back of the patient before operation, so as to throw up and forward the deep parts of the field. An excellent incision is that splitting the right rectus muscle. The cut may be carried up to the xiphoid cartilage and as low as required. By carefully packing off the neighboring viscera with gauze, the bile-ducts may now be brought into view, and may be handled readily unless there be extensive adhesions. Before proceeding further, neighboring organs should be examined carefully in order to ascertain complicating disease. If one decides on *cholecystostomy*, separate the gall-bladder from the liver; draw it to the surface; pack it off; aspirate off the contained fluid; open the gall-bladder; remove the stones with forceps or scoop; palpate the ducts throughout, removing any stones they contain; tie into the gall-bladder with catgut a rubber drainage-tube, and drop back the gall-bladder into the abdomen, leaving the tube guarded with one or two light gauze wicks. Bring the drainage-tube and wicks out through a stab-wound in the abdominal wall, 1 or 2 inches to the right of the long incision, and sew up the incision tight. Thus you will avoid subsequent hernia. The drainage-tube outside the dressing is led down into a receiving bottle attached to the binder or to the side of the bed. The wound is dressed in the ordinary fashion. Bile should drain copiously as long as the tube remains in place. The tube should be removed at the end of fourteen days, after which the resulting sinus will close permanently in a day or two.

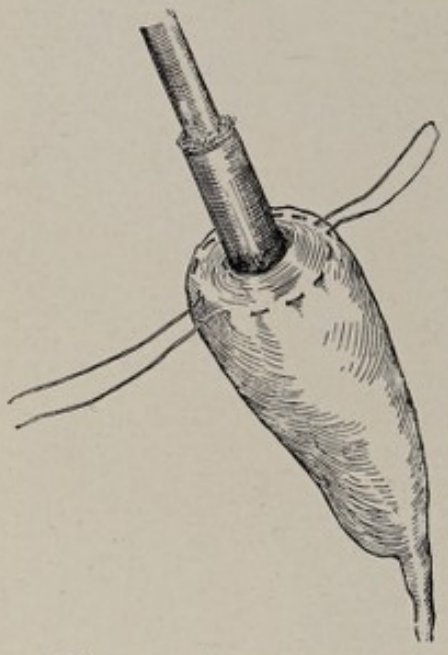

Fig. 96.—Catgut purse-string suture for compressing the walls of the gall-bladder tightly on a dressed tube. J. E. Summer's adaptation of Dawbarn's method to cholecystostomy (Mayo in Keen's Surgery).

Cholecystectomy is not a difficult operation, but its difficulties have been magnified by writers. Open the abdomen as already described, isolate the gall-bladder, draw it up as far as possible, open it, and remove all accessible stones; secure the cystic duct with a hemostat near the common duct; isolate and secure the cystic artery, cut away the gall-bladder, and tie the cystic stump. Provide for drainage of the stump, because occasionally its ligature gives way, allowing septic bile

to escape. In order to drain the stump, stitch into it, with No. 00 plain catgut, a rubber tube surrounded with gauze and led out through a stab-wound. In from six to ten days the catgut will be absorbed, when the drain may be withdrawn, leaving a fistulous tract which heals spontaneously.

The simple maneuvers already described do not explain or account for the treatment of such complications as numerous *stones in the ducts*, stone in the *ampulla* of Vater, *adhesions*, *fistulæ*, and *malignant disease*. Numerous stones in the ducts are sought by palpation and by probing. If they are long present, the ducts becomes so much dilated as easily to admit a finger for exploration. If you are convinced of their presence, you may remove them by pushing them up into the cystic duct, by cutting down upon them through the common duct, or, sometimes, in the case of stones in the hepatic duct, by fastening a drainage-tube into the

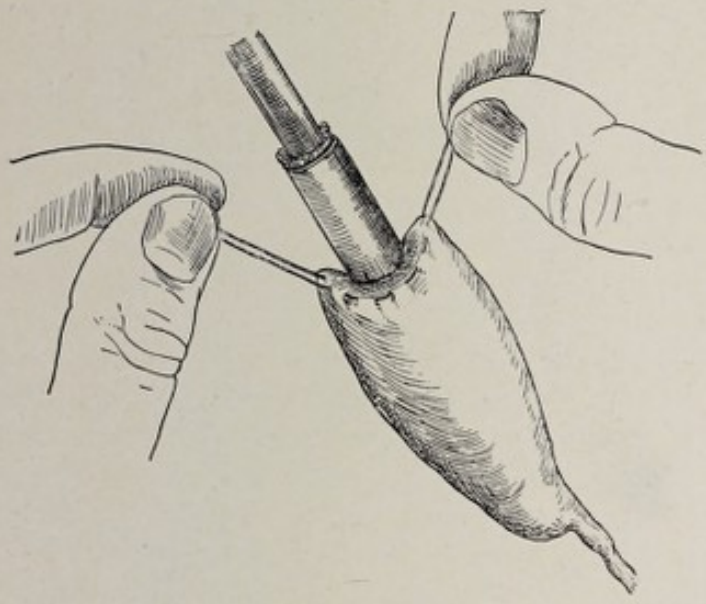

Fig. 97.—Holding purse-string while inverting cut margins of gall-bladder opening (Mayo in Keen's Surgery).



Fig. 98.—Purse-string suture tied (Mayo in Keen's Surgery).

latter and leaving it in place, when, in the course of time, stones will escape through it or through its tract after its removal. Sometimes it is necessary to perform a secondary operation for the removal of stones at the time of withdrawing the hepatic tube.

Stones in the ampulla of Vater may be removed by freeing the duodenum, turning it over on the stomach, and opening the common duct from behind; or, better, one may approach the ampulla by opening through the duodenum from the front. The duodenum, after being thus opened, must be stitched up. I prefer this latter method of approach: it is easy and direct, and involves no difficult dissection or the tearing up of adhesions.

When the ducts are opened for the removal of stones, the incision need not be stitched up. Abundant gauze drainage insures against infection, and the ducts always heal readily.

Extensive adhesions about the bile-passages must be broken up when the adhesions interfere with the proper removal of stones, or when they cause serious crippling of organs, but it is not wise always to break up fistulæ unless it is evident that their presence will involve future pain and invalidism.

Primary cancer of the bile-passages may be excised in a few rare instances, care being taken to provide for proper and physiologic biliary drainage, if necessary, through an anastomosis between the gall-bladder and the bowel. In most cases, however, when cancer is present, some palliative operation only is permissible—*cholecystostomy* or *cholecystenterostomy*.

The reader will observe that I have adhered throughout these paragraphs to our three cardinal rules—always removing stones and crippled

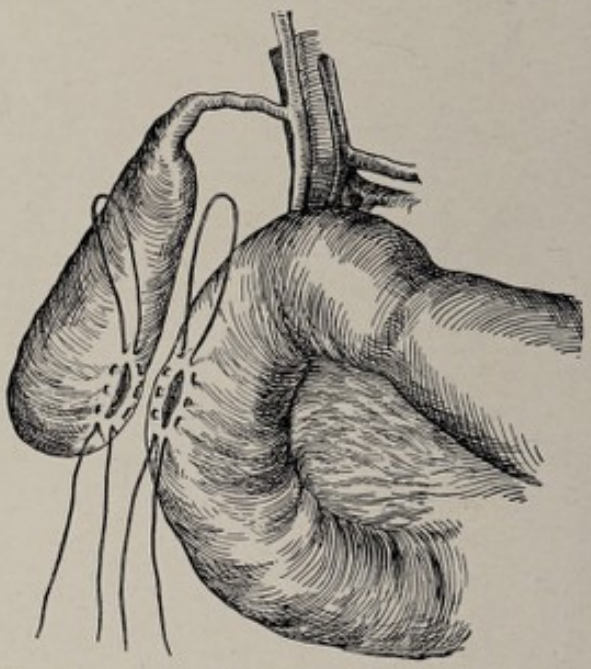

Fig. 99.—Cholecystduodenostomy. Circle sutures introduced and incisions made (Mayo in Keen's Surgery).

and disorganized tissue, when possible, and always draining the deep field.

Surgeons have debated the wisdom of removing gall-stones accidentally discovered in the course of some other abdominal operation—gastro-enterostomy, for instance. I believe that one should always remove gall-stones when the abdomen is opened for any purpose, provided the patient's strength will permit this prolonged operation.

We may not close our consideration of disease of the bile-passages without reflecting again upon the frequent elusiveness of the subject. I doubt if there is any series of ailments to which the organs of the body are subjected so frequently secondary to, and so frequently confused with, remote disease, as well as with neurotic phenomena, as are the diseases of the bile-passages. The following brief report of a case not yet completed is illuminating and instructive: The patient, a woman of

thirty, in fair health, had suffered for some ten months with monthly recurring attacks of pain in the region of the gall-bladder. The pain was often agonizing, and lasted for from twelve to forty-eight hours. Between attacks the region of the gall-bladder was tender, and during the attacks the pain radiated to the right shoulder. There was no jaundice, but this patient, whom I saw several times in consultation, seemed to be undoubtedly the victim of gall-stone disease. Her only other physical ailments were an obstinate and life-long constipation and pronounced chronic hemorrhoids. In 1902 this patient went to live in another city, and came under the care of a surgeon of excellent reputation and ability. He operated on her for gall-stones and found absolutely nothing abnormal, as he told me afterward. He drained the gall-bladder for three weeks, after which there was a remission of severe symptoms for about a year.

In 1903 the symptoms of gall-stone colic returned and persisted for two years. The patient was in constant fear of the attacks, and led the life of an invalid.

In 1904 she consulted an internist, who convinced himself that the disease and her sufferings were not due to a bile-passage disorder, but to a gastric hyperchlorhydria with periodic pyloric spasm. Acting on that conviction, he put her on a long and thorough course of antacids —especially sodium bicarbonate. She was greatly relieved for a year, when, becoming careless of treatment, her symptoms began to recur. At that time—1905—she happened to be in Boston, where she consulted another internist, who told her that her undoubted hyperchlorhydria and pyloric spasm were due primarily to tonic spasm of the sphincter ani, which resulted in constipation, improper drainage of the intestines, and a series of chemical changes resulting reflexly in her gastric irritation. This rather unsatisfactory explanation of her condition was accepted, and she had the sphincter ani dilated in accordance with the advice of this physician. There followed for seven years relief of all her symptoms. The constipation was cured; the hemorrhoids disappeared; the dyspepsia and the epigastric pain and distress were relieved entirely.

The reader will see at once that this case is incomplete and unsatisfactory. I have quoted it merely as an interesting object-lesson, as demonstrating the difficulties of diagnosis and the errors of treatment often seen in cases of disease of the digestive organs.

CHAPTER VI

THE PANCREAS AND SPLEEN

The Pancreas

The pancreas is a digestive organ so closely associated with the liver and bile-passages that we must think of it anatomically and surgically as a part of the same apparatus. The two are upon twigs of the same bough, which is implanted in the duodenum. Unfortunately, injury and disease of the pancreas are more common than we used to think—unfortunately, because the organ is not easily accessible and because operations upon it are difficult and hazardous. Sometimes one may treat it surgically through drainage of the gall-bladder, as I shall explain.

Observe that the pancreas is so deeply placed behind the stomach as rarely to be injured; that it is between 4 and 5 inches long; that its head lies partially surrounded by the duodenum; that the aorta, vena cava, and portal vein lie behind it; that it has two ducts (Wirsung and Santorini) which *may* open separately into the duodenum, and that it is nourished by branches of the splenic artery, which lies immediately above it. The "pancreatic point" of writers is a landmark which indicates the situation of the head of the pancreas. By pressure on this point one may cause pain in a zone corresponding to the head of the pancreas. V. F. Orlowsky[1] gives this rule for finding this point: On each side trace a line from the acromial end of the clavicle, crossing the anterior surface of the chest and abdomen to end in the middle of another line drawn from the symphysis to the anterior superior spine of the opposite side. These lines intersect each other about the middle of the abdomen. The head of the pancreas corresponds to the upper half of the obtuse angle formed on the right side by the junction of the two lines.

Of late it has become the fashion to discuss operations on the pancreas, but in practice you will find that, with the exception of two of its diseases,—chronic pancreatitis and cysts,—it rarely concerns the surgeon.

In general terms one may divide diseases of the pancreas into—

(*a*) Inflammations.
(*b*) Tumors (cysts).
(*c*) Injuries.

Of the three, inflammations are of the most importance surgically.

INFLAMMATIONS OF THE PANCREAS—PANCREATITIS

Pancreatitis may be *acute*, *chronic*, and sometimes *subacute;* while writers use sundry other terms, such as *hemorrhagic*, *suppurative*, *gangrenous*.

[1] Presse Médicale, April 8, 1911.

Acute pancreatitis may arise from a pancreatic apoplexy or from an infection, but whatever the cause, there is nearly always hemorrhage within the gland; hence the term, hemorrhagic pancreatitis.

Pancreatic apoplexy is an overwhelming disease, and usually ends rapidly in death. The hemorrhage occurs first; tissue is destroyed; the pancreatic secretion, consequently outpoured, causes a necrosis; more hemorrhage results, and the patient quickly succumbs. If the

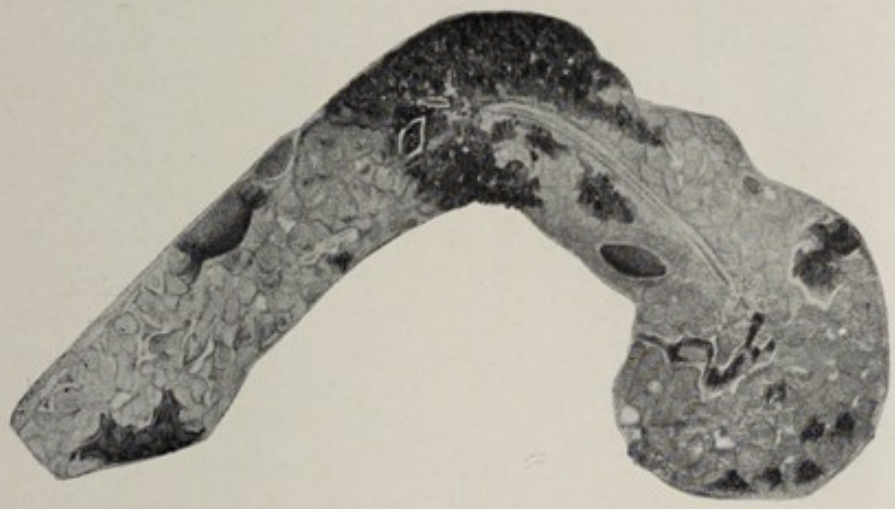

Fig. 100.—Acute hemorrhagic pancreatitis (Oser).

acute pancreatitis is from an infection, as is most often the case, it is due commonly to an invasion of septic material through the duct of Wirsung. Opie's familiar explanation is often the correct one, as I have seen in 2 of my own cases at operation: A small gall-stone comes down through the bile-ducts and lodges at the outlet of the ampulla of Vater. Then bile fails to get out into the intestine, but is shunted off into the pancreatic duct, and sets up an acute infection of the gland. This is one of the interesting and important relations between bile-duct and pancreatic disease. This infective form of acute pancreatitis, though grave, is not so immediately lethel as is that due to pancreatic apology. It sets up a very active inflammation, however, with hemorrhage, spreading infection, gangrene, suppuration. Some cases may run on into a subacute condition, and in nearly all cases a disseminated fat-necrosis will be found throughout the abdomen, and especially in the region of the pancreas, at autopsy or operation.

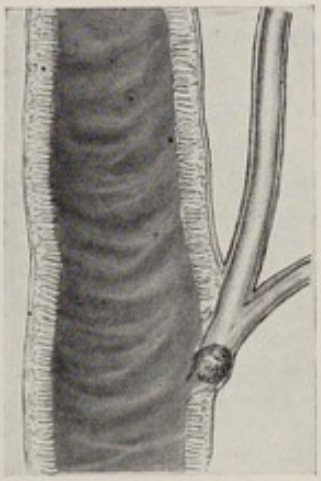

Fig. 101.—Stone in ampulla of Vater.

The *symptoms of acute pancreatitis* are seen in persons of previous presumably good health. The symptoms are immediately overwhelming: vomiting, collapse, with a rapid, thready pulse, clammy skin, and cold extremities. Quickly there supervene symptoms of peritonitis. Often the condition is mistaken for intestinal obstruction, but the

constipation is not absolute, and there appears within twenty-four hours a circumscribed tympanitic or resistant swelling in the epigastrium. These attacks run a varying course. Some patients die within forty-eight hours or some live for several weeks, the pancreas becoming disorganized. There is fever, due to suppuration, and there is a wide-spread fat necrosis; other patients form a small third class who may live a long time and may suffer repeated attacks of acute pancreatitis, which produce sclerosis of the pancreas. The cases of *subacute pancreatitis*, so called, are merely modifications of this third class. Abscess is a common outcome; the attacks come on with remissions; there is albumin in the urine, sometimes sugar, and rarely fat. Such patients usually die of the disease eventually, though spontaneous recoveries are known, with sloughing of the pancreas and its escape through perforation into the stomach or intestine.

The *treatment* of all forms of acute pancreatitis is strictly operative, so far as any treatment can be employed. But do not rashly operate upon first seeing a patient in the profound collapse of pancreatic apoplexy, else you will but hasten his death. Wait a few hours in the hope that he may rally, for the hemorrhage is not persistent, and stimulants and opium may alleviate the symptoms. Operate to remove the offending focus. Open the abdomen in the median line, tear through the gastrocolic omentum, expose the damaged pancreas, which will be found engorged, bloody looking, dark, surrounded by a hemorrhagic exudate and an area of fat-necrosis. Scoop out detritus, and drain with rubber tubing and gauze wicks. Investigate the condition of the common bile-duct and of the ampulla. Observe that a general peritonitis already may have become established, so that you will find it necessary to wash out the abdominal cavity with a hot saline solution, and to drain the pelvis through a tube inserted above the pubes. Conduct the after-treatment carefully; employ Fowler's position, cleansing enemata, and nutrient enemata; normal saline solution in the rectum, in the veins, or under the skin; strychnin, gastric lavage; nothing whatever by mouth for forty-eight hours—then begin with careful dieting and saline laxatives.

The less severe or subacute cases lend themselves more hopefully to treatment than do cases which have gone on to suppuration, extensive necrosis, and gangrene. In such less severe cases drainage again is our one expedient. Such drainage may be instituted from the front through the gastrocolic omentum, as already described (sometimes through the gastrohepatic omentum above the stomach, *if that organ is prolapsed*); or one may approach the pancreas through the back, on the left, thus securing dependent drainage. At the best, acute pancreatitis is extremely fatal, and with a proper operation even we cannot look for a death-rate much below 50 per cent.

Chronic pancreatitis is commonly associated with disease of the bile-passages, and cannot well be dissociated from it. Indeed, it must be regarded as part of the same general process. Other causes of chronic pancreatitis are pancreatic calculi, obstructions of Wirsung's

duct, pressure from without, typhoid fever, chronic alcoholism, syphilis, and gastric or duodenal ulcer. Whether the important factor be bile-passage disease or some of the less common causes, some form of occlusion of the pancreatic duct, limiting or obstructing completely proper drainage of the gland, is the important etiologic factor in chronic pancreatitis. Such obstruction results in a catarrh leading to a chronic interstitial process, the evidence of which is an induration and enlargement of the pancreas—usually the head of that organ.

The *symptoms* of chronic pancreatitis are elusive and various. As A. K. Stone has said, "*chronic interstitial pancreatitis*, from the operator's point of view, presents a brilliant series of happy blunders." The symptoms point usually to bile-duct disease, and on exploring that region one may find no gall-stones present, but an enlarged indurated head of the pancreas constricting the common duct, which passes through it, thus giving rise to jaundice. That is the common symptom—jaundice. There may be a low intermittent fever and possibly tenderness in the epigastrium, with considerable loss of flesh. Sometimes there is fulness above the umbilicus. Fat and muscle-fibers may be found in the movements. In general, the picture is one of rather constant epigastric distress, associated with bile-duct disease.[1] J. B. Deaver[2] gives us the following interesting

TABLE OF PANCREATITIS FINDINGS

	30 cases complicated by stones.	30 cases uncomplicated.
Male	7	17
Female	23	13
Acute severe pain	17	17
Jaundice	21	10
Vomiting	16	17
Belching	12	9
Previous indigestion	9	14
Recurrent attacks	29	21
Indigestion between attacks	8	9
Colicky pain	8	9
Seat of pain:		
Epigastrium	20	15
Right costal margin	16	12
Left costal margin	3	1
General abdominal	..	1
Lumbar	1	2
Referred pain:		
Right shoulder	12	8
Left shoulder	4	2
Back	14	8
Tenderness:		
Right costal margin	24	18
Left costal margin	3	4
Epigastrium	10	11
Gastric contents, free HCl:		
Normal	8	2
Subnormal	8	13
Above normal	1	1

[1] Robson and Cammidge, The Pancreas: Its Surgery and Pathology, 1907.
[2] Jour. Amer. Med. Assoc., July 1, 1911.

Treatment will usually concern itself with the disease of the bile-passages. If, on opening over the bile-passages one detects a tumor in the head of the pancreas, the proper procedure is to drain the ducts through cholecystostomy. Sometimes it may seem best to perform cholecystenterostomy, but the danger of infecting the gall-bladder from the intestine renders this inadvisable, as a rule. It is usually impossible, even with the abdomen opened, to distinguish chronic pancreatitis from cancer of the head of the pancreas, but drainage cures pancreatitis and does not affect cancer. I have been impressed with the brilliancy and success of these operations in relieving non-malignant pancreatic disease, and cannot too strongly urge upon the operator that he should examine the pancreas in all cases of operation upon the bile-passages. If the pancreatitis be due to pancreatic calculi, they may be removed by opening the duodenum and searching the duct of Wirsung through the ampulla. Pancreatitis due to other rare causes must be treated on the general principles applicable to these causes; but in all cases of doubt one should establish drainage of the bile-passages.[1]

TUMORS OF THE PANCREAS

Tumors of the pancreas may be divided, for practical purposes, into solid tumors and cysts. **Cancer of the pancreas** is not uncommon, and, like other diseases of the pancreas, is difficult of diagnosis. Its *symptoms* are quite similar to those of chronic pancreatitis, and it is often associated with disease of the bile-passages. Cachexia and wasting accompany it, but are not characteristic. Rarely you may feel the mass in a thin-walled abdomen. It cannot be cured, neither can it always be diagnosticated accurately, even when the abdomen is opened. If the surgeon is in doubt about the character of the tumor, he should drain the bile-passages in the hope that the disease may prove to be non-malignant.

Cysts of the pancreas are the surgeon's own. They may be diagnosticated, and, usually, they can be cured. Under the term "cyst" we group several different pathologic processes, which may be within the pancreatic tissue proper, or may be extrapancreatic, but connected with the gland and containing pancreatic fluid. This latter form of cyst is a pseudocyst. The pancreatic cysts proper are small and may not cause symptoms. Rarely they may reach a great size. There are also found within the pancreas proliferation cysts—adenomatous or epitheliomatous, as well as, rarely, hydatid cysts and the congenital cysts of children. Finally, there is the pseudocyst, which may develop spontaneously in the peripancreatic tissue or may be due commonly to a heavy blow or crush.

The *symptoms* of pancreatic cysts may be inconspicuous for a long

[1] W. J. Mayo, Pancreatitis Resulting from Gall-stone Disease, Jour. Amer. Med. Assoc., April 11, 1908.

time, until the tumor becomes so large as to press upon and interfere with the functions of organs; then there is gradually increasing pain, with vomiting, malnutrition, and rapid wasting. There may be fatty stools or undigested proteid material in the discharges. The bowels are often loose, and the pancreatic reaction of Cammidge [1] may be found in the urine. But the important and confirmatory sign is a palpable cystic tumor, found in the epigastrium.

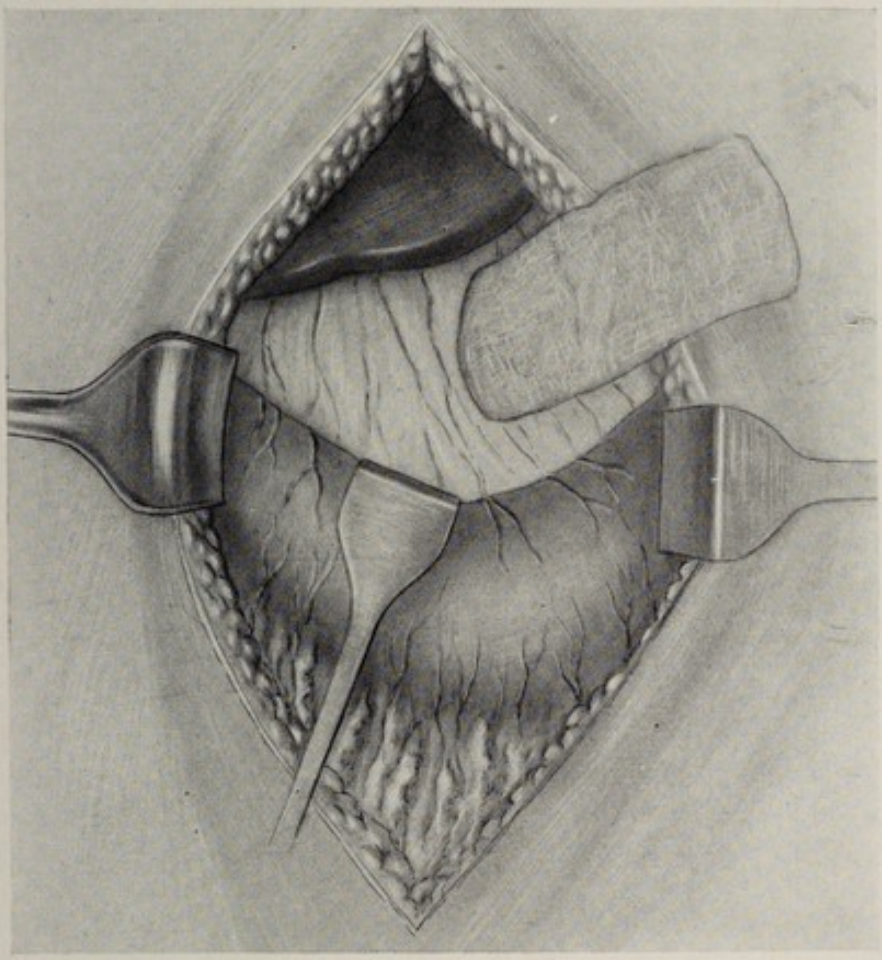

Fig. 102.—Drainage of pancreatic cyst.

The *treatment* of pancreatic pseudocysts is simple and highly successful—incision and drainage. The tumor usually presents between the stomach and transverse colon, though rarely it may appear above the stomach. The safest operation consists in evacuating the cyst, stitching the sac to the parietal peritoneum, and employing tubular or gauze drainage. Bear in mind that the cyst fluid contains pancreatic secretion. This may excoriate the skin, which must, therefore, frequently be cleaned, and should be protected by heavy applications of zinc oxid ointment and rubber protective. A drained cyst will heal in the course of months, but the patient may be up and about in three weeks. Sometimes the fistula will not close for a year or

[1] J. G. Mumford, Surgical Aspects of Digestive Disorders, p. 287.

more, but eventual healing is almost certain. True cysts, on the other hand, may usually be enucleated without producing any lesion of the parenchyma.[1]

TRAUMATIC INJURIES OF THE PANCREAS

Writers will tell you truly that the pancreas rarely is injured by violence, though their statistics probably do not take into account those injuries which fail to produce immediate symptoms, but are followed later by the development of pseudocysts. Many injuries to the pancreas are overlooked, doubtless, because other organs are involved and because death frequently supervenes. However all that may be, a severe crushing blow is required to damage the pancreas—a blow impinging upon the epigastrium and directed from before upward and backward, grinding the gland against the spinal column.

There are no immediately obvious signs and symptoms which enable us to diagnosticate an injured pancreas. We shall see marked evidence of profound shock, of hemorrhage, and later of peritonitis, all increasing. Other organs may be involved, but if the damage is in the epigastrium, a surgeon should always explore the region of the pancreas.

Operate by opening through the middle line of the abdomen above the umbilicus. If time allows, repair obvious damage to other organs; then, if one suspects a pancreatic lesion, examine the pancreas by tearing through the gastrohepatic omentum above the stomach. You will often find extravasated blood and pancreatic fluid in the lesser sac. Clean it out, and see to it that this fluid does not contaminate the general cavity. Wall off the surrounding viscera. If the pancreas is lacerated or bleeding, repair the wound with deep catgut sutures threaded upon blunt curved needles. Sometimes it is necessary to ligate *en masse* a lacerated section of the gland. In order to prevent further soiling of the general cavity, the peritoneum which forms the posterior part of the lesser sac may be stitched over the wounded pancreas, but, as a general rule, the surgeon will prefer to provide thorough and careful drainage by tube and gauze, with exit either through the anterior abdominal wound, through a special posterior stab-wound, or through both.

THE SPLEEN

The mystery of the spleen is a subject of the most fascinating surgical inquiry, as it is of physiologic inquiry. Physiologically, the spleen is unique because we have little accurate knowledge of its functions; surgically, it is unique because, when subject to operation, we must usually remove it entire. Writers recite 8 causes, with certain obvious exceptions, for its removal—8 causes about which there is general agreement: Injury, abscess, tuberculosis, cysts, new-growths, malarial

[1] W. Körte, Deutsche Medizinische Wochenschrift, March 23, 1911.

enlargements, splenic anemia, wandering spleen. Davis[1] remarks truly, "Until the physiology of an organ is known, its pathology is likely to be elusive. On the other hand, a study of its pathology is often rewarded by a clearer knowledge of its physiology."

INJURIES OF THE SPLEEN

We have all seen occasional injuries of the spleen in large hospital practice. They are not uncommon, but the *symptoms* are not characteristic, and the diagnosis is often obscure. There are shock, collapse, and evidence of persistent internal hemorrhage. Splenic hemorrhage, like hepatic hemorrhage, continues because there are few muscle elements in the gland to favor contraction of vessels and thrombus-formation. So the belly fills with blood. Quickly, fluid in the flanks is apparent; there is a tendency to vomiting, and there ensues rigidity of the abdominal muscles, especially in the left upper quadrant.

For convenience, Moynihan divides injuries of the spleen into 3 classes: *Prolapse*, penetrating wounds, subcutaneous rupture. The spleen may prolapse through an incised wound. If it can be properly cleansed, the surgeon may return it inside the abdomen and close the wound with drainage. If it is torn or foul, it must be excised.

Penetrating wounds of the spleen are generally found complicated with wounds of other organs—the diaphragm, pleura, stomach, liver, kidney, pancreas, etc. So the *symptoms* are obscure, and the condition is discovered only upon opening the abdomen, which should be done in all cases of penetrating abdominal wounds. If the splenic hemorrhage is excessive and the patient prostrated, the organ should be removed at once. The spleen is not essential to life. In rare cases it may be possible to control the hemorrhage by passing through-and-through heavy catgut, mattress, double stuures, threaded upon a blunt-pointed needle.

Subcutaneous rupture of the normal spleen is uncommon. The ordinary prerequisite for rupture is a pathologic enlargement, malarial or some other. The enlarged spleen of women in the last months of pregnancy has been ruptured. The elaborate paper of Lewerenz, published in 1900, is commonly quoted in connection with this subject. The *symptoms* of ruptured spleen are those of profound shock and hemorrhage, and a characteristic intense pain over the left shoulder.

The *treatment* of ruptured spleen is not the simple matter one would suppose, from the statements of certain writers, who advise invariable splenectomy. Hemorrhage from the wounded spleen can often be checked only by removing the spleen, and this is generally the safest course; but one may discriminate. Wounds of the hilus demand splenectomy, but many wounds of the convex border, especially slight wounds, may be treated by a gauze tampon or by the crushing and

[1] Bryon B. Davis, Indications for the Removal of the Pathologic Spleen, Jour. Amer. Med. Assoc., September 2, 1905.

suturing method advocated by Senn; that is, by crushing to a pulp, with heavy forceps, the bleeding surfaces, and then suturing together the crushed portions.

Splenectomy of the non-adherent spleen is not difficult. That organ may be approached through an incision along the left linea semilunaris, the opening being enlarged by a supplementary cut at right angles to the first, if you choose; or the surgeon may open the abdomen along the border of the ribs, resecting the eighth, ninth, and tenth cartilages. The pedicle of the spleen, composed mainly of the splenic vessels, must be secured carefully with several ligatures; while its slight attachments, especially the rather important phrenosplenic ligament, can be cut away readily between ligatures. Difficult splenectomies are those in which one encounters the extensive adhesions which form quickly about a damaged or diseased spleen—adhesions which must be removed cautiously on account of the great vascularity of the parts, especially of the spleen itself. These adhesions may frustrate entirely attempts at splenectomy. If the spleen be once safely excised, the abdominal incision may be sewed up tight or drained, according as the deep parts of the field are dry or ooze persistently.

ABSCESS AND TUBERCULOSIS OF THE SPLEEN

Abscess of the spleen is rare, though Spear,[1] in an admirable paper, maintains that it is more common than we have supposed. It is one of the complications of acute infectious diseases, especially of typhoid and malaria; or it may be secondary to some such primary infection as appendicitis. The *diagnosis* is difficult, and the absence of fever does not preclude splenic abscess. The abscess may be single or multiple. Splenectomy is the best treatment, though, rarely, incision (splenotomy) must be employed.

Tuberculosis of the spleen may be a reason for splenectomy, but, generally, a tuberculosis of the spleen is part of a wide-spread process, so that removal of the gland is useless.

CYSTS OF THE SPLEEN

Cysts of the spleen form quite another chapter, and, like cysts of the pancreas, are peculiarly amenable to surgical treatment. There are—(1) Non-parasitic[2] and (2) parasitic cysts—(*a*) serous cysts; blood cysts; lymph cysts; dermoid cysts; and (*b*) hydatid cysts. The most common non-parasitic cysts result from some subcapsular hemorrhage. A considerable literature of these cysts is now available, but we have not yet arrived at a satisfactory means of diagnosis. The symptoms are prostration, anorexia, wasting, headache, and the presence of a tumor which may reach to the pubes. Hydatid disease gives us

[1] Walter M. Spear, Abscess of the Spleen, Jour. Amer. Med. Assoc., 1902.

[2] Heinricius, Arch. f. klin. Chir., 1904, lxxii, 130; and Charles A. Powers, Ann. Surg., January, 1906.

the most common cyst. The cysts have been aspirated, opened, marsupialized, and drained; but the only satisfactory *treatment* is splenectomy, if it can be done.

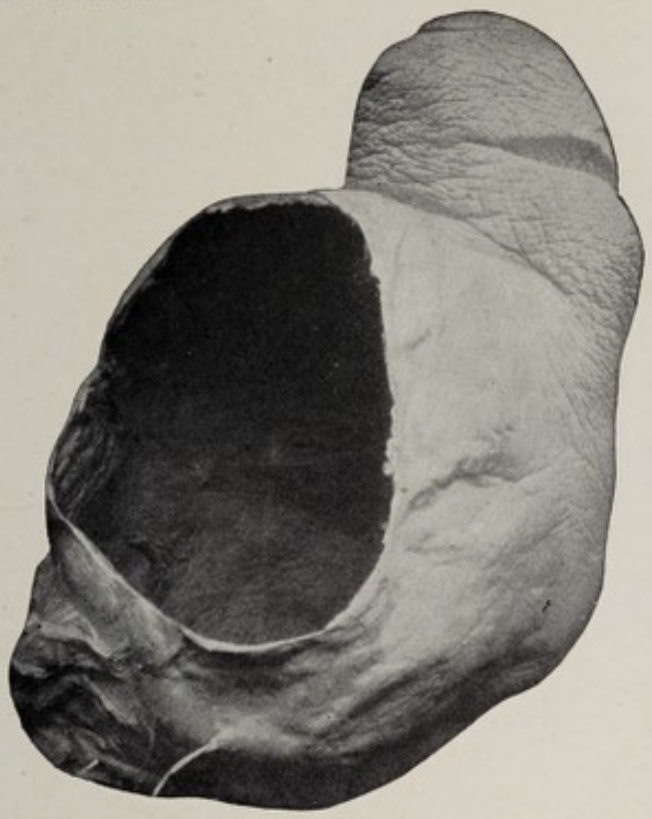

Fig. 103.—Hemorrhagic cyst of spleen (Moynihan).

NEOPLASMS OF THE SPLEEN

Neoplasms of the spleen[1] are extremely rare. There have been reported a few cases of sarcoma; fewer still of cavernous angioma, and some curiosities of surgery recorded as fibroma, endothelioma, myxoma, and lipoma. Splenectomy is the only operation which can be employed profitably in dealing with these growths.

SPLENIC ENLARGEMENT

Malaria is one of the commonest causes of splenic enlargement—an enlargement which sometimes may necessitate operation. The cases operated upon are not numerous, and few men have had more than one or two. Bessel-Hagen's[2] paper is frequently quoted, for he has collected the largest number of cases. The upshot of this discussion is that, if an enlarged malarial spleen becomes dislocated and causes constant pain, it may be excised. Some observers go further and assure us that an enlarged malarial spleen, not dislocated, is often the source of continuous malarial poisoning and should be removed—mark the proviso!—if persistent antimalarial treatment fails to cure.

[1] Jepson and Albert, Ann. Surg., 1888, vol. xi, p. 80.
[2] Arch. f. klin. Chir., 1900, vol. lxii.

Splenectomy for malaria should not be delayed until marked ascites has appeared, nor should the size of the spleen modify one's decision to operate. Spleens of all sizes are removed with equal safety. Splenopexy also has been performed in these cases.

Splenic anemia,[1] so-called splenomegaly, furnishes the surgeon with an interesting problem—a problem needlessly confused through a frequent misuse of terms. It is characterized by a decrease in the number of red corpuscles in the blood; no leukocytosis; primary splenic hypertrophy; hemorrhages from the mucous membranes; progressive weakness; vomiting; diarrhea and bronzing of the skin. The course may run as long as fifteen years, or the patient may be dead within a year. Late in the disease there is hypertrophy of the liver, with ascites. Particularly must splenic anemia be distinguished from splenic leukemia, which is characterized by a marked decrease in the number of red corpuscles and an increase of the white. Unfortunately for certainty of diagnosis, as Osler shows in one case, the leukocytosis of splenic leukemia may be slight or entirely absent. But note the important point—myelocytes averaging 30 per cent. invariably are present in splenic (myelogenous) leukemia.

The *symptoms* upon which we must base our diagnosis of splenic anemia are, therefore, splenic tumor, hemorrhages, which may become almost fatal, ascites, enlargement of the liver, a diminished "red count," a low percentage of hemoglobin (due probably to the hemorrhages), and a normal or diminished "white count."

Treatment.—In a certain proportion of cases, which should increase with increasing experience, splenectomy results in the cure of splenic anemia.[2] To prove successful, however, the operation should be done at a comparatively early stage of the disease, before the liver is enlarged or the ascites marked.

In splenic leukemia, splenectomy must not be done. That one much-quoted case of Richardson's, which seemed at first to contradict this assertion, died four years after the operation, and uninfluenced by the operation, as Richardson himself reported.[3]

PTOSIS OF THE SPLEEN

Ptosis of the spleen is occasionally seen associated with a general visceral ptosis; and, independently, the spleen may drop or "wander." Sometimes, hypertrophy causes the organ to fall out of place by its own weight. Sometimes a prolapsed spleen becomes hypertrophied secondarily. One of the chief dangers of wandering spleen is that the pedicle may become twisted through 180 or 360 degrees, or even more, with resulting engorgement, strangulation, and gangrene.

When a prolapsed spleen is enlarged or has a twisted pedicle, the organ must be excised. A large heavy spleen cannot be secured by stitching it into place. But in the case of a normal spleen, splenopexy

[1] Splenic anemia was described by Banti in the Berlin. klin. Woch., 1886.

[2] See report by J. E. Summers, Ann. Surg., June, 1908, p. 1006.

[3] M. H. Richardson, Splenectomy for Myelogenous Leukemia, Ann. Surg., November, 1905.

may suffice to fix it permanently, and the pocketing operation (behind the diaphragmatic peritoneum) of Rydygier; the method of Kouwer, by tamponade; or Basil Hall's [1] method—stitching the lower pole into the parietal wound—have proved satisfactory. But in his zeal for an early and prompt cure, the surgeon must not neglect conservative and safe methods. Often a prolapsed spleen, if not too large, may be replaced and may be held comfortably in position by a well-applied bandage, such as I shall describe in the chapter on Abdominal Ptosis.

Such are the diseases of the spleen for which operations may be employed. *Per contra*, we are agreed that splenectomy is always contraindicated in case of atrophic cirrhosis of the liver, in amyloid disease, and in splenic myelogenous leukemia.

[1] Ann. Surg., April, 1903.

CHAPTER VII

ABDOMINAL HERNIA

HERNIA has held the front rank in medical literature from the earliest writings until to-day. Among surgeons of the last generation abdominal herniæ were held to be the single exception to the general rule that the belly must not be opened for disease, so they magnified its importance. The literature of hernia is enormous—out of all proportion to modern conception of the significance of the lesion; but even to-day the text-books give it unlimited space. Thomas Bryant, publishing twenty years ago, devoted to hernia one-twentieth of his great volume; so did Druitt in 1859, and Chelius in 1847. Recent writers are more reasonable, but the subject is a favorite still, and it seems that custom cannot stale its infinite variety.

Hernia is, properly, the protrusion of a viscus or part of a viscus from the cavity normally containing it. The term, unqualified, applies to the viscera of the abdomen. A hernia is named from the region in which it appears—*abdominal, inguinal, scrotal;* or from the opening through which it passes—*obturator;* or from the organ protruded—*enterocele, epiplocele, cystocele.*

Inguinal hernia, the commonest form of hernia, is not easily to be understood by the beginner, just as formerly it was not easily to be cured. That may be a reason for our constant interest in the whole subject of hernia; yet, except for certain minor points of detail, the anatomy of most herniæ is not difficult of comprehension. Let me illustrate by a simple example what commonly takes place when a man is ruptured. Suppose I cover the outside of a snowbank with a sheet, then wrap my hand in a towel and thrust my fist through the snow from the inner side of the bank. No matter how far I push my hand, it will always carry before it the confining towel and the sheet on the outer side of the bank. In like manner a coil of intestine thrust through the abdominal wall will always carry before it the confining (parietal) peritoneum, and the skin and superficial fascia on the outer side of the abdomen. The hernia cleaves its way between muscles and aponeuroses, and it is wont to choose for its point of attack the weakest places in the abdominal wall. Generally, it seeks places low in the abdomen—the *inguinal* canal, where the spermatic cord or round ligament passes out; the *femoral* ring, where the femoral vessels pass under Poupart's ligament; the *umbilicus*, and such other points of least resistance. Besides the common hernial regions just mentioned, we have to deal with *ventral, epigastric, diaphragmatic, gluteal, sciatic,* and *lumbar* herniæ; while there are certain rare and interesting forms of internal

herniæ—*retroperitoneal* herniæ, which do not reach the surface of the body. Such are the anatomic terms describing the *site* of a hernia. There are also certain clinical terms which describe the *condition* of a hernia—*reducible, irreducible, incarcerated, inflamed, strangulated.*

Etiology.—A hernia may be either congenital or acquired. The congenital form is common, though it is often transient. Malgaigne stated that about 5 per cent. of all infants have congenital hernia—inguinal, femoral, or umbilical—and his estimate is probably correct. Congenital herniæ are due to an imperfect closure of canals or ducts which are patent in the fetus. Commonly, these congenital herniæ do not persist beyond infancy, and it is interesting to note that of adults

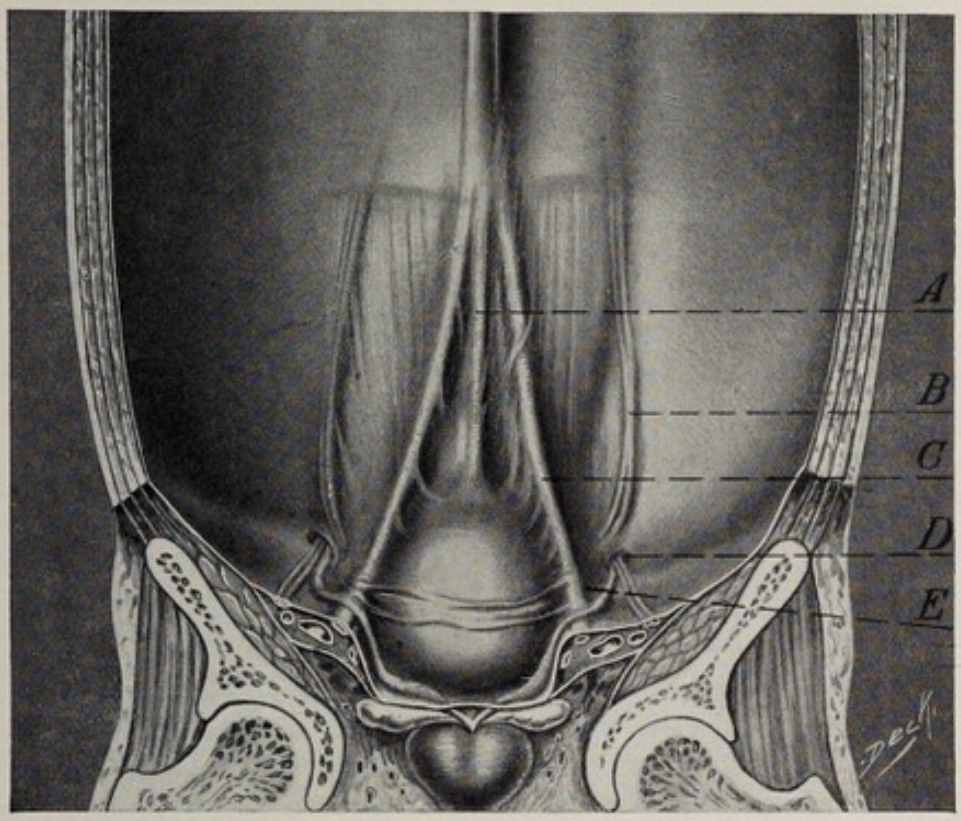

Fig. 104.—Anterior abdominal wall, viewed from behind, showing the peritoneal fossæ: *A*, Obliterated urachus; *B*, fold of deep epigastric artery; *C*, obliterated hypogastric arteries; *D*, fossa at the internal abdominal ring; *E*, fossa behind the external abdominal ring (Campbell, adapted from Sobotta).

suffering from hernia, but 5 or 6 per cent. will be found to have *congenital* herniæ. "This protrusion may occur after the person has reached adult life, even though the defect has existed during all the preceding years, but by far the greater number of congenital herniæ do occur in infancy or early childhood. When we speak of congenital hernia, therefore, it does not indicate at what age such hernia may have developed, but does clearly mean that the hernia has come down into a sac already formed."[1] Congenital hernia seems to be hereditary in many families, and to be found especially among the offspring of feeble and ill-nourished persons, as well as among rachitic, syphilitic, and

[1] W. B. De Garmo, Abdominal Hernia, p. 56.

undeveloped children. It is more common among the children of the poor than among the rich. Ill-nourished children with enfeebled digestive organs, with bloated abdomens, subject to colics and diarrheas, and with weak abdominal walls, induce and encourage hernia by their frequent crying, straining, and vomiting.

Beside the ruptures of infancy, hernia is a common affliction of adult life. About 5 per cent. of mankind suffer from it. The conditions predisposing to hernia are numerous, curiously complicated, and still subject to dispute. Some persons are the subjects of multiple herniæ, behind which tendency there appears to be a condition of faulty development. This faulty development is especially common in the umbilical region. Russell [1] states that femoral hernia results from the existence of a sac arising in an early stage of development when the limb buds are being formed, and that at this stage a diverticulum of the pleuroperitoneal cavity is drawn down into the limb. He believes also that inguinal hernia is due to a similar sacculation of the peritoneal pouch. The intestinal and properitoneal herniæ result from portions of the peritoneum being caught in the abdominal wall during its development.

As a fact, degrees of obliteration of the vaginal process or peritoneal protrusion vary. In the case of inguinal hernia after infancy, it is uncommon to find a communication between the vaginal process in the peritoneum and the scrotal end, though the process may remain patent in the region of the cord as far as the internal ring.

However all this may be, it is certain that there are weak places in some individuals—large abdominal rings and lax muscles and aponeuroses. In such individuals herniæ develop insidiously; the vaginal process may advance and distend gradually without containing viscera, so that it is only after the apparently accidental invasion of the viscera that the hernia becomes evident to the patient. There is an entirely different class of persons who develop hernia suddenly and painfully. These are active, vigorous men, athletes and laborers who, by some sudden and severe exertion, force down a hernia through a previously normal ring. The hernia may then become caught in the tightening ring, and the whole process may be associated with severe pain and distress. The *immediate* causes of hernia, in all classes of individuals, may be heavy lifting, stretching, straining, coughing, sneezing, and similar vigorous muscular acts. Excessive length of the mesentery, sometimes exists, and it may be that the pressure of a dependent and full loop of intestine weakens the lower part of the abdominal wall. In some cases a mass of fat forms and advances before the hernia, bearing to it a causative relation, and then, as Da Costa says, quoting Lucas-Championnière: "When a person begins to take on fat, it is deposited not only under the skin, but also in the omentum, mesentery, and subperitoneal tissues. This semifluid fat is easily influenced by pressure. The deposit of fat within the abdomen lessens the size of that cavity, intra-abdominal pressure is increased, and fat protrudes

[1] R. Hamilton Russell, Lancet, March 12, 1904.

at any weak spot in the wall. The protruding mass of fat adheres to and makes traction upon the peritoneum, and this membrane is drawn upon to form a sac, and the sac is surrounded by fat. This method of formation is frequently noticed in umbilical herniæ."

The pregnant state is a frequent cause of hernia in women, but males are three times as liable to rupture as are females.

Such being the causes of hernia, in general terms, it is interesting to study further certain characteristics common to all ruptures. I have spoken of herniæ as reducible, irreducible, incarcerated, inflamed, and strangulated. All herniæ have certain anatomic points in common also —coverings, a sac, and contents of the sac.

Reducible hernia, as is obvious from its name, is a hernia the contents of which may be caused to return into the abdominal cavity. This state of hernia is the commonest of all. Most of the patients who consult you for rupture have these herniæ which come and go. If the patient stands up and strains, a swelling will apear. If he lies down and relaxes, the swelling will disappear, or may be easily pushed back into the abdominal cavity by taxis, as the manipulation is called.

A word in regard to *taxis:* The student or inexpert practitioner should see taxis performed by an experienced hand if he is to realize what proper taxis means. Ordinarily, taxis is extremely simple—a small hernia can be put back readily by the patient himself; but it is in the cases of large, incarcerated herniæ that the expert finds his field. Lift the hernia mass directly upward, so that the contents of the sac tend to fall straight down into the ring. Then make the approach of the hernial contents toward the ring through a funnel-shaped canal formed by the manipulator's fingers. Usually the fingers of one hand form such a funnel, while the fingers of the other hand knead and mold the contents of the sac. Sometimes a modified Trendelenburg position helps; sometimes a hypodermic of morphin, or the long immersion of the patient in a hot bath before and during the manipulations. Femoral hernia in its early stages, and before the ring has become widely distended, offers the peculiarity of a curiously intricate canal, formed somewhat like the curl of the letter *J*. To reduce a small femoral hernia, therefore, the surgeon molds the contents of the sac downward, then backward, then upward.

Often, by palpating or percussing the hernia, one may discover the character of the sac's contents, and will conclude that there is present a mass of omentum or a knuckle of intestine. Sometimes, when the patient consults you, you will see no hernia, even when he stands up and strains, but you will be able to detect its presence, or potential presence, by inserting a finger into the suspected ring and directing him to cough or strain, when a distinct impulse will be felt, as of a water-bag impinging on the finger. These patients with reducible hernia rarely have troublesome symptoms, the most that they complain of being distress at the hernial opening, and more or less general bellyache when the viscera protrude. Sometimes there are dyspepsia, constipation, and nausea.

Irreducible hernia is another term which is self-explanatory. A patient comes to you with a rupture which cannot be returned into the abdomen, of which rupture he gives a history that it has been out a long time. It may be of any size—which is true also of reducible hernia—from that of a pullet's egg to an enormous sac containing most of the intestines and omentum. There are various causes for its being irreducible, the commonest being adhesions between the coverings of the sac and the sac with its contents—adhesions due to a low grade of peritonitis. Another cause is incarceration. An *incarcerated hernia* (or obstructed hernia) is one in which the fecal stream is dammed up and arrested when the hernia is down, so that the distended bowel cannot be returned through the ring, but the contents of the sac suffer no immediate anatomic change, because their circulation remains intact. In other words, an incarcerated hernia is not an immediate source of danger. It is a common outcome of irreducible hernia, and demands attention. It enlarges and becomes tender, painful, and dull on percussion; pressure reduces its size, but it cannot be completely reduced, and it still shows an impulse on coughing. There is apt to be associated nausea, and there is variable constipation, with occasional vomiting. An irreducible hernia may become *inflamed*, a condition to which I have already alluded. The mass becomes hot and tender, hard and distended. It cannot be reduced, and gives rise to the same symptoms as those of incarcerated hernia, with fever in addition; but there is still an "impulse on coughing," and the constipation is not absolute. With proper treatment the inflammation will subside usually, but it leaves behind it adhesions, and establishes a condition tending to subsequent incarceration and to possible future strangulation.

Strangulated hernia is the most serious form of irreducible hernia with which we have to deal, and it is about the subject of strangulated hernia that the greatest interest in hernia centers. Physician and patient alike must be taught to look toward strangulation as the possible outcome of every hernia. The condition is a frightful calamity, and the danger to life is imminent. The three great surgical emergencies of the old writers were hemorrhage, suffocation, and strangulated hernia, and of the three, strangulated hernia is still the most common and the most difficult of control.

In Chapter II we studied intestinal obstruction and intestinal strangulation, and saw that strangulation may be the last and serious stage of obstruction. So in the case of hernia—an incarcerated hernia contains usually obstructed bowel—an obstruction to the fecal stream. A strangulated hernia—a hernia from which the nutrition, the blood-supply, has been eliminated—may be the end-result of incarceration. Omentum as well as bowel may become strangulated. Observe further that strangulation may take place in an old irreducible hernia, and that it may take place suddenly also in a hernia hitherto reducible, or it may be the initial evidence of a fresh hernia. One must always distinguish the elastic constriction or strangulation from fecal impac-

tion or incarceration. Strangulated hernia occurs thus: a loop of intestine becomes crowded down into the sac, and when the increased amount of pressure diminishes, the hernial ring, which has been forcibly distended, contracts and grasps the loop with an elastic grip. Thus stoppage of the bowels is established, as well as interference with the gut's circulation. The circulatory disturbance may be venous only, or both veins and arteries may be shut off, and, according to the degree of strangulation, the further destructive processes are slow or rapid. If the arteries are still patent, the irreducible viscera become engorged, exudation follows, and strangulation gradually becomes complete. The bowel then becomes necrotic, often with astonishing rapidity, so that sometimes it is no longer viable after eighteen or twelve hours even. The terminal intestinal arteries do not anastomose. The lumen of the gut is loaded with active bacteria, under the most favorable conditions for making trouble. Much the same condition results when both veins and arteries are suddenly occluded. In either case there follow necrosis, ulceration, gangrene, peritonitis. Even if the gut be found viable at operation and be returned to the abdominal cavity, damage to its walls may have occurred in one or more places, so that later, with healing and scar-formation in the intestine, there may result stenosis and obstruction.[1] As a rule, however, if the strangulation is relieved early, the intestine will recover. If necrosis supervene and surgical relief is not provided, the patient will die of shock or general peritonitis. In rare cases—about 5 per cent.—the destructive process will penetrate the sac and skin, and the patient will recover with a fecal fistula or artificial anus.

The *symptoms* and *signs* of strangulated hernia are in large measure the classic ones seen in other intestinal strangulations. One finds that the hernia, perhaps formerly reducible, cannot now be replaced.[2] If not recently formed, it is larger than usual, tense, firm, or even hard; without resonance, *without expansile* impulse (a hernia incarcerated merely expands with straining; and in this fact lies an important distinction between strangulation and incarceration). The strangulated hernia is painful and tender on pressure, especially at its neck. The bowels do not act, though they may often be felt contracting, and may cause colic and spasmodic pains, especially at the navel and the pit of the stomach. With this pain there are commonly some tenderness and a feeling of tightness in the abdomen, particularly in the umbilical region, and between it and the hernia. The patient is often nauseated, and vomits nearly all the food and drink that he swallows, besides gastric secretions, bile, or the diluted contents of the small intestine. The pulse and respiration are usually quickened and rather feeble; the patient feels and looks wretched and miserable—"anxious," as we say. He cannot sleep or eat, and the hands and feet are apt to become cold, shrunken, and dusky.

[1] See important article by Percy W. G. Sargent, Ann. Surg., May, 1904.

[2] There is a graphic description of this condition in Sir James Paget's Clinical Lectures and Essays, 1875.

Whenever all these things are observed, and when they remain after reasonable attempts at the hernia's reduction without operation, you may hold that the operation should be done without delay. Much more, if possible, should it be done if all these phenomena be worse than I have described. When the integuments over the hernia are inflamed, thick, sodden, ruddy, or emphysematous; when the whole abdomen is swollen, tense, and tender; when the vomitus is like the liquid feces of the ileum; the pulse rapid, feeble, and small; the skin cold, dusky, and clammy; when the patient is dim in sense and mind or in an anguish of misery, with retching and hiccough—when all or the greater part of these elements of what the old writers call a *miserere* are combined, then, without trying any other method of reduction, you must operate instantly, though you may have only the slenderest hope of doing good, and a serious fear of seeming to do harm.

The foregoing fine account of strangulated hernia is taken almost verbatim from Paget's delightful book. His description will always apply, and there is little the modern surgeon can add for aid in the diagnosis. We note the temperature, which is frequently subnormal at first, rising as the primary shock passes and peritonitis develops. It may reach 102° or 103° F. The pulse, at first rapid, feeble, thready, becomes somewhat hard and wiry with the advent of sepsis; later it falls away to a flickering stream. There is almost always a slight leukocytosis—12,000 to 20,000. The urine becomes concentrated; the tongue is dry and furred, with red cracks across it; the breath is horribly offensive. Such is the scene.

We found our **diagnosis** on finding a hernia which is irreducible, non-expansile "on cough," and tender; on a feeble, rapid pulse; an anxious expression; a slightly distended abdomen, tender at the navel, epigastrium, and vicinity of the rupture; on nausea and vomiting.

Treatment.—Fortunately, the precision of our diagnosis does not involve so immediately the question of operating or not operating as was the case in former times. To-day one operates in all cases of troublesome hernia. One operates if in doubt, and solves his doubts by operating.

So different is the question of the treatment of strangulated hernia from the question of the treatment of the other types of hernia that I will anticipate by discussing briefly here the treatment of *strangulated hernia*. In many respects the problem of hernia is like the problem of appendicitis. Like appendicitis, hernia may be chronic or acute. It may come and go. One may procrastinate for long in the treatment, using palliative measures. Either appendicitis or hernia may wake up at any moment, to become alarming and deadly. Both kill through perforation, peritonitis, sepsis. In both, when quiescent, the radical operation is easy, rapid, safe, and sure. In both, when acute, the operation is inevitable, but not always life-saving. The term "radical cure of hernia" applies commonly to the treatment-at-leisure of chronic hernia, not strangulated. Now, when we have to deal with strangulated hernia, our endeavor must be to avert impending death by relieving

the strangulation. After that, if the patient's strength permit, one may perform a radical cure by sewing up the ring. Our previous discussion of intestinal strangulation and its treatment (Chapter II) applies to the matter now in hand. In a word, one cuts down upon the sac of strangulated hernia, opens it (herniotomy), and enlarges the ring so as to permit the viscera to slip back into the abdomen. Then, before replacing the viscera, the surgeon must make sure that they are viable. Obvious necrosis must be removed, even to the resection of intestine and excision of omentum; and such further steps—anastomosis, end-to-end suture (or Murphy button), or artificial anus—must be employed as the exigencies of the case and the condition of the patient will allow. The question of the viability of bowel is often difficult. Glossy, firm, purple bowel is viable. Dull, friable, black, stinking bowel is gangrenous. But there are many intervening stages. In general terms, doubtful looking gut that gradually improves in color on being replaced in the abdominal cavity, and then drawn down again for inspection, may be permanently returned. Bowel persistently dull and discolored should be excised, or at least incised for fecal drainage, and fastened into the wound for observation and further treatment. After the operation these cases demand anxious care. The questions of feeding and moving the bowels depend for their answer upon whether or not the intestine has been injured. In general terms a vigorous patient, with the viscera not wounded, may be pushed on rapidly, as after any exploratory abdominal section. But the presence of intestine wounded by resection necessitates rectal feeding, prolonged care, and such a slow convalescence as we have seen in the case of all operations on the intestines.

Let us now take up in more detail the anatomy of some of the commoner forms of hernia, with diagnosis and treatment.

INGUINAL HERNIA

Inguinal [1] hernia is the most frequent rupture in males. It occurs occasionally in females. There are two forms of inguinal hernia—the *direct* and the *indirect*. We must glance for a moment at their anatomy.[2] The inguinal region, for surgical purposes, is that portion of the abdomen bounded by Poupart's ligament, the external border of the rectus muscle, and a horizontal line drawn from the anterior superior spine of the ilium to the rectus. The parietal layers here are: (1) Skin and superficial fascia; (2) aponeurosis of the external oblique; (3) the internal oblique and transversalis muscles, which are not attached to the *inner half* of Poupart's ligament; (4) the transversalis fascia; (5) the subserous connective tissue, in which lie the deep epigastric artery and vein; and (6) the parietal peritoneum. Layers two, three, and four are penetrated by the spermatic cord in an oblique direction. The cord lies in the inguinal canal, which is a potential passage only, not open except when distended by a hernia. The stu-

[1] Lat., *inguen*, the groin.

[2] The teacher or student may use profitably D. N. Eisendrath's models, illustrated in his paper published in Jour. Amer. Med. Assoc., March 18, 1905.

dent must get clearly in his mind the position of the cord and its relations —that is a leading feature of our problem. The cord is always outside of the peritoneum. To trace it backward: it starts from the base of the bladder and, passing upward and outward, outside of the peritoneum, between it and the transversalis fascia, it turns sharply downward and forward into the *internal ring*, beneath the transversalis fascia and internal oblique fascia, which two fasciæ are here linked together to form the conjoined tendon. Passing through the internal ring and the inguinal canal, which is from 1½ to 2 inches long, the cord emerges from the canal through a slit in the external oblique aponeurosis—a slit known as the *external ring*. The cord is now beneath the superficial fascia, and drops over the spine of the pubes into the scrotum. At the point where the cord passes the transversalis fascia the latter

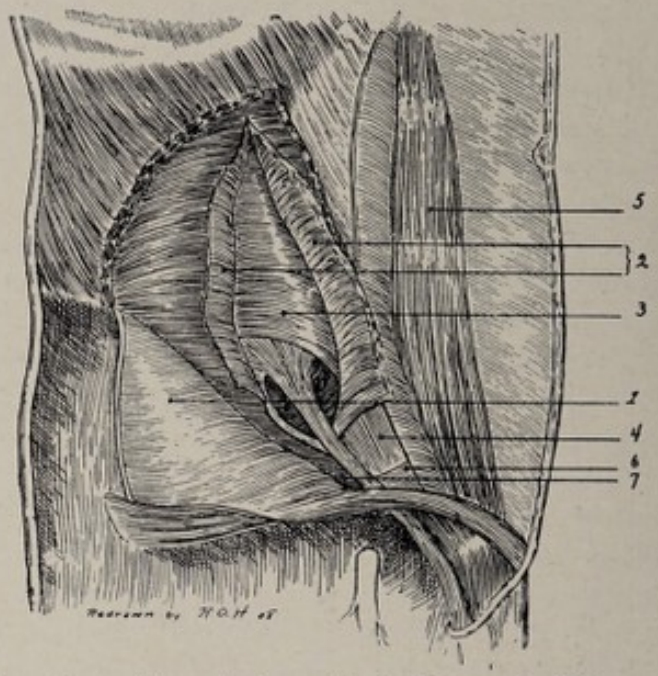

Fig. 105.—Dissection of inguinal canal: 1, External oblique, turned down; 2, internal oblique; 3, transversalis; 4, conjoined tendon; 5, rectus abdominis with its sheath opened; 6, triangular fascia; 7, cremaster (Heath).

structure sends out a prolongation called the infundibuliform fascia, which accompanies the cord into the scrotum and forms the *tunica vaginalis communis*. There are two other fasciæ accompanying the cord—structures of both anatomic and of practical surgical interest—the cremasteric fascia from the internal oblique, and the intercolumnar fascia from the external oblique. So we see that the cord, as it passes through the inguinal canal, is surrounded by sundry structures of varying strength. In front of it is the external oblique aponeurosis (and some fibers of the internal oblique in its outer part); behind it is the conjoined tendon of the internal oblique and transversalis and the transversalis fascia; within (upper wall) are the arching fibers of the conjoined tendon, beyond which lies the rectus muscle with its coverings; without (lower wall) is the stout Poupart's ligament. An im-

portant landmark is the deep epigastric artery, which springs from the external iliac, where it passes under Poupart's ligament, and runs upward and inward along the outer edge of the rectus muscle. The outer edge of the rectus, Poupart's ligament, and the deep epigastric artery form Hesselbach's triangle. The artery lies in the subserous connective tissue outside of the peritoneum. The relation of this artery to the two rings determines *direct* and *indirect* hernia. The artery passes upward behind and between the rings. Immediately to its outer side is the internal ring, the entrance to the canal (we are looking at these structures from within the abdomen). Immediately to its inner side lies the depression or fossa representing the external ring. The epi-

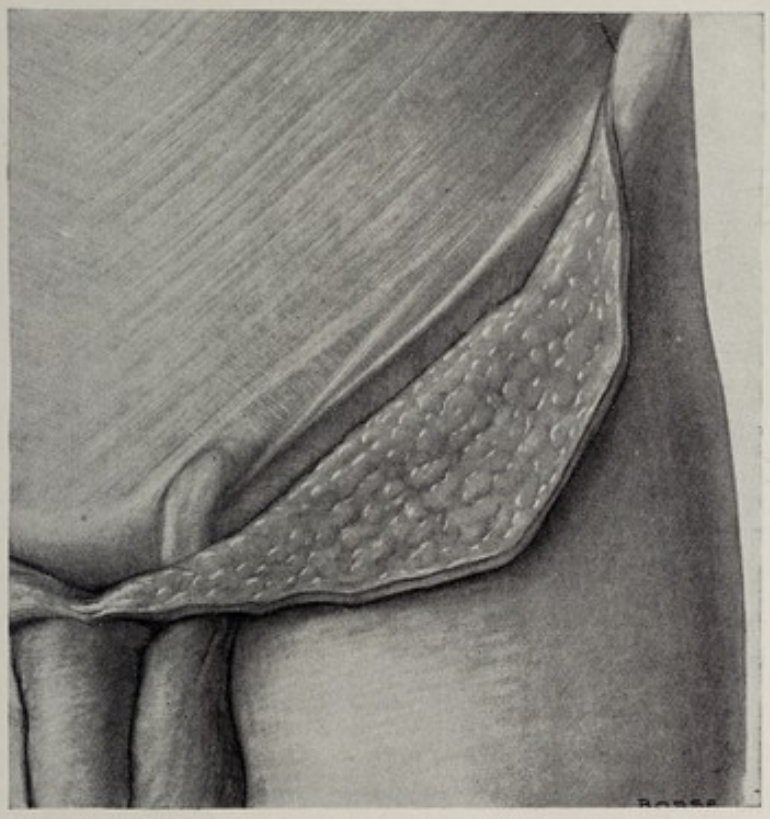

Fig. 106.—Aponeurosis of external oblique muscle, in which is shown the external ring covered by intercolumnar fascia (de Garmo).

gastric vessels, therefore, form a strong ridge, on either side of which lies a weak depression. Through these weak depressions herniæ protrude—direct hernia plunging through the wall, to the inner side of the artery, and emerging at the external ring; indirect hernia, forcing its way down through the internal ring and canal, in front of and across the artery, to emerge also at the external ring. So where they emerge the direct hernia carries before it the peritoneum, fascia transversalis, conjoined tendon, and intercolumnar fascia, much thinned, to be sure; while the oblique or indirect hernia, as it worms its way through the canal, carries before it none of these structures except the peritoneum. The nerve-supply of these parts is interesting, and it is wise to spare nerve-branches in operating upon hernia. The terminal branches of

the ilio-inguinal nerve emerge at the external abdominal ring, and the hypogastric branch of the iliohypogastric perforates the aponeurosis of the external oblique above and to the outer side of the external ring.

There are three arteries—two of them important: the spermatic artery, which supplies the testicle; the artery of the vas deferens, lying in the sheath of the vas; and the cremasteric branch from the epigastric. The veins forming the pampiniform plexus make up the bulk of the cord. If you understand the anatomy of this region, the various operations appear simple enough.

The **diagnosis of inguinal hernia** is usually easy, though occasionally it may offer difficulties. I have said that the swelling may disappear when the patient lies down. This fact of the disappearance

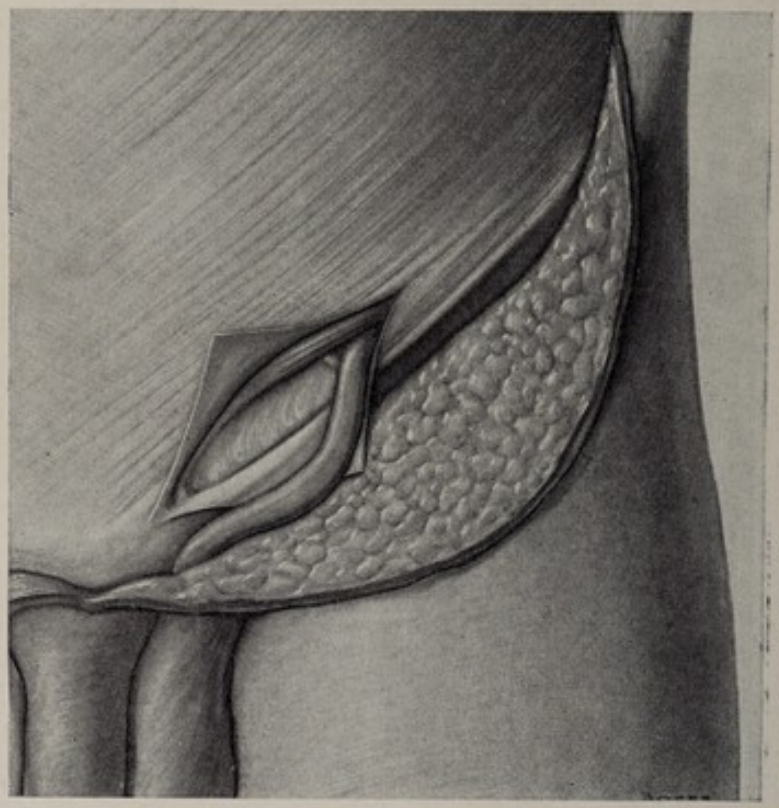

Fig. 107.—Aponeurosis opened to internal ring, showing lower border of internal oblique muscle; transversalis fascia in deep wall of canal (de Garmo).

of the swelling confirms the diagnosis of hernia. For further confirmation the surgeon may introduce his finger into the ring to ascertain the presence of "impulse on cough." It is not always possible to distinguish direct from indirect hernia, but the practitioner should remember that direct hernia rarely becomes large enough to descend into the scrotum; while, on the contrary, indirect hernia may descend and cause an enormous scrotal swelling. We differentiate hernia from inguinal adenitis, which presents a hard, unvarying swelling; from inguinal sarcoma, which is hard and unvarying also; from psoas abscess, which fluctuates and may be confused with inguinal hernia; from various hard and soft tumors of the testicle and cord, which tumors are constant; and from hydrocele, which most closely resembles hernia.

Hydrocele is fluctuant, dull on percussion, shows transmitted light when examined by the hydroscope, and is invariable in size, except, of course, in cases of congenital hydrocele, but congenital hydrocele is commonly associated with and a part of congenital hernia.

The **operative treatment** of both forms of inguinal hernia has now been brought to such perfection that palliative measures are rarely considered by surgeons. Yet palliative measures have their value, and by palliation I mean the use of the truss. One hesitates to advise a radical operation upon a feeble old person, and one shrinks from

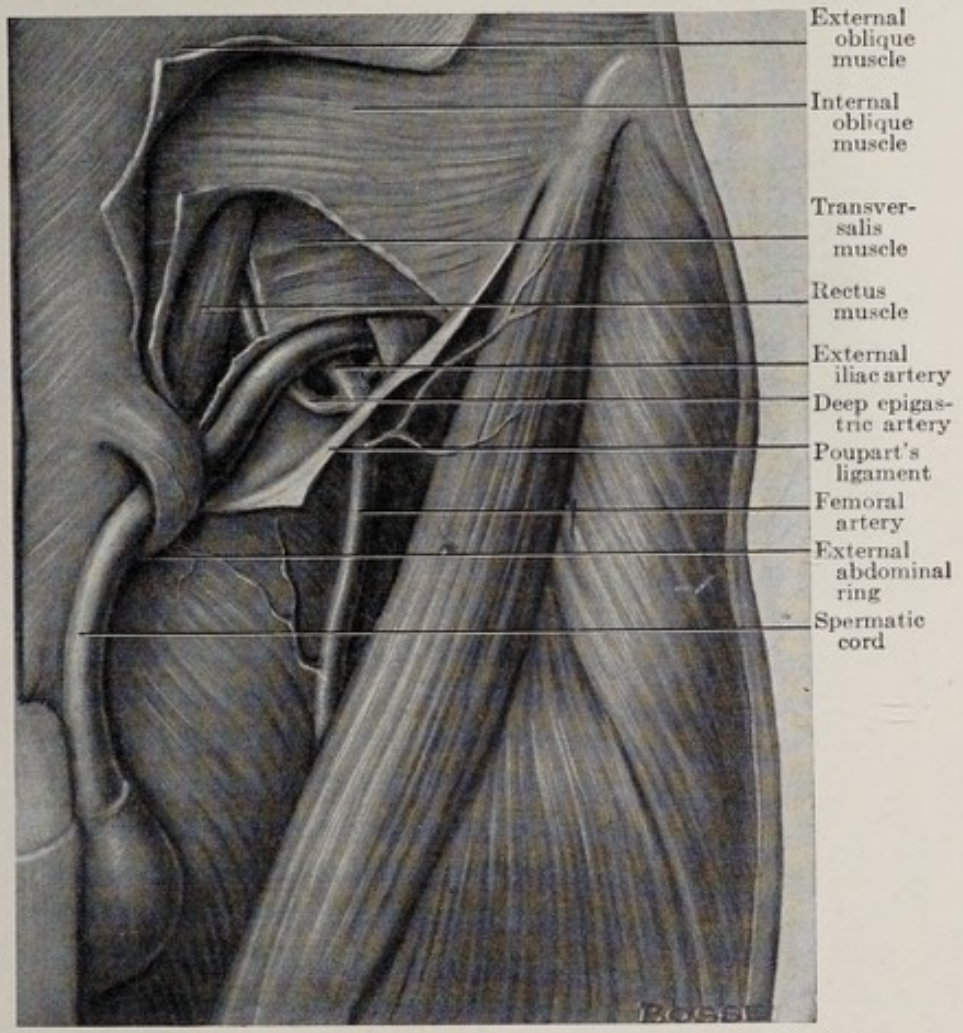

Fig. 108.—Deep dissection of inguinal and femoral canals (de Garmo).

operating upon persons with advanced organic disease—cardiac, pulmonary, renal, diabetic. Moreover, in a limited class of cases trusses will cure herniæ—the herniæ of children under four years of age (the home-made yarn-truss will often suffice); the small recent herniæ of young adults. In order to attain this result, however, you must enjoin the patient to wear the truss constantly that the hernia may not come down, else a single violent exertion may undo the good work of months. The only herniæ suitable for truss wearing are reducible herniæ. Irreducible herniæ are irritated and made worse by a truss. Large, irre-

ducible scrotal herniæ, however, may be supported in a well-fitting bag should the radical operation seem inadvisable. There is a great variety of trusses made by the instrument-makers, and the principle of them

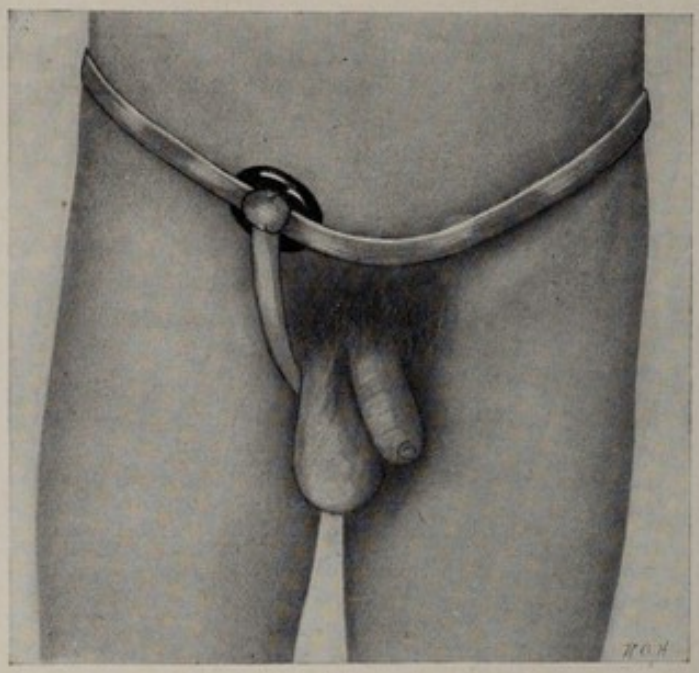

Fig. 109.—Truss in place.

all is a stout spring-belt encircling the waist and furnished with a pad to overlie the hernial ring. These pads are made of wood, leather, cork, and similar materials, but much the most effective and comforta-

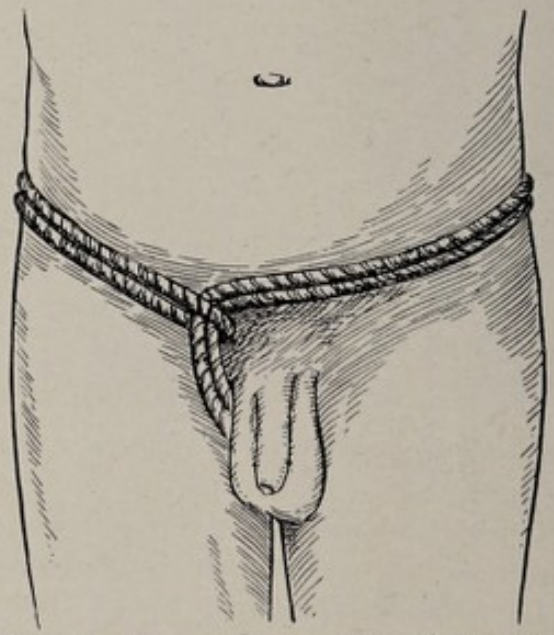

Fig. 110.—Yarn-truss for congenital hernia.

ble is the water-pad truss, devised by H. H. A. Beach some twenty-five years ago. A well-fitting, easy, water-pad truss will hold up an inguinal hernia perfectly, and enable the patient to lead a comfortable life and indulge in almost any form of active exercise.

Fifteen years ago we told patients that a radical cure would give about an even chance of immunity from relapse. To-day we are justified in saying that about 97 per cent. of our cases can be cured permanently by operation. The development of the operation for inguinal hernia forms an interesting historic study, but in this place I shall limit myself to describing a satisfactory operation for each form,—the indirect and direct,—and shall refer the reader to the literature of the subject should he wish to study a variety of operations. I have before me a list of 28 men who have devised or modified operations for inguinal hernia, and with a few exceptions these operations are quite similar. All of them depend for their success upon a perfect aseptic technic, for it is since the days of aseptic surgery only that these operations have proved satisfactory.

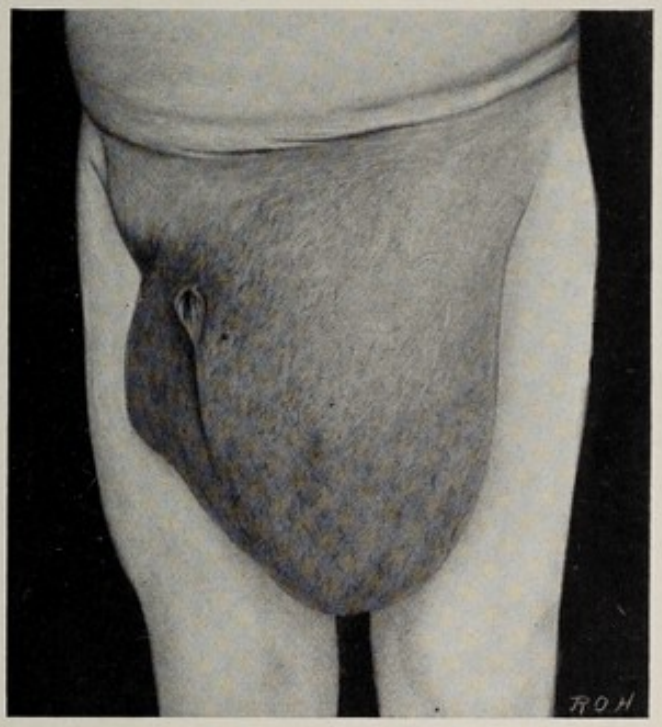

Fig. 111.—Irreducible hernia (de Garmo).

In operating for inguinal hernia the surgeon endeavors to meet and overcome three problems—the dealing with the sac, the dealing with the cord, and the secure closure of the canal or ring. Once it was thought that the fossa formed within the peritoneal cavity by the closed sac, after operation, gave a starting-point for recurrence, and doubtless this is true. It has been always recognized that the passage of the cord through the abdominal wall inevitably causes a weakening of the wall at that point, and this doubtless is true also. A long course of experimenting was necessary to determine just what structures in the abdominal wall should be sewed together in order to provide the strongest barrier against the recurrence of hernia. We have solved this problem and now know that stout aponeurotic tissue overlapped offers a firmer barrier than does muscle tissue. So we meet the three problems: first, by tying or suturing and cutting off the sac, and drop-

ping the stump well within the peritoneal cavity at a point not weakened by the passage of the cord, if possible. We transplant the cord, or bring it out through a new opening without transplanting it. Bearing in mind that the prime cause of weakness in the inguinal region is the lack of attachment of the *conjoined tendon to Poupart's ligament in its inner half*, we make good the defect by stitching the conjoined tendon to that inner half of Poupart's ligament and to Gimbernat's ligament—we attempt to improve on nature.

Method—Oblique Inguinal Hernia.—The patient is put to bed for a couple of days before operation and the bowels thoroughly evacuated by castor oil and enemata. An oblique incision is made 5 or 6 inches long, from the pubic spine upward and outward over the course of the canal, as far as the anterior-superior spine of the ilium, parallel to and two fingerbreadths from Poupart's ligament. The external ring

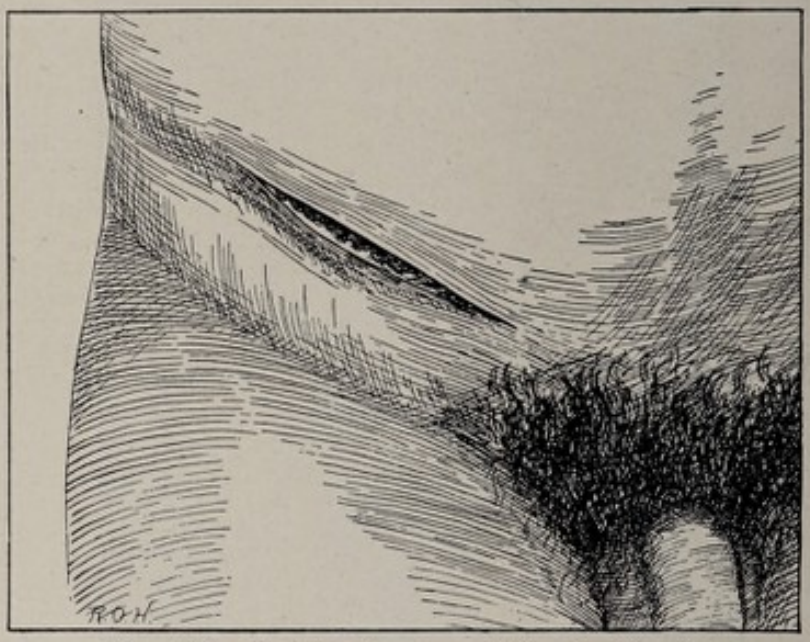

Fig. 112.—Incision for cure of inguinal hernia.

quickly is developed with the knife and with gauze dissection, and all bleeding points are secured, that their oozing may not obscure and soil the deeper field nor favor subsequent infection. For a space of about 3 inches around the incision the superficial tissues are swept back by a gauze wipe, so as thoroughly to expose the aponeurosis of the external oblique. This maneuver greatly facilitates the subsequent handling of that aponeurosis. The inguinal canal is then slit up with scissors, thus dividing thoroughly the external oblique and exposing the deeper parts. In doing this avoid the two nerves of the region. (Some surgeons prefer to open the external oblique aponeurosis half an inch above and to the inner side of the canal.) The edges of the opened aponeurosis are now seized, firmly retracted, and turned back from the underlying conjoined tendon with further gauze dissection. You will see that the deep parts are now thoroughly exposed down to the preperitoneal fat. The hernia bulges into the wound, its sac closely

associated with the coverings of the spermatic cord. The surgeon must next separate carefully the cord from the sac. One cannot always do this without tearing apart the structures of the cord, but this makes no difference so long as the vas, the arteries (especially the artery of the vas), and two or three good-sized veins are left. The sac is most easily separated from the cord by firm gauze dissection, and sometimes this maneuver is facilitated by opening the sac and holding it up upon the extended fingers inserted within it. The cremaster may be well developed, in which case one may utilize it in closing the abdominal wound. Split it off and separate its fibers from the sac. Now tip the patient about 25 degrees into the Trendelenburg position, elevate the sac, and

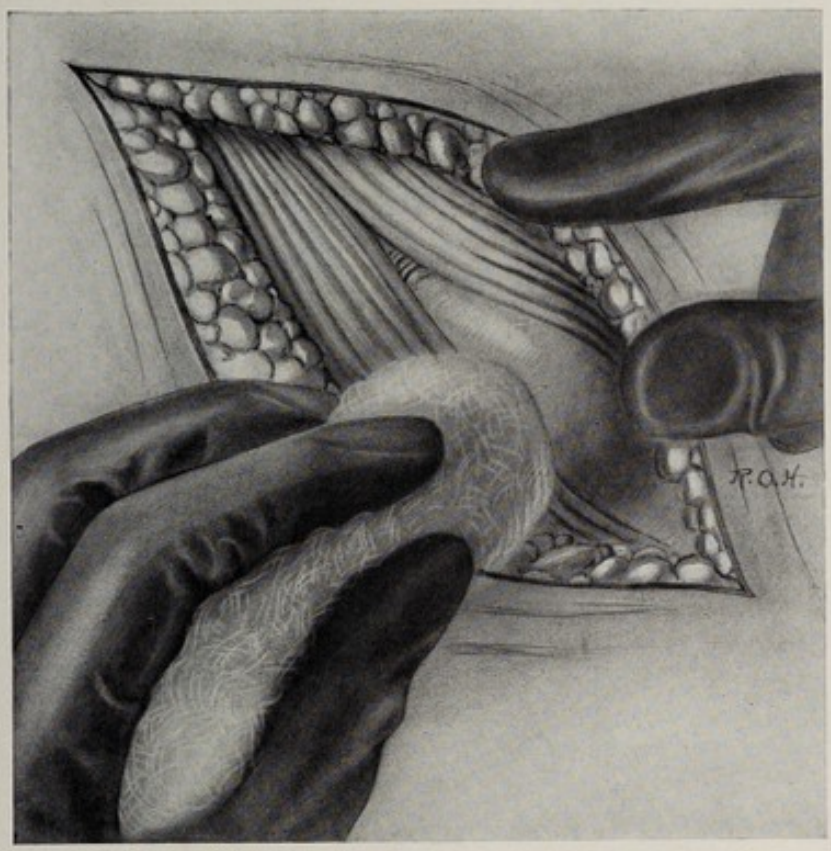

Fig. 113.—Oblique incision through skin and superficial fascia down to fascia of the external oblique muscle. Note the external abdominal ring, made apparent by slight bulging caused by full hernial sac (adapted from Scudder).

return its contents into the abdominal cavity. Secure the neck of the sac with a stout catgut purse-string suture; cut off the stump and push it back within the internal ring. The distal end of the sac may be dissected out or left, as you choose. This closure of the peritoneal sac must be made secure. If the peritoneum is thickened or is overlaid with fat, I recommend sewing up its opening with a catgut or silk buttonhole stitch rather than tying it off with a purse-string. Be sure also that the sac stump is free from all adhesions, both inside and out, that it may slip well back, freely, into the abdomen.

Then to close the abdominal wall—the canal: the problem is unlike other similar problems in abdominal surgery, because the cord is

in the way of a tight closure of the wound. There are two methods of treating the cord. Bring it out a little below (1 or 2 inches) the internal ring, stitch together the conjoined tendon and Poupart's liga-

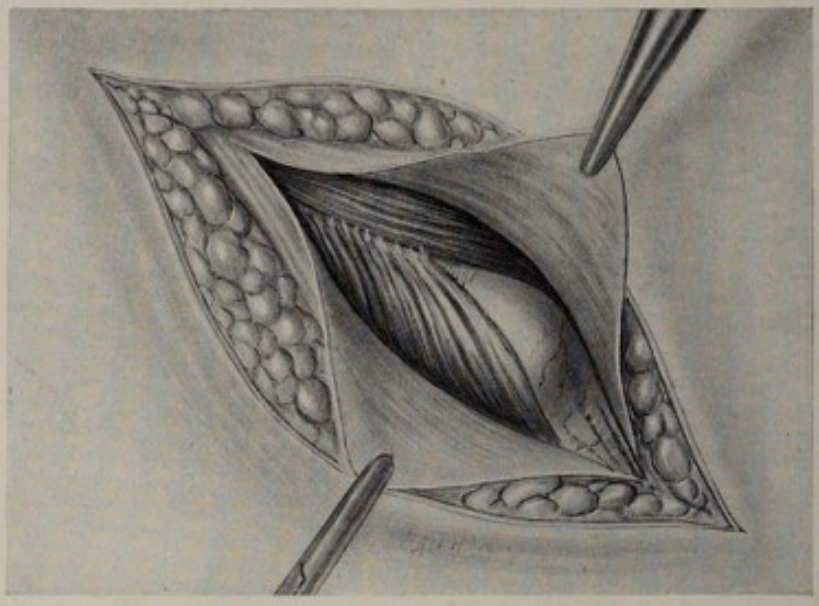

Fig. 114.—Oblique incision in line of fibers of the external oblique fascia. External oblique fascia freed from parts beneath: Note fibers above of internal oblique conjoined tendon, below well-developed cremasteric fibers, bulging sac of hernia, cord showing at inner angle of wound (Scudder).

ment, and let the cord lie upon them (transplanted) with the aponeurosis of the external oblique stitched over it to cover it in (Bassini). Or else carry the cord to the very bottom of the abdominal wound and

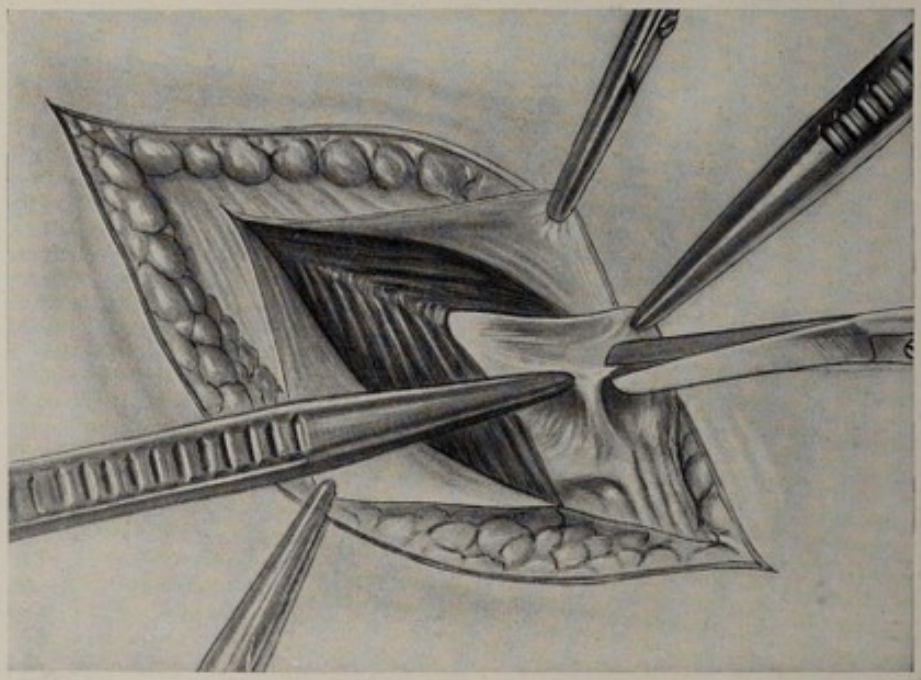

Fig. 115.—The sac of the hernia has been isolated sufficiently and raised by forceps. Note scissors opening the sac, cord in lower angle of wound (Scudder).

bring it out alongside of the pubic spine; with the cord thus out of the way the abdominal wall may be sewed up as though the cord did not

exist. Whatever the treatment of the cord may be, you must see to it that it is not unduly pinched where it emerges through its new arti-

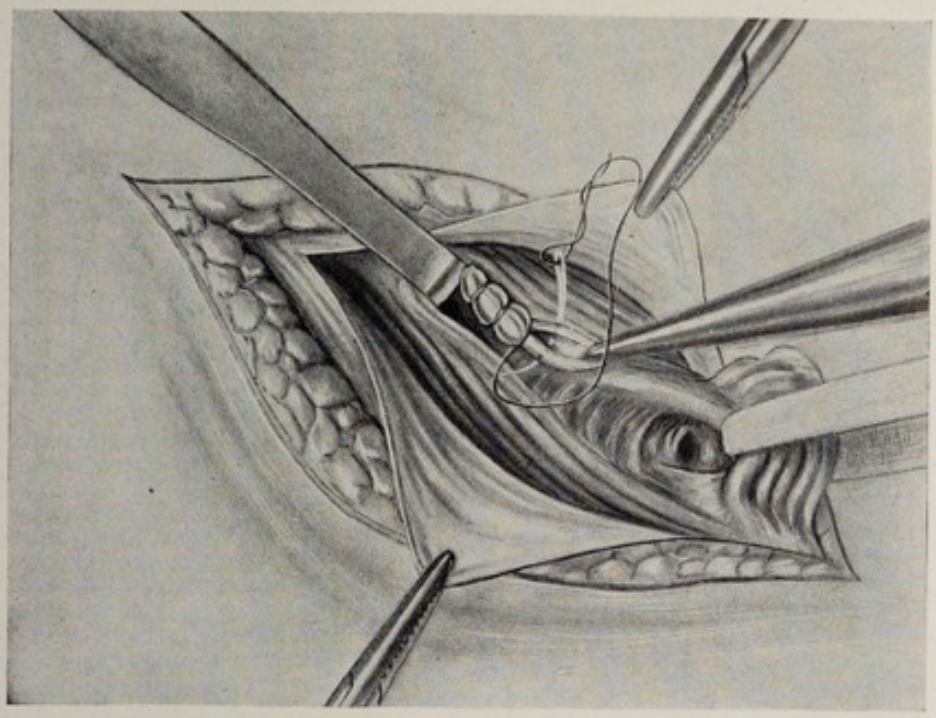

Fig. 116.—The suture is being taken through and across the neck of the sac. Note retractor keeping internal ring region well in view. Note lifting of cord by gauze-tape (Scudder).

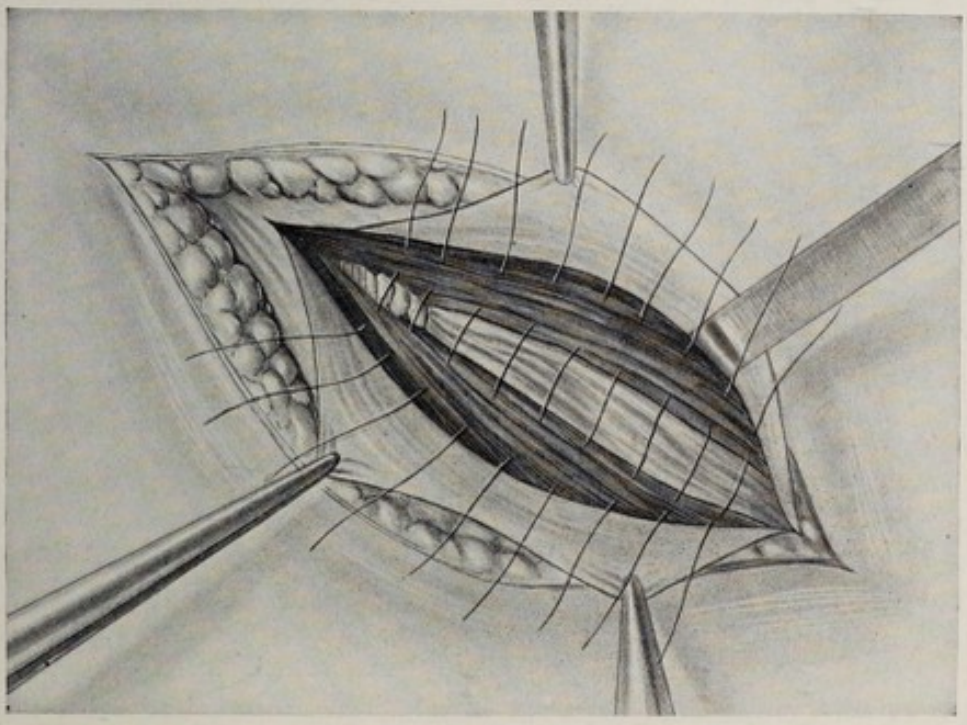

Fig. 117.—Closure of canal (Scudder).

ficial ring, and to that end it is well to thin it down somewhat if it be large. Thin it down by removing a few veins and any superabundant fat tissue.

In sewing up the abdominal wall—conjoined tendon to Poupart's ligament—I prefer to use a mattress suture of chromic gut, or gut prepared by Bartlett's method. The aponeurosis of the external oblique is then sewed up to cover in the deep field. I employ a button-hole stitch of catgut for the external oblique, and close in the skin wound with a running horse-hair stitch. Every student will recognize the fact that details of this method may be varied indefinitely. Some operators employ silk throughout; some kangaroo tendon; some silver or copper wire; the main principles are identical.

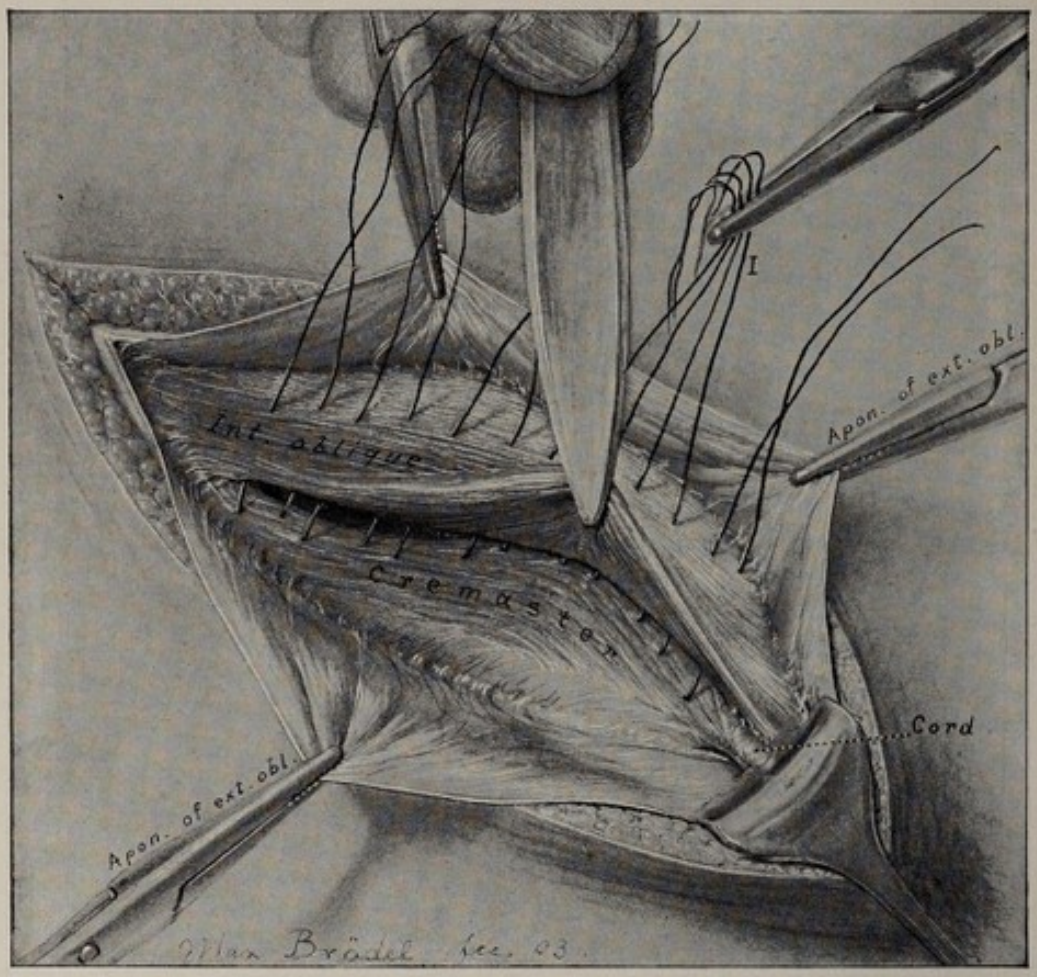

Fig. 118.—Halsted's operation. Mattress suture in closure of canal (Kelly).

In some large herniæ of long standing the conjoined tendon may be so thin or nearly obliterated that it cannot be employed. In such cases Bloodgood [1] recommends making use of the edge of the rectus instead of the conjoined tendon. The rectus sheath is exposed and divided in front of the muscle, in the direction of the muscle-fibers, upward from the pubic insertion. The muscle bulges from the cut and is caught with silk sutures. Deep stitches are then introduced, joining the rectus to Poupart's ligament. I have found this operation satisfactory in a number of difficult cases.

Direct Inguinal Hernia.—As Davis [2] points out, direct herniæ are

[1] Joseph C. Bloodgood, Johns Hopkins Hosp. Bull., 1896, vol. vii.
[2] G. G. Davis, Ann. Surg., January, 1906.

usually seen in one of two forms. One form pushes its way through the conjoined tendon and comes out at the external ring. This hernia is

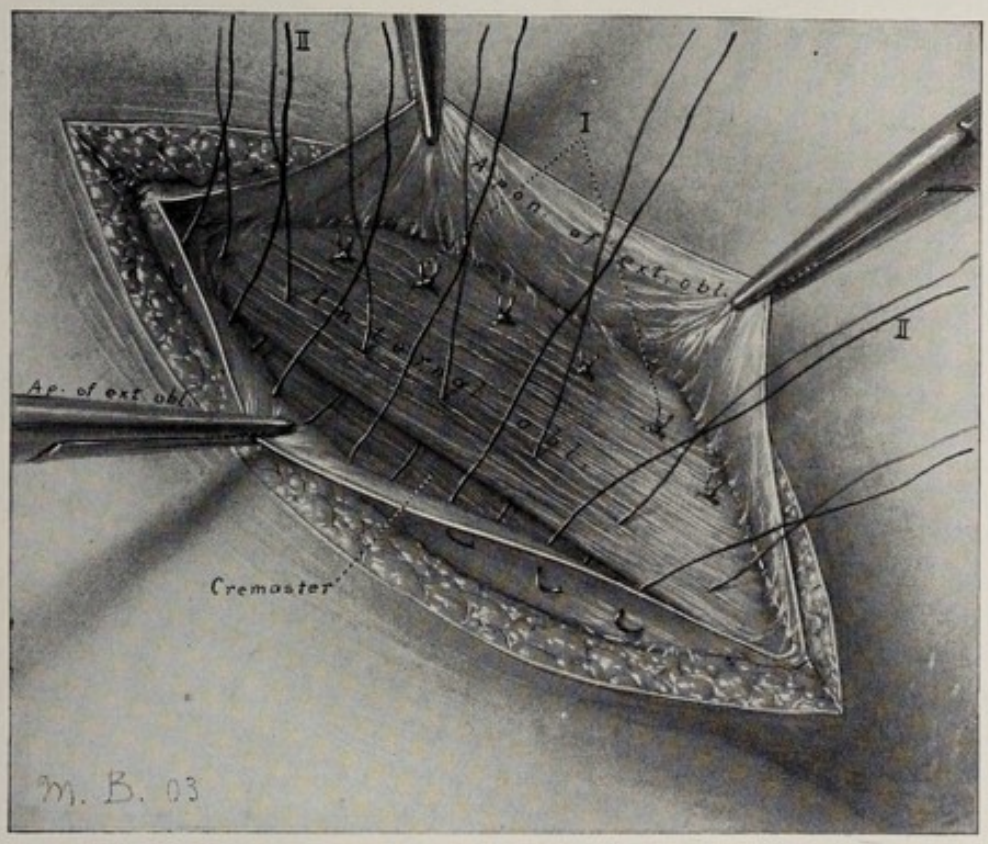

Fig. 119.—Halsted's operation. Mattress sutures tied (Kelly).

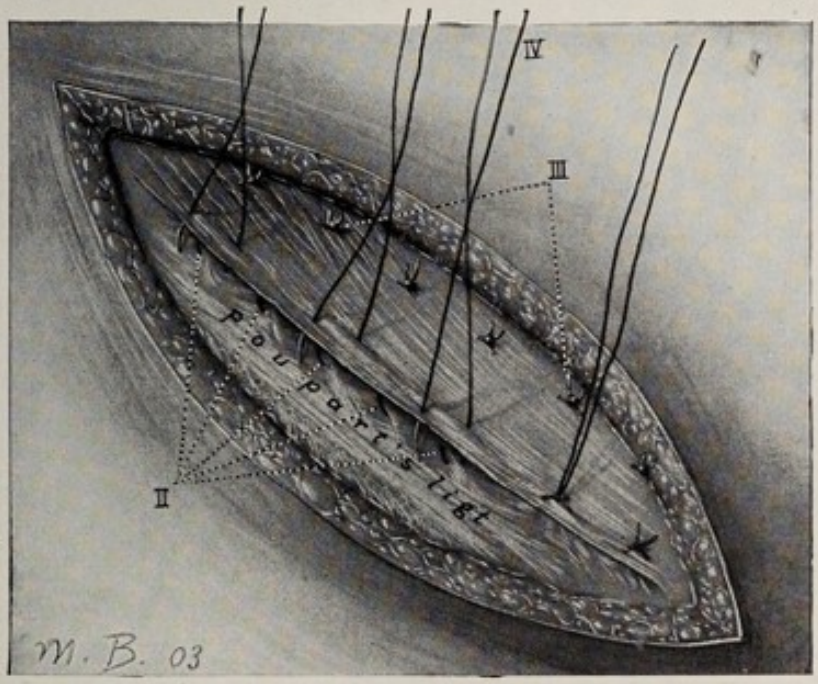

Fig. 120.—Halsted's operation. Suture of external oblique aponeurosis (Kelly).

covered with the structures I have already described in discussing the anatomy. The other form of direct hernia bulges around the outer or lower edge of the conjoined tendon and gradually decreases in size as

it extends outward toward the deep epigastric artery. In dealing with this form of direct hernia one may employ Bloodgood's rectus transplantation method already described.

In the case of the first form of direct hernia, the form covered by the conjoined tendon and other structures, Davis advises a plastic operation, employing the conjoined tendon alone, and I have used this method successfully in two cases. Davis's method consists in dividing the conjoined tendon transversely and sewing it up by the overlapping flap method. As a general rule, however, transplantation of the rectus has proved itself a satisfactory measure in these cases also. In all these hernia operations avoid damage to the iliac vessels, which are surprisingly near the wound. I have seen the vein pricked open.

So great is the number of writers on the subject of inguinal hernia, and so numerous are their methods, that I feel impelled to name some of them.

Czerny, in 1877, closed the sac and inguinal ring, He dropped back the sac and sewed the pillars of the ring together. Küster included the floor and wall of the canal in his operation. Championnière split up the external oblique. Hall and Barker modified the treatment of the sac by twisting it and stitching it into the wound. MacEwen does not cut off the sac, but folds it up into a pad which is made to lie in the preperitoneal space. Bassini, whose method is the basis of nearly all modern operations, employs the maneuver I have described in detail, transplanting the cord and isolating the sac at its neck, stripping it back to a distance from the ring. Wölfler has transplanted the cord by passing the testicle through the space between the two recti muscles, and I have employed a similar method, passing the testicle through the conjoined tendon, but long ago abandoned it. Kocher transplants the sac entire, slipping it under the external oblique and bringing it out well outside of the internal ring. Schede buries silver wire sutures deeply. Witzel has used buried wire netting, while Trendelenburg and Kraske have made a bone-flap which is turned upward from the pubes. W. S. Halsted, who shares with Bassini the honors of the best advanced work on inguinal hernia, published in 1903 an elaborate essay on his completed operation. In addition to the details I have already described, he makes a point of using the cremaster muscle to strengthen the scar in cases of long-standing and difficult herniæ. He ligates the sac at the highest possible point by transfixion or by a purse-string suture, and after tying this suture, carries out both ends under the internal oblique muscle, and passing through this muscle about half an inch apart, the suture ends are then tied. The principle is similar to that of Kocher. Both the deep stitches and the stitches of the external oblique are so passed as to effect an overlapping of the appropriate structures.[1]

Of the many writers upon the subject of inguinal hernia I mention Kingscote, Bishop, Phelps, Rotter, Frank, Ferrari, Magnai, Postenski, Girard, Coley, McBurney, Ferguson, and Fowler, whose contributions are well summed up in Dennis' and von Bergmann's Systems of Surgery.

[1] Johns Hopkins Hosp. Bull., 1903, vol. xiv, p. 208.

The **after-treatment** of these cases of hernia is important. The general routine is that which follows any clean abdominal section, but inasmuch as a sound closure of a rupture, long open, is essential to success, one must keep the patient in bed rather longer than ordinarily. I practise rest in bed for seventeen days, then have the patient get up gradually, walk about at the end of a month, and avoid active exercise for another month. Allow him to wear a truss under no circumstances: it thins down the cicatrix and favors a recurrence of the rupture. Should the patient be very restless during the first three days and put a strain on the wound by flexing his thigh, I dress the corresponding leg in a ham splint. This immobilizes the knee and keeps the leg quiet. The best dressing for the wound is a cotton and gauze cocoon over the incision, reinforced by a heavy sheet-wadding pad held in place with a firmly applied spica bandage of Canton flannel, which should be basted over to keep it from slipping.

In the case of fat persons or feeble persons, or if there be excessive postoperative oozing which cannot be checked, it is well to leave a cigaret drain in the lower angle of the wound, and remove it twenty-four hours after the operation. These general directions for after-treatment apply to both forms of inguinal hernia and to femoral hernia.

Inguinal hernia in women is one of the easiest herniæ to cure. The condition is not very common, and may be mistaken for femoral hernia, but a careful study of the position of the neck of the sac, and its relation to the pubic spine and to Poupart's ligament, will enable the practitioner to distinguish the two. A large inguinal hernia in a woman will descend into and fill up the corresponding labium majus, just as the large hernia in man descends into the scrotum.

In operating upon inguinal hernia in woman the question of dealing with the cord is practically eliminated. The round ligament in the female corresponds to the cord in the male. The various steps already described are followed, except that the cord need not be transplanted, but may be secured within the stitches which attach the conjoined tendon to Poupart's ligament. The surgeon must be careful not to cut off the round ligament, else its stump will slip back behind the internal ring, and by so much will weaken the uterine supports.

FEMORAL HERNIA

As the inguinal portion of the abdominal wall is weakened by the inguinal rings and canal, so the neighboring region below Poupart's ligament is weakened by the passage of the femoral vessels from behind the peritoneum into the thigh. A glance at the figure shows how the crural artery and vein lie in their separate sheaths, and how, between the vein and Gimbernat's ligament, there is an opening known as the femoral ring. This ring is patent except for a stray lymph-node, and into the ring a hernial pouch from the abdomen may protrude. This is the common form of femoral hernia, though very rarely a hernia may engage at some other weak point, at an opening in Gimbernat's ligament,

or along the sheaths of the vessels. These femoral herniæ, when small, appear as mere bulgings below Poupart's ligament, but if they press onward, they burrow beneath the fascia lata until they reach the weak cribriform fascia at the saphenous opening, when they protrude beneath the falciform process and appear as large swellings in Scarpa's triangle.

The dangers and inconveniences of these herniæ are such as I have already described. Femoral hernia is a common form of hernia in women; it is rare in men. A femoral hernia may be supported by a truss, but with more difficulty and discomfort than is the case with inguinal hernia.

The **operative treatment** of femoral hernia has been much debated, and sundry procedures are advocated, but, on the whole, we cannot feel sure of curing these herniæ as we feel in the case of inguinal herniæ.

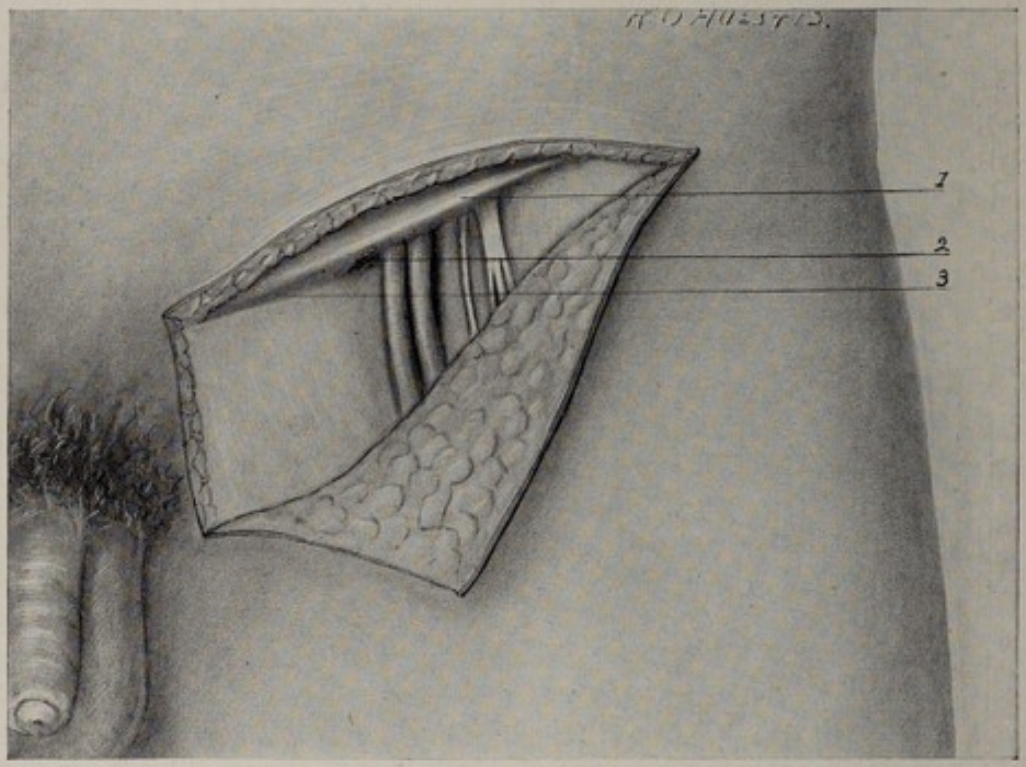

Fig. 121.—1, Poupart's ligament; 2, femoral ring; 3, Gimbernat's ligament.

During the past five years I have used the method advocated by C. H. Mayo, Ochsner, and others, and feel that our evidence of its value is strong. Make a five-inch incision one inch below and parallel to Poupart's ligament. Expose the sac and free it thoroughly well up into the abdominal cavity; open it and return its contents; then draw it down, ligate it as high as possible, and cut it off short, leaving the ligature ends long. Thread each long end into a needle and pass these needles up from within the abdomen through the abdominal wall, and tie them outside of the external oblique, 1½ inches above the femoral canal. This secures the peritoneal process away from the ring, and prevents the stump of peritoneum from passing into the canal during its healing. The canal is not further treated except to clear it from fat. The superficial wound down to the femoral opening is then closed with

catgut, except that the skin wound is sutured with superficial horsehair. On first thought, and in view of the elaborate treatment of the canal advocated by many surgeons, this operation sounds ineffective; but, in fact, the femoral ring, relieved of the pressure of the hernia, closes down to a normal size, and relapses have been rare in a large series of cases. Here three weeks' rest in bed and the subsequent avoidance of a truss are prescribed.

Of the other femoral hernia operations I mention that of Bassini, who ties the neck of the sac, cuts it off, and returns it into the belly, and then with deep sutures attaches Poupart's ligament to the pectineal aponeurosis as high up as the pectineal eminence. Kocher performs an operation somewhat similar to Ochsner's, but after exposing the sac, instead of cutting it off, he inverts it on the point of a forceps, forces it through the canal, and brings it out, apex first, above Poupart's ligament, where he secures it beneath the skin. He sews up the deep structures in much the same fashion as does Bassini. Nicoll [1] describes an interesting and elaborate procedure: after opening the sac he splits it, twists the neck, and interlocks the two halves by buttonholing one through the other. He then reduces the sac through the ring into the extraperitoneal space, and causes it to lie bunched up within the abdomen, between the peritoneum and the transversalis and iliac fasciæ, over the internal aperture of the femoral canal. He then closes the femoral ring by laying bare the pubic ramus from the femoral vein to the pubic spine, detaching the periosteum, drilling two holes through the ramus, and stitching firmly with mattress sutures Poupart's ligament to the ramus. In other words, he closes the femoral ring by reinforcing and extending into it Gimbernat's ligament. Kammerer [2] describes a further elaborate operation advocated by Lotheissen in 1898 and by Gordon in 1900; that is but another added to the list of the many operations proposed by many surgeons. Most of these operations are designed, and rather ineffectually designed, to close the femoral canal. The simple operation I described at first, which leaves the canal to close itself, is effective.

UMBILICAL HERNIA

Umbilical hernia is a subject which we may divide into—(1) *Congenital hernia of the cord;* (2) *umbilical hernia of infants;* (3) *umbilical hernia of adults.*

1. *Congenital hernia of the cord* (ectopia viscerum) is probably a malformation or monstrosity, and is due to a faulty closure of the vitelline duct. A large part of the abdominal contents may protrude through the opening. Sometimes operative measures may reduce or improve the deformity, but the condition is rare and should be studied in the large treatises on surgery.

[1] Brit. Med. Jour., November 8, 1902; Scottish Med. and Surg. Jour., December, 1903; Ann. Surg., January, 1906.

[2] Frederick Kammerer, Ann. Surg., June, 1904.

2. *Umbilical hernia of infants* is due to failure of the umbilical ring to close tightly during the first few weeks of life. A weak spot is thus left in the abdominal wall, and a small hernia may protrude, induced by the child's crying and straining. The condition is extremely common in infants, but rarely results seriously, and strangulation is a remote curiosity. This hernia in infants can almost always be cured by the use of a light support. Wrap a penny in gauze; press it down upon the ring of the reduced hernia, and strap it into place with a six-inch strip of adhesive plaster passed over the belly. Teach the nurse to reapply the plaster once a week. This usually will cure the hernia in two or three months. It the hernia persists as the child grows older, a specially constructed padded belt may be worn until a cure is effected. If it becomes apparent in the course of years that the ring is not closing, a simple radical operation may be done. Cut down longitudinally upon the hernia; reduce its contents; open the sac; free all adhesions; loosen the peritoneum about the ring, and sew the peritoneal edges together. Then excise the ring and sew up the abdominal wall. This operation is simple and effective. The after-treatment needs no special comment.

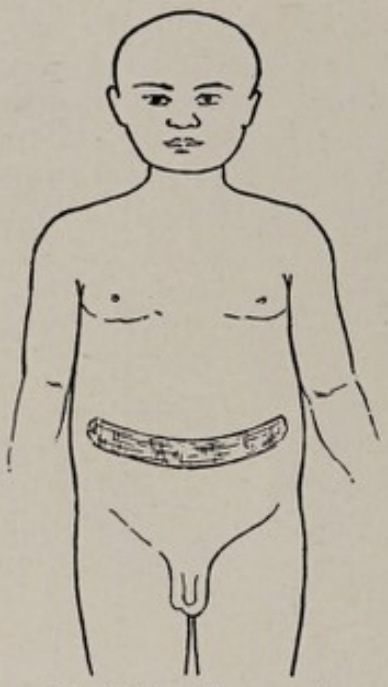

Fig. 122.—Diagram showing simple method of retaining umbilical hernia in an infant.

3. The *umbilical hernia of adults* is a far more complicated affair and merits careful consideration. This form of hernia is ten times commoner in women than in men. Unlike the umbilical hernia of children, it may reach an enormous size—as large or larger than a man's head, and the ring may be as much as three inches or more in diameter. Women are more prone to it than men, on account of the more sedentary lives of the former and the relaxation of their abdominal muscles, and especially from the abdominal distention due to pregnancy and large pelvic tumors. The hernia grows quite rapidly. Commonly, it contains omentum and small intestine, but may contain omentum, large intestine, and, rarely, the stomach or even the uterus. The coverings of these herniæ are thin and are composed of little besides skin and superficial fascia, so that the hernial sac, protruding between the recti muscles through the umbilical ring, is close to the skin and often adherent to it. These herniæ are frequently irreducible, but rarely become strangulated. Owing to the inevitable friction and irritation of the region, the sac, throughout its whole extent, may become adherent to the skin and the viscera to the sac.

The **treatment** of umbilical hernia may be the wearing of a truss belt if the patient chooses; and, in the case of feeble, elderly persons, such palliative treatment is the only reasonable measure. If the hernia

is reducible, the patient may thus be made comfortable. If the hernia is irreducible, however, one must resort to a radical operation unless it is

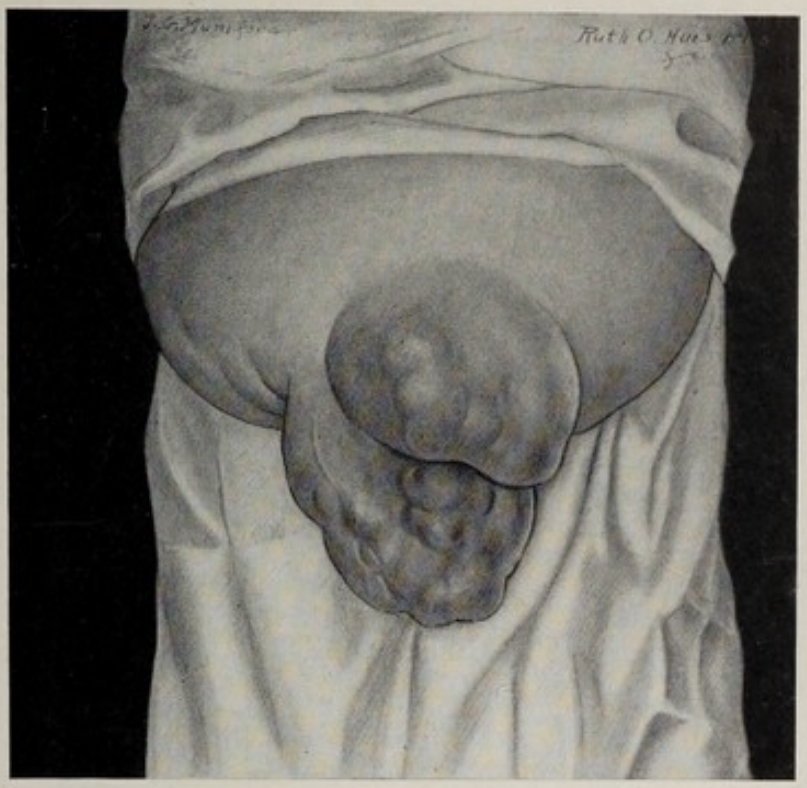

Fig. 123.—Adult umbilical hernia (Massachusetts General Hospital).

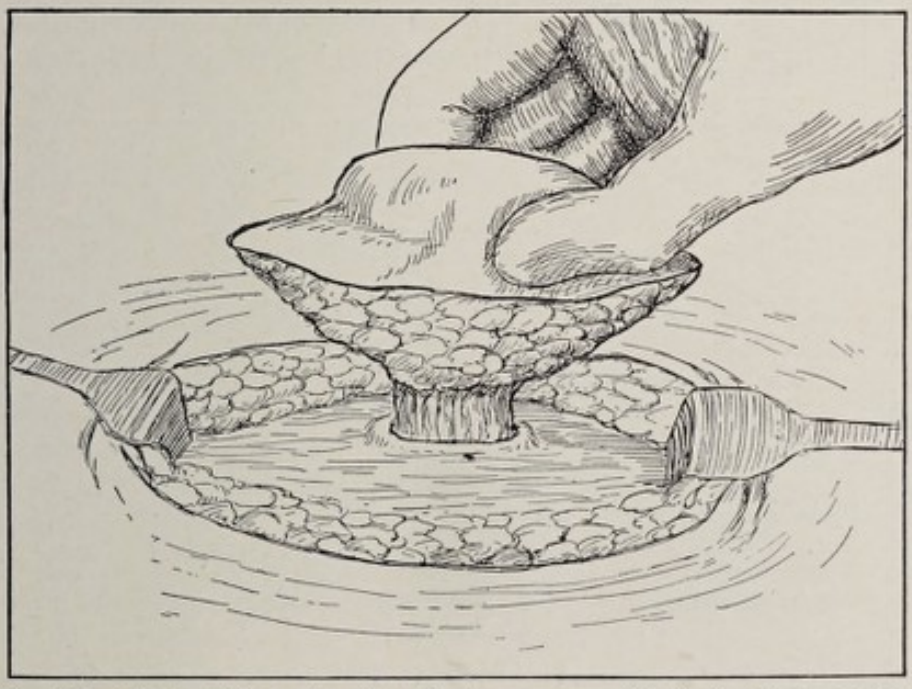

Fig. 124.—Mayo's operation, showing the transverse elliptic incisions and exposure of the neck of the sac (W. J. Mayo).

obvious that such an operation will endanger life. Until recent years the radical cure of umbilical hernia was unsatisfactory, for the method used was that of stitching together the two recti muscles. Muscles are

weak barriers. In these cases the recti are worn-out, flabby structures, which permit the hernia to relapse. Aponeuroses are needed for the work. Moreover, the great ring in these cases is almond shaped, with its greatest diameter from side to side. A satisfactory operation consists in drawing these aponeuroses together and overlapping them from above downward.[1] Make transverse crescentic incisions about the

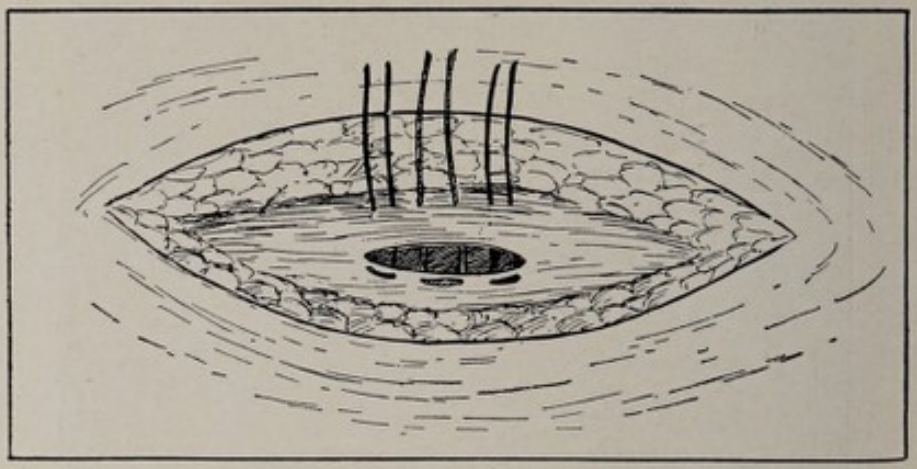

Fig. 125.—Three mattress sutures introduced (W. J. Mayo).

hernia and expose the base of the sac; then clear thoroughly by gauze dissection the aponeuroses for two or three inches around the neck of the sac. Cut away the fibrous and peritoneal coverings of the hernia, return viscera to the abdomen, and cut away redundant omentum. Enlarge the ring transversely for one or two inches at either lateral end of the hernial ring, and strip back the parietal peritoneum for an inch or

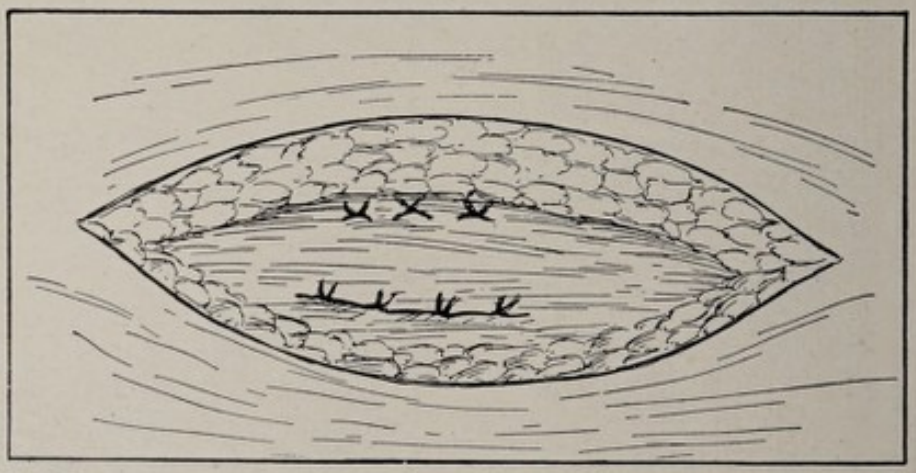

Fig. 126.—Mattress sutures tied above, and upper edge of incision stitched to surface of aponeurosis below (W. J. Mayo).

two. Our purpose next is to slip the lower aponeurotic edge of the ring beneath the upper edge—between it and the peritoneum. Pass a sufficient number of wire or silk mattress sutures from the lower to the upper flap, but before tying them, make upon them tension sufficient to

[1] W. J. Mayo, Jour. Amer. Med. Assoc., July 25, 1903; J. C. Warren, Boston Med. and Surg. Jour., October 8, 1903.

bring together the underlying peritoneal edges. Sew up the peritoneum with a running catgut stitch. Then fix the mattress sutures, and tack down the free upper edge to the lower aponeurosis with a buttonhole catgut stitch. Close the skin wound by your usual method. In the case of very fat persons, with pendulous abdomens, I have seen J. C. Warren excise, in addition, a great mass of adipose tissue, like the section of an orange, across and across the abdomen below the navel. This relieves the strain over the fresh umbilical wound, and seems to offer a better chance of permanent cure. In the after-treatment the abdomen should be supported in a well-fitting swathe for at least four months.[1]

VENTRAL HERNIA

Ventral hernia is a hernia through the abdominal wall at some point not normally weak; through the linea alba, above or below the navel; through the lineæ semilunares, etc. Writers distinguish hernia *para-umbilicalis* and hernia *epigastrica*. The causes of these herniæ are a weakening of the wall at the point affected —congenital, pathologic, or traumatic. Usually the anatomy of the hernia is similar to that of umbilical hernia, but sometimes the peritoneal sac is partially or entirely lacking. Many of these herniæ are of great interest. Epigastric hernia is rather common. It protrudes through weakened portions of the interlocking aponeurotic fibers in the median line, and gives rise to trains of obscure gastro-intestinal symptoms, especially colicky pains. Portions of omentum become caught; trifling painful swellings come and go, but the hernia rarely reaches a great size.[2] Another interesting hernia, unfortunately too common, is "hernia in a scar," a weak point due to imperfect closure of the wound after an abdominal section. This hernia is most common as a sequel of the operation for acute appendicitis, but we see it in all parts of the abdominal wall.



Fig. 127.—Bartlett's filligree for the cure of ventral hernia.

The **treatment of ventral hernia** is often difficult. The simple reducible protrusion, with a complete sac, is easily cared for, but the extensive hernia, irreducible, adherent, with numerous sacculations,

[1] See W. J. Mayo, Radical Cure of Umbilical Hernia, Jour. Amer. Med. Assoc., June 1, 1907.

[2] H. A. Lothrop, Boston Med. and Surg. Jour., March 4, 1897; D. D. Stewart, Amer. Med., July 29, 1905.

commits the surgeon to a long, laborious, painstaking dissection. The aponeurosis must be widely exposed for ease in sewing up; all adhesions must be freed; prolapsed and adherent omentum must be excised, and the viscera must be returned to the abdomen, leaving a free border of peritoneum on either side of the ring. The ring is often enormous; its edges must be refreshed; the various layers identified and separated, and repair of the ring must be made by carefully placed layers of stitches —silk or catgut—bringing the corresponding structures together from either side. The approximation of the aponeuroses must be made by overlapping, for by overlapping is a firm scar best secured. The patient must wear a well-fitting abdominal binder or belt for at least six months after most of these operations.[1]

DIAPHRAGMATIC HERNIA

Diaphragmatic hernia occurs occasionally. It may be due to congenital defects in the diaphragm, through which the abdominal contents escape into the thorax; or to wounds, accidental or inflicted during the course of an operation upon the chest-wall; for be it remembered that the lateral and dorsal portions of the diaphragm arch up along the chest-wall as far as the fifth rib, on expiration, leaving a narrow space only between parietal pleura and diaphragm. The operator may, therefore, easily penetrate the abdomen if he open hastily through the lower part of the chest-wall. Diaphragmatic hernia *may* or *may not* be covered with peritoneum in the form of a sac.

The **symptoms** of this form of hernia are difficult and obscure, for they point to both a thoracic and an abdominal lesion. There are dyspnea, palpitation, and pain in the chest. There are gastro-intestinal symptoms, pain, flatulence, and constipation; the pain is usually in the epigastrium. A physical examination may reveal tympany high in the chest and a displaced heart. Sometimes the *x*-ray will show the lungs crowded up and the heart in an abnormal position. Diaphragmatic hernia may become strangulated, in which case the symptoms are those of any other strangulation of the abdominal viscera.

The **treatment** of strangulated diaphragmatic hernia is obviously to open the abdomen, reduce the hernia, and treat the viscera as the condition indicates. Hitherto no operation is reported as performed upon non-strangulated diaphragmatic hernia. The permanent closure of the ring in the diaphragm is a difficult matter, for when closed, it is wont to open again and the hernia to return. The best suggestion hitherto made is to sew the stomach with two or three rows of stitches against the diaphragm and over the repaired ring.

Gluteal and sciatic herniæ are rare forms of hernia which protrude respectively through the greater and lesser sciatic notches—natural openings separated by the small sciatic ligament. When one of these herniæ becomes large, so as to be distinctly recognizable, it forms a tumor

[1] Bartlett's silver wire filligree buried beneath the aponeurosis strengthens the wound.

covering in the anal region and extending toward the median line. These herniæ rarely become strangulated, but when the symptoms are urgent, the surgeon must cut down upon the mass and follow it up into the sciatic notch in order to reduce and cure it.

OBTURATOR HERNIA

About 200 cases of obturator hernia have been reported. These herniæ are found chiefly in old women, and are often associated with herniæ in other regions. They appear as swellings at the upper portion of the adductor longus, internal to the femoral vessels. Make the examination with the thigh flexed, adducted, and rotated outward. The *diagnosis* is not easy. The hernia has never been operated upon hitherto except when strangulated. The results of operation are unfavorable, for it is extremely difficult to make the deep dissection and properly to treat the diseased bowel. I suggest that after loosening the sac and freeing the neck it would be well to open the abdominal cavity from above and handle the viscera from this point of vantage.

RETROPERITONEAL HERNIA

There are various forms of retroperitoneal hernia—hernia which burrows behind normal inoffensive looking peritoneal bands and folds.

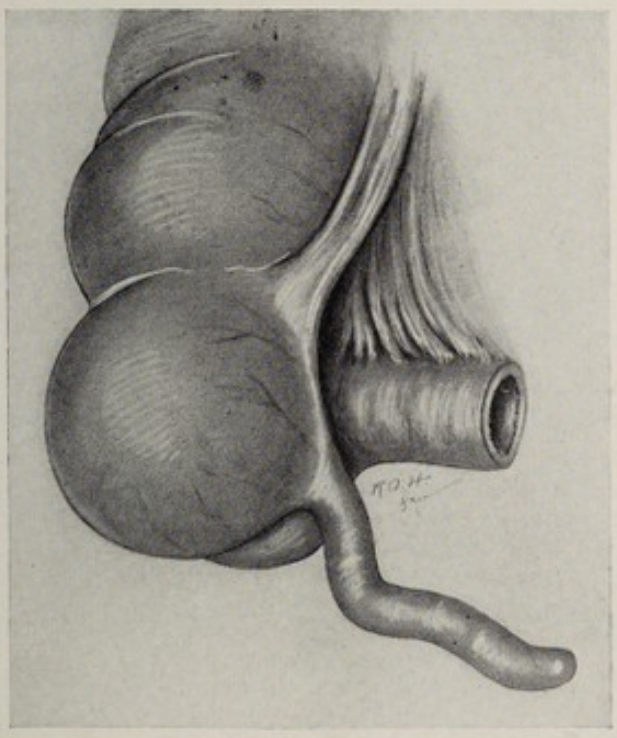

Fig. 128.—Site of retroperitoneal hernia.

J. B. Blake has described four such herniæ about the head of the cecum, and Moynihan has written an elaborate work on the subject, in which he deals especially with duodenal hernia—hernia through the foramen of Winslow and behind the duodenum. Hernia escapes also through

abnormal openings in the mesentery and the broad ligaments. Both Moynihan and W. J. Mayo describe a jejunal hernia in the neighborhood of a gastro-enterostomy operation field. Obviously, all these forms of internal hernia are impossible of exact diagnosis. The symptoms are those of intestinal strangulation, for which the surgeon must operate; he must treat, on general principles, the viscera as well as the hernial opening, and according to the conditions which he discovers.

Glancing back over the general subject of abdominal hernia, one observes that certain forms are common, and that other forms are extremely rare; that the whole subject is a subdivision of intestinal surgery; that strangulation is the possible serious outcome in all cases, and that a proper broad rule is to relieve and repair all herniæ wherever found.

CHAPTER VIII

PERITONEUM AND RETROPERITONEAL SPACE

THE subject of the *peritoneum* is one of the most difficult and intricate in surgery. The anatomy of the peritoneum is puzzling, its diseases are often obscure, and their treatment has been a matter of hot debate. When you find the treatment of a disease debated and opposing views taken almost with acrimony by competent men, you may assume fairly that the end is not yet. The best one can do is to adopt that course which appears to be supported by the greatest weight of rational opinion, provided it agrees with one's own sense of the rational and one's own experience. Generally, in the case of constantly debated subjects, you will find in the course of time that the best men are drifting toward definite and similar conclusions, however far apart they may have wandered.

The peritoneum is a serous membrane forming a cavity, and this cavity has been likened to a great lymph-sac. Its surface is extensive, probably somewhat greater than that of the skin of the whole body. It is a closed cavity in man; in woman it communicates through the Fallopian tubes with the outer world. It has a great capacity for absorption, especially in the diaphragmatic region, where the stomata in the central portion of the diaphragm drink up fluid with great rapidity. When irritated, the peritoneum throws out rapidly a copious exudate, which may be fibrinous and cause adhesions of the serous surfaces; or the exudate may be a fluid, rich in albumin, and easily changed in character, or it may be seropurulent. Owing to these peculiarities, the peritoneum may become rapidly involved in dangerous infections; at the same time, it has remarkable powers of recuperation. Its nicely adjusted mechanism resents irritation, but it can dispose of an immense volume of poison. Our greatest interest in the peritoneum centers, therefore, in *peritonitis*, of which there are various forms—acute, chronic, tuberculous, and malignant being the most important. Moreover, there are diseases of the retroperitoneal space—infections with their resulting inflammations and abscesses, diseases of the lymph-nodes, and tumors.

Injuries of the peritoneum make up another subject of broad general interest, which we have discussed already when we were dealing with injuries and special diseases of the abdomen.

ACUTE PERITONITIS

Acute peritonitis is divided anatomically into *localized* and *diffuse* peritonitis. I have treated of the former in describing certain forms

of appendicitis. Similar forms of *localized* peritonitis may develop about any diseased organ, as the Fallopian tubes, gall-bladder, duodenum, stomach, etc. This limited peritonitis results in an exudate of fibrinous character, which mats together neighboring organs, and locks up in separate pockets the secretions as they are produced. Colon bacilli, streptococci, and staphylococci are the organisms commonly concerned in these restricted inflammations, though pneumococci and other rare organisms sometimes are found. The symptoms are variable and depend on the extent and duration of the disease, as well as upon its point of origin. There are localized pain and tenderness, a fluctuating temperature, rarely high; sometimes nausea, and rarely vomiting, though there is usually distaste for food. There may be occasional chills; constipation is common, but absolute obstruction is rare.

The **diagnosis** of any localized peritonitis is based upon finding within the abdomen a mass, usually tender, varying in size and consistence, of recent origin, and associated with chills, fever, a quickened pulse, general abdominal discomfort, with malaise, dyspepsia, and constipation. This mass represents often an accumulation of fluid, which may remain pocketed for a long time; it may become absorbed or it may spread—sometimes into the general peritoneal cavity; sometimes into neighboring hollow organs; sometimes by burrowing through the skin. When such a mass or focus is discovered, it should be opened and drained. When its presence is suspected but the mass is not definitely located, one should explore for it.

One of the serious results of localized peritonitis is the formation of chronic adhesions, which may persist and cause great subsequent functional trouble. I shall refer to the treatment of these adhesions when we come to the subject of chronic peritonitis.

Subphrenic peritonitis and abscess is a special and interesting form of localized peritonitis. It may be due to extension from disease of the pleura, of the liver, or of the gall-bladder, and may be confined closely to the vicinity of the diaphragm, and be within the greater peritoneal sac. A more important and interesting form of subphrenic peritonitis is that which appears within the lesser peritoneal sac, behind and below the stomach and the anterior layers of the great omentum. The source of infection may be a perforation of the posterior portion of the stomach, the duodenum, or colon or an acute inflammation of the pancreas. There results a distention of the lesser sac, with the appearance of a tumor above the umbilicus. The colon always lies below this tumor, and never in front of it, as is the case in enlargement of the kidney. Osler mentions a remarkable form of subphrenic abscess containing air, called by Leyden *pyopneumothorax subphrenicus*. The **symptoms** in all these cases are those of acute localized intra-abdominal inflammation. When in the neighborhood of the diaphragm, the abscess may be reached either from the front or back and may be walled off and drained successfully. Abscess of the lesser sac is best reached through the gastro-colic omentum; but hitherto operation in this disease has been followed by a considerable mortality.

Diffuse Peritonitis

Diffuse peritonitis (general peritonitis, so called) is the great topic with which we have to deal in this chapter. The *pathologic* appearances of diffuse peritonitis vary in different patients, and in the same patient even, so that one portion of the abdominal cavity may differ in appearance from another. The progress of the disease is influenced both by gravity and by the lymphatic arrangements—for instance, the peritonitis which results from a perforating duodenal ulcer advances rapidly down the right flank, as the septic material descends by the side of the spinal column, over the right kidney, and ascending colon, toward the pelvis. Peritonitis starting from the appendix spreads at first into the pelvis, then extends around on to the left side, involving gradually the sigmoid, left renal, and splenic regions. At the same time it extends more slowly toward the liver, so that active organisms will be found in varying numbers in these places, while in the center of the abdomen there may be no organisms whatever, but nearly always an abundant exudate, rich in toxins. Von Mikulicz wrote a paper, often quoted, and described three forms of diffuse peritonitis—diffuse septic, gangrenopurulent, and fibrinopurulent. You cannot always distinguish these with certainty, save postmortem. In practice, the appearance of the exudate and of the peritoneum, the extent and rapidity of effusion, and the constitutional reaction of the patient determine for you the gravity of the condition.

Writers still talk about idiopathic peritonitis—an archaic term, which should find no place in our vocabulary. Sometimes we fail to isolate organisms from the abdomen in certain cases of diffuse peritonitis; but we may be certain that organisms somewhere are present, even though we fail to find them.

A chemical or traumatic, non-infecting form of peritonitis frequently occurs, but is always strictly limited, and is properly a reaction of the peritoneum—a process of repair following some injury, such as the insertion of a drainage-tube or wick, rough handling, the twisting of an ovarian tumor. These simple forms of peritonitis generally result harmlessly if promptly relieved, except in so far as they may give rise to adhesions destined to make trouble.

Diffuse infectious peritonitis agitates us especially. The sources of infection have been detailed already. The most virulent organisms come from the intestinal tract, and Harvey Cushing long ago showed that the upper portions of the canal have relatively few bacteria; that the ileum has the greatest number, while there is a sudden drop after passing the ileocecal valve. Besides the intestinal canal, from which bacteria may escape, there is the possibility of infection spreading from disease of the ischiorectal fossa and of the genito-urinary apparatus, and from penetrating wounds. The following table is interesting:[1]

[1] Von Bergmann's System of Surgery, vol. iv, p. 165.

SOURCES OF PERITONITIS IN 446 CASES

Appendicitis	115
Stomach and duodenum	68
The rest of the intestines	118
Female genitals	81
Gall-bladder	10
Kidney and urinary bladder	10
Pancreas	2
Spleen	1
Unknown	35
Post-operative	4
Hematogenous origin (nephritis, etc.)	2

These infections are most commonly due to colon bacilli, then to streptococci, staphylococci, and, more rarely, gonococci, pneumococci, gas-forming bacilli, and a few other rare organisms. The infection is usually mixed. According to the predominance of one or other of these organisms the progress of the disease is slow or rapid, and the morphologic appearances differ. The colon bacillus sometimes produces but slight irritation, even with a considerable seropurulent exudate, but occasionally it may produce an extensive irritating effect, causing a rapid distention of the cells of the peritoneum and occasionally gangrene even. Staphylococci cause a rapid fibrinous exudation with an abundant deposit; for this reason the quantity of pus in the cavity is usually small, but when it is large, it is of the seropurulent type. Streptococci give rise to little if any free pus, and the peritoneum has a peculiar dry, granulated, blistered appearance. As a rule, however, with mixed infections in which the colon bacillus predominates there is an abundant secretion of fluid, the peritoneal cavity containing many ounces of a rather thin, turbid material, with occasional patches of agglutination and excoriation, but with a variety of appearances in different portions of the abdomen.

Symptoms.—The symptoms of diffuse peritonitis are as various as are the pathologic appearances. One must consider, first, the initial disturbance—appendicitis, or whatever it may be—such disturbances as I have already described in detail. The localized symptoms due to these special lesions extend gradually as the inflammation extends until the symptoms and signs become wide-spread as large areas of the peritoneum are involved. In general terms there are superadded to the intense initial abdominal pain chilly feelings or an actual rigor. The pain extends over the abdomen and is aggravated by pressure and by moving. The patient lies on his back and tries to relieve the tension by drawing up his knees and having his shoulders raised. He breathes in a shallow, rapid fashion of the costal type, because contraction of the diaphragm increases his pain. He holds his abdominal muscles rigidly contracted in order to keep at rest the inflamed peritoneum. Gradually, the abdomen becomes distended, tense, and tympanitic; the pulse rapid, small, hard, and wiry, ranging from 110 upward. The temperature may rise to 103°, 104°, and 105° F. after a chill, but its average elevation is moderate. With collapse or later in the disease it becomes subnormal. The tongue, at first white and moist, becomes dry, red, and cracked.

Nausea and vomiting appear early, and vomiting causes great pain. The patient ejects first the gastric contents, then a yellowish and bile-stained fluid, then a greenish fluid, and often, late in the disease, a brownish-black liquid, broken-down blood with a fecal odor—the contents of the small intestine. There may be an initial diarrhea, but constipation rapidly ensues. Sometimes there is frequent micturition; less often, retention. The urine is scanty, high colored, and with a large quantity of indican.

The facial expression is the Hippocratic facies I have described before —"a sharp nose, hollow eyes, collapsed temples; the ears cold, contracted, and their lobes turned out; the skin about the forehead being rough, distended, and parched; the color of the face being brown, black, livid, or lead colored" (Sir James Paget).

When you come to the physical examination, you will find two distinct types of abdomen—the distended and the retracted. The distended abdomen is the more common. It may be enormously swollen, drum-like, very tense, glistening, slightly reddened; everywhere tympanitic, even over the hepatic and splenic areas; too exquisitely tender for satisfactory palpation; often the recti muscles show spasm on being irritated. Fluid may be made out in the flanks—fluid which shifts as the patient turns. Rarely the abdomen may be flat and board-like if there be no exudation and but slight intestinal distention in the case of a rapidly progressive infection.

Most cases of diffuse peritonitis proceed to a termination in death. The severe forms may kill within forty-eight hours, but more commonly the disease lasts four or five days. When the patient dies early, he dies from a rapid, overwhelming toxemia. If he lingers, he dies from a slow toxemia, in profound depression, in a low muttering delirium, with lips blue, extremities cold and clammy, the pulse irregular, the heart-sounds weak, the breathing shallow.

The leukocytosis is never a significant feature of these cases. It may be high or low, but often the patient dies with a white count which has never run above 15,000.

The **diagnosis** of diffuse peritonitis is usually obvious, and is founded upon the initial severe pain, the tenderness gradually extending, the abdominal distention, effusion, fever, collapse, vomiting, and constipation. One must differentiate it from sundry other diseases—*acute enterocolitis*, in which the pain is more colicky and a diarrhea frequent; *hysteric peritonitis*, which Osler describes as deceiving the very elect. It must be very rarely, however, that this cannot be distinguished from an infectious peritonitis; *intestinal obstruction*, in which the prostration comes on more slowly, and the pain, fever, and tenderness are less marked. However, intestinal obstruction is a frequent cause of peritonitis; *rupture of an abdominal aneurysm* or *embolism* of the *superior mesenteric artery; acute hemorrhagic pancreatitis;* and *rupture* of a *tubal pregnancy*. All those conditions may simulate peritonitis, and all may be associated with it, but whatever the true condition, the symptoms are those of an alarming intra-abdominal disease demanding immediate

treatment by operation if the patient's life is to be saved and if his condition permits.

In the **treatment** of diffuse peritonitis one cannot divide the disease, clinically, into "septic peritonitis" and "suppurative peritonitis," as is often asserted. Until he opens the abdomen no man may tell with what he is dealing. In like manner the diffuse septic, gangrenopurulent, and fibrinopurulent forms of von Mikulicz do not show definite clinical pictures; and then, different forms of peritonitis may be present at the same moment in different parts of the same belly. Nor does a knowledge of the etiology help us in a given case. The uterus infected at childbirth may cause, through lymphatic connections, an acute, overwhelming peritonitis, involving in a day almost the whole peritoneal cavity—a lethal toxemia; or an infection from the same source may be insidious, taking weeks to develop, gradually progressing, marked by extensive matting of the viscera, and with numerous pockets of pus. Therefore, the surgeon can never be sure as to the form of peritonitis with which he is dealing until he opens the abdomen; and even then he may be at fault until numerous cultures are taken or the problem is solved postmortem. You shall confidently open an abdomen which you take to be the seat of a localized appendicitis, when you will find a diffuse peritonitis. On the other hand, you may make a diagnosis of diffuse peritonitis, and then, upon operating, find a localized process only. These are exceptional experiences, of course.

Then there is the question of definition. We still talk erroneously about "general peritonitis," meaning an inflammation involving the whole of the peritoneum. Probably such a condition never exists. Certainly no man can determine it by looking through an operation wound. The most we can say at operation is that a peritonitis is extensive and is advancing without the establishment of barriers of adhesions. Nor, upon opening the belly, can we always foretell the outcome of a peritonitis, the extent of the disease, or its prospects of self-limitation. It is not surprising, therefore, that men do not always mean the same thing when they write or speak of diffuse or general peritonitis; and to the confusion arising from such misunderstandings is due much divergence of opinion and, to a degree, the wide variation in statistics.

In this chapter I mean by diffuse peritonitis an infectious inflammation, progressive, without definite barriers of adhesions, spreading rapidly by continuity throughout the peritoneal cavity.

There are three views to be taken, clinically, of any case of diffuse peritonitis. One may feel that it is not of a virulent type; that it is making slow progress, and that the patient will recover under non-operative treatment. Or the case may be so active and progressive that one may believe an operation to offer the only chance of cure. Or the disease may have advanced further, and the patient be so profoundly septic that it is obvious he would die at once if submitted to operation.

Surgeons are coming to find cases of the first class—the non-operative class—to be more and more rare, though some competent internists

still cling to the belief that many of these mild cases may best be treated "medically." My conviction is that peritonitis is a "surgical disease," just as cancer is a surgical disease. Thirty years ago and more the opium and rest treatment of peritonitis had an astonishing vogue under the teaching of Alonzo Clark, of New York, and his disciples. That treatment consists in giving immense doses of opium, thus locking up the bowels, paralyzing peristalsis, and promoting rest and limitation of the disease. A somewhat similar course is still advocated by some physicians, but they limit the dosage of opium to that which will suffice for the relief of pain, and they give it in the form of morphin hypodermically. They attempt to relieve the intestinal distention by giving high enemata of salts, glycerin, or turpentine; they nourish the patient by enemata or by small quantities of liquids by the mouth; and they allay thirst by allowing the patient to suck cracked ice.

I have given the foregoing description of one method of treating diffuse peritonitis because it is bad treatment, often followed. If you purpose to treat the patient without operation, you must resort to no such half-measures. The proper non-operative method is to put the intestines at rest by emptying the stomach through lavage, and then keeping it empty. The stomach-washing may be repeated if that organ fills up again with material regurgitated from the intestine. After washing out the stomach, put into it *nothing* until convalescence is established—no water, no food, no cracked ice. Give morphin for pain if there is pain. Nourish the patient by nutrient enemata, in four-ounce doses every four hours. Relieve his thirst by subpectoral infusions of normal salt solution, by intravenous infusions, or by rectal enemata. Stimulate him with strychnin. Such treatment, heroically followed, will often head off and subdue an advancing peritonitis. Such, essentially, is the treatment sometimes advocated by Ochsner.

Most surgeons, however, are loath to adopt these measures as a routine because they feel that the fountain-head of the trouble, the local lesion, —perforated appendix, duodenum, or whatever it may be,—is thus left to keep up its contribution of poison to the peritoneum. I am in hearty sympathy with this view. I believe in operating to remove the primary cause. How shall we operate? There again we are upon debated ground. The debate is so recent that some reference to the practice of sundry operators will be instructive. There are those who wash out the abdomen and those who wipe it out; those who eviscerate the patient, and those who handle his entrails as little as possible; those who drain the abdomen, and those who sew it up; those who insist upon a particular position of the patient to aid drainage, and those who disregard this factor; those who feed by the mouth, and those who feed by the rectum; those who drain the distended gut by enterostomy; and those who inject into it cathartics and food. Some of these practices I indorse; others I condemn. I have seen surgeons discard some of them after half-hearted and incomplete trials, and I have seen failures in my own hands, as well as in the hands of others, because we did not grasp the significance of conditions or the proper value of certain factors in technic.

Alonzo Clark and Ochsner are correct, of course, when they proclaim that the intestines must be put at rest; but others are correct when they assert that we must eliminate the primary focus of disease. Moreover, we must in some fashion provide for the escape of septic material from the abdomen; we must encourage the secretory organs—the kidneys, most of all—to take up their allotted task; we must nourish the organism; we must quench thirst; we must stimulate the flagging circulation; we must subdue pain. Every one of these details is important.

We have learned from the researches of Cannon and F. T. Murphy that certain impressions will check intestinal peristalsis, while others may be applied without that effect on the bowel. Those investigators put to themselves the question, why is it that a temporary intestinal paralysis follows almost every abdominal section? In their experiments on animals they opened the abdomen, exposed the viscera to the air for a time, and then sewed up the abdomen. No intestinal paralysis resulted.

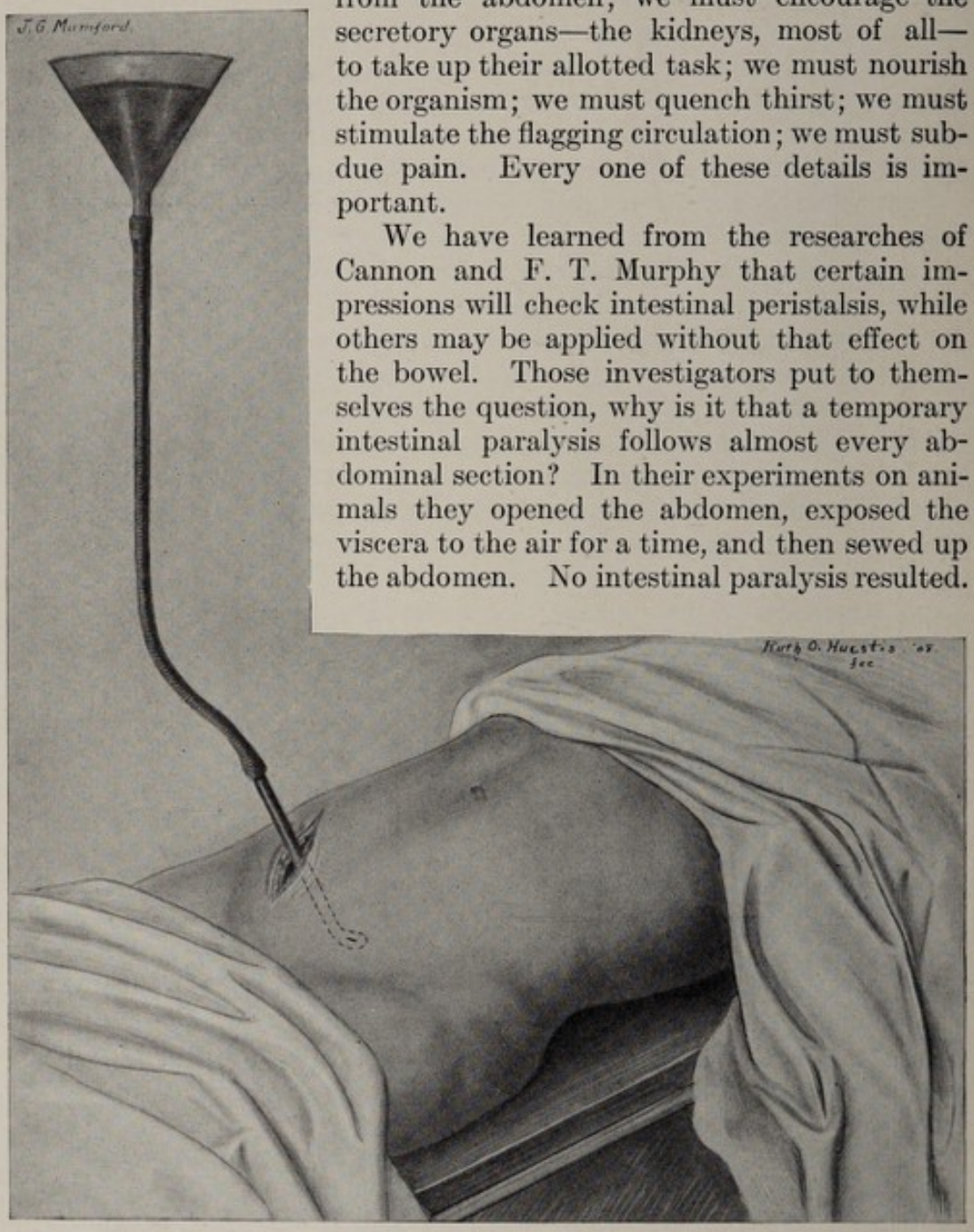

Fig. 129.—Flushing the abdominal cavity.

In like manner, after filling the abdomen with salt solution, no paralysis followed; but handling the bowel caused a paralysis of peristalsis, and the more and the rougher the handling, the longer the paralysis—for four, six, twelve, and even twenty-four hours.

Now, abundant flushing of the abdominal cavity in case of diffuse

peritonitis was an early and obvious expedient in treatment after removing the source of infection—flushing through a tube passed deeply into all parts of the cavity, using warm decinormal salt solution, several gallons, and leaving a goodly amount in the cavity. This method is employed by many surgeons. One must endeavor not to disturb and bruise the intestines, and should work through a single opening below the navel, when possible. Do not wipe the intestines; by so doing one adds to the traumatism and increases the paralysis. For like reason do not eviscerate. Do not sew up the abdomen: drain it. Fowler's position assists drainage; of that I shall speak later. Do not feed by the mouth until convalescence is established. As for enterostomy—direct drainage of the distended gut through a tube low in the ileum or in the cecum—that is a maneuver of questionable expediency. In an admirable essay Greenough [1] has discussed this subject, and concludes that the operation has a place in cases of extremely grave peritonitis. In this connection he formulates 17 interesting conclusions. Of these, note the following:

"The *obstruction* of the intestine in diffuse peritonitis is the result of a combination of causes.

"The most important cause is suspension or paralysis of peristalsis.

"Paralysis of peristalsis is due to inhibition, to toxic paralysis, and to the paralysis of distention.

"Mechanical causes, such as infiltration of the bowel-wall and light adhesions, in certain cases contribute to this paralysis.

"Enterostomy is indicated, in addition to other operative measures, in graver forms of diffuse peritonitis.

"Its greatest advantage is the drainage of the gases and decomposing contents of the bowel, and the relief of paralysis of peristalsis."

I have thus presented the main features of the argument of those who advocate enterostomy, because the importance of the subject warrants it, and because the matter is still *sub judice*, but the figures adduced and my own experience do not impress me with the value of this procedure.

After a careful study of many papers, much discussion with writers, an elaborate comparison of statistics, and a general hospital experience of twenty-five years, I have come to definite conclusions regarding the treatment of diffuse peritonitis. In general terms—every patient with diffuse peritonitis should be operated upon as soon as seen unless, in the judgment of an experienced surgeon, he is nearly moribund. The operation should be reduced to a minimum in time and extent. The viscera should not be handled except so far as is unavoidable in removing the primary focus of disease. Irrigation should be practised when the abdominal fluid is thick or contains numerous masses of fibrin and detritus. These should be washed out thoroughly with several gallons of warm decinormal salt solution. In the absence of these masses and when the fluid is thin, irrigation is needless. Adequate drainage should

[1] R. B. Greenough, Boston Med. and Surg. Jour., May 19, 1904.

be provided,[1] the intestines should be kept at rest after the operation, and the organism should be sustained.

To accomplish these objects I have followed for the past nine years the methods formulated by J. B. Murphy.[2] For these methods my respect is constantly increasing, and I, therefore, advise the following procedures.

Open the abdomen as low as possible, through a short incision, three or four inches long. Seek and remove the primary disease. By the short incision shock is minimized, as the intestines are but little exposed. They should not be allowed to escape from the abdomen.

Do not irrigate the abdomen except under such circumstances as I have described on p. 235. Under no circumstances attempt to wipe clean the peritoneum, inasmuch as the adherent coagulated lymph acts

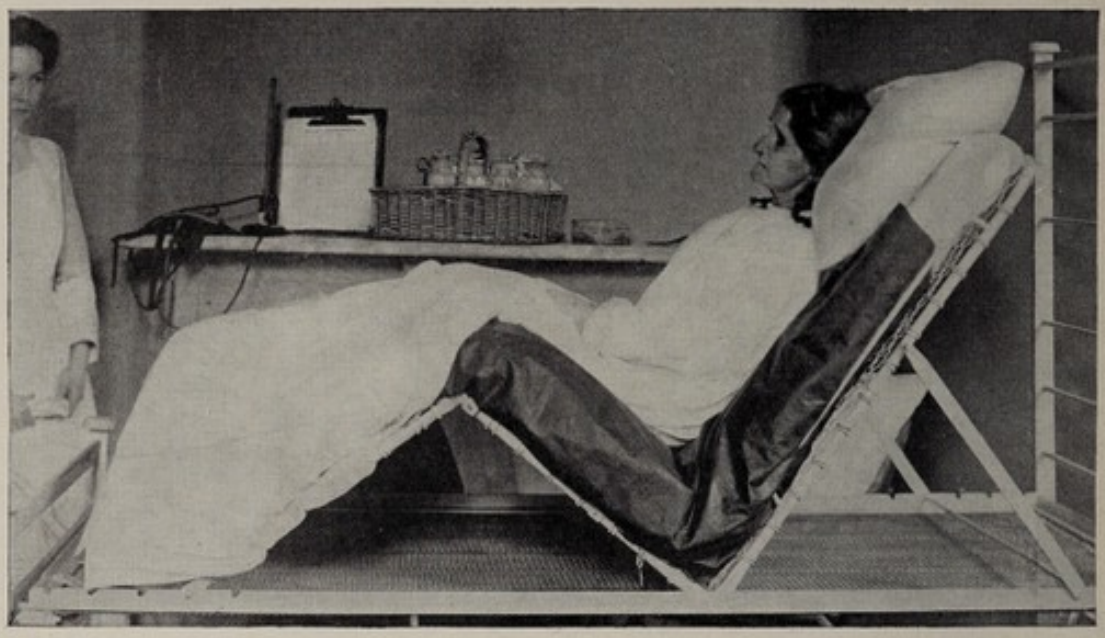

Fig. 130.—The iron bed in position on the springs of a ward bed. Draw-sheet arranged as for continuous irrigation (W. D. Gatch).

as a protective and its removal gives an opportunity for the absorption of fresh toxins.

Drain through the operation wound, and drain the pelvis through a stab-wound above the pubes. Van Buren Knott, in a valuable paper,[3] advises draining the pouch of Douglas in women through the vagina—an admirable measure. Employ Fowler's postural method to assist drainage. This method, described by George Ryerson Fowler,[4] of Brooklyn, in 1900, is an advance of great importance.[5] We have seen that the peritoneum in the region of the diaphragm is most rich in its lymphatic connections, while the pelvic peritoneum is relatively poor

[1] See Robert C. Coffey, The Principles and Mechanics of Abdominal Drainage, Jour. Amer. Med. Assoc., March 16, 1907.
[2] J. B. Murphy in the Practical Medicine Series, Surgery, series of 1903.
[3] Van Buren Knott, Ann. Surg., July, 1905.
[4] G. R. Fowler, Medical Record, January 16 and April 14, 1900.
[5] Russell S. Fowler, New York State Jour. Med., October, 1907.

in such lymphatics. For this reason peritonitis in the upper portion of the abdomen is more fierce in its course and more immediately overwhelming than is pelvic peritonitis. Our endeavor must, therefore, be to drain septic products away from the upper to the lower portions of the abdomen, and we know that the trend of peritonitis is largely dependent on gravity. We, therefore, employ Fowler's position, which consists in sitting the patient in a posture as nearly upright as he can maintain without distress or fatigue. Then the fluids gravitate to the pelvis and are drained away by tubes and wicks placed there to receive them. The pumping action of the diaphragm also forces the fluids down. As LeConte [1] remarks: " It must be remembered that it is not the quantity of fluid present which is harmful, but rather the extent of the peri-

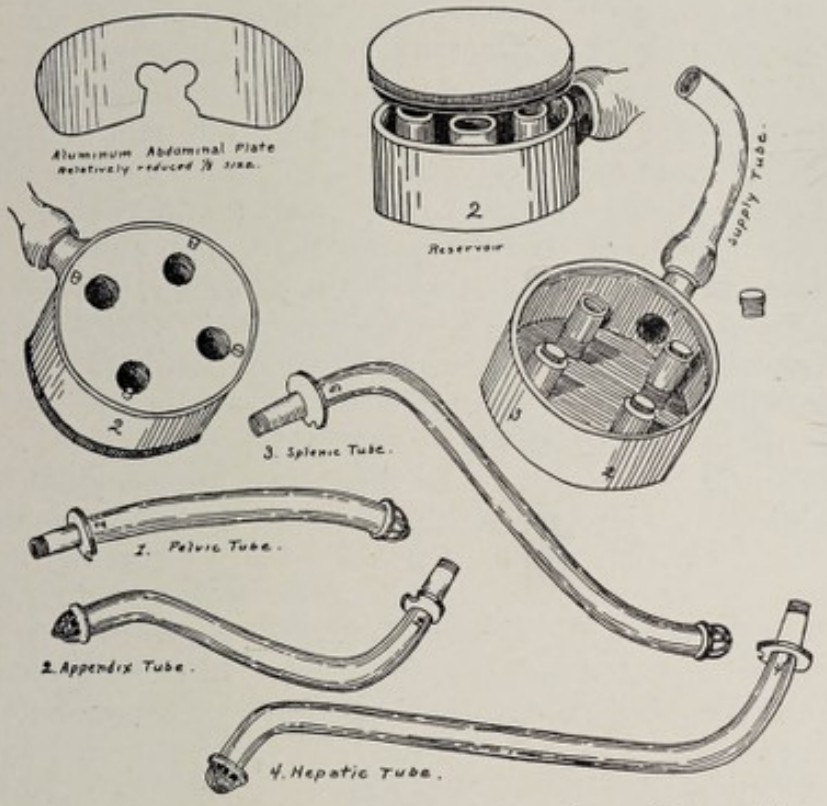

Fig. 131.—Special drainage-tubes (Crandon and Scannell).

toneal surface which comes in contact with it, so that a quart of pus contained in a round cavity would be less dangerous than an ounce thinly coating over the peritoneal surface."

I use large rubber drainage-tubes of the split pattern suggested to me by B. G. A. Moynihan—one tube through the operation wound to the initial focus of disease, one through the suprapubic opening to the bottom of the pelvis, and one in the vagina, if that is incised.

The wounds are covered with an abundant absorbent dressing, which must be changed frequently, as it quickly becomes soaked. The whole operation should take a short time in most cases, and the amount of anesthetic used should be small.

[1] R. G. LeConte, Ann. Surg., February, 1906.

I do not approve of multiple punctures of the bowel; as for a single puncture, that accomplishes nothing; nor do I approve of injecting saline cathartics into the bowel.

The after-care of the patient is an extremely important part of the treatment. Our purpose is to leave the bowels absolutely at rest until nature has had a chance to reassert herself. So we give *nothing* by the mouth, but we introduce abundance of water into the rectum by the well-known "seeping" method employed by Murphy.[1] For this purpose insert within the sphincter a large-sized nozzle with several openings, fed through a long tube from a reservoir elevated but a few inches above the level of the anus. A gentle trickle of salt solution is thus led into the rectum, and led so slowly that it is absorbed as fast as it flows in. Many quarts are thus taken up in the course of twenty-four hours, the stream being intermitted from time to time if it seems best. Thus two important objects are attained: first, the septic stream from the peritoneum into the lymph-channels is reversed; fluid pours into the peritoneum instead of away from it; the patient's upright position causes this fluid to gravitate to the pelvis, and an abundant discharge escapes and soaks the dressings. In the second place, the increased amount of water in the circulation stimulates the heart and kidneys; it allays thirst, and supplies nutriment. Moreover, if necessary, liquid absorbable food may be mixed with the solution injected. The seepage water may be kept warm by confining it in a Thermos bottle, or by immersing an ordinarily lighted incandescent light bulb in an open reservoir. The output of urine increases surprisingly, many pints being passed in twenty-four hours. It is interesting to observe in this connection that fluid thus indirectly introduced into the peritoneal cavity maintains continuously, effectively, and without irritation the action which we crudely attempted to produce when we pumped a great quantity of water into the belly at the time of the operation. Seeping supplants sluicing.

Whereas we expected a death-rate of from 70 to 80 per cent. from acute diffuse peritonitis under previous forms of treatment, it seems reasonable to expect, judging from the relatively few cases as yet available for statistics, that the mortality may be kept below 30 per cent. if we follow the treatment I have just described.[2]

CHRONIC PERITONITIS

Chronic peritonitis is an unsatisfactory term, for it is often hard to determine where acute peritonitis ends and chronic peritonitis begins. We recognize two forms: exudative chronic peritonitis and adhesive chronic peritonitis; while it would be proper enough to include tuberculous and malignant peritonitis under the caption *chronic*.

Exudative peritonitis is so closely allied clinically to tuberculous peritonitis that it is extremely difficult to distinguish the two. The condition is rather rare, and is characterized by a general and abundant fluid exudate. We do not know what causes exudative peritonitis,

[1] J. B. Murphy, Proctoclysis in the Treatment of Peritonitis, Jour. Amer. Med. Assoc., April 17, 1909.

[2] Murphy's last personal report gives 3 deaths out of 72 cases, 1912.

though it has been ascribed to catching cold and to traumatism. The fact that it is most common in young women and that it frequently starts in the pelvis suggests that its origin lies in the Fallopian tubes. Indeed, it has been observed to occur for the first time at the beginning of menstrual life. It comes on gradually with fluid slowly collecting in the abdomen, with or without pain. If the fluid accumulates in great amounts, it may interfere with the functions of the abdominal organs, especially the intestines. Sometimes small nodular masses like pebbles may be felt in the umbilical region. There is fever often. The general health is affected, and the patient becomes pale, weak, and emaciated. Not infrequently there is an associated pleurisy.

It is almost impossible, by an ordinary examination, to distinguish such a case from tuberculous peritonitis, but a proper conclusion may be reached through the tuberculin test, or by inoculating animals with the aspirated fluid. One must distinguish the disease from the various forms of ascites also. A majority of the patients recover under the use of internal remedies, mercurial inunctions, and hydrotherapy.

Treatment by operation is indicated in obstinate cases, especially if one cannot exclude tuberculosis. Sometimes the exudate will disappear after repeated tappings. Sometimes an abdominal section, with removal of the fluid and irrigation, cures promptly.

Chronic adhesive sclerosing peritonitis or **plastic peritoneal sclerosis** is an interesting disease, and not an uncommon one. Writers are wont to complain that text-books give scant attention to diseases in which they themselves happen to be especially interested, and I find Wetherill [1] remarking of sclerosing peritonitis that it "is treated but slightly and irregularly in American text-books." This disease occurs at one or at several points in the peritoneal cavity, but favors especially the region of the Fallopian tubes, the gall-bladder, the flexures of the colon, the posterior part of the peritoneum, the root of the mesentery, the mesosigmoid, and the omentum. There result a thickening and a shrinking of the peritoneum. The disease may also be a sequel of acute infection of the intestine and of traumatism. Moreover, it may start in a chronic form, and without an acute stage may develop far without the patient being aware of any cause for its onset. Histologically, one observes extensive subperitoneal scleroses. There is no exudate.

The *symptoms* are obstinate constipation, leading to obstruction even, with nausea and vomiting, pain, and tenderness. In the milder cases there are constant abdominal uneasiness, dyspepsia, malnutrition, and occasional attacks of colicky pain several hours after eating, since the dense adhesions interfere with the normal flow of the intestinal stream.

The surgical *treatment* of this disease is not always satisfactory, though it is the only treatment which gives any prospect of permanent relief. The operation consists in opening the abdomen and dividing the bands of adhesions which are found. It may be necessary also to remove organs which appear to be the source of disease—such organs as the appendix, the gall-bladder, and the Fallopian tubes. Sometimes

[1] Jour. Amer. Med. Assoc., March 5, 1904.

the patient is cured permanently by the operation; sometimes the disease recurs and may extend slowly until it involves the greater part of the peritoneum. Various methods have been devised to prevent the reformation of adhesions, such as the introduction of Cargile membrane between wounded surfaces, the copious dusting with aristol, and the interposition of omental grafts. These substances are often useful, and since one can never foresee the outcome of the operation, their employment is justifiable.

On the whole, we may not regard the outlook as favorable, though I cannot agree with Beck [1] in his statement that " my experience in cases of chronic, progressive, adhesion-forming peritonitis, as it is observed idiopathically, as well as after appendicitis, is absolutely bad. The nature of this peculiar condition, characterized by a multitude of cobweb-shaped bands, is not yet sufficiently elucidated."

Tuberculous peritonitis is one of the puzzles of surgical practice. It is insidious; it is confusing; it may simulate a great number of diseases. Whenever you see a patient with somewhat distended abdomen, with indefinite dyspeptic symptoms, and with an uncertain history of abdominal pain, you must think of tuberculous peritonitis. Appendicitis and tuberculous peritonitis are so common and so elusive often that they should always be in the mind of the surgeon when he examines an abdomen, though one may choose to relegate appendicitis to the group of acute diseases, and tuberculous peritonitis to the group of chronic diseases.

One finds three distinct forms of tuberculous peritonitis, which have been classified as—(1) The ascitic form; (2) the fibro-adherent; (3) the ulcerative. Hawkins, in a much-quoted article, describes four clinical varieties: the latent; the severe, with ascites and a spontaneous tendency to remissions or incapsulation; a cheesy, purulent form; a fibrous-adhesive form. Such classifications are all very well, but, unfortunately for the clinician, these forms are not always clearly marked, while more than one may be present in the same individual.

Tuberculosis of the peritoneum rarely is primary—a considerable majority of the cases are secondary to tuberculosis of the lungs, or the primary focus may be in the Fallopian tubes, the intestines, the appendix, and the abdominal lymph-nodes; the infection may be brought by the blood-stream to the peritoneum from a tuberculous center in some remote part of the body. We need not consider here the rather uncommon, acute, miliary tuberculosis, which is but part of a general tuberculosis.[2] We are dealing now with a chronic process.

Tubercles may be found scattered or thickly set over the peritoneum, associated with an exudate free in the peritoneal cavity, or one sees nodular masses undergoing caseous or ulcerative changes—the nuclei of further trouble. There may be extensive matting of viscera, with infiltration of the organs, producing a friable condition of tissue. There may be extensive involvement, ulceration, and destruction of organs. The omentum and the intestines are the parts most frequently affected.

[1] Carl Beck, Amer. Med., April 1, 1905.
[2] Brunn, Cent. f. allg. Path. u. path. Anat., 1902.

The *symptoms* of tuberculous peritonitis are extremely variable, but, as a rule, one finds pain coming and going, fever, emaciation, anemia, anorexia. The belly is ballooned; there is often ascites, with diarrhea alternating with constipation. Sometimes there appears an inflamed zone about the navel; rarely there are sinuses discharging pus or feces. Palpation is unsatisfactory; at different times different impressions are conveyed to the hand; lumps appear and disappear; fluid may be found free, or it may be locked up in pockets. One discovers a condition of tension or hardness in the abdominal wall—a peculiar elastic resistance. Thomayer's sign is often valuable: in the shortening of the mesentery resulting from infiltration the entire mass of intestinal coils may be drawn upward and backward to the right, while fluid will be found accumulated below and to the left. Sometimes the fluid of tuberculous peritonitis accumulates in great amounts. The figures of the Massachusetts General Hospital, gathered by Shattuck and W. H. Smith, show that the disease is most common between the ages of twenty and thirty, while liability to it diminishes as we approach the extremes of birth and old age. It is rare in infancy; rarer still after sixty.

In making the *diagnosis* one considers the common symptoms: *abdominal pain;* the frequent *diarrhea;* the *nausea* and *vomiting*, the *fluid* in the abdomen, the *masses* to be felt. *Leukocytosis* is infrequent; the *temperature* is usually slightly elevated, especially in the evening. The tuberculin test is generally positive, but a much more satisfactory test is the injection of the abdominal fluid into guinea-pigs.

Twenty-five years ago we were taught that tuberculous peritonitis is an invariably fatal disease. To-day we have abundant proof that it is not invariably fatal, and that patients often recover, under all varieties of treatment and under varying conditions of hygiene. A number of statistics show we are safe in concluding that, under proper care, 30 to 40 per cent. of the patients will recover.

In discussing the *treatment* of tuberculous peritonitis writers have been wont to quote the case of Spencer Wells, who operated upon a young woman for an ovarian cyst some forty years ago, and found a tuberculous peritonitis. He sewed up the belly and the patient got well. So, men have pointed to this case as a *post hoc, propter hoc.* In large measure, therefore, the discussion of the treatment of tuberculous peritonitis has centered around the question, to operate or not to operate. Until recently the discussion was largely futile, because only recently have we come to see clearly that operation is of benefit to those patients mostly from whom the focus of disease can be removed. Numerous cases are reported in which the abdomen was opened, or was opened and drained, or was irrigated or variously treated. In any case the operation was extremely simple, and many of the patients got well; so clinicians have been debating in what way the operation benefits. There have been numerous attempts at an explanation—most of them more or less meaningless. Eichberg [1] sums up the debate as to why laparotomy cures tuberculous peritonitis by saying "because it does not."

[1] Joseph E. Eichberg, Jour. Amer. Med. Assoc., October 3, 1903.

Such a statement is too sweeping. It is logical to doubt the beneficial effect of laparotomy when the abdomen has been opened, washed out, and sewed up without the removal of a focus, but with the subsequent recovery of the patient. In such a case one may reasonably claim that the patient would have recovered under medical treatment. On the other hand, I agree with J. B. Murphy when he says: "The benefit from an operation for tuberculous peritonitis will depend upon—(*a*) The removal of the source of continued supply, which can almost uniformly (?) be accomplished; (*b*) the degree of adhesions in the peritoneum; (*c*) the reparative stimulation produced in the peritoneum by the operation." [1]

Since the Fallopian tubes are a common source of infection, it is obvious that removal of the tubes, in the case of young women suffering from tuberculous peritonitis, will effect a cure. On the other hand, men are not such proper subjects for operation, and are wont more than women to recover under medical treatment. Further, those cases with few adhesions and abundant fluid in the cavity will often recover rapidly after the operation of opening and flushing.[2] Those cases in which the cavity is obliterated by adhesions are not improved by any operation. Finally, since we know that many cases of tuberculous peritonitis are due to extension from disease of the chest, and since we are assured that pulmonary tuberculosis does not contravene the possibility of a cure of peritoneal tuberculosis, we are justified in asserting that a large number of cases of peritoneal tuberculosis secondary to pulmonary tuberculosis will recover without operation. If no operation is done, do not keep the patient in the hospital. Insist upon a continuous out-of-door life, with an abundance of nutritious food and, if possible, eliminate mental strain and anxiety.

Malignant peritonitis—the involvement of the peritoneum in cancer or sarcoma—need not detain us further than to note that primary malignant disease of the peritoneum is rare, but that in advanced malignant disease of the ovary, intestines, and other abdominal organs, the peritoneum may become extensively involved in metastatic growths. The omentum especially may be found to be the seat of secondary growths. In such cases the abdomen usually contains an abundant, thin hemorrhagic fluid, which may be withdrawn by aspiration if it is so great as seriously to interfere with the functions of organs. Any further operation is useless, as the condition is fatal and operation always hastens death. Palliative measures alone are of service.

THE RETROPERITONEAL SPACE

The *retroperitoneal space* is not a space. It is all that indefinite, ill-defined area which lies *immediately* outside of the peritoneum. Now, it is the well-defined plane beneath the abdominal and back muscles;

[1] J. B. Murphy, Practical Medicine Series, General Surgery, series 1905, p. 288.

[2] The student should consult A. Döll's paper in regard to vioform irrigations, Arch. Internat. de Chir., 1907, No. 5; quoted also in the Practical Medicine Series, vol. ii, General Surgery, for 1908, p. 327.

again, it is that hypothetic area which lies in and follows the folds of the broad ligaments, omentum, mesentery, and other such structures. It is made up everywhere of more or less loose connective tissue, rich in lymph-channels, and with an abundant blood-supply. Its intimate relations with the peritoneum and abdominal cavity make it interesting, and magnify an importance which would be otherwise slight. Serious inflammations occur in the retroperitoneal space—inflamma-

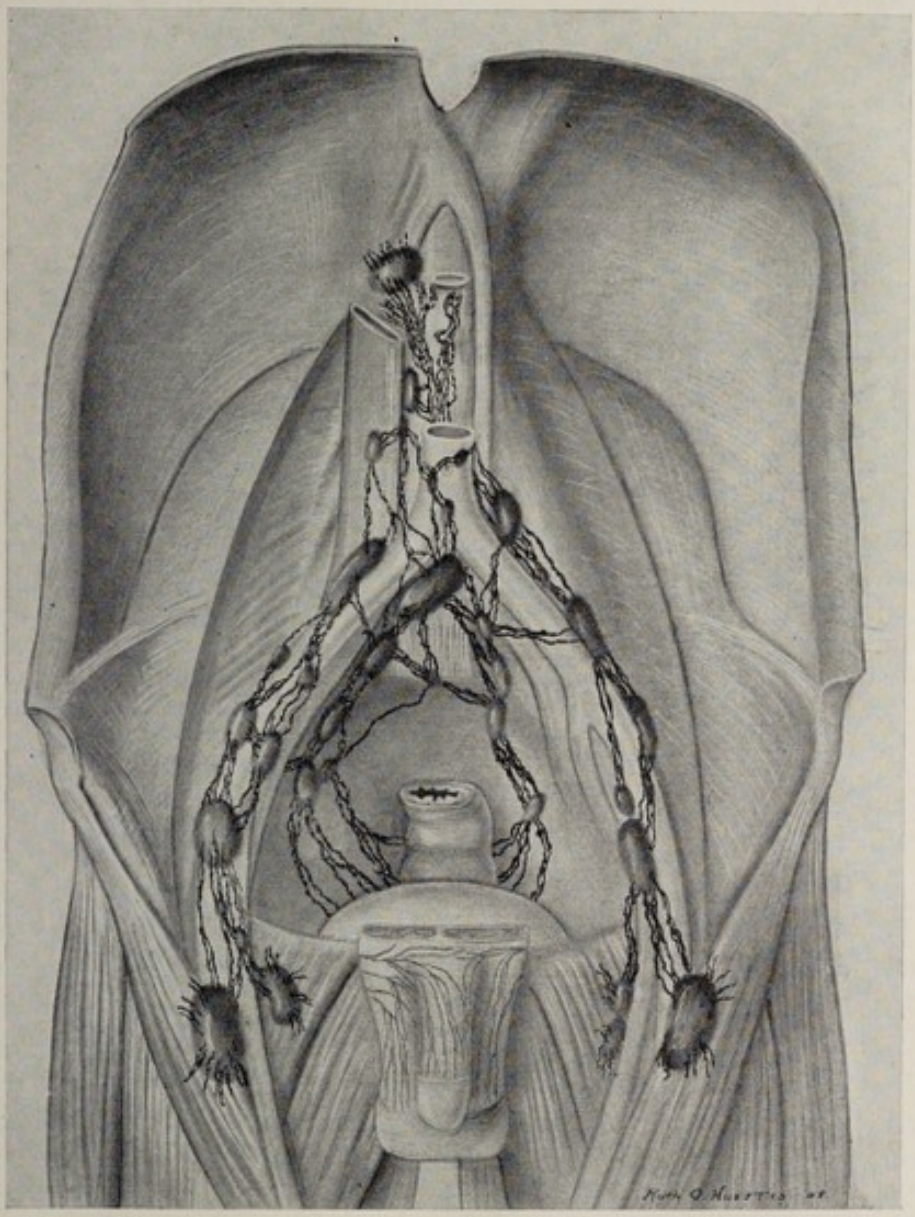

Fig. 132.—Retroperitoneal lymph-nodes (redrawn from Sobotta).

tions which may involve the neighboring peritoneum. Sometimes tumors arise there, and in the course of their development incommode abdominal organs and simulate tumors of the abdominal viscera.

Tuberculosis of the retroperitoneal lymph-nodes and the involvement of those nodes in Hodgkin's disease, cancer, and like affections form an interesting chapter, becoming more apparent with our increasing knowledge.

The nodes of the retroperitoneal space form two principal and equally important groups—the mesenteric group and the lumbar group. The mesenteric group of nodes lies in the mesentery of the intestines and is closely associated with the mesenteric vessels. These nodes form the filter for the intestinal lymphatics. The lumbar group of nodes lies close to the lateral and anterior portions of the vertebral column, from the origin of the superior mesenteric artery down to and below the bifurcation of the aorta; they have some slight connection with the alimentary tract through the lymphatics of the stomach and rectum, but their important connection is with the lymph-channels from the legs, the pelvis, and the lower parts of the trunk. They are connected with the thoracic nodes also.

Both sets of nodes are often involved in disease, especially in tuberculosis. There is the general miliary tuberculosis, which need not concern us as surgeons, as well as chronic tuberculosis, with a general involvement throughout the body. More rarely, the retroperitoneal nodes alone may be tuberculous, and this is especially true in the case of children.[1]

There are three important sources of infection: direct extension from adjacent tissues; infection through the blood-stream, and infection through the lymphatics. In children, the mesenteric group infected from the intestines [typhoid, etc.], is most commonly involved; in adults, the lumbar group. The course of the disease is slow, but while present, a tuberculous peritoneal node is always a serious menace to health and life. Nodes become enlarged and break down, forming masses of tuberculous detritus or calcification. They may become encysted and walled off and cease to cause trouble. More frequently, however, the disease of the lymph-nodes spreads, involving node after node, until the abdominal cavity seems to be filled with masses crowding the viscera, and associated with numerous adhesions. The disease may invade the peritoneal cavity and give rise to tuberculous peritonitis.

The *symptoms* are usually gradual, for a long time early in the disease there are occasional dull pains associated with deep localized tenderness. Later the abdomen may become distended and ascites or jaundice even may develop. At the same time there are cachexia, intestinal disturbance and chronic intestinal obstruction, with large, irregular, easily palpable masses within the abdomen. This is the condition which was formerly called tabes mesenterica. The patient dies from inanition and toxemia.

The *diagnosis* is by no means easy always. One must distinguish the disease from malignant neoplasms, vertebral tuberculosis, abdominal aneurysm, osteomyelitis, osteo-arthritis, infectious arthritis, and, as Painter and Ewing point out, from spinal rigidity due to intra-abdominal inflammatory disease. A common error is to mistake inflammation of the retroperitoneal lymph-nodes for appendicitis. One should never mistake inflammation of these nodes for *acute* appendicitis, but the

[1] P. F. Morf, New York Med. Jour., vol. lxxviii, p. 410; C. F. Painter and W. G. Ewing, Amer. Med., September 24, 1904; T. M. Rotch, Pediatrics, pp. 392, 843, etc.

adenitis does closely resemble *chronic* appendicitis, and I have several times seen the abdomen opened under this misapprehension.

The *treatment* is sometimes operative, but more often general hygienic measures suffice—the course familiar to us in the treatment of all forms of tuberculosis: an open-air life, with careful dieting and absolute rest. Sometimes, in addition to this, one may greatly help the patient by applying mechanical supports, such as the leather or plaster jacket which holds the body rigid, promotes comfort, and favors absorption. Operations are seldom useful, and one does them ordinarily only to relieve special symptoms, such as obstruction or other forms of general peritoneal involvement. Especially it may be necessary to remove large masses developing in and destroying the omentum or causing extensive omental adhesions. In these cases one must always drain the field of operation. The lumbar glands are the more frequent subjects of operation. On account of their nearness to the spinal column, their disease may simulate spinal disease—indeed, they may extend to and involve the spinal column. In any case they may give rise to extensive cold abscess, pointing in the lumbar region or below Poupart's ligament. If such an abscess is opened, its course will prove more rapid and its healing will be sooner and more final than is the case with the cold abscess of spinal caries.

On the whole, the outlook is not positively bad in case of tuberculosis of the retroperitoneal nodes. A great many patients recover permanently from the disease, especially if they have the benefit of rigorous out-of-doors treatment.

Tumors of the retroperitoneal space are not infrequent. Malignant tumors rarely are primary there, while malignant metastases can be treated on general palliative principles only.

On the other hand, *benign tumors* are often removed from this region and offer brilliant opportunities for radical surgery. The commonest tumors of this class are lipoma, fibroma, myxoma, and similar growths from the subserous tissue. They may arise from behind the solid viscera in the loins, or within the mesentery or omentum, and may attain great size. I saw recently the fragments of a large fibrolipoma removed by Edward Reynolds. The total mass, as it lay in a dish, appeared to be as great as a seven-pound baby.

These tumors are found in persons of all ages, and may cause serious symptoms through pressure on the abdominal organs—a marked pulsation suggesting aneurysm, dyspepsia, malnutrition, extensive wasting, pain, and marked abdominal deformity. Rarely there may be obstruction. The only method of *treatment* is radical excision; and since the *diagnosis* is necessarily obscure, the surgeon will generally open the abdominal cavity and remove the growth through the peritoneum. Often one must dig it out piecemeal. If the tumor involve the mesentery, one must be careful not to damage the intestinal blood supply. Tumors of the omentum may be removed intact, with the omentum itself.

Retroperitoneal cysts are about as common as the solid tumors. The rare echinococcus cyst is secondary, and is found within the peri-

toneal cavity proper, its favorite seat being the omentum. We occasionally find primary cysts, especially in the mesentery. These primary cysts are classed by Hahn as serous cysts, chyle cysts, and blood cysts. They are felt as rounded, tense movable tumors in the region of the navel. They may grow very large, reach the pelvis, and become attached to the uterus and other organs. The intestines lie in front of these cysts.

The *symptoms* of retroperitoneal cysts are not noticeable until a considerable tumor has formed, when the patient will often suffer grievously from intense abdominal pain, dyspepsia, constipation, and obstruction even.

A rare form of cyst is the epithelial variety, developing in the mesentery, from the remains of the omphalomesenteric duct.

Remains of the Wolffian and Müllerian ducts may develop into cysts,[1] and may possibly be removed through a lumbar incision, without an opening through the peritoneum.

The *treatment* of the more common cysts consists in opening and evacuating them, and removing as much as possible of the cyst-wall, without damage to vessels; then stitching the remains of the cyst-wall to the abdominal wound and packing the cavity. Perfect healing follows. An epithelial cyst must be removed entire, otherwise a fistula will persist. An echinococcus cyst cannot be removed, but must be opened and drained.

Teratoma of the peritoneum is a rare condition, and the growths are classed by Lexer as simple and complex dermoids, fetal inclusions, and teratoid mucous tumors. Simple dermoids are found in the mesentery or omentum, or in the loin behind the peritoneum. Complex dermoids spring from the ovaries or misplaced testicles and are found in the pelvis. Fetal inclusions lie between the layers of the transverse mesocolon or the omental bursæ. Teratoid mucous tumors are either solid or polycystic, and contain tissue from all three embryonic layers. These curious growths generally may be easily removed through abdominal section.

You will see from the rough sketch I have given in this chapter how numerous, complicating, elusive, and confusing are many of the conditions of disease originating in the peritoneum itself or beneath it. Nearly all these diseases have intimate relations with functional derangements of the abdominal organs, so that it is necessary for the surgeon, when confronted with abdominal disease, to bear in mind the possibility of the peritoneal or extraperitoneal origin of the symptoms which he studies.

[1] See also F. B. Douglas, Retroperitoneal Cysts, Jour. Amer. Med. Assoc., December 22, 1906.

CHAPTER IX

PTOSIS OF THE ABDOMINAL ORGANS—THE ABDOMINAL WALL

In this chapter I shall treat two subjects of widely different moment —*abdominal ptosis*,[1] a common condition, which may complicate and exaggerate other abdominal diseases; and *diseases* and *injuries of the abdominal wall*, common enough conditions, but of relatively minor concern.

ABDOMINAL PTOSIS

Abdominal ptosis is a subject of great importance. I shall not attempt a discussion of all its phases, but I shall point out briefly what clinicians may do to relieve the symptoms and the condition ptosis itself. Incidentally, too, I must say a word on the general subject of the etiology of ptosis, as there is a good deal of misunderstanding of that matter, so various are the views of sundry writers.

Virchow long ago recognized visceral ptosis, and movable kidneys have been observed for many years. In 1881 Landau wrote a monograph calling attention to the importance of movable kidney in women. Glénard, however, in 1885 was the first to show clearly and distinctly that by ptosis of the abdominal organs one may explain on anatomic grounds a group of clinical symptoms hitherto regarded as purely functional. Glénard maintained that sufferers from these functional disorders are cured of their dyspepsias, backaches, and neurasthenias through relief to the ptoses found in their cases. He gave the name "enteroptosis" to the most common assemblage of derangements which he was accustomed to find; namely, to ptosis of the intestines and stomach combined with a prolapsed right kidney. This combination of lesions has been called Glénard's disease. The term "splanchnoptosis" is applied to prolapse of all the abdominal viscera—a very rare condition. Some German writers and others recently have used the term "splanchnoptosis" in place of the older and more common term, enteroptosis. The displacement of single organs is designated by special words, "gastroptosis," "nephroptosis," "hepatoptosis," "splenoptosis," etc. Properly, the term "enteroptosis" should be employed to describe prolapse of the intestines alone, but I shall follow the common usage as established by Glénard.

Briefly, ptosis of the abdominal organs is due to a relaxation of their supports, so that they sag from their places. The consequent dragging upon vessels and nerves brings about certain changes in the circulation

[1] Parts of this chapter are borrowed from Surgical Aspects of Digestive Disorders, 1907, by J. G. Mumford and A. K. Stone.

and innervation of organs, especially of those organs in the female pelvis. So the uterus may be forced out of place, and further distressing symptoms may result. Moreover, ptosis of the intestines removes an important support from beneath the upper abdominal organs.

To distinguish cause and effect is difficult often, so closely are the various organs bound up together and dependent upon one another, and the clinician, according to his bias, is wont to regard a patient as a gastric, gynecologic, intestinal, or nervous case.

The underlying causes of ptosis are still in dispute, so diversified are the conditions found, and so great the range of symptoms accompanying them. In explanation of ptosis Glénard suggested weakness of the abdominal muscles and a loss of intra-abdominal pressure or tone, which permits the stomach, intestines, and kidneys to sag. In fact, great numbers of persons are the subjects of congenital ptosis, and the anatomists long ago pointed out that one person in every five is born with a mesentery upon the entire colon, and that the stomach also is more loosely attached. When such attachments fail to retract, the victim carries through life a gastrocolonic ptosis. In four-footed creatures these long attachments are normal. Many human beings carry these disablements through life without resulting damage; but other persons with ptosis, and with increasing frequency from childhood on, suffer from trains of symptoms traceable to these displacements. J. E. Goldthwait, in a series of brilliant papers, showed how the faulty posture of growing children and of women and young girls tends to weaken the skeletal supports and to place at a disadvantage the ligaments and muscles of the abdomen and back.[1]

Most women among us wear their clothes without regard to hygienic considerations. They hang heavy skirts by narrow bands from their waists, so that a drag is brought upon the intestines, which lie in the lower part of the abdomen. The crowded intestines, in turn, press upon the pelvic organs beneath them. Most corsets tend to exaggerate the waist-line; they crowd down what is below, and push up what is above. Straight-front corsets do not push the abdominal contents downward, as do the old-fashioned corsets, though straight corsets even may produce other unpleasant changes in the anatomy. Often, and fortunately, however, straight-front corsets, when properly applied, may suffice to correct enteroptosis. In the course of physical examination of elderly women, it is not uncommon to find a permanent furrow made in the costal margin by corset pressure. In view of these facts one cannot but conclude that bands, heavy skirts, and corsets are etiologic factors in ptosis. One encounters other cases in women whose symptoms all date from childbirth. Of such persons it is probable that

[1] J. E. Goldthwait, The Relation of Posture to Human Efficiency and the Influence of Poise Upon the Support and Function of the Viscera, Boston Med. and Surg. Jour., December 9, 1909 et seq.

Also, The Cause of Gastroptosis and Enteroptosis, with their Possible Importance as a Causative Factor in the Rheumatoid Diseases; *ibid.*, May 26, 1910.

Also, The Recognition of Congenital Visceral Ptosis in the Treatment of the Badly Poised and Poorly Nourished Child, Amer. Jour. Orth. Surg., November, 1911.

many of the displacements were present previously, but did not become troublesome until after the labor. The onset of such symptoms may date from the birth of a first child, or may be due to a precipitate or difficult and instrumental delivery. So there are many and various causes of abdominal ptosis. There are congenital ptoses and there are acquired ptoses; and the former probably far outnumber the latter.

What, then, is the process in the development of acquired ptosis? One cannot say definitely that in this or in that begins the vicious circle causing prolapse of the abdominal organs, yet in general terms one may use some such description as the following:

Owing to structural peculiarities, to flabby abdominal muscles weakened by severe illness, to improper clothing, or to pregnancies, the normal abdominal tension is diminished; the transverse colon is loosened, usually at the hepatic flexure, and sags downward; it crowds the coils of the small intestine, so that they in turn press upon the pelvic organs. With the loss of abdominal tone the whole colon then tends to collapse, and this collapse extends even to the rectum, so that there is no longer a dilated rectal ampulla behind and below the uterus. The muscles of the pelvic floor lose their resisting power, the uterus settles, and the coils of the small intestine are crowded still farther into the pelvis. There ensue modifications in the shape and position of the pelvic organs, and one finds a prolapsed, retroverted, and retroflexed uterus, and the various combinations familiar to gynecologists.

The stomach follows the intestines, for it no longer receives their normal support. As the stomach sinks, the aorta is left uncovered for several inches above its point of division. It may be palpated and may be seen to pulsate even. Indeed, this pulsation is often disagreeable and annoying to the patient.

Sometimes the sigmoid flexure becomes dilated with retained feces as a result of intestinal prolapse. The gut may expand greatly, and in the course of time may develop a tendency to volvulus. Consequently, intestinal obstruction may ensue, and unless this is relieved by high enemata and postural devices, there may supervene rapidly a strangulation demanding operative relief. In such case the condition of the patient may permit a palliative operation only; the operator may untie the obstructing twist and possibly may hold it by sutures, so that the volvulus will not return. When a patient suffers from repeated similar attacks, increasing in severity, operation must be done to anticipate strangulation. At the operation it may be necessary to resect a portion of the dilated bowel; for often resection alone promises a permanent cure. So after palliative operations, one may be obliged to perform a secondary operation of resection.

An example of the first or acquired type of ptosis is that of a lady, Mrs. K., whom I was asked to see some two years ago. She was a woman of thirty-five, always vigorous and active, and the mother of two children, the youngest one year old. Her story was that about two months after the birth of her last infant she began to be troubled

with frequent flowing, which persisted, varying in amount but continuing for some eight months. Her physician had endeavored to relieve the discomfort, but without permanent effect. He found the uterus retrocessed and retroverted, and finally recommended curettement and suspension of that organ. I was asked to perform the operation. I found the uterus in the condition commonly called subinvolution, lying low in the pelvis, pressing against the rectum, with the cervix looking toward the bladder. After curetting the uterus, I raised it and suspended it by securing the round ligaments outside of the recti muscles. This patient recovered perfectly from the operation and for two months thereafter regarded herself as well. Gradually, however, she became aware of pain, and increasing pain, in the region of the abdominal scar—pain which became extremely severe after long standing, but subsided entirely when she lay down. At first it seemed impossible that this pain could be in any way associated with the operation. Finally, I was asked to go to her house in the country to examine her. I then ascertained that the uterus was still in excellent position, but that the woman's abdomen was extremely relaxed and flaccid and that on standing the abdominal organs settled down upon the freshly attached uterus. This pressure, of course, was relieved when she lay down. In other words, an unnatural drag was exercised on the uterus by the abnormally motile abdominal viscera. This patient was completely relieved through having her abdomen supported by a properly constructed and well-fitting belt. Since that time she has regarded herself as perfectly well.

A type of *congenital* ptosis was that of a child, Lillian A., who at the age of four was a victim of chronic joint disease, a most obstinate constipation, a fretful temper, and disturbance of vision which eventuated in double cataract. The *x*-ray showed this child's stomach and intestines to be misplaced and to hang many inches below the normal position. The ascending colon was crumpled and lay in the false pelvis, while the transverse colon sagged below the pubes. Owing to the child's extreme youth and restlessness it was found impossible to correct this malposition by apparatus. A number of operations were done to relieve her, such as colostomy and transplanting the ileum into the sigmoid flexure. The upshot of the case at this writing is that her constipation is cured, her arthritis greatly relieved, her failing eyesight partially restored, and her peevish and irritable temper changed to a sunny disposition.

Of all the abdominal organs subject to ptosis, the *kidney* receives most attention—more attention, relatively, than it merits.

The wisdom of routine operating for nephroptosis is in dispute. In a series of 272 women recently examined clinically at the Boston City Hospital Larrabee found that 112 cases, or 41.5 per cent., had movable kidneys. At the Massachusetts General Hospital in 1904 Pratt looked for ptosis in all cases coming to his clinic, and found that 96, or 32 per cent., out of 271 women were the subjects of movable kidney. Such has been the experience of many others. Nephroptosis in men is

more frequent than is commonly supposed. Floating kidneys have been found in children.

Most women with movable kidneys are unaware of renal disturbance; such symptoms as they have are not referred distinctly to the displaced organ. On the other hand, though a patient have a kidney prolapsed in the first degree only, that errant kidney may cause severe symptoms. The case is parallel to that of a patient with a breaking-down plantar arch of the foot. When a foot is beginning to break down, the resulting symptoms may be severe enough to call urgently for relief. So with a kidney beginning to slip. Rarely, indeed, will slight displacements of the kidney require operation, but the physician must not forget that operation eventually may be demanded.

When slight displacements cause acute symptoms, one will find often that the ptosis is due to an injury, to a fall, a strain, or a wrench of the body, or to heavy lifting. A prolonged bicycle ride has been known to induce acute symptoms of nephroptosis. In making the diagnosis, assure yourself that the kidney is at fault, and that you are not dealing with a lesion of the sacro-iliac joint.

Another aspect of renal ptosis is that presented by a kidney long recognized as floating, and hitherto harmless, which, on a sudden, causes severe and distressing symptoms. The symptoms may be so serious as to suggest appendicitis; and, seen after the acute symptoms have subsided, there may remain so much local tenderness as to puzzle the physician and leave him in doubt whether the appendix or the kidney be at fault.

Clinicians talk of "Dietl's crises" as characteristic of floating kidney. Dietl's crises are supposed to be due to a twist or kink in the renal vein. Some experimenters believe a kink in the ureter to be the more usual cause.

Whatever the explanation, it is a fact that in a number of cases in which there is a floating kidney there are repeated attacks of pain and distress. These attacks, or Dietl's crises, begin frequently with a sense of weight and discomfort below the border of the ribs and near the median line; sometimes the first symptoms are pain in that region, and nausea followed by vomiting. If the symptoms persist, the affected area soon becomes tender, so that one suspects peritonitis. Often the patient experiences palpitation of the heart; the symptoms become very distressing; sometimes the mental condition suggests hysteria. The crisis may persist unabated for several days, or it may last but a few minutes. Frequently one may replace the kidney and relieve the symptoms by removing the clothes, by posture, and by manipulation, the patient being in a hot bath if necessary.

The experienced observer will notice that these symptoms are similar to those seen in the gall-stone attacks caused by a calculus attempting to engage in the cystic duct, but not passing out of the gall-bladder. Such hepatic colic is relieved usually by measures similar to those just described. It is associated with no other distinctive features of gall-stone disease, as jaundice or tumor of the gall-bladder.

Recurring renal crises make life a burden. The unfortunate victim never knows when or where the attack may seize her. When it comes, she must be prepared to loosen her clothes, apply heat, and call for the masseuse.

As the prolapsed kidney may come in contact with the bile-passages above, so it may drop upon the appendix below. The appendix lies in its path. We have told how one may mistake a tender kidney for a diseased appendix; more than that, an errant kidney may actually irritate the appendix and so cause a chronic appendicitis. So we must study carefully the nature of recurring pains in the renal-appendix region. Renal crises do not kill chronic appendicitis may become acute and lethal at any moment. Inflamed retroperitoneal lymph-nodes and stone in the right ureter also may give rise to symptoms suggesting renal ptosis or appendicitis.

A. T. Cabot pointed out that hematuria may result from ptosis of the kidney. Sometimes the bleeding is profuse and alarming; sometimes it is slight, but constant. For this hematuria we must operate; and when we have the kidney exposed and in hand, we must not forget to look in its pelvis for a small calcareous scale which the *x*-ray has not shown.

The *treatment* of floating kidney involves the treatment of general abdominal ptosis in a great many cases. One must study all the symptoms of the patient. Often one must perform an exploratory operation in order to make a diagnosis. By anchoring the kidney, biliary and appendiceal symptoms will be relieved frequently; therefore, when the symptoms are complex and obscure, it is well, for the sake of exploration, to open the abdominal cavity in front. Thus mistakes will be avoided. So there are certain invalids, few in comparison with the number of persons with displaced kidneys—certain invalids who really do have so much trouble from persistent hematuria, from the frequency of their renal crises, or from the constant dragging sensation and the burning pain along the line of the iliohypogastric nerve that they merit operation. The patient may, indeed, be nervous and irritable—what wonder!—but the pain and discomfort are constant and are found in the same location always. The true neurasthenic element is lacking. Such a patient may be a permanent invalid, nearly bedridden, always debarred from prolonged exertion, and cut off from the possibility of earning a livelihood. Operation will generally relieve the sufferer, and her chance of cure by operation is very good indeed.

But most displaced kidneys do not require an operation. In order to replace the prolapsed organs, lay the patient on her back, with the hips elevated—in a modified Trendelenburg position; manipulate and knead the organs into place,—stomach, kidney, or intestines,—and then bind them in position with the bandage.

What bandage shall be used? There is the difficulty. There has been a great deal of discussion of that question, and experiment and failure to find the correct bandage. Here is a simple device, which I have found satisfactory: Apply a roller bandage to the abdomen just as one would apply a roller bandage to the arm. The abdominal

roller should be of flannel, cut straight, 6 inches wide, and from 6 to 10 yards long. Before beginning to apply it see that the patient is properly elevated and that the viscera are rolled up toward the diaphragm. Begin bandaging by taking a binding turn about the patient's thigh; then quickly, smoothly, and firmly bandage the abdomen from pubes to ensiform. The bandage must lie fairly tight at the bottom of the belly, but looser at the top. It fits perfectly; it feels snug and secure. The patient will experience relief almost instantly.

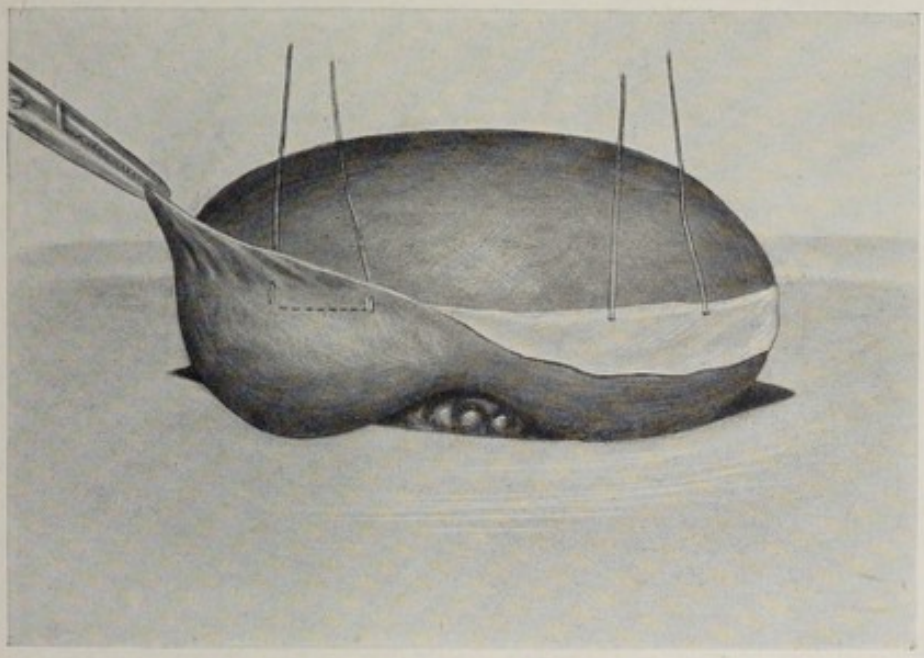

Fig. 133.—Showing two of the four suspension sutures passed through reflected and attached layers of capsule proper, without penetration of kidney substance. The two companion sutures passed on the opposite face of the kidney are not shown (Edebohls).

If this bandage is satisfactory and the patient wishes to go on with such treatment, the physician may have constructed an easily applied belt, but the patient will find no apparatus so comfortable as the simple roller bandage. The straight-front corset, properly fitted, is favored by many clinicians and is successful. There remain those few cases which bandages do not relieve; in which, if the kidney is obviously at fault and its fixation is demanded, the surgeon had best operate. He should approach the renal region through a lumbar incision. Many different operations have been devised and advocated for anchoring the kidney. The commonest error is to fasten that organ too high. Normally, the kidney has an excursion of from 1½ to 2 inches, so that it is well to anchor it at the lowest point of its normal excursion. If fixed too high, it will continue to be the subject of pain and will be more easily pounded loose by the moving liver above it.

Cut down upon the kidney through the back on the outer side of the quadratus lumborum muscle; tear through the fatty capsule; pull the kidney out of the wound; split its fibrous capsule from pole to pole, and

decapsulate the organ nearly to the hilus; then pass silk or chromic-gut stitches (it matters little which) through the loosely hanging capsule, as indicated in the illustration, and thus swing the kidney by capsule and stitches from the back muscles. By employing these measures you will not penetrate and lacerate the kidney tissue.[1] Then close the wound in the back by layers. These operations on the kidneys are facilitated by placing a hard round bolster beneath the upper portion of the abdomen, as the patient lies on his belly. The fixed kidney

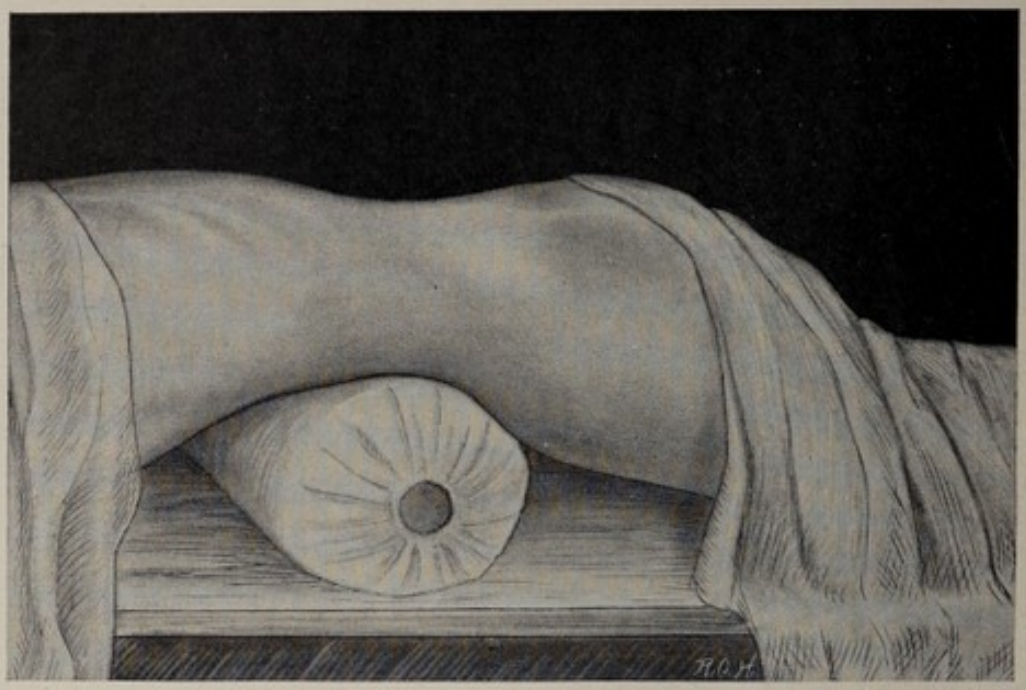

Fig. 134.—Edebohls' kidney air-cushion, and patient in position for operation.

may break away from its new attachments if the patient moves about too soon. It is my custom to keep him on his back, or on the affected side, with the head low, for at least three weeks after the operation. In the few properly selected cases for which one does nephropexy the results are gratifying. Pain is relieved, and the constantly recurring dyspeptic symptoms are banished.

J. E. Goldthwait has made an extensive study of ptosis in connection with joint diseases; and much of my own work on the subject has been done in association with Goldthwait. One of the most interesting observations of his relates to the posture of victims of ptosis. They stand in a round-shouldered, flat-backed attitude. He points out that this is due to the fact that the pull exercised on the superior supports of the diaphragm, overweighting the deep cervical fascia, is continuous in the pericardium, which in its turn has diaphragmatic attachments. In other words, we know that the diaphragm and the subdiaphragmatic organs have a superior support and are hung, as it were, from the neck. When ptosis becomes pronounced, and the drag on these superior supports becomes excessive, the patient stoops and thrusts forward

[1] This is essentially the operation of Edebohls.

his chin, in order to relieve the pull which in an abnormal degree has been established upon his neck.

It would be interesting to discuss the anatomic malpositions of the various abdominal organs concerned in ptosis. Let us, however, glance briefly at some of the proof. The stomach, held up largely by its omental supports, sags when these supports sag, but its fixed points at the cardia and the pylorus remain attached; as a result, kinking of the pylorus occurs, and conditions are established which favor pyloric obstruction, with resulting gastric hypertrophy and dilatation. The pancreas becomes more or less uncovered as the stomach sinks; it is dragged upon, its circulation is interfered with, and its ducts disturbed. The epigastric aorta becomes partially uncovered, so that epigastric pulsation is obvious both to the patient and to the physician. With the descent of the other abdominal organs, accompanied or not by the liver, the bile-ducts are put at an unnatural tension, and the question is raised whether or not this tension may not be a factor in bile-duct disease. Certain investigators have asked us seriously, "Is it not possible that such tension put upon the pancreas and the bile-ducts may lead to disturbance, or even to destruction, of the island of Langerhans, so that actual diabetes may be established?" With the stretching of the superior mesenteric artery and the unnatural descent of the small intestines, pressure is exerted over the lower portion of the duodenum; there results, therefore, duodenal dilatation, gastric dilatation, and occasionally that condition known to us as gastromesenteric ileus.

The right kidney, especially, seems to be associated with the ascending colon—at any rate, it is a rare thing to find a descent of the colon or hepatic flexure which does not combine with it a descent of the right kidney. I need only to suggest the frequency of right floating kidney and the infrequency of left floating kidney. The suspension of such a right kidney is not followed by complete relief of symptoms. The obvious reason is that suspension of the right kidney fails to suspend or to return to proper position the other misplaced organs. I have referred to the great number of displacements of the colon, but I must recall the important fact that the splenic flexure—that portion of the intestine at the beginning of the descending colon—is usually a fixed point high up beneath the diaphragm on the left.

With the general congenital abdominal ptosis, pelvic ptosis is almost always associated; so that we find displacements of the uterus and appendages in most of these cases.

The effects of ptosis on the functions of these various organs are often unexpected, surprising, and puzzling. I quote a case in illustration: Some months ago I saw in the Massachusetts General Hospital a woman forty years of age, who came in for her seventh abdominal operation. She told this story, which was supported by the hospital records: For some five years she had been a surgical invalid; first, she was operated on for appendicitis, and with apparently good cause, as she suffered from much pain and tenderness in the region of the appendix. The operation was followed by considerable relief of symp-

toms, but six months later she had an attack of jaundice with pain in the region of the gall-bladder. She was operated upon for the second time for this disturbance. No actual stones were found; the gall-bladder was drained. At the same time a chronic pancreatitis was observed. A year later, before she had completely recovered her strength, she suffered much from pain in the right kidney region. Her right kidney was found to be prolapsed, and was secured by the operation of nephropexy. This was the third operation. Some months later she became the victim of an exasperating dysmenorrhea with left ovarian neuralgia. For the fourth time she was operated upon; a cystic left ovary was removed and the uterus was suspended. A year later she suffered regular and distressing pains in the epigastrium with symptoms of intestinal obstruction. For the fifth time she was operated upon, and a collection of adhesions in the epigastrium was removed. Not long after this she was operated upon for adhesions, this time causing trouble low in the right abdominal quadrant. When she entered the hospital for the seventh time I examined her carefully, and could not but suspect that much of her previous trouble might have been due to visceral ptosis. Accordingly, an examination of her abdominal organs by means of the bismuth *x*-rays was made and showed a stomach low, with its lesser curvature at the navel, while the ascending colon was crumpled into an S shape and lay with the transverse colon deep in the pelvis. From this low point the transverse colon sought the position of the high normally placed splenic flexure. Throughout much of its length the transverse colon lay parallel with and closely applied to the descending colon. The woman was suffering obstinate constipation and obstruction, while most of her pain, being now transferred to the left side, obviously was due to the difficulty found by the fecal stream in passing the splenic flexure. Having established these preliminaries, I operated by excising the splenic flexure and implanting the transverse colon into the sigmoid flexure. She is now well. I have little doubt that the condition of exaggerated ptosis of her abdominal organs was a large factor in producing the various lesions for which she had been operated upon in the past.

The **symptoms** of congenital abdominal ptosis are numerous and are dependent upon the special organs prolapsed and on the extent of such prolapse. My own studies have been concerned especially with the prolapse of the stomach and intestines. A prolapse of the stomach leads commonly to stasis, to pyloric kinking and obstruction, to food retention, to fermentation, to toxemia, rarely to gastric tetany, frequently to loss of appetite with chronic nausea and occasional vomiting. With these symptoms there go headaches of various types, loss of flesh and strength, secondary anemia, changes in temperament, peevishness, irritability, marked symptoms of that condition commonly called neurasthenia, and a general breakdown of mental and nervous poise.

The extent of prolapse of the stomach is often surprising. Remember always that gravity enters into this problem, though gravity is not

exerted to its greatest advantage, for the contents of the abdomen sink gradually when subjected to gravity. There is no sudden falling out of place, as is often assumed. Nevertheless, one observes a marked distinction in the positions of the prolapsed organs of a person lying down and of the same person standing. Often in the case of the person lying down little or no prolapse of the stomach is obvious, when on standing it may be seen to fall below the navel. Such a prolapse may interfere with the important blood supply and innervation of the organ; so that it may well be that conditions favoring actual destruction of tissue are set up. At any rate, it is certain that gastric ulcer is not infrequently associated with these cases of prolapse, when the ulcer itself through perigastric adhesions is not an obviously causative factor in the prolapse.

Prolapse of the large intestine is probably far more significant than prolapse of the small intestine. Indeed, prolapse of the small intestine is more or less a normal condition, though such prolapse of the small intestine may be instrumental in causing the other abdominal organs to fall with it. I have indicated one result of prolapse of the jejunum when I spoke of obstruction of the duodenum and of gastromesenteric ileus.

Observe, now, that the colon also often has a long mesentery. When such a long mesentery is present, it is obvious that the colon will fall about a good deal as the small intestine falls about. One might well ask why such a falling about of the colon leads to a definite train of symptoms, when a prolapse of the small intestine is normal. The answer is unquestionably this: The colon has in mid-course definite points of fixation, the most important of which is the splenic flexure. One sees, then, that prolapse of the ascending and transverse colons is significant, especially when the splenic flexure remains fixed, because in this case the ascending and transverse colons may swing down from the point of fixation of the splenic flexure. As a matter of fact, this frequently happens. We see the downhanging caput, the crumpled and displaced ascending colon, the hepatic flexure eliminated, and the transverse colon sagging low in the abdomen, and often hanging straight down from the splenic flexure. As a result of these conditions the blood supply and innervation of the prolapsed colon are materially affected; the colon becomes more or less anemic and catarrhal; it loses its active peristaltic force, fecal accumulations bank up within it; the fecal masses ferment and increase the irritation of the mucosa, so that chronic catarrh of the intestines results, often with stercoral ulcer, with accumulations of gas, and with a pronounced, obstinate, and distressing constipation sometimes alternating with diarrhea. These patients may have infrequent and difficult bowel movements; the stools resembling those of the herbivora, being small, hard, and marble-like. Such small masses are demonstrated readily by the bismuth *x*-ray examination. The banked-up masses may lurk in crypts and folds of the colon, even though regular movements of the bowels are main-

tained; so that the patient may be a victim of destruction of the intestinal mucosa, of colitis, of fecal retention, and of a consequent general chronic toxemia.

This *toxemia* to which I have referred is one of the most important factors in the symptomatology of abdominal ptosis. We have long talked of auto-intoxication, often without a clear comprehension of its nature. I have found, when removing one of these so-called normal colons, abundant cause for such toxemia; in such a colon removed *in toto* I have found extensive areas of destruction of the mucosa; collections of extremely foul masses of feces; numerous ulcerations; in fact, all the conditions necessary to establish an easy channel for systemic intoxication from this cesspool of a colon.

The results of these toxemias are interesting and are still the subject of investigation. Certain results are definitely proved, others are hypothetic, others are matters of suspicion merely. Unquestionably, and in addition to the symptoms already enumerated, we get, in these cases, gastric and intestinal indigestion, serious forms of headache, certain forms of iritis, and disorders of the lens even; extensive mucous inflammations; irritations of the mucous sacs and cavities; manifold evidences of neurasthenia, so-called; mental and nervous phenomena, leading even to mental aberrations; perhaps a serious joint complication, as Goldthwait demonstrates; and not improbably disorders of the ductless glands.

In this last connection I may record an extremely interesting series of observations I made three years ago, and that in connection with exophthalmic goiter. I observed that certain of my cases of Graves' disease were victims of abdominal ptosis, and I began making careful observations of the abdomens of all cases of Graves' disease, with the result that I have 26 consecutive cases of Graves' disease, all of which suffered from severe abdominal ptosis. I am not yet able to draw any conclusions from these observations, but am waiting to collect data from a larger series. It is an extremely interesting fact, however, that recently, before submitting cases of Graves' disease to operation, I have attempted to correct the ptosis and have been able in several cases to give the patients marked relief from their Graves' symptoms; even though such correction of the ptosis has had perhaps, no effect on the course or duration of the exophthalmic goiter.

The **diagnosis** of abdominal ptosis is easy after one has become familiar with such patients. Often one can make a diagnosis when the patient enters the office. These persons are apt to stand in a faulty posture, with slightly rounded shoulders, protruding chin, and flattened dorsal spine. On stripping the individual, one observes that the epigastrium is flat, often pulsating, and that the belly below the navel protrudes in the characteristic fashion. With the patient standing, if you place your hand beneath the protruding belly, raise it gently, and at the same time with the other hand exert pressure over the lower dorsal spine, the patient will almost always exclaim, or admit, that she experiences relief.

With the patient on the examining table, one observes further obvious displacements, sometimes a slight descent of the liver; epigastric pulsating of the aorta; unusually broad tympany; the movable and easily replaced right kidney; the retrocessed and retroverted uterus. Examine the rectum and you will find that the finger enters the sphincter with difficulty; the sphincter is hypertrophied and the rectal ampulla is collapsed. A further and most important sign is the narrow costo-iliac space, *i. e.*, the space between the lowest rib and the iliac crest. In most normal individuals this space is as broad as the hand; in the victims of ptosis the lowest rib nearly touches the iliac crest, so that the space will barely admit a finger. If you wish to experiment by distending the stomach with air or water, you may gain some information regarding its size and position, but the undertaking is distressing to the patient and troublesome to the physician. The further, most important, and final element in the investigation is by the *x*-ray. *x*-Ray work on the stomach and intestines is in the province of the most skilled specialists; few *x*-ray operators as yet are doing satisfactory work. The method, in brief, consists in feeding the patient a large breakfast of cereal mixed abundantly with subcarbonate of bismuth. The *x*-ray picture of the stomach is taken instantly after the ingestion of this meal; the *x*-ray picture of the colon is taken twenty-four hours later, when the bismuth masses have filled the lower portion of the bowel.

The **treatment** of prolapsed abdominal viscera is intricate and is still the subject of study. I will hint at some measures. Treatment consists in postures; in the wearing of braces and belts; in exercises, and in operations. If I have a moderate case of abdominal ptosis to deal with, I give the patient these instructions: Three times a day, after meals, lie down for half an hour on a flat hard mattress without a pillow under the head, but with a small pillow between the shoulder-blades. At least once a day assume an exaggerated Trendelenburg position by raising the foot of the bed or sofa much higher than the head. Supplement the postures by shoulder-braces, which usually tend to correct the rounding shoulders and make easier a proper elevation of the head and dorsal spine. Employ such massage and light graded exercises under direction as shall stimulate and improve the condition of all the muscles, especially those of the back, abdomen, and shoulders. Have made, and wear continuously, except when in bed, a proper abdominal support. I must observe, parenthetically, that a proper abdominal support is extremely difficult to secure; I have myself been working at the problem for some five years, and with the assistance of a skilled corset-maker have now developed two "corset-belts," as I call them, which raise the abdomen and support the dorsal spine. These abdominal supports obviously cannot replace the prolapsed viscera, but they do lift them slightly and take the strain off the stretched mesenteries.

The *operations* which may be done are numerous. Suffice it to say that we endeavor to re-establish in proper continuity the fecal stream.

This is done sometimes by appendicostomy; sometimes by a temporary colostomy which supplies an artificial anus; sometimes by implanting the ileum into the sigmoid flexure; and sometimes by removal of the whole colon, so that the stream from the small intestines empties directly into the sigmoid.

We talk of "Lane kinks," "Jackson veils," and the like. These are very real conditions, and often cause serious obstruction symptoms; but their association with ptosis is their important feature, in my judgment. The conditions demand operation, freeing adhesions, and often short-circuiting the fecal stream, so that the ileum empties its contents into the sigmoid flexure.

In brief summary, the condition, visceral ptosis, must be regarded as part of a great symptom complex, and to be due to the state of physical evolution through which the human race recently has passed, or is passing. Mostly our skeletal frames and our internal organs were designed for, and adapted to, four-footed creatures. Human beings, through developing intelligence, have learned that the upright posture is that best calculated for mental, physical, and creative efficiency. The human frame with its organs has not yet completely adapted itself to the new conditions. To this fact are doubtless due many of the peculiar ills which distinguish human pathology from much that we see in the lower animals.

THE ABDOMINAL WALL

Diseases and injuries of the abdominal wall find their place in books of surgery, and of late years this subject has been given much attention by painstaking writers. For my own part, I cannot see that such lesions, with two or three exceptions, deserve special attention, because injuries, inflammations, and new-growths of the abdominal wall are much like similar phenomena elsewhere.

The practitioner should remember the general anatomic structure of the abdominal wall—how it is massive and unyielding behind, thin and elastic in front, with the anterior surface of the lumbar vertebræ nearer to the umbilicus than to the skin of the back in average individuals. The broad-lying muscles and dense aponeuroses of the abdominal wall favor the limitation of inflammations to special planes; and the gridiron-like arrangement of the muscles as they lie one above the other seems assigned ingeniously to strengthen the wall and prevent the development of herniæ, even after severely lacerating wounds.

The greatest interest in injuries of the abdominal wall centers in the possibility of lesions to the underlying viscera. That is a matter which we have discussed in Chapter II.

Contusions [1] of the wall are frequent and may result in extensive tearing of muscles and the formation of great hematomata. The *symptoms* are usually slight, and the *treatment* consists in absolute rest

[1] See Charles L. Scudder, Contusions of the Abdomen, Boston Med. and Surg. Jour., May 2, 1901. He gives a valuable bibliography.

and the application of cold. Sometimes it is necessary to aspirate off collected blood. The prescribing of rest is essential mainly because it is not always obvious whether or not the underlying viscera are involved.

Penetrating and lacerating wounds of the abdominal wall should be treated thoroughly. The patient should be etherized, if necessary, the wound opened and explored carefully, cleaned, and sewed up, with or without drainage, depending upon the amount of laceration and soiling of the parts. If several layers of muscle and aponeurosis are damaged, the wound should be closed in layers, with careful approximation to avoid subsequent hernia.

Inflammation of the abdominal wall is a somewhat favorite topic with writers, and here again the significance of the lesion is important mainly on account of the possibility of damage to deeper structures. These inflammations may be superficial or deep. If superficial, they may often be cured by the Bier treatment, by vaccine therapy, or by hot applications merely; but if obstinate, and especially if pus has formed, the abscess must be opened and evacuated. *Ubi pus, ibi evacua,* holds true here as elsewhere. The infections deep in the abdominal wall may be of serious consequence, as they may involve such important localities as the prevesical space or the region about the kidneys. The evidence of such deep infection is two-fold—constitutional and local. There is a " pus temperature," high at night and low in the morning, with a corresponding variation in the pulse-rate, constant leukocytosis, debility, wasting. Locally, there is increasing swelling, with pain and tenderness, except where the inflammation is confined by dense aponeuroses. In the case of deep inflammation, thorough opening with drainage is imperative.

There may be special forms of chronic inflammation, with ulceration of the abdominal wall, from such infections as tuberculosis, syphilis, and actinomycosis. *Actinomycosis* especially is interesting. It comes usually by way of the intestinal canal. The gut becomes adherent to the parietes; the disease spreads outward; fistulæ may form, and an extensive involvement simulating malignant disease may result. In Chapter II is described a case which I saw recently in the hands of a colleague—one of those cases which has all the gross appearance of sarcoma involving the intestine and the abdominal wall. The case seemed hopeless; but extensive dissection of the abdominal wall showed the mass to be an inflammation arising from the intestine, through which an infecting fish-bone had penetrated. The general forms of inflammation must be treated on general principles. Tuberculosis of the parts may be cureted, dressed with iodoform, and the patient given an out-of-doors life. Syphilitic ulcers must be dressed with iodoform or aristol, and the patient given full doses of potassium iodid, 20 to 90 grains daily. The *treatment* of actinomycosis is not purely operative: we open up fistulæ and dissect out involved tissue, and I supplement the operative treatment by the method of the Bevan clinic—" where a relatively large

number of cases have been treated lately (and), excellent results have followed the use of copper sulphate administered in a quarter-grain pill, three times a day, and irrigation of the focus, when possible, with a 1 per cent. solution of copper sulphate."

Tumors of the abdominal wall are of three main varieties—*connective-tissue tumors*, *desmoids*, and *epithelial tumors*.

The *connective-tissue tumors* are *angiomata*, *fibromata*, *lipomata*, and *sarcomata*. They must be treated by removal. The *lipomata* are the most common; they are usually well incapsulated, and can be easily removed by splitting and enucleation.

Desmoid tumors are the most interesting growths in this region. They spring from tendinous tissue, such as the aponeuroses or the transverse tendinous tissue of the recti muscles. These tumor masses usually are hard, and creak on being cut. The cut surface glistens and shows numerous fibrous bands crossing each other at right angles. Sometimes the tumors contain cysts. They are usually found in women, the proportion of women to men being as 9 is to 1; and most of the women affected are those who have borne children. Desmoids are usually found near the median line and are single. They must not be confounded with fibromyomata of the round ligament, which may grow within the inguinal canal. The *symptoms* of desmoids are due to pressure only, for the tumor may reach a considerable size, and interfere with the action of the intestines and bladder. The *treatment* of desmoids is their complete removal—they do not give rise to metastases, and the only point of interest in their removal is the control of hemorrhage, which may be considerable.

Epithelial tumors of the *abdominal wall* are not uncommon. Dermoid and sebaceous cysts occur near the umbilicus, and can be removed easily under local anesthesia. Primary cancer occurs also in this region, and should be removed radically. Secondary cancer from the abdominal organs sometimes involves the abdominal wall.

Echinococcus is rarely a disease of the abdominal wall. It gives rise to localized swelling, malaise, and wasting. The only rational *treatment* is incision, evacuation, and removal of the sac, if possible, or its packing with gauze to promote granulation from the bottom.

Pendulous abdomen scarcely deserves to rank as a disease, but it is a condition sometimes submitted to operation. A vast, flabby, low-lying mass of fat in the abdominal wall may cause invalidism, practically, and may be removed.

Malformations of the umbilicus and urachus are not infrequently subjects for surgery, and the commonest form of malformation is *faulty closure* of the *vitello-intestinal duct*. The vitello-intestinal duct, by which the bowel of the embryo communicates with the yolk-sac, disappears usually at about the eighth week of fetal life, but it may persist and result in sundry abnormalities, such as fistula at the navel, diverticulum, or cyst. Such an abnormality may be evident when the umbilical cord drops from a new-born infant, or a fistula may develop

weeks later. If one of these embryonic passages exists, it springs always from the small intestine, usually from the lower third of the ileum. If the duct is closed inside the abdomen, but persists in the umbilical cord, there will remain, after the cord falls, a tumor discharging mucus from its surface—hence the misnomer, enteroteratoma.

If the malformation is not extensive or specially troublesome, it may be treated by palliation. Sometimes cleansing lotions, application of the cautery, and close strapping of the wound may cause an obliteration of the fistula. It is not wise to perform upon a new-born baby an extensive radical operation for such a deformity. If mild measures do not avail, a radical operation may be done later—after the sixth month of life. Dissect out the umbilicus, explore the abnormality, remove the duct from the intestine, and close the intestinal wound in the ordinary way. The operation is a major one, and may be fatal.

A somewhat similar malformation of the urachus sometimes exists—the communication between the urinary bladder and the allantois. This urachus or duct becomes obliterated early in embryonic life, but may remain patent and discharge urine at the umbilicus after birth. Sometimes partial obliteration of the urachus occurs, so that there develops a blind fistula in some portion or a cyst of the urachus. More rarely similar conditions may be brought about after birth and are associated with or dependent on some obstruction to the normal outflow of urine through the urethra. With all these conditions there may be a coincident cystitis. *Treatment* must overcome obstruction to the urethra; it must cure the cystitis, and must remove the patent urachus, by some such operation as we employ in dealing with the patent vitello-intestinal duct.

Infections and inflammations about the umbilicus are common, especially in the new-born, and the most frequent cause is filth—a neglected collection of sweat and dirt in the umbilical pit. The obvious remedy is cleansing, antiseptic washes, poulticing, and incision if necessary. At any period of life an *inflamed umbilical fistula* may develop, for the umbilicus is the thinnest portion of the abdominal wall, and is a favorite seat for the escape of pus from an intra-abdominal abscess. Such a fistula, depending on its origin, may also discharge feces, urine, or bile. It may close spontaneously, on which account any radical operation for its cure should be delayed for six months at least.

Tumors of the umbilicus are not uncommon. These are the inflammation tumors—the granulomata of infancy and the papillary fibromata of later life. A granuloma is sometimes called an umbilical fungus; it must be distinguished from an enteroteratoma, which does not present granulations, but is covered with mucous membrane. The granuloma may be cured by cleansing and touching with silver nitrate, or it may be snipped off with scissors and the wound dressed with dry gauze.

The papillary fibroma of adult life is a firm tumor with a pedicle. It may grow as large as a walnut, and may become malignant. It must be excised thoroughly.

Connective-tissue tumors of the *umbilicus* occasionally are reported, but they are rare, especially the non-malignant forms. Sarcoma or fibrosarcoma is somewhat more common than the benign forms of connective-tissue tumors. Epithelial tumors of the umbilicus have been mentioned already in this chapter.

The foregoing paragraphs make plain the fact that there is now a considerable literature on the abdominal wall, but there is no great interest in the matter, and with the exception of those curious abnormalities and malformations connected with the umbilicus, the subject merits no more than a cursory discussion.

PART II

FEMALE ORGANS OF GENERATION

CHAPTER X

THE UTERUS

The general surgeon sees and treats uterine disease, in spite of the fact that gynecology has long been regarded as a specialty. I do not propose to deal elaborately with gynecologic problems in the following three chapters, but to discuss briefly the more important lesions of the female organs of generation. The uterus, tubes, and ovaries are abdominal organs, often involved with diseases of other organs, often themselves subjects for radical operations which every surgeon must undertake.

ANATOMY

The anatomy of the pelvic viscera is important, but in this brief treatise we have space for a few suggestions only. Surgeons are wont to regard the topography of these organs from two points of view—that from above through the abdominal wall, and that from below through the pelvic floor.

It is needless to discuss the anatomy of the abdominal wall as one approaches the uterus from above, though I cannot forbear referring the reader to Max Brödel's beautiful plates in Howard A. Kelly's Operative Gynecology. Suffice it to say that the patient should be placed in the Trendelenburg position, whenever work through an abdominal wound is to be done in the pelvis. By the aid of that position, the intestines—usually the ileum—may be easily held up out of the pelvis. When the beginner approaches the normal uterus, he is surprised to find it lying at an apparently unusual depth, far from the abdominal wall. It is in a position of anteversion, with the rounded cone of its fundus behind the symphysis. Grasp the fundus with double hooks and draw it up into the wound, when you will see three important structures centering at either side of it, and enveloped in the broad ligament—three structures: from before backward, the *round ligament*, the *Fallopian tube*, and the *ovarian ligament*. The bladder lies independently in front of the womb; it seems to be part of the abdominal wall, for it is outside of the peritoneum, and should have been emptied so as to cause its disappearance, almost, before the operation. The rectum, more clearly defined than the bladder,

drops straight down behind the uterus. The uterosacral ligaments spring from the posterior aspect of the uterus and pass on either side of the rectum to their sacral attachments. Now, if you dissect carefully

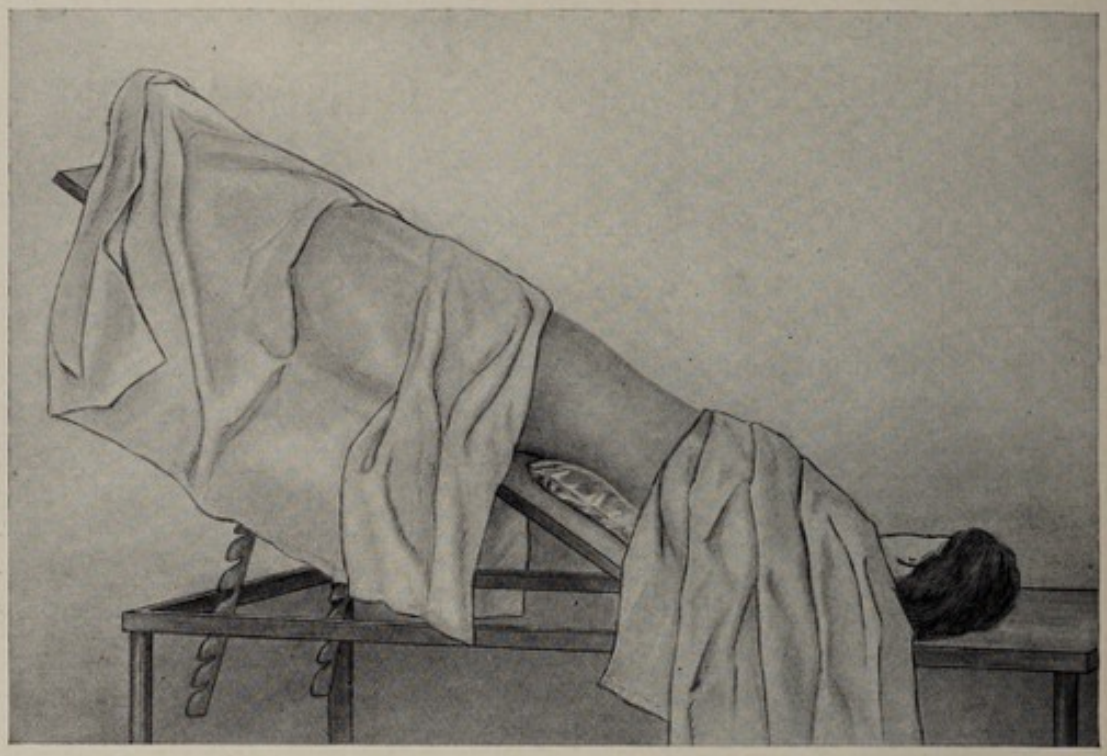

Fig. 135.—Patient in Trendelenburg position—correct. Knees straight.

away the broad ligaments, or split them, you will find the ureters deeply placed, running over the true brim to the bottom of the pelvis, where they



Fig. 136.—Patient in Trendelenburg position—incorrect. Knees flexed.

pass on either side of the cervix uteri to enter the base of the bladder. As the ureters pass the pelvic brim they rest upon the common iliac arteries. The ureters must be spared in the operation of hysterectomy.

The blood and lymphatic connections of the uterus are important and interesting. You may demonstrate the blood-vessels by an easy dissection. The student should learn accurately to determine the position of the ovarian arteries. They arise commonly from the aorta, though the left ovarian artery sometimes springs from the left renal artery. Passing down along with the ureters, they enter the suspensory ligament of the ovary. The ovarian veins on the right side empty into the vena cava, while on the left side, following the analogy of the left spermatic, they discharge themselves into the left renal vein. The uterine arteries are somewhat larger and more important structures

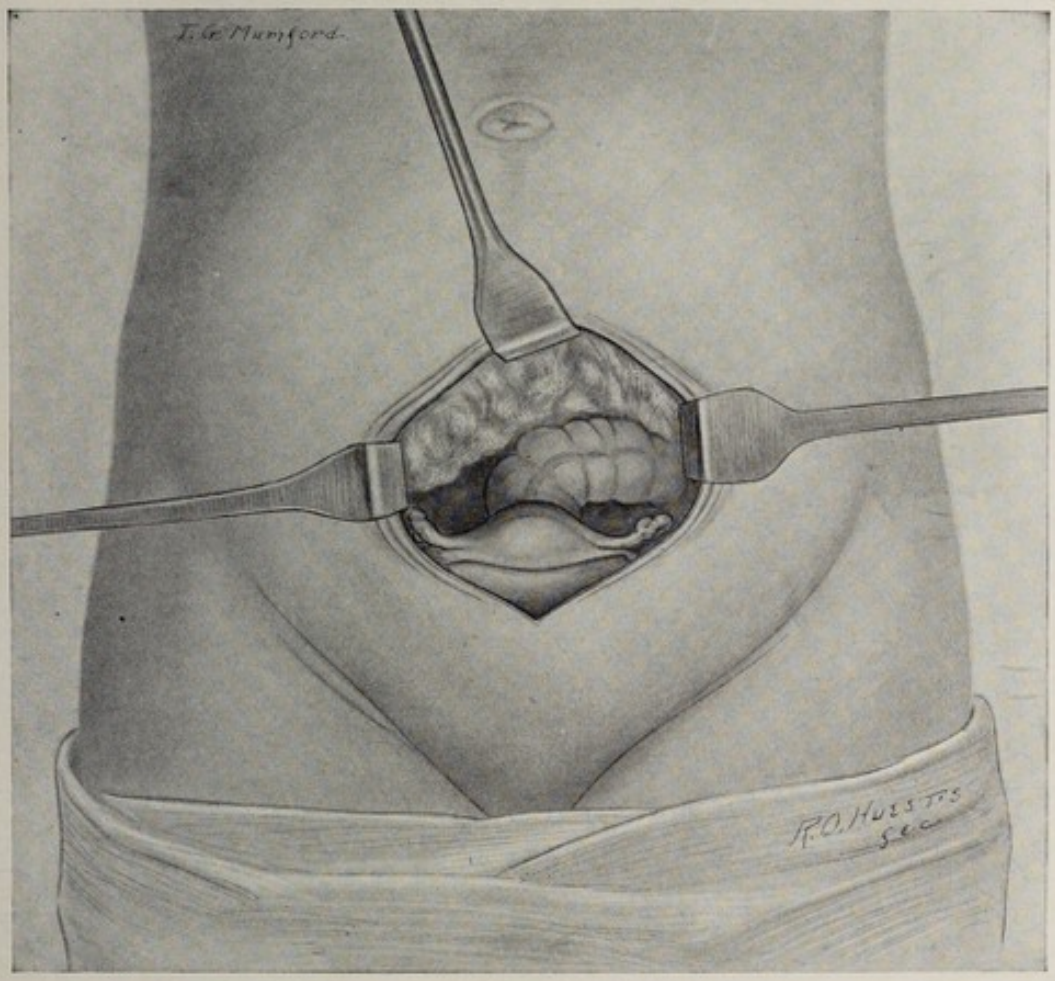

Fig. 137.—Walling off with gauze, patient in Trendelenburg position.

than are the ovarian arteries, and their dissection is not always easy. They spring from the anterior trunk of the internal iliac artery, deep in the pelvis, and follow a short course to the cervix uteri, where they enter the body of the uterus, giving off numerous branches, one of which is the vaginal. The ureter lies below the uterine artery and two of its veins, but above the large vaginal artery and uterine vein. The branches of the uterine vessels anastomose with the branches of the ovarian, both in the broad ligaments and in the body of the uterus itself.

The lymphatic connections of the uterus and vagina are abundant,

and seem at first to follow no particular arrangement. One finds on careful study, however, that lymphatic drainage from the lowest part of the vagina passes to the inguinal lymph-nodes, and through these to the system of nodes along the external iliac arteries. The lymphatic channels from the upper portion of the vagina and lower part of the cervix follow the uterine vessels and so form part of the internal iliac system, finally joining the external iliac system near the bifurcation of the common iliac artery. The lymph-vessels from the body of the uterus follow

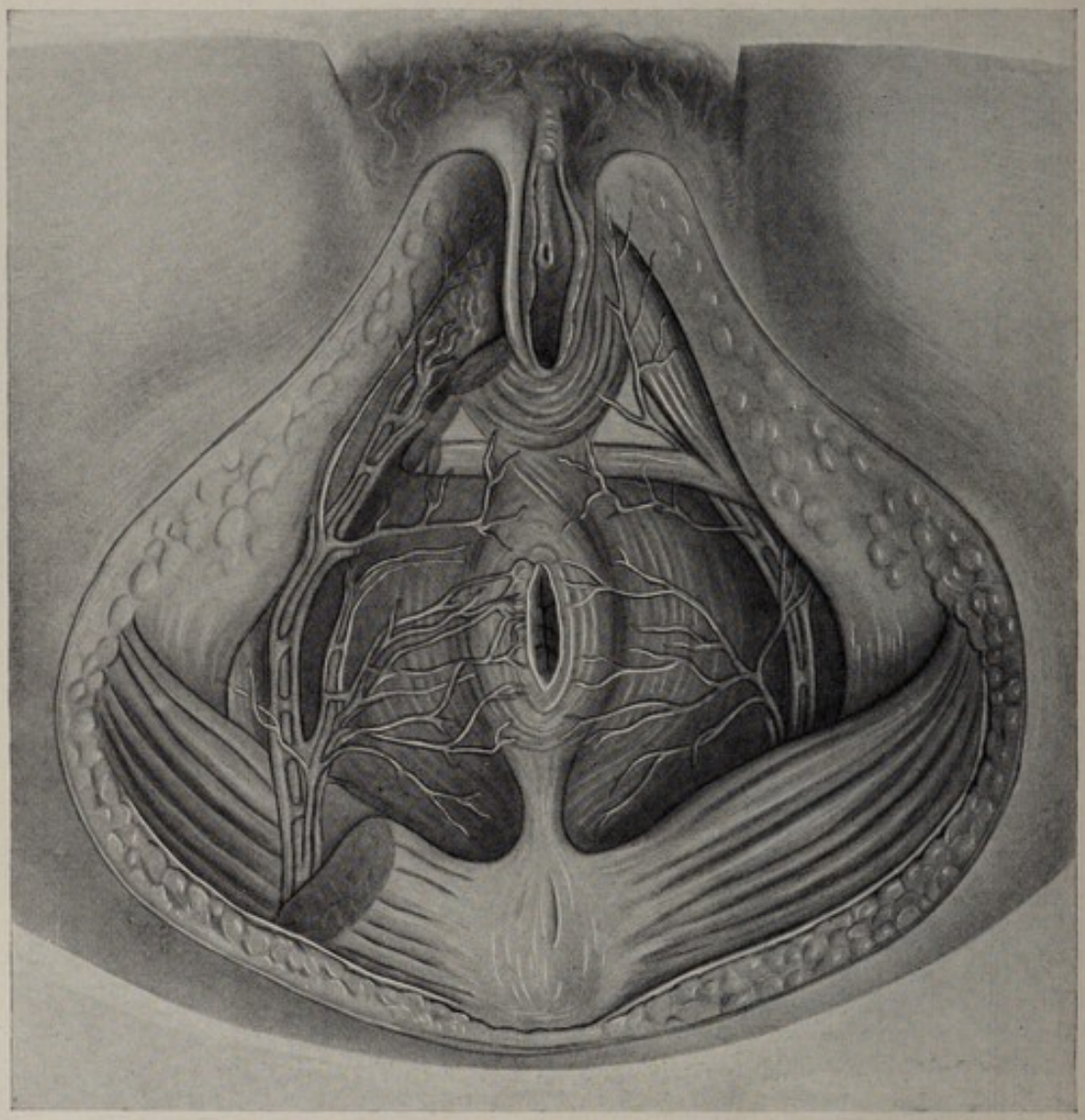

Fig. 138.—Showing deep and superficial muscles of the perineum (after Sobotta).

two courses—either along the round ligaments and so to the inguinal nodes, or along the ovarian vessels, the suspensory ligament of the ovary, and thus up to the lumbar nodes. Se we see that lymphatic channels from the lowest portion of the vagina, as well as from the fundus of the uterus, deposit their material eventually in the lumbar nodes, which lie high in the abdomen, upon the front of the aorta, in the region of the kidneys. The reader will recall our brief discussion of these lumbar lymph-nodes in Chapter VIII, when we dealt with the retroperitoneal

space. So much, in rough outline, for the relations of the pelvic organs, and their blood and lymph connections when viewed from above.

In approaching the uterus from below by the perineal route, one encounters another interesting series of relations, concerned mainly with the supports of the pelvic floor. The approach from above may be

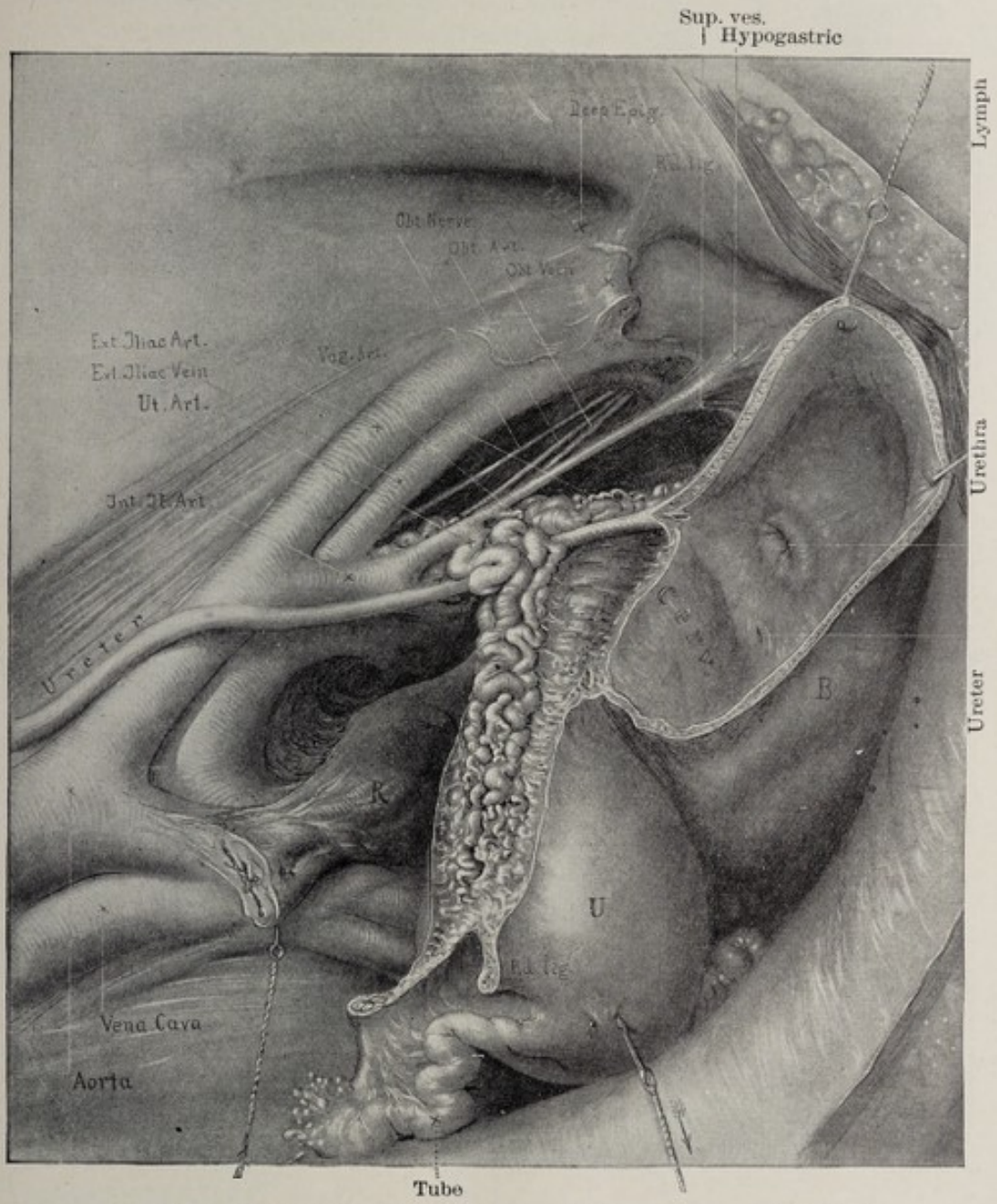

Fig. 139.—Relations of the ureters and the cervix uteri (Kelly).

regarded as in the field of major surgery. Sometimes the approach from below is regarded as in the field of minor surgery. If one remembers that the important structures in the pelvic floor—the anus, vagina, and urethra—are passages for elimination, and that they form weak points at the bottom of the abdominal cavity, one will comprehend the importance of weaving about them a muscular and aponeurotic network

which shall support the great weight of abdominal viscera pressing from above, but at the same time shall allow the urethra, vagina, and anus properly to functionate. In this connection it is interesting to observe that much of the damage and disease which occur in these dependent regions are concerned, on the one hand, with the breaking down of the pelvic floor and a dropping out of viscera, and, on the other hand, with obstructions or partial closures of the three channels of vent.

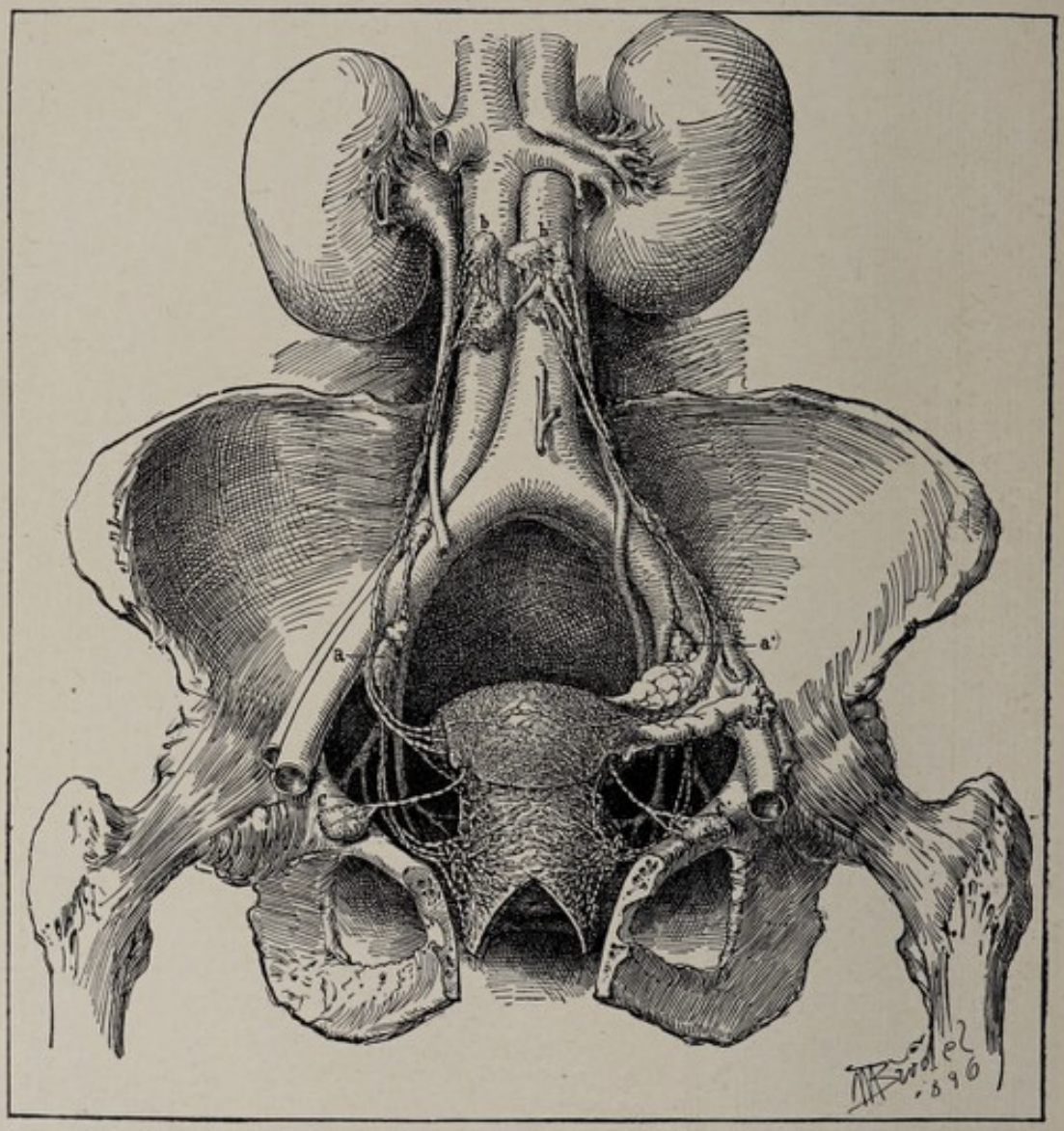

Fig. 140.—Distribution of lymphatics of the uterus (Kelly).

So observe the perineal supports. There is the sphincter ani, closely associated with the two transversus perinei and constrictor vaginæ muscles. These four form a delicate external network of muscles, whose function it is to control and regulate the outlets of the anus and vagina. These muscles have no great supporting strength. Above them, however, lies the true strength of the pelvic floor, the levator ani muscle, the powerful hammock in which rest the pelvic viscera. So one sees that damage to the external layer of muscles means damage of delicate func-

tion only; while injury to the levator ani muscle results in serious derangements of the pelvic and abdominal viscera.

Bearing in mind these important facts,—that in approaching the uterus from below the vagina offers an ample passage usually for operation, and that the ureters and uterine vessels lie low in the pelvis, against the upper portion of the vaginal wall,—let us proceed now to discuss the more common injuries and diseases of the uterus itself.

We limit ourselves in this chapter to the more serious and common lesions of the uterus with which the general surgeon deals—with *inflammations, lacerations, displacements, tumors.*

INFLAMMATIONS

Inflammations of the uterus are so closely associated with inflammations of other portions of the genital tract that it is difficult in practice to dissociate them. We speak of the uterus and adnexa. In truth and embryologically, the tubes and ovaries are no more adnexa of the uterus than are the spermatic cord and testes adnexa of the prostate; but clinically and conventionally we still talk of the uterus and its adnexa. When the uterus is inflamed, the adnexa frequently are involved. Now, the generative tract in women differs from all other mucous-membrane-lined tracts in either sex—it is continuous with a serous cavity; there is a direct communication from the external genitals through the vagina, uterus, and tubes to the peritoneal cavity. This fact renders serious the inflammations of the female generative organs, though, fortunately, inflammation of the tubes quickly seals their fimbriated ends, so that an associated local peritonitis is generally due to infection spreading through the walls of the uterus and tubes. Moreover, the lymphatic apparatus of these organs is so complex and extensive that infections are quickly and readily conveyed to other parts. Their nervous mechanism, too, is nearly associated with the general health and well-being of women. As a result of all this we must look upon uterine inflammations as important phenomena whenever and wherever they appear.

A discussion of the nomenclature of these inflammations and their division according to locality and duration is unsatisfactory. We talk of endometritis, endocervicitis, metritis, and parametritis, and we divide these processes into classes—acute, subacute, and chronic. As a fact, all these varieties overlap and run into one another, so that it is impossible often to tell with just what form we are dealing. Moreover, the tubes and ovaries may share in the infection, thus complicating further the problem of diagnosis and treatment.

Furthermore, in this discussion, as in the discussion of inflammations elsewhere, one should distinguish clearly the terms *infection* and *inflammation*, as Dudley points out.[1] By *infection* we mean that condition in which foreign media (bacteria) invade tissues and interfere with function. *Inflammation* is a result of infection. The irritation caused by invading organisms draws to the region leukocytes, with a resulting seroplastic

[1] E. C. Dudley, Principles and Practice of Gynecology, Chapter X.

infiltration, setting up a barrier to further invasion. This barrier is evidenced by swelling, heat, redness, and pain. That is inflammation; and, conversely, one observes that if no obstructing inflammation occurs, the infection may run an unchecked course and may advance rapidly until it overwhelms and kills the patient—*septicemia*.

The **etiology** of these infections is various. There are the predisposing causes—a generally lowered vitality from overwork, worry, or disease; and local causes—injury to any part of the genital tract from pregnancy or parturition, abortion, improper local treatment, operations, masturbation, catheterization, and from gonorrheal, syphilitic, and other such infections. Gonorrhea is perhaps the most common and the most serious

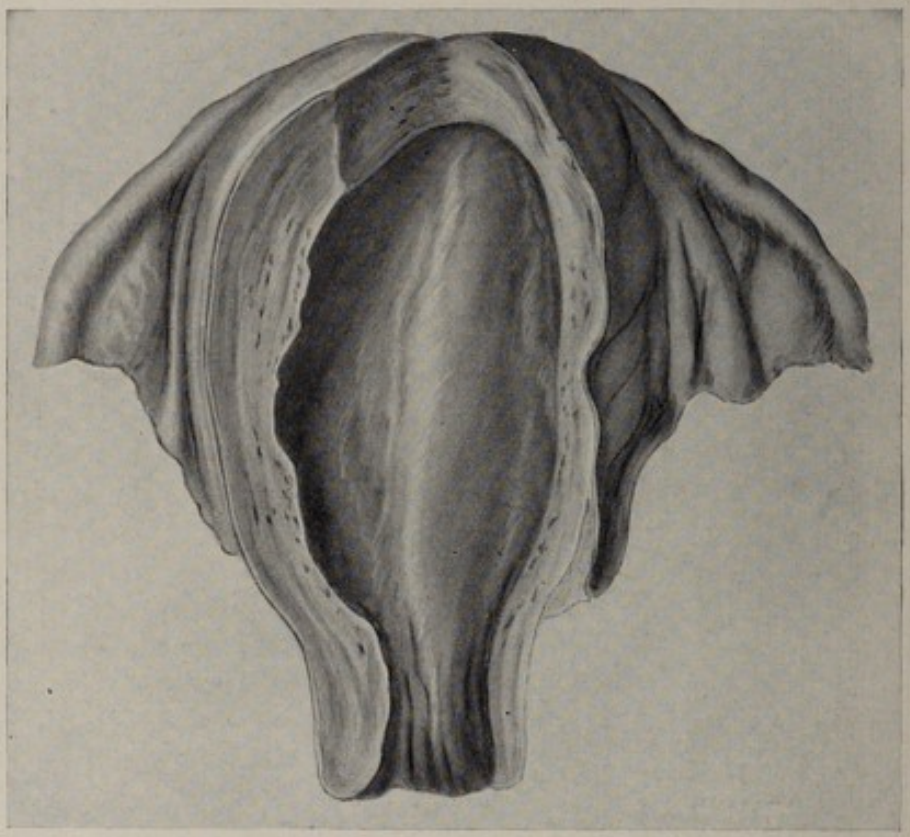

Fig. 141.—Uterus from patient dying on tenth day from pure streptococcic infection (Jewett).

form of infection. This disease attacks and finds ready lodgment in the external genitals and urethra; it invades the vagina with difficulty, but it runs riot and lingers long in the uterus, especially in the cervix, with its numerous and extensive crypts, tubules, and glands; and it passes easily from the uterus to the Fallopian tubes. This extension of infection, whether bacterial or some other, travels by continuity of the mucosa and by the lymphatics and blood-vessels.

In brief, one may distinguish the *acute* infections as those virulent forms which call out the defensive inflammatory processes I have described and, finally, produce local necrosis, with a termination in resolution or further advance to progressive suppuration. At any time the acute infection may break through the barrier and invade the whole

body. Sometimes the acute process becomes *chronic;* its intensity diminishes, little defensive action is provoked, so that instead of a localized destructive process there results an excess of construction. Or the disease may be subacute or chronic from the outset, and in turn may at any time become acute on due provocation. Let us discuss briefly and successively acute and chronic metritis and acute and chronic endometritis, with the subvariety, endocervicitis. Parametritis is but the beginning of a pelvic peritonitis, which we shall study in connection with disease of the tubes and ovaries.

Acute metritis, or inflammation of the whole of the womb, is one of the most puzzling and serious of diseases. The process begins ordinarily in the endometrium, but extends rapidly through the lymphatics to the body of the uterus and to the peritoneum and adjacent structures even. The causes of metritis are those I have already named, but probably the most common cause is childbirth or abortion, followed by the retention of some of the products of conception, which often become infected, and in their turn infect the uterus itself. The rapid and frequently fatal progress of acute metritis is due to the close relations through the lymphatic channels of the endometrium and the uterine peritoneum. Streptococci are the common offending organisms. One finds, three or four days after the beginning of infection, that the uterus is somewhat larger than it should be, smooth in outline, and doughy or soft. There is an extreme congestion, with bloody extravasation in the walls of the organ. The endometrium and parametrium are deeply engorged, and there is an abundant small-cell infiltration of all the tissues concerned. The lymph-vessels are distended, and the uterine glands secrete a copious fluid. The extent of all these changes depends, of course, on the virulence of the infection and the ability of the organism to set up a protective barrier. Abscesses seldom form in the uterine wall unless there be complicating myomata.



Fig. 142.—Uterus dilated. Acute metritis.

The *symptoms* are often grave, though they may be insidious and take weeks in development. The patient looks sick, and frequently has that peritoneal facies with which we are familiar. The temperature runs up, and fluctuates in a typhoidal fashion. There may be an initial chill. There is general abdominal discomfort, often associated with pain above the pubes, radiating to the back and thighs. Movements of the bowels are painful, and rectal tenesmus is common; the passage of urine is frequent and painful, because there is often an associated cystitis. Often, too, the patient complains bitterly of nausea, vomiting, and constipation. If the uterine inflammation persists through the time of a

menstrual period, the flow may be suppressed, though occasionally, when myomata are present, there may be a persistent and even dangerous hemorrhage. The flow consists of changed and clotted blood, mixed with the uterine secretions. Sometimes the laboring organ attempts to express clots and other collections, with the result that a pain or pains, like exaggerated labor-pains, ensue. If the inflammation extends to the adnexa, the pelvic connective tissue, and especially the peritoneum, we shall find, in addition, those severe and alarming symptoms of peritonitis which we have already studied (Chapter VIII). If unchecked and unopposed, the disease goes on to death by septicemia.

We make our *diagnosis* by observing the symptoms and by finding such physical signs as tenderness over the pubes, in the inguinal regions, and in the vagina; tense abdominal walls;[1] a vagina hot to the touch; an abnormal uterine discharge, and an enlarged and softened uterus. It may seem best to examine through the speculum the condition of the cervix and os, but probing of the uterine canal is dangerous and profitless.

The *treatment* of this alarming form of inflammation rarely is immediately obvious, and calls for the coolest and most patient judgment. Some of the gravest cases recover under palliative measures, while not infrequently cases mild at the outset go on to the severest complications and to death. In the face of no form of disease does one so frequently meet with so great a divergence of opinions among consulting surgeons in any given case. Writers talk about abortive treatment, palliative treatment, and expectant treatment. These are forms of treatment applicable in the early stages only, or else late, when any radical operation obviously would be fatal. The milder forms of treatment consist of absolute rest in bed, frequently changed hot poultices[2] upon the abdomen (I use creolin poultices, 1 : 200, and find the slight sting of the creolin grateful to many patients). Sometimes leeches to the cervix are effective, and leeches to the perineum and inguinal regions. Move the bowels thoroughly with calomel. The treatment may be carried further by giving small doses of opium for pain and hot lysol douches. In all cases cultures of the discharge should be made and the appropriate vaccines injected.

Such simple means are easy of application, but the strain upon the physician's resources is far greater than the limits of palliative therapeutics. He is face to face with a great problem, with which an indolent or an ignorant man only can rest easy. The intelligent practitioner must be agitated by the thought of the importance of active surgical intervention. Three questions should be uppermost in his mind: Is the source of this infection some focus of decomposition in the uterus—some disorganized products of conception? Or is the uterine mucosa the seat of infection—possibly a gonorrhea? Or has the disease spread and involved deeper tissues? Is the peritoneum involved, and are there infections of distant organs?

[1] As in other forms of peritonitis, the walls may be lax.

[2] The local induced anemia due to cold (ice-bag) is often extremely effective.

These are far-reaching problems, each one of which might be made the subject of a chapter. Briefly, if there has been recently an abortion or labor at term; if, after two days, the patient's temperature begins to run up; if tenderness over the uterus increases and the other signs and symptoms of infection appear, we have evidence of an intra-uterine irritation which must be removed. Not to encroach too much upon the literature of obstetrics, suffice it to say that cureting will eliminate the offending mass and relieve the symptoms. This is the case and the only case in which one may use the dull wire curet or the finger armed with rubber glove. You will find little difficulty in this simple operation. The patient should be drawn to the edge of the bed, or preferably placed upon a table and in the lithotomy position. The greatest

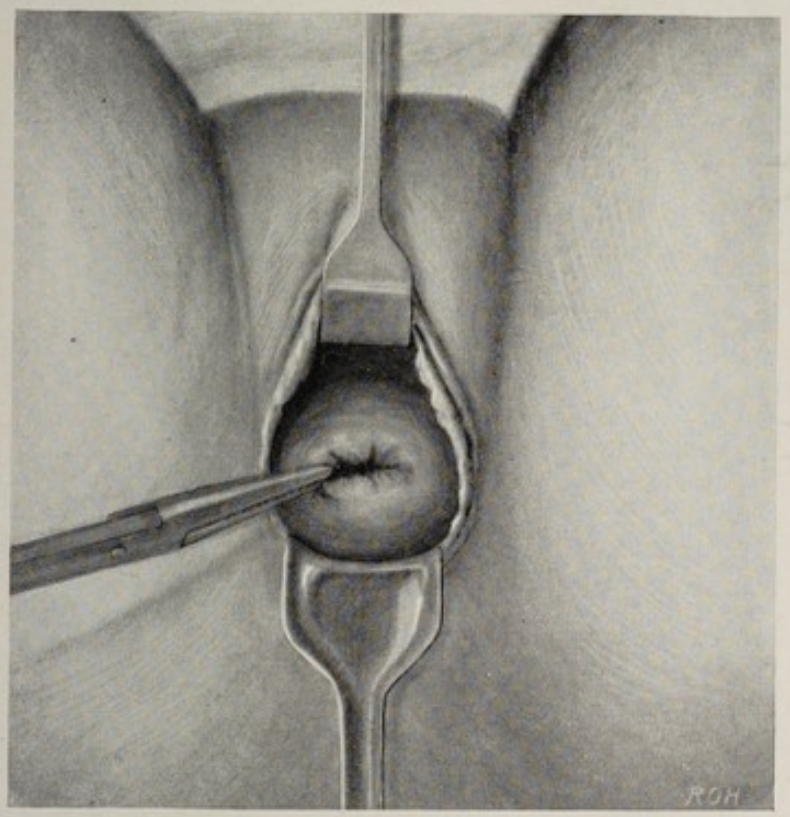

Fig. 143.—Position for curetage of uterus.

antiseptic care should be employed by shaving the external parts, scrubbing them with soap and water, and douching thoroughly the vagina with lysol (1 : 100) and sterile water. Often an anesthetic is needless. The os uteri is generally patulous, and admits readily a curet of fair size. Besides the dull wire curet a pliable douche-curet is a useful implement. The surgeon hoes out carefully the whole interior of the uterus, and follows this procedure by a copious intra-uterine douche of sterile water. Further intra-uterine medication is needless. If this operation is done properly and thoroughly, the patient will at once return to the normal.

In a few rare and unfortunate cases, however, extensive involvement of the uterine wall and surrounding tissues has already taken place,

and the process will not be checked by curetage. Here is one of the most trying and difficult of emergencies. The surgeon must approach it from a point of view similar to that from which he approaches a diffuse peritonitis from appendicitis. An active, septic focus is present, and that focus must be removed. Here again, one is governed by the conditions which he finds. If there be an inflammation limited to the pelvis and involving the para-uterine tissues and adnexa only,—possibly with an abscess pointing in the vagina,—it will suffice to incise the pouch of Douglas and drain the products of inflammation. In rare and desperate cases it may be necessary to open the abdomen and remove the uterus with its appendages. This should not be done in the face of impending death, and at the best or worst it is a desperate remedy. After such an operation, which should involve a minimum of disturbance to the intestines (provided for by the use of a modified Trendelenburg position), the surgeon should wipe out carefully the pelvis, and drain it through rubber drainage-tubes—one above the pubes and running to the bottom of the pelvis, one in the vagina, draining Douglas's pouch. Furthermore, there is a great advantage afterward in placing the patient in Fowler's position, and for the first twelve to twenty-four hours employing the seeping enemata described in our chapter on Peritonitis (Chapter VIII).

Those cases of metritis due to other infections (gonorrhea, etc.), involving the uterine mucosa call for a somewhat different course of surgical treatment. Generally they are less urgent and alarming than the puerperal cases, but many times they progress to the same fatal termination. If palliative measures fail, the next step is curetage—curetage of a more radical nature than that described in a previous paragraph. The dull curet is worse than useless here. One must give the endometrium a thorough scraping with a sharp spoon-curet, going over the whole interior of the organ in painstaking fashion, and being satisfied only when the curet conveys to the hand the characteristic grating feel, as though being drawn over sound tissue. The separated lining membrane is discharged through the cervix by uterine contractions, assisted by the curet. As a preliminary to cureting, the cervix must be dilated—not dilated violently and suddenly with the ratchet instruments in common use, but gradually; and I recommend the careful employment of the Hanks and Goodell-Ellinger dilators.

Fortunately, acute metritis of this form is a rare affection, but in case it extends further and threatens continued progress, one may be forced again to the radical operation of abdominal hysterectomy.

In case we have to answer affirmatively our third question—that is, in case there be a general systemic infection, treatment of local conditions may be of little avail. One should see to it, however, that abundant pelvic drainage is instituted, if possible, through the vagina; and one should endeavor to combat the general infection by such supporting measures as giving whisky and strychnin, with forced feeding and the injection, intravenously, of normal salt solution. Above all things, open-air treatment is essential. I have seen more than one patient who had dragged along for weeks when confined to the house recover rapidly

and completely upon being sent out-of-doors to live on the piazza or in a tent. The proper opsonins also will hasten convalescence.

Chronic metritis is properly an inflammation of the uterine muscle, and should be called more accurately myometritis. Like acute metritis, it starts usually in the endometrium and cannot readily be distinguished sharply from endometritis. Sometimes the term, chronic metritis, does not imply a definite infective process, but implies certain chronic changes in the quantity and quality of the glandular elements, muscularis, blood-vessels, lymphatics, and connective tissue. Many of these cases, therefore, are non-infective in origin, and Fothergill [1] points to the investigations of Theilhaber, Meier, and Donald as proving the existence of a non-inflammatory condition in which the symptoms are discomfort, menorrhagia, and leukorrhea, while the obvious pathologic feature is hypertrophy of the uterine mucosa. Certainly it appears that the uterine muscle probably plays a more important part in the causation of common pelvic disorders than hitherto has been recognized. So we may have an infective chronic metritis and a non-infective chronic

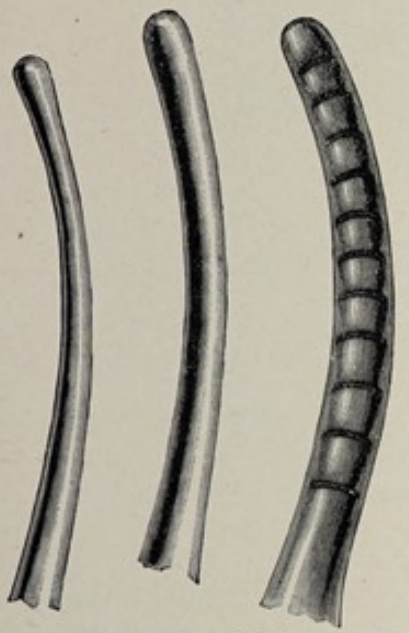

Fig. 144.—The dilating ends of the three sizes of the Ellinger and Goodell-Ellinger dilators (natural size), showing a slight curve and the relative sizes (Kelly).



Fig. 145.—Hanks dilator.

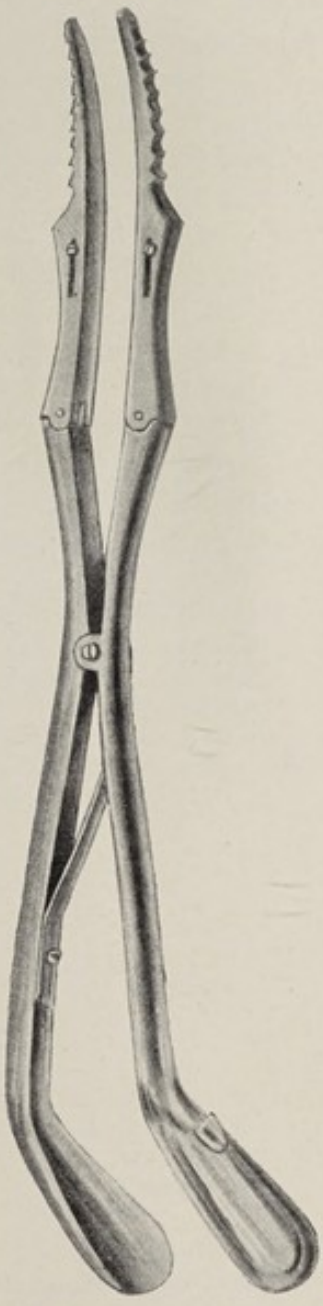

Fig. 146.—Goodell-Ellinger dilator with spring between the handles, but without a ratchet.

[1] Practitioner, March, 1904.

metritis, with quite similar appearances. One finds the uterus to be enlarged symmetrically, harder and firmer than normal. Later, atrophic changes may cause a shrinking of the organ to less than normal size. There is little tenderness on pressure, and there is not often an involvement of the appendages. The uterus may or may not be movable, and it may or may not be displaced, but enlargement of the cavity is demonstrable by the use of the sound.

Furthermore, chronic metritis must be distinguished from subinvolution, in which the uterus is large, often rather hard and insensitive, and subject to frequent and considerable hemorrhages.

The *symptoms* of chronic metritis are elusive often. There is rarely fever, nor is there acute pain, but there is a sense of aching, pressure, weight, and dragging in the back, hypogastrium, and thighs. There are frequent hemorrhages. Dysmenorrhea often is present. Such patients are usually sterile. Actions of the bowels and bladder are painful, and the patient suffers from all sorts of reflex symptoms—dyspepsia, headache, blurring of vision, and insomnia, resulting in malnutrition and chronic invalidism.

The differential diagnosis is correspondingly difficult. I take the following instructive table from Dudley's book:

Chronic Metritis.	Small Fibroid Tumors.	Early Pregnancy.
1. Menorrhagia and intermenstrual uterine hemorrhages not invariable.	1. Menorrhagia and uterine hemorrhage the rule.	1. Amenorrhea.
2. No signs of pregnancy.	2. No signs of pregnancy.	2. Signs of early pregnancy: (*a*) Morning sickness. (*b*) Breasts enlarged. (*c*) Blue discoloration of vaginal mucosa. (*d*) Softening of the cervix uteri.
3. Uterus hard and regular in outline.	3. Uterus hard and irregular in outline.	3. Uterus soft and regular in outline; may momentarily contract and harden on handling.
4. Uterus commonly in pathologic anteversion and descent; may be in retroversion.	4. Uterus liable to be displaced in any direction according to the mechanical influence of the fibroids.	4. Uterus commonly anteverted.

The *treatment* of chronic metritis in its elaboration falls properly to the gynecologist, who must consider the associated lesions—endometritis, parametritis, etc. Not infrequently one must resort to removal of the uterus, and for this operation the general surgeon should be prepared. While the abdomen is open, remove the appendix vermiformis. I am convinced, in spite of ancient prejudice, that the appendix should always be removed whenever the abdomen is opened for operation upon organs in its neighborhood.

Acute endometritis cannot well be distinguished from the general acute metritis I have described, but **chronic endometritis** is distinguish-

able as a separate process, limited to the endometrium; and chronic *endocervicitis* or cervical endometritis is a special form or subdivision of endometritis. The interior of the cervix is cut off by the internal os from the rest of the endometrium. The cervical portion especially is subject to infection—more so than the deeper and better guarded endometrium proper. The numerous glands of the cervix are a ready culture ground for invading organisms, and the infection commonly spreads to them from without—especially gonorrhea; or is set up from an infected puerperal laceration, from foreign bodies, tumors, or polypi, or from unclean instruments and fingers. The ordinary phenomena of a catarrh appear—engorgement, thickening, exudation, followed especially by

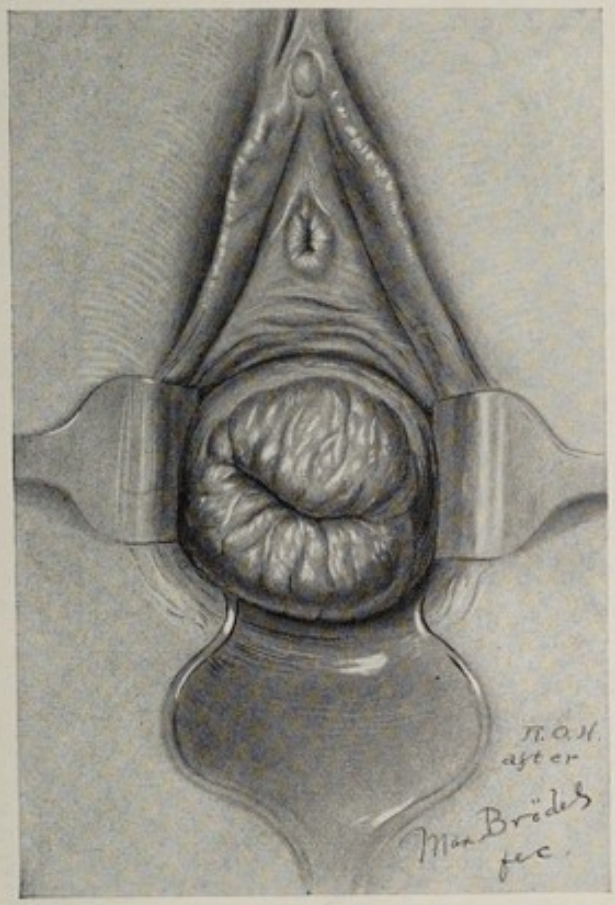

Fig. 147.—Erosion of the cervix (Cullen).

so-called erosion of the epithelium—properly a hypertrophy of papillæ and a condition of chronic ulceration, with a rolling out of the cervical mucosa. In multiparæ the engorgement sometimes blocks completely the external os and results in retention of the secretions, with dilatation of the cervical canal. Erosions and glandular enlargements are the conspicuous features of cervical endometritis, and from the latter there may result the development of mucous polypi and that form of cystic glandular enlargement with the formation of retention cysts known as ovula Nabothi.

The *symptoms* of endocervicitis are irregular and not characteristic. Such symptoms as these are may be due to complications, or there may

be no symptoms. Commonly we look for irregular and painful menstruation, sterility, pain in the region of the coccyx, a sense of weight in the pelvis, and sundry remote functional disorders—neuroses and dyspepsia. In the case of polypi there may be hemorrhages—frequent and some-

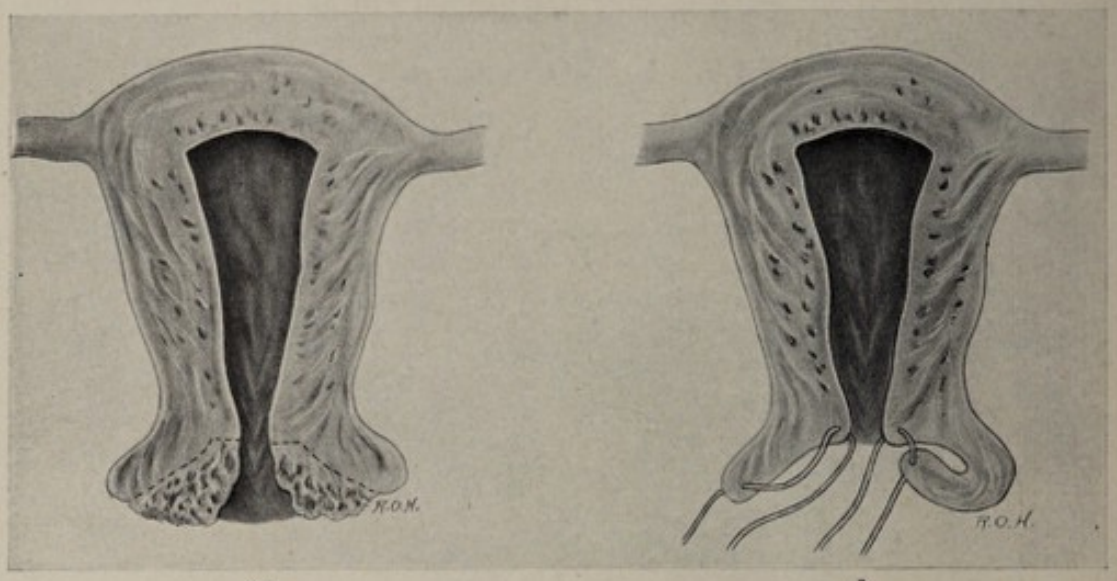

a *b*

Fig. 148.—Schröder's operation: *a*, Showing a thickened, diseased cervix requiring resection. The dotted lines show where the incisions should be made. *b*, Diseased tissues excised. Sutures in place for the union of the vaginal to the intra-uterine margins of the wound, but not yet tied.

times alarming, especially during the menstrual period. The *diagnosis* is based on a careful vaginal examination with the speculum.

The *treatment* of endocervicitis is topical and operative. It is by no means possible always to cure it by applications, and often when the

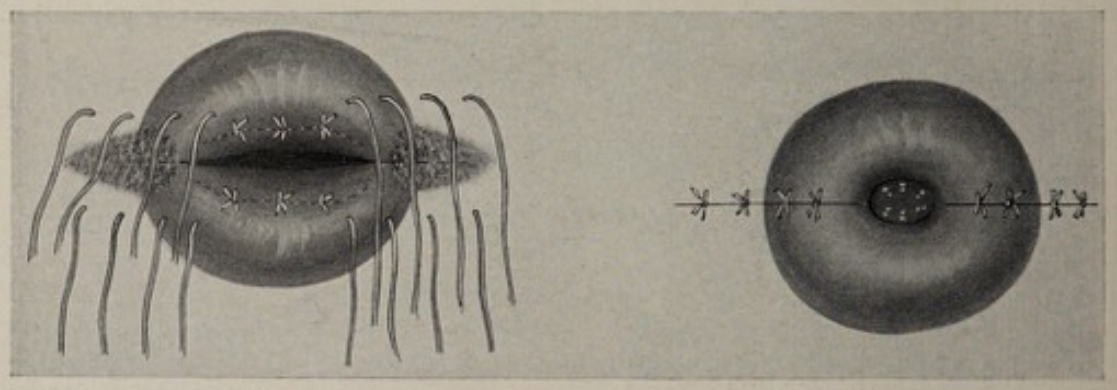

a *b*

Fig. 149.—Schröder's operation: *a*, Vaginal margins sutured to the intra-uterine margins of the wound. Lateral surfaces denuded and passed, but not yet tied. *b*, Lateral sutures introduced for the completion of the operation, and tied. The white dots in the os externum represent the ends of the protruding sutures, which are now rolled far into the cervical canal.

irritation persists one must perform a somewhat radical operation—removal of the affected area. In my opinion the best of these operations is that of Schröder. The sketches illustrate this procedure—the removal of tissue and the sewing up of the exposed raw surfaces.

If there are polypi, they must be twisted off after the external os has been dilated; and in the case of obstruction with distention of the canal, an operation similar to that of Schröder gives the best result. Little is gained by dilatation alone, or by scoring of the cervix without removal of tissue, for after such treatment recontraction of the os is almost sure to take place.

Endometritis of the body of the uterus presents a problem of greater difficulty than the subvariety, endocervicitis, which I have just considered, if, indeed, we can make a clear distinction between endometritis and endocervicitis. We recognize glandular endometritis, interstitial endometritis, and a combination of glandular and interstitial endometritis. These forms present the appearances which their names indicate, and are characterized by enlargement of the uterine glands, sometimes by their multiplicity (occasionally designated benign adenoma), by great increase of connective tissue in the endometrium at the expense of the glandular elements, or by a combination of all these conditions, which may result in the formation of polypi. Gynecologists describe six clinical forms of endometritis—post-abortion endometritis, exfoliative endometritis, senile endometritis, tuberculous endometritis, decidual endometritis, and septic endometritis; and in making the diagnosis we look for much the same symptoms as in the case of cervical endometritis: menstrual and intermenstrual disturbances, excessive mucous discharges, hemorrhages, sterility, dragging sensations in the pelvis, tympany, pain in the epigastrium, and vesical and rectal tenesmus. To confirm the diagnosis one should always depend upon a microscopic examination of scrapings from the endometrium, and this is extremely important in view of the possibility of cancer developing in the same organ. Moreover, a discharge supposed to come from the endometrium may have its origin in the Fallopian tubes.

The outlook for long-established cases of endometritis is not encouraging, and after apparent cure even relapses are common. The mildly infected cases yield readily to general treatment—tonics, change of air, etc.; but the more serious cases always require a surgical operation, and at the best the prognosis is discouraging in exfoliative, senile, and tuberculous endometritis.

The *treatment* of chronic endometritis may be discussed conveniently under three headings: (*a*) Systemic treatment; (*b*) topical treatment; (*c*) surgical treatment.

Those cases which mothers and old-fashioned persons refer to as "a female weakness" belong often to the class requiring systemic treatment, and I have already referred to the course of such treatment. The surgeon must inquire into the patient's general condition, he must combat anemia, rheumatism, constitutional syphilis, diabetes, renal and cardiac disease, and chronic constipation by appropriate measures; and, above all, he must place the patient in the most favorable hygienic surroundings.

Topical treatment is sometimes useful, but its value has been greatly exaggerated, just as the value of systemic treatment has been neglected. Unfortunately, as Dudley points out, applications which have the power

to destroy disease may destroy the endometrium, injure the myometrium, and reduce the uterus to a cirrhotic, cicatricial condition, with sterility and permanent irritability of all the pelvic organs as a result. This is not the place to discuss the infinite varieties of topical treatment; for that discussion I refer the reader to the text-books on Gynecology.

Surgical treatment concerns us especially, and the leading factor in surgical treatment is curetage, with thorough dilatation of the canal and irrigation, as I have already described them in this chapter. Sometimes, in the case of long-standing obstinate disease, it is well to apply to the endometrium, after curetage, a saturated solution of iodin crystals in 95 per cent. carbolic acid. I do not regard the gauze tampon as a necessary dressing. Good results are obtained without it because the natural drainage of the uterus after dilatation is excellent.

In spite of all such measures, however, permanent repair of the damaged uterus may be impossible, especially when the endometritis is complicated with such extensive disease as I described in discussing metritis. In that case curetage is not even palliative, and the best hope of comfortable life for the patient lies in a supravaginal hysterectomy.

LACERATIONS

Lacerations of the uterus are due to parturition commonly. Every woman who has been pregnant is the subject of some laceration of the cervix. The fundus uteri may be ruptured by a fall or blow; it may be pierced by a curet or sound; it may burst during labor even, and sundry rare and curious accidents may befall any portion of the uterus, but the ordinary lacerations of the uterus are labor tears of the cervix. General practitioners and general surgeons constantly see these cases, and not many years ago our advice to all patients so affected was that they have the laceration repaired. There was a furore for such work. We have now come to see that a laceration of the cervix does not necessarily cause distressing symptoms or invalidism. Many a deeply torn cervix in a healthy woman may be carried through a long life without her knowledge of the injury.

When **symptoms** are present, they may vary all the way from the discomfort of a cervical catarrh to a condition of frequent miscarriage or confirmed invalidism, with constant backache, dysmenorrhea, sterility even, and pronounced neurasthenia. Moreover, we feel confident that these tears, long neglected, and in a state of chronic irritation, frequently become the site of malignant disease. (I make this statement with a full knowledge of the assertion of certain surgeons that cervical lacerations do not enter into the etiology of uterine cancer.) Lacerations may take place at any portion of the cervical outlet, but the anterior and posterior tears heal so promptly that they are rarely observed by the physician. Lateral tears do not so heal. These are the tears which cause trouble, and the trouble is due directly to secondary causes—to infection, endocervicitis, and glandular enlargements and "erosions," so called, which are really poutings of the engorged

cervical mucosa. Such an inflamed and irritated cervix rarely can be cured without operation, while it is essential to bear in mind that the deep, thick cicatrices at the bottom of these tears prevent a proper falling together of the everted lips. Before operating by trachelorrhaphy the surgeon should see to it that the inflammation be in some measure subdued and the engorgement relieved so far as possible, for this relief will promote a more ready and a firmer healing. If practicable, the patient should be put to bed for two or three weeks and treated by hot vaginal douches, regulation of the bowels, puncture of the follicles, and scarification of the cervix so as to draw out a half-ounce of blood every four or five days if the patient can bear it.

Operation.—It is within the last thirty-five years only that the significance of cervical lacerations has been appreciated and their rational cure undertaken. We owe the operation to T. A. Emmet.[1]

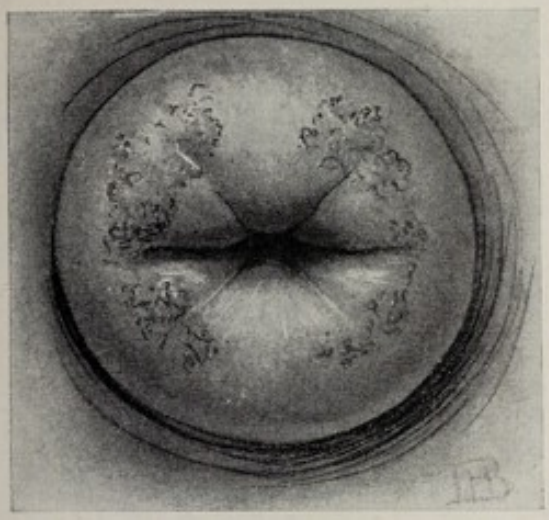

Fig. 150.—Bilateral laceration of the cervix, with puffy, infiltrated lips (H. A. Kelly).



Fig. 151.—Incisions into the angles of the laceration extending down through the scar tissue (H. A. Kelly).

After a careful antiseptic preparation, with shaving of the parts, the patient is put in the Sims' or the lithotomy position. I cannot see that the question of position is especially important. Before proceeding to the repair proper it is wise, generally, thoroughly to dilate and curet the interior of the uterus if there be evidence of inflammation. By this maneuver subsequent soiling and infection of the fresh wound is the better provided against. In operating seize the posterior lip of the cervix with bullet forceps, draw it down, and excise thoroughly the deep cicatrices on either side. Then, with scissors or knife, remove the diseased surface, exposing on either side of the os an elliptic wound with free, raw bleeding surface, as shown in Fig. 152. Denude from below upward, as in this way the blood will not cover the operation field as you

[1] T. A. Emmet, Surgery of the Cervix Uteri, Amer. Jour. Obstet., February, 1869. Laceration of the Cervix Uteri as a Frequent and Unrecognized Cause of Disease, ibid., November, 1874. The Proper Treatment of Laceration of the Cervix, Amer. Practitioner, January, 1877. Principles and Practice of Gynecology, Philadelphia, 1884, p. 466.

advance. Having denuded thoroughly on both sides of the os, leaving a broad strip of mucosa between the two wounds to form the new canal, grasp the anterior and posterior lips and bring them together before suturing, in order to make sure that a perfect approximation will be attained. Then pass the sutures. There has been much debate regarding the nature of the suture material to be used, because a prompt union is essential to success, and the nature of the suture is thought to have an important bearing on this matter. Silver wire, silkworm-gut, and catgut have their advocates. For some years I have employed, with great satisfaction, catgut buried within the wounds. By this means the denuded lips are brought firmly together, save for a thin border of mucosa at their edges. This mucous border may be secured later

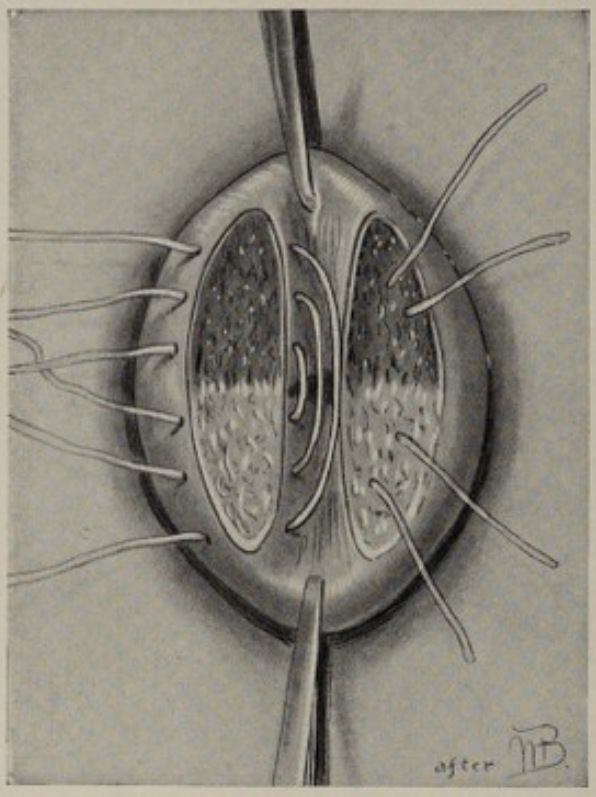

Fig. 152.—Sutures, two buried (after H. A. Kelly).

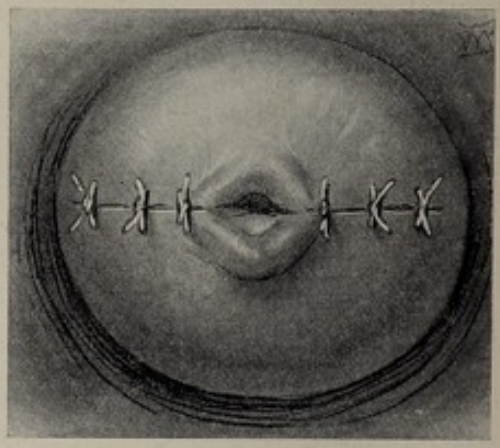

Fig. 153.—The cervix after all the sutures are tied on both sides (H. A. Kelly).

by a few superficial catgut stitches which cannot interfere with healing in the depths of the wounds. As a result of this operation you will secure a normal, well-formed cervix of proper length.

A light gauze sponge is left in the vagina for twenty-four hours to absorb discharges, and the patient is kept in bed for ten days. If discharge persist during convalescence, it indicates usually a continuance of endometritis, and suggests the possibility of a breakdown of the wound edges. In case of such a discharge, therefore, it is well to douche out the vagina daily with a weak solution of lysol or plain boiled water.

WOUNDS

Wounds of the body of the *uterus* are most commonly caused by instruments; furthermore, the *pregnant* uterus may be ruptured by a blow or may be crushed, just as the intestines or liver may be ruptured. Such a uterine rupture is followed immediately by a train of alarming

symptoms: by hemorrhage, collapse, and, if the patient survive, by peritonitis. As soon as the accident is discovered, the surgeon should open the abdomen, remove the fetus, and clean out and repair the injured uterus. He should treat peritonitis by the methods already described.

Perforation of the uterus by a sound, curet, or other instrument is a common accident. If reasonably careful, you will not thus perforate the normal, healthy uterus, but in the case of an organ septic or weakened by disease or pregnancy, it is easy to pass an instrument through the uterine wall into the abdominal cavity. Most surgeons have had such experiences, and the sensation, as the instrument suddenly sinks to its handle in a supposedly small uterus, is extremely alarming. As a rule, however, such an accident is followed by no ill effects if the instrument is a clean one. I have myself thus perforated the uterus, and have seen it so perforated by others.

Do not hastily open the abdomen to repair the damage. In the great majority of cases a minute hole only is made in the uterus, and the wound heals promptly if let alone. Therefore, let it alone. Keep the patient quiet on her back for a week, when all danger will have passed. Rarely a septic peritonitis follows the accident, and in that case the surgeon must open the abdomen and drain it according to the recognized rules.

DISPLACEMENTS

Displacements of the uterus are as common or commoner than lacerations. One finds them in women who have never borne children, as well as in mothers of families and at all ages. Our chapter on Abdominal Ptosis (Chapter IX) hints at one of the causes of displacements —a general relaxation of the visceral supports. This applies to all classes of women, but there are other special causes for uterine displacements in the case of women who have borne children.

Recall the anatomy of the uterine supports. The arrangements are extremely complicated. We were wont to think that the round ligaments and the perineum were the only structures concerned in holding the uterus in place. They are important parts, merely, of a complex mechanism. They alone are quite insufficient for the work. As with all other abdominal organs, the correct placing and securing of the uterus depends primarily upon the proper tonicity and normal relationship of surrounding organs. The natural position of the uterus is one of anteversion, when the rectum and bladder are empty. It moves backward and forward as those organs contract and expand. The uterine ligaments are all relaxed normally; they do not fix the uterus. Excessive backward displacement of the fundus is checked by the round ligaments and the vesicovaginal wall. Forward and downward displacements are controlled by the uterosacral ligaments, and lateral displacements by the broad ligaments. The pelvic floor has those muscles I have described, and contains structures divided into pubic and sacral segments. The pubic segment includes bladder, urethra, anterior vaginal wall, and bladder peritoneum. The sacral segment includes the rectum, perineum,

posterior vaginal wall, and strong tendinous and muscular tissue. Both segments spring strongly from powerful bony supports. So one

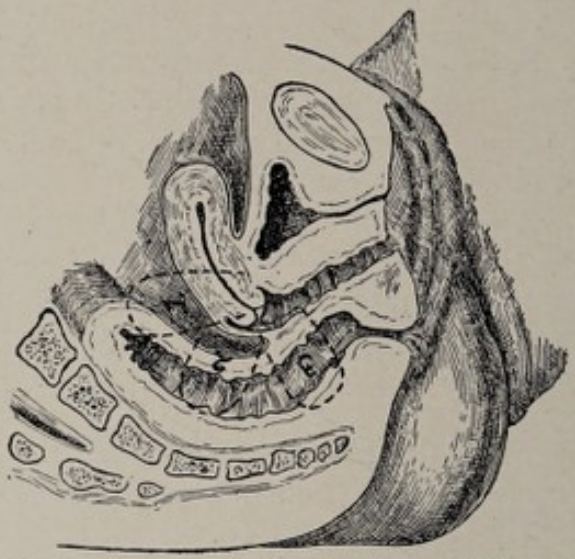

Fig. 154.—Retroversion (redrawn and adapted from H. Becker). Normal position of uterus, dotted lines showing 1, 2, 3, degrees of retroversion.

sees that malpositions of the uterus may be due to numbers of intricate, complicating, and interdependent causes. Remember, too, that dis-

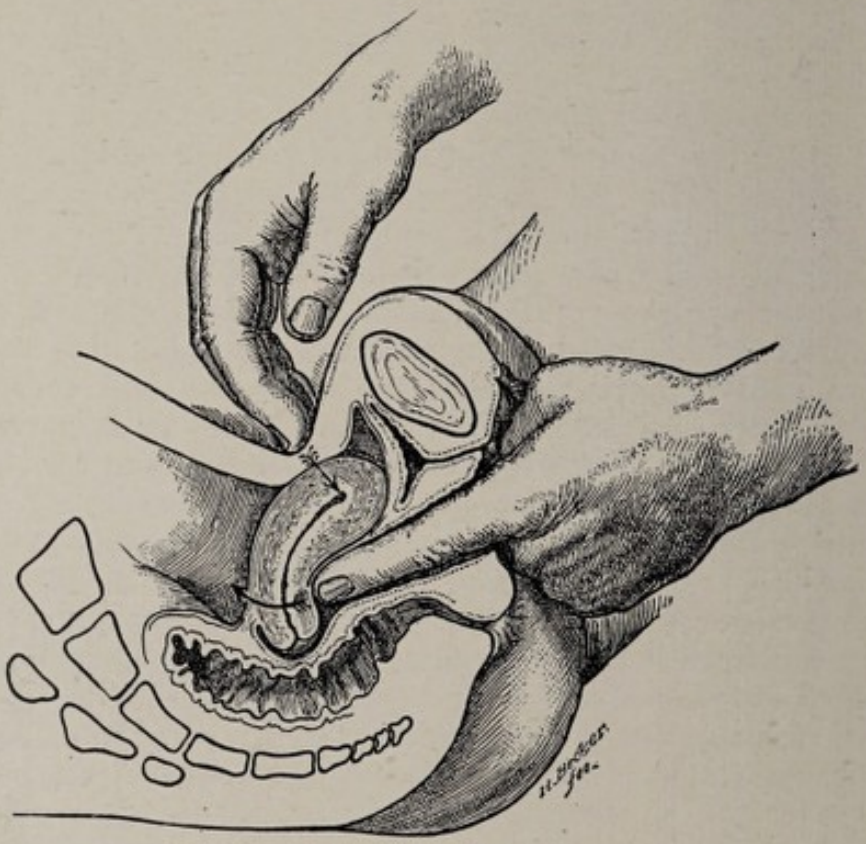

Fig. 155.—Anteversion (Kelly and Noble).

placements of the uterus do not in themselves constitute disease. Usually those displacements are but the index of other underlying troubles.

Surgeons are called upon to correct three common forms of displacement: (*a*) Backward displacements; (*b*) forward displacements, and (*c*) prolapse downward (procidentia), and all these displacements are wont to be associated, primarily or secondarily, with such complications as metritis, ovaritis, salpingitis, atresia, stenosis, cystitis, proctitis, tumors, etc. So the resulting symptoms may be correspondingly complicated and numerous. Each displacement may have its own special symptoms, which in turn depend on a various etiology. I have mentioned general abdominal ptosis, with which there is always associated general ill health and any of the familiar constitutional affections, such as anemia,

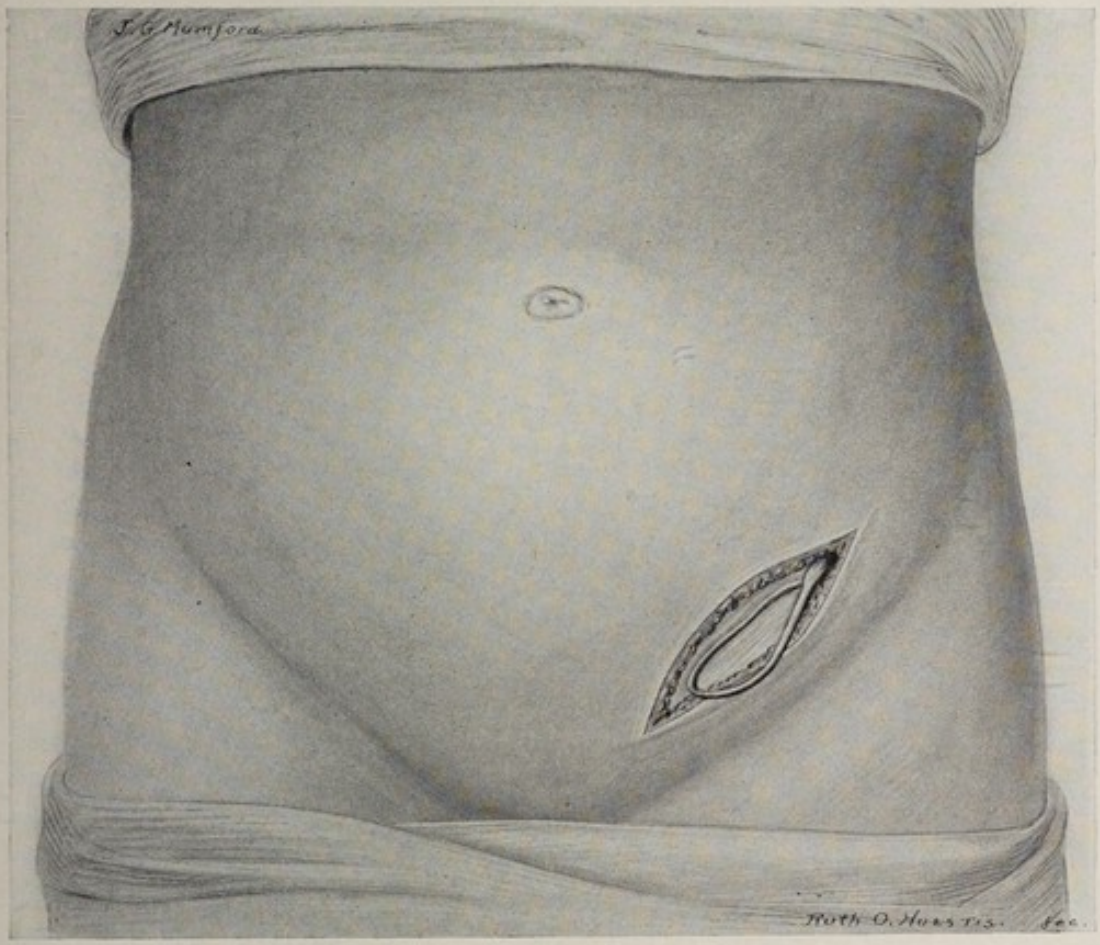

Fig. 156.—Alexander operation. Drawing out round ligament and stripping back investing peritoneum from the broad ligament (Dudley).

renal and cardiac disease, rheumatism, venereal disease, diabetes, etc. Uterine displacements may result from these general conditions, or they may be coincident merely, and by their presence add to the woman's misery.

Symptoms may be referred to the pelvic organs or to the nervous system. They may be absent at times; they are often influenced by posture, exercise, and diet. One observes dysmenorrhea, menorrhagia, sterility, recurring abortions, constipation, frequent, painful, or copious micturition. There may be sundry neuralgias, hysteria, dyspepsia, headaches, and blurring of vision. The **diagnosis** must rest upon the

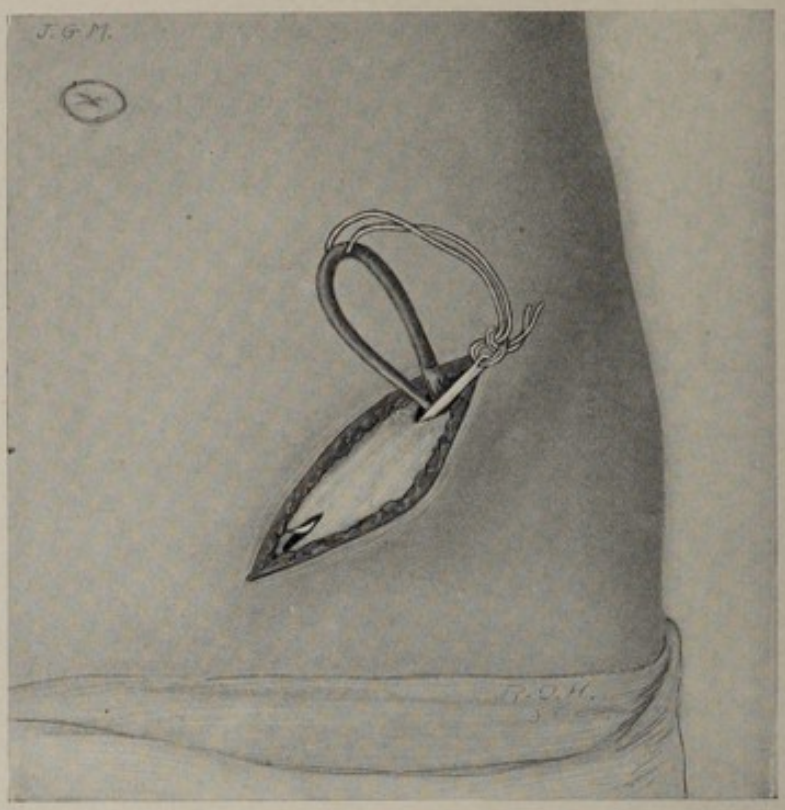

Fig. 157.—Alexander's operation—second step.

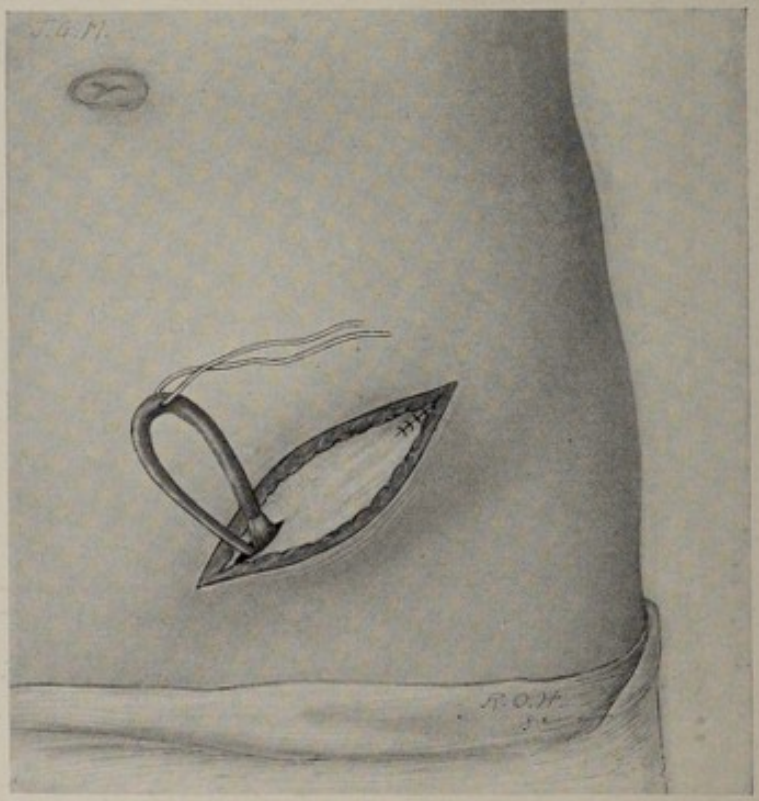

Fig. 158.—Alexander's operation—third step.

findings of examination: bimanual palpation, inspection with the speculum, and the passage of the uterine probe. Thus the position of the

uterus, as well as the presence of complicating disease, can be ascertained.

Retroversion of the womb is illustrated by the figures, and usually we recognize four stages or degrees.

Treatment of retroversion is by replacement, by the use of pessaries, or by surgical operation. Operation alone concerns us here. There are many operative procedures. As a preliminary to them all, treat associated conditions. Repair a torn cervix or a lacerated perineum. Remove complicating myomata, cysts, and diseased tubes. Having thus rendered the surrounding parts and conditions relatively normal, proceed to fasten up the uterus itself in its proper position of anteversion, after freeing any adhesions which may bind it down, and after stretching or cutting abnormally tight uterosacral ligaments.

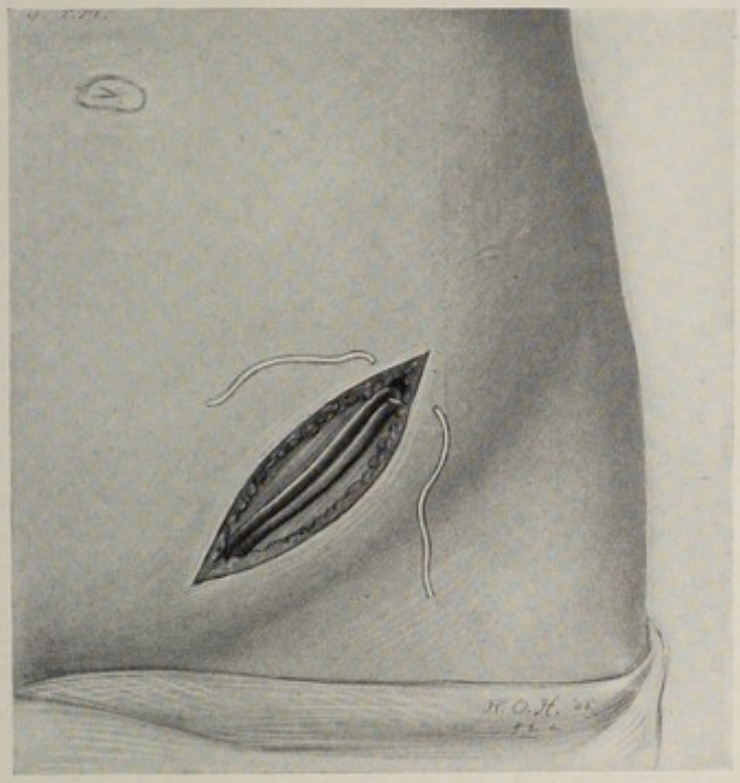

Fig. 159.—Alexander's operation.

The best measures for fastening forward the uterus aim at shortening the relaxed round ligaments, or at forming new artificial suspensory ligaments between the fundus uteri and the anterior abdominal wall. I use both procedures, and shall describe various methods with some few words of advice to govern the choice.[1]

Shortening the Round Ligaments Through the Inguinal Canal (Alexander's Operation).—This method carries with it the dignity of custom, authority, and considerable age, but it is often unsatisfactory, and should be undertaken in selected cases only. The plan of the operation is to shorten the round ligaments through the inguinal canal, and thus to hold up and forward the displaced uterus.

[1] See important paper by W. P. Graves on Retroversion and Its Treatment, an analysis of 500 cases, Boston Med. and Surg. Jour., July 4, 1907.

The patient should be carefully prepared by shaving and scrubbing, as for abdominal section. The inguinal canal is then exposed by incising over it, in a line parallel to Poupart's ligament, about two inches above the ligament and starting from the pubic spine on either side. Having discovered the canal, you may slit it up, or nick it in its upper portion over the internal ring and hook out the contents. Among these contents lies the round ligament, often considerably attenuated and sometimes hard to find. The uterus should then be elevated with the fingers

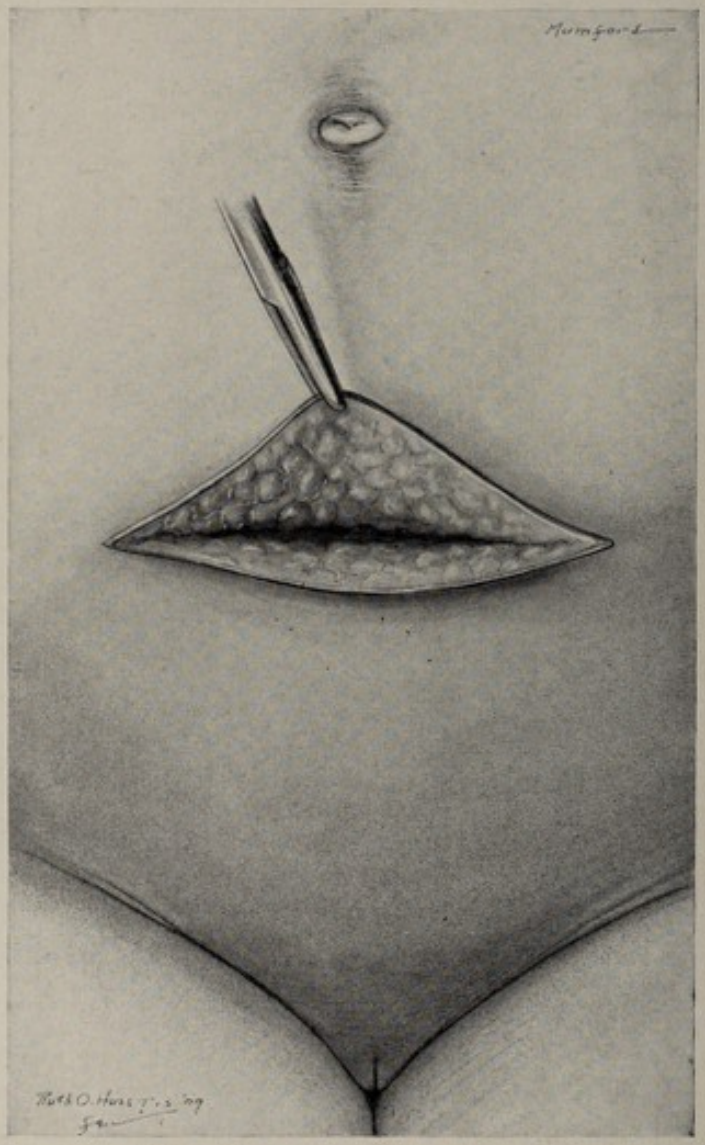

Fig. 160.—Suspension of uterus—step 1.

in the vagina, or with a preliminary packing, and in any case such a packing should be left in the vagina for three days after the operation in order to relieve pain and the strain on the ligaments. Having found the ligaments in the canal, one may secure them in various ways, after drawing them forward and stripping back the process of peritoneum—the canal of Nuck. They may be doubled upon themselves and sewed into the canal, or the ends may be pushed subcutaneously across the median line and sewed to each other where they overlap. The abdom-

inal wound should then be closed, and the patient should be treated as after any laparotomy, but eighteen days on the back should be insisted upon.

This operation is suitable for a young woman with normal uterus, free from adhesions and complications. In no other case is it to be recommended.

Suspension of the uterus through the vagina is to be mentioned only to be condemned. It is entirely unsuitable when complications exist, and in any case it fastens the uterus in a position of abnormal anteversion, with the great probability of causing pressure on the bladder with distressing bladder symptoms.

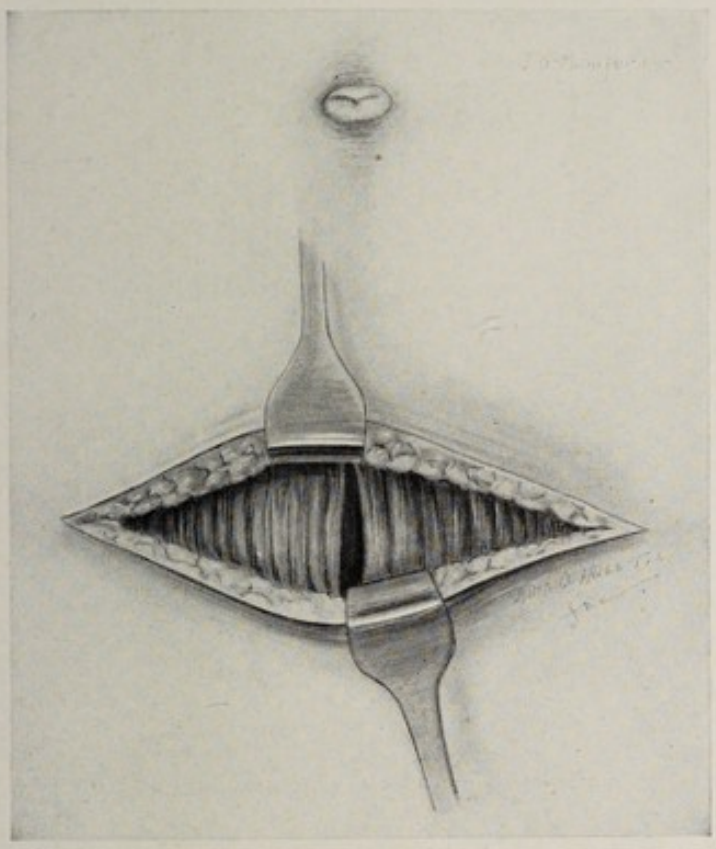

Fig. 161.—Suspension of uterus—step 2.

Suspension of the uterus through abdominal section is the method to be employed in most cases, for through the open abdomen alone can complications and adhesions be discovered and treated. No surgeon can determine always the presence and extent of complications by bimanual touch with the abdomen unopened.

The methods of operating by the abdominal route are numerous, and I shall describe two of them. The patient should be placed in the Trendelenburg position, at an angle of about 45 degrees.

Peritoneal Suspension.—Find the uterus and free it from all adhesions; treat appropriately diseased tubes and ovaries, and remove myomata; draw the uterus forward into the position of normal anteversion, and with stout silk or catgut stitches passed through the posterior aspect of

the fundus, fasten it to the peritoneum. Then sew up the peritoneum and repair the abdominal wall by layers. The stitches must be passed deeply through the uterine muscle, using the anterior uterine wall in young women, the posterior wall if the patient is past the menopause.[1] The result of this operation is that the uterus in a few weeks becomes suspended from the peritoneum by one or more processes of tissue which form new suspensory ligaments. The objections sometimes urged against this operation—that the new ligaments may become the cause of intestinal strangulation and that subsequent pregnancies are interfered

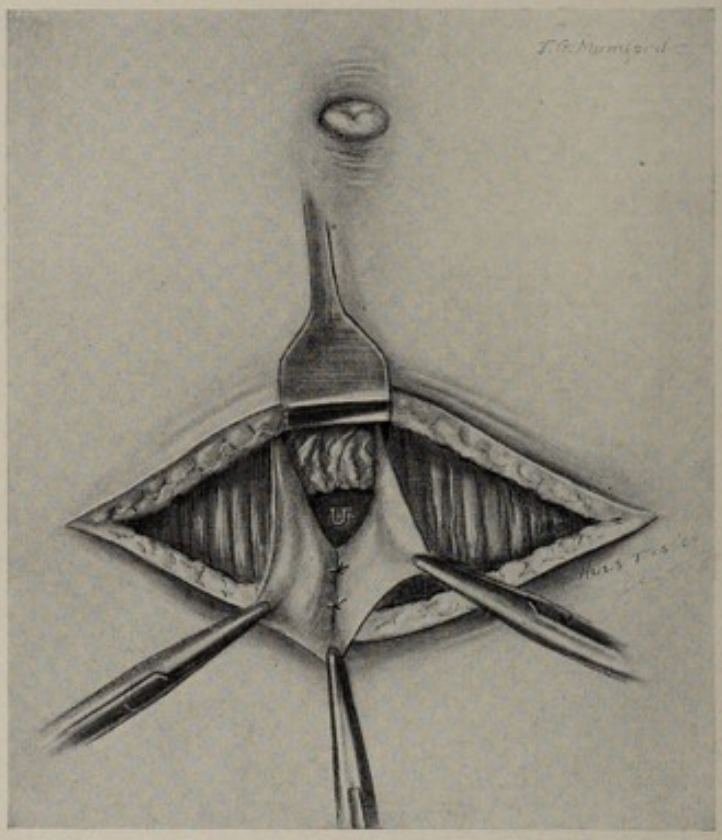

Fig. 162.—Suspension of uterus—step 3.

with—does not seem to hold good when the operation is properly performed.

Shortening the round ligaments by the intra-abdominal route is an excellent operation, and one which I have performed many times satisfactorily, combining the methods of Gilliam, Noble, Mayo, and Fowler. For this operation enter the abdomen by a transverse incision above the pubes, opening through the skin and aponeurosis (Pfannensteil), taking pains with gauze dissection to strip clean for five inches about the wound the aponeurosis and the underlying recti muscles. Then, with good retraction, split between the recti and open the peritoneum. I favor this transverse incision for entering the abdominal cavity, in this and other pelvic operations of lesser magnitude, because it gives a

[1] W. H. Baker's modification of this operation (commonly attributed to H. A. Kelly) is popular. Baker passes two suspension stitches, each at the cornua of the uterus.

resulting scar of great strength, while the exposure is ample. Having opened the peritoneum and relieved the uterus, seek the round ligaments in the broad ligament and put them on the stretch by hooking them away from the inguinal ring. Then make a new canal for them by drawing them through the border of the recti muscles, and fasten them together in front of the recti, sewing them outside of the aponeurosis, This operation is superior to that of Alexander for two reasons: it enables the operator to explore and treat the pelvis, and to deal with the strong

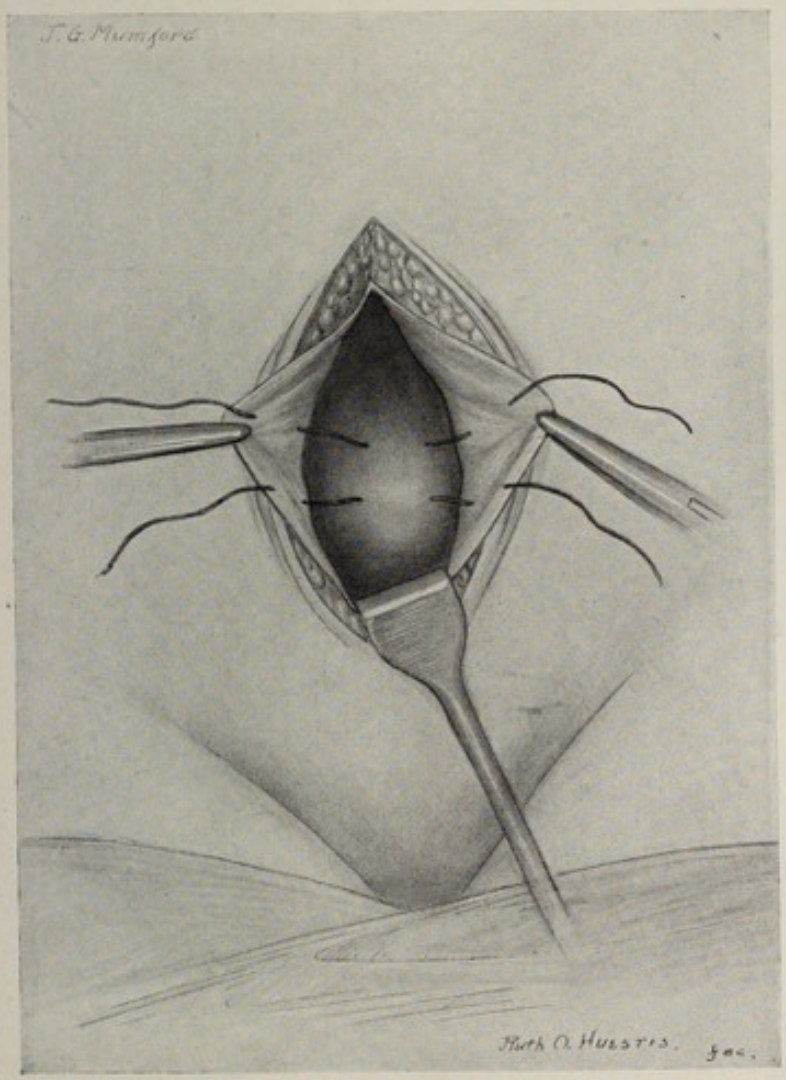

Fig. 163.—A method of suspending the uterus—step 3.

proximal portions of the ligaments, rather than with the frayed-out and weakened distal portions. Moreover, it enables him to secure the uterus in a normal position and to leave it freely swinging, and, under advantageous conditions, for a possible subsequent pregnancy. Several of my patients so treated have borne children afterward, while the pregnancies and labors have been in no way affected by the operation.

Other methods of shortening the round ligaments within the abdomen are advocated and practised, but I do not recommend them because they depend upon some form of infolding or doubling of the strong portion of

the ligaments, but leave the already weak distal attachments in the inguinal canal without reinforcement.

Retroflexion of the uterus is commonly associated with retroversion, and is due to much the same causes. Rarely, it is congenital. Infections, the pressure of tumors, and too early getting up after childbirth are the main factors in the etiology of acquired retroflexion. The *symptoms* are such as I have already described when speaking of retroversion, but particularly one observes painful and difficult defecation, frequent dyspareunia, and constant dragging or bearing-down pain in the region of the coccyx. The only satisfactory treatment is by operation through the abdomen. Remove the causes, straighten the organ after it has been dilated and cureted, and fasten it forward.

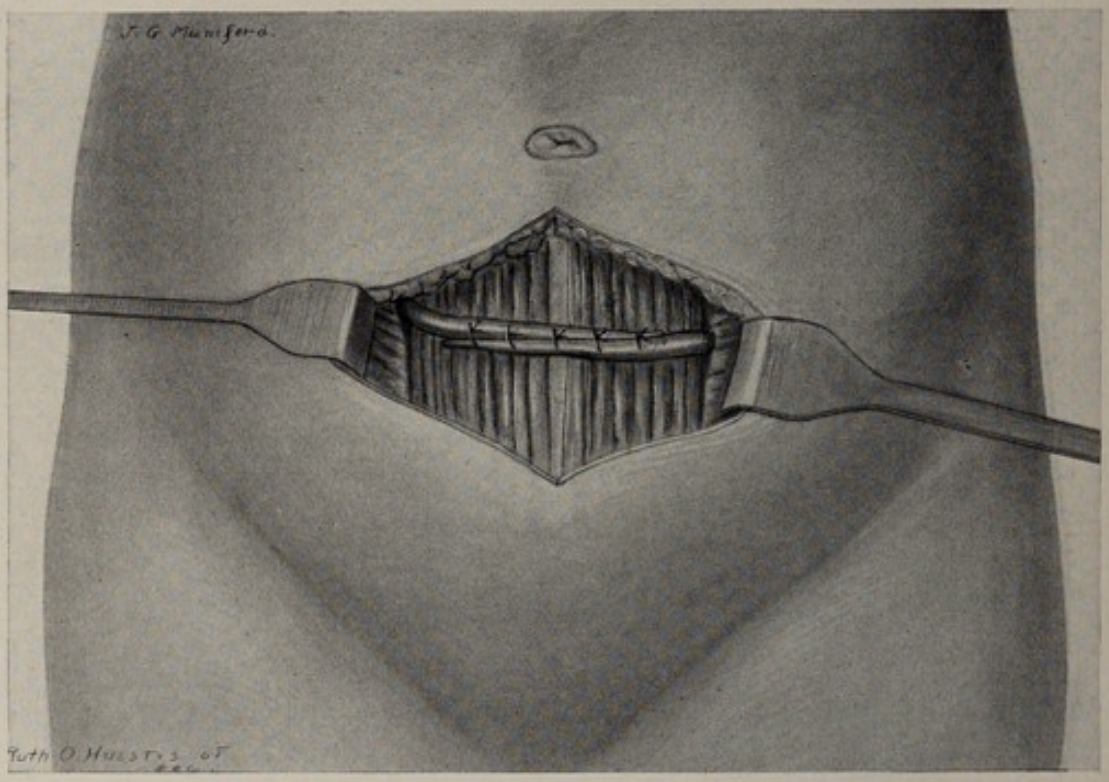

Fig. 164.—Shortening the round ligaments.

Anteversion of the uterus is a more nearly normal condition than is retroversion, but pathologic anteversion is much rarer than is retroversion. When anteversion does occur, it is sometimes associated with pathologic anteflexion. The *causes* of anteversion are adhesions, tumors, and metritis. Rarely, it may be congenital. The *symptoms* of anteversion are trifling, except when it is associated with anteflexion. (See Anteflexion.) The *diagnosis* of anteversion is made readily by bimanual touch, when the fundus is found to lie against the bladder, with the cervix pointing upward and backward toward the sacral promontory.

The *treatment* of anteversion is so closely associated with the treatment of its complications, or with the treatment of an accompanying anteflexion, that one must expend one's efforts on finding a remedy for these complications. The old-fashioned treatment by pessaries rarely

avails anything, for pessaries do not touch the complications. Inflammations of the mucosa must be treated by dilatation, cureting, and the application of iodin crystals, dissolved in 95 per cent. carbolic acid. Anteflexion must be treated as I shall describe in a succeeding paragraph, while para-uterine inflammations and tumors can be reached through abdominal section only. Indeed, you will be driven to exploration of the abdomen in many of these cases, and not infrequently you will find that hysterectomy alone will restore the patient to health. The result of hysterectomy in the case of elderly women for years the subjects of pelvic irritation, vesical pain, and frequency of micturition I have often found to be extremely gratifying.

Anteflexion of the uterus is not always distinguishable to the tyro from anteversion. Anteflexion means that the uterine body is bent at

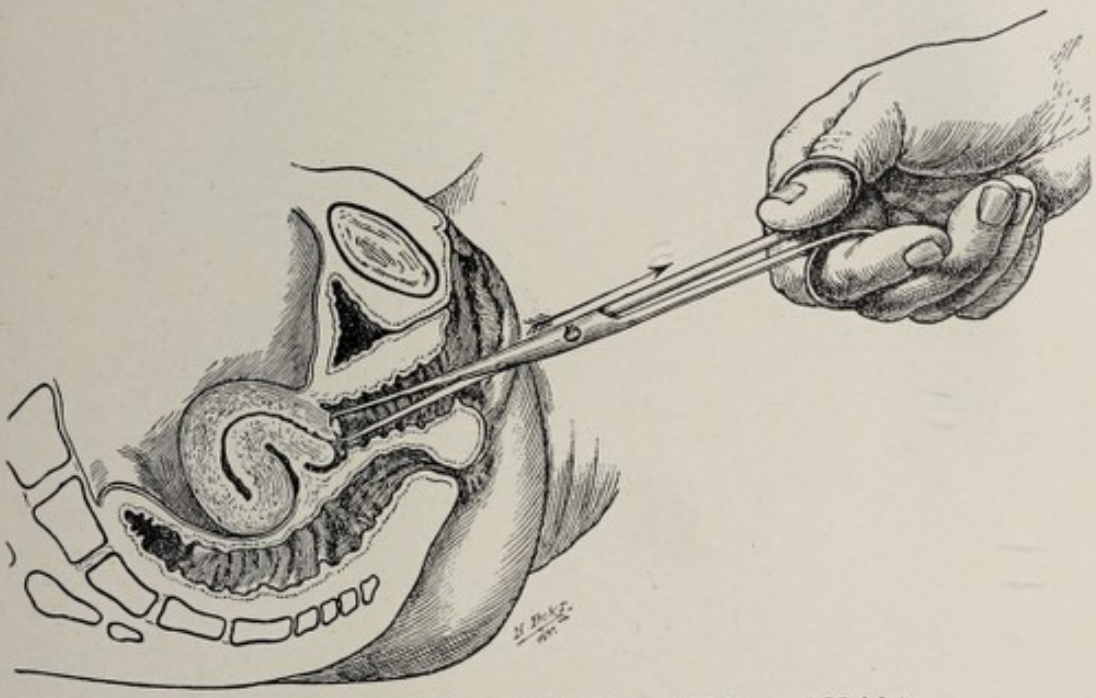

Fig. 165.—Retroflexion of the uterus (Kelly and Noble).

an angle with the cervix. On examination you will find the fundus in apparently normal position, or perhaps tipped over against the bladder, while the cervix points forward into the vaginal canal instead of pointing backward toward the coccyx in line with the fundus. There may be all manner of variations from this position, and flexions may be complicated with versions. The etiology of anteflexion is not always apparent. The condition may be congenital and may be due to inflammations or to tumors.

The *symptoms* are similar to those of anteversion, with the addition that bladder irritation is apt to be more urgent, and dysmenorrhea more painful throughout the flow, while sterility is extremely common. The *diagnosis* is made by the sense of touch, while one must appreciate that the fundus is bent at an angle with the cervix. An erroneous diagnosis of anteflexion is often due to the presence of a myoma in the an-

terior wall of the fundus—a myoma which gives to the examiner the impression that this tumor is the fundus itself bent forward. Exploration with the uterine probe is necessary to correct this false impression. The *treatment* of anteflexion is palliative or radical. In the case of an unmarried woman or a married woman who has not borne children, whose sterility is evidently due to the flexion, the deformity may be corrected by thorough dilatation and cureting and the wearing of a hol-

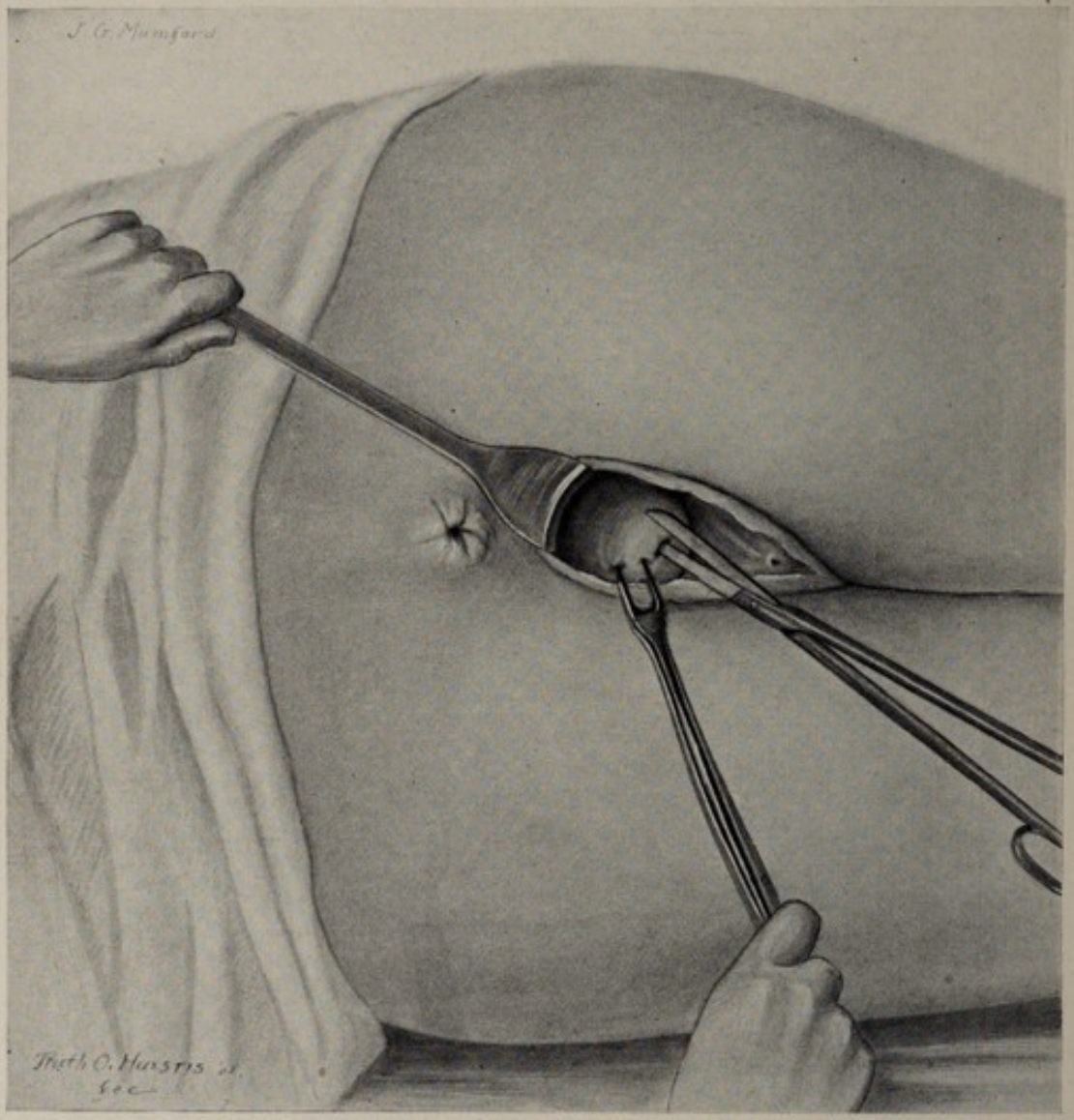

Fig. 166.—Dudley's operation for anteflexion of uterus—step 1. Patient in Sims' position, cervix held down with double hook tenaculum, scissors introduced.

low glass stem for several weeks. A previously sterile woman may promptly become pregnant after this operation, and the deformity may thus be cured, but, as a rule, the flexion will return after dilatation and cureting only.

E. C. Dudley's operation is one I have practised with satisfaction. It is illustrated by the figures. Dilate the uterine canal and curet it, then perform the following plastic operation: draw down the cervix and divide it backward in the median line, past the uterovaginal attach-

ment, nearly to the uteroperitoneal fold; hold the cut surfaces widely apart and deepen the wound in the uterine wall with a knife. Then excise from either side of the cut surface a small triangular notch, as shown in Fig. 167. Fold back the flaps and approximate the cut edges

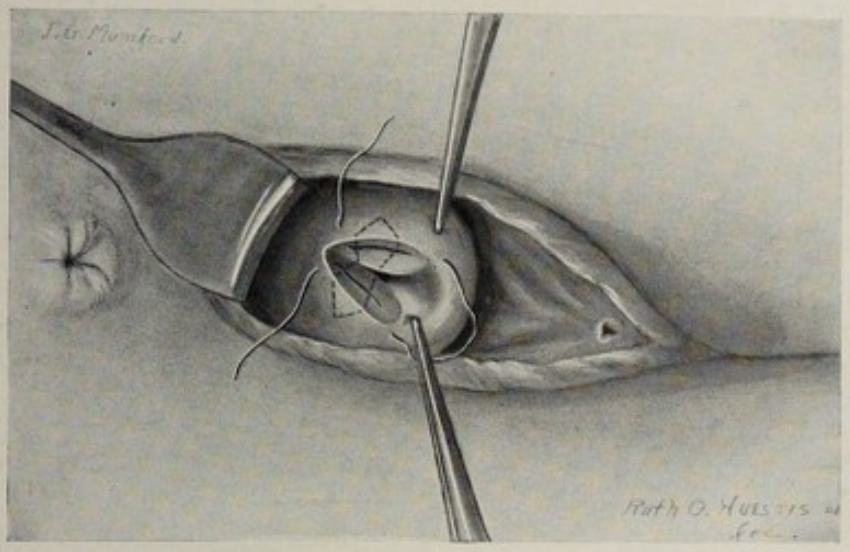

Fig. 167.—Dudley's operation for anteflexion of the uterus—step 2. The cut surfaces held apart by tenacula. The dotted lines show wedge-shaped pieces to be removed by scissors, in order to make the cut surfaces more readily fold upon themselves. Suture designed to fold cut surfaces on themselves, in place, but not tied.

from before backward, enlarging and changing the direction of the canal on the same principle as that employed in a Heineke-Mikulicz pyloroplasty. It is well to use silkworm-gut for this suture. As a

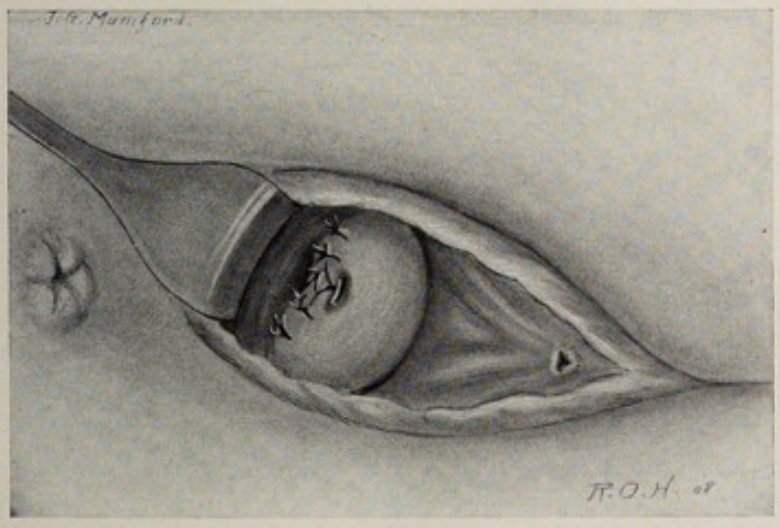

Fig. 168.—Dudley's operation for anteflexion of the uterus—step 3. Suture shown in Fig. 167 tied, and additional sutures designed to fortify this one also introduced and tied. This ordinarily completes the operation.

result of this maneuver the cervix is straightened backward and is made to point in the axis of the fundus. Dudley points out that in some cases there remains an abnormally long anterior lip.

Descent of the Uterus and Procidentia.—The various malpositions of the uterus which I have described are frequently associated with a general descent of that organ, and prolapse of the uterus through the vagina, even to the extent of its protrusion through the vulva, is common. After protrusion through the vulva the condition is called procidentia. Procidentia must not be confounded with inversion. Persons with prolapse of the uterus are commonly women who have borne children and have suffered from extensive weakening of the uterine ligaments and wide lacerations of the pelvic floor. But descent of the uterus is not confined to such persons. Occasionally, one finds uterine prolapse in women who have never been pregnant, but whose uterine supports have been weakened by hard work, constant standing, or pressure from above. These factors are often found also in the case of women

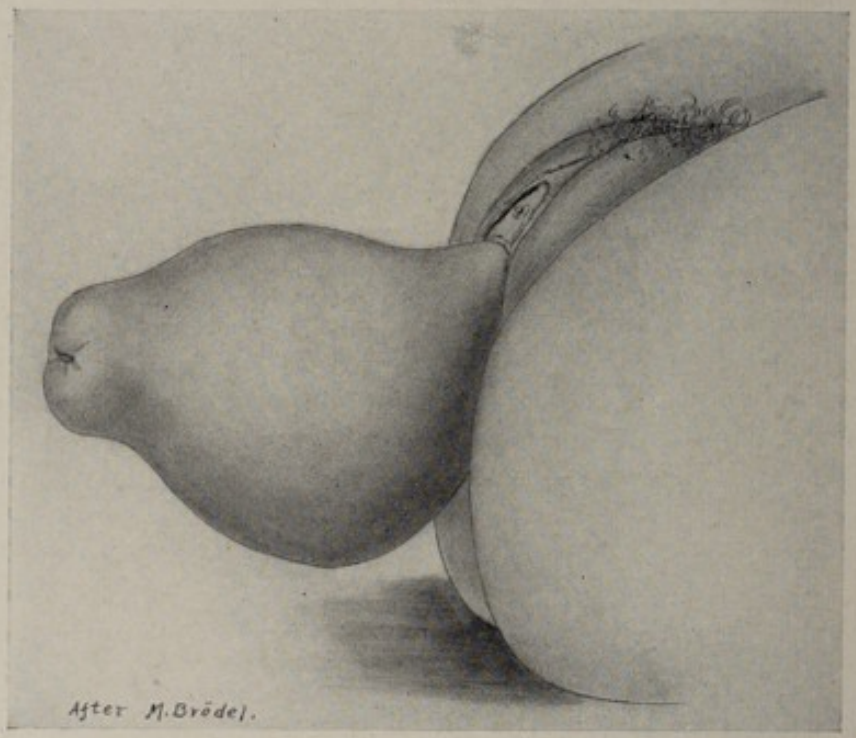

Fig. 169.—Complete prolapse of the vagina and uterus, with retroflexion (procidentia).

who have borne children. The figure illustrates the nature of *descensus uteri*. At first the organ sinks low in the pelvis, assumes a position of retroversion parallel with the vaginal axis, and then falls lower and lower, infolding the vagina below it until the whole uterus drops out through the vulva. There is associated with this prolapse a stretching of the bladder and rectum, so that one finds accompanying cystocele and rectocele. Such uteri are usually found to be heavy, engorged, subinvoluted, inflamed, lacerated, and often the seat of tumors and retention cysts. The *symptoms* are constant and distressing, as I have already stated when describing the general symptoms of uterine displacements. Furthermore, the presence of the uterus outside the vulva is a continual irritation, while the rectal and vesical distress becomes almost unendurable. The *diagnosis* is generally obvious, but if one is in doubt as

to the extent of the descensus, when the patient is lying on her back, he may readily solve the question by having her stand up and strain, when the uterus will protrude to its limit.

Treatment of Procidentia.—We need not concern ourselves here with palliative measures, such as replacement and the use of pessaries. Pessaries may be our only resource in the case of old and feeble persons, but the only hope of radical cure lies in some form of operation. Let me warn the student that operations for prolapse of the uterus are often disappointing in the long run, even after the organ seems to have been effectually secured high within the pelvis. The first desideratum is a



Fig. 170.—Primary prolapse of the uterus.

sound perineal floor, and the repair especially of the strong supporting levator ani muscle. I shall describe this repair in Chapter XII. But even with the perineal floor repaired, a heavy uterus, armed with a long conic cervix and otherwise unsupported, may still worm its way down through the tightest perineum. The terms *pelvic hernia* and *perineal hernia* have been applied to this condition of prolapse. The condition is properly one of hernia, so that after hysterectomy even one may find a protrusion of the abdominal viscera through the weakened pelvic outlet. In severe cases of procidentia, therefore, the surgeon is forced to some form of abdominal operation in addition to his repair of the perineum, and it may be well also to amputate a long cervix. If one be forced

to open the abdomen, he should carefully ascertain the state of all the abdominal viscera. He should remove tumors and should treat appropriately the products of inflammation. Ovarian cysts and uterine myomata are frequent complications of procidentia, and their removal alone may suffice for its cure. If the uterus is small and in fairly healthy condition, anchor it to the anterior abdominal wall. This operation of anchoring is properly called *ventrofixation*, and is a quite different matter from that *ventrosuspension* which I have described. To fix the uterus, denude a considerable patch of peritoneum from its fundus,—a patch as

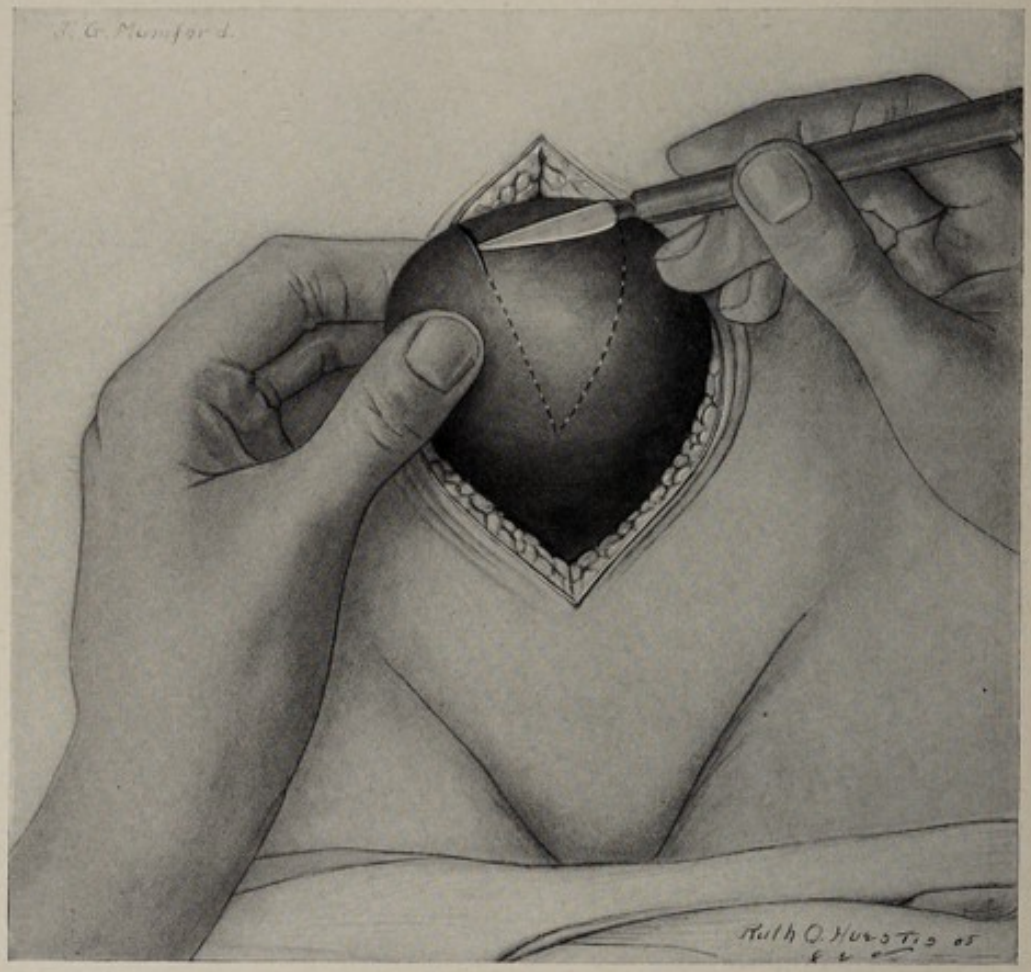

Fig. 171.—Operation for procidentia, as suggested by G. W. Crile. Dotted line indicates line of incision—step 1.

large, at least, as a fifty-cent piece,—and attach the uterus firmly at the denuded portion to the anterior abdominal wall, passing the stitches deeply through parietal aponeurosis, recti muscles, peritoneum, and uterus. This maneuver results in establishing broad and firm adhesions, which should not stretch or allow subsequent sagging of the uterus.

If this operation prove unsuccessful, it may be necessary to perform hysterectomy, which may be done either by amputating the uterus through the cervix, or by removing the whole organ and closing the vagina. If the uterus is amputated through the cervix, the shortened

stumps of the round ligaments should be stitched to the cervical stump for extra support of the perineal floor. But, as I have said, total hysterectomy does not insure the patient against a perineal hernia. To insure against hernia, various operations have been devised, but I recommend that advocated by G. W. Crile, as I have employed it frequently and with great satisfaction during the past five years. Briefly, his operation is this: Having opened the abdomen, seize the uterus and draw it up; tie off the ovarian arteries; perform a modified supravaginal hysterectomy, leaving long lateral tabs or fish-tails projecting up from either side of the cervix, and suspend the cervix by these long fish-tails,

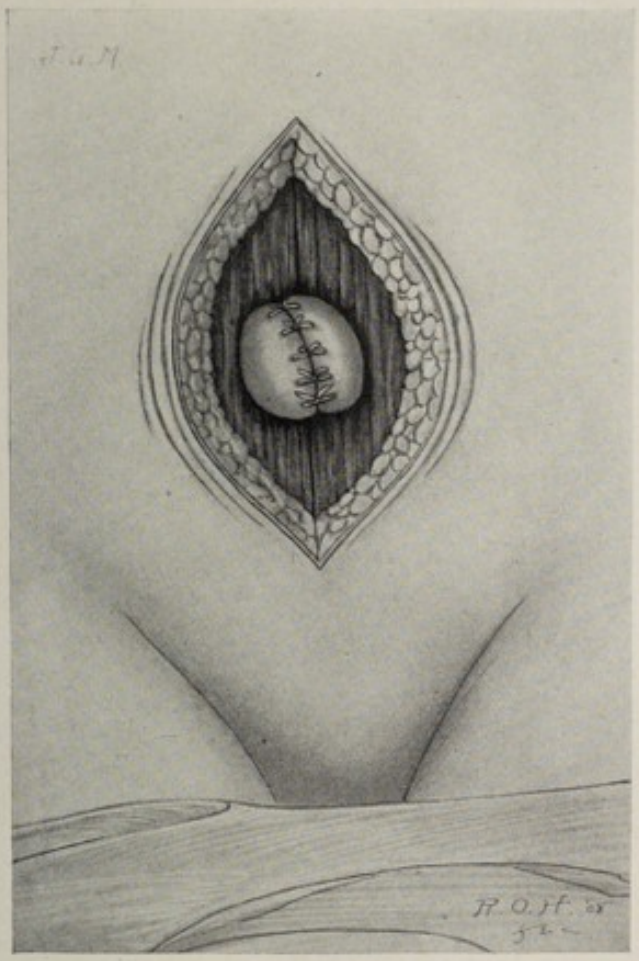

Fig. 172.—Operation for procidentia, after Crile—step 2.

drawing them through the bodies of the recti muscles, and stitching them together much as the round ligaments are stitched together above the recti in suspending the retroverted uterus.

After any of these operations upon the prolapsed uterus a long period of rest and care is needed. These women are usually debilitated from prolonged suffering and their tissues are relaxed and toneless. They have been the subjects of aggravated forms of hernia, which, at the best, have not been adequately repaired or restored to natural conditions, so that convalescence is tedious, demanding special care and upbuilding.

TUMORS OF THE UTERUS

Forty years ago amputation at the hip-joint was the great capital operation of surgery—rare and interesting. It was said that no surgeon had won his spurs until he had performed this operation successfully. Twenty-five years ago ovariotomy took the leading place in the estimation of operators, and fifteen years ago *hysterectomy* was to the fore. To-day, surgeons who are busied with new questions are venturing into other fields, but hysterectomy and other serious operations on the uterus still hold an important place in surgical literature. The history of hysterectomy is recent, and every surgeon of fifteen years' experience remembers the use of the Koeberle clamp, and how we fastened the cervical stump outside of the abdominal cavity. But interest in hysterectomy is far more ancient. It was probably practised by the Greeks; it was performed in 1560 by Andreas á Cruce; von Langenbeck removed the uterus in 1813; Sauter, in 1822, and sundry other operators, until we come to such well-known moderns as Billroth, von Mikulicz, and Freund. In 1887 Dudley had collected 38 cases by American surgeons, while to-day it is one of the commonest operations known in our amphitheaters.

MYOMA

The most frequent tumors of the uterus are myomata, which are non-malignant growths composed of non-striated muscle-fibers and fibrous connective tissue. The old term is " fibroid," or " fibromyoma," but,

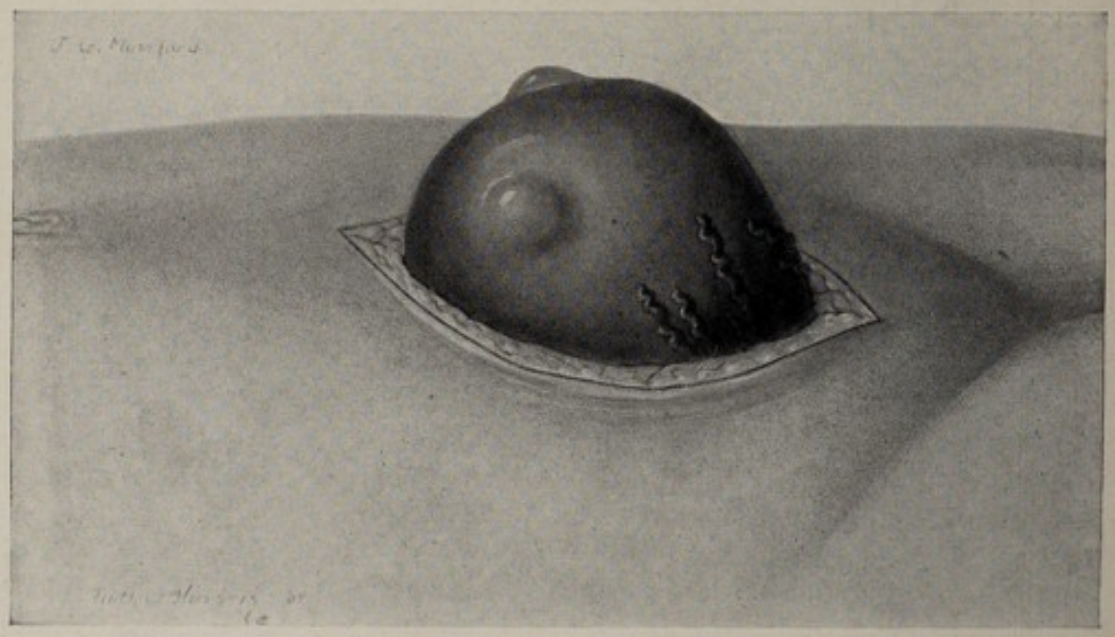

Fig. 173.—Myoma of uterus, showing greatly distended veins.

in fact, all these tumors arise from muscle substance and connective muscular elements, though the fibroid character often may predominate. We do not know the cause of these tumors. They grow during the period of sexual maturity. Rarely they appear before puberty or after the menopause. They are more common among negroes than whites.

There is no satisfactory evidence that they arise from traumatism. Myomata vary in size from a pea to a mass larger than a child's head; they may be multiple or single; they may be hard or soft, depending upon the preponderance of fibrous elements and the character of the blood-vessels, for sometimes the veins reach a great size and appear as dilated sinuses.

According to the site of these tumors they are designated variously as submucous, intramural, and subserous; they may undergo certain secondary changes: fatty degeneration; mucoid degeneration; cystic degeneration; calcification; septic infection, and malignant changes. Submucous fibroids encroach upon the lumen of the uterus and may obstruct it or render it tortuous. They may be pedunculated, and hang down as polypi in the uterus, and they may protrude from the os. Intramural myomata are usually multiple, and often cause an apparent enlargement of the whole uterus, so that the organ may seem to fill the abdominal cavity and distend its walls, giving the appearance of pregnancy at full term. Subserous myomata may be single or multiple, and may be associated with other forms of myomata —intramural and submucous. Subserous fibroids may appear merely as excrescences beneath the serosa, or may be pedunculated. Rarely isolated myomata free in the abdominal cavity have been described. Subserous fibroids may project from the sides of the uterus and distend the broad ligaments, in which case they are known as intraligamentous myomata. Commonly these uterine tumors are in the fundus, but infrequently they develop in the cervix, and they may appear in the vaginal portion only.

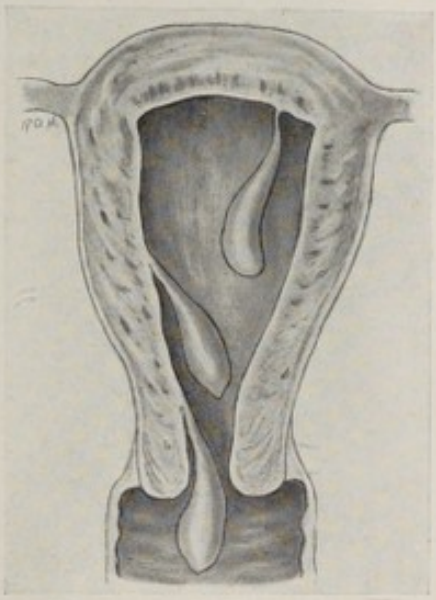

Fig. 174.—Polypi in uterus.

The **symptoms** of uterine myomata may be numerous and distressing, or there may be no symptoms. The disease may first make itself known during a pregnancy, at which time the tumor may grow rapidly. The common and alarming symptom of myomata is *hemorrhage*. This hemorrhage is due to endometritis, dependent on irritation by the growth. The blood does not come directly from the tumor itself. The flow comes on gradually, not suddenly and profusely, as is the case with hemorrhage from cancer. The patient notices that her menstrual periods come more frequently than common, and that the flowing is more abundant and more prolonged. This condition persists, and the disturbance increases until eventually the patient may be the victim of frequent attacks of long-continued and alarming hemorrhage, prostrating her and threatening life even. The advent of the menopause may or may not affect the hemorrhages. Sometimes the tumor shrinks at that period and the hemorrhage ceases. In other cases the menopause seems

to be the signal for renewed activity on the part of the tumor, which grows and causes more hemorrhage than ever.

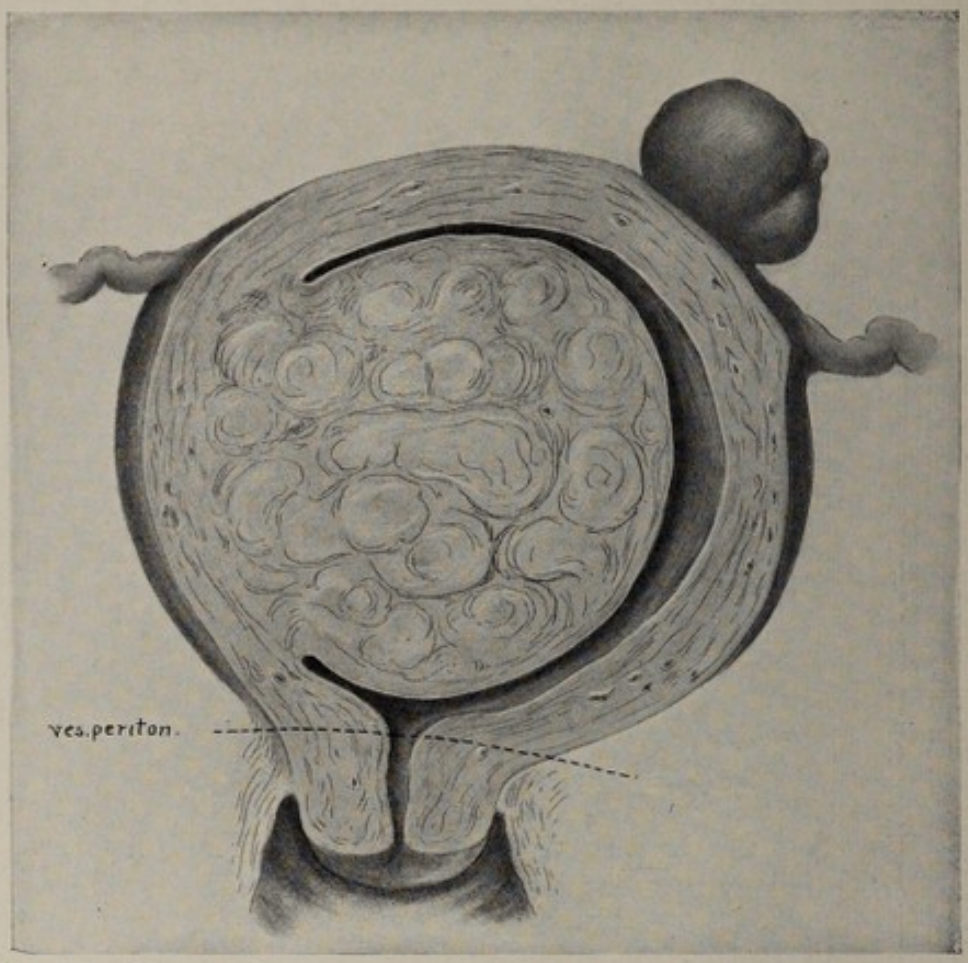

Fig. 175.—Large submucous myoma (H. A. Kelly). Adapted to removal by abdominal section by splitting open the uterus and enucleating the tumor, and then sewing up the uterine incision.

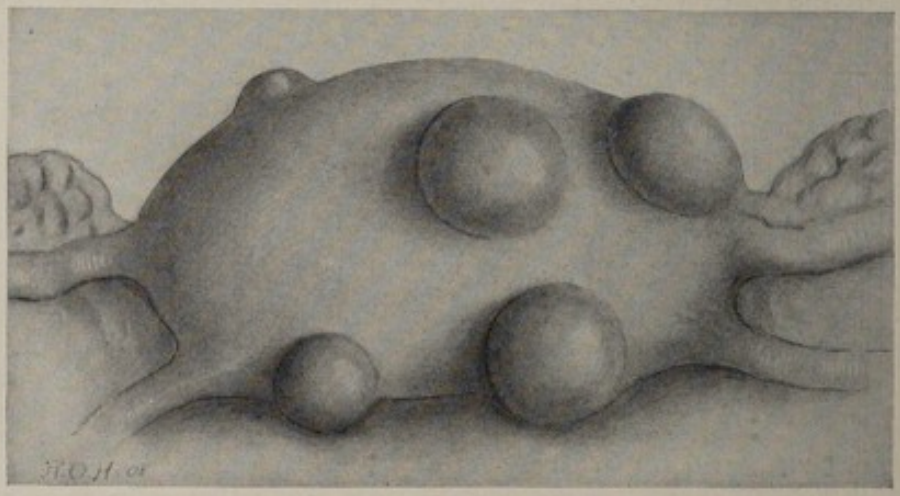

Fig. 176.—Myomata.

The symptoms of pressure, traction, pain, and discomfort are next in importance to hemorrhage. The causes and nature of these symptoms are obvious when one considers the position of the uterus and its rela-

tions to other organs. In most cases the uterus itself becomes somewhat enlarged, although an actual increase in the uterine body is not invariable. With its associated tumors it may press downward or upward, backward or forward. It may drag or press upon the rectum, the bladder, the urethra, the vagina, and may interfere with the functions of the intestines and other abdominal organs, for it may become inflamed and set up adhesions. As a result of all these derangements there may be obstinate constipation, frequent micturition, leukorrhea,—dysmenorrhea is common,—pain in the region of the coccyx or sacrum, colicky stomachache, dyspepsia, headache, nausea, blurring of vision, and many other indefinite abdominal and general nervous symptoms.

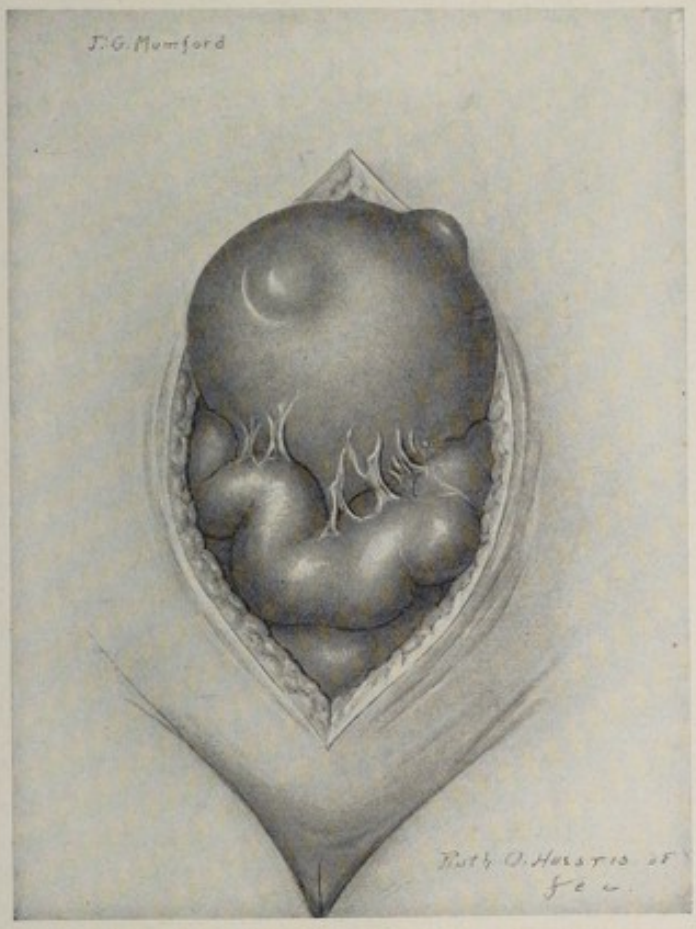

Fig. 177.—Adhesions to uterine myoma.

The **diagnosis** of uterine myoma is not so easy as would appear. Especially, these tumors must be distinguished from tumors of the ovary and from intraligamentous cysts. Often it is extremely difficult to distinguish a tense cyst from a soft myoma. The common symptom of hemorrhage is not pathognomonic of myoma; associated growths and extensive adhesions may render obscure the diagnosis to the examining hands. The surgeon should make a bimanual examination and map out the lower portion of the mass with fingers in the rectum as well as in the vagina. He should also endeavor to distinguish a uniform myomatous enlargement of the uterus from a pregnancy—often an extremely diffi-

cult matter. In this connection he should ascertain accurately the time, character, and amount of hemorrhage, the condition of the breasts, and the presence or absence of a fetal heart. Pregnancy may be present in a myomatous uterus. The uterine probe is a valuable adjunct in making the diagnosis of myoma, and usually it can be employed when the question of a possible pregnancy has been eliminated. The probe will follow the uterine canal often to a considerable depth,—4, 6, or 8 inches,—and by its means one may demonstrate the relation of the uterus itself to the associated new-growth. Other conditions to be differentiated from myoma are malignant growths, chronic metritis, inversions and displacements of the uterus, incomplete abortion, disease and pregnancy in the tubes, and floating kidney.

The **prognosis** of uterine myoma is a much-debated question. Deaver[1] wrote an extremely interesting article on the subject a few years ago, and claimed that the great majority of these cases come to no harm if let alone. It is a fair estimate that of all women over thirty-five years of age 20 per cent. are subjects of these growths, and undoubtedly great numbers of such women have no special discomfort beyond some increase of the normal flowing and some enlargement of the abdomen. As opposed to Deaver's view, many gynecologists assert that every uterine myoma should be removed on account of the danger to life from hemorrhage, exhaustion, and possible malignant degeneration. That question of malignant degeneration is extremely important; some statistics show that not more than 5 per cent. of these growths become malignant. However that may be, every surgeon of experience has seen cases of myoma associated with malignant changes, and in view of this fact one cannot but regard such malignant degeneration as possible in every case of myoma. On the whole, one agrees with Deaver that the majority of myomata do not endanger life, but one should bear in mind the possible dangers and should take his measures accordingly. My own practice is to advise removal of the tumor, the patient's general condition permitting, in all cases in which symptoms are persistent during the age of menstrual activity; and after the menopause, if the tumor continues to grow, whether or not troublesome symptoms be present.

The **treatment of myoma uteri** is operative, so far as anything more than mere palliation is concerned, though there are sundry traditional and tentative measures which the practitioner may be tempted to follow. Tonic doses of ergot or ergot and hydrastis canadensis are sometimes of value to control hemorrhage—15 drops every four hours or oftener. This dosage, combined with an ice-bag over the tumor, may check hemorrhage and allow of the building up of the patient preliminary to operation. Manipulation of the tumor may sometimes relieve incarceration below the sacral promontory, and so enable the patient to get along with less discomfort and pain. Excessive hemorrhage may be controlled by packing the uterus with gauze or by steaming. Steaming is remarkably useful in some cases. The technic is to introduce steam drawn from a small " steamer" and carried through a 3- or 4-foot tube, armed

[1] Amer. Med., April 15, 1905.

with a glass nozzle, through an intra-uterine speculum, directly into the cavity of the uterus. Let a stream of cold water play over the speculum to prevent its becoming superheated; inject the steam for forty seconds, then withdraw the nozzle for a couple of minutes, and introduce it again for thirty seconds. This treatment brings about a necrosis of the endometrium and results in thickening and scar formation—enough, often, to prohibit subsequent hemorrhage. Do not waste time with styptics to control hemorrhage, nor weary yourself and the patient with electrolysis, which is often dangerous as well as useless.

Surgical operations for these myomata may be performed through the vagina or by abdominal section. The latter is preferable in most cases. Moreover, these operations may be conservative or destructive

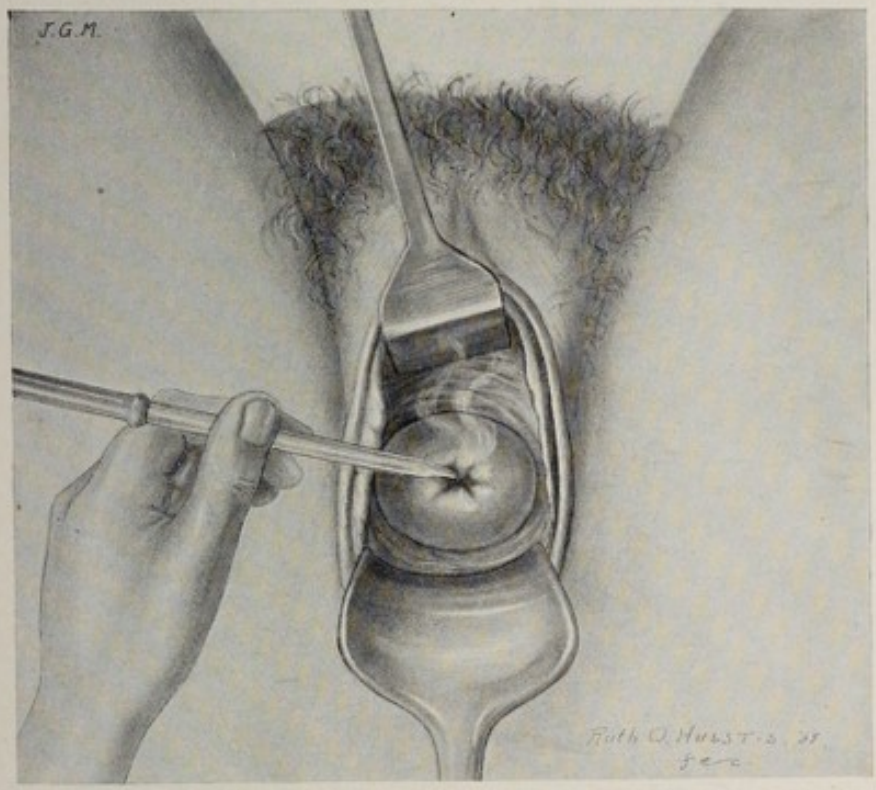

Fig. 178.—Steaming the uterus: Obviously, the surgeon must protect his hand with glove and wet sponge. A uterine speculum or hollow tube should be in the cervix to carry the steam to the endometrium.

—that is to say, they may be designed to remove the tumors or to remove the uterus with the tumors; and in the latter case the removal of the uterus may be total (panhysterectomy) or partial (supravaginal hysterectomy).

In addition to these operations, authors have claimed great things for milder measures. Gottschalk, of Berlin, ties the uterine arteries and claims thus to check the progress of the growths. Martin ties the broad ligaments, but does not include the uterine arteries. Battey, Tait, and others have claimed good things through the removal of the tubes and ovaries; but such procedures have not borne out their first promise.

Vaginal operations have their place in the treatment of myomata,

and usually are applicable to small tumors. By the vaginal route one may remove submucous polypi. By the same route one may remove the whole uterus or may enucleate tumors and leave the uterus. My experience with vaginal hysterectomy for myoma does not lead me to recommend this method, although the operation itself may be extremely easy. I cannot regard it as a proper routine surgical procedure, because it does not allow of a thorough inspection of the field and treatment of complications. The presence of extensive adhesions and inflamed tubes and ovaries may render the vaginal operation extremely difficult, and the ureters cannot always easily be avoided. On the whole, vaginal hysterectomy for myoma is as difficult or more difficult than abdominal

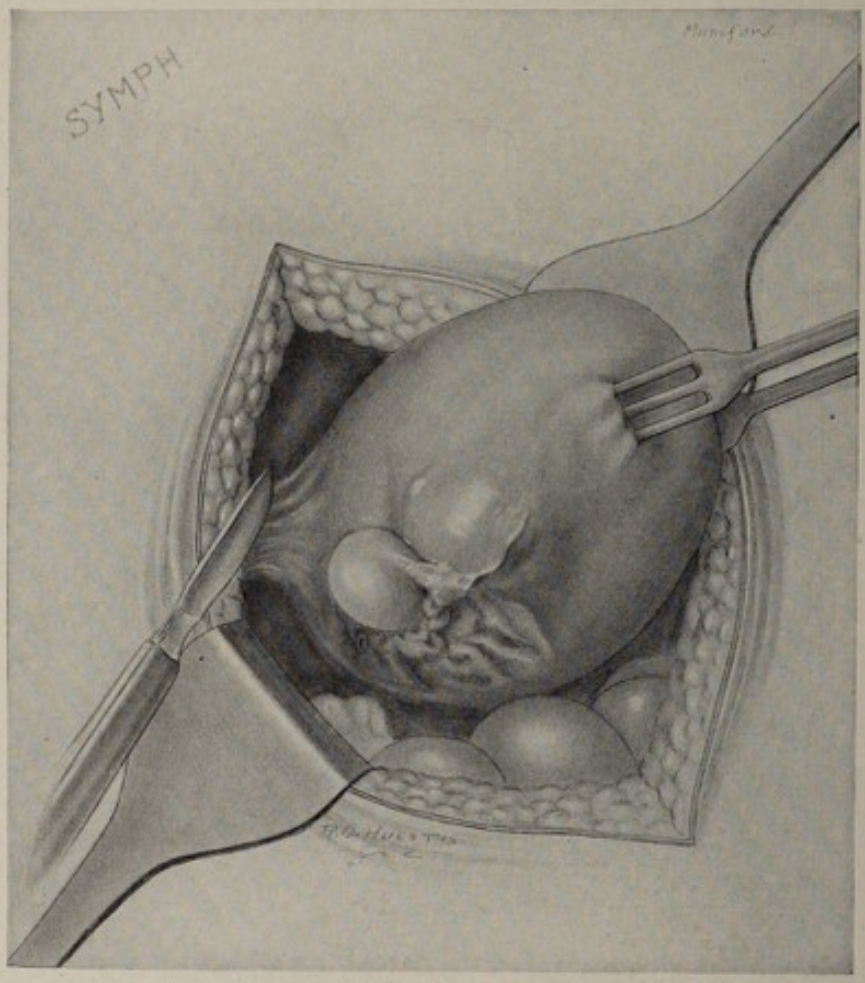

Fig. 179.—Removal of subserous myoma of uterus.

hysterectomy, and the mortality is no lower. I shall describe the technic shortly under the topic Cancer of the Uterus.

Vaginal enucleations and morcellation are operations of doubtful value. They are blind and unsurgical, and they leave the operator in the dark as to possible complicating conditions. Tumors confined to the cervix, however, and pedunculated growths in the uterine cavity should be removed by the vaginal route. For the removal of the latter the wire snare and scissors are generally sufficient, but it may be necessary to split up the cervical canal in order to allow of proper handling of instruments within the cavity and the removal of masses choking the os.

Abdominal Operations.—Myomectomy.—Strangely enough, the conservative operation of myomectomy came into general use long after the radical hysterectomy had become familiar. By myomectomy we

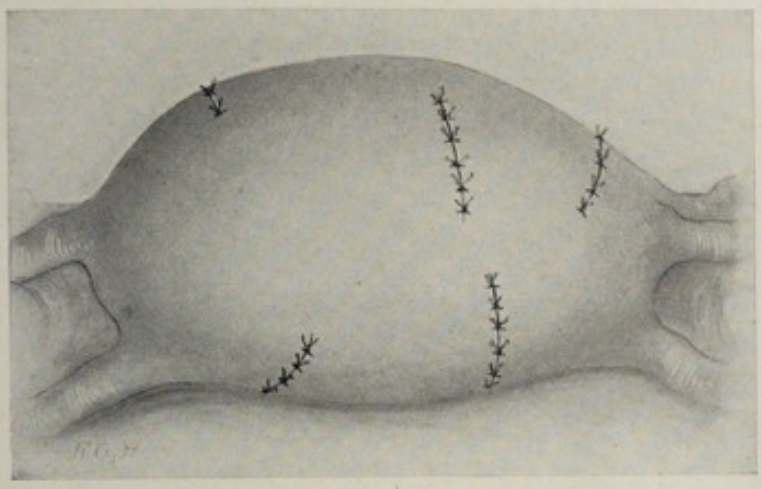

Fig. 180.—Removal of myomata.

mean shelling out the myomata, one by one, from the uterus. The operation is so easy in appropriate cases that nothing more than the illustrations are needed to demonstrate it. Open the abdomen; throw

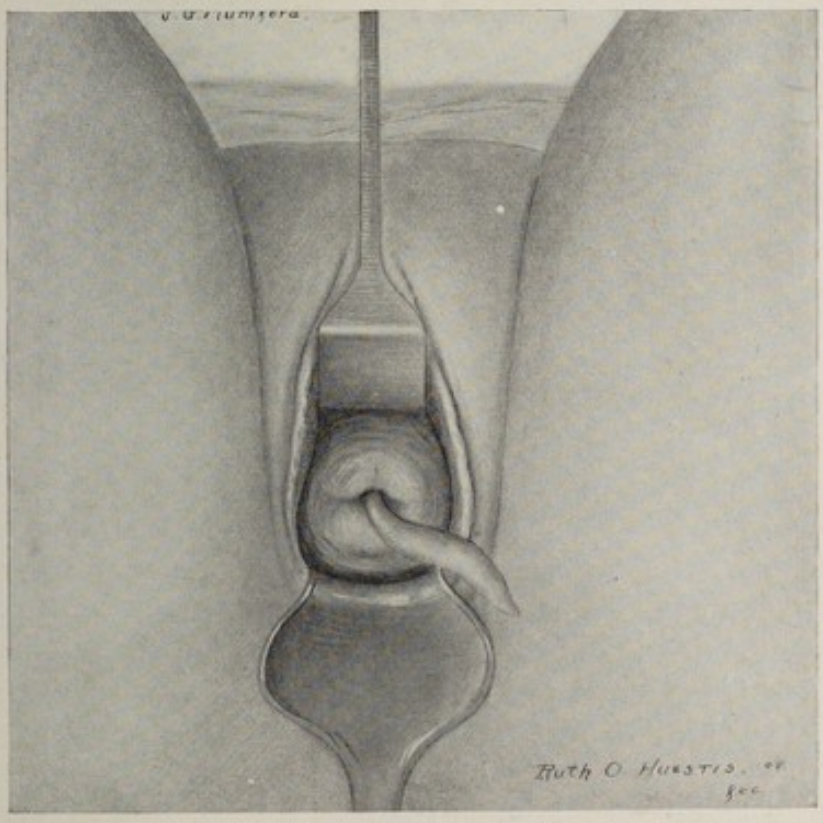

Fig. 181.—Uterine polyp removed with scissors.

the patient in the Trendelenburg position; wall off the uterus; pull it to the fore with vulsellum forceps, and enucleate the tumors individually with knife, scissors, and fingers. In properly selected cases the opera-

tion is extremely easy, and the hemorrhage into the resulting cavities is readily controlled by buried catgut stitches. Finally, sew up the wound in the uterus and suspend the organ if it seems inclined to drop back into an abnormal position. Wipe out the peritoneal cavity; replace the omentum, and close the abdominal wound. It often requires some nice surgical judgment to decide between myomectomy and hysterectomy. In general terms, myomectomy is preferable in case the mass of tumors be of moderate size, and the growths located mostly near the surface of the organ. Myomectomy for submucous polypi may well be done by the abdominal route. The operation consists in splitting

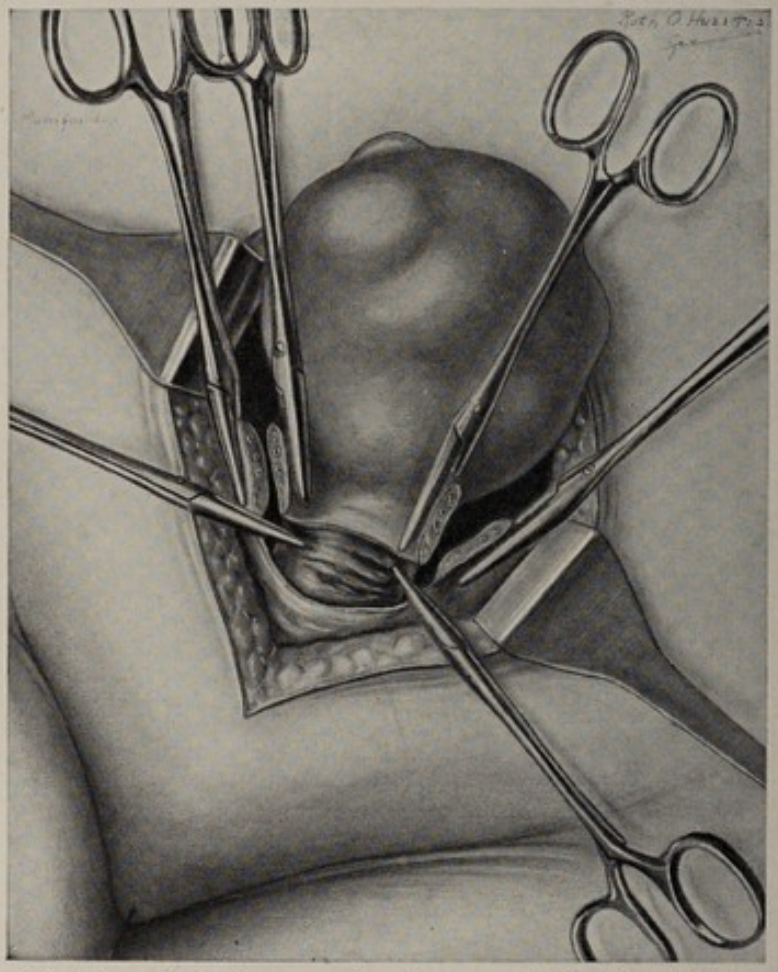

Fig. 182.—Ligation of uterine vessels, clamp applied (adapted from Dudley).

open the body of the uterus, cleaning out the submucous growths, and treating the inflamed mucosa with the curet and weak carbolic applications. Then sew up the uterus with catgut stitches, which shall not include the mucosa. This operation is easy, safe, and extremely effective—a great advance over many old-time dilatings and curetings. Low cervical polypi may be removed with scissors or the wire snare.

Supravaginal hysterectomy is the operation of common choice in cases of myoma uteri, and usually it is not difficult. Volumes have been written on the technic, and most of our best-known surgeons and gynecologists have had their word to say on the matter. When all is said, the operation is simple enough when the pelvic conditions are uncom-

plicated. The abdomen is opened through the left rectus muscle by a liberal incision, large enough to permit of the delivery of the tumor, when the surgeon seizes the mass with strong vulsellum forceps, and, if possible, turns it out through the abdominal wound. Complications may render difficult or impossible this delivery at once. Adherent viscera must be carefully dissected off from the tumor, diseased tubes and ovaries must be removed, incarcerated masses must be shelled out of the pelvis, and intraligamentous growths must be freed by splitting the broad ligaments.

Having delivered the tumor, the next step is the vitally important one of securing the four sources of blood-supply, the ovarian and uterine

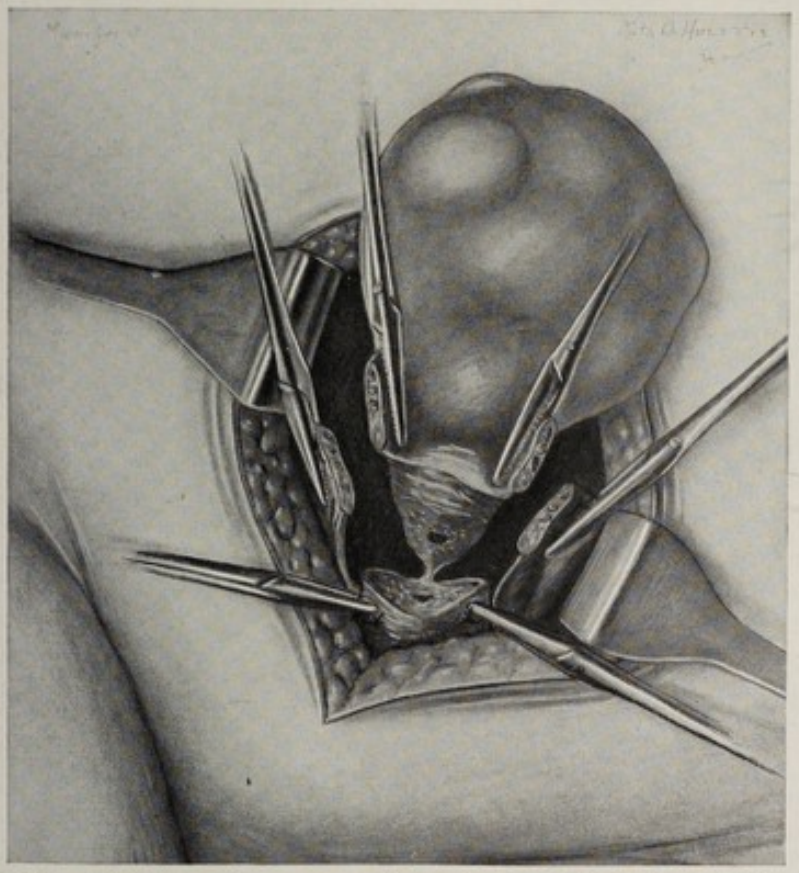

Fig. 183.—Fish-tail incision for amputation above cervix (adapted from Dudley).

arteries, and this rarely is difficult. I prefer to double-clamp the broad ligaments close to the mass and divide the tissues between the clamps. Then dissect off the peritoneum from the uterus about the cervix, just above the attachment of the bladder. Push this peritoneum well down on to the cervix, leaving exposed a broad strip of the cervical muscularis. Then pass a curved threaded needle about the deep-lying uterine vessels and tie tightly. I prefer not to use clamps for these vessels if I can help it, because clamps add to the complication of instruments in the narrow field. In securing the uterine vessels, and, indeed, in all manipulations about the tumor, one should have in mind possible danger to the ureters. These structures often are greatly displaced by myomata, and in the case of extensive intraligamentous growths the ureters may appear

to be far out on the side of the tumor. For this reason, in the case of difficult dissections, some operators do their work after having passed catheters through the urethra into the ureters.

The vessels being now controlled and the ureters isolated, amputate through the cervix with knife or scissors. I prefer to make a fish-tail incision, which may readily be closed like any other amputation stump, and before closing the stump I rim out the cervical canal with the actual cautery, or swab it with pure carbolic acid. Then close the cervical stump with buried catgut sutures. Draw over it and stitch in place the dissected peritoneum, and complete the operation by fastening the stump of the round ligaments into the remnant of the cervix. I regard this stitching of the round ligaments into the cervix as important for the

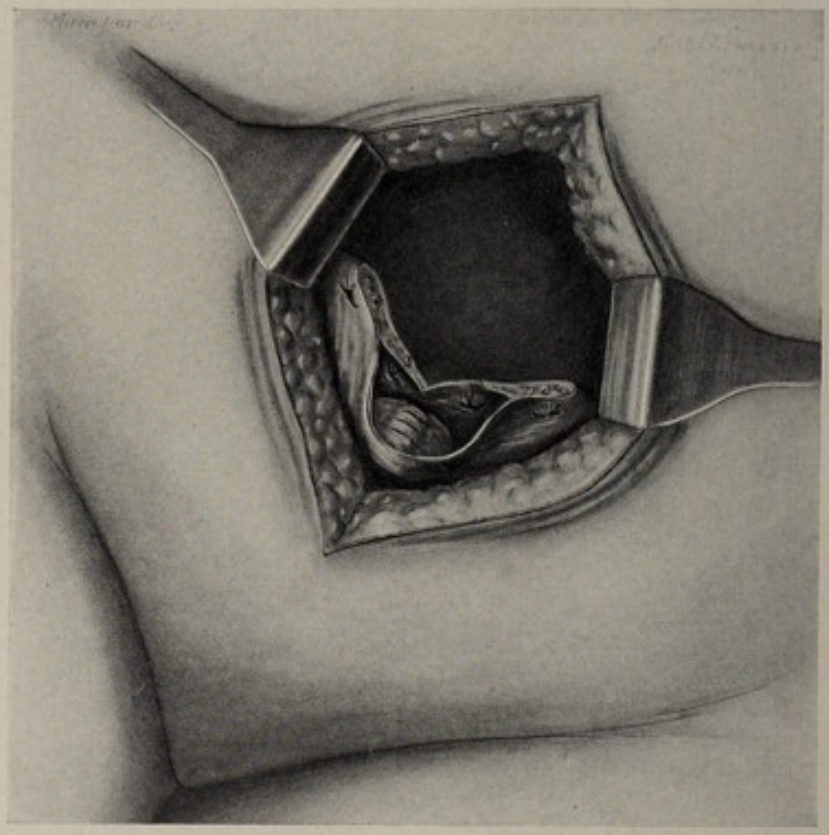

Fig. 184.—Suture of cervical stump (adapted from Dudley).

support of the perineal floor. Sagging of the cervical stump is thus prevented and the bladder is kept properly supported. E. C. Dudley advocates sewing the severed stumps of the broad ligaments to each other across the pelvis. This is an excellent maneuver when possible, but the same end is attained by such a treatment of the round ligaments as I have described.

The question of leaving one ovary, or a portion of an ovary, in the pelvis has agitated men. It is certain that removal of both ovaries at once from a woman who has not yet passed the menopause results in more serious nervous disturbances than when ovarian tissue is left. After the menopause the removal of both ovaries causes less disturbance.

The after-treatment of these cases is quite simple and consists in the usual care of diet and bowels, with rest in bed for from two to three

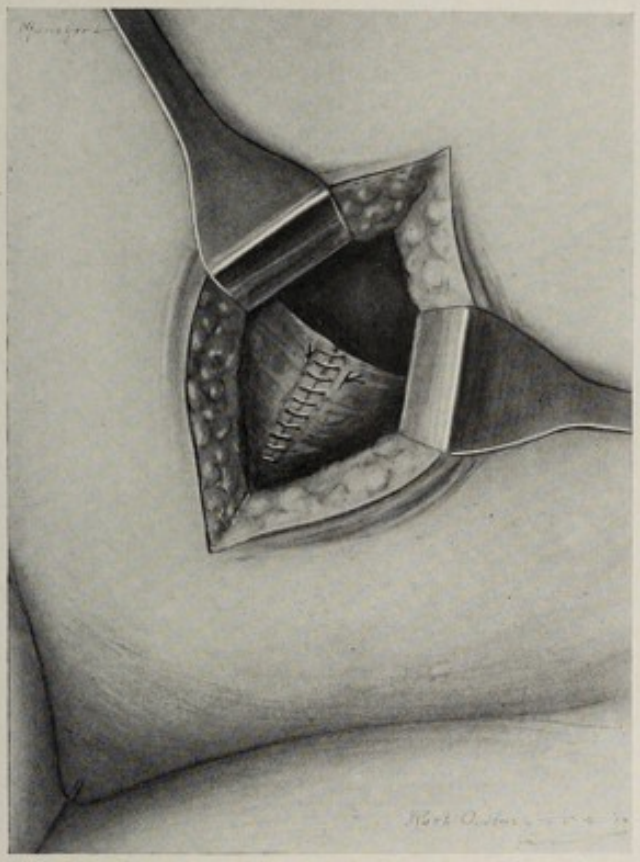

Fig. 185.—Repair of round and broad ligaments (adapted from Dudley).

weeks. If the patient be tightly and properly swathed, she may be turned about in bed as soon as she has recovered from ether.

Total Hysterectomy (*Panhysterectomy*).—In a small number of cases the surgeon may think it wise to remove the whole uterus, including the

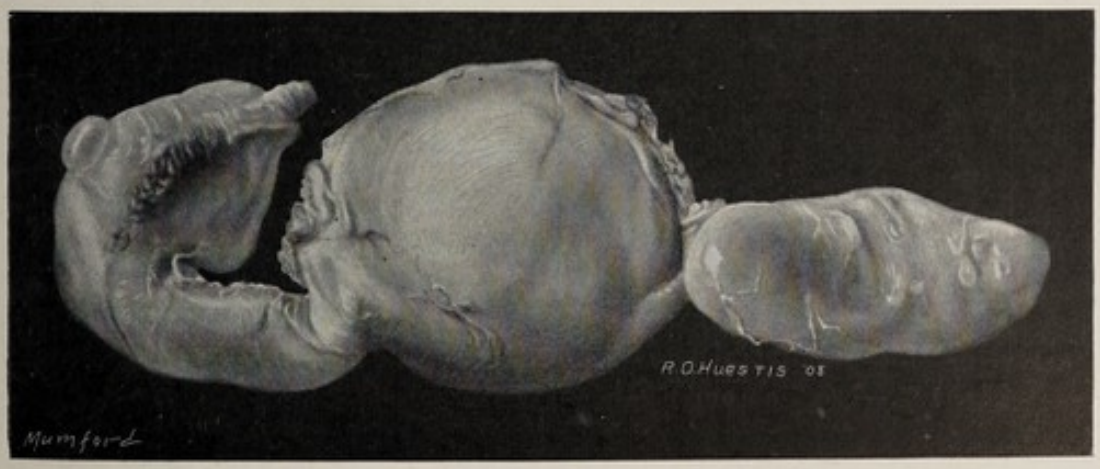

Fig. 186.—Combined panhysterectomy, diseased tubes (Massachusetts General Hospital).

cervix, for the organ may be so septic or otherwise diseased as to render the presence of the cervix dangerous to the patient; or the cervix

itself may be involved in the new-growth to such an extent as to render its removal imperative.

The technic of the operation is similar to that of supravaginal hysterectomy until one comes to dealing with the vaginal portion of the cervix. There are two ways for such dealing: one may loosen the cervix



Fig. 187.—Myoma complicating pregnancy (E. W. Mulligan's case).

from below by a complete incircling incision through the vagina, and by separating the bladder and rectum, taking pains not to wound the ureters; or, working from above, one may perform the entire operation, peeling down the para-uterine tissues until the vagina is completely freed, after which that structure should be clamped and cut off, allowing

the removal of the entire uterus. The further steps in the operation in either case consist in sewing up the vagina with a continuous catgut ligature, covering over the vaginal stump with the replaced peritoneum, and sewing together, so far as possible, the severed edges of the broad ligaments so as to bridge over and reinforce the pelvic floor. It is not usually necessary to establish vaginal drainage, but in case of sepsis, such drainage may be essential. Drain with a gauze wick leading out of Douglas' fossa, which has been covered in by the replaced peritoneum.

These extensive operations on the uterus should be followed by a relatively low mortality,—from 5 to 10 per cent.,—and in the hands of a practised surgeon such are the results.

Myoma Complicating Pregnancy.—This condition raises a question of extreme difficulty, calling for the most careful judgment. Myomata are wont to grow rapidly during pregnancy, and sometimes to interfere seriously with labor; but routine operation upon such myomata is not justifiable. The following propositions are generally recognized as sound by surgeons and obstetricians. Operations may be postponed and delivery at full term may be expected in case the tumor is small and of slow growth, or when it is so placed in the fundus of the uterus as not to threaten obstruction to delivery. Even when the tumor is in the pelvis it often rises above the brim late in pregnancy, leaving a free passage for the birth of the child.

On the other hand, operation is to be done if the fetus is dead, in which case abortion should be undertaken, followed later by a myomectomy or hysterectomy. If the child is alive, but cannot be born through the natural passage, Cesarean section or hysterectomy (Porro's operation) must be done. Rarely, the surgeon may be able to remove myomata without interrupting a pregnancy.

If the condition of pregnancy complicating myoma is discovered before the fourth month, an abortion is justifiable. After that time the dangers of abortion are great, and one should wait for full term if possible. The danger of abortion in late pregnancy is due to the difficulty of delivering the placenta and the probability of infection and hemorrhage. The operations of choice in late pregnancy, therefore, are Cesarean section and hysterectomy. In any case the dangers of the condition are grave.

Cancer of the Uterus

"A purulent or bloody vaginal discharge occurring in a woman who is near the menopause or who has passed the menopause should lead the general practitioner to insist on a local examination."[1] I should go further than that, and say that *any* abnormal flowing or persistent leukorrhea, even in a woman twenty-five years of age, should lead one to suspect the possibility of cancer of the uterus.

Cancer of the uterus is extremely common; nearly one-third of all cancers in women are uterine cancers. The thought of this disease is in the minds of most women who have fallen into ill health after the meno-

[1] W. L. Burrage, Boston Med. and Surg. Jour., July 24, 1902.

pause, for it is a disease notoriously distressing and offensive, and is regarded by the laity as incurable. Cancer may spring from any portion of the uterine mucosa—from the cylindric epithelium of the glands and from the pavement epithelium outside of the external os; and so the variety of growth corresponds with the type of epithelium from which it springs. Cylindric-cell carcinoma may appear to be situated outside of the external os. It is not truly beyond the os, but springs from everted cervical mucosa lining an old childbirth laceration. So we have two varieties of carcinoma of the uterus:

(*a*) Cylindric-cell carcinoma, adenocarcinoma, gland carcinoma.

(*b*) Pavement-cell carcinoma, squamous carcinoma, epithelioma.

Cancer of the cervix is far more common than is cancer of the fundus, but cancer of the cervix may extend to the fundus. Both varieties of car-

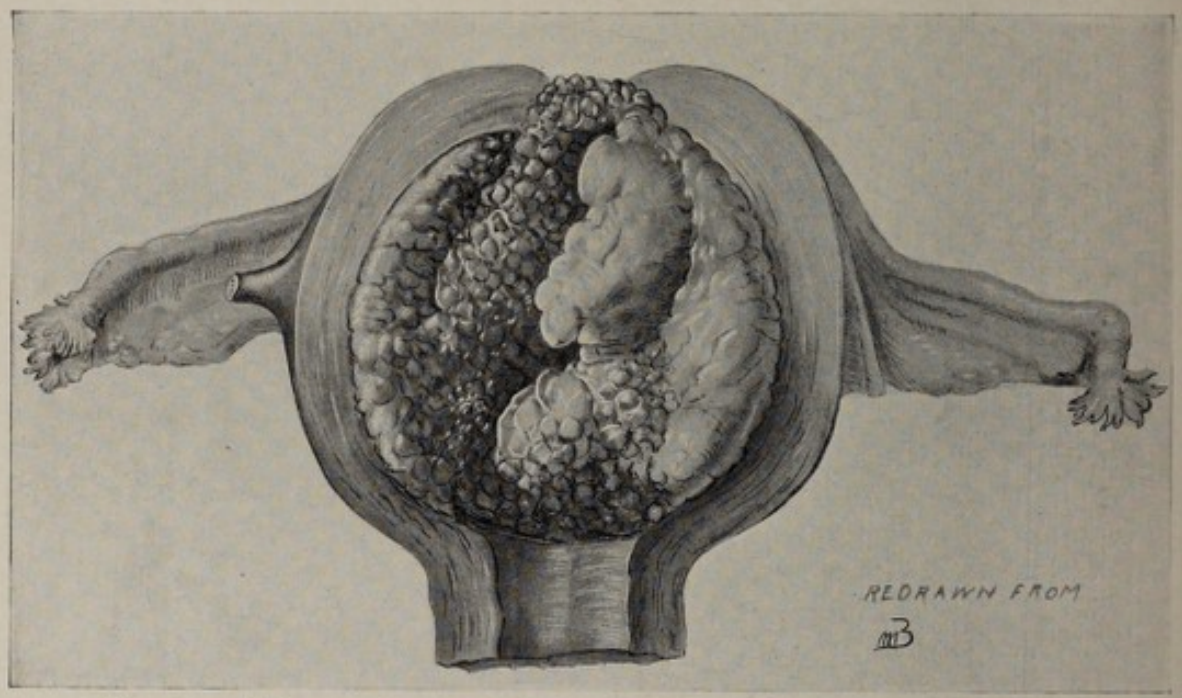

Fig. 188.—Adenocarcinoma of the body of the uterus cut through the anterior wall. In spite of the fact that the whole uterine cavity is choked with the disease, it does not invade the cervix ($\frac{2}{3}$ natural size) (Kelly).

cinoma—adenocarcinoma and epithelioma—may be present together The tendency of adenocarcinoma is to involve the submucosa, and the tendency of epithelioma is to confine itself to superficial areas. When the deeper tissues are involved, the affected portion is enlarged, hard, and friable. The surface is smooth, glistening, flattened, or nodular. Either variety extends rapidly and ulcerates readily. The margin of the ulcer is hard, irregular, and elevated. The base is rough and bleeds easily. The process may destroy the cervix, and when situated in the cervix, may extend variously and involve the vaginal vault, especially in front and at the sides; the broad ligaments, rarely the uterine appendages, the ureters, the bladder, the urethra, and pelvic bones; the fundus, the iliac lymph-nodes, after having invaded the broad ligaments; this delay, says Dudley, is because the squamous cancer-cells are too

large to pass through the lymph radicles of the cervix, but not too large to traverse the lymph-vessels of the ligaments. Furthermore, the kidneys may be involved in nephritis, hydronephrosis, or pyelonephrosis, and dilatation of the ureters is common. Metastatic cancer may be found in distant organs.

Cancer of the body of the uterus may extend in much the same fashion, but it implicates the lumbar lymph-nodes and abdominal organs more quickly than does cancer of the cervix.



Fig. 189.—Inoperable epithelioma of the cervix in which the chief involvement is at the internal os, where the uterus is perforated. In the mucous membrane of the fundus a few epithelial nests are found lying between normal uterine glands (natural size) (Kelly).

The **causation** of cancer of the uterus is as undetermined, with the exception of one factor, as is the causation of cancer elsewhere. That one factor is laceration of the cervix from labor.[1] This is an extremely important matter, and, in addition to others, Craig[2] has pointed out that among the victims of uterine cancer it is almost impossible to find one who has suffered from a cervical laceration which has been early and properly repaired. It is now accepted as a fact among observant

[1] I have referred already to the possibility of the malignant degeneration of myomata.

[2] Daniel H. Craig, New York Med. Jour., July 8, 1905.

practitioners that laceration of the cervix is a common cause of uterine cancer. One must consider also the age of the patient—uterine cancer is rare before thirty-five years, and is most common between forty and fifty. It is not common among negroes.

The early **symptoms** of cancer of the uterus are elusive; the late symptoms are flagrant. The subject has greatly agitated the profession of recent years, and a vigorous propaganda has been started in this

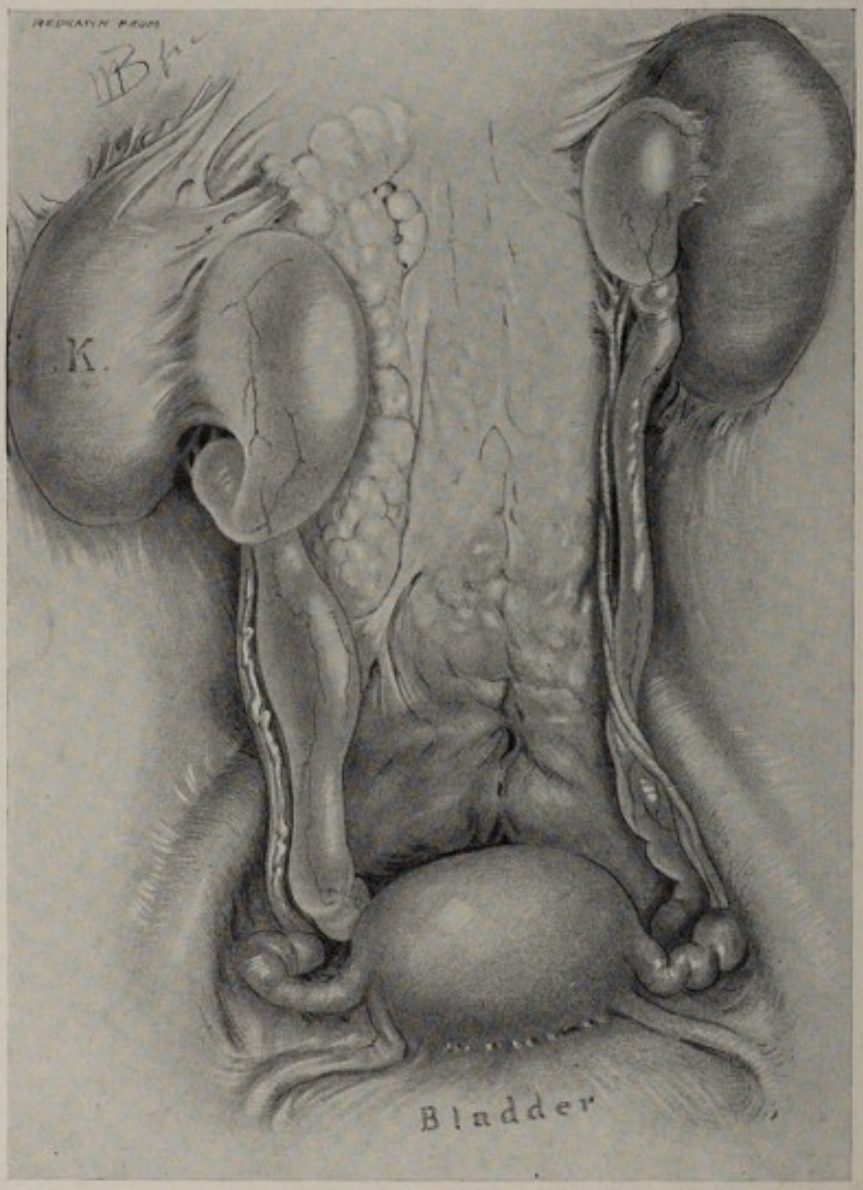

Fig. 190.—Double hydroureter due to advanced cancer of the cervix uteri (H. A. Kelly).

country, as well as in Germany, to inform the public and the profession of the need of treating cancer early. The result is that we are somewhat improving our operative statistics.

It has been commonly taught that *hemorrhage* is the first symptom of cancer of the uterus. This is not true always. A more frequent symptom is a thin, clear, watery discharge, followed after a few weeks by persistent and increasing *leukorrhea*. Sometimes pain in the coccyx

is the first symptom. The leukorrhea is due to a coincident endometritis and to the discharge from the cancer itself. At first innocent in appearance, it gradually becomes foul and rankly offensive. Hence much of the horror and disgust with which the disease is regarded.

Hemorrhage comes from the base of the cancer, and is due often to some slight traumatism, as from taking a vaginal douche. The bleeding may or may not be associated with menstruation. It usually comes on gradually, a little at a time, repeated after a few days or even after months. Then it becomes a persistent ooze, and the patient's strength becomes exhausted.

Pain is quite indefinite in frequency and character; when present, it is referred to the coccyx, perineum, or thighs. A spread of the cancer may involve other organs and cause abdominal pains of various sorts.

Sundry disorders of the abdominal viscera appear late—disorders of the kidneys, intestines, rectum, ureters, and bladder—as the disease invades those several parts.

Of course, there are the inevitable cachexia, wasting, debility, depression, and loss of appetite, with the dyspepsia and constipation which we see in nearly all cases of cancer.

The **diagnosis** of uterine cancer is based on such a clinical history as I have described, noting especially the hemorrhage, foul discharge, pain, and late cachexia; and on the physical signs, which are ascertained by bimanual examination and by inspection through the speculum. Inspection and palpation of the cervix are easy, but sometimes it is important to excise a bit of suspicious growth in order to confirm the diagnosis by microscopic examination. Scrapings are of little value for microscopic purposes. The diagnosis of cancer of the *body* of the uterus is more difficult than is the diagnosis of cancer of the cervix, and may be impossible. Says Dudley: " Frequently recurring glandular, hyperplastic endometritis, with much cystic development after repeated curetage, especially if associated with free hemorrhage and a watery discharge, should give rise to grave apprehension, and would justify the removal of the uterus on suspicion." In advanced cancer of the body of the uterus one finds that organ considerably enlarged, hard, nodular, and more or less fixed, with edema of the legs, involvement of the glands of the groin and abdomen, and evidence of such complicating abdominal disorders as I have described.

Cancer of the uterus must be distinguished from myoma, sarcoma, retained placental tissue, incomplete abortion, hypertrophy of the cervix, endometritis, syphilis, chronic metritis, ichthyosis, tuberculosis, laceration of the cervix, and subinvolution of the uterus.

Treatment of cancer of the uterus is *palliative* or *radical*, and radical treatment, like radical treatment of stomach cancer, is to be undertaken doubtfully and after a full understanding with the patient or her friends. There is no manner of doubt that early cancer of the body of the uterus and many cancers of the cervix may be removed successfully and permanently; but we can never promise a cure. There are other reasons, however, for advising operation: there is always the chance of cure;

there is a fair assurance of relief from suffering, and the abolishment of the foul discharge, with the possibility of prolonging life. Moreover, a sense of having something done is a great stimulus to many patients. Above all things, it is the duty of every practitioner to preach the gospel that cancer of the uterus is not always an incurable disease, especially when treated early.

Palliative operations on the uterus are undertaken to relieve pain and check the foul discharge for a time at least. The best palliative measures are a thorough cureting and cauterization with the Paquelin cautery.

There are two important *radical* operations for uterine cancer: vaginal hysterectomy and abdominal hysterectomy. The old-time high amputation of the cervix is not a radical operation.

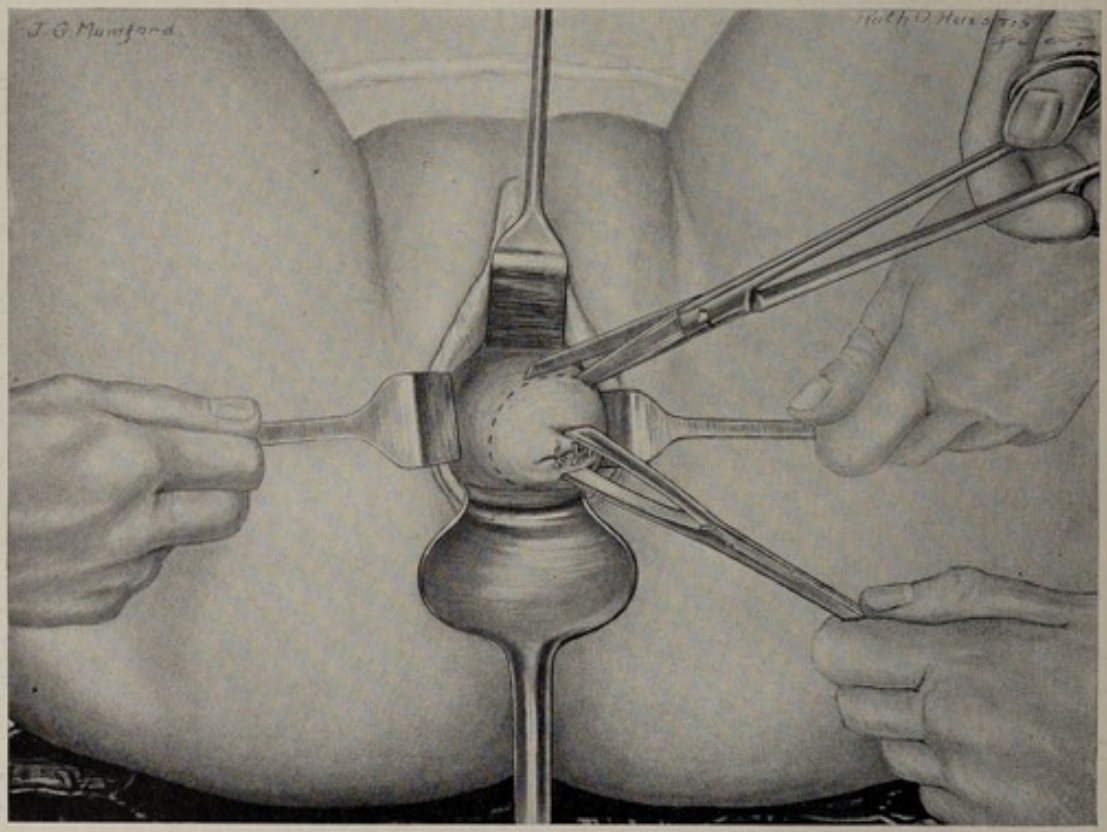

Fig. 191.—Vaginal hysterectomy—step 1 (adapted from Dudley).

Vaginal Hysterectomy.—This operation has long been popular and has a relatively low mortality. It never insures a cure, even when performed early in the disease, but the statistics of many operators show that it does sometimes cure. These statistics are so variable that they are hardly worth quoting. They show us that from 10 to 60 per cent. of all cases are well three years after the operation.

In the detail of the technic of vaginal hysterectomy two methods are advocated—hemostasis by forcipressure (clamping the broad ligaments and leaving the clamps in place) and hemostasis by ligature. I advocate the latter, as it is cleaner, is better surgery, and causes far less pain to the patient after her recovery from ether. The steps of the operation are

well illustrated by the diagrams, and briefly are as follows. With the patient in the lithotomy position, and with a strong light and plenty of

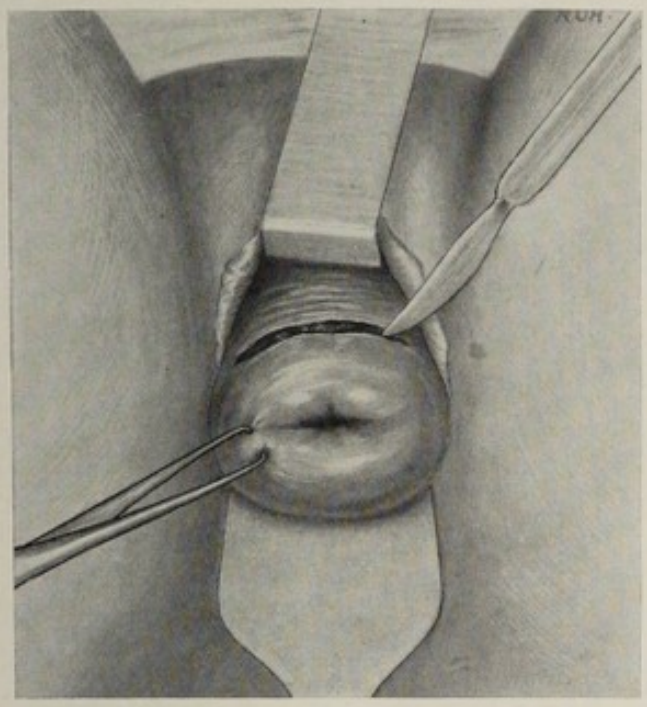

Fig. 192.—Vaginal hysterectomy—step 2.

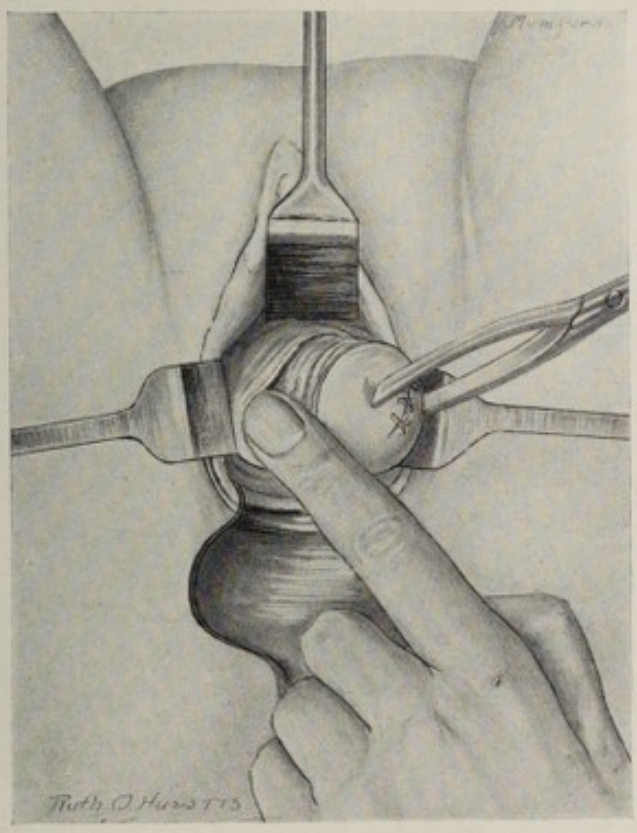

Fig. 193.—Vaginal hysterectomy—step 3.

assistance, the surgeon holds widely retracted the vaginal outlet. He seizes the cervix, after having cureted and cauterized obvious protruding

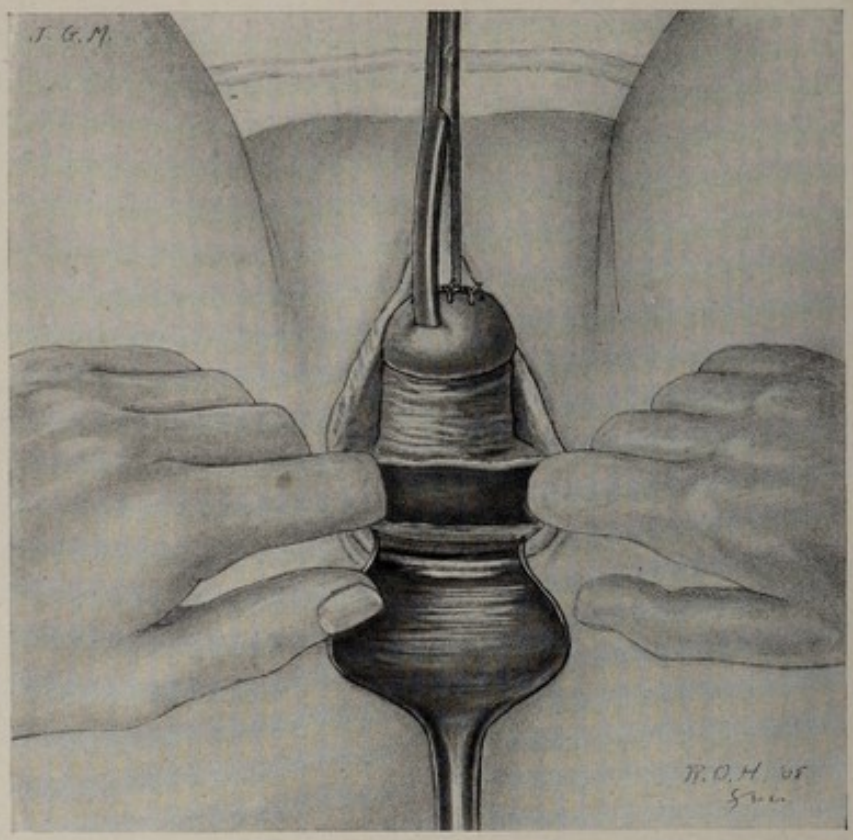

Fig. 194.—Vaginal hysterectomy—step 4 (adapted from Dudley).

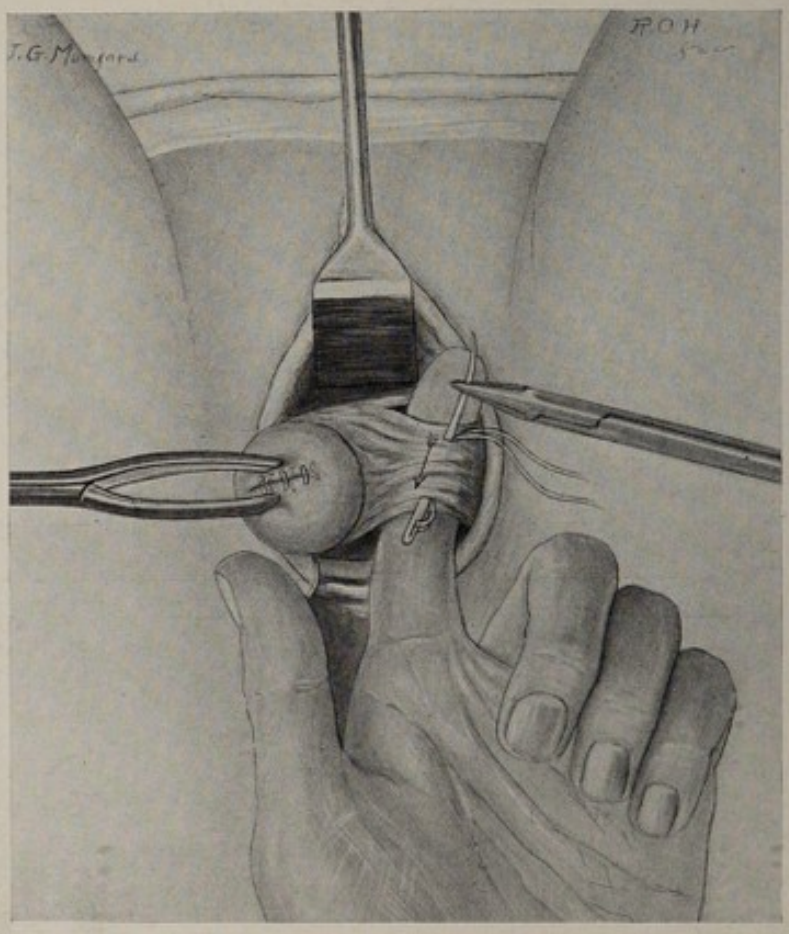

Fig. 195.—Vaginal hysterectomy—step 5 (adapted from Dudley).

disease, stitches up firmly the os, to prevent fouling of the wound by discharges, and with flat vulsellum forceps draws the cervix to the vulva. With scissors or knife he then incises the vaginal mucosa about the cervix and strips it back thoroughly on all sides for an inch or more, when the uteroperitoneal reflection will be recognized by the loose character of the tissues, and by the fact that under the finger the loose tissue slips over the peritoneum. The stripping back should be done with the finger. The operator then seizes with forceps the postperitoneal fold, which has been stripped loose from the rectum, and nicks through into Douglas' fossa. He enlarges this opening by tearing with

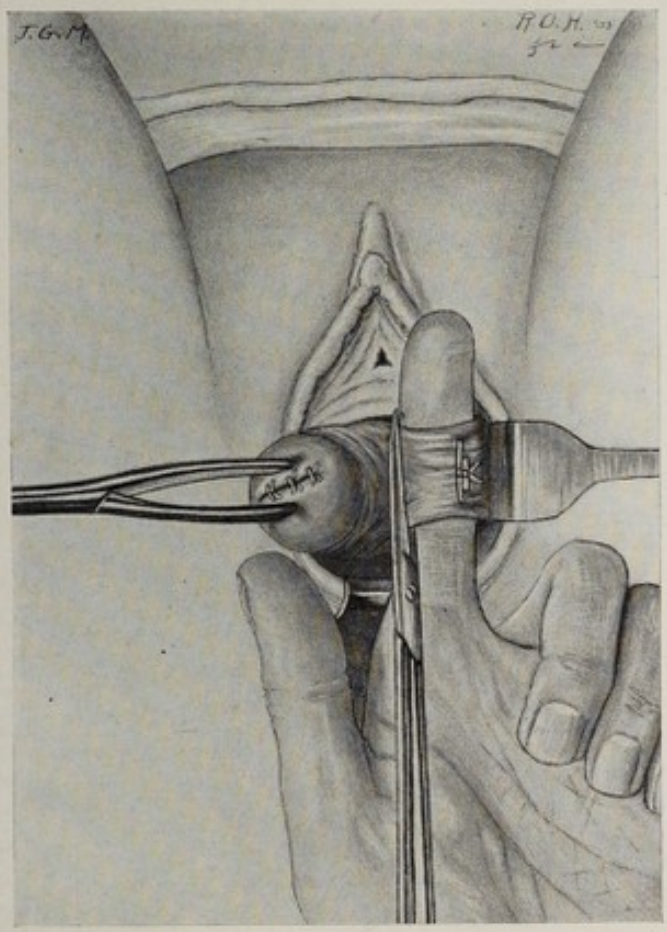

Fig. 196.—Vaginal hysterectomy—step 6 (adapted from Dudley).

the fingers. Then he opens anteriorly between the cervix and bladder in the same fashion.

With wide openings before and behind the uterus the surgeon is now ready to control the blood-supply. In suitable cases this may be done readily by passing the forefinger of the left hand up through the posterior opening and hooking down first the left and then the right broad ligament. Secure the ligaments with stout silk sutures, embracing first the ovarian artery, then the uterine artery, and then, behind these ligatures, the broad ligament itself *en masse*.

Having secured the vessels, cut away the broad ligament close to the uterus. Some surgeons, after cutting away the left broad ligament

drag down the fundus through the left opening, and thus put the right broad ligament on the stretch, when it may readily be secured and cut away with the parts practically outside of the vulva.

The uterus having been removed in this fashion, stitch up the peritoneum, bringing together the divided round ligament and broad ligament stumps, and then sew up the rent in the vagina. Drainage may be supplied by passing a gauze wick into the subperitoneal space through a small opening in the vaginal vault. These manipulations are facilitated by having the patient in a modified Trendelenburg position.

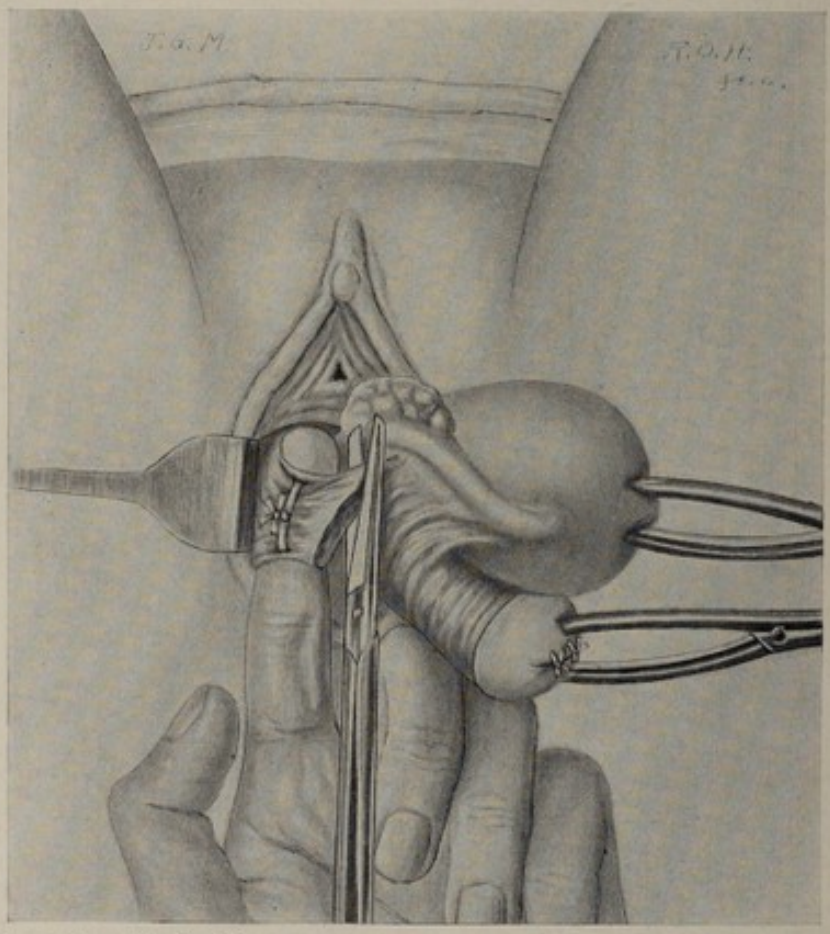

Fig. 197.—Vaginal hysterectomy—step 7 (adapted from Dudley).

There are certain dangers, difficulties, and complications in vaginal hysterectomy. The operation should not be undertaken in the face of involvement of the para-uterine structures—when the uterus is in any degree fixed, when the broad ligaments are thickened, when the tubes and ovaries are diseased, and when the lymphatic connections and glands are involved. It is by no means easy always to avoid injuring the ureters; they have often been cut by experienced operators even. They may be avoided by introducing catheters into them, and by clinging closely to the cervix in making the dissection.

We are as yet far from being able to remove the uterus through the vagina with such ease and clearness of vision, looking to lymphatic involvements, as in removing the breast and its associated lymph-nodes.

The presence of the ureters, lying within one-half inch of the cervix, renders almost impossible a wide and sure dissection by the vaginal route. In spite of these facts the vaginal route will always be a favorite route with operators, because in early cases the dissection is easy, the operative mortality low, the immediate results brilliant, convalescence short, discomfort slight, and recurrence reasonably infrequent.

Abdominal Hysterectomy for Cancer.—This operation is shown by statistics to be more fatal than vaginal hysterectomy, but such statistics are misleading, because abdominal hysterectomy is extremely difficult or impossible in the case of fat women, whose thick abdominal walls and densely packed pelves render manipulations difficult or impossible.

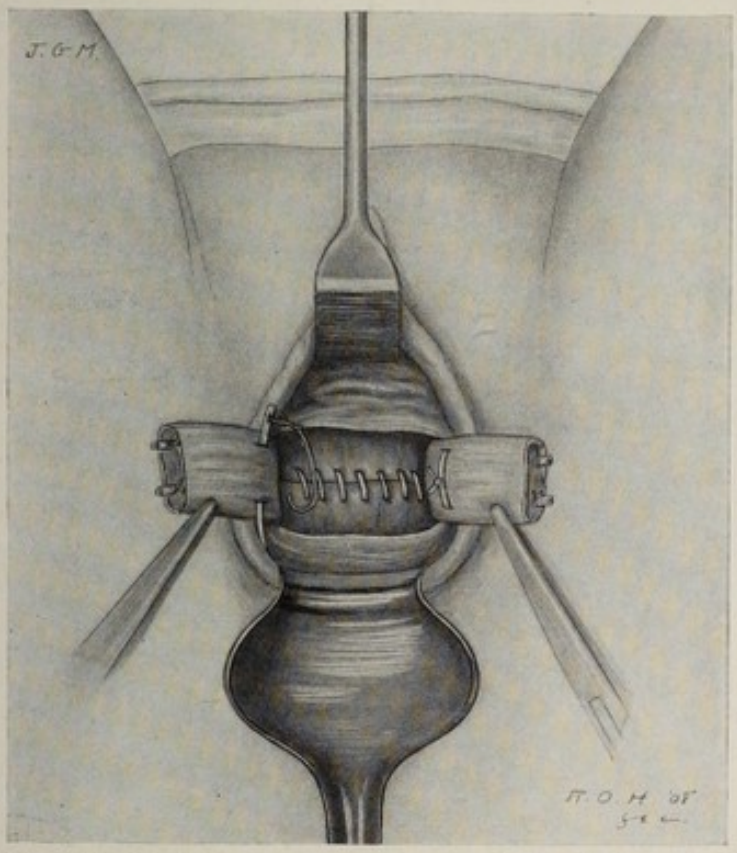

Fig. 198.—Vaginal hysterectomy—step 8 (adapted from Dudley).

Moreover, abdominal hysterectomy is commonly practised in the more advanced and complicated cases.

The development of abdominal hysterectomy for cancer of the uterus has been stimulated lately, in this country especially, by the researches, practice, and preaching of John A. Sampson,[1] but his extremely interesting and radical operation has not yet found entire favor with the profession, on account of the difficulty of following his technic without a resulting high mortality. I am convinced, however, that a more frequent resort to a modified, but still radical, abdominal hysterectomy for cancer of the uterus will result in improving our statistics.

[1] John A. Sampson, Jour. Amer. Med. Assoc., October 29, 1904; ibid., May 20, 1905.

The Operation.—With the patient well elevated in Trendelenburg's position and the intestines carefully isolated (the maneuver of stitching the parietal peritoneum to the posterior pelvic brim gives a particularly clear and free field), the uterus is removed in much the same fashion as I stated in describing panhysterectomy for myoma—the vaginal vault having previously been opened from below, if you choose. The broad ligaments may then be extensively dissected; the retroperitoneal space laid open by splitting the broad ligaments; the ureters, iliac vessels, and lymphatics exposed, and all suspicious tissue removed by careful knife

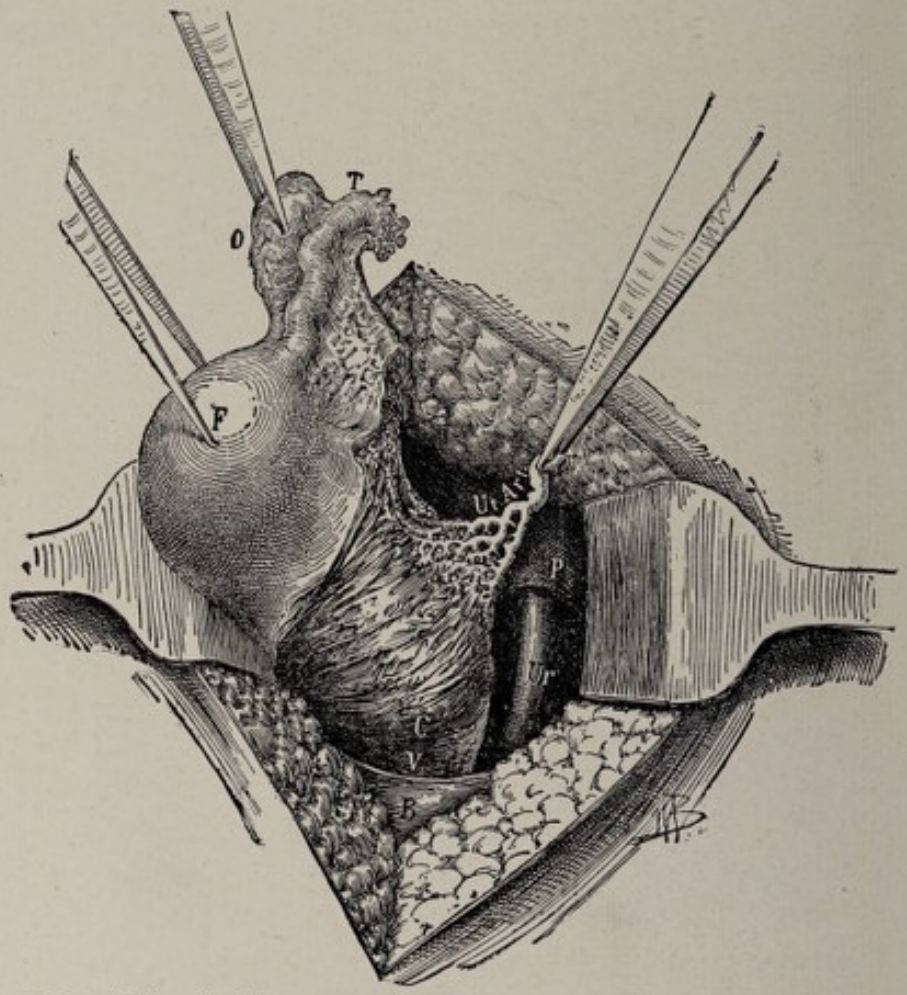

Fig. 199.—Abdominal hysterectomy for cancer. The uterus (F) being pulled far to the right, the uterine artery is tied and dissected away from the ureter (Ur) with a mass of pelvic cellular tissue. P is a posterior layer of peritoneum; B, the bladder; C, the cervix; V, the vagina (Kelly, after J. G. Clark).

and gauze dissection.[1] It will not do to remove too thoroughly all the tissues about the ureters, because such removal results in cutting off their blood-supply, and in consequent necrosis of the ureters. In case of the ureters being involved in the growth or necessarily denuded, they must be resected and implanted into the bladder.

The simpler abdominal hysterectomy may be no more effective for a cure than is vaginal hysterectomy; but abdominal hysterectomy

[1] The reader should supplement this brief description by studying Sampson's admirable articles.

does permit a more careful exploration of the field. Whether or not the extensive dissections I have last indicated shall prove of permanent usefulness remains to be demonstrated through time and experience.

The after-treatment of these cases, as well as the after-treatment of cases of vaginal hysterectomy, differs in no essential from that followed in cases of myoma.[1]

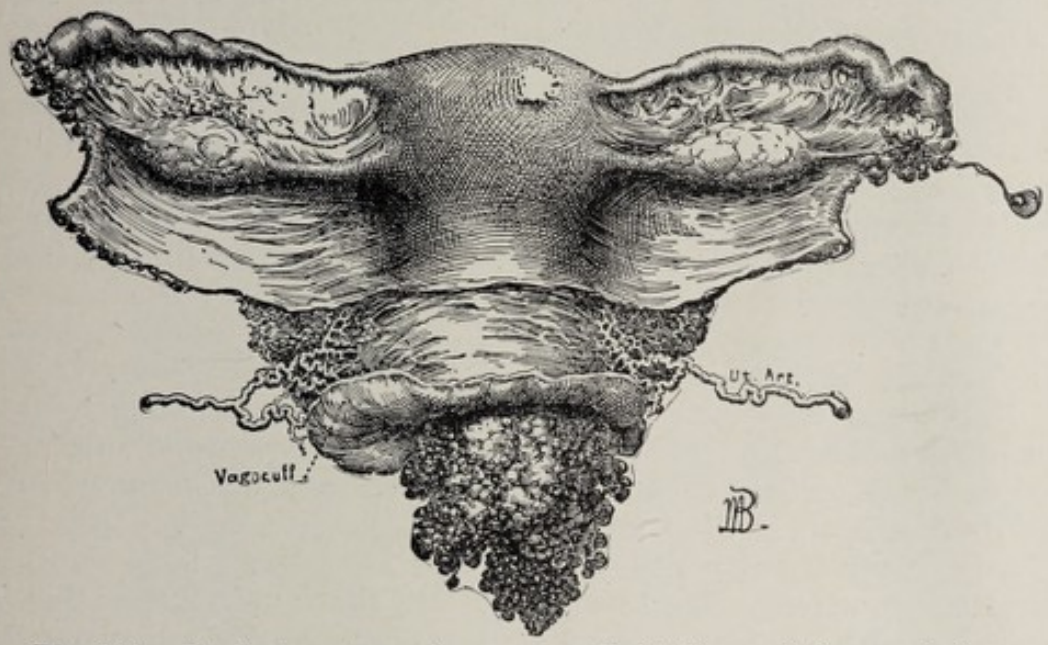

Fig. 200.—Panhysterectomy for cancer. Epithelioma of the cervix in grape-like mass. Showing the extensive removal of the uterus and the broad ligaments by the abdominal method (½ natural size) (Kelly).

There are sundry other diseases and tumors of the uterus, more or less rare and more or less unimportant, which it behooves us to mention in passing.

ENDOTHELIOMA

Endothelioma is a malignant tumor rising from the endothelium of the vessels or serous surfaces and closely resembling cancer. It is found in the fundus of the uterus as well as in the cervix, and may extend to neighboring organs. The course, symptoms, and treatment are similar to those of cancer.

SARCOMA

Sarcoma is rare in the uterus; it may develop in youth, in maturity, or in old age. Three forms are described: (1) Fibrosarcoma; (2) diffuse sarcoma; (3) racemose, grape-like sarcoma.

Fibrosarcoma resembles myoma in its location, though it is encapsulated rarely. Diffuse sarcoma may occur anywhere in the uterus, and is wont to invade the whole organ. Racemose is very rare; it generally starts in the cervix, and forms cyst-like masses resembling hydatids. It has been found in children as well as in adults. It grows rapidly and is extremely malignant.

[1] For a suggestion for the palliative treatment of uterine cancer see foot-note on p. 864.

Sarcomatous degeneration of a myoma may occur (spindle-cell sarcoma). One suspects it when hemorrhage from myoma increases; when the tumor grows after the menopause; when the growth returns after removal; when ascites develops suddenly; when cachexia appears rapidly. The **symptoms** of the various forms of sarcoma are in no way peculiar. Some of the sarcomata grow slowly; some are extremely malignant. Spindle-cell sarcoma, for instance, may not destroy life for many years; on the other hand, the diffuse, small, round-cell sarcoma is more malignant than is cancer. All the forms suggest cancer, symptomatically, but metastases are more numerous and more distant often than is the case with cancer, for the emboli of sarcoma travel by the veins, while cancer progresses through the lymphatics.

The **treatment** of sarcoma is the same as that of cancer. Indeed, it rarely happens that the two are distinguished from each other before operation.

Deciduoma Malignum

Deciduoma malignum (choriodeciduoma) is an excessively fatal tumor resembling sarcoma. It is often preceded by hydatidiform mole, and occurs commonly between the ages of twenty and forty. It was described so lately as 1889 only.[1]

The growth is unique, the essential element being a large giant-cell embedded in sarcoma-like substance. But the tumor is epithelial.

The growth appears as more or less circumscribed, dirty reddish brown, and friable, with frequent early metastases.

The **symptoms** suggest cancer, but the most characteristic symptom is a profuse hemorrhage occurring after labor or abortion. There is an abundant foul, watery or bloody discharge, often containing hydatid-like moles. There are, of course, the usual constitutional disturbances which we associate with malignant disease.

On examination one finds an enlarged uterus, movable or fixed, smooth or nodular. Often the uterine cavity will admit the finger, which detects masses of soft tissue and clots. One settles the *diagnosis* by the microscope.

Nearly 80 per cent. of all patients affected with choriodeciduoma die within six months.

The only possibility of cure rests in prompt hysterectomy.

In this chapter I have sketched in brief outline the common surgical diseases and injuries of the uterus. I have given such a picture as is familiar to the general surgeon—a picture which may help to guide the studies of the undergraduate and the practice of the physician. The numerous comprehensive text-books and systems of gynecology are essential to a wide understanding of these matters.

[1] Sänger, A System of Gynecology, Playfair.

CHAPTER XI

FALLOPIAN TUBES AND OVARIES

DISEASE of the uterus is often associated with disease of the tubes and ovaries, as I stated in the last chapter. This association is notably true when *inflammations* of the organs are concerned, but it is a significant fact that any disease of the uterus may be found associated with some disease of its adnexa, even though the nature of the disease of the adnexa be something quite other than what is found in the uterus. Thus uterine myomata may coexist with ovarian cysts, and solid tumors of the ovary may be associated with uterine displacement and endometritis. Cause and effect are often sufficiently obvious.

We shall consider *inflammations* of the adnexa and structures surrounding the uterus, solid tumors and cysts of the adnexa, and extra-uterine pregnancy.

SALPINGITIS

Salpingitis[1] is inflammation of the Fallopian tubes. The anatomy of the Fallopian tubes is interesting, and their development especially is interesting. They are formed by that part of Müller's ducts above the round ligaments. The uterus and vagina are formed from that part of the ducts below the round ligaments, together with the Wolffian ducts. The various uterine structures, mucosa, muscularis, and peritoneum are continued to the tubes, so that we have an endosalpinx, a myosalpinx, and a perisalpinx. The tubes spring from the horns of the uterus, and lie in the upper portion of the broad ligaments, being from 3 to 5 inches long. Their length is divided into an isthmus, an ampulla, and a fimbriated extremity.

The **causation** of salpingitis has been already sketched in our last chapter, when we described inflammations of the uterus. By far the greatest number of tubes involved in inflammation are infected from below, and the causes are the common causes of metritis—abortion, labor, instrumentation, gonorrhea, syphilis, tuberculosis. The writers discuss other causes also, among which appendicitis is important, and the acute exanthemata, various constitutional disorders, and the spreading of infection from other organs. Trauma—from a fall—cannot cause a salpingitis, though it may aggravate an already existing salpingitis.

There are various terms used by writers, and Dudley gives the following classification:

"1. Catarrhal salpingitis—salpingitis serosa.

"2. Purulent salpingitis—salpingitis purulenta.

[1] *Salpinx*, a tube.

"Catarrhal salpingitis may result in sactosalpinx serosa—hydrosalpinx.

"Purulent salpingitis may result in sactosalpinx purulenta—pyosalpinx.

"If sactosalpinx is complicated by hemorrhage into the tube, it is called sactosalpinx hæmorrhagica, or hematosalpinx; this is more common in serous than in purulent infections." Then there is tuberculous salpingitis.

The **pathology** of these various conditions is similar often, and the conditions themselves frequently are impossible to differentiate clinically. The infecting medium usually reaches the tube through the canal of the uterus, though tuberculosis may be implanted from above or by the blood-stream. The usual phenomena of inflammation take place after infection has occurred—such phenomena as are seen in metritis; but the results are different, because in the case of the uterus there is usually fair drainage, while in the case of the tube the isthmus frequently becomes choked or closed completely. The fimbriated end of the inflamed tube may remain open, but generally it becomes closed also. When the fimbriated end remains open, tubal secretions flow out and infect the neighboring peritoneum and the epithelial covering of the ovary; so that if there be present a freshly ruptured Graafian follicle, ovaritis may result. Again, infection may penetrate the wall of the tube, even when the fimbriated end is closed. In this case a perisalpingitis may arise with involvement of all the pelvic viscera. A Fallopian tube highly inflamed is somewhat analogous to an inflamed appendix, and acute salpingitis is in some degree similar to acute appendicitis—not so deadly, however, because the tube is a stronger organ than the appendix, its infections are less virulent, as a rule, and walling-off processes are more certain. In advanced salpingitis, however, we do get tubal perforation, peritonitis more or less extensive, adhesions, multiple pus-cavities, and, frequently, a thick, matted, angry mass of viscera, packing tightly the pelvis, apparently impossible of unravelment.

This condition of inflammatory involvement of the pelvic contents was commonly called *pelvic cellulitis*, for it was thought that the inflammation centered in the loose connective tissue about the sides of the pelvis, and in the broad ligaments and para-uterine structures, and that the tube, when involved, was involved secondarily. Doubtless the term pelvic cellulitis is proper enough under certain conditions, but most pathologists now agree that extensive inflammation of the pelvic viscera is commonly secondary to tubal inflammation. Pelvic cellulitis leading to salpingitis even does occur sometimes, through direct transmission of infection from the uterus, by means of lymphatic and venous channels. When this happens, there results, first, a perimetritis with inflammation extending into the adjacent viscera until eventually there is produced a condition similar to that which originates in a salpingitis. Clinically, however, one may often make this distinction, that whereas an extensive inflammation originating in the tube centers there, is there most destruct-

ive, and spreads from that focus, a pelvic cellulitis, on the other hand, originating in the uterus, involves that organ primarily, submits it to more or less destructive processes, causes para-uterine inflammation and abscess formation, and involves the tubes secondarily only. This distinction may have an important bearing upon prognosis and upon treatment, for a primary salpingitis calls for treatment of the tubes

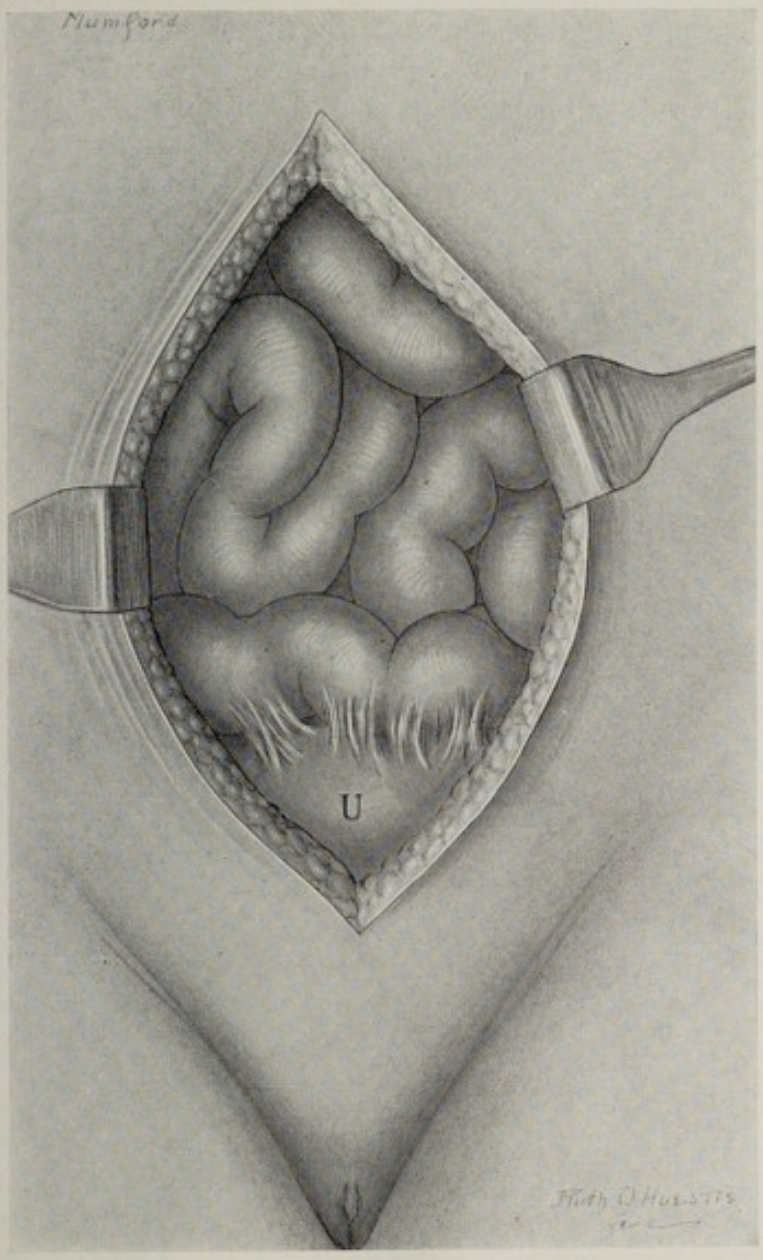

Fig. 201.—Matting of the viscera in salpingitis.

directly, while a pelvic cellulitis may necessitate more particularly the treatment of the uterus and the deep pelvic tissues. In the one case it may be proper to operate upon the tubes through abdominal section. In the other case it may be essential to drain a pelvic abscess through vaginal section. But bear in mind always that the two varieties of inflammation may eventuate in producing similar appearances and may necessitate similar methods of treatment.

Hitherto we have been considering the more virulent forms of inflammation. There are the milder forms, catarrhal salpingitis, resulting in hydrosalpinx and rarely in hematosalpinx. In these milder forms the inflammation remains confined to the tube.

The tube and ovary may be involved simultaneously in disease. For instance, we see the conditions known as *tubo-ovarian cyst* and *tubo-ovarian abscess*. Such conditions are brought about through the formation of inflammatory adhesions between the tubes and ovaries, a resulting sinus formation from one organ to the other, and the participation of each in the disease of the other. As a rule, inflammation of the ovaries is secondary to inflammation of the tubes; but ovaritis may occur independently of salpingitis, through infection, by means of the

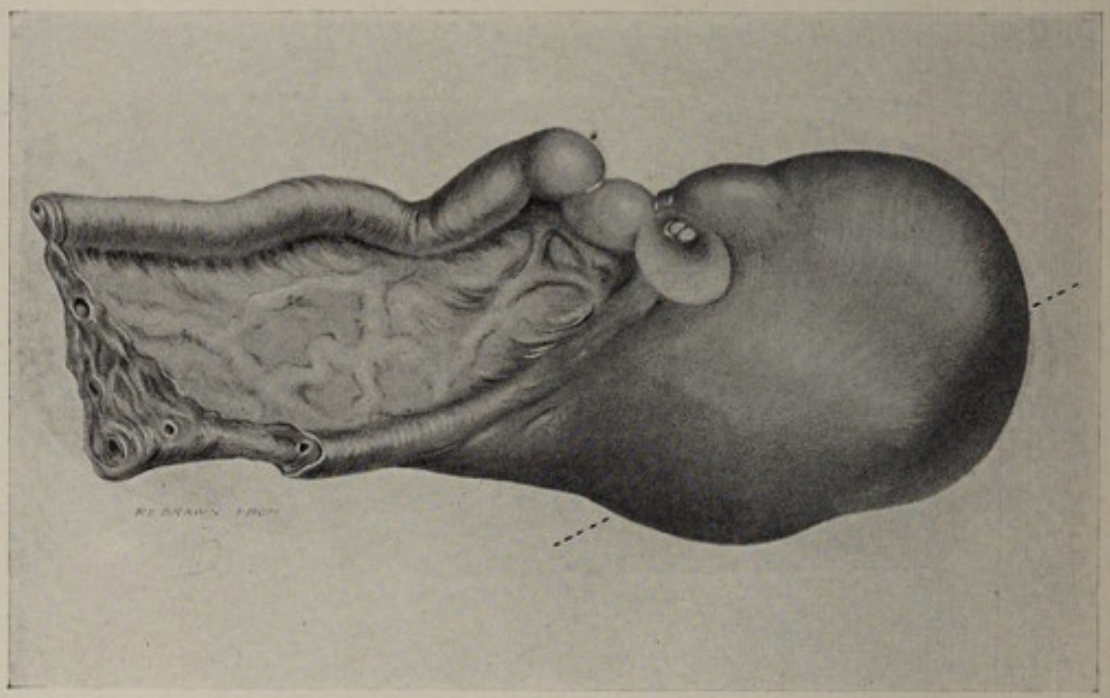

Fig. 202.—Tubo-ovarian cyst. The tube above ends in a bulbous extremity fused with the ovary, with only a slight sulcus between them. The ovarian ligament is shown below, leading out to the cystic ovary (path. No. 665., natural size) (H. A. Kelly).

lymph- and blood-channels from the uterus or from other organs, among which organs the inflamed appendix is the most common source of infection. The exciting organisms in the case of ovaritis are the gonococcus, the colon bacillus, the staphylococcus, the streptococcus, the pneumococcus, the typhoid bacillus, and the tubercle bacillus. A true primary ovaritis is extremely rare.

Symptoms of Salpingitis.—It is often impossible to distinguish the symptoms of salpingitis from those of ovaritis, especially when the ovaritis is a consequence of the salpingitis. Ovaritis due to other causes frequently may be distinguished. However, whether or not the inflammation involve the ovary, you will find the sufferer from salpingitis complaining of pain, dull or burning, constant or remitting, and of localized tenderness. There may or may not be recurring rises of tem-

perature, for that depends largely on the involvement of the peritoneum. Except for the fact that the focus of infection is in the pelvis, the symptoms suggest strongly those of appendicitis. Moreover, it is often impossible to distinguish sharply an acute salpingitis from a chronic salpingitis, since the two constantly run into each other. A chronic salpingitis may become acute at any time, just as an acute salpingitis may become chronic, and in most cases one looks for some symptoms of involvement of the uterus, such as I described in Chapter X.

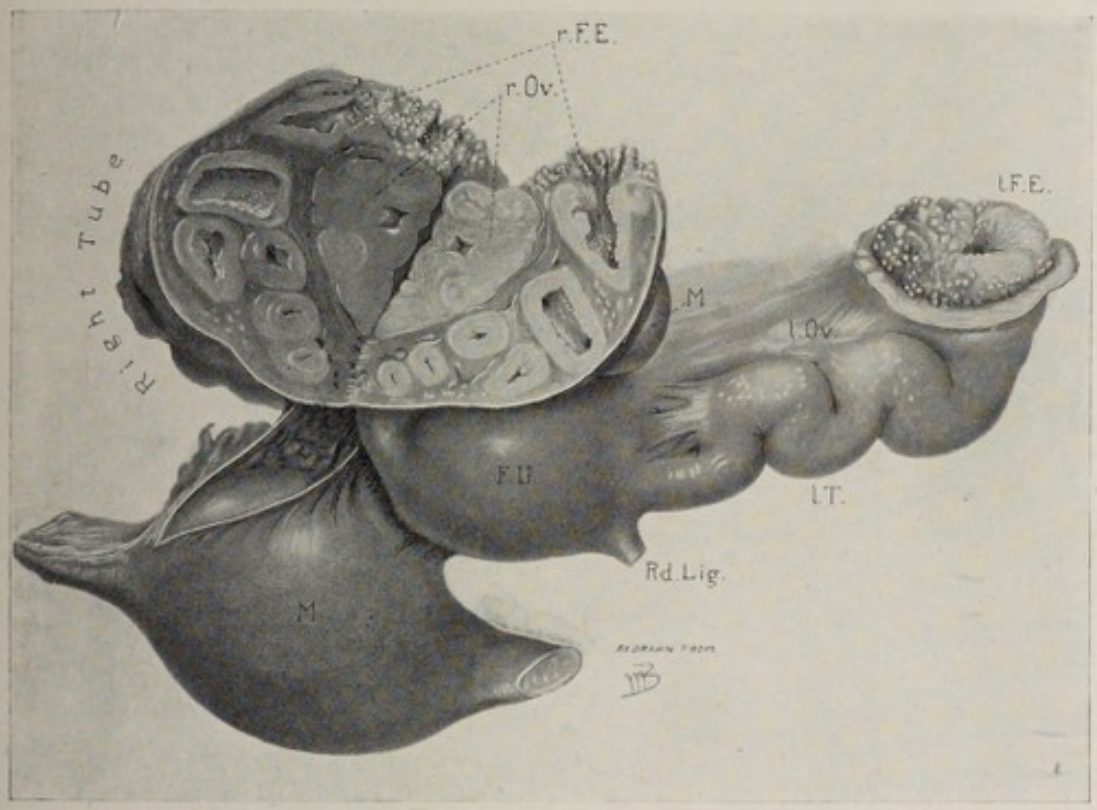

Fig. 203.—Tuberculous salpingitis. The right tube and ovary divided, showing the extent of the disease in the ovary and in the numerous cross-sections of the tube. *F.U* is the fundus of the uterus, and *M* a myoma attached to it. Between the uterus and the myoma is seen a portion of a large sac of an encysted peritonitis. The left tube is distended, convolute, and covered with tubercles; the fimbriated end is swollen and exhibits numerous tubercles. This is preëminently a case for extirpation of tubes, ovaries, and uterus. (Case of Dr. C. Cone, Johns Hopkins Hosp. Bull., May, 1897, $\frac{2}{3}$ natural size.—*Cullen.*)

On physical examination, which should be made bimanually, great varieties of conditions are found. The finger should explore both the vagina and the rectum, when one may discover all sorts of pelvic masses, from a merely thickened tube and broad ligament to a fixed and enlarged uterus, a collection of exudate filling the pelvis, fluctuating areas, and hard, porky, or brawny tumors. Often it is impossible to differentiate the component parts of this collection, or again one may distinguish satisfactorily the uterus from the tube, and the tube from the ovary, and may map out collections of pus.

The **diagnosis of chronic salpingitis** is founded upon such a history, symptoms, and physical signs as I have described—commonly

there is an old gonorrhea, made evident perhaps by the continuance of a chronically enlarged vulvovaginal gland; there is the story of long-continued uterine discharges, sterility, dysmenorrhea, a sense of weight, bearing down, tenderness, failing health, and invalidism. Such a composite picture may have been put together within a few days or weeks, and may have been associated with previously acute symptoms suggesting appendicitis. In the acute cases one frequently learns of a recent abortion or labor. Or the story may run over weeks or months, in which case one is apt to suspect rather a gonorrheal infection. All forms of infection may involve all the pelvic organs, and may result in similar pathologic appearances; but the puerperal infections, though frequently chronic, may run an acute and fatal course even, while the gonorrheal affections are those usually followed by chronic disease. When all is said, however, the surgeon frequently is surprised on operating to see very extensive structural changes out of all proportion to the trifling symptoms.



Fig. 204.—The T-tube.

Tuberculous salpingitis is not always distinguishable from the forms I have described. Between 6 and 8 per cent. of all tubal infections are tuberculous. The involvement of the tubes may be primary or secondary, and is often a part of a general tuberculous peritonitis. Tuberculous salpingitis also may be chronic or acute. When it is acute, the secretions escape usually through the fimbriated end of the tube, which is open frequently in acute forms. Chronic salpingitis is confined within a closed tube.

The *diagnosis of tuberculous salpingitis* is almost impossible of differentiation clinically from other forms of salpingitis, though in typical cases of chronic tuberculous salpingitis one finds loss of weight, a hectic temperature, a rapid pulse, frequent amenorrhea, an abdomen little if at all sensitive to pressure, sometimes ascites; and one looks for a history of tuberculosis and the involvement of other abdominal organs.

The **treatment** of all these pelvic infections is divided into medical and operative treatment. I shall not discuss the former further than to say that it consists in improved hygiene, an out-of-doors life, rest, careful feeding, tonics, ichthyol suppositories (an extremely useful

measure), hot packs, hot douches, tampons, and, in the hands of some physicians, pelvic massage.

The operative treatment of acute salpingitis presents questions for careful judgment. The answer to the question, when to operate, is not so easy as we found it in the case of acute appendicitis. We can lay down no rule that an inflamed tube should be removed at once, as we should say of an acutely inflamed appendix. An acutely inflamed tube rarely threatens life immediately. The inflammatory process is relatively slow, and the formation of protecting adhesions is almost certain. In a great majority of these cases rest, douching, and cold applications will relieve the symptoms and localize the process, so that a delayed operation, if any, may be anticipated. Rarely one sees fulminating peritonitis from an acutely inflamed tube.

On the other hand, with the subsidence of acute symptoms and with the establishment of a chronic salpingitis one finds often that non-operative treatment fails to cure.

Operative treatment of salpingitis is undertaken by two routes—the vaginal and the abdominal; and the old discussion as to choice still waxes and wanes. Without entering into the controversy I prefer to state that my own practice is to approach the disease *through the vagina* when pus-sacs are to be drained—especially pus-sacs which present in the vagina. The operation is not difficult. With the patient in the lithotomy position and the vaginal canal widely exposed, the surgeon incises Douglas's pouch behind the cervix, where pus usually collects; introduces his finger, explores the cavity, evacuates the pus, and drains with a T-shaped rubber tube. This operation takes no account of the more radical procedures sometimes advocated—the breaking up of adhesions, the opening of the general peritoneal cavity, the search for and the bringing down and packing of isolated, distended tubes, and the removal of organs. In any vaginal operation for drainage the surgeon should avoid injuring the ureters.

Effective drainage is established by the operation I have described, and in nearly all cases subsidence of inflammation follows, with reasonably prompt healing. The cavity should be washed out daily, and should be kept open with a gauze drain after the first week—so long as the discharge continues. Inflamed tubes and ovaries are not removed by these measures, but it is astonishing often to observe in how short a time exudates and masses will disappear, until the pelvis is returned to a nearly normal condition. Later, if distorted and crippled organs remain, the surgeon may think it wise to open the belly from above and deal with those organs by the abdominal route. Often at such a secondary operation he will be surprised to find the remaining structural changes extremely slight.

Abdominal section for pelvic inflammation was an extremely popular procedure a few years ago. We now employ it more intelligently and in selected cases—in cases of chronic salpingitis, rather, of long standing, and indolent inflammations; of extensive involvement of organs, with their matting, crippling, and disorganization. The operation may be

easy, or long, difficult, and dangerous. It is a simple matter to remove an isolated, thickened, functionless tube. It is far from simple to clean up and set right a pelvis filled with densely matted masses of viscera. For the sake of clearness I shall describe an easy operation—the removal of an inflamed tube, without complications. I shall then describe a difficult operation.

Simple Salpingectomy.—Trendelenburg's position is essential to comfortable work in the pelvis. The Fallopian tube must not be roughly isolated and removed, as is frequently done by inexperienced surgeons. After carefully packing back the intestines seize the fundus of the uterus with vulsellum forceps and bring it up into the wound, which should be large enough to admit of comfortable manipulations. Separate light adhesions by gauze sponging, taking pains not to damage intestines or to rupture a distended tube. Tie off with catgut the infundibulopelvic

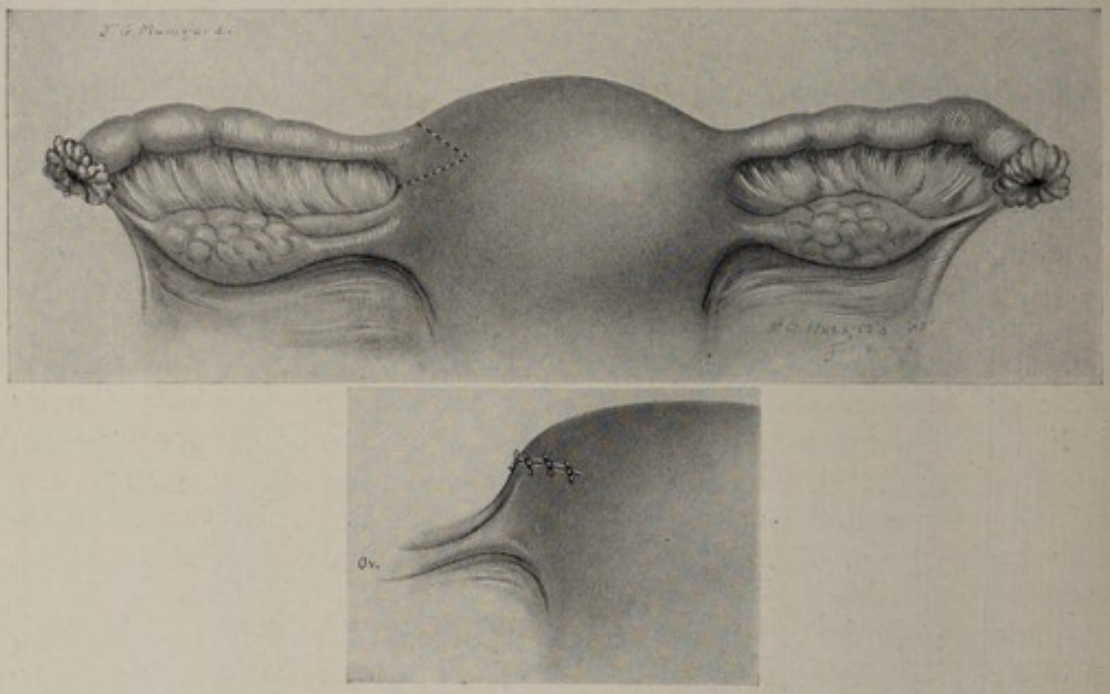

Fig. 205.—Incision for removal of diseased tube from uterus.

ligament between the ovary and the wall of the pelvis. Then ligate a small section of the broad ligament where it joins the uterus, close below, but not including the tube. These two ligatures control the blood-supply. Next seize the tube and ovary and excise them with scissors. Excise the whole tube, *dissecting it out from the fundus of the uterus*, and close the uterine wound with catgut stitches. Do not tie off the tube and leave a stump.[1] Such a stump may be a focus for future trouble. We

[1] The surgeon should have in mind possible future pregnancies. In this connection M. Storer writes in a personal communication: "I often cut the tube off an inch from the uterus and stitch the peritoneum to the endothelium, in those cases in which a subsequent pregnancy is desired. Sometimes these patients conceive later. If the tube is thickened all the way, I excise a wedge-shaped piece out of the fundus of the uterus; but if the uterine end be apparently normal, I hesitate about making it impossible for the patient to have another child—and I have had very few secondary operations."

now have to close the rent in the broad ligament. I usually sew it up with a buttonhole catgut stitch. Dudley sews it up by a shortening method, first converting the rent into a V-shape and approximating the distal to the proximal end. Either method is good, but Dudley's method doubtless furnishes the better support to the uterus.

If the tube and ovary have been removed in this manner without encountering complications and without soiling the peritoneum, the abdomen may then be closed, and a perfect convalescence expected.

Complications.—A discussion of the varying complications and difficult situations which may arise in clearing up a pelvis thoroughly infected and containing matted masses of viscera would involve us in many words. I shall *indicate* merely procedures to be followed, while the reader must bear in mind the intricate conditions I have already described. The presence or absence of pus is the leading question to be considered; next, the extent and intricacy of adhesions. Moreover, the pus may be sterile or infectious, and adhesions may be slight, or they may implicate the entire thickness of a viscus. If extensive parametric abscess be associated with pyosalpinx, whether or not the two communicate, it is best first to drain the abscess from below, as I stated when treating of vaginal section, though many competent surgeons advise and practise completing the operation and removing the tube through the vagina. Without entering into this controversy I must record my objection to the vaginal operation. It is impossible by the vaginal route to deal satisfactorily with densely adherent or possibly torn intestines or with a diseased appendix.

With the patient in the Trendelenburg position, and with the viscera carefully walled off so far as possible, one proceeds to the abdominal operation by gently and patiently disentangling the masses. One searches for the points of least resistance, insinuates the finger into yielding sulci, wipes out fluid, separates and packs off intestines, and repairs intestinal, bladder, or ureteral rents if they occur. Thus gradually the mass is broken up and the individual organs are isolated. When this is accomplished, there usually remains still an interesting problem to solve. Shall the uterus be removed with the tubes, or shall it be left? The answer to this question depends upon the extent of the metritis. This is a point which we considered in the last chapter, but in general terms be it said that it is safer to remove a highly inflamed uterus than to leave it as a source of continued infection. The teaching of the French school is that uteri should always be removed when the adnexa are removed. I do not subscribe to this view. Rarely one finds a case so difficult that completion of the operation is impossible on account of the imminent danger to life, through spread of infection and destruction of intestines. In such a case it is well to drain with gauze the pelvis both from above and from below. After some days or weeks of such drainage it may be possible to complete the operation at a second sitting. *Hemorrhage* is another complication which must carefully be guarded against. Extensive oozing is common, and bleeding vessels are often so obscure that they cannot be found. Secondary

hemorrhage is not infrequent. I have had three shocking cases of death from secondary hemorrhage following this operation. For these reasons, as well as on account of the septic condition of the deep field, abdominal drainage is essential after all operations for complicated pelvic inflam-

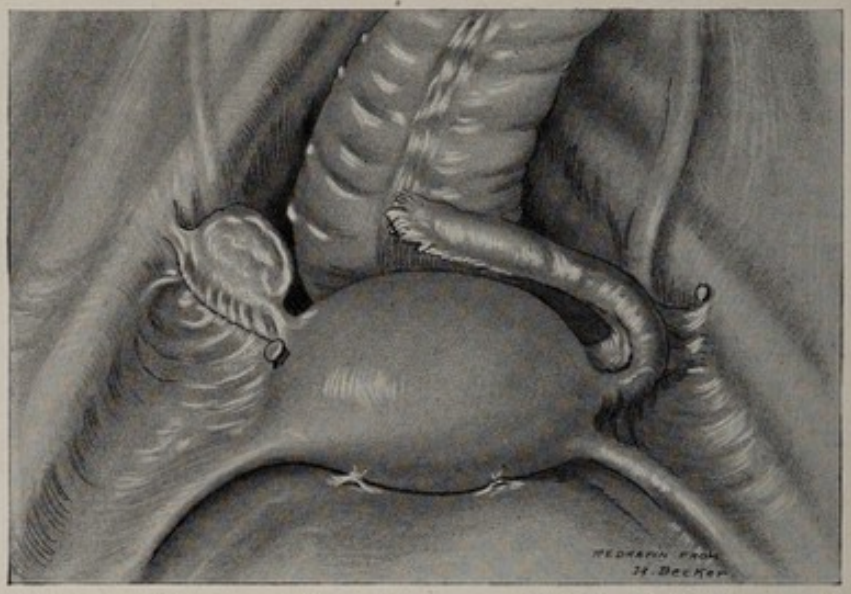

Fig. 206.—Diagram of the condition after removal of the right tube and left ovary, showing the distance separating the remaining tube and ovary (Kelly).

mations. I use and am satisfied with a cigaret drain passed through a stab-wound above the pubes and carried to the bottom of the pelvis. The abdominal wound is then closed tightly. By using this stab-wound

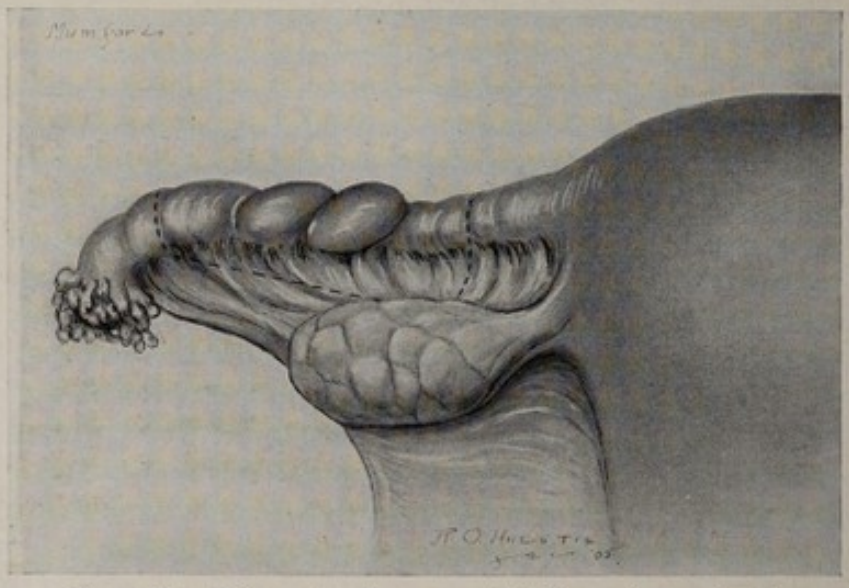

Fig. 207.—Diseased tube: area of obliteration excised.

one renders the abdominal wall strong and tight, little liable to hernia in the scar. In case of tuberculosis of the tubes they should be removed and the pelvis drained. When the uterus as well as the tubes is concerned in the tuberculous process, total hysterectomy should be per-

formed, unless extensive tuberculous involvement of other abdominal organs renders hysterectomy obviously futile.

Conservative operations on the tubes and ovaries have been advocated for the past twenty years. Schröder and Martin, as well as the American Polk, were advocates of such operations; while Dudley, Kelly, Morris, Storer, and Reynolds have made valuable contributions to the literature of this subject. In brief, these operations aim at preserving some small but sound portion of diseased ovaries, and at reestablishing the lumen of twisted and obstructed tubes. I shall have a word to say shortly in regard to the conservative treatment of ovaries; as for tubes, there is abundant evidence that in certain cases when damaged they may be restored to function, for after such operations conception and pregnancy have occurred—results impossible under the conditions found to exist before the operation. The obliterated end of a tube may be resected or rendered patent, and attached to a func-

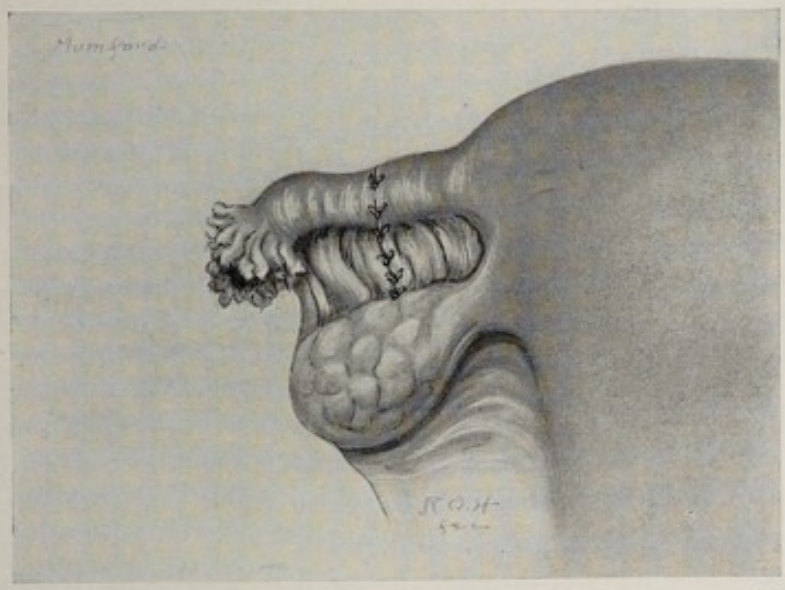

Fig. 208.—Conservative resection of tube, operation complete.

tionating ovary. Obliterating cicatrices are excised from the ampulla, and end-to-end suture performed, restoring the tube's lumen; while an ingenious operation, similar to that of the Heineke-Mikulicz pyloroplasty, will overcome tubal stenosis.

TUMORS OF THE FALLOPIAN TUBES

There are tumors of the Fallopian tubes—infrequent, little regarded. Inasmuch as the tubes contain the same histologic elements as the uterus, they may be the seat of tumors similar to uterine tumors. It is extremely difficult or impossible to distinguish clinically these growths from tumors of the ovary. Generally, the diagnosis is made on the operating table.

There are **tubal papillomata** springing from the adenomatous tissue of the mucous glands. Such growths are a menace to life because they are liable to invade the peritoneal cavity, there to spread rapidly and

involve other organs. The possible presence of such a tumor is always to be considered when one is dealing with pelvic neoplasms. This is a strong reason for removing all pelvic growths. If possible, a Fallopian papilloma should be excised promptly and entire. If it has invaded the peritoneum, its removal generally is impossible. One finds the abdominal cavity filled sometimes with these papillomatous growths from the tubes—growths easily bleeding and giving rise to a considerable accumulation of ascites-like, bloody fluid. Such growths, if unchecked, prove fatal rapidly.

There are **cystomata** of the Fallopian tubes—retention cysts of the mucous follicles found generally in the vestibule.

There are rare *myomata*.

There are **carcinomata** and **sarcomata** of the tubes—infrequent diseases, primary in the tubes almost never. Needless to say, they should be removed early, if at all.

THE BROAD LIGAMENTS

The broad ligaments may be the site of solid tumors and cysts less frequently than of inflammations. Rarely malignant disease may develop there, but benign disease is not uncommon. You will find cysts, myomata, lipomata, dermoids, cancer, sarcoma.

Cysts are the interesting broad-ligament growths. They are difficult to distinguish clinically from ovarian cysts. The terms *parovarian* and *intraligamentous* cysts are applied to them. In almost all cases they are developed out of the remnants of the Wolffian duct, which lies in the broad ligament below the Fallopian tube. These cysts are commonly unilocular and contain a thin, straw-colored fluid. If they have not become inflamed, they may be peeled out from the broad ligament.

The *symptoms* of parovarian cysts are in direct relation to the size of the cyst and the pressure it exerts on neighboring organs. Pressure may cause general pelvic discomfort, varying pains, dysmenorrhea, and irritation of the bladder and rectum. The treatment consists in enucleating the sac, and this generally can be accomplished. Sometimes, when there are extremely complicating adhesions, one may be obliged to pack the cavity after the cyst's removal and allow healing by granulation. In the rare cases of pedunculated parovarian cysts the surgeon usually ties off the growth. Rarely supravaginal hysterectomy must be our resource in dealing with intraligamentous cysts. In operating avoid injuring the ureters.

Hydrocele of the round ligaments is a condition analogous to hydrocele of the spermatic cord. The accumulated fluid is in the canal of Nuck, and appears as a fluctuating tumor at the internal ring, or even lower, in the mons or the tip of the labium. This condition cannot always be differentiated from inguinal hernia. The *treatment* consists in laying open and removing the hydrocele sac.

Solid tumors of the broad ligament usually lie between the peritoneal

folds, though rarely they may become pedunculated. They may grow to any size, if non-malignant, though nowadays they are usually discovered and removed when small. It is almost impossible to distinguish them from ovarian or uterine tumors before the abdomen is opened. The only *treatment* is operative. Open the abdomen either from above or through the vagina. Certain writers direct that the vaginal route invariably be chosen. Such advice is not consistent with good surgery. When difficult and complicating conditions exist in these cases, as in other forms of pelvic disease, it may be necessary to clean out the pelvis by removing the uterus and its adnexa.

Dermoid cysts have been found occupying the broad ligament. Their *symptoms* and *treatment* are quite similar to those of solid tumors.

Solid tumors of the round ligament [1] are rare. They may develop in the canal or within the abdomen. Except when large, they cause no special symptoms, but they should be removed when discovered.

Varicocele of the broad ligament is not infrequent; indeed, dilated veins are often found in various parts of the pelvis, associated with tumors and pregnancy. The common varicocele of the broad ligament is a dilatation of the veins of the ovarian pampiniform plexus. This varicocele generally is caused by an arrest of involution of the vessels following labor, by inflammation of the veins, or by the existence of long ovarian veins unable to propel the great weight of blood. Constipation and uterine displacements are other causes. The left ovarian vein frequently enters the left renal vein and may be obstructed by an overlying, heavy sigmoid flexure, loaded with feces. Such are some of the causes of these varices, though the etiology is not always clear. The patient suffers from dull, aching pain in the pelvis when she stands. Menstruation is wont to be frequent. The diagnosis may be obscure, though rarely, in thin subjects, one may palpate the varicocele. The only satisfactory *treatment* is abdominal section and excision of the veins.

Malignant disease of the broad ligament is uncommon, and when present, is usually secondary to disease of the uterus and other organs. Extirpation of such disease of the ligaments seldom is possible.

THE OVARIES

The ovaries are organs of such vital interest to patient and surgeons that they deserve more than the short notice I can give them in this chapter. They are interesting physiologically as well as pathologically. Their disease or removal means more than sterility to a woman, but we must limit ourselves to a brief consideration of their surgical diseases.

OVARITIS

Ovaritis as a complication of salpingitis is common, but the surgeon must be careful to distinguish true ovarian inflammation from ovarian hyperemia. The latter condition may be caused by malpositions, by

[1] Barton Cooke Hirst and Norman Knipe report an extremely interesting case of this nature in Surg., Gyn., and Obstet., 1907, vol. iv, p. 715.

twists of the ovarian pedicle, and by sundry traumatic irritations. *Acute ovaritis* is almost always due to the streptococcus. The gonococcus is more apt to give rise to a periovaritis. *Tuberculous ovaritis* is not especially uncommon. It arises from infection transmitted through the Fallopian tube, through a tuberculous vaginal lesion, through the peritoneum, or rarely through the general circulation.

It is not always possible to make a positive differential diagnosis of the above-named forms of ovaritis. All of them are characterized by general or localized pelvic pain, by dysmenorrhea, by local tenderness, by enlargement of the ovary, by its displacement, by adhesions, and sometimes by evidences of a general infection. Frequently the tubes, the uterus, and the peritoneum are involved in the process.

One must distinguish also between acute and chronic ovaritis. In typical cases *acute ovaritis* is characterized by an enlarged, tense, elastic ovary, with or without adhesions, together with the associated conditions I have mentioned; while *chronic ovaritis* is usually an outcome of acute ovaritis. In chronic ovaritis the ovary is at first swollen and hard; later, nodular and cystic, with symptoms of a less intense character, such as I described when speaking of chronic salpingitis. In general terms inflammations of the ovary are so closely associated with inflammations of the tube that we must consider both organs when we come to the subject of treatment.

Treatment.—If the attack is acute, general symptomatic treatment should be followed: absolute rest, the giving of saline laxatives, and hot vaginal douches and glycerin tampons on alternate days, with an ice-bag over the groin. Such treatment is indicated especially in the case of gonorrheal infection. When the inflammation is due to the streptococcus, the symptoms are wont to be more severe, and pus-formation is more certain, so that vaginal drainage may be our resort.

In the case of chronic ovaritis palliative measures, such as I described in the last paragraph, may suffice for a time; but for permanent cure we must resort usually to an operation. This subject of what operation to perform on chronically inflamed ovaries is intricate and difficult, because the operation depends largely for its success on the condition of the tubes. For the lazy surgeon it is easy to answer the question by removing both tubes and ovaries. Often, however, such radical procedures are needlessly crippling, and conservative treatment may be followed by a brilliant, satisfactory result. In any case a portion at least of one ovary should be preserved in order to obviate an artificial menopause, and to forestall the so-called reflex neuroses which so commonly afflict young women deprived suddenly of both ovaries. After the menopause the ovaries may be removed with more freedom. Conservative operations on the ovaries consist in the puncture and cauterization of cysts, the excision of scar tissue, and the stitching of the ovary into proper relations with the open tube. If the tube itself is diseased, one may treat it by some such plastic operation as I have described in a previous paragraph.

If the ovary is tuberculous, it should be removed, together with

the corresponding tube, and the operation should include complete extirpation of the tubal isthmus, with suture of the resulting wound in the uterus. If the ovary alone is removed, the pedicle should be

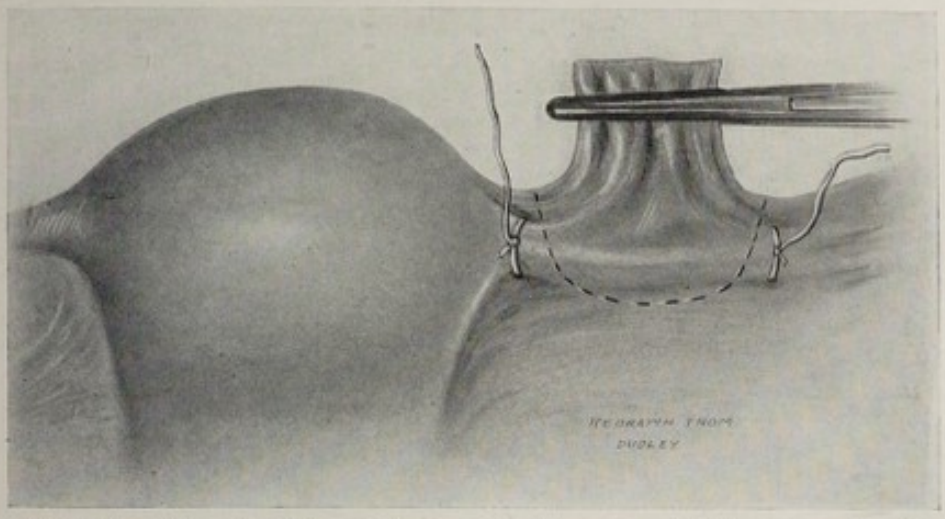

Fig. 209.—Repair of broad ligament after removal of ovary—step 1.

carefully secured by suture and the rent in the broad ligament repaired, after the fashion I described when speaking of removal of the tubes.

TUMORS OF THE OVARIES

Twenty-five years ago ovariotomy was the *magnum opus* of abdominal surgeons, and to-day even the operation creates a surprising amount of interest, for ovarian tumors generally can be removed entire,

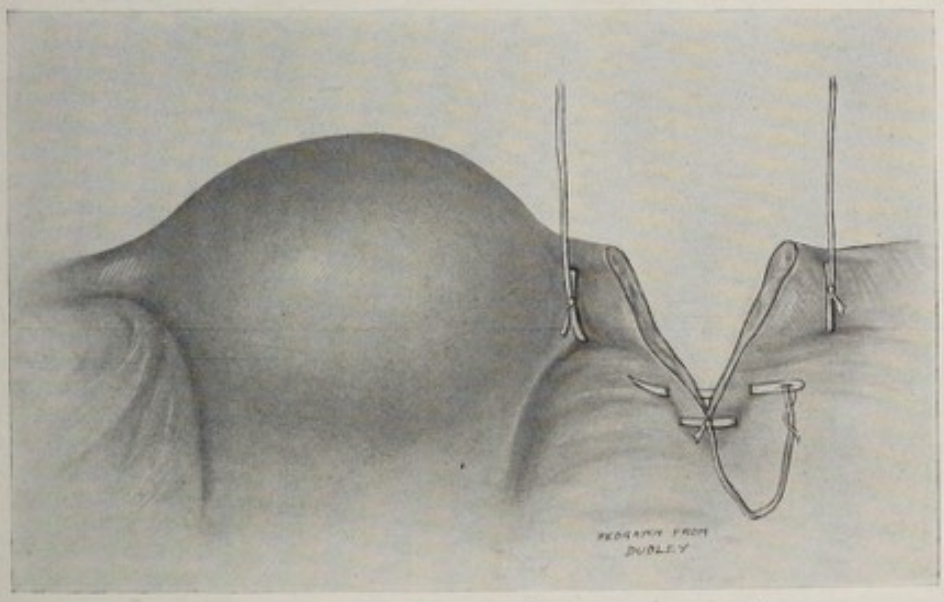

Fig. 210.—Repair of broad ligament—step 2.

and their removal releases the patient from painful, distressing invalidism, and returns her with promptness and completeness to vigorous, normal health.

As with tumors elsewhere, ovarian tumors are of great variety, though ovarian cysts are the tumors most familiar and most satisfac-

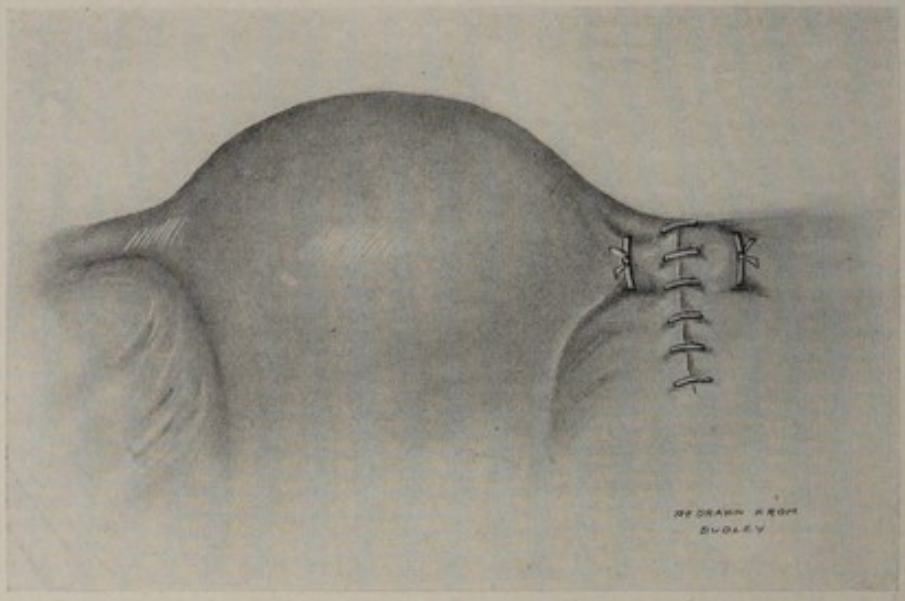

Fig. 211.—Repair of broad ligament—step 3.

tory in treatment. Ovarian tumors are benign or malignant. Primary cancer is the commonest form of malignant ovarian disease.



Fig. 212.—Enormous ovarian cyst. Weight, 128 pounds (Massachusetts General Hospital).

There are sundry forms of ovarian cysts: **Follicular cysts** are primarily dilated follicles, the result of previous inflammation. They

develop on the surface of the ovary, are of slow growth, and vary from the size of a bean to that of an adult head. These cysts may be single or multiple; gradually they destroy the ovarian tissue and appear as large water-bags containing straw-colored fluid or fluid turbid with changed blood. *Cysts* of the *corpus luteum* develop in a ruptured follicle. They grow slowly, and do not become so large as the follicular cysts; again, unlike the follicular cysts, they are usually single. They contain clear, serous fluid. *Tubo-ovarian* cysts develop in ovaries and tubes at once, but they are primary in the ovary; they are of follicular origin, and involve the tubes through inflamed adhesions. Rarely

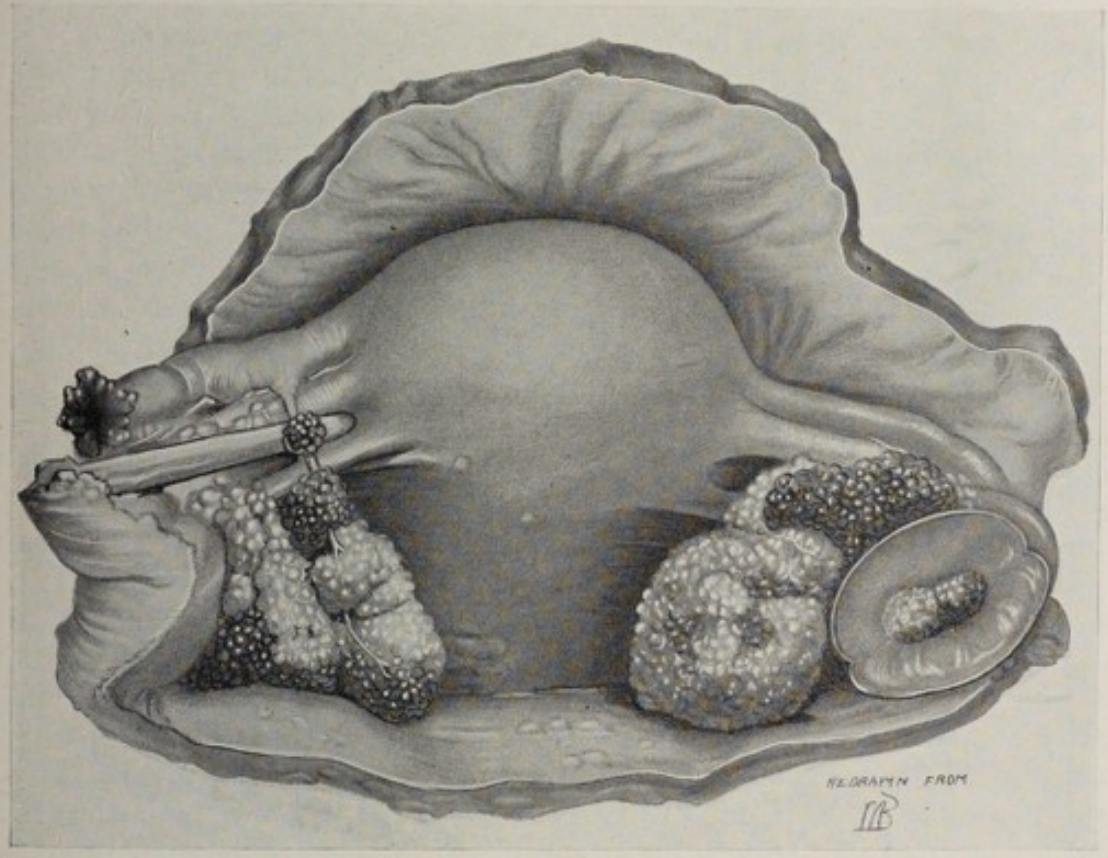

Fig. 213.—Papillomata of both ovaries seen from behind (Kelly). On the left side a series of mulberry masses are seen hanging from a delicate pedicle attached to the Fallopian tube; on the right, the ovary is transformed into a mulberry mass, and inside a cyst two masses are seen sprouting.

do they exceed an orange in size. They contain a clear fluid also, and are unique in this respect, that they may communicate with the cavity of the uterus, through which exit occasionally their contents may escape.

Proliferating or *neoplastic cystomata* are more rare. They are not retention cysts, but are true new formations, papillary or glandular, according as they contain papillary growths or not. Their contents may resemble mucin (pseudomucin) or may be serous. The papillary cysts may grow to a great size, and are most common in women who are unmarried or sterile. Such cysts generally are single, though they may be multiple. The fluid, when drawn off, is found to be of a thick, ropy consistency. The serous *cysts* are less common than the papillary

proliferating cysts, nor do they grow so large. These serous cysts often develop within the folds of the broad ligament, and are wont to form adhesions with neighboring organs.

We must note especially the proliferating cysts. Though histologically benign, they develop rapidly, and in their removal portions may become detached and implanted elsewhere in the peritoneal cavity. There they grow and multiply, forming metastases. Sometimes malignant degeneration occurs, when either carcinoma or sarcoma may develop. So these proliferating cysts are to be dreaded. If you open the abdomen to remove an ovarian tumor, and find in the peritoneal cavity free fluid, bloody and serous, look for a proliferating cyst; remove it entire, if possible, but give a guarded prognosis.

Dermoid cysts are the least common of ovarian cysts. Usually, they are pedunculated, though sometimes they may develop within the folds of the broad ligament. They grow slowly and rarely exceed in size an adult head. Commonly they are single, and contain various substances: fat-like material, hair, teeth, and bones. The probability is that these growths have their origin in the ovule, which possesses the elements needed for the development of human tissues and structures.

Solid tumors of the ovary are rare also. They are usually rounded, smooth, and pedunculated, though they too may lie in the broad ligament. Often they are associated with cysts. Of these tumors, fibromata are the most common. Myomata are rare. Within the fibromata myxomatous changes may occur and calcareous matter may be deposited.

We find primary cancer of the ovary, medullary carcinoma, and adenocarcinoma. *Medullary carcinomata*, like other solid ovarian tumors, are both pedunculated and intraligamentous. The *adenocarcinomata* are made up of cystic tumors, usually pedunculated, attaining the size of a child's head, frequently adherent to other organs, with papillary excrescences. It is not always easy at once to distinguish the adenocarcinomata from non-malignant proliferating cysts. Secondary malignant growths in the ovaries often result from uterine neoplasms. There are also ovarian *endotheliomata*, springing from the blood- and lymph-vessels of the ovary. Like other malignant diseases they occur in middle life, but may develop in childhood.

Hematoma of the ovary must be mentioned—a distinct tumor reaching the size of a small orange. It is rarely made out before operation.

The **symptoms of an ovarian tumor** vary with the nature of the growth and with its size and attachments. Most benign tumors cause trouble from their size and pressure only, though frequently, in the case of small ovarian cysts, the patient is aware of some pelvic discomfort, and may complain of exaggerated menstrual pain. An exception to this lack of frequent pain is the case of an ovarian tumor with a *twisted pedicle*. There is a great literature on this subject. Small ovarian tumors, as well as large ones, may become twisted, the twist being usually from left to right, or as the hands of a watch move. The pedicle may twist through many degrees, depending upon its length and

mobility. Twists of four or even five complete turns have been reported, though usually one complete revolution is enough to set up acute symptoms and send the patient to a surgeon. These twists cause strangulation of the vessels, engorgement of the tumor, and agonizing pain, which may be spontaneously relieved after a time by a partial untwisting. The twist may occur independently of menstruation. The great danger of the condition lies in the probability of a firm permanent twist resulting in gangrene of the tumor.[1] Another form of non-malignant tumor which gives rise to pain is the dermoid cyst. Ovarian cysts may rupture and apparently disappear. As a general thing, however, ovarian cysts reach a considerable size before causing pronounced symptoms; these symptoms may be amenorrhea or other menstrual disturbances, but the pronounced symptoms are due to mechanical pressure. One hears of bladder, rectal, and renal disturbances, with great swellings of the abdomen, of edema of the legs, of hemorrhoids, and sometimes of ascites. In the case of solid benign tumors the symptoms vary little from those which I have just described, but malignant tumors cause pain, cachexia, wasting, and the other conditions common to all late malignant disease.

The **diagnosis of ovarian tumor** may be easy, or it may be extremely difficult. The history and symptoms count for little, as tumors of other organs, especially of the uterus and tubes, give rise to similar symptoms. We must depend on our physical examination. A typical ovarian cyst may be handled bimanually. It feels like a rounded, smooth, elastic, movable mass, occupying the pelvis or lower portion of the abdomen. Nowadays these tumors rarely reach the great size shown in the old text-books as classic. Surgeons discover ovarian cysts early in their growth, and take them out long before the tumor fills the abdominal cavity. If the cyst is large, it may be confounded with ascites or other causes of abdominal distention. Note, however, that free fluid in the abdomen settles in the flanks and gives rise to shifting dulness when the patient turns. On the other hand, a great ovarian cyst is shown by central dulness which does not shift. But the small tumors usually found are mapped out as small tumors. Sometimes they are so soft and flabby as not to be felt. Sometimes they are so hard and tense as to be mistaken for solid tumors. Every surgeon has cut down upon an ovarian cyst under the mistaken impression that it was a myoma of the uterus. Extensive adhesions and concurrent new-growths complicate further the diagnosis. Solid ovarian tumors also may be distinguished as discrete, movable masses, or they may be mistaken for tumors of the uterus, tubes, or broad ligaments. Pregnancy may complicate and confuse the diagnosis. Rapidly growing tumors, rather than tumors of slow growth, are likely to be malignant. Sudden increase in size, associated with acute pain, is usually due to torsion of the ovarian pedicle. Pregnancy may be distinguished by the patient's vomiting, by enlargement of her breasts, softening of the cervix, placental bruit, and perhaps by fetal heart-sounds. Uterine

[1] See article by M. Storer, Boston Med. and Surg. Jour., November 5, 1896.

tumors are usually distinguished, among other signs, by elongation of the uterine canal, as shown by the exploring probe.

In spite of all tests, with which the literature of this subject abounds, the most experienced surgeon may make mistakes. In this case, especially if symptoms persist and become aggravated, one must resort to an exploratory operation.

The **prognosis** of ovarian tumors untreated is illustrated by the abundant and curious literature of the last century, and the prognosis varies as greatly as do the growths of which that literature treats. In general terms, benign tumors produce slowly developing invalidism, sterility, neuroses, exhaustion, impairment of the functions of the abdominal organs, wasting, and a lingering death after many years. Malignant disease of the ovaries advances rapidly in the familiar fashion, with metastases, extensive involvement, cachexia, and death in from one to two years. Furthermore, one may never say when the benign may become the malign, so that in every case extirpation of the growth is the surgeon's duty.

Ovariotomy.—The subject of removal of ovarian tumors marks one of the proudest chapters in American surgery. Ephraim McDowell, of Danville, Kentucky, in 1809, was the first surgeon to remove an ovarian tumor. Nathan Smith, of Dartmouth and Yale, in 1821, removed an ovarian tumor without knowledge of McDowell's work. Slowly the practice extended so that now, for a hundred years, ovarian surgery has been recognized and followed in this country. It was not until the development of aseptic surgery, however, that the practice became universally established. Ovariotomy is a misnomer. Properly, the term should be oöphorectomy,[1] but that word is commonly used to designate the removal of an inflamed ovary, while ovariotomy, meaning properly the cutting open of an ovary, has come to designate the removal of an ovarian tumor.

No form of treatment other than extirpation serves to remove ovarian tumors. Let me say a preliminary word in regard to the removal of solid tumors of the ovary. The technic is extremely simple; the maneuver differs in no essential respect from that of the removal of a tumor of the tube.

The surgeon opens the abdomen near the median line by a longitudinal incision; walls back the intestines, with the patient in the Trendelenburg position; seeks the tumor; clamps its pedicle, or dissects out the mass if it be intraligamentous; removes the growth, and repairs the rent in the broad ligament. All this is simple. So accomplished a surgeon as M. H. Richardson maintains that all ovarian tumors, cysts as well as solid tumors, should be removed entire in this fashion, for one cannot always foresee the nature of a cyst before it is opened. It may contain malignant elements, in which case its removal unruptured and entire will forestall subsequent malignant involvement of other parts. I sympathize entirely with this view, and recommend the total removal of ovarian tumors unruptured in most cases. Occasionally, however,

[1] Greek, ᾠόν, φέρω.

one encounters an ovarian tumor so enormous or so extensively adherent that its removal by a modification of the classic tapping method is inevitable. That classic method is still useful. As ovariotomy was the operation of pioneers in abdominal surgery, the subject was long involved in a voluminous and needless discussion relating to details of technic, and countless curious instruments and other matters with which early Listerism concerned itself. To-day the classic operation even is simple enough, and, as John Homans used to say, its only point of interest for the surgeon lies in his endeavor to operate through the smallest possible abdominal opening.

One enters the abdomen above the pubes through the rectus muscle, and at once explores the wall of the cyst, to ascertain the presence of adhesions. If the cyst is fairly free, the patient is turned on the right side, a gauze handkerchief is laid in to protect the peritoneum from discharges, and a Spencer Wells trocar is plunged into the cyst. Through the trocar the cyst fluid is led off by a rubber tube into a receiving bucket. With the emptying of the cyst its wall collapses and the surgeon's assistant hastens the emptying by pressing upon the patient's flanks. Should several large cysts be present, they may be tapped severally, the sac being gradually drawn out of the wound by grasping forceps and the tap incision being closed with Nélaton's forceps. Should there be no complications, the fluid contents may thus be almost completely evacuated, after which the collapsed sac easily may be drawn outside of the abdominal wound. The surgeon then double-clamps the pedicle and dissects it between the clamps. We used to apply the complicated Staffordshire knot to secure the pedicle. A better practice is to ligate separately the two divisions of the ovarian artery on either side of the pedicle, then to cut away the pedicle stump and repair the rent in the broad ligament. By this measure all danger of secondary hemorrhage is eliminated, for the student should remember, as a point of interest, that in the old days slipping of the ligature and fatal hemorrhage from the pedicle was an occasional accident.

The complication of adhesions and supplementary growths must be dealt with as I have frequently before described—by dissection and separation of adhesions, by repair of torn bowel, and by removal of growths.

Ovarian tumor complicating pregnancy is another serious condition which should be recognized early by the physician and promptly treated. The danger of this complication lies in the possibility of twisting of the pedicle, rupture of the cyst, abortion, obstruction to labor necessitating Cesarean section, or ovariotomy during labor. This complication, when discovered early, should be met by early ovariotomy. If the operation be simple, abortion is unlikely, especially if liberal doses of codein or the bromids be employed at once in the after-treatment.

TUBAL PREGNANCY

Tubal pregnancy is one of the great and interesting subjects of modern surgery. The danger of the condition is extreme; the situation is often unexpected; and prompt, heroic treatment frequently is demanded if life is to be saved.

We were formerly wont to talk about tubal pregnancy, ovarian pregnancy, abdominal pregnancy, but we now know that tubal pregnancy is properly the primary condition in most of these cases, and that apparent development of the fetus in the ovary or free in the abdomen is generally secondary to primary tubal pregnancy. *Extra-uterine pregnancy* is a proper term, as is *ectopic gestation.*

The cause of tubal pregnancy is now generally recognized to be a lodgment of the impregnated ovum somewhere in the tube. The ovum does not cling to the mucous lining of the tube, but apparently burrows into it, lodging in some crypt or fold or other abnormal formation, the consequence of a previous salpingitis. The site of lodgment generally is in the ampulla of the tube, though isthmic pregnancy and interstitial pregnancy (within the uterine wall) are not unknown. It is needless here to discuss the formation of the chorion, amnion, decidua, and placenta further than to state that these structures develop on lines similar to the normal, except that the placenta is derived almost entirely from the embryo and not from the tubal mucosa. As the products of conception develop, the wall of the tube becomes thinner and thinner, and in this thinning lies the danger of the condition.

The course of a tubal pregnancy runs uninterrupted usually for from three to ten weeks, but during the latter half of this period one of two accidents almost invariably occurs—tubal abortion or tubal rupture. Malcolm Storer[1] has shown that tubal abortion is a more common accident than at one time was supposed, and occurs usually about the sixth week of pregnancy, while tubal rupture occurs between the eighth and tenth weeks. Probably more than half the cases of tubal pregnancy end in tubal abortion. This phenomenon consists in the expulsion of the ovum through the open, fimbriated end of the tube, when it may become implanted upon the ovary or upon some other adjacent part.

The **symptoms** of tubal abortion are pain of varying intensity, together with an escape of blood from the uterus. The pain is rather characteristic—brief, stabbing, not colicky, and by no means so severe as is the pain of tubal rupture. The pain and the flowing lead the patient to consult a physician. The cause of the abortion is believed to lie in the fact that the glandless tubal mucosa hypertrophies but slightly, and does not form a decidua, as is found in the uterus. The chorionic villi of the growing ovum perforate this thin layer and open into the enlarged tubal vessels, thus giving rise to a hemorrhage which separates the ovum and results in the abortion.[2] In most cases of tubal abortion the ovum perishes with its expulsion from the tube, but hem-

[1] Boston Med. and Surg. Jour., January 7, 1904.
[2] Marshall, Lancet, March 26, 1904.

orrhage persists generally in both directions. Frequently blood is poured out into the abdominal cavity and within the folds of the broad ligament. Pelvic hematocele, so called, then results; the patient may become alarmingly weak, and prompt operative treatment be imperative. In rare cases the ovum lodges upon the ovary, where it develops and may continue even to full term. This form of pregnancy has been called *ovarian pregnancy*, and there is still debate whether the pregnancy ever is primary in the ovary, or is always secondary to a tubal pregnancy. Again, the ovum may lodge elsewhere in the abdomen and develop, in which case we speak of the condition as *abdominal pregnancy*. Abdominal pregnancy is always secondary to tubal pregnancy, and is the result of tubal abortion.

About half the tubal pregnancies may not result in tubal abortion, but in tubal rupture, in which case immediate death of the fetus ensues almost invariably. Tubal rupture is due to a great thinning of the tube, distended by the growing ovum, until the tube breaks, with discharge of the ovum and an accompanying profuse hemorrhage.

There are secondary changes in the uterus associated with tubal pregnancy. The uterus enlarges somewhat and forms a decidua, as does the tube. If the abnormal pregnancy advances far, the uterus becomes pushed to one side, while the vagina and cervix show the characteristic engorgement of pregnancy. The woman's breasts become enlarged and the areolæ dark. Such are the more common structural and tissue changes one sees in the case of ectopic gestation. Very little imagination is required to realize the gravity of the condition and the frightful accident which it may precipitate—an accident demanding prompt and thoroughgoing treatment.

The **symptoms and diagnosis of extra-uterine pregnancy** may be characteristic and obvious, or the reverse. In most cases the diagnosis is not made until some catastrophe occurs. Often, at first, menstruation is somewhat disturbed—retarded or irregular; while in a large number of cases it ceases altogether. There is frequently "morning sickness," and at times nagging pelvic pain with faintness. Sometimes persistent flowing will come on after six or more weeks of amenorrhea—persistent flowing, frequently mistaken for a miscarriage by the medical attendant. Or the physician may discover a tubal pregnancy, finding a doughy mass at one side of an empty but slightly enlarged uterus. At this stage he should base his diagnosis of extra-uterine pregnancy upon the four cardinal symptoms—disturbed menstruation; sharp pelvic pain and faintness; an extra-uterine mass, and an enlarged, empty uterus.

When we come to the *symptoms* and diagnosis of surgical calamity associated with tubal pregnancy, we are in deeper waters, and it is with calamity that the surgeon is generally concerned. I have already described the symptoms of tubal *abortion*, which are notably pain of an endurable character, but prolonged and distressing, extreme faintness, and the evidences of internal hemorrhage—rapid, thready pulse, cold extremities, blanched aspect, distended and tender abdo-

men, dyspnea, and subnormal temperature; or all these symptoms may be present, but in milder degree. Generally, a mass may be felt in the pelvis if the patient be not too fat or too tender for a proper physical examination. Usually, blood is seen to escape from the os uteri. Even with these signs the surgeon may be unable to determine accurately the nature of the accident that has occurred, but he sees that a grave abdominal emergency demanding operation is before him.

The *symptoms* of tubal *rupture* are more alarming even. The most obvious phenomena are the agony and prostration of the woman. Once witnessed, the scene cannot be forgotten: the blanched, exhausted patient, moaning or screaming in agony, writhing and involuntarily and uselessly attempting to discharge her load by frantic straining. The crisis passes in a few minutes, or may last several hours. The rending of the tube ceases. Pain becomes less, but hemorrhage does not stop at once, and a condition of almost pulseless exhaustion supervenes. We know that a great amount of blood has been poured out into the abdomen or extraperitoneally between the folds of the broad ligament. The patient may be so exsanguinated, and the heart so exhausted, that bleeding ceases spontaneously for a time, but we never know how soon the heart may revive or how soon a second and a third hemorrhage may ensue.

Such are the calamities—tubal abortion and tubal rupture—commonly resulting from extra-uterine pregnancy. A rare outcome of the condition is the expulsion into the abdomen of a living fetus which lodges, grows, develops, and reaches full term, or an age approximating to full term. The fetus then dies, the placenta becomes detached and disintegrates, while the fetus, as a foreign body, may be carried for years by the mother; it may become disorganized or calcified (lithopedion); it may form a focus of infection, and portions of it may penetrate the hollow viscera and be discharged through the rectum or vagina or through the abdominal wall even.

Such, in extremely brief detail, is the story of extra-uterine pregnancy, and the student will realize the grave difficulties which encouter him when he comes to consider treatment.

Treatment.—In those earliest stages of which I spoke, if the presence of an extra-uterine pregnancy is fairly well determined, the one and only course for the surgeon is operation. Open the abdomen and remove the enlarged tube. The operation at this stage is simple and the danger no greater than the removal of a chronically inflamed tube. I have already described the technic. In the case of the alarming symptoms associated with tubal abortion or rupture, operation is also imperative, but the moment for doing the operation is not always obvious. Indeed, surgeons still debate the question. A few years ago all were agreed that immediate operation was as urgent in all cases as though the patient was suffering from gunshot of the intestines. We have modified somewhat this view with time, and the mode of applying that modification depends entirely upon the experience and intelligence of the individual surgeon. If the woman be recently collapsed,

if pain be still present and the pulse fair,—120 or under,—I believe one should immediately open the abdomen and control the hemorrhage. On the other hand, if the patient be in profound shock and almost pulseless, one knows that a severe surgical operation may turn the scale and kill the victim. What, then, shall the surgeon do? Fortunately, we have learned from much experience that most women do not die at once under these alarming conditions—that hemorrhage spontaneously ceases and that the heart rallies. I do not think it safe actively to stimulate such patients except that I sometimes give a hypodermic injection of strychnin ($\frac{1}{60}$ or $\frac{1}{40}$ gr.) and watch closely the result. Of all things, give no saline infusions. In any event, we usually see the patient rally slowly from the condition of extreme shock. Then we know that hemorrhage has ceased temporarily, and that if we stand by, ready to operate at a moment's notice, the proper time will soon arrive. I have thus waited two, three, and four hours, and am convinced that in the case of persons suffering from extreme shock waiting is often the wiser course. In other words, catch your patient on the rebound, when you may operate and save her life. I submit that there are few surgical emergencies calling for greater tact, resourcefulness, judgment, and swift technical skill.

The *method* of the operation is simple. With the patient in the Trendelenburg position, open quickly through the rectus muscle over the affected side, sweep back the intestines, seize the uterus with double hooks, draw it into the wound, and clamp the ruptured tube at both ends. Then remove the tube in the fashion I have described, scoop out blood-clots and the products of conception, wash out quickly the abdomen with an abundant hot saline douche, close the wound, and put the patient back to bed as soon as possible. There may or may not be additional shock. Give a stimulating enema of black coffee, brandy, and salt solution, and repeat the salt solution (10 ounces) every four hours for twenty-four hours; inject strychnin carefully, and elevate the foot of the bed. The great majority of these patients recover if they come off the table alive. Those patients who die perish at once as the result of an operation undertaken *in extremis*. It is gratifying to watch the rapid convalescence of these women and their prompt restoration to health.

The treatment of extra-uterine pregnancy advanced to the rare condition of full term is another problem. The fetus, its placenta, and membranes are by that time implanted somewhere in the abdominal cavity outside of the tube, and can be removed, if at all, by abdominal section only. It is a simple matter to open the abdomen and remove the child, but the extraction of the placenta is a frightfully hazardous proceeding, on account of the inevitable hemorrhage which follows. Be it remembered that the loosening and removal of the placenta from the normal gravid uterus is relatively bloodless because the uterus contracts and shuts up its great vessels. On the other hand, when the placenta is attached to some non-contractile portion of the abdomen, its removal is not followed by closure of the vessels, so that excessive hemorrhage

results. Commonly, such an ectopic placenta receives its blood-supply through some portion of the uterus and adnexa, so that it would appear as though control of uterine and ovarian arteries would check hemorrhage from the placental site. Unfortunately, there is often a copious collateral blood-supply to the placenta, so that the ligation of uterine and ovarian arteries avails little. Removal of an extra-uterine fetus is, therefore, one of the most hazardous undertakings in surgery—to be attempted by the most skilful operator only, who may be obliged to compress the aorta in order to control hemorrhage. For this reason I recommend the easier and safer method of removing the child, stitching the sac into the wound, packing, and leaving the placenta to dislodge itself later.

These children, if they survive, may be as vigorous as those born in the natural manner.

PELVIC HEMATOCELE

Pelvic hematocele was formerly the term applied to most collections of blood within the pelvic cavity—pelvic hematocele and hematosalpinx. We are now assured that a majority of cases of pelvic hematocele and hematosalpinx are due to tubal pregnancy. Such collections of blood may be within the folds of the broad ligament, as I have described, and may burrow under the peritoneum in various directions, or the blood may be free in the pelvic cavity. We formerly practised vaginal section in order to clear out such hemorrhagic collections, but of late years we are convinced that the best practice is to open from above, so as quickly and surely to explore, to control hemorrhage, and to remove thoroughly all the products of gestation.

CHAPTER XII

PERINEUM AND VAGINA

Surgical interest in the female perineum centers in the treatment of its childbirth lacerations. There are numerous other perineal lesions, but they are mostly simple disturbances easily treated.

At the beginning of Chapter X some mention was made of the anatomy of the perineum, and it is well to repeat here the statement that, by the surgeon, the perineum must constantly be regarded as a floor, ingeniously constructed to support the pelvic and abdominal organs. Damage to this floor means displacement of organs, and often a far-reaching course of ailments, such as I have already described in speaking of uterine displacements and other ptoses of the abdominal organs. It remains for us now to consider means of repairing damage to the perineum. I pointed out in Chapter X also how the structures of the perineum are divided into superficial and deep layers. It is laceration of the deep layer which calls most urgently for surgical aid. Damage to the superficial layer results in local discomfort only.

PERINEAL LACERATIONS

The leading feature of deep perineal damage is laceration of the levator ani muscle—the great muscle which supports the pelvic viscera. Until recent years we failed to appreciate the significance of tears of this deep muscle, so that the old-time operations for repair of the perineum were directed to the reconstruction of damaged superficial parts—the skin, the fourchet, and sometimes the sphincter ani. Reynolds [1] showed, years ago, the form and character of fresh perineal lacerations and the mechanism of these lesions. As seen immediately after childbirth, the tear is somewhat Y-shaped, crescentic in the vagina, with a single prolongation through the labia. The crescentic portion of the tear is that which penetrates deeply through the levator ani muscle; the downward prolongation divides the skin and the sphincter ani even. A result of extensive tears of this nature is a relaxation and downward sagging of the pelvic floor, with the superimposed organs.

Treatment.—A description of the popular operations for repair of the lacerated perineum would necessitate a long, complicated historic essay, suitable for a special text-book only. Let us study the simple and effective operation which I favor especially, and then mention one or two of the other better known procedures. For a more clear understanding of the purpose of perineal repair let me again remind the reader that laceration of the levator ani makes for not only uterine displacement

[1] Edward Reynolds, Trans. Amer. Gyn. Soc., September, 1891.

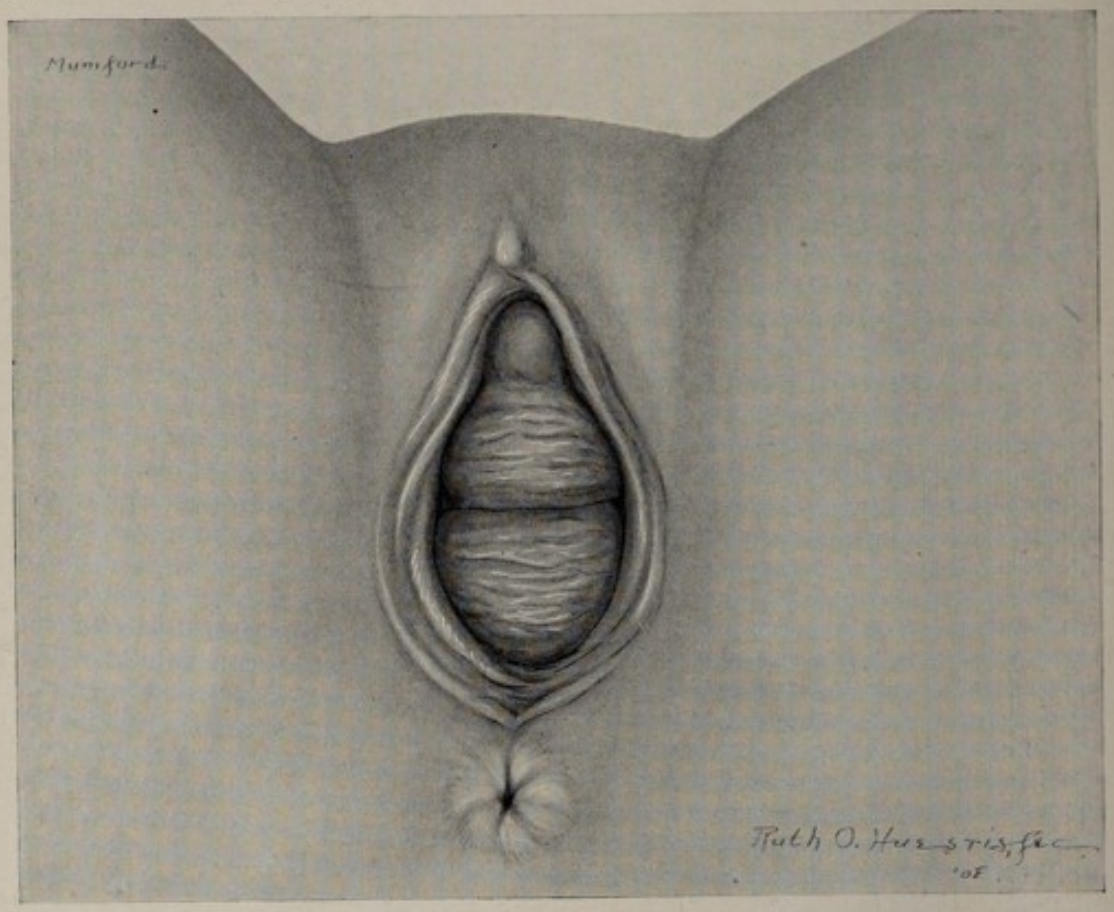

Fig. 214.—Cystocele and rectocele.

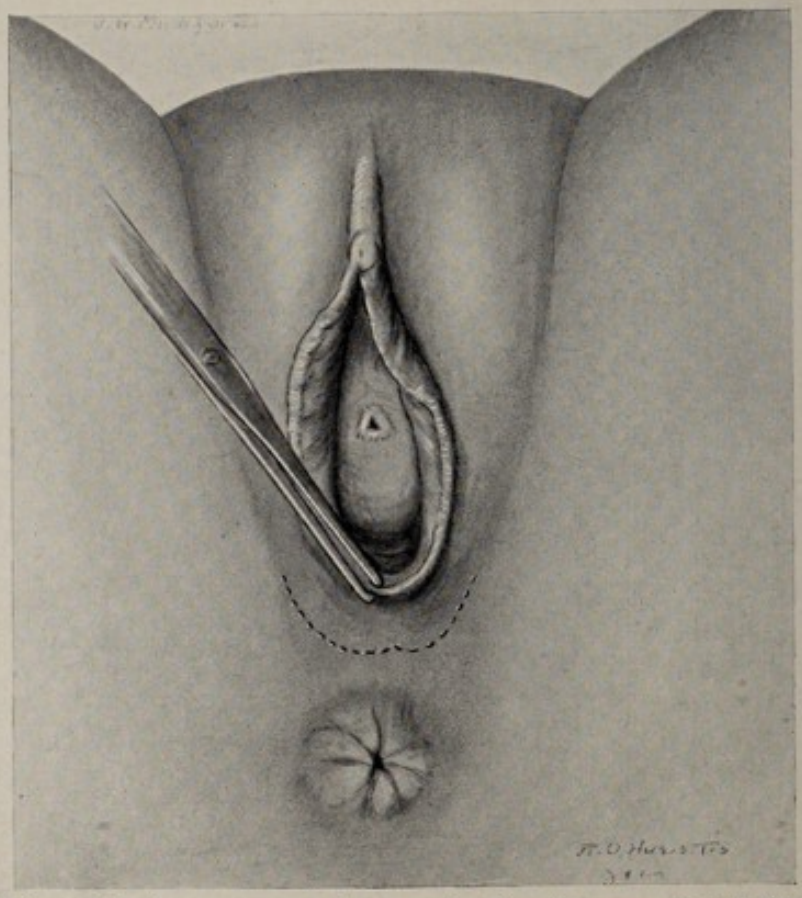

Fig. 215.—Flap-splitting operation for repair of perineum—step 1 (redrawn after Aitken).

and descent, but also for sagging forward of the anterior rectal wall (rectocele), and sagging backward and downward of the bladder (cystocele). The operation which I shall now describe remedies in great measure both rectocele and cystocele.

By the following operation we aim primarily to seek out and stitch together the ruptured fibers of the levator ani; to this end, split the septum between the vagina and rectum through a crescentic incision drawn around the lower border of the vagina or just within the vagina. The lateral portions of this cut enter readily through the skin and superficial fascia, and open the ischiorectal fossa. So far there is no diffi-

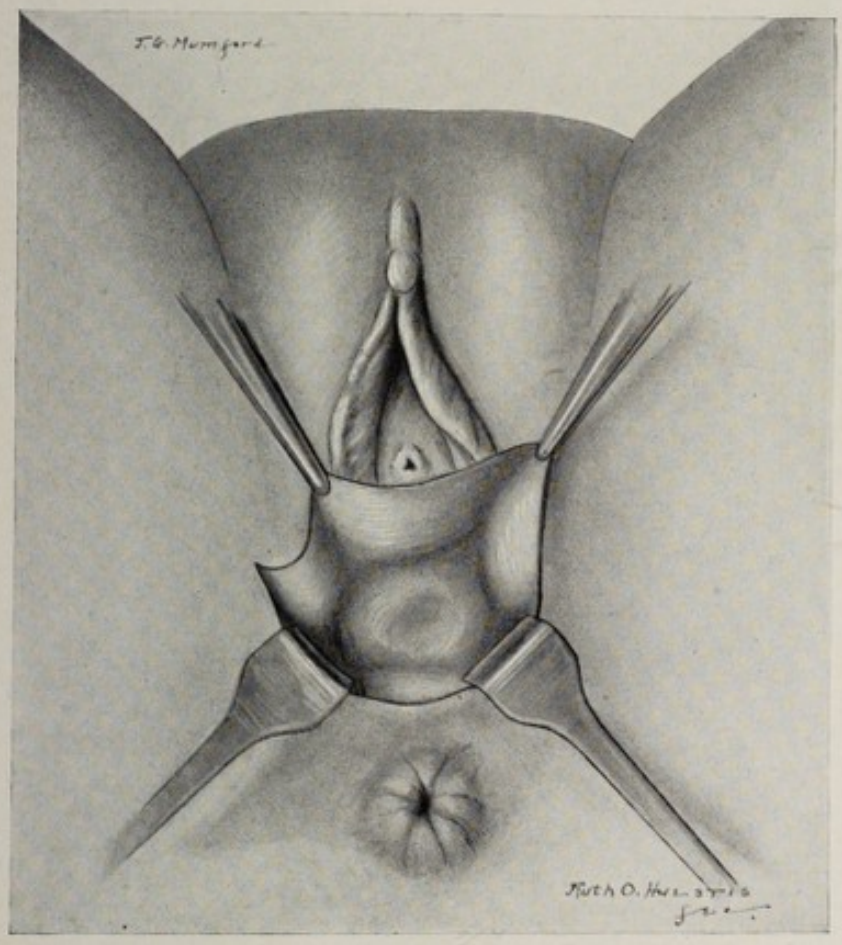

Fig. 216.—Repair of perineum—step 2 (redrawn after Aitken).

culty, but the separation in the median line, between the vagina and rectum, often demands a painstaking and laborious dissection through a great amount of tough scar tissue.[1] By keeping close to the vaginal flap, however, one may avoid opening the rectum—an awkward complication. When the scar tissue has been dissected through, the vagina and rectum peel apart readily, and then quickly with the fingers one deepens the wound if needful up to the uterine cervix. There is not the

[1] This operation is in many respects that practised by Lawson Tait twenty-five years ago, and still described as Tait's operation in many of the text-books. I recognize it as Tait's operation, but on carefully reviewing his description cannot find that he carried his dissection as deep as I feel generally to be advisable.

slightest danger of entering the peritoneal cavity. Often there is troublesome bleeding from large hemorrhoidal veins, which should be carefully secured as one progresses. The whole wound should be made as dry as possible, though the checking of all oozing is not easy.

With the depth of the wound now exposed and the sides held widely apart with retractors, one sees or palpates readily the strong edges of the divided levator ani muscle. The rest of the operation consists in placing the stitches properly and securely. For this the operator must

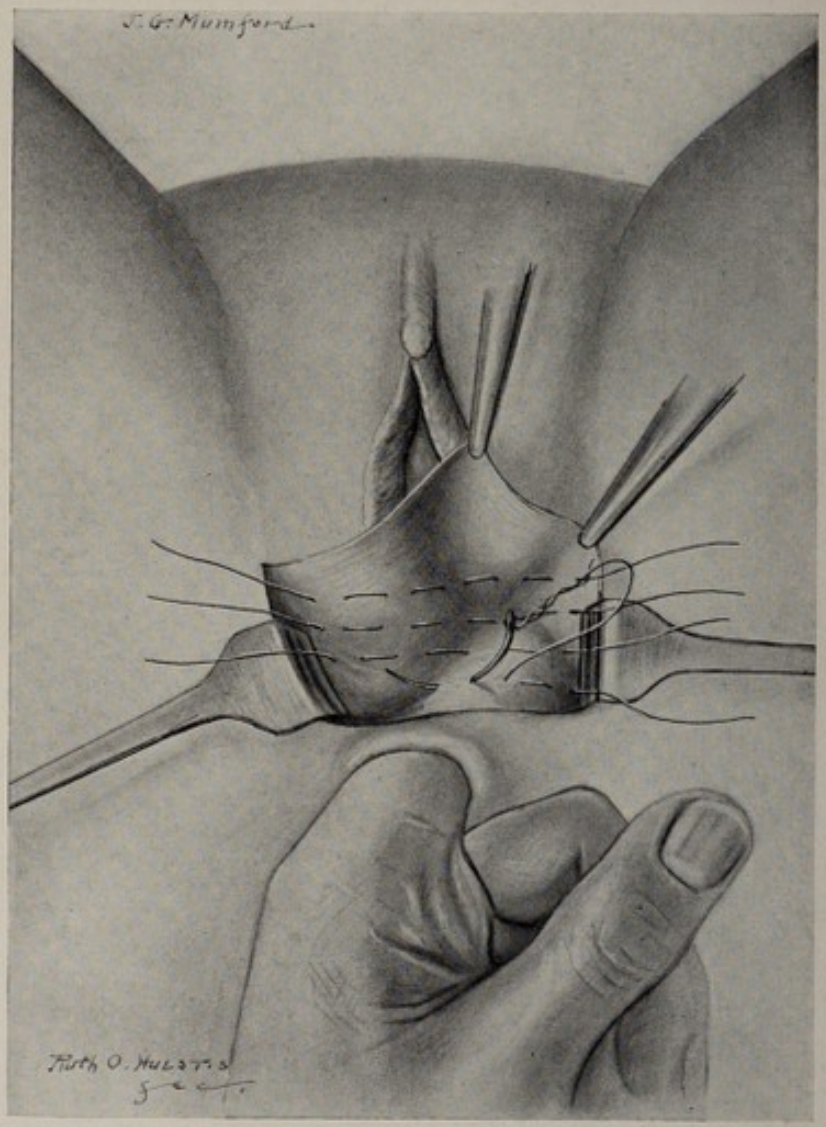

Fig. 217.—Repair of perineum—step 3 (redrawn after Aitken).

now sacrifice his left forefinger by introducing it into the rectum to act as a guide for the needle. Three or four heavy, deep, absorbable, buried catgut stitches are enough to unite the edges of the torn muscle. One may use the kangaroo tendon, chromicized catgut, or the catgut prepared by Bartlett's method, which I prefer. The torn edges of the levator ani muscle can be most effectively approximated by inserting figure-of-8 stitches. Having tied these deep stitches, a second row of lighter buried stitches is passed to bring together the more superficial

parts. If the sphincter ani be torn, the lowermost of these stitches may be passed deeply through the tissues on either side of the anus, so as to bring together the portions of that muscle. I sew up the skin-edges, and the loose vaginal flap which results from the dissection, with interrupted silkworm-gut stitches, leaving the ends long, and tying together in one sheath all the loose ends so as to prevent the intolerable irritation of the skin which would otherwise result. This comparatively simple method of perineorrhaphy has sufficed in my experience for perineal lacerations of every degree,—a mere tear of the skin, a laceration extending to the sphincter, and a laceration complete to the rectum,

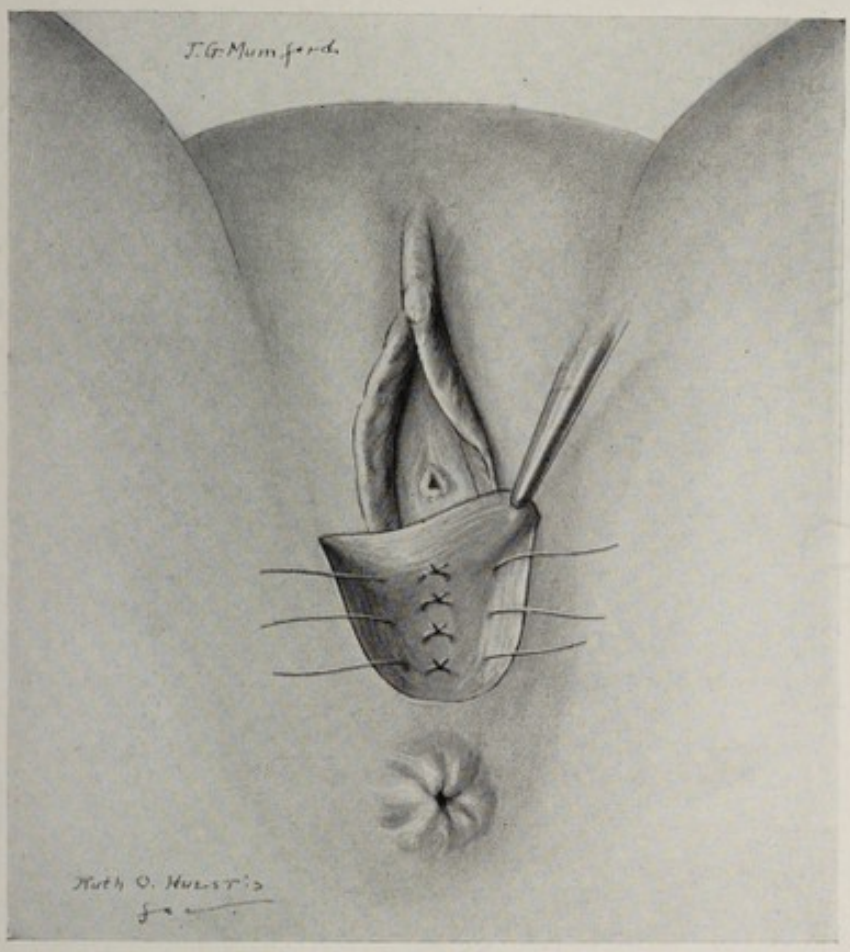

Fig. 218.—Repair of perineum—step 4 (redrawn after Aitken).

—but obviously the extent of the dissection will be in proportion to the tear with which one is dealing.

It is obvious at once that this operation, thoroughly performed, builds up a stout perineal body and cures rectocele. In many cases a prolapsed bladder is thus supported at the same time, as well as a falling uterus. In extreme cases, should cystocele and uterine descent persist, the surgeon must supplement this operation by suspending the uterus; and in the case of a long cervix, tending to bore through the new, narrowed vaginal passage, he may amputate the neck of the womb. I advise the student to read over the description of operations for procidentia (Chapter X) in connection with this subject.

The general practitioner and obstetrician will be interested to know that I have observed a number of women who have become pregnant and borne children subsequent to this operation on the perineum. In every case the vagina opened well before the advancing fetal head, and secondary lacerations were inconsiderable.

The familiar Emmet operation for ruptured perineum is based on the principle that by denuding superficially the scar tissue about the vaginal outlet, the rupture may be returned to the condition in

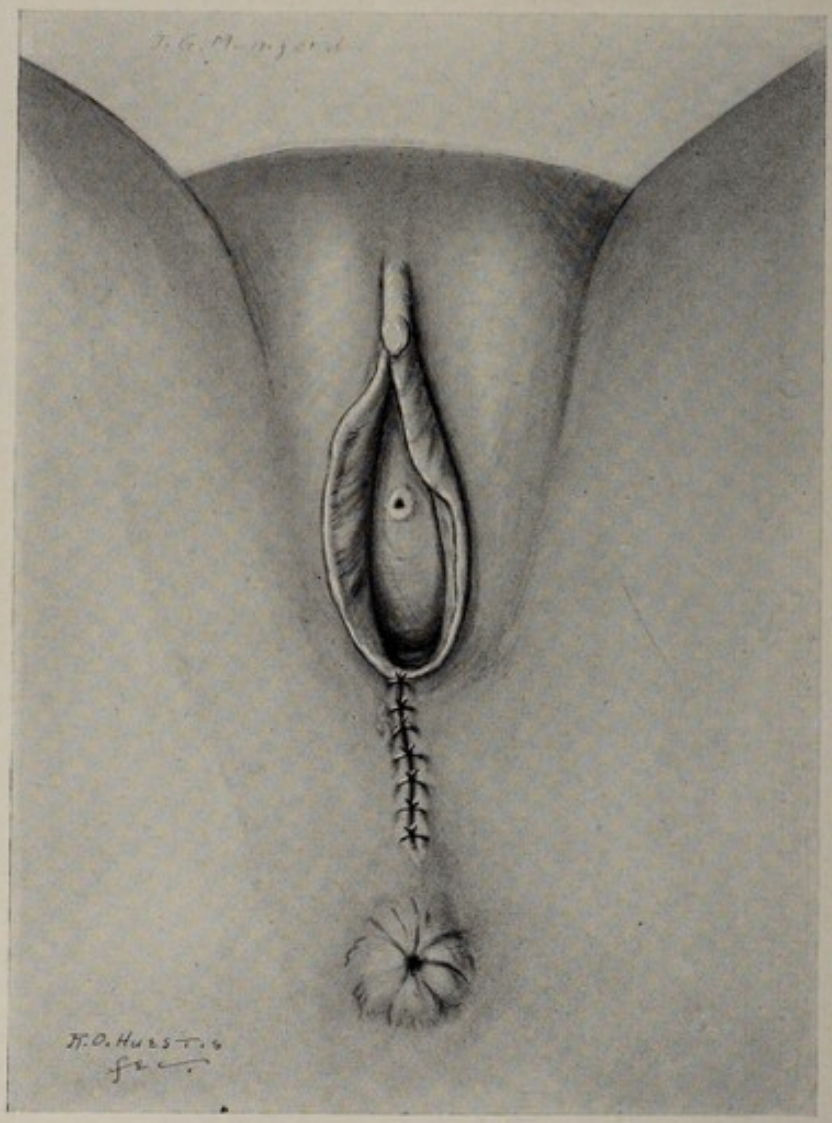

Fig. 219.—Repair of perineum—step 5 (redrawn after Aitken).

which it existed when fresh, immediately after the childbirth. After denuding, the surgeon binds together the wounded edges with silver sutures. This operation is applicable to slight tears only. The dissection does not reach the deep parts, so that the result, though presenting a seemly cosmetic scar, is of little value as a perineal support and yields at once in the case of a subsequent labor.

Noble's operation also is based on the principle of denudation, but the dissection is carried further, as shown by the illustration, so that an admirably strong perineal support is secured.

Among the well-known operations on the perineum are those of Martin, Dudley, Cleveland, Garrigues, Outerbridge, Reed, Goldspoon, and others.

The after-treatment for all these operations is of great importance. It consists of rest in bed for at least sixteen days, careful regulation of the bowels, and painstaking care of the wound, as after a childbirth. The bowels should be moved with an oil enema on the second or third day. If the patient voluntarily passes urine, the parts should be cleansed with an aseptic douche after each micturition.

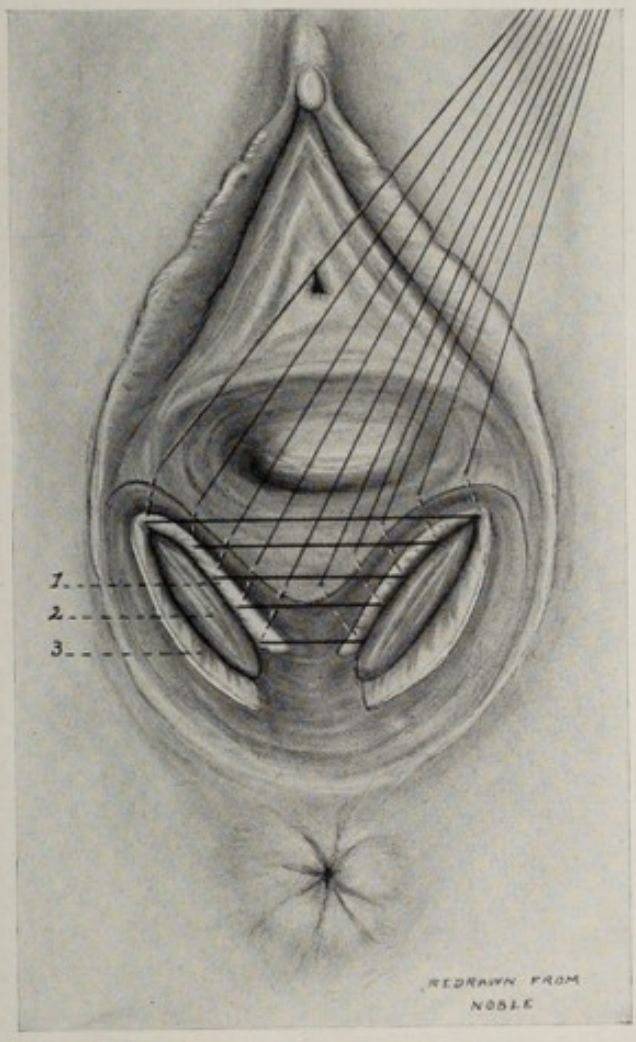

Fig. 220.—Noble's operation for repair of perineum.

The stitches may be removed on the tenth day. At the end of two weeks the patient may sit up in bed, but should not be allowed to stand until the expiration of three weeks. After the bowels have moved, a liberal diet may be allowed, with the use of laxatives or enemata to insure a comfortable daily evacuation of the rectum.

Lacerations of the perineum hold so conspicuous a place in the surgery of these parts that students often overlook a consideration of other local surgical lesions. There are sundry other such lesions, more infrequent than perineal rupture, but often distressing and important

to the sufferer. These are wounds, fistulæ, tumors, cysts, and the lesions of venereal disease. A common and apparently trifling disturbance is urethral caruncle.

URETHRAL CARUNCLE

This is an outgrowth at the orifice of the urethra. There are two forms of caruncle—the first is a capillary aneurysmal varix covered with mucosa, producing a bright red, erectile swelling at the inferior margin of the meatus. The second form is of the nature of a small hemorrhoid, a varicose condition of the urethral mucous membrane. The former type of caruncle is the more common. It develops in middle life usually.

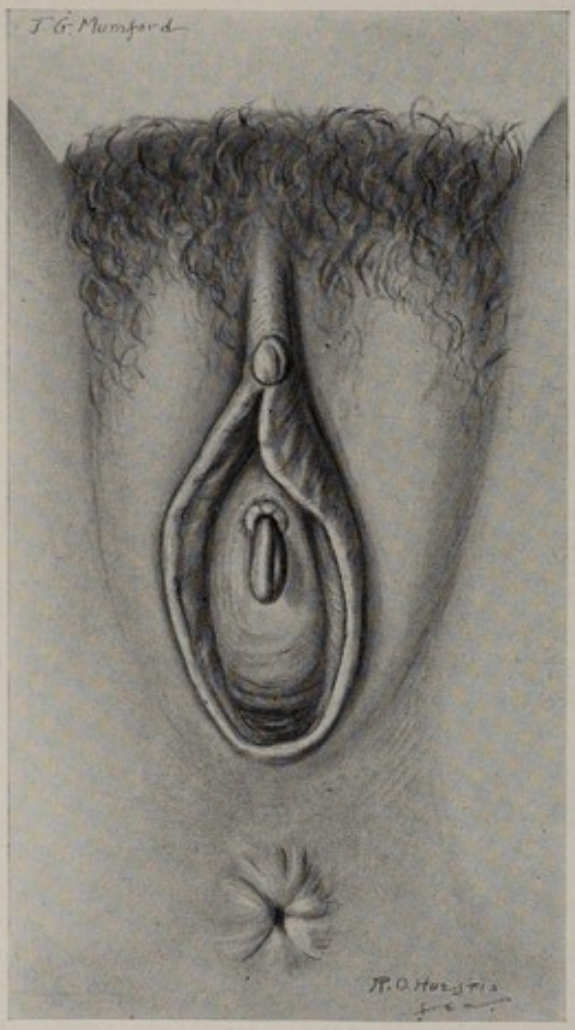

Fig. 221.—Urethral caruncle.

The **symptoms** are distressing often. The patient complains bitterly of scalding when she passes water, and often of a burning, throbbing sensation for some time after the completion of the act. If untreated, the caruncle persists, often growing larger and more irritating with time.

Treatment is simple and effective. With the patient under ether (sometimes cocain will suffice), dilate the urethra, then seize the little tumor gently with right-angled forceps, snip it off with scissors, and touch the base with the Paquelin cautery. Some surgeons prefer to remove the tumor entirely by the cautery. Stitch together, with fine catgut, the severed mucous edges. The patient recovers in a few days, though there may be some pain at first on passing urine. For three or four days after the operation the parts should be bathed carefully with sterile water after each micturition.

THE VULVA

We need not concern ourselves here with **wounds of the vulva,** which call for the same treatment as similar wounds elsewhere. **Inflammations of the vulva** (erysipelas and diphtheria especially) should receive the treatment appropriate to such inflammations. *Tuberculosis of the vulva* is frequently a part of a general tuberculosis, and calls for constitutional treatment. *Syphilis* must be treated con-

stitutionally with mercury and the iodids. *Elephantiasis* and *atrophy* call for no special mention; and *skin diseases* fall within the department of dermatology.

Tumors of the vulva are not especially common, and fall into the general classes of malignant and benign growths, such as fibromata, which may reach a considerable size, polypi and lipomata, rare afflictions.

Carcinoma of the vulva is not infrequently seen—carcinoma, springing from the skin or mucous surfaces of the labia, and, rarely, from the clitoris. Extirpation often promises well, for metastases are uncommon. *Sarcoma of the vulva* is extremely rare. Both round-cell and spindle-cell varieties are recorded, as well as melanosarcoma and myxosarcoma. Excision is the only treatment, but the prognosis is always bad.

There are *varices of the vulva*, comparable to varicocele in the male, to be treated by extirpation of the veins; and *cysts* developing commonly from the glands of Bartholin or from Gärtner's duct. These cysts, too, must be extirpated.

THE VAGINA

Vaginal lesions suitable for the surgeon's consideration are common enough, and far the most numerous of these lesions are those due to childbirth. The ordinary posterior tears of the vagina are associated commonly with ruptures of the perineum, and those I have already discussed. Almost equally important and far more difficult of treatment are vaginal fistulæ.

VAGINAL FISTULÆ

These fistulæ are found in a variety of situations, and you will encounter them in every general surgical ward as well as in the service of the gynecologist proper. They are due, usually, to pressure necrosis, resulting from a too long delay of the child's head during labor, and not to the use of forceps. Rather are they due to a delay in the use of forceps. The figures show such fistulæ. The most common is vesicovaginal fistula. More rarely one finds rectovaginal fistula, vesico-uterine fistula, vesico-uterovaginal fistula, and urethrovaginal fistula. The literature of vaginal fistula is enormous, for the problem was worked out, and its therapeutics put upon a sound basis, by Sims and Emmet, two of the greatest lights in American gynecology. The cure of vesical fistula is in the field of major surgery often. Operations are difficult, tedious, perplexing, and sometimes disappointing, while the condition to be relieved is extremely serious.

I have said that childbirth is the common cause of these fistulæ. Other causes are opening of the bladder by the surgeon for cystitis or for the removal of calculi. Accidental traumatism may result in fistula. Rarely, there may exist congenital fistula, or fistula may arise from sundry ulcerative processes, from the pressure of a neglected pessary, from syphilis, from cancer.

The **symptoms of urinary fistula** are fairly characteristic, and the diagnosis generally is easy. There is a quite constant dribbling of urine, especially when the patient stands. If the urine is passed regularly and freely by the urethra at the same time that it leaks from the vagina, one looks for a urethrovaginal fistula. These fistulæ cause cystitis often, while the leaking urine excoriates the vaginal mucous membrane and the skin, and forms deposits of salts on the ulcerated surfaces. One confirms the diagnosis by digital examination and by inspection. Frequently a probe may be passed through the urethra and be received upon the examining finger in the vagina.

The **treatment of vesicovaginal fistula** is operative, though occasionally a small fresh fistula may close spontaneously. The operable cases may be divided into two classes: small fistulæ with a slight amount of cicatricial tissue about them; and large, broadly indurated fistulæ.

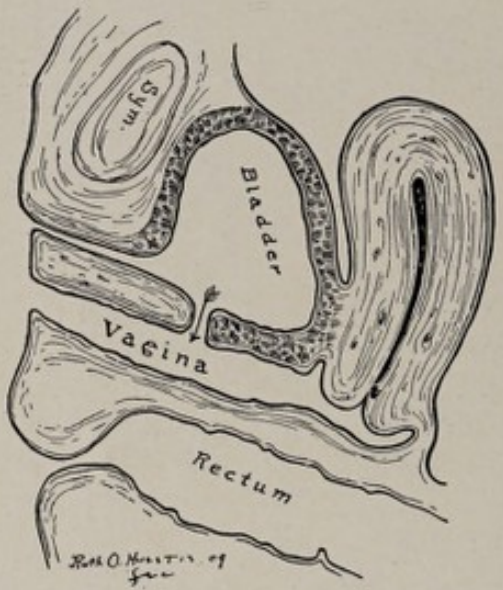

Fig. 222.—Vesicovaginal fistula (diagrammatic).

The small fistulæ may be closed often by simply refreshing the edges of the vaginal side down to the bladder mucosa, and sewing up the fresh wound with silkworm-gut stitches, taking care that there be no tension on the flaps; but in case there is much induration and thickening about the fistula, a period of preparatory treatment should be given. This preparatory treatment consists in keeping the urine acid for two or three weeks before operation,[1] so as to limit the amount of the deposits, and douching the vagina with a simple antiseptic three or four times daily. Sometimes it is necessary to scrape off the deposits and to touch the excoriated surfaces with nitrate of silver. At the same time cystitis must be combated with boric-acid bladder douches, and vesical calculi must be removed.

When this course of treatment has been pushed as far as seems best, the surgeon may proceed with the operation. Place the patient in Sims' position and retract the perineum with a Sims' speculum. Denude the vaginal surface so as to make the wound lie longitudinally, in the course of the vaginal canal; work gently, holding the flaps with bullet forceps and cutting with a sharp, curved scissors. Sew up with silkworm-gut, and leave the suture ends hanging outside the vulva. The after-treatment is important. *Constant* bladder drainage should be provided; the vagina should be kept lightly packed with gauze; drinking of the acid mixture should be continued, while drinking-water should

[1] To render the urine acid, use Emmet's mixture: benzoic acid, 2 drams; borax, 3 drams; cinnamon water, 12 ounces; a tablespoonful diluted four times daily.

be supplied copiously. The bowels should be regulated carefully. The stitches should remain in place for at least twelve days. With all these precautions even, union may not always take place, and a slight fistula may recur. In such case, on three occasions, I have finally and satisfactorily closed the trifling leak by injecting melted paraffin into the tissues about the fistula, thus bringing about union by pressure.

The second form of vesicovaginal fistula—the great irregular, indurated opening—demands often a serious and extensive operation. A number of different methods, many of them extremely ingenious, have been devised, such as these of Rydygier, Martin, Trendelenburg, Sänger, Walcher, von Winkel, Mackenroth, Kelly, Küstner, and others. Kelly describes the details of these procedures, and I refer the reader

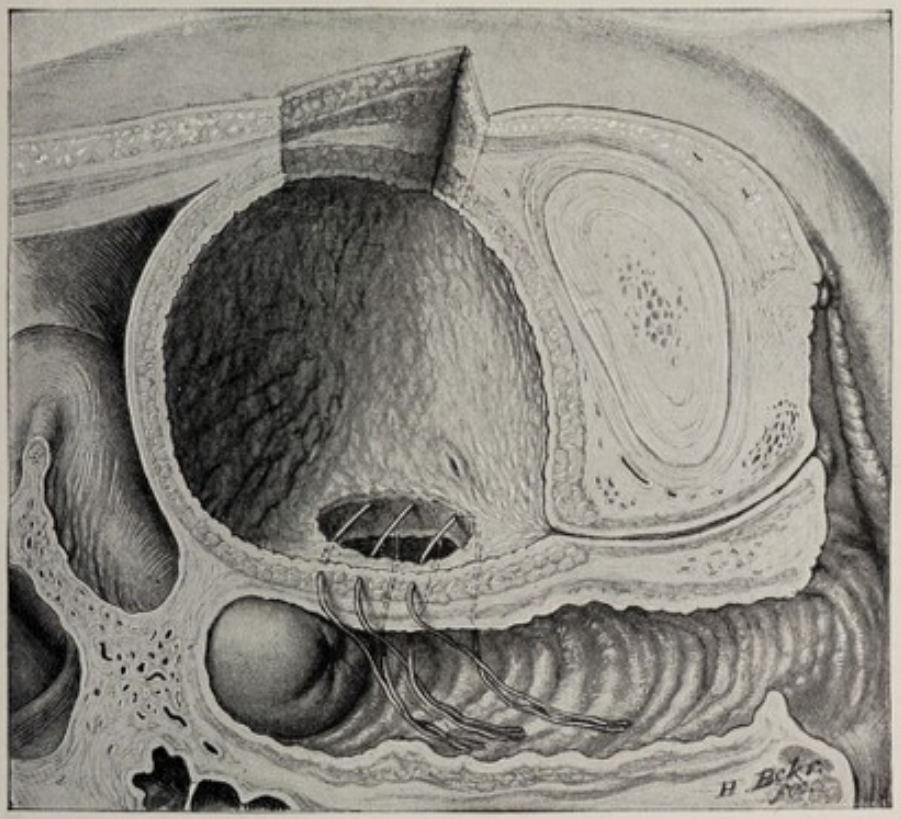

Fig. 223.—Suprapubic operation for vesicovaginal fistula (Trendelenburg), sagittal section. Suprapubic incision seen above (Kelly).

to his Operative Gynecology, vol. i, p. 336. For myself I have secured gratifying results through the employment of von Dittel's method, which follows the principle of all the others; that is to say, by some means one separates the bladder from the vagina and repairs the several rents of the organs independently. I advocate opening down upon the bladder from above the pubes and isolating the bladder without opening the peritoneum if possible. Often this is possible, but if not, one must go through the abdominal cavity, and in any case the dissection is facilitated by tipping up the patient on a Trendelenburg table.

Rectovaginal fistula is less common than vesicovaginal fistula, but it is even more distressing. The diagnosis is readily made by observing the contents of the rectum oozing from the vagina. The patient

herself also will observe often the uncontrollable escape of gas. The treatment of this condition is difficult, and repeated operations may be required. The old operation of Sims—the refreshing and sewing together of the edges of the fistula—rarely is successful. I have employed satisfactorily two somewhat similar operations. When the fistula is close to the outlet of the vagina, split the rectovaginal septum in a fashion similar to the method employed in Tait's operation for ruptured perineum. Then, through this liberal opening, one refreshes the edges of the fistula on both vaginal and rectal sides and sews up the openings independently. In closing the rectal portion of the septum use buried catgut sutures and take pains not to penetrate the rectal mucosa. Then close the vaginal portion of the septum with silkworm-gut stitches, inserted from the vaginal surface. If the fistula be too high up to permit of this simple operation, one may employ the technic of Lauenstein,

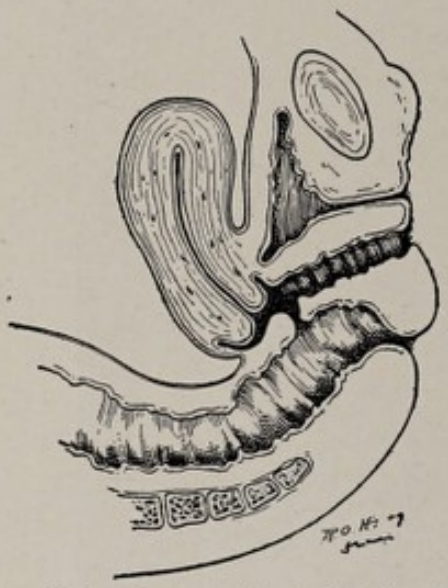

Fig. 224.—Rectovaginal fistula (diagrammatic).

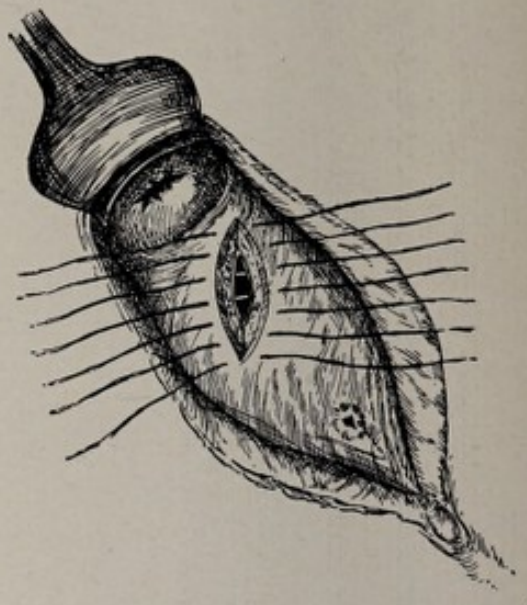

Fig. 225.—Repair of rectovaginal fistula. Lauenstein's operation (after Dudley).

which is similar in principle to the foregoing. Having carefully refreshed the edges of the fistula, split the vaginal mucosa longitudinally at either end of the fistula, and thus turn back liberal vaginal flaps. By this means the rectal wall, with its fistulous opening, is exposed. Then sew up the rectal wall with catgut stitches, and complete the operation by drawing over it independently the refreshed vaginal flaps, which must carefully be sutured into place.

Noble quotes with approval Dudley's ingenious operation for repair of rectovaginal fistula opening high in the vagina.[1] By this operation the rectum is dissected free from the surrounding tissues by the surgeon working through the anus. Having freed the rectum up to and beyond the fistula, the operator then pulls the gut outside of the sphincter until the rectal fistula is exposed. He then cuts off the bowel above the fis-

[1] G. H. Noble in Bovée's Practice of Gynecology, p. 132.

tula and stitches the rectal stump to the skin. The hole left in the vagina no longer communicates with the rectum and may now be closed or not, according to its extent and involvement. Recently I succeeded in closing a rather fresh rectovaginal fistula by giving the patient appropriate opsonic vaccines, which had the effect of stimulating the wound and causing a bridging over of the considerable rent with granulations.

INFLAMMATION

Vaginitis need not detain us further than to remark that the majority of vaginal inflammations are gonorrheal in origin and call for treatment appropriate to gonorrhea.

VAGINAL CYSTS

Vaginal cysts occasionally spring from the remains of the Wolffian or Gärtner's ducts. Benign and malignant tumors also arise in the vagina. A consideration of these rare conditions would mean a repetition practically of much of Chapter X. Extirpation through the vagina of such tumors is the only logical treatment.

ATRESIA OF THE VAGINA

Atresia of the vagina means closure of that canal, and is a somewhat infrequent condition. The closure may be complete or partial, and, according to the extent of the obstruction, menstruation and impregnation may or may not occur. The causes of atresia are defects in the fusion of the Müllerian ducts and canalization of the original cellular mass forming the rudimentary vagina. The upper extremity of the canal is the portion commonly thus deformed. Traumatism may be the cause of atresia. The diagnosis is readily made by inspection.

The only treatment is operative, and the nature of the operation must vary with the character and the origin of the condition. In congenital cases the examination should be made with finger in the rectum and sound in the bladder. Ordinarily, the operation consists in incising the obstruction in several places and distending and packing the vagina with iodoform gauze until healing is accomplished. Numerous writers advocate sundry radical measures. When the lesion is extensive and impossible to overcome by simple incisions, sometimes it is necessary to remove the uterus even, or at least its adnexa, in case the patient's life is rendered intolerable by obstinate atresia.[1]

The surgery of the perineum and vagina is a subject of interest to gynecologists. The variety and complicacy of the lesions are far greater than I have thought best to describe in this short chapter, but the general surgeon will scarcely find time to concern himself with such considerations.

[1] See interesting case reported by Heidenhain, Monats. f. Geb. u. Gyn., March, 1904, p. 445. Incision of the obstruction was followed by a long train of symptoms, eventuating in menstrual retention, pelvic abscess, fecal fistula, and death.

PART III

GENITO-URINARY ORGANS

CHAPTER XIII

KIDNEY AND URETERS

Mr. Thomas Bryant, writing in 1884, said of renal surgery that "this branch of surgery has reached a definite position, and if it rises in value as it has risen in interest, a wide surgical field has indeed been opened. It is to Simon, of Heidelberg, that we are indebted for its birth, in that he in 1869 first designedly removed a kidney with success." The last quarter of a century has shown the correctness of Bryant's foresight, for renal surgery has come to occupy a leading position among us, and eminent men have devoted themselves to genito-urinary diseases alone.

Surgery of the kidney is of profound interest and importance because it deals with a vital organ; because it approaches intelligently and boldly lesions formerly treated blindly and timidly; and because it affords relief or permanent cure for diseases once agonizing, lingering, and fatal. The subject is broad and intricate. Let us endeavor to formulate and grasp its outlines in a few pages.

In general terms surgery of the kidney embraces a consideration of that organ's—(1) Malformations and malpositions; (2) its injuries by violence; (3) its inflammations, including calculus formation; (4) its tumors. The reader must recognize always that for surgical purposes the ureter may be regarded as a part of the renal apparatus, because injuries and diseases of the ureter are intimately associated with renal disease. Functionally and anatomically the ureter is as much a part of the kidney as are the renal artery and vein. One might carry the analogy further and point out how the more distant parts of the urinary apparatus, the bladder and urethra, often are intimately concerned with renal disease. But such a thesis would carry us too far afield, though the association must be recalled from time to time.

ANATOMIC RELATIONS

The gross anatomic relations of the kidney must concern us here for a moment, but one must assume that the reader is familiar with the minute anatomy of the kidney itself. The surgeon may most quickly and directly expose the kidney by opening through the posterior lumbar

triangle[1] which is formed by the last rib and the tendinous aponeuroses of the oblique muscles. Through a 3-inch oblique incision the operator enters almost at once upon the fatty capsule of the kidney, no important structures being cut, but the aponeuroses being drawn aside or split. The kidney, thus exposed, is covered by 3 capsules—the tunica propria, the capsula adiposa, and the fascia renalis. None of these structures has any important part in holding the kidney in place, however. The kidney is not a fixed organ, but moves slightly up and down with the diaphragm in respiration. Such support as the kidney has is given by the renal vessels and ureter, the fossa in which it lies, and through the pressure of the peritoneum and superimposed organs. The two kidneys lie on either side of the spinal column and extend from the upper border of the twelfth dorsal vertebra to the lower border of the second lumbar. The twelfth rib crosses them at about their middle,



Fig. 226.—Kelly's method of approaching the kidney and ureter without opening the peritoneum (Kelly).

but the left kidney lies about a finger's breadth higher than does the right, which receives the constant impact of the liver. The distance between the upper pole of the kidney and the pleural cavity is but a fraction of an inch. Both kidneys lie behind the peritoneum. Among the most important relations of the right kidney are the liver above, the hepatic flexure of the colon, which lies upon its lower third, and the duodenum, which is adherent close to its inner edge. One recognizes the significance of these relations when a paranephritic abscess opens into the bowel. The left kidney in its upper third lies close to the stomach, from which it is separated by the splenic artery; its middle third lies against the pancreas, while its external border rests against the spleen and the descending colon. Those interesting and significant

[1] H. A. Kelly, Lancet, June 17, 1905.

organs, the suprarenal glands, are loosely connected with each kidney, to the right of the kidney's upper pole.

The **ureter** begins at the pelvis of the kidney, and throughout much of its length follows a fairly straight course to the base of the bladder. It is somewhat narrowed at its beginning, and at the point where it passes over the brim of the pelvis. Stricture may occur at these places. The ureter is behind the peritoneum, and in the greater portion of its course may easily be exposed through an incision extending from the twelfth rib diagonally past the anterior-superior spine of the ilium. Through this incision the peritoneum is reached and pushed aside, when the retroperitoneal space is disclosed. The ureter is found lying upon the psoas muscle. At the brim of the pelvis the ureter turns sharply backward to run along the side of the pelvis, to a point about one inch in front of the spine of the ischium; then it passes forward and inward on the upper surface of the levator ani muscle until it reaches the base of the bladder. The length of the average adult ureter is 12 inches.

In this brief essay there is not space to consider the various congenital malformations and abnormalities of the kidneys. The operating surgeon must not forget, however, when he proposes extirpation of a kidney, that there may be but one kidney. A common abnormality is horseshoe kidney, which should not properly be regarded as a single kidney, but as two kidneys connected by an isthmus of renal tissue. The double organ thus formed is usually displaced downward, and is situated in front of the spinal column. Double ureter from either kidney sometimes is found.

We need not consider further the question of *movable kidney* and the problems which it suggests. I have already discussed these matters in the first portion of Chapter IX.

DIAGNOSIS IN RENAL DISEASE

Let us now briefly turn to the more common methods of diagnosis in renal disease. Such diagnosis may be simple or may present some of the greatest difficulties in the whole field of surgery. The *history* of the case may or may not be important. The patient may tell of pain, paroxysmal or constant, suggesting calculus or tuberculosis. He may describe a long train of dyspeptic symptoms suggesting movable kidney. He may have noticed a pronounced tumor. He may have been troubled with the intermittent passage of great quantities of urine. He may have passed blood. He may tell a story of gradual and increasing debility, suggesting cancer or tuberculosis. He may tell of such associated symptoms as exquisite pain in one renal region, with nausea, vomiting, headache, wasting, and general prostration. The fact is that almost all lesions of the kidneys may be characterized by similar symptoms, and so it rarely happens that a positive diagnosis can be founded upon the patient's story. Furthermore, a trifling lesion may give rise to distressing symptoms, while, on the other hand, grave

kidney disease may run its full course without any pronounced suggestion of kidney disorder. *Palpation* of the kidney is sometimes easy, or may be extremely difficult, depending on the size of the kidney and the thickness of the patient's abdominal walls. Examine the patient as he lies on his back, again while he is in a half-reclining position, on his side, and in the hands-and-knees position. Movable kidneys and enlarged kidneys may thus be made to appear and disappear. Palpate bimanually as you stand facing the patient; pass the fingers of one hand up his back and beneath the twelfth rib; press deeply with the other hand below the costal arch. In the case of thin patients the opposing hands



Fig. 227.—Method of palpating the kidney.

may thus be brought close together, and sometimes a normal kidney may be felt. Palpation of the abdomen rarely reveals any disorder of the ureters, though extreme ureteral dilatation, or a large calculus impacted in the ureter, sometimes may be felt. Sometimes, again, beware lest you confound with renal tumor a tumor of the intestine, of the liver, or of the spleen. The distinction may be made by distending the colon with air, bearing in mind that that viscus lies in front of either kidney. Disease of the ureter—tuberculosis, dilatation, and calculus—sometimes may be ascertained by palpation through the rectum or vagina. *Analysis* of the urine is of service. The examiner looks especially for blood, for crystals, for tubercle bacilli, and

for shreds of tissue even. He should differentiate between hematuria and hemoglobinuria. He must try to distinguish whether the blood comes from the bladder or the kidney, and he must look for pus also and try to ascertain its origin. Such are the older and more commonly recognized methods of investigating renal disease. We may regard



Fig. 228.—Examination of the bladder in the dorsal position, with elevated pelvis (Kelly).

such methods as preliminary steps, but, not satisfied with results thus obtained, we must then proceed with examination by the cystoscope, and may employ sometimes cryoscopy and the phloridzin test.

The **cystoscope** within recent years has placed renal surgery on a new basis. This instrument enables us to make a visual inspection of

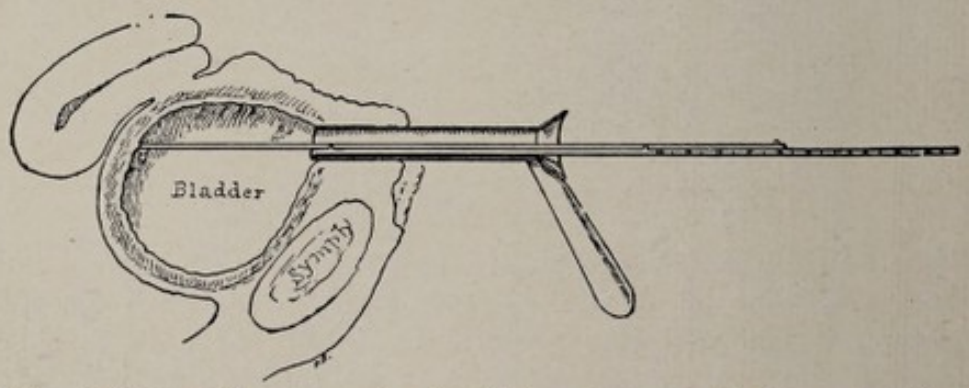

Fig. 229.—Instrument for measuring the distance between the internal orifice of the urethra and various portions of the vesical walls (Kelly).

the bladder, to watch the vesical openings of the ureters, and to catheterize the ureters, in order to segregate the urine from the individual kidneys. Inspection of the female bladder is easy compared with inspection of the male bladder. More than ten years ago Kelly popularized cystoscopy of the female bladder, and his method is still that commonly

employed. With the patient in the exaggerated knee-chest or the Trendelenburg position, the female bladder may be inspected directly through an open tube, the ureters may be observed, and the ureteral catheter may be passed. The illustration shows Kelly's method, but personal instruction in the clinic is necessary if one would learn and apply the technic. A more complicated instrument is required for inspection of the male bladder, but all the instruments used are adaptations of the well-known Nitze apparatus. I need not discuss the great variety of ingenious inventions and modifications of the cystoscope further than to mention the names of such investigators as Hill, Fenwick, Thompson, Boisseau, du Rocher, Casper, Akbarran, and Tilden Brown. Brown has devised one of the simplest of catheterizing cystoscopes. Such

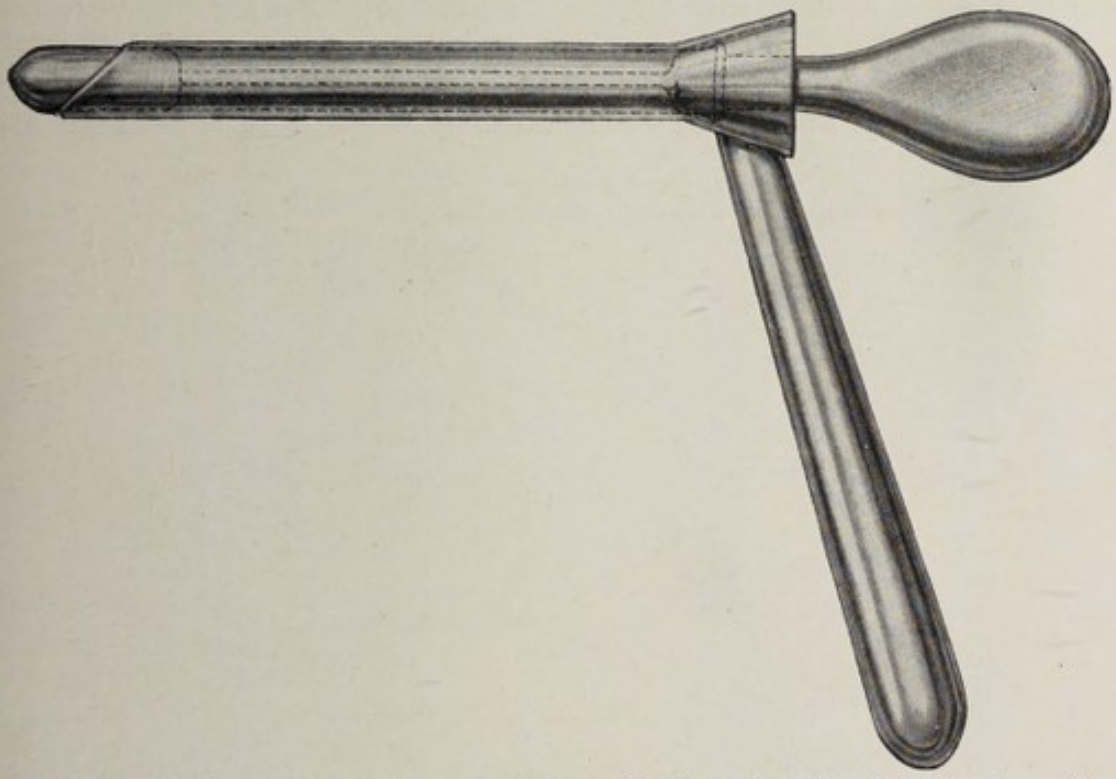

Fig. 230.—Speculum with oblique end for collecting the urine directly from the ureter (Kelly-Noble).

instruments generally can be used with the aid of local anesthesia only. First one explores thoroughly the bladder in order to determine the presence of stone, of tumor, of ulceration, or of other lesions which may complicate the diagnosis. Then one inspects the ureteral openings, noting any swelling, pouting, pus or blood from the ureters. By watching the contractions of the ureteral openings, the spurtings of urine and the intervals between them, one gains some information about the activity of the kidneys. By giving certain drugs which color the urine two purposes are answered. Methylene-blue and indigo carmin make the urinary swirl more visible, and in the case of normal kidneys the colored stream should appear in the bladder in from fifteen to thirty minutes after the drug has been taken. A crippled kidney passes on the colored stream after a longer interval. Having

made these observations, the surgeon catheterizes the ureters according to the following principles: As soon as the mouth of the ureter is found, the cystoscope should be so directed that the ureter occupies the lower margin of the inner field of vision. The ureteral catheter is then pushed slightly forward so that the direction of its point may be observed. Then, by a little manipulation of the instrument, the surgeon can direct the point of the catheter into the ureter. Some surgeons have objected to ureteral catheterization on the ground that the ureter and kidney may thus be directly infected from the bladder. In order to minimize this danger one should irrigate thoroughly, with 4 per cent. boric-acid solution, the bladder before passing the ureteral catheter.

As the collection of the urine from the individual kidneys is an important object of these investigations, and as some danger undoubtedly inheres in the use of the ureteral catheter, surgeons have sought other means of segregating the urine. M. L. Harris has devised a popular instrument which is illustrated by the cut. The principle of

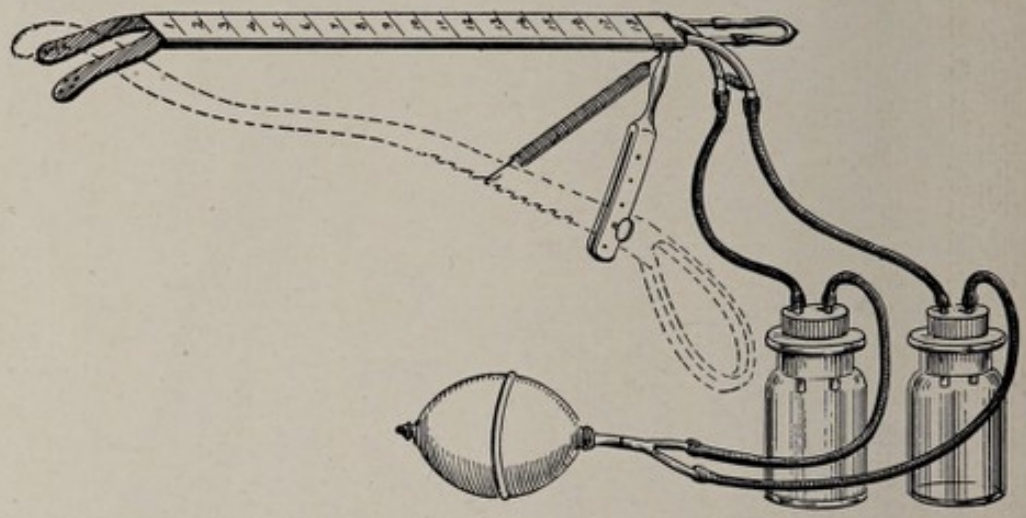

Fig. 231.—Harris's instrument fitted for use.

Harris's instrument is that it throws the base of the bladder into two small distinct pockets at the bottom of which lie the individual ureteral openings. When these pockets are formed, the urines from the two kidneys separately collect in them. Then from each pocket these segregated urines are drawn off by separate catheters and a suction apparatus. Luys and Cathelin also have devised segregating instruments, but Harris's is the most popular with us.

Cryoscopy is a method of investigation which is growing in favor and is giving increasingly satisfactory results in the hands of its more skilled advocates. The principle of cryoscopy is this: we have ascertained that normal urine freezes at a point between —1.20° C. and —2.30° C., while the freezing-point of blood in normal individuals is found practically constant at —0.56° C. If the kidney is doing less than its proper work and excreting an attenuated urine approximating the characteristics of water, the freezing-point of such urine will rise toward zero. If the freezing-point of blood falls below —0.56° C., one

must conclude that the blood is carrying abnormal constituents. If the freezing-point of a given specimen of blood sinks as low as —0.60° C., we conclude that operation on one of the kidneys would be unsafe, since with such blood as this it is improbable that proper urinary secretion would continue should a serious operation be performed. It is obvious that there are elements of error in the use of cryoscopy unless the method be supervised by a person skilled in the technic. Moreover, it is reasonably doubtful whether the old recognized methods of urinalysis may not give us data of greater value. The normal percentage of urea should be 2.02 per cent.; of uric acid, 0.04 per cent.; and the ratio between uric acid and urea should be about as 1 is to 50. When employing cryoscopy, the estimation of the freezing-point of the urine may lead into error the unwary, if he does not take into consideration the total amounts of urea and uric acid excreted in the twenty-four hours, but carried in a urine of low specific gravity. In general terms, however, we are justified in feeling that a thorough urinalysis, supplemented by cryoscopy, and especially by an estimate of the blood's freezing-point, will enable us to determine with safety the question as to whether or not we shall operate in a given case.

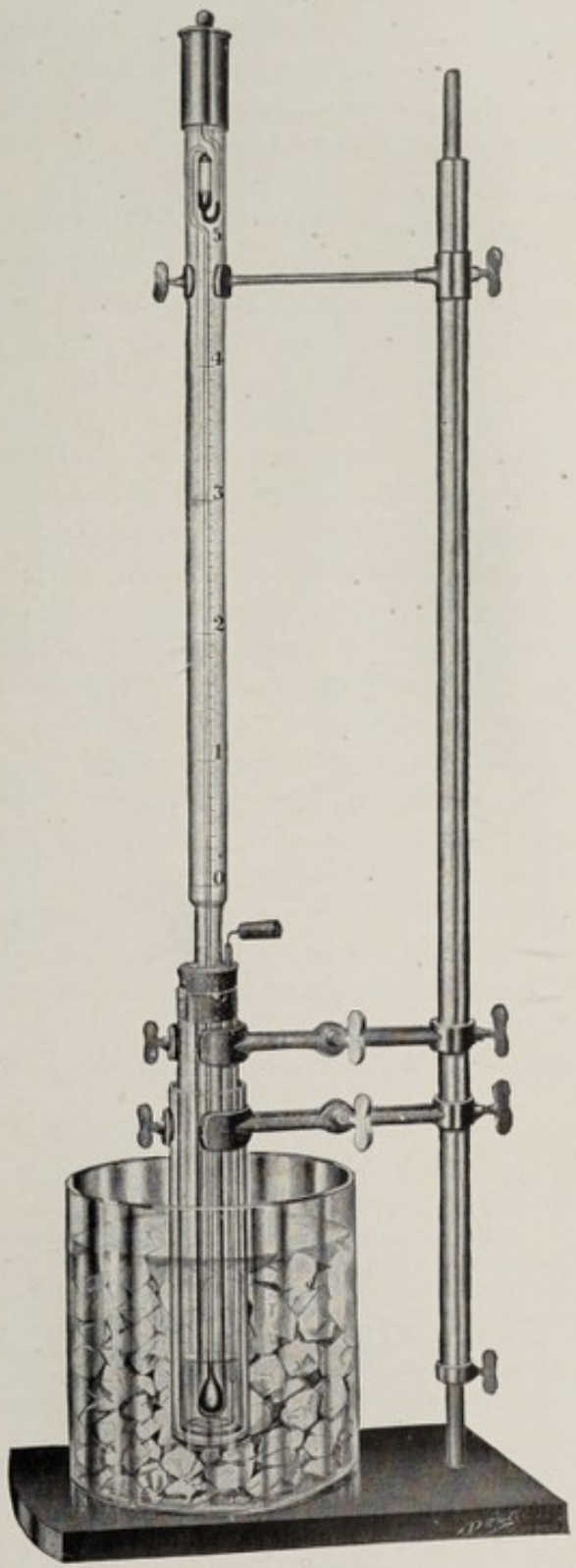

Fig. 232.—Apparatus for cryoscopy (Fowler).

I have spoken of the *methylene-blue test*. This is commonly known as the phloridzin test. The dose is given hypodermically—phloridzin, 0.05 gm. in 1 cc. of sterile water. The characteristic blue color should appear in the urine within half an hour if the kidneys be normal. Un-

fortunately, this test is not always reliable, as the blue urine of *damaged* kidneys sometimes appears within the half-hour.

Certain recognized *symptoms* bearing upon the diagnosis are looked for in all kidney diseases: hemorrhage, pain, frequency of micturition, pain on micturition, and a peculiar character of the stream. I shall not discuss these symptoms in detail here, but shall deal with them appropriately when describing special diseases.[1]

INJURIES OF THE KIDNEY

Injuries of the *kidneys* should be divided into two distinct classes—injuries from blows and injuries from penetrating wounds. By blows the kidney is crushed or ruptured and the vessels and ureter may be torn, while penetrating wounds give rise to a single lesion.

Ruptured Kidney.—A few years ago, at the Massachusetts General Hospital, I was asked to see a young man who had been brought there in a state of prostration. His story was that while carrying on his head a heavy mattress, a companion had jumped upon it in sport, and that he had doubled up and fallen, with the sensation of acute pain in his right loin. He became faint and helpless, and in that condition was carried to the hospital. The house surgeon discovered an area of tenderness in the region of the right kidney, and drew bloody urine with the catheter from the bladder. We made a diagnosis of ruptured kidney, but as the patient rallied somewhat, I decided to await developments. For three days he continued in a depressed condition, with a constant passage of bloody urine, and at the end of that time he began to develop a fever and other progressively alarming symptoms. Thereupon I cut down upon the kidney and found it extensively lacerated, with the lower third almost completely separated from the rest of the organ. Removal of the kidney was followed by the patient's recovery. I have related this case in order to show the difficulty of exact diagnosis. The extent of damage to the kidney cannot be ascertained

[1] Da Costa quotes Sir Henry Thompson's diagnostic questions as follows:

"1. Have you any, and if so what, frequency in passing water? Is frequency more manifest during the night or the day? Is frequency more manifest during motion or rest? Does any other circumstance affect it?

"2. Is there pain on passing urine, and if so, before, during, or after the act? What is its character—acute, smarting, dull, transitory, or continuous? What is its seat? Is it felt at other times, and is it produced or intensified by sudden movements?

"3. What is the character of the stream? Is it small or large; twisted or irregular; strong or weak; continuous, remitting, or intermitting? Does it come by the meatus, or partly or entirely through fistulæ?

"4. Is the character of the urine altered? What is its appearance, color, odor, reaction, and specific gravity? Is it clear or turbid, and, if turbid, is it so at the time of passing? Does it vary in quantity? Are the normal constituents increased or diminished? Does it contain abnormal elements, as albumin or sugar? What inorganic deposits are found? What organic materials are met with?

"5. Has the urine ever contained blood? If so, was the color brown or bright red? Were the blood and urine thoroughly mixed; was the blood passed at the end or the beginning of micturition; or did it come only with the last drops of urine; or was it passed independently of micturition?

"6. Inquire as to pain in the back, loins, and hips, permanent or transitory, and for the occurrence of severe paroxysms of pain in these regions."

before operation. Extreme laceration may be associated with apparently trifling symptoms, while a presumably slight laceration may be followed by alarming symptoms.

Kidneys are ruptured by the most diverse forces—by blows, kicks, crushes, and by such a doubling-up of the body as I have described. A stellate rupture, transverse and extending into the renal pelvis, commonly occurs. Then there follow hemorrhage, a more or less profuse soaking of blood into the pararenal tissues, and the passage of blood through the ureter into the bladder. Sometimes the ureter is damaged or obstructed, with a resulting escape of urine into the tissues of the back; or a hydronephrosis may develop, through distention of the renal pelvis with urine that cannot find its way to the bladder. Rarely, both kidneys are damaged simultaneously.

The *symptoms* of ruptured kidney are often more alarming than one would expect, and the shock and collapse are profound. The nervous mechanism of the kidney, through its associations, frequently produces unexpected reflex symptoms, such as vomiting, intestinal paralyses, and dyspnea. In addition to the profound shock the patient experiences extreme pain in the renal region, the pain sometimes radiating along the course of the ureter; and there may be retraction of the scrotum. Again, the pain may be slight, increasing perhaps with the progress of the hemorrhage. The passage of clots through the ureter causes intense pain. The most conspicuous diagnostic sign of ruptured kidney is bloody urine. The urine may be continually encumbered with clots and blood, showing that the canal of the ureter is open, or there may be but slight transient hematuria, suggesting rupture of the ureter. Such are the early symptoms. If the case progress without operation, later symptoms may develop, due to infection of the blood and urine poured out into the loin. So there may result pararenal suppuration, gangrene, or involvement of the peritoneum in peritonitis, with distention and the other acute abdominal symptoms familiar to us as associated with peritonitis.

The *outlook* in the case of ruptured kidney is always grave, and statistics show a mortality of about 47 per cent. Such statistics do not take into account modern methods of treatment, but, at the best, the surgeon faces a formidable injury.

Treatment.—The story of the young man crushed under the mattress suggests the difficulty of laying down precise rules for treatment. In general terms, one should not operate hastily, because we know that many of these patients recover spontaneously. If an operation be not our resort, the treatment is symptomatic; absolute rest, the cautious employment of morphin to control pain and reduce shock, an abundant milk diet with plenty of water to drink, and keeping the bladder drained and relieved of clots, by washing out, if necessary, with the Bigelow evacuator. On the other hand, if there is strong reason to suspect that the ureter is ruptured, and if hemorrhage persists or increases for a day or two, or even less, the surgeon must cut down upon the kidney and attempt to remedy the damage. I have found the most satisfactory

method of approaching the kidney in these cases to be through an oblique incision extending from the twelfth rib forward along the iliac crest. Thus the peritoneum may be sought and turned forward and a free opening made, extraperitoneal, rendering easily accessible the whole of the renal and ureteral region. A few years ago we invariably removed these damaged kidneys, and nephrectomy still is often imperative, but, thanks to the work of Küster and Keetley, published in 1891, we have learned to be more conservative. They showed that many ruptured kidneys can be treated successfully by a packing of the renal wound. In one case I sewed with plain catgut sutures a gauze tampon tightly into such a wound and checked the hemorrhage. The gauze was removed early on the fifth day. In case of suturing the kidneys with catgut the suture material is absorbed in twenty-four hours or less, so that it retains the gauze for a short time only, but long enough to control hemorrhage.

If one sees a case several days after the accident, when secondary symptoms have developed, operation may be impossible on account of the wretched condition of the patient; or an elaborate operation may be undertaken if the patient has the strength for it. Transfusion of blood may bring the patient into a condition suitable for operation. The kidney should be approached through the incision I have already described; blood-clots and the products of infection should be removed; and the wound should be drained extraperitoneally. If the peritoneum has been opened and infected, a drain should be inserted at the point of its opening, but no further treatment of the peritoneal cavity is advisable. The after-treatment of these cases embraces two considerations, depending upon whether or not the peritoneum has been infected. If we are dealing with an extraperitoneal wound, we should treat it on the simplest of principles—by local drainage, cleanliness, and general supporting treatment. If we are dealing with a peritonitis, we should follow the line of treatment I described in Chapter VIII—Fowler's position and salt solution enemata.[1]

Thus we have seen that subcutaneous rupture of a kidney is a condition of extreme gravity. Generally, these ruptures are uncomplicated, though in some extensive crushing accidents the damage to the kidney may be but part of a general visceral disorganization, with bruising or rupture of intestines, liver, stomach, and other organs. As a rule, however, ruptures of the kidney are not so complicated.

Quite otherwise is the fact with **penetrating wounds of the kidney**—stab wounds, incised wounds, and, most common of all, gunshot wounds. The reader will see at once that these penetrating wounds, especially gunshot wounds, may readily involve other organs. A bullet does not stop at the kidney, but may penetrate the abdominal cavity and injure the intestines, the liver, the stomach, the spleen, and the spinal column even. Such injured organs must be treated on appro-

[1] The most extensive and satisfactory description of these kidney injuries which I have seen was published by Francis S. Watson in the Boston Med. and Surg. Jour., July 9, 1903.

priate principles, but we are concerned here with the kidney especially, and in general terms much the same situation arises as we saw in the case of *ruptured* kidney. There are the primary shock, pain, and hemorrhage, varying in extent, but generally less conspicuous than with ruptured kidney. If the penetrating wound be extensive, the kidney may prolapse through it. The ureter is rarely injured, but the danger of infection is great. The *symptoms* are quite similar to those of ruptured kidney, and the *treatment* is analogous. It may seem wise at first simply to clean the wound and await developments. Later, if pain, hemorrhage, and collapse continue, and if sepsis supervene, one should cut down upon the organ and treat it by suture, tampon, or excision, as may seem wise at the time.

Open wounds of the kidney are rare as compared with subcutaneous wounds.

STONE IN THE KIDNEY

Stone in the kidney (nephrolithiasis; calculus), more than any other form of renal disease probably, concerns the surgeon. In studying the formation of gall-stones (Chapter V) we saw that they are dependent upon a primary infection—first, the infection; then, the inflammation; then, the formation of biliary concretions. The formation of renal concretions appears to follow a reverse order, so far as our studies have instructed us. Urinary concretions form commonly in the kidneys and in the urinary bladder, though they may be found anywhere in the urinary tract, but their deposition seems to be dependent upon a condition of the excreted urine itself, rather than upon any inflammatory condition of the renal or bladder mucosa. There are exceptions to this rule, as is seen in the formation of urinary concretions secondary to obstruction and inflammation somewhere in the urinary tract. The right kidney, like other structures on the right side of the abdomen, is the more frequently the seat of stone, though rarely both kidneys may bear calculi. As a rule, however, nephrolithiasis seems to be a part of a general condition. The older writers included it under the term " gouty diathesis." All the old writers talk of stone, and from the beginnings of surgery the treatment of stone has exercised general practitioners and specialists. For a deposit of these concretions an excess of certain of the solid constituents of the urine seems to be necessary. So long ago as 1776 Scheele discovered that uric acid was a normal constituent of the urine, and that many calculi were made up of uric-acid crystals. Since then we have learned that other salts may enter into the formation of stones—calcium carbonate, calcium phosphate, calcium oxalate, and the corresponding salts of magnesium and ammonium; more rarely cystin and xanthin, and very exceptionally indigo. As a rule, the calculi contain a mixture of these substances, especially of uric acid, but as one or the other predominates, they are known as uric acid, oxalate, or phosphatic calculi, etc. The extremely finely divided deposits found in the kidney substances of infants are known as infarcts, and are found in the renal parenchyma; but calculi of any appreciable

size are deposited in the larger spaces, in that portion of the urinary apparatus which, beginning with the papillæ, includes the renal calices, the pelvis of the kidney, the ureter, and the bladder. Renal calculi are found in persons of all ages, though such calculi are not common before puberty, and males are affected more commonly than are females. Not only are stones found independently in the passages, but they are frequently seen associated with such crippling diseases as tuberculosis, tumors, and any lesion which causes obstruction to proper urinary drainage. The stones vary in size from microscopic crystals to masses as large as a pullet's egg or larger. In the order of frequency one finds uric-acid calculi, oxalate calculi, phosphatic calculi, calcium carbonate calculi, and cystin calculi. The last two are rare, and rarer still are the xanthin and indigo calculi.

The **symptoms** of urinary calculi are obscure and variable. I have many times suspected calculi when they did not exist, and in common with all surgeons I have cut down upon the kidney and ureter only to find that they were free from stones. Diverse diseases simulate renal calculus—appendicitis, biliary calculus, floating kidney, renal tuberculosis, renal tumor, spinal caries, sacro-iliac disease, and other more rare ailments. There are four cardinal symptoms of renal calculus: (1) *Lumbar pain;* (2) *hematuria;* (3) *anuria;* (4) *pain on micturition.* One or all of these symptoms may be absent. An aseptic calculus, which lies quietly within the renal parenchyma or even in the renal pelvis, may cause no pain; but if infected and motile, it may cause excruciating pain, especially in its attempts to pass out of the pelvis into the ureter. There is a characteristic pain of renal calculus: pain beginning in the lumbar region and radiating toward the scrotum, extending even to the thighs, the buttocks, and the abdominal organs. The pain may be sudden and acute, or it may be of gradual onset and long continued. The agony of this pain will break down the sternest philosophy. The strong man trembles, sweats, groans, and collapses. There may be nausea and vomiting; there may be intense vesical tenesmus, with the straining out of a few bloody drops. If there be a mere slight passage of gravel through the ureter, all these symptoms may be present, but in milder form; and all these symptoms may not be due to the passage of a renal calculus. Renal calculus is a common cause, but any cause which produces an increased tension of the renal capsule may provoke the same symptoms. *Hemorrhage* may be microscopic in amount, or may be so profuse as to endanger life; the amount usually is small. Hemorrhage alone is not pathognomonic. It is found under other conditions, such as tuberculosis and tumor. In the case of calculus, it is part of a symptom-complex. *Anuria* is usually a grave symptom. The case is bad enough when a calculus completely blocks one ureter, but it is much more serious when, through reflex irritation, urine fails to flow from either kidney. Total anuria is well recognized, but is rare. Renal calculus may cause *bladder irritation,* with urgency and frequency of micturition and pain in the urethra at the close of the act.

Such are the leading symptoms of renal calculus, and on these symptoms one attempts to found a **diagnosis.** Pain and hemorrhage are of the first consequence. Sometimes one can feel an enlarged kidney, cystic from ureteral obstruction. Rarely one can feel a calculus in the ureter, either by abdominal palpation or by palpation through vagina or rectum. Some writers assert that strong percussion in the loin produces characteristic pain when calculus is present in the kidney. I have not found this to be true, though any manipulation in that region is often resented by the sensitive kidney. Intermittent hydronephrosis sometimes is present, due to the alternating impaction and retreat of a stone from the ureteral stoma. Analysis of the urine sometimes is of value. It is of value in the case of a movable and infected calculus, causing hemorrhage and inflammation. So we expect to find blood and pus. The condition of the urine varies; therefore numerous examinations should be made: sometimes there will be found a few casts and crystals of varying character. The cystoscope reveals alterations in the flow of urine from the ureter of the affected side—bloody urine, cloudy urine, or an actual suppression of urine. The *x*-ray reveals renal calculus often, but the density of *x*-ray shadows varies with the nature of the calculus. A calculus of oxalate throws a strong shadow, easily demonstrable, as a rule; but uric-acid calculi or calculi composed of urates throw such indistinct shadows that these shadows cannot always be recognized as a basis for diagnosis. One reason for the obscurity of these shadows lies in the fact that the kidney is not an immovable organ. Phosphatic calculi throw almost no shadow. We are coming to see that *x*-ray investigations for urinary calculi must be intrusted to the most experienced experts only. Finally, renal or ureteral calculi may be demonstrated by the wax-tipped ureteral catheter. H. A. Kelly was the first to employ such a catheter. The smooth surface of the wax is found to be scratched by the stone after the catheter has explored the ureter.

Thus we have seen the difficulties which encumber a diagnosis of renal calculus, and lend an element of uncertainty to treatment.

The **treatment** of renal calculus cannot be discussed casually, yet a satisfactory discussion of treatment is a long story. Every case has its own proper indications for treatment, or perhaps its lack of indications, since we are often uncertain in our diagnosis. Treatment is directed to three ends: to remove calculi, to repair damage caused by the calculi, and to provide against the recurrence of calculus. If a calculus be present, operation must be our resort.[1] The much-vaunted solvents of stone are of no value when once the stone is formed, though in order to bring the patient into good condition, systemic treatment is useful before operation, and must be continued after operation: a limited diet; little or no meat; the consumption of cereals, vegetables, and milk; abundant water-drinking, and iron for a long time.[2] The

[1] Urinary sand may sometimes be removed by the free use of diuretics and the drinking of piperazin water or lycetol (10 grains in water four times daily).

[2] Five grains of Blaud's pill before meals.

patient should exercise regularly between attacks, and strive in every way to build up his physical condition, especially regulating the bowels by such appropriate laxatives as Carlsbad salts and cascara sagrada.

Thirty years ago surgeons were beginning to operate for renal calculus, and the teaching in those days prescribed removal of the kidney as the only resort. Experience has taught that this is by no means always necessary, and we now preferably remove the stone, either by splitting through the parenchyma of the kidney, or, better, by opening the renal pelvis or ureters. Schede, quoting Israel, enumerates 5 indications for operation: (1) Calculus anuria, either unilateral or bilateral; (2) an acute suppurative process induced by calculus; (3) obstruction of a ureter by calculus; (4) severe renal hemorrhage; (5) intense pain or constant, long-continued, dull pain. Writers still debate whether or not it is proper to operate at once upon making the diagnosis, or to delay and employ palliative measures. I suppose the answer to this question must always remain doubtful, and must depend somewhat upon the circumstances and temperament of the patient. On the one hand, one would hesitate to operate, even with an assurance of finding stone, upon an old person with seriously damaged kidneys. On the other hand, one would operate at once upon a vigorous young person one of whose kidneys contained an aseptic calculus. My own habit is to operate always and early when a reasonably positive diagnosis has been made, provided the usual tests show that one of the kidneys is doing its work properly, and provided the patient is not suffering from any other serious organic lesion.

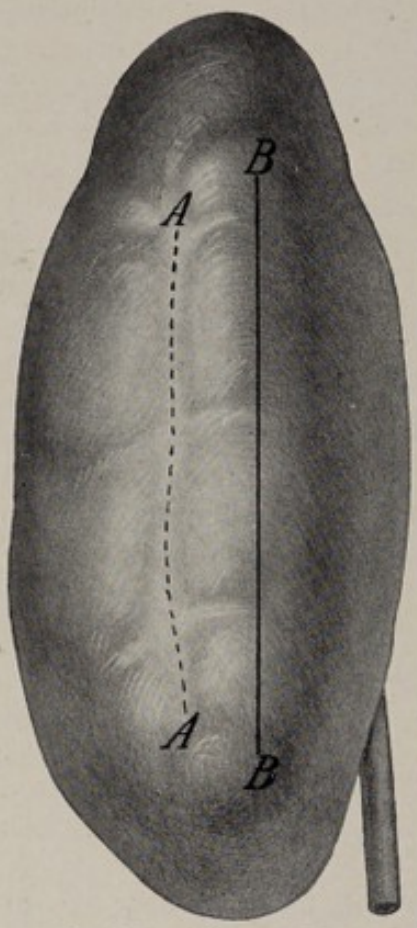

Fig. 233.—*A*, *A*, "Brödel's white line"; *B*, *B*, line of best incision for splitting the kidney (Campbell).

The best way to reach the kidney [1] is through the lateral oblique incision, which I have already described in this chapter, turning back the peritoneum, and giving a liberal exposure to the renal and ureteral regions. The kidney is then dislocated and brought well up into the wound. It has been suggested that if calculi are not readily palpated, they may be seen with the fluoroscope, but I cannot regard this test as essential, nor do I recommend it, because absence of the expected shadow does not necessarily mean absence of a uric-acid or phosphatic stone. With the kidney in hand, three methods of exploring it for stone have been in common use—needling, opening the pelvis, and splitting the

[1] For various methods of exposing the kidney I refer the reader to John F. Binnie's Manual of Operative Surgery, part iv, Chapter I.

parenchyma (nephrotomy). Needling has fallen into disuse, as it is uncertain. Surgical opinion is divided on the question of approach through the pelvis or through the parenchyma. Approach through the pelvis is gaining in popularity, and I personally prefer to employ it. It is extremely easy: the surgeon seizes the kidney in his hand; incises the pelvis; searches the pelvis and calices for stone; and repairs the rent with Lembert stitches. The wound must be drained, for its time of healing is uncertain. Healing may be complete in ten days or may require several weeks. A splitting of the parenchyma was and still is a popular method with many surgeons. At first thought one might suppose that it would give rise to uncontrollable hemorrhage, but the studies of Zondek and Brödel have shown that by splitting longitudinally in a line from 0.5 to 0.7 cm. (0.2 to 0.3 inch) behind the middle line, one will avoid wounding important vessels. The boundary line between the arterial system of the anterior and posterior portions of the kidney is sharply distinct. Split the cortex, then, and open one of the calices.

Splitting the kidney substance results in a considerable hemorrhage, which is sometimes alarming, but this may readily be checked by packing. Some surgeons control hemorrhage by placing a temporary rubber ligature about the renal vessels and removing it at the end of the operation. When one of the calices has been opened, it may be searched with an instrument or the finger, and through this opening the exploration may be continued into the other calices and the renal pelvis. In this way an exhaustive search readily is made, so that there is no excuse for overlooking the smallest calculus. Thus the surgeon may remove stones and may wash out and drain the renal pelvis. At the end of the operation he had best treat the kidney by gauze packing, securing it, if he so choose, by one or two light catgut stitches, which are soon absorbed. The parietal wound should not be closed tightly, but gauze or tubal drainage should be employed for two or three days. There is a leakage of urine through the fistula for a time, but if the operation has been done thoroughly, the fistula closes promptly.

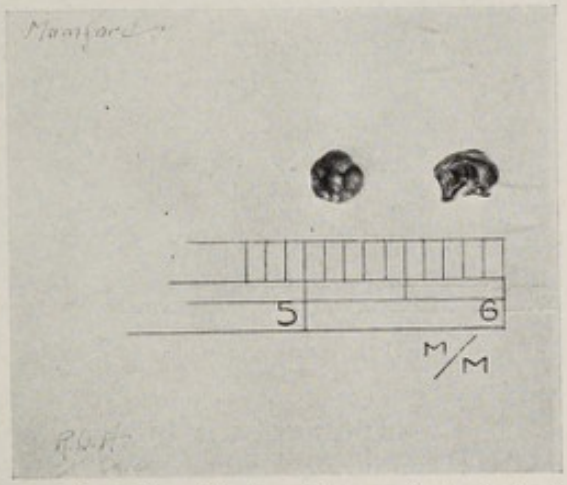

Fig. 234.—Ureteral stones (actual size), which caused excessive pain and were passed by patient per urethram.

I have described the most useful and generally applicable methods of dealing with these stones by operation. Rarely it may seem best to remove the kidney—when the parenchyma is in great part destroyed, when extensive suppuration is present, and when a restoration of function, without the subsequent formation of stones, seems improbable.

A small stone causing agonizing pain may be lodged in the ureter, in which case that canal must be explored and the stone removed. Stone

high in the ureter is reached by the lateral incision and by splitting longitudinally the ureteral tube. Sometimes stone low in the ureter is approached through the vagina or through the bladder, opened above the pubes.[1] Sometimes a ureteral stone may be pushed up into the renal pelvis and removed from this point, when the kidney has been opened for stone; or it may be possible to squeeze a ureteral calculus down into the bladder. J. H. Gibbon prefers the easy and simple approach to the ureter by the transperitoneal route through a short incision, such as is usually made to find the vermiform appendix. If one has opened the ureter, it may be closed satisfactorily with fine silk Lembert stitches. The surgeon must drain a sutured ureter through the external wound.

HYDRONEPHROSIS

Hydronephrosis is a dilatation with aseptic urine of the renal pelvis, but if infection takes place, the contained fluid becomes purulent, and the process may go on to involvement of the renal parenchyma. True hydronephrosis is due to a mechanical obstruction to the escape of urine from the ureter—congenital or acquired obstruction. Congenital obstacles are rare, such as imperforate ureter or ureter obstructed by an anomalous branch of the renal artery. The acquired obstacles are more common, and perhaps the most common of such obstacles is kinking of the ureter, due to prolapse of a movable kidney. Again, the ureter may be obstructed anywhere in its course by the pressure of tumors, by diseases and injuries of its own wall, by a calculus or foreign body, by inflammatory exudate within the bony pelvis, by disease or tumor of the bladder, or by operative ligation of the ureter (J. Dellinger Barney). Such obstructions may lead to a great accumulation of fluid not only within the renal pelvis, but within the kidney itself, through great dilatation of the calices, pouch formations, and stretching and thinning of the parenchyma and capsule. The hydronephrotic tumor may reach a great size—as large as a child's head even.

False hydronephrosis is a collection of fluid on the outside of the kidney.

The **symptoms** of hydronephrosis are gradual and vague in their onset, though one form, *intermittent hydronephrosis*, so called, due to the ureteral kinking of movable kidney, is characterized by recurring attacks of pain, the formation of a tumor, and subsidence of the swelling, with a sudden abundant discharge of urine into the bladder. Commonly, however, hydronephrosis is associated with dull pain in the loin and with a diminution of the urine passed. There is no fever; gradually a palpable tumor reveals itself. Sometimes there is an associated history suggesting renal calculus or the symptoms of malignant disease, with its characteristic pain and cachexia. We establish the **diagnosis** of hydronephrosis by observing such symptoms and feeling a fluctuating cyst.

[1] The transcystic route for stone in the terminal portion of the ureter is becoming increasingly popular. When the bladder is infected, it may be closed tightly in layers, gauze drainage being provided for the space of Retzius only. Employ penile catheter drainage for two days.

The **treatment** of hydronephrosis must be operative. When advanced coincident disease is present, such as cancer of some other organ, one should attempt nothing more than permanent drainage of the renal cyst, in order to relieve pressure and discomfort. Should the patient's condition admit, adventitious tumors are removed. Disease and injury of the ureter itself are to be treated by exposing the ureter and excising the damaged portion. In many cases one may then perform ureteral closure either by end-to-end suture or by implanting the upper into the lower portion, after the method of van Hook. Obviously, an impacted calculus, an obstructing blood-clot, or the rare ureteral neoplasm must be removed, and crippling pelvic exudation must be appropriately treated. Hydronephrosis, due to kinking of the ureter, commonly associated with movable kidney, sometimes with an abnormal branch of the renal artery, and intermittent symptoms, is an especially interesting condition, because its proper treatment restores completely the function of the kidney at the same time that it cures the disease. As long ago as 1892 Fenger, of Chicago, treated successfully this ureteral kinking by an operative procedure similar to the famous Heineke-Mikulicz pyloroplasty. We now apply this principle to stricture of the ureter. At the same time, if the kidney is movable, we fix it. Some surgeons have provided a free drainage to the renal pelvis by making an anastomosis between the pelvis and the ureter, while others have resected large portions of the wall of the sac. The literature of this subject is extensive, and the numerous operations proposed are extremely ingenious.

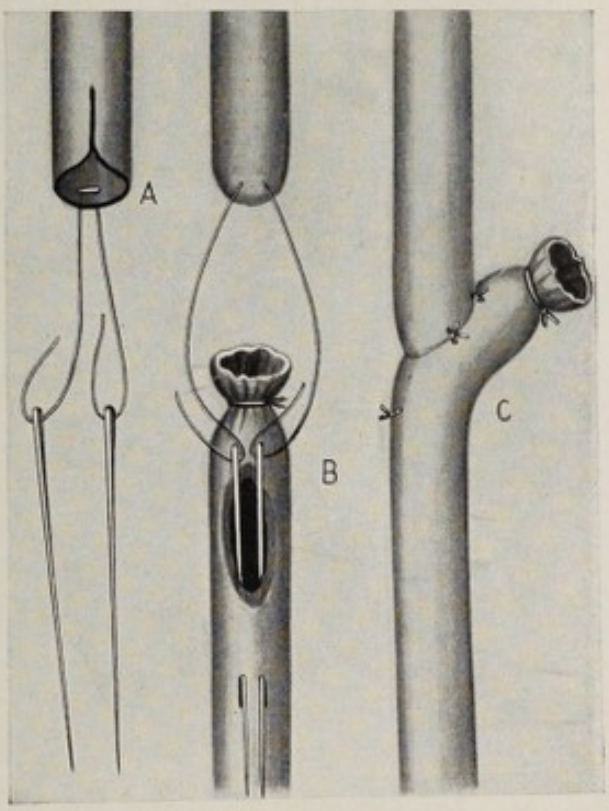

Fig. 235.—Van Hook's method of lateral implantation of the ureter: A, The renal portion of the ureter split longitudinally, the ends trimmed so as to admit of easy implantation, and the loop of catgut passed; B, showing the method of passing the needles so as to draw the renal portion into the vesical portion; C, the implantation completed (Fowler).

PYELITIS

Pyelitis, *pyelonephritis*, and *suppurative nephritis* are conditions distinctly susceptible of surgical treatment. Infections of the kidney and its pelvis come about through the blood-stream or by direct extension from below—from the bladder and genitals up through the

ureter. We were formerly taught that all renal suppuration came from below, but it is now apparent that this is not the case; and when one considers the excretory function of the kidney, one perceives how inevitably it is subject to damage in connection with all sorts of diseases. Pathogenic bacteria lodge in the kidney in the course of measles, smallpox, scarlet fever, typhoid fever, and tuberculosis; while the colon bacillus and pus-producing cocci all may pass through it. Gonorrhea, as well as infections from parturition, are common causes of renal suppuration. A familiar old term for these renal inflammations is "surgical kidney." We need not consider here the suppuration due

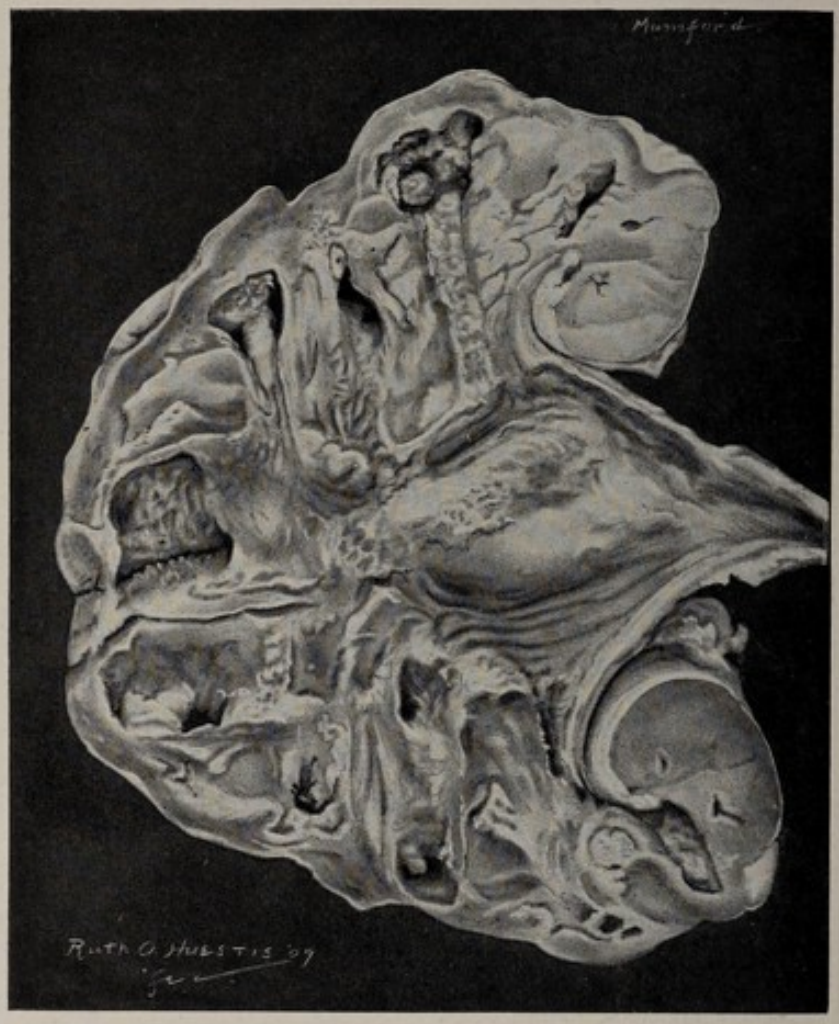

Fig. 236.—Surgical kidney (Warren Museum, Harvard).

to tuberculosis and calculi—the commonest of all forms of renal suppuration.

The progress of *surgical kidney* may be acute or it may be chronic. The disease may be limited to the renal pelvis, or the whole organ may be invaded and rapidly destroyed. The kidney becomes enlarged and softened. Blood is extravasated, so that one observes the general appearance of an embolic infarct. The infected tissue breaks down, and numerous small abscesses are formed throughout the kidney; or there may be affusion of many small abscesses into a few great pus-pockets, so that the kidney is changed into a network of degenerated

parenchyma, partly separating the abscess cavities. Then the fatty capsule shrinks; the kidney may become adherent to surrounding tissues; pus may break out through the capsule, or paranephritic infection may occur; so the process may be unlimited or limited to the pelvis or to the kidney proper or to both; while the symptoms of the condition and its gravity must depend on the virulence of the infection and the extent of the inflammatory reaction.

The **symptoms** of surgical kidney are extremely variable, and the diagnosis may be correspondingly difficult. A suppurative nephritis of embolic origin is accompanied by sharp attacks of renal colic, suggesting stone, and, indeed, a calculus may be present. After such an attack one finds great quantities of bacteria in the urine. Again, with an infection of gradual onset there is a dull ache merely in the loin, and a feeling of pressure. Or the case may drag on for years without any pain whatever. Usually there is an intermittent fever, which may run high and be associated with chills; there is almost always marked impairment of the general health. There may be anuria or an intermittent pyuria, in which latter case one may assume that one of the kidneys is unaffected, for between attacks, or during the temporary occlusion of one ureter, the urine passed from the bladder may be perfectly normal. There is almost always an enlargement of the affected kidney and marked tenderness in the loin, though, rarely, these symptoms are absent. As a usual thing, however, the picture is fairly characteristic and the diagnosis not difficult. With fever, pain or aching in the loin, pus in the urine, and a tumor present, one makes a diagnosis of surgical kidney. Cystitis must be ruled out, and one may settle the question of cystitis by the microscopic examination of the urine, which shows characteristic renal, pelvic, or bladder cells, depending on the source of the irritation. One observes also the absence or presence of frequency and vesical tenesmus. An acute pyonephrosis gives a classic group of symptoms: sudden, temporary obstruction to the urine, with rapid formation of a painful, tender tumor; then a clearing up of the urine, which previously contained pus, the patient meanwhile growing worse. Sometimes, as a supplementary study, a cystoscopic examination of the bladder, with segregation of the two urines, may be employed, though this is by no means always necessary. There is nearly always a leukocytosis, ranging from 15,000 upward. The initial symptoms of these renal infections in recent years have become the subject of special studies. Through these studies we have been brought to see that many of these cases formerly known as *surgical kidney* develop from a primary renal focus, which should be attacked early. *Acute unilateral septic infarcts* of the kidney is the term now used to express the condition I have referred to in this paragraph as a suppurative nephritis of embolic origin.[1] The infection may be mechanical, by actual infected tissue carried to the kidney, or emboli of bacteria themselves may be lodged in the kidney parenchyma. Women are more commonly affected

[1] See an excellent résumé of this whole subject by Farrar Cobb, Acute Hematogenous Infection of One Kidney in Persons Apparently Well, Ann. Surg., November, 1908.

than men. The infection may be extremely rapid and fatal, or, after a rapid onset, the symptoms may subside and the course become chronic. The symptoms of acute unilateral hematogenous infection are perplexing often. I have seen patients operated upon for diseases of the bile-passages and of the stomach, when the actual trouble was an acutely septic right kidney. One characteristic point in differential diagnosis is the extreme tenderness to palpation elicited high in the costovertebral angle, when the kidney is affected. On the other hand, there may be little pain, and the urine may show little disturbance, though most commonly it contains blood. With such an onset as this the disease, if not quickly fatal, runs on into that course which I have described under the old-fashioned caption "surgical kidney." The acute unilateral cases are alarming and fatal often. Usually the surgeon must operate without hesitation and remove the infected kidney if he is to save the life of the patient.

Treatment of Surgical Kidney.—Recently I saw in consultation a young woman who had contracted gonorrhea five months previously, in the sixth month of a pregnancy. She was delivered safely about three weeks before I saw her. She appeared to do well for a week after her labor, when she had a chill, followed by a hectic fever, dull pain in both loins, and the intermittent appearance of pus in the urine; there was no frequency or tenesmus; the microscope showed no evidence of bladder inflammation. Both kidneys were palpable and were tender to pressure. The patient lay languid and helpless in bed, with a dull headache, furred tongue, and a feeling of great prostration. I directed the application of hot poultices over the loins, a milk diet, the copious drinking of spring water, permanent drainage of the bladder by an in-lying catheter, daily bladder irrigation, and a strychnin and iron tonic. Within a week the patient was convalescent.

In the care of acute pyelitis, especially bilateral pyelitis, such treatment often will suffice. Thus the renal engorgement is diminished, copious excretion of urine is secured, constant drainage without backing up in the bladder is accomplished, and the patient's general tone is maintained. Writers have recommended catheterization of the ureters and washing out with boric acid of the renal pelvis in such cases. Though such pelvic irrigation often is effective, I regard it as hazardous, and not frequently or lightly to be undertaken. In that case of mine the recent spread of the infection and the fact that it had attacked both kidneys rendered an extensive operation inadvisable, unless as a last and desperate remedy.

Many cases of pyelitis and surgical kidney, however, must be treated by operation—when the disease is long established and fails to yield to other treatment, or when the infection is so acute and overwhelming that nothing save immediate renal drainage or extirpation of the kidney offers a chance of cure. Nephrotomy and nephrectomy are the commonly employed operations in cases of chronic surgical kidney. Nephrectomy, so urgently demanded in cases of *acute* hematogenous infections, seldom is necessary, and should be performed in case of most extensive

damage only in the cases of *chronic* surgical kidney. When this late nephrectomy is performed, the surgeon should remove the ureter at the same time, in order to anticipate empyema of the ureter; or he should stitch the proximal ureteral orifice, for drainage, into the external wound. But nephrotomy is the operation of choice. One performs it in the manner I described when treating of renal calculus. Split the parenchyma; open the calices; explore; wash out and drain all abscesses as well as the renal pelvis; control hemorrhage during the operation by a temporary ligature about the vessels of the hilus; and, finally, treat the kidney by tampon and external drainage. In the case of extensive suppuration, it is sometimes well to stitch the two halves of the split kidney separately into the external wound, and then to pack the kidney wound. The surgeon must realize that the dangers of nephrectomy do not lie so much in the operation itself, as in the condition resulting—the patient is left with one kidney only. After all these operations convalescence is slow and the outlook grave, for a time. One depends upon the sound kidney to do extra work; but gradually, if all goes well, the crippled kidney itself takes up its functions and a restoration to health may be anticipated. For weeks a fistula in the loin of operation persists, however, through which urine is discharged, necessitating abundant and frequent dressings. Meantime active general treatment must be pursued and the best of hygiene secured, if possible.

Paranephritic abscess must not be confounded with surgical kidney. It may be a sequel and direct result of surgical kidney; or it may arise from extraneous causes and run its course, leaving the kidney proper uninvolved. Such a paranephritic abscess as *follows* surgical kidney I have already described. That is the last and one of the most alarming complications of renal suppuration, and, as I have suggested, must be met by vigorous treatment involving often nephrectomy and free drainage. The more common forms of paranephritic abscesses do not originate in the kidney, but are concerned with the tissues about that organ—the fat, the muscles, and possibly the peritoneum and abdominal organs. Paranephritic abscess may break into and discharge through one of the hollow viscera, or may make its way into the pleural cavity, the lungs, and bronchi. One observes at once, therefore, that the commoner cases of paranephritic abscess are associated with little evidence of kidney disturbance. There is no pus in the urine, and such urinary changes as appear indicate nothing more than acute renal congestion. In other words, we have to deal with a lumbar abscess. We find the usual signs of abscess, pain, heat, redness, swelling, and fever. The only proper *treatment* is free drainage. With this, usually, the inflammation subsides and little more is necessary for the treatment of complications even. Fistulæ gradually close and the patient returns to a normal condition. In the after-treatment I sometimes employ large, hot creolin poultices, applied every three hours, but generally a dry gauze dressing suffices. I have found prolonged immersion of the patient in a hot-water bath to be a great comfort to him sometimes, when the inflammation was subsiding slowly, and an irritating open

wound persisted for a long time. If such bath treatment comforts and relieves the sufferer, one may feel confident that a cure is being hastened.

TUBERCULOSIS OF THE KIDNEY

Let us consider briefly this most common and most interesting form of renal infection. Primary tuberculosis of the kidney is probably rare. The infecting organisms generally reach the kidney through the blood-stream, being taken up from foci in the chest, the abdomen, or elsewhere. It was not long ago that we believed all renal tuberculosis to be an ascending process from the bladder and genital organs, but

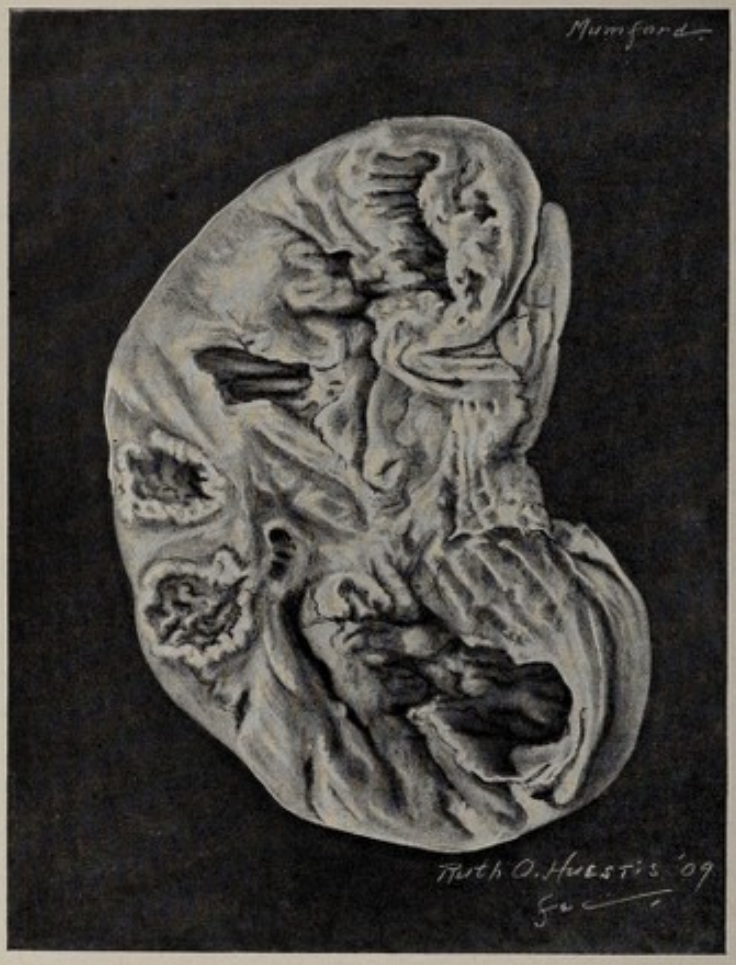

Fig. 237.—Tuberculous kidney (Warren Museum, Harvard).

there is now abundant evidence that this source of infection is not so common as that through the blood-stream. Infection through the blood-stream shows itself usually in one kidney, rarely in both. Infection through the genital tract seizes upon both kidneys. Fortunately for patients and surgeons, the blood-stream source is the commoner, and unilateral renal tuberculosis is more frequent than bilateral tuberculosis.

The disease is insidious usually, though it may develop rapidly in the course of a general tuberculosis. The pathologic process is similar to tuberculosis elsewhere. Small foci appear in the paren-

chyma of the organ; they spread, caseate, break down, and run together. Frequently a mixed infection supervenes; abscesses form, the parenchyma of the organ is destroyed; the morbid process gives rise to a considerable tumor, and sometimes extensive adhesions develop; frequently calculi are deposited, and the ureter is invaded by tuberculous invasion. That involvement of the ureter is an important fact. The tube becomes thickened, narrow, inelastic, and extensively adherent. Total occlusion may take place, with a resulting coincident pyonephrosis and distention of the ureter itself. The kidney is thrown out of action, though long before this situation is reached it may have been functionless.

Such is a picture of advanced renal tuberculosis. This stage may be attained in a few months, or the disease may run on for years, changing little in its pathologic aspects.

It must be obvious to the reader who has made himself familiar with the curiosities and amenities of pathology—it must be obvious to such a reader that the **symptoms** of renal tuberculosis will probably keep pace with the morbid changes, while, at the same time, a diagnosis may be extremely difficult, or may be instantly apparent. I protest that an early diagnosis is imperative, for we can often cure the cases taken early. We look for characteristic constitutional symptoms: emaciation, cachexia, hectic fever, sweating, rapid pulse, furred tongue, distaste for food, and anemia. Generally, there is bladder irritation, with tenesmus and frequency. The urine may be clear, or may be loaded with pus, and sometimes with blood. One is often disappointed in the physical examination of such patients. One expects to see a pallid, emaciated victim, but such appearances come late. I have found renal tuberculosis in plump, active, red-cheeked girls, in whom the disease had not been suspected. Often one finds a tumor in the loin, enlarged glands in the axilla, groin, or neck, and perhaps scars on the body. In the case of a woman one may feel by vagina an enlarged, cord-like ureter on one side, passing in front of the cervix. Sometimes in thin persons of either sex the thickened ureter may be felt through the abdominal wall. Examine the urine. Look for tubercle bacilli in the sediment. As a confirmatory test inject some of the urinary sediment into a guinea-pig. It takes from three to four weeks for tuberculosis to develop in the animal. Examination with the cystoscope is informing, and one may thus determine the source of the pus, whether from right or left ureter or from the bladder. That determination of right or left is vital.

The most experienced surgeon may be misled by symptoms alone, and may pronounce a left kidney tuberculous when the right is at fault.

Thus we make the **diagnosis,** observing especially pain, tumor, pus, and blood, and taking into account the hectic fever and the nature of the urinary sediment. And we must remember that calculi may be present to befog us, while surgical kidney has many factors in common with tuberculous kidney.

The **treatment of renal tuberculosis** still agitates surgeons, though many are coming into some manner of accord. Not long ago we thought the disease could be checked or cured by an out-of-door life. Doubtless this is often true, but it is impossible to secure such a life for the majority of patients. Many cannot find it, and many will not follow it.

The surgeon must prescribe carefully the mode of life and proper hygiene, nutritious, fattening foods and iron for every patient, whether or not an operation be undertaken. Now, that question of operating is no longer the extremely doubtful question that it was a few years ago. Most tuberculous kidneys must be operated upon, and the sooner the better. The probability of cure or arrest of the disease *without operation* is not nearly so great as in the cases of pulmonary or joint tuberculosis. As a rule, removal of the kidney is the operation of choice, for thus alone, in most cases, can we assure ourselves that the whole disease has been extirpated. If the kidney is small, it is well to follow Kelly's method and approach the organ through the posterior lumbar triangle; or one may operate by the lateral flank incision. Examine carefully the ureter and remove it also. *Partial* nephrectomy occasionally produces a cure, but in order to excise satisfactorily a portion of the kidney one must be sure that the tuberculosis is limited to one pole, and this can be ascertained only by a searching nephrotomy —a splitting the kidney from end to end, and making sure that unsuspected foci do not lurk somewhere in the organ. In the case of advanced disease, when the kidney is greatly enlarged, it may be difficult or impossible to remove it at once, entire. In such a case one may empty the sac by nephrotomy, and then, at a second sitting, extirpate the diminished organ. Always in such cases one must detach with care the upper pole, on account of possible adhesions to the vena cava and the duodenum. In all cases one should be sure of the condition of the opposite kidney—whether or not it be present, free from disease, and functionating. The removal of one kidney when its fellow is tuberculous is extremely hazardous and is commonly useless. Tuberculosis of the bladder, however, is not necessarily a contraindication to nephrectomy. Always remove the diseased ureter.

The results of these radical operations for tuberculous kidney are often extremely satisfactory. When the disease is seen early and is limited, the patient may recover perfectly through the operation.

TUMORS OF THE KIDNEY AND SUPRARENAL GLAND

Hypernephroma is the most interesting of kidney new-growths. Although P. Grawitz described and named hypernephroma so long ago as 1883, within recent years only has the profession at large recognized the significance of the disease. Every surgeon of experience can remember operating upon malignant tumor (sarcoma) of bone in cases in which renal symptoms and kidney tumor subsequently have appeared. Strangely enough, the association between these tumors of bone and tumors of the kidney for long went unrecognized. Indeed, only last

year I saw the specimen of a sarcoma of the clavicle removed by a surgeon who had failed to investigate the condition of the kidneys. After the excision of the bone tumor he discovered a considerably enlarged

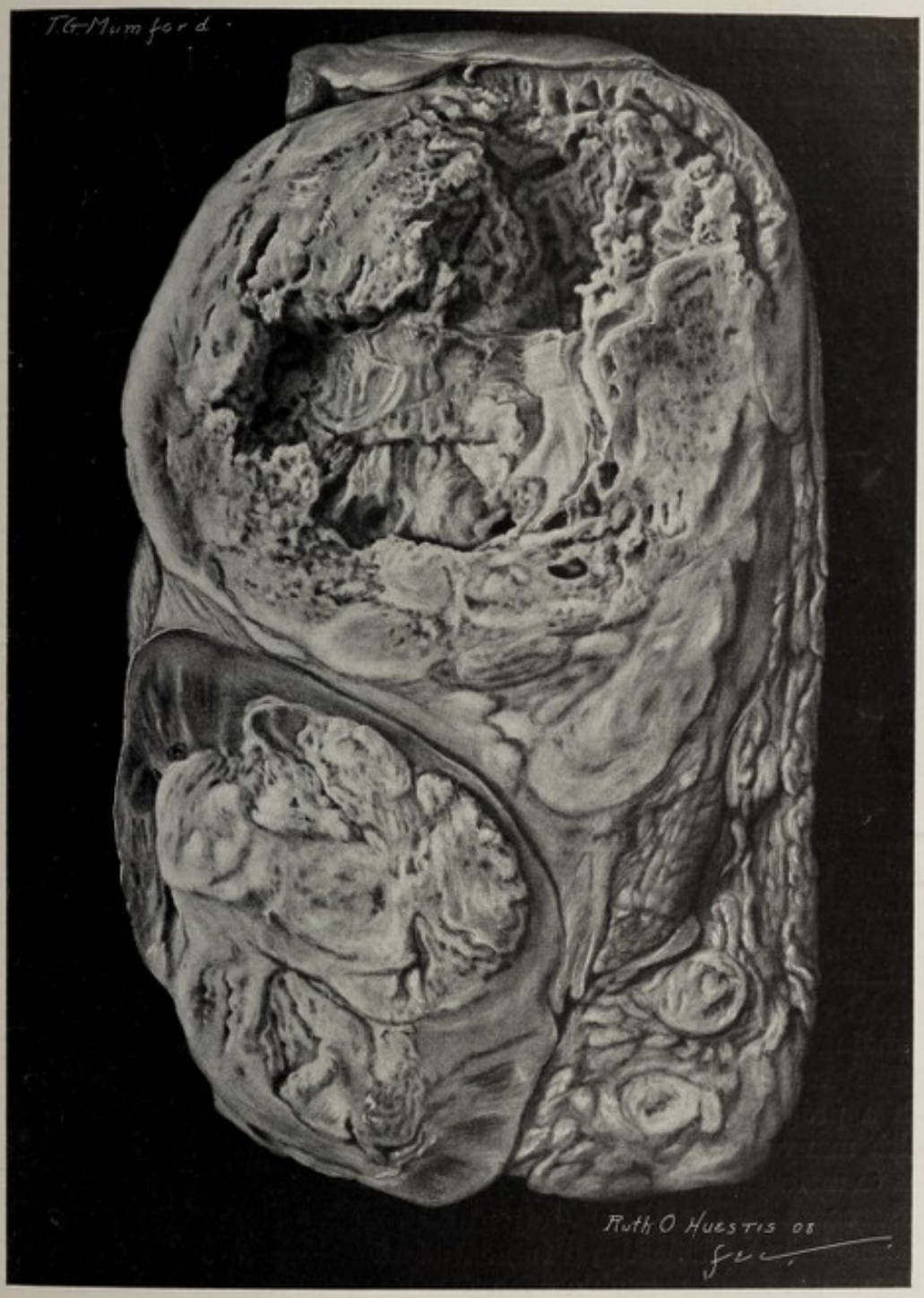

Fig. 238.—Hypernephroma.

right kidney. So we see that bone metastasis is one of the significant features of hypernephroma.

Grawitz gave the name to the disease. Frequently at postmortem, on stripping back a kidney capsule, one finds beneath the capsule small, fat-like bodies, the size of a pea or less. Grawitz pointed out that

these are inclusions,—portions of the suprarenal gland,—that they may remain indefinitely without causing damage, or that at any time during life they may take on growth and develop into considerable tumors—sometimes benign, sometimes malignant. These tumors are histologically characteristic, showing a delicate vascular stroma, within the meshes of which are strings or groups of polygonal cells, whose bodies contain few or many fat-drops; in their structure and in the character of their cells these nodules resemble closely the nodules which develop in the suprarenal gland. One never can tell at what moment hypernephroma may bring forth metastases. If the growth remain localized, one may regard it as benign. If it spread so as to involve other organs,—especially if growths of similar structure appear in distant bones,—it has become malignant,—one of the most malignant forms of tumor. Obviously, therefore, as soon as hypernephroma is discovered in the kidney, the whole organ should be extirpated.

The symptoms of hypernephroma are no more characteristic than are the symptoms of other renal diseases, but the following phenomena are fairly constant:[1] recurring attacks of hemorrhage associated with frequency of urination, often associated with clots which, in their journey through the ureter, stop the stream (for hours or days, as shown by diminishing amount of urine), and cause fairly severe pain. Between the hemorrhages are periods not characterized by "frequency," but by a diminished amount of urine and urea, and marked pain in the back, which persists until it disappears coincidentally with the onset of fresh hemorrhage. These alternations of pain and hemorrhage are quite different from the symptoms of renal calculus. The urine generally shows nothing characteristic when submitted to the usual tests. The further symptoms for which one looks are those common to advancing tumor-formation—pain, cachexia, and metastasis. The physical examination reveals a kidney but little enlarged at times, though frequently the organ reaches a great size. The general kidney outline is retained, and usually the surface is nodular. The **diagnosis** is suggested by the hemorrhages, alternating pain, and a diminished urea; by finding a tumor, and by the discovery of malignant disease of bone.

The **treatment** of hypernephroma is immediate nephrectomy, with a prognosis always doubtful. Some patients have survived in health many years after the operation; some quickly have fallen victims to metastasis.

Sarcoma of the kidney often can scarcely be distinguished from hypernephroma—indeed, all tumors of the kidney, whether benign or malignant, closely resemble each other clinically. Sarcoma develops in children as well as in persons of middle age. It often grows rapidly, and varies in malignancy according as do its histologic components. Usually spindle-celled or large-celled or round-celled, it may exist as a single tumor, or there may be multiple tumors. Frequently there are mixed forms of sarcoma, such as fibrosarcoma, and some of these tumors are

[1] P. Thorndike and J. H. Cunningham, Hypernephroma, Boston Med. and Surg. Jour., December 3, 1903.

relatively benign. Then there is the angiosarcoma which goes by various names, endothelioma among others. Sarcomata do not often bleed. They rarely obstruct the ureter. They invade the veins—especially the renal vein—and deposit metastases in distant parts of the body. Rarely sarcomata may be bilateral. Ordinarily, when one kidney only is affected, an attempt at its extirpation should be made, though this is possible early in the disease only. In this connection G. Walker [1] advocates tying the renal vessels by transperitoneal section before removing the kidney through an extraperitoneal route. One opens the abdomen in the median line, seeks the renal vessels, and cuts down upon them through the posterior peritoneum; then secures them by double ligatures, closes the peritoneum, and attacks the kidney by the lateral-flank or lumbar incision. These malignant tumors are best removed by an extraperitoneal route, for transperitoneal extirpation shows a 3 per cent. higher death-rate.

At the best the outlook for sarcoma of the kidney is grave.

Carcinoma of the kidney is another rapidly fatal disease. The growth originates in the uriniferous tubules and gradually destroys the parenchyma, invading in turn the renal vessels, the ureter, and, rarely, the bladder. Though sometimes primary in the kidney, cancer is much more often secondary there. It is characterized by pain, hemorrhage, cachexia, and metastasis. Sometimes, if situated in the upper pole, it cannot be recognized until far advanced; but when in the lower pole, it is palpable early.

Extirpation is the only logical *treatment* for renal cancer, though the outlook is even more grave than in the case of sarcoma, and the operative mortality-rate is as high as 50 per cent.

There are numerous non-malignant tumors of the kidney, but they are relatively rare, and often are not discovered clinically. A long list of such tumors is given by compilers of statistics: fibroma, lipoma, osteoma, chondroma, angioma, and lymphangioma, all of which cause symptoms through their size and by compression of other organs. It is impossible to differentiate them, but they may be treated successfully by nephrotomy or nephrectomy.

There are also **cystic tumors of the kidney.** *Simple cysts* show little tendency to destroy renal tissue, and are, therefore, harmless. *Echinococcus cysts* are uncommon. They develop slowly and give little pain. The diagnosis is impossible unless one of the cysts bursts, when daughter-cysts and hooklets may be found in the urine. The disease is cured by incision and drainage in a considerable proportion of cases. *Polycystic degeneration* may transform the kidney into a mass of cystic spaces, large and small, with obliteration of parenchyma. The process may be congenital [2] or may originate late in life and run a chronic course. The disease is bilateral usually. Nephrectomy is permissible in case the opposite kidney is proved competent. Probably the best operation is

[1] Jour. Amer. Med. Assoc., November 25, 1905.

[2] See especially F. B. Lund, Congenital Cystic Kidney, Jour. Amer. Med. Assoc., August 18, 1906.

nephrotomy: a breaking up of the cysts and suture to the lumbar muscles, with packing and abundant drainage.

A classification of **tumors of the suprarenal glands** is still imperfect. Probably 80 per cent. of suprarenal lesions are tuberculous. There are rare cases of primary cancer and sarcoma,[1] while adenoma is more common. Adrenal cysts occasionally are reported, while adrenal hematoma in the new-born is not uncommon. Some adrenal cysts may attain great size and require an extensive surgical operation for their removal. If complete extirpation is impossible on account of hemorrhage and extensive adhesions, the surgeon may resort to marsupialization.[2]

LUMBAR FISTULA

Fistula in the renal region may be a cause of obstinate, dangerous, and distressing symptoms. There are various types of these fistulæ. Some of them are not connected with the kidney. Perhaps the fistula most commonly seen is that which persists after a surgical operation—generally, a nephrotomy for hydronephrosis or for calculus. Fistulæ may be associated with tuberculosis. The presence of a calculus, of diseased cystic renal walls, of tuberculosis, or of ureteral stone may cause fistulæ to persist indefinitely. Those fistulæ which do not communicate with the renal apparatus may mark the site of an old paranephritic abscess.

Curious internal fistulæ are seen sometimes—fistulæ connecting the kidney with the intestine (intestinorenal, usually colon) or with the stomach (gastrorenal); and in these cases pus and urine will escape by the rectum, or undigested food may be passed from the bladder.

The **treatment** of these intricate conditions is by painstaking and laborious operation. The urinary passages must be explored, foreign substances removed, necrotic tissue excised, and kidneys, tuberculous or obstinately diseased, must be extirpated. At the same time the fistulous track must be explored and damaged viscera repaired.

CHRONIC NEPHRITIS

Within the last ten years decapsulation of the kidney has been employed for the cure of chronic nephritis. Ferguson has made some interesting and valuable observations on the subject, while Edebohls, in vigorous language, has advocated the measure. Many operators have experimented with kidney decapsulation for renal inflammations, so that the statistical reports now at our disposal are considerable. Unfortunately, conclusive evidence as to the value of decapsulation is not yet before us. There seems to be little doubt that many cases have been improved, and that some few cases have been cured, by this maneuver; but the final application of the measure to definite conditions is not yet clear enough to be taught in a brief treatise of this nature.

[1] See Ramsay, Johns Hopkins Hosp. Bull., 1902, vol. x.
[2] Cysts of the Suprarenal Gland, Andrew J. McCosh, Ann. Surg., June, 1907.

The technic of kidney decapsulation is extremely simple. The surgeon approaches the kidney through a lumbar incision, as though he purposed nephropexy. He seizes and extracts the kidney, splits the fibrous capsule, peels it off, and removes it as far down as the renal vessels. He then drops back the kidney into its place. The nature of the histologic changes which follow in the course of healing is still under discussion, and numerous ingenious observers have advanced various views. Whatever takes place, it is certain, as I have stated, that relief sometimes ensues, owing probably to the removal of pressure from the tense kidney tissue.

In the foregoing pages I have outlined the most frequent pathologic conditions in the kidney which concern the surgeon. Often they are related closely to disturbances in other parts of the urinary tract, and I shall, therefore, in the next chapter, continue the discussion, dealing especially with diseases of the bladder and prostate gland.

CHAPTER XIV

BLADDER AND PROSTATE

THE BLADDER

THROUGH the development of surgery it has come about that the bladder interests surgeons less than it did in the last generation. In current periodic literature discussion of bladder diseases is not conspicuous, yet in my student days stone in the bladder was held to be one of the most important subjects of surgical investigation, and the literature of vesical calculus was enormous. Doubtless this interest was due in part to the genius of Henry J. Bigelow, who then recently had thrown upon the subject a flood of light, and had advanced the operation for stone from its long-time perilous position to a situation of safety and certainty. All that is now ancient history. Surgeons are somewhat tired of bladder problems. The bladder is not a vital organ, so that the preservation of its structure and function is less urgently important than is the case with the kidney and the intestine. Indeed, individuals can get along without a urinary bladder. Unfortunate wretches are not infrequently born without a proper bladder. Such persons present the condition known as exstrophy of the bladder.

EXSTROPHY OF THE BLADDER

This curious condition, which amounts practically to an absence of the bladder, is a congenital defective development seen more commonly in male than in female infants. The anterior abdominal wall fails to close, and the anterior wall of the bladder is absent, so that the posterior bladder-wall, with the openings of the ureters, presents. The arch of the pubes is undeveloped, epispadias exists, and frequently the testicles do not descend. As a result of this condition the posterior vesical mucosa protrudes into the outer world, and urine constantly dribbles from the exposed ureters. The condition of the victim is loathsome.

There are various degrees of exstrophy, from a mere trifling opening or cleft in the lowest portion of the bladder to a wide furrow, exposing bladder, urachus, and urethra. It is obvious that the condition is found in poorly developed and congenitally defective subjects, and one questions sometimes whether the lives of the unfortunate victims are worth saving.

The only reasonable **treatment** consists in some form of surgical operation which shall confine the urine in its normal channel, or at least divert it from constantly flowing over the parts. The names of sundry

distinguished surgeons have been connected with endeavors to relieve exstrophy of the bladder. Until recently the aim of all was to restore the anterior bladder-wall by turning skin-flaps over the defects—skin-flaps with the epithelium turned in. These efforts have not been satisfactory. A continent bladder practically never is secured in this manner. Trendelenburg advocates bringing together the separated pubic bones after dividing the sacro-iliac synchondroses. The maneuver is hazardous, and the results uncertain. Certain surgeons advocate removing the bladder altogether and implanting the ureters in the urethra. This operation is not difficult, nor is it dangerous. It confines the urinary stream to a normal passage, from which the continual drippings may be collected in a suitable urinal. Of recent years a more radical operation for exstrophy has been advocated by various ingenious writers, and their questionable successes have roused some spasmodic enthusiasm. Simon, Maydl, Gersuny, Hochenegg, Peters, Rutkowski, and others have advocated extirpating the bladder and implanting the ureters in the rectum, the sigmoid, or the ileum. Maydl's method is intraperitoneal; Peter's method is extraperitoneal, and there are sundry modifications. The ureters with a portion of the trigone are excised and implanted within the gut. Bottomley advocates vigorously the implanting of the ureters in the skin of the loin behind the kidneys. Experience shows that urine escaping in the back is easily collected in a suitable apparatus, to the great comfort of the patient. As a secondary step in his operation, Bottomley excises the remnant of the bladder.[1] Several of these patients have recovered and have led fairly comfortable existences for a time. Probably some form of transplantation operation is the operation of choice, though the cases are as yet too few for us to know definitely the probable mortality from ascending pyelitis, the tolerance of the bowel, and the competency of the anus in those cases in which the ureters are implanted in the rectum.

ABSENCE OF BLADDER; DOUBLE BLADDER

Two other rare anomalies of the bladder are congenital absence of the bladder and double bladder.

The most common lesions of the bladder are inflammations, calculus formation, and tumors, and the most noticeable and important symptom for which the surgeon is consulted is retention of urine due to some obstruction to the bladder's outlet. As with the kidney, similar bladder symptoms may be due to divers causes, while similar causes may produce various symptoms; retention of urine may be due to stricture of the urethra or to prostatic hypertrophy, while stricture of the urethra may cause no other symptoms than frequency, and prostatic hypertrophy may be devoid of all symptoms whatever.

Let us consider first the familiar symptom, *retention of urine*, and after that, the conditions which give rise to retention.

[1] John T. Bottomley, Operative Treatment of Exstrophy of the Bladder by Transplantation of the Ureters on to the Skin of the Loin, Jour. Amer. Med. Assoc., July 13, 1907. Bottomley gives an excellent bibliography also.

RETENTION OF URINE

The condition of retention is an abnormal collection of urine within the bladder due to the more or less complete obstruction of the natural outlet. We recognize complete retention and partial retention, partial retention being the more common, for complete retention must be regarded generally as the last stage of a long-continued partial retention. A majority of cases of retention are due to some such obstruction as I have mentioned,—obstruction of the urethra,—though there is a second, rarer variety of retention in which the condition results from some diminution of vigor in the expulsive forces—some paralysis or other. Urethral stricture and prostatic enlargement are the most common causes of obstruction. In addition, retention may be due to acute inflammation causing swelling and choking of the urethra; to prostatic tuberculosis; to concretions; to abscess or tumors; to lacerations of the urethra, or to blood-clots and foreign bodies. Some modification of nervous force diminishing the expulsive power of the bladder gives rise to a common form of retention. For example, many persons, while lying on the back, cannot void urine; operations upon the abdomen and pelvis frequently cause such temporary retention. Moreover, there are the more general causes which, through sundry diseases, affect the tone of the bladder, and there are special diseases resulting in paralyses—such diseases as brain tumor and paresis. If the surgeon finds a patient with urine dribbling drop by drop from the urethra, he must not conclude that retention is absent, but must regard this dribbling as the overflow of an incompetent and overdistended bladder. In such case the presence of the distended bladder usually is obvious. It feels like a tense, smooth, football-like tumor, rising from behind the pubes as far as the navel often. The surgeon must distinguish carefully retention from suppression of urine. In the latter case no urine collects in the bladder; and he must recognize rupture of the bladder, in which case urine cannot pass through the urethra, but is disseminated throughout the soft tissues of the pelvis, a condition known as extravasation of urine.

The reader will see from this description of retention that its manifold causes demand manifold treatment. The nervous cases often can be set right by some simple device—by applying hot, wet cloths over the bladder and perineum, so as to relax spasm; by immersing the patient in a warm bath and directing him to pass urine in the tub; by the suggestion trick of pouring water slowly from a height into a basin; by giving a small opium suppository (gr. ½), or even by allowing the patient, if proper, to sit up or stand for a few minutes. Such devices, however, often fail, in which case, as well as in cases of organic obstruction, it is necessary to resort to the common panacea for retention—**catheterization.**

When there is no obstruction in the urethra, it is easy usually to pass a catheter, and the best instrument for general use is the flexible soft-rubber catheter (No. 8, 10, or 12, English size). In the case of a

woman, the nurse must have the patient's thighs widely separated, and must part the vulva with the fingers, when the pouting orifice of the urethra will appear immediately above the vaginal outlet and below the clitoris. Then the catheter, sterilized by boiling and well lubricated, readily may be passed into the bladder. Neglect of these various details leads often to trouble and misery. Not long ago I was called hastily to a suburban sanatorium, in the middle of the night, by the physician resident there, who informed me that he wished me to see a maniacal woman who was in agony with an overdistended bladder, which he was unable to relieve. On reaching the patient's room I had her brought to the edge of the bed, and held firmly in the lithotomy position. Then, upon parting the vulva, with a good light behind me, I had no difficulty in emptying the bladder at once with an ordinary soft catheter. It appeared that the physician had attempted the maneuver aided by the sense of touch only, and had succeeded merely in passing the catheter into the vagina. If for any reason a soft catheter fails to pass, it is well to try a gum-elastic instrument or a glass or silver catheter. In the case of a man with spasmodic retention, the passage of the catheter generally is extremely easy. The soft-rubber instrument suffices and can be carried quickly and directly to the bladder without difficulty.[1]

The student will learn the use of catheters in his dispensary studies and from text-books on operative surgery. Suffice it here to suggest a few principles: so far as possible use soft catheters; never employ force; remember that, in the male, the penis is held in such a position that the urethra resembles in its course the letter J; an extremely serviceable catheter is the so-called English gum-elastic, carrying a stilet which can be bent to any desired angle; the so-called coudé catheter, which has an obtuse elbow near the beak, is a useful instrument also; the silver catheter is not often used in these days; the beak of a catheter meets obstruction just beyond the bulbous urethra, and often, in old men, in the prostatic urethra; to pass these obstacles the beak should be elevated by lowering the shaft, and in the case of prostatic obstruction, a catheter with a pronounced S-shaped curve generally will enter the bladder; a familiar maneuver which aids in passing by a prostatic obstruction is to introduce the full-curved gum-elastic instrument as far as it will go and then to withdraw the stilet about an inch, when the

[1] As to a lubricant: ordinary carbolized vaselin or glycerin suffices, but since these materials, when frequently used, may damage the texture of a catheter, some such lubricant as the following, suggested by Gouley, may be employed:

Powdered white Castile soap	1 ounce
Mucilage of chondrus crispus	3 ounces
Formalin (40 per cent. solution formaldehyd)	10 minims
Thymol	5 grains
Oil of thyme	5 minims
Alcohol	15 minims

Heat the soap and water and stir until smooth. Add the mucilage (one ounce of chondrus crispus to one pint of water); when cool, pour in the formalin and then the thymol and oil of thyme mixed with the alcohol. Put up in two collapsible tubes and sterilize.

beak of the catheter springs upward and forward and enters the bladder. Catheters must be made scrupulously aseptic before their use, and for this purpose boiling, or immersion in 1 : 3000 corrosive sublimate solution, generally suffices. I have not considered here in detail the

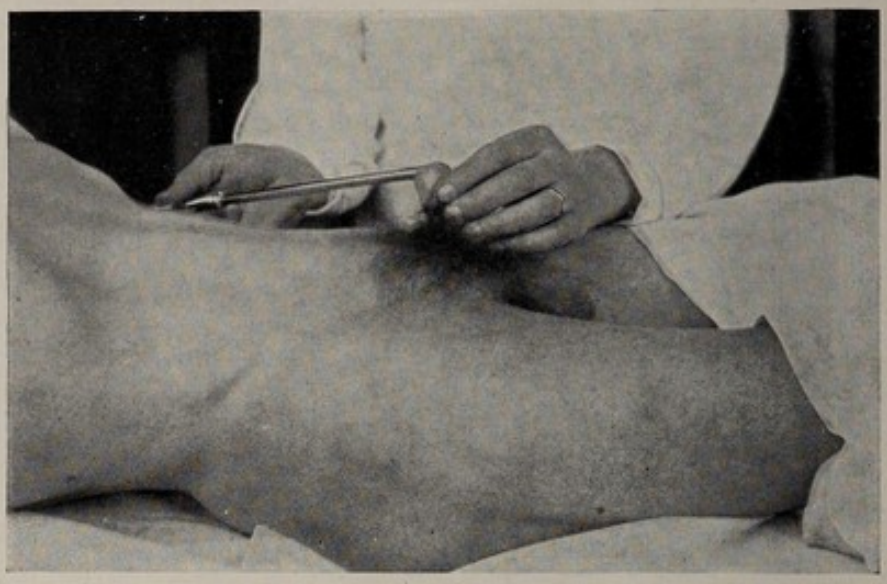

Fig. 239.—Passing the male sound or catheter (Hyde and Montgomery).

pathologic conditions, such as stricture, which may produce an impermeable urethra causing retention, but I shall speak of these conditions under appropriate headings.

Should the surgeon be unable to pass a catheter into the bladder, he may find it necessary to puncture that organ. This operation is

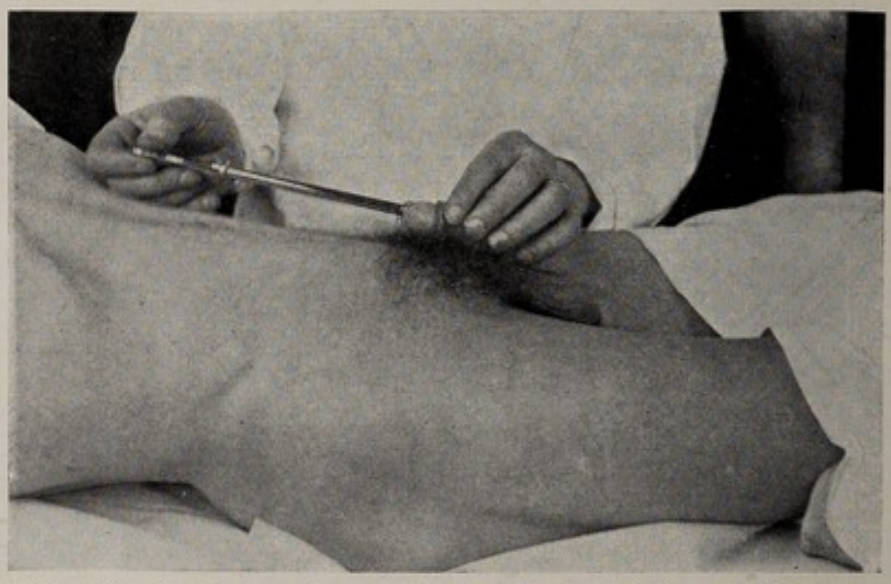

Fig. 240.—Passing the male sound or catheter (Hyde and Montgomery).

easy if properly undertaken. Remember that you are dealing with a distended bladder rising well above the pubes. Such a bladder, as it rises, carries before it and above it the peritoneum, so that there is left a small space, from one to three inches in extent, above the pubes,

where the bladder is uncovered of peritoneum. The surgeon punctures through this space. It is well first to anesthetize the skin in this region by injecting a few drops of 2 per cent. solution of cocain, so that the operation of puncture may be painless; then, with a four-inch straight

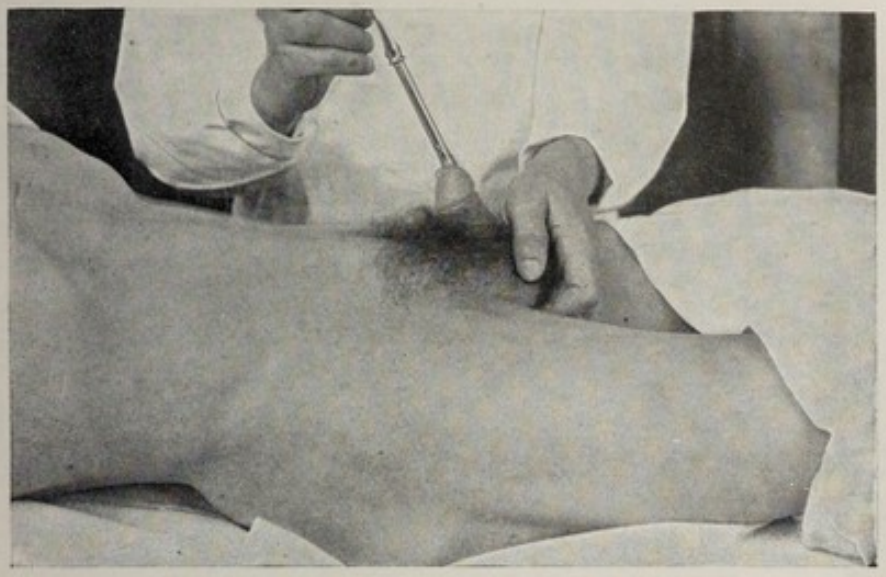

Fig. 241.—Passing the male sound or catheter (Hyde and Montgomery).

or slightly curved trocar and cannula, stab quickly into the bladder, hugging the pubic symphysis. Withdraw the trocar and allow the urine to escape through the cannula. It is an old teaching that the total amount of urine should not be withdrawn all at once, either by catheter or cannula, from a greatly distended bladder, as the sudden relief of

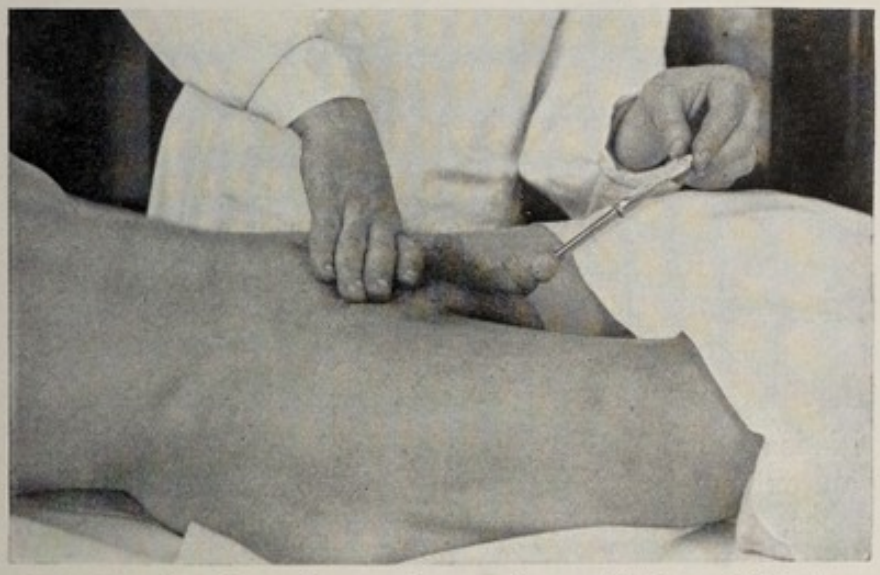

Fig. 242.—Passing the male sound or catheter (Hyde and Montgomery).

pressure causes a great engorgement of the venous plexus about the bladder, with frequent hemorrhage into that organ and occasional collapse. The urine should be drawn off slowly, about one-half at a time, that the veins may accommodate themselves to the condition of

altered pressure. Under certain circumstances, that is, when it is obvious that a recurrence of retention may follow the temporary relief, it will seem wise to the surgeon to institute permanent drainage, either by fastening a catheter into the urethra, or a cannula, passed above the pubes, into the bladder.

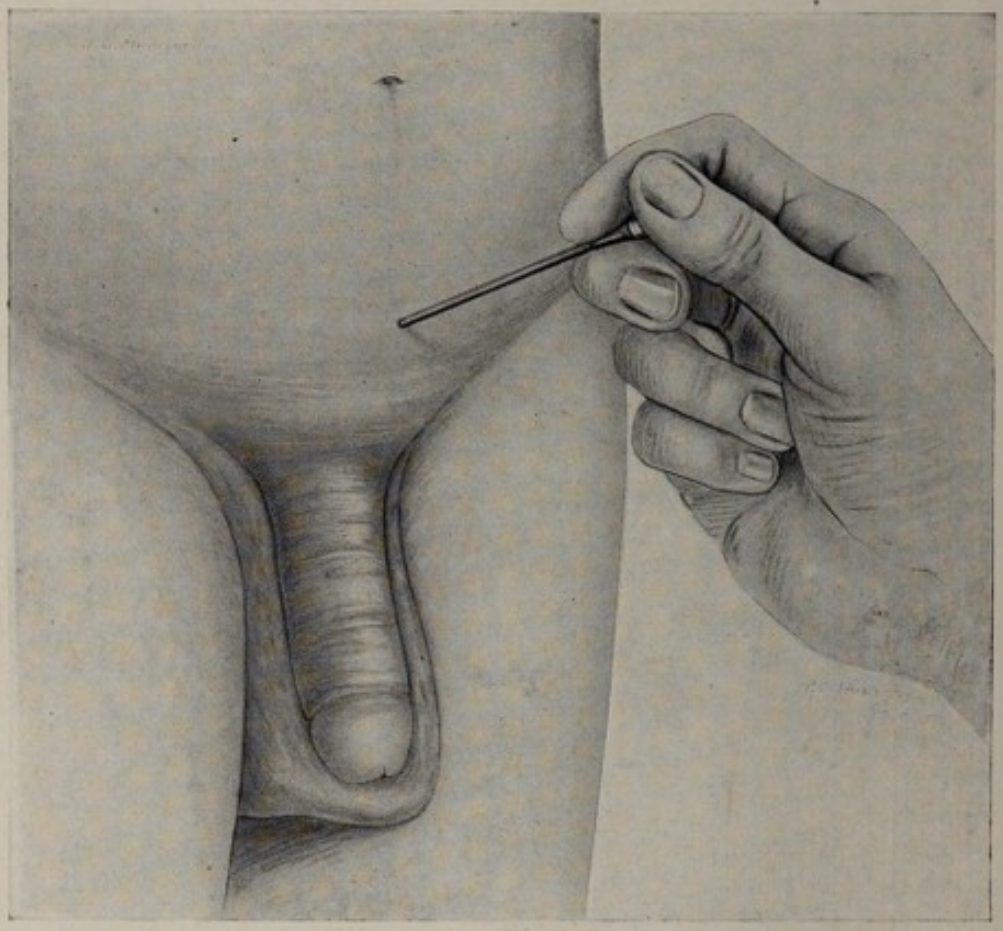

Fig. 243.—Suprapubic puncture of the bladder.

All these suggestions deal with intricate and perplexing problems difficult of satisfactory elucidation in a brief writing. In order to become familiar with these problems and their solution the student must serve a proper apprenticeship under the direction of an expert.

CYSTITIS

Cystitis is a constantly present feature in all diseases of the bladder, and is an extremely frequent complication of other genito-urinary disturbances. One often feels that inflammation of the bladder is almost the commonest form of mucous membrane inflammation. We encounter it in connection with all sorts of general infections, such as typhoid fever or pneumonia, besides which it is due to local causes. The pathologist describes 3 types of cystitis: (1) Superficial cystitis; (2) interstitial cystitis; (3) productive cystitis. *Clinically,* the most frequent forms observed are—(1) Gonorrheal cystitis; (2) tuberculous cystitis; (3) the cystitis of urethral stricture; (4) calculus cystitis; (5)

cystitis of tumors; (6) cystitis of prostatic origin; (7) cystitis of instrumentation.

It is impossible often to determine accurately the exact clinical type of cystitis with which one has to deal, but, in fact, the symptoms are much the same in all, for the disease is of bacterial origin and bacteria of similar character are present in all types—the bacteria of suppuration, colon bacilli, and, more rarely, typhoid bacilli and pneumococci. Some authorities still maintain that exposure to cold is a cause of cystitis, but even granting this, such exposure acts merely by reducing the resisting power of the tissues, so that organisms more easily find lodgment and work havoc.

So far as our understanding the type goes, the definitions—gonorrheal, tuberculous, etc.—carry their own explanation. Gonorrheal cystitis obviously is an extension of a gonorrheal process from the urethral mucosa. Tuberculous cystitis, like gonorrheal cystitis, is secondary, as a rule—secondary to tuberculosis of the kidneys, the prostate, the seminal vesicles, or the epididymis. Tuberculous cystitis generally runs a chronic course.

The **symptoms of tuberculous cystitis** are particularly important, and the gravity of the condition is great. You will observe increasing frequency of micturition, especially during the day, but later at night as well. There are often penile pain, bladder tenesmus, and, sometimes, a shutting off of the stream, with great distress. All these symptoms are wont to grow steadily worse in spite of the ordinary methods of treatment. Indeed, the drug, urotropin, commonly useful in other forms of cystitis, seems to work positive damage in tuberculous cases. The diagnosis of tuberculous cystitis is made certain by finding tubercle bacilli (to be distinguished from smegma bacilli) in the urinary deposit. Sometimes it is necessary to examine with the cystoscope, when the bladder mucosa will show at first infiltrated areas and ecchymoses, and later numerous circular ulcers.

The cystitis due to urethral *stricture* needs no special explanation, nor does the cystitis of calculus, except to remark that when a stone *forms* in the bladder, the formation follows a cystitis, while a bladder calculus of *kidney origin* precedes and causes the cystitis.

Tumors and prostatic enlargements are wont to obstruct the outflow of urine, and to damage more or less seriously the bladder-wall, changing its structure and tone and so favoring the lodgment and development of bacteria.

An extremely common cause of cystitis is instrumentation—the introduction into the bladder of infective organisms on catheters, sounds, and other instruments. It is difficult to prevent such infections, for a carefully cleaned catheter may pick up organisms from the vulva and urethra. Obviously, and for this reason, these parts should be cleaned, so far as possible, by bathing and by boric-acid irrigations.

The **symptom** which always suggests cystitis is frequency of micturition; then comes pain, during and after the act of micturition (tenesmus, the painful contraction of the bladder sphincter, with straining

and a sense of continued desire for micturition); pus is usually found in the urine; rarely there is bloody urine (hematuria). The increased frequency and the pain are constant factors, and these symptoms are greatest when the patient is upright and moving about. Observe that frequency due to prostatic enlargement is greatest during the night.

The inflamed mucosa is extremely sensitive to irritation, whereas the mucosa of the normal bladder is surprisingly tolerant. It is for the former reason that frequency arises, and the irritation is so pronounced that even after the passage of urine desire and tenesmus persist for some minutes. Early in the disease the urine may be acid when passed, but upon standing its contained bacteria multiply and alkalinity follows. Late the urine when passed is alkaline and is loaded with pus and bacteria. In *acute* cystitis, accordingly, we see these symptoms and signs: frequency, pain, and pus. Later, the disease may become chronic. The superficial inflammation gives place to the interstitial inflammation. The bladder becomes more or less thickened and permanently contracted. Sacculation or the formation of pockets may occur. The symptoms are then less urgent, though still constant. The diminished bladder must be emptied frequently; the tenesmus is less, but there is superadded a sense of burning and weight in the perineum; occasionally blood is passed, and the urine will be found to contain not only pus and bacteria, but ropy mucus, which settles in the urine glass and clings to the side of the vessel. Any albumin which may be present is due to the blood or concurrent renal disease, and is not due to the pus.

The picture presented by patients suffering from cystitis is distressing. They are wretched, constantly uneasy, in pain, with appetite diminished, sleep interrupted, and general health rapidly breaking down.

Fortunately, the **treatment** of cystitis is effective in most cases, except in tuberculous patients and in those suffering from concurrent ulceration of the bladder. From what I have said it is obvious that the causes and complications of cystitis, as well as the disease itself, must be considered and treated. Gonorrhea, stone, stricture, must severally be dealt with. Setting aside for the moment a consideration of the underlying causes of cystitis, we may regard those measures which relieve the symptoms and may be looked to for a cure of cystitis when uncomplicated.

For the pain and frequency opium is the best drug, and ordinarily it should be given by the rectum, in 1-grain suppositories. Hot applications over the pubes are an additional comfort, as is also immersion in a hot bath, when urine may be passed in the bath with little distress. The bowels should be kept open by salines and enemata, and the diet should be limited to milk, if the patient will bear it. In chronic cases one should allow a somewhat more liberal diet. At the same time certain diuretics are useful; best of all, urotropin, in 7½-grain doses, with plenty of water, every four to six hours. When the patient can bear it, irrigations of the bladder are useful in order to wash out the pus and mucus. Frequently it is necessary to cocainize first the urethra.

Ordinarily, there is no better irrigating fluid than a 4 per cent. boric-acid solution, which should be injected reasonably hot, the injections being repeated until the solution returns clear.[1] Sometimes the bladder will not tolerate irrigation, in which case *instillations* may be substituted, a few drops of argyrol (10 per cent.) being introduced with a Keyes syringe gently into the deep urethra. Occasionally, in extremely obstinate cases of cystitis, and as a preliminary to more radical measures, it is well to institute permanent drainage for a time. Such drainage is for chronic and not for acute cystitis.

Such are the measures generally found effective in the treatment of the inflamed urinary bladder. There is another condition, commonly called *irritable bladder*, which must always be distinguished from cystitis. Irritable bladder is a general and indefinite term. It is common in neurotic women who complain of frequent calls to urinate and of inability to suppress a sudden gush of urine. Sufferers from nephrolithiasis and gout also have irritable bladders—so do typhoid patients or any persons who secrete a scanty, concentrated urine. Such tumors as uterine myomata and ovarian cysts irritate the bladder. Irritable bladder often runs into that condition known as **incontinence of urine,** in which, for some cause, the bladder suddenly finds itself unable to retain its contents. As Fowler says, "in the true sense the term is applied to cases in which the urine escapes as soon as it reaches the bladder." These are the cases in which the bladder is paralyzed. Every surgeon who has had to deal with cases of "broken back" is familiar with incontinence of urine. We see then that urinary incontinence may be due to serious central lesions, or it may be due to some habit neurosis. Nocturnal wetting belongs to the latter class, and is particularly common in little boys.

The **treatment of incontinence** depends upon the cause, and the milder cases only can be treated directly. Sometimes women who are so troubled may be cured by a stretching of the urethral sphincter, while mental suggestion is of great value, especially through directing the patient to prolong the intervals between micturitions. Excessive acidity of the urine must be corrected by giving such alkalis as potassium acetate; while phimosis, balanitis, stricture, stone, pin-worms, and overheating with a multitude of blankets must be met by appropriate operations and suitable hygienic directions. Sometimes, for the nocturnal incontinence of children, benefit is found through elevation of the pelvis during sleep and giving increasing doses of tincture of belladonna until the physiologic limit is reached. In the case of adults, belladonna plus strychnin (gr. $\frac{1}{40}$ to $\frac{1}{10}$) helps. Incontinence yields slowly to treatment at the best, and I have known cases which recovered after long-continued change of residence or a distant sea-vogage only.

[1] This description applies to non-tuberculous cystitis of the male bladder. The treatment of such cystitis in the female bladder is still more simple and effective. See Edgar Garceau, Treatment of Tubercular and Non-tubercular Cystitis in the Female, Amer. Jour. Obstet., 1907, vol. lvi, No. 3.

STONE IN THE BLADDER

Stone in the bladder seems to be less common in this country and at the present day than as described by former writers. In some parts of the world it is still frequently encountered, especially among eastern peoples, among whom operators for stone find a large practice. The removal of stone is one of the most ancient of surgical operations. It is mentioned in the oath of Hippocrates, who protests that he will not himself perform the operation, but will leave it to those whose proper business it is.

We count as stone proper those vesical concretions which the bladder cannot expel through the urethra. These stones are usually made up of either uric acid and its salts, of oxalate of lime, or of phosphates or carbonates, sometimes combined with urate of ammonia. These various groups may be associated in the structure of a single stone or the stone may contain a single ingredient. Moreover, salts may be deposited about some albuminous substance, or some foreign body, which acts as the skeleton or nucleus for the calcareous collection.

The causes of stone formation are various and sometimes not altogether obvious. The disease is thought to be inherent in certain families, while diet and habit are factors often. Sundry diseases resulting in malnutrition, such as gout and liver diseases, predispose to stone formation of the uric-acid type, while phosphatic stones are the result of local conditions, such as alkaline fermentation of the urine from chronic cystitis, or retention of urine from any cause—prostatic enlargement, tumor, stricture, and the like. Finally, a renal stone discharged into the bladder may lie there and take on additional deposits.

The **symptoms** of stone in the bladder are not always characteristic; they may be extremely puzzling, and they may suggest some other lesion. The old-time questions put to a patient were: "Do you pass blood at the end of micturition?" and "Does driving over a rough road cause pain in the perineum?" A positive answer to these questions is suggestive merely. A patient may carry several large smooth stones in his bladder with little discomfort. On the other hand, one small rough stone may cause intolerable agony, especially when the patient moves about. Such a stone may have come down from the kidney with symptoms of renal colic, and may continue to cause discomfort and pain after it reaches the bladder. Stone in the bladder is more common in males than in females, so that most of the literature on the subject deals with the cases of men and boys. Accordingly the pain is frequently referred to the neighborhood of the glans penis, a little behind the meatus and below it, but pain is not invariable, and its absence does not prove the absence of stone. The pain is due commonly to contraction of the bladder about a stone. Sometimes it is due to irritation of the bladder mucosa by a rough stone. Frequently, cystitis is associated with stone, in which case the symptoms of cystitis may overshadow the symptoms of calculus. The passage of a few drops of blood at the end of mic-

turition is presumptive evidence of stone, but it is not a constant sign. A sudden shutting off of the stream during micturition sometimes occurs and is due to a stone's falling over and obstructing the internal urethral opening. In men with enlarged prostates this does not occur, as in such persons the stone always sinks behind the prostate to the bottom of the bladder.

In operating within the bladder for conditions other than stone, stones previously unsuspected often are discovered, for the presence of such calculi is masked by symptoms of cystitis, by bladder tumors, by prostatic enlargements, or by sacculations within which the stone may lie concealed.

The symptoms of stone, however, never demonstrate a final and positive diagnosis. The surgeon must feel and hear the impact of a sound upon the calculus; and if this does not suffice to clear up the diagnosis, he must inspect the bladder through the cystoscope. Sounding for stone is sometimes a delicate and difficult minor operation, not carelessly to be undertaken. It is best done with the patient lying on a hard table. As a first step one should thoroughly wash out the bladder with boric-acid solution, and should leave a small quantity of the solution in the bladder—2 to 3 ounces in a child, 8 to 12 ounces in a man. The patient's hips should be somewhat elevated, and a slightly curved sound or stone-searcher should be introduced through the urethra, previously cocainized. It is a needless barbarity to search for stone without having given some anesthetic, besides which the anesthetic keeps the patient quiet and makes easier the surgeon's work. Usually the stone, if present, is felt lying at the bottom of the bladder, a little below the internal meatus. Sometimes an elusive stone is brought to the beak of the searcher by a finger in the rectum, elevating the bladder. Sometimes the stone, overlaid with mucus, escapes entirely the examining touch. Sometimes a suspected stone is discovered by washing the bladder with a Bigelow evacuator, when a sudden checking of the stream or "fish-bite," proclaims the presence of a stone; sometimes a stone lurks in a bladder-pouch, or diverticulum. Not infrequently, a second or third examination is necessary in order to detect the stone, but always after the first examination it is well to employ ether anesthesia. If all these methods fail and the presence of stone is still strongly suspected, one should search for it with the cystoscope.

By whatever method a stone is found, its size should be determined, either by measuring with the searcher, or, roughly, by visual cystoscopic inspection. Should all other methods fail and stone or other serious bladder lesion still be suspected, the surgeon may be justified in exploring the bladder through a suprapubic cystotomy.

In the case of thin women and in young children it is often possible to palpate a stone bimanually, with one finger in the vagina or rectum and a hand above the pubes.

The **treatment** of stone in the bladder is a subject older than history, as I have intimated, and from the earliest times even fairly rational methods of extracting calculi have obtained. Obviously, a simple and straightforward manner of opening the bladder is the old one of

passing a staff, or sound, through the urethra and cutting upon it, by the perineal route, until the bladder is opened. That was ancient practice. In more modern times the bladder was opened by the lateral perineal route, a method still employed occasionally. Another ancient practice, popularized in recent years, is suprapubic opening of the bladder, while a fourth method, in great vogue during the past thirty-five years, is to crush the stone within the bladder by instruments introduced

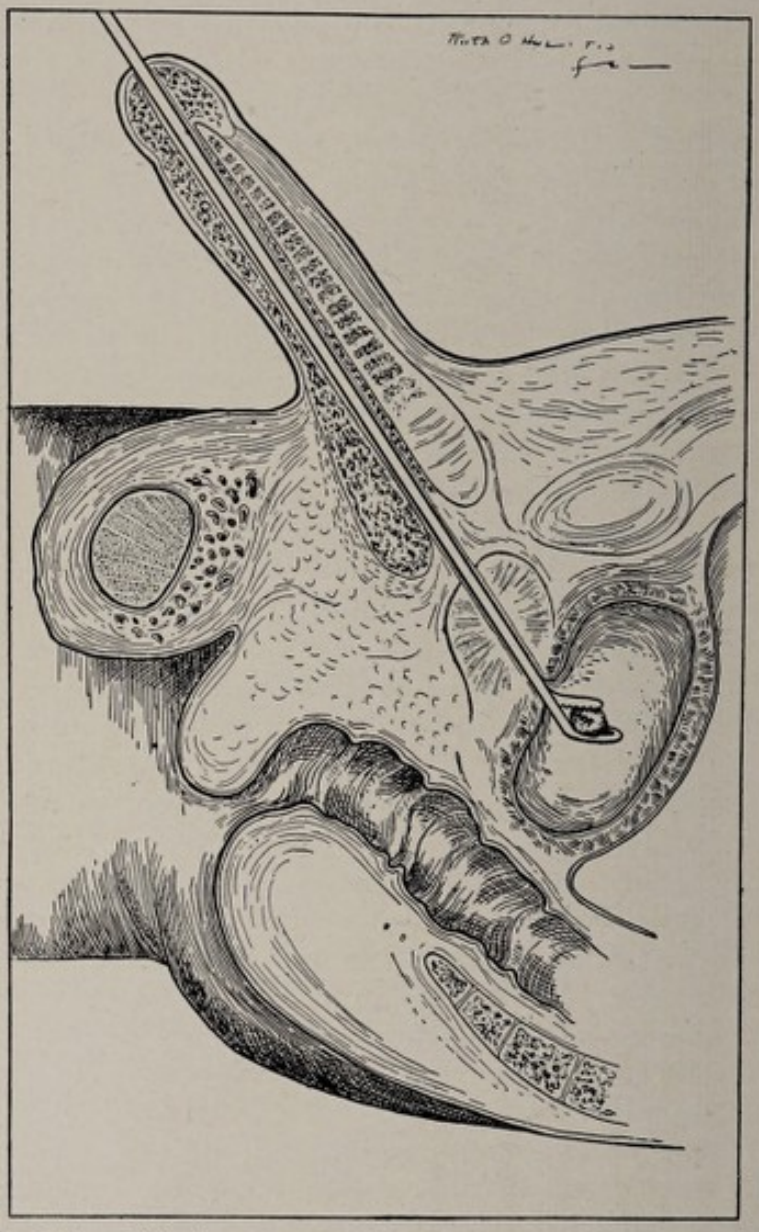

Fig. 244.—Litholapaxy; crushing the stone (diagrammatic).

through the urethra, and to wash out the fragments. This last procedure is known as litholapaxy.

Litholapaxy.—Jean Civiale, in 1824, was the first successfully to perform the operation of crushing a stone.[1] He did not wash out the fragments but left the patient to pass them. Many experimenters worked

[1] *Lithotrity:* crushing a stone. *Litholapaxy:* lithotrity followed by prompt removal of fragments of the stone through a tube, by suction.

to perfect a better technic, until Henry J. Bigelow, in the last quarter of the nineteenth century, developed the modern operation, crushing and evacuating at a single sitting—litholapaxy. For the general surgeon, and with suitable cases, litholapaxy is the operation of choice. The technic of this procedure was graphically described by Bigelow in a brilliant series of articles published in 1878 and subsequent years. The instruments required are lithotrites of various sizes, and an evacuat-

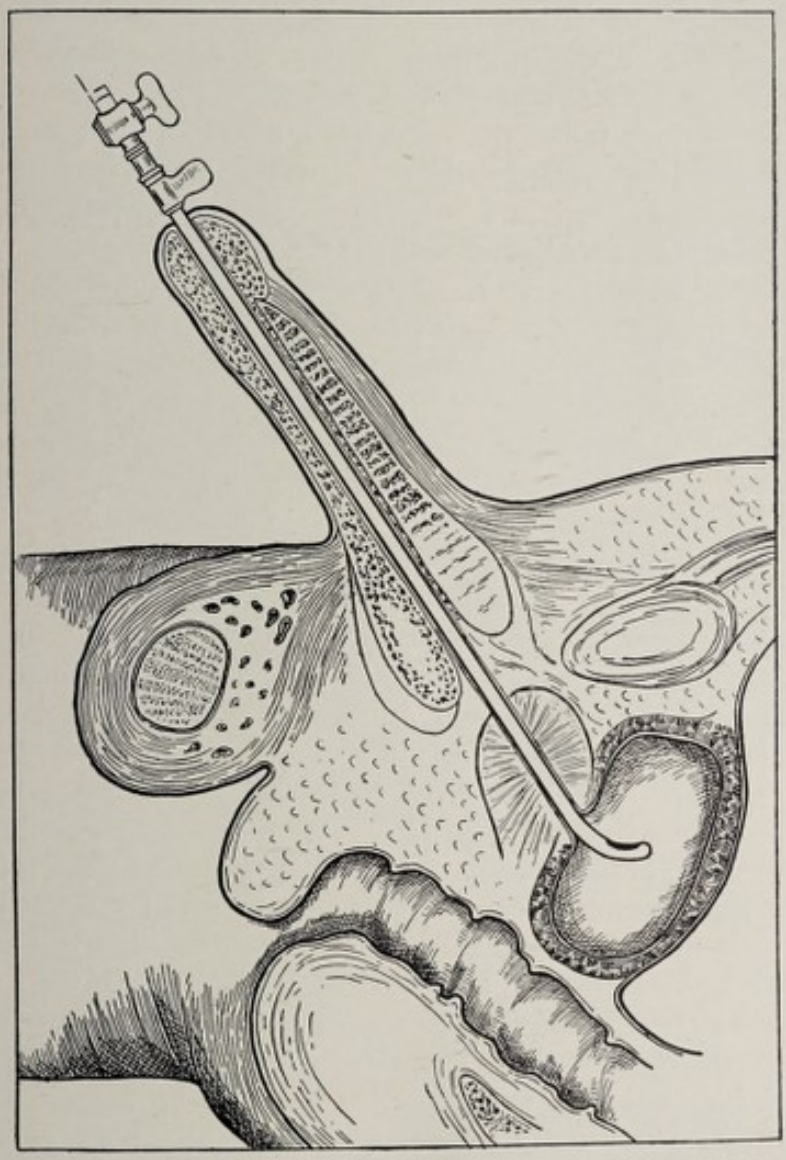

Fig. 245.—Diagram showing Bigelow's evacuator in place.

ing apparatus, such as is pictured in the text. Patients with impermeable stricture, with extremely hard calculi, with encysted stone, or with great prostatic enlargement, are not fit subjects for litholapaxy. In no case should the operation be performed hastily. The patient should be kept in bed for five or six days previously, on a limited diet, with abundant drinking of water and of milk, and any existing cystitis should be treated by urotropin and irrigation. Indeed, litholapaxy should not be undertaken in the face of an active cystitis. On the

operating table the patient should be tipped up in a modified Trendelenburg position, the urethra and bladder should be thoroughly irrigated, while 6 or 8 ounces of boric-acid solution (4 per cent.) should be left in the bladder. We are now ready for the actual crushing. The surgeon introduces a lithotrite, of the Bigelow or Forbes pattern, letting it glide gently into the urethra and passing the prostate without force. When the instrument is in the bladder, the handle should be depressed to an angle of about 30 degrees with the table, and with the beak upward, the instrument should be made to lie at the bottom of the bladder. The jaws are opened by pulling back the male blade. The surgeon waits for a moment until all currents have subsided, when the stone usually will be found to have fallen between the blades. It is then seized and crushed and the larger fragments are crushed again in turn until the whole mass has been reduced to gravel. After that the lithotrite is withdrawn, when the surgeon introduces the evacuating tube and washes out the fragments. This part of the operation must be performed carefully and thoroughly, so that no fragments be left to form the nucleus of a new stone. Throughout the operation, especially when using the lithotrite, the surgeon should make all movements carefully and gently, taking pains especially not to crush the stone until it is firmly grasped and not to pinch the bladder-wall within the jaws of the instrument.

The *after-treatment* is usually simple, and amounts to little more than keeping the patient in bed for a week, administering morphin for the early pain, and giving a light diet, with plenty of water. If retention, fever, or cystitis supervene, they must be met by such appropriate measures as catheterization, the administration of quinin and morphin, and daily irrigations of the bladder. The mortality from litholapaxy in proper cases is low, and even in children it is the best operation for routine practice.

Suprapubic cystotomy for stone is frequently employed. It is indicated in the cases of urethral stricture, of great prostatic enlargement, and of hard and multiple stones, as well as when stones are encysted and inaccessible to the lithotrite. The preparation is similar to that for litholapaxy, and the operation is facilitated by elevating the patient to 45 degrees in the Trendelenburg position, and introducing a distensible bag or colpeurynter (with which some surgeons prefer to dispense) into the rectum, in order to elevate the bladder above the pubes. From 4 to 8 ounces of boric-acid solution are then injected into the bladder to raise it further, so as to simplify the dissection and to roll back the peritoneum. Recollect that an anterior fold of the peritoneum falls over the collapsed bladder, while a full bladder pushes the peritoneum upward and out of the way. I recommend a transverse incision at the upper edge of the pubes through the skin and aponeurosis, as I have found that such an incision, when healed, gives a sense of perfect support to the abdominal wall. When the surgeon has dissected well back and separately the skin and aponeurosis, he splits the space between the pyramidales muscles and enters at once into the prevesical

space. Sometimes it is necessary to cut away from the pubes the muscle attachments. There is no excuse for blundering into the peritoneal cavity. Upon opening the prevesical space, dissect bluntly with the fingers down behind the pubic arch and distinguish the outline of the bladder; then explore it by pushing back the fat, and seize the bladder-wall with forceps or tenacula. Draw up the bladder, fix it firmly in the wound with two provisional stitches, one on either side of the median line, and held by an assistant. Then open the bladder, dissecting back the muscularis from the mucosa, and opening separately each layer. The bladder should previously have been packed off with gauze pads from the surrounding tissues. Evacuate the contained fluid, open the

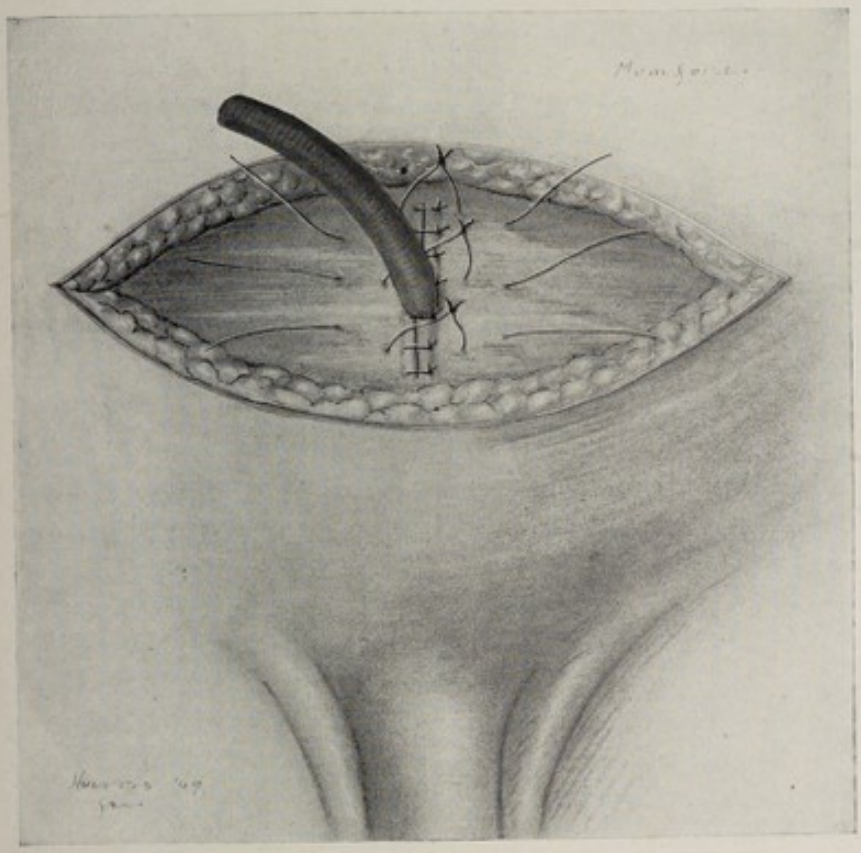

Fig. 246.—Suprapubic bladder drainage.

viscus widely with retractors, and inspect its interior by the aid of a head-mirror and reflected light. Frequently gauze sponging with mops or sweeps may be necessary. It is now an easy matter to remove calculi with stone forceps or the fingers, and to perform any further operation which may be indicated.

The *after-treatment* of the wound is somewhat in debate. I prefer to leave in a tubular rubber drain after sewing up the bladder-wall in layers with plain catgut stitches. Tight closure of the bladder is unwise, as these bladders are usually infected. I believe strongly in the use of a firmly drawn continuous stitch, and not in interrupted stitches. The stitches may penetrate the mucosa, and should be so placed in a double row as deeply to turn in the bladder-wall. The rubber tube, and a gauze wick draining the prevesical space, should be led out through a

stab-wound in the superior skin-aponeurosis flap, well away from the line of incision, thus favoring a rapid and aseptic healing of the original wound. I make a practice furthermore of tying into the bladder through the urethra a soft catheter, to insure constant drainage. If all goes well, the suprapubic gauze drain is removed at the end of three days, and the suprapubic rubber drain at the end of eight days. The resulting wound heals shortly, but the urethral drain is kept in place four or five days after the removal of the suprapubic drain.

No further after-treatment is indicated except in the case of complications, especially cystitis, which can be cared for readily by through-and-through irrigation from above.

The mortality after suprapubic cystotomy for stone is slightly higher than after litholapaxy, but I doubt if this is due to any disadvantage inherent in the operation itself. The true cause probably lies in the fact that we do the operation of litholapaxy in the simpler cases. The true disadvantage in cystotomy is the longer convalescence—three or four weeks—which it entails.

In this place it does not seem necessary to describe at length the various operations of perineal lithotomy. They are little practised to-day as compared with the operations already described. As I have stated, the principle of these perineal operations is the cutting into the bladder, either laterally or mesially, upon a staff, through the prostate. The operations in themselves are not particularly difficult, but they involve more or less groping in the dark, and the not infrequent danger of permanent damage to the ejaculatory seminal ducts. I refer the student to the text-books on operative surgery should he wish to study the methods of perineal lithotomy.

In women stone in the bladder is less common than in men, and is far more easily treated. Small stones may be removed through the urethra by dilating that passage, seizing the stone in forceps, and extracting it; or litholapaxy easily may be performed, or suprapubic cystotomy. I do not advise opening the bladder through the vagina, because that operation occasionally has been followed by a permanent vesicovaginal fistula.

In connection with the subject of cystitis and stone I must call the reader's attention to ulcer of the bladder.

ULCER OF THE BLADDER

This affection is not especially uncommon, and is seen more frequently in women than in men. There are two leading forms of ulcer, the tuberculous and that caused by erosion from long-continued irritation by stone or cystitis. There are also the small multiple erosions similar to gastric erosions in appearance.

These bladder ulcers may cause little trouble, or they may give rise to the most distressing **symptoms,** such as constant pain and tenesmus, especially after micturition. Sometimes blood is passed mingled with the urine, and there may be general constitutional disturbances.

The treatment of tuberculous ulceration is systemic and topical. I have not been able to convince myself that without general treatment local treatment is effective; but certain it is that the open-air life and improved hygiene often work remarkable cures.

The **diagnosis** of ulcer of the bladder can be confirmed by the cystoscope only, when areas, sloughing or granulating, usually bleeding, and sharply defined from the surrounding mucosa, appear. The character of the urine is not pathognomonic, but suggests a cystitis merely.

The **treatment** of bladder ulcer in addition to the general hygienic course already suggested, consists in local applications through the endoscope, and the drug commonly employed is some one of the silver salts. In the case of non-tuberculous ulceration I have often seen rapid improvement and cure by touching the base of the ulcer with a 10 per cent. silver nitrate solution, and sometimes by the pure caustic even, though the latter may cause great subsequent pain. At the same time patients should be put upon a bland diet, mainly milk and water, and should be given urotropin, 7½ grains every six hours. The same local treatment is of some value in the case of tuberculous ulcers. Furthermore, the injection of iodoform suspended in olive oil is valuable —one dram of iodoform to one ounce of pure olive oil, a dram of this mixture being left in the bladder once daily.

TUMORS OF THE BLADDER

Tumors of the bladder are among the rarer diseases of that organ, but are extremely interesting from the therapeutic as well as from the pathologic point of view. Often they cause distressing symptoms; they can be removed with difficulty only and they have a high mortality. Watson [1] states that in the case of benign tumors of the bladder even, including myxoma, the operative mortality is 17 per cent., while the operative mortality of cancer is 27 per cent., and that of sarcoma, 63 per cent.; from which it will be seen that many varieties of tumor occur in the bladder, and that it is dangerous to remove them. From the studies of Davis[2] it appears that calculus does not predispose the bladder to tumor.

All tumors of the bladder have a peculiar and interesting structure—whether benign or malignant, they tend to assume a polypoid character. This is probably due to the fact that they spring from a contractile base, constantly varying in size and position. There are the benign tumors, papillomata, single and multiple, mostly pedunculated, generally cauliflower in appearance, with a circumscribed base and little tendency to involve deeply the bladder-wall. A connective-tissue form of this growth sometimes undergoes transformation into *sarcoma*. Furthermore, there are fibrous polypi and myxomata, the former being true pedunculated fibromata and myxomata, being generally single and

[1] F. S. Watson, The Operative Treatment of Tumors of the Bladder, Ann. Surg., December, 1905.

[2] Lincoln Davis, Primary Tumors of the Urinary Bladder, ibid., April, 1906.

resembling nasal polypi. Then there are myomata, generally single, partially pedunculated, and attaining the size of a small orange even.

Of the malignant tumors, sarcoma is extremely rare, but carcinoma is more frequent; it is a common bladder tumor. Observe that carcinoma may develop out of papilloma; that primary carcinoma in its early stages resembles papilloma grossly, but that quickly it involves deeply the bladder-wall. Carcinoma is found most frequently springing from the trigonum, the prostate, or the urethral orifices, while the non-malignant forms of tumor are found anywhere upon the bladder-wall. Obviously, cancer of the bladder may be secondary, extending from cancer of the rectum and other organs, or rarely it may be metastatic. Watson's studies show that myxomata, which occur generally in young children, have a high mortality and recur quickly after operation.[1]

The **symptoms** of tumor of the bladder may be characteristic or they may be extremely confusing, and especially are they to be distinguished from the symptoms of stone, of ulcer, and of enlarged prostate. In the case of all tumors of the bladder the commonest symptoms are hemorrhage, frequency, and pain. Hemorrhage, without other symptoms, especially is to be observed. Whether the tumor be benign or malignant, it may give rise to the symptom of hemorrhage only, for many months or years—hemorrhage coming at the end of micturition often, sometimes abundant. Often extreme clotting takes place, filling the bladder, so that the patient suffers from retention of urine and tenesmus. There may result a hydronephrosis or pyonephrosis. Moreover, there is often an associated cystitis, which adds to the misery of the sufferer, but the cystitis does not occur early in the disease. And cystitis is the cause of pain, except in the case of cancer. Observe, then, that in differentiating benign from malignant tumors of the bladder we find both associated with hemorrhage, while the cystitis and pain are late in the case of benign disease, but are relatively early in the case of cancer. Indeed, in the case of cancer, pain sometimes precedes or accompanies the first appearance of blood.

In making the diagnosis of bladder tumor we have to differentiate between that condition and renal disease associated with hemorrhage, bladder-stone, tuberculosis, and prostatic enlargement. In tumor, the hemorrhage is usually constant and abundant; sometimes it is intermittent; in prostatic enlargement the frequency of micturition is increased *at night;* in stone, pain is aggravated by exercise. Analysis of the urine helps in the diagnosis of tumor, for frequently particles of the neoplasm may be discovered in the urinary sediment. Through bimanual examination the indurated base of a cancer may be detected by the finger in the rectum, though benign growths may thus rarely be demonstrated; and observe in this connection that bladder tumors are somewhat more common in men than in women. Moreover, according to sex, visual inspection with the cystoscope is facilitated, and in women

[1] The following revised classification is that of Davis:

1. Epithelial group: Papilloma. Carcinoma. Adenoma. Cysts.
2. Connective-tissue group: Sarcoma. Myxoma. Fibroma. Angioma.
3. Muscle group: Myoma.

digital touch through the urethra is made possible. Finally, in the case of tumor, as of stone, a suprapubic cystotomy may be necessary to ascertain the true condition.

A notable fact about tumors of the bladder, whether benign or malignant, is that, if not removed, eventually they kill the victim. In the case of a benign tumor, he dies of hemorrhage, or renal involvement through obstruction to the ureters, with hydronephrosis or pyonephrosis. In the case of a malignant tumor he dies a lingering death from extensive disease of the genito-urinary organs and from metastases—and, be it observed, that metastases appear late in the course of bladder cancer—sometimes not until the fourth or fifth year of the disease.

It is obvious, therefore, that energetic **treatment** is necessary, and extirpation of the growth is the only successful treatment. The field is relatively a new one. Either suprapubic cystotomy or transperitoneal cystotomy with excision of the growth is imperative in all cases. If the disease be *benign*, and, therefore, superficial, the margin of the dissection need not be wide so long as an uninvolved portion of the bladder-wall be removed with the tumor. Such an operation is not particularly dangerous, and gives a reasonable chance of permanent cure. The rent in the bladder-wall at the site of the tumor should be carefully repaired with a plain catgut suture, which will be softened and absorbed, or expelled, before it can become the nucleus of calculus. In the case of benign recurrence even a secondary operation may be followed by permanent cure.

The question of what operation to perform in the case of bladder *cancer* or *sarcoma* is not so easily answered. Should the growth be extensive and involve other organs, nothing more than curetage and cauterization is proper. By such means hemorrhage is checked for a time, and considerable relief is afforded. But in the earlier cases there is reason to hope that we may secure by excision longer immunity or a permanent cure, and with these cancers, as with all others, we should operate early. Indeed, bearing in mind the possibility of a benign bladder tumor's suffering malignant changes, the surgeon should insist always upon an early, radical operation for all bladder tumors. Hitherto, surgeons have contented themselves with resecting broadly the bladder-wall for cancer, opening from above through a liberal incision, and freeing the bladder thoroughly, so far as may be, on all sides of the growth. Sometimes it is well to provide a supplementary approach through the perineum, and I shall have a word to say on this matter when discussing cancer of the prostate. After removing the growth the bladder-wall is to be sewed up in layers, pains being taken not to damage the ureters. In this connection it is interesting to consider the important radical suggestion of Watson,[1] "that total extirpation of the bladder and of the prostate, if it be involved in the pathologic process, be done at the outset in all cases of carcinoma that have not extended beyond the limits of the above-named structures, and in which it is believed that there are no metastases; and that the same

[1] See footnote on p. 416.

measure shall be applied in all cases of *benign* growths in which recurrence has taken place after a primary operation for their removal."

Watson would provide for kidney drainage by bilateral nephrostomy, after extirpation of the bladder, as he is convinced that this is a measure less dangerous to renal structure than is implantation of the ureters in the bowel or in the skin. He asserts that the condition of the patient after nephrostomy can be made tolerable by the wearing of a proper receptacle for the collection of urine. I am not aware of any general resort to Watson's operation, but it seems probable that it offers the best chance of life for the patient should he survive the operation. Watson does not advocate bladder removal and nephrostomy at one sitting, but would perform primary nephrostomies on the first and second kidneys, with an interval of a month between, and would extirpate the bladder some weeks later. He would tie off the ureters both from above and from below.

Since 1893 the transperitoneal or intraperitoneal cystotomy of F. B. Harrington [1] has been gaining in popularity, and is now in common use, I find, in many American clinics. This approach is applicable especially in the case of tumors of the bladder's base—that is to say, for nearly 90 per cent. of all bladder tumors. The technic of this operation is simple: the abdomen is opened widely above the pubes; the intestines walled back; the bladder exposed and opened freely through the peritoneum. This opening gives an extremely wide and easy approach to bladder tumors, which may then be excised with a knife or the Paquelin cautery. The bladder is closed in three layers with interrupted catgut stitches.

I have employed with satisfaction a modification of Harrington's method; after the abdomen is opened and the bladder exposed, I have turned down a flap of peritoneum in the shape of an inverted U from the posterior surface of the bladder and have then opened the bladder-wall through a longitudinal incision beneath the flap of peritoneum. As a result of this maneuver the bladder wound, when sewed up, becomes an extraperitoneal wound.

In broad terms, it appears that the methods of treatment are still *sub judice*, and Davis' interesting conclusions are worth quoting:

"Surgical intervention at the proper time in the case of pedunculated papillary tumors of the bladder offers a very fair chance of long immunity, if not of permanent cure.

"The method of surgical intervention to be proposed in these cases is excision of the tumor *in toto*, with a margin of bladder-wall at its base, including mucosa, submucosa, and muscularis in part: the section need not penetrate the entire thickness of the wall."

SACCULATION OF THE BLADDER

Sacculations of the bladder are coming to be regarded as something more than surgical curiosities, or conditions suited to palliative treatment merely. Bladder sacculations are quite similar in structure to the

[1] Charles L. Scudder and Lincoln Davis, Harrington's Operation of Intraperitoneal Cystotomy, Ann. Surg., December, 1908.

diverticula found in the colon. They are either true sacculations of the whole thickness of the bladder-wall, or, more commonly, they are herniæ of the mucosa. If the sacculations are large and saucer-shaped, they give little trouble. Often, however, they are almost polypoid in shape—their lumina being of considerable size, while the entrance from the bladder into the sacculations is small.

The **symptoms** of sacculation are often extremely distressing. In it there becomes established chronic inflammation with constant pus-formation, which is persistently forced out into the bladder. Cystitis results; stones may be lodged or may form in the sacculation, and so add to the patient's misery. In general terms, therefore, the symptoms of sacculation of the bladder are the symptoms of a severe chronic cystitis. By the use of the cystoscope alone can the sacculation be discovered and the *diagnosis* established.

The **treatment** is difficult and unsatisfactory often. The only sure method is radical and severe—excision of the sacculation. Approach the bladder by the transperitoneal route; turn down a flap of peritoneum; dissect the bladder free from surrounding structures, especially toward its base; develop the sacculation; excise it; repair the rent with catgut stitches; sew up the peritoneal flap, with a drainage wick led out from beneath the flap to and through the *external* wound. Institute constant drainage by a catheter in the urethra. If the patient is not too much exhausted by long disease, this operation should restore him to health in from three to four weeks.

Besides the bladder lesions already described, the surgeon must be prepared vigorously to treat cases of injuries.

BLADDER INJURIES

Injuries to the bladder are conditions extremely familiar to every large general hospital. These injuries may be intraperitoneal or extraperitoneal, and the **intraperitoneal injuries** are three times the commoner.[1] Up to twenty-five years ago, intraperitoneal ruptures were held to be fatal, and it is within recent times only that we have been able to meet and remedy successfully this alarming lesion.

The condition involves rupture of all the coats of the bladder and of the peritoneum, with the escape of urine and blood into the peritoneal cavity, and the *symptoms* are extremely variable. There may be profound shock from the outset, or there may be little disturbance at first. In the course of a short time, however, evidence of shock appears—rapid pulse, collapse, pallor, and cold extremities. There is nearly always an associated hemorrhage, and shortly a general peritonitis. Peritonitis and shock are the common causes of death, while death from hemorrhage is rare. Operative *treatment* for intraperitoneal rupture is imperative and should be instant. The surgeon opens the abdomen in the median line, tips the patient into the Trendelenburg position, packs back the

[1] See important essay on this subject by Daniel Fiske Jones, Intraperitoneal Rupture of the Bladder, Ann. Surg., February, 1903.

intestines, finds the rent in the bladder, and sews it up. That placing of the sutures is important. Fine catgut is the best material, and a continuous suture here is superior to the interrupted suture, the catgut being so buried in the bladder-wall as to obviate the probability of stone formation. There should be three rows of stitches—the first to include the mucosa, submucosa, and muscularis, the second and third to repair the peritoneal rent and to turn in the line of incision. The abdominal wound should be closed with gauze drainage (stab-wound), and an inlying catheter should be left in the urethra. If symptoms of peritonitis exist or appear later, I institute the method of rectal injections described in Chapter VIII (proctoclysis).

Extraperitoneal rupture of the bladder is found in the region of the bladder base, and is due commonly to a direct crushing force which often fractures the pelvis and urethra. These injuries are dangerous also, but less fatal than the intraperitoneal ruptures. The shock is less profound, though hemorrhage may be considerable, while peritonitis is improbable. Blood finds its way behind the peritoneum, both upward and backward, distending with hematoma the perineum and the abdominal wall. If untreated, this blood deposit, mingled with urine, becomes septic, and extensive abscesses ensue. In such a case recently, when in doubt as to the exact site of the rupture, I opened into a great bloody cloaca near the navel, and not until I had cleared this out and found the source of bleeding was I able to determine that the peritoneal cavity was uninvolved. As a rule, therefore, these subcutaneous collections of blood indicate extraperitoneal rupture, intraperitoneal rupture affording exit for blood and urine directly into the peritoneal cavity.

In making the *diagnosis* of ruptured bladder a most valuable aid, and one resorted to as a routine, is catheterization. If rupture exists, especially if an hour or more has passed since the patient urinated, the catheter will draw nothing but a little pure blood, showing that the contents of the bladder have escaped inward. *Bloody urine* in any considerable amount suggests an injury to the *kidneys*, or possibly a mere contusion of the bladder, while *clear urine* proves the urinary apparatus to be undamaged.

The *treatment* of extraperitoneal rupture of the bladder may be simple or may be intricate. Catheter drainage by the urethra should be instituted, hematomata should be opened and explored, hemorrhage should be checked, and, if possible, the bladder rent should be repaired. But such primary repair rarely is possible. Generally, one can do no more at the first than evacuate the bloody collections and drain permanently the bladder, waiting for nature to act either in establishing a cure or in forming a urinary fistula, which later must be treated by excision and suture. At the same time damaged pelvic bones must be held firmly in place with a plaster swathe.

Gunshot wound is a rare injury to the bladder. When the peritoneal cavity is opened by a bullet, there result symptoms similar to those already described as due to ruptured bladder, and median abdomi-

nal section is necessary. If the wound be extraperitoneal, the condition is not so grave, especially since the track of the bullet affords some degree of drainage for the urine. Otherwise the *treatment* is much the same as in the case of rupture of the bladder.

Foreign bodies in the bladder are strangely frequent, and are found in women especially. The significance of foreign bodies in the bladder is that they act as calculi, and generally become nuclei for stone formation. Sexual perverts find strange instruments to use in assaulting their own bladders. Sometimes women introduce foreign bodies into their bladders when attempting to produce abortion, for the large female urethra gives a ready access to the bladder. Hospital museums show curious collections of these foreign bodies removed from the bladders of both sexes—hat-pins, hair-pins, shoe-strings, coins, thimbles, wire-nails, and so on in great variety. They may be removed with forceps and endoscope, by litholapaxy, or by suprapubic cystotomy.

Thus it will be seen that the bladder is an organ subject to a variety of diseases, intimately associated in its disease processes with the kidney and ureter, and fairly accessible to instrumentation. It will now be interesting to study the common diseases of that important appendage to the bladder—

THE PROSTATE

General interest in the surgery of the prostate is in marked contrast with interest in bladder surgery, if one may judge from a perusal of current literature. I find in my files of the last four years 48 essays on prostatic surgery as compared with 6 essays on bladder surgery. But, doubtless, with the settlement of debated questions, such a discrepancy will disappear. Although surgeons for many years have done some little work on prostatic disease, it is within the past ten or twelve years only that reasonably safe and sure relief for prostatic enlargement has been found through the development of an ingenious and rational operative technic.[1] The *hypertrophied prostate* especially has exercised surgeons, but there are other prostatic lesions of great, though minor, interest, and as a preliminary to a brief study of prostatic disease let us, in a few words, consider the anatomy of the prostate.

ANATOMY OF THE PROSTATE

Observe that the prostate gland lies entirely outside of the bladder and that it envelops the urethra. It does not lie below the urethra, as many students think. The urethra passes through the prostate. The prostate develops in the same manner as do other acinous glands, and grows laterally as well as in the median line. So we find formed two main lateral lobes, between which the urethra passes. The lobes are connected in front of the urethra by the anterior commissure, and beneath the urethra by the posterior commissure. The lower portion of the anterior commissure has been commonly and improperly associated

[1] F. S. Watson, The Operative Treatment of the Hypertrophied Prostate, Ann. Surg., June, 1904.

with the term, "middle lobe." The glandular tissue is interwoven with muscle tissue, the muscle tissue being arranged specially about the neck of the bladder, forming an internal and external sphincter, while the 20 or 30 glandular lobules are held together by stout bands of interwoven fibrous tissue and muscle-fibers, which make up the capsule also. Thus we have entering into the structure of the prostate three distinct types of tissue,—glandular, fibrous, and muscle,—and as a result we shall find, as we should expect, that these three types enter characteristically into the various forms of prostatic disease. Moreover, there are certain ducts, crypts, and other structures associated with the prostate. The ejaculatory ducts pass through it, and it contains its own prostatic ducts, as well as the urethral canal. The gland is compared in size and shape with an Italian chestnut, its base lying against the bladder and rectum, its apex pointing forward under the pubes. If you split open the prostate from above down into the urethra, you expose certain delicate and interesting structures on the floor of the urethra—the prostatic sinuses or gutters on either side of the verumontanum, and the sinus pocularis or blind canal, tunneling beneath the verumontanum; while upon or within its margins are the slit-like openings of the ejaculatory ducts. Though the prostate lies entirely behind the triangular ligament, its strongest attachments are to the posterior surface of that ligament, and it is quite firmly bound to the rectum also. The prostate is adherent to the deeper parts of the prostatic urethra, behind the verumontanum, and this fact explains the difficulty of removing the whole prostate without removing a considerable portion of the prostatic urethra. Furthermore, the whole gland is enveloped in a stout capsule, which is smooth over the lateral lobes, but is intimately connected with the gland in the median line, about the numerous vessels which are located there. The seminal vesicles lie entirely behind the prostate on the bladder-wall. Their ducts enter the prostate from below and pass through it together, close to the median line, until they empty into the urethra. On this anatomic fact Young [1] has founded his proposition of removing prostatic lobes through *lateral* incisions into the gland, so as to avoid injuring the vessels and the ejaculatory ducts.

So much for the anatomy of this organ, which has been abundantly studied and copiously illustrated by recent writers.

We may conveniently group diseases of the prostate under the headings *inflammations*, *hypertrophy*, and *tumors*, though it may be proper to regard hypertrophies as either inflammations or tumors.

INFLAMMATIONS OF THE PROSTATE

Inflammations of the prostate are acute and chronic, but we usually mean acute inflammation when we speak of prostatic inflammation. *Acute* inflammation of the prostate assumes the forms common to all glandular inflammations. Ordinarily in acute prostatitis there is an invasion by organisms of the ducts from without—from the urethra.

[1] Hugh H. Young, Jour. Amer. Med. Assoc., October 24, 1903.

Swelling, desquamation, necrosis, and suppuration supervene, the usual attendant efforts of nature to arrest the invasion. The gonococcus and other pus-producing cocci are the ordinary invading organisms, while rarely the organisms of tuberculosis and syphilis may be implanted here. The patient experiences a sense of weight, heat, and pain in the perineum. Often there are frequency of micturition and tenesmus from involvement of the bladder. There may be great prostration and a general constitutional disturbance. Frequently the onset of the attack comes with a chill. The abscess may open into the urethra, rectum, or bladder, or into the peritoneal cavity even, through burrowing upward. Either the parenchyma of the prostate or the muscular tissue or both may be involved. Sometimes there is urinary obstruction, and in extreme cases the process may go on to destruction of neighboring

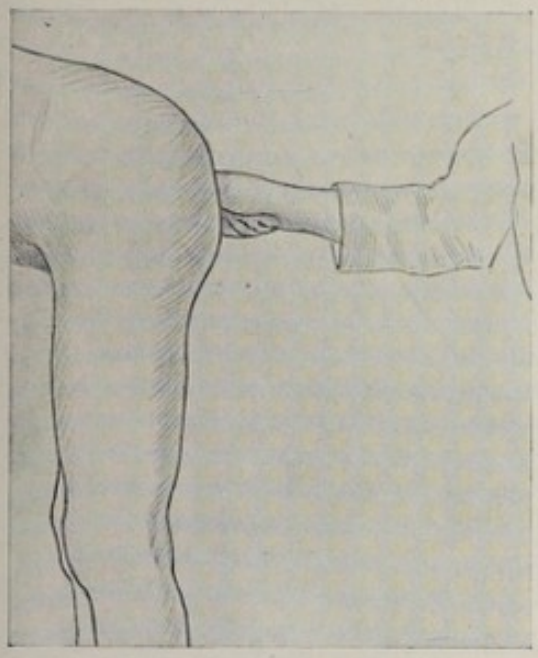

Fig. 247.—Massaging the prostate. Sketch showing position of hand and forearm.

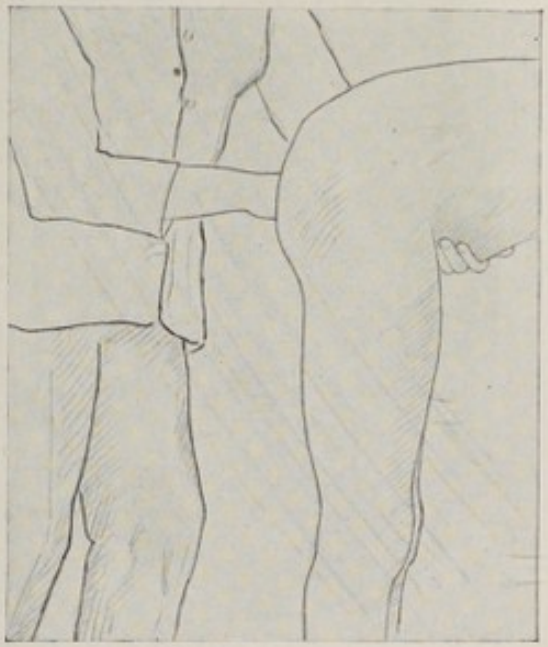

Fig. 248.—Sketch showing relative position of surgeon and patient.

parts through gangrene, to peritonitis, phlebitis, thrombosis, and pyemia. Occasionally *acute* symptoms gradually may subside, leaving behind a *chronic* process which is marked by a general thickening and enlargement of the prostate, associated with a cord-like thickening of the vesicles and ducts, and in some cases by a well-defined abscess. The most important symptom of *chronic* prostatitis is a discharge from the urethra of a milky fluid, in greater or less quantity, especially after defecation, followed by pain in the course of the urethra.

The reader will probably conclude that the **treatment** of prostatitis varies with varying forms of the disease. In *acute* prostatitis one enjoins absolute rest, thorough evacuation of the bowels, urotropin, and the application of either heat or cold to the perineum and hypogastrium. Sometimes constant cold rectal irrigations are a great comfort. If an abscess develops, it must be opened, preferably through the perineum

or urethra. If the prostatitis is gonorrheal, local urethral treatment must be abandoned temporarily or until the prostatic complication subsides. Burrowing pus and complicating infections must be treated by appropriate dissections. *Chronic* prostatitis is a difficult subject for treatment. It yields slowly, if at all, though sundry well-recognized remedies should be used and may be helpful. If gonorrhea or stricture is present, it must be cured, because it may be keeping up the prostatic irritation. Cold applications by rectal irrigation are comforting. Iodin in some form is valuable, and may be applied by inunction to the perineum, or, mixed with an ointment, it may be passed on a sound into the deep urethra. Most important of all, prostatic massage is extremely helpful. The seminal vesicles frequently are involved with the prostate, and massage of all these organs, by the finger in the rectum, should be practised for a time, at intervals of every third day. Frequently it is surprising to feel the induration subside under the finger, while the patient will return after the first or second treatment with the statement that he is greatly relieved. Certain enthusiasts have claimed great benefit from opening the vesicles and prostate through the rectum or through the perineum, but the experience of others suggests that this is a difficult remedy, and may be dangerous. The value of prostatectomy for chronic prostatitis is still *sub judice*. Patients afflicted with inflammatory prostatic troubles are apt to become wretched "neurasthenics," as the phrase is, and their general health should be looked to carefully, with tonics, mineral baths, and sanatorium treatment.

Tuberculous prostatitis usually is secondary, almost never primary, and its treatment should be symptomatic, as a rule—an out-of-doors life. If an abscess has formed, it may be opened, and the prostate curetted or enucleated through a perineal incision without opening the rectum. Unfortunately, these cases, as a rule, go on to a general tuberculosis.

PROSTATIC CALCULI

Prostatic calculi deserve mention, though they are relatively rare and may well be confounded with bladder calculi. They are generally phosphatic, and may be multiple, collecting in the prostatic sinuses. The *symptoms* simulate closely those of stone in the bladder, and the positive diagnosis often is difficult. Prostatic stones may be detected protruding into the urethra, by the examining finger in the rectum, while a sound in the urethra supports the prostate. Those calculi which protrude into the urethra may be picked out with long urethral forceps, while the larger and more deeply placed stones can be extracted by perineal section. These prostatic calculi, like gall-stones, are to be regarded as of inflammatory origin, their nuclei being generally the desquamated cells resulting from some previous infection.

By far the most interesting disease of the prostate, however, and one which many are coming to believe represents in an extreme degree the results of long-standing inflammation, is hypertrophy of the prostate.

HYPERTROPHY OF THE PROSTATE

Benign enlargement of the prostate is commonly called *hypertrophy of the prostate*. About this disease debate still centers. What is its cause? How shall it be treated? Briefly, let us consider these questions, as well as the questions of symptoms and diagnosis.

Statistics seem to show that 30 per cent. of men over fifty have some degree of enlargement of the prostate. Fortunately, as in the case of gall-stone victims, the lesion produces serious symptoms in a relatively small proportion of persons. It is rare to hear of prostatic disturbances in a man under forty-five, and it is still rarer that the initial symptoms of enlarged prostate appear after seventy. There is excellent reason for believing, however, that frequently the prostatic disease begins much earlier than the forty-fifth year. The question of **etiology** has given rise to an interesting discussion, as yet unsettled, but the studies of Finger, Ciechanowski, Crandon,[1] and others are so thorough, and their findings so convincing, that I believe we are justified in concluding a majority of these enlarged prostates to be of inflammatory origin. Crandon draws the following conclusions:

" (1) The underlying cause of the usual form of prostatic enlargement and of certain forms of prostatic atrophy is a slow formation of new connective tissue, due to infection or to infection aggravating a senile degenerative process.

" (2) The gonococcus is probably most often the specific infection(?) because—(*a*) of its great frequency; (*b*) other inflammatory causes are not common in the parts in question; (*c*) a great similarity exists between the histology of gonorrheal processes and those seen in these senile prostates.

" (3) Neoplasms, fibromyomata, and adenoma occur, but may be called rare."

Numerous other writers, from Morgagni and John Hunter down to those of our own time, have held varying views of the etiology, asserting that these enlargements are due to inflammations, to new-growths, to some relation between the testes and the prostate, to a general hypertrophy of prostatic connective tissue, etc.; but it now seems probable, as I have already stated, that a chronic inflammation of the glandular elements is the most important element in the etiology of prostatic hypertrophy. Doubtless, myomata and other new-growths occasionally play a part, while Young finds that prostatic cancer is found in about 14 per cent. of those persons who come under surgical treatment for prostatic enlargements.

The size and the shape of enlarged prostates vary, though the largest prostate is not likely to be more than four or five ounces in weight. The enlarged prostate may be spongy, or may increase in consistency up to a hard fibrous resistance, and there may be variation also of consistency in different parts of the gland. One lateral lobe only may be en-

[1] L. R. G. Crandon, The Pathogenesis and Pathologic Anatomy of Enlarged Prostate, Ann. Surg., December, 1902. For an interesting résumé of opposing views see article by Paul M. Pilcher, Ann. Surg., 1905.

larged, or there may occur the formation of a middle lobe. This last is an interesting condition. Formerly it was held that the middle lobe arises from the posterior portion of the isthmus, but later and more careful observations demonstrate that the polypoid middle lobe has nothing to do with the isthmus. The middle lobe develops from a few, isolated, prostatic acini, which lie between the vesical mucosa and the internal urethral sphincter. The middle lobe alone may be enlarged or it may be associated with enlargement of the other lobes. The most common form of enlargement is the bilateral form, and after that a uniform enlargement of the whole gland, including the middle lobe.

The student will observe, therefore, that enlargement of the prostate may or may not give rise to distortion or obstruction of the urethra,

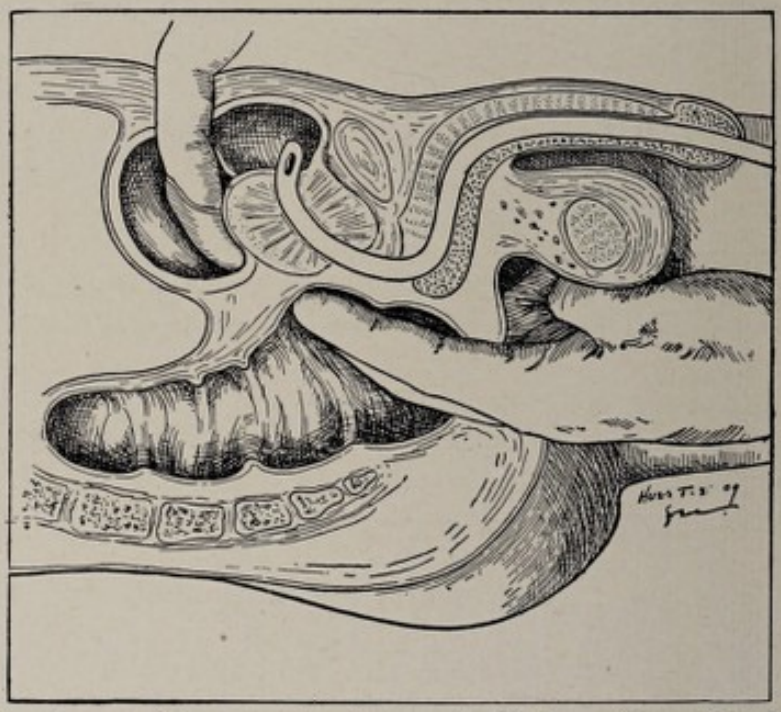

Fig. 249.—Suprapubic prostatectomy. Sagittal section of pelvis, showing finger enucleating the prostate from its sheath as counterpressure is made by the other hand in the rectum Shows also tortuous course of urethra through enlarged prostate.

according as the forms of the enlargement vary. An overdevelopment of one lobe will push the urethra to one side; an overdevelopment of both lobes will elongate the prostatic urethra. An upward protrusion of the prostate into the bladder will elevate and throw forward the internal urethral orifice, or there may result an actual bar formation at the neck of the bladder. The reader will observe also that the enlarged prostate may project as a whole beneath the bladder mucosa, rendering the tumor easily accessible from above; or the growth may project toward the rectum only, rendering the mass easily accessible from below. All these variations in size and shape may puzzle the student, but he should study the formations on the cadaver and in plates.

The *symptoms* of enlarged prostate should be obvious to the reader who is familiar with diseases of the bladder, for the prostate, when en-

larged, becomes essentially a tumor of the bladder-wall, while necessarily it involves the urethra at the same time. Therefore, the first and most characteristic symptom of enlarged prostate is *frequency* of micturition; and note this characteristic fact, that the frequency is most pronounced at night, and is due to a congestion of the bladder and prostate. Next the patient notices *difficulty* in passing water, so that the act is accomplished with straining and more or less pain. The difficulty increases with time, until the flow comes drop by drop. This difficulty is due to the tortuous course into which the urethra has been forced by the enlarging prostate, and to the consequent elevation of the internal

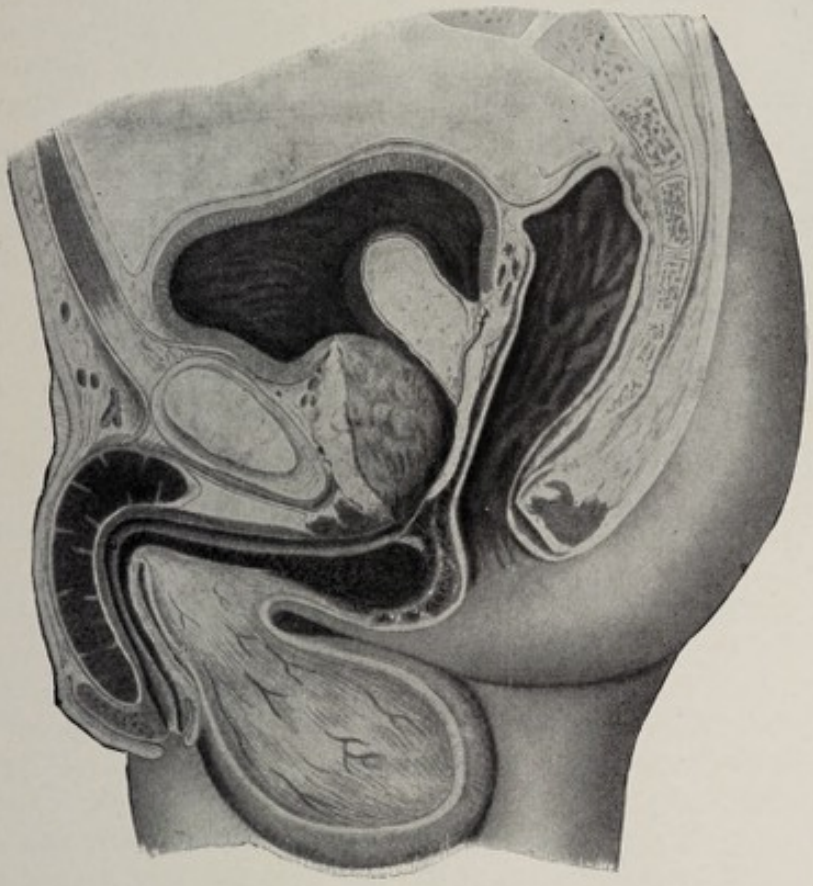

Fig. 250.—General prostatic enlargement with the formation of a median overgrowth and posterior pocket or sac. Illustrating how residual urine may be retained, as well as the difficulties of all kinds of instrumentation (Socin and Burckhardt)

meatus toward the front of the bladder-wall, where a valve-like opening is formed, which excessive straining closes. As the enlarged prostate encroaches upon the urethra within it, it throws the lower posterior part of the bladder into a cup-like fold, depressed beneath and behind the internal meatus. As a result, urine which cannot be evacuated collects in this pocket—so-called "residual urine," that which remains after the patient has evacuated all that he can (Fig. 250). With such conditions present one may easily picture the complications and results of prostatic enlargement. An underlying gonorrhea, exposure to cold and wet, some slight injury, or some intercurrent illness may be the

immediate cause of an acute infection, when there follow increased swelling of the gland, invasion of the bladder by septic organisms, cystitis with decomposition of the residual urine, increased frequency, pain, and further wretchedness.

The progress of prostatic hypertrophy so called is by no means uniform. A majority of the victims of prostatic hypertrophy live for many years with but slight difficulty. Their troubles are not constant, for their attacks come and go with varying frequency. Generally, they can be kept comfortable with care in the diet, regulation of the bowels, and a more or less quiet life. On the other hand, certain cases progress rapidly to complications. The prostate enlarges, the obstruction becomes more pronounced, inflammation is quite constant, residual urine increases in amount, the bladder becomes chronically inflamed, thickened, and sacculated, and finally the infection extends to the ureters and kidneys, so that the patient succumbs eventually to a pronounced general infection. Many of the patients are sufferers from arteriosclerosis and heart complications; their condition is anything but favorable, either for prolonged life or for operation.

One cannot lay down definite rules of **treatment**; each case must be handled on its own merits; for some, an early operation may seem best; for others, palliative treatment, in the hope that an operation may be avoided. Palliative treatment is extremely serviceable, and consists in the proper use of the catheter. The surgeon, so soon as he is convinced that "frequency" exists and that it is associated with more or less pain, should pass a soft catheter into the bladder and determine whether or not there be residual urine present. Usually, he will find it there, and if so, he should instruct the patient to empty the bladder with the catheter frequently enough to secure comfort. Some patients require catheterization but once a day, preferably in the evening. Others should catheterize themselves twice a day, others more often; but I doubt if it is wise ever to encourage a patient to use a catheter more than five or six times in the twenty-four hours.

The type of catheter to be used is all important. If the disease be not pronounced, if the prostate be small, and the passage fairly patent, the patient may use a No. 10 or 12 English soft-rubber catheter, which will easily enter the bladder. My preference is to limit patients to this type of catheter. I never feel safe in allowing them the use of stiff or sharply curved instruments, so that I have formulated this rule: if the patient can pass comfortably and safely a soft-rubber catheter, I allow him to do so, but no more than four times in the twenty-four hours. If more frequent catheterization is necessary, I take the matter out of the patient's hands and catheterize him myself, or advise a radical operation. The question of what catheter the surgeon himself shall use to enter the patient's bladder has provoked needless discussion: if I cannot pass the soft-rubber catheter, then my preference is for the gum-elastic English web, No. 10 or 12, armed with a stilet. When this is properly curved in an S shape, it may generally be passed into the bladder without difficulty. Hey's old maneuver of

passing it as far as possible, and then withdrawing the stilet about an inch so as to allow the beak of the catheter to jump forward and upward, is extremely useful still. There are the familiar instruments with curved angles, those of Mercier, of LeRoy, and of Guthrie. In an emergency, if the patient's bladder is full, if the catheter cannot be passed, and if relief must be secured at once, the bladder may be aspirated above the pubes—an easy operation and painless if a little 2 per cent. cocain has been injected under the skin previously.

In the use of catheters absolute cleanliness must be secured, and the utmost gentleness must be employed. In these patients the prostatic urethra is twisted and occasionally sacculated, so that any considerable force may cause the beak of the catheter to pass into the prostate gland itself. False passages thus are formed, which become infected, and the misery of the patient shortly becomes extreme.

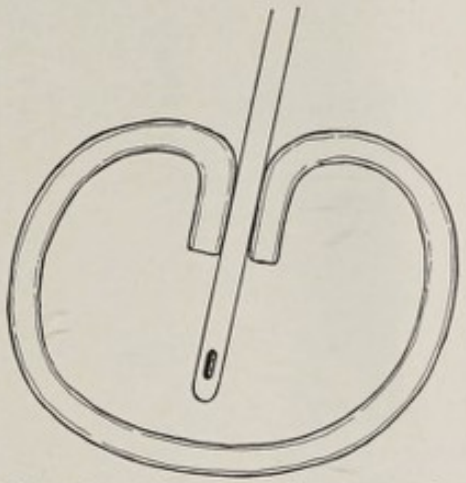

Fig. 251.—Diagram showing catheter placed for bladder drainage.

If catheterization is impossible, if aspiration above the pubes alone remains, and if operation is contraindicated by the poor general condition of the patient, constant drainage above the pubes may be secured by leaving the cannula of the aspirator in place. After a few days the cannula may be withdrawn and a small catheter inserted. This drainage, which has been established with little or no shock to the patient, acts kindly upon an inflamed prostate, relieving it of pressure, subduing congestion, and frequently bringing about the state of affairs which permits of the subsequent passage of a catheter by the natural route. If the patient's strength remains good, but the reëstablishment of urethral drainage is impossible, and a radical operation is too dangerous, it may seem well to the surgeon to establish permanently suprapubic drainage. This can be done with slight shock to the patient, and is a relatively easy operation. (It is accomplished essentially by the method I described when speaking of stone in the bladder—by suprapubic cystotomy or, in this case, cystostomy.) The bladder is brought up into the external wound, its wall is opened, and the catheter is inserted by the Witzel method or by that of Gibson. The catheter may be worn permanently, or may be withdrawn after ten days and the resulting sinus may be utilized for the passage of urine. A fairly competent stoma frequently results, so that the patient can retain a considerable amount of urine in the bladder, and then, by straining or pressing above the pubes, can empty the bladder without a catheter. The reader should not be confused, however, or led to suppose that this is a common outcome of the catheter life. Permanent drainage by suprapubic cystostomy rarely is necessary.

Let us now briefly consider methods of dealing directly with the gland itself—removing it or tunneling a proper passage through it. The prostate may be drilled through by the instrument of Bottini, or may be removed entire, either from above (suprapubic prostatectomy) or from below (perineal prostatectomy). That operation of Bottini is interesting; first developed by him in 1874, its technic has been greatly improved, especially by the author himself and by Freudenberg and Young, until the best modern instruments have assumed a form of efficiency which renders them accurate and effective. General anesthesia is not necessary for their use. The operation is frequently performed with the employment of cocain anesthesia only. Persons unfamiliar with the Bottini operation have claimed that it is blind, unsurgical, and dangerous; but the elaborate statistics of Watson and others show that the Bottini operation, in proper hands, is effective, and carries with it a low mortality. In a word, the instrument is a galvanocautery which burns deep grooves in the projecting prostatic lobes, and opens a free passage for the urine. Before employing this instrument it is imperative that the surgeon inspect the prostate and the bladder with the cystoscope. Without such visual inspection one cannot determine the relations of the enlarged prostatic lobes to each other and to the urethra, but, instructed by the cystoscopic inspection, the surgeon should be able accurately and deftly to burn the required tunnel. Young's improved instrument generally is used in this country. Its advantage is that it has a variety of blades enabling the surgeon to enlarge the opening required to any desired extent. Disinfect the urine with urotropin and one or two vesical irrigations. No other subsequent treatment is necessary. These patients have been allowed to go about after forty-eight hours even, but such radical haste is not to be commended. The patients generally are persons of advanced years, with an enfeebled cardiovascular system, and should be kept quiet in a chair, at the least, until the immediate ill-effects of the operation have subsided. Enjoin hot sitz-baths, a milk diet, diuretics, rest, and fresh air. In spite of the advantages of Bottini's operation, I cannot agree with those writers who assert that it is always the operation of choice. On the contrary, I believe that it is often the operation of last resort, and is to be employed in those cases only which cannot be submitted to the more radical operation of prostatectomy. In general terms, then, the surgeon should reserve the Bottini operation for those patients who are so enfeebled that one dare not inflict upon them a prostatectomy. The immediate results of the Bottini operation generally are good, but the end-results are not always satisfactory, for recurrence of the urethral obstruction not infrequently follows after an interval of one or two years.

Complete prostatectomy or *radical prostatectomy* is a subject which agitates operators to-day, and it has done so for the past ten years. Vigorous exponents of the suprapubic and of the perineal routes are still in conflict. It is not reasonable that such conflicts should continue. Any surgeon familiar with both operations will admit that each has its place.

Those enlarged prostates which encroach little upon the rectum and perineum, but project far into the interior of the bladder, are more easily attacked from above by the average operator, so that for those cases I advocate the suprapubic operation except for the expert. It can be done readily, satisfactorily, and effectively, and the results are almost always good. On the other hand, those prostates which encroach upon the rectum and lie almost entirely in front of the bladder are properly and easily to be removed by the perineal route. The statistics of both operations vary, and the weight of evidence seems to show that the suprapubic operation is somewhat the more dangerous, having a



Fig. 252.—Diagrammatic drawing, showing above, a flap of mucous membrane left by shelling out a prominent third lobe, and below, a remnant of the urethral mucous membrane extending back into the cavity from which the prostate has been removed—either of which would tend to form a valvular closure of the urethra (Cabot).

rather higher operative mortality rate. One questions whether this may not be because surgeons have failed to choose their method judiciously, but have employed the suprapubic route for cases which should have been operated upon by the perineal route.

Suprapubic prostatectomy is an easy operation, as a rule. The bladder should be filled with 4 to 6 ounces of boric-acid solution; the patient should be placed in a modified Trendelenburg position, and the surgeon should approach the bladder through a transverse, longitudinal or crescentic incision above the pubes. Then, having seized the walls of the bladder, he should open it by dissecting, when, with a finger in the rectum elevating the prostate,[1] that gland is brought immediately

[1] Some surgeons regard this elevation as unnecessary.

into touch with a finger entering the bladder from above. The surgeon then incises the mucosa over the tumor. It is now an easy matter to shell out the enlarged gland, which brings with it, usually, a portion of the prostatic urethra. Much has been said on the question of removing the prostatic urethra, but the best evidence shows that it is impossible to perform suprapubic prostatectomy without damaging the urethra. The after-history of these cases is so good, however, that many surgeons have come to feel such damage to the urethra to be by no means permanent—indeed, to be negligible. The advantages of suprapubic enucleation are that the operation is done through a wide incision, that the danger to the rectum and membranous urethra is

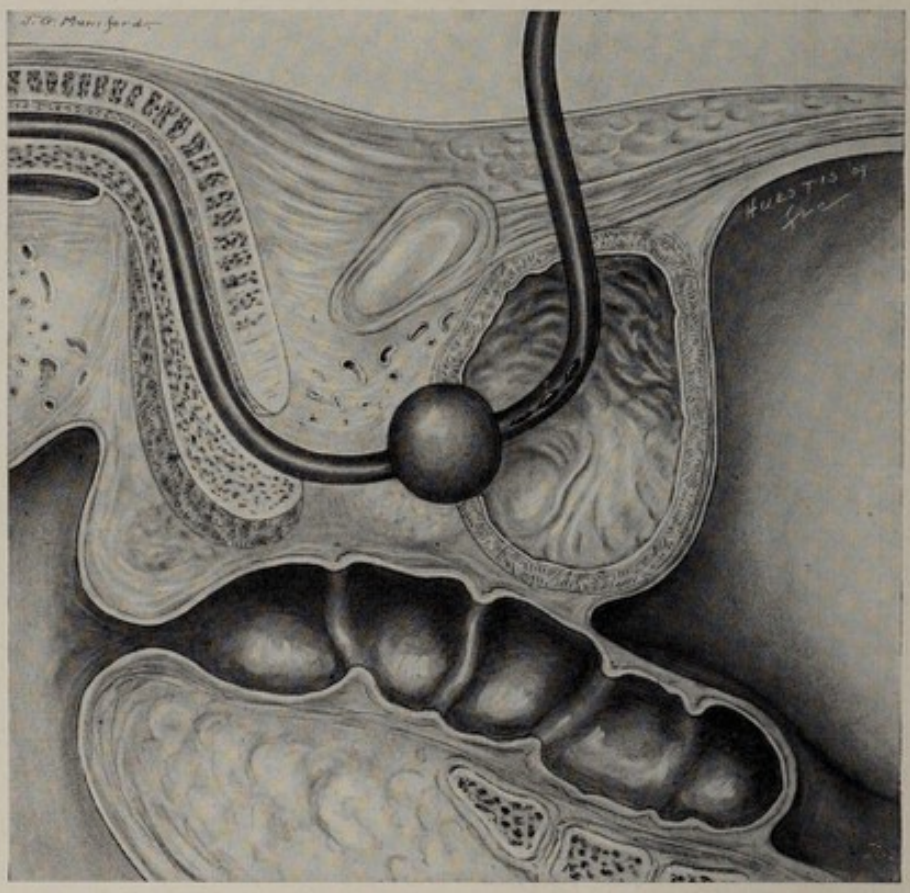

Fig. 253.—Hemostatic bulb and tube in place (J. E. Briggs).

slight, and that the whole maneuver can be performed quickly. Hemorrhage generally is inconsiderable. If the hemorrhage does not cease shortly with copious irrigation, one may well employ the hemostatic tube or bulb devised by J. E. Briggs, and shown in the accompanying cuts.[1] After the removal of the prostate, thorough drainage should be established and continued for at least ten days. My custom is to place an inlying catheter in the urethra, and to sew a drainage catheter into the bladder from above. I prefer to bring out the suprapubic drainage through the middle of the superior skin-flap, leading out with it at the same time a gauze wick which shall drain the prevesical space. The wick should be removed after four days, but the drainage catheter

[1] J. Emmons Briggs, New England Med. Gaz., April, 1906.

should be left for several days longer. Many surgeons place no stitches, or but one or two in the bladder-wall, pack the bladder, and allow the extensive wound to heal by granulation. Such practice has proved itself to be efficient, safe, and reasonable.

Frequently in the case of feeble old men I have established preliminary drainage of the bladder through suprapubic cystostomy. At the end of a week, or ten days often, it is observed that the patient's general condition has improved greatly; renal function has been improved, and the heart action is better than before. One may now proceed with enucleation of the prostate through the already opened suprapubic wound, or, if it seems best, one may perform perineal prostatectomy. Occasionally, it appears that the patient is too feeble to bear the secondary operation, in which case long-continued drainage above the pubes relieves congestion, eliminates cystitis, encourages shrinking of the enlarged prostate, and allows the patient, if necessary, to return to the catheter life.



Fig. 254.—Diagram of hemostatic tube.

The suprapubic operation has found its greatest favor among English and Indian surgeons, whose experience in this method has been large. Especially of recent years has the technic been improved, and has become associated with the name of Freyer, whose vigorous advocacy of a rather ancient practice has brought him into prominence before the surgical public.[1]

Among American surgeons, however, the operation of *perineal prostatectomy* is the favorite.[2] Numerous modifications of this operation have been devised. Indeed, it seems sometimes as though there were as many modifications as there are operators —so that I must content myself with describing what I believe and have found to be a satisfactory operation; essentially it is that of Young.[3] Before undertaking the operation of perineal prostatectomy the surgeon should have clearly in mind answers to the following five propositions: method of approach to the prostate; method of exposing the tumor; method of enucleation; preservation of the urethra and ejaculatory ducts; treatment of the wound.

The position for the patient is the exaggerated lithotomy position, which can best be secured by tipping up the Trendelenburg table. I employ the inverted V incision of Young (Fig. 255); rarely the simple median

[1] There have been humors even of this controversy. F. S. Watson recently alluded to the conspicuous advocate of suprapubic prostatectomy as "the universal usurper of previously preëmpted prostatic privileges."

[2] Within the past three years the pendulum has swung back again; and now many American surgeons again proclaim their preference for the suprapubic operation.

[3] Hugh H. Young, Conservative Perineal Prostatectomy, Jour. Amer. Med. Assoc., October 24, 1903, and February 4, 1905.

incision advocated by Samuel Alexander, and then in the case of thin patients only. On turning down the skin-flap the superficial muscles are exposed. There are now but two structures to cut in order to expose the membranous urethra and the prostate. The first structure is the central tendon of the perineum (Fig. 256), which passes forward and is inserted into the bulb of the urethra. Cut this, and by the same maneuver free the sphincter ani and the levator ani from their anterior attachments. This loosens the rectum also, though it is still held by the recto-urethralis muscle, which comes immediately into view. One must divide now this muscle, for it is the structure which holds forward the rectum. By its division that organ is allowed to fall back out of the way of further dissection. The division of the recto-urethralis and further blunt dis-

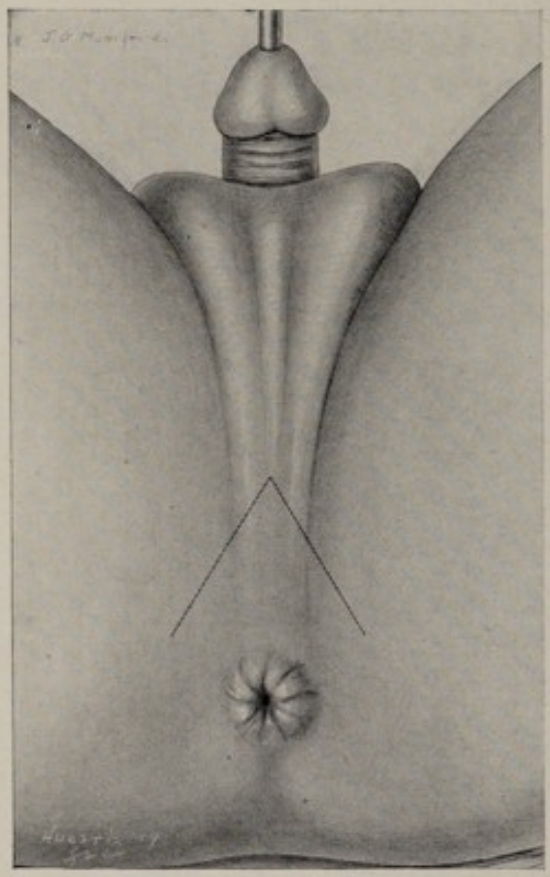

Fig. 255.—Perineal prostatectomy—step 1 (redrawn after Young).

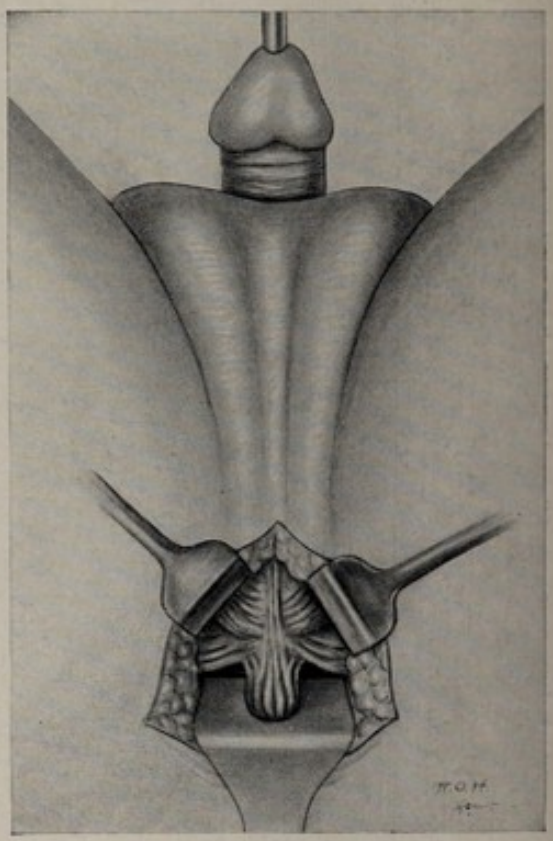

Fig. 256.—Perineal prostatectomy—step 2. Exposure of central tendon by bifid retractor (redrawn after Young).

section, with proper retraction, reveal the membranous urethra and the anterior portion of the prostate gland. At this point a grooved staff may be passed into the urethra, or the staff may have been inserted before beginning the operation. Open the membranous urethra upon the staff. The approach to the field of operation is now complete. In order to bring the tumor into proper view, use as a routine the well-known tractor of Young. One opens the membranous urethra, withdraws the staff, and passes the tractor into the bladder through the membranous and prostatic urethra. One then opens the blades, which

are made to lie across the lobes of the prostate. Then with gentle firm traction, draw the prostate well down into the field.

Next incise the two lateral lobes separately. Having opened down through the capsule, dissect out the lobes with a blunt dissector, seize them with forceps (Fig. 258), and drag them out until they hang by their prostatic attachments. At this point introduce a finger into the wound so as to make sure of not tearing through into the urethra or bladder. Then cut away with scissors the prostatic attachments of the lobe, and repeat the operation on the other side. In this way the urethra, the ducts, and the bladder itself may nearly always be spared serious damage.

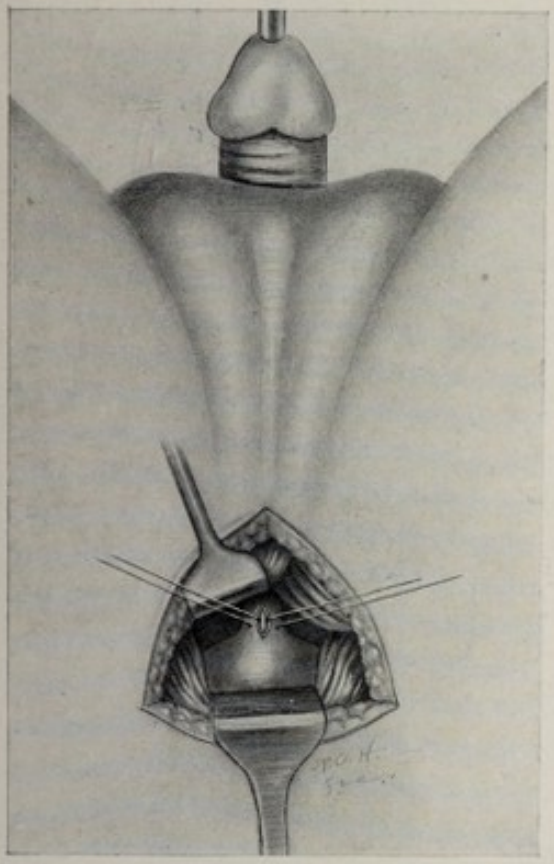

Fig. 257.—Perineal prostatectomy—step 3. Opening the urethra on sound preparatory to introduction of tractor (redrawn after Young).

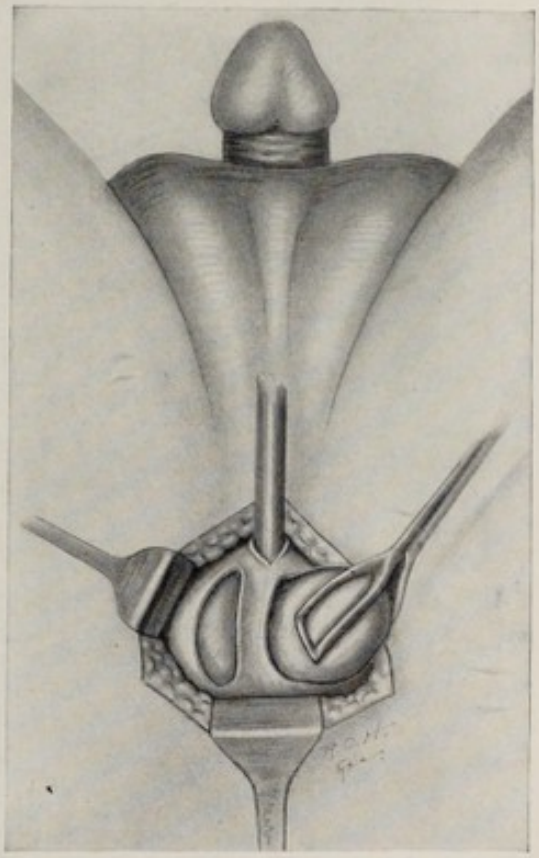

Fig. 258.—Perineal prostatectomy—step 4. Enucleation of lobes, forceps in position (redrawn after Young).

If there be but a small middle lobe, it may be forced down into one of the cavities left by the removal of the lateral lobe, and it may be seized and extracted in much the same manner as was the lateral lobe (Fig. 259). Sometimes there is a large middle lobe which cannot easily be managed by the tractor. In such a case enlarge the opening in the urethra, pass the finger into the bladder through the prostatic urethra, and thus easily bring down the middle lobe to within reach for extraction. Then, with the finger in the bladder, search thoroughly that organ for further abnormalities—sacculations and calculi, though such conditions should have been demonstrated previously by the cystoscope. The dressing of the wound is a simple matter. Thorough drainage of the bladder

must be instituted. For this purpose it is best to use a large drainage-tube and a small catheter, sewed together side by side, and introduced through the membranous urethra into the bladder. By the use of this instrument the bladder can readily be washed out. Then pack lightly the cavities with gauze wicks brought out at the lower angles of the V-shaped wound, the double drainage-tube being led through the middle of the flap. The cut muscles of the perineum may be restored with cat-gut stitches; the skin wound is then sewed up with interrupted silkworm-gut stitches. Of the numerous modifications and changes in the technic, I have employed on three occasions the method of Ferguson, who passes

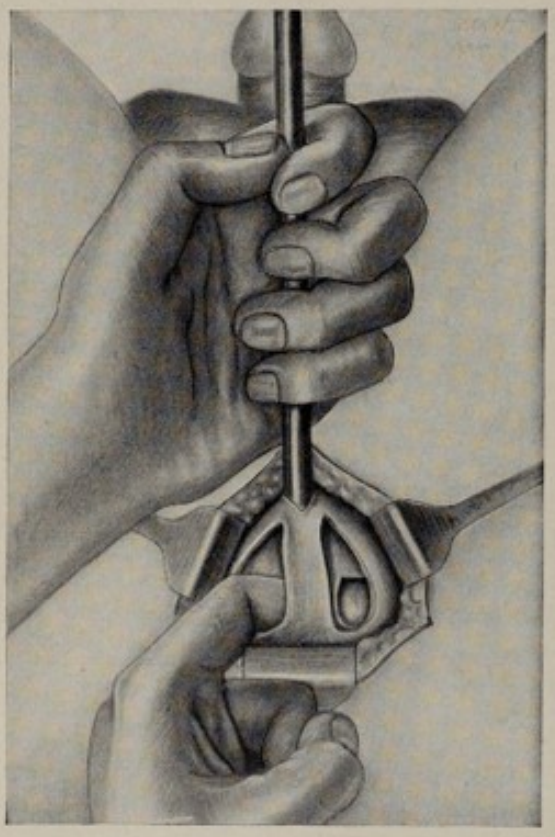

Fig. 259.—Perineal prostatectomy—step 5. Delivery of middle lobe into cavity of left lateral lobe (redrawn after Young).

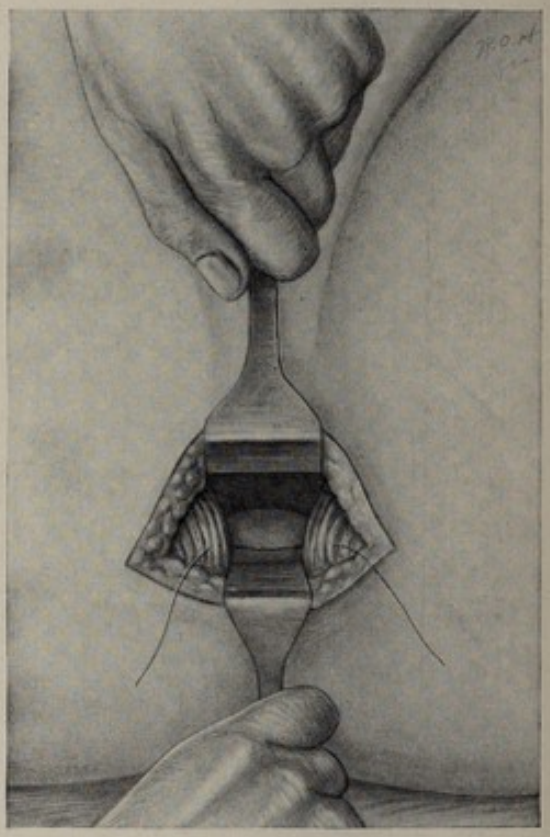

Fig. 260.—Perineal prostatectomy—step 6 (redrawn after Young).

a soft-rubber catheter through tbe urethral meatus for drainage, and so into the bladder. In closing he sews up the wound in the membranous urethra. Although this is an excellent maneuver in most cases, I found in one of my cases that it did not comfortably drain the bladder, and I have returned to the method described by Young—the double drainage-tube leading out through the perineum.

If all goes well, the subsequent history of these cases is uneventful. Remove the drainage-tube on the third day, and the gauze packing on the fifth day. There is often more or less perineal leakage, but generally the healing is sound. It sometimes happens that infection of the

wound or a persistent cystitis makes necessary frequent irrigation of the bladder. Or it may be that the drainage is unsatisfactory. Under such circumstances I have used with advantage the apparatus devised by A. J. A. Hamilton, and employed first at the Carney Hospital in Boston[1] (Fig. 261). By the end of three or four weeks the patient should be passing his urine by the natural channel. I like to get these patients up as early as possible, and frequently have them sitting up in a chair on the third or fourth day. As to the preservation of the sexual power, there is now abundant evidence to show that in a considerable proportion of cases this power is preserved, probably more surely than by any other method. By this method also there seems less probability of setting up an epididymitis. Convalescence generally is short and satisfactory, and the sense of well-being which promptly returns to the patient after operation is gratifying both to him and to the surgeon. The operation of perineal prostatectomy has long passed the experimental stage. Thousands of these cases have now been operated upon by American surgeons, with increasingly good results, so that we are justified in claiming for perineal prostatectomy a high place in surgical therapeutics.[2]

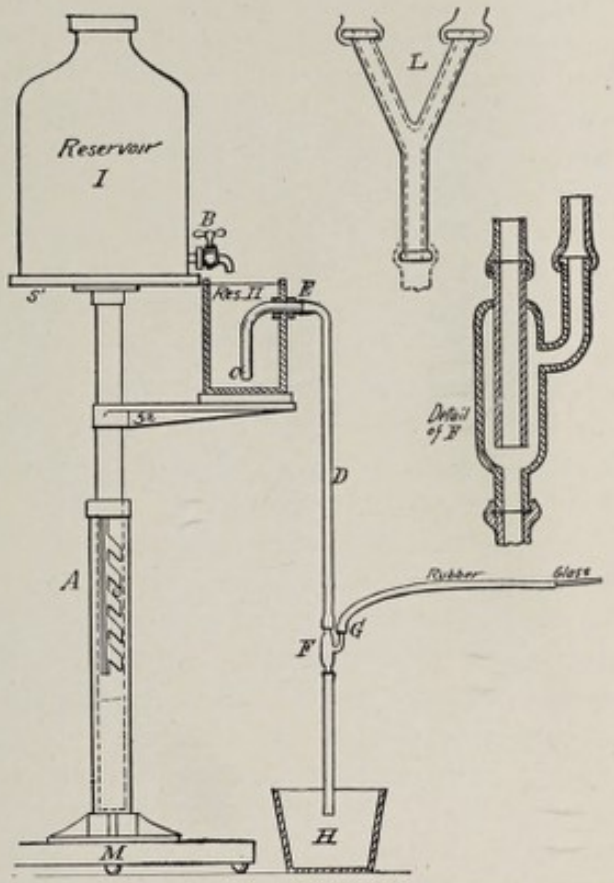

Fig. 261.—Hamilton's bladder drainage apparatus.

Numerous palliative operations for enlargement of the prostate have been advocated from time to time in the past, and I mention them only to protest against their employment. At one time orchidectomy, or removal of the testes, promised great things. But faith is necessary in its advocate to uphold a shadow of its claim. In the same way, vasectomy, or excision of portions of the vasa deferentia, was loudly heralded. Nowadays we hear little of these operations. If they are useful, it must be mainly for the mental effect which they produce. Possibly one of my readers may be inclined to employ them in the case of hysteric individuals who refuse a more radical operation, but rarely otherwise.

[1] A. J. A. Hamilton, An Apparatus for the Intermittent Post-operative Drainage of the Bladder, Jour. Amer. Med. Assoc., March 21, 1908.

[2] Many cases of functional failure after this operation have been found to be due to psychic causes For an important essay on this subject see Samuel Alexander, Contribution to the Surgery of the Prostate, Ann. Surg., August, 1908.

It is a surprising fact that the operation of orchidectomy has been followed by a considerable mortality in cases of old men. If either orchidectomy or vasectomy be done, I advise that the surgeon approach the organ by the high incision above Poupart's ligament, through which he may draw up and excise the testicle, or readily remove a portion of the vas.

CANCER OF THE PROSTATE

Cancer of the prostate is not especially uncommon and deserves our consideration—our serious consideration. Some genito-urinary surgeons are coming to look upon cancer of the prostate as less fatal necessarily than it was regarded a few years ago, and this feeling is due to recent successes in radical operations on prostatic cancer. Cancer and sarcoma both occur in the prostate, but cancer is nine times commoner there than is sarcoma. For years, writers have been asserting that cancer of the prostate has no relation to prostatic hypertrophy. I believe that this is a false view, judging from my own clinical experience and from Young's careful reports,[1] which state that about 14 per cent. of those patients who apply to him for prostatic obstruction are the victims of prostatic cancer, often associated with long-standing hypertrophy.

Early prostatic cancer is confined to the gland by the stout prostatic capsule. Extension comes late and involves the seminal vesicles, the bladder, the rectum, and other pelvic organs. Metastases are rare, appearing in but few lymph-nodes, and, curiously enough, involving the bones in many cases. The surgeon should have in mind the possibility of cancer whenever he has to deal with an enlarged prostate, but he will find the differential diagnosis difficult and the **symptoms** often obscure. At first there are difficulty of micturition and frequency merely; but in about one-third of the cases there is pain early, and pain in all the cases eventually. About 20 per cent. of the cases have hematuria first or last. The progress of the disease is more rapid than is benign enlargement of the prostate. One should not overlook especially the frequently extreme hardness of the gland, and on cystoscopic examination the absence generally of lobes projecting into the bladder, while at the same time the urethral orifice often appears normal. Pain is characteristic, and may radiate in various directions, the patient describing pain over the pubes or in the perineum, in the thighs, hips, rectum, buttocks, and along the sciatic nerves. There is also the common constitutional disturbance seen in cancer. So we base our **diagnosis** on the rapidity of the growth, the increasing pain, and the induration of the prostate; sometimes on a constricted prostatic urethra near the apex of the gland, and on the absence of intravesical lobes. Of course, all these signs and symptoms are not necessarily present together, but in any case, when in doubt, the surgeon should advise operative exploration of the prostate in order to establish the diagnosis, provided the patient's strength warrants this somewhat radical measure.

[1] Hugh H Young, Carcinoma of the Prostate, Jour. Amer. Med. Assoc., March 10, 1906

So recent a writer as G. R. Fowler, publishing in 1906, states that the **treatment of prostatic cancer** is purely palliative. I believe that this is true in advanced cases only. In the early cases a radical prostatectomy may cure the patient, or one of the extensive operations suggested and practised by Küster, Harris, or Young. Küster removed the whole bladder and implanted the ureters in the rectum. Harris excised the greater portion of the bladder and transplanted the ureters into the vertex of that organ. Young's operation is less dangerous than these, though at the best it is tedious, difficult, and hazardous except

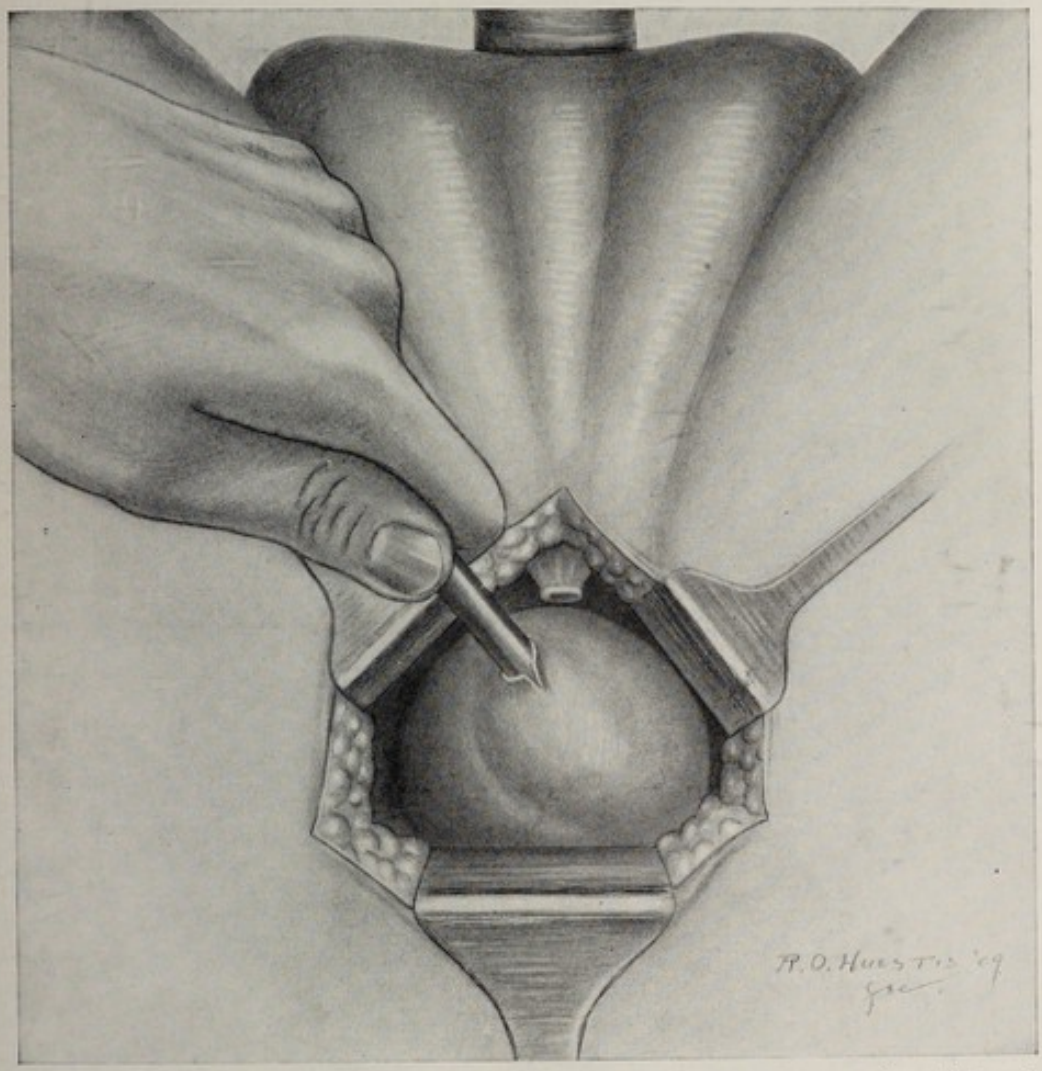

Fig. 262.—Excision of cancer of the prostate—step 1 (redrawn after Young).

in the most skilled hands. It has been successful with a number of patients.

Young's Operation.—Approach the prostate as for an ordinary perineal prostatectomy through the inverted V-incision. Open the membranous urethra upon a grooved staff, and introduce the prostatic tractor into the bladder and open the tractor. While making traction on the prostate with this instrument, separate thoroughly with scissors and blunt dissection the prostate and bladder before and behind from the neighboring tissues. By this means the mobilized bladder may be

drawn well down into the wound. Cut off the membranous urethra in front of the tractor; depress that instrument; open the bladder from in front with the knife, and then, with the scissors, excise the lower portion of the bladder with the prostate, seminal vesicles, and portions of the vasa deferentia, cutting off the base of the bladder about half an inch in front of the openings of the ureters. We have now brought away the malignant prostate with a large margin of bladder. The stump of the bladder falls far back, leaving a large rent to repair. It is not very difficult to fill the gap, as indicated by the diagram in the text. At one point in the anterior wall of the bladder a puckered opening is manufactured for

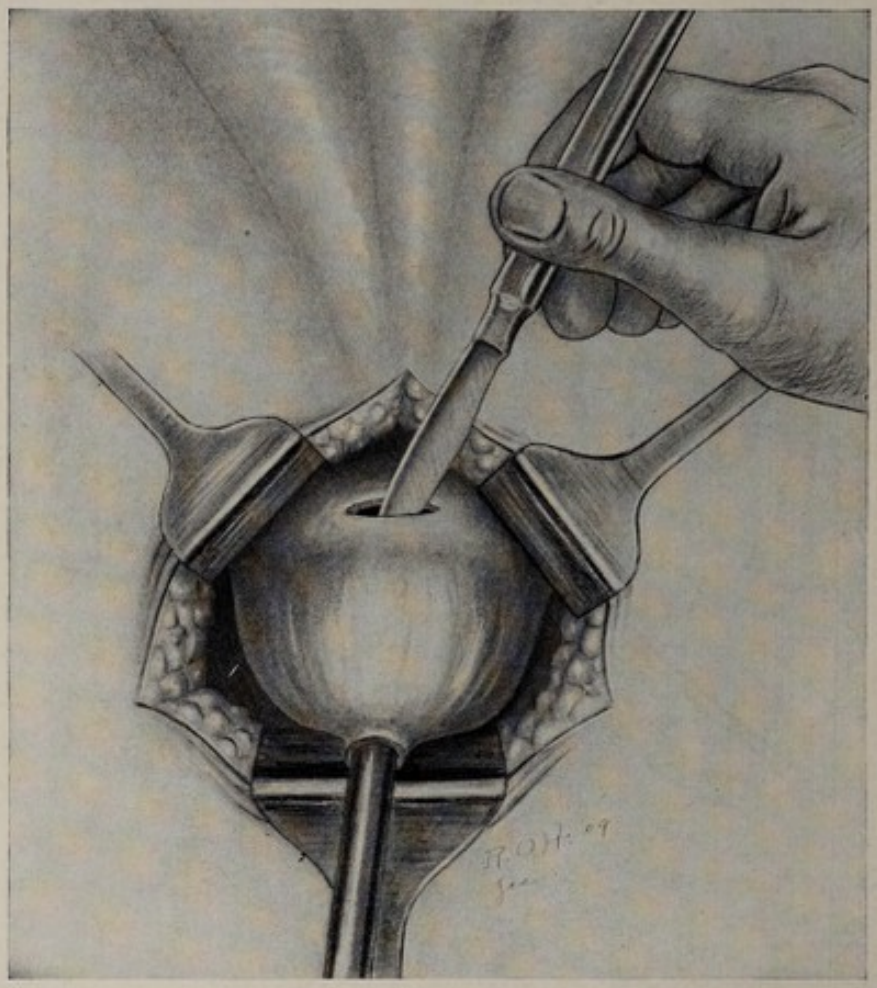

Fig. 263.—Excision of cancer of the prostate—step 2 (redrawn after Young).

suture to the stump of the membranous urethra. The remaining opening in the bladder-wall is then easily closed with stitches. Young recommends sewing up the rent with alternate catgut and silkworm-gut sutures, the latter being left long. The repair of the urethra may be made with silk or catgut stitches; then an inlying catheter is fastened into the bladder, passing throughout the length of the urethra. The depths of the wound are filled with light gauze packing, which is brought out through the perineal opening, the levator ani muscles are drawn together with two catgut stitches, and the skin-wound is closed so far as possible.

This radical operation, if successful, is followed by a relatively short convalescence, and the patient may be expected to regain comparative

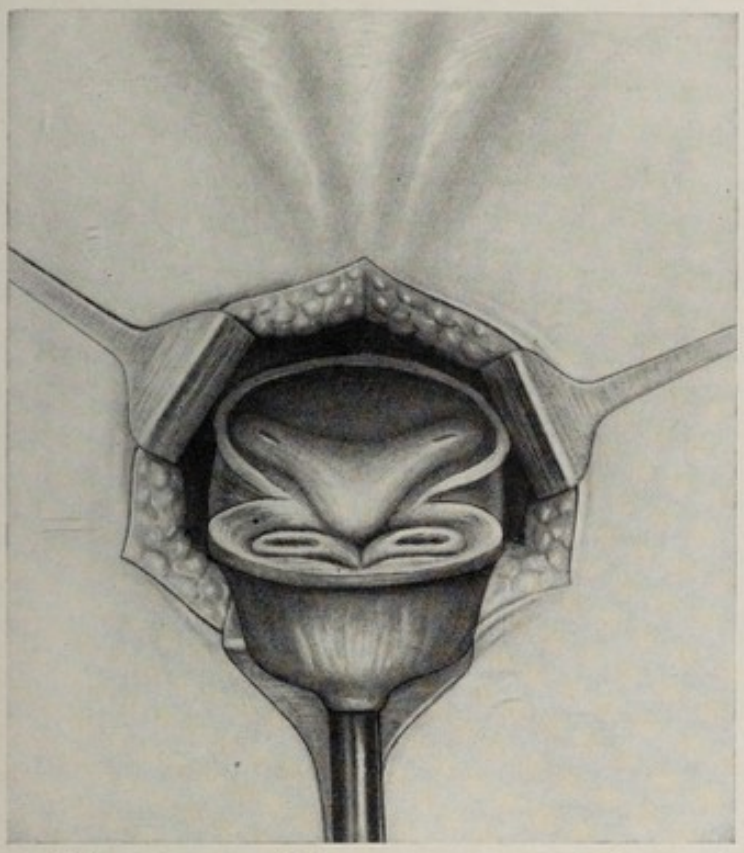

Fig. 264.—Excision of cancer of the prostate—step 3 (redrawn after Young).

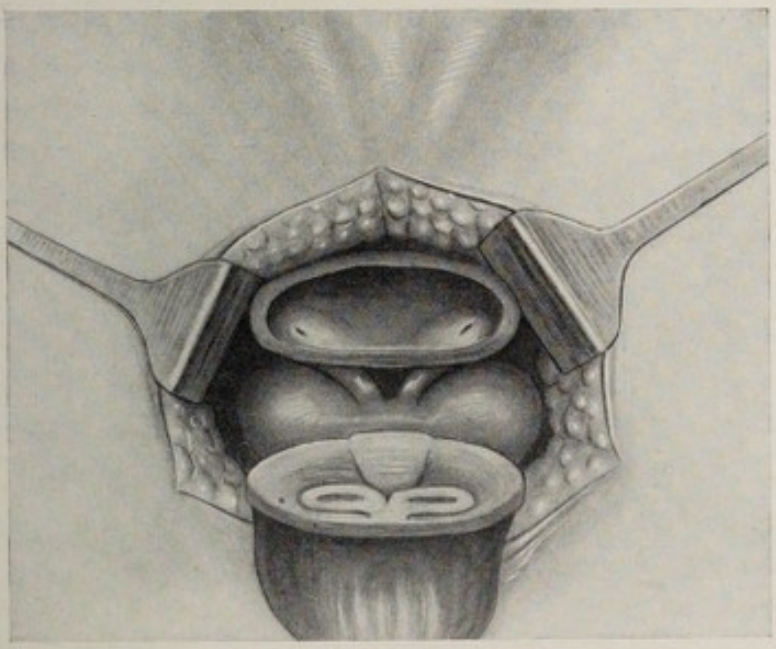

Fig. 265.—Excision of cancer of the prostate—step 4 (redrawn after Young).

strength. Urinary continence is scarcely to be hoped for, however, though in some of the cases the incontinence is not complete. The

dangers from hemorrhage and from shock during the operation are great. Viewed as a radical advance in surgery, the operation often

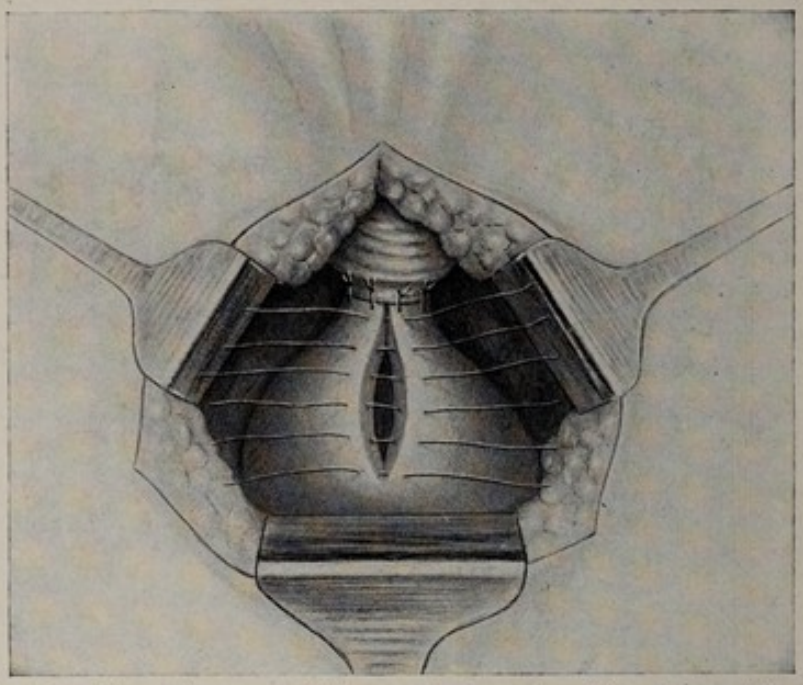

Fig. 266.—Excision of cancer of the prostate—step 5 (redrawn after Young).

may seem preferable to palliation with the certainty of an early death, and patients occasionally may be found who prefer to take the surgical risk.

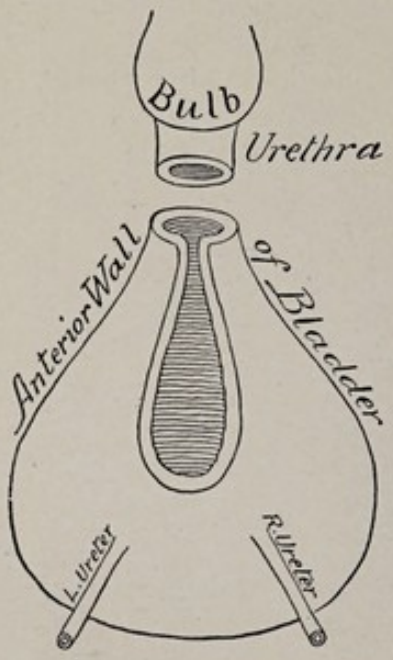

Fig. 267.—Diagram showing plan of vesico-urethral anastomosis (Young in Keen's Surgery).

The rare cases of **sarcoma of the prostate** have never been subjected to surgical operation, so far as I am aware; but the treatment of such tumors should be essentially the same as that for cancer.

There are a few other rare prostatic tumors which we have space to mention merely: hydatids; cystic dilatation of the prostatic vesicles; and retention cysts (distention of occluded glands or follicles). Papilloma of the prostate may develop in connection with papilloma of the bladder.

Such are the more common and important diseases of the bladder and prostate. I have pointed out their intimate association with disorders of the kidneys. In the next chapter we shall consider the terminal portion of the genito-urinary apparatus, whose diseases also are closely associated often with those of the prostate and bladder.

CHAPTER XV

PENIS, URETHRA, AND TESTES

The Penis and Urethra

Diseases of the penis and urethra concern all physicians as well as surgeons, for it has been estimated that more than 70 per cent. of mankind, first and last, fall victims to venereal disease, and venereal disease represents the vast majority of diseases of these organs. It is needless here to discuss the social and ethical questions involved, and, indeed, this subject has become a commonplace of medical literature. It is well, however, to remind the reader that venereal disease is a matter of first importance, not only to the immediate victim, but to his family and offspring. The penis in the male has no proper analogue in the anatomy of the female, for the penis is an organ of double function: it serves as a passage for urine, as well as for the act of procreation.

Let us consider briefly the **anatomy of the urethra.** The urethra in the male is about 7 to 8 inches long, and is divided into four portions: the fossa navicularis, which lies within the glans penis; the penile or spongy portion, occupying about 4 inches, and dilated at its internal end into a bulbous portion; the membranous urethra, about ½ inch long; and the prostatic urethra, about 1¼ inches long. The shape and caliber of the urethra vary and alter with each of these portions. At the extremity of the penis the urethra begins with the meatus—a vertical slit; then it widens immediately into the fossa navicularis, then narrows into the spongy or penile urethra, which ends in the sacculated bulb; immediately behind the bulb there lies within the triangular ligament the membranous urethra, which is narrow and inelastic, while behind the membranous urethra is the wider and distensible prostatic urethra. One sees that this canal is not a straight, uniform drainage-tube, but that with its broadening and narrowing it offers abundant chance for the lodgment of infecting material and collections of inflammatory exudate. Moreover, there are accessories to the urethra—accessories which give additional opportunity for the lodgment of infecting organisms. In the central portion there are the glands of Littré, and in the fossa navicularis one large gland or follicle on the upper surface, about an inch from the meatus. This is called the lacuna magna, and when it becomes infected with gonorrhea, it may remain locally inflamed long after other portions of the urethra are free from disease. Opening into the bulbous portion are the two ducts of Cowper's glands, while in the

prostatic urethra, in the middle line, lies the verumontanum, on each side of which are the prostatic sinuses, and in these the orifices of the prostatic glands. Near the crest of the verumontanum is the utriculus, which carries the openings of the ejaculatory ducts. Arranged about the membranous urethra, and lying in the folds of the triangular ligament, are the fibers of the compressor urethræ, or cut-off muscle, the great dividing line between the anterior and posterior urethra. I urge the student to remember this anatomic landmark, the triangular ligament, for upon its relation to the urethra depend numerous pathologic conditions and the application of sundry therapeutic measures.

Of what sort, then, is this venereal disease which afflicts mankind? We use the terms *syphilis* and *gonorrhea* to describe it. Up to the middle of the last century the best teaching informed students that syphilis and gonorrhea were identical, and we hear the pretty fable of John Hunter's inoculating himself with the virus of gonorrhea and producing syphilis. By this experiment he proved to the satisfaction of the scientific world that gonorrhea and syphilis are one. We must now suppose that he was mistaken in his original diagnosis of the case from which he took the virus. Doubtless he secured the exudate from a syphilitic chancre, thinking it to be gonorrheal pus. The great surgeon and teacher who differentiated gonorrhea from syphilis was Philippe Ricord, who published, in 1836, more than sixty years after John Hunter's hazardous experiment. In some fashion not altogether unworthy of present-day pathology Ricord explained the distinction between the two diseases. It is not surprising, however, that he failed to recognize the fact that gonorrhea is due to a specific virus. He asserted that it is a catarrhal condition induced by a variety of causes.

GONORRHEA

Gonorrhea begins as an acute localized inflammation, which may become chronic and may become systemic. The majority of cases cease with the acute stage, and are limited to an anterior urethritis; a considerable number of cases progress to a chronic involvement of the posterior urethra, the bladder, the seminal vesicles, the prostate, the vasa deferentia, and the testes; a comparatively small proportion involve serous surfaces, especially the joints, the heart, and the peritoneum. These statements apply to gonorrhea in the male. In the case of the female, as I stated in Chapter X, gonorrhea is limited at first to the urethra and vulva, and then, sparing the vagina generally, it penetrates to the uterine mucosa, the tubes, and ovaries. In this chapter we are dealing with gonorrhea in the male.

Although the infection takes place from direct sexual contact in most cases, there can be no doubt that rare unfortunate individuals are infected from contact with gonorrheal pus on towels and in unclean water-closets. A most lamentable instance of innocent gonorrheal infection is gonorrheal conjunctivitis, which is brought to the eye on soiled fingers and towels, or, in the case of the new-born, from the

infected parts of the mother, and sets up an alarming and destructive process within the orbit. In ordinary acute gonorrheal urethritis, however, the specific poison is deposited upon or within the meatus, where the organisms incubate for from two to five days; then an inflammatory reaction occurs and causes symptoms, which inform the patient of his misfortune. At first there is a slight itching and burning, with moderate scalding on micturition; then comes a purulent discharge, beginning as a mere drop, but rapidly increasing. At this time the infection has not progressed beyond the fossa navicularis. If you examine the discharge of pus, you will find early that it contains leukocytes with a few diplococci (gonorrheal cocci) outside the cells. Soon, however, the diplococci penetrate within the cells, and there characteristically they are to be found on proper staining. In every case of urethritis the surgeon should make three or four cover-slip preparations and examine for the diplococci. These are the gonococci of Neisser, who first, in 1879, demonstrated this organism as essential to true gonorrhea. After obtaining a lodgment the organisms penetrate rapidly through the epithelial layers of the urethra and enter the submucous tissue; then, with the onset of the inflammatory reaction, a fresh and more abundant discharge of pus takes place, and the acute stage of the disease progresses rapidly. The more abundant the suppuration, the more effectually are the gonococci removed from the tissues, so that the inflammation may properly be regarded as a salutary action of nature. In view of this fact, therefore, physicians have come to realize that measures for checking violently the early discharge are not properly employed. The infection, with its accompanying inflammation, spreads along the anterior urethra as far as the compressor urethræ muscle, and involves all this anterior portion of the membrane in the course of the first week from the appearance of symptoms. The rare cases of gonorrhea which progress without suppuration are to be dreaded, for in such case the disease destroys tissue at an astonishing rate. The cut-off muscle is the first anatomic barrier which a progressive gonorrhea encounters, and in many cases this barrier is the limit of the process. Frequently, however, gonorrhea proceeds and involves deeper structures. In the progress of the infection the discharge increases at first, and then subsides slowly, as more and more of the organisms are eliminated. The discharge becomes less purulent and more mucous, until it appears as a mere mucous secretion. In this form it persists and represents the chronic gonorrhea or gleet, the dread of patients and surgeons. It is difficult to say at what period in time an acute gonorrhea passes over into the chronic stage, but, in general terms, you may tell your patient that a urethritis is chronic which persists more than six weeks.

There are non-specific forms of urethritis—forms which are sometimes called bastard gonorrhea, and these forms are not uncommon. Mostly they are relatively simple and easily cured; sometimes they are obstinate and chronic. The commonest exciting causes of non-specific urethritis are so-called uric-acid excess, systemic fever, traumatism, syphilis, tuberculosis, and invasions of pus-producing bacteria other

than gonococci. Many of these infections subside quickly with simple cleansing irrigations, but others, notably tuberculous and syphilitic infections, seem hopelessly obstinate.

The **treatment of acute gonorrhea**[1] falls largely to young practitioners, for the acute gonorrhea of men is a disease of youth, and young men, in their mortification and distress, naturally hesitate to consult their elders. When a patient with suspected gonorrhea consults the surgeon, the first and important purpose of the latter is to confirm the diagnosis, and the one final test is to demonstrate the gonococcus of Neisser. With the diagnosis made, it is the surgeon's imperative duty to explain carefully the situation to the victim. He must point out to him the danger to himself and the danger to others. Incredible as it may seem, one meets frequently with ignorant patients who have been taught the old tradition that the best cure for gonorrhea is further repeated sexual intercourse. I have already indicated the danger to others. The immediate danger is transmission of the virus, and this should be guarded against by abstinence from venery; while the patient should be warned to use his own individual towels and underclothes, and to scrub his hands after every handling of the parts. To avoid needless danger to himself he should take pains not to rub his eyes with his fingers, not to bottle up the urethral discharge by packing a cotton plug about the meatus, and he should be instructed to wear a suspensory bandage from the start. The internal treatment is not to be neglected; the patient should eat a light diet, with meat once a day, with no fats, fruit, alcoholic drinks, or highly spiced dishes; and he should be encouraged to drink freely skimmed milk and some aërated water. I think the value of copaiba and sandalwood oil has been underestimated. One of them should be given, in five-minim capsules, and the daily dose should be increased up to the point where it causes gastric distress—3, 9, 12 capsules daily.

During the acute stage of the disease the patient should avoid all violent exercise; he should walk as little as possible; he should not ride or drive if it can be avoided, and, above all things, he should not take a railway journey. Rest in bed is his best course, if he can be persuaded to it. I have said that the surgeon should prescribe no strong antiseptic injections or irrigations to control the discharge for the first few days. This statement holds true of all antiseptics known to me with the single exception of argyrol. This drug, in the solution of 10 or 20 per cent., may be employed for injections by the surgeon in his office, and a 10 per cent. solution may be given to the patient to use at home. Argyrol acts best when injected three or four times a day, and held in the urethra for at least ten minutes at each injection. The theory is that it penetrates the tissues without damaging their structure, and reaches the organisms in sufficient volume and strength to destroy them.

[1] The careful researches being carried on in the MacArthur clinic in Chicago assure us that in the gonococcus vaccines we have a remedy which shortens and ameliorates the course of gonorrhea, especially when the ordinary cleansing and hygienic measures also are employed. This combination of treatment is effective in the case of women also.

Argyrol thus used certainly will cut short many cases of gonorrhea, sometimes limiting the duration of the attack to a week or ten days.

If the urine remains thready after a week of argyrol treatment has elapsed, especially if there continues a mucous discharge, the surgeon may prescribe a mild solution of astringents as an injection, to be used twice daily, and held in not more than one minute.[1] When employing injections of any kind, the patient should use a half-ounce blunt-nozzle syringe, which will not penetrate the urethra. The popular long-nozzle syringe, which can be passed up an inch or more into the urethra, is an abomination.

During the apparent subsidence of the acute attack the posterior urethra may become involved in the disease. To ascertain this, use the two-glass test—having the patient pass part of his urine into one glass, and the remainder into a second glass. Cloudy urine in both glasses shows that the disease has attacked the posterior urethra; cloudy urine in the first glass only shows that the gonorrhea is still anterior. In case one is dealing with a posterior urethritis at this time, an admirable treatment is to make deep instillations with 20 per cent. argyrol into the posterior urethra. This may be done with an Ultzmann syringe, a few drops only being injected. The anterior urethritis must be treated



Fig. 268.—Ultzmann's syringe for instillation (Greene and Brooks).

at the same time, as I have advised. Strong irritating injections of corrosive sublimate or silver nitrate should never be used in an acute gonorrhea, nor should instruments, such as sounds or the endoscope, be passed at this time to dilate the urethra or inspect its surface.

Chordee is a painful erection of the penis, and is due to the inability of the corpus spongiosum surrounding the urethra to distend properly in the act of erection. Chordee occurs commonly at night or in the early morning, when the bladder is full. It may be relieved by active walking about, by the application of ice, and, if obstinate, by a small dose of opium. To relieve the pain of urination immerse the penis in hot water during the act.

Epididymitis, single or double, may occur in the course of an acute gonorrhea. It is due either to the direct infection of the vasa deferentia and epididymis, from the inflamed posterior urethra, or to transmission through the lymphatics. As a rule, epididymitis yields readily to treat-

[1] An excellent astringent injection, which I have long used with satisfaction, is this:

℞. Sulphate of zinc	16	grains
Acetate of lead	16	"
Tinct. catechu	½	dram
Wine of opium	½	"
Water, ad	6	ounces.

ment. The patient should be put to bed, the testicles should be supported on a towel or a pillow between the legs, and an ice-bag should be applied to the parts. A liquid diet should be enjoined, potassium citrate being given freely, with abundance of water to drink, and opium suppositories, if necessary, for pain. An interesting feature of this complication is that during the height of the attack of epididymitis the urethral discharge is wont to disappear, reappearing again with the subsidence of the epididymitis. The swollen epididymis may distend the scrotum to the size of a hen's egg, or even to the size of two fists, and often the patient is afflicted by the discouraging thought that the affected testicle will remain functionless. Indeed, double epididymitis

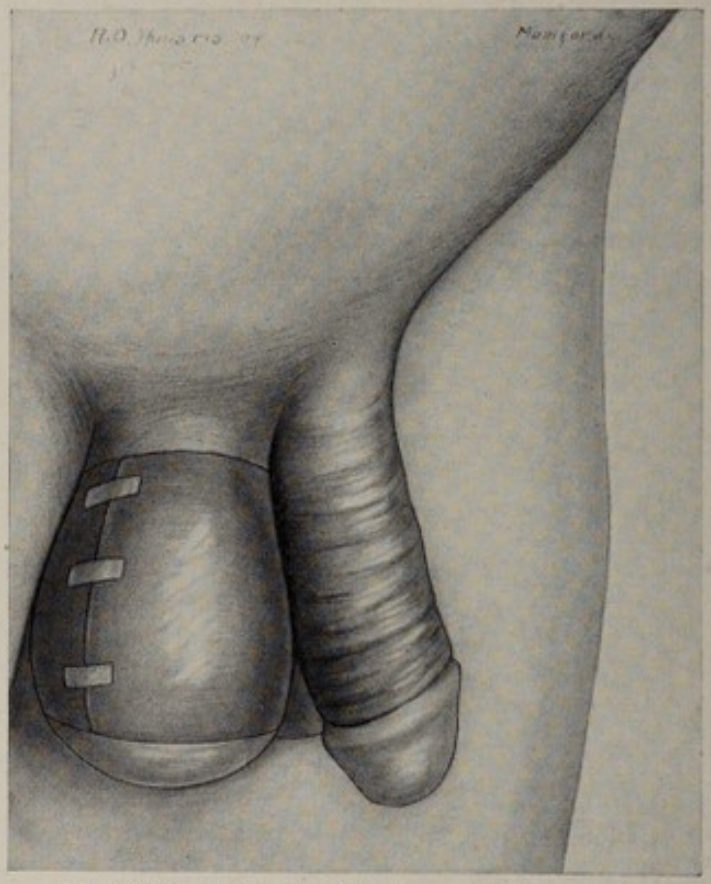

Fig. 269.—Adhesive plaster applied to testis.

is a common cause of sterility.[1] If the applications and remedies already suggested do not relieve the epididymitis, the actual cautery may be found effective, the skin over the inflamed organ being lightly touched with the white-hot point. This treatment is followed by the application of iodoform ointment. Sometimes a creolin poultice, 1:200, will relieve quickly pain and swelling. Strapping the testicle with bands of adhesive plaster occasionally serves a good purpose, but the strapping should be applied by an expert. In rare and obstinate cases the epi-

[1] In this connection see Edward Martin, Surgical Treatment of Sterility, Amer. Med., 1903, vol. vii, p. 791; and W. C. Quinby, Sterility in the Male: Its Operative Treatment when Due to Bilateral Epididymitis, Boston Med. and Surg. Jour., November 8, 1906.

didymis and testicle become extremely diseased, the contents of the scrotum breaking down into a suppurating mass. In such case our resort is orchidectomy. Sometimes, in the case of recurrent epididymitis, section of the vas deferens is necessary.

Acute prostatitis may be treated, when fresh, by instillations of 20 per cent. argyrol. I have already, in Chapter XIV, considered the further progress of prostatitis.

Gonorrheal bubo, or infection of the inguinal lymph-nodes, is a not uncommon complication of gonorrhea. If the case be taken promptly and proper remedies be applied, this adenitis will subside without special trouble. The proper remedies consist in active treatment of the urethra and in painting the bubo with tincture of iodin, putting on three or four coats every fourth night. If the bubo suppurates, it must be opened and packed. Of course, the hair in the groin should be shaved first.

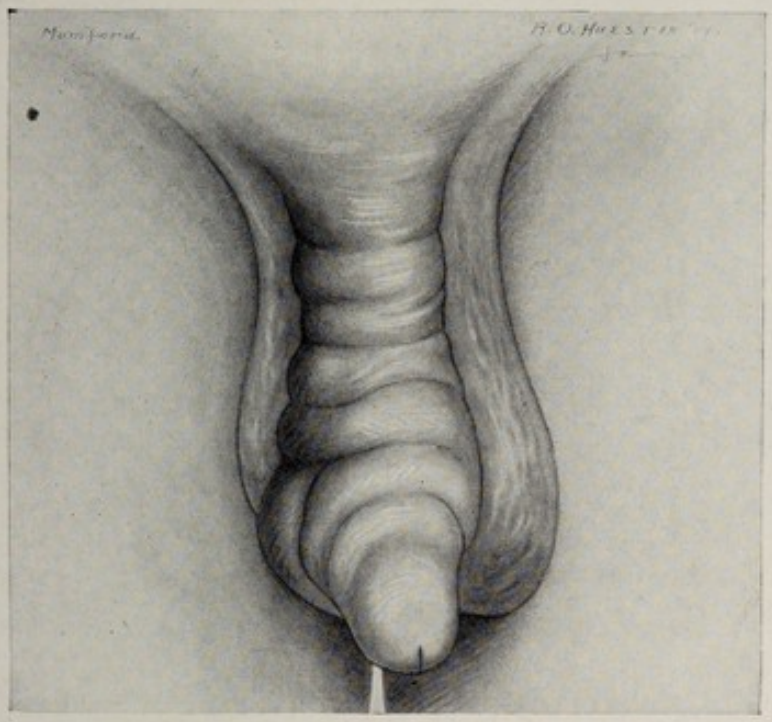

Fig. 270.—Paraphimosis.

Balanitis and **posthitis** are inflammations of the glans and prepuce, and are due to an extension of the gonorrheal process from the meatus. By proper cleanliness such complications should be forestalled. The surgeon may treat them by directing the patient to draw back the prepuce two or three times a day, to soak the penis in a warm solution of creolin and water, and to dust the glans with a drying powder of equal parts of borax and zinc oxid, to which, if you choose, a quarter part of powdered opium may be added. If there be actual ulceration, powdered iodoform makes an excellent application in spite of its disagreeable odor.

Phimosis and **paraphimosis** are akin. *Phimosis* is the result of inflammation of the prepuce, an inflammation so severe that the prepuce becomes distended and its orifice narrowed, so that it cannot be drawn

back over the glans. As a result, secretions accumulate beneath it and a foul condition of the organ results. If the swelling takes place when the prepuce is retracted above the glans, the constriction occurs behind the corona, with the result that the foreskin cannot be drawn down over the glans. This is the condition of *paraphimosis*, a far more serious affair than phimosis. The surgeon may treat phimosis by lead and opium lotions, or lead and carbolic lotions, at the same time keeping the parts thoroughly clean by injecting warm water beneath the prepuce. It is an excellent plan also to soak the organ in a tumbler of weak creolin and water two or three times a day. You will be tempted to perform circumcision, but such a procedure is unwarranted at this stage, because the inflamed prepuce is sure to slough when cut. A later circumcision should be advised. The reduction of a paraphimosis

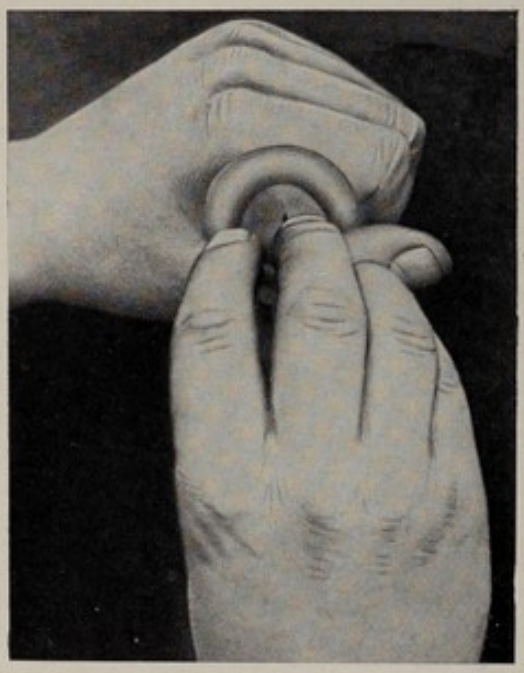

Fig. 271.—Reduction of paraphimosis —first method (Fowler).



Fig. 272.—Reduction of paraphimosis —second method (Fowler).

is rarely an easy matter. Sometimes the constricting band may be relieved by long immersion in cold water, after which digital reduction should be attempted. Before doing this it is well to give the patient a hypodermic of morphin. I show here, by illustrations taken from Fowler's excellent book, two methods of reducing a paraphimosis. If reduction cannot be accomplished by such means after twelve or twenty-four hours, the constricting band must then be cut. If it is left, gangrene of the prepuce and glans will follow. The band may readily be divided by passing a blunt-pointed bistoury beneath the prepuce and constriction and cutting upward until the foreskin slides back into place. After this little operation, cleanse the parts with creolin or bichlorid.

Gonorrheal cystitis yields usually and readily to treatment. Obviously, it is a sequel to posterior urethritis, and when associated with

acute gonorrhea, it may be demonstrated by the three-glass test. If the urine in the third glass contains pus and shreds, that is fairly good evidence of a gonorrheal cystitis. But far better evidence are the symptoms of the patient, who complains of straining, frequency, hematuria, and painful micturition. Usually a course of urotropin, 7½ grains in a glass of water every four hours for two or three days, will relieve completely the cystitis. This treatment may be supplemented by cold applications to the perineum and hypogastrium or by poultices; at the same time diluent drinks, especially skimmed milk, and abundance of water should be given, and pain should be controlled by opium suppositories.

Such are the commoner complications of acute gonorrhea. Let us now consider briefly the course, pathology, and treatment of chronic gonorrhea.

Chronic Gonorrhea, or Gleet.—When the patient comes to you with a history of a venereal disorder running over from one to ten years, he will lament in somewhat the following strain: he acquired his initial infection when a young lad; after a few weeks he thought himself cured and abandoned treatment; then he had, at intervals of a few months or years, fresh outbreaks of discharge from the urethra, for which he could not well account. These outbreaks were far less violent and distressing than the primary attack, but always subsided slowly. Then in the course of time he found himself continually annoyed by a slight discharge, appearing often in the morning only, as a drop (*goutte militaire*), sometimes being no more than a gumming together of the lips of the meatus. There have been a continual sense of discomfort about the organs, a feeling of weight in the perineum, frequency of micturition, perhaps a narrowing of the urinary stream, and a sense of chronically impaired health. Such a patient as this comes to hate himself often, and to curse existence. He may develop sundry neurotic symptoms and is continually on the lookout for improbable evils of which he may have read.

The location of the chronic disease, whose symptoms I have pictured, is a matter of first inquiry to the surgeon. If you recall the anatomy of the parts and the course of an acute gonorrhea, you will perceive how readily organisms may find lodgment in obscure lurking-places, where they appear to remain, in an almost dormant condition often, for years, aroused occasionally to make trouble, and always a burden. From the lacuna magna, through the glands of the penile urethra, Cowper's glands, the prostatic sinuses, and the various ducts and crypts of the deeper parts to the seminal vesicles and epididymis, foci of disease may be found. Moreover, there are often ulcerations, of greater or less extent, which in themselves produce a discharge and an increasing discomfort.

The surgeon must examine his patient with all these considerations in mind. He should strip the man and investigate carefully the whole region,—penis, meatus, urethra,—tracing with his fingers the thickened corpus spongiosum, inguinal nodes, prostate, seminal vesicles, and

testes. He should inspect the urethra with the endoscope to discover patches and inflamed crypts; he should pass proper bougies or exploring instruments to discover the caliber of the urethra and the possible presence of stricture, and he should determine the presence of gonococci in any discharge. At the same time, in making his cover-slip examination, he should note the relative proportion of leukocytes, mucus, fibrin, and epithelial cells. At this stage the two-glass test is of little value, for if there be but a slight exudate in the posterior urethra, it is carried out completely by the urine into the first glass. One may learn better the condition of the posterior urethra by washing out first through a soft catheter the anterior urethra with a 4 per cent. boric-acid solution. Then urine passed into a glass will carry with it detritus from the posterior urethra only. It has long been customary to draw conclusions from the appearance of urine thus passed. When the discharge is profuse, we find in the urine a turbidity which does not clear up as does a phosphaturia on adding acetic acid. When the discharge is scanty, we find floating particles—the so-called *Tripperfäden*. These are little casts of the tubules, and are composed of epithelium with other material more or less adherent. If there be adherent pus, the shreds sink quickly in the glass. If there be but epithelium, mucus, and fibrin, they float or sink slowly; but, after all, this sign is of no great value.

The *treatment* of gleet is simple enough in theory. It involves the finding and dislodging of gonococci, and in the resolving of areas of exudate and thickening. But in fact these measures are not easily carried out; you may proceed, however, in somewhat the following fashion, with the conviction that treatment steadily pursued for a long time usually will cure the patient—protargol and urethral dilators form the armamentarium. Lesions of both anterior and deep urethra are treated essentially on the same plan. To quote a well-known writer,[1] "The canal must be irrigated when it is desired to flush the urethra with any medicament. Applications of stimulating solutions or ointments are made by means of an applicator passed through an endoscope. Frequently it may be found inexpedient to irrigate the prostatic urethra or to irrigate it by inserting the endoscope; in such cases instillations may be made by means of the Keyes-Ultzmann or Guyon syringe, injecting from 5 to 10 minims of a 0.25 to 2 per cent. protargol solution, or a silver nitrate solution, 2½ grains to the ounce. Argyrol is valueless in chronic cases.

"Occasionally local treatment in chronic cases is continued over too long a period. When the discharge persists in spite of treatment, this should be discontinued, and efforts directed toward improving the patient's general health. Chronic gonorrhea may be followed by a urethrorrhea, which will disappear if treatment is omitted."

Briefly, the sundry complications may be dealt with as follows: there may be a false meatus or short, blind pouch in the glans. This pouch usually opens on one side of the true meatus and should be thoroughly cleaned out and touched with a stick of silver nitrate. A *tight meatus*

[1] Orville Horwitz, Keen's System of Surgery.

must be enlarged, for often a tight meatus admitting no more than a No. 20 sound is the terminus of a urethra of No. 35 caliber. Do not carelessly slash the meatus or snip it with scissors. Cocainize the glans, and enlarge the meatus cautiously with a blunt-pointed bistoury, cutting from within outward. Sundry meatotomes have been devised, but they have no special advantages. The meatus must be so enlarged, not only that it may admit instruments of the proper size, but that it may no longer dam back and prevent proper drainage of urethral secretions. The urethra itself varies in caliber in different individuals, as Otis long ago pointed out when he formulated certain rules regarding its size. It is not necessary accurately to follow rules when estimating the size of sounds which a urethra may take, but in general terms there is a relation between the caliber of the urethra and the circumference of the flaccid penis. For instance, a penis with a circumference of *three* inches should admit a urethral sound of No. 30 French; a 3½-inch penis should admit a No. 35 French sound; a circumference of 4 inches should call for a No. 40 French sound. These figures are approximate only, but will serve as a satisfactory working basis for the surgeon.

If the urethra shows anywhere in its course patches of ulceration or granulation when inspected with the endoscope, the surgeon may touch such patches with 4, 8, or 12 per cent. silver nitrate on a swab. As a rule, however, dilatation and the injection of strong protargol render needless such touchings. Chronic infections of the deeper urethral glands and prostatic sinuses often are cured by the measures described on the preceding page. However, if this does not suffice, especially if the seminal vesicles and ejaculatory ducts are involved, the surgeon must treat the patient by massage of these organs. Massage of the prostate and vesicles is an extremely satisfactory procedure in many cases, and be it remembered that a thorough rectal examination of these parts should be made in every case of gleet. In order most effectively to employ the massage, have your patient stand, leaning well over a table or the back of a low chair, with his knees straight, and his feet about 18 inches apart. The surgeon guards his finger with a cot or glove and introduces it slowly and carefully into the rectum, detecting enlargements, irregularities, and changes in consistency of the prostate; while beyond the prostate he feels for the vesicles; these may give to the finger the sensation of a thick cord or, if there be extensive periprostatic involvement, there may be the feeling of a general boggy enlargement merely of the whole region. The surgeon then methodically strips down with his finger the affected area, beginning at the highest point he can reach. At first the patient may complain of pain and an intense desire to urinate, but it is surprising often to find how these symptoms may subside as the treatment progresses, and what a sense of relief the patient experiences after the treatment. Urine passed after prostatic massage will contain pus, shreds, and semen generally. Some patients are free from symptoms after two or three such treatments, while other patients need many more. It is well not to massage the prostate and vesicles more than two or three times a week,

and I rarely give them a treatment of more than five or ten minutes at a time. Nearly all cases of chronic gonorrhea are benefited by a prostatic massage. This measure is the most important addition of recent years to the therapeutics of gleet. Eugene Fuller advises and practises enucleation of the vesicles through the rectum in cases of vesiculitis, but I have not yet encountered a case in which this seemed necessary.

Such, in brief outline, are the general principles on which we treat chronic gonorrhea. The vital question remains: When is the patient cured? Whitney gives a rule which is satisfactory:[1] "When there is no longer a discharge, when the shreds contain neither pus, gonococci, nor a large amount of epithelium; and when, furthermore, after producing a discharge by silver nitrate, no organisms are present; also when, after alcoholic or sexual excess, no discharge appears."

THE GENITAL LESIONS OF SYPHILIS

The genital lesions of syphilis rank with those conditions we have just considered. I shall not in this book discuss in detail the great subject of syphilis, referring the reader to special treatises and to the large systems of surgery. I shall mention here the syphilitic lesions of the external genitals, and shall say a word regarding the initial treatment of the disease.

As gonorrhea is due to the diplococcus of Neisser, so it now seems to be proved beyond much question that syphilis is due to the treponema (Spirocheta pallidum, first observed by Schaudinn and Hoffmann). Ordinarily, the writers on syphilis describe three periods of the disease—primary, secondary, and tertiary. More exact recent studies show that these divisions are more or less artificial, and that the three periods often overlap and run into one another.

(1) The period of primary incubation—the time elapsing between inoculation and the appearance of the initial lesion (chancre)—averages three weeks.

(2) The period of secondary incubation—the time elapsing from the appearance of the chancre to the development of cutaneous and mucous membrane lesions—averages six weeks. The secondary period lasts about two years unless the disease be cured by treatment.

(3) The tertiary period begins usually about three years from the time of the initial lesion, and lasts indefinitely, depending largely on the efficiency of treatment. In this period gummata develop, as well as the characteristic lesions of the bones and of the nervous system.

In the great majority of cases *chancre* is the first lesion of syphilis. It is a contact sore which appears in man usually on the prepuce, sometimes on the glans. At first, it seems a trifling abrasion. Gradually and painlessly it becomes larger, always surrounded by a characteristic induration. It must be always distinguished from the so-called "soft chancre" (chancroid). The true chancre is commonly spoken of as

[1] C. M. Whitney, The Etiology and Modern Methods of Treatment of Chronic Urethritis, Boston Med. and Surg. Jour., July 21, 1904.

"hard chancre." The hardness or induration is characteristic of the true syphilitic lesion. The hardness surrounds an ulcerating disk, which varies in apparent thickness, sometimes appearing as a sheet of tissue-paper, again as thick as blotting-paper. It rarely becomes larger in circumference than the little finger-nail. (The examining surgeon lifts up the whole lesion with his thumb and forefinger in order to ascertain its extent and consistency.) The induration of chancre remains for from one to six months after the ulcer is healed.

Chancre has the following nine characteristics:

(1) Incubation (time elapsed from contact exposure to appearance of sore) for from twelve to fifty days—average, three weeks.

(2) The sore is indolent, discomfort slight, discharge slight.

(3) The form is rounded.

(4) The sore is indurated and induration may precede ulceration.

(5) There is a painless enlargement of the adjacent lymph-nodes in the groin.

(6) The chancre persists in spite of local treatment.

(7) Scrapings from the sore will be found to contain spirochetæ.

(8) The sore heals as a result of constitutional treatment with mercury.

(9) The sore is single in from 80 to 90 per cent. of all cases.

We are discussing briefly genital chancres only, but the reader must remember that a chancre may develop on any surface of the body, especially near the mucocutaneous borders.

Note here, in contradistinction, the following seven characteristics of chancroid:

(1) Rapid development after exposure (two or three days).

(2) Two or more lesions.

(3) Pustular or ulcerating from the start.

(4) *Destructive* and inflammatory in type.

(5) Produces auto-inoculations—causing similar lesions on surfaces with which the discharge comes in contact.

(6) Soft, no surrounding induration.

(7) Early, painful, inflammatory lymph-nodes ("buboes").

Chancroid is due to a specific streptobacillus, described by Ducré as short and thick, with rounded ends, somewhat dumbbell shaped.

We shall concern ourselves here with the *treatment* of three lesions only—*chancre, bubo,* and, incidentally, *chancroid.*

The **treatment of the primary lesion—chancre**—has been the subject of active discussion. Many experienced surgeons have maintained that the chancre should be excised so soon as it is discovered, while a coincident constitutional treatment should be begun at once. Per contra, others used to believe that the early constitutional treatment of syphilis is frequently founded on errors in diagnosis; that a positive diagnosis of syphilis cannot be made until skin-lesions appear; and that to institute early constitutional treatment frequently may serve to abort skin-lesions, so that in a given case no positive diagnosis ever can be made. Nevertheless, the patient is doomed to go through

life with the stigma of syphilis upon him, when indeed he may never have had syphilis. Recent investigations and discoveries have changed all this, in the hands of experts, and when laboratory facilities are at hand. We determine the diagnosis by the Wassermann test; and we cure the disease by judicious hypodermic injections of salvarsan ("606").

It seems proper in this place, however, for the assistance of many practitioners, to describe the old-time and successful method of treatment still commonly employed. Salvarsan and neosalvarsan may be obtained from any of the large manufacturing chemists, and with proper directions for their use.

As to the conventional mercurial treatment, so soon as the diagnosis of syphilis is confirmed by the appearance of skin-lesions, begin constitutional treatment with mercury—either internally, in pill form, externally, by inunctions, or by hypodermic injection. Undoubtedly inunctions are the most effective if they are persistently employed, but they are an intolerable annoyance, and few persons can be found to use them faithfully.

Treatment by Mouth.—My custom is to begin with a pill of the prot-iodid of mercury, gr. $\frac{1}{6}$ by mouth, three times. After this dose I give one more pill daily until the patient begins to show symptoms of gastric or intestinal disturbance. By this time he may be taking 10, 12, or 15 pills daily. If, for example, his maximum dose is 12, we conclude that he can take one-half of that dose continuously. We, therefore, prescribe 6 pills daily to be taken for many months—usually for from twelve to twenty-four months. Under this treatment the syphilitic lesions disappear in a very few days, and most patients regain symptomatic health promptly.

Treatment by Inunctions.—An excellent mercury-bearing ointment is:

℞. Ung. hydrarg.,
Ung. petrolati carbolat.....aa ℥j.
M. Divide in 8 parts, placing each in wax paper or a cachet.
Sig.—Use one as a surface application immediately after a hot bath.

The patient must take pains not to cause excessive skin irritation by the use of ointments. He should rub in the ointment for five minutes, in a new spot every day, choosing surfaces covered by delicate skin—the inside of the thigh, the arm, the chest beneath the axilla.

Treatment by Hypodermic Injections.—Hypodermic injections are effective, but their employment is an intolerable nuisance to the patient, who must visit the surgeon frequently to receive them. Sometimes they are painful. They should be given deep into the lumbar and gluteal muscles. The ordinary dose is mercury bichlorid, gr. $\frac{1}{12}$ to $\frac{1}{8}$ daily. Edward Martin's excellent rule is to repeat this in appropriate doses until the syphilitic symptoms disappear, after which time it is continued in series of six doses, with intervals of six days' rest for the first year; and in series of three doses, with intervals of nine days' rest for the second year; the quantity being increased or diminished in accordance with the clinical indications.

Here is a useful formula:

R. Hydrarg. bichlor. corros..... gr. 4.8
Sodii chlorid..... gr. 3.5
Aqua destillat..... ℥j.
SIG.—10 to 30 minims, hypodermically.

The **treatment of chancroid** differs materially from the treatment of chancre. Chancroid must be attacked vigorously. If it is superficial and of moderate extent, cauterize it thoroughly with pure carbolic acid after careful preparation of the parts and the induction of anesthesia, either local or general. If the ulceration is deep and involves the skin and prepuce extensively, one may advantageously employ the Paquelin cautery. Often, however, cauterization is impossible on account of the objections of the patient and the extent of the lesion. In most cases wet dressings will be found comfortable, and nearly always in case of extensive chancroid the patient should be kept quiet in bed. I have the ulcer cleaned up twice daily with gentle applications of hydrogen dioxid, half strength, while the penis is kept soaking continuously in a weak corrosive sublimate poultice, made up of strips of gauze, wrung out of corrosive sublimate, 1:5000.

Vigorous constitutional tonic treatment with iron and an out-of-doors life are important. As yet I have seen no benefit from the use of opsonic vaccines.

The adenitis of the groin (bubo) resulting from chancroid is often vicious. A mass of broken-down lymph-nodes may develop in a few days from the onset of the disease. If the enlarged nodes are discovered early, before suppuration occurs, shave the parts and apply daily an ointment composed of mercury iodid, 10 parts; petrolati, 90 parts. Later, in case the mass suppurates, open it extensively, paint the interior of the wound with tincture of iodin, and pack it with iodoform gauze.

Chancroids with their associated buboes often cause pronounced constitutional disturbance. The patient seems very sick. His temperature may run high and his appearance may be typhoidal even. Keep him in bed, and treat him as a sick man until his temperature is normal and his wounds are granulating.

INJURIES OF THE PENIS

Injuries of the penis sometimes occur as the result of blows and falls astride. These injuries may cause tearing of the urethra, the corpus spongiosum, and the corpora cavernosa, and, according to the severity of the injury, may or may not call for operative treatment. In the case of rupture of the urethra the canal must be cut down upon through the corpus spongiosum and sutured; and it is wise, generally, to fasten a catheter into the bladder, through the urethra, to remain in place during the first week of convalescence. Such a ruptured urethra may give rise to extravasation of blood and urine, extensive infiltration and sloughing of the tissues, enormous swelling, and ecchymoses. A urethra ruptured

anterior to the triangular ligament and cut-off muscle, produces an extravasation into the scrotum, penis, and thighs. A urethra ruptured in the posterior portion gives rise to extravasation into the perineum, buttocks, groins, and abdominal wall. As I said in describing extraperitoneal rupture of the bladder, these extravasations must be searched out with the knife; all collections must be evacuated, the damaged urethra repaired, and hemorrhage checked. Rupture of the corpora merely must be treated by rest, ice-bags, and the control of hemorrhage.

GENITAL HERPES

Genital herpes is an eruption on the prepuce and behind the corona. It appears as a series of vesicles and is multiple. The patients are often much alarmed, and ask to have the condition differentiated from chancre and chancroid. Herpetic vesicles are multiple, small, soft, and without lymphatic enlargement; chancre is single, with an indurated base, ulcerating, and with lymphatic enlargements; chancroid is multiple generally, ulcerating and with a soft base, and generally with lymphatic enlargements (bubo). *Treat* herpes by cleanliness and the application of borax and starch, aristol, or some other simple drying powder.

VENEREAL WARTS

Venereal warts or *verruca* are small warty appearances upon the glans or prepuce—a hypertrophy of the papillæ, proliferation of the connective tissue, and increased vascularity. They may appear also on the scrotum and thighs. When on mucous surfaces, they are moist and soft; when on the skin, they are dry and hard. They may be single or multiple, and may grow to a considerable size. They may ulcerate and break down, giving rise to a discharge and a foul odor. You must differentiate these warts from the flat condylomata of syphilis. The condylomata are of late appearance and of slow growth; they may be of wide extent and are less likely to slough and become foul than are warts. Epitheliomata also must be distinguished, but epitheliomata, appearing in elderly persons, are of very slow growth, and their nature may be ascertained by the examination of a microscopic section. The cure of venereal warts generally is an easy matter. They may be aborted when seen early, by thorough washing, three or four times a day, with a 1:1000 bichlorid solution, and dusting with calomel. The best treatment when they are at all advanced is to cocainize the parts, thoroughly to curet away the growths, and dress the wounds with aristol.

Horns sometimes grow from the genitals, and J. B. Blake recently has reported the case of an extraordinary horn, half the size of the little finger, springing from the dorsum of the glans.[1]

CIRCUMCISION

The circumcision of infants is a useful old custom which we are returning to in these days. Parents often ask the purpose of this treat-

[1] J. B. Blake, Boston Med. and Surg. Jour., 1907.

ment. In the case of a child with a long prepuce of narrow opening, which cannot be drawn back over the glans after faithful effort, circumcision anticipates many troubles for the growing boy. It renders possible proper cleanliness; it prevents the collection of smegma beneath the prepuce; and smegma is an irritant which leads the child to masturba-



Fig. 273.—Circumcision—step 1.

tion, to nocturnal incontinence, and may set up irritating inflammations with phimosis. Circumcision properly done is a comforting operation. Circumcision improperly done produces an organ almost deformed. Cutting off too much skin results in a painful stripping of the glans; cutting off too little skin leaves absurd flapping dog's-ears. Don't

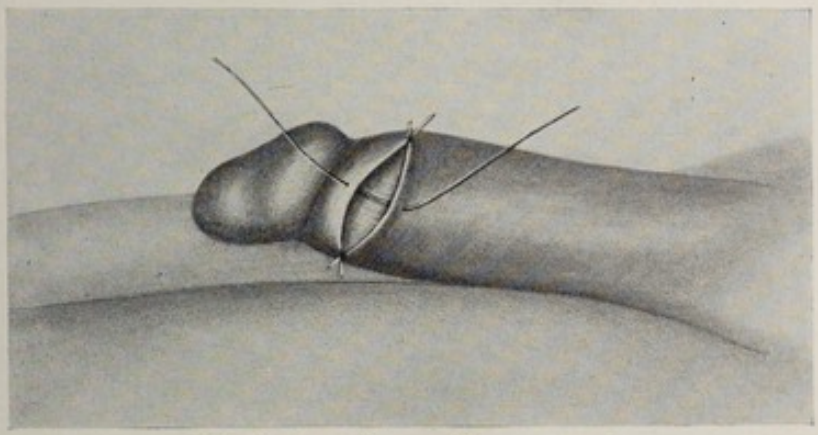

Fig. 274.—Circumcision—step 2.

operate with cocain anesthesia in the case of an infant. Use ether, for the patient should be properly anesthetized and the surgeon should be enabled, with painstaking care, to accomplish this little operation. Draw out the prepuce well beyond the glans and catch its edge on either side of the middorsal line with snap forceps; then, while holding it stretched, slit up the median line, as far as the corona, avoid-

ing any radicles of the large dorsal vein. Then trim off the resulting circular flap, taking pains not to make it too short. Tie all bleeding points with fine catgut, and sew together the cut mucocutaneous flaps incircling the glans with a fine, plain, continuous catgut stitch. If you work with care and deliberation, the wound should heal promptly in four or five days. Rough work will give rise to ecchymosis and painful swellings. There is no use in attempting to apply a permanent dressing, especially in the case of an infant, for dressings must be removed when the patient urinates, and at the best a baby's dressing is sure to become soaked. I have the patient wear a diaper, with a wad of sterilized gauze wrapped about the penis. With every act of urination the gauze is removed, the penis gently sprayed off with warm sterilized water, and fresh gauze and diaper applied.

The **circumcision of an adult** may be done under cocain anesthesia. The man should be directed to lie still for four or five days at least, as the irritation of walking about almost certainly leads to delayed wound healing. The figures illustrate an excellent method.

CANCER OF THE PENIS

Cancer of the penis[1] is a rather frequent tumor of indolent growth for malignant disease. Usually it appears first as a wart on the glans or

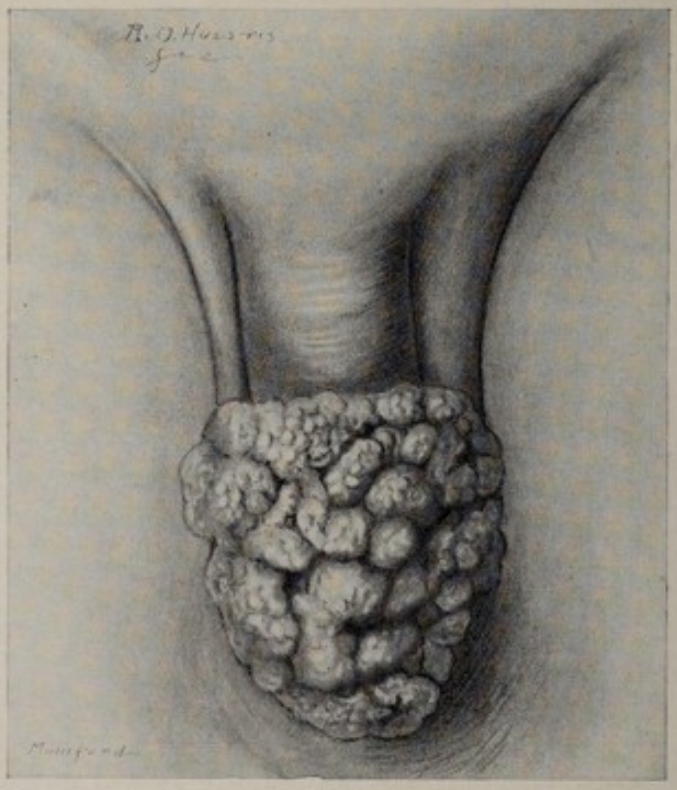

Fig. 275.—Carcinoma of the penis.

prepuce, and one finds it in men in middle life, commonly between the ages of fifty and sixty. In its course cancer destroys the penis if left

[1] I refer the reader to an extremely illuminating article on this subject by J. D. Barney, Ann. Surg., December, 1907.

untreated. It develops into an ulcerating area or a considerable cauliflower growth; it may involve the urethra,[1] giving rise to fistula, and it spreads to the inguinal and lumbar lymph-nodes even. As I said in speaking of warts, cancer must be distinguished from verrucæ, herpes, and chancre.

The only **treatment** is operative, and that is useless if considerable metastases have developed. The operation is amputation of the penis. Bigelow used to teach that the way to amputate the penis was to cut it off at a single stroke and sew the loose outer skin to the stump of the urethral mucosa. A much better operation is the combined dorsal flap and circular method. This requires a little careful dissecting. A flap of considerable length is taken from the dorsum, and the penis is amputated at the root of the flap, the corpus spongiosum being left a quarter of an inch longer than the corpora cavernosa. The dorsal

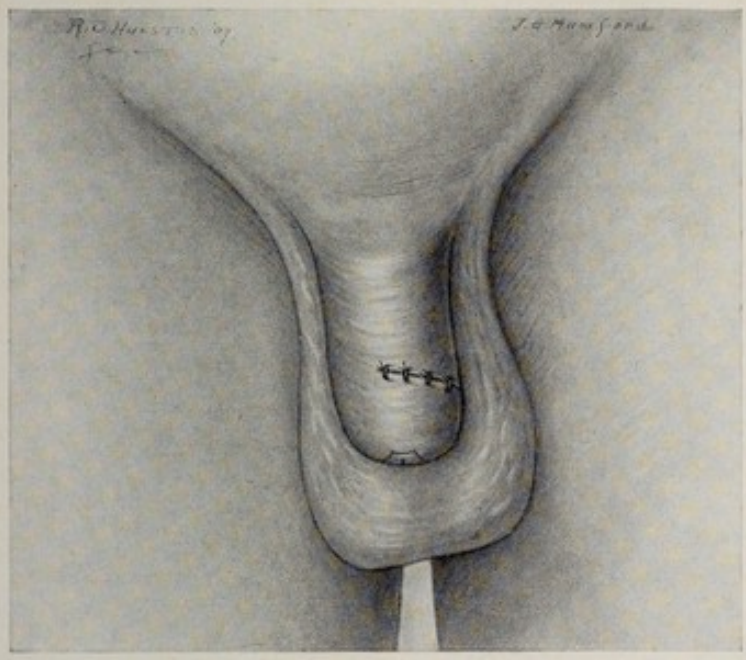

Fig. 276.—Amputation of the penis.

flap is then drawn over the stump and stitched into place on the opposite side. A hole is excised from the flap opposite the urethral stump. Through this hole the urethra is drawn and is fastened to the edges of the hole in the flap.

In early cases amputation saves the patient's life, but in far too many instances recurrence occurs in the penis or in the lymph-nodes.

FOREIGN BODIES IN THE URETHRA

Foreign bodies occasionally are found in the urethra, and serious injuries from them may result, with obstruction of the stream, ulceration of the canal, and the formation of abscesses and fistulæ. Children and persons with depraved instincts frequently are known to insert

[1] J. D. Barney, Cancer of the Male Urethra, Boston Med. and Surg. Jour., December 12, 1907.

foreign bodies into the urethra, and all sorts of curious articles have been found there. The bodies may be expelled by the stream of urine; or one may be obliged to search for them with the endoscope, and to extract them with fine grasping-forceps; or one may have to cut down upon them from without and open the urethra to extract them. In the last case sew up with fine catgut the urethra, and fasten into the bladder an in-lying catheter for four or five days.

Calculus of the urethra may form about a foreign body, or a urinary calculus from higher up may lodge in the urethra. Extract it in like manner as you would a foreign body.

PARA-URETHRAL ABSCESS

Para-urethral abscess may form as the result of ulceration by a foreign body in the urethra or as a complication of gonorrhea. Its presence is readily detected by the touch. Sometimes it may be opened with a fine-pointed knife or urethrotome from within the urethra. In any case the patient should be put to bed, and careful aseptic treatment with urotropin and irrigation should be instituted.

STRICTURE OF THE URETHRA

Stricture of the urethra should be ranked with venereal disease as one of the commonest afflictions known to man. Writers tell of congenital and acquired strictures. In fact, congenital strictures are extremely rare, except for that congenitally narrow meatus of which I have spoken; but acquired stricture is common enough, and there are two ordinary methods of acquiring it—by an injury or by a gonorrhea. In general terms a stricture, in whatever way acquired, arises from the formation of exudate or scar tissue pressing upon or actually involving the urethral mucosa.

Traumatic stricture occurs usually in the perineum, though it may occur elsewhere, and especially from the ulceration of a foreign body. The common cause of traumatic stricture, however, is from a fall astride of some such object as a fence, with a resulting rupture or bruising of the perineum, often involving the bulbomembranous urethra. Such a stricture as this may cause slight and temporary disturbance only, or may be a life-long affliction. As the wound heals and the scar contracts, the caliber of the urethra may be greatly narrowed or obliterated even. If the patient is seen immediately after the injury, and if there be such evidence of *laceration* of the urethra as complete retention, extravasation, or bloody urine, the surgeon should etherize the patient; place him in the lithotomy position in a good light; pass a staff or sound as far as possible into the urethra; cut down upon it through the perineum; control the hemorrhage; seek the torn parts of the urethra; sew them together with fine catgut (No. 00); and fasten a catheter into the bladder. Such prompt treatment will nearly always remedy permanently the damage. On the other hand, if urgency is not apparent and the injury is treated by palliative measures, and the wound is allowed to heal in

the natural manner, it heals with a resulting stricture often. The consequences of stricture I shall speak of at more length when describing that form which is due to gonorrhea; suffice it to say that in the case of traumatic stricture the patient's symptoms are wont to be progressive, often running over years before he consults the surgeon. He will then tell of a gradual narrowing of the stream, of difficulty in micturition, accompanied often by burning and pain, sometimes of frequency suggesting an associated cystitis. Sometimes there will be found a small, thick-walled bladder, at other times a thin-walled distended bladder.

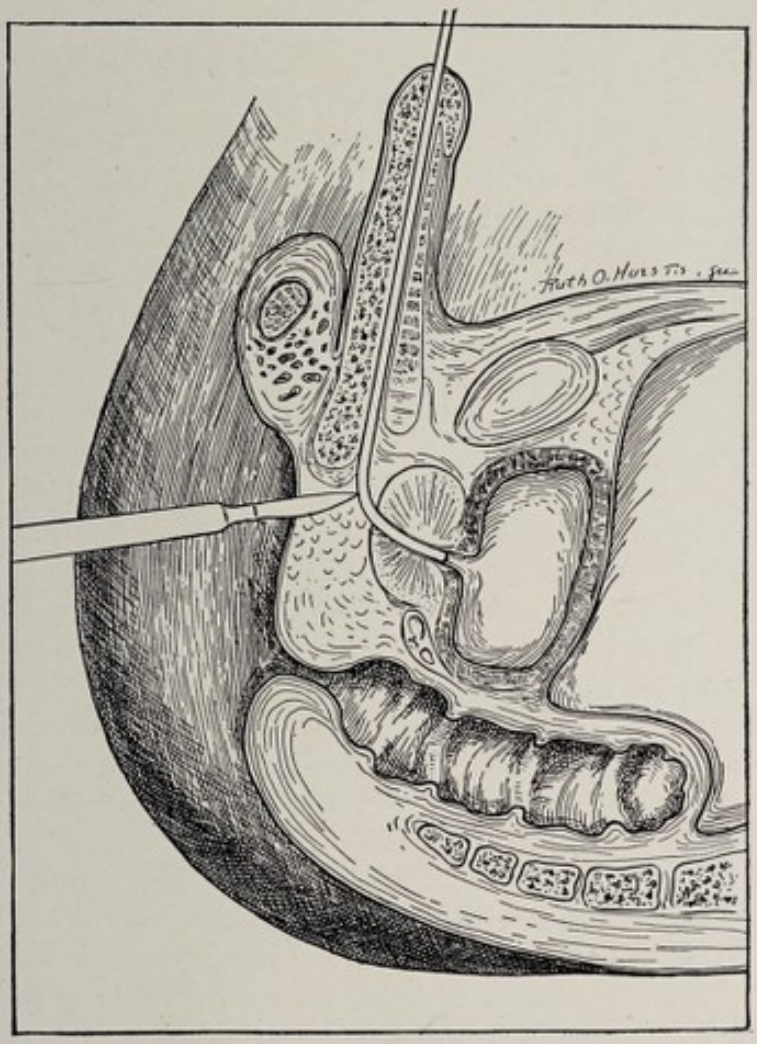

Fig. 277.—Perineal urethrotomy, cutting on the staff.

The *treatment of traumatic stricture* is imperative and is by operation. The patient is placed in the lithotomy position. A staff is passed down to the stricture and is cut down upon through the perineum. In these cases, cutting operations from within by the urethrotome are improper, though a gradual dilatation with sounds of a traumatic stricture is suitable, when sounds can be passed without violence. Unfortunately, however, it may be impossible to pass any instrument through the stricture into the bladder, because the course of the stricture often is extremely tortuous, even if it is not too narrow to admit the smallest instrument.

The operation of *perineal section* is our usual resort, therefore, and this may prove to be an operation of extreme difficulty. An assistant must hold the staff in the urethra so that the staff bulges the perineum. The surgeon then cuts down upon it, opens the urethra, and secures its edges with retention stitches. Usually there is a good deal of bleeding, which obscures the field if the hemorrhage be not controlled. The surgeon next endeavors to discover the uninjured proximal end of the urethra. This may necessitate a tedious and extensive dissection. If the scar tissue be insignificant in extent, it may be cut away, the proximal urethral stump discovered, and an end-to-end urethral junction established. The difficulty is to find the proximal end. There are a number of maneuvers in technic which help to accomplish this purpose. One is to discover and identify an important artery—a branch of the artery of the bulb, which runs forward along the course of the urethra and close to that canal. If one can isolate this artery, one may be sure that he is in close proximity to the sought-for urethra. Again, the elusive urethra may be discovered by forcing urine through it from the bladder, by pressure on the bladder above the pubes. To this end the surgeon should instruct the patient not to empty his bladder before the operation. Often no special difficulty is encountered, and almost at once, on opening the perineum, the surgeon finds the urethra and passes a probe, director, or Teale's gorget through it into the bladder. When once you have isolated the proximal portion of the urethra, do not lose it. The further treatment of the stricture is not especially difficult. If the two portions of the urethra can be brought together and sutured, the problem is solved at once. If this cannot be done, the surgeon should pass a large catheter or drainage-tube through the perineal wound into the bladder, and fasten it there for temporary drainage. At the end of five or six days, when granulations have begun to appear, the drainage catheter should be removed, and sounds of a proper size should be passed every other day through the penile urethra and into the bladder. The success of this maneuver in reëstablishing the normal passage depends upon the fact that the urethral mucosa has a curious capacity for bridging space, as we see illustrated in the restoration of the urethra after it has been torn out in the operation of suprapubic prostatectomy.

As a rule, the convalescence from perineal section is easy and surprisingly short. The perineal fistula closes in two or three weeks, and the urethra soon takes up its proper function. It is well to pass a sound occasionally, perhaps once or twice a month, for several months after the operation, in order to provide against recontraction of the canal. In some rare cases a permanent cure is not established, owing to the wide damage caused by the original traumatism. In such cases the patient's comfort through the rest of his life will depend upon the occasional passage of a sound.

Acquired stricture, the result of gonorrhea, may be inflammatory and temporary in exceptional cases, but is usually due to permanent tissue changes—organic stricture. There is also the **spasmodic stricture,** the result of a contraction of the circular muscle-fibers of the

urethra or of the compressor urethræ. This spasmodic stricture is a reflex affair commonly. It may be a neurosis; it may be due to terror, anxiety, or embarrassment, or it may be due to posture, such as lying on the back. I have already discussed it when speaking of diseases of the female genital organs. Analogous conditions exist in the male. Usually the spasm may be relaxed by hot applications over the bladder and on the perineum, by immersion in a warm bath, often by the sound of trickling water; if necessary, by the use of small doses of opium, preferably in suppository form (powdered opium, 1 grain), and if these measures fail, by the catheter.

Inflammatory stricture is a rare condition, and some authorities have doubted its existence, attributing the state to a previously existing organic stricture. I have convinced myself, however, from experience with a variety of cases, that inflammatory stricture, a swelling of the urethral mucosa, may sometimes exist so as to cause narrowing of the stream or its complete obstruction even without relation to organic stricture. The obstruction of inflammatory stricture may be easily overcome by immersion in the warm bath, or if that does not succeed, by a small soft-rubber catheter.

Organic stricture from gonorrhea is the condition with which we are concerned here; and organic stricture of gonorrheal origin is the stricture of daily experience. A long-standing gonorrhea sets up and leaves behind it in the mucosa areas of ulceration, or chronic injections and thickenings of the mucous lining. At the affected points, infective agents penetrate the mucosa and involve the para-urethral structures. Harrison has said that urine actually penetrates through the mucosa, but this is not necessary for the establishment of an inflammatory exudate. This exudate encroaches from without upon the lumen of the urethra and causes narrowing of that canal. In process of time cicatricial tissue takes the place of the exudate, with a resulting permanent contraction of the urethra—by cicatricial tissue which may or may not involve the urethral canal itself. The reader will perceive, therefore, that the extent and nature of the stricture may vary greatly. There may be the rare, single, encircling stricture; but more commonly the stricture is rather diffuse, and frequently there are multiple strictures. The urethral canal may present a mere, smooth narrowing, or it may be throw into folds and pockets so that the urine must pass in a labyrinthine course. From these conditions the reader will see that the treatment of stricture may be a simple undertaking or may be extremely complicated.

The **symptoms** of stricture vary with the character and degree of the contraction. Usually the patient will give a history running back over about two years. He tells of frequency of micturition and of narrowing of the stream, which may be double, flat, or spray-like, or may be passed in drops only. In advanced stricture there is diminished expulsive power and dribbling at the end of urination. Occasionally there is scalding. Rarely there is that retention of which I have treated in Chapter XIV. During the act of micturition there is wont to be vesical

tenesmus. Sometimes there is a constantly present slight urethral discharge of mucoid material; often the act of coitus is incomplete, and the patient may suffer from a condition of general debility induced especially by involvement of the bladder and kidneys and an extensive breakdown of the urinary apparatus.

In explanation of some of the above symptoms the reader should acquire a further knowledge of the nature of stricture and its sequelæ and of the complicated processes which it sets up. Bearing in mind that the normal urethra is a collapsible, elastic tube, through which urine flows without obstruction, and in which the pressure is everywhere equal during micturition, one perceives that stricture alters this normal condition—stricture of the largest caliber even. Whenever there is the slightest obstruction to the stream of urine, the pressure in the urethra behind the stricture is raised, and is lowered in front of the stricture, just as one sees the pressure in a common garden-hose affected by constricting the tube ever so slightly with the fingers. In the urethra the effects of the constriction slowly become manifest, and the remote symptoms from which the patient suffers eventually appear to be due to the constant back pressure rather than to the mere trifling inconvenience of emptying the bladder slowly. Behind the stricture the dilatable urethra is distended and may be permanently sacculated even, becoming a reservoir for small amounts of urine which dribble away after the act of micturition has been checked. In this dilated urethra there is encouragement for a process of chronic inflammation, which extends often to the prostatic sinuses, seminal vesicles, and testes. Behind the prostate the bladder is called upon for increased work in order to empty itself against the resistance of the structure; the bladder becomes hypertrophied and may become sacculated; later it may become thin-walled, flabby, distended, and incapable of proper contraction; frequently it is found to be the seat of a chronic cystitis; and, finally, the irritating process extends to the ureters, renal pelves, and kidneys, until the whole urinary tract is involved in a process of chronic inflammation. One sees then that strictures of both large and small caliber are not lightly to be regarded.

The **treatment of organic stricture** of gonorrheal origin is similar to that I have described in discussing traumatic stricture. The constriction or constrictions must be located. This may be accomplished roughly by palpation of the urethra from without and the determination of abnormal thickenings in its course. For the more accurate ascertaining of the location and extent of strictures, bougies or the instrument of Otis suffice. In my opinion the *bougie à boule* is most useful. Different sizes of this instrument are used, and as they pass into and beyond the stricture and are withdrawn, they are made to determine the stricture's location and caliber. They will fail to detect, however, a stricture of large caliber lying behind a stricture of small caliber. To determine this condition the urethrometer of Otis is invaluable. Frequently the surgeon is in doubt as to what constitutes a stricture of large caliber in a given urethra. He may determine this by the proportionate scale

of measurements of the flaccid penis, which I have already described. Having determined the site and extent of the stricture, the surgeon may cut it or dilate it gradually. In general terms the problem resolves itself into a consideration of the treatment of penile strictures or of strictures of the bulbomembranous portion. If the stricture be confined to the penile portion, and if an instrument can easily be engaged in it, the stricture can generally be stretched to a proper size by graduated steel sounds. This operation may be done with the aid of cocain anes-



Fig. 278.—Olivary bougie (Fowler).



Fig. 279.—Otis's urethrometer (Fowler).

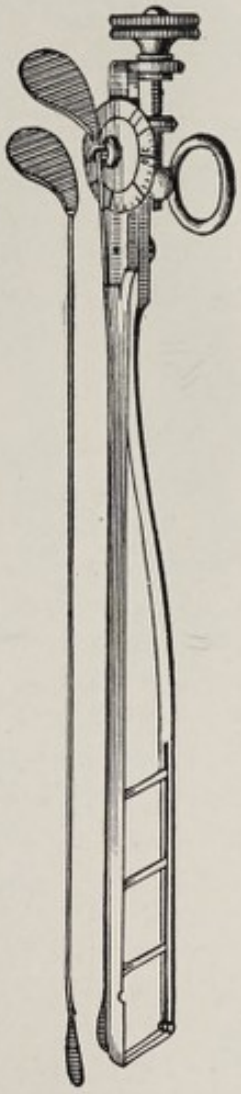

Fig. 280.—Dilating urethrotome of Otis (Fowler).

thesia (4 per cent.), the size of the sounds being increased gradually by three or four sizes at each sitting, and the instruments being employed once every five or ten days. By this means, in the course of a month or two, a stricture of moderate dimensions may be cured; but the patient should be instructed to have his urethra searched occasionally thereafter in order to anticipate a recontraction of the stricture. If the penile stricture be of small caliber, and if it does not yield readily, it may be cut with the Otis urethrotome, after which the use of sounds

must be continued for several weeks. The use of the urethrotome must be limited to strictures anterior to the bulbomembranous portion. I do not believe that the rapid divulsion of strictures in the penile portion is a proper operation except in the case of soft strictures of large caliber. Strictures of the bulbomembranous urethra may be treated with sounds when the passage of sounds is possible. In a large proportion of cases this treatment is sufficient. In the case of complicated, close, and unyielding strictures, however, the passage of sounds is impossible, so that under these circumstances the surgeon must resort to the perineal section, as I have already described it. Rapid divulsion of close, hard, deep strictures is not permissible, because rapid divulsion implies violent tearing up of tissue, which may cause serious hemorrhage, and leave the lacerated urethra in a condition which admits of infection and urinary extravasation.

So much for the treatment of stricture, one of the most obstinate and troublesome of the sequelæ of gonorrhea. Patience and tact, almost superhuman, sometimes are needed for the conduct of these trying cases.

URETHRAL FISTULA

Urethral fistula, a sinus between the urethra and the outside world, is a condition due to injury or to the breaking outward of a paraurethral abscess. It results from gonorrhea generally. These fistulæ may discharge a part or the whole of the contents of the bladder. Often they lie behind a stricture, which complicates the situation. They cannot be cured by mere cureting or touching with caustic or the cautery, as used to be attempted. The proper *treatment* is to divide them freely from without—practically an external urethrotomy, and then to curet them or excise them. At the same time the urethra must be cut or stretched to its proper size. This treatment results usually in a prompt cure.

URETHROSCOPY

Urethroscopy deserves a word of explanation, for it is the means by which most easily the interior of the urethra is examined. The principle of the urethroscope is similar to that of the female cystoscope (described in Chapter X). The instrument consists of a hollow steel tube which is passed into the urethra and is used in connection with a head-mirror, which throws a reflected light into its depths; or the direct light of a cold lamp near the distal end of the tube itself may be employed. In this fashion the surgeon inspects the lining of the urethra. He keeps the field clean with swabs of absorbent cotton passed through the tube, and notes such abnormalities as congestion, inflammation, patches of ulceration and cicatrices, and if he choses he makes applications directly to these places. In this way, avoiding copious injection, he is able to treat the abnormal processes without irritation or damage to the sound portion of the urethra. The most useful applications are silver nitrate and argyrol in varying strengths. The surgeon should not

use oil or vaselin preparations as lubricants to the urethroscope, for they smear the field and interfere with the proper action of applications. There is no better lubricant than glycerin. It may seem necessary to use cocain in some cases, but this should be avoided, so far as possible, lest it also modify the action of the silver drug.

HYPOSPADIAS AND EPISPADIAS

Hypospadias is an abnormality of the penis due to defects in development. The urethra opens short of the meatus. Hypospadias results from a failure of the two lateral halves of the penis to unite on the lower median surface. Hypospadias is not very uncommon. *Epispadias* is

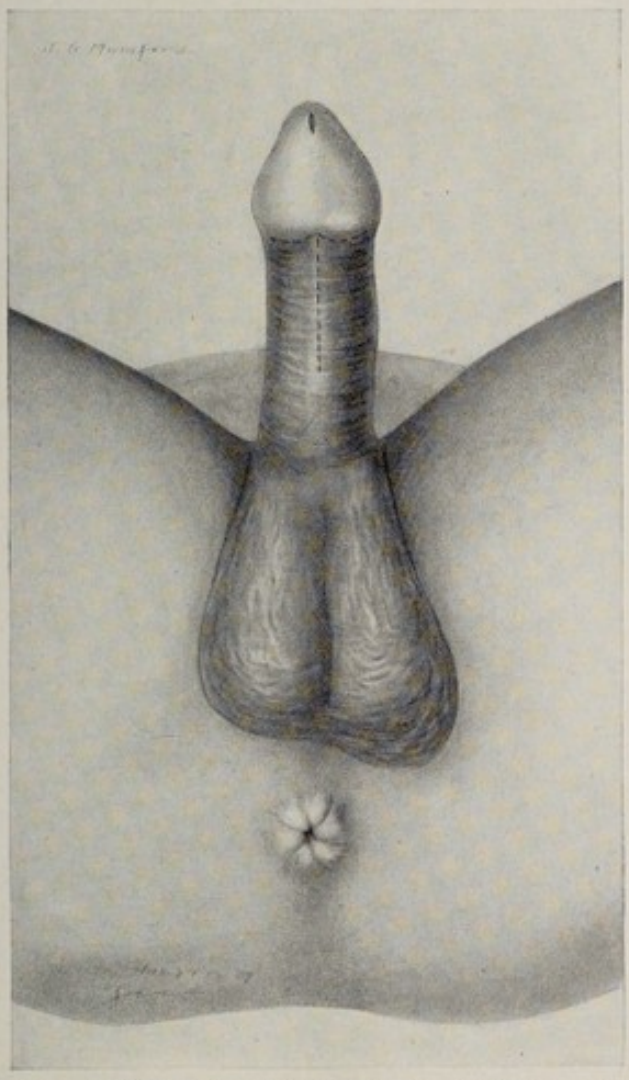

Fig. 281.—Beck's operation for balanitic hypospadias. Line of incision.

due to a failure of union of the upper penile surface, and is rare. I referred to it in discussing exstrophy of the bladder, and will say nothing further of it here, except to observe that hitherto most attempts to cure it by operation have been discouraging.[1]

[1] For an encouraging case see Carl Beck, A New Method of Operation for Epispadias, Med. Record, March 30, 1907.

Hypospadias is of varying degrees, and frequently has been relieved or cured by operation. It may appear as a mere enlargement of the meatus downward, or the urethra may end and discharge above the glans, or in the perineal form the urethra may end at the scrotum. The *symptoms* and annoyance of the condition vary with the location of

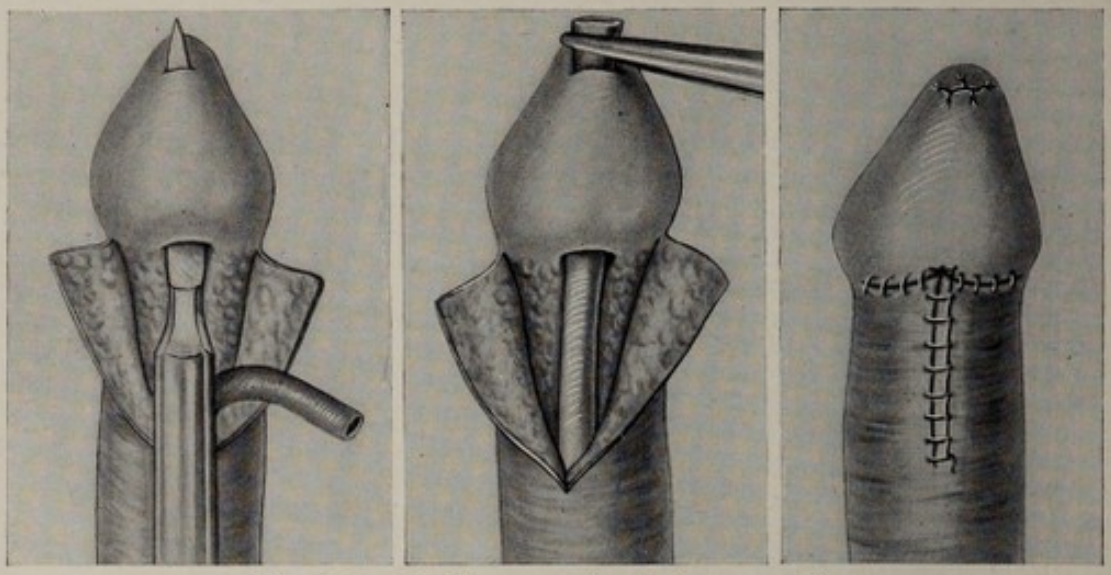

Fig. 282.—Beck's operation for hypospadias.

the urethral exit. If the exit be in the glans, there results discomfort merely and soiling during micturition, but there is no interference with procreation. When the urethra terminates near the root of the penis, however, both micturition and coitus are seriously interfered with, and procreation is impossible.

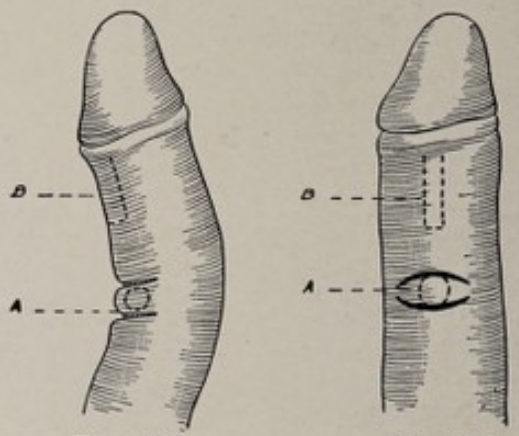

Fig. 283. Fig. 284.

Figs. 283 and 284.—Stinson's operation for hypospadias. Shows incurvation, prepuce retracted: *A*, Shows urinary orifice in body of penis; *B*, shows short blind groove in body back of glans penis.

The **treatment of balanitic hypospadias** (that form in which the urethra opens beneath the crown of the glans) is not difficult and usually is successful through the medium of Beck's operation. This consists in dissecting back two skin-flaps along the urethra for about two inches, and completely dislocating that canal. Then a false canal is formed in

the glans by plunging through it a narrow-bladed knife, which passes from the site of the present urethral exit out through the site of the meatus proper. The tip of the dislocated urethra is then seized with narrow forceps, is dragged through the new canal, and is stitched to the meatus. The skin-flaps are then replaced. Usually this operation

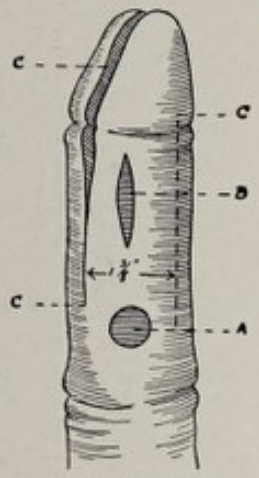

Fig. 285.—Shows urethral orifice (*A*) slit up to No. 33 French, separated from its surroundings, and edges trimmed evenly. *B* shows blind groove as in Figs. 283 and 284, but with prepuce well retracted. *C*, *C*, *C* show incisions made for the formation of the new urethra.

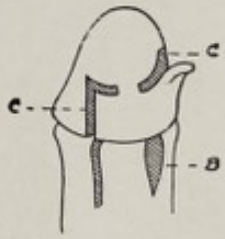

Fig. 286.—Shows incisions made and flaps of mucous membrane and skin being dissected up for new urethra in the glans and body of the penis. *C*, *C* show raw surface of the glans after lifting flaps.

results in a complete cure, but narrowing at the proper site of the fossa navicularis may occur after the operation and necessitate subsequent sounding. The treatment of penile or perineal hypospadias is by no means so easy, and is certainly difficult of demonstration. I have employed with satisfaction the method described by Stinson [1] This



Fig. 287.—The same as Fig. 288 except that dotted line (*D*) show flaps brought edge to edge.

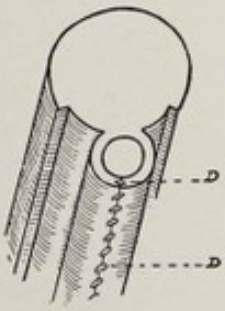

Fig. 288.—Shows the edges of the flaps taken from the glans and body, sutured to each other to form new urethra.

writer lays stress on the importance of rectifying the down curve of the penis, which is found at the site of the urethral orifice. This incurvation is remedied by dissecting the urethra from its attachments at that point and dividing all constricting bands by transverse incisions, so as thor-

[1] J. Coplin Stinson, Improved Operation for Hypospadias Involving the Glans and Penile Portion of the Urethra, Jour. Amer. Med. Assoc., December 2, 1905.

oughly to straighten the organ, taking pains at the same time not to damage the corpora cavernosa. The further operation is briefly as follows: (1) Drain the bladder by perineal section and maintain the drain-

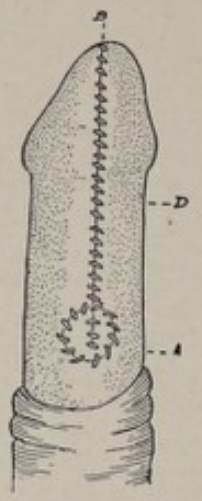

Fig. 289.—Shows same as Fig. 288, *A*, and anastomosis made between the new and old urethral orifices. *B* shows the end of new urethra in glans penis. *D* shows raw surfaces of glans and body whence the flaps have been taken.

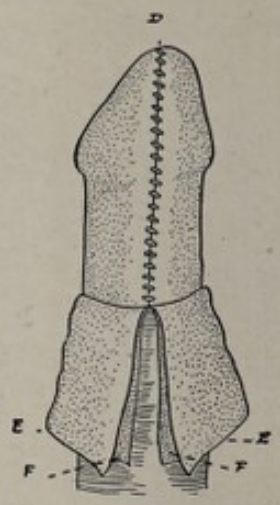

Fig. 290.—Shows the newly placed prepuce, cut down the median line and its layers of mucous membrane (*E*) and skin (*F*) being dissected from each other ready to be used to cover completely the raw surfaces of the glans and body of the penis, and also to bury the stitches uniting the edges of new urethra and forming anastomoses between the new and old urethras.

age during the patient's convalescence from the plastic operation on the penis. (2) Enlarge the urethral orifice with a No. 33 French sound;

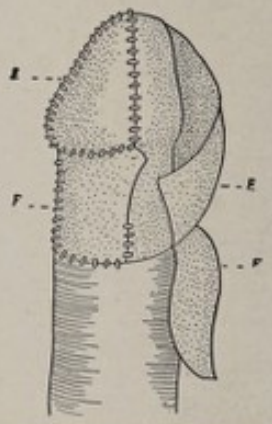

Fig. 291.—Shows layers of mucous membrane (*E*) and skin (*F*) separated from each other (shown on the right side of figure) trimmed, put in place in their respective positions, and sutured to the vertical cut edges of the glans and body, whence the layers were taken to form new urethra (*E* and *F*) (shown on left side of figure). The raw surface on left side is completely covered by the mucous and skin layers, which are also sutured transversely to each other.

form a new canal by turning over longitudinal flaps of skin and mucous membrane, and sew these flaps together longitudinally, skin side in, and to the old urethra at their proximal end. This establishes a new urethral

canal. The hood, or prepuce, is employed to cover over the raw surfaces. In order to bring this loose skin of the hood into position for this purpose, it is dissected back for a short distance from the corona; a transverse split is then cut in it on the dorsum, and through this slit the glans penis is passed. As a result of this maneuver practically the whole of the prepuce lies flapping beneath the glans and is ready to be utilized for

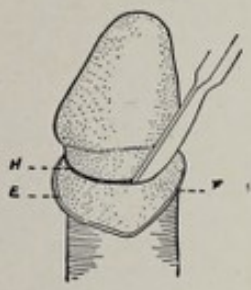

Fig. 292.—Shows separation of preputial hood (*F*), which consists of two layers, skin (*E*) and mucous membrane (*H*).

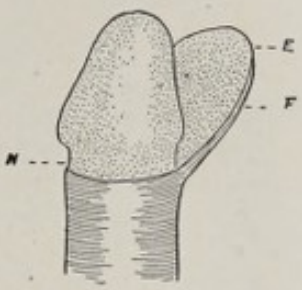

Fig. 293.—Shows the preputial hood brought down underneath the glans by carrying the glans through the transverse opening in the prepuce. *E* shows layer of mucous membrane. *F* shows layer of skin.

covering in the raw surface over the urethra. The loose prepuce is now cut down in its median line, if necessary, and its layers of mucous membrane and skin are dissected from each other, are trimmed as required, and are adjusted and sutured to the vertical cut edges of the glans and to the body of the penis, so as accurately to cover in the raw surfaces. If the original deformity presents as a perineal fistula, the raw surfaces



Fig. 294.—Shows the layers of mucous membrane and skin as in Fig. 284, *F*, sutured in their new positions to the vertical edges, transversely to each other, the cut down the median line sutured, and the skin-flaps at their lower parts sutured transversely to the skin of the body of the penis, thus completely covering all raw surfaces on the under aspect of the glans and body of the penis. While the cut down the median line was made in this case, usually this should not be done.

left by the infolding of skin in the operation may be covered by a loose flap taken from the scrotum. After completion of the operation the whole wound must be dressed carefully, and the part suspended in proper bandages, and the patient must be put to bed for ten days at least. During this time there will have been no soiling by urine, as the urine is drained away through the perineum. At the end of ten days a catheter

may be passed through the newly formed urethra into the bladder, and the perineal wound may be allowed to close. This is one of numerous



Fig. 295. Fig. 296. Fig. 297.

Figs. 295, 296, and 297.—Showing the correction of the convexity and the transverse constrictions on the upper surface of the body by making about an inch long vertical incision in the median line backward from the transverse incision made in separating hood and dissecting up and bringing forward and suturing it in the same line continuous with the transverse incision. This shortens the anteroposterior measurements and increases the transverse measurement.

operations devised for the correction of hypospadias. I have found it satisfactory and recommend it.

THE TESTICLES

Diseases of the testicles, of the *vasa deferentia,* and of the *seminal vesicles* are closely associated, and a clear comprehension of the anatomy of these parts is essential to the surgeon. In fetal life the testicles lie within the abdominal cavity, but at varying times, usually in the seventh or eighth months of intra-uterine life, they descend through the inguinal canal and are found in the scrotum at birth. In a considerable number of male infants, however, one or both of the testicles are found undescended at the time of birth, an abnormality which may well be a cause of serious anxiety to the child's parents when they regard his future.

UNDESCENDED TESTICLE[1]

Lack of descent of both testicles may threaten sterility, for after puberty undescended testicles seldom functionate. Furthermore, in any case of undescended testicle, whether the deformity be double or single, the retained organ is peculiarly subject to malignant changes, so that sarcoma of the undescended testicle has come properly to be dreaded. I have seen two grievous examples of this calamity. For this reason, when I am consulted by a man himself the victim of undescended testicle, I advise removal of the organ, for it is functionless in an adult, and liable to become the seat of sarcoma. In boys below the age of puberty, however, it is reasonable to attempt a proper placing of the dislocated organ. In a great majority of cases it is found outside of or within the inguinal canal, rarely within the abdominal cavity. In any case it may often be brought down into proper position. For centuries surgeons have endeavored to correct the deformity of undescended

[1] Walter B. Odiorne and Channing C. Simmons, Ann. Surg., 1904, vol. xl, p. 962, present an admirable résumé of this subject.

testicle, but with varying success. Certain procedures, however, have come to be regarded as serviceable, and in some half-dozen instances I have been satisfied to follow the technic of Bevan, who has operated satisfactorily on a large series of cases.[1] Bevan points out that, for clinical purposes, we may divide the condition of undescended testicle into four groups:

1. Simple failure of the vaginal process to close, giving us the picture of a congenital inguinal hernia.

2. Incomplete closure, complicated with such conditions as hydrocele of the cord.

3. Undescended testis, which presents four types: (*a*) in the abdomen in about its original position; (*b*) at the internal ring; (*c*) in the canal; (*d*) external to the external ring.

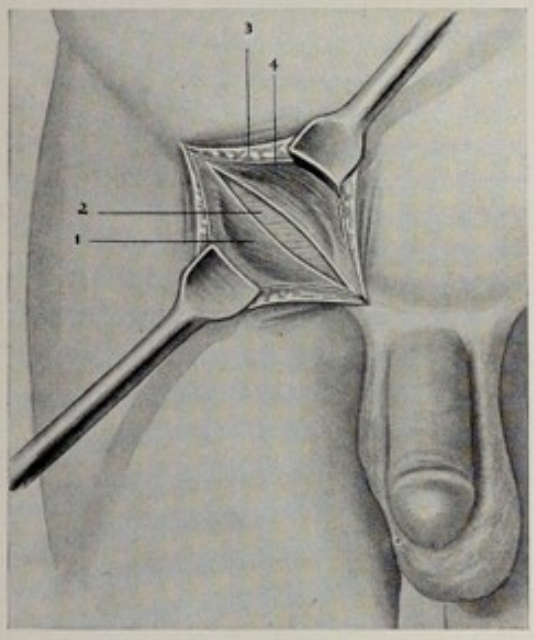

Fig. 298.—Bevan's operation. Incision through skin (3), superficial fascia (4), and external oblique (1); 2, cremasteric fascia (Bevan in Keen's Surgery).

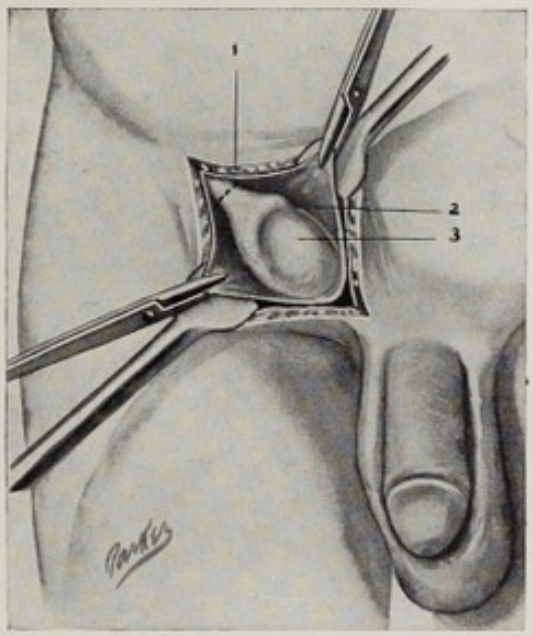

Fig. 299.—Bevan's operation: 1, Point where vaginal process of peritoneum is cut; 2, vaginal process open, exposing the testicle; 3, testicle (Bevan in Keen's Surgery).

4. Misplaced testicle: (*a*) in the perineum; (*b*) on the thigh below Poupart's ligament.

He further points out that statistics show the deformity to occur at least once in 500 male children.

Bevan asserts also that an operation to bring the organ down into the scrotum practically always is possible, and that there are few cases in which an operation is not indicated. As I have stated, I limit my operations for proper placing of the organ to the case of boys, and believe strongly that the undescended testicle in a man should be excised.

Bevan's operation for undescended testicle is performed as follows—and the sketches adapted from Bevan's article will illustrate the theme:

[1] Arthur Dean Bevan, The Surgical Treatment of Undescended Testicle, Jour. Amer. Med. Assoc., September 19, 1903.

Cut down upon the groin as though for the operation of inguinal hernia; open the inguinal canal, and lay bare the cord, testicle, and vaginal

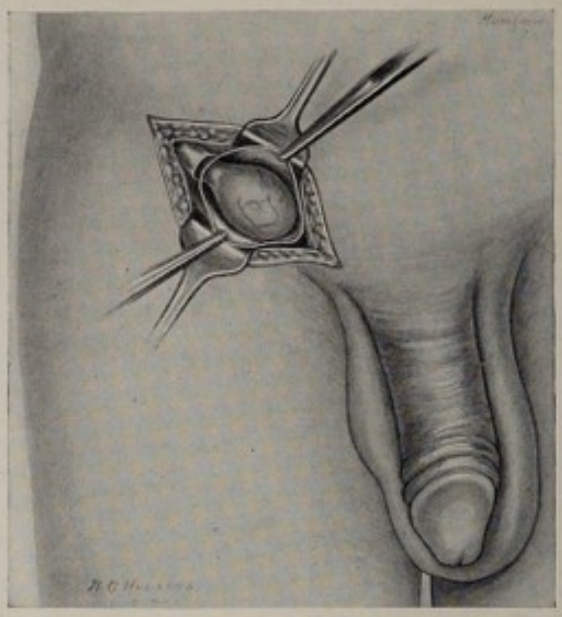

Fig. 300.—Bevan's operation—step 3. Showing vaginal process cut across above testis.

process (the large peritoneal sac containing the testes, and continuous with the peritoneal cavity). Open the sac, expose the testicle, and re-

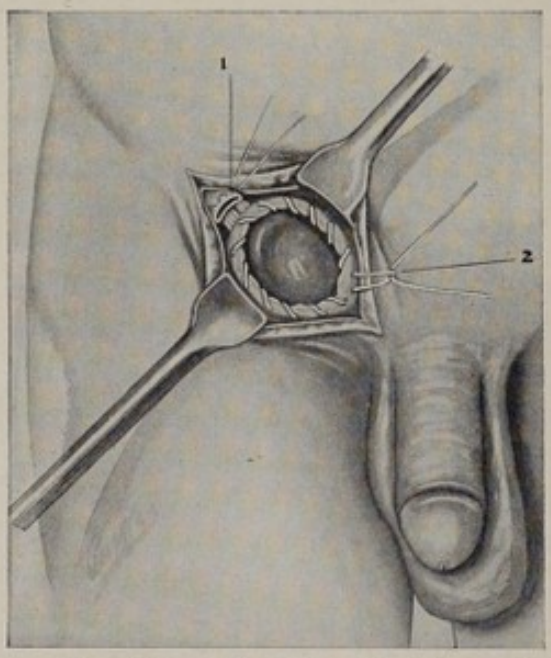

Fig. 301.—Bevan's operation: 1, Upper end of vaginal process of peritoneum ligated; 2, purse-string suture closing lower end of vaginal process and forming a tunica vaginalis for the testicle (Bevan in Keen's Surgery).

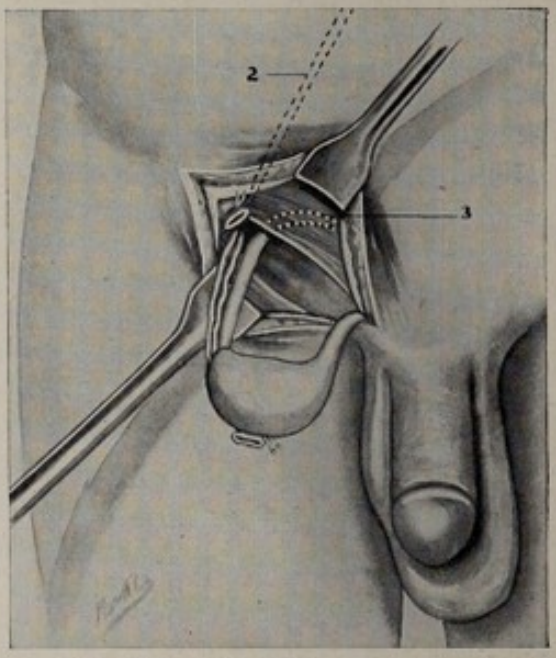

Fig. 302.—Bevan's operation. Cord lengthened and testicle freed and ready for replacement; 2, the spermatic vessels; 3, the vas deferens (Bevan in Keen's Surgery).

duce any hernia which may be present. Then cut across the vaginal process above the testicle and secure the proximal stump as in the case

of a hernia. Sew up the distal portion of the vaginal process about the testicle, and so furnish that organ with a tunica vaginalis. It now remains to bring the testicle into the scrotum, and this is done by a process of traction on the cord and the division of retaining bands. To this end the cord is stripped up, leaving nothing but the vessels and the vas, which in turn must be separated carefully from the parietal peritoneum. By this means, in nearly all cases, the cord may be elongated satisfactorily. A pocket in the scrotum is then readily made with blunt-pointed scissors and the fingers; the testicle is dropped into the pocket and is held in place by a catgut purse-string ligature, passed subcutaneously about the neck of the scrotum. The surgeon then restores the wounded canal, sews up the inguinal hernia, and dresses the

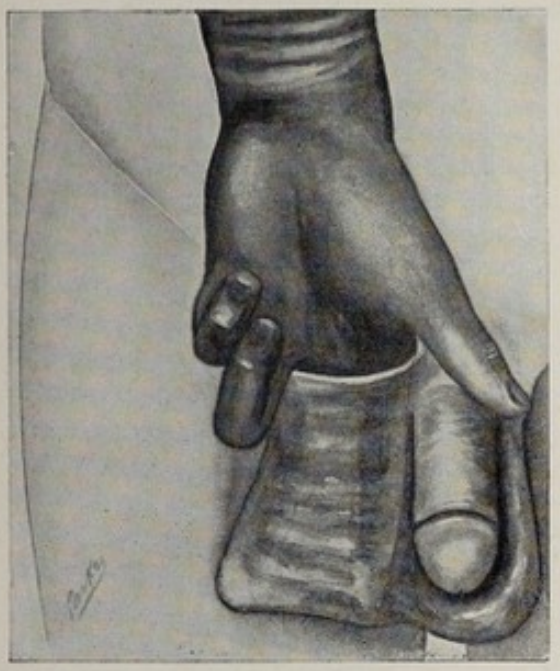

Fig. 303.—Bevan's operation. Making pocket in right side of scrotum for reception of the testicle (Bevan in Keen's Surgery).

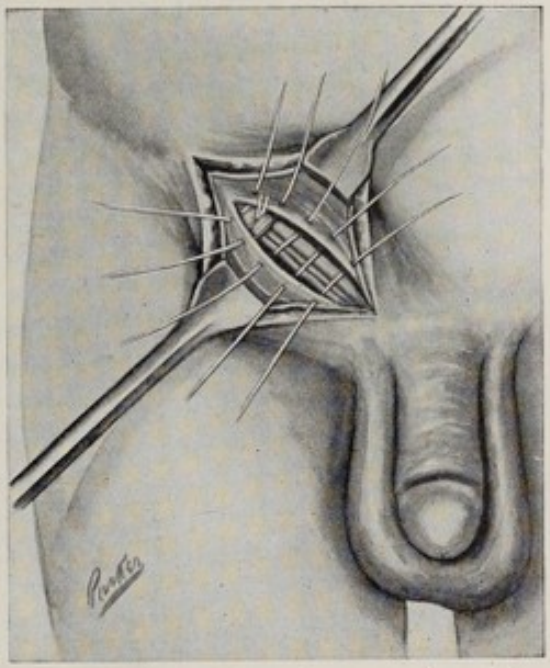

Fig. 304.—Bevan's operation. Sutures closing the wound (Bevan in Keen's Surgery).

wound with a firmly applied spica bandage. The patient should be kept in bed for two weeks at least after the operation.

In rare cases one finds that the cord cannot properly be drawn down and that this is due to short spermatic vessels, and not to a short vas. Bevan has found, and his experience coincides with my own, that the spermatic vessels may be cut away in such cases, without danger, leaving the vas and its vessels only. When this is done, a sufficiently long cord is obtained.

Absence of the testicle is a condition allied etiologically to undescended testicle. In two cases of apparent double undescended testicle I have been unable at operation to find more than one testicle in each patient. I did find, however, on the opposite side, an attenuated cord, terminating in a pinch of tissue which doubtless represented a rudimentary testicle. In such a case the cord with its terminal, useless

tissue should carefully be dissected away, while at the same time the undescended organ on the other side should be brought down into the scrotum.

WOUNDS AND CONTUSIONS OF THE TESTICLE

Wounds and contusions of the testicle are discussed by most writers on the surgery of this organ, but in truth such wounds and contusions differ in no essential from wounds and contusions of any of the soft parts, and the extent of treatment depends upon the extent of the lesion. The damaged structures should be cleaned up thoroughly and supported upon a pillow, between the legs, or on a towel sling. Mere contusions should be treated on the lines I have laid down for the treatment of epididymitis, because an acute and painful exudate with swelling is wont to occur. If the scrotum is found torn open with the testicle exposed or lacerated, the injured parts should be repaired so far as possible, and the testicle should be replaced in its normal coverings. Do not suture the proper tunic of the testicle (tunica albuginea). Take pains to drain carefully the vaginal sac, lest a troublesome hematoma form within it. The soft parts should be sutured with interrupted silkworm-gut stitches. Castration rarely is required in these cases, but when necessary, on account of sloughing, may be performed as a secondary operation.

Hematocele of the tunica vaginalis is a condition which I referred to above as a hematoma. It arises from an accidental injury or may occur through hemorrhage from a vein, wounded in the little operation of tapping a hydrocele. Hematocele of the cord is a condition analogous to hematocele of the tunica vaginalis, and occurs beneath the tissue which surrounds the cord. Obviously, having no marked barriers below or above, it extends up and down the cord and forms a sausage-shaped swelling. Both forms of hematocele may become absorbed under rest and cold applications if the damage is recent and the accumulation of blood is small. In the case of long-standing and large collections of blood the surgeon may have to resort to incision and drainage.

INFLAMMATION OF THE TESTICLE

Inflammation of the testicle proper (orchitis) is an infrequent condition, and when present, is usually associated with an epididymitis. Orchitis may be the result of an injury, or may be the sequel of a gonorrhea. The *treatment* which I have described for epididymitis is applicable to cases of orchitis. You must distinguish carefully the syphilitic and the tuberculous forms of orchitis from the ordinary traumatic and infectious varieties, and from syphilitic epididymitis.

Syphilitic epididymitis is marked by its slow progress, by its development first in the globus major, and by the relative absence of pain. Obviously, the *treatment* is by a supporting bandage and by antisyphilitic remedies.

Syphilitic orchitis proper (sarcocele) occurs as an infiltration of the testicle. One finds it usually between the second and fourth years

of the syphilis, in which respect it contrasts with syphilitic epididymitis, which develops commonly somewhere between the second and seventh months. In sarcocele there is a slow gummatous infiltration, with nodules, either single or multiple, and with little tendency to suppuration. Such pain as exists is inconsiderable. The process, if untreated, advances to destruction of the organ and its envelops, to fistula formation, and to involvement of the scrotum. In making his diagnosis of these syphilitic lesions the surgeon arrives at a history of syphilis and its sundry manifestations, and differentiates the condition from gonorrheal complications, which are acute and painful; from tuberculosis, which syphilis most closely resembles; and from malignant disease, which is slow, painful, and is a new-growth, rather than a destruction of tissue. The *treatment* of the syphilitic orchitis consists always in the administration of mercury and potassium iodid, and in the operative removal of detritus and all disorganized tissue.

Tuberculosis of the testicle and epididymis is a frequent affection. It is grave. Its treatment is interesting, and has been the subject of sharp debate. The disease is rarely primary, but when it is so, the epididymis is the first portion to be affected, and thence the process extends to the testicle proper. In fact, as Fowler says, the epididymis is the starting-point of urogenital tuberculosis in more than half the cases. It is needless to discuss the etiology of tuberculosis within the scrotum further than to observe that it occurs at all ages, though it is most frequent in young manhood. Tuberculosis within the scrotum, when present in young men, is primary often. When seen in the very young and in elderly persons, it is most often part of a general tuberculosis.

Tuberculosis of the testicle is seen almost always in the caseous stage, and the caseous deposits are multiple. They break down and form numerous pockets or abscess cavities. The vas is involved for varying distances.

The *symptoms* are insidious, for the disease develops slowly, as a rule, though in the case of a concurrent gonorrheal epididymitis a mixed infection results and the progress of the disease is rapid. Ordinarily, tuberculosis of the testicle gives little pain or evidence of tenderness at first. Gradually the organ breaks down, but the patient's first consciousness of trouble may arise from observing a complicating hydrocele or a slight urethral discharge. Generally, the disease begins in the globus major and extends in both directions. When a swelling of the testicle proper can be felt, one discovers it to be hard and nodular. The nodules increase in size and number, they break down, form abscesses with associated pain and tenderness, involve the skin, and produce one or more sinuses. Often, when the surgeon is consulted, he finds a discharging fistula leading to the broken-down caseous testicle. In making the diagnosis, when the case is seen fairly early, one must differentiate it from syphilitic testicle. The tuberculous testicle feels nodular; the syphilitic testicle feels uniform and smooth. Sometimes both testicles are involved in tuberculosis. *Per contra*, double sarcocele (syphilis)

is extremely rare. When a tuberculous testicle is discovered, the surgeon should examine carefully the prostate, vesicles, bladder, and kidneys to ascertain an extension of the process. Frequently he will find tuberculous disease of the prostate and vesicles; less often of the bladder, and more rarely of the kidneys.

I said that the question of *treatment* had been hotly debated. The opposing views taken in the discussion were, whether or not castration invariably should be performed. Opinions of surgeons are now fairly unanimous. Castration is the rule—castration unless an extensive general tuberculosis coexists. Tuberculous disease of the prostate and vesicles does not contraindicate castration. When castration is done for tuberculous orchitis, the surgeon should not rest content with the operation, but should prescribe invariably a long course of antituberculous treatment—an out-of-doors life; and the patient should continue this until his normal weight is reëstablished and his general condition is satisfactory to his adviser.

The operation of removal of the testicle (orchidectomy or castration) should be done through a long incision beginning over the inguinal canal and running down on to the skin af the scrotum. The surgeon should tie off the vas high *early* in the operation, and should perform his dissection from above downward, removing thoroughly with knife and scissors all involved tissue. He should not hesitate to sacrifice large areas of skin. This tying off of the vas high at the beginning of the operation is important, for, as George Walker has pointed out, failure to cut off the vas before manipulating the disease itself may result in the forcing of disease organisms up into the abdominal portion of the vas, with a consequent prompt development of tuberculous vesiculitis. The dissection wound in the scrotum should be painted with tincture of iodin, sewed up with interrupted stitches of silkworm or silver, and drained from the most dependent point. If the work has been done thoroughly, convalescence should be short, and the patient should be up and about at the end of two weeks.

HYDROCELE

Hydrocele means properly an accumulation of watery fluid within a sac, and the term hydrocele is applied to various structures and regions. Commonly, however, we mean by hydrocele an accumulation of serum within the tunica vaginalis. There is also hydrocele of the cord, similar to that hematocele of the cord of which I have spoken. There is congenital hydrocele, in which case the vaginal process has remained opened, so that the tunica vaginalis communicates with the peritoneal cavity. This condition commonly is associated with congenital hernia. Hydrocele of the tunica vaginalis may be either acute or chronic. The acute form is associated usually with inflammation of the testicle and epididymis, whether resulting from injury or disease. Such acute complicating hydroceles require little treatment beyond the care of the underlying lesion. Sometimes, if the accumulated fluid persists for long, it may

be drawn off through a trocar (aspiration of the distended scrotum with a hollow needle).

Chronic hydrocele of the tunica vaginalis is the condition commonly meant by the term "hydrocele." The cause of chronic hydrocele is not entirely apparent, though such recent observers as Kocher, Langerhans, and König have found evidence of inflammation both in the accumulated fluid and in the wall of the sac. Traumatism may be a cause of hydrocele, and small retention cysts (spermatocele), either in the testis or epididymis, may give rise in turn to hydrocele. Whatever the cause, chronic hydrocele develops slowly, often with thickening of the tunica, and an accumulation of fluid within its cavity. This form of serous accumulation differs markedly in its origin from effusion

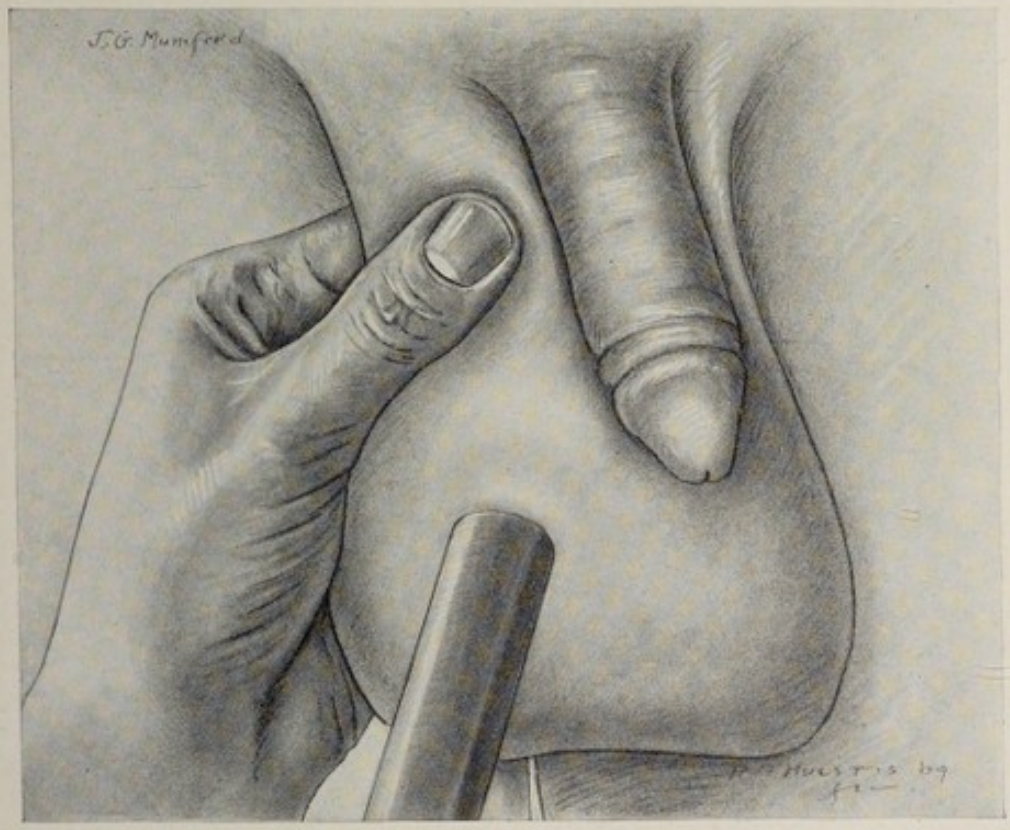

Fig. 305.—Use of the hydroscope for inspecting a hydrocele.

into the pleural cavity—an effusion commonly tuberculous. Long-standing hydroceles grow to a great size, and the sac often becomes one-fourth inch thick or more. The tumor may be as large as a child's head even. It is unilateral generally.

The **symptoms of hydrocele** are annoying rather than painful. Their onset is insidious. There is some sense of dragging and weight, but generally the patient complains of the size only of the tumor. The sac is rather ovoid in shape, and the swelling extends from the tip of the scrotum up toward the inguinal ring. You must differentiate it from inguinal hernia. Both fluctuate, but hydrocele is rather the more tense. Hydrocele does not vary in size with the position of the patient nor is there to be felt an impulse on coughing. The classic demonstra-

tion of hydrocele consists in looking through it at a strong light and using as an instrument of inspection a straight hollow tube (hydroscope), which is held firmly against the distended scrotum with the light on the opposite side of the tumor. When you look through the tube, you will see a translucent zone at the end of the hydroscope if the sac is distended with serum only. In the case of a hernia, such translucency is not apparent. There is one source of error in this method of determining a hydrocele: blood in the hydrocele fluid or an extremely thick wall may obscure the light, and one must make allowance for these conditions. Of course, other tumors of the scrotum, such as neoplasms, will obscure the light also. If the case remains in doubt after these tests, there is no harm in aspirating the sac and drawing off the fluid for examination.

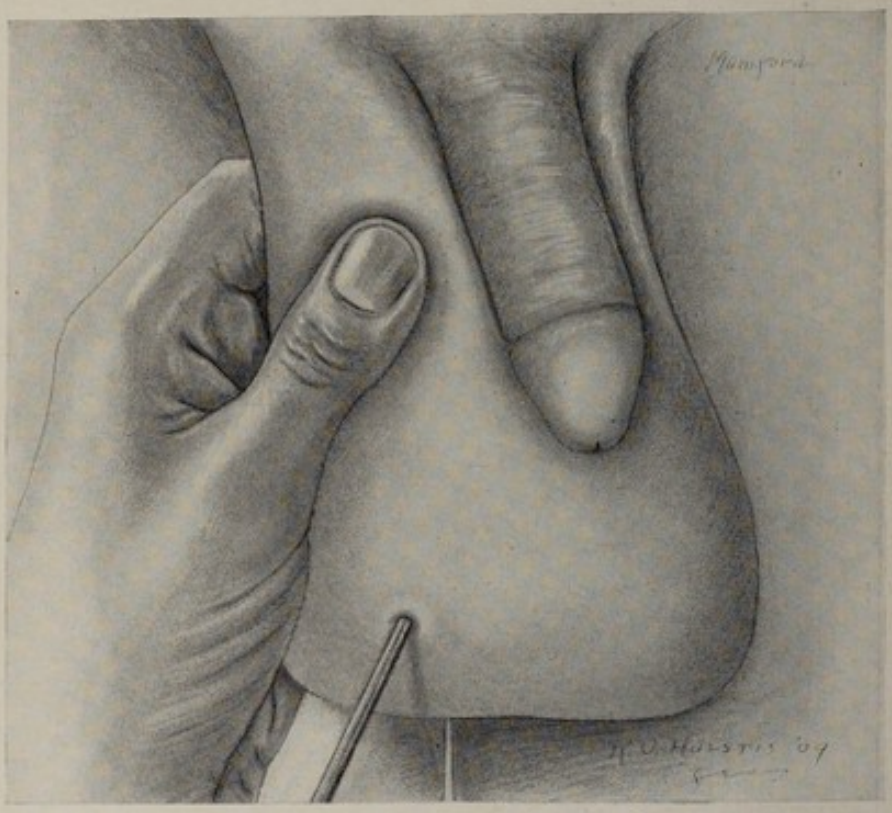

Fig. 306.—Tapping a hydrocele.

The outlook is good in cases of simple hydrocele, though extreme thickening of the tunic (peri-orchitis prolifera) may produce pressure atrophy of the testis.

The best **treatment of hydrocele** is operative. Palliative treatment is by the use of a suspensory bandage or by repeated tappings. Some persons, especially debilitated old men, prefer the tapping, and this little operation is not very painful. It may be rendered painless by cocainizing the area to be aspirated. To tap the scrotum, seize the mass firmly behind with one hand, and thus make tense the sac. Plunge the trocar into the sac in front about three-quarters of the way down. Guard the trocar against sinking in too deeply and wounding the testicle by holding the forefinger of the active hand firmly against the cannula about one inch from the tip. Select a spot free from veins, lest a blood-

vessel be wounded and bleed into the sac, thus setting up a hematocele. If tapping only be employed, it must be repeated from time to time as the sac refills.

The *radical cure* of *hydrocele* may follow tapping if proper injections be made into the sac. George W. Gay writes: "For a radical cure of hydrocele the best procedure I know is the following: draw off the serum, and then inject 2 to 4 drams of a mixture of equal parts of carbolic acid (95 per cent.), glycerin, and alcohol, and allow it to remain. The pain is not severe. The patient goes about his business, and the cure is reasonably certain." An adhesive inflammation results, which often cures the hydrocele after one operation. I prefer to keep the patient quiet for at least twenty-four hours after the operation, with the scrotum well supported and padded with cotton. Occasionally I have seen this method fail, the failure being due mainly to excessive thickening of the wall of the sac. Under such circumstances,—indeed, under nearly all circumstances,—if the surgeon so choose, one may revert to some one of the radical operations for hydrocele. It is needless here to discuss these various procedures. Volkmann's operation and Longuet's operation are favorites with many surgeons. For myself I have been abundantly satisfied with the so-called "high operation." This consists in cutting down upon the spermatic cord above Poupart's ligament, as in the operation for inguinal hernia; loosening the cord from its bed; enlarging the incision down to the root of the scrotum; and then everting the hydrocele sac, with the testicle, through the wound, and separating the tunica from its envelops by blunt dissection, with the occasional cutting of fibrous adhesions and enlarged vessels. This brings out upon the abdominal wall the loosely hanging hydrocele mass attached to the cord only. The next step consists in opening the sac and cutting away carefully the whole of the parietal layer, leaving the uncovered testicle hanging at the end of the cord. The testicle is then slipped back into the scrotum and the wound is sewed up. Frequently there is a good deal of hemorrhagic oozing from torn vessels on the interior of the scrotal wall. For this reason it is safe practice to drain with tubing the scrotum through a stab wound at its lowest point. Twenty-four hours of drainage should suffice. I advocate strongly this high operation for the following reasons: it cures hydrocele; it removes the external wound from the scrotal tissues, which are difficult to cleanse and render aseptic; the wound in the groin is far less irritating to the patient during his convalescence than is a wound in the scrotum, and it is more easily dressed; the trimming off of the tunic or the handling of the testicle and frequently associated enlarged veins is simplified by this method.

After the operation the patient should be kept in bed for a week or ten days and then be allowed to go about with a suspensory bandage for a month, when all danger of further irritation or recurrence should have disappeared.

As for **congenital** or **communicating hydrocele** of the new-born the treatment is simple. Usually a compressing truss or pad will bring about obliteration of the open vaginal process. Sometimes aspiration

of the sac may be necessary. Rarely, a cutting operation and tying off of the sac must be resorted to, but this need not be done within the first year after birth. *Under no circumstances* should one attempt to cure communicating hydrocele by strong irritant injections.

Spermatocele, a rare form of cystic tumor of the testis, simulates hydrocele and occurs after puberty. The contained fluid is loaded with spermatozoa. To cure it, try tapping first. If that does not succeed, incise, pack, and drain the cyst.

VARICOCELE

Varicocele of the spermatic cord is regarded by the ordinary citizen as a mysterious and baneful affection. Medical students even have been puzzled by it. It is merely a varicose condition of the veins in the cord and scrotum, and, as in the case of varicosities elsewhere, it may be cured by removing the veins. The left side of the scrotum is more commonly affected than the right. About 87 per cent. of the cases are on the left side alone; some 6 per cent. of the cases are on both sides, and some 7 per cent. of the cases are on the right side alone. The left side is affected more commonly because the left spermatic vein empties at some disadvantage into the left renal vein and not into the vena cava, as does the right spermatic vein. Moreover, the left spermatic vein lies beneath the sigmoid flexure, which, when loaded, presses upon and tends to obstruct it. It is hard to say just what is the immediate cause of varicocele, though numbers of patients have a story to tell of sudden violent strain preceding the appearance of the lesion. The varix may be trifling or extensive; when extensive, it involves all the veins of the cord and their tributaries, from the external ring to the bottom of the scrotum—and the swelling may be obvious and considerable. Men so afflicted complain of various symptoms—of a sense of weight and dragging in the scrotum, groin, and lumbar region, and sometimes of actual pain when standing and on exertion. Some men, especially neurotic persons, describe a loss of sexual vigor and pain on coitus. These sexual symptoms are accepted among the laity as the traditional symptoms of varicocele, so that the surgeon is inclined to believe the annoyance is often as much a mental as a physical one.

The **diagnosis** is easy. The condition is a disease of young manhood; the patient tells often of the sudden onset of a swelling, and the surgeon finds a characteristic collection of enlarged, tortuous, more or less elongated and corded veins, which are commonly described as feeling "like a bunch of worms." One must differentiate varicocele from hydrocele, which presents a smooth, uniform enlargement, from hydrocele of the cord, which is smooth and fusiform; and from inguinal hernia, which is smooth, varying in size and characterized by an impulse on coughing.

I said that the varices may be cured by cutting out the veins. Sometimes, in case the varix is small, the surgeon may prefer to tie off subcutaneously two or three of the veins. This method is not surely curative. A satisfactory operation is to lay bare the cord in the groin, and

to dissect out the veins, leaving one or two small vessels only, and avoiding carefully injury to the vas. In the case of greatly distended veins, which enlarge the scrotum downward, it may sometimes be necessary to amputate part of the scrotum with the veins. When this is to be done, the testes must be pushed snugly up toward the groin, when the scrotum may be clamped across and trimmed off and the stump sewed up. Many operations for varicocele are satisfactory in the end, especially

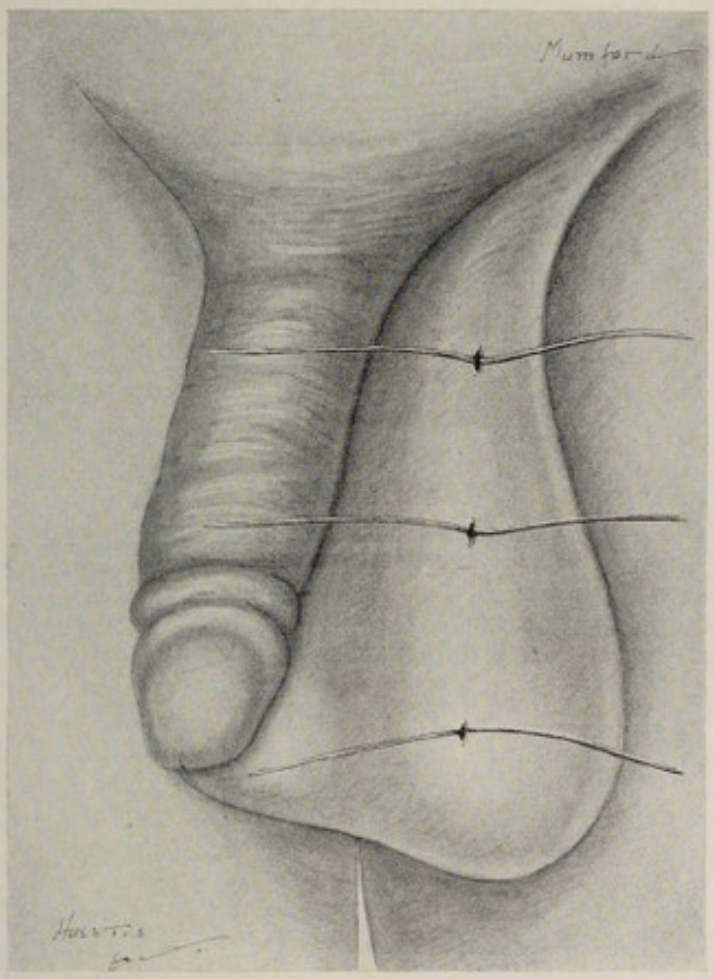

Fig. 307.—Subcutaneous tying of varicocele.

on account of the relief from mental and sexual annoyance which they afford the patient. I prefer the high operation—cutting down upon the cord in the groin and removing a section of enlarged veins there.

TUMORS OF THE TESTICLE

Tumors of the testicle are interesting to the pathologist especially; for there is no organ of the body in which there are so many varieties of structure as in the testicle. Accordingly, one finds there new-growths appearing at all ages. There are three principal types of these tumors: (1) Connective-tissue growths; (2) epithelial tumors; (3) dermoid cysts and teratomata.[1]

[1] An excellent brief clinical résumé of these tumors is Sarcoma of the Testicle, A. L. Wolbarst, Jour. Amer. Med. Assoc., April 6, 1907.

Of the first group, there are benign and malignant specimens—fibromata, lipomata, myxomata, enchondromata, osteomata, and myomata. None of these tumors are common. They may be found in children, and the surgeon should remove them, while sparing as much as possible of the testicle and its associated structures.

Sarcomata are not especially uncommon. They begin usually in the globus minor, and may progress slowly or rapidly. Some are soft and of quick development; some are hard and may remain apparently quiescent for a long time. The shape of the testicle may remain fairly normal, or it may take on a nodular outline. The round-celled sarcomata are of the more rapid growth. The spindle-celled variety are firmer, and often contain striated muscle-fibers. Sarcomata may not cause any great pain, though frequently they do so in their more advanced stages. If one testicle only is attacked, sexual vigor is not lost to the patient. The differential *diagnosis* is difficult and sometimes impossible. A long-standing hard nodule in the epididymis is suspicious, especially if it takes on suddenly a rapid growth. Sometimes there is breaking down of the organ with necrosis, hemorrhage, and mucoid softening. Late in the disease the cord and inguinal glands are involved. The surgeon must distinguish sarcoma from cancer, which occurs in middle



Fig. 308.—Keyes' needle for subcutaneous ligation of varicocele (Fowler's Surgery).

life or later, while sarcoma may be a disease of childhood,—from tuberculosis, which is characterized by softening and early fistula formation; and from syphilis, which closely resembles sarcoma and often can be distinguished from it by its reaction to a course of potassium iodid only.

Obviously, the only radical *treatment* for sarcoma of the testicle is its complete excision, with dissection of the cord and the inguinal lymph-nodes on the side affected.

Cancer of the testicle is the important tumor of the epithelial group. It develops in the testis itself and grows rapidly. It causes earlier and more severe pain than does sarcoma. The epididymis is involved late, but the disease, as a whole, develops more rapidly than does sarcoma. The growth may involve the skin, so that the patient may present a foul, ugly, cauliflower tumor. Obviously, complete extirpation of the growth and the adjacent glands is the only rational treatment.

Adenoma of the testicle occurs in children and in adults. The tumor grows rapidly without pain, and may reach the size of a child's head. Commonly, it contains cysts. It is smooth, firm, and elastic. The prognosis is uncertain, because adenoma may be associated with cancer and sarcoma. Castration is the only remedy.

Dermoid cysts and teratomata are not especially common, and

usually begin to develop in infancy. They grow to considerable size without causing pain, and may be carried for many years. They resemble adenomata often, but appear at an earlier age and contain embryonic structures—atheromatous fluid with hair, teeth, and bone. Aspiration or the *x*-ray will confirm the diagnosis often. Sometimes one may remove the tumor and save the testicle, but frequently castration must be our resort.

TWISTED CORD

Twisted cord, or strangulation of the cord by axial rotation, occasionally is seen—a curious and interesting condition. It is analogous to twisting of the pedicle of an ovarian cyst.[1] The condition is so unusual that an error in diagnosis readily may be made. The cause of the twisting is not obvious, though in every reported case there has been a long mesorchium. A normally placed normal testicle is not likely to suffer torsion. The *symptoms* are sudden, and follow violent exertion usually. There may be a hernia present. As a result of the rotation the vessels in the cord are strangulated, so that the testicle swells and quickly becomes the seat of hemorrhage, necrosis, and gangrene even. There are sudden pain, vomiting, shock, a swelling in the groin, and a swollen testicle readily obvious. There is no impulse on coughing. The condition simulates strangulated hernia, from which it must be distinguished. The *treatment* is by immediate operation. If the strangulation is recent, it may be relieved by untwisting the cord, but in most cases the testicle is found gangrenous, so that castration must be done.

Such are the tumors and swellings of the testicle. Their diagnosis is difficult often, but their treatment is almost invariably by the operation of castration.

CASTRATION

In the case of malignant disease, castration should include the whole, or a large part of, the scrotum. In the case of non-malignant disease, the tumor may be turned out of the scrotum through an incision in the groin. In either case, when the dissection is completed and the tumor mass is free and left hanging by the cord as a pedicle, the final section of the cord must be made carefully. Do not roughly tie it off and cut it en masse. Such treatment pinches nerves and fails securely to control vessels. Pain ensues, and secondary hemorrhage may take place as the cord slips back. Properly to amputate the cord, dissect carefully across it toward the abdominal cavity, tying the individual vessels as you go; then stitch the stump into the internal ring. After castration the patient should be kept quiet in bed for two weeks at least, that healing may progress properly and that no hernia may develop.

[1] See article by Charles L. Scudder, Ann. Surg., August, 1901.

PART IV

THE CHEST

CHAPTER XVI

THE BRONCHI AND LUNGS

Hitherto in this book we have studied regions and structures readily accessible to the surgeon, but in large part become accessible during the last thirty years only. We have been considering the diseases of organs associated with each other, either in their anatomic relations or in their functions—the organs of the abdomen, the genito-urinary, and the sexual apparatus. The surgeons of two generations or more ago dealt timidly with organs within the abdominal cavity, and somewhat fearfully with the bladder, kidneys, and testicles even, because those surgeons knew not how to eliminate sepsis. The abdominal cavity especially was an unknown land to most of them. Our present measure of success in dealing with these organs is known to all the world.

In these days we are turning our attention to a new field—surgery of the thoracic cavity.[1] We are approaching this field with some hesitation, though with less timidity than our forbears felt when they approached the abdomen. The dangers in this new work are not the dangers which confronted pioneers in abdominal surgery. They feared sepsis because they knew not what it meant or how to combat it. We understand sepsis, and usually combat it with success; but in thoracic surgery we must face dangers peculiar to the thorax and peculiarly difficult to meet. When we open the thorax, we have to deal with organs the wounding of which promptly is serious, if not fatal—organs incased in an unyielding cage, organs not readily accessible, of varying consistency and dimensions, easily escaping from operative control. In the abdomen you may excise the intestines and stomach, open widely the liver, or remove the spleen; indeed, many of the abdominal organs can be eliminated without danger to life. The intrathoracic organs, on the other hand, must be approached cautiously, opened with hesitation, if at all, and totally removed never. But one must not think of these organs in the chest as inaccessible to surgeons. Constantly, with increasing knowledge, we are more certainly cutting down upon the lungs, the bronchi, and the heart; and with increasing experience we are learning the possibilities of intrathoracic surgery and the extent of our

[1] See Trans. Amer. Surg. Assoc., 1909.

limitations. There is one exception to the novelty of operating for diseases within the chest—empyema and other pleuritic collections have been subject to operation since the time of Hippocrates.

When we consider diseases of the bronchi and lungs, we must think of the whole complicated apparatus which extends from the bifurcation of the trachea, opposite the third dorsal vertebra, through the primary, secondary, and terminal bronchi and the whole structure of the lungs, with their intricate arrangement of alveoli, bronchioles, and network of important vessels, all bounded by the visceral pleura. Within this complicated mechanism the surgeon operates for the following lesions

Foreign bodies in the bronchi.
Bronchiectasis.
Pulmonary abscess.
Pulmonary gangrene.
Hemothorax.
Tuberculosis.
Tumors.
Echinococcus cysts.
Actinomycosis.
Aneurysm.
Diseases of Esophagus. (See Chapter IV.)

FOREIGN BODIES IN THE BRONCHI

Foreign bodies in the bronchi were regarded as fatal up to a few years ago—fatal, if the foreign body lodged and could not be coughed up. Then sundry surgeons devised ingenious measures for opening the posterior or anterior mediastinum and performing bronchotomy. But these operations are difficult, with a mortality of almost 100 per cent. In more recent years surgeons who have concerned themselves especially with work upon the throat and trachea have devised instruments by means of which foreign bodies in the bronchi may be discovered and removed through the mouth or through a tracheotomy opening.[1]

The objects which reach the bronchi must be small enough to pass between the vocal cords, whence they drop into the right bronchus commonly, since that is given off from the trachea at a less acute angle than is the left. Coins and buttons are the objects most frequently inhaled, and usually by children. More than one case of a loosened tracheotomy tube discovered in the bronchus has been reported, and Coolidge pictures pins and a carpenter's nail, while D. W. Cheever graphically describes a beard of wheat flying up and down with respiration.

The lodgment of these foreign bodies induces a variety of symptoms. If the object is small and does not become immediately impacted, the patient experiences a sense of suffocation. He coughs, strangles, and may vomit. There may be pain in the chest, with bloody expectoration. Again, the object may completely plug a bronchus, thus throwing out

[1] A. Coolidge, Jr., Boston Med. and Surg. Jour., April 10, 1902; von Eichen, Arch. f. Laryng., Bd. xv, 3. Heft.; A. Coolidge, Jr., Boston Med. and Surg. Jour., October 13, 1904; Carl Beck, Surgical Diseases of the Chest, 1907, p. 239 et seq.

of commission a portion of the lung. This is an extremely rare condition. If the body remain long impacted, there may result a bronchitis, with asthma, or a pneumonia even; and, most serious of all, perhaps, pulmonary abscess or gangrene of the lung.

These foreign bodies lodge in the right bronchus, as I have stated, and the surgeon locates them first by means of the *x*-ray. Then, with the bronchoscope (Coolidge recommends Killian's) passed either through the mouth into the trachea or through a tracheotomy opening, the patient being under ether anesthesia, an expert may discover a foreign body and extract it with Killian's forceps. I have seen Coolidge do a number of these operations rapidly and dexterously, but, as a general surgeon, I have never undertaken them.

BRONCHIECTASIS

Bronchiectasis (bronchial dilatation) is one of the intrapulmonary ailments for which rarely surgeons have operated. According to W. B. Smith the infections are generally due to the influenza bacillus. There is no great enthusiasm for this operation, but occasionally it seems justifiable, and several successful cases have been reported. There are various forms of bronchial dilatation—the cylindric form, in which a single branch or several branches of the smaller or medium-sized bronchi are involved; the dilatation of a large bronchus alone, and a terminal, sac-like bronchiectasis, developing at the expense of the lung parenchyma. Grawitz reports a case of congenital bronchiectasis in which one of the lower pulmonary lobes had been changed to a lax sac with many cavities. In any case of bronchiectasis there may be a concurrent tuberculosis. In every form of bronchiectasis the disease runs a chronic course. The first **symptom** is a paroxysmal cough, most troublesome in the morning; the frequent "winter colds," which are sometimes attacks of influenza bronchopneumonia, and the cough frequently is associated with violent expectoration, when the patient may raise a great amount of sputum—often several cupfuls—suggesting the rupture of an empyema into a bronchus. The sputum may stink, or it may be odorless, and it is often mixed with blood. It is needless to dwell in detail on the various symptoms of this condition, but the diagnosis may be made by physical examination. Percussion and auscultation usually demonstrate signs of a cavity. There may be more or less dulness, followed by a resonant, tympanitic note, depending on the amount of contents in the bronchial cavity, and the change of percussion-note is striking also as the patient opens or closes his mouth or changes his position. At times one hears nothing on auscultation; at other times one may discover bronchial breathing, with coarse moist râles. Sometimes the *x*-ray will confirm a diagnosis. Serious complications of bronchiectasis are: purulent bronchitis, catarrhal pneumonia, gangrene of the lung, abscess of the brain, and meningitis. Emphysema is frequent and important.

The **treatment** of bronchiectasis is nearly always symptomatic, but Tuffier, in his classic monograph, reported 46 cases with 39 operations,

and of these patients 10 died, while 29 recovered. Numerous other reporters show similar statistics. The cases suitable for operation are those in which there is a great dilatation of one bronchus only, and the procedure consists in opening and draining the cavity as a preliminary procedure; and later, in proper cases, in excising the portion of lung affected. Those patients who have been improved or have recovered certainly have experienced great relief, so that we believe the operation for bronchiectasis must seriously be regarded as an important therapeutic measure. So much for the surgery of the bronchi as hitherto it has developed. Before going further into the discussion of intrathoracic surgery, let us consider the—

GENERAL TECHNIC OF OPERATING UPON THE LUNGS

Pneumonotomy obviously means opening into the lung; pleurotomy is an incision into the pleura.

Surgeons maintain the importance of occasional exploratory operations to determine the exact nature and location of diseases within the chest, although the *x*-ray has rendered such explorations less imperative than they were. The student should remember that the right primary bronchus descends into the lungs at a less acute angle than does the left; that the right lung is made up of three lobes, and the left lung of two lobes, while the extent of the thoracic viscera is from the apex of the lungs about an inch above the level of the first rib, to the base of the lungs, which rests upon the convexity of the diaphragm; while the heart, pericardium, and large vessels occupy an important space in the superior and anterior left central portions of the chest. The mechanical obstacles to operations within the pleural cavity are, first and most important, collapse of the corresponding lung, when the chest is opened, with pneumothorax; and the presence of a large, stiff-walled cavity. Most writers have maintained that adhesions existing between the parietal and visceral pleura are necessary in order that one may operate successfully upon the lung, because through such adhesions the surgeon may penetrate without danger of infecting the surrounding and uncontaminated pleura. There are various methods of entering the chest, the two most important being—(1) Through a small opening, by the removal of portions of one or two ribs over the supposed site of the lesion, and (2) the turning back of a large osteoplastic flap, as in Schede's operation for empyema. When the large flap is to be turned back, the surgeon should make a wide, U-shaped skin incision, going down directly upon the ribs over the lower part of the thorax in the posterior axillary region, and resecting broadly portions of several ribs—generally the sixth, seventh, eighth, and ninth. By this means a large free opening is secured, which enables the operator to work with some freedom inside the chest, to explore thoroughly the collapsed lung, if it is collapsed, and to establish dependent drainage. Before opening the lung, but after having laid bare the visceral pleura, the suregon may wall off the field of operation with iodoform gauze tampons, or he may provide against

infection by drawing up the collapsed lung against the chest-wall and fastening it there with deeply placed catgut stitches in order to bring about adhesions at that point. This latter method is advocated by many experienced operators.[1] The paramount objection to so extensive a dissection lies in the fact that most of the patients submitted to pneumonotomy are in wretched physical condition, little able to endure the shock of a prolonged operation. For this reason

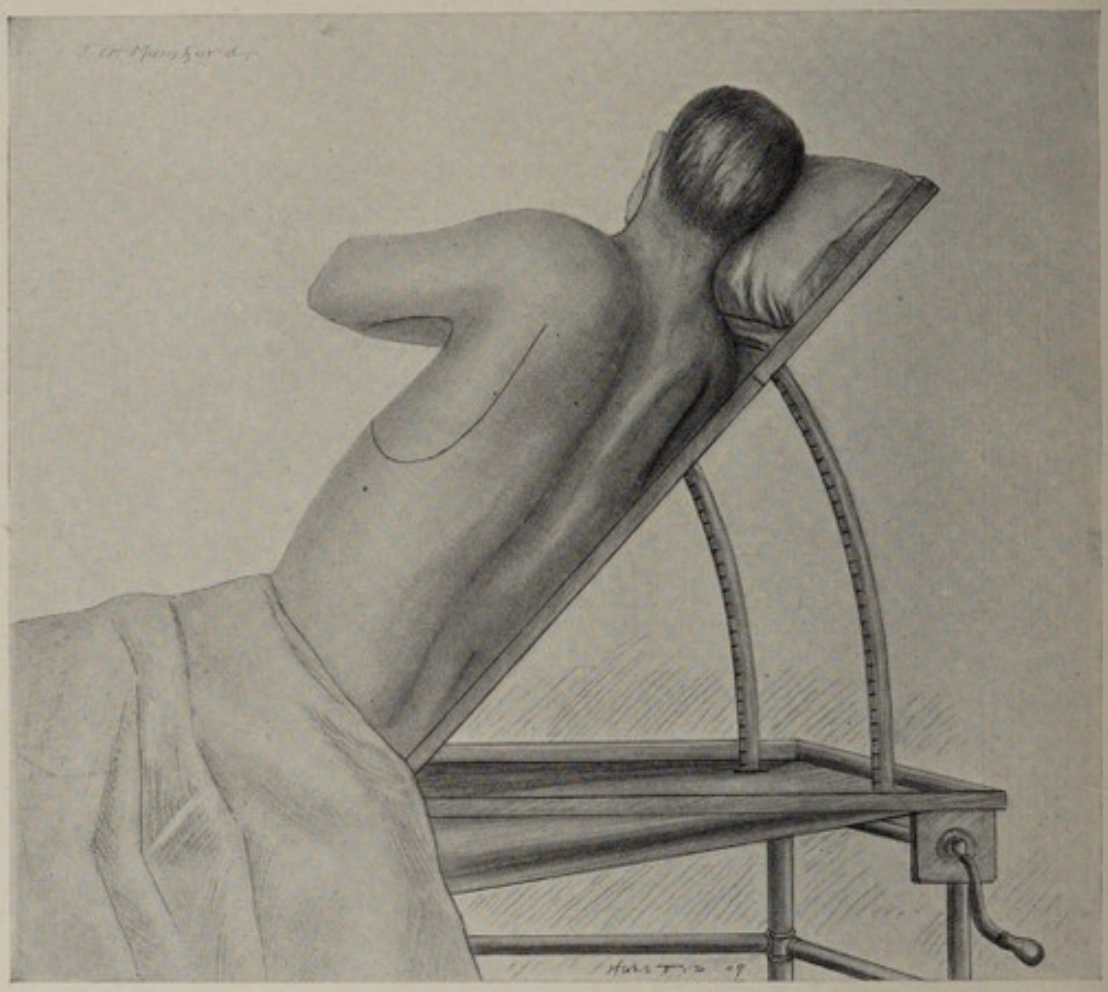

Fig. 309.—Schede's incision for opening the chest.

the more circumscribed operation must often be the operation of election. The technic of the circumscribed operation is simple enough. The surgeon approaches the chest through a straight incision along a rib over the site of the pulmonary lesion, and excises quickly bits of one or two ribs. Frequently the lung is adherent to the chest-wall at the point

[1] The Fell-O'Dwyer apparatus for inflating the lung is advocated by Matas and DaCosta. It is in principle a competent bellows, by the means of which air is forced into the lungs. The O'Dwyer tube is introduced into the glottis and the bellows is worked by foot-power. This instrument is moderately successful in preventing collapse of the lung. F. T. Murphy also has demonstrated an apparatus which acts on the principle of the Brauer positive pressure apparatus. More recently I have used with the greatest satisfaction some method of intratracheal anesthesia, which provides a proper supply of air plus ether to both sides of the chest. The apparatus perfected by Samuel Robinson is in common use at the Massachusetts General Hospital and the Clifton Springs Hospital.

of attack. If it is not, the pleural cavity must be guarded by tampons or stitching. However the lung is reached, when it is reached it remains for the operator to search the affected pulmonary area. In regard to this searching again, surgeons have differed in their methods, some using a long, narrow-bladed knife, others the cautery, and others the finger supplemented by instruments. I advocate the last method, as it is less likely to damage lung tissue, and it obviates troublesome hemorrhage. Most of these operations give rise to more or less pneumothorax, but this is a bugbear not seriously to be considered. Such operative pneumothorax usually takes care of itself.

Methods of artificial respiration in lung surgery have not been commonly adopted up to the time of this writing, but it is probable that before many years all surgeons will follow the lead of the advanced investigators in employing invariably artificial pulmonary pressure or, better, intratracheal insufflation.

The first and one of the most accessible lesions for which we operate is **abscess of the lung.**[1] This condition is fairly common. It may complicate lobar pneumonia or influenza pneumonia, or may occur suddenly in lung tissue previously healthy, from embolism,[2] from the lodgment of a foreign body, from inhalation, or as a complication of some such systemic infection as puerperal fever. Alglave and Mahé[3] report a vast mediastinal abscess originating in a carious tooth. Abscess may follow operations on the tonsils or jaws. Measles and whooping-cough are recognized etiologic factors also. The *symptoms* may be obscure or they may be characteristic. The condition is most often mistaken for a patch of pneumonia or for a localized empyema. The condition of the sputum is the best indication of abscess, and the sputum may be coughed up in large quantities—sometimes as pure pus, sometimes moldy, with a sour or sweetish odor, sometimes fetid. Under the microscope you will find connective-tissue and elastic fibers, and occasionally a deposit of black pigment, with fatty crystals and hematoidin crystals. The *diagnosis* often is difficult in the absence of the characteristic expectoration. After an attack of coughing look for a tympanitic note over an area previously dull. Abscess of the lung may be confused with gangrene also, but in gangrene the expectoration is extremely foul, and elastic fibers usually are absent. The outlook in these abscess cases is grave, though statistics appear to show that the best outcome in the case of pulmonary abscess follows abscess due to pneumonia. Medical *treatment* sometimes results in recovery, but if the abscess persists, especially if it is progressive, the physician should seek surgical advice with a view to operation. I have already described the technic of searching the lung for abscess. It is necessary to establish competent drainage when the abscess is found, and for this purpose there is nothing better than a

[1] See important case described by C. H. Cottle and J. R. Edward in Brit. Med. Jour., March 7, 1908.

[2] Trendelenburg's case, Deut. med. Woch., July 2, 1908, quoted in Practical Medicine Series, vol. ii, p. 215, series of 1909.

[3] Progrès Médical, August 7, 1909.

rubber tube wrapped in gauze. The drain should be changed every two or three days, lest it cause ulceration of a pulmonary vessel and give rise to serious hemorrhage. Several accidents of this nature have been reported. The results of treatment depend somewhat on the nature of the abscess. Pneumonia or influenza abscesses promise well, but abscess due to the lodgment of a foreign body is almost never found. The drainage, dressings, and supplementary care of the patient must be continued for a long time often, and so soon as may be the patient should be given an out-of-doors life.

Gangrene of the lung is closely associated with abscess of the lung in its origin and physical signs. I have told already how the foul character of the sputum differentiates it from abscess. Gangrene is a necrosis of lung tissue, produced by putrefactive bacteria, and is either circumscribed or diffuse. It is more rare than abscess. The common factors in its etiology are lobar pneumonia and pneumonia due to a foreign body. Sometimes it is preceded by an infarction. Alcoholic and diabetic subjects are the persons especially subject to pulmonary gangrene. I have already described the *treatment*, which is similar to that for pulmonary abscess. Circumscribed gangrene is the only form of gangrene amenable to surgical treatment. When the diagnosis is assured, the surgeon should insist upon operation, for spontaneous recovery is improbable.

Pulmonary tuberculosis at times has come within the purview of the surgeon, but such tuberculosis must be localized. A large number of operators in France and Germany have made experiments in this field, but such work has not yet appealed greatly to American surgeons. The method is to attack small localized tuberculous processes or cavities by injections of iodoform oil or by actual excision (pneumonectomy), with drainage. The excision should be made with the cautery. In all probability this method will fall into disuse before the superior advantages of hygienic treatment and the employment of the opsonins.

Echinococcus of the lung is fairly amenable to surgical treatment, and the lung, after the liver, is the organ most frequently attacked by echinococci. There is but one cyst cavity in the lung, as a rule, and this cavity may become extremely large, so as to fill completely one pleural sac and displace neighboring thoracic and abdominal organs. Strangely enough, small cavities may produce no symptoms for a long time, but large cysts induce sensations of tension, pressure pains, and dyspnea. Sometimes the cavity opens into a bronchus, so that the patient coughs up great quantities of pus and organisms. Unless the organism has been discovered, it is impossible to make the diagnosis. The organism may be isolated from the sputum or may be secured by aspiration. Echinococcus of the lung simulates pulmonary tuberculosis, or, when the cavity is large, suggests an intrathoracic neoplasm. The results of surgical treatment have been brilliant. For instance, Tuffier reported 55 recoveries out of 61 cases. Simple aspiration and washing out of the cavity is a dangerous procedure, and must be reprobated, because the cleansing fluid may flow into a bronchus and flood the lungs. The surgeon should

institute abundant drainage in the manner I have already described. In most cases recovery is slow, but usually certain.

Pulmonary actinomycosis demands a word in passing, though primary actinomycosis of the lung is rare. It is needless to describe in detail the character of the slowly advancing disease, which begins usually as a destructive inflammation about the bronchi, and involves gradually considerable areas of lung tissue, reaching finally the pleura and involving the skin, where it manifests itself in swellings and sinuses. The disease is mistaken commonly for tuberculosis. The few operations undertaken hitherto have been limited to opening, cureting, and draining sinuses and abscesses. Excision is the best treatment. Very few cures are reported.

Cancer of the lung (primary) does not seem to be especially rare, but its diagnosis is so difficult that operative treatment must be uncommon. It is mistaken for chronic pneumonitis and chronic abscess because of secondary changes following semi-obstruction of bronchi; for tuberculosis, chronic pneumonia, and pleurisy, though the *x*-ray may give valuable information as to its character. Circumscribed tumors, as large as a hen's egg even, rarely can be detected unless they are on the surface of the lung. Occasionally bits of the tumor in the sputum have furnished evidence on which to found a diagnosis. Seldom is there a pleuritic effusion, because the pleuræ become adherent. The ordinary physical examination suggests merely a localized consolidation of lung tissue, but the wasting and cachexia, with the examination of the sputum, may determine the diagnosis. Advanced cases of pulmonary cancer cannot be cured, but a few instances are reported in which small circumscribed pulmonary growths associated with tumors of the chest wall have been removed successfully. Intratracheal insufflation and differential pressure have served as important aids in such work.

Sarcoma of the lung is less common than cancer. The spindle-cell variety is seen occasionally, though a rare form of lymphosarcoma is described. The *symptoms* are misleading. As in the case of cancer, there is pain in the side, and a sense of oppression and cough, thought to be due to a persistent bronchial catarrh. The sputum is not characteristic. Metastases are more common in sarcoma than in cancer, and appear as direct involvement of neighboring organs. Surgical *treatment* of sarcoma is similar to that of cancer.

Secondarily malignant disease of the lungs, associated especially with malignant disease of the breast, is always inoperable.

The benign tumors, so familiar in other parts of the body, are almost unknown in the lungs so far as surgeons have investigated, although such growths occasionally are found postmortem.

Injuries of the lung are nearly always associated with complicating injuries to the chest-wall, and are due to crushing blows or penetrating wounds. So far as the lung is concerned, the interesting and significant symptom to be combated is hemorrhage. The blood may be expectorated or may fill the pleural cavity as hemothorax. The *treat-*

ment is conservative in most cases. The hemorrhage is not often alarming, and is controlled by keeping the patient recumbent and quiet, and by snugly strapping and bandaging the chest. Sometimes, however, continued alarming hemorrhage persists, so that it may seem best to the surgeon to operate for the purpose of controlling it. In such cases one should open the chest widely through an osteoplastic flap, should wipe out the blood and clots from the pleural cavity, and should seek the bleeding vessel. Seldom can such a vessel be tied, unless it is near the lung surface, but the wound may be opened with the cautery and packed with iodoform gauze, so as to control the bleeding. Drainage must be employed in these cases also, and particular care must be taken to strap and bandage the chest after the operation. The great subsequent distress of the patient should be relieved by small and frequently repeated doses of morphin.

CHAPTER XVII

THE PLEURA

Diseases of the pleura are subject to surgical operations more commonly than any other diseases within the thoracic cage. I have said that Hippocrates was cognizant of such operations. From his time to the present gradually an improved technic has been evolved, but even yet we cannot say that a technic for operations upon the pleural cavity has been perfected.

The cavity of the pleura is of simpler anatomic arrangement than is the cavity of the peritoneum, though it is quite analogous to the latter. The pleura is like a huge lymph-sac or bursa, interposed between the lung and the chest-wall. Its inner or visceral layer inwraps closely the lung and great vessels, while the outer or parietal layer is stretched over the inner wall of the thorax. The pleura has the structure and functions of other serous sacs. It is abundantly absorbent of toxic products; it secretes an abundant fluid when irritated. When normal, its smooth, shining, inner surfaces play over each other with the rise and fall of the chest. The ordinary movements within the pleural sac are far less excursive than are the movements within the peritoneum, for the play of the lungs and thoracic wall is relatively slight. From such considerations the reader will perceive that diseases of the pleura, though vital and troublesome, are not so intricate as are diseases of the peritoneum. For the sake of convenience let us consider diseases of the pleura under the following headings: Inflammatory effusions, hydrothorax, hemothorax, chylothorax, tuberculosis, and tumors.

INFLAMMATORY DISEASE

Inflammatory disease of the pleura rarely is primary. In the majority of cases it is an extension from disease within the lung or some other neighboring organ or structure—the liver, the peritoneum, the spinal column, the ribs. In recent years we have found many of these so-called simple effusions to be tuberculous. Pneumonia also is a common cause of pleuritic effusion. "Catching cold" may be a possible cause of effusions, and it is certain that many infections of the pleura are coincident with sundry joint infections—the origin of both being often difficult to determine, though an invasion of organisms through the tonsils or through the intestinal mucosa frequently explains the trouble. Effusions into the pleura may be general or may be localized and pocketed. General effusions fill the pleural cavity affected, compress the lung and heart, and bulge into the intercostal spaces, so that in extreme cases one lung is thrown out of commission and the heart is

dislocated. Localized or pocketed effusions are confined by adhesions between the visceral and parietal pleuræ, so that the collections impinge upon the lungs over limited areas only.

With an understanding of the pathologic anatomy the reader will conceive at once what must be the **symptoms** produced, though he will remember at the same time how symptoms will vary with the underlying or associated conditions—pneumonia, phthisis, and the like. Simple serous effusions cause mild symptoms, as a rule. The sharp, agonizing, initial pain of pleurisy precedes the effusion, and is due to the irritating contact of opposed, dry, inflamed layers of pleura. With the onset of effusion the layers are separate and pain is allayed. Then there ensue dyspnea, a varying fever, and constitutional signs.

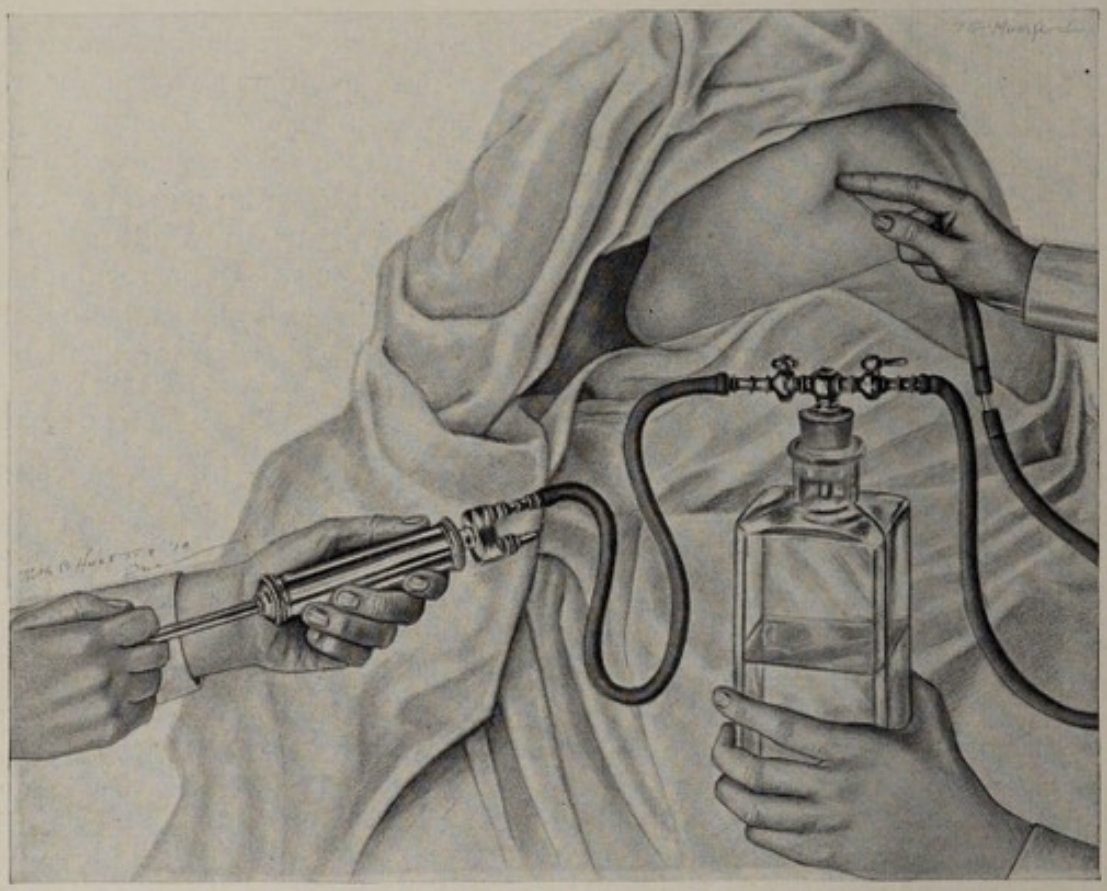

Fig. 310.—Thoracentesis.

Treatment.—In a great many cases these simple effusions are absorbed and their treatment is within the domain of the internist, with whose examination of the chest, by percussion and auscultation, we need not concern ourselves here. A considerable proportion of cases do not improve under medication, but may clear up quickly as the result of aspiration. Aspiration is best performed with a trocar, cannula, and suction apparatus, though long drainage through a simple canula may suffice, and the fluid withdrawn should always be examined critically in order to determine especially the presence in it of pus, of tubercle bacilli, or of other organisms. Sometimes guinea-pig inocula-

tion alone will demonstrate tuberculosis. The distinction between a simple serous effusion and a purulent effusion is one of degree only. The serous effusions contain few leukocytes and few organisms.

As a rule, then, a simple serous effusion will clear up after one or two aspirations, provided the operator has not infected the cavity at the time of aspirating. When the fluid in the chest has become purulent, or contains clear fluid-bearing organisms, the condition is one of pyothorax.

PYOTHORAX

Commonly, we speak of such collections of pus as *empyema*.[1] The pathologic and bacteriologic conditions vary in empyema, depending on the nature and source of the organisms. Pneumococci in the pus and an associated pneumonia are common in children; pneumococci, streptococci, and tubercle bacilli are found at all ages. Sometimes there are present organisms of decomposition. The pneumococcus pus is creamy or light green in appearance, nearly odorless, often full of large coagula, and easily disposed of by operation. The pus of tuberculosis nearly always is due to a mixed infection; it may be thick or thin, odorless or offensive, while the pus due to saprophytic bacteria is thin and very foul.

These various collections of pus cause various **symptoms,** in their turn, not differing materially in character from the symptoms of a simple effusion—discomfort, dyspnea, fever, and debility. But the symptoms do not subside when *pus* is present. Rarely, nature may find a vent for the fluid through the bronchi or through the chest-wall, but generally, if let alone, the process goes on. The pleura becomes more and more thickened, the lung more compressed and useless, and the thoracic cage fixed and deformed, so that in the course of time the patient presents himself as an emaciated, crippled, gasping, distorted invalid.

One invariable rule must guide us in the **treatment** of empyema. Drain the pus at once, as soon as it is discovered. Discover it more promptly than is now done always. If you have to deal with a chest which shows the physical signs of fluid, the nature of which is not apparent, do not await developments, but aspirate to ascertain the nature of the fluid, and, if you discover pus, operate forthwith. The *x*-ray may demonstrate a pus collection even when aspiration fails.

There are two leading types of empyema—leading types as regards their bearing on the nature of the operation—acute and chronic empyemata; and their treatment often is radically difficult. Take pneumococcus empyema as an example of acute empyema: empty the sac and establish drainage in a simple manner; employ local anesthesia, as a rule; though ether carefully given by an expert, with the patient in a sitting position, is no more dangerous to the lung than chloroform, and is less likely to depress the heart. If the empyema is on the left, and if the heart is greatly dislocated, it is wise often to aspirate off the pus,

[1] The term "empyema" is usually applied to a collection of pus in the pleural cavity, though we use it also to denote similar collections in the gall-bladder, the antrum of Highmore, etc.

a part at a time, lest sudden relief of pressure dislocate a possible cardiac thrombus, and kill the patient—an accident by no means unknown. Ordinarily, however, such preliminary aspiration is needless. Cut down upon the seventh or eighth rib, in the axillary, anterior axillary, or posterior axillary line, using either a transverse or a longitudinal incision; free the rib for about four inches; dissect off the periosteum with a blunt instrument; open and drain the pleural cavity, and insert a rubber tube—the best of which, for this purpose, is Henry's rubber drainage-tube or bobbin, which is self-retaining, and does not protrude either into the cavity or beyond the skin. Another admirable method of securing drainage is to stitch the parietal pleura to the skin. The opening must be lightly tamponed to prevent too early glueing up. It is not wise

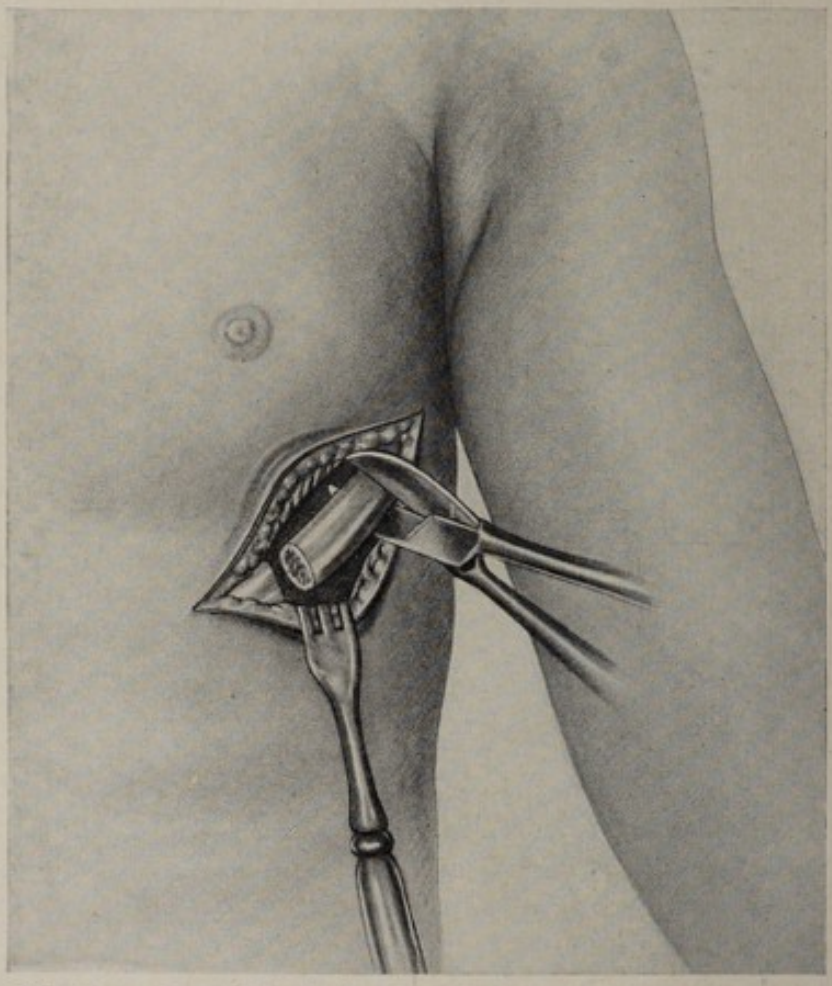

Fig. 311.—Resection of ribs (after Brewer in Keen's Surgery).

to wash out the cavity unless too abundant coagula are present. In such case usually one may wipe them out or gently irrigate the cavity before inserting the tube. Then sew up the skin-wound about the drainage opening and apply an abundant absorbent dressing. In most cases, if all goes well, especially if the case has been taken early, prompt convalescence will ensue. The patient should be encouraged to sit up as soon as he is strong enough, and should be taught graduated breathing exercises in order to encourage lung expansion.

I have recommended excision of a rib for drainage, and I repeat that recommendation: an excision is preferable to mere incision and drainage between ribs. The operation between the ribs fails to provide an avenue for proper inspection of the chest and for long-continued drainage. Drainage through a rib by means of a hollow tube screwed into a trephine hole is valuable. Through rib necrosis the tube becomes loose in the course of two weeks.

Be sure not to remove a rib behind so high up that the scapula may fall over it. If you operate through the back, take the ninth rib, and not the eighth or seventh.

In some cases the diaphragm rises as high as the fourth or fifth interspace, and lies close against the chest-wall behind. Be careful not to cut through the diaphragm in opening the chest. Most surgeons have been caught in this pitfall.

The **treatment of chronic empyema** is a different matter from that of acute empyema, but if all acute empyemas were operated upon prop-

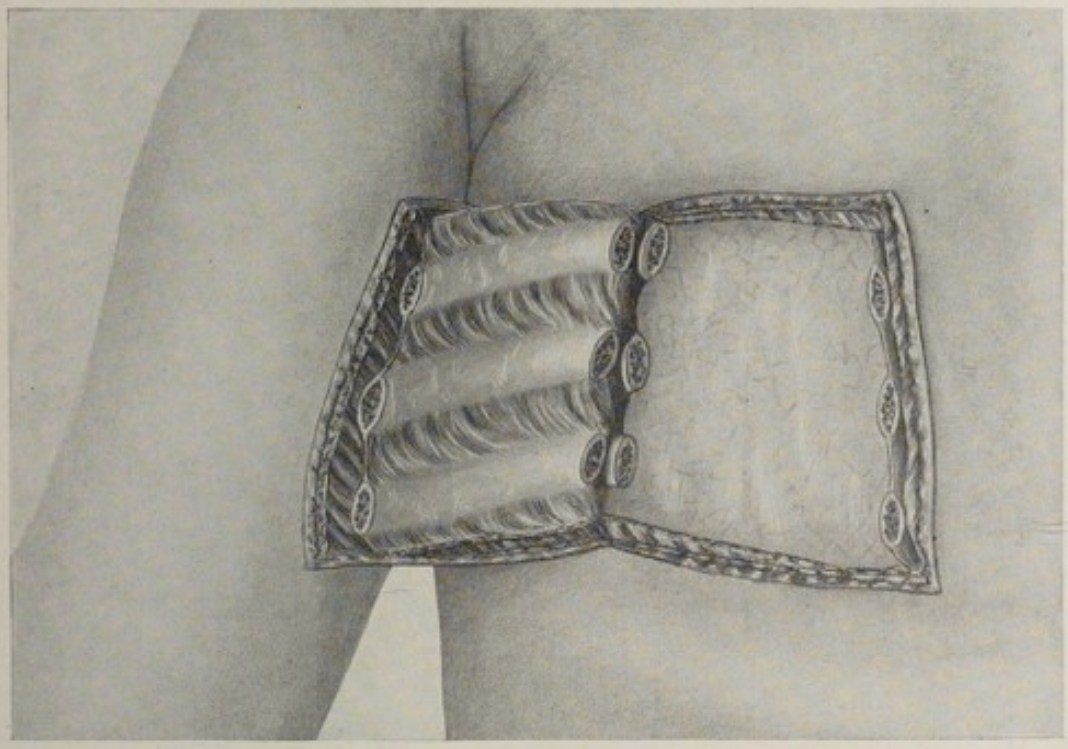

Fig. 312.—Osteoplastic thoracotomy (after Brewer in Keen's Surgery).

erly and promptly, chronic empyema would almost cease to exist. I beg the student to bear in mind carefully the distinction between the two conditions, acute and chronic empyema, and especially the distinction between methods for their relief. In chronic empyema the pleuræ become greatly thickened, so that those membranes assume the appearance of tough, strong, and tenacious envelops incircling the pus-cavity, lining the wall of the chest, and covering the surface of the lung corresponding to the affected area. One perceives, immediately, therefore, that mere aspiration or simple drainage of such a cavity cannot bring about a permanent cure, for the stiff wall of the cyst cavity re-

mains after drainage, holds the lung away from the chest, and persists as a pus-secreting membrane.

How shall we close up this abnormal cavity? Three methods within recent years have come into vogue, and these methods or their modifications often result successfully: Estlander's operation; Schede's operation, and Fowler's operation, sometimes called the operation of Delorme. All these operations are dangerous, and increasingly dangerous in the order I have given. In cases of chronic empyema the surgeon is dealing with patients weakened by long-standing illness. They endure badly capital operations, so that frequently it is necessary to proceed with these maneuvers at successive sittings. I have operated by Schede's method on the same patient seven successive times before curing him. In a word, *Estlander's operation* consists in removing parts of several

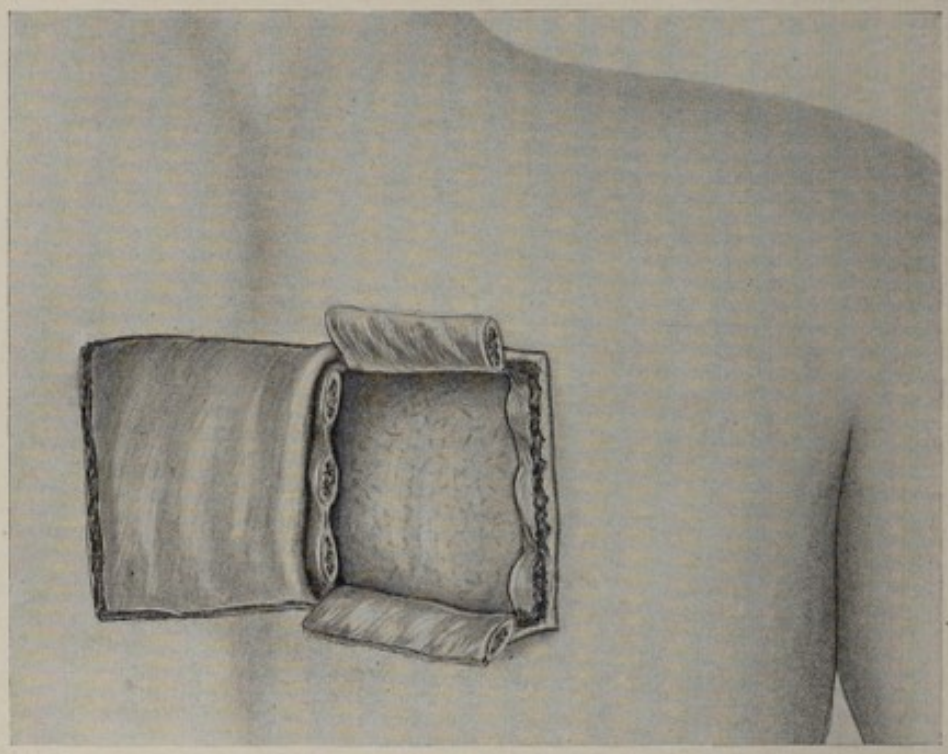

Fig. 313.—Bryant's operation (after Brewer in Keen's Surgery).

ribs over various parts of the affected lung, so as to allow the wall of the chest to collapse. This allows the parietal pleura to become adherent to the visceral pleura. Various incisions are employed by various operators—the T-incision; the L-incision; the U-incision. The U-incision is the one I prefer as I picture it in Fig. 313. Turn up a great flap of the soft parts, expose the ribs, cut up each rib to be excised and break it away with the periosteum in either direction. In many cases it may be advisable to *cut* the ribs away carefully over a given area. After removing the ribs, replace and sew up the soft parts and provide adequate dependent drainage. Convalescence is slow, and resulting deformity is the rule, but a fairly competent, useful lung is sometimes obtained. After this operation, as after all other operations for chronic empyema, the patient should be encouraged to lead an

out-of-doors life and practice pulmonary gymnastics—walking and hill-climbing—having due regard always to the condition of his heart. Schede's operation is a modification of Estlander's. Not content with removing the ribs, Schede supplements that procedure by excising all the thickened *parietal* pleura with the ribs and periosteum. As a result, the soft parts of the chest fall in at once upon and become adherent to the visceral pleura. Fowler's operation, in turn, is an extension of the principle of Schede's operation.[1] Not content with removing the parietal pleura, he extends the peeling-off process and removes all the thickened membrane from chest-wall, lung, and diaphragm, leaving a raw surface and a freed lung, which should now be able to expand and fill the cavity. The subsequent treatment consists in restoring the flap of soft parts and draining the wound. The question which confronts every surgeon when he approaches a given case is what operation shall he do, and how far shall he carry his dissection. One cannot lay down any rule which shall meet all conditions, but in general terms it is fair to say that the extent of the operation will depend upon the chronicity of the case, the amount of pleura involved, and, most of all, upon the condition of the patient. Usually one hopes to succeed by performing Estlander's operation, and if that fails to cure, one expects to follow it up with more extensive dissections after the manner of Schede or Fowler. I cannot but regard Fowler's operation as extremely severe, to be approached with hesitation and as a last resort.[2] There has been more or less confusion in the minds of surgeons as to the extent of rib resection which should be done in following Fowler's technic. As a rule, one need resect enough ribs only to allow of free manipulation and dissection within the chest cavity, but in certain cases it seems necessary to make a much wider resection of ribs, as is done in the Estlander operation. Ch. Girard (summarized by J. B. Murphy) concludes: "The prognosis of pleurocutaneous fistulæ (cavities), when left alone, is generally bad. Explorations may be done—though not without risk—by injections and sounding. Physical examinations, *x*-ray, auscultation, etc., are important, though they do not always furnish precise evidence. Pleuroscopy and digital exploration are very useful. While the minor degrees may be cured by pneumatic treatment or by respiratory gymnastics, these methods find their chief use as postoperative measures. Beck's paste is suited only for cases at once easy and stubborn. It is dangerous on account of intoxication and should be used cautiously. Estlander's

[1] George Ryerson Fowler, in New York Med. Rec., December 30, 1893, published his first reports of this operation. About this same time Delorme was working at the problem with conclusions similar to Fowler's. Although Delorme presented to the French Surgical Congress, in April, 1893, the results of his experiments in the cadaver, he did not do his first on a living patient until some months after Fowler had done so, and Fowler's early work was done without a knowledge of Delorme's experiments.

[2] Kurpjuweit, Beit. z. klin. Chir., vol. xxxiii, p. 627, has published statistical results showing that Fowler's operation, known as decortication of the lung, has given a percentage of 35.7 complete recoveries; 19.7 improved; 33.9 unimproved, and a mortality of 10.7. Estlander's operation, on the other hand, shows a percentage of 56.3 cured; 20 per cent. improved; 3 per cent. unimproved, and a mortality of 20 per cent.

operation is useful especially for extensive, though flattened fistulæ. When the cavity is both deep and large, Schede's operation is generally surer. Delorme's lung decortication and mobilization of the adherent lung often give excellent results, though not suitable for all cases. A combination of these with Schede's method is very advantageous. Tuberculous fistulæ with a large cavity, while having a grave prognosis, should not be abandoned to themselves. In some cases operation leads to cure. The dangers of extensive operations for pleural fistulæ may be greatly lessened, first of all, by local anesthesia, either for the whole or part of the operation, and next by making the operation in several sittings."

After all is said regarding these various radical operations for chronic empyema, we cannot often look for a perfect outcome. The mortality is high; failure to cure completely is frequent, and those persons even who are reported cured must expect to go through life with seriously crippled lungs and a depressed vitality. The corollary to all this has been often repeated—acute empyema should be operated upon early, and not allowed to progress to the chronic stage.

Hydrothorax develops in the course of some general circulatory disturbance, and is of the same nature as abdominal ascites. If the chest become so full of fluid that the lungs and heart labor in action, it may be necessary to perform aspiration. Otherwise the primary disease alone should be treated.

Hemothorax is a subject I have already mentioned in connection with surgery of the lung. It is produced by penetrating wounds, the crushing of ribs, or the pathologic erosions of vessels in the chest-wall (aneurysm, tuberculosis, etc.). I have already indicated the treatment, which is symptomatic generally—rest and bandaging, though rarely, when the symptoms are alarming, the surgeon may be obliged to open the thorax and ligate or tampon the bleeding vessel.

Chylothorax deserves little mention, for it is a rare condition. It results from an injury to the thoracic duct which produces an escape of chyle into the pleural cavity. A positive diagnosis can be made by an examination of the aspirated fluid, which is cream like, of low specific gravity, and contains sugar, lymphocytes, and minute fat-drops. No active *treatment* is practicable. Most patients recover under rest and bandaging.

Tumors of the pleura attracted some little attention a few years ago, for they were brought to our notice by such interesting writers as E. Wagner, Schulz, Fränkel, Lenhartz, and Lochet, but in practice such tumors rarely are seen. Especial attention has been called to a peculiar primary tumor of the pleura, an endothelioma which presents a diffuse pleural thickening, suggesting ordinary fibrous thickening. The microscope shows an extensive endothelial growth. The lung becomes compressed; there is dulness over the affected area, and the aspirating needle draws a chocolate-colored fluid containing characteristic nests and cells. Rare as are *primary* malignant growths in the pleura, *secondary* cancer and sarcoma are common enough, and are the result

of malignant disease in neighboring parts, especially in the breast. Malignant involvement of the pleura nearly always produces effusion, which is serous or bloody or beclouded with detritus.

In the case of primary endotheliomata operative treatment is of little value. We can do nothing but palliate the symptoms. As for secondary growths, it may rarely seem wise to resect extensively the chest-wall, but, as a rule, we can do no more than relieve pressure by aspiration and give morphin. In case a resection of the chest-wall be undertaken, one should employ a differential pressure apparatus to inflate the lung.

Echinococcus of the pleura is rare. I have already discussed this subject under the caption Echinococcus of the Lung.

CHAPTER XVIII

THE HEART AND PERICARDIUM

FIFTEEN years ago the heart had not been brought within the surgeon's field, and wounds of the heart especially were held to be beyond surgical treatment. Dennis,[1] writing in 1895, says: "The treatment of wounds of the heart consists in lowering the head to prevent cerebral anemia, the administration of opium to relieve pain and to control the inflammation, and the application of artificial warmth to the surface of the body"; but in the very next year, 1896, Farina reported the first recorded case of suture of the heart-wall for a penetrating wound. Farina's patient died of pneumonia on the fifth day, but that surgeon's operation seems to have been successful in repairing the damage to the heart. Operations on the pericardium antedated operations on the heart by nearly a century, and we read in the memoir of Baron Larrey how that distinguished French surgeon aspirated the pericardial sac in 1798. We see, therefore, that the surgery of the pericardium seemed possible to the older surgeons, and we find surgical literature dealing frequently with the subject.

The heart and pericardium form a portion of the circulatory apparatus, and many writers discuss their diseases in connection with the broader subject of circulatory disturbances. It seems more suitable to me, however, to treat of the heart and pericardium from the anatomic rather than from the physiologic viewpoint—to group the diseases of these organs with diseases of the chest, rather than with diseases of the blood-vessels, because clinically the surgeon deals with the heart and pericardium as isolated organs. There are two main divisions of the surgery of these structures: operations for fluid in the pericardium, including adhesions between the layers of that membrane; and operations for repair of penetrating heart wounds.

The popular notion that wounds of the heart are necessarily and instantly fatal is erroneous. Surgical writers from Paré to men of our own time relate cases of persons surviving such wounds for a longer or shorter period. Indeed, G. Fischer, in 1867, estimated, from a study of 452 cases of wounds of the heart, that from 7 to 10 per cent. of persons so injured recovered completely. The fact is known to all physicians that pathologic heart ruptures may be survived for a time. I myself had under my care a man of fifty who survived a cardiac rupture for nine days. Degeneration of the heart muscle renders futile repair of pathologic rents. Aspiration of the right auricle has been done to relieve the engorged heart in cases of acute pulmonary congestion,

[1] Dennis' System of Surgery, vol. iii, p. 218.

though the operation is desperate and rarely effective. Collections of fluid, from their pressure within the pericardium, may embarrass seriously or check the heart's action.

PERICARDIAL EFFUSIONS

The *simpler* forms of pericardial effusion may be dealt with by *aspiration* or *incision*. In such cases aspiration is comparatively easy and safe, because the heart is crowded back into the depths of the pericardium. Aspiration is not safe, however, in cases of *purulent* effusion into the pericardium, because then the heart's apex may be held forward to the anterior chest-wall by adhesions.

In recent years the possibilities of heart surgery or direct operative dealing with the heart have been made to appear as important future possibilities. George W. Crile, in 1903 and 1904, published an extremely interesting series of experiments and operations on the heart, showing that after apparent death in dogs and in man, even when half an hour of suspended animation has elapsed, the heart may be stimulated to resume its functions by direct rhythmic pressure over the pericardium, or by subdiaphragmatic massage,—the abdomen being opened for the purpose,—supplemented by artificial respiration and long-continued infusion of 1:50,000 adrenalin chlorid solution. Harvey Cushing, working in the Hunterian Laboratory of the Johns Hopkins University, has demonstrated the possibility of producing artificial cardiac lesions by intraventricular incisions of the cardiac valves, with a resulting recovery from the operation except for the cardiac lesion. This extremely interesting work suggests the possibility of intracardiac manipulations for the relief of valvular stenoses. Theoretic as these considerations may be, the work of such experimenters has proved conclusively that the heart may be approached and handled with boldness; at the same time the practical experience of many surgeons has shown the reasonableness and importance of operating upon the heart and pericardium for traumatic lesions of these structures. In all this we are considering a strikingly interesting and little explored field for surgery.

OPERATIONS UPON THE PERICARDIUM

Injuries to the pericardium may require the surgeon's intervention. They occur from crushing blows which fracture ribs and tear the pericardium, and they are due to penetrating wounds also—gunshots and stabs. Pericarditis may give rise to *serous*, *purulent*, and *hemorrhagic* effusions. Good practice in these days limits puncture of the pericardium to aspiration for the purpose of diagnosis. If fluid is to be evacuated properly, the pericardium should be opened with a knife. Commonly, the best place for puncture is in the sixth intercostal space, close to the edge of the sternum, for at this point there is the least danger of wounding the heart or the pleura.

Surgeons are not agreed as to the best method for incising the peri-

cardium (pericardiotomy). Some surgeons have advocated making a large costocartilaginous flap by cutting through the fourth, fifth, and sixth costal cartilages, and thus exposing a large opening. For many reasons this method is admirable, but there are the objections that it consumes much time and often involves wounding the pleura. This last objection may not be of serious consequence if the pleura has been damaged already by the violence which necessitated the operation. My own dissections of the cadaver have convinced me that Kocher's

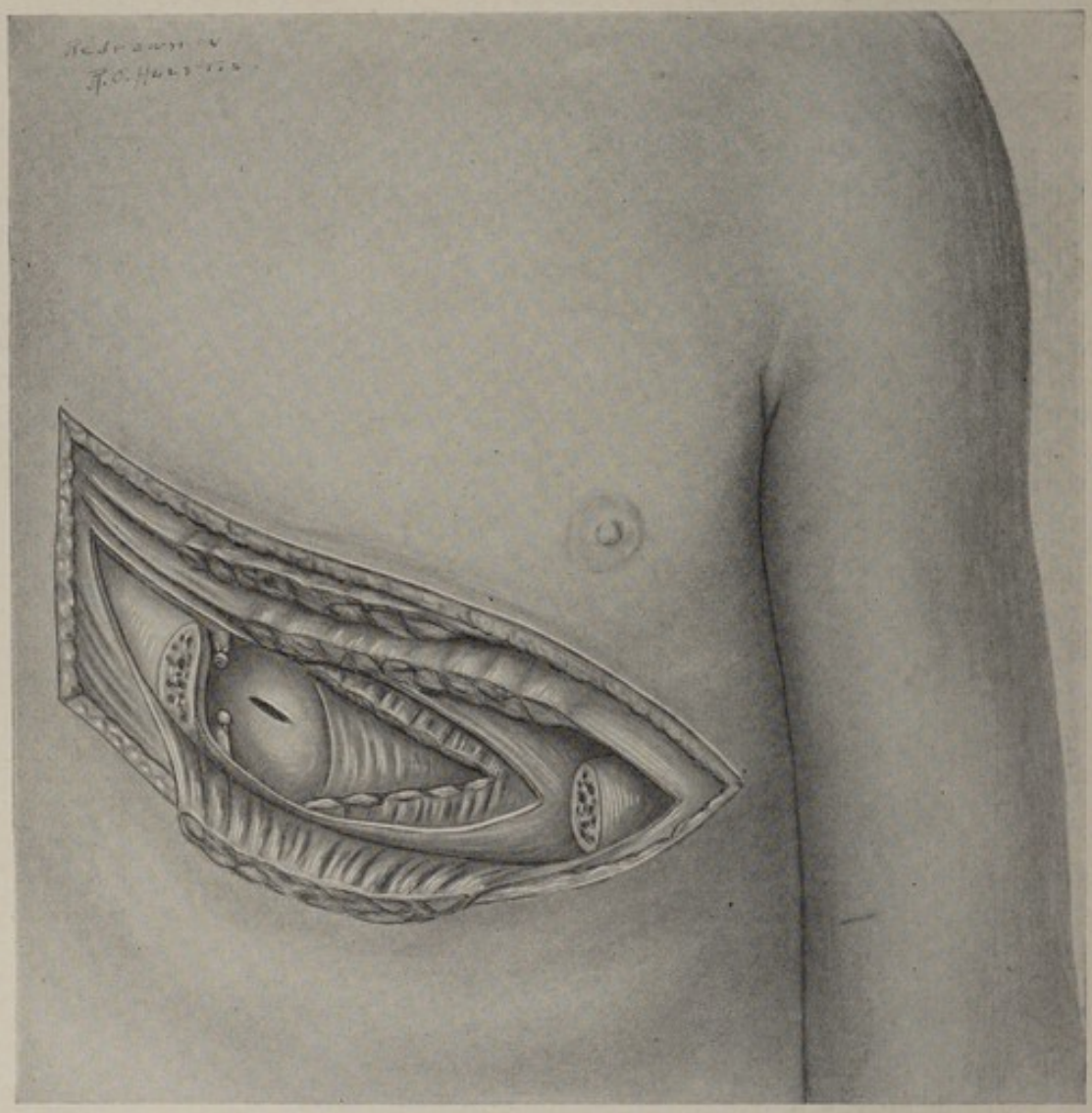

Fig. 314.—Kocher's approach to the pericardium.

method of approaching the pericardium is valuable. He makes a rectangular incision, one limb running down the middle of the sternum, the other outward along the sixth costal cartilage and rib. He turns up a flap of soft parts with the perichondrium of the cartilage and the periosteum of the sternum. He then divides the sixth costal cartilage, and pulls the sixth rib upward. If he looks for a greater exposure, he divides the fifth and fourth cartilages also. Then the intercostal muscles are stripped off and the internal mammary vessels are exposed.

One now perceives at the bottom of the wound the tough, glistening pericardium, which may be demonstrated more thoroughly by pushing aside with the finger the edge of the pleura (to be distinguished by the pad of fat covering it), together with the intercostal muscle and the internal mammary artery.

If the pericardium contain a non-purulent fluid, it is best treated by opening it low down along the edge of the sternum, drawing off the fluid, and sewing up without drainage the wound in the pericardium. The chest-flap is then replaced and repaired, with superficial drainage, to provide for the possibility of an intrathoracic infection.

Should the surgeon find a *pyopericardium*[1] present, he must drain the pericardial sac—preferably with a cigaret wick.

Adhesions between the heart and parietal pericardium or chest-wall are due to pericarditis or traumatism, and cause distressing symptoms—pain, dyspnea, and palpitation. The surgeon treats this condition by separating the adhesions (cardiolysis) or by cutting costal cartilages so as to allow the chest-wall to sink in and relieve the tension of the adhesions. The former operation, cardiolysis, must be performed carefully, and its completion must be abandoned if there appears to be danger of tearing the heart. The true cardiolysis operation does not contemplate opening the pleura. Section of cartilages is an operation relatively safe, and often satisfactory in its results.

WOUNDS OF THE HEART

Operations upon the heart have been confined practically to the repair of heart wounds, and paracentesis auriculi also has been employed. Heart wounds cause instant and alarming **symptoms:** pain; hemorrhage, often copious, sometimes slight; palpitation; dyspnea; syncope. The symptoms depend on the site and extent of the heart wound. Death is instantaneous if the ventricle is torn widely open or the center for heart-block is damaged, or the auricles injured. Fortunately, the ventricles are the parts commonly injured—the left ventricle much more often than the right.[2] A bullet or knife may wound the heart wall without perforating the ventricle. This superficial wound may bleed profusely and confuse the diagnosis. A perforating wound, if small, may bleed but little, owing to its being closed with every systole by the interlocking of the heart's muscles. Often there is but little external bleeding. An important complication of these wounds is coincident damage to the lungs and pleura, resulting variously in pneumothorax, hemothorax, or pulmonary atelectasis even.

The surgeon must take note especially of those victims of heart wound who do not die at once. Such are they in whom operative repair of the cardiac wound is imperative. The patient is seen in collapse, gasping, with cold extremities, cyanotic; the pulse is soft and rapid; the heart-sounds are muffled. Frequently there is hemorrhage from the heart into the pericardium, with a consequent throttling of the heart's

[1] Ellsworth Eliot, Jr., Suppurative Pericarditis, Ann. Surg., January, 1909.
[2] L. L. Hill, Wounds of the Heart, Med. Rec., September 19, 1908.

action. If the hemorrhage continues, the heart will be brought to a standstill. Our one and obvious expedient is to relieve the pressure by emptying the pericardium, and to check the hemorrhage by sewing up the wound in the heart.

The **treatment** I have outlined should be supplemented by proper stimulation—hot bottles and blankets, raising the foot of the bed, a hypodermic injection of morphin and atropin, the intravenous injection of a pint or more of normal saline solution, with adrenalin (1 : 50,000), and the application of Crile's pneumatic suit, if it is at hand, or, best of all, by the transfusion of blood. An anesthetic rarely is desirable, and if any is given, ether by the intratracheal method, or nitrous oxid and oxygen are preferable.

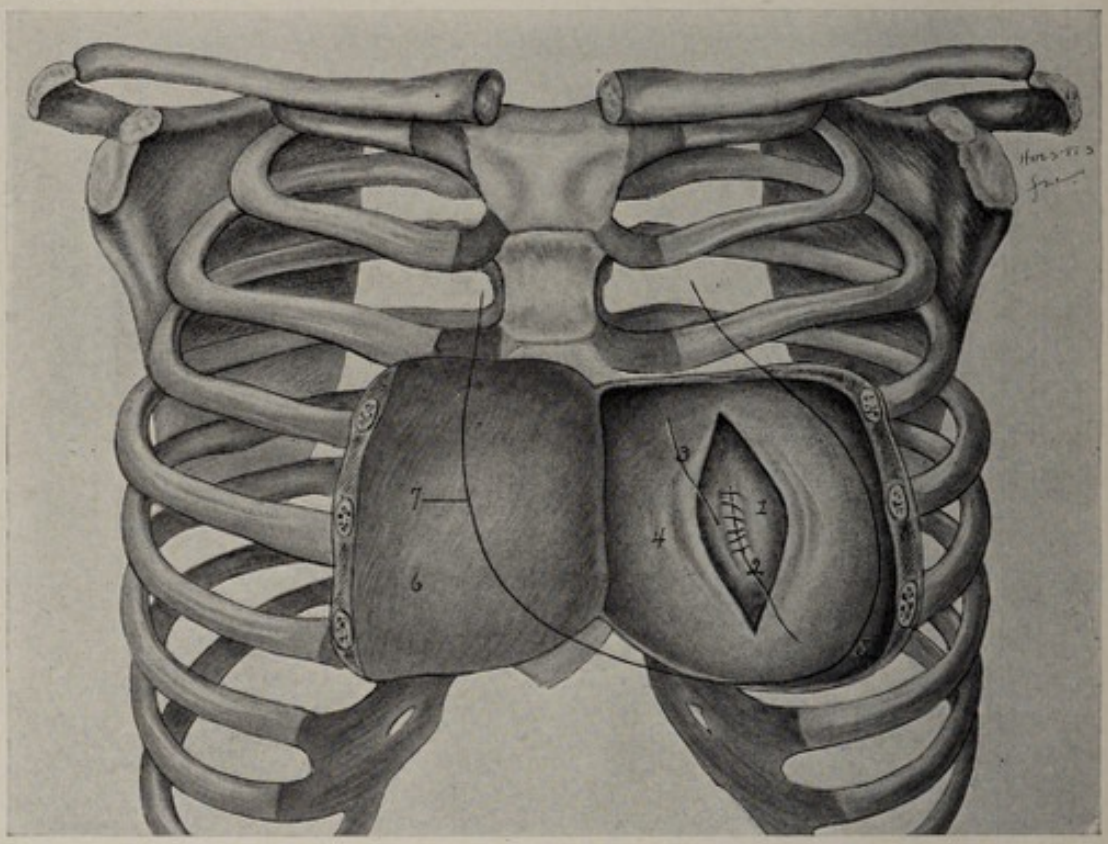

Fig. 315.—Vaughan's case of heart suturing (redrawn from sketch): 1, Heart; 2, deep sutures; 3, superficial sutures; 4, pericardium; 5, left pleural space; 6, flap of chest-wall, including fourth, fifth, and sixth ribs; 7, outline of heart.

The steps of the operation in detail are these:[1] With the patient in a modified Trendelenburg position, clean up rapidly the skin; enlarge the external wound, and ascertain the condition of the underlying cartilages and ribs. If they are found divided, advance through the opening thus provided. If they are intact, turn back a rib in the fashion I have already described. Seek and tampon any rent in the pleura. Expose the pericardium and find the wound in that membrane; enlarge the pericardial wound; empty the pericardium of blood and clots, and look for the wound in the heart. One may find great difficulty in discovering

[1] See important discussion by Brewster and Robinson, Ann. Surg., March, 1911.

this heart wound. Gibbon[1] reports an interesting and successful case, in which, being unable at once to discover the lesion by sight or touch, he passed his fingers behind the heart, lifted it forward to the pericardial opening, and so disclosed the heart wound, which was partly filled with a clot, and was situated in the right ventricle, near the auriculoventricular groove.

Having found the wound, the surgeon will make easier the sewing it up, by passing first two deep stay-sutures, one into either edge of the wound, and so holding forward the heart. Use round-pointed intestinal needles. Sew up the wound with a continuous silk or catgut suture, tie it during diastole, and avoid entering the endocardium. Then drop back the heart, sponge out the pericardial sac, and sew it up after providing drainage. Some surgeons protest that drainage is not necessary and that it promotes suppuration; but in view of the possibility of further leakage from the heart-wall and of the collecting of blood, serum, or pus in the pericardium, I cannot convince myself that it is safe to leave the sac undrained. Complete the closure of the wound by treating properly any rent in the pleura; drain it, if a rent exists. Replace the cartilage and skin-flap, and drain the superficial wound also. Apply a large absorbent dressing with a firm swathe, and put the patient quickly into a warm bed. If the patient lives, the surgeon will have an anxious time for a week or more. There are the dangers of recurring hemorrhage, of incomplete drainage, of cardiac collapse, of infection, of pneumonia, and of empyema. The first dressing should be done after twenty-four hours, and after that the various complications must be met and combated as they arise.

We are coming to see that wounds of violence to the heart offer brilliant opportunities for the surgeon. Without operation 90 per cent. of the victims die; with operation, 64 per cent., and the mortality is falling. All surgeons are impressed with the importance of prompt repair for penetrating wounds, for stab-wounds especially, as they are least likely to involve the ventricular septum. Shot-wounds are more fatal, for they penetrate deeper than stab-wounds, but shot-wounds even may sometimes be repaired. Too little regard has been paid to the after-effects of crushing wounds which fracture the costal cage and tear the pericardium. From such damage patients may recover, but later develop cardiac adhesions, with dilatation and symptoms of insufficiency. In several such reported cases cardiolysis, or, better, section of the overlying chest-wall, has given marked relief to the symptoms.

It may still be proper to feel that the whole subject of heart surgery is *sub judice*, but there can be no doubt that it offers a widening and important field for surgical endeavor.

[1] John H. Gibbon, Jour. Amer. Med. Assoc., February 10, 1906.

CHAPTER XIX

THE CHEST-WALL—THE BREAST

The Chest-wall

In the three preceding chapters we have been discussing diseases and injuries of the thoracic viscera—the bronchi, lungs, pleura, and heart. In this chapter we shall deal with lesions of the thoracic cage and its coverings. In general terms, the important external lesions of the thorax may be grouped under *inflammations, wounds,* and *tumors;* while far the most interesting of the special conditions in this relation for surgeons are penetrating wounds of the chest and breast tumors. To breast tumors especially surgeons in civil practice have turned their attention for generations, and the accumulated literature of the subject during the past one hundred years is enormous. We are now dealing with diseases on the surface of the body, diseases obvious to touch and sight; and we may well imagine how such disorders in all time must have attracted the intelligent interest of mankind. In like manner wounds of the chest-wall have always been objects of surgical activity, and military surgeons especially have dealt with them familiarly. We shall not discuss bone fractures in this chapter, but reserve that subject for special consideration in the chapter on Fractures.

The soft parts of the chest-wall are subject to such various contusions, wounds, and inflammations as are found in other parts of the body, but certain of these lesions when found upon the chest have their own characteristics.

CONTUSIONS OF THE CHEST

Contusions of the chest may be superficial or deep, and may be associated or not with damage to the viscera. In any case the pain which is experienced is increased by the movements of costal respiration. Skin-wounds call for the simple treatment which I shall explain in the chapter on Minor Surgery. Wounds of the muscles and ligaments may cause great inconvenience, while damage to the ribs gives rise to excruciating pain.

In all cases of thoracic wounds, therefore, the patient experiences peculiar symptoms—intermitting pain, increased by respiration; a frequent sense of suffocation; a feeling of collapse and prostation; sometimes dyspnea and palpitation. He is most comfortable in the semiprone or upright positions, and involuntarily he employs diaphragmatic breathing.

An unusual but frequently quoted result of severe chest contusion is *traumatic asphyxia,* a striking case of which condition was reported by Beach and Cobb[1] a few years ago. I saw the case at the time, and

[1] H. H. A. Beach and Farrar Cobb, Ann. Surg., April, 1904.

PLATE I.

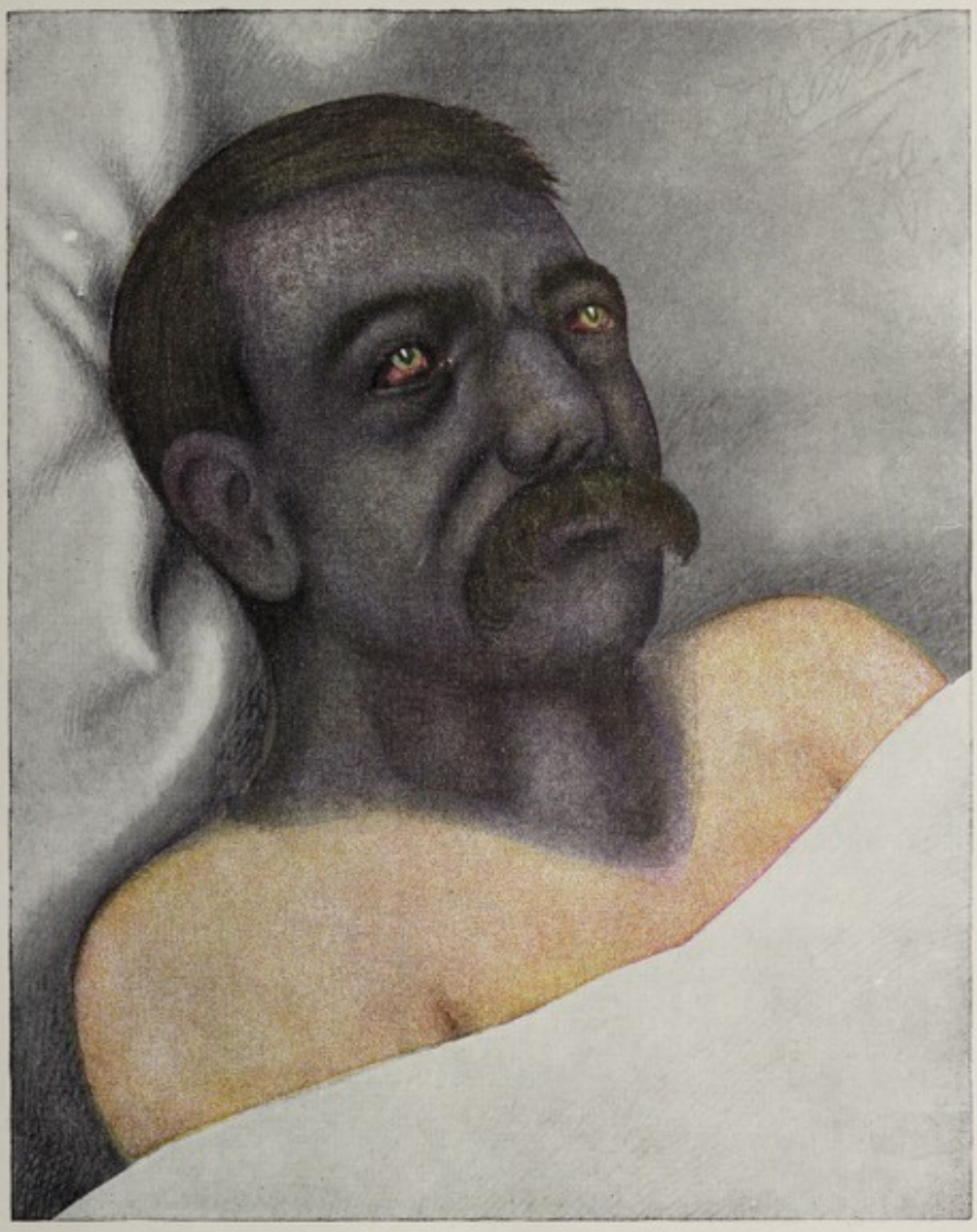

TRAUMATIC ASPHYXIA.
Discoloration following forcible compression of the thorax (Beach and Cobb, in "Annals of Surgery," April, 1904).

was impressed by the extraordinary appearance of the man, whose picture I reproduce (Plate I). Such conditions are due to heavy crushing forces exerted upon the thorax. The man in question was crushed in an elevator. The discoloration of the skin is due to stasis from mechanical overdistention of the veins and capillaries, and not to extravasation of blood into the tissues. The sharp limitation of color to the head and neck is probably due to the lack of valves in the jugular and facial veins.

The **treatment** for most chest injuries not involving the viscera consists of repair of the soft parts, the application of an abundant absorbent dressing, and fixation of the chest by plaster strapping, which should immobilize the ribs on the side affected, and should extend well over on to the opposite side, both behind and before. Cases of traumatic asphyxia seem to be little benefited by treatment, though writers have suggested that artificial respiration and the giving of oxygen might be of value immediately after the accident. In the case I have quoted, and in other similar cases which have recovered, the patients got well under rest in bed merely.

INFLAMMATIONS

Inflammations of the thoracic wall, especially suppurative inflammations, may involve much tissue, for the chest is overlaid by a series of broad flat muscles, between the planes of which pus burrows rapidly. Great abscesses form in the back and under the breast, causing severe constitutional disturbance and great local distress. Such inflammations must be treated promptly by opening and washing out and draining the abscess cavities. These cases of localized infection are peculiarly suitable for opsonic vaccination. I have seen prompt and striking improvement follow this treatment.

Burns of the chest occur frequently in civil practice. When they are at all extensive, they are grave. Indeed, death may follow apparently trivial burns of the chest. These lesions call instantly for careful treatment. One should give morphin to quiet the pain and diminish shock, and should carefully exclude the air by wrapping in oiled compresses covered with heavy absorbent dressings.

Boils and **carbuncles** are often found upon the chest, especially in the thick skin of the back. The treatment of these lesions is that treatment of boils and carbuncles which I describe in the chapter on Minor Surgery (Chapter XXVI). In addition, they are especially favorable objects for opsonic vaccinations.

Costal Perichondritis, Post-typhoid.—There are three forms: one characterized by dense thickening, which is absorbed and leaves no trace; a second, by suppuration; while a third leads to circumscribed chondromata. Says D. G. Zesas (quoted by J. B. Murphy): "These post-typhoid inflammations of the costal cartilages are rare. . . . The affection ordinarily commences six to eight weeks after the typhoid, and without rise of temperature. . . . There is no relation to the intensity of the primary fever. It is characterized by pain on deep expiration. There are often nocturnal exacerbations. Prognosis is good. Abscess formation and fistulæ are rare. The purulent forms

should be opened and curetted. In the chondromatous the hypertrophied cartilages are to be resected. [When they once form sinuses they are obstinate, and require the removal of one or more costal cartilages—the entire cartilage. The infection rarely extends to the bone.]"

Tuberculous sinuses, associated with tuberculosis of the ribs, clavicles, sternum, and vertebræ, burrow through the chest wall and appear at various points on the thorax. Often they become the subjects of prolonged and tedious treatment. The sinuses must be dissected out carefully and the underlying tuberculous focus must be exposed and removed. There results generally from the operation a large open wound, which must be packed carefully and made to heal from the bottom.

Actinomycosis of the chest-wall is not uncommon, while rarely *echinococcus disease* is seen. The surgeon must expose thoroughly these processes and remove or drain them, as best he may, under the circumstances.

NEURITIS OF THE INTERCOSTAL NERVES

Neuritis of intercostal nerves, commonly known as intercostal neuralgia, is a frequent affection, and its sources are manifold. Generally, it is associated with the so-called rheumatoid condition, but it may be due to disease of the nerves themselves, to disease of the cord, to disease of the spinal column causing pressure, to the pressure of tumors directly upon the nerves, or to disease of the ribs. These several etiologic factors must be investigated and the primary causes must be treated.

In addition to such traumatic and inflammatory lesions the surgeon will be called occasionally to treat tumors.

TUMORS OF THE CHEST-WALL

There is a considerable variety of such tumors, which develop sometimes from the soft parts, sometimes from the bones or periosteum. Moreover, metastatic tumors from growths in the vicinity, such as cancer of the breast, attack the chest-wall frequently. There are the common benign tumors, *nevi, sebaceous cysts, wens, dermoids, keloids, fatty tumors, fibromata, neuromata, cavernous hemangiomata, lymphangiomata, enchondromata,* and *compound tumors,* all of which may disturb the patient by their mere presence, by their size, and by the pain which they cause. These tumors are benign, and may be removed with the knife or cautery. In several instances I have removed successfully nevi and angiomata by the injection into them, subcutaneously, of several syringefuls of boiling water (Fig. (369), which causes a local necrosis, with resulting absorption of the mass.

Sarcoma and **carcinoma,** primary in the chest-wall, occasionally have been reported. Such tumors are distinguished from benign growths by the rapidity of their development, by the pain they cause, by the appearance of metastases, and by the development of cachexia in the patient. They are, unfortunately, fatal, usually, in spite of the most radical treatment. Frequently they attack the ribs, and they may invade the pleura. It is a serious matter to excise them, but excision

offers practically the only chance of cure. If the operation necessitate opening the pleural cavity, the surgeon should employ the Sauerbruch cabinet or some one of the positive pressure apparatus, to maintain a proper expansion of the lungs.

It is needless here to discuss the nature and treatment of penetrating wounds of the chest involving the thoracic viscera, as we have already considered this subject in Chapters XVI, XVII, and XVIII. Such, in brief outline, are the diseases and lesions located upon the thoracic wall.

THE BREAST

There remains for our consideration the subject of *diseases of the breast*. The breast is the most important and striking landmark upon the chest—the organ peculiarly liable to injury, infection, and tumor growth, especially in women, closely connected with the generative function, and of extreme interest to the surgeon.

Diseases of the breast have been the subject of intelligent surgical interest for generations, but it is within our own generation only that final and satisfactory conclusions regarding the pathology of this organ have been reached. After Virchow published his observations on cellular pathology and the nature of tumors, some measure of order in our conception of mammary diseases began to establish itself, but even to-day all men are not in accord as to the classification of certain breast tumors, and so lately as 1905 J. Collins Warren wrote, "In no department of surgery has the classification of the diseases of an organ or the pathologic nomenclature been more confusing than in the case of the diseases of the mammary gland." Most physicians, when they think of disease of the breast, think especially of the two most common lesions —cancer and abscess. There are numerous other lesions which we must consider in their order. Let us first, however, study the most common disease, *cancer*, and sundry less malignant breast tumors with which cancer may be confused.

A few words first on the subject of the anatomy and development of the breast must detain us, for without a clear understanding of these matters the reader cannot proceed intelligently.

ANATOMY

The breast in women—we need not consider here the rare breast diseases in men—extends normally from the third to the sixth or seventh rib, and from the margin of the sternum to the anterior axillary line. It covers most of the pectoralis major muscle, and is easily movable on the fascia of this muscle. Its 15 to 20 milk-ducts terminate by fine openings in the nipple. The areola contains sweat-glands and sebaceous glands, which may become cystic or inflamed. Numerous smooth muscle-fibers run down from the nipple and areola into the substance of the breast, and their stimulation causes an erection of the nipple. These fibers must not be confused with the fibrous processes which radiate from the skin of the breast down between the lobules of the gland.[1]

[1] The suspensory ligaments of Astley Cooper.

Various diseases of the breast may affect the muscles of the nipple and cause the nipple's retraction. Cancer of the breast may affect the fibrous processes of the skin, causing them to shorten, with the effect that the overlying integument appears pitted, with many minute dimples. At different periods of life the breast changes in size and in its histologic characteristics. At birth the gland is represented by a series of radiating ducts lined with an epithelium which is often in a state of active proliferation, causing swelling and tenderness of the baby's breast and a deposit of broken-down fat and epithelial cells, which may be squeezed in a milk-like fluid from the nipple. This is the so-called acute mastitis of infants. From infancy until puberty the breast is quiescent. Then comes the hypertrophy of puberty, when there appear acini lined with epithelium and a *characteristic myxomatous connective tissue*, which develops about the terminal ducts and the acini. Note must be made of this peculiar connective tissue, which was first described by Billroth, for it is the site of important new-growths, usually benign. This is that periductal connective tissue, for the tumors of which Warren[1] has suggested an important modified nomenclature.

With pregnancy another notable change takes place in the breast. The epithelial activity of the gland is then great, the acini multiply, and, as Warren remarks, the tree may be said to be in full leaf. The periductal tissue becomes stretched and less prominent. After lactation many of the acini disappear, the periductal tissue becomes relaxed, and the breast pendulous. The final period in the life-history of the breast begins in middle age. The gland slowly dries up, with obvious changes, noticeable both in the acini and in the periductal tissue. The epithelium no longer proliferates, but degenerates. Ducts become choked with epithelial débris or compressed by the contracting interstitial tissue, and blood-vessels become thrombosed and disappear. These changes are not uniform, but occur in scattered islands throughout the breast, so that the gland takes on the familiar "cobble-stone" feel. With advancing age these degenerative changes continue, so that in old women the mammary gland, much as in infancy, is represented by a few ducts merely, near the nipple, and small bands of fibrous stroma infiltrated with fat.

The breast receives its *blood-supply* from the axillary and internal mammary arteries and from certain branches of the intercostal arteries, and its *nerve-supply* from filaments of the sympathetic, the brachial and cervical plexuses, and the intercostal nerves. The lymphatic connections of the breast are far more important than the blood and nerve connections. The lymph-vessels and nodes of the breast are numerous. They are superficial and deep. Some lymphatics belong to the skin, and are found especially about the nipple, whence they penetrate within the structure of the gland itself. All the lymphatics of the breast join at the inferior external margin of the gland in two or three large trunks, which pass upward along the edge of the pectoral muscle and empty into the axillary nodes. The first node of this axillary chain lies on the third rib,

[1] J. Collins Warren, The Surgeon and the Pathologist, Jour. Amer. Med. Assoc., July 15, 1905.

beneath the pectoralis major. There are about a dozen axillary lymph-nodes. The more important are grouped about the axillary vein, where it receives its long thoracic and subscapular tributaries. Some of the lower cervical nodes, lying close above the clavicle, have lymph connections with the axillary nodes, and the deep lymph-nodes in the retromammary fat may communicate directly with the breast tissue. For convenience of gross anatomic description the breast is spoken of as divided into hemispheres and quadrants—the upper, the lower, the outer, the inner, etc.

CANCER OF THE BREAST

Cancer of the breast is common. After the stomach and the uterus, the female breast more often than any other organ is the site of cancer. Cancer is the most frequent tumor of the breast—far more common than benign tumors. Statistics vary. Authors estimate the frequency of cancer as between 70 and 82 per cent. of all breast tumors. Not only does cancer develop primarily, but frequently it appears as the outcome of changes in tumors heretofore benign. This is not the place for a discussion of that burning question, the etiology of cancer, but clinicians have come to think that breast cancer, like cancer elsewhere, may in some degree be dependent upon trauma—not trauma in the ordinary



Fig. 316.—Acinous and duct cancer (Warren Museum, Harvard).

sense of wound or bruise, but trauma in the sense of long-continued irritation, such as any actively functionating part must undergo.

Cancer of the breast, in most cases, springs from the epithelium lining the acini or from the epithelium lining the ducts. Hence the familiar terms, *acinous* cancer and *duct* cancer. Acinous cancer is far the more common. That is a histologic classification, but old-time convention has established a clinical classification which is still in common use among surgeons. For instance, we speak of *scirrhus* and *medullary* cancer (or *encephaloid*), of *colloid*, of *atrophic cancer*, of cancer *en cuirasse* and of *Paget's disease*.

By scirrhus we mean a hard growth merely, and this hardness is due

to the fact that the tumor contains much connective tissue and little parenchyma. Medullary cancer is softer, because it contains much parenchyma and little connective tissue. When the tumor undergoes colloid degeneration, we speak of it as colloid cancer. Atrophic cancer, or " withering scirrhus," produces so great a shrinking of the gland that

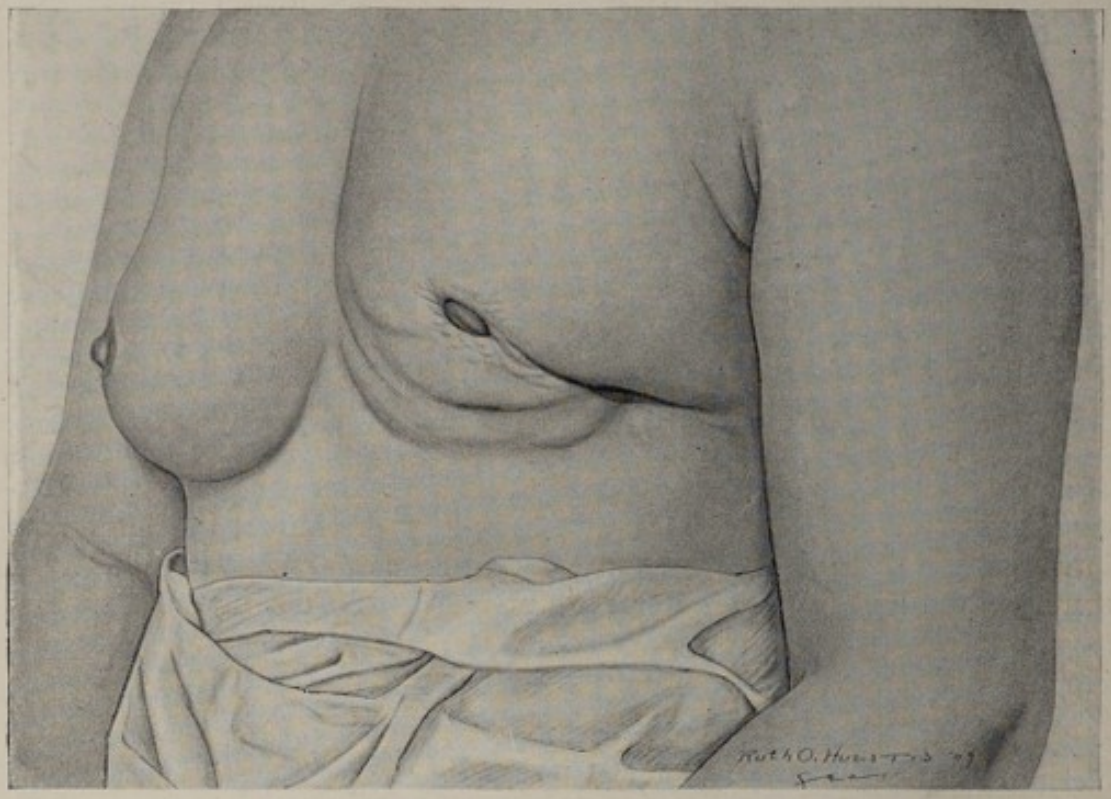

Fig. 317.—External appearance of scirrhous carcinoma (Massachusetts General Hospital).

little of the breast can be found. Then there is the so-called cancer *en cuirasse* of Virchow, which shows itself as a malignant growth involving extensively the lymphatics of the skin, as well as the thoracic wall. A considerable area of the chest seems to be set in a wide-reaching, firm

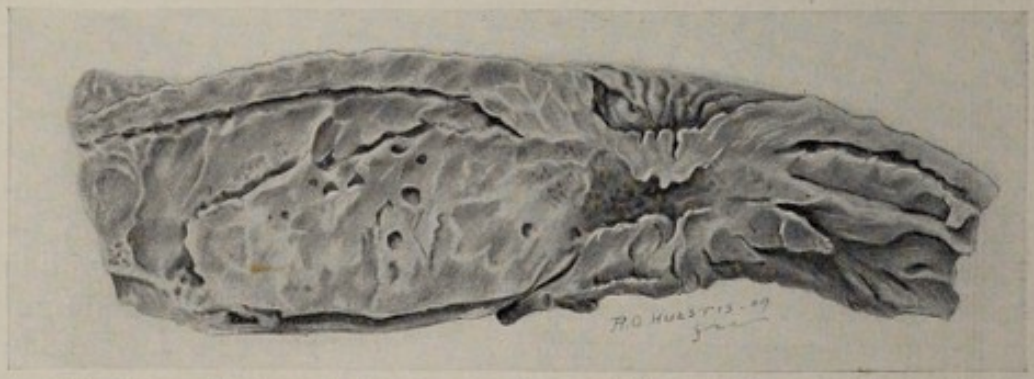

Fig. 318.—Section of scirrhous carcinoma (Warren Museum, Harvard).

corslet of disease. Paget's disease of the nipple is a somewhat rare condition, which leads to malignant involvement of the mammary gland. It starts as a chronic inflammation, suggesting eczema of the nipple and areola, and may last several years. It is not a simple eczema, and

does not yield to ordinary treatment. If left unchecked, it proceeds frequently to invasion of the epithelium lining the mammary ducts, until it produces a genuine duct cancer, with all the familiar characteristics of that affection.



Fig. 319.—External appearance of medullary cancer (Massachusetts General Hospital).

Cancer of the breast, like cancer elsewhere, has no capsule. It progresses by a general infiltration, though the different forms of cancer vary in their life-history, in their symptoms, and other manifestations.



Fig. 320.—Section of medullary cancer (Warren Museum, Harvard).

Scirrhus grows slowly, and may run a course of two or three years. It is most common in women who have borne children. Though not peculiar

to old women, it appears usually after middle life. The typical forms of atrophic scirrhus are peculiar to persons of advanced years. Medullary cancer is more common to persons in young middle life, and is found, rarely, among young women even. I have seen medullary cancer develop rapidly in an unmarried girl of twenty-one. Medullary cancer may kill the patient within a year. This is the form which early attacks

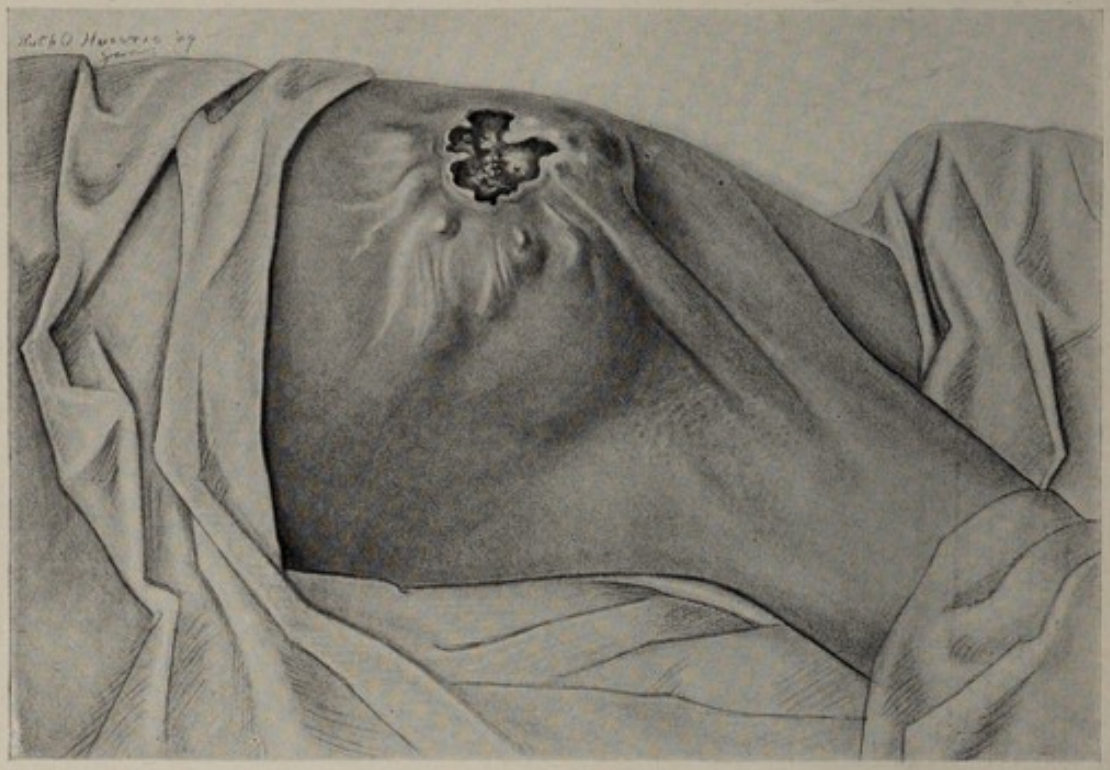

Fig. 321.—External appearance of colloid cancer (Massachusetts General Hospital).

the skin and underlying muscles, and results in the familiar ulcerating, cauliflower growths, which the laity usually associate with cancer of the breast. Not long ago I had under my care a stout woman of forty, the

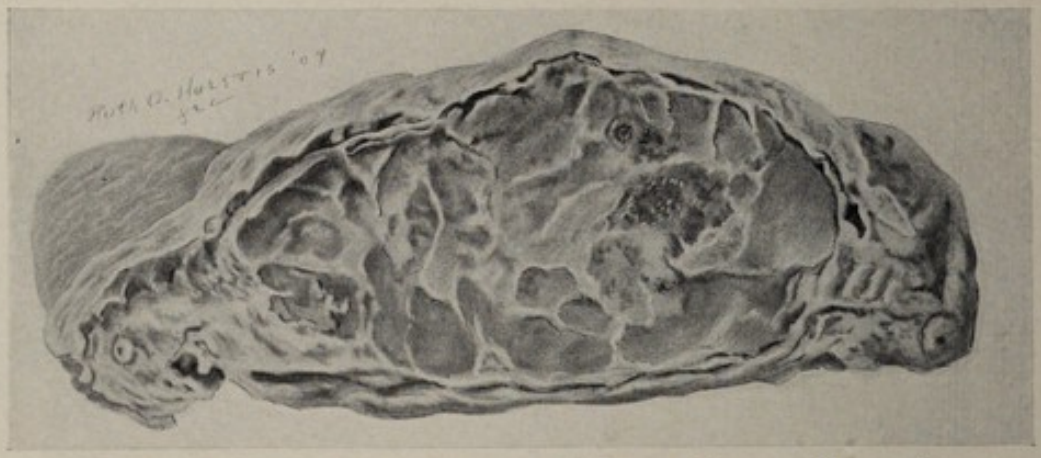

Fig. 322.—Section of colloid cancer (Warren Museum, Harvard).

victim of one of these tumors, which had destroyed the breast and a large part of the pectoralis major. It presented the appearance of a great granulating wound the size of a dinner plate, and with foul, elevated edges.

The progress of all forms of breast cancer is continuous. They invade early the neighboring lymph-nodes, especially those in the axillary group, whence the disease spreads to the lower cervical group.

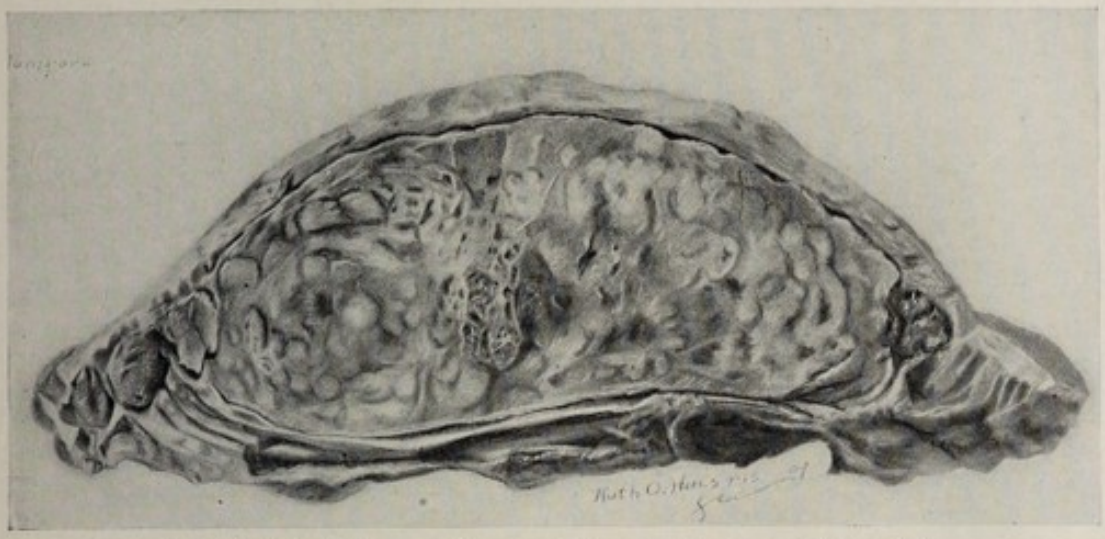

Fig. 323.—Adenocarcinoma (Warren Museum, Harvard).

Late, and more rarely, the subpectoral and the mediastinal nodes become involved. The patient dies with distinct metastases often—

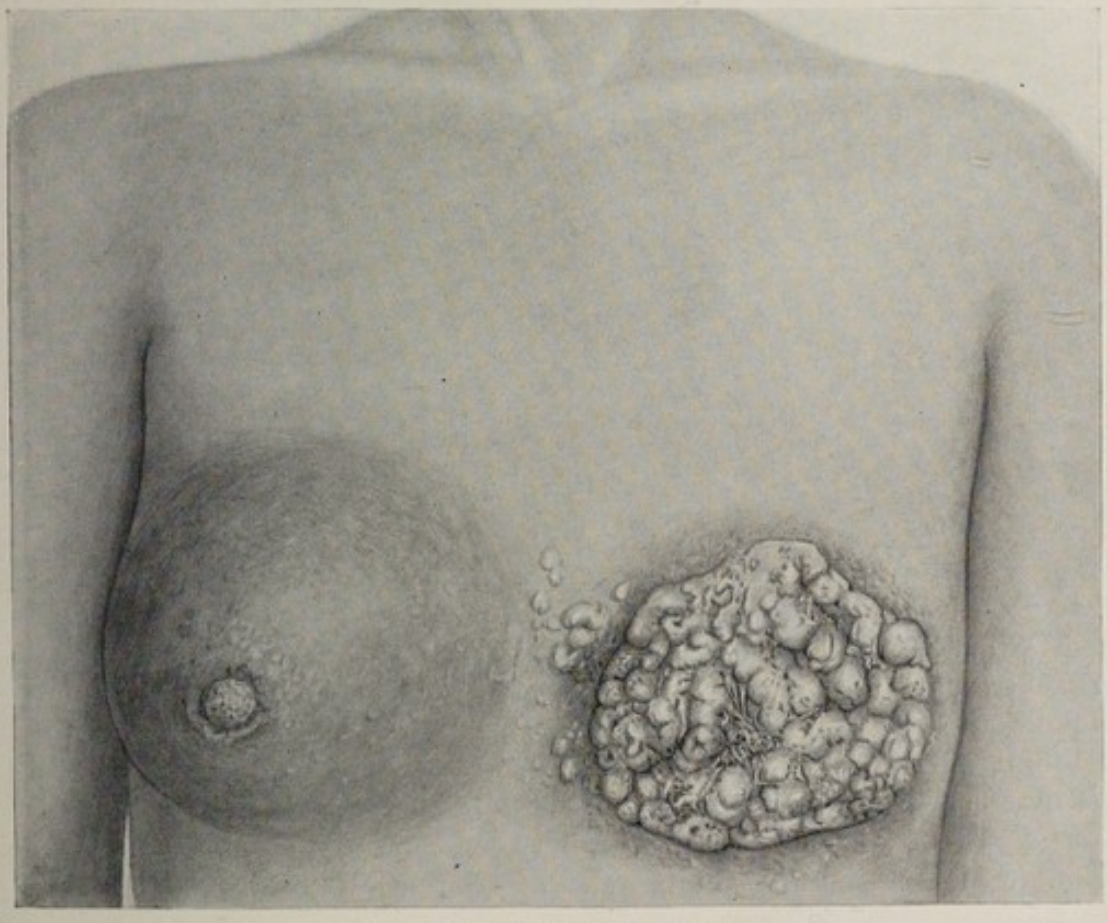

Fig. 324.—Cancer en cuirasse.

cancer of the lung and pleura, of the liver, the spinal column, or the brain. The exact method of cancer dissemination is still a matter of

discussion, and Handley[1] recently has advanced views at variance with those commonly accepted, namely, the belief in a spread through the blood and lymph-channels only. He asserts that the dissemination of cancer is accomplished in a more slow and subtle way by the actual growth of cancer-cells in all directions, from the tumor center along the finer vessels of the lymphatic plexuses. The author calls this "permeation," and states that it takes place as readily against the lymph-stream as with it. In this way the tissues are involved as by an invisible annular ring-worm, the growth extending like a ripple, in a wider and wider circle, with a healing process going on within its circumference, leaving behind it involved lymph-nodes which persist.

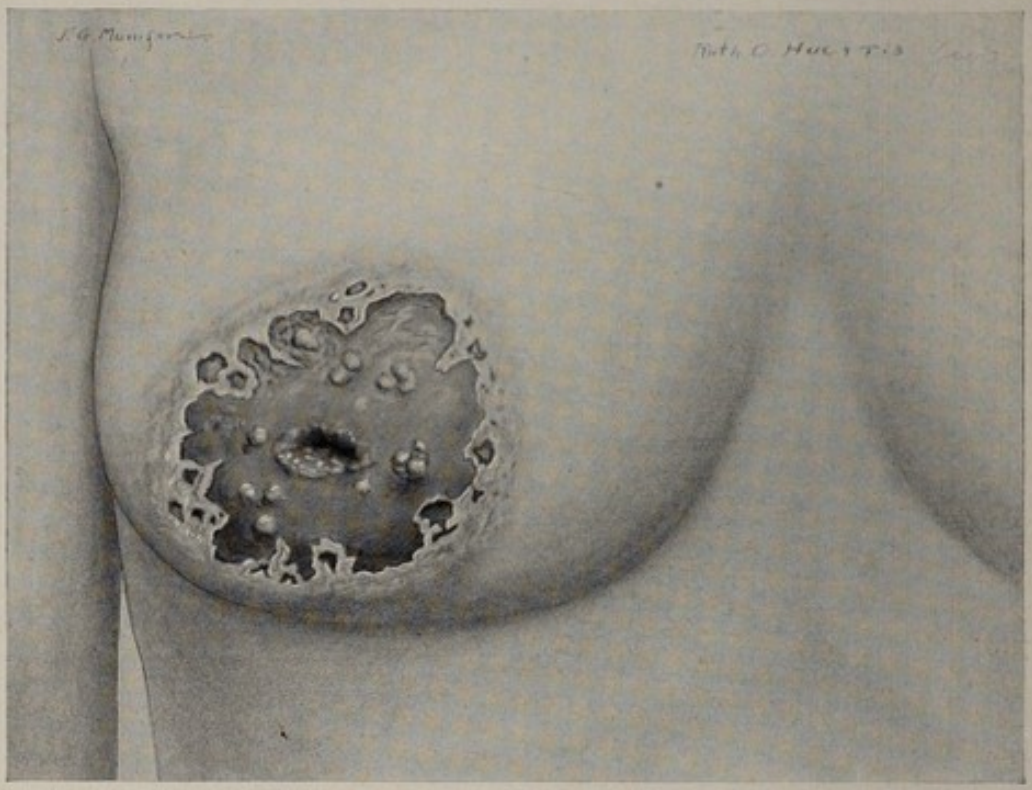

Fig. 325.—Paget's disease (Massachusetts General Hospital).

Thus he says a breast cancer with its invisible microscopic extension forms a mass shaped somewhat like a biconvex lens, the thin circumference of the lens situated often far beyond the limits of the breast, is formed by the cancer-filled lymphatics of the fascial lymph-plexus, and lies, as a rule, exclusively in the plane of this plexus. As one approaches the center of the lens, which center corresponds to the primary growth, the adjoining layers of tissue are invaded by cancer to a gradually increasing depth. However this may be, the surgeon in practice discovers clinically a mass in the breast and enlarged nodes in the axilla, but he may be sure that the region between the primary growth and the nodular metastases is itself the site of microscopic cancerous involvement.

Cancer occurs in the male breast also, springing from the rudimen-

[1] W. S. Handley, Glascow Med. Jour., December, 1905.

tary glandular epithelium. It is rare in men, though its exact frequency is somewhat undetermined. I have seen one male breast cancer in a group of 72 cancers of the breast. The figures usually given are 1 in 100.

Surgical literature abounds in protest against the common concealment of breast cancer practised by women, and it is hard to see why the victims of this disease so frequently attempt to keep all knowledge of it from their families and from their physicians even. We are coming to believe, however, that modern teaching and the insistence by our profession on the importance of early treatment are tending to abolish the old-time unhappy tradition of secrecy. Cancer of the breast was formerly regarded as a horror for which there was no hope. To-day we know that an increasing proportion of these cases are cured by operation.

The **symptoms** of cancer of the breast are elusive often, rarely characteristic in the early stages of the disease, sometimes not obvious to the patient until the growth has developed far. The symptoms depend on the age of the patient, the location of the tumor, and the histologic nature of the growth. Unfortunately, the symptoms, of diverse character, are never a sure indication of the exact nature of the growth, even though its malignancy be assured. We look for the following symptoms and signs: pain, tumor, dimpling of the skin, ulceration, retraction of the nipple, involvement of lymph-nodes. The pain may be early and may be the first indication of trouble. It may be dull and boring, or it may be lancinating and shooting, or there may be a stitch in the side, running into the shoulder and upper arm. Or there may be no pain for long, but a tumor may be the first evidence of trouble. A woman, robust and vigorous, may consult the surgeon and state that she has discovered recently a painless lump in her breast. The surgeon must examine the lump with suspicion, no matter what the age of the patient, and he must not be misled if the lump be found in that detached portion of the gland lying high toward the axilla. A cancer, small and deeply placed, is always fixed in the breast; it is not encapsulated, and cannot be moved about. If deep, it may not be felt by the examining hand lifting the breast in front. The surgeon should stand behind the sitting patient, and with his hand over her shoulder should roll under his fingers the breast, flattened against the chest, when he will find an infiltrating mass previously undetected. On the other hand, most cancers of the breast are easily palpable on the patient's first visit to the surgeon, and frequently the condition is only too apparent. As the disease advances the skin over the mass becomes pitted; later it breaks down in an ulceration; the nipple frequently retracts, and enlarged nodes in the axilla become apparent. An increasing cachexia accompanies those local signs of trouble. Appetite and strength fail, slowly at first, rapidly toward the end. There has been much discussion regarding the time in the progress of the disease at which enlargement of the lymph-nodes occurs. Older surgeons have gone so far as to assert that these nodular

metastases do not appear until the parent growth is a year old. Probably this is not true. The time of appearance of enlarged nodes depends upon the character and rate of growth of the cancer. Moreover, one observer may discover enlarged nodes undetected by another. In order to find axillary nodes, sit before the patient, whose arm should be raised, and press your fingers high into the axilla, with the palm of your hand against her chest. Then bring the patient's arm down to her side. One may detect palpable nodes against the ribs and along the lower margin of the pectoralis major. Late in the disease the cervical and clavicular nodes become involved. In the breast a single mass only can be felt, as a rule. Rarely two tumors are present, and the surgeon should never fail to examine the opposite breast also. In nearly 7 per cent. of the cases both breasts are involved.

The surgeon founds his **diagnosis** upon the evidence of a tumor, pain, and involvement of lymph-nodes. The characteristic cachexia is a *late* symptom. In many cases one is in doubt as to the diagnosis, especially when the only evidence of disease is the tumor. In such case, no matter what the age of the patient or the character of the mass, the surgeon should be extremely cautious in pronouncing against cancer, and should give a favorable diagnosis of benign tumor only when such a diagnosis of benign growth is clear. If there be the least doubt, he should explore the breast by the method of plastic resection which I shall describe, should have the tumor examined immediately, and should proceed with the radical operation if it prove to be malignant.[1] It is a safe rule to remove all tumors of the breast in women thirty-five or more years old.

The **prognosis** of breast cancer unremoved is always positively bad, and the duration of the disease before death depends on the age of the patient and the nature of the cancer. Medullary cancer may kill a woman of forty in a year. A woman of seventy may live with a scirrhus for three or more years. The prognosis after operation I shall discuss in a later paragraph.

The **treatment** of cancer of the breast is by radical operation. There is not the slightest evidence that other methods of treatment offer a hope of cure. Twenty-five years ago the profession was still convinced that removal of the tumor by operation was a desperate measure, but within the last fifteen years the results of such radical operators as Halsted, Joerss, Rotter, Cheyne, Warren, and many others have forced the conviction that breast cancer taken early and thoroughly excised does not return. The statistics of permanent cures under the treatment of competent surgeons vary all the way from 19 to 42 per cent. It is an interesting fact that local recurrences take place commonly in the scar or skin over the chest and not in the axilla. All reliable surgeons, with one or two exceptions, are now agreed that the dissection should be far-reaching and thorough, and should involve removal not only of the whole

[1] I deprecate strongly the use of the exploratory punch sometimes advocated, since it may bring away portions of the cancerous mass, and cause the rapid involvement of overlying skin.

breast, but of its overlying skin, a wide zone of adjacent fat tissue, both pectoral muscles and the fat and nodes of the axilla. A routine attack upon the clavicular and cervical nodes seldom is advocated. The dissection I have described implies an operation of great gravity—an operation requiring time and care, involving considerable loss of blood, shock often, sometimes extensive plastic repair of the wound, a slow convalescence, and more or less permanent crippling of the arm on the affected side.

Such in general terms is the problem before the surgeon; and so wide a removal of tissue seems necessitated from our conviction that cancer involves parts beyond any obvious macroscopic lodgment, that its microscopic presence may be found in the skin, in the lymph-spaces, in the fat, and in the underlying aponeurosis and muscles. J. B. Murphy alone of recognized authorities maintains that a removal of the pectoral muscles seldom is necessary, because the growth, when taken early, does not penetrate beyond the aponeuroses.

Operation for Cancer of the Breast.—The radical operation for removal of breast cancer is the only operation seriously to be considered if one anticipates a cure, though we may observe in passing that sometimes the surgeon dealing with hopelessly extensive cancer may think it best to do a palliative resection with the purpose merely of converting a foul, ulcerating area into a clean wound. Numerous radical operations in recent years have been devised, but all of them follow essentially the rules laid down by Halsted.[1] The variations in detail from Halsted's technic aim merely at treating the axilla so as to produce less impairment of the arm's function, and at attacking the malignant mass at some novel point. For several years I followed that method of procedure to which Warren's[2] name is attached. As Warren points out, we cannot observe anatomic landmarks or regard cosmetic effects when dealing with cancer, for cancer invades tissues indiscriminately, and the surgeon with his knife in like manner must invade them if he hopes to extirpate the disease; he must remove the entire growth with a wide margin, cutting into muscle, skin, aponeurosis, bone, vascular and lymphatic connections wherever he has reason to suppose they are involved in the cancer. I used with satisfaction and for many years the following technic: Enter the knife at the shoulder and carry it down toward the outer border of the breast along the anterior axillary fold, and about two inches to the inner side of it at the start. Sweep around the outer and lower border of the breast at the circumference of that organ. Warren points out that at this stage, if the operator is in doubt as to the nature of the growth, he can turn up the breast from below and excise a portion of the tumor for microscopic examination. Having determined that the growth is malignant, the surgeon now completes his sweep about the breast, and brings his cut up on the inner side to meet the original incision on a level with the axilla; he thus forms

[1] W. S. Halsted. Ann. Surg., November, 1894.

[2] J. C. Warren, The Operative Treatment of Cancer of the Breast, Ann. Surg., December, 1904.

a racket-shaped wound of great extent, the edges of which he will probably be unable to bring together. Next, with a view to the ultimate closing of the wound, he marks out a supplementary flap low in the axilla, such as is shown in Fig. 326. In order to provide for a possible dissection of the cervical triangles he marks out also a third incision running into the neck.

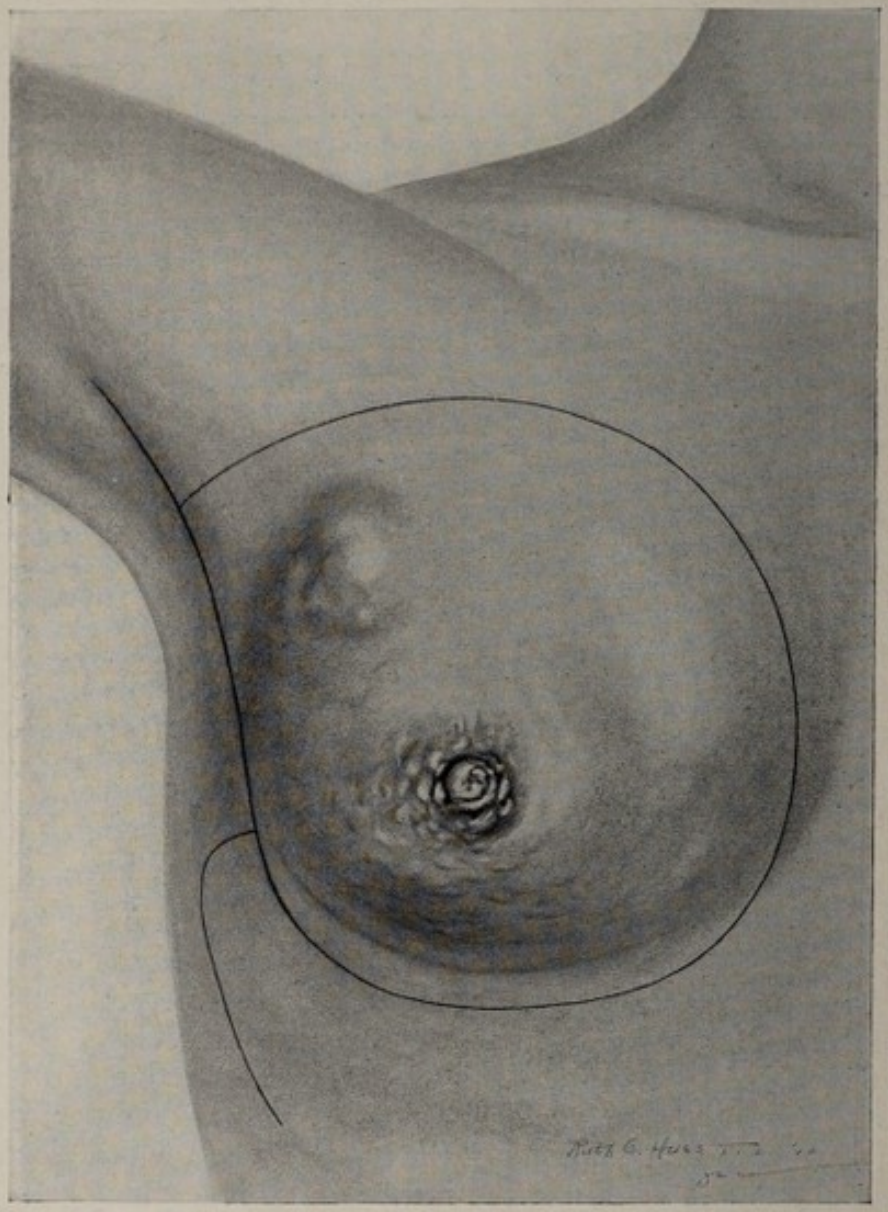

Fig. 326.—Warren's operation for amputation of the breast—step 1.

The second step in the operation is freely to turn back the skin on all sides and to dissect up the supplementary axillary flap. This dissection should be carried high enough in the neck to expose the clavicle. One now sees an extensive wound, shaped somewhat like a truncated cone, the untouched breast representing the base, with a considerable expanse of fat and muscle tapering off toward the axilla.

The third stage in the operation consists in removing entire the exposed suspicious tissues. Begin the deep dissection above, and turn

in the whole mass toward the sternal side. Strip up with the finger the insertion of the pectoralis major toward the humerus (leaving

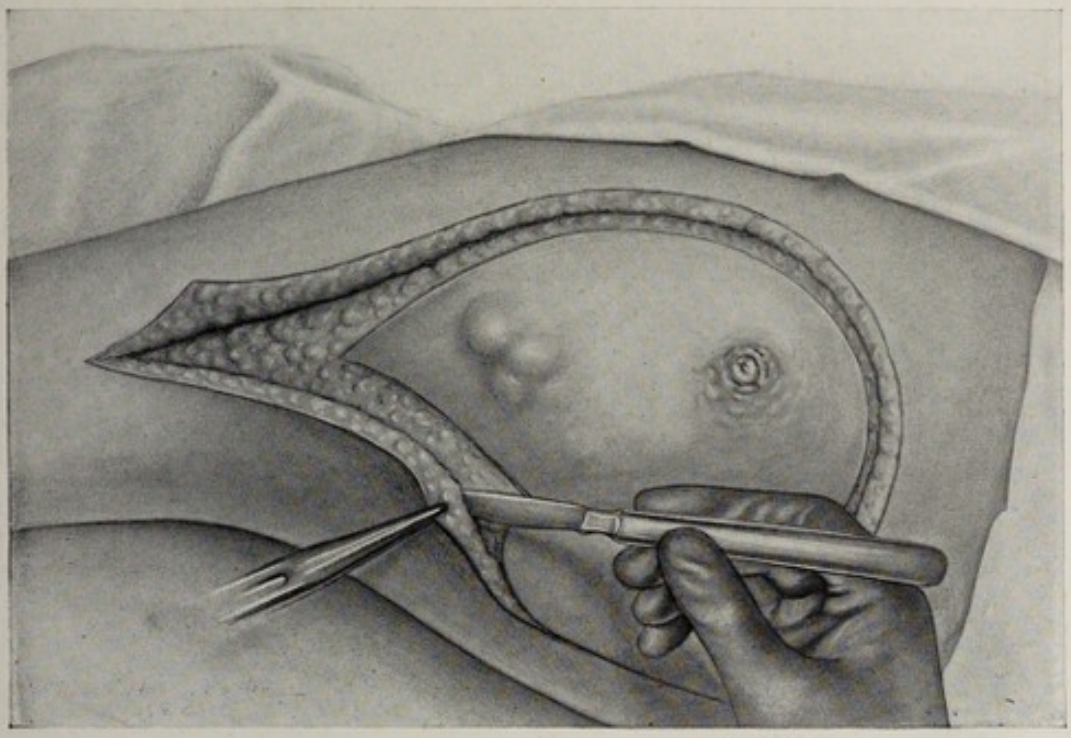

Fig 327.—Warren's operation for amputation of the breast—step 2.

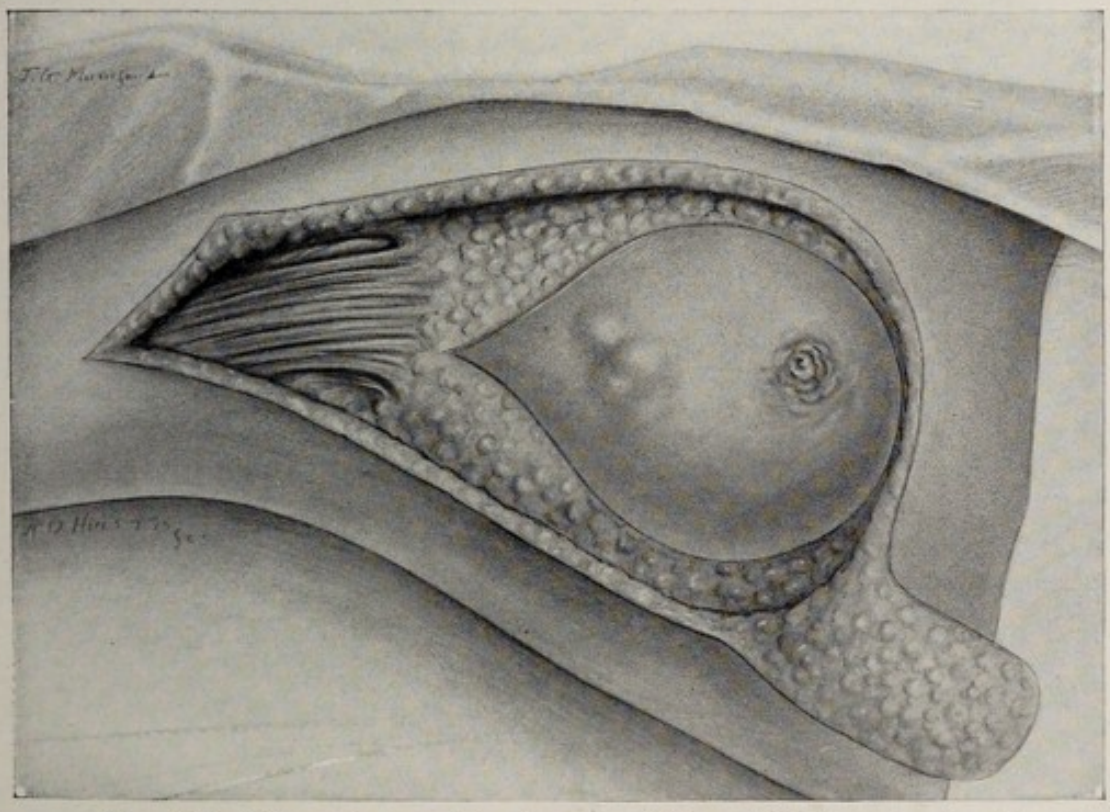

Fig. 328.—Warren's operation for amputation of the breast—step 3.

the clavicular portion), and cut away the muscle near the bone. Turn down the severed pectoralis major and expose the insertion of the

pectoralis minor; cut this away close to the scapula. Then, by firm retraction downward and inward, the surgeon exposes readily the axilla. He clamps the larger arteries and veins and cuts them away close to the axillary vessels, after which, rapid dissection with the knife and fingers exposes the posterior muscles and the serratus. The deep muscular attachments are now freed completely down to the ribs, when it is an easy matter to peel off by quick dissection the whole disease-mass toward the sternum, removing, as one goes, both pectoral muscles. After this a further cleaning of the parts high in the axilla may be done if needful, and a supplementary dissection of the cervical triangles through turn-

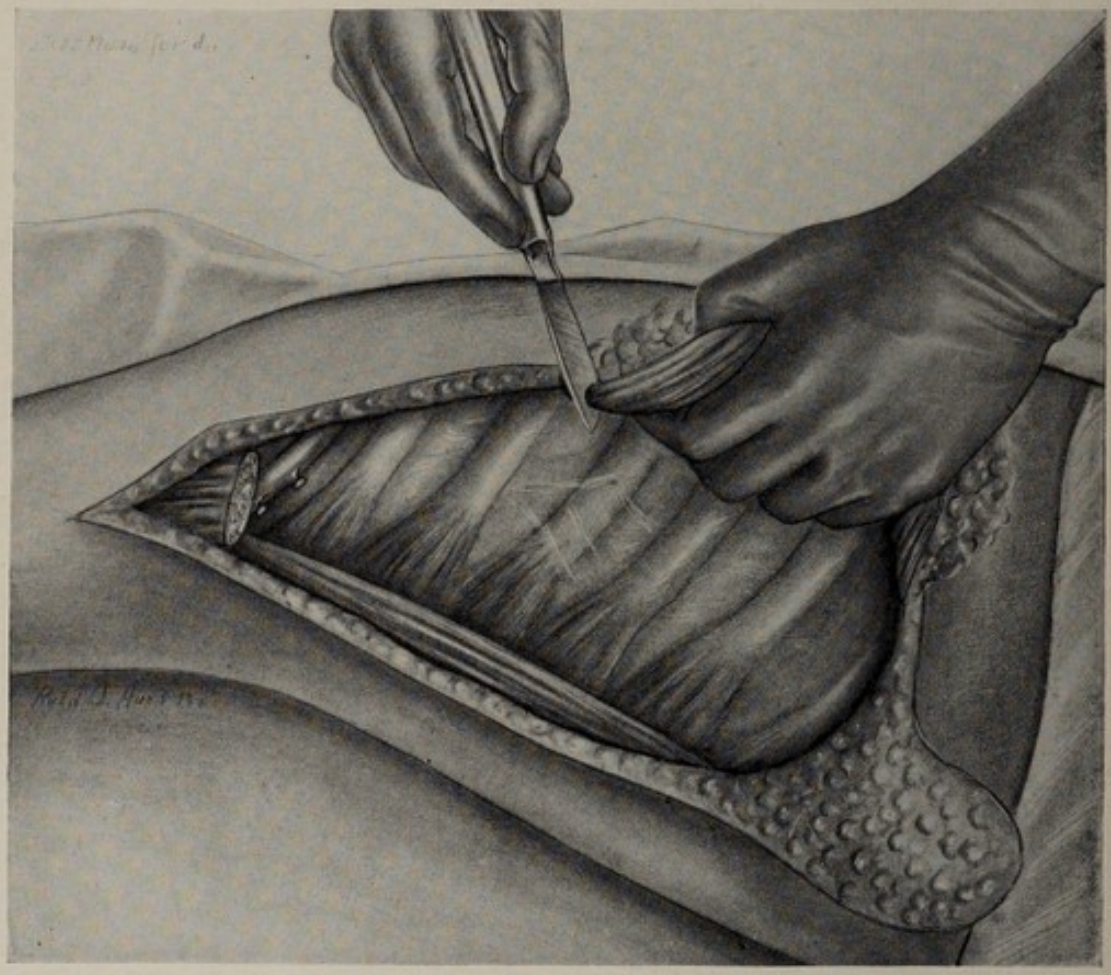

Fig. 329.—Warren's operation for amputation of the breast—step 4.

ing back the neck flap as I have indicated. It remains to close in the great wound, which can scarcely be done without utilizing the supplementary axillary flap. The figures show how easily and perfectly one may accomplish this, as a rule. I recommend draining the wound with a cigaret wick in the axilla for twenty-four hours.

Extensive scar-formation in the axilla may follow this operation—scar-formation which cripples seriously the action of the arm. The surgeon should endeavor, so far as possible, to obviate this condition by tucking the lower skin-flap high into the axilla and securing it there with a buried stitch. In consideration of the possibility of trouble with the

arm Murphy [1] advocates certain muscle-plastic procedures which are interesting. He points out that undesirable results of removal of the breast as commonly done are: (1) Fixation of the arm to the chest, with more or less limitation of motion; (2) venous stasis in the arm and forearm with edema; (3) pseudoelephantiasis; (4) neuralgia in the arm and forearm; (5) sensitive retracting scars. In order to forestall these calamities Murphy advises dressing the arm at a right angle to the chest and supporting it in a plaster splint during the early days of convalescence, and the interposing of muscle slips between the axillary vessels and the axillary skin. His arguments are ingenious and suggestive, and his methods appear feasible. He uses long and broad slips from the pectoralis major or latissimus dorsi. He justifies his use of the pectoralis major by asserting that its entire removal with the breast is needless,

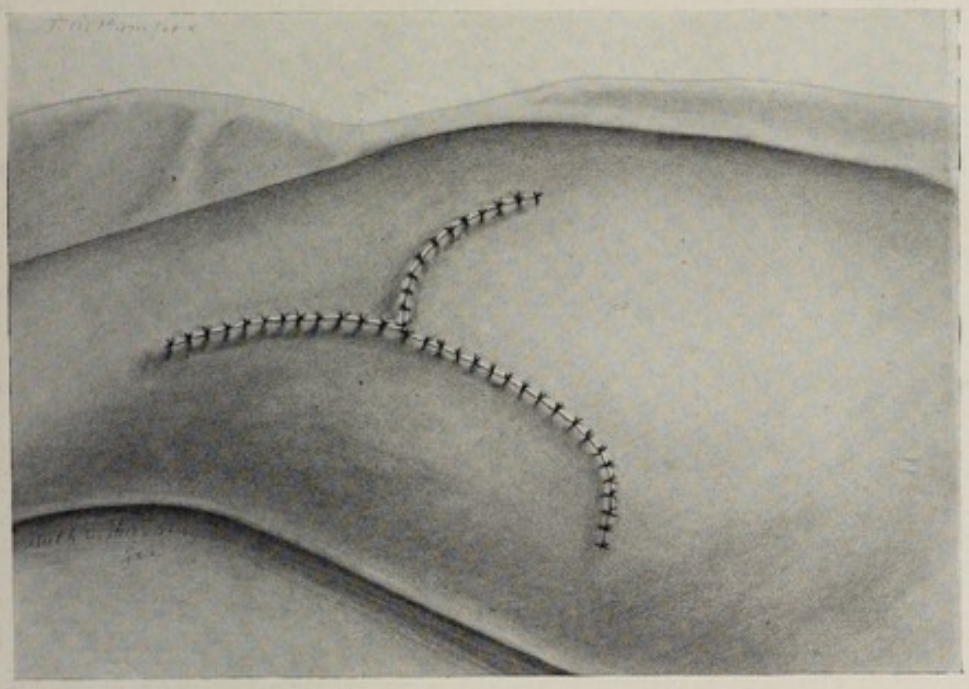

Fig. 330.—Warren's operation for amputation of the breast—step 5.

" as the aponeurosis and not the muscle carries the lymphatics in which metastases occur." Most operators, while agreeing in part with Murphy in this contention, will protest that no man may say whether or not the pectoralis major muscle itself is involved in the disease. The use of the latissimus dorsi, however, seems free from this objection, and the application of the plaster bandage with the arm held out from the side promises much. On the other hand, the disabilities rehearsed by Murphy are not so common as he might lead us to suppose. Careful surgeons endeavor to fill in snugly the axillary gap after the dissection, and excellent function of the arm under the old methods is the rule. I find that, by the careful obliteration of dead spaces, by draining the axilla for twenty-four hours, by padding abundantly the axilla so as to hold the

[1] J. B. Murphy, Axillary and Pectoral Cicatrices Following the Removal of the Breast, Axillary Glands, etc., New York Med. Jour., January 6, 1906.

arm well out from the side, and by the early use of passive movements I encounter rarely those disabilities which have been mentioned.

The *after-treatment* and a long-continued following up of these cases are important. One should get the patients out of bed at the end of a week—not earlier, because early moving about may dislodge a thrombus, with a fatal result, as in one of Warren's reported cases. In the second week of convalescence one should begin passive movements and massage, and keep up this treatment persistently for a month or longer. After the patient's health has been restored, she should make periodic visits to the surgeon for at least three years, that he may inspect the scar to discover possible recurrence of the disease. At the same time he should investigate the patient's spine, lungs, and other viscera. Nothing can be done with the knife for internal metastases, but local recurrence often may be treated by excision. The outlook after such thorough removal

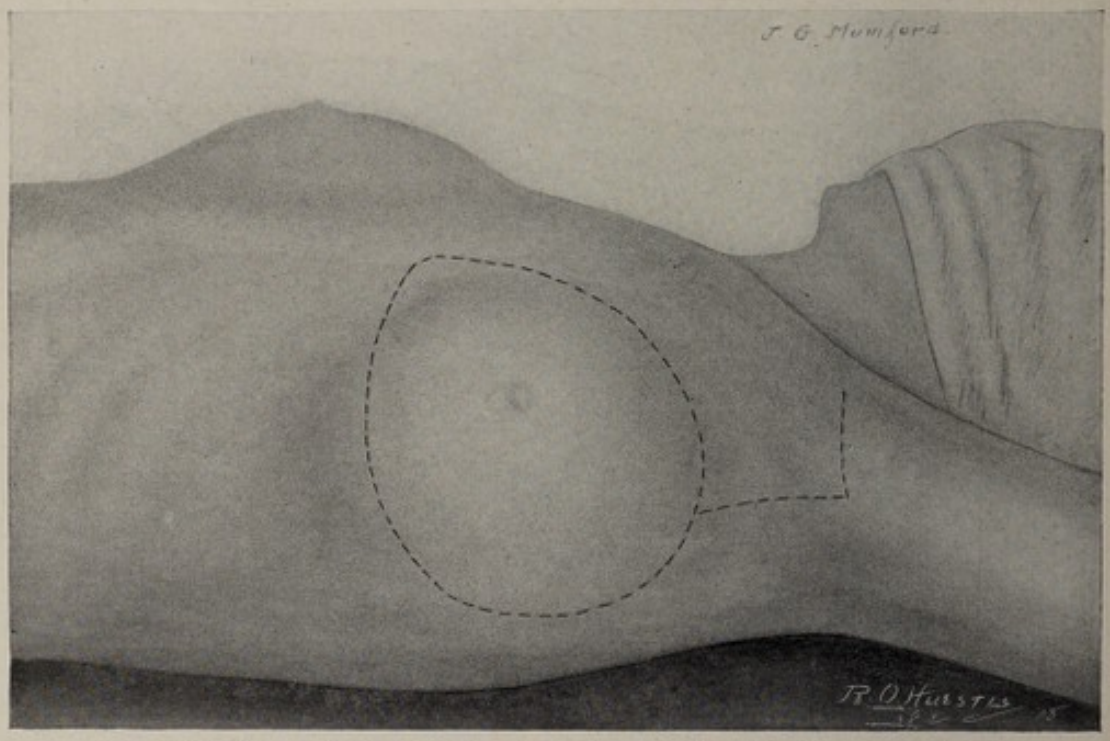

Fig. 331.—Line of incision for breast operation (Jackson's method).

of breast cancer is increasingly favorable, as I have said, and in direct proportion to the promptness and early date of the operation.

I have described in detail the steps of Warren's operation, pointing out that its principles coincide with those of all radical operations on the breast. Sundry other incisions and steps are advocated by other writers. Halsted's classic and pioneer work is not to be forgotten. His incision essentially is followed by Warren, but Halsted turns out the dissected mass toward the axilla instead of inward toward the sternum. Kocher advocates an interesting incision the outlines of which suggest a reversed figure 6. Willy Meyer [1] long ago described and advocated an operation similar to that I have given in detail, and Jackson [2]

[1] Jour. Amer. Med. Assoc., July 29, 1905.
[2] Jabez N. Jackson, ibid., March 3, 1906.

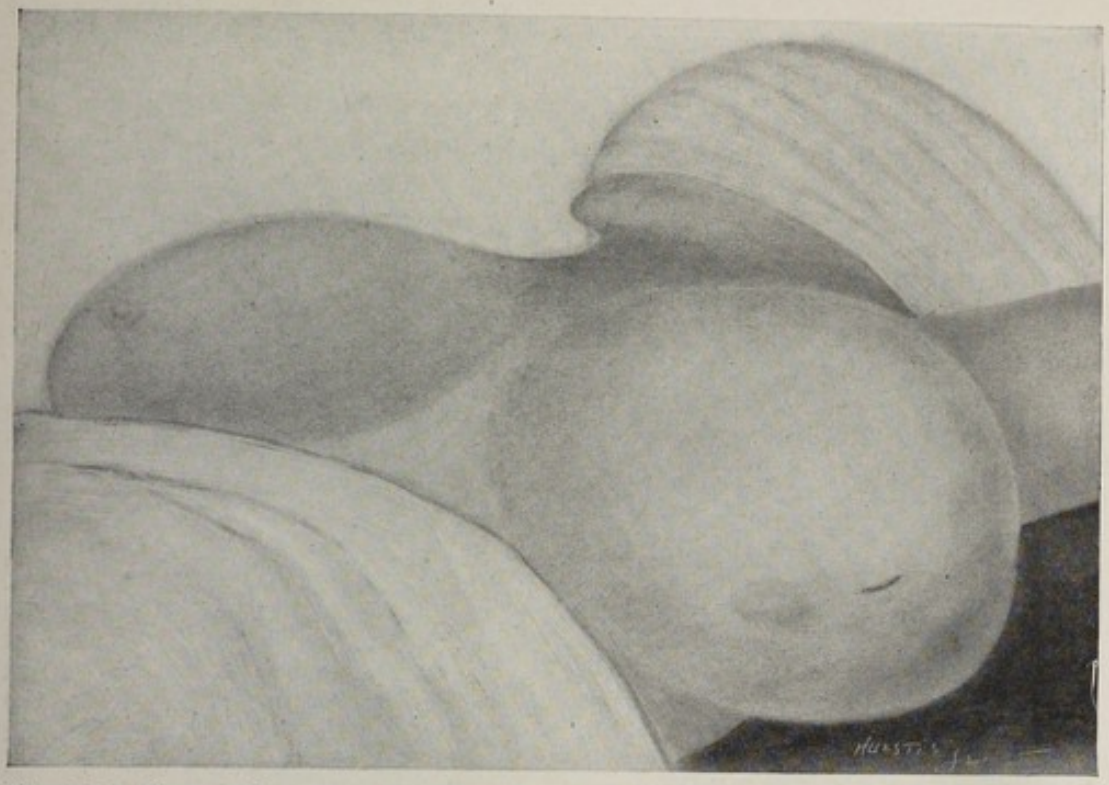

Fig. 332.—External appearance of cancer of breast. Removed by Jackson's method (personal case).

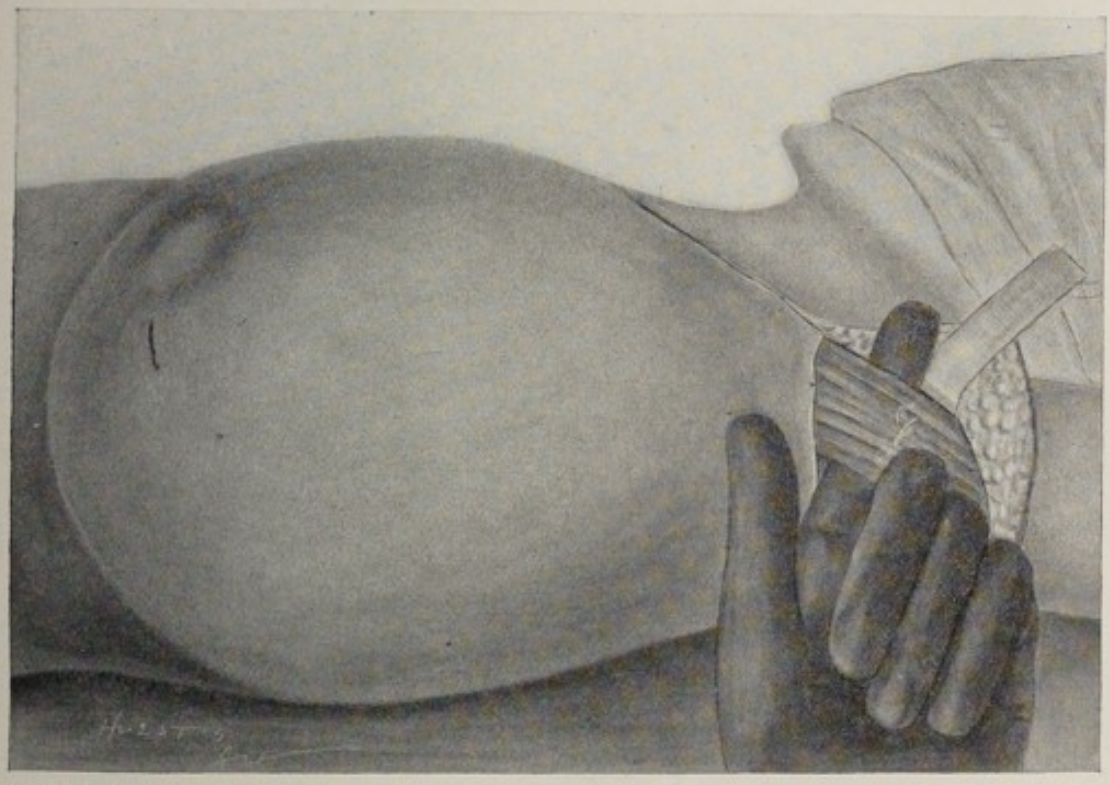

Fig. 333.—Operation for cancer of the breast; shows pectoralis major muscle (personal case).

describes an interesting incision which I have now adopted; but it is needless further to enumerate the countless modifications and suggestions upon this subject by recent writers.

In spite of the improvement in our statistics surgeons have not rested content with the results of radical breast operations, and numerous and carefully conducted investigations on other lines of treatment constantly are being made. So far such endeavors have accomplished little. The *x*-rays, violet rays, and radium are nearly valueless, though they may relieve pain; and the much-vaunted trypsin injections of Beard are not making good the claims of their original advocate. A few years ago Beatson's operation[1] seemed to promise something. Beatson's operation consists in removing the ovaries for the supposed effect which the loss of those organs has upon the epithelial cells in the breast. Although a few cases of notable improvement in breast cancer following Beatson's operation have been reported, the number of successes by this method are too few to warrant confidence in the procedure.

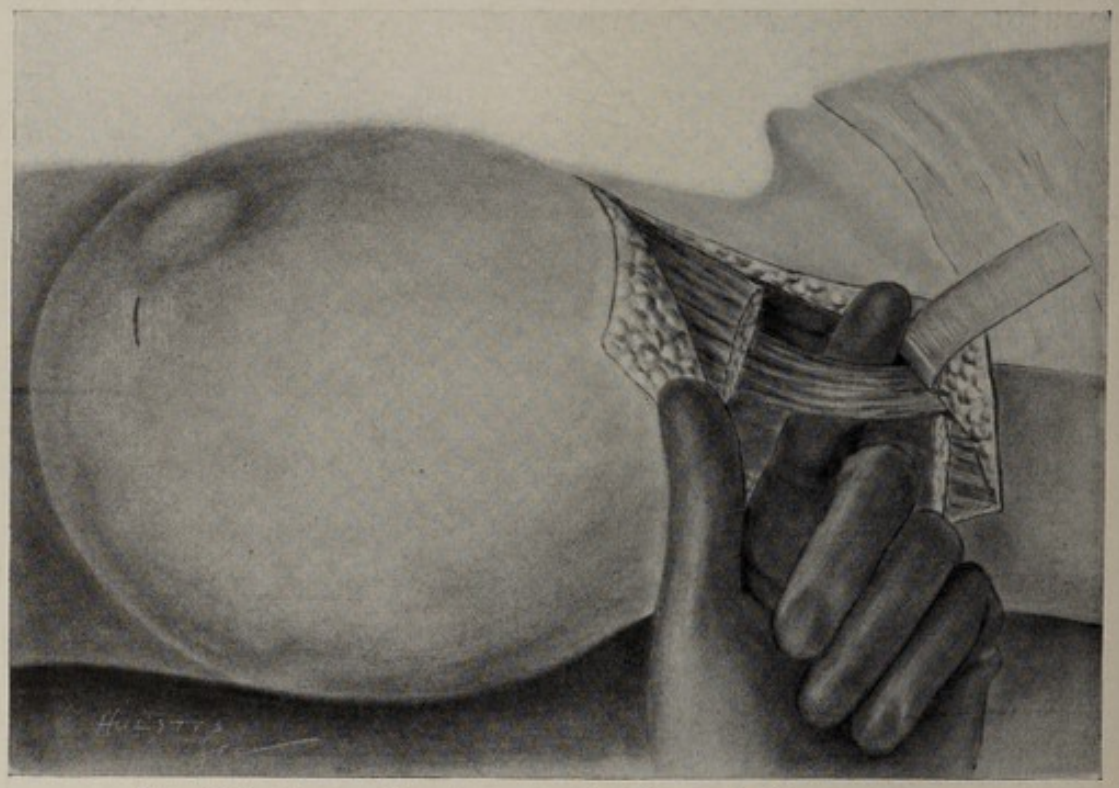

Fig. 334.—Pectoralis minor muscle dissected (personal case).

While cancer is that form of breast tumor most interesting and important because of its frequency and fatality, numerous other new-growths are to be found in the breast, some of them benign, some of them doubtful, some of them truly malignant. Fibroma is a common tumor of the benign class; sarcoma is a somewhat rare tumor of the malignant class. Most of these non-cancerous tumors are allied to each other in structure and origin, so that a brief consideration of the whole class sums up for us our knowledge of breast tumors other than cancer. In a previous paragraph I spoke of a characteristic myxomatous connective tissue which develops about the terminal ducts and acini of the normal breast. It is with this *periductal connective tissue* that we

[1] Jour. Amer. Med. Assoc., editorial, September 2, 1905.

have to deal when we consider benign breast tumors, and I avail myself of J. C. Warren's admirable classification, to which I have already referred. Warren points out that, owing to the intimate association of the periductal tissue with the epithelium lining the ducts, all tumors of the mammary gland contain some of the elements and take on some of the characteristics of both connective-tissue and epithelial growths.

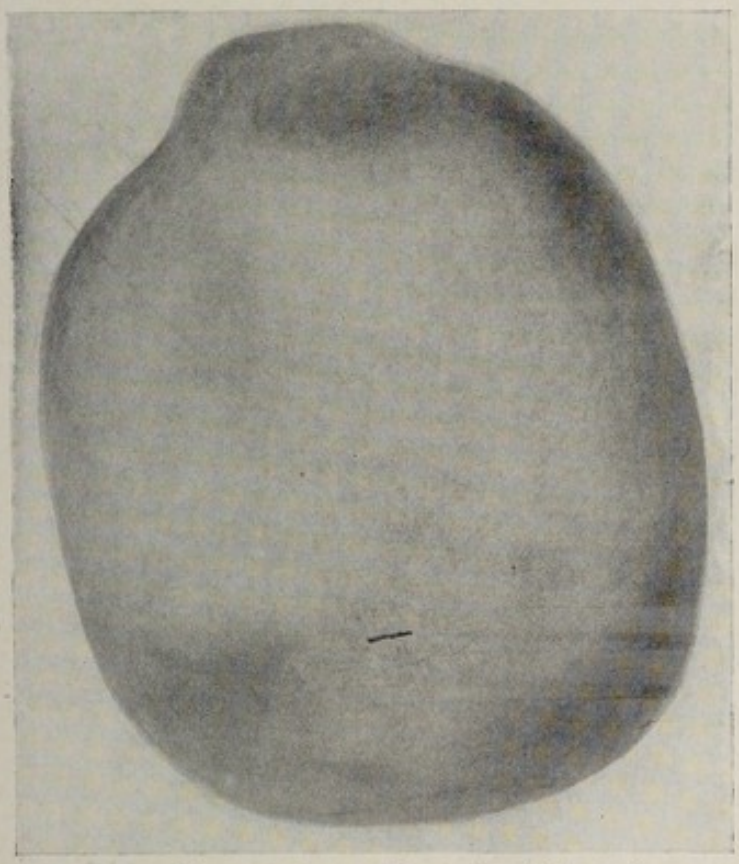

Fig. 335.—Large cancer of breast (personal case). External appearance of breast after removal (reduced). Length, 13 in.; width, 10¼ in.

Bloodgood [1] also deals at length with this subject in an illuminating article. Warren gives the following table of breast tumors:

"Carcinoma (already considered).
Fibro-epithelial tumors:
(1) Fibrous type:
1. Periductal fibroma.
2. Periductal myxoma.
3. Periductal sarcoma.
(2) Epithelial type (cystadenoma):
1. Fibrocystadenoma.
2. Papillary cystadenoma.
Hyperplasia:
1. Diffuse hypertrophy.
2. Abnormal involution.
Cystic.
Proliferative.

[1] J. C. Bloodgood, Senile Parenchymatous Hypertrophy of Female Breasts, Its Relation to Cyst Formation and Carcinoma, Surg., Gyn., Obstet., December, 1906.

Chronic inflammation:
1. Eczema of nipple.
2. Chronic abscess.
3. Ductal mastitis.
4. Tuberculosis.
5. Single retention cyst.

Non-indigenous tumors:
1. Sarcoma.
2. Lipoma.
3. Lymphangioma.

Supernumerary breast."

Periductal fibromata, myxomata, and sarcomata all are closely allied, and one must observe the fact that the " chief constituent of the tumors of the fibrous type is the peculiar, transparent, periductal tissue of the female breast." We may reserve the name " *adeno-*" for those tumors in which the epithelial elements play the important part. Cystic dilatation of the ducts or of the characteristic clefts of the periductal fibroma may occur, and is probably due to the obstruction of preëxisting ducts. The cysts thus formed are, therefore, secondary; and the tumors may be divided, according to their richness in cells or the character of their fibrous tissue, into the three groups, fibroma, myxoma, and sarcoma.

OTHER BREAST TUMORS

Periductal fibromata of the breast (intracanalicular papillary fibroma) are encapsulated tumors, varying in size from a bean to a cocoanut. They are single or multiple; sometimes they contain cysts. They are firm, white, and glistening in appearance on section. Commonly they are found in women between twenty and thirty years of age. They grow slowly; generally they are painless, though they may be sensitive at the menstrual period, and most frequently they lie in the upper outer quadrant of the breast.

Periductal myxomata differ little in their structure from the fibromata. We assign them to a special group because they appear larger, as a rule, and are composed of a myxomatous fibrous tissue, identified by a local edema. They are tumors of middle-aged women; are almost always hard; sometimes necrotic; sometimes associated with enlargement of the axillary nodes. Nearly always containing cyst cavities, they differ from the previous class in no important respect.

Periductal sarcomata constitute the third group of periductal tumors, and present the combination of a richly cellular stroma mingled with epithelial gland-ducts. These are large tumors; hard, often involving the whole breast, and reaching the size of a child's head. They are lobulated and encapsulated; often they contain cysts, and frequently they are ulcerated. The overlying skin is reddened and is traversed by dilated veins, but it is not always adherent. Rarely the axillary nodes are involved. These sarcomata are most common in middle-aged married women, and cause discomfort from their size rather than from pain.

The treatment of these three types of tumor is obvious. Fibromata and myxomata demand local removal of the growth only, while the sarcomata require, in addition, amputation of the breast and dissection of the axilla. So much for fibro-epithelial tumors of the fibrous type. There is another class belonging to the fibro-epithelial group, however, characterized by a conspicuous development of the *epithelial* or duct elements in the breast. This is the—

Epithelial Type (*Cystadenomata*).—These tumors are benign, as a rule, though they belong to the epithelial type. Warren describes them as adenomata (fibrocystadenomata and papillary cystadenomata), and their name describes graphically their structure; they are not especially common.

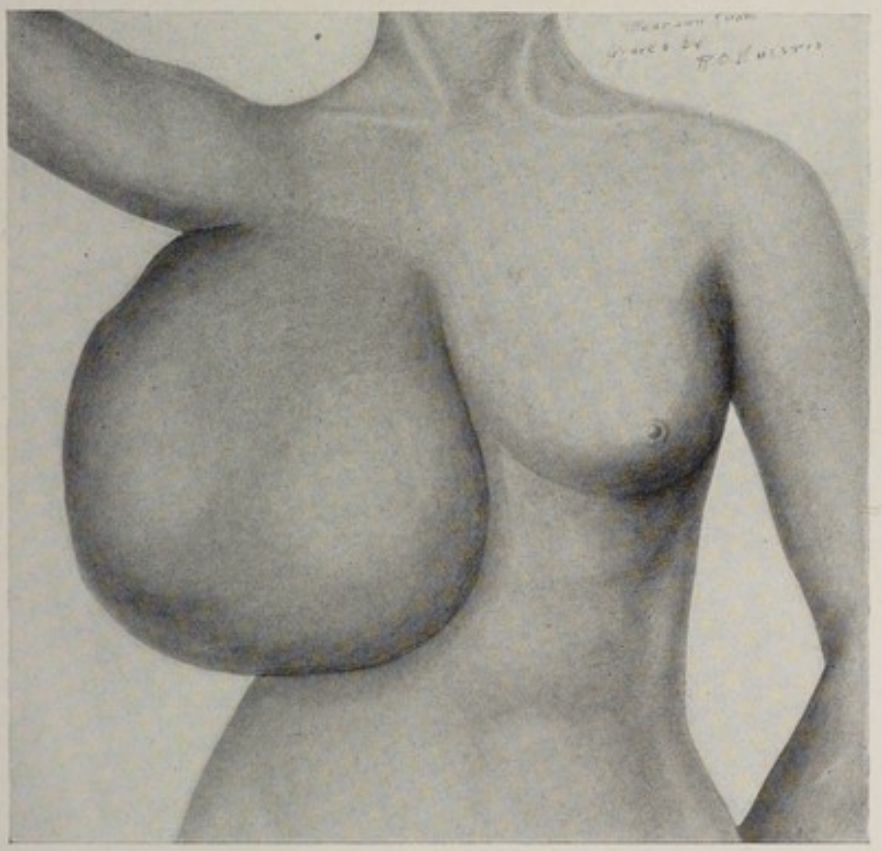

Fig. 336.—Periductal myxoma (W. P. Graves).

Fibrocystadenomata are made up of periductal fibrous tumors containing secondary epithelial new-growths.[1] They occur usually in young single women. They grow slowly and cause little pain. In extent they vary from the size of a walnut to that of a fist. They are lobular, hard, and movable. The axillary nodes are not involved. They are encapsulated and show a lobular structure containing cysts of various sizes, the cysts showing papillary outgrowths of connective tissue covered with epithelium. The gland-ducts rather than the acini are involved.

We must regard these fibrocystadenomata as approaching the

[1] These are tumors variously described as adenomata, papillary cystadenomata, cystadenoma proliferens, polycystoma, cystic fibroma, tubular adenoma, etc.

border-line of malignancy. Ordinarily, it suffices to remove them by a small local incision, but the histology of each tumor must be studied carefully, for there is always a possibility of its developing late into carcinoma.

Papillary cystadenomata constitute the second group of fibro-epithelial tumors. They are not common, but have distinct clinical and histologic characteristics. Like the periductal sarcomata, they occur commonly in middle-aged married women; they are of slow growth and long duration, and while not very troublesome and causing little pain, their characteristic symptom is the discharge of a bloody fluid

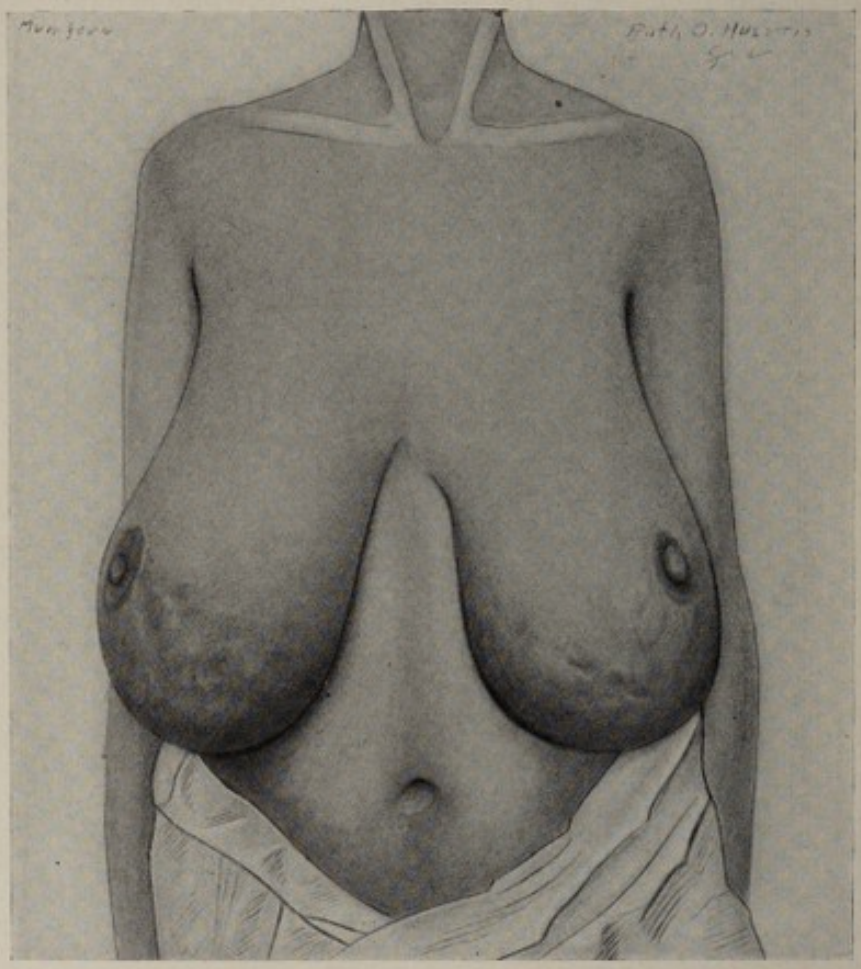

Fig. 337.—Diffuse mammary hypertrophy and pregnancy (Massachusetts General Hospital).

from the nipple. In consistency they are hard usually, though occasionally one may detect fluctuation; rarely is there involvement of the skin and axillary nodes. This tumor is most often found close beneath the nipple. If you examine the excised specimen, you will find, on section, a cyst cavity containing a bloody fluid, the walls of the cyst lined with papillary or villous outgrowths composed of connective tissue surrounded abundantly by epithelium of the ductal rather than the acinal cells.

In the case of small papillary cystadenomata, resection generally suffices for a cure, but when the tumor is of considerable size, of long

standing, and especially if the axilla be involved, one should do a total dissection of the breast and axilla. Such operations give every hope of a permanent cure, but the surgeon should remember that tumors of this type frequently become malignant when left untreated.

There is another class of benign breast enlargements which should not properly be grouped with the neoplasms I have just described. I mean those *diffuse* enlargements of the breast to which we apply the term " hyperplasia." This term signifies an increase in both the fibrous and epithelial elements, and may affect one or many lobules. Warren divides " hyperplasia" into two divisions: (1) Diffuse hypertrophy and (2) abnormal involution.[1]

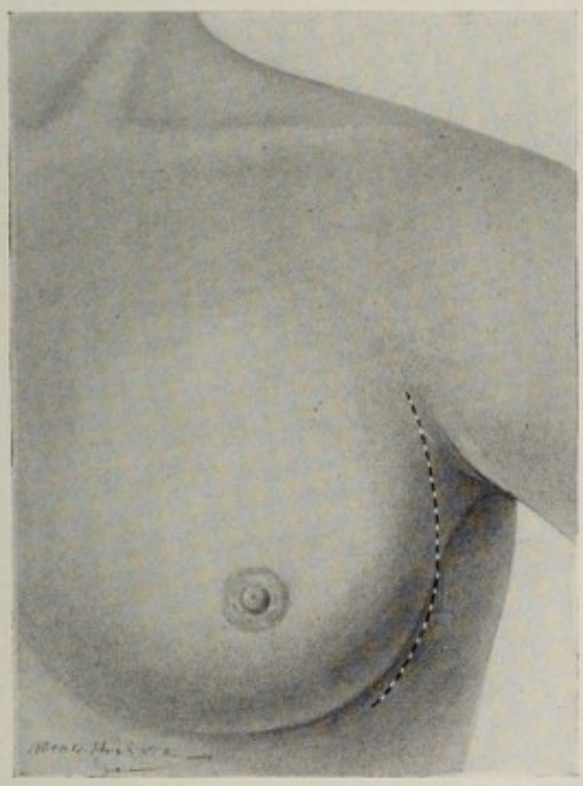

Fig. 338.—Plastic resection of the breast, line of incision—step 1.

Diffuse hypertrophy is a rare condition which may be found in women of all ages, especially before the menopause. One or both breasts may be affected, and the growths may reach an enormous size, so that their amputation to relieve the patient of their weight may be necessary.

Abnormal involution (senile parenchymatous hypertrophy) is a more common and more serious matter, and the important fact about it to be borne in mind is that it has a benign and a malignant stage. When it is found in the malignant stage, it must be treated by radical operation. In the benign stage, however, one finds two types of senile hypertrophy,

[1] This is the condition admirably described by Bloodgood under the term " senile parenchymatous hypertrophy." This is the chronic interstitial mastitis of the English writers; the chronic cirrhosing mastitis of Billroth; the chronic mastitis or diffuse fibro-adenoma of Wood; the cystic disease of the breast of Bryant; the fibrous hyperplasia with retention cysts of W. F. Whitney *et al.*

the cystic and the adenocystic. In the cystic type the fibrous thickening has produced dilatation of the ducts alone. In the adenocystic type the cysts are present also, but in addition there are proliferative changes in their epithelium.

Women in middle or advanced life are the subjects of abnormal involution. In many cases of both the cystic and adenocystic forms, both breasts are involved, though usually to a different degree, and the masses may present diffuse or local hardenings. A hardening may be firm and nodular, or soft and even fluctuant. In a great many cases there are pain and tenderness; in a few there are enlarged axillary nodes; frequently there is inversion of the nipple. In most cases the

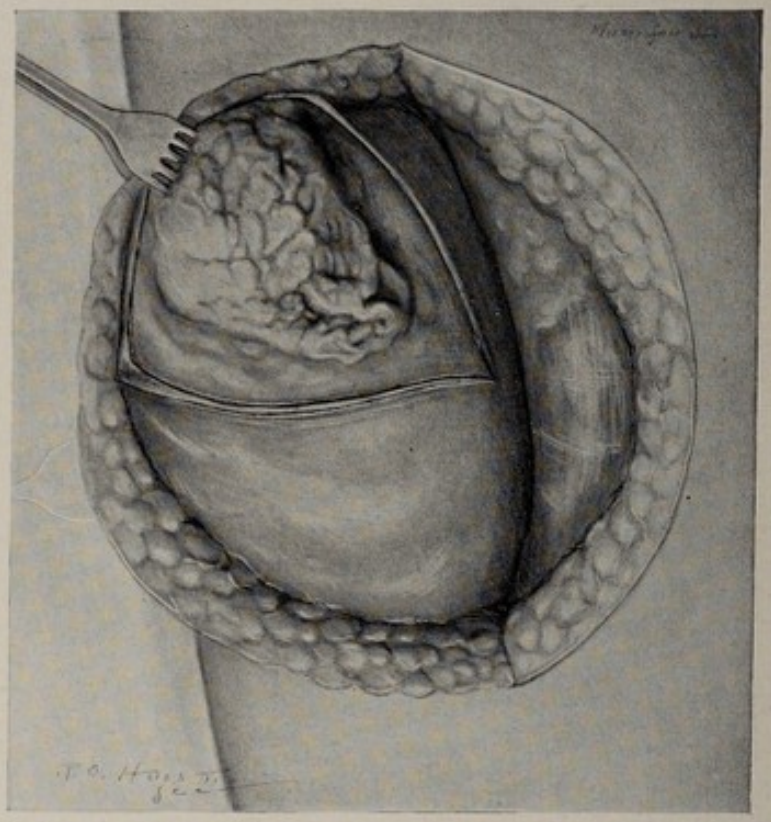

Fig. 339.—Plastic resection of the breast—step 2. Breast turned over and tumor exposed by triangular incision.

process is diffuse; rarely one lobule of the gland alone is affected, suggesting an encapsulated tumor. The microscope shows fibrous hyperplasia and secondary involvement of the gland structure, with cyst formation. In the adenocystic type of abnormal involution one may distinguish three groups, depending on the character or degree of the epithelial growth, as follows: (1) Proliferation of the acini; (2) papillary outgrowths of epithelium into cysts, and (3) adenomatous proliferation of epithelium. The first and second of these may possibly develop into carcinoma, while adenomatous proliferation is especially interesting, from the fact that in its presence chiefly we find the combination of involution and cancer. The reader will see, therefore, that these cases of senile hypertrophy are of striking and anxious importance. At first, on

examining them, no man can say whether or not they are malignant. For this reason, whenever one finds induration in the breast of a woman at the menopause or later, he should operate. He may do a plastic resection and remove the growth for immediate examination, and he may do a complete radical operation if it seems indicated.

The *operation of plastic resection* is simple, easy, and causes little or no disfigurement. The surgeon enters his knife at the periphery of the breast high in the anterior axillary line, and sweeps it down around the breast so as to take in one-half to two-thirds of the gland's circumference. He then dissects rapidly down to the aponeurosis of the underlying muscle and turns the breast up, when he may attack from below and remove tumors and other suspicious thickenings, as I have indicated in the accompanying figures adapted from Warren's paper.

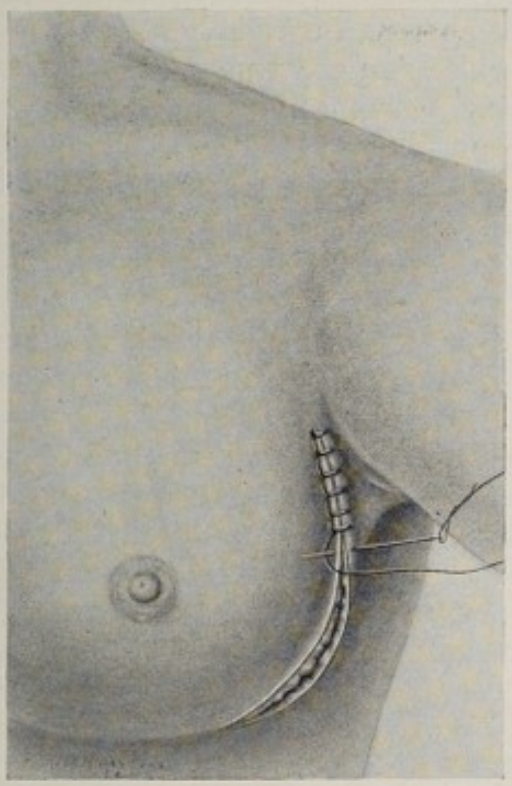

Fig. 340.—Plastic resection of the breast—step 3.

After excising the masses he closes with buried absorbable stitches the gap in the gland and replaces the breast; or, if necessary, he may proceed to the complete radical operation. The wound heals rapidly and kindly and a slight scar only remains. The simple plastic resection may be dressed with an empire bandage, and the convalescence should not last more than ten days. So much for our discussion of tumors of the breast, malignant and benign.

MASTITIS

Acute mastitis with abscess is that affection of the breast gland which next, after cancer, is most interesting to the physician, but as

this is a disease which concerns obstetricians especially, we need say little of it here. It is an inflammation of the nipple and breast ducts and is due directly to an infection in nursing women. One wonders perhaps that all women during lactation do not suffer from acute mastitis. The essentials for the setting up of such an inflammation are some slight crack or abrasion in the nipple, giving lodgment to infecting organisms, and a milk-producing breast which is imperfectly drained. Nurses speak of "caked breasts," by which we understand a backing up and stagnation of milk in the acini and ducts. If infecting bacteria reach these deeper parts, they set up readily an irritation to which the organism responds with the production of hyperemia, inflammation, and pus; as the infection progresses the breast elements break down, and shortly there is produced a considerable area of suppuration; indeed, the whole breast may become involved. When one examines a woman suffering from breast abscess, he finds her more or less prostrated with fever, with a rapid pulse and great pain in the breast, which looks distended, red, and glossy, varying in consistency, in one place exquisitely tender and fluctuant, elsewhere less tender, but hard and brawny.

The *treatment* of such infected breasts consists in stopping the infant's nursing, supporting the breast in a firm bandage with an ice-cap, and, in the early stages, applying massage to evacuate the milk. At the same time copious movements of the bowels should be obtained by the use of salts. When an abscess has formed, it should be opened thoroughly by incisions radiating outward from the nipple, but the cut should not involve the areola. This operation frequently leaves a badly scarred and deformed breast. Another method of operating—a method effective and less deforming, is to turn up the breast from below, as in the plastic resection operation. The abscess may then be opened at its base and drained after the breast has been replaced in position. Throughout the patient's convalescence the breast should be supported by comfortable bandages, and the abscess cavity should be irrigated daily. These patients, like so many others afflicted with local infections, may be helped greatly by appropriate opsonic injections.

Chronic infections of the breast are far less frequent than the acute infections, and may be divided into two classes—infections connected with lactation, and such specific infections as those due to the organisms of tuberculosis and syphilis. The much-abused term "chronic mastitis" should be applied to the lactation inflammation only. Chronic mastitis may be found in women toward the end of lactation, and appears as small multiple abscesses and necrotic foci distributed in close relation with the deeper ducts throughout the breast. These foci appear as tender, indurated masses and may be adherent to the skin, while the axillary nodes may be enlarged. There is an increased amount of fibrous tissue also, while the periductal tissue is infiltrated with small round-cells and leukocytes. The striking clinical characteristic is an irregular, extensive induration of the breast occurring shortly after lactation and affecting young mothers especially. Surgical treatment alone is effective.

Paget's disease of the nipple (malignant dermatitis) is an infection of doubtful etiology and nature. It consists in a chronic inflammation of the epithelial layer of the nipple and areola. It occurs usually in women beyond middle life, and frequently advances to epithelioma of the nipple and to duct cancer. It is not a simple eczema. The affected portion appears raw and red; from it there exudes a yellow discharge, and the disease may extend superficially over much of the gland. The axillary region becomes affected. When the surgeon has determined that local applications are useless, he should proceed with the knife thoroughly to extirpate the disease. This may involve radical removal of the breast with dissection of the axilla.

By **galactocele** we mean a breast retention cyst, the contents of which are of a milky character. If these cysts do not become infected, the harmless, neutral, milky fluid may remain indefinitely. Frequently one may relieve the patient by aspirating the cyst and strapping the breast.

The important specific inflammations of the breast are due to *tuberculosis, actinomycosis,* and *syphilis.*

Tuberculous disease of the breast is rare, and more rare in men than in women. The victims are usually between fifteen and thirty years of age, and are wont to show evidence of tuberculosis elsewhere. The disease manifests itself variously—sometimes as a cold abscess in the breast; sometimes there are isolated caseous nodules, and this form is the most common; sometimes the disease starts as an ulceration in the region of the nipple. The cold abscess may remain indefinitely; caseous nodules may break down and cause ulceration, with the formation of sinuses; superficial ulceration may spread, while in all forms the axillary nodes may be affected.

If the patient's condition is fair and extensive tuberculosis be not present elsewhere, the surgeon should amputate the breast and remove thoroughly all suspicious foci.

A few cases of **actinomycosis of the breast** have been reported. Like actinomycosis elsewhere, this is a chronic destructive process which goes on burrowing, forming abscesses and sinuses. To establish the diagnosis one must discover the characteristic fungus in the discharges. Total removal of the breast generally will destroy the disease, and promising results have been obtained by the use of copper salts after Bevan's fashion, which I described in dealing with abdominal actinomycosis.

Manifestations of **syphilis of the breast** are extremely rare and occur as gummatous mastitis late in the course of a syphilis. The lesions are circumscribed and may suggest cancer to the examiner. So uncommon is the condition that the true diagnosis probably will not occur to the surgeon. However, if syphilis is suspected, he should prescribe antisyphilitic remedies, and give them a trial for at least three weeks before attempting any operation. Should the diagnosis of syphilis be confirmed, he should do no operation.

Echinococcus of the mammary gland is uncommon; it should be treated by incision and removal of the sac-wall.

Besides such inflammatory diseases, there are a few additional breast lesions which deserve mention.

RETENTION CYSTS

Single retention cysts occasionally are found in the breast, and are of the same general character as those produced by the occlusion of a duct in other glandular structures. These cysts occur at any age after the development of the breast, and appear as isolated, painless, elastic, fluctuant tumors, in size varying from a walnut to a hen's egg, and of uniform and rapid growth. They should be enucleated either through a direct incision or by plastic resection.

Authors mention sundry other tumors of the breast which are designated *non-indigenous*—that is to say, they are situated in the breast accidentally, as it were, and have no special relation to the peculiar mammary gland structure as regards their origin. Such tumors are lipomata, lymphangiomata, enchondromata, and certain rare fibromata and sarcomata. Their treatment differs in no wise from that of similar tumors found elsewhere.

SUPERNUMERARY BREASTS AND NIPPLES

Supernumerary breasts and nipples occasionally are seen, but as they have no special tendency to disease, they deserve no special mention except that they are found in that so-called "milk line" extending from the clavicle to the groin.

One sees, therefore, that diseases of the breast are various and interesting. No other single gland in the body is of equal surgical importance; and upon it the activities of pathologists have concentrated themselves until study of the breast has become almost a specialty in itself.

PART V

THE FACE AND NECK

CHAPTER XX

HARELIP AND CLEFT-PALATE

We now come to the consideration of another ancient field of surgery. The earliest of medical writings describe superficial congenital abnormalities, and such abnormalities have been made the study of surgeons since remote times, with the result that an enormous literature upon the subject has been compiled. Yet it is within the last one hundred and fifty years only that satisfactory explanations of, and operations for, these lesions have been formulated. A variety of clefts and mal-

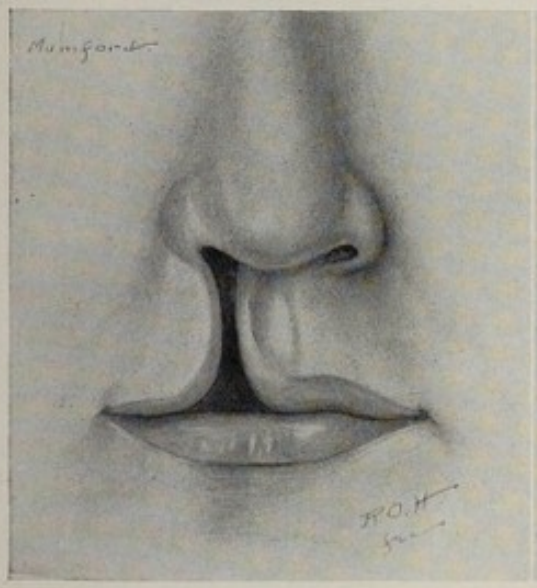

Fig. 341.—Single harelip and cleft-palate.

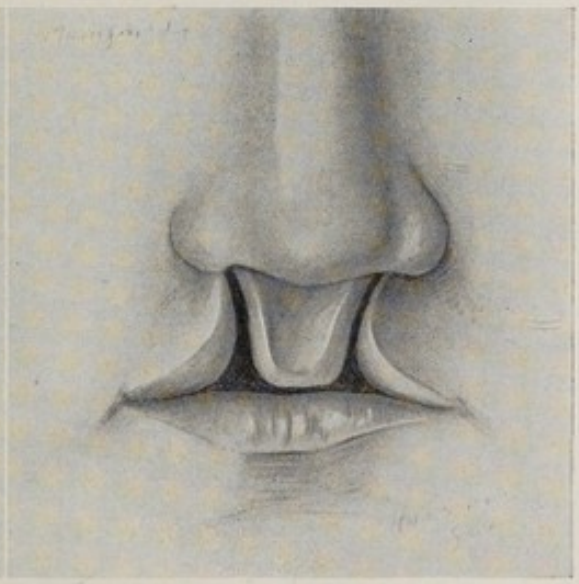

Fig. 342.—Double harelip.

formations of the face are described, but most of them are rare, nor, with the exception of harelip and cleft-palate, do they come within the every-day experience of practitioners. All these cleft formations result from an arrest or disturbance of development in early fetal life, as a glance at the face of a month-old embryo will show. We are apt to think of deformed lips as the only types of cleft to be considered, but surgical literature and every anatomic museum demonstrate extensive clefts and deformities not only of the lips, but of the nose, cheeks, fore-

head, eyes, and ears. It is needless here to detail the curiosities. Frequently they can be repaired and improved, and I refer the student to larger works on the subject for a discussion of their characteristics and treatment.

HARELIP

Harelip, however, is a common deformity, and has been dealt with by such distinguished writers as Lemonier (1776), Eustache (1779), John C. Warren (1820), and in more recent times by von Graefe, Roux, G. V. I. Brown, J. Collins Warren, and numerous others. The lower lip rarely is cleft; the vast majority of clefts are found in the upper lip, and these clefts or harelips are of three main varieties: (1) A notch in the vermilion border; (2) a deep notch extending nearly to the nares; (3) a cleft dividing completely the upper lip and penetrating the nasal canal. Harelip of all varieties may be single or double, and single harelip is

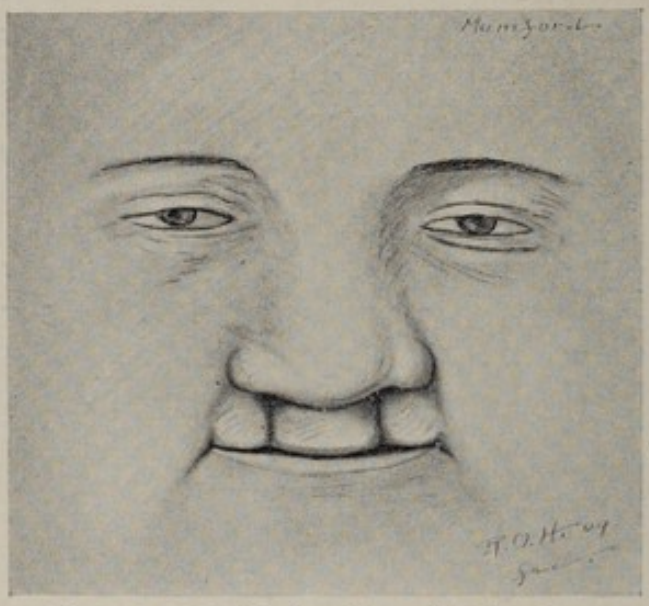

Fig. 343.—Double harelip and cleft-palate.



Fig. 344.—One-month embryo (magnified).

more common on the left side than on the right. All forms of harelip —especially complete clefts into the nares and double harelip—may be associated with cleft-palate, but we are considering here harelip only. Double harelip may present two simple fissures into the nostrils, with a bit of normal looking jaw and lip between them (a normally placed intermaxillary bone) or the intermaxillary bone may be thrust forward prominently so as almost to resemble a small proboscis protruding beneath the nose—a type of deformity in the highest degree disgusting and unsightly, and the physician who has the misfortune to attend in confinement a woman giving birth to an infant thus marked will never forget his own distress and perplexity on seeing the child's face, and the horror and shock of the parents.

The **diagnosis** of harelip is instantly obvious, but the symptoms and the disturbance to the infant develop gradually. Suckling is diffi-

cult or impossible; mouth-breathing is the rule, with an inevitable fouling of the buccal and nasal cavities and an occasional consequent bronchitis or pneumonia. These infants fail to get proper nourishment unless they have special care. As a result of such disadvantages harelip babies are proverbially feeble and rachitic—a condition not due necessarily to an inherent weakness or taint, but to lack of sufficient and proper food.

The **treatment** of harelip divides itself, therefore, into two parts—the feeding and sustaining of the infant and the repair of the deformity.[1] If the attending physician is not skilled in the problems of infant-feeding, he should consult an infant's specialist immediately after the baby's birth. Proper treatment consists in supplying the child with a normal amount of an accurately prepared cream mixture, plenty of water to drink, keeping the bowels properly open, cleansing the mouth thoroughly after each feeding, and feeding by means of a dropper, while the child is

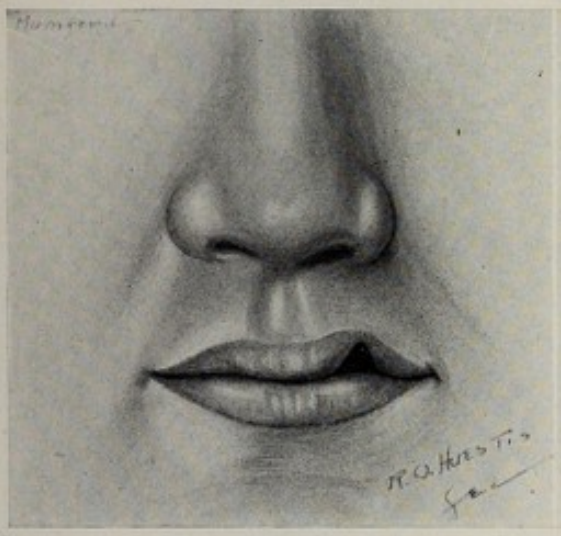

Fig. 345.—Simplest form of harelip.

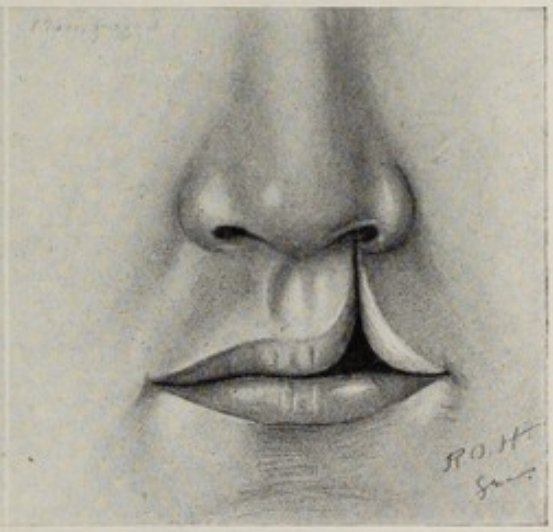

Fig. 346.—Single notch of lip.

held in the semiprone position. I believe in giving a little brandy as a stimulant for a week before operating.

The time for operating on harelip is in the sixth or seventh week of life, as a rule. By this time the baby will have begun to react well after birth and to flourish, its digestive processes and heart and lung action being ready for the strain of the operation. I regard ether as a safe and satisfactory anesthetic and the intratracheal method is to be chosen, because thus is a continuous stream of ether supplied, without interfering with the operator. The child, tightly swathed in a sheet, should be held upright in the arms of an attendant, behind whose shoulder stands the etherizer with his cone, if a cone be used, while the surgeon sits in front of the patient. The types of harelip operations are many, but the good operations are all much of a kind. In a word, a good harelip operation involves loosening with blunt-pointed scissors the cheek from the upper jaw,

[1] J. G. Mumford, Medical and Surgical Treatment of Harelip, Boston Med. and Surg. Jour., March 3, 1898.

so as to diminish subsequent traction, carefully trimming and adjusting with the knife the wound-edges to be sewed and everting downward a marginal flap so as to obviate the puckered notch which comes with the contracting scar of a badly done operation. There is a familiar and abominable operation, which consists in slashing with scissors the

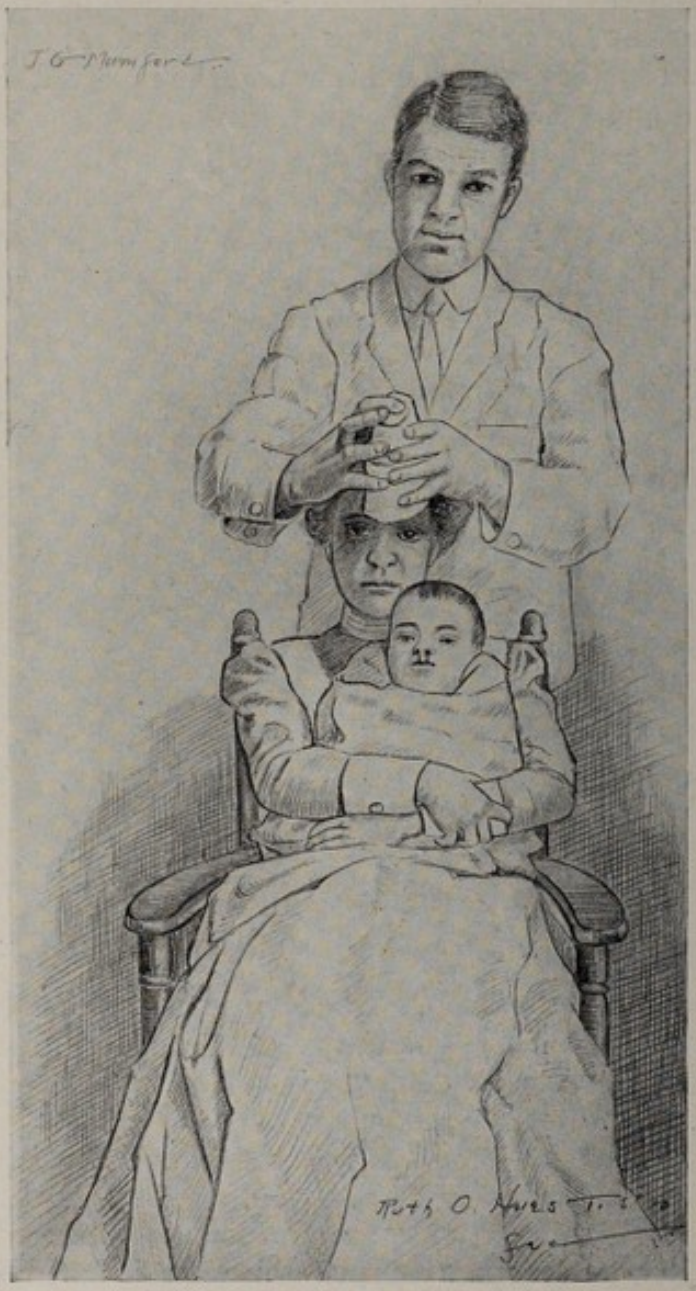

Fig. 347.—Infant held in position for harelip operation.

edges of the cleft, so as to transform it into a raw inverted V, and sewing it up with through-and-through stitches. Invariably there results an ugly notched lip. The text-books tell of the operations of Nélaton, Malgaigne, Mirault, von Langenbeck, Simon, and a dozen others. Nélaton's operation is applied to single notches. The required cuts are made through the lip above the notch with no sacrifice of tissue.

When the ends of the cuts are brought together the notch is converted into a nipple, the principle of the operation being similar to that of the Heineke-Mikulicz pyloroplasty. If the cleft in the lip be single and reach nearly to the nostril, it is necessary to sacrifice some tissue. But names and descriptions count for little; the accompanying diagrams show best how these operations may be done.

Double harelip is far more difficult to close successfully and properly than is the single harelip. The following description of the technic with modifications may be applied to harelip operations of all sorts, and the surgeon should remember that no routine fits all cases.

How shall one dispose of the *intermaxillary bone?* If the bone be not greatly displaced, and if it be readily pushed back and held in position beneath the nasal septum, one may proceed immediately with his

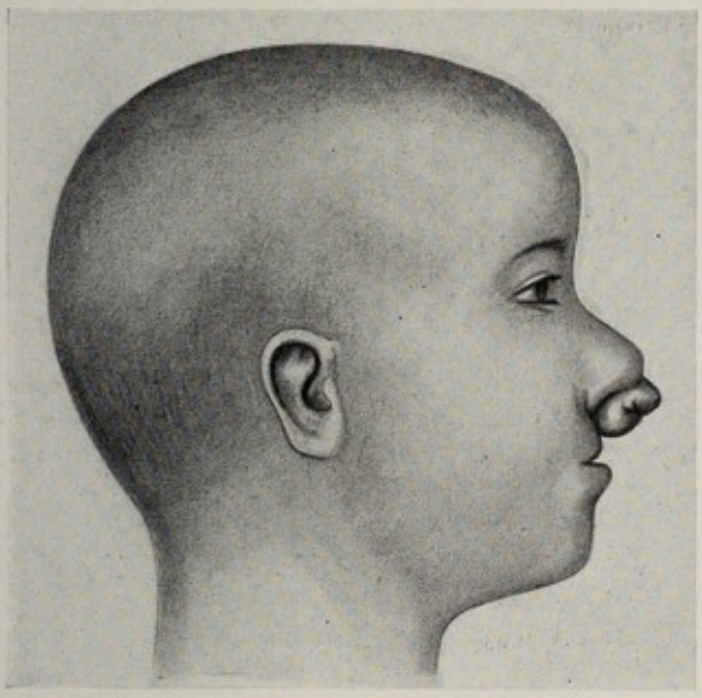

Fig. 348.—Intermaxillary bone.

plastic work. Occasionally, however, the intermaxillary bone cannot be pushed into good position, and upon this we are confronted with a conflict of authority. Some conservative surgeons assure us that the intermaxillary bone must be preserved at all costs, either by fracturing it and crowding it down or by slicing out a V-shaped bit from the vomer, and thus allowing room for replacement of the intermaxillary. Other surgeons excise the obtrusive bone from its mucocutaneous envelop. They point out that the intermaxillary bone is useless and fails to develop when crowded back, and that the incisor teeth which it bears are rudimentary and short lived. When the bone is removed, a gap is left in the alveolar line which must be filled by a plate or other dental apparatus. I advise removing troublesome intermaxillaries. Then in detail one may proceed as follows: an assistant on either side seizes the edges of the lip and holds them forward, at the same time controlling hemor-

rhage by pressure. The surgeon, using blunt-pointed scissors, then dissects up the cheek on either side of the alæ of the nose, hugging closely the bone, so as to avoid hemorrhage. He then refreshes the edges of

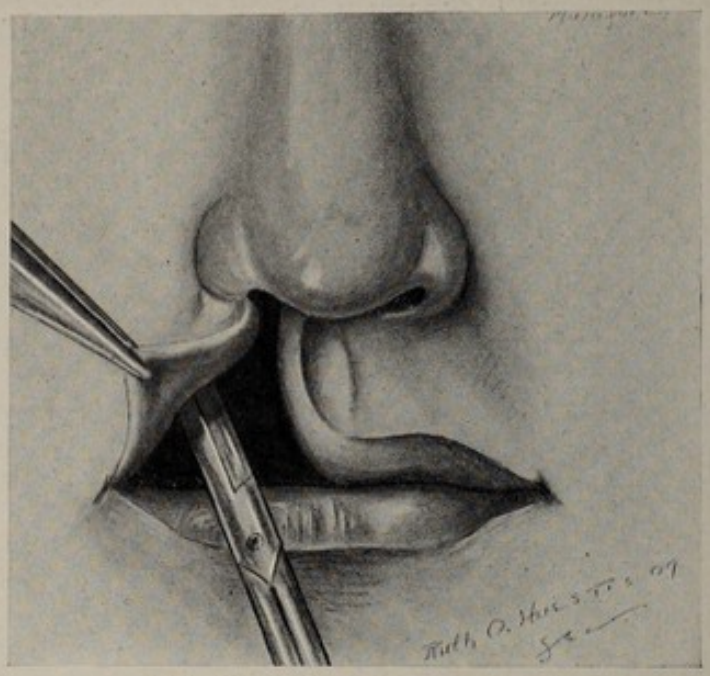

Fig. 349.—Loosening the cheek.

mucosa about the intermaxillary, working with a small sharp-pointed knife; he trims off the edges of the larger flaps, leaving at either angle tabs which may be brought down and out to form the required nipple-

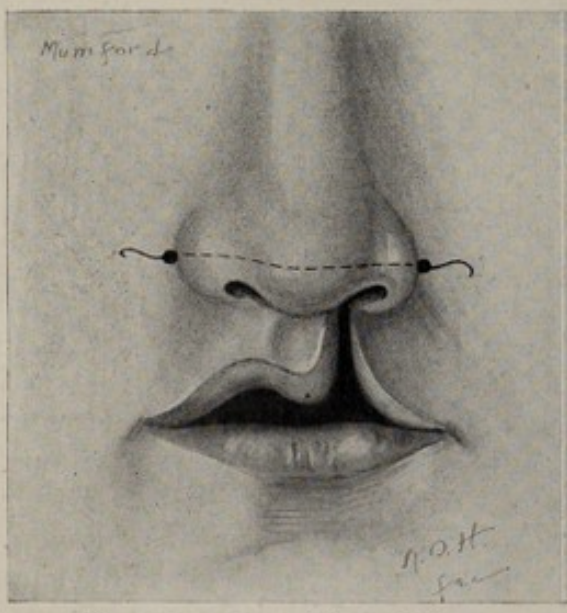

Fig. 350.—Deep silver stitch.

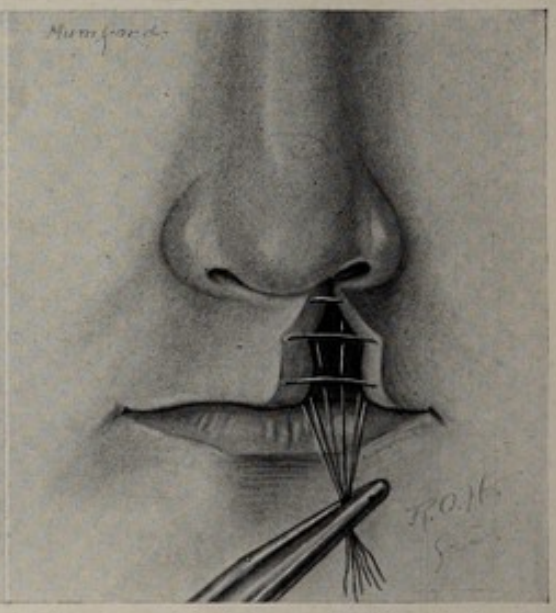

Fig. 351.—Final superficial stitches in place.

like projection which shall preserve properly the line of the upper lip. He places one deep and important stitch high, passing from sulcus to

sulcus of the alæ nasi. Remember that the nostrils generally are flattened by the existing deformity, and that this deeply placed stitch, preferably of silver and shotted, acts as a strong stay to hold closely the wide margin of the wound and to build up properly the alæ and tip of the nose. The placing of this deep silver stitch is somewhat difficult and is important. The rest of the operation is now easy and obvious. I complete the sewing up, using silk sutures threaded at either end into fine round cambric needles. These sutures do not take in the skin, but are passed through the subcutaneous tissues and mucosa from without inward, and are tied inside the mouth, the ends being left long. Practically this completes the operation; but if a slight gaping skin-line remains, one may close it with a few superficial intestinal stitches to be removed on the third day. Stitch abscess and ugly scars are obviated by this method of sewing. By no means the least important part of the operation is the dressing of the wound, which implies a supporting strap from cheek to cheek to take off traction from the line of incision. I use commonly a crêpe de lisse butterfly, drawn tightly and fastened with collodion.

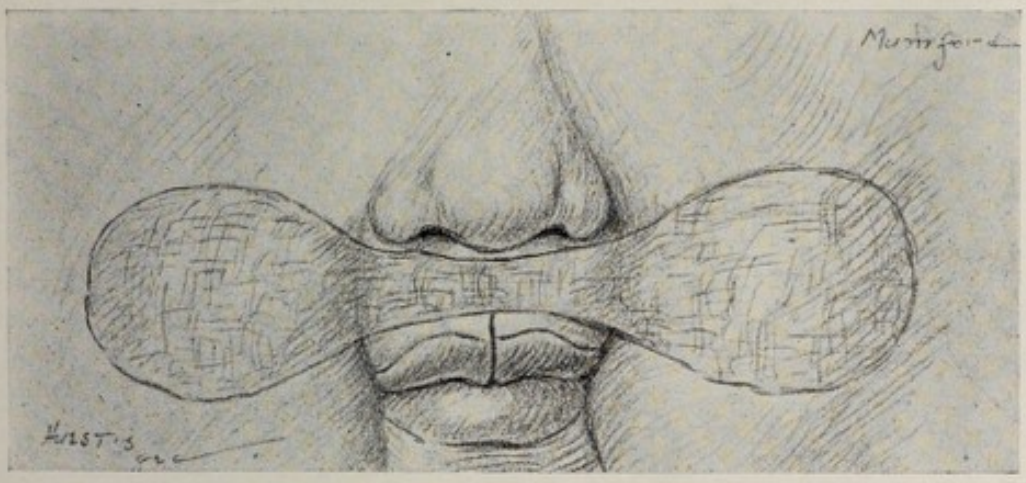

Fig. 352.—Sketch showing dressing completed.

Taylor[1] recommends the device shown in the illustration. It seems reasonable and useful.

The **after-care** of these cases is delicate and important. The operation causes a certain amount of shock, and the baby swallows a certain amount of blood. As a result there is usually some gastro-intestinal disturbance and imperfect assimilation of food for a time; so the after-care resolves itself into general treatment and special dressings of the wounded mouth. Six hours after the operation give the baby a dram of olive oil to clear out the bowels, and begin carefully with artificial feeding. After each feeding the mouth, tongue, lips, and nostrils should be wiped out thoroughly with a cotton stick dipped in boric acid (4 per cent.). All these operations are necessarily somewhat septic, so that one cannot expect perfect primary union in every case, but the lips of

[1] Alfred S. Taylor, A Dressing after Harelip Operation, Jour. Amer. Med. Assoc., vol. xlvii.

healthy children heal quite readily, and even if there be some gaping of the upper part of the wound beneath the nose, the lower part and vermilion border nearly always hold. If the vermilion border alone remains sound, one is justified in looking for eventual healing by second intention, and this is aided by careful strapping. By the end of two weeks the union should be so sound that all apparatus may be discarded.



Fig. 353.—Taylor's dressing completed.

If harelip operations be done properly and deftly, the improvement in the infant's appearance is remarkable, and few operations upon children gain so instantly the enthusiastic gratitude of parents.

CLEFT-PALATE

Cleft-palate often is associated with harelip, and demands our study in connection with it. A cleft may divide the soft palate only or may penetrate through the bony palate to the opening of the nostrils; and when the bony palate is cleft, the soft palate is always involved. Sometimes the cleft may be at one side, passing either to the right or left of the vomer, but more commonly the opening is in the middle line, with the vomer hanging free above it. Other peculiarities in the formation of the upper jaw are associated with cleft palate. The arch of the palate is abnormally high, so that the palate appears like a high-pitched roof

when looked at from below—the cleft being substituted for the ridge pole, while the cavities of the nose and mouth form a continuous whole. These skeletal imperfections are generally associated with harelip, though harelip alone, without cleft-palate, is common enough. I have noted the functional disturbances resulting from harelip, and one sees at once how much more serious must be the disturbances when cleft-palate is added to harelip. Suckling is impossible, and malnutrition is a common result. As the child grows the lack of proper incisor teeth is a disadvantage, while serious defects of speech develop later—defects which can never be overcome through operation or apparatus when once the bad habits are formed. Moreover, with the cleft open, particles of food become lodged in the nares and set up troublesome or foul catarrhs and spreading infections. One sees then the imperative need of treatment.

Treatment.—Not long ago there were two vigorously opposed opinions on this subject. Some men claimed the greatest benefit from obturators—plates devised by dentists for filling in the clefts in the hard and soft palates. Other men protested that the deformity could be repaired properly by operation. It is needless here to discuss the merits of this rather ancient controversy further than to state that although obturators have been of undoubted benefit in many cases, especially in adult cases, still to-day improvements in technic have convinced surgeons that an operation is best for young and vigorous patients. In spite of our confidence and conviction, however, one cannot be certain always of obtaining satisfactory speech or perfect cosmetic results. The cases are not numerous in the hands of any one man, but there are a few dental surgeons, in this country especially, who have greatly improved the operation.

Students of the subject recognize that the association of harelip and cleft-palate necessitates the treatment of both conditions as a pathologic unit, bearing in mind always that the deformity is evidence of developmental failure in utero, and that these children must be regarded as degenerates with unstable nervous systems. For this reason, if for no other, the surgeon should take every precaution to prevent shock, and should operate at as late a time as possible consistent with the preservation of the speech function.

In these cases then, and in simple harelip cases as well, one should begin, as soon as the child is born, by gentle means to draw together the parts. Assuming that a competent surgeon has in charge the child from its birth until the entire deformity is remedied, he should apply at once and have reapplied daily from cheek to cheek a strip of zinc oxid adhesive plaster. This bridges the labial cleft, hides the deformity, brings nearer together gradually both soft and hard parts,—for the palate cleft can be narrowed by such means,—and prepares them the better for subsequent operations. Thiersch favors a composite strap—a plaster—into the middle portion of which is set an elastic band to lie across the opening in the lip and the protruding intermaxillary. The elastic insert

exerts a constant contracting force at the same time that it gradually crowds back the intermaxillary. For the first six weeks the surgeon should take every pains that the infant be properly nourished and brought into condition for operation. Then in the middle of the second month

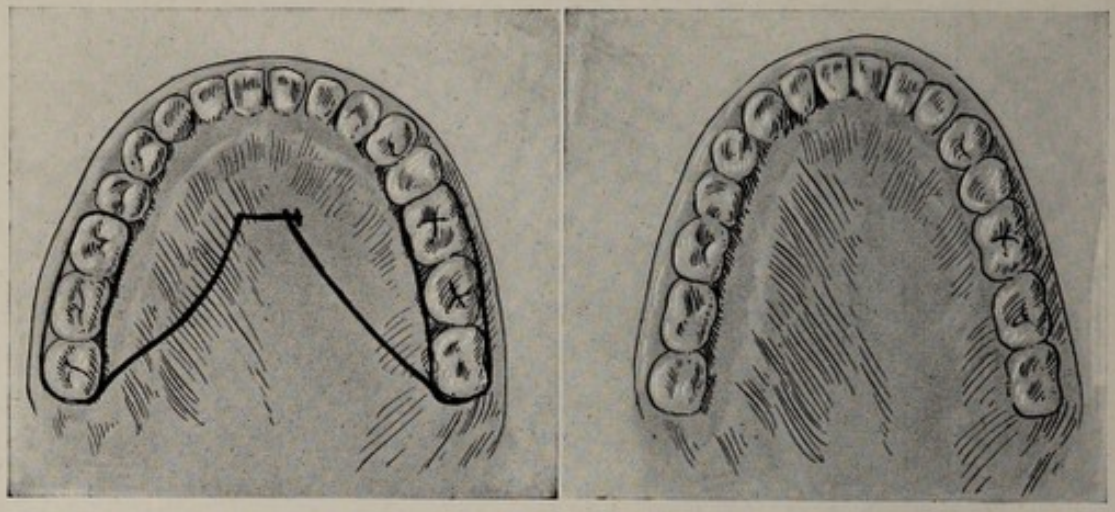

Figs. 354 and 355.—Brown's compression apparatus.

he should repair the harelip. Repair of the cleft-palate should not be done at this time under any circumstances. Some operators in the past have advised that the cleft-palate be repaired first, but experience has shown that little is gained by this measure as compared with the advantages secured by restoring first the lip. Furthermore, the opera-

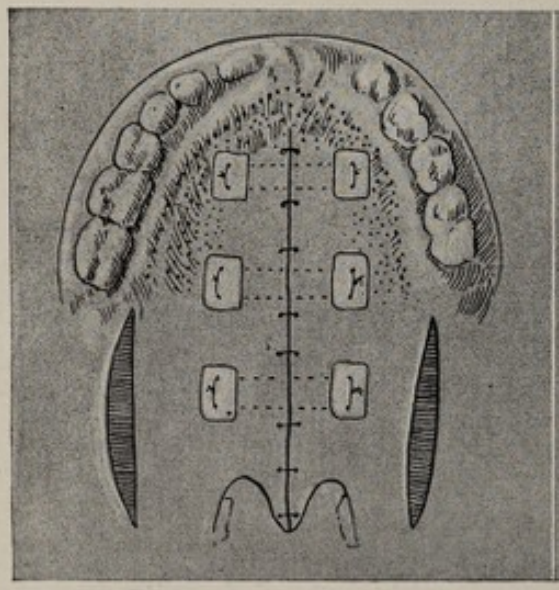

Fig. 356.—Fillebrown's silver discs.



Fig. 357.—Fillebrown's dissection of palatal mucosa.

tion for cleft-palate is severe and the infant mortality after it is high. Besides this, cleft-palate operations on young babies are extremely difficult, owing to the delicacy of the parts with which the surgeon must deal.

The restored lip exerts some slight compressing action upon the divided maxillary bones, but this is not by any means enough, so that it is advisable to employ some more effective compression apparatus for the six months preceding operation upon the palate. So long as the infant's molar teeth remain unerupted, the best means of compression is that I have already suggested, by a strap from cheek to cheek across the lip; but after the eruption of the molar teeth, they can be used as bases on which to fix a contracting screw.[1] This device exerts traction so effectively that by the end of a few months the cleft is materially diminished in width, and by so much is the operation rendered easier. When the healthy child is well advanced in its second year, the surgeon proceeds to the—

Operation for Cleft-palate.—The child is brought to the end of the operating table and the head is depressed in the position of Rose; the mouth is held open by a strong, well-fitting gag, and the whole cavity with the nostrils is swabbed out thoroughly with 70 per cent. alcohol, followed by boric acid. These fluids with accumulating blood are not swallowed or inhaled, but can be wiped away readily. The surgeon had best employ ether anesthesia, which may be administered in the ordinary fashion, but is well given through a nasal or mouth tube after the method of Crile or Fillebrown.[2] The surgeon must use small instruments—knives, scissors, vulsella, catch-forceps, periosteum retractors, and elevator, and a variety of curved needles with a needle-holder. Employ for sewing up fine silver wire and silk sutures, and make use of small silver discs, about the size of a gold dollar cut square, as supports for the quilted stitches. Following Fillebrown, in closing the hard palate cleft, I have given up the Langenbeck method of splitting away the mucosa parallel with and close to the alveolar processes; I recommend the following procedure: turn back from the cleft on either side and close to the opening an abundant flap of mucosa, and peel it off from the bone nearly to the alveolar process. Refresh the edges of the flaps or, preferably, split them for about ¼ inch in, and bring them together with three or four silver stay sutures quilted over the silver discs. This leaves loose flapping edges, which may be joined accurately, without tension, by interrupted silk stitches. Thus one has completed the repair of the hard palate, while the two halves of the soft palate remain flapping.

Frequently it is well to postpone for a time the operation on the soft palate, waiting until the first wound has healed and the child has recovered his vigor.

Repair of the soft palate is not altogether simple, whether the cleft be original and uncomplicated, or be left over after the hard-palate opera-

[1] J. D. V. Singley, Amer. Med., September 16, 1905.

[2] Fillebrown described his apparatus in 1893; it is on the plan of the "Junker system." It consists of a bellows, a wash-bottle containing ether, and a tube reaching to the patient's mouth. Air is blown over the ether in the bottle, and becoming charged with ether vapor, is led into the patient's nares or mouth by means of the tube.

tion. Earlier operators began by loosening up the flaps, cutting the tensor muscles of the palate and the pillars of the fauces. This is a needlessly mutilating performance, and leaves the repaired palate in so functionless a condition that correct speech thereafter is almost impossible. To relieve the tension on the soft palate it suffices to make lateral incisions external to the tonsils, and to dissect up the tissues with a blunt instrument, so as to avoid hemorrhage. Thus one forms lateral buttonholes which relieve sufficiently the tension. The flapping halves of the soft palate may then be refreshed at their edges, and brought easily together with interrupted silk sutures. Then the mouth is thoroughly douched and wiped out, and the child is allowed to recover from ether. When undertaking one of these cleft-palate operations, the surgeon must have abundance of time—two hours, if necessary—and the patience to pick his way along, taking each step slowly, carefully, and finally. The after-care of these infants and children is important. Blood has been lost, and it is well to assist the circulation by the use of salt solution enemata until the patient reacts well. Careful feeding must be instituted, and the child watched until all danger has passed. The mouth and nares must be wiped out several times a day. The silver stitches should be removed on the eighth day, and the silk stitches two or three days later. If all goes well, healing should be sound in two weeks.

Brophy's operation is also valuable and popular; somewhat in the words of J. F. Binnie the steps are as follows:

The special instruments needed are: two of Brophy's strong needles, a few strands of No. 20 silver wire, and lead plates No. 17 of the American gauge. Swab the mouth with adrenalin. This lessens the hemorrhage.

With the patient in Rose's position, pass a thread through the tongue and use it for traction. Pare the edges of the cleft in the hard palate, cutting away a little of the bone itself to insure thoroughness. Pare or split horizontally the edges of the cleft in the soft palate. Thread a stout-handled Brophy needle with strong silk or celluloid hemp. Raise the patient's cheek and pass the threaded needle through the superior maxilla from without inward at a point just back of the malar process, and high enough to be above the palate. When the needle appears in the cleft, pick up the thread which it carries with hook or forceps, withdraw the needle, and leave the loop of thread in position. Pass a loop through the opposite maxilla in the same fashion, secure the first thread with the second, and so carry the first thread out through and through both maxillæ. By means of this thread pass a strong silver wire through the same track. Then, by the same technic, pass two other silver wires through the anterior portion of the maxillæ above the level of the palate. Secure the ends of the wires in small lead plates outside the maxillary bones, the wires being drawn tight and all twisted together. Then with the thumbs forcibly press together the two maxillary bones until the cleft is closed, and again draw tight and

twist the wires so as to hold the cleft closed. The surgeon may now close the soft palate by easy suturing. Brophy advises that this operation be done before the end of the third month. It is not possible after the sixth month. If compression of the bones fails to close the cleft, the surgeon may divide the malar processes. This operation is followed by surprisingly little pain.

The establishment of proper speech habits is difficult in all cases. The developing children should be put under the care of a competent teacher if possible. When these operations are performed on half-grown children or on adults, one may expect an excellent anatomic result, but good speech habits cannot be expected. For years after the operation children should be under the frequent inspection of a dentist and a throat specialist, because all such abnormalities as faulty teeth, nasal spurs, deviated septa, and the like add to the physiologic errors and must be met and corrected.

Shocking as is the deformity of a harelip, it is scarcely more repulsive than numerous other lesions of the face, congenital and acquired, especially the deforming and often grotesque imperfections of the features. The unfortunate victims of such defects are always objects of repulsion on first sight, and the reacting mental effect upon the individuals themselves is often permanent and distressing. Frequently these lesions serve as a grevious handicap in life, though in rare instances one sees such unfortunates attain positions of conspicuous eminence. I have referred to the various unusual clefts and fissures of the cheeks, nose, eyes, and other regions, and the reader will recall a famous case in fiction, Victor Hugo's " l'Homme qui Ris."

PLASTIC OPERATIONS ON THE FACE

The remedy for these defects nearly always involves a plastic operation, and plastic operations on the face, though anatomically satisfying, since healing is prompt and sound, seldom give pleasing cosmetic results. The patient remains something of a monstrosity, painful to the beholder. **Nasal defects** especially are deforming, and the remedy, whether by some one of the ingenious plastics or by a false nose, is never satisfactory. These nasal defects appear as a partial or complete loss of substance of the nose. Rarely the condition is congenital; but syphilis is a common acquired cause; sometimes the cause is tuberculosis, or there may have been an injury. Operations for repair consist in turning down various flaps to fill in the vacancies. Flaps are taken from the forehead, the cheeks, and the side of the nose, as illustrated by the accompanying cuts. The cuts, however, give one little notion of the end-results. The defects may be closed in, the patient rendered more comfortable, and his visage less hideous, but the resulting scars are extensive and extremely ugly.

Ectropion, or eversion of the lower eyelid, is not uncommon, and may arise from a burn, ulcer, or injury. There are various operations for

its relief, which certainly improve the patient's appearance. Not only this, but they remedy the serious distress which the patient suffers from ectropion, as the everted lower lid continually pours out tears.



Fig. 358.—Method of rhinoplasty (Linhart).

Defects in the cheeks are remedied by some such operation as that of Schimmelbusch, who reflects upward a flap from the neck. The neck is a favorite region, when suitable, from which to take a flap, for the cervical skin is thin and elastic. In performing all these plastic operations, however, one should take pains not to fill in a normally hairless area, like the forehead or upper portion of the cheek, with a hairy flap. Cheeks and chins extensively scarred by burns are commonly subjected to these operations.

Powder face is a frequent misfortune, and is due to a close-range discharge of black gun-powder, which forces the powder grains into the skin. If the patient is seen at once before the grains have healed in, most of the particles can be removed by vigorous scrubbing with a stiff nail-brush, the patient being under ether. After the grains have healed in, however, the only remedy is to remove the particles patiently, by long-continued picking with a cataract needle or the point of a knife.

SALIVARY FISTULA

Salivary fistula results from wounds or disease of the salivary glands or ducts, and is a troublesome affliction, though not particularly deforming. If the fistula communicate directly with the gland, it will

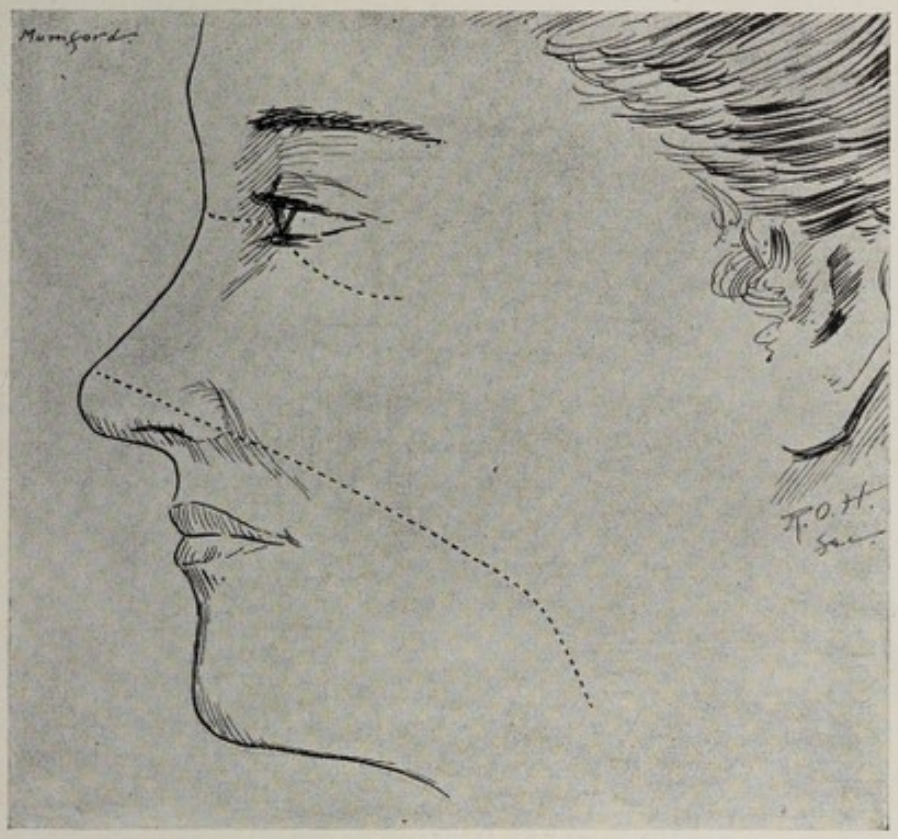

Fig. 359.—Codman's rhinoplasty—incision 1.



Fig. 360.—Codman's rhinoplasty—incision 2.

almost always heal, provided the gland be not diseased and the normal channel through the duct remain patent. The surgeon may rim out such a fistula with the cautery and apply constant compression, or he may merely bandage the lesion, being assured that eventually it will heal, with or without treatment.

Fistula from the ducts is a more serious affair, however, and Steno's duct is the one commonly affected. The surgeon should look for and eliminate any underlying cause for the fistula. I have seen cases of obstinate fistula due to tuberculosis and actinomycosis. There are various operations for closing fistulæ of Steno's duct, and these operations depend upon whether or not the distal end of the duct in the mouth be occluded. If the distal end be patent, the fistula will often heal of itself, or the surgeon may dissect out the duct and suture the divided ends. Sometimes it is necessary to open through the mucous membrane from within the mouth, to find the central end of the duct, and bring it out into the buccal cavity. The operation of de Guise is ingenious. He threads a piece of silk through two needles and carries the needles through the cheek into the mouth, so that the silk will embrace a bit of tissue half a centimeter in length. The silk is tied tightly within the mouth, the ends are cut off, and the margins of the fistula at the surface are freshened and sutured.

SALIVARY STONES

Occasionally the salts cantained in saliva are deposited as a calculus within a salivary gland or its duct. Such a calculus is more likely to give rise to swelling than to pain, so that a salivary cyst may result from the obstruction. The obvious *treatment* is to cut down upon the concretion, if possible, through the mouth, and remove it.

RANULA

Ranula is the name given to a cystic tumor situated beneath the tongue. The older surgeons described it as a retention cyst of a salivary gland duct, but this description is not always correct. More commonly, it is due to obstruction in the duct of one of the glands of Bochdalek, situated in the floor of the mouth, near the frenum of the tongue. There may be multiple cysts on either side of the tongue, but commonly the growth is single. Ranula is a chronic affair as usually seen, though *acute ranula* may develop suddenly as the result of irritation of a small cyst hitherto unnoticed. A ranula sac may project entirely beyond the floor of the mouth, and push up the tongue; it must be differentiated from a distended or cystic Wharton's duct, which may dilate greatly and press downward and appear beneath the chin. It must be distinguished from tumors of the sublingual gland itself also, from lipoma of the floor of the mouth, and from sublingual dermoids, all of which are rare, while ranula is common enough. It is by no means easy to cure ranula, and one of the faulty operations is to puncture or

dissect off the superficial portion of the sac and to cauterize its base. Frequently this procedure fails. The only final and satisfactory method of cure is by complete and painstaking dissection of the sac. In some cases, when other methods have failed, it may be necessary to approach the growth through the chin from below, and so to remove completely the whole affected gland with its duct.

THYROLINGUAL OR THYROGLOSSAL CYSTS AND SINUSES

Thyrolingual or thyroglossal cysts and sinuses are extremely interesting and not uncommon conditions. These formations result from imperfect closure of embryonic clefts, for in embryonal life the thyroid gland sends a duct from the thyroid isthmus to the foramen cæcum of the dorsum of the tongue. Looked at from above, this duct is found in life to pass from the base of the tongue down the middle line of the neck, to be connected with the hyoid body, the thyrohyoid bursa, and the upper portion of the trachea in front, where it divides to send a branch to each lateral thyroid lobe. So the duct which should be closed early in fetal life, generally by the eighth week, may persist in whole or in part. It may in part develop as a *sublingual dermoid,* while behind the hyoid bone it may become a subhyoid cyst. Moreover, that portion of the duct below the hyoid may develop into a cyst which may rupture and establish an incomplete *cervical fistula.* Should the whole of the sinus remain patent and a cervical fistula become established, the formation is known as a complete cervical fistula, the patency of which is demonstrated when a little quinin solution is injected into the lower opening and the patient experiences a bitter taste in the mouth.

The **treatment** of these cysts and sinuses is a difficult and tedious matter, and consists often of an extensive dissection. A general anesthetic is obviously necessary, and sometimes one must perform preliminary tracheotomy. The whole track, so far as it is open, must be dissected out, especially where it adheres strongly to the hyoid bone, which often must be divided and retracted in order to get at the cyst. Most surgeons have had the trying experience of operating four or five times on a single case before curing it.

Such are some of the minor and least frequent lesions about the face and mouth. We must now consider a lesion commoner and far more serious than harelip or cleft-palate even.

CANCER OF THE LIP

Epithelioma of the lip (squamous-celled cancer) is the most common of the malignant diseases of the face, and makes up nearly 50 per cent. of all cases of face cancer. It is an interesting fact that men, almost exclusively, are the victims of cancer of the lip; we see it so rarely in women that in them it is regarded as a curiosity. Moreover, the predisposition to cancer of the lip increases as men grow older, while the disease is extremely rare in persons under forty. The causation of lip cancer is

manifold. It may be due to various anomalies of the skin, which are common enough about the lips, such as warts, pigmented spots, papillomata, hypertrophies of glands and follicles, and chronic inflammatory diseases, but it is a curious fact that such common lesions rarely lead to cancer, except in the lower lip. Cancer of the upper lip is excessively uncommon. One cannot avoid the conclusion, moreover, that long-continued chronic irritation of the lip, as from an old scar, and especially from pipe-smoking, is an important element in the etiology of lip cancer. The disease is generally situated at one side, rarely in the middle of the

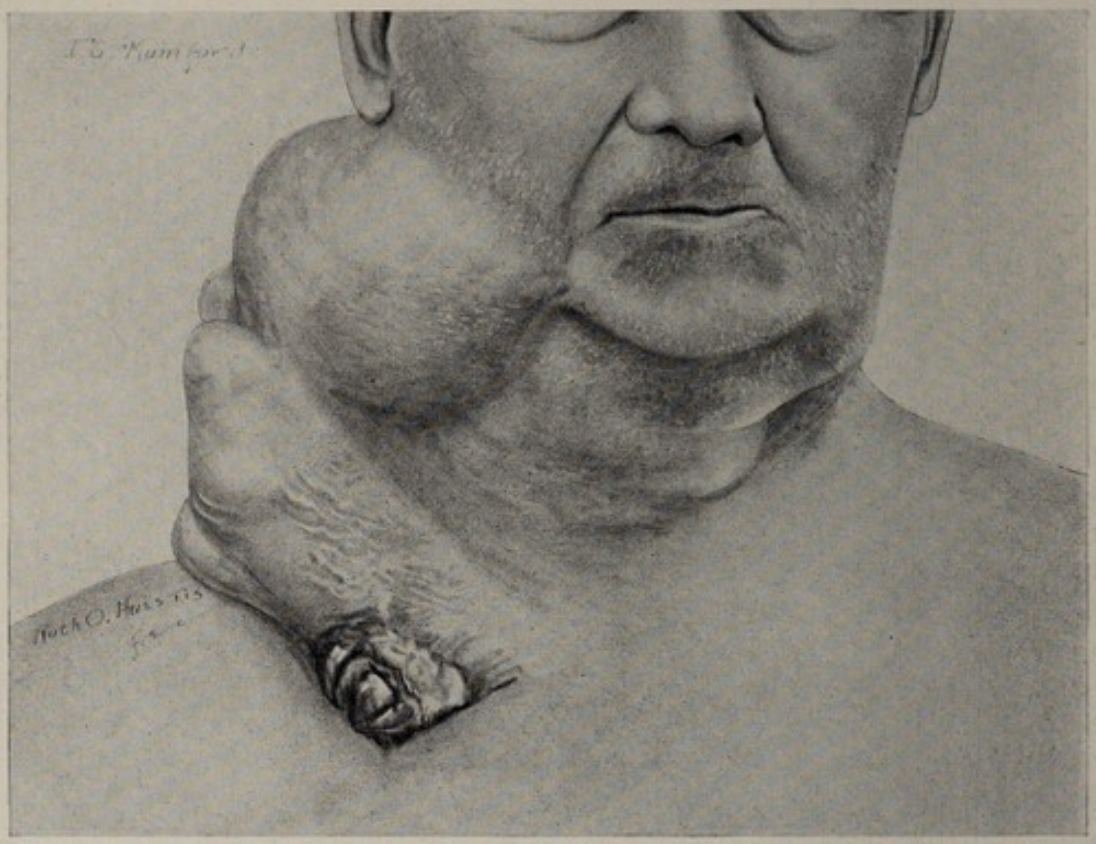

Fig. 361.—Carcinoma of neck, secondary to lip cancer (Massachusetts General Hospital).

lip, and is a process of slow progress. For this reason, as with other cancers of the face, and because these lesions are on the surface and quickly detected, it seems as though a cure of the growths should be common and easy. Cancer of the lip, however, differs from most other facial skin cancers in this respect, that it involves lymph-nodes much more early than do they.

Lip cancer appears at first generally as a scab covering a small, hard, granulating tumor,—perhaps a perithelioma,—no larger often than half a split pea. The patient picks off the scab or it falls off, and then gradually it forms again. This stage may last for two or three years, but eventually the growth spreads and exfoliates. When once started in this way it may increase rapidly, and within a few months the whole lower lip is a mass of foul, bleeding, fungus granulations, with an extensive in-

durated base. Although this state of progress in lip cancer should never be reached in any civilized community, the condition is seen not uncommonly. Perhaps unfortunately, the patient suffers little discomfort from lip cancer until it is well advanced, and he may carry with him for years a threatening nodule without being especially disturbed. In the later stages of the disease great distress comes on, especially pain, debility, pain in the jaw from involvement of the bone, and pain in the neck from metastases. If the disease runs an uninterrupted course, the patient dies in from three to five years, with great swelling of the neck, constant pain, perhaps pressure on the trachea, and obstruction of the

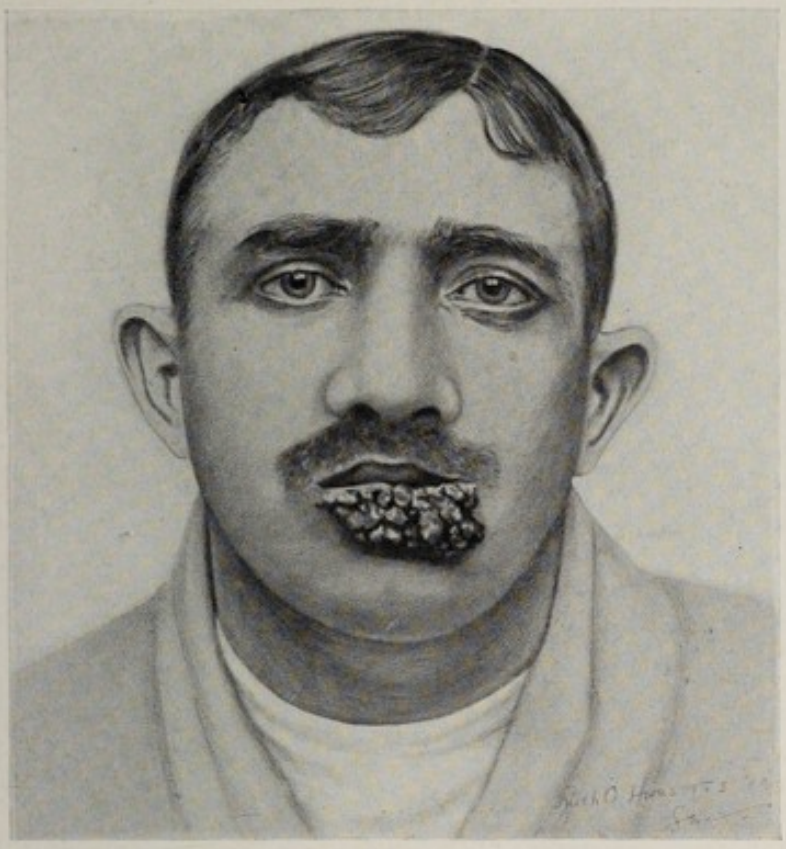

Fig. 362.—Extensive epithelioma of lip (Massachusetts General Hospital).

esophagus even. Distant metastases are uncommon, for the disease is nearly always limited by the collar of lymphatics above the clavicle. One should observe, moreover, that early lymphatic enlargements are confined to a few nodes in the submaxillary and submental regions; lymphatic swellings lower down in the neck along the edge of the sternomastoid appear late, and in this respect cancer of the lip differs from cancer of the tongue, in which latter disease deep lymphatic involvement is relatively early.

Probably no class of cancer patients have fallen victims to the malpractice of quacks so frequently as persons suffering from cancer of the lip, yet it should be obvious to every qualified physician that cancer of the lip in its method of growth is analogous to cancer of the breast, and demands equally thorough and far-reaching extirpation. I be-

lieve that a mere local removal of young lip cancer is always improper —as improper as the mere local removal of a small breast cancer.

The **treatment** of lip cancer must be thorough and early therefore, and when such treatment properly is followed, the surgeon should look for a large percentage of permanent cures. For some years I have followed the technic advocated by Crile.[1] While I believe firmly in extensive dissection of the neck for cancer of the lip, I agree with Crile that such extensive dissection need not be invariable. In operating for *early* cancer it is enough to remove thoroughly the growth in the lip and to dissect out the tissue—fat, platysma, vessels, and lymphatic and salivary glands in the digastric region, corresponding to the side on which

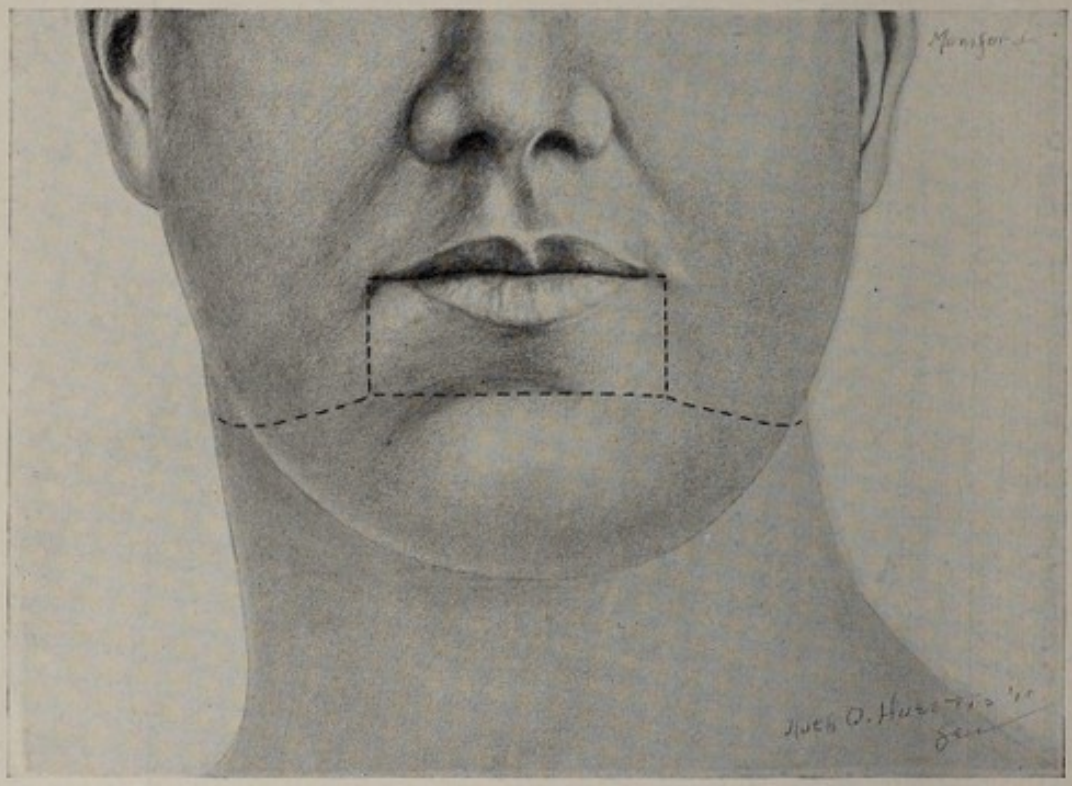

Fig. 363.—Grant's operation for cancer of lip—step 1.

the cancer is placed. The decision regarding more extensive operation sometimes is difficult. A good general rule is to dissect widely the neck only in case one finds that the superficial glands are involved.

The problem of the operation for lip cancer, therefore, divides itself naturally into two portions—the operation on the lip and the operation on the neck. The operation on the lip should be done more thoroughly than old convention enjoins. The common method has been to remove the growth by a V-shaped incision and to sew up the cleft. This is poor surgery, except in the case of minute growths, for when a large growth is removed in this manner, and the wide gap is sewed up, there results an ugly, disfigured mouth—the so-called "sucker mouth." The best incision for removal of the growth itself is the square incision, supplemented by

[1] George W. Crile, Jour. Amer. Med. Assoc., December 1, 1906, p. 1780.

such a flap operation as Grant's.[1] By this operation a wide clean excision of the tumor is made. From the inferior angle of the wound cuts are then carried down obliquely beneath the jaw; the submaxillary region is exposed; the suspicious area is dissected, and the resulting extensive wound is closed readily by a flap-sliding plastic. A fairly shapely mouth results from the most extensive dissection even, and, if necessary, any lack of mucous border may be supplied from a splitting plastic of the upper lip—Sandelin's cheiloplasty.

The more extensive and radical dissection of the neck (Crile) is an operation of the first magnitude, and in undertaking it one should have regard to three important considerations—infection, hemorrhage, and shock, as well as the primary consideration of radical cure. A suitable

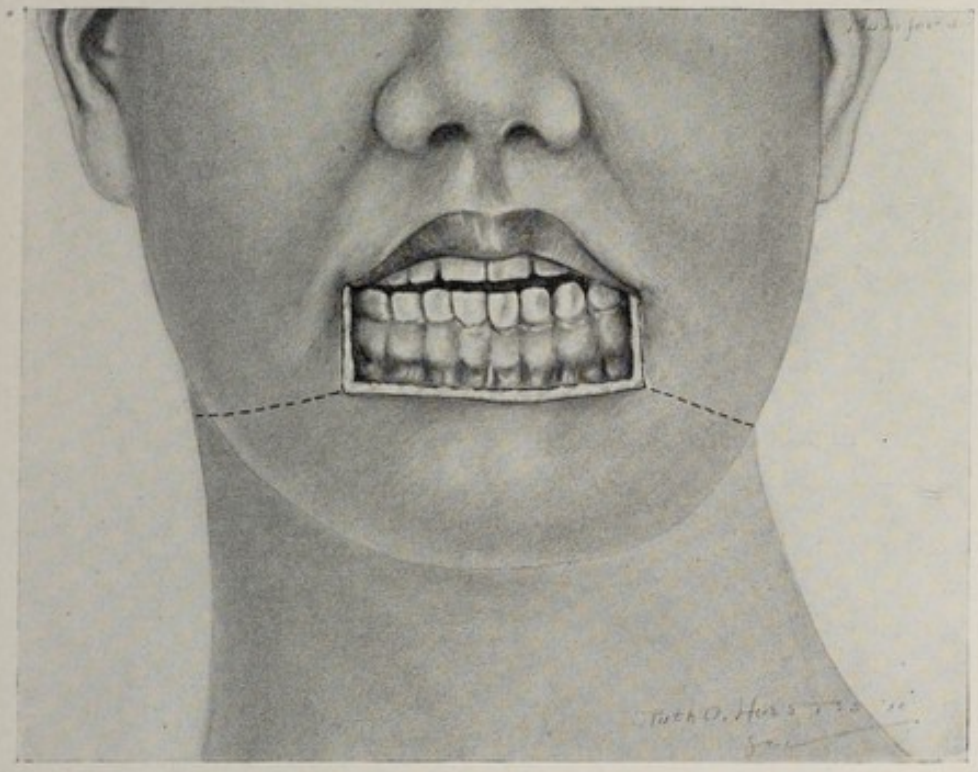

Fig. 364.—Grant's operation for cancer of lip—step 2.

method of approach is through a T-shaped incision—the horizontal running beneath the jaw from the symphysis to the mastoid; the perpendicular from the angle of the jaw to the middle of the clavicle, crossing obliquely the sternomastoid muscle. One turns back freely these flaps and proceeds, as in the removal of breast cancer, to take out the whole of the infected area, including in the dissection fascia, fat, salivary and part of the parotid glands, sternomastoid, omohyoid, and part of the stylohyoid muscles, the entire venous system, and all the lymphatic vessels and glands in this region. This comprehensive dissection is quite as extensive and complete as the thorough dissection for breast cancer. One begins the deep dissection from below, cutting away the sternomastoid close to the clavicle, reflecting it upward, tying the deep and su-

[1] W. W. Grant, Jour. Amer. Med. Assoc., September 30, 1905, p. 962.

perficial jugulars, and controlling possible hemorrhage by the temporary clamps of Crile placed upon the common carotid. With this as a begin-

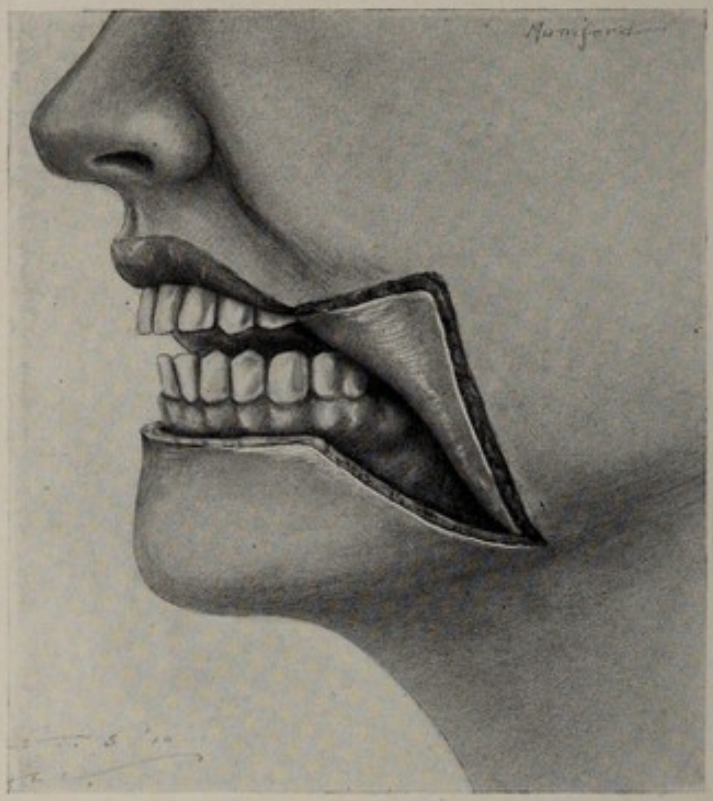

Fig. 365.—Grant's operation for cancer of lip—step 3.

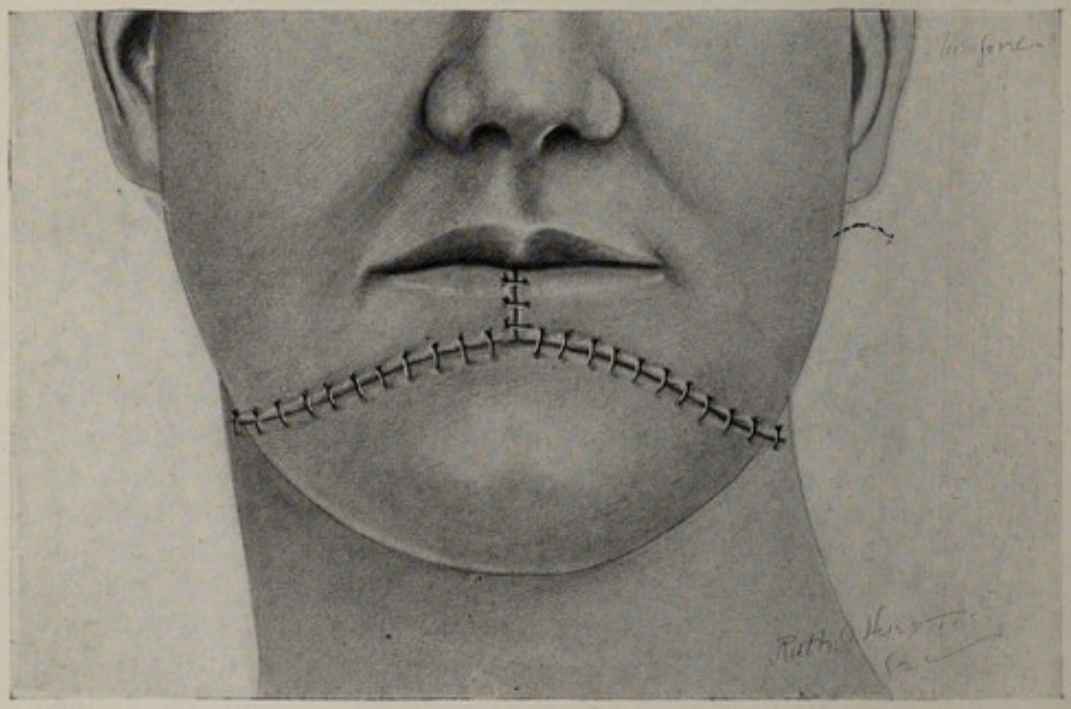

Fig. 366.—Grant's operation for cancer of lip—step 4.

ning, all the parts I have named may be freely and rapidly removed, peeling from below upward, avoiding possible infection by handling the mass as little as possible, minimizing hemorrhage by controlling quickly

all severed vessels, and obviating shock by the application of the pneumatic suit. As I have insisted previously in discussing the removal of cancer, we must not be goverend by considerations of anatomy. The loss of the sternomastoid and other muscles is quickly compensated; the loss of a large part of the venous system is of no moment whatever, for numerous veins, deep and superficial, quickly enlarge to supply the lack; control of the carotid is temporary only, and in a large experience I have seen no damage follow the use of Crile's clamp carefully applied to that vessel without forcible compression. This neck dissection is a somewhat formidable operation, and may result disastrously if any of the suggested precautions are neglected. Moreover, one should take every pains to avoid damaging the pneumogastric nerve with its connections. On completing the dissection one sees a broad, clean, deep wound, at the bottom of which lie arteries and nerves only upon the deep cervical muscles. Sew up the wound carefully, and leave a cigaret drain at its lowest angle. Rapid healing is promoted by supporting firmly the neck for a week in a Thomas collar or some similar device.

Let me say to the practitioner that I am aware some surgeons doubt the wisdom of this wide operation, but abundant experience of my own and the still wider experience of Crile and others have convinced me that nothing short of this gives reliable promise of permanent cure in grave cases of extensive cancer of the lip and neck. It seems almost needless to say that involvement of both sides of the neck with massive tumors, that profound cachexia, and the suspicion of distant metastases contraindicate positively any operation whatever.

Another form of cancer of the face is that curious and unique process which we call rodent ulcer.

RODENT ULCER

This is a cancer originating in the sebaceous glands. The disease may arise anywhere on the face—especially on the nose, eyelids, and



Fig. 367.—Rodent ulcer.

cheeks. It is nearly always above the level of the mouth, and is sometimes multiple. Its first manifestation is a little knob about the size of a split pea, harmless, and little noticed. The knob may remain for years,

when suddenly, without obvious reason, it begins to ulcerate and to progress, destroying all the superficial parts in its neighborhood—skin, muscles, fat, cartilage, eyeball, and bone—producing a horrible disfigurement. It grows unceasingly; it is painless; it gives rise to no metastases; it appears as a raw, sloughing, indolent ulcer. Its origin is in the sebaceous glands, as I have said, and the little original nodule is seen microscopically to consist of gland-ducts filled with epithelium.

For years surgeons have treated rodent ulcer by the cautery and by excision, followed by extensive plastic operations. Of late we have come to believe that when taken early and exposed to radium, the disease is aborted rapidly, and the *ulcer heals without leaving a scar*.[1]

There are sundry other injuries and diseases of the face, at a few of which it may pay us to glance.

INJURIES OF THE FACE

Injuries of the face, when promptly treated, heal rapidly, for the tissues of the face are remarkably vascular and primary union there occurs in a few hours. Infected wounds even are subdued more readily, as a rule, than are similar wounds elsewhere. One of the commonest types of infection of the face is—

Facial Erysipelas.—This is due to streptococci, which find lodgment in some crack or trifling abrasion. It is a surgical affection.[2] The resulting inflammation spreads rapidly—commonly about the eyes as a center. It presents the appearance of a uniform scarlet blush or injection of the skin, with a sharply marked outline. Generally, the disease runs a short course, and in a few days disappears spontaneously; but if unchecked, it may progress indefinitely over the body; the infection may burrow, and there may result extreme deep inflammations with pus—a condition known in former times as " phlegmonous erysipelas."

An excellent *treatment* in the early stages of the infection consists in the frequent application of a lotion composed of alcohol and carbolic acid.[3] In spite of the feebleness of this antiseptic it generally succeeds in quelling the disturbance in a few hours or days. Another popular treatment consists in painting the edges of the advancing inflammation with ichthyol. When the infection has progressed far and has involved deeper structures, it must be treated vigorously by incisions and antiseptic dressings. I am coming to believe that opsonic vaccines will mitigate or abort this infection, but at present the evidence is not conclusive.

Carbuncle of the upper lip deserves a word of mention here, in addition to the consideration of carbuncle in general, which the reader will find in Chapter XXVI. Carbuncle of the upper lip is peculiarly serious. It is situated in an extremely vascular region, and often goes

[1] Tumors, Innocent and Malignant, J. Bland-Sutton, 1907, fourth ed., p. 325; also E. S. Judd: Treatment of Cancer of the Face, Head, and Neck, St. Paul Med. Jour., March, 1909.

[2] A rather convenient cant term, which implies that the treatment of the case should be in the hands of a surgeon, as an operation may prove necessary.

[3] ℞. Acid. carbolic., 4.00; spirit. vini recti., 30.00; aquæ, ad 200.00.

unrecognized for many days—especially in the case of a bearded lip; often it is progressive and fatal even, involving eventually deep structures of the face and neck and spreading perhaps to the meninges. The surgeon should *treat* it vigorously at the outset, by excising the nidus of infection, if such excision does not mean extensive crippling of the face, or by deep crucial incisions and cureting. At the same time he should employ opsonic vaccines. If the inflammation has extended far, the surgeon must meet the indications by appropriate far-reaching incisions for drainage.

TUMORS OF THE FACE

Angioma, a tumor composed of an abnormal formation of blood-vessels, is common on the face, and is seen in three forms: (1) *Simple nevus;* (2) *cavernous nevus;* (3) *cirsoid aneurysm.* The *simple nevus* is far the most common, and is ordinarily designated "birth-mark." It may be small and superficial or it may be so extensive as to cover the side of the face—the so-called "port-wine stain." Nevi are composed of minute blood-vessels embedded in fat and communicating with an



Fig. 368.—Nevus (Massachusetts General Hospital).

adjacent artery or vein. *Cavernous nevi*, sometimes called erectile tumors, are made up of spaces and sinuses, the walls of which are merely fibrous septa lined with epithelium. Sometimes the cavernous nevi consist in part of vessels and in part of cavernous spaces. Like simple nevi, they are generally congenital, but, unlike simple nevi, they grow. They may burst and bleed; they may press upon such organs as the tongue and nares, and then rupture, endangering life even.

These two forms of nevus may be treated by excision if they be not too

extensive, or, in the case of cavernous nevi, by the injection of boiling water into the mass. The latter method is simple. Boiling water is forced through a common hypodermic needle, inserted in several places into and beneath the nevus, until all parts of the tumor have been reached. There results coagulation and necrosis, with subsequent absorption and more or less fibrous tissue formation, but ultimately with pleasing cosmetic results. More than one sitting may be required, and many months may pass before the swelling disappears entirely.[1]

Cirsoid aneurysm consists of numerous arteries arranged in a tortuous fashion. These angiomata are rare, disfiguring, troublesome, or

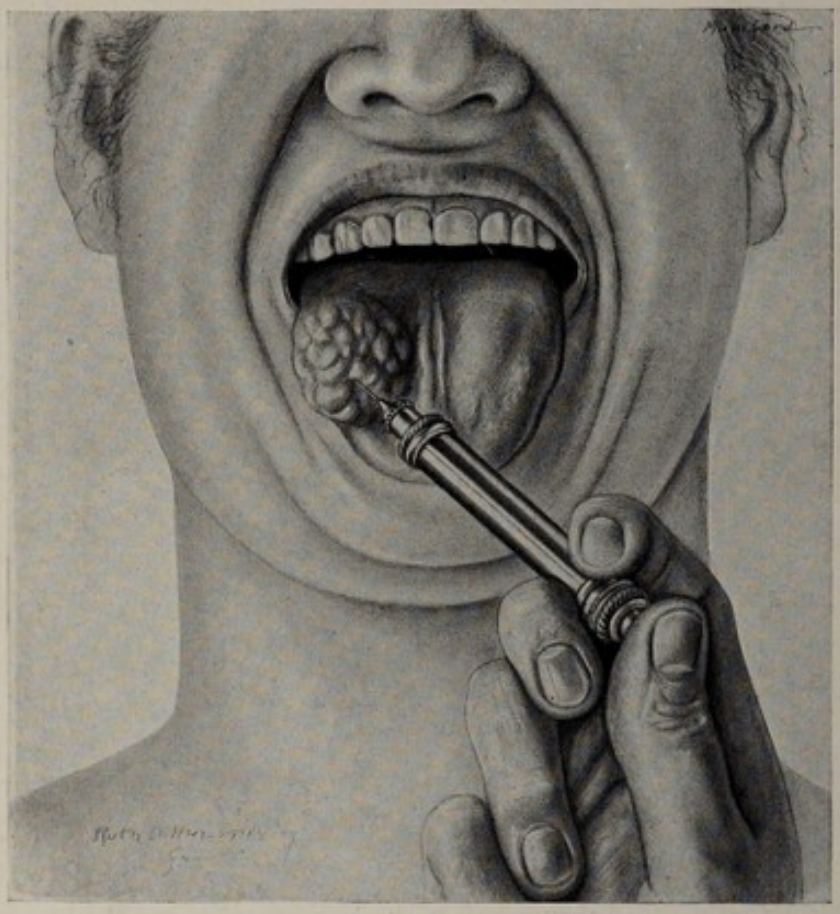

Fig. 369.—Treatment of nevus by boiling water.

in the end dangerous, and can be treated by careful excision only. When the whole mass becomes so extensive as to involve half the forehead or more even, its cure is extremely difficult, and requires numerous successive operations, with careful painstaking dissection.

So much for the lesions of the face which concern the surgeon especially. There are in this region numerous other disorders involving the skin and special organs, but for the study and treatment of these disorders I must refer the reader to appropriate special treatises.

[1] Carbon-dioxid snow as an application has become one of our most valuable agents in the treatment of nevi.

LIBRARY OF THE
PRESENTED
BY THE EDITOR OF
B. M. J.
BRITISH MEDICAL ASSOCIATION

CHAPTER XXI

JAWS, TONGUE, LARYNX, AND PHARYNX

THE JAWS

THE surgery of the tongue and jaws is associated closely with the surgery of the face,—the subject of the preceding chapter,—as well as with the surgery of the neck. The lesions of these parts are of supreme importance not only to life and health, but to comeliness and beauty, so that, in a large sense, they should fall to specialists. Indeed, certain portions of the problem have been divided among certain specialists—laryngologists and dentists—upon whose field I intend to trespass but little. There are, however, many associated lesions which fall as yet to general surgeons. There are fractures, deformities, malignant tumors, and infections in great variety, at most of which we must glance. A special study of all these lesions is impossible in our limited pages, but I shall take occasion to refer the reader to sundry important essays and monographs. Fractures and dislocations of the jaws will be considered under a special chapter of this book, on the general subject of fractures (Chapter XXIX).

The buccal cavity is peculiarly liable to infections, because the mouth is a swarming breeding-place of micro-organisms, which may find ready lodgment about the teeth and gums or in cracks of the tongue and lips, and so produce infections. Moreover, the mouth is a cloaca concerned with both the respiratory and the digestive tracts, so that infections and lesions of the mouth, fauces, stomach, and air-passages may be related and interdependent. The mouth, jaws, and tongue are peculiarly liable to injuries and irritations; the head and face are at all times exposed to the weather and to violence, while the tongue and cheeks, lying in contact with the teeth, may suffer from such contact, especially if the teeth be broken, jagged, and decayed. The development of the teeth themselves, their relation to health, to their own function in digestion, and to anatomic obstructions by tumors and deformities in the mouth, fauces, and nasal passages, all go to make up an independent and important chapter in surgery. As I said in speaking of face lesions, the surgery of all these parts differs from most other surgery in that it has in it a peculiar factor—the factor of possible cosmetic deformity. Aside from this factor, which one must constantly be considering, one must regard possible involvements of the special senses. There are, however, three main types of lesions which we must study in this chapter—infections, injuries (and their results), and tumors.

INFECTIONS

Alveolar abscess ("gum-boil") is a common and distressing affection. It appears as a painful, throbbing swelling of the gum, quickly followed by an associated swelling of the cheek, which assumes an appearance of ludicrous deformity within a few hours. The infection starts in or about the root of a tooth, quickly involves the periosteum, and spreads to the mucosa. If you examine it with your finger, you find a sensitive area on the gum over the affected tooth, with swelling of the gum extending to the cheek. Within a day or two you find the swelling to be fluctuant. If left untreated, this little abscess will open and discharge, but after a number of days only. In its early hours the inflammation may sometimes be aborted by the frequent use of hot myrrh mouth-washes and small internal poultices, worn within the mouth. Large external poultices are comforting, but one should not depend upon them too long, as they may encourage the burrowing of pus and its opening through the cheek, especially when the abscess springs from the lower jaw. In all cases, however, the surgeon should cocainize and open the gum-boil as soon as it shows signs of fluctuation. The relief is instantaneous and the cure prompt. Later, the patient should consult his dentist for repair of the tooth which has set up the trouble. Sometimes these infections progress deeply and result in osteomyelitis of the jaw bones.

Osteomyelitis may be due to other causes—to some general systemic infection, to some localized infection of the mouth, or to *phosphorus-poisoning*. The progress of such bone infections is rapid and extremely painful. Their seat commonly is in the lower jaw, because the mandible only has a medullary cavity. Destruction of considerable areas of bone or of the whole jaw even may result, with extensive suppuration, sequestrum formation, and dropping out of the teeth. Active surgical treatment is imperative—early free incision, opening of the medullary cavity, and competent drainage. If such prompt treatment has been neglected, the surgeon finds himself consulted by the patient in an advanced stage of chronic bone disease, with burrowing sinuses, at the bottom of which lie bare bone and necrotic sequestra. Such a condition necessitates a tedious form of treatment—laying open the sinuses, exposing the bone, removing the sequestra, and looking for a slow repair, should a proper amount of periosteum and endosteum be left for repair. A cure in such fashion cannot always be expected, however, and extensive destruction of the jaw, with serious crippling and deformity, may result. This unfortunate condition will tax to the utmost the resources of the surgeon, and will lead him to attempt some form of plastic reconstruction.[1]

There are other and more insidious forms of infections of the jaw bones. The so-called **necrotic caries** is a familiar example of chronic disease of the jaws—a disease which attacks by preference the superior

[1] Carl Beck, Plastic Reconstruction of the Lower Jaw, Jour. Amer. Med. Assoc., April 21, 1906.

maxillary bone at the infra-orbital ridge and the malar bone. It is usually of tuberculous origin, and must be treated by vigorous cureting, the removal of all obviously necrotic tissue, and the enjoining of an out-of-doors life. There results, after the healing, an ugly facial scar, often causing *ectropion* of the lid, which must be corrected by a subsequent operation.

One of the commonest and most obstinate infections of the upper jaw is that which involves the **antrum of Highmore** and leads to empyema of the antrum. This infection may originate either in the teeth or in the nasal bones. It belongs properly to the throat specialist, and I refer the reader to special monographs and larger works on this subject.

Besides these immediate and active results of acute infections of the jaws the surgeon must deal with their after-results, most conspicuous among which is **lock-jaw.** Mechanical lock-jaw originating in disease of the mandible is rare, but lock-jaw resulting from disease of the soft parts of the mouth and face, which cause contractions, is much more common. The latter form of lock-jaw is that which we see frequently in out-patient clinics, and its treatment taxes severely the surgeon's patience and ingenuity.[1] The contractures are due directly to solid, cord-like bands of tissue, following destructive ulcerative changes (noma) which have their origin, as a rule, in the buccal mucosa. The rare *arthritic* bony fusion must be treated by partial excision of the joint, but the treatment of the cicatricial *contractures* is another matter. These contractures, which occur most often in young children, are a grave menace to health; the jaw becomes set; mastication is impossible; the patient must live on liquid nourishment; the teeth become dwarfed, deformed, and diseased; the mandible itself fails of development, so that the facial expression and outline become distorted, and the patient suffers grievously in both mind and body. If these contractures be seen early and are unilateral, vigorous mechanical treatment may suffice for a cure. Implements are used for the purpose of forcing apart the jaws and enabling the patient to pursue a course of ruminant gymnastics. A great variety of apparatus has been divised for this purpose—wooden thumb-screws and wedges are the most familiar, but their use involves the serious disadvantage that they may break or otherwise damage the teeth. Moreover, their employment is extremely painful. Curtis[2] has employed a double screw-plate which is serviceable. By such means it frequently happens that a satisfactory jaw is secured. On the other hand, old neglected cases cannot be so treated. These are the cases in which the lesions are cicatricial and *bilateral*, and have persisted so long and are so deeply placed that degenerative and developmental changes in the mandible and its condyle have taken place. Sometimes one may gain a certain amount of motion by dividing the cicatricial bands and employing mechanical massage, but for the more serious cases

[1] Rudolph Matas, Operative Treatment of Bilateral Cicatricial Ankylosis of the Jaws, Jour. Amer. Med. Assoc., November 28, 1903.

[2] G. Lenox Curtis, Ankylosis of the Jaws, ibid., July 2, 1904.

some form of extensive plastic operation is required—splitting the cheek and turning into the buccal cavity skin-flaps from the face or neck. A number of ingenious procedures of this kind have been devised, for a study of which I refer the reader to Matas's valuable paper.[1]

TUMORS OF THE JAWS

Tumors of the jaws are common also, especially benign tumors, because the maxillary bones, on account of their peculiar formation, the fact of dentition, the presence of the antrum, and irritations arising in the buccal cavity are especially disposed to tumor formations. There is the **subperiosteal cyst of the alveolar process,** which originates in a subperiosteal abscess, with the separation of the periosteum and the subsequent formation of a new bony layer which may cause the formation of a considerable swelling, either crepitant or solid to the touch. Such a cyst sometimes is cured by drainage through the extraction of carious teeth; sometimes it is necessary to incise and curet the cyst.

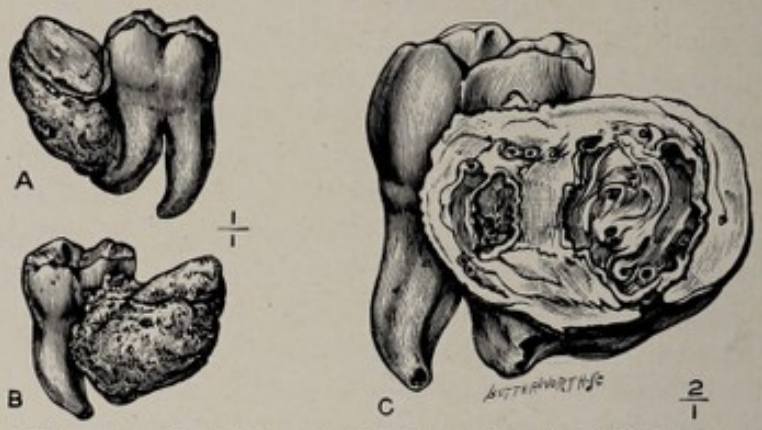

Fig. 370.—The second right mandibular molar of a Chinaman, aged nineteen years, with a swelling possessing the characters of a composite odontoma: A and B, Tooth, natural size; C, enlarged and in section (Keen's Surgery).

Fibromata of the jaws are not very common, but one finds them occasionally on the alveolar process about the canine teeth. Careful resection of the alveolar process is necessary for their cure.

Odontomata and **dental cysts** are the most troublesome and frequent tumors of the jaw. They spring from dental tissue at different stages of its development, from teeth germs or teeth still in the process of growth. Bland-Sutton[2] has given us an extremely interesting chapter on this subject in the last edition of his valuable book.

It is needless to discuss the seven varieties of odontomata. Suffice it to say that these peculiar growths consist of structures of varying histologic type and arrangement, and that they produce bone-like swellings of considerable size, which contain spaces in which are found fragments of teeth or whole teeth unerupted and embedded. Odontomata may occur in either the upper or the lower jaw, and the follicular species

[1] Rudolph Matas, ibid.
[2] J. Bland-Sutton, Tumors, Innocent and Malignant, fourth ed., 1907, p. 227.

is often multiple. That form known as the composite species may invade the antrum and attain the size of an infant's fist. An important point in their clinical history is that in nearly all these cases the tumor remains quiescent for a period, and that then there comes a time in which, like the teeth, it seems to erupt, making its way above the gum, and causing often profound constitutional disturbances of a septic character. This phenomenon of eruption occurs usually between the twentieth and twenty-fifth years. The diagnosis of these tumors has been a matter of great difficulty in the past, and the growths have been regarded often as malignant neoplasms. Fortunately, to-day the *x*-rays serve to clear up obscure diagnoses by showing cysts and unerupted teeth.

Odontomata have been objects of a deal of bad surgery in the past, and competent operators, influenced by mistakes in diagnosis, have removed large portions of the jaw. No such disabling operations are necessary. In the case of a questionable tumor of the jaw, especially in a young person, the surgeon should ascertain its peculiar character by the *x*-rays or by microscopic study, if necessary. An odontoma requires merely enucleation of the growth, while one peculiar form only, the follicular odontoma, demands complete removal of the sac.



Fig. 371.—A follicular odontoma from the right half of the mandible of a boy aged fourteen years (Bland-Sutton in Keen's Surgery).

Dental cysts are growths connected with the roots of teeth, from which they hang off as a cherry hangs from its stem. These cysts are fibrous bags filled with a mucoid fluid. They vary from the size of an apple seed to that of an English walnut, and frequently are connected with the dead roots of molars in either the upper or lower jaw. These cysts do not contain teeth, as do the true odontomata, with which one should not confound them. The cyst must be attacked by drawing the teeth involved, enucleating thoroughly the sac, and packing the cavity with sterilized gauze.

While the odontomata are the most interesting of benign tumors of the jaws, there are sundry other tumors which are more rare—*osteomata*, bony outgrowths which offend merely by their size and pressure upon special structures—nerves, the eye, the nasal cavities, and the mouth; *adenomata* and *chondromata* also; but they are quite uncommon as compared with malignant tumors.

Malignant Tumors.—Of these, sarcoma is somewhat more common than cancer, and the commonest form of sarcoma of the jaws is of that giant-cell type known to surgeons as epulis.

Epulis is one of the least malignant forms of sarcoma. It arises from the periosteum of the alveolar process, grows slowly, and tends to envelop the bone. It appears at the edge of the teeth as a curious pig-

mented excrescence, and is the only form of pigmented sarcoma that is not exceedingly malignant. If untreated, it spreads gradually so as to involve large portions of the jaw, and causes falling of the teeth until eventually, and after many years, it kills the patient through encroachment upon, and destruction of, important organs. It is not difficult to eradicate epulis early, but half-measures do not avail. The surgeon must draw the teeth in the neighborhood of the growth and excise thoroughly the tumor with the adjacent gum and a portion of the jaw, cutting freely about the disease by a margin of one-half inch at least. This operation, though strictly local and not especially deforming, cures the patient permanently in most cases. If the growth recurs, it



Fig. 372.—Epulis.

recurs locally and can be removed surely by the merest local treatment —by excision, the cautery, or the curet even.

Sarcoma of the body of the jaw is a far more serious matter than epulis. Epulis is a disease of young adult life, sarcoma of the body of the jaw is a disease of middle age. This latter form of tumor is a round-cell sarcoma with a scanty stroma. It appears in both the upper and the lower jaws and extends rapidly until it involves all the bones of the face, as well as the neighboring soft parts. It recurs commonly after being removed, and the only treatment which holds out any promise of cure is extensive and deforming resection of all the parts involved.

The upper jaw sometimes is the seat of a **periosteal sarcoma** arising

from the gums, though the common situation of periosteal sarcoma is in the antrum, where it causes great enlargement of the bone and encroaches upon the nasal passages, the orbit, and the sphenomaxillary, zygomatic, and temporal fossæ. This is a tumor of rapid growth. It occurs commonly in young adults, and may kill the victim within a year. Lymphatic involvements and distant metastases rarely are associated with these sarcomata of the jaws.

Cancer involves the jaws but secondarily, whereas sarcoma there is primary. Cancer spreads from the soft parts to the neighboring bones of the jaw. Seldom does it appear before middle life. Since cancer attacks the bones from without and through the mouth, it is almost always associated with infections and foul ulceration. The victim of cancer about the jaws is an object loathsome to himself and to those about him. Young cancer of the jaw may simulate epulis, and for this reason a careful microscopic study invariably should be made of growths about the base of the teeth. In distinguishing clinically between epulis and cancer, observe that cancer ulcerates, while epulis rarely does so; and that cancer produces enlargement of the lymph-nodes, which is not true of epulis. Extensive cancer may involve the bony fossæ within and behind the upper jaw, but such cancer rarely is primary there. Whether primary or not, the surgeon must distinguish it from the round-cell sarcomata which are the common growths of that region.

Cancer of the jaws progresses rapidly when once it has become established, and may destroy the patient within a year. It invades the orbit, the nasopharynx, the submaxillary region, and involves extensively the lymph-nodes of the neck, often attacking the skin, and appearing externally as an ulcerated, sloughing mass. One sees, therefore, that cancer in the deep parts of the face calls for early and thorough treatment.

Treatment must be by the most radical excision if it shall avail. Various forms of treatment other than excision have been advocated from time to time; but although the *x*-rays and radium have seemed to promise something, we cannot yet avoid the conviction that our only, though feeble, hope of cure rests in the knife. It is a disappointing fact that operations for cancer within and about the mouth and jaws seldom cure. So true is this that surgeons look upon a patient who is well three years or more after a radical excision of cancer about the mouth (except cancer of the lip) as a curiosity. Let us consider briefly the operations of—

Resections of the Upper and Lower Jaws.—These operations, with their various modifications and extensions, form the feeble staff on which we must lean when dealing with malignant disease of this region.

The *upper jaw* may be removed with a resulting deformity surprisingly slight when one considers the extent and severity of the operation. I apply a clamp to the carotid as a preliminary step. Then, following the method of Ferguson, one turns back a skin-flap through an M-shaped incision traced along the inferior rim of the orbit, the base of the nose, about the ala, and down through the upper lip. I prefer to

operate with the patient in the upright position, as he can thus be tipped forward readily for the expulsion and clearing out of blood and mucus from the mouth. However, there should be no considerable hemorrhage. Ether anesthesia with the ordinary cone is satisfactory. The surgeon enters the knife at the base of the zygoma, carries it at once down to the bone and completes the deep incision with a series of firm sweeps. Then he turns back quickly the soft parts of the cheek from the upper jaw, exposing completely, thoroughly, and easily all those bony structures which are to be removed. He then controls the hemorrhage in the flap and proceeds to the excision of the maxilla itself—an undertaking less difficult than would appear at first sight. A short, powerful saw, a stout knife, and a pair of heavy grasping bone-forceps are the im-



Fig. 373.—Lines of incision for resection of the upper jaw (Fowler).

portant instruments required. Detach from the bone the nasal cartilages at the edge of the incision. Divide then with the saw the nasal process of the superior maxilla, from the junction of the nasal process with the lower border of the nasal bone, and carry the cut to the margin of the orbit just below the canal of the nasal duct. Then follows the important step of preserving the eye; to this end raise the periosteum from the floor of the orbit (together with the origin of the internal oblique muscle) and retract upward these soft parts. Chisel obliquely across the orbital plate from the end of the saw-cut to the anterior end of the sphenomaxillary fissure. This clears the orbital and external surfaces of the malar bone. Complete the division of the malar bone, using the straight short saw or the Gigli passed through the spheno-

maxillary fissure and zygomatic fossa. It remains to extract the now loosened maxilla. To effect this, divide the mucoperiosteal covering of the hard palate in the median line, as well as the mucoperiosteal covering of the floor of the nose, cutting as near the septum as possible. Then make a transverse cut across the roof of the mouth at the junction of the hard and soft palates, and with a saw divide the horizontal plate and the palatal and alveolar portions of the upper jaw. Now grasp with a large bone forceps the separated jaw bone and break it away from its few remaining attachments. It separates easily, and one may catch with forceps successively the bleeding points which are thus brought into view. The upper jaw being removed, a vast gaping cloaca is re-



Fig. 374.—Resection of half of the upper jaw. Dissection of the flap from the bone (Fowler).

vealed, which I, as a young medical student, remember gazing upon with fascinated horror.

The healing of these extensive wounds generally is prompt and uncomplicated. The patient suffers surprisingly little discomfort, except from the sense of loss of substance. At the primary dressing of the wound there is need for considerable packing of the raw cavity, but granulations quickly spring up, and the packing must be removed and renewed almost daily after the third day. By the end of two weeks a fair degree of healing is established, so that no further dressings are necessary beyond the frequent irrigation of the mouth and pharynx, which must be continued so long as discharges persist. It is not difficult to feed these patients. They may be nourished through a nasal

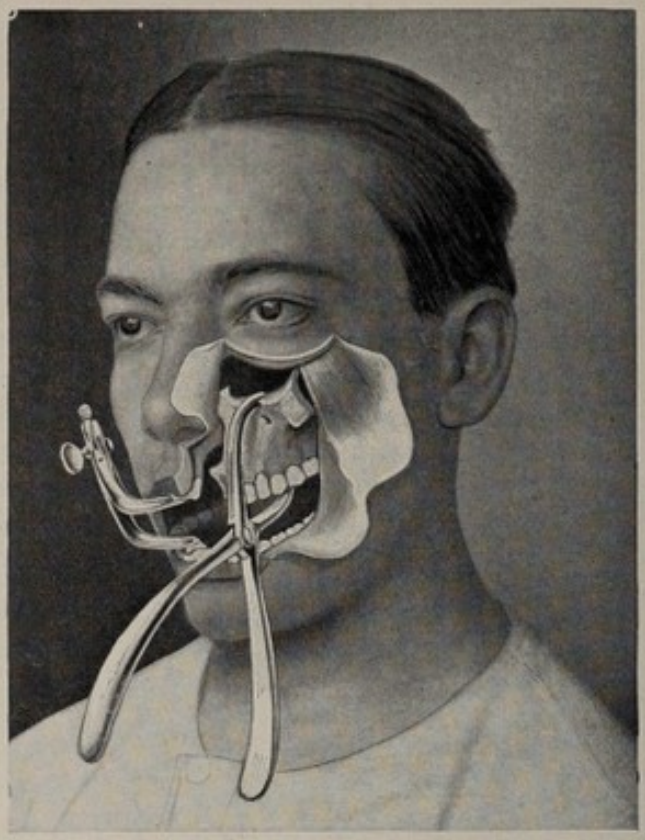

Fig. 375.—Lion-jaw forceps grasping the resected portion of the upper jaw (Fowler)



Fig. 376.—External incision for resection of half of lower jaw (Fowler).

feeding-tube for a few days, but they learn to swallow naturally in a short time.

I have said that the outlook in these cases is not encouraging. Occasionally sarcomata when removed do not return, but when the operation is done for cancer, that treatment must always be regarded as a palliation.

Excision of the lower jaw usually means excision of half of that bone. Removal of the whole bone is done rarely. The technic of removal of half of the lower jaw is as follows: Control hemorrhage by a temporary clamp on the carotid; beginning at the chin make a vertical cut from just below the border of the lip down to the jaw bone, and carry the cut around the angle of the chin; from this point, with the knife close to the bone, carry the incision along the mandible up to and beyond its angle nearly to the ear, stopping short of the facial nerve; take up the

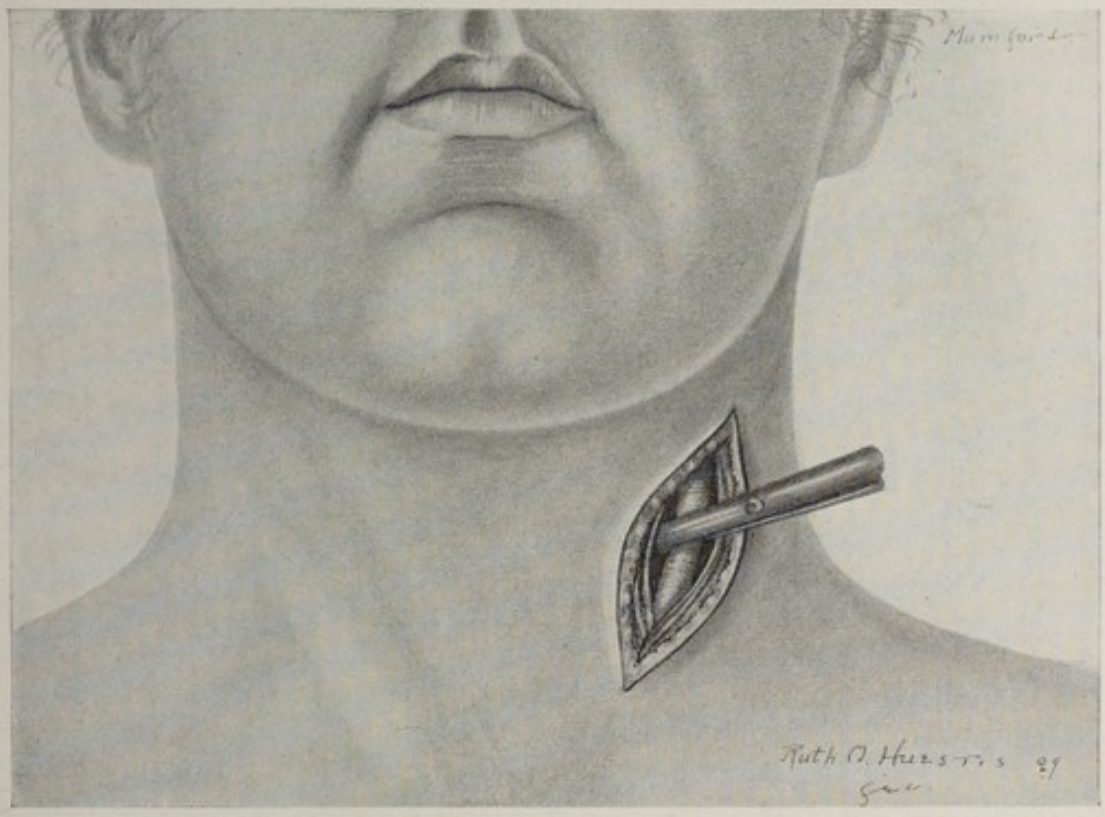

Fig. 377.—Temporary clamp (Crile's) on carotid.

facial artery as the knife passes it; then lift the periosteum from the external surface of the bone, from the symphysis outward; control hemorrhage; cut away the buccal mucosa from the line of the teeth; extract one of the incisor teeth, and saw through the symphysis; seize the loosened bone with heavy forceps, draw it outward and divide the various muscular attachments—the mylohyoid muscle, the internal pterygoid; the temporal and the external pterygoid; open the capsule of the joint; cut away the ligaments and remove the bone. Then control all bleeding points and sew up carefully the resulting wound. Take pains especially to make a close joint of the severed mucosa, for the mucous membranes heal readily when properly approximated.

As I have stated, in doing this operation and other extensive dissections about the neck and face I am accustomed to follow Crile's sug-

gestion of clamping previously and temporarily the common or external carotid artery, using for that purpose Crile's well-known artery clamp. I have been impressed also by the value of Crile's shock-suit, which I employ commonly when doing extensive operations about the neck and head, the patient being placed in a modified Fowler's position, at an angle of about 45 degrees. Dr. Crile himself tells me that he now employs transfusion in these cases, and has much less use for the pneumatic suit. In the case of old and feeble persons with advanced cardiovascular disease these extensive excisions are dangerous and the mortality high, the patients sometimes dying within a few hours or lingering on for a week. In the case of such patients, therefore, the surgeon should approach the operation with the greatest hesitation. Younger and more vigorous persons, however, rally promptly, and often live to enjoy a fairly comfortable existence, though the deformity, especially in the case of women, is regarded as considerable.

Excision of the entire lower jaw sometimes must be undertaken in cases of *phosphorus necrosis*, which causes an almost total destruction of the bone. The operation is a mere extension and duplication of that I have described already; or sometimes the bone may be removed from within the mouth. In any case the periosteum should be preserved so far as possible. Rarely a complete removal of the jaw is necessary.

The Tongue

The tongue is probably the most important organ, after the eye, concerned with the special senses. Inasmuch as its functions have to do with speech, taste, and deglutition, any ailment or lesion of the tongue becomes instantly of prime importance to the patient. The tongue, like the heart, is an organ of simple structure, made up almost entirely of muscles. It springs from the hyoid bone, is attached to the lower jaw, and is a much larger structure in extent than casual inspection would indicate. When the physician "looks at the tongue" as part of his routine inspection, he sees little more than its tip and the anterior quarter of its dorsum. Two sets of muscles compose the tongue—such extrinsic muscles as the hyoglossus and styloglossus, which pull the tongue back, and the genioglossus, which pulls the tongue forward; but the main important muscle is the lingualis, which arises from the hyoid and makes up the greater part of the tongue's bulk. The hypoglossal and chorda tympani nerves supply the tongue with innervation, while the most of its blood reaches it through the lingual artery, which springs from the external carotid. The circumvallate papillæ lie close to the larynx, in the root of the tongue, and numerous mucous glands cover the dorsum of the organ. The mucosa of the dorsum is thick and rough, but the mucosa beneath the tip of the tongue is extremely thin and delicate. The tongue throughout is intersected by large and frequent lymph radicles. It is a flexible, active, sensitive member, but, fortunately for the human race, it readily resists pathologic damage, so that in spite of its unique structure and exposed position, it is not often diseased.

The surgeon is interested especially in two types of tongue lesions—

inflammations and tumors. There are other abnormalities of the tongue which occasionally one sees—deformities, the most important of which is **macroglossia**—a gigantic overgrowth, which may be due to fibromyomata or lymphangiomata, when the tongue may become so large as to protrude from the mouth and hang over the chin. Macroglossia is congenital, and can be relieved by partial excision of the organ only.

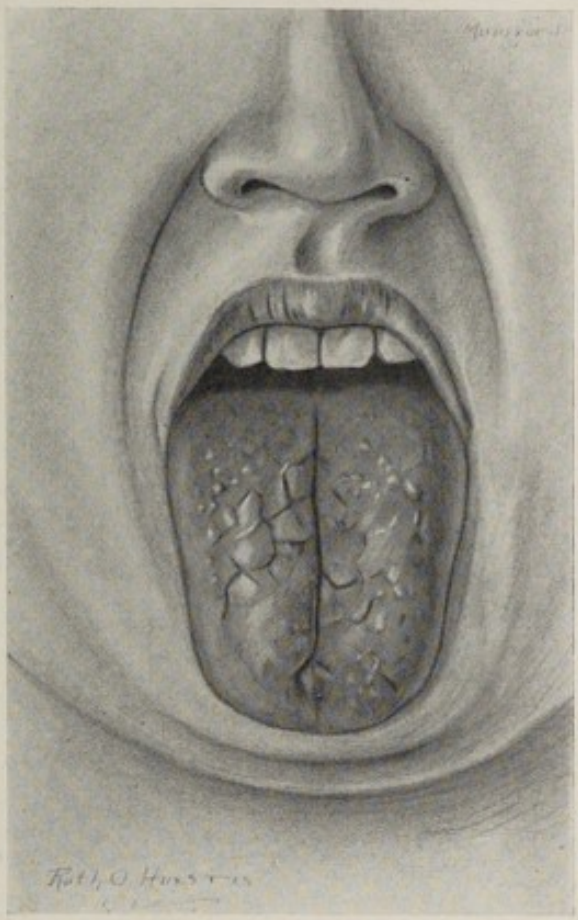

Fig. 378.—Macroglossia.

Tongue-tie (ankyloglossia) is a congenital deformity also, and is not very common. It is due to a short frenum, which anchors the tip of the tongue to the floor of the mouth. Most cases of tongue-tie need no treatment, for the tongue develops normally as the child grows; but if the condition persists, it is easily relieved by raising the tongue on an elevator and snipping with a pair of scissors the short frenum (that notched spatula, the handle of an ordinary grooved director was devised for this operation). There may be a smart little hemorrhage after this snipping, but this is readily controlled by allowing the patient at once to suckle.

Wounds and **lacerations** of the tongue are not very common—the most frequent cause of such lacerations is the patient's biting his tongue in an epileptic convulsion. Such damage is remedied by one or two stitches after the wound has been thoroughly cleansed.

INFLAMMATION

There are various forms of inflammation of the tongue, acute and chronic. The former are more common among children and the latter among adults. Acute inflammations have little interest for the surgeon. They usually disappear promptly under the use of bland, warm lotions, such as alum water, tincture of myrrh, or "alkalol." The chronic inflammations are much more intractable, and may lead up to serious conditions; they may be the precursors of malignant disease even. The term **chronic glossitis** embraces these various inflammatory changes, the important characteristic of which is a change of form, an overgrowth of the epidermis, **keratosis.** Bland-Sutton[1] has pointed out

[1] J. Bland-Sutton, Tumors, Innocent and Malignant, fourth ed., 1907, p. 333.

that in a fair proportion of cases cancer of the tongue is preceded by the changes known as **leukoplakia** and **ichthyosis.** Leukoplakia and ichthyotic patches are the names given to chronic white areas on the tongue and mucosa of the cheeks, the result of keratosis. Many observers believe that gouty conditions, syphilis, and excessive smoking are the usual causes of leukoplakia. The patient discovers the leukoplakia by accident, but later is troubled by stiffness of the tongue and impairment of the sense of taste. The outlook for leukoplakia is not especially encouraging, but improvement may be looked for under the use of alkaline washes, abstinence from irritating foods, tobacco, and alcohol, and the employment of appropriate syphilitic remedies. Ichthyotic patches do not necessarily become cancerous in every individual, so that after excision of a cancerous tongue even the stump may become ichthyotic and the disease not recur in it.

Tuberculosis of the tongue is a rare form of chronic ulceration, a condition not always easy to determine, but it should be differentiated from syphilis and cancer. Tuberculosis appears as a red, sloughing, superficial ulcer, usually on the dorsum of the tongue, sometimes associated with pulmonary tuberculosis, sometimes primary. In either case, if the diagnosis of tuberculosis be made—by the microscope—the ulcer should be excised.

Abscess of the tongue is a very rare condition also, and is due generally to the breaking down of a gumma. Situated in the median line of the tongue, it takes on a chronic course and appears as a deep elastic swelling which should be opened and cureted, while at the same time the patient should be put upon proper doses of potassium iodid.

Turning back now to those forms of chronic glossitis characterized by leukoplakia, we see in a certain proportion of cases that the condition runs into cancer.

CANCER

Carcinoma of the tongue, like carcinoma of the lips, ears, and buccal mucosa, is of the squamous-cell type. It may be called truly a dreadful disease, for it destroys life quickly, and while it lasts it renders the patient a loathsome object. I know no form of cancer fouler or more offensive. Cancer of the tongue must be distinguished always from syphilis and from tuberculosis, but the diagnosis is not especially difficult and should be confirmed by the microscope. Cancer begins commonly on the edges or tip of the tongue; the lesions of syphilis and tuberculosis are more common in the tongue's center. Cancer of the tongue spreads rapidly by direct continuity or along the lymphatic vessels. Metastatic growths in the internal viscera or long bones are extremely rare. It is hard to say just how early in cancer of the tongue the lymph nodes become affected, but it is probable that they are involved within the early months, and for this reason the surgeon should know the commoner sites of the nodes involved. One must have in mind the fact that the enlarged nodes are found in a variety of places—the submaxillary nodes, which receive the drainage from the lower surface, the middle,

and dorsum of the tongue and the entire floor of the mouth; the superior and inferior deep cervical nodes, which receive the drainage from the entire tongue and the floor of the mouth; and those intramuscular nodes situated in the geniohyoid muscles, which receive the drainage from the floor of the mouth and lower surface of the tongue. Moreover, nodes in the parotid region may be involved through retrograde lymph-currents. But the problem of lymphatic invasion is still more complicated, because, through the intercommunication of lymphatics, cancer of *one* side of the tongue may involve the lymph-nodes of *both* sides of the neck. The most important nodes perhaps are those situated at the bifurcation of the common carotid artery. One sees, therefore, that in order thoroughly to remove all possibly involved nodes, it may be necessary to dissect both sides of the neck and frequently the lower part of the parotid.[1]

The course of cancer of the tongue is distressing from the outset, and toward the end may become extremely painful. The ulceration may not be very extensive, but it is sore and foul, while it is characteristic of cancer of the tongue that the lymph-nodes involved may become enormous—out of all apparent proportion to the size of the primary growth. Death, which comes within fourteen months often, is due not so much to the original cancer, as to the extensive involvement of the nodes which press upon the trachea and esophagus and implicate rapidly all the great structures of the neck. The end of these patients is miserable: secondary developments often follow the most radical operations, and morphin alone remains to alleviate and cut short a wretched existence. For this reason surgeons welcome all endeavors to eradicate the primary disease, and recent extensive mutilating operations have been accepted with approval, while such statistics as those of Crile give us cause for a genuine optimism.

Operations for cancer of the tongue may be divided properly into two classes—those for the less advanced cases and those for the more advanced cases. In describing operations for cancer of the lip I recalled the familiar analogy between breast cancer and face cancer, and pointed out that the necessity for excision of lymph-nodes is equal in both.

In the case of early tongue cancer one sees that the amount of tissue to be removed depends upon the extent of the lesion, but in all cases I believe that a dissection should be made of the deep parts of the neck, as we dissect the axilla in cases of early breast cancer. If the initial growth is minute and on the anterior part of the tongue, one should remove the little tumor with a wide margin, taking in tissue somewhat beyond the median line; but if the tumor is well established, especially if it be encroaching upon the posterior parts of the tongue, that organ should be removed entire, and a deep dissection from the clavicles up should be made of both sides of the neck, as I described it in discussing cancer of the lip.

Various methods of removing the tongue have exercised the ingenuity of surgeons, and the books discuss the operations of Whitehead, Kocher,

[1] D. N. Eisendrath, A Plea for More Radical Operations in Cancer of the Lips and Tongue, Jour. Amer. Med. Assoc., September 29, 1906.

Billroth, and others. Any method is satisfactory for the practical surgeon so long as he removes the entire tongue, but the proper dissection of the neck is a matter of primary importance. Whitehead removes the tongue with scissors through the mouth. He passes a ligature through the tip and draws it well forward, dissects up the organ from the floor of the mouth, and divides the anterior pillars of the fauces. He then secures the lingual arteries; passes a second ligature through the glosso-epiglottidean fold, below the point of transverse section, to secure the stump and draw it forward, and then completes the extirpation. The parts are then thoroughly cleansed and painted with an antiseptic varnish.[1] The patient is fed freely from the second day. The ligature

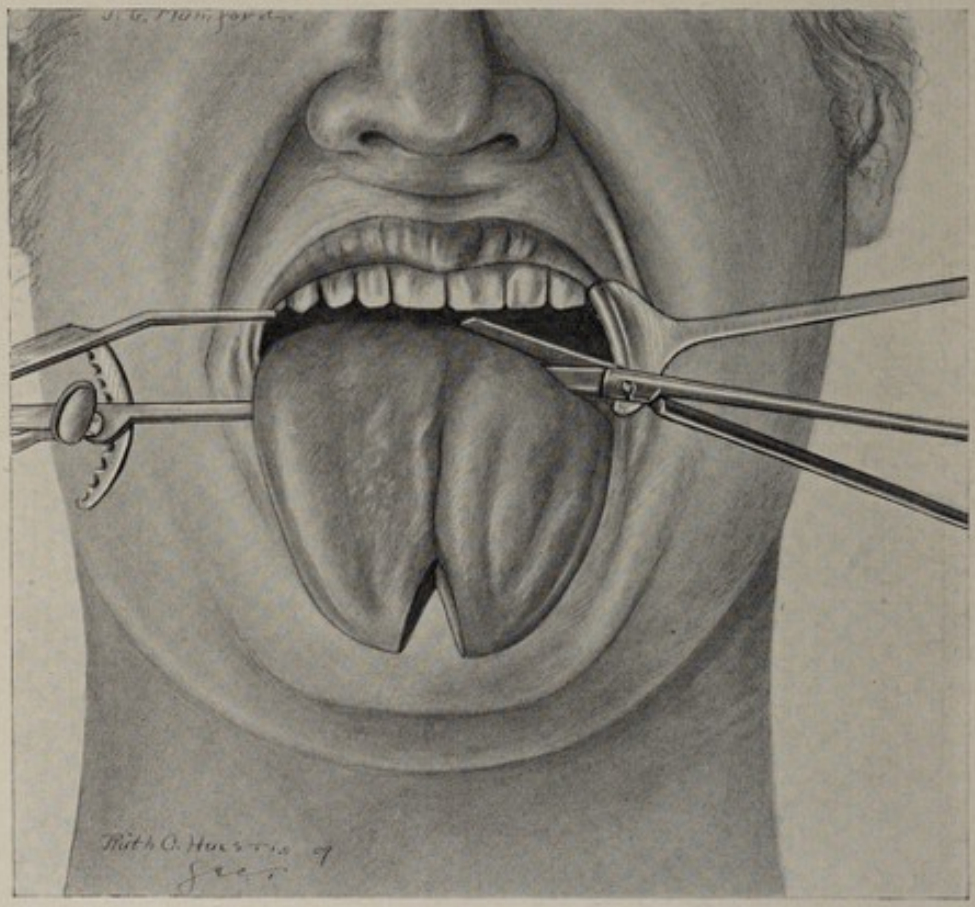

Fig. 379.—Whitehead's operation for cancer of the tongue.

at the base of the tongue is either fastened to the teeth or kept hanging out of the mouth by a pair of forceps, so as to prevent the stump from falling backward over the glottis. This ligature usually can be removed at the end of forty-eight hours.

Of the other operations for the removal of the tongue, I prefer and employ commonly one which consists in splitting down the cheek from the corner of the mouth, dividing the jaw with a saw, and so laying broadly open the mouth and pharynx. Through this same incision the external carotid artery may be controlled, so that the operation may be

[1] Compound tincture of benzoin, combined with an equal amount of saturated ethereal solution of iodoform.

performed without hemorrhage. After the tongue has been removed, the severed jaws should be wired and the soft parts carefully readjusted. The resulting scar is slight.

The *after-treatment* following complete excision of the tongue is extremely important, since these patients may die shortly of septicemia, septic pneumonia, or exhaustion. In simple cases even, the immediate mortality record of some operators runs up as high as 25 per cent. The after-treatment consists in inforcing cleanliness. It is well to dust the floor of the mouth daily with iodoform and keep the cavity washed with some antiseptic lotion, of which carbolic acid is as good as any. The patient should have the services of two nurses, who should wash out the mouth at least once an hour during the first two days. Saliva collects rapidly and mingles with the other discharges, so that the surgeon should provide adequate drainage by a drainage-tube led out through a drainage opening in the neck. Proper feeding to support the patient's strength is of primary importance. For the first twenty-four hours nutrient enemata suffice, but generally, after that, the patient can swallow liquids, and if not, he may be fed through a stomach-tube. Do not make an invalid of one of these patients. Get him up on the second day, keep him out-of-doors, and encourage him with the reasonable prospect of being able to go home within two weeks. At the best this treatment is difficult, but it is essential and must be persisted in until the patient has learned comfortably to manage the toilet of his mouth and the taking of food.

SARCOMA OF THE TONGUE

Some 40 cases of sarcoma of the tongue have been reported, so one sees that sarcoma of this organ is a rare disease. Sarcoma is by no means as malignant as cancer of the tongue. It kills slowly and through distant metastases. Most of these sarcomata are primary tumors of the round-cell variety. Ulceration is uncommon, and the patient may live more than two years after the onset of the disease. The surgeon should employ the same radical treatment as in the case of cancer of the tongue.

Rarely one sees *non-malignant* tumors of the tongue. A few tumors of embryonic origin are reported, as well as lipomata, fibromata, and cartilaginous and bony tumors. These growths readily may be removed locally by enucleation. The commonest non-malignant swellings are the angiomata, which may be treated by the cautery, by radical excision, by the application of carbon-dioxid snow, or by the injection of boiling water. My own preference is for carbon-dioxid snow, which is almost always effective; it is little mutilating and causes the patient very slight discomfort.

THE SALIVARY GLANDS

The saiivary glands are subject to sundry surgical diseases—to tumors especially. Chondroma is probably the most common of these

tumors. Chondroma occurs in the parotid gland, because the first branchial arch lies at the site of the parotid, and fetal cartilaginous structures become included during the gland's growth. In the same way cartilage of the second branchial arch becomes included in the submaxillary gland. These gland tumors appear as globular, nodular masses, of slow and painless growth, although late they may become converted into adenosarcomata and progress rapidly. Parotid chondroma is important because it produces deformity and may involve the branches of the seventh cranial nerve with a resulting facial paralysis. These chondromata must be distinguished from sarcomata, which appear quite like the chondromata, but are somewhat more elastic. Such sarcomata are spindle-celled; they involve neighboring structures, especially the skin, facial nerve, and pharynx, and should be removed as soon as suspected.

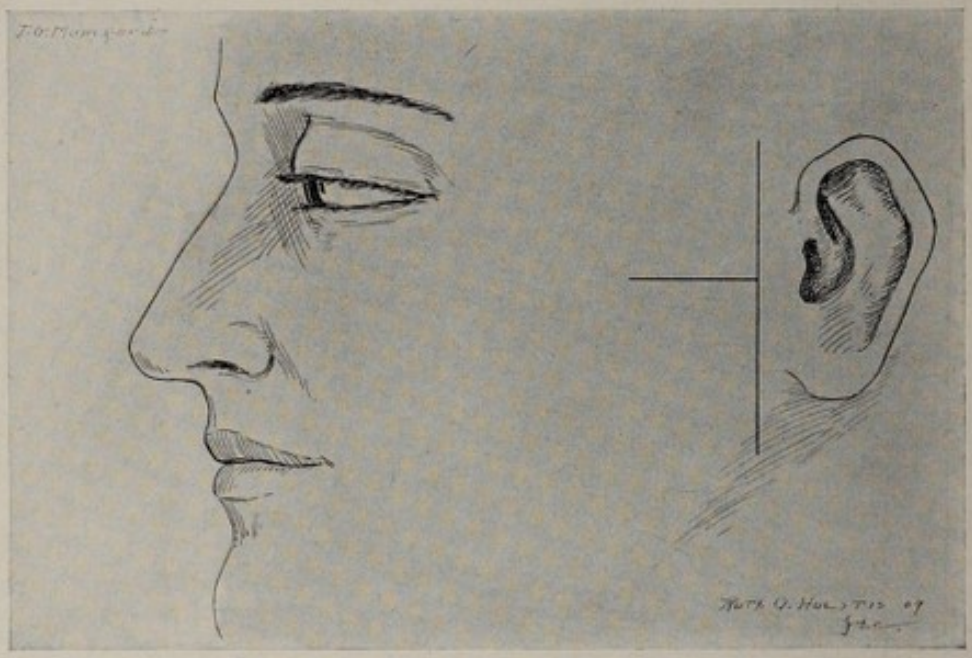

Fig. 380.—Sketch showing line for total excision of parotid gland.

A chondroma of the parotid gland generally can be shelled out without much trouble, but in the operation the surgeon should take pains not to damage the facial nerve. Sometimes a salivary fistula follows. It usually closes of itself. Sometimes it is necessary, in the case of malignant tumors, to remove the whole gland, a difficult operation, the steps of which are well described by Binnie,[1] somewhat as follows: make a T-shaped (or crescent-shaped) incision through the skin, and turn back the flap; loosen up the anterior edge of the gland and secure the vessels and Steno's duct; peel back the gland from underlying structures at its top and bottom; expose the upper end of the sternomastoid muscle, open its sheath, and retract the muscle backward; then, working from above, with blunt dissection lay bare the external carotid artery, which you may or may not tie, and free the tumor with the gland up to the level of the styloid process. The remainder of the operation

[1] J. F. Binnie, Manual of Operative Surgery, third ed., p. 146.

consists in separating carefully the gland from all deep structures, tying the vessels as one proceeds. In closing the wound the surgeon should provide carefully for drainage, and should look for a complete facial paralysis on the affected side, a condition which may be remedied, if thought best, by a faciospinal-accessory anastomosis.

Pharynx and Nasopharynx

Diseases of the pharynx and nasopharynx fall so distinctly within the field of a throat specialist's work that I shall not consider them in detail. There are, however, certain tumors and other lesions of these regions which the general surgeon frequently and properly is called upon to treat. I need but mention the great tonsils of **inflammatory** origin which block the throat and interfere wth proper breathing and swallowing. I am aware that any general surgeon can easily remove these masses, but I am convinced that such surgery should be left to throat specialists, because not only is their judgment superior regarding the treatment of individual cases and their technic more effective, but they can much more satisfactorily deal with the adenoids, nasal spurs, and middle-ear disease which commonly are associated with chronic inflammatory processes in the throat. I deprecate the treatment of these special lesions by general surgeons.

Malignant tumors of the tonsil are not uncommon. Sarcoma alone is primary there, while tonsillar carcinoma is an extension from a focus in the mouth. The diagnosis of sarcoma of the tonsil is not always easy. The patient complains of sore throat and debility. The surgeon examines the throat and finds a large, smooth tonsil, harder than an ordinary inflammatory swelling. He may mistake this for an inflamed tonsil, but if he attempts to remove it, its infiltrating nature and the sharp obstinate hemorrhage which results from cutting will show him his mistake. The cautious operator will have taken a bit of tissue from the suspected mass, and by the microscope will have confirmed the diagnosis of sarcoma.

The removal of such a malignant tonsil is far more of an undertaking than the removal of a hypertrophied tonsil. Commonly, the operation is called pharyngectomy, though properly it should be called tonsillectomy.

Extirpation of malignant disease of the tonsil cannot properly be done through the normal opening of the mouth. The surgeon must secure some wider avenue of approach, and various methods of approach through the neck or mouth have been advocated. My own preference is to enlarge the mouth-opening and saw through the lower jaw, as practised by J. C. Warren and others. One is enabled thus to work in a broad field and with a satisfactory view of the offending tonsil. The illustration (Fig. 381) shows how, in enlarging the mouth opening, the cut is carried down from the angle of the mouth obliquely to the middle of the body of the jaw. This is done with one firm, deep stroke, severing the skin, muscles, mucosa, and facial vessels. The operator then saws

through the jaw, and with retractors separates widely the divided parts. When he attacks the growth proper, he should do so freely and boldly, removing the tumor with a wide margin. The large rent in the back of the pharynx cannot be closed with sutures, but must be left to granulate, so that during the convalescence somewhat the same care must be employed as after excision of the tongue. A temporary clamp on the common carotid will be a great comfort to the surgeon in doing this somewhat hazardous operation. The severed jaw should be united at once with silver wire, the mucosa carefully stitched with catgut, and the skin wound united. The healing is rapid and satisfactory, the resulting external scar is slight, and the patient is able to be about within two or three days after the operation.

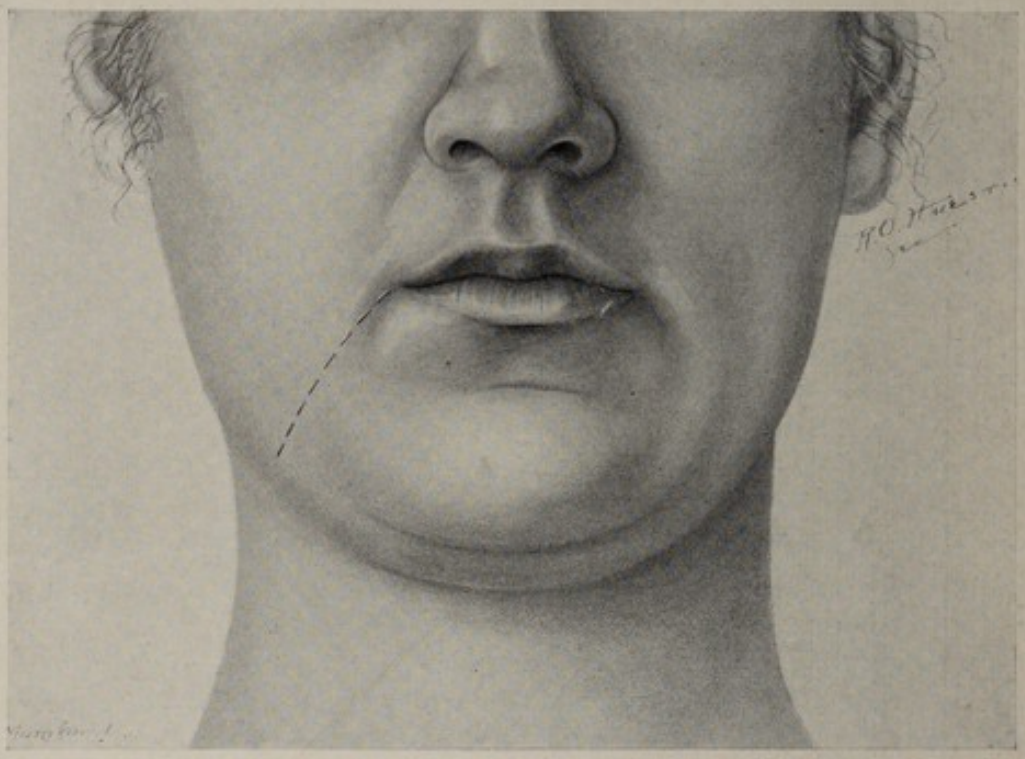

Fig. 381.—Method of approaching the fauces. Line of incision.

There are certain other interesting lesions of the pharynx, though few of them fall within the purview of the general surgeon. **Adenoids** of the nasopharynx should be left to the throat specialist, as should the simple inflammatory processes—tonsillitis and peritonsillar abscess. Small **foreign bodies,** such as fish-bones in the throat, may cause exquisite discomfort, and the patient will tell you that they are " stuck in the throat." It is the fashion with many practitioners to assume that the fish-bone is not so stuck, but that its passage has caused an irritation. In many of these cases, however, on careful searching with reflected light and the finger, you will discover the tip of the bone projecting from one of the tonsils in which it is buried. Remove it with a pair of long forceps.

" Choked to death " is a common phrase, and appears as a scare headline in the newspapers. Sometimes the statement is true. The

victim, in bolting a hasty meal, involuntarily deposits a large bolus of meat or other food in the depths of the pharynx, where it becomes wedged over the glottis. Air is cut off, the patient gasps, struggles, turns blue, and dies very quickly. The tragedy is so sudden, and the catastrophe so final, that rarely can medical aid be called in time to be of service. Sometimes, however, the glottis is not completely obstructed and the patient struggles on in terror and distress for minutes or even hours. The surgeon, if called in time, detects the offending bolus with his finger or by the head-mirror, and removes it with a long curved forceps. At a pinch, if other means fail, a hypodermic of apomorphin will induce violent vomiting and expulsion of the foreign body.

Sometimes the surgeon is called upon to treat **burns** and **scalds** of the *tongue*, *pharynx*, *glottis*, and *epiglottis*. The patient may have swallowed a boiling fluid or, if a fireman, may have inhaled flame or steam. The immediate result of such burns is horribly distressing. Intense congestion ensues, with blistering and edema. If the air-passages remain open, the surgeon can do no more than attempt to relieve the distress by feeding bits of cracked ice and applying cocain. If edema threatens to close the glottis, the surgeon must intubate the larynx or perform tracheotomy.

DISEASES OF THE LARYNX

Diseases of the larynx are closely associated in their causation and therapeutics with diseases of the pharynx and nasal passages, and their treatment falls generally to the laryngologist. As in the case of the pharynx, however, there are certain laryngeal ailments which the general surgeon must be prepared to treat. The anatomy and mechanism of all these parts are extremely intricate and difficult of comprehension. The musculature and innervation are curiously involved, and the functions of the structures intimately interdependent. Hearing, smell, speech, breathing, and deglutition form a curious complex, therefore, worthy the exclusive study of a specialist, and the rash tampering with these organs by the inexpert is reprehensible. Some few grave accidents or ailments of the larynx, however, do fall to the general surgeon—cut-throats, fractures of the hyoid bone and thyroid cartilages, and tumors of the larynx, while the surgeon should be prepared also to perform the operations of intubation and tracheotomy.

Cut-throat is a bugbear of fiction, especially the throat cut from "ear to ear." Ordinarily, a cut throat implies little more than a skin wound, though the "ear-to-ear" cut-throat conceivably may open the pharynx. These superficial wounds are easily repaired with stitches, and the patient usually recovers. The dangerous cut-throat is that low in the neck, at the level of or beneath the thyroid cartilage. This wound even must be so deep as almost to reach the vertebral column if the result is to be immediately fatal. A mere opening of the larynx or trachea will not kill the victim necessarily; to kill, the weapon must search out and sever the carotid, or jugular vessels or the pneumo-

gastric nerves. An opened windpipe may be sewed up, with a resulting recovery, though the patient runs the risk of a subsequent inhalation pneumonia; but he almost always dies promptly if the deeper structures are injured.

Sometimes a sharp blow on the front of the neck will **fracture the hyoid bone** or the **thyroid cartilages,** and serious results may ensue. The fracture frequently is complicated by laceration of the mucosa, by hemorrhage, and by obstruction of the air-passages through hematomata and edema. The immediate danger, therefore, is suffocation; the more remote danger is an inhalation pneumonia, so that prompt and radical treatment is imperative.

Treatment.—Fracture of the hyoid rarely is not very serious. The damaged bone may be supported by strappings about the neck, and healing may take place without special further annoyance; but damage to the thyroid cartilage is a more important matter. It may be necessary to perform tracheotomy in order to secure proper air-space, after which the injured larynx may be repaired at the surgeon's leisure. A safe, useful, and generally successful operation consists in splitting open carefully the larynx in the median line, replacing the dislocated fragments, and sewing up tightly the wound, or in establishing suitable drainage if the exudate be considerable. The breathing and speaking functions generally will be restored, unless there be damage to the recurrent laryngeal nerves.

A somewhat frequent, distressing, and serious accident is the passage of a **foreign body into the larynx and trachea,** and these foreign bodies may be of great variety—pins, bristles, tin whistles, buttons, and the like. D. W. Cheever describes a case in which a single bristle from a beard of wheat was inhaled into the trachea, and without becoming impacted, played up and down the windpipe until removed through a tracheotomy opening. The lighter and pointed foreign bodies may become engaged anywhere in the air-passages, penetrating to the bronchi even; while the more solid bodies, when inhaled, sink at once into the chest. In Chapter XVI, I have described the present ingenious methods of removing such foreign bodies through the bronchoscope inserted through the mouth or through a tracheotomy opening.

I have referred frequently in this chapter to intubation and tracheotomy, useful operations employed to facilitate respiration in the event of laryngeal or tracheal obstruction. Let us for a moment rehearse the details of these two operations before taking up a description of tumors of the larynx, the most important laryngeal diseases with which the surgeon has to deal.

Intubation of the larynx signifies passing a breathing-tube between the vocal cords. The operation is performed commonly for membranous obstruction due to diphtheria, but occasionally the surgeon may find it useful under other circumstances. A special set of instruments (O'Dwyer) is required, as pictured in the illustration: (1) Tubes with obturators adapted to the patient's age; (2) a gauge to aid in the selection of the proper tube; (3) mouth-gag; (4) tube introducer; (5) tube ex-

tractor. The operation is simple enough, and the surgeon performs it somewhat as follows: with the patient held upright and the jaws forced widely open, the surgeon attaches the proper tube to the introducer, a piece of thread being fastened to the tube at the same time and tied to the surgeon's finger, so that he may jerk out the tube quickly if necessary. He then holds his instrument in his right hand, seeks the tip of the epiglottis with the left index-finger, raises the epiglottis, and passes the tube quickly into the larynx, the left index-finger preventing it, as it passes, from falling into the esophagus. If the tube is properly placed, the patient's breathing is relieved at once. When the time comes for

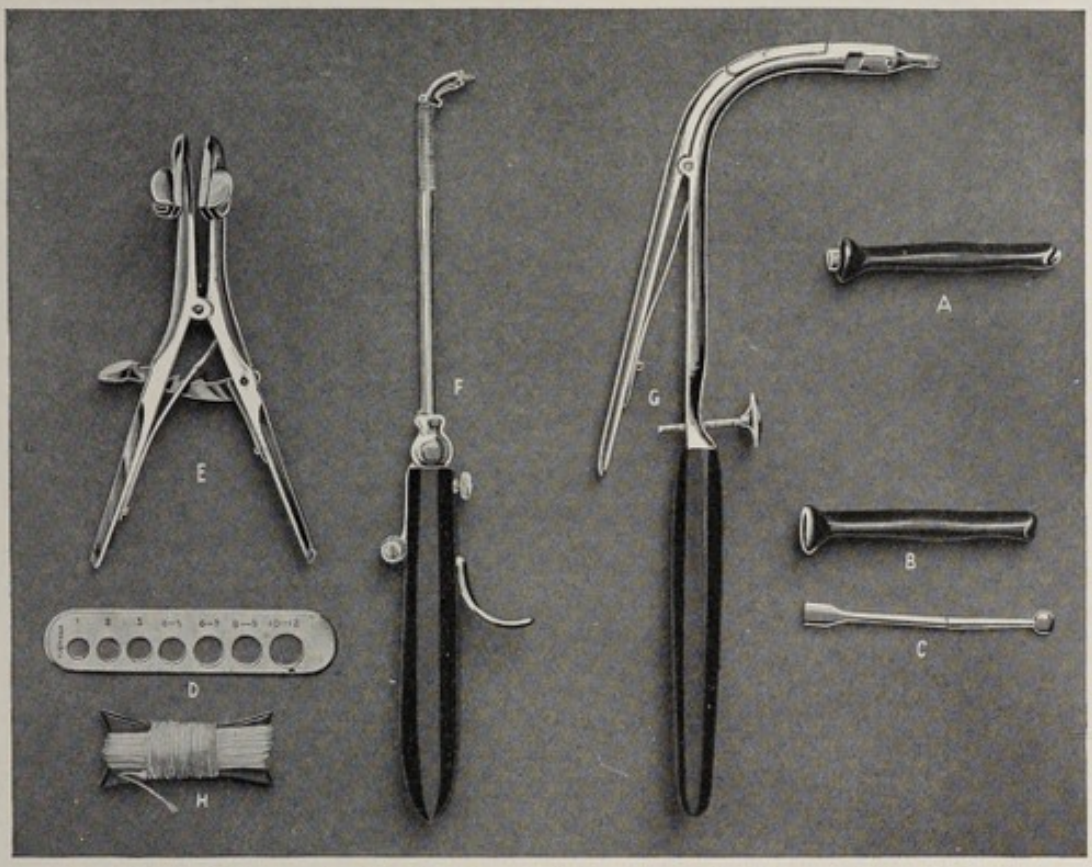

Fig. 382.—O'Dwyer's intubation instruments: A, Tube with obturator; B, tube; C, obturator; D, metal gauge; E, mouth-gag; F, introducer; G, extractor; H, silk cord (Fowler).

removing the tube, that operation is readily performed with the extractor and by a maneuver quite similar to the method of introduction.

Tracheotomy is one of the ancient operations of surgery. In former days it was resorted to for the removal of foreign bodies from the air-passages, and for centuries it was employed for no other purpose. Strangely enough, the older surgeons and physicians do not seem to have appreciated that opening the larynx or trachea is the proper measure for the relief of suffocation due to laryngeal obstruction. Probably the most eminent life sacrificed unnecessarily through the neglect of tracheotomy was that of George Washington. According to F. H. Hooper, the immediate cause of Washington's death was edema

of the larynx, and there is no doubt that a timely tracheotomy would have saved the patient. Hooper adds in a note, " I doubt if tracheotomy had ever been performed in Virginia in Washington's time." The surgeon responsible for this negligence was Craik, an excellent and faithful practitioner and a warm personal friend of his distinguished patient.[1]

The operations of tracheotomy and laryngotomy are quite similar in their performance. The former signifies opening the windpipe below the cricoid; the latter, opening the windpipe through the cricothyroid membrane or even higher. Elaborate descriptions are given of these operations, but, indeed, their performance is simple enough. The purpose is to put a curved tube into the windpipe. Every modern surgeon in a hasty emegency has opened the windpipe with a single stroke of the knife and inserted a tube, and this almost suffices for a description. If more

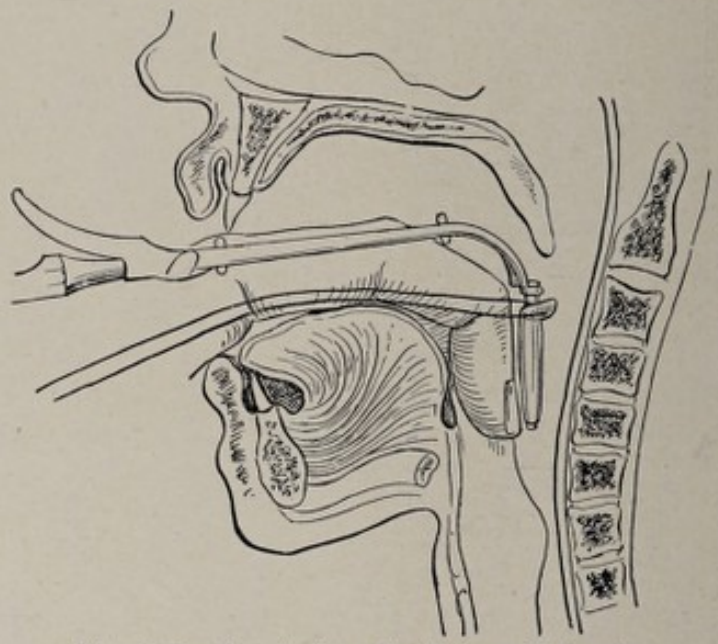

Fig. 383.—Intubating the larynx (Lejars).

time be given, the surgeon performs either the high or low operation, for both of which the same description answers. The patient should be placed in a good light, with the head somewhat elevated and fully extended, so as to put the trachea on the stretch. A general anesthetic or cocain may be employed. The skin is incised for two or three inches in the median line, the muscles and fascia are divided, the windpipe fully exposed by blunt dissection, disregarding the thyroid isthmus, the trachea is caught and steadied with a sharp hook and opened carefully with a knife—carefully so as not to wound the posterior wall of the trachea. The tracheal opening is then distended with forceps or a trivalve dilator, and the tracheotomy canula is introduced. Cohen's tracheotomy tubes are those commonly used. The complete tube (inner and outer) is inserted, the inner tube withdrawn, and the instrument secured in place with tapes passed about the neck. A moist sponge

[1] Henry Cabot Lodge, George Washington, vol. ii, p. 296.

or gauze pad should be fastened, as an air-filter, over the mouth of the tube. The skin wound should be closed and carefully dressed and, as a rule, the tracheotomy tube should be removed permanently as early

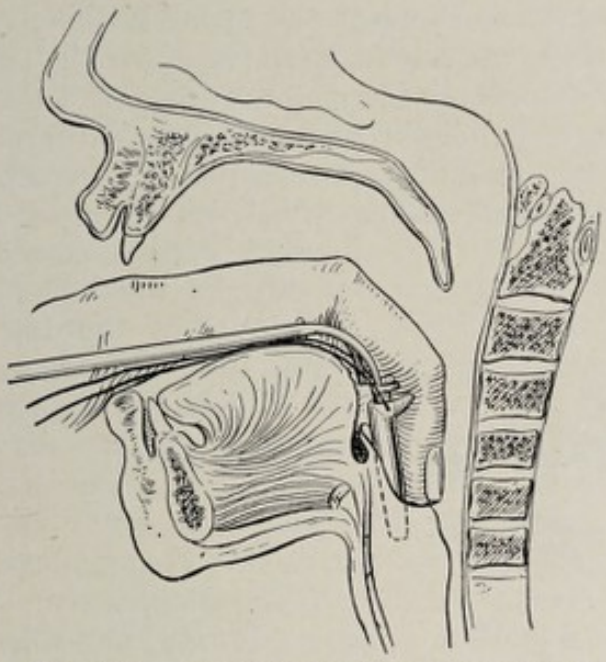

Fig. 384.—Intubating the larynx (Lejars).

as possible. The care of one of these patients after tracheotomy is a somewhat delicate and important matter. During the first hours a nurse

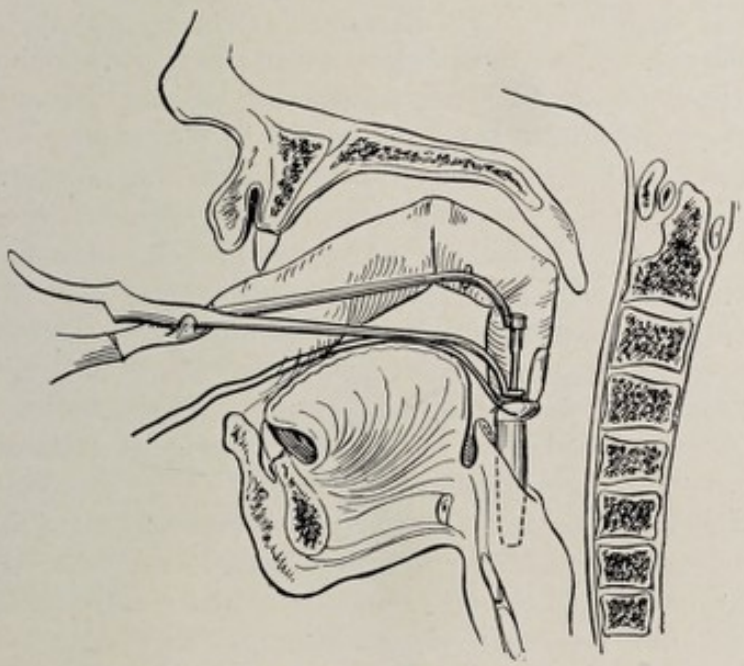

Fig. 385.—Intubating the larynx (Lejars).

should attend constantly to the tube, seeing that it is not plugged and that the patient breathes comfortably, attending to the condition of the sponge, and keeping the temperature of the room at about 80° F. It

is an unfortunate fact that these wounds frequently become infected, either from the skin or the tracheal mucosa. Special care in cleanliness is, therefore, required lest the patient contract an inhalation pneumonia.

In certain cases a more radical opening of the trachea than that I have described becomes necessary—an opening which shall cut off permanently and entirely the trachea from the upper air-passages. To this end the trachea is amputated completely at the selected point, the stump drawn forward, and its whole circumference stitched carefully to the skin. In this case, if a flattening of the trachea does not result, a tracheotomy tube is needless, for air should pass freely into the open trachea. After these preliminary considerations let us now turn to the difficult subject of—

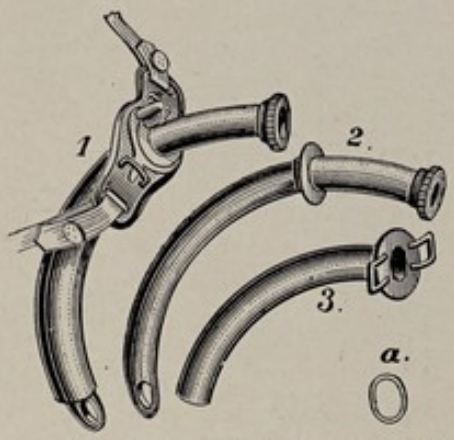

Fig. 386.—Cohen's tracheotomy tubes: 1, Outside tube and obturator; 2, obturator; 3, inside tube; *a*, cross-section of the tube (Fowler).

Tumors of the Larynx.—For the general surgeon malignant disease of the larynx, necessitating removal of that organ, is the only tumor of interest. Other neoplasms there are—papillomas and fibromas and others—which the laryngologist removes by an internal operation. Sarcoma of the larynx is rare, and when it does occur, springs from the lateral wall, but—

Cancer of the larynx is the most important malignant growth found in this organ. It may be primary or secondary. When secondary, it is an extension of the disease from the tongue, jaws, or gullet, and its removal under these circumstances is impossible or futile. Primary cancer of the larynx must engage our present attention. Primary cancer is divided by Krishaber into two classes—the *intrinsic* form, beginning in the vocal cords, the ventricular bands, or the parts below; and the *extrinsic* form, starting in the epiglottis, the arytenoids, or other parts outside of the larynx proper; and this classification is now commonly accepted by surgeons. Intrinsic cancer is papillomatous in character, warty in appearance, slow in growth, and associated rarely with lymphatic involvements. The extrinsic form, on the other hand, grows rapidly and early extends through the lymphatic channels. The reader will see at once, therefore, that the two forms present quite distinct problems. The intrinsic cancer, if taken early, may be removed with good hope of a permanent cure. The extrinsic cancer is a rapidly fatal disease, for which operation is a desperate remedy at the best. Fortunately, the location of laryngeal cancer brings the disease early to the attention of the patient and drives him to consult a physician. The sufferer perceives increasing hoarseness leading to aphonia, with pain as a late symptom. The surgeon, by the aid of the laryngoscope, discovers a tumor or ulceration, and should remove a bit of it to confirm the diagnosis of cancer, if possible, for that disease not infrequently has been mistaken for benign papilloma or for tuberculosis. If the case runs on

without operation, death takes place in one of two ways—by suffocation or by exhaustion through metastasis. The reader may remember that the latter event befell the late Emperor Frederick, of Germany, whose more urgent symptoms were relieved by a timely tracheotomy. Patients often are loath to submit to removal of the larynx, in which removal lies the only possible hope of cure, so that it is not uncommon to see these victims die after a miserable existence, prolonged by a palliative tracheotomy, which they always welcome gladly.

Various *operations* for the cure of laryngeal cancer are advocated by various authorities. There is intralaryngeal removal; removal by splitting the cartilages from without; Kocher's subhyoid pharyngotomy; excision of one-half the larynx, and total extirpation of the larynx, as first performed by Watson and Czerny, and improved by Keen, Glück, and others. I leave the discussion of the first three methods to other pens. I am not convinced of their efficiency, for neither *a priori* nor by statistics do they appear to be curative. Cancer of the larynx, like cancer elsewhere, calls for radical and sweeping excision. Most cases, therefore, should be treated by the total extirpation, a description of which may be modified to cover partial extirpation. Sundry methods of total extirpation are described, but I am convinced that W. W. Keen's method promises the best satisfaction. I must anticipate the description of Keen's method by reminding the reader that the great danger of operations upon the larynx and trachea lies in the possibility of subsequent sepsis and an inhalation pneumonia. The mortality from pneumonia is high. The operation of laryngectomy is not very difficult, and is not attended with great shock, so that the immediate after-condition of the patient seems excellent, but the diffuse bronchitis and pneumonia, which supervene so often, lend terror to an operation otherwise satisfactory. All operators, therefore, have endeavored to devise some means of cutting off the lower air-passages from the possibility of a contamination extending downward from the laryngeal wound. The steps of Keen's method are somewhat as follows: For a week prior to the operation the patient's mouth and fauces should be thoroughly brushed and gargled frequently, in order to clear up any possibly lurking source of infection. The operation is performed with the patient's neck extended over a pillow or in Rose's position, so as to make prominent the larynx and trachea. Expose the windpipe from above the hyoid bone to the third tracheal ring. Separate thoroughly, by blunt dissection, the structures to be removed, and check all bleeding. Then put the patient in the Trendelenburg position, divide transversely the trachea well below the disease, and attach the lower tracheal stump to the skin, either in the original skin incision or in a special skin buttonhole, and intubate the trachea, continuing the anesthetic through a rubber tube led out of the tracheotomy tube. The rest of the operation may be done safely and at leisure. Seize the upper tracheal stump and draw it forward with the attached larynx. Carefully separate the parts from the underlying esophagus, and if the esophagus be wounded, close it at once with stitches. Remove entirely the diseased larynx. Draw down

the epiglottis, remove it, and complete the operation by suturing the anterior wall of the esophagus to the tissues just below the hyoid bone, so as to prevent leakage from the mouth into the wound. Then remove the tracheotomy cannula and close the external wound, providing drainage for twenty-four hours. The dressings of the laryngeal wound and of the tracheotomy opening must be kept separate, and Binnie suggests strapping a small frame, like a pillow-box, over the tracheotomy opening, so as to protect it and supply a base for a gauze air-filter.

The time of after-treatment is an anxious time. The patient should be in bed without a pillow, the foot of the bed being slightly raised, and for two days he should be fed by nutrient enemata. After that he should be gotton out of bed daily, and should be encouraged to swallow, or to take nourishment through a stomach-tube, the nurse meanwhile attending constantly and carefully to cleanliness of the wound. If all goes well, the patient should be beyond danger by the end of the week.

Partial extirpation of the larynx is performed in much the same fashion, one half of the larynx, split from before backward, being removed.

An encouraging number of cures have been reported as a result of this operation, and the final condition of the patients is not so grievous as one might suppose. In some fashion they acquire an ability to talk, or to whisper at least, and the function of swallowing is completely restored.

CHAPTER XXII

THE NECK

Most American surgeons, when they deal with the surgery of the neck, will think of the brilliant recent work of Crile and of C. H. Mayo. Crile's advocacy of extensive block dissections, temporary occlusion of the carotids, and the use of the pneumatic suit to combat shock, constitutes an important advance in the surgery of this region; while Mayo's contributions to the treatment of goiter—especially exophthalmic goiter—are notable. We have already discussed many problems of neck surgery —incidentally, when we were considering malignant disease of the mouth and diseases of the upper air-passages. Certain important groups of glandular swellings and diseases of other cervical structures will occur to surgeons as presenting other important problems. In this chapter we shall consider deformities of the neck due to cicatrices, injuries, and neurosis; tuberculous adenitis; cervical abscess; tumors of the carotid body; enlargements of the lymph-nodes; abnormal cervical ribs, and thyroid tumors.

CICATRICIAL CONTRACTIONS

Cicatricial contractions due to extensive superficial burns of the neck produce some of the most distressing deformities with which we have to deal. The skin over the front of the neck is thin, delicate, and elastic, normally and necessarily so in order to allow of free excursions of the neck and chin. This skin, especially in childhood, is easily destroyed, when the dense scars which supplant it contract often into limiting bands which depress the chin, control cervical rotation, and hold open the mouth in a distressing, disfiguring, and humiliating fashion. The *treatment* of this condition is by no means easy. It does not suffice to cut away the bands, for new cicatrices then form. The surgeon must turn up great flaps, exposing considerable areas of raw surface, before the normal movements of the chin and neck can be restored; and he must then fill in the raw surfaces with flaps of true skin taken from the chest, shoulders, or sides of the neck. The chest skin-flaps are best, for skin from the chest is elastic and allows of ready stretching into place, while the consequent gap left on the chest can usually be filled in by drawing over it adjacent skin or by applying Thiersch grafts.

TORTICOLLIS

Torticollis, or wry-neck, is another distressing affection of the neck, but not so grievous generally as the cicatricial deformity. There are sundry forms and causes of torticollis: cicatrices may cause it, of a nature

similar to those already described; articular torticollis is due to an inflammation of the vertebral joints, and falls to the care of the orthopedic surgeon for treatment by apparatus; muscular torticollis is seen in new-born infants, born by the breech, and is the result of partial rupture of the sternomastoid fibers. A hematoma, suggesting a tumor mass, appears shortly, but the disablement is readily curable by simple surgical measures—bandaging and the wearing of a supporting collar.

Spasmodic torticollis interests us especially, though little advance in its treatment has been suggested since the publication of Walton's admirable paper in 1898.[1]

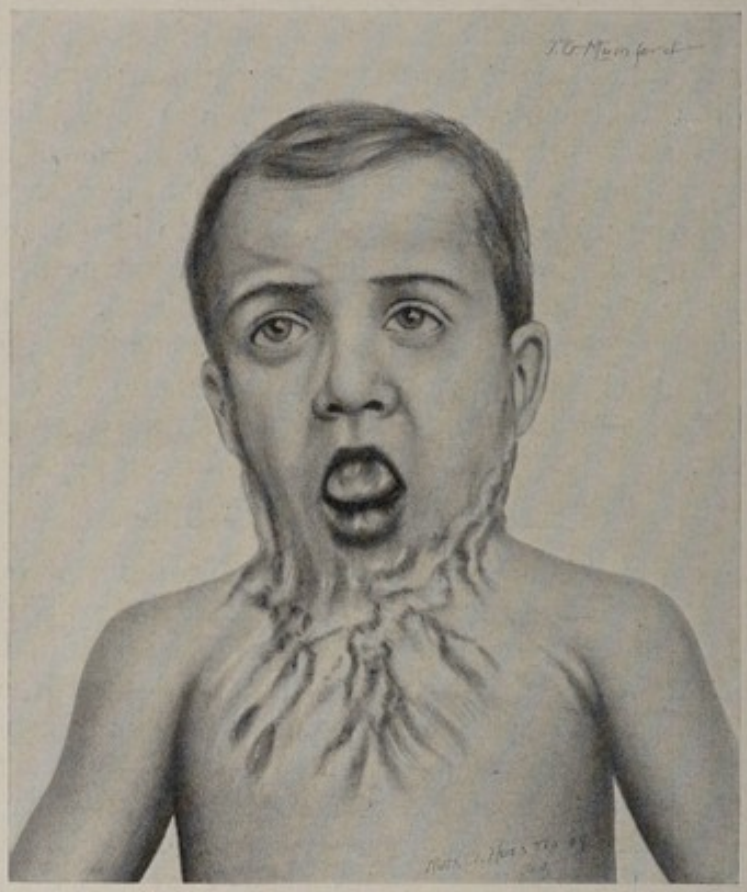

Fig. 387.—Cicatrix from burn. Personal case (Massachusetts General Hospital).

As Walton says, "spasmodic torticollis is a disorder of the cortical centers for rotation of the head." The pathogeny of the disorder is not altogether apparent, but symptoms of neurasthenia, and more rarely of hysteria or mental disease, may be associated with the ailment. The victims are commonly between thirty and fifty years of age, though young persons are not exempt. The patient may appear normal upon one's first inspection, but some slight irritation, not always obvious, brings on a spasm of muscles, throwing the head to one side in a painful, distressing, and somewhat ludicrous fashion. The muscles generally affected are the sternomastoid and trapezius, more rarely the splenius capitis, the complexus, the trachelomastoid, and the inferior oblique.

[1] G. L. Walton, Amer. Jour. Med. Sci., March, 1898.

In most cases the spasm attacks the sternomastoid of one side and the posterior rotators of the other, so that these two groups of muscles combine to rotate the occiput and give the chin an upward tilt. Rarely both sternomastoids alone are affected, or, still more rarely, the posterior rotators of both sides.

You can do little for these cases with drugs, electricity, massage, and similar remedies, though occasionally a confining collar will give the patient the desired comfort. Nor are operations altogether satisfactory, and such operations as we can do vary greatly in their severity from simple nerve-stretching to extensive tenotomies. If an opera-



Fig. 388.—Spasmodic torticollis (Massachusetts General Hospital).

tion be undertaken, therefore, it is good practice to resect first the spinal accessory nerve on the affected side, in the hope that this will relieve the symptoms. Should this operation fail, the surgeon may proceed to the more radical division and avulsion of the posterior branches of the three first spinal nerves on the opposite side (Keen); or even to tenotomies of all the muscles affected (Kocher). After the operation the patient's head should be supported for at least three weeks in a well-fitting Thomas collar, and the surgeon must attend specially to the patient's general condition, directing careful massage, suitable tonics, an out-of-doors rest-cure, or a long vacation. Persistence in these

measures will often relieve completely the sufferer; and the destruction of nerves and muscles, even, may be so far recovered from as to leave the patient with a useful and sightly neck.

CERVICAL ADENITIS

Cervical adenitis furnishes frequent occasions for operations upon the neck. The lymphatics of the neck drain a region peculiarly

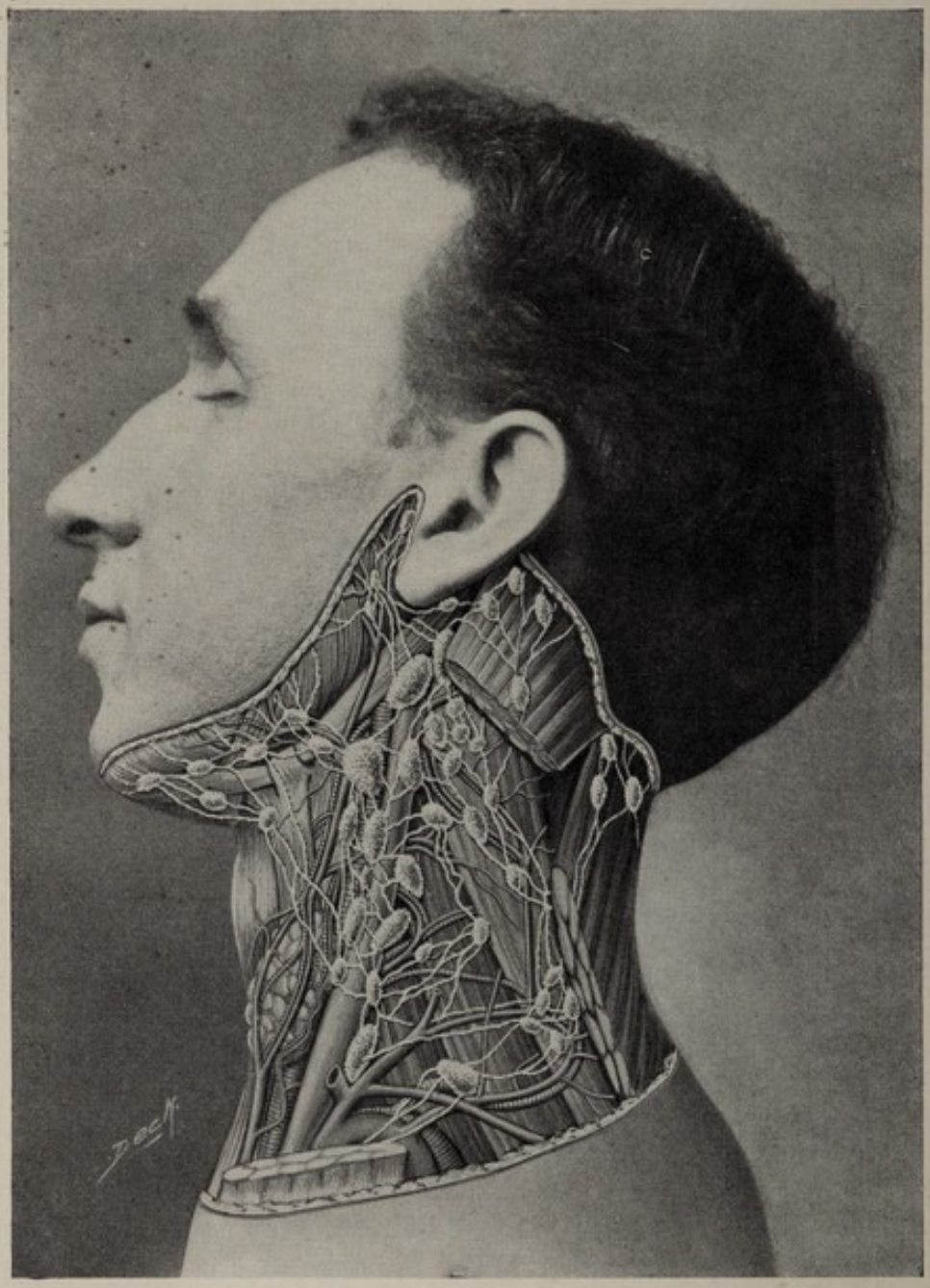

Fig. 389.—The lymph-nodes of the neck (Campbell).

susceptible to infection, and for this reason the nodes of the neck, more than any other group of nodes in the body, are wont to be found enlarged. Anatomists divide the cervical lymphatic nodes into two sets, the super-

ficial and the deep—those immediately below the platysma, and those resting upon the carotid sheath. For the clinician, however, no such invariable division is possible; the lymphatic channels communicate freely with each other, and infections of nodes, both superficial and deep, frequently coexist. Observe the interesting fact, recently pointed out by Crile: the lowest cervical nodes in the region of the clavicle seem to act as a collar or barrier, below which *malignant* processes extend slowly and late—malignant as compared with inflammatory involvements. The latter extend early below the clavicle. For the surgeon, then, dealing with cervical adenitis, the important nodes are those immediately behind the posterior belly of the digastric muscle, the nodes lying upon the carotid sheath, and those in the posterior cervical triangle. (See Chapter XX.) Be it noted, however, that the superficial cervical nodes communicate freely with the axillary nodes, while the deep cervical nodes are associated with the nodes of the mediastinum. When discussing malignant disease of the mouth, I pointed out that the buccal cavity, the tongue, and the lips drain into the cervical lymph-nodes. For this reason infections in the mouth set up inflammations in, and result in abscesses of, the neck; but the most important source of infection, as concerns the cervical nodes, is the tonsils. Especially does this appear to be true of tuberculous invasions, so that the surgeon, when confronted with a case of tuberculous cervical adenitis, should examine invariably the tonsils, and whatever be his treatment of the swollen neck, he should correct the lesion in the throat.

Children most commonly are sufferers from lymphatic infections of the neck,—infections especially of the tuberculous type;—but these diseases attack persons of all ages and of both sexes. In the old days these tuberculous patients were called "scrofulous," and the ailment was dubbed "scrofula." Such patients may present that typical, hectic, anemic appearance which we associate with victims of tuberculosis; but the typical appearance is by no means the rule. We find tuberculous nodes in the necks of robust-looking men. Most of the patients, however, appear ill. They are anemic; their appetites are poor, and they are often emaciated. Frequently they have fever, with a temperature ranging between 99° and 101° F. Such patients will tell you that they have been running down for a long time, and that, as a result of being run down, lumps have appeared in their necks. On examination the surgeon may find enlarged nodes in the axillæ and groins also, but in the neck especially, on one or both sides, he will find swellings, large or small, multiple or single, hard or fluctuant, sometimes resembling a chain of marbles lying on the front of the sternomastoid, sometimes presenting a single ovoid tumor under the angle of the jaw and as large as a man's fist. Frequently there is a history of recurring attacks of "swollen glands," enlarging and subsiding, with corresponding fluctuations in the patient's general health. Sometimes one finds pulmonary disease or evidence of tuberculosis within the abdomen or joints, but we are not dealing here with such complications of cervical adenitis.

The **treatment** of tuberculous cervical adenitis is not at all a simple

matter, and the treatment has varied greatly in the past fifteen years. At times it has been the custom to poultice the swelling and to open and drain it after it has ripened into an abscess. That is bad treatment. We recognize now the importance of eliminating these tuberculous masses as early as possible, lest they serve as foci for the spread of a general tuberculosis. But elimination of lymphatic tuberculosis does not always and necessarily imply incision. Very many of these persons will recover sound health under a careful régime and a persistent out-of-doors life. Unfortunately, numbers of the poor patients seen in large hospital clinics cannot secure the proper out-of-doors treatment, so that surgeons often become weary and skeptical in advising such a course. That skeptical attitude of the surgical mind is irrational. No theory of therapeutics is more certain and well established than that a great majority of cases of tuberculous adenitis will recover if they can pursue faithfully and uninterruptedly for six, eight, or twelve months a proper life in the open air. One must supplement this course by an abundance of good food and such tonics as iron, malt, and the various forms of fats. There will remain, however, a considerable proportion of patients who either cannot secure the out-of-doors treatment or fail to recover under that treatment. For some of these persons therapeutic injections of Koch's new tuberculin may be appropriate, injections administered under, and controlled by, the opsonic therapy of A. E. Wright. There remain finally the large number of cases which must look for relief or cure through a surgical operation.

Operative treatment of tuberculous adenitis concerns itself naturally with two classes of cases, according to the nature or extent of the inflammatory process: (1) There are the hard and nodular masses. It is a simple matter to cut down upon, isolate, and excise these masses, which have not suppurated or become caseous. (2) There are the abscesses. It is impossible to excise thoroughly tuberculous disease which has advanced beyond the node capsule, has invaded neighboring structures, and involved generally the soft parts of the neck in a degenerative process.

Briefly, the nodes which are still intact should be removed totally, so far as may be. Small masses of nodes in the upper part of the cervical region may be reached by Dollinger's method, which consists in making a curved incision along the line of the hair, starting from just behind the ear. The advantage of this method is that it leaves no perceptible scar; but it is not a satisfactory method by which to reach thoroughly all parts of the neck. It is a burrowing and somewhat blind performance, but I admit that I have found it useful in a few selected cases. Other groups of nodes, relatively small, may well be reached through a *transverse* incision at any level of the neck, and I recommend this incision in suitable cases, for it follows the natural line of cleavage of the skin, and there results an insignificant scar. There will remain always those more extensive and involved cases presenting masses of nodes filling the whole neck from the jugular fossa down to and below the clavicle, and extending widely into the posterior cervical triangles. To remove

these nodes necessitates an operation often as far reaching and crippling as the extensive block dissection of the neck for cancer—indeed, the description of these block dissections in Chapter XX of this book may be made to apply to extensive dissections of tuberculous disease, but with this difference, that tuberculous disease of the neck does not often involve other than lymphatic structures, so that the surgeon is not forced to remove muscles, vessels, and nerves even. Rarely, I have been obliged to excise a tuberculous sternomastoid muscle, but, as a rule, one can find abundant room for the dissection by cutting through and turning back out of the field the sternomastoid, to be restored carefully with stitches at the close of the operation. It is well, in dissecting out great masses of nodes, and after having turned back the skin-flaps and sternomastoid, to begin at the clavicle and work upward, making a clean

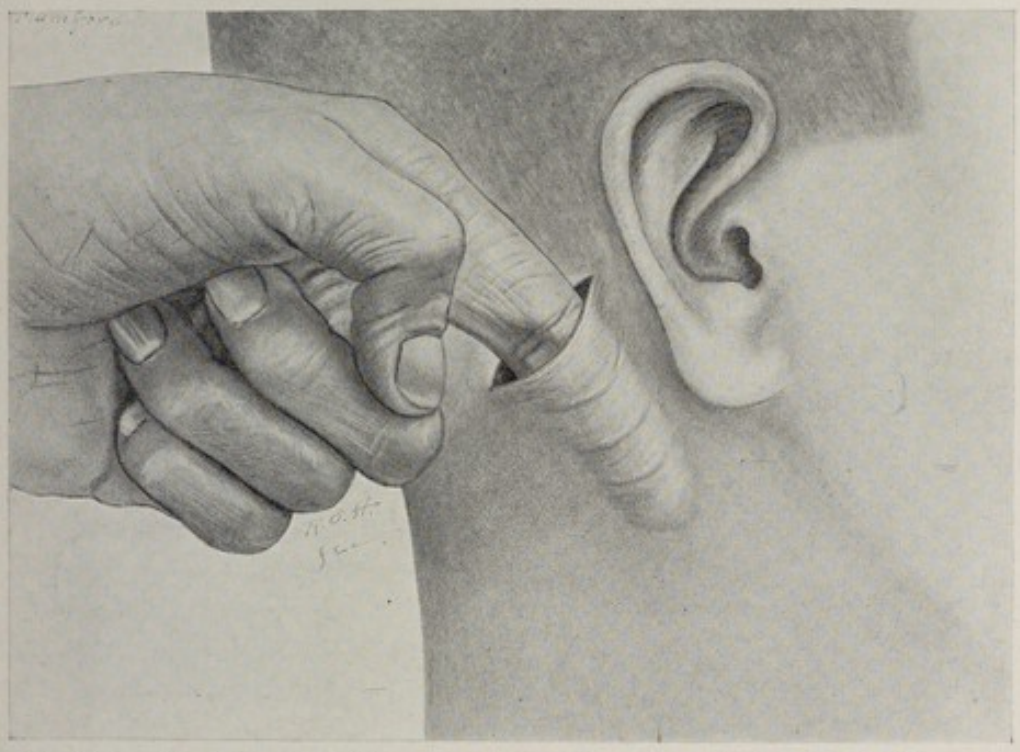

Fig. 390.—Scarless method for removing enlarged cervical nodes (Dollinger).

sweep of all the involved nodes to the last one, which is usually found almost as high up as the jugular fossa. Writers divide somewhat fancifully the groups to be removed,[1] discussing special maneuvers for special groups. It is true that enlarged nodes tend to follow well-defined planes of least resistance, that certain groups tend to remain limited to the digastric region and others to the carotid region, but it is impossible to assign all cases to definite classes. In general terms, however, the surgeon should attempt to follow Sutcliffe's three rules: (1) The operation should be as complete as possible; (2) the spinal accessory and other important nerves with the vessels should escape injury; (3) the incision should be planned so as to make the resulting scar as little visible as possible.

[1] W. G. Sutcliffe, Brit. Med. Jour., May 13, 1905.

Our discussion of the operative treatment of cervical adenitis hitherto has dealt with the removal of encapsulated masses. It remains to say a word regarding the broken-down, suppurating nodes involved in mixed infections. These inflamed nodes and the resulting abscesses are those which "point" beneath the skin, break through, and discharge externally, and in their healing leave those ugly scars of the neck with which we are all familiar. If a limited abscess has formed without extension to other nodes, it may be tapped, washed out, and drained through a fine cannula,[1] which should remain in place for about a week, when it may be removed, and the little sinus allowed to heal. An imperceptible scar usually results. Extensive, suppurating, burrowing tuberculous disease, on the other hand, must be opened thoroughly,

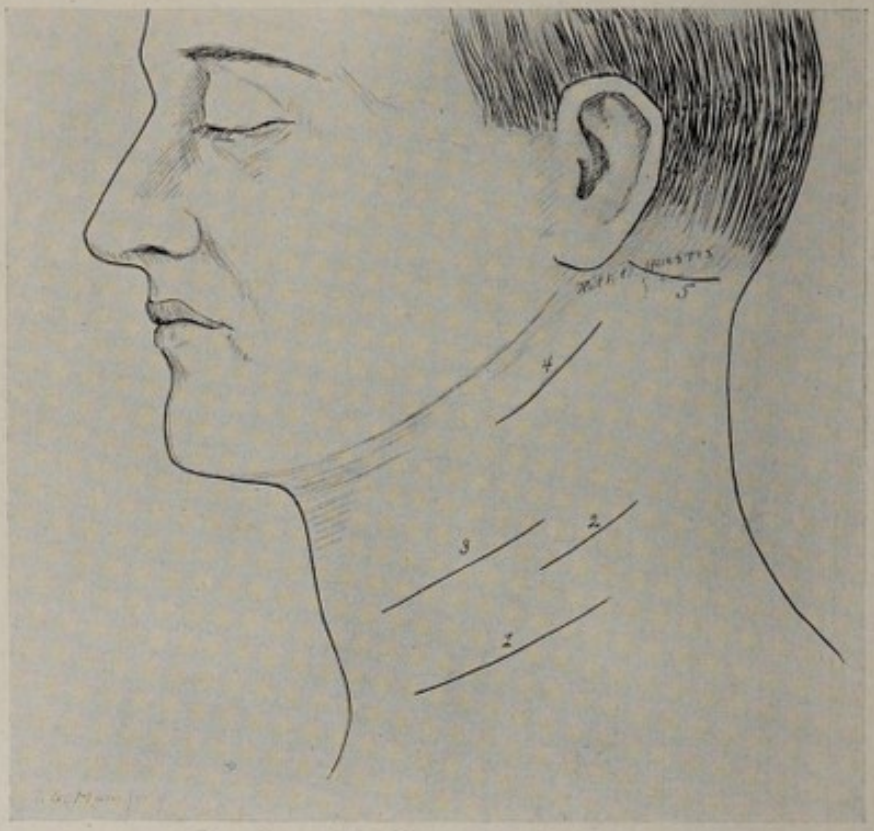

Fig. 391.—Small transverse incisions.

cureted, the deep parts painted with iodin, and the wound packed and drained, with a resulting ugly scar.

Such, in general, are the methods of treatment applicable to tuberculous cervical adenitis. The surgeon should remember always that after an apparent cure these patients are still subject to reinfection, and should be taught carefully the importance of leading properly regulated lives, under the best obtainable surroundings.

WOUNDS OF THE THORACIC DUCT

Wounds of the thoracic duct are reported from time to time, and every surgeon who has occasion to dissect extensively the deep tissues

[1] Briggs' cannula.

of the neck probably has been guilty of damaging this important structure. I have myself wounded the duct twice. Some years ago Allen and Briggs collected 17 cases from the reports of various operators.[1] Fortunately, the lesion heals in most cases without great trouble or special care. The wound in the duct cannot often be repaired, though sometimes it may be found and sutured. Allen's fourth conclusion is important—" until repair of the duct is thought to be complete, nutrition should be sustained on albuminous material, with possibly a small amount of carbohydrates, but with an absolute exclusion of fats."

DEEP CERVICAL ABSCESS

Deep cervical abscess is a serious condition, which may simulate or be confused with suppurating lymph-nodes, but the deep abscess to which I refer owes its origin to an inflammation of other structures, such as the parotid gland, the submaxillary gland, or the cervical vertebræ. These deep abscesses burrow far, and, following the fascia down the planes of the neck, may reach the chest and cause the most serious kind of trouble. Such abscesses, therefore, may be regarded generally as " cold abscesses."[2] They are painful; they are extremely tense; they are associated with a moderate rise of temperature; they cause profound prostration, and they must be **treated** by incision and drainage as soon as they are discovered. Some of them, located high in the neck and observed early in their course, may be cured after tapping by the injection of iodoform glycerin (3 drams of iodoform to 3 ounces of glycerin), but this maneuver has its dangers. It may not check the disease, in which case the abscess must be opened freely and drained as though *de novo*.

PEDICULI CAPITIS

Pediculi capitis (head lice) often cause infections of the superficial lymph-nodes posterior to the sternomastoid muscles. A soft abscess in the region of the mastoid process, especially in an ill-kempt child, always should prompt the surgeon to examine the patient's head. Often he will find in the hair lice associated with a diffuse dermatitis. The *treatment* consists not only in opening the abscess, but in making the proper applications of crude petroleum to the head in order to destroy the parasites.

LYMPHATIC CYSTS

Lymphatic cysts (one form of " hydrocele of the neck") are somewhat uncommon congenital cysts, which appear on one or both sides of the neck, usually anterior to the sternomastoid muscles. Rarely they may extend into the axilla or chest. They may be monolocular or multilocular. They originate beneath the deep fascia, but portions of them may become subcutaneous. They are thin walled and contain a translu-

[1] Dudley P. Allen and C. E. Briggs, Amer. Med., September 14, 1901.

[2] " Cold abscess," usually a chronic abscess forming slowly without marked inflammatory symptoms; or sometimes a collection of pus remote from its source of origin, *e. g.*, psoas abscess in the groin, the result of inflammation of vertebræ.

cent serous fluid, which often gives them the appearance, when inspected through the hydroscope, of scrotal hydrocele. Hydrocele of the neck appears in children; rarely it persists after the fifteenth year. It disappears spontaneously as a result of inflammatory or atrophic changes. These cysts may be aspirated and the sac injected with a 5 per cent. solution of carbolic acid—at once removed; or they may be left for a spontaneous cure.

THE CAROTID GLAND[1]

There lies in the fork of the carotid artery, where it divides into its external and internal branches, a minute structure, varying normally in size from 4 to 7 cm. in length, which recently has become the subject of active surgical interest, for it may take on malignant changes, may enlarge so as to disfigure the neck, and may cause distressing symptoms. Von Haller, in the middle of the eighteenth century, described the carotid gland, but not until 1891 was it recognized as a possible seat of tumors.[2] In 1906 Keen had collected 27 cases, and numerous other cases have been reported.

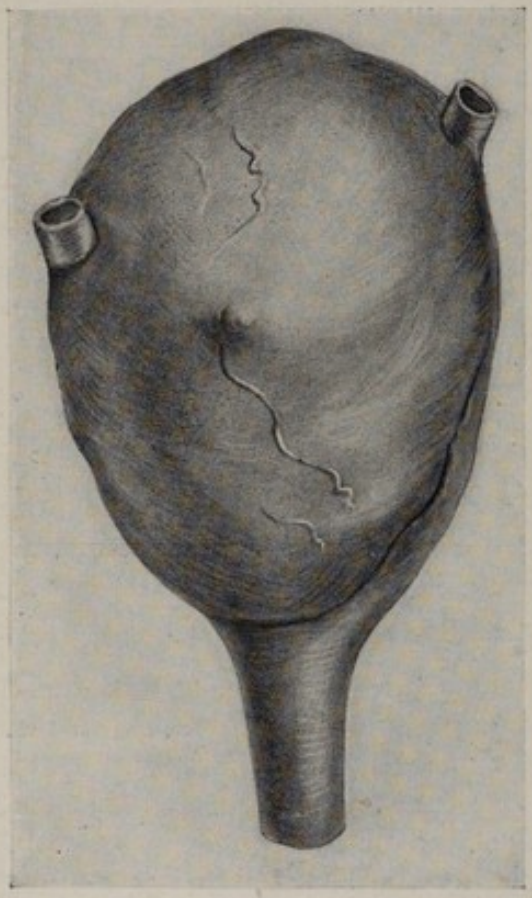

Fig. 392.—Carotid gland, showing the three carotids and their relation to the tumor (Scudder).

Tumors of the carotid gland appear in persons of all ages, though they are most common in early adult life, and are divided equally between males and females. The ordinary tumor of the carotid gland grows slowly and appears first as a small lump, a little larger than an almond. It reaches a considerable size and is ovoid and firm, with a well-defined capsule closely adherent to the vessels; while its substance, divided by numerous septa, is brown or brownish-red on section. It is fed constantly by a small artery from the internal carotid. While there is still a variety of opinion regarding the structure of the gland, it appears that the essential elements are blood-vessels and cells; and among the cells and in the stroma there are elements to which have been applied the terms "chromophile" and "chromofiffine," to which

[1] W. W. Keen and John Funke, Tumors of the Carotid Gland, Trans. Amer. Med. Assoc., section of Surgery and Anatomy, 1906. This is the most comprehensive and satisfactory article as yet published on this interesting subject.

[2] Marchand, Virchow's Festschrift, 1891, vol. i.

are attributed an important functional significance similar to that ascribed to elements in the suprarenal glands. "Mulon concludes that the chromafiffine cells secrete a substance which, when introduced into animals, acts like adrenalin in raising the arterial pressure."[1] The tumor is always intimately associated with the carotid vessels, and cannot be separated from them with safety. By its pressure it may encroach upon, or obliterate even, the artery's lumen.

A patient with one of these growths suffers little discomfort until the tumor has reached a considerable size. Rarely is there pain, dyspnea, or involvement of the sympathetic and pneumogastric nerves sufficient to cause changes in the pupil or in the heart-rate. The tumor may grow slowly for many years and then increase rapidly in size, so that the patient seeks relief for the deformity rather than for any actual discomfort. When the surgeon comes to examine one of these growths, he may mistake it readily for an enlarged lymph-node. The tumor lies under the sternomastoid muscle and presents a long, ovoid swelling in the line of the muscle, a swelling movable laterally, but not up and down. The skin is not discolored or adherent, and a transmitted pulsation, without thrill or expansile impulse, can be felt. In their early stages these tumors are not malignant, though prompt removal may be followed by apparent recurrence, probably, as Keen says, from microscopic rests which were overlooked. Later, with the development of the tumor, the histologic elements undergo marked and peculiar modifications, resembling somewhat those changes seen in the so-called hypernephroma. For the sake of a word, and in order to define the clinical status of the larger tumors of the carotid gland, it would not be improper to group them with the endotheliomata (Funke).

With this understanding of the clinical characteristics, the progress, and the nature of carotid gland tumors, the surgeon may be able to make a correct diagnosis, and should proceed guardedly to advise—

Treatment.—It is an interesting fact that the removal of these tumors is not the easy, safe, and curative process one would expect. The death-rate from operation is about 25 per cent., so that it is best to operate only in the face of serious functional troubles or the rapid evolution of an apparently malignant growth. In operating, and after exposing fully the growth, the surgeon should isolate it carefully from all neighboring nerves and other adjacent structures with the exception of the carotid vessels. He cannot safely separate it from these vessels. Then he must ligate the carotid artery and its two main divisions above and below the tumor, divide the arterial trunks, and remove the growth with the included vessels. If the patient survive the immediate shock of the operation, recovery should be prompt and uneventful, and the convalescence be completed within ten days. I have elaborated this subject of the carotid gland perhaps unduly on account of the novelty and recent interest in the matter.

Another subject for surgery in the neck, a condition shown by skiagraphs to be relatively common, is the cervical rib.

[1] Keen and Funke, ibid., p. 60.

CERVICAL RIB

This abnormality is not a true rib, but is a peculiar lengthening of the transverse process of the seventh cervical vertebra on one or both sides. No symptoms or special discomfort commonly are caused by a cervical rib, so that the patient may go through life without knowledge of this peculiarity in his anatomy. Occasionally, however, torsion of the subclavian artery may be caused by the rib, resulting, perhaps, according to G. Fisher, in subclavian aneurysm. The more common changes, however, are trophic, with an ischemia and consequent necrosis of some of the parts supplied by the artery affected. W. W. Babcock [1] reports an interesting case of this sort in which the right hand was cold, pulseless, and numb, at times, and affected by ulcers, with gangrene of three fingers. Excision of a cervical rib on the corresponding side cured the disorder.

We come now to a discussion of the most hotly debated, difficult, interesting, and promising subject in the whole field of surgery of the neck, namely, affections of the thyroid gland.

DISEASE OF THE THYROID GLAND

Goiter is the common and important disease of the thyroid gland, and I suppose goiter shares with cancer and "stone" the honors of literature—history and fiction. Goiter has always been regarded as a disease peculiar to mountain folk, and the Swiss especially are notable as victims of this growth. It is not surprising, therefore, that we find in Theodor Kocher, of Bern, the most eminent exponent of this interesting theme.

You will see in all the old surgeries the striking pictures of goiter, enormous tumors of the thyroid gland, as large as a man's head or larger. These are the classic pictures. Nowadays, thanks to the activities of surgeons, such great goiters rarely are seen, for we have learned how to combat the disease, have ascertained that many forms of goiter are amenable to medical treatment, and that the rest generally may be removed with safety. Two facts regarding goiter, interesting to surgeons especially, have been demonstrated in recent years: (1) That lying behind the lobes of the thyroid one finds four or more minute bodies, the size of small peas, and known as parathyroid glandules, the presence or absence of which has an extremely important bearing on function and on life; and (2) that that curious disease, exophthalmic goiter, first described by Graves in 1835, often may be cured by a surgical operation. These and kindred matters we shall discuss shortly.

Let us now consider systematically, but briefly, some of the details and conditions of the natural history and treatment of disease of the thyroid gland.

The gland—a ductless gland—is a horseshoe-shaped organ, lying across the trachea immediately below the cricoid cartilage; one lobe of

[1] Amer. Med., October 7, 1905.

the gland on either side of the trachea, the lobes connected by an isthmus. This is the normal, commonly accepted description, but the gland varies greatly in appearance. Often it is dumb-bell shaped. Often there springs from the isthmus and runs upward in the middle line of the neck toward the hyoid bone a third lobe, or pyramidal process. Albert Kocher states that this pyramidal process, round and worm-like, is found in most thyroid glands, that it varies greatly in length, and rarelv extends to the hyoid. The thyroid gland develops out of the ventral wall of the pharynx from a median proliferation. Observe then this important fact—this proliferation, or ductus, may fail to become obliterated, with the result that wandering or *accessory thyroids* are formed, usually trifling affairs, quite isolated from the main gland. One finds them above or below the hyoid, or in front of, or behind, the trachea. The wandering thyroids are to be distinguished carefully from the parathyroids.

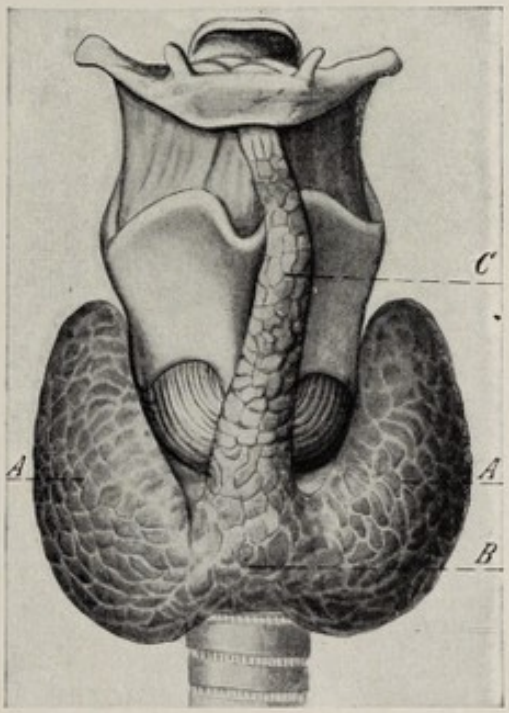

Fig. 393.—The thyroid gland: *A*, *A*, The lobes; *B*, the isthmus; *C*, the inconstant middle lobe (Campbell).

Parathyroids.—Wandering thyroids may develop tumors and goiters in unexpected positions. Parathyroids are structures of quite different origin and function from wandering thyroids. Parathyroids develop from the third and fourth bronchial pouch, and are constantly present in man. Generally, there are four parathyroids,—two upper and two lower,—so that they are, as it were, placed in pairs on either side of the trachea, embedded in loose connective tissue behind the thyroid gland itself. The tissue in which they lie is derived from the deep cervical fascia, and is known as the external thyroid capsule. Occasionally there exist wandering groups of parathyroid cells or glandules even, sometimes outside of the thyroid gland and sometimes within it.

The thyroid gland itself lies beneath the superficial muscles of the neck,—the platysma, sternomastoids, sternothyroids, etc.,—and is regarded as having two capsules—the loose external capsule of which I have spoken (which contains the recurrent laryngeal nerve) and the firm inner capsule proper, which strips with difficulty and sends prolongations between the lobes of the gland. As to the blood- and nerve-supply of the thyroid gland, suffice it to say that there are the two superior thyroid arteries and the two inferior thyroid arteries, with occasionally the thyroidea ima. The veins of the gland spring especially from the region of the isthmus, are exceptionally large and numerous, and the gland is extremely vascular. The nerves are derived from the

superior ganglion of the sympathetic and from the laryngeal branches of the pneumogastric, and they accompany the blood-vessels. The thyroid is a ductless gland, normally reddish or yellowish red in color, the cut surface finely granular and exuding in considerable amount a colloidal material—a clear, yellowish, slightly sticky fluid. The gland substance is made up of closed tubules, each containing the colloid material, completely filling the tubules or follicles. The *wandering thyroids* have a structure like that of the thyroid, but the *parathyroids* have a structure quite different—a thin, connective-tissue capsule sending out fibers into the substance of the little gland, with a stroma containing blood-vessels and lymph-vessels, and a protoplasm, either granular or clear.

A few words about the functions of the thyroids and parathyroids. As Albert Kocher states, " the high iodin-content of the thyroid gland is its most characteristic feature, and the iodin-containing albumin of the gland (iodothyrin) is capable of replacing the thyroid secretion. The amount of iodin in the gland usually is proportional to the kind and quantity of colloid material present. The secretion of the thyroid gland in some fashion enters the circulation, and we know that it exercises a metabolic function in the body. Through some unknown chemical process the gland has a special influence on the nervous system and vascular system; the skin and epithelial structures; the bones and sexual organs."

The parathyroid glandules have a function which is not so apparent, but the thyroid and parathyroids certainly act in conjunction and are not independent of each other. As C. H. Mayo writes, "Undoubtedly these bodies (the parathyroids) have much to do with the stability of absorption or excretion of the mineral salts of the body, and, therefore, upon the tissues dependent upon such salts; consequently, with their loss, if death from tetany does not result, there is apparently a decreased resistance against infections. . . . Should the parathyroids be injured and tetany ensue, the condition may be temporarily relieved by giving the lactate of calcium, repeating as necessary when indicated by a return of symptoms, and later feeding of parathyroids." We may assert truly one important and negative function of the parathyroids. When present, they are antitoxic. Remove the parathyroids and the patient will fall a victim to tetany. *At least two parathyroids* are necessary to sustain properly the function of these interesting organs.

Before taking up a discussion of the ordinary enlargements of the thyroid it will be instructive to consider briefly those diseases which may arise from interference with the functions of the thyroid and parathyroids. These so-called functional diseases are dependent upon suppression of the secretion or upon hypersecretion of the glands. Loss of the thyroid function produces sundry striking disturbances: the myxedema of cretinism, idiocy, disturbance of sexual function, neuroses, psychoses, epilepsy. One sees that these ailments are due directly to the loss of thyroid function, and the obvious treatment is to supply the loss. The physician may hold the disease permanently in check by feeding the patient with preparations of thyroid gland, while the

surgeon may succeed in improving or curing the condition by implanting in the individual, normal thyroid gland tissue, obtained preferably from man.[1] The implantation of parathyroid tissue has not yet led us to definite therapeutic knowledge.

Interesting as are the results of the *loss* of thyroid secretion, the results of *excessive secretion* are more interesting still. These cases of excessive secretion are grouped under the head of thyrotoxic diseases.

Thyrotoxic Diseases (*Graves' Disease; Basedow's Disease; Exophthalmic Goiter; Hyperthyroidism*).—The characteristic feature of these diseases is that the intoxication of the body is effected apparently through hyperplasia of the thyroid gland, so that, as we should expect, operations upon the gland are almost invariably followed by improvement in the patient's symptoms. In some measure these good results are paradoxic. The functional interrelation of the thyroid with other ductless glands—especially with the pancreas, the suprarenals, and with the pituitary body—have not been elucidated, important as these relations doubtless are. Moreover, general systemic toxemias appear to be causative agents in the glandular disorders; such toxemias as those due to intestinal stasis from enteroptosis. Certain it is that the phenomena of Graves' disease are very often associated with the toxemia of visceral ptosis. The work now being done in my clinic at the Clifton Springs Hospital is demonstrating that in certain groups of cases, marked by the coincidence of Graves' disease and visceral ptosis, proper treatment of the ptosis does relieve the Graves' disease phenomena—especially the tumor, the tachycardia, the tremor, the sweating, the digestive disturbances, and the apprehension.

The *symptoms of Graves' disease* are extremely numerous, and I shall sketch them in the briefest detail. The thyroid gland itself is enlarged uniformly, and one discovers in it a thrill, blowing murmurs, expansive pulsation, and enlargement of the arteries. The growth is usually soft, and there is loss of elasticity. The pulse is rapid (tachycardia) and of high tension, with commonly an increased blood-pressure. Slight capillary hemorrhages are frequent. You will observe tremors of the hands and feet, of the eyelids and lips. Bulging of the eyeballs (exophthalmos) occurs in acute cases, with lagging of the lids. The skin is moist, the hair drops, the nails crack, there are frequent pigmentations of the skin, suggesting Addison's disease. Diarrhea is common, and there may be nausea and vomiting. There are great lassitude and emaciation, while the menstrual flow diminishes or ceases entirely, and characteristic blood changes occur. Such are a few of the symptoms.

The disease may be acute or chronic, with acute exacerbations, but we need not follow its numerous and manifold terms further than to observe that if it develops suddenly, the course is more grave, and the prospect more gloomy than when it begins slowly. With these brief observations on the nature of Graves' disease let us consider its treatment.

Regarding the *treatment*, the most active and diverse views are still

[1] Albert Kocher, Keen's System of Surgery, vol. iii.

held. Many internists have pointed out that almost any treatment or no treatment at all will result in alleviation or even cure, while others, advancing upon more rational lines, have secured some benefit from serum therapy. On the other hand, surgeons, with increasing show of reason, are claiming and demonstrating that resection of the offending gland gives the greatest percentage of cures. I need not here consider at length the interesting problems of serum therapy, but refer the reader to the valuable contributions of S. P. Beebe and John Rogers.[1]

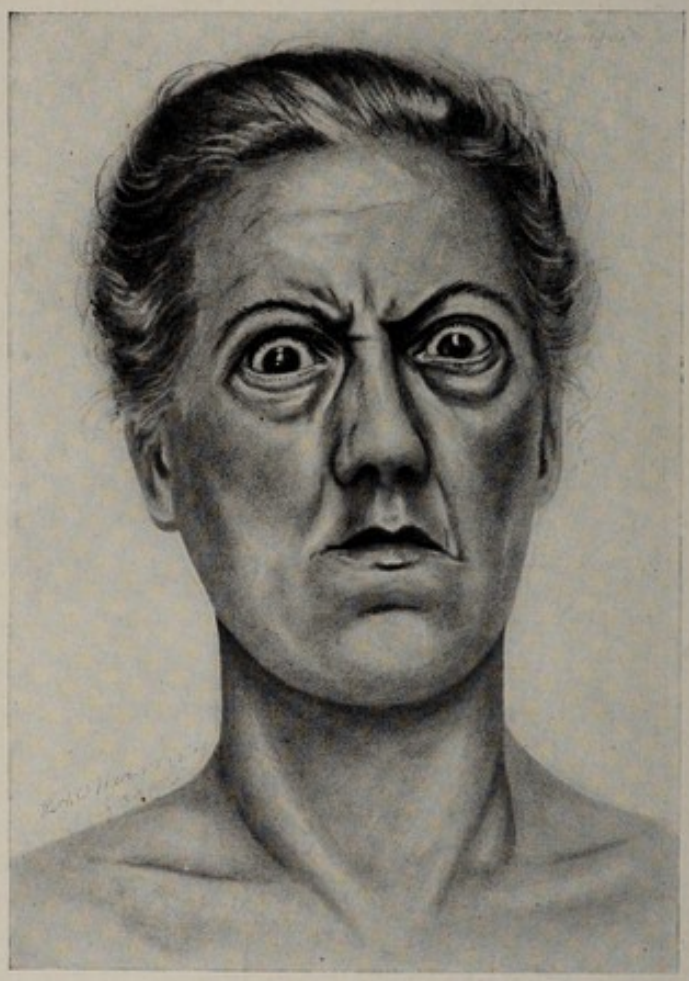

Fig. 394.—External appearance of exophthalmic goiter (Massachusetts General Hospital).

Of *surgical treatment*, Albert Kocher remarks: "To say that this is still the best is not enough. It has proved itself superior to any other form of treatment." C. H. Mayo also, in a series of convincing articles, and drawing upon a great experience, has demonstrated the value of these operations.

All cases of exophthalmic goiter must not be submitted indiscriminately to operation. Immediate operation should not be done in those

[1] S. P. Beebe, Jour. Amer. Med. Assoc., February 17, 1906, and Trans. Amer. Med. Assoc., 1907. John Rogers, Jour. Amer. Med. Assoc., February 17, 1906. See also important paper by James M. Jackson and L. G. Mead on The Value of Hydrobromate of Quinin, Boston Med. and Surg. Jour., March 12, 1908.

cases which show advanced cardiac changes, irregular pulse, low blood-pressure, or periodic attacks of *delirium cordis*. In such cases the subjects should be submitted to *x*-ray exposures and belladonna internally for a few days or weeks previous to the operation. Moreover, it is well in such cases to perform one or two preliminary ligations of the superior thyroid arteries. Indeed, we believe that in certain severe cases of Graves' disease the operation should be performed in one, two, or three sittings, beginning with tying the thyroids. The rest of the operation must depend upon the course of the disease and the condition of the enlarged gland; in the case of great enlargement, one should remove the more vascular half of the gland with the isthmus and pyramidal process. Under no circumstances should one remove the whole thyroid. In quite early cases it may suffice for a cure to ligate two or three of the thyroid arteries, and in all cases of resection of the gland the surgeon must avoid especially damage to the two lower parathyroids at least.[1]

The operation of thyroidectomy generally is more difficult in Graves' disease than in the ordinary forms of goiter, for in Graves' disease the vascularity of the tumor is greater, the vessels are more easily torn, the external capsule is more adherent, and the interstitial tissue is more brittle; and these are additional reasons for the occasional preliminary ligation of vessels. I shall have to speak further of the technic of the operation when discussing goiter proper.

Until recently section of the sympathetic nerve occasionally has been done as a therapeutic measure in Graves' disease, but this operation now is generally abandoned.

One need not often fear extensive toxic symptoms following thyroidectomy, especially if proper drainage be instituted for twenty-four hours, and if two parathyroids at least are left. In most of the cases the improvement in the patient's general condition is prompt and striking. He becomes quiet, his eyes appear less wild, the pulse-rate falls, tremor disappears, and within a very few days convalescence is established—conditions which contrast markedly with the results of the dreary, prolonged, and uncertain treatment of former times.

GOITER[2]

Writers still speak of goiter as *struma*, but to the student of etymology it is interesting to observe that struma means primarily scrofula, and secondarily goiter. Scrofula, in the modern acceptation of the term, means anything but goiter. Let us admit then that goiter signifies an enlargement of the thyroid gland, and let us eschew the confusing term struma. Students of the subject still debate the question of the classification of goitre, but I believe we shall make no mistake in adopting the classification of Kocher, bearing in mind always that goiter is a

[1] See G. W. Crile's important observations on the Psychic Aspects of Graves' Disease, Trans. Amer. Surg. Assoc., 1908, p. 391.

[2] Goiter: French, *goitre;* Latin, *guttur*—the gullet, the throat.

benign disease, not to be confused with inflammatory swellings of the gland or with malignant thyroid tumors.

We divide goiter into two main varieties—*diffuse goiter,* in which the entire gland is involved, and *nodular goiter,* in which portions only of the gland are affected.

Diffuse goiter occurs in six well-recognized forms: (1) Hypertrophic follicular goiter, a genuine hypertrophy of the whole gland, involving an increase of all its elements; (2) parenchymatous goiter or adenomatous goiter, in which the epithelial cells only are increased in number and size; (3) colloid goiter (cystic goiter), due to a stretching or enlargement of the follicles, which become distended with colloid material—

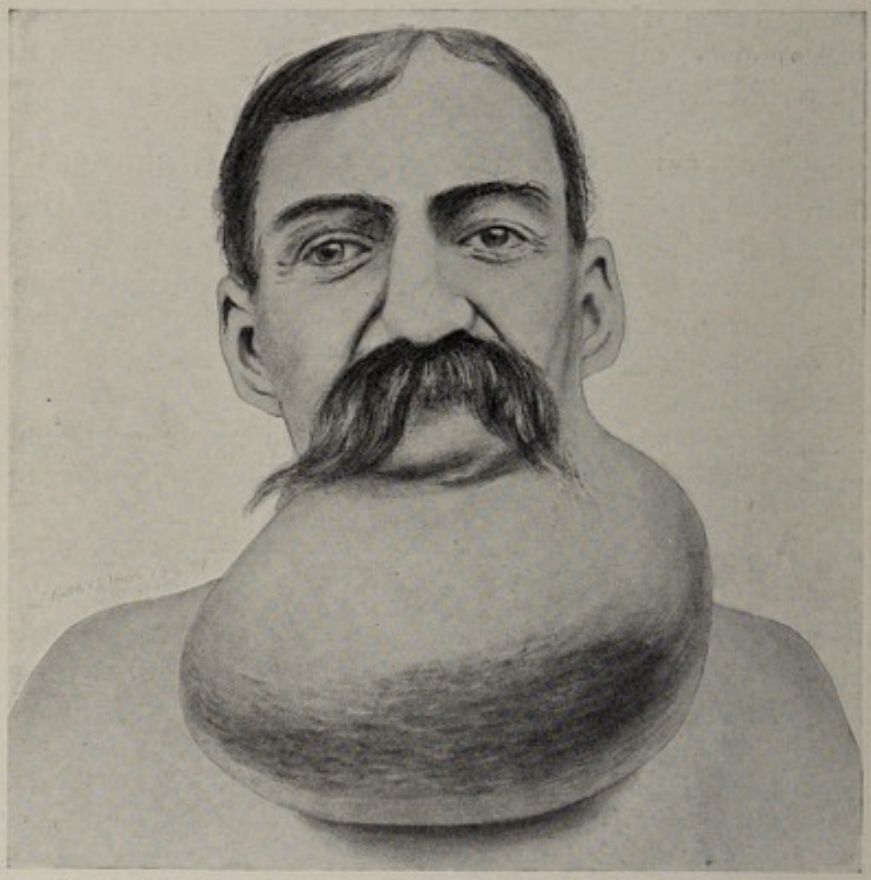

Fig. 395.—Cystic goiter (Massachusetts General Hospital).

this is by far the most common form of diffuse goiter; (4) vascular goiter, characterized by marked vascular changes, the arteries especially being greatly increased in volume. The other elements of the gland multiply also, but the vascular changes are the most conspicuous; (5) fibrous goiter, a rare condition, due to inflammation and excessive development of connective tissue; (6) recurring adenomatous goiter, marked by the new formation of small follicles, and resembling adenoma. Such growths are properly malignant, so that the term *adenoma malignum* is employed also. This is an extremely rare form.

Nodular goiter also has its six forms, corresponding to those of diffuse goiter, but portions or small areas of the gland only are involved. In

nodular goiter also increase of colloid material gives us the most prominent type, as in variety number three, already described. Surgeons speak of cystic goiter: this form is properly colloid goiter, and the apparent cysts are the distended follicles filled with colloid material. The reader will readily conceive how various may be the external appearances of goiter, depending upon the size, location, and multiplicity of nodules. Single isolated nodules are rare. Sundry degenerations take place in goiter, with the formation of new tissue which may also suggest at times teratomata. The enlarging gland, if undisturbed by treatment, will continue to grow indefinitely, as a rule, though after the patient's fiftieth year many goiters tend to shrink unless inflammation or malignant changes supervene.

Goiter may cause a great variety of **symptoms,** depending upon variations in rapidity of growth, in location of the nodules, and in histologic structure. For a long time there may be no symptoms, and the patient will complain of the deformity only, or there may develop various symptoms due to pressure. Distortion of the trachea may impede the breathing; pressure on the recurrent laryngeal nerve may cause hoarseness; the enlarged gland may push down into the thorax and alter the size and relation of blood-vessels, and the student should always remember the possibility of aberrant thyroids taking on goiter formation and developing puzzling tumors in unexpected localities—for instance, beneath the chin and at the base of the tongue.

We recognize six important facts in establishing the **diagnosis** of goiter: (1) The position of the tumor on the front of the neck, below the larynx and between the sternomastoid muscles; (2) the up-and-down movement of the tumor during deep respiration, and especially during the act of swallowing. If a large, deeply adherent goiter fails to move with these tests, a vigorous cough will cause the mass to protrude, and this cough test is especially useful in the case of intrathoracic goiters, which ordinarily are not readily visible or palpable; (3) note the easily recognized normal gland shape of the diffuse goiter, and the irregular appearance of a nodular goiter; (4) a goiter not fixed by inflammation may be moved about readily; (5) percussion and auscultation are most useful in the case of deeply placed goiters, for then one discovers characteristic dulness behind the sternum and dulness along the larynx and trachea, with diminished tracheal breathing in the side on which the goiter lies; (6) the superior thyroid artery and the great vessels of the neck often are pushed upward and outward by the tumor, so that these vessels become palpable.

The investigator should not overlook disturbances of the heart's action—disturbances which are common in goiter and are of grave importance often. We speak of *goiter heart,* which may be due to interference with the trachea, with the blood-vessels, or with the pneumogastric nerve. Such a goiter heart must not be confused with the toxic goiter heart or tachycardia of Graves' disease.

In this necessarily brief article we cannot well study in detail the various manifestations of different forms of goiter; but sufficient has

been said to enable the student to distinguish the three leading types—diffuse hypertrophic goiter, nodular adenomatous goiter, and cystic goiter.

The **causation and frequency** of goiter are subjects of interest sufficient for chapters of their own in the large surgical monographs. Suffice it here to point out that our general belief regarding the cause of goiter has not changed during the last three generations. The cause appears to be some peculiarity of drinking-water derived from the soil through which it passes; and the peculiarity of such water is believed to be a qualitative change in the iodin which it contains. No country is entirely free from goiter subjects, though the disease is especially constant or endemic in certain countries, generally mountainous. These cases of endemic goiter are generally of the colloid variety. Certain it is that improvements in water-supply have made the disease less frequent in famous goiter regions.

It is a fact familiar to surgeons that in great numbers of cases internal medication suffices for the **treatment of goiter.** With medicine, however, we need concern ourselves no further than to state that iodin is the one reliable drug for the relief of goiter. At one time experienced physicians maintained that 90 per cent. of all cases of goiter could be cured by iodin. This is probably incorrect, but the percentage is still large. The iodin may be given in the form of potassium iodid or in some of the forms of " soluble iodin," or the thyroid gland extract may be employed, although this in effect is but a form of iodin administration. We have to deal with the operative treatment of goiter, and may note accordingly the following conditions in which internal medication is not appropriate: (*a*) Nodular goiter undergoing degeneration—a condition recognized as gelatinous, fibrous, calcareous, hemorrhagic, and cystic; (*b*) diffuse colloid goiter, which may be attacked with iodin, but usually must be referred to the surgeon; (*c*) goiter causing pressure symptoms and cardiac symptoms; (*d*) abnormally situated goiter, especially when it projects into the thorax; (*e*) goiter developing suddenly and growing rapidly, and (*f*) any goiter which is sensitive to pressure or spontaneously causes pain. On the other hand, there are certain goiters which cannot safely be removed by operation—those which cause long-standing respiratory and circulatory disturbance, with impairment of the vital functions. Nor should one operate for goiter in persons with other serious organic derangements.

The *operations* are various, and the following six methods of operating are practised: (1) Excision; (2) enucleation; (3) resection; (4) combined methods; (5) exenteration; (6) ligation of arteries.

It seems needless to take up in elaborate detail these various methods, but the surgeon should have clearly in mind one method at least, the most useful and the most frequently applicable—excision.[1]

Certain considerations apply to all forms of operation upon goiter.

[1] For an excellent description of the common operations for goiter I refer the reader to J. F. Binnie's luminous article, Manual of Operative Surgery, third ed., pp. 212 to 221.

The method of anesthesia has been frequently and hotly debated. Kocher, Roux, and numerous other European surgeons employ local cocain anesthesia almost invariably, and claim that in thus dealing with a sensitive patient they avoid damage to nerves. One notes, however, that Kocher reports with satisfaction using general anesthesia upon his first 900 cases. English and American surgeons commonly use chloroform or ether for general anesthesia, and we hear little or no complaint of their results. We protest that the cocainized patients do suffer pain, that the surgeon operates more comfortably upon a profoundly anes-

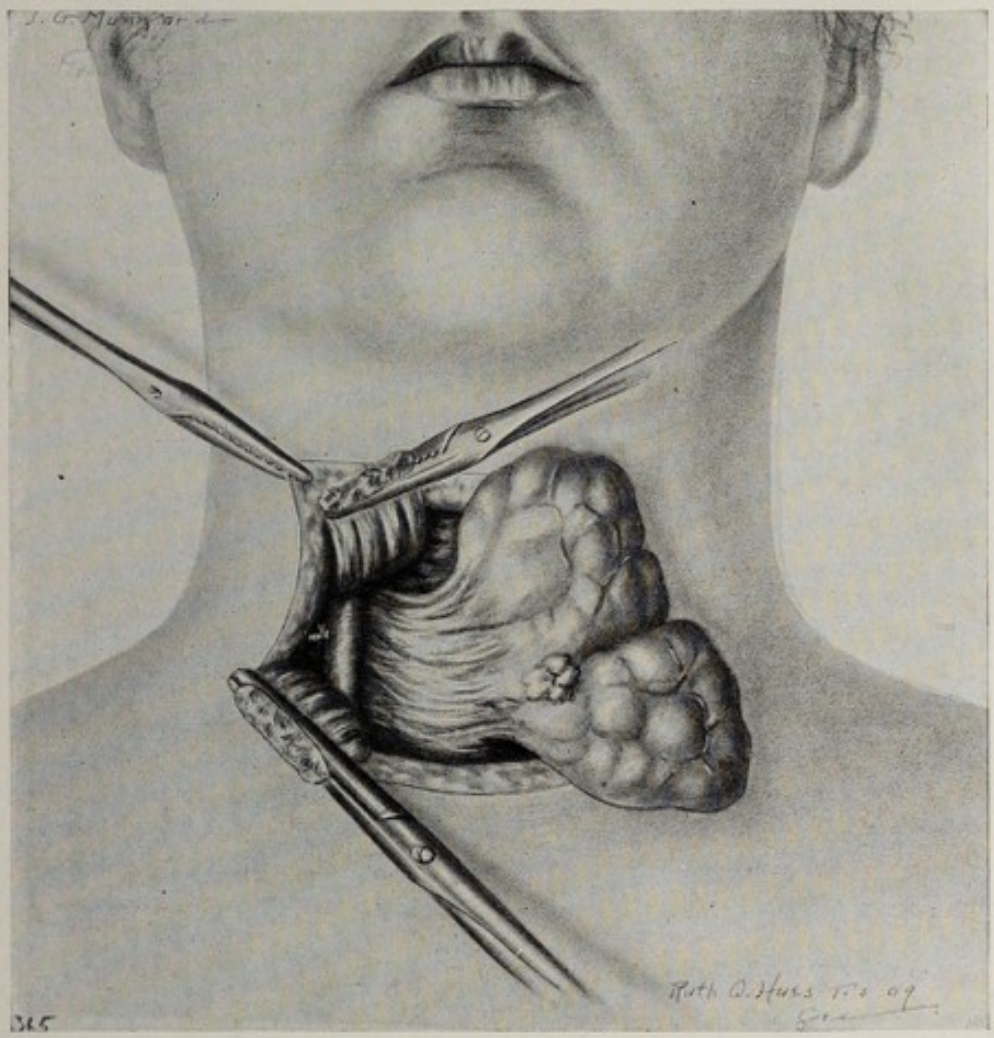

Fig. 396.—Cystic goiter, dislocated inward. Note severed sternothyroid muscle in clamps.

thetized patient, and that, with reasonable care, he should avoid damage to nerves. In a considerable experience I have seen no reason to abandon my own preference for ether anesthesia. The patient should be placed in a nearly upright position, with the head strongly extended over a roller, and the pneumatic suit should be put on ready for use in case an extensive operation is undertaken, or when there is reason to suppose that shock or hemorrhage is to be combated.

Kocher's method of *excision* or a modification of that method is the one most of us follow, and the student should remember always that ex-

cision means the removal of part of the gland only. Total extirpation of the thyroid gland and parathyroid glandules is absolutely unjustifiable, for such extirpation means tetany and death for the patient. Make a transverse crescentic incision from sternomastoid to sternomastoid. One cannot have too much room in which to work. Turn upward the skin and platysma, expose the sternohyoid, sternothyroid, and omohyoid muscles, divide them if necessary (they should be sutured into place later), and open transversely the external capsule of the goiter. This is the loose fibrous capsule which readily may be peeled back in all directions. At the same time the surgeon must be on the lookout for the frequent numerous large veins which pass from the capsule to the gland. These veins must be doubly ligated and divided. Now dislocate the goiter and pull it out of the wound, by this maneuver relieving pressure from the trachea. Before dislocating the goiter the surgeon must warn the anesthetist.

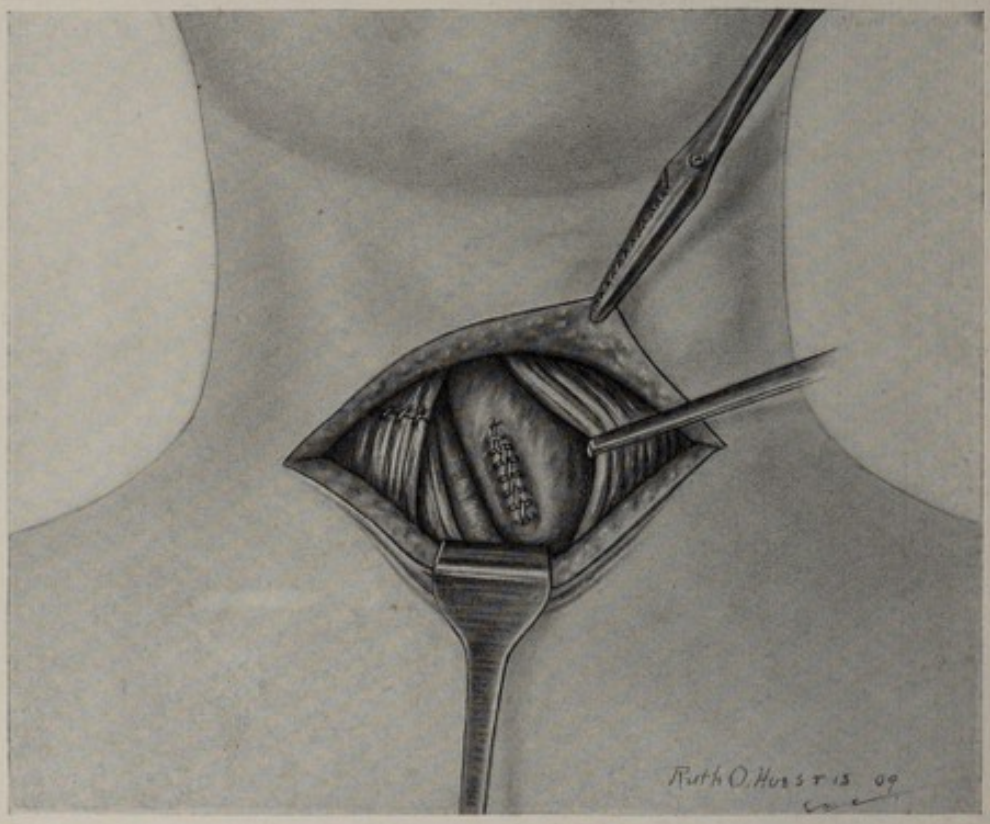

Fig. 397.—Operation of thyroidectomy completed. Sutures in stump and in muscle.

Next, doubly ligate carefully the superior thyroid artery and vein and divide them between the ligatures. Pull the goiter over toward the sound side, seek and find the inferior thyroid artery, which lies on the deep muscles of the neck, and tie it carefully—carefully, because close beneath it passes the recurrent laryngeal nerve. The thyroidea ima artery lies at the lower pole of the tumor and must be tied finally. The thyroid isthmus remains, and is readily dealt with by crushing with forceps and tying firmly with a linen ligature. If there be any further attachments, they are those which hold the gland by its inner margin with the trachea. Close at hand lies the recurrent nerve. It is well,

therefore, not to rip off these attachments, but carefully to dissect away the goiter at this point, leaving perhaps a little thyroid tissue to protect the nerve. The operation is now completed—it is not difficult, as a rule. The surgeon unites with catgut ligatures the cut superficial muscles, and sews up the wound throughout, providing at the same time for abundant tubular drainage, the tube to be removed at the end of twenty-four hours.

Such a description of thyroidectomy applies to removal of one lobe only of the gland. Frequently it happens that both lobes are extensively diseased or that the patient is the subject of exophthalmic goiter. In such cases the surgeon must remove a large part of the second lobe. He

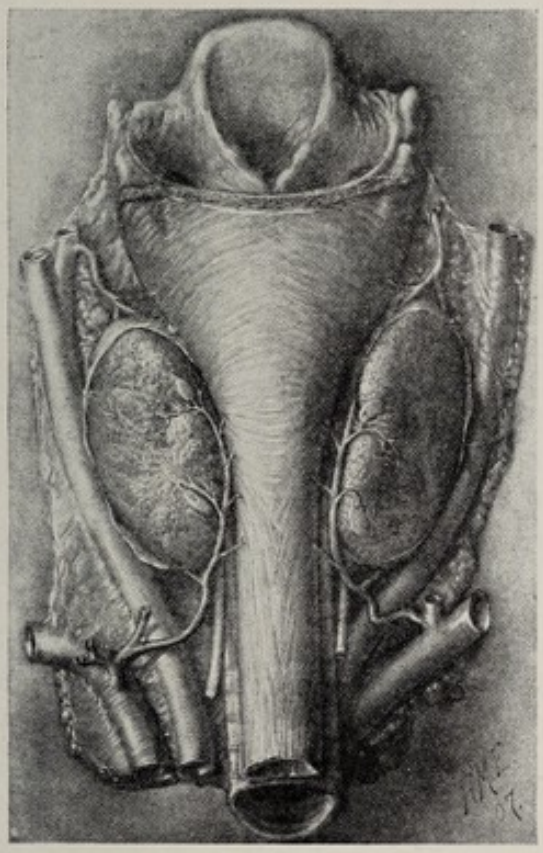

Fig. 398.—The thyroid gland and parathyroid glandules; blood-supply (posterior view) (Halsted and Evans).

leaves, for the sake of the thyroid function, a slice of gland adherent to the posterior capsule on one or both sides. By this maneuver he may feel sure that he is preserving also a sufficient number of parathyroid glandules. Before slicing off the thyroid he should tie securely the superior and inferior thyroid arteries within the substance of the gland. After removing the portion of the gland, it is well to cauterize with the Paquelin cautery the cut surface of the stump.

After thyroidectomy patients generally make a prompt convalescence. The modern operation should not be followed by severe symptoms; the patient should sit up on the third day and should be able to leave the hospital by the middle of the second week, with excellent prospect of permanent restoration to health.

Enucleation of goiter occasionally may be employed for the removal of nodules, especially when the other half of the gland is atrophied. *Resection*, after the method of v. Mikulicz, is useful in exceptional cases of diffuse goiter, especially when unilateral excision has been already performed or the tumor is very large in both inferior horns. It is a rather dangerous and bloody operation, and must never be done in cases of Graves' disease. *Exenteration* (or marsupialization) means incision of the tumor and evacuation of its contents. Exenteration may be employed when there are dense adhesions present, and in case of inflamed or malignant goiters, when a clean excision is impossible. Often we are forced to it in the case of intrathoracic goiter, especially when there is



Fig. 399.—Colloid goiter removed by author, leaving posterior capsule and part of left lobe (anterior view) ($\frac{1}{4}$ actual size).

danger of asphyxia and prompt relief is imperative. *Ligation* of the thyroid arteries is a useful procedure in the case of extremely vascular goiters, and especially as a preliminary to excision of the gland in Graves' disease.

Transplantation of the thyroid has been done in cases of myxedema and idiocy. The most successful case of this sort hitherto reported is that by Payr, to the German Surgical Congress in 1906. Payr implanted a bit of healthy thyroid from the patient's mother in the spleen of a girl of six years. Both patients recovered from the operation, and the psychic condition of the girl was improved at the time of Payr's last report.

Satisfactory as are operations for goiter, we must not lose sight of the fact that the tumor may recur so long as the underlying cause of the goiter formation persists. A "recurrence depends upon whether the operator has removed the factors which influence the growth of the tumor" (A. Kocher). Diffuse hypertrophic goiters recur rarely as compared with nodular goiters. In general terms, however, we may

assert that the recurrence of goiter is not common, but if compelled to operate upon such a recurrent tumor, we shall find difficulty often in dissecting through the mass of scar tissue and in leaving behind a proper amount of thyroid gland with the requisite parathyroids.

The thyroid gland is subject to sundry other affections far less common than goiter.

Malignant disease occurs in the thyroid gland—rarely, in the normal gland, commonly in a gland the subject of goiter; so that we may properly enough describe these growths as malignant degenerations of goiter. *Sarcoma* and *cancer* are the malignant tumors with which we are concerned. Sarcoma is far less frequent than is cancer—sarcoma of the spindle-cell variety, less often of the round-cell variety. These forms of sarcoma develop in nodular goiter and may be difficult to distinguish from lymphosarcoma. The tumor of sarcoma is soft and juicy. It attacks the walls of adjacent blood-vessels, and it undergoes softening. Metastases occur late, and the sarcoma kills slowly. There are other forms of thyroid sarcomata—fibrosarcoma, osteosarcoma, and angiosarcoma so called.

It is not possible always to differentiate these malignant growths from benign enlargements until the disease is far advanced. If metastases have not occurred, and if the sarcoma has not broken through the capsule proper, the tumor may be removed with a reasonable anticipation that it will not recur.

EPITHELIAL DISEASES OF THE THYROID

Epithelial disease of the thyroid gland is a fairly common disorder. Kocher's classification includes the following 7 forms: (1) Genuine carcinoma, which appears as a hard tumor, usually lobulated, the tissue opaque and dry, but tending to undergo softening, especially when it develops in a goiter; (2) proliferating goiter or malignant adenoma, which occurs either in nodules or diffusely throughout the gland, while the gland invariably contains portions of tissue of the normal thyroid type. Proliferating goiter has a firm, compact feel and is not large; (3) metastatic colloid goiter. This is a rare and curious growth, resembling closely the well-known nodular goiter; (4) papilloma, which may be nodular or diffuse; (5) cancroid squamous epithelial cancer—an extremely rare disease; (6) glycogen-containing epithelial goiter—a growth which develops in nodular goiter and grows rapidly. The cells are large and contain varying amounts of glycogen and large nuclei rich in chromatin; (7) small alveolar epithelial goiters, which are quite similar to the glycogen variety, except that the cells do not contain glycogen. Classes 1 and 2 are far the most common, and, when they occur, develop almost invariably in hypertrophic goiters and nodular goiters. These cancers are particularly interesting from the point of view of treatment. Often unexpectedly, one encounters them complicating a goiter presumed to be benign. Thyroid cancer, like cancer elsewhere, is marked by two characteristics—metastasis and extension to surrounding structures.

Unfortunately, the presence of these two features renders radical cure impossible, while the *diagnosis* is almost equally impossible before the development of these two features. For such reasons, if for no other, the goiter of a young adult should be removed if its growth cannot be controlled by iodin. And, further, the goiter of a middle-aged person invariably should be removed if it is seen at any time to take on a rapid growth, and particularly a rapid irregular growth.

The *treatment* of malignant goiter by operation differs in no important essential from the treatment of benign thyroid enlargement by operation, except that malignant disease must be removed more searchingly. Here again one encounters the problem of damage to the parathyroids, and finds one's self on the horns of a dilemma. If one must choose between complete thyroid extirpation for cancer and partial thyroid



Fig. 400.—Cancer of thyroid gland (Halstead).

extirpation for the sake of preserving parathyroids, one may be forced to concede that no operation whatever should be done. Fortunately, however, this predicament arises rarely, because operable carcinoma is confined usually to one side of the gland only. Far-reaching operations, involving structures outside of the thyroid gland, have been done frequently, but with questionable results. Surgeons have removed portions of the trachea and the esophagus, with permanent relief in a few cases. In one desperate case of cancer of the thyroid involving the trachea I obtained a symptomatic cure and relief for six months by removing all involved tissue down to the tracheal wall, leaving the wound wide open, and exposing to the direct Röntgen ray the remnants of the disease daily, and with enough persistence to keep up a mild dermatitis, following Crilé's method. At the best, however, there is little hope

for the cure of cancer developing in goiter unless the operation is done before the diagnosis of cancer is made.

Aberrant goiter exists. There are two forms: the genuine aberrant goiter, which has developed in embryonal remains of the gland; and false aberrant goiter, which develops in bits of gland secondarily and mechanically separated from the thyroid. The genuine form only need concern us. You will find the tumors in the median line always—an important diagnostic point. They lie above or below the hyoid, at the base of the tongue (lingual goiter), and much more rarely low down in the neck or behind the sternum. The *treatment* of aberrant goiter depends much upon the condition of the thyroid gland itself. If the thyroid be absent or its function impaired, one may succeed in curing the aberrant goiter by internal treatment; but if the thyroid gland be functionally intact, the aberrant goiter had best be excised.

Diseases of the parathyroids continue to engage the attention of clinicians and pathologists at this writing, and a few cases of parathyroid tumors successfully removed have been reported.

Inflammations of the thyroid gland are rare as compared with thyroid *tumors*, and inflammation of a goiter apparently is less common than is inflammation of the normal gland. We need not concern ourselves extensively with this subject further than to observe that inflammations are acute and chronic; that when *acute*, they give rise to the familiar symptoms of pain, heat, redness, and swelling; and when *chronic*, show slight enlargements of the gland with a proliferation of connective tissue, or present evidences of specific infection or of tuberculosis. The practitioner treats these inflammations on general principles—with applications, Bier cupping, opsonic vaccines, potassium iodid, and incisions.

In leaving the subject of disease of the thyroid gland one reflects that the topic is not yet complete, as are, for example, appendicitis and disease of the bile-passages, though one feels more and more strongly, as evidence accumulates, that all thyroid disease is coming within the surgeon's province—especially nodular goiter and Graves' disease. For this reason surgeons protest, as they have long protested in the case of appendicitis, that all diseases of these organs should be seen by a surgeon in consultation, for no man may say when or whether an operation may be necessary. Thyroid disease is a surgical disease.

PART VI

THE HEAD AND SPINE

CHAPTER XXIII

THE SCALP

Surgery of the head and spine, by which one understands especially the surgery of the nervous system, is beginning to occupy a far more important place than was thought possible less than twenty years ago; and those operators who have followed the course of the debate on the subject must have been impressed with a radical divergence of views in this field, associated always with a slow but steady progress, within the ken of the present surgical generation. In the later eighties, when operations within the abdominal cavity were becoming frequent and the confidence of abdominal surgeons was established, we tried to believe that an equally brilliant future awaited cranial surgery. The belief was founded upon our recently acquired appreciation of aseptic surgery. Men began to say that it would be no very serious matter to open the dura, to handle the brain, to explore its depths, and to remove its tumors; while operations upon the spinal column would increase likewise in frequency. Fortunately or unfortunately, the results of endeavors in neurologic surgery were not commensurate with the activity of enthusiasts. The death-rate continued high, the expected relief from symptoms was not secured or was found to be temporary only, and a resulting skepticism gradually was created from which to-day only are we beginning to recover. The painstaking and informing investigations of Waldeyer, His, Victor Horsley, Harvey Cushing, Frazier, Spiller, Walton, Starr, Von Bramann, Payr, Iselin, Wagner, Bereznegovsky, Auvray, Broca, Savariaud, and others are convincing the profession that there is a hopeful future in this field, but that neurologic undertakings are far more difficult in the diagnosis, the inception, the performance, and the after-treatment, than are similar undertakings in the field of abdominal surgery. Each operation, when it deals with the brain or spinal cord, must be carefully planned and studied, approached with a wise precaution, and carried through timely, elaborately, accurately, and intelligently. Already we see that the work on the nervous system by competent neurologic surgeons is far more effective than the often crude and hasty neurologic work of general surgeons; and so it becomes apparent that, for the present at least, and until neurologic surgery has been more highly developed, we must look to special experts for the best

results in the more obscure, difficult, and hazardous cases. Not that one would remove all head and nerve surgery from general surgeons—any well-equipped surgeon should be competent to open the skull, to drain a cerebral abscess, to open the spinal canal, and to operate upon the peripheral nerves; but as yet the judicious observer cannot but feel that the great uncompleted work on brain tumors and other structures within the skull is still pioneer work, and should be delegated to specially trained surgeons so far as they may be found. A serious obstacle hitherto to the more rapid and intelligent progress of neurologic surgery is the common ignorance of neurology on the part of surgeons and the ignorance of surgery on the part of neurologists. Our practice of referring neurologic cases to neurologists, in the first instance, who in their turn refer these cases to general surgeons for operation, must be deprecated. Our hope for the future lies in those surgeons who are versed in neurology —as yet a small and little appreciated band.

Before advancing directly upon the great subject of brain and nerve surgery it is well to consider in somewhat conventional fashion the more frequent diseases and injuries of the scalp and of the bones of the head and spine. More than twenty-five years ago Frederick Treves published his useful little book on applied anatomy, the first chapter of which deals with the scalp. So well did he exhaust the subject that nothing of material interest has been added to it since his first publication. The reader will remember that—

The *scalp*, or soft parts covering the vault of the skull, may be divided into five layers (the skin, the subcutaneous fatty tissue, the occipitofrontalis muscle and its aponeurosis, the subaponeurotic connective tissue, and the pericranium), and these five layers have their important influence in limiting or directing injuries and infections of the head. One perceives, therefore, that the skull has little external protection from violence, the only buffers of account being the thick temporal muscles on the sides of the head, the heavy occipital muscles behind, and the bones of the face in front. As Fowler observes, however, the elasticity of the cranial vault is such that, on account of its peculiar conformation, it may return to its normal shape after a severe blow, so that a contusion only of the soft parts may result.

CONTUSIONS OF THE SCALP

Contusions of the scalp are of importance only as they confuse diagnosis. A contusion is associated with extravasation of blood, and this extravasated blood in the scalp is so often sharply limited by dense aponeurosis or pericranium as to give to the examiner the impression of the sharp bony edge of a fractured skull. If the surgeon is satisfied, however, that the lesion is a contusion only, he need fear no ill results, and may treat the disturbance by ordering rest and cold applications. It is not too early in this discussion, however, to remind the reader that all injuries to the head should be regarded seriously and that the patient should remain quietly under observation for two or three days at least.

It is our habit at the Massachusetts General Hospital, in the case of a head injury in which there is the slightest doubt of diagnosis, to keep the patient in the ward until all suspicion of possible deep-seated damage is banished.

Hematoma of the scalp differs in degree only from simple contusion. If considerable veins or small arteries are torn, an abundant escape of blood may occur beneath the aponeurosis or skin. This may give rise to an extensive tumor covering half the head possibly. The blood-clot may become infected, with a resulting abscess formation. In any case if the clot does not disappear within a few days, the surgeon is justified in opening freely through the scalp, washing out thoroughly the blood and detritus, and closing the wound after providing for drainage. In each case in which such incisions are necessary the patient's head should be shaved over the area corresponding to the lesion. Wounds of the scalp heal rapidly, for the scalp is intensely vascular. The drain should be removed on the second day, and one should expect to find the line of incision closed firmly by the fifth day, when the stitches may be removed. A thick, elastic, gauze and cotton dressing, held in place by a head bandage, should be applied to these wounds, in order to absorb the discharges, and for the protection and comfort of the patient. Never use plasters.

Scalp wounds are the most common of extracranial lesions, and every practitioner first and last sees hundreds of them. They are easily cared for, as a rule. The familiar "broken head" of sporting parlance is a contused scalp wound commonly, and as the head is one of the most exposed parts of the body, it comes in for all sorts of violence. There is this interesting and rather peculiar fact about the effects of "cracks on the head": a straight cleft or incised wound apparently may be caused by a blow from any kind of implement—a knife, saber, bludgeon, brickbat, parlor floor, or bed-post. The scalp is so tightly stretched over the cranium that a sharp blow with the bluntest instrument causes the skin to tear in a fairly straight line, so that the appearance of an incised wound is produced, though about the wound there may be any amount of tissue crushed and disfigured. If incised wounds are transverse to the anteroposterior line of the skull and penetrate to the bone, they gape. Longitudinal wounds do not gape.

According to the nature of the wound, so shall you *treat* it. If it be incised, check the hemorrhage, clean the parts (after shaving the head about the lesion), and sew it up tightly. Incised scalp wounds heal promptly because the scalp's blood-supply is abundant. In two days you shall find the union sound. If the wound be contused, especially if it be filled with dirt, it must not be closed tightly. Shave the surrounding skin; cleanse thoroughly the damaged region; draw the edges of the wound together at two or three points with silkworm-gut stitches, leaving spaces for drainage, and apply a large absorbent dressing. In the case of such dirty wounds remove the dressings frequently and watch for erysipelas or extensive sloughing, which must be treated with irrigations, removal of necrotic tissue, and fresh clean dressings two or

three times a day. The ultimate source of anxiety in these cases is a possible extension of the infection through the diploë to the meninges.

A curiously striking, shocking, and disfiguring injury to the head is a complete scalping,—**avulsion of the scalp,**—an accident confined to women almost entirely, and to factory women, because the long hair of factory women becomes caught in machinery which tears the scalp from the head. The great raw wound which results, in its outline follows almost invariably the insertions of the occipitofrontalis muscle from eyebrows to occiput, and from ear to ear. The depth of the wound varies, depending upon the abundance and strength of the hair. The skin alone

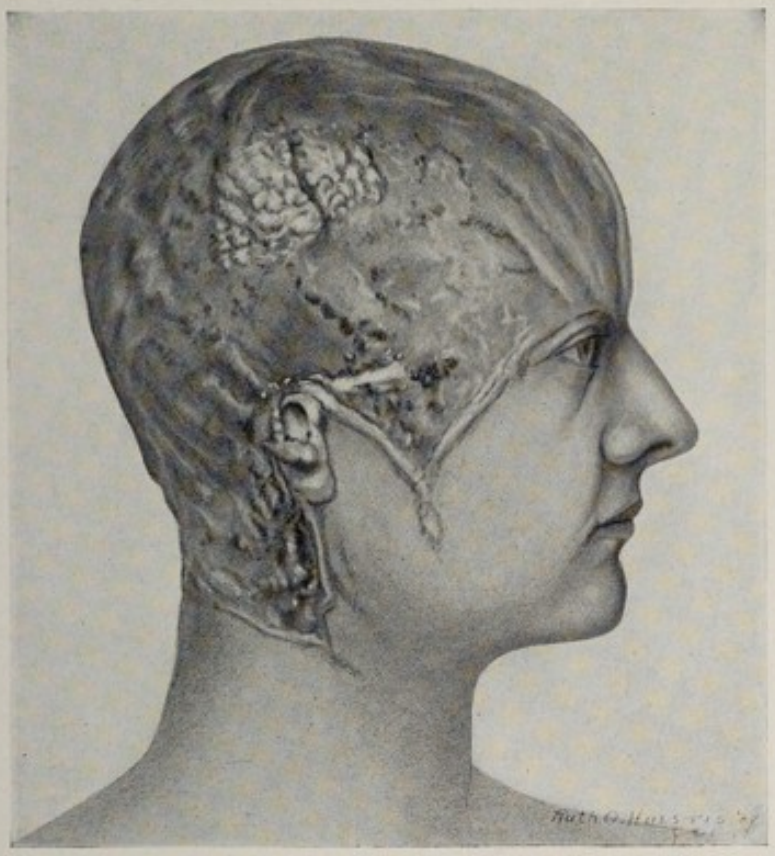

Fig. 401.—Avulsion of the scalp (Massachusetts General Hospital).

may be torn off, or all the soft parts may be involved down to and including the periosteum.

As Fowler points out, since these accidents happen to anemic and poorly nourished women, as a rule, the surgeon should begin *treatment* as soon as granulations have begun to form. The only treatment of any service is Thiersch grafting, over which the attendant must labor faithfully until grafts sufficient to cover the entire head have been taken. See to it that the grafts be not destroyed by needlessly tight bandaging.

TUMORS OF THE SCALP

Tumors of the scalp are extremely common—especially benign tumors; and of these, wens are far the most frequent. Wens are known

as sebaceous cysts. They appear to be epidermal inclusions, and grossly on dissection are found as thin-skinned sacs filled with sebaceous matter. They are often multiple, develop in any part of the head, are movable under the skin when not inflamed, and are easily removed. They are best taken out through a crescentic incision incircling the base. The surgeon burrows under the wen through this incision, lifts up the growth with the flap, and dissects off the wen from the flap. By working in this fashion he will get out the whole of the sac, which is essential, for a portion of the sac left behind may give rise to a recurrent wen.

Dermoid cysts of the scalp resemble wens, but they are less common, are congenital, and are usually found along the external portion of the supra-orbital arch and at the fontanels. The reasons for removing wens and other cysts are their increasing size and their absurd or offensive appearance.



Fig. 402.—Neurofibroma of scalp (Valentine Mott's case).

Helmholz and Cushing[1] describe an interesting case of **neurofibroma**[2] **of the scalp** (von Recklinghausen's disease), a rather rare condition giving rise to scalp tumors, with great relaxation of the scalp, sometimes allowing marked drooping of the ears or showing as pendulous, down-hanging masses from various parts of the head. The cure consists obviously in a thorough removal of the tumors and excision of portions of the scalp.

Other familiar but non-malignant tumors of the scalp are: cephalhematoma, lipoma, horns, and meningocele, a consideration of the last of which falls properly under the subject of diseases of the meninges (Chapter XXIV).

[1] H. F. Helmholz and Harvey Cushing, Elephantiasis Nervorum of the Scalp: A Manifestation of von Recklinghausen's Disease, Amer. Jour. Med. Sci., September, 1906.

[2] Molluscum fibrosum, see J. Bland-Sutton, Tumors Innocent and Benign, fourth ed., p. 145.

Malignant epithelial disease rarely attacks the scalp, and when it does so, is generally in the form of rodent ulcer, extending from the face, a description of which the reader will find in Chapter XX.

Sarcoma is a rare disease of the scalp. It has been observed occasionally in the occipital region, but is so infrequent that it may be regarded as a curiosity almost.

A characteristic phenomenon of the region of the scalp is **aneurysm** —generally the *cirsoid* or *racemose* variety. A simple aneurysm—a circumscribed dilatation of a portion of a single vessel—is very rare, but cirsoid aneurysm—a diffused dilatation of a number of connecting arteries—is not uncommon. This curious aneurysm, like varicocele of the scrotum, has been compared to a bundle of worms. Its appearance is striking and generally unmistakable. The arteries are enlarged in both circumference and length, and are forced into an extremely tortuous or serpentine course. One makes the diagnosis almost instantly by sight, while the touch confirms the impression of the arterial character of the disease. Far more rare than cirsoid aneurysms are *varices* of the scalp, which somewhat resemble aneurysm, but are less tortuous, are softer, and are devoid of pulsation. The *cure* of cirsoid aneurysm is by no means easy, and various different attempts at a cure have been made, with more or less success. The best course probably is that proposed by Dieffenbach, namely, to excise at repeated operations portions of the scalp bearing the aneurysm, allowing the wound to heal each time before operating again. Another excellent plan, to be adopted when the aneurysm is not too large, is totally to excise the aneurysmal area, with the skin, and fill in the gap with skin-grafts. Whatever the method employed, the surgeon will find the undertaking to present a nice and somewhat puzzling problem.

The practitioner will often encounter lesions and diseases of the scalp other than those I have enumerated here, but I have attempted in this chapter to discuss those problems only which are peculiar to the scalp itself.

CHAPTER XXIV

THE SKULL, BRAIN, AND MENINGES

In this chapter we shall consider an important group of subjects, and shall deal with regions and organs second in importance to none in the body. Many surgical writers have treated of the skull and brain as separate entities, and, anatomically, these structures are distinct; but clinically, lesions of the brain and of its bony covering are so intimately associated that the surgeon must always think of them together. Their injuries and diseases often give rise to a symptom-complex, while operations which deal with the one concern the other in great numbers of cases.

Surgery of the head ranks with surgery of the long bones as the most ancient form of surgery in the history of our art. Trepanning was practised in remote prehistoric times, as the skulls of Egyptians and Aztecs bear witness, while later Egyptian surgeons, followed by the Greeks and their disciples, the Romans, practised opening the skull, not only for the relief of fracture pressure, but for the cure of epilepsy. Throughout surgical history, the records of our best observers abound in descriptions of head injuries, and of the symptoms and operations for their relief, so that at the beginning of our own generation abundant material was in hand to aid us in such studies. Those former writings, however, were concerned always with a factor which marks off ancient cranial surgery from our own. Sepsis and its results were ever-present complications. Today, in considerable measure, we are not concerned with sepsis, except when treating fractures of the base of the skull. A *cracked skull* is a small matter in itself, for cracks in the bones of the head heal readily and intrinsically do no special harm. We dread a fractured skull for its complications and results; for the associated damage to the cranial contents.

Every general surgeon must deal with head injuries, though one may question the capacity of every general surgeon to deal adequately with many intracranial diseases. Let us consider broadly, therefore, certain important general topics: fractures of the skull—simple and compound, depressed and non-depressed, of the vertex and of the base; injuries to the brain—pressure, compression, hemorrhage, and other signs of cerebral disorder; injuries to and inflammations of the meninges; inflammatory affections of the bones and tumors of the bones; hernia and fungus cerebri; abscess, tumors, and foreign bodies within the skull; epilepsy, hydrocephalus, and the methods of demonstrating and treating these various profound lesions.

FRACTURES OF THE SKULL

We are taught that fractures of the skull group themselves naturally under four important headings—simple, compound, non-depressed, and depressed. From the earliest times a simple fracture of the skull has been taken to be a relatively trifling affair. It was formerly said, and is still thought by many careless practitioners, that a clean crack through the skull, without injury to the skin or depression of the bone, does no special harm. In some cases such a crack may do no special harm, but so diverse are conditions and so undetermined are the personal equations of patients that no man may say, at once or even after days and weeks, what will be the outcome of a skull fracture apparently simple and uncomplicated. The other day a man, two weeks convalescent from a crack on the head, was leaving the Massachusetts General Hospital to walk home. By chance he was met at the door of



Fig. 403.—Skull indented without fracture (Massachusetts General Hospital).

the ward by the visiting surgeon, who noticed a suspicious uncertainty in the man's steps. The surgeon countermanded the order for discharge and sent the man back to bed. That night the patient lapsed into unconsciousness and was dead within a week. At the postmortem a large area within the skull was found to be occupied by blood-clot and disorganized brain. The obvious skull damage was of no moment, but the concealed damage was fatal. Harvey Cushing gives us an interesting story of a young man who was tilted out of the back seat of a wagon and fell upon his occiput. His physician could find no evidence of external injury, and treated the case lightly as a probable simple fracture without depression; but undoubtedly there was considerable local hemorrhage between the bone and dura. At any rate, after two months the patient became an epileptic, and finally a year later, when he was operated upon, the surgeon discovered an adherent dura and a depressed scar over Broca's convolution. An experience of such cases gives one pause, and

leads to the conviction that any persistent symptoms of intracranial damage call for a trephining and exploration within the skull.

Such considerations will suggest to the reader the extreme difficulty of making a prompt and exact diagnosis of head injuries, and will indicate also the uncertainty of the surgeon when he comes to their treatment. The unique conformation of the skull adds to the difficulty of diagnosis, for in the skull we have to deal with an outer table, a diploë (corresponding to the medullary cavity of long bones), and an inner table. In the case of a simple fracture it *may* be possible to determine the extent of the injury by touch or by consideration of the immediate symptoms. Moreover, in young children, after an injury, there may exist a depression of the skull, without fracture, corresponding to the so-called green-stick

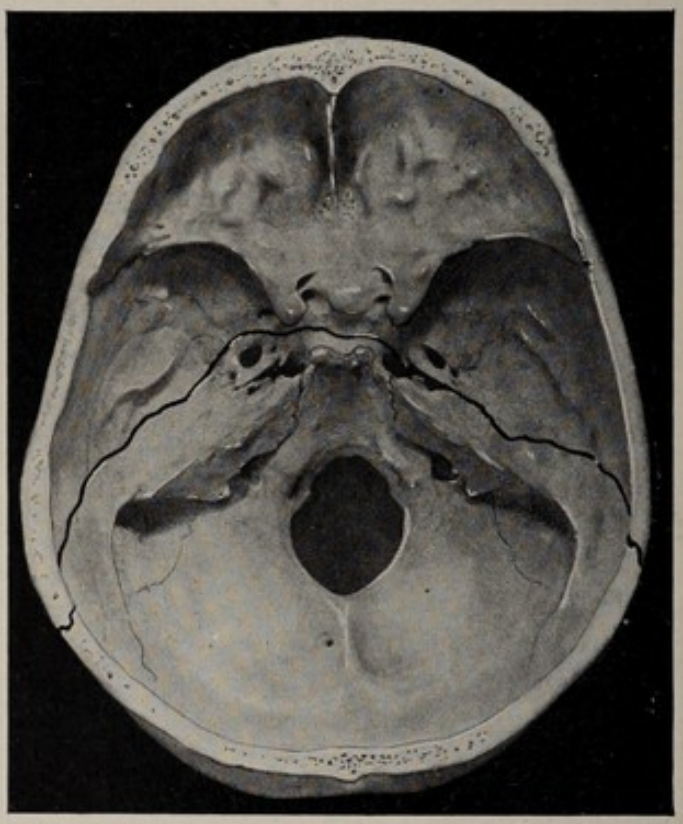

Fig. 404.—Incircling fracture of the skull (Keen's Surgery).

fracture in the long bones.[1] While a simple crack of the outer table is harmless enough, it is often impossible to say whether or not the inner table be damaged also, and we know that a trifling lesion of the outer table often is associated with an extensive lesion—splintering and depression—of the inner table.

One must distinguish also the difference, often vital, between simple fracture of the *vault* and fracture of the *base* of the skull, bearing in mind always that the two may be associated, on the one hand, as independent lesions, or, on the other, as a continuous lesion, in as much as a crack beginning in the base may run around to the vault (fracture by extension) partially or entirely incircling the skull. Conventional writings describe independent fractures of the vault and independent fractures of

[1] See also interesting case reported in Ann. Surg., April, 1910, by W. H. Luckett.

the base, but clinically one may not always draw such a distinction between these two fractures.

Most fractures of the vault are due obviously to direct violence—to a blow or fall upon the head—and these causes of injury are evident enough; but one variety of fracture of the vault deserves special mention—the *punctured fracture.* Recently I was asked by a physician to see a little boy whose history of injury ran somewhat as follows: Twenty-four hours before I saw him he was playing in a street trench which was being excavated for the laying of pipes. In the midst of his play he ran home with a thin stream of blood trickling through his hair, and told how a heavy, sharp-pointed spike had fallen upon the top of his head. The physician who was called thought little of the matter at first, but became alarmed after a few hours when the boy lapsed gradually into unconsciousness. I opened the skull and showed the condition to be one of punctured fracture of the inner table, with laceration of the meninges and brain, and extensive intracranial hemorrhage with meningitis.

The cause of *fracture of the base* of the skull is not always so obvious. Commonly, basal fractures are independent of fractures of the vault. We used to hear of fracture by *contrecoup*, and of fractures due to a compression and bursting force, but these explanations of basal damage and fracture no longer are held tenable, and physicists have come to accept Aran's theory of irradiation, perhaps with modifications, as explaining fracture opposite to the side on which the blow fell. Certain it is that in many cases force exerted upon one side of the head demonstrates itself by a lesion on the opposite side—at the base or elsewhere. However, direct violence is by far the most common cause of basal fracture—direct violence applied either from above or below. A crushing force descending from above may crowd the base down upon the spinal column; or a man falling from a height and landing on his feet may have his skull driven down and crushed at the base, in the same manner as when a carpenter forces down the head of his hammer by striking its handle upon the bench. A fracture of the base is more apt to be compound than simple. A glance at a skull will remind the reader that its base is divided into three fossæ—the anterior fossa, marked by the lesser wing of the sphenoid; the middle fossa, bounded by the lesser wing of the sphenoid in front and the petrous bone behind; and the posterior fossa, extending from the petrous bone to the lateral sinus behind, and containing the whole of the foramen magnum and basillar process. From this arrangement of parts the student will perceive that *simple* fracture of the base of the skull occurs in the posterior fossa only. Fracture of the anterior fossa becomes at once compound through opening into the sphenoid sinuses or upper nasal passages, so that blood and cerebrospinal fluid escape through the nose. Fracture of the middle fossa nearly always involves the petrous bone, and so becomes compound by communication with the outer air through the external auditory canal, by which blood and cerebrospinal fluid escape; but fracture of the posterior fossa, unless the basilar process be broken and the pharynx be

opened, remains simple, so that extravasated blood shows itself late, under the skin only, below the mastoid process.

Compound fracture of the vault differs from simple fracture of the vault in no material fashion, so far as anatomic changes are concerned, except that in compound fractures the damaged bone and deeper parts are exposed to the air through the rending of the soft parts, so that there results often septic infection of the brain and its coverings.

The characteristics of skull fractures vary. There may be a simple crack of the outer table or of both tables; there may be splintering of the bone into sundry fragments; and there may be depression of the broken bone, fragments being driven in and made to impinge upon the meninges and brain. The meninges may be torn, the brain may be lacerated, arteries and veins may be divided, hemorrhage may take place within the skull where the blood may lie compressing the brain, or the blood may make its way outward; while an extensive edema of the brain itself—the result of its rough treatment—may become established.

With this understanding of the appearance of fractures of the skull—of the vault and of the base, simple and compound—let us now consider the vital consequences which may follow these head injuries; bearing in mind always that whereas the symptoms due to simple fracture are dependent on pressure and possible laceration, in compound fracture, on the other hand, there are added often to these symptoms the grave evidences of sepsis.

The **symptoms and signs of simple fracture** of the vault are elusive. It is by no means easy, always and at once, to determine the presence of a vault fracture, because bruising and swelling of the soft parts may so mask the damage to the bone that one cannot accurately feel the fracture. In such case the surgeon may conclude that he had best wait for subsidence of the swelling or the development of later symptoms before making his diagnosis. The *x*-ray may decide the question. On the other hand, extensive fracture with marked depression of the bone may be instantly obvious. Should the patient's condition be at all serious—that is to say, should there be present unconsciousness or other evidences of cerebral disturbance—the surgeon had best turn back a flap of soft parts so as to determine the condition of the skull. *Compound fracture*, on the other hand, can be made out easily, for through the rent in the soft parts, enlarged, if necessary, the surgeon may introduce his gloved finger and feel the broken bone, taking pains always not to mistake normal suture lines and Wormian bones for a fracture.

Beyond the signs demonstrated through digital exploration there are sundry other evidences which may lead one to the conclusion that serious internal damage exists, and we shall now consider some of the classic symptoms of head injury.

Concussion of the brain may or may not be associated with fracture. Doubtless concussion is in itself a genuine entity, which alone may cause death, or, when associated with obvious brain lesions, may be a contributory cause of death. Since 1677, when Borel first described

concussion, the word has been familiar to surgeons, though their definition of concussion frequently has changed. We regard concussion as a positive condition, not anatomically demonstrable, not to be confused with contusion, compression, and laceration. A concussion of the brain results from a heavy blow or a series of light blows on the skull, and the experiments of Kocher, as explained further by Tillman, enable us to formulate the hypothesis that the violence inflicted upon the skull is transmitted to the brain, which, inclosed in its air-tight capsule of bone, is set in motion by the force of the blow. Since the white brain substance is of a higher specific gravity than the gray, it continues in motion for a longer time than the gray, with a hypothetic resulting distortion along the boundary between gray and white matter, which causes the loss of consciousness.[1] This explanation of concussion suggests that the distinction between *concussion* and *contusion* is one of degree only—indeed, Kocher assumes that concussion is a form of contusion, and proposes to drop the word concussion from surgical literature. However, since a contusion is commonly associated with actual and obvious anatomic changes, and since concussion is not, it seems well to the writer to retain the old word.

Concussion gives us a distinct clinical picture. The patient is unconscious; he appears to sleep; he breathes rapidly or irregularly; his pulse becomes slow, sinking to 40 or even less, but if the patient dies at this stage, the pulse rises and flickers toward the end. If he recovers, it rises slowly and strongly. In slight degrees of concussion the unconsciousness may be less marked, or so transient as to escape observation. There exist pallor and vomiting also, but the vomiting occurs once only, as a rule. There are often profound vasomotor disturbances. The reaction comes gradually; early or late, when consciousness returns, the face becomes reddened and the pulse grows full and strong. This stage of reaction is sometimes followed by glycosuria, polyuria, and albuminuria.

A favorite old examination question for medical students is—distinguish between concussion and compression of the brain.

Compression of the brain implies a distinct anatomic change within the skull—the presence of some unwonted substance pressing upon and crowding the brain from without. As Dennis has pointed out, one must not confuse the terms *compression* and *pressure*. Compression may be due to an effusion of fluid (blood or cerebrospinal fluid) beneath the skull, pressing upon the brain, a condition usually resulting from traumatism, the rupture of a blood-vessel, or from depressed bone. Pressure (intracranial pressure) is due to a force acting from within the brain. For instance, a growing tumor, or the collection of fluid within the ventricles, may raise greatly the intracranial tension and so give rise to pressure symptoms. It must be obvious that the compression exerted by a mere depression of bony fragments is not likely to cause immediate and profound symptoms unless there be associated damage to the brain, with extensive escape of fluid, or cerebral edema. The

[1] Von Bergmann, System of Surgery, American edition, vol. i, p. 186.

symptoms which occur in compression are probably due to the flowing out of cerebrospinal fluid from the meningeal spaces into the general ventricular cavity, into the spinal meninges, and by the opening of the inferior boundary of the fourth ventricle. Von Bergmann pointed out that, by the removal of this fluid support from the brain in the area where the large vessels enter, direct systolic impressions are conveyed to the cerebral mass. We have seen how the acute cerebral disturbances of concussion are due to mechanical violence, apparently affecting the brain in all its parts. In compression, on the other hand, the cerebral disturbances are not due directly to the traumatism, but to a secondary slowing of the circulation. In other words, the symptoms of compression of the brain are the result of a retarded circulation of fresh oxygenated blood. Cerebral anemia results. This slowing of the circulation, associated with the fall in the pulse, checks the activity of the central nervous system. There result certain characteristic *symptoms*, and these symptoms are to be divided clinically into two stages: the *stage of stimulation* and the *stage of paralysis*. That first stage of stimulation appears to be due to (Kocher) a compensatory rise of blood-pressure, which follows immediately upon the early increase of intracranial tension. In that stage the patient complains of headache, and he vomits; he is restless, delirious, with a flushed face and *contracted* pupils, while at the same time the observer finds with the ophthalmoscope choked disk; and the Riva Rocci apparatus shows a constant rise of blood-pressure, while the pulse slows. Afterward there comes the stage of paralysis. Increasing pressure within the skull causes increasing cerebral anemia; stupor and unconsciousness deepen into coma. The respiration becomes stertorous and of the Cheyne-Stokes type; the pulse becomes rapid and soft; feces and urine are passed involuntarily, the breathing becomes more or less irregular until it ceases, the heart beating for several minutes after the respiration has stopped, until death ensues.

It is worth our while briefly to consider in some detail these various symptoms. The *headache* is instantly present, growing more intense, always persistent, rarely localized, and is easily aggravated by motion or by external pressure. The *vomiting* is sudden, spontaneous, and not preceded by nausea. It is more persistent than the single act of vomiting seen in cases of concussion. *Headache, vomiting,* and *blindness* compose the triology indicative of serious intracranial disturbance of whatever origin, and we have seen that the choked disk leading to blindness frequently results from traumatic compression. In the early stage of compression the patient is constantly *restless,* rolling his head, groaning, and tossing his body. As the stage of paralysis supervenes the *pulse,* hitherto slow, becomes rapid—a most unfavorable sign, indicating an approaching paralysis of the vagus. In the stage of stimulation the *pupils* are contracted, but later, with coma, the pupils become widely dilated, as a rule; though rarely, and as a result of some special local irritation, they may vary, may contract and respond slowly, if at all, to light. Note the condition of the conjunctival reflex; if that is gone, the pupils will not react to light. The condition of the pupils, as I have described

it, applies especially to cases of general intracranial pressure, but a further and confusing situation arises when compression is exerted upon a portion of one cerebral hemisphere only. In such a case the pupil on the affected side is wont to be dilated and motionless even. *Choked disk* begins early, and continues to the end if the patient does not recover, and choked disk, if present while the patient is unconscious, and if long enough continued, leads to blindness. *Unconsciousness* may come on suddenly or gradually and may be partial or complete. Sudden unconsciousness is due to concussion or to apoplexy. A slowly increasing hemorrhage causes gradual unconsciousness. *Stupor* does not signify complete unconsciousness, for the patient in stupor may be roused to recognize his surroundings. Profound *coma* implies complete unconsciousness, the impossibility of being roused, abolition of the reflexes (which may have been active in the early stages of compression), flaccid muscles, incontinence of feces, and incontinence or retention of urine. The *temperature* is significant. For a short time after a head injury the temperature is always subnormal, indicating a condition of pronounced shock in which the patient may die. If the patient reacts from shock, the temperature rises, ascending many degress—up to 105°, 106°, or 107° F. This steady rise is a grievous sign. In other cases the temperature reaches a moderate height and there remains, marking time for a while. Its subsidence is a favorable sign; its subsequent rise, a fatal sign. These variations of the temperature—subnormal, high, and steadily rising, and moderate without variation—are important prognostic signs. The *nervous phenomena* are extremely interesting in cases of pressure and compression. If the compression be sudden and excessive, there results always coma without voluntary movement. General paralyses or paralysis of one side only (hemiplegia) may be present and depend upon the site and extent of the head injury. A general and excessive compression of the brain or the intrusion of a foreign mass, such as a blood-clot, between the brain and the bone at the base accounts for the symptoms of general paralysis. The presence of a foreign mass at one point, either over the vertex or at the base, without excessive general compression, gives rise to special localized nervous phenomena, such as accentuated reflexes at first from overstimulation, followed later by local paralysis as the pressure increases or is prolonged.[1]

The course of the symptoms depends upon their cause, and whether the pressure be exerted continuously, or be modified or relieved. One perceives, therefore, that continued bone depression produces permanent and constant encroachment on the cavity of the skull; extravasated blood may increase in volume so as to destroy life by compression, or the hemorrhage may be checked, or the blood may escape outward; an abscess rapidly forming progresses continuously and causes constantly increasing pressure. The surgeon, therefore, must watch carefully the symptoms to determine whether pressure is increasing, is stationary, or is diminishing. Lapse of time after the beginning of pressure symptoms is another important factor in the problem. A high

[1] L. B. Rawling, Lancet, April 9, 16, 23, 1904.

degree of pressure, lasting for a short time and then relieved, may not kill the patient, while a persistently moderate pressure eventually may destroy the individual, and one must remember that persistent pressure leads to increasing cerebral edema and a consequent further increase of tension. There is one common and most serious cause of compression which demands some further consideration:

Hemorrhage.—Let the reader remember that intracranial hemorrhage may be either traumatic or spontaneous. The vast majority of spontaneous hemorrhages come from the lenticulostriate artery and cause apoplexy, a disease within the province of the physician, in most cases. We have to consider here *traumatic* hemorrhage, in which the commonest source of bleeding is one of the branches of the middle meningeal artery. An uncommon source of bleeding is a torn sinus, or there may be a rupture of one of the small vessels in the pia. The middle meningeal artery is a branch of the internal maxillary, in its turn one of the main divisions of the external carotid. The middle meningeal enters the skull through the foramen spinosum, divides into three branches,

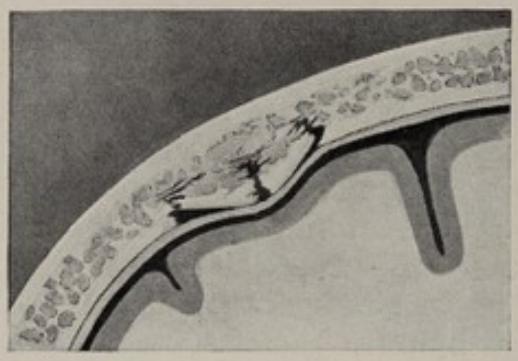

Fig. 405.—Fracture of the inner table with outer table intact (Campbell).



Fig. 406.—Fracture of the outer table with the inner table intact (Campbell).

and passes up on the inner surface of the cranium, which it furrows deeply, lying outside of the dura. This extradural position of the middle meningeal is important and significant in the case of head injuries, for damage of the middle meningeal causes extradural hemorrhage. Now there are three forms of traumatic intracranial hemorrhage: (1) *Extradural;* (2) *subdural* (between the dura and the brain), and (3) *cerebral* (within the brain substance). *Extradural hemorrhage* is probably the most common form seen in accident surgery, and the fashion in which the patient was hurt seems to have little bearing on the production of hemorrhage. Splintering and depression of the bone are not necessary. A short time ago I saw in the accident room of the Massachusetts General Hospital a boy of ten who had been struck above the *left* ear by a carriage-pole some two hours before he was brought to the hospital. He had been knocked down and dazed, had risen, vomited, and staggered (concussion); he had walked home, where, as his mother told me, he suffered from twitching of the *left* arm and became stupid. He was brought into the hospital. When I saw him he was in a state of increasing stupor, as the house surgeon testified; his left arm and leg were in a

state of paresis; both pupils were contracted and failed to react; the pulse was slow and hard, with tension of 180, and the whole condition was obviously one of increasing cerebral compression from hemorrhage. There was a slight bruise over the left ear, but no palpable evidence of fracture there. The reader will observe that the local symptoms of paresis were on the *left* side, indicating a cortical brain disturbance on the *right* side. I relate these facts in order to show how a severe and alarming lesion—a rupture of the middle meningeal artery—may arise without direct violence to the affected artery. In this boy's case the damage was by *cont ecoup*, as we still say. The blow upon the left side of the head had ruptured a blood-vessel on the right side. The subsequent conduct of the case was obvious, and the course satisfactory. The skull was opened over the anterior branch of the right meningeal artery; the torn vessel was found and tied; an extensive extradural blood-clot was washed out; the patient's symptoms improved instantly, and eventually he recovered. This story demonstrates a possible but somewhat infrequent cause of meningeal hemorrhage—indirect violence.

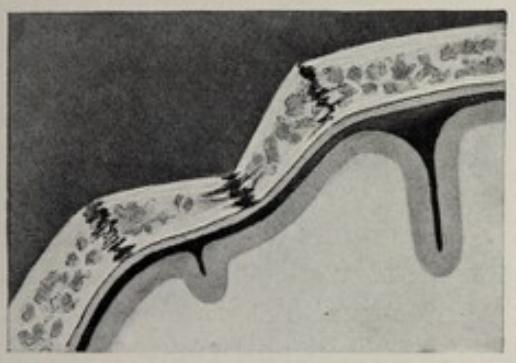

Fig. 407.—Both tables fractured and depressed (Campbell).

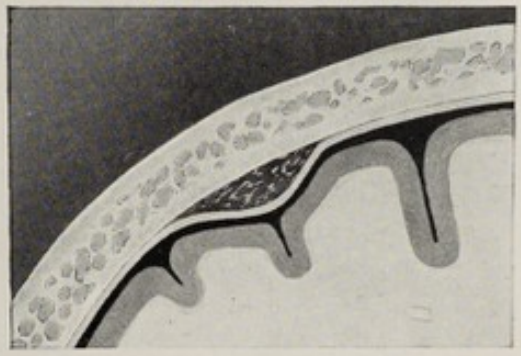

Fig. 408.—Compression of the brain caused by collection of blood or pus between the bone and the dura mater (Campbell).

A far more common cause is direct violence, with crushing of the skull over the vessels, and a tearing of the artery by splinters of bone. In either case unconsciousness may be delayed, so that stupor and coma are late symptoms, provided the initial violence has caused no marked concussion. With the enlargement of the clot toward the base the pupil on the same side ceases to react to light, becomes motionless, and dilates widely, while if the clot be on the left side, aphasia occurs. Then, with the continued bleeding, other cortical centers are involved. The face becomes paralyzed, and there follows paralysis of the arm, and finally of the leg, as the blood-clot extends up over the vertex. Convulsions are rare; the pulse becomes slow, strong, and full; the breathing labored and irregular, while the temperature falls at first and then rises, as I have already described it. Should the fracture be compound, blood and lacerated brain may be forced out of the wound, provided there be tearing of the dura.

Subdural hemorrhage is commonly due to depressed fracture, as I have said—to depressed fracture with a tearing of blood-vessels. It is

not always possible to distinguish subdural from extradural hemorrhage, for the symptoms of the two are usually identical. Commonly, however, subdural hemorrhage is associated with most active symptoms, with early coma and rapid fall in the temperature. An extremely important diagnostic measure is lumbar puncture, by which blood-stained cerebrospinal fluid is drawn.

Cerebral hemorrhage presents symptoms identical with those of apoplexy, and the treatment of the two conditions is the same, except that it is permissible, though hazardous in the case of cerebral hemorrhage from trauma, to ligate the common carotid artery on the side affected.

Compound fracture of the skull sometimes causes the rupture of a venous *sinus*, and occasionally sinuses have been wounded in the course of an operation. Obviously, the symptoms of hemorrhage from such a wounded sinus are quite similar to the already described symptoms of arterial hemorrhage, except that venous hemorrhage is slow and is controlled easily by pressure.

Harvey Cushing, writing in 1902, 1903, and 1905, demonstrated, in papers of remarkable interest, the possibility, if not the vital importance, of operating for the *intracranial hemorrhage of the new-born*.[1]

All physicians know the sad results of these hemorrhages in babies —results which have been grouped under the common term "birth palsy." These infants do not always die at once—indeed, they may live to grow up and attain to old age even. The immediate effects of these birth hemorrhages are seen in convulsions, followed by paralyses of one or both sides; by loss of vigor; by gastro-intestinal disturbances, stupor, coma, and death. Or if the hemorrhage be slight and confined to one side only, there may result corresponding paralyses of the leg, the arm, and the face, and the patient will survive to reach maturity in this crippled condition. Some of the victims become epileptics. Some are idiots. Cushing vigorously maintains the thesis that many of these infants may be saved with functions unimpaired; and his experience in a number of cases bears out his contention.

The hemorrhage is usually venous, and is due to rupture of some of the delicate and poorly supported venous radicles of the cerebral cortex. The cause of the rupture is some birth violence—the application of forceps, the undue overlapping of the cranial bones, or possibly asphyxia of the baby. Cortical hemorrhage is a common cause of infant mortality in those babies which die soon after birth, for the collections of blood may be as large as a cerebral hemisphere, and may penetrate into the cerebellar fossa even.

These cases are grave, urgent, little understood. Many of them can be made mild and simple, and should be recognized at once. A competent surgeon should be called to open the skull through a bone-flap, wash out the clot, restore the dura, and replace the severed outer parts.

Contusions of the brain comprise another variety of injuries asso-

[1] The Mütter Lecture for 1901, Amer. Jour. Med. Sci., September, 1902; ibid., June, 1903; ibid., October, 1905.

ciated often with the conditions we have discussed—fracture, concussion, pressure, hemorrhage. Contusions of the brain are conditions about which generations of surgeons have wrangled, confounding and identifying contusion with concussion. I have explained how such eminent authorities as Keen and Kocher regard concussion as a mild grade of contusion. In this writing I follow the teaching of von Bergmann, who limits the term contusion to those brain injuries which are actually associated with gross anatomic damage to the tissue. We distinguish also between *contusions* and *wounds* of the brain. A blow upon the skull which damages the underlying brain without exposing it to the outer air, whether the skull be fractured or not, produces a *contusion* of the brain. A blow upon the skull which damages the underlying brain directly by fracture and exposes it to the outer air results in a *wound* of the brain. Contused brain may vary in extent from a trifling point to an area as large as a whole cerebral hemisphere. Contused brain is a mass of blood, cerebrospinal fluid, and disorganized, crushed brain tissue. Contusions of the brain may be multiple or single, while the results and subsequent course of the contusion vary remarkably. Since there is no avenue for the advent of infecting organisms, sepsis does not follow contusions. At first there may be many of the symptoms characteristic of concussion and pressure. There may be unconsciousness, coma, vomiting, slowing of the pulse, a fall of the temperature, stertor, paralyses, choked disk, and the other familiar symptoms. If recovery ensues, the symptoms may disappear wholly or in part, but usually certain stigmata remain or develop, such as blindness, paralyses, epilepsy, or insanity; and these stigmata are due to the curious partial or ineffective healing of the damaged brain, which goes through a routine of reconstructive changes: blood and brain tissue are dissolved and absorbed, so that at the site of the contusion there results a cleft or cavity which becomes filled gradually and transformed into a *scar*, while sometimes a so-called *cyst* persists. Certain it is that extensive traumatic defects of the brain are not closed by a regeneration of brain tissue. Moreover, one sees occasionally cases in which, during the course of years, a degeneration of the nervous elements takes place, proceeding far beyond the limits of the original injury—yellow softening.[1]

Such in brief are the characteristics, conditions, and results of cerebral contusion, and one feels often that immediate death would be the happiest lot for the unfortunate patient.

Wounds of the brain take on many of the characteristics of contusions, but in the case of a wound, sepsis frequently lends additional gravity to the disaster.

Writers commonly divide wounds of the brain into three classes—*punctured*, *contused*, and *lacerated*. Such an artificial division is by no means always obvious—especially the distinction between contused and lacerated wounds. Nor is the distinction vital. Suffice it for the practitioner to recognize a penetrating wound of the skull with damage to brain tissue and the opening of an avenue for sepsis. The

[1] R. U. Krönlein, in von Bergmann's System of Surgery, vol. i.

history of brain injuries abounds in curiosities and amenities. Surgical writers from the times of Paré and of Larrey to the most modern of the Japanese tell numerous stories of the destruction and loss of brain tissue; of projectiles traversing the brain, and of foreign substances lodged in the brain, without subsequent notable results. These occurrences are in striking contrast to the deaths following slight blows on the head—deaths due to the tearing of vessels, with subsequent hemorrhage and compression. Punctured wounds of the brain are among the most curious of all the curiosities in our records, and none is more

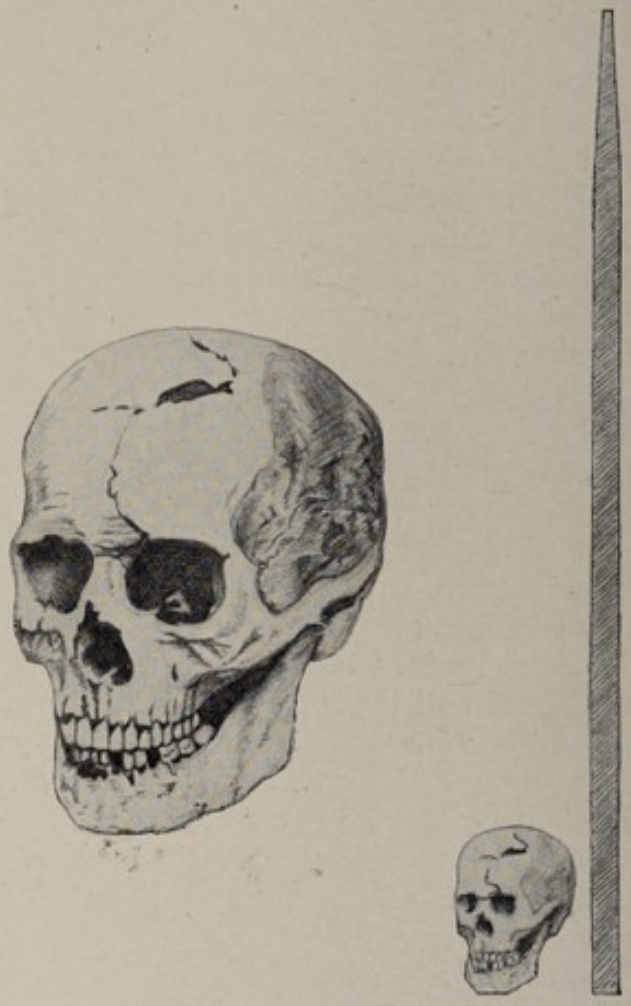

Fig. 409.—The Harvard "crow-bar case," with subsketch showing relative size of skull and crow-bar.

interesting than the famous "crow-bar" case of the Harvard Medical School—a case in which a quarryman's tamping iron entered from below the anterior fossa of his skull, passed out through the vertex, and left the man not much the worse for his surprising adventure. Years afterward when he died both the skull and tamping iron were recovered, and now repose together in the Warren Museum at Harvard.

It is needless in this place to rehearse the signs and symptoms associated with wounds of the brain. Those signs and symptoms are quite similar to the evidence of brain injury which I have already described—though one must constantly bear in mind the dangers of

sepsis in the case of brain wounds, and the frequent late evidences of sepsis. There are three forms of sepsis, to be studied further and later. Suffice it here to note the three: meningitis, cerebral abscess, sinus thrombosis; and to observe that, of the three, meningitis develops early—in from thirty-six to forty-eight hours after the injury; abscess, early or late—as early as the fifth or sixth day, as late as the third or fourth year; while sinus thrombosis appears usually toward the end of the first week.

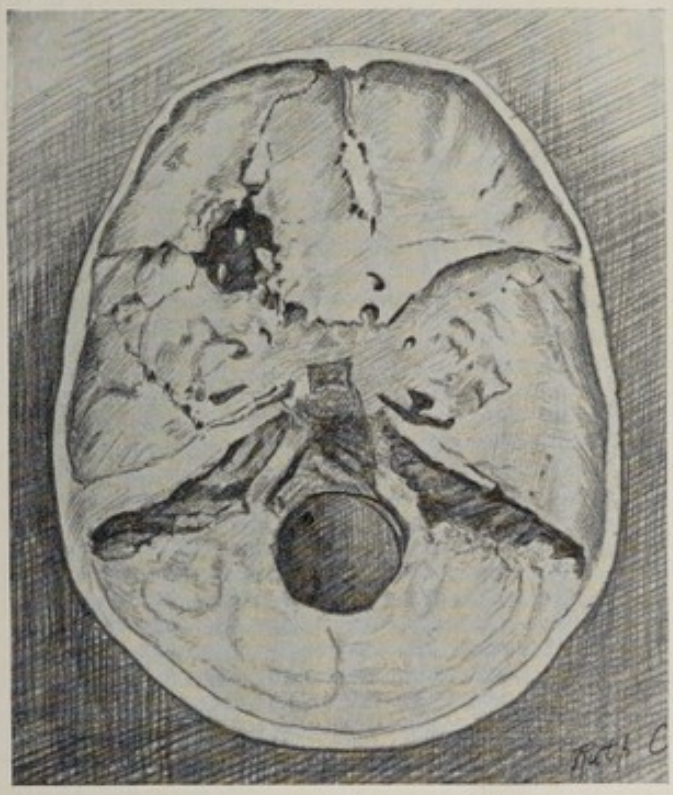

Fig. 410.—Harvard "crow-bar case." Note wound through anterior fossa on left. Patient lived many years after the accident.

In speaking of concussion and compression a few pages back I referred to the favorite old examination question—the distinction between concussion and compression. We are now ready briefly to sum up that distinction:

In Concussion.	In Compression.
The symptoms appear immediately after the accident.	The symptoms are usually delayed, and appear after a free interval.
Unconsciousness and vomiting.	Restlessness, stupor merging into coma.
No localizing symptoms.	Convulsions or paralyses indicating local cerebral damage.
The pulse is slow without increase of tension.	The pulse is slow and of high tension.
The respiration is slow.	The respiration may be stertorous or of the Cheyne-Stokes type.
The temperature changes little.	The temperature falls at first and then rises.
The pupils may be dilated or contracted.	The pupils are usually unequal—dilated on the side of injury and with a choked disk.
Lumbar puncture draws a negative fluid.	Lumbar puncture frequently draws a bloody fluid.

The reader will assume that, as a rule, a concussion is an affair less serious than is the condition of compression, but the outcome of the cases does not always follow this assumption. Severe cases of concussion may end in sudden death, while cases of compression may be relieved spontaneously or by a surgical operation, and the patient may recover perfect health.

We have now considered in somewhat brief fashion certain fractures of the skull, with their complications and results—concussion, hemorrhage, compression, and contusions and wounds of the brain. These complications and results are commonly associated with all the various forms of skull fracture. Before continuing this discussion further, we should examine in somewhat greater detail the subject of fracture of the base.

Fracture of the Base.—All experienced persons are familiar with the fact that basal fractures are more serious than vault fractures. A few years ago students were taught that nearly all basal fractures are fatal, so that when the diagnosis of basal fracture was followed by recovery of the patient, the latter fact was regarded as good presumptive evidence that the base had not been fractured. We know now, however, that fracture of the base is followed by recovery in a great many cases, though it is still *ipso facto* a more grave injury than vault fracture.

Why is basal fracture so serious? At the base are grouped the more important vital centers; an overwhelmingly large proportion of basal fractures are compound fractures; operations for the relief of basal damage are difficult or are ineffective.

The extent of a basal fracture can never be determined accurately. All three fossæ may be involved, or two or one. We often find at postmortem a fracture of the posterior fossa which had been overlooked entirely, for fractures of the posterior fossa often give no definite characteristic symptoms.

Moreover, there are dangers peculiar to each fossa: fracture of the anterior fossa promotes septic meningitis through infection from the nose and ethmoid cells. In fracture of the middle fossa infection advances from the nasopharynx and from the ear. Furthermore, injury to the middle fossa may involve the middle meningeal artery or the internal carotid; injury to the posterior fossa is seldom complicated by sepsis, but may result in extensive tearing of venous sinuses, with a consequent hemorrhage and pressure. One sees that fractures of the middle fossa appear at first as the most dangerous, though severe injuries to the brain are possible in fractures of all fossæ; yet since the more important brain centers lie in the posterior fossa, it is probably fair to estimate that the gravity of the prognosis in basal fractures increases in accordance with the position of the fracture from before backward.

In general terms, the mortality of fractures of the base is about 65 per cent., while the mortality of fractures of the vault is about 23 per cent.

Before entering upon a further consideration of head lesions—

sepsis, tumor, and chronic infections especially—let us at this point sum up and formulate the symptoms and diagnosis.

The Symptoms and Diagnosis of Organic Head Lesions.—The reader should recall again a fact, which cannot be too often repeated, that a striking and notable distinction between intracranial lesions and lesions within the other important cavities of the body, lies in the fact that the organs within the skull are packed into a firm, immovable case, *the organs themselves being non-collapsible.* It is for this reason that an addition to the cranial contents or increase of the intracranial tension is associated with the most alarming and fatal results even. One of the most common and most significant of the symptoms of brain damage is unconsciousness, but there are manifold reasons for unconsciousness, so that it is worth our while in a brief paragraph to consider the causes.

The Causes of Coma.—Coma is due to—(1) Brain injury; (2) apoplexy; (3) uremia; (4) epilepsy; (5) hysteria; (6) diabetes; (7) opium poisoning; (8) intoxication from alcohol, ether, and other anesthetic drugs. It is by no means always easy to determine the cause of unconsciousness if the surgeon is unfamiliar with his patient's previous condition. In police station and hospital practice especially puzzling cases arise, which often contain all the elements necessary for mortifying errors and for tragedy. When the attendant surgeon makes his examination, he should look with pains for evidences of injury,—damage to the scalp, the vault, and the base,—especially should he note bleeding from the ears or nose. But an epileptic, a drunkard, or a diabetic may fall unconscious and receive serious head injuries, and in such cases arise the puzzling problems. Search the patient for opium that he may be carrying; and note the odor of alcohol or opium on his breath. The victim of diabetes may smell of acetone (violets). Examine the urine drawn by a catheter and observe in it the specific gravity, albumin, acetone, or sugar. Examine the fundus of the eye for choked disk. A lumbar puncture may draw the bloody fluid due to subdural hemorrhage. Hysteric coma is most common in boys and young women, and the patient can swallow, though he cannot be roused. In postepileptic coma the state is one closely resembling sleep, and the patient can be aroused. In uremic coma one observes frequently localized edema, and there may be convulsions. In apoplexy there is often a subnormal temperature, and there may have been a single convulsion. In opium-poisoning look for the familiar pin-point pupil and a slow respiration, down to three or four a minute, remembering, at the same time, that hemorrhage into the pons will cause pin-point pupil, but paralysis as well, and a high temperature with sweating. Thus one sees that the problem which appeared so confusing at first may readily be resolved into elements more easy of explanation.

Cerebral localization, next after questions relating to coma, furnishes us with information of great importance when we come to deal with the diagnosis of intracranial lesions, yet cerebral localization is a matter much misunderstood and much abused. Cerebral localiza-

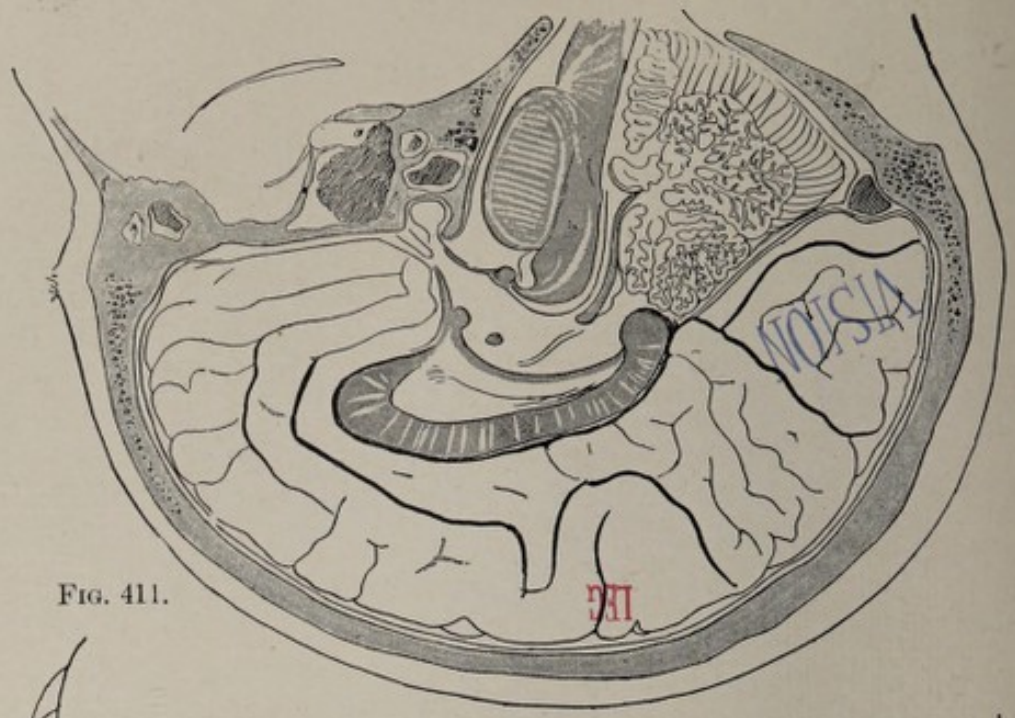

FIG. 411.

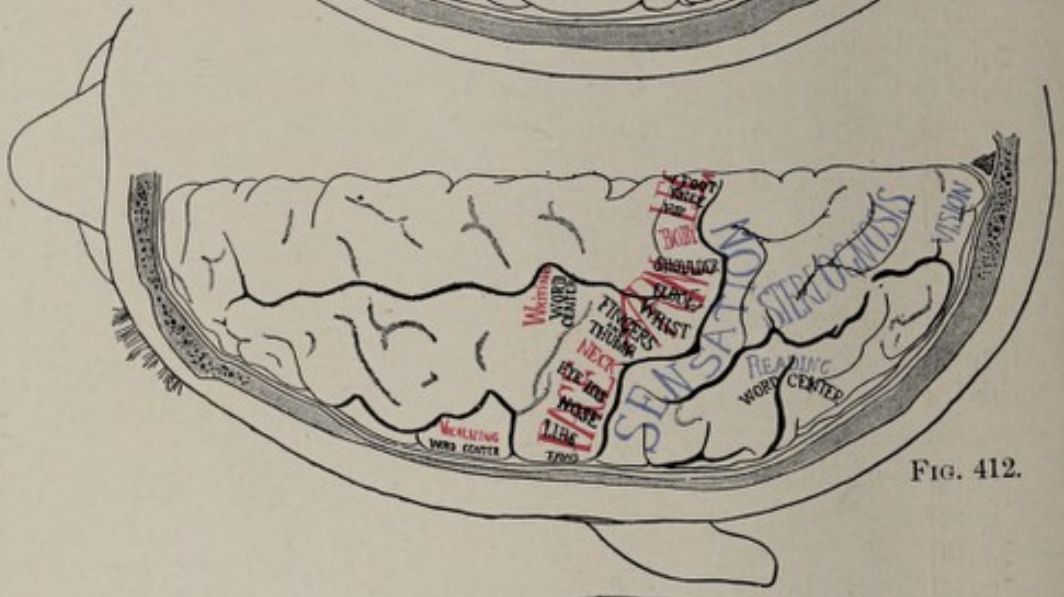

FIG. 412.

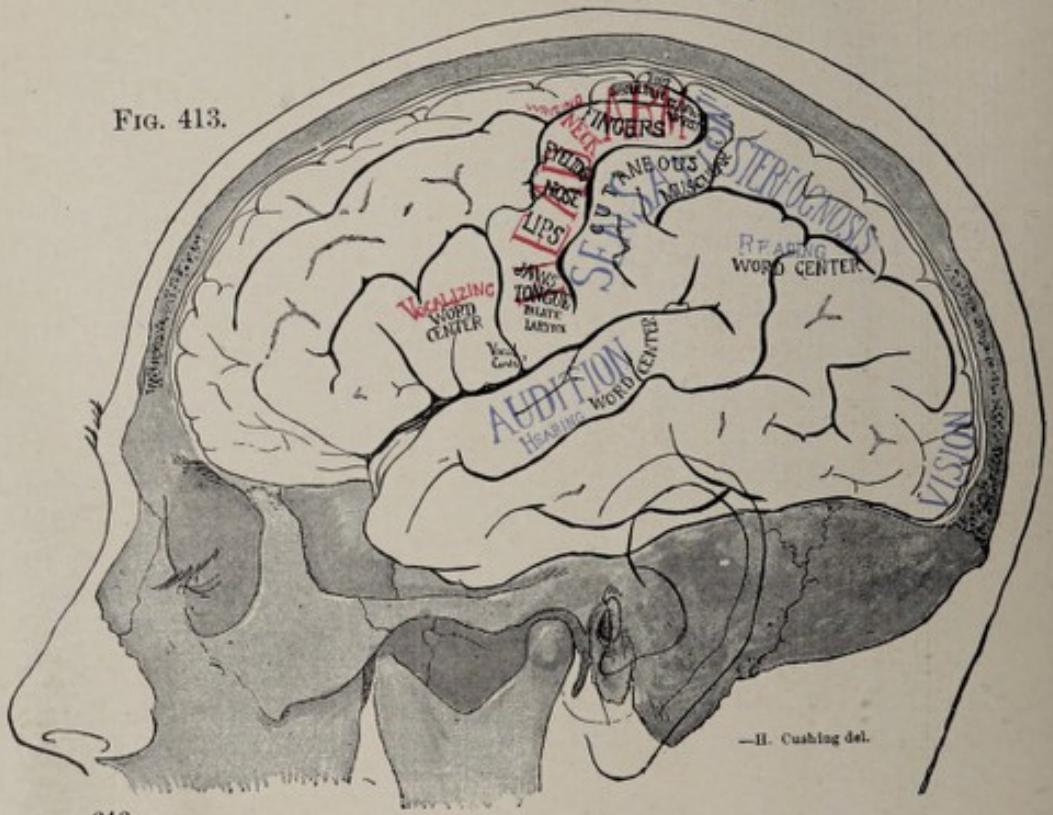

FIG. 413.

tion, first satisfactorily demonstrated by Fritsch and Hitzig, is that science which shows the relation of certain brain centers to special functions, voluntary acts and impressions, from which we deduce the conclusion that damage to, or destruction of, given brain centers will affect proportionately sensation and action. If this were all there is to it, cerebral localization would be a simple matter, and the exact site of brain lesions always could be determined, but, unfortunately, in the case of head injuries numerous factors complicate the problem; there may be multiple injuries; there may be damage by contrecoup; there may be secondary hemorrhage and late inflammation, or secondary destruction of brain tissue. Moreover, the immediate symptoms may seem to give an exaggerated picture of the damage, while, on the other hand, extensive laceration of the brain may appear to be accompanied by slight and disproportionate symptoms, as the damage may have been inflicted upon a so-called silent area. Some years ago I saw in the accident room of the Massachusetts General Hospital a young man of vigorous appearance, who seemed perfectly well except that five hours previously he had been rendered totally blind by a gunshot wound in the back of his head.[1]

He had been completely conscious since the accident; there were no paralyses, and all his reflexes were normal; the pulse was not slow. His only symptom was total blindness. The reader will see from Fig. 412 that the sight center of the brain is low down in the posterior region of either hemisphere. This patient had been shot with a 32-caliber rifle through the right side of the occiput. The puzzling question was, why should he be blind in *both* eyes—but an examination of the wound quickly solved the apparent mystery. The bullet had entered the right side, had destroyed the right visual center, and, passing through the falx, had lodged in the left visual center, which it seemed to have destroyed likewise. An extremely interesting surgical fact is that a bullet fired from a rifle should have done so little damage after entering the brain. I enlarged thoroughly the wound in the bone, drained both hemispheres, and the man recovered eventually, with a useful, though limited, field of vision. The application of the case to our text lies in the fact that a gunshot wound in so vital a region as the occiput was shown, by the objective symptoms, to limit its damage to a surprisingly small area of brain.

We see, therefore, the value of cerebral localization in one case, so far as a determination of the limits of brain damage are concerned.

[1] Henry C. Baldwin, Gunshot Wound Involving Both Occipital Lobes, Boston Med. and Surg. Jour., February 15, 1906.

Figs. 411, 412, and 413.—Diagrams illustrating the more definitely localized of the cortical centers of the exposed part of the hemisphere, in relation to the main fissures and convolutions; also the "word centers" (sensory and motor) involved in the special mechanism for speech. (Receiving sensory stations in blue; discharging motor stations in red.) Drawn by accurate orthogonal projection of actual dissection. Note that centers for lower extremity are practically invisible from side, and that the best view of the motor field is obtained from above (Cushing in Keen's Surgery).

Not many years ago Chipault published a great and exhaustive treatise on the subject of craniocerebral topography, and the purpose of his book was to enable the surgeon to cut down directly through the outside of the head upon any desired area. By the aid of careful measurements from such fixed points as the external auditory canal and the occipital protuberance we were shown how to find on the skull a point corresponding to that area of the brain, let us say, which controlled the movements of the right hand. This is interesting, but less important than at first it was thought to be, for skulls vary so much that rules cannot be made to apply to them all. Moreover, in these days we are accustomed to explore the brain through large windows in the skull, and to reach any given point by observing its relation to certain fixed and well-known fissures and sulci in the brain itself. The student should be familiar, however, with the recognized landmarks described by Broca:

The *pterion* is a point on the side of the skull, 1¼ inches posterior to the external angular process, on a level with the roof of the orbit. At the pterion the middle meningeal artery is found passing upward. The *inion* is a point marked by the external occipital protuberance.

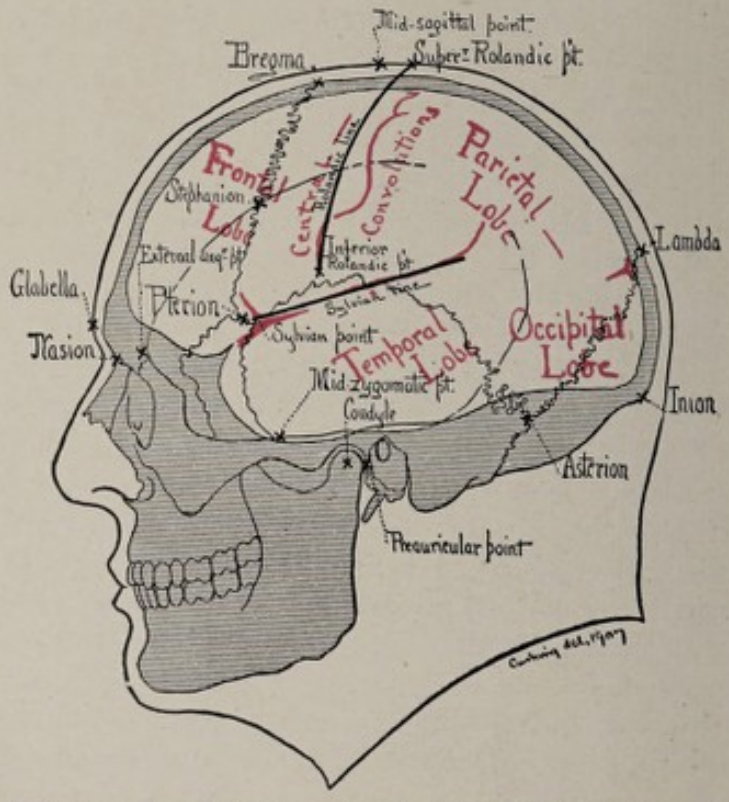

Fig. 414.—Diagram showing the various landmarks utilized as points of measurement in craniocerebral topography. Also, in red, main cerebral fissures and lobes of the exposed hemisphere (Cushing in Keen's Surgery).

The *glabella* is the midpoint of the smooth swelling between the eyebrows. The *bregma*, placed at about the junction of the sagittal and coronal sutures, is a point determined by the intersection of two lines —(1) the line connecting the two external auditory meatuses, and (2) the line connecting the inion and the glabella.

To find the *fissure of Sylvius:* draw a line from the external angular process to the occipital protuberance. The fissure of Sylvius begins on this line, 1⅛ inches behind the angular process, the main branch running toward the parietal eminence, the ascending branch lying beneath the squamosphenoidal suture.

The *fissure of Rolando* is the center of a most important area, and marks the posterior limit of the motor region of the brain. It begins near the median line, one-half inch posterior to the middle of the distance between the inion and the glabella. The fissure runs downward and forward at an angle of 67.5 degrees for a distance of 3⅜ inches. Chiene's method for finding the fissure of Rolando is as follows: take a square piece of paper and fold it into a triangle (see figure); the angle *b a c* of the triangle is 45 degrees; the edge *d a* is folded back on the dotted line *a e;* the angle *d a e* equals half of 45 degrees, or 22.5 degrees, and the angle *c a e* also equals 22.5 degrees. Unfold the paper in the line *c a;* in the figure thus formed *b a c* equals 45 degrees and *e a c* equals 22.5 degrees; *e a b* equals 67.5 degrees, which is the angle desired. Place the point *a* in the middle line of the head over the point of origin of the fissure of Rolando; the side *a b* is laid along the middle line of the head, when the line *a e* will be found to correspond to the fissure of Rolando—all of which is somewhat confusing, not very interesting, and is much simplified by using Horsley's cyrtometer, or applying Krönlein's craniocerebral topographic lines. Ingenious as all this is, the surgeon, and especially the expert neurologic surgeon, seldom employs these measurements. Modern operations, with their large plastic openings, disclose such extensive fields of the brain that accurate external measurements are no longer needed in order that one may strike upon special areas.

Let us return, therefore, to a short consideration of cerebral localization. I shall take many of the statements from Harvey Cushing's admirable essay.[1] We now know, through the accurate methods of cortical stimulation introduced by Sherrington and Grünbaum (1901), that that portion of the cortex which is directly excitable by a unipolar electrode consists of a narrow strip which lies anterior to the central fissure (Rolando), and extends to the depth of this fissure *on its anterior surface alone.* This is the true motor cortex. The central fissure divides the cortex into an *anterior motor* and a *posterior sensory field.*

The excitomotor cortex is limited to a narrow strip of the exposed part of the *central anterior gyrus,* but extends to the depth of the central fissure. Its chief portion, therefore, does not lie on the visible surface, so that a lesion which involves the motor cortex may be far out of sight. The Rolandic fissure is not a straight line, but is broken by two or three more or less well-developed angles (genua). Opposite the two upper genua the motor strip is narrow, and its representative movements not complex—the movements of the neck and trunk. Thus the genua are valuable surgical landmarks, particularly the middle and inferior genua, which are often brought into view in an operation. Above the upper

[1] Harvey Cushing, Surgery of the Head, Keen's System of Surgery, vol. iii, pp. 17–276.

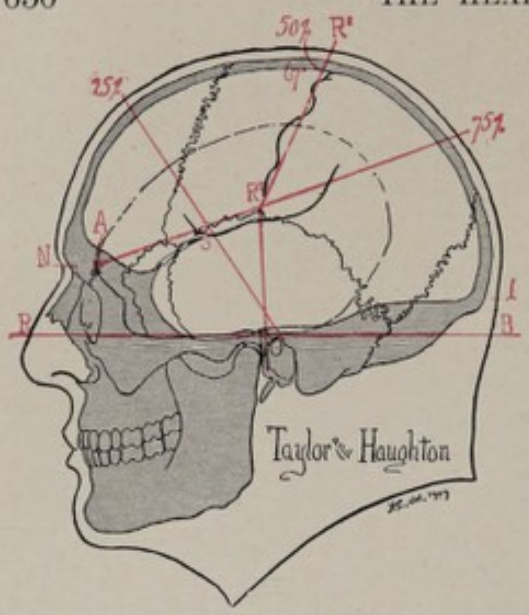

Fig. 415.—Sylvian line connects external angular process, *A*, with point 75 per cent. of distance *N* to *I*. Superior Rolandic point, *R'*, lies ¾ inch behind midnaso-inionic point (50 per cent.). Inferior Rolandic point, *R''*, lies at junction of Sylvian line with perpendicular to Reid's base-line, *R–B*, at preauricular point. Sylvian point lies at junction of Sylvian line with line from meatus to 25 per cent. of naso-inionic line (Cushing in Keen's Surgery).

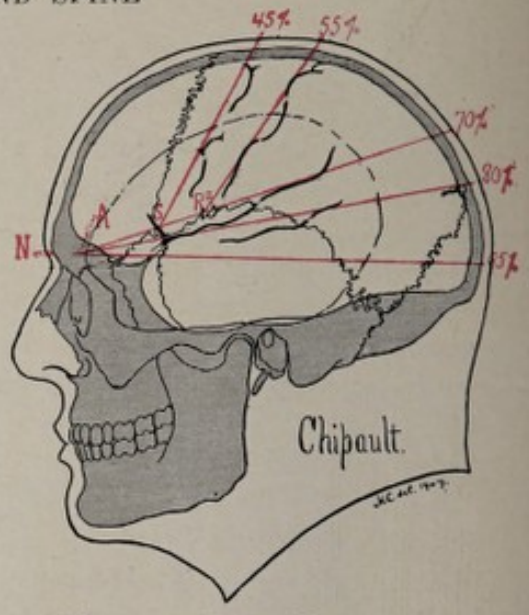

Fig. 416.—Forty-five per cent. of median naso-inionic line = prerolandic point; 55 per cent. = Rolandic point; 70 per cent. = Sylvian line; 80 per cent. = lambda; 95 per cent. gives lower edge of occipital lobe. Line from *A*, external angular process, to 70 per cent. gives Sylvian fissure. *S* = Sylvian point = junction of second and third tenths of this line, while *R''* = inferior Rolandic point = junction of its third and fourth tenths (Cushing in Keen's Surgery).

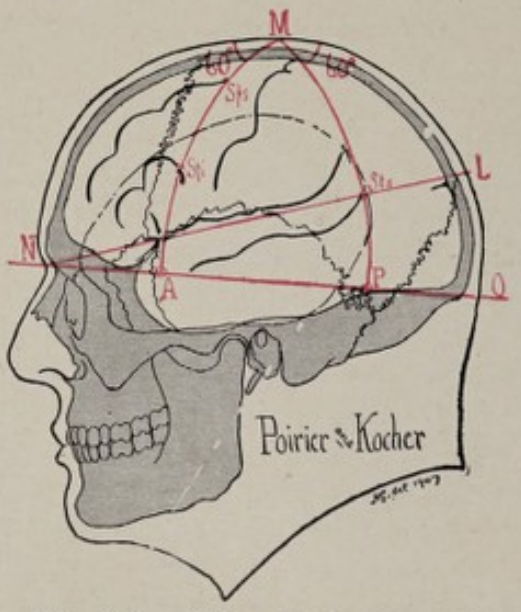

Fig. 417.—*NO* = Kocher's equatorial line, nasion to inion. *NL* = Poirier's Sylvian line from nasion to lambda. *MA* = Kocher's anterior meridian drawn 60° from meridian line at midsagittal point; lies over precentral convolution and crosses *NL* at Sylvian point. *Sfs* = superior frontal sulcus at one-third of *MA*; *Sfi* = inferior frontal sulcus at two-thirds of *MA*. *MP* = Kocher's posterior meridian, also 60° from midline. Lines crossing at *Sts* = superior temporal sulcus (Cushing in Keen's Surgery).

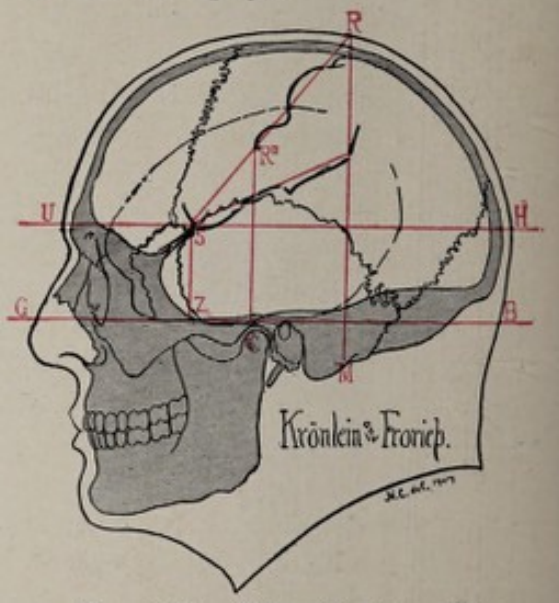

Fig. 418.—*GB* = German "baseline" from inferior edge of orbit through upper edge of meatus. *UH* = upper horizontal, parallel to *GB* through upper border of orbit. *M*, *C* and *Z* = perpendicular at posterior border of mastoid, at condyle and midzygoma. The Rolandic line unites the points of crossing of the posterior perpendicular and sagittal lines, *R'*, and the upper horizontal and anterior perpendicular, *S*. The Sylvian line bisects the angle *R' SH*. Inferior Rolandic point, *R''* (Cushing in Keen's Surgery).

genu there is a small triangle only of motor cortex which can be exposed. When stimulated, this triangle shows movements in the hip, the knee, and toes. Opposite to this upper genu lie centers for movements of the thorax and abdomen. Between it and the middle genu lie centers for the upper extremity, the shoulder being represented by a center higher than that of the fingers and thumb. Opposite the middle genu are the centers for the neck, and below it those for the face—eyelids above and lips below, etc. The centers for the jaws, tongue, vocal cords, pharynx, etc., are lower still, usually below an inferior genu.

If the above-named cerebral centers be damaged, there results a corresponding loss of motion, but sensation is not impaired.

We observe also that certain complex movements may be obtained by stimulating areas adjoining the true motor cortex. For example, one may obtain movements of sucking, chewing, sneezing, and speaking by stimulating the *pars opercularis* below the central anterior gyrus (this is, near Broca's vocal speech center).

The pathway downward from the motor cortex is by the pyramidal tract, whose fibers degenerate throughout their length, if their cortical cells be injured.

The *sensory field* lies behind the fissure of Rolando, and the researches of Campbell in particular seem to show that primary registration of "common sensation" occurs in the central posterior gyrus. This sensory area in its relation to the fissure of Rolando occupies much the same position posteriorly that the motor area holds anteriorly. As Cushing points out, the sensory field is largely hidden from view on the posterior surface of the fissure, and does not extend back over more than the anterior half of the exposed gyrus. The fibers to this sensory field pass from the thalamus in the "cortical lemniscus" of the *corona radiata*. These fibers, in their course, lie in the rear part of the internal capsule. In the post-rolandic region there are registered the tactile sense, the muscular sense, and the sense for discriminating points in contact. As one goes further back on the cortex, sensations become more complex, so that deeper and more extensive lesions are needed to interpret their transmission. The senses of *pain* and of *temperature* lie probably in the intermediate postcentral zone of Campbell, and that for the recognition of objects—the *stereognostic* sense in particular—is located as far back as the parietal lobe. *Visual* impressions are received on the mesial surface of the occipital lobe, in the calcarine region.

Auditory impulses are received apparently in the superior temporal gyrus, and are converted into conscious perceptions in adjoining parts of the temporal lobe. The center for the *sense of smell* is probably in the pyriform lobe, while the *center for taste* is not well determined, but lies presumably at the lip of the limbic lobe, in the neighborhood of the incus.

There appear to be *four cortical areas concerned* in *speech* in right-handed people. The center for the recognition of spoken words lies in the outskirts of the primary center for hearing, in the superior temporal gyrus of the left temporal lobe. The centers for vocal speech are taught

by Broca to lie in the posterior end of the inferior frontal gyrus. The visual word center employed in *reading* is in the angular gyrus, and the *writing* center, if such exists, is in the posterior end of the middle frontal gyrus.

So far as neurologic studies have gone, the foregoing description sums up briefly our present knowledge. Other areas of the cortex appear to be concerned with complex processes of association. Lesions of these areas are largely " silent," so far as our present methods of examination show us.

We have already considered in some detail the symptom *coma*. Let us now continue a consideration of the **symptomatology of organic lesions.**

Headache is one of the cardinal symptoms of head lesions. It is common enough in other connections, but bear in mind that the one symptom, persistent headache, long continued, should make the surgeon extremely suspicious of intracranial disease. Headache is constantly present in diseases of the meninges, particularly when the dura is involved; and the dura takes its nerve-supply almost entirely from the trifacial. Far the more important headaches, however, are those due to intracranial pressure—to tumor, edema, internal hydrocephalus, serous meningitis. Those headaches due to pressure have no relation to the seat of the lesion, as a rule. Headaches due to pressure are of all grades, from a dull sense of pressure to agonizing pain.

Vomiting is the next cardinal symptom of importance. It occurs in the presence of all sorts of cerebral lesions, and may be an early symptom of concussion or contusion. We must recognize especially the sudden projectile vomiting which is a common symptom of increased intracranial tension, due to brain tumor, to the edema of nephritis, etc.

Choked disk (" optic neuritis") is one of the most important signs of intracranial pressure. The surgeon should look for it in all cases of head injury or suspected intracranial disease. As Cushing says, " it is not sufficient for the examiner to be able to recognize a choked disk when it is full blown, but the slight edema of retina and nerve head, with early distention and tortuosity of the veins which precedes actual ' choking.' " Cushing asserts further, after an interesting discussion of the nature of choked disk, that the rapid subsidence of that condition after decompression operations leads him to believe that almost all, if not all, cases of choked disk are primarily of mechanical origin, and are not a true neuritis.

Besides the general symptoms of organic head lesions there are numerous so-called *focal* or localizing symptoms, which are often of extreme interest. There are disturbances of motion, of common sensation, and of the faculties of special sense—*irritative symptoms*.

Motor paralysis is always the most striking and obvious of these focal symptoms. It indicates the side of the brain which is involved. Sometimes it suggests the exact situation of the lesion. It may be hemiplegic, and involve an entire half of the body, or may involve the trunk and extremities only. It may be monoplegic and involve but one

extremity. It may be paraplegic and affect the legs chiefly, or diplegic and impair the use of both arms and legs.

Muscular *spasticity* with increased reflexes indicates a lesion of the intracranial portion of the motor pathway. Furthermore, such motor irritation is shown often by epileptiform convulsions. The process leading to convulsions may be quiescent—the cortical cicatrix of an old healed focus of hemorrhage; or the process may be progressive—a cyst or tumor.

Disturbances of *sensation* also may result from cortical and subcortical lesions. They may be irritative and associated with paresthesia, or paralytic and accompanied by anesthesia. A certain degree of motor impairment almost always accompanies these sensory disturbances.

Such, in general terms, are the symptoms which should suggest to the surgeon some localized intracranial lesion. The reader interested in this matter should consult the larger books and special monographs, particularly those treatises which discuss in detail regional diagnosis—the symptoms resulting from damage to special areas. He should not be misled, however, into a belief that with our present knowledge we can always determine surely, and from symptoms, the exact location of an intracranial lesion. In numerous cases we can so determine, however, and in most cases we may assert positively the presence of some disturbing element within the skull, though we may not state its location or its character.

THE MENINGES

The *meninges* are worthy of our most careful study, yet must we limit ourselves to a few brief paragraphs.[1] One recalls certain important anatomic facts: that there is no gross communication between the subdural and subarachnoid spaces; that the subdural and subarachnoid spaces of the brain can be injected from the corresponding spinal spaces; that the *dura* carries on its outer surface certain arteries of surgical interest, and that it incloses the great venous sinuses; that the dura in the young on its outer surface adheres more or less firmly to the skull, and that it acts as a periosteum; that as a protection for the brain the dura, owing to its smooth endothelial surface, is of great importance, and that it is separable into two layers, between which are inclosed such structures as the Gasserian ganglia. The dura is a strong membrane, and such of its prolongations as the falx and the tentorium furnish important supports for the hemispheres. The longitudinal sinus and other sinuses

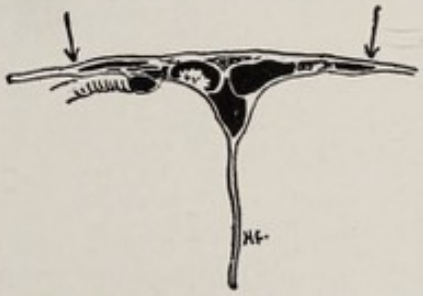

Fig. 419.—Sketch of cross-section of longitudinal sinus in its mid-course. Note width of parasinoidal sinuses (Cushing in Keen's Surgery).

[1] For a delightful discussion of meningitis, brain abscess, and brain tumor see Charles A. Ballance's published lectures, Some Points in the Surgery of the Brain and Its Membranes, 1907.

lie within the folds of the dura, and into the longitudinal sinus or its expansions enter many of the more important superficial cerebral veins. In its middle course the longitudinal sinus expands broadly (*lacunæ laterales*), and into these expansions project most of the so-called Pacchionian granulations, whose function is uncertain. They are tuft-like processes from the arachnoid and contain cerebrospinal fluid. The middle meningeal artery furnishes the chief blood-supply to the dura; and its nerve-supply is abundant, coming mainly from the trifacial. Cushing believes that headaches are due to the stretching of the dura or of its expansions.

The *pia* is a delicate vascular membrane which clings closely to the convoluted surface of the brain and dips into all its irregularities. The *arachnoid*, on the other hand, lying over the pia, bridges most of the irregularities. Remember that the subarachnoid spaces thus formed are not free, but are honeycombed by strands of delicate tissue which bind loosely together the pia and the arachnoid, while the subdural spaces, in contrast, are open and free for the circulation of fluid.

The *ependyma* is the lining membrane of the ventricular cavities—a layer of epithelial cells, mostly underlain by a thin layer of neuroglia. The cerebrospinal fluid is probably formed through the action of the ependyma. This fluid is not merely a lubricant or a water bed; it should be regarded as the lymph of the brain, though it is a true secretion and not an exudation. It passes from the meningeal spaces into the venous circulation by means of the Pacchionian granulations, so that its chief location of exit is into the venous sinuses.

DEVELOPMENTAL ANOMALIES

There are sundry developmental anomalies due to failure of closure of the cranium, and into these unclosed spaces portions of the cranial contents protrude—**cephalocele.** This protrusion is usually in the middle line of the head, and is most common in the occipital region, though it may protrude from the anterior fontanel. According to their structure and contents we classify cephaloceles as **meningocele,** membrane containing fluid; **encephalocele,** a tumor containing membrane plus brain, and **encephalocystocele,** a tumor containing membrane and brain which is itself distended with fluid communicating with a ventricle. True meningoceles and encephaloceles are extremely rare. Encephalocystoceles are not uncommon. In making the *diagnosis* one distinguishes the last readily from acquired hernia cerebri, though they may be mistaken for some of the rarer tumors. An infant the victim of cephalocele rarely lives long, and even if years are added, the life is of little value.

The only serviceable treatment is by operation. Frequent tappings avail little or nothing. A meningocele with a small pedicle may be removed successfully, after which the skull defect should be closed by a plastic operation with bone or periosteum.

HYDROCEPHALUS

Hydrocephalus is a sign of disease, not a disease in itself. We speak of hydrocephalus as chronic or acute, congenital or acquired, external or internal. The acquired condition is brought about in most cases by some obstruction to the ventricular outlets, with a consequent damming back of cerebrospinal fluid. The term, external hydrocephalus, appears to be a misnomer. Acquired internal hydrocephalus may result from tumor pressure, from inflammation of the meninges and ependyma, or from venous stasis in the velum interpositum. Such hydrocephalus usually causes death before any great ventricular distention is reached.

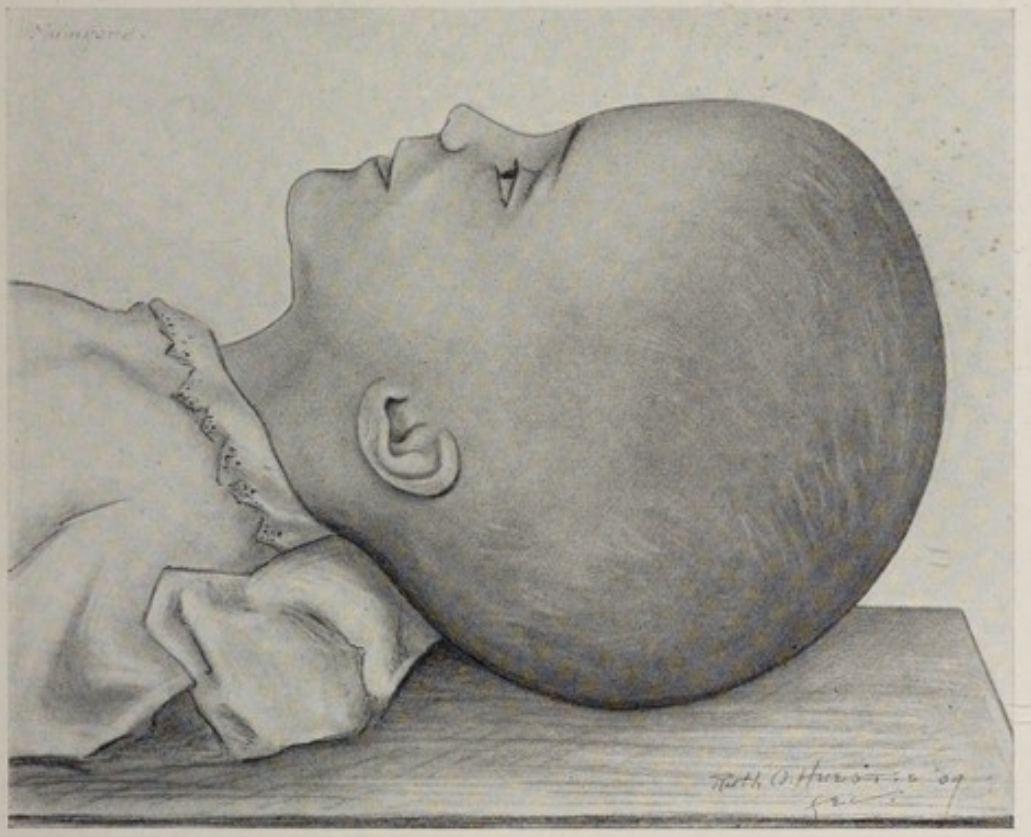

Fig. 420.—Hydrocephalus (Massachusetts General Hospital).

The **treatment** of such conditions is most unsatisfactory, as we should expect. Sometimes ventricular puncture may relieve; rarely, lumbar puncture in the less advanced cases, though the last maneuver is dangerous. At times, relief of symptoms has followed a simple decompressive operation on the skull, with puncture of the ventricle.[1]

Internal hydrocephalus of the congenital, progressive type is most characteristic in appearance. It may be due to a congenital syphilis

[1] W. W. Keen punctures the ventricle at a point corresponding with the posterior end of the temporal line, about 3 cm. behind and an equal distance above the external auditory meatus. Enter the needle in the posterior part of the first temporal convolution, aiming at the summit of the opposite pinna. Fluid will be found at a depth of 5 cm. E. W. Andrews, Surg., Gynecol., and Obstet., August, 1911, describes an improved technic by the use of glass tubes for subdural drainage of the lateral ventricles in internal hydrocephalus.

or to an abnormal increase in the amount of fluid secreted, or to both causes. It often accompanies cephalocele and spina bifida, and consists of an enormous distention of the ventricles of the brain, with a corresponding thinning of the cortex. The appearance of the unfortunate infant victims is striking, " the large, thin, flaring, cranial leaflets being perched on the small facial bones like the petals of a single water-lily on its calyx" (Cushing). These heads may reach a surprising size. Three liters and more of fluid have been reported as removed. The weight may be so great that the child cannot raise his head or move it even. These children do not cry, because crying increases the intracranial tension and causes pain. They may become victims early of gastro-enteric disturbances, and die. They may survive as physical and mental wrecks. They have been known feebly to reach adult years. Some of the milder cases have become arrested, however, either spontaneously or after the employment of simple tapping.

These cases of hydrocephalus must be differentiated from certain cases of rachitis. In rachitis evidences of bony changes elsewhere in the skeleton should suffice to establish the diagnosis, but the two affections may coexist. In doubtful cases a lumbar puncture may determine the diagnosis.

The *treatment of congenital hydrocephalus* has been the subject of no little discussion. Nothing but mechanical means will avail, and various such means have been advocated by sundry surgeons. Occasional tappings accomplish little, for the fluid quickly reaccumulates. Permanent drainage of various forms has been tried, either from the ventricles directly or through lumbar puncture. Cushing has had a considerable measure of success by his method of lumbar drainage, which is extremely ingenious.[1] He determines first the fact that ventricular fluid will flow freely from the lumbar regions. Then he opens the abdomen, trephines the body of the fifth lumbar vertebra from the front, and inserts a permanent silver cannula, which shall drain the cerebrospinal fluid forward into the peritoneal cavity. Ultimately, through processes of healing, the fluid is turned aside into the retroperitoneal space only, whence it is taken up by the radicles of the receptaculum chyli, as experimental observations have shown. This operation, of which Cushing reports 12 cases, is as yet too recent to give us definite knowledge of ultimate results. The method is applicable to selected cases only—those in which the foramina of Magendie and Luschka are open. Payr, at the German Surgical of 1911,[2] stated that for continuous drainage of the lateral ventricles he trephines behind the ear, introduces a trochar and cannula, and through the latter inserts fragments of a calf's artery and saphenous vein; then, opening the patient's jugular, he sutures into it the peripheral end of the transplanted vessels. Hydrocephalic fluid thus escapes directly into the patient's venous system. Payr "has performed this operation 18 times with 7 deaths.

[1] Keen's System of Surgery, vol. iii, p. 123.
[2] Presse Médicale, May 10, 1911.

In 3 instances the end results were satisfactory, cessation of convulsions and improvement in speech" (The Practical Medicine Series, Surgery, 1912). Such is the status at the present writing of the interesting and obstinate condition—internal hydrocephalus.

CEREBROSPINAL RHINORRHEA

A curious but rare discharge of cerebrospinal fluid from the nose has received the appropriate name of cerebrospinal rhinorrhea. This may be due to an injury, to a chronic hydrocephalus, to pituitary disease, or may occur spontaneously. The condition is serious because it may lead, through the open nasal channel, to an infection of the meninges from the nasal passages. The discharge may be abundant or occasional. The condition may prove quickly fatal or may last for years; and, most unfortunately, we have no means of treating it.

Before considering inflammation of the meninges (meningitis), let us discuss inflammations of the meningeal veins, and especially of the sinuses—inflammation, which leads to thrombosis.

SINUS THROMBOSIS

Sinus thrombosis is a serious malady. Rarely it may be primary (marasmic) and pass unrecognized while the patient lives. This form of thrombosis occurs in debilitated persons, especially in infants and the aged. The disease may spread and involve many sinuses. If thrombosis occurs in the straight sinus, it will set up most profound intracranial disturbances.

Since the disease occurs commonly at the end of long illness, the *symptoms* are not marked, and such as they are, they may suggest brain tumor. Sinus thrombosis from an injury, non-septic, occurs rarely also. Cushing records two notable cases of non-septic cavernous sinus thrombosis, one of which occurred after an operation upon the Gasserian ganglion. Thrombosis of this sinus results in an exophthalmos with extreme swelling and ecchymosis of the lids and conjunctivæ. Blindness is almost inevitable. Extensive non-septic traumatic thrombosis is associated with somewhat sudden symptoms—headache, delirium, stupor, perhaps vomiting and convulsions, and early choked disk.

Infective sinus thrombosis follows most commonly some form of chronic suppuration elsewhere—especially suppuration in the sphenoid cavities, the antrum, the mastoid, and the middle ear. Probably chronic otitis media is the cause of sinus phlebitis in two-thirds of all cases of such phlebitis, and the process seems to be more frequent on the right side. The sinuses close to the ear become involved first in inflammation resulting in thrombosis, and the process spreads, extending to the lateral, the sigmoid, and the sagittal sinuses, and into the jugular vein in the neck even, or the petrosal and cavernous sinuses may be the first vessels affected.

The **symptoms** of septic sinus thrombosis follow upon the long-standing chronic evidences of the initial disease (in ear, antrum, or elsewhere) and spread rapidly. There are chill, headache, nausea, dizziness, and vomiting. The temperature runs high, with remissions. The pulse is rapid. There are sweating and leukocytosis. The thrombus may break down, and septic particles may be carried into the general circulation, with a resulting pyemia. Abscesses develop in the lungs. The patient's mind may remain clear unless meningitis or cerebral abscess supervene.

One may not always and readily make a **diagnosis** of thrombophlebitis in the sinuses. Of course, the diagnosis may be easy when the source of the infection—in the ear or elsewhere—is discovered, and when there are present such obvious symptoms as tenderness along the jugular vein; pain, tenderness, and edema behind the mastoid; sudden exophthalmos and chemosis; paralysis of nerves, and the like. But these symptoms may not appear until late, and the disease may be mistaken early for some general systemic infection. If the infection run untreated, meningeal or cerebral complications supervene, with a general pyemia, under which the patient sinks gradually and dies usually in the course of a month or six weeks.

The **treatment** of sinus thrombosis is purely operative, and the exact point of attack is dependent upon the source of origin and location of the infection. We endeavor always, therefore, to open down upon the involved sinus and to clear it out. For example, in the case of sigmoid phlebitis the surgeon opens the mastoid cells, lays bare the sinus, and determines its contents by aspiration with a hypodermic needle. If the sinus be found occluded, the clots must be washed out. If the jugular vein is obviously involved, one may follow the brilliant method advocated by Zanfel in 1880; tie the jugular low in the neck, and wash out the clots in the vein and sinus by through-and-through irrigation. By such measures surgeons have been able to record a large number of brilliant and successful operations.

MENINGITIS

Meningitis proper is divided commonly into the subjects *pachymeningitis* and *leptomeningitis*, the former indicating inflammation of the dura; the latter, inflammation of the pia arachnoid.

When we consider *pachymeningitis*, we use sundry terms to indicate the area involved—pachymeningitis externa, pachymeningitis hæmorrhagica interna. External inflammation of the dura follows septic infections from injuries, middle-ear disease, and other local sources, and is the common precursor of internal inflammation of the dura and of the pia arachnoid. *Internal hemorrhagic pachymeningitis* is characterized by an easily detached membrane with numerous new-formed blood-vessels on the inner surface of the dura. The *symptoms* vary and may be those merely of progressive dementia, though there may

coexist often severe headaches with convulsions. We have no satisfactory treatment for this hemorrhagic form (which perhaps should not be designated meningitis at all), though certain cases seem to have been greatly relieved by decompressive operations. The *treatment* of *external meningitis* is much more satisfactory if the diagnosis can be made. Open the skull liberally by turning back a large bone-flap in the neighborhood of the infected area. Irrigate gently with hot salt solution the meningeal surface, and provide suitable rubber-tissue drainage. One may thus look for a striking, though somewhat protracted, recovery in many cases.

Leptomeningitis unfortunately follows dural infections, whether from traumatic tearing of the dura or from chronic bone suppurations. Moreover, leptomeningitis may be a primary and specific malady, which becomes generalized early. Secondary forms, on the other

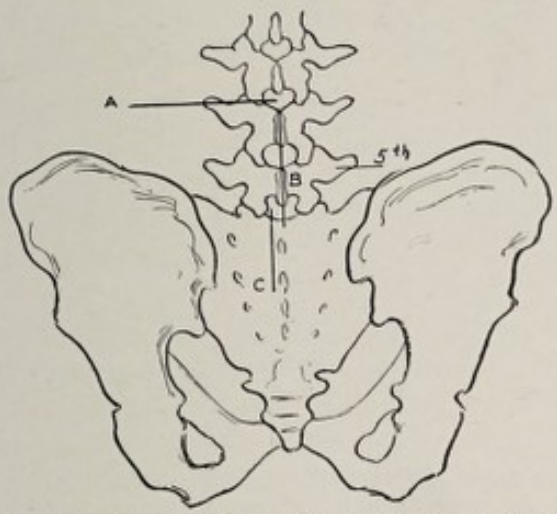

Fig. 421.—Lumbar puncture (Chipault): A, Method of Quincke; B, method of Marfan; C, method of Chipault. The simplest plan seems to be to puncture between the fourth and fifth lumbar vertebræ. The space between these vertebræ corresponds to the highest part of the iliac crests. Chipault, however, maintains that the lumbosacral space is preferable, since it is the largest, is surrounded by good landmarks, and is opposite the terminal enlargement of the dural sheath (Ballance).

hand, tend to remain localized. Leptomeningitis may be rapidly fatal in a few hours, therefore, or may run on for months. A specific form has received the name cerebrospinal fever ("spotted fever"), and is due to the Diplococcus intracellularis (Weichselbaum), the ailment being frequently epidemic.

It is needless here to discuss surgically this grave disease (cerebrospinal fever) beyond pointing out the fact that certain operative measures, with permanent drainage, offer promise of benefit. Lumbar puncture with the evacuation of fluid may avail if the basal foramina are open. In other cases the suboccipital drainage through trephining beneath the cerebellum, a method suggested by Charles A. Ballance, seems to be preferable. A further and still more promising measure is to tap the ventricles in the manner I have already described. This subject is still under discussion, however, at the present writing, and

I refer the interested student to the larger treatises on surgery. Happily, the serum treatment of Flexner is now supplanting all operative treatment.

Suppurative leptomeningitis concerns the surgeon especially, and the diagnosis of this condition is not always obvious. We may early confound it with "meningitis serosa," an extremely interesting condition described by Quincke in 1893. Meningitis serosa is not associated with suppuration, though there appears an abundant serous exudate, an increase in cerebrospinal fluid, injection of the meninges, and symptoms of intracranial pressure, which, if not relieved, may lead to death. In these cases lumbar puncture is our trump card. Lumbar puncture alone will serve to establish a diagnosis, and if the withdrawn fluid be sterile, drainage frequently will result in a cure of the serous meningitis.[1]

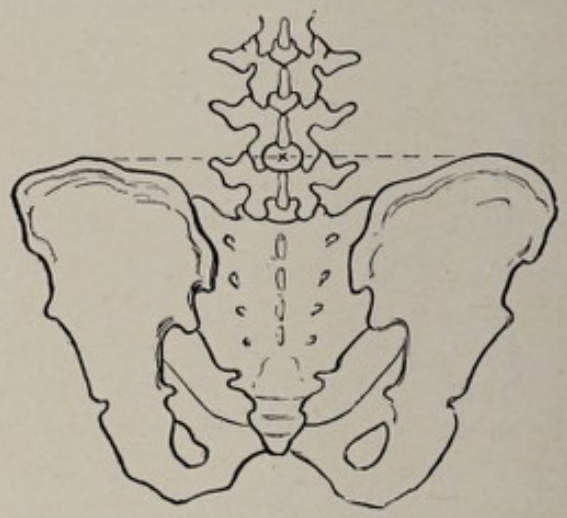

Fig. 422.—Sketch showing method of lumbar puncture. A line joining the highest part of the iliac crests bisects the space between the fourth and fifth lumbar vertebræ. This is the best guide in lumbar puncture. A fine hollow needle, 7 cm. long, is required (Ballance).

In suppurative leptomeningitis we find commonly the streptococcus, the Staphylococcus aureus, albus, and citreus, and sometimes the Bacillus pyogenes fœtidus and other rarer organisms.

The *symptoms* of purulent forms of meningitis present a picture which is sometimes characteristic and sometimes obscure. Commonly, fever begins within forty-eight hours of the infection, and rises gradually, running up to 104°, 105°, 106° F.; the pulse is quick, full, and bounding, and there are superadded the other familiar signs of intracranial pressure—headache, vomiting, choked disk, paralyses, and varying focal symptoms.

Operative treatment of suppurative leptomeningitis may cure, though the disease is still justly regarded as one of the most fatal known to us. Nevertheless, I have had brilliant recovery follow a liberal exposure and drainage of the meninges, the opening of the skull being made to depend, so far as possible, upon the original site of in-

[1] The cuts in the text illustrate admirably satisfactory methods of lumbar puncture, Charles A. Ballance, ibid.

fection. I reported in 1906 a case of leptomeningitis following fractured middle fossa, with a gradually resulting delirium associated with right-sided paralyses and incoherence of speech. I opened the skull and dura over the left Rolandic area, drained the field for some days, and was rewarded by the complete recovery of the patient. Irrigation is not to be commended. Frequently acute internal hydrocephalus complicates meningitis, when one must resort promptly to puncture of the ventricle.

From a considerable experience of my own, and from the records of other surgeons, I am convinced that the time has gone by for abandoning to their fate patients critically ill with meningitis. The disease is comparable to diffuse peritonitis. The patients will die if let alone. Occasionally they recover if prompt drainage be boldly instituted, supplemented by the exhibition of urotropin.

The *ependyma* lining the cerebral ventricles is subject to infection, and the resulting ependymitis is seemingly a specific malady, without any known association with meningitis. Cushing observes that these ependymal inflammations doubtless play a large part in hydrocephalus, and have received less attention than they deserve. The inflammations result in a sudden closure of one or another of the ventricular channels. Immediately symptoms of acute hydrocephalus supervene, with the familiar signs of intracranial pressure—headache, vomiting, and choked disk.

It is usually impossible to attack directly the source of trouble, but almost always an extensive decompressive operation will relieve the symptoms. Occasional cure may result. Sometimes aspiration of the ventricle at the same time will be advantageous.

Tuberculous and **syphilitic meningitis** are not generally regarded as surgical ailments, and their discussion here may not be appropriate, but one word regarding *treatment* is in place: The mechanical disturbances from pressure should be met by lumbar puncture, and when hydrocephalus is present, by ventricular puncture. In the case of syphilitic meningitis operative treatment should be preceded by a thorough course of potassium iodid, but this should not be persisted in to the neglect of operation for more than three weeks if there be no relief from the symptoms. Occasionally gummata may be attacked directly, but even when they are not found, *decompression* frequently will relieve the symptoms.

MENINGEAL TUMORS

Meningeal tumors occasionally are seen. If they spring from the pia arachnoid, they frequently can be located readily. If they are of dural origin, their position may not be so obvious. These latter tumors are often of the most malignant sarcomatous nature. They attack the cranial bones, and may penetrate them and appear externally as soft, pulsating swellings. I shall consider further this subject in connection with cerebral tumors.

THE CRANIUM

Diseases of the cranium belong as properly with meningeal disease as with scalp disease. We have just seen that certain malignant growths of the meninges may penetrate the skull from within. There are numerous other maladies of the bones which the writers describe—atrophy, hypertrophy, acromegaly, gigantism, osteitis deformans, osteomyelitis, cranial syphilis, and tuberculosis. All these are subjects which I pass over with their mention merely, and with the suggestion that they are not often amenable to surgical treatment.

TUMORS OF THE CRANIAL BONES

Tumors of the cranial bones merit some further notice, however. **Osteomata** are not especially uncommon. They are benign tumors, hard or soft, and arise either from the periosteum or from the cartilage. "Exostosis" is the term commonly applied to them. They may be external or internal. They may be multiple or single, and they vary in size from minute nodules to large, irregular, flat, or pedunculated masses. When on the inner surface of the skull, they may reach a considerable size without producing symptoms; or they may cause notable symptoms either of general pressure or of focal disturbance. They may appear in the accessory sinuses of the ethmoid and sphenoid, fill these cavities, and invade the neighboring spaces—the orbit, the nares, or the base of the skull. These latter osteomata are composed of a shell covering a central spongy portion. Generally they are recognized easily, but sometimes one mistakes them for sarcomata.

If osteomata are not unsightly and do not cause symptoms, they may be let alone; but if they are troublesome, the surgeon may undertake their removal. The removal of osteomata is not always easy and may be extremely dangerous, for the whole thickness of the skull may be involved, and in the case of tumors of the cranial sinuses, operation may be followed by septic infections. Writers have recorded a high mortality. The surgeon should consider carefully the question of drainage, and should certainly employ it in the face of suppuration and hemorrhage.

Malignant tumors of the cranial bones occur occasionally. **Sarcomata** may be primary there or secondary, and hypernephromata have been reported. Sarcomata and hypernephromata occur at all ages and in both sexes. Primary sarcomata arise from the diploë or from the dura, and abundant new bone-formation may be associated with their growth. It is an extremely interesting fact that their beginnings often seem to be associated with traumatism, so that the surgeon must bear in mind the possibility of present sarcoma when dealing with old head injuries followed by persistent local pain and symptoms of intracranial pressure. Unfortunately, early diagnosis of these internal malignant growths is generally impossible except through

an exploration of the skull, and here again is a further reason for operating early in cases of obvious and pronounced cranial or intracranial disturbance. Bloodgood has shown that, with the exception of myelogenous sarcomata, operations for sarcoma, even on the extremities, are futile. The same observation probably would hold true in the case of the skull. Myelogenous sarcomata, however, may often be cured by a purely local operation—excision or curetting even.

Cancer of the skull is always a metastatic process, except in those cases in which the skull is attacked by direct extension of cancer from the scalp.

Myeloma (Kahler's disease) is interesting, though little understood. It is a multiple tumor-forming disease of the marrow, associated with absorption of bone, pathologic fracture, and grievous deformities. As yet it is incurable and is recognizable by the presence, in the urine, of an albuminous body named from its discoverer, Bence-Jones. Myeloma of the skull is merely a local expression of a general disease.

The Brain

We are wont, in discussion, to distinguish *injuries* of the brain from *diseases* of the brain, and, for the sake of convenience perhaps, such a division of the subject is permissible. In fact, however, one cannot always divide injuries from diseases in any arbitrary fashion. Nor can we group brain lesions always apart from lesion of the brain's envelops and bony shell. The whole subject of the nomenclature of brain lesions is one of continually increasing difficulty and confusion the more we attempt to limit these considerations by arbitrary anatomic terms. We must study the head as a whole, but we must not depart so far from conventions as to make our discourse unintelligible. Hitherto in this chapter nominally we have dealt with the skull and the meninges, but inevitably we have been obliged to consider the topography and injuries of the brain, and we have constantly been bearing in mind the fact that damage to the skull and meninges is important only, and so far as it cripples the brain itself. Let us now advance more deeply into the field and consider diseases peculiar to the brain—inflammations and tumors and the remote results of certain brain lesions.

ENCEPHALITIS

Acute encephalitis [1] may exist, though it is not common. According to Strümpell, the process is similar to the acute poliomyelitis of the cord; the **symptoms** are those which accompany all severe, acute cerebrospinal affections, and are due to the intracranial tension—with headache, stupor, vomiting, fever, delirium, rapid pulse, and, in the graver cases, choked disk, coma, slow pulse, and stertor. There may

[1] This disease appears to be growing increasingly frequent and to develop in epidemics. The year 1909 saw a great number of these cases in both America and Europe.

be paralyses or epileptiform seizures. Children are the victims commonly, and they may recover as physical and mental cripples.

Treatment hitherto has been of little value, though Cushing records his opinion that an extensive decompression operation may be of service.

A much more common form of infection of the brain is that illustrated by cerebral abscess.

CEREBRAL ABSCESS

I have already hinted at the development of brain abscess as the sequel of local bone disease—in the middle ear, the mastoid, the frontal sinus, etc.; or abscesses may follow traumatic injuries to the head, and rarely some general infection, such as is set up by a suppurative pneumonia, by influenza, by typhoid fever, or by tuberculosis. Some of these abscesses are of slow development and long duration. Charles A. Ballance especially dwells upon that form of abscess which may be likened to the shirt-stud felon. In such a case the infection penetrates slowly through the cerebral cortex, burrowing, as it were, and leaving a track behind it. Deeper in the brain, in the white substance, the advancing infection spreads out rapidly in the softer tissues, producing the effect of a mushroom-shaped mass. Ballance reminds us also that brain abscess or sinus infection is a more common complication of chronic ear disease than is acute meningitis, whereas meningitis frequently has followed unskilful attempts to remove a foreign body from the ear. The abscess may increase rapidly and break through all barriers into the ventricles, or outward to the brain surface, or it may run a chronic course with few striking symptoms. A chronic abscess is encapsulated and may persist for months or years even. When **symptoms** of brain abscess appear, they are due to three factors—the presence of pus; the increased tension within the skull; the interference with or damage to function; so that we shall expect fever, chills, and vomiting; headache; choked disk; paralyses, anesthesia, convulsions, and loss or impairment of the special senses. One should attempt to distinguish, therefore, between cerebral abscess and such other inflammations as meningitis, ependymitis, and septic sinus thrombosis. Such differentiation frequently is impossible until actual exploration has revealed the true condition.

Brain abscess, like abscess elsewhere, must be *treated* by operation. We must evacuate pus. In the case of brain abscess, however, unlike abscess elsewhere in the body, we find ourselves dealing with a circumscribed collection of fluid which lies in an almost fluid medium. As pus flows out brain flows in, so that complete and thorough drainage is not easy. Moreover, our operations must be determined often by the source of origin of the abscess. Local bone disease must be investigated and removed; the further course of the spreading infection must be followed into the brain—if necessary, after a considerable removal of the bones of the skull; and the abscess, wherever found, must be thoroughly evacuated. As Cushing says: "Unfortunately, these opera-

tions continue to be conducted as a last resort in the 'manifest' or even near the 'terminal' stage of the disease. They should, on the other hand, be undertaken early without waiting for unequivocal symptoms."

Surgeons differ in their views regarding methods of exploring the brain for abscess which is not immediately apparent—whether to explore with a trocar or with a narrow-bladed knife. I am inclined to accept the dictum of Ballance, who advocates the use of the knife. After the pus is found and evacuated, we must institute gauze drainage, and the gauze should remain long in position. And we must not forget that there may be *multiple* abscesses, in which case the drainage of one may not be followed by the prompt relief of symptoms for which we looked. Then, again, if the patient's condition permit, there is no resource save another operation.[1]

TUMORS OF THE BRAIN

Ballance, in his splendid lecture on brain tumors, remarks: "It would be impossible, in the course of a single hour, to give any adequate account of so vast a subject as that of intracranial tumors." Our statements in this chapter accordingly must be of the briefest possible nature.

Here is Ballance's classification of intracranial tumors, the majority of which are of surgical importance:

INTRACRANIAL TUMORS.

I. Epiblastic tumors:
   - A. Cerebroma.
   - B. Glioma, gliosarcoma, angioglioma.
   - C. Epithelioma. Developed from the epithelium of the ependyma, the choroid plexus, the pineal gland, or the pituitary body.
   - D. Cholesteatoma vera.

II. Mesoblastic tumors:
   - A. Sarcoma—of skull, of meninges, of brain substance (probably arising from the walls of the intracerebral vessels), of the pineal gland, of the pituitary body.
   - B. Endothelioma—meningeal (the fibroplastic tumor of Lebert).
   - C. Fibroma; fibrosarcoma.
   - D. Psammoma; angiolithic sarcoma.

III. Secondary tumors; metastases from carcinoma or sarcoma of other regions.

IV. Cysts: Simple cysts, hemorrhagic cysts, parasitic cysts, intra- and extra-dural dermoids.

V. Tuberculous tumors.

VI. Gummata.

VII. Vascular tumors—aneurysm.

Of all these tumors, the infectious granulomata (tuberculous and syphilitic) are far the most common in our records. The tuberculomata are usually multiple, varying in size, and with a thick capsule which lends itself to enucleation. These tumors are most common in the cerebellum and in children. Syphilomata are most common in adults and are resistent to medication. They are dense, usually superficial, sometimes large and multiple; often they may be removed easily.

[1] The admirable essays of Ballance and Cushing should be read by the surgeon who is planning one of these difficult operations.

The commonest forms of true neoplasms are the **endotheliomata,** loosely attached, encapsulated, meningeal tumors which do not form metastases. They do their damage by pressure. A common seat is in the cerebellopontine recess, and they are favorable growths for excision.

Gliomata form a class by themselves. They are of the epiblastic type, and arise from the neurogliar connective tissue. They are soft, infiltrating growths, which may reach an enormous size and may degenerate and become cystic. They are vascular and frequently are the seat of hemorrhages, so that a so-called " stroke of apoplexy" may be the first indication of their presence.

Cystic tumors of a parasitic type (echinococcal or hydatid) or traumatic cysts occasionally are reported. They also give pressure symptoms, and may appear in any part of the brain.

Such are the commoner forms of brain tumor. Besides these, brain **cancers** occur, usually from metastasis, and true **sarcomata** as well.

We know little of the cause of the various primary tumors beyond the fact that great numbers apparently owe their origin to some *cranial injury.* The brain may be greatly displaced by these growths, more especially the cerebellar growths, and the crowding down of the cerebellum and medulla into the foramen magnum, which follows lumbar puncture in certain cases of brain tumor, probably accounts for the sudden deaths reported as following this little operation.

In arriving at the diagnosis of intracranial tumors we study the **symptoms** under two headings: general symptoms due to the increase of intracranial tension; and special or localizing symptoms, which depend upon the part of the brain involved.

The general symptoms of brain tumor are those which we should expect from our knowledge of intracranial pressure. The presence of a slowly growing tumor raises *gradually* the intracranial tension, so that commonly we do not see those acute alarming symptoms which are produced by the sudden pressure of a fresh intracranial hemorrhage. Though the symptoms of brain tumor develop gradually, and though the tumor may cause actual destruction of brain tissue, either by pressure or invasion, in the end severe and alarming symptoms develop which end only in death. The general pressure symptoms, then, are headache, nausea and vomiting, and choked disk ending in blindness. Observe especially that many of the symptoms of acute lesions are absent—a high blood-pressure, a slow pulse, and stertor.

These general symptoms, without localizing signs indicating the position of the tumor, may be present irrespective of the size, shape, and place of the growth. Frequently one may feel sure of the presence of a tumor, but may be quite unable to name its location when it lies in a so-called " silent area" of the brain. Moreover, a minute tumor may obstruct the foramina and cause an internal hydrocephalus, with resulting general symptoms, but no localizing signs. Consequently, tumors lying below the tentorium may lead early to pressure symptoms, while

frontal tumors may cause no disturbance until they have reached a considerable size.

The headache due to pressure upon the dura or its expansions is usually dull and diffuse, but may be insufferably violent. The vomiting may be frequent or rare, and is irrespective of food. Choked disk is probably due to mechanical pressure, to the stasis of cerebrospinal fluid leading to the optic sheath, and consequent destruction of the nerve. For this reason the term *optic neuritis* obviously is not justified. One or more of these general symptoms may be lacking in cases of brain tumor, though some degree of headache is usual, especially as a late symptom.

Localizing symptoms may or may not be present, as we have seen; and their localization depends obviously upon the tumor's presence within or near the various cortical centers which we have already studied. Localizing symptoms may appear early, resulting in such phenomena as Jacksonian epilepsy or focal palsy, which should lead the surgeon to a prompt exploration. So far as regards cortical growths, it is needless here to dwell further upon the phenomena which they excite. Tumors of the basal ganglia, if they lead to pressure on the internal capsule, produce hemiplegia, hemianesthesia, hemiataxia, or hemianopsia. Lesions of the thalamus frequently cause athetoid movements or tremor of the opposite limb. The deep reflexes may be increased; the superficial may be absent—Babinski's toe phenomenon in particular. Tumors of the corpora quadrigemina lead to a staggering gait, to a tendency to fall to one side and backward, to a failure of sight and hearing, and to sundry palsies of the eye muscles. Tumors of the crura cerebri, of the pons, and elsewhere in the midbrain, are not accessible for removal, and usually are unsuitable for decompression, according to Cushing, because they lead to obstructive hydrocephalus, which renders ineffectual the usual palliative measures.

Cerebellar tumors are frequent. Often they are accessible, and are, as a rule, localizable. Early they cause general symptoms from closure of the iter, so that there results choked disk. We must distinguish between extra- and intracerebellar tumors. The latter (intracerebellar) cause pressure symptoms, but they cause vertigo also, with the apparent or subjective movement of the individual or of surrounding objects. There are focal symptoms—muscular disturbances on the same side of the body as the lesion; a staggering gait, a tendency to fall toward the affected side, nystagmus, tilting of the head, and occasional convulsions. Often there is local tenderness under the occiput. Cranial nerve symptoms usually are absent. Extracerebellar tumors, on the other hand, produce cranial nerve symptoms. Those tumors which are removable frequently lie in the cerebropontine recess. They are supposed to arise from the acoustic nerve, so that tinnitus with one-sided deafness is often the first symptom. They enlarge slowly and may last for years, with resulting pressure paralyses of the facial, abducens, or trigeminal nerves. Eventually, they may close the iter. Pituitary body tumors, lying back of the optic chiasm, affect the fibers passing to the inner side of each retina, and lead to bitemporal hemianopsia.

Acromegaly as well as hypopituitarism may be associated with pituitary tumors, severe headache is common, and vomiting.[1]

We see then that there may be a great variety of definite symptoms, a puzzling absence of symptoms, and a confusing presence of contradictory symptoms when we undertake the **diagnosis of brain tumors.** Moreover, certain other lesions may simulate tumors—abscess, gumma, hydrocephalus, and the cerebral symptoms of chronic nephritis.

The course of brain tumors varies obviously with their nature and their location. A non-malignant tumor may progress slowly and exist for years without special disturbance if it be located in a silent area.



Fig. 423.—Case of cerebellar tumor. Note dull facies and expression of eyes (Massachusetts General Hospital).

On the other hand, an infiltrating tumor (glioma) may progress rapidly from the start. Writers describe relief of pressure by natural processes —rare processes, indeed—either in childhood, by separation of the cranial bones and protrusion of the tumor; or an any time of life, by detruction of the overlying skull through atrophy and extrusion of the tumor. The average duration of life in cases of brain tumor is estimated at three years.

The **treatment of brain tumors** has only recently begun to emerge from a position of almost hopeless chaos, and to-day even many competent general surgeons are skeptical of any practical benefit from opera-

[1] For a full discussion of diseases of the pituitary body, the reader should consult Harvey Cushing's valuable and exhaustive monograph, The Pituitary Body and Its Disorders, 1912.

tions. I cannot believe that their attitude is justified. A little retrospection reminds us of many other surgical conditions now benefited by operation, toward which operations the profession was long skeptical. And disease of the brain furnishes a branch of surgery peculiarly difficult of diagnosis as well as of operative treatment.

In general terms, we have now *three* well-recognized measures at command for our attack upon brain tumors—medicinal treatment, palliative operative treatment, and curative operative treatment.

Medicinal measures are sometimes extremely effective, but are effective in the case of one class of tumors only—syphilitic gummata. We have seen that gummata are common. Sometimes it is easy and consoling for the practitioner to persuade himself that the suspected tumor is a gumma. Often he relieves the symptoms by a vigorous course of potassium iodid. But let him beware of overconfidence and of inconsiderate overdrugging. If the symptoms do not promptly—within the month—show signs of abating, he must reflect that the tumor is either not a gumma or is a gumma of such a character that potassium iodid will not dissipate it. Moreover, let him not neglect the condition of the patient's eyes. In the case of a gumma even there may be so long a delay in the relief of pressure through medication that the affected optic nerves may go on to complete degeneration, so that the patient is cured of his tumor, but is left blind. A prompt decompressive operation might have relieved the choked disk and have saved the eye-sight.

Palliative decompressive operations are extremely valuable in nearly all classes of brain tumors except those which, through pressure upon the iter, have caused an obstructive hydrocephalus. In these cases the newly formed cranial defect gives but temporary relief, if any; more fluid accumulates in the ventricles, and the old high tension returns. In many cases of brain tumors, however, decompression gives brilliant results, even though the patient eventually die, unrelieved of his tumor. After the decompression, headache disappears, vomiting ceases, the eyesight is restored, paralytic conditions improve, and often the patient is enabled for a year or more comfortably to go about his business. The undiscovered tumor may continue to grow, but the great gap in the skull provides for escape of the brain as a hernia, and the old intracranial tension does not return.

These palliative operations are undertaken in the case of presenting irremovable tumors as well as of those which cannot be localized. The surgeon should take some pains in selecting the site for decompression, because the extruded brain is wont to become more or less functionless. As a general rule, therefore, one should operate over a silent area, in right-handed patients, under the right temporal muscle in case of a cerebral tumor, and under the suboccipital muscles in case of a subtentorial growth. Spinal puncture, with the withdrawal of cerebrospinal fluid for the relief of intracranial tension, at one time looked promising. It is now less used except for transient relief. It is dangerous also on account of the occasional sudden pressure to the basal structures which results.

Curative operations are rare, but with increasing experience such surgeons as Victor Horsley, Cushing, Ballance, and others are demonstrating that certain varieties of tumors may be removed entire, with a fair chance of permanent cure. As Cushing says, certain important questions are always raised in case one is able to cut down upon and explore a tumor of the brain: What is the tumor's nature? how great a loss of function has it produced already? will its removal result in the improvement or in the increase of symptoms already present? One may not answer accurately these queries in every case, but we may state in general terms that an encapsulated tumor can be removed entire, while an infiltrating tumor must be left in part. There may result immediately an increase in functional disturbances, but growing experience in operations and through animal experimentation has demonstrated that damaged brain often shows a surprising power of re-establishing function apparently lost.



Fig. 424.—Fungus cerebri following exploration of brain (Massachusetts General Hospital).

RESULTS OF INJURIES AND DISEASES OF THE BRAIN

Before considering in more detail methods of operating upon the brain, let us observe here certain *results of injuries and diseases of the brain*.

Hernia cerebri and **fungus cerebri** are sequelæ of quite different types, though their nature has often been misunderstood. Hernia is due to pressure from within, and is a protrusion of normal brain, covered

with sound skin. A fungus is a protrusion of brain through an open wound in the scalp—a serious condition, owing to the prospect of infection and meningitis.

Cushing calls attention to the existence of a wide-spread, but curiously erroneous, notion that mere exposure of the brain, on opening the dura, will always lead to a protrusion of brain through the dural opening. Quite otherwise is the fact, for normally the brain recedes when exposed, owing to atmospheric pressure. Under certain circumstances, however, the brain will protrude—perhaps from the presence



Fig. 425.—Hernia cerebri.

of a tumor, perhaps from venous stasis, perhaps from an improper handling of the cortex, leading to edema and increased pressure. Under these conditions the surgeon may find it impossible accurately to replace the dura, but generally relief of tension may be secured by elevating the head, by pricking the arachnoid so as to allow cerebrospinal fluid to escape, or, if necessary, by a lumbar puncture. The herniæ established by decompression may reach enormous size, especially if they are unprotected by overlying muscle. In these days a fungus rarely is seen.

Epilepsy.—This is no place in which to discuss fully that most difficult and often indeterminate disease, characterized by the symptom-complex convulsions, and conveniently called epilepsy. "Epilepsy" itself is no proper term to designate the disease. Epilepsy—a "falling on"—is but a symptom. The causes of many epileptic or epileptiform attacks are numerous and obscure, varying from psychic disturbances to true histologic changes in the motor cortex. We must believe it proved that certain reflex irritations, as from an ovarian tumor or an ingrowing toe-nail, may cause epileptiform seizures; and certain toxemias, especially those occurring in renal disease, may lead to

convulsions. Whatever the cause of the epilepsy, it is obvious that some irritation of the cortex, whether due to psychic or mechanical causes, is at the bottom of the attack. We are concerned here, however, with those forms of epilepsy especially which are due to definite, gross, organic lesions, and we must remember that organic epilepsy, as distinguished from idiopathic epilepsy, is characterized by focal or so-called Jacksonian attacks, preceded by a more or less definite aura. This distinction is not always reliable, for cases of reflex epilepsy even may have focal symptoms, while actual organic cortical lesions may cause no focal symptoms.

We may not discuss here the intricate subject of the causation of epilepsy further than to remind the reader that, in addition to the well-recognized etiologic factors, epilepsy may be due to meningeal adhesions following meningitis, to cerebral syphilis, to brain tumors, to brain damage following traumatism, and especially to those injuries leading to what are known as birth palsies—injuries to the infant's head overlooked at birth, but leading later to pronounced nervous and mental derangements.

From what has been said, and assuming the reader's general knowledge of the subject of epilepsy, we see that the *symptoms* which justify a surgical operation are often difficult and confusing. Moreover, we must reflect that an individual case, taken early, may be susceptible of cure by operation, whereas the same patient, if left a sufferer for months or years, may not be benefited in the least by a late operation, because he has formed the "epileptic habit." There are sundry types of epileptics whom operations may benefit, especially those persons suffering from so-called Jacksonian attacks—attacks beginning with a distinct aura and marked by convulsions strictly localized at first to the hand or foot, and later perhaps becoming general. Then there are the cases in which the seizure is general from the outset, though these cases themselves may earlier in their careers have been marked by distinctly focal symptoms. The cases of focal epilepsy—Jacksonian—appear to be due to a cortical irritation occasioned by some form of obvious lesion—depressed bone, meningeal adhesions, a tumor. Those cases distinguished by general convulsions may likewise be due to focal irritations, and it is in this class that we may often group that large number of birth palsies sometimes called idiopathic cases.

The *treatment* of epilepsy is operative so far as the surgeon is concerned, though there are cases which undoubtedly have been greatly benefited after operation by resorting to the use of bromids or psychotherapy in order to break up the epileptic habit. At this writing certain forms of epilepsy ("essential") seem to be benefited, or cured even, by the therapeutic use of *crotalin*, the dried venom of *crotalus horridus*, or rattlesnake.[1]

There is a diversity of opinion as to what should be the nature of

[1] See interesting article by J. B. Woodruff, New York Med. Jour., January 11, 1913.

an operation upon the brain for epilepsy. One fact is certain, that the old-fashioned, small trephinings, the peeping at the brain through a little hole, and the scratching of the arachnoid with a needle-point, are of little benefit. The main reason for discouragement over the history of the operative treatment of epilepsy lies in the fact that the operations have been utterly inadequate. Whatever the nature of the intracranial lesion may be, we have not yet determined how it affects nervous tissue so as to produce convulsions. There are those who believe that the presence of an adhesion alone is sufficient cause for irritation leading to convulsions. There are others, notably Kocher, who assume that the local lesion in itself is non-irritating except when, from any cause, a slight increase in the intracranial tension induces a special irritation at the site of the local lesion. My own experience in operating for epilepsy leads me to agree with the teachings of Kocher. Whatever one's views on this difficult point, all competent surgeons are now agreed that in operating we should cut down on the brain through a large bone-flap. Horsley, Cushing, and others have conducted considerable operations upon the meninges and the brain itself for epilepsy, going so far even as to remove small areas of the cortex which were thought responsible for the focal symptoms. Other surgeons have contented themselves with removing obvious abnormalities, and trusting to extensive decompressive measures to lighten the brain of future pressure and local irritation. This last is Kocher's teaching. Certain it is that through both methods great numbers of patients have been improved or cured. Mark the distinction in the methods of finishing the operation. By the Horsley method the dura and bone are carefully returned into place. By the Kocher method the dura is replaced, but the bone-flap is removed entirely. A great deal has been said and written regarding the importance of replacing smoothly and accurately the dura. In two cases I have been obliged to remove the dura, leaving the arachnoid to become adherent to the skin-flaps, a condition which is usually represented as leading to serious subsequent cortical irritation. In both of these cases no disturbance has resulted, as the wide removal of bone provides for comfortable expansion of the brain. In spite of such experiences, however, sound practice teaches that when it is possible, we should secure a smooth replacement of the dura in order to avoid adhesions. The conditions one finds within the skull—the conditions presumably causative of the epilepsy—are numerous, and sometimes obscure and puzzling. Depressed fragments of bone, adhesions, and tumors are obvious enough, but frequently one finds nothing beyond a wide and somewhat indefinite thickening of the arachnoid, giving to its surface a slight bulging aspect and a pearly blue color. Frequently surgeons fail to recognize this as an abnormal condition. In fact, the condition is one of thickening of the arachnoid, due probably to a long antecedent cortical hemorrhage. One questions whether such an obscure cause as this may not explain certain types of so-called idiopathic epilepsy. This condition of thick-

ened arachnoid may be benefited by tearing the arachnoid with a needle-point in several places and so permitting the escape of cerebrospinal fluid. Surprising improvement sometimes follows this operation, whose advantages may be due to an alteration established in the cortical circulation. My personal inclination in such cases is to complete the operation by decompression.

After operation these patients should be handled with the greatest care. Auvray estimates the mortality at from 12 to 38 per cent. The wound should be sewed up dry and drained with rubber tissue. The patient should lie with the head slightly elevated. His room should be kept at a moderate temperature, and with strong light excluded; noisy and inconsiderate attendants should be kept at a distance, and rest in bed should be enjoined for three or four weeks. At the same time the diet should be carefully regulated and the bowels should be moved daily. If the surgeon can find time for the extra attention, he may greatly relieve the strain upon the patient and facilitate the convalescence by gentle suggestive treatment, which should encourage the patient to look for a restoration of health.

There are sundry other disabilities and serious complications which are associated with cranial injuries and intracranial disease—**psychoses, insanity, imbecility,** alterations of temperament and intellect. A discussion of these far-reaching topics is impossible here, further than to state that such mental disabilities sometimes are remedied by suitable operations, especially by decompressive operations. I believe that all cases of intellectual impairment which can be traced directly to causative head injuries should have the benefit of a surgical operation.

A few years ago we were told that certain cases of insanity and congenital imbecility are due to permanent closure of the cranial sutures, this closure producing a crowding and a checking of development of the brain. Surgeons endeavored to remedy the condition by establishing artificial sutures and so promoting cerebral growth. These conceptions and endeavors have been shown to be without value and inconsistent with just reasoning, and we now know that the process is the reverse of what was assumed; an early closure of fontanel and suture is due to a primary failure of growth of the encephalon.

Operations have been found useless in the case of these unfortunate persons. Those victims who are not hopelessly imbecile may be taught simple tasks, and may possibly attain to self-support through the schools for feeble-minded.

Cranial defects,[1] especially those defects due to injuries and operations, have been the subject of considerable discussion, and many surgeons have maintained that these defects may lead to serious cerebral disturbances, such as epilepsy, and that they should be closed. I am not convinced that this conclusion is justified by the facts. Certainly operations for decompression of the brain are demonstrating that skull

[1] E. R. Rost, Ann. Surg., April, 1910, reports an ingenious operation for closing large defects or openings in the skull.

defects in themselves are often a benefit. It is not impossible that in those cases of skull defects which are associated with cerebral disturbances the irritation may be due to thick adhesions or to lack of proper decompression. On the other hand, Dudley P. Allen has been able to report the records of certain patients affected with epilepsy associated with skull defects who have been benefited by closing the defects with bone-flaps. I am myself inclined to adopt the view of Cushing, " that closure of a defect should be limited to those cases in which it is in an obtrusive situation and makes an unsightly deformity; to those in which local pain or tenderness promises to be lessened; or occasionally when the patient has an associated obsession in regard to its presence."

INTRACRANIAL OPERATIONS

The *technic of intracranial operations* is still a subject of considerable debate. I shall not endeavor to describe in detail the various methods which are advocated by various surgeons, but shall content myself with explaining the method which I myself use,—essentially the method of Harvey Cushing,—observing at the same time that this method itself may soon become antiquated. It is not difficult; it is somewhat slow; it is reasonably safe.

A striking and fundamental distinction exists between present methods of opening the skull and all those methods in use up to fifteen years ago. Throughout surgical history the mere piercing of the skull, especially when associated with opening the dura, was regarded as a most serious undertaking; and the constant endeavor of surgeons was to make the opening as small as possible. To this end they used small trephines; they shrank from injuring the dura; they looked in through little holes at the membranes and the brain; they saw little, and their endeavors were generally ineffective. In speaking of epilepsy, I explained how it is that these insufficient operations seldom resulted in the accomplishment of good. Not only did they fail to afford space sufficient for proper inspection, but they failed to accomplish the relief of pressure or to give room for the removal of adhesions, of cysts, and of tumors.

The **osteoplastic craniotomy** is the operation of to-day, and is an immense advance in the surgery of the head. It consists in turning back a large disc of bone (as large even as the palm of the hand) with the overlying skin-flap.

Careful surgeons themselves attend to certain details of the preparation for operation. So far as may be, the patient should be brought to the table in a placid state of mind and body. A normal movement of the bowels is important, but preliminary drastic purges are an offense. The patient's head should be shaved completely and this should be done deftly and gently, preferably on the operating table. Then the anesthetic should be given, and for this I use ether, given preferably by the intratracheal method. With the patient unconscious, cleanse the skin, and over the whole head throw a wet bichlorid

compress; then pass about the head, from inion to glabella, the rubber tourniquet, which shall control the vessels of the scalp. The patient

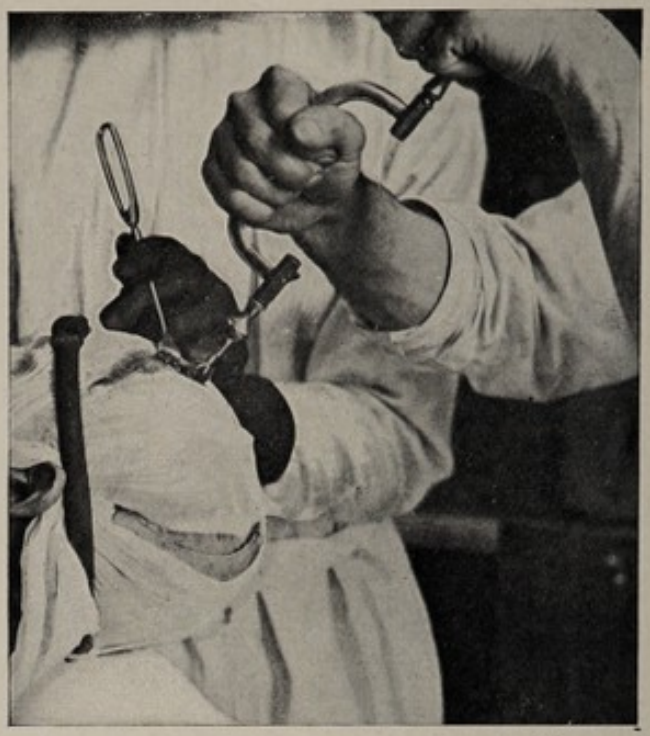

Fig. 426.—Opening the skull—step 1 (Cushing in Keen's Surgery).



Fig. 427.—Opening the skull—step 2. Dahlgren forceps used for incision of lateral edges of bone-flap when approaching thinner portion of cranium in temporal region (Cushing in Keen's Surgery).

should lie upon the table in the position most favorable for operation, and as a routine he should be elevated in a modified Fowler's posi-

tion, as hemorrhage is thus controlled more easily. I use the pneumatic suit with a view to counteract the shock, and in a few cases have found it valuable.

With the patient anesthetized and with the field clear (and be it remarked that a specially skilled anesthetist is a desideratum), turn down

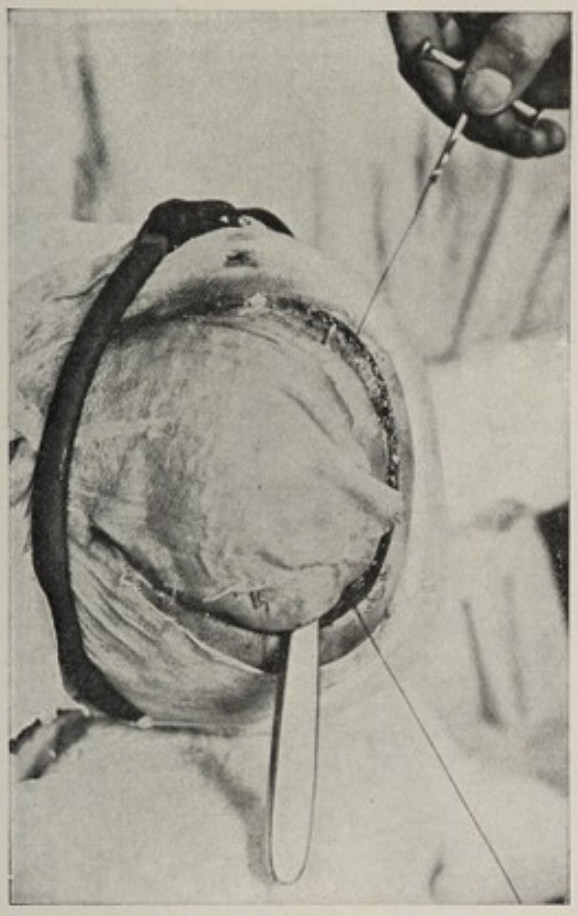

Fig. 428.—Opening the skull—step 3. Showing Gigli wire saw in use for making beveled mesal edge of flap, with dural guard introduced through the two cranial openings (Cushing in Keen's Surgery).

a large skin-flap, carrying the knife directly and firmly to the bone. The hemorrhage should be slight, or there should be none at all. Open the skull through two ½-inch trephine openings at the upper angles of the flap.[1] Gnaw away the bone with a De Vilbiss forceps, from the trephine openings downward, making the lines of opening approach each other somewhat, and then—a most important step—complete the section by sawing away the bone, on the bevel, between the trephine openings. We accomplish this best by the use of a Gigli saw, passed along a large grooved director between the bone and dura from one opening to the other. The Gigli saw is made to divide the bone on the bevel in order that when the bone-flap is replaced, the bone shall rest in its bed without

[1] Says J. B. Murphy, "The instrument devised by Dr. J. M. Neff (Spokane, Washington), as now constructed, is the best craniotome placed on the market up to the present. It is safe, extremely rapid, and there are no complications attending its use.

pressing down upon the underlying brain. Various other methods ot cutting through the skull are favored by various surgeons, who use ingenious saws and osteotomes. These are useful instruments in the hands of experts, but I believe that the method I have described here is the simplest and most generally applicable.

The bone being divided, the bone-flap is completed by forcing an instrument beneath the calvarium and breaking back the flap, which falls over on its hinge of scalp. The surgeon may now proceed to inspect the dura, and to open it through the large bone window he has provided. In opening the dura take great pains not to wound the thin-walled and delicate vessels of the pia. If they must be cut, hemorrhages should be



Fig. 429.—Opening the skull—step 4. Osteoplastic flap and dura reflected. Note broad level of upper edge of bone-flap, also concentric, rather than superimposed, openings through scalp, cranium, and dura (Cushing in Keen's Surgery).

controlled near the site of their section by delicate, split, black silk ligatures, needled around the vessels, and not by hemostatic forceps. Indeed, in all these manipulations of the membranes and cortex the greatest delicacy of touch should be practised. Rough handling may frustrate all our purposes by stimulating hemorrhage and even by bringing about a troublesome edema. If the patient's blood-pressure falls after the skull is opened, and if signs of shock appear, it is proper to close the wound and to complete the operation some days later—indeed, some surgeons employ two or three sittings as a routine measure.

The *closure* of the wound is an important step, not to be slurred, Whenever possible, the dura should be accurately and carefully stitched into place. When permanent decompression is required, this replacing

of the dura may be inadvisable, and if the dura is to be removed, it should be trimmed away close to the bones' edge, lest pressure from within crowd it against the rough bone and cause troublesome headache. Then one should suture the scalp accurately and carefully in its turn, and I believe it is best to control all superficial bleeding points in the scalp before suturing is done. If drainage must be established, we should use cigaret wicks led out through a special stab-wound beyond the edge of the skin incision, and as low down on the head as may be. Finally, the head should be dressed in an abundant absorbent, elastic compression dressing, to be changed on the third day, when all stitches and drains should be removed. After all operations on the brain, and especially after traumatic lesions, give the patient urotropin (gr. 7½ t. i. d.), which shall anticipate and check any possible infection.



Fig. 430.—Cushing's method of closing scalp before removal of tourniquet. Note ridge of tissue made by sutures when tied (Cushing in Keen's Surgery).

Decompressive operations, whenever possible, should be done through muscle tissue. For example, in case the surgeon plans a decompression to palliate the symptoms of a cerebral tumor of unknown site, he may make his opening through the squamous portion of the temporal bone, and approach that bone by splitting the temporal muscle. By this maneuver one may expose a considerable area of bone, may excise it, and may cover in the gap with temporal muscle, aponeurosis, and skin, thus delimiting and controlling an excessive hernia.

Suboccipital explorations are well made through an approach by Cushing's cross-bow incision. In this fashion, as the drawing illustrates, one may lay bare comfortably the lower portion of the occiput and may remove bone, covering in the gap subsequently by heavy layers of muscle and aponeurosis.

Surgeons approach the base of the skull by other routes and in other quarters—the anterior fossa through the temporal bone or even through the frontal bone; and operators have sought the pituitary fossa by going directly under the frontal lobes after turning down a large frontal bone-flap, or by working through the nasal passages and accessory sinuses. These operations about the base are almost always associated with obstinate, and sometimes with serious, hemorrhage from large veins, so that the operations must be undertaken with caution, pains, and discretion. It is not probable that such difficult and delicate explora-

tions will find favor with general surgeons in the near future. These are matters more particularly for the carefully trained neurologic surgeon.

At the beginning of this chapter I made some mention of the difficulties and of the promise of intracranial surgery. In its modern aspects

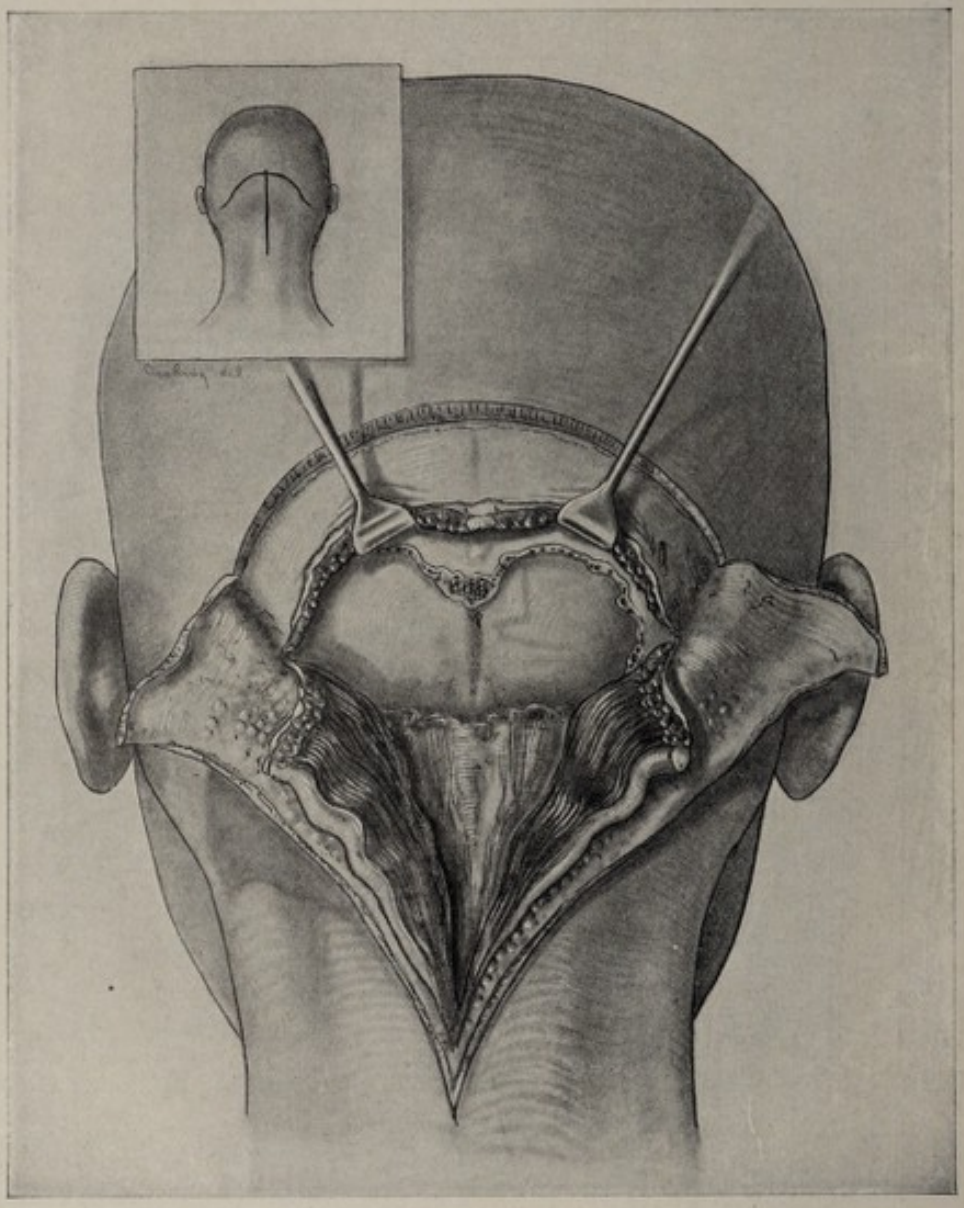

Fig. 431.—The suboccipital exposure, showing opening partly made, and Cushing's "cross-bow" incision (Cushing in Keen's Surgery).

the subject is a new one, not altogether formulated as yet, or determined in many of its aspects; but I hope I have shown in this brief sketch the nature of what is now being done, and the purposes of those men who are skilled in this field, and have made clear the reasons of their hope for the future.

CHAPTER XXV

THE SPINE AND THE PERIPHERAL NERVES

The Spine

The surgery of the spine, like the surgery of the head, has been strangely shrouded in clouds and mystery. Doubtless, this mystery has surrounded the surgery of the spine for two excellent and interdependent reasons: the anatomy and physiology of the nervous system have not been elucidated until recent years; and the surgeon, when he deals with the spinal cord and its component nerve-fibers, deals with microscopic structures. Minute, numerous, and complex structures are our study, and their functions are correspondingly intricate. But their arrangement, so far as it has been explained, should no longer baffle the intelligent student. The arrangement of the nerve-fibers is no more confusing than is the arrangement of tracks in a great railway freight yard; and the study of their function is no more difficult than is the study of electric science.

Hitherto the general surgeon, when confronted by spinal lesions, has been content to serve as the tool of the neurologist; he has been the neurologist's mallet and gouge. The positions should be reversed, and the surgeon, if he be not himself a skilled neurologist, should use the neurologist as his instrument of precision—as his stethoscope or thermometer. It would seem as though thus only can present progress be made in knowledge of the pathology and the treatment of lesions of the central nervous system in man. Through the nature of his work the surgeon seeks to excel in therapeutics, and the neurologist in diagnosis. Special training and study doubtless are needed to develop neurologic surgery to its maximum, and, as I remarked in speaking of cranial surgery, the expert neurologic surgeon is still rare among us.

Surgery of the spine is analogous to cranial surgery in many respects. The factor of central interest is the cord in the former case, as is the brain in the latter case; but mark this distinction, damage to the skull in itself is of little consequence so long as the brain be not involved; but damage to the vertebræ may be serious, crippling, and fatal even, though the cord remain untouched and unimpaired.[1]

This statement must not mislead the surgeon, however, especially when he deals with traumatic injuries of the spine. He must investigate the condition of the cord and the spinal nerves in all spinal lesions.

Spinal surgery, like cranial surgery, is no new thing. Its history furnishes a fascinating subject for the thoughtful student. Galen himself, in the second century, was probably the first surgeon cogently

[1] For example, certain fatal cases of spinal caries.

to demonstrate the functions of the central nervous system, and the relation between encephalon, cord, and peripheral nerves. He recognized the distinction between sensory and motor nerves also, and seems to have had some conception of anterior and posterior nerve-roots. He advocated operating for damage to the spine with paralyses. Sundry others of the ancients adopted his views, notably Paul, of Egina, in the seventh century; while throughout surgical history we find bold men—Paré, in the sixteenth century, for example— urging operations for spinal fractures. So we come down the line, noting some of the great physiologists and surgeons, Charles Bell, Astley Cooper, Cline, Magendie, Heister, and many such, until, by the middle of the nineteenth century, surgeons and neurologists alike are seen to have become convinced that the operative treatment of spinal lesions has a place in our therapeutics. In spite of such conviction, however, the purposes of neurologic surgeons were long undirected, and their measures haphazard and largely futile. Only recently, out of a growing clincial experience and a better knowledge of physiology, have we begun logically to approach this great field, as yet so crudely tilled.

ANATOMY AND PHYSIOLOGY OF THE CORD

The anatomy and physiology of the cord and spinal nerves merit our careful study, but space forbids more than a passing glance here. Physiologically, the cord begins with the medulla, within the cranium. Surgically, the cord begins at the foramen magnum, and ends at the tip of the conus medullaris, at the upper border of the second lumbar vertebra; although the terminal nerves, the cauda equina, are given off above this point, opposite the bodies of the eleventh and twelfth dorsal vertebræ. The cauda equina itself is inclosed for a part of its course in the dural pouch, which ends like a glove finger-tip at the second sacral vertebra. So the cord is suspended from the brain, as it were, but is chiefly supported and steadied by the nerve-roots emerging between the spinal vertebræ and the denticulate ligament or ligaments.

The cord itself differs strikingly from the brain in this respect—that its gray matter is its inner substance, and its white matter its outer. Its white cortex, so to speak, is composed of conducting fibers which lie immediately beneath its envelop of pia arachnoid. Within the gray matter lie the centers for reflex action, in their turn presided over by the higher brain centers, which send their messages down through the fibers of the white matter and receive messages in return. One remembers further that the cord is divided into two lateral halves by the anterior and posterior fissures; that the posterior (sensory) nerve-roots enter the cord on either side near the posterior fissure, and form the posterior lateral fissures. Analogous, but much less obvious, anterior lateral fissures are formed by the emerging anterior (motor) nerve-roots. The gray matter, with its rough H shape, comprises much the smaller part in bulk of the cord, the major part of which is made up of the white ascending and descending fibers arranged in columns.

These are the columns which the student would fain remember accurately, if he shall arrive at a capacity for the careful diagnosis of cord lesions. Within the gray matter, in the midst of the commissure, runs the central canal of the cord, a deep well, which drops from the bottom of the fourth ventricle and ends blindly at the tip of the cord within the filum terminale. This central canal is lined with a continuation of the ventricular ependyma, and is important for its relation to spina bifida and syringomyelia.

The accompanying figure, taken from Toldt, will recall diagrammatically to the reader the structure of the neurons, those units which make up the substance and structure of spinal nervous elements.[1]

The reader will observe that the axones of the peripheral nerves, outside the spinal canal, are furnished with a protective neurilemma (sheath of Schwann), while the fibers in the cord substance have no such sheath. Where the sheath does not exist, regeneration of a damaged nerve-fiber *does not* take place; but where there is a neurilemma (Schwann), the nerves regenerate eagerly. In surgical practice, therefore, we observe that when the *cord* (devoid of a neurilemma) has been damaged in whole or in part, there results a permanent loss of

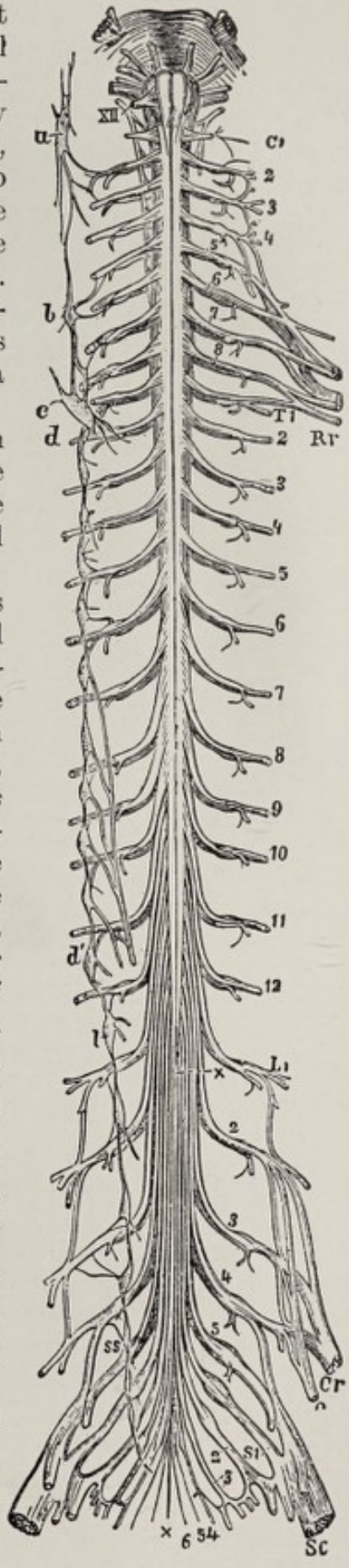

Fig. 432.—Spinal cord connected above with the medulla oblongata and pons: V, Nervus trigeminus; XII, nervus hypoglossus; C, first cervical nerve; C, 2–8, second to eighth cervical nerves; T, 1–12, first to twelfth thoracic nerves; L, 1–15, first to fifth lumbar nerves; S, 1–5, first to fifth sacral nerves; 6, nervus coccygeus; xx, filum terminale; from the root, marked L to x, corda equina; Rr, plexus brachialis; Cr, nervus femoralis; Sc, nervus ischiadicus; O, nervus obturatorius. The enlargements opposite L, 3, 4, 5, represent the spinal ganglia on the dorsal roots. On the left side of the figure the sympathetic trunk is shown: *A*, to *SS*, ganglia; *a*, ganglion cervicale superius; *bc*, ganglion cervicale medium and inferius; *d*, first thoracic ganglion; *d*, last thoracic ganglion; 1, first lumbar ganglion; *ss*, first sacral ganglion (from Rauber).

[1] J. B. Murphy, Surgery, Gynecology, and Obstetrics, April, 1907, gives an admirable practical review of this subject.

sensory and motor function in the parts below the damage. There is no satisfactory evidence that the severed cord can be repaired by either surgical or natural means.

Severed or damaged *peripheral* nerves (with sheath of Schwann), on the contrary, may and do repair themselves by natural processes; may be repaired surgically; and will regain function completely.

If a nerve be divided, that part of it toward which impulses travel will degenerate. In motor nerves the degeneration takes place therefore *toward the periphery* of the body; in sensory nerves, *toward the center*, or cord-ward; but degeneration progresses only so far as the immediate axones concerned, and does not attack associated axones.

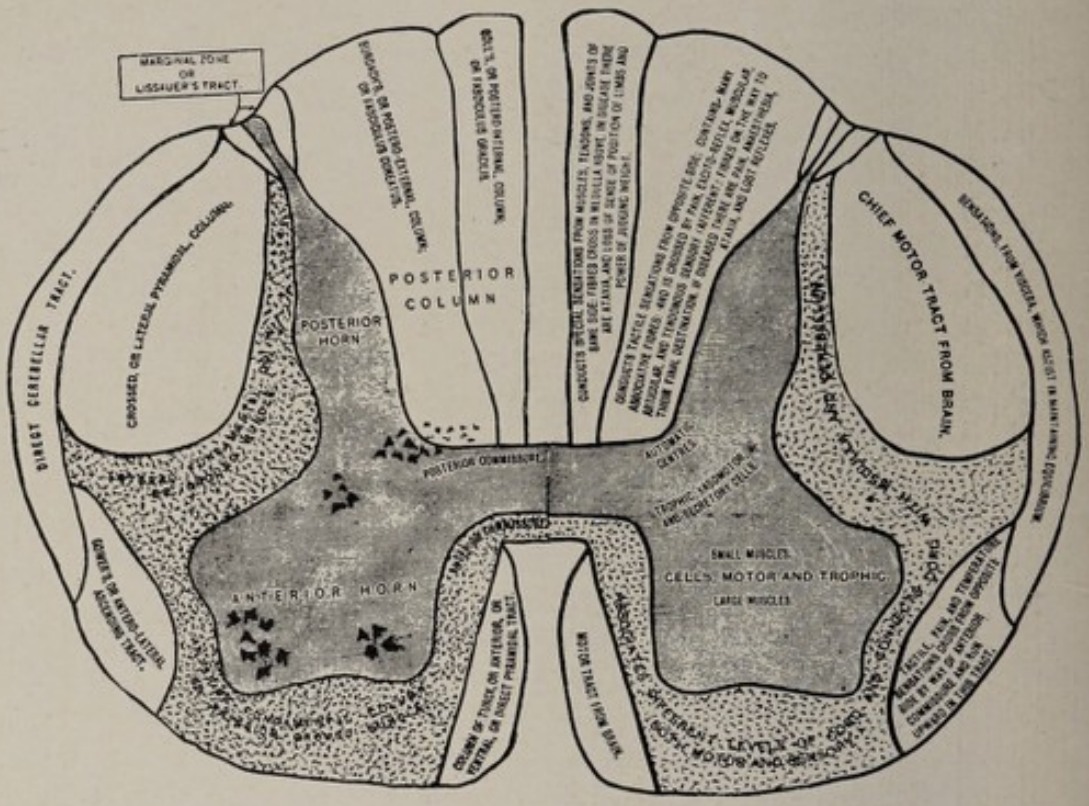

Fig. 433.—Showing the tracts and the functions of various tracts of spinal cord (Butler).

We remember always, however, that peripheral nerves (neurilemmic) are capable of repair and regeneration for months after their damage—witness the astonishing repair and functional restoration of the trifacial nerve—repair which may take place long after the nerve has been divided for trifacial neuralgia.

In general terms, in the case of the spinal cord, when it is damaged or interfered with, we see results quite similar to those which follow like damage to the brain. We know that much of the gravity of lesions within the skull is due to intracranial pressure—that the brain fills completely a closed box, and that the slightest addition to the contents of that box will cause an increase of intracranial tension. The cases of the spine and cord are similar, though in the case of the spine,

the box, or bony tube, is less tight than is the skull, so that there is some room for slight expansion through the various vertebral foramina. Nevertheless, pressure on the cord, slight pressure even, may give rise to serious motor and sensory symptoms—general symptoms when the

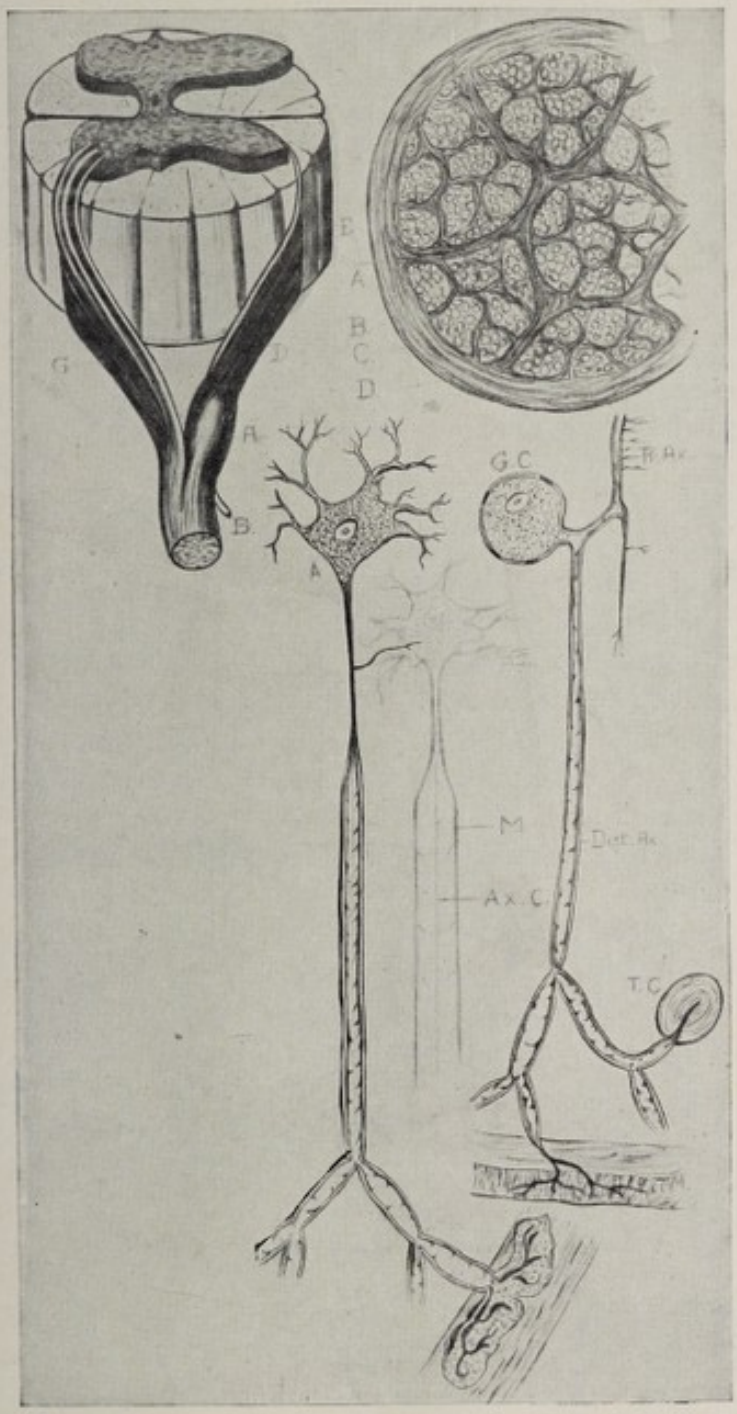

Fig. 434.—Showing: *a*, Cross-section of spinal cord with anterior and posterior roots and ganglia; *b*, cross-section of nerve-trunk, showing the perineural and interfascicular connective tissue; *c*, motor neuron; *d*, sensory neuron (Murphy).

pressure is diffuse, as in the case of effusion from meningitis; focal symptoms, disturbances in limited areas, when the pressure is exerted on particular points of the cord. In a sense, local pressure on the cord is a more serious matter than local pressure on the brain. For example,

an intracranial meningeal tumor, especially if located over a "silent area," may exist for months or years without producing marked disturbances; but a tumor pressing upon the cord within the spinal canal, inevitably will cause serious disturbances or loss of function to all parts of the cord below it. There are no silent areas in the cord. Brain substance, in certain areas, may be lost without special distress following. Cord substances may not be lost without permanent distress following its loss.

From such general considerations we conclude, therefore, that any increase of intraspinal tension—from inflammatory exudates, syringomyelia, tumors, bone pressure from fracture or disease, exostoses, tuberculomata, and sundry other lesions, will inevitably result in disturbances to the cord's structure or function. By their symptoms, we shall know them; though the elaborate study of symptoms would lead us far into the field of neurology, we must touch upon these matters, and consider briefly the remedies which surgery may offer.

CONCUSSION AND CONTUSION

We speak of *concussion* of the spine and *contusion* of the spine, and we find that the terms are in debate, as are the terms *concussion* and *contusion* when applied to the brain. More than thirty years ago the term "railway spine" was introduced by Erichsen,[1] who meant a symptom-complex—paralyses, hyperesthesias, and similar disturbances —which follows slight injuries to the back and disappears eventually, leaving the patient well. Many observers to-day prefer to describe these disorders as *traumatic neuroses*. "Concussion of the spine" seems justified clinically, and may be regarded as a temporary reaction on the part of the cord, but without definite morbid changes. Erichsen describes the following case: A man of forty-four was thrown from his carriage, and received no obvious external injury. A day or two after the accident he observed anesthesia and monoplegia of the right arm, followed later by cervical and dorsal pain and hyperesthesia of the left arm. Three days later both legs became paraplegic, but the sphincters remained unaffected. He recovered gradually. J. B. Murphy relates a similar accident in the case of a woman, who died of pneumonia ten days after the injury. No changes whatever in the brain or cord were found at the autopsy.

Contusions of the spine are more serious affairs, and they may be of varying grades of severity—from bruising of the ligaments and vertebral processes to bruising of the nervous elements, with consequent paralyses, but without division of the axones. Frequently there results an escape of blood into the spinal canal or cord, or a traumatic zonal inflammation. The symptoms of such damage may not develop for several hours or days even after the injury; and they present us with no typical clinical picture whatever. There may result pains in the extremities or back, paralyses, anesthesias and hyperesthesias, involv-

[1] John E. Erichsen, On Concussion of the Spine, Nervous Shock, 1875.

ing one or more of the extremities. Often the patient is completely crippled, but so long as the axones are not divided, restoration of function is possible, through the resolution and absorption of exudates, and the resulting relief to irritation of the cord and nerve-roots. Convalescence is extremely tedious, however, and may require months or years. Many of these patients may be greatly helped in regaining the use of their limbs by a course of careful, systematic training and by electric stimulations.

From this explanation of the nature of cord contusions, as they are commonly understood, we see that they differ essentially from many contusions of the brain. Contusion of the brain implies generally an actual destruction of nervous elements.

WOUNDS OF THE CORD

Wounds of the cord are far more serious affairs than are concussions or contusions. Wounds of the cord may be from punctures or from crushing forces,—by a bullet, a knife, or a fracture of the spinal column,—and these wounds imply an actual destruction of the cord's elements. Writers point out that a majority of punctured wounds of the cord occur in the cervical and upper dorsal regions, for an assailant aims to damage his victim in the head or the thorax. We know also that knife wounds generally sever one-half the cord only.

Wounds of the cord are extremely serious affairs, for the axones once divided there, never regenerate.

The **symptoms** appear at once in these cases, and not late, as after contusion. At least a quarter of the patients die; many improve, but none recover completely.

The surgeon can do little for these cases. He cannot restore by suture the wounded cord; a laminectomy is almost certain to increase the existing damage. Laminectomy may be necessary, however, to relieve an increasing hemorrhage which aggravates the intraspinal pressure and makes worse the symptoms from which the patient is suffering. One should not perform laminectomy, however, without doing a preliminary lumbar puncture; and lumbar puncture alone, which establishes the diagnosis, may often suffice to relieve many of the paralytic symptoms. Then a bullet or a bone spicule may be discovered by the *x*-ray, and should be removed.

The hemorrhage to which I have referred may be distributed variously—it may be extradural, beneath the meninges, or in the substance of the cord itself. When the blood lies beneath the meninges, the condition is called hematorachis; when within the substance of the cord, it is called hematomyelia.

It is difficult without lumbar puncture to make a diagnosis of these various forms of hemorrhage. The nature of the injury may suggest the condition, but does not distinguish between hematorachis and hematomyelia. Yet for the purposes of treatment and prognosis one should attempt to make the distinction. The patient may recover

from hemorrhage beneath the meninges. Hemorrhage within the substance of the cord results in permanent but varying paralyses. The symptoms of *hematorachis*, in general terms, are pain in the spine, intermitting and burning; pains along the courses of the nerves; sometimes muscular spasms, convulsions, and finally paraplegia. The succession of these symptoms suggests closely the succession of symptoms resulting from intracranial hemorrhage—first, a stage of excitement; second, a stage of paralysis. These hemorrhagic paraplegias are of gradual onset and are quite different from the sudden and complete paraplegias which follow spinal fractures. The slowly increasing hemorrhage may not result in paraplegia for two, three, or more days. Fortunately, most of the cases of hematorachis recover spontaneously in from one to two months. *Hematomyelia*, hemorrhage into the substance of the cord, is a much more serious affair, as I have said, especially as it is wont to occur in the upper regions of the cord, with resulting paraplegia of all the parts below, depending upon the exact site and location of the effused blood. Hemorrhage into the gray matter only, especially when high in the cord, is recognized by wasting of muscles and anesthesia of the upper limbs; but the much more common hemorrhage, involving the white substance, causes paraplegia below the level of the lesion. The outlook for all these cases of hematomyelia is extremely doubtful. Some of them may recover in part, but always with a resulting weakness due to the destruction of the ganglion-cells of the motor neurons at the point of hemorrhage.

DISLOCATIONS AND FRACTURES OF THE VERTEBRÆ

Dislocations and fractures of the vertebræ are generally associated the one with the other, except those rather common dislocations of the atlas on the axis, which frequently occur without a concurrent fracture. Dislocations and fractures of the vertebræ in general produce pressure or other damage of the cord also, with resulting nervous phenomena—except, again, in the case of atlas dislocations, which may not damage the cord. In *all* cases, however, recovery is possible if the cord be not wounded and if pressure be relieved timely.

All manner of violence may cause vertebral fractures and dislocations —violence direct and indirect—crushing blows, forcible flexions of the trunk ("jack-knifing"), and falls upon the feet or head. The laminæ and spinous processes may be broken off and driven into the cord, the vertebral bodies may be crushed, and commonly the vertebral ligaments are torn, so that one or more of the vertebræ are forced out of place (dislocation), causing pinching of the cord.

The **symptoms and signs** of spinal fracture with dislocation are two-fold—anatomic and functional. There is a circumscribed antero-posterior deformity, often with obvious crepitus; and if the cord be compressed or severed, there are paralyses. The surgeon is especially concerned with estimating the extent of damage to the cord, for on his

ascertaining the fact of this depends his treatment and prognosis. Nevertheless, there are surgeons who assert that the spinal canal should be opened and explored in every case of fractured spine, for no man may say what is the extent of existing damage. I cannot concur in this advice for invariable operation, because I am convinced that certain cases give certain evidence that the cord is severed, and in a severed cord repair is impossible.

If a positive diagnosis always were possible before operation, we might conveniently divide spinal fractures into the three classes which Harvey Cushing suggests; but he himself says that elements of error may be present in this classification. As a working rule, or point of departure, however, the surgeon may well have in mind these three

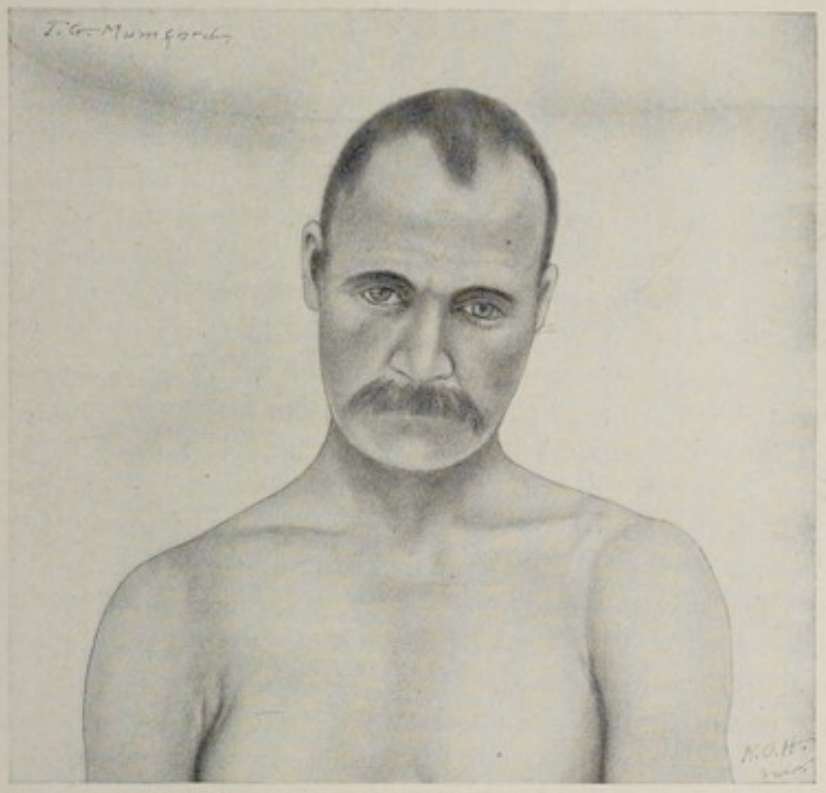

Fig. 435.—Dislocation of atlas on axis. Note characteristic tilting of the head (Massachusetts General Hospital).

types of cases, so as not blindly and in routine fashion to open down upon all damaged spines. The three types are: (1) Those cases in which an operation is contraindicated because it can do no good, and may increase the damage already done. To this group belong the traumatic hematomyelias, recognizable from the symptoms alone, without a radiograph, and, to a certain extent, able to recover by natural processes. (2) Those common cases of fracture-dislocation which are beyond all hope of cure because there is a complete transverse lesion of the cord. The site of the injury—above the first lumbar vertebra—and the total bilateral paralyses render these cases fairly obvious. We may operate and do no harm; but we can do no good. (3) Cases of slight damage to the cord,—short of complete section,—with symp-

toms which are increased or perpetuated by pressure from a foreign body, such as a fragment of bone. In these cases we must operate, but operate so judiciously as not to increase the existing damage.

Diagnosis is by no means always easy, and in an obscure case a surgeon may persuade himself that he is dealing with an example of group (3); while Walton is frequently quoted: "We have no symptoms from which we can assert from the outset that the cord is crushed beyond at least a certain degree of repair. It has been said that where there is complete loss of sensation, motion, and patellar reflexes the cord is completely crushed, and consequently recovery cannot be expected." I know of no case in which these signs of paralysis, and the abolition of reflexes, has not proved to be conclusive of total division of the cord.

In group (3), however, we do see fracture with bruising, contusion, or partial destruction of the cord, and we see motor *or* sensory paralysis below the line of damage. But the paralysis is rarely immediate, as is the paralysis in class (2), and is never complete and annular of *both* sensation and motion. From these irregularities of class (3) we conclude that certain columns of the cord are intact. The paralytic symptoms come on after hours or days, are preceded by a zone of hyperesthesia, and are accompanied by abolished reflexes in this zone.[1] The motor phenomena will be present if the anterior columns of the cord are involved; the sensory phenomena, if the posterior columns are injured. Observe also that precisely the same gradually increasing symptoms may be present if compression of the cord exists without contusion. We cannot differentiate contusion from compression. We see then that we must operate in the cases of group (3) as I have described them in these paragraphs. We must not operate for hematomyelia lest we make a bad matter worse; we must not operate for complete section of the cord—for we shall do no good—provided we make the diagnosis in these events.

So far, our arguments have applied to damage to those parts of the spine which inclose the cord proper; but a quite different situation exists in case the spine is fractured below the twelfth dorsal vertebra. In that case we may have the paralyses and other evidence of total section of the cord, but it is not the cord which is damaged. It is the cauda equina—a bundle of peripheral nerves whose axones are covered by neurilemma, or the sheath of Schwann. These nerves within the spinal canal, after division and suture, *will regenerate.* Their function may return completely. The cord, which is devoid of neurilemma, cannot by natural processes or by operation be made to regenerate. We must operate, therefore, on all cases of lumbar fracture, and attempt to repair by suture the damaged cauda equina. These lumbar fractures, even if unrepaired, are those which the patients may long survive, though paralyzed.

Fractures of the spine, therefore, are extremely grave affairs, and their mortality is high at best. Why do the patients die? and how

[1] J. B. Murphy, ibid.

may life be prolonged and made endurable, even though recovery be impossible?

The **course** of spinal fracture-dislocation leads to death in a majority of cases; and the patients die from a variety of causes, which may be summed up as damage to essential spinal-cord centers. Fractures high in the *cervical* region may kill in twenty-four hours, with the patient lethargic, in a high fever, which may reach 106° or 107° F. even. This lethal fever is due to the destruction of the center of temperature-control. In the high fractures also the excursion of the diaphragm will be halted through damage to the phrenic nerve in the fourth and fifth cervical region. Upper *dorsal* fracture causes serious disturbance to the abdominal organs. Peristalsis is paralyzed, and the belly may become greatly distended. In all spinal fractures above the second lumbar, control of the sphincters is abolished; and the loss of control may occur after low lumbar fracture also, through injury to the cauda equina. One of the most troublesome and disheartening complications in all these fracture cases is the early development of bed-sores, which quickly attain great size and a foul appearance, owing to the degeneration of the trophic nerves of the region. One sees these sores over the sacrum, buttocks, and heels especially. Loss of control of the bladder and anus is equally common. Urine is retained; the bladder becomes septic, usually from catheterization, and an ascending infection invades the kidneys, causing death.

We must direct our **treatment,** therefore, especially to care of the back, the bladder, and the bowels. I am accustomed to place the patient on a large Bradford frame, which allows of easy access to the strategic points. We must keep the back clean and dry; sponge it frequently with alcohol and dust it with toilet-powder. We must avoid using the catheter, so far as we may. Preferably we may allow the bladder to overflow, starting the stream by pressure with a finger behind the prostate; or we may establish at once suprapubic drainage, as Harvey Cushing advises. Of course, all such operations as suprapubic cystostomy are painless to the paralyzed patient. The rectum should be cleaned out daily with an enema of soap-suds. The nutrition of the patient may be fairly well sustained by a careful, easily digested diet.

These unfortunate patients, especially those with low dorsal or lumbar fractures, may live many months or years. They often seem to acquire a surprising degree of patience and fortitude. Indeed, their sufferings are mainly from lassitude and ennui. There is little or no physical pain.

In spite of occasional successful operations the mortality for all cases of spinal fracture is extremely high,[1] but the pessimist even must

[1] Charles H. Frazier and Charles K. Mills, Jour. Amer. Med. Assoc., December 21, 1912, p. 2202, describe an extremely important case of damage in the upper lumbar region resulting in paralysis of the rectum and bladder. Frazier operated by laminectomy, opening the dura within the spinal canal, and anastomosing the first lumbar and third and fourth sacral nerve-roots. Nerve conduction to the paralyzed parts was thus re-established, and the condition of the patient was very greatly improved.

admit that operations occasionally have cured when the cord has not been severed; and so observing the gradual onset of symptoms in our class (3) we must operate to remove pressure. Other cases of supposed complete destruction of the cord at the point of fracture, later may give signs of returning function, showing that the paralyses were due to other concurrent injuries and not to crushing destruction (to hemorrhage, pressure). In some of these cases of class (3) late secondary operations have served.

SPINAL MENINGITIS

Inflammation of the spinal membranes plays no such important part in the work of surgeons as does cerebral meningitis—inflammation of the membranes of the brain. Nevertheless, suppurative and serous meningites do occur within the spinal canal, and are amenable to surgical treatment. **Epidemic meningitis** (cerebrospinal fever) also is common. I have discussed this disease in the chapter on the Brain, and have pointed out how lumbar drainage may relieve the symptoms and lead to a cure. We have now learned, however, to depend upon the serum therapy of Flexner.

Suppurative meningitis results from wounds of the spine or from extension from cerebral meningitis. The *symptoms* are general and local, and are fairly characteristic. The patient's fever runs high. He appears intensely septic, and his course to death is generally short. The local symptoms are due to pressure, and we observe rigidity and retracted head, sometimes convulsions and opisthotonos; and later, paralyses due to degeneration of cord centers. Surgeons, with the increased confidence born of experience, are feeling that drainage operations save some of these desperate cases, but the drainage must be established early.

We may *operate* in the following manner: By lumbar puncture we obtain fluid for culture and the making of a diagnosis. Through this same channel we may establish continuous drainage, though frequent tappings generally will suffice. In addition we may arrange for through-and-through drainage from the fourth ventricle to the lumbar opening, or we may open a lateral central ventricle, as I have shown in the last chapter. Murphy's description of sacral drainage is admirable.[1] "The skin, subcutaneous tissue, fat, and muscles are divided until the sacral foramina are exposed. With the bone-cutting forceps, one blade in the sacral canal, the laminæ are divided on either side until the sacral dura is exposed at the third body. This is easily accomplished. The sacral dura bulges very conspicuously in the field, and corresponds to the middle of the third sacral body, 1½ inches from the coccygeal tubercles (or lower postero-internal tubercles of the sacrum). It (sacra dura) forms quite a large area or pouch, which is called the sacral cerebrospinal cistern. Before opening the cistern it is advisable to aspirate the blood (in the field) by siphon, so as to have a clear view. This accomplished, the dural sac is split and sufficient cerebrospinal

[1] Murphy, ibid., p. 423.

fluid allowed to escape to relieve tension. At this step the region should be temporarily abandoned," and the skull opened behind the foramen magnum over the cerebellar cistern. This allows through-and-through irrigation to the sacrum. If the foramen of Magendie is closed, a V-shaped piece of the velum can readily be removed with scissors, establishing a direct communication from the fourth ventricle to the subcerebellar cistern. Murphy employs this operation in cases of central hydrocephalus also.

Serous meningitis (meningitis serosa) may lead by pressure through a chain of general symptoms—delirium, headache, choked disc, paralyses—to death; but without any considerable fever often. Serous meningitis may be relieved or promptly cured by lumbar puncture and by drainage.

After all such operations, and, indeed, throughout the course of any meningitis, the general care of the patient is of the greatest importance. In hospitals we often see elementary precautions grossly neglected. Patients should be kept absolutely quiet, in a darkened room, remote from a noisy ward. Nurses and other attendants should be gentle and speechless for the most part. We must keep up a good ventilation; keep the patient warm, and attend scrupulously to the proper evacuation of his bladder and rectum. Loud talking, rapid footsteps, drafts, strong light, rough handling, often will bring on needless convulsions, which exhaust and may kill even the patient. *Verbum sapienti:* all others should be excluded from the patient's presence.

SPINA BIFIDA

Spina bifida is a common abnormality of the spine—a deformity instantly obvious, as a rule. It may be associated with cephalocele, which is its cranial analogue. "This congenital defect of development (spina bifida) involves a cleft or defect of one or more of the neural arches, with the protrusion of a hernia-like sac formed by some of the spinal membranes, with or without the cord or nerve-roots. It occurs about once in 1000 births" (Woolsey).

We remember that the cord and other nerve elements are derived from the ectoderm through infolding; while the bony envelop of the cord comes from the mesoderm. If this mesodermic structure fails properly to unite about the cord, a protrusion of the cord or its membranes may occur—usually toward the rear, sometimes toward the front. Generally the abnormal window in the bone is small, so that the protruding nervous elements resemble a hernia. Rarely the whole of the bony sheath on one side of the cord may be absent.

There are **varieties** of spinæ bifidæ, as there are varieties of cephalocele. Of spina bifida we have: (1) *Meningocele*, membranes and fluid only—rare; (2) meningomyelocele (hydromyelia), membranes, fluid, and cord, including the cauda equina; (3) syringomyelocele,[1] which is only a special form of meningomyelocele, with a great dilatation of the central canal and its ependyma. The symptoms, the prognosis, and, above

[1] *Syrinx* (L.); σῦριγξ, a fistula, a pipe, a syringe.

all, the possibilities of treatment depend upon the variety of spina bifida with which one is dealing; and the varieties and subvarieties are more numerous than the three terms I have used seem to indicate. For example, there are three forms of *meningocele:* (*a*) That simplest form in which the only defect is in the bone. The skin, membranes, and cord are intact; and the tumor we see is composed of the dura alone, which bulges with its contained fluid through the bone cleft. (*b*) Another form of meningocele is like the last, except that the arachnoid, as well as the dura, bulges. The contained fluid is subarachnoid. (*c*) Quite another subvariety of meningocele is that in which the dura, as well as the bone, is cleft. The arachnoid, with its fluid, bulges through this opening; but the skin, the pia, and the cord are normal and intact.

There are varieties of meningomyelocele or myelomeningocele—the terms are interchangeable. Obviously, the terms signify a tumor containing membranes and nervous elements. It is not possible always to distinguish this form from syringomyelocele. Most properly, the condition present is a myelocele—a deformity characterized by a cleft in the skin itself, an opening in the posterior bony wall of the spinal column and in all the membranes, while the posterior surface of the cord itself is split or absent. Thus the central canal of the cord is left open to the air. The spinal hernia which is present is due to collections of fluid between the pia and arachnoid on the opposite side of the cord, anterior to the cord. This fluid, collecting in large amounts, causes a protrusion of nervous elements. The protrusion or tumor is not covered with skin, therefore, though the skin surrounds its base; and such a sac as there is consists of pia covered by the spread-out substance of the cord. Myelocele does not necessarily protrude. Such a myelocele as I have described may exist potentially, and for lack of fluid collected in front of the cord there may be no actual hernia, while the interior of the cord itself will be found to lie deep in its normal groove, but exposed to the air.

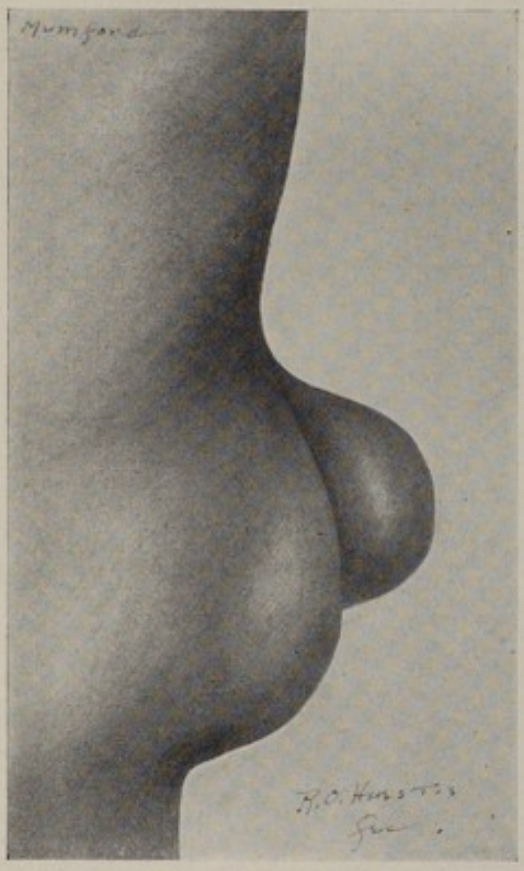

Fig. 436.—Spina bifida (side view).

Syringomyelocele, sometimes called myelocystocele, is more common than myelocele. In syringomyelocele the bony wall and the dura are cleft, but the arachnoid and pia are intact, while the *central canal* of the cord is distended with cerebrospinal fluid. There results a hernia composed of skin, arachnoid, pia, and nervous elements, while the center of

the mass is occupied by cerebrospinal fluid. The nervous elements are spread out thinly over the inside of the sac.

We see then that spina bifida, so called, is a general term which designates spinal tumors of varying character and gravity. For example, meningocele may give rise to few symptoms; may inconvenience the patient from its size merely; may be carried through many years of life, and may be threatening only from its liability to ulceration and rupture. Spinal hernias containing nervous elements, on the other hand, generally cause various paralytic symptoms—especially paralyses of the bladder and rectum, and motor and sensory disturbances of the legs. Myeloceles are inoperable and are early fatal from septic infections. We need regard them as surgical curiosities only, for they are incurable. They are commonly associated with other abnormalities also—defects of development, such as hydrocephalus, club-foot, extrophy of the bladder, etc.

The **diagnosis** of myelocele is easy and instant, for the abnormality has no covering of skin; but it is not always so easy at the time of the



Fig. 437.—Spina bifida (meningocele) (Massachusetts General Hospital).

infant's birth to distinguish meningocele from myelocystocele. The differential diagnosis must be founded on the absence of symptoms in meningocele, and on the paralytic conditions in myelocystocele.

The only possible effective treatment in either of the more favorable forms of spina bifida (meningocele and myelocystocele) is by some form of operation. We can, however, assure the child's parents that meningocele is not necessarily very serious; but that a child the victim of myelocystocele, if it should not die young, will continue in a wretched, crippled condition only.

Taking all forms of spina bifida, we learn from statistics that their prognosis is bad, for ulceration and rupture, followed by meningeal infection, is the probable outcome. Sometimes a palliative aspiration, repeated as seems advisable, will postpone the inevitable rupture.

The aspiration should be done through the base of the tumor, and the needle should be introduced obliquely where the coverings are thickest.

Operative treatment is commonly by excision, though rarely injection methods are still used. For injections, Morton's fluid has been most favorably regarded—a composition containing 10 grains of iodin; 30 grains of potassium iodid; 1 ounce of glycerin. The injection is given two or three times at ten-day intervals. The surgeon withdraws first an ounce or more of cerebrospinal fluid and then injects half an ounce of Morton's mixture, in the hope of causing adhesions of the sac and a resulting cure. I have never met a surgeon who had any enthusiasm for this method.

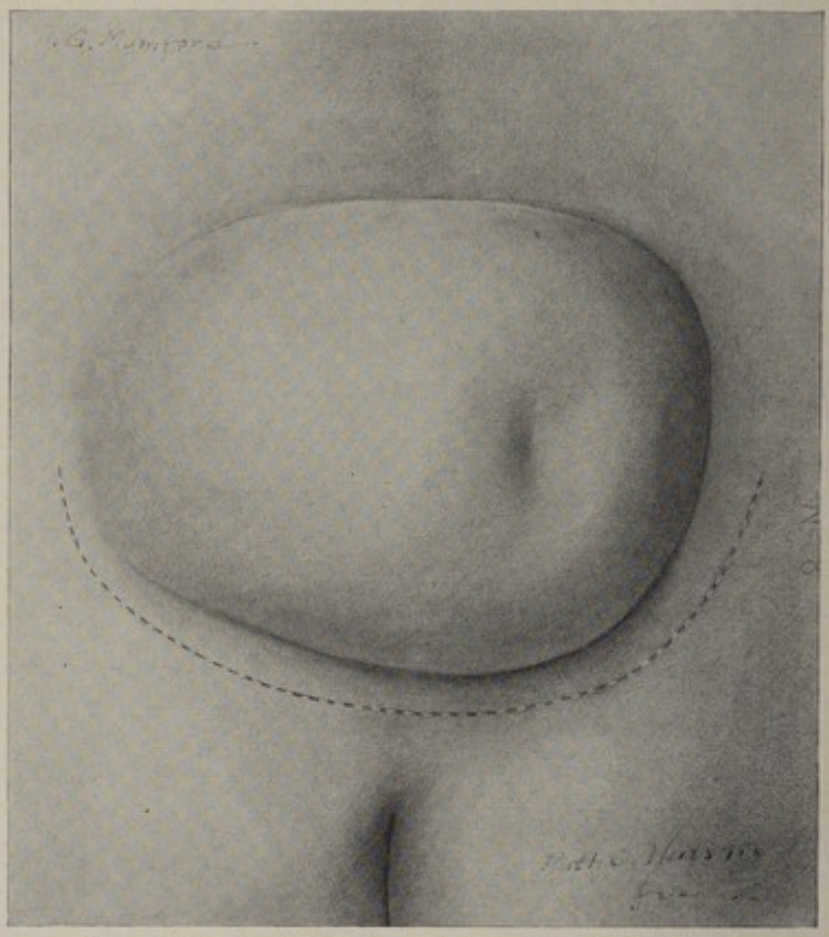

Fig. 438.—Spina bifida, showing line of incision.

Open operations show a reasonable percentage of good results, especially in the cases of meningocele. The dangers are from sepsis. We must, therefore, operate with the greatest aseptic care. Often the dissection is tedious and laborious. I have employed satisfactorily the transverse, crescentic skin incision, incircling the base of the tumor with the convexity of the incision downward (Fig. 438).

Thus we expose the sac, and reflect the skin-flap upward across the tumor. With the sac laid bare, incise it longitudinally and expose its contents. If nervous elements lie disengaged within the cavity, tuck them into the spinal canal. Nervous elements may appear closely adherent to the inner surface of the sac, bunched mostly in the middle

line, with their general course from the summit to the base of the sac, that is, parallel with the incision. Separate the adherent nerves from the sac, so far as possible, and reduce them, with as much of the sac as cannot be separated from them, into the spinal canal; then excise the excess of sac and sew up the wound, stitching the stump of the sac with double rows of chromic-gut stitches. Trim off redundant skin and close the wound without drainage, tacking the skin-flaps close to the underlying aponeurosis. If the bony opening is so large as to favor a recurrence of the hernia, it is well, before closing the skin wound, to reduce the size of the opening by bringing strips of aponeurosis across the stump of the sac. Some surgeons have advocated repairing the vertebral clefts by an osteoplastic operation, taking bone from the crest of the ilium; but this must rarely be necessary.

If the spina bifida is a pure meningocele, the operation is rendered easier by the absence of nervous elements. The sac of a simple meningocele is trimmed away, and the wound closed as I have already described.

After all is done, the surgeon must remember that the outcome is in doubt until firm union has been established. Unfortunately, the wound may break down and a spinal fistula become established, with its attendant danger of infection. If it be established, one must attempt to close it through a reopening of the wound.

TUMORS OF THE SPINE

Tumors of the spine are somewhat analogous to tumors of the cranium, for we have in the spine—(*a*) Spinal-column tumors, originating in the bone or involving the spinal column from a tumor elsewhere in the body; (*b*) meningeal tumors, extradural and intradural; (*c*) tumors of the cord itself; (*d*) tumors of the nerve-roots, cauda equina, and conus medullaris. All these tumors may be grouped obviously as benign and malignant, as primary and secondary.

Tumors of the vertebræ are like tumors of bone elsewhere, which I describe in another chapter. Those which are malignant are inoperable mostly, and cause pressure symptoms, often agonizing, generally leading to paralyses. Their diagnosis rests upon such focal symptoms as we have already considered. Benign tumors of the vertebræ, more especially *exostoses*, are operable often, and their removal in some cases has been followed by brilliant recoveries. These exostoses and other benign tumors of the bone are generally limited to one vertebra, commonly to the body of the vertebra, and cause symptoms by local pressure upon the cord and nerve-roots. These symptoms are such as I shall describe —pain, anesthesia, and paralyses. Their course is slow, but even so, from their symptoms one cannot distinguish them from some of the small malignant tumors until an operation or an autopsy has revealed their true nature.

Myeloma is a form of tumor which I have already mentioned in speaking of tumors of the cranium. It is composed of tissue identical with the red marrow of young bone, and formerly was called myeloid

sarcoma. It is often a general disease, and is found in the cancellous tissue of several bones in the same individual, especially in the tibia, the radius, and the jaw bones. Bland-Sutton states that he has never seen a myeloma in a vertebra, but other writers have described the tumor in that location. The diagnosis must be based on the albumosuria, or Bence-Jones' reaction, which is regarded as pathognomonic. It is almost impossible to remove a myeloma.

Other tumors of the bones of the spine are sacrococcygeal tumors, parasitic tumors or teratomata—irregular pendulous masses attached to the coccygeal region. They are composed of undifferentiated tissue, and often contain rudiments of the skeleton or various organs. Sometimes they are operable, though it frequently happens that their removal may involve destruction of the coccygeal nerves. Every such tumor must be studied independently. If its excision should involve extreme paralyses, the surgeon may think it best to let it alone.

Meningeal tumors are found both without and within the dura. The extradural tumors are of many varieties—fatty tumors, sarcomata, tuberculomata, echinococci, myxomata, fibrosarcomata, and carcinomata. Meningeal tumors are more common within than without the dura. While all the varieties of spinal tumors show similar symptoms, tumors of the meninges grow slowly so that the compression exerted upon the cord is gradual and it is continuous. We know of tumors which have caused symptoms for four, six, or eight or more years before the diagnosis of tumor has been made. Since extradural tumors are more commonly malignant than are intradural tumors, they kill the patient sooner. But intradural tumors have been found in greater numbers—in the relation to extradural tumors of two to one. Intradural tumors also are the more commonly encapsulated, while their situation is generally on the posterior or lateral aspect of the cord. The greatest number are in the thoracic region, and next to that, in the cervical region. Both extra- and intradural tumors spring commonly from the dura, the intradural occasionally from the arachnoid or the nerve-roots. Usually meningeal tumors are single, though sarcomata, neuromata, and parasitic tumors may be multiple.

Meningeal tumors cause no symptoms until they are large enough to press upon the spinal nerves and cord, but the symptoms, even then, do not depend so much upon the size of the tumor as upon its location and density. Continued pressure upon the cord leads eventually to marked changes in that structure—to edema, softening, degeneration of centrifugal axones below, and centripetal axones above, the point of compression; and to meningeal hypertrophy. As Murphy states, however, we must remember that the conductivity of the cord persists, partially at least, even after long-continued pressure.

The *symptoms of meningeal tumors* are for long, intricate, and misleading. The disease is relatively rare, so that physicians are generally led away into other diagnoses—neuritis, rheumatism, tabes, lead colic, sacro-iliac disease, and such abdominal diseases even as gall-bladder infection, gastric ulcer, and appendicitis. And yet, the symptomatology

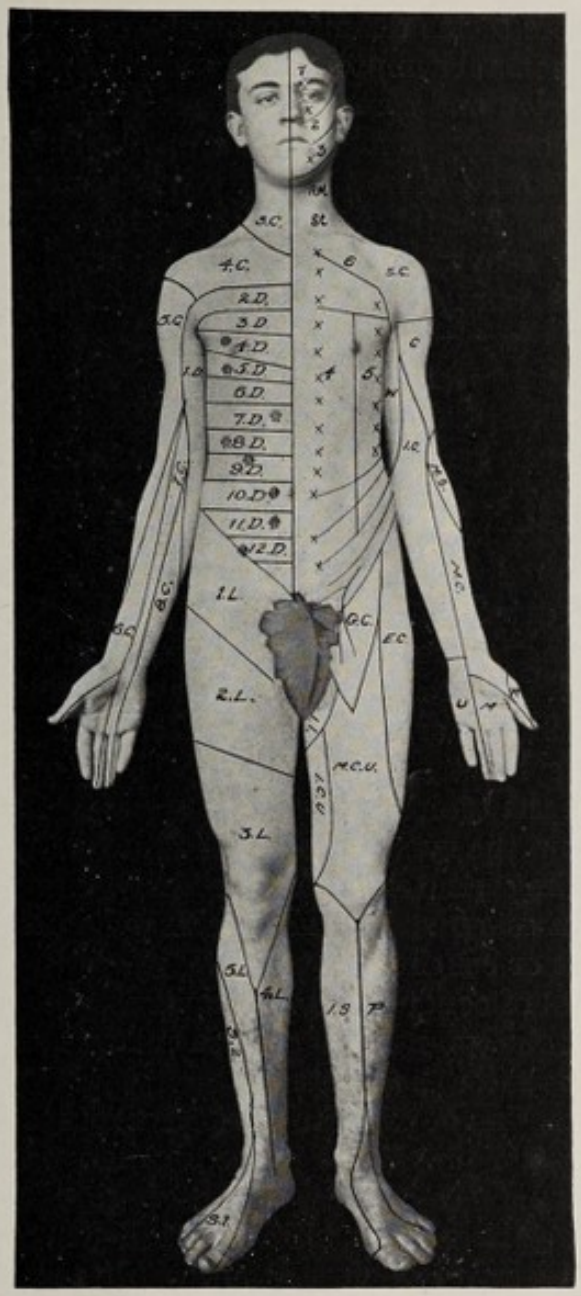

Fig. 439.—Anterior view of the areas of distribution of the sensory nerves of the skin (shown on the left side of the body), and distribution of sensation according to segments of the spinal cord (shown on the right side of the body): 1, Ophthalmic nerve; 2, superior maxillary nerve; 3, inferior maxillary nerve (the points of exit of the supra-orbital, infra-orbital, and mental nerves are shown by the markings X); 4, points of exit of the anterior intercostal branches of the intercostal nerves; 5, points of exit of the lateral branches of the intercostal nerves; 6, intercosto-humeral nerve; *A.M.* and *S.C.*, area of distribution of the great auricular, superficial cervical, and supraclavicular branches of the cervical plexus; *C*, circumflex nerve; *W*, nerve of Wrisberg; *I.C.*, internal cutaneous area; *M.S.*, musculospiral area; *M.C.*, musculocutaneous area; *U*, ulnar; *M*, median; *R*, radial; *G.C.*, genitocrural area (the nerve is seen as distributing its branches to the genital region and to the upper portion of the thigh); *E.C.*, external cutaneous area; *I.I.*, ilio-inguinal area; *I.C.U.*, internal cutaneous area of the thigh; *M.C.U.*, middle cutaneous of thigh; *I.S.*, internal saphenous; *P*, external popliteal branches area (on the right side the division according to segments is seen, the letters *C*, *D*, *L*, and *S* standing respectively for cervical, dorsal, lumbar, and sacral segments of the cord. On the right side, from the fourth dorsal to the twelfth dorsal (inclusive), the maximum points, according to Head, of the abdominal viscera, are shown in relation to the spinal segments) (Eisendrath).

of meningeal tumors seems definite enough when we come to write it down. There are general symptoms and special topographic symptoms; symptoms of sensation and symptoms of motion.

The important sensory symptoms are *root symptoms*—pain, hyperesthesia, and anesthesia. The pain may be accentuated by irritating the cutaneous part corresponding to the cord segment involved, by percussion and by movement. The pain is severe, but not always constant; it is unilateral or bilateral. It precedes the anesthesia and the motor disturbances.

The *motor symptoms* are due to pressure upon, and degenerative changes in, the cord itself—spasms, muscular atrophy, reaction of degeneration, and paralyses. At first the paralysis may be limited to one limb, or it may be of the Brown-Séquard type (paralysis on the side of the lesion; anesthesia on the opposite side, owing to the decussation of the sensory fibers immediately after their entrance into the spinal cord). An extensive tumor may involve both sides of the cord and cause complete paraplegia. The reflexes are increased at first and are then abolished. There are trophic changes—herpes zoster, glossy skin, decubitus. There are vasomotor disturbances, and there are paralyses of the sphincters. Sometimes the spinal column appears fixed at the site of the tumor.

Murphy sums up the symptoms as follows:

(*a*) Long-standing neuralgia, which disappears as soon as the paralysis of motion sets in. It is noticeable even then, however, when the patient sneezes or coughs.

(*b*) Gradual loss of conductivity of impulses.

(*c*) Marked spasticity and exaggerated reflexes, with persistence of complete paraplegia after the onset.

(*d*) The exaggeration of pressure symptoms due to local compression without spreading the pathologic process above or below the initial point of compression.

(*e*) Absence of a tuberculous taint; a good general health.

It is not easy always to determine precisely the site of the tumor even when the diagnosis of tumor has been made. One must be familiar with certain topographic facts in order to trace *local symptoms* to the exact point of their pathologic causation. One must know the exact relation of points in the cord to their corresponding topographic bony landmarks. Observe that, as a rule, the level of the sensory paralysis is nearly on a level with the involved segment of the cord. Nevertheless, there is always danger of estimating the site of the tumor to be lower than it actually is. One should look for the tumor at operation not at the upper level of anesthesia, but two vertebræ above that level. The reason for the unexpectedly high level of the tumor is that many of the affected dorsal nerves emerge from the spine and find their way to the skin at a point somewhat lower than the tumor which is causing their degeneration. Before going on to a consideration of the treatment of these meningeal growths we must study briefly those rarer growths which spring from the cord itself.

Intramedullary Tumors.—These tumors again may be likened to brain tumors. They are of much the same type, and, as is the case with brain tumors, they are far less common than meningeal tumors. In adults the most common cord tumor is the glioma. The next most common is the tuberculoma. In the case of children, on the other hand, the tuberculoma is the more common. Sarcomata and myxomata also involve the cord, but are usually extensions from the meninges or from the spinal nerve-roots. Gliosarcomata occasionally develop in the cord, and are generally diffuse, involving the entire length of the cord, including the medulla. Syphilomata and angiogliomata occasionally have been reported.

The *symptoms* of these cord tumors are similar to those of the dural tumors, but the pain is not quite so severe. Nevertheless, it is generally impossible to differentiate intramedullary from extramedullary growths. If one were obliged to point out clinical distinctions, one would say that with intramedullary growths there is little or no local spinal stiffness, and that movements of the spine do not increase the pain. Moreover, the pain frequently is not in the spine itself, but is remotely cutaneous. Of course, there are atrophy of muscles, paralyses, and the reaction of degeneration. The reflexes are at first exaggerated and then abolished; anesthesia is present only in case the posterior columns of the cord are affected, while the usual trophic changes are found. True cord tumors differ also from meningeal tumors in the rapidity with which they progress. There are no years of pain preceding paraplegia. In other words, if pain be absent and motor disturbances alone persist, we are fairly justified in assuming that the tumor is intramedullary.

There are tumors of the **conus medullaris** also and of the **cauda equina.** Neurologists have come to believe that we must differentiate caudal tumors from tumors of the conus because tumors of the cauda often yield to surgical treatment, while tumors of the conus do not so yield as a rule. Tumors of the conus cause a bilateral, symmetric impairment of sensation—especially anesthesia of the skin over the penis, scrotum, perineum, anus, inner aspect of the buttocks, and posterior surfaces of the thighs. Late in the disease there are incontinence of urine and feces, loss of sexual power, and the usual decubitus.

Tumors of the *cauda equina*, on the other hand, spring from nerve structures of the peripheral type. Anatomically, therefore, caudal tumors are quite other than cord tumors, but clinically one may not so readily distinguish them. The caudal nerves are neurilemmic; therefore they may regenerate after damage; but they are bunched together within a meningeal sheath; therefore their tumors give the symptoms of cord tumors. A tumor of a caudal nerve will give us a clinical picture suggesting a tumor of that section of the cord from which the nerve has sprung. On the other hand, tumors of the cauda may reach a considerable size before causing pronounced symptoms, for the caudal nerves lie loose in a comparatively spacious pouch, so that a small tumor there causes no pressure.

We are told that trauma is a common cause of caudal tumors, but this was not the case with a remarkable tumor which killed a patient under my care not long since. She was a young married woman, five months pregnant with her first baby when she consulted me for excruciating but intermittent sciatic and sacral pains. I was unable to make a diagnosis; but supposed for a time that she suffered from that form of sacro-iliac damage common with puerperal women. A well-known orthopedic surgeon agreed with me, and applied various pelvic and lumbar supports, which relieved the patient for a time. Then there followed in three months more pains, anesthesia, paralyses, incontinence of the sphincters, headache, nausea, choked disk, delirium, and death. A month before she died she gave birth to a premature infant after an absolutely painless labor. During the latter weeks of her life she was seen by a number of other consultants—obstetricians, internists, neurologists—whose diagnoses varied all the way from neurosis to transverse myelitis; and at the autopsy we found a sarcoma obviously springing from the cauda, destroying the lumbar cord, invading the whole cord as far as the cervical region, choking the spinal canal, and leading to a hydrocephalus, with the resulting intracranial pressure symptoms which I have mentioned.[1] No case could illustrate better the difficulties of diagnosis and the uselessness of operation in a rapidly growing caudal tumor spreading by continuity to the cord itself.

On the other hand, caudal tumors may be secondary to meningeal, brain, and cord tumors disseminated through the cerebrospinal fluid.

The *symptoms* of typical caudal tumors are: Pain, sacral and sciatic—"a more wide-spread pain than the pain of cord tumors," if only one might distinguish. The pain is increased by movements of the legs. Next there are a progressive sensory paralysis of the perineum, anus, buttocks, and genitalia, and paralysis of the bladder, rectum, and legs. As in the case of cord tumors, the reflexes are at first increased, then diminished, and finally lost. Other lesions of the lumbosacral region, especially sacral tuberculosis, must be differentiated. The one leading and most conspicuous symptom of early caudal disease is pain.

The **treatment of cord tumors** and of tumors of the **meninges, conus medullaris,** and **cauda equina** is the least difficult part of our problem, when once an understanding of spinal tumor has been reached. To be sure, the subject is relatively new, and surgeons are too apt to rely on the directions of neurologists—not working with them, but under them. However, for the surgeon acquainted with the leading features of spinal diseases the mere operating seldom presents serious difficulties. Before operating, it is well to try a short course of anti-syphilitic treatment, for under such treatment most unexpected cures sometimes are achieved. Four weeks should be the maximum of such treatment if there be no improvement. One should endeavor also to eliminate the chance of tuberculosis being present before operating;

[1] This case is admirably reported by E. W. Taylor, Boston Med. and Surg. Jour., February 7, 1907.

and in case a neoplasm is reasonably demonstrable, one should determine, if possible, its character and the question of there being two or more such growths.

In estimating diagnostic points and planning an operation one should have clearly in mind certain relations which exist between the spinal cord, the points of emergence of the nerves, and the spinous processes. I have already indicated these relations. Binnie, in his admirable manual, quoting Chipault, gives the following rules:

"It is important to recognize certain easily remembered relations which exist between the spinal cord and the spinous processes. These relations are thus described by Chipault:

"(*a*) The terminal culdesac of the dura mater corresponds to the fifth lumbar interspinous space.

"(*b*) The inferior limit of the spinal cord is situated in men at the level of the first, in women, of the second, in infants, of the third, lumbar spinous process.

"(*c*) The cervical segment of the cord terminates at the level of the sixth cervical interspinous space; the dorsal, at the ninth dorsal; the lumbar, at the inferior border of the twelfth dorsal spine; the sacral segment ends at the superior border of the first lumbar spine.

"(*d*) The relations of the summits of the spinous processes to the nerve-roots may be expressed by a simple formula which, while not mathematically correct, is sufficiently so to act as a guide in surgical intervention.

"For adults, the formula is: In the cervical region to find the nerve which emerges at the level of any individual spinous process, add the numeral *one* to the number of the process, *e. g.*, it is the third cervical root which emerges opposite the second spinous process. In the superior dorsal region add the numeral *two* to the number of the process. From the sixth to the eleventh dorsal processes add the numeral *three*. The inferior part of the eleventh dorsal spinous process and the subjacent interspace corresponds to the origin of the sacral nerves."

Laminectomy is the operation which gives the surgeon access to the spinal canal and cord. In cases of vertebral damage by trauma, laminectomy is our frequent resort. Laminectomy is analogous to operations for opening the cranium, and has thus further similarity to such operations on the skull that the defect produced in the spine is relatively harmless in itself and need not be repaired. Laminectomy does not greatly weaken the spinal column, for the strength of the spine lies in the bodies of the vertebræ. Sundry methods of laminectomy are advocated. All of them call for care in order that nerves, nerve-roots, meninges, or cord be not damaged; but with any reasonable caution the following simple operation may be performed readily by the surgeon who knows the use of his tools and is familiar with human anatomy.[1]

[1] I know a surgeon of considerable experience who mistook the intact dura for the cord after he had opened the spinal canal.

Make a deep, liberal, vertical cut, five or six inches long, directly down upon the spinous processes; then convert this straight line into an H by making two short transverse cuts at either end of it. Thus one is enabled to turn back freely the skin-flaps.

With the knife, and by blunt dissection, scrape back the muscles from the spinous processes and laminæ, first on one side thoroughly,

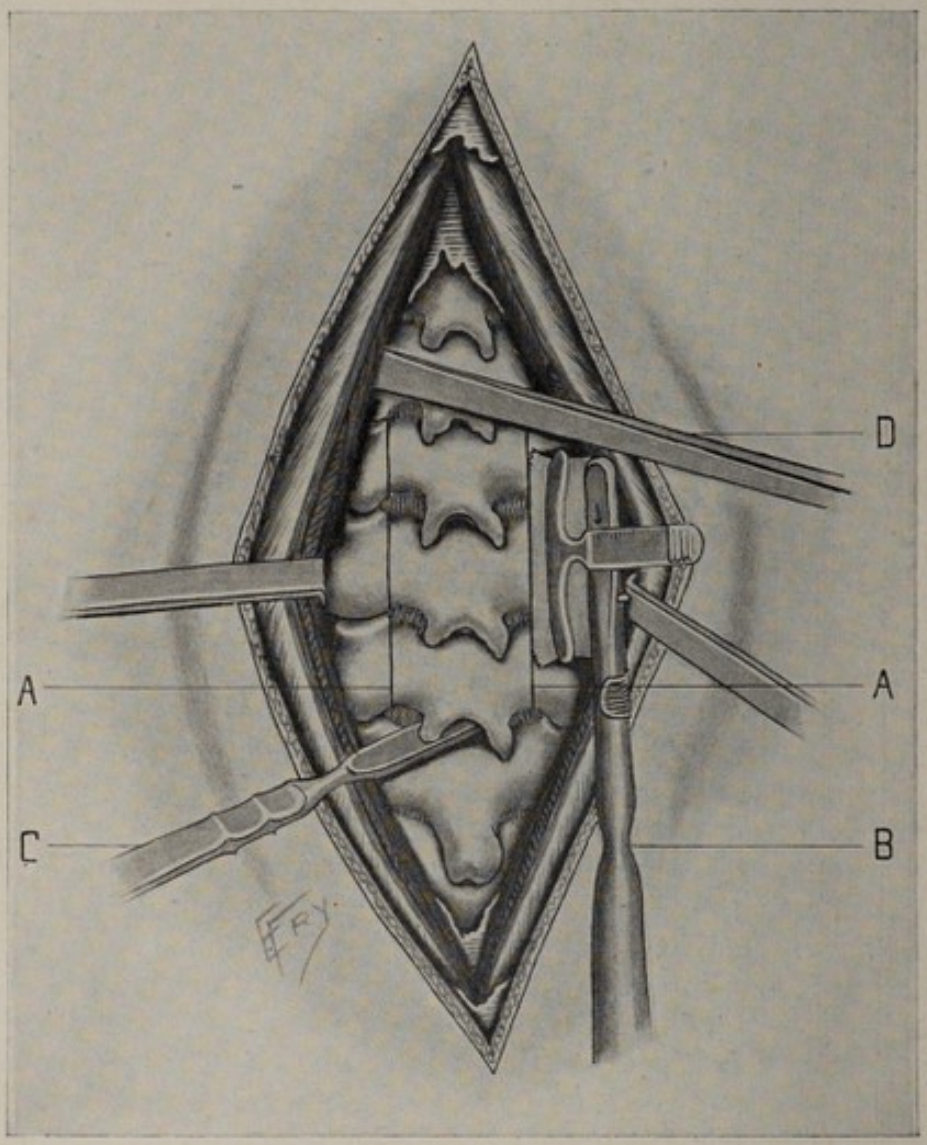

Fig. 440.—Cervical laminectomy: A, A, Saw-cuts through the laminæ, just within their junction with the articular process; B, Doyen saw in act of dividing the laminæ at a right angle to their surface, its guard (determining the depth of section) being entirely raised at the beginning of the division; C, knife dividing the ligamenta subflava; D, osteotome levering away the muscles of the vertebral grooves, using the spinous processes as fulcra (Bickham).

and then on the other. There is sharp bleeding generally. Check it by firm packing. Before going further see that the bones are widely exposed and that all bleeding is stopped. The steps so far are tedious and often laborious.

Entering through the bones of the canal is not difficult. Divide the interspinous ligament at the bottom of the proposed bone window, remove with rongeur forceps all the spinous processes in view, and

cut away part of the lowest lamina. Then, with stout cutting forceps

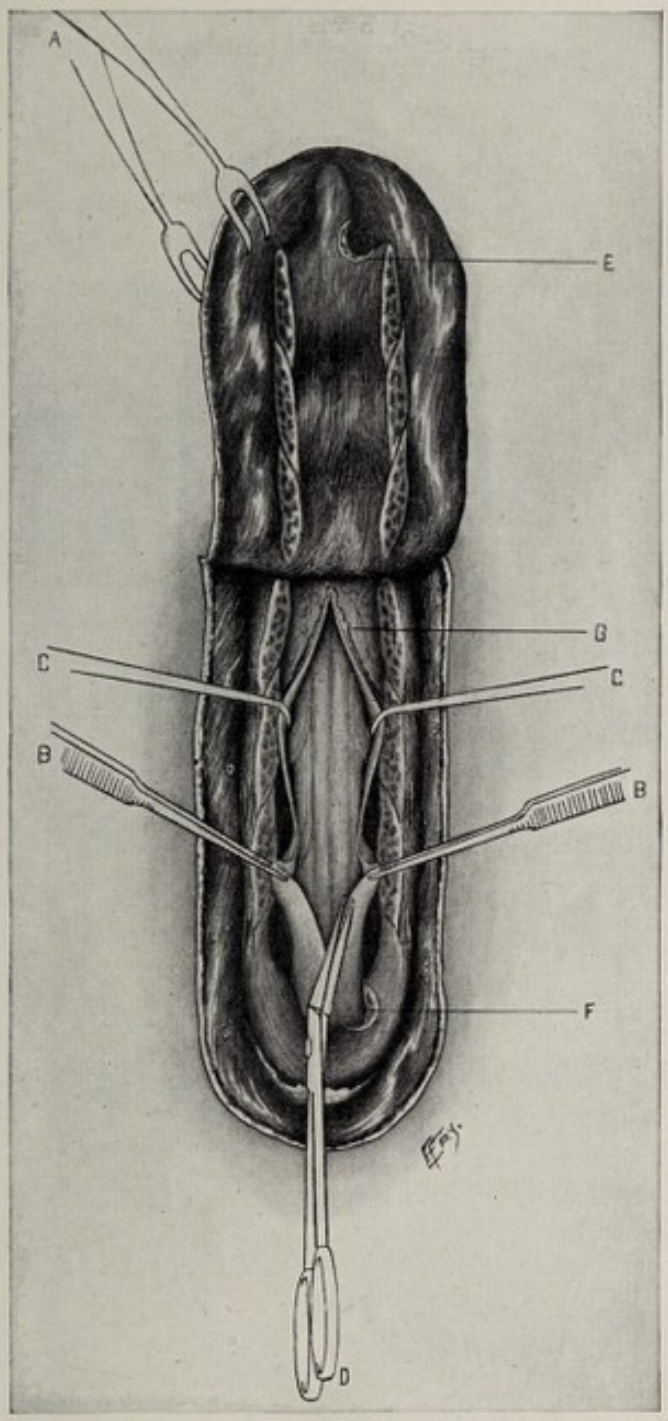

Fig. 441.—Osteoplastic resection of the spine: A, Tenaculum forceps holding back composite flap; B, B, delicate forceps grasping and elevating membranes and forming a transverse ridge; C, C, tenacula holding apart edges of incised membranes; D, angular scissors used in incising membranes; E, half-button of bone bitten out of lower margin of last lamina in flap by rongeur forceps; F, similar half-button bitten out of upper margin of next stationary lamina below, the two half-buttons forming a circular opening, when in contact, for drainage; G, vascular fatty areolar tissue covering membranes. The stump of the excised spine is shown, in impression, through the turned-back flap (drawn from cadaveric operation) (Bickham).

(or with chisel, osteotome, or saw), cut away a suitable number of laminæ on either side, and remove the excised sections of bone.

Now we have the dura exposed and may see the nerves emerging from it. The remainder of the operation is obvious enough, and its exact nature depends upon our purpose in opening the spinal canal. We elevate or remove bone fragments, open the dura, inspect the cord, see to our hemostasis, excise, if necessary, painful nerve-roots and tumors (suture the severed cord if we hold to the strength of an erroneous conviction), and, above all things, provide adequate drainage, lest operative blood and clots pressing on the cord leave our patient's last state worse than his first.

In all this we must handle the nerves, dura, and cord with such care as to avoid the common and needless bruising, and we must repair with fine gut stitches our operative rent in the dura.

The closure of the wound and the dressings are commonplace matters, but in the after-treatment we must observe the same solicitude that I have enjoined for the care of fracture-dislocations of the spine.

Several experienced surgeons make a bone-flap through a U-shaped incision in the skin and replace the flap *in toto*. I have no personal experience with this method.

The results of laminectomy for intraspinal tumors are encouraging. Pain is relieved, and if the aneurilemmic fibers of the cord be not degenerated, function returns in greater or less degree. Tumors may recur, to be sure, but sarcomata even are less liable to recur than sarcomata elsewhere. The mortality (from meningitis and shock) is not much above 10 per cent.; and at the worst we may feel assured that death is inevitable without operation. We are justified in asserting that here is a branch of neurologic surgery already successful and full of promise.

The Peripheral Nerves

The surgery of the peripheral nerves is a subject comparatively recent—much more recent than is the surgery of the head and spine. Until the development of aseptic surgery, physicians thought that nerves did not lend themselves to surgical treatment so far as any power of regeneration in them was concerned. Modern studies teach us, however, that neurilemmic (peripheral) nerves are capable of regeneration and may be sutured and grafted with excellent prospect of restoration of their function. I have already in this chapter referred briefly to this matter.

The manner of restoration of the structure and function in the distal portion of a severed peripheral nerve is still a subject of active controversy. We know that after the division of a peripheral nerve the distal portion regains its function even though it has been separated and isolated from its proximal portion for many months. Neurologists are not in accord as to the nature of this regeneration. There is the "central theory," and there is the "peripheral theory." The "central theory," based on the teaching of Waller, hangs upon the neuron doctrine—on the conception of the entity of the neuron—that is to say, of the nerve ganglion with its dendrites and single axone, or

peripheral nerve filament. If this axone be anywhere divided, the "central theory" teaches that the distal isolated segment degenerates and cannot be restored to structure and function until it has reunited with the living proximal portion of the axone. The "peripheral theory," maintained especially by Albrecht Bethe and by Ballance and Stewart, appears to demonstrate that after section of the axone, although degeneration in the distal portion does take place, nevertheless, regeneration occurs in the same distal portion without, and independently of, a reunion with the proximal portion of the divided axone. At the same time function in the distal parts is not restored until the severed parts are reunited. As Woolsey truly remarks: "Two clinical facts, the lack of regeneration, after division, of the axis-cylinders of the spinal cord, which have no neurilemma or neurilemma cells, and the very rapid return of sensation, after secondary suture, support the theory of peripheral regeneration." We may not discuss further this intensely interesting subject, though, as surgeons, it concerns us nearly, but we observe the fundamental fact that whatever the theory of regeneration, certain it is that divided neurilemmic nerves, when properly approximated, do regain their histologic structure and their function.

There are three leading purposes in the surgery of the peripheral nerves. We operate for the relief of pain, by section; for the repair of nerve injury, by suture and by anastomosis; and for the relief of palsy by nerve transplantation. Let us now consider in some detail these three topics and the surgical measures at our command.

NEURITIS

Neuritis is a common cause of the pain, for which we may be forced to cut a nerve. The term neuritis is generally taken to signify inflammation of a nerve. It is usually an inflammation of the endoneurium, perineurium, or epineurium, which, through thickening and swelling, constrict the axones. Perineuritis is the accepted term, and the disease in this form is generally confined to a single nerve-trunk. Multiple neuritis, a painful affection of many peripheral nerves, is a degeneration of the nerve-fibers themselves rather than an inflammation. Multiple peripheral neuritis commonly runs a self-limited course, and does not especially concern the surgeon, who has to deal rather with "localized" or "simple" neuritis.

Simple neuritis arises from nerve injuries, wound infections, callus-formations, the pressure of new-growths; or it is due to such chemical poisons as alcohol and ether, as well as to exposure to cold; or it may arise as the sequel of some general infectious disease. The damage to the nerve may be strictly localized or may spread along throughout the nerve's course. Although the inflammation is acute and violent at the outset, the active symptoms may subside quickly and be followed by a long-continued chronic course, with hyperplasia of the connective tissue, causing more or less destruction of nerve-fibers.

The **symptoms** of the patient vary greatly, but always there is marked perversion of function, ranging from hyperesthesia to complete anesthesia. The pain is often severe,—stabbing, boring, or shooting,—and is in the course of the affected nerve. It is worse at night than in the day, and is aggravated by movements. Tenderness also develops along the course of the nerve. There is frequent numbness, with tingling and loss of tactile sensation. There may be weakness or even paralysis of the motor nerve-fibers, with preceding twitchings and spasms.

Sometimes, if the neuritis be long continued, serious secondary changes—structural and trophic—occur in the adjacent parts—mus-

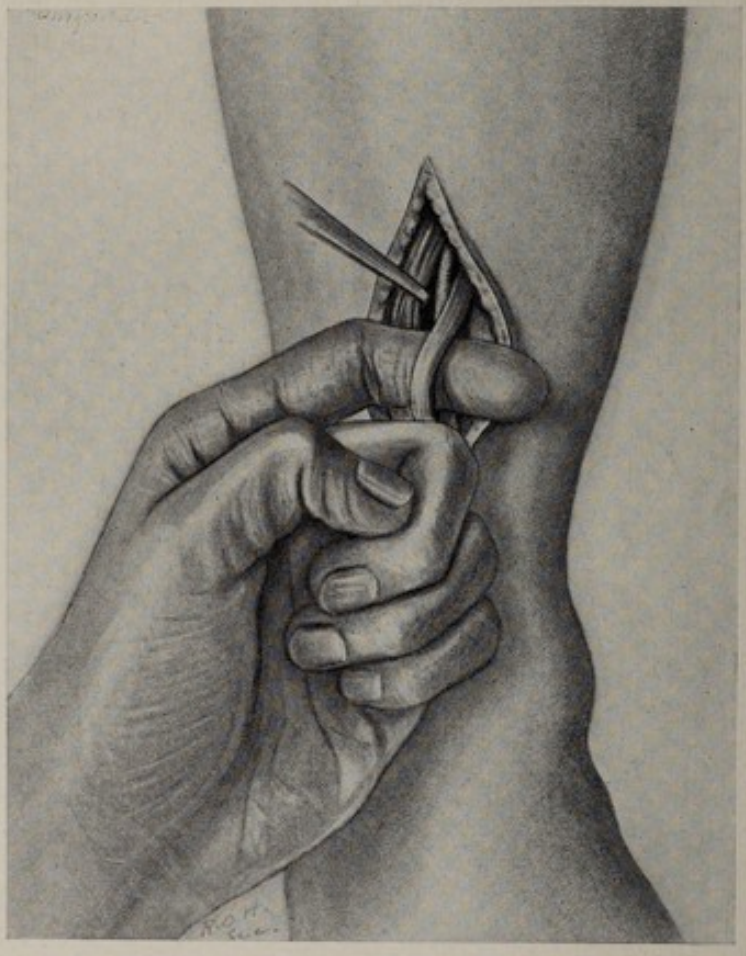

Fig. 442.—Nerve-stretching.

cular atrophy; contractures; nail ridges with nail thickenings; an atrophic, glossy, thickened skin; alterations in the sweat-glands; herpes, ulcerations, and gangrene even. Perforating ulcer of the foot (mal perforans) may follow neuritis of the tibial nerves. There are changes too in the electric excitability of the nerves, and the reaction of degeneration results.

As a rule, the prognosis in acute neuritis is good; and after months even we may look for recovery.

As for **treatment,** the surgeon has slight concern for that until called upon by the neurologist, whose non-operative measures have

failed; but in advanced cases especially—those cases characterized by trophic changes, by gangrene and ulceration—nerve-stretching has been of marked value. Indeed, certain surgeons have carried still further the principle of nerve-stretching, and have shown this measure to be of service in cases of varicose ulcer, Raynaud's disease, and many other neurotrophic conditions. The technic of nerve-stretching is simple: lay bare and isolate the nerve-trunk which supplies the affected part. Then take the nerve on your fingers and stretch it vigorously by pulling it up (Fig. 442). One may put many pounds of pull upon a nerve-trunk without breaking it. Experimental researches show that the nerve is traumatized—axis-cylinders and myelin—and that degenerative changes follow. Gradually the later regeneration takes place. Meantime we expect to see improvement in the lesions for which the nerve-stretching is employed.

NEURALGIA

Neuralgia is an inadequate term for which we have as yet found no substitute. It means *pain in the course of a nerve.* Neuritis may be the cause of the pain, or the cause may be some constitutional disease (gout, syphilis), or a local lesion like mastoiditis or a tumor; or there may be any one of a hundred similar causes. The neuritis causing a neuralgia may be limited and superficial, or it may involve the whole of a nerve-trunk and its associated ganglia.

Neuralgic pains are fairly characteristic. They are sharp, stabbing, boring, or burning, of varying intensity, and occur in paroxysms. They may be mild, or they may be so persistent and excruciating as to tempt the victim to suicide. The pain may linger dully between the paroxysms, or it may disappear entirely. Its onset is uniform: it appears at the accustomed spot and follows the accustomed course. Sometimes it becomes diffused, to the confusion of the patient and the physician. Do not mistake the characteristic, localized pain of a neuralgia for those simulated, bastard pains of which the hysteric complains.

Victims of serious neuralgias, if unrelieved, go on to a life of constant and hopeless distress, and become slaves to drug habits. Their general health becomes seriously impaired, and they fall victims in turn readily, and cheerfully often, to other chance diseases.

We **treat** neuralgia by drugs, by hygiene, by hydrotherapy, by electricity, and similar measures, and in most cases we succeed in curing the ailment. Some few cases, however, resist such endeavors, and we find ourselves driven to surgical operations. These operations include some of the most difficult and hazardous measures known to therapeutics. Let us take up in brief detail certain forms of neuralgia and their treatment by surgical means.

Trigeminal neuralgia, or neuralgia of the fifth cranial nerve, is common, but the cases vary greatly in severity. The mild cases are easily cared for; the severe cases demand operations of the first magni-

tude. Accordingly, we divide the disease into sundry types, and refer to these types as—(1) Neuralgia minor—a mild affection in which one branch only of the nerve is affected; (2) reflex neuralgia, or visceral referred pain; and (3) neuralgia major, or *tic douloureux*.

Let us deal briefly with those first two forms. Neuralgia minor occurs commonly in neurotic girls and young women, and may be due to a variety of debilitating causes. Any anemia is apt to be associated with this form of neuralgia or tic. The reflex neuralgias, on the other hand, are due to some true anatomic lesion—ulcer, tumor, carious teeth, astigmatism, ear disease, etc.—which gives rise to an irritation in the neighboring trifacial nerve.

The *symptoms* of both neuralgia minor and reflex neuralgia (trigeminal) are quite similar, and the leading symptom is pain—pain confined commonly to one branch of the nerve. The pain is usually intermittent; it follows the course of the nerve, and is associated with tenderness of the surrounding skin—tenderness which often remains after the actual neuralgic pain has subsided. Sometimes, but not commonly, the pain is felt in quite distant, unrelated parts. You will observe that these symptoms are not particularly definite; indeed, it is not possible generally to distinguish the symptoms of a neuralgia minor from the early symptoms of tic douloureux. We must, therefore, watch all these cases anxiously, with the thought of a graver neuralgia in mind.

As for the *treatment* of the milder forms of trifacial neuralgia, we endeavor to remove the causative irritant—in nose, ear, or mouth,—and we seek to improve the patient's general condition by good hygiene, food, iron, quinin, electricity, and an open-air life; and most often we succeed. If we fail, we may be driven to a resection of the affected nerve, after the method of Thiersch, which I shall describe presently; or to the injection of alcohol into the nerve-trunk.

So far, we have been considering relatively mild forms of trifacial pain. Let us turn to that most grievous and special form, **tic douloureux.**

A well-established tic douloureux differs in many essentials from the milder forms of tic. It is not a disease of young women, but appears in both sexes, and in middle life or later. The victims frequently are the subjects of marked arteriosclerosis. At first changes of climate, weariness, overwork, or any other causes tending to depress the circulation may bring on attacks. The exact nature of the process, however, is unknown to us. As Cushing says, "Let us hope that some one with new histologic methods and possibly more extensive material may solve this pathologic riddle, for not until the lesion is known may we expect to discover its causal agent."[1] In other words, we find no constant histologic lesion in these cases. Certain writers regard the disease as an ascending neuritis, beginning in the peripheral branches of the fifth cranial nerve. In any case the Gasserian ganglion eventually becomes involved in degenerative changes, so that only its extir-

[1] Harvey Cushing, Jour. Amer. Med. Assoc., April 8, 1905.

pation or severance from its central connections suffice to put an end to the patient's sufferings.

Those sufferings are illustrated by a train of *symptoms* which are characteristic in their agony when once the disease is well established. At first, as I have said, one scarcely distinguishes this severe form of tic from the milder forms. Usually, the second or third divisions of the nerve are attacked primarily—more rarely the first division. The pain begins in brief paroxysms, darting along the course of the nerve, in the lips, the tongue, the nose. Gradually attacks become more frequent and more prolonged, agonizing in character, so that the sufferer groans or screams with the intensity of his distress. The slightest irritant may bring on the attack—a breath of air, a touch, an unexpected start. Natural sleep becomes almost impossible; and the victims are given to the constant use of opium, and may contemplate suicide even. Such symptoms as I have described should serve to establish the *diagnosis*. The examiner will find, in addition, that tender points may be determined at the places where the nerves find exit from their bony canals. Moreover, there are notable vascular changes and trophic and secretory disturbances, with flushing of the face, congestion of the eyes, outpouring of tears and saliva, running of the nose, falling or whitening of the hair or beard, and local sensations of swelling or fulness. All these phenomena occur on one side of the face only.

We have been accustomed to state that treatment is palliative and radical. As a matter of fact, palliative treatment is of little service and gives but temporary relief. Nowadays one thinks of radical treatment as consisting in some operation on the Gasserian ganglion, but that operation has a decided mortality except in the most experienced hands, and lesser operations often prove of service—operations on the peripheral nerves themselves.

If the disease be relatively recent, and if the pain be assuredly confined to one branch only of the nerve, the surgeon may advantageously extirpate a large part of that nerve, with the fairly assured hope that the patient's pain will be relieved for several months, if not for years. Putnam and Waterman found the relief after peripheral operations to last for some ten months. This estimate is probably too short, for the statistics of these observers were founded upon operations of the older type—on simple resections of the nerves. We know that these neurilemmic nerves regenerate rapidly. The resection of Thiersch, therefore, is recognized as the proper operation to-day. Thiersch's method consists in cutting down upon the nerve, seizing it, and twisting out centrally as much of it as possible from its canal. One, two, or more inches may be removed in this way. The second and third divisions are best suited for this form of treatment. Let me warn the practitioner against assuming that the pain is due to carious teeth. We see patients who have had all their teeth extracted from one side of the jaw, in the vain belief that thus their pains might be abolished.

Sundry injections into the nerve-sheaths and into the nerves have been found beneficial of recent years. The favorite injections are osmic

acid and 70 per cent. alcohol (osmic acid, 1 cc. of a 1 per cent. solution; alcohol, 1.5 cc.), or, preferably, alcohol alone. The results are excellent, and relief may last for months. Then reinjections may be required. Probably a degeneration of the nerve-trunk toward the ganglion results.

A more or less persistent local anesthesia results from these peripheral operations, but the maneuvers are practically safe always.

It seems scarcely necessary to describe in detail the method of seeking and resecting these nerves, except the second and third divisions. Every anatomist knows how the supra-orbital nerve emerges beneath the brow toward the inner angle of the orbit; while the infra-

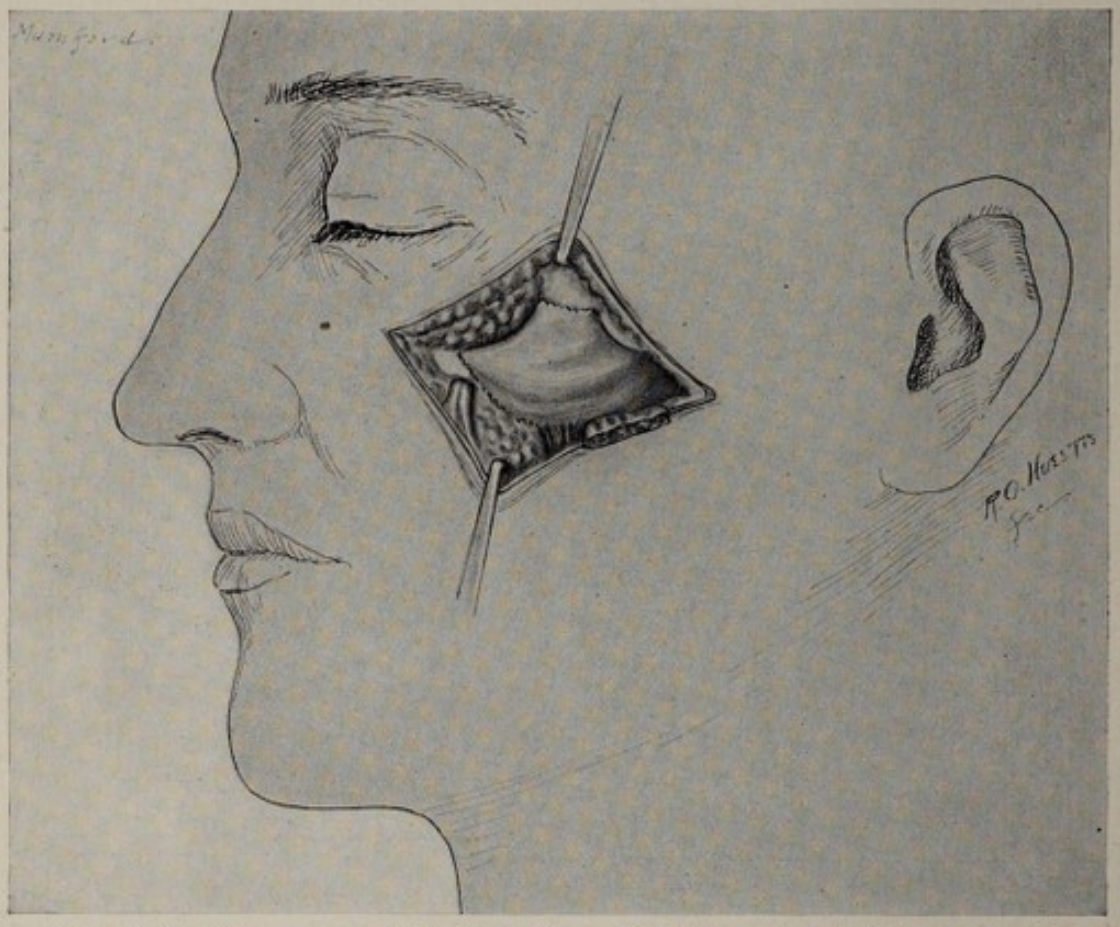

Fig. 443.—Neurectomy, trifacial. Second division—step 1 (adapted from Kocher).

orbital nerve may be reached at the infra-orbital foramen, one centimeter below the orbital margin, at the upper end of the canine fossa, and vertically below the supra-orbital notch. The second division sometimes is sought at a deeper level behind the antrum, and Kocher's operation is a favorite method by which to reach it: The incision below the orbit is carried outward and downward to the zygoma. The foramen and nerve are thus exposed. Then, at the outer end of the incision, the surface of the malar bone is scraped bare and the bone is divided with a chisel so as to open the sphenomaxillary fissure and to remove the roof of the infra-orbital canal. This opens the antrum. The incision is then retracted upward so as to expose the frontomalar

suture, and from here the chisel is carried downward, inward, and backward toward the posterior part of the sphenomaxillary fissure, through the orbital plate of the sphenoid. The zygoma being divided, the malar bone is dislocated outward and upward, and the contents of the orbit are raised, when the infra-orbital nerve may be followed back to the foramen rotundum, where the nerve is seized and pulled out.

The third division of the trigeminal nerve leaves the skull by way of the foramen ovale, and divides into anterior and posterior branches. The posterior branch is sensory and in turn divides into the auriculo-

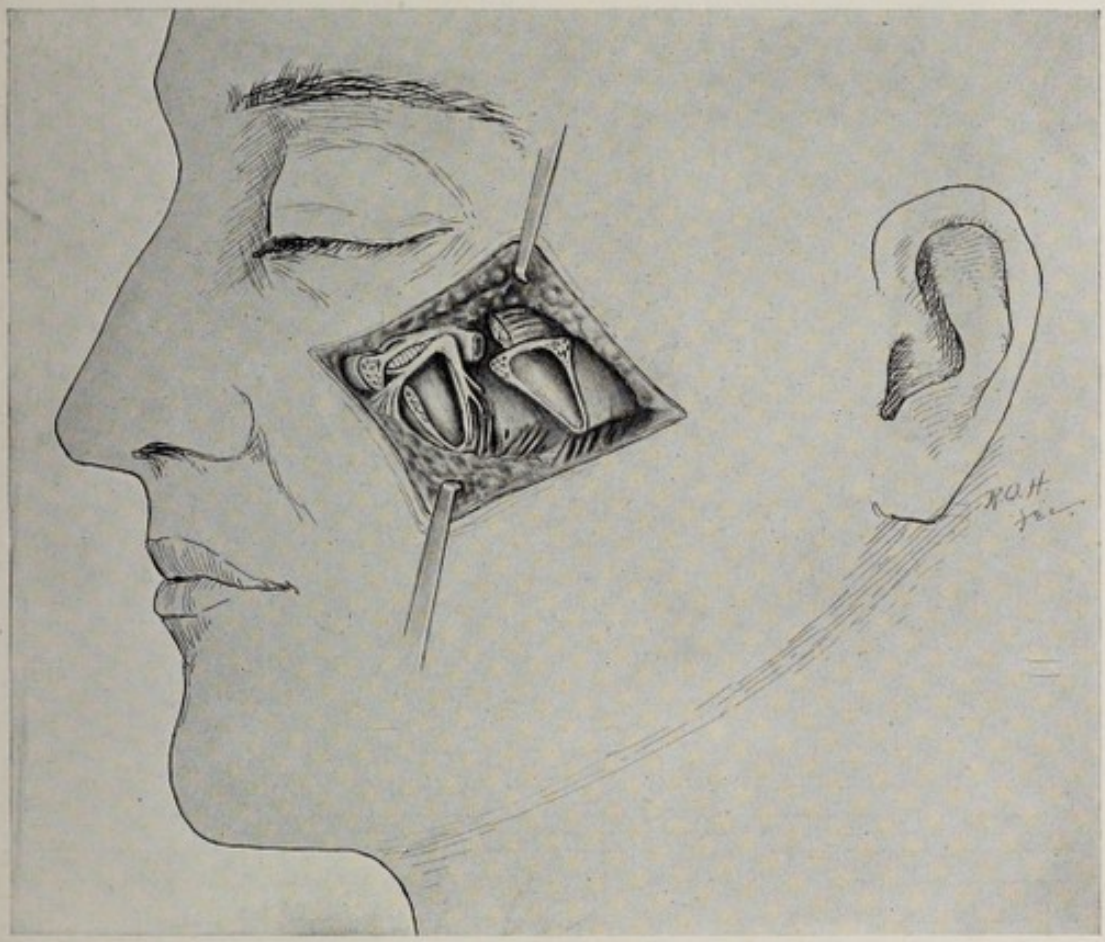

Fig. 444.—Neurectomy, trifacial. Second division—step 2 (adapted from Kocher).

temporal, the lingual, and the inferior dental. The lingual and inferior dental are most commonly concerned in tic, and their excision is part of one operation which Binnie admirably describes somewhat as follows: Begin the incision at the middle of the zygoma and carry the cut backward and downward to a point just below the tragus; then continue along the posterior margin of the jaw to its angle, and follow the horizontal ramus for about an inch. This cut is a skin cut, and should not involve the facial nerve, Steno's duct, or the parotid gland. Now make a transverse incision below and parallel to Steno's duct down upon the bone, striking the ramus about quarter of an inch below the sigmoid notch. Expose thoroughly the bone and trephine it through

and through. Then, with rongeur forceps, gnaw away the bone between the trephine opening and the notch. Now retract forward the temporal muscle, remove obstructing particles of fat, expose the external pterygoid, and retract it upward, when the lingual and inferior dental nerves will appear lying upon the internal pterygoid muscle. Secure each nerve with a suture, draw it down, trace the nerves up to the foramen ovale, and divide them there. Then drag out by torsion their peripheral portions.

Such are the best accepted methods of operating upon the peripheral parts of the trifacial nerve. After all is said, however, we must remember that these operations frequently do little more than palliate,

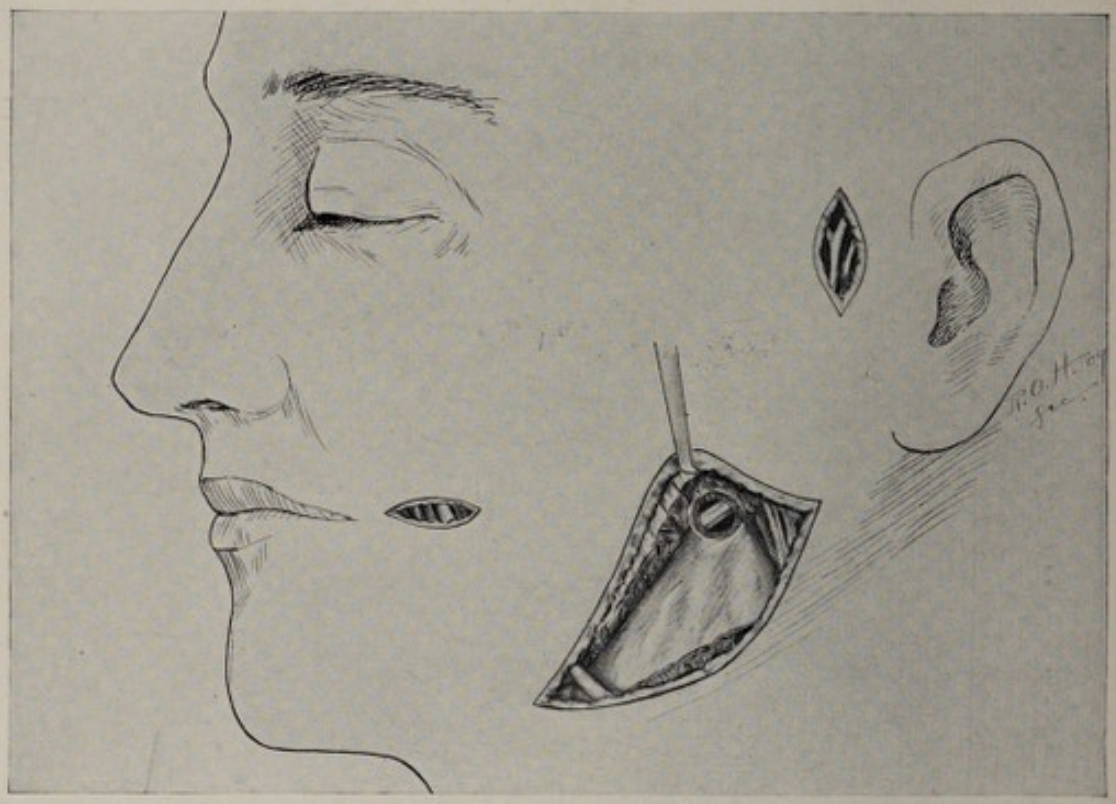

Fig. 445.—Neurectomy, trifacial. Third division (adapted from Kocher).

and that the truly radical operation must be directed to the Gasserian ganglion.

The literature of **Gasserian ganglion operations** is now enormous, and the names of several well-known neurologic surgeons are associated with the subject. We may not refer in general terms even to the different methods advocated and the various technics employed. Suffice it to say that surgeons have reached the ganglion by operating from above and from below—by the high temporal, the median direct, and the low pterygoid routes, and that with these routes are associated the names of Rose and Andrews, of Hartley and Krause, and of Cushing.[1] I am convinced that Harvey Cushing's method is admirably satisfactory, for it preserves the nerve-supply to the brow, avoids the middle

[1] Binnie gives an admirable brief description of these operations in the third edition of his Manual of Operative Surgery, 1907.

meningeal artery, and exposes the ganglion by the most direct route.

Cushing's operation upon the Gasserian ganglion is step by step as follows: the field of operation about the ear is shaved, for the purpose of the surgeon is to seek the base of the skull through the temporal muscle. A slightly curved incision with convexity upward is made almost entirely behind the hair margin. To quote Cushing: "The skin-flap is reflected downward and forward by blunt dissection. . . . . The temporal fascia thus exposed is incised in a line concentric with the skin incision and likewise reflected. The zygoma, which has thus been brought into view at the lower angle of the wound, is then shelled out of its periosteal sheath, not as formerly described, by making an

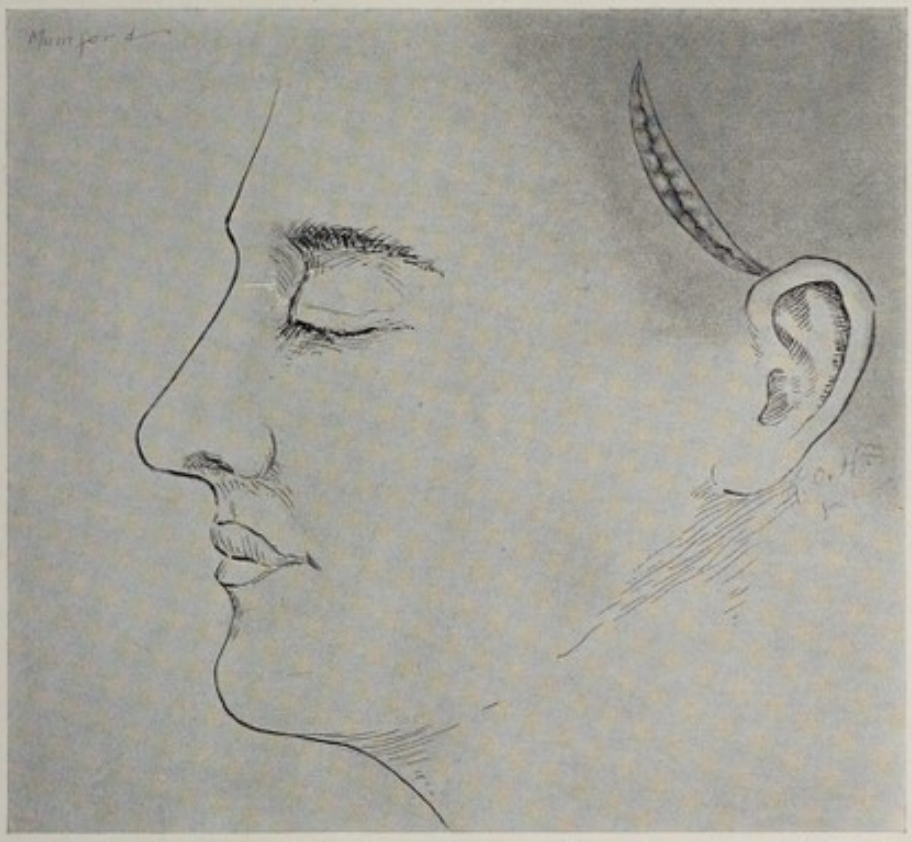

Fig. 446.—Cushing's method of reaching the Gasserian ganglion (Cushing).

incision along its external surface, but by crowding forward its covering en masse. The exposed fibers of the temporal muscle may then be divided as usual, and the muscle scraped away with a periosteal elevator as far down as the base of the skull. In order satisfactorily to expose the skull, a little deeper retraction of the flap is necessary than by the older method. With the soft parts and zygoma retracted downward, the surgeon opens the skull with chisel or gouge at the lowest possible point, and enlarges the opening until it measures about 1½ inches. The middle meningeal artery lies on the dura and runs obliquely across the opening in the skull. Lift the dura with the artery from the base of the skull and dissect it cautiously away with a blunt instrument until you reach the foramen ovale. Then retract cautiously with a pliable

spatula the cerebral structures. The surgeon himself should hold the retractor. The inferior maxillary nerve now serves as a guide from the foramen ovale to the ganglion; split the sheath of the ganglion (the outer layer of the dura) and expose its upper surface. Working still with a blunt dissector, isolate the ganglion and its sensory root. Then, with a blunt hook, pick up the sensory root, seize it with a hemo-

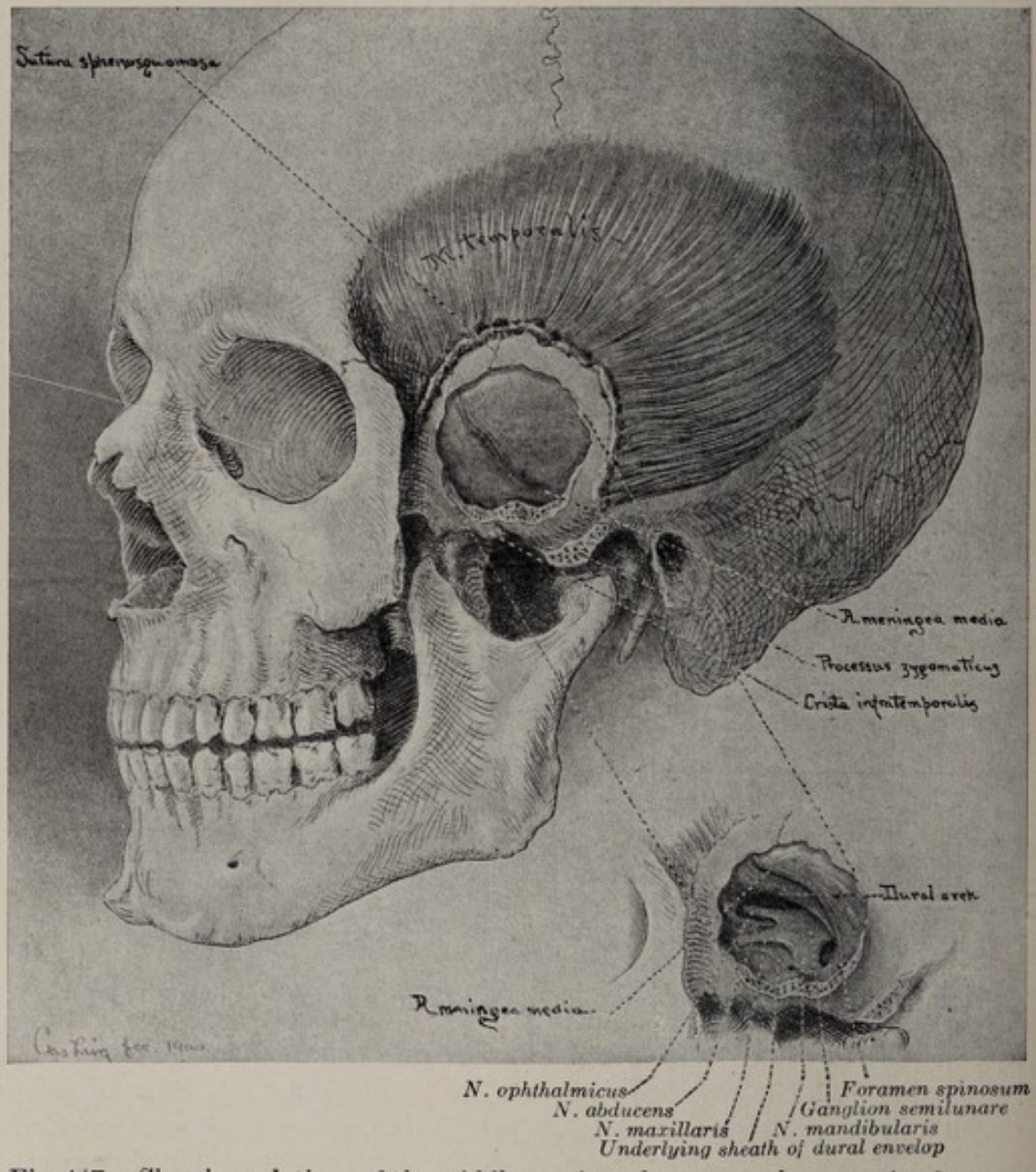

Fig. 447.—Showing relations of the middle meningeal artery to the operative foramen before and after elevation of the dura and exposure of the ganglion (Cushing).

stat, and drag it out of its deep attachment in the pons; thus you turn the nerve out of the opening which it traverses at the attachment of the tentorium; and now it lies loosely across the ganglion." This completes the operation as Cushing now does it. The ganglion, with its deep attachments torn out, is left lying in its bed, while the three divisions of the nerve—the ophthalmic and the two maxillary divisions

—remain undisturbed; for as the author of this operation states, "the liberation of these branches is the chief cause of operative delay in many cases, owing to the resultant bleeding."

The wound is closed with drainage, the temporal muscle and fascia being carefully sutured. The drain may be removed usually after forty-eight hours.

In my own experience this operation has proved more satisfactory than the operations of Hartley, of Abbe, and the others, because it is more free from hemorrhage than are those older and commonly accepted procedures.

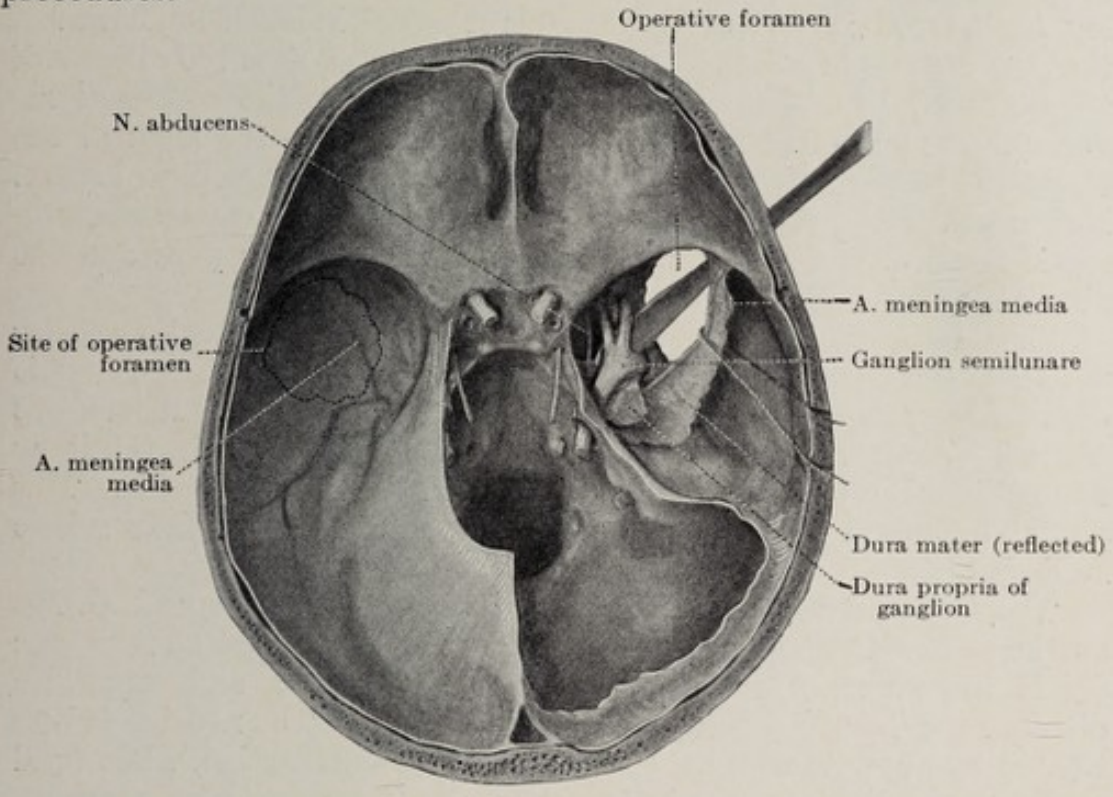

Fig. 448.—Showing on the right, after reflection of the dura, the ganglion and its intracranial branches liberated from their dural envelop and elevated by the blunt dissector introduced through the operative foramen; on the left, the dura *in situ* and the relation of the operative foramen to the ganglion and middle meningeal artery (Cushing).

All persons experienced in operating upon the Gasserian ganglion agree that, at the best, the operation is a serious one, and that it carries with it a definite mortality, not low. No man should attempt it without careful study and practice upon the cadaver.

If the patient recover, he is left free from pain, though with an extensive area of anesthesia involving half the face and brow—an anesthesia which will be permanent.

Sciatica is another serious affection which may baffle the most carefully considered treatment, and its causation is manifold. Sometimes it is benefited by surgical measures.

We must remember that the sciatic nerve springs from the sacral plexus, that the nerves which go to make it up are derived from the lowest segment of the spinal cord; that they are known as the cauda

equina where they traverse the spinal canal; and that after emerging from the sacrum they lie within the pelvis in near relation to the pelvic viscera and the sacro-iliac joints. It will, therefore, be seen that the radicles of the sciatic nerve, from their associations, are peculiarly liable to damage. Spinal injuries, sacro-iliac and lumbosacral disturbances, pelvic tumors, inflammations, and neuritis all must be considered when we seek for the cause of sciatica; and often the causative ailments may be remedied by surgical means.

The *symptoms* of sciatica differ somewhat in different cases,—the disablement being sometimes continuous and sometimes spasmodic,—and again there will be sharp paroxysms of pain. It is seldom, however, that the distress of sciatica is so acutely agonizing as is the distress of trifacial neuralgia. Sometimes pain extends along the course of the nerve, but more often it centers in certain regions—the back of the thigh, the sciatic notch, the back of the calf, and in the popliteal space. Not infrequently, especially when sacro-iliac disease causes symptomatic sciatica, the leg pain is associated with lumbar pain and the ailment is confounded with so-called lumbago.

Should neuritis cause the sciatica, there may be present muscular weakness and atrophy, numbness, tingling, a feeling of coldness, trophic disturbances, and herpes.[1] The patient often attempts to relieve this distress by relaxing the normal tension on the nerve—relaxing it by tilting his pelvis and bending his trunk toward the affected side. This almost involuntary maneuver may lead to the characteristic sciatic scoliosis.

The *treatment* of sciatica in any given case must depend always on the cause. A central lesion (tumor of the cord) must be removed; pelvic tumors must receive surgical consideration; and sacro-iliac disease must be attacked by rest and apparatus. The neuritis is best treated by absolute rest, by splinting, and immobilization, while local applications, the actual cautery, blisters, and sometimes massage, often are effective. Above all things, withhold morphin. Neurectasis has been beneficial sometimes, and the nerve-stretching may be done with considerable vigor, many pounds of tension being put upon the affected nerve. The common site for stretching of the sciatic nerve is just below the gluteus maximus muscle, where the nerve lies beneath the skin and the deep fascia, in a line from the middle of the popliteal space to the junction of the middle and inner third of that line which connects the ischial tuberosity with the outer border of the great trochanter. At the best, all these operative methods are as yet *sub judice*. Our reliance must be upon rest and massage and removal of the offending cause whenever it may be found.

There are numerous other peripheral nerve ailments which are coming more and more within the surgeon's province. Let us consider briefly and in a few paragraphs the technic of operations upon the nerves, for neuromata, wounds of the nerves, and sundry forms of tic.

[1] For an admirable account of peripheral nerve surgery see the chapter on The Surgery of the Nerves, by George Woolsey, in Keen's Surgery, vol. ii, p. 686.

OPERATIONS UPON THE NERVES

Whatever theory we may choose to adopt regarding the **regeneration of severed nerves,** or nerves damaged by disease, certain it is that regeneration can be accomplished only through a complete anatomic reunion of the distal portion with the sound central portion of the affected nerve. Even though we admit that the peripheral portion of a nerve may regenerate without a central union, that regenerated portion must remain functionless until the union be reëstablished. Within recent years only have surgeons met with any degree of success in reëstablishing sound anatomic nerve-paths in damaged nerves. For the satisfactory repair of nerves certain factors are essential, while the mechanics of the operation are difficult and delicate. We must expose carefully and thoroughly the nerve upon which we are to work. We must avoid damage to its structure while we free it from surrounding

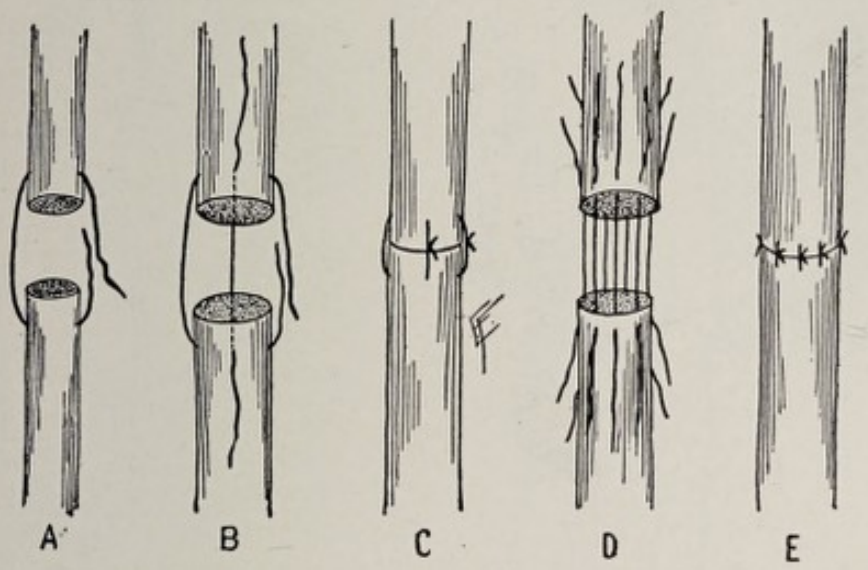

Fig. 449.—Methods of nerve suturing: A, B, C, Sutures passing through entire thickness of nerve and sheath; D, E, sutures passing through nerve-sheath only (Bickham).

scar tissue. After freeing it, we must stretch it carefully in order to render easy the desired approximation. In stretching the nerve we must not handle it roughly with forceps, but must seize its end in fingers guarded by gauze; and, finally, after we have made our new sutured union, we must provide against subsequent encroachment by scar-tissue about the line of suture. For this purpose I have found Cargile membrane wrapped about the nerve to be efficient. Some writers, J. B. Murphy especially, advocate the use of living fascia rather than Cargile membrane, but both substances are effective. We must employ careful after-treatment—immobilizing the affected parts until sound wound-healing has taken place; and then by employing massage, active and passive movements, and electricity for many months. These measures of treatment have no effect in stimulating nerve regeneration, but we employ them to prevent

muscle apathy, and those trophic changes which are liable to occur in the body structures long cut off from nervous stimuli.

Many surgeons in the past have neglected the methods of after-treatment which I have described—have centered their efforts upon the mechanical repair of the damaged nerve, and when functional failure has resulted, have been led to feel that nerve surgery is of little or no value. On the contrary, we know from abundant experience that damaged nerves, when properly handled, regenerate eagerly, with a final though delayed restoration of function.

The **suture of nerves,** however, is a mechanical act demanding our most careful effort. Divided nerves often can be stretched into approximation, and when approximated, must be made to lie in easy

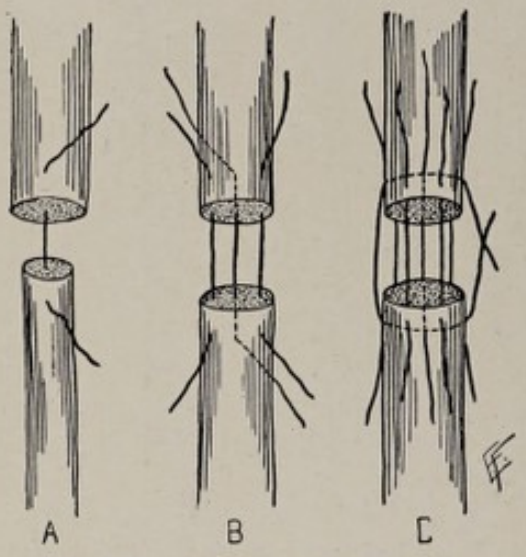

Fig. 450.—Methods of nerve suturing: A, B, Sutures passing through sheath and part of nerve; C, sutures through sheath, reinforced by relaxation suture through entire nerve (Bickham).

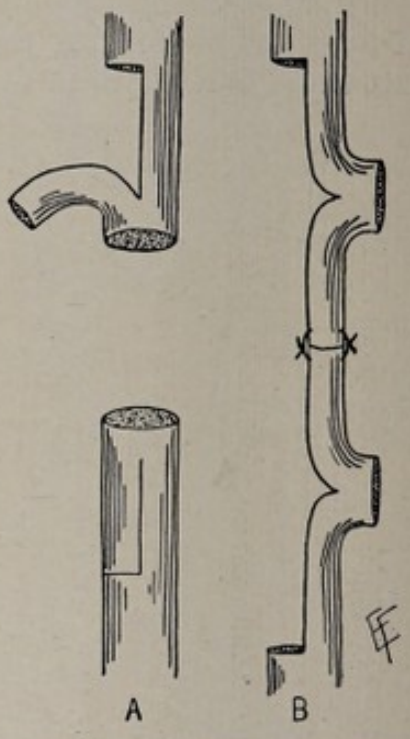

Fig. 451.—Neuroplasty—union by splitting both ends of nerve and uniting split ends end to end (Bickham).

apposition, that there be no strain upon the retaining sutures. We must endeavor to avoid damage to nerve-fibers when passing our sutures. Frequently several strands of the finest silk passed through the nerve-sheath will answer our purpose, or it may be necessary to pass deeply through the nerve itself one or two sutures of chromicized catgut.

It often appears, however, especially in the case of nerves nipped in bone fractures, that a ready approximation of the divided ends is impossible. We must then endeavor in some fashion to bridge the gap. **Neuroplasty** has been for many years a favorite method of joining the remote nerve-ends. This method has not infrequently failed, perhaps because the time elapsed since the injury was too long to permit

of a peripheral end regeneration. Other methods have been attempted, but with limited success. Nerve transplantation—the insertion of a bit of foreign nerve into the gap—has been advocated. Ballance and Stewart point out that the inserted nerve does not itself regenerate, but serves as a trellis for the training of the new down-shooting fibers. This operation has proved of small value. In the same way a trellis of catgut between the nerve-ends has been tried with small effect, and a tubular trellis (hollow bone tube) has served no purpose. In certain desperate cases some surgeons have resected the long bones themselves in order to allow of proper nerve approximation.

Nerve anastomosis, however, gives the greatest promise for the regeneration of damaged nerves, and the brilliant work of Cushing, Frazier, Spiller, and van Kaathoven in these lines seems full of promise. The mechanical principle of the operation is easy. A portion of a sound nerve, lying in the neighborhood of its damaged fellow, is transplanted into the peripheral damaged end. The accompanying figures, taken from Woolsey's article, illustrate admirably the purpose and technic of this operation. We shall have occasion in subsequent paragraphs to study briefly some of the more important nerve anastomoses.

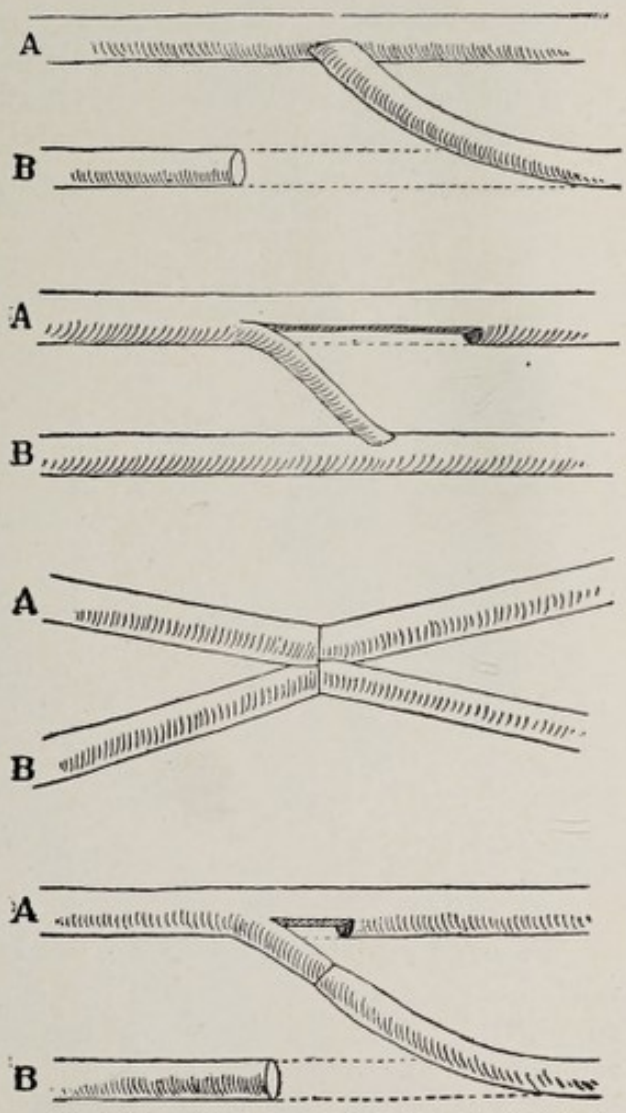

Fig. 452.—Various modes of anastomosis: A, Represents the unaffected nerve, B, the affected nerve (Spiller, Frazier, and van Kaathoven).

Neuromata, especially "amputation neuromata," are extremely painful nerve tumors. True neuromata are rare and small. *Neurofibromata* are common enough and reach a considerable size—as large, perhaps, as a small peanut. The amputation neuroma is properly a neurofibroma. When the nerve is severed in the amputation, its inherent force of regeneration stimulates often a rapid development of this small tumor, at the nerve's cut end especially, when the nerve-end lies in an irritative cicatrix. The common maneuver of pulling the nerve well down so as to cut it high by no means does away with the possibil-

ity of the neuroma's occurrence. These neuromata cause a constant, nagging, burning pain. They prevent the wearing of an artificial limb, and make the cripple wretched. Recently we have been able to do away with these amputation neuromata through an operation which leaves no nerve-ends. We take the nerve-ends in the amputation stump and suture them to each other. This is a primary suture and is followed by a prompt union with each other of the central nerve-stumps.

The *treatment* of the neuromata themselves is simple enough, though the results are not always entirely satisfactory. Nerve-end neuromata should be excised, and the nerve-stumps should be so placed as to be free from irritation by the cicatrizing of the wound. This may be accomplished by laying the nerve smoothly in fascial planes, or by wrapping it in Cargile membrane. Best of all is the practice of drawing out the refreshed nerve-ends and stitching them to each other in the fashion of an end-to-end anastomosis, as described in the last paragraph. By this maneuver all nerve-ends are eliminated so that the ordinary amputation neuroma finds no lodgment. When the neuroma lies upon the nerve-sheath in the course of the nerve, and not at its end, the little tumor may readily be shelled out. In all these operations on nerves the surgeon must observe careful hemostasis, and must enjoin absolute rest of the part for at least two weeks. The results of these operations are good, as a rule.



Fig. 453.—Nerve anastomosis in stump. A diagram showing cross-section through lower third of the right leg, the nerves being enlarged to show sutures.

Wounds and injuries of nerves occur frequently and are of importance only as they concern the subsequent function of the parts supplied by the nerve. When the nerve is but partially severed, reunion may take place without special treatment, provided the wound be kept free from infection. Lacerations of nerves are of manifold character and significance, and subsequent degenerations of the peripheral ends of the nerve may occasion a great variety of symptoms. No man may say at once from the symptoms observed how extensively a nerve is injured. It is well, therefore, always to expose the suspected nerve and to examine its condition. A laceration, a parently trifling, may lead to extensive changes within the nerve substance and in the sheath of Schwann, with a resulting soar formation completely blocking the nerve. Or a nerve apparently little damaged, but lying in a field of lacerated tissue, may become nipped and thrown out of action by a resulting extensive cicatrix. For all such reasons, suspicion of nerve damage imposes upon us careful exploration and investigation. We must clear away the blood-clot; must place the nerve as far as pos-

sible from damaged bone; must repair obvious gross lesions in the nerve; must strip off carefully extraneous tissue, and replace the nerve, preferably wrapped in Cargile membrane, in a bed which shall admit of ready healing without undue external pressure. Be it remembered always that severed nerves, under favorable conditions, unite promptly, though a restoration of function will be many weeks delayed. Primary

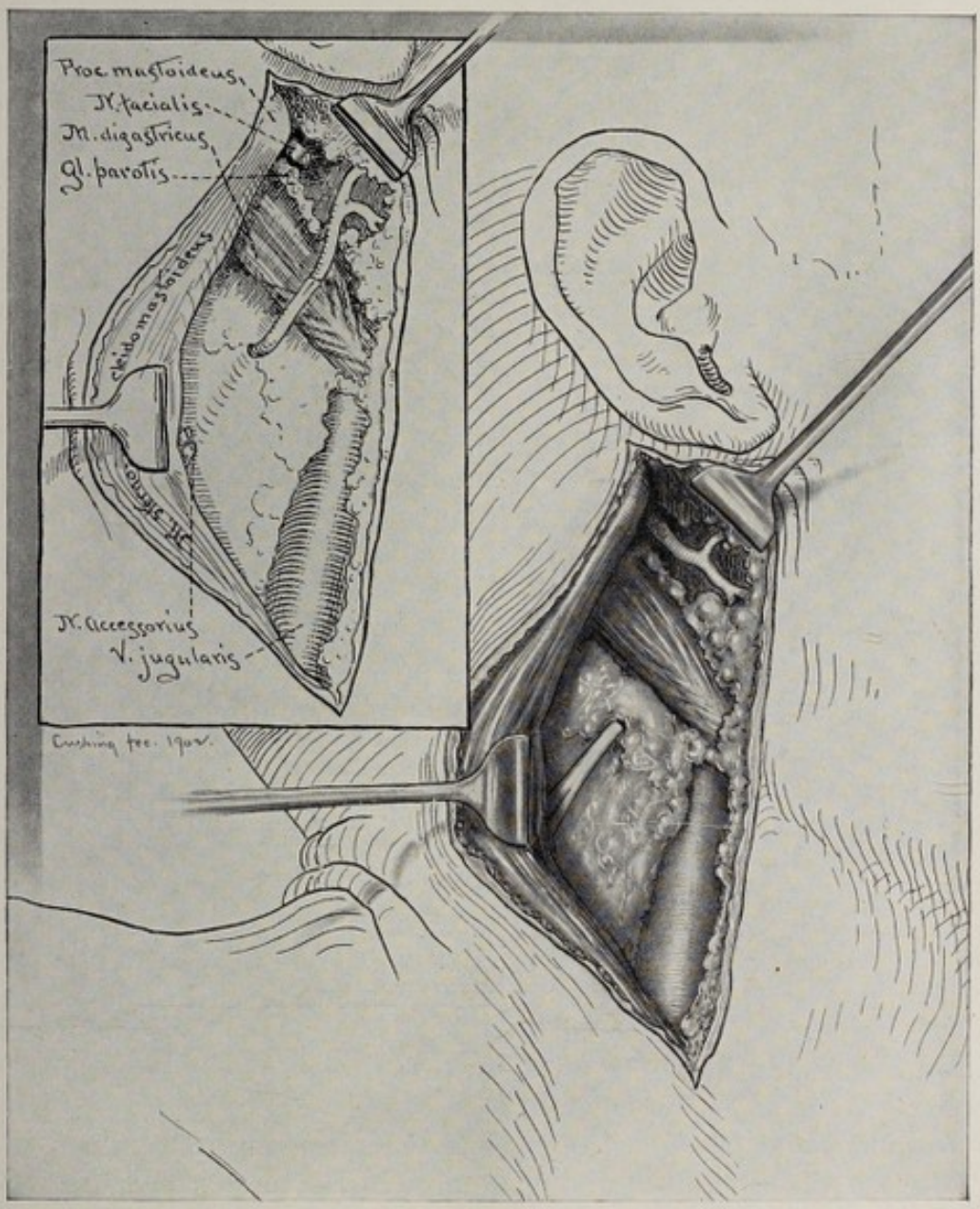

Fig. 454.—Illustrating method of spinofacial anastomosis (Harvey Cushing).

suture of damaged nerves gives a far better prognosis for anatomic and functional restoration than does late suture, though recent experience teaches that late suture, even after the lapse of two or more years, sometimes may be followed by excellent anatomic repair and functional improvement in the parts supplied by it.

Nerve anastomosis and **nerve-grafting** are coming to occupy an important place in nerve surgery—for paralyses and to relieve spasm.

Paralysis of the facial nerve is a not uncommon condition and may be the result of various operations and injuries. It may follow disease of the petrous bone and of the middle ear. It may result from operations upon the parotid gland and from operations on the neck just below the ear, as well as from fractures at the base of the skull. Rarely it may be possible to secure the divided ends of the facial nerve, and to unite them by direct suture, but more commonly the surgeon is unable to find the proximal portion of the nerve, so that a restoration of facial function seems impossible. In such a case, as numerous investigators have demonstrated, one may graft into the distal portion of the facial nerve an active and functionating nerve in its neighborhood. The spinal accessory and the hypoglossal nerves have been used for this anastomosis. While some operators claim special advantages for the use of the one nerve or the other, it has seemed to me that the spinal accessory nerve is subject to fewer disadvantages than is the hypoglossal nerve, when so treated. The spinal accessory nerve normally supplies structures whose loss of function is of no particular importance, and every surgeon knows from his experience in operating for spasmodic torticollis that section of the spinal accessory nerve rarely results in a permanent paralysis of the muscles supplied by that nerve. Cushing especially advocates the spinofacial anastomosis, and I have reproduced here his own interesting sketch which illustrates the procedure (Fig. 454). The operation is not easy. The nerves involved are small, and their suturing demands painstaking care. If the operation is properly done, however, a gradual return of facial function is seen, so that in the course of months little deformity remains.



Fig. 455.—Facial paralysis—six weeks after injury. Effort to close eye (Harvey Cushing).

Facial spasm or **convulsive tic** is another condition which may be cured by the spinofacial anastomosis. In these cases, however, the operation must be regarded as a last resort. Few patients are willing to submit to the possibly complete facial paralysis which results if the anastomosis fails; while convulsive tic may often be relieved by some operation for disease of the teeth, eyes, nose, stomach, uterus, etc., inasmuch as the tic not infrequently is of a reflex character.

To find the spinal accessory: Make an incision 3 inches long from the mastoid process downward along the anterior border of the sternomastoid muscle. Draw the muscle backward. Plunge the finger into the wound and feel the transverse process of the atlas, which is covered

by the digastric muscle. The digastric is the guide to the nerve, which passes between the bony process and the muscle, emerging at the lower edge of the digastric and passing to the sternomastoid. The inexperienced operator will always be surprised to find that the nerve lies much higher than he had expected.

Spasmodic torticollis, or wry-neck, frequently is due to an irritation of the accessory nerve—an irritation usually of central origin. Division of the spinal accessory nerve may benefit the ailment, but must always be regarded as an experimental operation. Often the muscular branches of the cervical nerves must be divided also. Keen's well-known operation involves paralyzing the large posterior root of the neck muscles through the section of the first, second, and third cervical nerves. The largest of these nerves is the occipitalis major, which first should be found and resected. It is a landmark which serves to identify the others. The steps of the operation are these: Make a four-inch incision transversely across the neck, starting three-fourths of an inch below the lobule of the ear. Sever the trapezius muscle. Raise the trapezius and isolate the occipitalis major, whose level is about half an inch below the level of the skin incision. Carefully cut through the complexus, following the nerve in its course through that muscle. By this dissection one finds the nerve's bifurcation from the second cervical, and should excise a long piece from both nerves. Then search for and resect the first cervical, which lies deep in the wound above the second. One finds it by outlining the suboccipital triangle, bounded by the two oblique muscles and the rectus capitis posticus major. Search for and resect the external branch of the posterior division of the third cervical, which lies about one inch below the second, already cut. The surgeon may then reunite the muscles in order to obviate a needless deformity. After any operation upon the nerves of the neck involved in spasmodic torticollis accurate wound healing must be sought through perfect hemostasis, approximation of the cut surfaces, and many weeks of immobilization and support by a Thomas collar or some similar apparatus.

Incidentally, one observes, as a matter of no slight importance, that the relief or cure of spasmodic torticollis sometimes is secured by other than operative measures—by long-continued immobilization with appropriate apparatus.

The **phrenic and pneumogastric nerves** sometimes may be subject to surgical operations—operations following nerve injuries from wounds of violence or from operations. Injury of one phrenic nerve paralyzes half the diaphragm, so that the repair of the injured nerve should be sought, though its reunion is not absolutely essential to life. This nerve is the most important branch of the cervical plexus, and lies upon the scalenus anticus muscle, where it may easily be found.

Division of the pneumogastric (vagus) nerve on one side only causes no marked change in the pulse-rate, the respiration, or the digestive organs, but it does result in a paralysis of the vocal cord on that side. It may be possible successfully to suture the vagus.

The **brachial plexus** frequently is the site of serious damage, either from traumatism at birth or, more commonly in men, from heavy crushing injuries. The resulting paralyses must be studied carefully by a neurologic expert, for it is extremely difficult to determine readily the site of the laceration in the complex anastomotic mechanism. The accompanying figures, taken from Woolsey's article, illustrate this anastomosis. Operators have attempted to repair these damaged nerves, but with varying and uncertain results. The obvious indication is to cut down upon the plexus through a long incision in the neck, and thoroughly and carefully to expose the injured structures. Rarely is

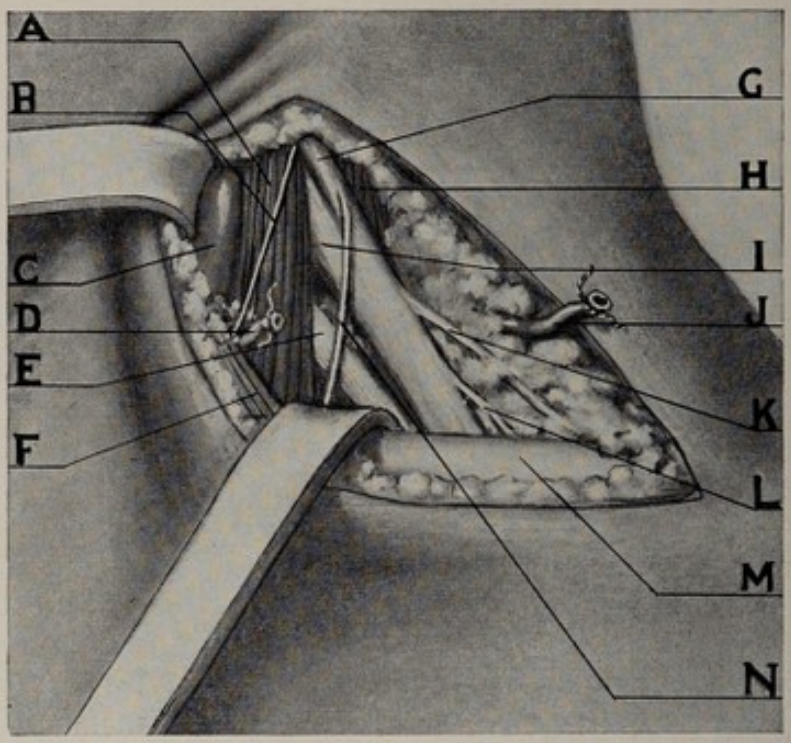

Fig. 456.—Dissection of the operative field in brachial birth palsy (Clark, Taylor, and Prout): A, Scalenus anticus muscle; B, phrenic nerve; C, internal jugular vein; D, transversalis colli artery, divided; E, seventh cervical root; F, omohyoid muscle; G, fifth cervical root; H, scalenus medius muscle; I, sixth cervical root; J, transversalis colli artery; K, suprascapular nerve; L, nerve to subclavian muscle; M, clavicle; N, nerve to scalenus anticus muscle (Woolsey in Keen's Surgery).

it possible directly to unite in their proper relations the severed nerves. The construction of new and complicated anastomoses may be imperative. The functional results depend upon two factors: the accuracy of the wound healing and the ability of the patient to coördinate in the presence of the strange new nerve-relationships established. This last difficulty, however, is not peculiar to nerve anastomoses in this region, but is true of all nerve anastomoses.

The various terminal nerves of the brachial plexus are subject to their own injuries likewise, and as they control the complex movements of the arm and hand, their damage is of vital importance to all men. It is needless here to take up in detail these subjects further than to remind

the reader of two or three of the more important injuries to the nerves of the arm.

Fracture of the humerus or an extensive wound of the upper arm may destroy the *musculospiral* nerve, when the characteristic wrist-drop ensues.

The ulnar nerve may be damaged or destroyed through a fracture about the elbow-joint. There results the so-called "claw-hand," due

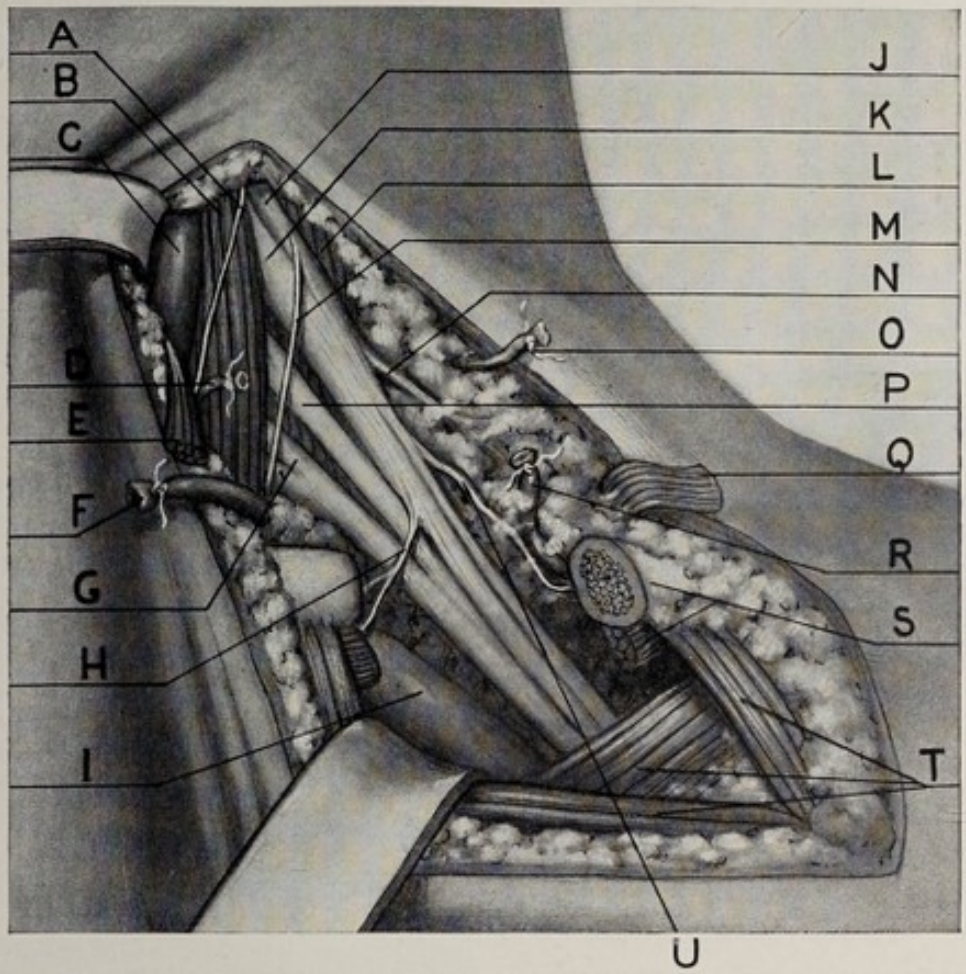

Fig. 457.—Dissection of the operative field in brachial birth palsy (Clark, Taylor, and Prout): A, Phrenic nerve; B, scalenus anticus muscle; C, internal jugular vein; D, transversalis colli artery; E, omohyoid muscle divided; F, suprascapular artery divided; G, eighth cervical and first dorsal roots; H, external anterior thoracic nerve; I, subclavian artery; J, fifth cervical root; K, sixth cervical root; L, scalenus medius muscle; M, nerve to scalenus anticus muscle; N, suprascapular nerve; O, transversalis colli artery; P, seventh cervical root; Q, omohyoid muscle, divided; R, suprascapular artery; S, clavicle and subclavius muscle, divided and retracted; T, deltoid, pectoralis minor, pectoralis major (muscles); U, nerve to subclavius muscle (Woolsey in Keen's Surgery).

to paralysis of the flexors in the proximal phalanges, except of the thumb. There is an associated cutaneous anesthesia which varies on account of the uncertain nerve anastomoses which may exist.

The median nerve supplies those flexor muscles of the forearm and hand not supplied by the ulnar. Damage to the median nerve causes loss of flexion of the second phalanges of all the fingers, and of the third phalanges of the forefinger and middle finger, with loss of flexion,

abduction and opposition of the thumb, so that the thumb lies in extension, adducted against the forefinger—the so-called "ape-hand." Pronation of the forearm is lost and the flexion of the wrist is weak.

Injuries to these nerves result, however, in curiously uncertain phenomena. I have here described the characteristic phenomena, but immediate suture after damage may in certain cases cause a variation in the nature of these paralyses, greatly to the confusion of the examiner. In case continued doubt of the nature of the injury exists, the surgeon may justifiably cut down upon the nerve and ascertain its exact condition.

There are sundry other peripheral nerves which the surgeon may have occasionally to search out and operate upon in various ways.

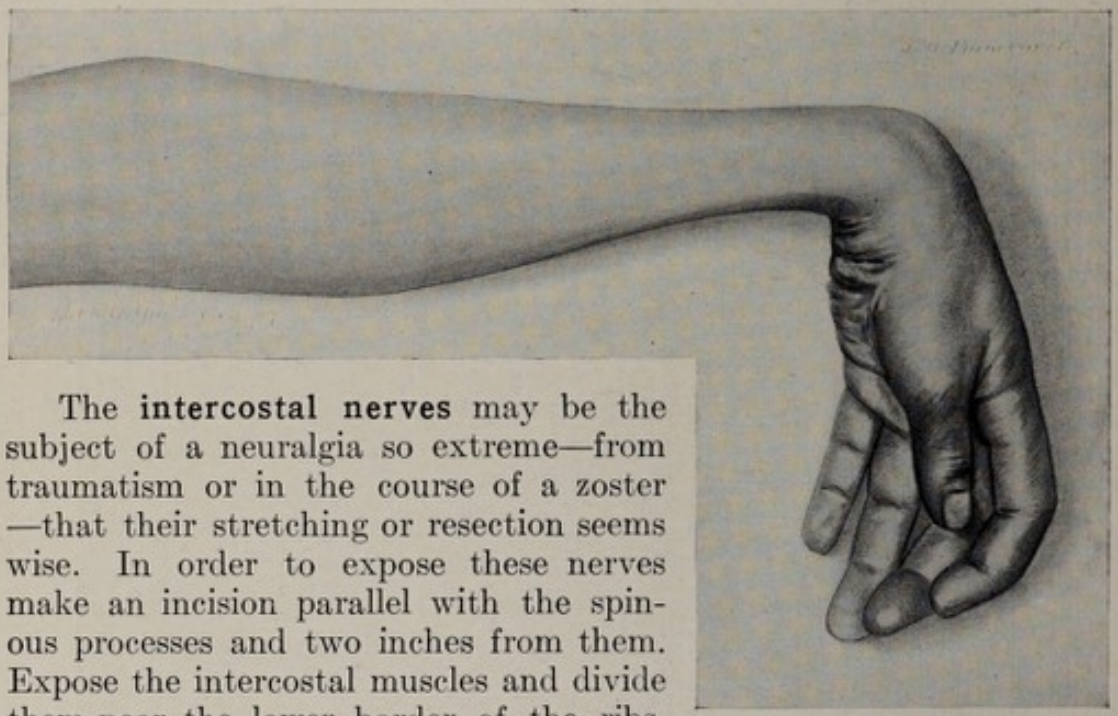

Fig. 458.—Wrist-drop from musculospiral paralysis (Massachusetts General Hospital).

The **intercostal nerves** may be the subject of a neuralgia so extreme—from traumatism or in the course of a zoster—that their stretching or resection seems wise. In order to expose these nerves make an incision parallel with the spinous processes and two inches from them. Expose the intercostal muscles and divide them near the lower border of the ribs. Thus you will bring into view the nerve lying below the vessels. The operation is an easy one.

I have already spoken of stretching the *sciatic nerve* which lies behind the head of the femur at the point of election for stretching. The sciatic nerve rarely suffers traumatism from any cause, but may be involved in a tumor, and may be resected and sutured with expectation of its restoration. In all cases of sciatica the surgeon should bear in mind the possibility of sacro-iliac disease or injury.

The **external popliteal** or **peroneal nerve,** which winds around the fibula just below its head, is sometimes injured. This nerve supplies the anterior tibial group of muscles, which are frequently affected in anterior poliomyelitis. In such cases the surgeon will have an opportunity to reinnervate the paralyzed muscles through anastomosis of the intact internal popliteal nerve with the distal portion of the peroneal.

The **cervical sympathetic nerves** occasionally are attacked by the surgeon for such conditions as glaucoma, exophthalmic goiter, epilepsy, and trifacial neuralgia. I see no reason to believe that this mode of treatment will remain in vogue for these diseases, but one should not overlook the technic of the operation. The maneuver is called by the extraordinary term "sympathectomy," and you should perform it as follows: Make an incision from the mastoid process downward along the posterior border of the sternomastoid muscle to an inch below the clavicle, avoiding the spino-accessory nerve. Free the muscle, and draw it toward the median line, together with the vessels and nerves of the neck. Look for the sympathetic nerve in the middle of the wound, either on the posterior sheath of the vessels or on the vertebral column, where it lies in a special sheath. The books say you shall find it easily, but this depends upon your skill as an anatomist. In order to make sure of its identity, trace the nerve upward to its superior ganglion—then divide the ganglion fibers and tear away the nerve-



Fig. 459.—Claw-hand. Griffin clutch of Duchenne (Fowler).

trunk which leads upward toward the skull. Next seek out the inferior thyroid artery through pulling it up from its bed by tension on the already freed sympathetic nerve which surrounds it. Elevate the nerve and the artery together and separate them carefully. The next step is to remove the inferior ganglion—a difficult undertaking, since the ganglion lies deeply embedded at the base of the neck behind the clavicle, against the head and neck of the first rib, between the scalenus anticus and longus colli muscles, and just above the pleura. We use the already liberated trunk of the nerve as a guide, and penetrate to the ganglion which is adherent to the vertebral artery, embracing it in a fine meshwork. Then remove the ganglion. The reader will see that this is an operation not lightly to be undertaken, even by the skilled anatomist. The operation is tedious, somewhat bloody, not without danger, and most uncertain in its effects upon the offending organ. After the operation is over one must attend carefully to the dressings and the wound healing, for a septic infection deep in the neck is a serious matter.

The surgeon should repair the damaged structures carefully layer by layer; he should employ deep drainage if there is persistent oozing; and, finally, he should support the neck carefully and immovably in a heavy dressing until all danger of sepsis and hemorrhage be past.

Rhizotomy, or resection of the posterior roots of spinal nerves, was first done in 1888 by Abbe,[1] at the suggestion of C. L. Dana. The patient suffered from violent painful spasm of the right arm. Previous amputation had given no relief. Abbe then divided the sixth and seventh cervical nerves where they emerge from the dura, but inside the vertebral canal. No benefit. Two days later he split up the dura and cut the posterior roots of the seventh and eighth nerves. After an uncertain convalescence the patient had much less pain. Then for two years he abandoned morphin and gained 20 pounds. Later he claimed that the pain returned in some degree, but on account of his seeking a pension the claim of pain seems to have been largely discounted. He survived the operation twenty-two years.

Rhizotomy has been employed for the gastric crises of tabes. It is indicated in other diseases only when there is genuine reflex spasticity as the result of the loss of the cortico-inhibitory fibers, but not the diseases of the type of chorea, athetosis, mobile spasms, and spasmodic torticollis. (See Summary in Practical Medicine Series, Surgery, 1912, p. 567.)

The reader will see, from his perusal of this chapter, that the surgery of the spine and peripheral nerves is reaching out in many new and unwonted directions. This is a field little cultivated formerly, of strange and unexpected possibilities, vigorously tilled of late by an increasing number of investigators. Even as one writes he feels that much which is here said shortly must be revised. Like all new surgical fields, this is one of growing interest and of surpassing possibilities.

[1] Med. Rec., March 4, 1911.

PART VII

MINOR SURGERY
DISEASES OF STRUCTURE

CHAPTER XXVI

MINOR SURGERY[1]

THE EXAMINATION AND STUDY OF CASES; WOUNDS; FRACTURES; LOCAL INFECTIONS; MASSAGE

ABOUT twenty years ago some one coined the phrase "antiseptic conscience." I think it was Howard A. Kelly, of Baltimore. That phrase and the thought it contains were once essential, because twenty years ago most of the men who were doing the surgery of the world belonged to the generation which in its youth knew the old sepsis. To them the principles and practice of antiseptic surgery came haltingly and often imperfectly. They had, indeed, need to cultivate the antiseptic conscience; but they had conscience for many other things—great principles underlying good surgery, principles as important to-day as ever they were. One is impressed at times with the conviction that many of those sound, ancient principles latterly are being pushed back into a subordinate position.

To-day a majority of the surgeons in active practice have grown up with the antiseptic idea. In the course of their development the antiseptic conscience has become part of their being. That intangible thing which we call *surgical instinct* includes and partakes of this same conscience. There is no danger of any man who has received his training in the past twenty years going far astray with that conscience to prompt him. Every source of surgical infection has been so thoroughly and universally studied that, with one or two exceptions, our aseptic technic is now perfect, or as near perfection as it is likely soon to become.

But there are those other general principles which were so important to the former generations.

[1] This chapter is a reproduction, in large part, of a little book I published in 1903, Clinical Talks on Minor Surgery. That book was cast in the direct, personal, lecture-room form—a form which may not be thought appropriate for a more formal treatise on general surgery, but the "Clinical Talks" has been so kindly received that I am persuaded to embody it, with little change, in this volume.

If I name some of those principles, they seem commonplace enough, and men will say, perhaps, that they have them always in mind; but such is not by any means the conclusion of observers who watch the detail of work in our great hospitals.

The most important lesson which a surgeon has to learn is to estimate the patient's general condition. I put that as essentially above any question of therapeutics. That matter of the general condition is a very large part of diagnosis. One has various routine questions which one asks in a perfunctory fashion: the patient's age, birthplace, residence, occupation, family history, and previous condition of health, and in some sort one learns the answers—but those answers are not idle babble: they have a very real bearing on the matter in hand. In a surgical clinic one is altogether too prone to assume that every case is an operative one pure and simple, and one looks no further. This is one of the deplorable results of specialism gone mad. In the old days it was required of the surgeon that he have a good practical working knowledge of general medicine. Operations were a last resort; John Hunter and Liston told their classes that the knife was an opprobrium, and should be used when all other means failed. Of course, that extreme view has long ceased to prevail—modified, first, by the introduction of anesthetics and later by the development of asepsis. Indeed, for long the pendulum was swinging the other way, when the knife was deemed the only reliable measure. Now, again, thanks to increased knowledge, we are appreciating that there are other resources.

Every one of those data which the clinical clerk takes down by rote may be of the greatest importance. Age may rule out many things, such as cancer, arteriosclerosis, and the like; the place of birth and the race may suggest tuberculosis or malaria, as may the residence. The other day I saw a case of anthrax of which the diagnosis was rendered probable by the patient's surroundings; there are numerous occupation diseases—lead-poisoning and "housemaid's-knee" will at once occur to the reader. That matter of family history or hereditary tendency is important, in spite of the new light we are constantly getting on the whole question of etiology; and especially the patient's previous condition of health is to be studied.

Take, for example, a patient who illustrates in his own person many of the points we are considering. He is a young man. His age is twenty-three. He is of American parentage and of vigorous stock. He was born, reared, and now works in a town which is notorious for its unwholesome location, being low-lying, ill drained, and inadequately supplied with water. The young man is assistant to a sewer contractor, and spent most of one summer overseeing a gang of men engaged in laying drains. In September he became ill with typhoid fever, as appears from his physician's statement and the story he himself tells. Typhoid was epidemic in his town. Recovering, after an illness of some two months, he returned to work. After an interval of six months he was seized with acute pain in the region of the right shoulder. The pain increased, and became severe—of a boring, throbbing, agoniz-

ing character. The patient looks like a sick man. He is flushed, with a coated tongue, the bowels are constipated, the urine is scanty and high colored. The man supports his arm in his hand; he favors it, as we say, and is evidently in great suffering. On examining him we find his pulse to be bounding and rapid, with a rate of 116, and a blood-pressure recorded as 190 by the Riva-Rocci apparatus.

When we handle the arm we find some slight swelling and a sense of bogginess about the shoulder-joint; but the joint itself is not especially tender on pressure, and the patient seems to refer his pain rather to the head of the humerus.

Here is a very definite picture. On the history alone one should be able to make a correct diagnosis. The man is obviously the victim of an acute infectious process. He has been for long exposed to unsanitary conditions, and he has recently had typhoid fever. The leukocytosis in his case is 40,000, and the temperature 104° F.

What are we to conclude from this collection of signs and symptoms? There are but two processes which suggest themselves at once—an acute infectious arthritis (articular rheumatism) and an acute osteomyelitis. To distinguish between these two conditions is of the utmost importance. In the two diseases the signs and symptoms are in many respects identical, but we have two points as guides: the bone rather than the joint is the seat of pain, and the patient has recently had typhoid fever. We know that acute general infections are frequent precursors of osteomyelitis, and we are justified in concluding that we are dealing here with that process. A correct decision is urgent. Such a case should be admitted to the hospital at once, and the shaft of the humerus opened and drained, when doubtless he will recover with a useful arm. A few days' or even hours' delay might mean for him a systemic infection, septicemia, and death.

To take up the thread of our main topic again: there is that indefinable thing we call the patient's **general condition.** One cannot too soon begin to bear that thought constantly in mind. Sir Benjamin Brodie used to say that he could often make a diagnosis by the smell of the patient's bedroom. It is unnecessary for the modern student to know such shrewd tricks as that, but he must learn to put all senses into action. He goes to the clinic fresh from his laboratory studies. Hitherto he has learned the use of the sense of sight only, now he must cultivate his hearing, touch, and smell even, like old Sir Benjamin; and he must come gradually to appreciate that nebulous aura of physical condition which every man, sick or well, carries with him. When to these things he adds those instruments of precision, the uses of which he has learned, there will be an accuracy and finality to his decisions which were impossible for the ancient men.

One concludes from what I have said that a competent surgeon must be a very thoroughly equipped all-round man. Exactly that is my meaning. One must study general medicine as well as surgery, and must follow carefully both sets of clinics. There was a time, fifty years ago and less, when all surgeons were general practitioners. Then,

with the development of specialties, came a natural and proper narrowing of the surgeon's field. For years we devised new operations, we attacked organs previously regarded as inaccessible, we learned and perfected a new practice and a new technic. It has come about with this development of our branch of the art of medicine that many diseases as well as organs have become the surgeon's own,—his own in part at least,—diseases and organs with which he never thought to tamper a few years ago. So again it is becoming apparent that he must be familiar with a great variety of processes which, a few years ago, concerned him little if at all. In that second stage of the surgeon's development he was often little more than a thorough anatomist and a clever handicraftsman. We have outgrown that stage. We now realize that the surgeon must know and be ready to apply the principles of physiology, chemistry, pathology, and bacteriology, as well as those of anatomy and physics. He deals with almost every known disease and with every organ of the body. He must be familiar with the structure and function of those organs, the nature of their disease processes, and the appropriate methods of treatment, if he is to put to their best and proper uses the therapeutic measures with which he is especially equipped. He must not stand idly by until his medical confrère says "cut." He must cut when the time comes, of course, but must use his own matured judgment to sustain the advice of his colleague.

Before now, following the old blind method, the chest has been opened for empyema when no pus was there; the appendix has been removed when typhoid fever was the cause of the symptoms, and the gall-bladder has been opened for the cure of lumbricoid worms. I have even known a colleague to scoff at a surgeon who used a stethoscope, and to look upon a microscope as an instrument outside of his ken.

A surgeon's duty is the treatment of disease by proper and recognized surgical measures; but he should have a sound knowledge of all disease as well, recognizing his own limitations; and while his medical colleague is at work with his proper investigations and remedies, the surgeon should stand by, waiting to be called upon for the employment of his own peculiar skill.

Given then the particular case, such as that of the man with osteomyelitis: One has looked the ground over, has ascertained the gravity of the general condition, and now turns his attention to the special lesion under consideration. That lesion is in the arm near the shoulder-joint; and without further doubt one makes the diagnosis and recommends appropriate treatment. But take another patient as a foil to the first. He, too, is a young man—not more than thirty-five; his previous condition of health is unimportant, and he, too, has a disease near the shoulder-joint. It is in the nature of a swelling or tumor, and he has had it for some fifteen years. It is a chronic process, therefore.

When we see a swelling, there are two questions which should suggest themselves at once: Is this an *inflammatory* process or is it a *neoplasm?* For the purpose of practical exclusion run over rapidly the old formula which applies to acute inflammations—Is there *pain, heat, redness,*

swelling, and *impairment of function?* In this case all these are absent save swelling; moreover, this is a chronic process. Then call up the other familiar formula which applies to a swelling—What is its exact *location, size, shape, color, consistency?* One must have these two formulæ always in mind. This swelling has none of the characteristics of inflammation, and the patient's general condition is excellent. Therefore it is probably a neoplasm and of a benign type. It is situated just below the acromion process, over the middle of the deltoid muscle. It is about the size of a small orange; it is spheric and uniform in outline; its color does not differ from that of the surrounding skin; it is soft, rather gelatinous to the touch, but it does not distinctly fluctuate. It is subcutaneous, movable, not adherent to the skin, and the adjacent glands show no metastasis.

Observe carefully the method of approaching the patient and handling the little mass. See that he sits or stands at ease before you, with a good strong light upon him, while your own back is turned to the window. Gain his confidence by assuring him that you do not expect to hurt him. He will then sit relaxed and will not shrink or grow tense at your touch—an important desideratum. Now pass your extended palm gently over the tumor, once or twice. In that way you will gain a great deal of information, and if the parts are sensitive, you will give no pain. The *tactus eruditus* does not belong to the heavy-handed surgeon. One cannot too strongly urge upon the student the great advantage and importance of gentleness. Patients recognize it at once. The patient knows when he is being handled by a man who knows his business. The reputation of being rough or brutal never helps a surgeon.

See the thoughtless, inexpert man plunge at a painful, sensitive region as though he were kneading dough! One can tell the neophyte at once by his roughness. The gentle outspread palm and fingers of the examiner are extremely sensitive to tactile impressions and can be educated to a rare facility. It is seldom necessary to prod and poke with the finger-tips.

Passing one's hand over the tumor in question, one readily defines its outline, its extent, its density, its mobility, and notes the absence of sensitiveness. Now one may pick it up in the finger-tips and determine, if necessary, its lack of fluctuation and the depth of its attachments.

That is the whole story. We have the list of benign tumors in mind and, running over them, we see at once that this must be a fatty tumor or lipoma. After all, it makes little difference what we call it. The method of examination concerns us at present, and if one has learned to take a broad view of the case, to approach it without rush or flurry, and to observe accurately those few important details of which I have written, the giving a name and the assigning treatment will naturally and readily follow.

INCISED WOUNDS

Thirty years ago Sampson Gamgee published in London one of the best books in English that is known to me on the treatment of wounds and fractures.

After describing in some detail the pathologic conditions which are met with in these phenomena, he goes on to lay down the cardinal principle of *support for the injured part*, and this he recognizes as the one essential in the therapeutics of traumatic surgery.

We shall have much to say as to the meaning of that word "support." In the time of Gamgee's writing the word *asepsis*, in the modern sense, had hardly been invented; but it has now come not altogether justly to usurp the honors of surgical support; for in the consideration of all wounds, whether of the soft or hard parts, in which there has been any sort of disturbance of continuity, you should have constantly in mind that that severed continuity must promptly be restored; that those restored parts must be absolutely immobilized and supported, and that this work must be done under aseptic conditions.

Take a simple case in point. The patient is a tinsmith, thirty years old, sound and vigorous. About two hours ago, while at his work, he cut through the skin and fascia of his palm, leaving a clean, straight wound, extending about three inches across the hand.

Let us see how we may apply our two principles, support and asepsis. We must regard what we have to do as a surgical operation. The whole field of the wound—and in this case the field is the man's hand—is sterilized, so far as may be—by a thorough scrubbing with soap and water, followed by immersion in chlorinated soda and wiping with cotton sponges dipped in 75 per cent. alcohol. The hand is then immersed for two minutes in an alcoholic solution of bichlorid of mercury, 1 : 3000. The hand and arm are then wrapped in a clean steamed towel, and the patient sits before the surgeon with his arm outstretched, palm upward, upon the table. Meanwhile the surgeon has cleaned his own hands with soap and water and alcohol, and has put on rubber gloves which have been sterilized by boiling. I have gone into this matter in some detail, because details in asepsis are the *sine qua non* of successful surgery.

Let us now examine the wound. We must be sure always that no foreign substance remains in its depths, and in this case we find none. As the wound is held open, we see the extensive tear in the palmar fascia. One is scrupulous to close this, for by so doing we hasten the restoration of function. It is closed with three interrupted catgut stitches, and with the use of the curved needle rather than the straight one. There remains the skin-wound of the palm, which lies together without gaping. The severed edges are dusted with a simple drying powder, aristol; a bit of crêpe lisse laid across and secured with collodion further supports them. One then applies a bit of absorbent cotton also held down with collodion about the edges, forming what we call the "cocoon dressing."

Now one would say that sufficient has been done to assure a prompt and sound healing by the "first intention"; but observe that the second only of our cardinal principles has been applied up to this point. A reasonably accurate asepsis has been provided; why is not that sufficient, and why do we go on to apply the first principle—support and immobilization? A very simple experiment on one's own fingers will illustrate the reason. If I prick my finger sharply, tie an elastic band around it, and let it hang down for a few minutes, I find that the whole finger shortly will throb painfully, and the pricked wound will smart and ache. Now I remove the rubber band, place my hand upon the opposite shoulder, and hold it there steadily; I experience quickly relief and a sense of comfort. The series of phenomena which I have experienced are not dissimilar from what will occur in this man's wounded palm. Were we to leave his hand unprotected, except for the cotton and collodion, he would naturally swing it at his side. Almost at once the process of repair will have begun—there will be the inevitable increased blood-supply in the wounded parts, a certain amount of exudation will go on, the venous circulation will be slightly impeded, and all these conditions will be accentuated by hypostasis if his hand hangs down; in other words, the reparative process will be interfered with.

Hitherto surgeons have been able to devise no means of disinfecting thoroughly the skin. The epidermis may be scrubbed and treated with chemicals until it is fairly free from micro-organisms, but the corium cannot be touched by such methods, and in the corium normally there are to be found pathogenic organisms, mostly the Staphylococcus epidermidis albus. You must bear in mind, too, that in the aseptic operations of surgery we have three principal sources of infection to consider: First, the instruments; second, the dressings and suture materials; and, third, the skin, whether of patient or operator. At the present time we have advanced so far that we have eliminated the first two sources. Instruments properly boiled carry no organisms; dressings and suture materials properly steamed and prepared are sterile. So we come to the third source, the skin. Even that to a larger extent may be ruled out, for we now wear aseptic gloves,—surgeons and all assistants,—so that we are left with the patient himself as the one most important carrier of possible infection; and after the most scrupulous care in preparation, the patient's skin must carry in its deep parts pathogenic organisms, as we have seen. One asks, Why do not these bacteria always produce sepsis? Because to do so they must be present in great numbers, or else they must fall upon suitable soil, or both.

One need not review here the well-known fact that in varying degrees patients carry in their own tissues disease-resisting elements; suffice it only to remind the reader that organisms which will grow and multiply in and infect one man will fall harmless upon another; and here is the practical point, that in a great many cases, by appropriate treatment, one may help to bring nearer to immunity, and may fortify the resisting powers of an individual patient.

So it is practically in the patient's own skin, and there chiefly, that we must look for a source of sepsis.

What became of the organisms at the time our patient received his wound? Some of them were undoubtedly carried into the deeper parts, some of them still remain on the cut edges, and others will be forced into the wound itself and into the general circulation during the early hours of repair. Now this man's hand has been relieved of a large number of organisms by the antiseptics we have applied. We must strive to render the deep parts of the field infertile. No better medium exists for the growth of organisms than a stagnant or sluggish blood-supply, and that condition exists to perfection when we leave the man's hand hanging at his side. So we place it high upon his chest and secure it in a sling.

We have now provided for *asepsis* and *elevation*. It remains for us to secure surgical *immobilization*.

If we leave the man's hand unconfined except by the light, supporting sling, there will be nothing to prevent his withdrawing it from the sling, and there will be nothing to prevent his using the hand and fingers, even if they be elevated.

Here, again, one asks, What harm can possibly result from such use? We have conceived of an exudation essential to the healing process in the palm; we have conceived of an increased flow of blood to the part; we can further see how the support of the arm has improved the venous circulation, and it takes very little imagination to understand how the action of the muscles dragging, pulling, and contracting may well keep up an irritation which, superadded to the other conditions, will permit of a bacterial activity and initiate a sepsis.

These are simple conceptions, but they illustrate a condition which, after all, is simple enough; again we come back to our point and say that the one thing left and needful for the repair of this man's wound is immobilization.

Perfect immobilization, in the surgical sense, is far from being the simple thing one might suppose. It is not readily attained; and it cannot be attained without giving careful thought to the anatomy of the parts. Take the instance of the man's wounded hand. What are the important structures which go to make up the anatomy of the palm and adjacent parts? Obviously, they are the skin and fascia, the underlying tendons and muscles, and the bones. We cannot keep the wound in a state of surgical rest unless we immobilize the adjacent structures, and that means that we must tie up the muscles of the part. Those muscles are the extensors and flexors of the hand, and their origin is about the condyles of the humerus and in the forearm, a fact elementary and obvious enough, but surprisingly often overlooked. So we must bandage carefully and restrain the movements of the forearm. Observe now a point which we must emphasize repeatedly. Never apply for immobilization a bandage close to the skin or over a thin intervening pad. Learn always to use *elastic compression*. We cover the patient's hand and forearm with six or eight layers of sheet-wadding

—an elastic, very slightly absorbent material, which will not become caked and matted with perspiration. Between alternate layers of the wadding place four strips of moistened mill board—two laid straight down the arm and two twisted spirally about it. These harden as they dry, and lend an added stiffness and elasticity to the dressing. So far the application looks cumbersome and unwieldy, but with this cotton roller we now carefully and snugly bind the whole into place. Pull the bandage tight, greatly diminishing the bulk of the dressing, so that when completed it appears to be of moderate proportions. If you handle the completed dressing you find that it is quite elastic to the touch, and that it exerts everywhere a perfectly equable compression. It controls absolutely the muscles; no movement can go on underneath it, yet it is extremely comfortable. It is tight, but it does not constrict. By its firm contact everywhere with the underlying parts it moderates and controls the circulation, but it does not occlude it. Here we have illustrated on a large scale the principles of compression which one applies when he seizes and compresses gently and brings comfort to his sore thumb, which throbs and aches with the beginning of a "run-round." Thus one sees employed the four remedies which one must learn to apply in the dressing of all wounds: *asepsis, elevation, immobilization,* and *compression,* and the last three imply *support*—remedies which may be modified in degree often to suit special conditions—perhaps they are employed with overscrupulous care in this particular case; but they are always important, always to be borne carefully in mind; to become as much a part of one's instinct and training as that antiseptic conscience of which we have heard tell.

Consider next two cases which illustrate the results of proper and improper treatment. A lad received a ragged, four-inch wound of the wrist from falling on a broken bottle some ten days ago. The skin cut one sees, but more than that, the superficialis volæ artery and one tendon of the flexor sublimis digitorum were severed. When brought to the hospital, about three hours after the accident, the boy's arm was found tied up tightly with a knotted handkerchief,—as a tourniquet,—the wound gaping and ugly looking, where cobwebs—a favorite domestic remedy—had been smeared over it, blood still oozing from the artery, and the whole hand livid, swollen, and painful.

The patient was laid on the operating table, the handkerchief removed, the arm elevated in the air and supported by an assistant for about five minutes, when the bleeding was found to have ceased, the swelling to have subsided, and the hand to be normal looking and painless. Then the whole arm and hand were cleaned and disinfected—washed, scrubbed, and soaked, not dabbed at and mopped over with a futile corrosive sponge.

The two ends of the cut vessel were secured and tied with catgut, the severed tendon was united by fine silk stitches, the skin-edges carefully and accurately approximated with four silver wire points,—which I prefer in the case of these ragged cuts of the wrist,—and the hand and arm put up in the manner demonstrated in the case of the tin-

smith. In this case, of course, the wrist was secured in a position of slight flexion to relieve tension on the severed tendon. After the first dressing the patient felt perfectly comfortable; his temperature was normal and his bodily functions undisturbed. Twice during this time an additional tight bandage was applied over the dressing, which had become somewhat loosened.

The apparatus being removed, we observe the entire limb to be pale and shrunken. That is as it should be. The hand looks thin and normal; the fingers are flexible; the wound is a simple red line—not puffy, not tender, not painful. The old cocoon dressing shows a little dry, blood-stained exudate. One removes carefully the silver stitches which have admirably supported the irregular skin-edges, and the wound is found practically healed. Of course, there is more to the case. That tendon wound will be slow in healing, and the hand must be protected and supported for some weeks on that account, but so far as our simple incised wound is concerned, it need trouble us no more. The dressing was *dry* and it was *infrequently* renewed. Napoleon's famous surgeon, Baron Larrey, was the great exponent of that method a hundred years ago. Read what he says in his delightful "Memoirs" on the subject of infrequent dressings.

Turn your attention to a man whose story is not so happy. He is a postman. Five days before we saw him he received a cut on the back of the left forearm, being struck by a piece of falling window-glass. The cut was about six inches long. Only the skin, thick fascia, and some fibers of the muscles of the extensor group were cut. There was little bleeding. The wound was cleaned and covered in with the greatest care, but a supporting bandage and sling were omitted, at the man's request, as he said they would interfere with him and that he would be careful not to use his arm.

On the sixth day he reports for the first time after five days of active running about, swinging the arm at his side. We see the state of his wound and compare it with that of the lad with the severed tendon. In the postman's arm is a distinctly reddened area, extending for an inch all about the cut, the edges of which are infected and slightly swollen. We remove one stitch and find it is followed by a drop of pus. The man says that the wound has ached for the past two days, and that he has felt "feverish" and uncomfortable. His temperature is 99.4° F. The arm has not the shrunken, cool, almost anemic look that we saw in the last case, but is distinctly warm and full. Fortunately, no great damage has been done as yet. By appropriate treatment the initial sepsis may be checked, but the man has delayed his convalescence by several days, and we have a series of troublesome dressings to occupy us.

So much for the three cases of simple incised wounds. They have been striking types and have told their own story, yet one must qualify that story in a few words.

All incised wounds carefully cleaned and put up with compression and elevation do not heal promptly, nor do all the wounds, lacking that

support, become septic. If there is any one thing true of surgical therapeutics, it is that there is in it no place for dogma. Beware of the surgeon or physician who says, thus and thus shall it be done and not otherwise. Such precepts make of surgery an exact science, which it is not, and the men who presume to apply to it iron-clad rules have to change their dogma from year to year.

But there are broad general principles which the student will find safer than dogma. Two of those broad principles we have studied—*asepsis*, rigid asepsis, must be the sheet-anchor in all surgical work; physiologic *support*, immobilization, compression, next after asepsis, are essential for the safe and prompt healing of the great majority of wounds.

SIMPLE OR CLOSED FRACTURES

Percival Pott fell down in a London street and broke his leg a hundred and forty years ago. He got well and wrote about it, and since then surgeons have known more about fractures than they knew before. Pott's famous fracture marks an era in our annals. From that time to the present our knowledge of fractures has been growing more definite, until to-day, with *x*-ray plates for aid in diagnosis, there is small excuse for any surgeon's going far astray. Yet men, even the expert, do go astray. Probably there is no class of cases presented to us which is so easy of misapprehension, and in which the results of misapplied treatment are so deplorable. We shall not now consider fractures in detail, but glance at two or three simple cases and note the methods of handling them, of making the diagnosis, and applying a suitable treatment. We shall regard closed fractures only, or, as they are more commonly called, simple fractures.

The analogy between lesions of the soft parts and of bones is a close one. The processes of repair are not dissimilar, and the rules of treatment do not diverge greatly. But our analogy is incomplete in one important particular. In the case of severed soft parts union will take place though the apposition be imperfect, and though the united structures themselves be dissimilar—with a delayed result, to be sure, and with more or less impairment of function: there we have nature, unaided, working out her faulty solution of the problem. But in the case of a broken bone, our *art* must be carefully and constantly applied if the injured member is to be restored to any sort of usefulness.

For example, take the case of a boy, sixteen years old, who, while running, fell against a curbstone and injured his forearm. We see him supporting the damaged limb with his hand and complaining bitterly of pain half-way between the elbow and the wrist. Let us proceed with our examination carefully and painlessly to him, so far as we can.

In the first place, the patient's clothes are stripped off to the waist, thus allowing of easy inspection—an important point. In removing the various garments, slip off the coat-sleeve from the sound side first; then the injured arm can be uncovered without undue straining. Cut the shirt down the front and slip it off as you would a coat.

Allow both his arms to hang down, and observe any differences in them. We see that the affected arm hangs limp and motionless; the boy cannot raise it. It appears slightly swollen, and one may detect a slight backward bowing. So much for inspection.

Then compare the two arms by measurement. Observe that on the sound side the distance from the tip of the olecranon to the ulnar styloid is ten inches. On the affected side it is nine and one-quarter inches. Obviously, there is a shortening of the bones; that means fracture. Is it a fracture of one or both bones? Of both certainly; for if the ulna alone were broken, the radius would act as a splint and maintain the length of the arm with little if any shortening. So we have concluded that we are dealing with a fracture of both bones of the forearm, and so far we have caused not the slightest pain. It remains to locate the exact seat of the fracture. Now it may be necessary to hurt the patient somewhat, but if we proceed cautiously, he will bear it well. It is best to employ an assistant—two assistants are even better. The patient sits with his arm extended upon a table. One assistant supports the elbow firmly, the other holds steadily the lower part of the forearm, making gentle traction; for there are spasm and contraction of the bruised muscles. The examiner now runs his hand gently up and down the arm and comes at once upon an area of thickening, about five inches above the wrist. That area is the seat of fracture. Grasping the arm firmly above and below the injury, while the assistant continues to make traction, the surgeon molds the bones into position, reducing the overriding where the distal fragments have slipped over and behind the proximal. While so molding, the operator experiences that sensation of grating or "crepitus" of which we hear so much. While we keep up the traction observe that the arm has been brought back to the same measurement as its fellow. If the spasm had been very strong and reduction of the fracture impossible without causing great pain, we should have given the patient an anesthetic.

We come now to the difficult question of the **support** and **immobilization** of fractures. As John Hunter said, "The first and great requisite for the restoration of injured parts is rest." Shall we employ our cotton rollers and mill-board strips with elastic compression? That certainly would give rest to the parts, and it has at times been used with success in these cases. If this were the fracture of but one bone, we should use that dressing. As a rule, however, its very elasticity renders it unsafe when we need extension or traction to keep the bones from overriding again. There are innumerable splint materials, from plain strips of wood to molded gutta-percha, wood fiber, felting, and plaster-of-Paris. The first of these, known among us as "splint wood," and the plaster-of-Paris are convenient and are in common use. I shall use splint wood in this case, as the arm will probably swell, and splints of splint wood can be removed easily and readjusted.

There remain two other important points to consider before we apply the dressing. We can lay it down as a safe general rule in dealing with all fractures of the long bones that the adjacent joints at either

extremity must be immobilized, otherwise the play of the muscles will not be held in check, and with the movements of the joints there will be a constant displacement of fragments. Moreover, without immobilizing the joints the required extension cannot be maintained. In this case we must fix the elbow and the wrist.

The second point is that with fractures of both bones of the forearm and the possible large resulting calluses which sometimes form, the position must be such as to keep the shaft of the radius as far as possible from that of the ulna, else all four wounded bone surfaces might become united in a common callus, and future rotation be impossible. In supination, with the palm turned upward, the shafts are well apart; in semipronation they are somewhat further apart; in extreme pronation they are thrown close together, and if there be extensive laceration of soft parts, it is possible even for the distal fragment of the radius to become united with the proximal fragment of the ulna.

Applying Splints.—In the present case we have the arm held firmly in semipronation and proceed to apply the splints—a simple matter now.

The splints of light, thin wood should be a quarter of an inch wider than the forearm. The posterior splint extends from three inches above the fracture to the metacarpophalangeal joints; the anterior splint from the same point of the forearm to the middle of the palm, and a large crescentic groove is cut out of its side to avoid pressure on the thenar eminence. The splints are carefully padded with six sheets of wadding, with extra small pads on the anterior splint to conform to the contour of the wrist. Then an "internal angular" splint of molded tin is similarly prepared to support the elbow.

While the arm is held steadily by an assistant, who stands on the patient's outer side, the surgeon applies these splints and fastens them firmly but not tightly in place by four-inch adhesive straps passed round one and a half times. There are three straps—one about the proximal end of the splints, one about the wrist, and one about the palm, embracing the posterior splint only. This last strap is very important, as by its firm pull on the posterior splint it keeps up traction. Then the elbow splint is applied with three straps—one at each end and one just below the bend of the elbow. The whole we cover with a cotton roller, snugly put on. That is a fairly comfortable dressing, but one must still be on the lookout for trouble. Keep the patient in sight for half an hour, and see that there is no return of pain before he leaves the hospital. Increase of pain, throbbing pain, especially if the fingers become swollen or blue, means that splints are too tight. One must remove and reapply them. Then we must support the arm in a comfortable sling before sending the patient out. If he goes from the hospital in pain, we may be certain that he will suffer greatly before morning, and the frequent swelling of the arm, against the immovable splints, may give rise to ugly skin sloughs.

As for the **after-treatment**—that is not always easy; it calls often for the best judgment and, when neglected, may lead to serious

deformity. Moreover, forearm fractures not uncommonly result in non-union, and against that we must guard.

One advantage of the use of open splints is that they are easily removed for inspection of the wound. We shall ask the boy to return daily for three days. If we find the arm painless and the swelling not conspicuous, we shall have him wait until a week from the accident has elapsed before changing the splints.

Another patient has a similar fracture *ten* days old. We see that on removing the bandage the position of the bones appears good, the swelling has subsided, and the plaster straps are a little loose. The splints are taken off, when a slight callus is felt over the seat of the fracture. The skin is shrunken and pale, and the elbow and wrist are moved with some pain and difficulty. Here is an opportunity, if we wish to help the union and hasten convalescence, to do a piece of work usually neglected, but work for which the patient will bless us. We shall call in a competent masseur, and have him manipulate the elbow, the wrist, and the tissues about the fracture for half an hour every day. The arm must be securely held on a firm cushion or on the padded table while the masseur is at work. He kneads the muscles about the joints, he loosens slight adhesions, he restores the stagnant lymphatic circulation, he stimulates the circulation of the whole arm, and by thus improving the nutrition of the parts, he hastens the union of the broken bones. I have employed massage for years in such fracture cases as have come under my care, and am constantly impressed with its advantages—in the hastening of repair, in the early restoration of function, perhaps, best of all, in the sense of well-being given at the time, and in the feeling of security and confidence so soon as the patient reaches the stage at which active movements begin to succeed these passive ones. Under the old-fashioned treatment the arm was like a prisoner confined for weeks in a dark, narrow cell, to emerge at the last, pale, timid, spiritless, broken down—who must wait weeks yet before his proper vigor returns to him. With massage you let in air and light upon your captive; his windows are thrown open daily, and he is taken for a brisk walk, as it were, about the prison yard. At the end of his confinement he returns to the former life with his force but little abated and his zest sharpened for the work of the world.

LACERATED WOUNDS

Let us study a case, that of a teamster, forty years old, sound and vigorous. Twelve hours before our inspection, while unloading his wagon, he let fall a heavy iron bar, the end of which struck his calf and inflicted a ragged triangular wound. Some six inches of skin were torn up, the muscles lacerated, and the head of the fibula exposed. The bleeding was inconsiderable. At the time, he wrapped an old handkerchief about the leg, passed a painful night, and entered the hospital in the morning.

Fifty years ago, in the days of the Civil War, such an injury

might eventually have led to amputation; even now it is not without its dangers. Septic material has undoubtedly been carried deeply into the leg. The iron bar itself was unclean, and the man's well-worn, sweat-soaked working trousers were far from aseptic, while the skin of the leg itself is loaded with organisms.

Two courses are open to us in such cases—to clean up the leg and the wound, apply wet antiseptic dressings, and look for a slow healing by granulation, or to bring the severed skin and soft parts back into place and try to obtain a prompt healing by primary union.

We adopted the latter course, and through the application of our two great surgical principles—asepsis and physiologic rest—we looked for a good result. That pleasant old Frenchman, Le Dran, in 1735, used to tell his classes that in such cases as this he always tried for a primary union, because if that failed through *catching cold* in the wound, he could take out his stitches and expect a second intention. I suppose that phrase "catching cold" is as old as Hippocrates.

Of course, Le Dran's reasoning still holds good, though to us now such a method seems a half-hearted way to approach a surgical problem.

In the case of the teamster we begin our proceedings by etherizing the patient. It is cruel as well as stupid to attempt a painful and extensive dressing without an anesthetic. The leg is shaved and thoroughly scrubbed, then the wound is mopped out with dioxid of hydrogen, followed by bichlorid alcohol 1 : 3000. Bits of torn clothing and dirt are picked out first. If we look carefully, we see that the fragments of torn muscle are viable; they bleed easily and can be reunited. The *sewing of them properly* is important for two reasons—because if left loosely flapping, no good muscle union will result and the leg will by so much be weakened, and because the drawing of them together fills up the cavity between and prevents the collection of blood where it would serve as a culture-medium in that "dead space." Let me quote Le Dran, who said that in a deep wound in which the muscles are divided obliquely the deep stitches should be passed so as to run parallel with the muscle-fibers, and not obliquely, as would be natural in sewing up an incised wound.

Having closed in the deep parts, we lead into the bottom of the wound a single strip of absorbent tape or wick, placing it gently and loosely, that it may act as a drain and not as a cork. The skin is now drawn over the restored muscle, and stitched into place with a half-dozen silver or silkworm-gut stitches. The leg is again washed with bichlorid alcohol and elevated in the air, thoroughly to drain the veins and promote freer circulation. Asepsis is complete; then comes the second step—support and immobilization.

In this case we bind the muscles from the toes to the middle of the thigh;—first, covering the wound with a handful of loose absorbent gauze, to act as a drain and reservoir for the inevitable discharges, then firmly and snugly applying our mill-board and wadding rollers. One sees how securely they hold the leg and how the knee and ankle both are immobilized without discomfort.

We cannot put the leg in an ordinary sling as we did the arm, but we can keep it elevated, and so add greatly to the patient's comfort. Of course, this man lies in bed for a few days. We swing a gauze hammock from a rod which is stretched from the headboard to the foot of his bed. In this hammock the whole leg rests, from foot to hip. That is a most satisfactory, comforting device. It gives us our required support and elevation, and as it swings, it allows the patient to shift himself about and even turn in bed without disturbing the wounded leg; for as the body moves, the hammock swings, but the leg remains relatively at rest.

On the second day the wick is removed under the strictest aseptic precautions; the leg is bound up again, and at the end of a week we show it soundly healed.

Ambroise Paré wrote to his *petit maistre* in 1580: ' M. le Prince de la Roche-sur-Yon, who dearly loved the king of Navarre, drew me aside and asked if the wound were mortal. I told him Yes, because all *wounds of great joints*, and especially contused wounds, were mortal"; and in the sequel the King of Navarre died.

Fifteen years ago a friend of mine, while leading a landing party on the coast of Cuba, was shot through the elbow by a Mauser rifle. The wound was properly dressed and supported, and in the course of a month the use of the arm was restored perfectly.

A patient who illustrates our subject—*wounds of joints*—is an Italian recently in a street row. He came out of it with an ugly, ragged cut, which nearly severed the insertion of the triceps tendon and laid open freely the elbow-joint from behind. As we hold the edges of the wound apart, we see the articulating surface of the olecranon and a bit of the internal condyle. Let us attempt to save the arm with a useful joint.

The man is etherized, the arm carefully disinfected, and while an assistant holds the wound open, we wipe out the joint with little gauze sponges dipped in bichlorid alcohol, and then douche it thoroughly with sterilized water, taking pains all the time not to bruise or otherwise injure the serosa, lest we set up an adhesive inflammation which might lead to ankylosis.

Next, with fine catgut stitches, we sew up the rent in the capsule and unite accurately the severed ends of the triceps muscle. In sewing up the capsule take special pains to evert the edges, that no rough surface be turned into the joint to cause mechanical irritation. Then the skin-wound is brought together, and covered in with gauze pads. In the final binding of this arm we have to meet a problem which differs from most of those encountered in the upper extremity. We cannot flex the elbow and support it in a sling, for by so doing we should run the risk of tearing the freshly sewn triceps. So the arm is put up in extreme extension, with our mill-board strips to preserve fixation, and plenty of cotton rollers to give elasticity and comfortable, even compression.

This man is not allowed to go out with his arm swinging at his side. The wound is a serious one, and demands great care for a few days.

He is put to bed and the arm kept at an angle of 45 degrees, either on pillows or, as I prefer, in our gauze hammock.

Not long ago I was asked by a physician in a neighboring town to see a patient, with a view to an amputation. The man was suffering from a wound somewhat similar to this last one, but in the knee-joint.

He had received his injury ten days previously. Not realizing its gravity, he had neglected to call a physician, contenting himself with lying in bed and keeping the knee wet with applications of "listerine." My friend had seen him only a few hours before my visit. I found the patient to be a middle-aged, sturdy sea-captain. He was lying in bed and was evidently in pain. There was a punctured wound on the outer side of his right knee-joint. The edges were gray and sloughy looking, and a thin pus could be pressed out through the opening. A culture from this discharge showed later a staphylococcus infection. The whole knee was red, boggy, tender, and swollen, the dimples on either side of the patella being obliterated, and the synovial pouch distended three fingers' breadths above the patella. The man's temperature that morning was 100° F., and his pulse 110; his face was flushed, appetite *nil*, and the picture that of a very sick man. There was present a leukocytosis of 26,000.

I agreed with my consultant that an amputation must be considered, but advised making an attempt first to save the leg. The patient was etherized, the leg cleaned up, and the wound enlarged so as to admit of thorough exploration of the joint. The serosa was seen to be deeply injected, and several ounces of pus were evacuated, but the integrity of the joint apparently was not yet affected. The whole interior surface was carefully and laboriously mopped with dioxid of hydrogen and douched with sterilized water. Counteropenings on the inner side of the patella and in the popliteal space were made for drainage and tapes were inserted in all the wounds. Then a large absorbent pad was placed about the knee, the leg thoroughly wrapped and supported after our familiar fashion—the dressing extending from the toes to the groin. The leg was slung in a hammock, ¼ grain of morphin hypodermically was administered, and the patient was left with careful directions that his bowels be kept open by salines and his strength supported by frequent liquid nourishment and a drink of Scotch whisky three times a day.

Of course, in this case we did not look for the restoration of a sound, flexible knee-joint. The best outcome to be expected was the saving of the leg with a stiff knee. I did not hear of that man again for seven days, when my friend again asked me to see him and to do the dressing. The picture he presented was most refreshing. Except for pallor and feebleness, all evidence of sickness had left the patient and he received me with the comfortable assurance that he was well. During the week the wicks had been changed three times by his attendant, and I removed them for good and all. On taking off the dressing I found the leg pale and the skin shriveled in appearance, with the familiar contour of the joint restored. There was slight though rather painful motion,

which I did not encourage. The two wounds were granulating well. Eventually the patient recovered with joint motion of 20 degrees.

This was a gratifying result. I attribute it to the man's remarkably good general condition, supplemented by the strict enforcement of our cardinal rules—asepsis and support.

Let us return for one moment to that other man—the tinsmith, whose cut hand we sewed up.

It was not seen for ten days, though he reported to assure us of his comfort and the absence of pain. Freed of its dressings, the wound is found to have healed *per primam*, as was to be expected. We confine the hand in a light bandage for five or six days longer and then send the man back to his work.

All these are good results only, but one must not conclude from them that surgeons are wizards. Bad results—unavoidably bad results—come often enough, and we see a plenty. For the present, we are illustrating the constant saying of Ambroise Paré, "I dressed him, and God healed him."

COMPOUND (OPEN) FRACTURES

In connection with the subject of lacerated wounds we must consider compound fractures. They are no more than special varieties of lacerated wounds.

These fractures were regarded with extreme alarm in the old days, and are still not to be treated cavalierly. Chelius, of Heidelberg, wrote in 1821 that "the inflammation is always very great and requires strict antiphlogistic treatment, blood-letting, leeches, cold applications, and opium," and that mortification and delirium tremens may occur especially in old people. "If sleep do not take place, death is the consequence. On dissection frequently there is exudation on the arachnoid, pus in the joints and in the sheaths of the tendons." All of which, of course, results from the fact that we have to deal with a lacerated and easily infected wound, which involves a structure of low vitality.

Our effort, therefore, must always be to substitute a closed fracture for an open one, and then to treat the damaged bone on the ordinary principles. Here again we come back to that matter of rigid asepsis and immobilization, the latter being of great importance, for broken bones which are not held strictly at rest keep up an irritation of the wounded soft parts, delay healing, favor the continued outpouring of a serohemorrhagic exudate, and so provide a medium for the development of micro-organisms.

The young woman whose case we consider first was jostled against a moving cart, and her arm, thrust between the spokes of the wheel, was severely mangled. On being brought to the hospital shortly afterward, it was found that both bones of the forearm were broken in the middle third and that the two upper fragments were protruding through a hole in the skin on the dorsum. The house surgeon who dressed the case very properly was not content with mere reduction of the fracture, but with pains and elaboration restored the continuity of all the severed

parts. The wound was enlarged by free incisions, all bleeding completely checked, the bone fragments placed in apposition, the wound thoroughly douched with antiseptics, torn muscles and fascia sutured, the skin wound closed, and the arm carefully dressed and secured in wooden splints.

This free opening and cleaning up of compound fractures is especially important when the forearm is involved, for in it non-union frequently occurs, owing to the interposition of muscle fragments or tendons between the ends of the bones.

In the present case the arm was bound firmly to the side to insure perfect rest. After recovering from ether the young woman experienced little pain; the next morning her temperature was 99° F. It never rose higher, and we presumed fairly that the superficial wound had healed satisfactorily after six days. On removing the dressings we found our presumption to be justified. The skin wound was soundly healed; there was no swelling or redness, and we were left to treat the case as a simple fracture.

Another case was a much more difficult one, illustrating a point which I have made before. The man, a brakeman, was forty years old. Four months previously he had his left humerus broken by being crushed between two freight cars. The fracture was a compound one, but the external opening healed readily, and under a properly applied plaster-of-Paris dressing union of the bone was going on well, as we supposed. After a month, however, non-union was apparent, and after two months the condition had not improved. A careful investigation of the man's past history then revealed the fact that some five years before this he had a venereal sore, followed by an inguinal adenitis and a skin eruption, for which he submitted to about six months only of treatment. He was now put on mercurials and iodids for a presumable syphilis, with the result that after another month fair union was established, so that we find his left arm as sound as its fellow. That question of an old syphilitic infection is never to be lost sight of in these cases of delayed union. The other more frequent general diseases which may complicate recovery are tuberculosis, diabetes, malaria, and that indefinite thing which we call rheumatism.

Our third case was a more serious affair than either of the two preceding, but is interesting because it shows how bad may be the results which sometimes follow the careful conservative surgery even of to-day.

The subject is a man of sixty who has all the appearance of having led a laborious life. He has an obvious arteriosclerosis, though a thorough examination of the chest and kidneys elicits nothing abnormal. As old John Abernethy remarked on opening his surgical lectures a hundred years ago: "Now I say that local disease, injury, or irritation may affect the whole system; conversely, that disturbance of the whole system may affect any part." That ancient fact is the crux on which this case turns.

The man is a weaver. About six weeks before I saw him his left hand was caught in his machine and severely torn at the wrist. The

radius was fractured, the ulna dislocated, the wrist-joint opened, the skin and other soft parts over the dorsum severely mangled, and he was brought to the Massachusetts General Hospital with the hand hanging off, attached only by the skin and tendons of the front of the wrist. There again was the question of completing the amputation which the machine had begun, or of attempting to save the hand. I determined on the latter seemingly hopeless undertaking.

After the usual careful preparation, two loose fragments of the radius were removed, including the articulating surface, and the protruding end of the ulna was cut off, in order to convert the injury from a compound fracture and dislocation into a compound fracture which would be more likely to heal than would the contused and lacerated joint. As a result of this removal of the ends of the forearm bones, we produced a partial resection of the joint, which would mean for him at best a hand with considerable impairment of motion. Then the torn tendons were secured, trimmed up, and united, tape drainage was inserted, the skin wound sewn with silver wire, and the arm put up in the mill-board apparatus. The patient was put to bed and the limb slung in a hammock.

The case went as badly as it could well have done. That night the patient's temperature was 100° F. and his pulse 100. The next morning the temperature and pulse were 101° and 90 respectively. The dressing was taken down, the skin stitches removed, and the wound cleaned up, but that night the temperature had reached 103° and the pulse 120. The next day, two days from the accident, the patient's condition was alarming. With temperature at 102° and pulse 112, he had every appearance of being thoroughly septic, as it is called. Evidently the wound was an active streptococcus factory, pouring pyogenic organisms and their products into the general circulation. The patient's arm showed a striking picture—such a picture, fortunately, as we seldom see in these days. The wound was sloughy looking, and exuded a thin, sanious pus. The whole forearm and hand were swollen, tense, red, and shiny. The skin of the back of the hand was blue and necrotic looking, and it was evident that we had to deal with the inception of an acute gangrene.

Not least significant was the patient's general appearance. He was hectic, anxious, and restless, with that almost indefinable septic look, with saffron skin and injected conjunctivæ, which experience teaches us to associate with these alarming cases.

Of course, there was but one thing to do. The rotting arm was killing the man, and it must be taken off. I amputated it about 3 inches above the limits of the old wound, left the flaps wide open for the sake of more complete drainage, and had the satisfaction, the next day, to find him established on the road to convalescence. The further story is uneventful.

One will scarcely find a case to illustrate better the extreme danger of some of these compound fractures, and the bearing which the patient's state of general health may have on the local lesion. Here the man's

premature old age, and the general impoverishment of his system, consequent upon an inefficient circulation, were the underlying and salient features. He could put up no fight against the overwhelming bacterial invasion, and so capitulated only in time to save his life.

In a city the place to see compound fractures is at a general hospital. —you will rarely see these cases in private practice. Such injuries occur mostly among handicraftsmen, day laborers, and those persons engaged in extra-hazardous vocations, such as railway trainmen, linemen, roofers, firemen, and the like; and these men, when injured, are commonly taken at once to a hospital. So, too, with any person in any walk of life who may be injured in a street accident—he is immediately hurried to the hospital by the zealous bystanders or police. It is fortunate that this is so, for in a hospital is found the fullest equipment to meet these emergencies, and a competent surgeon is always on hand.

The commonest and perhaps the most important of these compound fractures are mangled and lacerated hands. We see them daily. Let us study a man suffering from such an injury. I say that these accidents to the hand are most important because serious crippling or loss of the hand means a loss of livelihood to the victim, and to the surgeon each of these cases presents a fresh problem of great interest. Every half-inch of finger saved and every joint restored is of importance. Most of all the thumb, that distinctive mark of a higher evolution, is to be preserved if possible. The thumb without the fingers may still adorn a stump capable of grasping a tool and doing work, but a hand deprived of the thumb is a futile member.

The present patient is a machinist, whose right hand was caught between cog-wheels. We take off the bloody wrappings and find all four fingers mangled, but the thumb uninjured. A flap of skin over the dorsum, with its pedicle toward the wrist, was torn up, disclosing the second and third metacarpal bones, which were fractured. The whole of the forefinger was mashed, the joints opened, and the distal phalanx wanting. There was no prospect of saving that forefinger, but the other fingers, though lacerated, might be saved. Such a hand means a study in reconstruction, and perhaps two hours of painstaking work at patching and mending. Ether and asepsis are our first steps; all bleeding is checked, every torn tendon is stitched and replaced, bits of destroyed tissue are trimmed away, hopelessly comminuted bone fragments are removed, each finger is treated as a separate problem and given its appropriate dressing, skin-flaps are drawn up to cover exposed stumps, and the forefinger is amputated at the middle of the first phalanx. When all this is accomplished satisfactorily, the hand is spread out upon a well-padded splint, with dry gauzes about and between the fingers, and the limb to the elbow is put up in an abundant elastic-compression dressing. It is important, in such a case, as in the case of the man with a cut palm, that the muscles of the forearm and hand be immobilized absolutely. We must have no dragging on those freshly united tendons and delicate, new-forming tissues.

Then the arm is supported carefully in a sling or held high on the chest in a Velpeau bandage. If all goes well, the patient may expect the use of his hand by the end of two months, but we can give him no such positive assurance. Skin-flaps may lose their vitality; bones may suffer from osteomyelitis and become necrotic; tendons may slough; sinuses leading to deep-seated inflammations may persist for weeks, and many and various minor, secondary operations may be necessary before we are through with the case. But the great preliminary care is worth the patient's while and ours. With such care we can promise him a useful hand; without it he would have to expect a crippled, helpless claw.

In connection with this subject of lacerated hands I must warn the reader that he will find the treatment of *lacerated feet* a still more difficult matter. It is not because there is anything peculiar in the structure of the feet, but because, owing to their dependent position, their circulation is not so good as is that of the hands, except in the case of the young and vigorous.

Take two similar cases—a man with a jammed thumb and a man with a jammed toe. One may dress up the former and send him home, to find, in the course of a couple of weeks, that he is quite well. One may dress the man with the jammed toe and send him off about his business, and what does one find? By the end of two weeks, in spite of careful oversight, the toe is far from healed: it is red, tender, and slightly septic; the whole foot is swollen and tender, and very likely there is a bit of necrotic phalanx to be felt. This untoward result is due to no lack of aseptic precautions, but to the fact that we have failed to observe our second cardinal principle—support. One cannot safely send these patients out to knock about the streets. Either they must be put to bed with the leg elevated—the best thing by far—or they must be instructed to bear no weight on the foot and to keep it up on a chair or sofa except when necessarily in use. The point sounds like a small one, but it is salient.

So much for compound fractures—perhaps the most important division of traumatic surgery. We have but skirted the border of a great subject, but sufficiently near, I trust, to show that here, as in the lesser lesions considered, the same broad, inevitable principles constantly must be applied.

GRANULATING WOUNDS AND VARICOSE ULCERS

There exists in the minds of students, and often of practitioners as well, a confusion regarding ulcers and granulating wounds. It is a natural confusion, for the two conditions overlap and run into each other. An ulcer may be described as a superficial solution in continuity, which shows *no tendency* to heal; a granulating wound, as a solution in continuity, which shows a *tendency* to heal. Of course, such a definition is a general one, but it will answer our present purposes.

Ordinarily, there is no question when we are dealing with a granu-

lating wound. We see the red, velvety granulations shrinking in area steadily, with little projections of new skin shooting in, and the process of repair so constant and inevitable that one may appreciate the changes from day to day.

In regard to such a healthy granulating wound there are two questions which the student is always asking, and about which he seems to feel that he gets very little light. With what applications shall it be treated, and how often shall the dressing be changed?

Ordinarily, the answer to that first question is a very simple one when the wound is in a healthy individual. I have shown, for instance, a woman, whose breast was removed for sarcoma some three weeks before. The skin-flaps were not drawn tightly together at one point, with the result that she had on the front of the chest a superficial open wound about the size of a silver dollar. It was clean, flat, bright crimson, and did not bleed easily. It will heal over in a few days, no matter how treated, provided only and this is important—provided it be kept clean. One can wash it with corrosive alcohol or creolin, put on a gauze cocoon, and leave it for three or four days. The raw area shrinks from day to day. Such wounds as this require no special care.

On the other hand, take the case of a granulating wound on the back of the neck in a patient fifty years old who has 2 per cent. of sugar in his urine, for which he is under treatment. Two weeks previously he showed on the back of his neck a carbuncle the size of an English walnut. We excised cleanly the carbuncle, and so stopped the process. There was no return of the active local infection, but the wound did not heal. The raw surface, as large as the top of an egg-cup, remained without healing, the granulations dark purple, soft, spongy, bleeding easily when handled, and overlapping in fringes about the edges. That overlapping we call *exuberant granulations;* it is a perfectly harmless condition, and is easily remedied. It is the condition known to the laity as "proud flesh," and is always referred to with horror by them —just why is not clear.

There are various methods of treating such granulations, but all methods come down to this, that the granulations must be trimmed down and the wound stimulated into proper activity, so that it shall have the vigorous healthy appearance which we saw in the case of the woman. With the scissors cut off these redundancies,—they are absolutely insensitive,—and after checking the oozing by sponge pressure, wipe over the whole wound with the stick of silver nitrate. Then apply a dry gauze dressing. Every other day the man returns, and we soon see the wound closing in. Another excellent method of treating such a wound, after trimming the granulations, is to dust it thickly with some simple drying powder, such as dermatol or aristol. But after all, what one must bear in mind is that the wound is to be kept clean and the granulations frequently trimmed down. Our familiar supporting bandage must never be omitted, for the pressure it exercises helps the circulation in the parts.

A third type of granulating wound is seen in a boy who received a severe kick on the shin about a month before I showed him to my class. The periosteum and bone were not injured, but he showed a superficial wound, long and narrow, as though one had torn up the skin for a distance of 5 inches with the finger-nail. One week later this long, narrow wound, in the apparently healthy lad, began to be lined with small, flat, dull, red granulations, and thus it had remained. It refused to heal. It had been scarified, cureted, and wiped frequently with the caustic, but without avail. We had the lad get out into the country to see what out-of-doors life would do for him. Meantime I dressed the wound daily with a stimulating lotion on gauze and bandaged the leg from toes to mid-thigh.

In such cases we find diluted tincture of myrrh, 1 part in 20 of water, or pure balsam of copaiba, to be excellent. I have always been pleased,

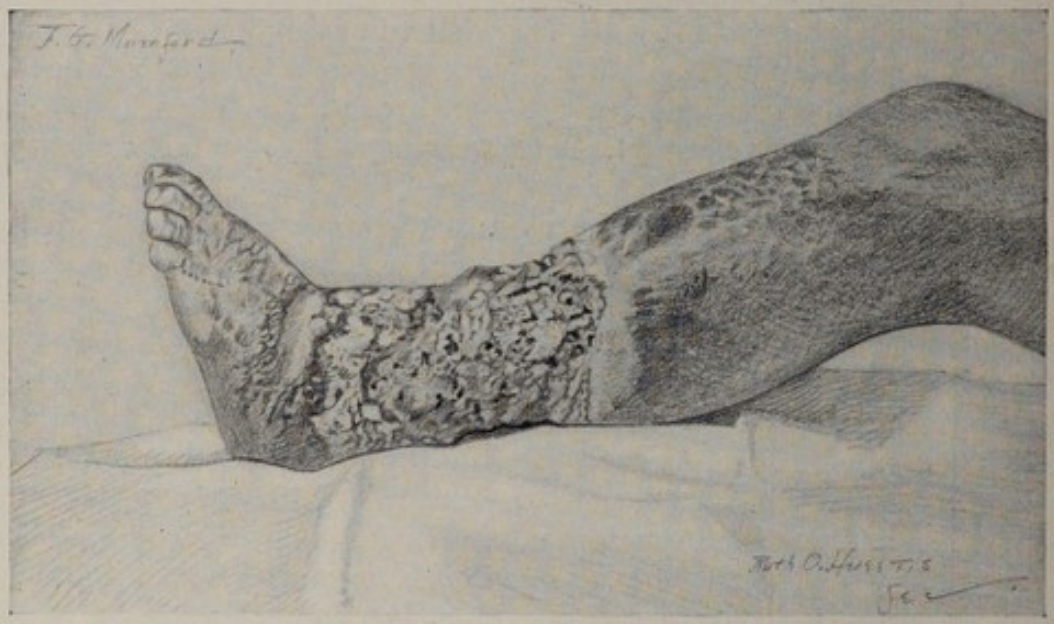

Fig. 460.—Incircling ulcer of the leg (Massachusetts General Hospital).

too, with the action of Gamgee's favorite application: Borax, 1 part; compound tincture of lavendar, 8 parts; glycerin, 4 parts; water, 24 parts.

Such, briefly, are some of the methods of treating these open wounds. We find in the books and are told by physicians of innumerable other lotions, ointments, and applications. Many of them doubtless are useful—certainly most of them are harmless; but, after all, what we must remember is to keep the wound clean and to give nature a chance.

Now let us regard another class of cases—**varicose ulcers,** allied to granulating wounds, cases which are a weariness often to students and dressers, for long-standing ulcers become an opprobrium to the clinic. Yet they should not be so. These ulcers are grievous afflictions to their victims; they belong to an interesting class of pathologic processes, and they heal under proper treatment.

For hundreds of years surgeons have talked and written about

varicose ulcers, and the opinions of the best surgeons regarding their nature and treatment have always been correct, yet even to-day one sometimes sees the cases drag on an interminable course, submitted to a treatment which is amazing and discouraging.

One may usually tell a varicose ulcer at a glance. It is on the shin, below the middle of the leg; above and about it are enlarged superficial veins, and commonly the leg is swollen more or less. In few lesions is the cause of the trouble as obvious as in the case of these ulcers. Knowing the cause, one must remedy that, and in so doing attack the disease at its source. These ulcers are due to varicose veins, so we must cure the varicose veins, or at least we must support and relieve them.

This is such a transparent truism that it seems as though it should be apparent to the meanest intellect, yet wise men are seen to pass it by. Think for a moment of what the complex process is. First, there arises the dilatation of the veins, a condition lasting perhaps for years; gradually, as the walls of the veins become thinned and inelastic and their valves incompetent, a condition of venous stasis results. A thin serum oozes out into the surrounding tissues and causes the edematous swelling. At the same time there is an exudation of red blood-corpuscles, which produce an extensive pigmentation of the skin, associated not infrequently with an eczema. As a result of all this the nutrition of the leg is greatly impaired, and the ideal conditions favoring an infection with destruction of tissue are present. Sometimes, as a result of thrombosis of the veins and malnutrition of the surrounding parts, a phlebitis or a periphlebitis is seen; there may be rupture of a vein even with serious hemorrhage; but more commonly, as a result of some slight blow, or even scratch, a superficial skin lesion is caused. This refuses to heal in the sodden tissues, bacteria rush in, and a destructive ulcer is formed.

It is for this ulcer that the victim seeks advice at last. He seeks advice, and I regret to say he sometimes is given plasters and washes, —ostensibly for the eczema, I suppose. With our knowledge of the cause of his trouble we say that such treatment is preposterous.

Now let us consider one of these unfortunate patients. He is a man of forty-five; a day laborer; a man who stands constantly on his legs. The pain of his disease has disabled him utterly. One observes, in the first place, the great size of his calves and feet. He is not a large man; he weighs perhaps 165 pounds, but his right leg, which is the seat of the ulcer, measures 20 inches. The whole leg below the knee is of a dark, reddish-brown color, mottled and shiny. There the veins are disguised, but behind the knee, in the popliteal space, and along the course of the internal saphenous you see the veins standing out in great bunches. Over the front of the shin, and spreading back into the calf, is an irregular ugly ulcer, as large as one's outspread hand. Its edges are indurated and elevated, and it is lined with sloughy, dull red, flabby granulations. As the man says truly, it is a very sore leg.

The patient has been lying on the examining table for half an hour, with his leg supported at an angle of 45 degrees. That has demonstrated

two things: It has given us an idea of the extent of the swelling, for now we find the calf to measure but 16½ inches in circumference,—a shrinkage of 3½ inches,—and it has given us an important clue as to treatment. Indeed, it has brought us back to our first principles, and shown us the importance of *elevation* and *support*. For let me assert that the method by which most quickly we should secure a healing would be to put the man to bed, to bandage properly the leg and swing it in a hammock. Thus the veins would be kept constantly emptied by the action of gravity; the circulation would be quickened and the nutrition reëstablished; the exudate would be absorbed in a few days, and the ulcer would be converted into a granulating wound.

For various reasons such an admirable method of treatment may not be instituted in the case we are considering, so we must adopt the next best method, and, on the whole, it is the one most practicable in such cases.

In the first place, when there is any considerable edema present, always order the half-hour of elevation. At the end of that time we find that we have to deal with a leg of a more nearly normal size, with edema diminished, and veins emptied of their accumulations. Next, to clean up the sloughy ulcer with its indurated border, let us apply a gauze pad wrung out of pure glycerin, overlapping the edges. The glycerin acts to draw out the serum from the tissues and rapidly softens the indurations. If we choose, we may etherize the patient and curet the ulcer and its edges, but this rarely is necessary. Then from toes to mid-thigh apply firmly, snugly, and with uniform elastic compression our wadding rollers of many thicknesses and a cotton bandage.

Now, whatever position the patient assumes, the veins cannot again become distended, the leg cannot swell, and the nutrition of the parts cannot seriously be disturbed. The patient is directed to keep as quiet as possible for three or four days and to have his leg up on a chair most of the time, but within the week he will go back to work in some degree of comfort. After the first day he will return to have the glycerin pad removed and the bandages reapplied.

Consider next a second man, who is suffering from a similar ulcer and has been under treatment for three days. He was dressed with our glycerin pad and supporting bandage, which has been once renewed. We find now a condition very different from that of our control patient. The leg is still swollen and edematous, but not markedly so. The veins are inconspicuous, and the ulcer itself, instead of being indolent and sloughy looking, is lined with red and fairly healthy granulations; in other words, it is taking on the characteristics of a granulating wound. As for further treatment, the important thing is to continue our support, without which the lesion would quickly relapse into an ugly ulcer. To the granulations apply sterilized absorbent gauze. Nothing else is needed, and by continuing in this course for three weeks, we should find the wound nearly healed and the man going about in normal, comfortable fashion.

FELON; WHITLOW; PARONYCHIA; PALMAR ABSCESS

We shall find it hard to define the first three words, which give a title to this paragraph. *Felon* and *whitlow* have no proper etymologic reason for existence; *paronychia* is derived obviously from *Παρά, around,* and *ὄνυξ, nail; palmar abscess* is self-evident.

I make this seemingly needless discourse about definitions because no two surgeons will be found to agree about the meaning of those first three words, and the medical dictionaries even are at loggerheads.

Felon means *one guilty of felony,* a *wicked cruel person,* hence the word has been applied to a cruel infection. Whitlow means literally *a white flame;* "a painful inflammation tending to suppurate, in the fingers or toes." [1] That seems a fairly good definition. Many surgeons regard *whitlow* as identical with *felon;* I do so myself, and as I find no great authority or even well-established custom to oppose me, I shall continue to do so. For us whitlow and felon are interchangeable terms.

But *paronychia*—there is our rock of offense, for fully half the authorities make it identical with whitlow and felon.[2] So we are left to follow our own fancies, and I have taken the liberty of following mine so far as to contrive two definitions which I believe to be descriptive, convenient, and fairly accurate:

As whitlow is felon, and the latter word is in more common use, I shall drop the term "whitlow."

A *felon* is an acute infection of the finger (or toe), progressive, with a tendency to involve the bone.

A *paronychia* is an acute infection of the finger (or toe), progressive, situated near the nail, which it tends to involve.

Bear in mind that paronychia may spread further and involve the whole finger—in which case it should more properly be called a felon. And bear in mind also that the great majority of felons are situated over the terminal phalanx.

This is a beginning only of the controversy. We could go on for an hour juggling terms and disputing as to what does or what does not constitute felon.

Felon.—Conceive, then, of felon as an acute, progressive infection, situated anywhere on the finger. It may be superficial, it may be deep, it may be both superficial and deep. Take that last conception as an example of a common form of felon and examine a special case.

One week ago a patient pricked her finger with a carpet-tack. The little wound healed apparently, but after three days the end of the finger became red, and the skin over the pulp become elevated, somewhat in the form of an ordinary blister. But there was pain, and

[1] Chambers' Etymological Dictionary.

[2] Foster, Dunglison, Keating, Gould, and Duane group felon, whitlow, and paronychia under one head, and call the hybrid affection "periphalangeal abscess." The Century Dictionary: "Felon, an acute and painful inflammation of the deeper tissues of the finger and toe, especially of the distal phalanx; generally seated near the nail."

there is pain now—throbbing, wearing pain. We tie a rubber tourniquet about the base of the finger and inject a few drops of 2 per cent. cocain along the course of each lateral nerve. Then, with the scissors, we trim off the blister. That leaves a sore with a red, mottled surface about the size of a silver dime. It looks like a granulating area. All the seropus contained in the blister has been evacuated, and one would suppose that here was an end of the affair. If now I take the finger in my hand and gently squeeze it, you see a minute drop of pus exude slowly from a point in the granulations. That means that there is a little track connecting the superficial cavity we have opened with a deeper cavity. This felon is a compound affair, with two pus chambers in tiers, one above the other. They are connected by the minute channel which was perhaps the original track of the carpet-tack, or perhaps was caused by the inflammatory action itself.

Treatment.—This form of felon with its two chambers has been felicitously termed a "shirt-stud abscess." There may be two or more connecting channels, but the name is just as good. So, when we open a superficial felon, let us remember that a felon is progressive, and search for that second chamber. Now we open the deeper pocket, and find ourselves on the periosteum. We clean out the little cavity; wipe it thoroughly with dioxid of hydrogen, lay in it gently a bit of absorbent tape, wrap the finger in a hot creolin poultice, bandage the hand and forearm with elastic compression, and suspend them in a sling.

Let me say one word about *poultices.*[1] They have been used from time immemorial for the comfort they bring to the affected part. Their action is to stimulate the superficial circulation, and thus, by relieving congestion, to check inflammatory action and allay pain. Such a use of poultices is as comforting to-day as ever it was.

A poultice must supply *heat* and *moisture;* deprived of either, it is no longer a poultice. The materials of which poultices have been made are many, but mostly surgeons try to employ some vehicle which shall retain heat. Such vehicles are found in Indian meal, flaxseed, and the various cereals. They remain moist and warm for a long time, but they are beautiful culture-media. For a vigorous infection-spreading agent, recommend me to the old-fashioned bread-and-milk poultice.

With Listerism there came in the so-called antiseptic poultice. As commonly used it is not antiseptic. The best that can be said of it in that regard is that it is often aseptic. When properly prepared, it is a useful dressing, because it is sterile and because, by supplying heat and moisture, it stimulates the reparative processes. Then, too, it is easily applied.

So one sees that in the use of the properly constructed and applied poultice we return again to our first principles—we support the part and we stimulate and equalize the circulation.

That form of antiseptic poultice which I prefer is made of sheet-wadding pads wrapped in absorbent gauze and covered with some waterproof material, like oiled-silk or parchment paper. The pads

[1] Compare the action of poultices with the Bier treatment.

are wrung out of a hot creolin solution, 1:200. One may use bichlorid or boric acid, but carbolic acid never. The poultices should do much more than cover the affected region only. If the whole *finger* is involved, wrap the *hand;* if the hand is involved, include the *forearm* in the poultice. Thus we shall quiet the adjacent muscles and protect the efferent lymphatics. It is well also to put on a light splint outside of the poultice for more perfect immobilization of the parts.

Then as to the drainage of these abscesses—gauze wicking is usually sufficient. Do not *pack* the cut with gauze. That will cork up the

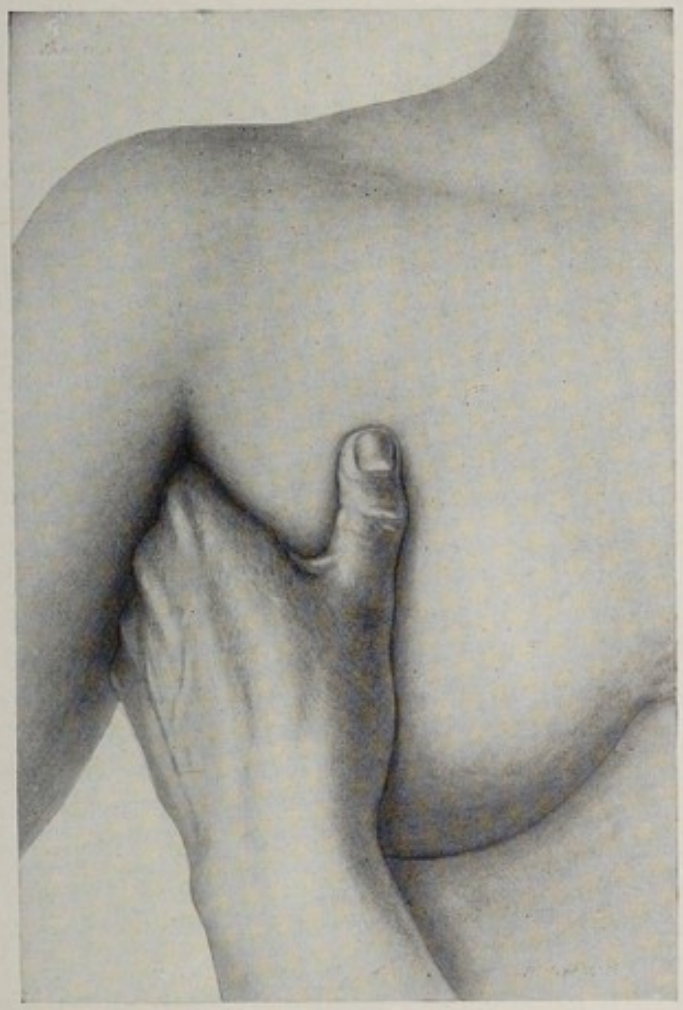

Fig. 461.—Examining infected axilla.

pus. Gauze *packing* is never used except to check hemorrhage. To *drain,* lay gently into the cut one or two wicks or tapes. These will carry off by capillarity the secretions, and, being interposed between the cut edges, will prevent a superficial gluing together of the skin wound and a consequent pocketing and burrowing of pus in the deeper parts.

To demonstrate further the treatment of felons let us consider a second case. The patient has been aware of a throbbing pain, increasing in severity, for four days, over the middle phalanx of his ring-finger. The primary cause of the trouble is unknown to him. We observe that the whole finger is hot and swollen, and on compressing

between one's thumb and finger the lateral vessels on either side of his finger one plainly feels them throbbing. That is a distinctive and interesting point in the diagnosis of localized inflammations of this type. You will not discover that pulse in cases of sprains or rheumatoid affections. The man's finger is not only swollen throughout, but its palmar skin is reddened, elevated, and excessively tender. In feeling carefully in his axilla, one detects an enlarged and painful node. His body temperature is not elevated, his pulse is not rapid, nor is there a noteworthy leukocytosis—the white count being 9000; but he is tired from loss of sleep and weary with the constant pain. On carrying the knife deeply down through the skin and laying bare the tendon-sheath, we give vent at first to an abundant bloody oozing, which is good. Then there follow half a dozen drops of pus, in which one will probably find streptococci in pure culture. If, now, content with this cut, we apply the dressing, to-morrow may show us the superficial parts mostly glued together. That is a condition we do not want, for the wound must be made to heal by granulation from the bottom. To favor such healing, trim off the skin-edges so that they cannot readily be brought together—a simple and very useful maneuver. Now we apply the poultice, light splint, bandage, and sling.

Properly the poultice should be changed twice a day at least, and by the fourth day we should begin to see a clean, granulating wound. The man may have pain, and may need a small dose of morphin. A certain amount of pain nearly always follows a cocain operation on a felon, but by the next day the patient should be in comfort.

These two cases have been simple ones, but all felons are by no means so easy of treatment. The pus burrows; tendons, bones, and joints are involved; slashing incisions and amputations may be necessary, and at the best some impairment of function is apt to ensue. Such results you shall see daily in my clinic. The therapeutic measures to be applied differ in degree only from those you have seen. Pus is to be sought out, drainage is to be maintained, asepsis and support are vigorously to be enforced, pain is to be relieved, and, always, the general condition of the patient is to be considered and strengthened so far as well may be.[1]

Let us study a third patient, who presents us with an example of **paronychia.** In the limited sense in which we use the term, "paronychia" is the common nursery "run-round." This child pulled a hangnail a few days ago until she drew blood, and so infection entered in. Two days before she came to us the skin about the base of her nail was reddened and painful, forming a crescentic swelling. On our first inspection there is pus obviously present, for it shows creamy through the thin pellicle.

There is a common way—a common but wrong way—of opening these little abscesses. That wrong way is to cocainize the finger and draw the knife in a semicircle through the skin about the base of the nail.

[1] The opsonins and Bier's treatment are giving us constantly better results in the treatment of these serious infections.

So one will evacuate the pus, but will have left an ugly sore to granulate slowly up with the underlying nail at its bottom.

Here is a better way. Lay a narrow-bladed knife flat upon the nail with the knife-point against the inflamed skin, and by a little gentle prying, which should be painless, insert it along the skin-edge and the base of the abscess. Withdraw the point, when we see it followed by a jet of pus. By a little manipulation the cavity is now evacuated; a poultice is then applied. Unless the nail and matrix have become involved in the infection, sound healing should now be a matter of two or three days only.

As in the discussion of felons, so here, we have scarcely more than touched upon a broad subject. This infection may rapidly invade the finger. It may attack and destroy nail and matrix, and involve periosteum, bone, joint, and tendon. There is no limit to its possible



Fig. 462.—Opening paronychia along nail.

ravages, but for the avoidance of confusion, when the infection has passed beyond the region of the nail, we speak of it as felon and not as paronychia.

Palmar abscess is a further development of these hand infections. To it felon and paronychia naturally and inevitably lead. It is a lesion of great interest—in its pathology, its treatment, and its capacity for far-reaching damage. In it the infection usually starts in the palm, but it may begin in one of the fingers and spread to the palm.

The methods of infection are therefore various, but perhaps the commonest method is that seen in the hand of the laboring man. Take the case of a gardener, for example. His hand bears heavy callosities, which have become so hard as to press upon and irritate the underlying soft structures. This bruising has caused a considerable blister, which has become infected from the overlying skin, and in turn has passed on its irritating properties to the deeper parts.

As one looks at the hand, it appears everywhere swollen—back as well as front. That puffy, reddened dorsum is swollen from edema. If one were to cut into it, one would draw serum and blood only. But the palm shows a condition quite different. It is not so greatly distended in appearance as is the dorsum, for its deep structures, bound down by the dense palmar fascia, cannot greatly swell. The pain is there, however; and it is all the more severe because the fascia does so limit the swelling. In order to escape without our aid the pus must burrow up under the annular ligament, into the forearm, and that is what we fear. So you see the palm of the hand to be tense and brawny, but not greatly swollen. It is exquisitely sensitive to pressure. The pus must be let out quickly, and here again we are presented with a problem which is rendered interesting by reason of anatomic complications. Few other regions of the body contain so many and such diverse structures compressed into so small an area. There is here a labyrinth of tendons, nerves, vessels, and fasciæ—to say nothing of tendon-sheaths, small muscles, and bones. All these structures are essential to the proper use of the hand—that wonderful piece of mechanism. We cannot go roughly slashing into it without crippling it, yet to get out the pus we must in a fashion slash.

It used to be taught as a safe rule, and those who so taught were in the main correct, that when cutting into the palm one should make incisions short, multiple, and parallel to the bones, thus avoiding, so far as possible, the delicate structures of the hand. That plan is not a bad plan—indeed, it is the one commonly followed still, but it has this disadvantage, that through these straight incisions the pus is sought somewhat blindly and with difficulty, while the incisions tend to early closure, thus damming in the discharges and necessitating a second operation often. Moreover, such wounds heal with disabling scars, which are bound closely to the underlying parts and seriously limit motion.

My colleague, W. A. Brooks, Jr., has devised an incision which I prefer. The patient is etherized. While his hand is held firmly outspread, we outline a semicircular flap which includes the whole of the palm practically. Enter the knife over the second metacarpophalangeal joint, and after sweeping it round the palm, bring it out at the base of the thenar eminence; in other words, the flap is to be turned back on the thumb as a pivot. Rapidly dissecting away the skin, we now expose completely the palmar fascia. A little pus oozes through it at various openings. Enlarge the openings with a blunt scissors and rapidly, without damage to structure, follow up and clean out all the cavities. Thus we have dealt with a really beautiful and well-exposed dissection of the palm, and have avoided easily the important arteries, nerves, and tendons, for we have seen them, and we have searched out the burrowing pus far more thoroughly than was possible by the old blind method. Now disinfect carefully the whole hand.

As for drainage and the after-treatment:

Wicks are led out from all the pockets; a thin layer of gauze is

spread over the whole exposed surface, and the skin-flap is laid back over the gauze. In the subsequent dressings, when necessary, the skin-flap may again be turned aside and the depths of the wound may again easily be explored. Judging by experience, we should find the inflammation subsiding in a day or two, when the wicks gradually will be removed. By the end of a week the palm and the under surface of the flap will be covered with granulations. Then, if all looks clean and sound, we stitch the skin back into place and look for a rapid healing by a delayed first intention. To facilitate the sewing back of the flap we usually pass so-called provisional stitches at the time of the original operation. When the time comes, they will be tied.



Fig. 463.—Brooks' incision for palmar abscess.

For the first four or five days it is well to dress the hand and forearm in a large creolin poultice with a splint, but this may be abandoned soon for the gauze dressing with elastic compression and elevation.

One is surprised to see how useful and comely a hand will result from all this. The scar will be there, of course, but it will not be especially troublesome, and the function of the hand will generally be much better than was the case when multiple linear incisions were used.

Again, let me warn the reader, that in spite of what I have said of a flap at the thenar eminence one must never operate by *rule of thumb*. Broadly, this operation is a good operation, but diverse conditions will present themselves. No two cases are alike, and while one must strive always to observe general principles, he must apply also a broader common sense.

BOILS; CARBUNCLES

Boils.—The treatment of boils may seem to be a very minor part of minor surgery, yet there are few curable conditions more troublesome than furunculosis.

Some months ago there came to see me a man who is the chief of police in a town near Boston. He had upon the back of his neck two boils and the scars of half a dozen others. For four months he had been suffering from these pests—in constant discomfort, with a sore and painful neck; his sleep broken, his appetite impaired, and his health becoming undermined. On inquiry I learned that he had gone ten years without a day's vacation, and that for six months before the appearance of his boils he had been feeling run-down and debilitated from that condition of faulty metabolism which we call muscular rheumatism.

I gave him a simple cleansing wash for the neck and a course of aperient waters. I enjoined a two weeks' vacation, and the following tonic: sulphate of iron, 2 drams; sulphate of magnesia, 6 drams; dilute sulphuric acid, 6 drams; syrup of ginger, 4 drams; water, 9 drams. The dose is one teaspoonful in water after meals. To the boils I applied a soft protective cotton dressing merely. Ten days later the man wrote to me that his boils had disappeared and that he was feeling well.

That case illustrates one of the most important points one must make in this connection. It is the point I have so often made before. We must regard the patient's general condition. And boils are usually a manifestation of a general condition. They indicate some form of malnutrition, and must be treated on that basis.

Billings' Dictionary defines a boil as "a painful conic or rounded swelling of the skin, due to inflammation about a hair-follicle, a Meibomian gland, or a sweat-gland." That is a fair enough definition, and if we turn to page 172 of Warren's Surgical Pathology we shall find the nature of the process exhaustively described. The point of it all, so far as the clinician is concerned, is that the organisms normally present in the skin gain lodgment in some of the glands or ducts and then multiply. The active development of these colonies of bacteria produces small areas of connective-tissue necrosis. This necrotic portion acts as a foreign body, and nature proceeds to throw it off as a "core." The process of throwing it off gives rise to further inflammation, with the resulting pus-formation and swelling. After the core is thrown off, there remains a little pit, which must heal by granulation. So, we see, there are three stages in the life history of a boil, and each stage demands its appropriate treatment. There is the first stage, when we see a small superficial pustule only; the second stage, when we see a much larger mass—elevated, indurated, and painful, containing its core; and the third stage of a crater-like but subsiding swelling.

Commonly, a patient comes to the surgeon with a well-developed boil in the second stage, and, in its neighborhood, two or three incipient boils or pustules. If the case is a chronic one, make up your mind

about the patient's general condition, especially as regards diabetes and "rheumatism."

Take another patient as a good example of what we are describing. He is a night watchman whose daytime sleep is disturbed. He is given to rather excessive whisky drinking, and is feeling pretty well "done up." He has a poor appetite, constipation, a furred tongue, and is a striking type of the tired man who is burning the candle at both ends. I need not trouble you with details of general treatment in his case except to say that we should stop his liquor, and give him a course of Carlsbad salts, with 5 grains of Blaud's pill before his meals. Looking now at the back of his neck, we see on the right side a conic swelling the size of a silver "quarter." It is reddened at the center, where it is beginning to break down and soften, but everywhere else it is indurated. It is very tender to the touch, painful on pressure, and the man says it "feels sore all round." To the left of it are three little pustules, with reddened areolæ, each about half the size of one's little finger-nail. In the first place, as regards these incipient boils, let me assert with much assurance that they may be aborted. The old-fashioned method was to poultice the back of the neck and bring the whole crop "to a head." Do not do it. There are scoffers who will say that boils cannot be aborted. I doubt if they have tried faithfully any method. Here are two methods. One may prick the little pustule and wipe out the minute cavity with a probe dipped in pure carbolic acid. That often will suffice, but I have not found it so successful as the hypodermic injection of very small quantities of some strong antiseptic.

In the first place, we cleanse the neck with soap and water and alcohol. Then inject 5 or 6 minims of cocain, in 4 per cent. solution, under the infected areas. Now into this anesthetized zone, along the cocain track, inject under each pustule 2 minims of pure styron—an ancient but efficient balsamic antiseptic. I prefer it to carbolic acid, because more thoroughly it permeates the affected tissues. The result of this injection is to destroy the active bacteria and to convert the infected area into an aseptic eschar. The immediate outcome, so far as the patient is concerned, is that the sense of burning and discomfort disappears in a few minutes; without further sensation, the eschar is thrown off and the little wound heals up. Remember to use cocain before these injections of styron, for the styron used without such preliminary treatment causes a few moments of severe pain.

I am satisfied, from a fairly wide experience with this method of aborting boils, that it will usually be found successful. A young man consulted me recently who had pustule after pustule appear on his neck for a period of several weeks. One of them ran a severe course and had to be opened and cureted twice. Into the other incipient furuncles—perhaps a dozen or more, as they appeared from week to week—I injected styron and checked them at once. Finally, with tonics and general treatment, the malady subsided.[1]

[1] In these cases I think highly of opsonic vaccines (Staphylococcus aureus).

There is another method of treatment which another patient, a medical student, illustrates. He had a slightly septic finger, which healed without trouble, but he became "run down" and developed a crop of boils on his left arm. They were treated by his friends and the surgeons in various dispensaries, where he kept at his work. They were opened, injected, poulticed, time after time, but continually recurred until he became discouraged and his life became a burden. I had seen him several times, but was unable to check the process, and there seemed to be nothing for it but to send him away on a long vacation.

Finally, when he came here I determined to take a leaf from the book of my friend, H. L. Burrell, and try the effect of a carefully applied *Gamgee dressing*. At that time the forearm had on it three incipient boils and the healing scars of a half-dozen others. The arm was carefully disinfected, wrapped in absorbent gauze, and put up, from fingers to shoulder, in our wadding and mill-board apparatus, with firm compression. A sling, of course, completed the equipment.

That dressing was put on one Friday and remained undisturbed until the following Tuesday. I then removed it, to find the arm clean and shrunken, the little red boils shriveled, and the old scars practically sound. That was an interesting experiment, and certainly it shows in a most striking manner the ever-present value of our familiar first principles—support, immobilization, elevation.

When a boil has developed fully, or "come to a head," as the saying is, the treatment is simple and obvious. There is then no special interest in it. We must open it and clean it out. Cocainize it first, of course, by one or two deep injections along its borders. Make a crucial incision or, what is better, excise a little cone at its apex, about half as large as a silver dime. This excision will usually bring with it the core. Then scrape the cavity clean and drain it with a bit of gauze. For a day or two a creolin poultice will be a great comfort to the patient; after that, until the wound is healed, a cotton dressing is convenient and comfortable. One little note: never plaster a cotton dressing down with adhesive strapping. It is dirty and ineffective compared with collodion, and the taking-off process is painful. The collodion dressing may always easily be soaked off with alcohol.

Carbuncle.—When we come to deal with carbuncles, we have a quite different problem—different in the extent and gravity of the process, but not so different in its causation and development.

Observe two patients. The first, a woman, has below the occipital protuberance, and above the line of her hair, a conic swelling about the size of a silver dollar. Part the hair and expose the swelling, when we note that its apex has an excoriated look, and that there are three little craters from which a drop or two of pus may be squeezed. The little mass is brawny to feel and is quite deeply seated. Take it as a whole, however, it resembles closely a boil, and one might readily mistake it for a boil. It is a carbuncle in its early stages.

In comparison, the process in the second patient, a man, is much further advanced. It is in the common location on the back of the

neck, on the left side, below the line of the hair, and to look at appears to be as large as the top of a small tea-cup; when we handle it, however, it is found to be deeply seated, with a widely indurated base, nearly as large as one's palm, about it. It is flattened at its top and has a half-dozen little craters from which pus oozes and bits of white sloughs protrude. That is a large carbuncle. Both patients are de-

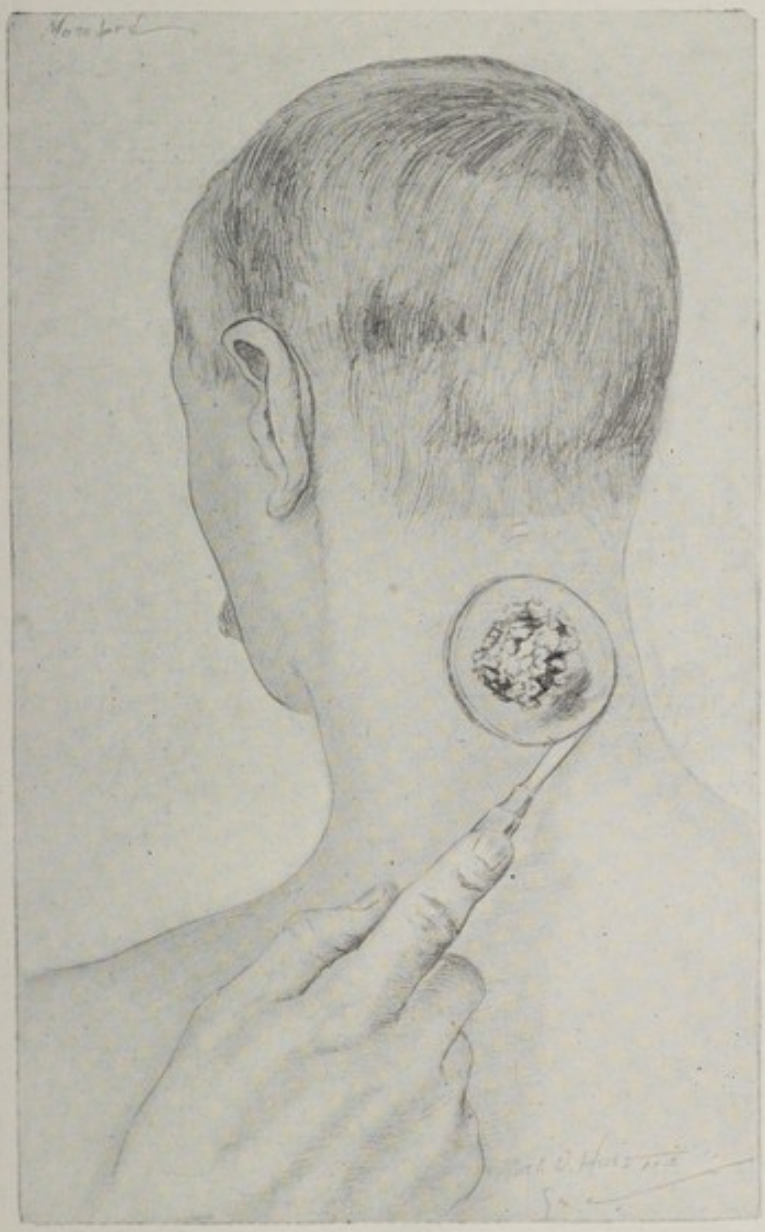

Fig. 464.—Excision of carbuncle.

bilitated—the woman from a week's pain and discomfort, the man from nearly three weeks of a similar experience. Both cases are uncomplicated. The urines are free from sugar; both patients are in their prime and of previous good health.

What is a carbuncle and wherein does it differ from a boil?

Billings' Dictionary defines carbuncle as "A circumscribed inflammation of skin and subcutaneous connective tissue, terminating in a slough." More than that, it is usually a gangrenous inflammation. It

begins on the skin, as does a boil, but it spreads much deeper and, as one would expect, it is produced by the Staphylococcus pyogenes albus and aureus. Do not confuse this process with anthrax, as did Billroth and the older pathologists. Anthrax has many of the appearances of carbuncle, but it is far more rapid, it has a wide reddened zone about it, it has not the characteristic elevated flattened surface, it is nearly covered with a gangrenous eschar, and it is caused by the Bacillus anthracis.

The characteristic carbuncle begins then as a superficial skin inflammation about a hair-follicle or gland, and works rapidly downward along the *columnæ adiposæ* into the connective tissue; there it spreads rapidly, involving other *columnæ* and other glands, pressing upward all the time, elevating the overlying skin, finding numerous points of exit, and causing extensive necrosis of the connective tissue which it involves. It is usually a local process, but rarely it may destroy the dense aponeurosis of the underlying muscles and extend widely to other structures. When we find it in its usual seat on the back of the neck, we need not fear it greatly, for tough structures limit it below, but when situated in regions of greater vascularity and more delicate composition, as on the cheek and lip, it may spread rapidly, cause serious disfigurement, and even threaten life.

Let me say a very decided word about *treatment* in these two cases before us. There is one method, and that method is nearly always sure and final—*excise* the carbuncle.[1] Do not dally with applications and poultices or even with the old-time deep crucial incisions. They imply delay, if they do not cause an extension, of the process. The necrotic mass in each case must come out. If we poultice or incise, we do not prevent a loss of substance—substance has been lost already. It is far better thoroughly to excise it at once.

Take, as our best example the man with the large inflammation. He is etherized, for the operation is a considerable one, and the knife is carried cleanly and completely around the carbuncle, outside of the necrotic area. The blade bites down to the underlying fascia, and the whole sloughing mass is dissected out. The bleeding is checked, the cavity packed with absorbent gauze, and the wound left to granulate. When we look at the size of it, we exclaim perhaps that here is a needless sacrifice of tissue, and that the resulting scar will be enormous. One will be surprised, in the course of two or three weeks, to see how the sound parts have come together, and how trifling, after all, will be the evidence left of the great wound. It is interesting also to hear the patient's own account of himself the next day. The old *incisions* gave but little relief at the time; the *excisions* are followed by an almost immediate reaction; and when next the man comes in we expect to hear from him that he has passed a good night, has eaten a hearty breakfast, and is practically free from pain.

Don't coquette with a carbuncle. Cut it out as you would a cancer, and you will never regret it.

[1] In the case of carbuncles the opsonins cure often.

BUNIONS; INGROWING NAILS; CORNS; AND WARTS

Bunion.—Bunion is a condition frequently associated with *hallex valgus*. Hallex valgus, an extreme deformity and outward displacement of the great toe, was for centuries called *hallux valgus*. As such one finds it described in all the books on surgery. Robert H. M. Dawbarn, of New York, was the first to point out the error, and that was but a few years ago. The word *hallex* itself is archaic. It means literally a *scoundrel;* and you shall search your dictionaries to find, at last, "Allex (hallex) in *Isid. Gloss.* est pollex pedis."

However all that may be, bunion is a good Greek word. A bunion is an inflamed bursa, situated usually to the inner side of the metatarsophalangeal joint of the great toe, and if it becomes inflamed, it makes trouble. Persons who go barefoot or wear sandals do not have bunions, but if one puts a foot into an ill-fitting boot and crowds it forward, the great toe will feel the impact and be thrown outward across the second toe. Sometimes the deformity is so extreme that the great toe appears to be at right angles to the axis of the foot.

When this deformity takes place, the toe is partially dislocated at the metatarsal joint, and upon the knuckle so formed comes the constant pressure of the side of the boot. Here lies the bursa over the knuckle, and, as a result of the pressure, it becomes irritated, thickened, and inflamed. The condition is a compound one, both bone and bursa being involved.

Operate by making a sweeping incision about the dorsal side of the joint, and turn down upon the sole of the foot the flap, which is about 2 inches in diameter. The exposed bursal sac we next open and dissect out. It is distended with a flocculent fluid, and there is often at its base a little opening, which leads directly into the joint. This illustrates an important point, namely, that we are never safe in operating hastily upon a bunion, for we cannot always tell beforehand whether or not it may communicate with the joint. Every surgeon has had patients come to him from ignorant "corn doctors," who have attempted to pare off one of these bunions, with a resulting opening in the joint and a severe septic arthritis.

Following up such a sinus, lay open the joint, of which the ligaments are so relaxed from the inflammation that their function is destroyed, the phalanx being in a state of subluxation. The joint cavity is found to contain some of the fluid that we saw in the bursa, and the articulating surfaces are roughened and diseased; in other words, we have shown that apparently simple thing called a bunion to be an extensive disease of bursa, joint surface, and bone.

There is no possibility of success from palliative measures in such a case. The toe cannot be straightened, even with the joint laid open. The only thing to do is to excise the end of the metatarsal. This we do accordingly, with the chain saw, and find that the normal line of the great toe now can easily be restored. The rest of the treatment follows naturally. Bleeding is checked, and the deep parts over the joint

are closed with buried catgut sutures, in order that the false joint at which we aim may have a firm lateral support. Those deep buried stitches are essential for success. The skin-flap is then stitched into place and the toe is held in its new straight position by a light tin splint. Over all is wrapped firmly a wadding and mill-board dressing to the knee, and the patient is put to bed. By the end of the week we take the dressing down and hope to show a soundly healed wound.

The above case was an extreme one. Hallex valgus is its conspicuous feature, but consider a couple of simpler cases which admit of simpler treatment. Both have a slight outward bend of the toe and an inflamed tender bursa or bunion on the inner side. The first patient, a woman, has a toe which is easily pulled back into place. We content ourselves with ordering a proper pair of broad, square-heeled, laced boots, with straight sole on the inner side. Over the bunion fit a piece of felt, cut like a large corn-plaster. That will protect the bursa from pressure, and the properly made boot will allow the slight deformity of the toe to correct itself. Such cases are frequently associated with a breaking-down of the longitudinal arch of the foot and a consequent flat-foot, but that is another story.

The second patient, a man, has a hallex valgus and a bunion similar to the woman's, but the toe is not so readily pulled into place. For him we arrange a hard-rubber spoon splint. The bowl of the spoon has a handle at either end. When the padded bowl is laid over the bunion, the upper handle extends along the side of the foot and the lower along the toe. With the upper handle strapped into place pull the toe inward toward the lower handle, and so correct the deformity. By his wearing this simple apparatus for a few weeks, and by the fitting of a proper boot, we hope permanently to correct the deformity.

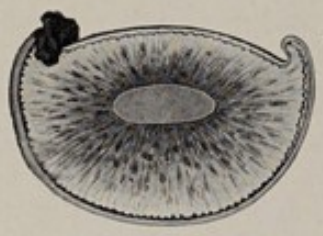

Fig. 465.—Transverse section through phalanx of great toe, showing ingrowing toe-nail and mass of granulation tissue (Fowler, after Hueter).

Another crippling affection of the foot is **ingrowing toe-nail.** This also is a disease peculiar to civilized peoples who are boot-wearers, and is not seen in those who go barefooted.

Years ago an old army surgeon told the writer that he had no trouble with ingrowing toe-nails among his men after he had taught them how properly to trim their nails. They were to cut them straight across instead of making a rounded corner. We have found that simple maneuver to be a valuable prophylactic measure.

The common seat of ingrowing nail is on the outer side of the great toe. As with bunion, it is due to ill-fitting or tight boots. A case will illustrate the usual story. A young woman noticed that the outer side of her toe began to feel sore. It was red and tender. To relieve the discomfort she trimmed the nail down on the side. That answered well enough for three or four days, but by the excision of that strip of nail the pulp was given so much the greater latitude for bulging

inward. It continued to encroach upon the nail, became irritated and eroded by the rough nail edge, took on the characteristics of a chronic ulcer, and threw out exuberant granulations, which overlapped that side. The part became exquisitely sensitive to pressure, and a little pus exuded from under the granulations.

Nothing short of an operation can be done. Palliation is useless. There are two or three operations of value.

Cotting's operation was devised by a well-known Boston surgeon. It consists of passing the knife, at right angles to the plane of the nail, into the pulp, and shaving off the whole of the soft parts, together with a narrow sliver of nail on that side of the last joint of the toe. The wound is left to granulate, and a contracted scar instead of normal pulp is the result. Ingrowing nail cannot occur again there, for there is no pulp for it to grow into. The operation

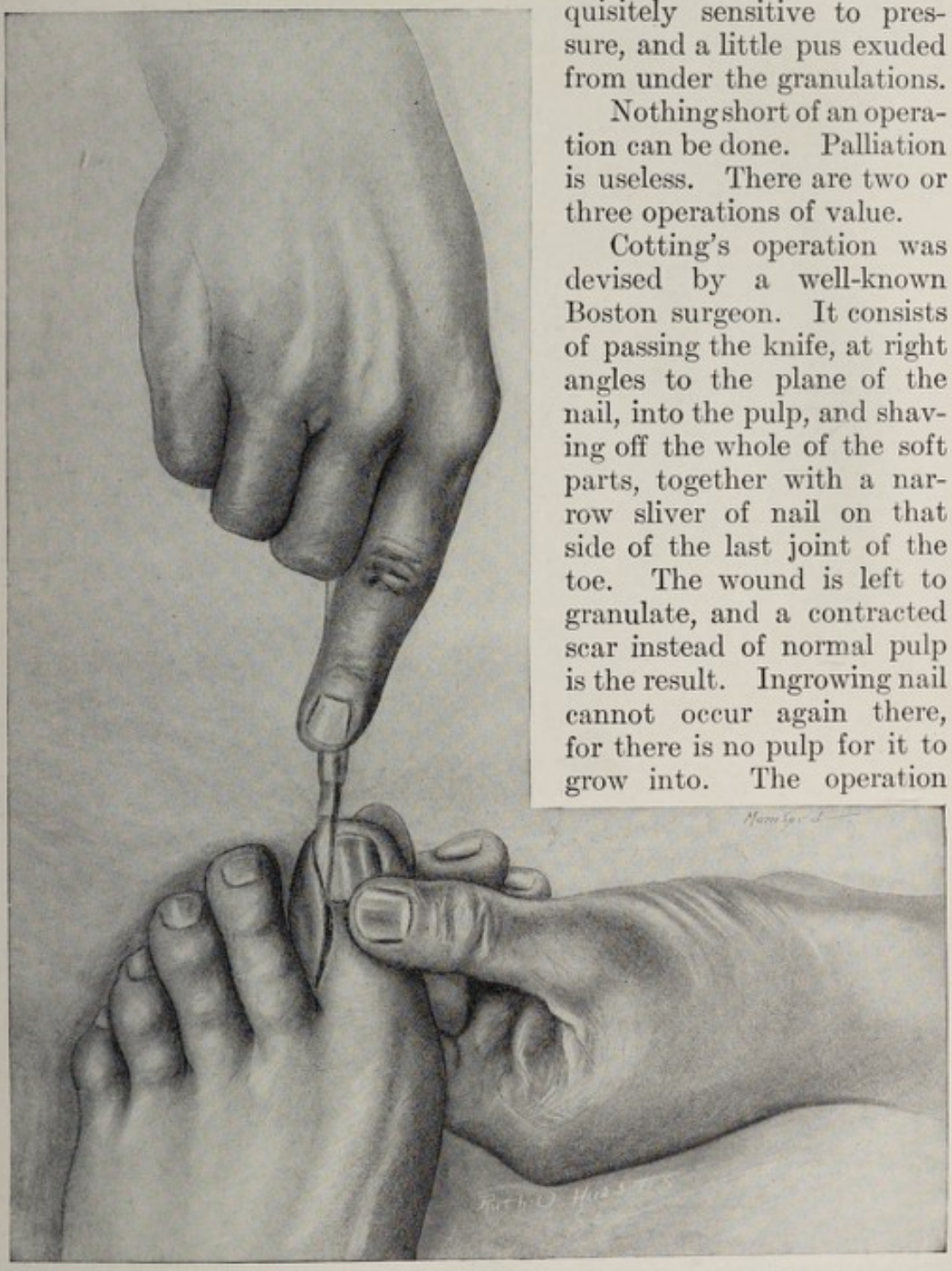

Fig. 466.—Cotting's operation for ingrowing toe-nail.

is radical and effective, but leaves the patient with a sore toe for weeks. Then here is a similar operation which consists of cutting out a "piece of pie," as it were, from the pulp and sewing up the hole.

A third useful operation: The toe being cocainized, seize the nail

deeply and firmly with a strong pair of plying forceps, and twist it out entire; then curet off the granulations. At the end of several months, when the new nail has grown out, the wounded pulp will have healed and shrunk, and the patient will then be as though no trouble had ever been. The operation is simple, the laceration is slight, and the resulting incapacity of very brief duration. A simple vaselin and gauze dressing is all that is required.

Let us say an important word about palliation in the incipient cases. Palliation means properly fitted boots, and the packing of cotton under the nail. If one pack skilfully, one may so treat a fairly bad case.



Fig. 467.—Packing ingrowing toe-nail.

Few men do so pack. Do not roughly and quickly thrust in the cotton. We shall grievously hurt the patient, and will not get the cotton in. With the patient's foot on the surgeon's knee, take a strand of absorbent cotton, lay it by the side of the nail, use the back of a narrow-bladed knife, and gently and patiently, with a succession of pushes, insinuate the cotton under the edge. The patient will experience prompt relief. Repeat the performance once a week until a cure is established.

Corns (Clavus).—A few months ago a young fellow from the college in Cambridge came to me complaining that he had run several splinters of wood into his foot when walking barefooted on the "float" at the

boat-house. He had pulled out two splinters half as long as his little finger, but a third had been healed in and caused him constant pain in walking. I examined the foot, and could distinctly feel the foreign body, as large as a medium penknife blade, deep under the skin at the base of the second toe. There seemed no reason to doubt the presence there of a splinter. I made an incision deeply into the foot and went down for nearly half an inch through a stratum of tough callus, until I reached normal tissue. There was no splinter there. The seeming foreign body was nothing but a great callus, which I excised, and so cured the lad of his painful foot—but I had learned my lesson.

This callosity was of the nature of a corn, which is made up of a circumscribed excessive development of the epidermis and of a central portion or core. The core extends quite deeply into the tissues, in the form of an inverted cone, the base being directed outward, appearing on the surface as a rounded area, the apex of the cone resting on the papillary layer of the corium and causing pain when pressed upon. In this case I performed a radical cure in the only manner which is possible, namely, by excision. Nothing else will do it. The "corn doctors" do not wish to cure. Their palliative measures merely relieve pressure for a time, but the patient returns repeatedly for further treatment.

After all, few patients will consent to so radical a measure as excision, especially with the prospect, if they are not careful, of a fresh corn developing about the site of the scar. So the sufferer comes back again and again to parings and plasters, and will continue so to do as long as boots are worn and corn doctors abound in the land.

As regards **warts,** there are several facts which one should bear in mind about them. There are four principal varieties: The ordinary horny warts of children (verruca vulgaris), the smooth multiple warts on the faces of old persons (verruca senilis), the little worm-like warts which we see hanging from the lids (verruca filiformis), and, lastly, venereal warts (verruca acuminata). There is reason to suppose that all these varieties are due to some infecting organism, though this is not definitely proved. The common wart of children, seen mostly on the hands and fingers, may appear and disappear in an inexplicable manner. It is composed of a papilla containing a vascular loop; this is covered by a very much thickened horny layer, which in turn is covered by a hypertrophied rete.

Take the case of a boy with three such horny warts on his fingers. One we pare down with a sharp knife and touch the base with the nitrate of silver stick; the second, after paring, we touch with nitric acid; and to the third we apply a mixture of salicylic acid, the important ingredient of most of the patent "wart cures." It contains salicylic acid, ½ dram; extract cannabis indica, 5 grains; flexible collodion, ½ ounce. This is painted on the wart twice a day for five days until the growth becomes necrotic. The finger is then soaked for fifteen minutes in hot water, when, if all goes well, the wart will drop off.

The soft, flat warts of elderly persons are permanent and are not

especially disfiguring, but they have this important fact connected with them, that they may become epitheliomata of a malignant type. The patient may pick at one until it bleeds or he partially dislodges it, when he finds that it does not heal; that the little ulcer, so formed, spreads, and that he is concerned with a troublesome sore. When you see such an affair, cut it out first, and then let the microscope settle its exact nature.

Those offensive looking filiform warts which we see hanging from the lids and necks of patients may be very simply treated. A snip of the scissors and a touch with the lunar caustic suffice for them.

Then there are the *venereal warts* which are seen upon the genitals and are due to sexual contact. The patients are often much frightened and think the warts are indicative of serious venereal disease; but one can assure them that such is not the case. The growths will disappear if washed persistently with a solution of tannin in alcohol, one dram to three ounces; after washing, the wart is dried and dusted with salicylic acid.

After all is said, however, these various forms of warts seldom make trouble, and their treatment may be regarded as a very subordinate branch of cosmetic surgery.

MASSAGE

We began this chapter by describing the value and effect of immobilization. Let us now discuss the value of *motion* in certain injuries, of motion in a limited sense only—massage. That is a subject about which there has long been much misconception among surgeons, and even to-day this useful therapeutic measure is availed of less than it deserves.

Massage is no new, fanciful, or untried thing. It is one of the oldest practices in medical history, and is referred to not only by the earliest writers on surgery, but by poets who wrote long before medical literature began. If a boy bumps his shin, he rubs it; if a dog bruises his foot, he licks it. There you have nature prompting to a primitive massage, the uses of which have been elaborated into the skilful manipulations of our modern experts.

The practice of massage was in bad odor for long in this country because of the preposterous claims of its many ignorant exponents and the frequent danger they inflicted upon unsuitable cases. In the course of years all that was changed: educated persons, many of them trained in Sweden and France, took up the practice; the operators, both men and women, came to see that their work was as assistants to surgeons and not as their rivals, until to-day we find a considerable number of such competent persons in every community. Lately there has developed a curious outcome of these conditions. A so-called "school" of medicine has grown up. Its followers apply to themselves the meaningless term "osteopathists," and they essay on their own responsibility various forms of massage.

Students often ask their instructors how they can learn about the

methods of massage and whom they shall employ, and I find there is much misconception as to the limits of its usefulness. A common error also is to suppose that any nurse or orderly can learn to give it well after a short course of instruction. I believe, other things being equal, that the best masseuse may be developed out of the trained nurse, but I affirm that the best masseuse can remain the best by constant practice only. The tactile sense required is quickly lost if allowed to rust, and the strong, lithe muscles of the skilled workman become inexpert and feeble when long unused. Constant practice is as essential to the masseur or masseuse as to the pianist, the artist, or the football player. The professional model will pose immovable for an hour, if need be, before the "life class" in the studio; but I am told of the strong man Sandow being asked to pose in one of our art schools recently, and how, after enduring the strain for ten minutes, he was forced to drop his arm in exhaustion and chagrin. The average nurse can give excellent rubbings and friction when required, but when we want proper, expert massage, we must go to a specialist who does nothing else.

Let us consider some of the conditions in which massage is valuable to the surgeon. One of the commonest of injuries—an injury for long a reproach to our art—is *sprained ankle*. It was the practice up to fifteen years ago—and the practice is still followed by the indifferent—to immobilize sprained joints. The result was that patients so treated were tied to crutches for weeks or months, the time depending on the severity of the sprain—and after the splint and crutches were thrown aside, they limped about as cripples for an indefinite period. It used to be a common saying that a man must expect to feel his sprain occasionally for the rest of his life, even if he be not left with a joint permanently stiff and painful. That such were the results sometimes seen, every surgeon of twenty years' experience can tell you. A recent writer has said: "Supposing a prize of ten thousand dollars were offered for the quickest way to make a well joint stiff, what more effectual means could be resorted to than first to give it a wrench or sprain, and then do it up in a fixed dressing so that the resulting inflammation would have an opportunity of producing adhesions of the parts?" [1]

Consider the patient who has slipped from the curbstone and "turned his ankle" while running for a street-car, and on rising has found himself unable to stand or walk without agony. He is carried home, and shortly after the removal of his boot finds that his ankle is swollen, discolored, and very painful.

The one important lesion which we have to distinguish from simple sprain of the ankle is Pott's fracture—which you know to be a fracture of the fibula just above the malleolus, with eversion of the foot and rupture of the internal lateral ligament. Palpation of the sprained ankle shows us no such fracture, and the *x*-ray plate demonstrates sound bones of the leg and tarsus.

But what do we see and feel? The foot is swollen and boggy, especi-

[1] A Treatise on Massage, by Douglas Graham, M.D.

ally over the internal malleolus, and the skin is stained a pale yellow from extravasated blood and serum. Doubtless the man violently wrenched his foot, bruising the synovia of the joint surfaces, stretching and bruising the tendons and tendon-sheaths, and tearing a few of the fibers of the lateral ligament. As a result there has been a certain amount of escape of blood from the damaged soft parts; and a serous exudate, stimulated by the increased flow of blood to the part, is nature's primary attempt to repair damages. The exudate has infiltrated the tissues, with a resulting discoloration. As time goes on the exudate will settle out more and more toward the surface, and the staining of the skin will become darker, until, by the end of four or five days, we shall see the skin over the dorsum deeply pigmented and the ecchymosis, following the tendons and muscle interspaces, appearing well up on the calf.

Here then is our problem: Shall we leave all this exudate to remain quiet and to organize and cause adhesions of tendon and joint surfaces, thus impeding the circulation and impairing the nutrition of the parts? or shall we endeavor to remove the exudate and, by stimulating the circulation, promote repair and the reëstablishment of function? We have learned the results of the former practice. The masseur demonstrates the alternative.

The patient's leg is bared to the hip, so that there shall be nothing to constrict or impede the circulation as he lies upon the examining table. Observe the operator begin his manipulations gently and at a distance from the joint. It is a pretty sight to watch the work of an expert. He kneads and rolls the muscles of the calf, urging always the return flow of lymph and venous blood away from the ankle. Shortly the circulation begins to improve. The puffy, indurated "feel" of the leg is less pronounced, and the pain diminishes in the area worked upon as the exudate is forced along into the lymph-spaces where the stimulated current is beginning to take it up and carry it on into the general circulation. Gradually the manipulations are carried into the region of the damaged joint; the toes, the sole, and the dorsum of the foot receive their share of attention, until the operator is actually rubbing and kneading upon the joint itself, where, half an hour ago, the pain and tenderness were so great that the patient could scarcely endure the weight of the examining hand. Having thus kneaded and stimulated the parts, and diminished the pressure so that the painful distention is no longer so apparent, put up the foot in a carefully applied flannel bandage from toes to knee, and allow the patient to walk with the aid of his crutches. He finds that he can now bear some weight upon his lame foot. This treatment is repeated daily for a week or ten days, by the end of which time the man should be well.

We must bear in mind that complications may be looked for in these joint injuries and may call for treatment. One of the commonest of them is acute articular "rheumatism," in those persons who are given to that affliction; for we know that "rheumatism," like tuberculosis, is wont to attack the parts weakened for resistance. Always bear in

mind this possibility of "rheumatism," and during the convalescence from sprains forbid alcohol and look carefully to the patient's general condition, especially to his secretions. That question of tuberculosis is an important one also. We all know how frequently the development of a localized tuberculosis may be traced apparently to some trauma, so we must appreciate the fact that a sprained joint, which remains unsound for long, especially when treated by the old-fashioned immobilization, gives us excellent conditions for the subsequent development of a chronic infection. One can well imagine how such a joint, ill nourished, anemic, with an impeded blood and lymph current, partially ankylosed, and associated naturally with flabby, atrophied muscles, presents an admirable seat of lodgment for infective bacteria; so here we find further reason in the case of fresh sprains for expediting a healing.

Another lesion which furnishes us with an opportunity for brilliant results from massage is *dislocation*. We have considered the value of massage in fractures, but in dislocation its use is even more satisfactory.

Here is a typical case—a man with a subcoracoid dislocation of the humerus. He is a stout man, and the diagnosis is not immediately apparent. One does not readily make out the flattening of the deltoid and outward trend of the humerus away from the side, but if one will practise bimanual palpation of the axilla on both shoulders, one cannot fail to establish the diagnosis. On the sound side, with one finger below the coracoid process and the other high in the axilla, one can almost make the fingers touch through the pectoralis major, which alone intervenes. Try the same palpation on the affected side, and one finds that, push as hard as he will, a great interval still separates his fingers. That interval is occupied by the head of the humerus, dislocated under the coracoid. The patient is etherized at once, and the dislocation reduced. On the next day he returns for massage. For the first week this will be given for twenty minutes daily while the arm is supported motionless in a sling. The same method in general that we have seen employed on the ankle will be followed. Pain quickly will be relieved, and the nutrition of the parts improved. After a week, gentle passive and active movements will be begun, and by the end of three weeks of such practice we hope to have established a cure.

That matter of combining movements with massage in these cases is an important one. We shall find, for instance, in old shoulder dislocations which have been reduced and subsequently immobilized for a long time, according to the ancient practice, wasting, weakness, and stiffness resulting. If, then, we attempt by massage to restore the parts, we shall succeed very likely in rendering the joint supple, but we shall not increase materially the size and power of the muscles. Faradism will then help, by causing muscular contractions, but we can accomplish the same thing by active, resistive, and passive movements. So remember that in all joint injuries massage must be supplemented by movements, in order properly to restore normal function.

There are numerous other conditions in which massage is of the

greatest value,[1] especially in contractures and deformities left by old injuries or inflammatory processes which have subsided. In those cases patience and faith are often required for a long time, but the final results usually justify the treatment. As to the use of general massage after major operations and prostrating surgical affections, let me say that I have employed it commonly in such conditions, and with the most gratifying results, for the secretions are thereby increased, the circulation improved, the appetite, sleep, and mental state stimulated, and the convalescence, after the patient's getting out of bed, materially and happily abridged.

[1] Mechanical massage (Zander treatment) and hydrotherapy are valuable substitutes for manual massage.

CHAPTER XXVII

SHOCK; BLOOD-VESSELS; LYMPHATICS; MUSCLES; TENDONS; BURSAE; SKIN

Shock and Collapse

Shock and collapse are two ancient terms used by surgeons to indicate an extreme bodily depression; and a distinction between the two conditions has been asserted from old time. In truth, one cannot but feel that such a distinction is artificial, and that, as the words are commonly employed, shock is a state of extreme collapse, or vice versâ, if you please. Nevertheless, Crile differentiates the two in a recent writing, regarding shock as an *exhaustion* of the vasomotor center, and collapse as an *inhibition* of the vasomotor center.

Nearly thirty years ago William S. Savory, publishing in Holmes's System of Surgery: wrote: "Life may be destroyed by certain agents which leave no visible traces of their operation in any part of the body. Some forms of injury, as, for instance, a blow on the epigastrium, may produce sudden death, and yet the most searching scrutiny shall fail to detect the slightest physical or chemical change in any organ or structure. Nay, further: life may be abruptly terminated by causes yet more subtle, such as sudden and powerful emotions of the mind. This kind of death is very expressively termed death from shock." In recent years, thanks to the inquiries of Crile, Howell, Porter, and other physiologists, we have learned to estimate more nearly the causes of shock—through investigation upon living animals, though physiologists are not yet in accord. To quote from Bloodgood: "For practical purposes shock shall be considered a condition of general depression produced by various causes. These factors act through the medium of afferent nerves upon various centers in the spinal cord and brain, especially the vasomotor centers. Howell, from his physiologic experiments, recognizes a cardiac shock as well as a vasomotor shock. It is a question whether the sympathetic ganglia are also deleteriously influenced by the various factors which may produce shock."

These quotations will show the reader that the situation is not yet clear, though it is becoming increasingly evident that exhaustion and paralysis of the vasomotor center are important elements in shock, while at the same time there is excellent reason to suppose that the heart's action may fail through causes not connected with the vasomotor center; for example, through irritation or damage to the important cervical sympathetic ganglia. In this brief writing one is not permitted to discuss at length the interesting and important physiologic

experiments bearing upon the subject of shock, but I refer the reader to the admirable publications of Crile, Howell, Boise, Porter, Bloodgood, Mummery, and Sheen.[1]

The most notable physiologic phenomenon in the condition of shock is the abnormally low blood-pressure, though low blood-pressure may be found associated with conditions other than shock. In shock there are further changes also—an alteration in respiration and the heart's action, a modified or depressed mental state, loss of power in both forms of muscles, a diminution in the glandular secretions, a lowering of the body's temperature. The condition of the circulation is extremely interesting, and we seem justified in concluding that a great part of the body's blood does not circulate freely through the arteries, but accumulates in the venous trunks, especially in the abdominal veins, so that the condition is equivalent to an internal or intravenous hemorrhage. The condition of shock, therefore, simulates closely the condition seen in cases of hemorrhage, and we know that hemorrhage is one of the important factors in the production of shock.

The leading **symptoms** of shock are those of an acute anemia. The blood-pressure is low, often below 50 mm. of mercury, and the pulse is usually rapid and soft, though it may rarely become slowed. The output of the heart constantly diminishes as the shock deepens; the face becomes blanched; the breathing becomes rapid, sighing, irregular, and of the Cheyne-Stokes variety; the muscular systems are relaxed; the reflexes are diminished; the sphincters are relaxed, and voluntary muscular action is abolished. The functions of digestion and of renal secretion fail also, while the skin becomes moist and cold. The patient usually is apathetic, though he may be talkative and excitable rarely. The blanched face appears shrunken, pinched, and elongated, while the chin droops and languor marks the expression. The eyes grow dim and turn upward beneath the half-closed lids, but the pupils react markedly to light. Should the patient die, the symptoms persist, becoming constantly more marked until the end. In case of recovery, however, one notes first a slight improvement in the rate and volume of the pulse, after which the color returns gradually and the patient begins to rouse himself and take notice of his surroundings, or he may fall into a quiet and normal sleep.

The **causes** which produce shock are manifold—the most important are those sensory impulses (traumatic) which affect the medullary centers; the next is hemorrhage. Additional causes are general anesthesia, long-continued pain, extensive surgical operations, extreme heat and cold, certain drugs, and strong psychic impressions, while various general bodily states also conduce to shock—anemia, diabetes, nephritis, sundry infections, starvation, and autointoxication (Bloodgood).

[1] George W. Crile, Blood-pressure in Surgery; Surgical Shock; Shock and Collapse, in Keen's Surgery, vol. i, p. 922; J. C. Bloodgood, Surgical Shock, in Bryant and Buck's American Practice of Surgery, vol. i, p. 463 (including a résumé of Howell's article); Eugene Boise, The Nature of Shock, Amer. Jour. Obstet., January, 1907; J. P. L. Mummery, Lancet, April 1, 1905; W. Sheen, Lancet, June 30, 1906.

The **diagnosis** of shock is sufficiently obvious from the foregoing description of the symptoms. For surgeons probably the most interesting feature in its causation is hemorrhage, and hemorrhage and shock frequently are associated. It is not possible, however, to distinguish shock from hemorrhage under certain conditions, since shock may exist without hemorrhage, and hemorrhage may exist without shock. *Hemorrhage* produces, in addition to the general symptoms already described, certain quite characteristic symptoms—an impairment of vision, irregular tossing, frequent yawning, great thirst, nausea, and sometimes convulsions. The hemoglobin is enormously reduced, while in shock it is unaltered. In hemorrhage the attacks of syncope are recurrent; in shock such attacks do not occur. In concealed abdominal hemorrhage one may distinguish by examination evidence of accumulated blood in the flanks, while the exhaustion is slow and progressive. Shock is generally of rapid onset, and does not suggest slow exhaustion.

The **treatment of shock** is a subject of constant and intense interest to surgeons. It deserves careful study. Crile is probably weary of hearing himself quoted on this subject, but in these days his sayings must fill the page of the writer who treats of shock. However the physiologists dispute as to the cause of shock, no practical surgeon who has watched Crile's treatment of shock can doubt its efficiency. For the last seven years I have been following his advice with satisfaction, and for the past three years I have been deeply convinced in my own practice of the truth of his teaching, which shows that the proper elimination of shock is best attained by dissociating local physical traumatic impulses on any part of the body from their registration, through nervous impulses upon the brain (*anoci-association*). One endeavors: (1) To prevent further shock; (2) to support the circulation; (3) to secure physiologic rest. I can well illustrate the *rationale* of treatment by quoting in full sundry paragraphs of E. H. Risley[1]—an admirable summary of the anoci-association method:

"Extensive experimentation shows, therefore, that in shock the essential factors to be considered are trauma, the anesthetic, a primary rise with a following fall in blood-pressure, decrease in body temperature and vasomotor inhibition, paralysis, and then exhaustion. In addition to these physiologic changes more recent experimental work of Crile and his associates has shown another, and perhaps entirely unlooked for, physiologic and pathologic process to take place in the presence of shock. I refer to the recent work showing extensive cytologic changes in the brain as a result of trauma, fear, infection, etc. Animals were overtransfused so that the factor of anemia of the brain was wholly excluded during the application of the shock-producing trauma. In every instance morphologic changes in the cells of all parts of the brain were found, especially in the cortex and cerebellum. It required more trauma to produce equal changes in animals protected against low blood-pressure than in those whose blood-pressure gradually declined during the experiment. The structural changes include

[1] E. H. Risley, Boston Med. and Surg. Jour., January 23, 1913.

changes in the absolute size of the cells, in the size relation of the nucleus, plasma, surrounding membrane of the cell, nucleus, and the general contour of the cell. As to gross size, the increase varies from slight to even eight times the normal, the nucleus becomes relatively larger, the limiting membranes may be even ruptured, causing distortion of the cell. In extreme shock the cell completely loses its contour and presents the appearance of a disorganized mass of protoplasm.

"At first, in shock, there may be increase in the reaction to Nissl stain, but later, as shock increases, the reaction becomes less, and in the final stage there is little or no stain reaction. Even in cases of fatal shock, however, not all of the cells are thus altered. On morphologic grounds, when the nucleus, nucleolus, and the cell body become so broken down as to have an undifferentiated mass of protoplasm, the cell is almost certainly dead and will never regenerate, *i. e.*, the brain cell is finally deprived of its discharging nervous energy and becomes exhausted, just as exhaustion follows too prolonged muscular exertion. The gravity of a given case is well indicated by the percentage of cells that are thus damaged. It has been shown, likewise, that the cells of the brain in various diseases also experience the same changes as the one found in shock. A nerve cell that has been impaired by overwork, anemia, infection, drug poisoning, or Graves' disease, obeys the same general law of change. Therefore, the changes that are seen in the brain cells are not in the least specific for any etiologic factor, for they appear to be common to all of the above-named conditions so far studied.

"These studies only serve to further illustrate more forcibly how complex a state shock is and how many factors enter into its physiology. These cytologic changes would rationally explain many of the post-operative neurasthenic states so often seen.

"Crile goes further, and states that there is strong negative evidence that traumatic impulses are not excluded by ether anesthesia from the part of the brain that is apparently asleep. For if this factor of fear be excluded, and if, in addition, the traumatic impulses are prevented from reaching the brain by cocain, then, despite the intensity or duration of the trauma within the zone so blocked, there are found no morphologic changes in the brain cells. If, on the other hand, no blocking was used, cell changes are everywhere present. Therefore, although ether anesthesia produces unconsciousness, it apparently protects none of the brain cells against exhaustion from the trauma of the surgical procedure. Ether is, so to speak, but a veneer that covers the deeper suffering of the patient (or patient's brain cells).

"Crile believes that ether alone is one of the determining factors in the production of shock. In a series of parallel experiments on animals with ether and with nitrous oxid it was found that the damage to brain cells under ether was four times greater than under nitrous oxid.

"Having reviewed the factors on which Crile believes shock is based, we are now in a position to consider the logic of his solution of the

problem of treatment. It seems to me it is an extremely logical and reasonable line of deduction. Some of it is old, but a great deal is certainly new and advanced, well-founded on experimental work, and extremely efficient from a practical point. He adds practically nothing new to our routine of treatment in cases in which shock has already developed, *i. e.*, heat, rest, morphin, intravenous infusion, bandaging of extremities, elevation of the foot of the bed, and transfusion. He believes that intravenous infusion is of prime importance because it causes, in the first place, an increase in the venous pressure in the vena cava, and consequently the output of the heart is at once increased, the amplitude of the strokes lengthened, and, the chambers being full, the contractions become more forcible and blood-pressure begins to rise. The combination of small, frequently repeated hypodermic injections of strychnin together with saline infusion produces a more constant pressure than ether alone. Overstimulation is followed by greater depression, hence large doses of strychnin are absolutely contra-indicated, for such doses produce vasomotor paralysis and shock the same as trauma does. It is as reasonable to treat shock with large doses of strychnin as to treat strychnin-poisoning with trauma. No justification can be found, experimentally, for the use of alcohol, nitroglycerin, or amyl nitrite as stimulants. As regards alcohol, in not a single instance was there a sustained improvement in the blood-pressure or respiration. On the contrary, the most constant and marked effect on the blood-pressure was a decline. The final breakdown was more sudden with drugs than in control animals. Adrenalin, however, administered cautiously and continuously, with a limited amount of saline, proved the best stimulant, in addition to external pressure by Crile's rubber suit or bandaging of extremities.

"The great advance made by Crile in the treatment of shock has been in elaborating a logical *prophylaxis*. This we are in a position to study and to use clearly his reasons for.

"It is an unpleasant thought that although our patient is unconscious from general anesthesia, yet the nerve impulses inaugurated by operative injury of the nerves reach the brain and produce harmful changes there which are the precursors of shock. It is clear that if general anesthesia cannot prevent the damage done to the brain in the course of operation, some means must be devised to prevent this damage. It is known that cocain, in addition to its ability to block sensory impulses, also blocks impulses that cause the response of the entire nervous system under general anesthesia. If we combine, therefore, a local with a general anesthesia and avoid fear previous to operation, the use of sufficiently large doses of morphin to bring the patient to the operation in a quiet, contented frame of mind, it matters not how poor the risk or how extensive the operation, the nervous system is protected and the immediate operative risk is eliminated.

"The elimination of the factor of fear is an extremely important one, and can be entirely accomplished only by the most careful co-operation on the part of the nursing and operating staff. The patient should be

told of all the preparations to safeguard his welfare before, during, and after operation; his room should be quiet and free from outside disturbances.

"Fear is stronger than will, but under morphin a mental state is produced in which one is neither brave nor a coward, because this drug destroys the associated power of the brain, and the patient is left in a quiet state of mental and physical repose.

"If we can, therefore, prevent fear and obtain an innocuous substitute for ether, and block harmful nerve impulses from the brain, we have a condition best described by the word *anoci-association*, that is, one in which the patient is both mentally and physically protected from nocuous impulses or influences.

"(The difference between anoci-association and anesthesia is as follows: Although inhalation anesthesia confers the beneficent loss of consciousness and protects from pain, it does not prevent the nerve impulses from reaching and fatiguing the brain cells, and hence does not prevent shock or the train of later nervous impairments so common following shock, *i. e.*, neurasthenic postoperative states.)

"The *prophylaxis*, therefore, which is to produce a state of *anoci-association*, consists first in gaining the confidence of the patient, reassurance of a favorable outcome, the generous enough use of morphin before operation to produce a state of mental relaxation and content, nitrous oxid and oxygen anesthesia, nerve-blocking by cocain or novocain, great care to prevent loss of body heat, injury to tissues handled, and trauma to any but the immediate site of operation, speed reasonable to safety, and a similar innocuous after-care. Crile, in abdominal operations, uses the quinin and urea hydrochlorate injected into the peritoneal edge before sewing up. The anesthesia produced locally by this drug lasts for twenty-four to forty-eight hours and protects the patient almost entirely from the wound pain, as it is the pulling of the peritoneum which is the greatest factor in the causation of the postoperative wound pain."

The prevention of shock runs into and overlaps that equally important matter—the treatment of present shock—and this leads us to our second topic, *support of the circulation*. That is a matter about which opinions have differed widely, though, fortunately for suffering humanity, surgeons are coming to agreement. We recognize two distinct divisions of this subject—two methods of supporting the circulation: (1) By external applications and posture; (2) by the administration of internal remedies. The first or mechanical method is ancient, and has always been more or less popular, though its exact manner of working only recently has become clear. By compressing the peripheral circulation of the body blood is forced into the internal organs, the heart is stimulated to increased exertion, and the nervous system is encouraged through vasomotor stimulation. At the same time the great veins of the abdomen which have been drinking up the patient's blood and keeping it out of commission, as we say, are

forced to disgorge their contents. An excellent means of exerting peripheral pressure is by tight bandaging of the limbs and trunk with broad flannel or rubber rollers. A still more effective method—a method vastly more effective in my experience—is the application of Crile's pneumatic rubber suit, which can be inflated in a minute. It is extremely interesting, during its application, to watch the surprising and almost instantaneous improvement in the patient's pulse. A simple and easy method of seeking the same end, but a method much less effective, is to throw the patient into a modified Trendelenburg position, by which maneuver the heart's action is relieved and the basal centers are flooded by fresh blood. At the same time keep the patient warm with hot bottles, or a hot-water bed and blankets.

Saline solutions introduced into the circulation may be regarded either as mechanical aids or as internal remedies, but, however that

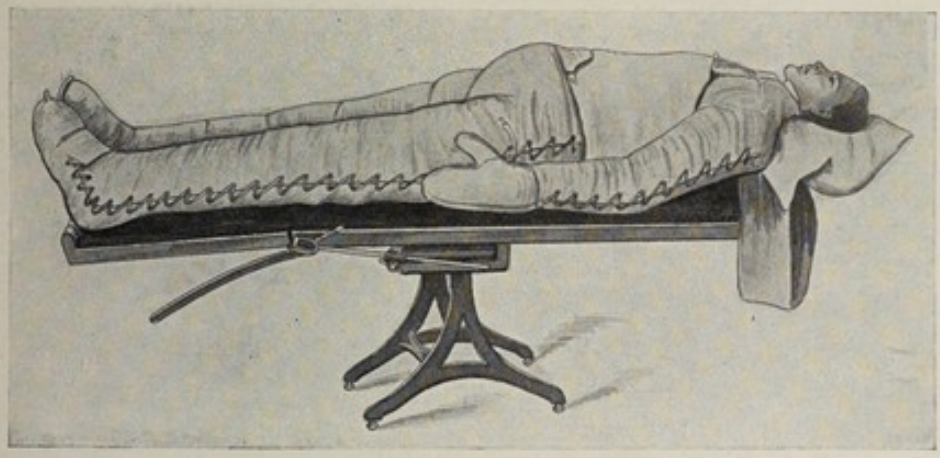

Fig. 468.—Crile's pneumatic suit (Keen's Surgery).

may be, it is certain that the mere presence of an increased volume of fluid in the circulation serves for a short time to relieve shock, and is, most of all, valuable if there be hemorrhage. There are five methods of introducing saline fluids: (1) By intravenous infusion—the injection of the solution through a cannula directly into a vein, choosing preferably one of the veins of the calf or at the bend of the elbow; (2) by intra-abdominal infusion; (3) by rectal injections; (4) by subcutaneous injections; (5) by direct transfusion of blood. As Crile remarks, it is well to give the intravenous infusion gradually, since a great amount of fluid may cause acute dilatation of an anemic heart. One should not give more than a pint, as a rule, but this amount may be repeated at frequent intervals. The intra-abdominal infusions are commonly practised in the course of abdominal operations, the opened belly being filled with salt solution and sewed up. This included solution is absorbed quickly. Rectal injections are easy and comparatively painless, especially if given by Murphy's seeping method (proctoclysis), which I described in Chapter VIII, or by McArthur's method, through the gall-bladder. Subcutaneous injections (hypodermoclysis) are easily

given also, though they are painful. We inject the fluid under some easily distensible area of skin, beneath the breasts, the loin, the thigh.

Such remedies suffice for most cases of shock, but there are times when it will seem well to supplement them by internal medication. The most efficient drug at our command is adrenalin chlorid (1:1000), 15 minims of which may be added to 500 cc. of the saline solution; or in cases of extreme urgency we may inject into the vein a continuous infusion of 1:20,000 adrenalin solution at the rate of 2 cc. a minute.

You shall hear much talk of sundry drugs which clinical experience seems to have proved valuable—alcohol, ether, strychnin, digitalis, nitroglycerin, atropin, etc. Of these, strychnin and atropin alone are

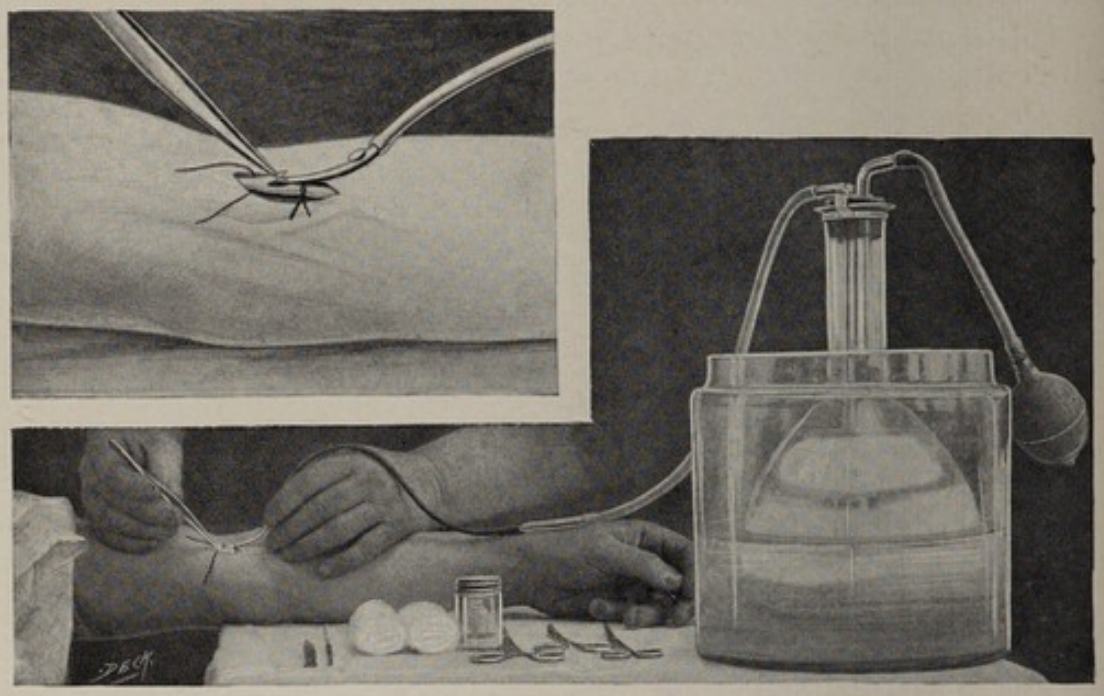

A B

Fig. 469.—Intravenous saline infusion. A, The lower ligature is tied and the upper ligature is in place ready for tying. The valve-shaped opening in the vein is shown ready to receive the cannula. B, Flask containing the saline solution. This flask is an ordinary wash-bottle, the long glass tube of which is connected to the infusion cannula and the short glass tube to a rubber bulb with valves. By pumping air into the flask above the solution the latter is forced into the veins (Fowler).

of value, and that only in appropriate and well-considered cases. We know the oft-quoted remark of Mummery: "The administration of strychnin in shock is like beating a dying horse; it may call forth an effort if we beat hard enough, but it hastens the end." However, there are frequent cases in which strychnin certainly helps to tide a patient over a long, tedious operation. In the course of an extensive dissection, when the pulse runs slowly or acts with diminished force, a $\frac{1}{40}$ or a $\frac{1}{30}$ grain of strychnin frequently will improve the situation. Again, in that condition which we call secondary shock—a rising, feeble, or irregular pulse supervening a day or two after recovery from the primary shock—small doses of strychnin are effective—$\frac{1}{40}$ grain

every four hours. Atropin is a useful drug occasionally in shock, particularly when the skin appears moist. As Da Costa says, quoting Hare, it is a sedative to the vagus; but what makes it particularly valuable is that it acts upon the vasomotor system, combats the dilatation of the blood-vessels, maintains vascular tone, prevents stagnation of the blood in any vessels, and increases the amount of moving blood.

In addition to the methods of treatment I have already described there is the transfusion of blood, which we are now finding to be of great value in cases of shock and of hemorrhage. Transfusion, an ancient and discredited operation, has been successfully revived in the past three years. Direct transfusion of the arterial blood of the donor into a vein of the donee—transfusion without intervening apparatus—is meeting physiologic ideals. Transfusion must usually be reserved as a last resort on account of the difficulty of securing a donor and the tediousness of the operation itself. I believe, however, that, with a wider popular understanding of its importance, and with improvements in the technic of the operation, transfusion will be frequently and successfully used in the future.[1]

A brief summary of the treatment of shock, therefore, will include the following points: quiet the pain and apprehension by a hypodermic injection of morphin; keep the patient warm; employ the Trendelenburg position; bandage the limbs and abdomen, or apply the pneumatic suit; use saline infusions; add adrenalin to the infusion; if an anesthetic is to be used, employ ether; if an operation is imperative, block the great nerve-trunks with intraneural injections of cocain, but, so far as possible, avoid all operations during shock; endeavor to keep the patient comfortable and tranquil; and in extreme cases employ direct transfusion of blood—by far the most valuable measure at our command.

SURGERY OF THE BLOOD-VESSELS

Surgery of the blood-vessels is no novel thing, though the furor of present-day progress might lead the unsuspecting to assume that this is a new branch of surgery. The history alone of the subject forms a fascinating chapter, and one recalls the fact that wounds of the arteries were treated for centuries by application of the actual cautery; that Hippocrates dealt intelligently with the subject; that Galen, in the second century A. D., introduced the ligature for arteries wounded in continuity; that Paré in the sixteenth century applied the ligature to arteries severed in amputations; that the ancients treated aneurysm by digital compression; that Antyllus, in the third century, devised the operation of double ligature and laying open the sac for aneurysm—an operation more recently modified by Purmann, who excised the sac; that John Hunter, in the eighteenth century, taught the operation of proximal ligation for aneurysm, and finally that Matas, of New Orleans, in 1903, described his extremely valuable method of aneurysmal suture.

[1] J. G. Mumford, The Blood in Surgery, Ann. Surg., January, 1910.

Wounded arteries and aneurysms do not furnish the only material for surgery of the blood-vessels. There are diseases of the veins and capillaries—inflammations, dilatations, and vascular tumors. Let us consider shortly some of the latter lesions, and then pass in review the more important advances of latter-day surgery of the arteries.

Surgery of all blood-vessels is in some respects analogous to surgery of the intestinal tract, while in other respects it differs widely. Both blood-vessels and intestines have their three coats and their moving contents, but the blood-vessels are lined with an endothelium similar to the peritoneal and meningeal serosa—a smooth, glistening membrane which, when irritated, forms ready adhesions and easily acts to cause a coagulation of the contained blood. But the contained blood is aseptic, whereas the intestinal contents are highly septic. *Veins* have their own peculiarities as distinguished from arteries; they are thinner walled; they contain competent valves; when subject to infection, they become inflamed readily, and this inflammation spreads quickly to their outer coats; consequently we find the conditions known as phlebitis and periphlebitis.

PHLEBITIS

Phlebitis and *periphlebitis*, the latter being associated frequently with lymphangitis, is an inflammation of the lymphatics along the venous walls.

Acute phlebitis results from injuries from childbirth, from erysipelas, from such superficial lesions as varicose ulcers, and from general infective processes—especially diphtheria, typhoid, pneumonia, and gonorrhea. The phlebitis of typhoid is extremely common. As a rule, phlebitis runs a short and painful course to recovery, but in the more serious cases a general pyemia may supervene, resulting in death.

Chronic phlebitis is a common affair, and comprehends an inflammation of a proliferating type, followed by more or less organization. Occasionally *phlebitis obliterans* occurs as a sequel of syphilis and other chronic infections, as well as after various operations upon the veins.

The *symptoms of acute phlebitis* are unmistakable when the veins are superficial, but are obscure when the veins are deep. According to the situation of the veins, the skin may or may not become dark blue or dusky red or remain unaffected. The vessel, when palpable, feels cord-like. Fever comes on and rises; the inflamed area is exquisitely tender, and usually there is pain. The blood contained within the veins clots, and if this clotting be extensive, edema of the parts results. If no collateral circulation be available, the result to the parts drained by the affected veins may be extremely serious, and gangrene even may follow. The terms *phlegmasia alba dolens* and *milk-leg* describe a painful swelling of the leg due to portal, pelvic, and femoral phlebitis. One cannot readily determine the more deeply seated inflammations, but may infer their presence from the fever, the extensive tenderness, the pain, and the swelling. One sees, moreover, that deep-seated phlebitis

of important veins may result quickly in the most frightful calamities. Mesenteric phlebitis may cause mesenteric gangrene and peritonitis. Hemorrhoidal phlebitis may extend to the higher abdominal veins, with fatal result. Umbilical phlebitis kills newborn infants, while the sinus phlebitis associated with middle-ear disease is a common cause of death in the latter ailment. Moreover, infected thrombi dislodged from any vein may be carried into distant parts to set up the metastatic abscesses of a general pyemia.

The *treatment* of phlebitis, therefore, takes on sundry and quite diverse phases. The acute surgical forms, especially phlebitis of the limbs, generally may be subdued by rest—absolute physiologic rest. Many surgeons employ cold applications and ichthyol or silver (Credé) ointments. My own preference is for mild creolin poultices, applied over the whole limb and bound gently into place under thickly wadded

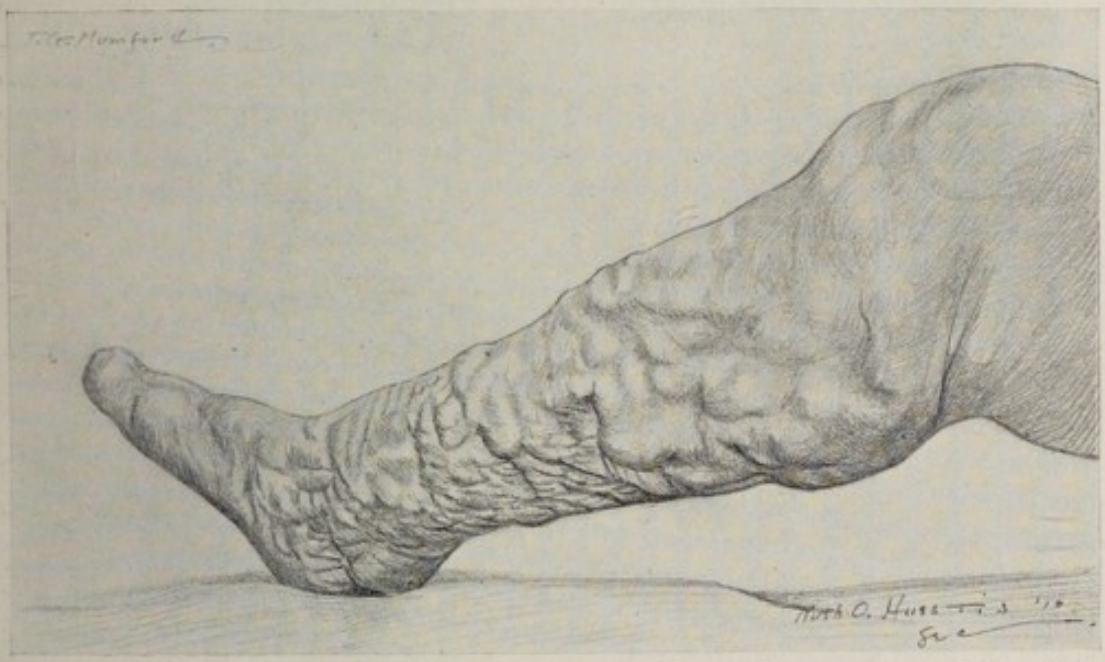

Fig. 470.—Varicose veins of the leg, extreme type (Massachusetts General Hospital).

bandages. The warmth is extremely agreeable, and the creolin solution seems to maintain its heat for a long time. One should change these poultices every three or four hours.

In all cases the septic focus from which the phlebitis originates should be treated. Otherwise no direct interference with the inflamed veins can be effectual. As an example of this, one sees "milk-leg" running an obstinate course because a septic infection of the pelvic organs has escaped observation. In the case of deep infections causing thrombophlebitis in the veins of the pelvis, the neck, or the head, the surgeon must often open the veins and turn out the clots at the same time that he attacks the localized underlying disease.[1]

Chronic phlebitis shows its commonest forms in varicosities of the leg, the scrotum, and the anus. I have already considered the two

[1] Professor Dr. F. Trendelenburg, A Review of Surgical Progress, Trans. Section on Surgery and Anatomy, Jour. Amer. Med. Assoc., 1906.

latter, but it is interesting to see how, recently, varicosities of the leg have come to be treated. It seems probable that the essential predisposing cause is a congenital defect in the vessels or their innervation. Immediate causes enter in also—occupations involving long standing, and probably injuries, constipation, and child-bearing. Gradually the veins become enlarged and obvious to sight and touch, sometimes giving a sense of fulness in the leg, while there may ensue edema, pains, a constant heaviness, and painful cramps at night. The skin becomes ill nourished, glossy, eczematous, with a frequently resulting ulcer. Occasionally a vein ruptures, giving rise to a sharp hemorrhage. In Chapter XXVI, I discussed at some length the simpler treatment of varicose ulcers, and one must believe that sound and permanent cure of these ulcers depends upon cure of the varicose veins.

The *treatment* of varicose veins in the leg is the affair of the surgeon, but it is often hard to convince the sufferer of this fact. A patient comes into a physician's office and shows a bunch of varicose veins. The busy physician recommends an elastic stocking, and thinks no more of the matter. That is all very well, for if the patient will wear a proper elastic stocking or, better, a well-made flannel bandage from his toes to above the knee, he will get along comfortably enough,



Fig. 471.—Mayo's vein enucleator.

but he will find the wearing irksome, and after a time will abandon the treatment. Then the varices will grow larger, and the last state of that man is actually worse than the first.

For years surgeons have endeavored, by extensive dissections and excisions, radically to cure these varicosities. They were working in a septic field, and although they often cured the varix, they submitted the patient to a long and distressing convalescence. Trendelenburg has devised a useful operation—ligation and section of the internal saphenous vein in the upper portion of the thigh. Schede's operation is popular,—the so-called circumcision of the leg,—but I have come to rely almost entirely upon the ingenious procedure of C. H. Mayo—subcutaneous enucleation: seek the internal saphenous vein, ligate and cut it in Scarpa's triangle. Enucleate the distal severed portion with the long-handled ring-enucleator pictured here. With gentle force pass the instrument along the vein, tearing off the branches for six or eight inches. Then bring out the end of the instrument through a small incision. Often the removal of this six or eight inches is enough to establish a cure, or the surgeon may repeat the performance, taking out several sections of veins throughout the length of the leg. In the calf the enucleation is somewhat more difficult, and slight hemorrhage more frequent. For this one should elevate the leg, take out small sections of the vein at a time, and tie obstinate bleeding radicles. After

the operation I dress the leg in the Gamgee dressing I described in Chapter XXVI.

Aneurysmal varix is a dilatation of the veins due to an anastomosis or connection of one of them with an artery, from which arterial blood flows into and dilates them, causing their pulsation. A *varicose aneurysm* is usually a false aneurysm (such as formerly occurred commonly after the operation of venesection at the bend of the elbow), lying between a vein and artery and communicating with both. *Rupture* of a varicose vein, of an aneurysmal varix, or of a varicose aneurysm may occur, and obstinate and alarming hemorrhage may result. Simple venous hemorrhage, as from a ruptured vein in a varix of the leg, is easily controlled. It suffices usually to elevate the limb and apply a firm compression dressing for a few hours. If the hemorrhage persists, however, the surgeon may find it necessary to cut down upon the damaged vessel, and to tie it off above and below the damaged point. Aneurysmal varix may be treated on the principle of Matas, as I shall explain later in this chapter. Varicose aneurysm may be excised and the wounded vessels sutured with through-and-through chromic gut stitches.

ANGIOMA

An *angioma* is a tumor composed of blood-vessels, and we group angiomata as capillary, cavernous, and arterial.

Capillary angioma, or *nevus*, is that common form which I have already described in Chapter XX. A nevus may be excised, deeply scored with the Paquelin cautery, treated by injections of boiling water, or, best of all, by carbon dioxid snow.

Cavernous tumors are similar in structure to the corpus cavernosum, for the vessels become not merely dilated, but cavernous in arrangement. We see these tumors in the tongue, the voluntary muscles, the liver, the breast, the larynx, and under the peritoneum. They may also be treated by excision, by boiling water injections, by electrolysis, or by carbon dioxid snow.

Arterial or *plexiform angiomata* are also called *cirsoid aneurysms*. We treat them by careful and wide dissections, often repeated, until the whole mass of affected vessels has been removed.

THE ARTERIES

Surgery of the arteries finds expression in three directions—in ligation, in the treatment of aneurysm, and in the suture of arteries—the last a new and increasingly important topic.

LIGATION OF ARTERIES

In former times, when sepsis raged, when secondary hemorrhage was common, and hemostatic instruments were crude, the ligation of arteries was taught as one of the most important branches of surgical

handicraft. To-day it is rare for the operating surgeon to seek and tie an artery in continuity, except for the treatment of aneurysm. He may occasionally expose and control temporarily a vessel with Crile's clamp in order to render bloodless a distant field of operation.

Text-books of operative surgery deal extensively with the ligation of arteries. I shall content myself with describing the method of approaching and securing a few of the more important vessels.

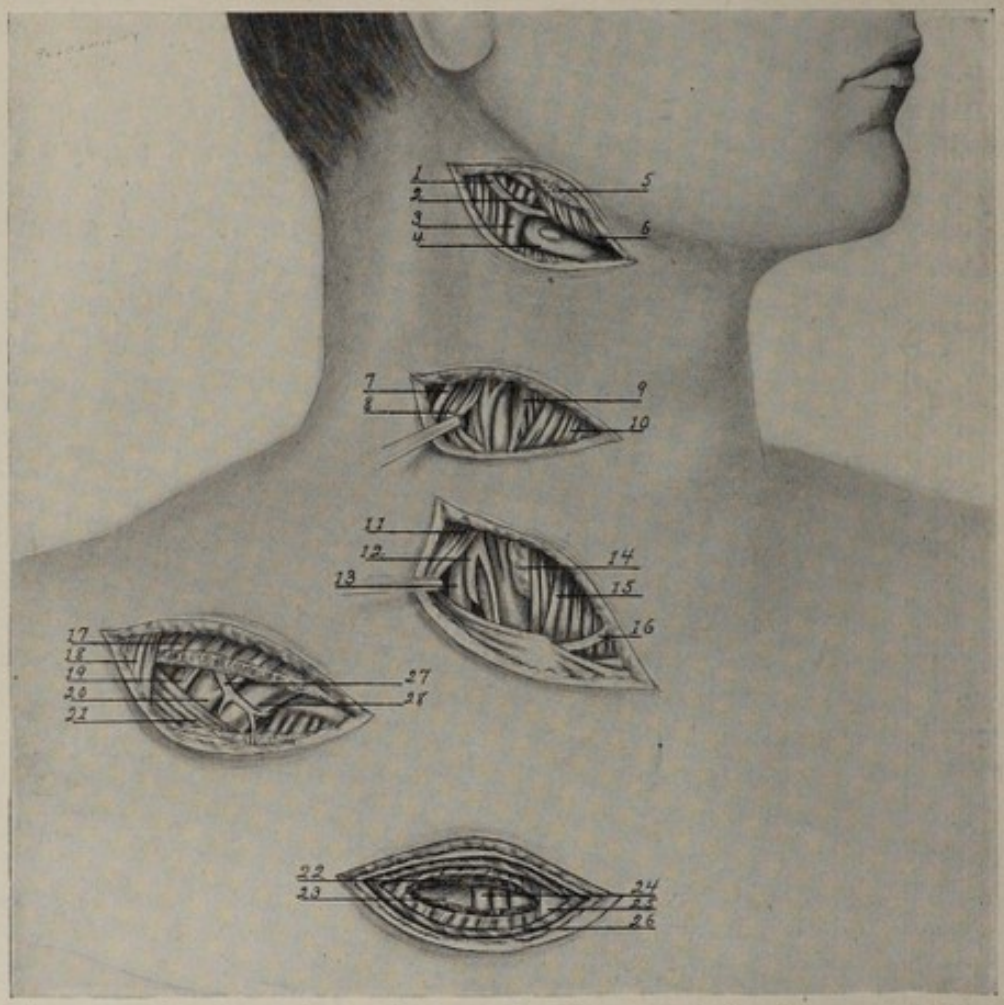

Fig. 472.—Ligation of arteries in neck, chest, and shoulder: 1, Hypoglossal nerve; 2, facial artery; 3, external carotid artery; 4, great cornu of hyoid; 5, submaxillary gland; 6, digastric and stylohyoid; 7, external jugular vein; 8, sternomastoid muscle; 9, descendens noni nerve; 10, omohyoid; 11, sternomastoid muscle; 12, vagus and recurrent laryngeal nerves; 13, internal jugular vein; 14, thyroid gland; 15, sternohyoid muscle; 16, anterior jugular vein; 17, clavicular portion of pectoralis major; 18, deltoid muscle; 19, median nerve; 20, axillary artery, first part; 21, pectoralis major muscle; 22, internal intercostal muscle; 23, pleura; 24, internal mammary artery; 25, edge of sternum; 26, pectoralis major muscle; 27, external anterior thoracic nerve; 28, axillary vein.

The **innominate artery** was tied first on the living in 1818 by the distinguished New York surgeon, Valentine Mott; his patient died a month later. In 1864 A. W. Smyth, of New Orleans, tied the innominate, and his patient lived. Up to 1905 the innominate had been tied some thirty-five or forty times, according to Roswell Park. An excellent account of ligation of the innominate, with a complete bib-

liography, is Herbert L. Burrell's,[1] who performed the operation in 1895. His patient died in the fourth month.

The approved steps of the operation are as follows: Make the incision along the anterior border of the sternomastoid muscle, down to the clavicle, and then along the inner third of the bone, thus forming a flap. Divide the sternal and clavicular attachments of the muscles, and free the upper border of the sternum, taking pains to avoid the anterior jugular vein and the pneumogastric and recurrent laryngeal nerves. Burrell cut away the end of the sternum. Find the common

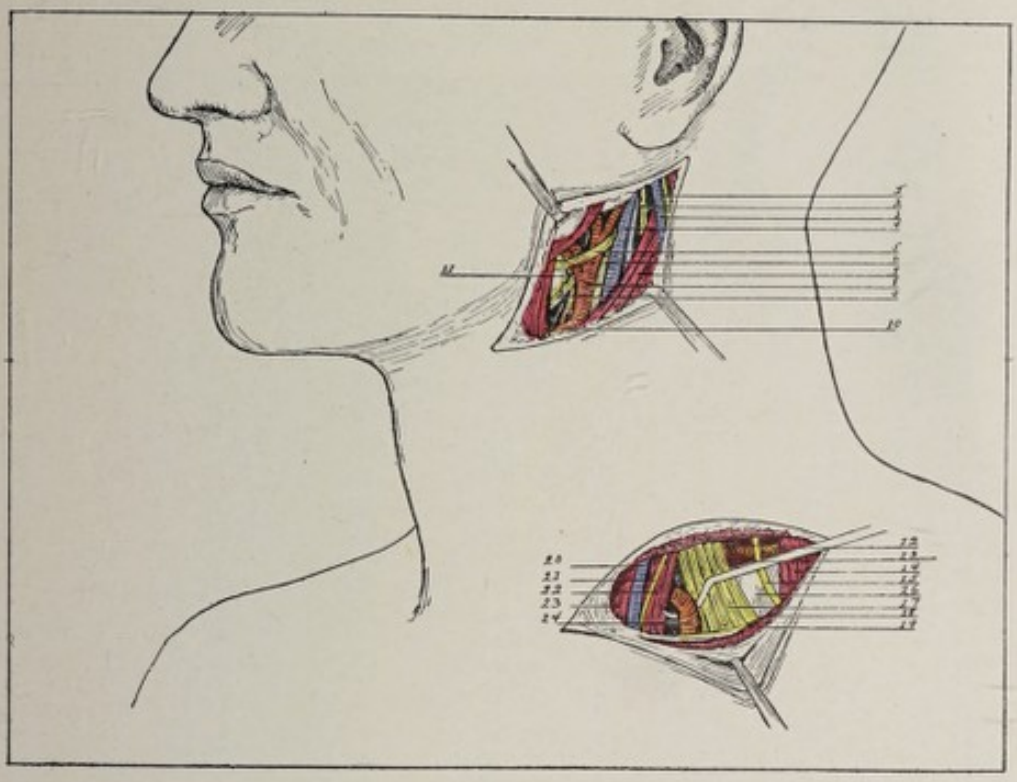

Fig. 473.—Certain nerves, vessels, and muscles of neck and shoulder (redrawn from Kocher): 1, Great auricular nerve; 2, spinal accessory nerve; 3, external jugular vein; 4, internal jugular vein; 5, hypoglossal nerve; 6, descendens noni nerve; 7, sternomastoid muscle; 8, external carotid artery; 9, superior laryngeal nerve; 10, superior thyroid artery; 11, greater cornu of hyoid; 12, transversalis colli artery; 13, scalenus medius muscle; 14, trapezius; 15, clavicular superficial cervical nerve; 16, first rib; 17, brachial plexus; 18, omohyoid; 19, platysma; 20, external jugular vein; 21, phrenic nerve; 22, scalenus anterior muscle; 23, sternomastoid muscle; 24, subclavian artery.

carotid, trace it down to the innominate, and with careful manipulation throw a silk or linen ligature about the innominate and tighten slowly the thread. If one is tying the innominate for subclavian aneurysm, he should tie the common carotid at the same time. Park suggests that, as an additional step in the technic, one might well follow Crile's method in the removal of goiters—placing the patient in a semi-upright position and applying the pneumatic suit. As the innominate is being tied, lower the patient and lessen the pneumatic pressure.

[1] H. L. Burrell, Trans. Amer. Surg. Assoc., 1895.

These wounds should be drained, the arm warmly wrapped and kept at rest, and pain relieved by frequent doses of morphin.

The **common carotid** is easily reached and tied by splitting down through the sternomastoid muscle at the level of the cricoid cartilage, turning aside the deep jugular, and separating carefully the artery from its sheath before applying the ligature.

The **external** and **internal carotids** are readily found also by carrying the cut a little higher, seeking the anterior border of the sternomastoid, and finding the origins of the two arteries at the bifurcation of the common carotid. The pulsation of all these arteries may be detected readily by the exploring finger.

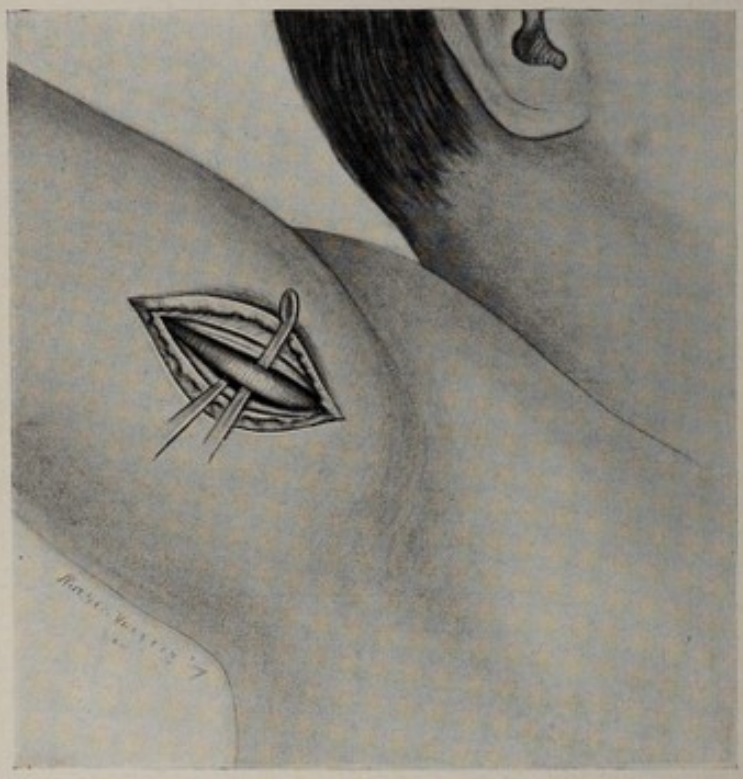

Fig. 474.—Ligation of axillary artery (after Park).

Tie the **lingual artery** by turning up a crescentic flap beneath the jaw, exposing the digastric triangle, and finding the artery immediately above the digastric muscle.

Tie the **facial artery** on the edge of the jaw, where it is felt to beat at a point half-way between the symphysis and the angle of the jaw.

It is needless to detail here directions for finding the various other small arteries of the head and neck. The curious student may consult books on surgical anatomy or operative surgery.

The **axillary artery** is divided into three portions by the pectoralis minor muscle, and is usually tied in its third portion. Approach it through an incision in the midaxilla; expose and divide the deep fascia; draw outward the coracobrachialis muscle and the musculocutaneous nerve, and detect with the finger the pulsating artery.

Find the **brachial artery** in the middle of the arm on the inner border of the biceps, taking pains to avoid the median nerve.

Find the **radial artery,** high in the forearm, by opening between the supinator longus and the pronator radii teres. The artery lies beneath the supinator on a direct line with the brachial. In the middle of the forearm the radial lies along the border of the supinator longus, and it maintains the same relation at the wrist.

Sir Astley Cooper performed the pioneer ligation of the **abdominal aorta** in 1817, approaching the vessel through the linea alba. His patient lived forty hours. A few bold men have followed Cooper's example. In America, Hunter McGuire, of Richmond, performed the operation in 1868. Experience seems to prove useless the daring experiment. All the patients have died. Ligation of the aorta has always been done for aneurysm, and it may be that the occlusion bands of Halsted, the artery suture of Matas, or electrolysis shall successfully accomplish that in which ligation has failed, though in the case of sacculated aneurysms only. It is not difficult to reach the aorta by an extraperitoneal route, opening down upon the peritoneum along the crest of the ilium, and turning back the peritoneum with its contained viscera. This is an easy method, as one eliminates thus the difficult packing off of the intestines required when opening in the median line. By the extraperitoneal route a wide and deep field is exposed, in which one finds readily both the aorta and the **common iliac.**

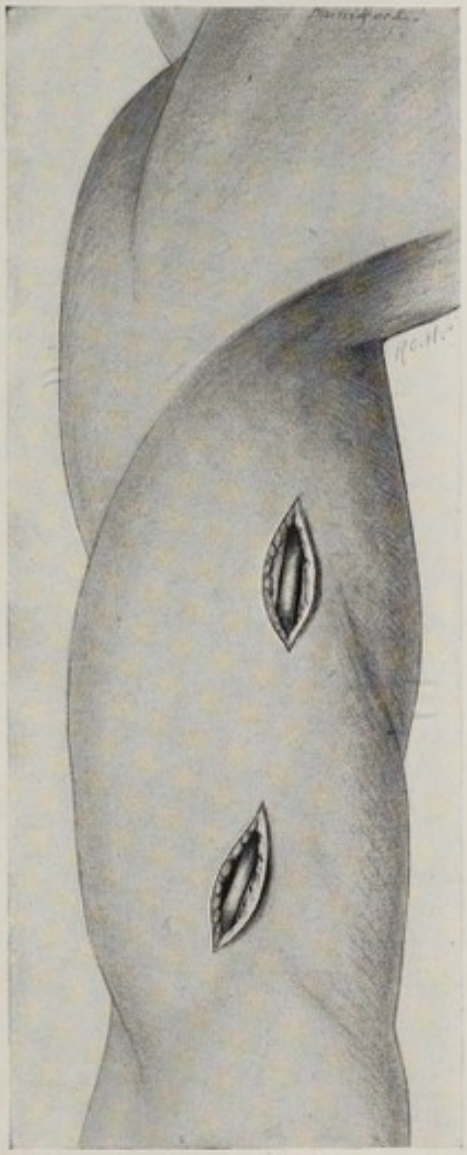

Fig. 475.—Ligation of brachial artery.

To tie the **external iliac,** cut down parallel to, and just above Poupart's ligament, turn back the peritoneum, and find the artery at the midpoint between the pelvic symphysis and the anterior superior spine of the ilium.

The line of the **femoral artery** runs from the midpoint of Poupart's ligament to the internal tuberosity of the femur at the knee. We tie it either high at the apex of Scarpa's triangle, or in Hunter's canal beneath the long saphenous vein, near the outer edge of the sartorius muscle, between the adductor magnus and the vastus internus muscles.

The **posterior tibial artery** lies in a line between the middle of the popliteal space and a point midway between the internal malleolus

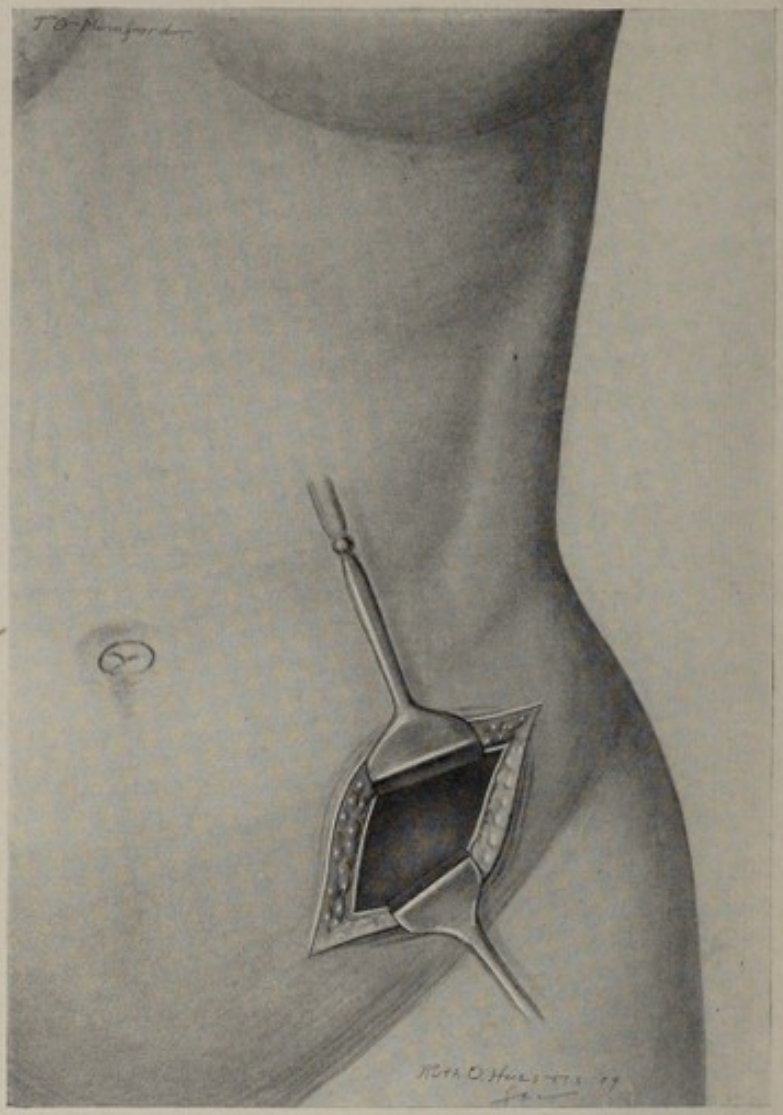

Fig. 476.—Approach to abdominal aorta and common iliac artery.

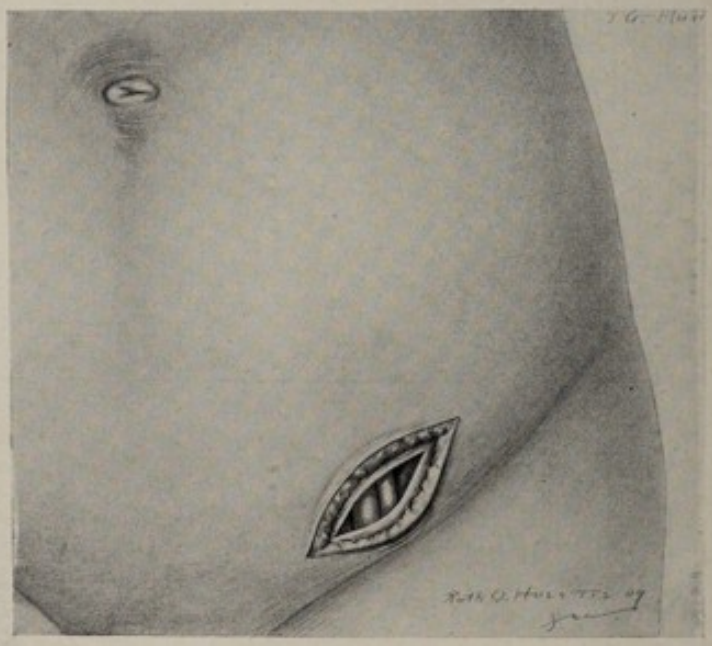

Fig. 477.—Ligation of external iliac artery.

and the tip of the heel. High in the calf one seeks the artery by finding the tendon of the plantaris between the two heads of the gastrocnemius, following it down and feeling the artery beneath the soleus. Lower down one readily finds the artery lying in its proper line, on the flexor longus digitorum, and to the inner side of its own accompanying nerve.

The **anterior tibial artery** lies on the front of the leg, in a line drawn from a point between the head of the fibula and the outer tuberos-

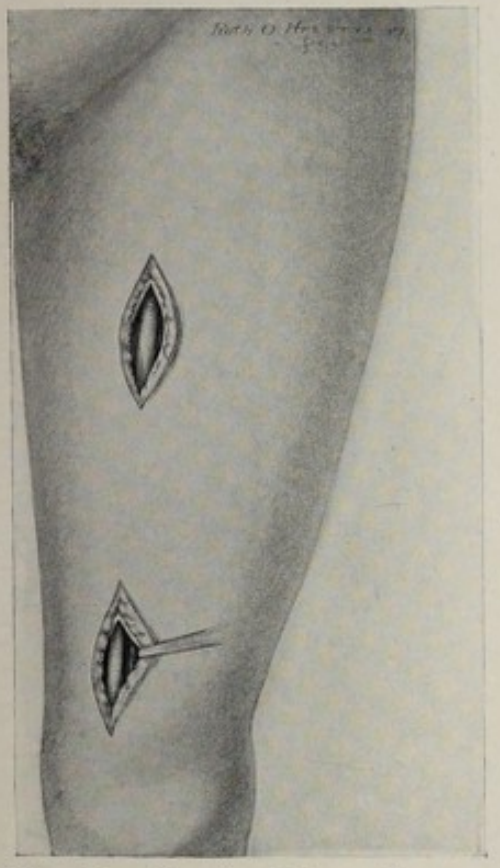

Fig. 478.—Ligation of femoral artery.

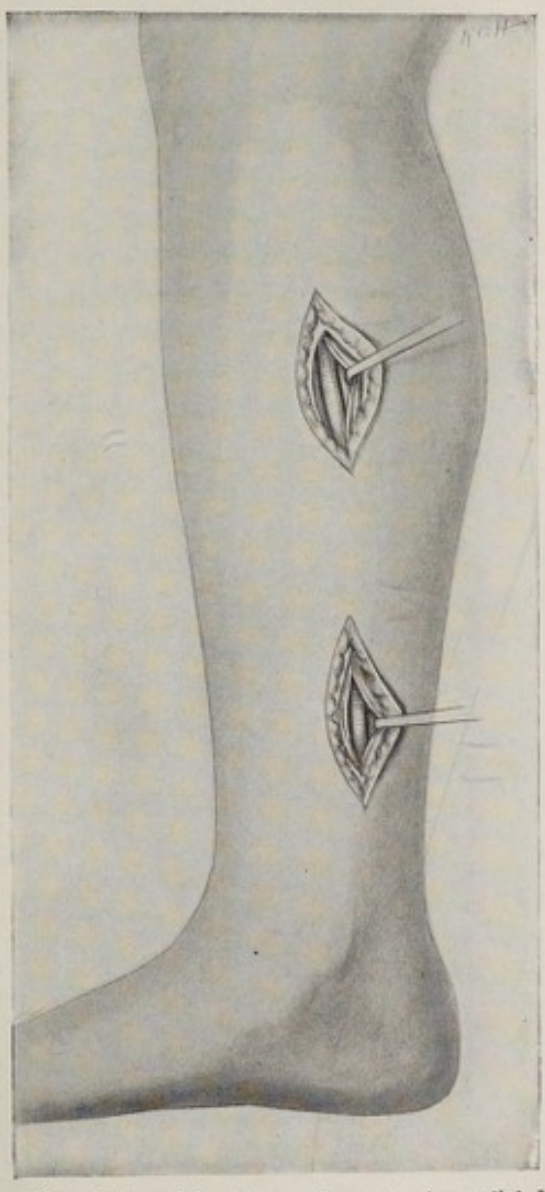

Fig. 479.—Ligation of posterior tibial artery.

ity of the tibia, to the middle front of the ankle-joint. One exposes it easily in this line, and finds it lying between the tibialis anticus and the common extensor of the toes.

In any case, when seeking the arteries of the leg, one should flex the limb so as to render dissection the least difficult, and to bring the vessels into their easy normal relations.

After tying an artery in one of the extremities, close the wound snugly with stitches, elevate the limb, and strive to equalize its circulation by well-padded bandages applied throughout its whole length.

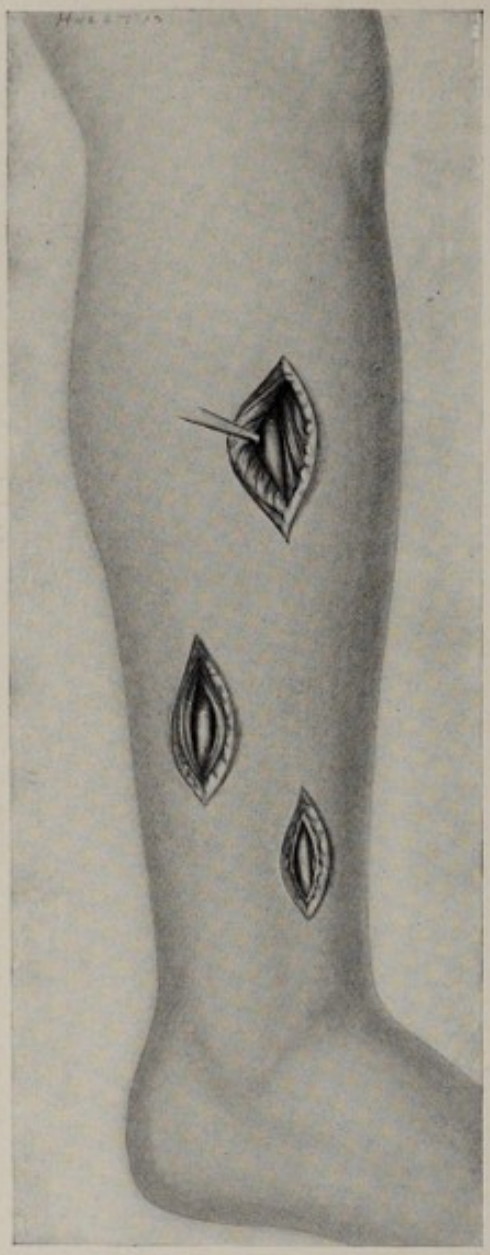

Fig. 480.—Ligation of anterior tibial artery (peroneal).

ANEURYSM

Bryant[1] defines aneurysm as "either a sacculated tumor containing blood communicating with the canal of an artery and formed more or less from its walls, or a fusiform dilatation of an artery." That is a sufficiently satisfactory definition, though every writer has his own fancy. There are true aneurysms and false aneurysms —when the blood is contained within all three arterial coats, or when one or more coats are ruptured and a sort of hernia of the remaining coats occurs. Again, aneurysms are fusiform, are sacculated, are dissecting, as the cuts taken from Holmes show graphically. There are arteriovenous aneurysms, in which the lumen of an artery having become connected with that of a vein, the heart's action causes the walls of the latter to pulsate and dilate. This form is sometimes called an aneurysmal varix. And there is the varicose aneurysm also.

Few studies in surgical history are more fascinating than this of aneurysm, and great writers through all time seem to have dwelt upon it as upon a matter concerning that noblest of our physical functions, the circulation of the blood. Yet no writer from Galen's day until near the end of the nineteenth century appears to have conceived of any cure for aneurysm save that involved in the extermination of the affected artery. It remained for an American surgeon, Matas, first experimenting in 1888, to show that the damaged vessel may be repaired, that the aneurysm may be eliminated directly by mechanical means, and that the offending artery may be reëstablished in normal function through direct circulation past the site of the obliterated disease.

The causes of aneurysm are either a previous disease of the vessel

[1] Thomas Bryant, Practice of Surgery, edition of 1885.

or an injury by which the arterial coats are weakened or ruptured. Syphilis or some toxemia leads to aneurysm through an endarteritis or its continuation into atheroma. In this way an atheromatous ulcer may cause a breaking down of the intima of the vessel and the escape of blood between its coats—dissecting aneurysm. Or all the coats of the vessel may stretch; or an actual traumatic tearing of the vessel may

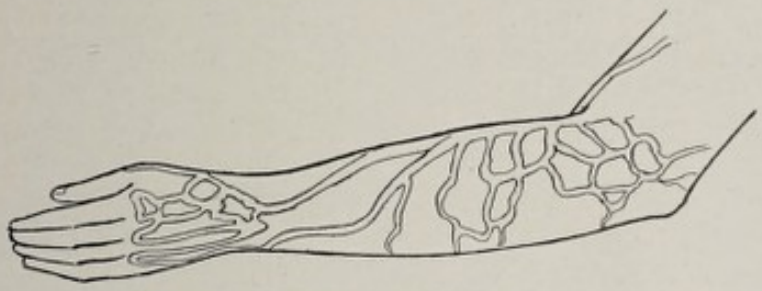

Fig. 481.—Aneurysmal varix (Bryant).

allow blood to escape into the surrounding tissues, where it becomes fully encapsulated—a form of false aneurysm. Internal aneurysms—those within the cavities of the body—seldom come within the surgeon's purview, while external aneurysms—in the arteries of the limbs—properly come to him for treatment.

The **progress** of the disease may be uninterrupted up to the point of rupture, or there may be spontaneous checking through coagulation

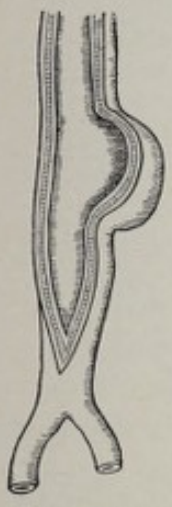

Fig. 482.—True aneurysm; the sac formed by all the coats (Holmes).

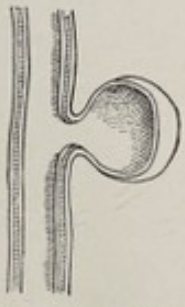

Fig. 483.—False aneurysm; the sac formed by the outer coat only (Holmes).



Fig. 484.—Dissecting aneurysm (Holmes).

and the formation of a clot within the aneurysm. This clotting of the blood takes place in thin layers along the walls of the aneurysm, so that on dissection of a large aneurysmal clot one finds a lamellated appearance. Through the formation and absorption of these layers the aneurysmal wall is strengthened or weakened and the final catastrophe is often more or less postponed. But a growing aneurysm always

encroaches upon surrounding structures. It pushes aside movable organs; it causes atrophy of fixed soft parts; it erodes bone.

Aneurysms may be single or multiple; large or small; and no artery of the body is exempt from the disease, but the aneurysms of the large vessels of the extremities are those especially which interest the surgeon.

The **symptoms** of aneurysm are manifold and depend largely upon the situation of the disease. The patient complains of discomfort, such as that caused by a rapidly growing encapsulated tumor, pain, indefinite aches, a sense of weight and fulness, general debility, lassitude, sometimes emaciation. He may notice the swelling if it is near the surface, and he may be distressed by the constant throbbing. The



Fig. 485.—Aneurysm of innominate artery (Massachusetts General Hospital).

surgeon makes his diagnosis of internal aneurysm with some difficulty. He may distinguish an obscure tumor by its dulness or flatness on percussion. He may hear a characteristic bruit, synchronous with the cardiac systole. He may feel the expansile pulsation. If the aneurysm is superficial, the examiner should make his diagnosis without great difficulty—from the history, the presence of a tumor with its characteristic expansile pulsation, its bruit, and the fact that it can be emptied by pressure. Moreover, it is located in the course of one of the arterial trunks. Often there is edema of the parts with venous congestion, so extreme as to threaten or actually to cause gangrene. Should the other methods of examination fail to determine the aneu-

rysm, especially if it be internal, the *x*-ray picture often gives striking and conclusive evidence.

The **treatment** of aneurysm has, until recent years, been dependent upon two principles which may be regarded as branches of one—(1) An endeavor to assist nature by favoring the formation of clots, and (2) the actual shutting off of the affected artery by ligature, thus causing stagnation and clot formation. The first method must still be considered, especially when one is dealing with large internal aneurysms. In order to favor clotting surgeons have prescribed absolute rest in bed, a starvation diet, and cardiac sedatives; to this have been added, of recent years, more active intervention by the use of gelatin injections into the circulation, and the introdution of wire, with or without the use of electricity, into the aneurysmal sac. The last method has been moderately successful. Hobart A. Hare,[1] of Philadelphia, thus treated 11

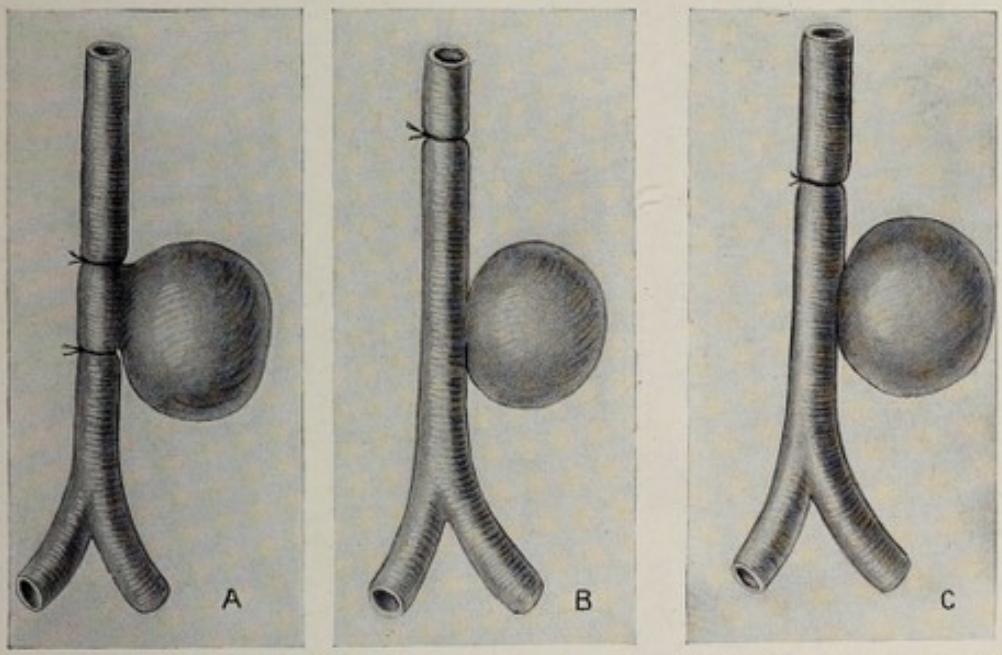

Fig. 486.—A, Operation of Antyllus; B, operation of Hunter; C, operation of Anel.

cases, in all of which there was undoubted symptomatic relief, though permanent cures were not established. The method consists in passing into the aneurysm a considerable length (many feet) of a fine silver wire, and submitting it to electrolysis for twenty minutes or half an hour. Clotting promptly occurs and the wire is left *in situ*.

E. Lancereaux[2] has succeeded in arresting the progress of internal aneurysm by injections of gelatin serum, which he asserts to be harmless if the serum is aseptic. The essential weakness of these clot-favoring methods, when applied to the great terminal arteries, is that they may lead to complete obliteration of the vessel—an event to be avoided. *Per contra*, should a channel for the blood-current remain, there is the inevitable danger of return of the disease.

Halsted's metallic bands give promise of usefulness. His work is

[1] Therap. Gazette, July 15, 1905.

[2] Gaz. des Hôp.

experimental as yet. It consists in binding the affected artery with a thin, broad metallic circlet which shall limit, but not cut off, the blood-stream, and shall favor coagulation in the aneurysm beyond the band.

Open division of aneurysm is a method of treatment running back into antiquity. It is known as the method of Antyllus, a surgeon of the third century A. D., and has been practised by many surgeons in modern times. It is a common-sense method, and in these days of asepsis shows a comparatively low mortality. The technic is simple, but is applicable to external aneurysms only. After controlling the vessel with a tourniquet the surgeon cuts down upon the tumor, opens it, turns out the clots, and secures by ligature its afferent and efferent vessels above and below the aneurysm. Some operators have seemed to think that, in its essential principles, this operation does not differ greatly from that of Matas. That conception is erroneous.

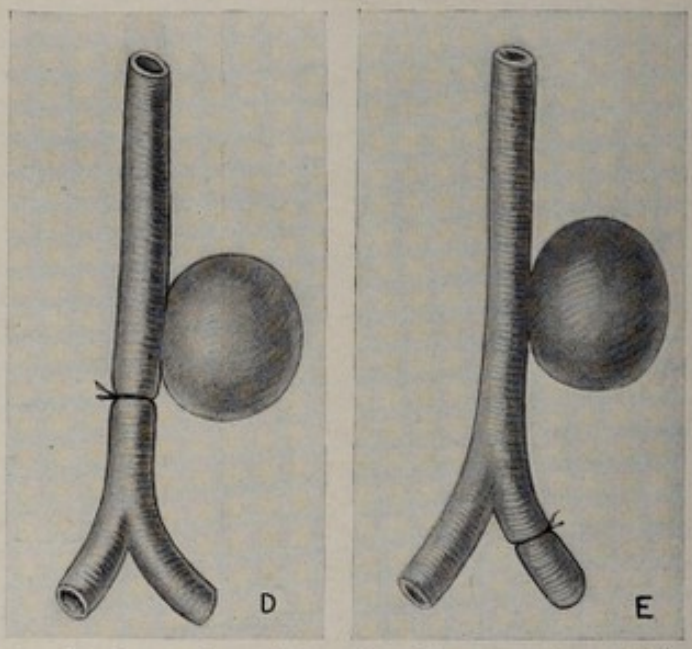

Fig. 487.—D, Operation of Brasdor; E, operation of Wardrop.

Extirpation of the sac is a modification of the Antyllian method, and has been favored by many modern surgeons. Undoubtedly, it is an improvement upon the Antyllian method, but it has its disadvantages, as I shall show.

Far the most popular operation until recent years has been that of Hunter—proximal ligation of the artery at a distance above the aneurysm, but below the large anastomosing vessels. John Hunter's classic operation, performed in 1786, was done for popliteal aneurysm. He tied the femoral in Hunter's canal below the profunda and secured a brilliant result.

The disadvantages and dangers of the Antyllian and Hunterian operations may not offset the advantages, but it is worth our while briefly to consider this question. The original operation of Antyllus has the advantage of occluding the artery close above the aneurysm and close below it, so that the higher anastomotic branches of the main

artery are not disturbed, and are left to carry blood to the distant parts of the affected limb. At the same time, however, as Matas has

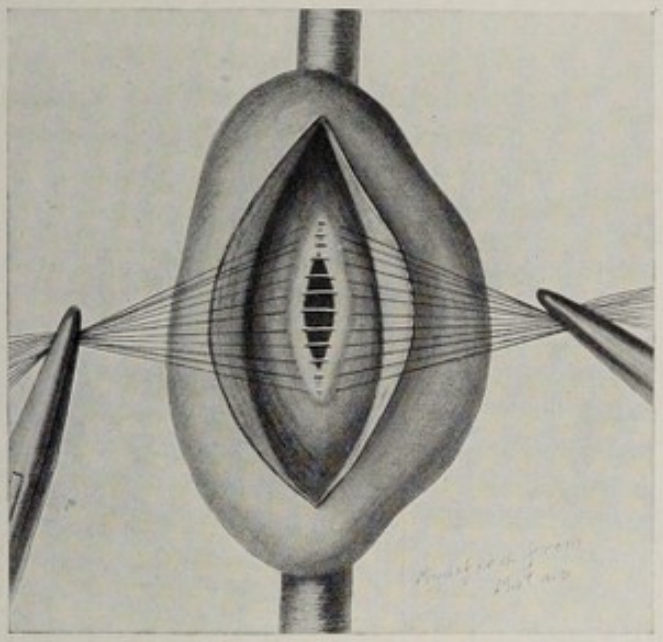

Fig. 488.—Operation to restore current in saccular aneurysm, first stage: Placing of interrupted sutures through borders of arterial opening into aneurysm, leaving channel of vessel intact (Matas).

shown, this operation does not control supernumerary feeders to the aneurysm. These feeders may dilate and bleed into the sac after the

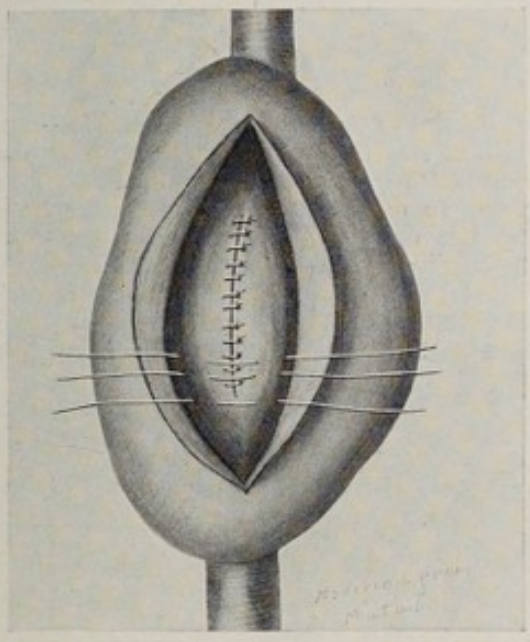

Fig. 489.—Operation to restore current in saccular aneurysm, second stage: The interrupted sutures through the borders of the arterial opening have been tied. A second tier of interrupted sutures overlying and outlying the first is being placed through the inner coats of the aneurysmal sac, which, upon being tied, will bury the first tier and ridge up the floor of the aneurysm in the median line (Matas).

operation, for we must remember that an essential step in the operation of Antyllus consists in opening and clearing out the sac. In recent

years surgeons have substituted excision of the sac for opening it—an interesting advance in treatment; but excision of the sac involves the removal often of many small vessels, and sometimes of nerves and other structures embedded in the aneurysm's wall. Even so, the operation of Antyllus, modified by excision, has shown admirable results during the aseptic period—the operative mortality being zero, and subsequent gangrene being recorded in but 2.77 per cent. of the cases. One concludes then that extirpation constitutes an extremely valuable operation. The Hunterian operation seems easy and little formidable at a first glance. It consists in tying the affected artery

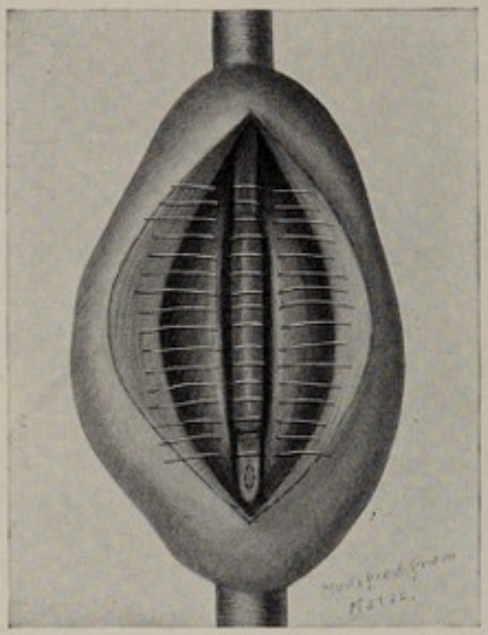

Fig. 490.—Aneurysmorrhaphy: Operation to restore current in fusiform aneurysm. Suturing borders of opening and of connecting groove over a temporary rubber tube, the ends of which are seen projecting into the lumen of the vessels at either end. The interrupted form of suture is here shown (modified from Matas).

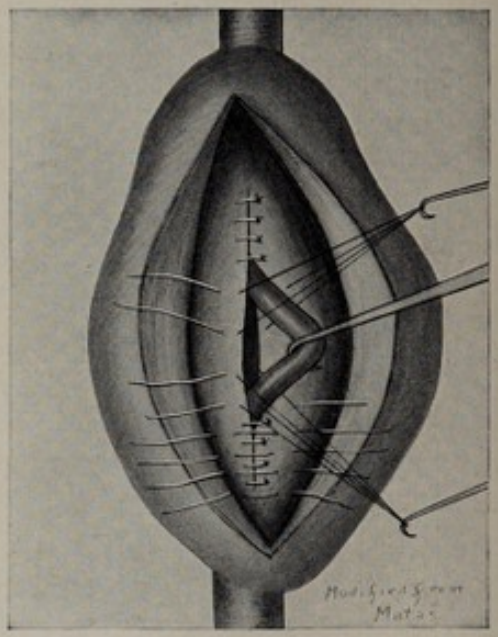

Fig. 491.—Aneurysmorrhaphy: Operation to restore current in fusiform aneurysm. The interrupted sutures placed in the preceding figure have been tied at the two ends, while those in the center are being held apart during the withdrawal of the rubber tube, after which these also are tied. Some of the second tier of sutures are shown in place, ready to be tied (modified from Matas).

well above the aneurysm, but below the largest anastomotic branch of the vessel affected (for example, in the case of popliteal aneurysm one would tie the femoral artery a little below the origin of the profunda). Hunter's operation has the advantage of shutting off effectively the blood-supply of the aneurysm in nearly all cases, but it has the disadvantage of interfering seriously with the circulation of the limb, so that even in recent years it has been followed by an operative mortality of 8.32 per cent.

Many surgeons still advocate digital compression of the artery above the aneurysm, with the purpose of favoring clot-formation in the sac. I cannot recommend this procedure. It is extremely uncertain, tedi-

ous, for it involves often several days of treatment, painful, and is occasionally followed by gangrene.

The foregoing statements represent the experience and views of surgeons up to the year 1902, when Rudolph Matas described his method of *aneurysmorrhaphy*.[1] At that time numerous investigators, both in Europe and America, had demonstrated the possibility of operating upon blood-vessels by various methods of suture, so that the fact was well established that wounded vessels heal readily, and that the intima of vessels, like the peritoneum and serosa elsewhere, glues quickly to itself. *Serosa to serosa* and *intima to intima* are axioms. Acting upon this acknowledged fact, Matas showed in a remarkable series of cases that it is possible to open an aneurysmal sac and to sew up the mouths of the arteries opening into it. Promptly intima adheres to intima, so that all the vessels concerned are obliterated. But Matas went further, and demonstrated, by careful studies, that the preservation of the sac itself is an important element of success in these cases. He retains the sac, therefore, infolding and crumpling it as the illustrations show; for the sac is vascular, and its contained arterioles are of service in preventing local necrosis. The principle of Matas is applicable to all forms of aneurysm when the aneurysm is accessible to operative manipulations. The sacculated aneurysm, with its single orifice, may be treated readily without interference with the main arterial trunk. The typical false aneurysm may be cleaned out and the damaged artery repaired; while in the case of fusiform aneurysm, all the arterial openings may be closed without subsequent ill effects so far as present knowledge teaches. In a few selected cases of fusiform aneurysm it is possible to restore the arterial trunk by stitching up the sac so as to leave behind a channel. Progressive surgeons with enthusiasm have followed the lead of Matas. More than 80 cases of his operation have been reported with resulting cure of the aneurysm, preservation of the limb, and avoidance of gangrene in nearly all the cases. We are justified in asserting, therefore, that

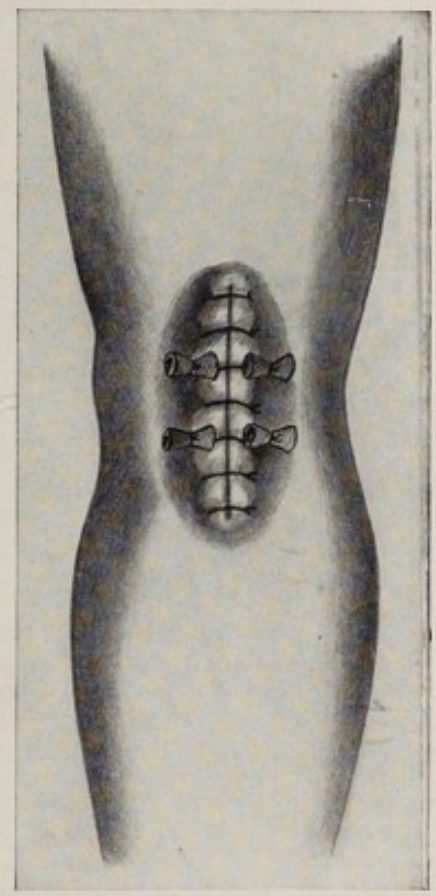

Fig. 492.—Aneurysmorrhaphy: Final stage of operation. The walls of the aneurysm sac and the integuments are sutured to the floor of the sac over gauze rollers, thus firmly approximating the former to the latter (Bickham, modified from Matas).

[1] Ann. Surg., February, 1903; see also Medical News, Philadelphia, October 27, 1888, in which Matas described his first successful case, though he did not at that time propose suture as the routine treatment of aneurysm.

Matas' operation is the operation of choice whenever its performance is possible.

The standard text-books discuss sundry other methods of ligation of arteries for aneurysm—Anel's method, which consists in placing a single ligature immediately above the aneurysm; Brasdor's method, the ligation of the artery immediately below the sac; and Wardrop's method, the ligation of the highest main branch given off below the sac. The last two methods may be our only resort in the case of certain aneurysms deeply placed and difficult of access—innominate aneurysm, for example, for which one might be forced to tie the subclavian, the common carotid, or both. When all is said, however, our operation of choice must be by Matas's method or by excision.

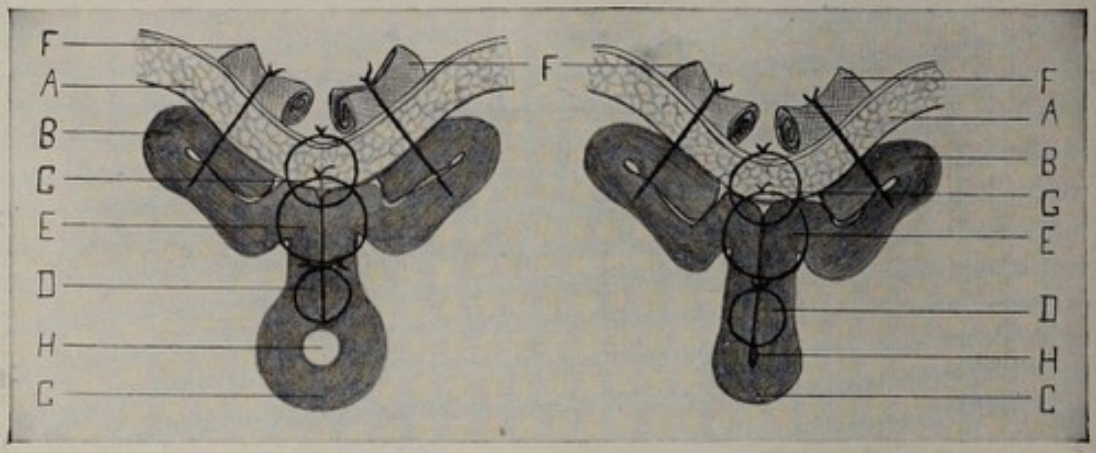

Fig. 493. Fig. 494.

Fig. 493.—Aneurysmorrhaphy: Cross-section of the parts involved in the operation where the current is restored, together with the complete obliteration of the sac of the aneurysm: A, Integuments; B, aneurysmal sac; C, walls of blood-channel; D, first tier of sutures, approximating walls of blood-channel; E, second tier of sutures, approximating floor of sac over first tier; F, F, sutures through walls and into floor of aneurysm, approximating former to latter; G, suture through margin of integuments and into floor of sac, over second tier; H, restored blood-channel (modified from Matas).

Fig. 494.—Aneurysmorrhaphy: Cross-section of the parts involved in the operation where the blood-channel, together with the aneurysmal sac, are completely obliterated. The figures are the same as in Fig. 493, except that H here represents the obliterated blood-channel (Bickham, modified from Matas).

Aneurysmal varix, if treated at all, may be cured by applying the principle of Matas—laying open the distended vein and suturing from within the anastomotic opening.[1]

In any case of operation for any form of aneurysm the surgeon should see to it that the patient has careful after-treatment. The wound should be dressed with abundant, elastic compression dressings; the involved limb should be bandaged throughout its entire length; should be well supported, and should be kept at rest for two or three weeks or until satisfactory collateral anastomosis has been fully established. If all goes well, the patient should be able to get about and use the arm or leg freely at the end of a month.[2]

[1] Warren S. Bickham, Ann. Surg., 1904, vol. xxxix, p. 767.

[2] The progress of the past three years has added nothing essential to the conclusions described above.

SUTURE OF THE BLOOD-VESSELS

Suture of the blood-vessels is a subject which suggests itself at once in connection with Matas's treatment of aneurysm. I have already dealt with suture of the heart in Chapter XVIII, but recently a new branch of surgery has been developed in the suture of the blood-vessels (angiorrhaphy).[1] One may not dwell profitably in this place upon the great literature which has grown up about the subject. Suffice it to say that beginning with Lambert's first pin suture of a wounded artery in 1759—an operation forgotten for nearly one hunderd and fifty years—a large number of well-known investigators have worked at the suture problem, especially within recent years. **Lateral arteriorrhaphy,** the sewing up of a wound in the side of an artery, is now a well-recognized procedure. One may use fine silk or chromicized catgut and sew up the rent with through-and-through stitches. Wounded veins may be treated in the same fashion.

Circular arteriorrhaphy, or end-to-end anastomosis, is a more difficult but far more interesting operation. Experiments to this end have been numerous, but the more popular methods now in vogue among us are those of J. B. Murphy, by invagination, and of Alexis Carrel, by direct marginal suture. Carrel's[2] method is likely to prove the more popular. The experimental work has already demonstrated the possibility of transplanting organs, limbs, and heads even, and gives promise of developing into a great and valuable new field of surgery.[3]

SURGERY OF THE LYMPHATIC SYSTEM

Of late years writers have been telling us that the lymphatic system is becoming increasingly important to the surgeon. I doubt how that may be. The lymphatic system has always been important—probably never more so than in the old days of sepsis, when operation wounds were continually infected, with a complicating extension of inflammation through the neighboring lymphatic vessels.

Surgery of the lymphatic system deals with the lymph-channels and with the lymph-nodes. The old term "lymph-gland" is a misnomer. The nodes which occur frequently through the lymphatic system are not glands. They are not secretory organs, but rather filters and reservoirs. The lymph-channels are subject to two important types of affection—occlusions and inflammations. The lymph-nodes also are subject to two main varieties of affections—new-growths and inflammations, in which respect, indeed, they resemble true glands, though the spread of disease through the lymphatic system is peculiarly active.

[1] Rudolph Matas, The Suture in the Surgery of the Vascular System, 1906; also Keen's Surgery, vol. v.

[2] Alexis Carrel, formerly of Lyons, now at the Rockefeller Institute, New York City.

[3] Arteriovenous anastomosis, the turning of the arterial stream into a vein (femoral artery into femoral vein) in order to re-establish circulation in the face of advancing gangrene, is still under debate. The results of this operation, owing to the obstruction of valves in the veins, and owing to subsequent closure of the anastamotic opening, are less satisfactory than was hoped.

Here is Fischer's classification of these ailments:

AFFECTIONS OF THE LYMPH-VESSELS:

1. Acute inflammation of the lymph-vessels.
2. Chronic, non-specific inflammation of the lymph-vessels.
3. Tuberculosis of the lymph-vessels.
4. Lymphangitis syphilitica.
5. Carcinosis of the lymph-vessels.
6. Dilatation of the lymph-vessels.

AFFECTIONS OF THE LYMPH-NODES:

1. Acute inflammation of the lymph-nodes.
2. Chronic, non-specific inflammations of the lymph-nodes.
3. Tuberculosis of the lymph-nodes.
4. Syphilis of the lymph-nodes.
5. Primary tumors of the lymph-nodes.
6. Secondary tumors of the lymph-nodes.
7. Lymphadenocele.

Such a classification is admirable, so far as it goes, but it takes no account of those diseases resulting in obstruction of the lymph-channels, with secondary hypertrophy of the adjacent tissues, frequently due to the organisms, filariæ, and resulting in the diseases of which lymphangiectasis and elephantiasis are the most conspicuous.

A few words upon the **physiology of the lymphatic system.** We recall that there are four different types of lymph, according to Hall:

1. Tissue lymph, which fills the intercellular spaces throughout the body.

2. Circulating lymph, which passes through the lymph capillaries into the circulatory system by the way of the thoracic duct.

3. Chyle, the peculiar circulating lymph of the intestinal tract, which carries nutritive material.

4. Serous lymph—the contents of the serous cavities.

All these fluids, except chyle, contain at least 95 per cent. of water and nearly 4 per cent. of proteids.

To quote the excellent statement of Roswell Park, the lymph is the only fluid which comes into contact with all the living cells of the body. Blood, on the other hand, comes into contact with the endothelial cells only of the vessels, and with those cells in the splenic pulp, and perhaps other localities which have to do with its elaboration. These are but a minute proportion of the total cells of the body. All the other body cells receive their nutrition and oxygen from the lymph, which takes its supply from the blood. Moreover, nearly all the waste materials of the body are emptied into the lymphatic system, and thence into the blood. Thus one sees that the lymph is the almost universal vehicle of exchange between blood and tissues through the body, and that its rôle in the economy is of the highest significance and importance.

The larger lymph-streams have been shown to flow in thin-walled vessels with valves, but the great bulk of lymph in the tissues circulates freely in spaces, so called, among the tissue-cells.

Let us first survey briefly and hastily the affections of the lymph-channels.

In view of what I have said regarding the inevitable presence of lymph-channels and a lymph circulation everywhere throughout the body, we realize how grave may be the infection of these channels.

LYMPHANGITIS

Acute lymphangitis is due commonly to an infection introduced from without, although it may arise in connection with some internal or systemic derangement—for example, typhoid fever or puerperal

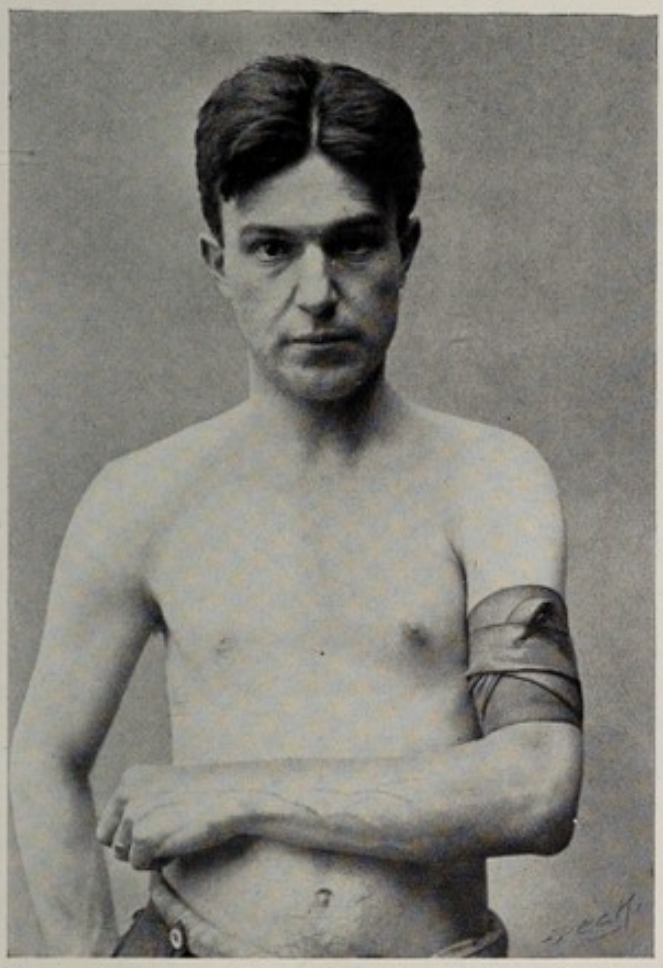

Fig. 495.—This illustration shows the application of the elastic bandage around the arm, with its end tucked under (Meyer and Schmieden).

septicemia. In the hospital wards and in general practice you shall find lymphangitis of the arm by far the most common form of lymphangitis. The finger of the victim is the seat of a small punctured wound often; thence organisms promptly enter into the lymph circulation; they propagate and spread with amazing facility, so that frequently the main lymph-channels of the arm, even to the axilla, are seen to be defined as red, tender lines, following especially the course of the larger blood-vessels. One or two nodes above the external condyle may check for a time the process, but quickly it spreads upward to the more

numerous axillary nodes. If the disease runs unchecked, there may result thrombi, infection of the adjacent tissues, a general breaking down of the parts, and extensive abscess formation through the efforts of nature to combat the poison.

As regards routine *treatment*, this is both local and general. Vaccine therapy always should be employed whenever vaccines can be secured but, unfortunately, in the practice of most men, vaccines, except stock aureus vaccines, are not available. It remains, therefore, to accept the best local and general treatment, aside from the vaccine treatment. The patient should be stimulated and sustained by tonics of strychnin, iron, and whisky; his bowels and kidneys should be kept



Fig. 496.—Zander room for mechanical therapeutics at the Massachusetts General Hospital (formerly the old Bigelow amphitheater).

active—a factor never to be neglected; he should be kept in the open air; should receive abundant simple nourishment; and, above all things, should not be forced to depend upon his own efforts for anything; he should be nursed. Good local treatment consists in the encouragement of stasis hyperemia by Bier's method;[1] the opening of all collections of pus; and careful bandaging and support of the arm, as described in Chapter XXVI.

We recognize two forms of lymphangitis: the *reticular*, in which a minute network of vessels is affected, giving to the skin an erysipeloid appearance; and the *tubular*, which affects the larger vessels only.

[1] I refer the reader to the valuable publication of Willy Meyer and Victor Schmieden on Bier's Hyperemic Treatment, published in 1908.

Commonly, the two forms coexist, while the treatment is much the same in both.

Writers discuss antiseptic lotions in the treatment of lymphangitis. Hot, frequently applied lotions are extremely comforting, and are valuable adjuncts to Bier's treatment. They act by increasing the hyperemia of the parts, but there is no reason to suppose that their antiseptic qualities are advantageous. I employ, as a rule, large poultices of creolin (1:200), changed every two hours.

Chronic lymphangitis is a rather uncommon outcome of such an infection as I have described. The condition is annoying rather than dangerous. The lymph-channels are obstructed; the tissues may or may not become thickened and brawny, while interference with the function of the parts is more or less likely. The patient should be given an out-of-doors life, good food, and exercise, and if possible should have daily massage, or the Zander treatment, over the affected region.

Tuberculosis of the lymph-vessels is always associated with tuberculosis of the lymph-nodes. The vessels become somewhat thickened and tender, but tuberculosis of the lymph-channels alone is relatively insignificant from the point of view of both prognosis and treatment. In Chapter XXII, I have already discussed tuberculosis of the lymph-channels and nodes of the neck. The disease there shows us the typical points of lymphatic tuberculosis.

Syphilitic lymphangitis exists. *Carcinosis of the lymph-vessels* concerns us, and I shall have something to say on this subject in the chapter on Tumors (Chapter XXVIII).

LYMPHANGIOMA, LYMPH VARICES, LYMPHANGIECTASIS, AND LYMPHADENOCELE

These are terms used variously to denote obstruction and dilatation of lymph-channels. Tumors and enlargements result from obstruction; usually they are congenital, sometimes they are acquired. The growths progress rapidly; the channels are usually filled with a translucent, milky fluid, probably identical with normal lymph. These tumors are benign, but from their size they may cause distress.

Lymphangiomata spring from lymph-channels; they consist of the dilated channels, bound together with a framework of connective tissue. The resulting tumor resembles the common hematogenous angioma.

Lymph varices resemble closely ordinary varices.

Lymphangiectasis also is a term applied to collections of dilated lymph-vessels—dilated from obstruction. The causes of such obstructions are numerous and the resulting conditions manifold. Common causes are cicatrices, tumors, and ascites, while the most frequent cause leading to chronic obstruction is the presence of the Filaria sanguinis communis. In tropical countries especially this chronic lymphatic obstruction, known as *filariasis*, is of extreme importance. The *filarium* is a parasitic worm which lives in the lymphatics and

blood-vessels of man. It gives off an enormous number of ova, from which embryos quickly develop and circulate in the blood. They may be found readily, especially at night, for during the day they are confined to the abdomen and thoracic vessels. They are active; their length is about 4 mm.; their diameter that of a red blood-corpuscle. Certain mosquitos carry them.

The *symptoms of filariasis* are not necessarily severe, but the patient may be a life-long sufferer, and may have to endure great and continued discomfort. Swellings appear in various parts of the body—lymph tumors. The groin in particular is affected, and there follow



Fig. 497.—Elephantiasis (Massachusetts General Hospital).

various forms of elephantiasis, especially of the scrotum, the vulva, and the legs. Patients may have chills and fever, and are especially subject to erysipelas and other concurrent infections. This elephantiasis is due, as a rule, to the same causes which produce the swelling in lymphadenocele,—to the plugging of the lymph-vessels,—but the disease is local, especially in the skin and subcutaneous tissues, where there is a chronic hyperplasia. We make the diagnosis sure by finding filaria in the blood.

The *treatment of filariasis* is still unsatisfactory. We have no specific drug which can destroy the parasite. Lacking that, our best

course is to remove the patient, if possible, from the afflicted region; and, by surgical measures, to remove the tumor growths so far as possible. All this is far from satisfactory, and the surgery is far from brilliant. Our hope for future treatment lies in the discovery of a proper chemical antidote.

LYMPHADENITIS

Adenitis, or *acute inflammation of the lymph-nodes*, follows such an infection as I have described in speaking of lymphangitis. We think of the lymph-nodes as barriers or filters. They hold up the advancing organisms and are themselves in turn infected and destroyed. There is good reason to believe that new lymph-nodes may develop after the destruction of the old ones.

The inflammation and swelling of certain nodes are recognized by surgeons as suggesting certain definite sites of infection. For example, inflammation of the nodes in Scarpa's triangle suggests an initial lesion in the foot; inflammation of the nodes along Poupart's ligament suggests a lesion of the genitalia; inflammation of the nodes behind the elbow suggests a lesion of the hand; inflammation of the nodes in the axilla, a lesion of the hand, arm, or breast; an abscess immediately below the mastoid suggests an infection of the scalp, often from head-lice; while inflamed nodes in the anterior triangle of the neck point to damage about the mouth, lips, tongue, throat, and face.

The **symptoms of acute inflammation of the lymph-nodes** are the familiar symptoms of developing abscess, to which, from time immemorial, surgeons have attached the terms, *dolor*, *calor*, *rubor*, *tumor*, and *functio læsa*. The *pain* is due to tension upon the delicate nerve terminals; the *heat* is due to the increased blood-supply which nature throws into the part in her endeavor to meet the bacterial invasion; the *rubor*, or *redness*, may or may not be apparent, depending on the nearness of the abscess to the skin; the swelling or *tumor* is always present; while *impairment of function* is due to the pain of movement rather than to any actual destruction of the nerves or muscles.

The **treatment of these infected lymph-nodes** (infected by pyogenic organisms) can be nothing short of free incision, with the evacuation of the broken-down lymph-structures; free crucial incision, because a straight incision may glue up and not allow the wound to heal from the bottom, as it should.

Sometimes the abscess formation in a node may be prevented if the source of infection be eliminated promptly by treating the infected node with poultices, with lead iodid ointment (10 per cent.); or with Bier's cupping-glasses.[1] As a rule, however, these infected lymph-nodes should be opened, thoroughly cleansed, packed lightly with

[1] I do not agree with those writers who see no advantage in external applications. Nearly twenty-five years of experience in large hospital clinics convinces me that external applications frequently are not only of value in subduing early infections, but are of extreme comfort to suffering patients. There are other remedies.

gauze, and the parts immobilized (as I have described in Chapter XXVI) with abundant, absorbent, elastic-compression dressings.

Chronic lymphadenitis may develop out of an acute lymphadenitis, or may be slowly progressive from the start. The condition is common enough, and is not always noteworthy. A great many persons have, in various parts of the body, small, slightly enlarged lymph-nodes which never trouble them. Should these nodes become troublesome, they may be removed easily.

Tuberculous lymph-nodes, on the other hand, have marked and distinct dangers. Tuberculous lymph-nodes of the neck give rise to that condition known in the old days as scrofula, a term long since abandoned. I have already discussed tuberculous lymphadenitis of the neck in Chapter XXII, and merely remind the reader here that, through the cavity of the mouth and through the tonsils, tuberculous organisms can enter the lymph circulation. For this reason some 90 per cent. of all tuberculous lymph-nodes are in the neck. We *treat* the disease in reasonably robust persons by enjoining an out-of-doors life. If the infection be progressive, however, we must excise all the affected parts.

HODGKIN'S DISEASE

Hodgkin's disease is quite another ailment than ordinary lymphadenitis, and it has been described under many names, such as *adenia, adenoid disease, adenolymphoma, splenic anemia,* etc. In a monograph before me I find 31 terms used to indicate Hodgkin's disease, yet the exact nature of the ailment is not clear to us. Some authors maintain that it is tuberculous; others, that it arises from sundry infecting organisms not yet identified; others that it is sarcomatous. Hodgkin's disease manifests itself in a great swelling of the lymph-nodes and of the spleen. The disease is not common, and the best present authority asserts that it is not to be confounded with splenic anemia. The enlargement of the nodes depends upon an overgrowth of the cells and of the lymphocytes—hence the term, *lymphocystomata;* while many of the cases are characterized by histologic changes resembling a chronic inflammatory process with proliferation of endothelial and reticular cells, the formation of giant-cells, and the presence of many eosinophiles with a progressive fibrosis. As Warthin states,[1] the clinical complex of Hodgkin's disease has at present no pathologic entity, but may be produced by a variety of conditions quite different in nature. We make the diagnosis by the aid of the microscope, and limit the term Hodgkin's disease to that ailment in which the enlarged lymph-nodes are of a chronic imflammatory type.

The **clinical course** is somewhat as follows: The patient is commonly a young man in good health, who observes a swelling on the side of his neck. This enlarges, and similar swellings appear elsewhere—on the other side of the neck, in the axillæ, the groins, and the great body cavities. The tumors, if of rapid growth, are soft; if of slow

[1] Osler's Modern Medicine, vol. iv, p. 829.

growth, they are hard. The nodes, at first discrete, eventually merge. Deformity may be great. The spleen may become enormous. The patient experiences no pain or soreness. Suppuration does not occur, but there develops extreme anemia, weakness, emaciation, cachexia. There is slight occasional fever, there is progressive dyspnea, loss of appetite, indigestion, headache, and dizziness. The limbs become edematous; a general anasarca develops, the patient becomes progressively more feeble, and dies at last of exhaustion.

The *blood examination* shows a diminution of all the peculiar constituents of the blood, but there is no marked disproportion between the red and the white corpuscles. The hemoglobin may be very low. Cultures from the blood and nodes are sterile.

The **treatment of Hodgkin's disease,** after such a description, is obviously unsatisfactory. We know no specific remedy. Surgery, or rather the knife, can do no more than palliate the symptoms, and occa-

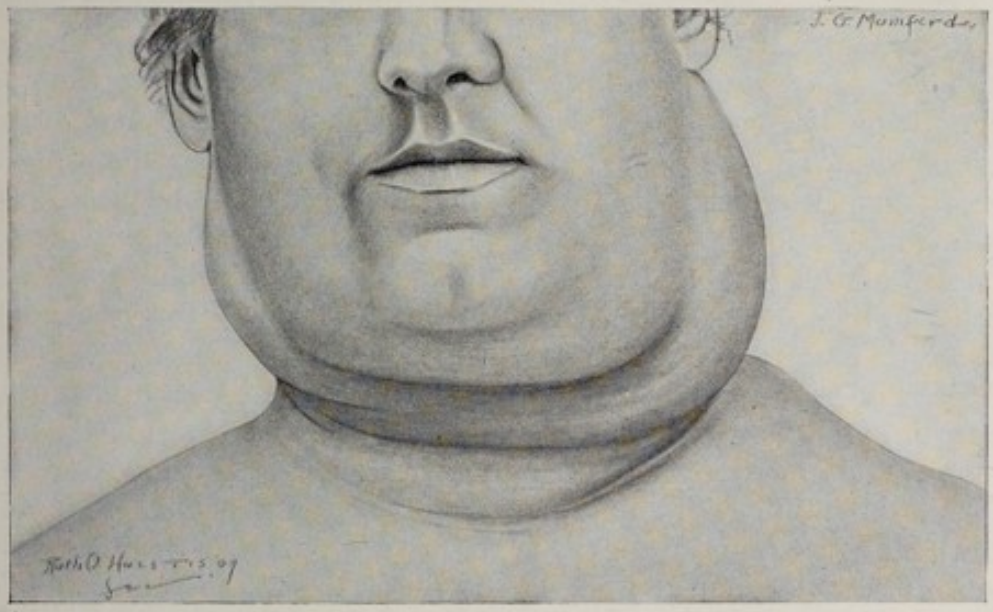

Fig. 498.—Hodgkin's disease (Massachusetts General Hospital).

sionally relieve deformity. There is good evidence that arsenic helps—arsenic begun in small doses, which are gradually increased up to the limit of tolerance, when a small dose again is given and the process repeated.

Hodgkin's disease at the present day is exercising the ingenuity of the surgeon as well as of the physician; we know not what it is, and the tendency of modern research stimulates us to further investigations.

Malignant disease of the lymph-nodes, especially cancer, is relatively rare as a *primary* disease. *Secondary cancer of the lymph-nodes* is extremely common. I shall discuss these matters in the chapter on Tumors. *Sarcoma* of the lymph-nodes is *primary* often enough. The tumor includes usually a group of nodes. It is smooth, movable, painless, and grows rapidly. The neoplasm invades neighboring tissues, and metastases occur in the internal organs. When the tumor is situated in the neck it may compress fatally the windpipe and

gullet; while in its last stages this form of sarcoma is marked by perforation of the skin, by hemorrhage, and by suppuration. The diagnosis is difficult in the early stages of the sarcoma, and the prognosis is always grave.[1]

SURGERY OF THE MUSCLES, TENDONS, AND BURSÆ

MUSCLES

Lesions of muscles seem almost to belong to the subject of minor surgery. Muscle damage is cared for by nature herself in the great majority of cases, yet there are certain muscle lesions with which the surgeon should be familiar as a part of his general training.

Muscles are subject to **atrophy,** and muscular atrophy may be simple or associated with degenerative changes—fatty or amyloid. Simple muscular atrophy concerns us most nearly, and is due commonly to long-continued disuse of the muscle from such causes as paralyses and the surgeon's splinting. In anterior poliomyelitis the muscles atrophy as their associated nerves become functionless, so that as a result of this disease we may find the muscles replaced by connective-tissue bands. These are the so-called sclerosed muscles, which are less common than the soft, flabby, atrophic muscles. The results of muscular atrophy appear as various deformities. For example, when the extensors of the foot are thrown out of action, the opposing healthy muscles go to work, draw the foot down, and throw it into a condition of paralytic club-foot.

Of recent years we have heard a good deal about **Volkmann's contracture,** or **ischemic atrophy.** This condition is seen mostly in the forearm, and is due usually to the long-continued application of overtight splints and dressings. Commonly, the flexor group of muscles becomes densely infiltrated, and, unless the splints are removed within a day or two, must degenerate. Usually portions of the muscles undergo subsequent contraction. The patient may or may not suffer pain, since pain in these cases depends upon an associated neuritis which is not always present. The deformity of a Volkmann's contracture is permanent, crippling, and unsightly. The forearm and hand appear greatly emaciated, the fingers are flexed on each other, but the metacarpophalangeal articulations remain extended. In extreme cases the wrist becomes flexed as well as the fingers.

The *treatment* of cases of *muscular atrophy* is concerned with removal of the cause; provision for proper and sufficient nutriment; exercise; prevention of deformity. That is to say, we must keep the patient in prime condition; supply him with expert daily massage and electricity; and place the affected limb in such a position that traction deformities in extension shall not arise.

As to *Volkmann's contracture*—in early cases massage may result in

[1] I refer the reader who would study more fully the surgical diseases of the lymphatics to Charles N. Dowd's article in Bryant and Buck's, American Practice of Surgery, vol. ii, p. 525.

a cure. Later, when the contraction is well established, we must operate in one of two ways—by lengthening the flexor tendons, or by shortening the radius and ulna to compensate for the contracture of the muscles; or we may combine the two maneuvers. At the best, the resulting function of the arm is far from perfect.

Muscles become *inflamed*—**myositis.** There is *simple myositis*, so called, and there is *infective myositis*. *Simple myositis* is not a true inflammation; it results from an injury which damages the connective tissue of the muscle and causes the formation of granulation tissue. The process is a process of repair, and ends in the substitution of scar tissue for muscle tissue.

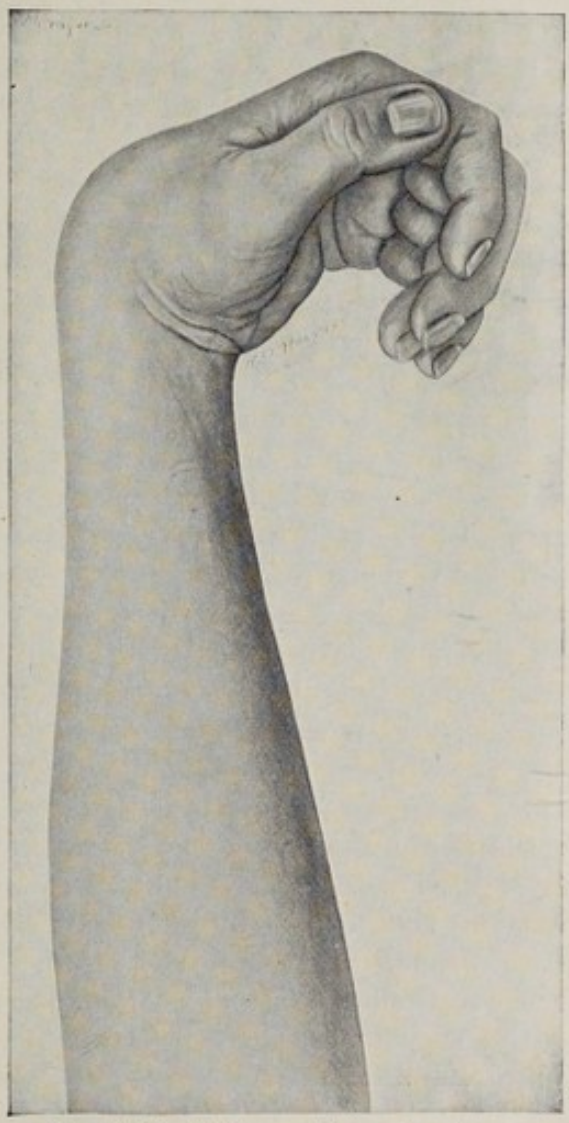

Fig. 499.—Volkmann's contracture.

Infective myositis is rare. The abundant blood-supply of the muscles fights off infections, as a rule, but an infection once started may destroy large muscle areas. Muscle tissue eventually may be lost; scar tissue may be substituted for muscle tissue, and sometimes cartilage or bone even may develop within the muscle itself. This last condition is designated *myositis ossificans*. There is a progressive form of this disease which begins early in life, involves the muscles of the back, and eventually renders the patient helpless. A wretched creature of this type will be shown in a museum as "the ossified man." Myositis ossificans of a milder type may result from injuries, but it is capable of cure through surgical operations.

Tuberculosis may also invade and destroy muscles.

In all these forms of myositis surgical operations may be of great benefit. Acutely infected muscles should be laid open and treated on antiseptic principles, and the resulting deformities and contractures should be treated by exercises, the lengthening of tendons, and by nerve transplantations. Tuberculous muscles should be excised.

Syphilis and **actinomycosis** involve muscles. Syphilis must be treated constitutionally, while actinomycosis must be attacked with vigor—with the knife, curet, and copper salts—as I have described in Chapter II.

Hydatid cysts may be treated by injections of mercury biniodid, by excision, and by drainage. Complete excision is the preferable method.

Trichiniasis is distinctly a muscle affection. The embryos of the **trichina spiralis** enter the muscle through the blood-stream. The flat muscles are those usually involved. The embryos become encapsulated and die, leaving small, hard, calcified nodules. When the parasites are numerous in the muscles, they cause pain and swelling, with general symptoms of prostration, loss of appetite, and edema of the extremities. The disease is self-limited. Surgery can do little for it, but while it lasts the patient should be treated with purgatives and tonics.

Malignant tumors appear in the muscles. The *carcinomata* are secondary, but the *sarcomata* often are primary. They are primary in voluntary muscles, and arise from the connective tissue and from the muscle sheaths. Moreover, they are more common in women than in men. *Angiomata* also occur in the muscles, and the various *granulomata*. All such tumors must be excised promptly and thoroughly.

Injuries to muscles are of considerable interest to surgeons. Muscles are ruptured in whole or in part by direct violence. For example, the rectus femoris often is partly ruptured in football by a kick. I have seen the biceps ruptured in violent lifting. These muscle ruptures may or may not involve the muscle sheaths. The diagnosis is not difficult. Commonly a hernia-like tumor appears. When you ask the patient to "put up" his muscle, the corresponding limb does not move normally, but a bunch appears in the neighborhood of the damage, and a well-marked groove may be seen and felt below the bunch. No man can state definitely and positively the extent of the injury in one of these cases of muscle rupture. I have seen a damaged rectus abdominis the cause of a medicolegal suit, when an ill-advised physician swore positively that the muscular belly was ruptured, but that the sheath was intact. The accurate determination of the condition properly requires careful dissection by a competent anatomist.

Nevertheless, it is an easy matter to determine some degree of damage to the suspected muscle; while the treatment demanded is definite and obvious. The surgeon should cut down upon the injured structure and should repair it with sutures. The after-care of the wound is important. The parts should be put in splints, with extreme relaxation of the wounded muscle, and should be kept immobilized and free from all violence for at least six weeks. We obtain excellent recoveries under this treatment.

THE TENDONS

The tendons also are subject to their own peculiar lesions. The student who would gain a proper comprehension of the lesions of the motor mechanism of the body must not think of that mechanism's various parts as independent. Those parts are interdependent, and though their individual lesions may seem unrelated, we must remember

always that they may be closely related. The motor mechanism is composed grossly of bones, muscles, tendons, and nerves. Their relationships are as intimate, and their disease processes as difficult of conventional differentiation, as are the relationships and disease processes of the digestive organs which I have described in Part I of this book.

Inflammations and tumors of bone frequently involve or cripple the action of muscles, tendons, and nerves. Affections of the nerves may destroy the functions and structure even of bones and muscles. In like manner diseases of the tendons and tendon-sheaths may produce anatomic and functional changes in the bones, muscles, and nerves.

The tendons which we must briefly consider here are embryologically and structurally parts of the muscles, but they are subject to ailments more frequently than are the muscles themselves. The tendons suffer early from acute infective processes; they are subject to tumor formations; they become involved frequently in chronic infections originating in other structures, and their surgery is intimately dependent upon paralyses due to nerve lesions.

Traumatic tenosynovitis[1] is recognized as a definite entity. It is an affection most commonly of the tendons about the wrist or ankle. The disease is properly an ailment of the tendon-sheaths, but the tendons themselves become directly involved. The disease originates from some strain or blow which causes a congestion, a roughening, and an exudation within the tendon-sheath. This is a condition which we associate commonly with the term "sprain." At first the distressed tissues are free from infection; hence we speak of non-infective tenosynovitis; but should the lesion remain long untreated and become chronic, pathogenic organisms may find a nidus there, with a resulting serious infection, inflammation, and disablement.

In another place (Chapter XXVI) I have discussed massage, and have sketched its method of action. Massage is essentially the remedy for these cases of synovitis—massage or some similar agent—Bier's hyperemia and electricity, for example, which improve the circulation, break up and hinder adhesions, and promote a prompt return to normal efficiency.

The appearance of the affected parts (sprain) is characteristic, and the symptoms are familiar. The soft tissues are swollen, edematous, and tender. There is always subcutaneous hemorrhage, which in a few days may stain the skin varying shades of yellow, dark purple, or even black. All movements are painful and are involuntarily restricted. Later, as the swelling subsides and the exuded serous fluid is absorbed from the tissues, limited movements become possible—especially passive movements, while the examiner's hand laid flat and gently upon the affected part perceives often a pricking or grating about the tendons.

Active *treatment*, such as massage, is imperative in these cases. The old-time immobilization with splints or a plaster bandage is an unpardonable offense.

[1] The term "thecitis" is sometimes employed instead of "tenosynovitis."

Infective tenosynovitis is a far more serious matter. It may be acute or chronic. The acute form results commonly from septic wounds about the distal insertions of the tendons. Felon, palmar abscess, and inflammatory ingrowing toe-nail are common sources of tenosynovitis, and the most familiar location by far is in the hand and wrist. The surrounding parts become tensely swollen, red, hot, edematous, and painful. The lymph-channels are involved; the muscles are invaded; and the whole limb takes on that angry appearance familiarly known to us as the "septic arm." The patient suffers quickly from a systemic invasion. His temperature runs high; his pulse is bounding and quick; he experiences loss of appetite, constipation, and diminished renal action until the disease, if not successfully treated, results in a septicemia and the death of the sufferer. These infections are less common than of old, but even now they are greatly to be dreaded, and they demand energetic treatment.

Treatment.—We need not here consider in minute detail the management of septic infections beyond reminding ourselves again that treatment is two-fold—general and local. We must stimulate the bowels and kidneys; calomel catharsis and abundant water-drinking usually suffice. We may well prescribe citrate of iron and quinin in 10-grain doses; but, most important of all, we must ascertain the nature of the invading organism, and must supply the patient's circulation with the indicated opsonins. The Bier bandage also is of great value.

Such general measures must be supplemented by local treatment. We must open all collections of pus—open them freely and widely with long incisions; we must clean out necrotic tissue; we must wash thoroughly the parts with formalin, hydrogen dioxid, and sterile water: and keep open the wounds with gently applied gauze wicks for drainage —not with tightly packed iodoform gauze stuffing. These operations must, of course, be done with the patient under a general anesthetic, preferably nitrous oxid or ether. Often the tedium, pain, and throbbing of these wounds may be relieved by placing the affected limb in a hot sterile bath for hours at a time. Sometimes, in spite of our most zealous endeavors, the bones become involved in the infective process, so that we are forced to corrective amputations.

Acute and **chronic tenosynovitis** may also arise from various organisms reaching the seat of action through the blood- and lymph-streams. Among these organisms the gonococcus of Neisser plays an important rôle. A so-called idiopathic tenosynovitis, associated with edema, pain, loss of function, and other evidences of inflammation, should always lead the surgeon to the investigation of a possible antecedent gonorrhea in the patient. The commonly accepted *treatment* is absolute rest, with immobilization of the parts, while the primary gonorrhea, if present, must be combated at the same time. Friedreich maintains that multiple small skin incisions or punctures are essential. Certainly, this measure gives great relief; some observers are encouraged to use the gonococcus vaccines also in these cases.

Tuberculous tenosynovitis, sometimes called "compound gan-

glion," is an obstinate, chronic, and extremely troublesome affection. The tendon-sheaths become tuberculous and obstructed; fluid collects in the confined spaces within them; an oblong cystic tumor results. The disease may remain self-limited at this stage, or gradually may advance so as to involve several tendon-sheaths and the surrounding parts. The ancient method of rupturing this "ganglion" with a blow is futile. The surgeon should dissect out carefully all the diseased tissues; should close the wound completely with a proper skin-flap; should immobilize the limb for a number of weeks, and should prescribe emphatically a proper hygienic life.

Tumors of the tendon-sheaths are rare. Perhaps *lipomata* are the least rare, while connective-tissue tumors have been recognized. These tumors must be treated by careful and thorough excision.

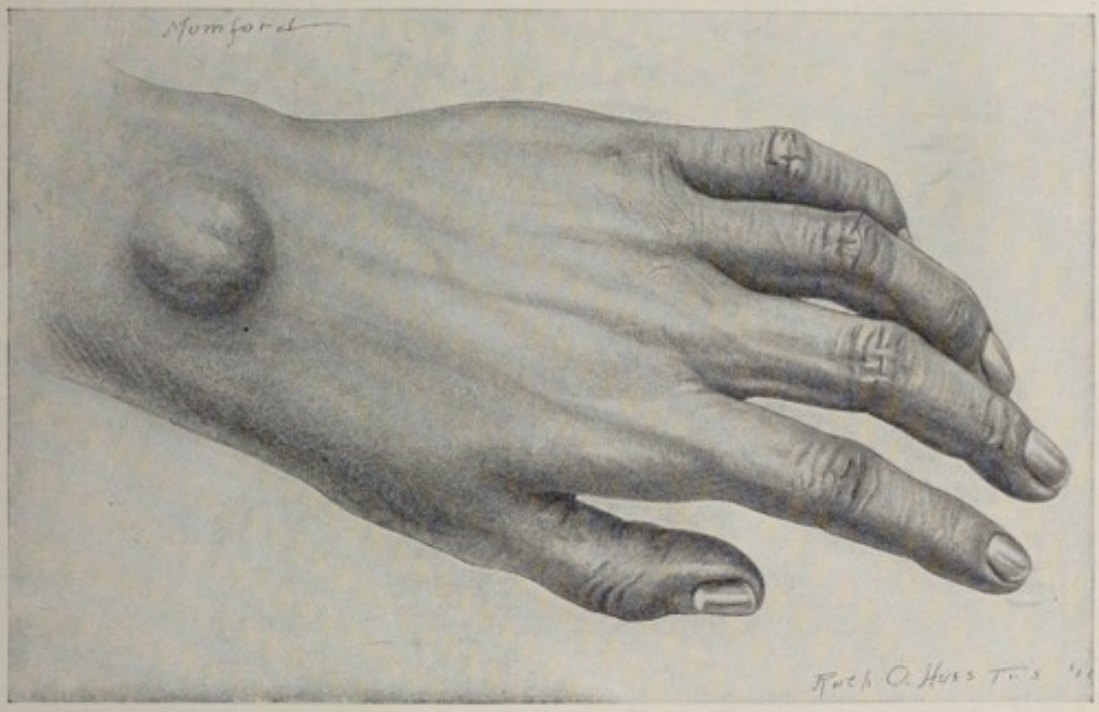

Fig. 500.—Ganglion.

Paronychia, felon, and *palmar abscess* are described in Chapter XXVI.

I have spoken of *tuberculous ganglion;* there is a non-infective **ganglion** also—a cystic tumor, appearing usually on the dorsal side of the carpus. It is associated with little pain and is troublesome mainly from the slight disability and weakness which it causes. This form of ganglion also must be removed by excision, and I prefer the crescentic skin incision.

Wounds of tendons are common enough. I have already explained how infected wounds of the tendons, such as those resulting from felon, must be cleaned out and allowed to heal from the bottom. Infected tendons and their sheaths propagate sepsis with extreme rapidity, and demand energetic treatment.

Clean wounds of the tendons, especially operative wounds, must be treated on quite another plan. The tendons must be sought out, and

carefully approximated and sutured, for the purpose of restoring func-

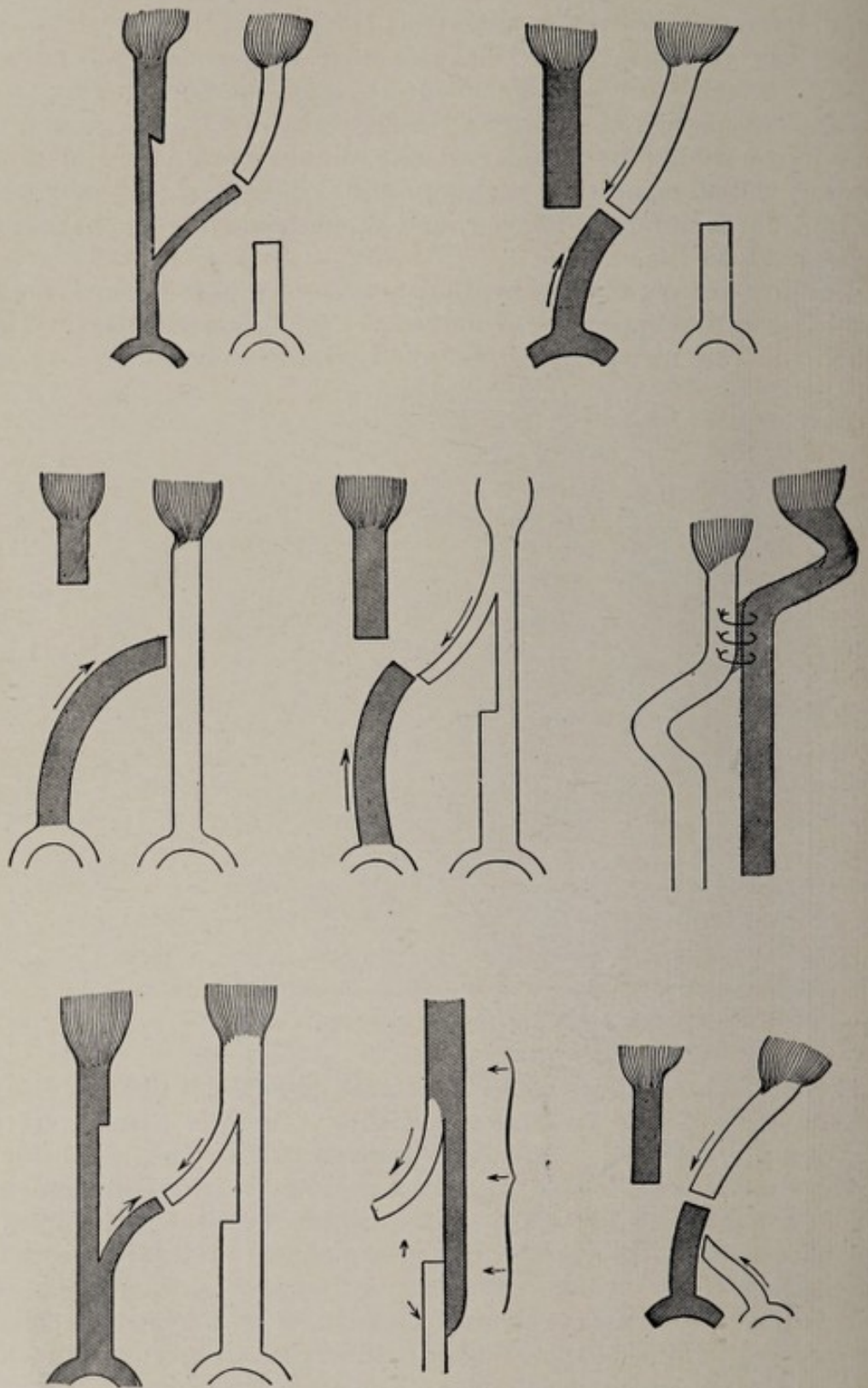

Fig. 501.—Illustrating various methods of dealing with tendons in tendoplasty (after Vulpius).

tion. This operation is somewhat similar to the operation of nerve-suturing. Unlike severed nerves, however, severed tendons retract from

sight, owing to the pull of the muscles above. For this reason, if several tendons—*e. g.*, the flexors of the wrist—are severed at once, it will be difficult or impossible to approximate truly each stump to its fellow. But in any case, the surgeon must do his best. Use fine silk sutures to draw the tendons together and employ the technic illustrated in the figures. If possible, repair accurately the tendon-sheaths. So far the operation goes well enough, and the result may seem admirable. Unfortunately, adhesions may form between the tendons and the skin, so that free play of the tendon is delayed or becomes permanently lost even. Aseptic precautions in the operation are imperative. A slight fault in the technic will result in imperfect repair and in uncertain function.

Tendon transplantation[1] for the relief of paralyses has been a favorite operation with orthopedic surgeons during the past fifteen years. In these days we are substituting for it *nerve transplantation*. The best results of tendon transplantation have been attained in cases of anterior poliomyelitis in which one year at least has elapsed since the onset of the disease; and the tendons employed have been commonly those of the leg below the knee. The technic of this operation is most painstaking, and the surgeon attempting it should study carefully the larger monographs on the subject, and should obtain the advice of an experienced neurologist.

THE BURSÆ

The bursæ deserve the serious attention of surgeons—never more than to-day, when the intricate relations of bursæ with the joints are becoming more obvious than formerly.

Bursitis of various forms is the subject of our study, and bursitis may or may not be infective. Indeed, the forms of bursitis are quite similar to the forms of tendon-sheath inflammation, for both structures are made up on similar lines.

Traumatic bursitis results from injuries, and is manifested at first by swelling, pain, tenderness, and loss of function; later by atrophy of the parts, stiffness of the neighboring joints, and pain on motion. One of the most interesting types of this form of bursitis is *inflammation* of the *subdeltoid bursa*, which E. A. Codman has described in a series of brilliant monographs.[2] The studies of this writer show that this bursa is more extensive than the anatomies have taught, and that its relations are intimate, not only with the shoulder-joint, but with the associated tendons, especially with the rotator group.

The *suprapatellar* bursa (or bursæ), the bursa beneath the *ligamentum patellæ*, the bursa behind the *olecranon*, and many other similar bursæ are of great surgical importance. These bursæ, when damaged by blows, become deeply injected, and secrete an abundant fluid, which may be hemorrhagic; while later, when the fluid becomes absorbed,

[1] H. Augustus Wilson, The Advantages of Tendon Transplantation, Amer. Med., April 8, 1908.

[2] Transactions Massachusetts Medical Society, 1908.

there may result adhesions between the opposing bursal surfaces. These are the adhesions which cause permanent crippling and pain.

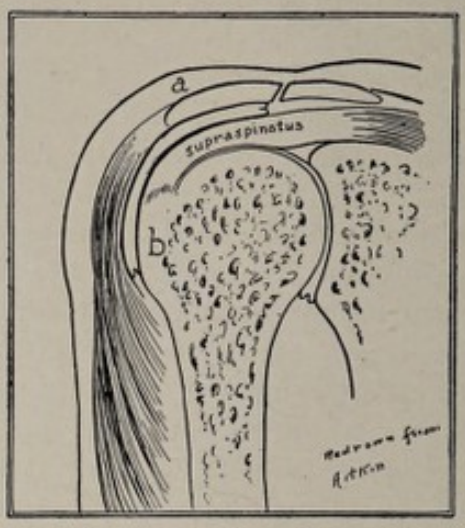

Fig. 502.—Diagram from frozen section. Notice the deltoid and its origin from the edge of the acromion. Notice the subdeltoid or subacromial bursa with its roof made by the under surface of the acromion and by the fascia beneath the upper portion of the deltoid. Its base is on the greater tuberosity and the tendon of the supraspinatus which separates it like an interarticular fibrocartilage from the true joint (E. A. Codman).

The *treatment* of traumatic bursitis may be extremely simple, or it may be intricate and prolonged. The freshly damaged limb should be immobilized in a position to relax the overlying muscles—the arm

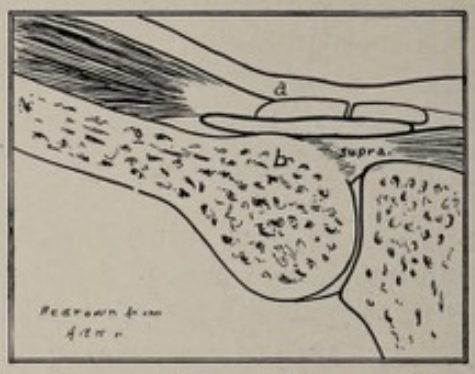

Fig. 503.—Illustrating the condition which would be found in abduction, the tuberosity having passed under the acromion and the point (*b*) having passed the point (*a*). The elastic deltoid has taken up the slack at one end and the supraspinatus at the other. It is obvious that the floor of the bursa, as it lies on the tendon of the supraspinatus and the tuberosity, must be a smooth, even, round surface. As a matter of fact, the first time one cuts into the bursa one is almost startled to find how much the floor of it looks like the cartilaginous surface of the bone. It is obvious that if the surfaces of the bursa between the points *a* and *b* in Fig. 502 were adherent, it would be impossible for the joint to pass into the position shown in Fig. 503 (E. A. Codman).

somewhat elevated, in the case of *subdeltoid bursitis;* the leg extended in the case of *prepatellar bursitis.*[1] If the effusion into the bursa per-

[1] *Prepatellar bursitis* is known by the ancient term "*housemaid's knee.*" *Postolecranon bursitis* is commonly called "*miner's elbow.*"

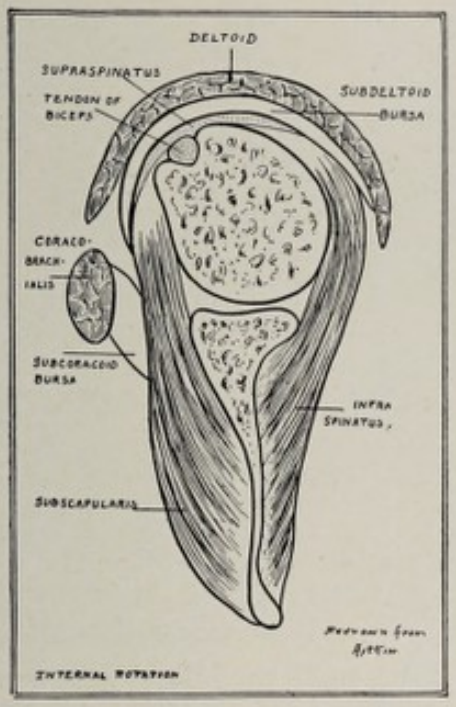

Fig. 504.—A diagrammatic representation of a horizontal section through the head of the humerus to indicate the lateral extent of the bursa, and the necessity for its existence to allow the greater tuberosity to rotate beneath the deltoid. Notice also how the tendon of the subscapularis is stretched around the head in the opposite direction in external rotation. This stretching occurs not in the tendons themselves, which are very short, but in the muscles which, by their construction, take up the slack of the capsule of the joint. In fact, the capsule of the joint is really made up of the tendons and muscular bellies of these short rotators. It can easily be imagined how a simultaneous spasm of these muscles would lock the joint, for in the normal motion one must relax as the other contracts. Notice also the cross-section of the coracobrachialis and the necessity for the subcoracoid bursa which lies between it and the subscapularis. Since the two muscles work at right angles to one another the bursa is indispensable (E. A. Codman).



Fig. 505.—See Fig. 504 (E. A. Codman).

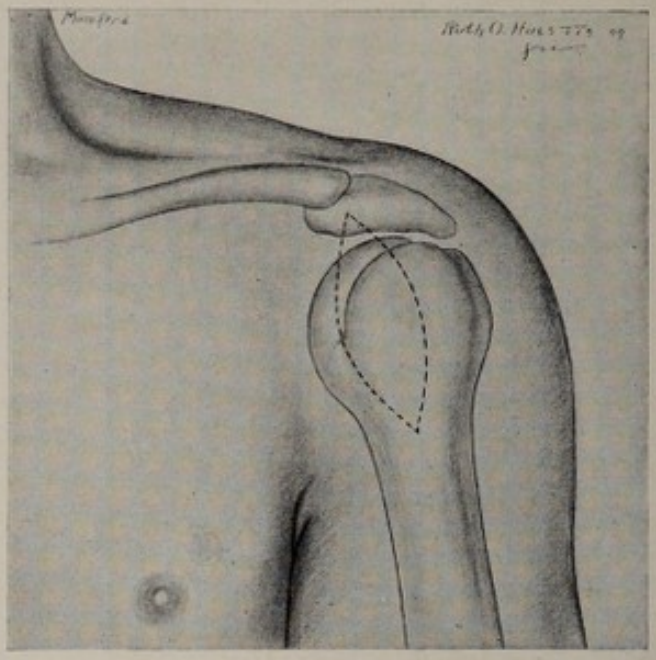

Fig. 506.—Dotted line showing incision used for demonstration of the bursa. For enlargement see Fig. 507 (E. A. Codman).

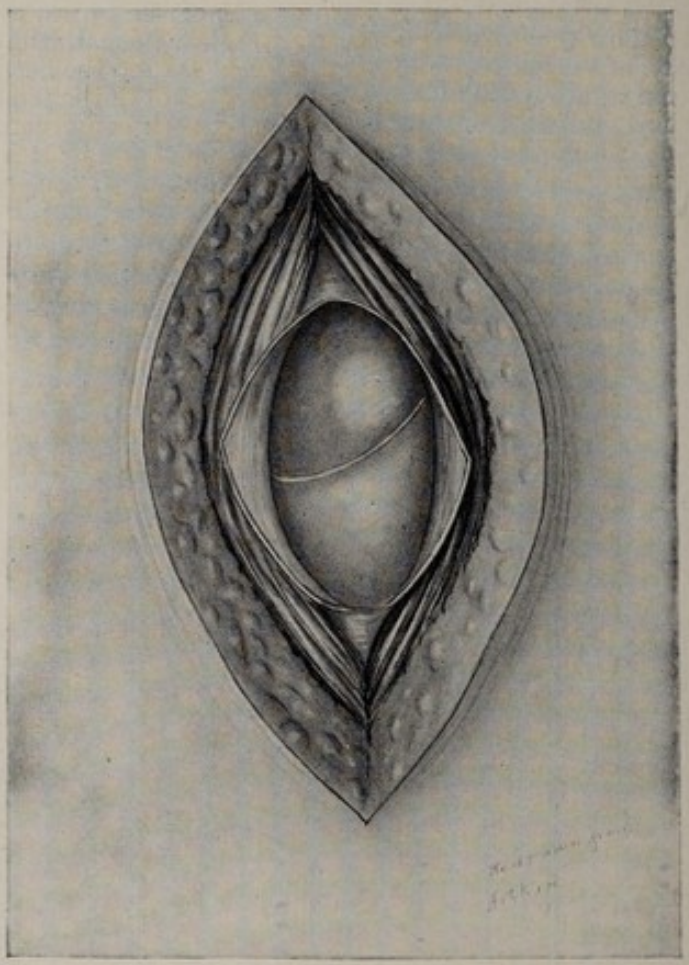

Fig. 507.—Illustrates the appearance when an incision is made into the normal bursa (E. A. Codman).

sists for more than ten days, the bursa should be opened, evacuated, wiped out with 95 per cent. carbolic acid, followed by 70 per cent.

alcohol, and closed securely without drainage. If pain and impaired function follow the subsidence of distention, the surgeon should employ massage, Bier cupping, and passive movements, with intervals of immobilization. Usually four or five weeks of such treatment will establish a cure, except in the cases of subdeltoid and subcoracoid bursitis,[1] which are often so obstinate as to cripple the victim for months or years even. *Subcoracoid bursitis* is especially interesting, since it is constantly confused with "neuritis" and with subdeltoid bursitis. Indeed, they often coexist. The subcoracoid bursa, lying in front of the coracoid, is kept in irritation by shoulder-droop, when the head of the humerus lies against it and keeps up an irritation. This bad posture may be corrected by holding the shoulder back by braces or by back-strapping. The patient experiences almost instant comfort and relief.

Acute infective bursitis is due either to a punctured wound or to a hematogenous infection. The acutely inflamed bursa calls for prompt and radical *treatment*. It should be opened freely, the sac excised, and the cavity swabbed out with carbolic and alcohol or with Harrington's solution. The wound should be packed, but not closed tightly.

Chronic bursitis may result from an acute bursitis, as in the case of the subdeltoid bursa; or it may be due to long-continued irritation, such as the pressure of the boot over the first metacarpophalangeal joint—pressure which gives rise to a bunion. I have described bunion in Chapter XXVI. Chronic bursitis is best *treated* by excision of the bursa.

Tuberculosis of bursæ is a fairly common condition, difficult at first of diagnosis, similar in its morphology to tuberculous tenosynovitis. Tuberculous bursæ may be excised.

There are **tumors of bursæ** which need not concern us further than to reflect that they too must be excised.

We have passed in rapid review the diseases of muscles, tendons, and bursæ—topics of grave concern often—topics of acute interest to the painstaking surgeon who is familiar with anatomy. Most of the operations which I have described in this chapter are "anatomic operations" —that is to say, they demand of the surgeon that sort of minute anatomic knowledge which was probably more familiar to the great surgeons of the early decades of the nineteenth century than it is to the operator of to-day.

Surgery of the Skin

Surgery of the skin concerns the dermatologist; but certain of its phases concern the general surgeon also; at those phases let us glance briefly.

Dermatology delights in archaic terms, and we might well, at the conclusion of this chapter, already too long, indulge ourselves in sonorous classic words. Most of those words and terms, however, pertain properly to the domain of dermatology—not to the domain of general surgery, although the conventional text-book of surgery describes at

[1] Goldthwait, Painter and Osgood, Diseases of the Bones and Joints, p. 660.

length many skin lesions. Such lesions, for an account of which I refer the reader to text-books of dermatology, are *comedones, milium, molluscum contagiosum, dermatitis venenata, dermatitis gangrenosa, sunburn, lupus, blastomycosis,* etc.

There are certain other skin lesions, however, with which the surgeon must concern himself. Some of these I have already described elsewhere in this book—*wen, furuncle, carbuncle, corn, callus, nevus, cutaneous horns, malignant disease of the skin.*

There remain a half-dozen or more skin affections which we must consider here—*burns, cicatrices, frost-bites, chilblains, keloid,* and *malignant degeneration of scars and ulcers* (*Marjolin's ulcer*).

Burns are not necessarily and properly limited to the skin surface. They vary in depth, and according to their depth we define them as of the *first, second,* and *third degrees.* The *first degree* is characterized by a simple erythematous inflammation, sometimes followed by desquamation. The *second degree* shows inflammation with blisters, which may or may not appear until a day or two after the injury. The true skin is not destroyed. The *third degree* signifies a burn which destroys the skin and underlying structures to a varying extent.

Any substance hot or acrid enough to cause a necrosis of tissue will give rise to a burn—fire, hot metal, boiling water, boiling oil, acids, and even the useful hot-water bag if long enough applied.

The depth and extent of burns rarely at once are obvious; while, unfortunately, prognosis depends entirely upon the depth and extent. The shock is often out of all proportion to the first appearance of the injury; and the patient, if he recovers, may do so after weeks and months of suffering, and may carry with him thereafter great, crippling, and disfiguring scars. A wide burn of the limbs or of the head even may not necessarily kill the patient, while a relatively small burn of the trunk shortly may cause death. Shock and pain are leading *symptoms* at first, and these symptoms may be succeeded by internal inflammations, such as pneumonia, pleurisy, meningitis, peritonitis, and duodenitis (leading to ulcer). There is often marked leukocytosis; the urine is high colored, scanty, and loaded with albumin and casts.

The early deaths are undoubtedly due to shock; the late deaths, to pyemia or to some other general infection. Children, aged persons, and the alcoholic fall ready victims to burns. Recurrent vomiting is an ominous sign, suggesting gastric or duodenal ulcer, often associated with hemorrhage.

The *treatment* of *burns* is symptomatic, and is directed to the varying degrees of burns. In the burns of the *first degree* we strive to relieve pain by anodynes and by excluding air from the affected area. Applications of carron oil or of vaselin usually suffice for the latter purpose, while immersion of the part in a warm solution of sodium bicarbonate is grateful to the patient.

Burns of the *second degree* are treated on much the same plan, except that the extensive destruction of the epidermis requires often a longer course of treatment. We must open the numerous blebs,

dress them with drying powders and ointments, and must repeat the dressings frequently—sometimes two or three times in twenty-four hours. Comforting dressings are an ointment of boric acid and vaselin, Squibb's compound alum powder, or silver foil. The continuous bath in warm soda solution is extremely comforting and effective.

Burns of the *third degree* test our resources. Give to the patient at once morphin sufficient to relieve his pain. Dress the wound with an abundant oily dressing; and then concentrate effort upon combating shock. Stimulate renal secretion by the infusion of normal salt solution; give a brisk purge (calomel or a saline cathartic); add adrenalin to the infusion. If these measures fail to relieve the shock, employ the transfusion of blood—a final but extremely hopeful resort.

With the subsidence of shock the patient enters upon a long course of tedious and distressing wound healing, during which a great variety of remedies may be employed. The wounds must be kept strictly clean by the removal of all sloughs, and by frequent gentle washing with such non-irritating lotions as warm 5 per cent. boric acid, or normal salt solution. Simple boric-acid ointment may suffice for a dressing. After convalescence has been established it may be possible and advisable to cover the raw surfaces with skin-grafts, if skin can be obtained. In spite of all these measures the wounds sometimes remain sluggish for months, and show little tendency to close. Under such circumstances I have found open-air treatment of the wounds extremely effective. The wound is exposed for many hours of the day, or continuously, to the open air, while we protect it properly from dust and insects. Surgeons who have not tried this method will be astonished often at its efficiency in the case of obstinate and long-standing granulating wounds.[1]

Superficial cicatrices of great extent, grievously deforming, may result from healed burns. The most familiar of these deforming cicatrices are those of the neck, the elbow, and the wrist. As these cicatrices contract, the chin is drawn down in a truly hideous fashion; the elbow is drawn up so as seriously to cripple the arm, or the wrist becomes so twisted as to render useless the fingers. The only satisfactory *treatment* for these deformities is some plastic operation, associated perhaps with grafting. Writers claim that careful prophylaxis by extension in splints during convalescence will head off these deformities. I regard this notion as Utopian. The less extensive scars sometimes may be helped by such mild measures as Gersuny's method of

[1] Extract from Jour. Amer. Med. Assoc., 1908: "*Hot Horse Serum in Treatment of Burns.*—R. Petit's communications on the efficacy of hot horse serum in local treatment of wounds have been summarized in these columns from time to time. He now announces that it is proving the best topical application for extensive burns. The Presse Médicale, June 13th, quotes some of his case histories, showing that healing was much more rapid in the burns treated with the hot horse serum than in other burned patches in the same child treated with picric or boric acids, etc. He believes that the horse serum revives the injured cells, possibly including the nerve-cells, so that they recuperate and aid in the healing process, instead of dying and generating poisons. The serum also summons the leukocytes to the spot, while its harmlessness has been demonstrated."

injecting liquid vaselin into the tissue beneath the cicatrix; by douches, baths, massage, electricity, tenotomy. Claude Martin employs traction and continuous pressure, which sometimes render the scars supple. Occasionally the *x*-rays will bring about absorption of scar tissue. Such treatment is applicable to the milder cases only.

Operative treatment calls for careful planning and painstaking execution. We must loosen up thoroughly the scar tissue in flaps until the affected parts are completely mobilized. We thus secure a new and wide area of raw surface which must be filled in. Sometimes we can fill in the surface with Thiersch or Wolff grafts. Again, we may turn in plastic flaps of sound skin from the neighborhood, taking pains always that the newly applied flap shall be more than abundant, and that it shall lie in place easily and without tension. It is a mortifying calamity sometimes to find that the newly applied skin-flap at the end of four or five days is sloughing on account of undue tension and an insufficient blood-supply. We complete the operation with carefully applied and abundant absorbent dressings, which must be reinforced by splints, if necessary, so as to hold the parts in their normal relations.

Frost-bite is a condition analogous to burn—indeed, we may recognize three degrees of frost-bite. The exciting cause ordinarily is exposure to cold air, but cold applied in a limited fashion, and locally, may damage the skin. I have seen extreme sloughing of the abdominal wall follow the long-continued application of an ice-bag.

The early *symptoms* of frost-bite differ materially from the symptoms of a burn, for in the former case the parts become numb and analgesic. The analgesia persists just so far as the tissues are necrotic. Later, if recovery take place, the patient experiences tingling and pain with the return of circulation in the part. That skin which is without sensation for twenty-four hours must be regarded as dead. We are warned against the diagnostic needle-prick, as it may lead to gangrene.

The *treatment* of frost-bite must be cautiously conducted. Patients should be kept for a time in a room at a low temperature, while the affected part is immersed in ice-water. After fifteen minutes the surgeon or nurse should take the limb in hand and begin gentle friction with ice-water or snow. As the circulation returns and the normal temperature is established, apply stimulating friction with spirits of camphor or alcohol and water. Gradually raise the temperature of the room, and cautiously give warm drinks—hot tea with a little rum, hot bouillon, hot milk, etc.

By such means the milder forms of frost-bite may be successfully treated. The deeper frost-bites, which destroy tissues and cause gangrene of the parts, must be treated on general surgical principles—by trimming off the sloughs and by appropriate amputations.

Chilblains (*erythema pernio*) are localized areas of impaired circulation in the skin. The victims commonly are persons in poor general condition. Patches of skin on the hands and feet become bluish or purple, swollen, tender, cold to the touch, itching and burning to the sensation of the patient. Neglect and too much rubbing make matters

worse, so that blisters and ulcerations even, with possible gangrene, may result.

Treat the disorder by general tonics, by protecting the exposed parts with proper clothing, by exercise, and locally by immersing the affected region in hot saturated solution of alum. In mild cases balsam of Peru or 10 per cent. ichthyol ointment may be rubbed in twice a day.

Keloid is a connective-tissue overgrowth in the corium. Sometimes it arises spontaneously; more often it is a result of traumatism. We call the spontaneous keloid *true keloid*, and that resulting from injury *false keloid*. These growths look like greatly thickened scars. Negroes especially are subject to false keloids, which may appear anywhere in the body. The true keloid is seen most commonly over the sternum.

The growth is situated in the central and lower portions of the cutis. It begins on the walls of the larger vessels, and when fully

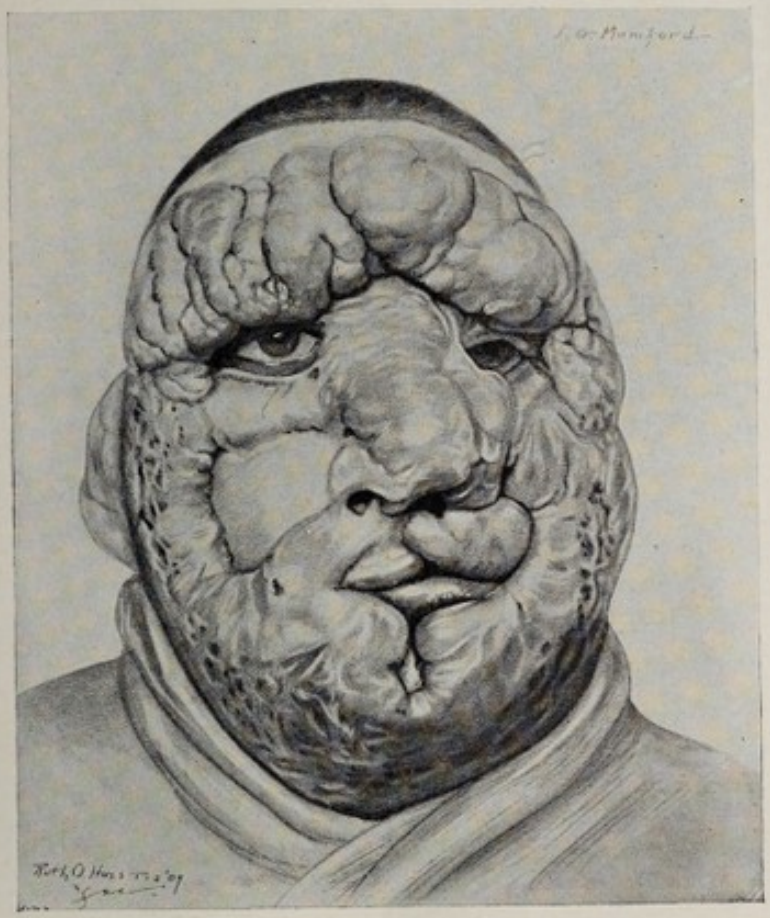

Fig. 508.—Extensive keloid of face (Massachusetts General Hospital).

developed, is composed of dense bundles of fibrous tissue which are mostly arranged parallel with the long axis of the tumor.

The patient usually complains of nothing except the deformity, though occasionally there may be slight pain, while rarely the keloid undergoes malignant degeneration.

The *treatment* of keloid is far from satisfactory. The obvious measure

is to excise the tumor with a wide margin, in the hope of replacing it by a narrow linear scar. Unfortunately, in many cases a new keloid appears at the site of the new scar. I have seen some excellent results follow the long-continued use of the *x*-rays after excision of the growth.

Every hospital has on its list of chronic patients some of these cases of keloid,—patients who return year after year to have their deformities improved if possible,—upon whom the surgeon comes to look with ever-increasing dismay.

Malignant degeneration of scars and ulcers occurs in various parts of the body. Marjolin described the condition half a century ago, and Da Costa wrote of it again in 1903 (Marjolin's ulcer). The term is applied to chronic ulcers which have undergone malignant changes. Cicatricial tissue also may undergo similar changes. *Lupus* and *syphilis*

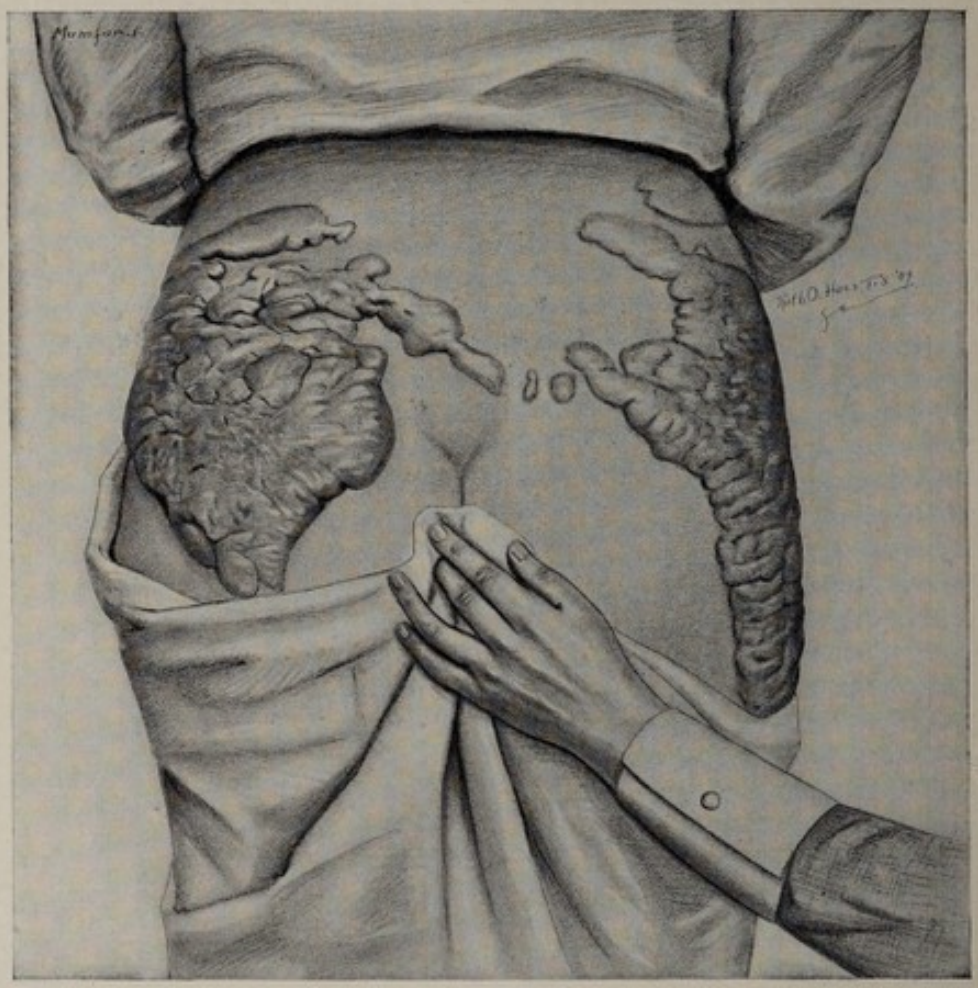

Fig. 509.—Keloid (Massachusetts General Hospital).

are among the etiologic factors. The ulcer takes on malignant characteristics about its margins, and these malignant changes, when once started, may progress rapidly. The ulcer's edges become hard and elevated; the granulations large and hemorrhagic; there is often great pain and a fine bloody discharge; the adjoining lymph-nodes become involved, and the ulcer runs the characteristic malignant course.

The *treatment* is obvious—a prompt and wide excision.

Pilonidal sinus is a congenital inclusion cyst (an infolding) or sinus of the skin in the midline; and is seen at the upper end of the fold of the nates. It is lined with skin and hair, and extends often to the periosteum of the sacrum, which may be involved in its inflammations. The sinus is innocuous until it becomes inflamed, when its outlet becomes choked and its lumen filled with pus. A considerable external swelling may then appear—a fluctuating abscess. Necrosis of the sacrum even may result. In its normal state the sinus seems a mere skin dimple, into which a small probe may be passed. It must not be mistaken for fistula in ano. The only *treatment* for pilonidal sinus is thoroughly to dissect it out from the bottom. Frequently stray hairs or masses of hair are turned out.

CHAPTER XXVIII

TUMORS

In this chapter I propose to discuss briefly the subject of tumors, although by so doing I must violate the promise in my introduction that I would not deal in this work with matters of general pathology.

Tumors, however, belong esentially to surgery as distinguished from medicine. Except when hopeless—and who may say what is hopeless?—tumors have no place in medical wards or under the care of the internist. A distinguished American surgeon recently said to me: "I visited one of your famous hospitals and went through the medical wards with the visiting physician. He showed to me a number of patients whose ailment was cancer of the stomach. What were cases of cancer of the stomach doing in the wards of an internist? He could not cure them." Such is the radical surgeon's view—and it is a view which is gaining new adherents daily.

The term *tumor* is a clinical rather than a proper pathologic term. It signifies a swelling merely; and, literally used, might well be applied to tuberculous joints or to ascites. Commonly, the physician means by the term *tumor* a solid new-growth—a neoplasm. Roswell Park's definition is:[1] "A tumor is a new formation, not of inflammatory origin, characterized by more or less conformity to the tissue in which it has its origin, and having no physiologic function."

The terms *neoplasm* and *new-growth* are interchangeable.

We speak of *benign tumors* and of *malignant tumors*. A *benign tumor* is a new-growth which increases by the proliferation of its own intrinsic elements without destroying neighboring structures. It remains generally confined to its own capsule and causes no known hematogenous changes. A *malignant tumor* is a new-growth which spreads unconfined, and destroys neighboring structures as it advances. It produces remote metastases; it is associated usually with hemolytic changes, and it kills the patient.

Benign tumors may and sometimes do destroy life, but, as Bland-Sutton puts it: "The baneful effects of innocent tumors depend entirely upon their environment, but malignant tumors destroy life, whatever their situation."

Benign tumors may become transformed into *malignant tumors*, while there are intermediate varieties which cannot be assigned to either group. Uterine myomata may be multiple—one of these associated myomata may require a saw to divide it; another may be as soft as a ripe fig; while a third may be as viscous as jelly. One of these

[1] Roswell Park, Modern Surgery, p. 255.

tumors may remain innocent, while another may go on with changes of structure until it becomes definitely a carcinoma.

CLASSIFICATION

The classification of tumors made by authors is various, and at times surprising. We know little as yet of the etiology of tumors, and are unable, therefore, to classify them on an etiologic basis. We group them accordingly, on a basis of histology, assigning to them names which designate the more important elements in their structure.

In general terms we can divide tumors into four groups—*cysts, dermoids, connective-tissue tumors,* and *epithelial tumors.* Such a classification is doubtless too limited for convenient practice, though it is essentially that of both Bland-Sutton and Roswell Park; while Nicholls,[1] drawing largely on the work of Adami, gives an extremely complicated classification, based largely on the differentiation between the primary cell-layers in the fetus—the *lepidic* or *lining membrane* tissues; and the *hylic* or *pulp* tissues. Adami's classification has certain elements of great value, as it enables us to distinguish, for example, the endothelial from the epithelial growths. In this brief treatise, however, I shall employ a more familiar, even though unsatisfactory, classification, as follows: (1) *Cysts;* (2) *dermoids;* (3) *teratomata;* (4) *connective-tissue tumors;* (5) *neuromata;* (6) *epithelial tumors;* (7) *corium epitheliomata;* (8) *odontomata.*

CAUSATION OF TUMORS

The causation of tumors is one of the burning questions of medical science—a question so intricate, so hotly debated, and so far from settlement that I shall attempt no special expression of opinion regarding it in this brief and elementary writing. It is well, however, that the general reader should have some notion of the opinions and clash of authorities.

The *traumatic cause* of new-growths was accepted without question until the last generation. To-day traumatism as a cause of tumors is regarded variously by sound observers. Those who take the negative side of the argument assert that we have no positive experimental evidence that traumatism causes new-growths—and by this we mean commonly malignant disease. They remind us that every patient who suffers from malignant disease can point to some antecedent injury to the part affected; but, these critics say, what person lives who cannot recall some slight injury to every region of his body? Moreover, experimenters have been unable to produce neoplasms by purposeful damage to any structure. Observe, however, that by *traumatism* we understand not only immediate and obvious tissue damage by blows or other irritating forces, but structural disturbances, gradually produced through long-continued slight pathologic actions, which at first may not have been seriously regarded. In this latter class of trauma-

[1] Bryant and Buck, American Practice of Surgery, vol. i, p. 294.

tisms we include damage to the uterus by child-bearing; damage to the stomach by hyperchlorhydria, leading to ulcer formation; damage to the gall-bladder by inflammatory affections leading to calculus formation; damage to the breast through lactation; and damage to the lip, in men, through the habit of pipe-smoking—a cause of damage as rarely operative in women as is epithelioma of the lip in women. In view of such facts many surgeons have returned to the view that traumatism, especially long-continued traumatism, is a potent element in the causation of malignant disease.

Cohnheim's *embryonal hypothesis* has been, and still is, a favorite explanation of tumor formation in a certain number of cases. He founds his hypothesis on the anomalous embryonic arrangements of certain cells, and asserts that in the early stages of embryonal development there are produced more cells than are necessary for the constitution of a certain part, so that a number of cells remain superfluous. Large groups of superfluous cells may exist, producing superfluous organs and limbs even. In other cases certain small groups of cells, hitherto unrecognized, may be roused into activity and produce a neoplasm.

Heredity was regarded for centuries as an important element in tumor formation, but we have little reliable evidence that it is important.

The *parasitic theory* of tumor formation has become popular within recent years. New evidence in its favor is being accumulated and new arguments are being advanced. The controversy is now with us, but I feel that it is no part of this writing to deal with a question so recent, of a literature so voluminous, and so far from solution.

CYSTS

A cyst is a sac distended with fluid. The sac may contain a single cavity or it may be divided into countless compartments. Cysts result from the abundant dilatation of preëxisting cavities or tubules. There are *retention cysts, tubulocysts, hydroceles* or *distention cysts,* and *gland cysts.*

A familiar form of *retention cyst* is *hydronephrosis* due to ureteral obstruction with a consequent dilatation of the renal pelvis.

Tubulocysts are cystic dilatations of certain functionless ducts and obsolete canals. Bland-Sutton describes seven species of tubulocysts: (1) Cysts of the vitello-intestinal duct; (2) cysts of the urachus; (3) paroöphoronic cysts; (4) parovarian cysts; (5) cystic disease of the testes; (6) cysts of Gärtner's duct; (7) cysts of Müller's duct. Several of these forms are embryonal; several of them are so extremely rare as to be surgical curiosities. I have already described in Chapter XI the more familiar forms of cysts connected with the female generative organs; and in Chapter XV, the analogous cysts of the male organs.[1]

[1] I refer the reader who seeks more detailed knowledge to Bland-Sutton's exhaustive article in Keen's Surgery, vol. i, p. 863, and to Albert G. Nicholls' essay in American Practice of Surgery, vol. i, p. 291.

Nicholls reminds us of the important distinction between *cysts* and *cystomata*. In general terms we may define a *cyst* as a pathologic cavity containing fluid; but we do not think of new formed tissue as a cyst of this type. A *cystoma* is a true neoplasm, resulting from the proliferation of a matrix that tends to form cavities.

Cysts of the vitello-intestinal duct make themselves evident commonly in small, cherry-like tumors, red, soft, and velvety, connected with the navel by slender pedicles. These tumors are derived from the intestinal canal, as their histology shows. They are easily removed with the cautery.

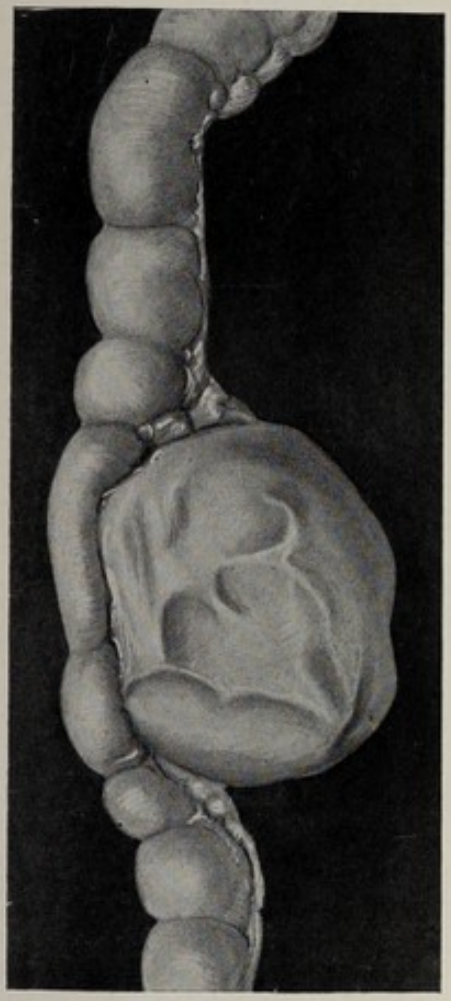

Fig. 510.—Cyst of the mesentery (Vander Veer).

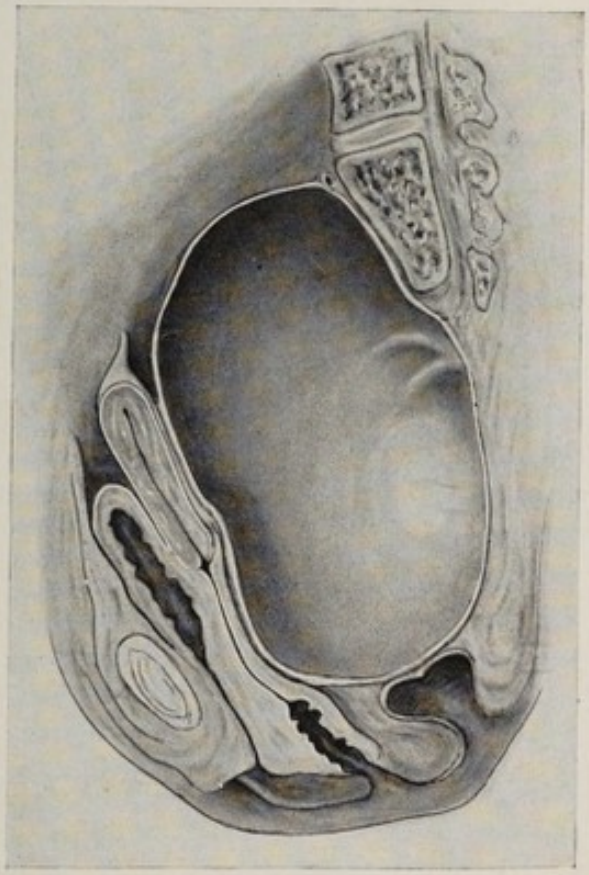

Fig. 511.—Congenital cyst of the pelvis (Ahlfeld).

Cysts of the urachus or cord passing from the urinary bladder to the naval are quite rare. They are difficult of diagnosis also, and suggest a distended bladder, rather than any of the more common forms of cysts. These cysts may be easily removed and the communication with the bladder closed through an abdominal section.

Echinococcus cysts ((Tænia echinococcus) are due to an intestinal worm whose normal habitat is the dog. The worm is about 4 mm. in length and consists of four segments, of which the fourth and largest only becomes mature. These creatures produce enormous quantities of eggs, which may be conveyed with food to the viscera of man. There they mature and the resulting embryos pass into the blood-vessels and

are conveyed to various organs, especially the liver. In the organs of the afflicted person the embryos becomes transformed into cysts, commonly called *hydatid cysts*.[1] Each cyst-wall has a peculiar structure—an external elastic layer, and an inner layer of granular matter, cells, muscle tissue, and a vascular system. These cysts are held in a fibrous capsule, and are maintained within it in a fluid medium. If one removes this fluid by tapping, the external capsule, or so-called "mother cyst," at once collapses, while the fluid withdrawn is found to contain numerous small "daughter cysts,"—suggesting grape-skins,—hooklets, and various other constituents, such as sodium chlorid, succinic acid, and occasionally leucin, tyrosin, and sugar.

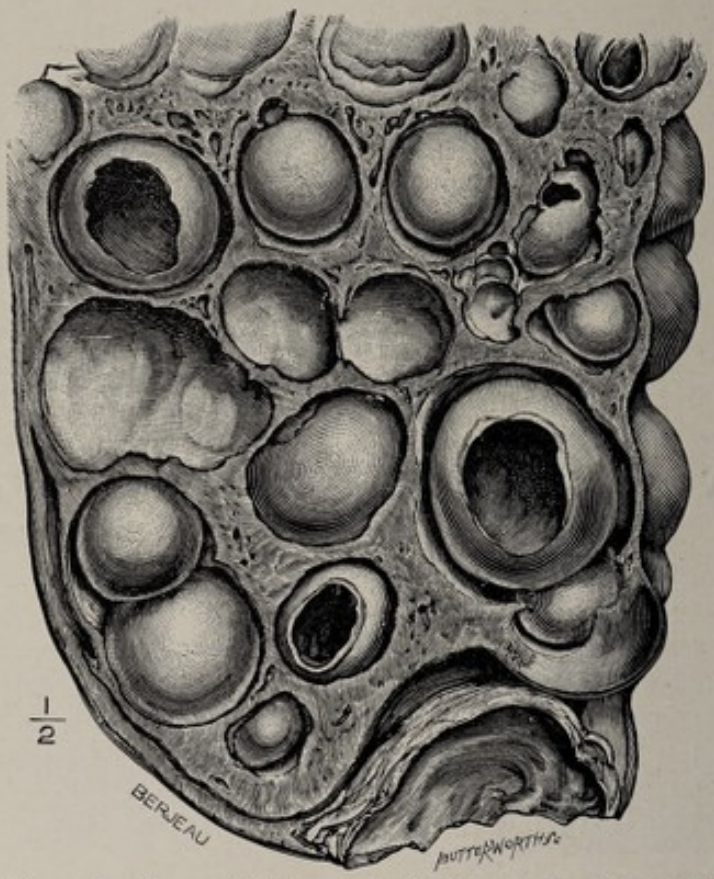

Fig. 512.—Portion of a liver which weighed 25 pounds thoroughly infested with echinococcus cysts (Bland-Sutton).

Echinococcus disease is peculiar especially to certain latitudes, and is endemic in Iceland. A patient from Iceland, who is the victim of a tumor, should always be suspected of echinococcus disease.

The *symptoms* and *diagnosis* of echinococcus disease depend entirely upon the location of the disease, whether in the liver, kidney, brain, or elsewhere. In general terms, we find that the damage caused by the disease is in direct proportion to the size of the cyst and to its interference with the function of the organ in which it lies. As a general rule, the diagnosis is made by accident in the course of an operation, the

[1] The word "*hydatid*" means properly *an encysted vesicle*. It is not applied to echinococcus disease alone, as many think.

surgeon having explored the affected region with the purpose of evacuating pus or removing a tumor.

As to the *treatment* of this disease, I have hinted at it in the foregoing paragraph. In most cases, owing to the deep site of the tumor

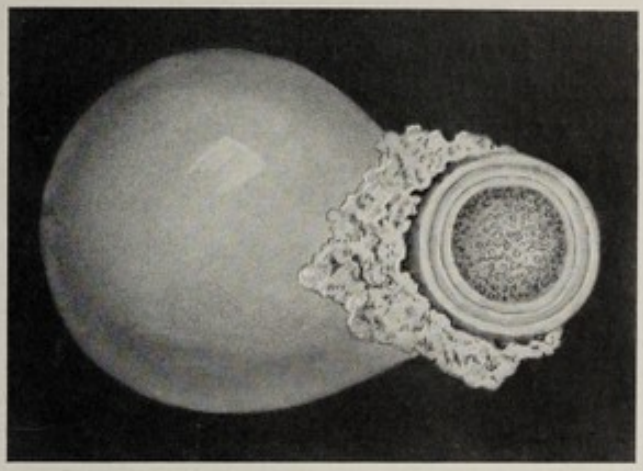

Fig. 513.—An echinococcus cyst, showing the peculiar lamination of its walls (Leuckart).

and its relation to the vital organs, it cannot be removed entire, but must be subjected to drainage and to long-continued irrigation with such aseptic fluids as potassium permanganate or weak bichlorid solution. Rarely, the surgeon may be able completely to enucleate the "mother cyst."

As for **hydrocele,** I have already discussed specific instances of the disease, such as *hydrocele of the tunica vaginalis, hydrocele of the cord,* etc.; *hydrocele of the neck* is an ancient term used to describe cystic collections of congenital origin due to dilatation of the branchial ducts. Neck hydrocele is far from common, and is generally mistaken for a deep abscess or for masses of tuberculous glands.

Ranula is the common example of a *gland cyst.* It is a *retention cyst,* due to obstruction of the submaxillary or sublingual ducts.

There are *pseudocysts* which properly are distended diverticula, such as I have already described as springing from the esophagus or intestine.

There are so-called *neural cysts;* for example, *hydrocephalus* and *spina bifida.*



Fig. 514.—Tænia echinococcus (Leuckart).

In other chapters of this work I have dealt with the various characteristics of special forms of cysts. It is needless here to repeat those descriptions beyond reminding the student that in most cases cysts are readily amenable to operative treatment, but that permanent cure depends upon the destruction and removal of the cyst-wall, and not upon its simple drainage—an ancient, easy, and fatuous procedure.

DERMOIDS AND TERATOMATA

Dermoids and teratomata [1] are tumors often confounded with each other by the thoughtless speaker. Indeed, they are conditions of distinctly different origin.

Dermoids are cysts or tumors containing tissues and appendages which are developed from the epiblast. A simple form of dermoid is a cyst whose interior is lined with skin bearing hair and sebaceous glands. The cavity of such a cyst is usually filled with a mixed thick liquid made up of fat, water, cholesterin, and growing hairs. A common location of dermoids is in the median line and in the region of the embryonic fissures. We see dermoids of the back associated with spina bifida and dermoids over the sternum. There are dermoids of the scalp, which are frequently called wens, and dermoids of the dura

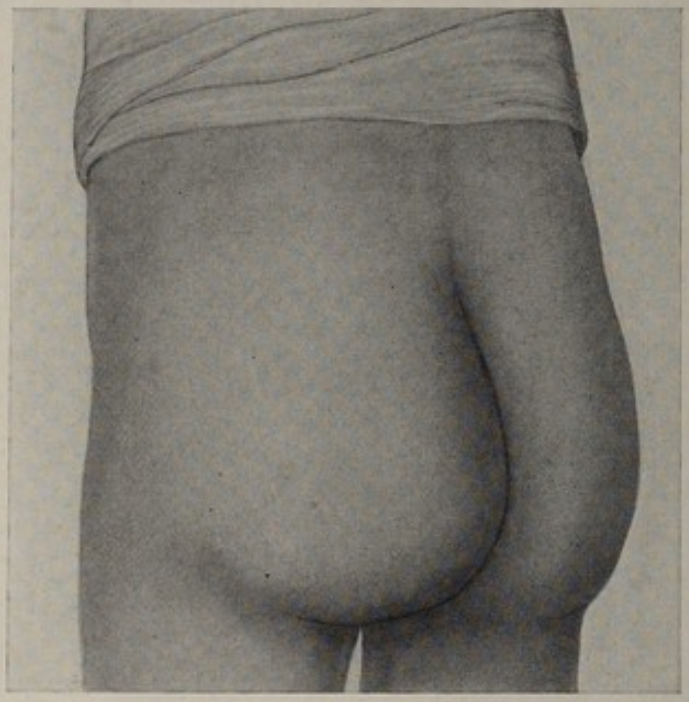

Fig. 515.—Solid dermoid tumor escaping from the pelvis (Park).

mater even. Dermoid cysts are found most commonly in the ovary and may there attain a large size.

Sometimes these forms of tumor may degenerate into sarcomata, or may even develop as cancers.

In their ordinary form, and when non-malignant, dermoid cysts cause such *symptoms* as we should expect from any other benign tumor, encroaching upon organs and interfering with their functions.

The *treatment* is radical extirpation, and the extirpation must be thorough indeed, for if any of the epithelial lining of the cyst be left, a new tumor of similar type is likely to form.

Teratomata are structures far more complicated than are dermoids. They may contain mere fragments of embryonic tissue, or they may contain portions of jaws, teeth, limbs, and even the trunk of a partially

[1] *Dermoid*, from *derma*, skin; *teratoma*, from *terata*, monstrosity.

formed embryo. The so-called "double monsters," museum curiosities, properly are teratomata.

Bland-Sutton's definition is: "A teratoma is an irregular conglomerate mass containing the tissues and fragments of viscera belonging to a suppressed fetus, attached to an otherwise normal individual. It is a significant fact that external teratomata are found almost exclusively in connection with the vertebral column and skull."

As Roswell Park states: "The presence of supernumerary members is largely connected with what is called *dichotomy*, alluding thereby to cleavage either at the anterior or posterior end of the developing embryo. When the whole embryonic axis divides, twins may be produced, but should the cleavage be partial, we may have a monster with two heads, if it be anterior; or one with three or more limbs, if it be posterior."



Fig. 516.—A postrectal dermoid with hair and a tooth (Bland-Sutton).

More commonly, however, the surgeon finds teratomata as tumors within the abdomen or thorax, or upon the face or neck, and these tumors may contain a few vertebræ or processes resembling fingers or portions of viscera. Such a tumor may be found in the larynx also, hanging by a small pedicle, or in the sacral or coccygeal regions.

Teratomata, like dermoids, may take on malignant changes, which condition seems to lend strong support to Cohnheim's hypothesis regarding the origin of tumors.

The *symptoms* and the *treatment* of teratomata differ in no obvious degree from the symptoms and treatment of dermoids, as I have described them.

TUMORS OF THE CONNECTIVE-TISSUE TYPE

Tumors of the connective-tissue type constitute a large class—probably a majority—of all tumors; and we divide them into two main groups—the benign and the malignant. We need not here consider in detail the structure and characteristics of all these growths, but we may well name them severally, and glance at those factors in their make-up and their life history which are of special interest to surgeons.

A **lipoma** is a tumor composed of fat, and is one of the most common of new-growths. There are encapsulated lipomata and diffuse lipomata, the former being surrounded with a sheath of fibrous tissue, while the

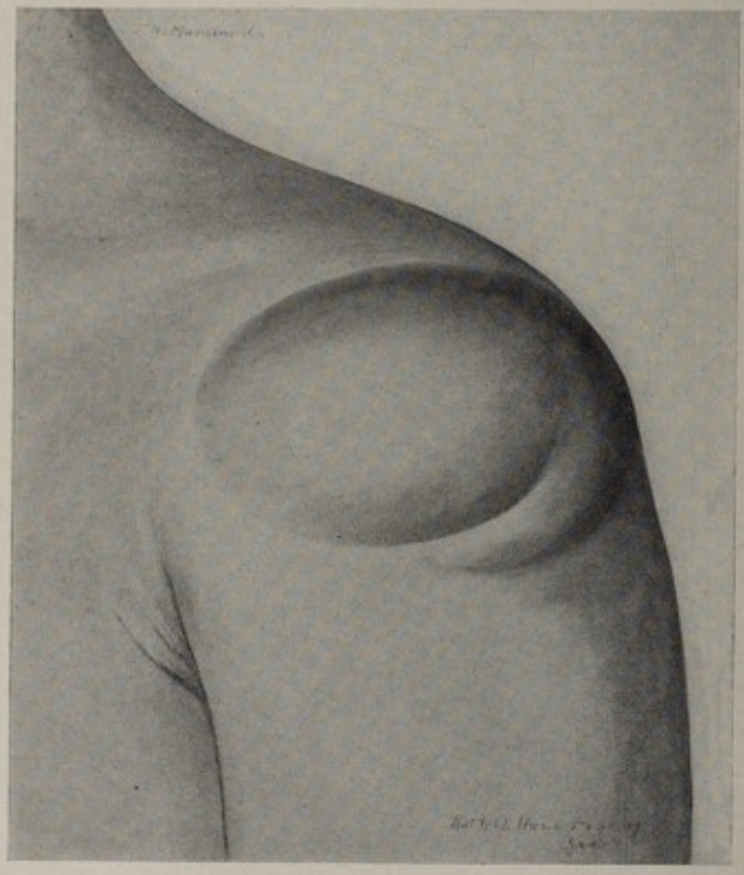

Fig. 517.—Lipoma of shoulder. Removed. Local anesthesia (author's case).

latter extend in all directions without a well-marked fibrous limit. *Encapsulated lipomata* are found in all parts of the body—under the skin, the serosa, and the mucosa; within the joints; and beneath the peritoneum. These encapsulated lipomata are more or less intimately adherent to their fibrous sheaths. Sometimes one may be shelled readily out of its sheath—sometimes it must be removed by careful dissection. As with all benign tumors, lipomata cause disablement just so far as they interfere with function. A fatty tumor as large as a dinner-plate, when situated between the shoulders, is not troublesome. A fatty tumor the size of a man's thumb, if it protrude into the knee-joint, may cause great pain and result in serious crippling. The "lipoma arborescens" of Müller is the common example of the latter

form, the joint lipoma, and is often associated with rheumatoid arthritis. *Subserous lipomata* situated behind the peritoneum may attain enormous size; may occur at almost any age; may seriously interfere with visceral function; and may be mistaken for grave abdominal tumors. *Diffuse lipomata* are seen most commonly on the back of the neck. Such lipomata spread without a limiting barrier and may cause ugly deformities.

The *treatment* of all forms of lipomata is excision. Those encapsulated growths which are found on the *anterior* surface of the body may be shelled out readily, while lipomata of the *back* call for a more painstaking dissection. Deep-seated encapsulated lipomata usually

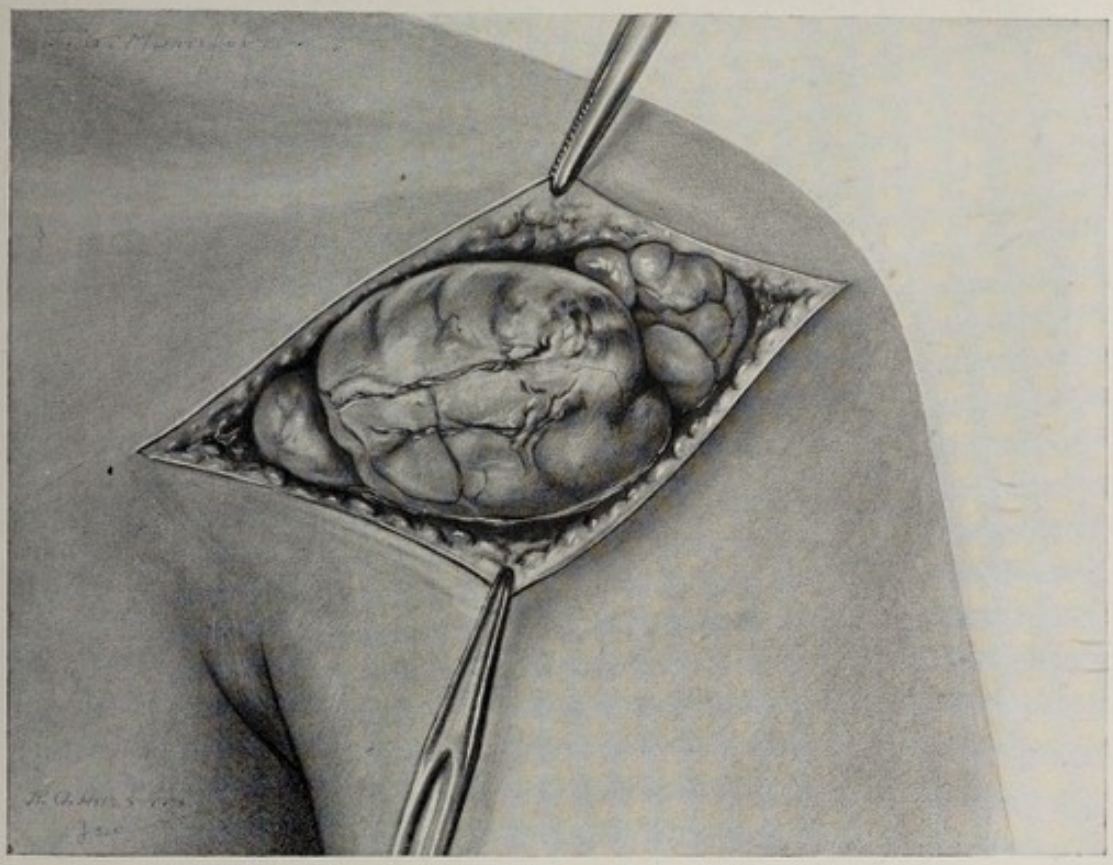

Fig. 518.—Dissection of lipoma of shoulder.

may be scooped out without great trouble. *Per contra,* diffuse lipomata must be removed with the greatest care in order that no portion of the growth remain. This form of fatty tumor recurs unless it be removed thoroughly.

A **fibroma** is a tumor composed of fibrous tissue; and the pure fibroma is not especially common. Mixed fibromata occur often enough, however, such as *fibrolipomata, fibromyomata, fibrosarcomata,* and the like. We find the pure fibromata in the female generative organs, the intestine, the gums, nerve-sheaths, and skin. Even so, many of these pure fibromata are mere curios. Certain of the fibromata of the gums and skin have been already described in other chapters. I have mentioned also those fibrous tumors termed *desmoids*—small

growths springing from the muscles, tendons, and aponeuroses. Rarely they may attain a considerable size. A *psammoma* is a hard fibrous tumor of the dura mater. Psammomata are fairly common intracranial tumors, and though benign, they may destroy the patient through gradually increasing intracranial pressure.

A **chondroma** is a tumor composed of hyaline cartilage. It is usually found connected with the epiphyses of the long bones. Chondromata are dense, hard, and immovable when young; but when mature they may be the seat of cystic degeneration. They may become calcified or ossified.

The *treatment* of chondromata is not always easy. Obviously, they call for thorough excision, but thorough excision, if it compromise the



Fig. 519.—Diffuse lipoma (Massachusetts General Hospital).

epiphyses of the long bones of young persons, may result in a permanent shortening of the limb. On the other hand, the chondroma may attain a great size, and may so far involve the integrity of the bone that its removal implies the amputation of the limb. One may see that the removal of chondromata may call for the highest degree of experience and skill, and that each individual case must be treated upon its individual merits.

An **osteoma** is a bone tumor, which we must distinguish from an *exostosis* and from an *odontoma*. Exostoses are irregular outgrowths of bone, while osteomata are distinct tumors composed of bone-like tissue; and odontomata are tumors of dental origin and structure. Moreover, osteomata may be regarded as ossifying chondromata.

As for *exostoses*, we borrow from Bland-Sutton a classification of three forms: (1) Those produced by ossification of tendons; (2) subungual exostoses which grow beneath the toe-nails; (3) exostoses due

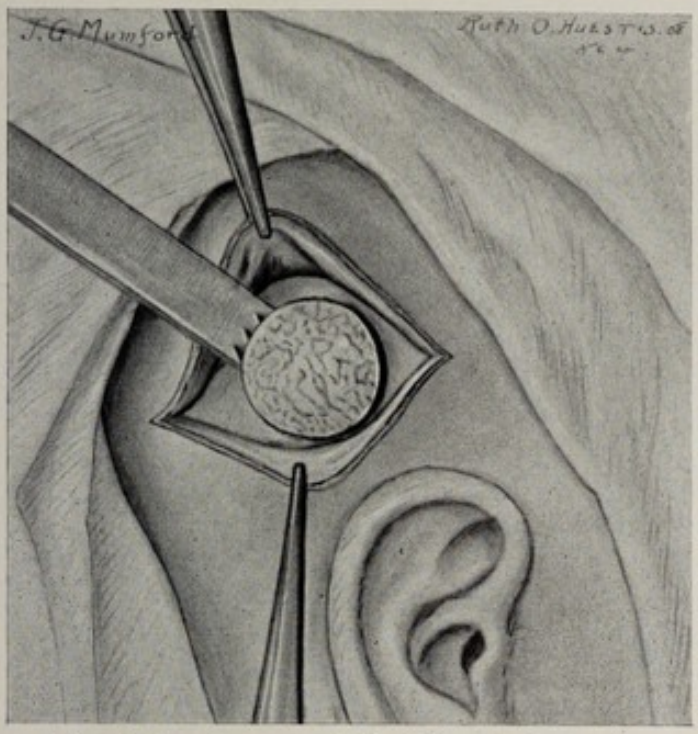

Fig. 520.—Osteoma of skull (author's case).

to calcification of inflammatory exudates, including that condition known as *myositis ossificans*.

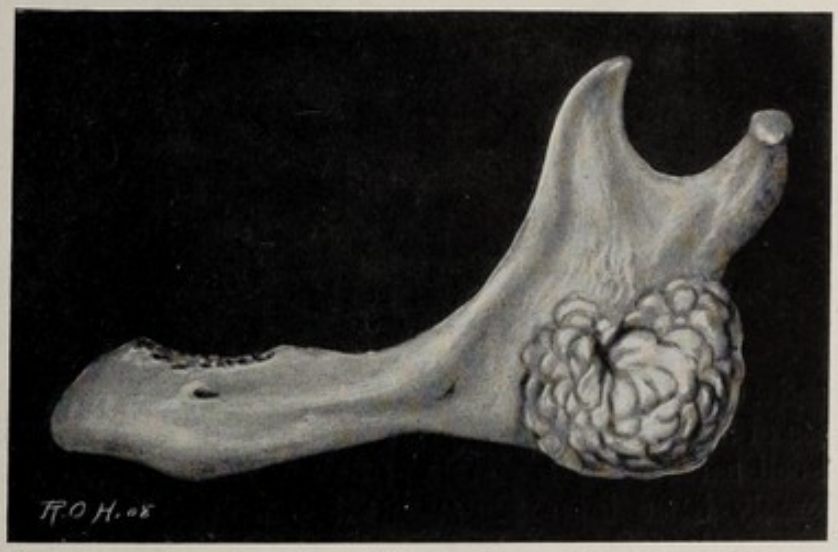

Fig. 521.—Osteoma of mandible (redrawn from Bland-Sutton).

The *treatment* of these bony tumors is quite similar to that of cartilage tumors. Thorough removal usually suffices for a cure—rarely we must amputate.

Sarcoma.[1]—It is hard to see just why the ancients applied the

[1] σάρξ, flesh; *sarcoid*, resembling flesh.

term "fleshy tumor" to this growth, for many of its forms resemble grossly certain forms of cancer. At any rate, the term "sarcoma" was loosely used until recent years, and was applied to many varieties of tumor. To-day "sarcoma means a tumor composed of immature mesoblastic or embryonic tissue in which cells predominate over intercellular material."[1] Or, as Bland-Sutton puts it: "A sarcoma may be regarded as a malignant tumor-disease of connective tissue." Accordingly, it may arise in any part of the body where connective tissue exists—and connective tissue is omnipresent. Moreover, sarcomata know no limitation of age.

Commonly, hitherto we have divided sarcomata into three classes, according to the shape of their cells and their disposition: (1) Round-cell; (2) spindle-cell; (3) myeloid.

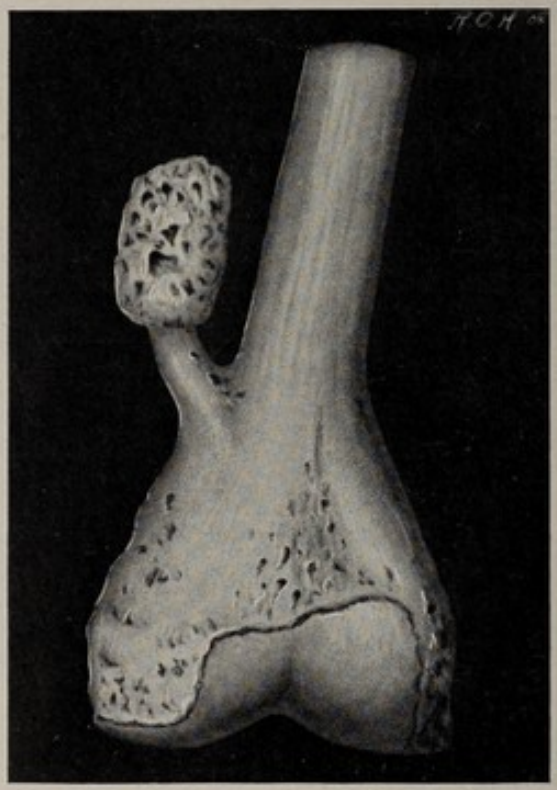

Fig. 522.—Exostosis of the femur produced by ossification of the tendon of the adductor magnus (Bland-Sutton).

The reader of this book is familiar, doubtless, with the various appearances of sarcoma; suffice it, therefore, to remind him merely that the round-cell sarcoma is a simple structure consisting of round-cells with extremely little intercellular substance. Round-cell sarcomata have no lymphatics; they are extremely vascular; they grow rapidly; infiltrate easily; recur quickly; and cause numerous metastatic deposits. It is said that the smaller the cell, the more malignant the tumor. *Lymphosarcoma* is a variety of the round-cell sarcoma. Its numerous cells are inclosed in a meshwork resembling that of a lymph-node, but the tumor is in no way to be confounded with the granulomata involving lymphatic structures.

[1] Roswell Park.

Spindle-cell sarcoma presents on microscopic section a different structure from the round-cell sarcoma. The cells have a spindle shape

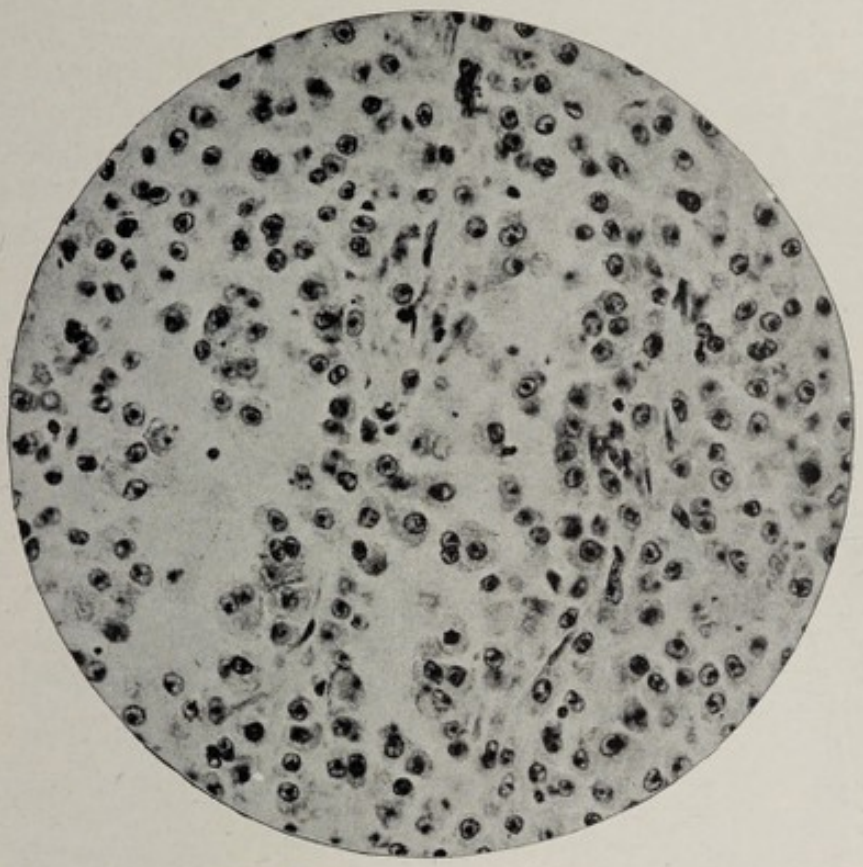

Fig. 523.—Large round-cell sarcoma of skin (after Karg and Schmorl).

and run in all directions. In this tumor, again, the smaller the cell, the more malignant the growth. *Alveolar sarcoma* is a rare subdivi-

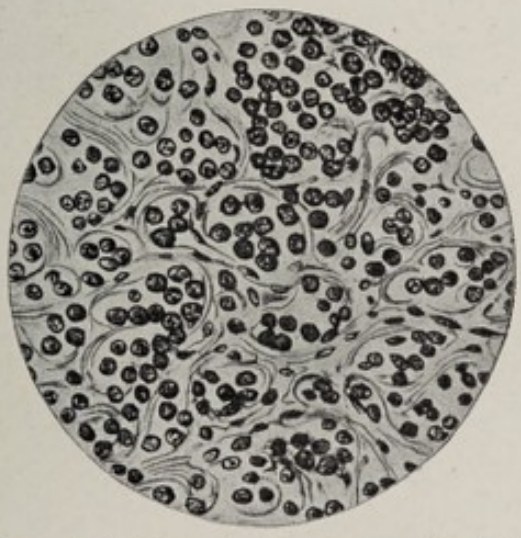

Fig. 524.—Round-cell sarcoma (Fowler).

sion of this form. The spindle-cells assume an alveolar arrangement suggesting the epithelial cells of carcinoma. We observe, however,

in alveolar sarcoma a delicate reticulum between the cells—an arrangement never met with in carcinoma.

Myeloid or *giant-cell sarcoma* resembles structurally the red marrow of growing bone and contains many multinuclear cells in a matrix of round- or spindle-cells. These are the tumors of long bones, and constitute also the majority of those growths known as *epulis*. When round-cells, spindle-cells, and giant-cells are found in nearly equal proportion, the tumor commonly is called a *mixed-cell sarcoma*.

Osteosarcoma, as Roswell Park points out, is more than a sarcoma of bone, for mere sarcoma of bone may spring from the adjacent fibrous or the medullary elements. Osteosarcoma is sarcoma of the bone-forming connective tissue, including the osteoblasts and the osteo-

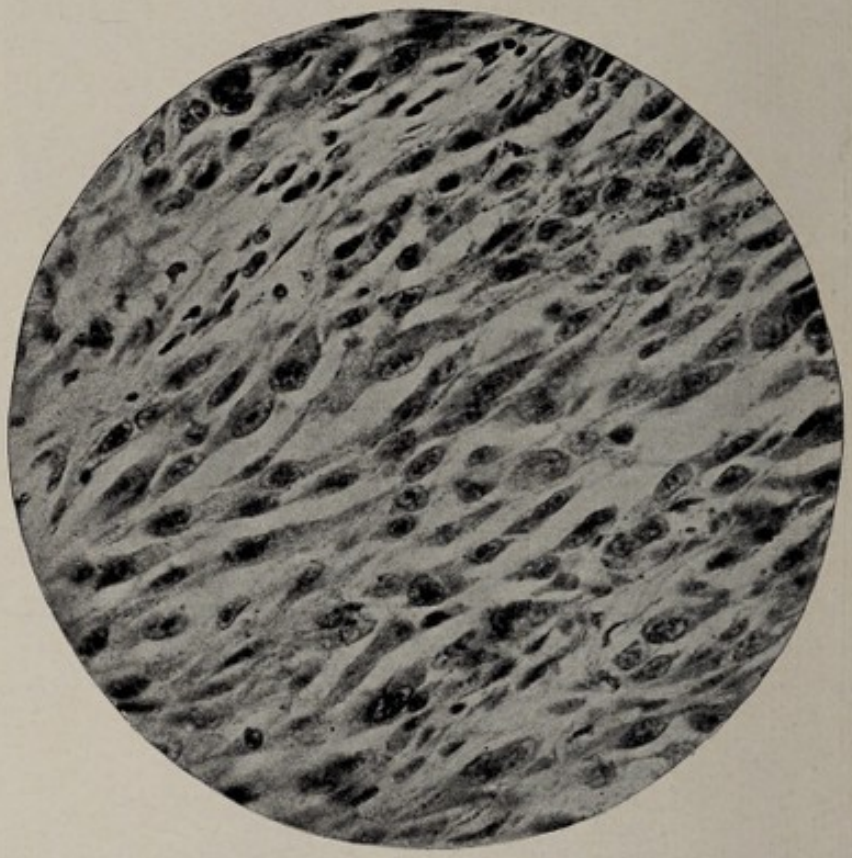

Fig. 525.—Small spindle-cell sarcoma of the skin (× 250) (after Karg and Schmorl).

clasts; in other words, the stroma of bone. Consequently genuine bone develops throughout the tumor, which is essentially a neoplasm. We must distinguish these tumors, clinically as well as histologically, from the medullary sarcomata which develop within the bone, and expand it sometimes to enormous proportions, the bony covering becoming a mere shell. *Chondrosarcoma* resembles osteosarcoma. It is a sarcoma springing from the stroma of cartilage-producing tissue.

Says Bloodgood[1]: "When the *giant-cell tumor* occurs as a medullary growth, it expands the bone (like a bone cyst). It may be as slow of growth as a cyst. The *x*-ray shadow does not distinguish it positively

[1] Joseph C. Bloodgood, Conservative Operations on Bone Tumors, Jour. Amer. Med. Assoc., February 1, 1908.

from any other tumor having a bone shell. *This tumor has been permanently cured by simple cureting.* Recurrences have followed cureting, but were permanently eradicated by a second operation of cureting, resection, or amputation. . . . One should not attempt cureting unless there is a thick shell of bone, so that the curet or chisel removes a zone of bone beyond the tumor. . . . As this tumor is relatively frequent, and as in this country amputation has been the operation of choice, a knowledge of its (the tumor's) characteristic appearances should be acquired by surgeons. . . . This tumor has a characteristic appearance in the fresh state. When first seen at the exploratory incision, it strikes one by its very hemorrhagic, mottled coloring. The

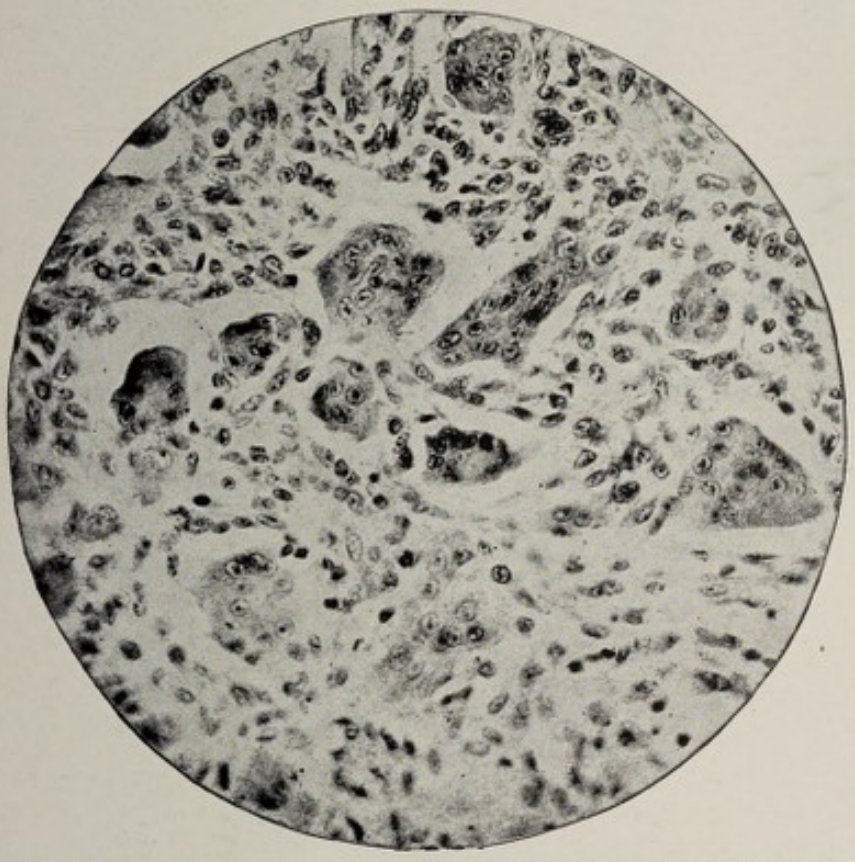

Fig. 526.—Giant-cell sarcoma of upper jaw (× 250) (after Karg and Schmorl).

majority of areas are red, with here and there specks or smaller masses of a pinkish white. The tumor is friable and can be broken up into irregular masses. At first sight it resembles hemorrhagic granulation tissue, but it is firmer and less succulent."

Says Bloodgood further: "I am of the opinion that the term osteosarcoma should be given only to the bone tumor associated with new bone formation. As a matter of fact, this is observed, to any extent, only in the periosteal tumor. This sarcoma of bone, characterized by spicules of new bone formation radiating from the shaft between which tumor tissue is present, occurs most commonly on the lower jaw. In my experience none of the cases has given metastasis. Local resection should be the operation. The tumor has a distinct capsule and does

not infiltrate the surrounding muscles; it must, however, be removed with the shaft of the bone which it surrounds."

Bloodgood makes the following interesting observation on the character of the urine in cases of bone tumors: "In the multiple myeloma of bone, Bence-Jones bodies are present. Clinically, this hopeless disease of medullary tissue may in a few instances present itself as a single bone lesion. In this stage, even *x*-ray studies of other bones may fail to show any other lesion. If the urine is not examined, the surgeon would proceed to a radical operation on the apparent single bone lesion without any suspicion of its multiple nature. The medullary growth of the myeloma in its early stage expands bone and resembles



Fig. 527.—Enormous fibrosarcoma (Massachusetts General Hospital).

the giant-cell sarcoma or bone cyst. Later, the bone capsule is destroyed. It is important to remember that in some instances the benign bone cyst may be a multiple lesion. The cases thus far recorded have been associated with osteomalacia."

Endothelioma is a form of tumor whose true character has been only recently determined. It is made up of those endothelial cells which line the lymph-spaces, and it occurs most often in the skin, especially in the parotid region, in the genital glands, in the bones, the lymph-nodes, and the dura. The growths frequently simulate epithelioma. Endotheliomata grow rapidly, and often are extremely malignant, while metastases occur early. The only hope of a cure is in prompt and most thorough extirpation.

There are sundry other forms of sarcoma, not very common.

Angiosarcoma is a sarcoma arising from the adventitia of blood-vessels; thus it differs from the endothelioma, which springs from the



Fig. 528.—Mixed tumor of the parotid gland (Massachusetts General Hospital).

lining of the lymph-spaces. Angiosarcoma is astonishingly vascular, and on section is found often to be the seat of numerous hemorrhages

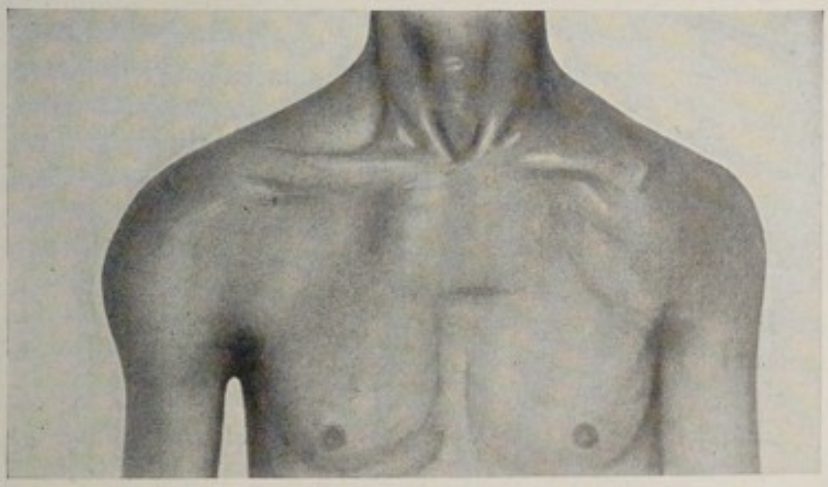

Fig. 529.—Sarcoma of humerus, round-cell. Two months' duration (Coley).

which take place into its own structure. Often, therefore, it is deeply pigmented. A subvariety of angiosarcoma is the *perithelioma*, which grows especially in the bones, the kidneys, and the skin. Perithelioma

arises in the perithelial cells between the capillaries and the perivascular lymph-spaces. Both of these forms of sarcoma—angiosarcoma and perithelioma—are extremely malignant and difficult of extirpation. We apply the term *cylindroma* to a tumor of the angiosarcoma type, in which hyaline changes have occurred, so that the cylindric masses of altered cells appear along the course of the vessels.

Certain sarcomata take on a deeply pigmented appearance and are known as *melanosarcomata*. These tumors are not to be confounded with the pigmented angiosarcomata, though, indeed, they are equally or more malignant. Melanosarcomata appear uniformly and deeply stained, the staining being due to a deposition of blackish pigment both in the cells and in the intercellular substances. When removed, these tumors (known commonly as melanomata) almost



Fig. 530.—Osteosarcoma of the humerus (Massachusetts General Hospital).

invariably recur. We must observe that the term *melanoma* is confined almost invariably to tumors of the sarcoma type. Epithelial tumors rarely, if ever, become melanotic.

In regard to all sarcomata the reader should remember that, although they often seem quite isolated from the adjacent tissues, and even to be surrounded by a sort of capsule, nevertheless careful examination shows the cells to have invaded the surrounding tissues. There they proliferate rapidly, and detached foci may be found at a considerable distance from the parent tumor. Sarcoma has the power also of producing metastatic deposits often so small and numerous that the term *sarcomatosis* is used to describe the condition. The metastases of sarcoma, however, occur later in the course of the disease than do the metastases of carcinoma, so that a local return of sarcoma may take place several times after operation before generalization of the growth occurs.

Sarcomatous metastases take place along the course of the blood-vessels rather than of the lymphatics, although in the case of osteo-sarcoma the lymph-nodes may become involved.

Early in its career sarcoma often is but slightly malignant. It may long appear to remain stationary, so that when we attack it early we may reasonably expect completely to eradicate the growth in many cases.

Myxoma is a term applied to tumors composed of mucous tissue, such as the Whartonian jelly of the umbilical cord. We must distinguish the true myxoma from *myxomatous degeneration*. We find myxomata as gelatinous polypi in the nose and in the external auditory canal; as sessile tumors hanging from the skin of the perineum and labia; and as neuromyxomata, involving the nerve-trunks. All myxomata should be thoroughly extirpated and the wound cauterized, for although these growths are not properly malignant, they tend to recur again and again, giving rise to chronic and long-continued disturbances.

A **myoma** is a tumor composed of unstriped muscle-fibers; hence we find these growths, as we should expect, in certain definite locations —in the uterus, Fallopian tubes, the vagina, esophagus, alimentary canal; in the prostate, bladder, and skin. The tumors are encapsulated commonly, and are composed of fusiform muscle-cells with rod-like nuclei. Often they grow as mixed tumors, so that when found in the uterus especially we describe them by the term *fibromyoma* or *myofibroma*. They are properly non-malignant, but accumulating experience teaches that a uterus long the seat of a myoma may eventually develop carcinoma. The complete removal of a myoma cures the disease.

Angioma is the term applied to tumors composed of blood-vessels —*nevus*, *cavernous angioma*, *arterial angioma*, etc. I have already described these growths elsewhere in the chapters on Regional Sugery, especially in Chapter XXVII.

By the term **lymphangioma** we mean a tumor composed of lymph-vessels—a tumor resembling in many respects an angioma. There is the *lymphatic nevus*, a mass of lymphatics found sometimes upon the surface of the body, but most often on the lip and tongue. The tongue so affected may become greatly enlarged, and protrude from the mouth. This form of enlarged tongue is called a *macroglossia*.

Cavernous lymphangioma is a condition in which the lymph-vessels become greatly distended and sacculated.

Lymph cysts are still more exaggerated forms of lymph-vessel dilatation. These cysts are usually encapsulated, and give rise to that peculiar condition I have already described (Chapter XXVII) under the caption *Elephantiasis*.

A word about the *treatment* of the lesser forms of *lymphangioma:* formerly they were removed by dissection, by electrolysis, and by injections of boiling water. Recently we have found that the application of liquid air, or, better, carbon dioxid snow, suffices to cure the ailment, and that the resulting scar is trifling.

So much, briefly, for the connective-tissue group.

The **neuromata** constitute our fifth group, and with the neuromata I have already dealt in Chapters XXIV and XXV.

We must say a word further of **glioma.** This is a malignant tumor found generally in the brain, rarely in the spinal cord. It is extremely malignant; springs from the nervous tissue; and appears as a translucent swelling infiltrating the surrounding tissue. It has a thin, gelatinous consistency, and, microscopically, it resembles neuroglia. It does not form metastases; it is extremely vascular; it proves its malignancy by destroying adjacent structures. It may appear in the orbit and the eye; and it is more common in the young than in the old. Fortunately, glioma is one of the rare forms of nervous tissue tumor. Though operations for its relief have been undertaken, they have given no more than temporary relief.

We have already discussed *neuroma* and *plexiform neuroma* (Chapter XXVII).

Malignant neuroma is properly a sarcoma of the nerve structures —a sarcoma usually of the spindle-cell variety.

EPITHELIAL TUMORS

Epithelial tumors constitute our group *six*. Like tumors of the connective-tissue group, they are benign and malignant, but the most benign epithelial tumors (moles and warts) even may become malignant,

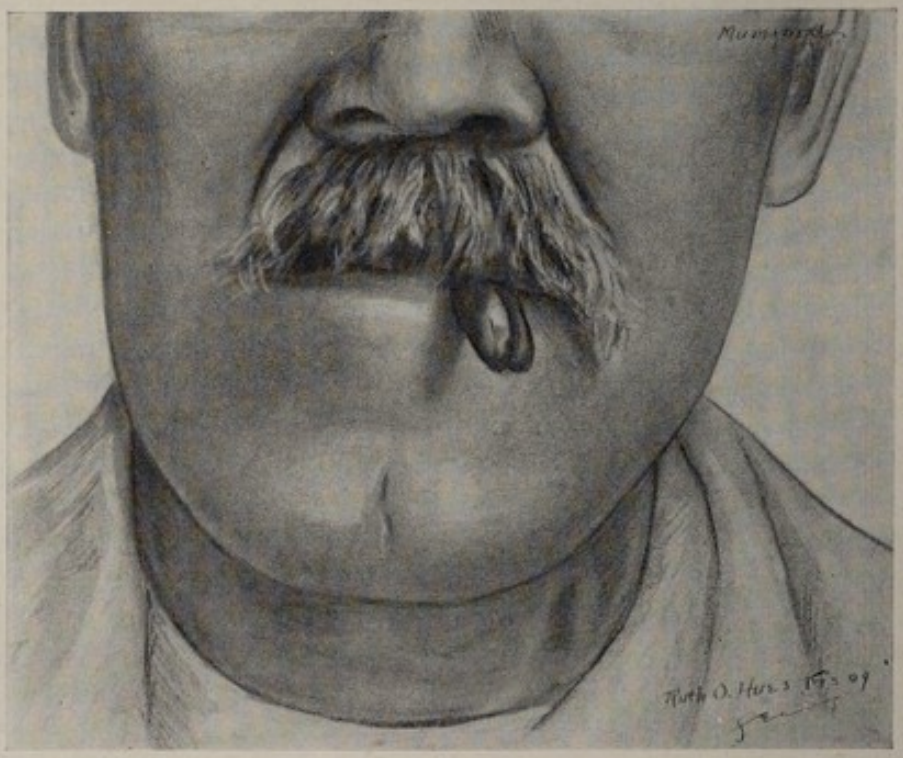

Fig. 531.—Cutaneous horn (Massachusetts General Hospital).

as recent observers have demonstrated. **Papilloma** is the common type of a non-malignant epithelial growth, and of papilloma there are several varieties. *Warts* I have already described in Chapter XXVI.

Of the innocent wart, let us recall this significant fact: when of long standing, and in an individual no longer young, it may develop into a truly malignant epithelioma; for the benign wart, which springs upward and grows without damage to surrounding structures, later may progress downward, may sink deeply into adjacent tissue, and may become a true cancer. For this reason we should not hesitate radically to remove warts and "moles" of long standing.

Villous papilloma grows in the bladder and in the pelvis of the kidney. This tumor springs from the mucosa. It has long, fern-like villi, and disturbs the patient by hemorrhage only or by choking the urinary channels. Villous papilloma may arise from the choroid plexuses of the lateral ventricles of the brain. Villous papillomata, when accessible, should be removed, lest they become malignant.



Fig. 532.—Cutaneous horn (Bland-Sutton).

There are *intracystic villous growths* and there are *ovarian papillomata*. The ovarian papilloma may be malignant, for if broken up at the time of operation, the particles seem to attach themselves to the peritoneal surfaces, and there to grow luxuriantly.

Cutaneous horns are epithelial growths. Bland-Sutton has a long and interesting chapter on cutaneous horns. He describes *sebaceous horns, warty horns, horns growing from cicatrices*, and *nail horns*. These are all benign growths and should be thoroughly removed.

We have already described in their appropriate chapters various forms of *epithelial disease of the thyroid gland* (*goiter*) and of the *ovaries*, especially that form of *glandular cystoma*, the multilocular cyst, with numerous cavities filled with fluid, and containing a small number of

epithelial cells, while the cyst-wall may contain tubular, gland-like structures reaching into the surrounding connective tissue; and the *papillary cystoma*, a cyst presenting projecting papillomatous growths into the cyst cavities—growths covered by cylindric epithelium; and we recall that the glandular and papillary types frequently are blended.

An **adenoma** (also *fibro-adenoma*) is a tumor whose type is the normal secreting gland. Now the adenoma differs from the gland in that it is an abnormal outgrowth; and further in that it has not the power of secretion peculiar to the analogous gland which it represents. Adenomata are circumscribed tumors found most commonly in the breast, the parotid, the thyroid, the liver, and the mucous lining of the bowels and uterus. Adenomata may be single or multiple; they may be small or very large; they do not involve the lymphatics or give rise to metastases. They are easily confounded with cancer, into which they may readily degenerate; or the two may coexist. A cancer of the adenomatous type is commonly referred to as an *adenocarcinoma*.

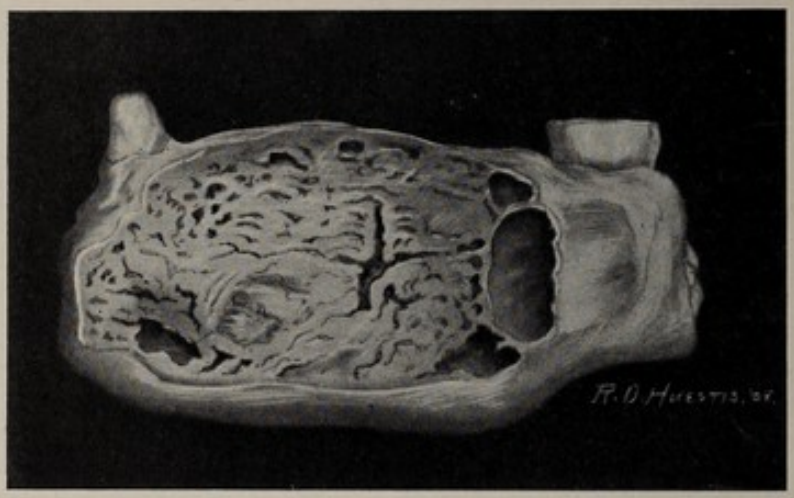

Fig. 533.—Epithelial odontoma (redrawn from Bland-Sutton).

Fibro-adenoma is a small hard tumor found commonly in the breast of young women, encapsulated, usually superficial, movable, and often multiple.

Of recent years it has become the fashion, following the lead of Bland-Sutton, to classify separately tumor diseases of the teeth—*odontomata*. More properly, perhaps, these tumors should be classed either with the connective-tissue or with epithelial groups.

"An **odontoma** is a tumor composed of dental tissues in varying proportions and different degrees of development, arising from teeth-germs, or teeth still in process of growth" (Bland-Sutton). We must recognize three distinct elements in the developing tooth—the enamel-organ; the papilla, from which the dentin is derived; and the tooth-sac, which furnishes the cementum. Early in its development the various tissues of the tooth are soft and enveloped in a sac which lies buried along the borders of the jaws.

Accordingly, we have *epithelial odontomata*, which have a capsule, and appear usually as a series of cysts containing mucoid fluid, while

the growing portions have a red tint, not unlike sarcoma. Epithelial odontomata are seen most commonly about the twentieth year of life.

Follicular odontomata are those tumors which have commonly been called "dentigerous cysts." Unlike the epithelial odontomata, these growths arise in connection with the prmanent teeth, especially the molars. They may reach a considerable size and cause a marked deformity. The tumor is made up of a wall—the expanded tooth-follicle—and of a cavity containing viscid fluid, as well as some portion of an imperfectly developed tooth. The cyst-wall always contains calcareous material. These tumors rarely suppurate.



Fig. 534.—Follicular odontoma (Bland-Sutton).

Fibrous odontomata also arise in connection with developing teeth. They are formed of dense connective tissue, and appear as tumors with a firm outer wall and a loose inner texture—blending at the root of the tooth with the dental papilla. The developing tooth thus becomes inclosed within the tumor capsule before it protrudes from the gum. These tumors are more common in cattle than in man. The growths often are multiple.

A *cementoma* is a fibrous jaw tumor whose capsule has calcified. It springs from a developing tooth which becomes embedded in a mass of dental cement. These tumors are most common in horses.

Compound follicular odontomata contain a number of masses of cementum resembling small teeth, or they may amount even to well-

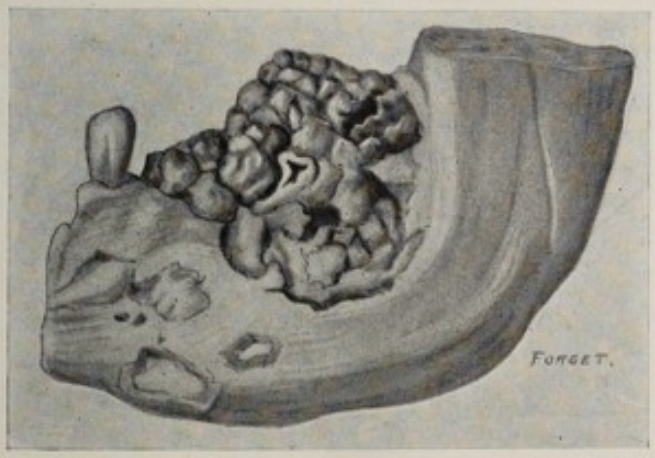

Fig. 535.—Composite odontoma (Bland-Sutton).

developed but misshapen teeth, composed of all three dental elements. In these compound follicular odontomata many teeth are found. Human beings are frequently subject to this disease.

Radicular odontomata spring from the dentin and cementum after the crown of the tooth has been formed, and while the roots are still developing. These growths are more common in animals than in man.

Composite odontomata are hard tumors composed of enamel, dentin, and cementum. Thus they contain all the elements of the tooth-germ, but they bear little resemblance to normal teeth. They are found in man only.

These tumors of the jaws seem to have attracted the attention of the older rather than of the more recent writers, yet present experience shows us that they are quite common, especially in young persons. An extremely significant fact is that frequently odontomata are mistaken for sarcomata, so that we learn this lesson: all tumors of the jaws which are not obviously malignant should be explored carefully for the detection of odontomata before a resection of the jaw is done. The odontomata can always be satisfactorily treated by a complete excision, which should leave little deformity, and should result in the restoration of a normal and useful jaw.

CANCER

Cancer is a term of wide-reaching significance. In ancient times writers seem to have used the word to describe all manner of malignant growths; and in our own day, clinical writers in general terms have applied the word "cancer" to tumors structurally as different as sarcoma and malignant epithelioma. Commonly, however, we mean by cancer *carcinoma*,[1] "a tumor composed chiefly of epithelial cells, differing more or less in their type and arrangement from the usual epithelial structures, and having a tendency to an unlimited growth. These cells grow into the surrounding connective tissue, which is thereby stimulated to increased development. Carcinoma is composed, therefore, of two distinct structures—epithelial cells and the vascular stroma" (Warren).

Cancer is a disease of paramount importance because, when untreated, it is almost invariably fatal, though recent studies in immunity are leading us to believe that the occasional spontaneous cure of cancer is credible. Cancer is marked by its insidious onset; by its painlessness in its early stages; by its progressive and irresistible destructiveness; by its mysterious dissemination (see the Theory of Handley in Chapter XIX); by its involvement of the lymph-nodes; by its metastases in remote parts; by the hopelessness, misery, and pain it produces when fully developed; and by the extreme difficulty of its extirpation. I shall have occasion shortly to point out our present hope for its cure.

Carcinoma and *epithelioma* are terms which should be obvious enough, yet modern writers still employ the words in a somewhat confusing sense. For example, Roswell Park says of carcinoma that it is a tumor springing from preëxisting gland tissue; and of epithelioma, that it is common especially where there is transition from one kind of epithelium to another; while Bland-Sutton[2] does not use the term *epithelioma* at all.

[1] Greek, *καρκίνος*, a crab, a term, according to Celsus, applied to malignant growths on account of a crab-like appearance, due to the great enlargement of superficial vessels centering about the tumor.

[2] Keen's Surgery, vol. i.

I prefer to use the word *epithelioma* and *carcinoma* as interchangable. By *epithelioma* we understand a malignant tumor composed chiefly of epithelial cells, and that definition applies also to *carcinoma*, a disease which is not limited by any means to gland tissues. This confusion of terms, as Warren reminds us, is due to the fact that in past times the word *epithelium* was used to describe cancers consisting of pavement epithelium.

Carcinoma (or epithelioma), accordingly, has various subdivisions, all of them differing from the non-malignant papilloma in that they are not limited by a basement membrane, but pass beyond it into the

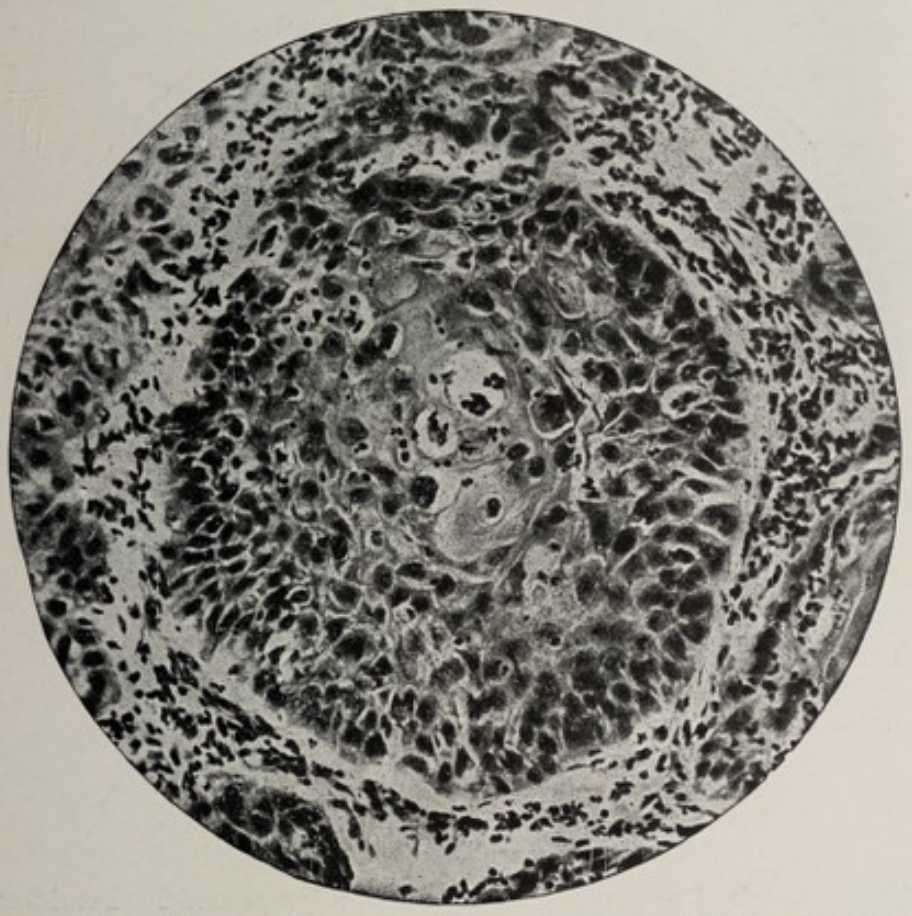

Fig. 536.—Epithelial pearl formation in squamous epithelioma (middle power) (Park).

underlying connective tissue. Wherever epithelial structures exist, there carcinomata may develop, and our opportunities for observing the appearances of cancer depend upon the cancer site. A cancer of the tongue, the lip, or the penis is instantly obvious, and may be studied from the outset. Cancer of the stomach, of the intestine, or of the uterus is long latent, and usually comes into the field of observation when the disease is well advanced only. Incidentally we see that for these reasons the early observed superficial cancers frequently are cured, while internal cancers, observed late, are cured far more rarely.

Superficial cancer—squamous-cell cancer—appears usually as "a

wart-like growth or nodule, which quickly becomes an ulcer with elevated edges, the ulceration being due to the necrosis of the cells farthest from the periphery; or, again, the disease may start as an ulcerated fissure,—ulceration and infiltration keeping pace,—in which case there is a sharply defined ulcer with undermined edges. A third variety of squamous-cell cancer often seen upon the lips comprises a projecting mass, with a more or less horny surface. In nearly all of these, however, characteristic cell-nests, with their onion-like arrangement of cells, will be found" (Roswell Park). Such is the superficial epithelioma.



Fig. 537.—Metastasis of squamous epithelioma in a lymph-node. Pearl formation (middle power) (Park).

All observers dwell upon the invariable lymph-node involvements which accompany cancer. The lymph-nodes in cancer are invaded early. Sometimes our first intimation of malignant disease comes from finding the enlarging lymph-nodes; later we may discover the original cancer focus. I have referred more than once to Handley's ingenious theory of cancer dissemination, and have described it in Chapter XIX. Moreover, our studies of cancer in the chapters on Regional Surgery render needless further and special description of cancer here. I refer the reader especially to Chapters XX and XXI for descriptions of rodent ulcer, that most shocking, chronic, and disfiguring of diseases; and of cancer of the tongue, lip, and jaws.

The varieties of cancer referred to in the preceding paragraphs are

commonly known as *squamous-cell cancer*—cancer which makes its appearance on any surface covered with stratified epithelium. It may be worth while to recapitulate some of the important locations where such cancers are found: on the lips, tongue, cheek, vulva, anus, scrotum, glans penis, conjunctiva, pinna, urethra, about scars and chronic ulcers, and on the neck of the uterus.

Of late years we have heard much of precancerous conditions, and Bland-Sutton and other writers have dealt especially upon *leukoplakia* of the tongue and buccal mucosa as a condition precedent to cancer. Doubtless such precancerous conditions are extremely common, if only surgeons might observe them and recognize their significance.

Gland cancer is important equally with cancer of the squamous-cell variety. Gland cancer resembles the gland tissue from which it springs, except that the structural similarity is incomplete. The epithelial cells collect in irregular clusters, fill the acini, obstruct the ducts, and invade the surrounding tissues. These cancers may arise from any secreting gland; they spread rapidly. Distant metastases appear early, and it is an extremely interesting characteristic of these metastases that they *reproduce almost perfectly the type of primary tumor* whence they spring. For this reason the study of such a metastatic growth frequently gives us definite information as to its origin.

The classic types of gland cancer are found in the breast, and the intricate and numerous manifestations of breast cancer have already been described in detail in Chapter XIX. I need add nothing here to what I there stated beyond naming other organs subject to this disease—the salivary glands, liver, kidney, ovary, and testicle. Moreover, the squamous and gland types of cancer may overlap and coexist.

For a brief description of *malignant chorio-epithelioma*, or the *deciduoma malignum*, and of *suprarenal epithelioma—hypernephroma*, I refer to Chapters X and XIII.

The following tables, taken from Roswell Park's Modern Surgery, may assist the student in his study of tumor diagnosis:

TABLE I.—DIFFERENTIATION BETWEEN BENIGN AND MALIGNANT GROWTHS.

Benign Growths.	Malignant Growths
Common at all ages.	Rare in early life.
Usually slow in growth.	Usually rapid in growth.
No evidences of infiltration or dissemination.	Infiltration in all cases, dissemination in many.
Are often encapsulated, nearly always circumscribed.	Never encapsulated, seldom circumscribed.
Rarely adherent unless inflamed.	Always adherent.
Rarely ulcerate.	Often ulcerated—nearly always when surface is involved.
Overlying tissue not retracted.	Overlying tissue nearly always retracted.
No lymphatic involvement when not inflamed.	Lymphatic involvement an almost constant feature.
No leukocytosis.	Leukocytosis often marked.
Elimination of urea unaffected.	Deficient elimination of urea (?).

TABLE II.—DIAGNOSIS BETWEEN SARCOMA AND CARCINOMA.

Sarcoma.	Carcinoma.
Occurs at any age.	Rare before thirtieth year of life.
Disseminates by the blood-vessels (veins).	Disseminations by the lymphatics.
Arises from mesoblastic structures.	Arises from glandular (epithelial) tissues.
Distant metastases are more common.	Less so.
Contains blood-channels rather than complete blood-vessels.	Contains vessels of normal type.
Less prone to ulceration.	More so.
Involvement of adjacent lymphatics not common.	Almost invariably adjacent lymphatics are involved.
Secondary changes and degenerations are more common.	Degenerations not common; other secondary changes rare.
Sugar present in the blood.	Peptone present in the blood.

TABLE III.—DIAGNOSIS BETWEEN EPITHELIOMA AND TUBERCULOSIS (LUPUS).

Epithelioma.	Tuberculosis (Lupus).
Preceded usually by continued irritation or warty growths.	Irritation plays no figure. Preceded usually by nodules.
Diathesis plays no known part.	Diathesis evident. Coincident evidences of tuberculous disease elsewhere.
Rarely multiple.	Often multiple.
Area of thickening ahead of ulceration.	Extension of ulceration not preceded by thickening.
Ulceration advancing from a central focus.	Various foci, which may coalesce.
Border usually raised and everted, regular in outline.	Border abrupt, eaten, irregular, thickened, firm, often inverted, irregular in outline.
Often assumes fungoid type.	Never fungoid.
Base may be deeply excavated.	Base nearly level with surface.
Usually painful.	Seldom painful.
Bleeds easily.	Seldom bleeds.
Never tends to cicatrize.	As marginal ulceration proceeds there is often cicatrization at center.
Most rare in the young.	Common in the young.
Discharge is very offensive.	Discharge rarely offensive.
Lymphatic involvement nearly always.	Rarely.

After all is said, what shall we tell the student and the general practitioner regarding the surgeon's attitude toward the cancer problem, and the question of its cure? This is no place in which to discuss the great question of the causation of cancer, as I have already stated. Doubtless should investigation prove to us that cancer is of parasitic origin, the inevitable next step of finding its antidote would follow. To-day, however, we are faced with the problem of present treatment, and surgeons are finding that the careful and extensive modern operations are lowering cancer mortality. I have already said that superficial cancer may and should be attacked early. As Crile remarks in his illuminating paper,[1] we should not wait for the disease to develop

[1] Oration in surgery before the American Medical Association, published in the Jour. Amer. Med. Assoc., June 6, 1908, p. 1883; also, Jour. Med. Research, 1908, xlvii, 385.

itself in order to establish a diagnosis; we should remove the disease as soon as it is seen, and then establish our diagnosis. In several foregoing chapters of this book I have already described the various and elaborate methods of operation now in vogue.

Our endeavor must be, therefore, to arrive at an early diagnosis. How shall we do this in the case of those cancers which are hidden from view? Says Crile: "I have often thought that, pending a more general enlightenment, it would be a great boon to mankind if the words 'glandular enlargement and cachexia,' as denoting symptoms of cancer, were stricken from every text-book of medicine. These are terminal symptoms, and indicate that the surgical opportunity is forever lost. Were the result not so tragic, such professional simple-mindedness would be ludicrous." Through his studies in hemolysis, Crile has arrived at an extremely interesting and probably valuable hypothesis which he is applying to the diagnosis of early cancer. To quote: "The blood-serum of a cancer patient may hemolyze normal corpuscles, but normal blood-serum usually does not hemolyze the red corpuscles of a cancer patient. In some patients—thus far only those with inoperable cancer—there was reverse hemolysis. The cancer corpuscles were hemolyzed by normal serum. In some cases there was no reaction. If this reaction is to be of diagnostic value, then it must occur in cancer cases only or in diseases not readily confused with cancer." In other words, we have in the hemolysis blood-test a promising method for the determination of early internal cancer; and Crile's statistics, already considerable, show this test to be fairly reliable.

Crile makes this further intensely interesting statement: "The work of Gaylord and Clowes, Beebe and Ewing, Ehrlich, Loeb, and others, demonstrating a not infrequent immunity against cancer, was utilized by Beebe and myself in an attempt to cure transplanted sarcoma in dogs by maximum bleeding of the 'tumor dog' and heavy over-transfusion from an immune dog. By this method we have cured of sarcoma nine out of eleven dogs, some of which were cachectic and had metastases. The cured animals in turn became immune and were successfully employed for curing and immunizing other dogs. . . . Arguing from this work and from the fact that among the lower animals certain ones are naturally immune, we have transfused normal blood into six human subjects having sarcoma, their tumors having been removed previously to transfusion. Sixteen months have now elapsed since the first case was so treated (without recurrence). . . . Should these patients be cured (after three or more years) and become immune, it is likely that they may be available for curing others, so that eventually a group of immunes may be established." Crile goes on to say, properly and guardedly, that "the whole matter of immunizing against sarcoma is at this time wholly experimental, and my statements are presented with that understanding."

Besides the knife, various measures have been and are to-day employed for the cure of malignant disease. The *x*-ray and radium have an apparent curative effect in certain superficial cancers. In

doubtful cases after operation on deep-seated tumors the skin-flaps may be retracted and the *x*-rays applied daily and directly to the depths of the wound.

Coley's well-known treatment with the mixed toxins of erysipelas and the Bacillus prodigiosus has had promise, and the method has still a vogue. The best results have been obtained by Coley himself.

Numerous other measures have been advocated and are still advocated, such as ultraviolet rays, pyoktannin, formalin, etc.[1] One of the most interesting of these measures is that of Beatson, of Glasgow, who suggests the benefit of the removal of the ovaries in hopeless cases of mammary cancer. He has reported instances of apparent cure. The so-called "trypsin treatment" of malignant tumors was promulgated by Beard, of Edinburgh, and still finds its advocates, who assert that although the record of cases is far from perfect, still the reasoning on which the treatment is founded should prove correct when worked out in more detail.

In brief and unsatisfactory detail such is the problem of the treatment of malignant tumors as we see it to-day. Save for the campaign against tuberculosis, no campaign in all medicine is being more actively pushed than this cancer campaign; and we have strong reason to believe that within the years immediately coming we shall arrive at a clear understanding of the nature of malignant disease, and shall obtain a rational, safe, and sound remedy.

[1] Skene Keith and George E. Keith report great relief from pain and marked improvement in the general condition of the patients from the hypodermic use of a compound of iron, sodium, and iodin. To quote: "This strong standard injection consists of a solution of iodipin in oil, arseniate of iron, cacodylate of iron, and cinnamate of sodium. The iodipin is a 25 per cent. solution in oil. The arseniate of iron contains $\frac{1}{4}$ grain of iron and $\frac{1}{45}$ grain of arsenious anhydrid in 1 cc. The cacodylate of iron contains 3 grains of iron in 1 cc. The cinnamate of sodium is a saturated solution containing $1\frac{1}{2}$ grains to the cubic centimeter. . . . The average proportions of the emulsion which we have used most are as follows: 1 dram of the iodipin and 20 minims each of the other three. . . . The dose varies also. Some patients appear to do well with 5 cc. of the emulsion given every second day or even every day, while it seems to be advisable with others not to give more than 2 or 3 cc."—Cancer, Relief of Pain and Possible Cure, p. 33.

Almost equally useful apparently is the treatment advocated for cases of inoperable cancer by G. W. Gay, of Boston, a treatment I have used myself with satisfaction: Give 5 drops of the compound solution of iodin three times a day and increase the dose rapidly until, by the end of a month, the patient is receiving 60 to 100 drops in the twenty-four hours. Frequently, by the use of this drug, pain is allayed, the rapidity of the tumor's growth seems to be checked, and life is prolonged. It may be necessary to supplement the iodin by small doses of the tincture of opium given by rectum and repeated at short intervals—3 or 4 drops every three hours, the surgeon being careful not to saturate the patient with the drug.

CHAPTER XXIX

FRACTURES AND DISLOCATIONS

FRACTURES

A FRACTURED bone is a broken bone. I know of no phrase or combination of terms that sums it more accurately. In spite of the *x*-ray, the treatment of fractures does not form a popular division of surgical practice. Most surgeons would shun fractures if they could. Fractures comprise a department of surgery distinct and unique. Moreover, in a book of this character, it is impossible adequately to deal with the great subject of fractures. For proper details the *surgeon* should consult the well-known books of Hamilton, Stimson, or Scudder. It will be useful, however, for the *student* to gain some general idea of fractures and their treatment from such a brief essay as I can address to him here.

In the first place, let us consider some general topics in connection with fractures, and then briefly review special fractures and their treatment.

Commonly, fractures are described in various terms. To quote Eisendrath,[1] fractures are classified:

I. According to their degree.
II. According to the direction of the line of fracture.
III. According to their location.
IV. According to their etiology.
V. According to their relation to the overlying skin.
VI. According to the number of fragments.
VII. According to whether or not they are complicated.

This classification is good, and certainly expresses recognized conditions.

I. Fractures are *complete* or *incomplete* and we use also the terms *green-stick* and *subperiosteal*.

II. Fractures are *transverse* or *oblique*.

III. Fractures are *epiphyseal* when the epiphyses, commonly in young persons, are separated; while the fracture remote from the epiphysis is spoken of as a fracture of the shaft. We speak of joint fractures also, meaning fractures involving the joints adjacent to the break.

IV. We describe a fracture as *direct* and *indirect* also—referring to the manner in which it was received. A direct fracture is one caused by a crushing force applied to the seat of fracture. An indirect fracture is due to muscular violence, straining the bone until it breaks.

[1] Daniel N. Eisendrath, Fractures, Keen's Surgery, vol. ii.

V. Perhaps the most important division of this classification is that which separates fractures into *simple* fractures and *compound* fractures. A simple fracture is one in which there is no communication between the broken bone and the outer air. A compound fracture is one in which there is a wound leading to the fracture through the skin and soft parts. Of recent years many writers, following the phrasing of Scudder, have substituted the terms *closed* and *open* fractures for simple and compound fractures.

VI. In case the bone is splintered into three or more fragments, we use the term *comminuted* fracture. The term *multiple* implies a some-

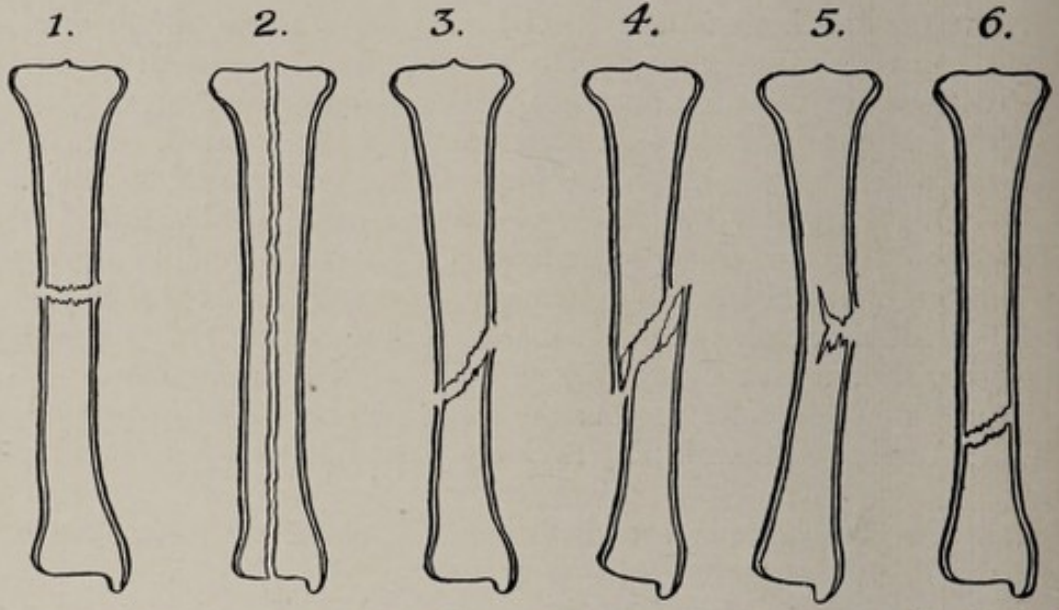

Fig. 538.—Various forms of lines of fracture: 1, Complete transverse; 2, longitudinal; 3, oblique; 4, spiral; 5, incomplete or green-stick; 6, subperiosteal (Eisendrath).

what different condition, and signifies that one or more bones are broken at several points.

VII. When a fracture is but a part of the injury received, that is, when soft parts and organs as well as bones are damaged, we employ the term *complicated fracture*, though this is, perhaps, a fanciful and needless classification.

GENERAL CONSIDERATIONS

Certain considerations recently have become prominent in the discussion of all fractures, considerations which are more interesting perhaps to the general surgeon than are questions of the diagnosis and treatment of the average fracture. We are discussing and questioning the inevitable value of the *x*-ray. We are considering the more frequent treatment of fractures by opening down upon and wiring or otherwise fixing the fragments beneath the skin. We are devising methods of treating the old deformities which sometimes result from faulty union of fractures; while one of the most important of recent discussions deals with the treatment of delayed union and especially of the non-union of fractures.

After the introduction into practice of *x*-ray examinations, some fifteen years ago, it was felt at first that at last we had secured a positive and unfailing method of reaching the exact diagnosis of a given fracture. *X*-ray pictures were assumed to be infallible, not only as indicating the position of the bone fragments, but as demonstrating surely the functional results of treatment—that is to say, the value of the limb to the patient after the bone had healed. Such conceptions of the use of the *x*-ray have been greatly modified. Its indiscriminate employment has done harm as well as good. It has led to the superficial and careless palpation of fractures; it has induced young and inexperienced practitioners to rely entirely upon the *x*-ray picture, and it has imposed upon juries the notion that bones, the fragments of which are not approximated absolutely and accurately, must be of faulty function after union, and must show careless treatment. As a matter of fact, it is rare that closed fractures can be absolutely approximated, while it is the experience of surgeons for ages that imperfect apposition commonly may coexist with almost perfect function.

Cotton [1] has very properly stated that the most important use of the *x*-ray is to determine the position of the bone fragments after the surgeon has reduced the fracture. That writer would employ the *x*-ray when convenient, as an aid in the determination of the exact nature of the fracture, bearing in mind always that other and common methods of investigation should not be neglected; but after the fracture has been reduced and has been held in its new position for a time sufficient to allow the healing process to begin, he would then secure another *x*-ray picture. By the aid of this latter picture the surgeon is able to determine whether or not his treatment is effective, and, if necessary, he can then remedy malposition. After union is complete and the limb is again in use, the *x*-ray is of no value whatever, provided function is satisfactory. For, as I have said, the perfectly functionating limb may be supported by a bone which shows a marked deviation from the normal.

The **open treatment of fractures** is too seldom used. In general terms it is true that a closed fracture, well approximated, promises a good result without further molestation; but many fractures, after reduction has been attempted, show continued deformity, marked failure of apposition, and a tendency to delayed union. Cotton questions the frequency of the interposition of soft parts as a cause of malposition and delayed union. My experience is somewhat different. I have seen several cases of fractured fibula and ulna in which interposed tendons obviously prevented a proper apposition of the bone fragments. In such cases I advise the surgeon to cut down upon the damaged bone, without hesitation, to push aside the soft parts, and to wire the fragments. Again, in the case of a comminuted fracture involving a joint—especially the elbow-joint—frequently it occurs that with the patient etherized, proper motion of the joint is found to be impossible. The joint

[1] F. J. Cotton, Notes on Fractures and Their Treatment, Boston Med. and Surg. Jour., July 27, 1905.

locks. It can neither be extended nor flexed normally. In such a case the surgeon should explain the situation to the patient; should make clear to him the impossibility of satisfactory function without an operation, and the possible dangers of an operation, and should insist that the patient himself, or his friends, if necessary, elect the course of procedure.

In connection with this matter of simple and compound, or closed and open fractures, let me remind the student that until the antiseptic era the dangers of the open fracture were incomparably greater than the dangers of the closed fracture. Open fractures were nearly always complicated by suppuration, frequently by bone necrosis, often by extensive infections, and commonly by pyemia and death. It was a realization of this shocking situation which led Lister to his studies in antisepsis. We still insist upon the distinction between compound and simple fractures, although the dangers of the former have been nearly eliminated, but danger does still exist, especially when the joints are involved, so that one may not rashly and unadvisedly transform a simple into a compound fracture. Nevertheless, the dangers are now slight. In such cases of joint injuries as I have described—simple comminuted fractures involving the joints, with the prospect of a stiff joint should no operation be done—one finds one's self confronted with a choice of evils. Good practice in these days recognizes and approves cutting down upon such injuries and removing or fixing properly the bone fragments.

Old deformities resulting from the malunion of fractures present to the conscientious surgeon some of the most serious and difficult questions which he can encounter. The questions involved are those of the propriety of former treatment; the possible incompetence of the surgeon who originally reduced the fracture; the possibility of a law suit against that surgeon, and one's own proper action in the premises; with the uncertainty as to whether or not a present late operation will materially improve the unfortunate condition of the patient. These are questions which cannot be answered positively and in general terms. I advise the young practitioner, especially, to avoid involving himself without consultation in one of these cases. If two competent surgeons agree that a secondary operation will probably improve the patient's condition, then and then only should the attending surgeon undertake the operation. We are finding that a cutting operation directed immediately at the deformity is often of less value than an osteoclasis somewhat removed from the seat of damage. It may be well, for example, to do osteoclasis for "gun-stock elbow," or supra-malleolar osteoclasis for a twisted ankle, at the classic point above the joint, entirely irrespective of the seat of the old damage.

Delayed union must not be mistaken for *non-union*. Delayed union is common, especially in persons of advanced years, of tuberculous or syphilitic taint, or in poor general health. Such patients should receive painstaking general care with perfect hygienic surroundings, tonics, and proper food; while the underlying systemic derangement

should be treated. It is not uncommon to find union of the long bones, for example, the humerus, the femur, and the bones of the forearm—it is not uncommon to find their union delayed for two, four, or six months. In these cases our duty is faithfully and continuously to immobilize the damaged limb. I have seen union take place after twelve months of non-union.

In certain rare cases, however, **non-union** persists, and it is often impossible to determine why it persists. The patient seems to lack proper bone-forming activities, whatever that may mean. The ends of the fragments may atrophy and an actual false joint—pseudarthrosis—may develop. I have at this moment among my patients an active, sound, and vigorous woman of thirty-five, apparently in perfect health, who has carried for four years an ununited fracture of the ulna, and that in spite of numerous operations for its repair. Happily these cases are extremely rare, though they furnish a great amount of discussion in our fracture literature.

The *treatment* of non-union has come to follow a certain fairly regular routine: (1) Immobilization persisted in for at least six months; (2) irritation of the ends of the bone fragments by friction against each other, with the patient anesthetized; (3) incision down upon, and wiring[1] of the fragments. Each operation should be followed by a further, long-continued immobilization.

Recently certain investigations in metabolism, in immunity, and in the processes of wound healing have seemed to lead to a hope of benefit from novel measures. A considerable number of cases of non-union appear to have been cured by the employment of Bier's passive hyperemia; while a still more interesting method is the surrounding of the bone-ends with an aseptic blood-clot, purposely introduced into the tissues, after which the wound is allowed to heal *per primam*.

At this stage of our discussion we need not consider special forms of treatment for fractures in general, but it is interesting to reflect that from time to time in the past strange and radical changes in treatment have been undertaken, have been abandoned, and have been revived. As I have said in Chapter XXVI, the beginner would do well to read with care the illuminating essays of Sampson Gamgee on the treatment of fractures, published more than twenty-five years ago. That discursive but delightful writer makes clear the vital importance of **rest and immobilization** for damaged bones and joints. For generations surgery has recognized the importance of this principle; but surgery has for generations also endeavored in some fashion to accelerate union even while maintaining rest and immobilization.

Massage of recent fractures is an ancient practice, long in disuse among modern surgeons, until within recent years. In the chapter on Minor Surgery I have already written at some length on this topic. Surgeons misapprehend often the limits and possibilities of massage

[1] This word "wiring" is used as a general term to indicate some form of fixing, whether by silver wire, by nails, by screws, or by one of the numerous forms of plates or clamps which have been devised.

for broken bones. There is the too frequent custom of postponing masage until after the splints have been removed permanently, and the patient has begun voluntarily to move the limb. Massage at this time is of some value, but its greatest value is found in following the so-called French custom of employing massage daily from the time of the injury. I employ this method with great satisfaction. Massage stimulates the circulation, especially in the lymphatic vessels, and brings fresh blood to the part, in which the massage induces a condition of active hyperemia. One sees, therefore, that in a sense one of the principles of the Bier treatment is thus attained—indeed, Willy Meyer and other surgeons in this country who have employed faithfully the Bier method, find that it is of distinct value in the routine treatment of fractures.

In the case of simple fractures my routine method is to remove the bandages on the third day or as soon as excessive swelling has subsided; and then, with the limb firmly supported by strapping upon splints, carefully and thoroughly to apply the massage. If convenient and possible, such massage is renewed daily, or every second day, throughout the patient's convalescence.

Not only is union accelerated by these measures, but the muscular tone and the circulation are so well sustained that almost as soon as the splints are finally removed the patient finds himself able in fair measure to make use of the affected limb.

Let us now take up a consideration of simple and of compound fractures.

SIMPLE FRACTURES

While we understand by this term a fracture which does not communicate with the outer air, we must realize that there are varieties of simple fractures. There are *traumatic* fractures—fractures due to violence. There are *pathologic* fractures—fractures due to the breaking of a bone weakened by disease (osteomyelitis, tuberculosis, syphilis, sarcoma, carcinoma, rickets, the atrophy of old age, and other similar lesions).

Simple fractures may consist of *fissures* only in the bone; of *subperiosteal* fractures, in which case the periosteum is not broken, the fragments are not displaced, and the ordinary signs of fracture are not apparent. Frequently this condition has been mistaken for a sprain. There are *green-stick* fractures, in which case one side only of a long bone is splintered. There are fractures known as *spiral* fractures, *oblique* fractures, V-fractures, T-fractures, Y-fractures—the meanings of all of which terms are sufficiently obvious, and they are employed to indicate merely the shapes into which the bones are splintered. The following table, copied from Eisendrath's excellent article—a table for which he acknowledges his indebtedness to Scannell, of the Boston City Hospital—is an interesting statement of the frequency of various simple fractures.[1]

[1] Simple fractures entered at Boston City Hospital between 1864 and 1905.

Simple Fractures.	Cases.	Per cent.
1. Radius	4657	(13.45)
2. Humerus	3517	(10.16)
3. Ribs	3196	(9.23)
4. Femur	2898	(8.37)
5. Clavicle	2756	(7.96)
6. Fibula	2344	(6.77)
7. Metacarpus	1285	(3.71)
8. Tibia	1259	(3.63)
9. Skull	992	(2.86)
10. Tarsus	947	(2.73)
11. Phalanges (upper extremity)	798	(2.30)
12. Inferior maxilla	692	(1.99)
13. Patella	660	(1.90)
14. Ulna	630	(1.82)
15. Facial bones	538	(1.55)
16. Carpus	495	(1.43)
17. Vertebræ	331	(0.95)
18. Scapula	256	(0.73)
19. Pelvis	208	(0.60)
20. Metatarsus	168	(0.48)
21. Phalanges (lower extremity)	78	(0.22)
22. Superior maxilla	70	(0.20)
23. Sternum	40	(0.11)
24. Coccyx	20	(0.05)
25. Hyoid	1	(0.002)
Both bones of the leg	3902	(11.20)
Both bones of the arm	1875	(5.10)

The **symptoms** and the **diagnosis** of simple fractures fall naturally into a common paragraph. We hear much of the *history* of the accident, its general effect upon the patient, and of the age of the patient. These are more or less interesting topics, but in fact they have but the most indirect bearing upon the diagnosis. The symptoms even of the patient are of far less consequence than are the objective signs which the surgeon observes. For example, in describing a fracture a writer will tell you that the patient fell 25 feet, that he landed upon his knee, that he experienced great shock, that he is seventy-five years of age, that he was unable to rise, that his leg is paralyzed, and that there is a bunch on the outer side of his thigh. This is all very well and might lead the reader to the conclusion that the patient is suffering from a fracture of the shaft of the femur; whereas he may have a fracture at the base of the skull, or a rupture of the kidney, which will account for all his symptoms, while the swelling on the outer side of the thigh is a mere hematoma. No; the truly important, characteristic, and final evidence is to be found upon an examination only of the patient's body by the surgeon himself.

There are certain classic, well-recognized, and positive signs of fracture: deformity, loss of voluntary motion, abnormal mobility, and crepitus or grating, while the evidence of the *x*-ray confirms the diagnosis. Such is the positive and final evidence for which we look. The other facts in the history are more or less interesting, and may have their bearing upon the treatment of the case, but they are not of first importance.

I ask the reader to refer again to Chapter XXVI for a description of a proper method of handling and examining cases of sus-

pected fracture. Moreover, as Scudder states in the first edition of his admirable book on the Treatment of Fractures, "The general employment of anesthesia in the examination of the initial treatment of fractures, especially of those near or involving joints, has made diagnosis more accurate and treatment more intelligent. . . . This great certainty in diagnosis has suggested more direct and simpler methods of treatment. . . . The attention of the student is diverted from theories and apparatus to the actual conditions that exist in the fractured bone, and he is encouraged to determine for himself how to meet the conditions found in each individual case of fracture."

The patient's interest in his own case is a factor in the situation which will often puzzle the beginner or the inexperienced practitioner. The patient wishes to know how perfect will be his use of the damaged limb, and how long he is to be laid up. His interest in the case goes no further than this, unless, as frequently happens, he is contemplating a suit for damages. It is the meeting of these questions so difficult of accurate answer, and the annoyance, with the possible reflection on his own skill, associated with a pending legal suit—it is these considerations which have rendered the subject of fractures a grievance and an offense to many a surgeon.

The **clinical course** of an average simple fracture of one of the *long bones* presents certain characteristics. The limb in the neighborhood of the fracture is swollen and tense from extravasated blood and lymph. The parts become pigmented, the limb aches and is extremely painful on being moved, or from involuntary muscular twitching, if the parts are not kept at rest by splints and bandages. During the first week there is commonly a slight rise of temperature (the so-called aseptic fever). If the limb is severely crushed, particles of fat may escape into the circulation, may cause fat embolism in various organs, and may be excreted in the urine.

If all goes well, however, and the injury be promptly treated, the swelling subsides gradually, and the pain diminishes and disappears, so that, in the course of a week, the patient rests comfortably, and is conscious only of a disabled and useless limb. In the course of a few days the reparative changes about the seat of the fracture become apparent. Gradually, a soft tumor or collection of exudate of varying size develops. This is known clinically as the "callus." At first soft, it gradually becomes harder, and in the course of weeks smaller. It constitutes nature's plastic mold or splint, which binds together the damaged fragments. For some weeks also one can ascertain the progress of the convalescence by examining this callus. While it is soft, the bone fragments move easily within it. As it becomes hard and ossified the union of the bones becomes firmer, so that, in the course of time, a solid union within the callus is assured. The repair of cartilage as well as of bone follows this course.

The time required for the repair of a simple fracture is usually about sixty days. I find it stated in the General Surgery of Lexer and Bevan that two weeks are required for the repair of fractures of the

phalanges, three weeks for those of the metatarsal bones and the ribs, four weeks for those of the clavicle, five weeks for those of the bones of the forearm, six weeks for those of the humerus and fibula, seven weeks for those of the neck of the humerus and the tibia, eight weeks for those of both bones of the leg, ten weeks for those of the shaft of the femur, and twelve weeks for those of the neck of the femur; while consolidation occurs much more rapidly in children and is complete in most of their bones in from two to three weeks.

The **treatment of simple fractures** follows naturally enough upon the diagnosis. A great mass of nebulous talk and writing has been indulged in regarding the treatment of fractures. There are, in fact, two vital principles involved. If these principles are observed, all should go well.

The fragments of bone must be brought into reasonable apposition and held there.

The patient must be made comfortable.

Simple as are these two principles, one is astonished constantly at finding them neglected. Ordinarily, it is not difficult to bring fragments into apposition. As a general thing, the patient must be anesthetized,—with gas, ether, or chloroform,—when promptly the tense muscles relax and the fragments can easily be brought together. If there is still difficulty in making the approximation, the surgeon may do tenotomy—especially of the tendon of Achilles—or, if comminuted fragments interfere with each other or protrude into a joint, he may cut down upon and straighten out the tangle. We use the term *reduction* to indicate the process of bringing the fragments into apposition. The popular word "set" has little meaning. It is far more difficult to fix and immobilize the reduced fragments than it is to reduce them, for with returning consciousness, after anesthesia, the patient involuntarily contracts his muscles, and muscular contraction tends to throw the fragments out of place. The surgeon must, therefore, apply splints which shall hold the fragments and shall counteract muscular contraction. Splints must be long enough to hold fixed the adjacent joints, and must be so molded and padded as to lie comfortably and snugly upon the limb.

We employ two distinct types of splints—those which but partially encircle the limb, leaving open spaces through which the seat of fracture may be readily inspected from time to time; and encircling splints molded entirely about the limb. Strips of wood properly padded are types of the first class of splints; plaster bandages are types of the second class, and each class of splints has its appropriate place. In general terms, we use the removable wooden splints upon fractures which have been reduced with difficulty, which tend readily to slip out of line, and are surrounded by swelling and distention of the soft parts; while, conversely, we employ the confining and encircling plasters (the popular term "plaster cast" is erroneous) to hold in position some fractures readily reduced and associated with little or no swelling. At the same time, if the surgeon is not employing frequent massage, he

may well dress the first class of fractures in plaster after soft union has begun and the primary swelling has subsided.[1]

There are sundry special apparatus for special fractures, such as the familiar Buck's extension for fracture of the femur. I shall mention these apparatus when I come to discuss the treatment of special fractures.

COMPOUND FRACTURES

Compound fractures call for special and important initial treatment in order to render them simple. When once simple, we treat them upon the rules already laid down. A compound fracture presents an extremely ugly form of lacerated wound, with tearing up of the soft parts, extravasation of blood, sometimes protrusion of a broken bone, and commonly a small punctured opening through the skin. We treat the wound of the soft parts, and then the fracture.

The surgeon should invariably see that the patient is anesthetized for the first dressing. He must then shave and disinfect a large area of skin about the wound, employing the ordinary method of skin disinfection; he must wash out the wound, using hydrogen dioxid and sterile salt solution; he must remove loose fragments of bone, and he must provide adequate drainage. Frequently it may seem well to him, while the wound is open, to fix the fragment by wiring. Having thoroughly cleansed and dressed the seat of fracture, he must then put up the limb in fixation splints. For this purpose splint-wood strips are commonly most convenient, for they may readily be removed when the superficial wound is to be dressed. In some cases of a simple character it may seem best to fix the limb in plaster bandages, and to cut out a window from the plaster which shall give access to the wound for its subsequent dressings.

Compound fractures are less common than simple fractures; and various statistics show the proportion of compound to simple to be about as one in four; though certain bones, such as the phalanges, are more subject to compound fracture than to simple fracture.

The following table, taken from Eisendrath's article, gives one an excellent idea of the relative frequency of the various compound fractures. The student should read this table in connection with the table on simple fractures which I gave on p. 871.

Compound Fractures.[2]

	Cases.	Per cent.
1. Skull	525	(14.45)
2. Phalanges (upper extremity)	488	(13.43)
3. Metacarpus	272	(7.48)
4. Tibia	238	(6.50)
5. Humerus	219	(6.02)
6. Tarsus	203	(5.58)
7. Carpus	152	(4.80)
8. Femur	146	(4.01)
9. Facial bones	119	(3.27)

[1] Plaster bandages may be fashioned so as to be removed and reapplied readily by splitting them down after they have dried upon the limb.

[2] Compound fractures entered at Boston City Hospital between 1864 and 1905.

	Cases.	Per cent.
10. Phalanges (lower extremity)	69	(1.88)
11. Inferior maxilla	66	(1.80)
12. Radius	64	(1.70)
Ulna	64	(1.70)
13. Fibula	62	(1.70)
14. Metatarsus	27	(0.74)
15. Superior maxilla	10	(0.27)
Clavicle	10	(0.27)
16. Ribs	8	(0.22)
17. Patella	7	(0.19)
18. Pelvis	6	(0.16)
19. Scapula	3	(0.08)
20. Vertebræ	1	(0.02)
Sternum	1	(0.02)
Both bones of the leg	610	(16.70)
Both bones of the arm	262	(7.02)

We may not leave the general subject of fractures and their treatment without referring to the possibility of the surgeon himself causing further damage to the injured limb through his own ill-regulated treatment. I have already spoken of malunion and the disastrous results of failure properly to disinfect a compound fracture. Another not infrequent and doleful result of treatment is the so-called *Volkmann's contracture*. By this term we understand a contraction or flexion of the fingers and the wrist following the treatment of fractures about the elbow-joint and in the forearm. Volkmann's contracture appears often within three or four days after the patient's accident. It is associated with loss of power in the muscles of the forearm, most commonly in young children. It is an extremely serious matter, though if we recognize it early, we can check its progress. The cause of the contracture is probably an ischemic necrosis of the muscles, dependent upon too great a pressure by splints against the soft parts. Such pressure interferes with the blood-supply, so that the muscle dies and is replaced by scar tissue. I have already discussed this condition and its treatment in Chapter XXVII.

Let us now consider briefly the more important—

SPECIAL FRACTURES[1] AND THEIR TREATMENT

Fractures of the *skull* and of the *vertebræ* are discussed in Chapters XXIV and XXV of this book.

Ribs

The *ribs* and *costal cartilages* are broken most commonly by blows and crushing forces. There results instant and characteristic distress: shortness of breath, stabbing, localized pain with each respiration, and sometimes the spitting of blood if the lung be damaged. The surgeon can bring out a point of pain by manual compression of the thorax, which tends to "start" the involved rib at the point of fracture. He

[1] I am indebted to C. L. Scudder for permission to draw largely upon his illustrations in The Treatment of Fractures, sixth edition, 1907. The reader is referred also to L. A. Stimson, Fractures and Dislocations, fifth edition, 1907.

may feel crepitus on palpating the seat of injury,—although crepitus is by no means a constant sign in fractured ribs; but perhaps, most important of all, he can hear creaking with every respiration of the patient, by placing his stethoscope upon the suspected area.

There may be distressing complications in connection with a rib fracture—compound openings and lacerations of the pleura and lung. I have already discussed this matter in Chapter XIX.

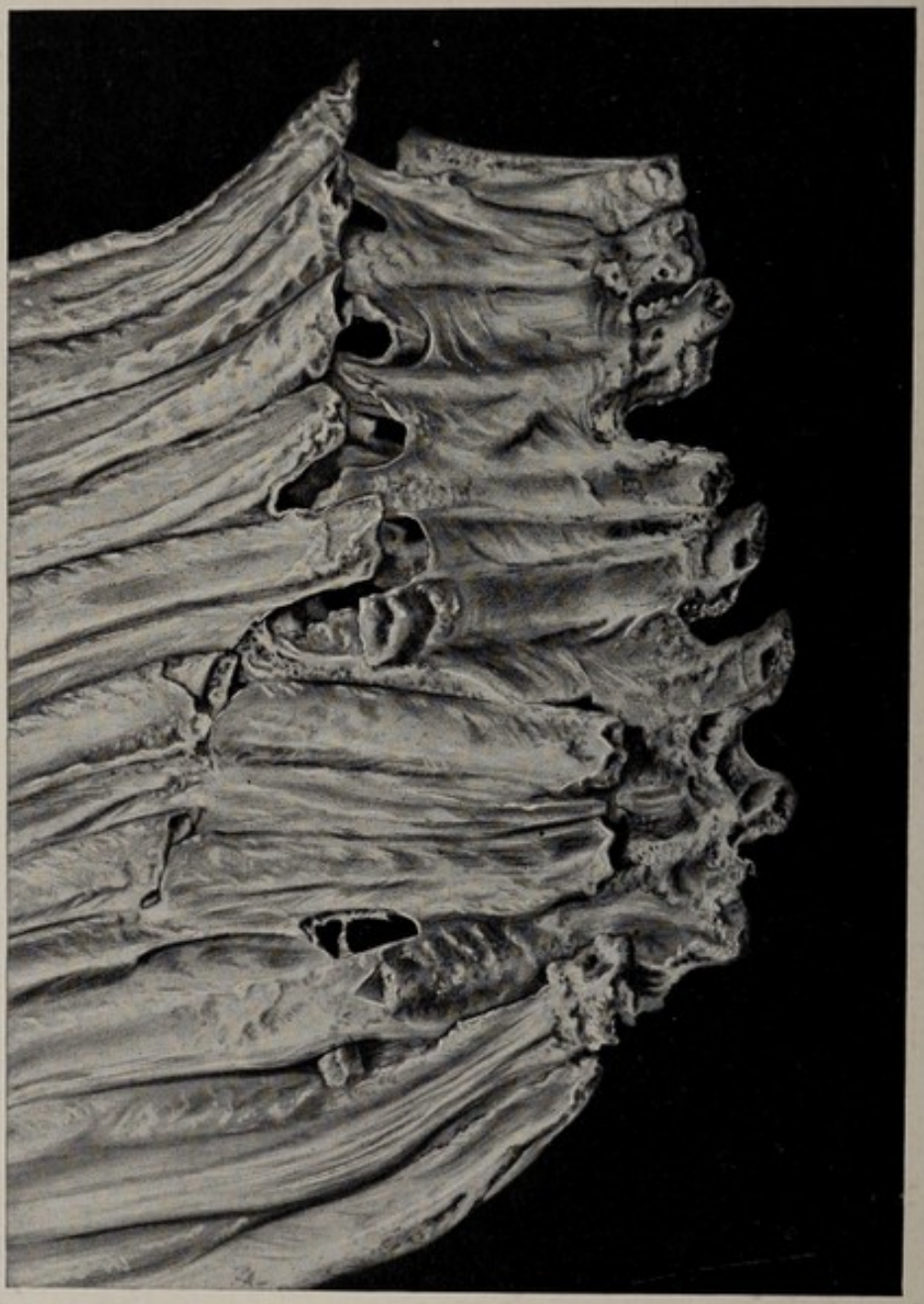

Fig. 539.—Fractured ribs (Warren Museum).

Compound fracture of ribs, however, is not common, and far the most frequent cases are the simple single fractures whose victims present themselves at the dispensary or the surgeon's office. These people are in constant distress, and I know of few bone injuries which are capable so promptly of being relieved.

The **treatment of fractured rib** consists in immobilizing the thoracic cage so as to limit costal respiration and force the patient to respiration by the diaphragm. There are numerous methods of immobilizing the chest, but by far the most effective is wrapping it in a firm swathe of surgeon's plaster; or, if a swathe be not at hand, in successive layers of plaster strips encircling the chest and laid on in the manner of clapboards.



Fig. 540.—Fracture of the ribs. Starting the application of the adhesive-plaster swathe to encircle the trunk. Fixation of initial end of the swathe at the spine. Notice that the swathe is held taut as it is applied (Scudder).

After this dressing, the patient is usually so comfortable that he walks about without distress, and often can return at once to his occupation.

STERNUM

The sternum is fractured, the most frequent fracture being at the point of union of the manubrium and the body of the bone. I have seen one such fracture in the case of a football player whose manubrium was crushed in by a blow. The symptoms are quite similar to those of fractured rib, and the deformity is so characteristic that the diagnosis is extremely easy. The patient stands in a hollow-chested attitude, while the examiner's finger sinks at once into the pit formed by the depressed fragment.

The fracture is often reduced spontaneously through the patient's coughing or sneezing. Sometimes the surgeon may reduce the fracture by turning the patient on his back and making traction upon the

arms, while an assistant steadies the chest. If this maneuver fails, one may easily cut down upon the fragment and elevate it. After the



Fig. 541.—Position in, and method of reduction of, fracture of the sternum. Notice positions of hands of surgeon and assistant (Scudder).

bones are replaced, the patient should be enveloped in a plaster swathe and kept quietly in bed for three weeks at least.

Pelvis

Fracture of the pelvis is frequently seen in large hospital practice, and, as Scudder points out, pelvic fractures fall into two groups—fractures of the individual bones without injury to viscera, and fractures at different points in the pelvic ring associated with damage to the viscera.

One can palpate with fair thoroughness the whole pelvic ring, in spite of the apparent inaccessibility of the bones involved. For with a little care and patience fingers in the rectum or vagina may search out all parts of the pelvis. Moreover, the external examination alone reveals fractures often. The surgeon grasps the iliac crests and by pressure and rotation detects the fracture.

The treatment of these pelvic injuries has been too much slighted and made a matter of routine. Commonly, we see the patient wrapped snugly in a plaster swathe and left to roll about in bed without further support. The plaster swathe is a valuable remedy, but its value is greatly increased if the patient be bound upon a well-fitting Bradford frame, for thus immobility is made more certain, and the care of the patient's bowels and back is made much more easy. In case the acetabulum and pubis are fractured, it is often well to immobilize the patient's legs by the application of long confining outside splints, which shall extend from the axillæ to six inches below the heels.

It frequently happens that the urethra, the bladder, and other pelvic structures are torn when the pelvic bones are displaced. Extravasation of urine leading to peritonitis even may result. I have already, in Chapters XIV and XV, discussed these complicated conditions.

CLAVICLE

The clavicle is not broken as frequently as is generally supposed, though its fracture is common enough. It stands fifth in the Boston City Hospital list, and seventh in other lists which I have consulted. When one remembers that the clavicle is subcutaneous throughout its extent, that it is a weight-bearing bone of great importance; and that every motion of the arm is transmitted to it, one sees how inevitably it is subjected to fracture by both direct and indirect violence. A collar-bone broken by the victim's falling from a horse, by being struck upon the shoulder, or by being jammed between wagons, is broken by in-

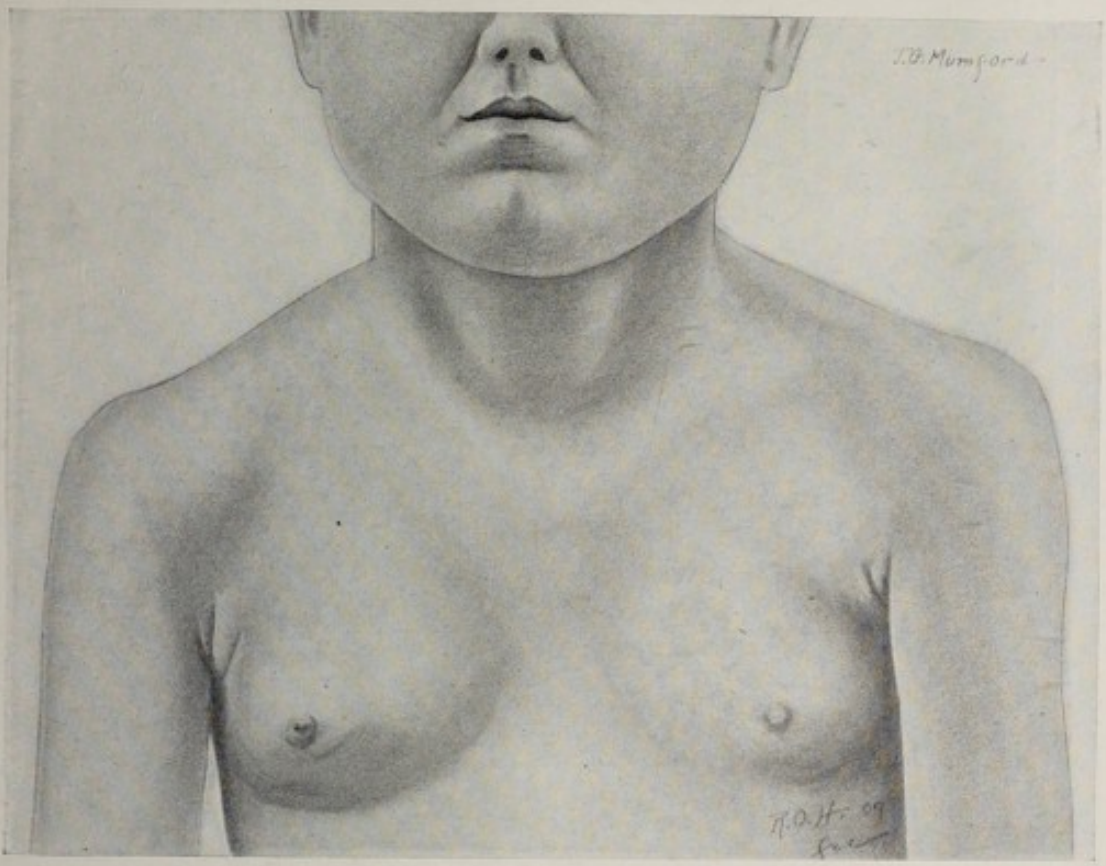

Fig. 542.—Fracture of right clavicle (Massachusetts General Hospital).

direct violence, and such is the nature of the injury which usually causes fracture of the clavicle. A direct violence fracture of the clavicle is not common. One sees also that indirect violence may cause green-stick fracture of the clavicle in young children—the common form of collar-bone fracture in childhood.

A clavicle commonly breaks in its middle third, though direct violence, as by a bullet, may shatter it at any point in its course. With the clavicle broken, the shoulder falls forward and drops inward so that the outer fragment of the bone is carried below the inner fragment and overlaps it in front, while the inner fragment, to which the sternomastoid muscle is attached, is tilted slightly upward. The patient stands with his head inclined to the injured side, so as to relax the pull of his sterno-

mastoid muscle. He relieves his pain further by supporting his injured arm in the opposite hand.

If a child is the victim of a green-stick fracture of the clavicle, the characteristic attitude is much less marked. The shoulder droops less, while a tender swelling appears at the seat of the fracture. In the case of a very obscure fracture, a characteristic point of pain can be brought out by the surgeon's placing a hand on the outer side of either shoulder and crowding the shoulders together.

The **treatment** of a completely fractured clavicle is not always satisfactory. The displacement can be corrected and the proper position can be maintained, but this is not always accomplished. Obviously, the indications for treatment are to carry the shoulder with the outer fragment of the clavicle upward, outward, and backward. As the old writers have pointed out, the proper position can best be secured by laying the patient flat on his back on a hard mattress with a small pillow between his shoulders. Few patients, however, are willing to submit to treatment in bed for this rather trifling injury.

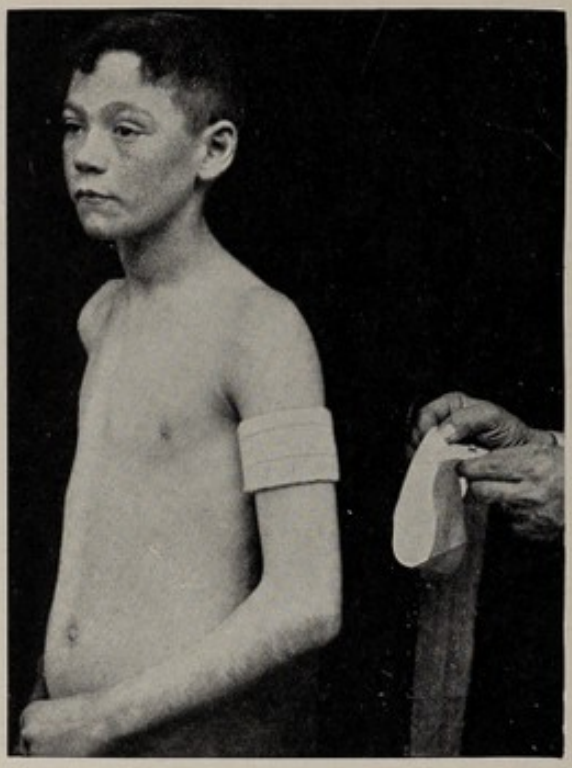

Fig. 543.—Fracture of the left clavicle. Modified Sayre dressing. Towel circular of upper arm held by adhesive plaster. Adhesive-plaster strap ready (Scudder).

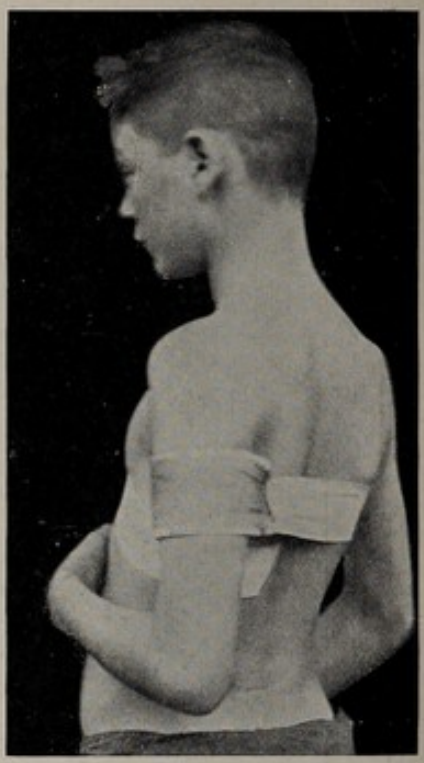

Fig. 544.—Fracture of the left clavicle. First adhesive-plaster strap applied. Shoulder carried backward. Fixed point established above middle of humerus (Scudder).

The modified Sayre dressing is usually satisfactory, however; it holds the fragments in fair position and allows the patient to walk about. This dressing is made of adhesive plaster: "Provide three strips of plaster, 4 inches wide, and long enough to extend once and a half around the body. The skin surfaces that are to come in contact—

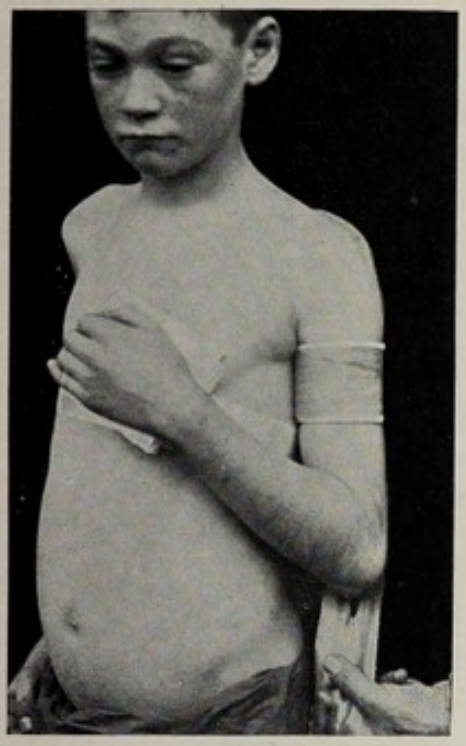

Fig. 545.—Fracture of the left clavicle. First adhesive-plaster strap applied. Second adhesive-plaster strap being applied. Hole in plaster for olecranon visible. Note pad for wrist and folded towel protecting skin of arm and chest (Scudder)

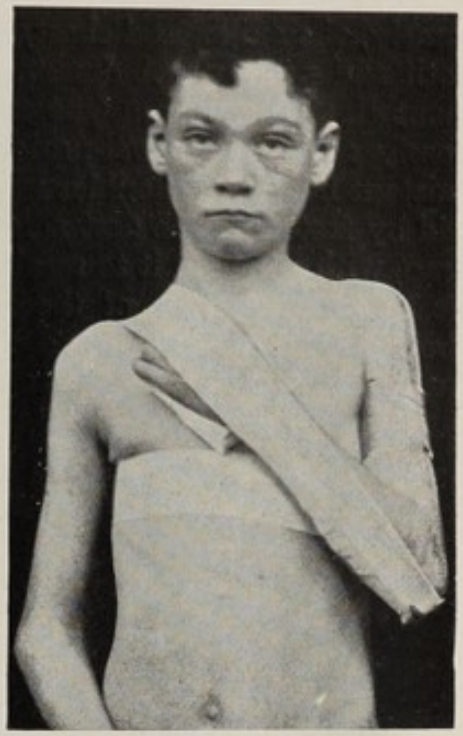

Fig. 546.—Fracture of the left clavicle. First and second adhesive-plaster straps applied. Pad in left hand. Shoulder pulled backward and elevated (Scudder).

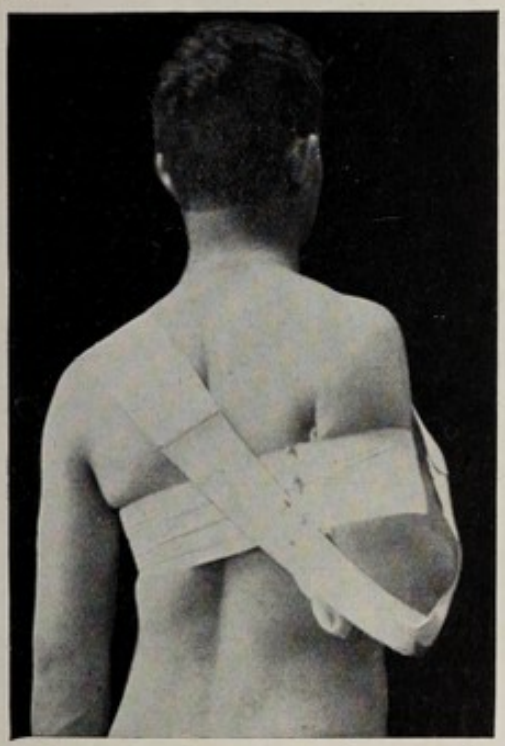

Fig. 547.—Fracture of the right clavicle. Modified Sayre dressing. Posterior view. Shoulder elevated and pulled backward. Folded towel seen in axilla for protection to skin (Scudder).

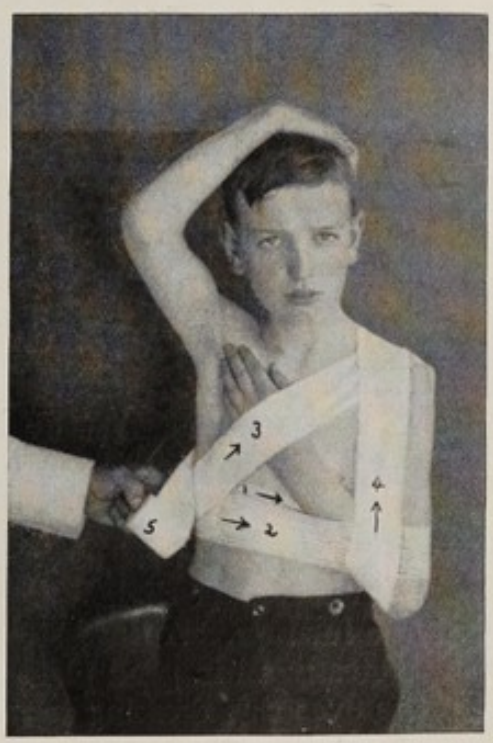

Fig. 548.—Fracture of the clavicle. Method of application of a Velpeau bandage. Note the order and direction of the turns 1, 2, 3, 4, and 5. Note position of the forearm and arm of the uninjured side (Scudder).

namely, the axilla, and chest, and forearm—are separated by compress cloth and powder. A dressing towel folded is snugly pinned high up about the upper arm. One end of the first adhesive strap is fastened loosely about the towel-protected arm with a safety-pin. While an assistant holds the shoulder well back, the arm is carried backward and held by fastening the first adhesive strap about the body. The second strap, with a hole in it to receive the point of the elbow, is started upon the posterior surface of the injured shoulder and carried under the elbow of the injured side and over the sound shoulder. The forearm is thus flexed and rests upon the chest. In applying this second strap the

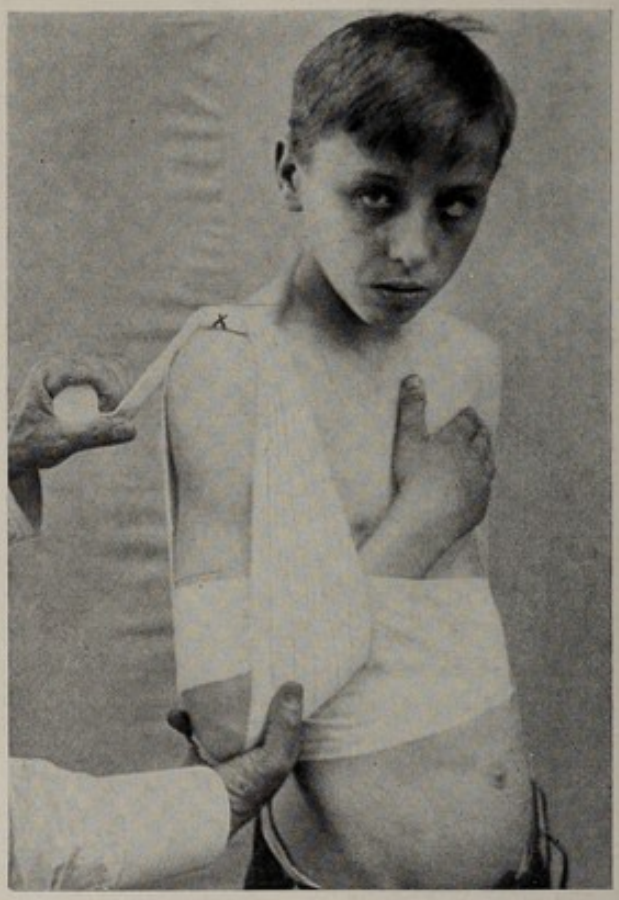

Fig. 549.—Fracture of the clavicle and subluxation of the acromioclavicular joint. Notice elevation of shoulder by pressure on the flexed elbow and counter-pressure on the clavicle by a bandage and a pad (×) placed internal to the acromioclavicular joint (Scudder).

patient's shoulder is raised, and his elbow is carried forward, thus forcing the shoulder slightly upward and backward to the fixed point used as a fulcrum. A third strap may be placed around the trunk and arm to steady all in good place."[1] The surgeon may apply a Velpeau bandage over this dressing to give the patient increased comfort.

The results of treatment are usually satisfactory so far as function is concerned, though it commonly happens that some slight deformity remains for a long time. This must be inevitable in the case of any broken bone the fragments of which cannot be seized directly, manipu-

[1] C. L. Scudder, ibid.

lated, and splinted. For this reason it may seem well in the case of badly overriding and irreducible fragments of the clavicle to cut down upon and wire the bones.

SCAPULA

The scapula is one of the most complicated bones in the body, so that its fractures are manifold. We have to consider the great wing-like *body* of the scapula, the *glenoid cavity*, the *coracoid process*, the *spine*, and the *acromion process*.

This bone is usually fractured by direct violence—by a crushing blow. There are no characteristic signs or symptoms of fractured scapula. The patient knows merely that he suffers great pain in the

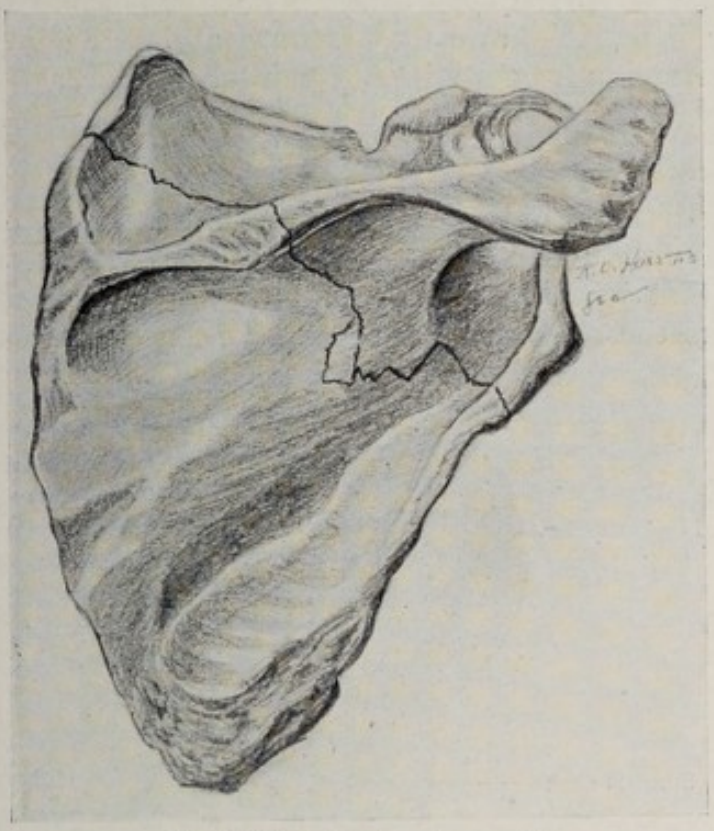

Fig. 550.—Fractured scapula.

neighborhood of the shoulder and that he must support the corresponding arm in order to obtain any relief. The surgeon discovers grating, swelling, and tenderness, while the *x*-ray must be relied upon for the accurate diagnosis.

If the acromion process alone be broken, the line of fracture ordinarily is outside the acromioclavicular joint. If the fracture happens to lie on the inner side of this joint, there results a considerable flattening of the shoulder. This injury may be mistaken for a dislocation of the humerus, but one eliminates this dislocation by finding the head of the humerus in the glenoid cavity.

The rare fracture of the neck of the scapula, however, may well be mistaken for a dislocation of the shoulder.

All treatment of fractures of the scapula is directed to raising and immobilizing the shoulder. The bone fragments cannot be approximated accurately except by open treatment, which is not usually advisable. We realize that the shoulder muscles, especially the deltoid and the rotators, bind together in a natural swathe all parts of the scapula. The surgeon may, therefore, feel reasonably confident, in the case of uncomplicated scapula fractures, that he can secure a satisfactory result by enveloping the shoulder in a large thick pad of wadding, bringing the corresponding hand toward the opposite shoulder, and binding all the parts firmly together in a comfortable Velpeau bandage.

The fragments unite quickly—usually in from three to four weeks. After removing the final dressings, the surgeon should see to it that the patient be given frequent massage and active and passive movements, daily if possible, and for a month at least, if he is to escape permanent crippling from a stiff and painful shoulder.

HUMERUS

The humerus is one of the important bones entering into the shoulder-joint, so that fractures of this bone may affect vitally the value and function of that joint. Practitioners sometimes speak as though the humerus were the only important bone concerned with the shoulder-

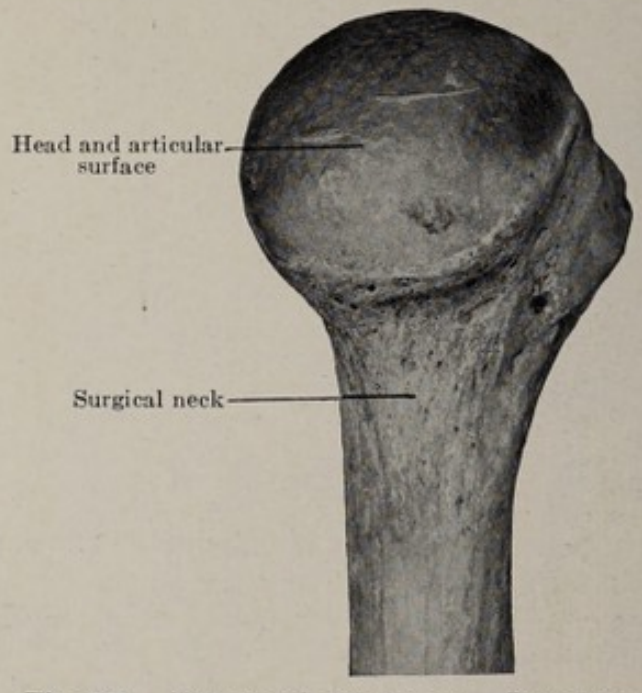

Fig. 551.—Upper end of humerus. Inner view (Scudder).

joint, but our brief discussion of fractures of the scapula must have shown that both scapula and humerus are of nearly equal value to the proper movements of the shoulder-joint.

The accompanying three cuts will remind the reader of the bony outlines of these parts. Fig. 551 especially shows how the point of the shoulder is formed by the head of the humerus and not by the acro-

mion, while the close relation of the coracoid process with the humerus is a fact generally overlooked.

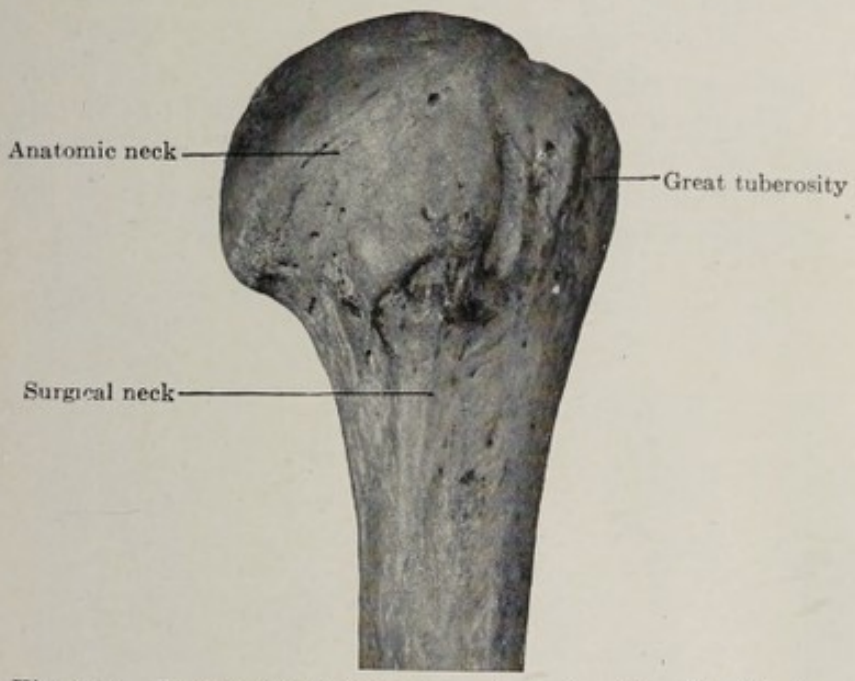

Fig. 552.—Upper end of humerus. Anterior view (Scudder).

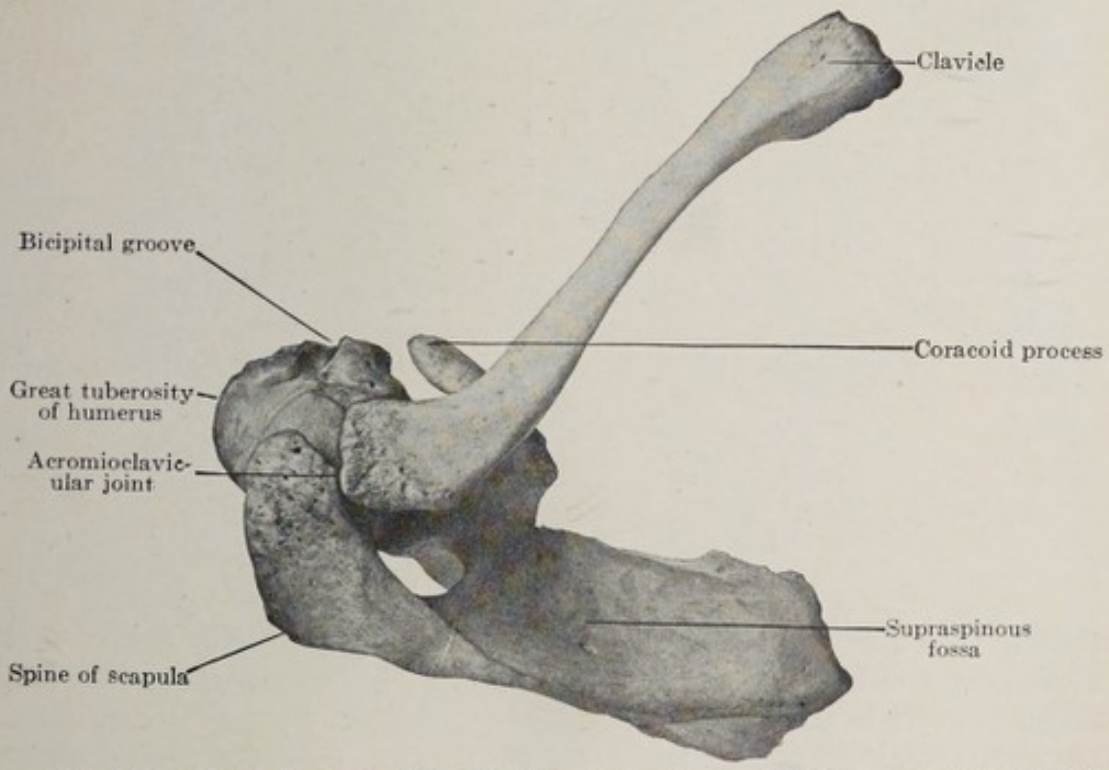

Fig. 553.—View of bones of the shoulder from above. Notice acromioclavicular joint, its relations to bicipital groove and coracoid process. The point of the shoulder is made by the great tuberosity of the humerus (Scudder).

There are three important types of injury to the humerus in the neighborhood of the shoulder-joint—a fracture through the anatomic neck; a fracture through the surgical neck; and a fracture at either

one of these points, associated with dislocation of the head of the bone out of the glenoid cavity.

If a fracture of the humerus in the region of the shoulder be suspected, the patient should be anesthetized for proper and complete examination. Without anesthesia, even though the *x*-ray be used, it is not always possible accurately to determine the extent of the injury; while anesthesia is of great assistance to the surgeon in the reduction and fixation of the fragments, especially and obviously if he is compelled to treat them by the open method. It is of first importance to be certain

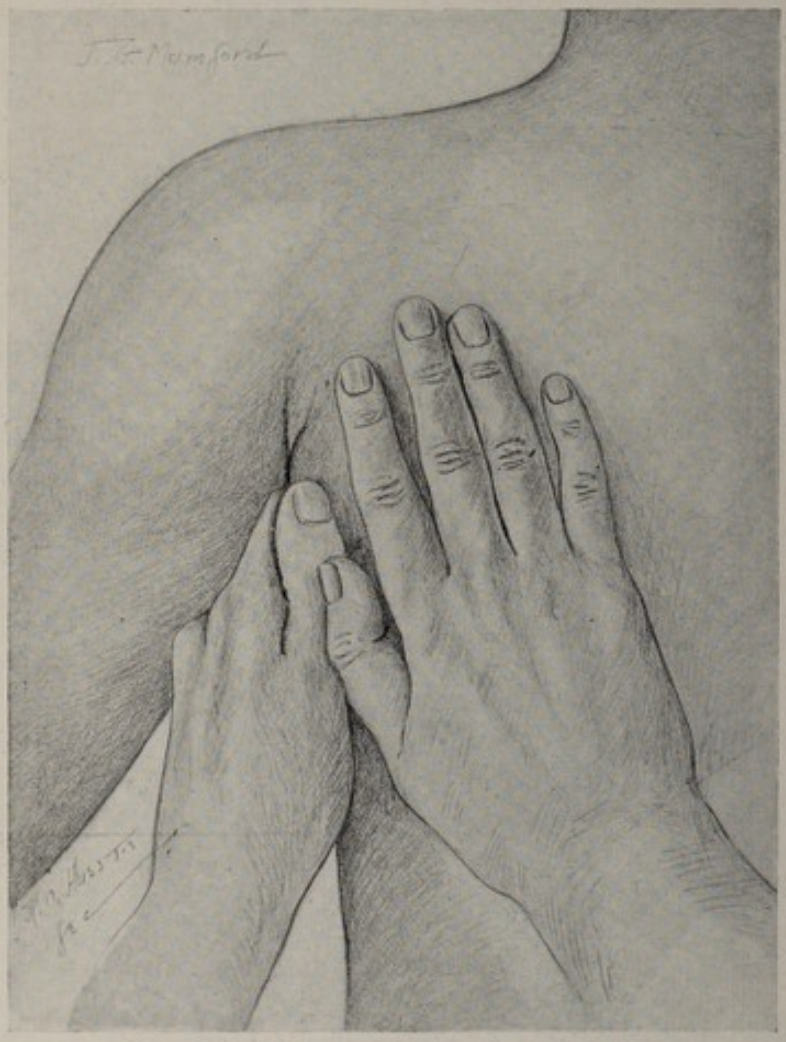

Fig. 554.—Bimanual palpation of axilla.

that the head of the bone is in the glenoid cavity. One can almost always ascertain this fact by the method of bimanual palpation—the fingers of one hand being pushed high up into the axilla beneath the pectoralis major muscle, while the fingers of the other hand press down upon the opposing fingers through the pectoralis major. If the head of the humerus is in its socket the surgeon will find nothing but the pectoralis muscle intervening between his two hands, which may then be closely approximated. On the other hand, if the head of the bone be outside of its socket, it will lie somewhere within the axillary folds, and will present an abnormal and clearly felt obstacle

between the examining fingers. I have never known this bimanual test to fail, though I have never seen it mentioned in text-books. The other ordinary methods of examining the shoulder are well illustrated in the figures of the text.

The surgeon's first interest then in making an examination of the shoulder is to determine whether the injury is a mere dislocation of the head of the bone or is a fracture of the humerus. The presenting deformities of each injury often appear quite similar. In the case of a simple *dislocation*, however, one sees the familiar flattening of the deltoid; while the elbow is carried out from the side, the forearm apparently is lengthened, the hollow in front of the shoulder is obliterated, and the subpectoral groove is lowered, as the figure illustrates. In the case of many *fractures*, on the other hand, the pectoral line is accentuated rather than flattened, the arm hangs limp and flail-like, while the apparent length of the upper arm is diminished as compared with its fellow.

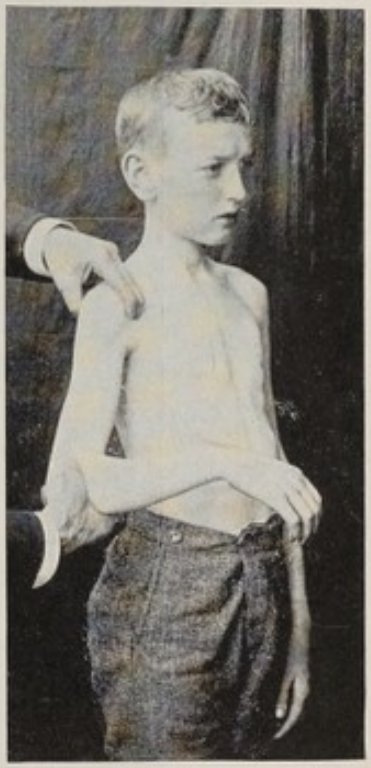

Fig. 555.—Examination of shoulder. Method of palpating head of humerus with thumb and fingers. Elbow grasped by other hand (Scudder).

In all cases of shoulder injury examine first the sound side and then the affected side.

Fracture of the anatomic neck of the humerus is quite common in elderly persons. It can be made out readily with a patient under anesthesia, but not often without anesthesia. Crepitus may or may not be felt. The fragments may or may not be impacted; and the fracture is wholly intracapsular. This injury often goes unrecognized; it is mistaken for a "sprain," so that there results a permanently stiffened and painful shoulder.

If the fracture be obviously impacted, the fragments must not be broken up, but the arm must be slung and held immobilized until the swelling of the soft parts has subsided. After that—say, in ten days or two weeks from the accident—the joint should be treated actively—by passive movements, by heat, by Bier's hyperemia, and by massage, while the patient should be encouraged to use the arm as much as possible within the limits of serious discomfort.

Separation of the upper epiphysis in children is a lesion quite similar to a loose *fracture through the anatomic neck* in adults. This fracture should be *treated* by immobilization for a varying time—three to six weeks. If the head of the bone be not dislocated from its socket, an extremely simple apparatus will suffice—a proper pad in the axilla to hold the shaft away from the side, and a firmly applied Velpeau bandage making snug the fragments. If there be marked and irreduci-

ble displacement of the shaft, however, especially if the head of the bone be dislocated, open treatment is necessary. In operating one may be obliged to remove the head of the bone entirely, or simply to divide or displace the parts preventing reduction; and it is never possible before operating to foretell just which procedure will be necessary.

We see, therefore, that fractures of the anatomic neck offer a wide range of possibility as regards the outcome of the injury. In simple cases we may look for a perfect restoration of function. In the more complicated and difficult cases we must forecast nothing better than a permanently stiffened shoulder, with a marked diminution in the arc of motion.



Fig. 556.—Examination of shoulder. Movements of the shoulder. Normal maximum abduction. Notice method of grasping head of humerus (Scudder).

Fracture of the surgical neck of the humerus means properly any fracture below the epiphyseal line and within the upper fourth of the shaft of the bone. This is a common fracture and is seen at all ages. The head of the bone rests in its socket, movements are painful, crepitus is present, and there is abnormal mobility, while the arm is distinctly shortened, as shown by measuring the shaft from the acromion process to the external condyle of the humerus.

In the case of children, subperiosteal fractures of the surgical neck are not uncommon. Such fractures cannot be diagnosticated without the aid of the *x*-ray.

Fractures of the surgical neck of the humerus are not easy of *treatment*, for approximation of the fragments is difficult to maintain.

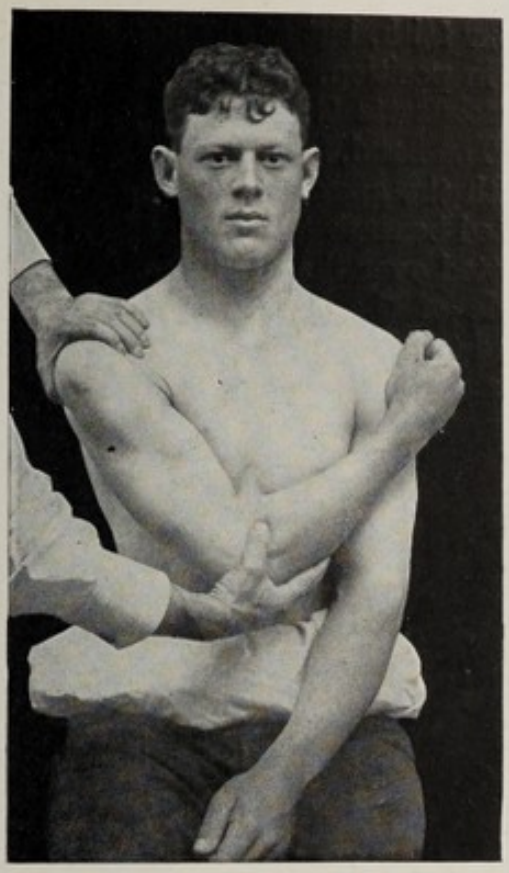

Fig. 557.—Examination of shoulder. Maximum adduction. The bend of the elbow, when the forearm is flexed to a right angle, comes to the median line of trunk (Scudder).

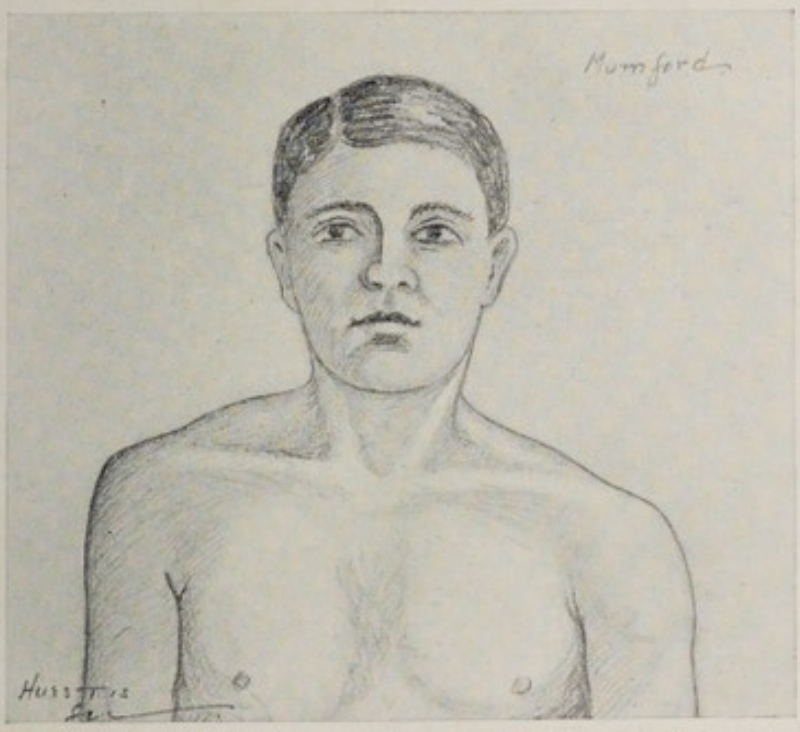

Fig. 558.—Outline of shoulder in case of fracture of clavicle.

We have taught ourselves to believe that traction, countertraction, and manipulation will secure coaptation of the fragments. Sometimes

we are justified in our faith, but at the best it is hard or impossible to hold the fragments in position. The following method has long been in use at the Massachusetts General Hospital and produces a fairly satisfactory result: The hand, forearm, and elbow are bandaged firmly; a V-shaped pad (with the apex of the V in the axilla) constructed of sheet-wadding is fitted beneath the arm; and a shoulder-cap of wire or plaster of Paris is fitted over the whole shoulder and down the arm to the external condyle of the humerus. The arm is then bandaged firmly to the side and the forearm is hung in a sling.

Other similar methods are sometimes more effective, though they may be cumbersome and expensive.

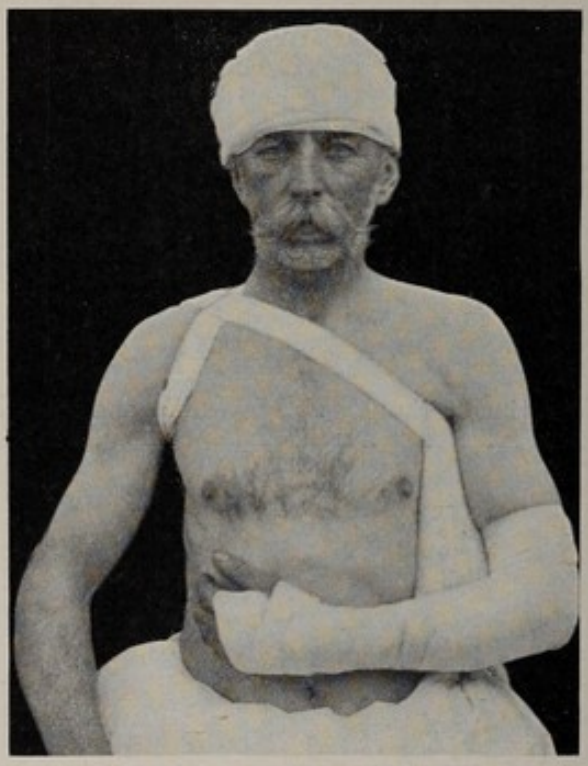

Fig. 559.—Fracture of the upper end of the humerus. Note hand, forearm, and elbow bandaged evenly and without compression; axillary pad and strap (Scudder).

Whatever the apparatus used, we find that it is continually difficult to hold the fragments in place. The dressing must be removed frequently and regularly—at least once a week—so that the surgeon may inspect the limb and correct malposition, if possible. He must look out also for pressure sores, and will do well to have the shoulder and arm massaged each time the arm is exposed. At the end of two or three weeks soft union should take place; and fairly firm union in from four to six weeks.

These fractures of the surgical neck are excellent examples of fractures suitable for the open treatment. Delayed union, or non-union, is not uncommon. Perfect apposition without operation is almost impossible. I, therefore, recommend wiring the bones in the case of persons who are not old or afflicted with any serious organic disease.

Fracture of the shaft of the humerus does not differ greatly from fracture of the surgical neck, except that oblique and spiral fractures

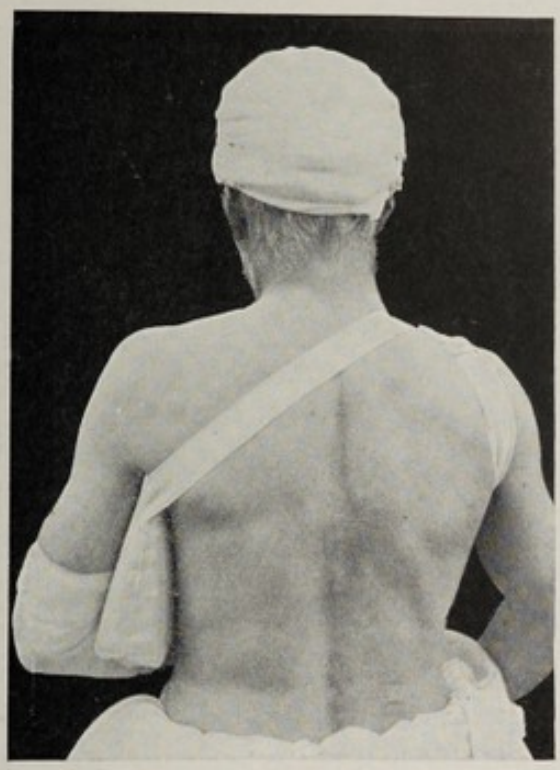

Fig. 560.—Fracture of the upper end or shaft of the humerus. Posterior view. Note bandage to forearm and elbow; axillary pad and strap. Note shape of axillary pad (Scudder).

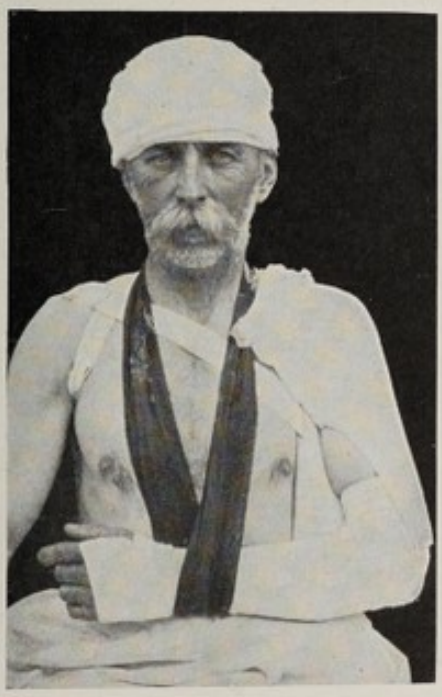

Fig. 561.—Fracture at upper end of the humerus. Note hand, forearm, and elbow bandaged; axillary pad and strap, plaster-of-Paris shoulder-cap, sling (Scudder).

are nearly as common in the shaft as are transverse fractures. I myself had the mortification to cause a spiral fracture of the humerus in an

old man whose shoulder-joint dislocation I endeavored to reduce by Kocher's method.



Fig. 562.—Fracture of the shaft of the humerus. Note bandage to hand, forearm, and elbow; axillary pad and strap; coaptation splints and sling. Bandage does not cover fracture (Scudder).



Fig. 563.—Fracture of the shaft of the humerus. Note bandage to hand, forearm, and elbow; adhesive-plaster swathe holding arm upon axillary pad and covering coaptation splints. Sling (Scudder).

One should not fail to recognize a fracture of the shaft of the humerus. The arm is shortened and is limp; there is abnormal mobility; there

are pain and swelling, while the gentlest manipulation discovers crepitus.

Let the surgeon bear in mind the possible involvement of the musculospiral nerve in one of these fractures. The nerve may become included in new-forming callus, or it may be pinched between bone fragments. If the surgeon has reason to believe that the nerve is involved, he should cut down upon the fracture, displace the nerve, and wire the fragments.

The *treatment* of fracture of the shaft may be simple and successful or may be difficult and disappointing. Let the *x*-ray determine. Proper treatment is quite similar to that I have described for fracture of the surgical neck: anesthesia; a proper axillary pad; a bandage to the forearm; splints carefully applied about the seat of fracture; a sling and a confining bandage.

The progress of the case should be simple, and at a rate quite similar to that of a surgical-neck fracture. Be on the lookout, however, for wrist-drop—a characteristic deformity resulting from injury to the musculospiral nerve. In the case of wrist-drop, change the method of treatment to the open method.

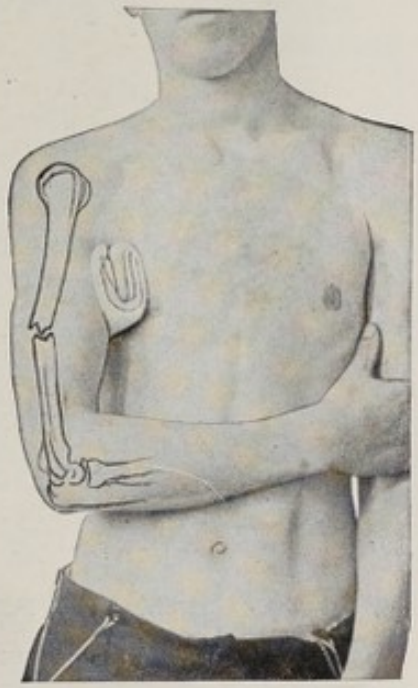

Fig. 564. — Showing effect (bowing outward) of too short an axillary pad upon a fracture of the shaft of the humerus (Scudder).

Fractures of the Elbow

Interesting and important as are humerus fractures of the shoulder and shaft, humerus fractures at the lower end of that bone are even more important and difficult of treatment. These low fractures of the humerus are so frequently associated with fractures of the ulna and radius that we consider this group of lesions under the caption *fractures of the elbow*.

The student should turn to the bony skeleton and study again the relations of the parts about the elbow-joint, making note especially of three bony points—the external condyle, the internal condyle, and the olecranon process. These are the bony points most frequently fractured. But there are two other important structures which often are damaged—the head of the radius and the coronoid process of the ulna. That is to say, we have in the elbow-joint a combination of three bones with a remarkable variety of projections, depressions, and articular surfaces. The elbow-joint is a hinge-joint of extremely complex mechanism. It is a most useful joint. From all these facts it results that damage by fracture about the elbow-joint may have a far more crippling effect often than the apparent bone lesions might

lead the observer to expect. Moreover, these various bony points are associated with a great variety of muscles which tend to pull the frag-

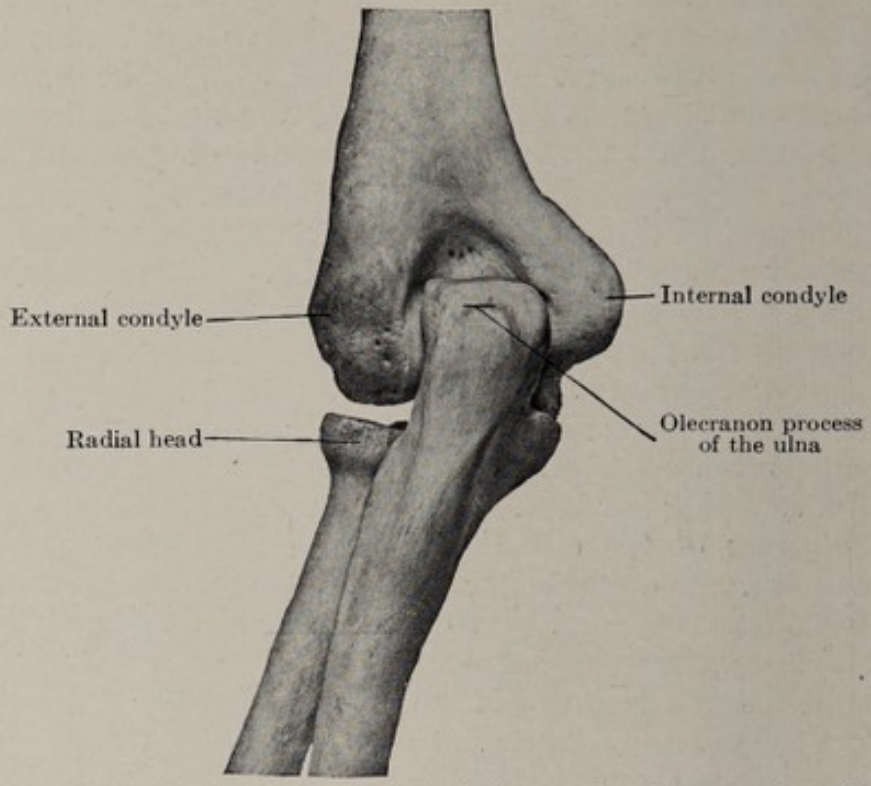

Fig. 565.—Note the bony relations of the internal and external condyles of the humerus and the olecranon process of the ulna in complete extension of the forearm. The three points are almost in a straight line (Scudder).

ments out of position when loosened by a fracture. Furthermore, damage to the synovial surfaces frequently results in painful and dis-

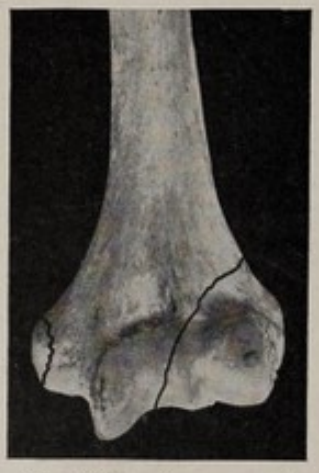

Fig. 566.—Lower end of humerus, anterior surface. Note lines of fracture of internal epicondyle and of fracture of external condyle (Scudder).



Fig. 567.—Lower end of humerus, anterior surface. Note lines of supracondyloid fracture and of fracture of internal condyle (Scudder).



Fig. 568.—Lower end of humerus, anterior surface. Note lines of T-fracture (Scudder).

abling adhesions, while nearly always loosened fragments, sliding out of place and out of their normal relations, tend to block the joint and limit its proper movements.

We must be careful, painstaking, and final in our examination of a damaged elbow-joint, and must have in mind a definite routine while making the examination. The surgeon, seated before the patient, seizes the hand of the injured arm in his own corresponding hand and rests the patient's forearm upon his own other forearm, supporting the damaged elbow with his hand. The surgeon's fingers supporting the elbow then investigate the following bony points: the internal condyle, the external condyle, the olecranon, the head of the radius, and the coronoid process. The surgeon then gently puts the injured arm through the motions of flexion, extension, and rotation. If there be great swelling of the elbow or great pain on manipulation, the patient should be anesthetized. Indeed, it happens commonly that anesthesia is useful as an aid in the proper reduction of the fracture. Finally, two or more *x*-ray plates, taken in different planes, are necessary accurately to elucidate the details of the fracture. There is an excellent old maxim that in reducing one of these fractures the surgeon should go through the movements of reducing a dislocation backward of the elbow. Indeed, great swelling may mask a dislocation, while at the same time a fracture and a dislocation may coexist.

The details of these fractures are as follows:

Lesions of the Lower End of the Humerus:

(*a*) Fracture of the internal epicondyle.

(*b*) Fracture of the internal condyle.

(*c*) Fracture of the external condyle.

(*d*) Transverse fracture of the shaft of the humerus above the condyles.

(*e*) Separation of the lower epiphysis of the humerus.

(*f*) T-fracture into the elbow-joint.

Lesions of the Radius and Ulna

(*g*) Dislocation of the radius and ulna backward with or without fracture of the coronoid process of the ulna.

(*h*) Subluxation of the head of the radius.

(*i*) Fracture of the olecranon process of the ulna.

(*j*) Fracture of the neck or head of the radius.

Besides these fractures, which appear frankly as fractures in adult bones, there are the corresponding fractures in the forming bones of children.

The *treatment* of these lesions about the elbow-joint taxes the ingenuity of the surgeon, and frequently proves extremely discouraging. We endeavor to bring the fragments into apposition, and we attempt to secure union without a coincident impairment of motion.

It is true, as Scudder states, that the object of treatment is to restore the elbow-joint to its normal condition; but I should qualify that by saying the object of treatment is to restore the elbow-joint to usefulness. It is by no means always possible to restore the joint to its normal condition; but generally it is possible, in spite of extreme damage and loss of bone substance even, to bring out a useful joint.

At first, and so long as great swelling persists, we can do little more than keep the elbow comfortably at rest on a pillow. When the swelling has subsided, we should put up the arm in a permanent dressing. We must not long delay this dressing, for ossification about the elbow-joint proceeds with great rapidity.

We should treat **fractures of the internal epicondyle, of the internal condyle, of the external condyle, and T-fractures into the joint** in the acutely flexed position. H. L. Smith, of the Boston City Hospital, was the first surgeon to demonstrate the value of the acutely flexed position,[1] and a wide experience of many surgeons has shown that this position actually reduces and holds reduced the fractures we are discussing.

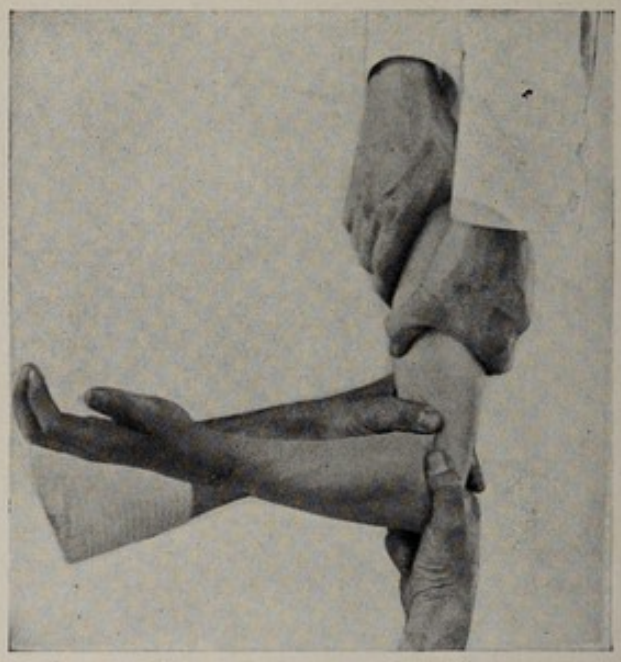

Fig. 569.—Supracondyloid fracture of the humerus. Method of reduction before applying retentive splint. Countertraction on upper arm. Traction on condyles of humerus with right hand; backward pressure with thumb of left hand. Also illustrative of method of beginning acute flexion (Scudder).

Says Scudder in regard to method: "The condyles of the humerus are grasped by the thumb and finger of one hand; a finger of the other hand is placed in the bend of the elbow. Traction is made upon the forearm, and it is slowly flexed to an acute angle. While the forearm is being flexed, traction and lateral pressure are brought to bear upon the loose fragments of the humerus, to correct existing malposition." The degree of flexion will be determined by the obstruction offered by the local swelling. This acutely flexed position is maintained by an adhesive-plaster strap. There are certain precautions to be taken and dangers to be avoided in our use of the acutely flexed position; especially must we inspect daily the arm during the first week, and we must see to it that proper circulation is maintained in the hand. At the

[1] H. L. Smith, Position in the Treatment of Elbow-joint Fractures, Boston Med. and Surg. Jour., October 18, 1894.

end of three weeks, in the average case, we can begin passive motions with the damaged elbow; we have secured good flexion and even if perfect extension is not obtained, the imperfect extension will be a less serious disadvantage to the patient than would be inadequate flexion.

Transverse fracture of the humerus above the condyles is an ugly fracture, and difficult to fix, for there is a constant tendency of the lower fragment to slip backward, and thus to produce a deformity which resembles a backward dislocation of the bones of the forearm. This low fracture of the humerus is fairly well held in place by the

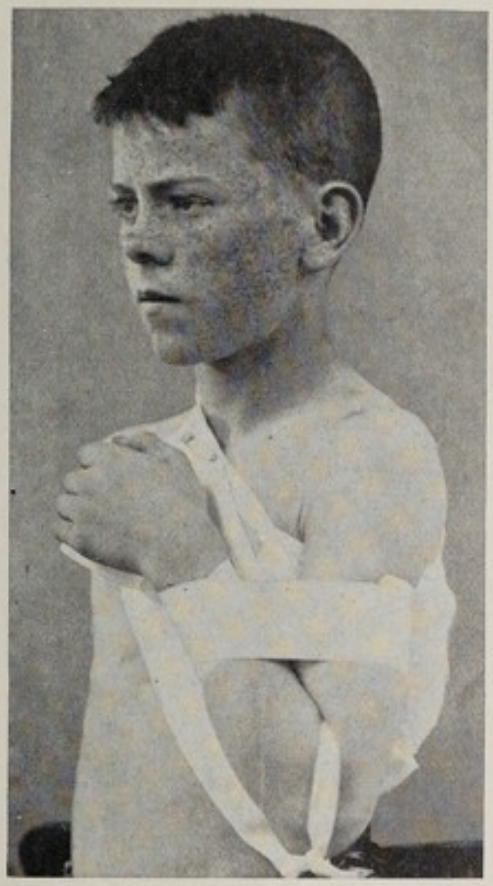

Fig. 570.—Left elbow in position of forced flexion. Gauze in bend of elbow. Thin axillary pad. Pad under hand and wrist. Gauze protection under forearm, held by safety-pin from slipping. Adhesive plaster maintaining flexion. Skin protected on upper arm by gauze compress from cutting of adhesive plaster (Scudder).

internal angular splint, such as the illustration shows. This splint must be padded carefully and must be strapped with two straps upon the forearm and two above the elbow, that it may be held absolutely without shifting. The outlook and rate of healing in these low fractures of the humeral shaft are quite similar to the outlook and rate of healing of higher fractures of the humerus.

A dislocation backward of both bones of the forearm is easily reduced when the patient is anesthetized; and the replaced bones may be held comfortably in position on the internal angular splint.

Fracture of the neck of the radius is best treated by support on the internal angular splint.

Fracture of the olecranon produces a situation, and calls for the solution of a problem, of a new type. Integrity of the olecranon is

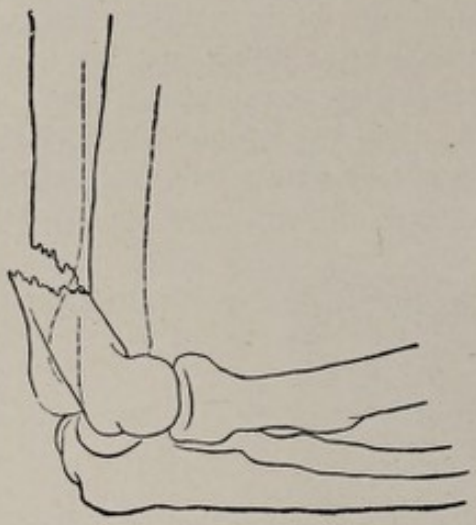

Fig. 571.—Supracondyloid fracture. Obliquity of the line of fracture from behind downward and forward. Diagram showing deformity with elbow flexed and little sliding of fragments (Scudder).

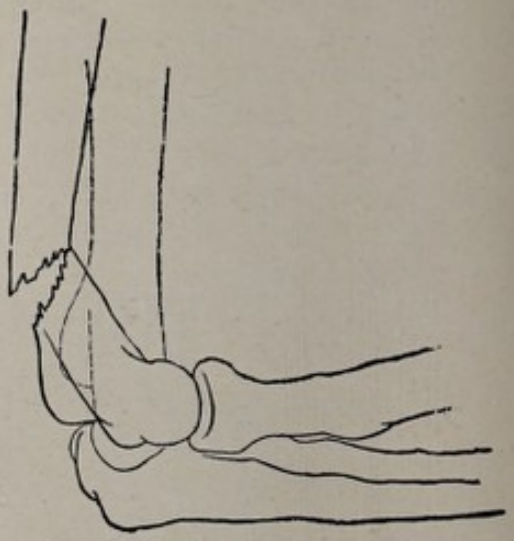

Fig. 572.—Supracondyloid fracture. Obliquity of the line of fracture from above downward and backward. Diagram showing tendency to posterior deformity if acute flexion of forearm is attempted (Scudder).

essential to the strong and proper extension of the forearm; the elbow fractures we have discussed hitherto interfere with proper flexion mainly. In these cases we have seen that a restoration of flexion is sought, but a dressing of the elbow in a flexed position is not suitable for a fracture which involves impairment of proper *extension*.

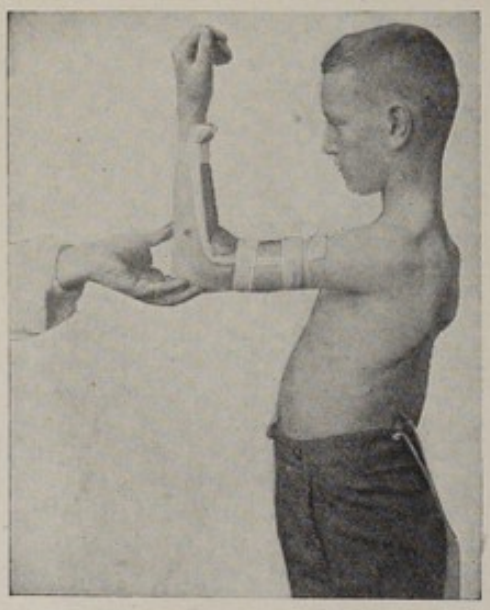

Fig. 573.—Third strap is necessary to hold the splint close to the flexed elbow (Scudder).

We recall the fact that the brachialis anticus muscle is inserted into the base of the coronoid process of the ulna; that the triceps muscle is inserted into the posterior part of the upper surface of the olecranon and into the fascia of the posterior surface of the forearm, and that the small epiphyses of the olecranon unite with the shaft about the sixteenth year.

The olecranon is usually broken by great violence, and at a point from one to two inches from its tip. Thus the elbow-joint is always opened when the olecranon is fractured. Sometimes there is a marked deformity and a depression between the bone fragments, into which depression one's examining finger sinks; or there may be little or no separation of fragments.

The *treatment* of an olecranon fracture depends somewhat upon the extent of separation of the fragments. If the fragments lie close together, the arm may be dressed satisfactorily, and most comfortably for the patient, in the right-angled splint; but if there be obvious separation, the arm should be extended straight and should be bound upon a long splint reaching from the axilla to two inches beyond the finger-tips; while the small upper fragment of the olecranon should be secured and held down in place by a special adhesive strap. If it be found impossible by this means to bring the upper fragment into proper

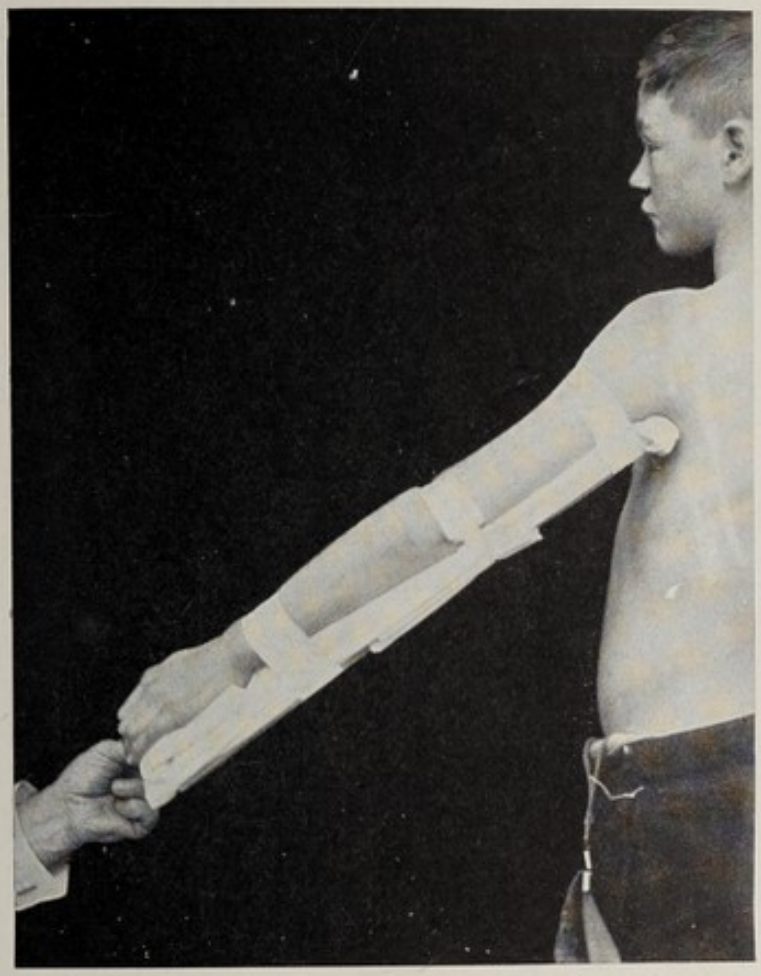

Fig. 574.—Fracture of the olecranon. Arm in extension. Long anterior splint. Note pad and strap above olecranon fragment; pad in palm of hand (Scudder).

position, the surgeon will do well to cut down upon and to wire the fragments. If the fracture is a compound fracture, the surgeon must take special pains as a preliminary step thoroughly to disinfect the elbow-joint, after which he may wire the fragments.

Such are the main points in the diagnosis and treatment of fractures about the elbow-joint.

A word about **old neglected fractures of the elbow-joint or malunion** in spite of treatment. These are peculiarly difficult cases, which fall into that class I have already described as calling for most careful consideration and consultation prior to any radical operation.

The classic operation for old crippling deformities of the elbow-joint (usually ankylosis) is a complete excision or removal of the joint and adjacent broken bones. This leaves the patient with a flail-joint, but generally with a strong and serviceable arm. Another method of operating is that advocated by J. B. Murphy, who constructs a new joint by separating the fused and adherent fragments of bone, and then interposing between them strips of fascia turned down from the arm, from which fascia it comes about that there develop new joint surfaces resembling synovial surfaces. Sometimes the joints thus formed are but little inferior to normal joints.

Fractures of the Bones of the Forearm

These fractures are both complete and incomplete—green-stick fractures of these bones are not uncommon in children. Whatever the nature of the break, the arm cannot be used without pain. There may be considerable bowing and deformity, or the deformity may be slight. There is usually some shortening, and the arm hangs flaccid

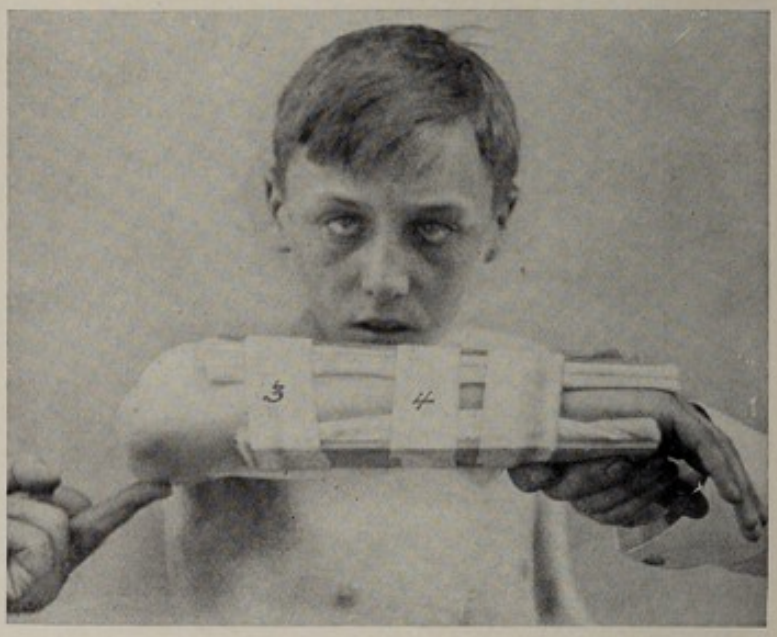

Fig. 575.—Fracture of both bones of the forearm. Ulnar view of the anterior and posterior splints. Note length of splints and position of straps. Straps of the internal right-angled splint, 3 and 4 (Scudder).

and useless. The fracture is generally either in the middle or lower third of the forearm, while if *both* bones be fractured, the break in the ulna is somewhat lower than is the break in the radius. Crepitus is usually obvious except when the fracture is of the green-stick variety.

The *treatment* of fractures of both bones of the forearm is more difficult than at first would appear, because even after splints are applied the pull of the long muscles tends constantly to cause over-riding at the seat of fracture, with a consequent shortening. At the same time there is apt to result delayed union or non-union; while the displacement of the fragments narrows the interosseous space and

may result in a fusing together even of all four of the fragments; so that subsequent rotation of the arm becomes impossible, and the usefulness of that limb is greatly impaired.

Green-stick fractures cannot be straightened successfully. Such fractures must be made complete fractures by the surgeon, who accomplishes this by bending the arm in the direction of the original breaking force.

For fractures of both bones of the forearm we may use a plaster-of-Paris bandage or anterior and posterior splints. Commonly, the patient should be anesthetized, and painstaking care must be employed to insure perfect bone apposition through traction upon the lower fragments. The arm should be put up in a supinated position, as

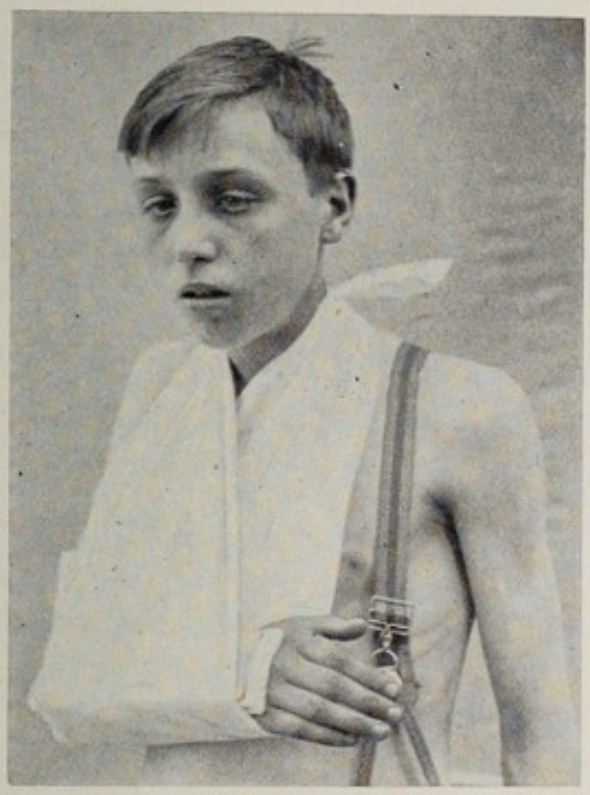

Fig. 576.—Fracture of both bones of the forearm. Proper position of arm in sling. Note hand is unsupported by sling and arm rests on ulnar side. Notice height of arm (Scudder).

thus the greatest space between the bones is maintained. In order to secure a proper fixing of the fragments in one of these fractures the adjacent joints also must be immobilized—the elbow by an internal angular splint or by plaster, and the wrist by anterior and posterior splints or by plaster. I prefer to use the right-angled and wooden splints for the first ten days after the injury. Such splints can be removed more readily for inspection of the arm than can plaster-of-Paris splints. The healing of properly treated bones of the forearm is rapid. Adult bones are sound in about four weeks. The bones of children are often sound in two weeks; but children should not then be released from splints, for they may refracture their bones at the seat of the fresh union.

A fracture of the shaft of *one* of the forearm bones only is easily treated, and on lines laid down in the preceding paragraphs. When one bone only is broken, its intact fellow serves as an additional splint.

Non-union of bones of the forearm is fairly common.

Fracture of the head and neck of the radius is recognized to-day as a not infrequent injury. The *x*-ray shows it, though it is obscure to the surgeon's touch. Fracture of the head alone is intracapsular. The fragments may remain in place, or may be crowded into a remote part of the joint, where they must be sought and removed with difficulty through operation by the open method.

Treat this fracture of the radius head, if simple and not complicated, by fixation in a right-angled splint, and look for prompt union with a useful joint.

Fracture of the coronoid process of the ulna is associated with a backward dislocation of the ulna, and is rare. Suspect the presence of this fracture in every case of dislocation backward of the elbow, and confirm the diagnosis by the *x*-ray. This coronoid fracture may prove extremely troublesome. If the displacement be slight, the position good, and flexion satisfactory, we may look for prompt union and a useful elbow through the employment of the right-angled splint. If there be considerable displacement and locking of the joint by the fragment, we must open down upon the bone and remove the fragment.

COLLES' FRACTURE

Colles' fracture was described first by Abram Colles more than one hundred years ago. The fracture of which Colles wrote was a fracture of the radius within an inch and a half of its lower end—a fracture loose

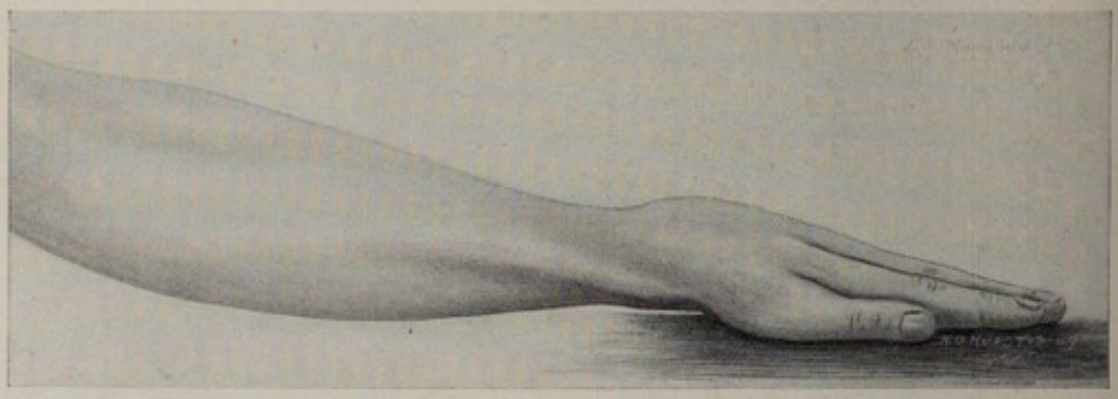

Fig. 577.—Colles' fracture. Note "silver-fork" deformity.

or impacted, and characterized by the so-called silver-fork deformity. It must not be confounded with the Barton fracture, in which case the deformity is the reverse of the Colles, the forearm bones riding over the carpus instead of under the carpus, as in Colles' fracture.

Of recent years a variety of fractures concerned with the bones of the carpus have been studied—fractures which, before the day of the *x*-ray, frequently were mistaken for Colles' fractures. As Scudder insists,

in all cases of damage to the wrist the surgeon should first study carefully the uninjured wrist, that he may compare it with its damaged fellow. We must remember that normally, when viewing the wrist from the front, we see the base of the thenar eminence to be lower than the base of the hypothenar. Normally, the styloid process of the ulna is obvious with the marked depression below it; while on the radial side one observes the backward curve of the radial shaft from the



Fig. 578.—Colles' fracture. Crowding the fragments together for diagnosis.

point where the radial styloid joins the shaft. One should put the patient through the normal movements of the hands, wrist, and arm, flexion, extension, and rotation.

Then we observe the abnormalities of the damaged arm; the wrist appears unnatural; in extreme cases we may see at once the familiar silver-fork deformity; the thenar eminence is higher and nearer to the wrist than normal. The whole hand is somewhat abducted and the styloid process of the radius is no longer found on a level lower than

the styloid of the ulna, but at the same level or at a higher level even. Sometimes the ulnar styloid is fractured, in which case the relation of these two points appears normal.

One may often elicit pain by palpating the end of the radius. In case of a doubtful fracture an excellent test is to seize the patient's hand, and, while supporting his arm above, to crowd the hand gently

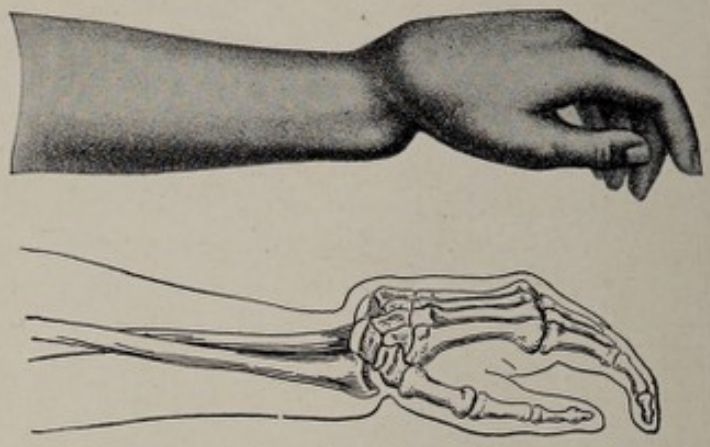

Fig. 579.—Dorsal dislocation of the wrist. Note deformity at wrist-joint—neither above nor below it (after Helferich) (Scudder).

upward. This invariably will bring out a point of pain near the lower end of the radius if a fracture exists. If there be a sprain merely, this crowding upward of the hand gives relief rather than pain. In Colles' fracture the fragments may be impacted or may be loose; and the exact condition of the radius, as well as of the other bones about the wrist, is faithfully demonstrated by the *x*-ray.

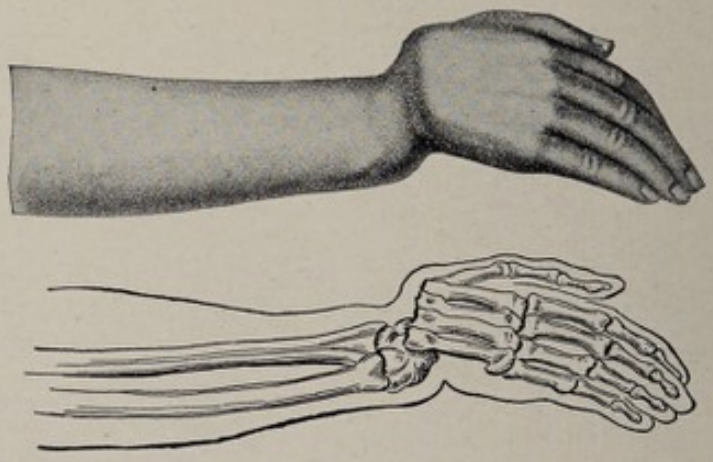

Fig. 580.—Dorsal dislocation of the hand at carpometacarpal joints. Note deformity below wrist (after Helferich) (Scudder).

Dislocation of the wrist must not be mistaken for a Colles fracture. A fracture of both the forearm bones near the wrist appears as an exaggerated Colles', but the crepitus of the two bones readily is discovered. In persons under twenty-one years of age separation of the lower epiphysis of the radius simulates a Colles fracture. The damage

is less grave generally than is a Colles fracture, although the treatment of the two conditions may be similar.[1]

The **treatment of Colles' fracture** has been a subject of interest and controversy for one hundred years. A broken wrist is a serious



Fig. 581.—E. M. Moore's dressing for Colles' fracture.

matter, for though the bones may unite well, they may not unite accurately, so that the resulting malunion causes stiffness of the wrist, inter-



Fig. 582.—Reduction of Colles' fracture. Note position of hands in forcibly hyperextending the lower fragment; breaking up impaction (Scudder).

ference with the motions of the tendons and joint surfaces, and a distressing and permanent crippling of the hand. One's endeavor then is

[1] E. M. Moore taught correctly, forty years ago, that a displaced radial epiphysis, after reduction, is successfully and easily treated by wrapping a single two-inch strip of adhesive plaster about the wrist—not overlapping it on the ulnar side; the arm is then supported in a narrow sling bandage. The hand naturally falls toward the ulna, and maintains the bones in position. I have employed Moore's method with satisfaction.

carefully to reduce the fracture, *breaking up the impaction* if one exists, to secure the fragments properly immobilized, and finally—a matter of the greatest importance—to relieve the hand of the confining splints at the earliest possible moment consistent with fixation of the fragments. We anesthetize the patient; we drag down the hand, turning it slightly into abduction (or ulnar flexion), carefully mold the bones into position, and fix the parts firmly in two splints, as the figure illustrates.



Fig. 583.—Reduction of Colles' fracture. Note grasp upon forearm and the lower fragment of the radius, traction and countertraction being made; breaking up the impaction (Scudder).

An interesting and important consideration in the treatment of Colles' fracture is the care of the hand during the two or three weeks of convalescence. Union is almost always prompt, and displacement of the fragments after a week is extremely improbable. For this reason we may begin early the gradual removal of splints, lightening the apparatus and employing massage. After one week I get rid of the

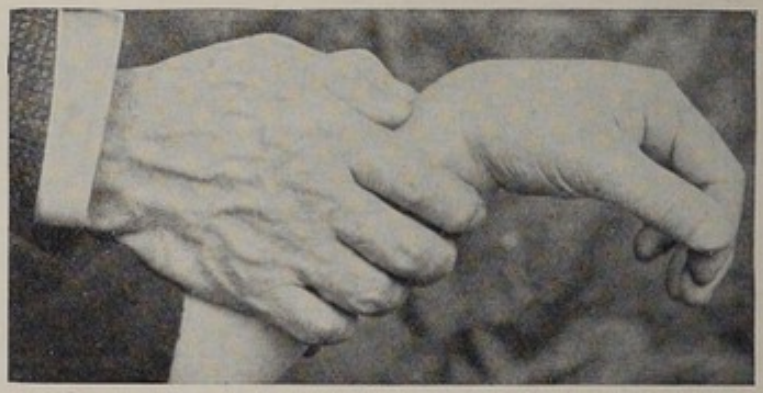

Fig. 584.—Reduction of Colles' fracture. Note position of the thumbs and fingers. Lower fragment is pushed into place, while counterpressure is made by the fingers upon the upper fragment (Scudder).

anterior splint, and hold the hand in a single posterior splint during the second week. At the end of this fortnight the posterior splint is removed, and a short dorsal splint, with an anterior pad, is secured upon the wrist, which is hung in a narrow sling. This splint in turn may generally be renewed at the end of the third week, when systematic, skilful daily massage of the arm, elbow, wrist, and hand is begun, and

is continued until the patient's strength is restored. We encourage a normal use of the released fingers in the second week, or as soon as the first heavy dressing is removed.

Old Colles' fractures, neglected and badly united, offer a serious problem to the surgeon. If the patient be young and vigorous, an operation may give him a useful hand. If the patient be old and the

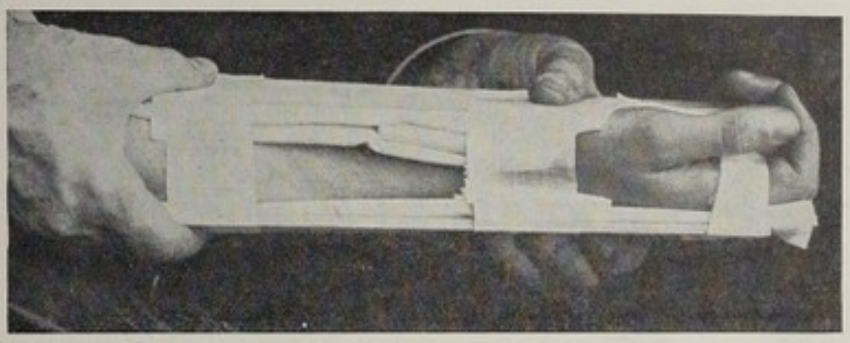

Fig. 585.—Fracture of the forearm near the wrist-joint. Notice wrinkles in the straps. The straps are loose from the pressure of the two splints together. Thus is illustrated the fact that the straps should retain splints in position without exerting much pressure (Scudder).

injury of long standing, we may be able to do little more than relieve the pain and correct deformity. H. A. Lothrop describes a useful operative technic:[1] Approach the damaged bone from the radial side and isolate the soft parts; with a small drill perforate the bone at several points in the line of union, and complete the new fracture with a chisel. Then trim off the fragments and approximate them carefully. If the ulna is so long as to interfere with correction of the deformity,

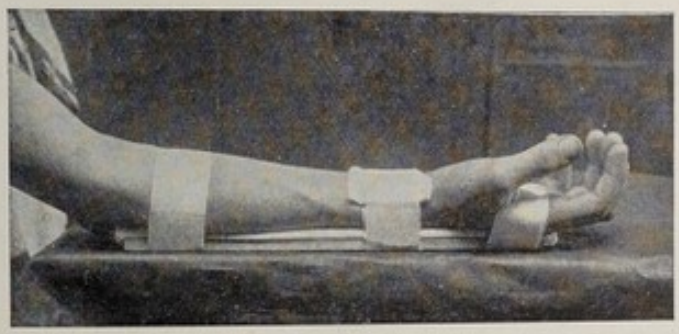

Fig. 586.—Posterior splint, three straps, and pad at the seat of fracture. Note comfortable position of forearm and hand (Scudder).

that bone may be shortened by excising a small section about two inches from the joint. Then reduce and fix the fragments in the usual manner after having closed the wound, and treat the case as an ordinary fracture of both bones of the wrist.

Fractures of the Carpus

Fractures of the carpus are frequently mistaken for sprained wrist or for Colles' fractures even. Now that we have the *x*-ray, such mis-

[1] Quoted by C. L. Scudder, ibid.

takes should never be made. Damage to the carpus occurs commonly from a fall upon the extended hand. It may be that some of the smaller bones of the carpus thus become dislocated, but the common carpal injury is a fracture of the scaphoid. Our *x*-ray tracing shows how the scaphoid lies against the articulating surface of the radius, and thus takes the weight of the body in the case of a fall.

Surgeons see two types of scaphoid fracture—the acute and the chronic type. The acute fracture causes pain and tenderness in the wrist, over the scaphoid, together with swelling, spasm, and a loss of function. If we ascertain the nature of the damage at once, we may correct it by fixing the hand in a splint for two or three weeks; and we follow up this treatment by active and passive movements and by massage.

The chronic cases are brought to the surgeon because of a long-standing weakness of the patient's wrist and pain when his hand is

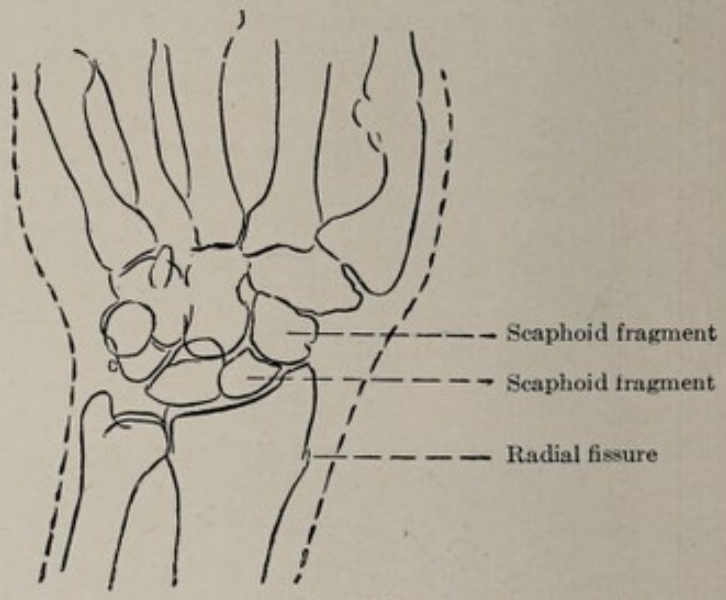

Fig. 587.—Case: Fracture of the scaphoid and fissure of radius (*x*-ray tracing) (Balch) (Scudder).

overextended. In such cases one finds the wrist movements to be limited, and spasm to be present in the extreme of motion. There are swelling on the radial side and tenderness over the scaphoid, while the *x*-ray discovers a fracture, usually transverse, across the bone.

E. A. Codman has worked out the proper *treatment* for these cases. If rest and massage do not improve the condition, cut down upon the scaphoid from behind and remove the smaller fragments of bone. One should not remove the whole bone if such removal can be avoided, for loss of the whole scaphoid leaves the wrist permanently weak.

Fracture of the Metacarpal Bones

The third and fourth metacarpal bones are the metacarpals commonly broken, and they are broken by indirect violence usually, a

blow upon the knuckles, such as may happen through a straight thrust in sparring. There is a characteristic deformity, as the photographs show. The dorsum of the hand is swollen, and the knuckle of the damaged bone is sunken, while the end of the lower fragment often

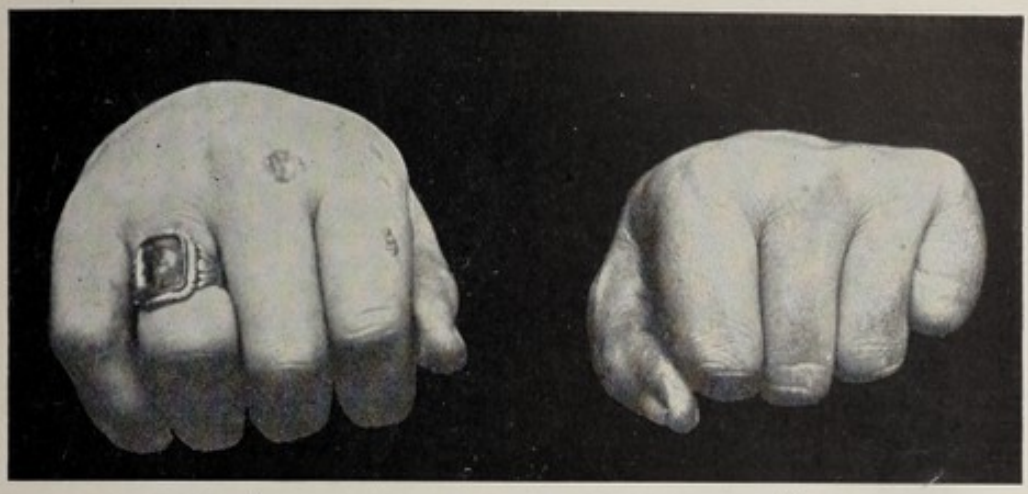

A B

Fig. 588.—A, Fracture of neck of fourth metacarpal bone. Swelling of finger and knuckle. Knuckle has dropped downward toward the palm. B, Normal hand. Line of knuckles shown. Contrast with A (Scudder).

can be felt in the palm, and there is pain, with crepitus. Do not mistake this injury for a dislocation.

It is not always easy successfully to *treat* a fractured metacarpal. We reduce the fracture by traction and pressure, and support the hand and forearm upon an anterior splint, with a pad in the palm of

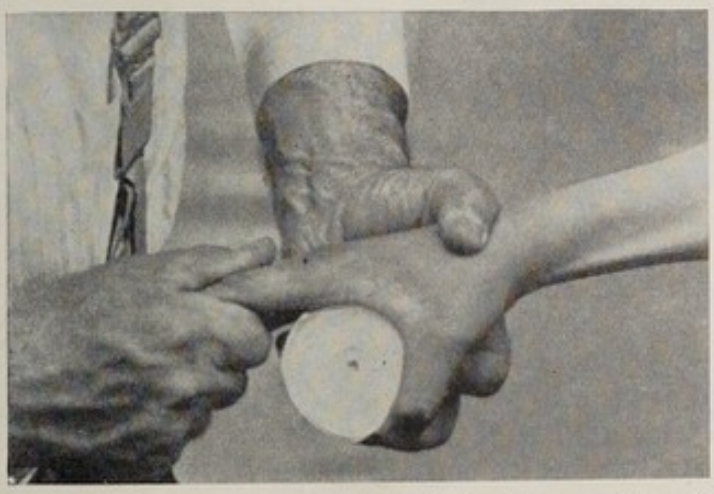

Fig. 589.—Fracture of the metacarpal of the index-finger. Use of roller bandage. Position of roller bandage. Method of traction and countertraction (Scudder).

the hand and a pad over the dorsum. If this apparatus does not hold the fragments in position it may be well to employ a simple traction apparatus with adhesive straps and rubber tubing, as the cut illustrates. Fracture of the second metacarpal may be well treated by binding the finger over a roller bandage.

Bennett's Fracture.[1]—In 1881 E. H. Bennett, of Dublin, described a peculiar fracture of the metacarpal of the thumb.

This fracture has come to be known as "stave" of the thumb. It is a fracture of the proximal end of the bone; oblique and into the trapezium joint. The metacarpal bone is displaced backward, and



Fig. 590.—Fracture of the neck of the second metacarpal. Method of securing extension. Note adhesive plaster, rubber tubing, peg, padding to finger, pad over proximal fragment. Counterextension by adhesive plaster about wrist. Ready for the application of a bandage (Scudder).

the fracture may well be mistaken for a dislocation at this joint. Sometimes the fracture through the bone is transverse merely and does not open the joint. For such a simple case any immobilizing apparatus will suffice. Samuel Robinson describes a useful device for correcting

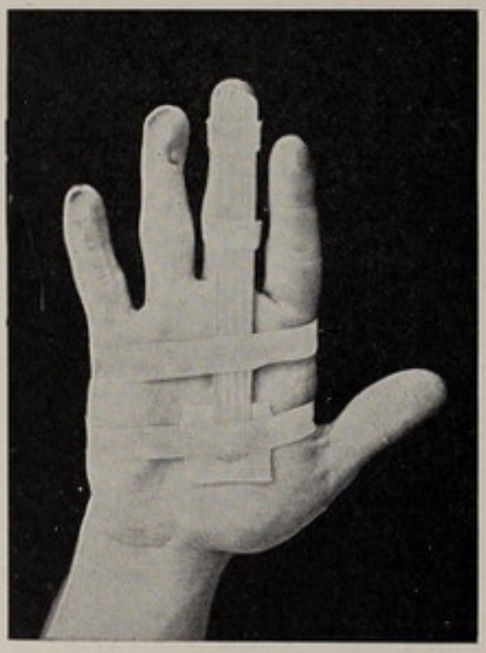

Fig. 591.—Fracture of the finger. Wooden splint applied to the palmar surface. Note straps and length of splint (Scudder).

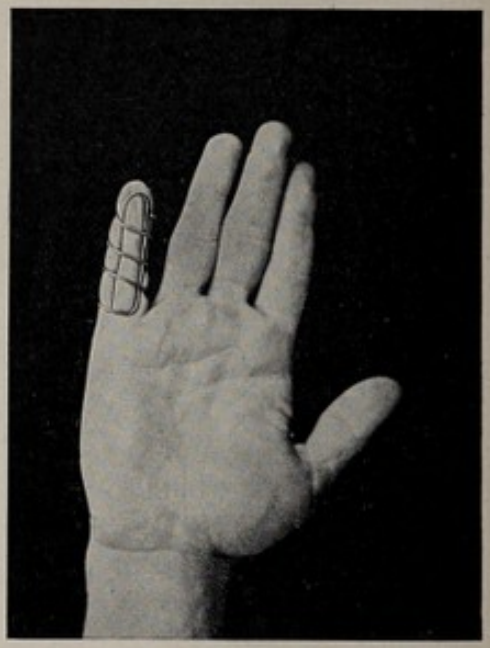

Fig. 592.—Finger splint of copper wire applied (Scudder).

and holding the worst form of the Bennett fracture—an apparatus of plaster of Paris, combined with extension and side splints. The apparatus should remain in place for about two weeks.

[1] Samuel Robinson, The Bennett Fracture of the First Metacarpal Bone. Diagnosis and Treatment, Boston Med. and Surg. Jour., February, 27, 1908.

Phalanges

Fracture of the phalanges is so apparent that it scarcely needs description; though occasionally the fracture may be a mere crack, when the *x*-ray alone can demonstrate it. Ordinarily, however, the bones, lying close under the skin, may easily be palpated.

In the *treatment* of these phalanx fractures one must take every pains to see that the delicate and important mechanism of the fingers be not seriously disturbed. A perfect alignment of the fragments must be maintained, and, as Scudder says, rotation of the lower fragments upon its long axis must be guarded against. In case of great swelling a temporary dressing upon a long palmar splint will suffice, but when the swelling has subsided the surgeon must apply carefully a small

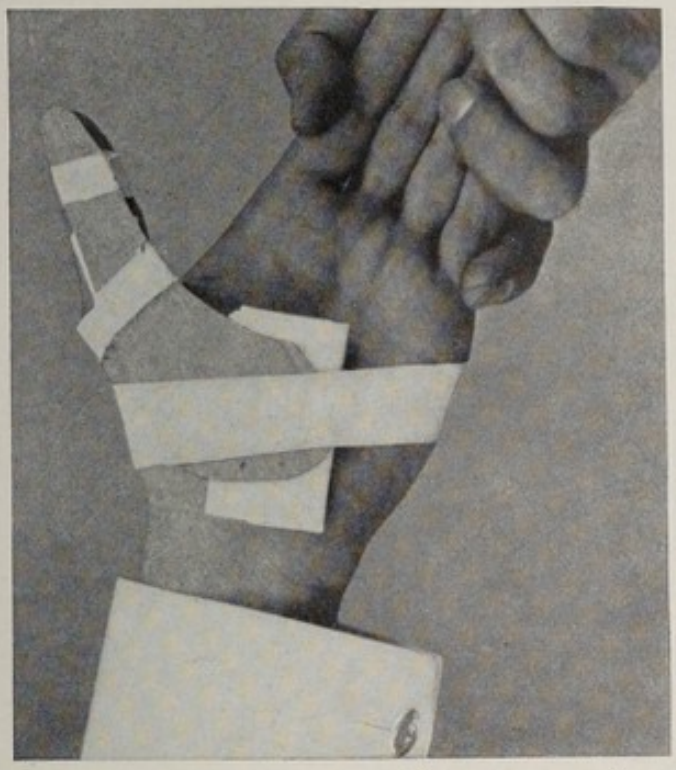

Fig. 593.—Palmar wooden thumb splint Note shape, pads, straps, position (Scudder).

well-fitting splint of tin or wood. Fractured phalanges unite in two or three weeks.

Compound fractures of the phalanges sometimes become infected and lead to extensive suppuration with destruction of bones. Healing eventually will take place under antiseptic dressings and splinting, but the affected finger will almost surely be stiff. In such a case a patient may choose to have his finger amputated.

Femur

Fractures of the femur are various in character and in location, and are difficult of treatment. Fracture of the femur is the *pons asinorum* of the surgical tyro. The complicated upper end of the

femur is the part most frequently broken, while its close relationship to the hip-joint renders its proper treatment essential, if permanent crippling is to be avoided.

We must recall certain lines, angles, and triangles which are useful in studying damage to the upper end of this bone. These lines are illustrated by the figures. Nèlaton's line especially is useful. We determine it by stretching a tape from the anterior-superior spine of the ilium to the tuberosity of the ischium. Normally the top of the great trochanter lies just below this line about opposite to the symphysis pubis. The internal condyle of the femur looks in the same general direction as the head and neck of the femur. We determine the relative length of the legs by measuring from the anterior-superior spine of the ilium to the tip of the malleolus of the tibia.



Fig. 594.—Femur; head and neck. Note structure.

Fracture of the *neck of the femur* is an extremely important type of injury. It occurs most often in elderly persons, though it may be found at any age. In the old it may occur without any obvious traumatism—indeed it is probable that the delicate shell of bone in the neck of an ancient femur may be broken by the mere weight of the patient's body, by a slight twist, or by a trifling fall. Fracture of the neck of the femur may be loose; or may be solidly impacted, with a slight resultant shortening of the whole leg. The fracture may be within or without the capsule, but that is of extremely small importance as compared with the question of impaction. Impacted fractures unite rapidly. Unimpacted fractures may never unite.

A patient the victim of fracture of the neck of the femur lies upon the ground helpless and in a characteristic attitude—the foot *everted*, the leg rolled outward. There is a slight fulness in the upper part of Scarpa's triangle; there is always slight shortening, which may be as much as two inches after the lapse of three or four days. The great trochanter is above Nélaton's line.

If the fracture be loose, one feels crepitus. Never break up an impacted fracture in order to produce crepitus. In rare cases of impaction of the anterior portion of the neck, *inversion* of the foot takes place. Eversion is the common position. In all cases of impacted fracture with permanent rotation of the foot the surgeon must assure himself that a *dislocation* is not present. On such symptoms and signs as I have named one establishes the diagnosis of fractured neck of the femur, remembering always that he must not manipulate the joint and handle the leg in a prolonged search for crepitus.

Bryant's well-known method of measurement is useful: With the

patient lying on his back and the limbs equally outstretched, mark upon the skin the tip of the trochanter, draw a perpendicular line from the anterior-superior spine to the bed on which the patient is lying, and stretch a line from the trochanter to this perpendicular. If there is fracture of the neck of the femur this last line will be shorter on the affected side than on the sound side.

The *course* and the *outlook* in the case of a fractured neck of the femur vary greatly—depending largely on the age, the vigor, and the general condition of the patient. Feeble old persons with this injury fre-

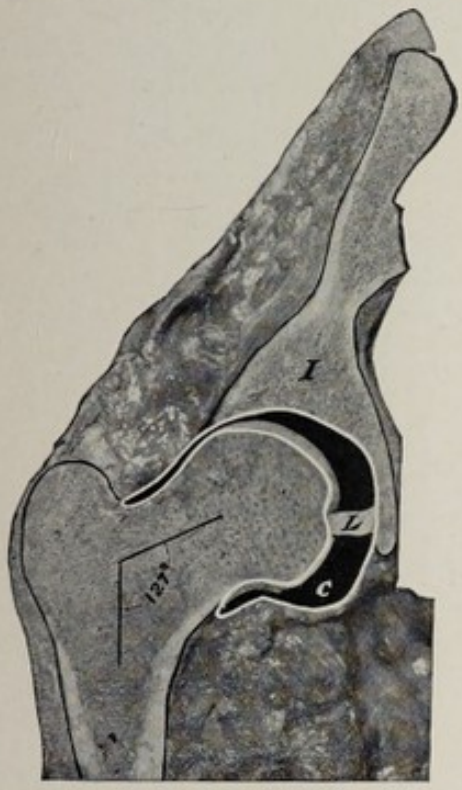

Fig. 595.—Vertical section of hip-joint, seen from behind. The angle which the head under normal conditions forms with the shaft (127 degrees) is marked out: *I*, Rim of acetabulum in vertical section; *C*, cavity of joint (exaggerated), showing the extent of the joint capsule; *L*, ligamentum teres (Eisendrath). (Scudder.)

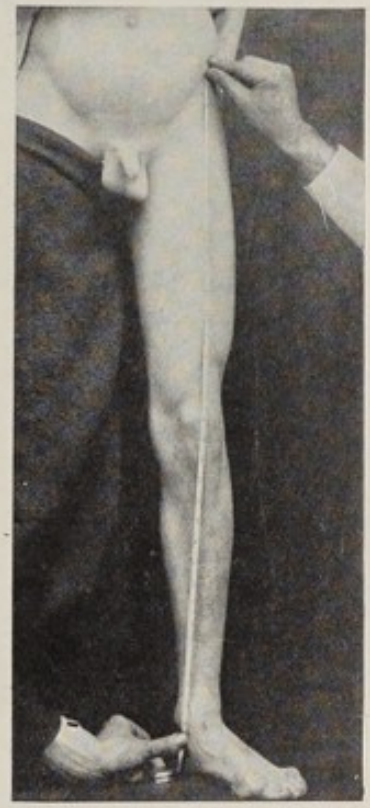

Fig. 596.—Measurement of lower extremity. Patient lying on the back looked at from above. Position of tape, hands, and limbs to be noted (Scudder).

quently die from the shock, or from the confinement to bed,—being carried off in the latter case by hypostatic pneumonia. Our rule, therefore, is to have old patients sit up as much as possible, in bed or in a chair, fixing the fracture in plaster if the fragments be loose; while if the fracture be impacted no fixation apparatus is required frequently. The bones of the impacted cases always unite, but in the case of loose fractures permanent non-union even is not inconsistent with a useful leg, especially if the patient be provided with a proper ambulatory apparatus.

The treatment of "fractured hip" deserves some further con-

sideration than we have given it in the preceding paragraphs. We recognize four methods of treatment in use at the present time: (*a*) The method of traction and countertraction, by weight and pulley and elevation of the foot of the bed, together with lateral traction when such traction is indicated; (*b*) the Thomas hip splint, with or without traction; (*c*) forcible abduction and fixation by plaster of Paris, with or without continuous traction; (*d*) the method of pegging.

(*a*) The traction method must be employed with the patient upon a proper surgical bed, a firm and narrow mattress. Rest his knee upon a pillow, fasten extension strips of adhesive plaster from his ankle to the hip; hang a five-pound weight over a pulley upon the extension strips; rotate the foot into a normal position, and raise the foot of the bed about 6 inches so that the patient shall not slide down

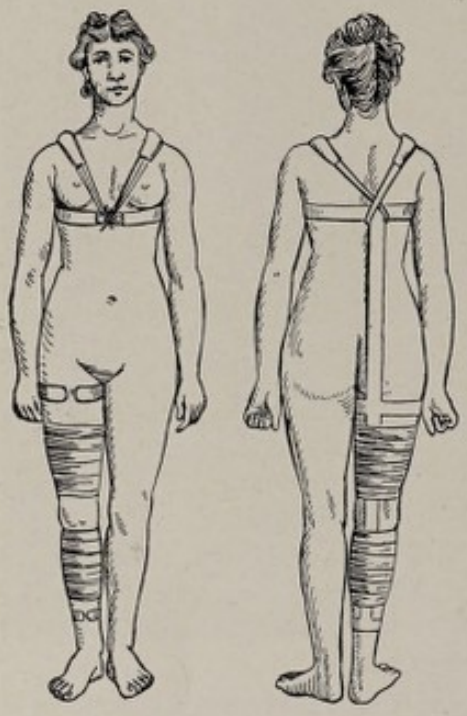

Fig. 597.—Thomas' single hip-splint in position (Ridlon).

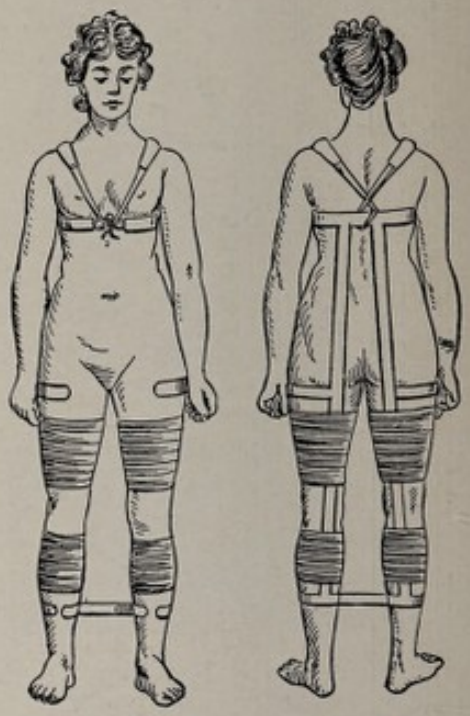

Fig. 598.—Thomas' double hip-splint in position (Ridlon).

under the traction of the pulley; steady the whole leg with long heavy sand-bags, and protect the heel, with a proper ring or other support, from undue pressure.

(*b*) The Thomas hip splint has been a favorite with a few surgeons who claim for it excellent results. I reproduce here the figures of Ridlon [1] and refer the reader to his article, or to the admirable description given by Scudder in his book on Fractures.[2]

(*c*) Forcible abduction and immobilization with or without traction is known as Whitman's method, and purposes to bring the bone fragments together and to hold them in the normal position, with restoration of the proper *angle* between the shaft and the neck of the bone.

[1] Transactions of American Orthopedic Association, 1887.
[2] C. L. Scudder, ibid., p. 342.

This method is applicable especially to the cases of young persons in whom the *angle* is far more obtuse than it is in old persons.

The patient is anesthetized, while his pelvis is supported by a block on the table. The injured limb is then abducted through 45 degrees so that the fragments lie in a normal relation to each other. A plaster-of-Paris spica bandage is applied to the pelvis and thigh (including the foot in young persons). Sometimes we must flex the thigh in order more perfectly to reduce the fragments. "Traction, abduction, flexion, lifting the trochanter forward (to prevent sagging), rotation (to correct abnormal eversion or inversion of the foot), immobilization, these are the steps of the procedure."

We employ Whitman's treatment in selected cases and we keep the plaster spica in place for about eight weeks. The weight of the body should not be allowed to fall upon the hip for many weeks thereafter, the leg meanwhile being supported in a Taylor hip splint, and the patient using crutches.



Fig. 599.—Illustrates the restoration of the normal angle by forcible abduction (Whitman).

Whitman's method is logical and extremely attractive, and deserves a wider application.

(*d*) The so-called pegging method[1] is a method of secondary resort only. In proper cases it is an extremely valuable procedure, but its field of usefulness is limited. In general terms we employ it in sound adults with fracture of the neck of the femur when apposition of the fragments is shown by the *x*-ray to be so faulty as not to permit of proper union.

In **old ununited fractures** of the hip also we may employ the pegging method. An ivory peg or, better, a coin-silver nail is driven through the great trochanter and through the long axis of the neck of the bone. In the case of an ununited fracture it is well to open the joint and to peg the fragments in plain view. The best incision is a straight one on the outer side of the great trochanter. We may leave the peg permanently, or may remove it at the end of a month. The best dressing for a pegged hip is the plaster-of-Paris spica.

The following rules for pegging will be found satisfactory: The affected leg is adducted; a four-inch nail is entered one-half inch from the anterior edges, and two finger-breadths from the top of the great trochanter. It is directed upward and inward, making an angle of about 70 degrees with the shaft of the bone, and is driven into the loose head. One should take a skiagraph of the joint after the pegging.

Fracture of the neck of the femur in children has been discussed

[1] See H. Augustus Wilson, Treatment of Ununited Fractures of the Neck of the Femur by the Use of Coin-silver Nails, Amer. Jour. Orthop. Surg., January, 1908.

recently by a number of writers, especially by Whitman. This fracture, which is properly an epiphyseal separation, is especially important on account of its apparent insignificance, and because frequently it goes unrecognized. It results commonly from a fall on the foot, and causes a slight shortening of the leg, with a little outward rotation and

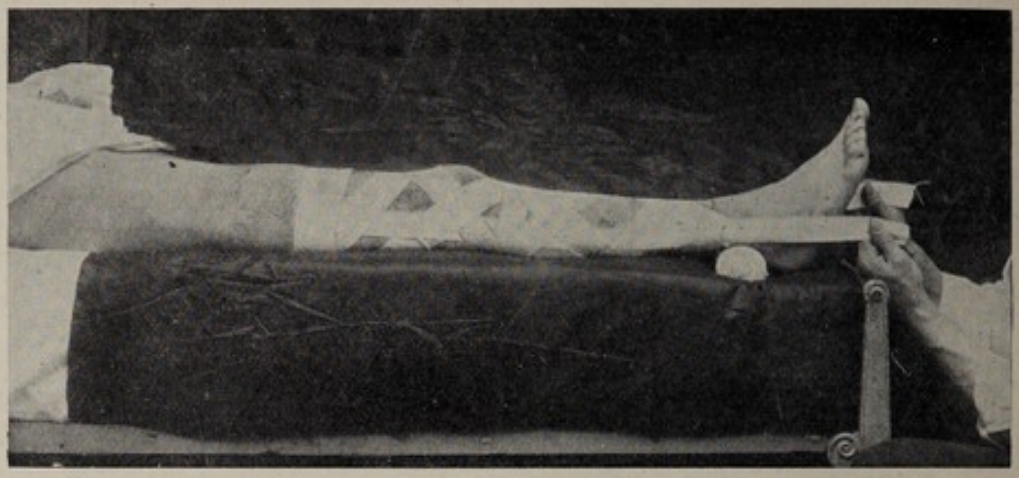

Fig. 600.—Fracture of the thigh. Adhesive-plaster extension strips; long, upright, circular, and obliquely applied strips (Scudder).

a tendency to limp. The child recovers with some lameness, but years afterward may develop a coxa vara.

In dealing with a child the surgeon must distinguish (by the *x*-ray) a true hip fracture from hip disease; and treat the fracture by fixation and abduction in a plaster splint.

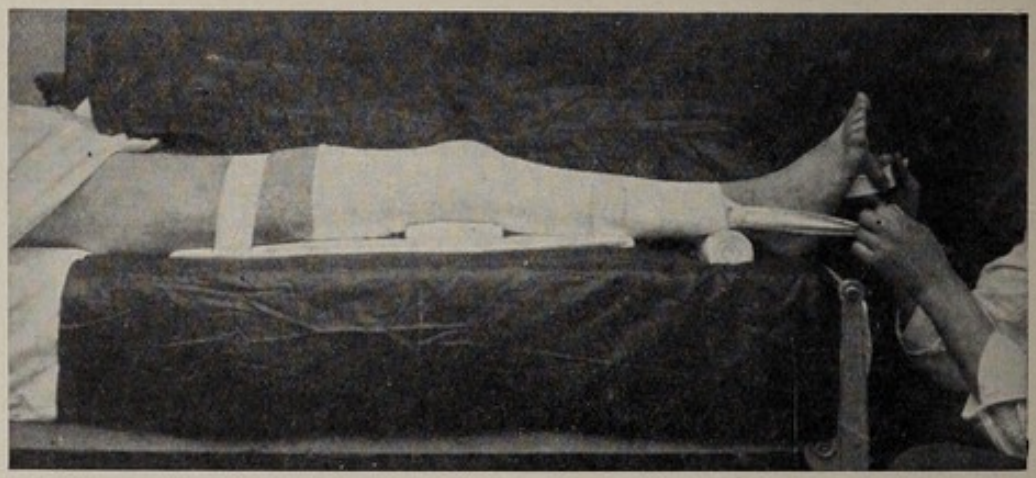

Fig. 601.—Fracture of the thigh. Extension strips applied, covered by bandage. Ham-splint applied; two straps and pad in ham (Scudder).

Fracture of the shaft of the femur is the fracture of this bone next in importance to fracture of the neck of the femur. These shaft fractures are generally oblique, and occur in three favorite locations: (1) Just below the lesser trochanter; (2) at the center of the shaft, and (3) above the condyles. Such fractures are always due to great violence, the shaft of the femur being extremely resistant, so that extensive

damage to the soft parts often is caused even when the fracture is not compound.

You will find the patient with a fractured femoral shaft lying helpless, often in shock and pain; the leg rolled inward or outward, and the thigh deformed by a marked swelling, while crepitus is apparent. The surgeon should measure such a leg to determine its shortening relative to the shortening of the sound leg. Measure from the anterior-superior spine to the tip of the internal malleolus.

To the student familiar with gross anatomy, or to the unlearned observer even, it must seem incredible that a fractured femoral shaft could be treated by a graduate in medicine, with the result of a striking deformity and serious shortening of the leg; yet I have been a witness in an entirely justifiable law-suit brought against a reputable physician who treated for three months a fractured femur in a child of six years, with the result that the femur was allowed to unite at a right angle

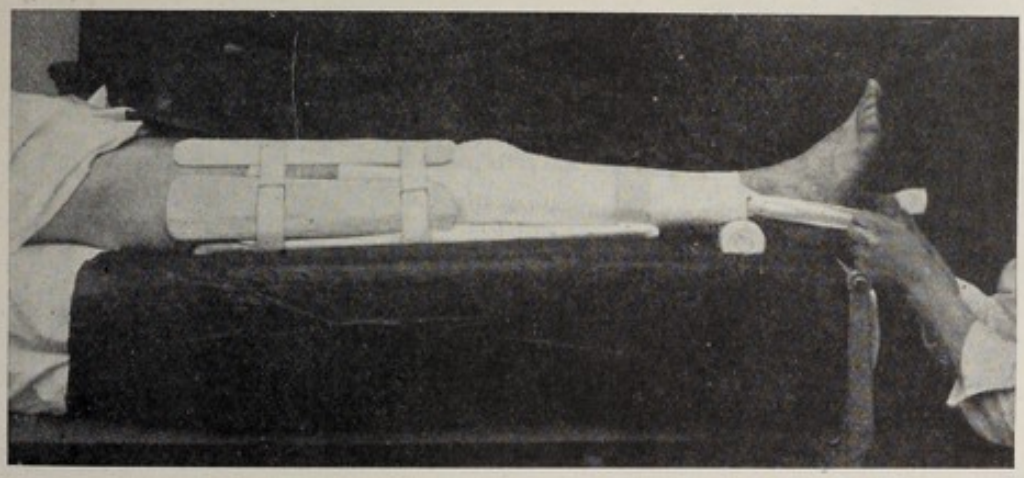

Fig. 602.—Fracture of the thigh. Extension strips applied. Cotton bandage. Ham-splint, straps, pad, and coaptation splints about the seat of fracture. Straps and buckles (Scudder).

and with marked shortening, while the child walked with an ugly limp. Fractures of the femur are not easy to treat. They call for constant inspection, frequent measurements, the reapplication of apparatus, and *x*-ray studies.

The *treatment* of fractures of the shaft of the femur is a subject more or less open to discussion. There are those who maintain that the best treatment is by abduction, extension, and immobilization in a plaster-of-Paris spica extending from the toes to the spine of the ilium. I do not feel that this is a proper dressing for a fracture of the shaft in the case of an adult. Sometimes it may do in the case of a restless and intractable child. Fractures of the femoral shaft are extremely difficult of coaptation and of proper immobilization. For this reason such fractures should be dressed in an apparatus which will permit of frequent inspection and the correction of displacements. The familiar Buck's extension with coaptation splints on the thigh, posterior ham-splint, and a long outside splint, is the apparatus which

meets the necessities of the case. The coaptation splints are such as I have already described. They are shown in the accompanying figure. The ham-splint should be carefully adapted to the length of the leg and to its curves, and should be heavily padded. The long outside splint should reach from the axilla to immediately below the ankle, while the internal splint should reach from the perineum to just below the ankle. The illustration shows the appearance of this apparatus and its application.

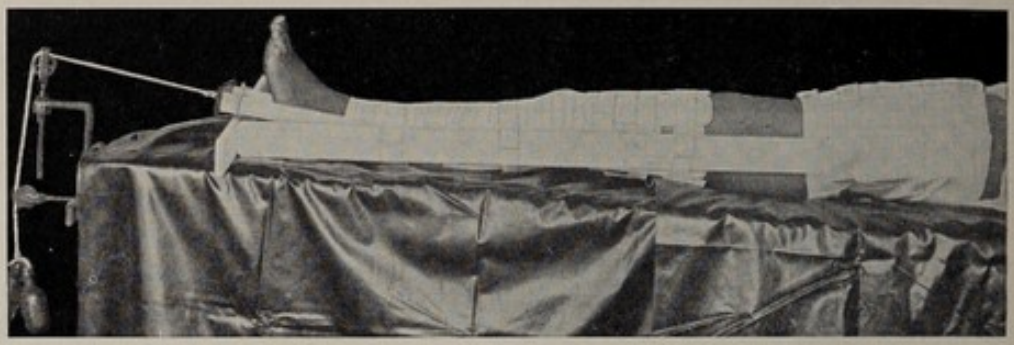

Fig. 603.—Fracture of the thigh. Completed apparatus, as in Fig. 602, and in addition a long outside T-splint, straps, and swathe. Weights applied (Scudder).

The most important feature of the dressing, however, is the extension. Extension straps are carried from one inch below the seat of the fracture out to a pulley, such as is figured in the text, and the foot of the bed is raised for counterextension, as in cases of fracture of the neck of the femur. "Buck's extension" is a convenient apparatus for the treatment of compound fractures, as well as for the treatment of simple

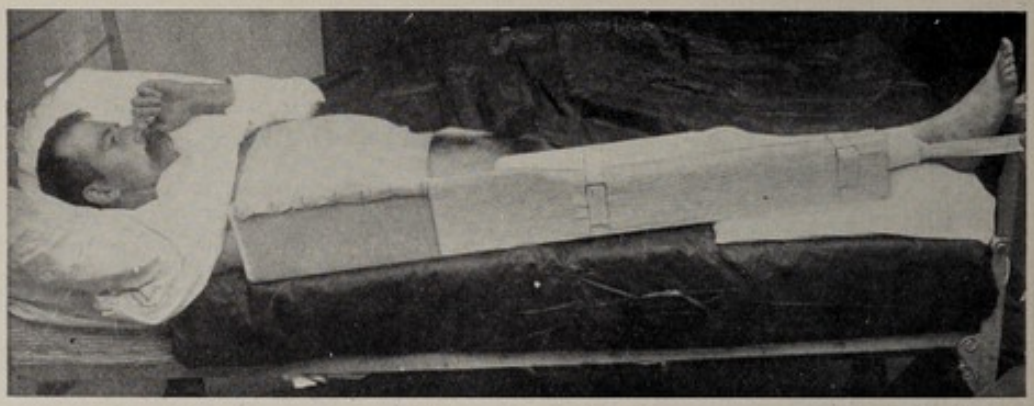

Fig. 604.—Fracture of the thigh. Completed apparatus with bed elevated. The outside splint is broad and without the T foot-piece. The swathe is very snugly applied (Scudder).

fractures. The complete reduction of the fragments is not always immediately possible by its use, but the surgeon will observe, during the first few days of convalescence, that the affected leg gradually becomes longer until, under proper conditions and with careful employment of the extension apparatus, the length of the two legs will often be found to vary not more than half an inch.

The surgeon must guard carefully against malunion of the fragments

through outward rotation of the leg and foot. This outward rotation is a detail of the treatment which must be seen to carefully. Frequently, at his morning visit, the house-surgeon will find the patient's foot turned outward and lying nearly flat upon the bed, being displayed to a right angle almost. Various methods are employed for correcting such a malposition. I reproduce here two sketches taken from Scudder. They demonstrate well the type of malposition to which I refer and a simple maneuver for its correction.

Supracondyloid fracture of the femur gives rise often to an awkward relation of the fragments, and frequently to a serious deformity in the leg, for the reason that the gastrocnemius muscle rolls backward the condyles of the femur, while the shaft fragment shoots forward toward the patella. This results in apposition of the smooth anterior surface of the lower fragment, with the fractured end of the upper fragment—a position which often prohibits absolutely a firm union.

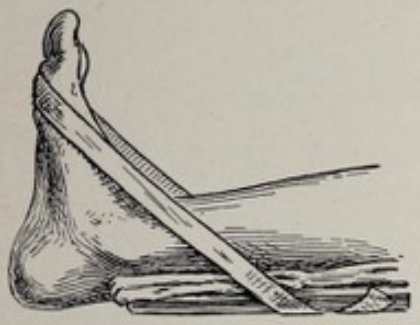

Fig. 605.—Form of stirrup to prevent the foot assuming an equinus position (Scudder).



Fig. 606.—Diagram of section of leg and splint to show how a strap carried from the back of the leg over the long side-splint can prevent eversion of the foot and leg (Scudder).

I have had admirable success, as have many others, in coaptating and immobilizing such fragments by placing the knee in the right-angled position. One may dress the leg in the old fracture-box arranged at a right angle, or, perhaps more conveniently, one may employ in these cases a firm plaster-of-Paris bandage. It is often well, however, to operate for the reduction of a supracondyloid fracture. If the leg were mine, I should choose the operation. The surgeon, when he operates, must search thoroughly for all fragments of bone; he must remove them from the loose spaces behind the knee; must do tenotomy, if necessary, upon the attachments of the gastrocnemius muscle, and must wire the long fragments in their proper position. After such an operation the leg may be held in an apparatus of open splints for a few days until the superficial wound be healed, after which the whole leg, from toes to crest of ilium, may be secured in a plaster-of-Paris dressing.

Fractures of the Thigh in Children.—At the Massachusetts General Hospital we have for many years dressed these fractures in a suspended position. This dressing is perfectly comfortable. The child lies upon a Bradford frame and has draped over him such appar-

atus as is figured in the text. The pulley exercises constant and proper extension; a certain amount of movement of the body is permissible, the child lies restfully, and the results of treatment are satisfactory.

The *prognosis* of all fractures of the shaft of the femur is somewhat dubious. We can, as a rule, promise the patient a useful leg; but we cannot justly promise him always a leg without deformity, or a leg free from a certain amount of stiffness and weakness. We should keep him under observation, if he be an adult, for six months at least, and for a year if possible, seeing to it constantly that he does not bear his weight upon the soft callus in his impatience to hasten convalescence.

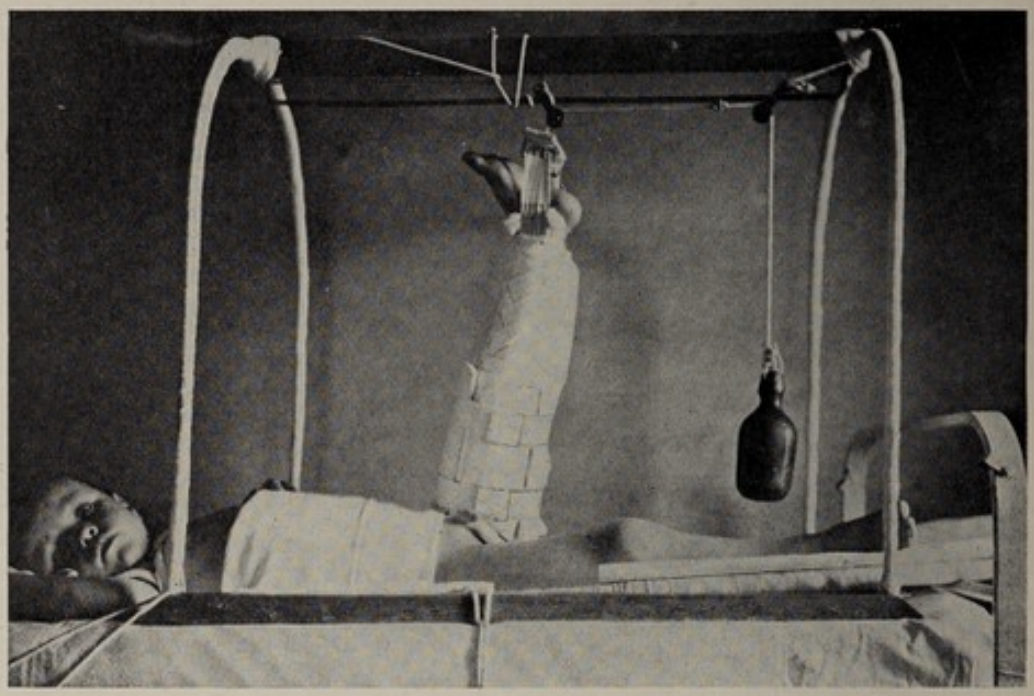

Fig. 607.—Fracture of the femur in a child. Note Bradford frame on which child rests; the position of the lower extremity. Shoulders and trunk of child held fixed by straps and swathe. Note coaptation splints, extension, weight, and pulley. A comfortable position for child. An efficient method of treatment (Scudder).

Children also must be kept for at least four months under observation; though the prognosis as regards deformity and function is generally good in their cases.

We pass now to another interesting fracture, the treatment of which has of late years provoked no little discussion.

Fracture of the Patella

A certain class of radical operators—not well advised, I believe—have asserted that in every case of fracture of the patella the surgeon, as soon as he sees the patient, should cut down upon the bone and should suture it. There are two elements in this argument which are dangerous and objectionable; the immediate operation on a recent fracture is followed by a high percentage of infections; while the indiscriminate operating upon all types of fracture of the patella is need-

less. Certain fractures of the patella show very little separation of fragments and heal promptly under conservative treatment.

We need not here discuss the intricate and interesting relations of the patella to the surrounding parts other than to remind the student that the patella lies entirely upon the articulating surface of the femur; that its lower border reaches as far as the head of the tibia in some cases, and never lies upon it; that the inferior surface of the patella is an articulating surface, and is formed of two facets separated by a marked ridge, and that while the patella is a sesamoid bone within the substance of the quadratus femoris tendon, it is not a bone essential to the extension of the leg, since the quadratus finds a broad insertion into the lower leg through its aponeurotic expansion entirely independent of the patella. Fracture of the patella involves always a fracture into the knee-joint.



Fig. 608.—Expectant method of treating fracture of the patella. Same as Fig. 615, with the addition of two lateral splints, padding, and straps (Scudder).

The patella, like other bones, is fractured by both direct and indirect violence. The fracture by *direct* violence is commonly characterized by a splintering of the bone alone—sometimes into two fragments, sometimes into half a dozen or more. The surrounding aponeurotic supports, however, are not torn in such cases of direct violence, so that the bone fragments remain in fair apposition. A fracture by *indirect* violence, on the contrary, as when a man falls from a height and lands on his feet with knees bent, is nearly always associated with extensive tearing of the soft parts in the neighborhood of the patella. In this case the violence results in wrenching the patella in two, but a comminution does not follow. The two fragments immediately become widely separated, and their approximation, without the surgeon's open incision, is almost impossible. In both direct and indirect violence fractures there is marked loss of power of extending the leg, but the loss of power is greater in the case of an indirect violence fracture than in the case of

a direct violence fracture. Without any treatment of the direct violence fracture the symptoms may subside, and a fair use of the leg may be restored, but it will always remain weak, with the kicking or extending force far below normal.

All fractures of the patella are associated with a collection of fluid in the knee-joint, for the parts about this bone are abundantly supplied with blood, which pours out into the damaged joint. There results a clot, bruising of the serosa, a copious serous effusion, and great swelling of the parts about the knee.

From what I have stated it must be obvious that the treatment of a patella fracture depends largely on the nature of the violence causing the fracture. In the case of a direct violence injury, with little separation of bone fragments, the surgeon may secure an admirable result, with firm union and a sound leg, by following the conservative method—that is, by supporting the leg in a ham-splint for at least six weeks, and by holding the fragments firmly in apposition by strapping them with surgeon's plaster. Obviously, this apparatus should not be applied until the primary and extensive swelling has subsided. When union has been fairly established, the patient's leg may be put up in a long plaster-of-Paris bandage reaching from the ankle to the groin, and he may then be allowed to go about upon crutches. At the end of eight or ten weeks from the time of the injury the stiff bandage should be removed, passive movements should be begun, and active massage should be employed until fair function has been restored to the leg.

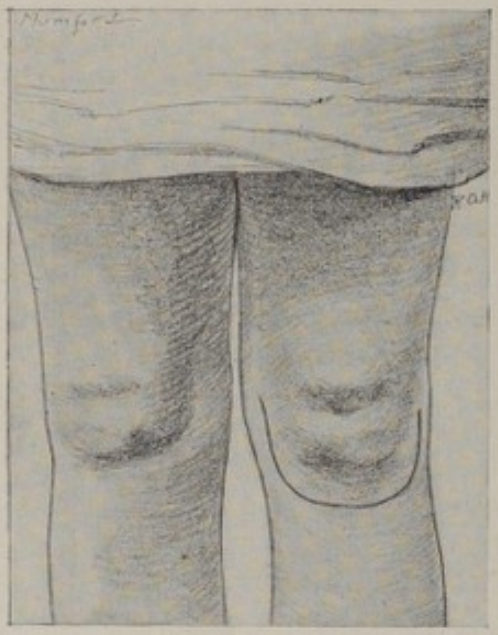

Fig. 609.—Sketch showing line of incision for operation on patella.

Unfortunately, the patella, once fractured, remains always somewhat weak, so that it is a frequent experience to see secondary fractures of this weakened bone.

Fractures of the patella by indirect violence, with wide separation and great effusion into the joint, call for operative treatment in case the patient is fairly vigorous and in condition to withstand the shock of an operation and the possibility of infection. Numerous statistics, especially those collected by the late Carleton P. Flint, of New York, have demonstrated that immediate primary operation, that is to say, operation within five days of the accident, is always inadvisable. Immediately after the accident the parts are peculiarly susceptible to infection. After five days, however, preferably about the tenth day, operative treatment of a fractured patella is reasonably free from risk.

The question of method in operating upon a fractured patella

has agitated the profession for a great many years, and a variety of plans and procedures are advocated by surgeons. Especially there are the champions of burying wire in the fragments, and there are those who advise suturing the bone with some absorbable material. It is needless in this place to elaborate this discussion.

An excellent practice, and one that I have followed with satisfaction, is as follows: Turn back a long crescentic skin-flap over the patella without opening the joint. Thus one removes the line of skin incision far from the field of operation, and by so much diminishes the opportunity for infection through the skin. Having exposed the aponeurosis over the patella, clean it carefully, dissect away the frayed and torn edges, expose the fragments of bone and the lacerated parts on either side of the joint, gently irrigate the joint through a soft-rubber tube, secure perfect hemostasis, sew up torn soft parts with a running stitch of catgut, and approximate carefully the bone fragments by drawing them together with interrupted catgut stitches which shall include the aponeurosis and periosteum only. Close the skin incision; insert a small drainage wick, put up the limb in a firm posterior wire-splint or other similar splint, and support the freshly united bone fragments with strappings of surgeon's plaster. In this manner we secure conditions which result in prompt bony union. Commonly, at the end of two weeks I substitute a plaster-of-Paris splint for the primary dressing; get the patient about on crutches for a couple of weeks, and then four weeks after the operation begin passive movements and massage of the joint. I am satisfied that the earlier passive motions and active treatment of the joint advocated by certain writers are hazardous, and in the long run unsatisfactory. Some surgeons prefer silk or kangaroo tendon to catgut in suturing the bone. I am quite ready to admit the value of such suture materials.

A fractured patella treated on the lines I employ should remain firmly united, and the leg should become nearly as useful as formerly. Unfortunately, we cannot promise the patient a perfect restoration of function. It is rare to find a case of old patella fracture years afterward to be free altogether from some slight stiffness and weakness of the joint. I am unable to corroborate Scudder's optimistic statement that "at the end of three months the knee should be functionally perfect."

Fractures of the Leg

The bones of the leg are in some measure analogous in their relations to the bones of the forearm, but the analogy is by no means perfect. The tibia is the large and important bone of the leg; the fibula is relatively far less important than is either of the bones of the forearm. The tibia alone enters into the anatomy of the knee-joint, but both tibia and fibula are concerned with the ankle-joint. The bones of the leg admit of no rotation, as do the bones of the forearm; indeed, one may regard the two bones of the leg as mortised together in a fashion, and as forming one broad and solid support for the body. One recalls the

fact also that the front edge of the tibia is subcutaneous practically throughout its extent; while the fibula is deeply buried in muscles

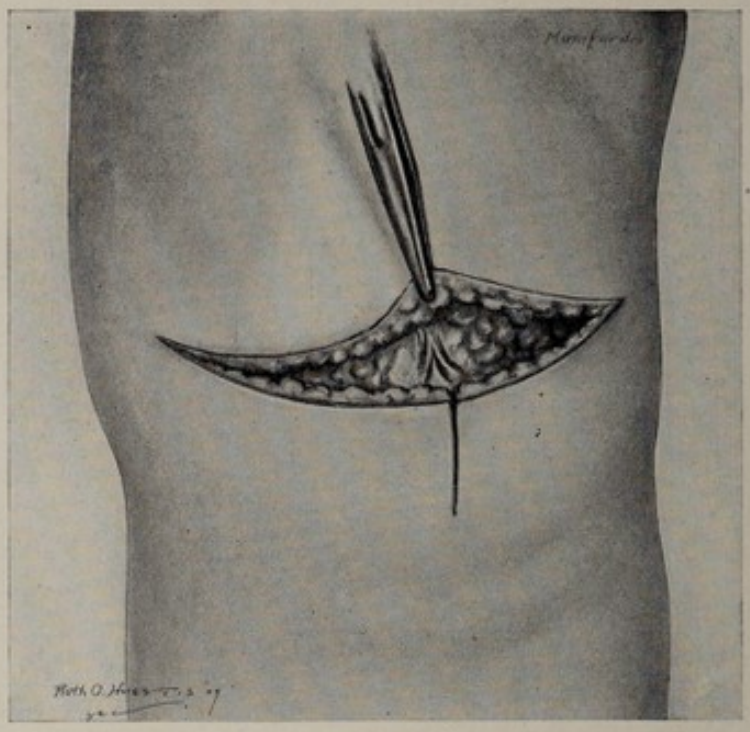

Fig. 610.—Rupture at tubercle of tibia. Operation—step 1 (author's case).

except its head, and the external malleolus, which is subcutaneous for a space of some three or four inches above the ankle.

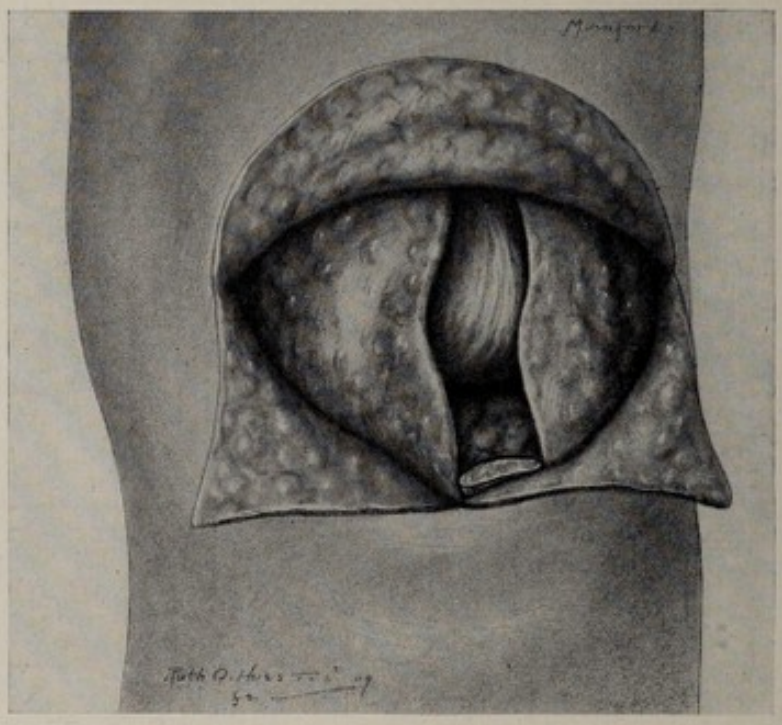

Fig. 611.—Operation on tubercle of tibia—step 2. Note ligamentum patellæ torn off and turned into joint (author's case).

The tibia suffers fracture more frequently than does the fibula; both bones are often fractured at the same time, while fracture of the

fibula alone, except just above the ankle, is rare. Most of the fractures of one or both bones are due to direct violence.

Injury to the tubercle of the tibia is not very uncommon. It is an accident of vigorous young men, and is due to a starting of the upper epiphysis of the tibia, usually from indirect muscular violence. This injury is followed by acute pain at the point of damage, with some little swelling, tenderness, and a marked diminution of the power of extension. Then there follows a more or less permanent sense of weakness, with a return of pain on exertion. As Osgood says: "The condition presents no complete loss of function, but is a severe handicap to the active athletic life which this class of patients wish to lead."

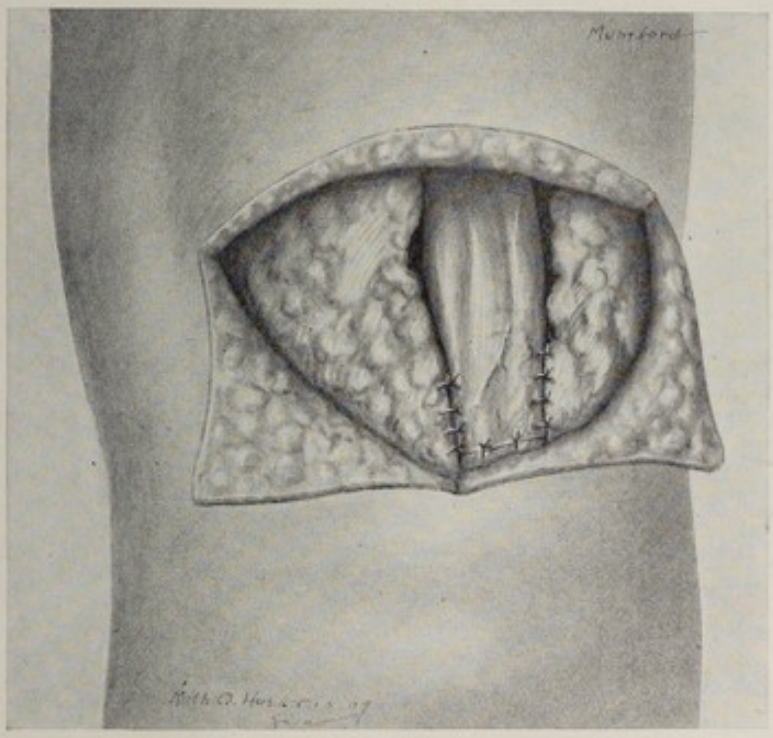

Fig. 612.—Operation on tubercle of tibia—step 3 (author's case).

We can bring about a cure by immobilizing the knee-joint for from three to six weeks; and if this simple method fails, we can secure the damaged fragment by pegging or by sewing it down to the periosteum.

A frank fracture of one only of the bones of the leg is not always obvious, for the sound bone may act as a splint, and so steady the damaged bone as to mask the ordinary evidences of fracture. Of course, a fracture of both bones, or a compound fracture will readily be determined. Generally, the experienced surgeon discovers abnormal mobility and crepitus by seizing the leg firmly above and below the point of injury and cautiously manipulating the parts. He can bring out distinctly the point of pain by approximaing strongly his two. hands. His diagnosis of fracture will be confirmed by the *x*-ray. It is needless to dwell upon the familiar symptoms—pain, swelling, loss of power—which are common to all fractures.

In discussing the subject of *treatment* of fractures of the leg Scudder

adopts four divisions or groups, which are admirable, for the sake of systematic discussion:

1. Fractures with little or no swelling or displacement.
2. Fractures with considerable swelling.
3. Fractures with a displacement of fragments difficult to hold corrected.
4. Open fractures.

Fractures with little or no swelling are fractures of one bone only, as a rule. The surgeon may elevate the leg for a few minutes in order to diminish what slight swelling is present, and then he may dress the limb in a plaster-of-Paris bandage, including the ankle and the knee; or he may employ a temporary dressing with open splints for the first week and then substitute for this primary dressing the plaster-of-Paris bandage.

Fractures with considerable swelling and fractures with a displacement of fragments difficult to hold corrected require far more careful investigation and treatment than do fractures of the preceding group.

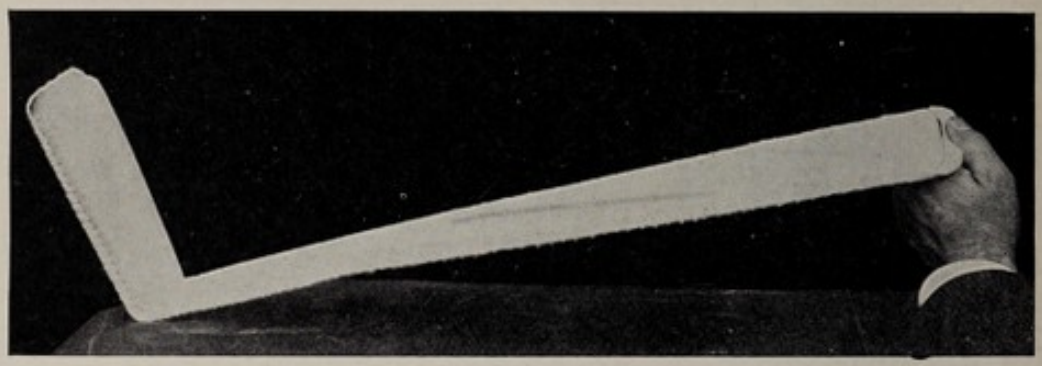

Fig. 613.—The Cabot posterior wire splint padded completely. Note the foot-pad of pasteboard covered by cotton cloth pinned to the foot-piece of the splint for greater security (Scudder).

The swelling is due to an effusion of blood and lymph. Both bones may be involved. The skin about the seat of fracture may be the site of numerous blebs of varying sizes, while there may be marked shortening of the leg. It is obviously unwise to dress a leg so damaged in a tight immobilizing plaster bandage, since the circulation may be thus interfered with, and gangrene of the foot may result; or swelling may subside so rapidly that the plaster splint will fail to hold the parts in place, and a marked deformity gradually will develop.

For such reasons it is advisable to put up the limb in a temporary dressing until the great swelling has subsided. At the Massachusetts General Hospital it has long been our practice to support one of these fresh fractures in a pillow splint, reinforced with firm wooden splints on the sides and beneath the pillow. This is an admirable and comfortable dressing, in which the patient should lie until the primary swelling has subsided. We then employ as a permanent dressing the so-called posterior wire splint of A. T. Cabot—a splint which is well demonstrated by the illustration in the text. Numerous other forms

of apparatus have been used, especially the well-known molded felt and plaster splints. The leg having been dressed and firmly secured, I recommend the use of the hammock or sling. This raises the leg from the bed, and holds it comfortably supported and immobilized, while through its use the patient is enabled to move his body about slightly, and thus to relieve the strain of the dorsal position. If the leg sling be not used, the patient is not able to move at all without pain in the leg.

Under the best of circumstances it is rare to secure by the closed method of treatment a perfect approximation of the damaged bones.

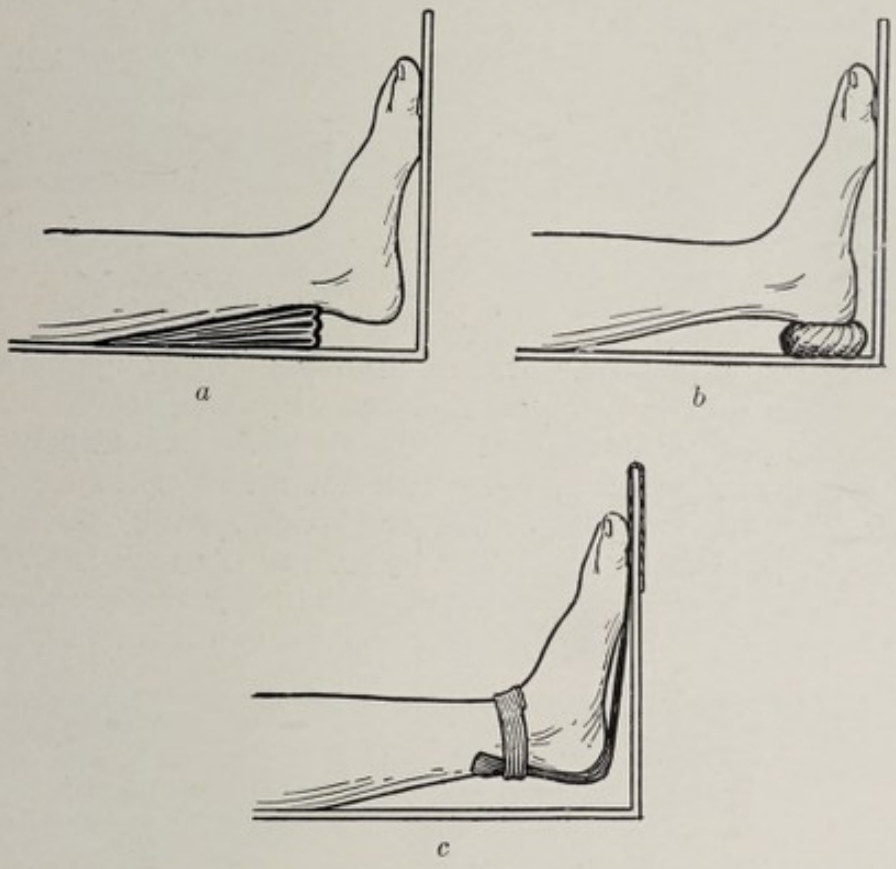

Fig. 614.—Methods of supporting the foot in fractures of the leg when using a posterior splint: *a*, Padding beneath tendo Achillis; *b*, ring under heel; *c*, sling of adhesive plaster (Scudder).

The heel will drop, the foot will become everted, and the calf-muscles will exert undue traction, so that in one fashion or another the bone fragments are constantly being pulled out of position. We employ various devices to obviate these difficulties. We pad the heel, we roll in and secure the foot; while one of the best of all maneuvers is the application of the short Desault splint, which exerts a continuous uniform traction upon the foot and aids materially in securing a reduction and a fixation of the fragments. The figure copied from Scudder shows how the screw at the foot exercises traction, while the long splints, with their plaster straps at the top, enforce a permanent counter-traction.

For the house surgeon there is probably no one subject in the field of fractures so common, so difficult, and so interesting as this subject of fractures of the leg. The problem is one requiring for its successful solution constant patience and a study of the invalid's comfort. Again I refer the reader to the admirable works of L. A. Stimson and C. L. Scudder on this topic.

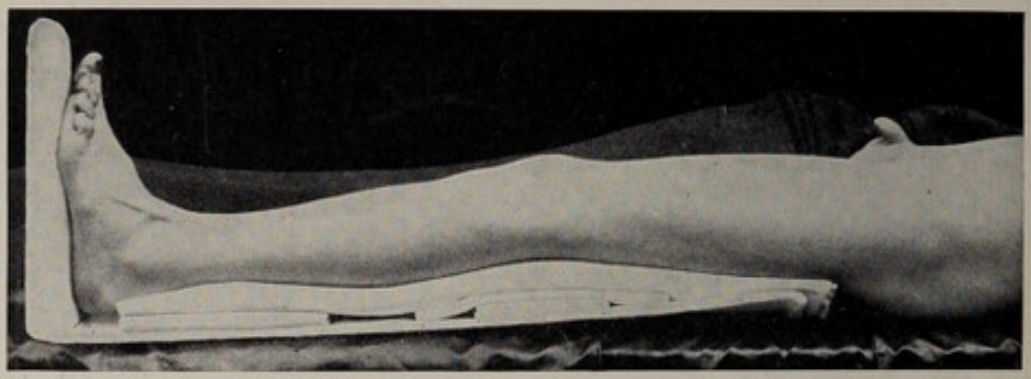

Fig. 615.—Fracture of the leg. Cabot posterior wire splint padded properly according to the curves of the normal leg. Notice that the heel is free from the splint (Scudder).

Open or compound fractures of the leg offer many opportunities for the ingenuity of the surgical dresser. In one of the early paragraphs of this chapter I discussed in general terms the compound fractures. The tibia suffers from compound fracture more commonly than does any other one of the important long bones, for the tibia is placed immediately beneath the skin. The surgeon or the assistant who first sees and dresses a compound fracture of the leg is responsible for the life of the patient, because it rests with this attendant, by his primary

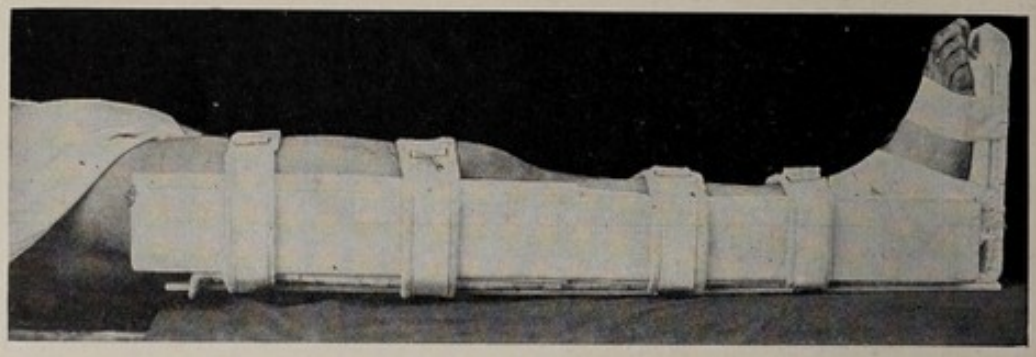

Fig. 616.—Fracture of the leg. Cabot posterior wire splint, side and posterior wooden splints held by straps. Adhesive plaster to foot and ankle (Scudder).

care to secure asepsis, wound healing, and bone union; or it remains for him by his inefficiency to lead the patient into a condition which shall conduce to infection of the wound with a possible loss of limb or life.

In making the primary dressing the surgeon should operate with the patient anesthetized; he should wash the leg with soap and water, and scrub it with gauze sponges and the nail-brush after the hair of

the whole leg has been thoroughly shaved away. Then he completes his cleansing of the parts by scrubbing the leg with liquid chlorinated soda (1:20) which removes effectually all grease and oily dirt.

The surgeon then turns his attention to the damaged soft parts. He enlarges the wound sufficiently to permit of a digital exploration of the deeper tissues; he washes out the clots and detritus with a long-sustained irrigation of hot salt solution; he checks hemorrhage, and completes his cleansing by soaking the parts in hydrogen dioxid and washing that away finally with another long douche of hot salt solution. If the bones are badly splintered, he removes the loose fragments; if the larger fragments are not brought easily into apposition, he secures them with silver wire; he then inserts a small drain deep in the leg, applies an ordinary dry aseptic dressing to the outer parts, and puts up the leg in a permanent posterior wire splint such as I have described.

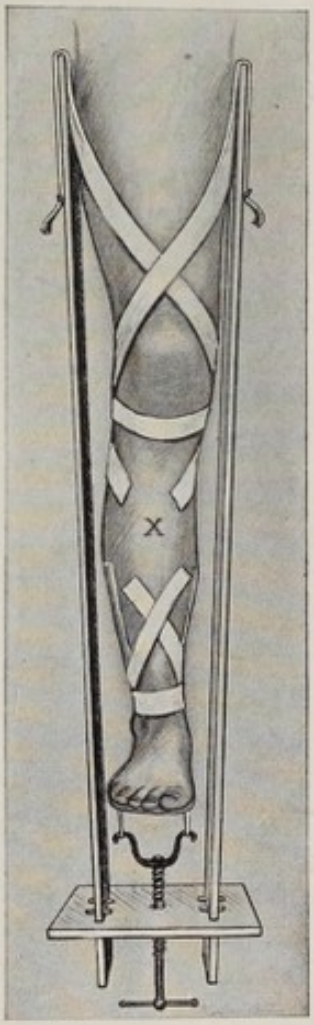

Fig. 617. — Short Desault splint for the application of traction to lower leg fractures. Fracture at x. Extension strips *up* from the fracture are fastened at the top of the splints. Extension strips *down* from the fracture are fastened to the foot-piece. Tightening the screw at foot-piece makes traction and countertraction (Scudder).

Pott's fracture of the fibula, like Colles' fracture of the radius, is one of those familiar and much-talked-of fractures of which the literature is enormous. In Chapter XXVI I have already described how Percival Pott broke his ankle, studied the ailment, and then told about it. In spite of much talking and writing, however, one finds that students are curiously ignorant of the exact nature of Pott's fracture. Pott's fracture is a fracture of the fibula, associated with an outward displacement of the foot. Scudder put it neatly thus: "The lesions . . . in this fracture are a rupture of the internal lateral ligament, a fracture of the tip of the internal malleolus, a separation of the lower tibiofibular articulation, an oblique fracture of the fibula two or three inches above the tip of the external malleolus, a fracture of the outer edge of the lower end of the tibia. . . . Mechanism: As a foot is abducted, the strain is felt at the internal lateral ligament and at the inferior tibiofibular interosseous ligament, and these give way. If the force continues, the fibula breaks. If the force still continues, the internal malleolus is pushed through the skin and an open fracture results. If the internal lateral ligament holds

against this lateral force, the tip of the internal malleolus may be pulled off."

One would suppose that the symptoms of this complicated injury would be obvious enough, yet it frequently happens that physicians

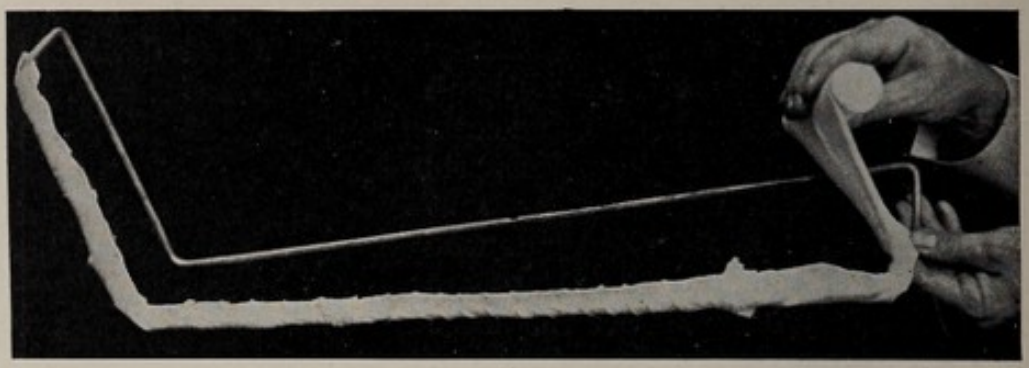

Fig. 618.—Padding the Cabot posterior wire splint. Applying sheet wadding. The shape and proportion of the Cabot splint are apparent (Scudder).

treat Pott's fracture as a sprained ankle. The deformity is fairly characteristic, however, and the swelling is great. Compare the two feet and you will see the damaged foot dropping somewhat lower than

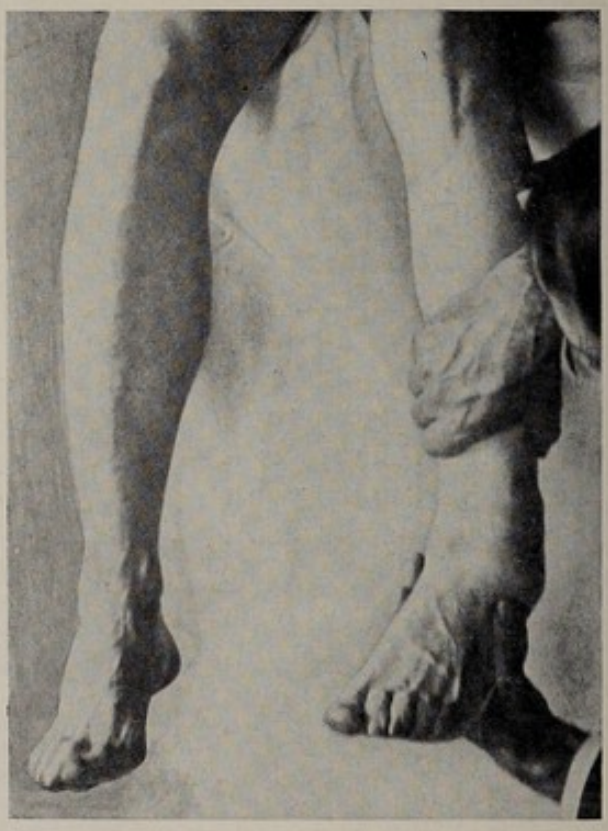

Fig. 619.—Pott's fracture of left ankle. Method of examining ankle. Lateral mobility shown. Note the grasp of the foot and the leg (Scudder).

the sound foot as the patient lies upon his back. Seize the damaged leg firmly in your hand, about 4 inches above the ankle, and squeeze the two bones of the leg together. You will bring out a sharp point of characteristic pain at the seat of the fracture in the fibula. Sometimes

you may feel the splintered tip of the internal malleolus. The *x*-ray tells the story.

Treatment of this form of fracture is entitled to the greatest respect, for treatment ill advised, half-hearted, or inappropriate may land the surgeon in the court-room. The first object of treatment is to reduce the fracture of the fibula by inverting the foot so as to restore its normal relations, and to bring the astragalus back again against its opposing articulating surface at the end of the tibia. It may happen, as I have

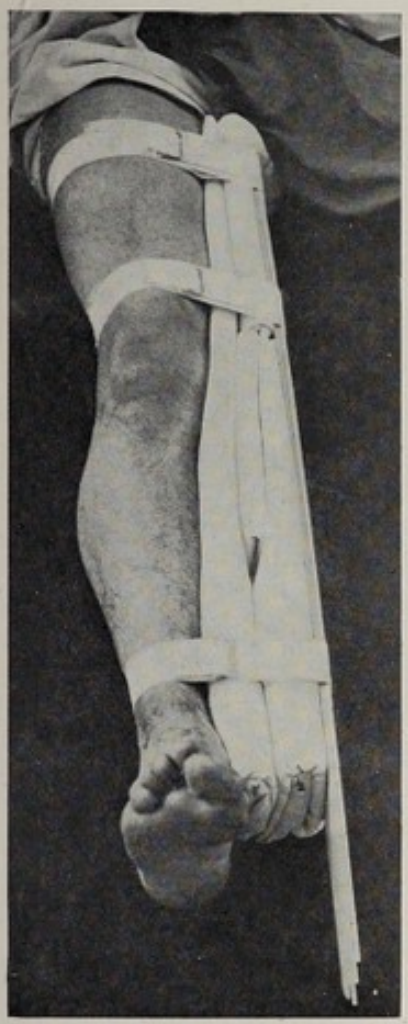

Fig. 620.—Pott's fracture. Dupuytren's splint. Note length of splint; position of straps; arrangement of padding; space between foot and splint (Scudder).



Fig. 621.—Pott's fracture. Dupuytren's splint. Note serrations of splint and turns of bandage adducting foot (Scudder).

stated elsewhere, that damaged tendons or the soft parts will interfere with a proper approximation of the fibula fragments. In such cases the surgeon must transform the simple fracture into a compound fracture at the point of fibula fracture; and he should wire together the fragments.

Having reduced the fracture, how shall we retain the foot in place? Constantly it tends to fall outward. I have been satisfied for years with the familiar splint of Dupuytren. This holds the foot and leg

comfortably, and secures a positive and constant inversion of the foot. The posterior wire splint of Cabot or a plaster bandage may do well enough for mild cases of Pott's fracture, but they rarely suffice for the extreme forms.

Should the Pott's fracture be originally a compound fracture with an opening into the ankle-joint, the surgeon should dress the foot with the greatest care, should cleanse thoroughly the joint, should wire the fibula, should place the limb upon a posterior wire splint, and should give a guarded prognosis. Rarely, and under the best conditions, I have seen these injuries lead to severe and extensive suppuration necessitating amputation of the foot. Modern methods of fighting infections—the employment of proper opsonic vaccines and constant antiseptic lotions—are rendering these formidable compound injuries less serious than they were ten years ago.

Bones of the Foot

Fractures of the bones of the foot, especially fractures of the tarsus, frequently can be determined through the use of the *x*-ray only. These fractures are often due to falls from a height, or to such a crushing force as is exerted by a heavy wagon-wheel rolling over the foot. Frequently the lesion is compound. One may discover crepitus, but the great swelling of the foot may obscure the grating. Injuries to the foot, whether of the bones or soft parts, differ markedly from injuries to the hand in this respect—that except in the case of children these lesions heal slowly. The circulation in the foot is sluggish as compared with the circulation of the hand, so that a fractured bone or an extensive cut of the foot frequently will require two or three times as long for its healing as a similar lesion in the hand. For such reasons damaged feet must be watched and treated for a long time, and, so far as possible, the patient must be advised and encouraged to keep his bed, frequently for weeks, rather than to get up and move about on crutches as his inclination prompts him.

One of the tarsal bones commonly fractured is the **astragalus.** Its fracture is often mistaken for a simple sprained ankle. Discover it with the *x*-ray. Dress it in a plaster-of-Paris bandage, running from the toes to the knee. Remove the plaster at the end of two weeks. Employ proper massage for a month, when a satisfactory result will be secured, though the foot may not be perfectly comfortable until four or even six months have elapsed.

The **os calcis,** or heel bone, is often fractured, especially by a fall. Sometimes the fragments are greatly separated through being pulled apart by the gastrocnemius muscle. The *x*-ray will show the extent of the damage. In order to reduce the fragments it may be necessary to perform tenotomy of the tendon of Achilles, or to remove even some of the bone splinters. When the fragments have been brought well together, the injured foot should be dressed in a plaster-of-Paris bandage.

Both the astragalus and the os calcis may be the subject of com-

pound fracture, in which case the damaged bones should be carefully cleansed and treated on the lines already laid down in our discussion of compound fractures.

The other smaller bones of the tarsus occasionally are crushed by direct violence. One ascertains the exact nature of their fracture through *x*-ray investigation. Treatment is by rest and an ice-bag until the swelling has subsided, after which the whole foot should be put up in a plaster bandage.

Fracture of the **metatarsal bones** is frequent, and is due nearly always to direct violence. The first and fifth metatarsals are the bones commonly broken, and the symptoms are swelling, crepitus, pain, abnormal mobility, and inability to stand on the foot. There is never great displacement, but an approximation of the fragments is necessary in order that the patient may be able to walk freely and easily after union has taken place. In the case of great displacement it may be necessary to employ temporary traction by special wooden splints, but ordinarily a plaster splint embracing the whole foot will suffice. These plaster splints for fractures of the bones of the foot should always extend from the tips of the toes to above the swell of the calf.

Fracture of the phalanges of the foot is a rather rare accident. I have known cases in which the patient fractured a phalanx of the toe by stubbing the toe while walking barefoot. The displacement in these cases is slight and union is fairly prompt. Generally, a simple wooden plantar splint, properly padded and held in place with adhesive straps, is sufficient. The plantar splint which covers the entire sole of the foot is the most comfortable. Sometimes it is well to immobilize the ankle-joint also in plaster. The patient should usually be kept quiet with the foot elevated until fair union has taken place.

Bones of the Face

Fractures of the bones of the face are interesting and extremely important, because upon the integrity of the facial bones depends the expression of the countenance and the familiar alinement of the features. The bones of the face are not long bones; their structure is irregular, while their outlines are various; moreover, they are mostly so placed as to permit of no proper splinting or immobilization, so that often it is necessary for the surgeon to contrive and adopt special maneuvers for the treatment of special fractures.

The **nasal bones** are subject to fracture, while their damage may cause a marked deformity. Moreover, they are functionally concerned with breathing, so that their displacement may seriously interfere with the comfort of life.

The nasal bones are usually fractured near their lower edge, and the fracture is compound, either into the nose or through the skin, while at the same time the cartilage of the septum is generally damaged. The *upper lateral cartilages* also may be torn from their attachments to the nasal bones, when there results a deformity which simulates fracture of those bones.

Fracture of the nose is not painful after the initial injury, but there is nearly always marked swelling and crepitus with the deformity.

Before undertaking the *treatment* of a nasal injury the surgeon should examine carefully, with the aid of a head-mirror, the interior of the nostrils, and should correct any obvious displacement of the septum. Cocain anesthesia or general anesthesia may be necessary to accomplish this result, for the manipulation is painful. Then the surgeon should replace the fractured bone if there be a fracture, using within the nose a proper elevator. Roe's elevator is a useful instrument. The surgeon must then endeavor to hold the replaced bones in position. He may do this fairly well by packing the nostrils with gauze, if the fracture be high; while if there is a low deviation, he may well use the Asch tube. In the case of a crushed nose he may model or reconstruct the nose over the Asch tube, one tube being placed in



Fig. 622.—Fracture of nasal bones. Elevation of depressed bone by instrument introduced into the nostril (Scudder).



Fig. 623.—Cobb's splint applied to a case of fracture of the nose. The head-band is so adapted to the shape of the head that it remains fixed and offers a point of counterpressure (Scudder)

each nostril to preserve its contour and lumen. In those rather frequent cases which do not show deformity one need use no splint. Always when the mucous membrane of the nose is damaged, with a coincident compound fracture, the nares must be kept scrupulously clean with gentle douching, for which there is nothing better than a 50 per cent. alkalol wash, or Seiler's solution.

Various external splints have been devised. I reproduce Cobb's splint and Coolidge's splint, either of which is effective, though the Coolidge splint is much the cheaper.

Make no promise as to the resulting deformity, for until the initial swelling has subsided and union is complete, no man may say whether a deformity will be permanent or not. In case of a slight depression

or deviation following healing, the surgeon may remedy the defect by the judicious subcutaneous injection of paraffin.

Fracture of the malar bone generally results in a deformity of the face, in a depression, which may or may not be noticeable to the patient's friends, though the man himself is sure to complain of the slightest imperfection. Indeed, it is not easy always to make out a fracture of the malar bone. The best method of examination is to stand behind the patient, and with the finger and thumb of either hand to seize both malars, when a deviation of the affected side will generally be apparent. Fracture of the body of the bone

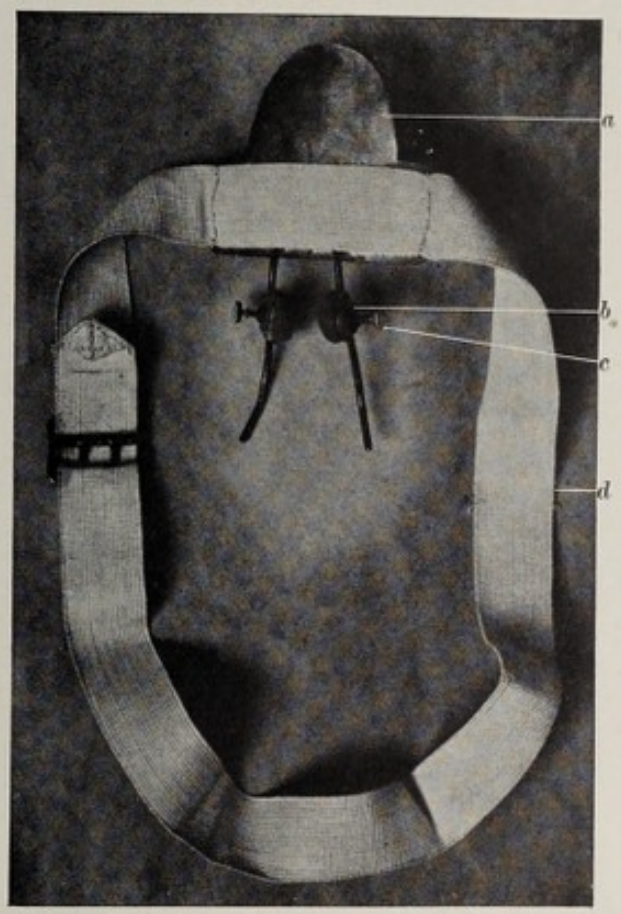

Fig. 624.—Coolidge's nasal splint: *a*, Forehead plate; *b*, pad; *c*, screw controlling position of pad; *d*, head-strap (Scudder).

is not common, but fracture of one of its processes is seen not infrequently. Often the bone appears depressed as a whole, or sometimes tilted inward toward the zygomatic fossa. The deformity is a depression outside of and beneath the eye. There is often a stiffness, or even immobility of the lower jaw dependent either upon hemorrhage into the soft parts or upon bone pressure. At the same time the coronoid process of the mandible may be fractured and a subconjunctival hemorrhage may appear in the orbit of the affected side.

We *treat* fracture of the malar bone variously—either by manipulations or by seizing through the skin with bullet forceps (E. A. Codman) and elevating the fragments of bone, always with the patient

anesthetized. Sometimes the depressed fragment may be elevated with a blunt instrument introduced under the malar bone from inside the cheek without opening the mucosa; or we may succeed by making a small incision in the mucous membrane, and thus approaching the seat of damage; or by opening the antrum in the canine fossa and introducing an elevator which shall press up the fractured bone from within.

Never undertake an external incision if it can be avoided, for an external incision may prove of little value for the elevation of the bone, while it will be certain to leave a noticeable scar.

Fracture of the upper jaw is rather more common than fracture of the malar, for the upper jaw is a more delicately constructed bone than is the malar. A jaw fracture is usually caused by a direct blow

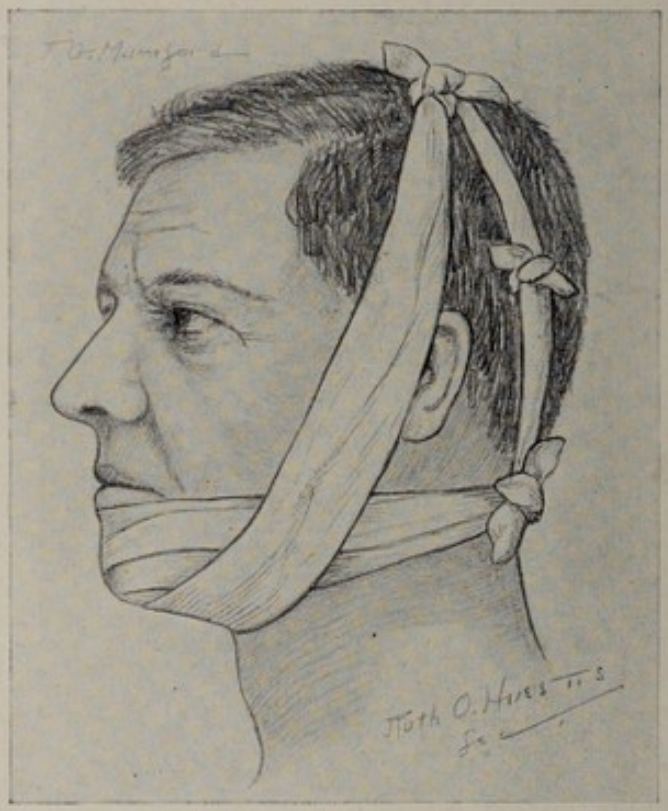

Fig. 625.—Four-tailed bandage for fracture of the lower jaw.

upon the cheek bone, resulting in the crushing in of the external wall of the antrum of Highmore. Lothrop[1] has recently published an interesting and valuable essay on this subject. After discussing the nature and anatomy of upper jaw fractures, he describes three methods of operative treatment, pointing out truly that operative treatment is the only satisfactory mode of treatment: First, operation by incision over the malar—a method to be discarded; second, the introduction of blunt instruments pushed up through the mouth—less objectionable than the first method, but generally ineffective and inadvisable. Third, Lothrop's own method, which I believe, from my personal experience, to be far the most valuable. This method consists in elevating the

[1] Howard A. Lothrop, Fractures of the Superior Maxilla: A Method for the Treatment of Such Fractures, Boston Med. and Surg. Jour., January 4, 1906.

malar, together with the various fragments of the maxilla, working through a small opening into the antrum through the canine fossa. The operator makes a short horizontal incision along the junction of

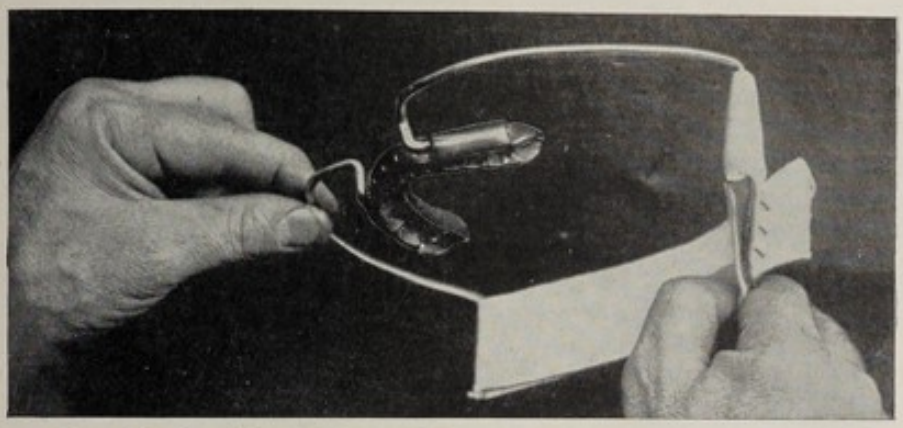

Fig. 626.—Hard-rubber splint, with arms and posterior strap (Scudder).

the mucous membrane of the alveolus and cheek; he feels the line of fracture often, after having cut down upon the bone. He then pushes a director through the opening into the antrum—an easy procedure.



Fig. 627.—Hard-rubber splint, with arms and bandage applied. Similar to Fig. 626 (Moriarty).

He enlarges this opening sufficiently to pass into the antrum a steel sound (No. 24 French). With this instrument, and by a little forceful manipulation, the operator may press the fragments of bone up into their position and can hold them there by packing firmly the antrum with

gauze. The gauze should be left in place for four or five days, when it is withdrawn, the bone cavity carefully syringed out, and with proper aseptic precautions allowed to heal. I have seldom been obliged to keep these patients more than a week in the hospital.

Fractures of the lower jaw can nearly always be determined by palpation, for the lower jaw is superficial, with the exception of a small portion of the ramus. Fractures of the ramus are rather rare, and fractures of the condyloid and coronoid processes are extremely rare. One sees that most fractures of the lower jaw must necessarily tear the mucous membrane of the mouth and must therefore be classed as compound fractures. The result is that these fractures are more serious, more dangerous, and more difficult of treatment than would at



Fig. 628.—Lateral view of the Matas splint in situ, as shown on adult skull (Scudder).

first appear. The secretions of the mouth enter into the wound; sepsis results, with consequent necrosis and possible abscess formation, so that in the treatment of these injuries the surgeon must employ constant and scrupulous cleansing—mouth-washes, douches, and aseptic irrigations.

The *treatment* of fracture of the jaw: Anesthetize—for the procedures are painful, not only the cleansing for the prevention of serious infection, but, what is of almost equal importance, the manipulations for the preservation of the alinement of the teeth. We attain this proper alinement by a complete reduction of the bone fragments, if necessary, by removing loose and obstructing teeth which may interfere with such reduction.

As for the common fracture, that of the body of the bone, the fragments may as well be retained primarily by the old-fashioned four-tailed bandage until a permanent splint has been manufactured and applied. There are many varieties of permanent splints, and most of them, being made from molds of the jaw, fall naturally to the province of the dentist. Indeed, it is a common practice among surgeons in municipal hospitals to transfer to the hospital's dental department simple cases of fractured jaw. I reproduce here illustrations of certain dental splints which are in ordinary use. At one time it was common practice to attempt immobilization of the fragments by wiring together the two teeth on either side of the fracture. This practice is



Fig. 629.—Compound fracture of lower jaw, caused by fist blow. Line of fracture oblique, bisecting lower jaw at angle and terminating above behind last molar tooth. Great displacement and mobility of fragments. Reduction and apposition only obtained by splint. Barton bandage used to immobilize jaws with the splint. Splint worn eighteen days and followed by excellent results (Matas).

ineffective, since such wiring loosens or pulls out of place the teeth so treated. There is a satisfactory method of wiring, more or less in vogue, however. This consists merely of fastening together, as it were, in a wire splint a large number of teeth on either side of the fracture, weaving a pliable silver wire in and out among them. For practical purposes I have found this method serviceable. It is cleanly, it allows of ready access to the damaged parts, and it is not especially disagreeable to the patient, since it does away with the cumbersome splints and harness which are frequently employed in hospital practice.

Fractures of the ramus of the lower jaw are much more difficult to hold in place than are fractures of the body of the jaw. These frac-

tures of the ramus may be fairly well immobilized by a carefully applied four-tailed bandage, or, better still, is the molded leather splint of Moriarty, or the ingenious but somewhat cumbersome splint of Matas.

We have now considered the common and important fractures of the bones throughout the body. It is not possible in this writing to deal adequately with the numerous and distressing complications of fractures. One remembers also that many serious wounds of the soft parts are associated with fractures, and that the treatment of such fractures is a subordinate part of the care of the patient. There are, further, certain special types of fractures due to special forms of injury, many of the most important of which are gun-shot fractures. *Gunshot fractures* are necessarily compound fractures, and the accident or damage to the bone is in proportion to the velocity of the projectile and the character of the bullet. The old-fashioned leaden bullet, of low velocity, gives often an ugly wound with an extensive splintering of the bone; while the modern high velocity conic bullet may do little more than pierce the bone and cause a slight splintering. *X*-ray plates are needed in order to determine the exact nature of these various fractures; and the treatment of such fractures must be decided on general surgical principles. In broad terms, one may say that a bone extensively splintered must be cut down upon and trimmed, while a bone merely pierced will probably heal without any great disturbance. It is rarely necessary to search for a bullet embedded in the tissues, unless the bullet is obviously a source of present irritation. A bullet, like any other foreign body, may remain indefinitely in a patient without creating noticeable damage.

Pathologic Fractures

Pathologic fractures, by which we mean fractures resulting from new-growths, from infections, and from bones rendered brittle by disease, occasionally are seen. Such fractures call for no special discussion in this place. It is obvious that fractures due to malignant disease are subordinate to the primary disease which must be the object of the surgeon's care; while fractures due to such non-malignant processes as rickets, etc., must be treated on ordinary principles, and the surgeon must make every endeavor to rectify the underlying ailment which led to the fracture.

Dislocations

Stimson gives the following excellent and comprehensive definition of a dislocation: "A dislocation is a permanent, abnormal, total or partial displacement from each other of the articular portions of the bones entering into the formation of a joint." A dislocation may be partial or complete. When it is partial or incomplete, it is frequently called a subluxation.

Writers tell of predisposing and immediate causes of dislocations. These refinements need not concern us especially, for the fact is that

the ordinary dislocations which are presented to the surgeon for treatment are dislocations of normal joints which have been torn asunder by extreme and external violence. Rarely the patient's own muscular action may cause a dislocation, as, for example, a dislocation of the lower jaw through excessive yawning; or the habitual and recurring dislocation of the shoulder-joint, produced by muscles acting upon a joint constructed with extremely relaxed ligaments.

A dislocation long unrecognized and unreduced results in firm adhesions about the parts, rendering their subsequent reduction impossible without an open operation. These old dislocations, like old unrecognized fractures, are frequent subjects for law-suits. Perhaps the most common of the old unreduced dislocations is that of the shoulder-joint. One would suppose that a dislocation of the shoulder-joint should be easy of recognition. On the contrary, in obese persons with heavy shoulders and flabby muscles, especially if they be short, stout women, the deformity of a dislocation of the shoulder-joint is by no means obvious; the palpation of the region is difficult, and without an *x*-ray or bimanual manipulation the correct diagnosis frequently is not made.

That we may distinguish clinically between *dislocations* and *fractures* we must recognize certain striking points of difference. While there is pain in both conditions, the deformity of a dislocation is more marked than is the deformity of a fracture, and the loss of power after a dislocation is less considerable than after a fracture; but the most striking distinction is this—a fracture results in abnormal mobility, while a dislocation results in diminished mobility, or in a fixing of the bones in their new position.

The course and outlook of a dislocation are shorter and more favorable than is the case with a fracture. We can compare best the contrasted features of the two injuries by considering special regions; for example, a *dislocation* of the elbow-joint should incapacitate the patient for not more than two or three weeks, and the use of the joint should be completely recovered; while a *fracture* into the elbow-joint means many months of treatment, often resulting in a permanent impairment of function. Again, the dislocation of one of the phalanges implies a disablement of not more than a week or two, with perfect restoration of motion; while a fracture of one of the phalanges is followed by disablement for from four to six weeks, with occasionally permanent limitation of motion and power.

The *treatment* of dislocations is interesting and, in general terms, is active. The sooner a dislocation is discovered, the more easily may it be reduced. The original force causing the injury and the force necessarily applied to correct it imply a great deal of traumatism to the joint, as well as a certain amount of tearing of the capsule. Often this traumatism results in irritation of the joint serosa, in an outpouring of a considerable exudate, in effusion into the surrounding tissues even, and not infrequently in a straining, stretching, and tearing of the ligaments. For such reasons the surgeon must enjoin absolute rest for the joint

for a day or two after the dislocation has been reduced. It is not necessary to put up the limb in an immobilizing dressing of plaster of Paris, but it is necessary to hold it snugly and comfortably in place with heavily padded bandages. During these first few days the effusion subsides; the injection and hyperemia of the parts diminish; the swelling disappears, and the region becomes normal in appearance.

In order to facilitate these natural processes we then prescribe massage for the joint and surrounding parts, and as the subsequent healing progresses, we stimulate and hasten it by continued massage. Old practitioners will recognize this treatment as quite different from the long-continued immobilization of former times. The present-day active measures return the joint to a normal and useful function with surprising rapidity; instead of waiting for many months, as used to be the case, we now expect a return of usefulness in a joint in a far shorter time.

SPECIAL DISLOCATIONS

Special dislocations offer special considerations to the student, and some of these considerations we have already taken up. In Chapter XXV, I have discussed briefly the question of dislocations of the vertebræ,

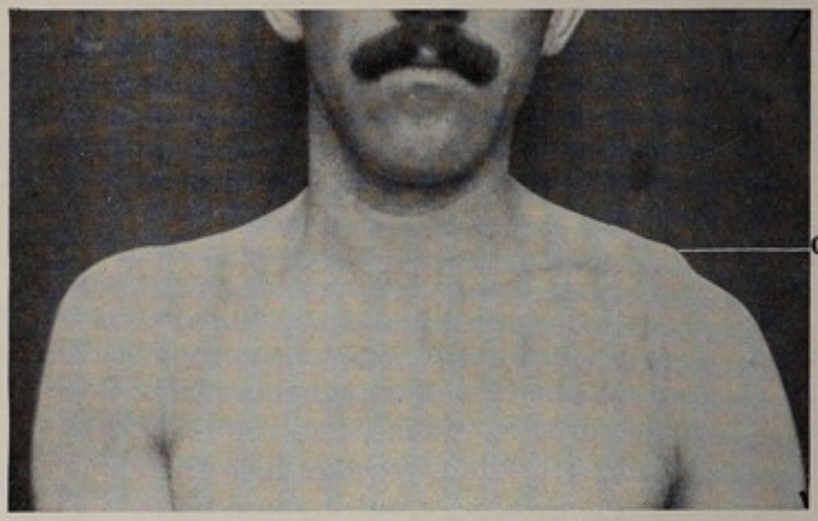

Fig. 630.—Acromioclavicular dislocation. Dislocation of the outer end of left clavicle upward. Complete form. Disability of upper arm, certain movements painful. Treatment of this dislocation is often successful by pressure applied after reduction, as shown under Fracture of Clavicle. Open incision and suture are indicated if reduction is impossible and disability exists (Scudder).

especially of the cervical vertebræ; and I have already in this present chapter referred to dislocations of the ribs, especially of the ribs upon the costal cartilages. These dislocations of the ribs are essentially similar to fractures of the ribs in their general effect upon the patient, and their treatment is similar to the treatment of fractured ribs.

Dislocations of the Clavicle.—The clavicle may be dislocated at either its proximal or its distal end, and these dislocations may be found extremely difficult of reduction and fixation. In general terms, when the dislocation is at the *proximal* end of the clavicle, we perceive

that reduction is brought about by manipulations of the shoulder: by drawing the shoulder outward and backward, and by manipulating the dislocated bone, we can usually bring it back into place. The difficult task of retaining it in place will put the surgeon to his trumps. The shoulder must be bandaged and strapped into such a position as to favor present retention of the bone, and, if necessary, the patient must be kept quiet in bed for weeks even. So difficult and so disheartening are these cases often, however, and so persistently does the dislocation recur, that the surgeon frequently finds himself on the horns of a dilemma; either he must submit to the forces of nature and allow the dislocation to remain unreduced, or he must transform the simple dislocation into an open one and retain the bone in place by suturing. I have found this last measure to be satisfactory.

Dislocations of the clavicle at its *distal* end are extremely difficult of treatment also. It is a simple matter to reduce them, but their retention again is a problem. We reduce them by manipulating the shoulder. We retain them theoretically by such strapping as I have illustrated in the sketch. As a matter of practice, however, we find that the most efficient method of holding these dislocations in place is by wiring, provided the patient is not willing to submit to the slight deformity of a permanent dislocation and the trivial loss of function which this entails.



Fig. 631.—Dressing for dislocated clavicle.

Dislocation of the shoulder is one of the commonest of dislocations. The head of the humerus nearly always leaves the joint through the lower portion of the capsule, and goes to rest either beneath the glenoid cavity (subglenoid dislocation) or beneath the coracoid process (subcoracoid dislocation). There is also a subspinous or backward dislocation—a condition of the greatest rarity. For the purposes of treatment it matters little whether the dislocation be subglenoid or subcoracoid.

Either one of the forward dislocations gives rise to a characteristic and definite picture and chain of symptoms: The patient sits bent forward and supports in his hand the elbow of his injured arm; the normal outline of his shoulder is changed; the deltoid is flat instead of rounded; the elbow protrudes from the side and is fixed in that position; the head of the bone may be palpated bimanually in the axilla. The surgeon should confirm these observations by the *x*-ray, through which

means also he must determine upon the presence or absence of a coincident fracture.

The *treatment* of dislocation of the shoulder is extremely easy in case the dislocation be recent. The head of the bone will slip back into its

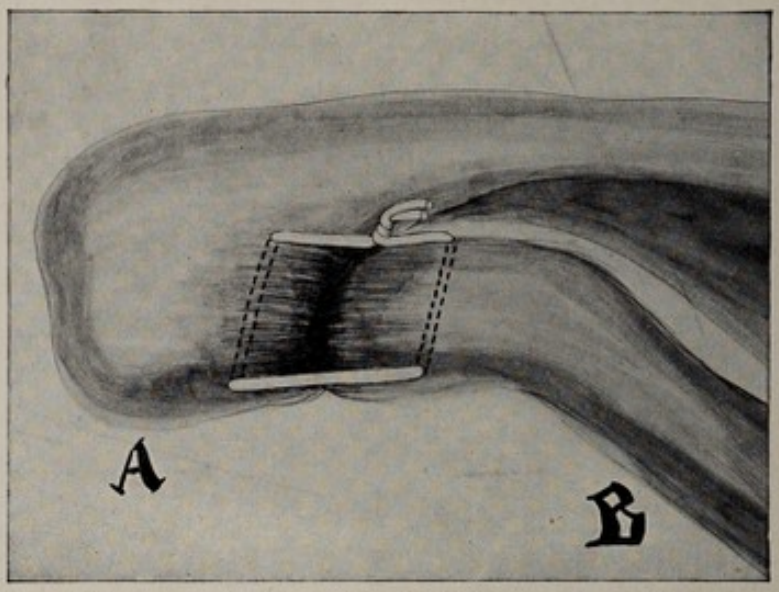

Fig. 632.—View of the acromioclavicular joint from above. To illustrate a suture passed through transverse drill holes in the acromion *A* and clavicle *B* (Scudder).

socket almost at the touch often, if the patient be etherized; and he should generally be etherized for the examination and reaction.

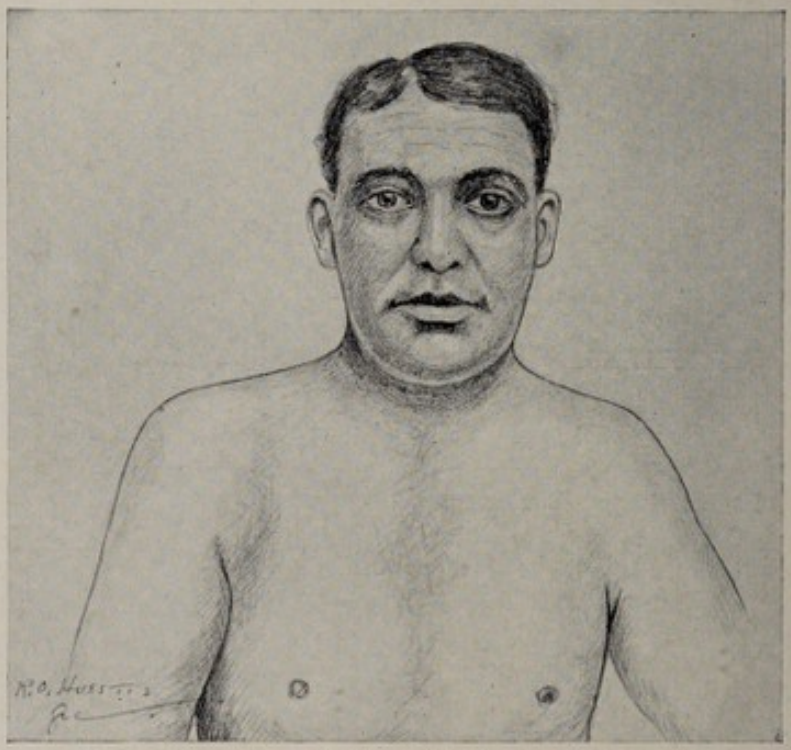

Fig. 633.—Dislocated left shoulder.

The old method of reducing a shoulder dislocation is to make traction upon the humerus by grasping it at the elbow while the arm is

extended at a right angle to the body. An assistant holds the patient firmly upon the table, if necessary, with a folded sheet strapped about the chest. While the surgeon makes traction upon the arm with one hand, he brings the elbow gradually to the side and manipulates the head of the bone back into its socket with the other hand, or he may have these shoulder manipulations done by an assistant. An excellent

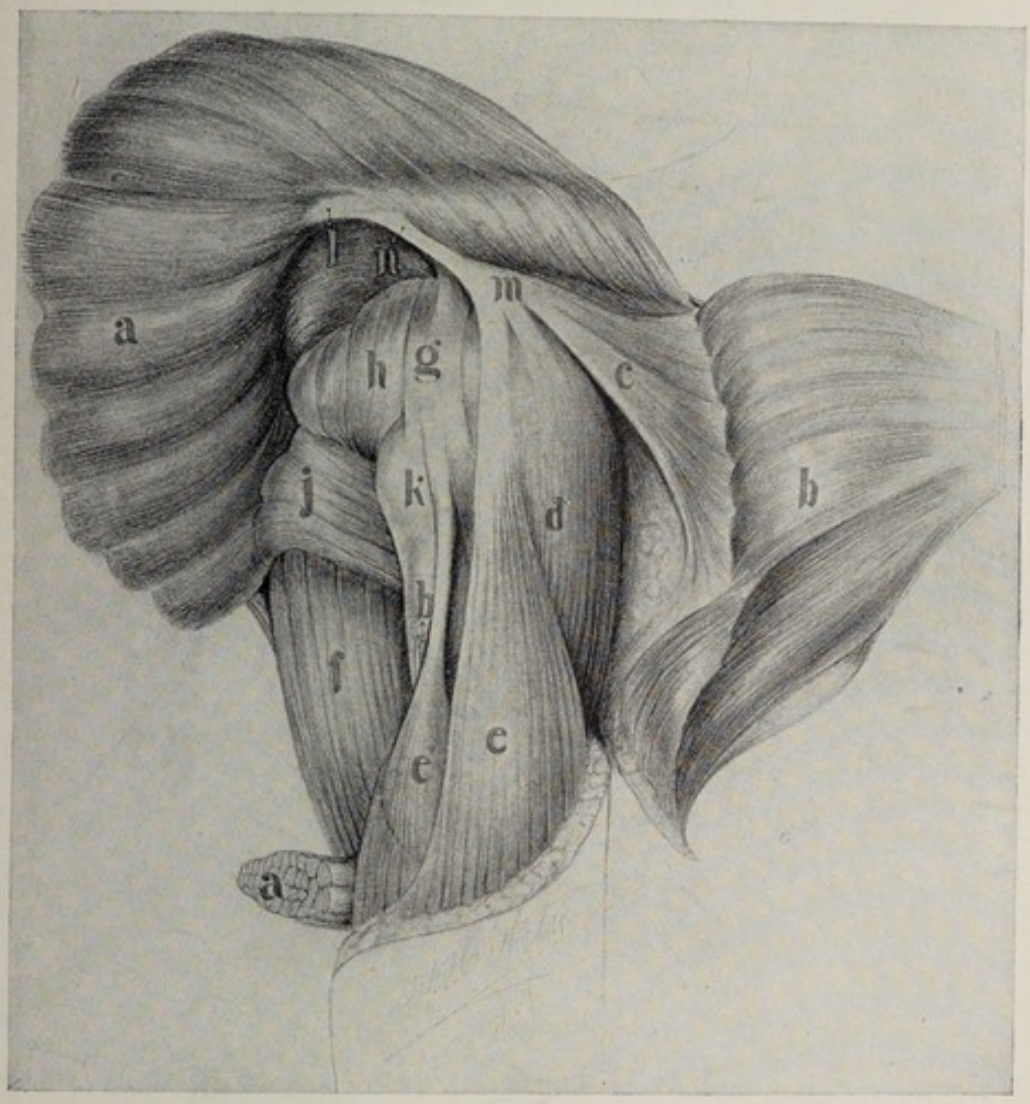

Fig. 634.—Reducton of subcoracoid dislocation of the shoulder. *First position* (see Fig. 635); *elbow at side, forearm rotated outward*. Note fulness (head of humerus) beneath coracoid process (*m*); absence of head of humerus under acromion (*l*); relaxed muscles (*g, h, j*); *a*, deltoid; *b*, pectoralis major; *c*, pectoralis minor; *d*, coracobrachialis; *e*, biceps, two heads; *f*, triceps; *g*, supraspinatus; *h*, infraspinatus; *j*, subscapularis; *k*, humerus; *l*, acromion process; *m*, coracoid process; *n*, coracoacromial ligament (Scudder).

old-fashioned method, often useful, is for the surgeon to pry back the bone into the socket with his unbooted foot placed in the axilla.

Theodor Kocher's method of reducing a dislocated shoulder is the best method, and is in common use.[1] Ceppi, a pupil of Kocher, gives the following rule: "In the subcoracoid dislocation the posterior por-

[1] Revue de Chirurgie, 1882, p. 831.

tion of the capsule and the tendons of the posterior scapular muscles which cover and strengthen it are untorn and are stretched over the glenoid fossa. The inferior portion of the capsule which forms the

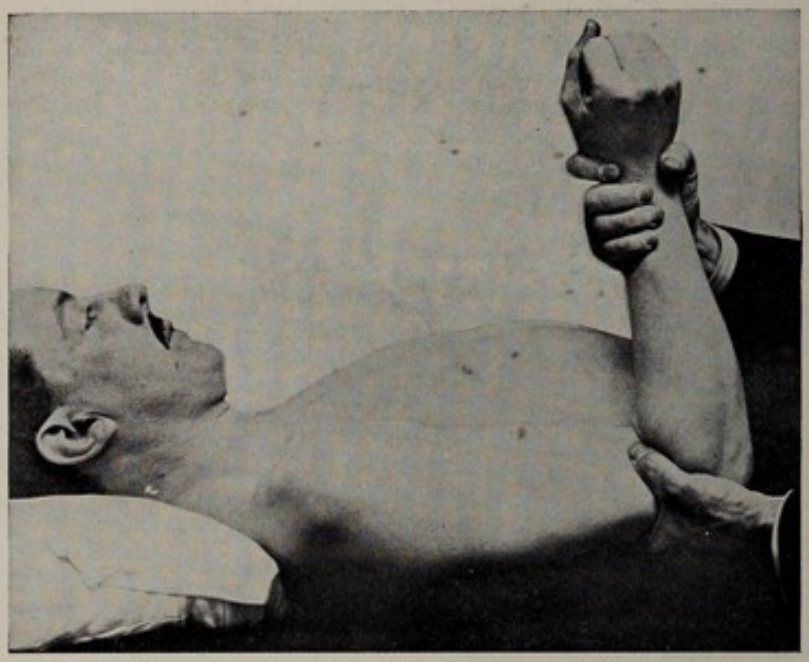

Fig. 635.—Reducing dislocation of the shoulder. Note shoulder over edge of table; patient on back. *First step:* Elbow at side. Note method of grasping above elbow and wrist (Scudder).

lower border of the rent is also very tense. But the tension is greatest at the upper part of the capsule, and especially between the long tendon of the biceps and the upper border of the subscapularis, where it is

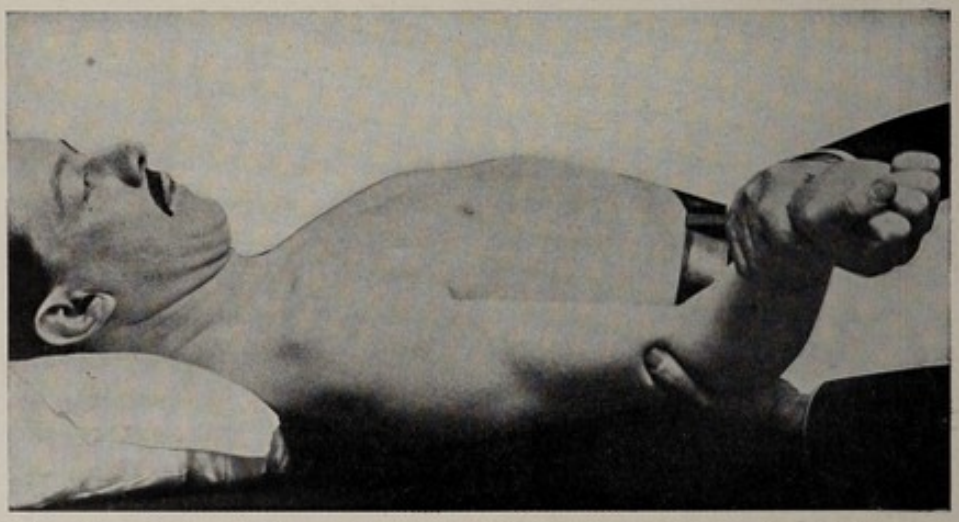

Fig. 636.—*Second step:* Elbow at side. Rotation of forearm outward to the extreme limit of rotation (Scudder).

reinforced by the fibers of the coracohumeral ligament. This portion of the capsule is twisted in the dislocation, and stretched in the form of a solid cord. If now, the humerus is rotated externally until the flexed forearm is turned directly outward, this cord will be at the same time

rotated outward, the posterior part of the capsule will be widely removed from the fossa, and the rent in the capsule will gape; but the head of the humerus will still remain solidly fixed against the anterior edge of the glenoid fossa, because the upper and lower portions of the capsule have not been relaxed by this movement. It is only when the elbow is carried forward and raised in the sagittal plane, while the arm is still held in external rotation, that the upper part of the capsule is seen to relax, and the head of the humerus, thanks to the tension of the lower portion, which keeps it from moving forward, to enter the socket. Rotation inward then completes the reduction."

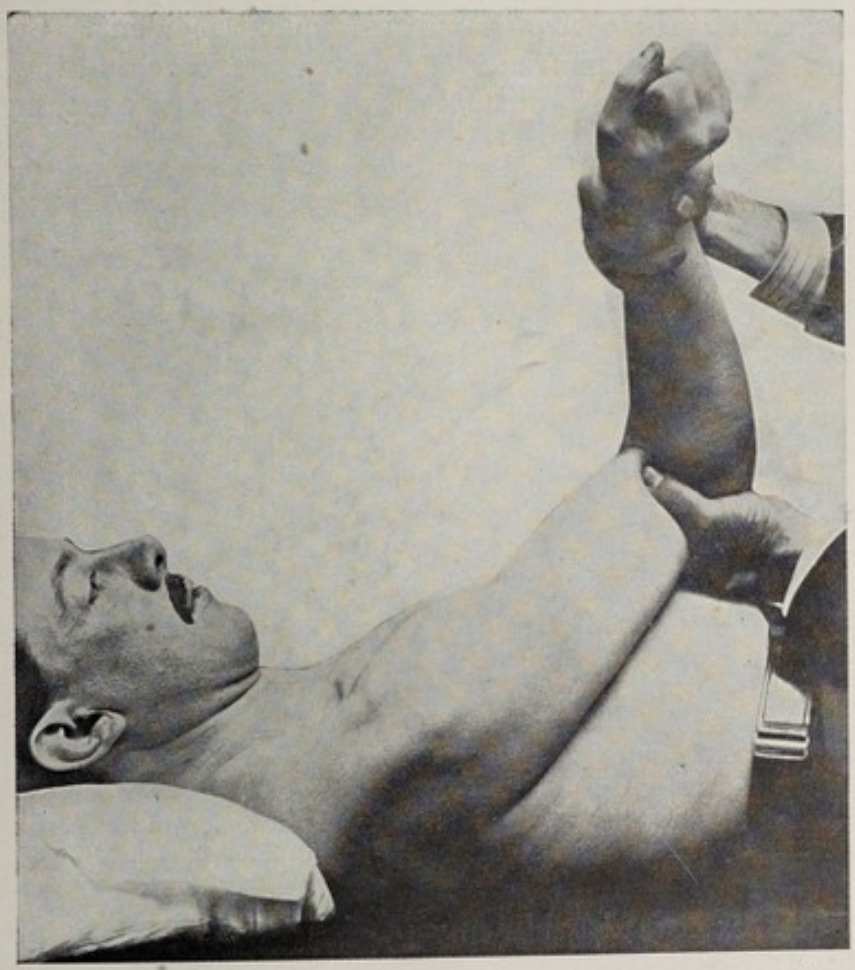

Fig. 637.—*Third step:* While external rotation is maintained, traction downward is made and at the same time the elbow is carried in adduction to the midline of body (Scudder).

Old unreduced dislocations of the shoulder offer some of the most difficult of surgical problems. We never know the limit of time which must prohibit an attempt at reduction in a given case. Sometimes a shoulder dislocated for six weeks may be reduced successfully; again a shoulder dislocated for three weeks may resist all attempts at reduction. Moreover, if the surgeon be dealing with old and brittle bones, he runs the risk of causing a fracture of the humerus, while he fails to reduce the dislocation. For such reasons the operation of reduction must be undertaken cautiously, and the patient must be forewarned

of its possible outcome. Kocher's method of reduction offers to the surgeon so firm a leverage in his manipulations of the humerus that he must use special precaution when employing this method. He must resist the temptation violently to rotate the humerus. Perhaps the safest method in these old cases is the ancient method of traction, and manipulations of the head of the bone by an assistant, the patient being under an anesthetic, of course. If the surgeon fail in his attempts at reduction after a reasonable trial, and if the patient consent, the operator is justified in cutting down upon the joint and in lifting the bone back into place if possible; or he may even think it wise to excise the head of the humerus so as to establish a false joint.

Dislocation of the elbow is a not infrequent accident. Commonly, both bones of the forearm are dislocated backward behind the condyles of the humerus. The lesion usually is obvious. The olecranon is seen

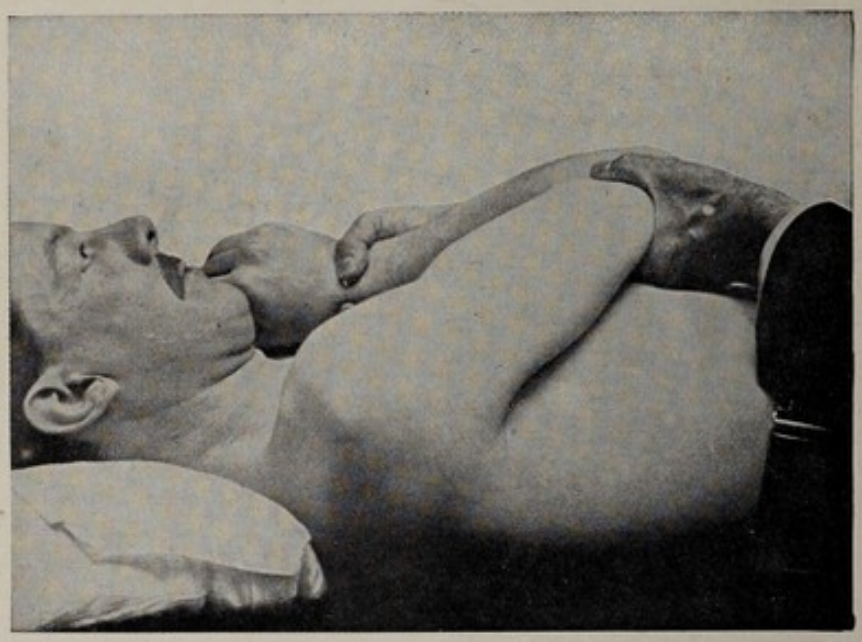

Fig. 638.—*Fourth step:* While traction is being made, rotation inward is made of the arm by placing hand upon opposite shoulder (Scudder).

and protrudes backward, while any motion in the joint is absolutely prohibited unless the patient be anesthetized when one finds that lateral mobility exists. I referred to this injury in discussing the fractures about the elbow-joint, and pointed out that fractures may be associated with dislocations. The head of the radius also alone may be dislocated when there appears the characteristic deformity.

The *treatment* of elbow dislocations is simple enough when the dislocation is recent, but, as has been so well said by Stimson, "in the reduction of any dislocation the displaced bone should be reduced by the path along which it came when dislocated. A haphazard method of reduction of a dislocation is unsurgical." When the elbow dislocation is uncomplicated, use two steps for its reduction: First, extend completely the forearm, which frees the coronoid from the olecranon fossa and the posterior surface of the humerus; second, employ firm

traction upon the forearm and flex it, when the bones slip back into place. The reduction being completed, put up the arm in an internal

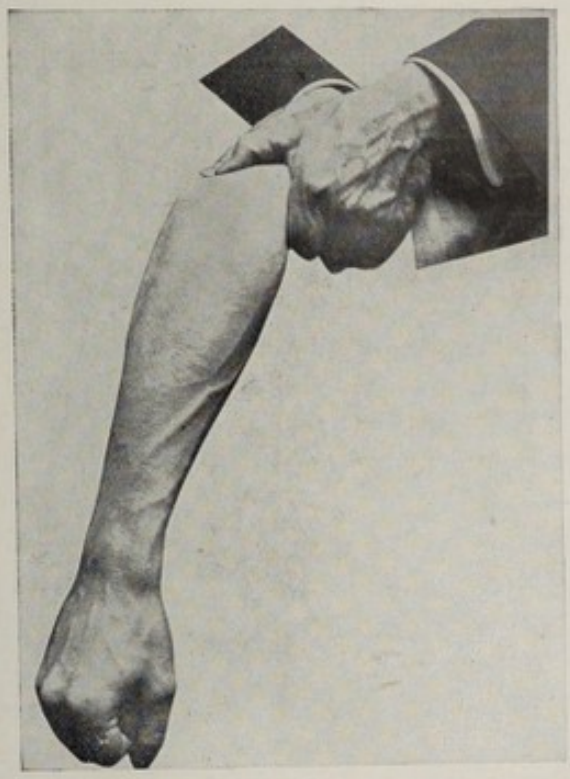

Fig. 639.—Showing a method of reduction of a dislocation of the elbow backward. Note partial extension of forearm on arm; position of thumbs of surgeon behind olecranon making pressure forward while fingers make pressure backward (Scudder).

angular splint for two or three days, after which remove the splint, bandage the arm, and massage it as I have already described. We



Fig. 640.—Old dislocation of the head of the radius outward and backward. Functional usefulness of the elbow unimpaired. Pronation and supination normal. In such a dislocation, were there present any serious disability, excision of the head of the radius would be indicated (Codman) (Scudder).

should expect a useful and sound elbow after three weeks of such treatment.

Old unreduced dislocations of the elbow are almost impossible of reduction, so that our one resource in these cases is an operation. We should use that method which, with the least damage to the joint, exposes all the affected bones, and we can usually accomplish this through cutting down upon the parts from behind, or, if we prefer, through Kocher's lateral incision. Sometimes we may advance most successfully by removing the olecranon. We then trim away all adventitious and frayed tissue and reduce the dislocation. If the articular surfaces appear normal, we may look for the restoration of a useful joint; if, however, the joint surfaces are damaged, and if there be loss of substance in the articular cartilages, it may be wise to perform arthroplasty after the method of J. B. Murphy—the insertion within the joint of a fat-fascial flap taken from the posterior surface of the arm. In some extreme cases it may be wise to do a partial or complete excision of the joint. After any of these operations we can scarcely look for a restoration of normal function, but we may expect fair motion and a reasonably strong arm.

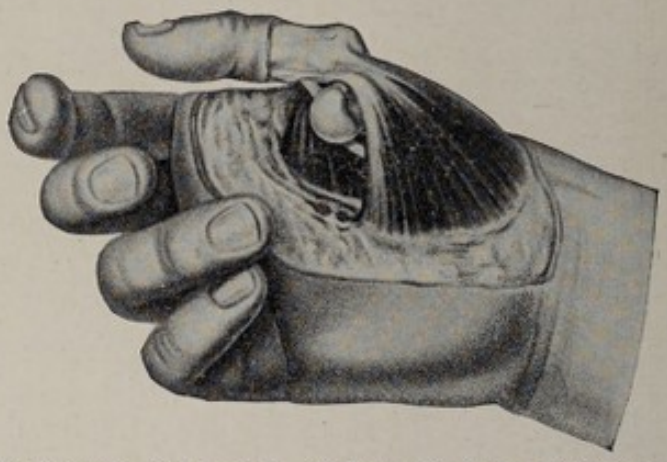

Fig. 641.—Backward dislocation of first phalanx of thumb. Note head of metacarpal and how it is held by adductor brevis and flexor longus pollicis (Helferich).

Dislocations of the wrist call for no special mention. They are obvious; they are easily reduced if fresh, while, if old and fixed, they may best be treated by a partial excision of the wrist.

Backward dislocation of the first proximal phalanx of the thumb is often found to be extremely difficult of reduction. The two lateral ligaments are torn, and the phalanx slips backward and over the head of the first metacarpal bone. Ordinarily, we increase the difficulty by making traction. We must manipulate the bone back into place by extending completely the thumb, so as to relax the tendons of the adductor brevis and flexor longus pollicis, and then push the base of the phalanx forward, advancing at the same time the torn glenoid ligament over the end of the metacarpal bone; we then, by flexion, complete the reduction, and dress the thumb on the proper fixation splint.

The other bones of the hand are subject to dislocations which may easily be reduced and held in place.

Dislocations of the Hip.—Forty years ago the subject of hip dislocations was one of prime interest to surgeons and to medical students, for in those days Henry J. Bigelow was investigating and writing upon this interesting topic. The genius of the man illuminated and made conspicuous the theme. In fact, dislocations of the hip are extremely rare, and most physicians will live through a lifetime of practice without seeing one. So rare and so interesting is the condition that to-day even at the Massachusetts General Hospital, where Bigelow conducted his clinical investigations on the subject, a dislocated hip is still regarded as a precious curio, which must not be reduced by the casual house-surgeon, but must be reserved for the inspection and treatment of the visiting surgeon himself.



Fig. 642.—The Y-ligament (Bigelow).

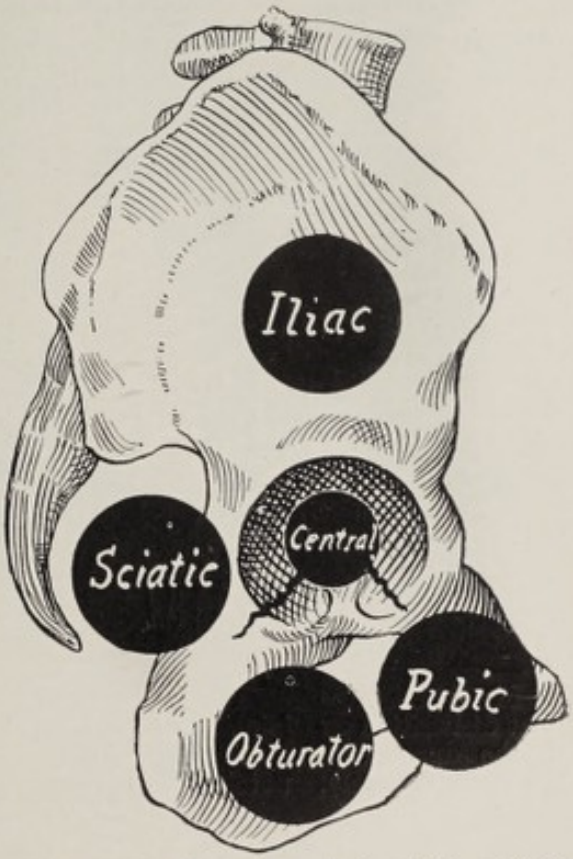

Fig. 643.—Location of head in various forms of dislocation of hip.

Bigelow's studies and explanation of hip-joint dislocations are of especial interest, because he was able satisfactorily to demonstrate how it is that the anterior portion of the capsule of the hip-joint forms a strong band shaped like an inverted Y, which obstructs the return of the dislocated bone into its socket, when the old-time method of reduction is used. Bigelow demonstrated that this Y-*ligament*, as he called it, may well be used as a fulcrum, upon which the surgeon may rely to assist him in reducing hip dislocations by simple methods of manipulation. Surgeons other than Bigelow had reduced hip dislocations by somewhat similar maneuvers, notably Little, of Texas, and Reed, of Rochester, N. Y., in this country, and various others in Europe; but it remained for Bigelow, and later for Allis, to put manipulation methods upon a rational basis.

Scudder[1] briefly and lucidly sums up the anatomy and mechanism of hip-joint dislocations in the following words: "A line drawn from the anterior superior spinous process of the ilium to the tuberosity of the ischium passes about midway across the acetabulum. The portion of the bony pelvis posterior to this line is called the outer plane of the pelvis. The portion of the pelvis anterior to this line is called the inner plane of the pelvis (Allis). The hip is dislocated by a force bringing leverage to bear upon the hip bone when the thigh is flexed upon the abdomen. The head of the femur leaves the acetabulum through a rent in the under portion of the capsule of the joint.

"The first movement of the head in being dislocated is downward. According as the head of the bone slips to the outer or the inner plane of the pelvis will the dislocation be classified as an outer or an inner dislocation, that is, a posterior or an anterior dislocation. Of course, in either position, whether the outer or the inner, the head of the bone may



Fig. 644.—Hip-joint dislocation on to the dorsum of the ilium (Cooper).



Fig. 645.—Hip-joint dislocation into the sciatic notch (Cooper).



Fig. 646.—Hip-joint dislocation into the obturator or thyroid foramen (Cooper).



Fig. 647.—Dislocation on pubis (Cooper).

be high up or low down. The anterior portion of the capsule of the hip-joint is far thicker than any other portion of the capsule. This thickened portion Bigelow called the Y-ligament."

Surgeons have for years subdivided the class of *anterior* dislocations into dislocations into the obturator foramen and dislocations upon the pubis; while the common *posterior* dislocation is classified as a dislocation upon the dorsum of the ilium—"dorsal dislocation." Dislocation into the sciatic notch is a posterior dislocation also, and may be regarded as a rather exaggerated form of dorsal dislocation.

The *signs* and *symptoms* of inward or anterior dislocations are as follows: The thigh is flexed upon the abdomen, abducted and rotated outward, while the heel is raised and the foot is everted. In the case of an outward or dorsal dislocation, the limb is inverted, somewhat shortened, and flexed slightly, while the toes rest upon the instep of the

[1] C. L. Scudder, ibid., p. 603.

sound foot. The interesting figures taken from Astley Cooper's classic work represent admirably the appearances of these various dislocations.

If the surgeon will but bear in mind the position of the Y-ligament, which extends from the anterior inferior spine of the ilium to the line below the two trochanters of the femur, and if he will reflect that this ligament forms a fulcrum about which the head of the bone revolves in dislocations, he will perceive readily the directions in which the head must be turned in order to reduce the various dislocations. The old cuts from Bigelow's well-known work illustrates these anatomic points.

Treatment.—In order to reduce an inward or *anterior* dislocation we may observe one of the following methods:



Fig. 648.—Dorsal dislocation (Bigelow).



Fig. 649.—Obturator dislocation (Bigelow).

Bigelow's method of reduction of obturator or anterior dislocations: The surgeon flexes the thigh on the abdomen to a right angle, abducts it, rotates it inward with adduction, and then extends it vigorously, when the bone should slip into place.

Allis's indirect method: Extension, adduction, and outward rotation are the movements made. We place the patient on a blanket upon the floor and flex the femur. The surgeon then supports the flexed knee upon his own bent elbow, and grasps the ankle with his other hand; he then extends the latter with traction in the line of the long axis of the femur, adducts, and rotates outward.

Needless to say, in all manipulations for the reduction of hip dislocations the patient should be profoundly anesthetized.

The reduction of outward or *dorsal* dislocations: If the case be uncomplicated, the surgeon may properly follow the directions of Stimson. Lay the anesthetized patient on his belly upon a table,

with both his legs protruding their length beyond the table. An assistant holds up the sound leg, while the damaged leg is allowed to drop. The surgeon now grasps the affected leg and flexes the knee to a right angle, when the weight of the leg itself, pulling upon the muscles about the hip, aided by a little pressure and rotation on the part of the surgeon, promptly reduces the dislocation.

The methods of Allis and Bigelow in the case of a dorsal dislocation are somewhat similar to each other and differ radically from the method I have just described, in that reduction is effected while the patient lies upon his back, when the dislocated femur is lifted up into place.

(1) Allis' method: The patient lies on a blanket on the floor, his pelvis held firmly by assistants, while the surgeon kneels at his side and flexes and elevates the leg with his own arm beneath the patient's knee; he now turns the bent leg outward, lifts the leg inward and rapidly extends and drops the whole limb upon the floor, by which maneuver he effects reduction.



Fig. 650. — Pubic dislocation (Bigelow).

(2) Bigelow's method for the reduction of a dorsal dislocation: The patient lies upon his back on a blanket upon the floor; the surgeon flexes the affected thigh with his own elbow beneath the knee, adducts the limb, inverts it slightly, lifts it, circumducts the leg outward, and then strongly extends and drops it, when reduction should be found complete.

Observe that these maneuvers are not always immediately successful. They are successful if the capsule be widely torn and if there be no soft parts to interfere with rotation of the bone back into its socket. Furthermore, *long-standing dislocations* may be found impossible of reduction by these methods on account of a partial closure of the rent in the joint's capsule. If he finds it impossible to reduce a hip-joint dislocation by manipulative measures, the surgeon should cut down upon it through a long incision over the great trochanter; should free the head of the bone; should investigate the joint, and should return the head to its socket, under easy inspection.

If one has reduced the bone without a cutting operation, he should confine the patient to bed for at least two weeks, after which he may carry on the treatment by the use of crutches, massage, passive motions, and the gradual reëmployment of the limb; six weeks at least must elapse before the patient can walk with reasonable comfort. If the surgeon is forced to cut down upon the joint in order to reduce a dis-

location, a longer and more tedious convalescence will follow, though with proper asepsis and with sound wound healing the question of convalescence will be one of time only, and not of any material variation in the treatment.

The **patella** is sometimes dislocated. The accident occurs through a blow upon the inner side of the knee, forcing the patella out of plumb, and carrying it over the edge of the femoral condyle even. If the patella rests, balancing upon the condyle, we call the condition subluxation. A curious and more unusual form of dislocation is that spoken of as *vertical rotation*, in which case the patella is turned up on its edge. The mechanism of these various displacements is obvious, and the treatment is the most simple conceivable. Often it is necessary merely to anesthetize the patient and lift the leg toward the abdomen, when the patella at once falls back into place. If it does not spontaneously retreat, it can easily be manipulated back into its normal bed.

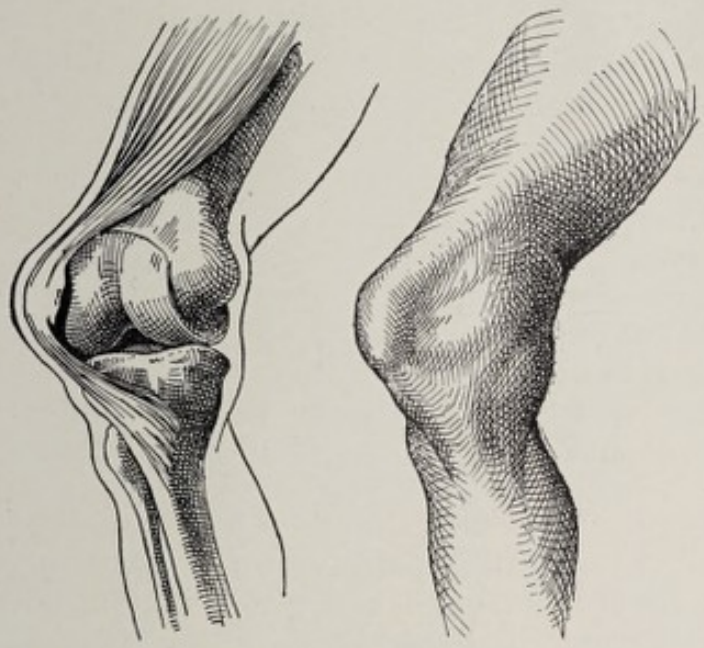

Fig. 651.—Outward dislocation of the patella (Hoffa).

A good deal of swelling and pain may follow the reduction, but this subsides in a few days under bandaging and massage.

The **knee** is dislocated rarely. Theoretically, the knee may be dislocated in any direction, backward or forward, right or left, though the backward displacement of the tibia on the femur is the most common form of displacement. Those forms of subluxation of the tibia which are associated with tuberculous disease of the knee-joint illustrate a common picture of dislocations of the knee.

When the femur underrides the head of the tibia, we find the patella forced upward out of its close association with the femoral condyles. In this way there is produced a double dislocation or a dislocation of two joints, as it were—the tibia from the femur and the femur from the patella. It is obvious in the form of dislocation, such as Lothrop

reports, that the patella must leave the femur, for the patella is attached closely to the head of the tibia by the strong ligamentum patellæ.

We can usually reduce knee dislocations readily by the employment of strong traction and manipulation, the patient being anesthetized.

Occasionally the **semilunar cartilages** are torn loose and displaced —sometimes displaced so far as to project over the margin of the tibia. I shall refer to this matter later in our brief discussion of bone and joint diseases. Suffice it here to state that the loosened semilunar cartilage had best be removed.

After all these injuries to the knee-joint the limb must be kept at rest on a splint until exudation has subsided and the movements of the joint can be produced without especial distress. A patient in good health should recover perfectly the use of the knee-joint after dislocation in the course of from six weeks to two months.

Dislocations of the Bones of the Foot.—An ankle-joint is sometimes dislocated, though this injury is much more rare than popular statement asserts—I mean a dislocation without a fracture. We have seen that a dislocation outward of the ankle is a common accompaniment of Pott's fracture. Simple dislocations of the ankle are extremely rare, however, on account of the solid mortising of the joint. When such dislocations do occur, however, they are associated with an extensive laceration of the joint ligaments. Always make sure that there is no fracture present.

Rarely the other bones of the *tarsus*, the *os calcis*, and the *scaphoid* may be forced out of place by strongly applied direct violence, but it is most uncommon to find these dislocations except when they are associated with extensive lacerations and fractures of other bones. The *metatarsal* bones and the *phalanges* of the foot likewise may be dislocated.

The *treatment* of all these dislocations at the ankle-joint and below it is obvious. The surgeon should have proper *x*-rays taken to ascertain the exact nature of the damage, and then, having determined that no fracture or other untoward complicating lesion is present, he should manipulate back into place the displaced bones and should apply a carefully padded bandage for two or three days. Then he should employ massage. There are no joints of the body perhaps which demand so emphatically the use of massage for their restoration of function. Every joint of the foot is a weight-bearing joint; the force brought to bear upon it in every-day life is extremely great; it will not answer to treat such a joint lightly, or to assume its ready healing under the old-fashioned methods of immobilization. A damaged joint of the foot must be taken in hand from the beginning, and must be massaged and manipulated thoroughly, and watched carefully, until convalescence is established.

Dislocations of the Lower Jaw.—Obviously, a dislocation of the upper jaw is an impossibility, so that all dislocations of the jaw are dislocations of the lower jaw. The books furnish us with descriptions of manifold types of jaw dislocations. As a fact, nearly all dislocations

of the jaw are dislocations forward. To be sure, there is the dislocation backward accompanied by fracture, a lesion so complicated and difficult of adjustment that usually the surgeon is obliged to cut down upon the damaged bones, and either wire and reduce them, or more commonly remove the head of the bone and endeavor to institute a false joint. Certain writers—LeFevre, Robert, Neis, and a few others—have reported rare dislocations of the jaw upward and outward, but these anomalies need concern the student but little. The common forward dislocation of the lower jaw is usually caused by muscular action—by laughing, yawning, or vomiting, or rarely by a violent blow upon the angle of the jaw from behind, when the victim had his mouth open. The mechanism of the dislocation, is, therefore, simple enough, but the relation of the parts after dislocation has not been so obvious. The capsule is



Fig. 652.—Double dislocation. Note open mouth; displaced articular process; empty glenoid. Capsule uninjured; temporal muscle taut (after Helferich) (Scudder).

not necessarily torn, though it may be. It is always tightly stretched, while as a reflex result the temporal muscle is thrown into a condition of tonic spasm, by which the jaw is fixed, and firmly held in its abnormal position outward and forward. As a result of the position of the bone and the displacement of the coronoid process, the mouth is forced widely open and thus held, while the chin is markedly protruded. The dislocation may be either one-sided or bilateral, but in both cases the deformity is practically the same.

Reduction of jaw dislocations is simple and easy when properly undertaken—that is to say, when the patient is thoroughly relaxed by an anesthetic. Perhaps in the case of no other dislocation is a thorough relaxation so important. I learned this as a student while endeavoring, in the accident ward of the hospital, to reduce the dislocated jaw of a

man imperfectly etherized. I could make no impression whatever on the dislocation, but a senior surgeon, chancing to go by, pushed the ether until the patient was completely relaxed, when the head of the bone slipped back into its socket almost at a touch.

Our sketch shows the method of reducing a dislocation of the jaw. After its reduction the bone should be held in place for three or four days by a four-tailed bandage, and the patient should not be allowed to chew until the soreness has nearly disappeared.

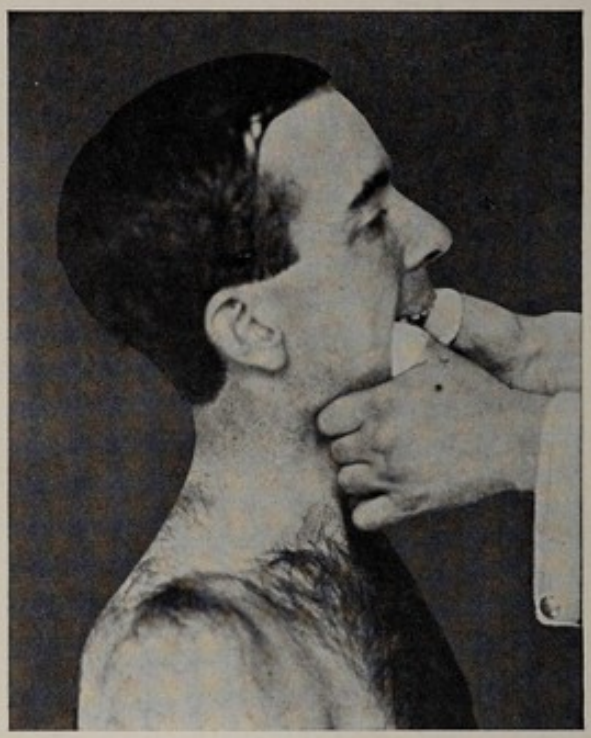

Fig. 653.—Method of reduction of dislocation of the jaw. Both thumbs, having been covered with several turns of a roller bandage, are inserted into the mouth over the molar teeth, the fingers of both hands being placed on the outer side of the jaw. Pressure is made in a downward direction by both thumbs, as described in the text (Eisendrath).

We have now discussed the more important dislocations which are seen in every-day private and hospital practice. There are other and rarer forms of displacements of bone—of bones seldom dislocated, of bones dislocated by spontaneous muscular action, of bones habitually dislocated; but the treatment of such conditions must be obvious to the student who has once grasped the principles we have studied in this chapter.

CHAPTER XXX

BONES AND JOINTS (ORTHOPEDIC SURGERY)

THE surgery of the bones and joints is the most ancient chapter of surgery known to us. Orthopedic [1] surgery—that is to say, surgery which deals with deformities is a relatively modern branch of the art of surgery. Although orthopedic surgery concerns itself with structures other than bones, at the same time the greater portion of its interest is with bones, so that it seems well to me to consider some phases of orthopedics in this chapter in connection with the subject of diseases of the bones and joints. Orthopedic surgery has been developed, in America, into a great and special art, with an enormous literature of its own, and ponderous text-books. Obviously, therefore, it would be impossible, if not improper, for us in this place to take up at length the numerous questions with which orthopedic surgery is concerned. They are within the province especially of orthopedic surgeons. At the same time the student and the general practitioner must deal frequently with certain of the more familiar forms of orthopedic lesions. Such lesions I shall describe briefly in the following pages, taking them up incidentally, perhaps, in connection with bone and joint diseases.

THE BONES

The surgery of *bones* began to find development in remote times because bone lesions were common, or reasonably obvious, and were vital to the physically active peoples of early days. Fractures especially engrossed the attention of ancient surgeons, and we learn from the writings of the Egyptians and of the Jews that fracture surgery had attained a remarkable degree of development thousands of years before our era. We have discussed fractures in a previous chapter; let us therefore at present consider more especially certain bone diseases.

As Roswell Park remarks, we must bear in mind the fact that the osseous system is subject to much the same diseases as affect the softer structures of the human frame. Bone is a tissue; it becomes inflamed, it degenerates, it hypertrophies, it is the seat of tumors. Moreover, bones are complex structures; they are vascular; they are of varying hardness; they have differing densities, and we apply to the parts of bone the familiar terms cancellated, ivory, medulla, endosteum, periosteum, and marrow—all of which terms must be well known to the reader. Moreover, special bones are adapted to special purposes. We recognize the peculiar lightness, resiliency, and strength of the dome-

[1] ὀρθός, straight; παῖς child.

shaped bones of the skull, while the intricate structure of the upper portion of the femur has long been the admiration of intelligent architects.

The reader's studies in embryology have already taught him something of the growth and structure of young bones; and we recall the fact that the developing bone of the child and youth may be quite different in its construction from the firm bone of the adult. Especially must we bear in mind always, when dealing with young bones, that they are in process of formation; that their centers of ossification are still separated, and that their epiphyses may have but the frailest of attachments to the long and firm diaphyses.

Nichols[1] divides the lesions of bone into five classes: (1) Those lesions produced by various pathogenic organisms; (2) those which are apparently due to some diathesis—*e. g.*, rickets, acromegaly; (3) lesions produced by disuse—atrophy; (4) tumors of bone; (5) cysts, which may be primary or may be due to the presence of echinococci.

Let us consider first certain *congenital* conditions or defects in the bones. Bearing in mind that human bones are preformed in cartilage, we can understand how, through an interference with the normal formation of this cartilaginous mass, the final condition developed may be retarded, or may be turned in a wrong direction. Occasionally we find that a whole bone is lacking. This is curiously illustrated by the well-known case of Lund, which was published by that surgeon some years ago, and has frequently been reproduced.

On the other hand, the reverse of this process is seen, namely, an abnormal number of cartilaginous masses may be deposited and may be developed into bones, in which case we find, for example, superfluous limbs or parts of limbs. The six-fingered hand is a familiar example of this—the so-called polydactylism; or there may be a perversion of development of these extra bones, resulting in curious combinations of fingers, producing the well-known condition known as syndactylism. It is needless to multiply examples of these conditions, which are familiar to all surgeons.

Bones are subject to *atrophy*, as are other anatomic structures; and we know that various causes lead to bone atrophy. In the case of old persons bone atrophy, or "lacunar resorption," is often very great, and has received the clinical term "senile atrophy." We see it in the skull and in the long bones, and we know that it is responsible for the frequent fractures of the long bones in old persons. Disuse, as well as old age, may lead to "lacunar resorption"; indeed, we see such resorption in bone-stumps after amputation and in cases of limbs paralyzed by some central nervous disorder.

Bones are subject to *hypertrophy* also, in which case great enlargement of the bones, either of the skull or in the limbs, may take place. Such hypertrophy may be due to a new formation of periosteal bone in its attempts at repair, or the process may be a true hypertrophy in no way associated with previous destruction of bone. Hypertrophy is seen sometimes in the amputation stumps of young persons.

[1] E. H. Nichols, in Keen's Surgery, vol. ii, p. 21.

Of far more practical interest to surgeons, however, than the rather curious and unusual conditions which I have described are the familiar active processes in bone and in the periosteum—especially the *inflammatory* processes. Of these processes, usually due to infections, one of the most familiar is *periostitis*. E. H. Nichols reminds us that the older text-books always laid great stress upon the occurrence of an acute infectious inflammation of the periosteum; but he affirms that in his opinion acute suppurating periostitis alone does not occur, and that most of the cases so described are really mild cases of superficial osteomyelitis, with abscess formation beneath the periosteum, and possibly inflammation of the periosteum itself.

Periostitis gives rise to an acute localized pain, exquisite tenderness, loss of function, and fever, with or without chills. Untreated, such cases go on to a serious and extensive involvement of the whole bone affected. For this reason prompt and energetic *treatment* is essential: free incision into the affected area, cleaning out the cavity, and cleansing with irrigation and packing until the wound has healed from the bottom. These are the cases of the so-called acute periostitis.

On the other hand, we recognize—

Chronic periostitis, a long-continued irritation of the periosteum, with a proliferation from the bone-forming cells of that structure. Chronic periostitis is a sequel and an associate of many general infectious diseases,—of syphilis, of typhoid,—as well as of injuries and long-standing superficial ulcerative processes (*e. g.*, varicose ulcers). These chronic inflammations may or may not give rise to pronounced symptoms. A patient may experience constant dull pain and loss of power in the part; or he may be relatively free from discomfort and go about ignorant of the true condition. Unfortunately, we cannot always promptly and readily *treat* or cure a chronic periostitis. We must direct our attention, of course, to the underlying disease, and we must remove all the irritative factors. In spite of us, however, many of these cases run on in an indefinite course, little affected by the endeavors of the enthusiastic surgeon.

Caries and **necrosis** are familiar terms, signifying a destruction and death of bone. Ordinarily surgeons regard caries as due to a tuberculous process, which brings about a molecular softening and destruction of the bone. Ultimately, this process may be extensive, while there is present at no time any appreciable mass of dead bone. Necrosis, on the other hand, is generally due to some pathologic process, which causes the death of large bone areas at once, in which case the mass of dead bone lies like a foreign body encased in the living bone, and is termed a "sequestrum." Clinically, therefore, we distinguish caries from necrosis—the former, as due to a tuberculous process; the latter, as due to an acute pyogenic infection. Caries is found commonly in the neighborhood of joints which themselves become involved in the disease; while necrosis more frequently is seen in the shafts of bones. Both caries and necrosis, if long continued, bring about an inflammation of neighboring soft parts, the destruction more or less

of overlying tissues, the development of sinuses leading outward, and the establishment of chronic running sores.

Modern surgery retains the words caries and necrosis merely as clinical terms of convenience. We shall discuss their underlying causes shortly and at greater length in our paragraphs on osteomyelitis and on tuberculosis.

Acute osteomyelitis is one of the most urgent, painful, and destructive of inflammatory processes. It is a suppuration of bone, and is due to an infection of the bone-marrow by pyogenic organisms. It has been called "bone furunculosis." The infection may involve the entire marrow of the bone affected. Generally the active organism concerned is the Staphylococcus pyogenes aureus; less often, the typhoid bacillus, the streptococcus, or the pneumococcus. The disease may be due to certain general causes also—in young persons whose bones are undeveloped; in persons exhausted from long illness, from fatigue, from exposure; and especially in persons the subjects of acute general infections. Osteomyelitis follows upon local bone injuries also, which diminish the resisting qualities of the bone; such injuries especially as compound fractures. Osteomyelitis begins nearly always in the diaphysis, though rarely it may begin in the epiphysis, and so may simulate tuberculosis. The bones commonly affected are the tibia and the femur, though no bone is exempt.

In Chapter XXVI, I said a word regarding the urgent nature of a case of acute osteomyelitis, and spoke of the imperative need of immediate treatment. Acute osteomyelitis, beginning then in the diaphysis of a long bone, runs riot through the medullary canal, involving the endosteum and then the cortical bone proper, which may become necrotic over an extensive area. The periosteum becomes stripped from the bone, and the cortex, in varying degrees necrotic, may lie dormant as a sequestrum if the patient lives to tell the tale. In most cases a general toxemia of an extreme type develops, with excruciating pain in the affected limb, with a high fever, and with other familiar signs of septicemia. The patient may die of the disease in a week or less. Again, the inflamed area may become so thoroughly disorganized that spontaneous openings will develop with a free natural drainage, so that the constitutional symptoms subside, and the patient goes on to an unsatisfactory and halting recovery. In these cases the sequestrum persists, keeping up an irritation, and encouraging a chronic running sore. If the reparative processes go on, they are brought about by the formation of new bone through the activity of the periosteum—new bone which becomes deposited in circular layers—involucrum—about the old necrotic shaft. This involucrum is attached at either end of the remnant of the original shaft which has not been destroyed. There results a walling-off of the sequestrum from the sound bone by a plug of bone which in time becomes dense and is of varying width. As Nichols describes the condition; "In cases of spontaneous osteomyelitis, areas of new endosteal bone may be irregularly distributed or may form a wall surrounding and inclosing definite circumscribed

areas of purulent inflammation, *i. e.*, there may be an abscess with a wall of dense endosteal bone." Now the integrity of the cortex depends entirely upon the vitality of the endosteum within and the periosteum without. "The necrosis and inability of repair of the cortical bone are the chief causes of the persistence of sequestra and sinuses in chronic osteomyelitis."

The *symptoms of acute osteomyelitis* are extremely severe, as a rule, and begin with a sudden localized pain, usually in the shaft of a bone. The neighboring joints are usually tender and painful also, so that the patient and the physician himself may regard the case as one of "articular rheumatism." It has been pointed out that gentle pressure at some point over the shaft at a distance from the area of pain brings out and accentuates localized pain in the lesion. After the onset of the attack there soon develops a swelling of the soft parts about the bone, with redness and tenderness and acute edema. The patient's temperature rises to 103° or 104° F.; the pulse mounts, and the picture is one of an acute constitutional disturbance. The leukocyte count runs high —even to 40,000.

A careful surgeon should be able to distinguish this disease readily from the various joint infections and from tuberculosis, for acute osteomyelitis is localized in the shaft of the bone and is ushered in by symptoms far more alarming and overwhelming than is tuberculosis or other infectious joint lesions.

The *treatment* of acute osteomyelitis is not always easy, and depends upon the stage of the disease. Nichols divides the course of the disease into four stages: (1) That of infection, necrosis, suppuration, general intoxication; (2) the subacute stage, which begins with the evacuation of pus; (3) the chronic stage, marked by the formation of sequestrum, involucrum, and sinuses; (4) the chronic stage of localized bone abscesses.

In the acute stage the surgeon must cut down upon the bone, trephine the shaft, and drain the bone-marrow, frequently through an extensive opening through the cortex; and he should, if possible, curet, and wash out thoroughly all involved marrow, tracing out and following up suspicious areas in the diaphysis and even in the epiphysis.

In the subacute stage there are a necrotic shaft and a proliferation of the periosteum, and this is the stage which is often the most difficult of treatment. In this connection Nichols urges the employment of a careful routine adapted to varying conditions of this subacute stage. There are three classes of conditions which warrant three definite and defined procedures: "(1) Removal of the necrotic sequestrum before a definite involucrum has been formed, while the periosteum, although proliferating, is still plastic. (2) Removal of the sequestrum just as soon as a sufficient amount of involucrum has been formed to carry on the function of the original shaft. In the early stages such a young involucrum has a limited power of central growth, and in favorable cases may obliterate the cavity left by the removal of the sequestrum. (3) Removal of the sequestrum after the involucrum has become dense bone.

In such cases a cavity always is left surrounded by dense involucrum lined with granulation tissue, and such a cavity will persist indefinitely because the dense involucrum has no power of central growth."

It is obvious that such descriptions of osteomyelitis and its treatment appear to confound acute osteomyelitis with chronic osteomyelitis. Indeed, chronic osteomyelitis develops out of acute osteomyelitis. Chronic osteomyelitis is the condition of bone which is seen toward the end of that stage which Nichols, somewhat to our confusion, calls the second part of the subacute stage. In other words, when the disease presents sequestrum, sinus formation, abscess formation, and the growth of involucrum, we may fairly describe the condition as one of *chronic osteomyelitis*.

The treatment of the chronic stage with dense involucrum and extensive sequestrum is by mallet and chisel. We remove the sequestrum and give drainage, but the bone defect does not heal, and a filthy discharging cavity remains for years. Surgeons have long sought a remedy for this trying condition—a remedy which shall close the bone defects. The first desideratum for closing these defects is thoroughly to disinfect the bone cavity—an extremely difficult matter. It should be undertaken, however, again and again if at first it fails, and a fairly successful method is as follows: Scrape thoroughly and cut away all infected tissue, smear the fresh surface with strong carbolic acid; wash away the carbolic with a 70 per cent. solution of alcohol; turn in skin-flaps so that they shall lie snugly along the bottom of the cavity and cover it completely. If the preparation of the bone has been perfectly made, these skin-flaps will "take." The after-care of these cases must be followed in a most painstaking fashion. The wound must be dressed frequently and must be kept scrupulously clean, else some slight point of infection may develop fresh trouble, and undo totally the new skin-grafts.

Chronic localized bone abscesses develop variously. They may be small or may occupy nearly all the shaft of the long bone. They cause no definite sequestrum. Drain them through a trephine opening, and you will have left a dense bony wall. It is extremely difficult to close these cavities. If they be rendered aseptic, they may be filled with blood-clot which will organize, or they may be treated by the skin-flap method.

Bone tuberculosis is a common affection. The tubercle bacillus gains entrance through the blood-stream, usually, to the bone-marrow, where it causes the formation of miliary tubercles. Other secondary tubercles then arise; caseation results, and extensive softening of the bone-marrow is produced. Then the bony trabeculæ become involved and a definite tuberculous abscess cavity is formed.

Bone tuberculosis nearly always begins in the epiphysis of the long bones. The process extends toward the neighboring joint, so that we commonly find a joint tuberculosis superimposed upon and masking, as it were, a bone tuberculosis. We shall concern ourselves somewhat later with a description of joint tuberculosis.

In rarer cases, however, the bones alone are involved—such bones especially as the ribs and the pelvic bones. In these purely bone cases the symptoms are quite different from the symptoms of joint tuberculosis. Bone tuberculosis develops slowly; it destroys the bone gradually, forming abscesses, and in a mild degree involves the surrounding soft parts, which break down and become riddled with sinuses; or the abscess may remain latent for a long time, giving us a true picture known as "cold abscess."

Bone tuberculosis shows no clear and definite symptoms. Usually there is pain, not very severe; sometimes a thickening in the bone can be felt, especially in that form of tuberculosis in young children which is called tuberculous dactylitis—a spindle-shaped enlargement of one of the phalanges. Often, too, we find evidences of tuberculosis in other parts of the body, in the cervical lymph-nodes or in the lungs, while the *x*-ray gives us a picture of disorganized bone. The familiar tuberculin test, either by injection or by instillation into the eye, may give us useful information.

The *treatment* of bone tuberculosis is not so simple a matter as some recent writers have claimed. We are not to treat tuberculosis of bone as though it were a malignant disease—that is to say, we are not, under all circumstances, to excise the disease with a wide margin. Indeed, coincident tuberculosis elsewhere may contraindicate such treatment in advanced cases; while in incipient cases, especially in fairly robust persons, we are justified in resorting to properly conducted fresh-air treatment. Wholesome living in a dry climate without operation is more likely to eradicate bone tuberculosis than is an operation followed by residence in the city slums.

Syphilis of bone is both congenital and acquired, and the gumma is its most important manifestation. Gumma develops in the periosteum or in the medulla, or it may extend to the bone from a neighboring tissue. The gumma is a lesion of late syphilis, as a rule; and whether the syphilis be inherited or acquired, its processes are similar and characteristic and its treatment does not vary. Two processes go hand in hand as the gumma progresses—destruction and construction. The granulation tissue of the gumma infiltrates the bones, causing necrosis; at the same time the surrounding tissue is stimulated to produce bone. For these reasons the surface of the diseased bone appears irregular, roughened, and eroded, while the bone as a whole may be larger than normal. If the entire bone is involved, it may become hardened and thickened (eburnation); or as the result of excessive lacunar absorption the bone may become thin and frail, so that it is easily fractured. In both forms periostitis frequently develops early, and often simultaneously, in different bones—upon the frontal and the parietal bones, the tibia, the sternum, and the clavicle. This form of periostitis appears as a flat elastic nodule covered by normal skin, which may become red and edematous as the nodule enlarges. During the later stages of syphilis a gummatous process in the periosteum develops slowly—on the inner layer of the periosteum, from

which it penetrates the bone. In these cases the nodules are flat, circumscribed, little painful, and found in much the same places as in early periostitis.

Gummatous osteitis may accompany periostitis or be secondary to it. It occurs in the hard palate and the nasal and facial bones; it perforates and destroys them. We recognize such a patient, in the one case, by his articulation, in the other by his characteristic saddle-nose.

Gummatous osteomyelitis is more rare. Gelatinous foci as big as a pea or a nut develop in the bone-marrow and in the medullary spaces. Sometimes these foci cause no pain, or again the pain may be excruciating. The foci infiltrate the bones; they are multiple; gradually they liquefy, while the surrounding bone becomes thickened and sclerotic. A syphilitic sequestrum forms and separates slowly, and may lie bare at the bottom of the open wound for years without becoming detached from the surrounding involucrum. We see this condition especially in the frontal and parietal bones. The gaping, filthy sores of the victim are familiar in European clinics, but are less common in this country.

Syphilitic dactylitis resembles outwardly tuberculous dactylitis. It is a congenital disease. A gumma develops within the short finger-bones, which become expanded and thickened. Ulcers and fistulæ may result, and the entire phalanx may become extruded, or absorbed without an accompanying suppuration.

There are diffuse forms of syphilitic periostitis and gummatous osteomyelitis. These forms run their course with suppuration, and there may be extensive destruction of the bones of the skull, of the forearm, and of the leg. The affected bones become thickened and heavy, or they may become brittle and light. If this diffuse form of bone syphilis occurs in early childhood, a curiously characteristic deformity develops, especially in the bones of the leg. The tibia becomes elongated, curved forward, and thickened, and a prominence develops upon its anterior surface in contrast to the straight line of the other leg.

Such and such-like are some of the more common syphilitic affections of the bones. The diagnosis of syphilis is usually easy when the disease is well advanced, but is correspondingly difficult in its early stages, for so-called gouty deposits and tuberculous abscesses attached to the bones may resemble closely these gummatous lesions. Usually we must make our diagnosis by careful study of the history of the case, and often by exclusion and through the use of antisyphilitic remedies. It does not suffice to *treat* these cases with medicine merely. The good results of medicine may be extremely slow, but we may sometimes hasten recovery by judicious surgical measures—by laying bare the diseased bone, by removing sequestra, by cureting gummata, and by draining abscesses. It is with bone gummata as with those intracranial gummata of which I have written—medicine alone may cure in time, but during the time the patient may die from the coincident effects of the local ailment.

Rickets or **rachitis** is a peculiar disease of the bones of children. Perhaps it is congenital—we cannot regard it as parasitical—and it is characterized by nutritional disturbances and striking structural irregularities. The most marked pathologic feature of rickets seems to be a deficiency of the calcium constituents of the bones, so that the bones, being soft, are made, through muscular and weight-bearing action, to assume peculiar relations and forms. The familiar rachitic lesion is constantly seen along the line of junction between bones and cartilages, especially in the chest, where, owing to the activity of growth of the cartilage and the slow formation of the bone, there result apparent bony prolongations into the cartilaginous tissue. When examining such a chest one feels rows of small, irregular nodules lying by the side of the sternum—"rosary." There appears to be an obscure but apparently undoubted relationship between rachitis and status lymphaticus.

Rachitis results in certain marked skeletal changes—a thickening of the shafts of the long bones, the flat bones, and of epiphyseal extremities, with a frequent stunting of bony development, so that the bones do not attain their normal length. The periosteum frequently becomes warped and curved; and this curving adds to the singular irregularity of the bone structure. In extreme cases the bones are so soft that they bend readily, when the child may develop an extraordinary degree of bowlegs or bow-arms, flat feet, club-feet, and clubbing of the fingertips, while the fontanel of the skull may remain open unduly long. The bones of the face also are soft and undeveloped in rickets; the face appears absurdly small; dentition is delayed, and erupted teeth decay early.

Changes other than those of the bones occur in rachitis: There may be hydrocephalus, spina bifida, enlargement of the liver and spleen; while the child is sickly, fretful, irritable, dull, sweats easily, and stands with heavy, nodding head and protuberant belly.

Rachitis is always discussed, however briefly, in text-books of general surgery, and I have followed convention, but I doubt if rachitis properly can be regarded as within the field of the general surgeon; at any rate, its *treatment* usually is medical; that is to say, its treatment consists in abundant feeding of the child, especially with fattening foods; in the use of hypophosphites, and sometimes phosphorus; moreover, we are beginning to believe in the employment of extracts of the thyroid and pituitary bodies.

The orthopedic surgeon, however, finds occasion to treat rachitic children. Up to the age of three years mechanical treatment is of little value. When the child is three years old, however, the orthopedic surgeon may employ the familiar leg brace to straighten bowlegs and knock-knees. In the case of an older child we operate for mild forms of bowlegs and knock-knees by osteoclasis, which consists in the fracture of the bone by means of an osteoclast. In the case of an adult we perform osteotomy—and a linear osteotomy is preferred by orthopedic surgeons to a removal of a wedge of bone, which shortens the leg.

Other operations on the bones occasionally may be undertaken, but it is upon the leg bones especially that the orthopedic surgeon will be inclined to exercise his ingenuity. After these fracturing operations the limb must be dressed in a plaster splint and treated as a fracture, although in most cases the time of convalescence will be shorter than is the case with ordinary traumatic fractures of these bones.

There are various other diseases of bone with which the pathologists and at times the surgeons must deal. There is **osteogenesis imperfecta**—a congenital disease characterized by fragility of the bones, with resulting fractures—a disease due to the lack of formative power in the bony tissues.

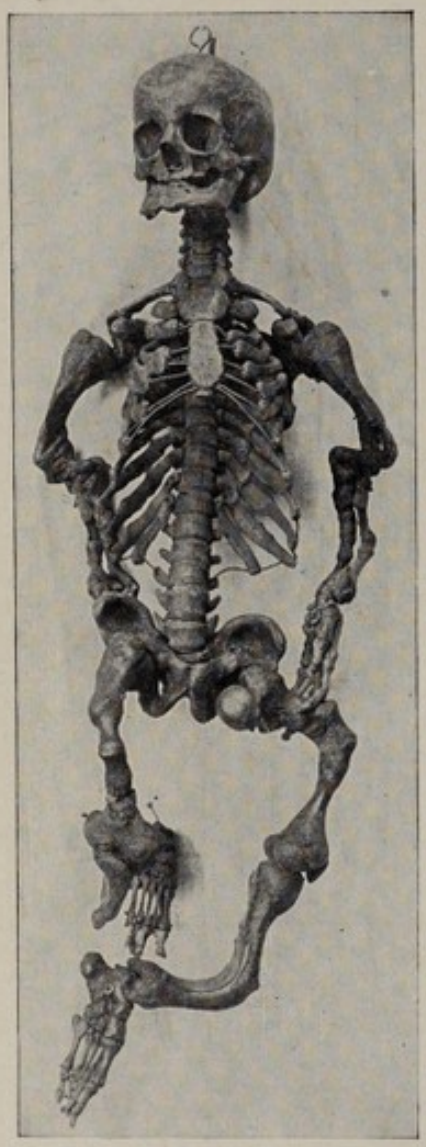

Fig. 654.—Fragilitas ossium (Warren Museum, Harvard Medical School). Skeleton of an adult Indian. Probably adult osteogenesis imperfecta (Nichols, in Keen's Surgery).

There is **chondrodystrophia fœtalis,** another rare congenital disease, described by Müller in 1860. He distinguished it from cretinism and from rickets, and showed that the failure of the long bones to develop is due to a disturbance of the zone of proliferating cartilage at the epiphyseal line. The disease is frequently mistaken for rickets, and doubtless is that condition which has received the name "fetal rickets."

There is **fragilitas ossium** (osteopsathyrosis). This is a condition not uncommon. It is not a definite disease, but expresses rather a clinical condition, and there are various causes which bring about a symptomatic fragility of bones. Old persons especially, as we have seen, are the subjects of fragile bones, and the cut illustrates well this extraordinary condition.

There is **leontiasis ossium,** a disease of the skull bones, in which new-growths or hyperostoses develop, diffuse and tumor-like. Sometimes these hyperostoses cause an enormous enlargement of the skull; the new bone may extend over the whole face, as well as over the vault. The normal skull openings may become closed, so that the cranial nerves are obliterated and the orbits are covered.

Obviously, such diseases as osteogenesis imperfecta, chondro-dystrophia fœtalis, fragilitas ossium, and leontiasis ossium are little susceptible to treatment.

Osteomalacia is a disease characterized by a softening of the bones and by other changes which suggest rickets. Unlike rickets, however, osteomalacia is a disease of adults. Curiously enough, *men* seldom are

subjects of osteomalacia, although the disease is not uncommon in women. It is not hereditary, and it may develop in persons previously robust. We know not its etiology, although writers talk of cold, wet, malnutrition, and starvation. Nichols suggests that osteomalacia may be a result of some complicated organic secretion—some internal glandular secretion, the bones becoming friable, soft, and fragile, the cortex thin, and the periosteum thickened. Such bones may easily be cut. The disease has been most obvious especially at the woman's time of puerperium, when the bones of the spine, the thorax, the shoulder, and the limbs are affected. Moreover, the disease begins irregularly to progress, being more active during pregnancies. Sometimes the process ceases and the woman recovers; again the patient may live for a number of years and then die of the disease.

Osteomalacia at first is characterized by a dull pain in the bones. Pregnant women have pain in the pelvis. Then there are muscle cramps and contractions. Patients assume characteristic bending positions in order to relieve the pain through the pelvis and legs. These patients do not lose flesh, their appetites are good, and their nutritional functions are not disturbed for a time. Later, extreme deformities develop—bowlegs and flat feet—and fractures occur. Gradually these recurring misfortunes wear out the victim, and if the case be steadily progressive, she dies of exhaustion.

We can help these persons often by *treatment*, especially if we see the cases early. We must institute careful dieting, and a life free from activities and cares, so far as possible. Women should avoid pregnancies, and in other rational and common-sense ways attempt to maintain their general health. No drugs are of service. Some enthusiastic surgeons have thought to benefit the patients by ovariotomy. They do not benefit them, so far as now appears. Our suggestions for treatment are the stereotyped, commonplace, and conventional suggestions. Unfortunately, however, most of the patients are among the poor and laboring classes. They cannot be put in the way of life most beneficial to their condition. They go on gradually to invalidism and to premature death.

Osteitis deformans is a chronic disease of the bones which results in their deformity. The disease is not particularly uncommon, as we are learning through recent researches, especially those of Locke. Sir James Paget described osteitis deformans in 1877, and the disease is sometimes called by his name. It is an ailment of advanced years, and may affect one or several bones, especially the bones of the legs. It is progressive, and it leads ultimately to extreme deformities. The *x*-ray helps us in the diagnosis, for without the *x*-ray osteitis deformans in its early stages might well be mistaken for several other diseases—for *acromegaly* especially.

Osteitis deformans should not be mistaken for *arthritis deformans*, which is a disease confined to the joints, whereas the disease we are considering is confined to the bone-shafts themselves.

We know not the cause of osteitis deformans. Paget and von

Recklinghausen held various theories which need not disturb us, while Park suggests plausibly that two or three different types of bone changes are coincidentally present—trophoneurotic atrophy and irritative hypertrophy side by side. At any rate, the changes in the bone are a combination of absorption and atrophy. New bone forms over the skull and new bone develops along the shafts of the long bones, especially of the legs, so that the legs become bowed and are strikingly unsymmetric.

The disease is insidious, tedious, deforming, long continued, painful. The legs become stiff and weak. The patient walks with a characteristic waddling gait. Spontaneous fractures may occur. Treatment is largely palliative. If the surgeon is consulted by one of these patients, however, he must do something, and he may be able to do a great deal to relieve the most distressing symptoms, though he may not cure the disease. Most of these patients are in wretched condition; they must be fed up, given an out-of-doors life, and provided with cod-liver oil, arsenic, and massage. Some physicians feel that potassium iodid helps these cases. I have seen no benefit from it. One must attempt to relieve the pain. Such counterirritants as the actual cautery are extremely useful at times for this purpose.

Like so many other chronic bone diseases, however, osteitis deformans is a melancholy ailment, depressing to the patient, little stimulating to the surgeon, save to the most optimistic.

Acromegaly (gigantism) has been but recently described, for acromegaly formerly was confused with osteitis deformans, with syphilis of bone, and with various other chronic diseases of the bone. Acromegaly causes enlargements of the bones—enlargements especially at the extremities of the body, the brows, the chin, the fingers, and the toes. Acromegaly involves other tissues also in its career—the hands become large and coarse; the features lose their familiar outlines and become heavy and dull; the eyelids become thickened; the nose becomes flattened; and, finally, even the larynx, the large vessels, and the heart become affected. The care of the disease falls properly to both internist and surgeon. Acromegaly is one expression of hyperpituitarism, of tumor, or hyperplasia of the hypophysis. Often the surgeon may relieve the symptoms through approaching the gland directly by the sphenoidal or frontal route, decompressing the sella, removing portions of the growth, and enucleating cysts.

THE JOINTS

The *joints* are structures of more varied and constant surgical interest than are the bones, for the joints are extremly complex in their make-up; and an injury or a disease of a joint comprehends lesions far more complicated than are the corresponding lesions of a bone. For these reasons joint lesions are often more difficult of diagnosis, and far more difficult of treatment than are bone lesions. When we study

joint lesions we have to consider damage to synovial membranes, to cartilages, to ligaments, to bones, to tendons, to muscles, to bursæ, and sometimes to nerves and blood-vessels—for all these structures enter intimately into the composition of a joint, or are closely associated with it. In a certain sense, joints and joint cavities are similar to such great serous cavities as the peritoneal pouch or the pleural cavity. For this reason joint infections may be highly dangerous, and joint injuries and inflammations far more significant than at first appears. The rectus femoris muscle may be extensively torn and befouled, but with reasonable care the patient quickly will recover; whereas the neighboring knee-joint, when punctured by a delicate needle, may receive an infection which will lead to septicemia with the loss of limb or life.

We divide joint lesions into familiar classes: into injuries and diseases; and these two classes are subdivided into such injuries as contusions, sprains, and dislocations, with their various trains of sequelæ; while the diseases of joints partake of the nature of disease processes in the surrounding structures, and are mainly inflammations, either acute or chronic. We must now take up consecutively the various joint ailments.

A **contusion** of a joint is caused by violence, and results in varying degrees of damage to the parts which enter into the joint. It is a subcutaneous injury. The synovial membrane may be bruised, the ligaments torn, and the soft parts lacerated. Immediately there results an outpouring of fluid into the synovial sac, which effusion causes the joint to swell. The fluid may be clear serum; it may contain flakes or masses of fibrin; or it may be bloody; and the greater the quantity of blood, the greater the amount of fibrin and clots collected in the joint cavity. At the same time the intrinsic cartilages concerned with the joint may be loosened or torn away from their beds.

The *symptoms* and signs of such a condition are generally at once obvious and striking. The patient suffers great pain. His joint appears swollen, with its normal outlines obliterated. It is usually extremely tender to the touch and is warm. The surgeon detects readily fluctuation, showing an excess of fluid; and the patient cannot move the joint without pain. If such a joint be left to itself, in the case of a robust person, the damage will disappear eventually, but convalescence will be long—in marked contrast to the prompt recovery which ensues upon intelligent and careful treatment.

Treatment.—The care of one of these joints is in direct relation to the stage of the healing process. The initial swelling, effusion, and inflammation must be met by absolute rest. As soon as reaction has begun, however, and the absorbent processes are at work, measures which shall stimulate absorption are of the greatest value. I have already discussed these matters when considering the massage of dislocations. Our routine treatment, then, in the case of a contused joint is to immobilize it absolutely in splints for two or three days; then, while keeping the patient quiet, daily to employ massage or dry baking, or

both, gradually lengthening the time of the massage and varying it with passive and active movements until function is restored. The time of convalescence for a joint so treated will vary for from a week to three months.

We talk about **sprains,** but who may define "sprain," or explain its distinction from a contusion? Good writers have said that a sprain is "an injury in which there is a sudden momentary displacement of the bones entering into a joint, the parts returning immediately to their normal relations." [1] Numerous other writers define sprains in cumbersome, bewildering, or enlightening paragraphs. In fact, a sprain may be regarded as a mild form of contusion. The parts about the joint swell more or less; fluid may be poured out into the synovial sac; ligaments may be slightly torn even, but one of the most constant and most interesting features of the ordinary mild sprain is the damage to tendons and tendon-sheaths, which is evidenced at once by an acute tenosynovitis. In the case of a sprained ankle especially our only evidence of sprain sometimes will be the fulness or swelling about the tendons below the malleoli and along the dorsum of the foot.

We have, in Chapter XXVI, already discussed sprains and their treatment, nor need we here rehearse the discussion of *dislocations,* which the reader will find in Chapter XXIX.

"Acute synovitis" is the term given to that form of active inflammatory exudation into a joint—a non-infective inflammation, sometimes, if you choose—which I have described in the preceding paragraphs.

Suppurative inflammation of the joints is a matter far more serious than contusion, sprain, or dislocation. These inflammations are the result of infections, and are often due to damage from without, from missiles or weapons, or they may be associated with compound fractures of bones. Pyogenic organisms enter into the joint and an acute purulent inflammation is produced. Then the joint-cavity rapidly is filled with pus or a purulent fluid, the synovial membrane becomes injected, dark, or purplish-red in color, and thickened, often extremely thickened, while the joint-cavity may become enormously distended. The ligaments become softened and disorganized, the bone epiphyses become eroded and necrotic, while the infection, passing beyond the joint, produces most grave constitutional disturbances.

This last fact—constitutional disturbance—leads us to a further important consideration regarding the *etiology* of joint suppurations. I have spoken of their origin from traumatism, but they may arise from a great variety of general systemic diseases, from pyemia, from gonorrhea, from cerebrospinal meningitis, diphtheria, dysentery, erysipelas, glanders, measles, pneumonia, and many other bacterial infections. As Lovett says,[2] quoting Poynton: "It is no easy task

[1] Lexer-Bevan, General Surgery, 1908.

[2] R. W. Lovett, Remarks on the Infection of Joints, Boston Med. and Surg. Journal, May 24, 1906.

to grapple with the subject of arthritis, . . . for around gout, rheumatism, and rheumatoid arthritis theory has cast her bright and attractive mantle, beneath which gray and sober fact is liable to be stifled."

If a suppurating joint remain untreated, disastrous results generally follow. The best we can hope for is a gradual subsidence of the acute process and the establishment of a chronic condition—thickening of all the parts of the joint, adhesions, and a considerable or complete limitation of motion, with marked muscle atrophy, while at the worst we anticipate death from septicemia.

Treatment, and proper treatment, is, therefore, imperative. Proper treatment consists in draining the joint at the earliest possible moment. Take an infected knee-joint, for example: The surgeon may operate by making openings at the side of the patella and in the popliteal space by washing out the joint with salt solution, and by inserting rubber drainage-tubes for the shortest possible distance into the joint consistent with adequate drainage. In graver cases the surgeon may find it necessary to lay the joint widely open by an anterior transverse cut, and to search out its depths, to remove all diseased tissue, and to excise the bone-ends even. After such a formidable operation he must look for nothing better than healing with complete ankylosis. Some desperate cases have been saved by a high amputation as a last resort.

Chronic arthritis is a term which covers a multitude of thoughts and a great variety of conditions. Surgeons and pathologists for years have been discussing the nature of chronic arthritis, and at last, in some fashion, have developed a classification which is rendering chronic arthritis reasonably intelligible. A number of different terms have been used in the discussion of chronic arthritis. Let us rehearse these terms, that we may be sure of the ground on which we stand: *Rheumatoid arthritis; rheumatic gout; osteo-arthritis; dry arthritis; chronic rheumatic arthritis; proliferating arthritis; chronic rheumatism; arthritis deformans*, etc.

While pathologists and surgeons debate, it will be useful for us in this reading to adopt the definite clinical classification of Goldthwait:[1] (1) *Villous arthritis;* (2) *infectious arthritis;* (3) *atrophic arthritis;* (4) *hypertrophic arthritis;* (5) *chronic gout.*

A few words of definition: *Villous arthritis* is marked by a chronic overgrowth of the synovial membrane; masses and tags project into the joint—tags composed of granulation tissue or of cartilage or of bone. Observe that these tags may be pinched off and may become loose in the joint, when they form that type of so-called "foreign body" known as joint-mouse."

By *infectious arthritis* we mean a large group of chronic joint affections, often periarticular, which are thought to be caused by impair-

[1] J. E. Goldthwait, Differential Diagnosis and Treatment of the So-called Rheumatoid Diseases, Boston Med. and Surg. Journal, November 17, 1904.

ments of nutrition, associated with micro-organisms in the joint, which may become greatly distended with fluid.

Atrophic arthritis constitutes a rarer type, seen in the cases of debilitated patients, and characterized by a progressive atrophy of the joint structures—both cartilages and bones—and their erosion. These are the cases commonly classed as *rheumatoid arthritis*.

The *hypertrophic*, or formative, type of arthritis develops on quite another plan from the atrophic type. In the hypertrophic type there are ulcerations of cartilage, but there is always a striking development of *new bone* about the margin of the joint and beneath the ulcerated cartilage. The new bone at the edge of the joint arises from the periosteum, while the new bone beneath the cartilage arises from the thickened endosteum. This hypertrophic arthritis is the common chronic rheumatism of old people, and we see it seated especially in the fingers, the hip, and the spine, with resulting deformities (arthritis deformans). These changes often lead to the characteristic distorted fingers of old age, and to the clinical appearances known as "Heberden's nodes."

Chronic gout calls for no consideration here.

Symptoms.—All these forms of chronic arthritis are non-suppurative. They are progressive, and are associated with pain, swelling, loss of function, stiffness, and deformity. One joint alone or many joints may be involved. When the hands and feet are affected, the disease is usually polyarticular. The knee is the one complicated joint which may be involved alone. Moreover, the symptoms of chronic arthritis vary, and yet in all the different forms they are not dissimilar. The attack may be acute and may be mistaken for acute "articular rheumatism," or the attack may begin gradually—the most common condition.

In these latter insidious cases the joint becomes irritable and painful when used; it becomes a little stiff after being rested; it may creak, and some thickening about superficial joints may be detected. The patient may complain of numbness in the joint, and may notice a reddening of the skin and sensations of dryness and burning in the joint. At times the general health may suffer from the outset of the disease, and there may be slight fever, a rapid pulse, and loss of appetite. There are usually remissions, so that the patient speaks of having attacks of rheumatism. While there is joint stiffness, at first due to muscular irritation, there follows in the later stages stiffness due to actual joint changes—to effusion, to a diffuse and pulpy swelling, and later to a fusiform swelling, which involves synovial membrane, capsule ligaments, and bone. Then there may occur distortion, either from muscular contraction or from actual changes in the bone ends.

"Chronic rheumatism" (arthritis) is not necessarily confined to adults. Children have it in that form spoken of as "Still's disease," in which many joints are involved, with much joint thickening, and with enlargement of the lymph-nodes and the spleen. In nearly all

cases the *x*-ray shows characteristic joint changes—marginal deposits of bone and a narrowing of the spaces occupied by the joint cartilages.

Thus we see that the disease is not always easily to be distinguished from tuberculosis. In doubtful cases the surgeon may use for diagnosis injections of tuberculin, or may aspirate the joint and practice inoculation experiments.

The course of a chronic arthritis is usually steadily and unfavorably progressive, though sometimes the disease may be checked, even if it cannot be cured. The rare cures are seen generally in children.

We undertake *treatment* of chronic arthritis with the understanding that the disease is something more than a local infection: (1) We must increase the patient's resisting powers by improving his general condition; (2) we must stimulate elimination by the intestines, the kidneys, and the skin; (3) we must improve the local circulation and protect the joint against injury.

A few words in regard to the treatment[1] of special types of chronic arthritis:

Chronic villous arthritis calls for the usual general treatment, while at the same time the surgeon should not neglect the special conditions present. Hot-air baking, with temperature well above 200° F., should be employed, together with supporting bandages and splints if necessary. If the villi persist, the surgeon is justified in opening the joint and removing them. The joint fringes and loose bodies being removed by this operation, a marked improvement in the patient's condition may follow.

Infectious arthritis may start in with severe symptoms, but in this type, even more than in the others, active hyperemia treatment by baking is often of surprising value, while in certain cases Bier's passive hyperemia is of advantage. We must not keep these joints fixed too long, although fixation is needed to relieve pain; but we should supplement our other treatment by frequent massage and by passive movements—under an anesthetic if necessary. If there be obstinate contractures, we should do tenotomy, or break up the contractures perhaps by forcible extension with the patient under an anesthetic.

Atrophic arthritis is extremely obstinate, and may be helped by residence in a hot climate only. Further, we must persistently employ massage (Zander) and passive movements. Moreover, we must correct obvious deformities, especially flat-foot, which alone often renders the patient's life utterly miserable. We must extend contracted knees, and hold them extended on proper splints.

Hypertrophic arthritis is even more resistant to local treatment than is atrophic arthritis, because hypertrophic arthritis is characterized by mechanical ankylosis due to bone proliferation. In this last type forced motion and passive movements are apt to do more harm than good, though massage and hyperemia may give relief. Our principal

[1] Edwin A. Locke and Robert B. Osgood, The Treatment of Non-tuberculous Chronic Arthritis, Jour. Amer. Med. Assoc., February 2, 1907.

resource is mechanical support for the mild cases, adhesive-plaster strapping, and flannel bandages; for the severe cases fixation in leather splints or plaster splints. Thus by reducing the local irritation of the soft parts, there may be secured some return to painless function. Occasionally, when the *x*-ray shows conspicuous bone overgrowths locking the joints, we may operate to remove such growths, and then continue the treatment by fixation.

I have said that the prognosis of chronic arthritis is progressively bad. Locke and Osgood seem to take a less pessimistic view, for they say: "We can no longer consider this group of diseases as hopelessly incurable. The success of modern therapy offers the greatest encouragement. . . . In cases of simple *villous arthritis*, after a fair trial of conservative methods, radical operation is advised. In the *infectious* cases early motion and as little fixation as possible are indicated. In the *atrophic*, a judicious combination of fixation and motion affords the greatest relief, and in the *hypertrophic*, partial or complete fixation with as little motion as possible most favorably arrests the process." Let us trust that these views will be justified by further experience.

Tuberculosis of the joints is probably the largest subject which confronts the orthopedic surgeon—and it still concerns the general surgeon as well, especially in its later manifestations. General surgeons have not yet ceased to excise and to amputate for the cure of tuberculous joints.

Joint tuberculosis has been recognized for upward of one hundred years. Brodie and Nélaton were among the early writers on the subject; while Virchow, Rokitanski, and other continental investigators said much about the prevalence of bone and joint tuberculosis.

We used to talk of "white swelling," meaning tuberculosis of the knee-joint in the modern sense. Now we have learned, through the researches of Nichols especially, that tuberculosis infects the joints secondarily from a tuberculous focus in an adjacent epiphysis. The disease is of hematogenous origin—first, the blood-stream, second, the epiphyses, third, the joint. The process reaches the joint either by erosion of the joint cartilage or by extension along the ligaments. Then the bacilli are set free within the joint cavity, when, through the synovial fluid as a medium, and by the action of the limb, they are worked thoroughly into the recesses of the joint.

It is needless to describe in minute detail the pathology of the disease further than to state that all parts of the joint caseate and break down. The serosa is destroyed, the ligaments are infiltrated and weakened, and the cartilages and bones are eroded. In advanced cases the surrounding structures take part in the tuberculous disease, when, by the formation and coalescence of tubercles in these soft tissues, an abscess may develop of the so-called "cold-abscess" type.

Unlike those joints the seats of acute pyogenic infections, or those joints involved in chronic arthritis, tuberculous joints may heal, for tuberculosis is a self-limited disease, and if the active process ceases,

repair may occur. Repair is brought about by the formation of a granulation tissue which springs from that reactive granulation tissue surrounding all tuberculous lesions. The new granulation tissue then encapsulates or grows into and absorbs the tuberculous areas. As a result of this process, the joint surfaces may become adherent to the fibrous tissue, so that a fibrous ankylosis is established, or if the process has advanced still further, the adjacent bone surfaces may become adherent in a bone ankylosis, and the joint cavity may be obliterated. In spite of such apparent healing, however, it often happens that diminutive tuberculous foci remain encapsulated in the neighborhood of the joint. In later years these foci may become active and give rise to a genuine recurrent tuberculosis. Clinical experience has taught us that the reparative process is much more vigorous in children than in older persons. The tuberculous hip or knee of a six-year-old child may be cured through open-air treatment, fixation, and good feeding; the tuberculosis of a young adult may be cured through an erasion or excision of the joint, but the older the individual, the less certainly can we count upon a successful outcome of our therapeutic endeavors.

The *symptoms* and signs of joint tuberculosis are in general the same for all joints, but the careful student of the disease must learn to recognize special signs for the lesions of special joints. The patient suffers from general systemic complaints—emaciation, impaired appetite and digestion, weariness, hectic fever. Leukocytosis is rare. Moreover, tuberculous disease of the joints takes on certain characteristic manifestations, so that König divides the disease into three types or classes: tuberculous hydrops, granulating tuberculous arthritis (fungus articuli, tumor albus), and suppurative tuberculous arthritis.

Tuberculous hydrops is most frequently observed in adults, especially in the knee-, ankle-, and elbow-joints, while the symptoms usually develop gradually, rarely acutely. A serous exudate fills the joint, with a resulting distention and the evidences of fluctuation. The diagnosis of the condition is not always easy. The swelling and the consequent limitation of motion are not especially characteristic, so that the clinician may be driven to aspiration of the fluid and its injection into an animal. This form of tuberculosis may disappear gradually, and there may be spontaneous healing, but recurrences of the disease are common. Tuberculous hydrops may be the first form or the forerunner of—

Granulating tuberculous arthritis—the common form of joint tuberculosis. The joint affected by this disease tends to assume a characteristic spindle shape, as soft masses of granulating tissue invade and surround the articulation. These masses give to the palpating finger a sense of indistinct fluctuation, which may resemble the true fluctuation of tuberculous hydrops. Again, the swelling may be hard and resistant as cicatrization takes place, while the overlying adherent skin is tense, shining, and anemic (tumor albus). The joint may heal with extensive cicatrization, but the bones commonly are left ankylosed, and often in

bad position, unless proper treatment has been employed. These malpositions are due to muscular contractures. Sometimes the granulations do not cicatrize promptly, but break down and suppurate, so that abscesses and fistulæ develop. This is the condition especially which gives rise to a fluctuating hectic fever.

We often see this form of tuberculosis in knee- and ankle-joints. The tibia becomes permanently dislocated backward (subluxation), while characteristic sinuses appear in its neighborhood.

The clinician must not confuse early fungous tuberculosis of the joint with a sarcoma of bone developing in the neighborhood of the joint. Generally the *x*-ray will determine the diagnosis.

Suppurative tuberculous arthritis (cold abscess of the joint) is not common. König maintains that it is secondary to a primary synovial tuberculosis, while other observers believe that this synovial tuberculosis is itself an early sequel of epiphyseal disease.

The three forms of tuberculous arthritis are not so readily distinguishable, however, as writers seem to maintain. Tuberculous joint disease may take on one or all of the characteristics we have described, and the various forms may run into and overlap each other.

The *outcome* of a tuberculous arthritis is dependent on many factors—upon the patient's general condition, upon his environment, upon the dissemination of tuberculosis in the individual, and very largely upon treatment. Those persons who die, die of tuberculosis of the viscera, of exhaustion, and of amyloid degeneration. Or they may die of an acute general miliary tuberculosis or of septicemia following a mixed infection. Age also has a bearing on the prognosis, as we have already observed. Children below the age of fifteen have a better outlook than adults. Rarely is the function of the joint restored completely. A limitation of motion is common and ankylosis is frequent.

The *treatment* of joint tuberculosis is a subject which we may not here consider in complete detail, for the care as well as the determination of tuberculosis of special joints is a great topic, for the study of which I must refer the reader to special works on orthopedic surgery. In general terms, however, the clinician must employ two inevitable measures in all forms of tuberculous arthritis. He must enjoin an open-air life for the patient and he must place the joint at rest. Recent studies in sanatoria, and especially in the Convalescent Home of the Boston Children's Hospital, have demonstrated beyond question the immense and life-saving value of out-of-doors living for these unfortunates. The routine is possible in severe climates even, where both children and adults quickly adapt themselves to and learn to enjoy this rather novel mode of existence. The best of food and forced feeding even must be employed also, while general tonics and the proper care of the skin, bladder, and bowels must never be neglected.

Local treatment of joint tuberculosis is almost as important as the general treatment. We have seen that tuberculous arthritis tends to heal spontaneously. For this reason the surgeon must not rush into operative treatment, but must employ conservative methods in the

beginning of an attack of joint tuberculosis. He may be forced to operate later. By conservative methods we mean mechanical treatment: Fixation of the affected joint; protection of the joint from bearing weight; traction which shall separate the diseased joint surfaces, and shall minimize that wearing away of the articular surfaces which is induced by the constant normal pull of the muscles. If the joints of the leg are at fault, we must keep the patient in bed, and we generally can secure rest and fair traction by applying plaster-of-Paris bandages. Observe, however, that it is well to overcome the traction of the muscles by a period of weight-and-pulley treatment before the plaster-of-Paris is applied. The plaster bandage should be changed after six or eight weeks, when the skin should be thoroughly cleansed and powdered, and all sores and abrasions should be treated. Should fistulæ form about the joint, we must provide for their care and their discharges by cutting windows through the plaster over them.

When the painful stage has passed, often after many months, and when the swelling has subsided, we may reapply a snug plaster or other proper local apparatus and allow the patient to go about on crutches. If the disease is in a joint elsewhere than the leg, we need never keep the patient in bed unless his prostration is extreme.

Surgeons may find occasion to employ local measures which shall supplement apparatus. Bier's *passive hyperemia* is coming into constantly wider use, especially in the early stages of joint disease, and is followed frequently by marked benefit. As to *tuberculo-opsonic* vaccines—their use is still in the experimental stage, but promises benefit, especially when they are combined with other appropriate vaccines in cases of mixed infection. The use of the *x*-ray in cases of tuberculous arthritis is still *sub judice* also—the exposure of the affected joint continuously to the action of the rays—while compression of the joint by a flannel bandage is sometimes serviceable in the wrist, knee, and ankle, in addition to the measures I have already described.

The *operative treatment* of tuberculous arthritis should be reserved for special and advanced cases of the disease. The question often arises whether or not we should operate on a seriously diseased joint when there is tuberculosis of some of the viscera also—of the lung or the kidney. We are justified in operating on tuberculous joints in those cases only in which there is reasonable ground for hope that such a delimitation of an extensive joint disease may give the patient a chance to rally so that the visceral tuberculosis may have a better opportunity of healing.

Operations on tuberculous joints should be performed with the parts made dry by an artificial ischemia through the use of a tourniquet, and we should make incisions which shall expose thoroughly all of the diseased parts. There are several special methods of operating. We employ *incision* of the joint to relieve tension, especially in the deep-seated joints; to evacuate an abscess; or to explore a joint for the sake of diagnosis even and for the removal of sequestra. At the best, however, a simple incision has little or no effect as a curative

measure; indeed, after incision we must look for a subsequent mixed infection of the wound, and this prospect must render us extremely cautious of such an exploration.

We practice *erasion*, as it is called (arthrectomy), for the purpose of removing the whole of the diseased tissue, and we employ erasion in the cases of children chiefly, for whom we must make every effort to save their epiphyseal lines, so as not to curtail the growth of the limb. After erasion we look for ankylosis. We perform this operation with the knife, scissors, and curet, and remove all the diseased tissue which we can reach—especially and most carefully all of the synovial membrane, spooning away tuberculous foci in the adjacent bones. If we find, however, that the bones themselves are extensively diseased, we must go further and perform—

Excision of the joint (resection), limiting this operation, however, as far as possible, to adult patients. We must always bear in mind that excision is to be employed for the most severe cases only—when "mechanical treatment" has failed; when there are large sequestra; when drainage and erasion seem useless; and when, with a rapidly failing general condition, the extreme operation of excision seems inevitable. It is one of the operations of last resort. A further operation of last resort is amputation, especially in the case of adults and when there coexists visceral tuberculosis, or extensive and obstinate mixed infections.

It is needless here to describe in detail all the numerous operations which the surgeon may perform upon special joints, but it is well to discuss certain resections—resections of the elbow, the wrist, the hip, the knee, and the ankle, especially since these joints sometimes are resected for conditions other than tuberculosis.

Excision of the elbow may be accomplished through various incisions —Langenbeck's long, straight incision, with its middle point over the olecranon; Ollier's bayonet-shaped incision, as illustrated in the text, and Kocher's J-shaped incision. All these incisions are designed to give free access not only to the elbow-joint itself, but to the soft parts about it. Perhaps Kocher's incision accomplishes this object most effectively, though the straight incision is the common and popular incision among American surgeons.

The patient lies on his back; the elbow is held in flexion, with the arm across the patient's chest. We carry the cut, about six inches long in the long axis of the arm, down upon the humerus, the olecranon fossa, the olecranon process, and the posterior surface of the ulna; we expose the bones thoroughly, and then, with periosteal instruments, scrape away from them all the soft parts until the posterior aspect of the joint is laid bare. The great ulnar nerve, lying behind the internal condyle, is the one important structure to be avoided. Frequently we are able to turn aside all the soft parts without even seeing this nerve. The incision has split the triceps muscle and its tendinous insertion, but its extension into the deep fascia of the forearm must be preserved carefully. We now have the bones everywhere exposed

except upon their anterior surfaces. Open the joint from behind, force the end of the humerus out through the wound, grasp it with lion forceps, and cut it squarely off. Then perform the same maneuver with the bones of the forearm—the upper end of the ulna and the head of the radius. This disposes of the diseased bone, but the surgeon must not close the wound without inspecting carefully all the neighboring soft parts, and removing thoroughly with the knife and scissors every suspicious focus.

Our ultimate object in performing excision of the elbow is to provide the patient with a healthy flail joint—often an extremely strong and

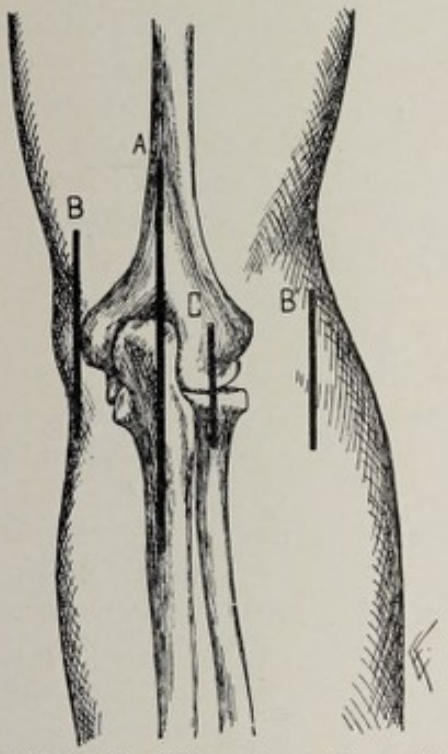

Fig. 655.—Excisions about elbow: A, Excision of elbow-joint by posterior median incision (Langenbeck's operation); B, B′, excision of elbow-joint by radial and ulnar lateral incisions; C, excision of superior radio-ulnar articulation by posterior vertical incision (Bickham).

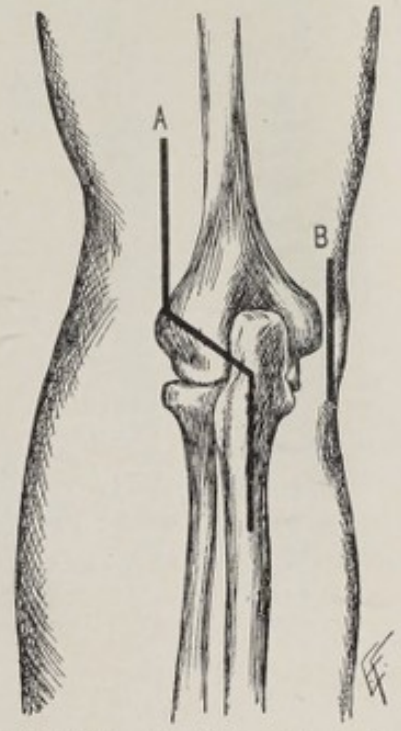

Fig. 656.—Excisions about elbow: A, Excision of elbow-joint by bayonet-shaped incision (Ollier's operation); B, ulnar incision, added to bayonet-shaped incision, if needed (Bickham).

useful joint. In order to secure this we must suture carefully with catgut the various soft parts in layers, must drain the wound, and must fix it finally and firmly upon a right-angled splint with the severed bone-ends well separated, lest bony ankylosis subsequently occur. The operation is not difficult, and the surgeon should perform it so carefully as to avoid damage to essential muscles, tendons, nerves, and vessels. Ten days after the operation we must begin massage and gentle passive motions, and may look for a fairly useful joint at the end of two months.

The *wrist-joint excision* is performed commonly through the single dorsoradial incision—the Boeckel-Langenbeck operation. Make a

straight incision along the back of the radius between the extensor communis digitorum and the extensor longus pollicis tendons; this incision extends from the lower half of the second metacarpal up over the radius to about two inches above the joint. In making the incision we must avoid, if possible, the radial nerve branches running to the middle finger. Now deepen the incision toward the second metacarpal, the trapezoid, the scaphoid, the joint capsule, the posterior annular ligament, and the radius; drawing aside the tendons which come into view, and dealing with the soft parts and involved tendons by excision, however, if their retention seems impossible. From this point on we handle diseased bone, stripping back the periosteum and ligaments so far as seems wise; removing the involved carpal bones; freeing the ends of the radius and ulna, turning them out of the wound by strongly flexing the hand, and sawing off their involved ends. The after-care of this wound is simple, and consists in immobilizing the arm and hand in a plaster splint for two or three weeks. We aid later in restoring function by gentle massage and gradually increased active and passive movements. The resulting wrist is often extremely useful. Fair strength may be restored to it, and in favorable cases a somewhat movable joint even may be recovered.

Excision of the hip-joint may be expected to result in a useful limb. Ankylosis is the exception, though there is always some atrophy and some shortening of the leg. Langenbeck's straight incision operation is the operation generally serviceable. With the patient lying on his sound side, the affected thigh is flexed at an angle of 45 degrees and rotated inward; the surgeon cuts down in the axis of the femur upon the great trochanter, making an incision about six inches in length. This cut passes through the skin, the fascia, and the gluteus maximus, when the gap between the gluteus medius in front and the pyriformis behind is sought, and widened by retraction. Thus we expose the capsule of the joint and divide that structure down to the bone. With a curved periosteal elevator raise the anterior and posterior periosteal flaps; then cut the cotyloid ligament with a knife thrust within the rim of the acetabulum, when air will enter the joint and allow the joint surfaces to be separated. Next raise and cut away the muscles attached to the great trochanter, while an assistant grasping the knee and foot rotates the thigh outward. Then divide the ligamentum teres and dislocate the head of the bone either forward or backward. Saw off the bone, usually below the great trochanter, with slight obliquity from above downward and from without inward. Scrape out the acetabulum; trim away all the synovial membrane and all suspicious tissue; drain the joint; suture the capsule, the muscles, and the skin, and put up the leg in extension with a weight and pulley.

The crippled leg must be kept at rest and in extension for many weeks. Gradually, however,—perhaps in six weeks, when a false joint has formed and the wound has healed,—we may proceed actively with massage and movements, reasonably expecting to secure good use of the leg.

Excision of the knee-joint has come to be regarded as an almost classic operation. Twenty years ago the old-fashioned open incision —still popular—was familiar to all students. Last year I was surprised to learn from ten members of the Harvard graduating class that not one of them had seen an operation for excision of the knee. Our reflection on this statement must be that the radical operations for tuberculous arthritis are less common than they were in the student days of the last generation.

The excellent and familiar excision of the knee-joint by the *open method* is performed in a fashion not dissimilar to that of excision of the elbow-joint. With the patient on his back and his leg extended, apply a tourniquet and make a curved transverse incision, passing either above or below the patella; turn back the skin-flap; open the joint by means of a deep transverse cut above the head of the tibia; flex the knee firmly, bringing the heel up to the buttock; strip back the soft parts from the femur—the soft parts both within and without the joint; remove the patella, thus freeing the femur, which may easily be drawn outside of the wound; saw off the necessary amount of bone. Now trim the tibia in similar fashion; scrape back the soft parts before and behind; expose thoroughly the head of the tibia and saw it off smoothly, and in such a way that its cut surface, when brought into apposition with the cut surface of the femur, will lie straight and evenly against it at right angles to the shaft of the bone. Trim off thoroughly all diseased soft parts; remove the tourniquet; secure perfect hemostasis; wire the two bones together at two or three points, and put up the limb on a splint which shall provide for drainage after the wound has been closed in layers. Our object in excising the knee-joint is to secure a sound leg with ankylosis—an object directly the reverse of the object looked for after excising the elbow or the hip, in which we aim at a movable joint.

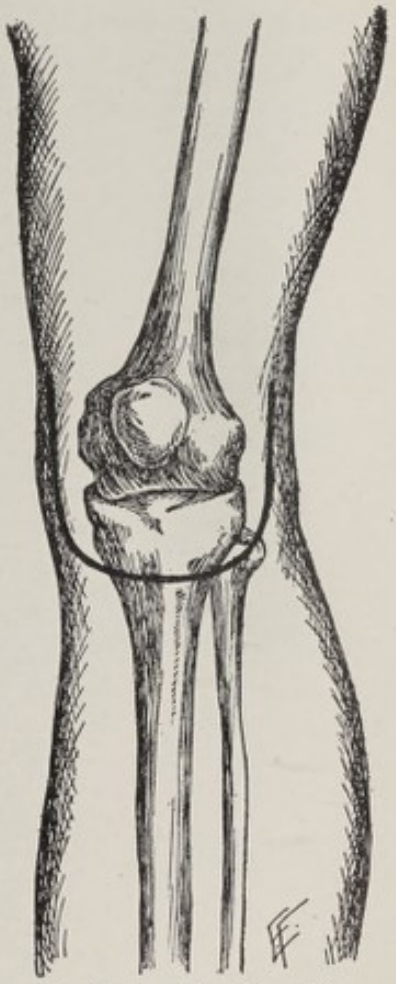

Fig. 657.—Excision of knee-joint: By anterior U-shaped incision (Bickham).

We must keep the leg fully extended on a splint for from six weeks to three months, and must prescribe crutches for many months thereafter. If we succeed in curing the tuberculosis, the patient may expect to walk strongly with a stiff leg and a limp, as the least possible evil.

Excision of the knee-joint by the *closed method*, as devised by Flint,[1]

[1] Carleton P. Flint, A New Method of Excision of the Knee-Joint without Opening the Joint, Ann. Surg., March, 1906.

has been gaining in favor during the past four years. His proposition and purpose are to remove the diseased mass of bone and cartilage without opening the mass and soiling the surrounding structures. He removes the knee with a wide margin, as one would remove a mass of malignant disease. The method is ingenious and effective, and is well illustrated by the sketches in the text, adapted from Flint's article.

The long U-shaped skin incision exposes a large surface of soft parts; the short U-shaped incision through the rectus muscle permits of the turning up of that attachment above the outside of the joint pouch, thus exposing the pouch or subcrural bursa. The oblique lateral

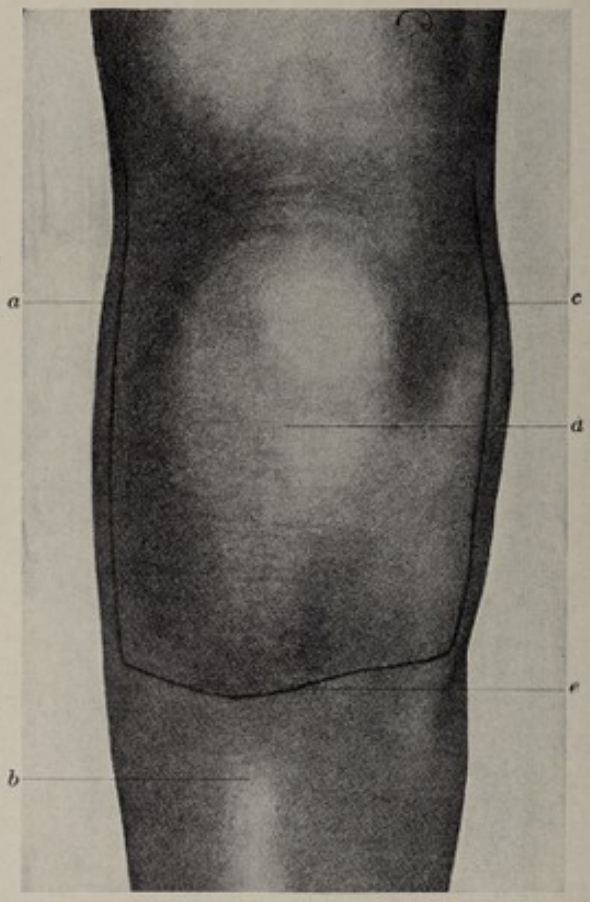

Fig. 658.—Flint's excision—square incision in skin: *a*, External lateral incision; *b*, tubercle of tibia; *c*, internal lateral incision; *d*, patella; *e*, transverse incision (Flint, in Annals of Surgery).

incisions free the remaining muscular attachments from the femur. The operator does not bend the patient's knee, but cuts through the head of the tibia with the leg extended. He cuts through upon a metal director or guard which previously has been slipped behind the head of the bone. Then he seizes the head of the bone, flexes the leg backward, and frees the soft parts behind the joint until he is well above the condyles of the femur: "As soon as the posterior region of the condyles is exposed, the femur is sawed through from behind forward and slightly downward at a level sufficient to clear the cartilages behind. This saw-cut is carried forward until it reaches the margin of the cartilage on the anterior surface of the femur, when the saw is withdrawn. . . .

It is easy to be deceived as to the exact position of the cartilage behind. One's examination should be particularly careful at this stage of the operation, lest the cut in the femur be made too wide. After withdrawing the saw from the femur, the leg is once more placed in a horizontal position. The saw is then introduced in front, behind the subcrural bursa at the upper margin of the articular cartilage, and a cut is made to meet the posterior saw-cut." That ends the operation

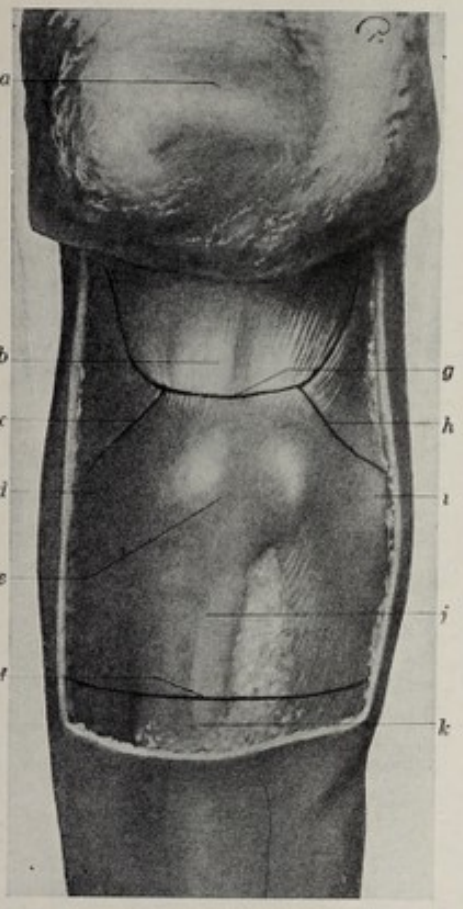

Fig. 659.—Flint's excision. U-shaped incision in quadriceps extensor; internal and external lateral excisions in facial expansion of quadriceps. Transverse incision over head of tibia: *a*, Skin-flap turned up; *b*, quadriceps extensor tendon; *d*, joint; *e*, patella; *f*, transverse incision; *g*, U shaped muscle incision; *h*, internal lateral incision; *i*, joint; *j*, patellar tendon; *k*, tubercle of tibia (Flint, in Annals of Surgery).

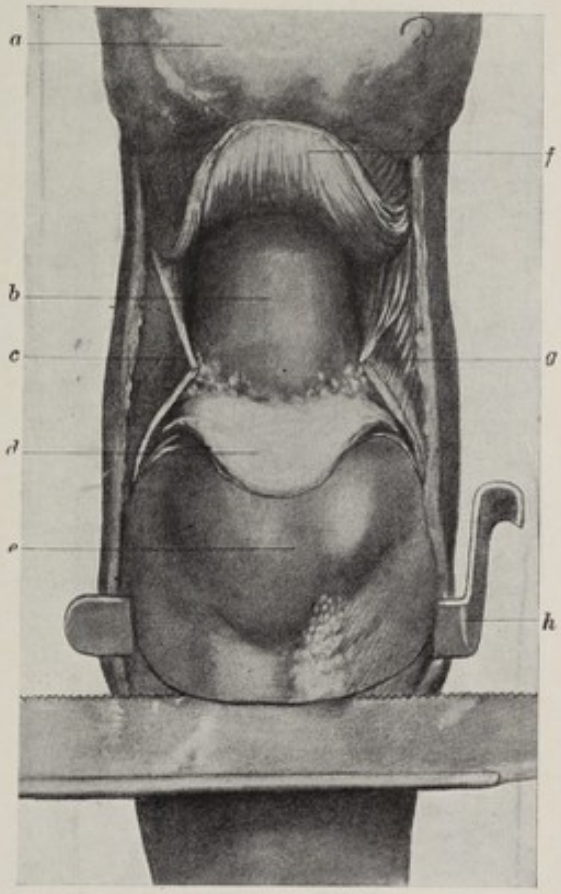

Fig. 660.—Flint's excision—muscle incisions; bursa turned down; retractor in place and saw cutting tibia; *a*, Retracted skin-flap; *b*, femur; *c*, subdural bursa; *e*, patella; *f*, quadriceps extensor turned up; *g*, vastus internus; *h*, retractor behind tibia (Flint, in Annals of Surgery).

practically, for the surgeon may now lift out entire the mass of tuberculous disease, wire the bones together, and treat the limb as after the ordinary open excision.

Excision of the ankle-joint is an easy matter and scarcely warrants a detailed description after one has mastered the principles of joint excisions as we have already described them. The incision for the operation is made behind and below the astragalus on the outer side. The incision is curved so as to permit of a free skin retraction. Then

the deeper parts are dissected up; the tendons held aside; the joint opened and disarticulated, and the involved bones and soft parts removed. Diseased foci in the tibia and fibula call for removal of the ends of those bones. Diseased foci in the small bones of the tarsus call for the extirpation of the small bones involved. Excision of the ankle-joint frequently fails of its purpose; the disease may return, while at the best we must look for healing with ankylosis and a deformed and crippled foot.

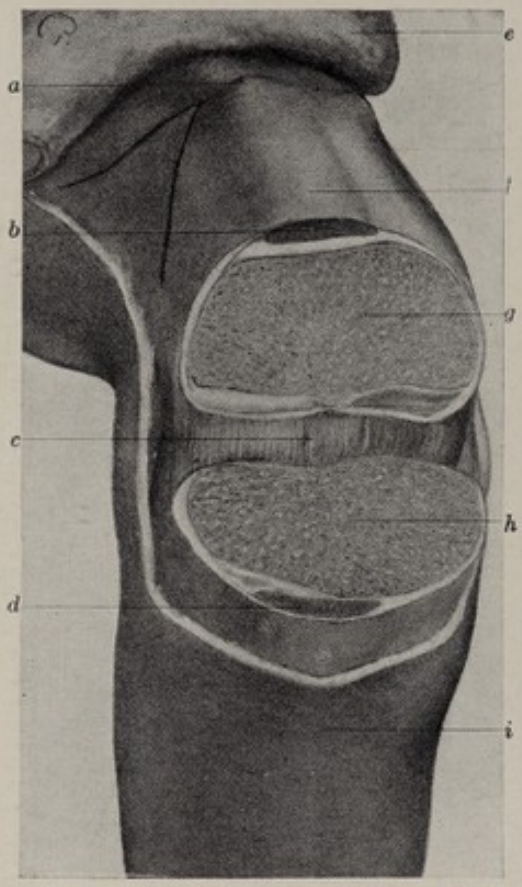

Fig. 661.—Flint's excision—tibia sawed through; leg flexed; structures at knee above fallen into place: *a*, Patella; *b*, patellar tendon; *c*, popliteal structures; *d*, patellar tendon; *e*, skin-flap turned up; *f*, patellar tendon; *g*, tibia; *h*, tibia; *i*, tubercle of tibia (Flint, in Annals of Surgery).

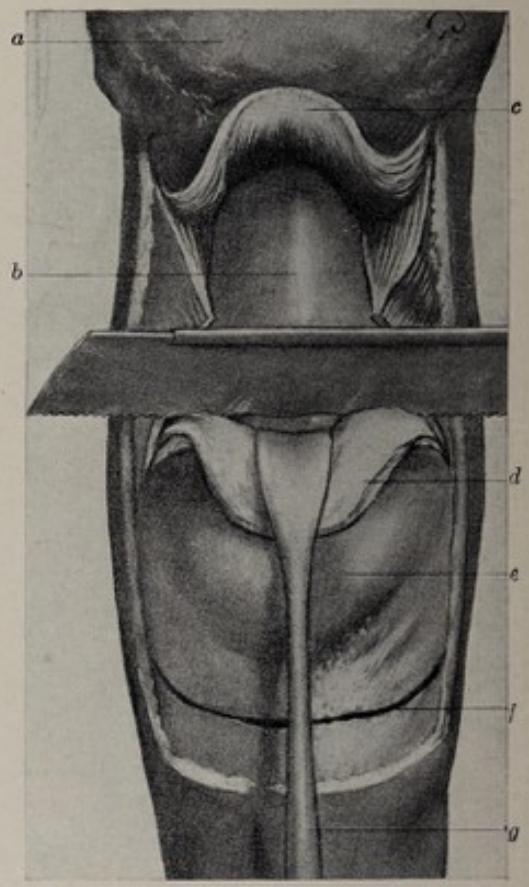

Fig. 662.—Flint's excision—leg horizontal; bursa turned down; saw in place: *a*, Retracted skin-flap; *b*, femur; *c*, quadriceps extensor; *d*, bursa turned down; *e*, patella; *f*, saw cut in head of tibia; *g*, retractor (Flint, in Annals of Surgery)

I shall not describe excisions of other joints, for the principles are already indicated, and are they not all described at length in countless volumes of operative surgery?

Coxa Vara.[1]—Strangely enough, the term *coxa vara* does not appear in surgical literature until within recent years. Billings' Medical Dictionary of 1890 does not contain the words, though the condition has long been appreciated. Bent hip is a characteristic of *rickets*, and one finds it described in discussions of that disease. Bent hip may be due to an injury also—traumatic coxa vara.

[1] *Coxa*, hip; *vara*, bent

Coxa vara is that condition of the femur in which the outer end of the neck of the bone is forced upward so that the trochanter rides above Nelaton's line, while the head of the femur remains in the acetabulum. The patient notices at first pain and a limp on the affected side, while the surgeon discovers a shortening of that leg unless the disease is bilateral; an abnormally high position of the trochanter; and inability to abduct the leg. The foot and leg are generally rotated outward, but all the motions are fairly free except abduction.

If the disease be present in both hips, we discover a lordosis or forward curvature of the lumbar spine, to compensate for the tilting of the pelvis caused by the coxa vara. The *x*-ray should discover the exact position of the femora.

Traumatic coxa vara may be found at any age, but especially in childhood. It results from an impacted fracture of the neck of the femur, due to a fall on the hip. The patient may suffer immediate disability, but with time and bony union a permanent deformity may result, so that the patient walks with a limp and suffers from pain in the joint. A child with this disablement may have night cries, and the clinical picture may resemble strongly that of the early stages of *hip disease*. We should call in the aid of the *x*-ray to settle every question of obscure hip lesion. We must distinguish coxa vara from a *congenital hip dislocation* also, as well as from hip disease.

Congenital coxa vara is a condition recognized within the last fifteen years only.[1] This form of the disease appears to have no relation to rickets, but to be due to intra-uterine conditions through which the femur is adducted instead of being normally abducted.

The *treatment* of all forms of coxa vara is directed toward restoring the normal angle of the neck of the femur. If the patient is an infant or young child, and if the case is recent and traumatic, the patient should be anesthetized and the femur should be bent out to the proper angle; the leg should then be held in a plaster-of-Paris spica bandage for at least two months, in the new position. When the bandage has been removed, the convalescence should be stimulated by massage and by carefully protected use of the leg.

There are many cases which do not permit of the forcible correction described above. In such cases we should employ such a protective splint as is used in cases of hip disease. The patient may then go about on crutches, with the strain of weight-bearing taken off the femur. In extreme cases of the disease the surgeon may perform a subtrochanteric osteotomy by a linear incision through the femur below the trochanter. He may then correct the improper rotation of the leg, and may hold the fragments in place with a plaster-of-Paris bandage until firm union has been restored. We see, therefore, that there is much to do for cases of coxa vara, and that a restoration of fair function may be expected with confidence.

[1] Kredel, in 1896, was the first observer to call special attention to the condition; and the literature of the subject is well summarized by Henry O. Feiss in the Jour. Amer. Med. Assoc., February 24, 1906.

There are many other rare affections of the joints at which we must glance briefly.

Coxa valga is a condition the reverse of coxa vara. In coxa valga the angle of the neck of the femur is increased. The disease may be either unilateral or bilateral. It occurs as a congenital ailment; in infantile paralysis; after long disuse of the leg; after amputations; and in rickets and osteomalacia. The deformity is characterized by an outward rotation and abduction of the leg, with limitation of the opposite movements; flattening of the trochanter; lengthening of the leg; pain in the hip; and a limp in walking. The *x*-ray establishes a diagnosis. So far as *treatment* has been successful, it has been by osteotomy of the neck of the femur, and restoring the normal angle by pushing up and nailing or wiring the shaft to the neck at the normal angle.

Charcot's disease is a chronic and destructive affection of the joints and is usually seen in adults. One or many joints may be involved, and the symptoms resemble those of arthritis deformans—swelling, effusion, loss of function, variable pain, and disintegration of the joint, followed by laxity and dislocation. Ankyloses and suppuration are rare; and although the disease is progressive, as a rule, it may cease spontaneously. The disease is extremely difficult of diagnosis unless the surgeon recognizes the invariable underlying and coexisting organic nervous affection, the discovery of which is an aid in determining Charcot's disease; while the *x*-ray is of great value also.

Treatment influences but little the progress of the ailment; nevertheless, we may look for some improvement by fixation of the joint and by protecting it with proper splints from damage. Resection of the joint is of little or no value, and amputation may be followed by a failure of wound healing.

Spondylitis deformans, a chronic and progressive stiffening of the spine accompanied by pain, comes within the province of the orthopedic surgeon, and the student should consult monographs on orthopedic surgery for a satisfactory study of this disease.

Neuromimesis of the joints, *hysteric joints,* have interested surgeons for many years, and Sir Benjamin Brodie in the second quarter of the last century wrote the first satisfactory and convincing papers on the subject. In spite of the name we are coming to believe that many joints which seem to cause great pain without a deformity or organic lesion may not always be assigned to the hysteric class, since we may at times discover in these joints slight grades of arthritis deformans. Young women are the common sufferers from neuromimesis. There is often a story of injury; sometimes there are medicolegal complications, and then a long history of pain and debility, with little or no apparent anatomic cause. Every experienced surgeon is familiar with these cases, and recognizes in them either malingery or a highly emotional temperament. Moreover, one should look in the patient's eyes for errors in refraction, and should investigate the condition of her pelvic organs. A careful neurologic study, based on the temperament of the patient and the history of the case, is necessary to determine

positively the presence of a hysteric joint; or it may be of a neurasthenic spine.

It is needless here to discuss in detail the complex and extensive subject of *treatment* for hysteric joints. Treatment largely is general and moral—the building up of health, the improvement of the appetite, the regulation of functions, and the bringing of the patient to a realization of her true condition. In addition we prescribe such commonplace factors in right living as an open-air life; cold bathing; exercise; regular meals, and abundance of sleep. Massage is often of great benefit, and the search for and pursuance of a congenial and useful occupation.

CHAPTER XXXI

AMPUTATIONS

In the old surgeries the subject of amputations was probably the most important subject which writers had to discuss, for in the old days before asepsis surgery was destructive, mainly. To-day it is constructive. Twenty-five years ago the teacher of surgical anatomy exercised his students for weeks at amputations upon the cadaver. To-day few students learn how properly to perform an amputation. In the old days he was the most skilful surgeon who cut off a limb with the greatest despatch consistent with preserving tissue enough to form a stump; and that despatch was a tradition inherited from the time before anesthetics were known. To-day, the careful surgeon amputates painstakingly and cautiously. Indeed, the most important purpose in an amputation to-day, aside from the purpose of a thorough removal of diseased tissue, is to provide the patient with a painless, serviceable, and sightly (*sic !*) stump.

In these days amputations are relatively infrequent, because asepsis makes possible the saving of limbs which would have been sacrificed in old times. So lately as the American Civil War nearly all compound fractures were amputated. To-day we amputate in traumatic cases only when it is reasonably obvious that the soft parts of the limb have been damaged beyond salvation. Who may say what extent of tissue destruction shall render impossible the saving of a limb? The answer to this question depends upon a variety of factors. A robust young man with sound heart and kidneys, without taint of syphilis, tuberculosis, or diabetes, may suffer a crushing injury, of extreme severity to his leg, yet the conservative surgeon may save for him a useful member. On the other hand, the very young or the old, the alcoholic, the diabetic, the syphilitic, the victim of arteriosclerosis, after his accident may retain little power of recuperation for the mending of a shattered limb, so that an amputation is our feeble and only resort in his case.

Such considerations are general considerations. Then there are considerations of special or local significance. The possibility of saving a damaged member is dependent largely on the amount of skin left uncrushed. An extensive area of sound and viable skin is more necessary for the preservation of a crushed limb than is sound bone or sound muscle; and the surgeon must assure himself that the circulation remains good in that part of the limb beyond the seat of damage also. A just estimate of all these factors will come from practice and experience only.

We operate "in continuity" when we cut through the bone in an amputation. We operate "in contiguity," or by disarticulation, when we remove the limb through a joint.

We speak of amputations as "immediate," as "primary," and as "secondary." Immediate amputations are those which are done at once, while the patient is still in shock, usually in from one to six hours after the injury. Primary amputations are done after the patient has reacted from shock, but before an infection has become manifest—usually within twenty-four hours after the injury. Secondary amputations are done at any later period, and frequently after the establishment of an infection.

The reasons for amputations are commonly three: (1) A serious crushing injury; (2) a destructive tissue disease (*i. e.*, tumor; tuberculosis); (3) a deformity or mutilation which the amputation may remove or correct.

I have already discussed in general terms the *traumatic* class of cases. The principal *diseases* for which we amputate are destructive osteomyelitis; extensive chronic ulcers of the soft parts; tuberculosis or advanced sepsis; the gangrene due to vascular or diabetic conditions; and tumors, usually of the malignant type. The victim also of a hopelessly *deformed* and useless hand or foot may call for its amputation.

One sees from this description that we may properly employ two other terms designating the urgency of an amputation: amputations of *necessity*, and amputations of *expediency*. Furthermore, according as amputations are those of necessity or expediency, so the technical nature of the amputation may be varied. There are the *typical* or *classic* methods which we employ when we can operate at leisure and follow the best and most satisfactory procedures; and, on the other hand, in an amputation of necessity we may be obliged to perform an *atypical* operation, cutting through where we must, and saving what we can, in order to secure a useful stump.

Every experienced surgeon recognizes a further and marked peculiarity of the necessary amputation as contrasted with the expediency amputation. The necessary amputation is done frequently upon a robust person, active and well up to the time of receiving his injury. His circulation is vigorous, and his reflexes acute. As a result, the amputation itself, in addition to the shock of the accident, is a serious affair for him. Such a patient is liable to become extremely prostrated; to suffer intensely from shock; to recuperate slowly; and to experience a tedious wound healing. On the other hand, in the case of an expediency amputation, one observes frequently that the invalid, the victim of localized tuberculosis or malignant disease, experiences little shock from the operation. The removal of the diseased member seems to act almost as a stimulant. He rebounds at once from the primary shock of the amputation; his general condition improves promptly; and his wound heals readily and kindly, so that one may expect him to be in better general condition in a few days than he was before the operation.

Regarding the technic of major amputations, let us consider three

important issues: the questions of *shock* and its control; of *hemorrhage* and its control; and of the molding of the *stump*.

The shock to which I refer is not that shock which resulted from the injury and existed before the patient was brought to us for operation. That form of shock I have already considered in Chapter XXVII of this book. Suffice it to remind the reader here that opium and the transfusion of blood are our most valuable remedies for that shock. The shock which occurs during the amputation, however, whether the amputation be one of necessity or expediency, is an additional shock. Though it is often inevitable, it is shock created by the procedure of the surgeon himself. For this reason one may call it *induced* shock, and may in a measure take means both before and during the operation to prevent it.

This *induced shock, anesthesia shock, operation shock,* or whatever we may choose to call it, is primary shock, always in the case of amputations of expediency (for tumors, deformities, etc.); but in the case of all amputations the surgeon must anticipate a certain amount of shock. We prepare for the contingency of shock by giving morphin and atropin (morphin sulphate, gr. $\frac{1}{8}$–$\frac{1}{4}$; atropin sulphate, gr. $\frac{1}{100}$–$\frac{1}{60}$). We employ an anesthetic with discretion. In the case of minor amputations and sometimes in the case of major amputations even we may make use of local anesthesia. In certain selected cases, especially when the patient is old and a sufferer from arteriosclerosis or renal disease, it may be well to use for anesthesia, tropococain, stovain, and strychnin by lumbar puncture. As a rule, however, we must employ a general anesthetic, and of the general anesthetics, we may rely upon nitrous oxid and oxygen, or ether—alone or combined. The administration of the anesthetic should always, when possible, be confided to a skilled anesthetist, who should use the least possible amount of the drug. Further expedients for eliminating shock are the placing of the patient upon a hot-water mattress during the operation, and the cocainizing of the large nerve-trunks before cutting them. This last maneuver (nerve cocainization) was first advocated by Crile some ten years ago, and has met with general approval. Expose the nerve and introduce within its sheath by a hypodermic needle 4 to 6 minims of a 4 per cent. cocain solution.

Intimately associated with the question of shock is that of the control of hemorrhage—of hemorrhage which leads so directly to an increase, and a prolongation, of the shock. We control hemorrhage by producing a general ischemia of the limb to be operated upon, and by checking promptly the bleeding vessels in the wound itself. For the general ischemia we render the limb as bloodless as possible by elevating it for a few moments before operating, and by applying a tourniquet. Some operators still employ the Martin rubber bandage to squeeze the blood out of the limb, supplemented by the rubber tourniquet, after the method of Esmarch. I believe that, as a rule, however, this use of the Martin bandage should be discountenanced; for in the case of a crushed limb, the bandage may give rise to embolism; while in the case of an

infected limb, or a limb the site of malignant disease, it is possible by the rubber bandage to force the products of disease into the circulation. Elevate the limb, therefore, and apply a tourniquet. I frequently employ the pneumatic suit also, as I have described its use in Chapter XXVII. We must observe a further precaution in the use of the familiar rubber tourniquet. If we draw it too tight or leave it in place too long, it may so press upon the underlying nerves as to cause their degeneration, with a subsequent paralysis. This rarely happens in case the tourniquet be applied to the thigh, but it has happened frequently after the application of a tourniquet to the arm. When the

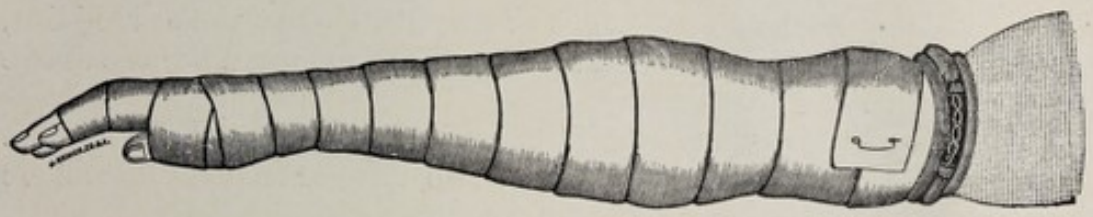

Fig. 663.—Esmarch's elastic bandage and tourniquet (Esmarch).

arm is to be constricted, therefore, a few folds of towel should be laid beneath the tourniquet, and the tourniquet itself should be ribbon-shaped, and not made of the usual elastic tubing.

The molding or shaping of the stump has become a matter of extreme interest in recent years, and we have come to see that the rapid, old-fashioned circular amputations often leave the patient with a stump poorly adapted for the wearing of an artificial limb. The treatment of the nerve-ends so as to avoid subsequent painful neuromata is another important desideratum. The old-fashioned circular amputation was

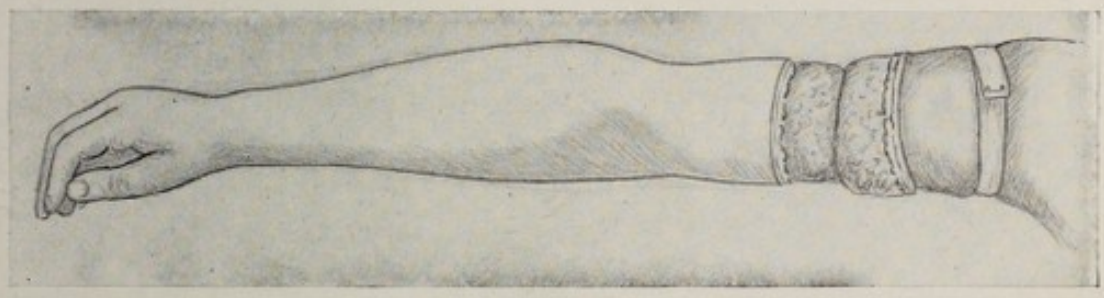

Fig. 664.—Circular flap.

made by turning back a cuff of skin, by cutting squarely through the limb at a level slightly higher than the cuff level, and completing the stump by drawing down and stitching the cuff immediately below the raw surface. This method of amputating is rapid, and gives us a symmetric and seemly stump. Unfortunately, however, it leaves the end of the stump in a condition easily subject to injury; while on account of its structure this stump may become extremely painful. Some six years ago F. T. Murphy[1] made an exhaustive study of a large number of the end-results of amputations in the Massachusetts General

[1] F. T. Murphy, A Study of Amputations of the Lower Extremity, Boston Med. and Surg. Jour., July 14, 1904.

Hospital clinic. His conclusions are valuable and are worth quoting here in full:

"Anterior and posterior muscle flaps, when obtainable, are to be preferred to the circular cuff of skin.

"The fibula should be cut off at a higher level than the tibia in leg amputations, and care should be taken to bevel off bony prominences, such as the sharp anterior tibial edge.

"Suture of the periosteum and approximation of the muscles and fasciæ are desirable.

"Drainage of the stump is advised, unless the dead space is obliterated by means of buried sutures.

"Partial amputations of the foot or amputations at the ankle-joint, except under unusual conditions, are not as satisfactory as those above the ankle-joint.

"Tibial stumps between 6 and 8 inches long are the most serviceable.

"Amputations through the knee-joint are inferior to those just above the condyles.

"The longer the thigh stump the better, provided the condyles have been removed.

"In general, in tibial amputations down to 4 inches, and in thigh amputations down to 5 inches, sacrifice bone in order to obtain good muscle-flaps."

These observations of Murphy are sound, and while his studies embrace amputations of the lower extremity only, the general tenor of his conclusions is applicable to the upper extremity also. Let us note one exception, however, when we come to a consideration of arm amputations; in arm amputations the circular cuff method is often valuable, while it rarely leads to a painful stump.

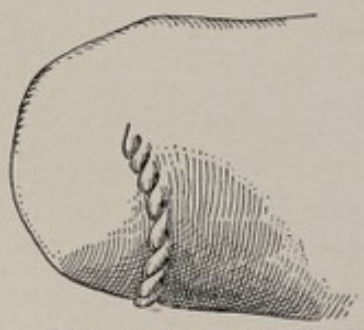

Fig. 665.—Position of line of sutures by the oblique incision (Kocher).

In regard to the whole subject of stumps, let us note further that recent studies, notably those of Matas, von Mikulicz, Gritti, Bier, Hirsch, Berger, Küster, and numerous other writers, have dealt largely with the treatment of the bone itself. There is a general agreement, moreover, that muscle flaps—not mere skin-flaps—should be used; that the eventual line of skin suture should fall behind the limb, so that the bone stump may not press upon the soft cicatrix, and that the amputation should be made with the same painstaking care as that employed in amputating a breast or a uterus. The old-time hurried slashing is improper. For such reasons many surgeons have abandoned entirely the ancient amputating knives, and cut off the leg or the arm with an ordinary scalpel, much as they would cut off the breast. Neudörfer goes still further and abandons the saw itself. He cuts through the bone as a preliminary step in his operation, employing a sharp chisel or a Gigli saw (Fig. 666).

The question of whether or not to cover the bone stump with periosteum is still debated. Many surgeons believe that a proper periosteal covering promotes prompt bone-healing and a painless stump; while

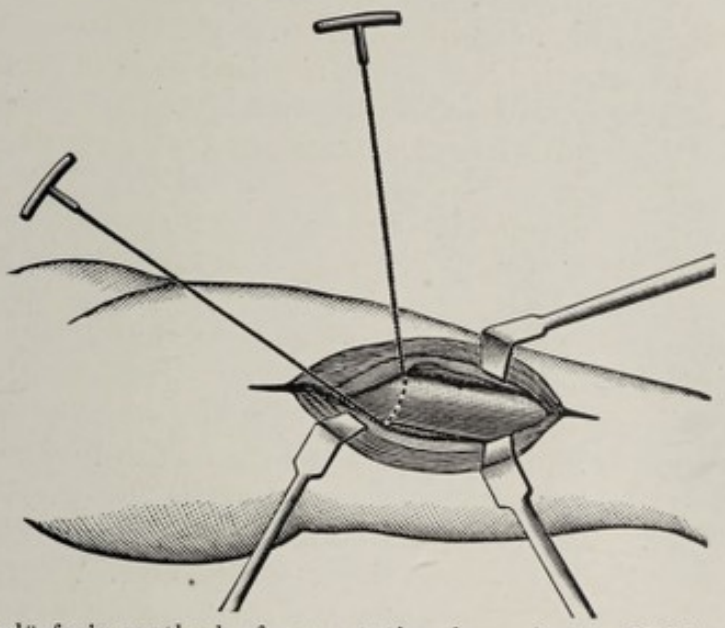

Fig. 666.—Neudörfer's method of amputation by primary division of the bone before shaping the flaps (Matas).

others, especially Hirsch, have contended that the periosteal covering is unnecessary, and Bunge maintains that the periosteum over the end of

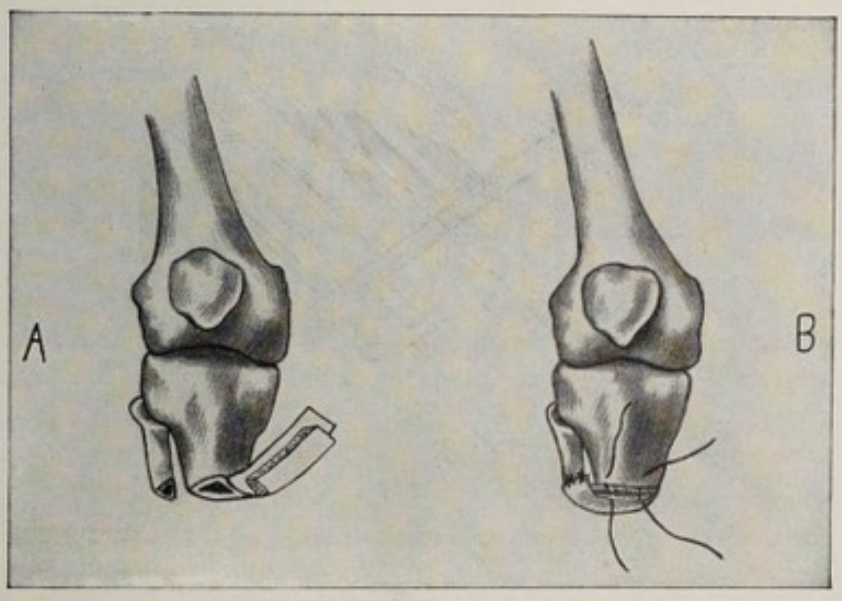

Fig. 667.—Bier's osteoplastic amputation of the leg: A, Showing manner of raising an osseoperiosteal flap from tibia; B, showing bone-flap brought over sawed ends of tibia and fibula, and its periosteal margins sutured to the margins of periosteum around tibia and fibula. The osseoperiosteal flap is here shown separated from its soft parts, to which it should be adherent. (Bickham, modified from Bier.)

the bone is extremely sensitive. Bier, on the other hand, prefers an osteoplastic method—a covering of the bone-end with a transverse strip of new bone taken from higher up upon the shaft (Fig. 667).

My own conviction and practice favor the use of periosteum to cover the bone-end. I have seen no special value in Bier's osteoplastic flap. I regard the proper treatment of the muscles and the skin-flap, however, as of superlative importance. In our amputations we provide considerable muscle-flaps, which can be drawn over the bone-end, and we lace them together with buried absorbable stitches, so as to promote prompt union, a perfect hemostasis, and a reasonably shapely stump. In an amputation of the leg, the line of suture should fall posterior to the bone-end, as Fig. 667 illustrates.[1]

Painful Stump.—Neuralgia of the stump may complicate the end-results after any form of flap- or stump-molding. Painful stump may be due obviously to a badly placed cicatrix, to a breaking down of the scar and ulceration, or to an unduly long bone; but all these calamities are avoidable and remediable by a secondary operation—shortening the stump. There is one form of painful stump, however, the cause of which is much more deeply seated—a neuritis or growth of neuromata on the severed nerve-ends. These neuromata may be the despair of surgeon and patient alike. The pain is often excessive and extremely wearing, so that the patient's life becomes almost unbearable. The surgeon opens down upon the affected nerves, removes the neuromata, and resects the nerves, but often to no purpose; the pain returns; higher resections are made, and, finally, in desperation, the surgeon may remove the limb entirely or dissect the posterior nerve-roots of the cord. These are radical procedures, and often are a source of mortification to the surgeon. For the last four years I have been following the practice of joining to each other the severed nerve-ends in the stump itself—nerve anastomosis—

[1] Theodor Kocher, in his Text-Book of Surgery, second English edition, p. 393, lays down the following interesting rules, which correspond with the conclusions we have drawn in the text:

"An oblique incision (combined, if necessary, with a longitudinal one in the form of a racket or lanceolate incision) through skin and fascia. After retracting the elastic skin the muscles are divided obliquely down to the bone. The periosteum is also to be divided obliquely. The periosteum is then separated along with the superficial layer of the cortex of the bone, by means of a sharp raspatory or chisel, or, when possible, a flap of bone having a movable periosteal hinge is made by means of the saw; lastly, if only a thin shell of the cortex has been raised up along with the periosteum, the end of the bone is simply rounded off, while, if a distinct flap of bone (osteoplastic method) has been sawn up, the end of the bone must be sawn in a curved direction so as to fit it.

"The periosteal or bony flap is sutured over the sawn surface of the bone to its periosteum. The stumps of the muscles or tendons are sutured to each other or to the surface of the bone at a distance from the sawn surface. Lastly, the skin and fascia are sutured. But in cases where a periosteal flap, or a flap of bone and periosteum, cannot be obtained in a normal relation to the other soft parts, it is better to remove the periosteum entirely from the end of the stump, to scrape out the medullary cavity (according to Eiselberg and Bunge), and to round off the edges of the bone as dentists do.

"In disarticulating, care for the shape of the end of the bone is unnecessary; the upper cartilaginous surfaces should be preserved, as they are insensitive and used to pressure. In addition, the points which we have emphasized in excisions are to be borne in mind, viz., to retain the attachments of the tendons, muscles, and ligamentous capsule to the cortical layer of bone subjacent to them. In other words, the subcapsular method is to be added to what we have just described as the normal, so that the disarticulation is performed by what may be termed the periosteo-plastic-subcortical method."

with the purpose of securing a continuous nerve channel, and leaving no nerve-ends whatever to serve as the seats of neuromata. In my list of 23 cases this maneuver has proved successful. I believe we are now warranted in employing it in all major amputations as a preventive of painful stump.

SPECIAL AMPUTATIONS

Amputation of the Toes.—As a rule, the surgeon should not amputate through the phalanx of a toe, but should disarticulate at the metatarsophalangeal joint. The racket-shaped incision is the best incision, for by its use a plantar flap may be turned up over the wound, which is thus comfortably protected. After making the flap, the surgeon sharply flexes the toe at the selected point, and passes his knife rapidly

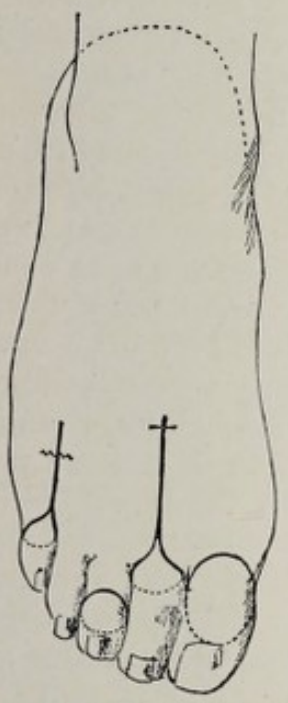

Fig. 668.—Disarticulation of the great toe at the metatarsophalangeal joint, and of the second toe along with its metacarpal bone; amputation through the third toe and through the fifth metatarsal bone (Kocher).



Fig. 669.—Disarticulation of all the toes at the metatarsophalangeal joints (Kocher).

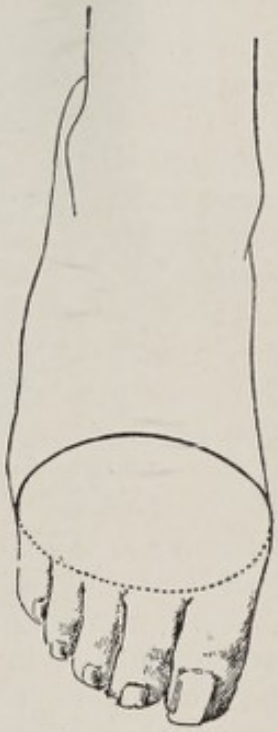

Fig. 670.—Amputation through the metatarsus (Kocher).

through the joint cavity, remembering that he must enter the cavity at a point the bone's breadth beneath the knuckle. There are usually two terminal arteries to be tied. Be careful not to include nerve twigs in the ligatures. Do not sew up the flaps without providing for drainage between the sutures. Interrupted sutures are best. The inevitable slight leakage behind the flaps finds its way between the sutures, and if the wound has been made clean, healing is prompt.

In the case of amputations of the great toe and of the little toe, make the cut somewhat toward the median line of the foot, so that

the line of suture, when completed, shall not be subject to lateral pressure in boot-wearing.

Partial Amputations of the Foot.—Amputations through portions of the foot have been modified by many surgeons, and various names are given to the various foot amputations. We are coming to the conclusion that most of these amputations through the bones of the foot are objectionable, because the resulting stumps are weak, inconvenient, and painful. Total removal of the foot (at the point of election, 6 to 8 inches below the tibial tubercle) gives the patient a more useful limb. The amputations through the foot are sometimes useful, however, their designated names are classic, and the student should be familiar with their nature.

Lisfranc's operation is a disarticulation of all the toes at the tarsometatarsal joints—so obvious an operation that the student of surgical history wonders why any one man's name should have been associated with it. Lisfranc's operation is performed with a short dorsal and a long plantar flap—in other words, the sole of the foot is dissected off and turned up over the stump. The surgeon seizes the toes with his left hand and begins his incision just behind the base of the fifth metatarsal bone. He carries the cut straight along the outer aspect of the foot for about an inch, and then rounds out to the dorsum, crossing the foot to its inner edge, and carries his knife back so as to complete the flap just above the cuneiform metatarsal articulation of the great toe, somewhat nearer the plantar than the dorsal aspect. He then forms his plantar flap, which should extend nearly to the tarsophalangeal joint. The surgeon deepens his cuts, retracts his flaps, and then firmly extends the foot, when the disarticulation is an easy matter. He then removes the tourniquet and picks up the bleeding vessels. I believe it is wise to drain the wound with a rubber wick for twenty-four hours. The stump should be put up in a large elastic compression dressing reaching to the knee. The foot should be supported on a pillow, or slung in a hammock for at least a week, when healing should be sound enough to permit of the patient's beginning to move about on crutches.

Hey's operation is similar to Lisfranc's, except that, in addition to the disarticulation of the metatarsal bones, the end of the internal cuneiform bone is sawed off, so as to provide a smooth and even bone stump.

Chopart's operation is a disarticulation of the anterior part of the foot at the mediotarsal joint, that is to say, the astragaloscaphoid joint and the calcaneocuboid joint. The operation provides flaps similar to the Lisfranc flaps, except that they are made somewhat longer and are started opposite the calcaneocuboid joint.

Syme's operation—disarticulation of the foot at the ankle-joint. Syme's operation preserves the plantar surface and the soft parts of the tip of the heel, which is made to cover the lower ends of the tibia and fibula, whose malleoli are removed. The surgeon makes his incision directly down to the bone from the tip of one malleolus across the sole

and up to the other. He then forces the foot into extreme plantar flexion, and carries a second incision directly across the dorsum, thus joining the two ends of the first incision. He then opens the ankle-joint in front; divides the lateral ligaments and disarticulates the astragalus forward. Next he separates the soft parts of the heel from the os calcis, which he removes. He has now left the articulating ends of the tibia and fibula. He saws off the malleoli and turns the heel-flap up over the stump.

Pirogoff's operation—disarticulation of the foot at the ankle-joint, with removal of the malleoli, the articular surface of the tibia, and the anterior part of the os calcis. As Kocher remarks, Pirogoff's operation

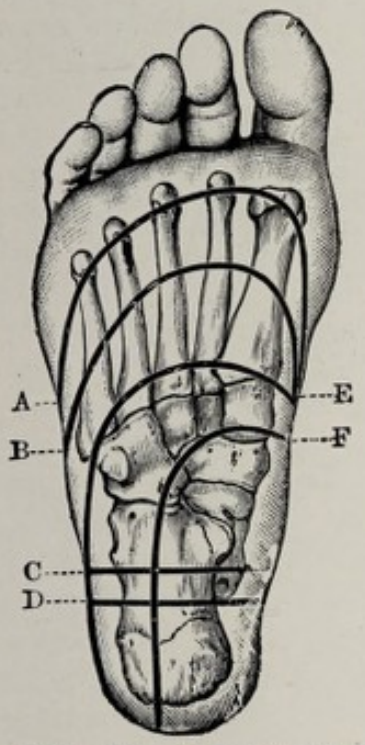

Fig. 671.—Plantar incisions: A, Lisfranc; B, Chopart; C, Pirogoff; D, Syme; E, Farabeuf's subastragaloid amputation; F, Farabeuf's amputation at the ankle (Dennis).

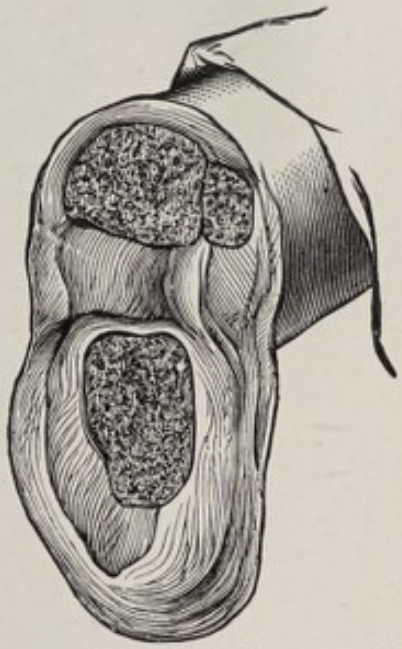

Fig. 672.—Pirogoff's amputation. Appearance of the parts after removal of the malleoli (Erichsen).

derives its importance from the fact that it was the first osteoplastic operation introduced. It dates from 1854.

Pirogoff's operation resembles Syme's in many of its features. The Syme incision is employed, and all the bones of the foot are removed *except* the posterior portion of the os calcis. This slip of bone is shaped by the use of a small saw as indicated in the cut. It is well to begin Pirogoff's operation by a tenotomy of the tendo Achillis, thus allowing the heel-bone readily to be drawn up and implanted upon the stumps of the tibia and fibula. The Pirogoff stump is fairly useful, and is more satisfactory than that of Syme.

Amputations of the Leg.—The subject of leg amputations has been one of no little controversy, the matters in dispute being particularly—

(1) The best point at which to amputate; and (2) the method of amputation. Surgeons are now agreed that amputations should be made as low as possible consistent with the production of a stump capable of bearing an artificial leg. So we have coined the term "point of election," by which we mean a point on the tibia about eight inches below the tibial tubercle. Amputations above this point are not of election, so that the nearer we come to the point of election, the more satisfactory will be our results. In the lower and middle thirds of the leg the bulk of the muscles is posterior; when we operate in this region, therefore, we find that a posterior flap gives the best covering for the stump. When we operate in the upper third of the leg, where the bulk of the muscles is postero-external, we aim to secure a flap chiefly external. Whatever flap be made, we should cut the fibula

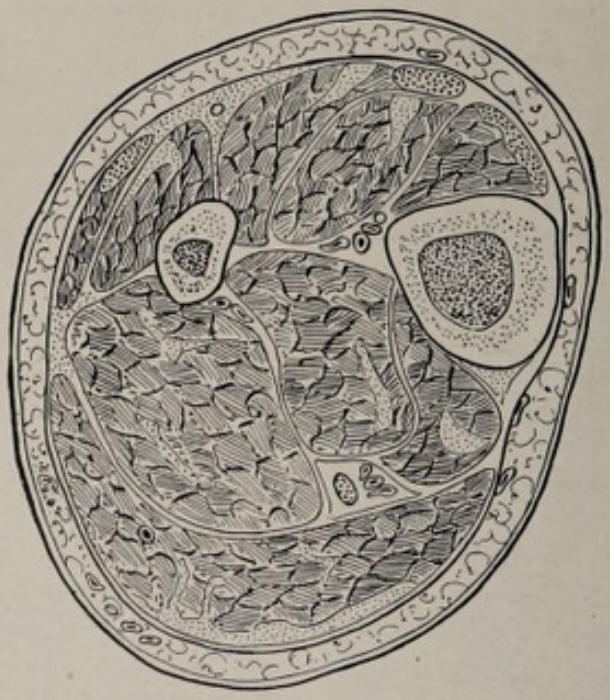

Fig. 673.—Cross-section of lower third of the right leg (adapted from Bickham).

slightly higher than the tibia, as the fibula in the stump is easily drawn out of position and exposed to pressure. In sawing through the bones of the leg we should be careful to bevel the anterior edge of the tibia before making the transverse cut. There is little difficulty usually in finding the arteries and controlling hemorrhage from a leg stump. The important arteries are the anterior tibial, the posterior tibial, and the perineal, whose positions are shown in the illustration taken from Bickham's Operative Surgery.

We need not here consider the great variety of special amputations which have been devised for special conditions, but we may suggest, by means of the illustrations in the text, the nature of the various incisions which we recommend.

For amputations at the point of election, if we discard the old-time

cuff method, we shall do well to follow the line of Stephen Smith's operation, and turn up a long posterior flap, observing that the cut through the bones is made at the highest point attainable above the base of the flap.

In making these leg amputations the surgeon should have in mind and should follow a proper routine if he is to have his operation come off smoothly and easily. The patient should be drawn well over the end of the operating table; the sound leg should be tied down out of the way, and an assistant should hold the foot to be amputated in a somewhat elevated position in order that the surgeon may have every part of the leg circumference well within the sweep of his knife. He may make a large skin-and-muscle flap by transfixion and cutting outward with the long amputating knife; or he may dissect a skin-flap back carefully with a scalpel. After he has completed his flaps, he may employ the old-time Catlin in order to clean away the interosseous tissue, or he may dissect this tissue away with a scalpel. My own preference is to use a small knife through most of the operation, for with the small knife one works more accurately and may quickly expose the bone-ends, from which periosteum is to be stripped back before the bones are sawed. Having turned back the periosteum and the soft parts, and having sawed through the bones, the surgeon searches at once for the important arteries with their veins, and ties them all; he has the tourniquet removed; he picks up with catch forceps all the smaller bleeding points, and checks entirely all hemorrhage, tying the vessels with silk or plain catgut, according to his convictions regarding ligature material; he draws out the nerve-ends and stitches them accurately together end to end. He then completes the hemostasis, if that be needed, and molds the stump by careful suturing and lacing of the muscles across the bone-end. Finally, he brings the skin-flap accurately into place. Some redundancy of skin-flap is an advantage rather than the reverse. If the hemostasis be absolute, drainage wicks are unnecessary, but, as a rule, it is well to drain the stump for twenty-four hours at least. At the time of the operation the surgeon may deem all hemorrhage checked, but later, when the patient has been put to bed, when shock has subsided, and when the

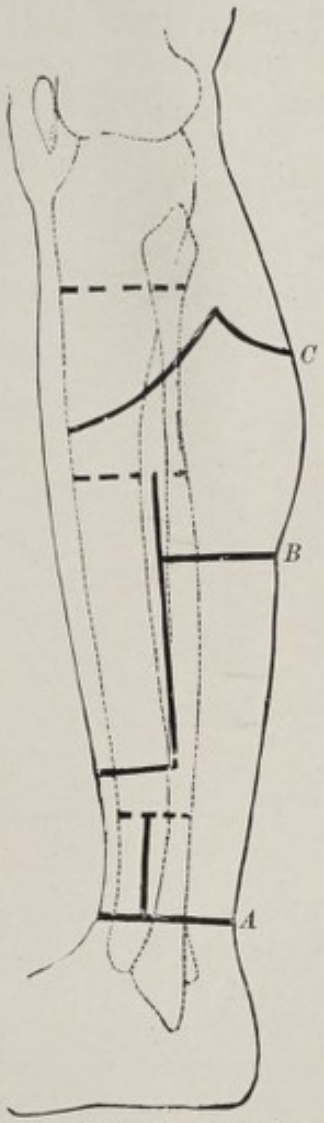

Fig. 674.—Amputation of leg: A, Modified circular; B, rectangular flaps; C, antero-posterior flaps, upper third.

arterial circulation again has become vigorous, a secondary oozing into the stump is common. The leg should be dressed in an abundant absorbent dressing, reaching well above the knee, and the whole limb should be carefully immobilized upon a comfortable splint.

Many surgeons prefer the Teale method of amputation. The Teale method is that of providing a long anterior flap. The resulting stump is seemly and useful, while the operation is somewhat easier than that I have just described.

Amputations through the middle of the calf are performed on much the same plan, for the arrangement of the parts does not differ materially from their arrangement in the lower third of the leg.

When we come to amputations in the upper third of the leg, or immediately below the knee, we have to consider the possibility of adapting the short stump to an artificial leg. Many surgeons believe that we should never make a tibial stump less than four inches long, but that the surgeon should perform his amputation by disarticulating the knee-joint, or by amputating above the femoral condyles. I have

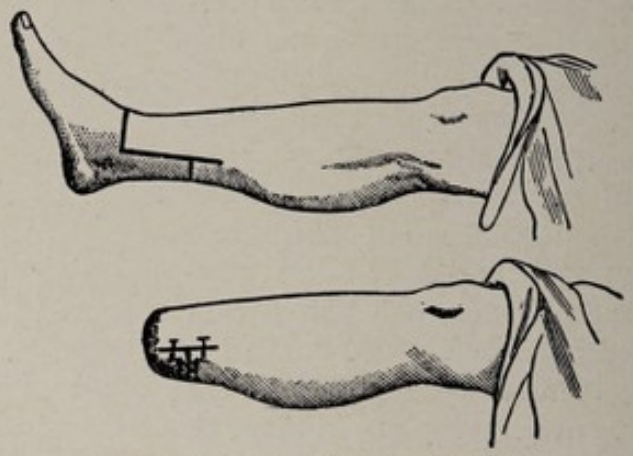

Fig. 675.—Teale's amputation.

found, however, that a short *tibial* stump, which is often troublesome on account of the back pull of the hamstring muscles, can be made useful if we perform a tenotomy on the hamstrings.

Many surgeons still amputate through the knee-joint. At the Massachusetts General Hospital we rarely perform this operation, as we are convinced that amputation above the condyles of the femur gives the patient a more useful stump.

Should the surgeon think it wise, however, to perform knee-joint disarticulation, he may well follow the commonly adopted bilateral method of Stephen Smith. Begin the incision one inch below the tubercle of the tibia, and carry it downward and forward around the side of the leg and so up into the popliteal space, making a lateral flap. Duplicate this flap on the other side. Separate the soft parts from the bone; divide the joint ligaments and remove the leg with the patella. Some observers maintain that this disarticulation causes less shock than does a regular amputation. Be that as it may, we secure a far better stump by supracondyloid amputation.

Supracondyloid Amputation.—Probably the best method for this operation is that suggested by Stokes and Gritti, which consists of section of the femur above the condyles with an osteoplastic flap, formed by the split patella. The authors point out that by this means the strong anterior weight-bearing patellar surface becomes the end of the stump.

As we approach the hip-joint in our amputations, the danger of shock increases, coincident with a rise in the operative mortality. For such reasons surgeons should amputate the thigh with great care and forethought, using every means to minimize shock and hemorrhage—especially by elevation of the leg; by careful application of the tourniquet; by perfect hemostasis, and by nerve cocainization. I

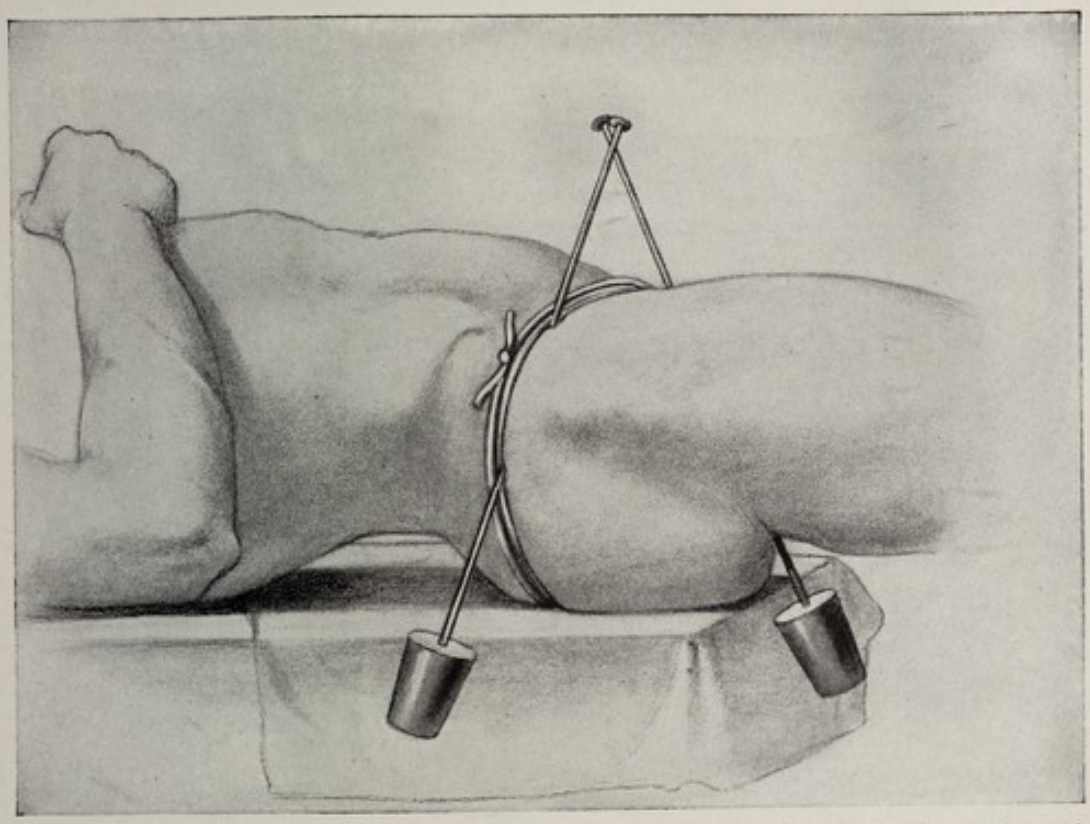

Fig. 676.—Wyeth's hip-joint amputation: Pins and rubber tube tourniquet in position. The Esmarch bandage has been removed (Wyeth).

prefer long muscle-flaps when they are available, and a thorough lacing together of the flaps in completing the suturing of the stump. In mid-thigh amputations the surgeon has to find and secure especially the femoral and popliteal arteries, while he must take pains to treat the sciatic and anterior crural nerve-ends by a proper anastomosis.

The **hip-joint amputation** has always been a matter of keen interest to surgeons since amputations at the hip-joint have been done, for the operation is a relatively modern one.[1] The shock is often extreme, and the hemorrhage not always easy to control, while death from complications may follow unexpectedly. Not long ago I had

[1] Walter Brashear, at Bardstown, Kentucky, in August, 1806, performed the first successful amputation at the hip-joint.

occasion to amputate at the hip-joint for sarcoma of the thigh in an apparently vigorous young man. The operation went off satisfactorily, but unfortunately the patient never rallied and died in about two hours. An autopsy revealed the fact that he was a victim of status lymphaticus, so that I found what consolation I could in the probability that he would have died from any minor operation.

In hip-joint amputations, or, more properly, in hip-joint disarticulations, for the operation always involves disarticulation, one must guard especially against hemorrhage. With a view to minimizing hemorrhage, various methods of operating have been devised, and the operation of John A. Wyeth has found a just popularity. For myself, I have always been satisfied with an amputation preceded by a preliminary ligation

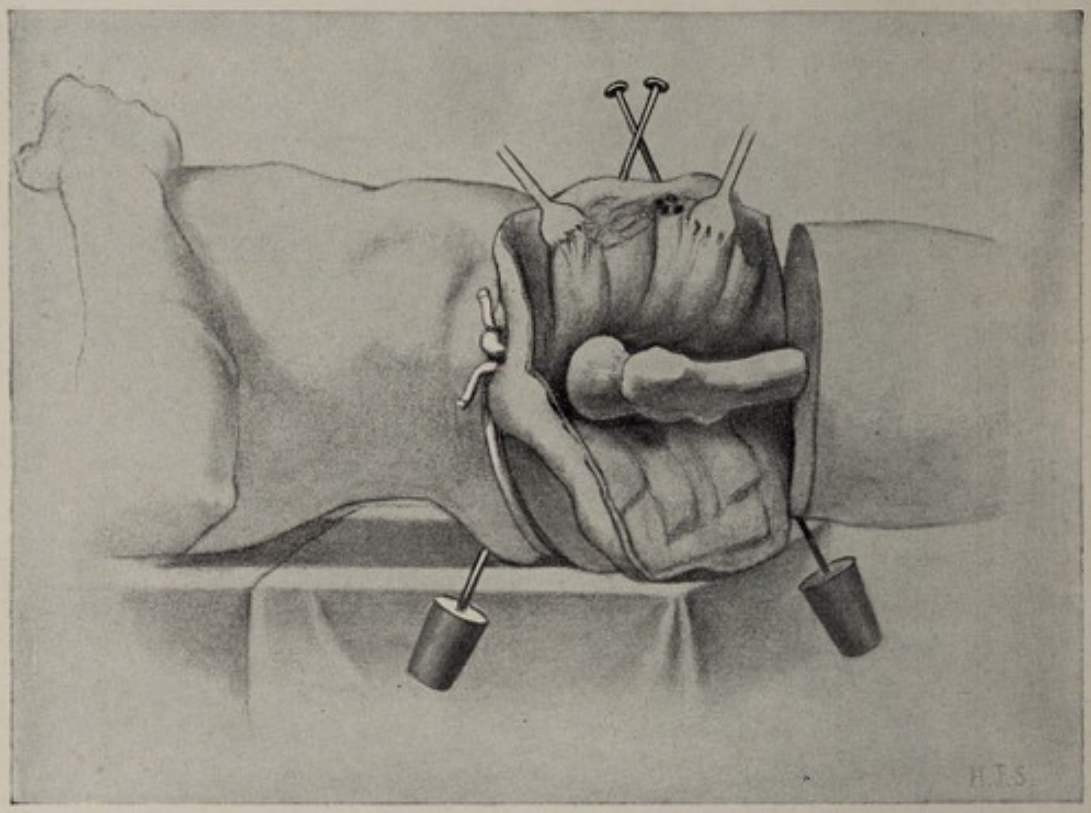

Fig. 677.—Same as Fig. 676, showing the soft parts dissected from the bone and the capsule exposed (Wyeth).

of the femoral artery at Poupart's ligament, the turning back of large anterior and posterior flaps, and the careful dissecting away of the bone, taking up the smaller severed vessels as one takes up vessels in a breast amputation. I then cocainize the anterior crural and sciatic nerves and join them by the usual anastomosis.

Wyeth's Method.—In his admirable essay on disarticulation at the hip-joint, Wyeth reminds us of Ashhurst's writing in 1881: "The removal of the lower limb at the coxofemoral articulation may be properly regarded as the gravest operation that the surgeon is ever called upon to perform, and it is only within a comparatively recent period that it has been accepted as a justifiable procedure. The most pressing risk is that of hemorrhage."

The notable feature in Wyeth's operation is his method of controlling hemorrhage by pins and a rubber tourniquet, which render the procedure nearly bloodless. As that surgeon writes, the limb to be amputated should be emptied of blood so far as possible, and while the leg is elevated, the tourniquet is applied: "The object of this constriction is the absolute occlusion of every vessel above the level of the hip-joint. . . To prevent any possibility of the tourniquet slipping, I employ *two large steel needles* or skewers, $\frac{3}{16}$ of an inch in diameter and 10 inches long, one of which is introduced $\frac{1}{4}$ of an inch below the anterior-superior spine of the ilium and slightly to the inner side of this prominence, and is made to traverse superficially for about 3 inches the muscles and fascia on the outer side of the hip. . . . The point of the second needle is thrust through the skin and tendon of origin of the adductus longus muscle half an inch blow the crotch, the point emerging an inch blow the tuber ischii. The points should be shielded at once with a cork to prevent injury to the hands of the operator. No vessels are endangered by these skewers. A mat or compress of sterile gauze, about 2 inches thick and 4 inches square, is laid over the femoral artery and vein as they cross the brim of the pelvis; over this a piece of strong white rubber tubing, half an inch in diameter when unstretched, and long enough when in position to go five or six times around the thigh, is now wound very tightly around and above the fixation needles, and tied."

As to the further conduct of the operation, Wyeth allows himself to be guided by the condition of the patient. When permissible, he employs a modified racquet incision; turns back a cuff; divides the soft parts transversely to the bone; disarticulates, and finally secures the vessels. He then completes the hemostasis and suturing in the usual manner.

We see that by employing Wyeth's method we eliminate hemorrhage. If the patient survive the primary shock, he should recover promptly with sound and satisfactory wound healing. Wyeth's "bloodless method" of amputating is equally applicable to the shoulder-joint.

Amputations of the Upper Extremity.—All amputations from the fingers to the thorax are interesting—more interesting perhaps than the corresponding amputations of the lower extremity. The lower extremity is concerned mainly in strong and coarse movements, so that it endures a good deal of mutilation without serious loss of function; but the upper extremity is concerned largely with delicate and finely coördinated movements, such as writing, sewing, and work in the mechanical arts. For such reasons we must be chary of mutilating the hand and arm, and must retain, so far as possible, every structure in its normal relations. The fingers especially must be treated with the most respectful consideration; every possible fraction of an inch must be saved, and the tips of the stumps must be made tactile and prehensile.

In operating upon the fingers and hands, it has become customary in dispensary clinics to use cocain anesthesia. My experience has led me gradually to the conviction that cocain is not always the best anesthetic for these delicate operations, but that frequently sensitive patients

with more or less intricate lesions had best be given a general anesthetic.

We approach—the joint if we are to disarticulate, or the phalangeal shaft if we are to amputate—by an incision which leaves a long anterior flap—the tactile palmar surface. In disarticulating it is not well to leave the synovial joint surface as a finger-tip.



Fig. 678.—Removal of index-finger (Erichsen).



Fig. 679.—Removal of little finger (Erichsen).



Fig. 680.—Results of amputation above metacarpophalangeal articulation (Erichsen).



Fig. 681.—Hand after removal of metacarpal bones and three fingers, leaving thumb and little finger (Erichsen).

It is better to scrape or trim off the synovial membrane, which is a structure of low vitality and subject to infection and necrosis, which may cause tedious wound healing. The thumb is best removed at an articulation by a single palmar flap without the preservation of the sesamoids, which belong to its short flexor. The figures in the text, taken from Roswell Park's Modern Surgery, illustrate the various flaps employed. That writer reminds us of the useful suggestion of

Lauenstein; when the first three fingers are to be removed, leaving only the thumb and little finger, he makes a small, properly placed incision with cutting forceps, which divides the metacarpal bones of the thumb and little finger at about the middle, and then, by giving these metacarpals a little twist toward each other, he produces a two-fingered claw, which is capable of grasping objects strongly.

We were formerly taught that when a single finger is amputated, its metacarpal bone had best be taken with it, as thus a more sightly hand is produced. I doubt this. It is a matter of taste. Certainly the hand of a laboring man is greatly weakened by the removal of one of his metacarpals. The wounds of finger amputations heal rapidly if not infected. Ten days after amputation a finger stump should be comfortable and even useful.

Hand Amputations and Wrist Disarticulations.—Although an arm without a hand may seem more useless than a leg without a foot, we must not think of such an arm as a contemptible member. Artificial hands may be fitted to arm-stumps for cosmetic reasons; but such artificial hands are of no practical service. After all is said, the stout old-fashioned hook, for general purposes, is the most useful substitute for a hand.

Disarticulations of the hand may be made below or above the carpus; indeed, it makes little difference at which level we disarticulate. The form of flap is of some importance, however, for the tough palmar skin of the hand drawn over the stump gives us a member somewhat more useful than one furnished with delicate dorsal skin.

Amputations through the forearm call for no special mention except reminding the reader that carefully executed cuff amputations give suitable stumps.

Disarticulation through the elbow-joint is sometimes useful, and is not open to the same objection as is disarticulation through the knee-joint. The major portion of the flap to cover in the elbow should be taken from the front of the arm and the scar should be made to lie behind the humerus.

Above the elbow the arm furnishes no points of special interest in amputations. The circular cuff is of service, or the rapid transfixion method with long muscle-flaps may be employed. In either case, and, indeed, in all amputations, we must bear in mind the frequency of stump neuromata, and must treat our nerve-ends accordingly by anastomosis.

The *shoulder-joint amputation*, or disarticulation at the shoulder, is similar in many respects to disarticulation at the hip, and in a minor degree its dangers are the same—hemorrhage and shock. Many surgeons control the hemorrhage by the use of wire pins. I have disarticulated at the shoulder-joint many times without them, and invariably have tied the subclavian as a preliminary step. Perhaps I have followed this method from habit or fancy. Certain it is, I believe, that Wyeth's method with pins is most generally applicable.

We may make an incision of the racquet form, starting from the acromion process and carrying the cut down to and around the arm;

or we may use the double flap method—turning up first the whole deltoid; disarticulating the humerus; then seizing the vessels in the axilla and completing the interior or axillary flap.

Removal of the Whole Upper Extremity.—This is known as the *interscapulothoracic*[1] *amputation*, and is gradually coming into favor with progressive surgeons. Its sole purpose practically is for the removal of extensive malignant disease of the arm and shoulder. As Cobb points out, the important points in the operation are the control of hemorrhage, and the prevention of shock when dividing the great nerve-trunks. Death from the operation is usually from shock, with or without hemorrhage. In these cases, as in disarticulation at the hip-joint, surgeons have found the cocainization of the nerve-trunks before dividing them to be of great value.

There is little divergence of opinion among surgeons regarding the technic of this operation, the one important point of debate being as to the removal of the whole or a part of the clavicle. I prefer sawing through the clavicle at its middle third, and leaving its sternal portion, as I am convinced that its total removal adds to the shock of the operation.

The steps of the operation are as follows: Cut down upon and secure the subclavian vessels at their middle third, and divide the clavicle at this point. Cut the subclavian vessels between the ligatures, the artery first and later the vein, after the arm has been emptied of blood by elevation. The steps to this point are preliminary. Now comes the actual amputation. The incision is continued from the point over the divided vessels and curved downward to the anterior axillary fold. The clavicular portion of the pectoralis major is separated with the finger from the costal portion of the muscle up to the anterior axillary fold; the clavicle is pulled down, the subclavians stripped off, and the pectoralis minor is divided, when the whole axilla is found to be fully exposed. At this point the surgeon should cocainize the nerves of the brachial plexus, and sweep the axilla, cleaning up nerves and vessels.

The next step is to carry the posterior incision from the original cut backward and downward to the inferior angle of the scapula, and then up to meet the anterior incision. Dissect back the skin and fascia; divide the trapezius, and secure bleeding points; divide the omohyoid muscle, and in succession the remaining muscles attached to the scapula. This completes the operation practically, for the upper extremity may now be lifted out. Should the growth for which the operation is undertaken make necessary an irregular dissection, skin to close in the open space may be secured from the inner aspect of the arm. Usually the skin-flaps come together nicely, when with abundant dressing and careful bandaging a comfortable wound results. The mortality from this operation is not low, for patients who come to it are generally debilitated from long-standing disease. The resulting mutilation is great. Few persons realize the peculiar conic shape imparted to the upper portion of the thorax by the removal of the whole upper extremity.

[1] Admirable reports of this operation have been published by Robert G. LeConte, Ann. Surg., October, 1902, and by Farrar Cobb, ibid., February, 1905.

INDEX

Abbe, Robert, 119, 717
Abdomen, contusions of, 260
  pendulous, 262
  penetrating wounds of, 55
Abdominal aorta, ligation of, 795
  belts, 62
  drainage, 236
  hernia, 196
  hysterectomy for cancer, 325
  pregnancy, 351
  ptosis, 169, 247
    diagnosis, 258
    Graves' disease and, 258
    symptoms, 256
    treatment, 259
  wall, diseases of, 260
    tumors of, 262
Abernethy, John, 749
Aberrant goiter, 623
Abscess, alveolar, 570
  bone, 964
  brain, 664
  breast, 539
  cerebral, 664
  "cold," 965
  deep cervical, 605
  ischiorectal, 95, 96
  liver, 159
  lung, 493
  of spleen, 192
  palmar, 757, 761
    Brooks' incision for, 766
  paranephritic, 389
  paraurethral, 462
  subdiaphragmatic, 131
  tongue, 582
  tubo-ovarian, 332
Absorbent tape, 745
Accessory thyroids, 609
"Acid dyspepsia," 133
Acromegaly, 668, 970
Actinomycosis, 69, 70
  of breast, 541
  of esophagus, 127
  of intestines, 69
  pulmonary, 495, 514
Adami, 835
Addison's disease, 611
Adenia, 814
Adenitis, 813
  cervical, 600
  tuberculous, treatment of, 602
Adenocarcinoma of breast, 521
  of uterus, 316
Adenoid disease, 814
Adenoids, 588
Adenolymphoma, 814
Adenoma, 856
  of testicle, 486
Adhesions, gastric, 146
Adrenalin in shock, 783
Aitken, H. F., 356, 357, 358, 359, 360
Akbarran, 373
Albert, 193
Alcohol in shock, 783
Alexander, Samuel, 437
  operation, 287, 288, 289
Alglave, 493
Allen, Dudley P., 605, 675
Allingham, 101
Allis, O. H., 951, 953
Alveolar abscess, 570
  process, cyst of, 572
American Medical Association, 35
Ampulla of Vater, 181, 185
Amputation, 990
  immediate, 991
  neuromata, 721
  of breast, Warren's operation, 526
  of foot, 998
  of hand, 1007
  of hip-joint, 1003
  of penis, 461
  of shoulder-joint, 1007
  of toes, 997
  of upper extremity, 1005
  primary, 991
  secondary, 991
  Teale's, 1002
Anal resection, 110
Anastomosis, accessory, 587
  arteriovenous, 807
  end-to-end, 54
  lateral, 68
  nerve, 723
    in stump, 722
  spinofacial, 723
Anders, 92
Andrews, E. W., 655
Anel, operation of, 801
Anel's method, 806
Anemia, splenic, 194, 814
Anesthesia, intratracheal, 492
Aneurysm, 798
  cirsoid, 567, 568, 629, 791
  of hepatic artery, 170
  of innominate artery, 800
  treatment of, 801

Aneurysm, varicose, 791
Aneurysmal varix, 791, 799, 806
Aneurysmorrhaphy, 805
Angioma, 100, 567, 791, 853
  plexiform, 791
Angiosarcoma, 851
Ankle-joint, excision of, 985
Ankyloglossia, 581
Ankylosis of jaws, 571, 572
Ano, fistula in, 97
    operation for, 99
Anoci-association, 781, 784
Anteflexion of uterus, 295
Anterior tibial artery, 797
Anteversion of uterus, 286, 294
Antrum, empyema of, 571
Antyllus, 787
  operation of, 801
Anus, artificial, 52, 82, 83, 84, 92, 111
    Kocher's, 86
  cancer of, 106
  fissure of, 94
  imperforate, 90, 91
  prolapse of, 103
  syphilitic affections of, 93
  tuberculosis of, 94
  tumors of, 105
Aorta, ligation of abdominal, 795
Apoplexy, 640
  pancreatic, 186
Appendectomy, Battle's method of, 32
  early, 32
  McBurney's method of, 32
Appendiceal colic, 22
Appendicitis, 17
  acute, 22
  chronic, 22, 25, 26, 29, 30, 40, 54
  diagnosis of, 31
  etiology of, 20
  forms of, 23
  gangrenous, 22
  in children, 25
  pathology of, 22
  prognosis of, 31
  relapsing, 22, 25, 29, 40
  simulated, 25, 59
  symptoms of, 26
  treatment of, 31
  with peri-appendicular involvement, 28
Appendicostomy, 64
Appendix, vermiform, anatomy of, 17
    catarrh of, 22
    function of, 20
    hydrops of, 22
    segmented, 24
    stump, treatment of, 41
Arachnoid, 654
Aran's theory of irradiation, 633
Arteries, ligation of, 791
Arteriorrhaphy, 807
Arteriovenous anastomosis, 807
Artery, anterior tibial, 797
  axillary, 794
  brachial, 795
  cystic, 180
  facial, 794
Artery, femoral, 795
  hepatic, aneurysm of, 170
  innominate, 792
    aneurysm of, 800
  lingual, 794
  posterior tibial, 795
  radial, 795
  superior hemorrhoidal, 795
Arthrectomy, 980
Arthritis, chronic, 973
Ashhurst, 64
Asphyxia, traumatic, 512
Astragalus, 932
Atlas, dislocation of, 689
Atresia of vagina, 367
Atrophy, ischemic, 816
Auvray, 624, 674
Avulsion of scalp, 627
Axilla, examining infected, 759
  scar-formation in, 528
Axillary artery, 794

Babcock, W. W., 608
Babinski, 667
Bacillus, Oppler-Boas, 149
  typhosus, 171
Baker, W. H., 292
Balanitis, 449
Balch, F. G., 908
Baldwin, Henry C., 646
Ballance, Charles A., 653, 660, 664, 665, 670, 707
Bandage, four-tailed, 936
    Martin, 992
Bands, Halsted's metallic, 801
Banti, 194
Barker, L. F., 216
Barney, J. D., 460
Bartlett, W., 214, 358
Bartlett's filigree, 223
Base, fracture of, 633, 644
Basedow's disease, 611
Bassini, 216, 219
Battey, 307
Battle, 32
Beach, H. H. A., 208
Beard, 864
Beatson, 864
Beck, Carl, 240, 469, 489, 570
Beck's paste, 503
Becker, H., 286
Beebe, S. P., 612, 863
Beer, Edwin, 60
Bell, Charles, 682
Belts, abdominal, 62
Bence-Jones, 663, 698, 850
Benign growths, 861
  tumors, 834
Bennett's fracture, 910
Bereznegovsky, 624
Berger, 994
Bessel-Hagen, 193
Bethe, Albrecht, 707
Bevan, Arthur Dean, 71, 475
Bevan's operation, 475

Bickham, 179, 719, 720, 806, 981, 983
Bier, 994
Bier's hyperemic treatment, 261, 810
Bigelow, Henry J., 398, 411, 951, 953
Bigelow's evacuator, 377, 409, 411
Bile-passages, 171
  acute inflammation of, 174
  cancer of, 176, 182
  reasons for operation on, 176
  three laws of operative treatment of, 177
Bilious, 173
Billroth, 127, 153, 154, 584
Binnie, John F., 179, 382, 554, 586, 616, 703, 713
Birth-mark, 567
Bishop, 216
Bladder, absence of, 399
  double, 399
  drainage of, 413
  examination of, 372
  exstrophy of, 398
  extirpation of, total, 417
  foreign bodies in, 421
  gunshot wound of, 420
  injuries to, 419
  irritable, 407
  rupture of, diagnosis of, 417
    extraperitoneal, 417
  sacculation of, 418
  stone in, 408
  suprapubic puncture of, 404
  tumors of, 415
    diagnosis of, 416
  ulcer of, 414, 415
Blake, J. B., 225, 458
Bland-Sutton, J., 566, 572, 573, 581, 628, 698, 834, 836, 841, 856
Blood, transfusion of, 378
Bloodgood, Joseph C., 214, 216, 533, 537, 780, 848
Blood-vessels, 787
  suture of, 807
Boils, 764
Boise, 780
Boisseau, 373
Bone abscess, 964
  intermaxillary, 547
  syphilis of, 965
  tuberculosis of, 964
Bones and joints, 859
  malar, 935
  nasal, 933
  of cranium, 662
  of face, 933
  of foot, dislocation of, 956
  of forearm, fracture of, 900
Borel, 634
Boston City Hospital, 159
Bottini, 430
Bottomley, John T., 399
Bougies, olivary, 467
  Trosseau's olive-tipped, 113
Bovée, 366
Bowels, anatomy of, 43
Brachial artery, 795
Brachial plexus, 726
Bradford (E. H.) frame, 691, 919
Brain, 630, 663
  abscess of, 664
  compression of, 635, 643
  concussion of, 634, 643
  contusion of, 640
  tumor, 665
    symptoms of, 666
    treatment of, 668
  wounds of, 641
Brasdor method, 806
  operation, 802
Brashear, Walter, 1003
Brauer, 492
Breast, abscess of, 539
  actinomycosis of, 541
  amputation of, Warren's operation, 526
  and nipples, supernumerary, 542
  "caked," 540
  cancer of, 517
    colloid, 520
    en cuirasse, 518, 521
    Jackson's operation for, 530
    medullary, 517, 519
    scirrhus, 517, 518
    "withering scirrhus," 518
  cystadenoma of, 535, 536
  cysts of, retention of, 542
  echinococcus of, 541
  fibrocystadenoma of, 535
  fibroma of, periductal, 534
  galactocele of, 541
  hypertrophy of, diffuse mammary, 536, 537
  involution of, abnormal, 537
  mastitis of, 539
  myxoma of, periductal, 534, 535
  resection of, plastic, 537
  sarcoma of, periductal, 534
  syphilis of, 541
  tuberculous disease of, 541
  tumors, Warren's classification, 533
Bregma, 648
Brewer, G. E., 60
Brewster, 510
Briggs' cannula, 604
Briggs, C. E., 64, 67, 605
Briggs, J. E., 432
Broca, 624
Brödel, Max, 265, 382, 383
Brödel's white line, 382
Brodie, Benjamin, 733, 976
Bronchi, 488
  and lungs, 488, 497
  foreign bodies in, 489
Bronchiectasis, 490
Brooks, W. A., Jr., 20, 762
Brooks' incision for palmar abscess, 763
Brophy, 554, 555
Brophy's operation for cleft palate, 554
Brown, G. V. I., 544
Brown, Tilden, 373
Brown's compression apparatus, 552
Brunn, 240
Bryant, Thomas, 179, 196, 368, 798

Bubo, 457, 458
gonorrheal, 449
Buck, Gurdon, 17
Buck's extension, 917
Bulb, hemostatic, 432
Bullet, embedded, 940
Bunge, 995
Bunions, 769
Bunts, F. E., 143
Burkhardt, 165
Burns, 828
cicatrix from, 598
of chest, 513
of neck, 597
Burrage, W. L., 315
Burrell, Herbert L., 766, 793
Bursa, 816, 823
subdeltoid, 823
suprapatellar, 823
tuberculosis of, 827
tumors of, 827
Bursitis, 823
acute infective, 827
chronic, 827
prepatellar, 824
subcoracoid, 827
traumatic, treatment of, 824
Butler, 684

Cabot, A. T., 252, 926
Cabot, Hugh, 431
Cabot's posterior wire splint, 926
Cahier, Leon, 59
Calcium lactate, 610
Calculi, pancreatic, 186, 188
prostatic, 424
renal, 380
ureteral, 381
urethral, 462
urinary, symptoms of, 380
Callosity, 773
Callus, 872
Cammidge, 187, 189
Campbell, 197, 382, 399, 638
Canal of Nuck, 290
Cancer, gastric, 126, 147
gland, 861
of anus, 106
of bile-passages, 176, 182
of breast, 517
colloid, 520
en cruiasse, 518, 521
Jackson's operation for, 530
medullary, 517, 519
prognosis of, 524
scirrhus, 517, 518
withering, 518
symptoms of, 523
treatment of, 524
of cervix, 316
of esophagus, 125, 126
of fundus, 147, 326
of ileocecal region, 80
of intestines, 77, 78
of jaw, 575
Cancer of kidney, 395
of larynx, 594
of lip, 559
Grant's operation for, 562
of lung, 496
of neck, 560
of pancreas, 188
of penis, 460
of prostate, 425, 438
excision of, 439, 440, 441, 442
of rectum, 107, 108
percentage of deaths from, 108
symptoms of, 108
treatment of, 108, 110
of testicles, 486
of thyroid gland, 621
of tongue, 582
operation for, 583
of uterus, 315
diagnosis of, 319
symptoms of, 318
treatment of, 319
scirrhus, 107
squamous-cell, 859
Cannon, W. B., 234
Cannula, Briggs', 604
Carbon-dioxid snow, 568, 853
Carbuncle, 764, 766
excision of, 767
of upper lip, 566
Cardiolysis, 509
Cardiospasm, 120
acute, 120
chronic, 120, 121
Cargile membrane, 240, 719
Caries, 961
necrotic, 570
Carlsbad, 173
Carotid artery, external, 794
gland, 606
internal, 794
Carpus, fracture of, 907
Carrel, Alexis, 807
Cartilages, semilunar, 956
Caruncle, urethral, 362
Cases, study of, 731
Caspar, 373
Castration, 480, 487
Catarrh of appendix, 22
Cathelin, 374
Catheter, ureteral, 374
Catheterization, 400
Catlin, 1001
Cauda equina, 690
tumors of, 701
Cavernous tumors, 791
Cellulitis, pelvic, 330
Cephalocele, 654
Ceppi, 945
Cerebellar tumors, 667
Cerebral abscess, 664
hemorrhage, 640
localization, 645
tumor, 665
Cerebri, fungus, 670
hernia, 670, 671

Cerebrospinal fever, 659, 692
rhinorrhea, 657
Cervical abscess, deep, 605
adenitis, 600
rib, 607
Cervix uteri, cancer of, 316
erosions of, 279
ureter and, 269
Championnière, Lucas, 198, 216
Chancre, 454
treatment of, 455
Chancroid, 455
treatment of, 457
Chaput, 143
Charcot's disease, 988
Cheever, D. W., 124, 489, 590
Cheiloplasty, Sandelin's, 563
Chelius, 748
Chelius' Surgery, 196
Chest-wall, burns of, 513
contusions of, 512
tumors of, 514
Cheyne, W., 524
Chiene, 649
Chilblains, 830
Children, fracture of thigh in, 919
Chipault, 646, 703
Choked disk, 637, 652
Cholangitis, 128, 170, 171, 172, 173, 174
acute, 175
Cholecystduodenostomy, 182
Cholecystectomy, 177, 178, 180, 182
Cholecystendysis, 178
Cholecystenterostomy, 178, 182, 188
Cholecystitis, 170, 171, 173, 174, 175
Cholecystostomy, 177, 180, 188
Choledochenterostomy, 179
Choledocholithotomy, 178
Choledochotomy, 178
Cholesterin, 171
Chondrodystrophia fœtalis, 968
Chondroma, 844
of parotid gland, 586
Chopart's operation, 998
Chordee, 447
Chylothorax, 497, 504
Cicatricial contractions of neck, 597
Cicatrix from burn, 598
Ciechanowski, 425
Circulation, portal, 73
Circumcision, 458, 459
of leg, 790
Cirrhosis, 129
gastric, 146
of liver, Hanot's, 167
Cirsoid aneurysm, 567, 568, 629, 791
Civiale, Jean, 410
Cladothrix, 70
Clamp and cautery, 97
Clark, Alonzo, 233, 234
Clark, J. G., 326
Clavicle, dislocation of, 942
fracture of, 879
Claw-hand, 727, 729
Cleft-palate, 542, 550
Brophy's operation for, 554
Cleft-palate, operation for, 553
Cleveland, 361
Cline, 682
Closed fractures, 741, 868
Clowes, 863
Coagulation time, 180
Cobb, Farrar, 387, 1008
Cobb's (F. C.) splint, 934
Codman, E. A., 823, 824, 825, 826, 935
Codman's rhinoplasty, 557
Coffey, Robert C., 236
Cohnheim's embryonal hypothesis, 836
"Cold abscess," 965, 976
Coley, W. B., 216, 864
Colic, appendiceal, 22
Colitis, 63
mucous, 63
Collapse, 779
Colles' fracture, 902
old, 907
Colloid cancer of breast, 520
goiter, 621
Colon, idiopathic dilatation of, 76
prolapse of, 257
Colostomy, 64, 92, 111
Coma, 645
Comminuted fracture, 866
Common iliac artery, 795
Compound fracture, 748, 866, 874, 928
of vault, 634
Compression apparatus, Brown's, 552
elastic, 738
of brain, 635
Concussion of brain, 634
of spine, 686
Condyloma, 106
Cone, C., 333
Congenital hernia, 197
hydrocele, 483
imbecility, 674
Conjunctivitis, gonorrheal, 444
Connective-tissue tumors, 842
Contracture, Volkmann's, 816, 817
Contrecoup, 674
Contusion of abdomen, 260
of brain, 640
of chest, 512
of joints, 971
of scalp, 625
of spine, 686
Conus medullaris, tumors of, 701
Convulsive tic, 724
Coolidge, A., Jr., 489
Coolidge's (A.) splint, 934
Cooper, Astley P., 515, 682, 795, 952
Cord, spermatic, twisted, 487
spinal, anatomy and physiology of, 682
wounds of, 687
Corns (clavus), 769, 772
Coronoid process, fracture of, 902
Corpus luteum, 345
cysts of, 345
Corset-belts, 259
Costal perichondritis, posttyphoid, 513
Cotting's operation, 771
Cottle, C. H., 493

Cotton, F. J., 867
Courvoisier's law, 176
Cowper's gland, 443
Coxa valga, 988
  vara, 986
Craig, Daniel H., 20, 317
Craik, 592
Crandon, L. R. G., 237, 425
Cranial bones, tumors of, 662
  defects, 674
Craniocerebral topography, 646
Craniotomy, osteoplastic, 675
Cranium, 662
Credé, 789
Cremaster, 211
Crile, George W., 300, 507, 553, 562, 580, 597, 601, 613, 779, 781, 782, 783, 784, 793, 862, 863
Crile's clamp, 565, 579
Cross-bow incision (Cushing's), 679
Crotalin in epilepsy, 672
Crow-bar case (Harvard), 642
Cullen, 333
Cunningham, J. H., 394
Curling, 92
Curtis, G. Lenox, 571
Cushing, Harvey, 64, 67, 229, 507, 624, 628, 631, 640, 648, 649, 651, 653, 656, 661, 664, 665, 668, 680, 689, 710, 717, 723, 724
Cushing's method of closing scalp, 679
Cutaneous horn, 854, 855
Cut-throat, 589
Cylindroma, 852
Cyrtometer, Horsley's, 649
Cystadenoma, 535
  papillary, 536
Cystic artery, 180
  goiter, 615, 617
Cystitis, 404
  acute, 406
  gonorrheal, 450
  in female, 407
  treatment of, 406
  tuberculous, 405
Cystocele, 196, 356, 357
Cystoma, 345, 837
Cystoscope, 372
Cystoscopy, 374, 375
Cystotomy, suprapubic, 412
  transperitoneal, 418
Cysts, dental, 572
  dermoid, 192, 346, 840
  echinococcus, 160, 514, 838
  follicular, 344
  hydatid, 188, 192, 838
  lymphatic, 605
  of alveolar process, 572
  of breast, retention, 542
  of broad ligament, 340
    dermoid, 341
  of liver, 160
  of mesentery, 837
  of scalp, dermoid, 628
  of spleen, 192
  of testicle, dermoid, 486
Cysts, ovarian, 344
    twisted, 346
  ovula Nabothi, 279
  pancreatic, 188, 189
  retention, 836
  retroperitoneal, 245
  thyroglossal, 559
  tubo-ovarian, 332, 335
  vaginal, 367
Czerny, 216, 595

Da Costa, J. C., 198, 376, 492, 787, 832
Dactylitis, 965, 966
Dartmouth, 348
Davis, Byron B., 191
Davis, G. G., 214, 216
Davis, Lincoln, 415
Dawbarn, Robert H. M., 769
Deaver, J. B., 17, 31, 36, 187, 306
Decapsulation of kidney, 396
Deciduoma malignum (choriodeciduoma), 328
Decompressive operations, 679
DeGarmo, W. B., 197, 205, 206, 209
Degeneration, myxomatous, 853
  of scars and ulcers, malignant, 832
de Guise, operation of, 558
Delagenière, 167
Delayed union, 868
Delorme, operation of, 502, 504
Denans, 42
Dennis, F. S., 216, 506, 635
Dental cysts, 572, 573
Dermoid cysts, 840
    of broad ligament, 341
    of ovaries, 486
    of scalp, 628
    of testicle, 486
Desault splint, 929
Desmoids, 262, 843
DeVilbiss forceps, 677
Diaphragmatic hernia, 196
Diarrhea, tubular, 63
Diathesis, gouty, 379
Dieffenbach, 629
Dietl's crisis, 251
Dieulafoy, 130
Diffuse goiter, 614
  lipoma, 843
Digestive organs, 128
Dilatation of the colon, idiopathic, 76
  gastric, 61
Dilators, Goodell-Ellinger, 277
  Hanks', 277
Disarticulation, wrist, 1007
Disinfecting skin, 737
Dislocation of atlas, 689
  of clavicle, 942
  of elbow, 938
    old unreduced, 950
  of forearm, backward, of both bones, 897
  of foot, bones of, 956
  of hip, 951
  of jaw, lower, 956

Dislocation of knee, 751
of patella, 751
of radius, head of, 949
of shoulder, 943
old unreduced, 947
of thumb, first phalanx of, 950
of vertebræ, 688
of wrist, 950
Diverticulitis, 58
treatment of, 60
Diverticulum, 114
Meckel's, 50, 57, 58, 59
of esophagus, 122, 123
of sigmoid, 59
Dollinger's method, 602, 603
Donald, 277
Douglas, F. B., 246
Dowd, Charles N., 816
Druitt, 196
Drummond, 166
Duct, bile-, 171
ejaculatory, 422
Müller's, 329
of Santorini, 172
of Wirsung, 171, 172, 185
pancreatic, 172
prostatic, 422
thoracic, wounds of, 604
vitello-intestinal, 57
Wolffian, 329
Dudley, E. C., 271, 281, 287, 310, 311, 312, 316, 319, 322, 323, 325, 329, 337, 339, 361, 366
Dudley's operation for anteflexion, 296
Dunham, Theodore, 119
Duodenal ulcer, 30, 129, 130, 131, 133, 144, 176
Duodenum, 113, 128, 171
Dupuytren's splint, 931
du Rocher, 373
"Dyspepsia, acid," 133
Dysphagia, 116, 123, 125

Echinococcus disease, 160, 514, 838
of lung, 494
of mammary gland, 541
of pleura, 505
Ectopic gestation, 350
Ectropion, 555
Edebohls, George M., 253, 254, 396
Edward, J. R., 493
Effusion, pericardial, 507
Ehrlich, 863
Eichberg, Joseph E., 241
Einhorn, 116
Eisendrath, Daniel N., 203, 583, 865, 912, 958
Elastic compression, 738
Elbow, dislocation of, 948
old unreduced, 950
excision of, 980
fracture of, 893
Elbow-joint, fracture of, neglected, 899
Elephantiasis, 812
Eliot, Ellsworth, Jr., 169, 170, 509
Elting, A. W., 98
Embolism of mesenteric vessels, 71
Embryonal hypothesis, Cohnheim's, 836
Emmet, T. A., 283, 360, 363
Empyema, 499
of antrum, 571
chronic, treatment of, 501
Encephalitis, 663
Encephalocele, 654
Encephalocystocele, 654
Endocervicitis, 279
Endometritis, 281
acute, 278
cervical, 279
chronic, 278
Endothelioma, 666, 850
of uterus, 327
Enema, lime-water, 93
Enlargement, prostatic, 400
Enteritis, membranous, 63
Enterocele, 196
Enterolith, 56
Enteroptosis, 60, 247
Enterostomy, 52, 235
Enucleator, Mayo's vein, 790
Ependyma, 654, 661
Epidemic meningitis, 692
Epididymitis, 447
syphilitic, 478
Epilepsy, 671
crotalin in, 672
focal, 672
Jacksonian, 667, 672
treatment of, 672
Epiphysis, separation of upper, 887
Epiplocele, 196
Epispadias, 469
Epithelial tumors, 854
Epulis, 573, 574
Erasion of joints, 980
Erichsen, John E., 686, 1006
Erosions, 130
exulceratio simplex, 130
gastric, 130
of cervix, 279
Erysipelas, facial, 566
toxins of, 864
Erythema pernio, 830
Escher, 165
Esmarch, 90, 992
Esophageal stricture, 114, 115
diagnosis of, 118
treatment of, 118
tube, Symond's, 116
Esophagitis, 120
Esophagoscope, 114, 121, 124, 126, 127
Esophagoscopy, 115
Esophagotomy, 114, 124, 125
Esophagus, 113
actinomycosis of, 127
cancer of, 125, 126
diverticulum of, 122, 123
foreign bodies in, 123
inflammation of, 127
injuries of, 126
kinking of, 120

Esophagus, tumors of, 125
ulcers of, 127
Estlander's operation, 501, 502, 503
Ether in production of shock, 782
Eustache, 544
Evans, 619
Ewing, W. G., 244, 863
Excision of ankle-joint, 985
of cancer of prostate, 439, 440, 441, 442
of carbuncle, 767
of elbow, 980
of hip-joint, 982
of jaw, 579
of joints, 980
of knee-joint, 983
of parotid gland, 586
of wrist-joint, 981
Exophthalmic goiter, 608, 611
abdominal ptosis and, 258
Exostosis, 844
Exploration, suboccipital, 679
Extension, Buck's, 917
Extradural hemorrhage, 638

Face, bones of, 933
injuries of, 566
plastic operation on, 555
powder, 556
tumors of, 567
Facial artery, 794
erysipelas, 566
paralysis, 724
spasm, 724
Fallopian tubes, operation on, conservative, 339
tumors of, 339
Farina, 506
Fat-necrosis, 185
Fear, elimination of, in prevention of shock, 783, 784
Fecal fistula, 52, 71, 82, 83, 84
treatment of, 84
tumors, 57
Feeding by gastrostomy, 155
Feiss, Henry O., 987
Fell-O'Dwyer apparatus, 492
Felon, 757
Femoral artery, 795
hernia, 199
ring, 196
Femur, fracture of, 911
neck of, 912
shaft of, 916
supracondyloid, 919
Fenger, 385
Fenwick, 373
Ferguson, A. H., 216, 396, 436
Fever, cerebrospinal, 659, 692
"spotted," 659
typhoid, 65
Fibroadenoma, 856
Fibrocystadenoma, 535
Fibroid, 302
Fibroma, 843
of breast, periductal, 534
Fibroma of jaw, 572
Fibromyoma, 302, 843
Fibula, Pott's fracture of, 929
Filaria sanguinis communis, 811
Filariasis, 811
Fillebrown, 552, 553
Finger, 425
Finney, J. M. T., 132, 134, 136, 142, 143
First intention, 737
Fischer, G., 506, 608, 808
Fissure of anus, 94
of Rolando, 649
of Sylvius, 649
Fistula, 52, 71, 82, 83, 84, 96
complete, 97
operation for, 99
external, blind, 97
fecal, 52, 71, 82, 83, 84
treatment of, 84
forms of, 98
in ano, 97
internal, 82
blind, 97
rectovaginal, 363, 365
salivary, 556
umbilical, 263
urethral, 468
urethrovaginal, 363, 364
urinary, 364
vesico-uterine, 363
vesico-uterovaginal, 363, 364
vesicovaginal, 363, 364
Fitz, R. H., 17, 30, 76, 157
Flexner, S., 660, 692
Flint, Carleton P., 922, 983, 984, 985, 986
Focal epilepsy, 672
Follicular cysts, 344
odontoma, 573
Foot, amputation of, 998
bones of, dislocation of, 956
phalanges of, 933
Foramen of Winslow, 76
Forearm, bones of, dislocation backward of both, 897
fracture of, 900
Foreign body in bladder, 421
in bronchi, 489
in esophagus, 123
in intestines, 56
in larynx, 590
in rectum, 92
in trachea, 590
in urethra, 461
Fossa, intersigmoid, 76
navicularis, 443, 445
retrocecal, 76
retroduodenal, 76
Fothergill, 277
Four-tailed bandage, 936
Fowler, George Ryerson, 40, 216, 236, 292, 375, 385, 439, 450, 503
Fowler, Russell S., 236
Fowler's operation, 502, 503
position, 55, 81, 235, 237, 798
Fracture, 865, 869
Bennett's, 910

Fracture, closed, 741, 868
Colles', 902
compound, 748, 866, 874, 928
greenstick, 870
gunshot, 940
immobilization of, 742
open, 748, 868
treatment of, 867
pathologic, 870, 940
periosteal, 870
punctured, 633
simple, 741, 866, 870, 871
spiral, 870
of base, 633, 644
of carpus, 907
of clavicle, 879
old, 907
of coronoid process, 902
of elbow, 893
neglected, 899
of femur, 911
neck of, 912, 915
shaft of, 916
supracondyloid, 919
of fibula, Pott's, 929
of forearm, bones of, 900
of humerus, 884
anatomic neck of, 887
lower end of, 895
surgical neck of, 888
of hyoid, 590
of jaw, lower, 938
upper, 936
of leg, 923
of patella, 920
of pelvis, 878
of phalanges, 911
of radius, head and neck of, 902
neck of, 897
of ribs, 875
of scaphoid, 908
of scapula, 883
of skull, 631
of sternum, 877
of thigh in children, 919
of thyroid, 590
of vault, compound, 634
simple, 634
of vertebræ, 688
Fragilitas ossium, 968
Frame, Bradford, 919
Frank, Jacob, 166, 216
Frankel, 504
Fraxier, Charles H., 624, 691, 721
Frederick, Emperor, 595
Freudenberg, 430
Freyer, 433
Fritsch, 646
Frost-bite, 830
Fuller, Eugene, 454
Fundus uteri, cancer of, 316
Fungus cerebri, 670
Funke, John, 606

Galactocele, 541
Galen, 681, 787
Gall-bladder, enlarged, 175
Gall-stones, 172
Gamgee, Sampson, 736, 744, 869
dressing, 766
Ganglion, Gasserian, 711, 714
Cushing's operation upon, 715
tuberculous, 821
Gangrene, 22, 73
of lung, 494
Gangrenous appendicitis, 22
Garceau, Edgar, 407
Garrigues, 361
Gastrectasia, 128
Gastrectomy, 151
Gastric adhesions, 145
cancer, diagnosis of, 149
symptoms of, 149
cirrhosis, 146
dilatation, 61
erosions, 130
hemorrhage, 143
ptosis, 61
surgery, 127
tetany, 129, 146
ulcer, 128, 133
Gastroduodenostomy, Finney's, 136
Gastro-enterostomy, 127, 134, 142, 144, 182
anterior, 134
posterior, 135
Gastrogastrostomy, 145
Gastromesenteric ileus, 52, 255
Gastroplasty, 132
Gastroptosis, 129, 146, 247
Gastrostomy, 64, 121, 126, 154, 155
feeding by, 155
preliminary, 119
Witzel's, 64
Gatch, 34, 236
Gay, George W., 101, 483, 864
Gaylord, 863
General condition, 732
Genital herpes, 458
lesions of syphilis, 454
Genito-urinary organs, 368
Gerhardt, 73
Gerlach, valve of, 18, 20
Gersuny, 399
Gersuny's method, 829
Giant-cell sarcoma, 848
Gibbon, John H., 510
Gibson, C. L., 48, 75, 429
Gigantism, 970
Gilliam, 292
Gimbernat's ligament, 217
Girard, 216, 503
Glabella, 648, 676
Gland cancer, 861
carotid, 606
Cowper's, 443
in neck, 600
lymph, 811
of Littré, 443
parotid, excision of, 586
salivary, 585
suprarenal, 392

Gland, suprarenal, tumors of, 396
swollen, 601
thyroid, 608
cancer of, 621
Glandules, parathyroid, 608, 619
Gleet, 451
treatment of, 452
Glénard, 60, 277, 248, 249
Glénard's disease, 60
Glioma, 666, 854
Gliosarcoma, 701
Glossitis, chronic, 581
Glück, 165, 595
Gluteal hernia, 196
Goiter, 608, 613
aberrant, 623
causation of, 616
colloid, 620
cystic, 615, 617
diagnosis of, 615
diffuse, 614
exophthalmic, 608, 611
abdominal ptosis and, 258
malignant, treatment of, 622
treatment of, 616
Goldspoon, 361
Goldthwait, J. E., 248, 254, 973
Gonococci of Neisser, 445
Gonorrhea, 279, 444
acute, treatment of, 446
chronic, 451
of rectum, 93
Gonorrheal bubo, 449
conjunctivitis, 444
cystitis, 450
Goodell-Ellinger dilators, 277
Gottschalk, 307
Gould, A. H., 135, 136
Gouley, 401
Grafting, nerve, 723
Grafts, Wolff, 830
Graham, Douglas, 775
Grant, W. W., 563
Grant's operation for cancer of lip, 562
Granulating wounds, 752
Granulations, exuberant, 753
Pacchionian, 654
Granuloma, infectious, 665
Graves, W. P., 289
Graves' disease, 611
abdominal ptosis and, 258
psychic aspect of, 613
treatment of, 611
Grawitz, P., 392, 393
Greenough, R. B., 166, 235
Green-stick fracture, 870
Gritti, 994
Growths, benign, 861
malignant, 861
Grünbaum, 649
Guaiac test, 132
Gunkel, 100
Gunshot fractures, 940
wounds of bladder, 420
"Gunstock elbow," 868
Hall, Basil, 195, 216
Halstead, A. E., 57
Halsted, William S., 216, 525, 619, 622
Halsted's metallic bands, 801
operation, 214, 215
Hamilton, A. J. A., 437
Hand amputations, 1007
Handley, W. S., 522
theory of, 858
Hanks' dilators, 277
Hare, 787
Harelip, 542, 544
double, 547
operation, a dressing after, 549
position for, 546
treatment of, 545
Harrington, F. B., 418
Harris, M. L., 167, 374, 439
Harte, R. H., 64, 67
Hartley, 717
Hartwell, John B., 107, 108
Harvard, 58, 129, 130
Hawkins, 30, 240
Head, 624
lesions, symptoms, and diagnosis of organic, 645
Headache, 652
Heart, 506
wounds of, 509
Heath, 204, 349
Heidenhain, 367
Heinricius, 192
Heister, 682
Helferich, 904, 950, 957
Helmholz, H. F., 628
Hematocele, 478
pelvic, 351, 354
Hematoma of ovary, 346
of scalp, 626
Hematomyelia, 687, 688
Hematosalpinx, 330, 354
Hemorrhage, 992
cerebral, 640
extradural, 638
gastric, 143
intestinal, 65
intracranial, 638
of newborn, 640
subdural, 639
Hemorrhoids, 89, 100
external, 100, 102
internal, 100
mixed, 100
operation for, 102
Hemostatic bulb, 432
Hemothorax, 497, 504
Hepatic artery, aneurysm of, 170
Hepatoptosis, 168, 169, 247
Hernia, abdominal, 196
cerebri, 670, 671
congenital, 197, 219
diaphragmatic, 196, 224
direct, 205
duodenal, 225
epigastric, 196
femoral, 199, 217

Hernia, femoral, treatment of, 218
gluteal, 196
incarcerated, 200
indirect, 205
inguinal, 196, 203
direct, 214
in women, 217
oblique, 210
internal, 76
in women, 199
irreducible, 200, 209
lumbar, 196
multiple, 198
obturator, 225
pelvic, 299
perineal, 299
radical cure of, 202
reducible, 199
retroperitoneal, 197, 225
sciatic, 196
scrotal, 196, 208
strangulated, 200, 201
treatment of, 202
umbilical, 219
of adults, 220
treatment of, 220
of infants, 220
ventral, 196, 223
Herniotomy, 203
Herpes, genital, 458
Hesselbach's triangle, 205
Hey, 428
Hey's operation, 998
Hill, L. L., 373, 509
Hip, dislocation of, 951
fracture of, ununited, 915
Hip-joint, amputation of, 1003
excision of, 982
Hippocrates, 408, 497, 787
Hippocratic facies, 50, 231
Hirsch, 994
Hirst, Barton Cooke, 341
His, 624
Hitzig, 646
Hochenegg, 399
Hodgkin's disease, 814, 815
Hoffa, 955
Hoffmann, 454
Holm, 165, 246
Holmes, 799
Homans, John, 17
Hooper, F. W., 592
Horns, 458
cutaneous, 854, 855
Horse serum, 829
Horsley, Victor, 624, 670
Horsley's cyrtometer, 649
Horwitz, Orville, 452
Hotchkiss, Lucius W., 39
Hough, 34
"Housemaid's knee," 824
Howell, 779
Humerus, fracture of, 884
lower end of, 895
neck of, anatomic, 887
surgical, 888
"Hunger pains," 133
Hunter, John, 425, 444, 742, 787
operation of, 801
Hupp, 107
Hutchinson, Woods, 20
Hydatid cysts, 838
Hydatidiform mole, 328
Hyde, 402
Hydrocele, 480, 839
congenital, 483
of neck, 605
of round ligaments, 340
of tunica vaginalis, 481
treatment of, 482
Hydrocephalus, 655
Hydromyelia, 693
Hydronephrosis, 381, 384, 385
false, 384
intermittent, 384
Hydrops, 977
of appendix, 22
Hydrosalpinx, 330, 332
Hydroscope, 481
Hydrotherapy, 778
Hydrothorax, 497, 504
Hydroureter, 318
Hyoid bone, fracture of, 590
Hyperemia, passive, 979
Hyperemic treatment, Bier's, 810
Hypernephroma, 392, 393, 394
Hyperthyroidism, 611
Hypertrophy, diffuse mammary, 536, 537
of prostate, 425
of rectal valves, 90
Hypodermoclysis, 785
Hypopituitarism, 668
Hypospadias, 469
balanitic, treatment of, 470
Stimson's operation for, 470
Hypothesis, Cohnheim's embryonal, 836
Hysterectomy, 302
abdominal, for cancer, 325
pan-, 307, 313
for cancer, 327
supravaginal, 307, 311
vaginal, 320
Hysteric joints, 888

Ichthyosis, 582
Icterus, 173, 175
Idiopathic dilatation of colon, 76
peritonitis, 229
Iliac artery, common, 795
external, 795
Ileocecal cancer, 80
tuberculosis, 69
Ileum, 21
valves of, 21
Ileus, dynamic, 48
gastromesenteric, 52, 255
mechanical, 48
Imbecility, 674
congenital, 674
Immobilization, 738
of fractures, 742

Imperforate anus, 90
rectum, 90
Incised wounds, 736
Incontinence of urine, 407
Indigo carmin, 373
Infarct, acute, unilateral, septic, 387
Infection, acute hematogenous, 387, 388
Infectious granuloma, 665
Infective bursitis, acute, 827
Inflammation about umbilicus, 263
of bile-passages, acute, 174
of esophagus, 127
of prostate, 422
of rectum, 92
gonorrheal, 93
of testicle, 478
of thyroid gland, 623
of tongue, 581
of uterus, 271
Inflammatory stricture, 465
Infusion, intravenous saline, 786
Ingrowing nail, 769
toe-nail, 770
Inguinal canal, 196
hernia, 196
Inhalation pneumonia, 595
Inion, 648
Innominate artery, 792
aneurysm of, 800
Insanity, 674
Intercostal nerves, 728
neuralgia, 514
Intermaxillary bone, 547
Internal carotid artery, 794
fistula, 82, 97
hemorrhoids, 100, 101
hernia, 76
Intersigmoid fossa, 76
Intestinal cancer, 77, 78
diagnosis of, 79
incurable, 79
symptoms of, 78
treatment of, 79
hemorrhage, 65
lesions, symptoms of, 46
localization, 43, 44
obstruction, 47, 185
acute, 48
diagnosis of, 50
pathology of, 49
treatment of, 50
chronic, 53, 68
symptoms of, 53
treatment of, 54
perforation, 55, 56
traumatic, diagnosis of, 55
ptosis, 61
treatment of, 62
stenosis, 69
strangulation, 50, 51
Intestines, actinomycosis of, 69
foreign bodies in, 56
injuries to, 54
prolapse of, 257
sarcoma of, 77
tuberculosis of, 67
Intestines, tumors of, 76
benign, 77
Intracranial hemorrhage, 638
of newborn, 640
operations, technic of, 675
tumors, 665
Intramedullary tumors, 701
Intraspinal tumors, laminectomy for, 706
Intratracheal anesthesia, 492
Intravenous saline infusion, 786
Intubation of larynx, 590, 592
O'Dwyer's, 591
Intussusception, 58, 73, 74
Invagination, 73, 74, 78
Involution, abnormal, 537
Ischemic atrophy, 816
Ischiorectal abscess, 95, 96
Iselin, 624
Israel, 382

Jackson, Henry, 159
Jackson, James M., 71
veils, 260
Jacksonian epilepsy, 667, 672
Jackson's (Jabez N.) operation for cancer of breast, 530
Jacobson, 179
Jaundice, 180
Jaw, 569
ankylosis of, 571, 572
cancer of, 575
fibroma of, 572
lower, dislocation of, 956
excision of, 579
fracture of, 938
reconstruction of, 570
resection of, 575
sarcoma of, 564
tumors of, 572
upper, fracture of, 936
resection of, 576
Jejunojejunostomy, 134
Jejunostomy, 121, 156
Jepson, 193
Jewett, 272
Joerss, 524
Joint, ankle-, excision of, 985
disease, abdominal ptosis in connection with, 254
hip-, excision of, 982
knee-, excision of, 983
wrist-, excision of, 981
"Joint-mouse," 973
Joints, 959, 970
contusions of, 971
excision of, 980
hysteric, 988
tuberculosis of, 976
wounds of, 746
Jones, Daniel Fiske, 419
Judd, E. S., 566

Kader, 156
Kahler's disease, 663
Kammerer, Frederick, 219

Kausch, 78
Keen, W. W., 67, 166, 595, 606, 641, 655
Keetley, 378
Keith, George E., 864
Keith, Skene, 864
Kelly, Howard A., 41, 214, 215, 265, 269, 270, 283, 286, 292, 295, 304, 316, 317, 318, 326, 327, 332, 338, 339, 345, 365, 369, 372, 381, 731
Keloid, 831, 832
Keratosis, 581
Kidney, 368
  carcinoma of, 395
  decapsulation of, 396
  floating, 251
    treatment of, 252
  horseshoe, 370
  infection of one, acute hematogenous, 387
  injuries of, 376
  palpating, 371
  ruptured, 376, 377
  sarcoma of, 394
  stone in, 379
  surgical, 386, 387, 388
  tuberculosis of, 390
  tumors of, 391
  wounds of, 378
Killian, 490
Kingscote, 216
Klebs, 125
Knee, dislocated, 955
Knipe, Norman, 341
Knott, Van Buren, 163, 164, 236
Koch, 602
Kocher, Albert, 609, 611, 612, 620
Kocher, Theodor, 86, 110, 111, 153, 166, 179, 216, 219, 481, 583, 617, 635, 641, 712, 996
  method, 945
    for artificial anus, 86
König, 481, 978
Körte, 82, 192
Kousnetzoff, 166
Kouwer, 195
Kraske, 109, 110 ,111, 216
Kraus, 120
Kredel, 987
Krishaber, 594
Krönlein, R. N., 641, 649
Kurpjuweit, 503
Küster, 216, 378, 439, 994
Küstner, 365

Lacerated wounds, 744
Laceration, perineal, 355
Lactate of calcium, 610
Lacunæ laterales, 654
Laminectomy, 703, 704, 706
Lancereaux, E., 801
Landau, 247
Lane kinks, 260
Langerhans, 481
Lannelongue, 162
Larrabee, R. C., 250
Larrey, Baron, 506, 642
Laryngectomy, 595
Larynx, cancer of, 594
  extirpation of, partial, 596
    total, 595
  foreign bodies in, 590
  intubation of, 590, 591, 592
  tumors of, 594
Lateral anastomosis, 68
  perineal route, 410
Lauenstein's operation, 366, 1007
LeConte, R. G., 237, 1008
Le Dran, 745
Leg, amputation of, 999
  circumcision of, 790
  fracture of, 923
  ulcer of, 754
  varicose veins of, 789
Lejars, 592
Lembert, 42, 84, 123, 144
Lemonier, 544
Lenhartz, 504
Leptomeningitis, 659
  suppurative, 660
    treatment of, 660
Leukemia, myelogenous, 194
  splenic, 195
Leukoplakia, 582, 861
Lewerenz, 191
Lexer, 246
Leyden, 228
Lice, 605
Ligament, broad, cysts of, 340
    dermoid, 341
  tumors of, 340
  varicocele of, 341
  of Treitz, 135
  round, hydrocele of, 340
  uterosacral, 289
Ligamentum patellæ, 823
Ligation of arteries, 791
Lilienthal, H., 41, 180
Lime-water enema, 93
Lingual artery, 794
Linhart, 556
Lip, cancer of, 559
  upper, carbuncle of, 566
Lipoma, 842
  arborescens, 842
  diffuse, 843
Lisfranc's operation, 998
Lister, 17, 42
Litholapaxy, 410, 412
Lithotomy, perineal, 414
Lithotrite, 412
Lithotrity, 410
Little, 951
Liver, 158
  abscess of, 159
  approach to, transthoracic, 162
  cirrhosis of, 166
    Hanot's, 167
  cysts of, 160
  ptosis of, 62
  resection of, 165
  syphilitic, 163

Liver, tumors of, treatment of, 164
Lochet, 504
Locke, Edwin A., 975
Lock-jaw, 571
Lodge, Henry Cabot, 592
Loeb, 863
Lothrop, Howard A., 105, 907, 936
Lobett, Robert W., 972
Lower jaw, fracture of, 938
Luckett, W. H., 632
Lumbar hernia, 196
  puncture, 659
Lund, F. B., 395, 960
Lung, 488
  abscess of, 493
  cancer of, 495
  echinococcus of, 494
  gangrene of, 494
  injuries of, 495
  sarcoma of, 495
Luys, 374
Lymph nodes, 807, 808
    disease of, malignant, 815
    of neck, 600
    retroperitoneal, tuberculosis of, 243
    tuberculous, 814
  varices, 811
  vessels, 808
Lymphadenitis, 813
  chronic, 812
Lymphadenocele, 811
Lymphangiectasis, 811
Lymphangioma, 811, 853
Lymphangitis, 809
  chronic, 811
Lymphatic connections of uterus, 267, 270
  cysts, 605
  system, 807
    physiology of, 808
Lymphatics of stomach, 148
Lymphocystoma, 814
Lymphosarcoma, 846

MacCarty, W. C., 148
Mackenroth, 365
Macroglossia, 581
Magendie, 682
Magnai, 216
Mahé, 493
Malar bone, 935
Malaria, 193
Malformation of umbilicus and urachus, 262
Malgaigne, 197, 546
Malignant degeneration of scars and ulcers, 832
  disease of lymph nodes, 815
  growths, 861
  tumors, 834
Malunion, 868
Marchand, 606
Marjolin's ulcer, 832
Marshall, 350
Marsupialization, 620
Martin bandage, 992
Martin, Claude, 830
Martin, Edward, 307, 339, 361, 365, 448, 456
Massachusetts General Hospital, 64, 70, 93, 221, 313, 344, 492
Massage, 62, 744, 774
  of prostate, 423, 454, 869
Mastitis, 539
Matas, Rudolph, 492, 571, 572, 787, 795, 803, 805, 807, 939, 994
  splint, 938
Maunsell, 112
Maydl, 399
Mayo, C. H., 218, 292, 597, 610, 612
  vein enucleator, 790
Mayo, W. J., 60, 80, 82, 108, 112, 129, 130, 135, 139, 140, 147, 150, 151, 152, 153, 154, 165, 188, 221, 222, 226
McArthur, L. L., 446
McBurney, Charles, 17, 27, 216
  incision, low, 32, 41
  method, 32
McCosh, A. J., 25, 396
McDowell, Ephraim, 348
McEwen, 20, 21, 216
McGraw, 80
McGuire, Hunter, 795
Mechanical therapeutics, 810
Meconium, 91
Meier, 277
Melanoma, 852
Melanosarcoma, 852
Melena, 132
Membranous enteritis, 63
Meningeal tumors, 661, 698
Meninges, 630, 653
Meningitis, 658
  epidemic, 692
  serosa, 660, 693
  spinal, 692
  suppurative, 692
    urotropin in, 661
Meningocele, 654, 693
Meningomyelocele, 693
Mesenteric embolism, 71
  thrombosis, 71
Mesentery, 87
  cyst of, 837
  injuries and diseases of, 87
Metatarsal bones, 933
Metritis, acute, 273
  chronic, 277
    symptoms of, 278
    treatment of, 278
Meyer, Willy, 799, 810, 870
Milk-leg, 788
Mills, Charles K., 691
Miners' elbow, 824
Minor surgery, 731
Mirault, 546
Mixter, S. J., 119, 120
Moles, 855
Molluscum fibrosum, 628
Monks, George H., 43
Montgomery, 402

Moore, E. M., 905
Morf, P. F., 244
Morgagni, 425
Moriarity, 937
Morris, Robert T., 27, 173, 339
Morrison, 166
Morton's fluid, 696
Mosher, H. P., 116
Mott, Valentine, 628, 792
Moynihan, B. G. A., 135, 142, 146, 170, 179, 191, 193, 225, 226, 237
Mucous colitis, 63
  polypi, 106
Müller's ducts, 329
Mulligan, E. W., 314
Mulon, 607
Mummery, 780, 786
Munro, J. C., 135
Murphy button, 42, 69, 81, 203
Murphy, F. T., 234, 492, 993
Murphy, John B., 26, 40, 56, 112, 236, 238, 242, 503, 513, 525, 529, 677, 683, 690, 692, 693, 698, 700, 719, 807, 900
Musculospiral paralysis, 728
Myelocystocele, 694
Myelogenous leukemia, 194, 195
Myeloid, 848
Myeloma, 663, 697
Myofibroma, 853
Myoma, 302, 853
  complicating pregnancy, 314, 315
  intramural, 303
  submucous, 303, 304
  subserous, 303, 308
  uterine, symptoms of, 303
    treatment of, 306
Myomectomy, 309
Myositis, 817
Myxoma, 833
  of breast, periductal, 534, 535
Myxomatous degeneration, 853

Nail, ingrowing, 769
Nasal bones, 933
  defects, 555
Nasopharynx, 587
Neck, burns of, 597
  carcinoma of, 560
  contractions of, cicatricial, 597
  dissection of, 563
  hydrocele of, 605
  lymph nodes of, 600
  wry, 697
Necrosis, 961
  fat, 185
  phosphorous, 580
Necrotic caries, 570
Neff, J. M., 677
Neisser, gonococci of, 445
Nélaton, 546, 976
  forceps, 349
Nélaton's line, 912
Neoplasm, 834
Nephrectomy, 388
Nephritis, chronic, 396
Nephrolithiasis, 379
Nephroptosis, 247, 250, 251
Nephrotomy, 383, 388
Nerve cocainization, 992
Nerves, anastomosis of, 723
    in stump, 722
  grafting of, 723
  injuries of, 722
  intercostal, 728
  operations upon, 719
  peripheral, 706
  peroneal, 728
  phrenic, 725
  pneumogastric, 725
  regeneration of, 719
  suture of, 719, 720
  wounds of, 722
Neudörfer, 995
Neuralgia, intercostal, 514
  major, 710
  minor, 710
  reflex, 710
Neurasthenia, 61
Neurectomy, trifacial, 712
Neurilemma, 683
Neuritis, 707
  optic, 652
Neurofibroma of scalp, 628
Neuroma, 721, 854
  amputation, 721
Neuromimesis, 888
Neuroplasty, 720
Neuroses, 686
Nevus, 791
  cavernous, 567
  simple, 567
  treatment of, by boiling water, J. A. Wyeth's, 568
Nicholls, Albert G., 836
Nichols, Edward H., 960, 961, 969
Nicoll, 219
Nipple, disease of, Paget's, 522, 541
  supernumerary, 542
Nitze apparatus, 373
Noble, G. H., 286, 292, 295, 360, 366
Noble's operation, 360
Nodular goiter, 614
Noma, 571
Non-union, 868, 869
Nothnagel, 48, 157
Nuck, canal of, 290, 340

Obstruction, intestinal, 47, 185
    acute, 48
      diagnosis of, 50
      pathology of, 49
    chronic, 53, 68
      symptoms of, 53, 68
      treatment of, 54
  pyloric, 128, 141
    treatment of, 142
Obturator, 196
Occlusion of rectum, 90
Ochsner, A. J., 35, 218, 233, 234
  treatment, 36

Odiorne, Walter B., 474
Odontoma, 572, 856
follicular, 573
O'Dwyer, 590
intubation, 591
Omentum, diseases of, 87
injuries of, 87
Oöphorectomy, 348
Optic neuritis, 652
Orchidectomy, 437, 438, 480
Orchitis, 478
Organic head lesions, symptoms and diagnosis of, 645
lesions, symptomatology of, 652
stricture, 465
treatment of, 466
Orlowsky, V. F., 184
Orthopedic surgery, 959
Os calcis, 932
Osgood, Robert B., 827, 975
Osler, William, 65, 67, 157, 194, 228, 231
Osteitis deformans, 969
Osteogenesis imperfecta, 968
Osteoma, 844
Osteomalacia, 968
Osteomyelitis, 570
acute, 962
chronic, 964
Osteoplastic craniotomy, 675
resection of spine, 705
Osteopsathyrosis, 968
Osteosarcoma, 848
Otis' dilating urethrotome, 467
urethrometer, 467
Outerbridge, 361
Ovarian cyst, 344
twisted, 346
tumor, symptoms of, 346
complicating pregnancy, 349, 351
Ovaries, 329, 341
hematoma of, 346
operations on tubes and, conservative, 339, 342
papilloma of, 345
tumors of, solid, 346
Ovariotomy, 343, 348
Ovaritis, 332, 341
acute, 342
chronic, 342
tuberculous, 342
Ovula Nabothi, 279

Pacchionian granulations, 654
Pachymeningitis, 658
Paget, Sir James, 201, 202, 231, 969
Paget's disease of nipple, 518, 522, 541
Painter, C. F., 244, 827
Palmar abscess, 757, 761
Brooks' incision for, 763
Pampiniform plexus, 341
Pancreas, 184
cysts of, 188, 189
sclerosis of, 186
tumors of, 188
Pancreatic apoplexy, 185, 186
Pancreatic calculi, 186, 188
ducts, 172
point, 184
Pancreatitis, 128, 184, 185, 186
acute, 184, 185
chronic, 184, 186
subacute, 186
Papillary cystadenoma, 536
Papilloma, 106, 854
of ovaries, 345
of rectum, 106
villous, 855
Paralysis, facial, 724
musculospiral, 728
Paranephritic abscess, 389
Paraphimosis, 449, 450
Parasitic theory of cancer, 836
Parathyroid glandules, 608, 609, 610, 620
tumors, 623
Parathyroids, feeding of, 610
Para-urethral abscess, 462
Paré, Ambroise, 506, 642, 682, 746, 787
Park, Roswell, 792, 793, 834, 841, 846, 959, 970, 1006
Parker, Willard, 17
Paronychia, 757, 760, 761
Parotid gland, chondroma of, 586
excision of, 586
Patella, dislocation of, 955
fracture of, 920
operation on, 922
Patellæ ligamentum, 823
Pathologic fracture, 870, 940
Paul of Egina, 682
Payr, 620, 624, 656
Péan, 127
Pediculi capitis, 605
Pelvic hematocele, 351, 354
viscera, anatomy of, 265
Pelvis, fracture of, 878
Penis, 443
amputation of, 461
cancer of, 460
injuries of, 457
Pennington, J. R., 93
Penski, 166
Peptic ulcer, 129, 133
of esophagus, 127
treatment of, 133
perforating, 144
Perforation, intestinal, 65
of uterus, 285
symptoms of, 65
typhoid, 64
Pericardial effusions, 507
Pericardiotomy, 508
Pericarditis, 507
Pericardium, 506
operations upon, 507
Perichondritis, costal, posttyphoid, 513
Periductal connective tissue, 532
fibroma of breast, 534
myxoma, 534, 535
sarcoma, 534
Perigastritis, 128
Perineal lacerations, 355

Perineal lithotomy, 414
prostatectomy, 430, 433, 436
section, 464
urethrotomy, 463
Perineum, 355
muscles of, 268
operation for repair of, 356
Perineuritis, 707
Periosteal fracture, 870
Periostitis, 961
Peripheral nerves, 706
Perithelioma, 851
Peritoneum, 227
teratoma of, 246
Peritonitis, 28, 49, 73, 185, 190
acute, 227
circumscribed, 49
diffuse, 49
chronic, 238
adhesive, sclerosing, 239
diffuse, 28, 229, 232
symptoms of, 230
treatment of, 232
exudative, 238
general, 229, 232
hysteric, 231
idiopathic, 229
localized, 228
malignant, 242
sources of, 230
subphrenic, 228
tuberculous, 240
operation for, 242
Peroneal nerve, 728
Pessary, 289, 295, 299
Peters, 399
Petersen, W. P., 107
Pfannensteil, 292
Phalanges, 911
fracture of, 911
of foot, 933
Phalanx of thumb, dislocation of first, 950
Phantom tumor, 76
Pharynx, 587
Phelps, 216
Phimosis, 449
Phlebitis, 788
obliterans, 788
Phlegmasia alba dolens, 787
Phloridzin test, 375
Phosphorus necrosis, 580
Phrenic nerve, 725
Pia mater, 654
Piles, 89, 100
strangulated, 100
Pilonidal sinus, 833
Pin worms, 93
Pirogoff's operation, 999
Pituitary body, 667
Plastic operations on face, 555
resection of breast, 537
Playfair, 328
Pleura, 497
echinococcus of, 505
tumors of, 504
Pleurisy, 498
Pleuroperitoneal cavity, 198
Plexiform angioma, 791
Plummer, 119, 120, 125
Pneumatic suit, 785, 993
Pneumogastric nerve, 725
Pneumonia inhalation, 595
Pneumonotomy, 491
Polk, 339
Polypi, 281
in uterus, 303
mucous, 106, 279
Ponfick, 165
Porro's operation, 315
Portal circulation, 73
vein, 172
Porter, Charles Allen, 71, 779
Porter, Charles Burnham, 17
"Port-wine stain," 567
Postenski, 216
Posterior tibial artery, 795
urethritis, 450
wire splint, Cabot (A. T.), 926
Posthitis, 449
Posttyphoid costal perichondritis, 513
Posture, knee-chest, 111
Pott, Percival, 741, 929
Pott's fracture of fibula, 929
Poultices, 758
Powder, face, 556
Powers, Charles A., 112, 192
Precancerous conditions, 861
Pregnancy, abdominal, 351
extra-uterine, 350, 351
ovarian, 351
tubal, 350
Prepatellar bursitis, 824
Probang, 114
Procidentia uteri, 287, 298, 359
treatment of, 299
Proctitis, 93
Proctoclysis, 244, 785
Proctoplasty, 92, 105
Proctoscope, 90, 93, 104
Proctotomy, 105
Prolapse of anus, 103
of colon, 257
of intestine, 257
of rectum, 103
of spleen, 191
of stomach, 249, 256
of uterus, 298
Prostate, 398, 421
anatomy of, 421
calculi of, 424
cancer of, 425, 438
excision of, 439, 440
enlarged, 400, 425
symptoms of, 426
inflammation of, 422
massage of, 423, 454
sarcoma of, 442
Prostatectomy, perineal, 430, 433, 436
suprapubic, 426, 430, 431
Prostatitis, acute, 449
chronic, 424

Prostatitis, treatment of, 423
tuberculous, 424
Proud flesh, 753
Pruritus ani, 93
Psammoma, 844
Pseudocyst, 188, 190
Psychic aspects of Graves' disease, 613
Psychoses, 674
Pterion, 648
Ptosis, 128
abdominal, 247
bandage for, 169
diagnosis, 258
Graves' disease and, 258
in connection with joint disease, 254
symptoms, 256
treatment, 259
gastric, 61
of liver, 62
visceral, 63
Pulmonary actinomycosis, 496
tuberculosis, 495
Puncture of bladder, suprapubic, 404
lumbar, 659
Punctured fracture, 633
Purmann, 787
Putnam, James J., 711
Pyelitis, 385, 388
Pylorectomy, 127, 142, 152
Pyloric obstruction, 128, 141
stenosis, 131, 147
hypertrophic, 147
in infants, 129, 143
Pyloroplasty, Finney's, 134, 142
Pylorus, spasm of, 129, 146
Pyonephrosis, 387
Pyopneumothorax, 131, 228
Pyosalpinx, 330
Pyothorax, 499

Quimby, W. C., 71, 448
Quincke, 659
Quinin and urea hydrochlorate, 784

Radial artery, 795
Radius, head of, dislocation of, 949
and neck of, fracture of, 902
neck of, fracture of, 897
Ranula, 558, 849
Rattlesnake venom in epilepsy, 672
Rawling, L. B., 637
Rectal lymphatics, 109
tenesmus, 79
valves, hypertrophy of, 90
Rectocele, 356, 357
Rectopexy, 104
Rectovaginal fistula, 363, 365, 366
Rectum, cancer of, 107
imperforate, 90
inflammation of, 92
gonorrheal, 93
occlusion of, 90
papilloma of, 106
prolapse of, 103
Rectum, resection of, 109
anal method, 110
combined, 110
dorsal, 110
sacral, 110
stricture of, 104
syphilitic affection of, 93
tuberculosis of, 94
tumors of, 106
ulcer of, 93
Reed, 361, 951
Regeneration of nerves, 719
Reichmann's disease, 146
Reinbach, 100
Renal calculi, 380
treatment of, 391, 392
disease, diagnosis in, 370
Resection of breast, plastic, 537
of jaw, upper, 576
of jaws, upper and lower, 575
of posterior roots of spinal nerves, 730
of rectum, combined method, 110
dorsal method, 110
sacral method, 110
of ribs, 500
of sigmoid, 80
of spine, osteoplastic, 705
Retention cysts, 836
of breast, 542
of urine, 399, 400
Retrocecal fossa, 76
Retroduodenal fossa, 76
Retroflexion of uterus, 294, 295
Retroperitoneal cysts, 245
hernia, 197
lymph nodes, tuberculosis of, 243
space, 242
tumors of, 245
Retroversion of uterus, 286
treatment of, 289
Retzius, 384
Reynolds, Edward, 245, 339, 355
Rhinoplasty, 556
Codman's (E. A.), 557
Rhinorrhea, cerebrospinal, 657
Rhizotomy, 730
Rib, cervical, 608
fracture of, 875
resection of, 500
Ribbert, 21
Richardson, Maurice Howe, 17, 93, 122, 123, 124, 194, 348
Rickets, 967
Ricord, Phillipe, 444
Ridlon, 914
Riebold, 122
Riedel's lobe, 170
Risley, E. H., 781
Riva-Rocci apparatus, 733
Robinson, Samuel, 492, 510, 910
Robson, Mayo, 187
Robson's point, 172
Rodent ulcer, 565, 629
Rogers, John, 612
Rokitanski, 75, 976
Rolando, fissure of, 649

Rosary, 967
Rose, 553
  position, 595
Rost, E. R., 674
Rotch, Thomas Morgan, 244
Rotter, 216, 524
Roux, 142, 143, 544, 617
  operation, complete, 142
Russell, R. Hamilton, 198
Rutkowski, 399
Rydygier, 127, 170, 195, 365

Sacculation of bladder, 418
Sactosalpinx hæmorrhagica, 330
  purulenta, 330
  serosa, 330
Safety-pin, 56, 92
Saline infusion, 786
Salivary fistula, 556
  glands, 585
  stone, 558
Salpingectomy, 336
Salpingitis, 329
  catarrhal, 329, 335
  purulent, 329
  symptoms of, 332
  treatment of, 335
  tuberculous, 330, 332, 334
Salvarsan, 456
Sampson, John A., 325, 326
Sandelin's cheiloplasty, 563
Sanger, 328, 365
Santorini, duct of, 172, 184
Sarcoma, 845
  giant-cell, 848
  of breast, periductal, 534
  of esophagus, 125
  of intestines, 77
  of jaw, 574
  of kidney, 394
  of lung, 495
  of prostate, 442
  of stomach, 156
  of testicle, 486
  of tongue, 585
  of uterus, 327
Sargent, Percy W. G., 201
Sausage-shaped tumor, 74
Savariaud, 624
Savory, William S., 779
Scalp, avulsion of, 627
  closing, Cushing's method of, 679
  contusion of, 625
  cysts of, dermoid, 628
  hematoma of, 626
  neurofibroma of, 628
  tumors of, 627
  wounds of, 626
Scannell, David D., 237, 870
Scaphoid, fracture of, 908
Scapula, fracture of, 883
Scars, malignant degeneration of, 832
Schaudinn, 454
Schede, 216, 382
Schede's operation, 492, 502, 503, 790
Scheele, 379
Schiassi's operation, 168
Schimmelbusch, 556
Schmieden, Victor, 809, 810
Schröder, 280, 339
Schröder's operation, 280
Schulz, 504
Schwann, sheath of, 683
Sciatic hernia, 196
Sciatica, 717
Sclerosis of pancreas, 186
Scrotal hernia, 196
Scudder, Charles L., 143, 211, 212, 213, 260, 418, 487, 866, 872, 875, 878, 880–882, 884, 885, 887–894, 896, 898–901, 904–908, 910, 911, 914, 916–918, 920, 925–935, 937, 936, 942, 944, 945–949, 952, 957
Section, perineal, 464
Seelig, M. G., 41, 125
Seeping method, 40, 238
Semilunar cartilage, 956
Senn, Nicholas, 192
Sequestrum, 961
Serous meningitis, 693
Serum, horse, 829
Shattuck, Frederick C., 241
Sheath of Schwann, 683
Sheen, 780
Sheldon, John G., 37
Sherrington, 649
Shipton, 42
Shock, 779, 992
  diagnosis of, 781
  prophylaxis of, 783, 784
  treatment of, 781, 787
Shoulder, dislocation of, 943
    old unreduced, 947
Shoulder-joint amputation, 1007
Sigmoid flexure, diverticula of, 59
    resection of, 80
Sigmoidopexy, 104
"Silver-fork" deformity, 902
Simmons, Channing C., 474
Simon, 368, 399, 546
Sims, Marion, 363
Sims' position, 364
  speculum, 364
Singley, J. D. V., 553
Sinus, pilonidal, 833
  thrombosis, 657
  tuberculous, 514
Skin, 827
  disinfecting, 737
Skull, 630
  fracture of, 631
  opening, 676
Small, E. H., 91
Smith, H. L., 896
Smith, Nathan, 348
Smith, Stephen, 1001
Smith, W. B., 490
Smith, William H., 241
Smyth, A. W., 792
Sobotta, 197, 243, 268
Society of Clinical Surgery, frontispiece and 71

Sounding for stone, 409
Sounds, bulbous, 113
  Schreiber's dilating, 114
  Starck's diverticulum, 114
Spasm, facial, 724
  of pylorus, 129, 146
Spasmodic stricture of urethra, 464
  torticollis, 598, 599, 725
Spasticity, 653
Spear, Walter M., 192
Spermatocele, 481, 484
Spiller, William G., 624, 721
Spina bifida, 693, 694, 695, 696
Spinal meningitis, 692
Spine, 624, 681
  concussion of, 686
  contusion of, 686
  "railway," 686
  resection of, osteoplastic, 705
  tumors of, 697
Spinofacial anastomosis, 723
Spiral fracture, 870
Splanchnoptosis, 247
Spleen, 190
  abscess of, 192
  cysts of, 192
  pathologic, 191
  prolapse of, 191
  ptosis of, 194
  rupture of, 191
  tuberculosis of, 192
  wandering, 194
  wounds of, 191
Splenectomy, 190, 191, 193, 194, 195
Splenic anemia, 194, 814
  enlargement, 193
  leukemia, myelogenous, 195
Splenomegaly, 194
Splenopexy, 194
  Rydygier's, 170
Splenoptosis, 247
Splint, Cabot's posterior wire, 926
  Cobb's, 934
  Coolidge's, 934
  Desault, 929
  Dupuytren's, 931
  Matas, 938
  Thomas hip, 914
Splints, applying, 742
  types of, 871
Spondylitis deformans, 988
"Spotted fever," 659
Sprain, 972
"Stab wound," 180, 181
Staffordshire knot, 349
Starr, M. Allen, 624
Steno's duct, 558
Stenosis, intestinal, 69
  of pylorus, 131, 147
    hypertrophic, 147
    in infants, 129
Sternum, fracture of, 877
Stewart, 707
Stimson, L. A., 875, 948, 953
Stinson, J. Coplin, 471
Stinson's operation for hypospadias, 470
Stomach, 113, 127, 171
  cancer of, 147
  distortion of, 129, 131, 144
  hour-glass, 129, 131, 144
  lymphatics of, 148
  prolapse of, 249, 256
  sarcoma of, 156
  wounds of, 156
Stone, Arthur K., 187, 247
Stone in bladder, 408
  in kidney, 379
  salivary, 558
  sounding for, 409
Storer, Malcolm, 336, 339, 347, 350
Strangulated hernia, 200, 201, 202
  piles, 100
Strangulation, intestinal, 50, 51
Streptothrix, 70
Stricture, acquired, 464
  inflammatory, 465
  of esophagus, 114, 115
    diagnosis of, 118
    treatment of, 118
  of rectum, 104
  organic, 465
  spasmodic, 464
  traumatic, 462
  urethral, 462
Struma, 613
Strümpell, 663
Strychnin in shock, 783
Study of cases, 731
Stump, nerve anastomosis in, 722
  painful, 996
Subcoracoid bursitis, 827
Subdeltoid bursa, 823
Subdural hemorrhage, 639
Subinvolution of uterus, 278
Suboccipital exploration, 679
Summers, J. E., 194
Suppurative leptomeningitis, 660
  meningitis, 692
    urotropin in, 661
Supracondyloid fracture of femur, 919
Suprapatellar bursa, 823
Suprapubic cystotomy, 412
  prostatectomy, 426, 430, 431
Suprarenal gland, 392
    tumors of, 396
Surgical kidney, 386, 387, 388
Sutcliffe, W. G., 603
Suture of blood-vessels, 807
  of nerves, 719, 720
Sylvius, fissure of, 649
Syme's operation, 998
Synovitis, 972
Syphilis, 444
  genital lesions of, 454
  of anus, 93
  of bone, 965
  of breast, 541
  of liver, 163
  of rectum, 93
Syphilitic epididymitis, 478
  orchiditis, 478
Syringomyelocele, 693, 694

Tait, Lawson, 307, 357, 366
operation, 366
Talma, 166, 167, 170
Tape, absorbent, 745
Taxis, 199
Taylor, Alfred S., 549
Taylor, E. W., 702
Teale's amputation, 1002
Tendon, 816, 818
conjoined, 210
sheaths, tumors of, 821
transplantation, 823
wounds, 821
Tendoplasty, 822
Tenesmus, rectal, 79
Tenosynovitis, 819
tuberculous, 820
Teratoma, 840
of peritoneum, 246
of testicle, 486
Terrier, 64, 168
Testicles, absence of, 477
adenoma of, 486
cancer of, 486
cysts of, dermoid, 486
inflammation of, 478
sarcoma of, 486
tuberculosis of, 479
tumors of, 485
undescended, 474
wounds of, 478
Tetany, gastric, 129, 146
Thecitis, 819
Therapeutics, mechanical, 810
Thigh, fracture of, 919
Thomas collar, 123
hip splint, 914
Thompson, George, 143, 373
Thompson, Henry, 376
Thoracentesis, 498
Thoracic duct, wounds of, 604
Thorndike, Paul, 394
Three-glass test, 451
Thrombosis, mesenteric, 71
sinus, 657
Thumb, dislocation of first phalanx of, 950
Thyroglossal cysts and ducts, 559
Thyroid, accessory, 609
fracture of, 590
gland, 608
cancer of, 621
inflammation of, 623
Thyroidectomy, 618
Thyrotoxic disease, 611
Tibia, rupture of tubercle of, 924
Tibial artery, anterior, 797
posterior, 795
Tic, convulsive, 724
douloureux, 710
Tileston, Wilder, 127, 167
Tillmanns, 165, 635
Toe-nail, ingrowing, 770
packing, 772
Toes, amputation of, 997
Toldt, 683
Tongue, 580
abscess of, 582
cancer of, 582
operation for, 583
inflammation of, 581
sarcoma of, 585
tie, 581
tuberculosis of, 582
tumors of, non-malignant, 585
wounds of, 581
Tonsil, tumors of, 587
Torticollis, 597
spasmodic, 598, 599, 725
Toxemia in abdominal ptosis, 258
Toxins of erysipelas, 864
Trachea, foreign body in, 590
Transfusion of blood, 378
Transposition of viscera, 59
Traumatic asphyxia, 512
bursitis, treatment of, 824
neurosis, 686
stricture, 462
Treitz, ligament of, 135
Trendelenburg, F., 216, 789
position, 199, 211, 266, 365
Treves, Frederick, 76, 625
Trichina spiralis, 818
Trichiniasis, 818
Trifacial neurectomy, 712
Truss, 207, 208
Trypsin treatment, 864
Tubal abortion, 350, 351
pregnancy, 350
rupture, 350, 351, 352
Tube, Einhorn-Jackson-Mosher, 116
Symond's esophageal, 116
T-, 334
Tuberculosis, ileocecal, 69
of anus, 94
of bone, 964
of bursæ, 827
of intestines, 67
of joints, 976
of kidney, 390
of retroperitoneal lymph nodes, 243
of rectum, 94
of spleen, 192
of testicle, 479
of tongue, 582
pulmonary, 494
renal, 391, 392
Tuberculous adenitis, treatment of, 602
cystitis, 405
disease of breast, 541
ganglion, 821
lymph nodes, 814
ovaritis, 342
peritonitis, 240, 242
prostatitis, 424
salpingitis, 330, 333, 334
sinuses, 514
tenosynovitis, 820
ulcers, 58
Tubular diarrhea, 63
Tubulocysts, 836
Tumors, benign, 834

Tumors, causation of, 835
cavernous, 791
cerebellar, 667
connective-tissue, 842
epithelial, 854
fecal, 57
intracranial, 665
intramedullary, 701
intraspinal, laminectomy for, 706
malignant, 834
meningeal, 661, 698
of abdominal wall, 262
of anus, 105
of bladder, 415
diagnosis of, 416
of brain, 665
symptoms of, 666
treatment of, 668
of breast, Warren's classification of, 533
of broad ligament, 340
of bursæ, 827
of cauda equina, 701
of chest-wall, 514
of conus medullaris, 701
of cranial bones, 662
of esophagus, 125
of face, 567
of Fallopian tubes, 339
of intestines, 76
benign, 77
of jaw, 572
of kidney, 392
cystic, 395
of larynx, 594
of liver, 162
treatment of, 164
of pancreas, 188
of pleura, 504
of rectum, 106
of retroperitoneal space, 245
of scalp, 627
of spine, 697
of suprarenal gland, 396
of tendon-sheaths, 821
of testicle, 485
of tongue, 585
of tonsil, 587
of umbilicus, 263
of uterus, 302
ovarian, complicating pregnancy, 349
solid, 346
symptoms of, 346
parathyroid, 623
phantom, 76
round ligaments, solid, 341
sausage-shaped, 74
Tunica vaginalis, hydrocele of, 481
Tuttle, 102
Twisted cord, 487

Ulcer, acute, 129, 130
chronic, 129, 130
duodenal, 30, 129, 130, 131, 133, 146, 176
malignant, degeneration of, 832
Ulcer, Marjolin's, 832
of bladder, 414
treatment of, 415
of esophagus, 127
peptic, 127
of leg, 754
of rectum, 93
peptic, 128, 129, 130, 133
perforating, 144
rodent, 565, 629
varicose, 752, 754
Ultzmann's syringe, 447
Umbilicus, inflammations about, 263
malformations of, 262
tumors of, 263
Upper extremity (shoulder-girdle), amputation of, 1005
jaw, fracture of, 936
Urachus, malformations of, 262
Ureter, 369
and cervix uteri, relations of, 269
double, 370
injury of, 385
kinking of, 385
Ureteral calculi, 381, 383
catheter, 374
Urethra, 443
anatomy of, 443
calculus of, 462
foreign body in, 461
stricture of, 462
Urethral caruncle, 362
fistula, 468
Urethritis, non-specific, 445
posterior, 450
Urethrometer, Otis', 467
Urethroscopy, 468
Urethrotome, Otis' dilating, 467
Urethrotomy, perineal, 463
Urethrovaginal fistula, 363, 364
Urinary calculi, symptoms of, 380
Urine, incontinence of, 407
residual, 427
retention of, 407
segregating, 374
Urotropin, 679
in suppurative meningitis, 661
Uterosacral ligaments, 289
Uterus, 265
adenocarcinoma of, 316
anteflexion of, 295
Dudley's operation for, 296
anteversion of, 286, 294
cancer of, 315
diagnosis of, 319
panhysterectomy for, 327
symptoms of, 318
treatment of, 319
deciduoma malignum (choriodeciduoma), 328
descent of, 298
displacements of, 285
endothelioma of, 327
inflammations of, 271
lacerations of, 282
lymphatic connections of, 267, 270

Uterus, myoma of, symptoms of, 303
treatment of, 306
perforation of, 285
polypi in, 303
procidentia of, 287, 298, 299, 300
retroflexion of, 294, 295
retroversion of, 286
sarcoma of, 327
steaming, 307
subinvolution of, 278
suspension of, 290
through abdominal section, 291
vagina, 291
tumors of, 302
wounds of, 284

Vaccine therapy, 261
Vagina, atresia of, 367
Vaginal cysts, 367
fistula, 363
process, 198
Vaginitis, 367
Valve of Gerlach, 18, 20
Valvulæ conniventes, 43, 44
Vander Veer, Albert, 837
van Hook, 385
van Kaathoven, 721
van Zwalenburg, C., 21
Varices, 100
lymph, 811
Varicocele, 484
of broad ligament, 341
Varicose aneurysm, 791
ulcer, 752, 754
veins, 789
Varix, aneurysmal, 791, 799, 806
Vasa recta, 45
Vasectomy, 437
Vaughan, George T., 510
Vein, enucleator, Mayo's, 790
portal, 172
Venereal warts, 458, 777
Venom, rattlesnake, in epilepsy, 672
Ventral hernia, 196
Ventrofixation, 300
Ventrosuspension, 300
Verruca, 458
acuminata, 773
filiformis, 773
senilis, 773
vulgaris, 773
Vertebræ, dislocation of, 688
fracture of, 688
Verumontanum, 444
Vesico-uterine fistula, 363
Vesico-uterovaginal fistula, 363
Vesicovaginal fistula, 363, 364, 365
Vessels, lymph, 811
Villous papilloma, 855
Vincent, Beth, 25
Virchow, 60, 247, 515, 976
Viscera, pelvic, anatomy of, 265
transposition of, 59
Visceral ptosis, 53
Vitello-intestinal duct, 57, 262
Volkmann's contracture, 816, 817
Volvulus, 73, 75
Vomitus, coffee-ground, 132
von Bergmann, 216, 229, 636, 641
von Bramann, 624
von Dittel, 365
von Eichen, 489
von Graefe, 544
von Haller, 606
von Langenbeck, 546, 553
von Mikulicz, 78, 80, 81, 82, 114, 115, 120, 121, 127, 147, 229, 232, 620, 794
von Recklinghausen, 970
von Recklinghausen's disease, 628
von Winkel, 365
Vulpius, 822

Wagner, 624
Wagner, E., 504
Walcher, 365
Waldeyer, 624
Walker, George, 395, 480
Waller, 706
Walton, G. L., 598, 624, 690
Wardrop method, 806
operation, 802
Warren, J. Collins, 515, 516, 524, 525, 533, 544, 587, 858
Warren, John C., 222, 544
Warren Museum (Harvard), 58, 129, 386, 390, 517, 518, 519, 520, 521, 642
Warren's (J. Collins) classification of breast tumors, 543
operation for amputation of the breast, 587
Warthin, 814
Warts, 769, 773
venereal, 458, 773
Wassermann, 456
Waterman, G. A., 711
Watson, Francis S., 378, 415, 417, 418, 421, 430, 433, 596
Weichselbaum, 659
Weir, Robert, F., 64, 112
Wells, Spencer, 241, 349
Wen, 627
Wetherill, 239
Wharton's duct, 558
Whitehead's operation, 102
for cancer of tongue, 583
Whitlow, 757
Whitman's method, 914
Whitney, W. F., 537
Williams, C. A., 40
Wilson, H. Augustus, 823, 915
Winslow, foramen of, 76
Wirsung's duct, 184, 185, 186, 188
Witzel, 427
Witzel's gastrostomy, 64, 154, 216
Wolbarst, A. L., 485
Wolff grafts, 830
Wolffian ducts, 329
Wölfler, 81, 127, 216
Wood, 157
Woodruff, J. B., 672

Woolsey, George, 21, 693, 707, 718, 726, 727
Wounds, granulating, 752
  incised, 736
  lacerated, 744
  of abdomen, penetrating, 55
  of bladder, gunshot, 420
  of brain, 641
  of cord, 687
  of heart, 507
  of joints, 746
  of kidney, 378
  of nerves, 722
  of scalp, 626
  of spleen, 191
  of stomach, 156
  of tendons, 821
  of testicle, 478
  of thoracic duct, 604
  of tongue, 581
  of uterus, 284
Wright, A. E., 602
Wright, James Homer, 69, 70
Wrist, disarticulation of, 1007
  dislocation of, 950
Wrist-drop, 728
Wrist-joint, excision of, 981
Wry-neck, 597, 725
Wyeth, John A., 1003, 1004

Yale, 348
Young, Hugh H., 422, 425, 430, 433, 438, 439

Zander, 810
  treatment, 778
Zanfel, 658
Zesas, D. G., 513
Zondek, 383
Zuckerkandl, 21

WELLCOME LIBRARY INSTITUTE

SAUNDERS' BOOKS

on

Practice, Pharmacy, Materia Medica, Therapeutics, Pharmacology, and the Allied Sciences

W. B. SAUNDERS COMPANY

WEST WASHINGTON SQUARE PHILADELPHIA

9, HENRIETTA STREET, COVENT GARDEN, LONDON

Garrison's History of Medicine

History of Medicine. With Medical Chronology, Bibliographic Data, and Test Questions. By FIELDING H. GARRISON, M. D., Principal Assistant Librarian, Surgeon-General's Office, Washington, D. C. Cloth, $6.00 net; Half Morocco, $7.50 net.

JUST ISSUED—THE BAEDEKER OF MEDICAL HISTORY

The work begins with ancient and primitive medicine, and carries you in a most interesting and instructive way on through Egyptian medicine, Sumerian and Oriental medicine, Greek medicine, the Byzantine period; the Mohammedan and Jewish periods, the Medieval period, the period of the Renaissance, the Revival of learning and the Reformation; the Seventeenth Century (the age of individual scientific endeavor), the Eighteenth Century (the age of theories and systems), the Nineteenth Century (the beginning of organized advancement of science), the Twentieth Century (the beginning of organized preventive medicine). You get all the important facts in medical history; a *biographic dictionary* of the makers of medical history, arranged alphabetically; an album of *medical portraits;* a complete *medical chronology* (data on diseases, drugs, operations, etc.); a brief survey of the *social and cultural phases* of each period.

Musser and Kelly on Treatment

A Handbook of Practical Treatment. By 82 eminent specialists. Edited by JOHN H. MUSSER, M. D., and A. O. J. KELLY, M. D., University of Pennsylvania. Three octavos of 950 pages each, illustrated. Per volume: Cloth, $6.00 net; Half Morocco, $7.50 net. *Subscription.*

IN THREE VOLUMES

A PRACTICE FOR QUICK REFERENCE AND DAILY USE

Every chapter in this work was written by a specialist of unquestioned authority. Not only is drug therapy given but also dietotherapy, serumtherapy, organotherapy, rest-cure, exercise and massage, hydrotherapy, climatology, electrotherapy, *x*-ray, and radial activity are fully, clearly, and definitely discussed. Those measures partaking of a *surgical nature* have been presented by *surgeons*.

THE EMINENT CONTRIBUTORS

A. C. Abbott, M.D.
Isaac A. Abt, M.D.
Sir Clifford Allbutt, M.D.
James M. Anders, M.D.
John F. Anderson, M.D.
Lewellys F. Barker, M.D.
Joseph C. Bloodgood, M.D.
George Blumer, M.D.
Sir Lauder Brunton, M.D.
Charles W. Burr, M.D.
Richard C. Cabot, M.D.
James Carroll, M.D.
John G. Clark, M.D.
Rufus I. Cole, M.D.
Warren Coleman, M.D.
Matthew H. Cryer, M.D.
Clinton T. Dent, M.C.
Francis X. Dercum, M.D.
George E. deSchweinitz, M.D.
George Dock, M.D.
Isadore Dyer, M.D.
David L. Edsall, M.D.
William A. Edwards, M.D.
Arthur W. Elting, M.D.
John M. T. Finney, M.D.
Charles H. Frazier, M.D.
M. Howard Fussell, M.D.
Thomas B. Futcher, M.D.
John H. Gibbon, M.D.
Joel E. Goldthwait, M.D.
Edward H. Goodman, M.D.
Samuel McC. Hamill, M.D.
Hobart A. Hare, M.D.
Charles Harrington, M.D.
Ludvig Hektoen, M.D.
Albion Walter Hewlett, M.D.
Guy Hinsdale, M.D.
John Homans, M.D.
Guy L. Hunner, M.D.
Chevalier Jackson, M.D.
Henry Jackson, M.D.
Theodore C. Janeway, M.D.
J. H. Jobson, M.D.
Maynard Ladd, M.D.
Egbert Lefevre, M.D.
James Hendrie Lloyd, M.D.
G. Hudson-Makuen, M.D.
Charles F. Martin, M.C.
Edward Martin, M.D.
Charles H. Mayo, M.D.
William J. Mayo, M.D.
Alexius McGlannan, M.D.
R. Tait McKenzie, M.D.
Herbert C. Moffitt, M.D.
Jesse M. Mosher, M.D.
B. G. A. Moynihan, M. S.
George P. Müller, M.D.
John H. Musser, M.D.
Edward O. Otis, M.D.
Henry K. Pancoast, M.D.
Roswell Park, M.D.
Richard M. Pearce, M.D.
George M. Piersol, M.D.
Charles W. Richardson, M.D.
David Riesman, M.D.
Samuel Robinson, M.D.
Milton J. Rosenau, M.D.
Joseph Sailer, M.D.
J. F. Schamberg, M.D.
Henry Sewall, M.D.
Bertram W. Sippy, M.D.
William G. Spiller, M.D.
J. Dutton Steele, M.D.
Alfred Stengel, M.D.
Charles G. Stockton, M.D.
James E. Talley, M.D.
E. W. Taylor, M.D.
James Tyson, M.D.
George H. Weaver, M.D.
J. William White, M.D.
Alfred C. Wood, M.D.
Horatio C. Wood, Jr., M.D.

Cabot's Differential Diagnosis

Differential Diagnosis. Presented through an Analysis of 385 Cases. By RICHARD C. CABOT, M. D., Assistant Professor of Clinical Medicine, Harvard Medical School, Boston. Octavo of 764 pages, illustrated. Cloth, $5.50 net.

THE NEW (2d) EDITION

EIGHT LARGE PRINTINGS

Dr. Cabot's work takes up diagnosis from the point of view of the *presenting symptom*—the symptom in any disease which holds the foreground in the clinical picture: the principal complaint. It groups diseases under these symptoms, and points the way to proper reasoning in coming to a correct diagnosis. It works backward from each leading symptom to the actual organic cause of the symptom. This the author does by means of *case-teaching*.

Chas. Lyman Greene, M.D., *University of Minnesota.*

"It is one of the most valuable books that has been published in recent years, or indeed at any time."

Morrow's Diagnostic and Therapeutic Technic

Diagnostic and Therapeutic Technic. By ALBERT S. MORROW, M. D., Adjunct Professor of Surgery, New York Polyclinic. Octavo of 775 pages, with 815 original line drawings. Cloth, $5.00 net.

JUST THE WORK FOR PRACTITIONERS

Dr. Morrow's new work is decidedly a work for you—the physician engaged in general practice. It is a work you need because it tells you just how to perform those procedures required of you every day, and it tells you and *shows* you by clear, *new* line-drawings, in a way never before approached. It is not a book on drug therapy; it deals alone with physical or mechanical diagnostic and therapeutic measures. The information it gives is such as you need to know every day—transfusion and infusion, hypodermic medication, Bier's hyperemia, exploratory punctures, aspirations, anesthesia, etc. Then follow descriptions of those measures employed in the diagnosis and treatment of diseases of special regions or organs: proctoclysis, cystoscopy, etc.

Journal American Medical Association

"The procedures described are those which practitioners may at some time be called on to perform."

Faught's Blood-Pressure

Blood-Pressure from the Clinical Standpoint. By FRANCIS A. FAUGHT, M. D., formerly Director of the Laboratory of Clinical Medicine of the Medico-Chirurgical College of Philadelphia. Octavo of 281 pages, illustrated. Cloth, $3.00 net.

WRITTEN SPECIALLY FOR THE PRACTITIONER

Dr. Faught's book is designed for practical help *at the bedside*. It meets the urgent needs of the general practitioner, who heretofore had no book to which to turn in case of emergency. Every effort has been made to provide here a practical guide, full of information of a clinical nature, and presented in a way readily available for daily use by the busy man. Besides the actual technic of using the sphygmomanometer in diagnosing disease, Dr. Faught has included a brief general discussion of the process of circulation. The wonderful strides made in our knowledge of blood-pressure, and the practical application of sphygmomanometric findings within recent years, make it imperative for every medical man to have close at hand an up-to-date work on this subject.

Anders & Boston's Medical Diagnosis

A Text-Book of Medical Diagnosis.—By JAMES M. ANDERS, M.D., PH.D., LL.D., Professor of the Theory and Practice of Medicine and of Clinical Medicine, and L. NAPOLEON BOSTON, M.D., Adjunct Professor of Medicine, Medico-Chirurgical College, Philadelphia. Octavo of 1175 pages, with 443 illustrations, a number in colors. Cloth, $6.00 net; Half Morocco, $7.50 net.

THE MODERN DIAGNOSIS

This new work is designed expressly for the general practitioner. The methods given are practical and especially adapted for quick reference. The diagnostic methods are presented in a forceful, definite way by men who have had wide experience at the bedside and in the clinical laboratory.

The Medical Record

"The association in its authorship of a celebrated clinician and a well-known laboratory worker is most fortunate. It must long occupy a pre-eminent position."

JUST OUT

Ward's Bedside Hematology

Bedside Hematology. By GORDON R. WARD, M.D., Fellow of the Royal Society of Medicine, London, England. Octavo of 400 pages, illustrated.

JUST OUT—INCLUDING VACCINES AND SERUMS

Dr. Ward's work is designed to be of service to the man in general practice. It gives you the exact technic for obtaining the blood for examination, the making of smears, making the blood-count, finding coagulation time, etc. Then it takes up each disease, giving you the synonyms, definition, nature, general pathology, etiology, bearings of age and sex, the onset, symptomatology (discussing each symptom *in detail*), course of the disease, clinical varieties, complications, diagnosis, and treatment (drug, diet, rest, *vaccines and serums*, *x*-ray, operation, etc.). There is a special chapter devoted to the *medical treatment* of hemorrhage, giving you the exact doses of the various drugs indicated, and the methods of their administration, the *serum treatment*, transfusion, etc. Another chapter is devoted to the value of blood findings in *surgical diagnosis*, pointing out their value in differentiating benign from malignant growths, infectious from other diseases, appendicitis from typhoid fever. The final 30 pages are given over to a summary of the blood conditions in the various diseases, arranged alphabetically.

Smith's What to Eat and Why

What to Eat and Why. By G. CARROLL SMITH, M.D., Boston. 12mo of 312 pages. Cloth, $2.50 net.

FOR THE PRACTITIONER

With this book you no longer need send your patients to a specialist to be dieted—you will be able to prescribe the suitable diet yourself just as you do other forms of therapy. Dr. Smith gives the "why" of each statement he makes. It is this knowing why which gives you confidence in the book, which makes you feel that Dr. Smith *knows*.

Pennsylvania Medical Journal

"All through this book Dr. Smith has added to his dietetic hints a great many valuable ones of a general nature, which will appeal to the general practitioner."

Slade's Physical Examination and Diagnostic Anatomy

PHYSICAL EXAMINATION AND DIAGNOSTIC ANATOMY.—By CHARLES B. SLADE, M.D., Chief of Clinic in General Medicine, University and Bellevue Hospital Medical College. 12mo of 146 pages, illustrated. Cloth, $1.25 net.

"In this volume is contained the fundamental methods and principles of physical examination, well illustrated, largely by line drawings. The book is to be strongly recommended."—*Boston Medical and Surgical Journal.*

Bastedo's Materia Medica

Pharmacology, Therapeutics, Prescription Writing

Materia Medica, Pharmacology, Therapeutics, and Prescription Writing. By W. A. BASTEDO, PH. D., M. D., Associate in Pharmacology and Therapeutics at Columbia University, New York. Octavo of 602 pages, illustrated. Cloth, $3.50 net.

REPRINTED IN FIVE MONTHS

Dr. Bastedo's discussion of his subject is very complete. As an illustration, take the pharmacologic action of the drug. It gives you the antiseptic action, the local action on the skin, mucous membranes, and the alimentary tract; where the drug is obsorbed, if at all—and how rapidly. It gives you the systemic action on the circulatory organs, respiratory organs, nervous system, and sense organs. It tells you how the drug is changed in the body. It gives you the route of elimination and in what form. It gives you the action on the kidneys, bladder, urethra, skin, bowels, lungs, and mammary glands during elimination. It gives you the after-effects. It gives you the unexpected—the unusual—effects. It gives you the tolerance—habit formation. Could any discussion be more complete, more thorough?

Boston Medical and Surgical Journal

"Its aim throughout is therapeutic and practical, rather than theoretic and pharmacologic. The text is illustrated with sixty well-chosen plates and cuts. It should prove a useful contribution to the text-book literature on these subjects."

McKenzie on Exercise in Education and Medicine

Exercise in Education and Medicine. By R. TAIT MCKENZIE, B. A., M. D., Professor of Physical Education and Director of the Department, University of Pennsylvania. Octavo of 393 pages, with 346 original illustrations. **Cloth, $3.50 net.**

D. A. Sargeant, M. D., *Director of Hemenway Gymnasium, Harvard University.*

"It cannot fail to be helpful to practitioners in medicine. The classification of athletic games and exercises in tabular form for different ages, sexes, and occupations is the work of an expert. It should be in the hands of every physical educator and medical practitioner."

Bonney's Tuberculosis

Second Edition

TUBERCULOSIS. By SHERMAN G. BONNEY, M. D., Professor of Medicine, Denver and Gross College of Medicine. Octavo of 955 pages, with 243 illustrations. Cloth, $7.00 net; Half Morocco, $8.50 net.

Maryland Medical Journal

"Dr. Bonney's book is one of the best and most exact works on tuberculosis, in all its aspects, that has yet been published."

Anders' Practice of Medicine

A Text-Book of the Practice of Medicine. By JAMES M. ANDERS, M. D., PH. D., LL. D., Professor of the Practice of Medicine and of Clinical Medicine, Medico-Chirurgical College, Philadelphia. Handsome octavo, 1335 pages, fully illustrated. Cloth, $5.50 net; Half Morocco, $7.00 net.

JUST READY—THE NEW (11th) EDITION

The success of this work is no doubt due to the extensive consideration given to Diagnosis and Treatment, under Differential Diagnosis the points of distinction of simulating diseases being presented in tabular form. In this new edition Dr. Anders has included all the most important advances in medicine, keeping the book within bounds by a judicious elimination of obsolete matter. A great many articles have also been rewritten.

Wm. E. Quine, M. D.,

Professor of Medicine and Clinical Medicine, College of Physicians and Surgeons, Chicago.

"I consider Anders' Practice one of the best single-volume works before the profession at this time, and one of the best text-books for medical students."

DaCosta's Physical Diagnosis

Physical Diagnosis. By JOHN C. DACOSTA, JR., M. D., Associate in Clinical Medicine, Jefferson Medical College, Philadelphia. Octavo of 557 pages, with 225 original illustrations. Cloth, $3.50 net.

NEW (2d) EDITION

Dr. DaCosta's work is a thoroughly new and original one. Every method given has been carefully tested and proved of value by the author himself. Normal physical signs are explained in detail in order to aid the diagnostician in determining the abnormal. Both direct and differential diagnosis are emphasized. The cardinal methods of examination are supplemented by full descriptions of technic and the clinical utility of certain instrumental means of research.

Dr. Henry L. Elsner, *Professor of Medicine at Syracuse University.*

"I have reviewed this book, and am thoroughly convinced that it is one of the best ever written on this subject. In every way I find it a superior production."

Sahli's Diagnostic Methods

A Treatise on Diagnostic Methods of Examination. By PROF. DR. H. SAHLI, of Bern. Edited, with additions, by NATH'L BOWDITCH POTTER, M. D., Assistant Professor of Clinical Medicine, Columbia University (College of Physicians and Surgeons), New York. Octavo of 1229 pages, illustrated. Cloth, $6.50 net; Half Morocco, $8.00 net.

THE NEW (2d) EDITION, ENLARGED AND RESET

Dr. Sahli's great work is a practical diagnosis, written and edited by practical clinicians. So thorough has been the revision for this edition that it was found necessary practically to reset the entire work. Every line has received careful scrutiny, adding new matter, eliminating the old.

Lewellys F. Barker, M. D.

Professor of the Principles and Practice of Medicine, Johns Hopkins University

"I am delighted with it, and it will be a pleasure to recommend it to our students in the Johns Hopkins Medical School."

Friedenwald and Ruhrah on Diet

Diet in Health and Disease. By JULIUS FRIEDENWALD, M. D., Professor of Diseases of the Stomach, and JOHN RUHRÄH, M. D., Professor of Diseases of Children, College of Physicians and Surgeons, Baltimore. Octavo of 857 pages. Cloth; $4.00 net.

JUST READY—THE NEW (4th) EDITION

This new edition has been carefully revised, making it still more useful than the two editions previously exhausted. The articles on milk and alcohol have been rewritten, additions made to those on tuberculosis, the salt-free diet, and rectal feeding, and several tables added, including Winton's, showing the composition of diabetic foods.

George Dock, M. D.

Professor of Theory and Practice and of Clinical Medicine, Tulane University.

"It seems to me that you have prepared the most valuable work of the kind now available. I am especially glad to see the long list of analyses of different kinds of foods."

Carter's Diet Lists

Just Ready

DIET LISTS OF THE PRESBYTERIAN HOSPITAL OF NEW YORK CITY. Compiled, with notes, by HERBERT S. CARTER, M. D. 12mo of 129 pages. Cloth, $1.00 net.

Here Dr. Carter has compiled all the diet lists for the various diseases and for convalescence as prescribed at the Presbyterian Hospital. Recipes are also included.

Kemp on Stomach, Intestines, and Pancreas

Diseases of the Stomach, Intestines, and Pancreas. By ROBERT COLEMAN KEMP, M. D., Professor of Gastro-intestinal Diseases at the New York School of Clinical Medicine. Octavo of 1021 pages, with 388 illustrations. Cloth, $6.50 net; Half Morocco, $8.00 net.

NEW (2d) EDITION

The new edition of Dr. Kemp's successful work appears after a most searching revision. Several new subjects have been introduced, notably chapters on *Colon Bacillus Infection* and on *Diseases of the Pancreas*, the latter article being really an exhaustive monograph, covering over one hundred pages. The section on *Duodenal Ulcer* has been entirely rewritten. *Visceral Displacements* are given special consideration, in every case giving definite indications for surgical intervention when deemed advisable. There are also important chapters on the *Intestinal Complications of Typhoid Fever* and on *Diverticulitis*.

The Therapeutic Gazette

"The therapeutic advice which is given is excellent. Methods of physical and clinical examination are adequately and correctly described."

Deaderick on Malaria

Practical Study of Malaria. By WILLIAM H. DEADERICK, M. D., Member American Society of Tropical Medicine; Fellow London Society of Tropical Medicine and Hygiene. Octavo of 402 pages, illustrated. Cloth, $4.50 net; Half Morocco, $6.00 net.

Frank A. Jones, M. D., *Memphis Hospital Medical College.*

"We have been waiting for many years for such a work written by a man who sees malaria in all its forms in a highly malarious climate."

Niles on Pellagra

Two Printings in Six Months

Pellagra. By GEORGE M. NILES, M. D., Professor of Gastro-enterology and Therapeutics, Atlanta School of Medicine. Octavo of 253 pages, illustrated. Cloth, $3.00 net.

This is a book you must have to get in touch with the latest advances concerning this disease. It is the first book on the subject by an American author, and the *first* in *any* language adequately covering *diagnosis* and *treatment*. Pathology, heretofore an echo of European views only, is here presented from an American point of view as well, much original work being included. The clinical description covers the manifestations of Pellagra from every angle.

AMERICAN EDITION

NOTHNAGEL'S PRACTICE

UNDER THE EDITORIAL SUPERVISION OF

ALFRED STENGEL, M.D.

Professor of Medicine in the University of Pennsylvania

Typhoid and Typhus Fevers

By DR. H. CURSCHMANN, of Leipsic. Edited, with additions, by WILLIAM OSLER, M. D., F. R. C. P., Regius Professor of Medicine, Oxford University, Oxford, England. Octavo of 646 pages, illustrated.

Smallpox (including Vaccination), Varicella, Cholera Asiatica, Cholera Nostras, Erysipelas, Erysipeloid, Pertussis, and Hay Fever

By DR. H. IMMERMANN, of Basle; DR. TH. VON JÜRGENSEN, of Tübingen; DR. C. LIEBERMEISTER, of Tübingen; DR. H. LENHARTZ, of Hamburg; and DR. G. STICKER, of Giessen. The entire volume edited, with additions, by SIR J. W. MOORE, M. D., F. R. C. P. I., Professor of Practice, Royal College of Surgeons, Ireland. Octavo of 682 pages, illustrated.

Diphtheria, Measles, Scarlet Fever, and Rötheln

By WILLIAM P. NORTHRUP, M. D., of New York, and DR. TH. VON JÜRGENSEN, of Tübingen. The entire volume edited, with additions, by WILLIAM P. NORTHRUP, M. D., Professor of Pediatrics, University and Bellevue Hospital Medical College, New York. Octavo of 672 pages, illustrated, including 24 full-page plates, 3 in colors.

Diseases of the Bronchi, Diseases of the Pleura, and Inflammations of the Lungs

By DR. F. A. HOFFMANN, of Leipsic; DR. O. ROSENBACH, of Berlin; and DR. F. AUFRECHT, of Magdeburg. The entire volume edited, with additions, by JOHN H. MUSSER, M. D., University of Pennsylvania. Octavo of 1029 pages, illustrated, including 7 full-page colored lithographic plates.

Diseases of the Pancreas, Suprarenals, and Liver

By DR. L. OSER, of Vienna; DR. E. NEUSSER, of Vienna; and DRS. H. QUINCKE and G. HOPPE-SEYLER, of Kiel. The entire volume edited, with additions, by REGINALD H. FRITZ, A. M., M. D., Hersey Professor of the Theory and Practice of Physic, Harvard University; and FREDERICK A. PACKARD, M. D., Late Physician to the Pennsylvania and Children's Hospitals, Philadelphia. Octavo of 918 pages, illustrated.

SOLD SEPARATELY—PER VOLUME: CLOTH, $5.00 NET; HALF MOROCCO, $6.00 NET

AMERICAN EDITION

NOTHNAGEL'S PRACTICE

Diseases of the Stomach

By DR. F. RIEGEL, of Giessen. Edited, with additions, by CHARLES G. STOCKTON, M. D., Professor of Medicine, University of Buffalo. Octavo of 835 pages, with 29 text-cuts and 6 full-page plates.

Diseases of the Intestines and Peritoneum **Second Edition**

By DR. HERMANN NOTHNAGEL, of Vienna. Edited, with additions, by H. D. ROLLESTON, M. D., F. R. C. P., Physician to St. George's Hospital, London. Octavo of 1100 pages, illustrated.

Tuberculosis and Acute General Miliary Tuberculosis

By DR. G. CORNET, of Berlin. Edited, with additions, by WALTER B. JAMES, M. D., Professor of the Practice of Medicine, Columbia University, New York. Octavo of 806 pages.

Diseases of the Blood (*Anemia, Chlorosis, Leukemia, and Pseudoleukemia*)

By DR. P. EHRLICH, of Frankfort-on-the-Main; DR. A. LAZARUS, of Charlottenburg; DR. K. VON NOORDEN, of Frankfort-on-the-Main; and DR. FELIX PINKUS, of Berlin. The entire volume edited, with additions, by ALFRED STENGEL, M.D., Professor of Medicine, University of Pennsylvania. Octavo of 714 pages, with text-cuts and 13 full-page plates, 5 in colors.

Malarial Diseases, Influenza, and Dengue

By DR. J. MANNABERG, of Vienna, and DR. O. LEICHTENSTERN, of Cologne. The entire volume edited, with additions, by RONALD ROSS, F. R. C. S. (ENG.), F. R. S., Professor of Tropical Medicine, University of Liverpool; J. W. W. STEPHENS, M. D., D. P. H., Walter Myers Lecturer on Tropical Medicine, University of Liverpool; and ALBERT S. GRÜNBAUM, F. R. C. P., Professor of Experimental Medicine, University of Liverpool. Octavo of 769 pages, illustrated.

Diseases of Kidneys and Spleen, and Hemorrhagic Diatheses

By DR. H. SENATOR, of Berlin, and DR. M. LITTEN, of Berlin. The entire volume edited, with additions, by JAMES B. HERRICK, M. D., Professor of the Practice of Medicine, Rush Medical College. Octavo of 815 pages, illust.

Diseases of the Heart

By PROF. DR. TH. VON JURGENSEN, of Tübingen; PROF. DR. L. KREHL, of Greifswald; and PROF. DR. L. VON SCHRÖTTER, of Vienna. Edited by GEORGE DOCK, M.D., Professor of Theory and Practice of Medicine and Clinical Medicine, Tulane University. Octavo, 848 pages, illustrated.

SOLD SEPARATELY—PER VOLUME: CLOTH, $5.00 NET; HALF MOROCCO, $6.00 NET

Goepp's State Board Questions

JUST READY—NEW (3d) EDITION

State Board Questions and Answers. By R. MAX GOEPP, M.D., Professor of Clinical Medicine, Philadelphia Polyclinic. Octavo of 715 pages. Cloth, $4.00 net; Half Morocco, $5.50 net.

Pennsylvania Medical Journal

"Nothing has been printed which is so admirably adapted as a guide and self-quiz for those intending to take State Board Examinations."

Stevens' Therapeutics

New (5th) Edition

A TEXT-BOOK OF MODERN MATERIA MEDICA AND THERAPEUTICS. By A. A. STEVENS, A. M., M. D., Lecturer on Physical Diagnosis in the University of Pennsylvania. Octavo of 675 pages. Cloth, $3.50 net.

Dr. Stevens' Therapeutics is one of the most successful works on the subject ever published. In this new edition the work has undergone a very thorough revision, and now represents the very latest advances.

The Medical Record, New York

"Among the numerous treatises on this most important branch of medical practice, this by Dr. Stevens has ranked with the best."

Butler's Materia Medica

New (6th) Edition

A TEXT-BOOK OF MATERIA MEDICA, THERAPEUTICS, AND PHARMACOLOGY. By GEORGE F. BUTLER, PH. G., M. D., Professor and Head of the Department of Therapeutics and Professor of Preventive and Clinical Medicine, Chicago College of Medicine and Surgery, Medical Department Valpariso University. Octavo of 702 pages, illustrated. Cloth, $4.00 net; Half Morocco, $5.50 net.

For this sixth edition Dr. Butler has entirely remodeled his work, a great part having been rewritten. All obsolete matter has been eliminated, and special attention has been given to the toxicologic and therapeutic effects of the newer compounds.

Medical Record, New York

"Nothing has been omitted by the author which, in his judgment, would add to the completeness of the text."

Sollmann's Pharmacology

New (2d) Edition

A TEXT-BOOK OF PHARMACOLOGY. By TORALD SOLLMANN, M. D., Professor of Pharmacology and Materia Medica, Western Reserve University. Octavo of 1070 pages, illustrated. Cloth, $4.00 net.

The author bases the study of therapeutics on systematic knowledge of the nature and properties of drugs, and thus brings out forcibly the intimate relation between pharmacology and practical medicine.

J. F. Fotheringham, M. D., *Trinity Medical College, Toronto.*

"The work certainly occupies ground not covered in so concise, useful, and scientific a manner by any other text I have read on the subjects embraced."

Arny's Pharmacy

PRINCIPLES OF PHARMACY. By HENRY V. ARNY, PH. G., PH. D., Columbia University, New York. Octavo of 1175 pages, with 246 illustrations. Cloth, $5.00 net.

George Reimann, Ph. G., *Secretary of the New York State Board of Pharmacy.*

"I would say that the book is certainly a great help to the student, and I think it ought to be in the hands of every person who is contemplating the study of pharmacy."

Hinsdale's Hydrotherapy

Hydrotherapy: A Treatise on Hydrotherapy in General; Its Application to Special Affections; the Technic or Processes Employed, and a Brief Chapter on the Use of Waters Internally. By GUY HINSDALE, M. D., Fellow Royal Society of Medicine of Great Britain. Octavo of 466 pages, illustrated. Cloth, $3.50 net.

INCLUDING CROUNOTHERAPY

The treatment of disease by hydrotherapeutic measures has assumed such an important place in medical practice that a good, practical work on the subject is an essential in every practitioner's armamentarium. This new work supplies all needs. It describes fully the various kinds of baths, douches, sprays; the application of heat and cold; the internal use of mineral waters and all other procedures included under hydrotherapeutic measures.

The Medical Record

"We cannot conceive of a work more useful to the general practitioner than this, nor one to which he would resort more frequently for reference and guidance in his daily work."

Kelly's Cyclopedia of American Medical Biography

Cyclopedia of American Medical Biography. By HOWARD A. KELLY, M. D., Johns Hopkins University. Two octavos, averaging 525 pages each, with portraits. Per set: Cloth, $10.00 net; Half Morocco, $13.00 net.

IN TWO VOLUMES

Dr. Kelly, in these two handsome volumes, presents concise, yet complete, biographies of those men and women who have contributed noteworthily to the advancement of medicine in America. Dr. Kelly's reputation for painstaking care assures accuracy of statement. There are about one thousand biographies included.

Swan's Prescription-writing and Formulary

PRESCRIPTION-WRITING AND FORMULARY. By JOHN M. SWAN, M. D., formerly Director Glen Springs Sanitarium, Watkins, N. Y. 16mo of 185 pages. Flexible leather, $1.25 net.

Stewart's Pocket Therapeutics and Dose-book

Fourth Edition

POCKET THERAPEUTICS AND DOSE-BOOK. By MORSE STEWART, JR., M.D. 32mo of 263 pages. Cloth, $1.00 net.

GET THE BEST

American Illustrated Dictionary

THE NEW STANDARD

New (7th) Edition—5000 Sold in Two Months

The American Illustrated Medical Dictionary.—By W. A. NEWMAN DORLAND, M. D., Editor of "The American Pocket Medical Dictionary." Large octavo of 1107 pages, bound in full flexible leather. Price, $4.50 net; with thumb index, $5.00 net.

KEY TO CAPITALIZATION AND PRONUNCIATION—ALL THE NEW WORDS

Howard A. Kelly, M.D., *Professor of Gynecologic Surgery, Johns Hopkins University.*

"Dr. Dorland's dictionary is admirable. It is so well gotten up and of such convenient size. No errors have been found in my use of it."

Thornton's Dose-Book.

New (4th) Edition

DOSE-BOOK AND MANUAL OF PRESCRIPTION-WRITING. By E. Q. THORNTON, M.D., Assistant Professor of Materia Medica, Jefferson Medical College, Philadelphia. Post-octavo, 410 pages, illustrated. Flexible leather, $2.00 net.

"I will be able to make considerable use of that part of its contents relating to the correct terminology as used in prescription-writing, and it will afford me much pleasure to recommend the book to my classes, who often fail to find this information in their other text-books."—C. H. MILLER, M. D., *Professor of Pharmacology, Northwestern University Medical School.*

Lusk on Nutrition

New (2d) Edition

ELEMENTS OF THE SCIENCE OF NUTRITION. By GRAHAM LUSK, PH. D., Professor of Physiology in Cornell University Medical School. Octavo of 402 pages. Cloth, $3.00 net.

"I shall recommend it highly. It is a comfort to have such a discussion of the subject."—LEWELLYS F. BARKER, M. D., *Johns Hopkins University.*

Camac's "Epoch-making Contributions"

EPOCH-MAKING CONTRIBUTIONS IN MEDICINE AND SURGERY. Collected and arranged by C. N. B. CAMAC, M. D., of New York City. Octavo of 450 pages, illustrated. Artistically bound, $4.00 net.

"Dr. Camac has provided us with a most interesting aggregation of classical essays. We hope that members of the profession will show their appreciation of his endeavors."—THERAPEUTIC GAZETTE.

The American Pocket Medical Dictionary

New (8th) Edition

THE AMERICAN POCKET MEDICAL DICTIONARY. Edited by W. A. NEWMAN DORLAND, M. D., Editor "American Illustrated Medical Dictionary." 677 pages. Flexible leather, with gold edges, $1.00 net; with thumb index, $1.25 net.

Pusey and Caldwell on X-Rays

Second Edition

THE PRACTICAL APPLICATION OF THE RÖNTGEN RAYS IN THERAPEUTICS AND DIAGNOSIS. By WILLIAM ALLEN PUSEY, A. M., M. D., Professor of Dermatology in the University of Illinois; and EUGENE W. CALDWELL, B. S., Director of the Edward N. Gibbs X-Ray Memorial Laboratory of the University and Bellevue Hospital Medical College, New York. Octavo of 625 pages, with 200 illustrations. Cloth, $5.00 net; Half Morocco, $6.50 net.

Cohen and Eshner's Diagnosis.

Second Revised Edition

ESSENTIALS OF DIAGNOSIS. By S. SOLIS-COHEN, M. D., Senior Assistant Professor in Clinical Medicine, Jefferson Medical College, Phila.; and A. A. ESHNER, M. D., Professor of Clinical Medicine, Philadelphia Polyclinic. Post-octavo, 382 pages; 55 illustrations. Cloth, $1.00 net. *In Saunders' Question-Compend Series.*

Morris' Materia Medica and Therapeutics.

New (7th) Edition

ESSENTIALS OF MATERIA MEDICA, THERAPEUTICS, AND PRESCRIPTION-WRITING. By HENRY MORRIS, M. D., late Demonstrator of Therapeutics, Jefferson Medical College, Phila. Revised by W. A. BASTEDO, M. D., Instructor in Materia Medica and Pharmacology at Columbia University. 12mo, 300 pages. Cloth, $1.00 net. *In Saunders' Question-Compend Series.*

Williams' Practice of Medicine

ESSENTIALS OF THE PRACTICE OF MEDICINE. By W. R. WILLIAMS, M.D., formerly Instructor in Medicine and Lecturer on Hygiene, Cornell University; and Tutor in Therapeutics, Columbia University, N. Y. 12mo of 456 pages, illustrated. *In Saunders' Question-Compend Series.* Double number, $1.75 net.

Todd's Clinical Diagnosis

The New (2d) Edition

A MANUAL OF CLINICAL DIAGNOSIS. By JAMES CAMPBELL TODD, M. D., Professor of Pathology, University of Colorado. 12mo of 469 pages, with 164 text-illustrations and 10 colored plates. Cloth, $2.25 net.

Bridge on Tuberculosis

TUBERCULOSIS. By NORMAN BRIDGE, A. M., M. D., Emeritus Professor of Medicine in Rush Medical College. 12mo of 302 pages, illustrated. Cloth, $1.50 net.

Oertel on Bright's Disease

Illustrated

THE ANATOMIC HISTOLOGICAL PROCESSES OF BRIGHT'S DISEASE. By HORST OERTEL, M. D., Director of the Russell Sage Institute of Pathology, New York. Octavo of 227 pages, with 44 text-cuts and 6 colored plates. Cloth, $5.00 net.

Arnold's Medical Diet Charts

MEDICAL DIET CHARTS. Prepared by H. D. ARNOLD, M. D., Dean of Harvard Graduate Medical School, Boston. Single charts, 5 cents; 50 charts, $2.00 net; 500 charts, $18.00 net; 1000 charts, $30.00 net.

Eggleston's Prescription Writing

Just Ready

ESSENTIALS OF PRESCRIPTION WRITING. By CARY EGGLESTON, M. D., Instructor in Pharmacology, Cornell University Medical School. 16mo of 125 pages. Cloth, $1.00 net.

Jakob and Eshner's Internal Medicine and Diagnosis

ATLAS AND EPITOME OF INTERNAL MEDICINE AND CLINICAL DIAGNOSIS. By DR. CHR. JAKOB, of Erlangen. Edited, with additions, by A. A. ESHNER, M. D., Professor of Clinical Medicine, Philadelphia Polyclinic. With 182 colored figures on 68 plates, 64 text-illustrations, 259 pages of text. Cloth, $3.00 net. *In Saunders' Hand-Atlas Series.*

Lockwood's Practice of Medicine.

Second Edition, Revised and Enlarged

A MANUAL OF THE PRACTICE OF MEDICINE. By GEO. ROE LOCKWOOD, M. D., Attending Physician to the Bellevue Hospital, New York City. Octavo, 847 pages, with 79 illustrations in the text and 22 full-page plates. Cloth, $4.00 net.

Barton and Wells' Medical Thesaurus

A THESAURUS OF MEDICAL WORDS AND PHRASES. By W. M. BARTON, M. D., and W. A. WELLS, M. D., of Georgetown University, Washington, D. C. 12mo of 535 pages. Flexible leather, $2.50 net; thumb indexed, $3.00 net.

Jelliffe's Pharmacognosy

AN INTRODUCTION TO PHARMACOGNOSY. By SMITH ELY JELLIFFE, PH. D., M. D., of Columbia University. Octavo, illustrated. Cloth, $2.50 net.

Stevens' Practice of Medicine

New (9th) Edition

A MANUAL OF THE PRACTICE OF MEDICINE. By A. A. STEVENS, A. M., M. D., Professor of Pathology, Woman's Medical College, Phila. Specially intended for students preparing for graduation and hospital examinations. Post-octavo, 573 pages, illustrated. Flexible leather, $2.50 net.

Saunders' Pocket Formulary

New (9th) Edition

SAUNDERS' POCKET MEDICAL FORMULARY. By WILLIAM M. POWELL, M. D. Containing 1831 formulas from the best-known authorities. With an Appendix containing Posologic Table, Formulas and Doses for Hypodermic Medication, Poisons and their Antidotes, Diameters of the Female Pelvis and Fetal Head, Obstetrical Table, Diet-list, Materials and Drugs used in Antiseptic Surgery, Treatment of Asphyxia from Drowning, Surgical Remembrancer, Tables of Incompatibles, Eruptive Fevers, etc., etc. In flexible leather, with side index, wallet, and flap, $1.75 net.

Tousey's Medical Electricity and X-Rays

MEDICAL ELECTRICITY AND THE X-RAYS. By SINCLAIR TOUSEY, M. D., Consulting Surgeon to St. Bartholomew's Hospital, New York. Octavo of 1116 pages, with 750 practical illustrations, 16 in colors. Cloth, $7.00 net; Half Morocco, $8.50 net.

Hatcher and Sollmann's Materia Medica

A TEXT-BOOK OF MATERIA MEDICA: including Laboratory Exercises in the Histologic and Chemic Examination of Drugs. By ROBERT A. HATCHER, PH. G., M. D., and TORALD SOLLMANN, M. D. 12mo of 411 pages. Flexible leather, $2.00 net.

Riley Dunn & Wilson Ltd
EXPERT CONSERVATORS & BOOKBINDERS

