

The Roentgen rays in medicine and surgery as an aid in diagnosis and as a therapeutic agent designed for the use of practitioners and students / by Francis H. Williams.

Contributors

Williams, Francis H. 1852-1936.

Publication/Creation

New York : Macmillan, 1902.

Persistent URL

<https://wellcomecollection.org/works/r5679v3x>


License and attribution

This work has been identified as being free of known restrictions under copyright law, including all related and neighbouring rights and is being made available under the Creative Commons, Public Domain Mark.

You can copy, modify, distribute and perform the work, even for commercial purposes, without asking permission.





Wellcome Collection
183 Euston Road
London NW1 2BE UK
T +44 (0)20 7611 8722
E library@wellcomecollection.org
<https://wellcomecollection.org>





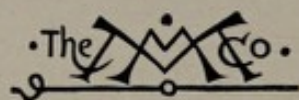
22101778769





THE ROENTGEN RAYS
IN MEDICINE AND SURGERY

129950 · A



59632

THE ROENTGEN RAYS

IN MEDICINE AND SURGERY

AS AN AID IN DIAGNOSIS AND AS
A THERAPEUTIC AGENT

Designed for the Use of Practitioners and Students

BY

FRANCIS H. WILLIAMS, M.D. (HARV.)

Graduate of the Massachusetts Institute of Technology; Visiting Physician at the Boston City Hospital; Fellow of the Massachusetts Medical Society; Member of the Association of American Physicians; Member of the American Climatological Association; Fellow of the American Association for the Advancement of Science; Fellow of the American Academy of Arts and Sciences, etc.

WITH FOUR HUNDRED AND TEN ILLUSTRATIONS

SECOND EDITION. WITH ENLARGED APPENDIX

New York

THE MACMILLAN COMPANY

LONDON: MACMILLAN & CO., LTD.

1902

All rights reserved

215847

COPYRIGHT, 1901,
By THE MACMILLAN COMPANY.

Set up and electrotyped November, 1901. New edition with additions,
March, 1902.

| WELLCOME INSTITUTE LIBRARY | |
|-------------------------------|----------|
| Coll. | weIMOmec |
| Call | |
| No. | WN100 |
| | 1902 |
| | W72r |
| | |

Norwood Press
J. S. Cushing & Co. — Berwick & Smith
Norwood Mass. U.S.A.

PREFACE

THE following pages are rather a report of progress than a final presentation of this growing subject.

I planned to include as complete a list as possible of the publications on the medical and surgical uses of the Roentgen rays, but when it was found that the list would add nearly one hundred pages, it was omitted; had I foreseen this, I should have referred in the text to many other important papers.

My own contribution is the result of two opportunities. The one, by permission of Professor Charles R. Cross, was in the Rogers Laboratory of Physics of the Massachusetts Institute of Technology. With the most cordial and efficient assistance of Messrs. Charles L. Norton and Ralph R. Lawrence, of this department, I obtained my first equipment at a time when many difficulties had to be overcome. From the late Professor Emeritus S. W. Holman, whose rare character and ability made itself felt by all who had the good fortune to be his friends, I have sought and received both advice and assistance during the course of my studies.

The other opportunity has been at the Boston City Hospital. To my colleagues on its staff I am indebted for the interest they have shown by referring to me from their services many patients requiring X-ray examination or treatment.

In the reproduction of the X-ray photographs there has been no retouching.

I wish it were possible for me to express the gratitude I feel toward Dr. William Rollins for his unfailing aid in my efforts to obtain apparatus suitable for these examinations, and particularly for the new and better forms of vacuum tubes that he has devised.

It is my privilege to express my obligation to my wife, for her devoted assistance in the preparation of this book.

PREFACE TO SECOND EDITION

THE first edition was unexpectedly exhausted within three months, and there has been but little time in which to prepare a second; some forty pages have been added, however, chiefly on apparatus and the therapeutic uses of the X-rays, which will be found in the Appendix.

March, 1902

TABLE OF CONTENTS

CHAPTER I

NATURE AND PROPERTIES OF THE X-RAYS

| | PAGE |
|--|------|
| Origin and nature of the X-rays | I |
| Properties common to X-rays and to light | I |
| Properties in which the X-rays appear to differ from light | I |
| Property of the X-rays of peculiar value | 2 |
| Law of absorption | 2 |
| Atomic weight | 2 |
| Absorptive power of fat, muscles, bones, etc., of the body | 3 |
| Absorptive power of air and gases | 4 |
| Opacity of blood to X-rays compared with that of water | 6 |

CHAPTER II

X-RAY EQUIPMENT

| | |
|--|----|
| Static machines | 8 |
| Induction coils | 19 |
| Portable apparatus | 27 |
| Generator for isolated situations | 31 |
| Vacuum tubes : | |
| Proper forms | 32 |
| Resistance of tube | 42 |
| Methods for changing resistance | 44 |
| Tube holder | 47 |
| Diaphragm | 47 |
| Fluorescent screen | 54 |
| Fluoroscope | 56 |
| Photographic plate | 56 |
| Bromide paper | 57 |
| Precautions to be taken when using X-ray apparatus and making X-ray examinations | 58 |
| Harmlessness of X-ray examinations if proper precautions are taken | 58 |

CHAPTER III

METHODS FOR MAKING X-RAY EXAMINATIONS WITH THE FLUORESCENT
SCREEN AND X-RAY PHOTOGRAPH

| | PAGE |
|--|------|
| Support of patient | 59 |
| Relative position of patient, tube, and screen or plate | 62 |
| Method of securing a constant position for the target | 65 |
| Examination of patient lying, sitting, or standing | 66 |
| General rules for examination with fluorescent screen | 74 |
| Methods for recording appearances seen on fluorescent screen | 77 |
| Methods of localization | 81 |
| Method of examination by X-ray photograph | 86 |
| Examination with screen before photograph is taken | 88 |
| Position of plate in photographing different parts of the body | 88 |
| X-ray negatives compared with X-ray photographs | 96 |
| Length of exposure | 96 |
| Importances of two views | 98 |
| Comparative advantages of screen and photograph | 99 |

CHAPTER IV

INTRODUCTION TO THORAX

| | |
|---|-----|
| General view | 100 |
| Normal lungs | 100 |
| Experiments with abnormal lungs | 103 |
| Clavicles and ribs | 103 |
| Standards of measurement. Densitometer | 103 |
| Diaphragm lines | 106 |
| Average normal excursion of diaphragm | 106 |
| Heart | 108 |
| Blood-vessels | 108 |
| Relative usefulness of fluorescent screen and X-ray photograph in examinations of the thorax | 108 |

CHAPTER V

PULMONARY TUBERCULOSIS

Appearances seen on the fluorescent screen :

| | |
|--|-----|
| Darkened lung | 111 |
| Restricted excursion of diaphragm | 111 |
| Displaced heart | 111 |
| Illustrative cases | 113 |
| Appearances seen in early tuberculosis | 115 |

TABLE OF CONTENTS

ix

| | PAGE |
|---|------|
| Definition of early tuberculosis | 117 |
| Directions for making X-ray examinations | 117 |
| Comparative value of fluorescent screen and X-ray photograph | 120 |
| Usual means of diagnosis | 120 |
| Early physical signs at apex | 121 |
| Tuberculin test | 121 |
| Test for tubercle bacilli | 121 |
| X-ray examination an aid in early diagnosis | 122 |
| Diagnosis not made by X-rays alone | 122 |
| Final test tubercle bacilli | 123 |
| Classes of cases in which X-rays are of value | 124 |
| As an aid in diagnosis | 125 |
| Old lesions of tuberculosis | 148 |
| More accurate determination of existing conditions | 149 |
| Determining progress and extent of disease | 151 |
| No signs by X-rays in two cases of tuberculosis | 158 |
| Prevalence and mortality of tuberculosis | 159 |
| Hopeful prognosis where there is early diagnosis | 160 |
| Importance of X-ray examination in young people under certain conditions | 162 |
| Use of all three methods, auscultation, percussion, and X-ray examination | 163 |

CHAPTER VI

PNEUMONIA

| | |
|--|-----|
| Introduction | 164 |
| Appearances seen in pneumonia on the fluorescent screen : | |
| Darkened lung | 164 |
| Diaphragm lines | 167 |
| Displacement and enlargement of heart | 167 |
| Usual region affected | 167 |
| Method of examination | 168 |
| Comparative value of fluorescent screen and X-ray photograph | 169 |
| Outline of pneumonia sharply defined | 173 |
| Persistence of X-ray signs | 174 |
| Excursion of diaphragm limited by adhesions | 180 |
| Pneumonia with obscure physical signs | 183 |
| Differential diagnosis : | |
| Pleurisy with effusion or pneumonia | 186 |
| Pneumonia or tuberculosis | 191 |
| Pneumonia with "la grippe" | 191 |
| Severe cold | 192 |
| Empyema overlooked | 192 |
| Appendicitis confounded with pneumonia | 192 |
| Absence of pneumonia determined | 192 |
| Broncho-pneumonia | 192 |

TABLE OF CONTENTS

CHAPTER VII

EMPHYSEMA OF THE LUNGS. BRONCHITIS

Emphysema of the Lungs

| | PAGE |
|--|------|
| Appearances seen on the fluorescent screen in emphysema of the lungs : | |
| Lungs brighter than normal | 193 |
| Diaphragm lower down in chest ; movement restricted on upper side | 193 |
| Heart lower down and its long axis more vertical ; its position changed less between inspiration and expiration | 193 |
| Successful use of percussion hindered by emphysema | 198 |
| Physical signs of tuberculosis hidden by emphysema ; abnormality of lungs seen by X-rays | 198 |

Bronchitis

| | |
|--|-----|
| Appearances seen on fluorescent screen in bronchitis | 200 |
| Foreign body in bronchus suggests reason for appearances seen in chest by X-rays | 200 |

CHAPTER VIII

PLEURISY WITH EFFUSION. EMPYEMA

| | |
|--|-----|
| Appearances seen on the fluorescent screen in pleurisy with effusion | 202 |
| Methods of examination | 205 |
| Untrustworthiness of percussion in determining the presence of fluid in the chest by means of a displaced heart | 213 |
| Encysted pleurisy | 216 |
| Interlobar empyema or pleurisy | 218 |
| Diaphragmatic pleurisy | 218 |
| Pleurisy with effusion and emphysema | 218 |
| Pleurisy with effusion and pneumonia | 218 |
| Pleurisy with effusion and pulmonary tuberculosis | 222 |
| Pleuritic adhesions | 229 |

CHAPTER IX

HYDROTHORAX. PNEUMOTHORAX. EMPYEMA WITH PERMANENT OPENING.
PNEUMOHYDRO- OR PNEUMOPYOTHORAX

| | |
|---|-----|
| Appearances seen on fluorescent screen in hydrothorax : | |
| Lower portion of chest darker than normal ; darkened area extending higher if disease is more marked ; outlines of diaphragm obscured or obliterated | 234 |
| Appearances seen on fluorescent screen in pneumothorax : | |
| Affected side of chest clearer than normal | 234 |
| Diaphragm pushed down | 234 |
| Organs displaced to opposite side | 234 |

TABLE OF CONTENTS

xi

| | PAGE |
|---|------|
| Method of examination | 235 |
| Method for withdrawing air | 237 |
| Improvement watched by fluorescent screen | 239 |
| Empyema with permanent opening | 241 |
| Appearances seen on fluorescent screen in pneumohydro- or pneumopyothorax: | |
| Sitting position. Chest resembles tumbler half full of ink. Heart displaced to opposite side. Lung on affected side retracted | 241 |
| Recumbent position. Affected side of chest dark throughout | 244 |
| Improvement watched by fluorescent screen | 244 |
| Immediate relief by operation | 245 |

CHAPTER X

HEART

Section I. Normal and Abnormal Heart

| | |
|---|-----|
| Conditions necessary for seeing the heart | 247 |
| Appearances seen on the fluorescent screen in the normal heart, with patient lying on his back | 247 |
| Pulsations | 249 |
| Apex beat | 252 |
| Experiments made by Ludwig and Hesse on the form of the heart in systole and diastole | 253 |
| Position of blood vessels and borders of heart studied at autopsies | 257 |
| Appearances on screen with patient lying on his side and light going through him horizontally. Triangle. Wedge-shaped space | 258 |
| Width of normal heart | 260 |
| Location of right and left borders of heart by distance from median line | 260 |
| Width of heart in relation to height of individual | 261 |
| Appearances seen on the fluorescent screen in abnormal heart | 262 |
| Instrument for observing heart while listening to its sounds | 262 |

Section II. Methods of Examination

| | |
|--|-----|
| Intensity of light | 263 |
| Position of patient | 263 |
| Recumbent and sitting position | 263 |
| Errors to be avoided in determining width of heart | 263 |
| Proper position of tube and manner of recording outlines | 263 |
| Comparative value of photograph and screen in examination of heart | 270 |

Section III. The Importance of knowing the Size of the Heart. Inaccuracy of Percussion in determining its Size as shown by X-Ray Examination

| | |
|--|-----|
| Prognosis and diagnosis | 270 |
| Comparison of percussion and X-ray examination | 272 |

| | PAGE |
|---|------|
| Width of heart obtained by percussion compared with weight of heart obtained at autopsy. (Tables) | 272 |
| Comparison of percussion with X-ray examination in determining width of heart. (Tables) | 273 |
| Illustrative cases | 280 |
| Small hearts and congenital malformations | 283 |
| <i>Section IV. Displaced Heart</i> | |
| Causes of displacement : | |
| (a) Fluid or gas in pleural cavities | 285 |
| (b) Changes in position and excursion of diaphragm | 286 |
| (c) Tuberculosis and unequal excursion of diaphragm | 288 |
| (d) Pneumonia and unequal excursion of diaphragm | 288 |
| (e) Aneurisms and new growths | 290 |
| (f) Contractions and adhesions | 290 |
| Heart attached; movements unusual during full inspiration | 294 |
| Displacement of heart simulating enlargement by percussion | 295 |
| Chlorosis | 297 |
| Unusual positions of heart and malformations | 297 |
| Apparent dextrocardia | 298 |
| <i>Section V. Other Abnormal Conditions of the Heart</i> | |
| Pulsations | 298 |
| Pericardial effusion | 300 |
| Mobility of the heart | 301 |
| <i>Section VI. Effect of Treatment watched by X-Ray Examinations</i> | |
| Improvement watched by X-ray examination during treatment | 302 |
| Avoidance of too early cessation of treatment | 305 |
| Enlarged hearts with murmur | 305 |
| Warning of serious condition given | 305 |
| Timely warning of disease | 306 |
| Want of efficient pulmonary circulation shown by X-rays. Alcoholics | 306 |
| Passive congestion shown to be absent by X-rays | 308 |
| Precautionary and preventive X-ray examinations | 308 |

CHAPTER XI

THORACIC ANEURISMS

| | |
|---|-----|
| Appearances seen on the fluorescent screen and by X-ray photograph in thoracic aneurism : | |
| Shadow cast to left or right of sternum, or on both sides of sternum | 310 |
| Heart often displaced or enlarged if aneurism is large | 310 |

TABLE OF CONTENTS

xiii

| | PAGE |
|---|------|
| Difficulty of diagnosis by ordinary methods | 310 |
| Method of examination by X-rays | 310 |
| Early diagnosis possible by X-rays | 312 |
| Aneurism suggesting pulmonary tuberculosis; X-rays showed thoracic aneurism . | 313 |
| Aneurism of aorta with perforation into œsophagus. Aneurism and size of heart as determined by the X-rays confirmed at autopsy | 315 |
| Subclavian aneurism; X-ray examination before operation to exclude extension below clavicle. Result of examination confirmed by autopsy | 317 |
| Diagnosis of aneurism confirmed by X-ray examination | 317 |
| Aneurism suggesting intercostal neuralgia; suspected aneurism confirmed by X-ray examination. X-rays enable us to determine whether an aneurism is or is not increasing | 319 |
| Extent of aneurism determined only by X-ray examination | 320 |
| Diagnosis of aortic aneurism by X-ray examination confirmed by autopsy. Posi- tion of left border of heart obtained by X-ray examination confirmed at autopsy | 321 |
| Aneurism unsuspected by physical examination determined by X-ray examination . | 322 |
| Aneurism unrecognized by auscultation and percussion seen by X-ray exami- nation | 323 |
| Aneurism recognized only by X-ray examination | 323 |
| Aneurism suspected on account of hoarseness; X-ray showed no aneurism was present | 324 |
| Tentative diagnosis of thoracic aneurism | 324 |
| Aneurism of the ascending aorta; enlarged heart; X-ray and percussion lines compared; X-ray outlines confirmed by autopsy | 327 |
| Importance of examination by fluorescent screen and careful interpretation of X-ray photograph | 328 |

CHAPTER XII

NEW GROWTHS. ENLARGED GLANDS. ABSCESS AND GANGRENE OF LUNG

| | |
|--|-----|
| Introduction | 332 |
| Method of locating a new growth | 334 |
| Diagnosis of new growth made by aid of X-rays confirmed by autopsy | 338 |
| Tumors in chest. Results obtained by X-ray examination and auscultation and percussion compared | 339 |
| Tumors in head | 340 |
| Differential diagnosis | 340 |
| X-ray appearances of an extensive new growth and an interstitial fibrous pneu- monia compared | 343 |
| New growth in chest wall | 345 |
| Echinococcus of the lung | 346 |
| Malignant disease of the abdomen; question of extension into thorax | 346 |

| | PAGE |
|---|------|
| A bunch of enlarged glands simulating the outline produced by an aneurism when examined from one direction | 347 |
| Enlarged bronchial glands; disease extending into lungs | 349 |
| Abscess and gangrene of lung | 351 |

CHAPTER XIII

CONCLUSION OF THORAX

| | |
|--|-----|
| Differential diagnosis | 353 |
| Acute and chronic processes compared | 354 |
| Association of an acute and chronic process | 354 |
| Association of two acute diseases | 354 |
| X-ray examination of the whole chest, not of one organ alone | 354 |
| X-ray examinations made by trained physicians; preferably, specialists of thoracic diseases | 355 |
| X-ray examination part of physical examination | 355 |
| Need of X-ray apparatus by physicians | 355 |

CHAPTER XIV

X-RAY EXAMINATION OF THE ŒSOPHAGUS, ABDOMEN, AND PELVIS

| | |
|--|-----|
| Œsophagus: | |
| Stricture of the œsophagus | 357 |
| Diverticulum | 357 |
| Abdomen: | |
| Introduction of air or gas | 358 |
| Use of bismuth | 358 |
| Stomach: | |
| Methods for observing the stomach | 359 |
| Position of stomach when standing and lying down | 360 |
| Movement of the stomach during respiration | 362 |
| Changes in shape of stomach during digestion | 364 |
| Physiology of digestion | 372 |
| Digestive tract observed by means of capsules | 373 |
| Liver | 373 |
| Spleen | 373 |
| Kidneys | 374 |
| Ascites | 375 |
| New Growths: | |
| Carcinoma of the stomach | 376 |
| Carcinoma of the liver | 376 |
| Cancer of the pylorus | 377 |
| Phantom tumors | 377 |
| Intestines | 378 |

TABLE OF CONTENTS

xv

| | PAGE |
|--|------|
| Pelvis : | |
| Method for taking a photograph of the pelvis | 379 |
| Sacrum | 379 |
| Measurement of transverse diameter of the pelvis | 379 |
| Gravid uterus | 382 |
| Determination as to whether a foetus has or has not breathed | 383 |

CHAPTER XV

CHILDREN. CALCIFICATION OF THE TISSUES. ANÆMIA. PHYSIOLOGY

Children

| | |
|--|-----|
| Children more easily penetrated by the X-rays than adults | 384 |
| In cases suggesting tuberculous meningitis, X-ray examination of value to determine whether or not tuberculous foci exist in the lungs | 385 |
| Same general rules for making examination of adults apply to children | 385 |

Calcification of the Tissues

| | |
|--|-----|
| Calcification of the tissues | 385 |
|--|-----|

Anæmia

| | |
|--|-----|
| Appearances seen on the fluorescent screen in anæmia and pernicious anæmia | 388 |
| Small hearts | 388 |
| Error possible as to width of heart by ordinary methods | 388 |

Physiology

| | |
|---|-----|
| Physiology of the voice and speech | 389 |
| Effect of excessive exercise on the heart | 390 |

CHAPTER XVI

THERAPEUTIC USES OF THE X-RAYS. THEIR ACTION ON BACTERIA

Diseases of the skin :

| | |
|--|-----|
| Effect of X-rays on normal and abnormal skin | 392 |
| Mode of action of X-rays | 393 |

Lupus :

| | |
|--|-----|
| Illustrative Cases | 394 |
| Susceptibility of the patient | 398 |
| Cumulative action of the rays | 399 |
| Protection of patient | 399 |
| Distance of the tube | 401 |
| Length and frequency of sittings | 401 |
| Lupus erythematodes | 404 |
| Syphilis simulated by lupus | 406 |
| Eczema | 407 |

| | PAGE |
|--|------|
| Nævus flammeus or vasculosus | 412 |
| Sycosis and favus | 414 |
| Sycosis non parasitaria | 416 |
| Hypertrichosis | 416 |
| Lymphomata colli | 417 |
| Psoriasis | 418 |
| Acne | 418 |
| Tuberculosis | 418 |
| Trigeminal neuralgia | 420 |
| New Growths : | |
| Carcinoma of breast and stomach | 421 |
| External forms of cancer | 421 |
| Rodent ulcer | 437 |
| X-rays as an analgesic | 445 |
| Articular Rheumatism | 445 |
| Changes produced on the skin by exposure to an excited vacuum tube | 447 |
| Cause of the so-called X-ray burn | 447 |
| Effect of X-rays on bacteria | 448 |
| Effect of X-rays on developed colonies | 451 |
| Effect of concentrated light on bacteria | 452 |
| Effect of X-rays on animals inoculated with bacteria | 452 |

CHAPTER XVII

INTRODUCTION TO SURGERY

| | |
|--|-----|
| Surgical uses of the X-rays | 454 |
| Degree of power needed in the apparatus | 455 |
| X-ray photograph and fluorescent screen | 455 |
| Knowledge of normal bones and joints. Interpretation of X-ray pictures | 455 |
| Value of negative | 457 |
| Two or more negatives made | 457 |
| Stereoscopic pictures | 457 |
| Comparison of well and affected bone | 457 |
| Importance of two views | 457 |
| Importance of good negatives | 457 |
| Swelling about a fracture and swollen joints | 458 |
| Bones and soft tissues | 458 |

CHAPTER XVIII

DEVELOPMENT OF THE SKELETON. CONGENITAL MALFORMATIONS.
FRONTAL CAVITIES. MUSCLE

| | |
|--|-----|
| Development of the skeleton : | |
| Epiphyses | 459 |
| Epiphyseal lesions in children | 461 |

TABLE OF CONTENTS

xvii

| | PAGE |
|--|------|
| Disturbance of the development of the bones in cretinism | 461 |
| Ossification of the cartilage of the larynx | 462 |
| Congenital malformations : | |
| Deficiency and arrested development of bones | 462 |
| Spina bifida | 464 |
| Frontal cavities | 464 |
| Muscle | 465 |
| Myositis ossificans | 465 |

CHAPTER XIX

FRACTURES AND DISLOCATIONS

| | |
|---|-----|
| Methods of examination : | |
| Examination with fluorescent screen | 468 |
| Examination with radiograph | 468 |
| Importance of photographs from two points of view | 469 |
| Stereoscopic pictures | 469 |
| Errors to be avoided | 471 |
| Advantages of permeable splints and dressings | 471 |
| Examination of special bones of the body illustrated by radiographs : | |
| Skull | 475 |
| Spine | 475 |
| Shoulder | 481 |
| Elbow | 485 |
| Lower end of radius, ulna, and wrist | 488 |
| Supposed fracture of radius ; none found by X-rays | 488 |
| New and old callus about a fracture | 490 |
| Fracture of phalanges and metacarpal bones liable to be overlooked without X-rays | 491 |
| Hip | 493 |
| Thigh | 495 |
| Knee | 499 |
| Leg and ankle | 501 |
| Absence of fracture indicated by X-rays ; fracture by ordinary methods | 522 |
| Advantage of comparing injured and uninjured leg | 522 |
| Tarsus | 522 |
| X-rays show true cause of chronic swelling of foot | 522 |
| Dislocations | 526 |

CHAPTER XX

FOREIGN BODIES

| | |
|-----------------------------------|-----|
| Methods of localization : | |
| With fluorescent screen | 531 |
| By X-ray photograph | 533 |

| | PAGE |
|--|------|
| Localizers : | |
| Foreign bodies | 533 |
| Copper in eye | 538 |
| Bullet in head | 539 |
| Half dollar in œsophagus | 539 |
| Steel in arm | 540 |
| Importance of two views. Needle in os calcis | 543 |
| Needles | 545 |
| Precautions to be taken | 545 |
| Glass in finger | 550 |
| Small pieces of metal visible in body | 550 |
| Whistle in pelvis | 551 |
| Shot in foot | 552 |

CHAPTER XXI

MILITARY SURGERY

| | |
|--|-----|
| Successful use | 553 |
| Need of apparatus at base hospitals | 553 |
| Use of the X-rays in late war with Spain | 554 |

CHAPTER XXII

DISEASES OF THE BONES AND OF THE JOINTS

| | |
|--|-----|
| Detection of chemical changes in bones by the X-rays | 556 |
| Diseases of the bones : | |
| Methods of examination | 559 |
| Periostitis | 558 |
| Osteitis | 560 |
| Spina ventosa | 562 |
| Regeneration of bones after operation | 562 |
| Osteomyelitis | 564 |
| Rickets | 575 |
| Coxa vara | 575 |
| Acromegalia | 578 |
| New growths | 578 |
| Osteosarcoma | 579 |
| Differentiation of bony from other tumors | 582 |
| Chondrosarcoma | 583 |
| Tumor of the left hand | 585 |
| Exostosis | 586 |
| Metastatic carcinoma | 587 |
| Joints and cartilages : | |
| Methods of examination | 587 |

TABLE OF CONTENTS

xix

| | PAGE |
|--------------------------------------|------|
| Tuberculosis of joints | 587 |
| Tubercular osteitis | 594 |
| Coxitis | 594 |
| Caries of the spine | 594 |
| Syphilitic diseases | 596 |
| Rheumatoid arthritis | 598 |
| Osteo-arthritis | 598 |
| Cartilage : | |
| Hyaline cartilage | 598 |
| Loose cartilage | 598 |
| Cartilage affected by gout | 598 |
| Flat foot | 598 |
| Bony and fibrous ankylosis | 598 |

CHAPTER XXIII

DENTAL SURGERY

Suitable apparatus :

| | |
|---|-----|
| Generator | 603 |
| Tube ; sharp definition ; proper degree of resistance | 603 |
| Tube-holder and diaphragm | 604 |
| Screen | 605 |
| Position of patient | 606 |
| Position of plate or film | 606 |
| Main uses of X-rays in dentistry | 606 |
| For information in regard to | |
| (a) Unerupted teeth | 607 |
| (b) Regulation of teeth | 607 |
| (c) Pulpless teeth | 611 |
| (d) Alveolar abscess | 612 |
| (e) Fractures of roots | 613 |
| (f) Root canals | 613 |
| (g) Fluid in antrum | 613 |

CHAPTER XXIV

CALCULI

| | |
|---|-----|
| Tests on permeability of calculi of organic and inorganic composition | 615 |
| Method of examination of kidneys and ureters | 617 |
| Comparison of X-ray negatives and photographs | 620 |
| Comparison of X-ray negative and fluorescent screen | 620 |
| Fenwick's method of examination of kidney outside of body | 621 |
| Method of examination of bladder | 621 |

| | PAGE |
|---|------|
| Instrument for photographing calculus in bladder | 621 |
| Cases | 623 |
| Gall stones | 630 |
| Absence of calculus not definitely determined by X-rays | 630 |
| Determination of presence of calculus | 630 |
| Conclusions : | |
| New method of diagnosis | 631 |
| Difficulty of diagnosis by ordinary methods | 631 |
| Direct and indirect use of X-rays | 631 |

CHAPTER XXV


USEFULNESS OF X-RAY EXAMINATIONS TO LIFE INSURANCE COMPANIES.
MEDICO-LEGAL USES OF THE X-RAYS

| | |
|---|-----|
| Usefulness of X-ray examinations to life insurance companies: | |
| Kidneys, lungs, and heart | 633 |
| Determination of diseased condition the important consideration | 633 |
| Medico-legal uses of the X-rays : | |
| Evidence from radiographs in court | 634 |
| Data needed on radiograph | 634 |
| Radiographs interpreted by a surgeon trained in the use of them | 634 |

APPENDIX

| | |
|---|-----|
| ORIGIN OF X-RAY DEPARTMENT AT THE BOSTON CITY HOSPITAL. System | |
| pursued in examining patients | 635 |
| X-RAY EQUIPMENT : | |
| Generator; static machine; coils | 636 |
| Norton and Lawrence apparatus | 638 |
| Portable apparatus | 639 |
| Static machine and coils compared | 639 |
| Intensifying screens | 640 |
| Stereoscopic fluoroscope | 640 |
| Tube and regulator | 640 |
| Times of exposure for X-ray photographs | 641 |
| HEAD AND NECK | 642 |
| THORAX : | |
| Emphysema | 642 |
| Pneumohydrothorax | 642 |
| Pleurisy with effusion | 642 |
| ABDOMEN : | |
| Movement of food through the intestines. Cannon's experiments on cats | 645 |

| | PAGE |
|--|------|
| THERAPEUTIC USES OF THE X-RAYS: | |
| Apparatus; resistance of tube; tube holder | 646 |
| Method of treatment | 647 |
| Time of exposure; exposures made by physicians | 649 |
| Lupus vulgaris | 651 |
| Lupus erythematosus | 652 |
| Chronic eczema | 652 |
| Sycosis hyphogenes | 653 |
| Psoriasis | 653 |
| Acne vulgaris and acne rosaceæ | 654 |
| Leprosy, elephantiasis, pruritus ani and vulvæ, warts | 655 |
| New growths | 655 |
| External new growths | 657 |
| First group: early cases and cases of slow growth | 657 |
| Second group | 663 |
| Third group: inoperable cases and cases that decline operation | 663 |
| Treatment after operation | 666 |
| Papilloma of larynx | 668 |
| Rodent ulcers | 668 |
| Recurrence | 669 |
| Cancer of breast | 670 |
| Internal forms of cancer | 672 |
| Rollins' experiments on guinea pigs | 672 |
| Summary of experience with new growths | 674 |
| Tuberculous glands | 674 |
| Tuberculous sinuses | 674 |
| Old ulcerations | 675 |
| Hodgkin's disease | 675 |
| Exophthalmic goitre | 679 |
| Disease of cornea | 679 |
| Fluorometer | 681 |
| INDEX | 683 |



LIST OF ILLUSTRATIONS

| | PAGE |
|--|------|
| 1. X-ray photograph of equal bulks of substances which represent the constituents of the body in a general way | 5 |
| 2. X-ray photograph of two cups containing blood and water respectively | 7 |
| 3. Front view of static machine | 9 |
| 4. End view of static machine | 11 |
| 5. Detail of metal parts of static machine | 12 |
| 6. Side view of static machine | 13 |
| 7. Diagram of static machine, tube, and adjustable spark-gap | 15 |
| 8. Adjustable multiple spark-gap | 16 |
| 9. Medium-sized static machine | 18 |
| 10. Diagram showing construction of coil | 19 |
| 11. Heinze interrupter | 21 |
| 12. Primary battery, Ritchie coil, Hammer interrupter and tube | 23 |
| 13. Storage battery, Ritchie coil, Hammer interrupter and tube | 23 |
| 14. Small dynamo, Ritchie coil, Hammer interrupter and tube | 24 |
| 15. Ritchie coil, Wehnelt interrupter and tube | 24 |
| 16. Heinze electrolytic interrupter, Ritchie coil and tube | 25 |
| 17. Adjustable multiple spark-gap on Ritchie coil | 25 |
| 18. Adjustable multiple spark-gap for coil | 26 |
| 19. Portable apparatus | 27 |
| 20. Diagram of high frequency coil | 28 |
| 21. A. W. L. universal coil | 29 |
| 22. Diagram of A. W. L. universal coil | 31 |
| 23. Combination of storage battery and gravity cells | 33 |
| 24. A. W. L. rotary target tube with movable target | 34 |
| 25. A. W. L. rotary target tube with movable target and internal diaphragm | 34 |
| 26. Cooled target tube | 36 |
| 27. Section of cooled target tube | 36 |
| 28. A. W. L. tube for direct currents | 36 |
| 29. Details of rotary target | 37 |
| 30. Faulty type of tube | 37 |
| 31. Cut illustrating formation of cathode stream and X-rays | 38 |
| 32. Double focus tube for high frequency coils | 39 |
| 33. A. W. L. tube for high frequency coils | 40 |
| 34. A. W. L. tube with cooled target | 40 |

| | PAGE |
|---|------|
| 35. A. W. L. tube with rotary target | 41 |
| 36. Tube with continuous metallic conductor | 41 |
| 37. Diagram showing method of determining resistance of tube | 43 |
| 38. Tube with regulator | 45 |
| 39. Diagram showing the effect of the resistance of the tube on the X-ray picture and the advantage of the adjustable multiple spark-gap | 48 |
| 40. Tube-holder | 49 |
| 41. Tube-holder with tube in box | 51 |
| 42. Tube-holder with tube in box | 52 |
| 43. Tube-holder with box open | 52 |
| 44. Detail of device for connecting tube with terminals | 53 |
| 45. Tube-holder with box closed | 53 |
| 46. Tube-holder box open | 54 |
| 47. Tube-holder box closed and ready for use | 55 |
| 48. Showing method of examining patient in prone position | 60 |
| 49. Apparatus at Boston City Hospital, static machine | 61 |
| 50. A. W. L. universal coil at hospital | 63 |
| 51. Tube, plate, and pins | 65 |
| 52. X-ray photograph of pins | 67 |
| 53. Diagram showing effect of distance of tube from object and inclination of plate | 68 |
| 54. Indirect plumb-line | 69 |
| 55. Showing method of using indirect plumb-line | 70 |
| 56. Showing method of examining thorax with patient sitting | 71 |
| 57. Rear view of Fig. 56 | 72 |
| 58. Showing method of examining thorax with patient sitting | 73 |
| 59. Showing method of examining thorax with large open screen | 76 |
| 60. Showing method of examining thorax with screen with celluloid cover | 78 |
| 61. Showing method of drawing X-ray outlines on chest while looking through fluoroscope | 80 |
| 62. Diagram showing method of localization | 82 |
| 63. Diagram showing method of localization | 83 |
| 64. Diagram showing method of localization | 84 |
| 65. Diagram showing method of localization | 85 |
| 66. X-ray photograph of hyoid bone and part of trachea | 88 |
| 67. X-ray photograph of cervical vertebræ | 90 |
| 68. X-ray photograph of cervical vertebræ | 91 |
| 69. Method of taking an X-ray photograph of fractured leg | 92 |
| 70. Method of taking an X-ray photograph of fractured hand | 94 |
| 71. Method of photographing heart and lungs | 95 |
| 72. Method of photographing spine | 97 |
| 73. Method of examining negative | 98 |
| 74. Diagram of thorax in health | 101 |
| 75. X-ray tracing of normal heart and diaphragm lines | 102 |
| 76. X-ray photograph of thorax | 104 |
| 77. Densitometer | 105 |

LIST OF ILLUSTRATIONS

XXV

PAGE

| | | |
|------|--|-----|
| 78. | Photograph of diaphragm lines traced on chest by X-rays | 107 |
| 79. | X-ray tracing of normal thorax | 107 |
| 80. | X-ray photograph of tuberculous lung | 112 |
| 81. | Diagram of pulmonary tuberculosis | 115 |
| 82. | X-ray tracing of early pulmonary tuberculosis | 116 |
| 83. | X-ray tracing of early pulmonary tuberculosis. Tina M. | 126 |
| 84. | X-ray tracing of early pulmonary tuberculosis. M. F. | 128 |
| 85. | X-ray tracing of early pulmonary tuberculosis. M. G. | 131 |
| 86. | X-ray tracing of early pulmonary tuberculosis. M. G. | 132 |
| 87. | X-ray tracing of early pulmonary tuberculosis. M. G. | 133 |
| 88. | X-ray tracing of M. G., chest nearly normal | 136 |
| 89. | X-ray tracing of M. G. after taking cold | 137 |
| 90. | X-ray tracing of M. G. after return from sanitarium | 138 |
| 91. | X-ray tracing of chest where physical signs indicated tuberculosis, but X-rays did not | 145 |
| 92. | X-ray tracing of pulmonary tuberculosis. J. M. | 150 |
| 93. | X-ray tracing of pulmonary tuberculosis. J. H. | 151 |
| 94. | X-ray tracing of acute pulmonary tuberculosis. Sarah H. | 152 |
| 95. | X-ray tracing (second) of Sarah H. | 153 |
| 96. | X-ray tracing (third) of Sarah H. | 154 |
| 97. | X-ray tracing (fourth) of Sarah H. | 154 |
| 98. | X-ray tracing of pulmonary tuberculosis. L. B. C. | 156 |
| 99. | X-ray photograph of pneumonic lung | 165 |
| 100. | X-ray photograph of pneumonic lung | 166 |
| 101. | Diagram of thorax. Pneumonia | 168 |
| 102. | X-ray tracing of C. P. Pneumonia | 169 |
| 103. | X-ray photograph of thorax of C. P. | 170 |
| 104. | X-ray tracing of pneumonia. E. R. | 171 |
| 105. | X-ray tracing of pneumonia. F. G. | 172 |
| 106. | X-ray record of pneumonia. B. McL. | 174 |
| 107. | X-ray record of pneumonia. G. R. | 176 |
| 108. | X-ray record (second) of G. R. | 177 |
| 109. | X-ray record (third) of G. R. | 178 |
| 110. | X-ray record (fourth) of G. R. | 179 |
| 111. | X-ray tracing of Simon G. Pneumonia | 181 |
| 112. | X-ray tracing (second) of Simon G. | 182 |
| 113. | X-ray tracing (third) of Simon G. | 182 |
| 114. | X-ray tracing (fourth) of Simon G. | 183 |
| 115. | X-ray tracing of Clara B. Central pneumonia | 184 |
| 116. | X-ray tracing (second) of Clara B. | 184 |
| 117. | X-ray tracing of pneumonia. Julia F. | 187 |
| 118. | X-ray tracing (second) of Julia F. | 187 |
| 119. | X-ray tracing of pneumonia. Essie L. | 189 |
| 120. | X-ray tracing (second) of Essie L. | 189 |
| 121. | X-ray tracing of pneumonia. Joseph S. | 190 |
| 122. | Diagram of emphysema of lungs | 194 |

| | PAGE |
|---|------|
| 123. X-ray tracing of emphysema of lungs. Patrick W. | 196 |
| 124. X-ray tracing (third) of Patrick W. | 197 |
| 125. X-ray photograph of emphysema. Henry B. | 199 |
| 126. X-ray tracing of chest of boy who had swallowed a walnut shell | 201 |
| 127. Diagram of pleurisy with small effusion | 203 |
| 128. Diagram of pleurisy with large effusion | 204 |
| 129. X-ray record of pleurisy with effusion. P. McM. | 206 |
| 130. X-ray record of pleurisy with effusion. M. E. H. | 208 |
| 131. X-ray record of pleurisy with effusion. T. R. | 210 |
| 132. X-ray record (third) of T. R. showing improvement | 211 |
| 133. X-ray record (fifth) of T. R. showing further improvement | 212 |
| 134. X-ray tracing of pleurisy with effusion. C. D. | 214 |
| 135. X-ray tracing of pleurisy with effusion. J. L. | 215 |
| 136. X-ray record of encysted pleurisy. W. T. | 217 |
| 137. X-ray tracing of pleurisy on left side and pneumonia on left side and at right apex. D. M. | 219 |
| 138. X-ray tracing (second) of D. M. showing improvement | 221 |
| 139. X-ray record of pleurisy with effusion. Mary F. | 223 |
| 140. X-ray record (second) of Mary F. Tuberculosis and pleurisy, the latter diminished | 224 |
| 141. X-ray record (third) of Mary F., still less effusion | 225 |
| 142. X-ray tracing of pleurisy with effusion and tuberculosis. John J. L. | 226 |
| 143. X-ray record of pleurisy with effusion. Andrew J. K. | 227 |
| 144. X-ray record (second) of Andrew J. K., showing improvement | 229 |
| 145. X-ray tracing of John F. Pleuritic adhesion | 231 |
| 146. X-ray tracing of James A. W. | 232 |
| 147. Diagram of pneumothorax of left side and tuberculosis of right side | 235 |
| 148. X-ray tracing of pneumothorax of left side and tuberculosis of right side. Delia H. | 236 |
| 149. X-ray tracing (second) of Delia H. | 237 |
| 150. X-ray tracing (third) of Delia H. | 238 |
| 151. X-ray tracing (fourth) of Delia H. | 239 |
| 152. Diagram of pneumohydrothorax | 242 |
| 153. X-ray tracing of pneumohydrothorax. C. P. W. | 243 |
| 154. X-ray tracing of pneumohydrothorax. Tony M. | 245 |
| 155. X-ray photograph of heart in full inspiration | 250 |
| 156. X-ray photograph of heart in quiet breathing | 251 |
| 157. Diagram of heart movements | 254 |
| 158. X-ray tracing of triangle and heart lines | 259 |
| 159. X-ray tracing showing faulty method of recording heart outlines, and error by percussion. M. C. | 266 |
| 160. X-ray tracing (second) of M. C. | 267 |
| 161. X-ray tracing (third). M. C. | 268 |
| 162. X-ray tracing of, and percussion outline of, heart compared. Mary F. D. Pleurisy | 280 |
| 163. X-ray tracing of, and percussion outline of, heart compared. Harry M. | 281 |

| | PAGE |
|---|------|
| 164. X-ray tracing of, and percussion outline of, heart compared. John W. M. | 282 |
| 165. X-ray tracing of, and percussion outline of, heart compared. Catherine P. | 283 |
| 166. X-ray tracing of, and percussion outline of, heart compared. Alex. M. | |
| Pleurisy | 284 |
| 167. X-tracing of, and percussion outline of, heart compared. C. D. Pleurisy. | 285 |
| 168. X-ray tracing of heart. Paul S. | 287 |
| 169. X-ray tracing (second) of Paul S. | 287 |
| 170. X-ray tracing of thorax. Michel F. Early tuberculosis | 289 |
| 171. X-ray tracing of thorax. Mabel L. | 290 |
| 172. X-ray tracing of thorax. Mary I. | 292 |
| 173. X-ray tracing of thorax. D. F. W. | 293 |
| 174. X-ray tracing of thorax. Edward W. | 294 |
| 175. X-ray tracing of John C., showing heart's axis nearly horizontal | 297 |
| 176. Diagram of John D. Aortic insufficiency | 299 |
| 177. X-ray record of thorax. Ella H. | 302 |
| 178. X-ray record (third) of Ella H., showing improvement | 303 |
| 179. Diagram of passive congestion, or œdema of lungs | 307 |
| 180. Diagram of an aneurism of descending aorta | 311 |
| 181. Photograph of X-ray outlines of aneurism drawn on chest. M. J. | 314 |
| 182. X-ray tracing of aneurism of aorta. E. H. | 316 |
| 183. X-ray tracing of aneurism. C. S. | 318 |
| 184. X-ray tracing of aneurism. E. M. | 319 |
| 185. X-ray tracing of aneurism of aorta. James L. | 320 |
| 186. X-ray tracing of aneurism and heart compared with percussion lines | 321 |
| 187. X-ray tracing of aneurism of descending portion of aortic arch. A. B. | 323 |
| 188. X-ray tracing of aneurism. O. D. | 326 |
| 189. X-ray tracing of aneurism of ascending aorta | 327 |
| 190. X-ray tracing of new growth in thorax. Daniel M. | 334 |
| 191. X-ray tracing of new growth in thorax. Daniel M. | 335 |
| 192. X-ray tracing on right side of Daniel M. | 336 |
| 193. X-ray photograph of new growth. Daniel M. | 337 |
| 194. X-ray tracing of sarcoma of lungs. Jacob D. | 338 |
| 195. X-ray tracing of sarcoma of lungs. George D. | 342 |
| 196. X-ray tracing of interstitial fibrous pneumonia. Richard S. | 344 |
| 197. X-ray tracing and diagram. Martin F. | 345 |
| 198. X-ray tracing of thorax. Lymph-adenitis. M. C. | 348 |
| 199. X-ray tracing of thorax. Carcinomatous bronchial glands. Mrs. S. | 350 |
| 200. X-ray tracing of gangrene of lung. Mary C. | 351 |
| 201. X-ray tracing of stomach of child of seven years of age, one hour after eating | 361 |
| 202. X-ray tracing of stomach of James W. during digestion | 362 |
| 203. X-ray tracing of stomach (second) of James W. during digestion | 363 |
| 204. X-ray tracing of stomach (third) of James W. during digestion | 364 |
| 205. X-ray tracing of stomach (fourth) of James W. | 364 |
| 206. X-ray tracing of stomach of M. W. during digestion | 365 |
| 207. X-ray tracing of stomach (second) of M. W. | 366 |
| 208. X-ray tracing of stomach (third) of M. W. | 367 |

| | PAGE |
|--|------|
| 209. X-ray tracing of stomach (fourth) of M. W. | 368 |
| 210. X-ray tracing of stomach (fifth) of M. W. | 369 |
| 211. X-ray tracing of stomach (sixth) of M. W. | 370 |
| 212. X-ray tracing of stomach (seventh) of M. W. | 371 |
| 213. X-ray tracing of thorax of B. B. Cancer of liver | 376 |
| 214. X-ray photograph of pelvis | 380 |
| 215. X-ray photograph of pelvis | 381 |
| 216. X-ray photograph of calcified radial artery | 386 |
| 217. X-ray photograph of calcified pleura from autopsy | 387 |
| 218. Showing method of treating lupus by X-rays | 400 |
| 219. Photograph of boy with lupus before treatment | 402 |
| 220. Photograph of boy with lupus after treatment | 403 |
| 221. Photograph of woman with lupus before treatment | 404 |
| 222. Photograph of woman with lupus after partial treatment | 405 |
| 223. Photograph of epidermoid cancer of lip before treatment. Front view. H. N. | 422 |
| 224. Photograph of epidermoid cancer of lip before treatment. Side view. H. N. | 423 |
| 225. Photograph of H. N. after treatment. Front view | 424 |
| 226. Photograph of H. N. after treatment. Side view | 425 |
| 227. Photograph of epidermoid cancer of eyelid before treatment. J. C. | 426 |
| 228. Photograph of J. C. during treatment | 427 |
| 229. Photograph of epithelioma of lip before treatment. B. F. Side view | 428 |
| 230. Photograph of B. F. before treatment. Front view | 429 |
| 231. Photograph of B. F. after about six weeks' treatment | 430 |
| 232. Photograph of B. F. about a month later | 431 |
| 233. Photograph of epidermoid cancer of hand at beginning of treatment. D. K. | 432 |
| 234. Photograph of hand of D. K. Side view | 433 |
| 235. Section of carcinoma of hand of D. K. before treatment | 434 |
| 236. Photograph of hand of D. K. after some treatment | 435 |
| 237. Section of carcinoma of hand of D. K. after some treatment | 436 |
| 238. Section of carcinoma of hand of D. K. after some treatment | 437 |
| 239. Photograph of rodent ulcer of face before treatment. J. H. | 439 |
| 240. Photograph of J. H. after treatment | 440 |
| 241. X-ray photograph of fœtus | 459 |
| 242. X-ray photograph of epiphysis of radius | 460 |
| 243. X-ray photograph of congenital malformation of hand | 463 |
| 244. X-ray photograph of congenital malformation of right thumb | 464 |
| 245. X-ray photograph of both bones of right leg | 470 |
| 246. Modification of Wheatstone stereoscope | 471 |
| 247. X-ray photograph of bandages, splints, etc. | 472 |
| 248. X-ray photograph of fractured leg | 474 |
| 249. X-ray photograph of fracture of surgical neck of humerus | 476 |
| 250. X-ray photograph of fracture of surgical neck of humerus | 477 |
| 251. X-ray photograph of healed fracture of lower third of humerus | 478 |
| 252. X-ray photograph of fracture of lower end of humerus and olecranon | 479 |

| | PAGE |
|---|------|
| 253. X-ray photograph of fracture of olecranon and head of ulna | 480 |
| 254. X-ray photograph of fracture of ulna | 481 |
| 255. X-ray photograph of ununited fracture | 482 |
| 256. X-ray photograph of supposed fracture of radius | 483 |
| 257. X-ray photograph of fracture of left radius before operation. S. D. | 484 |
| 258. X-ray photograph of S. D. two months after operation | 485 |
| 259. X-ray photograph of open fracture of radius. Frederick F. Antero-posterior view | 486 |
| 260. X-ray photograph of Frederick F. Lateral view | 487 |
| 261. X-ray photograph of fracture of radius | 488 |
| 262. X-ray photograph of Colles fracture | 489 |
| 263. X-ray photograph of fracture of left radius and tip of styloid process of ulna. Antero-posterior view. Gertrude F. | 490 |
| 264. X-ray photograph of radius of Gertrude F. Lateral view | 491 |
| 265. X-ray photograph of fracture of third metacarpal bone | 492 |
| 266. X-ray photograph of fracture of phalanx of second finger of right hand | 493 |
| 267. X-ray photograph of fracture of fourth metacarpal bone of left hand | 494 |
| 268. X-ray photograph of fracture of fifth metacarpal of hand | 495 |
| 269. X-ray photograph of fracture of thumb | 496 |
| 270. X-ray photograph of fracture of femur. Lateral view | 497 |
| 271. X-ray photograph of fracture of femur. Antero-posterior view | 498 |
| 272. X-ray photograph of fractured patella | 499 |
| 273. X-ray photograph of fractured patella. Front view | 500 |
| 274. X-ray photograph of fractured patella. Side view | 501 |
| 275. X-ray photograph of fracture of tibia. John S. Lateral view | 502 |
| 276. X-ray photograph of fracture of tibia. John S. | 503 |
| 277. X-ray photograph of fracture of fibula | 504 |
| 278. X-ray photograph of fracture of both bones of leg. Antero-posterior view. William A. | 505 |
| 279. X-ray photograph of William A. Lateral view | 506 |
| 280. X-ray photograph of fibrous fracture of fibula. Antero-posterior view. John C. | 507 |
| 281. X-ray photograph of John C. Lateral view | 508 |
| 282. X-ray photograph of fracture of both bones of right leg. James H. G. | 509 |
| 283. X-ray photograph of fracture of tibia and longitudinal split in fibula | 510 |
| 284. X-ray photograph of fracture of tibia and fibula | 511 |
| 285. X-ray photograph of fracture of tibia | 512 |
| 286. X-ray photograph of uninjured leg | 513 |
| 287. X-ray photograph of fracture of tibia of boy six years old | 514 |
| 288. X-ray photograph of uninjured leg of boy six years old | 515 |
| 289. X-ray photograph of fracture of both bones of leg and callus | 516 |
| 290. X-ray photograph of fracture of both bones of leg | 517 |
| 291. X-ray photograph of fracture of both bones of leg, due to torsion | 518 |
| 292. X-ray photograph of fracture of both bones of leg, caused by blow | 519 |
| 293. X-ray photograph of fracture of tibia and fibula | 520 |
| 294. X-ray photograph of fracture of epiphysis | 521 |

| | PAGE |
|---|------|
| 295. X-ray photograph of injured foot | 523 |
| 296. X-ray photograph of uninjured foot | 524 |
| 297. X-ray photograph of fracture of phalanges of great toe and fracture of first phalanx of second toe | 525 |
| 298. X-ray photograph of dislocated thumb | 526 |
| 299. X-ray photograph of dislocation of both bones of forearm | 527 |
| 300. X-ray photograph of dislocation and separation of lower end of femur. Hugh C. | 528 |
| 301. X-ray photograph of Hugh C., taken nearly three months later | 529 |
| 302. X-ray photograph of subdislocation of metatarsus | 530 |
| 303. Mackenzie Davidson exposor | 533 |
| 304. Mackenzie Davidson localizer | 534 |
| 305. X-ray photograph of half dollar in œsophagus | 540 |
| 306. X-ray photograph of whistle in œsophagus | 541 |
| 307. X-ray photograph of steel in arm. Antero-posterior view | 542 |
| 308. X-ray photograph of steel in arm. Lateral view | 543 |
| 309. X-ray photograph of needle in os calcis | 544 |
| 310. X-ray photograph of needle in hand | 545 |
| 311. X-ray photograph of needle in hand. Antero-posterior view | 546 |
| 312. X-ray photograph of needle in hand. Lateral view | 547 |
| 313. X-ray photograph of needle in wrist. Antero-posterior view | 548 |
| 314. X-ray photograph of needle in wrist. Lateral view | 549 |
| 315. X-ray photograph of glass in finger | 550 |
| 316. X-ray photograph of whistle in pelvis | 551 |
| 317. X-ray photograph of shot in foot | 552 |
| 318. X-ray photograph of acute periostitis of radius | 557 |
| 319. X-ray photograph of chronic periostitis of fibula and tibia. Augusta G. | 558 |
| 320. X-ray photograph of diseased hand of Augusta G. | 559 |
| 321. X-ray photograph of osteitis of tibia and fibula | 560 |
| 322. X-ray photograph of osteomyelitis of lower jaw | 561 |
| 323. X-ray photograph of osteomyelitis of tibia. Alex. S. Lateral view | 563 |
| 324. X-ray photograph of osteomyelitis. Alex. S. Antero-posterior view | 565 |
| 325. X-ray photograph of osteomyelitis. Mary P. Before operation | 566 |
| 326. X-ray photograph of osteomyelitis. Mary P. After operation. Antero-posterior view | 567 |
| 327. X-ray photograph of Mary P. Lateral view after operation | 568 |
| 328. X-ray photograph of osteomyelitis of tibia. H. T. S. Antero-posterior view | 569 |
| 329. X-ray photograph of H. T. S. Lateral view | 570 |
| 330. X-ray photograph of osteomyelitis of radius. Delora A. S. Antero-posterior view | 571 |
| 331. X-ray photograph of Delora A. S. Lateral view | 572 |
| 332. X-ray photograph of osteomyelitis. Roy H. Antero-posterior view | 573 |
| 333. X-ray photograph of Roy H. Lateral view | 574 |
| 334. X-ray photograph of rickets | 576 |
| 335. X-ray photograph of coxa vara | 577 |

LIST OF ILLUSTRATIONS

xxx

| | PAGE |
|---|------|
| 336. X-ray photograph of osteosarcoma of humerus | 579 |
| 337. Photograph of knee. Mary K. | 580 |
| 338. X-ray photograph of knee of Mary K. Chondrosarcoma of femur | 581 |
| 339. X-ray photograph of hand of Mary K. Antero-posterior view | 582 |
| 340. X-ray photograph of hand of Mary K. Lateral view | 583 |
| 341. Photograph of hand of A. B. | 584 |
| 342. X-ray photograph of hand of A. B. | 585 |
| 343. X-ray photograph of exostosis | 586 |
| 344. X-ray photograph of exostosis. Antero-posterior view | 588 |
| 345. X-ray photograph of exostosis. Lateral view | 589 |
| 346. X-ray photograph of tuberculosis of ankle | 590 |
| 347. X-ray photograph of tuberculosis of foot | 591 |
| 348. X-ray photograph of tuberculosis of foot | 592 |
| 349. X-ray photograph of tuberculosis of hip | 593 |
| 350. X-ray photograph of diseased bones and joints | 595 |
| 351. X-ray photograph of rheumatoid arthritis of third finger joint | 597 |
| 352. X-ray photograph of loose cartilage in knee joint | 599 |
| 353. X-ray photograph of osteo-arthritis of great toe joint | 600 |
| 354. X-ray photograph of flat foot | 601 |
| 355. Oven for heating tube | 604 |
| 356. Apparatus in position for photographing upper front teeth | 605 |
| 357. Films for photographing teeth | 606 |
| 358. Metal film-holder | 607 |
| 359. X-ray photograph of unerupted cuspid | 608 |
| 360. X-ray photograph of unerupted cuspid | 608 |
| 361. X-ray photograph of superior front teeth | 608 |
| 362. X-ray photograph of superior arch | 608 |
| 363. X-ray photograph of floor and antrum | 609 |
| 364. X-ray photograph of superior teeth | 609 |
| 365. X-ray photograph of unerupted molar | 609 |
| 366. X-ray photograph of superior teeth | 609 |
| 367. X-ray photograph of superior arch | 609 |
| 368. X-ray photograph of superior arch | 609 |
| 369. X-ray photograph of unerupted permanent central incisor | 610 |
| 370. X-ray photograph of unerupted cuspid | 610 |
| 371. X-ray photograph of superior arch | 610 |
| 372. X-ray photograph of superior arch | 610 |
| 373. X-ray photograph of unerupted cuspid | 610 |
| 374. X-ray photograph of unerupted cuspid | 610 |
| 375. X-ray photograph of imbedded left central | 611 |
| 376. X-ray photograph of malplaced inferior third molar | 611 |
| 377. X-ray photograph of curved root of lateral | 611 |
| 378. X-ray photograph of bridge work | 611 |
| 379. X-ray photograph of abscess of upper jaw | 612 |
| 380. X-ray photograph of abscess of lower jaw | 612 |
| 381. X-ray photograph of abscess | 612 |

| | PAGE |
|---|------|
| 382. X-ray photograph of broken instrument in jaw | 612 |
| 383. X-ray photograph of broken instrument in jaw | 612 |
| 384. X-ray photograph of broken lower incisor | 612 |
| 385. X-ray photograph of calculi, gall stones, etc. | 616 |
| 386. X-ray photograph of vesical calculus | 618 |
| 387. X-ray photograph of renal calculi | 619 |
| 388. X-ray photograph of renal calculi, after removal | 620 |
| 389. X-ray photograph of kidney, after removal | 620 |
| 390. Instrument for photographing calculus in bladder | 622 |

APPENDIX

| | |
|---|-----|
| 391. Norton and Lawrence apparatus | 638 |
| 392. Pleurisy with effusion on left side | 643 |
| 393. X-ray apparatus with stretcher and tube holder | 648 |
| 394. Cut showing method of treating patient in a prone position | 649 |
| 395. Glass speculum for use in treating cancer of the tongue | 650 |
| 396. A. B. Psoriasis. After five exposures to the X-rays | 654 |
| 397. Alfred T. Epidermoid cancer of lower lid. Before treatment by the X-rays | 658 |
| 398. Alfred T. After treatment by the X-rays | 658 |
| 399. Thomas H. G. Epidermoid carcinoma of temple. Before treatment by the X-rays | 659 |
| 400. Thomas H. G. After treatment by the X-rays | 659 |
| 401. John M. D. Epithelioma of nose. Before treatment by the X-rays | 659 |
| 402. Mrs. S. Epithelioma of cheek After two exposures to the X-rays | 660 |
| 403. Daniel K. Tuberculosis of foot before treatment by the X-rays | 662 |
| 404. Alex. J. Epidermoid cancer of neck. Before treatment by the X-rays | 664 |
| 405. Dennis R. Carcinoma. Before treatment by the X-rays | 665 |
| 406. Arthur B. Spindle-celled sarcoma; recurrence. Before treatment by the X-rays | 667 |
| 407. Mrs. J. Carcinoma of breast. After three exposures to the X-rays | 671 |
| 408. John McC. Hodgkin's disease. After one exposure of the right cervical glands to the X-rays | 676 |
| 409. John McC. Hodgkin's disease. Cut showing outline of spleen before treatment by the X-rays | 677 |
| 410. Fluorometer | 682 |

THE ROENTGEN RAYS
IN MEDICINE AND SURGERY



THE ROENTGEN RAYS IN MEDICINE AND SURGERY

CHAPTER I

NATURE AND PROPERTIES OF THE X-RAYS

THE discovery by Professor Roentgen, in 1895, that in the space around certain vacuum tubes through which an electric discharge was passing there was present a form of radiation by means of which the bones of the hands could be seen, has provided a new method in diagnosis, both for the physician and the surgeon, and a new therapeutic agent. To this radiation the discoverer gave the name of X-rays.

Origin and Nature of the X-Rays. — The X-rays are generated by the cathode rays, and proceed in all directions from the solid object struck by the latter (see Chapter II, Fig 31). Various theories are entertained as to the nature of the X-rays, but the balance of opinion¹ seems to be in favor of their being some form of transverse ethereal vibration. Stokes² considers that the X-rays, the Becquerel rays, and the light rays form a series, at one end of which stand the X-rays and at the other the light rays: the X-rays being a succession of irregular independent impulses; the Becquerel rays still irregular, but to a less degree than the X-rays; and the light rays a succession of orderly disturbances of the ether.

Properties Common to the X-Rays and to Light. — Both the X-rays and light rays produce shadows, cause fluorescence, and have a chemical action on a photographic film.

Properties in which the X-Rays appear to differ from Light. — Certain properties of light have been claimed for the X-rays, such as polarization, refraction, and diffraction; but Roentgen, in the experiment

¹ "Radiation," by H. H. F. Hyndman.

² "On the Nature of the Roentgen Rays," by G. G. Stokes; printed in "Roentgen Rays," a book edited by G. F. Barker (Harper & Bros., 1899).

described in his first Communication,¹ did not succeed in polarizing them, nor in refracting or regularly reflecting them to any appreciable extent. Several observers have stated that they have obtained diffraction bands, but Hyndman² considers that no satisfactory demonstration of the existence or non-existence of these phenomena has been given. The shadows cast by the X-rays are sharper than those of light, when the source of X-rays is sufficiently narrow, and the absence of diffraction would account rationally for this fact.

Property of the X-Rays of Peculiar Value. — The X-rays have the power of penetrating in different degrees certain substances which are opaque to light, and it is this property which gives them their peculiar value. For instance, flesh is fairly transparent to the X-rays, as are also wood, leather, paper, and most fibrous materials; bone is less permeable by them, while most metals and their compounds absorb them. Thus, if, in a dark room, the hand is placed between the vacuum tube and a fluorescent screen, a shadow of the hand will be seen on the screen, the bones being sharply marked and the flesh showing but faintly; or if a block of soft wood containing a nail take the place of the hand, the nail will show clearly, and the wood scarcely at all. If the photographic plate is used instead of the screen, similar results will follow.

Law of Absorption. — The law of absorption of the X-rays has not been fully investigated. Roentgen, in his first Communication, states that experiments indicate that the transparency of different substances of equal thickness is essentially dependent upon their density. Further experiments show that the transparency of different metals is not equal even when the product of the thickness and density is the same, the transparency increasing far more rapidly than this product decreases. But for present purposes the law of absorption is nearly enough as follows: The percentage of the rays absorbed by equal thicknesses of different substances is not far from proportional to their specific gravities or densities. The percentage absorbed by layers of the same substance, but of different thicknesses, increases with the thickness, but less rapidly than in direct proportion to it, and the effect of thickness increases far more rapidly in the more opaque than in the less opaque materials; for example, more rapidly in bone than in flesh.

Atomic Weight. — A glance at this subject from a chemical standpoint will be helpful. The density of a substance is largely dependent

¹ "Roentgen Rays," edited by G. F. Barker (Harper & Bros., 1899).

² "Radiation," by H. H. F. Hyndman.

upon its atomic weight, and as the human body is what concerns us here, the following table, which gives the atomic weight of those elements which enter chiefly into its structure, is suggestive:—

TABLE I

| ELEMENT. | ATOMIC WEIGHT. | ELEMENT. | ATOMIC WEIGHT. |
|---------------------|----------------|-----------------------------|----------------|
| Hydrogen | 1 | Phosphorus. | 31 |
| Carbon | 12 | Sulphur | 32 |
| Nitrogen | 14 | Chlorine. | 35.5 |
| Oxygen | 16 | Potassium | 39 |
| Fluorine. | 19 | Calcium | 40 |
| Sodium | 23 | Iron (to small amount only) | 56 |
| Magnesium | 24 | | |

It may be noted that although the atomic weight of the known elements ranges from 1 to 239.4 (uranium), yet in normal constituents of the human body we have to deal with elements ranging only from 1 to 56, and in effect only from 1 to 40, if we disregard iron, which enters only in minute quantities.

Absorptive Power of Fat, Muscles, Bones, etc., of the Body.—Water is the chief constituent of the soft tissues of the body, and enters into the composition of all parts of it, and this liquid contains, as its heaviest element, oxygen, with an atomic weight of 16. Fats are lighter than water and more readily traversed by the rays. Muscle, and the various liquids of the body in addition to water, are made up of organic substances consisting largely of compounds of carbon (atomic weight 12), oxygen (16), nitrogen (14), and hydrogen (1). They contain no heavier element, except in minute quantities, than does water, and thus (except in so far as their molecules may be more or less closely grouped) they should have an absorptive power differing little from that of water; and such is the observed fact. On the other hand, bone, although largely made up of water and organic substances similar to the other tissues, is composed also of a considerable proportion of triphosphate of calcium; it thus contains the heavier elements, phosphorus (31) and calcium (40). We should therefore expect that it would show, as it does, a markedly greater absorptive power than the other tissues. Similarly, as uric acid is a compound containing only carbon, hydrogen,

and oxygen, calculi composed of this substance would have a less absorptive power than would calculi consisting of oxalate of calcium, which is made up largely of calcium (atomic weight 40), at least, unless the molecular grouping was very different in the two cases. Observation shows, as will be seen in the chapter on Calculi, that this contrast in the respective absorptive powers of these two kinds of calculi obtains.

Absorptive Power of Air and Gases. — Air and other gases, owing to their small densities as compared with liquids and solids, may be regarded for the present purpose as wholly transparent to the X-rays. The importance of this contrast will be evident, especially when we come to the study of thoracic diseases, and to diseases of the stomach and abdomen. The difference in permeability of air and water is particularly worthy of notice, as air makes up a certain bulk of the body, a large part of the chest is filled with it, and water is one of its most important factors, as already noted.

The picture of the body, then, seen on the screen or photographic plate, is due to the fact that substances of different chemical composition, molecular grouping, and thickness absorb different amounts of the rays. For instance, two muscles lying side by side may be distinguished, probably through difference in bulk, but we should not expect to distinguish in the radiograph the outlines of two tissues of similar composition and thickness, if they are contiguous. If a layer of less dense substance, such as adipose tissue, separates them, however, we get by contrast the outline of the muscle on both sides of the fat. The outlines of the arteries, such as the brachial, radial, and ulnar arteries, show, partly, I think, because their walls are more transparent to the X-rays than the blood they contain and than the adjacent tissues. In radiographs which I took in 1896, of healthy individuals, both young and middle-aged, I distinguished bones, arteries, muscle, skin, tendons, and adipose tissue. When making an examination of the body, therefore, the respective chemical composition of the liquids and solids composing it in health and disease, as well as the thickness of the parts, must be borne in mind; likewise the fact that air and gases offer practically no obstacle to the rays.

The following radiograph, which I took in 1896, in order to gain some conception of the permeability of the various constituents of the body by the X-rays, is pertinent here. The substances radiographed were enclosed in small pasteboard boxes.

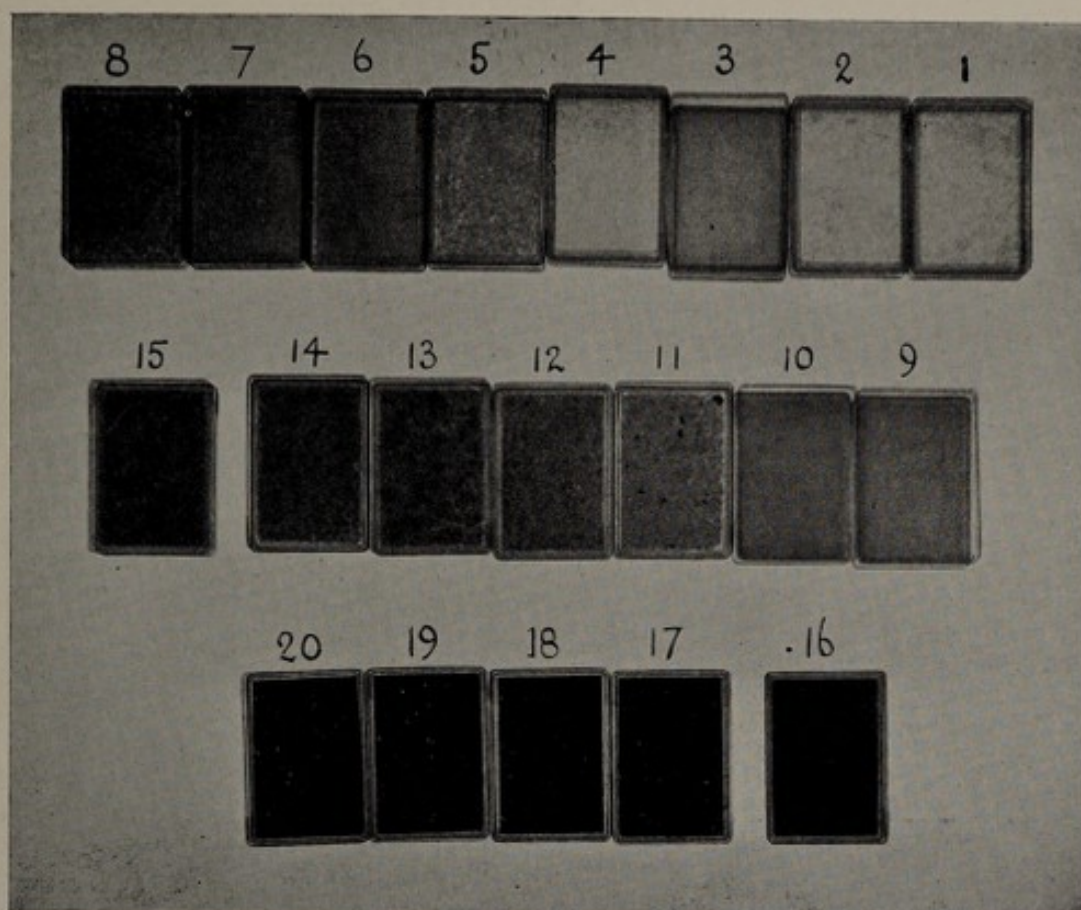


FIG. 1. Radiograph of equal bulks of various substances which represent the constituents of the body in a general way.

| WEIGHT | | WEIGHT | |
|-------------------------------------|--------------|---|---------------|
| 1. Carbonate of magnesium . . . | 1.6 grammes. | 5. Gelatin | 4. grammes. |
| 2. Stearic acid | 3.8 " | 6. Dried egg albumen | 6.4 " |
| 3. Oleic acid | 3.5 " | 7. Carbonate of sodium | 5.9 " |
| 4. Palmitic acid | 4.4 " | 8. Milk sugar | 11.7 " |
| 9. Glycerine | 4 grammes. | 13. Phosphate of calcium | 2.6 grammes. |
| 10. Water | 14 " | 14. Sulphate of sodium | 10.8 " |
| 11. Oxalic acid | 12.2 " | 15. Magnesium ammonium phos- phate | 12.5 " |
| 12. Phosphate of sodium | 10.6 " | 19. Carbonate of calcium | 15.3 grammes. |
| 16. Chloride of sodium | 8.5 grammes. | 20. Fluoride of calcium | 11.7 " |
| 17. Sulphur | 13.9 " | | |
| 18. Chloride of potassium | 10.1 " | | |

This experiment suggests how we may recognize some changes in chemical composition made in the body by pathological processes. The ability to do this without beaker or reagent, or without disturbing the vital processes, is a step in the application of chemistry and physics to practical medicine which hints at what the future may have in store for us.¹

¹ Medical and Surgical Report, Boston City Hospital, January, 1897, "A Study of the Adaptation of the X-Rays to Medical Practice," by Francis H. Williams, M.D.

Experiments continued. — At this same time I also made the following series of experiments to determine whether or not the different fluids found in the body in health and disease could be distinguished by X-ray examinations, using water as a standard of comparison:—

A vulcanite cup 8 centimetres deep was filled with water, and beside it was placed a similar cup filled with pleuritic fluid. The fluorescent screen was put over these two cups, and the shadows cast by them were compared. So far as I could tell, there was no appreciable difference between the two. I then poured out about one-fifth of the pleuritic fluid, and compared the remaining quantity with a cup filled with water, and it could be easily seen that the cup containing the pleuritic fluid cast much less shadow on the fluorescent screen than the cup filled with water. While I watched the shadows of both fluids, the cup containing the pleuritic fluid was gradually filled to the brim, and when it was so filled, the shadow of the two cups was practically the same. I then chose other fluids, and compared them with the same volume of water, and found there was no marked difference between the fluid from hydrocele, ascitic fluid, or pus, as compared with the water. See also chapter on Pleurisy, page 205.

Opacity of Blood to X-Rays compared with that of Water. — It has been suggested that blood may be more opaque to the rays than other portions of the body on account of the iron it contains; but as the amount of iron is only about one two-thousandth of the weight of the blood, this would not make any great difference in the shadow cast, as compared with that cast by an equal volume of water, for the atomic weight of iron is not very great (56). Moreover, the specific gravity of blood is 1.055, which is only slightly greater than that of water; so there is no reason to suppose that blood would cast a much greater shadow than the same volume of water.

Test. — To test this point I took two vulcanite cups and filled one with water and the other with blood to the depth of 8 centimetres, and exposed them at the same time on the same photographic plate. In order to eliminate any source of error that might arise from a possible difference in the thickness of the cups, I repeated the experiment, putting blood into the cup that had previously held the water, and water into the cup that had contained the blood. Both experiments gave similar results. The shadow cast by the cup containing even so great a thickness of blood as 8 centimetres was but little darker than that cast by the

cup holding an equal thickness of water, and the outline of the bottom of the first cup was less sharply defined.

Enough has been said to show that the chemical composition of substances may furnish a most important clew in regard to their respective power of absorbing the X-rays, and the question need not be further dwelt upon here. The details of the subject will have a greater interest

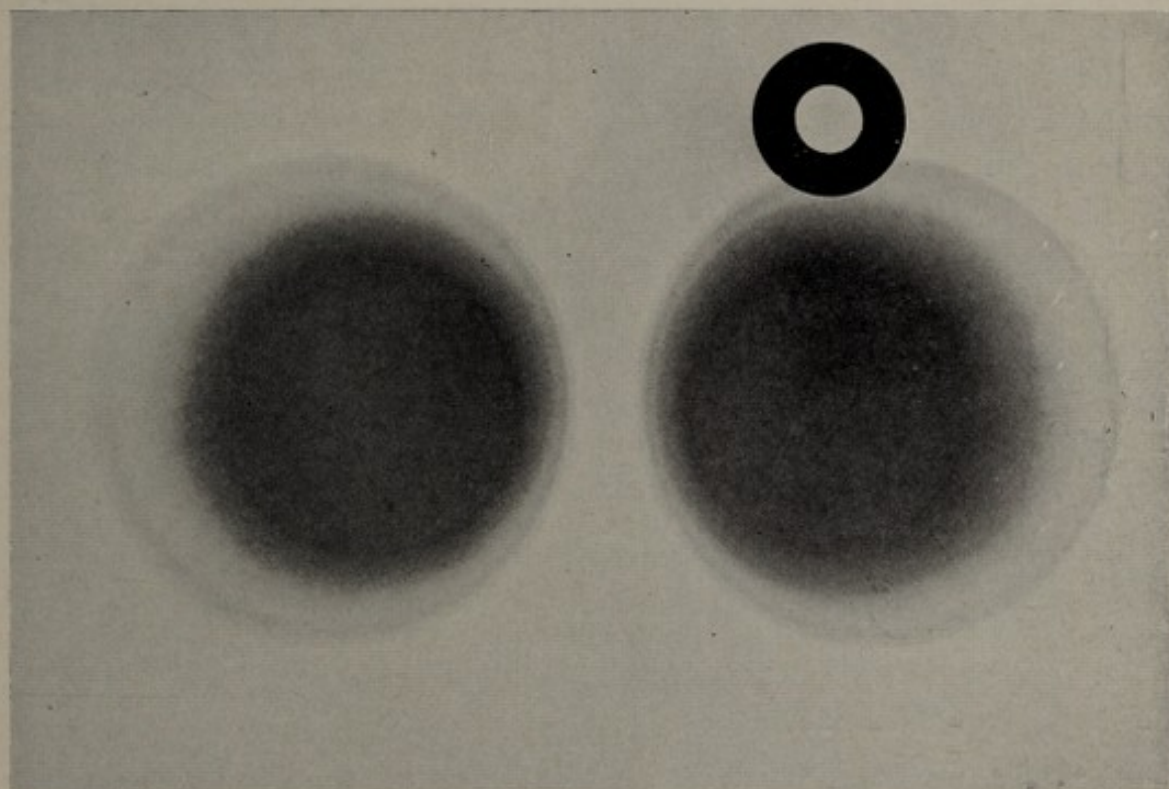


FIG. 2. Cut made from a radiograph of two similar vulcanite cups. The one containing water, the other blood, in equal amounts; the cup holding the blood has a metal ring beside it.

in the future, as now the profession is naturally more interested in the well-marked distinctions which are observed, rather than the finer ones that are more difficult to obtain. But it is desirable to call attention to the surprisingly slight differences in chemical composition that may be differentiated by radiographs, and to point out to all who are making a study of the application of the X-rays to medicine that the question of chemical composition is an important one to bear in mind; the X-rays give us something more than evidence of physical change.

CHAPTER II

X-RAY EQUIPMENT

THE chief parts of an X-ray outfit are a static machine, or an induction coil; the vacuum tube with its supporting apparatus; the fluorescent screen or fluoroscope; and the photographic plate.

The X-rays are produced in the vacuum tube, and this tube may be excited by

1. *Static Machine*; the two types of which are

- a. Influence Machine.

Forms of : Holtz,
Toepler-Holtz,
Voss,
Wimshurst.

- b. Planté Rheostatic.

Form of : Thomson Dynamo Static.

2. *Induction Coil*; the two types of which are

- a. Ordinary Page, or Ruhmkorff, coil.

- b. Tesla, or high frequency coil.

Form of : Thomson coil.

1. **Static Machine.** — The static machine may be driven by hand, or by any form of motor such as an electric or water motor, or a gas engine; and may be self-exciting or be excited by a small Toepler-Holtz or Wimshurst machine.

2. **Induction Coil.** — The electric current for the induction coil may be obtained from

- a. Primary battery (low voltage).

- b. Storage battery (low voltage):

1. Charged by gravity cells;

2. Charged from street main.

- c. A dynamo which generates a continuous or alternating current of either high or low voltage.

- d. The street main (high voltage); current continuous or alternating.

STATIC MACHINE

In discussing this type of machine I will describe the one which I had made and have used in my work at the Boston City Hospital. In designing it I studied simplicity and stability.




FIG. 3. Large static machine with four revolving plates 183 centimetres (6 feet) in diameter, and four fixed plates 193 centimetres (6 feet 4 inches) in diameter. Front of case has been removed.

My machine is of the Holtz form and has four revolving plate-glass plates 183 centimetres (6 feet) in diameter, and four fixed plate-glass plates 193 centimetres (6 feet 4 inches) in diameter. These eight plates weigh about 1000 pounds. The plates of a static machine may be made of glass, hard rubber, or mica, but glass is the best material.

The machine, for the purpose of insulation, rests on eight or ten glass blocks 15×20 centimetres and 3 centimetres or more thick, so placed as to bear its weight most advantageously.

It is run by a one horse-power electric motor.

When a static machine is properly constructed it never reverses while in action.

The static machine is given its initial charge by an auxiliary machine of the Wimshurst type with plates 40.5 centimetres (16 inches) in diameter. When it is desired to start the large machine, one pole of the exciter is connected with one terminal of the large machine, and the other pole with an armature brush on the opposite side of the large machine.

In order to bring the terminals conveniently near each other the terminal on the right (Fig. 3) is extended by a brass rod to a brass ball (hung on a wooden rod) near the middle of the machine. To shut off the light in the tube it is only necessary to short-circuit the machine by connecting the terminals. This is readily done by lowering a brass rod so that it rests across them. This rod is shown in Fig. 3 and also at the upper part of Fig. 8, and is controlled by a cord which hangs near the patient.

All the brass and iron work of the machine has had two or three coats of varnish to protect it from corrosion.

The machine is very durable, as it is run at slow speed, the bearing surfaces of the shaft are amply large, and there is no vibration.

It is provided with condensers (see Fig. 3), the object of which is to regulate the size of the electric discharges, but I have not found it necessary to use them.

The tubes excited by it are not used up so quickly as by a coil.

The working drawings show the design of the machine sufficiently well, but it may be desirable to direct attention to one or two points.

Method of holding Plates. — As the revolving plates are heavy, it is necessary to have them firmly supported. Each pair of plates is held on the shaft between two iron collars about 30 centimetres in diameter, one collar of each pair being turned true upon the shaft. On

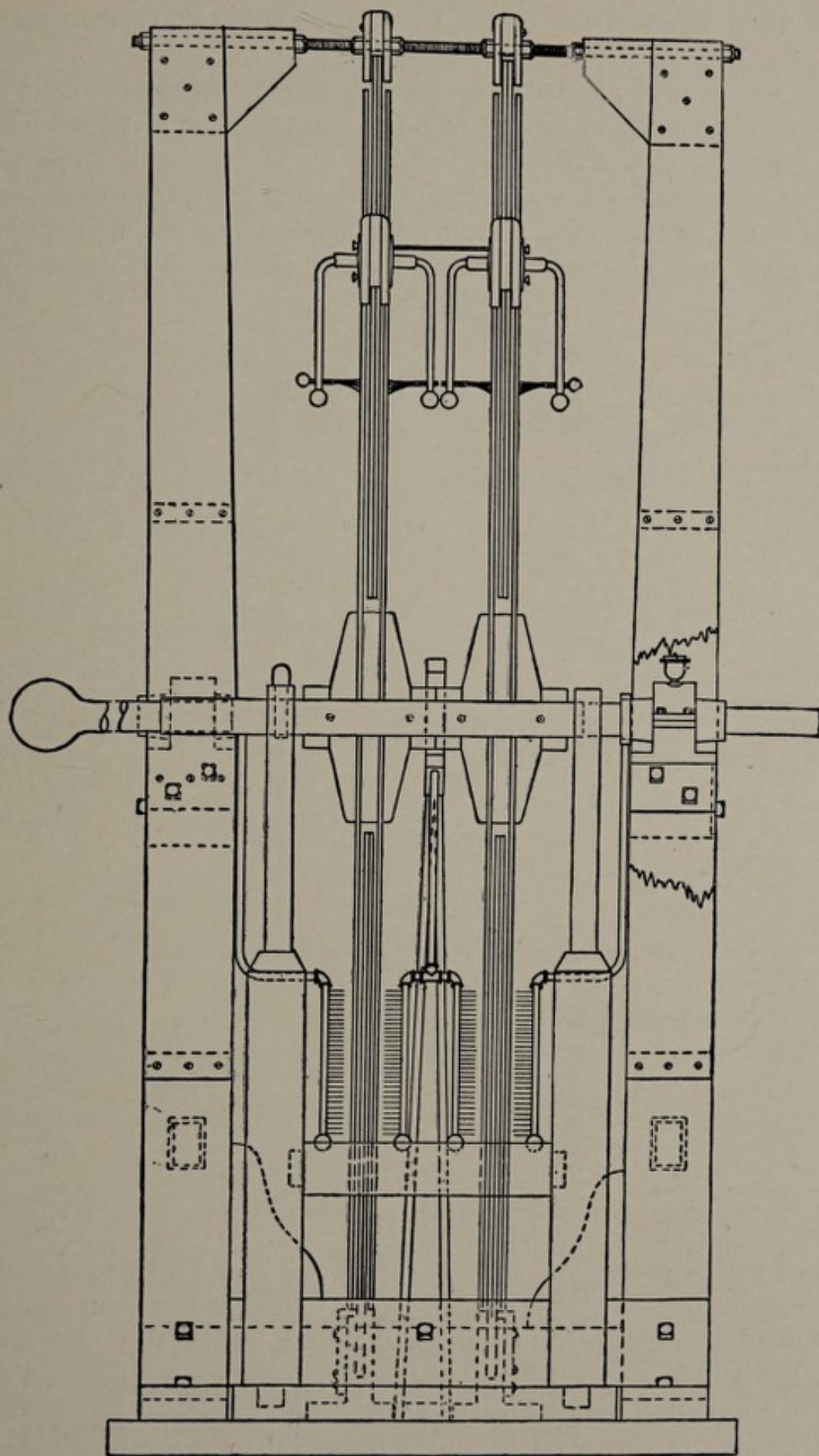


FIG. 4. End view of static machine. Cut also shows some details of shaft and attachment of plates.

when the plates are put on they must be turned on the shaft until the point is found where the two sides balance each other. If this method is pursued before the plates are secured tightly in place, they will have no tendency to come to rest at one point rather than another, and the best conditions for speed and steadiness will be procured.

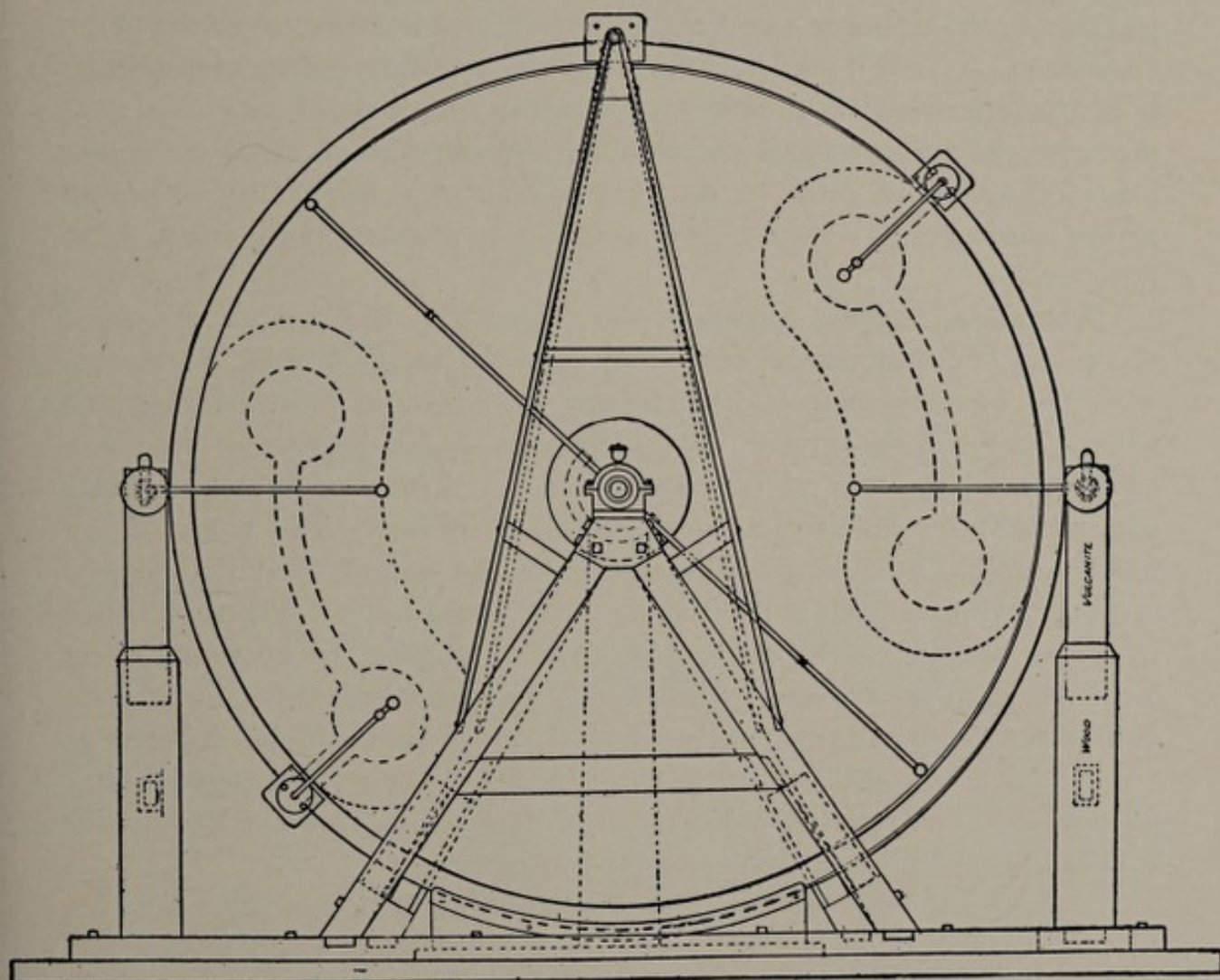


FIG. 6. Side view of static machine. Revolving plate 183 centimetres (6 feet) in diameter, stationary plate 193 centimetres (6 feet 4 inches) in diameter.

The stationary plates are supported at the bottom on pieces of wood, which should rest on glass to insure good insulation. The grain of the wood should run at right angles to the plates and not parallel with them, because if the piece of wood should shrink it would become narrower and thus change the position of the plates after they had been adjusted. The plates are held at the top by means of clamps, threaded on a transverse rod, both of which are clearly shown in Fig. 4.

Speed Controller. — The speed of the plates may be varied from 50 to 250 revolutions per minute by means of the speed controller, which determines the speed of the motor, and thus a greater or less amount of energy may be obtained.

Leakage of Electricity. — During damp weather the leakage of the electricity from the static machine is greater, and a smaller amount is generated, than in dry weather; therefore, the machine must be large enough to give out a sufficient amount of electricity even when the air is moist, otherwise the practitioner is at the mercy of atmospheric conditions. A simple way of ascertaining the amount of electricity available for use is to look at the brush discharge above the collecting combs; when this is wide the amount is greater than, when it is narrow.

Precautions against Moisture. — 1. *Case.* If the plates are kept warm and dry they can be depended upon to do good work, no matter what the weather may be. Therefore, the machine must be provided with a case. The case of my machine is 244 centimetres long, 228 centimetres high, and 90 centimetres wide. A case should be of this size, at least, for plates of the dimensions described. The shaft of my machine might well be 5 centimetres or more longer than that shown in the drawing, so that if desired the case could be put a little farther from the machine, as by this means the latter could be surrounded by a thicker layer of air, and therefore the leakage of electricity would be diminished. The case is made of pine doors, that can be ordered at a factory, of any size desired. These doors make an inexpensive and good case. The interior and exterior of the case is varnished to give it a surface that will not absorb or give out moisture.

2. *Removal of Dampness from Plates.* — Some method, also, must be adopted for removing the dampness from the plates. There are various ways of accomplishing this object. Chloride of calcium, for instance, and other forms of drying material may be used, placed in a dish inside the case, but I have found them insufficient in themselves to take the moisture from the plates; moreover, if chloride of calcium is employed, there is the risk that fine particles of it will fall upon the plates and thus coat them with a covering that absorbs moisture. It is evident, therefore, that this method of getting rid of the moisture is not altogether satisfactory. The most convenient and efficient method is the use of some form of heater, such as an electric heater. The heaters, one placed at either end of the case, warm the air in the case,

the plates themselves then become warm, and the moisture is driven from their surface.

3. *Cleaning Plates.* — The plates should be cleaned at regular intervals, in order to lessen the leakage. Whiting and alcohol may be used for this purpose in the same way as for a plate-glass window. I have found that glass plates that have been covered with some preparation, such as shellac, are not so satisfactory as those without coating, as the former cannot be kept perfectly clean.

4. *Place of Machine.* — The machine should be in a dry, warm room; mine is in a basement room, the floor of which is 90 centimetres below

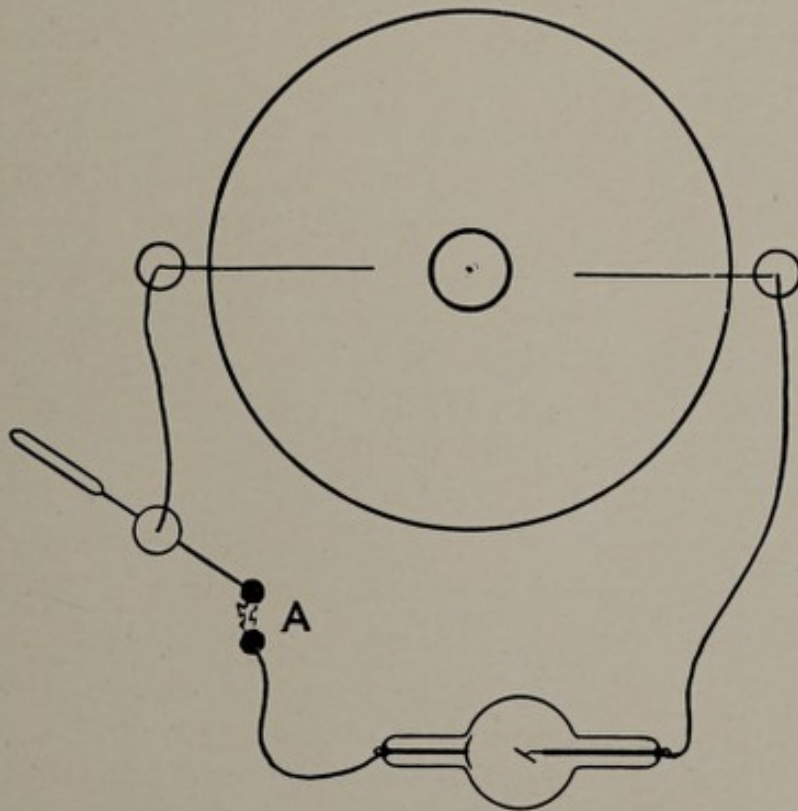


FIG. 7. Diagram of static machine and tube. Adjustable spark-gap at A.

the surface of the ground and less than that distance above high-water mark. Sea-going vessels come to wharves within 150 metres of the room. But although the situation is as unfavorable as possible, the machine is in daily use throughout the year. Since these lines were written the room has been divided crosswise into two rooms by a board partition. In the one in which the static machine and motor stand a radiator has been placed, which keeps the machine warm and dry and yet does not overheat the other room, in which the patients are examined and which contains the stretcher, tube, and other appliances.

In the partition there are two plates of glass, near the centre of each of which is a small hole through which the wires pass from the static machine to the X-ray tube.

Adjustable Spark-gap. — The spark-gap in series with the tube is the air space through which the current must leap before reaching the tube. (See *A*, Fig. 7.) In all forms of X-ray apparatus some means is necessary for varying the amount of light, and this variation may be




FIG. 8. Adjustable multiple spark-gap.

accomplished in part by means of a spark-gap. The spark-gap is also essential because it enables the practitioner to use tubes of lower resistance than would otherwise be possible, and, as will be seen later, tubes of low resistance have certain advantages over those with a high resistance. (See pages 46, 48.) If the spark-gap is several centimetres in length, the light may not be quite steady and there is noise.

Adjustable Multiple Spark-gap.—To permit the use of a considerable length of spark-gap and at the same time insure, for purposes of examination with the fluorescent screen, the requisite of a perfectly steady light I some years since devised what I have called an adjustable multiple spark-gap (see Fig. 8), which consists of a series of small brass balls $1\frac{1}{4}$ centimetres in diameter, fastened about 3 millimetres apart along the edge of a strip of vulcanite 1 centimetre wide. This strip, with its balls, is free to move up and down through a vertical brass tube. When the electricity is turned on, a discharge is seen to go from ball to ball, and a larger or smaller number of these small spark-gaps can be brought into the circuit, according to the amount of light desired. In 1898 the machine was provided with two of these adjustable multiple spark-gaps, one at each terminal, and they are controlled by the cords with counter-weights which are seen hanging at the left of the cut (Fig. 59, Chapter III), nearly over the patient's head. When this spark-gap is used the light is steady and there is little noise; when the tube does not require a spark-gap the heart sounds can be heard while its pulsations are watched on the screen.

Capacity of Machine.—The capacity of this machine is indicated by the larger part of the work described in the following pages; the lesser portion has been done with smaller static machines, or a Ritchie coil, or an A. W. L. Universal coil.

Capacity of a still Larger Machine.—Dr. William Rollins and I, while using his static machine, so far as I am aware the largest ever made, which has plates of the same size as mine, but double the number, could plainly see the heart of a man at a distance of about 9 metres (30 feet). A partition prevented us from observing it at a further distance. Dr. Rollins's machine and mine were built at about the same time, but his was completed earlier and I profited greatly by his experience.

Small Machines.—For the extremities of the human body small and inexpensive static machines would answer in dry weather, but when the practitioner desires to make examinations of the trunk, a small machine is unsuitable. A machine of several plates of about 90 centimetres in diameter is necessary for medical work, but larger machines are more satisfactory.

This generator (Fig. 9) was lent me by Dr. Rollins, and was used for some time in my work at the Boston City Hospital before I had a larger machine made. The plates are one metre in diameter. In dry

weather this generator will produce sufficient light with a good tube for work with the fluorescent screen. By means of a simple reversing switch, devised by Dr. Rollins, shown on the top of the case, the current can be sent in either direction through the tube. As it is impossible to tell




FIG. 9. Medium-sized static machine, with four revolving plates one metre in diameter. (Rollins.)

which terminal of a static machine will be positive before the machine is started, this is a convenient arrangement.

Thomson's (Elihu) Dynamo Static Machine. — This machine is not so much influenced by moisture as the Holtz machine, and it occupies a smaller space.

INDUCTION COILS

The usual form of induction coil consists of a primary coil, through which the exciting current of electricity is passed, and a secondary coil, — these two coils being separated by an insulating tube of hard rubber;

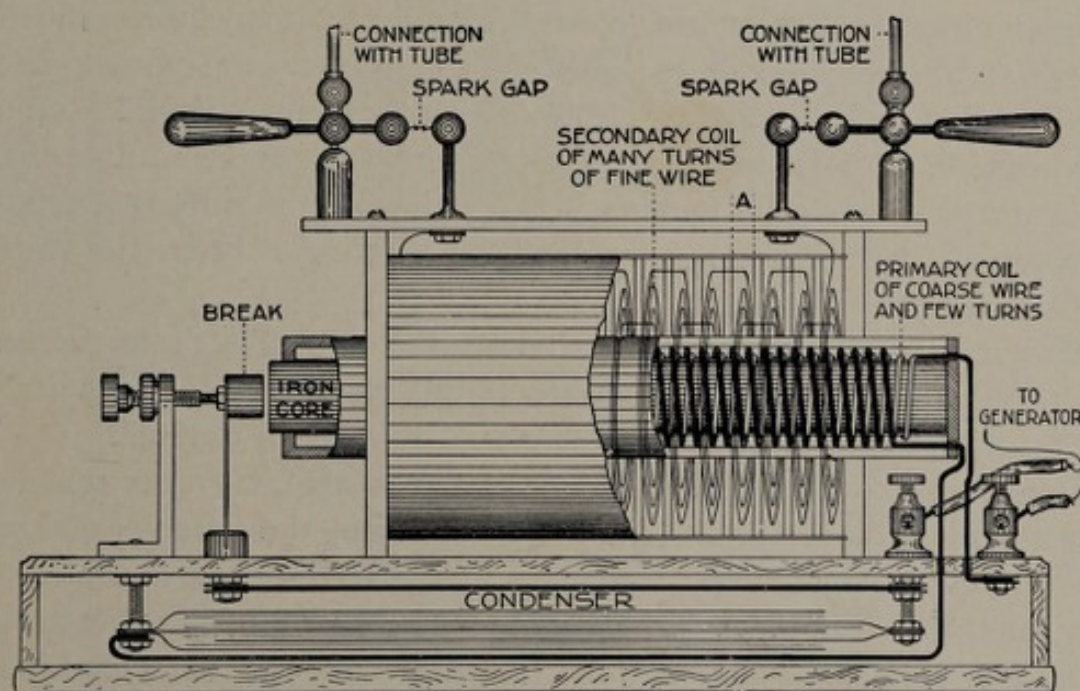


FIG. 10. Diagram showing the construction of an induction coil. (Rollins.)

the primary coil is made up of a comparatively few turns of coarse wire that is usually wound around a soft iron core; the secondary of many turns of fine wire that is generally wound over the tube covering the primary coil, but is sometimes so arranged as to be near it, not over it. Ritchie invented the now generally adopted method of winding the secondary in sections. In the circuit of the primary is a break which interrupts the current; every time the current is made or broken in the primary, a current of higher voltage is induced in the secondary. It is this latter current which is sent through the vacuum tube.

Condenser. — A condenser, that is made up of many sheets of tin foil insulated from each other by paper coated with shellac, is placed in the primary circuit to make the interruptions of the current more

sudden, and thereby the spark-length of the coil is increased. A condenser is not required when an electrolytic interrupter is used.

Size of Coil. — The size of the coil is estimated by its maximum spark-length. A coil giving a spark-length of 25 to 30 centimetres is usually considered sufficient, but coils with a higher potential are better because tubes with much lower resistance can be used with them than with those of lower potential.

Interrupter. — Many devices for breaking or interrupting the current through the primary have been employed. Most of them have drawbacks which in practice form the chief obstacle to the use of the coil if high voltage currents are used. There are many different interrupters, and the kind best adapted for use is dependent on the voltage; detailed description of most of them may well be omitted. In general it may be said that interrupters that make and break the circuit through metallic contact wear somewhat rapidly, especially if the voltage is as high as 110 volts. This wearing is often the cause of troublesome breakdowns.

Mercury Interrupter. — To overcome this difficulty, interrupters in which the circuit is made and broken by means of a jet of mercury, and which are known as mercury interrupters, have been devised.

Electrolytic Interrupters. — With the powerful currents which can be used with Rollins's tubes (see pages 34 to 41), the hammer and rotary interrupters in their various forms are neither steady nor durable. The most durable mechanism for breaking such currents is some form of the electrolytic break invented by Spottiswoode and described in Vol. XXV, pp. 547-550 of the Proceedings of the Royal Society for 1876-7. With electrolytic interrupters the usual expensive and troublesome condenser is not required, and two small Leyden jars suffice for tuning.

The construction of the electrolytic interrupter of the form suggested by Wehnelt is as follows: Through a glass tube passes a small platinum wire, which projects from the sealed end of the tube only enough to expose 1 or 2 square millimetres of platinum surface; it is immersed in a mixture of sulphuric acid and water having a specific gravity of 1.2. Into this liquid there also dips a lead plate. The current is sent through the solution by means of these electrodes. The platinum terminal should be connected to the positive wire of the supply circuit, and the lead plate to the negative wire. A convenient method of ascertaining which is the positive pole is to place a strip of moistened

litmus paper upon a dry board or other insulating material, and to touch one end of the strip with a wire from one terminal of the circuit, and the other end with a wire from the other terminal. The litmus paper will be colored red about the positive terminal. Caution is necessary to avoid touching the two sides of the circuit at the same time with the

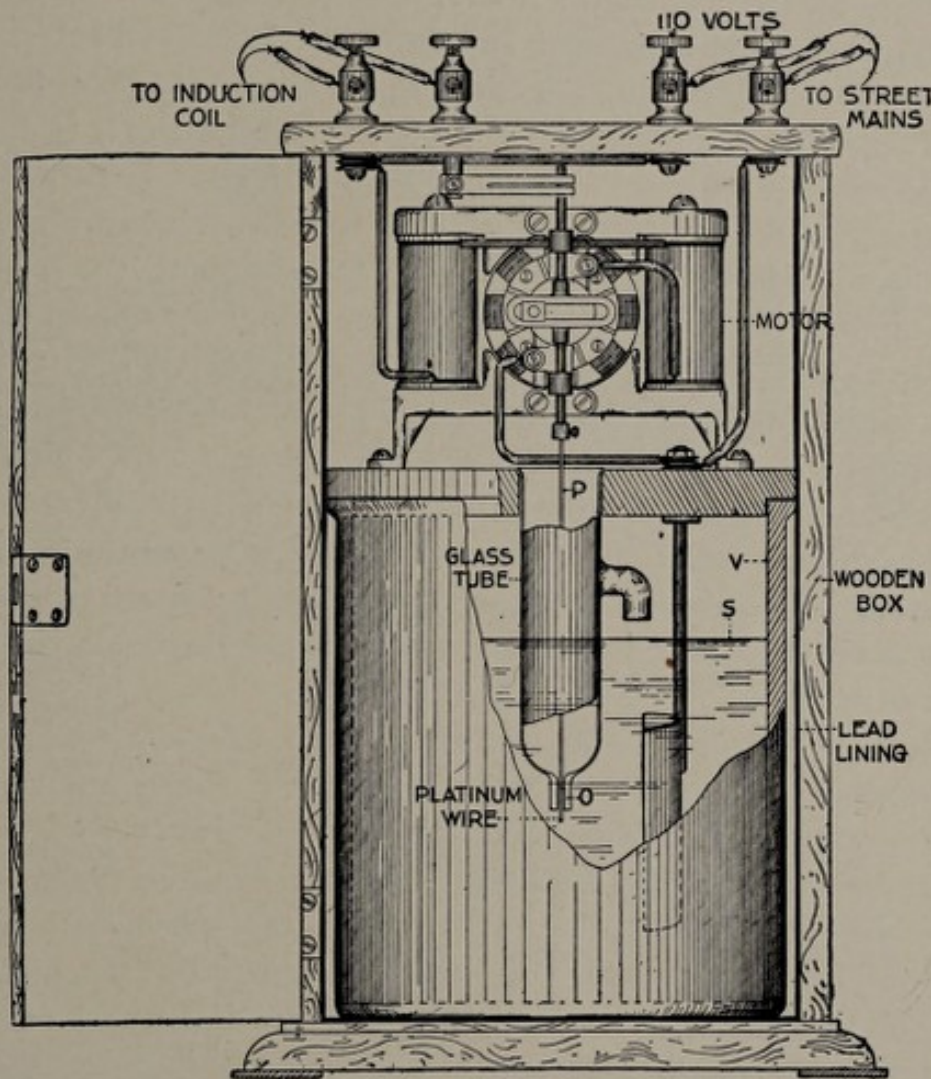


FIG. 11. Heinze interrupter. *O*, end of platinum wire; *V*, earthenware jar; *S*, sulphuric acid solution. (Rollins.)

A platinum rod is moved up and down by a small motor through the opening of a glass tube immersed in dilute sulphuric acid, the rod being the positive terminal through which the current enters. The negative terminal is a lead plate. This is the steadiest form of electrolytic break yet introduced.

hands, as this contact might result in disagreeable shocks or burns; direct connection, technically called "short-circuiting," between the two terminals of the supply should also be avoided.

This interrupter gives a very rapid make and break of the circuit, produces a powerful secondary discharge, and may be placed directly in

the 110-volt circuit, but cannot be used with a current of much below 50 volts. Its disadvantage is that it is liable to stop altogether after a short time. This serious difficulty I have overcome by putting a commutator in the circuit with the interrupter. By this means the severe strain on the coil and the tube, the production of which is the disadvantage of all electrolytic interrupters, is lessened. To this combination I have given the name of Interrupted Electrolytic Interrupter.¹

By the use of the principle of interrupting the electrolytic interrupter, Heinze has constructed an electrolytic interrupter (see Fig. 11), a cut of which is here given; recently he has devised a better form.

Source of Current. — A supply from the street mains, when available, forms the most convenient source for obtaining the primary current. The house wires from the street may be connected through the interrupter to the primary terminals.

Apparatus for reducing Voltage. — The street supply is usually 110 volts. This high voltage rapidly destroys some forms of interrupter, and therefore when such forms must be used it is advantageous to reduce the voltage either by means of a motor generator (which is an electric motor and dynamo combined); or a small storage battery. The former is preferable, but by either means the voltage can be reduced as low as is desired.

Rheostat. — This instrument is used, when necessary, to reduce the amperage when employing a street current. There are three usual forms: the water, the carbon, and the wire rheostat.

Adjustment for varying the Light. — When the fluorescent screen is used it is essential to be able to vary the amount of light while the examination is being made, and this end may be accomplished by adjustments which enable the operator to vary the speed of the interrupter, the amperage, the amount of the condenser, and the length of the spark-gap. All coils for use with the fluorescent screen should therefore have some or all of these adjustments.

A. Page or Ruhmkorff Type of Coil

The following cuts will serve to illustrate ways in which a coil of this type may be excited. The coil shown in the figures is a Ritchie coil, and with a current of low voltage (8–10 volts) the usual hammer

¹ *Electrical Review*, July 26, 1899.

break or vibrator is used; with a current of high voltage (110-220 volts), some more durable form of interrupter than a vibrator should be employed, — such an one, for instance, as the electrolytic interrupter shown on page 21.




FIG. 12. Shows primary battery, Ritchie coil with hammer interrupter, and tube. The place for one of the two multiple spark-gaps is indicated in this and the following cuts by a card on which are the letters *SG*.




FIG. 13. Shows storage battery, Ritchie coil with hammer interrupter, and tube.




FIG. 14. Shows motor-generator, Ritchie coil with hammer interrupter, and tube. A motor-generator is a small dynamo combined with an electric motor. Instead of a motor-generator a small dynamo may be used that can be run by a water motor or a gasoline engine.




FIG. 15. Shows Ritchie coil charged from street main, Wehnelt electrolytic interrupter, and tube.

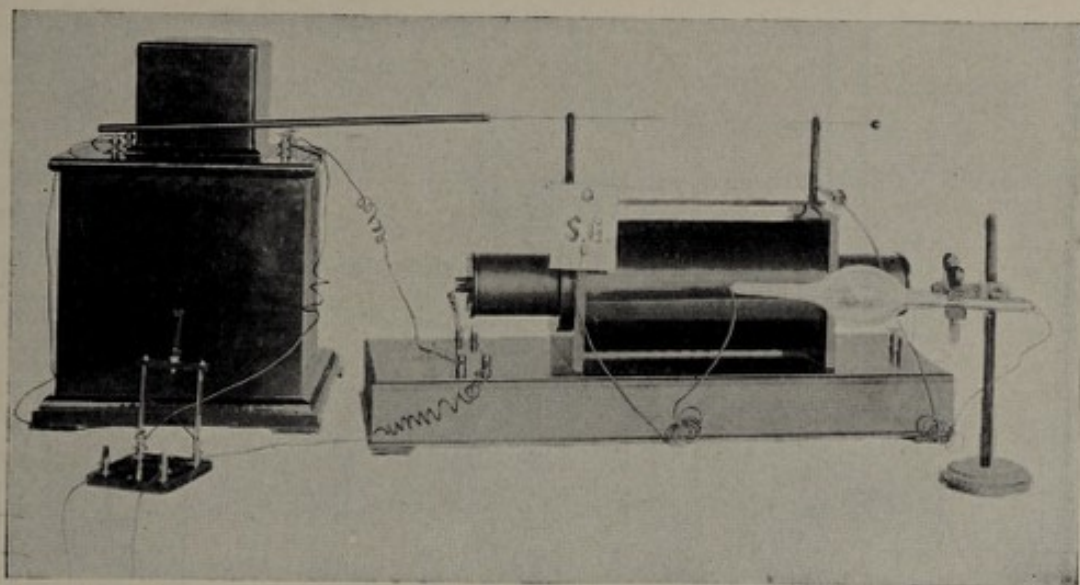


FIG. 16. Heinze electrolytic interrupter, Ritchie coil, and tube.

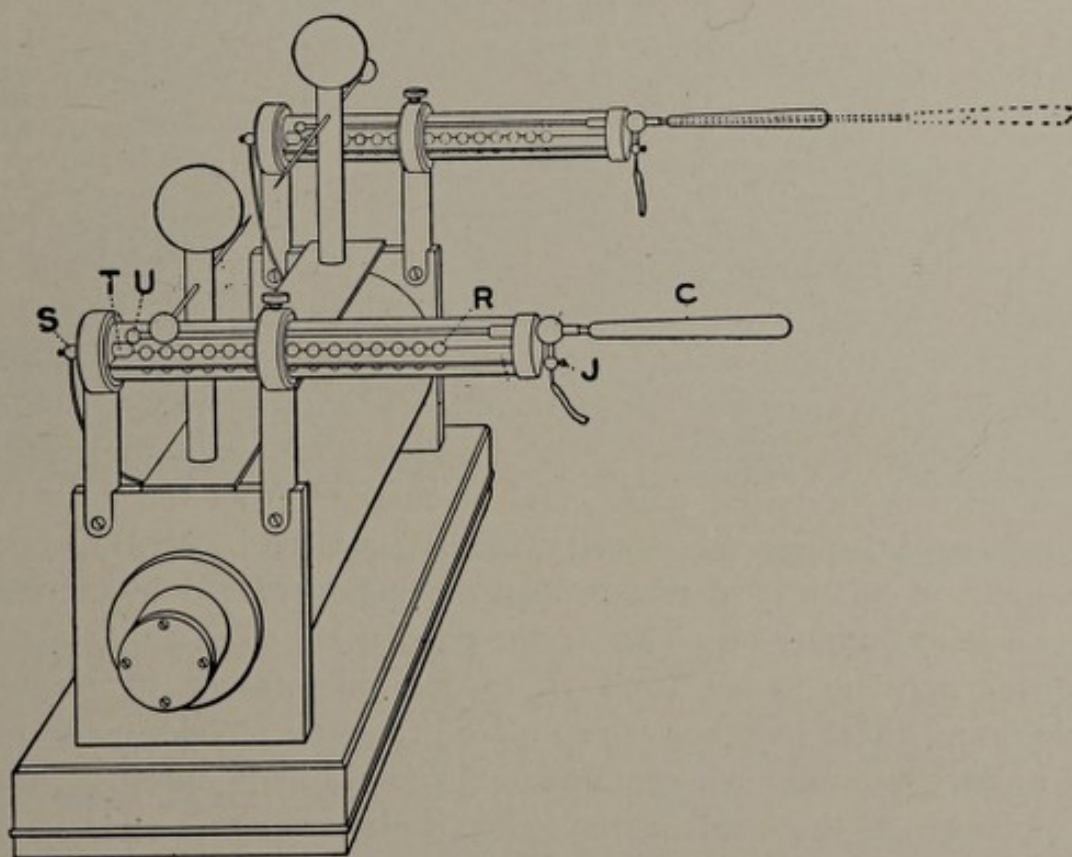


FIG. 17. Adjustable multiple spark-gap on Ritchie coil, as arranged by Rollins. *S* and *T*, terminals of coil; *U*, ball on end of spark-gap rod *C*; *R*, row of brass balls on strip of mica; *J*, wire to vacuum tube. (Rollins.)

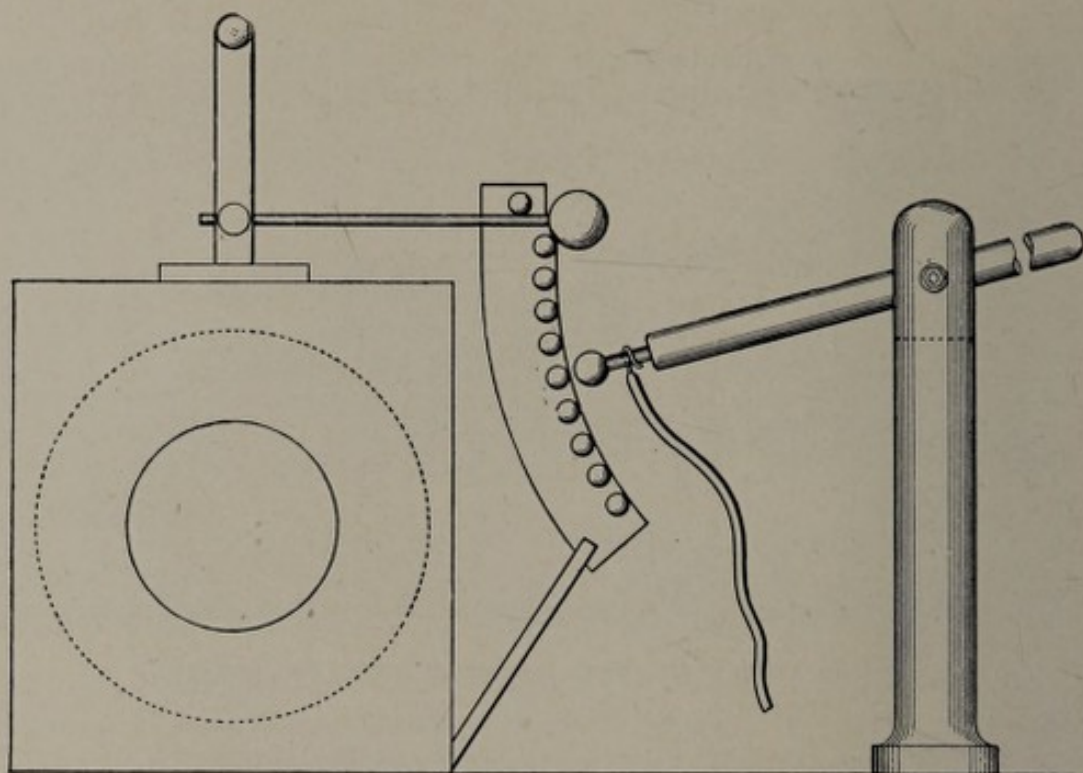


FIG. 18. Adjustable multiple spark-gap for coil.

This cut shows an end view of the coil, with a simple form of adjustable multiple spark-gap, in which the brass balls are held on the side or edge of a strip of insulating material. There are two of these on the coil, one at each end of the secondary. The letters *SG* in the preceding cuts indicate the position of one of the spark-gaps. Dr. Rollins has previously used another form of adjustable multiple spark-gap with brass balls supported on mica on his coil (see Figs. 21 and 22); later he used it on a Ritchie coil.

Norton and Lawrence Apparatus.¹—This apparatus was devised by Messrs. Norton and Lawrence of the Massachusetts Institute of Technology; it has a short primary of thick wire, and was designed to be supplied directly from the street main. The condenser consists of sheets of tinfoil placed between larger sheets of insulating material, such as mica or prepared paper, and is charged from the interrupter and discharged through the primary (method devised by Mr. Lawrence), the amount or quantity of the discharge being increased by increasing the surface or number of plates of the condenser. The amount of the condenser may be varied from 10 to 200 microfarads by means of switches, and these switches are so placed that the physician can reach them while continuing his examination, and throw in more or less of the condenser, as the needs of the moment may require.

In order to adapt to medical practice the above-mentioned apparatus,

¹ A description of this apparatus may be found in the following journals: *Science*, February 26 and March 26, 1897; *Nature*, March 18, 1897; *Electrical Engineer*, March 24, 1897.

Messrs. Norton and Lawrence, at my suggestion, subdivided the condenser, made the speed of the interrupter variable, and put in an adjustable spark-gap (see page 26). Without these adjustments the apparatus would not be suitable for examinations of the chest. I also found it desirable to use a slate wheel, and to employ Van Depoele's principle of carbon brushes instead of metallic contacts on the interrupter, and experiment showed me that two or more brushes were better than a single one. I have run this commutator on a 220-volt circuit

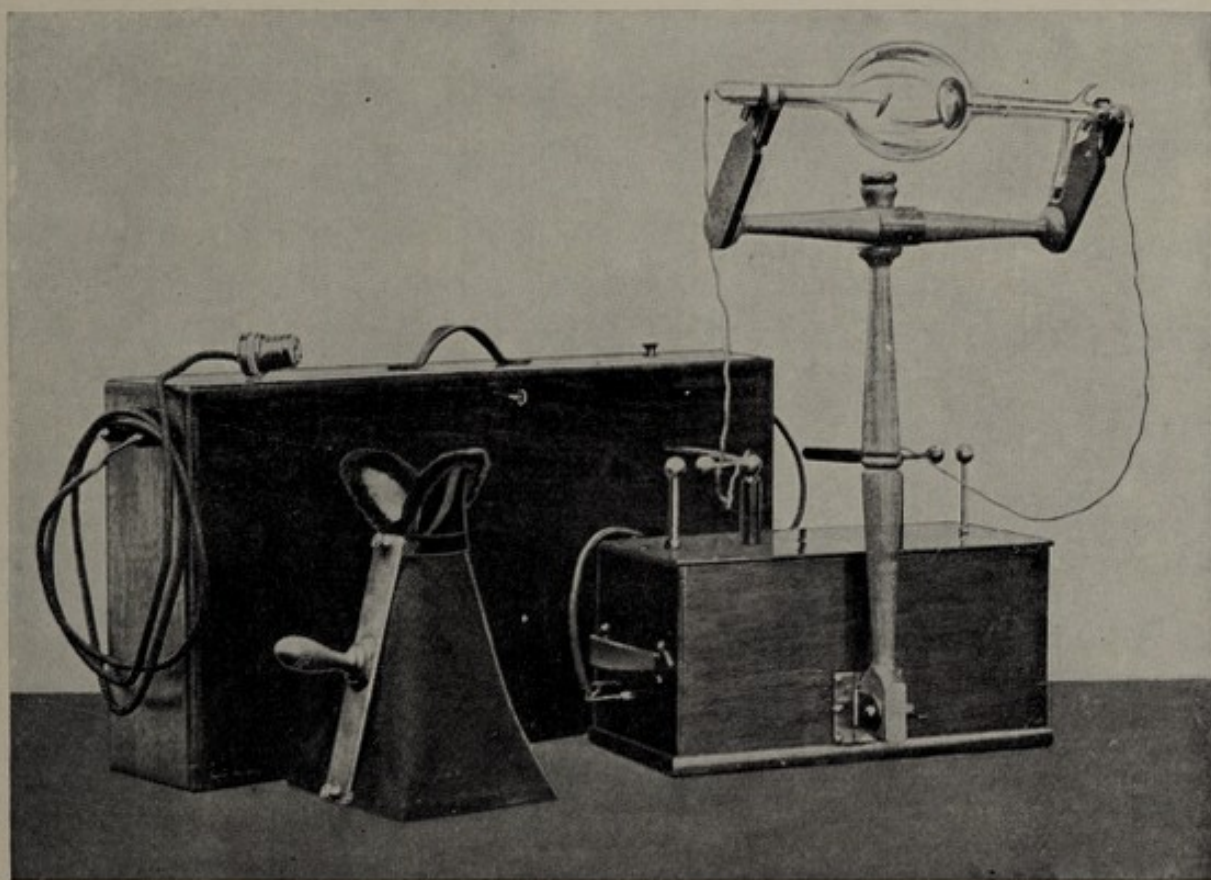


FIG. 19. Cut of portable apparatus for use on 110-volt circuit. The smaller box contains the coil; the larger, the interrupted electrolytic interrupter, two vacuum tubes, and the tube-holder. The tube-holder is shown fastened to the smaller box.

continuously for four hours; at least half of this time with a flow of $2\frac{1}{2}$ to 3 amperes. The tube used was a self-regulating one devised by Dr. Rollins, and it gave a steady light during the whole of this time.

Portable Apparatus.—This whole apparatus (Fig. 19) weighs 40 pounds and can be easily carried by a man, one box in each hand. In places where no 110-volt circuit is available, I have used an electric cab or carriage by running insulated wires from the storage battery in the cab to the patient's room, and connecting them with an X-ray apparatus.

B. High Frequency Coils

In the high frequency coil the potential is increased by sending through its primary the current from the secondary of an ordinary induction coil. The diagram, Fig. 20, illustrates the construction of a high frequency coil. It has a primary of coarse wire, through which is passed the current from the secondary of the first coil, a spark-gap and condenser

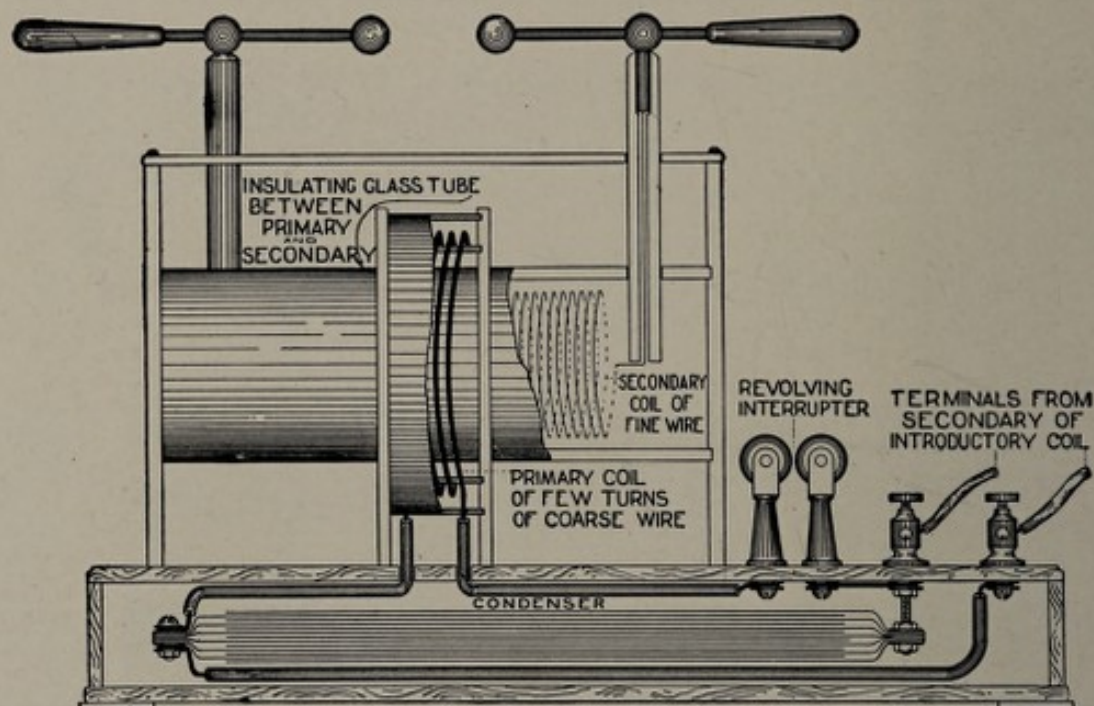


FIG. 20. Diagram of high frequency coil. (Rollins.)

being inserted; and a secondary that has but a few turns of fine wire. Instead of the construction shown in the figure, the primary and secondary may be wound flat and made to face each other. In most high frequency coils the insulation is so difficult that all the parts are immersed in oil.

A. W. L. Universal Coil

This is a form of coil for X-ray and electrotherapeutic work that was designed by Dr. Rollins and named the A. W. L. Universal Coil, and was first used in December, 1900. Through Dr. Rollins' kindness I had the use of the first one at the Boston City Hospital. It is run on a 110-volt circuit, and when an electric main is not available, as in the country, the current may be obtained from a small dynamo run by a small gasoline engine. This coil differs from others in several ways.

First: The thick, hard rubber tube used in all coils to insulate the primary from the secondary is not employed in this one, for Rollins found by experiment that mica was the best material, and that mica tubes, two centimetres thick, made by the Micanite Company, of Schenectady, New York, will allow a strong current to be used to excite a tube, without risk of injury to the coil.

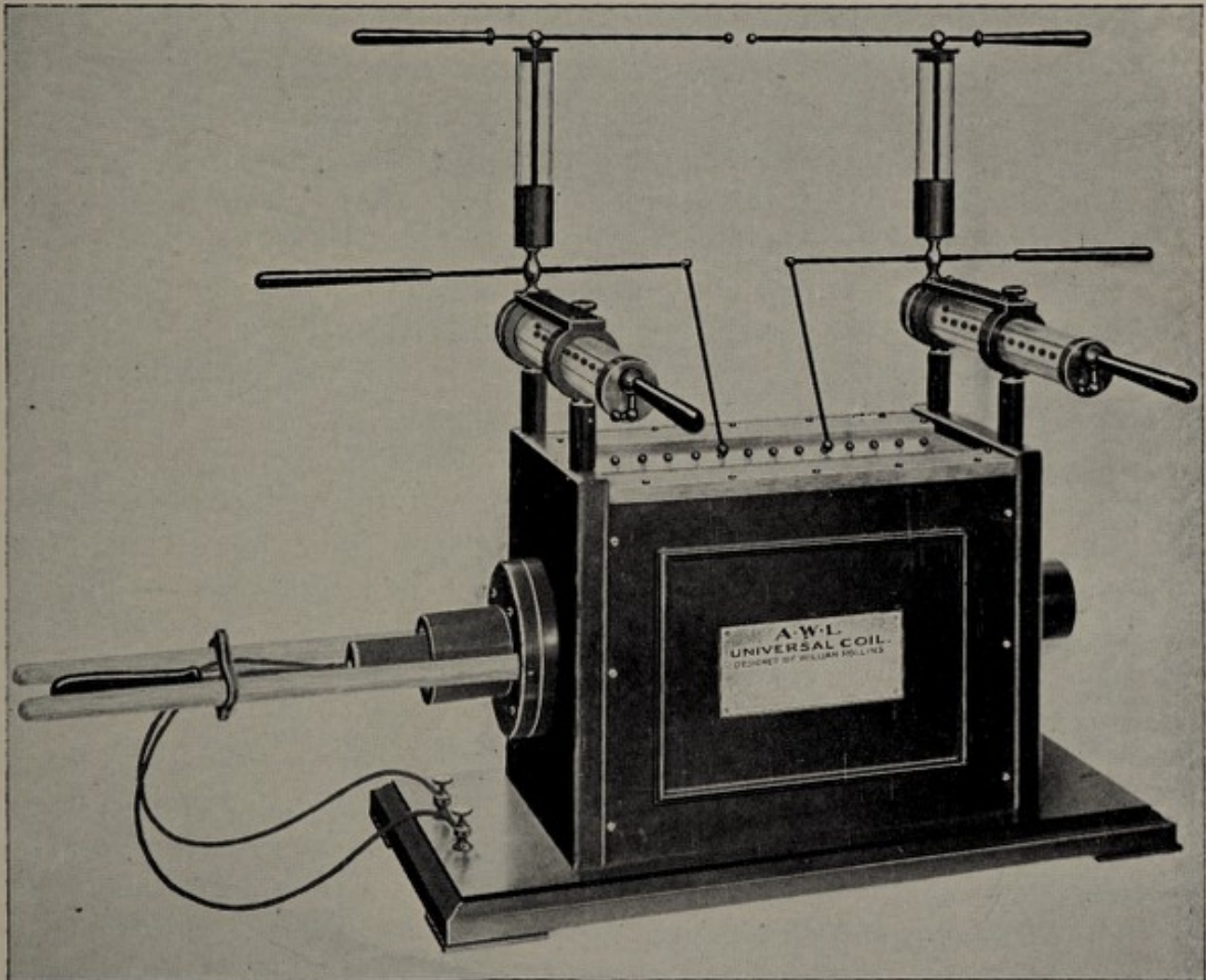


FIG. 21. A. W. L. universal coil. 43 centimetres. (Rollins.)

In this coil the amperage and potential of the currents are under perfect control. With a 43-centimetre coil, the current can be varied from a discharge of great power to one so light as to be but slightly felt when it passes through the body. All forms of currents used in electrotherapeutics can be obtained with it.

Second: The universal methods of insulating the coils of the secondary with wax or oil are not used; air takes their place. The secondary is entirely free from the tube surrounding the primary. Each sub-coil of the secondary is permanently attached to a sheet of glass two millimetres thick which serves to separate it from the next sub-coil. Two of

these form a section; and these sections, varying in number from 56 upward, according to the size of the coil, are strung loosely, like beads on a string, on a micanite tube which separates the secondary from the primary coil.

With the previous types of coil it was difficult to make repairs, because it was necessary to draw off the oil or to melt out the wax before the secondary could be reached. Even when this had been done the defect was hard to find. With this new type of coil the short circuit can easily be located, as the wires from each section can be tested without disturbing the secondary; when the defective section has been found, the micanite tube is simply withdrawn far enough to permit the removal of this section. A new section, always kept in reserve, can then be put in.

Third: The potential and amperage of the coil can be regulated without changing the current flowing in the primary.

The potential can be varied by means of wires brought up from every seventh section to a row of brass balls in a glass plate above the coil. The number of sections used, and thus the potential, can be changed as desired from one centimetre to the full length of the coil.

The amperage is changed by an arrangement which allows the primary to slide in or out, and thus the amount of current induced in the secondary is varied. This method of regulating the amperage has been employed in very small coils, but not on coils suitable for exciting X-ray tubes.

The power to control the potential and amperage, and the other means to be mentioned later for varying the discharges, enables the physician not only to excite X-ray tubes with this coil, but also to use it for electrotherapeutic work, and therefore a static machine and a high frequency coil in addition become unnecessary. Dr. Rollins, therefore, believes that the static machine will gradually retire to the seclusion of the physical laboratories from which it emerged when the X-rays were discovered.

Fourth: A multiple spark-gap is provided for controlling the current so that it may be sent in discharges suitable to the condition of the tube. The importance of employing this appliance or some other form of resistance on a coil as well as on a static machine (see page 17 and page 48) is easily shown by using a tube of low resistance. Without this multiple spark-gap or some other form of resistance no light is seen, but with it bright light is produced.

Fifth: Methods are provided for varying the kinds of current used. The coil gives the so-called unidirectional current when the connection is made with the principal terminals. If an alternating current is desired, connection is made with the terminals of the interior coatings of the Leyden jars. If a current of still higher frequency is wanted, a small Tesla coil is inserted in the Leyden jar circuit. If a current for cautery is required (one of low voltage and large amperage), a step-down transformer of a few turns of coarse wire is slipped over the primary, which is partly withdrawn so that the wire may be put on.

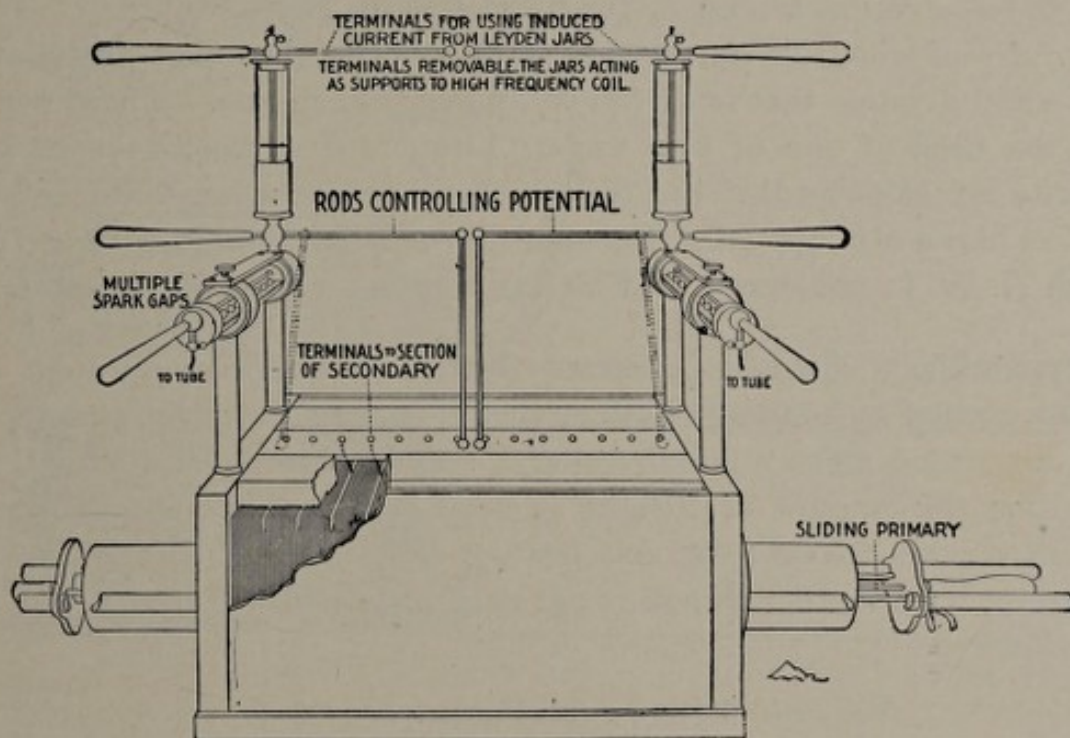


FIG. 22. Diagram of A. W. L. universal coil. (Rollins.)

Sixth: The spark-gaps are enclosed in tight tubes of glass to prevent the escape of gases that irritate the respiratory mucous membrane; these gases may be removed by means of an aspirator connected by a rubber tube with the spark-gaps. This aspirator can be attached to the nearest basin faucet when desired, and the gases be discharged into the water pipe. The metal balls of the spark-gap, and the interior of the glass tubes, will become coated with substances having an acid reaction, as the coil is used; and as in this case they become conductors, they must be cleansed with ammonia water and then dried.

Apparatus for Physicians in the Country, where an Electric Main is not Available. — A. *A Static Machine* which may be run by a gasolene engine.

B. 1. *A Coil* which is run by a combination of storage battery and gravity cells. The apparatus shown (see Fig. 23) consists of a 30-centimetre Ritchie coil which is placed on the top of a case containing 24 gravity cells that are permanently attached to four Willard storage batteries of 50 ampere hours. As the gravity cells are constantly sending electricity into the reservoir there should always be enough energy stored to enable the operator to use 40 watts, which, with the aid of Ritchie's remarkably economical induction coil, Dr. Rollins has found to give ample light for one hour a day, if suitable tubes are used, for work with the fluorescent screen or for taking X-ray photographs.

2. *A Coil* which is run by means of storage cells that are charged by a small dynamo that is driven by a gasolene engine. These storage cells are used in one of two ways. First, four storage cells of large capacity are employed, if the coil is wound to use a low voltage (about 8 volts) like a Ritchie coil. Second, fifty smaller storage cells are used for an A. W. L. universal coil which is run on an 110-volt circuit.

Trowbridge's directly Connected System.—The vacuum tube may also be excited by a storage battery that is charged from the street main. This apparatus gives a unidirectional, steady current, and with a suitable tube the amount of X-light is very great. The tube is directly connected with 10,000 to 20,000 storage cells in series through a water rheostat. This method is not as yet used in practice.

VACUUM TUBES FOR PRODUCING X-RAYS

Whether one uses a static machine or an induction coil as an exciter, the vacuum tube still remains the most important portion of the apparatus and the most difficult to keep in proper condition. It consists mainly of a glass bulb about 10 centimetres in diameter, in the interior of which are supported on metal stems two or three metallic objects, according to the kind of tube employed.

A. *Double Focus Tubes.*—These tubes are used on an alternating current and contain three pieces of metal—the two terminals, called respectively the cathode and the anode, and the third the anticathode, or target. See Figs. 32–35.

B. *Single Focus Tubes.*—These tubes are used on a direct current and contain the two terminals called respectively the cathode and the anode; this latter terminal acting as a target also. See Figs. 24–28, 30–31.

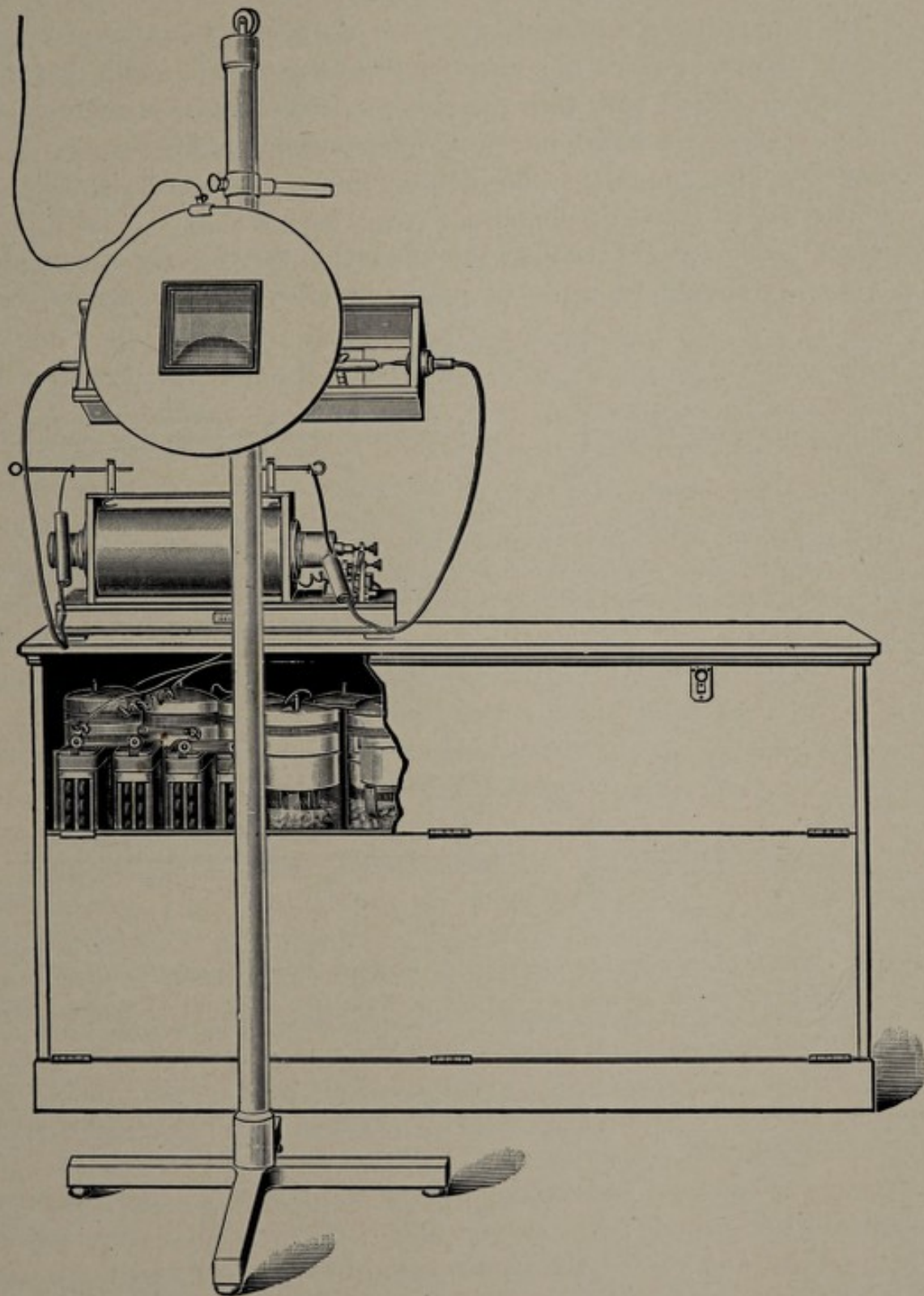


FIG. 23. Combination of storage battery and gravity cells. The tube holder is seen in position, with one side removed so that the tube is visible. In front of tube is a circular diaphragm with an aluminum wire screen in its centre. The case is filled with storage batteries and gravity cells, some of which are seen on the left. (Rollins.)

Cathode. — The cathode is made of aluminum, and is usually a concave disk, which has a radius of curvature of about 3.5 centimetres, and should be placed at twice this distance from the target. The diameter of the cathode should vary with the size of the discharges used to excite the tube; if these are large, the cathode should be large.

Anode. — The anode, in the double focus tube, that is, when a terminal only, is made of aluminum (see Figs. 32-35).

Target. — The target receives the impact of the cathode stream (see Fig. 31). It should be made of platinum alloyed with iridium, and

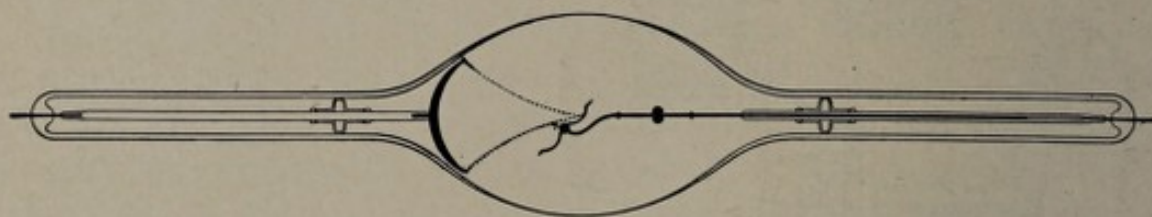


FIG. 24. A. W. L. rotary target tube with movable target. (Rollins.)

This cut shows a curved target supported by a strong stem which can be slid in or out by the action of a sliding weight attached to it (the dark mass on the stem represents the weight), and thus the distance between the target and cathode can be changed until the best distance has been determined.

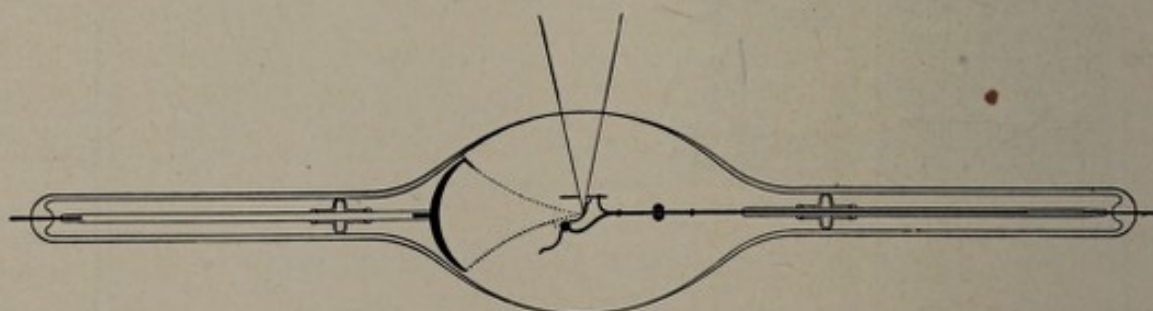


FIG. 25. A. W. L. rotary target tube with movable target and internal diaphragm. (Rollins.)

This cut shows a similar adjustable target with a diaphragm, supported on the same stem, above it. The cone of rays, and the widening of this cone as its distance from the target increases, is represented by the two lines running at an angle to the diaphragm.

should be placed at an angle of fifty-six degrees with the cathode stem in the real focus, but not in the centre of curvature, of the cathode.

Crookes, Roentgen, and others placed the target in the centre of curvature of the cathode; Frei, whose tubes were superior, soon departed from this type, and placed the target from three to four times this distance. Rollins has found by experiments with his movable terminals (see Fig. 24 and Fig. 25) that when the tube was exhausted to the degree of resistance required for the most economical production of X-rays, the real focus of the cathode stream was between these two

extremes. In his Notes, published in the *Electrical Review*, he has suggested as an explanation of this phenomenon that the particles of the cathode stream are charged with the same kind of electricity, and therefore would repel each other, with the result that they would come to a focus beyond the theoretical point.

The two preceding figures represent two of the early forms of experimental single focus tubes devised by Dr. Rollins for the purpose of ascertaining the best distance of the target from the cathode.

Good tubes now have the target placed in the position recommended by him; that is to say, about twice the theoretical distance. The matter is of practical importance, as the ability to obtain sharp definition is partially dependent upon the position of the target.

Anode and Target United.—The anode and target are combined in the single focus tube (see Figs. 24–31), and under these circumstances this object should be made of the alloy above described, and placed at the same angle with the cathode, as is the target when it is an independent object. Lodge and Rowland have observed that when the target was united with the anode, the tube was more efficient than when separated from it. Rollins states that this increased efficiency is due to the fact that the particles in the cathode stream, being negatively charged, are attracted as they approach the target when it is combined with the anode, for the latter is always positively charged, and consequently strike it at a higher velocity.

The target, whether independent or combined with the anode, should be 0.43 of a millimetre or more in thickness in order to withstand so far as is practicable, by means of size, a strong electric current; for if the exciter has much energy and the metal is thin, it becomes hot sooner and is more easily melted. To further resist the effect of a strong current, Dr. Rollins devised for me, in 1896 and 1897, two very ingenious forms of target, the target being placed at twice the theoretical distance from the cathode, as described above. The first is hollow (see Figs. 26, 27) and is closed at one end but open at the other, so that a stream of water may be kept running through it, or a current of air may be driven through it, and thus the target is prevented from becoming hot and being destroyed. So far as I am aware, this is the only form of target that will withstand extreme amounts of electric energy. The second is a rotary target (see Figs. 28, 29), and is supported on a pivot in its centre, so that if one part of the target is destroyed by having a small hole melted in it, a slight shaking of the tube will bring another portion

of the target into the focus of the discharge from the cathode. In a third form, Fig. 24, the target was made concave in the hope that this form would collect the X-rays that would otherwise be lost. In these tubes the supports of the terminals are strong stems of metal, and the glass wrappings (see Fig. 30) are dispensed with.

Single Focus Tubes for Use with the Direct Current.

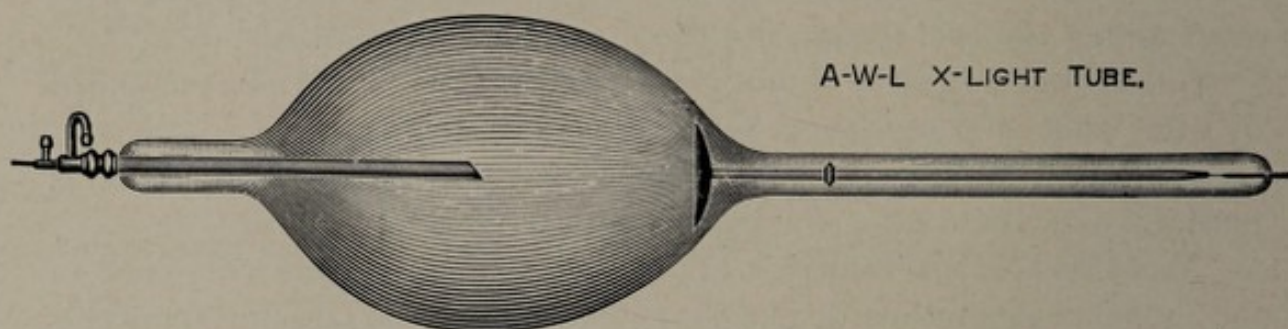


FIG. 26. Cooled target tube. The tube is 43 centimetres long. (Rollins.)

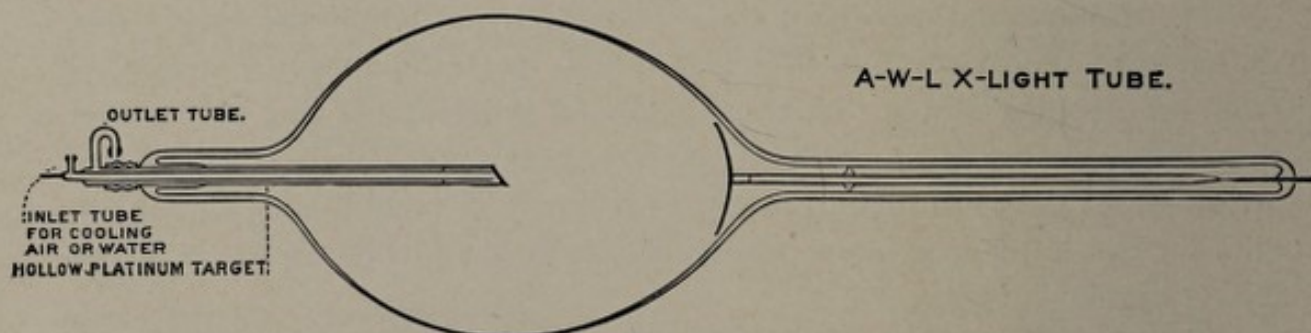


FIG. 27. Section of cooled target tube. (Rollins.)

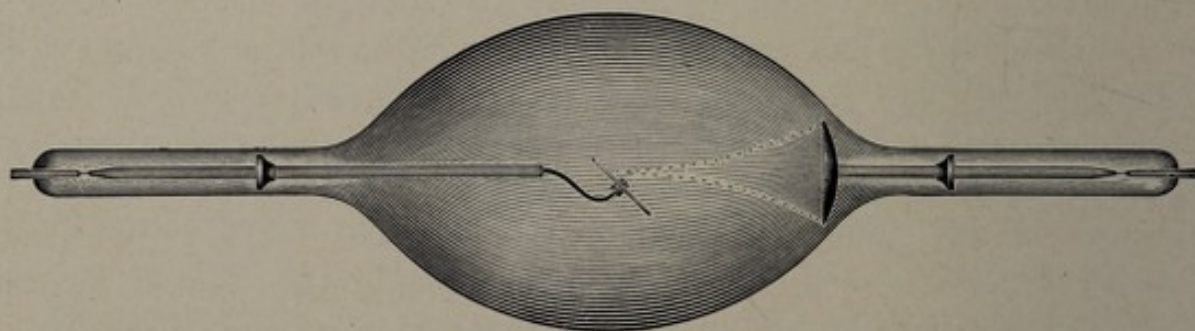


FIG. 28. The A. W. L. tube for direct currents. Rotary target type. (Rollins.)

This illustrates a form of tube which I have used in some of my work. It was designed for me by Dr. Rollins. The target may be rotated by jarring the tube. If a hole should be melted in the target by the heat produced by the impact of the cathode stream, a fresh surface can be brought into position, thus making the tube as useful as a new one. If, however, the target is sufficiently thick, it is rarely melted. It must be remembered that when this fresh surface is first used the resistance of the tube may be temporarily lowered, as gas is liberated.

The curved disk on the right of the glass bulb is the cathode, and is made of aluminum. The metal disk in the middle of the bulb is the anode, upon which the rays from the cathode are focussed.

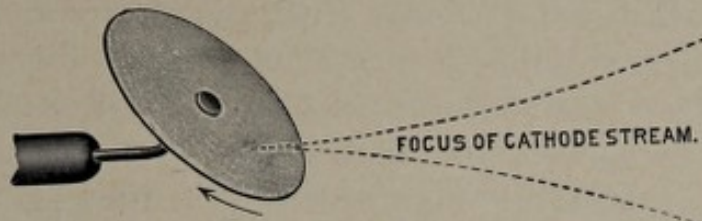


FIG. 29. Details of rotary target. Full size. (Rollins.)

The rotary target is liable to be turned somewhat on its pivot if the tube is transported some distance, and as the effect of exposing a new surface to the impact of the cathode stream may be to lower the resistance of the tube (see page 45), a tube of this type should be examined by the practitioner before it is used, in order that he may learn whether or not the target has been so shaken that it has turned on its pivot. This point can be determined by observing whether or not the spot that has been roughened by the impact of the cathode stream is in line with the centre of the cathode; if not, it must be shaken into line.

The following figure illustrates a not uncommon form of construction, which is faulty, in that the target is in the centre of curvature of the cathode disk, and that the wrappings of the stem are of glass, which are liable to break both in use and in transportation, with the result that the terminals get out of line.

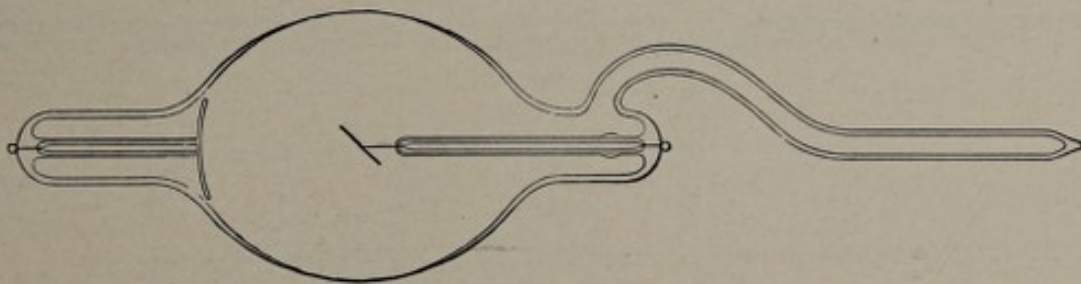


FIG. 30. Tube of a faulty type of construction. Target in centre of curvature of cathode; wrappings of stem are of glass.

Double Focus Tubes for Use with an Alternating Current. — With the powerful currents that may be used with high frequency coils, holes are liable to be melted in the target by the heat produced by the impact of the cathode stream, and the tubes be rendered useless. To overcome this defect, Dr. Rollins has designed double focus tubes containing either his cooled or rotary target. A second objection to the double focus tubes is that they have two sources from which the X-rays originate (see Fig. 32); the definition, therefore, is not so good as it may be with a single focus tube. To obviate this objection to the use of alternating currents, Dr. Rollins has designed the tubes shown in Figs. 33-35 — one the cooled target type, and the other of the rotary target type. When these tubes are used as double focus tubes with high frequency currents, one radiant area is formed on the back of the target, or that side facing

away from the patient. The X-rays from this radiant area are sent out of the field, exerting no injurious action on the definition, if the tube is in a suitable opaque box, as shown in Fig. 33. Dr. Rollins prefers to use these tubes in another way, however, the central piece of metal being always one terminal through which the current passes, instead of simply a target, having no connection with the generator. There is in

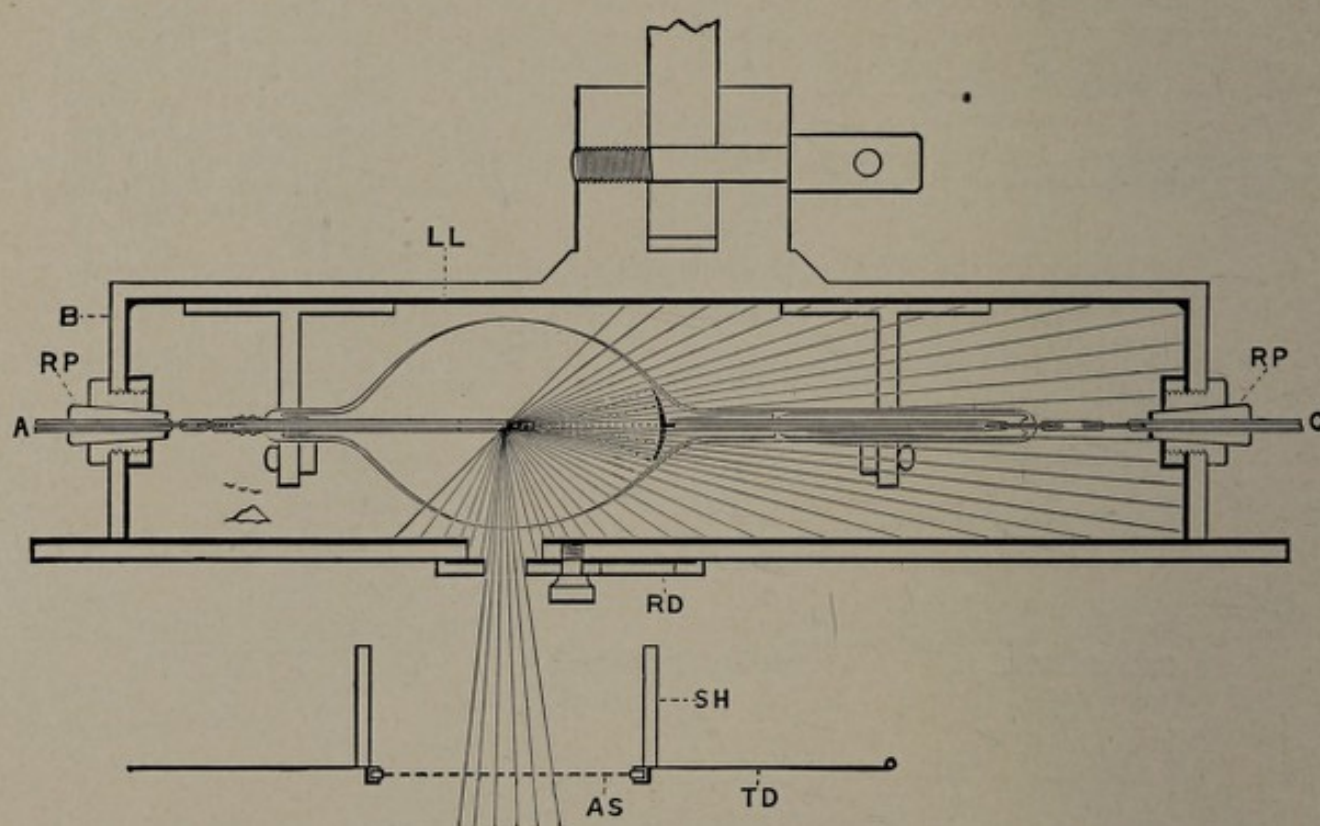


FIG. 31. Illustrates the formation of the cathode stream and X-rays. (Rollins.)

The cathode stream is represented by dotted lines, the X-rays by unbroken lines. When the cathode stream strikes the target, X-rays are given off in all directions from the point of contact, but only one-half of the sphere is seen, as the other half is obstructed by the platinum of the target. In the figure these rays are represented as passing through the aluminum of the cathode and the glass walls of the tube until stopped by the white lead lining of the box. A cone of X-rays, large enough to cover the part of the patient to be examined, is allowed to escape through the hole in the revolving diaphragm plate. *LL*, lead lining composed of white lead and japan; *RP*, rubber plugs through which pass the wires *A* and *C* from the electric generator. *RD*, revolving diaphragm plate, lined like the box, with lead; *SH*, screen holder, carrying the opaque iron screen *TD*, which is provided with an aluminum gauze window, *AS*. The screen is grounded.

consequence but one radiant area on the target from which the rays can arise, for the target is struck by but one cathode stream. During the periods when the central piece of metal acts as a cathode, it sends a diffused cathode stream toward one end of the tube, but as the X-rays formed by the impact of this stream arise from whatever area it strikes, they are not intense enough when they escape through the opening in

the diaphragm to seriously injure the definition. The second cathode is never connected with the generator until the first used cathode is so exhausted of gas that the resistance of the tube is too high, then it may take the place of the exhausted cathode, thus delaying for a longer time the necessity of using the regulator for introducing fresh gas (see page 45). The single focus or vacuum tube may be used with high

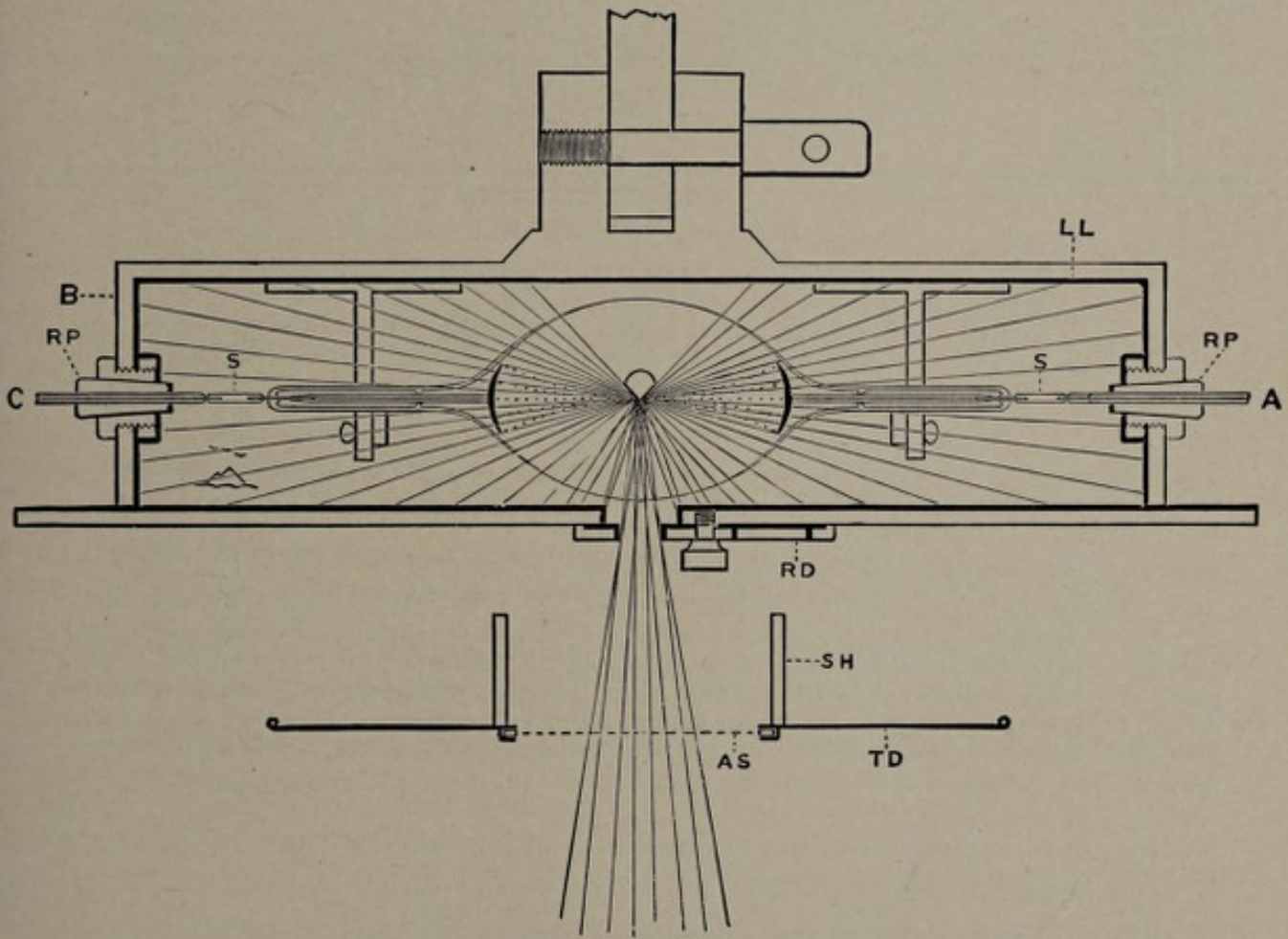


FIG. 32. Double focus tube for high frequency coils. (Rollins.)

The cathode streams are represented by dotted lines, the X-rays by full lines. There are two cathode streams, and consequently two sources from which X-rays arise. This double source of light is a defect of the type. The cooled target designed by Rollins has been added to this tube: for further description, see page 35, Figs. 26 and 27.

frequency currents on the same principle; the diffused X-light arising from the spreading cathode stream given off by the target, when acting as a cathode, cannot injure the definition seriously, if the tube is always used, as it should be, in an opaque box as shown in Fig. 31.

Tube with Continuous Metallic Conductor. — Professor Trowbridge has produced, with a high potential, brilliant X-rays in a vacuum tube

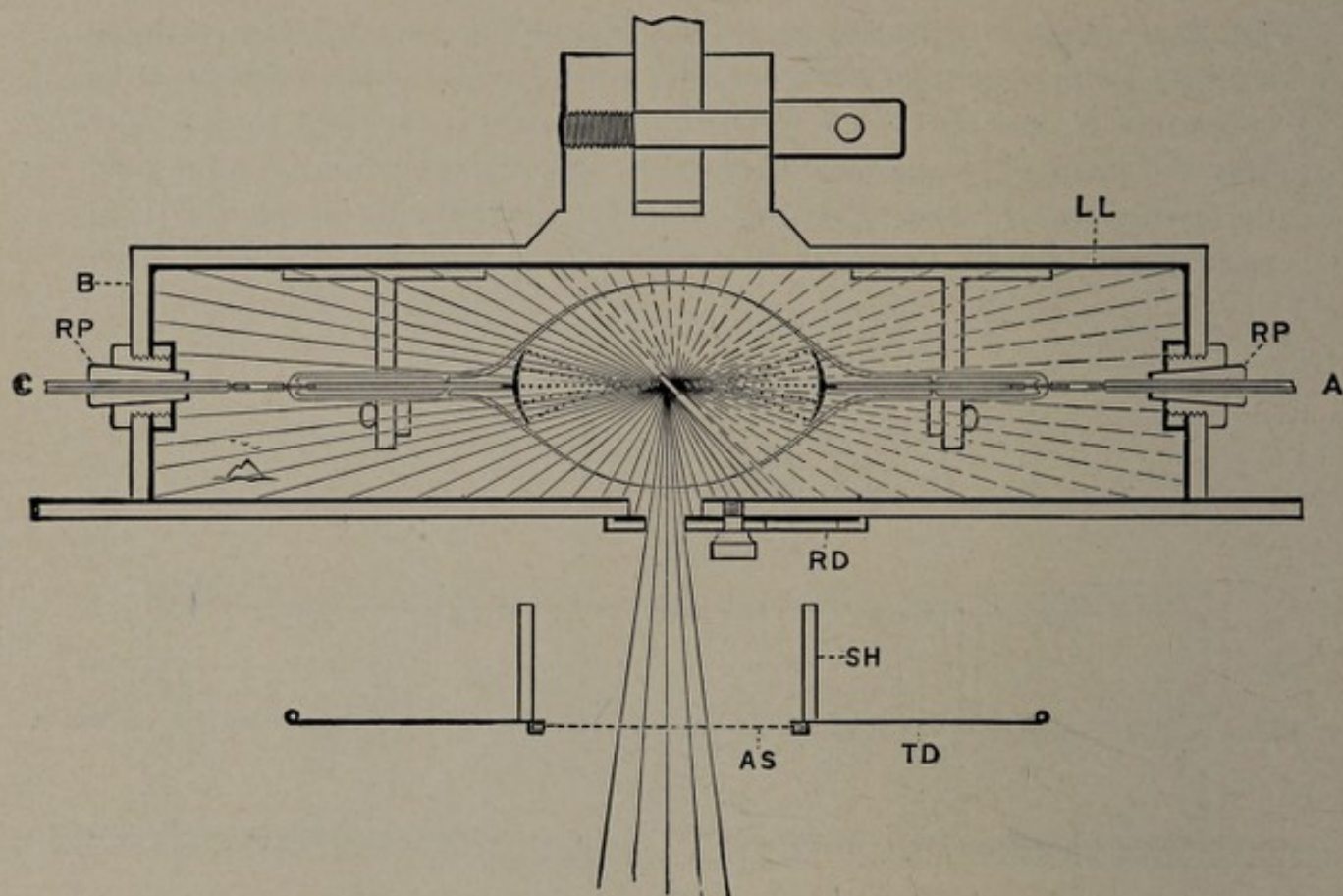


FIG. 33. A. W. L. X-light tube for high frequency coils (cooled target type). (Rollins.)

A form of tube for use with high frequency coils. Two cathode streams, represented by dotted lines, strike the target, producing two sources from which X-rays arise; the rays from one source, which are represented by full lines, are those used. The rays represented by broken lines are discarded, being thrown away from the patient and absorbed by the opaque lining of the box, and thus they do not injure the definition. This figure should be compared with Figs. 31 and 32, which show the origin and disposition of the rays in two other types of tubes.

with a continuous metallic conductor, which shows that to produce X-rays separate terminals are not necessary. (Fig. 36.)

Effect of the Glass on the Passage of the Rays. — How little obstacle the thin portion of the glass bulb offers to the passage of the rays may

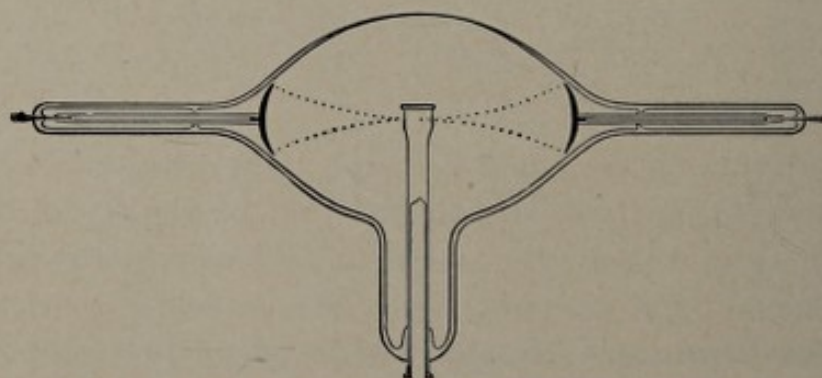


FIG. 34. A. W. L. tube with cooled target (for alternating currents). (Rollins.)

be determined by interposing a tube of good construction between the excited tube and the fluorescent screen, and observing how slight is the shadow cast upon the latter.

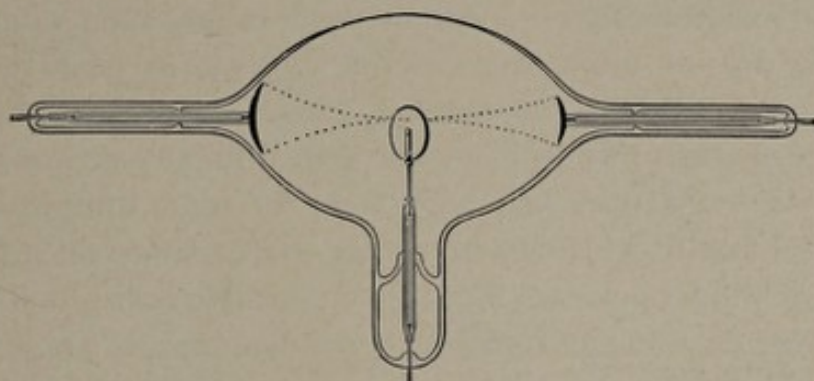


FIG. 35. A. W. L. tube with rotary target (for alternating currents). (Rollins.)

In these tubes, one cathode stream striking the back of the target is sent out of the field. As only one radiant area on the target sends light to the patient, the image on the plate or screen is as sharp as when a single focus tube is used with a direct current. The tubes may be used as single focus tubes with a direct current by making the target act as an anode also. This tube is the same type as that seen in Fig. 33, which shows the origin and distribution of the X-rays.

Exhaustion of Tube. — The vacuum tube should be exhausted to a suitable degree, and this exhaustion may be accomplished by a mercury or mechanical pump, the tube being kept during the earlier part of the process at about 350° F. When the proper point of exhaustion has been reached the tube is "sealed off." There are various precautions that must be taken against moisture, and in the adjustment of the tube to the proper vacuum, but they are chiefly of interest to the manufacturer and need not concern us here.

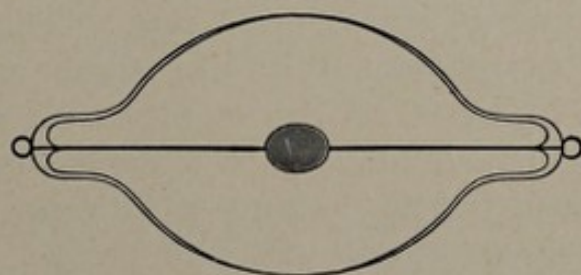

FIG. 36. Tube with continuous metallic conductor. (Rollins.)

Arrangement for connecting Tube with Generator. — Metal stems run from the terminals to the outside of the tube, and are then joined, when desired, to the wires coming from the static machine or the coil. The positive wire should be connected with the target; the negative with the cathode. A tube should always be in shunt circuit, and to avoid as far as possible any danger of puncturing it the spark-gap between the

terminals of the coil should only be long enough to prevent the discharge from passing between them instead of going through the tube.

Resistance of the Tube. — All vacuum tubes, even when similar in construction, do not allow the electric current to pass through them with equal ease. When the current passes easily the tube is said to have a low resistance; when it passes with difficulty or not at all, a high resistance. When a tube has been used for some time its resistance is increased, and finally becomes such that the current will no longer pass through it. Rollins¹ believes that this increase in resistance is partly due to the removal of the gas from the terminals and its absorption by the glass walls of the tube.

High and Low Resistance Relative Terms. — But the terms high and low resistance are only relative, because the resistance in a tube that was low for one form of apparatus might be too high for other forms. Tubes of lower resistance may be used on static machines than on some coils. For instance, I have observed that the tubes which have been used on my large static machine until their resistance is too high for it, are then just right for my coil. Thus a tube which is too high for a static machine may be right for a coil, but this depends on the kind of coil and the current used.

Method of measuring Resistance by Means of Spark-Gap. — The amount of obstacle to the passage of the current through the tube, or in other words, the resistance of the tube, may be readily measured by finding out through how long a distance in the air the electric current will jump rather than go through the tube. This amount may be roughly estimated as follows: With the static machine, tube, etc., arranged as in Fig. 37, the spark-gap in the series with the tube being closed, the operator places one end of a curved metal rod which is fixed into an insulated handle, in contact with one of the wires connecting the static machine with the wire of the vacuum tube, and approaches the other end toward the second wire connecting the static machine with the other wire of the tube. A point is thus soon found at which the current prefers to go from the static machine wire, through the rod, and then jump across more or less air space to the other static machine wire at *B*, rather than go through the tube. If the resistance is high the current will jump across 20 or more centimetres rather than

¹ Rollins has discussed this and other important points relating to tubes, in articles published in the *Electrical Review*, during 1897-1898-1899-1900.

go through the tube. If, on the other hand, it is low, the current will go through the tube rather than jump an air space of a millimetre or less. The amount of obstacle to the passage of the current, then, may be indicated by saying that the tube has a resistance of so and so many

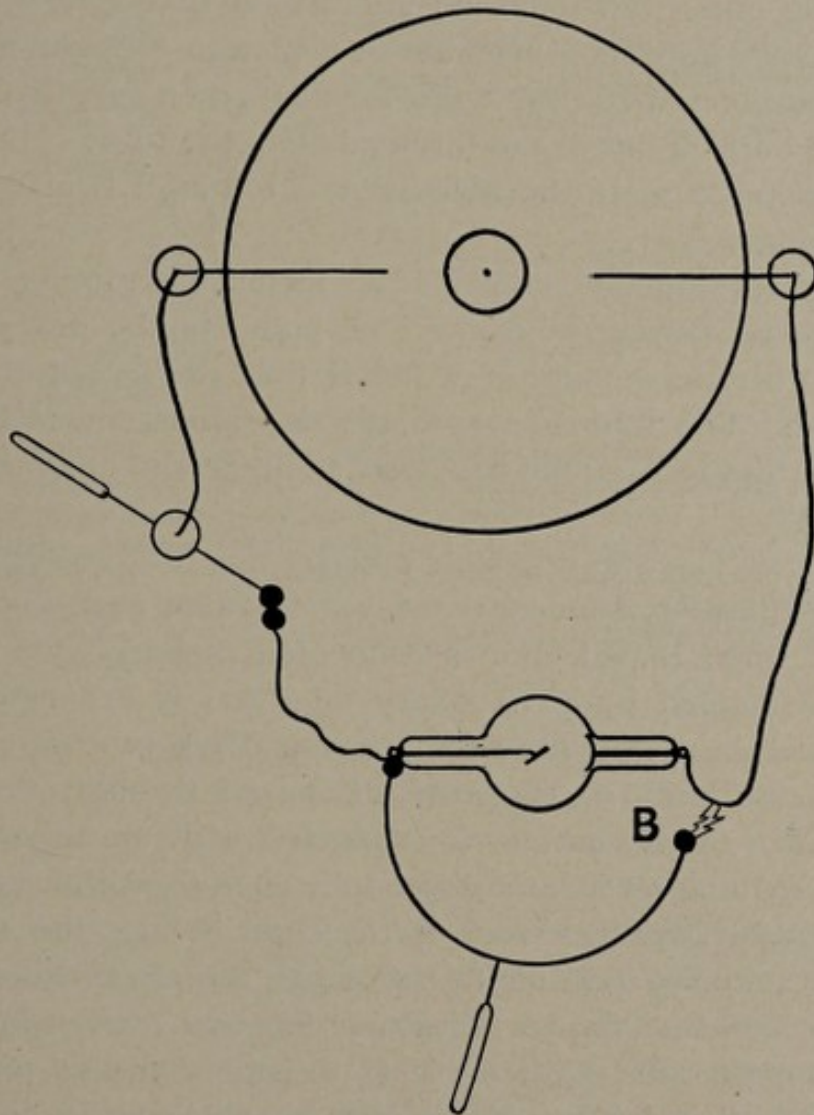


FIG. 37. Cut showing method of determining the resistance of the tube.

The current jumps across the air space at *B* rather than go through the tube. When the resistance of the tube is low, the current will pass through the tube even when the distance at *B* is a millimetre or less. When it is high it will jump across the air space at *B*, even when the distance is 13 centimetres (about 5 inches) or more.

centimetres or millimetres. This means of measurement is equally applicable to a coil, but is carried out a little differently; the two terminals of the coil take the place of the two wires connecting the static machine with the tube, and the rod may be straight instead of curved.

METHODS FOR CHANGING RESISTANCE

Low Resistance. — If the resistance becomes much too low it is best to send the tube back to the maker to be repumped, because the process of raising the resistance by running it on a machine of ordinary power is a very long one. It should be understood that a new tube which gives satisfactory light on a machine of moderate capacity may become too low in resistance if run for a few moments on a very large machine, because gas is driven out of the terminals into the tube.

High Resistance. — If the resistance is too high it may be lowered in the following ways:—

1. By the introduction of gas from an auxiliary bulb. (*a*) By an auxiliary bulb containing potash. This bulb may be heated by means of a lamp; a certain amount of vapor is thus driven out of the potash into the tube. The tube in which this ingenious device is employed was invented by Crookes and has been adopted and modified by Sayen and others.

*Sayen's Tube.*¹ — The regulator used on this tube consists of a small bulb which contains a chemical that gives off vapor on being heated and reabsorbs it when cooled, and is connected directly with the vacuum tube and surrounded by an auxiliary tube that is exhausted to a low Crookes vacuum. The cathode in the auxiliary tube is opposite the above-mentioned bulb, so that any discharge through this tube will heat the bulb. This cathode is connected with an adjustable spark-point which may be set at any desired distance from the cathode in the main tube. When the resistance of the latter is high, the current goes through the auxiliary tube and thus heats the chemical in the small bulb until a sufficient amount of vapor has been driven into the main tube to make that the path of least resistance. The resistance, by means of the regulator, may be varied by placing the spark-point at a considerable distance from or close to the cathode of the main tube. This method is an excellent one for automatically regulating the resistance, and enables the operator to use the same tube and yet have the resistance high or low as he desires. The tubes are made in Philadelphia.

(*b*) By an auxiliary bulb containing other chemicals. Rollins has devised regulators which are operated either by heating the bulb or by passing an electric current through it, oxygen, nitrogen, or hydrogen being thus liberated, according to the chemical used.

¹ *Electrical Review*, New York, May 12, 1897, p. 226.

2. By the liberation of gas from the terminals. If the tube is new and a powerful machine is used, the gas may be set free from the terminals by driving an electric current through the tube.

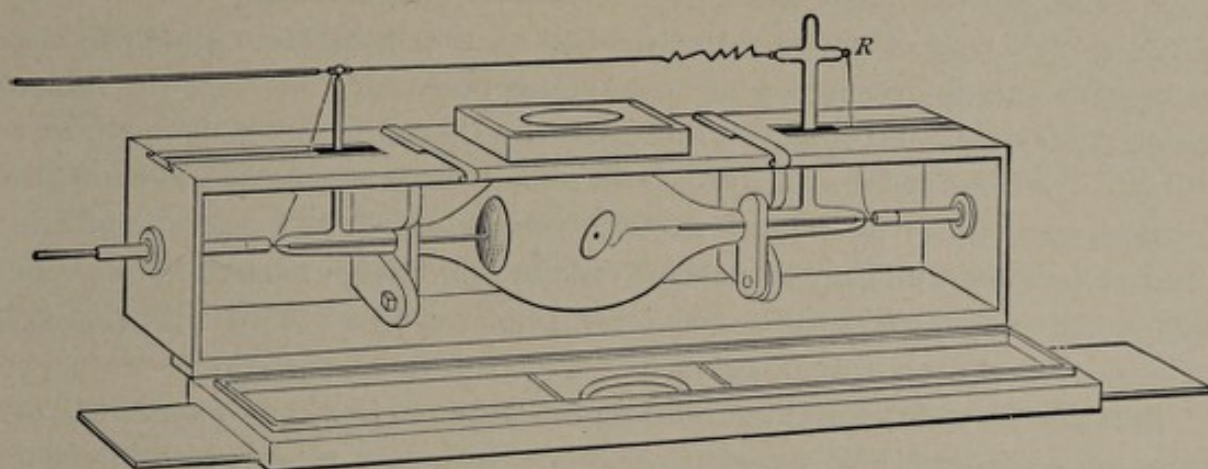


FIG. 38. A. W. L. X-light tube with a rotary, sliding target and an automatic regulator (Rollins).

This regulator *R* can be used to lower permanently the high resistance of the tube or to vary the resistance as the examination proceeds. The resistance can be temporarily lowered by pushing in the rod, seen on the upper part of the cut, and raised again by drawing it out. This regulation of the resistance is accomplished by means of a substance, placed in the arms of the cross, that is mixed with a conducting powder. In this mixture a great number of spark-gaps are formed and gas is liberated when the electric current passes, and absorbed when it ceases. The resistance may be permanently lowered by heating the head of the cross, as this head contains a substance which liberates gas, when heat is applied to it, that is not reabsorbed.

3. By the liberation of gas from the walls of the tube. This may be accomplished by baking the tube in an oven at about 500° F., (see Fig. 355, chapter on Dental Surgery), or by enclosing it in a box containing incandescent lamps, or by holding a lamp beneath the tube while it is turned, care being taken in the latter case to avoid cracking the tube.

All regulators appear finally to fail in their effects, for when the resistance has been lowered by them a number of times the tubes require more energy to run them than when they were new, and the quality of light is not as good as that given off by a new tube.

The length of time a tube may be run without using the regulator or repumping depends largely upon the amount of energy sent through it. A tube may be run on my large static machine at the Boston City Hospital, and give a perfectly steady and excellent light for twelve or more hours without a moment's interruption. It can be used for the examination of patients in periods which add up to a total of at least eighteen hours before the regulator is required, but every time thereafter that the regulator is employed, the intervals between its periods of service become somewhat shorter, until finally repumping is necessary.

Quality of Light. — The penetrating power of any given quality of light depends upon its amount. With a tube of high resistance the power of penetration is greater, but the differentiation of tissues is not as marked, as with light from a tube with lower resistance.

A simple way of testing the quality of the light is to examine the hand with the fluorescent screen. If the resistance is high the bones will be nearly as light as the flesh; if the resistance is low, the bones will be a little darker absolutely and also darker relatively. The light is good, especially for taking radiographs, when such a picture of the hand as is shown in Fig. 39 is seen on the fluoroscope at the distance of half a metre from the tube, and shows little difference in the quality, at more than double this distance.

Suitable Term for defining Character of Tube. — Instead of speaking of tubes of high and low vacuum, or hard and soft tubes, I think it is better to define the character of the tube by its air resistance; that is to say, when specifying the kind of tube that is most suitable for a given purpose, to state that its air resistance is equal to 1, 2, or more centimetres, as the case may be, because it is impossible by any means at present known to determine accurately the degree of the vacuum.

Resistance of Tube for Fluorescent Screen and Radiograph. — For work with the fluorescent screen, or for photography, the tube should be such as will give the greatest differentiation possible between the tissues. When a static machine — which is capable of maintaining a great difference of potential between the terminals, 35 centimetres or more — is used, the resistance of the tube may be 1 millimetre only, and yet by using a multiple spark-gap the best conditions for seeing may be produced. The advantage of such a tube is that it can be used longer before its resistance is so increased by use that it is necessary to lower it than when it is received from the maker with a high resistance. One cause of this high resistance, as indicated above, is the more thorough removal of gas from the terminals, and therefore the life of the tube is shorter, for Rollins states that it is on the supply of gas in them that we partly depend for the X-rays.

For many coils, however, it is desirable to use a tube with a higher resistance — about 6 to 10 centimetres — because the greater amount of current which the coil sends through the tube liberates gas rapidly, with the result that the resistance is lowered quickly to such a point that the tube becomes unfit for use.

Amount of Light necessary for Photograph and Screen. — For taking radiographs a stronger light is required than when the fluorescent screen is used, because when the latter is employed the current can be economized by sending it in less frequent discharges; the light will appear continuous to the eye if the interruptions are 1200 per minute; but for photography the discharges must be larger in amount and more rapid, in order to get the best results in a reasonable time. Coils, as a rule, take radiographs more quickly than static machines.

Effect of the Resistance of the Tube on the X-Ray Picture thrown on the Screen, and the Advantage of the Multiple Spark-Gap. — The following diagram is taken from an article by Robert Kienböck.¹ It is used by him to illustrate the effect of the resistance of the tube on the picture produced on the screen, and also to show that in certain degrees of resistance no picture is produced. I insert it here for the same purpose, and also to indicate the advantage of the multiple spark-gap.

Forms of Tubes. — The most satisfactory tubes, both for static machines and coils, that I have used, are made in accordance with the directions of Dr. Rollins.

The question of vacuum tubes has been considered at some length because so much depends upon the tube. It is neither necessary nor desirable, however, that every one using the X-ray apparatus should have all varieties of tubes.

Aluminum Screen. — This screen is interposed between the tube and the patient, and grounded as recommended by Tesla for the protection of the patient. (See Fig. 47.)

Tube Holder. — It is sometimes an advantage, during an examination with the fluorescent screen, to move the vacuum tube, for by this means the position of the shadow of the object examined is altered, the given object is seen from more than one point of view, and thus additional information is obtained. Figure 40 shows a tube holder which I devised in 1896 for accomplishing this purpose. It consists of a wooden upright, on a base, which carries a horizontal wooden rod that supports the vacuum tube, and can be moved into any desired position, up or down, or from side to side.

Diaphragm. — The electric currents used to excite the vacuum tube are not perfectly unidirectional, and at times the whole of the tube may become a source of X-rays instead of a small point on the target only;

¹ "Ueber die Einwirkung des Röntgen-Lichtes auf die Haut," Wien. klin. Woch., Dec. 13, 1900, 1153-1166.

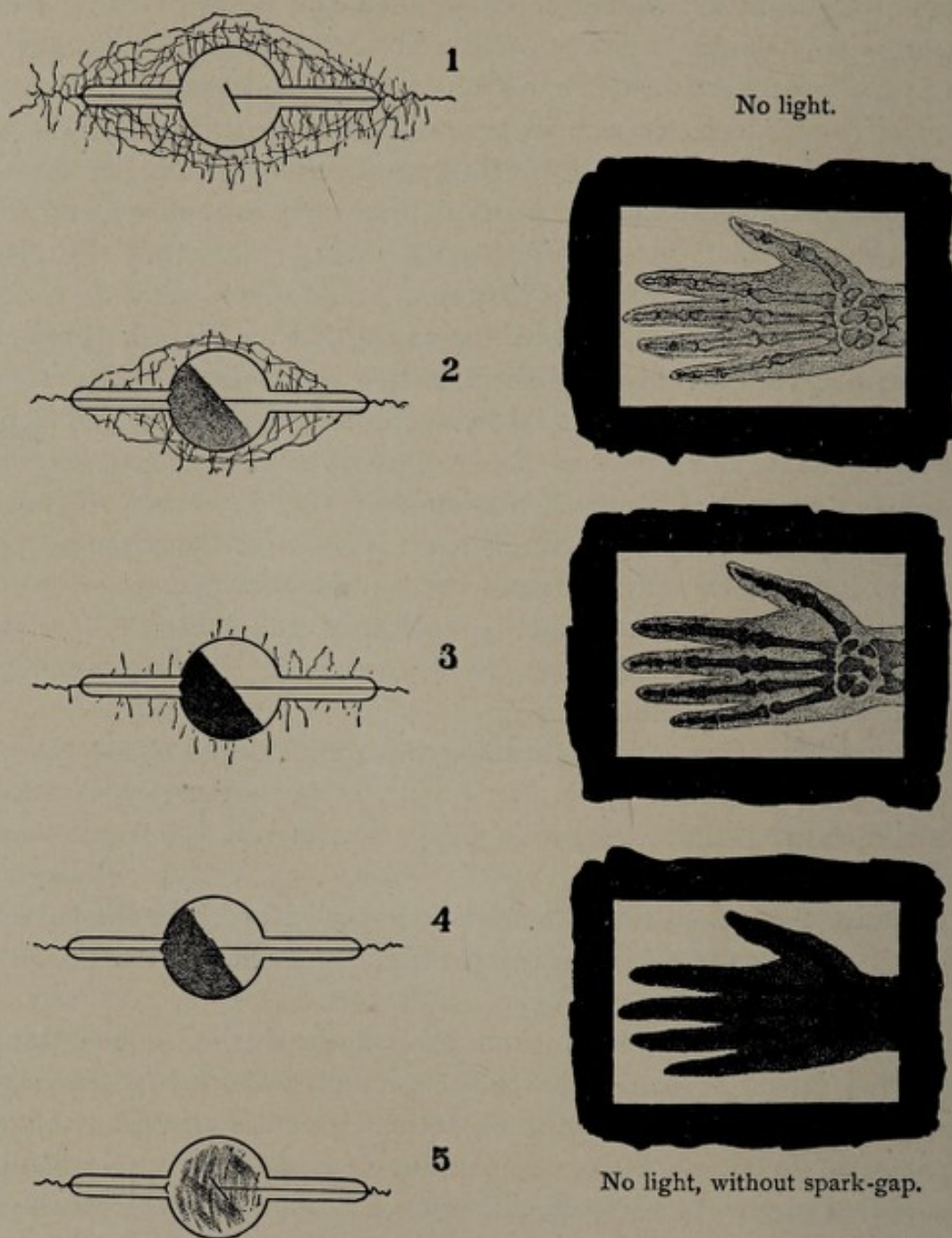


FIG. 39. Diagram showing the effect of the resistance of the tube on the X-ray picture thrown on the screen and the advantage of the multiple spark-gap. The direction of the light is downwards and to the left.

No. 1. The current does not pass through this tube, as the resistance is very high (a tube of such high resistance may be easily punctured). The amount of this resistance can be ascertained by measuring its equivalent of air resistance, as described on p. 43.

No. 2. The resistance of the tube is high; the picture of the hand on the screen is bright, but without contrast.

No. 3. The resistance of this tube is not so high as in No. 2. The picture of the hand is a good one, with well-marked contrast between the bones and flesh.

No. 4. The resistance of this tube is low; the picture of the hand on the screen is dark, and the contrast between the flesh and the bones is not marked. By using a multiple spark-gap, described on p. 17, with the tube the light is excellent and the picture becomes like that seen in Fig. 3.

No. 5. The resistance of this tube is very low, about one-half a millimetre, but by using more of the multiple spark-gap than for No. 4 the light becomes good.

The light which gives most penetration is that obtained from No. 2, but the differentiation of the soft tissues is not accomplished as well with it as with a tube of lower resistance. In order to increase the penetrating power of a tube with lower resistance, more energy must be passed through it.

From what has been stated above, it will be seen that a spark-gap is an essential part of every apparatus, as without it such tubes as Nos. 4 and 5 are useless, but with its aid they become good tubes. If a spark-gap is employed with the X-ray apparatus, the range of resistance within which a tube or tubes can be used is increased, and thereby the life of the tube is lengthened.

second, the practitioner may desire to expose a small surface to the rays; in either of these cases the rays may be prevented from passing into the room in the direction of the patient, except where desired, by the use of a diaphragm, which consists of a sheet of lead in which a




FIG. 40. Tube holder.

This cut is taken from my article, "A Study of the Adaptation of the X-Rays to Medical Practice," in the Medical and Surgical Report of the Boston City Hospital, for January, 1897, and shows a tube holder and two kinds of diaphragms devised by me in 1896.

When it was desired to darken the room absolutely, the light from the tube was shut out by means of a cover made of thin black fibre. (Cover not shown in cut.) Dark cloth or velvet could also be used for this purpose.

hole has been cut. The diaphragm should be near the tube, and the hole as small as will allow a cone of rays to pass of sufficient size to cover the area to be examined. Figure 40 shows a diaphragm, which I used at this time, in position for service. The pieces of wood seen

on either side of the vacuum tube are grooved, and into these grooves the diaphragm is slid. As a protection to the observer, sheets of lead were fastened outside these wooden side pieces, to cut off the rays coming in his direction. Now that tubes of lower resistance are used than formerly, the lead plates forming the diaphragm, and those opposite the sides of the bulb, can well be wider, and thus the X-rays except those coming through the opening of the diaphragm and from either end, can be shut out.

Hand Diaphragm.—The picture on the fluorescent screen may be more clearly seen by the use of a special diaphragm the opening of which may be circular or rectangular, as desired. Figure 40 shows one of several of the latter kind lying on the base of the tube holder. The fingers should be protected from the rays while holding the sheet of metal, and to accomplish this purpose leather straps are fastened to the metal so that the fingers may be inserted under them on the upper side. The diaphragm may be moved about and any special part examined. After the observer has taken a general survey with the fluorescent screen, the part of the body that is to be carefully examined is selected, and the metal plate held under and against the stretcher in such a position that the X-rays fall directly through the opening, while they are cut off from the surrounding area.

2. A larger tube holder which I have devised and found to answer very well, and which may be made by any carpenter, consists of a wooden upright 213 centimetres (7 feet) high, mounted on a base having three castors. The arm which carries the vacuum tube is joined to a piece of wood that slides up or down on the upright, the counterpoise and arm being connected by a cord going over a pulley at the top of the upright; the arm is fastened to the upright by a wooden pin that permits a hinge-like motion, and allows the arm to swing parallel with the floor. By this means the tube may be placed in any desired position, either above or below the patient, with the face of the target directly opposite the patient.

3. A more complete tube holder is one devised by Dr. Rollins. It consists of an upright brass tube, inside of which is a leaden counterpoise for the arm carrying the vacuum tube. The tube, as in the other tube holders, may be adjusted to any position. (See Fig. 41.)

Box for Tube.—The tube is held in a box with a sliding cover which Dr. Rollins has had made for me, painted on the inside with many coats of white lead, in which a hole five centimetres in diameter

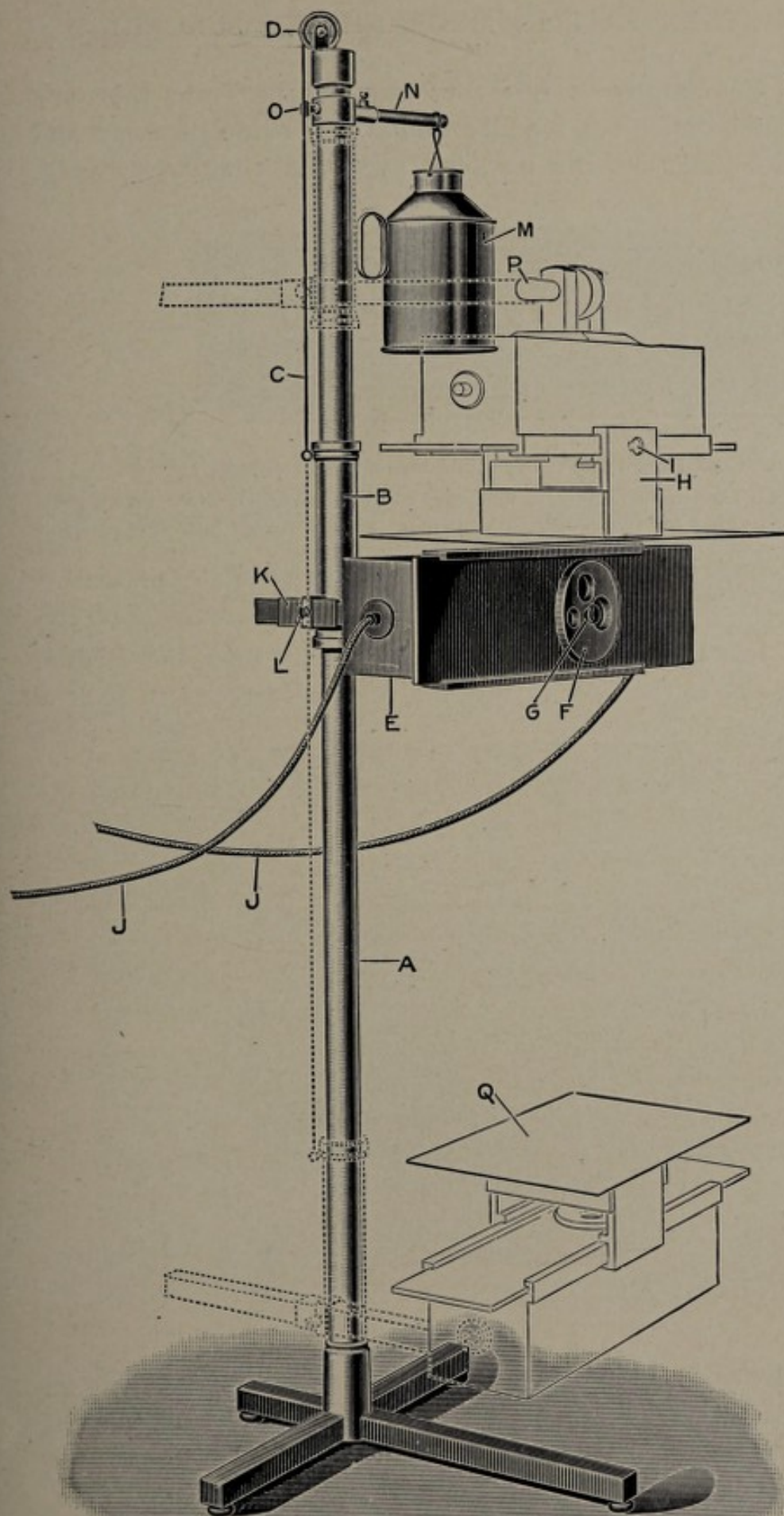


FIG. 41. Tube holder. *A*, brass tube 7 feet high. *B*, sleeve with ball bearings sliding on tube *A*, and supporting a box *E* containing the tube. The front of this box can be removed by sliding it sideways in the grooves shown. This movement also allows any opening of the diaphragm plate *F* to be brought opposite the radiant area of the target of the tube. *G* is a screw which acts as a pivot and clamp for diaphragm plate. The distance of the tube box from the upright *A* can be changed by sliding the bar to which it is attached by the pivot and clamp screw *P* in the metal sleeve *K*. *L* is a clamping screw. *H*, sliding holder for Tesla screen. *I*, clamp. *Q*, screen. *C*, cord attached to sleeve *B*. It passes over a pulley *D*. To the other end is attached a lead weight sliding inside the tube *A*, and serving to balance the tube box *E*, which therefore remains in any position without fastening it. *M*, water-can for cooling the water for hollow target tube. *N*, insulating supporting rod. *O*, clamp to collar which allows the height of can to be changed. The tube holder moves in altitude about the axis of the clamping screw *P*. It can be brought above or below the patient, as shown in the outlines. *J*, terminals from generator, insulated from tube box by heavy rubber disks. (Rollins.)

has been cut. Comparatively few rays can escape from this box except through the hole. A circular diaphragm made of wood and coated with white lead, like the box, fits over the circular opening.

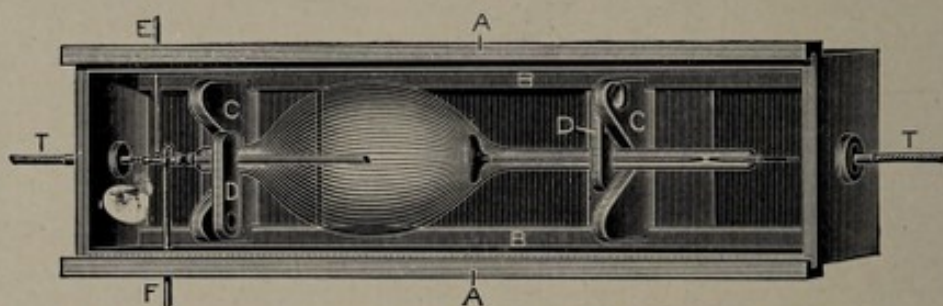


FIG. 42. Cooled target tube in box with cover removed. (Rollins.)

Detail of tube box. The terminal wires are not attached to the terminals of the tube, as this might endanger the tube. They are held firmly in taper plugs in hard rubber insulating plates at each end of the tube box, and simply rest in contact with the tube terminals. *CC*, supports for tube; *DD*, clamps for tube; *E*, inlet tube for cooling water; *F*, outlet tube for cooling water; *BB*, bars to allow *CC*, the supports, to slide for the purpose of adjusting their position for different tubes.

This diaphragm has three round holes of different sizes, the largest corresponding in size to the hole in the box, and is fastened in such a




FIG. 43. This cut shows the box devised by Dr. Rollins, with some slight modifications which I have made.

This box has a hinged instead of a sliding cover. It has also a sliding diaphragm. Lines are marked on the inside of the box, on either side of the hole cut in the cover and on the bottom. The target of the tube should be placed opposite these lines. Corresponding lines are likewise marked on the outside of the cover (see Fig. 45), to indicate to the practitioner the position of the target when the box is closed. When one tube is changed for another, the connection of the new tube with the terminals may be readily made by means of the device at *A*, which is shown in detail in Fig. 44.

way to the box, when in use, that it can be turned, and thus the desired aperture can be brought opposite the opening in the box. It should

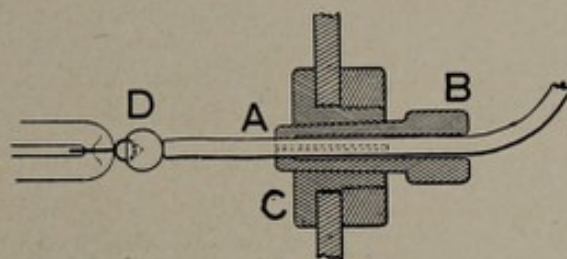


FIG. 44. *B* is a vulcanite plug in which four longitudinal cuts have been made reaching half its length, and carries the insulated wire *A*.

When *B* is pushed into place, the wire is clamped and held at *A*. *D* is a brass ball 1.25 cm. in diameter, which is soldered to the insulated copper wire *A*, and on its opposite side has a cone-shaped hole bored out of it, which fits over the wire terminal on the outside of the tube.

be remembered in choosing this aperture that the diameter of the cone of rays increases with its distance from the tube. (See chapter on Therapeutic Uses, page 400.)




FIG. 45. The same box as shown in Fig. 43, with cover closed. The thin aluminum screen 15 cm. wide which fits across and close to the cover over the circular opening is not shown.

Aluminum Screen and Diaphragm.—I have devised an aluminum screen and diaphragm combined, to be used with this box, which is placed over the circular diaphragm just described, and grounded. This screen has one hole in it corresponding in size to the largest hole in

the circular diaphragm and the box, and can be turned so that its opening coincides with their largest one; while the screen is in this position the proper place for the target is found by means of the light issuing from the tube through this hole. The screen is then turned until its solid portion is brought over the aperture in the box and circular diaphragm in order that the room may be perfectly dark while the examination with the fluorescent screen is being made.




FIG. 46. Tube holder open.

This tube holder (Fig. 46) consists of a box, the upper and lower parts of which are of equal size and are hinged together at the back. It has a hole cut at either end which is large enough for the stems of the tube, which protrude somewhat, to go through. In the top, front, and bottom of the box, which is coated inside with white lead, as proposed by Dr. Rollins, are three circular openings, each of which is $6\frac{1}{4}$ centimetres in diameter. Over each of these above-mentioned sides, as a protection from the X-rays, is a sheet of lead $2\frac{1}{4}$ millimetres thick, which slides in grooves. When it is desired to use a given opening, the sheet of lead is taken out and another sheet of lead, perforated with a circular hole of the size desired, is slid into place. The three openings are made in order that the tube may be used above, below, or in front of the patient without turning the box, although of course the tube must be turned. (See also Fig. 47 and Appendix for more recent form of tube holder.)

FLUORESCENT SCREEN

This screen is made by coating one side of a piece of cardboard with crystals of tungstate of calcium, or with platino-cyanide of barium; and great care must be exercised in making it. The crystals of either salt must be of proper size and spread uniformly in a layer of a suitable thickness over the surface of the cardboard. The tungstate of calcium is white, and the light is more suitable for many purposes than the more brilliant though slightly colored fluorescence obtained from the platino-

cyanide of barium. Screens of the latter kind are less durable than others; they are injured by pressure, and should not be kept in a warm room; but each kind has its respective uses.

Tungstate of Calcium Screen. — Certain of the tungstate of calcium screens are phosphorescent as well as fluorescent — that is, in a dark room they retain the image of an object opaque to the rays for a moment after the tube has been shut off. They should therefore be tested in the following way before being purchased: —

After the physician has been long enough in the dark room to get his eyes into condition to see the fluorescence, the vacuum tube should be excited and the light from it should be excluded by covering




FIG. 47. Tube holder closed and ready for use.

the tube with a dark cloth, or by placing it in the box already described. A piece of heavy metal should then be placed under the fluorescent screen and held in the same position for a minute or two. While the physician is thus observing the screen, the current should be shut off from the tube. If the screen has simply fluorescent properties it will instantly become dark, but if the part protected by the metal remains dark, and the other portions retain any brightness, the screen has phosphorescent as well as fluorescent properties, and should be discarded. Mr. T. B. Kinraide, of the Spring Park Laboratory, Boston, Mass., has succeeded, by his careful and laborious investigation, in making tung-

state of calcium screens that are without phosphorescence. They are very satisfactory, and I prefer them to any others that I have used.

Tungstate of Calcium Screen better for Examinations of the Thorax than Platino-Cyanide of Barium. — For examinations of the heart and lungs the character of the light from the tungstate of calcium screen is more satisfactory than that from the platino-cyanide of barium.

Platino-Cyanide of Barium Screen. — The platino-cyanide of barium screens which I had from Kahlbaum of Berlin were not as good as those I obtained in the United States from Aylesworth & Jackson (now Francis E. Jackson) of Orange, N. J. The first screens made by the latter firm deteriorated rapidly, but this difficulty has been partially overcome by them, and probably also by Kahlbaum.

Size of Screen. — The screen for examining the thorax should be at least 25×30 , or, still better, 30×35 centimetres, so that both sides of the chest may be seen at once and thus be readily compared; for ordinary uses 20×25 centimetres. For examination of the neck a screen small enough to go between the clavicle and the jaw is necessary.

Sheet of Glass or Film of Celluloid. — A thin sheet of glass or a film of celluloid may be placed over the surface of the screen, upon which the outlines seen during an examination may be traced with a pencil. When glass is used the lines may be drawn with an ordinary pencil, if the glass is ground; if, on the other hand, the celluloid is used, or clear glass, a lithographer's pencil is necessary. (See Chapter III.)

FLUOROSCOPE

The fluoroscope is a pyramidal truncated box, the base of which is formed by the fluorescent screen and the top of which has an opening which fits over the eyes in a way to exclude the light from the room. (See Chapter III, Fig. 61.)

Comparison of Fluorescent Screen and Fluoroscope. — The fluoroscope, shown in Chapter III, Fig. 61, is a very convenient form of apparatus, but usually I prefer to make X-ray examinations of the chest with an open screen, the edges of which are strengthened by a frame. (See Chapter III, Fig. 59.)

PHOTOGRAPHIC PLATE

The general rules of photography apply in developing, fixing, and preserving the X-ray negatives, and therefore only a few suggestions will be given here.

Make of Plate. — Any quick plate which is the product of a good maker, and *not too old*, may be used. Those made in this country are, I believe, as good as any. The Carbutt, Seed, Cramer, Hammer, and Stanley plates are satisfactory.

Protection of Plate. — It is well to keep the photographic plates elsewhere than in the X-ray room, and while temporarily in this room they should be kept in a box made of lead 6 millimetres thick, and placed as far as possible from the vacuum tube, and be brought out when it is time to use them. The plate immediately prior to its exposure should be put into two light-proof envelopes — plates deteriorate if kept for a long time in these envelopes — and directly after the exposure it is wise to put it again into the lead box; for if the vacuum tube should happen to be excited when the plate was not thus protected it would be spoiled. The plate must be protected from moist substances or from a patient who perspires freely, and this protection can be effected by wrapping the plate in a thin sheet of rubber or in a paper envelope thinly coated with shellac.

Photographic Paper. — Any photographic paper may be used for printing the X-ray negatives. The Velox gives good detail and needs only very short exposure to artificial light. After the Velox prints are mounted nothing should be allowed to touch the surface until the print is dry.

Bromide Paper. — If an X-ray picture is desired very quickly, bromide paper in light-proof envelopes may be used instead of a plate, and developed as an ordinary negative would be, — bromide paper requires a longer exposure than a plate; — by this means it is quite practicable to obtain an X-ray picture within an hour. One or more pieces of bromide paper may be exposed at the same time, and thus the likelihood of getting one good picture is increased. Fig. 248, in the chapter on Fractures, was made in this way.

Development of Films. — Slow development gives the most certain results. A good length of time is 15 minutes, with the solution at a temperature of 71° F.

Developer. — A good developer is made as follows: Water, 250 cubic centimetres; metol, 0.5; dry carbonate of soda, 0.25; sulphite of soda, 5. The water should be pure and the chemicals pure and dry. Fresh developer should always be used.

Test of Light for Development. — The light from the developing lamp may be tested by holding a film 30 centimetres from the lamp for

5 or 6 minutes. If the film shows any trace of an image, more red paper should be used in the lamp, as the slightest fog on the negative is injurious to the definition.

Fixing in Hyposulphite of Soda Solution. — The usual washing in water after development is unnecessary; the plates should be thoroughly fixed.

Washing the Negative. — When the negative has been removed from the hyposulphite of soda, it should be placed in running water if available; if not it must be washed in several changes of water, the water being kept in motion by gentle rocking.

Precautions to be taken when using X-Ray Apparatus and making X-Ray Examinations. — Instances of burns resulting from X-ray examinations have occurred in the early days of the use of the X-rays, before the precautions which should be taken were generally understood, and when the vacuum tube was placed very near the patient. Now there is no reason for anxiety in regard to any ill effects from these examinations in the hands of experienced persons. The tube must be placed at a considerable distance from the patient, enclosed in a suitable box, and a thin aluminum screen, which should be grounded as recommended by Tesla, should be interposed between the tube and the patient.

Harmlessness of X-Ray Examinations if Proper Precautions are Taken. — The fact that several thousand of X-ray examinations have been made at the Boston City Hospital alone, and always without any unpleasant results following, demonstrates the entire harmlessness of these examinations when they are carried out with proper care.

For later experience with X-ray equipment, see Appendix.

CHAPTER III

METHODS FOR MAKING X-RAY EXAMINATIONS WITH THE FLUORESCENT SCREEN AND X-RAY PHOTOGRAPH

IN 1896 I saw that differences could be distinguished between health and disease in some of the organs in the body by means of examinations made with the fluorescent screen, and that, in order to increase the value of these examinations in diagnosis, some systematic method of procedure must be adopted. It was necessary that every examination should be carried out with a clear understanding of the importance of the fundamental principle that the source of light must be in definite and suitable relation to the part to be studied. With this end in view I devised the method of examination which I will presently outline. By means of this method, variations in the appearances obtaining in different diseases can be recognized with accuracy, and, further, after a number of observations have been collected, they can be compared, their differences and similarities noted, and the observations interpreted in a way which would otherwise be impossible. The accurate observation and record of movements of organs, especially in the thorax, could only be accomplished by some such method. This method not only permits a ready comparison of examinations made at different times by the same physician, but enables two physicians living in different cities to compare the appearances seen in the same patient at different periods, and to note whether changes have or have not taken place. In devising the method I have studied efficiency and simplicity.

Support of Patient during X-Ray Examination; Recumbent Position.—It is important both for the patient and the physician that the position of the patient during an examination should be a comfortable one, and also one that can be exactly resumed should, subsequently, a second examination be needed. Since clothing and fabrics of various kinds are easily penetrated by the rays, a canvas stretcher affords a simple, convenient, and comfortable means of supporting a patient, being

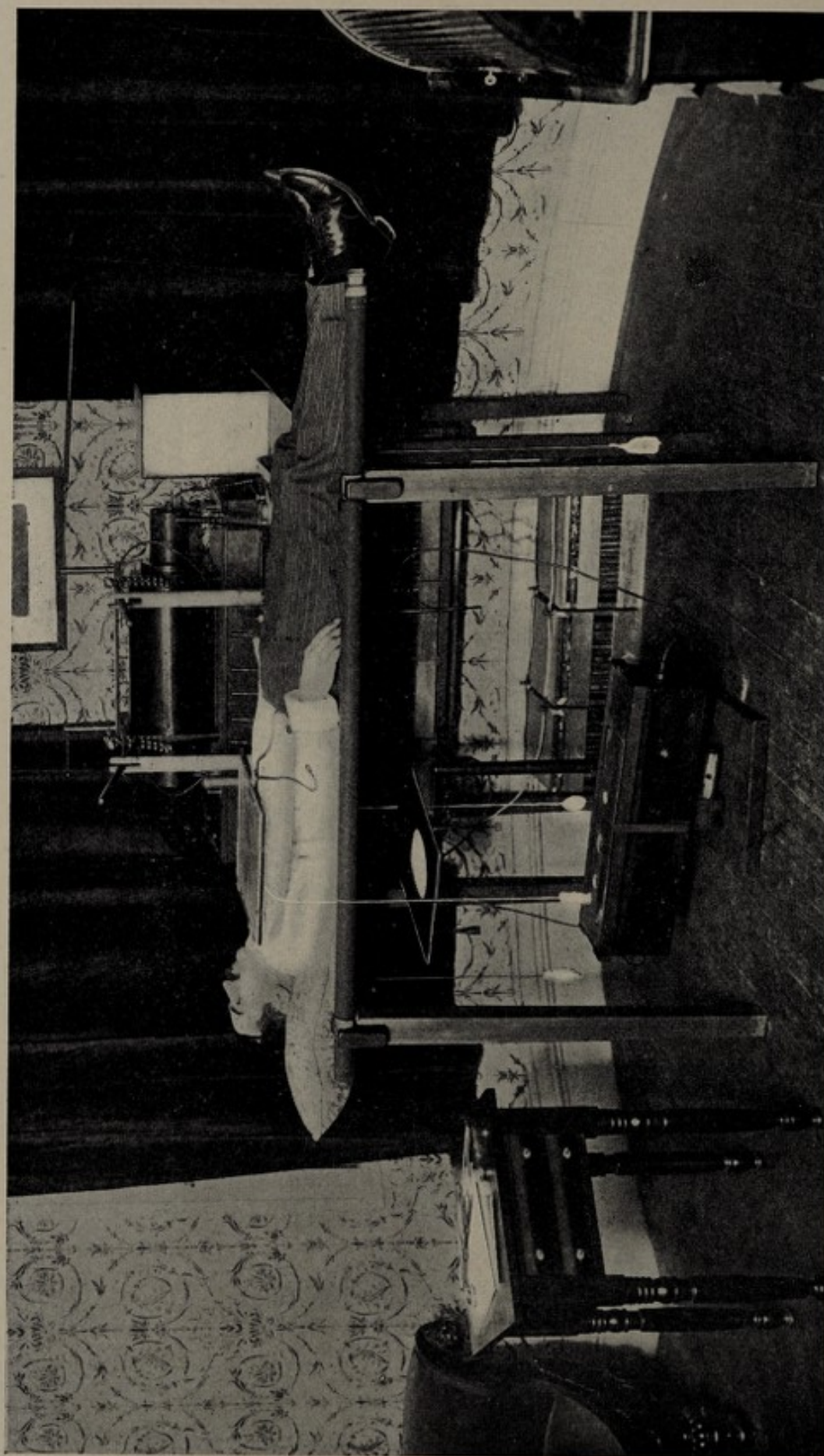


FIG. 48. Office apparatus.

This cut shows stretcher, plumb-lines, and box containing tube, with diaphragm suspended above it and underneath the stretcher. When the stretcher is removed, the legs upon which it rests are slid in under the table upon which the coil stands, and the apparatus is then conveniently arranged for use, if it is desired to examine the patient in a sitting position. See Fig. 58, page 73. On the chest of the patient is seen a seehear, designed by Dr. Rollins. It consists of a fluorescent screen placed above a vulcanite plate of equal size, and separated from it by about 1 centimetre. A stethoscope is connected with the air-space between the plates, so that the chest can be looked at by means of the fluorescent screen, and the cardiac or other sounds listened to at the same time. This is a more recent and better form of seehear than that referred to in the chapter on the Heart.

equivalent so far as the X-rays are concerned to suspension in mid-air. This stretcher should be 51 centimetres (20 inches) wide only and 183 centimetres (6 feet) long, and should be supported about 4 feet above the floor (see Fig. 49). A low chair or other convenient step to




FIG. 49. The general arrangement of the apparatus at the Boston City Hospital is shown in this cut. The poles of the stretchers used in the hospital are kept apart by steel rods, at the head and foot, which have an opening in each end through which the ends of the stretcher poles pass. Fastened to the wooden horses at either end, there is a step on which the orderlies stand when they lift the stretcher with the patient lying upon it on to the horses; the horses would be too high to reach without this aid. Under the stretcher is seen the tube holder described in Chapter II, page 55, with a very thin aluminum screen, which is grounded, above it.

enable the patient to get on to the stretcher easily should be at hand. The height and horizontal position of the stretcher facilitate the work of examination, and if it is desired to examine the patient from the side, or when lying on his face or back, he can readily turn on the stretcher. The stretcher forms an equally convenient support during either screen or photographic examination.

Relative Position of Patient, Tube, and Screen or Plate. — It is to be remembered that the X-ray picture on the screen or photographic plate is of the nature of a shadow such as that cast by an opaque substance on a flat surface by candlelight. The following considerations must, therefore, be regarded in X-ray work: First, the shadow will always be somewhat larger than the object if the tube is not properly placed, but the enlargement will diminish as the distance between object and screen diminishes, and as that between object and tube increases. If the tube is 90 centimetres (3 feet) away, the enlargement of a small object is so slight that it may be neglected; if, however, it is desired to determine the diameter of a large object without error, this may be done by first placing the tube directly under one border and marking its position, and then under the other and marking that (see page 263).

Second, the shape of the shadow will depend upon the angle at which the rays strike the screen or plate. For instance, the optical shadow of a ball is oval when the surface on which the shadow falls is not perpendicular to the rays from the source of light. Third, the outline of the shadow of an object will also vary with the angle at which the object is placed relatively to the screen or plate; for example, the optical shadow of a heart would vary in shape in accordance with its position in regard to either of them.

Distance of the Vacuum Tube. — The distance of the tube from the photographic plate may range from 60 to 92 centimetres (2 to 3 feet), according to the apparatus used and the part to be photographed; but it should always be at a considerable distance from the patient, both on account of the patient himself and also for the effect on the picture. Even with a small apparatus the tube should be at least 40 centimetres away. Because of the desirability of uniformity of place for the tube, I generally put it at a fixed distance from the plate or screen, and have found, as a rule, for my static machine, that of 75 centimetres the best, whatever the part to be observed or photographed, with the exception of the abdomen, pelvis, and hips. Plates must be exposed longer when the tube is at a distance than when

nearer, because the amount of light is inversely as the square of the distance, but the difference in time is rarely sufficient to cause inconvenience to the patient. When speed is necessary, thin parts, such as




FIG. 50. Cut of A.W.L. universal coil, at hospital.

On the right, lying on the adjustable addition to the wooden horse, is seen the fluorescent screen in an open, shallow box, and the dark cloth used to throw over the head of the observer. The stretcher is seen leaning against the wall on the right. On the left of the cut the diaphragm is seen. This diaphragm is made of wood, has a circular opening 15 centimetres in diameter, and its square end is covered with a sheet of lead which has an opening corresponding in size and shape to that of the wood. The diaphragm is held close under the stretcher by means of its long arm, as indicated in the cut, and as seen in Figs. 55 and 60 (indirect plumb-line and others). This manner of support permits movement in a horizontal plane. In this cut, only one cross-piece for holding the arm is seen; there is another on the other side to support the diaphragm when it is turned end for end for the purpose of examining the head.

the hand, may be clearly and more quickly photographed with the tube at half this distance. Exceptions may also be made in favor of shorter distances for other parts when the condition of the patient requires haste. But varying the distance of the tube from the plate

with each exposure makes another point to be considered in estimating the proper length of the exposure; it is, therefore, simpler as a rule to place the tube at the same distance from the plate for a given apparatus.

The following experiment serves to illustrate the effect on the picture of the distance, near or remote, of the tube from the screen or photographic plate, and from the object examined; also of the distance, near or remote, of the object from the plate.

Two pieces of cork .5 centimetre thick and about 10 centimetres square, were taken, and a line ruled diagonally across them. They were then placed upright upon a table, parallel to each other, and 2 centimetres apart, while eight pins of the same size, 2.5 centimetres long, were inserted horizontally through the two pieces of cork along the diagonal line at such intervals that the first pin was 1.25 centimetres, and the last pin 10 centimetres above the table. Four photographs of these pins were taken with the tube at a distance of 30, 45, 61, and 92 centimetres respectively. Figure 51 shows the relative position of the tube, pins, and plate. It will be seen by examining the cut (see Fig. 52) that the first pin, 1.25 centimetres from the plate, was clearly outlined in all four radiographs, but most so where the tube was 92 centimetres from the plate. The pin that was 2.5 centimetres (1") from the plate was not clearly defined when the tube was 30 centimetres from the plate, whereas the pin 5 centimetres (2") from the plate was defined with tolerable sharpness with the tube 92 centimetres from the plate and 87 centimetres from the pin. The pin 10 centimetres (4") from the plate, with the tube at a distance of 30 centimetres from the plate, was most exaggerated in size and least sharply defined of all the pins in the four photographs. It is unnecessary to describe the cut further, as it speaks for itself. If the object examined has a length greater than the length of the pins used in this experiment, of course the error would be greater. This experiment demonstrates that to get the best definition and to prevent exaggeration in the size of the object that is to be photographed, or observed on the fluorescent screen, the object must be near and the tube distant from the plate; and that the nearer the tube to the plate the more important is it that the object also be near the plate.

Position of Tube and Screen or Plate. — The tube should be so placed that the rays will fall as perpendicularly upon the screen or photographic plate as the given conditions will permit. The following diagrams, like the cuts of the pins (see Figs. 51 and 52), direct attention to the effect

on the picture of the position of the tube and plate with reference to the part to be photographed, or examined with the fluorescent screen, and likewise point out the importance of having the plate as nearly as pos-




FIG. 51. Cut of photograph showing relative position of the cork containing the pins, the photographic plate, and the vacuum tube when Fig. 52 was taken.

sible at right angles to the direction of the rays (see Fig. 53). The target of the tube should be directly opposite the part to be examined.

Method for securing a Constant Position for the Target in Relation to

the Patient. — This constant position is of primary importance, and may be obtained in the following way.

Plumb-lines. — The stretcher support should be provided with two plumb-lines, one hanging from either end of its median line; or if the floor of the room is uncarpeted a line may be drawn upon it parallel with this median line. The stretcher is narrow and sinks a little with the weight of the patient, so that it is easy to place him in the middle of it and get his median line directly over that of the stretcher. The physician must be sure that the patient lies perfectly flat. After the patient is comfortably placed flat on his back, as described, a cord 150 to 180 centimetres (5 or 6 feet) long, with a small weight on either end, is put across his chest on a level with his fourth rib. The ends of this line will hang down on either side and form a second pair of plumb-lines. The physician then sights from one end of this line to the other, and from end to end of the first pair of plumb-lines described, and places the target of the vacuum tube at the point where a line drawn between the first pair of plumb-lines would intersect a line drawn between the second pair of plumb-lines (see Fig. 48); the target is thus brought immediately under the point where the median line of the body crosses a line joining the fourth ribs on the front of the chest, and secures for the tube a position well adapted for the examination of the thorax, and one which may be readily found for a second examination. Of course any other determinate point than the one described might be chosen. (See page 92.)

I tested the correctness of the plumb-lines as a guide to the position of the tube, by making two successive examinations, the patient getting up and the tube being moved after the first examination, and both patient and tube being arranged again for the second. The outline of the heart and ribs, traced by means of the fluoroscope in these two examinations, differed only by the width of the line marked on the skin.

Various other methods may be used to determine the proper position for the target, but it is unnecessary to detail them here.

Indirect Plumb-line. — When the median line is not available as a point of reference, an indirect plumb-line (see Fig. 54) may be used. The method of using this plumb-line is shown in Fig. 55.

Relative Position of Patient, Tube, and Screen or Photographic Plate Noted. — The comparison of two or more X-rays examinations made at different times, of a diseased organ or part, or the comparison of a diseased with a normal organ or part, is often essential; therefore the relative position of patient, tube, and screen or plate should be noted at the

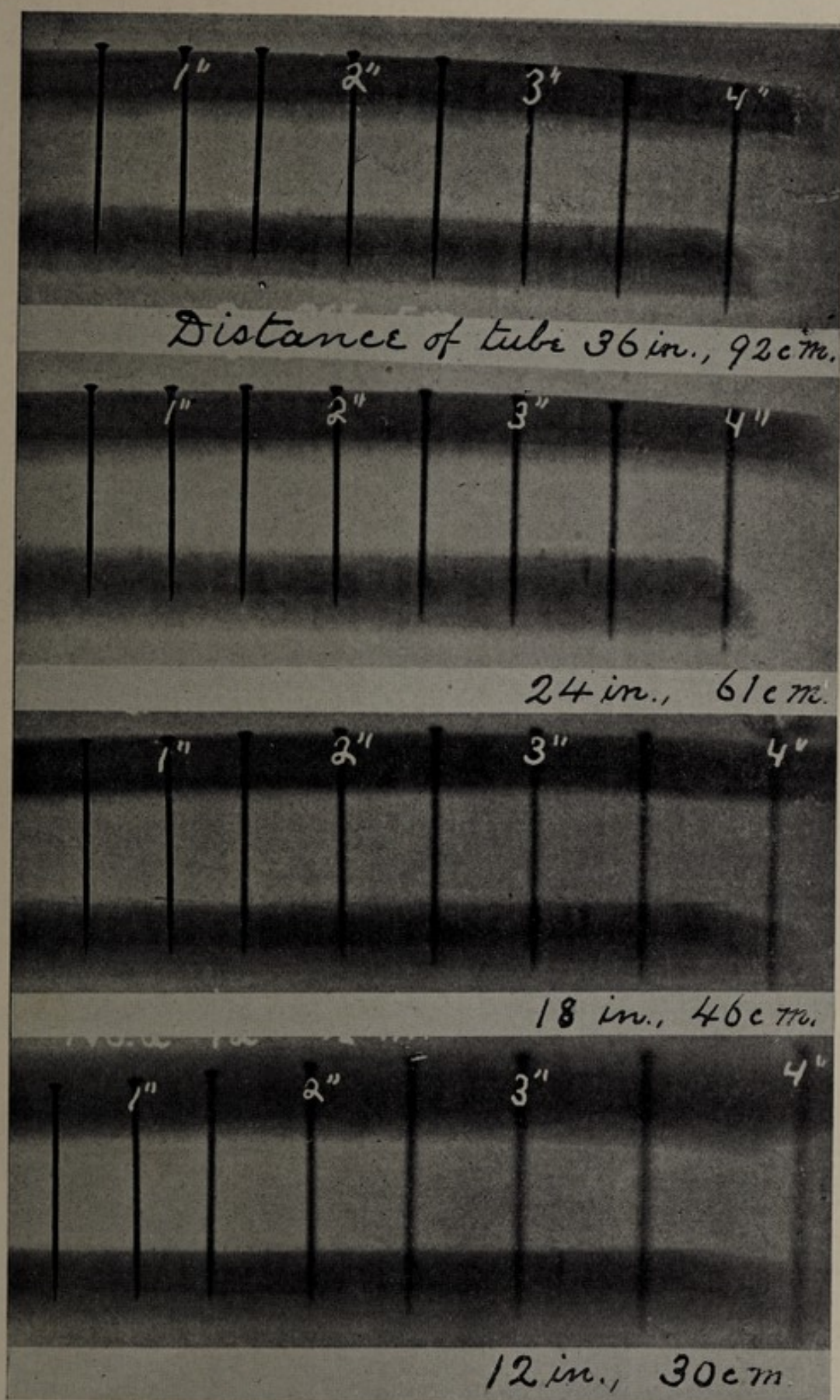


FIG. 52. Full size of radiograph of pins inserted into cork at various distances from the vacuum tube and plate respectively. The figures in black give the distance of the plate from the tube; those in white, the distance of the pins from the plate (in inches).

first examination, so that these same positions may be renewed at the second or third examination.

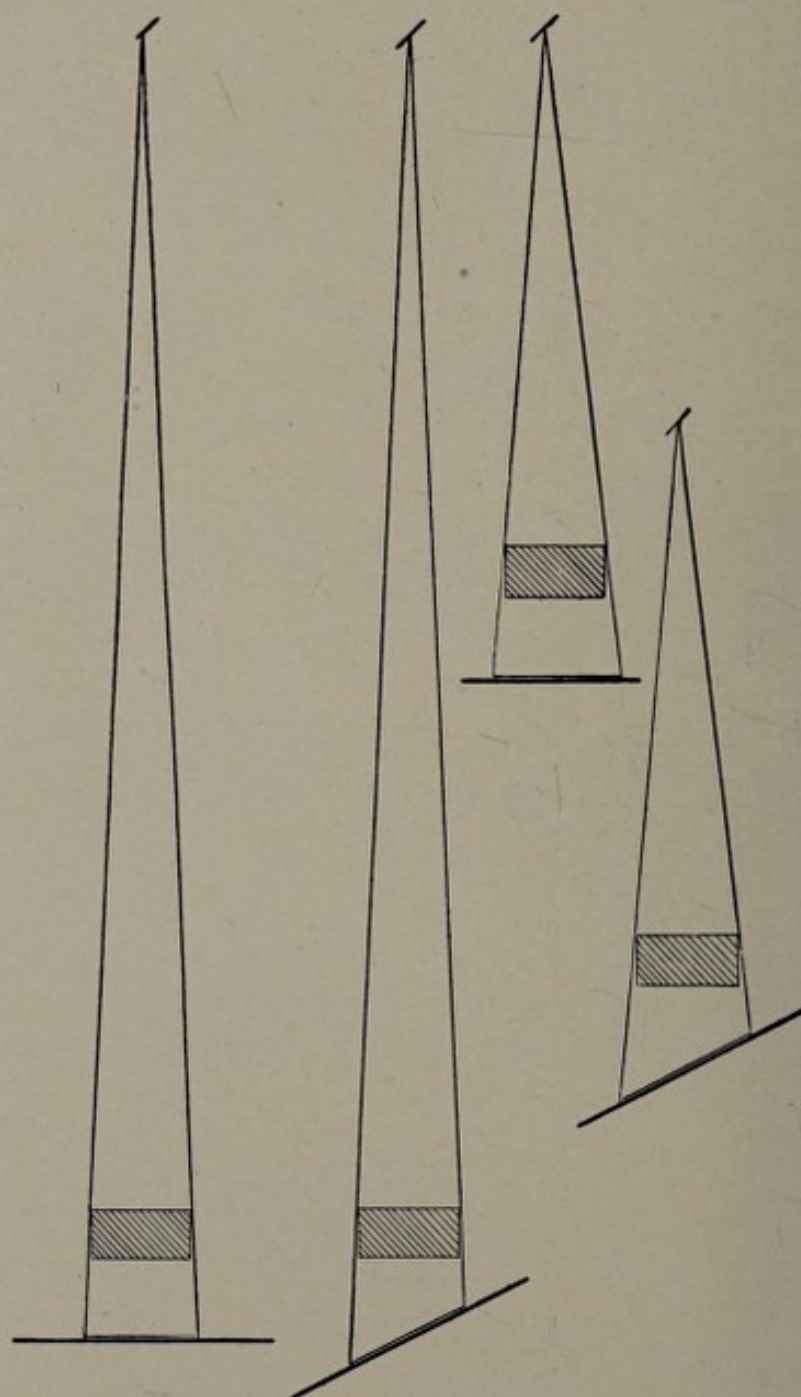


FIG. 53. The diagrams are drawn to scale. In the two left-hand diagrams the target of the tube was 75 centimetres (30 inches) from the plate; in the two right-hand diagrams, 38 centimetres (15 inches) from the plate. The object is 6 centimetres wide (about $2\frac{1}{4}$ inches), and the upper surface is 7.5 centimetres (3 inches) above the plate or screen.

The shadow of the object is indicated by a line just above the line representing the screen or plate.

These diagrams illustrate the effect on the shadow when the object to be examined with the fluorescent screen, or photographed, is at some little distance from the screen or plate; when the target is at a distance or near the screen or plate; and, third, the effect of the inclination of the plate or screen on the picture.

It is more comfortable for the patient and more convenient for the practitioner to examine patients in the hospital reclining on the stretcher on which they have been brought to the X-ray room from the ward.

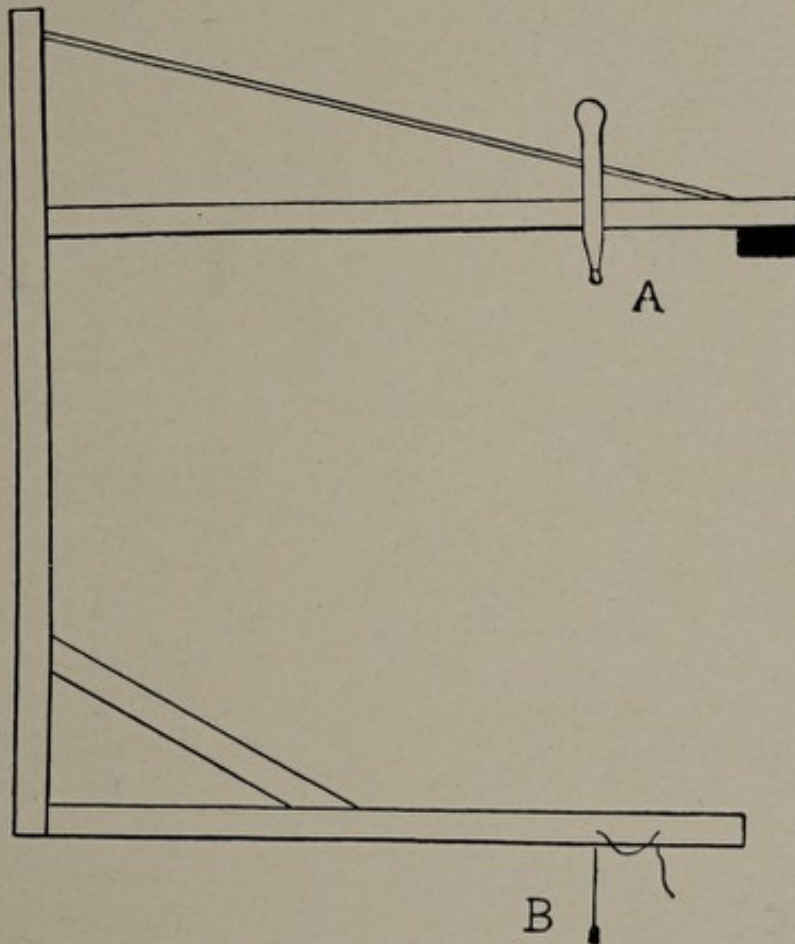


FIG. 54. Indirect plumb-line. Scale $\frac{1}{4}$.

An instrument, which is a form of plumb-line, to be used when the patient is lying on the stretcher, that I have devised for determining the exact position of the vacuum tube when it is desired to place it directly under the point to be examined. This instrument is especially useful in cases where the median line is not available as a point of reference. By it the proper position for the tube may be obtained when it is desired to determine the right and left borders of a large heart separately.

This instrument is made of strips of cedar 3 millimetres thick and 2.5 centimetres wide. There is a counterpoise of lead on the end of the arm beyond *A*. The vertical piece from which the arms *A* and *B* extend is made of two strips of cedar, fastened at either end and separated 2 centimetres in the middle by a piece of cork. This is done to give stiffness.

A piece of thin wood about 5 centimetres square, with a depression in the centre (not shown in the figure), is placed on the patient so that the depression is over the point to be examined, directly under which it is desired to bring the vacuum tube. The rounded point, *A*, is placed in the depression, and the rest of the instrument being free to swing, the weight, *B*, will hang directly under *A*; the position for the target of the tube is just under *B*.

But out-patients and all those well enough to walk to the X-ray room may be examined, if desired, while sitting or standing; though even for such patients the reclining position has advantages, not the

least being the fact that the patient is in a restful position and the examination is the reverse of irksome to him.

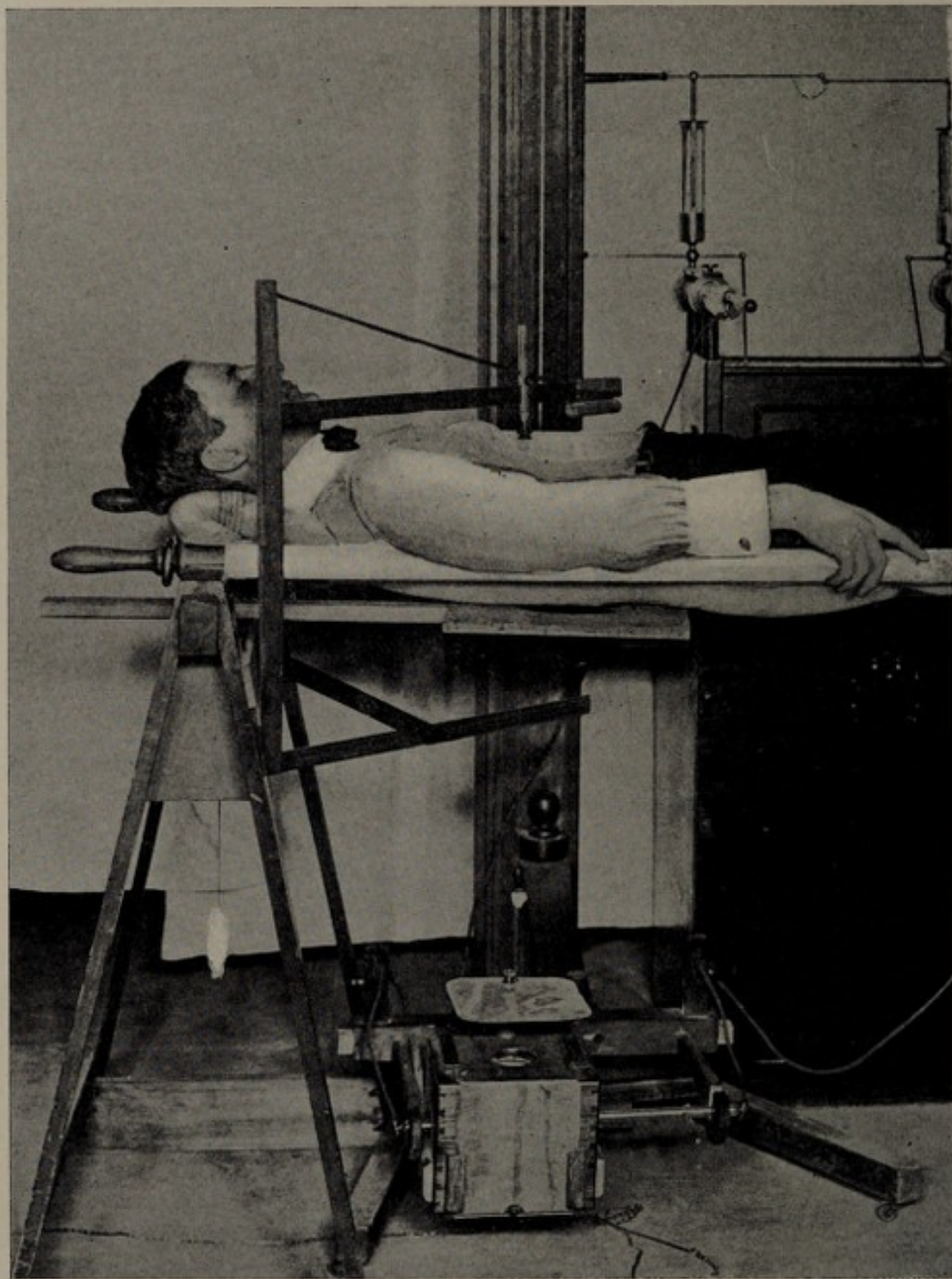


FIG. 55. Shows method of using indirect plumb-line.

At times, patients who have serious chest disease cannot lie down without discomfort, and they should, of course, be examined while sitting up. In pneumohydro or pneumopyothorax the sitting position

should always be used, and in obscure diseases of the chest it is well to look at the patient both when sitting up and lying down.



FIG. 56. Shows a patient sitting on a high stool with his back resting against a vertical canvas support.

The fluorescent screen is in a shallow wooden box supported on the frame which carries the vacuum tube. The tube, which has been temporarily removed from the lead-lined box, is 71 centimetres (28 inches) from the screen, directly and squarely behind the patient, and opposite the median line of the body. The frame which carries the screen and the tube can be moved up or down at pleasure, its weight being supported by a counterpoise inside the square upright on the patient's right. The vacuum tube can also be swung horizontally.

When the physician is seated in the chair, his eyes are about on a level with the patient's heart. This method is not as convenient as that in which the swivel chair described below is used. (Fig. 58.)

Sitting Position. — For examining the patient in a sitting instead of a recumbent position, the following arrangements are convenient.

The patient is placed on a stool as in Figs. 56, 57, or better in a revolv-

ing arm-chair, as in Fig. 58, the height of which is adjustable, similar to what is known as an office chair, but provided with a screw at one side to clamp it and prevent it from moving when not desired. The back is made of leather, through which the rays pass easily, and is straight, so that the patient can lean against it and yet hold himself in an upright position.

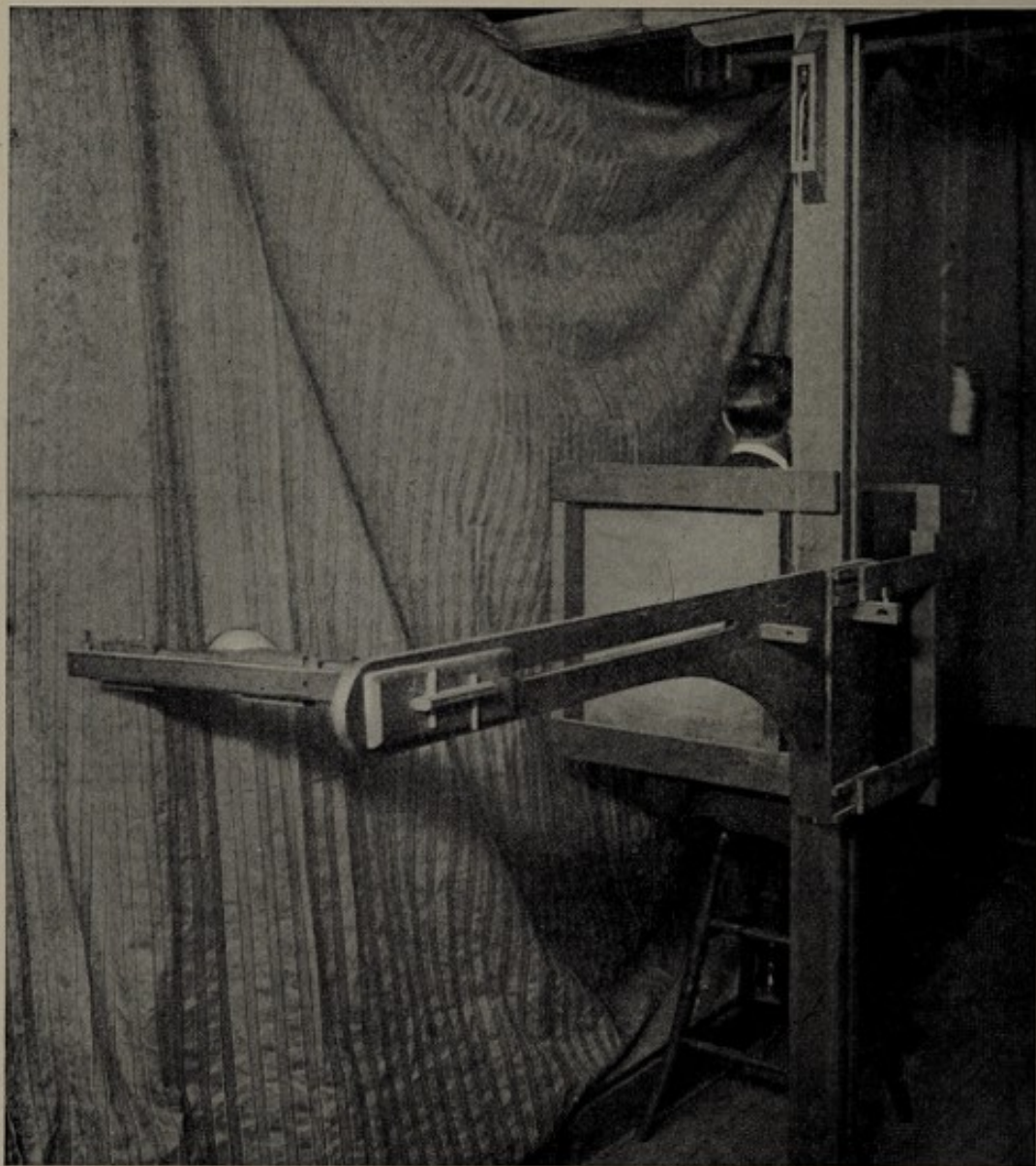


FIG. 57. Gives the rear view of Fig. 56.

The position for the feet of the chair, with regard to the target, should be marked on the floor.

The tube, held in a stand with a vertical adjustment so that it can be raised or lowered, is placed behind the patient at a distance of 75 centi-

metres from the screen, on a level with the fourth rib. The tube can also be swung horizontally by means of a simple adjustment, so that the




FIG. 58. Shows the method of examination when a sitting position is desired.

The patient is seated in a revolving chair which has a leather back through which the rays can pass. The height of the seat can be adjusted to suit the patient. The tube is in the box seen at the left of the picture. The aluminum screen which belongs in front of the box has been removed. The stretcher shown in Fig. 48 has been taken away, and the legs that support it have been pushed into their grooves. One heavy curtain has been drawn back to show the three shades used in addition to this curtain for darkening the room. The practitioner is so seated that he can control with his right hand the length of the spark-gap, the amount of the condenser, and the speed of the commutator; therefore he can vary the light to suit his needs as the examination proceeds.

light can pass through the body at an angle, if desired, or the tube may be arranged as in Fig. 58.

The target should be placed 75 centimetres from the patient and opposite the median line where it is crossed by the fourth rib. To obtain the proper distance from the patient, a line of the desired length may be drawn on the floor at right angles to the middle of the back of the chair; to determine the proper height, the distance from the floor to the fourth rib may be measured by a rod from the floor up.

The physician should be seated on a low stool or chair, of such a height from the floor that his eyes are at a convenient level for looking at the chest with the fluorescent screen, the seat of the patient being higher than an ordinary chair; 55 centimetres from the floor is a convenient height for the seat of the patient's chair, and 35 centimetres for that of the physician's. The chair should be turned all the way around during the examination so that the organs of the chest may be examined from all points of view, the arms of the patient being held over his head when they interfere with the examination.

Standing Position. — The patient can also be examined while standing if it is desired, the tube being held in the required position by means of an adjustable tube holder.

These cuts show the method of examining the chest with the target of the vacuum tube placed at a point opposite the junction of the median line of the body with a line drawn across the fourth ribs; but cases occur in which the chest must also be examined from other points of view, in order to obtain all the information desired. Some of these cases are taken up in later chapters, but it is unnecessary to discuss them all in detail, as the principles upon which they rest have been sufficiently indicated.

GENERAL RULES FOR EXAMINATION WITH THE FLUORESCENT SCREEN

Dark Room. — All examinations with the fluorescent screen or fluoroscope should be made in a dark room, and light from all sources should be excluded; even that from the vacuum tube by enclosing it in a box. Before making an examination during the daytime the physician must remain in the dark room for about 10 minutes, and if he goes into this room directly from out-of-doors, he must wait longer on light than on dark and cloudy days. This delay is irksome but necessary, unless he adopts the simple expedient of wearing dark glasses for 15 or 20 minutes before going into the X-ray room. At one time it seemed to me that the above-mentioned delay might prove a serious

obstacle to making X-ray examinations, but I found that by wearing dark glasses during the last portion of my hospital visit, my eyes, on going into the dark room, were soon in a condition for seeing the image on the fluorescent screen. When a photograph is to be taken, the dark room and dark glasses, or the waiting, are of course unnecessary.

Adaptation of the Eyes to the Dark Room. — After exciting the tube, if it is uncovered, the eyes see nothing in the dark room except the green light in the tube itself; all else is black darkness; but after a few moments the eyes begin to recognize objects in the room, and as soon as this can be done their ability to see other objects augments rapidly, and within a few seconds many things are seen that could not be recognized at first. When the eyes are once adapted to the darkened room the power of seeing there is not temporarily lost even if it is left for a moment to go into a lighted room. Certain changes or adaptations to conditions of light, which occur in the eyes, require time.

Eyes of different individuals do not see equally well the appearances on the fluorescent screen. It is not a question of acuteness of vision only, I think, but eyes differ in this respect.

Examination with the Open Fluorescent Screen. — The advantage of this method (Fig. 59) is that the eyes may be at a distance from the screen when it is necessary to study the whole of a large picture, as in comparing one side of the thorax with the other, — this view is of great importance in diseases of the chest, — or near to it, if desired, when some detail is to be considered. The following cut shows the method of examination by means of the open screen, which is the one I habitually use, and for examinations of the chest it is the most satisfactory. The screen is 30 × 35 centimetres (12 × 14 inches) in size, and is in a shallow box open at the top. A portion of the plumb-line at the head of the stretcher is seen in the cut, and both ends of the plumb-line, that is passed across the chest on a level with the fourth rib, are also seen. These lines, as already described, are used to determine the position of the target. The line across the chest is usually removed before the examination, but is left in the picture to show the method. The observer generally stands on the patient's right, but is seen here standing on his left in order not to obstruct the view, as the position of the static machine did not permit the photograph to be taken from the left side.

When it is desired to compare the apices of the lungs, a screen with a curved piece cut out of one of the sides, so as to admit the chin, is use-

ful, as by this device the screen can be raised higher up on the chest, and a more complete view of the apices can be obtained.

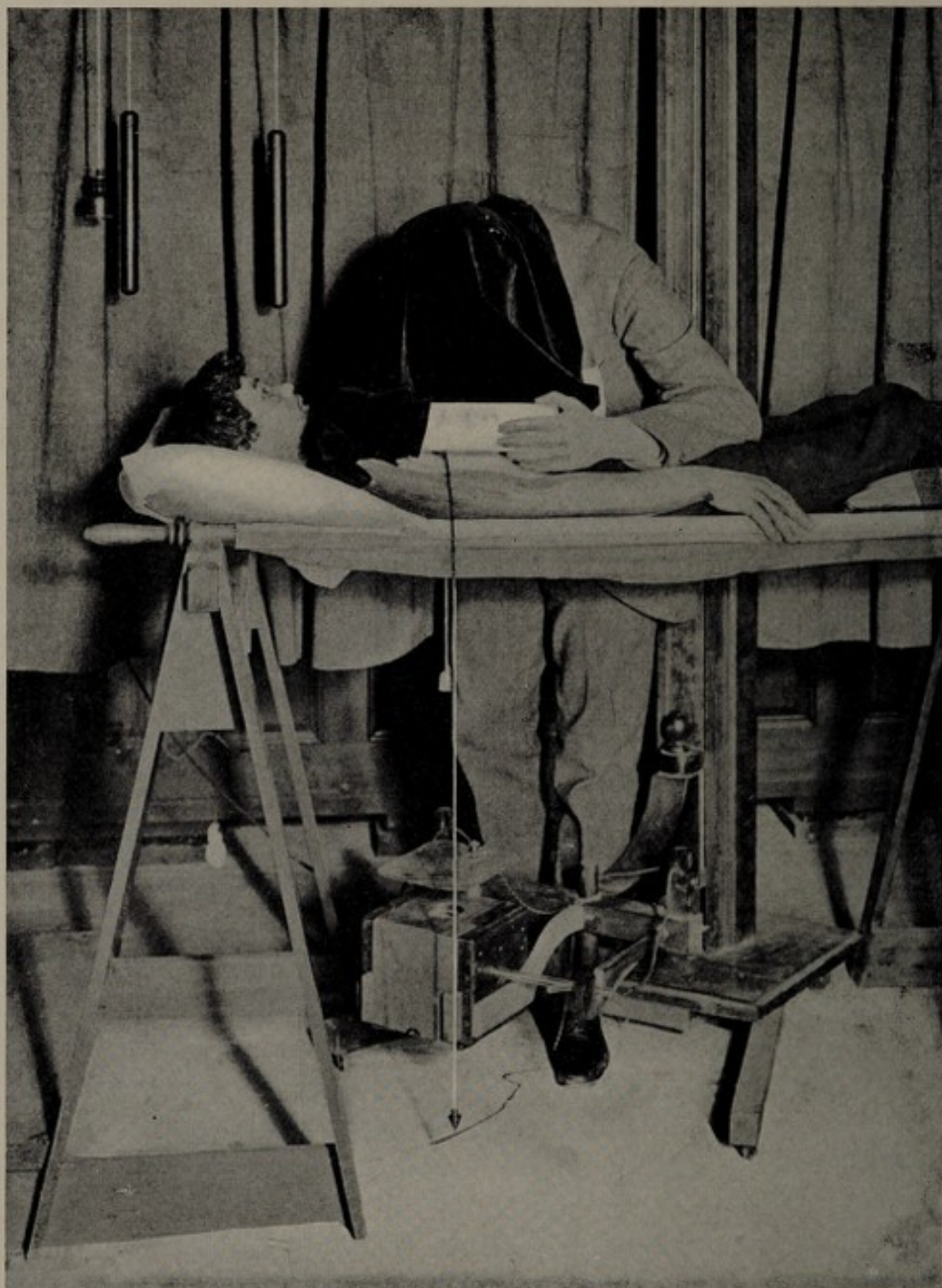

FIG. 59. This cut shows the method of examining the whole thorax with a large open screen, 30 by 35 centimetres, placed in a shallow box, the side of which is shown under the hand, the dark cloth being drawn aside for the purpose. The method here shown is the best for comparing one side of the thorax with the other. The observer is standing on the left side of the patient, in order that the latter may be visible. The observer should stand on the right side and have one hand on one of the long handles seen above the patient's head, as by this means the amount of light, which should be varied as the examination proceeds, is controlled.

The practitioner should be so placed, as shown in Fig. 58, and indicated in Fig. 59, that he can vary the amount of light as the examination proceeds, without lifting his eyes from the fluorescent screen; but the light must be adjusted, as seems best, for the actual moment of drawing. It can and should be altered, however, when needed, from time to time, as the different organs to be traced demand.

Examination from Different Points of View. — It is often an advantage to examine the thorax or the extremities from different points of view. To this end the patient may turn on the stretcher, or the screen may be moved, or both. More specific directions for examining special organs will be given in the chapters devoted to the consideration of special diseases.

METHOD FOR RECORDING THE APPEARANCES SEEN ON THE FLUORESCENT SCREEN

The photograph makes a record in itself, but the appearances seen on the screen must be made permanent for further reference. They may be recorded without removing the clothing, or with the part to be examined bared. The latter is the better way when the thorax is in question.

Without Removal of Clothing; Tracings made on a Thin Sheet of Glass or Film of Celluloid. — First, points of reference are necessary in order that tracings made at different periods may be compared, if desired; and these may be obtained by placing pieces of metal over certain parts. For instance, when examining the thorax, a piece of metal rod covered with rubber is placed over the sternum in the median line, and other pieces of metal over the nipples. The screen is then covered with a thin sheet of glass or film of celluloid and placed on the chest (see Fig. 60). The shadows of the points of reference are first drawn in with a lithographer's pencil, and afterward the appearances the physician desires to record. The celluloid or glass may be washed with alcohol and used again after the lines drawn on it have been traced on paper.

With Removal of Clothing; Tracings made upon the Skin. — The pencil used for drawing in the outlines seen should make a good mark on the skin with the slightest touch, and it should be placed in a metal holder or be provided with a narrow strip of lead along its length, because this metal casts a shadow, and therefore the physician is able to follow its point as he traces the appearances observed. I have had some special pencils made, but the crayons, in brass tubes, which actors

use for pencilling the eyebrows answer the purpose very well. No metal is necessary for obtaining the points of reference as is required in the method just described. A mark is made on the skin, with the

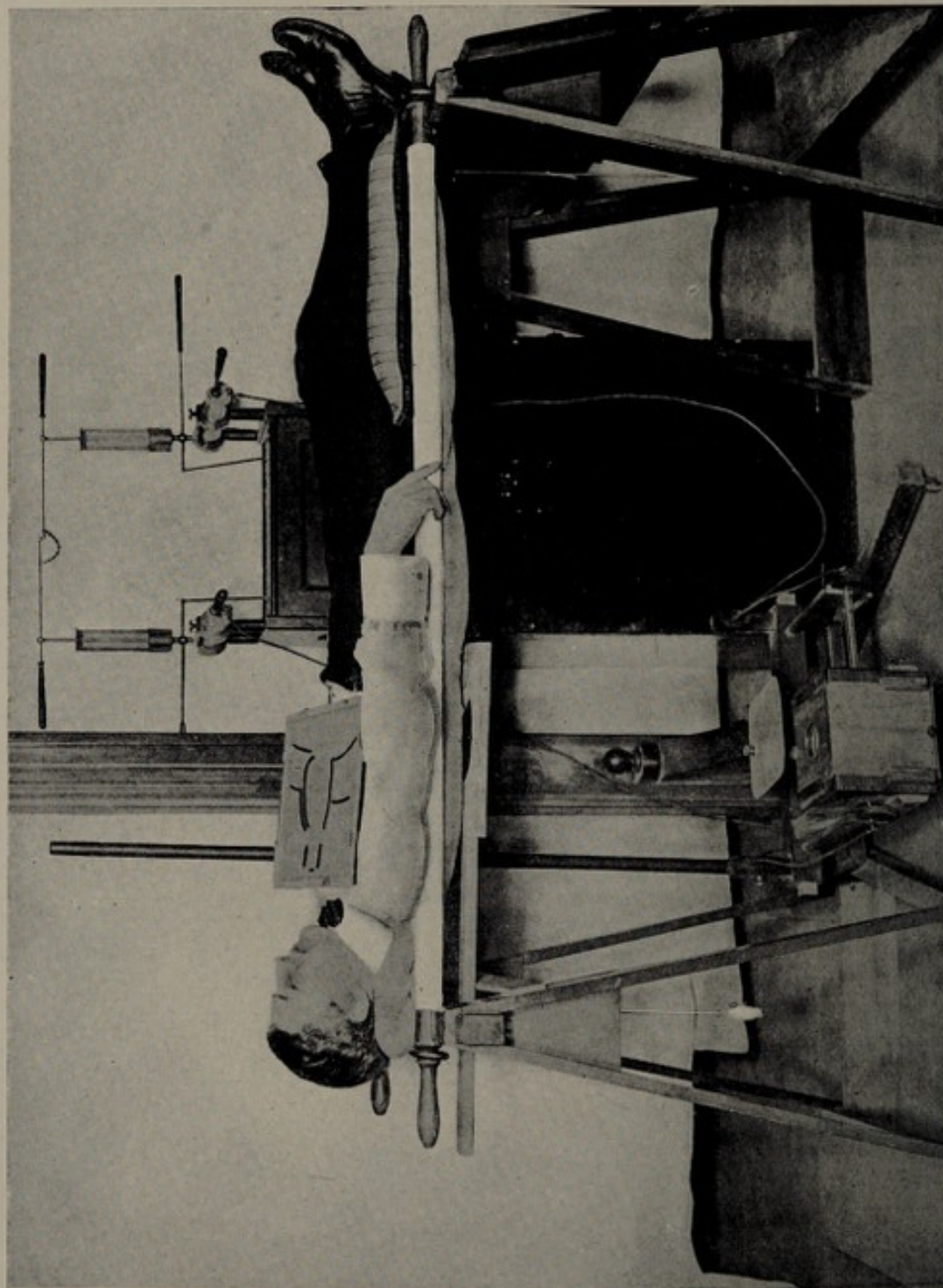


FIG. 60. Shows method of examining a patient with the screen with celluloid cover, on which the outlines of the heart and diaphragm have been traced. The diaphragm under the stretcher is pulled a little out of place so that it may be better seen; it should, of course, be directly under the outlines, as they are being drawn on the screen, when an examination is made.

radiographic pencil described, over the sternal notch, and another over the ensiform cartilage, in order to indicate the median line, which has been obtained by drawing a line from the umbilicus to the sternal notch. The screen is then held sufficiently above the surface of the body to allow the hand to move freely while tracing upon the skin the appearances observed on the screen (see Fig. 61). It is well to go over all the lines traced a second time (after the patient has taken several deep inspirations), and to check them carefully, in order that no mistakes may be made. The border of an organ may often be determined with advantage by a series of dots, which can be joined after the screen has been removed, instead of by full lines; for if dots are made there is less likelihood that the skin will be pushed out of position by the pencil as it moves over its surface, and although it is not liable to be moved out of place in any case unless the tracing is clumsily done, still these dots are a simple precaution. The next step is to copy these lines on to tracing cloth.

Outlines made on the Skin traced on to Tracing Cloth. — A piece of tracing cloth or tracing paper about 30 centimetres square, across the middle of which a straight line has been ruled, is placed upon the chest in such a position that its median line falls directly over that of the body. The sternal notch, ensiform cartilage, and the nipples should be traced upon the cloth, and, if desired, the outlines also of any of the ribs and the costal border may be added; but the former are usually sufficient as points of reference. The tracings made on the skin are then retraced on to the cloth. The cloth must be held firmly but gently while these tracings are made; it must not be allowed to slip from its original place, nor must it be pressed so hard as to slide it, and thus its position or that of the skin be disturbed. The tracings on the chest should be retraced on to the cloth before the patient has changed his position, and after these lines have been copied the physician should see, before removing the cloth, that the tracing upon it agrees perfectly with the tracing upon the skin. The lines on the skin are easily removed by means of a little alcohol.

Measurements made on Chest transferred to Blanks. — The appearances seen on the chest may be also recorded on suitable blanks. Some fifteen or twenty years ago I had a plate made that gave the outlines of the chest, which was copied from an anatomical plate, but reduced so that it was one-half the normal size. The blank made from this reduced plate I used for making records of auscultation and percus-

sion, as any measurements made on the chest could be transferred to the blank by reducing them one-half. These blanks I now also use for records of X-ray examinations. The outlines drawn on the chest may be measured, reduced, and transferred to the blanks as was done with

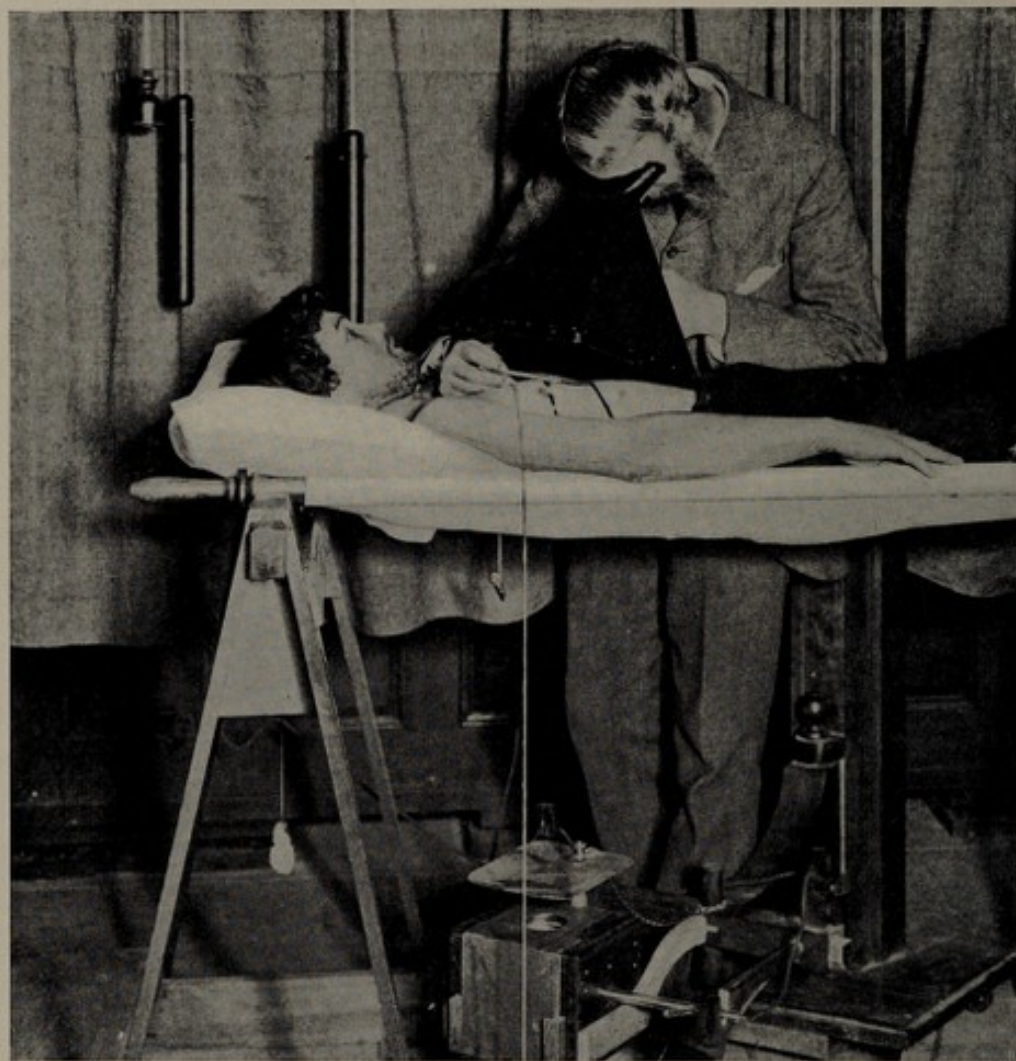

FIG. 61. Shows the method of drawing the outlines on the patient's skin while looking through the fluoroscope. The fluoroscope is held farther away from the patient than is necessary in practice, in order that the pencil which is under it may be shown in the picture. The observer usually stands on the patient's right, but in order to show the method of examination better, he is seen standing on the patient's left.

The diaphragm (see Fig. 60), which is placed under the patient's chest in order to obtain a better definition of the outlines, does not show in this cut.

the records of auscultation and percussion. Some of the cuts given in the following pages to illustrate the appearances seen in the chest are photographic reproductions of the records thus made (see Fig. 106), while others are from photographs of the tracings made on the tracing cloth (see Fig. 82); both kinds of cuts are about one-third life size.

Additional Records. — The name and age of the patient, the volume and page of the records, the diagnosis, and any memoranda referring to the X-ray examination, should be made upon the tracing cloth as soon as it is removed from the chest, or on the blank described, in order to reduce the chance of any mistake to a minimum; or these additional data (together with the physical examination, history, etc.) may be made upon blanks of the same size prepared for the purpose, and pinned to the tracing cloth after the outlines have been drawn upon it. A complete and convenient record of a case is thus obtained for filing.

Methods of Localization. — Various methods have been devised for locating the position of foreign bodies and of new growths in different parts of the body. Many of them are very ingenious, but somewhat complicated for use by the general practitioner. The subject of localization will be further discussed in later chapters, but I will outline four simple methods that require no special apparatus by which the observer may determine whether the object to be located is nearer the front or the back of the chest. These methods are based in part on the fact that if the outline of the shadow is sharp and not exaggerated, the object casting it is near the screen.

The principle involved requires that two examinations be made with the fluorescent screen, each from a different point of view; or two X-ray photographs may be made, except when the third method is used. The first method requires the movement of the tube only, after the first examination has been made, the position of the screen remaining constant in the two examinations; the second method demands that both the screen and the tube be moved, their respective positions with regard to the patient being reversed; the third method depends upon the movement of the object to be located; and the fourth upon the movement of the part of the body in which the given object is situated. The last method is described in some detail in the chapter on Foreign Bodies, pages 531 and 532.

First Method. — The screen is placed on the back or front of the chest, as the case may be, and the tube opposite the screen on the other side of the patient. The position of the shadow cast upon the screen is then noted. Next the tube is moved — vertically if the patient is examined sitting up, and horizontally if he is lying down — through a distance of 30 to 60 centimetres, and the position of the shadow is again noted. If the object which makes the shadow is near the screen, there will be little difference between the two positions

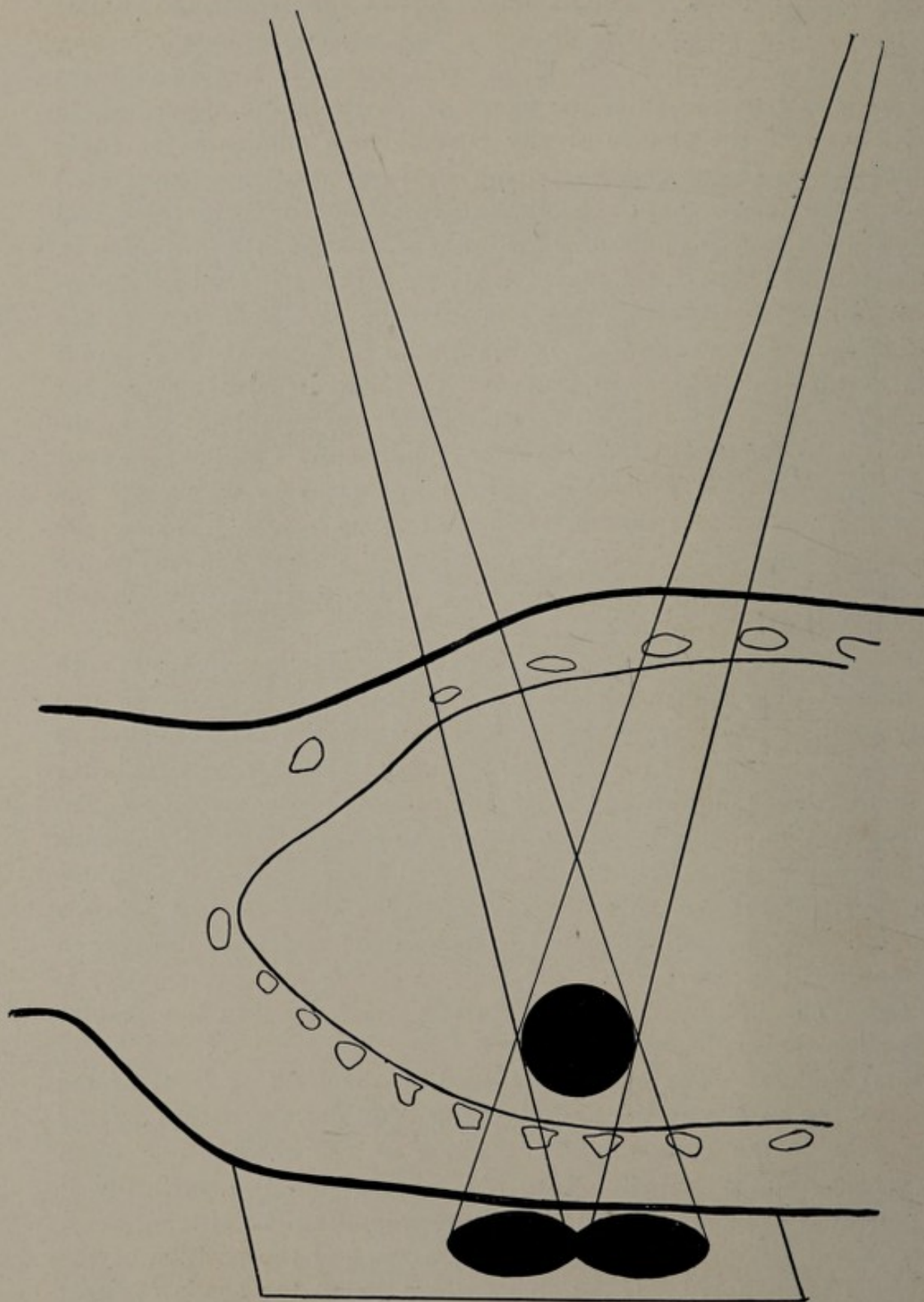


FIG. 62. First Method: Tube (not shown in cut) 60 centimetres from screen. First position; the tube is about as high as shoulder; second position, about on a level with umbilicus. The two shadows cast on the fluorescent screen, which is against the patient's back, are near together and more sharply defined: the object, therefore, is near the screen.

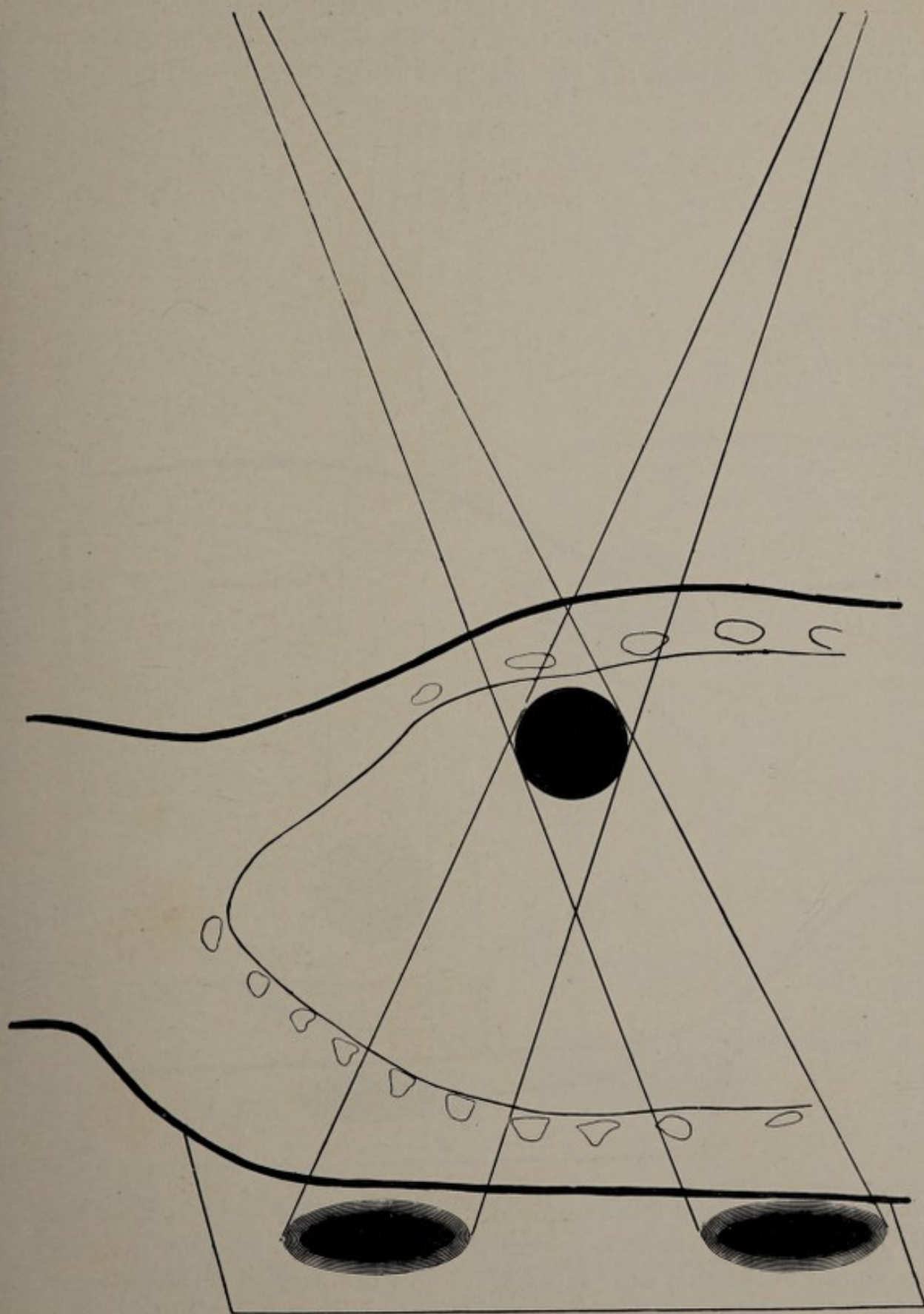


FIG. 63. First Method: Tube (not shown in cut) 60 centimetres from screen. First position of the tube, about as high as shoulder; second position, about on a level with umbilicus. The two shadows cast are farther apart, larger, and less sharply defined when the object is distant from the screen. Compare with Fig. 62.

of the shadow and the shadows will be more sharply defined. If, on the contrary, the object is distant from the screen, there will be considerable difference between the two positions of the shadow, and the shad-

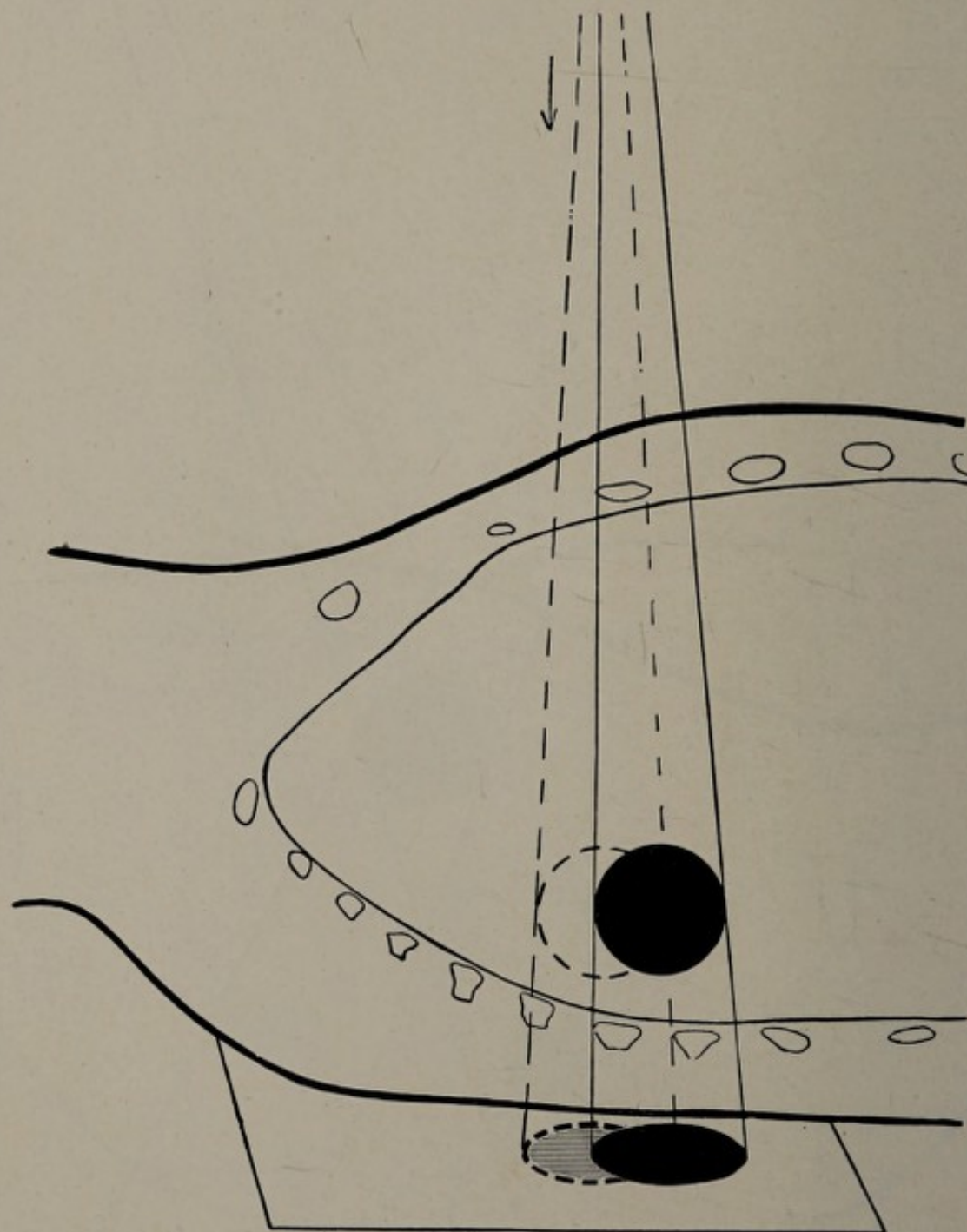


FIG. 64. Third Method: Tube (not shown in cut) 75 centimetres distant from screen. Movement of the shadow in expiration and inspiration when the object was near the screen.

ows will be larger and less sharply defined. Figures 62 and 63 illustrate this method. The screen is against the back of the chest and the tube (not shown in the cut) was placed in front of the patient, 60 centimetres (2 feet) distant from the screen, and about as high as the shoulder when

the lower of the two shadows was cast, and about on a level with the umbilicus when the higher was cast. The object in Fig. 62 is seen near the back of the chest and therefore the shadows are sharply defined and near together. In Fig. 63 the object is near the front of the chest,

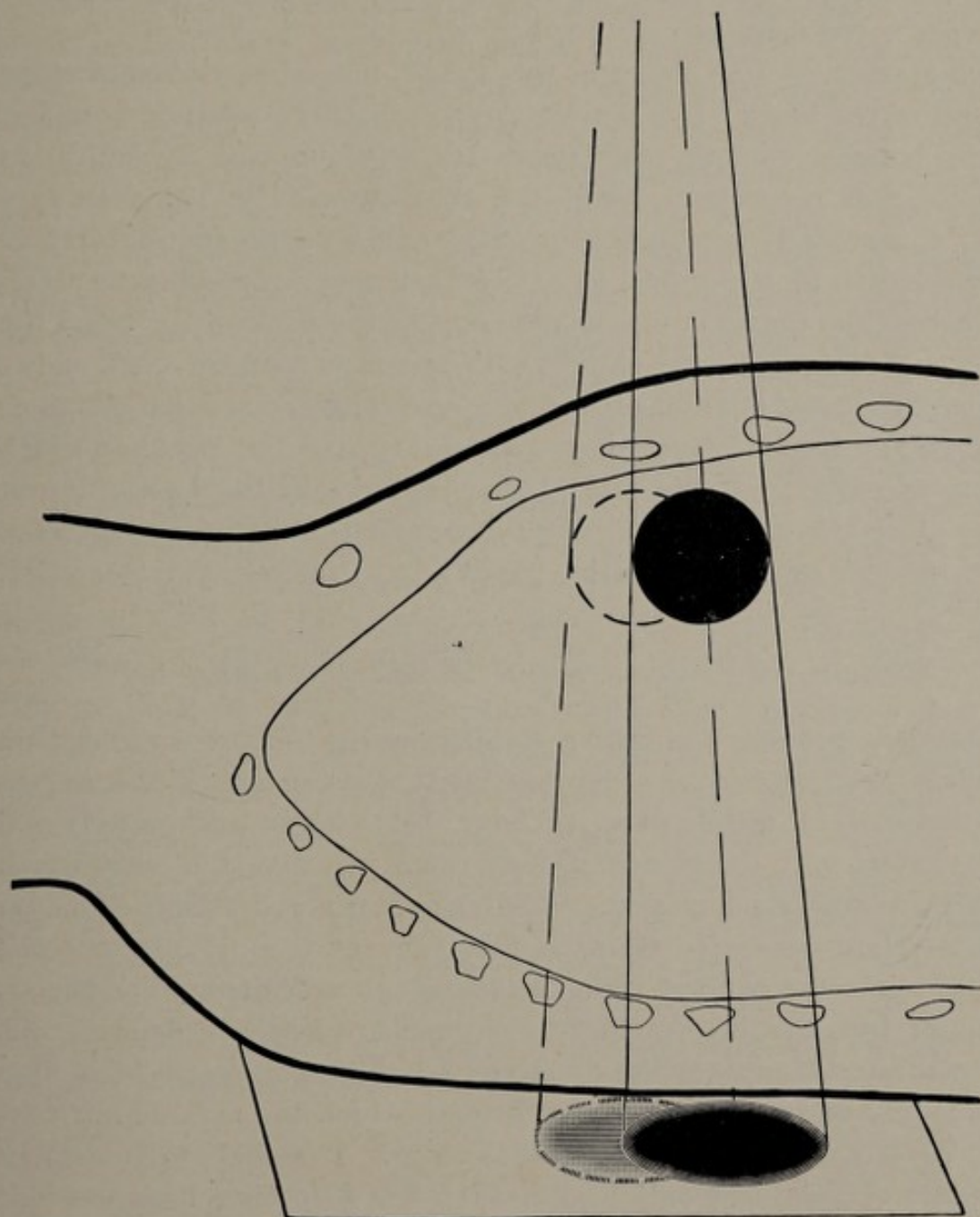


FIG. 65. Third Method: Tube (not shown in cut) 75 centimetres from the screen. Movement of shadow in expiration and inspiration when the object was distant from screen. The shadow moved more and was larger than when the object was near the screen. Compare with Fig. 64.

and therefore the shadows are seen farther apart, and they are larger and less sharply defined.

Second Method. — The screen is placed on the back of the patient and the tube in front of his chest, and the definition of the shadow on the

screen is noted; the positions of the tube and screen are then reversed and the definition of the shadow is again noted. By comparing the respective sharpness of definition of the two shadows it is obvious that the observer will be able to determine whether the object is nearer the front or the back of the chest, for the nearer the object is to the screen the sharper is the definition of the shadow.

Third Method. — The object in this case is moved by the respiratory movement of the lung. If it is near the screen there will not be much difference between the two positions of the shadows cast in expiration and inspiration respectively, and the shadow will be more sharply defined; if distant from the screen there will be a greater difference, the shadows will be larger and less sharply defined. In order to determine whether the object is nearer the front or the back of the chest the observer should examine the patient with the screen on the back of the patient and the tube in front of him, and next with the relative positions of the tube and screen reversed, and then compare the distance which the shadow moves and the size of the shadows in the two different positions of the tube and screen. Figures 64 and 65 illustrate this method. See also chapter on New Growths, pages 333 to 338, case of Daniel M.

METHOD OF EXAMINATION BY X-RAY PHOTOGRAPHS

Precautions necessary in taking Radiographs. — Before a radiograph is taken all metal should be removed from about the part as far as possible. Buckles of metal, glass or bone buttons, or splints of metal would interfere with the picture if they came just over the parts which it is desired to show most clearly. Wooden splints and dressings of cotton do not interfere except in so far as they prevent the plate from being brought close to the bone of which a radiograph is desired. The bone is thus out of focus, as it were, and its outlines are less well defined. If, however, plaster is used, or the dressings are thick and moist, or if they contain iodoform, or any substance through which the rays do not pass readily, the picture cannot be so satisfactory. It is well to remember that a piece of iodoform may be mistaken for a foreign body, as it is quite as opaque to the rays as some of the metals (see chapter on Fractures, Fig. 248). The advantage of wooden splints and cotton dressings will be discussed in the chapter on Fractures. Sticking plaster may cast a shadow which would suggest a defect in the bone. In medico-legal cases, where there is a question of a bullet in the body, no clothing

should be allowed to remain over the suspected part, as a bullet might be concealed in the clothing.

Data on Negative. — The distance of the tube from the plate should be noted on the negative for reference, and the point on the skin directly opposite which the target is placed should be marked by means of a metal washer which can be fastened in place (see Fig. 263), if necessary, by a small bit of plaster. Before the metal is removed a minute quantity of staining fluid may be dropped into the hole of the washer; a mark is thus left on the skin which enables the surgeon to know the point of view from which the radiograph was taken. These reference points are an aid to the practitioner in the interpretation of the negative (see Chapter XIX, page 473, for further remarks on this point), for it is important, in order to understand the negative, to know the direction and distance of the source of light; with these reference points the practitioner can put himself in the same place with regard to distance and direction when observing the negative as the target occupied when the radiograph was taken. As stated on page 65, the target should be directly opposite the object to be examined, so far as may be, but in the case of a possible injury to the bone, for instance, this exact place may not always be found, although this is often possible if a preliminary survey is taken by means of the fluorescent screen. The diagram shown on page 68 indicates how distance and direction would alter the shadow cast.

For further identification of the position of the negative with regard to the part photographed, small brass letters half a centimetre high, that can be bought at hardware stores, may be fastened on to the envelope that holds the plate, or to the patient's body, while the exposure is being made. For example, *R* and *L* would indicate upon which side of an extremity, head, or trunk the plate was placed; *A* and *P* whether it was on the anterior or posterior surface. The radiograph would show whether a leg or arm had been taken, but the word "leg" or "arm" could be added if desired.

| | | | |
|--------------|---|--------------------|--------------------|
| <i>R. O.</i> | = | Right (leg or arm) | outer side. |
| <i>R. I.</i> | = | " " " | inner side. |
| <i>R. A.</i> | = | " " " | anterior surface. |
| <i>R. P.</i> | = | " " " | posterior surface. |

The position of the plate can be more quickly identified if these letters are always in one part of it; therefore it is well in all cases to place them in the upper right hand quadrant, for instance.

Examination with Screen before Radiograph is Taken. — Before the plate is put over the part to be photographed, it is often an advantage to examine this part with the fluoroscope, in order to learn the best position for the plate. The plate is then put gently over the desired spot without moving the patient or disturbing the part.

Position of Plate. — As a rule the plate should be placed above the part to be examined, and the tube be put below the patient; in this case the picture is not reversed as regards right and left; there are,

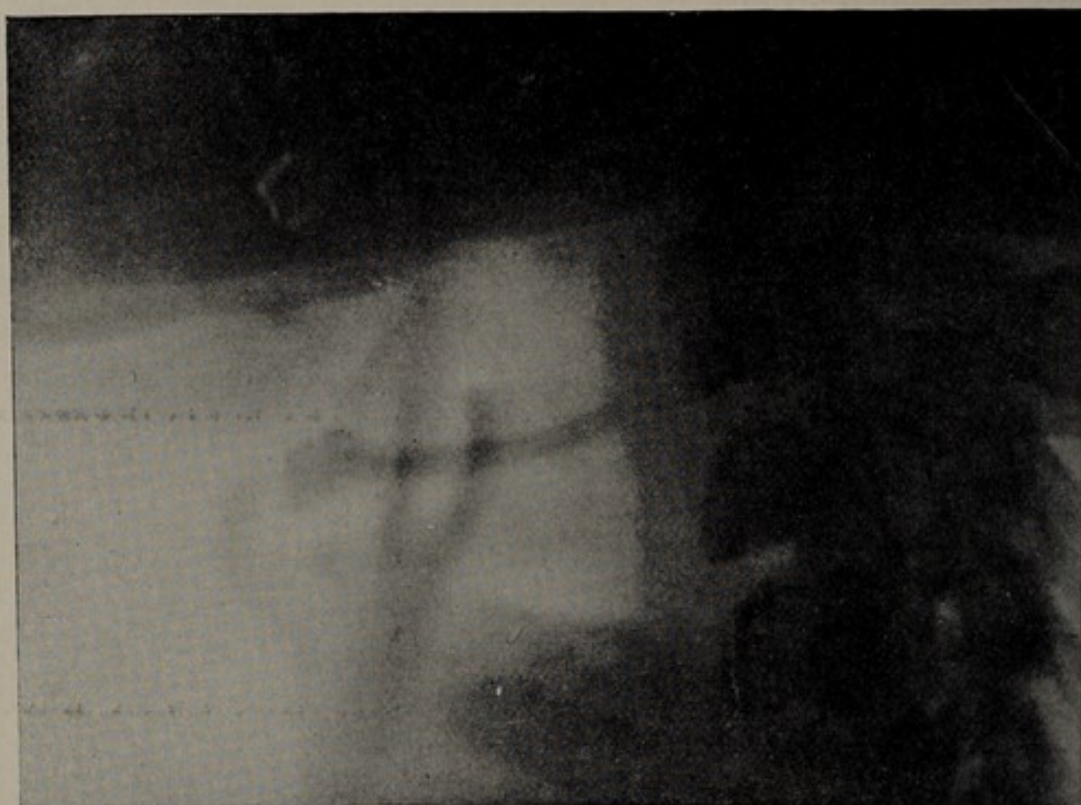

FIG. 66. M. G. Cut shows hyoid bone and part of trachea. Plate against side of neck.

however, some parts, as the spine, for instance, where the radiograph can be more conveniently taken with the position of these objects reversed.

If an X-ray photograph of the head is to be taken, the tube may be placed either above or below the patient, but it is more comfortable for the patient to place it in the latter position and to rest the plate gently upon the upper side of the head, the plate being partly supported by a block under one corner and steadied by a folded cloth placed over it.

The plate should be brought as near as possible to the part to be photographed; for example, in taking a photograph of the larynx, plates 7.5 or 10 centimetres wide should be used, in order that they

may be placed between the lower jaw and the clavicle, and thus be brought close against the larynx.

X-ray photographs showing the hyoid bone, the thyroid and cricoid cartilages, may be made by placing a narrow plate close against the side of the neck (see Fig. 66).

It is somewhat better to place the film side of the plate against the patient, for two reasons: first, if the other side is next the patient, some portion of the rays do not reach the film, as they are absorbed by the glass; second, the film is a little farther removed from the part to be photographed, and therefore the picture will be less sharply defined. To interpret an X-ray picture as regards right and left, it is necessary to know the relative positions of the film side of the plate, the patient, and the tube. When the arrangement is as in Fig. 69, fractured leg, right and left are not reversed on the print. The interpretation of the X-ray picture is an important point, and is further discussed in Chapter XVII, Introduction to Surgery, and Chapter XI, on Aneurisms.

The shoulder may be photographed with the patient lying on his back or on his face on the stretcher. If on his back, the plate is placed on the front of the shoulder, or it may be supported under the stretcher, as described below; if on his face, on the shoulder blade.

If a photograph of the knee is desired, the patient may lie on his side on the stretcher and the plate be put above the knee. A folded sheet or cloth may then be placed on the plate; the cloth should be large enough to extend beyond the plate and rest on the stretcher, and by its weight steady the plate and assist in keeping it in its proper position.

The arch of the foot usually shows best on the plate when a side view of the foot is taken, that is, with the plate resting against the inside of the ankle; two views may be useful and are quite practicable: one with the patient standing and throwing the weight of his body on the foot; and the other sitting. To take a radiograph of the foot with the weight resting upon it, the patient should stand on a wooden stool, the tube should be placed on a level with the top of the stool opposite the outside of the foot, and the plate be held against the inside of the foot. To make the outlines of the bones on the inner side more easily distinguished from those on the outer side of the foot, the tube may be placed only 30 or 40 centimetres from the plate; thus only the bones near the plate are sharply defined (see photograph of pins on page 67).

The method for photographing different parts of the body is illustrated by the following cuts, and will be further discussed and illustrated in the chapter on Fractures.

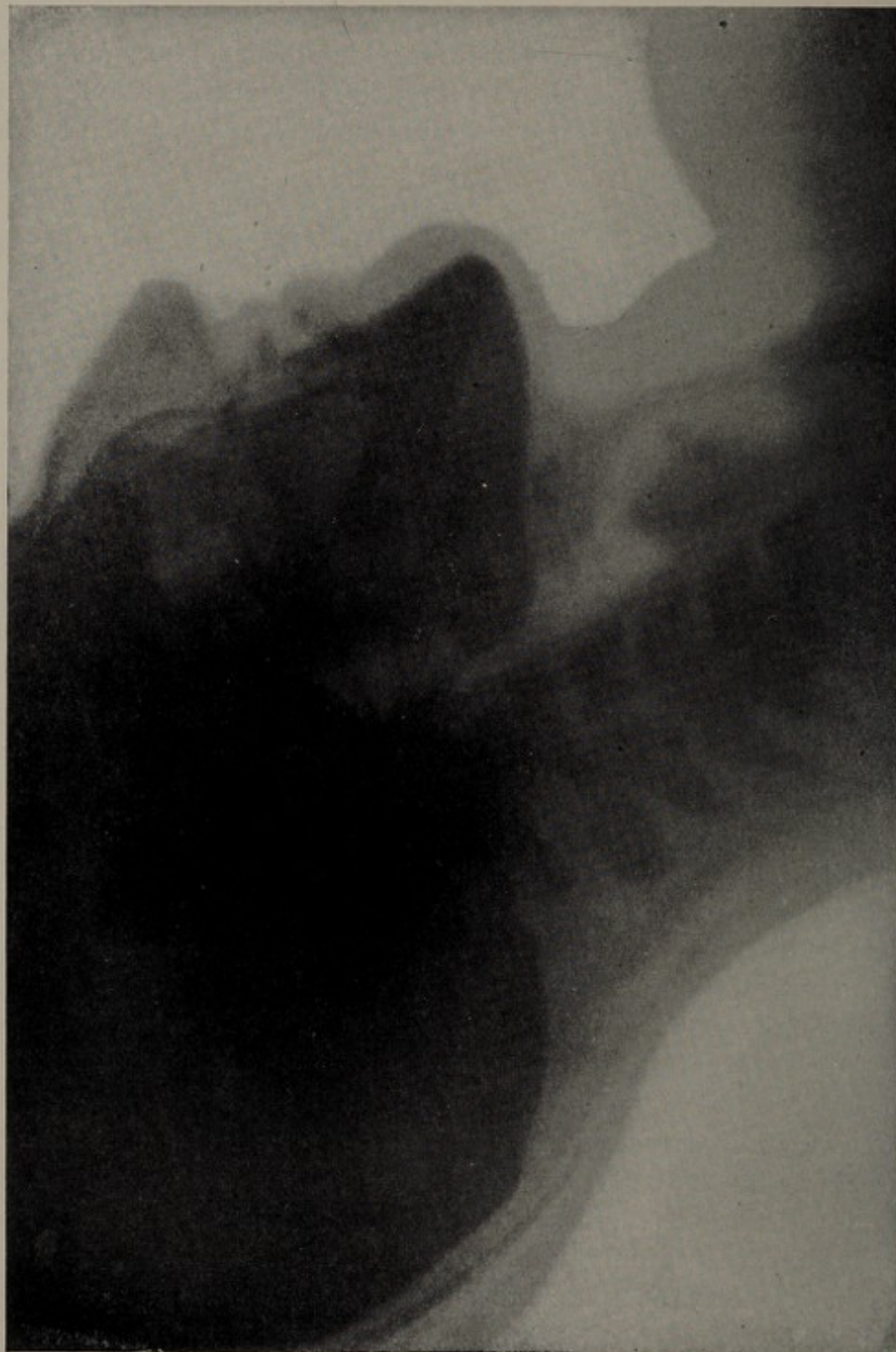


FIG. 67. Showing cervical vertebrae and position of some of the parts in front of them. In the negative much more detail can be seen than in the cut; the inner and outer line of the occipital bone, for example.

Fractured Leg. — The cut on page 92 (Fig. 69) shows the method of photographing a fractured leg. The patient has been brought from the hospital ward into the X-ray room on a stretcher which was placed on the wooden horses shown in the picture. The stretcher is lengthened at the patient's head by means of a shelf, hinged on to one of the horses, which may be turned up when it is desired to make the stretcher longer, as in this case.

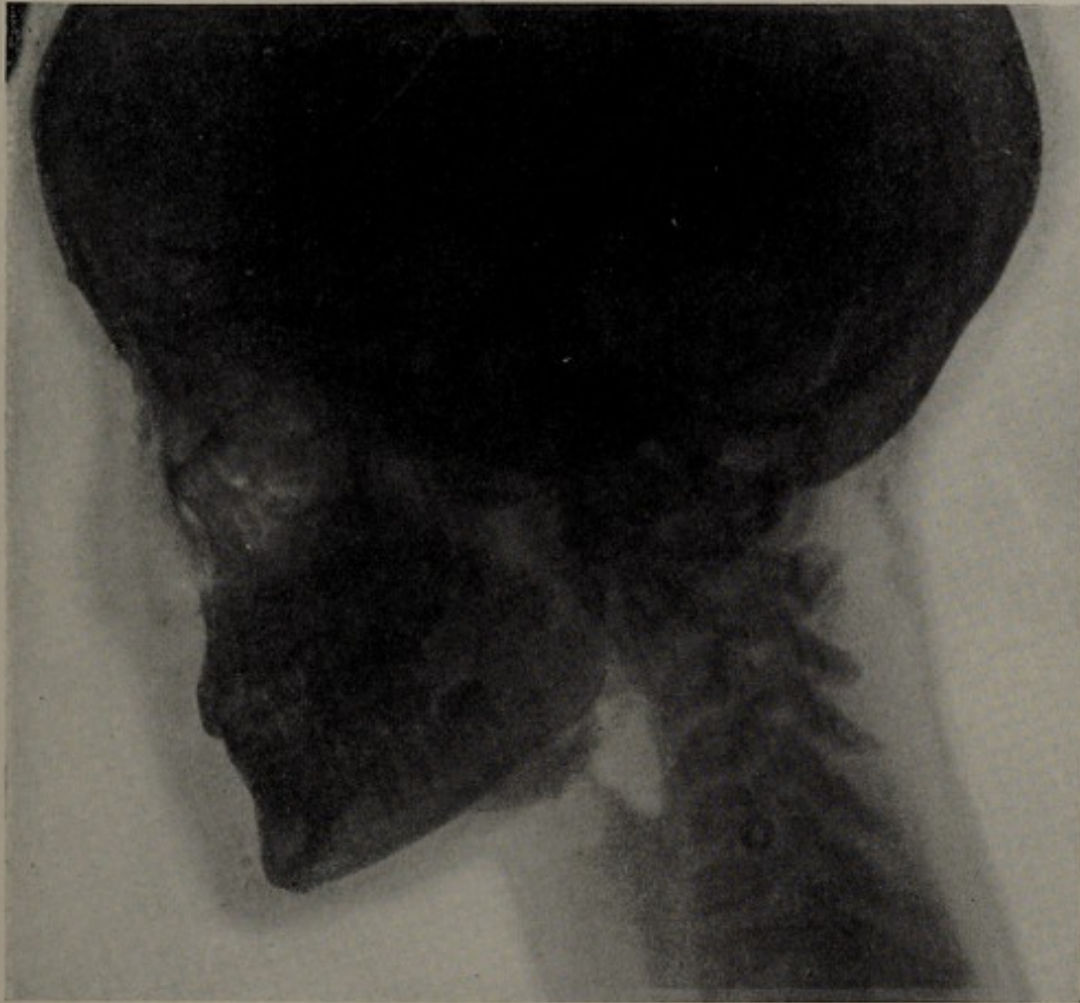


FIG. 68. Another cut showing cervical vertebrae and position of some of the parts in front of them. In the negative much more detail can be seen than in the cut.

The box containing the X-ray tube is seen beneath the stretcher, separated from the patient by an aluminum screen, which is grounded, as suggested by Tesla. The target of the vacuum tube in the case of a fractured leg or hand, for instance, is not placed, of course, under the median line, but directly under the point to be photographed. The same principle for finding the proper position which is described on page 66, however, applies in this case. A line with weights on either end is thrown

over the body and across the part to be photographed, forming two plumb-lines, a line joining which would be at right angles to the length of the

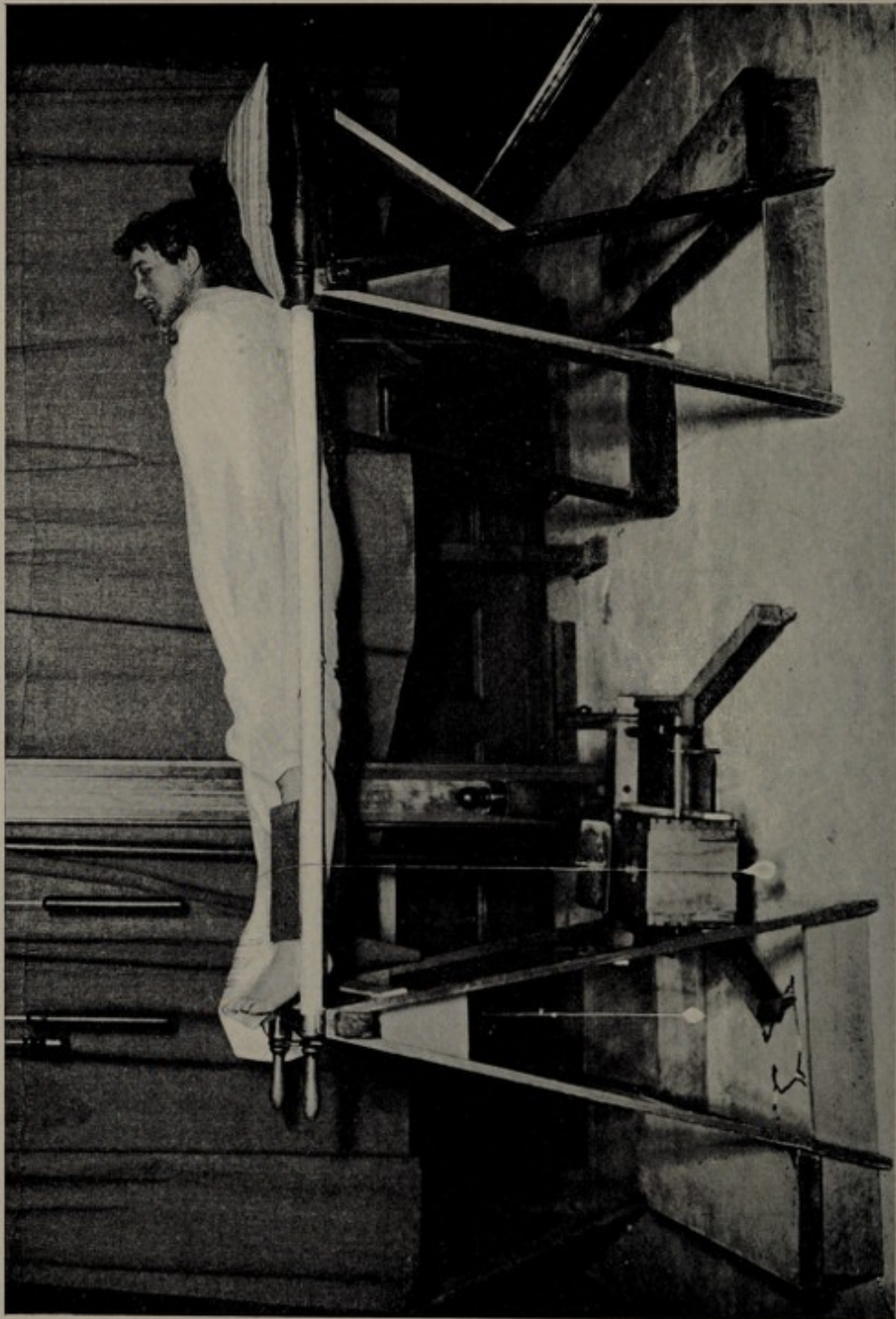


FIG. 69. Method for taking a radiograph of a fractured leg.

stretcher. Next, the distance between the metal washer (see page 87) and the plumb-line near it against the stretcher is measured, and is

found to be x centimetres. The physician then sights from plumb-line to plumb-line to obtain the line on which the tube should be placed, and finds the exact point on this line for the target by measuring off on it x centimetres, using the end of the plumb-line hanging over the side of the stretcher, near the metal washer, as a starting-point. The target is thus brought directly under the metal washer.

The curtain seen in the background of the picture hangs in front of the machine in order that the apparatus may not excite the apprehensions of the patient. There is no noise to disturb the patient, as the static machine is noiseless unless the spark-gap is used, and if the tube is such that the use of the spark-gap is not required, the heart sounds can be listened to and heard while the apparatus is in motion. (See Chapter II, page 17.) The handle hanging in front of the curtain on the left is used to open or close the circuit; the other two control the spark-gap, and by them the amount of light in the tube may be varied. The speed controller, another means of controlling the amount of energy going through the tube, is within convenient reach, but is not shown in the picture; it regulates the revolutions of the electric motor used to drive the static machine, and by varying the speed of the plates the amount of electricity adapted to various needs may be obtained, as stated in Chapter II.

If the hand and forearm are to be photographed, the given part may rest upon a table while the patient sits in a comfortable chair, but these and all other parts of the body are conveniently photographed with the patient lying on the stretcher. The position is a comfortable one, and enables the patient to keep the given part at rest.

Fractured Hand. — The following cut (Fig. 70) is likewise illustrative of the method for photographing the leg, knee, or shoulder.

Ringel¹ found that he obtained a better photograph of the hand if it were compressed with a rubber bandage and all the blood driven out, than if it were taken in its natural condition.

Method for photographing Heart or Lungs. — The cut (Fig. 71, given on p. 95) shows the method for taking a photograph of the heart or lungs, or any organ or growth lying nearer the front than the back of the chest. The patient is seen lying on the stretcher with the photographic plate on the front of his chest and pressed squarely against it by a weight placed on a cross-piece of wood. The ends of the cross-

¹ "Zur Diagnose der Nephrolithiasis durch Roentgenbilder," Arch. f. klin. Chir., Berlin, 1899, lix, 167-174.

piece are supported on blocks which are set on strips of thin pine board that lie on the horses, one on each side of the stretcher.




FIG. 70. Fracturea hand.

This cut shows the method of taking a radiograph of hand or arm, wrist or elbow. The part is supported on a thin pine board, which rests on the horses, and is placed along the side of the stretcher.

Method for photographing Spine. — It is uncomfortable for the patient to lie on a hard glass plate, and pressure or the moisture of perspira-

tion may injure its surface; there is also the risk of breaking it to be considered, even when it is supported on a board; but the comfort of the patient and the safety of the plate may be secured when the spine,




FIG. 71. Method for photographing heart or lungs, with plate on front of chest.

for instance, is to be photographed, by simply supporting the plate on the diaphragm, as shown in Fig. 72. In this way the plate is brought into close contact with the spine, the patient is comfortably supported

by the canvas stretcher, and yet no moisture from or weight of the patient comes upon the plate.

X-Ray Negatives compared with X-Ray Photographs. — X-ray negatives show more detail than the prints made from them; and, further, the negatives themselves may show some things in the process of development which are lost in the finished negative. Negatives when dry are denser and better than when wet.

Careful Examination of Negative. — A negative should be examined carefully and systematically by a suitable and variable illumination in order to see best what it shows. Sometimes certain things are seen most clearly when the negative is held above a large sheet of white paper which reflects the light from a window; often certain points are observed which we should otherwise overlook when the light comes through the negative at a very acute angle rather than at right angles. The negative should be so held that the light goes through it without coming directly into the eyes of the observer, and moved about so that it may be examined from different points of view. The following way is an excellent one for studying the negative (see Fig. 73).

Thin negatives require but little illumination, dense ones more, and very dense ones need direct sunlight in order that details may be revealed.

Two or More Negatives Made. — Under certain conditions two or more negatives should be made. This point will be discussed in more detail in Chapter XVII.

Intensifying Screens. — Screens of tungstate of calcium, if put next the photographic plate, diminish greatly the time of exposure, but they likewise lessen the clearness of the picture. I used screens of this kind some five years ago, but discarded them because the quality of the picture was not as good with as without them. (See Appendix.)

Length of Exposure. — The length of exposure necessarily varies with each form of machine, the part to be taken, and the tube used; these points must be determined by a few trials with each apparatus. If the details of the bones are required, a longer exposure may be given than when a photograph of the soft parts, such as the ligaments and muscle, is desired. The proper length of exposure may often be estimated by examining the part with the fluoroscope held a few centimetres above the plate and noting the amount of light coming through. After some experience the correct exposure for a given part may be well determined in this way.

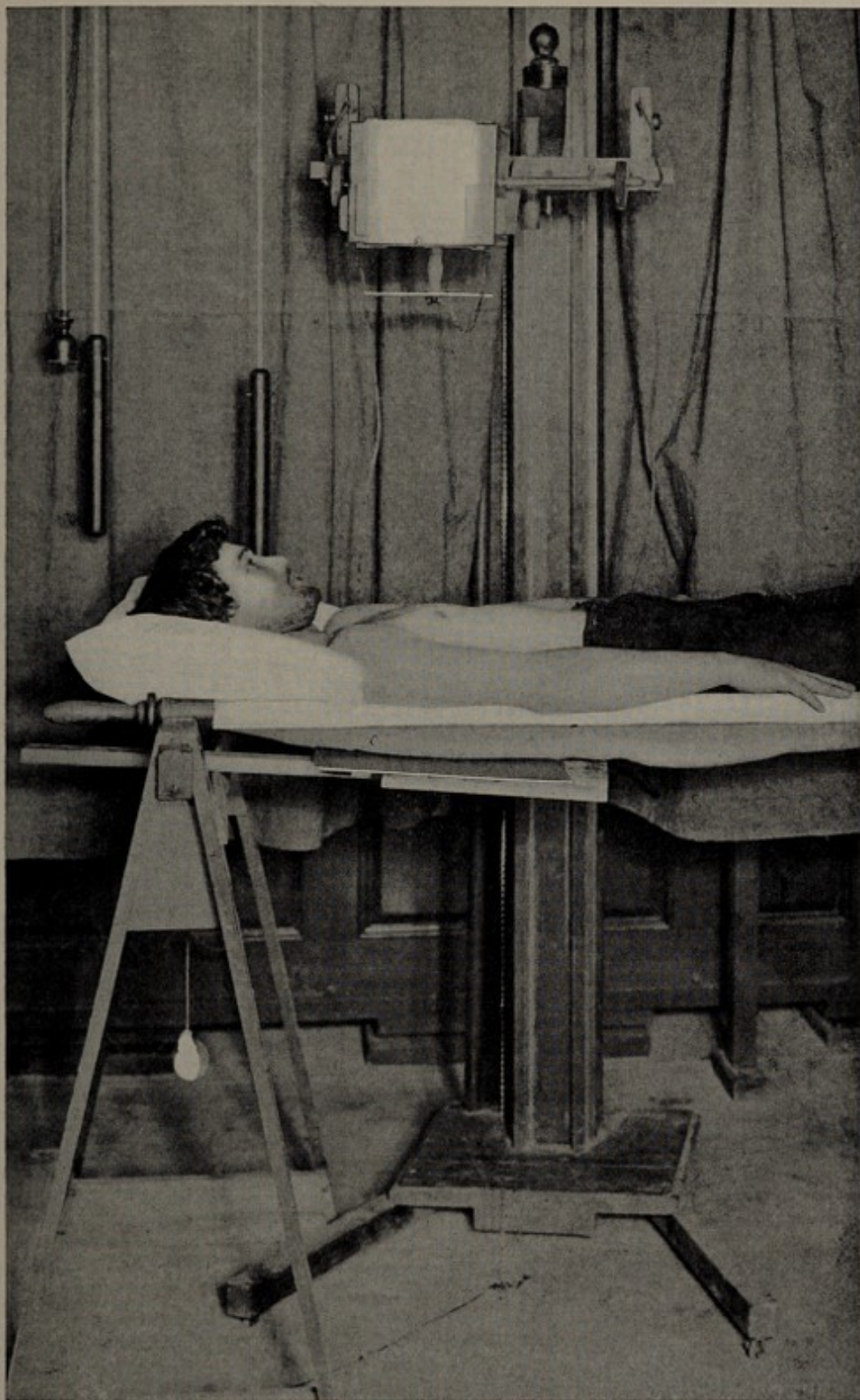


FIG. 72. Shows the photographic plate, supported by what is ordinarily used as a diaphragm, which is pressed up against the patient's back. The tube with the aluminum screen below it is seen above the patient. The clothes should be removed when taking such a picture, and a blanket thrown over the patient, as the shadows cast by the buttons, for example, might be misleading.

In taking photographs of parts of unequal thickness, for instance the fingers and wrist, it is impossible to get the proper exposure for all parts unless the thinner parts are protected during a portion of the time of exposure. This may be done by passing a plate of lead to and fro between the fingers and the tube, and making the exposure long enough to give a satisfactory picture of the wrist. In a hand which I made in

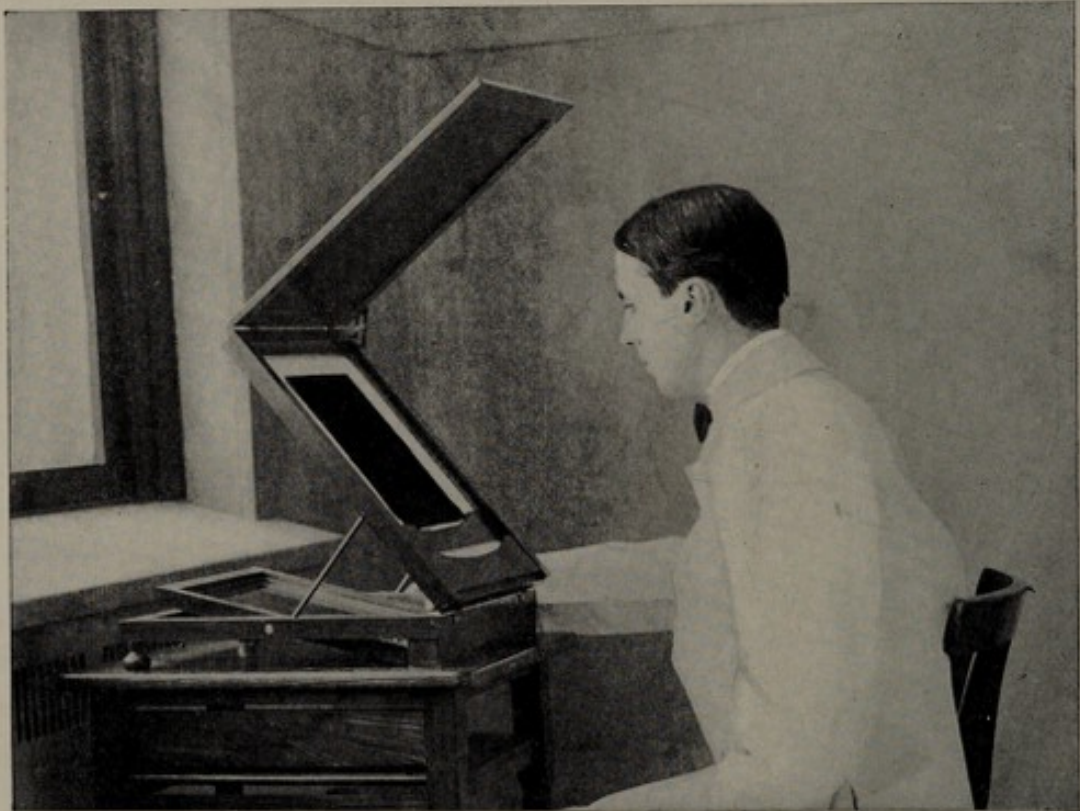


FIG. 73. Shows a simple way of examining a negative by a suitable and variable illumination.

The negative is placed in a frame which is hinged at the bottom to a stand, as shown in the picture. The lower half of this frame contains a piece of ground glass, upon which the negative is laid; the upper half forms a shade for the negative; this shade may be made more effective, if desired, by fastening a piece of dark cloth (not shown in the cut) on either side of it. Behind and below the negative is another frame, which can be tilted. This frame carries a mirror, or, if preferred, a dull white surface can be used. The angle of the mirror should be varied while the negative is studied, in order to obtain the most suitable light for the special portion observed. This stand is placed on a table near a window, and the observer sits in front of it to study the negative, as shown in the cut.

1896, this method was resorted to, the result being a good picture of the wrist, also showing clearly the details of the fingers and the finger nails.

Importance of taking Two Pictures each from a Different Point of View when making an Examination. — It is often necessary to take two views of a fracture, a new growth, or a foreign body; for instance, one from a lateral, and the other from an antero-posterior point of view. This subject will be further dwelt upon in the chapters on Surgery.

Comparative Advantages of Screen and X-Ray Photographs. — It is more convenient to use the fluorescent screen in many cases than to take an X-ray photograph. With the screen the results of the examination may be obtained directly; and when the organs are movable, as the lungs or heart, the amount of this movement and the changes taking place under different respiratory conditions may be studied, a point of the utmost importance. Therefore, for studying the conditions of the thorax it is generally an advantage to use the screen rather than the X-ray photograph. Likewise, in locating foreign bodies, the screen is sometimes better than the X-ray photograph; also the screen affords a convenient means for making a preliminary examination to secure the most advantageous points of view for taking radiographs. On the other hand, the radiograph gives more detail, and by its means much may be recognized which would wholly escape observation if the screen alone were used. For instance, a case of fracture, where there is no displacement, would be overlooked with the screen and seen in the radiograph. Both methods of examination should be used in some cases.

Speaking generally, the X-ray examination by the photograph is better, as a rule, than that by the fluorescent screen for all parts of the body except the trunk, but more especially except the thorax. I may say that the photograph is more suitable for the surgeon, and the fluorescent screen for the physician. The relative usefulness of the screen and photograph will be further discussed in succeeding chapters.

In making examinations with this new method, as with the older ones, the three following stages should be kept distinctly and separately in mind: —

First: Attention should be given to observing carefully the appearances which present themselves.

Second: A careful record should be made of these appearances in some simple and direct way which shall be a record of facts, not of opinions.

Third: The observations made should be well considered by themselves and in connection with information furnished from other sources, the evidence from each source being given just, but not exclusive, consideration before making the diagnosis.

CHAPTER IV

INTRODUCTION TO THORAX

To use the Roentgen rays successfully in practice, the physician must first become familiar with the appearances on the screen or photograph, or both, which present themselves in health; this statement applies particularly to the thorax, and the picture of this part of the body when seen on a large fluorescent screen presents so much that it should be studied systematically.

General View.—The trunk is lighter above than below the diaphragm, and the rise and fall of this muscle, which appears dark on the screen, is distinctly seen. The chest is divided vertically by an ill-defined dark band, which includes the backbone, on each side of which the lungs, forming the brightest part of the picture, are crossed by the darker ribs. The pulsating heart is seen, especially the dark ventricles, and, under favorable conditions, the lighter right auricle, and on the left side above the ventricles the pulmonary artery is made out. A small portion of one side of the arch of the aorta may be observed in the first intercostal space to the left of the sternum. After this general view has been taken, the special parts should be examined separately. Let us begin with the lungs.

Normal Lungs.—These organs appear bright on the fluorescent screen, but there is a difference in the degree of their brightness at different periods of respiration. In full inspiration they are brighter than during expiration, as shown by the following experiment which I made in 1896: When a pasteboard box containing water 2.5 centimetres deep was held over the chest of a large healthy man, I could see its shadow during full inspiration, but not in expiration. That is to say, in the latter case there was not sufficient difference in the amount of light coming through the lungs, and the lungs and the water, during expiration, for a difference in the shadow to be observed.

Another experiment which I made at the same time shows how readily the substance of the lung is traversed by the X-rays. I com-

pared a normal lung, taken from a post-mortem examination, and blown up to about the distension of full inspiration, with a measured depth of water, and I found that the shadow cast by this lung where it was 7.2

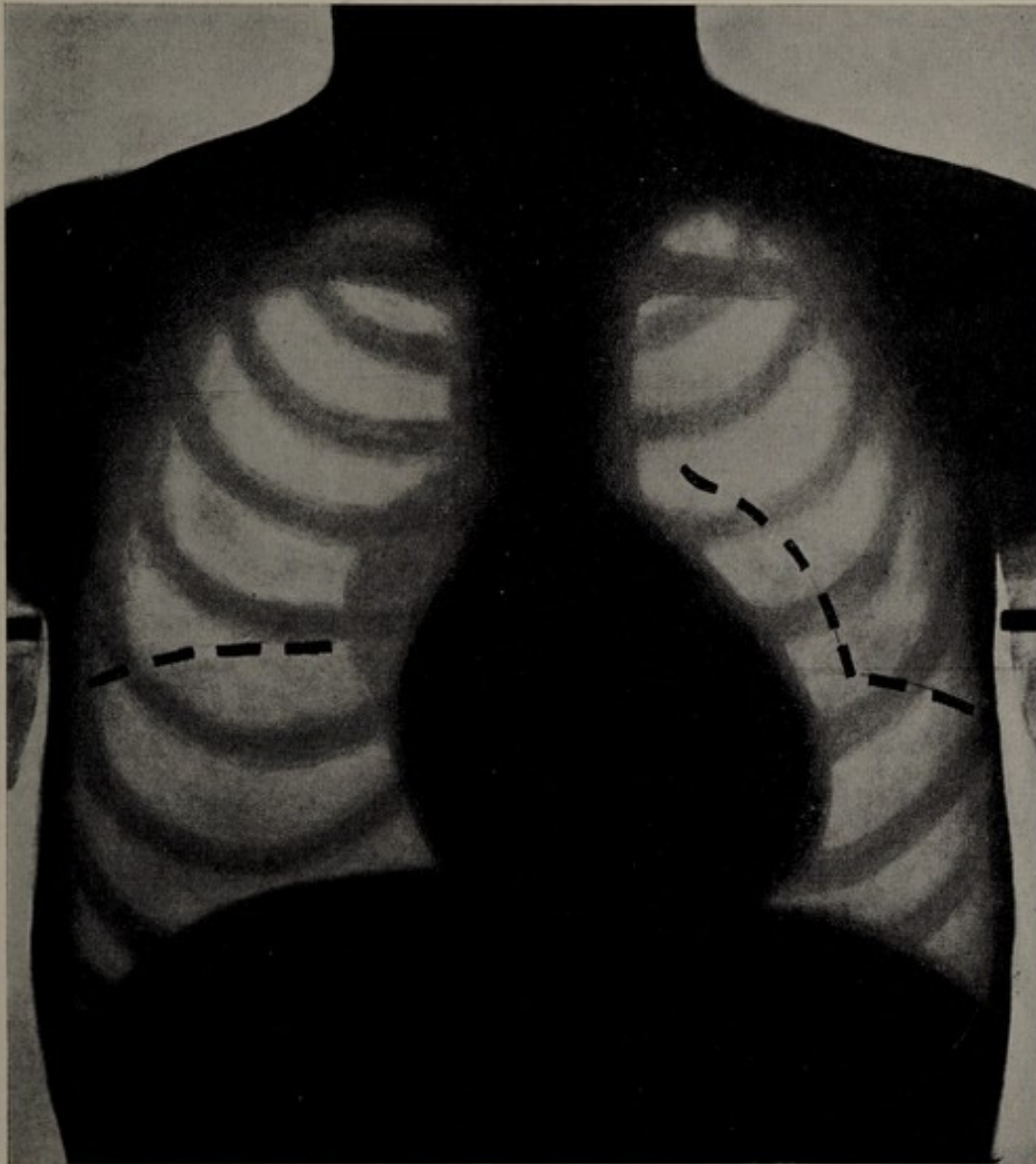


FIG. 74. Diagram of full inspiration during health.

The broken lines show the position of the diaphragm and heart in expiration, but the diagram does not indicate that during this time the light area is narrower. The level of the nipples is indicated by the dark lines at the sides of the cut and near the axillae. The target of the vacuum tube would be placed under the median line, where it is crossed by a line joining the nipples, to obtain such a picture.

centimetres thick corresponded to that thrown by water only 6 millimetres deep.

In thin persons the lungs appear lighter than in stout, because in the latter there is a thicker layer of tissues between the screen and the

tube; therefore, in determining whether or not the pulmonary area is of normal brightness in a given individual, we must take into account the thickness of the chest walls; in persons of average size and build these walls would offer about as much obstruction to the rays as water

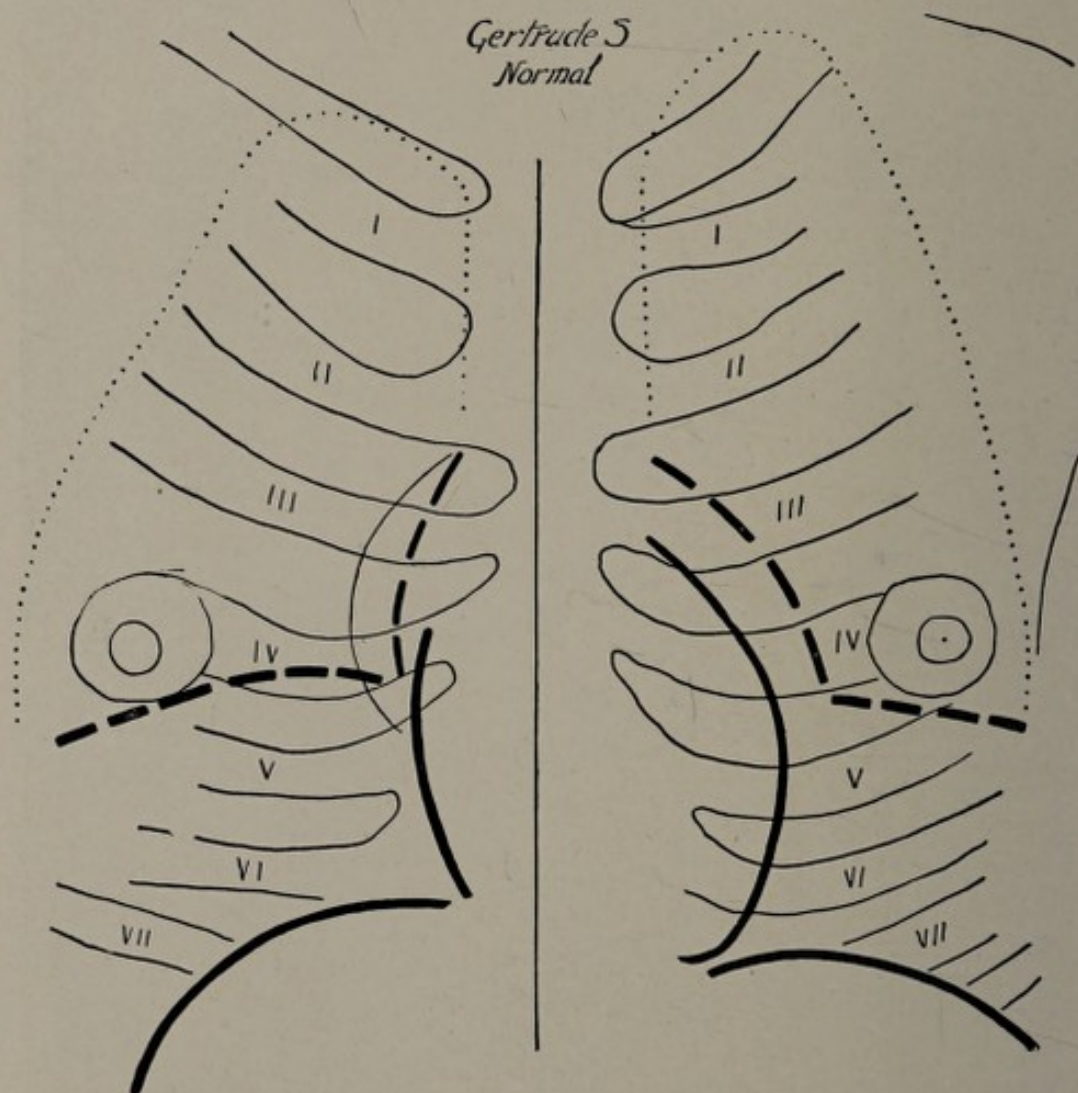


FIG. 75. Gertrude S., 25 years old. X-ray outlines of normal chest. (One-third life size.)

These outlines, including those of the ribs and clavicles, are reduced photographically from the tracing made of the outlines drawn on the front of the patient's thorax. The full lines, with the exception of the outlines of the bones, indicate the position of the parts in deep inspiration; the broken lines in expiration; the dotted line shows about the limit of the bright pulmonary area.

The ribs on the back are not shown, as they would confuse the picture.

The target of the vacuum tube was placed under the point where the line joining the nipples was crossed by the median line.

from 5 to $7\frac{1}{2}$ centimetres deep. It has seemed to me that the right apex was normally darker than the left apex (I have not yet compared the chests of left-handed persons with right-handed persons of the same build). The normal brightness of the lungs during full inspiration and

expiration should be observed, for as we note different degrees of pallor by reference to our standard of color in health, in the same way it is necessary to know the normal amount of light that should penetrate any given part in order to recognize any variations from the normal. The eye must be trained in the use of the X-rays, as is the ear for auscultation and percussion. Moreover, as in percussion, and to some extent in auscultation of the lungs, we recognize differences in different individuals, which may be within normal limits, and learn to know what note to expect from a thorax of a given size and build, so must we learn by experience to recognize normal differences, dependent on these same conditions, in the appearances seen on the fluorescent screen.

Experiments with Abnormal Lungs. — Experiments that I have made with tuberculous and pneumonic lungs taken from autopsies showed that the abnormal portions cast a dark shadow on the screen. (See chapter on Pneumonia, page 165, and chapter on Tuberculosis, page 112.) Another lung, from an autopsy that I examined, was normal, except for a small red nodule less than 1 centimetre in diameter; this nodule was seen on the fluorescent screen as a dark spot on a bright ground, even this small area casting a well-defined and conspicuous shadow.

Clavicles and Ribs. — The normal outlines of the clavicles and ribs should also be noted; the observer should see not only the outline of the ribs on the front of the chest, but also those at the back during full inspiration (see Fig. 76). If they are not seen, either the chest offers more obstacle to the rays than obtains under normal conditions, the lungs are somewhat congested, or the apparatus is not working satisfactorily, or the eyes of the observer are not in good condition for seeing.

Standards of Measurement. — The readiest way of deciding whether the tube and the eyes are or are not at fault is to examine the bones of the hand with the screen, and determine at how great a distance they can be differentiated from the flesh as compared with what has been observed on former occasions when the tube and the eyes were known to be fit for use; in doubtful cases, where these possibilities of error have been eliminated, the appearances seen on the fluorescent screen may be compared with those observed when a normal individual was examined.

The instrument described below may also be used as a standard of comparison.

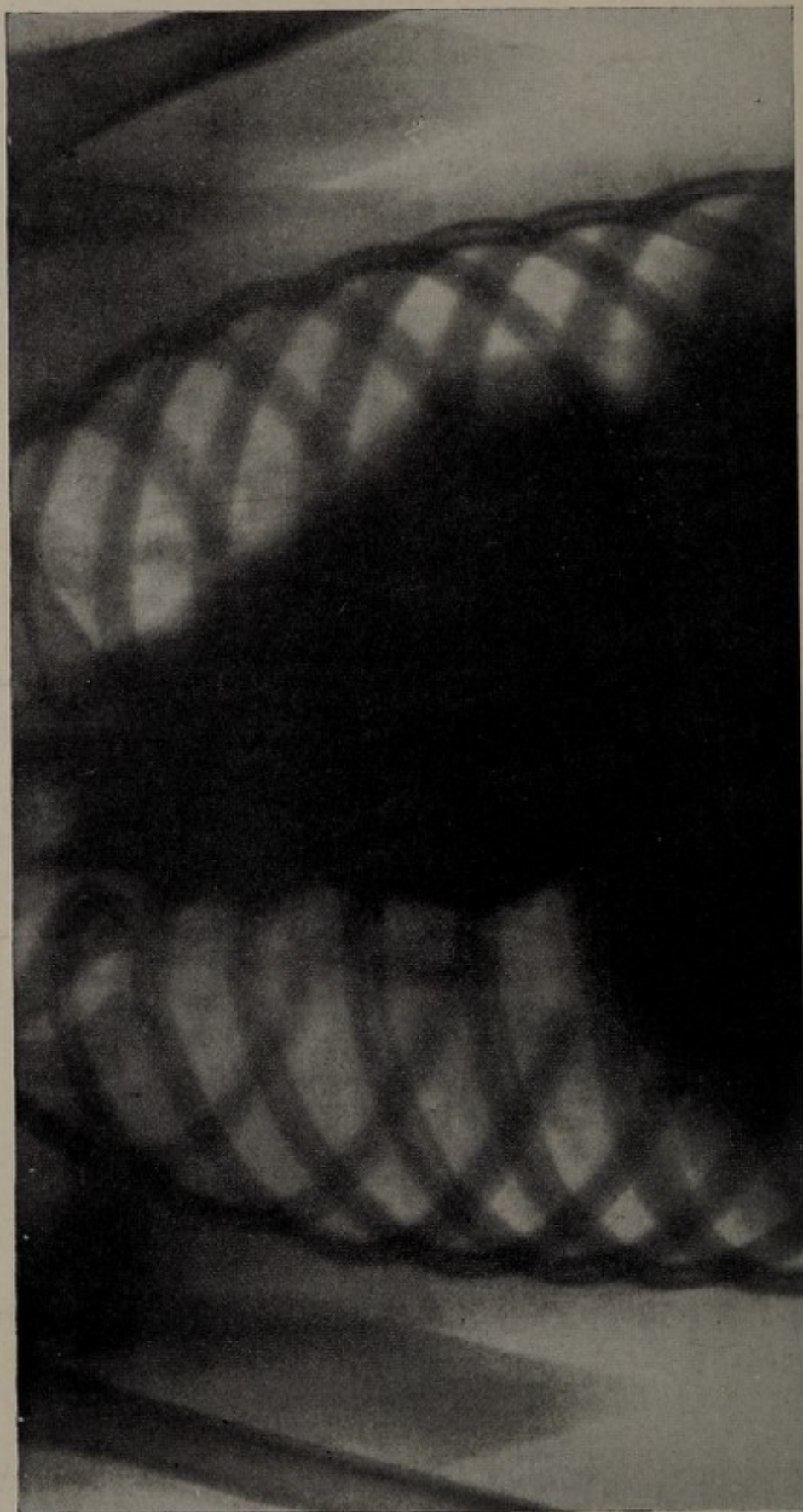


FIG. 76. Cut of radiograph showing clavicles and front and back part of the ribs, with lattice-work effect.

Densitometer. — I designed this instrument, to which I have given the name of densitometer, in order to measure the density of any part of the thorax, and I chose water as a means of measurement, because this liquid is most akin to the soft tissues of the body, they being chiefly made up of it, as well as to the pathological deposits in the lungs.

The instrument consists of an oval box with two bottoms, and is divided into halves, *A* and *B*, by a partition that reaches nearly to the

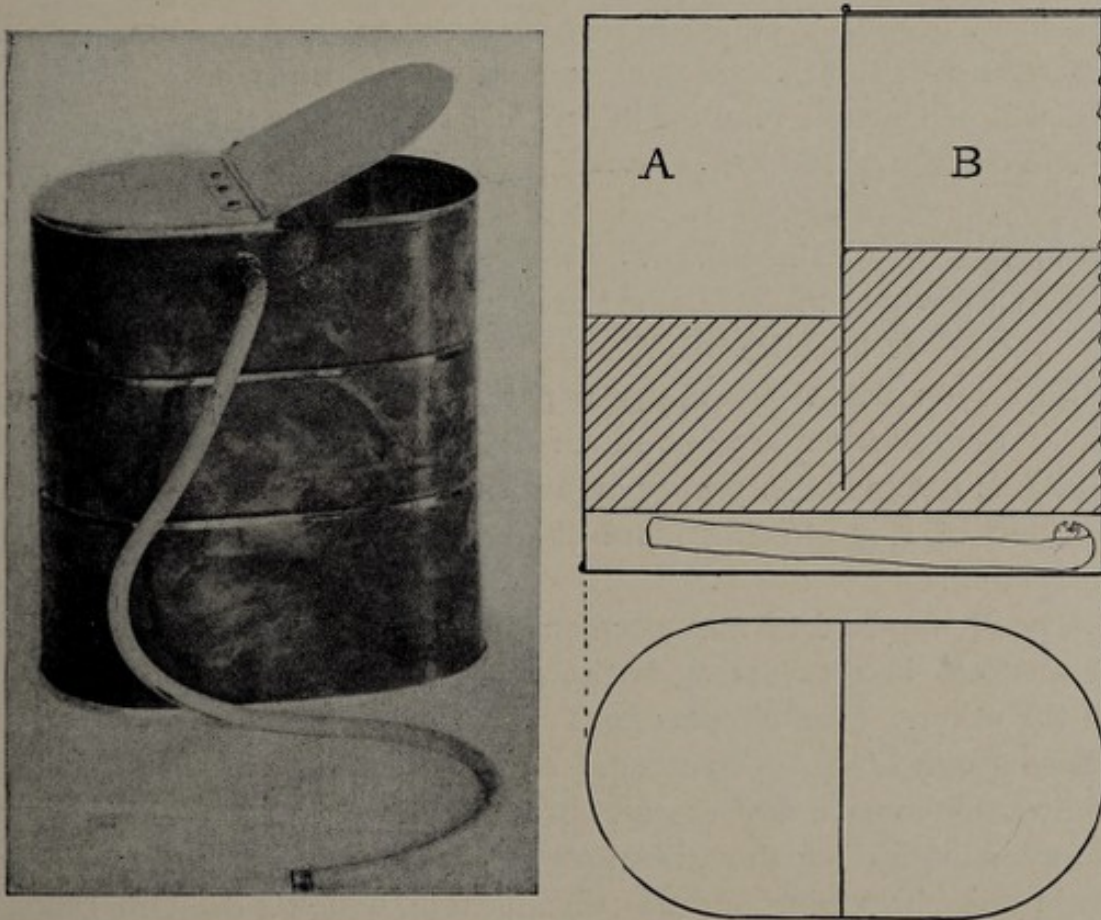


FIG. 77. Densitometer. Instrument for measuring density of thorax. Section and plan.

false bottom. The sides of this box and the partition are made of copper, the top and both bottoms of thin sheets of aluminum. The half *A* is closed above, and is supplied with a stopcock and a rubber tube; the half *B* is covered with a lid. Between the two bottoms are placed pieces of two or three ribs, or pieces of ivory, corresponding in density to the ribs, may be used. There are grooves on the inside of the half *B* which are 1 centimetre apart (see Fig. 77). The section of the box is shown at the right of the cut.

Directions for its Use. — The stopcock in the half *A* is closed; the lid of the half *B* is opened, and water poured in until it is nearly filled; the stopcock in *A* is then opened, and the water flows under the partition and rises into this half. When the instrument is thus prepared, it is placed close beside the patient's chest, and between it and the arm, and while the chest is examined with the fluorescent screen, the level of the water in *B* is changed as desired by blowing air into *A* or sucking air out of *A*. When the shadows of the ribs in the body and in the densitometer are equally dark, and the light on the portion of the fluorescent screen over *B* corresponds to the light on the portion of the screen over the thorax, the stopcock is closed, the lid is opened, and the depth of water is read off in centimetres.

The density of the lungs or any part of the thorax in a given patient may be thus measured, and any changes obtaining at a subsequent examination may be noted. The instrument can also be used to make a scale with which to determine the respective density of the thorax and other parts. It likewise enables us to know whether the shadow seen on the screen when examining a patient is due to the fact that the eyes of the observer are not in a suitable condition for seeing, or that the tube is not giving a proper amount of light, or that the chest or any given part of it is offering more obstruction to the passage of the rays than normal.

A good standard of measurement in diseases of the lungs, and one that answers in most cases, is the comparison of one side of the chest with the other. (See chapter on Tuberculosis, page 119.)

Diaphragm Lines. — The curve of the diaphragm and the excursion made by this muscle during quiet breathing, and during full inspiration and forced expiration, should be noted. Figure 78 shows the diaphragm lines in quiet breathing and deep inspiration, which I drew in 1896:¹—

Average Normal Excursion of Diaphragm. — In twenty-eight men recently examined, between twenty and thirty years of age, who were not suffering from any disease, I found the average excursion between expiration and full inspiration to be 6.8 centimetres on the right side, and 7.1 centimetres on the left side. In eighteen of these the diaphragm moved during quiet breathing 1.7 centimetres on the right side, and 1.5 centimetres on the left. In fifteen of these the diaphragm,

¹ Cuts showing the diaphragm lines are also given in an article which I published October 1, 1896, "A Method for more fully determining the Outline of the Heart by means of the Fluoroscope, together with Other Uses of this Instrument in Medicine."

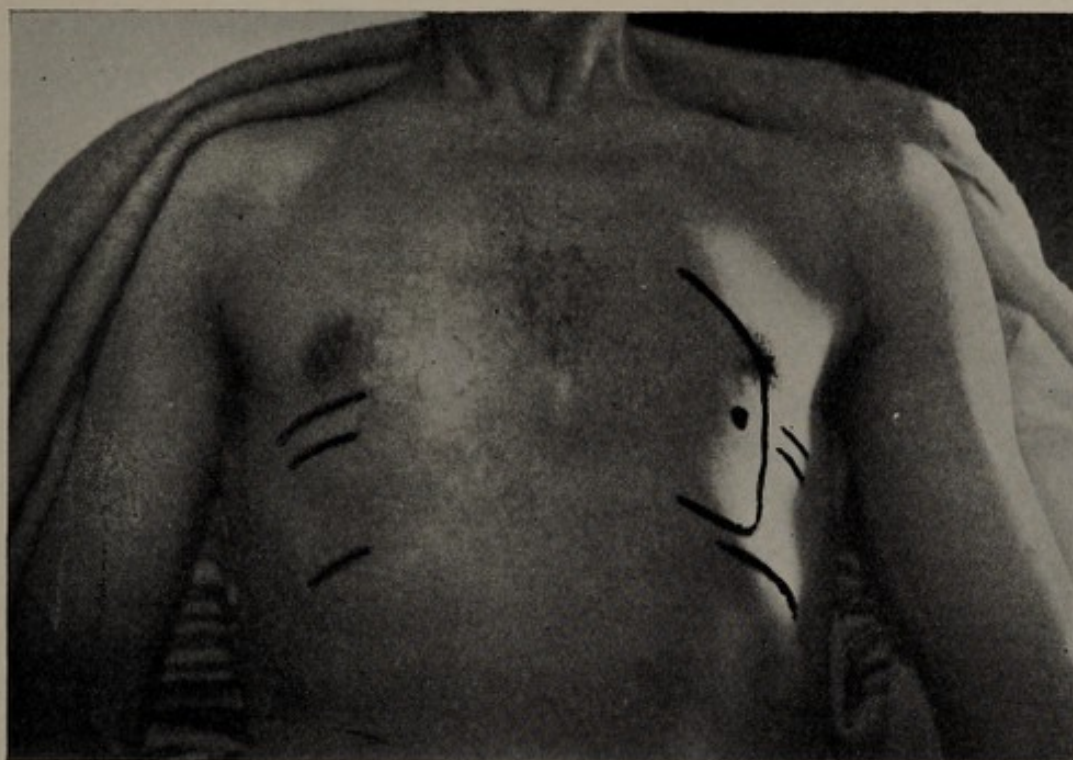


FIG. 78. Chest of man, showing diaphragm lines in quiet breathing and deep inspiration, and part of the outline of the heart. (From *Med. and Surg. Report*, Boston City Hospital, January, 1897.)

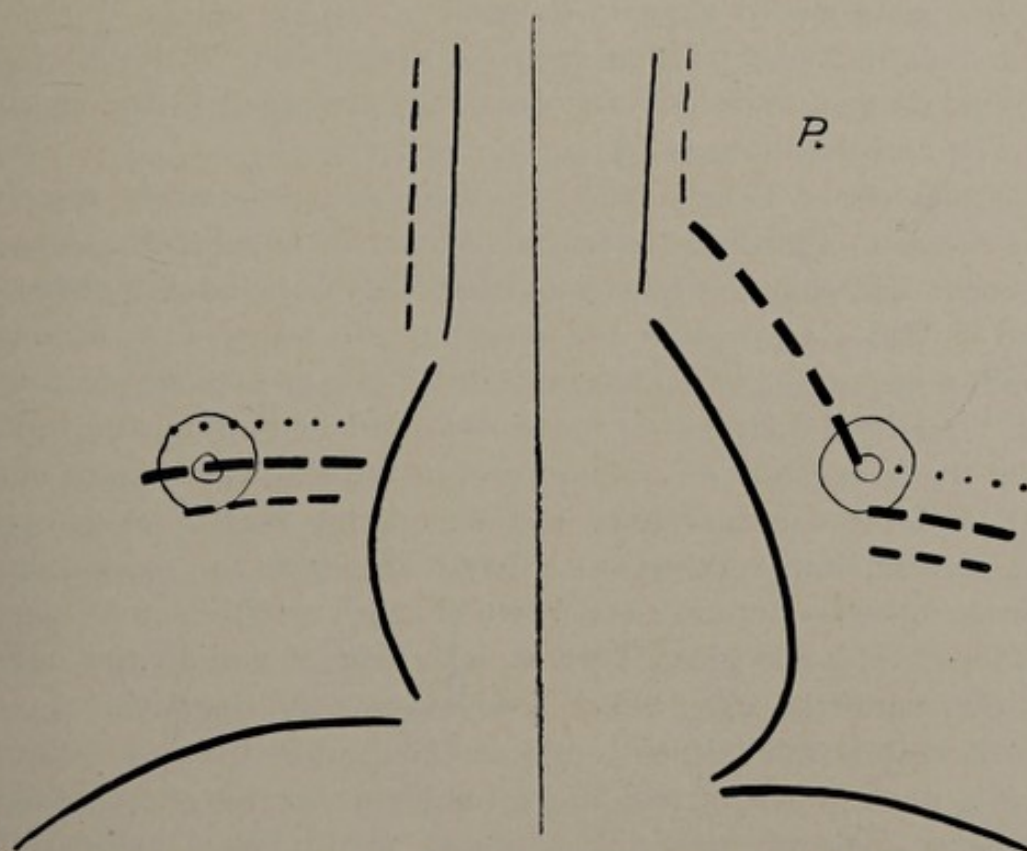


FIG. 79. Tracing from normal chest of a man twenty-eight years old. Diaphragm lines; the lowest full curved lines are the diaphragm lines in deep inspiration; the two broken lines parallel to these, the lines in the inspiration and expiration of quiet breathing, respectively; the dotted lines above these, the diaphragm lines in forced expiration. (One-third life size.)

during forced expiration, was raised 2 centimetres higher than the point reached in ordinary expiration on the right side, and 2.3 centimetres on the left.

In forty-five normal adults, thirty-one men and fourteen women, of various ages, the average excursion of the diaphragm was somewhat greater in the younger adults than in the older.

I have made a number of other measurements of the movement of the diaphragm, but the cases in which this has been done are not sufficiently numerous to give the results here.

In quiet breathing the average excursion is about $1\frac{1}{4}$ centimetres when both lungs are normal, but if one lung has to do more than its share of the work, the diaphragm on the well side has a greater excursion than normal.

The normal excursion of the diaphragm varies with the dimensions of the chest. In tall persons with a long thorax the excursion is longer than in short persons with a very deep chest; therefore it might be short on both sides in a patient who is perfectly well. This point must be borne in mind, for otherwise the practitioner may think an abnormal condition exists where none is present.

Heart. — The appearances seen on the screen when the heart is normal, as well as when it is abnormal, are discussed in the chapter on the Heart, and therefore need not be dwelt upon here.

Blood-vessels. — The position of the large pulmonary vessels, the arch of the aorta and the venae cavae, should be noted so far as possible.

Relative Usefulness of Screen and Radiograph in Examinations of the Thorax. — The screen gives the observer the opportunity of watching the moving organs, as indicated in Chapter III, to note and measure the excursion of the diaphragm in inspiration and expiration, and the movement of the heart and its amount, during the different stages of respiration; and these observations can be quickly made. A photograph cannot give as sharp outlines of moving organs as the screen, unless it is an instantaneous picture; often two or more would be necessary, and even then would not give as much information, and in the nature of things there must be some delay in developing the negative.

Further, it is difficult to judge of the proper time of exposure in making a photograph of the lungs, for instance; too short or too long an exposure may interfere with success; again, prints made from the same negative may vary. I have tried to overcome this possible source of error by taking two or more prints from a given negative

and comparing them. Likewise the photograph made from a plate placed on the front of the chest of a given patient may show a smaller amount of diseased area than when the plate is placed on the back. To overcome this disadvantage two photographs should be taken, the patient lying on his back in both cases unless he is suffering from pneumohydrothorax. Again, the X-ray photograph does not always show any definitely recognizable difference between the clearness of the outlines of the clavicle and the ribs near the apex of the diseased lung, and those on the unaffected side during deep inspiration, nor between the density of the two lungs; and yet this difference would be easily seen on the fluorescent screen.

Moreover, it is very desirable when examining the chest to use all the methods — inspection, percussion, auscultation, and X-ray examination — at the same visit, as these different methods support and assist each other, and to base the diagnosis on the result of this collective examination.

Again, if it is a question of determining the position of a new growth, for example, in the thorax, it is very desirable to turn the patient and examine him with the light going through the chest in various directions, and the screen enables the observer to do this with ease and quickness (this point will be illustrated in the chapter on New Growths and elsewhere); if the photographic method were used, two or more pictures would be necessary. The screen also shows readily whether or not the new growth moves during deglutition or respiration, and the photograph could not easily demonstrate this point.

It has been argued as a disadvantage of the screen that it does not afford a mechanical record of the results obtained, as does the X-ray photograph and the thermometer. The same is true of other methods of examination successfully carried out, for example, those made by auscultation and percussion; but we could not afford to do without these, nor can we dispense with the screen, as the following pages will show.

For examination of the chest I am satisfied that the screen gives fuller evidence and is altogether more serviceable. The question of the comparative usefulness of screen and photograph in diseases of the thorax will be taken up again in succeeding chapters.

Reproductions of X-ray photographs of the chest have been given in a few cases only, because the half-tone shows so little as compared with the negative that it is unsatisfactory.

X-Ray Examination of Chest. — There are two objects to be attained when making X-ray examinations of the chest. First, the correct observation and record of the appearance obtaining; this point has already been touched upon in Chapter III, and will be further discussed in its appropriate place. Second, the proper interpretation of these observations.

CHAPTER V

PULMONARY TUBERCULOSIS

It was early recognized by many practitioners in various countries that the dense lung in this disease would cast a shadow which might be observed on the fluorescent screen. It seemed to me, also, that we might find in the X-rays another means of recognizing pulmonary tuberculosis in its earliest stage, and with this end in view I took every opportunity to examine early cases of this disease. In a short preliminary article which I published in the *Boston Medical and Surgical Journal*, October 1, 1896, I find the following sentence, "I have examined about forty cases of pulmonary tuberculosis, and find not only that the fluoroscope is of value in determining the extent of the disease, but also sometimes reveals its location where and when it would otherwise have been unsuspected." During that year I showed that in pulmonary tuberculosis changes in the excursion of the diaphragm take place, and may point out to us very early an abnormal condition of the lung, and also, like others, that the dense lung in this disease casts a shadow on the screen. Let us take up these signs of tuberculosis in a little more detail.

APPEARANCES SEEN ON THE FLUORESCENT SCREEN IN PULMONARY TUBERCULOSIS

Darkened Lung. — The diseased portion of the lung or lungs is darker than normal, owing to its increased density (see Fig. 80).

Diaphragm Lines. — The diaphragm is restricted on the affected side or sides, and usually in the lower part of its excursion.

Displaced Heart. — The heart may be drawn toward the affected side, especially during deep inspiration; but it must be remembered that the greater excursion of the diaphragm on the normal side, if only one lung is diseased, would contribute to such a displacement during full inspiration.

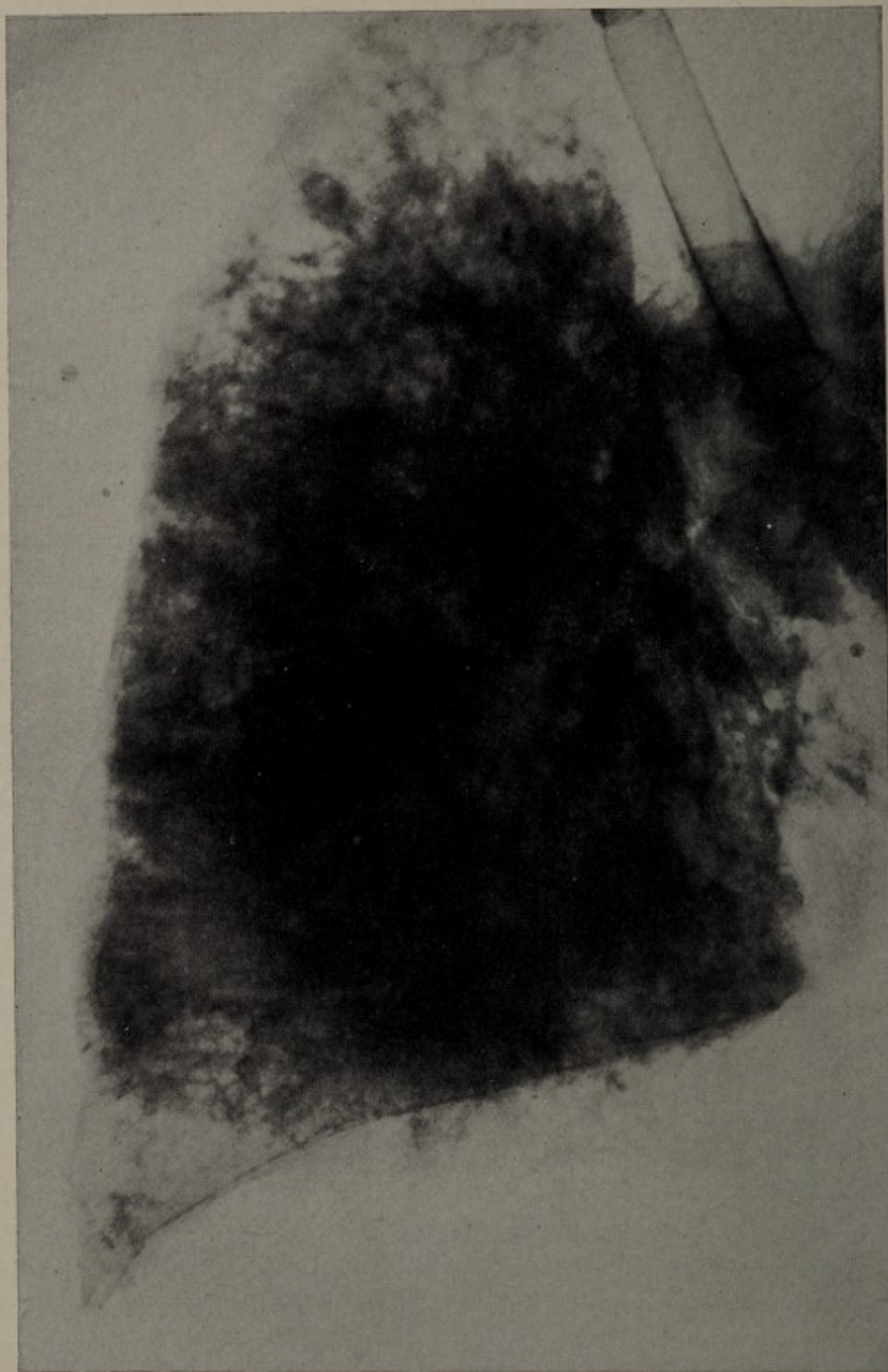

FIG. 80. John H. Cut from radiograph of tuberculous lung. The lightest portions are not involved. See Fig. 93 for X-ray tracing of this patient's chest.

ILLUSTRATIVE CASES. — The following five cases are illustrative of the first two points; they are selected from eighteen cases, some of which I reported at a meeting of the Boston Society for Medical Improvement, October 19, 1896, and all of which were published in the Medical and Surgical Report of the Boston City Hospital, January, 1897. These five cases were under the care of other physicians and the diagnosis of tuberculosis had been established; but it will be noticed that I was able by means of the X-rays to recognize the diseased condition of the second apex before it was pointed out by physical signs. This observation led me to feel more confidence in the signs of pulmonary tuberculosis, as indicated by the X-rays, in those cases in which no other signs had been observed.

The following case¹ is of especial interest to me, as it is one of the first cases of tuberculosis that I examined with the X-rays. The patient was under the care of one of my colleagues at the Boston City Hospital, and was suffering from tuberculosis of the right lung. He was brought at my request to the Massachusetts Institute of Technology, that I might examine him with an X-ray machine belonging to the Institute. His hospital record was as follows: —

CASE I. January 31, 1896, C. B., aged twenty years. Left lung negative; dulness at right apex, and just below this an area of tympany, over which is heard amphoric breathing. At apex, expiration prolonged and fine moist and crackling râles. Dulness in back nearly to scapula, with numerous fine, moist and crackling râles.

April 14. Dulness in upper two-thirds of right back; tubular respiration on top and rather obscure breathing below, with rather dry râles over area of dulness. Percussion at second space dull rather than tympanitic. Tubular respiration rather more circumscribed, and most marked toward anterior axillary line. Fine dry râles, increased by cough, extending about two-thirds down.

After looking at this patient from behind for a moment only, the difference in the amount of rays which passed through the two sides of the chest was very striking, as seen in the fluoroscope, the diseased lung being darker throughout than the normal lung. The ribs on the left side were much more distinct than those on the right.

CASE II. B. J., twenty-seven years old, entered the Boston City Hospital September 24, 1896. Service of Dr. Sears. Tuberculosis.

¹ "Notes on X-Rays in Medicine," Transactions of the Association of American Physicians, April, 1896; and "Note on X-Rays," *Boston Medical and Surgical Journal*, April 30, 1896.

Tuberculous family history. Hæmoptysis. During past month, dyspnœa; weakness; night sweats; little cough. Marked signs of tuberculosis below second rib over whole *left* side; right lung negative.

Examination with Fluoroscope.—Whole of left lung much darker than normal; no heart outline; no diaphragm outline seen on left side. *Right apex* also darker than normal to lower border of second rib.

CASE III. L. C., forty-four years old, entered the hospital November 21, 1896. Service of Dr. Tenney. Tuberculosis. Dulness, with râles over *left* side down to third rib in front and middle of scapula behind. Has had hæmoptyses every day for two weeks.

Examination with Fluoroscope.—Somewhat darker at *both apices* down to lower border of third rib, and to some extent below; excursion of diaphragm much less than normal, 2.2 centimetres on right side, 2.0 centimetres on left.

CASE IV. H. A., twenty years old, entered the hospital September 10, 1896. Patient of Dr. John L. Ames. Tuberculosis (?). Duration four weeks; family history not tuberculous. Medium dry râles at *left* apex, with slight dulness; right apex normal.

September 15. Some hæmoptyses; at left apex, few râles; expiration prolonged; breathing higher in pitch.

Examination with Fluoroscope.—Left lung extending to level of fourth rib very dark; also some involvement of *right apex*. The maximum respiratory movement of the diaphragm on the left side is only 2 centimetres; on the right side 2.5 centimetres. This is less than half the normal.

September 17. Tubercle bacilli found in sputum.

A second X-ray examination one week later showed the upper half of the right lung and upper third of the left lung darker than normal. Movement of the diaphragm the same as at the previous examination.

CASE V. R. J. M., forty-four years old, entered the hospital July 16, 1896. Patient of Dr. C. E. Edson. Tuberculosis. Anorexia; loss of flesh; considerable expectoration. Dulness at right apex, front and back, to third space and middle of scapula; expiration prolonged; râles, especially after cough; increased voice sounds. *Left side normal.*

Examination with Fluoroscope.—Right lung darker from apex to fifth rib; *left lung* darker than normal from apex to second rib.

July 28. Tubercle bacilli found in sputum.

Appearance of the Lungs on the Fluorescent Screen in Early Tuberculosis. — The apex of one lung is seen on the fluorescent screen to be darker than normal, owing to the increased density of this portion of the lung; and, second, the excursion of the diaphragm is seen to be

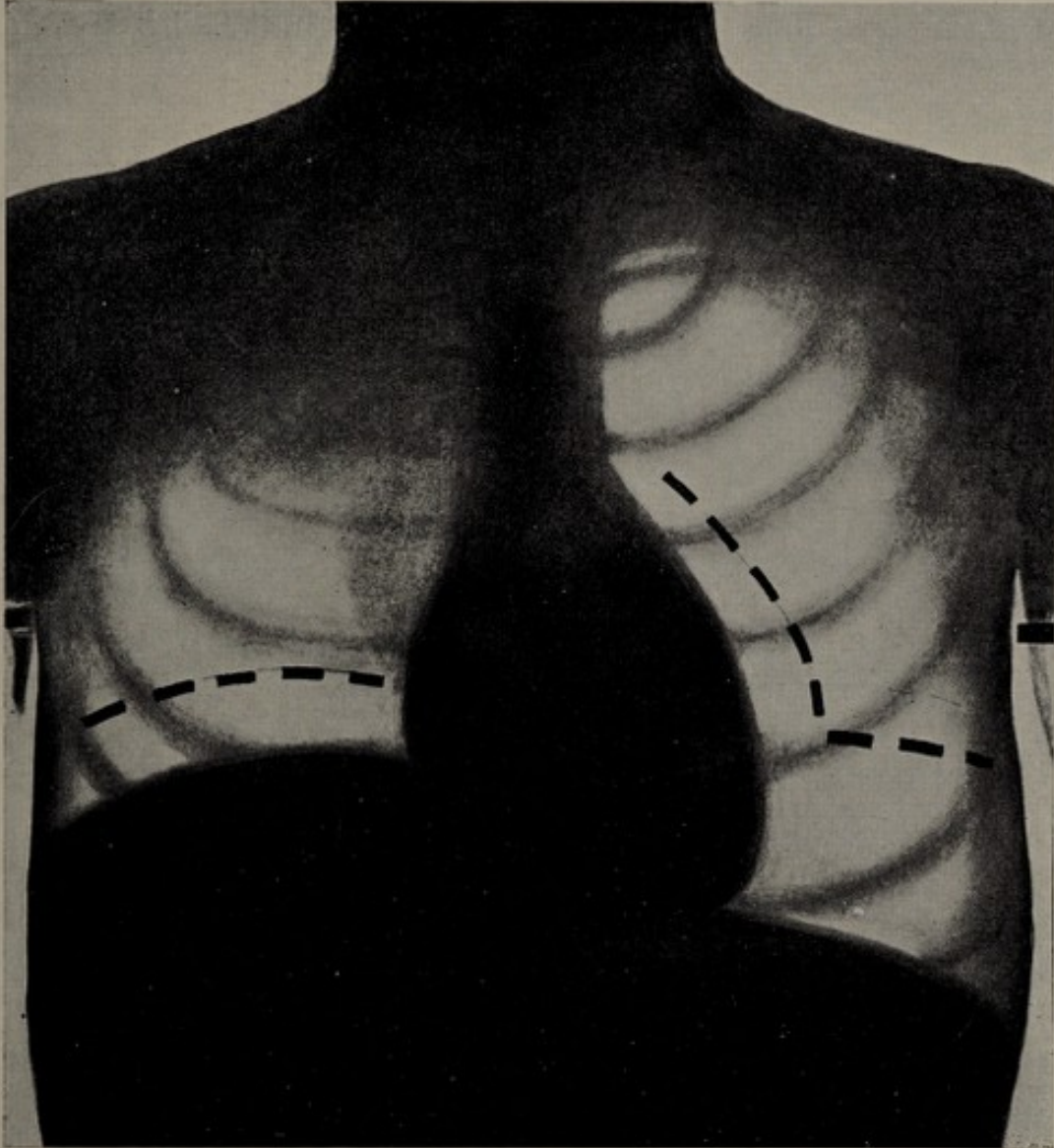


FIG. 81. Diagram of pulmonary tuberculosis. Right side.

Right apex darker and excursion of diaphragm shorter than normal on right side. In the early stage the slight shadow cast is best detected at full inspiration.

In this diagram the apex is darker, and the excursion of the diaphragm is more restricted than in the very early stage of the disease; partly for purposes of illustration and in the case of the apex also because it is difficult to get a slight amount of shadow reproduced in the half-tone.

restricted on the affected side, and usually in the lower part of its excursion. The heart also is oftentimes drawn toward the diseased lung. The diagram (Fig. 81) indicates the first two signs mentioned, but the shaded area at the right apex is a little darker than is found

in the early stages of the disease, for two reasons: first, it is very difficult to get a slight amount of shadow reproduced in a half-tone; and, second, the shadow is exaggerated here for purposes of illustration. The right diaphragm line is also shortened more than is natural in such cases, for the same purpose. In the early stages the disease is rarely found at the same time in both apices, and it is interesting to note that

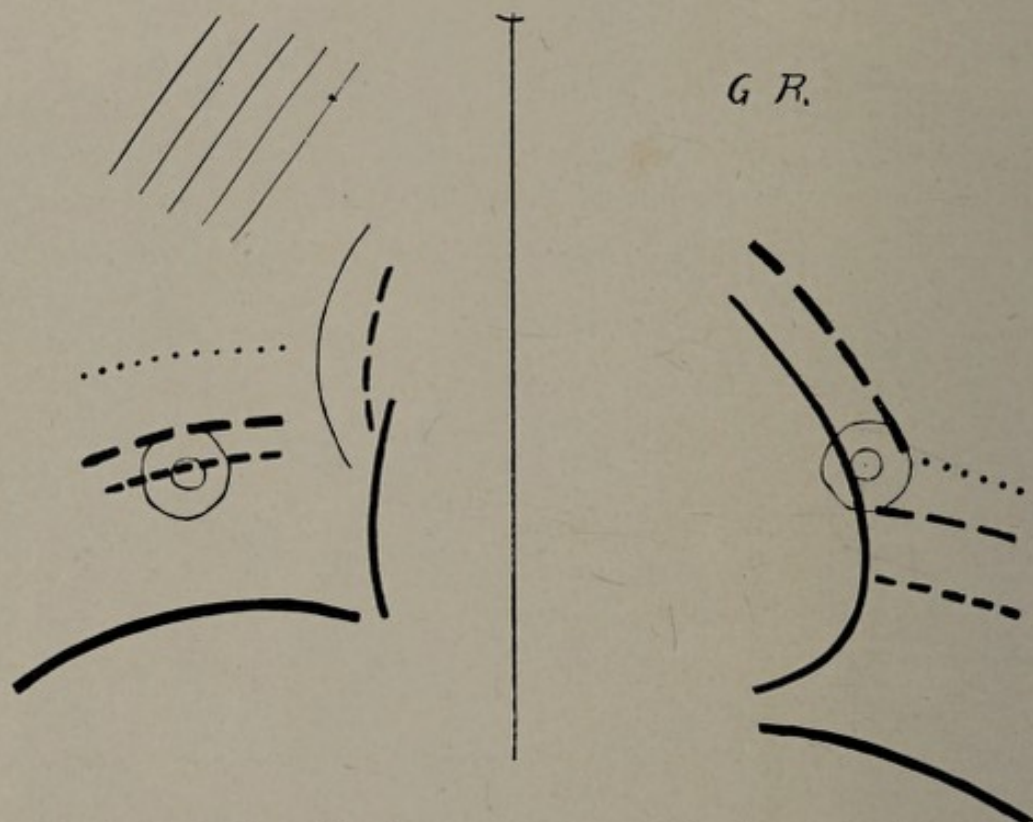


FIG. 82. G. R. Outlines taken from a case of very early tuberculosis. *Density*: darkened right apex. *Diaphragm lines*: The lowest full curved lines are the diaphragm lines in deep inspiration; the two broken lines above these, the lines in the inspiration and expiration of quiet breathing, respectively; the dotted lines above these, the diaphragm lines in forced expiration. It will be seen that the excursion of the diaphragm in quiet breathing is shorter on the diseased than on the normal side, and that during expiration the diaphragm ascends higher than on the normal side. This tracing is given to indicate that we should study the movements of the diaphragm not only between expiration and deep inspiration, but also during quiet breathing and forced expiration. (One-third life size.)

thus far I have seen it by X-ray examinations more often in the right than in the left apex.

Instead of the appearances above mentioned we may find now and then only a general diminution in the clearness of the lungs and ribs. This latter condition probably obtains in cases where the disease is disseminated. It is not easy to recognize this slight departure from the normal unless the physician has had large and continuous experience in making X-ray examinations.

Appearances seen on the X-Ray Photograph. — The photograph may show a uniformly darkened apex, or the apex may have a mottled appearance, and this mottling may extend over the whole of the lung when it becomes diseased. This effect is not so marked on the screen.

Definition of Early Tuberculosis. — Perhaps, before going further, it will be well to define what I mean by "early" or "incipient" tuberculosis, as these terms are quite indefinite and do not present the same picture to all physicians. The words "incipient tuberculosis" bring to my mind a case like the following: A young person who has anæmia, irregular rise of evening temperature of about one degree, digestive symptoms, together with others of a general character, but without definite signs in the lungs, and without cough. Such patients have come under my observation, not because they had symptoms pointing directly to the lungs, but because they had been suffering from anæmia or rheumatism, or had recently been through some serious illness such as diphtheria. In many of these cases an abnormal condition of the lungs was found in what I may call an accidental way. For example, while making an X-ray examination of a patient who had a weak, rapid heart after diphtheria, in order to determine the size of this organ, I found a slight shadow at one apex and a shortened excursion of the diaphragm on that side. The tuberculin test confirmed the signs obtained by the X-ray examination. My suspicion of the presence of this disease — a suspicion afterward confirmed — has often been aroused by these signs, discovered during an X-ray examination of the heart, when my attention was not at the time of that examination particularly directed to the lungs. It is obvious that if the physical signs are slight and the patient is complaining of some other than a pulmonary trouble, the presence of tuberculosis of the lungs in its earliest stages may be overlooked if only the ordinary methods are used. Therefore, in cases which are open to suspicion, an X-ray examination should be made.

The number of patients in whom I have detected the first signs of this disease by the X-rays during the last five years is such that I have been much impressed with the advantage which this examination may be to young persons who have a tuberculous family history, and who are run down, but have slight or no physical signs of tuberculosis in the lungs.

DIRECTIONS FOR MAKING X-RAY EXAMINATIONS. — In tuberculosis, especially in its early stage, and in fact in all examinations of the chest with the fluorescent screen, the apparatus should be provided with an

adjustment which will allow the physician to increase or diminish the light while observing the appearances on the screen; because certain appearances which will show clearly in one light will be lost if the light is stronger or weaker than that best adapted for giving them prominence. The general directions as to the disposition of tube, screen, and patient, and the methods for recording the observations made, have already been given in Chapter III, therefore it is unnecessary to consider them further here. We will suppose the patient lying on the stretcher in the proper position, with a large screen 30×35 centimetres (12×14 inches) placed on his chest.

Diaphragm Lines. — The excursion made by the diaphragm in quiet breathing should be noted, and the point to which this muscle rises in inspiration and expiration, on both sides of the chest, should be traced on the skin or the celluloid covering the screen, according to the method adopted. The patient should then be asked to take a full breath, and the point to which the diaphragm descends should be noted; the first full inspiration should be followed by two or three more, and the lowest point of the diaphragm again noted, for it sometimes happens that the muscle will descend to a lower position on one or both sides after a few full inspirations have been taken than at first. Next, the point to which the diaphragm ascends in forced expiration should be recorded. By making these several observations we sometimes find that one set of measurements corroborates or supplements the other; for instance, where the excursion of the diaphragm from expiration to deep inspiration is shortened on one side, we often find the excursion during quiet breathing is diminished also on this side; or that the diaphragm rises much higher than normal, during forced expiration, above the line of quiet expiration on this side (see Fig. 82).

When one lung is diseased in whole or in part, some suggestion of the amount of disease present may be obtained not only by noting the excursion of the diaphragm on the abnormal side, but also that on the well side during quiet breathing; the normal excursion during this period of respiration is about 1.25 centimetres (see page 108, Introduction to Thorax), but this excursion is increased if one lung is obliged to do more than its share of the work.

Darkened Apex. — The lungs should be carefully observed, particularly the apices. The darkened areas seen on the screen should be indicated on the skin or celluloid. These areas may be more evident during full inspiration than during expiration. To detect the shaded

apex it is necessary for the physician to compare the brightness of the two apices and to observe the comparative distinctness with which the clavicle and the first and second ribs stand out in contrast to the lighter intercostal spaces on the two sides of the chest. These comparisons should be made during both inspiration and expiration, and with the light so adjusted that the suspected side is barely illuminated. With the light thus regulated, even a slight difference in brightness on the normal side would be more marked, because under these circumstances the contrast between the two apices would be greatest. That is to say, with the light such that in full inspiration there is very little or almost no light coming through a suspected apex, the greater brightness of the normal apex is more apparent. In many cases the slightly darkened apex is easily recognized, while in others, by careful adjustment of the light, — turning it up or down during the various stages of respiration, — the practised eye will see that there is undoubtedly a difference in the amount of light coming through the two apices. In the cases where both apices are slightly diseased, the recognition of this slight increase in density is more difficult, as then the physician must compare the brightness as found in the apices with his mental picture of what it should be for an individual of that build; for, as already indicated, in very stout persons the lungs would not be normally quite as bright as in thinner people. In the early stages, however, as mentioned above, the disease very rarely, if ever begins, in both apices at the same time, and if it has progressed so far as to affect both apices its presence would be very evident.

General Diminution in Clearness of Chest Outlines. — The thorax should be carefully examined to determine whether or not there is a general diminution in the amount of light coming through the chest as a whole. If the light is only slightly diminished, this diminution is only recognized after the practitioner has gained experience by examining persons of various sizes and different ages.

Bronchial Glands. — In some cases of pulmonary tuberculosis we may be able to recognize the shadows of the hypertrophied bronchial glands. This is another indication of disease to be looked for on the fluorescent screen.

Position of Heart. — The position of the heart should be examined and noted (see chapter on Heart for methods of examination).

Second X-Ray Examination. — A second X-ray examination, at least, should be made after an interval of several days. If the above men-

tioned signs persist, the physician should be diligent in his search for other indications of tuberculosis, which will only too frequently be found to develop later.

Comparison between the Value of the Fluorescent Screen and X-Ray Photograph in Early Tuberculosis. — In order to compare the results obtained by an X-ray photograph of the chest with the appearances as determined by means of the fluorescent screen, I have used both methods of examination in some cases, in the same patient, in an early stage of the disease. I made this experiment in the early stage advisedly, because in the later stages we have so many ways of making a diagnosis that X-ray examinations are only useful in determining the progress or the extent of the disease. In some of the patients in whom I have found signs in the apex of one lung with the fluorescent screen, the photograph also showed that the same apex was darker than the one on the other side. On the other hand, in certain cases where I found signs by the fluorescent screen, X-ray photographs showed no difference between the two sides. While the X-ray photographs show clearly that the lungs are denser than normal when the disease has passed the very earliest stage, thus far I have been able to detect an abnormal condition of the lungs in early tuberculosis better by means of the fluorescent screen than by means of the photograph. The screen is a readier and more certain test. This result has been a surprise to me, as I supposed the photograph would prove to be the better. Instantaneous photographs can now be taken of the lungs by means of intensifying screens; this method, which has been used by Van Ziemssen and Rieder, and others, is discussed in the Appendix.

USUAL MEANS OF DIAGNOSIS. — In this disease, as in many others, we derive the data for a diagnosis from various sources. The personal and family history of the patient must be considered; then his general condition, that is, whether or not he has lost in weight or strength, has or has not anæmia, indigestion, a daily rise in temperature, or a rapid pulse, etc. Only one or two of these symptoms may be present in any one case, however, and they may be due to other causes than tubercle bacilli. As the disease progresses, signs referable to the respiratory system appear, such as increase in the expiratory sounds and in tactile fremitus; the throat is affected; there is morning cough; or hæmoptyses; dulness; râles, etc. But, as already indicated, many of the general symptoms are common to other diseases, and likewise some of the

local signs. The finding of tubercle bacilli in the sputa establishes the diagnosis, or the tuberculin test may be used.

Early physical signs at the right apex, — namely, increase in respiratory murmur or in tactile fremitus; slight dulness, etc. It is true that tuberculosis frequently begins at the right apex, but there is often in health an increase in the respiratory murmur on the right side as compared with the left. There may also be an increase in tactile fremitus, or a slight dulness on the former side as compared with the latter. Therefore these slight physical signs at the right apex have less value than they otherwise would have. This point will be taken up again later.

The Tuberculin Test. — If we use the tuberculin test as a guide where the general symptoms suggest tuberculosis, we shall employ it in many cases where this disease is not present. On the other hand, if tuberculosis does exist, but is in an early stage, it may be overlooked unless more than one dose is given. For example, in the early stages patients do not react to one milligramme of tuberculin; sometimes not to five; or perhaps not even to larger amounts. We are obliged, then, in using tuberculin, to give it to many patients who prove not to have tuberculosis, and to give it to them a number of times to prove or disprove the tentative diagnosis, because we are not justified in inferring that tuberculosis is absent when there is no reaction to a small dose. Likewise if a second or third injection is required, there should be an interval of several days between the injections, and therefore time is consumed.

Great care is required to carry out the tuberculin test, and experience to interpret its results, for it may not be easy to decide whether the effects produced should or should not be interpreted as a reaction.

Further, some physicians are unwilling to use this test, partly because no reaction may follow until several injections have been made, and partly because other diseases react to tuberculin. Likewise, there are many patients who will not permit its use.

Again, even if the patient reacts to tuberculin, the test does not locate the lesion nor give its extent. It may be a pulmonary tuberculosis or a tuberculosis of some other part of the body; the test does not show whether or not the lungs are involved. The seat of the disease is of course of importance in treatment — a patient with tuberculosis of the foot need not be sent to Colorado.

Test for Tubercle Bacilli. — In the early stage of the disease there is usually no expectoration, therefore this test cannot be employed; and

even in cases where there is expectoration the bacilli are not always found when looked for. It sometimes happens that five or six negative examinations are made. I recall one patient who was examined six times with a negative result, but reacted well to three milligrammes of tuberculin. In some cases no bacilli are found during the whole course of the disease, but are found at the post-mortem examination.

X-RAY EXAMINATIONS AS AN AID IN THE EARLY DIAGNOSIS OF TUBERCULOSIS. — This method gives us a new aid in the early diagnosis of tuberculosis, and one which is without risk or discomfort to the patient. Even if we decide to use the tuberculin test it is well to precede its use by an X-ray examination in order to determine the extent of the disease in the lungs, to estimate how much it would be wise to give, and to avoid the risk of giving too large a dose of tuberculin. The X-ray examination may make the tuberculin test superfluous. I find its use less and less necessary as my experience with X-ray examinations, used in connection with other methods of examination, increases. I say "in connection with other methods of examination" advisedly. For example, we may find slight or doubtful signs in one lung by auscultation and percussion, suggestive of tuberculosis, and if the X-rays give evidence confirmatory of this disease, there is plainly less need for the use of the tuberculin test than there would otherwise have been, or it may not be required at all. On the other hand, the X-rays may be of service in pointing out the cases in which the tuberculin should be used, that is, cases where this test is the only means of confirming the diagnosis suggested by the X-rays.

Diagnosis not made by X-Rays Alone. — By X-ray examinations we detect abnormal conditions of the lungs, their change in density, elasticity, and volume; and to some extent they assist us to make a differential diagnosis, as will be seen later; but the shaded apex and shortened excursion of the diaphragm seen in pulmonary tuberculosis may also point to a recent pneumonia in the upper lobe, and the history of the case would be necessary to enable us to discriminate between this cause and tuberculosis; or again, the movement of the lung might be restricted by a pneumonia with pleurisy which had caused adhesions. Therefore the inquiry should be made as to whether or not the patient had previously had pneumonia or pleurisy. But the darkened apex and shortened excursion of the diaphragm should always make the physician consider pulmonary tuberculosis, and put him on his guard

against a beginning or an old and healed tuberculosis. The history of the case, however, and further examinations, are necessary to make a positive diagnosis. In other words, the diagnosis of phthisis is not made by the X-ray examination alone, but it does give us early warning of a departure from the normal in the lung, which puts us on our guard and enables us, in conjunction with the history, etc., to make the diagnosis, and thus in many early cases of tuberculosis to arrest its progress by proper care.

The service which X-ray examinations can render in giving early warning of tuberculosis is well illustrated by the following case:—

C. B., a young man, one of whose parents died of tuberculosis, was brought to see me in consultation and for an X-ray examination. He had a history of recent rapid loss of flesh, but there were no physical signs, no temperature, no cough, and the pulse was not rapid.

The *X-ray examination with fluorescent screen* showed a darkened apex of one lung and a much shortened excursion of the diaphragm on the same side.

Both his physicians suspected tuberculosis, and he was being kept under observation to see if any signs developed in the lungs; but as the X-ray examination showed that they were already present, I saw no reason for delay, and advised that he should go directly where he could have good food and lead an out-of-door life for some months. This advice was followed, and four months later his family reported him as better than he had ever been in his life.

I believe that we may regard the successful care of early tuberculosis as dependent largely upon maintaining the condition and well-being of the patient at as high a point as possible. If there is delay in making the diagnosis, not only are time and money wasted, but also, what is of vital consideration, the chance of recovery is greatly lessened. Effectual care does not by any means necessitate a journey to another climate, — although, as just indicated, it may be advisable when possible, — for it has been shown that even in some of the worst climates consumptives do well under proper direction.

Final Test Tubercle Bacilli. — We cannot make a final diagnosis of pulmonary tuberculosis by the X-rays; but if we exclude the test for bacilli, which cannot be made until cough and expectoration appear, — and even then the bacilli may not be found until after death, as already stated, — we also see that in the early stage of the disease there is no test that is without question.

IMPORTANCE OF EARLY DIAGNOSIS. — The practical point then is the ability, founded on the best evidence available, to warn patients of danger before they begin to cough, if possible, for it is unwise to wait, for fear of making a mistake, until this symptom has appeared. It does not take skill in diagnosis to send the sputum to the laboratory and receive a report that tubercle bacilli are or are not present. But to weigh the history, symptoms, and signs, X-ray as well as the usual physical signs, and at the earliest moment foresee the probabilities with considerable certainty, does demand skill and experience in pulmonary disease. Very little harm will be done if the physician now and then sends away a patient for a timely vacation because he suspected early tuberculosis, which did not exist — for if such suspicions are aroused the patient probably needs a rest for other causes — as compared with the irreparable injury committed by keeping patients under observation and delaying effective measures until a medical student can make the diagnosis.

CLASSES OF CASES OF PULMONARY TUBERCULOSIS, IN WHICH THE X-RAY EXAMINATION IS OF VALUE. —

A. As an Aid in Diagnosis. — *First*, in cases where there are no physical signs, or where they are very doubtful.

Second, in cases where there are slight physical signs only.

Third, in cases where an accompanying emphysema, bronchitis, pleurisy, or pneumonia may disguise the physical signs of tuberculosis.

Fourth, in cases where the physical signs indicate tuberculosis, which the X-rays do not confirm.

Fifth, in cases of tuberculosis of some other portion of the body than the lungs, to see if they are also affected.

Sixth, in patients between fifteen and thirty years of age where the family history is tuberculous. Precautionary X-ray examinations.

B. In Old Lesions of Tuberculosis.

C. For determining Existing Conditions more accurately.

D. In determining the Progress and Extent of Disease. — *First*, in cases where the progress of the disease is rapid, X-ray examinations made at intervals of a week or so will often show marked increase in the diseased area, although to physical signs the progress is not so evident. *Second*, in cases where the progress is not rapid and the patients gain steadily in weight and improve in color and general

condition, and have no temperature, yet the X-rays show that the disease is steadily advancing.

E. In determining the Extent of Disease. — In cases in which the X-rays assist us to determine the extent of the disease as well as its progress, and enable the physician to determine whether the patient should or should not remain at home.

F. In Acute Miliary Tuberculosis.

G. In showing Cavities in the Lungs.

A. AS AN AID IN DIAGNOSIS

This method gives us another means of learning that the lungs are in an abnormal condition, and thus diminishes the chance that the disease may be overlooked in the early stage. Moreover, the signs by the X-rays may be so decisive in character as to demand search for other signs and symptoms. Thus the early warning given by X-ray examinations contributes to prompt and therefore hopeful treatment; and the ease with which they are made, so far as the patient is concerned, together with their entire harmlessness, makes them serviceable in the early diagnosis of pulmonary tuberculosis. Let me illustrate this point by the following cases:—

First, those without Physical Signs. —

CASE I. Bertha N., aged twenty years. Entered my service at the Boston City Hospital February 18, 1899.

Family History. — Father died of tuberculosis.

Personal History. — Typhoid fever eight years previously.

Present Illness. — Bad cold for two weeks; sore throat; no cough. Some pain in mid-chest on deep inspiration. Chills three or four nights before entrance. For past two days feet have been sore, and, soon after, knees became swollen and painful. No vomiting.

Physical Examination. — Heart: right border at right sternal border; left border 8 centimetres to left of mid-sternum. Apex in fourth space. Action tumultuous; no murmurs heard; pulmonic second accentuated. Lungs: resonance and respiration good.

Two X-ray examinations with fluorescent screen showed a darkened apex and a shortened excursion of the diaphragm on the right side.

Patient reacted to 10 milligrammes of tuberculin. Temperature 101.2° F.; malaise.

CASE II. T. M., twenty years old, entered my service at the hospital April 21, 1897, for phlebitis in the right leg.

Family History.—Two of her sisters died of tuberculosis.

Personal History.—Five weeks ago, pain in the right calf. Two weeks ago, pain in left side, worse on breathing.

Physical Examination.—Heart's area, action, and sounds, normal. Lungs: good resonance and respiration throughout. Examination of the blood gave 30 to 35 per cent of hæmoglobin, 4,300,000 red corpuscles, 9000 white corpuscles.

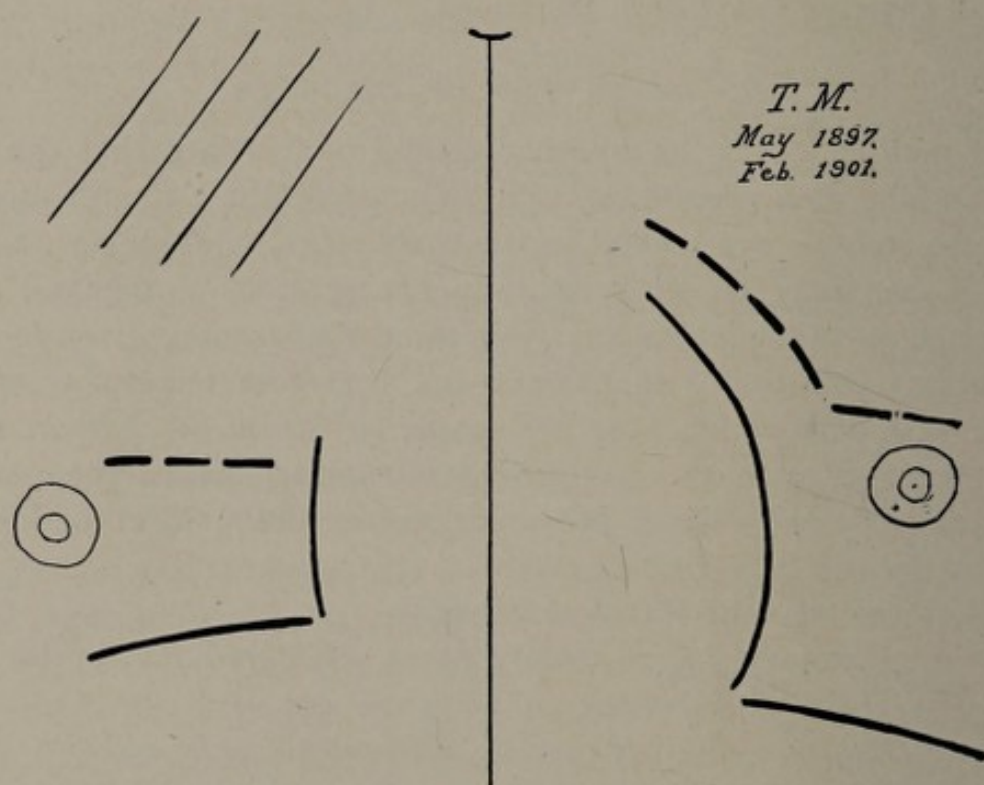


FIG. 83. T. M. X-ray tracing (one-third life size). Right lung shaded; excursion of diaphragm on right side 4.5 centimetres; on left side 7.5 centimetres.

May 12. X-Ray Examination with Screen.—Right lung shaded. Excursion of the diaphragm on the right side 4.5 centimetres, on the left side 7.5 centimetres (see Fig. 83).

May 22. Reacted to 5 milligrammes of tuberculin. Temperature 104.8° F.

May 27. Physical examination shows nothing abnormal in the lung. Patient has no cough, is well developed and well nourished. No symptoms pointing to trouble in the lungs.

June 12. Several careful physical examinations of the lungs made during the past month gave no evidence of tuberculous process. Resonance and respiration good. Discharged.

1897. Went home to Canada and remained a year.

1898-1899. Had cough and night sweats during the winter.

November 23, 1899. Unusually well developed and nourished; great increase in weight, present weight 170 pounds. Appears well.

February, 1900. The patient has been perfectly well since November, 1899. The X-ray signs remain the same as in 1897 (see Fig. 83).

March, 1901. Has been at work continuously; seems now perfectly well.

Second, Cases where there are Slight Physical Signs only. —

CASE I. Michel F., aged twenty-four years. Diagnosis: acute articular rheumatism, cardiac. Entered my service at the Boston City Hospital December 2, 1898. *Family history*, negative. *Personal history*: was in the hospital with acute articular rheumatism in ankles and right wrist, in June, 1898, for two weeks, and again in July and August, 1898, for four weeks. Lungs were then normal, temperature such as might be expected with rheumatism, not suggestive of tuberculosis. After his discharge from the hospital in August his ankle continued to trouble him, but he kept at work until the middle of November. Then both ankles were painful, and the right wrist was also affected. December 2, 1898, says he has felt feverish and slept poorly on account of pain; no headache, no cough, appetite good. Physical examination: well-developed and well-nourished man, general condition good. Pulse 76. Lungs: resonance and respiratory sounds normal.

December 17. *X-ray examination with screen* was made in order to determine the size of the heart. Heart shows slight enlargement, both to the right and left. I noticed while examining this organ that the right lung, from the apex as far as the third rib, was darker than normal, and the excursion of the diaphragm was diminished on this side, being 5.25 centimetres on the right side and 7.5 centimetres on the left side.

On the same day the physical examination was made *after* X-ray examination: expiration somewhat more marked in the right apex in front. Tactile fremitus slightly increased in the right back between the scapula and the vertebral column. Patient when asked if he had not lost in weight during the past few months, thought that he had. December 22, 1 milligramme of tuberculin was given; no reaction. December 27, 3 milligrammes of tuberculin were given; no reaction. December 30, 5 milligrammes of tuberculin were given; reaction well marked. Temperature 102.5° F., with malaise. December 30, morn-

ing and evening temperature for three weeks had been 98° to 99° F. No cough at any time.

January 2, 1899. Prolonged expiration, slight increase in tactile fremitus in the right back between the scapula and spine, opposite

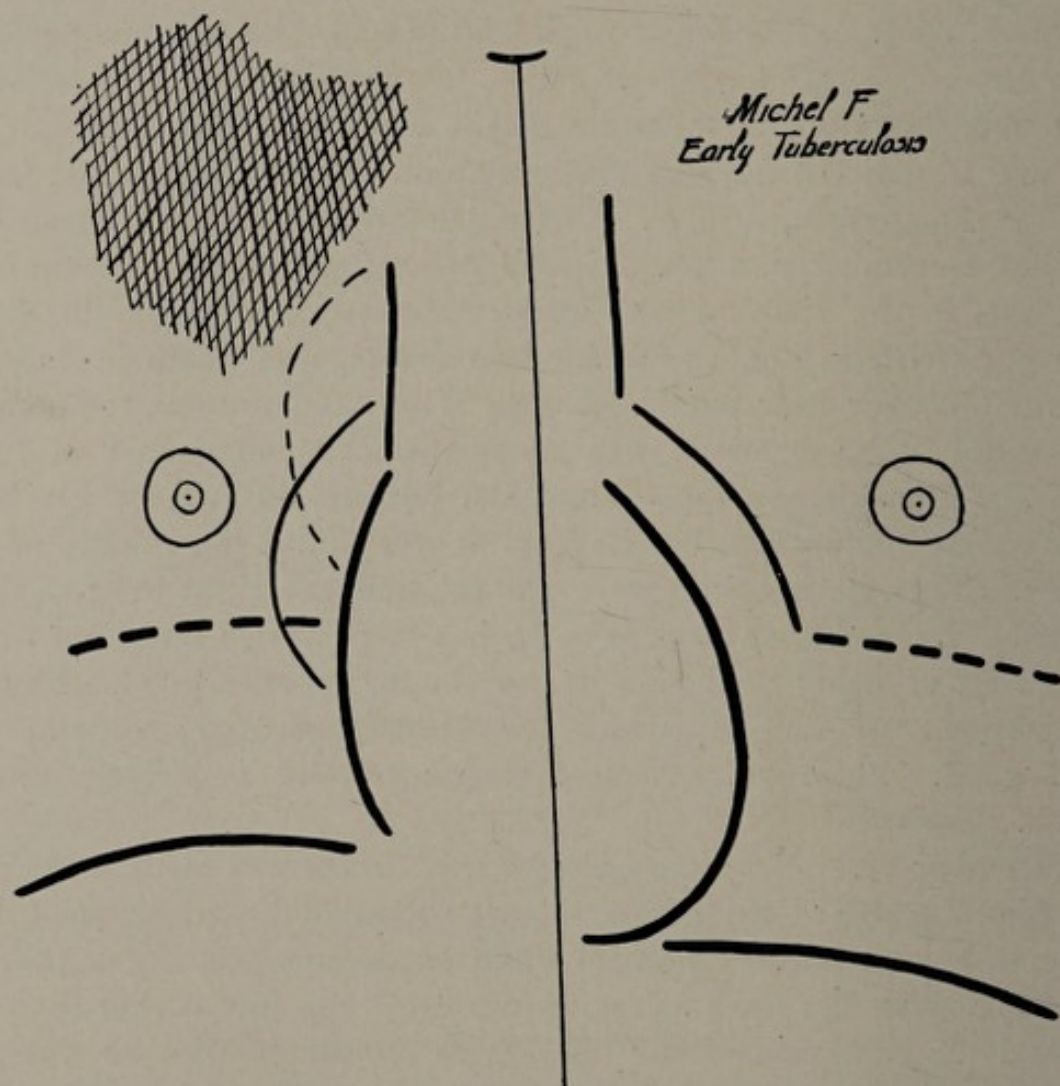


FIG. 84. Michel F., December 17, 1898. Diagnosis: acute articular rheumatism. X-ray examination with screen shows that the apex on the right side is darkened. Broken and nearly horizontal lines on either side show position of diaphragm in expiration; the full lines below, in forced inspiration. It will be noticed that the excursion of the diaphragm on the right side is shorter than on the left. The heart during forced inspiration moves more to the right than normal, because the right lung expands less than the left. (One-third life size.)

the spine of the scapula. Discharged. His appearance at this time was that of a well man.

In March, 1899, this patient had another attack, and returned to the City Hospital. He was under Dr. V. Y. Bowditch's care. Diagnosis: rheumatism. With Dr. Bowditch's permission I insert here the note he

made of his physical examination of the lungs: "Percussion note is slightly high in pitch, and slight dulness at right apex to the third rib in front and spine of scapula behind. No change in respiratory murmur and no râles. Resonance and respiration good over balance of chest."

In March, 1899, I made another *X-ray examination*, and found the same darkened area of the lung and shortened excursion of the diaphragm as on December 17, 1898.

CASE II. Michael H., aged thirty-six years. Entered my service at the hospital March 7, 1898, with acute articular rheumatism, which began five weeks before entrance with swelling in the knee, extended to one hip, then to the other, then to the left ankle. Ten days before entrance both hands became red, swollen, and painful; five days before started again in the knee, right hip, right hand, and shoulder. Physical examination of the lungs showed good resonance and respiration throughout. On March 10 the left wrist was red and painful. On March 18 this condition improved under salicylates. Practically well.

March 8. X-Ray Examination with Screen.—This was made to determine the size of the heart, as I was then making X-ray examinations of this organ in all cases of acute rheumatism. The apex of the right lung was found to be shaded as compared with the left lung; excursion of the diaphragm on the right side 5.5 centimetres, on the left side 8 centimetres.

After this examination auscultation and percussion showed slight dulness on the right side from the apex to the second rib. Tactile fremitus increased, expiration prolonged.

March 14. Second X-ray examination pointed to the right lung as the seat of the trouble, as before.

One milligramme of tuberculin given, later 2 milligrammes given, finally 4 given. Patient reacted to this last dose. Discharged April 7, 1898.

In May, 1899, he returned to the out-patient department, and Dr. John W. Bartol kindly reported to me that he found no physical signs in the lungs.

It is, of course, a serious matter for a patient or for his friends to be told that he has trouble in the lungs; but it is much more serious for the physician to fail to make an early diagnosis and take prompt action. Moreover, the natural apprehensions of the patient may be

very reasonably allayed by a hopeful prognosis in view of the early discovery of the disease.

Association of Tuberculosis and Acute Articular Rheumatism.—It will be noticed that these two cases had acute articular rheumatism. I have been struck with the frequent association of rheumatism and tuberculosis.

Result of Physical Examination before and after X-Ray Examination.—The physical examination in some cases of early tuberculosis has revealed nothing abnormal to the physicians examining them until after attention was drawn to the abnormality of the lungs by my X-ray examination. After this had been made, however, auscultation and percussion over the site indicated by the X-rays has frequently revealed an expiratory murmur a little more marked on this side than on the opposite side. In some cases, also, the dulness has seemed a little more prominent, and the tactile fremitus has been found to be slightly increased. It is much easier, I think, when the conditions are very little removed from the normal, to recognize these slight differences after the X-ray examination has suggested where we should look for them. Again, there are other cases where the tactile fremitus, slight dulness, or slightly harsher respiration on one side as compared with the other, may be within normal limits, but where an X-ray examination shows less doubtful signs of disease.

Early Warning given and Conditions watched by the X-Rays.—The following case is given in some detail to show how a case of tuberculosis can be watched on the fluorescent screen, and the physician aided to take suitable measures:—

Case I. Margaret G., eighteen years old, entered my service at the hospital October 26, 1899. Diagnosis: chlorosis; rheumatism.

Family History.—Father and mother living. Mother well. Father has had chronic cough for two and one-half years; was in the hospital two years ago for operation on fistula. During the first year of cough had occasional night sweats and hæmoptyses. Cough of late has been better. Five brothers and two sisters living and well.

Personal History.—Pneumonia two years ago in left chest. Peritonitis same year. Muscular rheumatism eighteen months ago. Catamenia at sixteen years of age, irregular since. Previous to entrance patient had worked in a book-bindery, where there was much dust and poor air; was seated most of the time; work lasted nine hours with a varying interval of from fifteen to sixty minutes' nooning; had a cold lunch always. Gives no history of cough or fainting attacks. Has

had much trouble with eyes, which has been relieved much of the time by glasses. Does not think that she had lost any flesh up to September 1, 1899, when she went on a vacation to Milford, N. H., feeling tired out and "all run down," and with much headache. Returned to work, having gained three pounds, but not feeling much better, headache having continued while away. Did not notice that color was improved; did, however, feel rested. At end of two weeks was forced to give up work because of increasing weakness and malaise.

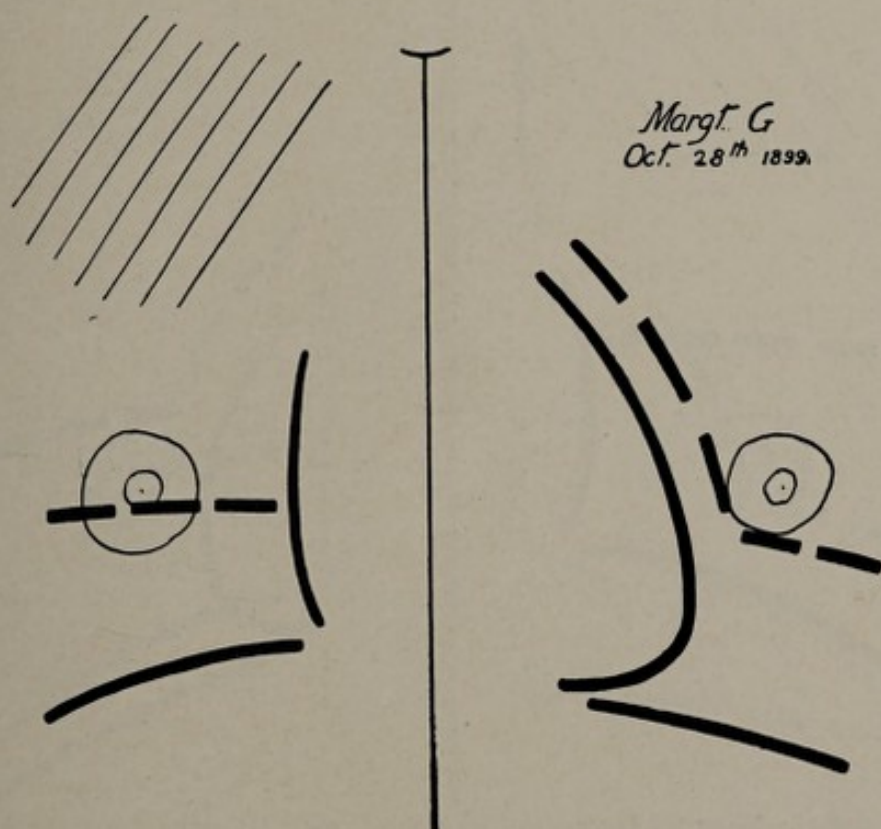


FIG. 85. Margaret G. X-ray tracing made October 28, 1899. (One-third life size.) Right apex darker than normal; excursion of diaphragm shortened on right side.

At this time was sleeping very poorly and had no appetite. From time of resuming work up to that of entering the hospital (*i.e.* five weeks) had lost eight pounds.

Physical examination. — Well developed and nourished. Anæmic.

Eyes: sclera bluish. Pupils dilated.

Tongue: moist, slight coat.

Pulse: regular; good volume and tension.

Heart: right border 3 centimetres to right of median line; left border 12 centimetres to left of same line. Apex felt in fourth inter-

pace, outside the nipple line. Action regular. Soft, blowing systolic murmur heard all over cardiac area to left of sternum, loudest in second left interspace. Systolic murmur also heard in base of left neck. Pulmonic second slightly accentuated.

Lungs: resonance and respiration good throughout except prolonged expiratory murmur and increased tactile fremitus and vocal resonance at right apex, front and back. No râles.

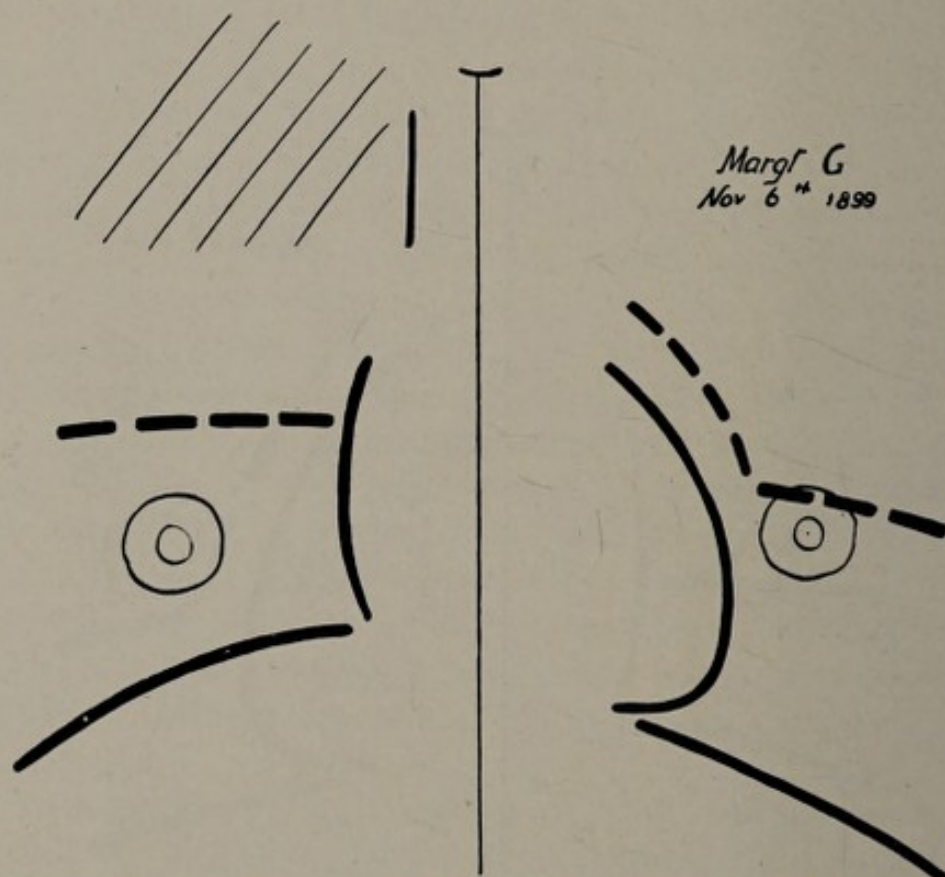


FIG. 86. Margaret G. X-ray tracing made November 6, 1899. (One-third life size.) Right apex still darker than normal, and excursion of diaphragm shortened on right side.

Liver, spleen, and abdomen negative, except slight dulness at seventh rib.

Extremities: very slight œdema. Over inner malleolus of left limb, redness, swelling, heat, and tenderness.

October 28. X-Ray Examination with Screen. — Right apex darkened. Excursion of diaphragm on right side shorter than on left side (see Fig. 85).

November 1. Has improved in color.

November 3. Physical examination shows prolonged expiration at right apex. The increased tactile fremitus at first noticed is now absent.

Patient has better color and has apparently gained in weight and strength.

November 6. No murmurs heard over second interspace in neck.

X-ray examination with screen on same date shows shortened excursion of diaphragm on the right side, and that the shading at right apex persists (see Fig. 86).

November 10. Patient appears to be gaining. Is up and about ward each day. No cough.

November 13. Patient as at last note; gains steadily. Has had two

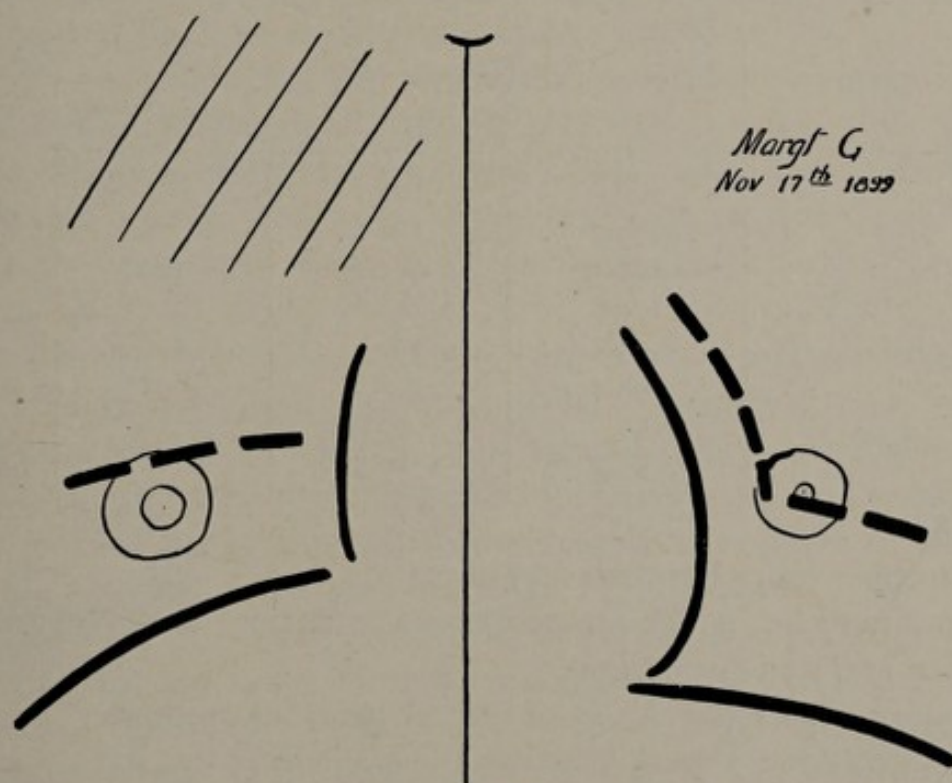


FIG. 87. Margaret G. X-ray tracing made November 17, 1899. (One-third life size.) Right apex darker than normal; excursion of diaphragm shortened on right side as compared with the left.

doses of tuberculin; first on November 6, of 1 milligramme, and again November 13, of 3 milligrammes, without reaction to either, except for the very slightest rise in temperature following the second. Patient was given 5 milligrammes of tuberculin on the evening of the 16th, at 6.30 o'clock. On the following morning face became flushed, patient felt chilly, and temperature rose to 102.6. These symptoms, with severe headache, ceased some hours after.

November 17. X-Ray Examination with Screen. — Appearances indicate tuberculous process at right apex, but no increase in signs due to

tuberculin, from which she is now reacting, it having been given eighteen hours previously.

Physical examination on this date shows dulness and increased tactile fremitus at right apex; expiratory murmur slightly greater under right clavicle than under left; slightly better resonance at left apex; both sides alike behind to percussion, and no increase of tactile fremitus; both backs normal. Aortic second slightly accentuated.

November 21. Patient weighed to-day in same clothes as worn on entrance; has gained one-half pound; weighs 106½ pounds.

| | TEMPERATURE | | PULSE | |
|-------------------|-------------|---------|---------|---------|
| | Morning | Evening | Morning | Evening |
| Oct. 26 | — | 100.1 | — | 82 |
| " 27 | 99.5 | 102.2 | 72 | 102 |
| " 28 | 100.1 | 101.2 | 102 | 108 |
| " 29 | 100.8 | 100.8 | 110 | 110 |
| " 30 | 99.5 | 100 | 106 | 98 |
| " 31 | 98.4 | 100.2 | 95 | 88 |
| Nov. 1 | 99 | 99 | 78 | 88 |
| " 2 | 98.2 | 89.5 | 82 | 88 |

Respirations were between 20 and 24.

After November 3 her temperature was normal until November 28, 1899, when she was discharged.

November 28. Physical examination was as follows; expiratory murmur slightly more marked under the clavicle at the right apex, with the Bowles stethoscope; no dulness at either apex. Behind, above the spine of the scapula on the right side, and between it and the spinal column, the expiratory murmur with the stethoscope was rather more marked than on the left side. Above the clavicle on the right side, the expiratory murmur was rather more marked than on the left.

[*Examination of Right Apex in Patients whose Lungs were presumably Normal.* — The X-ray examination of this patient had directed my attention strongly toward the right apex, and as this apex differs normally from the left, it occurred to me to compare the two apices in several patients, in whom, so far as known, there was no pulmonary disease, in order to better decide how much weight should be given to the physical signs on the right side. On this same morning (Novem-

ber 28), therefore, I examined carefully four other patients in my wards, with a view to making the above comparison.

James D., a boy fifteen years old, convalescent from typhoid fever, had dulness at the right apex, and expiration more marked than at the left apex.

Benjamin C., twenty-five years old: the right apex in front was dull as compared with the left; tactile fremitus increased, and respiratory murmur more marked.

James T., fourteen years old, convalescent from typhoid fever; right side in front slightly duller than left; expiratory murmur more marked in the right front below clavicle than on the left side.

Roy W., fourteen years old, arthritis of knee joints: percussion note slightly increased at the right apex; tactile fremitus the same on both sides; expiratory murmur more marked at the right apex in front than over the same area on the left. X-ray examination of this patient on this morning showed the lungs to be perfectly clear.]

December 19, 1899. The patient, Margaret G., was admitted to Dr. Trudeau's Sanitarium in the Adirondacks, and remained there, through his kindness and that of a friend, until about April 1. She was then so well that Dr. Trudeau was willing she should return to her work.

The report of her case made at the Sanitarium is given below:—

"M. G., admitted December 19, 1899. Dr. Williams.

"*Family History.*—Father has been suffering with pulmonary tuberculosis for past five years. Mother frequently has articular rheumatism.

"*Personal History.*—Measles during childhood. 'Inflammation of bowels' three years ago. Pneumonia two years ago, from which she entirely recovered. Has led an indoor life for past four years. Occasionally has attacks of articular rheumatism, last attack six weeks ago.

"*Present Illness.*—Knew nothing of her pulmonary trouble until it was discovered upon her admission to the Boston City Hospital for acute articular rheumatism and chlorosis. Had lost weight rapidly before her admission to hospital, and had dyspnoea upon exertion. No cough, expectoration, or sweats. Has had pain over right apex for past four weeks.

"*Present Condition.*—Fairly well nourished; not particularly anæmic; no cough, very occasional expectoration; no dyspnoea; feels as well as ever. Has gained in weight since she left the hospital, pain in right apex being all of which she complains.

"December 20. *Physical Examination*.—Inspection: negative except for slightly lessened expansion on right.

"Palpation: negative.

"Percussion: no impairment of resonance.

"Auscultation: some loss of vesicular murmur at right apex, with fine dry pleuritic sounds and few fine dry crepitations.

"Heart: no signs of endocarditis.

"February 10. *Physical Examination* (by Drs. Trudeau and Williams).—Prolonged expiration at right apex, with a few fine dry crepitations. Some weakness of breathing at left apex.

"Sputum: tubercle bacilli found December 24, 1899.

"Urine: negative.

"Weight: present, $106\frac{1}{2}$; normal, 113. March 1, 1900, 120 pounds.

"March 16, 1900. Cough and expectoration have entirely disappeared."

April 5. *X-ray examination with screen* after return from the Sanitarium. The following cut shows the appearances I found in the chest after her return from the Sanitarium. They were nearly normal.

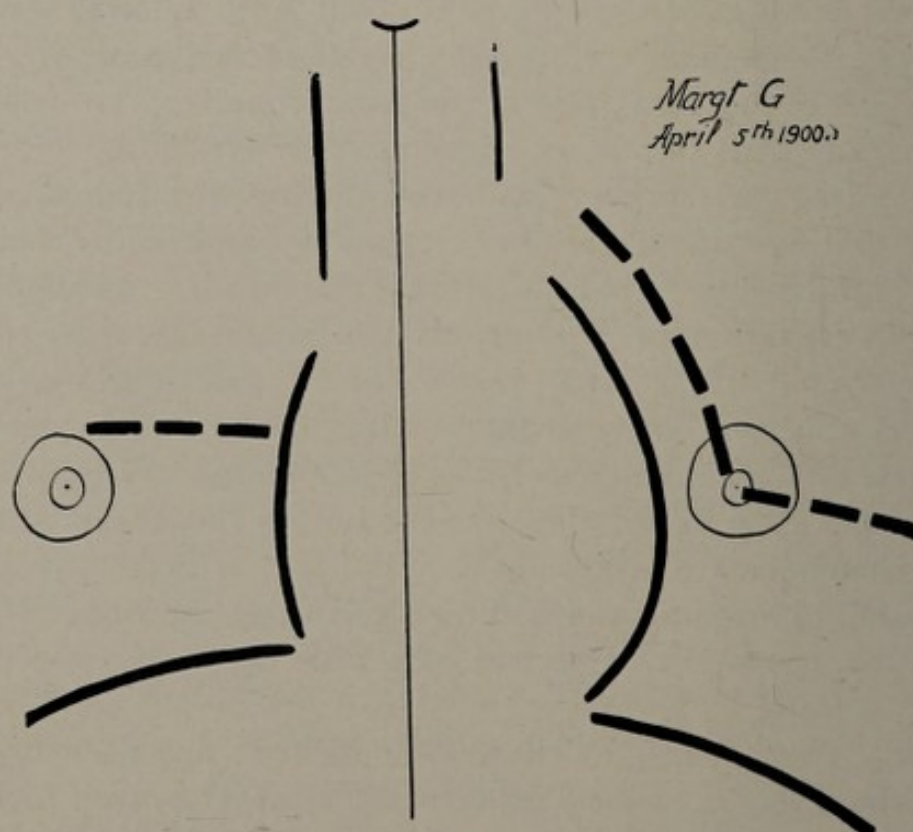


FIG. 88. Margaret G. X-ray tracing made April 5, 1900. (One-third life size.) Chest nearly normal.

May 1. The patient caught a cold, which lasted about ten days, that was accompanied by some cough and expectoration night and morning. She came to see me on May 21.

May 21. X-Ray Examination with Screen. — The following cut shows the result of this examination. The right apex was slightly shaded, and the excursion of the diaphragm was shortened on the same side.

Physical Examination. — Very slight dulness over the right clavicle, that is to say, there was a slight difference between the two apices, but as already shown there may be normally a little difference between them.

Temperature at 3 P.M. 99.6; pulse 72; respiration 24.

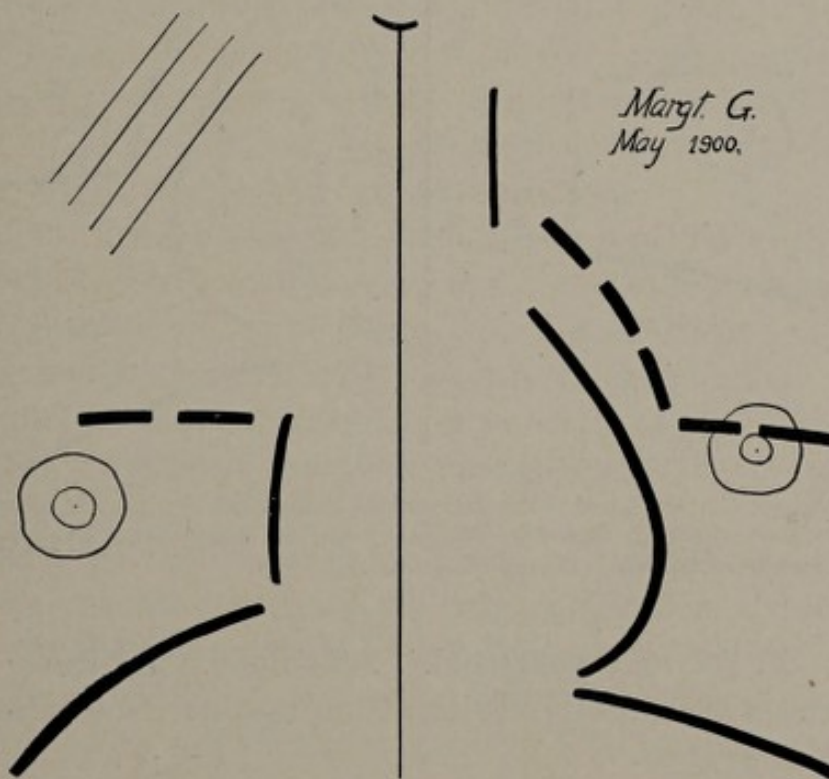


FIG. 89. Margaret G. May 21, 1900. X-ray tracing. (One-third life size.) Right apex shaded; excursion of diaphragm shortened on this side.

In consequence of the conditions found by this examination, the patient, through the kindness of a friend, was sent back to the Sanitarium in June, 1900.

February 11, 1901. X-Ray Examination with Screen. — See Fig. 90.

Temporary conditions in the lungs may be followed by means of X-ray examinations in some cases. For example, if a patient who has slight pulmonary signs takes a bad cold, owing to some exposure, the X-rays may show a shortened excursion of the diaphragm and a more

marked darkness at the site of the disease. These signs will be seen to improve at subsequent examinations as the patient recovers from the cold; if they persist, a renewal of the treatment is demanded.

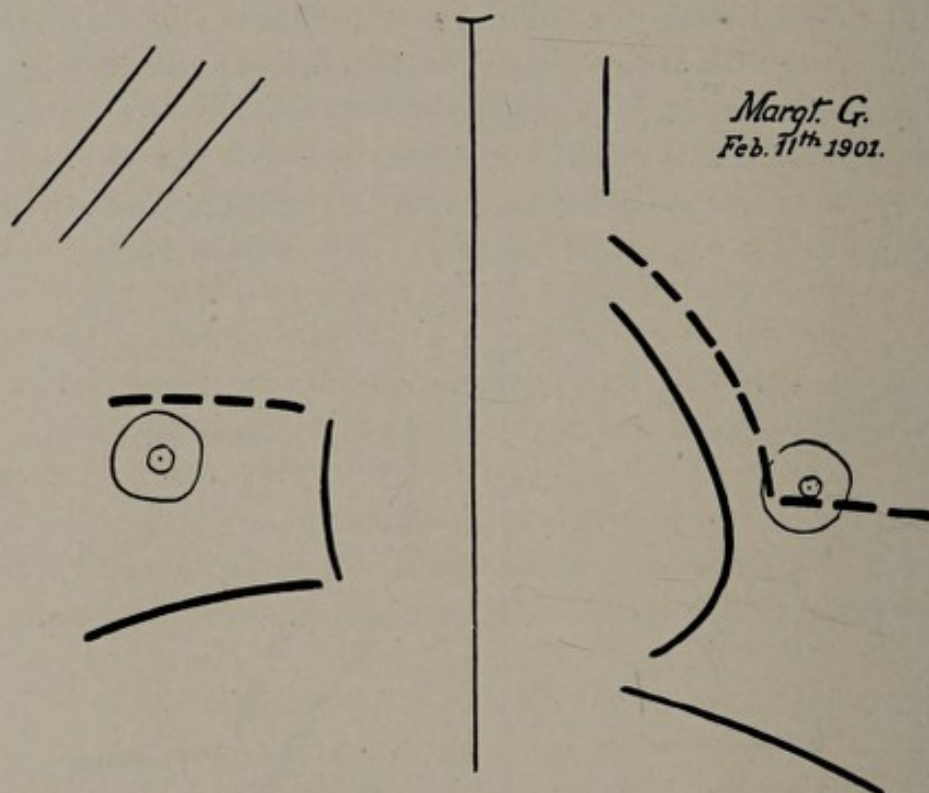


FIG. 90. Margaret G. Returned to the Adirondack Sanitarium in June and remained there four months more; she came back in excellent condition. My last X-ray examination, with screen, February, 1901, gave the above results. (One-third life size.)

CASE II. F. A., nine years old. Schoolboy. Entrance diagnosis: typhoid fever. Entered my service at the hospital November 14, 1898.

Family history good.

Personal History.—Had diphtheria three years ago, otherwise has always been well. For the past month has felt poorly; went to bed a week ago; complains of pain in the epigastrium and in front of chest. Has headache and feeling of weakness. Appetite poor and sleeps poorly. No chills, no nosebleed, no cough. Well-developed and well-nourished boy in excellent general condition. Color good. Had at entrance a temperature of 100° ; pulse 108, regular and rather weak. Enlargement of the spleen, questionable; no rose spots. Serum reaction negative. Liver dulness from sixth rib to one finger's breadth below costal border.

Lungs: in right apex in front and behind there is an increase in vocal

resonance and fremitus and whispered bronchophony. Lungs otherwise normal. No change in percussion note and no râles heard.

November 18. By percussion over the heart its area was found to be increased to the right, but in a few days this enlargement disappeared. The temperature had run a slightly elevated course, 99° morning, 100° evening, for some days; this is, I think, very suggestive of tuberculosis.

November 22. X-Ray Examination with Screen.—The right lung above the fourth rib not so bright as left. Excursion of diaphragm shorter and higher up on right side than on left side, 3 centimetres on the former, 5 centimetres on the latter. Heart displaced to right.

November 27. One milligramme of tuberculin given. No reaction.

December 1. Three milligrammes of tuberculin given at 6 P.M. The following day at 11 A.M., temperature 102.5°; marked malaise.

December 3. Second *X-ray examination* ten days after first; signs corresponded with those of the first examination.

December 5. Was discharged, having been up and about the ward for some time. General condition good. No cough, and appears perfectly well. Sleeps well; appetite good; color excellent. This patient was in the hospital eighteen days under careful observation.

Unfortunately, the parents could not be made to realize that the boy was not perfectly well, and therefore the directions I gave them were not carried out.

On February 27, 1899, he came to me for another *X-ray examination*. I found the upper portion of the right lung darker than the left, and the excursion of the diaphragm on the right side 3 centimetres, on the left side 4.7 centimetres. There was some dulness by percussion over the upper portion of the right lung in front. His condition was not as good as when I saw him in December; he looked a little pale.

Some months later the boy's loss of health and strength became evident to the parents, and, appreciating that he was really ill, they removed to better quarters in the outskirts of Boston, and carried out as well as they could the advice I had given them.

September, 1900. The patient is much improved.

Incipient Pulmonary Tuberculosis.—I have seen thus far over thirty cases, where there were slight or no physical signs, in which X-ray examinations showed signs of pulmonary tuberculosis. In all of these cases the X-ray examination was confirmed by finding the tubercle bacilli or by the tuberculin test. In twenty-two cases I have made

the diagnosis of incipient pulmonary tuberculosis by means of X-ray examinations in conjunction with other indications of tuberculosis, such as one or more of the following: hæmoptysis, loss in flesh, morning cough, night sweats, evening rise in temperature, slight physical signs. In these cases the diagnosis was not confirmed by finding the tubercle bacilli, and the tuberculin test was not used; therefore I do not ask others to accept the diagnosis.

Added Evidence from X-Ray Examination. — The following case is illustrative: —

CASE I. George S. B., teacher, thirty-two years of age. Lost his mother and one brother by tuberculosis. Hæmoptysis, June 5, 1897. In Dr. Folsom's service in Boston City Hospital for ten days. Nothing found in his chest. Subsequently to June had several slight hemorrhages. In July Dr. M. P. Smithwick found a few small râles above the right clavicle.

September 17. Dr. Smithwick found no râles at right apex, but thought he found a few in the right axilla; otherwise there were no physical signs. No rise in temperature; no tubercle bacilli found, though the sputa had been examined several times. Dr. Smithwick brought the patient to see me on September 17.

September 17. X-Ray Examination with Screen. — Right apex to lower border of second rib was darker than the left apex. Excursion of the diaphragm on right side 3.5 centimetres, on left side 6 centimetres. This, together with what had gone before, led me to state that I had little doubt the patient had tuberculosis.

October 3. Dr. Smithwick found tubercle bacilli.

This patient went West and in April, 1901, was doing well.

Early Indications by X-Rays further emphasized; Involvement of Second Apex. — In many cases where the disease was indicated in but one lung by the usual signs, I have been able to recognize it by the X-rays in both lungs.

Third. Association of Tuberculosis and Some Other Disease. — When tuberculosis is associated with another disease, as with emphysema, bronchitis, or pleurisy with effusion, its presence may be unsuspected, or may not be readily recognized by the ordinary methods of examination; here again the X-rays are of value in aiding us to make a more complete diagnosis.

a. Tuberculosis with Emphysema. — The increased density in the lung due to tuberculosis may be so obscured by emphysema that it is not

recognized by physical signs, but this emphysematous condition offers no obstacle to the X-ray examination. On the contrary, it is rather helpful, inasmuch as the increased brightness in the chest due to this condition brings out the darkened tuberculous part of the lung by heightening the contrast that obtains under ordinary conditions. The helpfulness, then, of the X-ray examination when tuberculosis and emphysema are both present, is two-fold: it may not only enable us to recognize tuberculosis when by physical signs it is undetected, but also to make a diagnosis of emphysema which had previously not been suspected on account of the tuberculosis from which the patient was suffering.

The following case shows that the presence of emphysema and tuberculosis may be learned and suggested respectively by an X-ray examination, and sometimes in patients where neither had been suspected. A. B. entered the hospital with a diagnosis of malaria. There was a history of hæmoptyses seven years previously. The X-ray examination showed signs of emphysema and a darkened right apex. *After* this dark apex had been pointed out by the X-rays, the physical signs noted were as follows: Heart area normal. Lungs: good resonance over all; slight increase in vocal fremitus at right apex front and back, perhaps within normal limits; expiration prolonged at right apex; whispered bronchophony more marked at left apex.

Patient reacted to tuberculin.

Emphysema not suspected by Physical Signs. — The following case is illustrative of this point: —

B. O., thirty-two years old, entered my service at the hospital November 14, 1898. Diagnosis: tuberculosis.

November 23. Many tubercle bacilli found in sputum.

X-ray examination with screen showed an increased density of both lungs, and that the patient was suffering from emphysema on both sides. This latter condition was not indicated by the physical examination.

b. Tuberculosis and Bronchitis. — It may be more correct to say that such cases are cases of tuberculosis that have been mistaken for bronchitis by the usual methods of examination. The point to be noted is that the X-ray examination directs our attention to their tuberculous character, thus rendering the physician less liable to mistake a bronchitis for a pulmonary tuberculosis. The following case illustrates this point: —

Eliza T., fifty-six years old, entered my service at the hospital February 18, 1897. Father died at ninety-eight; mother at eighty-seven

years of age. Husband died of tuberculosis. The patient had had cough for about ten months, with considerable expectoration; dyspnoea on exertion, and weakness. Physical examination of lungs showed that both chests were hyper-resonant in front and back; chest walls thin; breathing rather harsh; expiration prolonged; a few coarse moist râles in back. Diagnosis: bronchitis.

February 25. *X-ray examination with screen* showed that the excursion of the diaphragm was 5.25 centimetres on the right side and only 3 centimetres on the left side. This limited movement suggested tuberculosis.

* * * * *

Discharged.

Eleven months later the patient reëntered the hospital in Dr. George B. Shattuck's service.

My *X-ray examination* showed that the whole of the left side was less clear than the right, and that the apex of the right lung, as far as the second rib, was less clear than normal; that there was hardly any movement of the diaphragm on the left side; and that on the right side the excursion was only 3 centimetres.

The patient had had several small hæmoptyses. Rather indefinite physical signs at both apices. Tubercle bacilli found.

c. Tuberculosis and Pleurisy with Effusion. — I have seen some cases of pleurisy with effusion¹ in which the X-ray examination gave evidence of increased density at the apex of one lung, although this was not then detected by physical signs. The testimony of the fluorescent screen was confirmed by the finding of tubercle bacilli or by the tuberculin test.

In the following case suspicions of tuberculosis on the same side as the effusion were suggested to me by the X-ray examination: —

Gustav L., forty years old, entered my service at the hospital February 6, 1897. Four weeks previously had had a chilly sensation, and seven days before, pain in the right side which was worse on respiration; some expectoration.

Physical Examination. — Slight dulness at the right apex; somewhat diminished breathing; vocal and tactile fremitus not increased. In the right back, dulness below the level of the angle of the scapula, with

¹ "A Study of the Adaptation of the X-Rays to Medical Practice," Medical and Surgical Report of the Boston City Hospital, January, 1897.

diminished breathing and voice sounds. Left chest: good resonance and respiration over all.

March 13 and 19. No physical signs.

Second and Third X-Ray Examinations with Screen. — The signs of pleuritic effusion present on February 15 had disappeared, but tuberculosis was indicated by diminished clearness of the whole right side, the apex was darker than the remaining portion, and the restricted excursion of the diaphragm; right side, 2.5 centimetres; left side, 5.5 centimetres.

Examination of the sputa showed the presence of tubercle bacilli, which confirmed the suspicions aroused by the X-ray examination.

I have recognized by means of X-ray examinations, *tuberculosis with emphysema* in nine cases; tuberculosis with bronchitis in eight cases; and tuberculosis with pleurisy in thirteen cases. In most, though in not all, of these thirty cases the diagnosis was confirmed by finding the tubercle bacilli or by the tuberculin test.

Fourth. Tuberculosis indicated by Physical Signs but not by X-Rays. — The foregoing statements and illustrative cases testify to the trustworthy character of the X-rays, and to their assistance in making an early diagnosis. The signs afforded by the X-rays in tuberculosis are not pathognomonic of this disease. Not every patient with these signs is suffering from phthisis, nor is every individual with a good movement of the diaphragm and clear lungs necessarily free from tuberculosis; but if we find clear lungs and normal outlines in an otherwise well individual, we have an excellent assurance that pulmonary tuberculosis is absent. The X-rays are a valuable means for warning us of this disease or for indicating that we should reconsider an unfavorable diagnosis.

It is clear that caution should be exercised concerning the weight to be attached to negative indications by the X-rays in cases where there is a history suggestive of tuberculosis, or some physical signs indicating the presence of this disease. I hesitate to speak of this class of cases, lest the mention of them should be regarded as an attempt to claim too much for the X-ray examinations in diseases of the lungs. On the other hand, I think it would be unwise to pass them by, as they represent a very definite line of experience which is too important to remain unnoticed. In some cases seen by me the symptoms and physical signs indicated pulmonary tuberculosis, but the X-ray examinations showed normal lungs. These examinations led me to state that these patients were probably not suffering from this disease; and the subsequent history or the tuberculin test indicated that this interpretation of the

appearances seen on the fluorescent screen was correct. While the absence of tuberculosis could not be demonstrated in these cases, they do show that the X-rays have proved of value in aiding me to decide what the patient should do. That is to say, the patients have been able to remain at home, as was indicated by the X-ray examination, instead of seeking another climate, as was suggested by the suspicions excited by the history and physical examination. The importance of repeating the X-ray examination at frequent intervals, in such cases, is very evident. Likewise, in such cases reliance should be placed upon X-ray examination only by those who are perfectly familiar with the disease in all its forms, as well as with the use of the X-rays.

I have seen several cases in which an X-ray examination prevented me from taking too unfavorable a view, though the physical signs had indicated beginning tuberculosis. In none of these has tuberculosis developed, and in such of them as I could test with tuberculin, there was no reaction. The following cases are illustrative:—

CASE I. David G., thirty-nine years of age, entered my service at the hospital, September 20, 1898.

History.—Old pleurisy.

Present Illness.—Caught cold and had a chill and knifelike pains in left side.

September 28. Physical Examination.—In the right apex in front and behind, prolonged expiration, which is pitched slightly higher on the right side; vocal resonance slightly increased; marked whispered bronchophony; in the right base behind, numerous medium moist râles heard best at inspiration; no change in percussion and voice sounds; two negative examinations of the sputum.

October 6. Condition had improved and he was discharged from the hospital.

October 18. X-Ray Examination with Screen.—Lungs perfectly clear, and the excursion of the diaphragm 7 centimetres on both sides.

October 20. Reëntered the hospital. Slight dulness in the right apex in front and behind, with some increase in vocal resonance and fremitus, and considerable whispered bronchophony; no râles heard over this area; lungs otherwise normal.

November 4. 1 milligramme of tuberculin.—November 5, 5 milligrammes of tuberculin; on the following day his temperature rose to 102.5 and this rise was *attributed* to the tuberculin, but on November 8 his temperature rose still higher, although he had taken no tuberculin,

namely, to 105.5; later the plasmodium malariae was found and he was given quinine. On November 12 another five milligrammes of tuberculin was given, but there was no reaction. Examinations of the sputum for tubercle bacilli have always been negative.

November 16. X-Ray Examination with Screen. — Good appearance of the lungs on both sides; excursion of the diaphragm on the right side 7 centimetres and on the left side 6.5 centimetres.

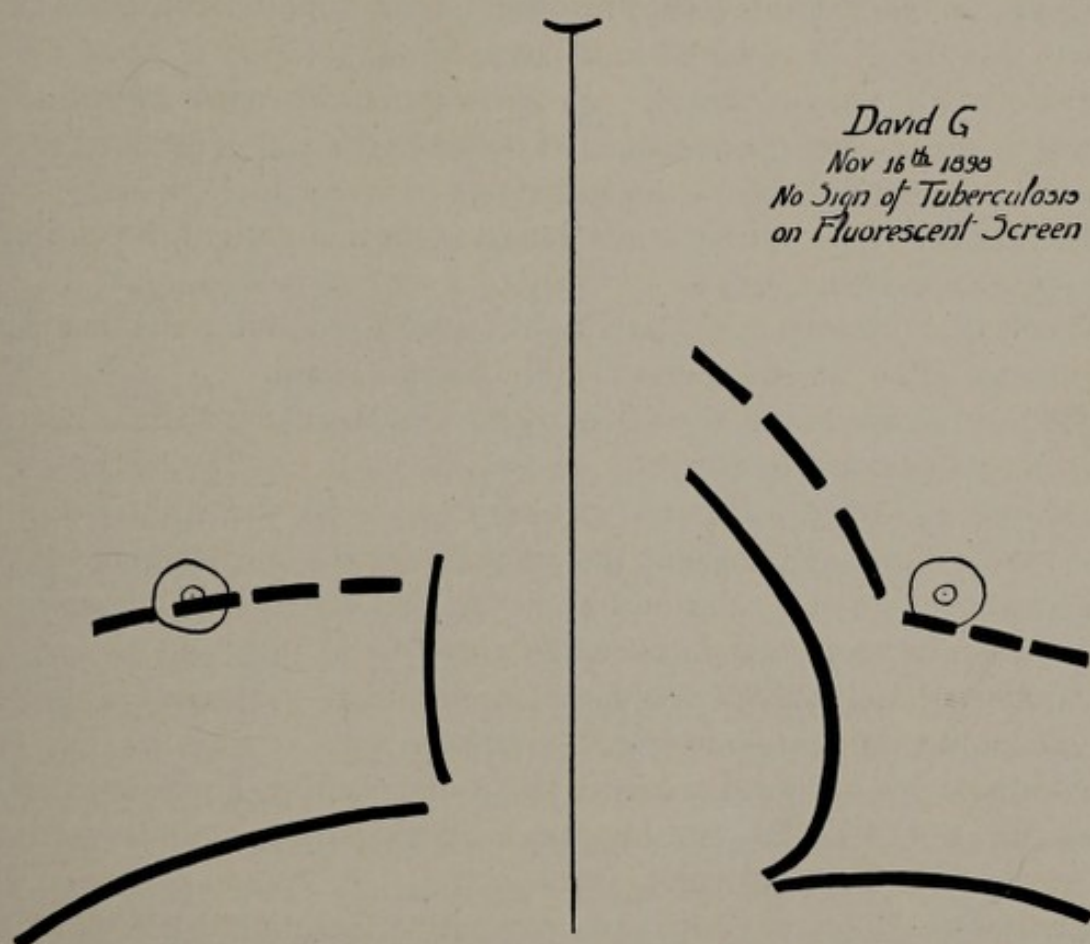


FIG. 91. David G. November 16, 1899. X-ray tracing. (One-third life size.) Good appearance of lungs on both sides. Excursion of diaphragm on right side, 7 centimetres; on left side, 6.5 centimetres.

Physical examination on the same day; Left side: prolonged and harsh expiration, and tactile fremitus increased as far as the third rib; tactile fremitus also increased in the right back, and a slight dulness over the whole of the right back.

March 20. X-Ray Examination with Screen. — Patient returned to the hospital at my request for an examination. The same appearances were found by the X-rays as at the two previous examinations; that is, on October 18 and November 16.

When this patient entered the hospital he was thought to be suffering from pleurisy, and perhaps tuberculosis. He had been losing in strength and weight, and his friends and physician deemed it desirable for him to go to Colorado. The rise in temperature directly after the administration of tuberculin — which was in reality due to malaria — would have naturally, if the plasmodium malariae had not been found, been considered a reaction to the tuberculin. The diagnosis, also naturally, in connection with the other signs, would have been tuberculosis, and the X-rays would have seemed at fault.

October 30, 1899. Another X-ray examination with screen, at my request: lungs clear; excursion of diaphragm 7.5 centimetres right side and 8.7 centimetres on the left side.

In January, 1902, when I last heard from this patient, he continued to be perfectly well.

CASE II. James G. R., twenty-five years old, entered the hospital August 23, 1898; in the service of Dr. Buckingham.

History. — Well and strong until he went to Cuba; there acquired a dry cough and lost in weight.

August 23, 1898. Physical examination. — In the right axilla and right base behind, as far up as the level of the angle of the scapula, are heard numerous moist râles and an occasional whistle, with inspiration. No increase in voice sounds over this area.

September 1. Second Physical examination. — Marked dulness at the apices but no change in vocal fremitus.

September 6. No râles heard in front of chest, but some dry and moist ones in the back. Sputum has been examined a number of times, but no tubercle bacilli found.

October 6. The patient gave a positive reaction to Widal's test.

I examined this patient with the X-rays, with the following result: —

October 31. X-Ray Examination with Screen. — Lungs clear and normal on both sides; excursion of diaphragm 6.2 centimetres on each side.

August 10, 1899. I met this patient on the street, and he was well, and had been well since he left the hospital.

CASE III. M. E. F., October 6, 1898. This patient was sent to me by her physician to decide whether or not she should go away.

Present Illness. — Loss in weight; weighs now 101½ pounds; cough and expectoration for three or four weeks; still some cough in the

morning; dyspnœa on exertion; pain at the right apex and increased vocal fremitus. Husband died of tuberculosis in November, 1897.

X-Ray Examination with Screen. — Lungs perfectly clear; no signs of tuberculosis. I advised waiting.

December 30, 1898. Second X-Ray Examination with Screen. — Lungs still perfectly clear. The patient had gained $9\frac{1}{2}$ pounds in weight, and the cough had stopped a month before.

June, 1900. The patient came to me again for an examination, and I found her in excellent health.

Fifth. X-Ray Examinations of Lungs where Tuberculosis is in some other portion of the Body than these Organs. — It is sometimes of great importance, when a tuberculous process has started in some other portion of the body than the lungs, to learn if these organs have also become involved. If they are diseased, it might be necessary that the patient should change his career; if not, there seems to be no good reason why he is not better off in his own home, doing a moderate amount of work, but taking care at the same time to have good food, sunshine, and fresh air free from dust, and avoiding, so far as possible, everything detrimental to his health. The assurance which X-ray examinations, made from time to time in such cases, can give, that the lungs are not in an abnormal condition is of great practical value and a source of relief to both the patient and his physician; and I believe that if we find the lungs normal, both by physical and X-ray examination, and these examinations are made at suitable intervals, the patient runs no serious risk in staying at home, and it is not necessary to advise him to sacrifice his business and the other plans of his life too hastily.

In the following cases and in the case mentioned above X-ray examinations made at certain intervals are of value:—

Sixth. Precautionary X-Ray Examinations. — X-ray examinations should be made from time to time in persons from fifteen to thirty years of age if the family history is tuberculous, and there is reason to fear that the given individual may develop tuberculosis. In this way, if the disease should develop, early warning would be given, and the best opportunity for its arrest obtained.

Relief given by X-Ray Examination. — Many persons dread pulmonary tuberculosis, or fear they have it on account of the family history, or because they suffer from debility, or have had a persistent cough, or other symptoms which have aroused suspicion in the minds of their

physicians. To such individuals, the assurance which careful X-ray examination can give, in connection with other signs and symptoms, that the lungs are normal as seen by the fluorescent screen, is a great relief.

Prognosis. — Whether the disease is progressing or improving is often indicated by comparing successive X-ray examinations.

B. OLD LESIONS OF TUBERCULOSIS

Successive X-Ray Examinations. — Old lesions which have resulted from tuberculous conditions long healed may be perceived, and the precautions which their existence would suggest may then be taken. The physician is thus enabled to guard his patient against the dangers of lighting up the disease afresh. It must be clearly appreciated, however, that a single X-ray examination cannot tell us whether we have to deal with an old or a recent pulmonary tuberculosis, — whether the disease is in an active stage or not is to be learned in other ways, — but if the disease is progressing, successive examinations will indicate the fact.

The following case shows that an old tubercular lesion gives signs which can be observed by an X-ray examination: —

B. C. came to see me on October 21, 1898, and was interested to learn whether or not an X-ray examination would disclose any evidence of an old but slight lesion which he had had in November, 1892. I had no history other than the above; did not know on which side the trouble had been during the attack of six years previous; and I purposely made no examination except with the X-rays.

October 21, 1898. X-Ray Examination with Screen. — Left apex was darker than the right, and the excursion of the diaphragm was shorter on the left than on the right side. In other words, the X-ray examination indicated that the trouble had been at the *left apex*.

Through the kindness of B. C. and Dr. Trudeau, I give a copy of the records made at the Saranac Sanitarium by the latter in 1892–1893: —

“Twenty-nine years old, family history non-tuberculous. Personal history; healthy, but not vigorous until November, 1892. Cough and expectoration; tubercle bacilli found. All symptoms disappeared by October, 1893; none since.”

“Lesion located at the left apex; pleuritic friction at the right base.”

At my suggestion Dr. Trudeau kindly made a physical examination of B. C., shortly after the X-ray examination, that is, November 6, 1898. He found "slight dulness on the left side, appreciable only at the apex in front; vocal fremitus about the same on both sides. Auscultation: no râles; vesicular murmur more feeble at the right apex, and at left apex prolonged and slightly broncho-vesicular; expansion on level of nipple line $1\frac{1}{4}$ centimetres more on the right side than on the left. Should not consider these signs by themselves, and in the absence of microscopical evidence or constitutional disturbance, anything more than suggestive."

C. FOR DETERMINING EXISTING CONDITIONS MORE ACCURATELY

More Definite Signs by X-Rays than by Auscultation and Percussion. — The following case shows that the X-ray examinations may give unequivocal signs when they are not frankly marked by auscultation and percussion: —

John M., thirty years old, entered my service at the hospital February 21, 1899. Diagnosis: malaria.

Family history, negative. *Personal history*: fever and ague fourteen years ago; about seven years ago had a bad cough, lasting for some months, and one hemorrhage in which he lost about half a cupful of blood; a year later, another hemorrhage of about the same amount; has not been troubled with cough since. *Present illness*: chill and fever every other morning for two weeks; vomited once; considerable cough and expectoration during this time; no hemorrhage; pain across chest when he coughs; chill this morning.

March 2. X-Ray Examination with Screen. — This examination, made on the same day as above, showed that the right apex, to the lower border of the third rib, was darker than normal, and the excursion of the diaphragm was shorter and higher up on the same side, $5\frac{1}{2}$ centimetres on the right side and $7\frac{1}{2}$ centimetres on the left side; and that the heart moved more to the right than normal during inspiration, because the left lung expanded better than the right. (See Fig. 92.)

March 2. Physical examination, made after X-ray examination: Heart area normal, action regular, no murmurs. Lungs: resonance good over all; slight increase of vocal fremitus at right apex front and back, perhaps not more than normal. Expiration prolonged at right apex and whispered bronchophony more marked than normal.

The diagnosis of tuberculosis in part suggested by the X-ray examination was confirmed by the tuberculin test.

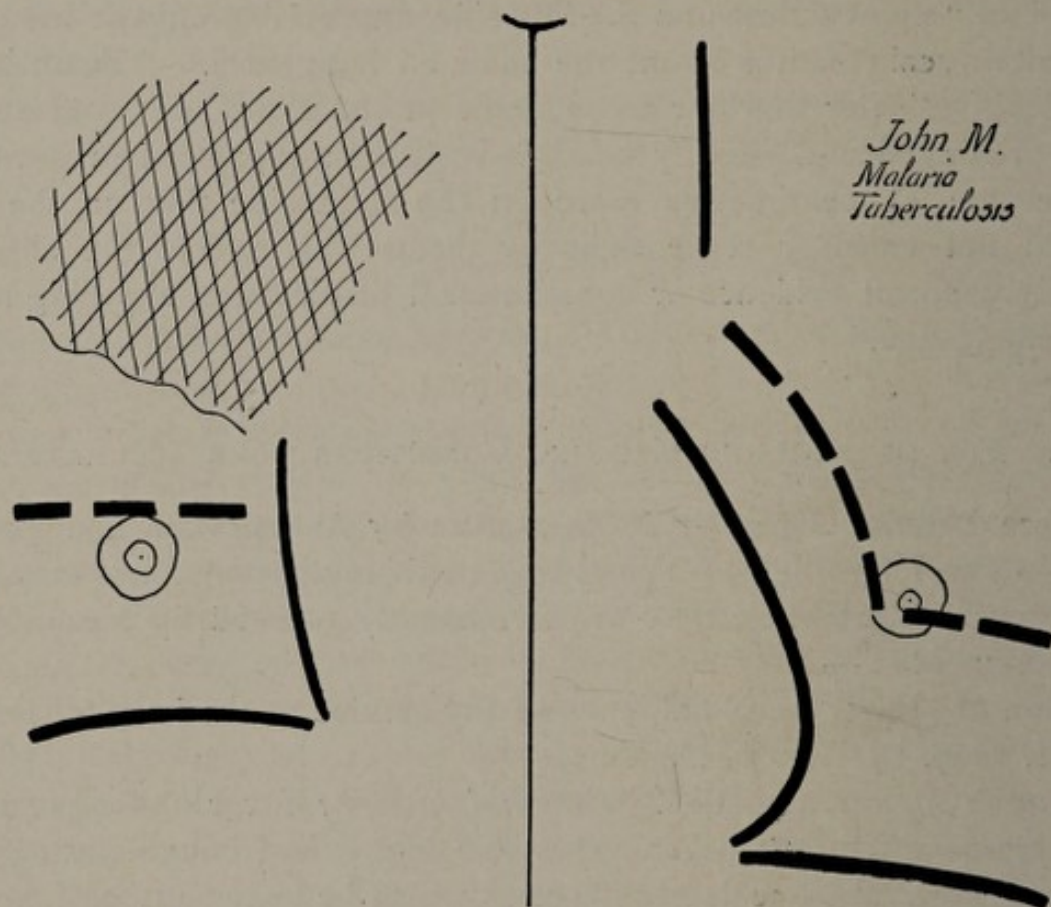


FIG. 92. John M. X-ray tracing. (One-third life size.) Right apex darker than normal; excursion of diaphragm shorter and higher on right side.

Greater Accuracy of X-Ray Examination confirmed by Autopsy. — This case affords confirmation of the greater accuracy of X-ray examinations in indicating what portions of the pulmonary areas are denser than normal, as compared with auscultation and percussion.

John H., 60 years old, entered my service at the Boston City Hospital on December 30, 1899.

Diagnosis: old tuberculosis.

One careful examination for tubercle bacilli was negative.

The physical signs were as follows: Heart: right border 3 centimetres to right of median line; left border 14.5 centimetres to left of median line; upper border at second rib; apex in fifth space, 2.5 centimetres outside; no murmurs. Lungs: dulness at right apex in front, down to third interspace, and at both apices behind. Respiratory sounds harsh. Vocal resonance increased at both apices. Numerous medium and fine crackling râles throughout chest at times.

January 3, 1900. X-Ray Examination with Screen.—From the physical examination I supposed that we should find the apices of both lungs to be the parts chiefly affected, but the X-ray examination showed that the apices and bases of both lungs were less involved than the other portions.

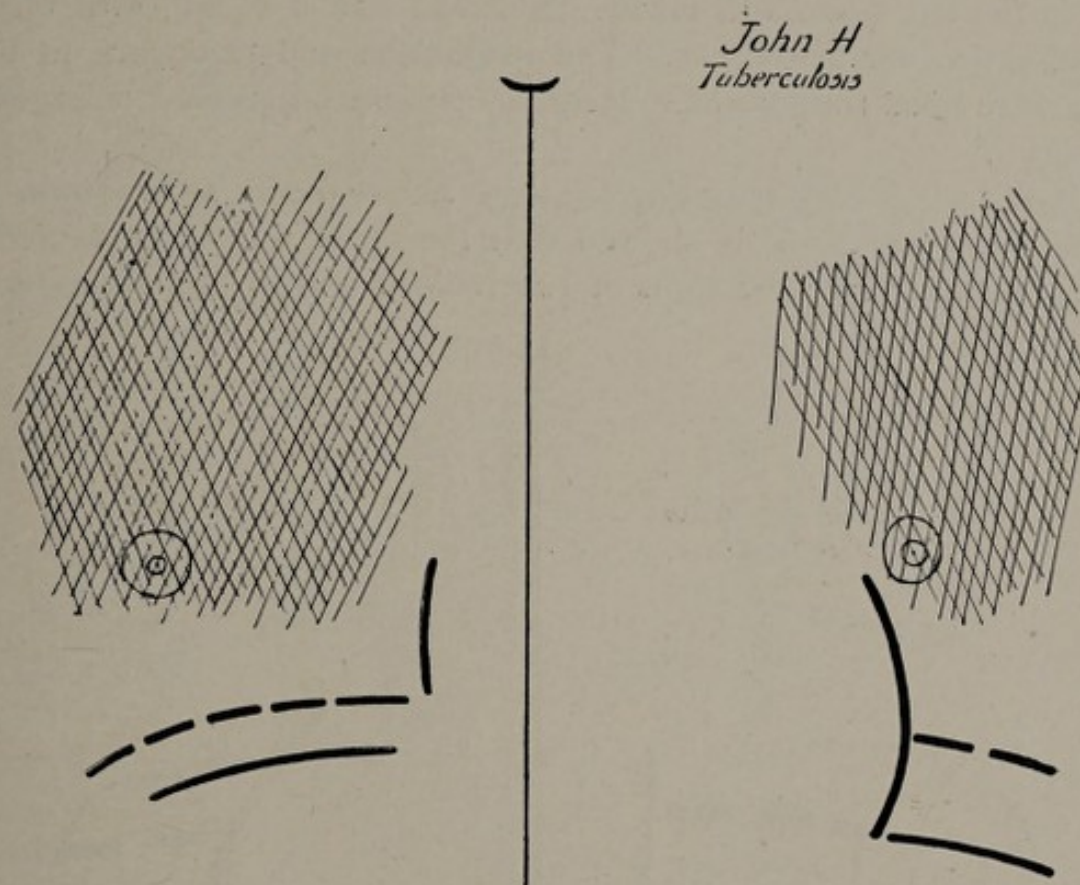


FIG. 93. John H. January 3, 1900. Tuberculosis. X-ray examination with screen showed darkened lungs, but apices and bases less affected than physical signs indicated. Autopsy confirmed X-ray examination. Excursion of diaphragm shortened on both sides. See Fig. 80 for half-tone of a radiograph of lung. (One-third life size.)

The patient died on the following day, and the post-mortem examination confirmed the X-ray examination and proved that it had afforded a better picture of the distribution of the disease than had auscultation and percussion. Dr. Mallory kindly let me have an X-ray photograph of the lungs made after they were removed from the chest, and I have had the photograph of the right lung reproduced (see Fig. 80); to include both lungs would have reduced the scale of the cut too much.

D. FOR DETERMINING THE PROGRESS OF THE DISEASE

Acute Tuberculosis.—In acute cases, where the progress of the disease is rapid, by making successive X-ray examinations we may see

the extent of lung area involved increase almost from week to week, and be thus warned of the patient's imminent danger.

CASE I. Sarah H., aged twenty-three years. Entered the Boston City Hospital April 20, 1898, and was placed in my service. She had been suffering from acute articular rheumatism, first in the right ankle, then in the left ankle and elbow. She had had a cough, with bloody expectoration, for two weeks. The respiration and resonance in both lungs were good throughout. Heart by percussion seemed enlarged to the right.

April 24. *X-Ray Examination with Screen, made to determine the Size of the Heart.* — This showed that the heart was not enlarged to the right, but there were signs of tuberculosis on the left side, namely,

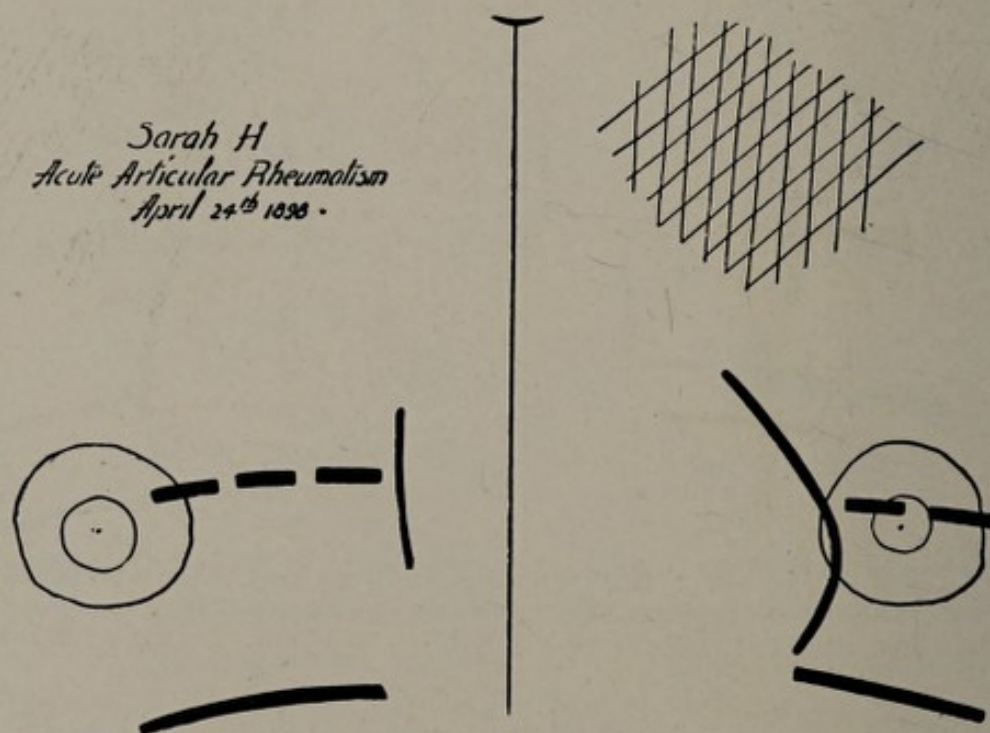


FIG. 94. Sarah H. April 24, 1898. X-ray tracing. Left apex darker than normal. Excursion of diaphragm on left side, 5 centimetres; on right side, 6.5 centimetres. (One-third life size.)

the left apex was shaded, and the excursion of the diaphragm on the left side was 5 centimetres, while on the right side the apex was clear and the excursion of the diaphragm was 6.5 centimetres.

April 29. A few tubercle bacilli found in the sputum.

May 4. *Physical Examination.* — Slight dulness over lower left back, where many crackling râles were heard at the end of full inspiration. *Right apex normal.* Also dry crackling râles over left front and axilla.

May 6. X-Ray Examination with Screen. — Nearly the whole of the left lung was shaded, and the excursion of the diaphragm was shortened by 1.25 centimetres and moved 3.7 centimetres only. The *apex* of the *right lung* was now also darker than normal, and the excursion of the diaphragm was 5.3 centimetres.

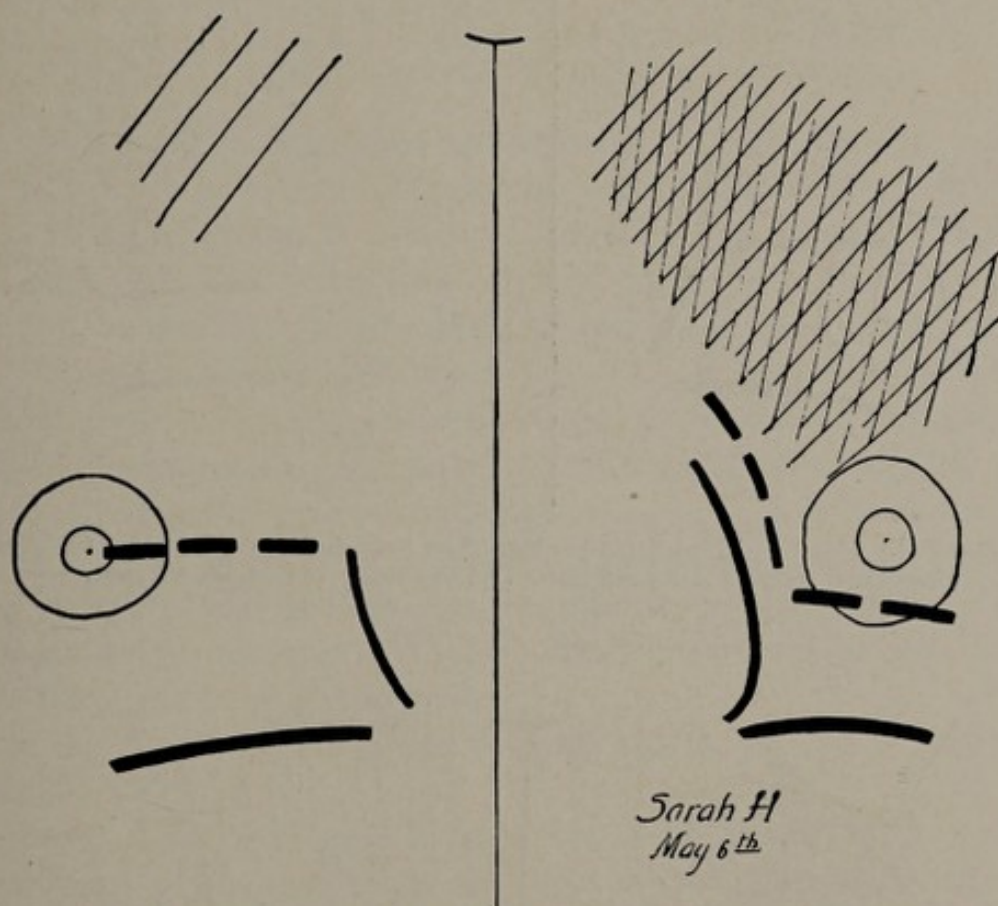


FIG. 95. Sarah H. May 6, 1898. Second X-ray tracing. Increase in darkened area of left lung and right apex also shaded. Excursion of diaphragm on left side, 3.7 centimetres (1.25 centimetres shorter than on April 24); on right side, 5.3 centimetres (1.25 centimetres shorter on this side also than on April 24). (One-third life size.)

May 12. Physical Examination. — Many coarse, moist, and fine dry râles over left back and axilla, below level of spine of scapula. A few fine dry râles and wheezy expiration over lower part of right axilla. Over this area resonance is diminished slightly and tactile fremitus is increased.

May 12. X-Ray Examination with Screen. — The left lung was still darker than it had been, and the excursion of the diaphragm was reduced to 2.5 centimetres. Patient up and about.

May 12 and 14. Sputum examined, but no tubercle bacilli were found.

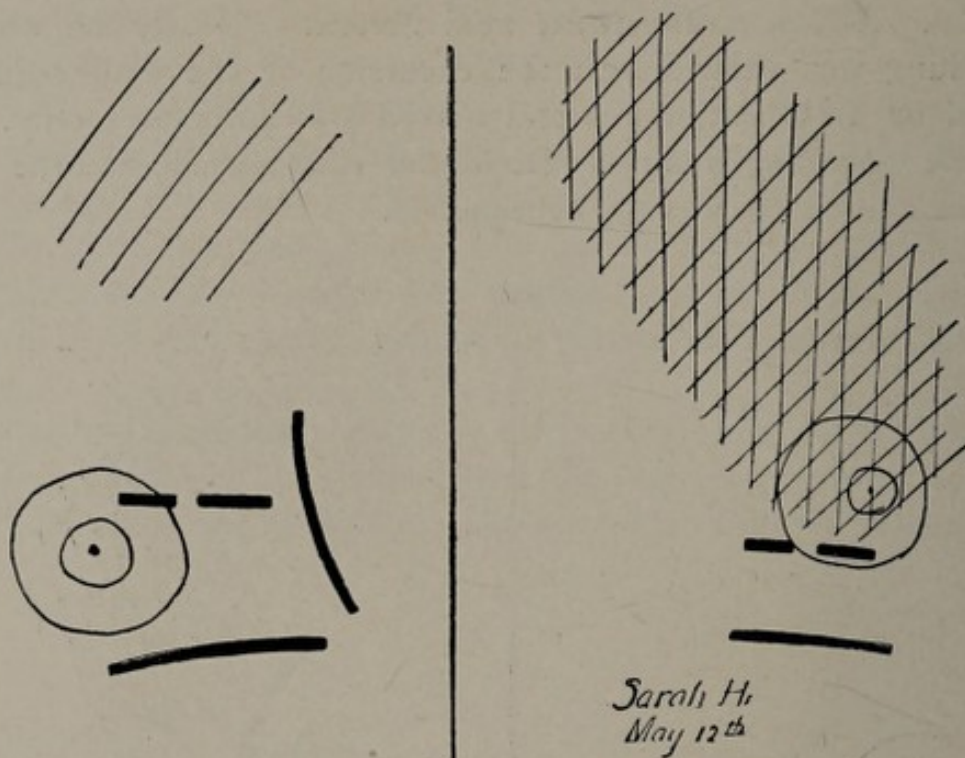


FIG. 96. Sarah H. May 12. Third X-ray tracing. Left lung darker than on May 6; excursion of diaphragm reduced to 2.5 centimetres on this side. (One-third life size.)

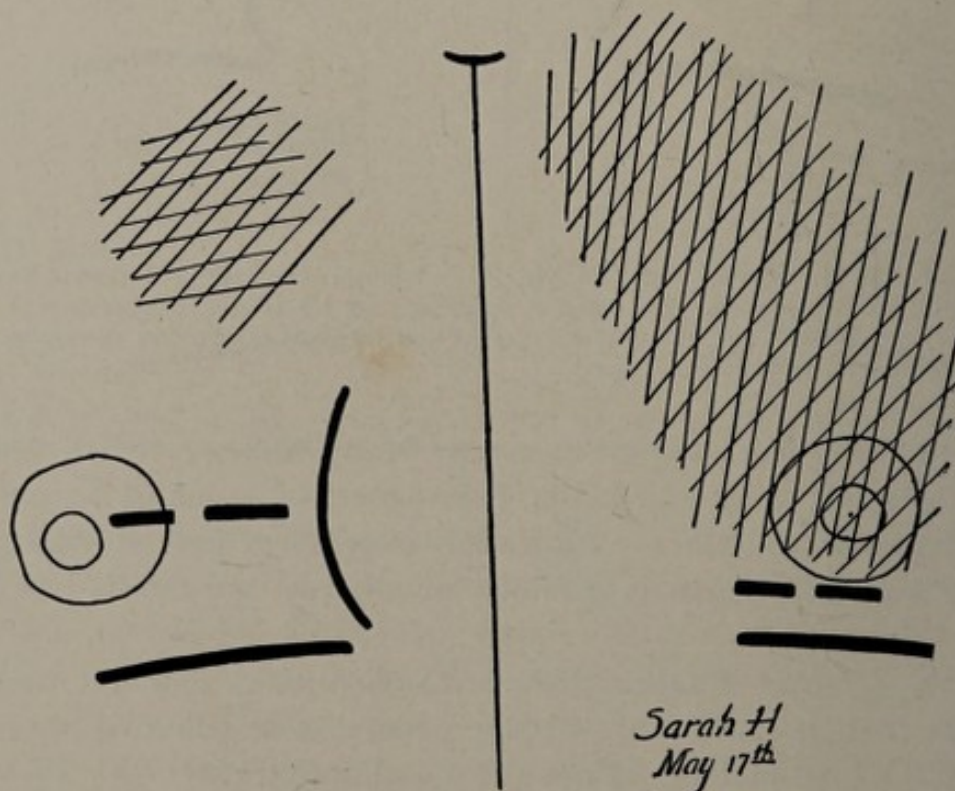


FIG. 97. Sarah H. May 17. Fourth X-ray tracing. Excursion of diaphragm 1.25 centimetres on left side; 3.7 centimetres on right side. (One-third life size.)

May 17. X-Ray Examination with Screen. — The excursion of the diaphragm was reduced still further, namely, to 1.25 centimetres on the left side, and to 3.7 centimetres on the right side.

May 17. A few tubercle bacilli were again found.

Patient died in July, 1898, within three months after entrance.

E. IN DETERMINING EXTENT OF DISEASE

In making successive X-ray examinations of patients who were suffering from tuberculosis at one apex, as indicated both by an X-ray and a physical examination, in order to watch the progress of the disease, I have observed that as the process went on, signs were evident in the other apex, by an X-ray examination before there were physical signs there. Likewise, I have seen by a single X-ray examination, when the tuberculosis was well advanced, that the disease was more extensive than the physical examination indicated. This information aids the physician to decide whether the patient should go away or remain at home, and to avoid the mistake of sending him away when he is beyond a reasonable hope of recovery, and of thus exposing him to the cruelties of a forlorn and expensive journey, and separating him from friends as well as home.

The following case is illustrative:—

CASE I. L. B. C., twenty-nine years old, a patient of one of my friends.

History. — For past two months has had cough, with yellowish expectoration; about one week ago sputum was streaked with blood; slight dyspnœa after exertion; no sweating; appetite fair.

May 11, 1898. Physical Examination. — Lungs normal, save that the breathing was somewhat jerky in places, and the fremitus slightly increased all over the right chest. Rest of physical examination normal. Diagnosis: phthisis.

May 13. At inner edge of left scapula a few râles; no difference in fremitus or voice.

May 14. An occasional indeterminate râle here and there over chest, not permanent in character; no abnormality in breathing or voice; resonance good.

May 15. Breathing very little qualitatively modified. As before, there are occasional râles, and in right axilla after cough they are more numerous than elsewhere. *Tubercle bacilli found in sputum.*

I examined this patient with the X-rays, with the following result:—

May 16. X-Ray Examination with Screen.—Right side dark throughout; excursion of diaphragm 2.5 centimetres; this muscle does not descend to the lower portion of the chest; on left side, excursion 7 centimetres (Fig. 98).

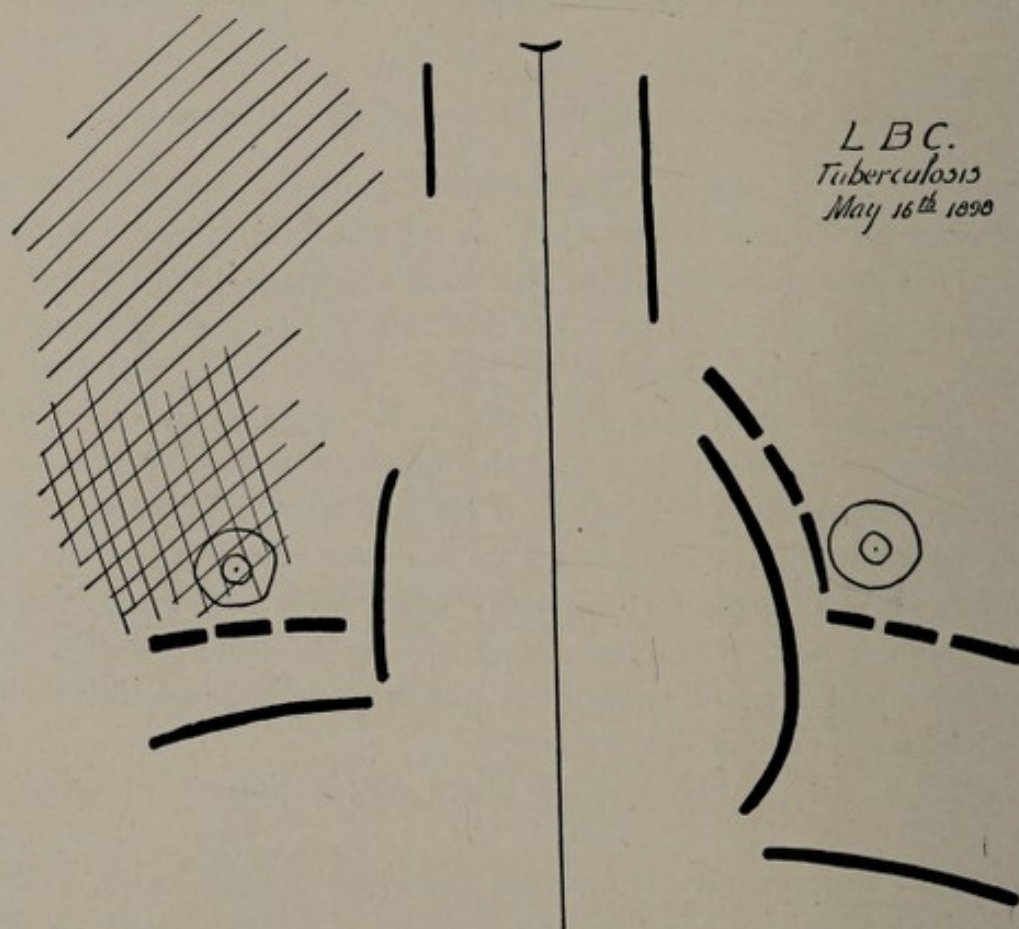


FIG. 98. L. B. C. May 16, 1898. X-ray tracing. Right side dark throughout; excursion of diaphragm limited on this side to 2½ centimetres. (One-third life size.)

August 22. Physical Examination.—Moist râles present in both axillæ; dulness at both apices, and moist bubbling râles; at right apex bronchial breathing, with increased resonance and fremitus.

August 22. Third X-Ray Examination.—Right side much darker throughout than left; excursion of diaphragm .5 centimetre on right side and 2 centimetres on left side.

At this time the patient's plans were made to go to Denver, and these plans were carried out; but the journey was strongly contraindicated to my mind because of the amount of disease present, and the rapidity with which it had increased, as shown by the X-ray examinations. He remained in Colorado a few days, and then turned his face homeward, dying shortly after his arrival in the East.

F. ACUTE MILIARY TUBERCULOSIS

I have examined with the X-rays a lung taken from a patient who had died of miliary tuberculosis, and found that where it was 5 centimetres thick it cast a shadow on the screen as dark as that made by water 3 centimetres deep, held in an aluminum cup.

Acute miliary tuberculosis sometimes offers difficulties in diagnosis, and is confounded with some other disease, typhoid fever, for example. In some cases there may be no physical signs by auscultation and percussion, and we may therefore be inclined to consider that pulmonary disease is absent; but an X-ray examination will draw attention to the fact that the lungs are abnormal, and indeed show very marked signs, thus directing the physician to a correct diagnosis.

X-ray examinations may also render service when the process is diffuse, and assist us to determine whether the disease is localized or disseminated, and how extensively the lung or lungs are involved.

G. CAVITIES IN THE LUNGS

These cavities, when filled with fluid or mucus, would appear as dark areas on the screen; when filled with air only, as light areas if the surroundings are suitable. That is to say, the recognition of a cavity depends to a considerable extent upon its size, as compared with the thickness of the encompassing dense lung. Small cavities in a dense tuberculous process would not be perceived.

CASE I. G. A., thirty-five years old, entered the Boston City Hospital October 14, 1896, in the service of Dr. A. L. Mason. Diagnosis: tuberculosis.

Good resonance in right chest except at apex, where resonance is lacking; breathing rather high-pitched and an occasional râle after cough. Left lung: resonance high-pitched at apex, becoming markedly dull below on front and back; breathing broncho-vesicular; increased tactile and vocal fremitus and whispered bronchophony; numerous fine, moist, and crepitant râles over whole chest. Tubercle bacilli found. At Dr. Mason's request I examined this patient by means of the X-rays.

X-Ray Examination with Screen. — On right side, from apex to lower border of fifth rib, the lung is darker than normal, though the outlines of the ribs are seen. On the left side the lung is dark throughout, except between the first and third ribs, where there is a light area

which suggests a cavity. The left border of the heart is not seen; the diaphragm on the left side is barely made out.

After the X-ray examination another physical examination gave the following result: left apex, percussion rather high-pitched and tympanic in quality; breathing amphoric.

No Signs observed by X-Ray Examination in Two Cases of Tuberculosis.—In two patients who undoubtedly had tuberculosis I found no satisfactory signs by X-ray examination. It may be that it was so distributed as to be difficult of recognition by X-ray examination, or that my experience with a new method was insufficient, or that a certain proportion of cases are better recognized by other methods.

Probability that the Shadows cast upon the Fluorescent Screen in Pulmonary Tuberculosis are due in Part to Congestion.—First, an experiment that I made with a much congested lung $2\frac{1}{2}$ centimetres thick, taken from a post-mortem examination, showed that this lung, which did not sink in water, cast a shadow corresponding to that thrown by water nearly $2\frac{1}{2}$ centimetres deep.

Second, the improvement which takes place in some cases of tuberculosis, as indicated by the diminishing shadow cast on the fluorescent screen when X-ray examinations are made at intervals of a week or so, could hardly be due to any improvement in the tuberculous process—the change is too rapid; but it might easily be caused by a diminution in the amount of congestion in that portion of the lung.

In passive congestion or œdema of the lungs in mitral disease, the lower portions of these organs may be darker than normal without giving signs by auscultation and percussion, but soon become clear after rest and the administration of digitalis. Also in persons suffering from debility, and who do not react to tuberculin, we may find a dark area in the lung which clears up after a rest of a week or two.

It is, of course, impossible to know exactly what is going on in the lung, and to distinguish between the portion of the shadow cast by the increased density of the lung, and that cast by an increased amount of blood in the lung, due to local congestion; or between the shadow due to a tuberculous process, and that cast by a process which may be acute in character, and due to some deposit in the lung, as in pneumonia. The history and symptoms must aid us in this last discrimination.

But the result of my experience thus far, with a considerable num-

ber of cases, shows it to be quite possible that some of the changes which take place in the lungs, as seen on the fluorescent screen, are due to the temporary presence of more than the usual amount of fluid or some semi-solid substance, which can be absorbed.

The recognition of a congestion, especially at the apex, may be valuable in some cases as an early warning of a beginning tuberculosis, and it should certainly cause us to make a careful investigation with this diagnosis in mind. In those cases in which our suspicions are excited by a first examination, or in doubtful cases, another X-ray examination should always be made after an interval of some days, in order that the second examination may verify or disprove the first, for various conditions may temporarily give rise to signs similar to those observed in pulmonary tuberculosis.

Therapeutic Uses of the X-Rays in Pulmonary Tuberculosis. — The therapeutic uses of the X-rays are considered in another chapter, to which the reader is referred.

CONCLUSION

The earlier cases cited indicate the aid the X-rays give in pulmonary tuberculosis; the service which they may render in the early diagnosis of this disease stands first, and perhaps their value in this direction will be appreciated more strongly if the following statements are considered.

First: Pulmonary tuberculosis is well known to be the most widespread of all diseases, and to cause the death of more persons than any other malady — one-seventh to one-eighth of all deaths are due to this disease. In Massachusetts the report of the State Board of Health for 1896 shows that 643 out of 1000 persons dying between the ages of twenty and thirty, died of tuberculosis, and 597 out of 1000 of pulmonary tuberculosis. Likewise at post-mortem examinations, signs of an old and healed tuberculosis are recognized in many cases where the patients have died of some other disease.

Two factors are of importance when considering the development of this disease: first, the exposure of the given individual to the tubercle bacillus, and second, the condition of the individual so exposed; his powers of resistance are of course diminished if he has been suffering from disease of any kind, overwork, or bad surroundings, or if he has a predisposition to tuberculosis.

Second: It is also well known that early recognition of pulmonary

tuberculosis is of the first importance, as then food, sunshine, and fresh air can frequently arrest it: the air of course should be free from dust. A striking and hopeful illustration of the importance of early diagnosis in disease is the present percentage of cures in diphtheria as compared with the past. More than nine-tenths of the patients suffering from diphtheria now recover if they are properly treated in the earliest stages; and while we have no drug like antitoxin with which to treat pulmonary tuberculosis, yet it is universally recognized, by those who have had a large experience, that even in our climate success follows suitable hygienic and dietetic treatment intelligently and persistently carried out, in a large percentage of cases, provided this disease is detected in its earliest stages.

Too much stress cannot be laid upon the importance of the early recognition of an abnormal condition of the lungs when there is a question of tuberculosis. The chances of recovery are far greater in the early stage of the disease, and the time required for convalescence is much less; nor is it by any means always necessary that a patient should seek another climate. The fact is well established that under proper conditions and surroundings tuberculosis of the lungs may be arrested by a natural process, if taken in the earliest stages. Not only do post-mortem examinations demonstrate the frequent occurrence of healed tuberculous areas in the lungs, but direct evidence of the arrest of the disease is abundant in life. The best time for successful treatment is very early, before there is cough, and before there are physical signs or when these are not definite. To keep the patient under observation while suspicion grows into apprehension, and apprehension into certainty, may involve a fatal result.

It will be said that comparatively few patients can afford the time or the money necessary for a cessation from work and for a change of climate, though this latter point is not always required, as noted above. The length of time demanded, then, to arrest the disease, is an important element in this consideration from a money point of view. Let us suppose, for instance, that a patient in whom the disease has progressed so far as to give some physical signs at one apex, may, under suitable conditions, recover in two years; he, like most others, could not afford to be idle for so long a time. But, on the other hand, if the diagnosis could have been made in such an early stage of the disease that six months would have sufficed, the problem would have been much simpler; for it is plain that the number of those who could afford to rest six

months would far exceed those who could give up two years. But time and money are not the only or the chief considerations. This "money" need, which often covers the "time" need, can in some cases be supplied by friends, but no friend can make good the encroachments of this disease if it is too far advanced. The percentage of recoveries from tuberculosis, when this disease is in such an early stage that six or even four months is sufficient for an arrest of the process, will be much greater than in the class of cases in which two years are necessary; for this added length of time means that the disease has progressed further.

Let us return to the money point of view again for a moment. It is quite conceivable that the cost of maintaining a hospital for consumptives for patients who are comparatively well would be less than that where the inmates needed greater care. Moreover, the shorter the time necessary for the patient to remain in the sanitarium, the greater the number of patients who could be cared for during a given period. If the time required for treatment was only six months, twice as many patients could be taken care of than if a year were necessary. In other words, the cost of maintenance would be distributed over twice as many families; and if the shorter time only were necessary, it is fair to suppose that the patients or their friends could afford to pay a larger proportion of the cost of maintaining the hospital. Thus, for those whose means are limited the hope of recovery is far greater by a very early diagnosis, not only so far as the disease itself is concerned, but also because it brings within their means the remedy for the disease.

Certain of my patients have been able to give up work while they were still comparatively strong, and go into the country to stay with some relative, where the conditions were more favorable for recovery than in their old environment, and they have done well. This again shows how a very early diagnosis may make it possible for the family of a patient to assist him to a cure. The important factor, then, in the arrest of this disease, is the means for making an early diagnosis; and I think it will be admitted by all those who have had a large experience in making examinations of the chest, that any method which yields signs in the very early stage of tuberculosis is of importance and deserving of careful study.

The number of cases of early tuberculosis which have been examined by me with the X-rays is naturally not very large, because these cases present themselves as it were by accident. The patients who come to a physician for an examination of the lungs after cough, hæmoptyses,

or other symptoms have directed their attention to the respiratory system, would in the nature of things very much outnumber those who came to him for such an examination when there were as yet no symptoms to lead them to suspect their lungs. As X-ray examinations come into wider use, however, and—hand in hand with this point—when general practitioners learn that young patients who are anæmic, who have lost flesh, who suffer from dyspepsia, etc., are in a suspicious condition, and should, therefore, have their lungs carefully examined, the number of cases in which the diagnosis is made at an early and useful stage will be greatly increased, and therefore, also, will be the percentage of recoveries. In other words, while we have no specific remedy for tuberculosis, an early diagnosis and proper treatment will accomplish the desired end in the majority of cases. I therefore wish to emphasize the significant warning given in these general symptoms to the family physician—which may anticipate any of the usual signs in the chest—and the importance of making as careful and complete an X-ray examination of the lungs as possible after these symptoms have been noticed. With the use of the X-rays, in connection with other methods of examination, tuberculosis in its early stage will be less frequently overlooked than formerly.

The importance to the community of a method of examination which affords timely assistance in detecting this disease is obvious when we consider the prevalence and high mortality obtaining in tuberculosis.

After twenty years of practice I do not undervalue any of the present methods of examination, nor is it my purpose to advocate giving up any of them for making an early diagnosis or for later examinations—we need all the available aids; but I do strongly urge the addition to them of careful X-ray examinations, and I desire to emphasize the value of this method in affording indications of pulmonary tuberculosis in the earliest stage of the disease,—not only because an early diagnosis gives the best opportunity for arresting the disease, but also because patients may be taught simple precautions which may prevent them from becoming a source of contagion to others should cough and expectoration develop. We have had two methods of examining the heart and lungs, auscultation and percussion. Each of these in suitable cases gives valuable information; they require a trained ear and experience with many patients to make them serviceable. In some cases auscultation is of the greater value, in others percussion. More fre-

quently they are best when used together. To these we may now add a third method, that of X-ray examination, which also requires special training.

All who are experienced in making physical examinations of the thorax recognize the necessity of controlling one method of examination with another. Not infrequently we understand best the conditions present, as just suggested, by taking into consideration the information obtained from inspection, percussion, and auscultation together, and if we fail to do this we may err in our diagnosis. The X-rays give another and valuable method for controlling the results obtained in other ways, and also add to them. We may, by their use, not only control one method by another, but with the eye supporting the ear we also control one sense with another.

CHAPTER VI

PNEUMONIA

THE abnormal condition of the lungs in pneumonia is shown on the fluorescent screen, not only by the obstruction which the affected parts offer to the rays, but also by the restriction of the excursion of the diaphragm on the lower side. The first point is demonstrated by the following test, which I made in 1896:—

Through the kindness of Dr. W. T. Councilman, I obtained for a few moments from the pathological department of the Boston City Hospital the lungs of a patient who had died of pneumonia. I put them on a photographic plate, enclosed in paper which had been shellacked to make it waterproof, and then made an X-ray photograph which is reproduced in Figs. 99, 100. The dark portions represent the densest parts of the lungs, the lightest portions the normal. It will be seen that the contrast between the two is very marked. By further experiment I found that where the lung was most dense, and 5 centimetres thick, it cast a shadow corresponding to that made by water about 5.5 centimetres deep, and that such portions of the lung sank in water. Other portions which barely floated in this liquid offered the same resistance to the passage of the rays as did an equal depth of the liquid, both when examined under the fluorescent screen and by means of an X-ray photograph. The normal part of the lung offered very little obstruction to the passage of the rays.

APPEARANCES SEEN IN PNEUMONIA ON THE FLUORESCENT SCREEN

First: Darkened Lung.—The foregoing experiment shows that in pneumonia the dense lobes cast a dark shadow on the fluorescent screen, in marked contrast to the light areas of the normal portions of the lung. The absorption of the rays may be so marked as to indicate that all of the pulmonary area on one side, and much of it on the other, is nearly or quite as dense as the liver. When

the lung has increased in density in any portion, — as well in a part near the middle of the chest as near the surface, — it will cast a shadow

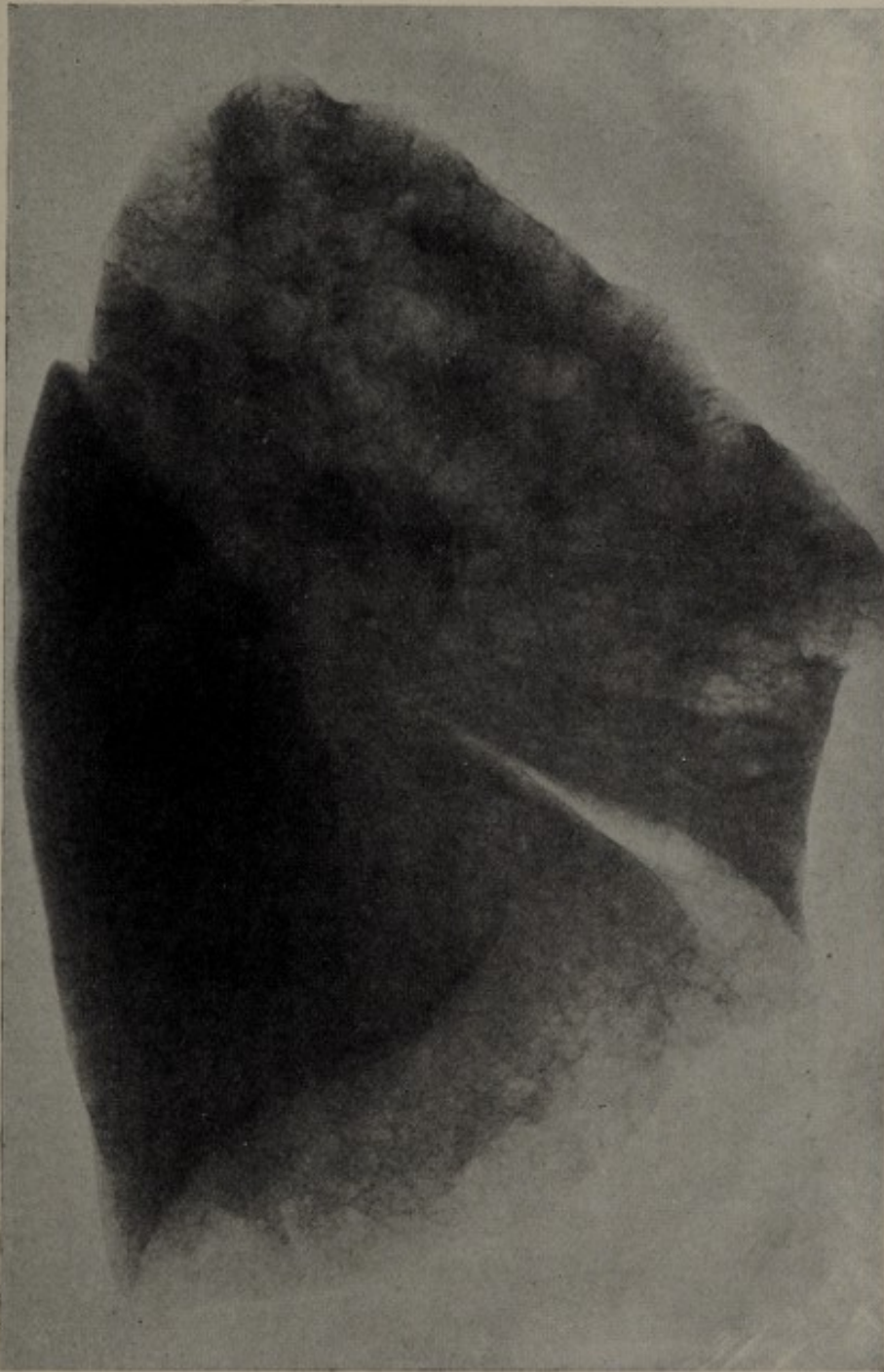

FIG. 99. Lung of a patient who died of pneumonia. The lightest portion is healthy; the darkest parts have been more affected by the pneumonic process than those that are less dark. It is noteworthy that the smaller bronchi show as light lines in the dark portions of the lungs. This lung was taken on the same plate with that shown in the next figure.

on the fluorescent screen. In this fact lies one of the advantages of an X-ray examination over percussion; for while by the latter method we

detect modifications in density in portions not far from the chest wall, we may fail to get a change in the percussion note when the denser

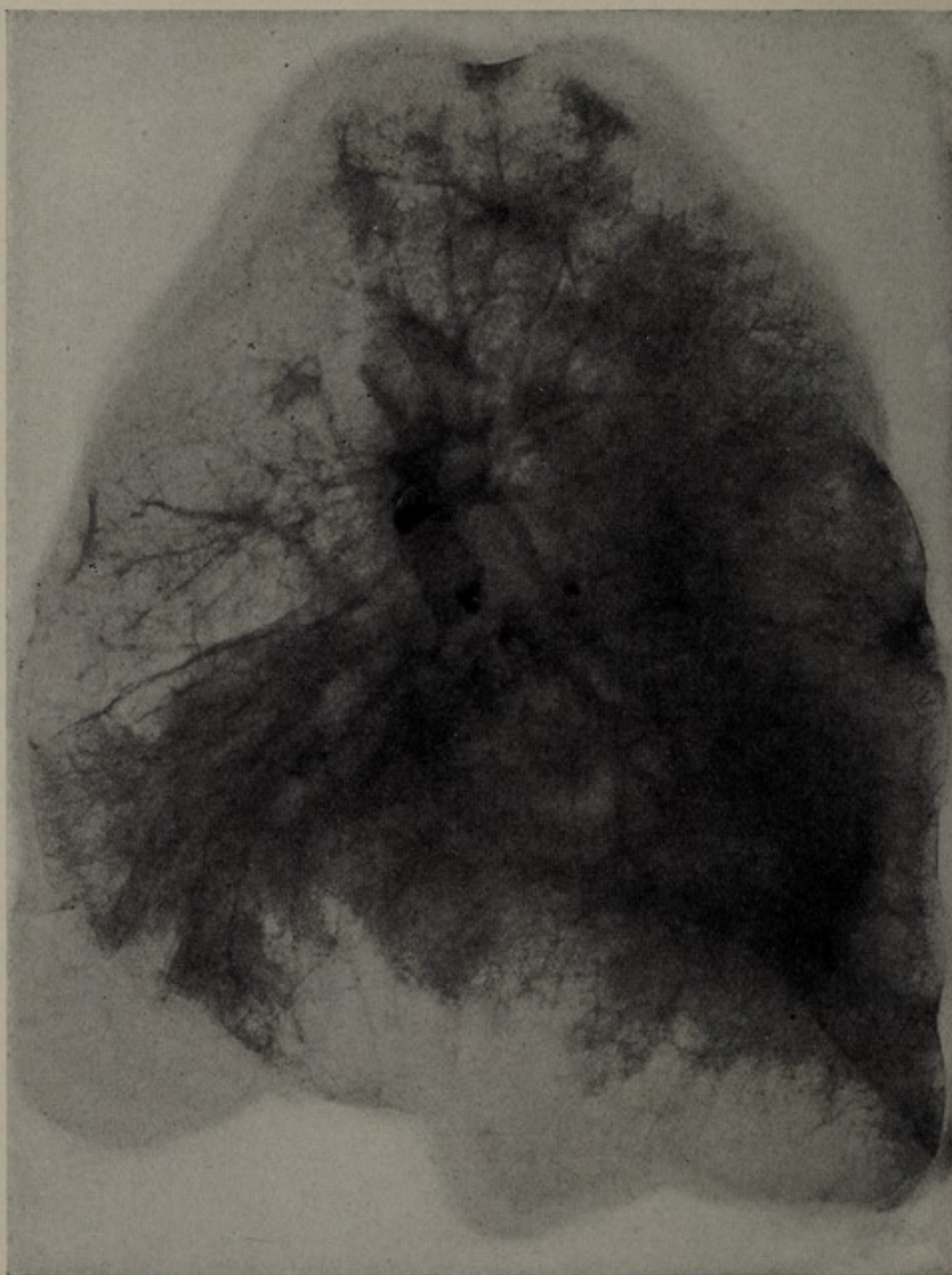

FIG. 100. The other lung of a patient who died of pneumonia. The lightest portion is healthy; the darkest parts have been more affected than those that are less dark. This lung was taken on the same plate with that shown in the preceding figure.

portions of the lungs are more remote. If the density is much below the surface, as in central pneumonia, its presence is not recognized by physical examination; a shadow, however, of the consolidated portion

of the lung is cast on the fluorescent screen just as surely as if the pneumonic process were near the surface, as suggested above. My X-ray examinations have demonstrated the presence of such dense central portions or central pneumonias, and have also shown that in cases of convalescence from pneumonia we may see the shadow of the dense parts of the lungs which are distant from the surface when they are not recognized by auscultation and percussion. These observations and others noted on page 158, Chapter V, show why we may detect increase in density with the X-rays in cases where it is not found by auscultation and percussion, and that under some conditions the X-rays are the more delicate test.

Second: Diaphragm Lines. — The excursion of the diaphragm is shortened in pneumonia, and shortened as a rule on its lower side, on one or both sides of the chest, owing to the failure of the lung or lungs, as the case may be, to expand to their normal extent because of their increased density, and also perhaps because of pleuritic adhesions. In some cases the diaphragm lines are a more delicate test than the shadow cast on the screen by the dense portion of the lung. If the pneumonic process is extensive the diaphragm lines may be altogether obliterated on one or both sides of the chest.

Third: Displacement and Enlargement of the Heart. — If the distribution of the pneumonia is such that the outline of the heart can be followed, this organ is seen to be enlarged, especially on the right side, and in some cases a much enlarged right auricle can be made out. Where the pneumonia is on one side only, there is apt to be some displacement. If the lower portion of the left lung is involved, the right border of the heart may be seen on the screen farther to the right than in health: partly because the heart is enlarged, as it is frequently seen to be in pneumonia; and partly because the dense lung pushes the heart a little to the right. Where the process in the lung is so distributed that the size of the heart may be observed by means of the X-rays through the active stages of the disease, it becomes evident that the size and position change, the enlargement lessening, and the heart approaching nearer and nearer to the normal in position and size as the lung improves.

Usual Region affected. — The middle portion of the lung, that is to say, the part between the second and fourth ribs, is the region most frequently affected when the pneumonic process is not extensive. We often find the apex and the base comparatively free from disease. The

following diagram indicates the appearances frequently met with when only a small part of the lung is involved; it is made from the examination of a patient with the fluorescent screen on the seventeenth day of the disease: —

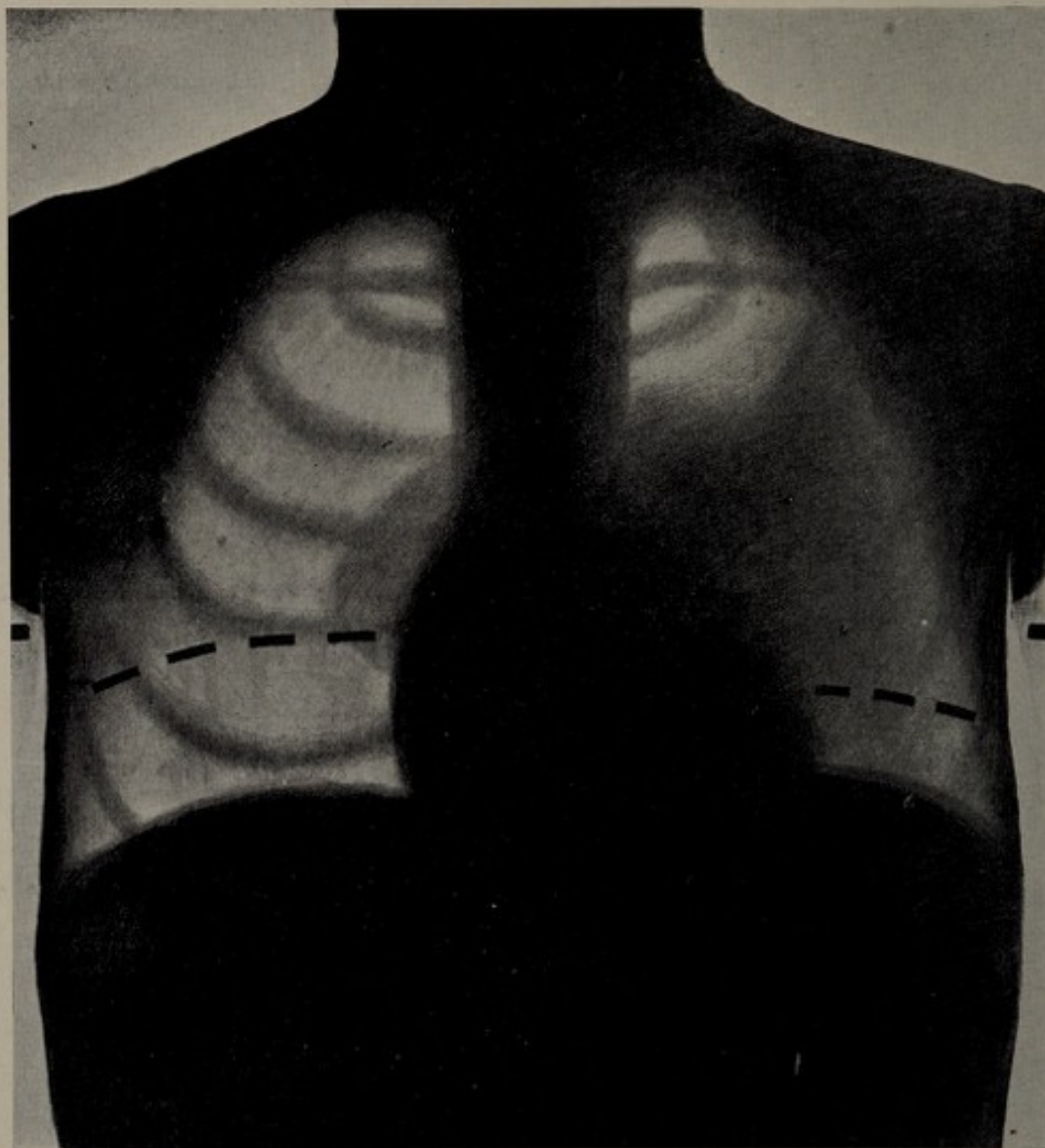


FIG. 101. Diagram of pneumonia. Seventeenth day of disease. No physical signs on or after this day.

Dark area and restricted movement of the diaphragm on the left side; the movement is also less than normal on the right side. The dark area diminished gradually, and the excursion of the diaphragm on both sides increased from week to week. There were still X-ray signs on thirty-second day.

Method of Examination. — The methods of examination for this disease are sufficiently indicated in the general directions given in Chapter III, and the special ones in Chapters V and X and by the following cases and cuts, and need not be further discussed.

Comparative Value of the Fluorescent Screen and X-Ray Photograph in Pneumonia.—It seemed to me important to compare the two methods of X-ray examination in pneumonia, and the result demonstrated the superiority of the screen over the photograph in this disease. I will give an outline of one of the cases in which a comparison was made, in order to show how the experiment was carried out.

CASE I. Christine P., aged six years; pneumonia; entered my service at the hospital on the third day of the disease. The physical signs were not well marked, but the X-ray examination made on the following day indicated a dense area 7 centimetres wide, extending

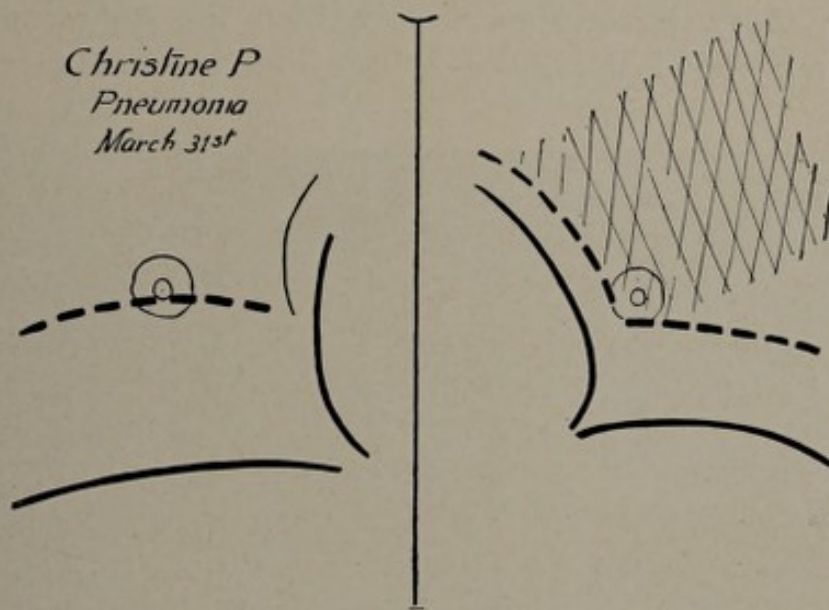


FIG. 102. Christine P. Pneumonia on left side in girl six years old. X-ray tracing made on the sixteenth day of disease. There were no signs by auscultation and percussion, though as shown by the above copy of the X-ray tracing, the signs by the fluorescent screen were still well marked. X-ray photograph showed no increase of density in the lungs, but a slight increase is seen in the reduced picture shown on page 170 (see Fig. 103). (Cut one-third life size.)

outward and upward from the left border of the heart. The excursion of the diaphragm on the left side was 0.6 centimetres; on the right side 2.5 centimetres. On the sixteenth day of the disease the darkened area had grown much lighter, but was still readily perceived, and the excursion of the diaphragm was 2.5 centimetres on the left side, and 4.7 centimetres on the right side. (See Fig. 102.)

As at this date there were no physical signs in the lungs of this patient, nor had been for four days, although the signs of departure from the normal were very patent on the fluorescent screen, the case seemed to me a favorable one in which to make the comparison between

the value of the X-ray photograph and the screen in this disease. Three photographs of the chest were taken, one on March 30, and two on March 31, to see if variation in the time of exposure, or tubes of different resistance would bring out anything. Several prints were made from each of these negatives, and in none of them did I find evidence of increased density in the left lung as compared with the right. There were no indications of the presence of pneumonia by means of the X-ray photograph, although the signs on the screen at this time, as just stated, were obvious, the darkened area and the restricted excursion of the diaphragm being visible. This latter condition was probably due in part to pleuritic adhesions limiting the movement of the lung.

After the above paragraphs were written the following half-tone was made from one of the radiographs. The half-tone (see Fig. 103)

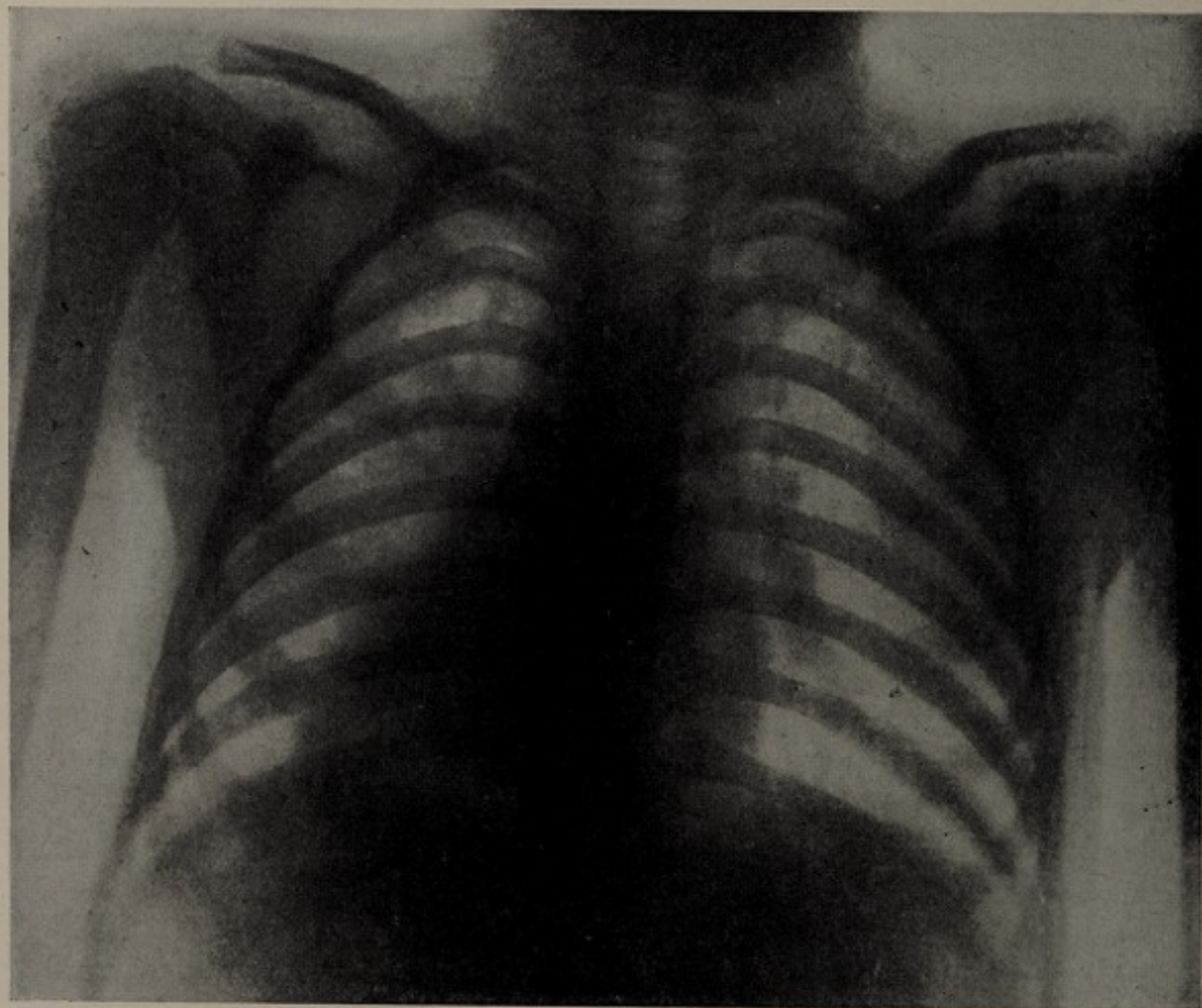


FIG. 103. Christine P. Cut from radiograph which was made on the same day that the radioscopic tracing was drawn. X-ray tracing (see Fig. 102) shows well-marked signs.

shows a slight increase in density on the left side which was not visible in the radiographs themselves. This slight density seems to have been made evident by the reduction in size of the X-ray photograph.

The following case shows the appearances seen in pneumonia, namely, the limitation of the movement of the diaphragm on the affected side, and the darkened lung; likewise the difference between the signs observed by X-ray examination, and by auscultation and percussion:—

CASE I. Edward R., twenty-five years old, entered my service at the Boston City Hospital, March 11, 1898. Diagnosis: pneumonia.

Family History.—Negative.

Present Illness.—For three days, cough; pain in right side; vomiting. Had been drinking heavily.

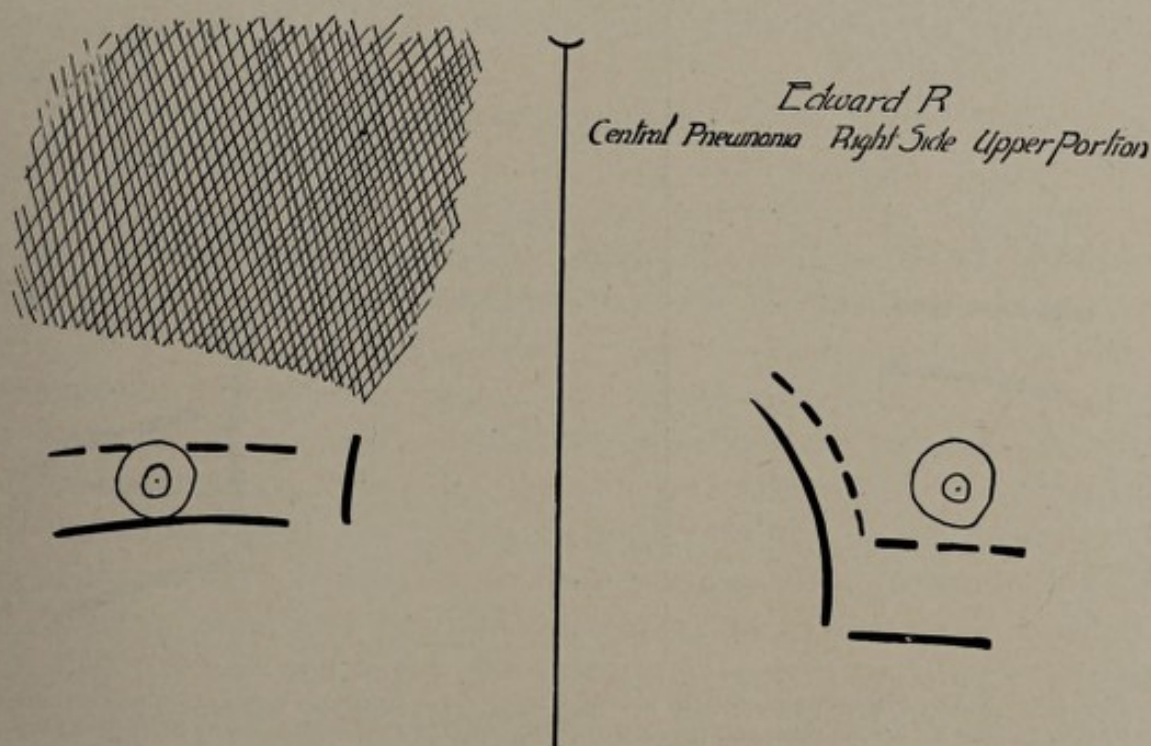


FIG. 104. Edward R. March 12. Cut of X-ray tracing. Central pneumonia; right side; upper portion. Heart enlarged to the right. Physical signs indicated that disease was present in the lower part of right chest. X-ray examination confirmed by autopsy. (One-third life size.)

Physical Examination.—Heart: right border 2 centimetres to right of sternal border; left border in nipple line; apex beat in fifth space in nipple line; no murmurs. Lungs: resonance good throughout; respiration over right lung, *below third rib in front and spine of scapula behind, harsh.*

Temperature 103 to 104; pulse 120 to 130; respirations 32 to 36.

March 12. X-Ray Examination with Screen.—The tracing (see Fig. 104) made on the chest of this patient showed that the *upper part* of the right lung was very dense, and below that point it was much lighter. The excursion of the diaphragm was much shortened on that side.

Developed delirium tremens and died on March 14.

March 16. Autopsy showed the *upper lobe* of the right lung com-

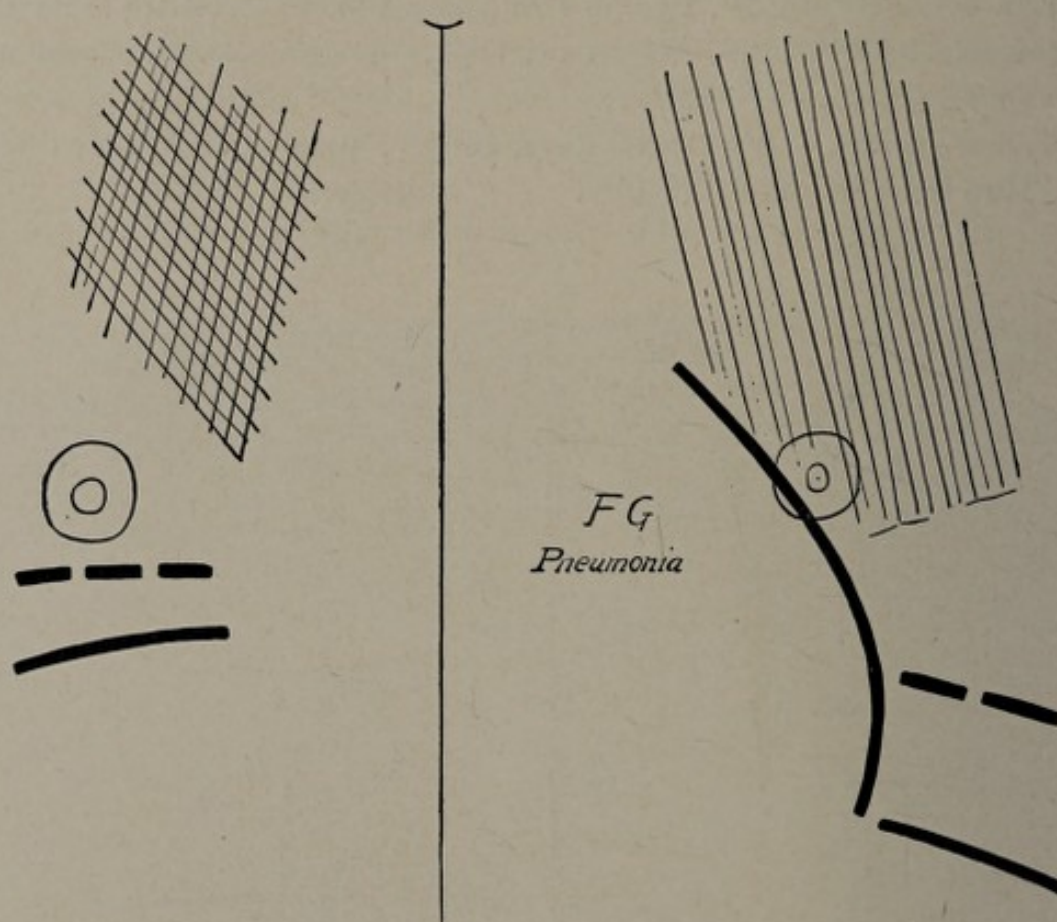


FIG. 105. F. G. Pneumonia on both sides. Cut of X-ray tracing. Signs more marked on left side by X-rays than by auscultation and percussion; more marked on both sides by fluorescent screen than by X-ray photograph. (One-third life size.)

pletely distended and solidified throughout; middle and lower lobe slightly increased in density.

This patient entered the hospital on the fourth day of the disease. The physical signs indicated that pneumonia was present in the *lower part* of the right chest, below the second rib in front and the spine of scapula behind. The only indication given by physical signs, however, was the harsh breathing. The resonance was good throughout.

The physical examination was made on March 11, the X-ray exami-

nation on March 12, and the patient died on March 14. It is instructive to compare the conditions found by the physical examination with those found by X-ray examination and at the autopsy. It is evident from these latter that the disease had been chiefly present in the *upper lobe*, which was completely solidified throughout. (See Fig. 104.)

Comparison of X-Ray with Physical Signs, and of Screen with X-Ray Photograph. — F. G., forty years old, entered my service at the hospital January 4, 1900. Diagnosis: pneumonia on both sides. (Fig. 105.)

The interesting points in this case were, first, that the signs observed on the left side by the X-rays were more marked than those obtained by auscultation and percussion; second, the appearances seen on both sides were more marked on the screen than on the X-ray photograph.

Extent of Disease. — The X-rays show the extent of the disease; whether or not it is limited to one lobe, or includes the whole of one lung and part of another.

Outline of Pneumonia sharply defined. — The outline between the normal and abnormal portion of the lung may be sharply defined on the fluorescent screen. The following case illustrates the sharp definition of the dense areas that sometimes obtains, as well as the significance of the diaphragm lines and the limitation of the disease to one lung: —

CASE I. Bernard McL., nineteen years old, entered my service at the hospital February 11, 1897. Diagnosis: pneumonia.

Physical Examination. — Marked dulness over upper right chest down to fourth rib; breathing intensely bronchial with a few moist râles and increased vocal and tactile fremitus; dulness in right axilla with harsh breathing. In right back, dulness from apex to level of middle of scapula; breathing broncho-vesicular; many fine moist râles. In left chest, front, and back, there is good resonance; many fine and coarse moist râles at base and back.

February 13. X-ray examination with screen on *seventh* day of disease; right lung dark from middle of first intercostal space to fourth rib, the upper and lower border of this dark area well marked. Outlines in chest rather less clear than normal on both sides. Diaphragm moved 0.6 centimetres on the right side and 4 centimetres on left side.

It will be seen that the limits of the dense lung were well defined both above and below (Fig. 106). The physical examination did not show that the lung was clear at the extreme apex.

X-Ray Examination with Screen. — *Fifteenth* day of disease; diaphragm moved 2.5 centimetres on the right side, 6.25 centimetres on

the left side. *Twentieth* day of disease; diaphragm moved 5 centimetres on right side, 7 centimetres on left side; original dark area has grown steadily lighter, but is not yet so bright as other portions of

Name *Bernard McL.* Age *19* Date *Feb. 13 1897*
 Address _____ Occupation _____ Vol *417* Page *222*
 Diagnosis *Pneumonia*

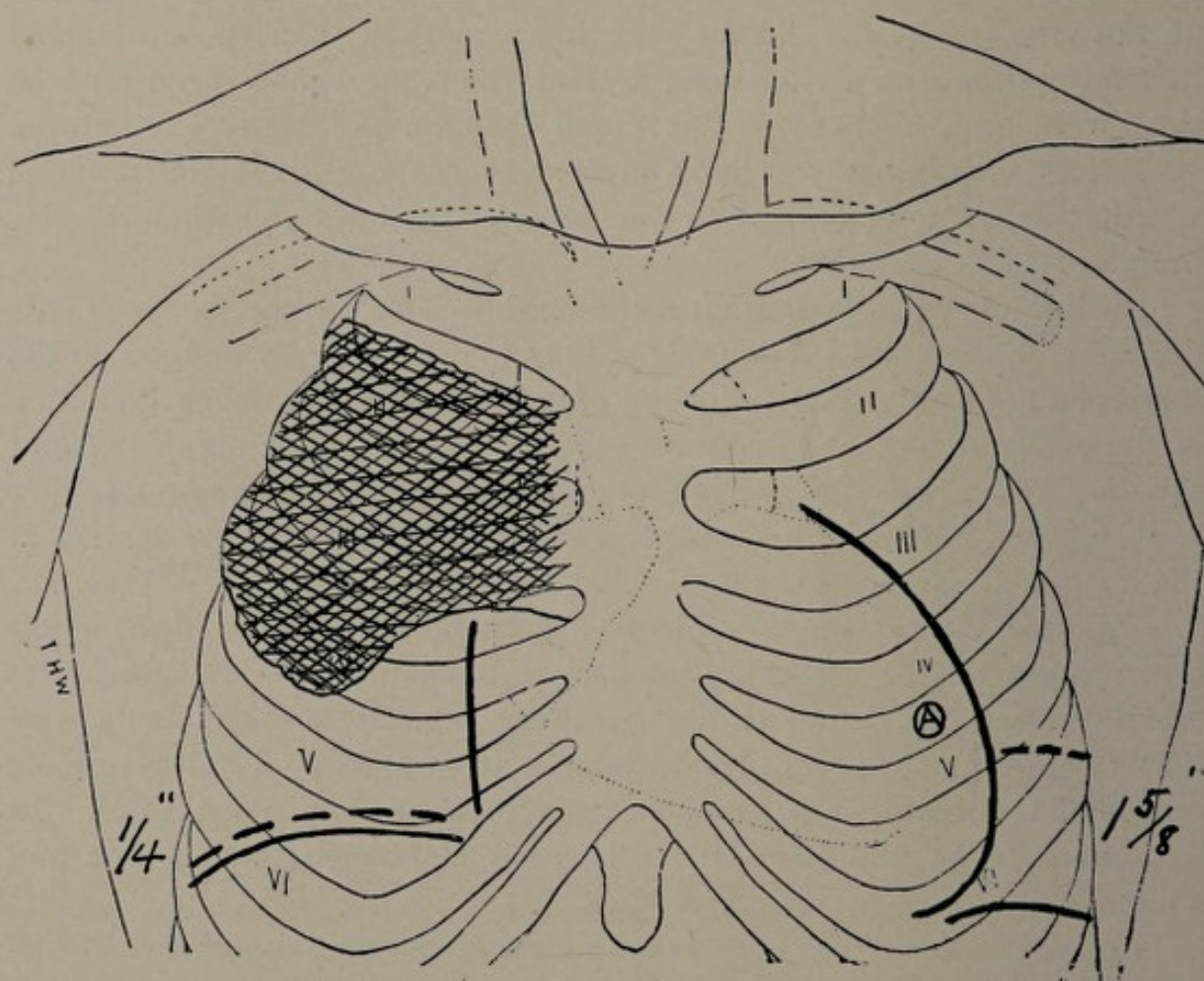


FIG. 106. Bernard McL. Pneumonia. X-ray examination with screen; seventh day of disease. Outline of pneumonia sharply defined. Lung clear at apex. Physical examination did not show this fact. Movement of diaphragm on right side, 0.6 centimetres; on left side, 4 centimetres. (One-third life size.)

the lung. *Twenty-second* day of disease; diaphragm moved 6.25 centimetres on the right side and 7.5 centimetres on the left side.

Persistence of X-Ray Signs. — *Improvement watched on the Fluorescent Screen.* However much the lungs may be affected in pneumonia, we may see by means of successive X-ray examinations with the fluores-

cent screen that, as the patient begins to improve, the dark areas seen on the screen become lighter and lighter, and diminish in extent, until they finally disappear. We may also watch the diaphragm and see that its excursion, which has been restricted, and restricted on the lower side, gains in length as the lungs clear up. The following case is given to illustrate these points, and also to show that the results of the pneumonic process may be followed on the fluorescent screen when there are no longer signs by auscultation and percussion. The position of the heart is only referred to briefly.

The X-ray examinations in this case, seven in all, were made on the following dates, namely, March 7, 13, 19, and 24; April 1, 8, and 12; but I only give reproductions of the tracings made on March 7, 13, 24, and April 8. It will be seen by examining them that as the lungs cleared up the excursion of the diaphragm increased in length. On March 7 this muscle had but a short excursion on the left side, and could not be seen on the right side. On March 13 the diaphragm could be seen on both sides, and moved about 1.25 centimetres on each side. On March 24 it moved 2.2 centimetres on the right side, and 3.4 centimetres on the left side; April 8, 3.4 centimetres on right side, 4 centimetres on left side. It will also be seen in the notes of the case that there were no physical signs on April 1, or subsequently, although signs of an abnormal condition of the lungs could be seen on the fluorescent screen on April 6, 8, and 12. The details of this case are given at some length.

CASE I. G. R., thirty-three years old, entered my service at the hospital February 21, 1897. Diagnosis: pneumonia.

Nine days before entrance patient had chill, fever, and sweating; severe headache; pain in right chest; dyspnoea; cough with rusty expectoration.

Physical Examination. — Tympany over upper right chest, with loud harsh breathing and moist râles; below fourth rib in right front dulness on percussion extending into axilla; breathing diminished; increased vocal and tactile fremitus. In right back dulness begins at spine of scapula, flatness from angle of scapula to base; breathing over this area intensely bronchial in character with great increase in whispered and spoken voice sounds; many fine moist râles at end of inspiration. Some dulness in lower left back with increased voice sounds; many fine and coarse moist râles; breathing bronchial but not so intense as on right side; breathing harsh at left apex. Good resonance over left chest in front, with harsh noisy breathing and loud coarse râles.

February 24. *Physical Examination.*—Whole of right chest perfectly flat on percussion; breathing amphoric, with fine moist râles; breathing rather diminished in axilla, and of bronchial character. Whole of right back flat on percussion; breathing intensely bronchial, with increased

Name *G. R. (male)* Age *33* Date *March 7. 1897.*
 Address _____ Occupation _____ Vol. _____ Page _____
 Diagnosis _____

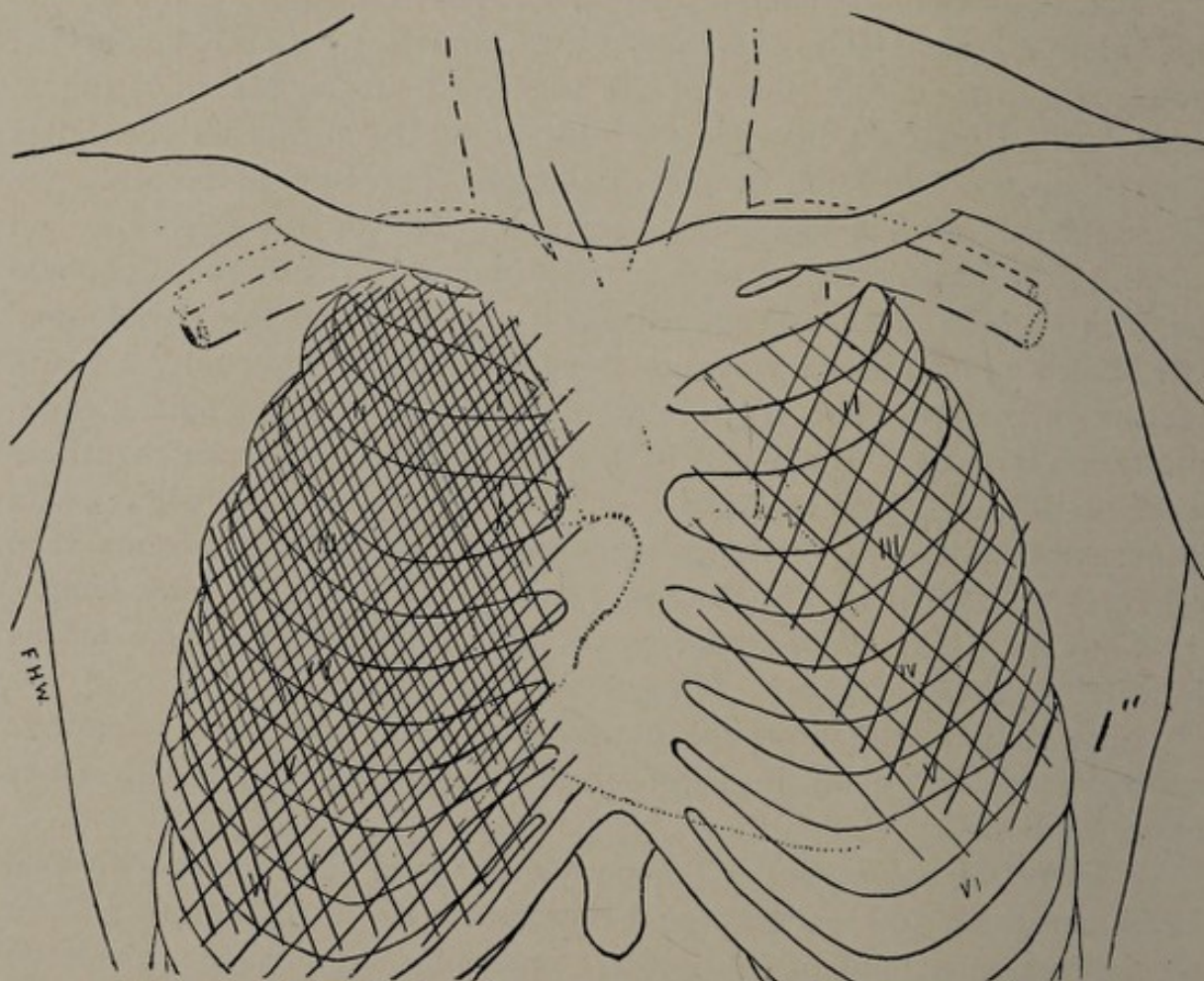


FIG. 107. G. R. First X-ray examination with screen. Pneumonia on both sides. Diaphragm not seen on right side as the lung is too dense; excursion on left side 2.5 centimetres. (One-third life size.)

voice sounds and tactile fremitus; many fine moist râles over whole back. Signs in left chest as at first examination.

February 26. Temperature fell by crisis from 103 to normal.

March 7. *Physical Examination.*—Right chest in front, percussion rather higher pitched than on the left; vocal fremitus increased; many

râles; in right back, percussion duller than in left back, and vocal fremitus increased. Left chest: in front, harsh breathing over most of the left side; in back, breathing better than in right back; vocal fremitus increased.

| | | | | | |
|-----------|-------|------------|--|------|---------------|
| Name | G. R. | Age | | Date | March 13. 97. |
| Address | | Occupation | | Vol. | Page |
| Diagnosis | | | | | |

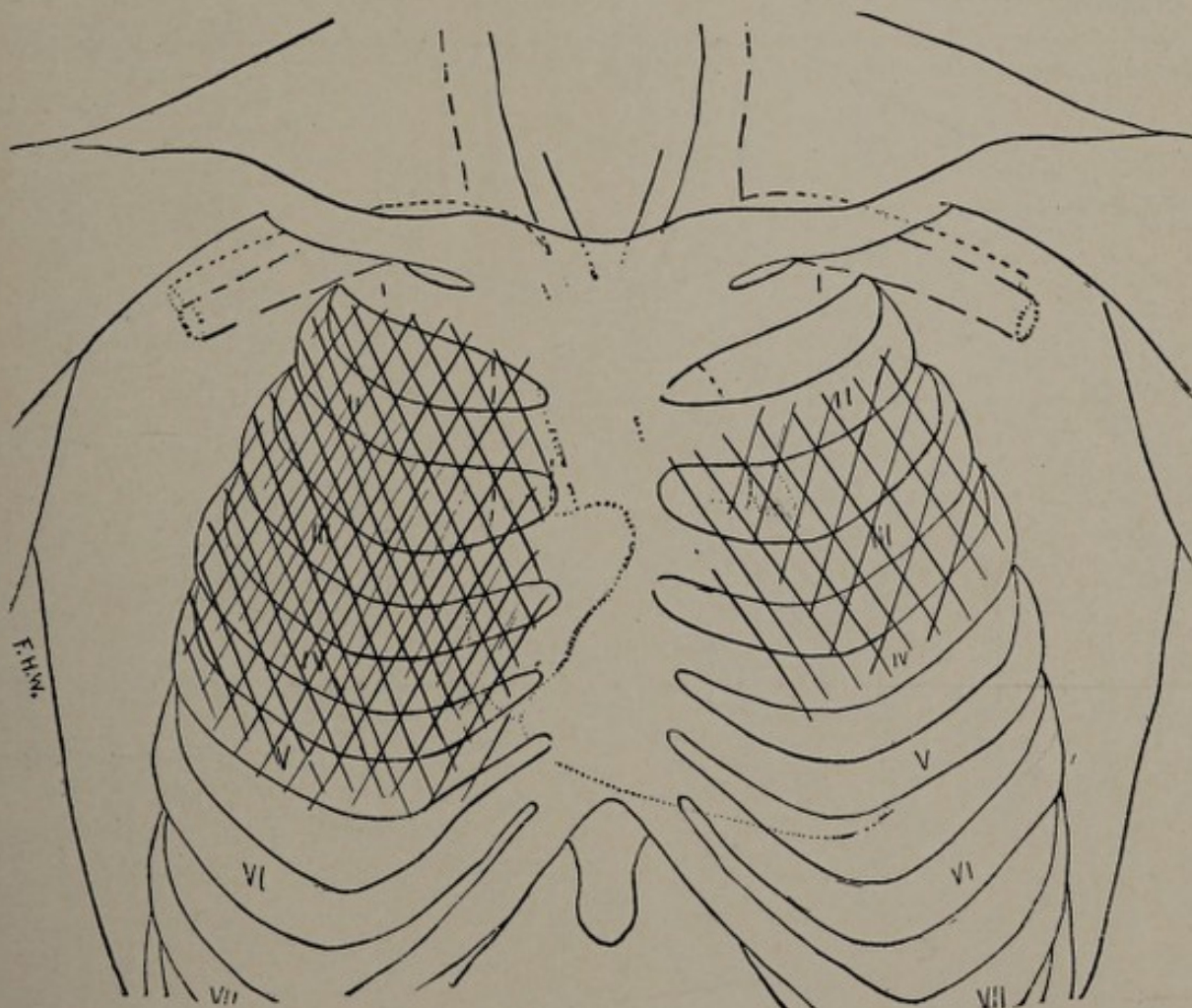


FIG. 108. G. R. Second X-ray examination with screen. Patient improving. Excursion of diaphragm 1.25 centimetres on right side; increased on left side. (One-third life size.)

March 7. X-Ray Examination with Screen, as shown in cut of tracing made on this day (see Fig. 107). — The whole of the right chest was dark; no outlines seen; the lower portion of the right chest rather lighter than the upper portion, which indicated consolidation of the lung and not pleurisy with effusion. The heart was not displaced to

the left. On the left side the upper three-fourths of the left chest was less clear than normal; some movement of the diaphragm could be followed.

March 13. *X-Ray Examination with Screen.*—The chest was much clearer on both sides than on March 7. The ribs were very faintly visible

Name *G. R.*

Age

Date *March 24 97*

Address

Occupation

Vol.

Page

Diagnosis

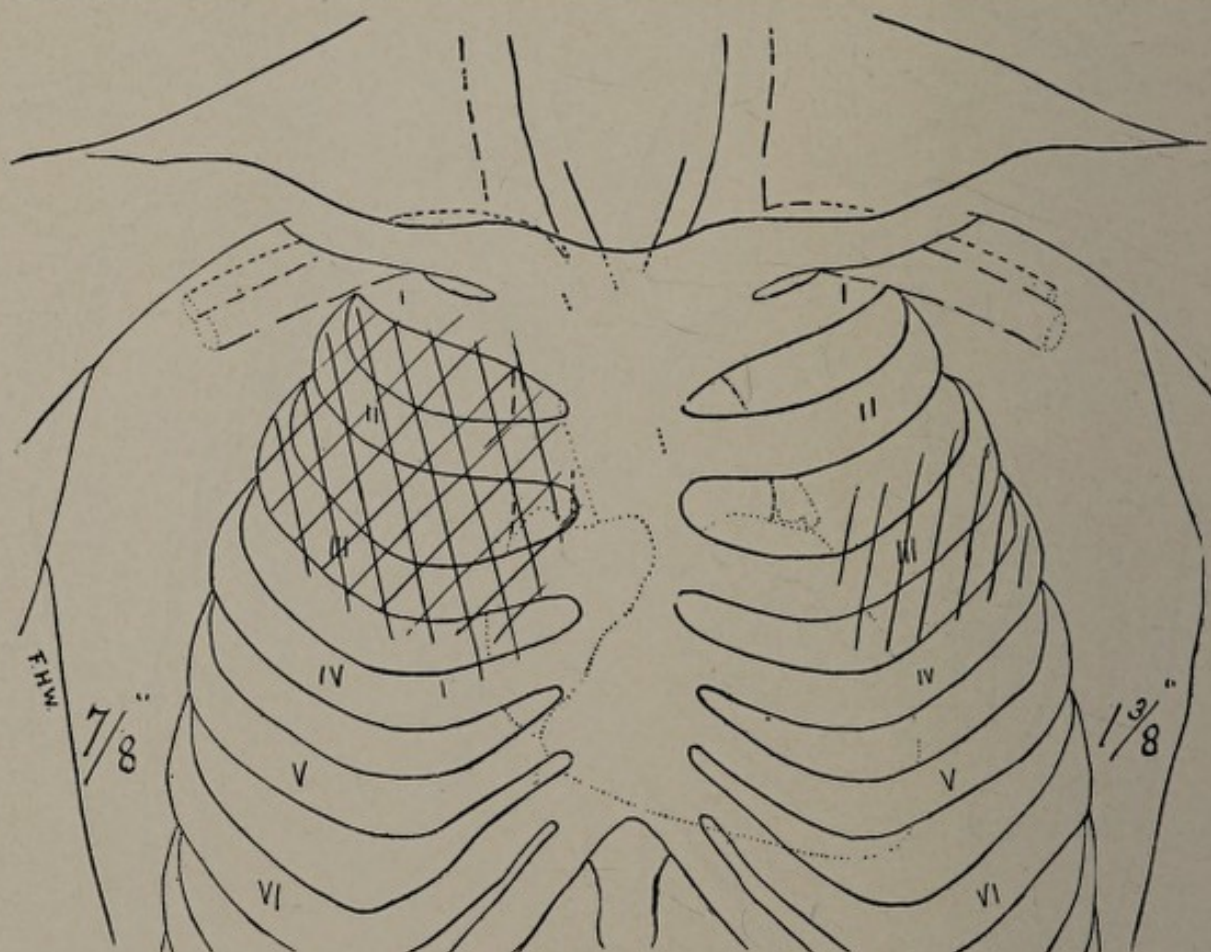


FIG. 109. G. R. Third X-ray examination with screen. Still further improvement. Excursion of diaphragm on right side, 2 centimetres; on left side, 3.5 centimetres. (One-third life size.)

on the right side, and a shortened excursion of the diaphragm could be barely made out. On the left side, from the second to the fourth ribs, inclusive, the chest was darker than normal. Below the fourth rib on this side was the lightest part of the thorax. Excursion of the diaphragm 1.25 centimetres. (See Fig. 108.)

On *March 19*, *X-ray examination with screen* (of which no tracing is reproduced) showed the whole of the right side darker than the left. The diaphragm on this side was the width of a rib higher than on the left side and had an excursion of 1.25 centimetres. On the left side the excursion of the diaphragm was 3 centimetres.

| | | | | | |
|-----------|-------|------------|--|------|----------------------------|
| Name | G. R. | Age | | Date | April 8 th '97. |
| Address | | Occupation | | Vol. | Page |
| Diagnosis | | | | | |

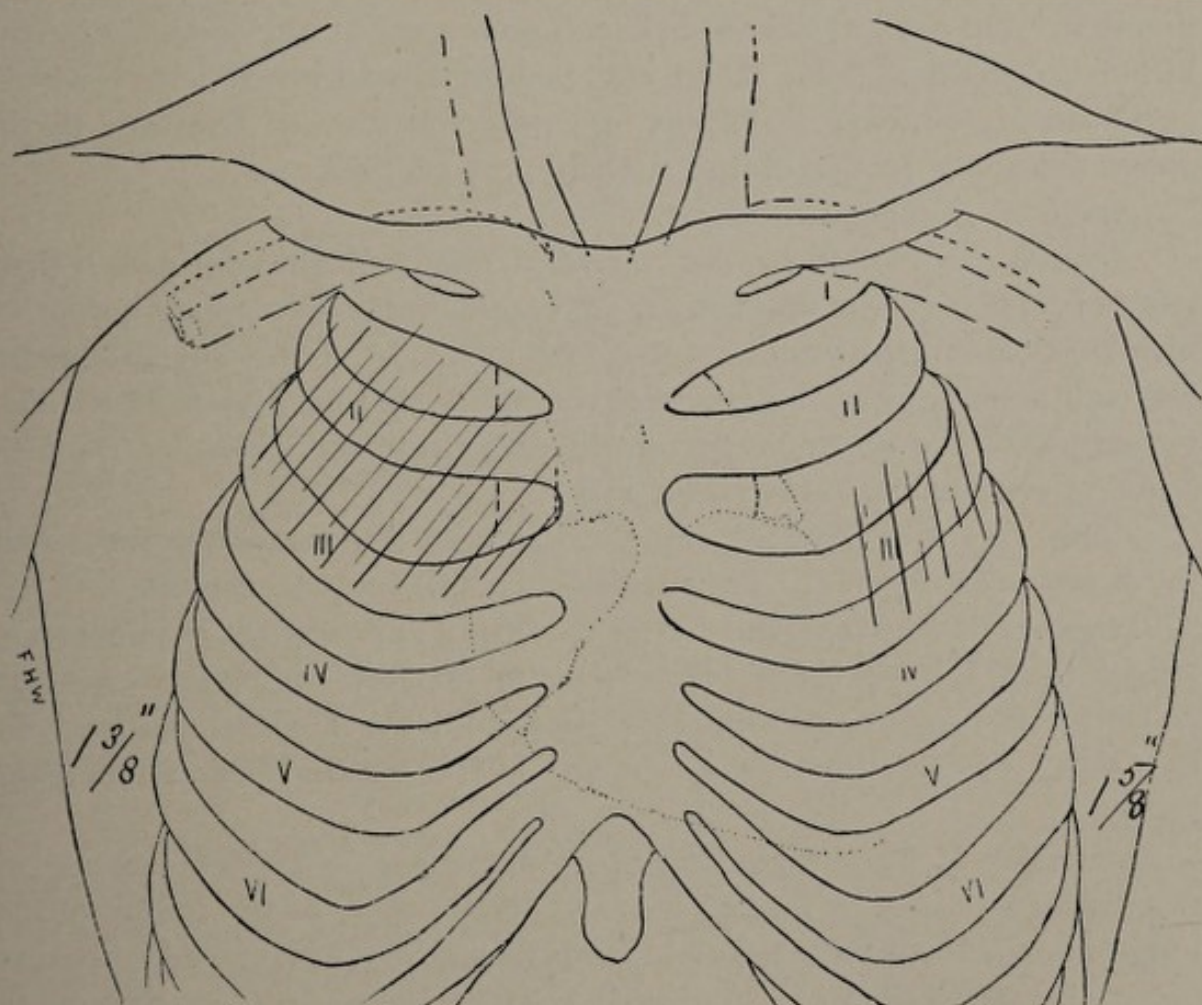


FIG. 110. G. R. Fourth X-ray examination with screen. Signs by X-rays; shaded lungs and excursion of diaphragm restricted on both sides. No physical signs at this time. (One-third life size.)

March 24. Physical Examination. — Slight increase in dulness on the right side; respiratory murmur shorter than on the left side.

March 24. X-Ray Examination with Screen. — Dark area on the upper portion of the right side, as far down as the third rib. Dark area about

over the third rib on the left side. Excursion of the diaphragm on the right side, from about the upper border of the fourth to the upper border of the fifth rib, 2 centimetres; on the left side, from the middle of the fourth intercostal space to the lower portion of the fifth intercostal space, 3.5 centimetres. The diaphragm was higher on the right side than on the left. Heart enlarged on the right side. (See Fig. 109.)

April 1. No signs by physical examination.

April 1. *X-ray examination with screen* (no cut given) showed the whole of the right side less clear than the left; excursion of the diaphragm on this side, from the middle of the fourth intercostal space to about the middle of the fifth intercostal space, in the nipple line, 2 centimetres. On the left side the shaded area seen at the examination of March 24 could still be made out, though it was much less marked; excursion of the diaphragm from the upper border of the fifth rib to above the upper border of the sixth rib, 2.5 centimetres.

April 8. No physical signs.

April 8. *X-Ray Examination with Screen.*—Right apex darker than left; excursion of the diaphragm 3.5 centimetres from upper border of fifth rib to about the middle of the fifth space. On the left side there was still a small shaded area over the third rib; excursion of the diaphragm from the upper border of the fifth rib to the middle of the fifth space, 4 centimetres. (See Fig. 110.)

April 12. No physical signs. Signs by *X-ray examination* about the same as on April 8. Patient discharged from the hospital.

It would be instructive to follow the X-ray appearances in pneumonia longer than I have usually been able to do, but the patients become so well that they are unwilling to remain in the hospital, although by the X-ray examination the lungs are by no means clear when they go out.

Excursion of Diaphragm limited by Adhesions.—The movements of the diaphragm may be limited by two causes: first, by the failure of the lungs to expand to their normal extent during deep inspiration, because of the increased density, as already stated; and second, on account of pleuritic adhesions. When the patient is convalescing from pneumonia, and the lung has become quite clear, we sometimes find that the excursion of the diaphragm has not reached its normal limit. If this limitation is not due to the former cause, it may well be due to the presence of pleuritic adhesions. The following case, with its accompanying tracings, illustrates this point.

Tracings were made from the chest of the patient on October 4, 7, 10, and 17, 1899, and April 21, 1900. Copies of these are given below, with the exception of that made on October 10.

CASE I. Simon G., fourteen years old, entered the service of one of my colleagues at the hospital September 25, 1899, and soon after came under my care. Diagnosis: pneumonia.

Illness of five days' duration. Patient had sharp pain in left chest, with slight cough, raising nothing.

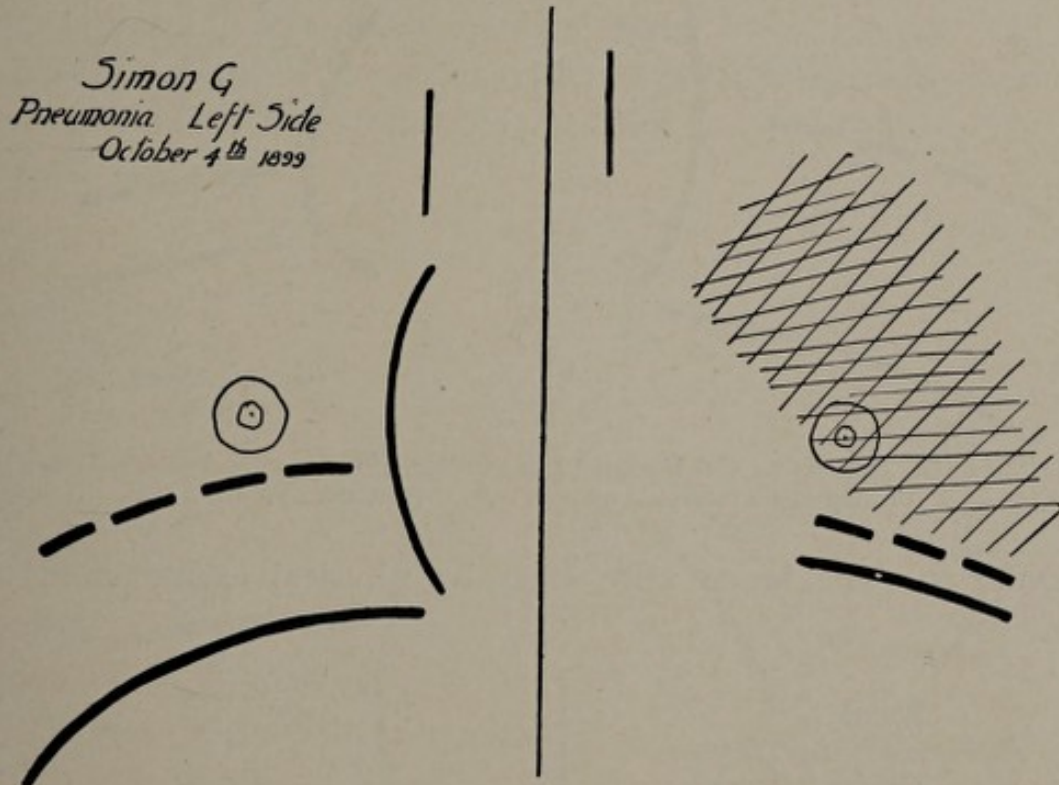


FIG. 111. Simon G. Oct. 4, 1899. Cut of first X-ray tracing. Pneumonic process in left chest. Shaded left lung and restricted movement of left diaphragm. X-rays indicated that there had been some pneumonia on right side also, as shown by shortened excursion of diaphragm; but it was not detected by physical signs. (One-third life size.)

Physical Examination. — Resonance and respiration good throughout both fronts; an occasional sonorous râle; below the level of angle of left scapula, dulness, bronchial respiration, whispered and spoken bronchophony, and subcrepitant râles; tactile fremitus slightly increased at left base.

Temperature at entrance $103\frac{1}{2}$, pulse 110, respirations 40.

On the seventh day of the disease temperature fell by crisis to normal. Slight cough with greenish expectoration.

October 4, 1899. X-ray examination with screen showed a pneumonic process which had not yet cleared from the left chest. It also

suggested that there had been some pneumonia on the right side which had not been detected by the physical examinations. (See Fig. 111.)

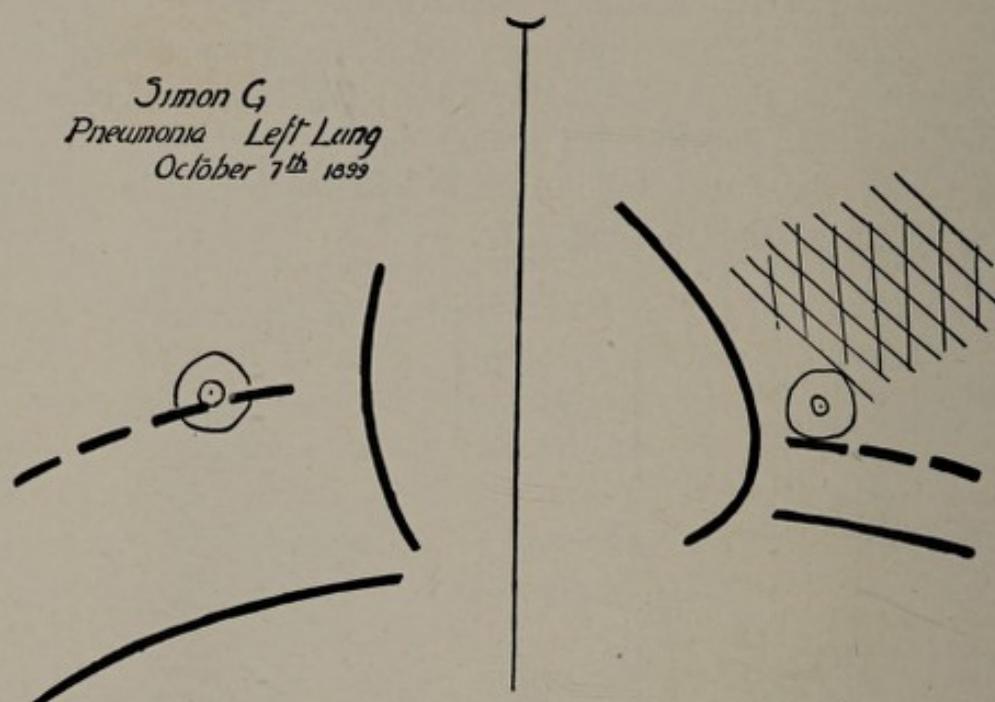


FIG. 112. Simon G. October 7. Cut of second X-ray tracing. Shaded area diminished; movement of diaphragm increased on both sides. (One-third life size.)

October 10. The lungs were clear by physical examination. No cough.

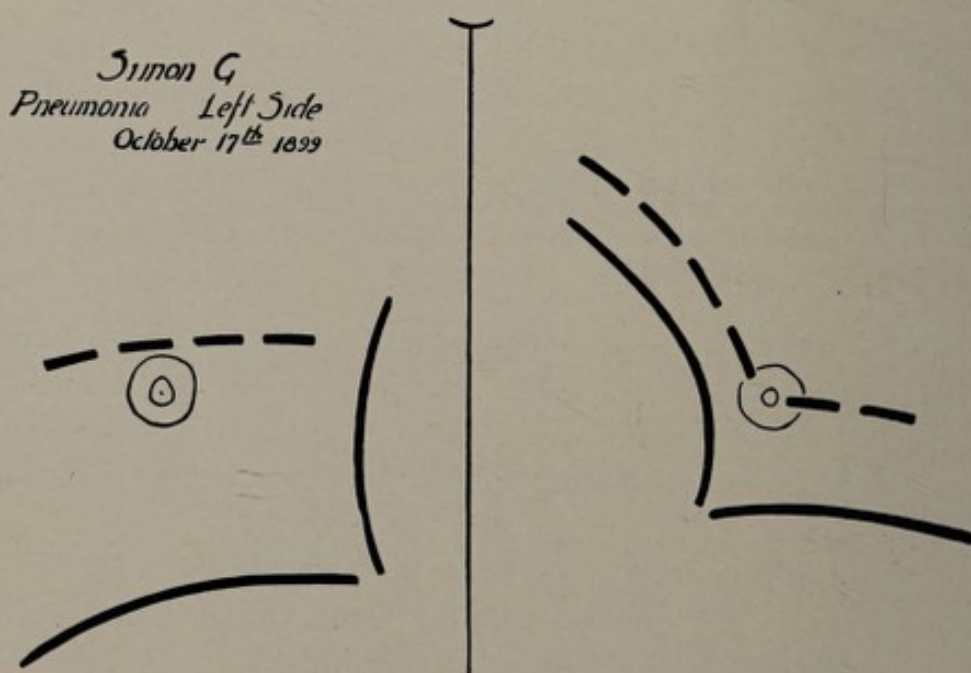


FIG. 113. Simon G. October 17. Cut of third X-ray tracing. Both lungs nearly alike in brightness. Diaphragm on left side moves more than at last X-ray examination, but its movement is not yet normal. This abnormality may be due to pleuritic adhesions. (One-third life size.)

October 15. Physical signs had all disappeared. Patient out of doors each day.

October 17, 1899. *X-Ray Examination with Screen.* — Both sides nearly alike in brightness, but it will be seen that the excursion of the diaphragm on the left side was less than half as much as that on the right. (See Fig. 113.)

Patient *now complains of pain about the left nipple when he sneezes*, which is probably due to dry pleurisy, that may limit the expansion of the lung and the excursion of the diaphragm.

April 21, 1900. The patient returned to the hospital at my request, for a further X-ray examination, the result of which is shown in the following cut.

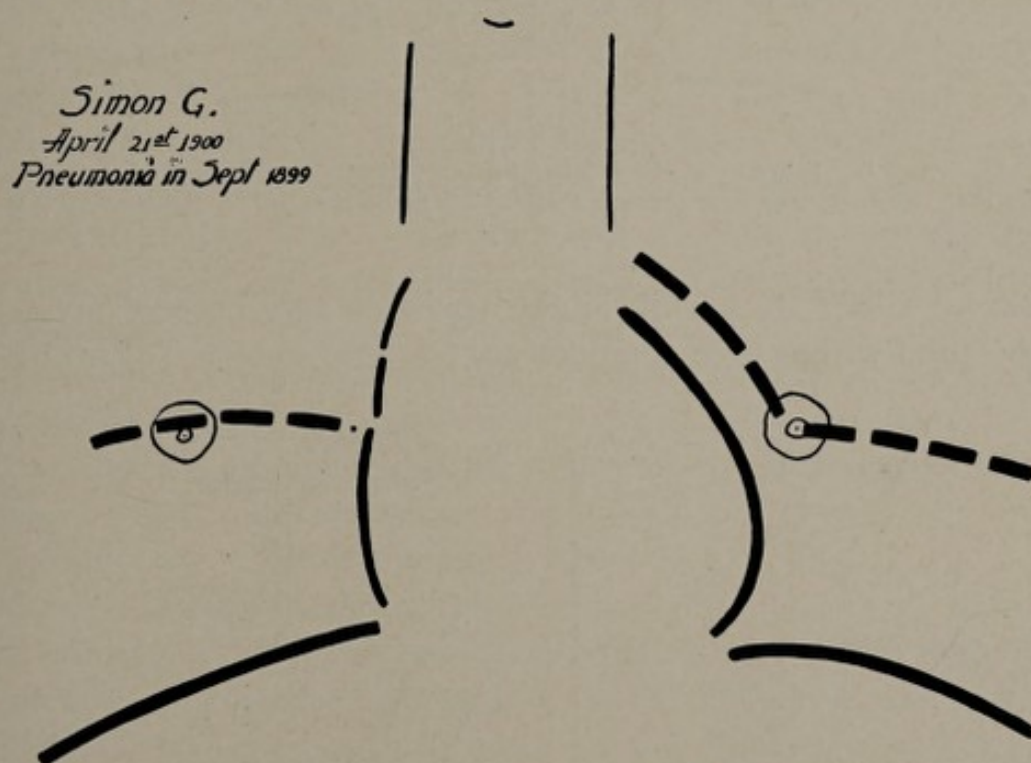


FIG. 114. Simon G. April 21, 1900. Fourth X-ray tracing. (One-third life size.)

Pneumonia with Obscure Physical Signs. — A pneumonia in its early stages, or even through its whole course, may give no signs by auscultation and percussion, and the physician may find it difficult to make the diagnosis. In some of these cases a doubtful diagnosis may be made a more certain one by the use of the X-rays. This point could be illustrated by citing a number of cases of central pneumonia, but three will be sufficient, in which the diagnosis was made clear and definite by an X-ray examination, and in which this diagnosis was confirmed by the

subsequent history of the case; the termination of the fever by a crisis; rusty expectoration; or, in some cases, by the development of physical signs of pneumonia as the disease progressed.

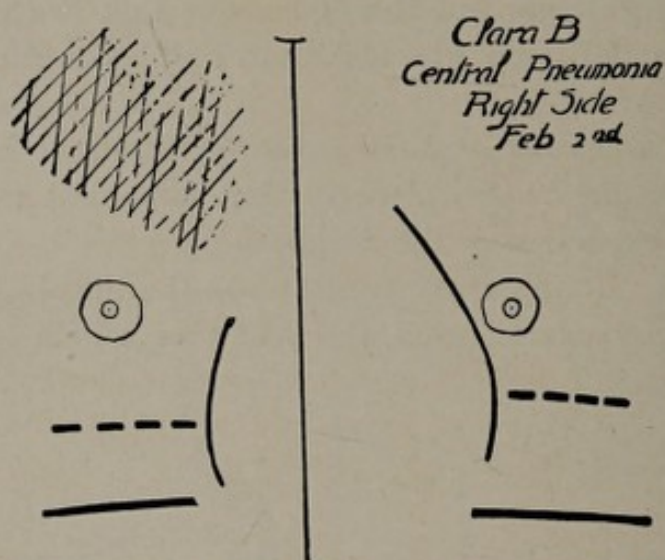


FIG. 115. Clara B. February 2. First X-ray tracing. Central pneumonia of right side in girl eight years old. Shaded lung and shortened excursion of diaphragm on right side. (One-third life size.)

CASE I. Clara B., a child eight years of age, entered my service at the hospital with a high temperature; a leucocytosis (25,000); pain

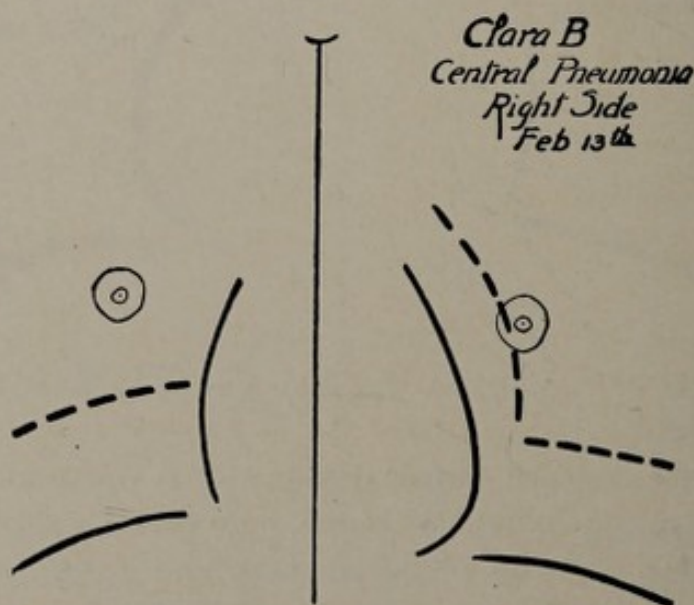


FIG. 116. Clara B. February 13. Second X-ray tracing with screen. Lung clear; good excursion of diaphragm. (One-third life size.)

and stiffness in the back of the head and neck, the neck so rigid that it could not be flexed. She did not know how long she had been ill, and

no friends came to visit her. There was no history, and no physical signs were found in the chest after a careful examination by two physicians. My house physician also found nothing in the lungs, and I was inclined to accept the diagnosis of cerebro-spinal meningitis which had been made by the physicians who had seen the patient. I made an X-ray examination, however (see Fig. 115), in order to obtain further information, and found a dark area over one lobe and a shortened excursion of the diaphragm on that side; and the diagnosis of pneumonia was made without hesitation. This diagnosis was confirmed later by a marked crisis, and by a rapid clearing of the lung as determined by X-ray examinations. (See Fig. 116.) At no time during the course of the disease did I obtain signs of pneumonia by auscultation and percussion.

CASE II. Elizabeth B., thirteen years old, entered my service at the hospital November 22, 1898. Admission diagnosis: typhoid fever and bronchitis.

Illness of seven days' duration; came on by a chill, followed by fever; headache; pain in legs; weakness; pain in shoulder; no cough.

Physical Examination.—Heart: area and action normal. Lungs: respiratory sounds and resonance normal. Temperature 105, pulse 130, respirations 35.

November 23. Widal test positive; positive again on November 30, and again on December 5.

November 25. Respirations 48. During the next eight days they ran from 45 to 50. Temperature about 103.

November 29. Leucocyte count 17,000.

December 4. Temperature fell by crisis.

December 7. *X-Ray Examination with Screen.*—Both lungs darker than normal, especially on the right side. Excursion of the diaphragm very limited, being 1.25 centimetres on the right side and 2.5 centimetres on the left side.

The sudden onset, chill, fever, the leucocyte count of 17,000, the rapid respirations, and the fall of temperature by crisis all confirmed the appearances of a pneumonia (accompanying the typhoid) found in the lungs by X-ray examination.

Pneumonia in Old People.—In such cases the diagnosis of pneumonia offers difficulties which are not generally encountered in younger patients. As is well known, pneumonia may occur in old patients without the presence of fever, and the physical signs may not be well marked, or may be such that the physician makes some other diagnosis.

CASE III. Julia F., seventy-seven years old, entered the service of one of my colleagues at the Boston City Hospital September 30, 1899, and soon after came under my care. The physical signs were such that I, as well as the physician who had charge of her prior to me, thought she had a bronchitis and did not recognize the pneumonia. I made an X-ray examination, as she had an arterio-sclerosis with calcification of the right radial artery, with a view to determining whether or not the aorta was also calcified. The fluorescent screen showed that the whole of the right side was dark below the level of the second rib, and this darkness indicated that the lung was increased in density. Another careful physical examination, given below, and made after the X-ray examination, indicated that we might have to do with a pneumonia in the lower and middle portion of the right lung.

Physical Examination. — Respiration harsh throughout both lungs, with numerous sibilant and sonorous râles over all. Slight dulness at left apex behind and over whole lower right back. Few rather fine moist râles in left axillary region; medium and coarse moist râles over lower two-thirds of right lung front and back. Tactile fremitus more marked over lower right back.

Temperature normal or subnormal during her three weeks' stay at the hospital; pulse 90; respirations 34 on October 1, and 25 on October 2, after which time they were about normal.

The following tracing gives the condition of the chest as seen at the first X-ray examination, made on October 5; and the second as seen on November 7, when the right lung had cleared up.

These three cases show how the X-ray examination may assist in pointing out an abnormal condition of the lungs when it is either not clearly shown by auscultation and percussion, or is not recognized by these methods of examination.

Differential Diagnosis. — A familiarity with the appearances of the lungs in pneumonia is necessary in order to make a differential diagnosis between this and some other disease.

a. **Pleurisy with Effusion or Pneumonia.** — In some patients the physical signs may be such that it is difficult to decide whether we have a pleurisy with effusion or a pneumonia, but if the area of lung involved is not sufficient to prevent us from seeing the outline of the diaphragm in full inspiration, that is, if the fluorescent screen shows a lighter area below the dark pneumonic one, we may be sure that no liquid is present unless it be much above the diaphragm and encysted, an uncommon

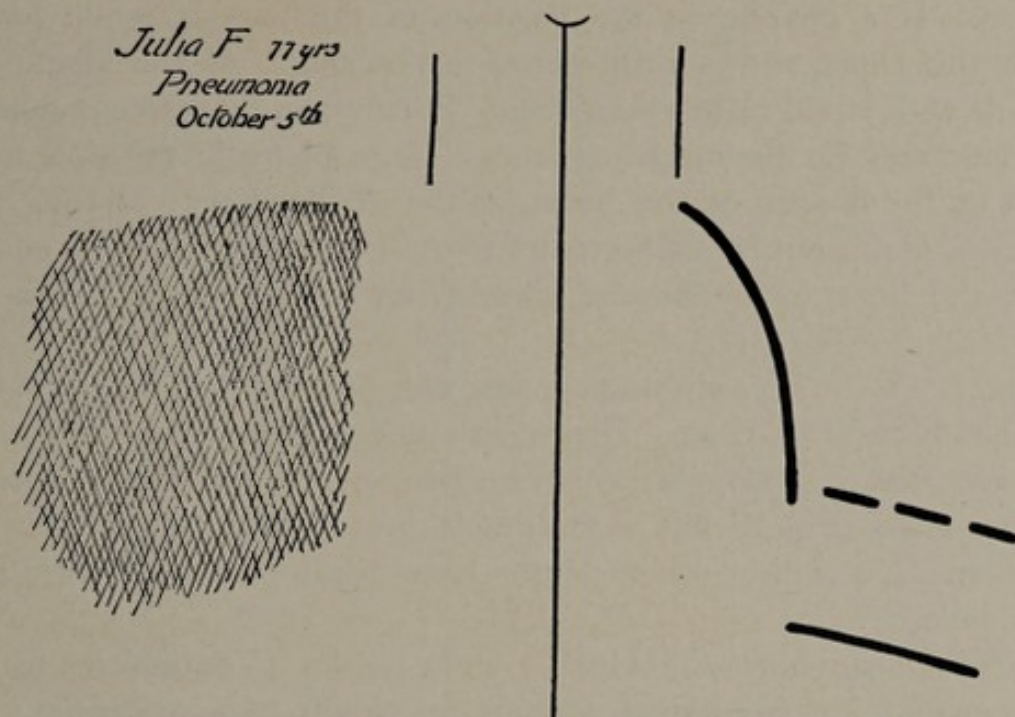


FIG. 117. Julia F. October 5. First X-ray tracing. Pneumonia, right side. Diaphragm lines obliterated on this side. (One-third life size.)

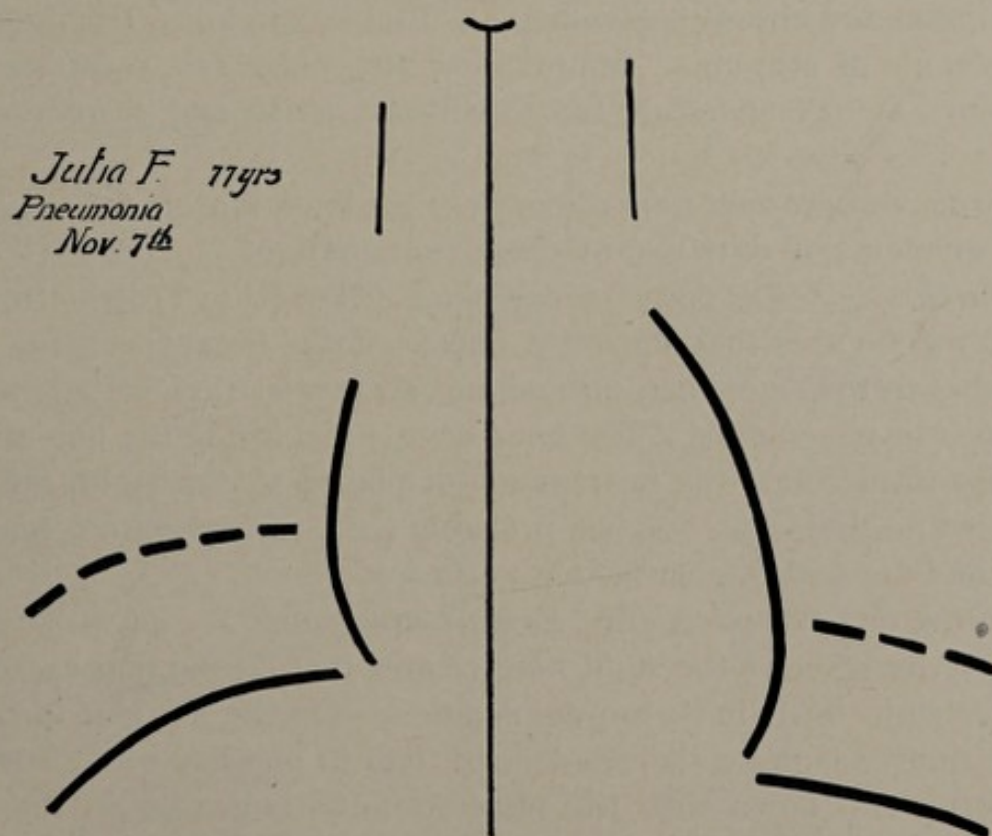


FIG. 118. Julia F. November 7. Second X-ray tracing. Lung clear; diaphragm lines seen. (One-third life size.)

condition. If a change in the position of the patient, while looking through the chest, shows a difference in the shape of the shadow, we have to do with liquid rather than solid. Further, an extensive pneumonia of one side may be distinguished from a large pleuritic effusion by the position of the border of the heart, as the displacement of this organ when liquid is present is much greater than in pneumonia. The enlargement of the heart in pneumonia should not be overlooked in this connection.

CASE I. Essie L., eighteen years old, entered my service at the hospital February 28, 1899. Diagnosis: pneumonia.

Present Illness. — Cough for two weeks. Seven days before entrance began to have pain in left side, much increased by cough or deep inspiration. No chill or other pain. Expectoration tinged with blood for two days.

Physical Examination. — Heart: right border 4 centimetres to right of midsternum, left border 8.5 centimetres to left of midsternum; apex in fifth space inside nipple line; action regular; no murmurs. Lungs: resonance and respiration good over fronts and right back; over left back respiration good at apex, bronchial between spine and inferior arch of scapula, and absent below angle. Tactile and vocal fremitus absent below angle of scapula. Temperature 103, pulse 110, respirations 40.

March 6. Temperature fell to normal; pulse and respirations also fell.

X-ray examinations with screen were made on March 1, 6, 23, and 30, but I give cuts of only two of these examinations.

March 1. X-Ray Examination with Screen (Fig. 119). — In the first cut it will be seen that the right border of the heart (probably dilated) is farther to the right than normal, but no farther than we might expect to find it in pneumonia. The apex beat is just inside the line of the left nipple and therefore the heart is not displaced to the right, but simply enlarged on that side, and we probably have to deal with a pneumonia only, and not with a pleurisy with effusion.

March 6. Second X-Ray Examination with Screen. — The second cut (Fig. 120) shows the right lung clearer than at the first examination, and the right heart in its normal position. On the left side of the chest the dark area is more sharply defined than in pleurisy with effusion, and moves up and down with the respiration, as indicated on the tracing, the wavy broken line indicating the position of the shadow in expiration, and the full one in inspiration.

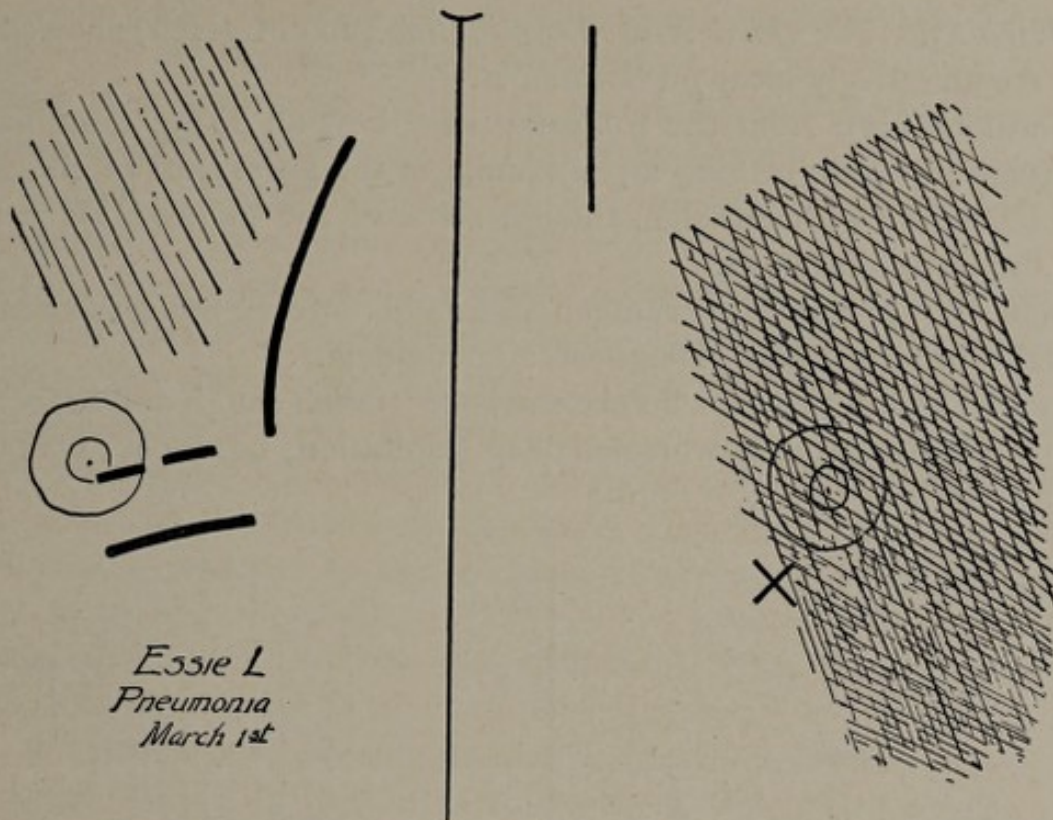


FIG. 119. Essie L. March 1. First X-ray tracing. Pneumonia, left side. Darkened left lung. Right border of the heart farther to right than normal. (One-third life size.)

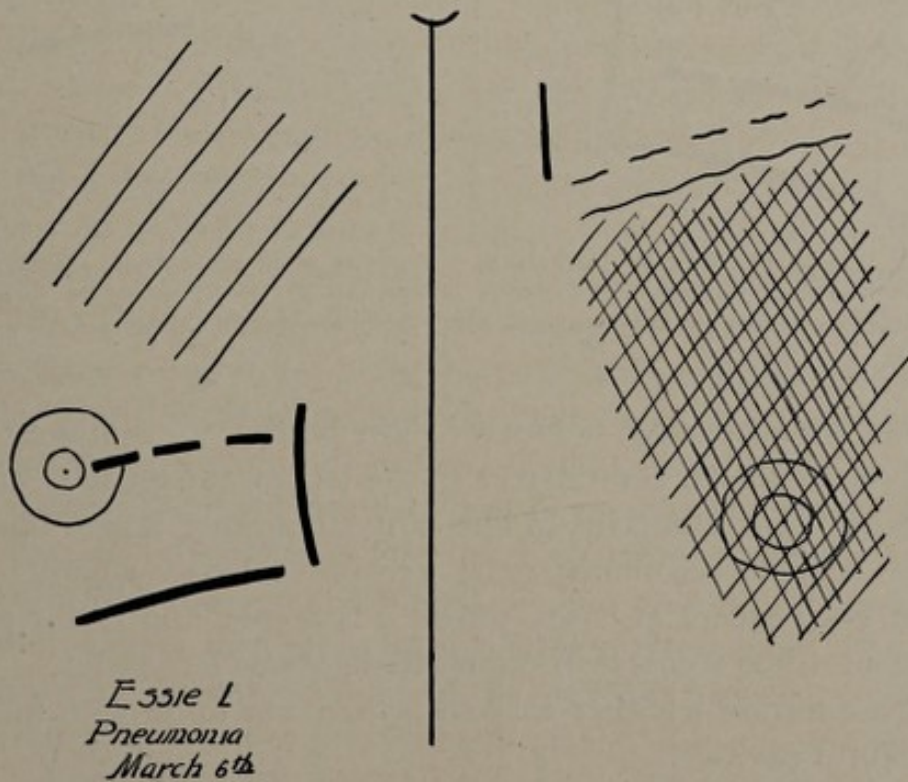


FIG. 120. Essie L. March 6. Second X-ray tracing. Broken line shows position of darkened area in expiration; full line in inspiration. Right heart in normal position. (One-third life size.)

March 23. The third X-ray examination (no cut given) showed the lungs comparatively clear on both sides.

It will be seen from the following case how an X-ray examination may assist in distinguishing a pneumonia in the lower part of the chest from a pleurisy with effusion, though some of the physical signs may favor the latter diagnosis.

CASE II. Joseph S., seventeen years old, entered my service at the hospital April 29, 1899. Diagnosis: pneumonia.

He had a chill two days before entrance; much cough and expectoration; pain in the left side, worse on deep inspiration; headache; vomiting.

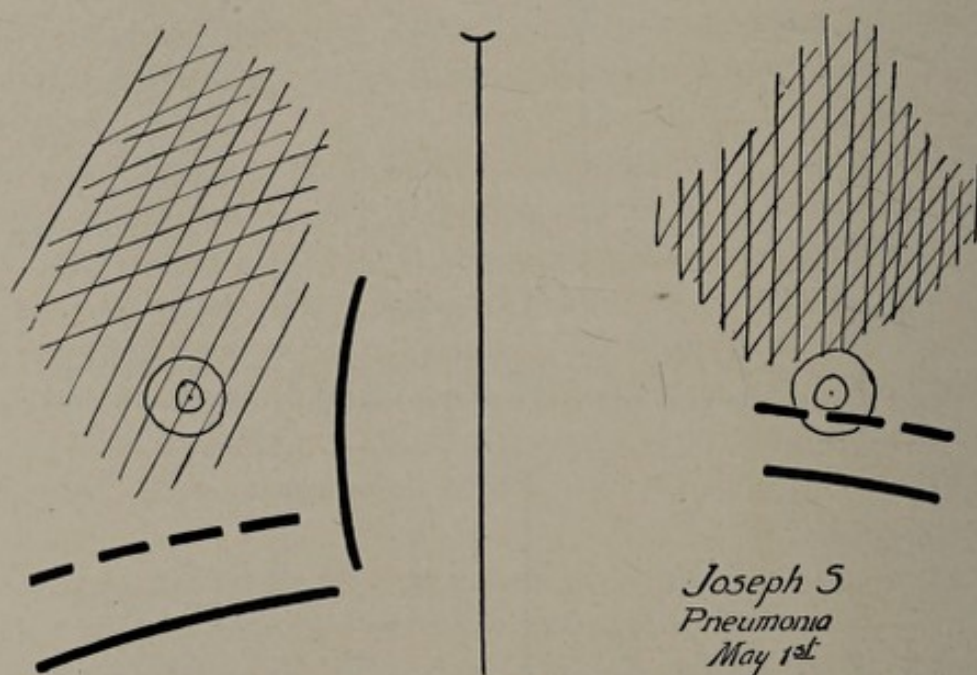


FIG. 121. Joseph S. May 1. Pneumonia. Question of pleuritic fluid. X-ray examination with screen showed there was no fluid in either pleural sac, as the outlines of the diaphragm were clearly seen, and the shadow did not change its shape when the patient changed his position. (One-third life size.)

Physical Examination. — Heart: right border 3.5 centimetres to the right, and left border 6 centimetres to the left of the median line; apex in fifth space, 6.5 centimetres to left of median line; action regular; no murmurs. Lungs: resonance good except at bases, where it is flat; respiration good except at bases, where it is feeble, and tactile and vocal fremitus diminished; coarse friction rub in lower left axilla.

It was a question whether we had or had not to do with fluid in one or both pleural cavities.

May 1. X-ray examination with screen (Fig. 121, Joseph S.) showed clearly that there was no fluid in either pleural sac, as the outlines of the

diaphragm were clearly seen, and the shape of the shadow did not change when the patient changed his position.

CASE III. George B., thirty-six years old, entered the hospital in September, 1896. Service of Dr. George B. Shattuck.

This patient had a pneumonia in the lower portion of the left lung, which began ten days before entrance.

X-Ray Examination with Screen.—I found the right side was perfectly clear; heart not displaced; on the left side, from the third rib downward, the shadow was so dark that the outline of the heart, ribs, and diaphragm was wholly obscured.

The apex of the heart was felt in normal position, indicating that this organ was not displaced. I therefore considered that the shadow on the screen was due to the presence of the pneumonia rather than to fluid in the pleural cavity.

This case illustrates how palpation and X-ray examination may supplement each other.

b. Pneumonia or Tuberculosis.—The history and usual methods of examination generally enable us to distinguish readily between these diseases, but there are exceptions to this general rule in which the X-rays may be of assistance. The examination with the fluorescent screen may aid us in discriminating between pneumonia and tuberculosis in those cases in which the patient has had a pneumonia at the apex some weeks before entering the hospital, of which the physician gets no history. If the disease is pneumonia, rapid improvement would probably be seen in the lungs at successive X-ray examinations made at intervals of a few days or a week, whereas a tuberculous process would not be likely to show this rapid gain. The X-ray examination may also assist by pointing out the position of the pulmonary density.

The above cases show that more than one X-ray examination is necessary to determine the diagnosis in many cases, and also indicate how we may discriminate between an enlarged and a displaced heart, which is an important question, and will be discussed in the chapter on the Heart.

Pneumonia with "La Grippe."—I have found, by means of an X-ray examination, appearances in the lungs of some of my patients who had influenza, that led me to suppose they also had pneumonia, although no signs of pneumonia could be found by auscultation and percussion. Later, however, the diagnosis suggested by the X-ray examination was confirmed by the physical signs or the progress of the disease. In other words, some cases of influenza are accompanied by a pneumonia

which is not sufficiently marked at first (in certain of them not at any stage) to be determined by the usual physical signs, and there may be no leucocytosis. X-ray examinations have shown me the necessity of keeping patients in bed whom I should otherwise have allowed to get up, and of detaining them in the house longer than would have seemed requisite if this condition of the lungs had not been recognized.

Severe Cold. — Individuals with apparently a severe cold, only, may sometimes show dark areas in the lungs, indicating, perhaps, a slight pneumonia, which should warn the physician to see to it that this patient carefully avoids further exposure for some days at least.

Empyema overlooked. — All physicians of experience know that an empyema after pneumonia may be overlooked, but the failure to recognize this condition could hardly occur were X-ray examinations made, as fluid in the pleural sac would cause a marked shadow on the screen, and the outline of the diaphragm would be obliterated.

Appendicitis confounded with Pneumonia. — It has happened that patients have been operated upon for appendicitis when no inflammation of the appendix existed. The symptoms simulating appendicitis afterward proved to be due to pneumonia. Should there be any uncertainty as to the presence of pneumonia in any such case, the doubt could be set at rest by an X-ray examination.

Absence of Pneumonia determined. — By means of the X-rays we can also absolutely determine the absence of pneumonia in the acute stage.

Broncho-Pneumonia. — In this form of pneumonia the area involved casts a well-marked shadow, as I have found by examination of the lungs during life with the fluorescent screen, and by examination of lungs taken from the body after death, both by screen and X-ray photograph. The following case is illustrative: —

Jas. W. W. November 5, 1896. Broncho-pneumonia following typhoid fever.

Autopsy. — In the lower lobes of both lungs and the upper lobe of the left lung there were extensive foci of consolidation around the bronchi. The consolidated areas were very red, varying in size from 1 to 2 centimetres in diameter. The surrounding lung tissue was intensely congested and œdematous. Anatomical diagnosis: broncho-pneumonia of both lungs, partly confluent.

The radiographs taken of these lungs showed a marked increase in density, and that the shadow cast by them was much greater than that cast by normal lungs.

CHAPTER VII

EMPHYSEMA OF THE LUNGS. BRONCHITIS

EMPHYSEMA OF THE LUNGS

Appearances seen on the Fluorescent Screen in Emphysema. — (See Fig. 122.) The pulmonary area is more extensive and brighter than in health, and reaches not only lower down but higher up in the chest. The diaphragm is lower down in the thorax, and its excursion is restricted, and is restricted in the upper part of its usual movement. It sometimes happens that the diaphragm is so low down during full inspiration that it has a peculiar outline, this outline being made up of two curves on each side, instead of one, and following the outline of some of the organs directly under it. But though in quiet breathing the diaphragm may be low down in the thorax, it may be brought much higher up in the chest during a forced expiration. This increased excursion may be caused by the upward pressure of the contents of the abdominal cavity, a pressure arising from the contraction of the abdominal walls. The cardiac outline, which it is difficult and frequently impossible to obtain by percussion in pulmonary emphysema, stands out with unusual clearness on the fluorescent screen, as do the other outlines, such as the ribs and clavicles. The heart changes its position far less than usual during deep inspiration; it is lower down in the thorax than in health, so much so that its pulsation may be felt over the ensiform cartilage, and its long axis is in a more vertical position. The lower position of the diaphragm gives the axis of the heart when viewed both from the front and side of the chest this vertical direction, and is one of the reasons why this organ, when looked at from side to side, is at a greater distance from the sternum in emphysema than in health. Frequently the right ventricle and the right auricle are seen to be enlarged, and the latter is more clearly seen, both because the lungs are brighter, and the auricle is larger than normal.

Methods of Examination. — The method of examining a case of emphysema, and of recording the observations made, are sufficiently indicated in the directions given for examinations of the chest in Chapters III, V, and X.

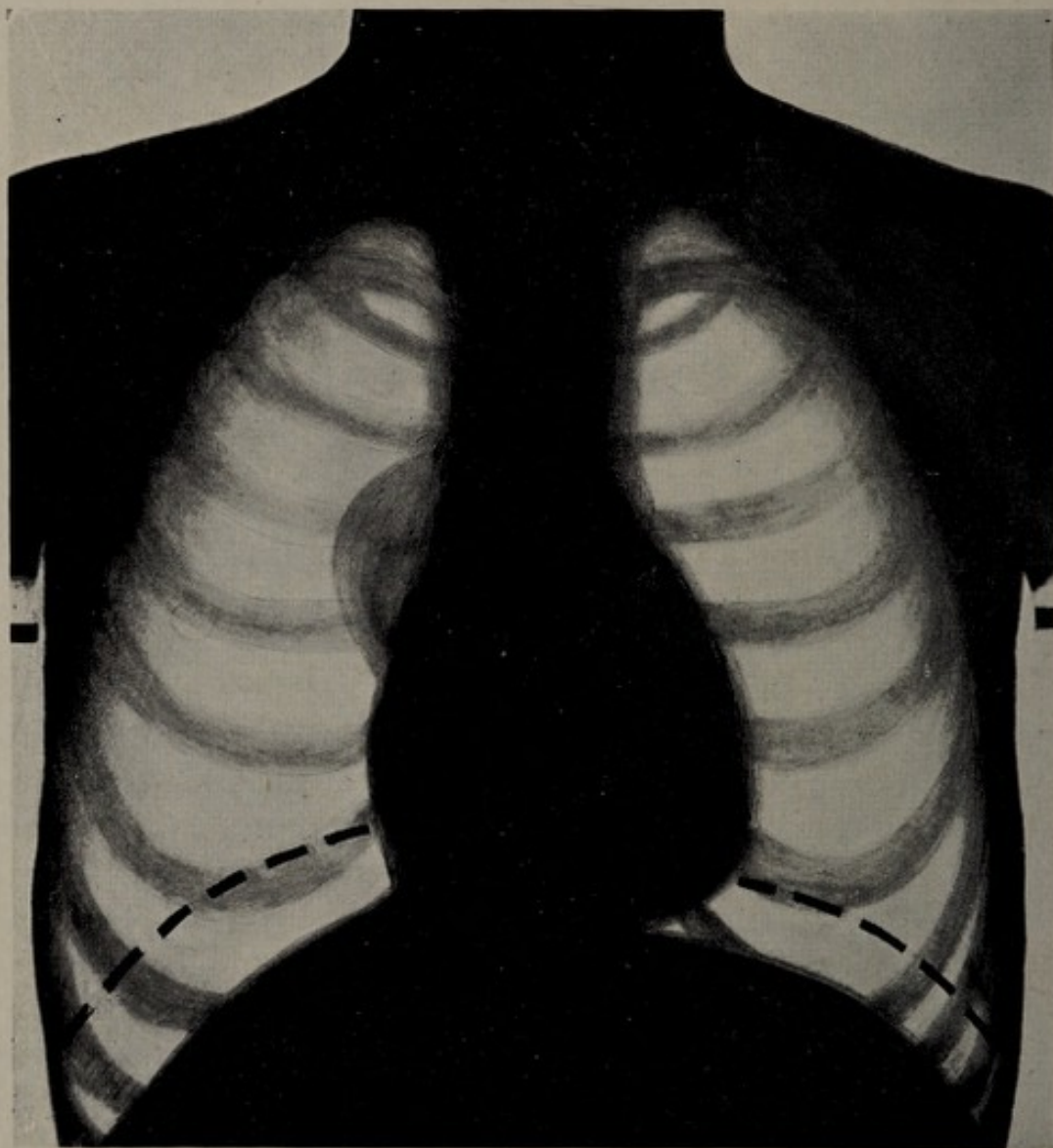


FIG. 122. Diagram of emphysema of both lungs in full inspiration. Broken lines show position of diaphragm in expiration. Nipple level indicated by heavy lines under axillæ.

Lungs brighter and long axis of heart more vertical than normal; excursion of diaphragm shorter than normal, and low down in the thorax.

In this disease the X-rays may be especially serviceable; they enable us, even, to make the diagnosis of emphysema without the aid of any of the usual physical signs, and to recognize it in some cases where it has been overlooked by these signs; further, they can assure us that no considerable amount of emphysema is present even when the physical

examination has indicated it. They likewise indicate to what extent the heart is enlarged.

The following cases are illustrative:—

CASE I. John S., 42 years old, entered my service at the Boston City Hospital April 6, 1898. He had pleurisy with effusion on the right side, the heart was somewhat displaced to the left; and he suffered very much from dyspnœa; why, I could not understand, since the amount of fluid did not seem to me sufficient to give rise to the dyspnœa.

An *X-ray examination with screen*, however, made this clear, for I found by this means that he had a very marked and extensive emphysema; the excursion of the diaphragm on the left side was low down, and had a maximum movement of 2 centimetres only.

CASE II. Frank B. Entered the Boston City Hospital in December, 1896. Service of one of my colleagues. He was thought to have emphysema and asthma.

My X-Ray Examination with Screen.—No signs of emphysema. Remarkably good excursion of the diaphragm: 6.25 centimetres on right side, and 7.5 centimetres on left side.

The following case is chosen, not only to illustrate the appearances seen in emphysema, but also because of other conditions present which give it additional interest:—

CASE III. Patrick W., forty-seven years of age, entered my service at the Boston City Hospital January, 1900, with a diagnosis of new growth in the lung. He gave a history of a severe cold which had begun five weeks previously, and which had prevented him from working for the past four weeks. He had had chills which obliged him to remain in bed for nine days; cough, dull pains in the right chest, slight dyspnœa.

Physical Examination.—Lungs: right lung does not move as much at extreme end of inspiration as does left; slight dulness throughout right back and in front above third rib; slight increase in tactile fremitus; increased whispered and spoken voice; no râles heard. Heart: right border 5.3 centimetres to right of median line, left border 9.5 centimetres to left of median line. Pulse: of good volume and tension; slight thickening of the radial arteries.

January 17. X-Ray Examination with Screen.—Lungs brighter than normal except for a darkened right apex, and all outlines clearer than normal. Diaphragm low down in the chest and its excursion limited on

the upper side. Long axis of the heart nearly vertical; right side enlarged; little or no difference in position of heart in inspiration and expiration.

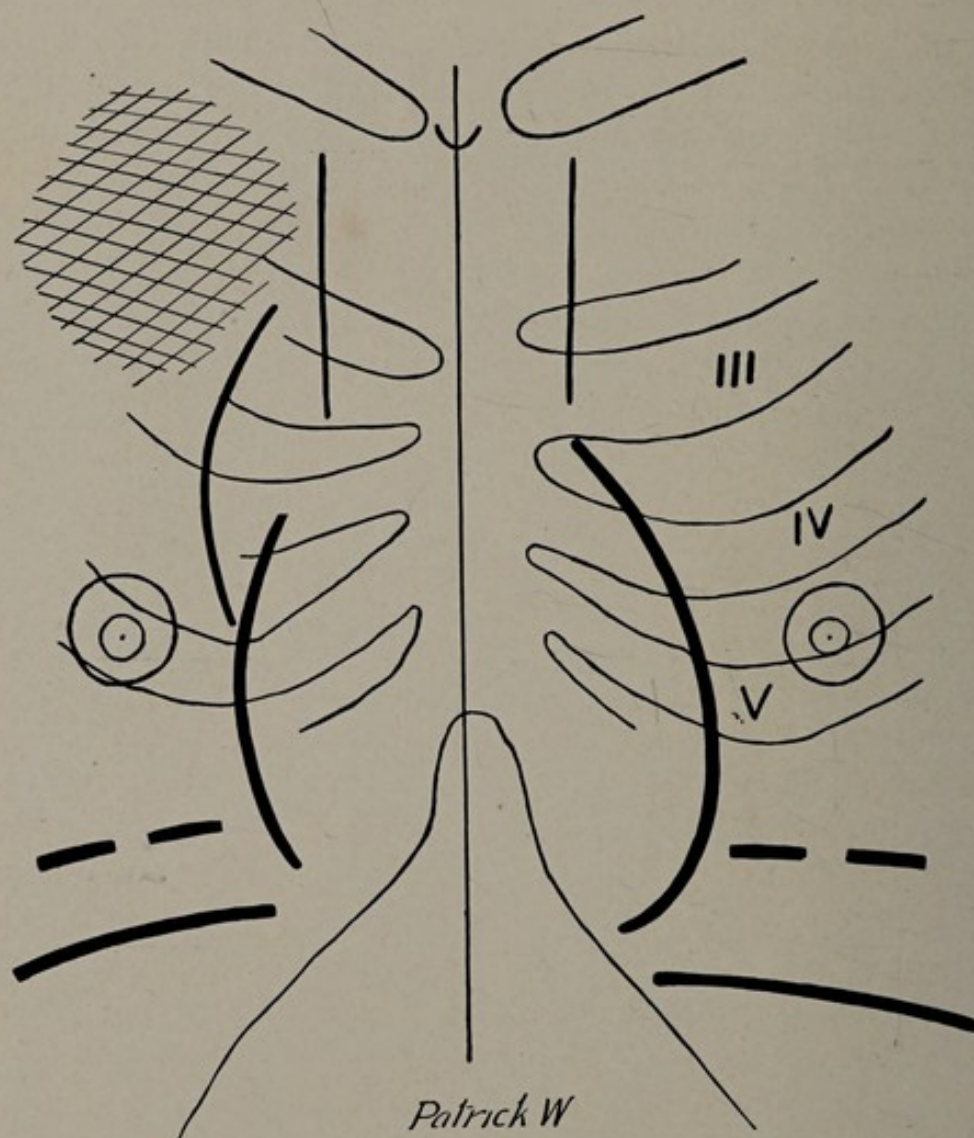


FIG. 123. Patrick W. January 17, 1900. Emphysema. First X-ray tracing. Lungs brighter than normal except for darkened right apex. Diaphragm low down in chest; excursion limited on upper side. Long axis of heart nearly vertical, right side enlarged; little or no difference in position of heart between inspiration and expiration. (One-third life size.)

January 30. Second X-Ray Examination with Screen (X-ray tracing not given). — Similar outlines to those seen January 17.

Eight examinations of the sputa made; no tubercle bacilli found.

Discharged February 6.

May 13, 1900. Third X-Ray Examination with Screen. — The patient came to me at my request for another examination. The apex of

the right lung was clear (see Fig. 124), so that it is not improbable that he had on entrance to the hospital the remains of an acute pneumonia at the right apex. It is not probable that it was tuberculosis, because he had improved in his general condition and the apex had cleared up in so short a time. The dotted lines indicate the point to which the diaphragm rose in forced expiration. This high point was probably

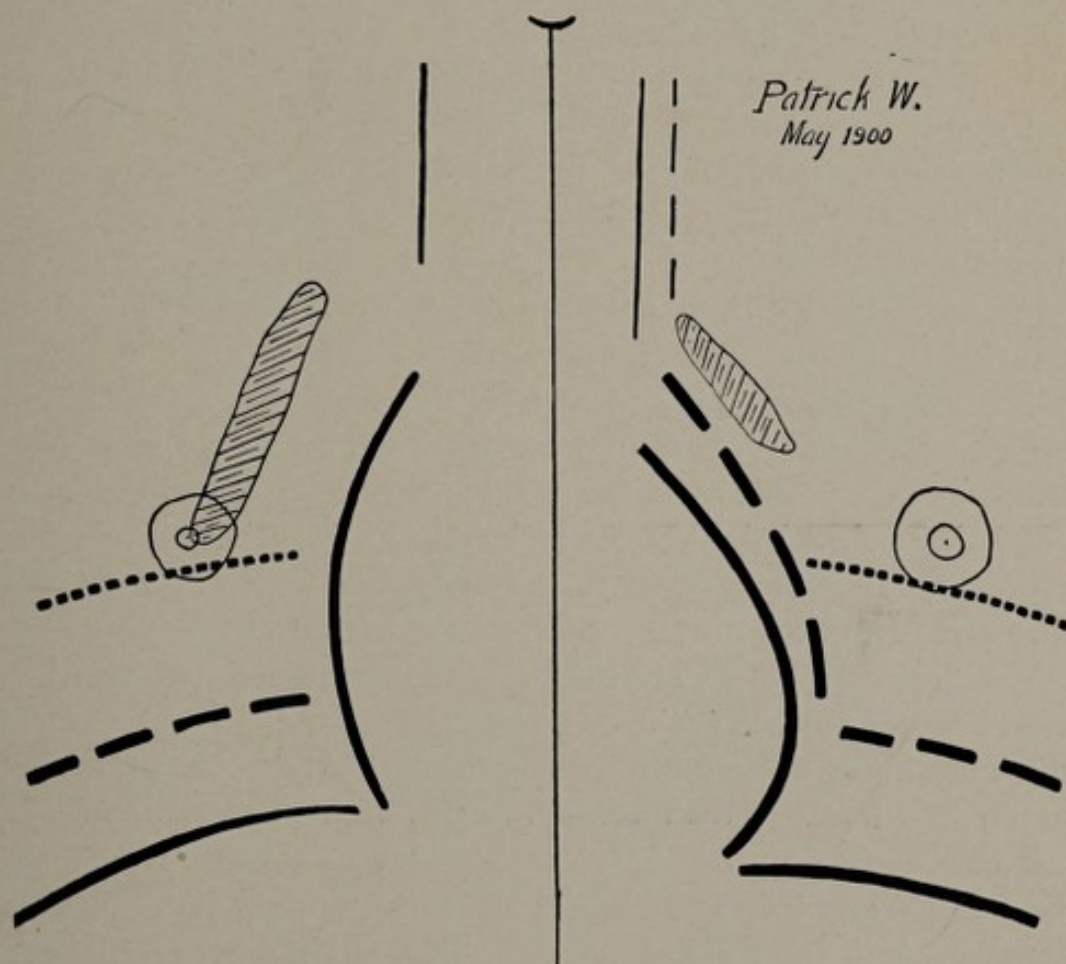


FIG. 124. Patrick W. May 13, 1900. Third X-ray tracing. Apex of right lung clear, showing that the shaded area was probably not due to tuberculosis but perhaps to remains of acute pneumonia. Broken and full parallel lines indicate position of diaphragm in expiration and inspiration respectively; dotted lines parallel to them, diaphragm line in forced expiration. (One-third life size.)

reached, as already suggested, because of the upward pressure of the contents of the abdominal cavity, brought about by contraction of the abdominal walls.

This explanation would indicate that in treating emphysema the abdominal muscles should be trained to assist in expiration.

A second X-ray examination should be made after a week or two if there is a question of the diagnosis, in order to be sure whether or not

the appearances seen are due to emphysema. For instance, in some cases of bronchitis the excursion of the diaphragm may be low down in the chest and much shorter than normal, as in emphysema, but the lungs would not be clear, and as they improved the excursion of the diaphragm would increase. If, then, bronchitis were associated with emphysema, the former disease would diminish the brightness of the lungs that obtains in the latter, and the emphysema, therefore, might be overlooked at the first examination and the abnormal excursion of the diaphragm attributed to the bronchitis only, but a second X-ray examination would correct the first if the bronchitis had meanwhile improved.

Emphysema a Hindrance to Percussion. — The following case illustrates the obstacle which may hinder the successful use of percussion in emphysema of the lungs: —

CASE IV. Henry B., a patient brought to me from the out-patient department by Dr. H. D. Arnold.

X-Ray Examination with Screen. — The heart was smaller than percussion had indicated; its anterior border could be plainly seen when the patient was examined with the light going through the chest from side to side, and also a clear bright area which separated the heart from the sternum (the patient was a small thin man); the outside of the chest was 5 centimetres from the anterior border of the heart when he was standing. The first three ribs were thickened where they joined the sternum, and Dr. Arnold found that over this part the percussion note changed, which shows how a variation in the thickness of the chest wall may alter the percussion note. This note had misled him in determining part of the cardiac outline.

A radiograph was also taken of this patient, which shows the appearances seen from the side. (See Fig. 125.)

Physical Signs of Tuberculosis hidden by Emphysema; Abnormal Condition of Lungs seen by X-Rays. — The same cause that makes it difficult or impossible to recognize the cardiac area in pulmonary emphysema by percussion affects the usefulness of this method where this disease is accompanied by a pulmonary tuberculosis, and not infrequently I have found dense pulmonary areas readily by an X-ray examination when they were not obtained by auscultation and percussion. Where emphysema and pulmonary tuberculosis occur together, the emphysema may conceal the physical signs of tuberculosis. (See pages 140 and 141.)

The X-rays then offer an additional means of examining the chest in cases of emphysema where tuberculosis is suspected, and they may

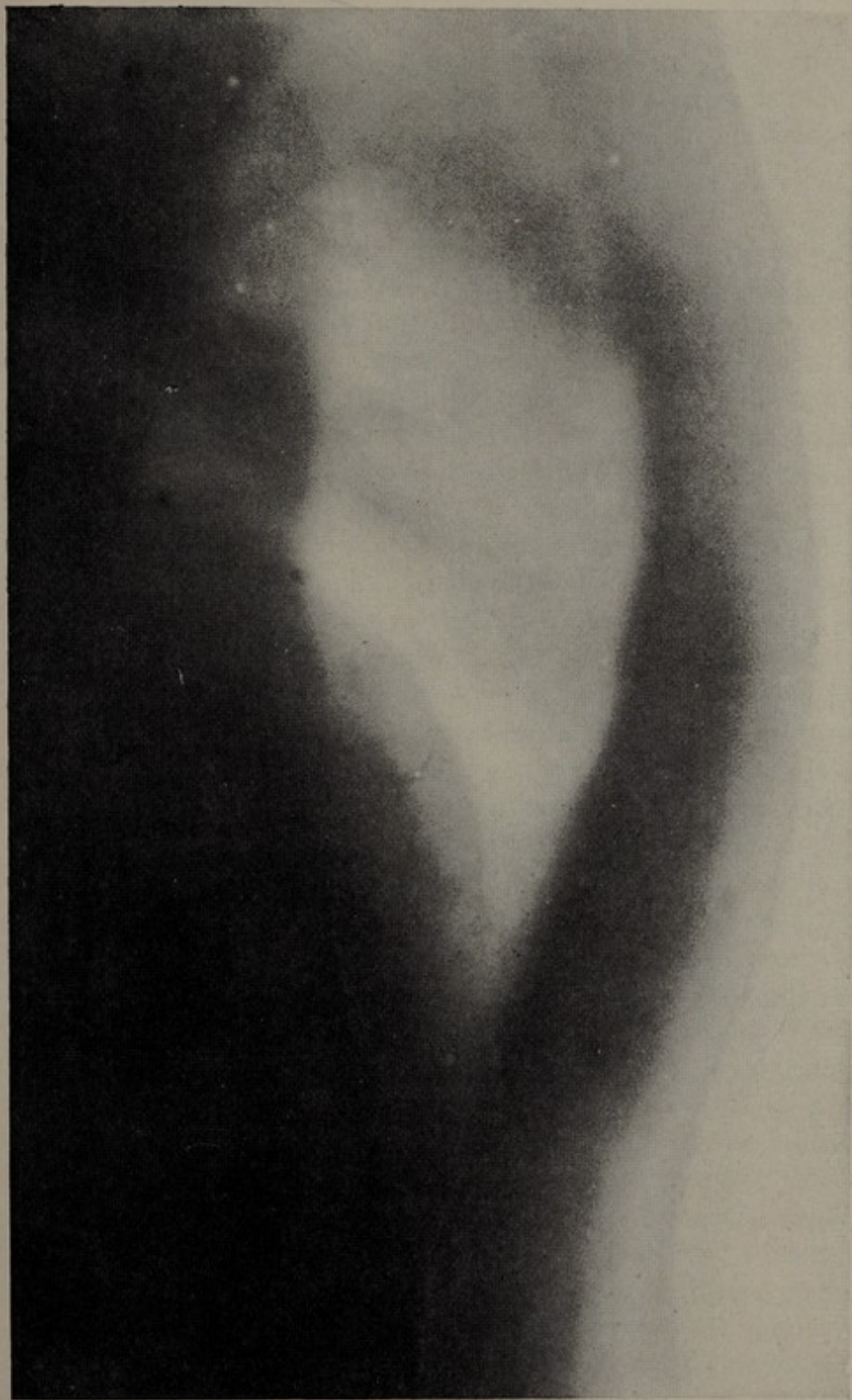


FIG. 125. Henry B. Patient with well-marked emphysema. Light area in radiograph, which was taken in quiet breathing, shows that the heart was at some distance from the chest wall. The patient was sitting up when the radiograph from which this half-tone was made was taken, and the tube was placed on a level with the heart and opposite the left side of the patient, so that the light went through the chest from one side to the other, but in front of the heart. The plate was placed against the side of the chest away from the light. Heart may also be pushed forward in emphysema. (See Appendix.)

show signs of consolidation where they had not been suspected; or they may show that the lungs are perfectly clear, although auscultation and percussion had given cause for suspicion of pulmonary tuberculosis.

BRONCHITIS

The number of cases of bronchitis which I have had an opportunity of examining is not large, about twenty-five in all. It has been difficult to get more than one examination in most of these cases, and I have, therefore, not been able to determine what changes take place in the appearances on the screen as the patients improve.

Appearances seen on the Fluorescent Screen in Bronchitis. — In some of these patients the whole chest was less clear than normal; that is to say, the ribs and outlines of the organs were less well marked than in health. In fifteen cases the excursion of the diaphragm was about normal; in nine it was more or less limited on both sides; and in the remaining case I have no record of its movement.

I have observed the effects of obstruction to the air passages on the screen in a few cases, and they seem to give a hint which may explain the appearances seen in some cases of bronchitis. When the air passages are obstructed by a foreign body in one bronchus the excursion of the diaphragm may be limited on that side and limited as in emphysema; that is, its excursion is rather low down in the chest. I have seen the same appearances where the bronchus was probably pressed upon on the left side by an aneurism, and another where a new growth obstructed the trachea; in this last case both lungs were distended to their fullest extent, and the diaphragm moved very little. (See pages 347-349.)

The following case is illustrative: —

Henry McC., nine years old, entered the hospital November 6, 1899. Service of Dr. John C. Munro. Three weeks before, while eating a small walnut, he swallowed a portion of the shell, which lodged apparently in the right bronchus. He soon developed pneumonia, which lasted ten days. At entrance to the hospital there were no subjective symptoms except that every morning he coughed, and raised considerable matter on getting up. A physical examination on the right side showed general dulness and diminished respiration.

November 7. X-Ray Examination. — I examined this patient with the fluorescent screen, and saw no signs of consolidation of the right lung except over a small narrow area between the third and fourth interspace, extending downward and to the right from the median line.

The excursion of the diaphragm was much shorter on this side than on the left. (See Fig. 126.)

November 24. Dr. John C. Munro did tracheotomy and withdrew the piece of nutshell, and on December 2 the patient was discharged.

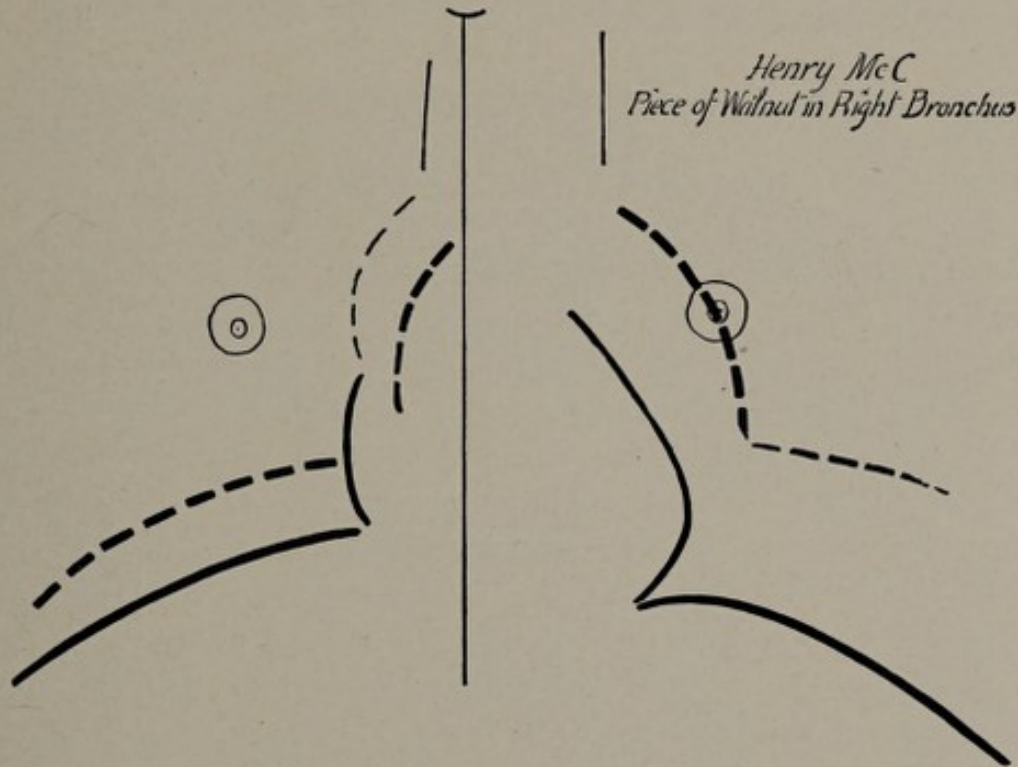


FIG. 126. Henry McC. November 7, 1899. X-ray examination with screen before removal of walnut shell; excursion of diaphragm shortened on right side.

I sent for this boy after his discharge from the hospital, and made another X-ray examination of the chest. This examination showed a good excursion of the diaphragm on the right side, the same length as on the left.

In bronchitis, especially of an acute or sub-acute form, or a bronchitis following measles, the shortened excursion of the diaphragm, and the restriction of its movement to the lower part of the chest, may be due to the obstruction of the smaller air passages; and the somewhat shaded pulmonary area to a marked pulmonary congestion, and the increased secretion obtaining in bronchitis. It follows, therefore, that in making a diagnosis where such acute conditions are present, we should try the effect of coughing on the movement of the diaphragm, for if, after the passages have been relieved of mucus, the excursion increases, the indications are in favor of a bronchitis instead of an emphysema, but we may not be able to establish the diagnosis until after two or three X-ray examinations have been made with an interval between them.

CHAPTER VIII

PLEURISY WITH EFFUSION. EMPYEMA

Appearances seen on the Fluorescent Screen in Pleurisy with Effusion.—I will begin this chapter by quoting a few lines from an article I published October 1, 1896,¹ as it is interesting to see how much could be seen even in the early days of the X-rays:—

“In pleurisy with effusion the outline of the diaphragm in the fluoroscope is less defined, or obliterated altogether, according to the amount of fluid present, as are also some of the ribs in the upper portion of the affected side; the lung is also denser, being compressed by the fluid, if there is much effusion. I observed in one case that the line separating the fluid surrounding the lower part of the lung from the compressed upper portion ran from about the junction of the sixth rib with the sternum toward the outer end of the clavicle.”

While this line is in no sense sharply defined, it is often more definite when the patient is examined in a sitting position than when lying down. A very marked displacement of the heart, when there is any considerable amount of fluid present, is another striking feature to be seen on the fluorescent screen in pleurisy, the displacement, as a rule, given the same amount of fluid, being greater when the fluid is on the left side of the chest and the heart is displaced to the right, than when the fluid is on the right side of the chest and the heart is displaced to the left. Further, the triangle below and behind the heart, described on page 258, is seen to be wholly or largely obliterated according to the amount of effusion present. The following cuts, made from diagrams, show the picture seen on the fluorescent screen: first, in pleurisy with a small effusion of the right side (Fig. 127); and second, in pleurisy with a large effusion of the same side (Fig. 128).

¹ “A Method for more fully determining the Outline of the Heart by Means of the Fluoroscope, together with Other Uses of this Instrument in Medicine.” *Boston Medical and Surgical Journal*, October 1, 1896.

It will be noted in Fig. 127 that the diaphragm line could not be seen on the affected side, and the lower part of the chest was dark on this side.

Figure 128 shows the affected side dark throughout. No diaphragm or ribs visible. The heart is much displaced to the left; the diaphragm

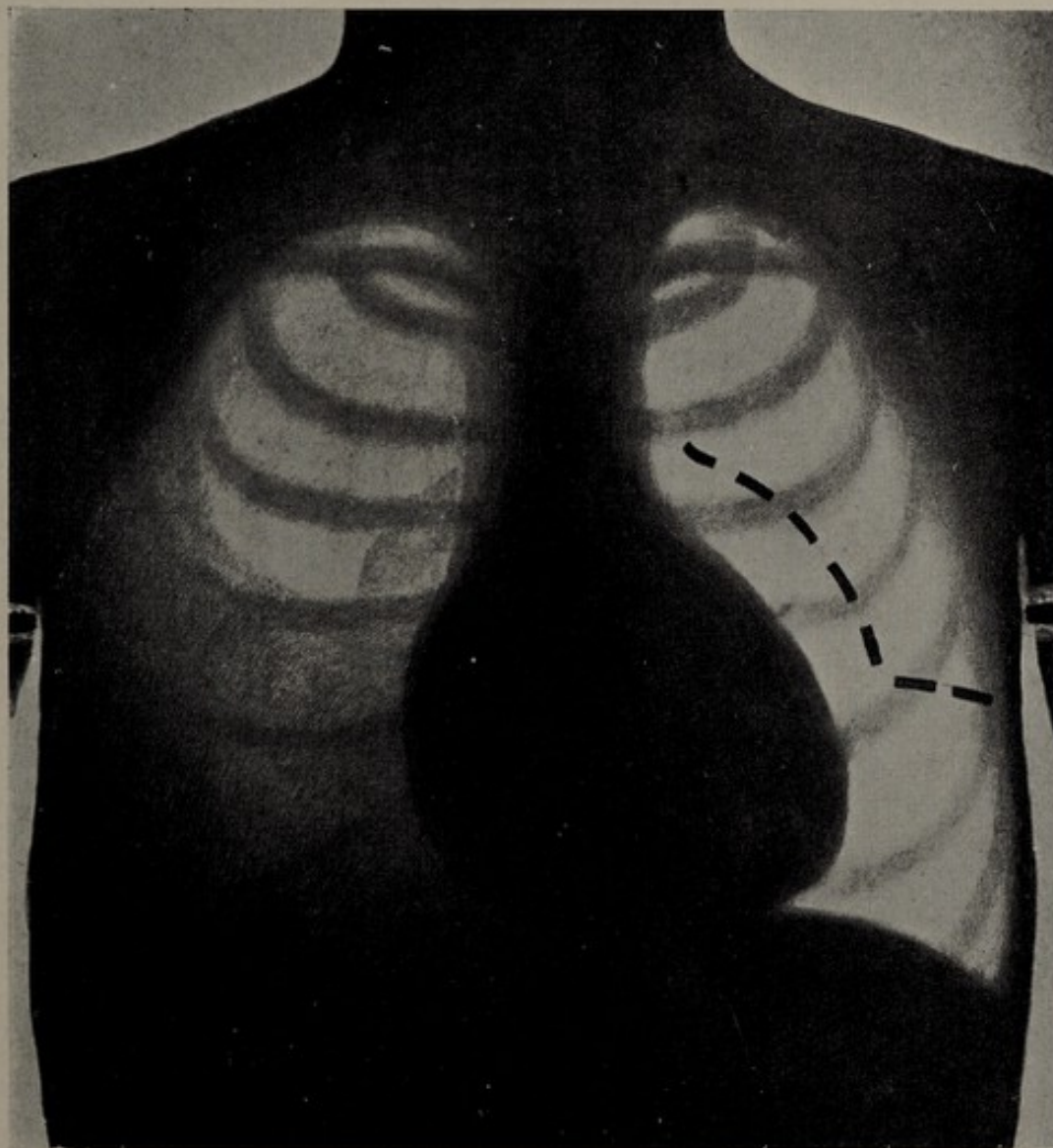


FIG. 127. Diagram of pleurisy, with small effusion; inspiration.

Lower portion of right lung darkened by the effusion and diaphragm lines obliterated on this side. Broken lines on left side show position of heart and diaphragm in expiration.

pushed down on that side and its excursion diminished. After the X-ray examination with the screen was made in this case, I drew off 126 ounces of fluid. The heart then returned to a more normal position, and the excursion of the diaphragm on the left side increased and this

muscle went higher up in the chest. The fluid had pressed the heart to the left, and the left half of the diaphragm had been crowded or pulled down, and interfered with the action of the left lung.




FIG. 128. Diagram of pleurisy, with large effusion; inspiration. Broken lines show position of diaphragm in expiration.

Right side darkened throughout by presence of fluid. Heart pressed to left by fluid and action of left lung interfered with. After four litres had been drawn from the right side, the excursion of the diaphragm on the left side became much greater and was higher in the thorax.

A downward displacement of the liver may, of course, take place with a large effusion, but an X-ray examination would not be necessary to detect this.

When the fluid partially fills the pleural sac but does not extend to the upper part of the chest, we may still expect to find the apex of the

lung, on the diseased side, somewhat darker than that on the normal side, owing to the fact that the first lung is compressed, and is thus a little denser than that on the well side.

The appearances in empyema would be similar to those seen in some cases of pleurisy with effusion. This point is illustrated by the following experiment made in 1896. I placed under the fluorescent screen a vulcanite cup full of pus, and beside it another full of serous fluid, and found there was no difference between the respective shadows cast on the screen. (See Chapter I, page 6.)

If we examine the chest with the fluorescent screen, we can never fail to recognize an abnormal condition of the thorax if a pleuritic effusion or an empyema be present.

Methods of Examination. — In making X-ray examinations of a patient suffering from pleurisy with effusion, the outline of the dark area as well as the other outlines in the thorax may be seen to change in most cases when the patient changes his position. Therefore the patient should be examined when he is lying on his back and when he is sitting up, and the outlines thus seen be traced and compared. (See Appendix.) He should also be examined both when lying on his right side and on his left side, the tube being on a level with his thorax, and the light going through the chest horizontally when it is desired to distinguish, as far as may be, between a possible fluid in the chest and other conditions, such as a dense lung. The position of the heart and parts above it should be noted, and the obliteration of the lines of the diaphragm, or the movement of this muscle, if any part of it can be seen.

Comparison of Fluorescent Screen and X-Ray Photograph. — The screen is better than the photograph for examining cases of pleurisy.

The appearances seen on the fluorescent screen in pleurisy with effusion are still further illustrated by the following notes of cases, and by the accompanying figures made from the tracings which I first drew on the skin of the patient, reduced one-half and transferred to the blanks described on pages 79–80. The cuts are reduced still further, so that they are about one-third life size.

CASE I. Patrick McM., twenty-one years of age, entered the Boston City Hospital August 29, 1896. Service of Dr. Sears.

Physical Examination. — Lungs : dulness in the right front from apex to fourth rib ; flatness at fifth intercostal space ; in axilla, dulness from level of fourth rib downward and in right back from one inch above spine of scapula, becoming flatness at angle of scapula ; respiration,

tactile fremitus, and voice sounds diminished from above downward. Heart: right border not determined; left border just inside nipple line; apex beat in fifth space; action regular; no murmurs.

Name *Patrick Mc M.* Age _____ Date *Aug. 1896*
 Address _____ Occupation _____ Vol. *114* Page *186.*
 Diagnosis _____

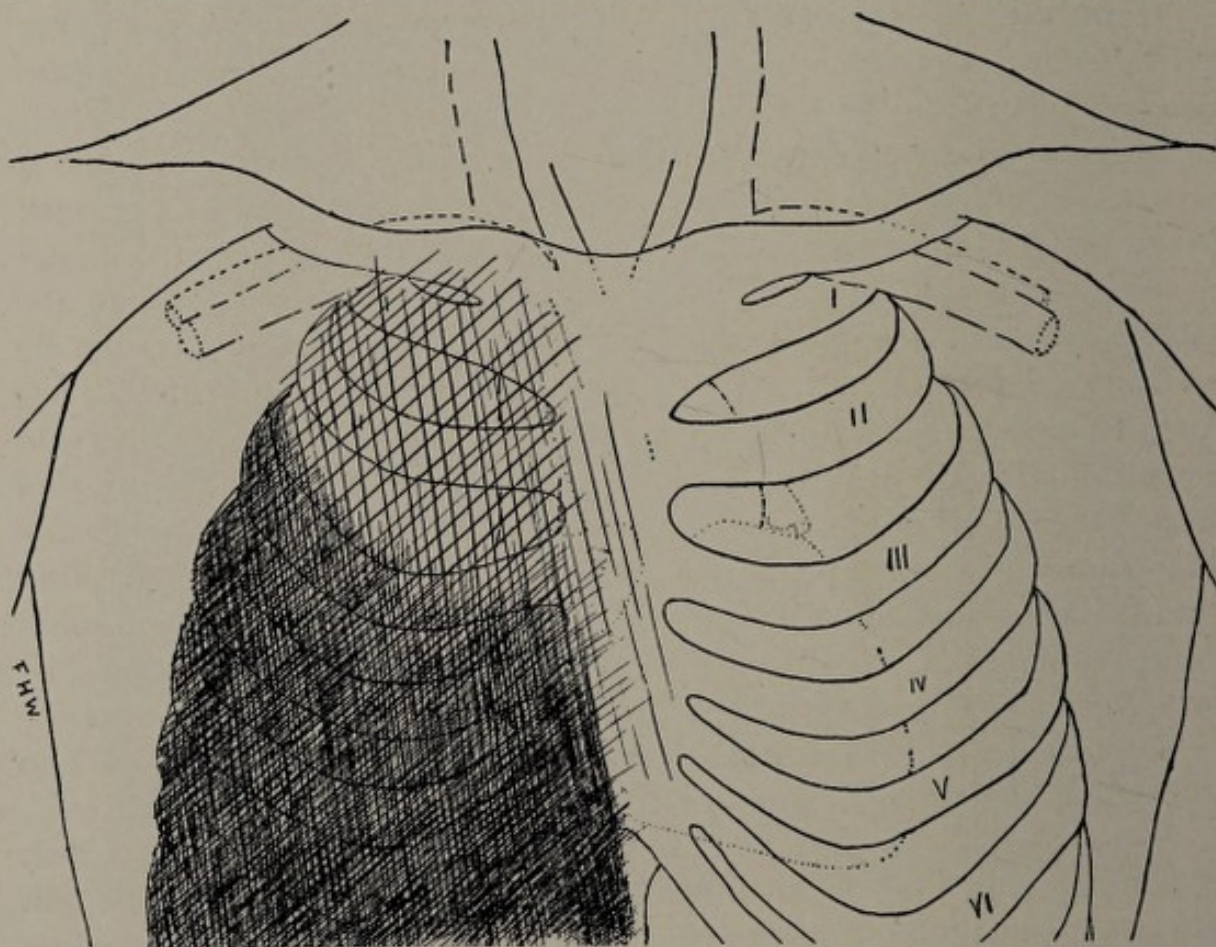


FIG. 129. Patrick McM. Pleurisy with effusion. X-ray examination with screen. Darkened area on right side; no ribs and no outline of diaphragm could be seen on this side. Heart displaced to left (not shown in cut, nor are the diaphragm lines on the left side). (Cut one-third life size.)

X-Ray Examination with Screen. — I found the contrast between the two sides of the chest was very marked. On the right side, below the third rib, there was no light, or only as much as comes through the liver ordinarily, and this much-darkened area extended to the level of the upper border of the third rib; even above this point there was less light than on the opposite side. No ribs and no outline or movement of the dia-

phragm could be seen on the right side. (See Fig. 129, Patrick McM.) The heart was displaced to the left.

September 6. Twenty-five ounces of fluid were withdrawn from the patient's chest.

At a second *X-ray examination* the upper half of the chest was found to be much clearer than at the previous one, though not as clear as on the opposite side. The ribs could be seen on both sides, but the outline of the diaphragm was only faintly visible on the right side. The heart was still somewhat displaced to the left.

CASE II. Mary E. H., thirteen years old, entered the hospital August 29, 1896. A patient of Dr. John L. Ames. Diagnosis: acute miliary tuberculosis and meningitis.

It was a question whether or not fluid was present in this patient's chest. Thoracentesis had been performed by Dr. Ames, but no fluid was obtained.

Physical Examination. — Lungs: dulness in right front from clavicle, becoming flatness at fourth rib; in axillary space, dulness throughout, becoming flatness at level of fourth rib. In the back, on right side, dulness from spine of scapula, becoming flatness one inch above angle of scapula. Tactile fremitus diminished over dull area, absent over flat area. Bronchial respiration over lower half of chest; in the upper half respiration exaggerated. Respiration also exaggerated in the left lung. Heart: right border not determined; left border 9.25 centimetres to the left of the median line; apex in fifth space.

September 3. Twenty-five ounces of clear serous fluid withdrawn.

September 4. Physical Examination. — In right front, dulness from fourth rib, and from same level in axilla; in right back, from just below angle of scapula; respiration heard to base; voice sounds and tactile fremitus absent. From third to fourth rib in front, bronchial respiration, with râles.

September 4. My X-Ray Examination with Screen. — As indicated in the cut (Fig. 130), the right side of the chest was divided into a dark and a light area, the line between these two running from the point where the cartilage of the sixth rib joins the sternum in a direction upward and outward towards the lower end of the right clavicle. Above this line the pulmonary area was darker than the corresponding area of the left lung, but much lighter than the area below it on the right side. Later, the chest was again tapped and fluid withdrawn.

It will be noticed that in Figs. 129, 130, the shadow against

the thoracic wall is darker and higher up than that near the sternum. One reason, certainly, for this fact is the following: The fluid naturally rises between the costal and pulmonary pleuræ, and therefore if the screen were on the front of the chest, with the tube

Name *Mary E. H.* Age _____ Date *Aug. 1896*
 Address _____ Occupation _____ Vol. *114* Page *184*
 Diagnosis _____

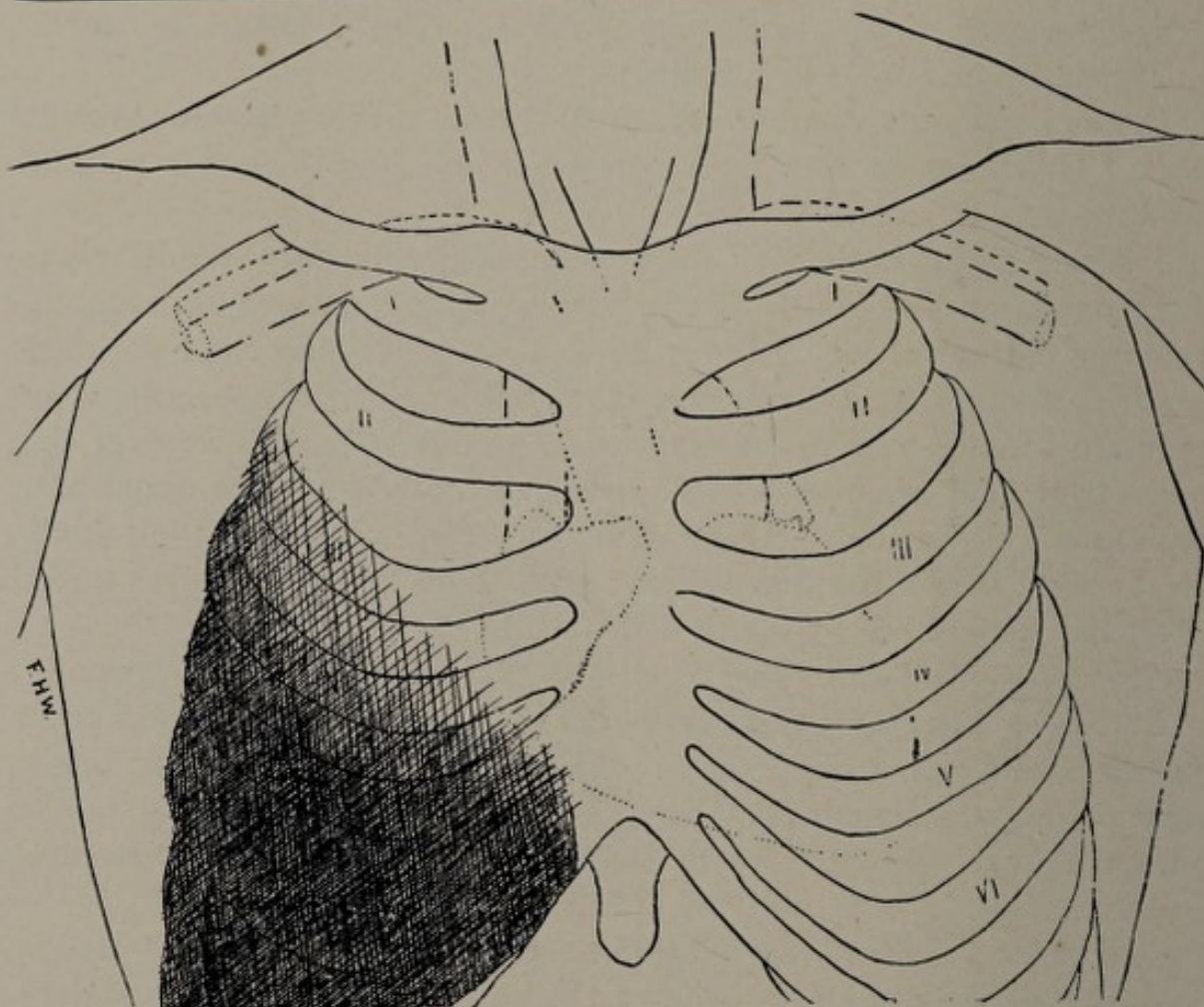


FIG. 130. Mary E. H. Pleurisy with effusion. X-ray examination with screen September 4th. Darkened area on right side, running from junction of cartilage with sixth rib to outer end of right clavicle. (Cut one-third life size.)

behind the patient, the rays falling near the costal wall of the thorax must pass through a layer of fluid that is as thick as the chest is deep, whereas in the neighborhood of the sternum the rays traverse a layer of fluid at the back and front of the chest, respectively, which is sepa-

rated by the transparent lung, and therefore not so much obstruction is offered to the rays in the latter case as in the former. Likewise the shadow is very dark below the lung, as there also the rays are obstructed by an unbroken layer of fluid. The upper line of the darkest part of the shadow reaching from the outer wall of the thorax to the sternum, therefore, is curved, unless the whole side of the thorax is perfectly dark as in Fig. 128.

CASE III. Thomas R., thirty-eight years old, entered my service at the hospital March 9, 1897. Diagnosis: pleurisy with effusion.

History. — Malaria eighteen months before. Hard drinker.

Present Illness. — Pain in left side for fourteen days, worse on breathing; cough, with yellow sputum; headache; cannot lie on left side; unable to sleep on account of pain.

Physical Examination. — Good resonance and respiration over right lung. Left lung: in front breathing somewhat exaggerated over left upper chest; slight hyper-resonance; breathing diminished; marked friction rub. Beginning at third rib, dullness, becoming flatness at fifth rib, and extending into axilla. Over this area breathing very faint, almost absent. Vocal and tactile fremitus much diminished. In left back, percussion over upper third lacking, with increased tactile fremitus and diminished breathing; dullness beginning two centimetres below angle of scapula, flatness from angle of scapula to base. Over this area breathing much diminished, with diminished vocal and tactile fremitus.

March 12. *X-Ray Examination with Screen.* — First and second ribs seen faintly. The whole of the left chest dark. Heart displaced to the right (Fig. 131).

March 17. Ten ounces of fluid withdrawn. Needle inserted in the back, below angle of scapula.

March 29. Sixteen ounces of fluid withdrawn.

April 26. *Physical Examination.* — Dullness in left back from angle of scapula to base, also in left axilla; dullness in front from fifth rib to base. Breathing somewhat diminished; voice sounds distant; diminished tactile fremitus.

April 26. *Third X-Ray Examination with Screen.* — Right side perfectly clear. On the left side the first, second, third, and fourth ribs seen; no outline of the left border of the heart. Heart still displaced to the right (Fig. 132).

May 11. Discharged.

Patient again entered the hospital May 31, 1897.

Physical Examination.—Heart: area, action, and sounds normal. Lungs: in front dulness in left chest and axilla below level of fifth rib,

| | | | | | |
|-----------|-----------|------------|--|------|--------------|
| Name | Thomas R. | Age | | Date | March 12. |
| Address | | Occupation | | Vol. | 419 Page 162 |
| Diagnosis | | | | | |

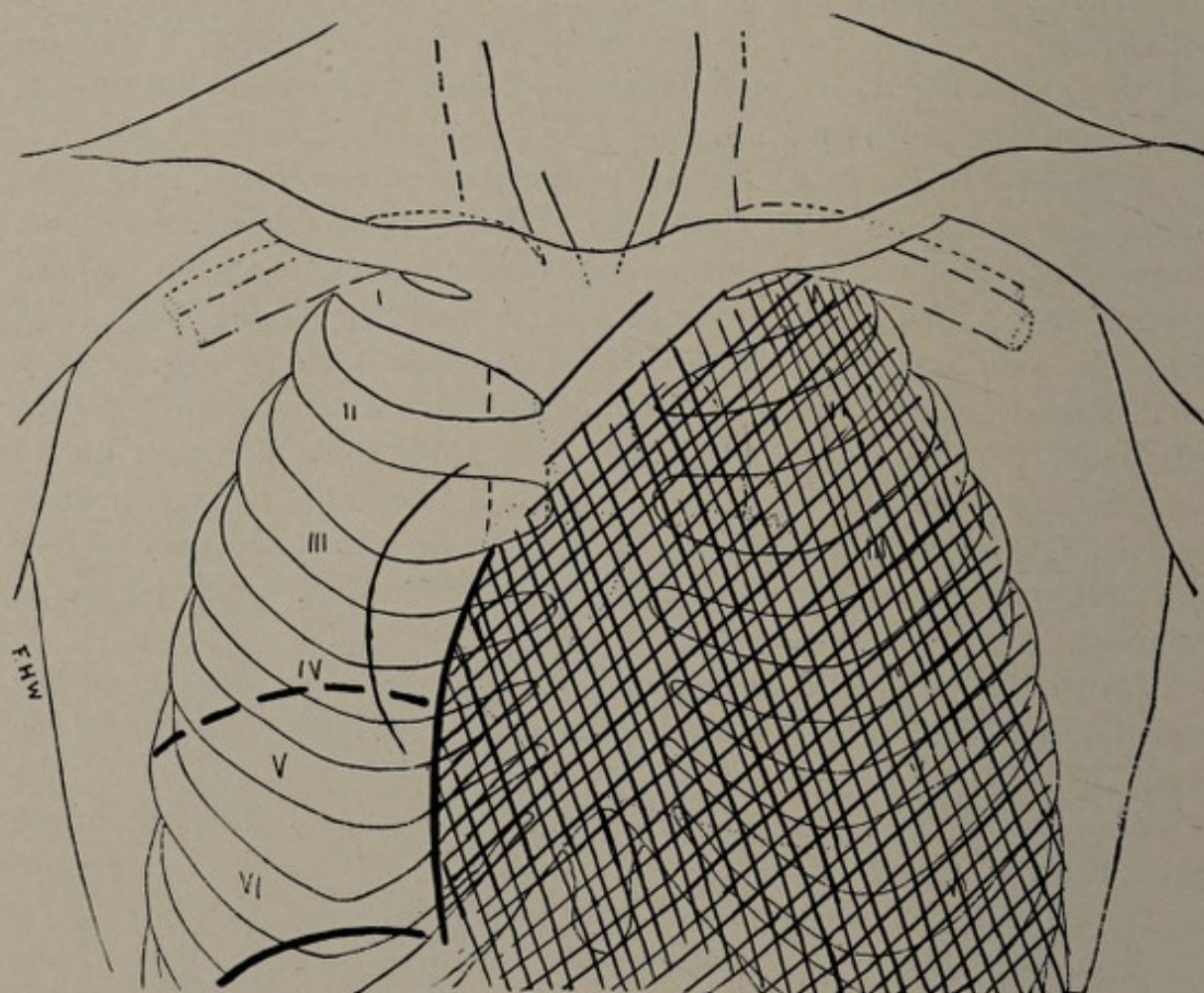


FIG. 131. Thomas R. March 12, 1897. Pleurisy with effusion. First X-ray examination with screen. Whole of left chest dark; first and second ribs seen faintly; heart displaced to right. (Cut one-third life size.)

with diminished breathing and voice sounds; tactile fremitus much diminished; in the left back the same signs, most marked from below angle of scapula to base; at base, flatness by percussion; respiratory murmur absent.

June 5. *X-Ray Examination with Screen.* — On the left side the ribs could be seen from the first to the fourth rib, though less clearly than on

Name *Thomas R.* Age _____ Date *April 26*
 Address _____ Occupation _____ Vol. _____ Page _____
 Diagnosis _____

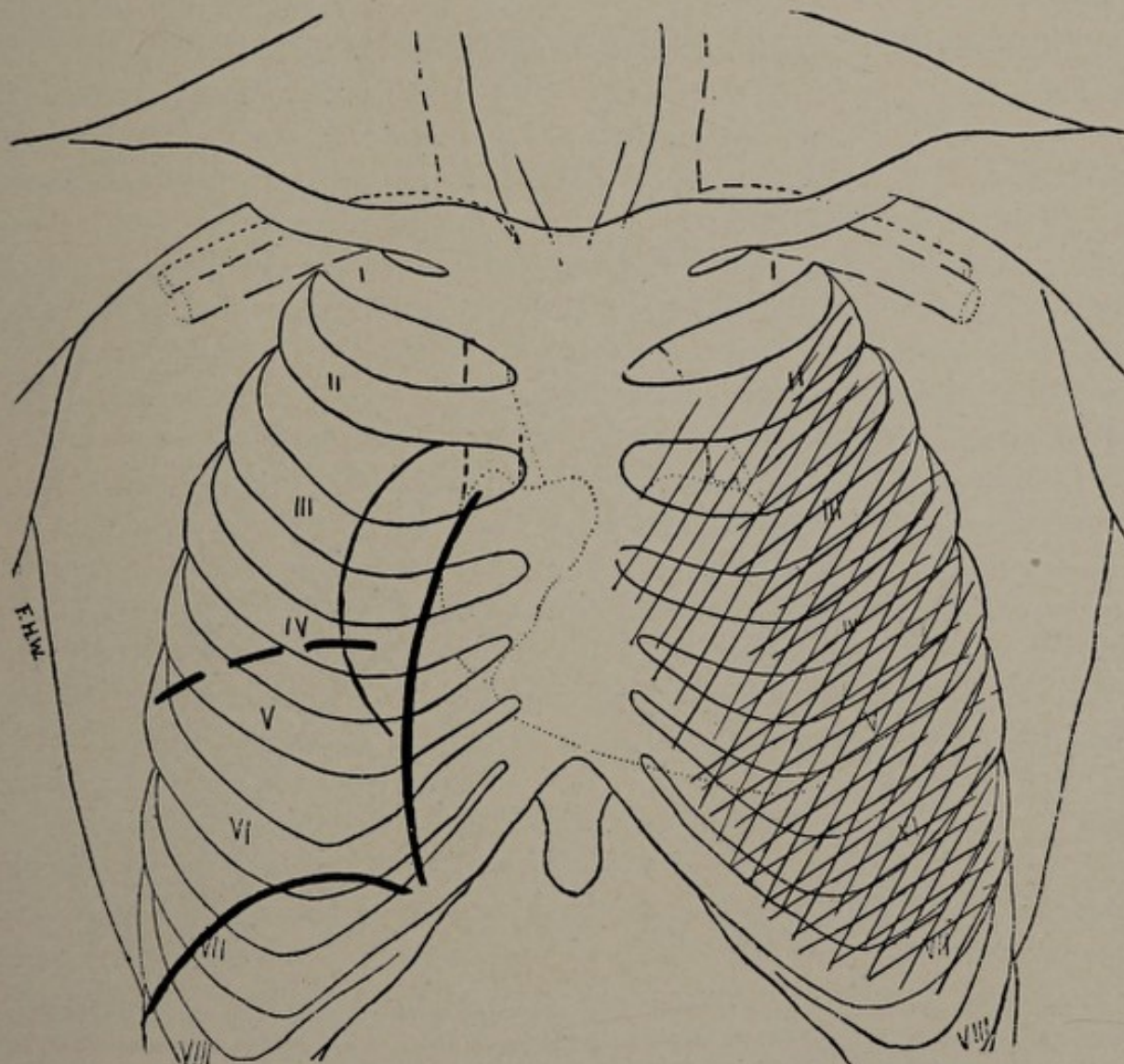


FIG. 132. Thomas R. April 26. Third X-ray examination with screen. Right side perfectly clear; first, second, and third ribs seen on left side; no outline of left border of heart visible; heart still displaced to right. (Cut one-third life size.)

the right side. A portion of the left border of the heart could be made out. No diaphragm lines were seen on the left side, even in full inspiration. The upper portion of the fluid, though of course not well defined,

was rather more so while the patient was sitting up than while lying down. (See Fig. 133.)

June 8. The physical signs were the same as on May 31.

Name *Thomas R.* Age _____ Date *June 5th*
 Address _____ Occupation _____ Vol. _____ Page _____
 Diagnosis _____

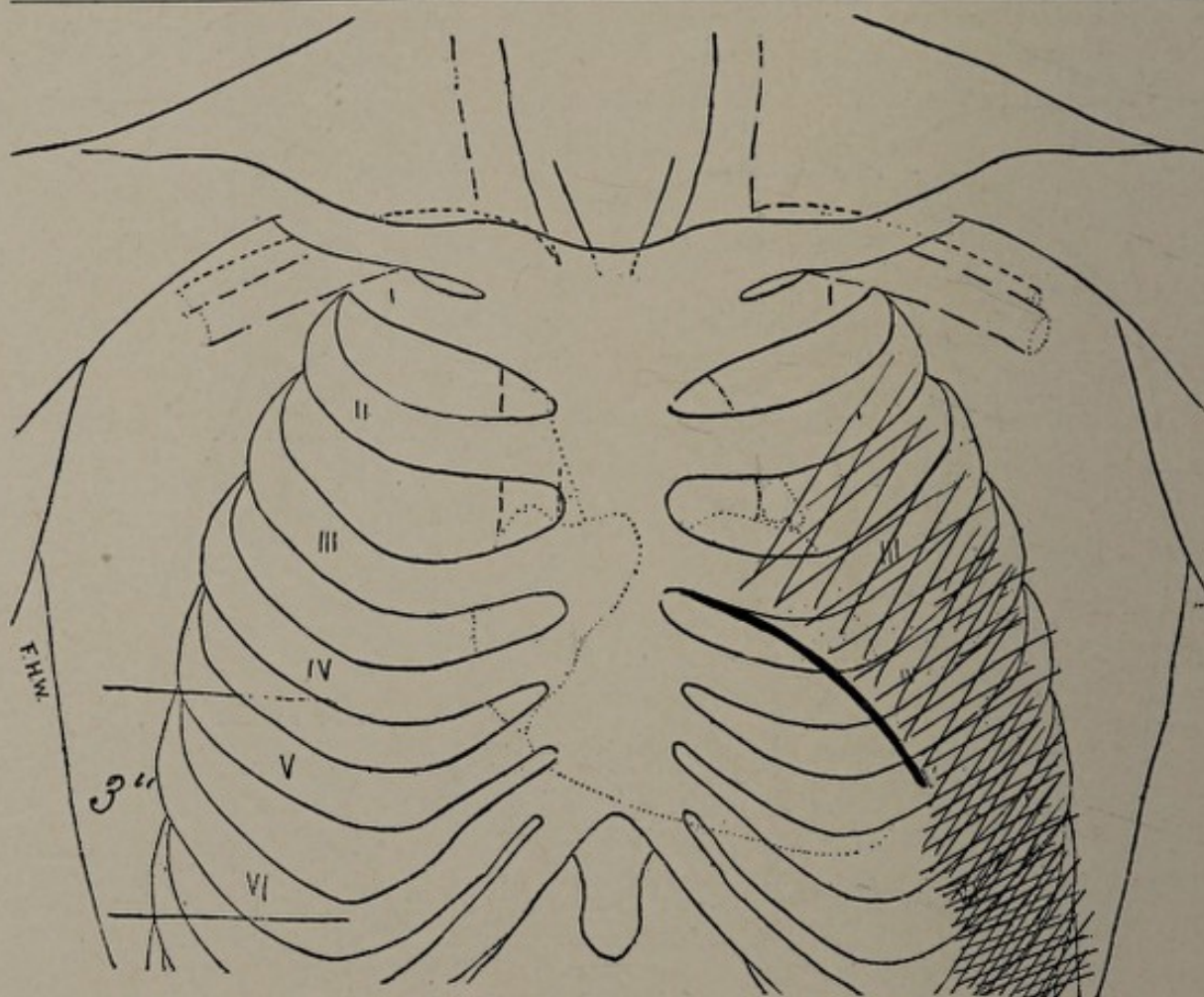


FIG. 133. Thomas R. June 5. Fifth X-ray examination with screen. Left side, ribs seen from first to fourth rib, though less clearly than on right side. Portion of left border of heart visible; no diaphragm lines seen on left side, even in full inspiration. Excursion of diaphragm on right side. 7.5 centimetres (3 inches). (Cut one-third life size.)

Five *X-ray examinations* of this patient were made, as follows: March 12, April 7, April 26, May 10, June 5.

The records of those made on March 12, April 26, and June 5, only, are given in the accompanying cuts.

These three cases, Patrick McM., Mary E. H., and Thomas R. show that the level of the fluid in pleurisy is not horizontal, as we shall see later that it is in pneumohydrothorax; that the heart is displaced, and that one border may be easily seen. The last case also indicates the way in which the appearances seen in the chest change as the fluid is absorbed.

The X-ray examination may be of assistance in making the diagnosis, and in directing the physician where to insert the needle when the chest is to be tapped.

Untrustworthiness of Percussion in determining the Presence of Fluid by Means of a Displaced Heart. — The displacement of the heart, caused by fluid in the chest, as shown by the tracing (see Fig. 134), may be very marked and still not be detected at all by percussion, or if detected, its extent may not be accurately estimated. The displacement of the heart to the right is often less readily recognized by this means than that to the left. It is obvious, therefore, that failure by this method to recognize the presence of fluid by means of a displaced heart in those cases in which the physical signs do not point clearly to a pleuritic effusion, and the physician has called percussion to his aid, does not justify him in assuming that no displacement and fluid are present. The X-ray examination is the more trustworthy test of a displaced heart in pleurisy with effusion than percussion. The following cases illustrate this point. The first tracing shows how marked the discrepancy may sometimes be between the border of the heart, as determined by percussion, and its actual border, as seen by an X-ray examination, and that the X-rays give more direct and definite signs of fluid in the chest than auscultation and percussion in some patients.

CASE I. Constantine D., twenty-four years of age, entered my service at the Boston City Hospital January 20, 1899.

History. — In bed for four weeks with malaria; cough, with considerable expectoration, and pain in the left side on deep inspiration; diarrhœa for one week; pulse regular and of fair strength; heart not displaced.

In the lungs, at the right apex, there was slight dulness and harsh breathing; numerous sonorous and sibilant râles in both chests, back and front; slight increase in tactile fremitus at the right apex.

January 22. Physical examination. — In the left back, just below spine of scapula, there was an area of the size of the palm of the hand where there was dulness and harsh breathing, with marked increase in voice sounds, but no increase in tactile fremitus.

January 23. Physical Examination.—In the left back, below the spine of scapula, there is still harsh breathing, with increase in voice sounds and absence of tactile fremitus.

An *X-ray examination with screen* on this same date showed that the left chest was dark throughout; also that the heart was displaced so

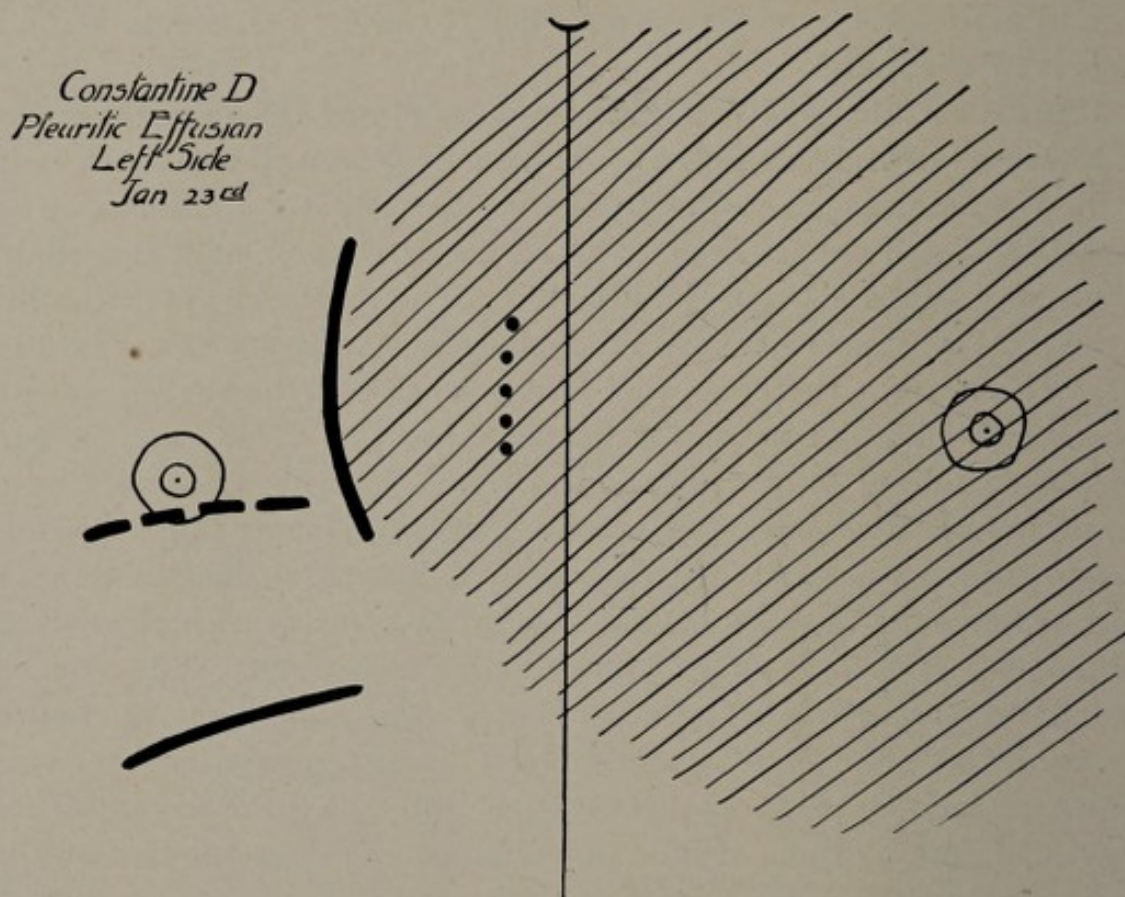


FIG. 134. Constantine D. January 23. Cut of X-ray tracing. Pleuritic effusion on left side; heart displaced to right. Dotted line indicates position of right border as determined by percussion; full curved line to the right of it, the position of the right side of the heart as determined by the fluorescent screen. The broken and full lines below the right nipple show the position of the right half of the diaphragm in expiration and full inspiration respectively. (Cut one-third life size.)

that its right border was nearly 7 centimetres to the right of the median line. This condition showed that there probably was fluid in the chest. (See Fig. 134.)

The full line indicates the right border of the heart as seen by X-ray examination, and the dotted line this border as found by percussion. This case is also given in the chapter on the Heart.

On January 25 I drew out 56 ounces of serous fluid from the left chest.

Later this patient developed pneumohydrothorax.

In the following case the X-rays show that the heart was pushed farther to the left than percussion indicated, and that the parts above the heart were also pushed to the left, and that their shadow had a strong slant in this direction instead of being vertical as in health:—

CASE I. James L., sixty-two years old, entered my service at the hospital February 9, 1899. Diagnosis: pleurisy with effusion.

History.—Shortness of breath for nine months.

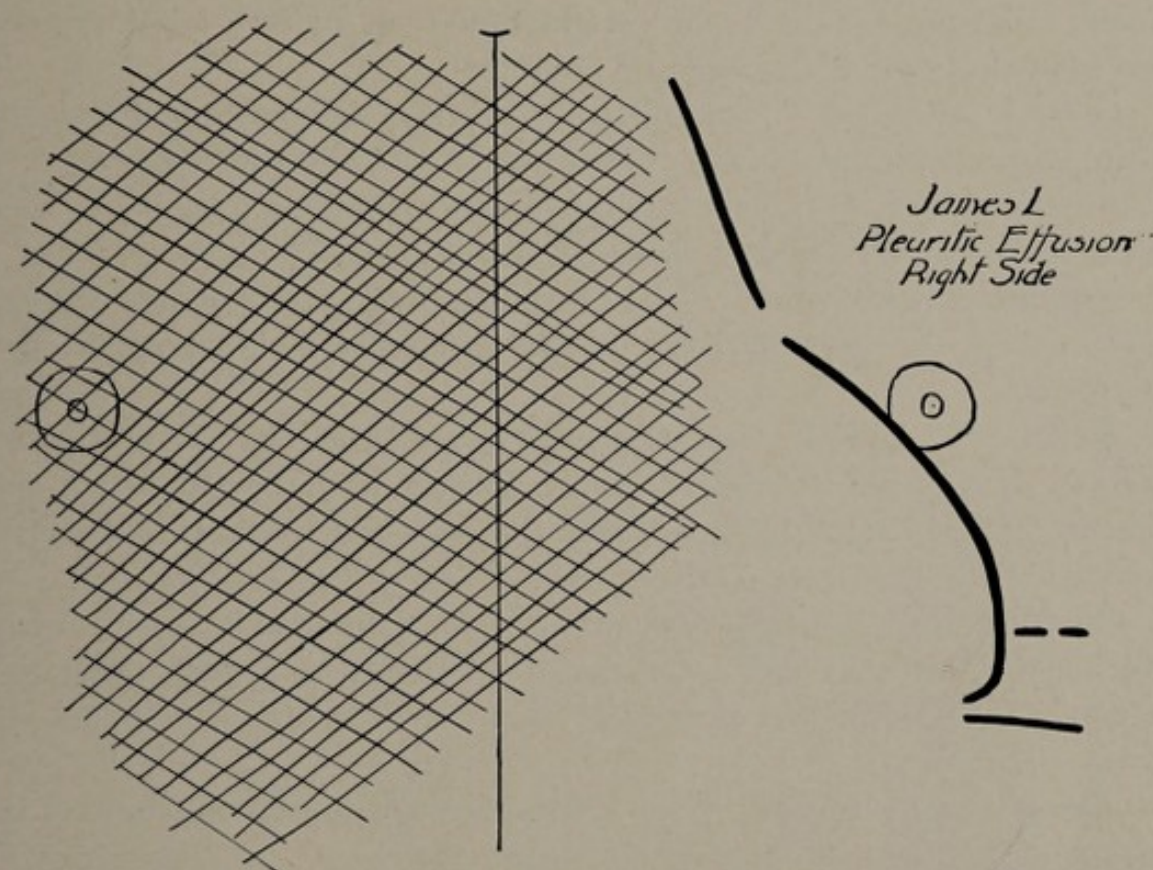


FIG. 135. James L. February 13. Cut of X-ray tracing. Pleuritic effusion on right side. Heart and contents of mediastinum displaced to left. Diaphragm on left side pulled down and excursion limited, as indicated by broken line and full line below it. (Cut one-third life size.)

Present Illness.—Some cough; excessive shortness of breath and weakness.

Physical Examination.—Arteries thickened and tortuous. Pulse irregular and weak. Heart: right border just to right of right sternal border; left border in nipple line; apex in fifth space in nipple line; action regular; sounds weak and distant; no murmurs detected. Lungs: resonance good over right lung to third space in front, and to spine of scapula behind, below which is flatness. Respiration over right chest above flat area, and over left chest, is harsh, with prolonged wheezy and

sonorous expiration. Respiration of the same character is heard over area of flatness, but much diminished.

February 13. *X-ray examination with screen* showed that the heart was displaced to the left, and the line of the blood vessels above the heart were also displaced to the left, as indicated by the oblique line. (See Fig. 135.)

Encysted Pleurisy. — In cases of encysted pleurisy the physical signs may be difficult to interpret, and the real condition present may be more clearly indicated by an X-ray examination than by any other method. The following case illustrates this point: —

CASE I. William T., colored, forty years of age, entered my service at the hospital March 4, 1897. Diagnosis: pleurisy with effusion.

Present Illness. — Cough for four weeks; vomiting; no pain; some shortness of breath due to abdominal distension.

Physical Examinations. — The lungs showed good resonance everywhere except for slight dulness in the left axilla, where respiration is diminished.

March 17. *X-ray examination with screen* (Fig. 136) showed a dark area extending from the third to the ninth rib, as indicated in the cut. The excursion of the diaphragm on the left side was 2.5 centimetres, and on the right side 4.5 centimetres.

On March 18 a needle was inserted into the middle of the dark area on the left side and a syringe of cloudy, yellowish fluid withdrawn. An attempt had previously been made to obtain fluid, but was unsuccessful.

March 19. A second *X-ray examination with screen* showed the same condition as had obtained on March 17.

The patient died on April 6.

An autopsy was made by Dr. F. B. Mallory, who found on the outer side of the left chest, corresponding to the dark area seen by X-ray examination, an old encysted pleurisy with walls 1.25 centimetres thick.

The autopsy record was as follows: "The pleura over the lateral and posterior aspect of the left lung, and over the whole lower lobe, and the lower half of the upper lobe, was enormously thickened and could be freed with difficulty from the costal pleura by the use of the knife. The costal layers of pleura vary in thickness from 2 to 3 centimetres; the parietal pleura from 1 to 1.5 centimetres in thickness. Between the two was a mass of broken-down yellowish white softened material. The thickened pleura consisted of an external and

extremely dense layer of fibrinous tissue. The inner layer was soft and more or less gelatinous. This was a mass of old organized pleurisy."

Name *William T.* Age *40* Date *March 17, 1897.*
 Address _____ Occupation _____ Vol. _____ Page _____
 Diagnosis _____

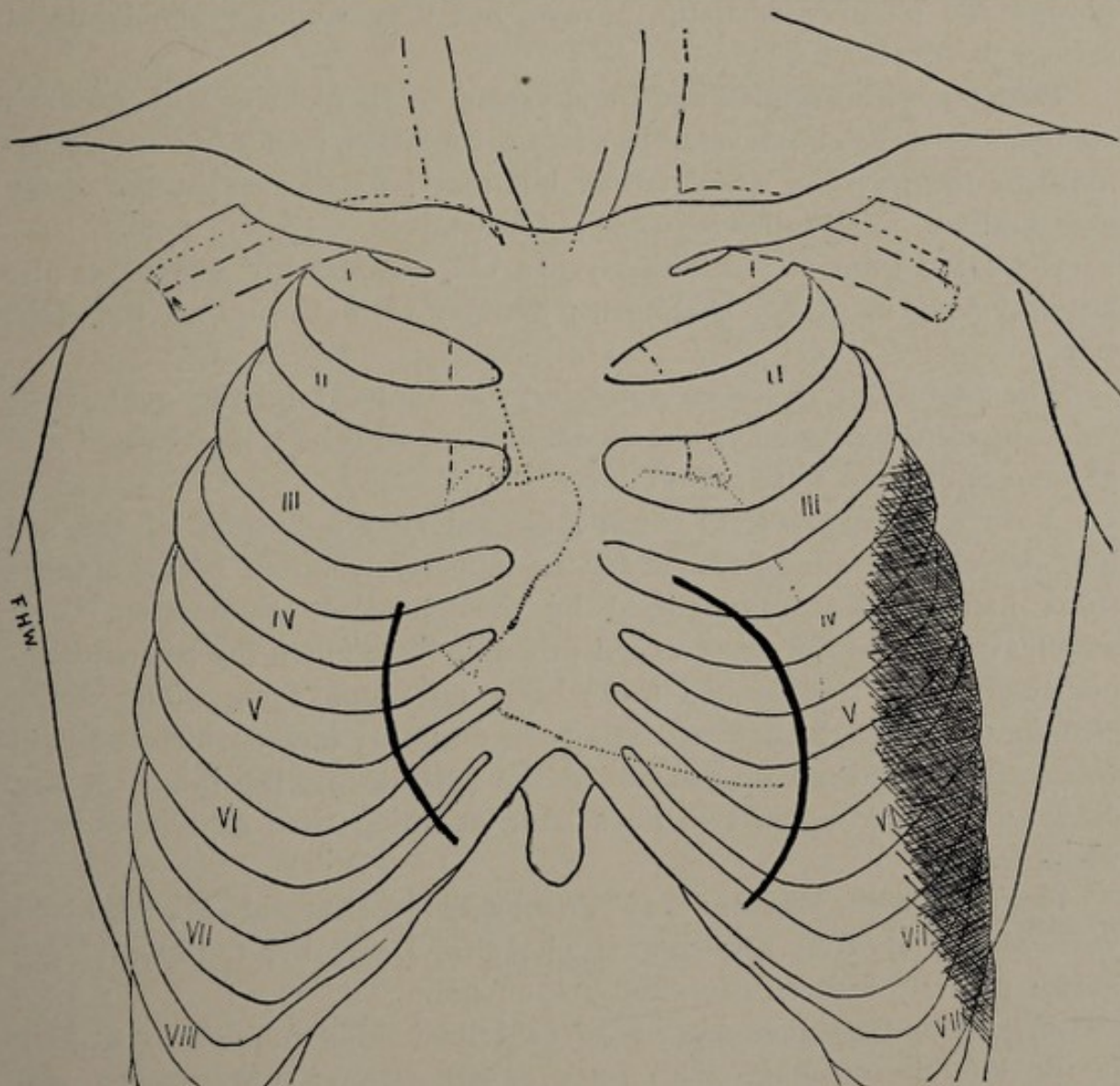


FIG. 136. William T. March 17, 1897. X-ray examination with screen. Encysted pleurisy. Darkened area from third to ninth rib. Diaphragm lines not shown. Excursion 4.5 centimetres on right side; 2.5 on left side. (Cut one-third life size.)

This case is of interest, as showing how much more definite information was obtained by the X-ray examination than had been yielded by auscultation and percussion.

Interlobar Empyema or Pleurisy. — Fluid may not only be encysted in the pleura against the thoracic wall, but may also be enclosed in the pleural membrane between the lobes of a lung, and such a collection of fluid would cast a shadow if the lung surrounding it were at all clear. Physical signs would not give as direct information as the X-ray examination.

Diaphragmatic Pleurisy. — I have never examined a case of diaphragmatic pleurisy with the X-rays, but they would probably be of service here also.

Pleurisy with Effusion and Emphysema. — In pleurisy with effusion complicated with emphysema the latter condition is not always recognized by the physical examination, but may be indicated by the X-ray examination. The following case is illustrative:—

CASE I. John S., forty-two years old, entered my service at the hospital April 6, 1898. Diagnosis: pleurisy with effusion on the right side.

The amount of dyspnœa obtaining was unusual for the quantity of fluid apparently present in the chest. On April 6 he was aspirated and 56 ounces of fluid were withdrawn.

X-ray examination with screen indicated an emphysema of the left lung, which accounted perhaps for the unusual dyspnœa. This emphysema had not been recognized by the physical examination. The amount of fluid in the chest would probably have given the patient comparatively little trouble had there been no emphysema. The X-ray examination, then, by demonstrating the disability under which the lung was suffering, led me, on account of the dyspnœa, to tap the chest and draw off the fluid again two days later, at which time 42 ounces were withdrawn.

Pleurisy with Effusion and Pneumonia. — Dougald M., eighteen years old, entered my service at the hospital December 1, 1899. Diagnosis: pleurisy with effusion and pneumonia.

History. — Patient caught severe cold; had chill, with dyspnœa; pain in the left chest; cough with rusty expectoration; temperature 104, respirations 30.

Physical Examination. — Heart: right border 3.7 centimetres to the right, and left border 8.25 centimetres to the left of the median line; action regular; slight presystolic murmur at apex, not transmitted, but heard in fifth interspace where apex is best located. Lungs: at right apex, above clavicle, prolonged respiratory murmur; whole right back

from apex to just above angle of scapula is more dull than left; above the spine there is broncho-vesicular respiration, with increased tactile fremitus. Left chest moves apparently more than right in respiration, though seat of chief pain is in right side; percussion note not good anywhere; left side in front slightly more dull than right, except at apex, where note is less high-pitched than on right; respiratory murmur not

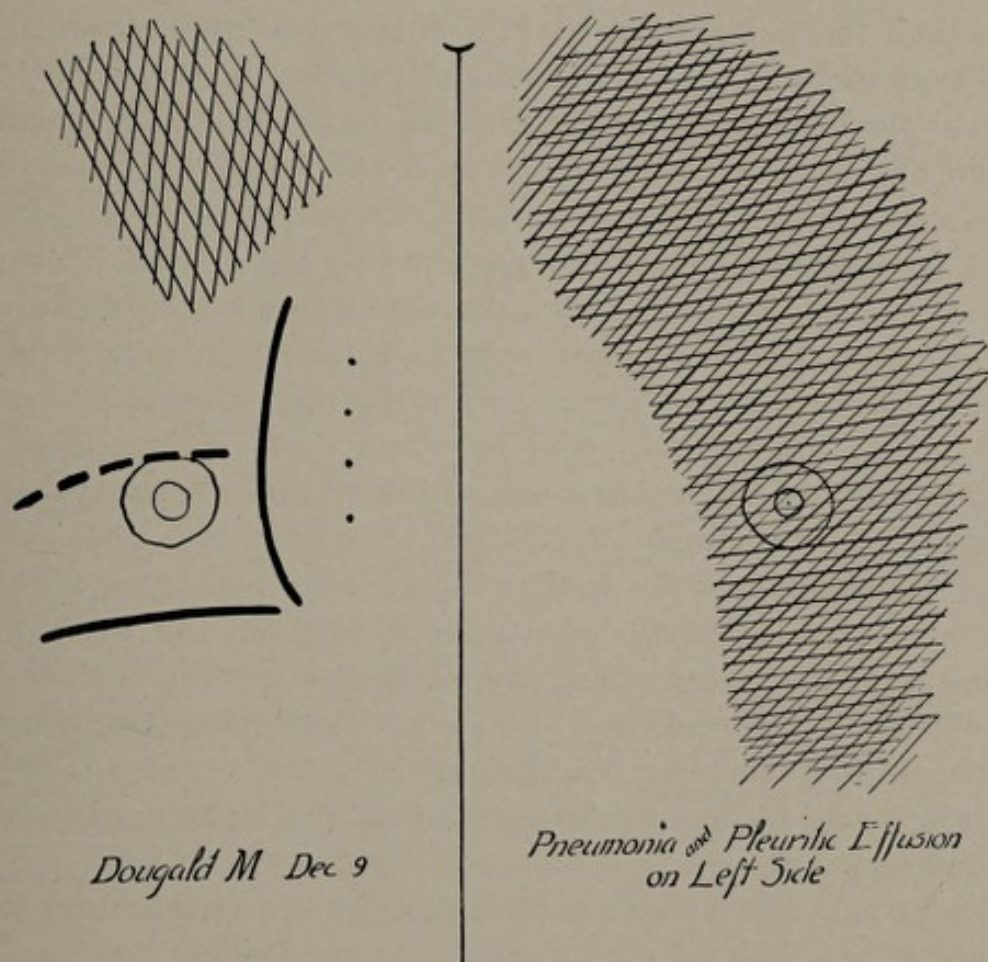


FIG. 137. Dougald M. December 9, 1899. First X-ray tracing. Pneumonia on left side and at right apex; pleurisy with effusion on left side; heart much displaced to right. Dotted line shows right border of heart by percussion; full line, by X-rays. (Cut one-third life size.)

good anywhere; tactile fremitus about the same on both sides. A few râles heard in left back.

December 3. Diminished respiratory murmur heard in left back.

December 5. Tactile fremitus increased over left scapular region and increased voice sounds. No râles heard.

December 8. Over lower left chest, front and back, is diminished tactile fremitus, distant but bronchial respiration, and suggestion of ægophonic voice; a few medium moist râles in middle front and back;

resonance in upper left chest tympano-vesicular with increased tactile fremitus.

December 9, 1899. X-Ray Examination with Screen.—Left chest (see Fig. 137) dark throughout, no diaphragm lines seen, and the heart somewhat displaced to the right and also enlarged, especially on the right side, as it usually is in pneumonia. These appearances suggest a pleuritic effusion in the left chest; and the extension of the darkened area to the apex and the enlarged heart, in connection with the physical signs, indicate that there is also a pneumonic process on this side. If the quantity of fluid present were sufficient to darken the apex, greater displacement of the heart to the right would be looked for than obtains. The right apex is also darkened and the excursion of the diaphragm on the right side shortened. As the patient has pneumonia, there is no present reason to consider the appearances on this side as due to tuberculosis, although the X-ray signs on this side, if taken by themselves, might be caused either by a pneumonia at the right apex or by a tuberculous process.

December 10. The left chest was aspirated and 32 ounces of clear serous fluid was siphoned off. After aspiration the physical signs were as follows: dulness below sixth rib in front, and below a line half-way between spine and angle of scapula behind, on the left side; tactile fremitus absent; respiratory sounds distinctly bronchial and voice sounds ægophonic; resonance in upper left chest much less tympanitic, and tactile fremitus not so much increased.

December 14. Dulness quite marked at the right apex, with prolonged expiratory murmur.

December 24. Fluid seems to have disappeared; respiratory murmur very slight at base behind; signs present at right apex.

January 1, 1900. Second X-Ray Examination with Screen (Fig. 138).—There is no fluid in the lower part of the left chest, as the diaphragm on this side is clearly seen in inspiration, but much of the left side is still dark owing to the pneumonia. The darkness is most marked below, and in this portion of the chest is probably due to pneumonia and a thickened pleura. The heart is still enlarged. On the right side the improvement is very marked. The apex is much lighter and the excursion of the diaphragm greater than at the X-ray examination made three weeks before.

The special point of interest in this case is the fact that the physical signs in the lower part of the left chest, when taken in connection with

the knowledge that the patient had had a pleuritic effusion, indicated, although fluid had been recently drawn from the left pleural cavity, that some was still remaining there. The *X-ray examination* made at this time, however, showed that no fluid was present. The physical signs in the left chest at the base, which suggested that some fluid still remained, were probably due to the density persisting in the lung from the pneumonic process. This same X-ray examination also showed that the right

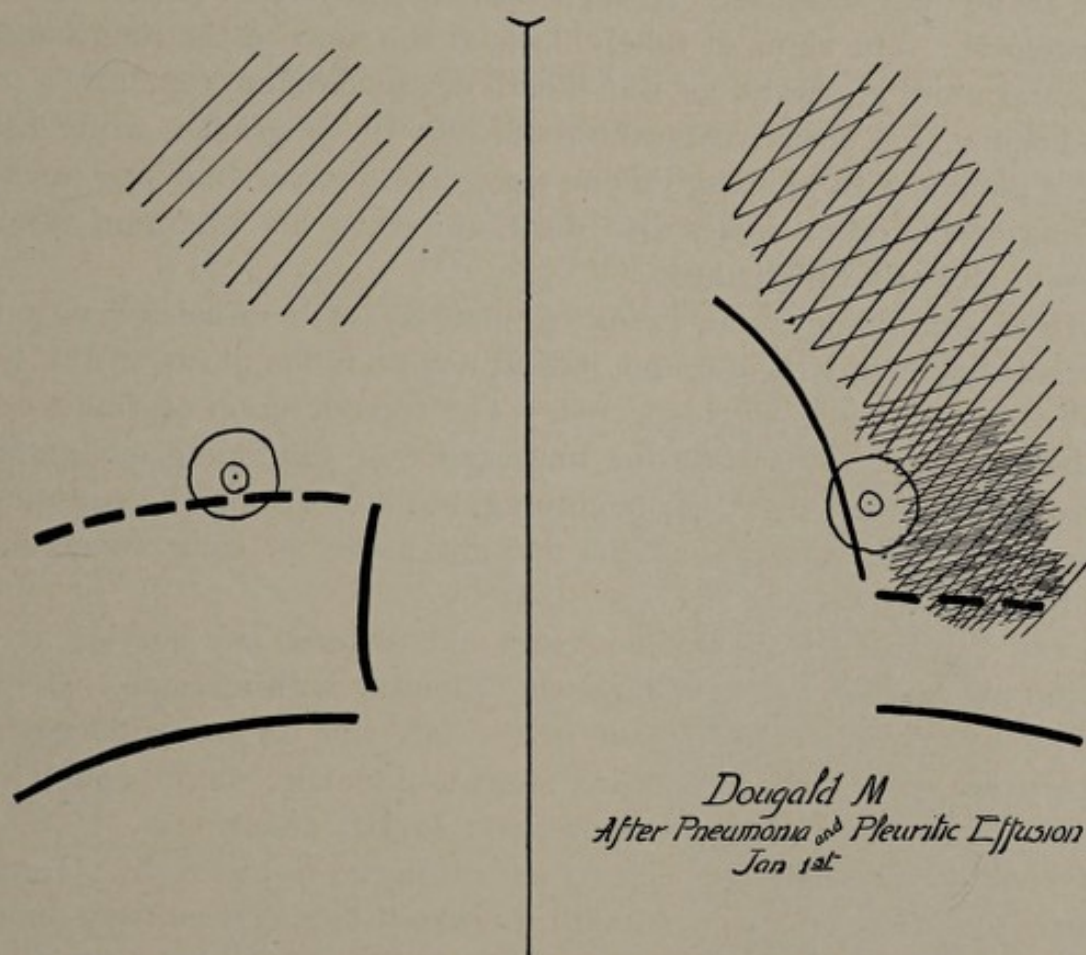


FIG. 138. Dougald M. January 1, 1900. Second X-ray tracing. (Compare with first tracing of this patient, Fig. 137). Improvement at right apex and increase in excursion of diaphragm on that side. On the left side the lung is less dense and there is no pleuritic effusion, as the diaphragm lines can now be well seen. (Cut one-third life size.)

apex had improved very much, therefore that the process was probably not tuberculous. Six examinations of the sputa were made and no bacilli found. The patient had evidently had a pleurisy and pneumonia on the left side and a pneumonia at the right apex. It is a great satisfaction in such a case as this to see the improvement in both lungs, and to be assured that there is no fluid in the left chest and that the patient is making excellent progress.

Pleurisy with Effusion and Pulmonary Tuberculosis. — Pleurisy with effusion and tuberculosis, as is well known, are not infrequently associated. If by means of the fluorescent screen the physician examines at intervals a patient suffering with a pleuritic effusion, he will sometimes find that, although the chest becomes clearer in its lower portion, as the fluid is absorbed, it remains dark above, and that an increasing light area may be seen in some patients between the upper and lower part of the chest as the fluid subsides. In such cases the physician should look for tuberculosis. The signs of tuberculosis at the apex of the lung become more and more apparent as the liquid disappears on that side; they have been at first obscured by the fluid. Or the physician, while examining a patient with pleurisy on one side, may observe that the apex of the lung on the other side is also dark, and thus his attention may be drawn to an early tuberculosis.

While examining some cases of pleurisy with effusion¹ with the fluorescent screen, I have found indications of tuberculosis in the lung which was not previously suspected. The consideration of three cases will be sufficient to illustrate the importance of examining our patients by the X-rays, not only at the beginning, but also during the subsidence of the fluid; if these examinations are not made, an early tuberculosis may be overlooked.

CASE I. Mary F., nineteen years old, entered my service at the hospital on April 8, 1897. Diagnosis: pleurisy with effusion.

Present Illness. — Sharp pain in the left side on inspiration, which began seven weeks ago; breathing short and quick; slight cough; for two weeks has had sense of oppression in left chest.

Physical Examination. — Heart *not* displaced to the right. Lungs: tympany over left upper chest, with increased tactile fremitus; dulness beginning at fourth rib, becoming flatness in axilla; above fourth rib respiration rather harsh; below fourth rib and in axilla breathing diminished and almost absent at base, with voice sounds distant; vocal and tactile fremitus much diminished. In left back good resonance to middle of scapula; dulness beginning 2.5 centimetres above angle of scapula, with flatness at the base; vocal and tactile fremitus diminished, with distant breathing. In right front slight dulness at apex, with normal respiration; tactile fremitus increased; good resonance and respiration in right back.

¹ "A Study of the Adaptation of the X-Rays to Medical Practice," Medical and Surgical Reports of the Boston City Hospital, January, 1897.

April 10. *X-ray examination with screen* showed that the heart was much displaced to the right and that the left chest was dark, the darkened area extending throughout the apex of the lung (Fig. 139).

Name *Mary F*

Age *19*

Date

April 10. 97.

Address

Occupation

Vol.

Page

Diagnosis

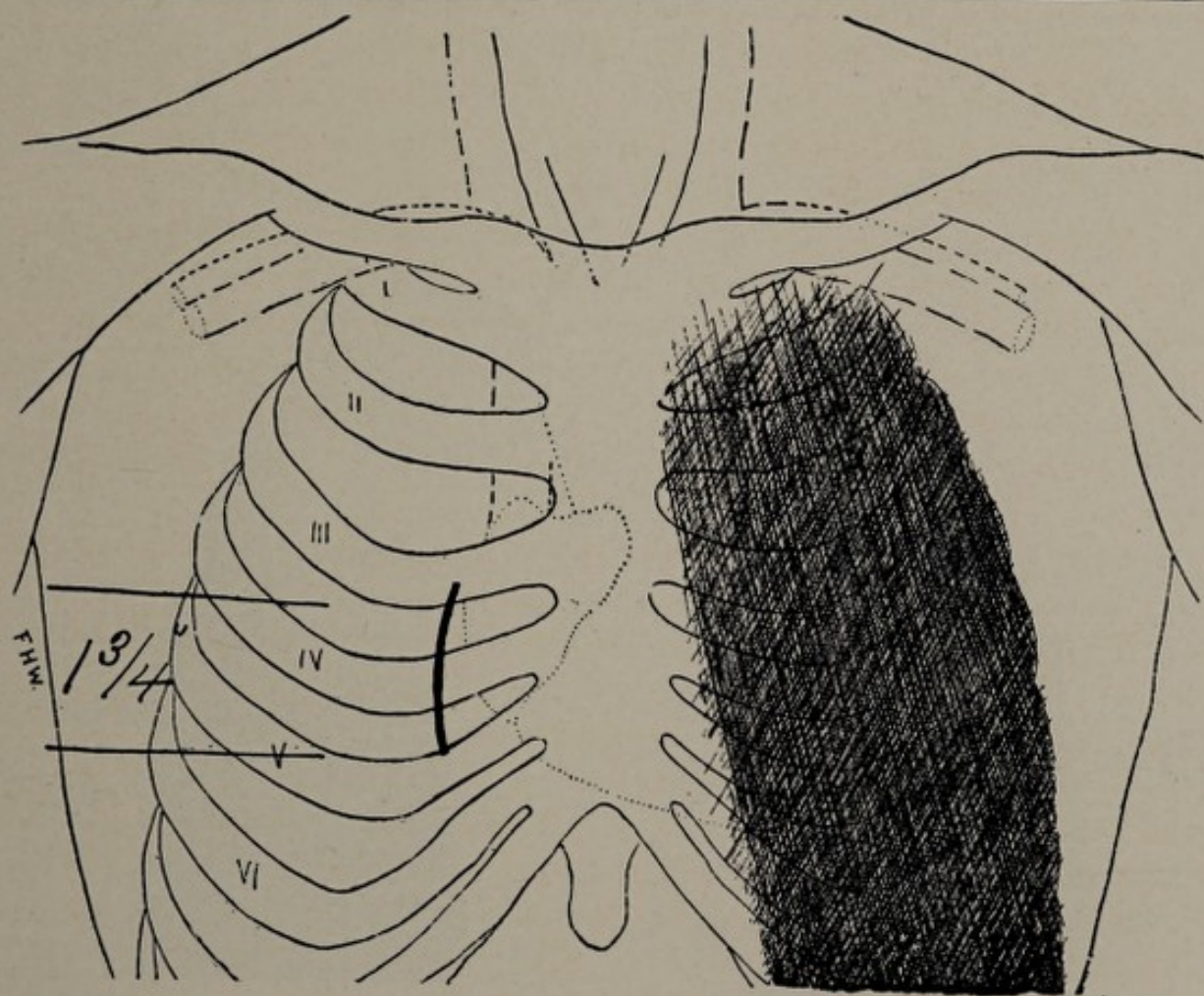


FIG. 139. Mary F. April 10, 1897. First X-ray examination with screen. Pleurisy with effusion on left side; heart displaced to right. Excursion of diaphragm 4.5 centimetres, shortened on right side. (Cut one-third life size.)

After the X-ray examination was made, 17 ounces of slightly bloody fluid were withdrawn from the left chest.

May 12. *Second X-Ray Examination with Screen.*—A light area between the upper and lower portion of the lung showed that the fluid

had subsided. The apex of the lung still remaining dark suggested the presence of tuberculosis. (See Fig. 140.)

The patient was given 1 milligramme of tuberculin and there was a well-marked reaction.

| | | | | | |
|-----------|---------|------------|----|------|-------------|
| Name | Mary F. | Age | 19 | Date | May 12 '97. |
| Address | | Occupation | | Vol. | Page |
| Diagnosis | | | | | |

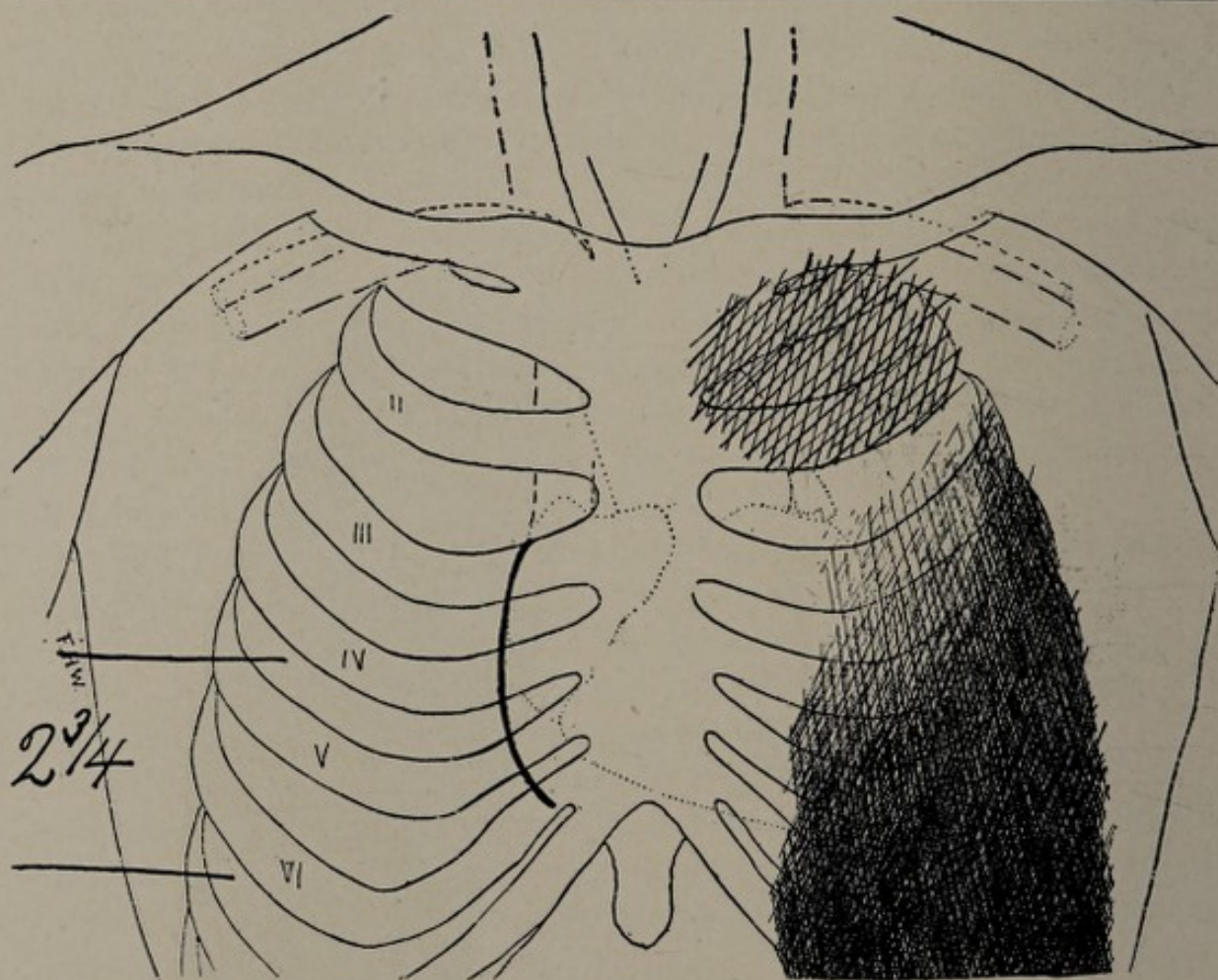


FIG. 140. Mary F. May 12. Second X-ray examination with screen. Less effusion in left chest. Darkened left apex from tuberculosis. Light area seen between the effusion and darkened apex. Excursion of diaphragm on right side 7 centimetres greater than at first examination. (Cut one-third life size.)

May 18. *Third X-Ray Examination with Screen.*—The light area noted on May 12 had become so broad that a part of the left border of the heart could be seen. This increase in the light area showed a further subsidence of the fluid. The darkened apex still persisted (Fig. 141).

The next case, John J. L., illustrates the appearances seen on the screen when the patient is suffering from pleurisy with effusion on the right side and tuberculosis at the left apex:—

Name *Mary F.* Age *19* Date *May 18*
 Address _____ Occupation _____ Vol. _____ Page _____
 Diagnosis _____

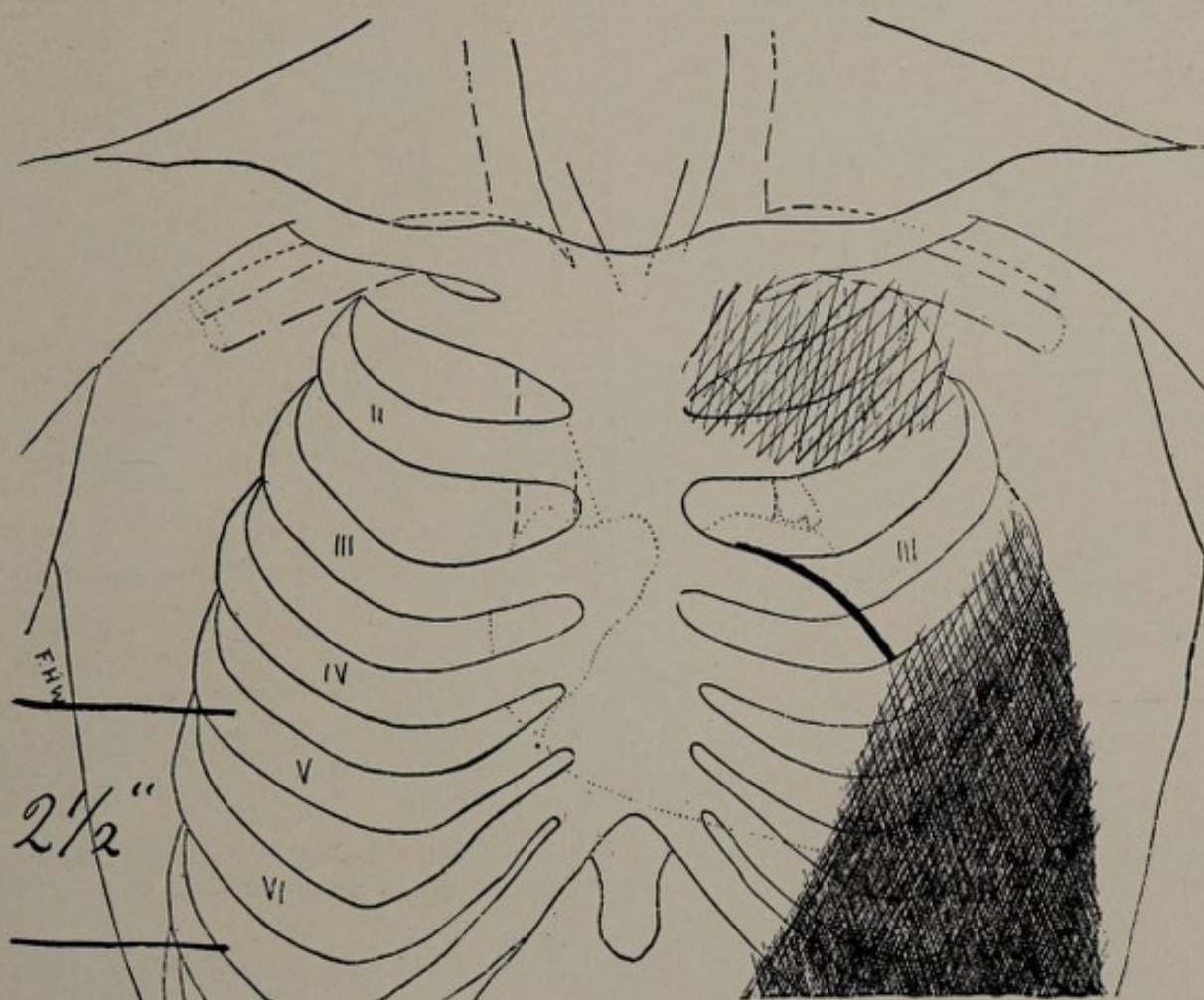


FIG. 141. Mary F. May 18. Third X-ray examination with screen. Still less fluid in left chest. Light area between tuberculous left apex and fluid is larger. A portion of the left border of the heart can now be seen. Excursion of diaphragm on right side 6.3 centimetres. (Cut one-third life size.)

CASE II. John J. L., thirty-four years old, entered my service at the hospital May 10, 1899. Diagnosis: pleurisy with effusion.

Family History.—Mother died of Bright's disease, and her three brothers of tuberculosis.

Personal History. — Excessively alcoholic; frequent attacks of vomiting.

Present Illness. — For some weeks, pain in epigastrium and much vomiting; slight dry cough for two months; some loss of weight but no night sweats; chilly sensations a week previous to entrance; no dyspnœa; anorexia; bowels loose.

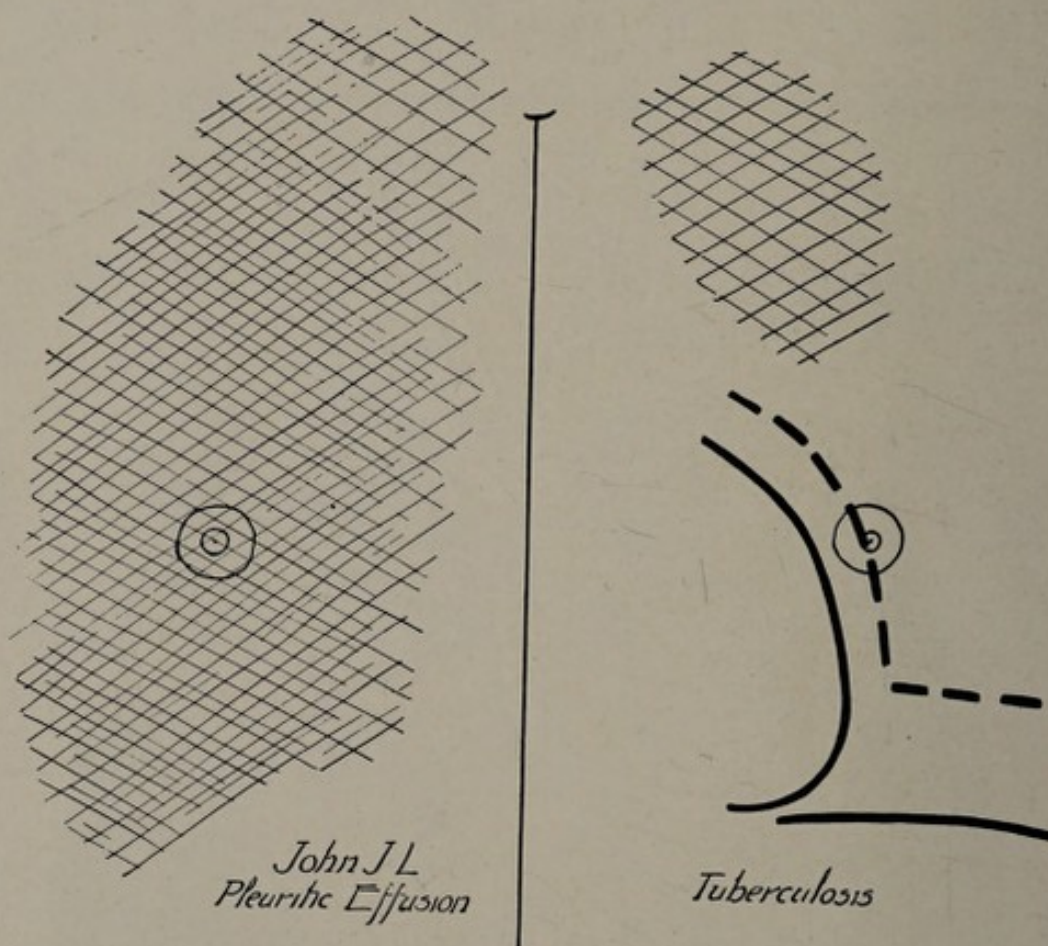


Fig. 142. John J. L. May 29, 1899. Cut of X-ray tracing (one-third life size). Pleurisy with effusion on the right side. Heart displaced to left. Shaded left apex shows a tuberculous area.

May 12. — Forty-three ounces of clear fluid aspirated from right chest.

May 18. *Physical Examination.* — Heart: right border 2 centimetres to right; left border and apex 9.5 centimetres to left of median line; action regular; no murmurs. Lungs: flatness with absent breathing and tactile fremitus below mid-scapula in right back; resonance good above and in front; respiration slightly harsh, with expiration prolonged. Left side: nothing abnormal found on this side; respiration good.

May 29. X-ray examination with screen showed the right side dark throughout; no diaphragm lines or ribs seen; the left apex shaded and the excursion of the diaphragm shortened (Fig. 142).

Tubercle bacilli were found in the sputum.

Name *Andrew J. K.* Age *47* Date *April 12, 1897.*
 Address _____ Occupation _____ Vol. *421* Page *82.*
 Diagnosis _____

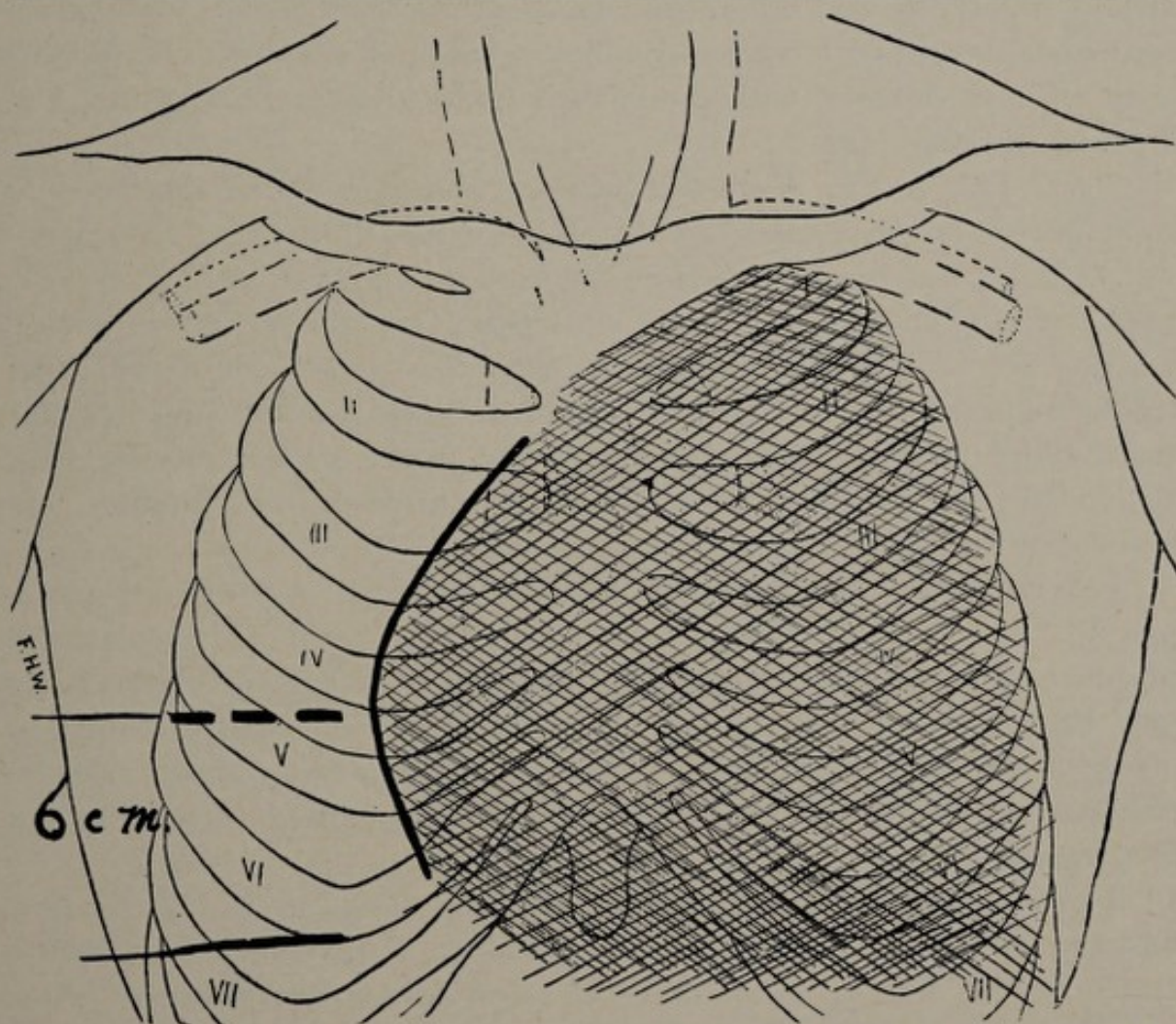


FIG. 143. Andrew J. K. April 12, 1897. First X-ray examination with screen. Pleurisy with effusion; much displacement of heart. The amount of fluid present was not as large as the displacement of heart and mediastinal contents (see dark curved line in cut) indicated. (Cut one-third life size.)

CASE III. Andrew J. K., forty-seven years old, entered my service at the hospital April 10, 1897. Diagnosis: pleurisy with effusion.

Family History. — Father died of tuberculosis; mother of cancer.

Personal History. — Slight cough for past two years.

Present Illness. — More or less pain in left side since November, 1896. For five or six weeks, sense of oppression in left chest; for past ten days, constant pain; some dyspnœa; slight cough; no loss of weight.

Physical Examination. — *Heart: area, action, and sounds normal.* Lungs: good resonance and respiration over right chest, front and back. Some pain in left chest on deep inspiration; good resonance over upper part of left chest; respiration somewhat harsh; dulness at about level of fifth rib and in left axilla, with diminished voice sounds, distant breathing, and diminished tactile fremitus. In left back, good resonance down to 2.5 centimetres below angle of scapula. Below this level to base dulness, with diminished vocal and tactile fremitus and diminished breathing.

April 12. X-Ray Examination with Screen. — Heart displaced to right *nearly to nipple line*; whole of left chest dark (Fig. 143).

April 22. X-ray examination the same as on April 12.

Later, 40 ounces of fluid were withdrawn from the left chest.

May 10. X-Ray Examination with Screen. — Left side darker than right; diaphragm seen on full inspiration; lower part of lung brighter than upper portion. The density of the upper portion of the lung shown by this examination was not recognized by auscultation and percussion (Fig. 144).

Judging by the physical signs obtained on April 10, I did not anticipate that the X-ray examination made two days later would indicate the presence of so large an effusion as the great displacement of the heart (see Fig. 143) seemed to show; and in view of the X-ray examination made on May 10, it is probable that this great displacement, as compared with the amount of fluid drawn off, was caused in part by the increased density of the left lung.

The X-ray examination suggests tuberculosis at the left apex, because the thorax is nearly or quite free from fluid, as indicated by the clearness with which the diaphragm is seen in deep inspiration. Auscultation and percussion had not suggested tuberculosis.

It is hardly necessary to point out how seriously such appearances as are shown in Fig. 144, aside from the pleuritic signs, affect the prognosis. I have repeatedly had my attention called to a beginning tuberculosis by such signs in patients suffering from pleurisy with effusion, when otherwise the tuberculosis might not have been recognized until a later stage of the disease, or might have been overlooked altogether,

if only auscultation and percussion had been used. It follows, therefore, that all patients with pleuritic effusion should be submitted to a careful X-ray examination before they are freed from medical oversight. If the X-rays show that the pulmonary area is clear and the excursion

Name *Andrew J. K.* Age _____ Date *May 10. 1897.*
 Address _____ Occupation _____ Vol. _____ Page _____
 Diagnosis _____

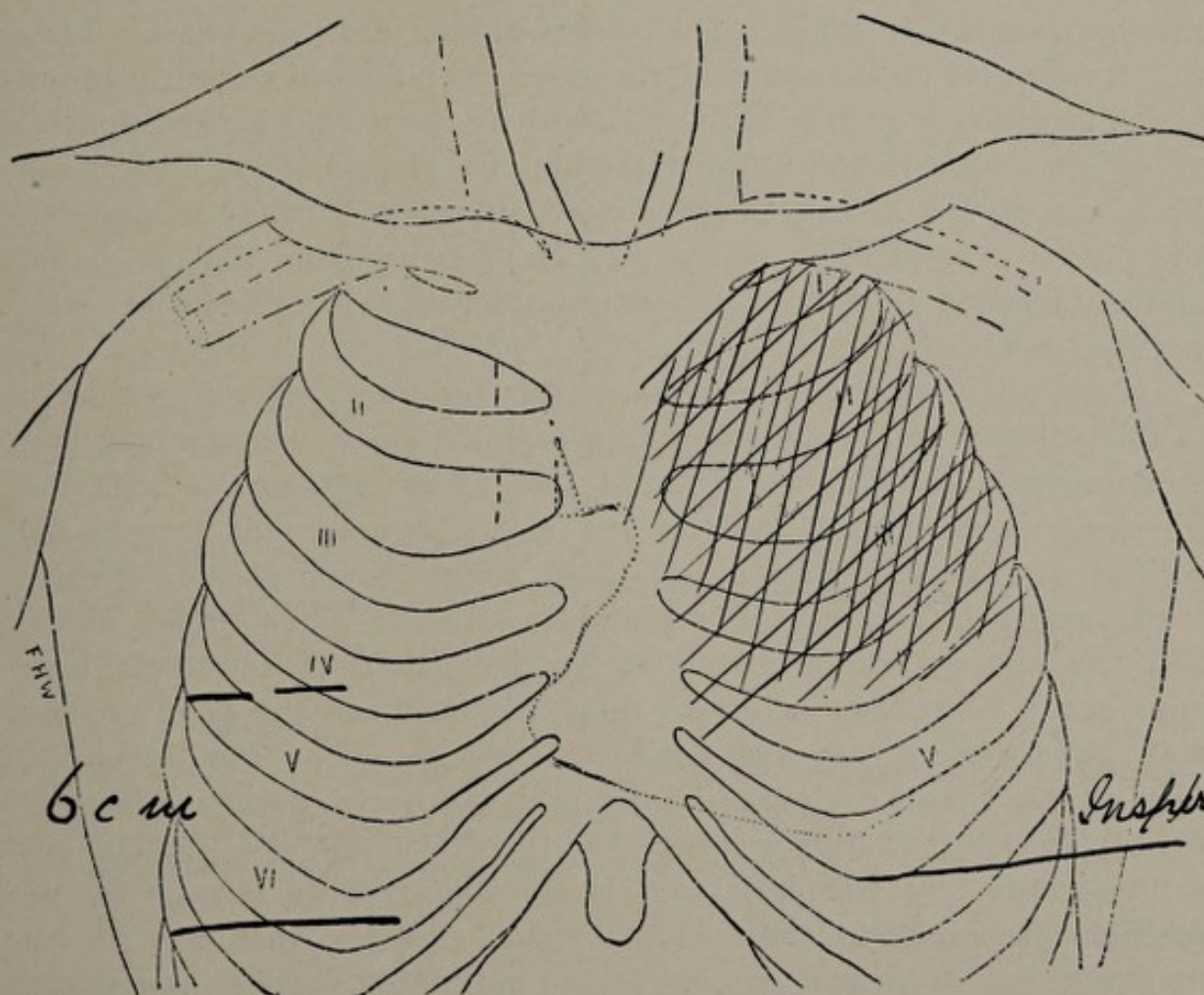


FIG. 144. Andrew J. K. May 10. Second X-ray examination with screen. The left side is now nearly or quite free from fluid, as the outline of the diaphragm is seen in full inspiration. From the apex downwards this side is increased in density from tuberculosis. (Cut one-third life size.)

of the diaphragm normal on both sides, we have the best assurance of a good prognosis.

Pleuritic Adhesions. — As is well known, there may be adhesions of the surfaces of the pleuræ following inflammation, and these may affect

the excursion of the diaphragm in various ways. A few unusual cases will show how the presence of these adhesions may be suggested by X-ray examinations.

In Fig. 127 (see page 203, pleurisy with small effusion) it will be seen that the diaphragm was clearly defined on the left, but not on the right, side of the chest. It will be observed, I think, that even a very small amount of fluid free in the pleural sac would flow into the angular space between the outer end of the diaphragm and the chest wall. Therefore, if the diaphragm line on a given side can be followed and this angular space is shown to be clear by the X-ray examination, there is no fluid present on this side unless it is encysted higher up in the chest. Thus the X-rays give us assurance of the absence of fluid in certain cases in which its absence or presence is doubtful by the usual physical signs.

It is a simple matter to prove the absence of fluid in the pleural sac by means of the X-rays, but it is more difficult to distinguish between the presence of pleurisy with a very small effusion on the one hand, and a thickened membrane, or a lung increased in density in its lower portion, on the other.

If the angular space in the thorax referred to is not clear, a change in the position of the patient during examination from a standing to a reclining posture, with the affected side uppermost, may enable the physician to distinguish, on the one hand, between fluid free in the pleural sac, and, on the other, thick adhesions or greater density than normal in the lung. For example, with the patient lying down, and the affected side uppermost, an indication of the dark area seen in the chest may be drawn upon the skin, and the same process may be repeated with the patient standing. If, on comparing the two sets of lines, a change in the position of the darkened area is seen, this change might indicate that there is liquid present and not a dense lung. If the dark area is not altered by a change in the position of the patient, the evidence favors the view that it is caused by something other than liquid. If the outline of the diaphragm can be followed, with the patient sitting or standing, to the outer side of the thorax, there is probably no free fluid in the chest.

CASE I. John F., twenty-two years old, entered my service at the hospital March 14, 1899. Diagnosis: pleurisy with effusion.

Present Illness. — Chill and pain in left side for two weeks; considerable cough, with slight expectoration; headache and malaria; diarrhoea for two days.

April 13. X-Ray Examination with Screen.—The diaphragm line on the left side can be seen in both inspiration and expiration, therefore there is now little or no fluid in the left chest, but the excursion of the diaphragm is shortened on this side, and its limited movement suggests that there are adhesions; the darkened area seen above the left diaphragm lines in the cut (Fig. 145) is due to thickened pleura or deposit of inflammatory tissue.

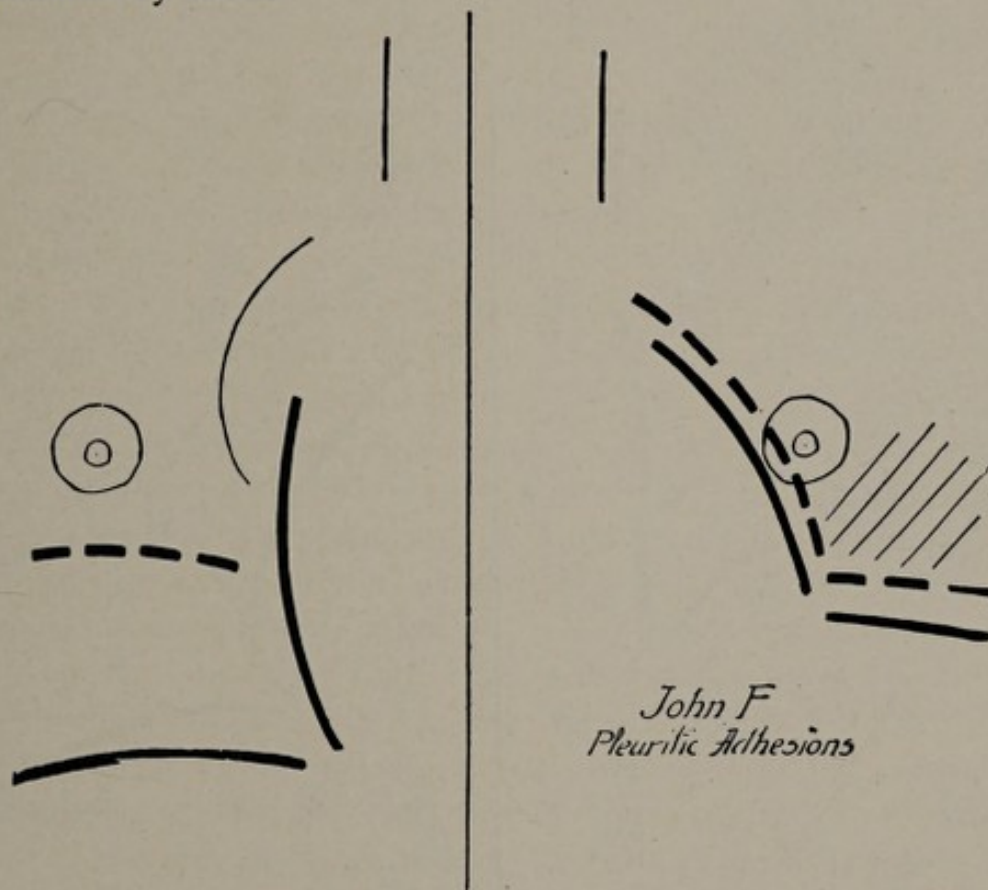


FIG. 145. John F. April 13, 1899. Cut of X-ray tracing (one-third life size). Pleuritic adhesions on left side, indicated by the restricted movement of the diaphragm and heart on that side. The darkened area at the lower part of the lung may be due to thickened membrane, though to cast a perceptible shadow it would have to be exceedingly thick or calcified.

The above case shows how the X-rays may assist in indicating the absence of fluid in the pleural sac, and at the same time suggest the cause of the remaining difficulty.

CASE II. James A. W., twenty-eight years old, entered the hospital October 7, 1899. He was a patient of one of my colleagues, and the tentative diagnosis was pleurisy with effusion on the right side.

October 5. Physical Examination.—Lungs: in the right chest, from fifth rib in front, and from angle of scapula behind, extending up into axilla, flatness, absent respiration, and diminished vocal and tactile

fremitus; at upper border of above area a few coarse moist râles; throughout the rest of the chest the breathing is exaggerated.

October 25. *Physical Examination.* — In right base, below angle of scapula behind, and level of nipple in front, there remains dulness on percussion, with diminished tactile fremitus. Respiratory sounds diminished, but vocal resonance good. No râles heard.

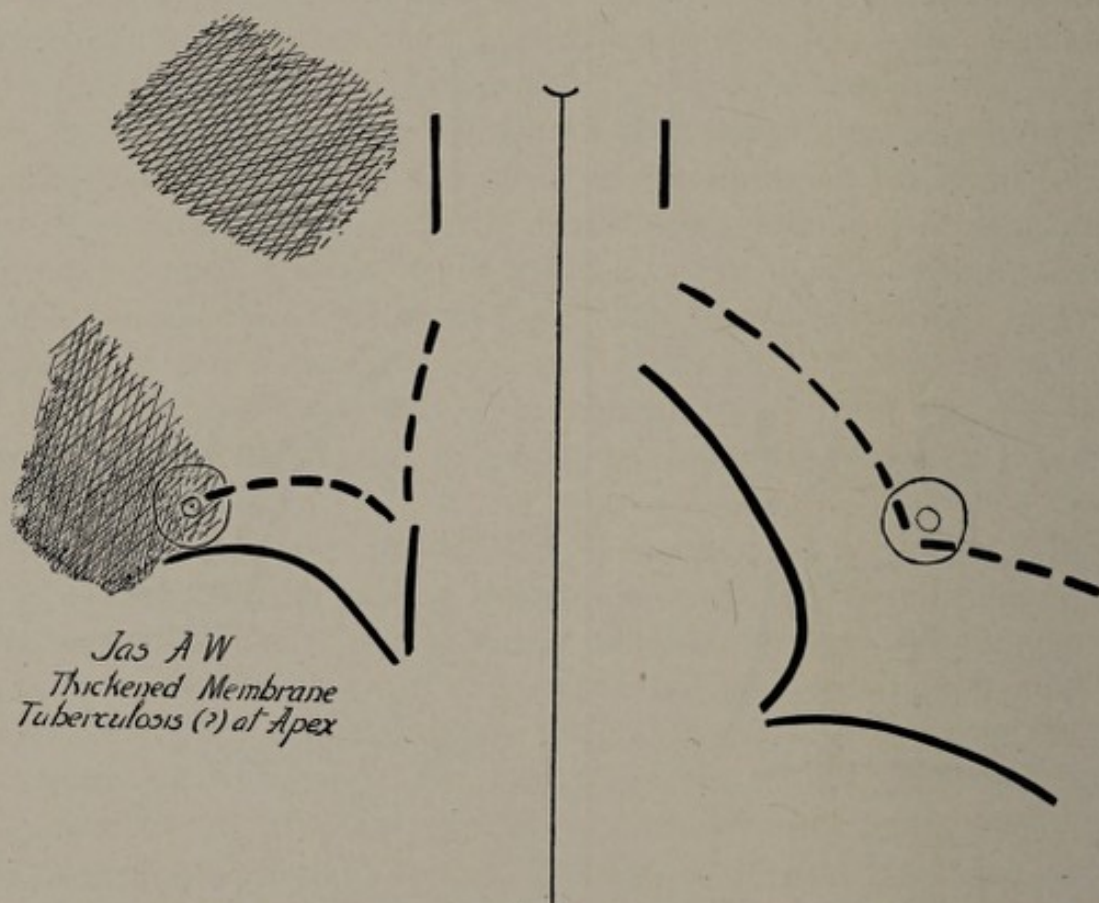


FIG. 146. James A. W. November 2, 1899. Cut of X-ray tracing (one-third life size). Darkened area at right apex, suggestive of tuberculosis.

November 2. My *X-ray examination with screen* showed a darkened area at the right apex, suggestive of tuberculosis.

On the next day my colleague found signs at the right apex by percussion, and also signs of a little fluid in the right chest.

If the tracing made from this patient is referred to (Fig. 146), it will be also seen that the movement of the diaphragm on the right side is not only limited but has an unusual curve. It moved less freely in its middle portion, and the outer part of its line was not seen. It may well be that there was a small amount of fluid left in the chest, but added to this he probably had adhesions which limited the movement of the dia-

phragm, particularly in its outer portion. Whether all the darkened area could be the result of a much thickened pleura, without any fluid, or whether we had to do with a small amount of fluid and adhesions, would be a subject for careful consideration.

A pain in the side, or a "stitch" in the side after exertion or after cough, or attacks of pain in the side coming on at irregular intervals, are sometimes shown by X-ray examination to be associated with pleuritic adhesions. I have observed this fact in a number of cases, for example:—

Daniel J. R., one of my patients at the hospital, had attacks of pain in the side, etc. *X-ray examination with screen* showed that the patient had emphysema, but also that the excursion of the diaphragm on the right side was shorter than on the left. His heart was drawn to the right (since the right border was much outside the sternum). This change in position was not due simply to the enlargement of the right side of the heart which occurs in emphysema, since I found the left border farther to the left than normal. The position of the heart in this case may be most simply explained by the presence of adhesions drawing the heart to the right, and it is not improbable that this same condition was the cause of the attacks of pain which he had.

Further, for cases of this character, which in some ways illustrate this condition better than those here cited, see pages 293 and 294.

In patients who have a pain in the side we should, I think, consider not only the muscles and nerves of the chest wall as the possible site of the trouble, but also the condition of the pleuritic membrane; we may by X-ray examination be able to find the probable cause. These adhesions do not show themselves on the fluorescent screen or in an X-ray photograph, unless there is a very great thickening of the pleuritic membrane; a thickness of 3 millimetres, for example, would cast so little shadow that it would not be seen unless there was calcification of the membrane (Fig. 217, Chapter XV, shows a calcified pleura), but their presence might be inferred by the limitation of the movements of the lungs or heart, or by the displacement of the heart.

An adhesion may modify the appearances seen in pleurisy with effusion, for if it fastens one portion of the lung to the chest wall, the dark area caused by the fluid may at this point be divided into two parts, as it were, and separated by the light area of the normal portion of the lung. In this case the outline of the fluid would be different from that usually seen in this disease on the fluorescent screen.

CHAPTER IX

HYDROTHORAX. PNEUMOTHORAX. EMPYEMA WITH PERMANENT
OPENING. PNEUMOHYDRO- OR PNEUMOPYOTHORAX

HYDROTHORAX

Appearances seen on the Fluorescent Screen in Hydrothorax. — The lower portions of both sides of the chest are darker than normal, and the outlines of the diaphragm cannot be seen. If the hydrothorax is more extensive the dark area extends higher up in the chest.

PNEUMOTHORAX

Appearances seen on the Fluorescent Screen in Pneumothorax. — (See Fig. 147.) The affected side of the chest is unusually clear, and the light area in this region is larger than normal; the lung is retracted; the diaphragm is pushed low down in the chest and has little or no movement, and the organs on this side are displaced to the opposite side. The amount of displacement varies according to whether the air in the chest is or is not under greater than atmospheric pressure; if air is pumped in during the respiratory movement through a valvelike opening, and the pressure in that side of the thorax is thereby increased, the displacement of the organs may be very great.

Method of Examination. — The patient is examined lying on his back on a stretcher, and the appearances above indicated are traced on the skin or the celluloid, according to the method adopted.

The tracings made from the following patient, Delia H., show a pneumothorax of the left side. The heart was much displaced to the right; the outline of the retracted left lung was not so clearly seen in this patient as it is in some cases. The patient also had tuberculosis of the right lung. The case is given because it illustrates how successive X-ray examinations show the gradual improvement that takes place in pneumothorax as the air is absorbed. It also shows that

subsequently to the pneumothorax, the presence of pleuritic fluid on the same side was recognized by an X-ray examination, and these appearances were confirmed by tapping the chest.

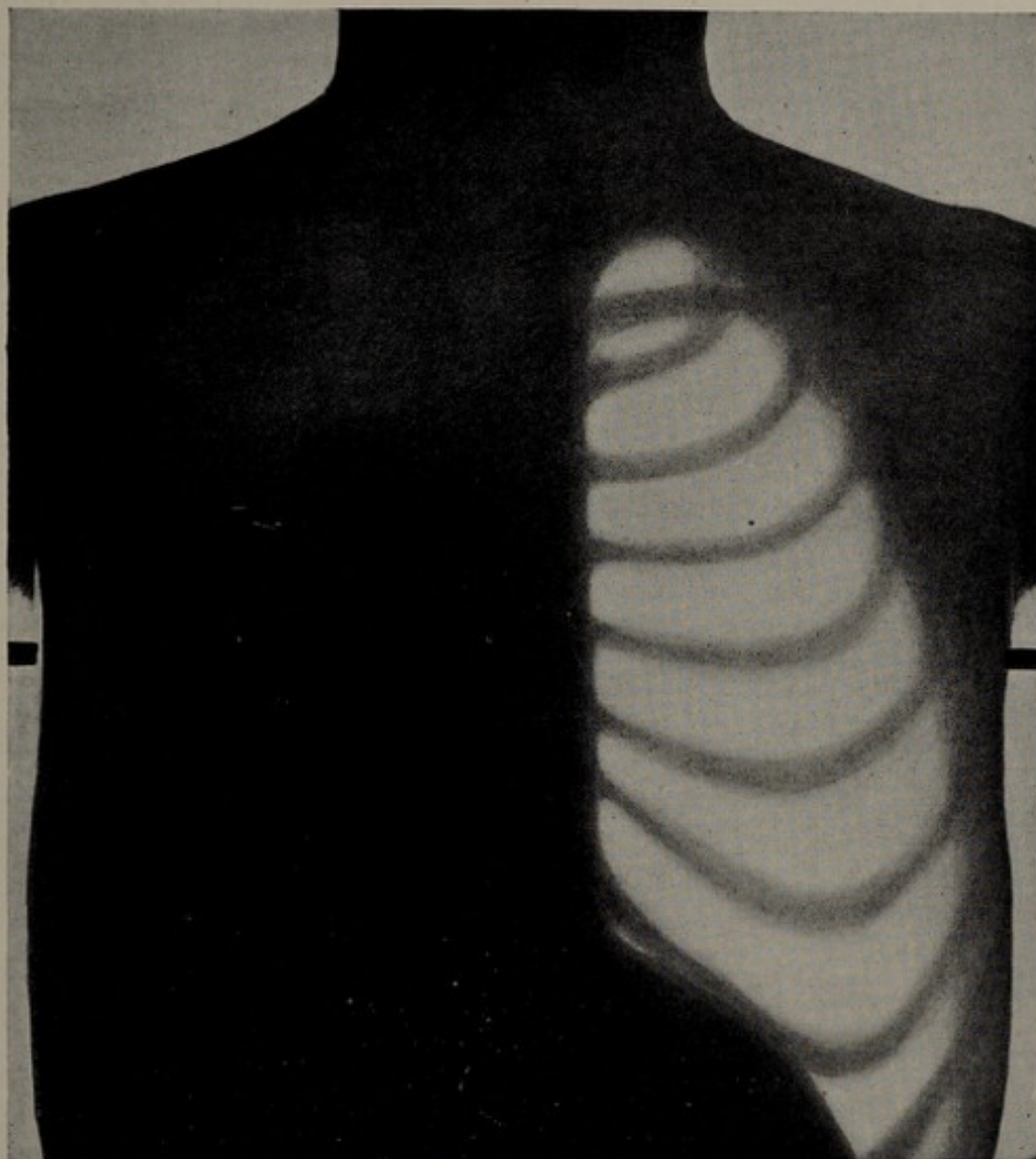


FIG. 147. Diagram of pneumothorax on left side, and tuberculosis on right side. Left side brighter than normal and bright area more extensive. Diaphragm low down in chest; little or no movement. Organs on left side displaced to right. Heavy lines under axillæ indicate level of nipples.

CASE I. Delia H., twenty-five years old, entered my service at the Boston City Hospital April 3, 1898. Alcoholic. Had had much cough and expectoration. One week before had suddenly had a sharp pain in the left side, which increased. She was unable to take a deep breath.

Physical Examination. — Cardiac area not determined; chest hyper-resonant. Apex not determined. No cardiac sounds heard to the left of sternum. On right of sternum heart sounds are heard indistinctly, loudest in fifth space, sternal border, no murmurs detected. Lungs: resonance increased over entire left lung, front and back. Tactile

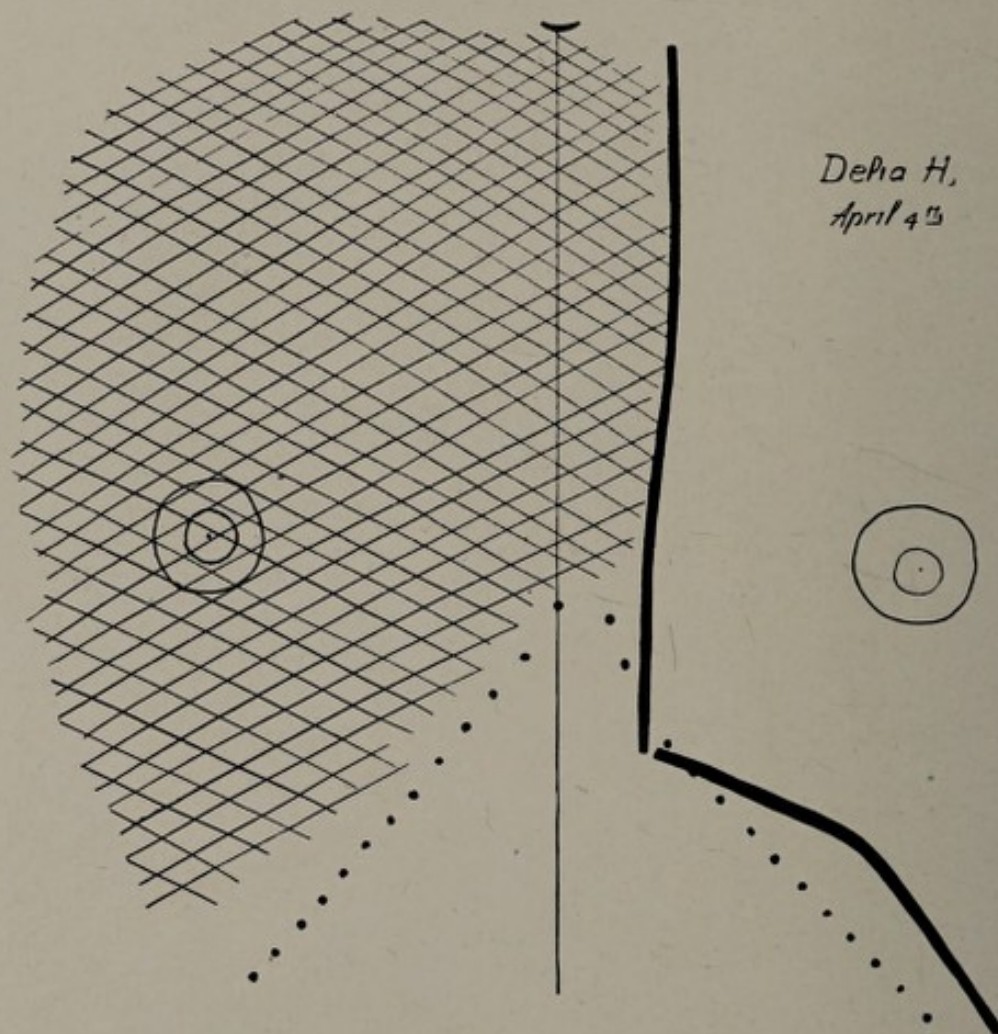


FIG. 148. Delia H. First X-ray tracing. Pneumothorax of left side; tuberculosis of right side. Whole of left side abnormally bright; right side very dark; the full dark, nearly perpendicular line gives the border of the light area; the dotted line indicates the costal border. The diaphragm line is seen to be very low down in the chest on the left side; this side of the muscle had little movement during respiration, and this movement was chiefly at the median end, as if the motion were imparted to it from the right half of the diaphragm. The outline of the contracted left lung was not distinctly seen, although in other cases I have been able to follow it. (One-third life size.)

fremitus and voice sounds decreased over this area. Over right back there was marked resonance, and respiration was broncho-vesicular. Many crackling râles were heard. Over right front resonance is fair. Respiration is here accompanied by many râles.

April 4. Physical signs the same as on April 3.

April 4. X-ray examination with screen was as shown in the tracing. (See Fig. 148.)

The condition of the patient on this day was serious, and as I had observed that great relief is obtained in cases of pleurisy with effusion when the first part of the fluid is drawn off, I thought, in this case, the withdrawal of a moderate amount of air would likewise give relief. I therefore tapped the chest of this patient immediately after making the

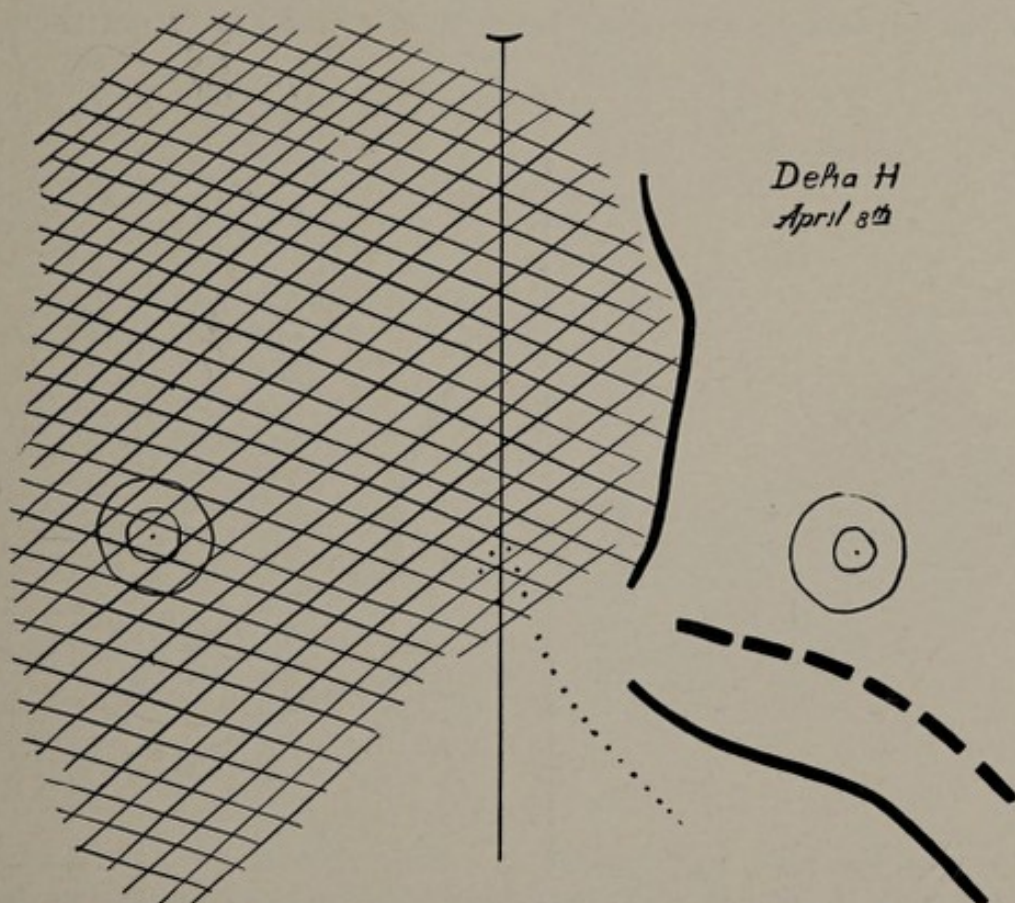


FIG. 149. Delia H. Second X-ray tracing, after a litre of air had been withdrawn from the left side. The diaphragm was higher, had some excursion during respiration, and the border of the light area was farther to the left of the median line than at the first examination. (Size one-third.)

X-ray examination. A quart seemed to me a suitable amount of air to withdraw, for to take out too much might cause the opening from the lung into the pleural sac to open again, and thus require a repetition of the operation. The procedure, devised on the spur of the moment, was as follows:—

Method for withdrawing air.—I sent for a large bottle and a stopper with two holes in it. The bottle was then filled with water and placed on a table near the patient. Through one of the openings in

the stopper, a glass rod was inserted, which reached to the bottom of the bottle, and to whose upper end was attached a rubber tube, long enough to connect with a measuring glass on the floor. This tube acted as a siphon to suck the water out of the bottle. The other opening in the bottle was connected by means of a rubber tube with a small hollow needle. The sterilized needle was inserted into the left pleural cavity in the sixth space in the mid-axillary line, and as the water was drawn out of the bottle by the siphon, air from the patient's chest was drawn in. When a quart of water had been thus withdrawn from the bottle,

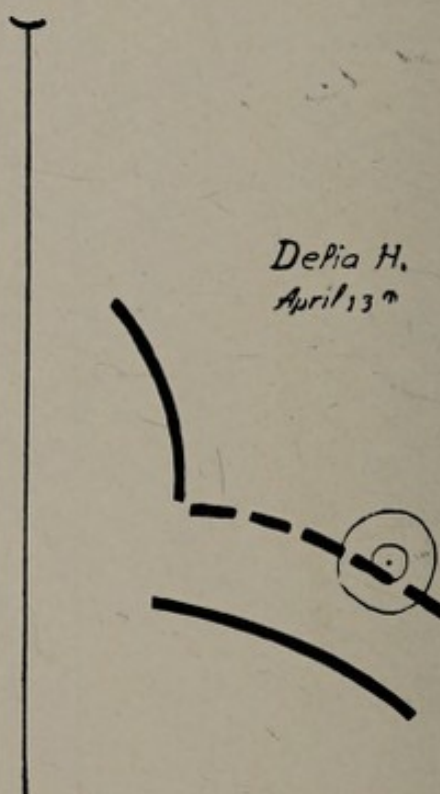


FIG. 150. Delia H. April 13. Third X-ray tracing. This cut does not indicate the dark right side of the thorax, but is given to show the farther improvement in the position of the diaphragm and that the left border of the heart may be seen. (One-third life size.)

and a quart of air taken out of the patient's chest, I lifted the siphon tube until water no longer flowed through it, and, as at this height the siphon had some suction power, I knew that there could not be a free opening between the pleural sac and the air in the lung. The immediate improvement in the patient's condition was very marked. Just before the operation, the breathing was shallow and rapid (forty-four per minute); when the aspiration was stopped, it was slower and deeper (thirty-five per minute); and soon after this the respirations had come down to twenty-eight per minute. Not only was her breathing made

easy, but her color and circulation were improved. Her change for the better was very prompt and permanent, so far as concerned the pneumothorax.

April 8. Second X-Ray Examination with Screen.—The diaphragm moved 3 centimetres on the left side, and the left border of the heart could be seen 4.5 centimetres to the left of the median line. (See Fig. 149.)

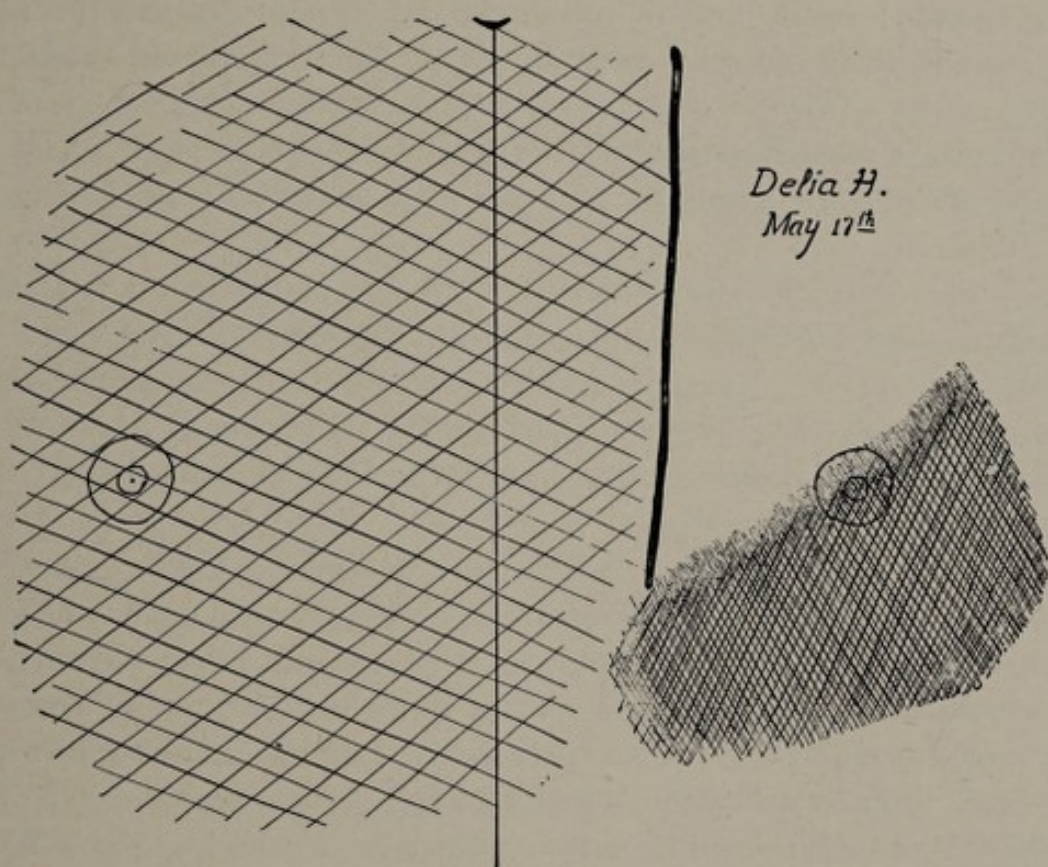


FIG. 151. Delia H. May 17. Fourth X-ray tracing. Right thorax dark from tuberculosis. Left chest dark from pleurisy with effusion. (One-third life size.)

April 13. Third X-Ray Examination with Screen.—Further improvement; the diaphragm moved higher up in the chest on the left side, and the left border of the heart was farther to the left of the median line than in the previous examination. On the right side, the right border of the heart and the movements of the diaphragm could be dimly seen, but these outlines are not given in the tracing, as it was made to show the changed position of the diaphragm only. (See Fig. 150.)

April 20 and 28. X-ray examinations made on these dates showed still further improvement. The tracings are not given.

April 28. The patient was discharged from the hospital. The right side of the chest remained much darker than normal, owing to an extensive tuberculous deposit referred to above.

May 16. The patient returned to the hospital, and reported that she had been feeling very well up to May 13. Physical examination made on May 16 showed dulness and many râles of every variety over entire right chest; over lower part of left chest there was dulness and absence of voice sounds; upper half of left chest was hyper-resonant, but respiratory sounds were present and distinct. Tubercle bacilli found in sputum.

May 17. X-Ray Examination with Screen.—The right chest was dark, and there were signs of pleurisy with some effusion in the left chest. (See Fig. 151.)

After the outlines, from which this cut was made, had been traced, a little clear fluid was withdrawn from the left side.

CASE II. D. C., twenty-eight years old, entered the hospital August 30, 1896. In the service of Dr. G. G. Sears. Alcoholic.

History.—On August 26, 6 P.M., felt a sudden pain in the left side; no dyspnoea.

* * * * *

September 3. Physical Examination.—Tympanitic note over whole of right front, amphoric respiration marked at right base, with metallic tinkling. Over upper and lower thirds of right front, axilla, and right base, marked amphoric voice and whisper. Edge of liver could not be felt. Heart dulness a finger's breadth to left of sternum.

September 4. X-ray examination with screen that Dr. Sears kindly allowed me to make at my request. Whole of right side was clear; bright area extended far down and over to the left side. Diaphragm on left side extended nearly to the lower costal border; its motion on inspiration and expiration was much limited; its median end had more motion than the outer end. The appearances on the left side were unusual; there were two bright areas divided from each other by a vertical dark area which included the heart. The heart was pushed far to the left with the lung and vessels. The examination was not complete, as the patient was not strong.

The displacement of the heart and lung was so much greater in this patient than is found in patients with a permanent opening in the chest, as after an operation for empyema, that the air in the right side of the thorax was probably under more than the atmospheric pressure, and

had probably been pumped into the pleural sac through a valvelike opening.

September 5. Physical examination showed that the apex beat was in the fifth space, 3.7 centimetres outside the left nipple line. Patient rather cyanotic, respiration somewhat hurried. Right chest somewhat more prominent than left, but moved well with inspiration. Metallic tinkling was absent. Edge of liver could not be felt, as patient's muscles did not easily relax.

These patients show, I think, that the X-ray examinations may assist us to determine the exact conditions present in this class of cases. I have never appreciated these conditions so clearly as by means of an X-ray examination.

EMPYEMA WITH PERMANENT OPENING

The appearances seen on the screen vary with the amount of lung involved; the amount of diseased tissue present in the chest which is denser than the lung; the extent of the cavity; the pleuritic adhesions, etc. That is to say, the darkened area is more or less extensive, and varies in its degree of darkness in accordance with the absence or presence of the conditions just enumerated. The diaphragm is seen to be more or less depressed, but not to the extent represented in the diagram of pneumothorax.

After a permanent opening has been made in empyema, X-ray examinations may be serviceable by enabling the physician to recognize how large the sinus is. This point may be ascertained by injecting iodoform in suspension, or subnitrate of bismuth, or a solution of iodide of potassium, or even sterilized water, as all these substances cast a shadow on the screen; the X-rays will also be of use in showing the condition of the lung, — how much it is able to expand as improvement takes place, and whether or not there is an accompanying tuberculosis.

PNEUMOHYDROTHORAX — PNEUMOPYOTHORAX

Pneumohydrothorax, or Pneumopyothorax, like empyema and pleurisy, is usually, of course, a symptom rather than a disease, and, except when caused by trauma, should suggest tuberculosis.

Appearances seen on the Fluorescent Screen. Sitting Position. — When the patient is examined while sitting up, with the tube behind him, about on the level with the fourth rib, and the screen on the front of the chest, the affected side is seen to be divided into two parts, the upper of which

is unusually light and the lower very dark. The general appearances on this side may be likened to a tumbler partially filled with ink; when the patient moves backward or forward, the level of the fluid changes; if he is taken by the shoulders and gently shaken, the surface is disturbed, and the splashing of the fluid is clearly seen. When the fluid

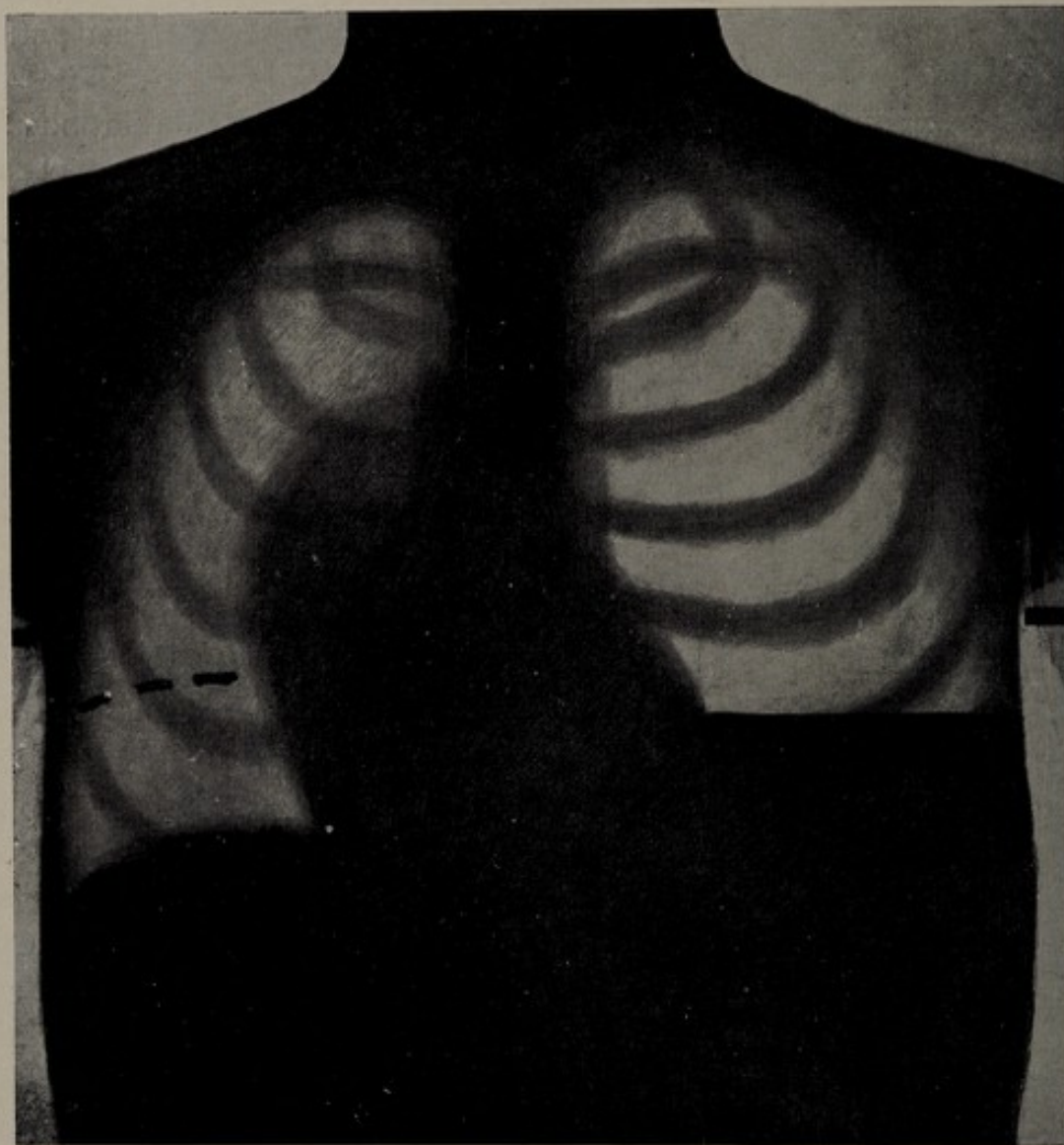


FIG. 152. Diagram of pneumohydrothorax. Left side. Sitting position. Level line of fluid seen in left chest. Heart displaced to right. Retracted left lung not indicated; it would make a slight shadow in upper portion of left chest.

is at a certain level, especially if the pneumohydrothorax is in the left side, the pulsations of the heart disturb its surface, and the waves caused by the partially submerged and beating heart can be observed.

In the upper portion of the chest, and toward the median line, the slight shadow of the retracted lung may often be seen; if the lung is

tuberculous, it would be darker than if it were not diseased, and would not be so much retracted as if it were healthy. The heart is much displaced to the opposite side. The fluid may be seen to rise with inspiration, because of the pushing up of the diaphragm on the diseased side when this muscle descends on the well side and to fall with expiration.

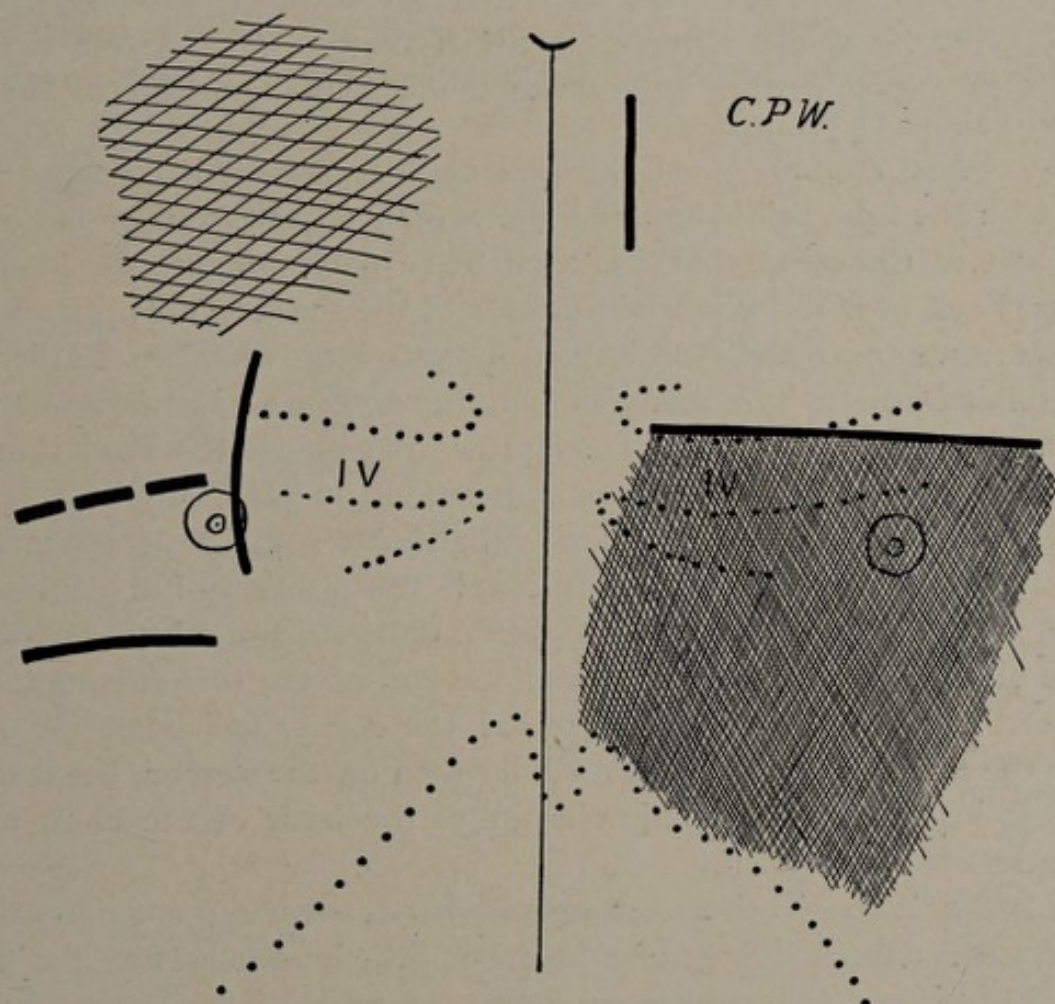


FIG. 153. C. P. W. Pneumohydrothorax on left side. Appearances seen with patient sitting up. (When lying down, the whole of the left side was dark.) Tuberculosis at right apex. Heart drawn to the right. The level of the fluid sharply defined, as indicated by the dark line over the fourth rib on the left side. When the patient was inclined to the right or to the left, the surface of the fluid remained level. When the patient was gently shaken, the splashing of the fluid could be followed. (One-third life size.)

It is said that the fluid may rise slightly with each systole while the breath is held, but I have not seen it. The expansion of the lung, consequent upon the subsidence of the fluid and the absorption of the air, may be watched upon the screen if the perforation closes.

The tracing given above (Fig. 153) also illustrates the appearances seen on the screen in pneumohydrothorax. The patient from whom it

was made was in the service of Dr. Buckingham, but was examined by me with the X-rays on June 5, 1897. This examination also suggested that the patient had a tuberculous infiltration of the right apex, and this indication was confirmed later by the finding of tubercle bacilli in the sputum.

On June 17, Dr. Buckingham withdrew 39 ounces; on June 29, 45 ounces; and on August 6, 64 ounces of fluid from the chest. The patient was discharged from the hospital, September 25, 1897, improved; he had gained 15 pounds.

Recumbent Position. — If the patient is examined lying flat on his back with the tube below him and the screen on the front of his chest, the whole of the affected side is seen to be dark, because the fluid distributes itself over the whole of this side of the thorax; the appearances seen resemble those observed in pleurisy with large effusion; in pleurisy with small effusion, as already shown, the dark area in the lower part of the chest shades off into the lighter area above, the fluid remains near the diaphragm, and changes its position comparatively little.

The affected side of the chest will present a different appearance with the patient in this same position, if the position of the tube and screen is changed. If the tube is placed opposite and a little below the centre of the side of the thorax, and one end of the screen is rested on the chest and the other is a little raised, the X-rays will enter the chest above the fluid, and a light area will be seen on the screen, because, as we have just seen, the fluid gravitates to the back of the chest when the patient is lying down.

This condition of things can be still better shown in some instances if the patient, after lying down, turns a little on one side as the fluid, instead of being distributed evenly over the back of the chest, flows in toward the sternum and gives the X-rays a still better opportunity to demonstrate the air in the portion of the thorax near the front of the chest wall.

The following tracing is taken from the chest of a boy five years old, a patient of Dr. H. W. Cushing on the surgical side of the hospital, whom I examined with the X-rays, and represents the appearances seen both when the patient is sitting up and lying down.

In the former position the fluid rose to the level indicated in the X-ray tracing by the full horizontal line just above the nipple. The chest below this point was dark, while above this line it was light, as in the case of C. P. W. When the boy was lying down the fluid distributed

itself over the chest, as shown by the crossed lines above the horizontal line. This tracing also indicates that the position of the diaphragm in pneumohydrothorax may be similar to that in pneumothorax.

Immediate Relief by Operation. — In pneumohydrothorax the pressure may become so great that the patient may be in imminent danger. It seems to me probable that this serious condition may be due to a valvelike perforation that allows the air to be drawn in but does not permit it to go out, so that the amount of air in the affected side of the

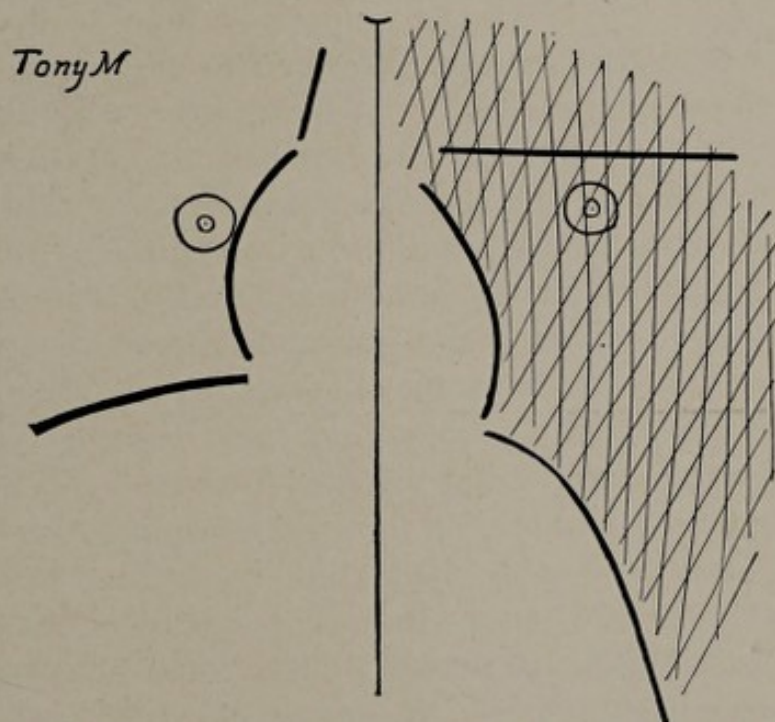


FIG. 154. Tony M. Five years old. Tracing one-third life size. Pneumohydrothorax (traumatic). *Recumbent position.* — This tracing, with the omission of the horizontal line on the left chest, indicates the appearances seen on the screen when the patient was recumbent and the tube below him. That is, the chest was darkened throughout; the diaphragm was low down in the thorax, and the heart was drawn to the left. *Sitting position.* — When the patient sat up and the tube was behind him, on a level with the fourth rib, the left chest below the horizontal line was dark, and above it very bright. This horizontal line indicates the level of the fluid. The fluid remained level when the patient bent from side to side.

chest increases to such an extent as to displace the heart to a marked degree; that is, the pressure from within becomes greater than the pressure from without. Tapping the chest in such cases gives immediate relief, and the X-rays enable us to estimate the amount of displacement of the organs, the quantity of air present, and whether or not an operation should be done directly. The following case illustrates the danger to which a patient suffering from pneumohydrothorax may be subjected : —

The patient, Daniel S., thirty-five years of age, was in my service at the Boston City Hospital. He was unconscious and evidently in a dying condition. I inserted a hollow needle into the left chest between the axillary lines, while the patient was lying on his back; when it was directed so that its point was toward the back of the chest the fluid ran out; when the needle was reversed, the air came out. The operation gave immediate relief.

In conclusion, in these conditions or diseases the X-rays give less equivocal and more complete evidence than can be obtained by the physical signs.

CHAPTER X

SECTION I

NORMAL AND ABNORMAL HEART

X-Ray Examinations of the Heart. — In order to determine the borders of the heart with the X-rays, it is essential that the lungs and pleuræ be clear. If, for example, the lung is dense on the left side in its lower portion, it will be impossible to distinguish the left border of the heart; or if there is pleuritic effusion on the left side, of a considerable amount, it would likewise be impossible to determine this border. In a word, it is evident that X-ray examinations cannot be used to determine the borders of the heart unless the contrast between this denser organ and the lighter pulmonary area is sufficiently marked.

The heart may be examined when the patient is standing, sitting, or lying down. Let us suppose first that he is placed flat on his back, exactly in the middle of the canvas stretcher already described; that the position of the vacuum tube has been determined by the plumb-lines; and that the target has been placed under the stretcher about 75 centimetres (30 inches) away from the screen, and at the point where the median line crosses the fourth rib. Since to get accurate results it is necessary that the two sides of the body be at equal distances from the tube, a small level may be placed across the sternum to make sure that one side is not higher than the other. Now let us place the fluorescent screen on the chest and examine the normal heart.

APPEARANCES SEEN ON THE FLUORESCENT SCREEN

Normal Heart. — The heart hangs in the thorax, resting, during expiration, on the diaphragm, in such a position that its long axis is at an angle with the median line of the body. But when a deep breath is taken, as I pointed out in 1896,¹ the outlines of the heart can be seen

¹ "A Method for more fully determining the Outline of the Heart by Means of the Fluoroscope, together with Other Uses of this Instrument in Medicine," *Boston Medical and Surgical Journal*, October 1, 1896.

most fully. At this time the heart moves downward and inward, the whole of the left border is clearly seen, and the right border also becomes visible on the right side of the sternum; therefore the best view of the heart is then obtained. In other words, the inclination of the long axis of the heart becomes more horizontal as the diaphragm rises in expiration, and more vertical as the diaphragm descends during deep inspiration, and this change in direction of its axis takes place chiefly during the latter portion of the descent of the diaphragm, when its pull on the pericardium becomes stronger and the lungs distend. At this latter period of the respiratory movements the transverse diameter of the heart is somewhat diminished, and its pulsations are lessened in amplitude. This temporary decrease in diameter and shortening of the pulsations of the heart seem to be partially due to the downward pull of the diaphragm to which reference has just been made. The axis of the normal heart is more inclined in some persons than in others, a point which will be considered when discussing the accuracy of percussion.

In quiet breathing both borders of the heart may be well seen in some individuals, and in such cases this organ can be measured at that time. In those cases where they cannot both be well seen at this time, the left border can be first traced on the skin or celluloid, as the case may be, and when a little further inspiration, before full inspiration is reached, brings the right border into better view that may be added.

The heart can be better seen during full inspiration than during expiration, for the following reasons: First, the diaphragm descends during the former part of the respiratory period, and therefore a much larger portion of the cardiac outline is brought into view. Second, the lungs are more transparent to the rays during deep inspiration, and therefore the pulmonary area on the screen is brighter, and consequently the contrast between it and the heart is more marked. The right side of the heart is better seen because this organ is a little more to the right in full inspiration than in expiration. The inferior vena cava (as also the superior) is pushed toward the median line, and the blood vessels in the right lung, which have a direction downward and outward from the root of the lung, are carried farther from the median line of the body, so that the right border is more clearly seen during deep inspiration because the blood vessels whose shadow would tend to confuse and obscure it are moved from the position which they hold during expiration. Full inspiration is therefore, as a rule, the best time for measuring the transverse diameter of the heart; but it must be remembered that

the more vertical position of the heart's axis obtaining at this time makes the horizontal distance between its right and left borders less than during expiration, at which time the axis of the heart is more inclined, so that the width of this organ, measured at deep inspiration, varies from that obtaining at expiration.

The following cut (Fig. 155) is a reproduction of an X-ray photograph of the heart ¹ which I took during a full inspiration. The cut is about one-half the original size of the photograph, and shows, above the fourth ribs, the outer border of the superior vena cava and of the aorta; below the fourth ribs, the heart. The diaphragm is seen at the bottom of the picture.

The pulsations of the heart diminish the sharpness of the outlines of this organ in the X-ray photograph, and in the process of reproducing this photograph the clearness even of the original is lost. The dark areas on each side of the heart, which have in general a direction downward and outward, are the shadows of the pulmonary vessels. In the original negative, there is seen on the right side, above the heart, the outline of the outer side of the superior vena cava, and within it, that of the ascending aorta. The curve of the descending aorta may be easily followed in the negative, but is almost lost in the half-tone; in the original, nearly the whole of the outer curve of the ascending, transverse, and descending arches of the aorta may be followed.

As, then, the heart may be measured during different stages of the respiratory movements, the period at which the measurement has been taken should be noted, so that if a second examination of a given heart be made, for the purpose of comparison, the same period may be used. Likewise the period at which the measurement has been taken is of importance, and should be noted if tables giving the widths of a large number of hearts are being compiled for the purpose of comparison with some other method of examination, or for other purpose.

Levy-Dorn, at the meeting noted below,² showed two pictures of the heart, the one in deep inspiration, the other during forced expiration; and they indicated that the diameter of the heart was greater during expiration.

Pulsations.—The pulsations of the heart seem to be less marked during full inspiration than during expiration, or the inspiration of

¹ Communications of Mass. Med. Society, June 13, 1899.

² "Zur Untersuchung des Herzens mittels Roentgenstrahlen," Verhandlungen des Congresses für Innere Medicin, 1899, also *Fortschritte a. d. Geb. d. Röntgenstr.*, p. 216, B. II, 1898.



FIG. 155. Half-tone of radiograph of heart of a man forty-seven years old, taken during a full inspiration. He was lying on his back on the stretcher, with the plate on the front of his chest.

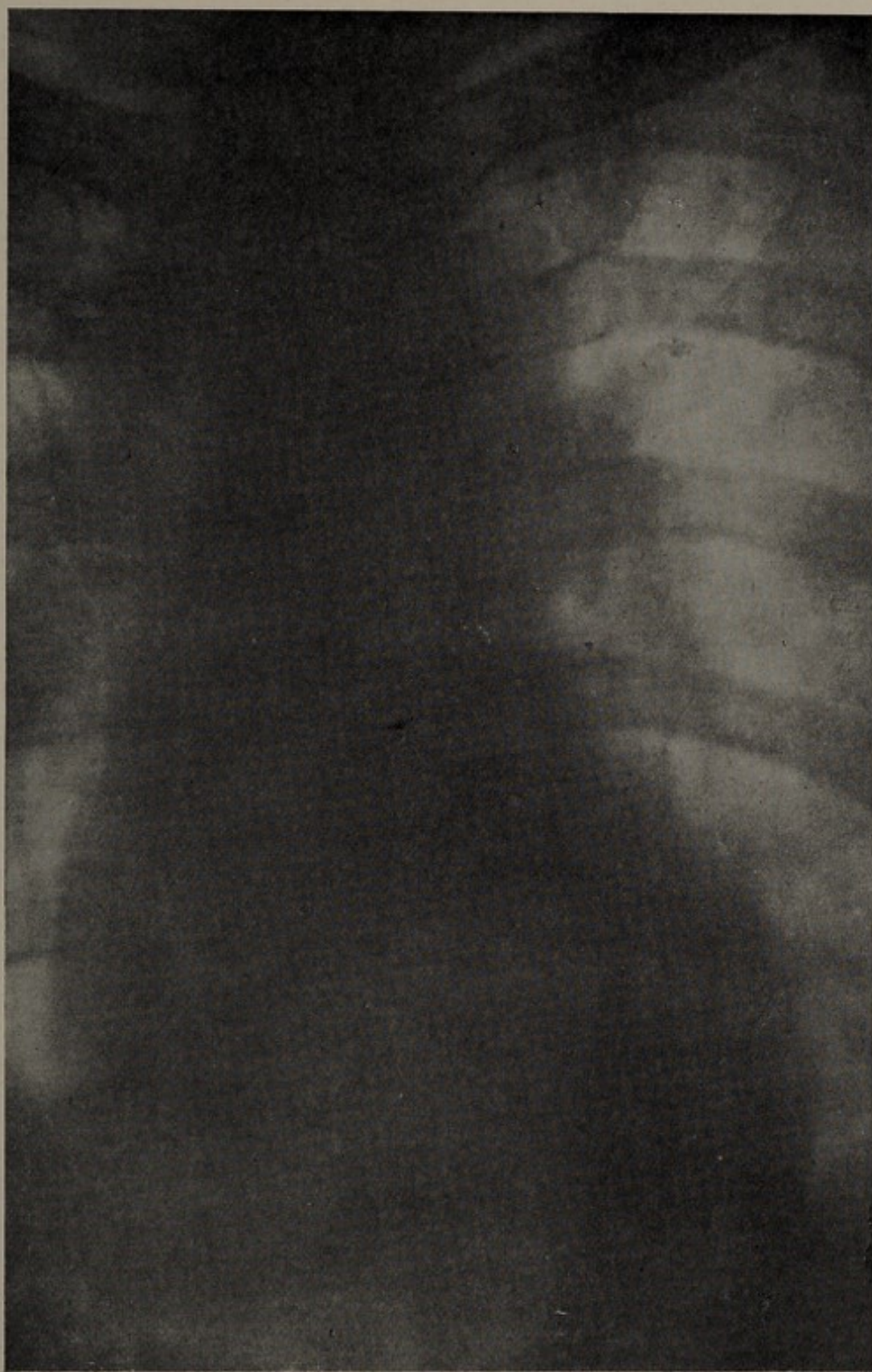


FIG. 156. Half-tone of radiograph of heart of the same man as in Fig. 155, taken during quiet breathing (about the position of expiration).

quiet breathing. This diminution in the extent of the pulsations may be due to several causes: to the descent of the heart when the diaphragm is lowered; to the stretching of the pericardium by the descent of the diaphragm; and to the turning of the heart so that a portion with less amplitude of pulsation is silhouetted on the screen.

The pulsations of the left border of the heart may be best followed on the fluorescent screen during full inspiration, and the observer may easily see that it changes its outline chiefly over the cavity of the left ventricle, toward the base of the heart, and that its apex does not shorten very much. The pulsations of the right ventricle may be followed, when its border is clearly defined beyond the edge of the sternum, during full inspiration, and in some cases in the inspiration of quiet breathing; and may be more fully observed at these periods than during expiration. After a full breath has been held, the pulsations of the ventricle are not only more rapid, but more ample during the succeeding expiration.

The right auricle casts a faint shadow on the screen, and its pulsations may be followed in health under favorable conditions, that is to say, if the apparatus is good and the individual is thin; but more easily if emphysema is present or if the auricle is distended by disease.

The pulsations of the ventricle are more easily seen than those of the auricle, because the former is denser and therefore casts a more marked shadow. The physician should become familiar with the character of the pulsations and their amplitude in health, for, as we shall see later, they may be modified in cardiac disease.

The heart does not work to its full capacity when the individual is quiet, but, like the lungs, can be called upon to do much more when required. The excursions from systole to diastole are seen on the screen to be ampler after active exercise.

Apex Beat. — The impulse felt on the chest wall is not always the beat of the apex of the heart; but in health is sometimes the blow given by the ventricle against the chest wall. This point is easily demonstrated by the X-rays, for, on looking into the chest, the anatomical apex may sometimes be seen lower down than the point where the impulse is felt. In disease, when the heart is displaced to the right, the impulse felt to the right of the sternum and attributed to the apex, is in some instances the blow from the right ventricle. The following case is illustrative: —

Bernard McL.,¹ nineteen years old, entered my service at the hospital February 11, 1897. Diagnosis: pneumonia.

February 13. X-ray examination with screen showed in the right lung a dark area, well defined above and below, as indicated in the tracing (see Fig. 106, chapter on Pneumonia), and that the outlines in the whole chest were rather less clear than normal.

The apex beat of the heart, indicated in the tracing by the letter *A*, appeared to be in the fourth interspace 8.25 centimetres from the mid-sternal line, whereas the X-ray examination showed that the real apex of the heart was more than 2.5 centimetres below this point.

If the apex beat is especially well marked, it suggests that the pulsations are stronger than normal, or that the heart is held against the thoracic wall more firmly than usual, either by a lung denser than normal or by a *somewhat* emphysematous lung. If the lung is so emphysematous that it intervenes between the heart and the chest wall, of course the apex beat could not be seen on the chest by the unaided eye.

It is evident that in studying the heart it is well to examine its outlines on the fluorescent screen, during both inspiration and expiration, but they are most fully brought out when the patient takes a deep breath. If studied during the various phases of the respiratory movement, nearly the whole of the left, and, as a rule, more or less of the right, border of the ventricles may be seen. The following diagram is illustrative of this (Fig. 157):—

EXPERIMENTS MADE BY LUDWIG AND HESSE ON THE FORM OF THE HEART IN SYSTOLE AND DIASTOLE

In connection with the changes in the size of the normal heart as seen on the fluorescent screen, the experiments made by Ludwig and Hesse on the physiology of this organ, and published in 1880 ("Beiträge zur Mechanik der Herzbewegung," *Arch. für Anat. und Phys.*, p. 329) are of interest. I will therefore take up this subject briefly, using for the most part the lecture by Donald Macalister ("Remarks on the Form and Mechanism of the Heart," *Brit. Med. Jour.*, October 28, 1882), though practitioners who are interested in this question will find it well worth while to consult the original.

¹ This case and the tracing are given in the chapter on Pneumonia, so that further details are unnecessary here.

"Galen and Vesalius taught that the heart lengthened in systole; Harvey that it shortened. In the seventeenth century the famous medi-

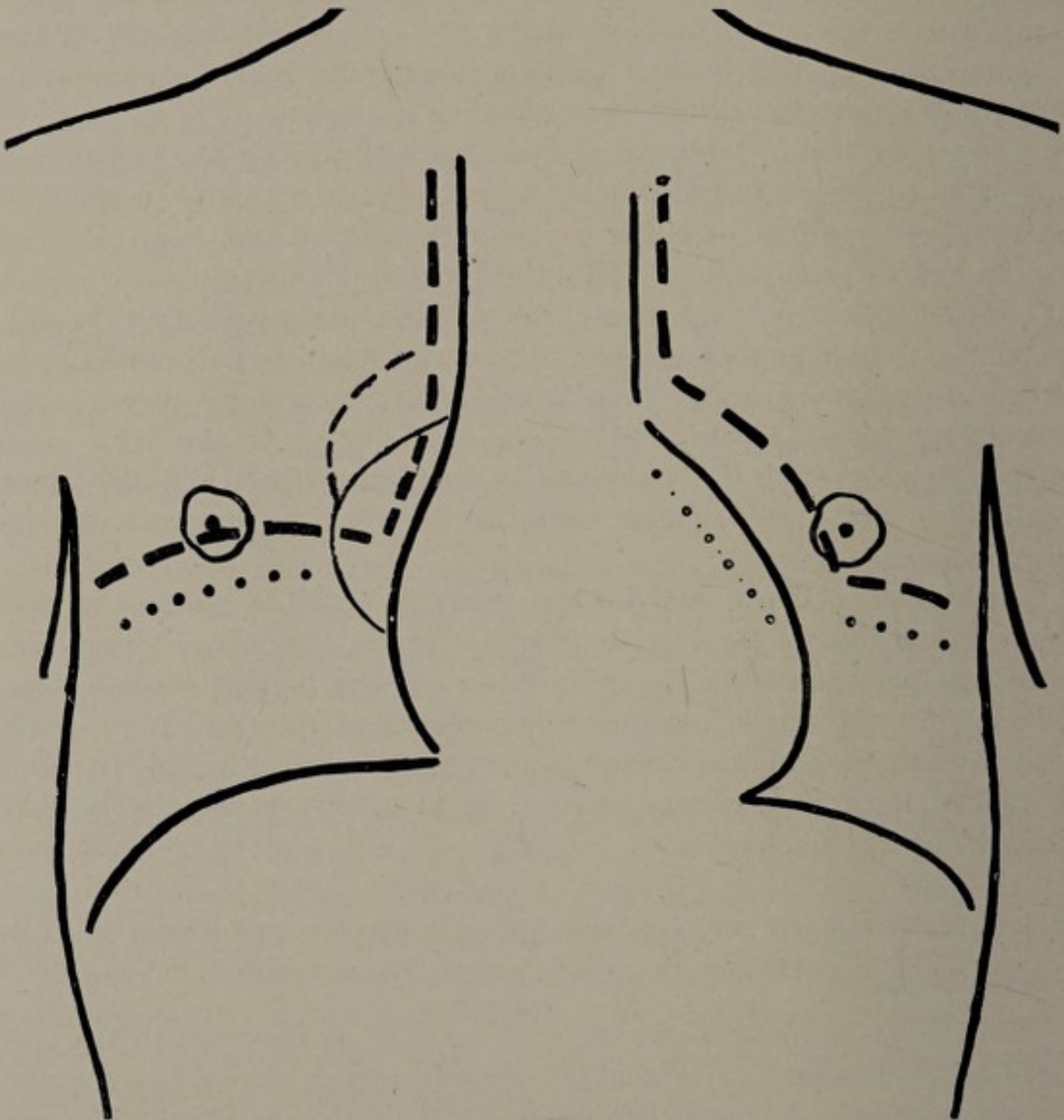


FIG. 157. Diagram of heart movements.

Diagram representing the borders of the blood vessels, heart, and diaphragm — the full lines in deep inspiration, the broken lines in expiration, the dotted lines just below the broken ones the position of the diaphragm in ordinary inspiration.

The line of large and small dots inside the left border of the heart shows the position of the left border in systole, the full line in diastole, during full inspiration. The other movements of the heart — namely, those of the apex, the right ventricle, and the right auricle — are not indicated in the diagram.

cal schools of Montpellier and Paris fought fiercely, but chiefly with dialectic weapons, on Galen's side and on Harvey's, respectively. At length Bassuel asked triumphantly, 'How, if the ventricle lengthens, can the

auricular valves, anchored to its walls by the tendinous cords, ever succeed in closing?' No answer was forthcoming from the south, and so victory remained in Paris. Since then the text-books tell you that the heart shortens when it contracts. It is not hard to see how Harvey, and other observers since, have got this impression from watching the still acting heart *in situ*."

* * * * *

The procedure adopted by Ludwig and Hesse to obtain the form of the heart in diastole and systole was as follows:—

"A dog is rapidly bled from the carotids; the chest is opened; the auricular vessels are ligatured; straight, graduated glass tubes are tied into the pulmonary artery and the aorta, and the heart is then removed from the body and suspended by the tubes, which are kept vertical. The blood of the animal has been meanwhile freed from fibrin, and it is now poured into the vertical tubes so as to dilate the ventricles, until the pressure is equal to the mean blood pressure during life (150 millimetres). The auricles at once begin to pulsate rhythmically, and continue to do so for nearly an hour. The ventricles remain soft, pliable, and irritable all this time. The heart muscle, in contact with nutrient blood, and prevented from cooling or drying, is in fact alive. Certainly for the first few moments of this hour no change in its vital properties can have occurred. Little pins are quickly inserted into the muscle at certain spots to serve as reference marks, and then a thin layer of very quickly setting plaster is lightly applied. A minute or two is enough to let this harden sufficiently, and then it is broken off by a skilled hand, who is able to set together the pieces again, and so to form a mould from which casts may be taken. . . . It was in this way, then, that this cast of the diastolic heart was made. . . ."

"To obtain this [a cast of the same heart in typical systole] the heart, still living and uninjured (for the auricles still pulsate), is emptied of blood, and then plunged quickly into a hot saturated solution of bichromate of potassium at 50° Cent. (Fahr. 122°). One rapid and final contraction of the ventricular muscles takes place; this is permanent, for the muscle passes into *rigor caloris*, . . . and in this state it is fixed, and its textures hardened, without shrinkage or alteration by the bichromate. We can let it stay in the solution till the hardening is complete, and take a cast of its outward form at leisure."

Casts of the outward form of the heart being thus obtained, Ludwig

and Hesse proceeded to get casts of the form of the cavities of each ventricle. The method was necessarily different, for, although plaster could be poured into the dilated cavities, the mould could not be set free without destroying the heart. Therefore, after making preliminary experiments with several pairs of young dogs, two were taken of the same make and size from the same litter. They were similarly fed and grew together, and it was found after death that the hearts were similar as were the dogs. The heart of one of these dogs was dilated, as in the first experiment, with its own blood, and then lowered into cool bichromate solution; it was thus slowly hardened in its diastolic form. The heart of the other was brought to contract by hot bichromate solution and hardened in systole. When the hardening was complete, casts of the cavities were made in plaster or fusible metal, and corresponding transverse sections of the two hearts were cut to show the relation of the walls to the lumen. On comparing these corresponding transverse sections it was found that the muscle area was the same in systole and diastole. Any change in the contents of the outer circumference was entirely at the expense of the lumina. This experiment shows that the systole is effected by the diminution of the cross section everywhere without change of the length.

The article goes on to indicate the reason why the heart changes its form in this way.

"The arrangement of the muscular fibres of the heart is extremely complex. If it were composed of circular fibres alone, it is plain that, as they contracted so that the circumference of each ring shortened, its thickness must at the same time increase. The result would be that the heart would lengthen on the whole. If the heart were mainly made of longitudinal fibres, they would thicken and shorten simultaneously when they contracted, and the heart would shorten on the whole. In the actual heart both sets are present, and they conspire as to the diminishing of the cavity, but they conflict as to changing the length of the heart. The result is, on the one hand, increased efficiency in expelling the blood; on the other, a balance between the opposing forces which keeps the length of the heart unchanged. This latter balance is not an idle refinement. The mutual checking and restraining of each other's play calls out the elasticity as well as the contractility of the muscles. In systole they are in strained equilibrium. The result is that, as soon as the effort of contraction ceases, the elastic action will set up a springlike reaction, and the ventricles begin to dilate actively.

. . . Marey and Fick, Goltz and Gaule, . . . have shown that in the beginning of diastole there *is* such an active element in the dilatation."

Appearances seen on the Fluorescent Screen to the Right of the Sternum.—The appearances seen on the screen to the left of the sternum can be readily interpreted, but those on the right border of the sternum may vary in different individuals and may sometimes be quite puzzling; therefore to properly interpret them it is necessary not only to carefully study them, but also to study the measurements showing the position of the blood vessels and the right auricle and ventricle during expiration and full inspiration.

On the right of the sternum the shadow of the blood vessels may be seen in expiration, but not always that of the right border of the right ventricle.

I have studied the position of the blood vessels and of the borders of the heart at autopsies made at the Boston City Hospital, and taken measurements of the position of this organ after death, but the number observed was too few to afford a basis for positive conclusions. The measurements obtained, however, show, when compared with the appearances which I have seen on the fluorescent screen, that the position of the right border of the heart with reference to the sternum varies in different individuals, and also under different pathological conditions brought about by disease in itself or in neighboring organs. For instance, in a man who died of arsenical poisoning, I found, after the sternum had been removed, that the right border of the right ventricle was 0.5 centimetres to the right of the median line. When the diaphragm was pulled down, the right border of this ventricle was 1.25 centimetres to the right of this line. It probably could not have been seen in this patient even in full inspiration. The border of the superior vena cava, in the fourth intercostal space, was 4.5 centimetres to the right of the median line (its shadow could have been seen), and the left border of the ventricle was 9 centimetres to the left of the same line.

Again, at the autopsy made on a man who died of pneumonia, I saw that the right ventricle would evidently have reached, during a full inspiration, much beyond the right of the sternum. The right auricle extended from the lower border of the second rib to the lower border of the fifth rib, and 3.5 centimetres to the right of the median line. In the case of a patient with a normal chest, that I had examined radio-

scopically a few days before his death, and on whose skin the outlines of the heart still remained, I found that the heart after death was a little higher in the thorax than in life. These instances show, therefore, that the question of what could and could not be seen on the fluorescent screen should be carefully studied, and measurements taken at autopsies after the sternum has been removed, and both before and after the pericardium has been opened. The distance from the median line to the border of the heart is readily found by measuring the distance from a string stretched from a point midway between the clavicles to the pubes.

We have been observing the movements of the normal heart with the patient lying on his back and the screen on the front of the chest; a better position for an examination than if he were lying on his face and with the screen on his back, because ordinarily the heart is nearer to the front of the chest than to its back. After the heart has been examined with the patient in this position, he may be turned on one side or the other, or lie on his face, or partly on one side, if it is desired to see the heart from different directions. The physician should familiarize himself with the outlines of this organ as seen when the patient is placed in different positions.

If the patient lies on his right side, with his arms held forward or up so that they will not be in the way, and the screen be applied to the left side, and the vacuum tube be so placed that the light is opposite the middle of the right side and the lower border of the heart, a bright area, usually triangular in shape, which, so far as I am aware, was first demonstrated by me,¹ will come into view during deep inspiration. This triangle is made up of three curved lines, the lowest being the outline of the diaphragm; the upper and anterior one, the posterior border of the heart; and the posterior one the outlines of the spine or of the tissues immediately in front of it. This triangle is usually closed at the anterior angle, but did not happen to be in the patient from whom the following diagram was made. The outline of the anterior border of the heart may also be followed in some patients, as well as much of the lower and posterior border.

Likewise, when the patient is examined with the light going through the body from side to side, a space, broad above and narrower below, is

¹"X-Rays in Medicine," Transactions of the Medical Society of the State of New York, January, 1898.

seen between the anterior and upper portion of the heart and the chest wall. This area is seen to widen and lengthen in full inspiration. That is to say, the heart moves downward, and the upper portion slightly backward, as more lung intervenes between the upper part

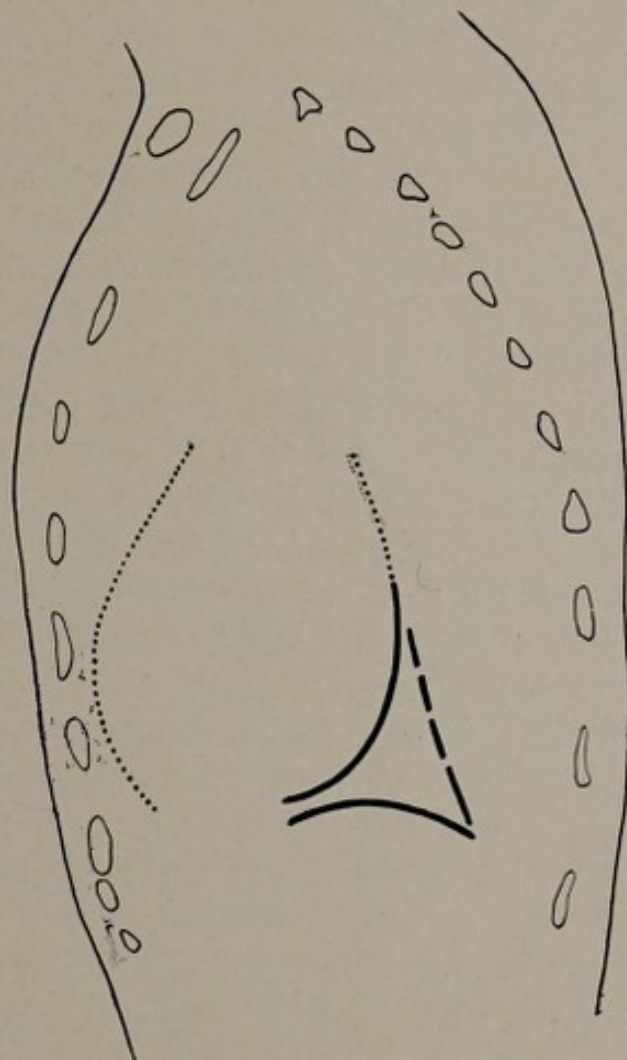


FIG. 158. Triangle.

The outline of the body and the ends of the ribs have been traced from an anatomical plate, which represents a section of the body through the left parasternal line. The heart line and the outlines of a portion of the diaphragm and spine, or rather what lies in front of the spine, form the triangle, and were drawn on the skin, together with the remaining heart lines, while looking through the patient during full inspiration, with the fluorescent screen placed on the left side. These lines were then transferred to the drawing from which this cut was made. The outline of the heart is indicated in the cut partly by a full and partly by a dotted line. The full line shows the extent of the lower and posterior border usually seen in health on the fluorescent screen; the dotted line, the additional amount seen in this individual in health.

of the heart and the front chest wall than between the lower part of this organ and this chest wall. I observed this movement and the consequent increasing of the above-mentioned space very well in one of my patients, J. H., a well-built man twenty years of age, who was

convalescent from typhoid fever. This distance of the heart from the chest wall would prevent an accurate determination of the upper borders of this organ by percussion, especially in full inspiration. (See chapter on Emphysema, page 198.)

The width of the dark area which is back of the sternum and above the heart varies with the position of the patient; it is a little wider when he is lying down than when he is sitting, and in expiration than in deep inspiration. The width of the heart also varies in like manner and from the same cause. The heart and blood vessels are farther away from the screen when the patient is lying than when he is sitting down, and therefore, for optical reasons, the dark area alluded to, and the heart, cast a broader shadow on the screen when he is in the former than in the latter position. This difference in width, however, may be neglected for clinical purposes, if the source of light is at the proper distance from the patient.

Width of Normal Heart. — I found the average width of the heart, as determined by an X-ray examination of forty-eight men, was 3 centimetres from the median line to the right border, and 8.6 centimetres from the median line to the left border; total 11.6 centimetres. In thirty-one women the width was 2.5 centimetres from the median line to the right border, and 8.7 centimetres from the median line to the left border; total 11.2 centimetres. These cases indicate that the heart in women lies a little more to the left than in men, but these observations are of course too few and too incomplete for definitely determining the average width of the heart.

It is important not only to obtain the size of the heart as a whole, but also the size of the right heart as compared with that of the left; and we must always bear in mind the conditions which may draw the heart in one or another direction, or push it one way or another. This point will be taken up later.

If we note carefully the width of the heart on the right side of the median line, as well as of that on the left side, and the total width, we may infer from these figures whether or not the heart is displaced or one side is more enlarged than the other.

Location of the Right and Left Borders of the Heart by Distance from the Median Line.¹ — The determination of the right and left borders of the heart by the distance from the median line is a more accurate

¹ "Location of the Right and Left Borders of the Heart by the Distance from the Median Line," by F. H. Williams, M.D., *Boston Medical and Surgical Journal*, June 21, 1899.

method than the one now generally used, of designating its left border by reference to the nipples, and its right border by reference to the sternum. In women the nipple line is too indefinite to be considered, and in men the position of the nipples varies considerably; for instance, in 21 men in one of my wards at the Boston City Hospital, the distance between the nipples averaged 21.5 centimetres; the shortest distance was 18.5, the longest 25.5 centimetres. In other words, in 21 patients the variation between the extremes was 7 centimetres from nipple to nipple, or 3.5 between the median and the nipple lines. Thus we see that the position of the nipples may vary in their distance from the median line by more than 2.5 centimetres. Such a variation in the size of the heart as this might mean serious disease. The statement that the left border of the heart is a little inside the nipple line would not strike us so forcibly as if we were told that it was 2.5 centimetres farther to the left than in health. Moreover, if we determine the right border of the heart as so many centimetres or inches to the right of, and the left border as so many centimetres or inches to the left of, the median line, we determine not only how much it is to the right or to the left, but by adding the two quantities together we readily get the total width of the heart. The width cannot be obtained so accurately when the right border is determined with reference to the sternum, and the left border with reference to the nipples.

Width of Heart in Relation to Height of Individual.—Levy-Dorn ("Zur Untersuchung des Herzens mittels Roentgenstrahlen," Verhandlungen des Congresses für Innere Medicin, 1899) measured the size of the heart in twenty-four individuals by means of the X-rays, and determined what its normal diameter should be with reference to the height of these individuals. The following table shows his results:—

| HEIGHT. | | | | | | DIAMETER OF HEART. | | | | | |
|---------|---|---|---|---|---------|--------------------|---|---|---|---|--------------|
| 1.25 | . | . | . | . | metres. | 9 | . | . | . | . | centimetres. |
| 1.5 | . | . | . | . | metres. | 11 | . | . | . | . | centimetres. |
| 1.75 | . | . | . | . | metres. | 12 | . | . | . | . | centimetres. |

If the diameter of the heart is considerably greater or less than the figures given, Levy-Dorn considers it indicative of pathological conditions.

Abnormal Heart.—When the heart is in an abnormal condition, we may sometimes obtain a more complete outline of it on the fluorescent screen than when it is normal. A much-distended right auricle may be seen if the lungs are clear, but it frequently happens that when this auricle is much distended the circulation in the lungs is such that the contrast between the shadow of the pulmonary area and the auricle is not sufficiently marked to enable the physician to distinguish between the former and the latter on the screen. On the other hand, if emphysema is present, the lung is unusually permeable by the rays, and there may be a good opportunity to note the size and follow the pulsations of a distended right auricle. The left auricle might, I think, be seen under unusual conditions if it were very much distended. In examining the heart the physician should note carefully whether or not either ventricle is enlarged, or if the right auricle is dilated; also whether or not the heart changes its position during full inspiration and what the changes are. In estimating the enlargement of the heart, the observer should not only consider the increase in the transverse diameter, but also how much the relations between the lower border of the heart and the diaphragm differ from those found in health. In the latter condition there is ordinarily a free space between this organ and the muscle during deep inspiration. The heart is then supported by the blood vessels and does not rest on the diaphragm.

The *lateral borders of the dark area above the heart* are cast by the blood vessels and soft tissues which lie between the backbone and the sternum, and in drawing the outlines seen on the screen we should note with care their lines. Here we get changes in outline due, for example, to the beginning of an aneurism or some new growths, but more frequently to a deviation towards one side or the other, the consequence of displacement by fluid in the opposite dark side of the thorax; or, if the heart is drawn toward the darker side, the displacement may be due to contraction of the lung or pleura on that side.

I have made some hundreds of tracings of heart outlines in various diseases, which indicate not only the size and position, but also the mobility of this organ.

By the use of an instrument which I have devised,¹ it is possible to listen to the heart's sounds while the movements of the heart are followed on the screen. A better form of this instrument has been devised by Dr. Rollins. (See Chapter III, page 60.)

¹ *Boston Medical and Surgical Journal*, October, 1896.

SECTION II

METHODS OF EXAMINATION

Intensity of Light. — In examining the heart with the fluorescent screen, the light should be of suitable intensity, neither too bright nor too faint, as in either case the borders of the heart would be ill defined. In young people special care must be taken that the light is not brighter than necessary, for, if too bright, not merely will the borders of the heart become indistinct, but the whole organ will cast no shadow.

Position of Patient. — When a patient is to be examined, the position in which he is placed should be carefully noted, so that he may assume it again exactly in case a second examination is desired for purposes of comparison. (See Chapter III.)

Recumbent and Sitting Position. — The patient may be examined either lying down or sitting up; in some cases, as stated in Chapter III, the latter position is preferable because the patient cannot lie down with comfort owing to the diseased condition of his heart. The arrangements for an examination in this position have been given in Chapter III.

Errors to be avoided in measuring the Width of the Heart. — In examining the heart for the purpose of measuring its width, there are two sources of error in technique to be avoided; first, that which would result from the unsuitable position of the tube; and second, from the manner of recording the outlines.

Position of Tube. — The tube must be at a considerable distance (70 to 75 centimetres) from the heart in order to avoid an exaggeration of its shadow on the screen. If the heart is much enlarged, the tube should be placed directly under the left border when that is being determined, and moved to a position immediately under the right border when that is to be obtained. (See Chapter III, page 62.) These positions may be determined by the use of the indirect plumb-line already described. The change in the position of the tube prevents the exaggeration in size which would otherwise result. In a normal heart this change is not necessary, as the slight exaggeration that is caused by determining the right and left borders with the tube in the same position can be just about neutralized by drawing the outline of the heart's border on the inner side of the shadow instead of on the outer side.

Position of Screen. — If the patient to be examined is stout, or is a woman with well-developed breasts, so that the screen must be at some

distance from the heart, the size of this organ, especially on its left border, will be exaggerated, that is to say, the shadow will fall too far to the left. Therefore in such cases also the tube must be placed directly under the border to be determined, and this point may be obtained by means of the indirect plumb-line already described.

Tracings on the Skin. — If the outline of the left border of the heart when marked on the skin is in about the same plane as the sternum, its distance from the median line can be measured correctly¹ by stretching a tape measure along the skin from the median line to this point, but if the outline of the left border falls so far to the left that the tape-measure, in following the skin, must go around to the side of the chest, it is evident that the measurement, so taken, from the median line to this point would be too great. To avoid this source of error, one end of the tape-measure should be held at the median line and the measure be then drawn out horizontally, and the left border marked upon it at the point where this outline of the heart would fall when projected upon the measure at right angles to it.

A similar course must be pursued under similar circumstances if the outlines traced upon the skin are retraced on tracing cloth; for if the cloth were folded around the chest and the heart were so enlarged or displaced that the outline of the left border fell upon the curved portion of the cloth, the width of the heart measured upon the cloth would be greater than the reality. Therefore, to avoid this exaggeration, the cloth, like the tape-measure, must be held in a horizontal plane and the line already drawn upon the skin be projected upon the cloth.

The size of the heart would be exaggerated under similar circumstances if the line of the skin were followed from the median line to the left border, in making a measurement of the width as determined by percussion.

Tracings on a Thin Sheet of Glass or a Film of Celluloid. — If, instead of tracing the outlines of the heart directly upon the skin, we put over the screen a thin sheet of glass or a transparent film of celluloid, and draw them upon this glass or film, as the case may be, the shadow of the heart would be projected upon a horizontal plane, and the error just referred to would be avoided. The disadvantage of this method is the fact that it is not easy by its use to determine the median line, but this difficulty can be overcome by the means described in Chapter III.

¹ The error caused by the position of the diaphragm is taken up later in this section and in Section IV.

Comparison of Tracing Cloth with Glass or Celluloid Film. — As most of the measurements in the chest which require accuracy are those about the heart, and as in most cases these lines fall upon the front of the chest, I think as a general rule the more practical way is to draw the outlines upon the skin and then copy them carefully on to tracing cloth, the line of the heart being projected on the cloth if it falls too far to the left to allow the cloth to remain close to the chest and yet be in a horizontal plane.

The tracings given below and belonging to the following case, illustrate two of the sources of error which must be guarded against in measuring the width of the heart: first, that caused by a faulty manner of recording the outlines on the tracing cloth; and second, that due to the position of the diaphragm. They also indicate that points of reference on the tracing cloth or film are necessary in order to avoid the error that might otherwise arise if a comparison were made between the widths of the heart of a given individual determined at different periods of time.

M. C., fifty-three years old. Patient of Dr. H. D. Arnold at the out-patient department of the Boston City Hospital.

Family History. — One brother and one sister died of phthisis.

Present Illness. — Distress and soreness in præcordial region, with dyspnoea and sense of suffocation, worse at night, for two or three weeks. Palpitation. Feet cold and swell at times. Deep breathing causes pain followed by sense of relief.

January 17. Physical Examination. — Arteries very markedly sclerotic; pulse regular and of moderate rate and low tension. Heart impulse seen widely diffused; apex in sixth interspace about 2 centimetres outside nipple. Heart flatness begins about top of fourth rib and extends to right border of sternum. At apex is heard a systolic murmur of great intensity, which is transmitted to back, entirely replaces first sound, and at apex no second sound is heard. The murmur can be heard everywhere throughout the præcordial area and also in neck. At base, second pulmonic was markedly accentuated.

February 11. Thorough and detailed examination by Dr. Arnold at the out-patient department of the Boston City Hospital. Venous and subclavian pulse while lying down, disappears on sitting. Murmur as before.

I examined this patient with the fluorescent screen on February 11 and March 25, 1899, and March 1, 1900, and the results of these X-ray

examinations may be seen in the following figures which were made from tracings taken from the patient's chest on the dates given above. In all of these tracings the borders of the heart obtained by the X-ray examination are indicated by full lines, and those determined by percussion by dotted lines, except in the third tracing, in

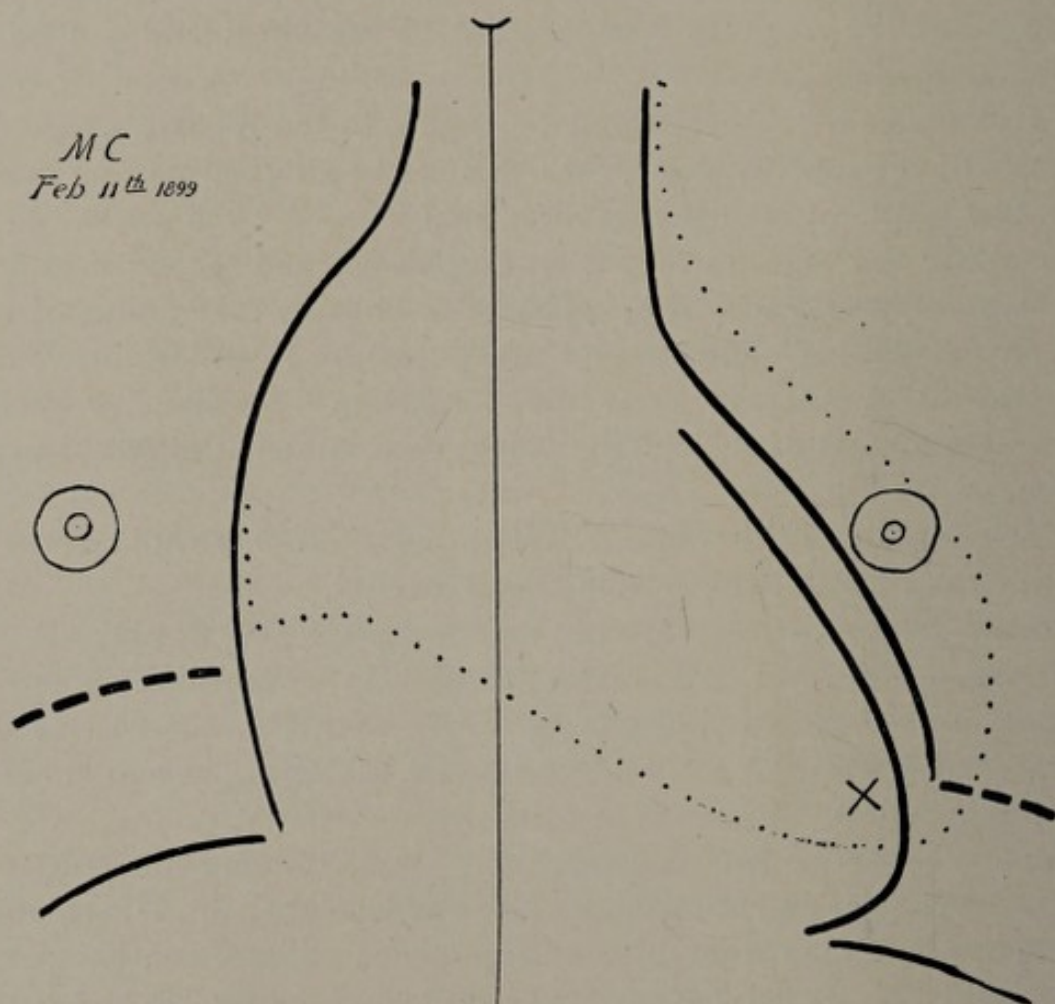


FIG. 159. M. C. First X-ray tracing (one-third life size). Cardiac. The dotted line indicates the cardiac outline as determined by percussion; the full line (except of course the median line and the curve indicating the suprasternal notch) and the broken lines, the outlines of the heart and diaphragm as obtained by the X-rays. The outer full line on the left indicates the position of the heart in expiration; the inner, in full inspiration. The distance between the median line and the left border of the heart as obtained by the X-ray examination is slightly exaggerated, owing to the manner in which the outlines are recorded on the tracing cloth. The error is still greater by percussion.

which the line obtained by percussion for the left border is the same as that by the uncorrected X-ray line, and therefore only one line is given. The agreement in these two lines may be the result of the position of the heart with regard to the chest wall, for when this organ is more nearly in contact with this wall, a larger portion of its border can be

determined by percussion than usual, and therefore by this method the width seems increased.

These tracings are given to call attention to a faulty method of measuring the width of the left side of the heart by the X-rays (Figs. 159 and 160).

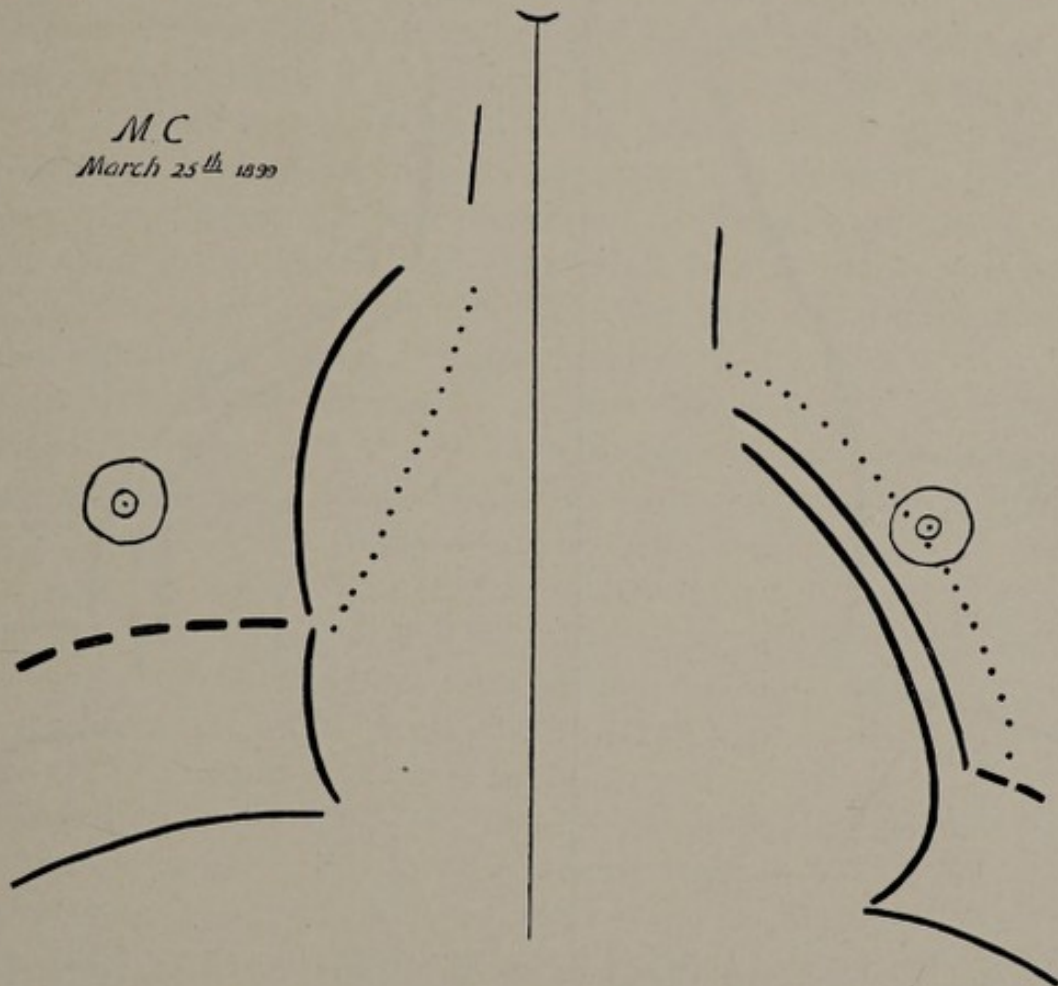


FIG. 160. M. C. Second X-ray tracing (one-third life size). The dotted line indicates the cardiac outline as determined by percussion; the full line (except of course the median line and the curve indicating the suprasternal notch) and the broken lines, the outlines of the heart and diaphragm as obtained by the X-rays. The outer full line on the left indicates the position of the heart in expiration; the inner, in full inspiration. The distance between the median line and the left border of the heart as obtained by the X-ray examination is slightly exaggerated, owing to the manner in which the outlines are recorded on the tracing cloth. The error is still greater by percussion.

Figure 161 illustrates the result of a faulty method of measuring the left border of the heart by the X-rays, but more especially the difference obtained between the width of the heart when it is measured with the diaphragm higher up in the chest than normal, and the width determined when the diaphragm is in its natural position.

Position of Tracing Cloth. — In these tracings the cloth was wrapped round the chest, and therefore the width of the heart between

the median line and the left border is slightly exaggerated in the two first tracings, and very much so in the third tracing. The greatest exaggeration is found in this latter case because the left border, on account of the more horizontal position of the heart obtaining at this

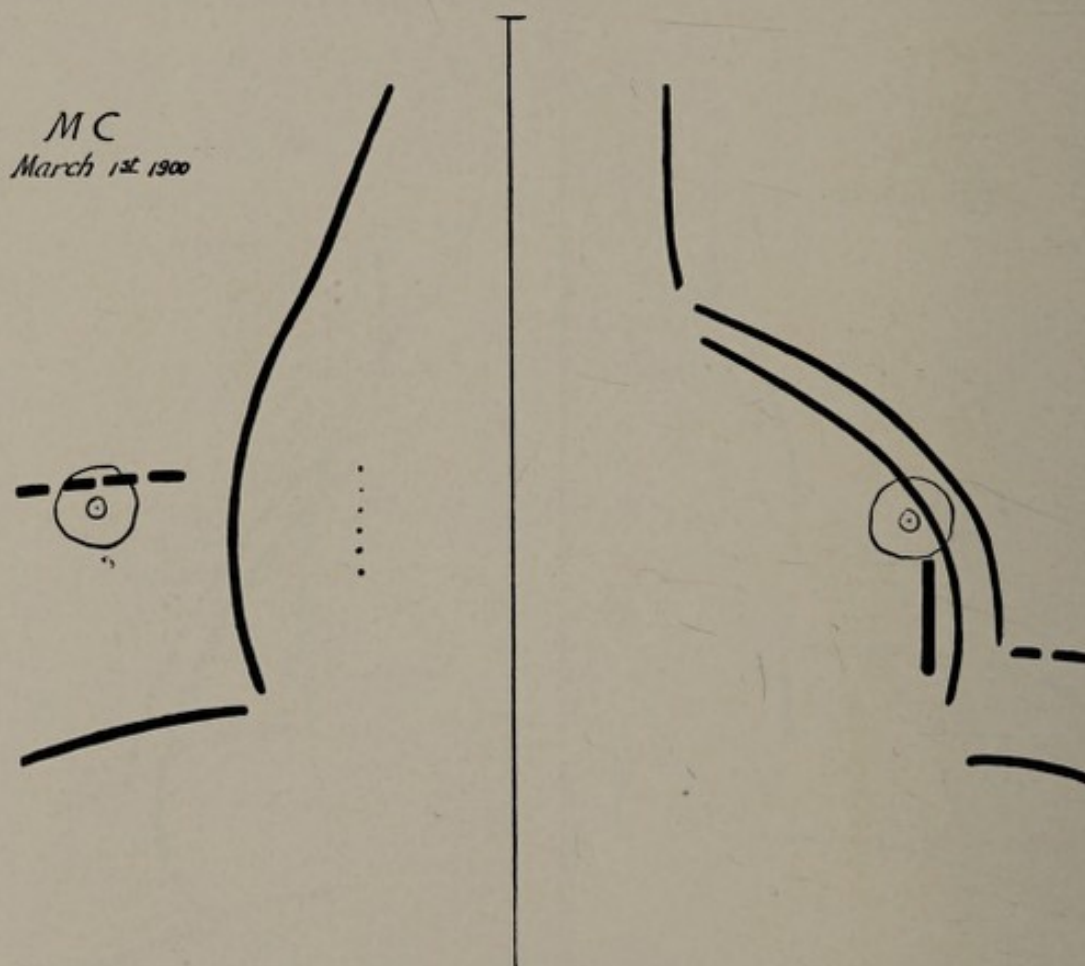


FIG. 161. M. C. Third X-ray tracing (one-third life size). The short vertical line below the left nipple indicates the distance of the left border of the heart from the median line measured in a plane parallel with the front of the chest, by means of the X-rays; the curved lines its too great distance when the outline is traced on the cloth where it lies folded around the body. The line by percussion coincides with this latter line, and, like it, is in error.

As compared with the previous examinations, the heart is increased in width. The diaphragm is now, however, higher in the chest than before, and the long axis of the heart is therefore more horizontal. Another examination, with the diaphragm lower down in the chest, would be necessary in order to have the lines obtained at this examination comparable, as to the width of the heart, with those determined at the preceding ones. The position of the *right* border of the heart by percussion is shown by the dotted line.

examination, and perhaps greater enlargement falls farther to the left than at the two former examinations, and therefore the tracing cloth went farther round the chest. It is evident that the farther the cloth must curve round the chest to reach the left border of the heart, the longer will be the line following the skin which extends from the median line

to the point marking this left border, and the more will it differ from the line giving the width of the heart when measured in a horizontal plane; therefore the error arising from measuring the heart by folding the tracing cloth round the chest increases as the left border of the heart falls farther to the left. The third tracing best illustrates the error made by the improper position of the tracing cloth. The width of the heart between the median line and its left border, which extends beyond the nipple line in expiration, is 13.5 centimetres, but the width obtained by holding the cloth in a horizontal plane, as already described, and projecting the left border upon it, is 12 centimetres; that is to say, the difference in the width due to the two positions of the tracing cloth is 1.5 centimetres. The heart is also wider than normal in this tracing apart from its possible enlargement, on account of the position of the diaphragm, as stated below.

Error Greater by Percussion. — These diagrams also show that in determining the width of the heart, not only by X-ray examination but also by percussion, we must measure the distance from the median line in a plane parallel with the front of the chest, and not from the median line around the chest. This source of error is not one which is special to X-ray examinations. It will be observed in two of the tracings that the error made by folding the cloth around the chest and then tracing the outlines of the left border of the heart, as seen by the X-rays, upon it, was not so great as that made by percussion.

Position of Diaphragm. — If these tracings are compared it will be seen that the width of the heart is much greater in the tracing made in March, 1900 (the third X-ray examination), than in the other two. This greater width may be partially due to increase in size, but two other causes certainly are concerned. The first is the position of the diaphragm. This muscle was higher up in the chest when the third tracing was made than when the previous ones were drawn, and the axis of the heart was therefore more horizontal (see Section IV); the second is the position of the tracing cloth.

Points of Reference. — These tracings also call attention to the necessity of the points of reference, for if the tracings had been made on a transparent film placed above the fluorescent screen, and the nipples and sternal notch had not been indicated on the tracing cloth when held horizontally on the chest, another error referred to above (see page 265) would have arisen. That is, when the lines shown on the third tracing were compared with those of the other two, the change in

width noted might have been ascribed as wholly due to enlargement of the heart, but for the nipples as points of reference, whereas, with these, it is clear that the diaphragm was higher and the axis of the heart more horizontal in the tracing made in March, 1900, than in those made in 1899.

Photograph of Heart. — A photograph of the heart, taken during full inspiration, gives a definite outline and leaves no room for doubt in regard to the trustworthiness of the X-ray determinations of the borders of the heart, if these are made under suitable conditions and with proper precautions. The photograph is best made during a deep inspiration as already stated.

Comparative Value of Radiograph and Screen in Examinations of the Heart. — The photographic method is not so satisfactory as the screen for examinations of the heart, for the pulsations blur the outline in the photograph somewhat, and the changes in position during different stages of respiration cannot be studied by this method as on the screen. Further, time is necessary to take a photograph and develop it, and this delay prevents the physician from gathering directly the results of all the different methods of examination for the purposes of diagnosis.

SECTION III

THE IMPORTANCE OF KNOWING THE SIZE OF THE HEART. INACCURACY OF PERCUSSION IN DETERMINING ITS SIZE AS SHOWN BY X-RAY EXAMINATIONS

In cardiac diseases the size of the heart is of the utmost importance, not only in diagnosis, but also in prognosis.

Prognosis. — If, for example, we find by examining the heart from time to time that its size is increasing, and that this enlargement is due to dilatation, the prognosis would be unfavorable. If, on the other hand, we find, especially in the acute forms of relaxation of the cardiac walls from overwork, overstrain, etc., that the size of the heart is diminishing under rest and suitable remedies, we have additional evidence on which to base a favorable prognosis. It is important to know the size of the heart as a whole, as well as the size of the right heart as compared with the left, as already stated; it is also important to watch changes going on in the left, — and in the right side of the heart so far as may be, — to observe the increase of this organ brought about by the insuf-

iciency in the valves due to the relaxation of the circular fibres about the auriculo-ventricular opening on one side, or the papillary muscles on the other, which gives rise to murmurs that may cease when the heart approaches more nearly the normal size again.

Diagnosis. — In the minds of many, cardiac enlargement is chiefly associated with valvular disease, but there are other causes acting outside the heart which may give rise to an increase in the size of this organ. A murmur is to some pathognomonic of heart disease; but this indication is not to be wholly relied upon, for we may of course have murmurs without organic cardiac disease, and cardiac disease without murmurs.

If the heart is larger than normal, we have an indication of disease which has its origin either inside or outside of the heart; except, of course, in those cases in which physiological hypertrophy exists as a result of athletics, or of the excessive amount of work entailed by some occupations. On the contrary, if the size is normal, it is not probable that any serious chronic lesion of the valves is present in a young person.

It is also important to know when the heart is smaller than normal, for those persons whose hearts are not as large as the body demands should avoid pursuits and exercises beyond their strength. With the usual means of examination a small heart is frequently overlooked.

A brief reminder of some of the conditions in which the size of the heart departs from that found in health is in place here, since the importance of knowing its size may be best appreciated by considering the conditions under which this occurs. I shall exclude from this category the acute changes in the size of the heart which may accompany excessive exercise, or acute diseases such as pneumonia, or acute dilatation of the heart.

The chief causes of enlarged heart may be divided into two groups: first, those acting from within the heart wall; second, those from without. In this first group, according to Howard, are valvular lesions, and, of less frequent occurrence, fatty heart, tuberculosis, and aneurism of the heart.

In the second group, causes originating outside of the heart are in the order of their frequency: —

- | | |
|---------------------------------------|------------------------|
| Arterio-sclerosis. | Pericardial adhesions. |
| Nephritis. | Excessive work. |
| Alcoholic intemperance. | |
| Tumors (pressing on vascular trunks). | |

Causes involving enlargement of the right side of the heart are obstructions in the pulmonary circulation, and these are found in various pulmonary diseases, especially emphysema.

The recognition of an enlarged heart may not only warn us of the presence of an otherwise unsuspected valvular lesion, arterio-sclerosis, or chronic nephritis, but if its borders are well determined they may also assist us in recognizing the gravity of the conditions causing the enlargement, and careful determinations of the size of the right and left ventricles may aid us in prognosis.

Let us now consider whether or not our present methods enable us to determine the size of the heart with accuracy.

Comparison of Percussion and X-Ray Examination. — In a considerable number of cases which I have examined during the past five years, I first determined the borders of the heart by percussion and recorded these outlines on the skin with a blue pencil, and then determined the outline of the heart by an X-ray examination and drew these outlines with a black crayon. On comparison of these two sets of lines I was much struck by their frequent discrepancy in either one or more borders of the heart, and by the greater completeness of the cardiac outlines as obtained by X-ray examination.

Width of Heart obtained by Percussion compared with Weight of Heart obtained at Autopsy. — It occurred to me to test still further the accuracy of the determination by percussion of the right and left borders of the heart, by comparing the *width* of the heart as found in the clinical record with the *weight* of the heart as determined by the post-mortem examination. — It is obvious that this method of comparison may err, for a heart may be so distended during life as to give a large cardiac area to percussion, although it may not weigh much more than normal. On the other hand, if the weight of the heart is much increased, it must have been enlarged during life. — With this end in view I attempted to compare the size of the heart in one thousand patients as found by percussion and given in the clinical records of the Boston City Hospital, with its weight as found in one thousand consecutive autopsies, including both medical and surgical cases. For the use of the autopsy records I desire to thank Dr. W. T. Councilman, under whose direction the pathological department of the hospital is conducted.

Four hundred and fifty-four cases were *not* used for the following reasons : —

1. The patients were under twenty years of age.
2. No heart weights were given.
3. The records were incomplete.
4. The patients had emphysema, or were stout, and in these cases *percussion* is at a great disadvantage.

Five hundred and forty-six cases were used.

The average weights of hearts, as determined by Dr. H. D. Arnold at the Boston City Hospital, is 290 grammes for men and 260 grammes for women. I have divided the 546 cases (370 men and 176 women, the men and women being classed separately) into six groups each, according to their weight, as will be seen in the following table, marked *A* :—

A.—HEART WEIGHTS COMPARED WITH HEART WIDTHS

MEN. AVERAGE WEIGHT IN HEALTH 290 GRAMMES

Group I.—Weights below 225 grammes. Nine cases.

7, area normal by percussion.

1, area enlarged by percussion. Small size not recognized in 88 %.

Group II.—Weights 225–349 grammes. One hundred and sixty-eight cases.

11, area diminished by percussion.

Group III.—Weights 350–399 grammes. Seventy-four cases.

56, area normal by percussion.

6, area diminished by percussion. No enlargement recognized in 83 %.

Group IV.—Weights 400–449 grammes. Twenty-six cases.

15, area normal by percussion.

1, area diminished by percussion. No enlargement recognized in 61 %.

Group V.—Weights 450–499 grammes. Twenty-four cases.

9, area normal by percussion. No enlargement recognized in 37 %.

Group VI.—Weights 500 grammes and over. Sixty-nine cases.

18, area normal by percussion.

1, area diminished by percussion. No enlargement recognized in 27 %.

WOMEN. AVERAGE WEIGHT IN HEALTH 260 GRAMMES

Group I.—Weights below 200 grammes. Eight cases.

7, area normal by percussion. Small size not recognized in 87 %.

Group II.—Weights 200–324 grammes. Ninety-nine cases.

¹ 12, area enlarged by percussion.

Group III.—Weights 325–374 grammes. Twenty-six cases.

17, area normal by percussion.

1, area diminished by percussion. No enlargement recognized in 69 %.

¹ The weights of these 12 hearts were as follows: One weighed 230 grammes; two, 245; one, 250; one, 260; one, 270; one, 280; four, 300; one, 315.

Group IV. — Weights 375-424 grammes. Fifteen cases.

5, area normal by percussion.

2, area diminished by percussion. No enlargement recognized in 46 %.

Group V. — Weights 425-474 grammes. Twelve cases.

4, area normal by percussion.

1, area diminished by percussion. No enlargement recognized in 41 %.

Group VI. — Weights 475 grammes and over. Sixteen cases.

1, area normal by percussion.

1, area diminished by percussion. No enlargement recognized in 12 %.

This comparison between the *weight* of the heart as determined at the autopsy and the *width* of the heart as obtained by percussion shows that : —

Group I. — Men. In 9 men with hearts weighing below 225 grammes (average weight of normal heart 290 grammes), the diminished size was not recognized by percussion in 88 per cent of the cases. The number of cases in this group is small, but in the corresponding Group I of the women the results are similar; some hearts, of course, in both these groups may have been dilated during life.

Group II. — In 168 men with hearts varying in weight from 225 to 349 grammes, a variation which I have allowed as normal either side of the 290 grammes, 11 were diminished in size by percussion. The weights of these 11 were as follows : —

| I weighed 250 grammes | | | | I weighed 320 grammes | | | |
|-----------------------|---|-----|---|-----------------------|---|-----|---|
| 1 | " | 280 | " | 1 | " | 325 | " |
| 2 | " | 290 | " | 1 | " | 330 | " |
| 1 | " | 300 | " | 1 | " | 340 | " |
| 2 | " | 310 | " | | | | |

Group III. — In 74 men with hearts weighing from 350 to 399 grammes (average weight of normal heart 290 grammes) no enlargement was recognized by percussion in 83 per cent of the cases, and 6, indeed, were even recorded as smaller by this means of examination.

Group IV. — In 26 men with hearts weighing from 400 to 449 grammes (average weight of normal heart 290 grammes) no enlargement was recognized by percussion in 61 per cent of the cases, and, as in the previous group, 1 was diminished.

Group V. — In 24 men with hearts weighing from 450 to 499 grammes (average weight of normal heart 290 grammes) no enlargement was recognized in 37 per cent of the cases.

Group VI. — In 69 men with hearts weighing 500 grammes and over (average weight of normal heart 290 grammes), no enlargement was recognized by percussion in 27 per cent of the cases, and one was recorded as diminished in size by this method.

It is not necessary to go over the table for women in detail, as it is of similar import.

In this comparison I have given the clinical record the benefit of the exclusion of all cases of emphysema and stoutness.

It is worthy of notice that both these tables show that when the heart is about normal the error made by percussion is least frequent; when smaller than normal, very frequent; when somewhat enlarged, nearly as frequent; as the heart grows larger and larger, the frequency of the error made by percussion decreases, but the amount of error in a given case becomes greater.

Let us now return to Group IV for a moment. In this group of 26 men, with hearts weighing from 400 to 449 grammes, no enlargement was found by percussion in 16 of the cases; in only 2 of these were there murmurs; in the remaining 10, which were recognized as enlarged by percussion, 4 had murmurs.

In Group V, 24 men, with hearts weighing from 450 to 499 grammes, 9 hearts were given as normal by percussion; in only 2 of these were there murmurs; in the remaining 15, which were recognized as enlarged by percussion, 8 had murmurs. This may mean that when murmurs are found closer attention is given to the size of the heart.

It is evident from the comparison we have made between the size of the heart as obtained by an autopsy and by percussion that the latter method is inaccurate; but the cases are too few to determine the amount of the inaccuracy.

Comparison of Percussion with X-Ray Examinations in determining Width of Heart. — Now let us see how percussion stands as to accuracy when compared with an X-ray examination, a method which, like percussion, is used during life. It is unnecessary to compare the two methods of determining the outlines of the heart so far as completeness goes; the X-ray examination gives much fuller outlines.

First, let us examine the table marked *B*, which gives the result of this comparison in 155 cases of various diseases. The left border in these cases was determined by its distance from the median line in both methods of examination. I have taken the left border in comparing the two methods because it is the one more easily determined by percussion.

The figures give the *difference* in the distance of the left side of the heart from the median line as determined by percussion and X-ray examination in each patient. The comparison shows that percussion is in error in a certain proportion of cases (how large a proportion it is yet too early to estimate), and unfortunately we cannot in practice determine without using the X-rays in which cases percussion is wrong. The plus mark means that percussion made the heart larger than did the X-ray examination, and the minus mark that percussion made the heart smaller.

The table consists of four double columns; in the first column the difference between the left border as determined by percussion and X-ray examination was less than 1 centimetre. This we will call agreement.

In the second column the difference was 1 centimetre or more, and less than 2.

In the third column the difference was 2 centimetres and less than 3.

In the fourth column the difference was 3 centimetres or more. The table also shows that the disagreement between the two methods was about as often plus as minus in the 155 cases.

In the cases in the left-hand side of each double column the total width of the heart by an X-ray examination was less than 13 centimetres; in those in the right-hand side it was 13 centimetres or more.

This table shows the discrepancy between the position of the left border from the median line as obtained by X-ray examination and percussion, but the cases (155) are too few in number by which to measure the exact amount of discrepancy that would obtain as a rule between these two methods.

B. — DIFFERENCE OF X-RAY AND PERCUSSION DETERMINATIONS OF LEFT HEART BORDER ON LEVEL WITH NIPPLE, DURING EXPIRATION IN 155 CASES.¹ (81 MEN, 44 WOMEN, 30 CHILDREN)

| MEN | | | |
|-----------------|------------------|-------------|-----------------|
| Less than 1 cm. | 1-2 cm. | 2-3 cm. | 3 cm. and over. |
| | Aneurism. | Aneurism. | |
| | +1.75 -1.75 | +2.50 | |
| Bronchitis. | Bronchitis. | Bronchitis. | |
| .0 | +1.50 | +2.00 | |

¹ + means percussion made the heart larger than the X-ray examination. — means percussion made the heart smaller than the X-ray examination.

The left-hand column in each of the four double columns contains the cases in which the heart's width was less than 13 centimetres; the right side those in which it was 13 centimetres and over.

MEN (*Continued*)

| Less than 1 cm. | 1-2 cm. | 2-3 cm. | 3 cm. and over. |
|--------------------------|--------------------------|-------------------------|---------------------------------------|
| Arterio-sclerosis. .0 | Nephritis. + 1.00 | | New Growth. - 3.25 |
| Cardiac. .0 | Cardiac. + 1.25 | Cardiac. + 2.00 | Cardiac. - 3.00 |
| .0 | + 1.50 | + 2.00 | + 3.00 |
| .0 | + 1.50 | + 2.00 | |
| .0 | - 1.00 | + 2.00 | |
| .0 | + 1.00 | - 2.00 | |
| .0 | - 1.50 | - 2.50 | |
| .0 | - 1.00 | - 2.25 | |
| .0 | + 1.00 | | |
| .0 | | | |
| .0 | | | |
| .0 | | | |
| .0 | | | |
| .0 | | | |
| Rheumatism. .0 | Rheumatism. + 1.50 | Rheumatism. - 2.25 | |
| .0 | + 1.40 | | |
| Pleurisy. .0 | Pleurisy. - 1.50 | | Pleurisy. - 3.00 |
| Tuberculosis. .0 | Tuberculosis. - 1.50 | Tuberculosis. + 2.00 | Tuberculosis. - 3.25 |
| .0 | - 1.50 | + 2.50 | |
| .0 | - 1.25 | + 2.00 | |
| .0 | + 1.00 | | |
| Meningitis. .0 | | | Pericardial Ad- hesions. - 4.00 |
| Pneumonia. .0 | Pneumonia. - 1.25 | Pneumonia. - 2.50 | |
| .0 | + 1.25 | + 2.00 | |
| .0 | - 1.50 | | |
| .0 | | | |
| .0 | | | |
| Typhoid Fever. .0 | Typhoid Fever. + 1.00 | | |
| | - 1.00 | | |
| Emphysema. .0 | Emphysema. + 1.75 | Emphysema. - 2.00 | |
| Malaria. .0 | Malaria. - 1.50 | | |

WOMEN

| Less than 1 cm. | 1-2 cm. | 2-3 cm. | 3 cm. and over. |
|---------------------------------|--|--|-------------------------|
| Bronchitis. .0 | | | Aneurism. + 3.00 |
| | Cardiac. + 1.60 - 1.50 + 1.75 - 1.75 | Cardiac. + 2.50 + 2.00 - 2.00 - 2.00 | |
| Anæmia. .0 .0 .0 | | Anæmia. - 2.50 | |
| Rheumatism. .0 | Rheumatism. + 1.00 - 1.50 + 1.50 | Rheumatism. + 2.00 | |
| Pleurisy. .0 | Pleurisy. - 1.00 | Pleurisy. - 2.00 | Pleurisy. - 3.00 |
| Tuberculosis. .0 .0 .0 | Tuberculosis. - 1.50 + 1.50 - 1.50 | Tuberculosis. - 2.50 + 2.00 | Tuberculosis. + 3.50 |
| Debility. .0 | | Arterio-sclerosis. + 2.00 | No Aneurism. + 3.00 |
| Tape Worm. .0 | | Malaria. + 2.00 | Hysteria. + 3.00 |
| | Emphysema. - 1.75 | | |
| Pneumonia. .0 .0 | | Pneumonia. - 2.00 | |

CHILDREN

| | | | |
|----------------------------|--|--------------------|-----------------------|
| Cardiac. .0 .0 .0 | Cardiac. + 1.50 - 1.00 - 1.25 + 1.50 | Cardiac. + 2.00 | |
| Anæmia. .0 | | | |
| | Synovitis. - 1.50 | | |
| | | | Rheumatism. - 3.00 |

CHILDREN (*Continued*)

| Less than 1 cm. | 1-2 cm. | 2-3 cm. | 3 cm. and over. |
|------------------------------------|--|----------------------------------|-------------------------|
| Tuberculosis. .0 .0 .0 | Tuberculosis. - 1.25 | | Tuberculosis. + 3.00 |
| Pneumonia. .0 .0 .0 .0 | | Pneumonia. - 2.00 - 2.00 | |
| Typhoid Fever. .0 .0 .0 | Typhoid Fever. + 1.25 + 1.00 + 1.25 + 1.50 Spinal Meningitis. + 1.25 | | |
| Total 62 | Total 49 | Total 31 | Total 13 |

It should be stated that I have taken pains, from time to time, to get other physicians to determine by percussion the size of the heart in some cases, and I then compared it with that obtained by an X-ray examination; as yet I have found no one whose percussion, like mine in the same cases, did not give the size of the heart incorrectly when tested by an X-ray examination.

If we consider the table (*B*) in a general way, and look at the groups of diseases, it seems that percussion is very likely to err in finding the position of the left border of the heart when it is of the most importance to have accurate information about this organ, namely, in cardiac disease when the heart is enlarged. Percussion also errs when the heart is displaced, and the error under these conditions is, I think, more frequent and on the average greater than when the heart is enlarged.

The following cases, and cases given on pages 285 and 286, illustrate this point:—

Mary F. D. Entered my service at the Boston City Hospital May 7, 1898. The right chest contained fluid which pushed the heart to the left; this displacement was recognized by the X-rays, but not by percussion. It may be that displacements are sometimes not readily recognized by percussion because the heart is pushed into the body of the lung rather than along or near the chest wall. (See Fig. 162.)

Harry M. Fig. 163. Entered my service at the Boston City Hospital January 28, 1899. This case was an unusual one. There was fluid in the left chest which displaced the heart to the right, but as the patient had also at the same time pneumonia in the lower part of the right lung, the heart was not pushed directly to the right, but was forced upward. Hence the right border of the heart was found to the right and above a line joining the sternal notch and the right nipple.

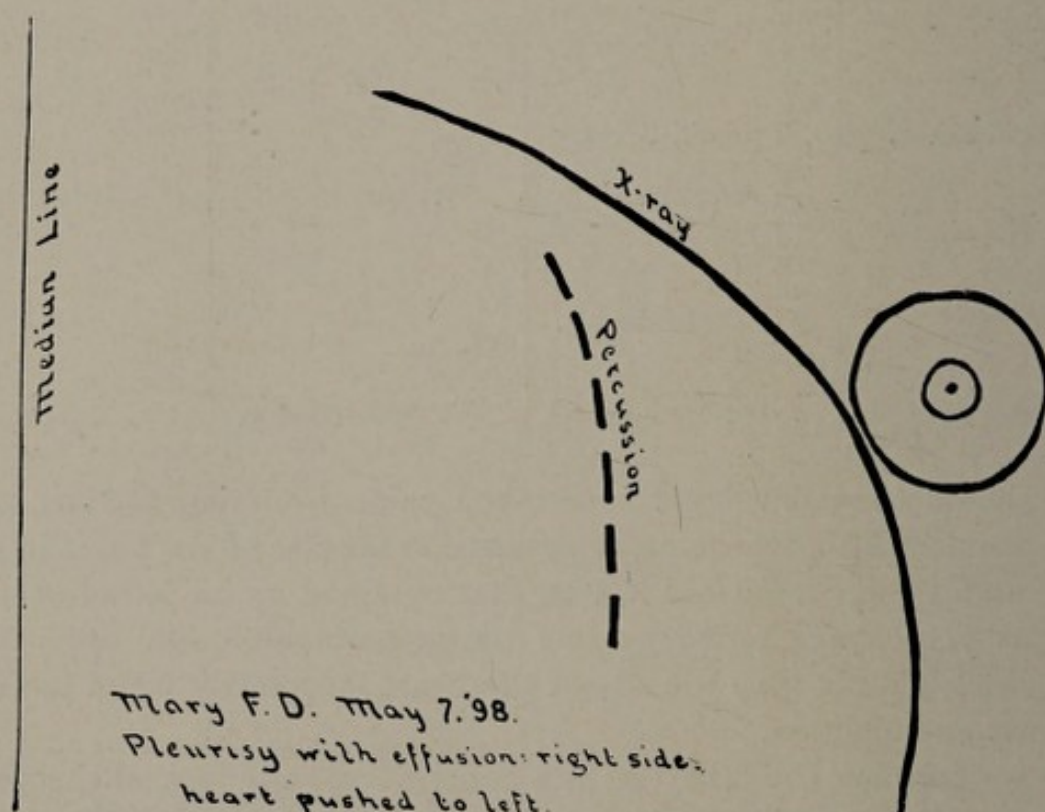


FIG. 162. Mary F. D. May 7, 1898. X-ray tracing. Full line shows the left border of the heart; broken line shows this border as determined by percussion. (Cut one-third life size.)

The following cases show how the left border of the heart, when obtained by percussion, may differ from that seen by X-ray examination. In the first case the percussion line was inside, in the second case outside, of the X-ray line.

John W. M. Fig. 164. Entered my service at the Boston City Hospital December 2, 1898. The X-ray line of the left border of the heart was outside of the percussion line.

Catherine P. Entered my service at the Boston City Hospital December 23, 1898. The position of the left border of the heart as determined by the X-ray examination was inside of the line indicated by percussion (Fig. 165).

In the few cases in which I have had an opportunity to compare the size and position of the heart, as shown by an X-ray examination, with that found at autopsies, they have all agreed; except that after death the heart, as already stated, was somewhat higher than in life.

When the heart is normal in size, its border, so far as it can be obtained by percussion, can usually be obtained correctly if the patient




FIG. 163. Harry M. February 27, 1899. X-ray tracing. Full line shows the position of the right border of the heart; broken line shows its position as determined by percussion. (Cut one-third life size.)

is not too stout and no pulmonary emphysema is present; when it is of abnormal size, whether smaller or greater, this condition may not be exactly indicated by percussion, and an abnormal size of the heart may be overlooked.

In some cases the X-rays show, for example, that by percussion the upper portion of the left border of the heart appears to be nearer the

sternum than is the case. They also show in some cases of a heart enlarged on the left side that, when this organ approaches nearer the side of the thorax than in health, percussion may give dulness closer to the axillary line than normal, because there is too little lung tissue between the left side of the thorax and the heart to give the usual resonance to percussion, and therefore the width of the left heart would be overestimated by percussion.

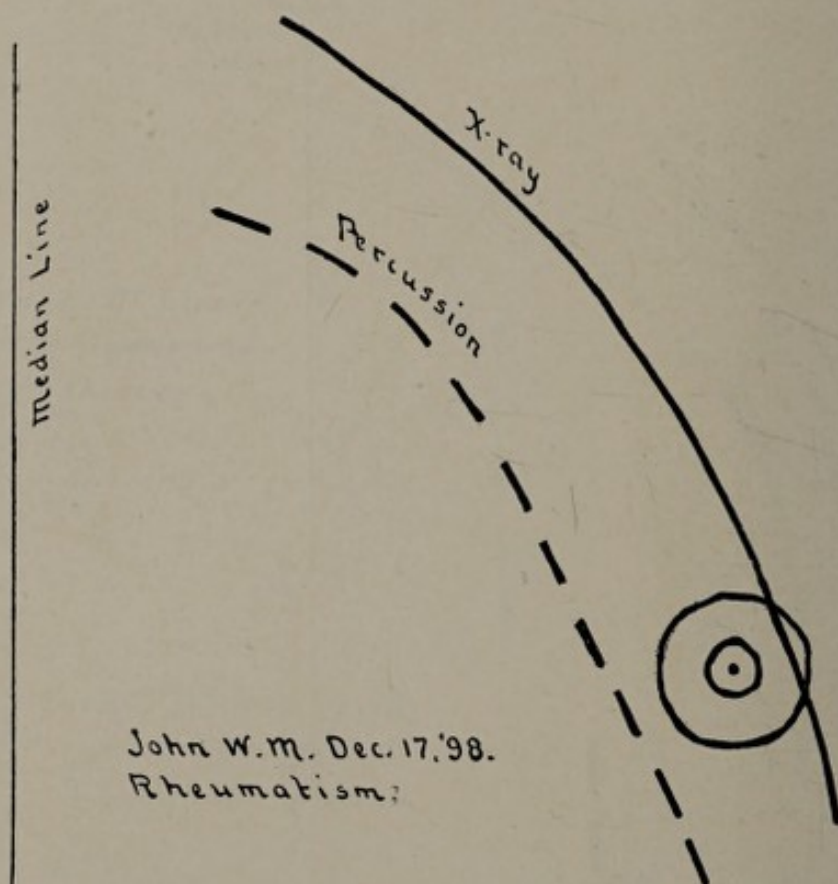


FIG. 164. John W. M. December 17, 1899. X-ray tracing. Full line shows position of left border of heart; broken line, its position as determined by percussion. (Cut one-third life size.)

The right border of the heart is often difficult to place by percussion, because it lies away from the chest wall. The thickness of this wall is another important factor to be taken into account when considering the accuracy of percussion. That is, varying distances of the border of the heart from the chest wall and variations in the thickness of this wall would affect the results obtained by percussion.

In a word, percussion as a rule indicates what lies near the inner side of the chest wall (but not much beyond, as is shown by the failure to determine the cardiac border in pulmonary emphysema); but when

a heart is much enlarged to the left it may lead the practitioner to a wrong interpretation of the conditions present.

Small hearts may be recognized by an X-ray examination, and also the presence of an abnormal condition in congenital malformations. The ability to recognize with certainty that the heart is smaller than normal may be of much service to the patient both in treatment and prognosis.

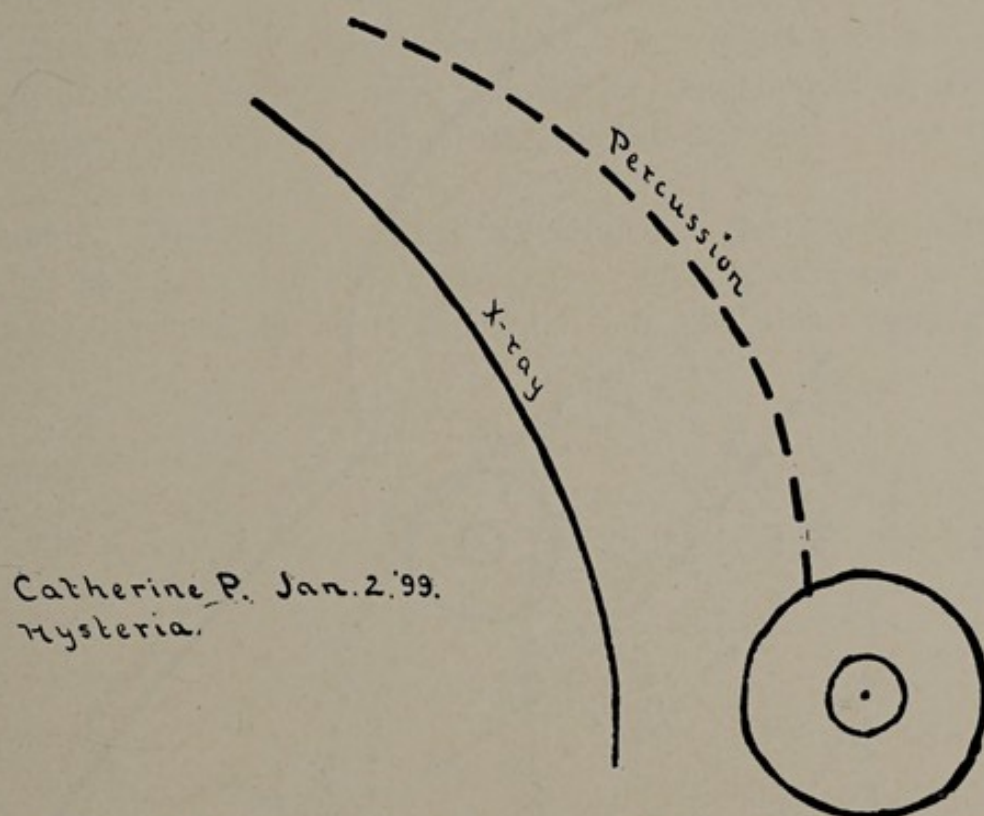


FIG. 165. Catherine P. January 2, 1899. X-ray tracing. Full line shows position of left border of heart; broken line, its position as determined by percussion. (Cut one-third life size.)

If by an X-ray examination we find in any patient (excluding acute diseases) an enlarged heart, we should consider among the probable causes the presence of valvular lesions, arterio-sclerosis (especially in middle age and after), renal disease, and emphysema of the lungs; this last condition would be very obvious by an X-ray examination.

SECTION IV

DISPLACED HEART

We will now further examine the heart when the normal outlines described in the first section have been modified by conditions existing outside of this organ. Various causes acting from without may change

the position of the heart, and this variation in position from the normal may suggest to the physician the diseased condition that has produced this change.

Displacement of the Heart.—The heart is suspended from above, and is surrounded by the pericardium, which is attached to the blood

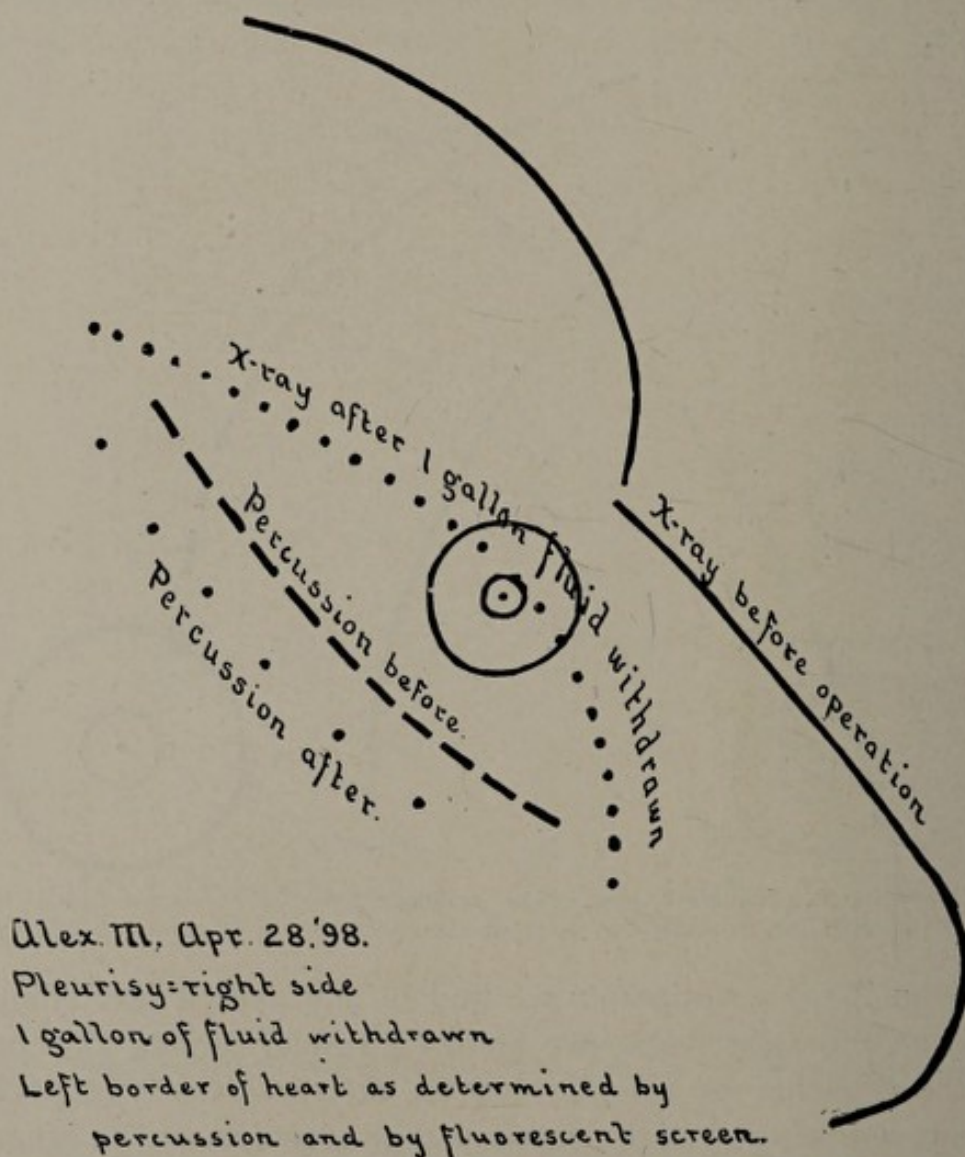


FIG. 166. Alex. M. Cut shows the difference in the position of the left border of the heart as determined by the X-rays and by percussion both before and after operation. (Cut one-third life size.)

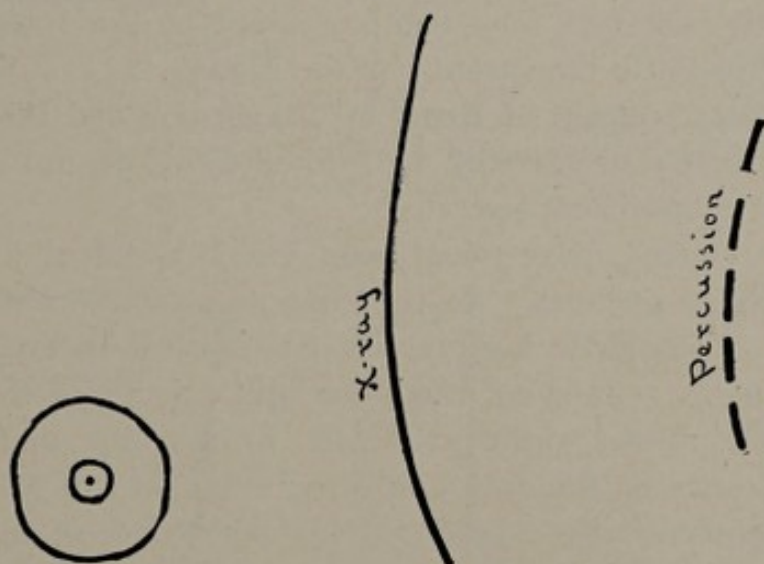
vessels above and to the diaphragm below; and its position may be much changed. It appears possible to find it either pushed or pulled into almost any portion of the thoracic cavity. It may be found so low in the chest that its pulsations are felt under the ensiform cartilage; it may be so pushed to the left that the apex is much outside the nipple line; or upward and to the right, so that the right border is above the

line extending from the right nipple to the inner end of the clavicle (see Fig. 163, Harry M., Section III, page 281); or it may be pushed still farther upward to the very top of the thoracic cavity. Figure 168 (P. S.) shows the diaphragm pushed high up in the chest. The pulsations of the heart could be made out above this point.

CAUSES OF DISPLACEMENT

(a) **Fluid or gas in pleural cavities.** — The heart may be moved to one side or the other by a large amount of fluid or gas in the pleural cavity, more especially in the pleura on the left side. The following cases are illustrative: —

CASE I. Alex. M. Entered my service at the Boston City Hospital April 28, 1898. He had a very large pleuritic effusion in the right side, which pushed the heart far to the left and much outside the left nipple.



Constantin D. Jan. 23, '99.

Pleurisy with effusion left side.

heart pushed to right.

FIG. 167. Constantin D. Cut shows the difference between the right border of the heart as determined by the X-rays and by percussion.

X-Ray Examination with Screen. — The position of the left border of the heart before the fluid was withdrawn is shown by the full line (see Fig. 166); after its withdrawal by the dotted line crossing the nipple. The position of the same border as determined by percussion before the operation is shown by the broken line; after operation by the dotted line inside of it.

CASE II. Constantin D. Entered my service at the Boston City Hospital January 20, 1899.

X-Ray Examination with Screen.—The right border of the heart, which is indicated by the full line (see Fig. 167), was pushed toward the right nipple by fluid in the left chest. The broken line indicates this border as determined by percussion. There was an error of 4.7 centimetres by the latter method. (See also cases in Section III.)

(b) **Changes in Position and Excursion of Diaphragm.**—The position of the heart and the inclination of its long axis seems frequently to depend upon the position of the diaphragm. If the muscle is rather higher than normal, the long axis of the heart becomes more inclined toward the horizontal, and if lower than normal, the long axis approaches the vertical. The heart may be pushed up by the diaphragm when this muscle is forced upward by gas or fluid in the abdominal cavity, and its axis may thus be made more horizontal. By percussion this change in position may be mistaken for an enlargement of the heart to the left, but it would be rightly interpreted by the X-rays.

CASE I. **Displacement of Heart by Diaphragm and Distended Abdomen.**—P. S., forty-four years of age, entered the Boston City Hospital July 1; in Dr. Abner Post's service.

History.—During past twenty-one years had had attacks which were called angina pectoris. In 1885 had an attack of abdominal pain; another in 1894, similar to the present one, but less severe.

Present Illness.—June 29, 1899, cramplike pains in the belly, later localized in the lower right abdomen; in evening began to vomit; bowels moved once on the 29th and three times on the 30th, but not on July 1. At entrance the abdomen was distended, rigid, tender, and tympanitic; tenderness in the region of the appendix; pain in the upper left chest. The heart's border, by percussion, was 2.5 centimetres to the right of the sternum; apex 1.25 centimetres inside of nipple line; dulness on the right of the sternum extended to the clavicle; heart's sounds appeared normal. At 7 P.M. the patient was sitting up, with intense pain in the cardiac region; abdomen rigid; respiration rapid and painful.

July 2. Patient fairly comfortable; less pain around the heart; respiration still increased; stomach did not retain milk; movement of bowels after enema.

July 5. Patient steadily improving; bowels moved by enema without disturbance.

July 7. My *X-ray examination* showed a marked displacement upward of the heart. The diaphragm is also pushed high up in the chest, above the nipples; excursion 1.9 centimetres on the left side; 2.5 centimetres on the right side. Abdominal symptoms have improved, but patient complains of pain in the lower right chest. (See Fig. 168, Paul S., first examination July 7.)

Paul S
Heart Pushed Up
1st Exam July 7th

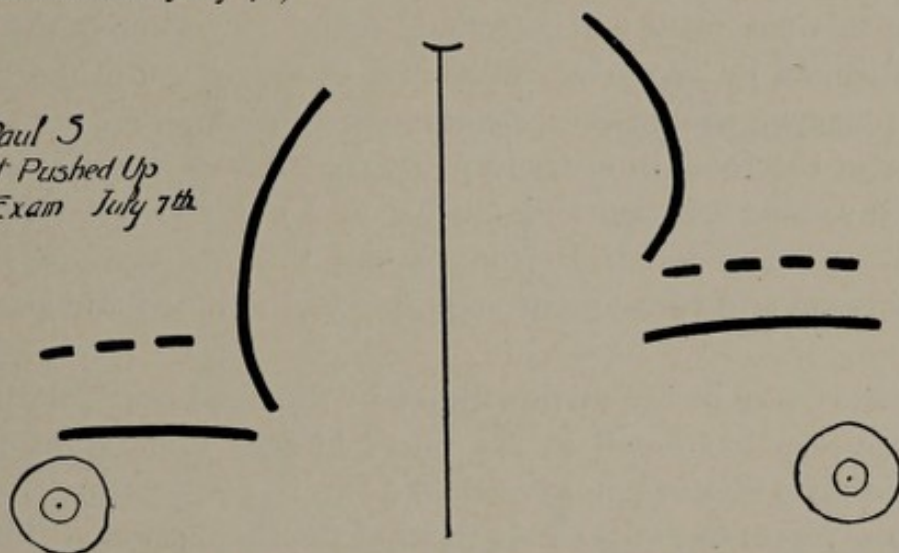


FIG. 168. Paul S. July 7. Cut of tracing from first X-ray examination. (Cut one-third life size.)
Heart pushed up.

Paul S
2nd Exam July 14th

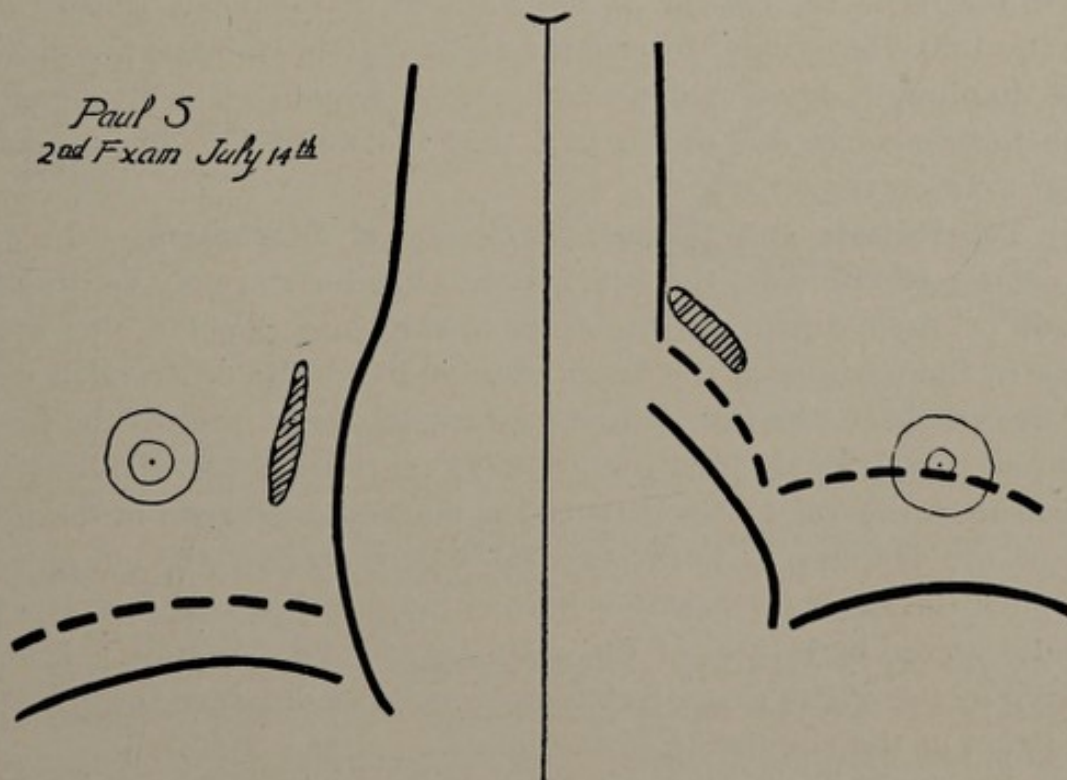


FIG. 169. Paul S. July 14. Cut of tracing from second X-ray examination. (Cut one-third life size.)
Position of heart nearer the normal.

July 12. Patient up in a chair in blankets. July 9 and 14, respectively, had an enormous movement from the bowels. Clothes on July 14.

July 14. Second *X-ray examination* showed that the heart was in a more nearly normal position, and the excursion of the diaphragm was lower in the thorax. (See Fig. 169, second examination July 14th.)

Discharged from the hospital July 15.

From this patient it will be readily seen how seriously the heart may be handicapped by excessive abdominal distension, and in a disease like typhoid fever we should exercise extreme caution about the amount and character of the food, in order to prevent distension; and if it is present, we should reduce it by suitable means, and not allow it to progress so far as to seriously handicap the patient through upward pressure of the diaphragm and consequent crowding of the lungs and heart.

The heart may be drawn downward by the diaphragm, normally when the muscle goes low down in the chest in deep inspiration, and abnormally when the diaphragm is pushed down in emphysema.

Unequal Excursion of the Two Sides of the Diaphragm. — The effect on the heart of unequal excursions of the diaphragm should be noted. When the movement of the diaphragm is much greater on the left side than on the right, the change in the position of the heart during deep inspiration may be greater toward the right than it would be if both sides of the diaphragm descended normally. An unusual lateral movement of the heart may be due to the fact that the excursion on one side is greater than on the other.

(*c*) **Tuberculosis and Unequal Excursion of Diaphragm.** — In early tuberculosis of one side, the heart, at full inspiration, may be drawn or pushed, or both drawn and pushed, toward the affected side. This change in the position of the heart may be due to the contraction of the lung, the result of which would be to draw the heart toward the former organ; or it may result from the greater excursion of the diaphragm on one side than the other; for if there is a marked difference in the movement of the diaphragm in the two sides of the chest, the effect would be to push the heart farther over toward the diseased side than it would naturally go did both sides of the diaphragm move normally. Later in the disease the right side of the heart may be enlarged, owing to the obstruction of the circulation in the lung.

(*d*) **Pneumonia and Unequal Excursion of Diaphragm.** — Displacement may be caused by a solid pneumonic left lung. I do not think

that the position of the right border of the heart further to the right than normal, which occurs in left-sided pneumonia, is wholly due in all cases to enlargement of this organ, but in some patients to a displacement which is caused by the dense and resistant left lung.

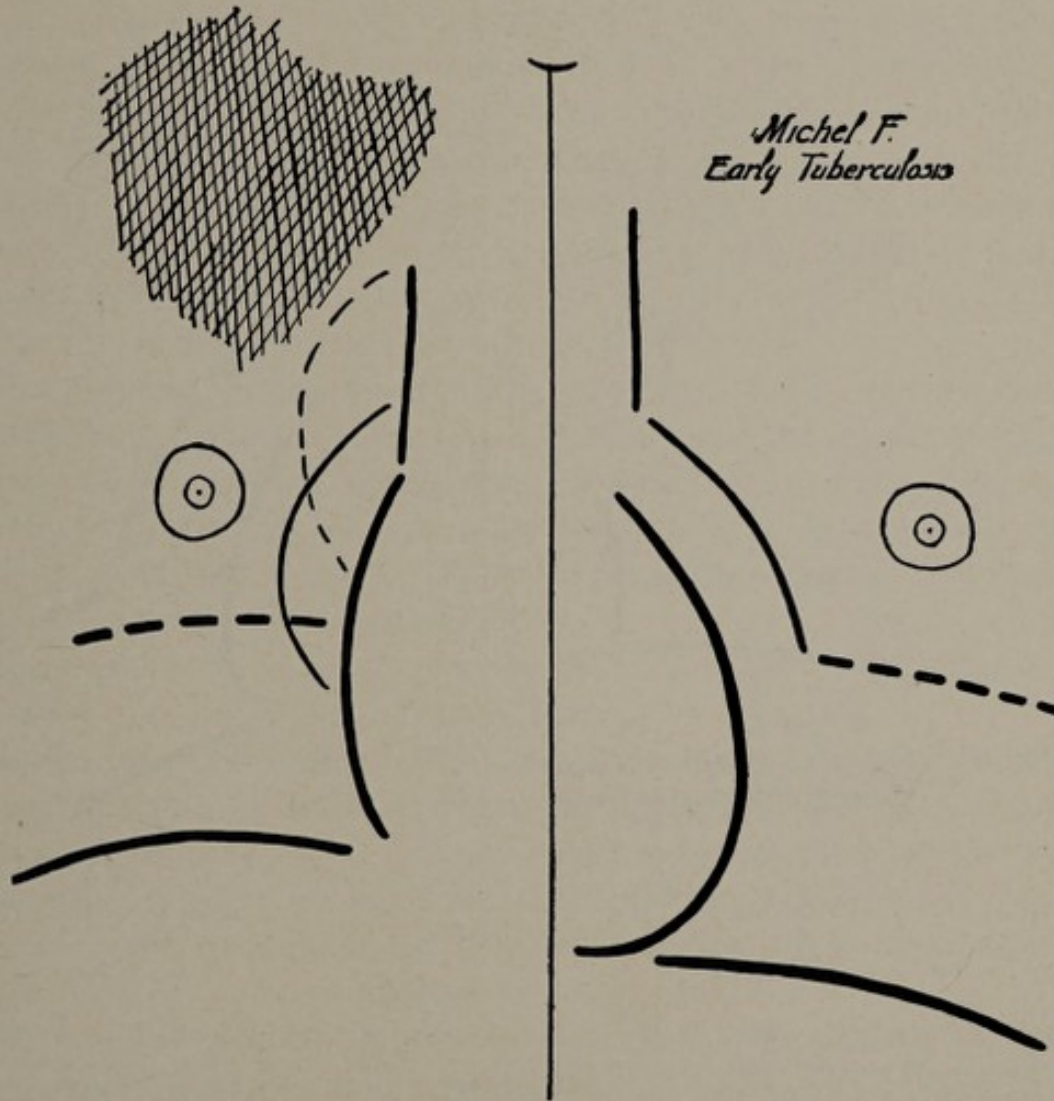


FIG. 170. Michel F. December 17, 1898. Diagnosis: acute articular rheumatism. X-ray examination shows that the apex on right side is darkened. Broken and nearly horizontal lines on either side show position of diaphragm in expiration; the full lines below, in forced inspiration. It will be noticed that the excursion of the diaphragm on the right side is shorter than on the left. The heart during forced inspiration moves more to the right than normal, because the right lung expands less than the left. (Cut one-third life size.)

The heart is not able to sink into the lung tissue as deeply as usual. During convalescence from pneumonia on one side, the heart may have an unusual lateral movement in deep inspiration, owing to the unequal excursion of the respective sides of the diaphragm.

In one of my patients, Mabel L. (Fig. 171), the movement of the dia-

phragm on the right side was 1.9 centimetres and on the left side 5 centimetres, and the distance between the left border of the heart in expiration and inspiration was 3 centimetres. This point will be better understood by comparing this tracing with Fig. 75 (Gertrude S.), page 102, in which the heart moves normally.

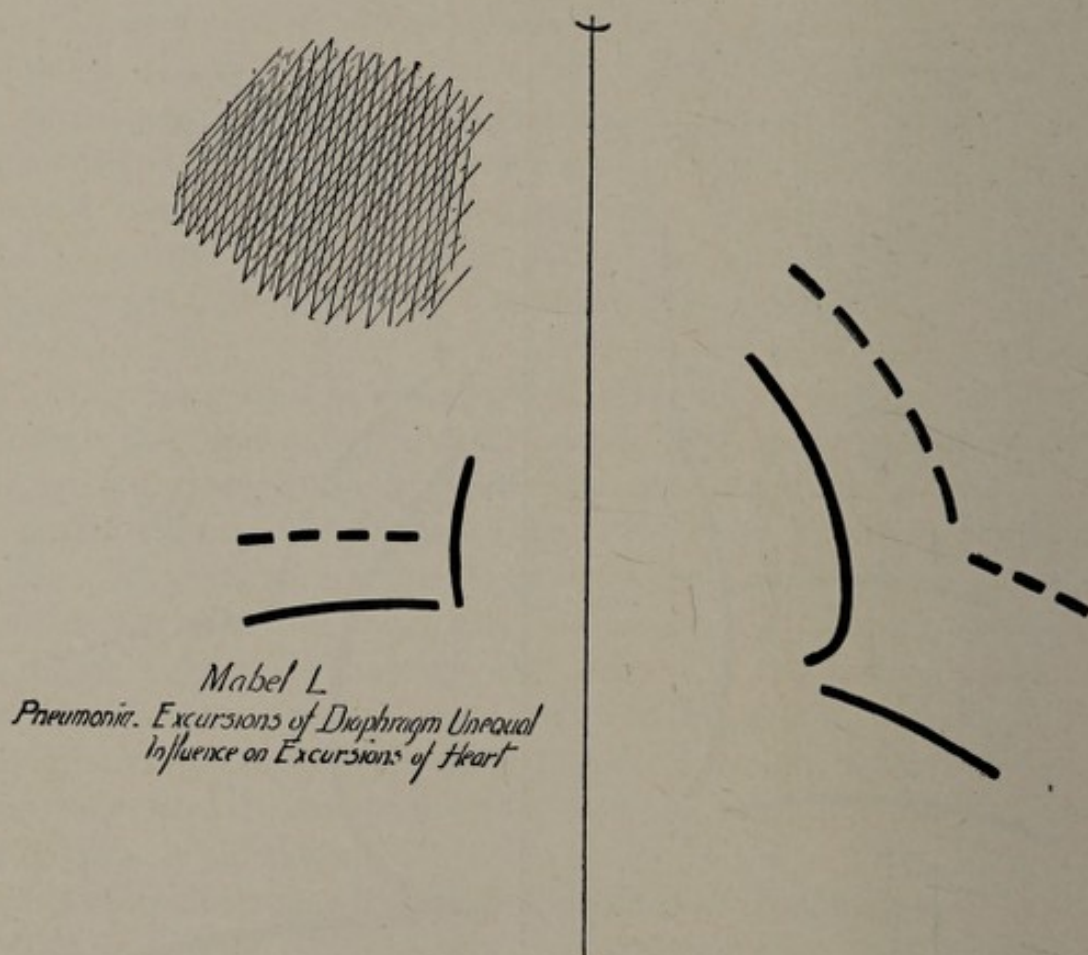


FIG. 171. Mabel L. Cut of tracing made with screen on front of chest. (Cut one-third life size.) Pneumonia of right lung; excursion of two sides of diaphragm unequal. Influence on movement of heart, which is drawn to the right by the diminished expansion of the right lung and pushed to the right by the relatively greater expansion of the left lung. Compare normal outlines shown in Fig. 75, Gertrude S.

(e) **Aneurisms and New Growths.**—The heart may also be pushed out of place by aneurisms in the thoracic cavity, or by new growths in this cavity or the abdomen. The subject of aneurisms and new growths is taken up in Chapters XI and XII respectively, therefore need not be further discussed here.

(f) **Contractions and Adhesions.**—There are cases in which the heart is drawn out of, rather than pushed out of, position. Its place may be changed by the diminution in the volume of one lung, as in

early tuberculosis; or by the contraction of one lung and pleura; or by pleuritic adhesions.

During full inspiration the heart is made to assume a lower position in the chest, and its axis becomes more nearly vertical than in expiration, but it sometimes happens that though the excursion of the diaphragm is normal, the heart at this period of the respiratory movement is tilted in some peculiar manner, or fails to move, owing to the presence of adhesions. Adhesions near the upper left border of the heart may so hold it that its apex moves upward and to the left during inspiration, instead of downward and to the right. Or if adhesions are present in the right lower border, this organ may be suddenly jerked to the right toward the end of inspiration.

The following cases are illustrative:—

Pleurisy and Pulmonary Fibrosis causing Displacement of Heart.—

The following patient shows how the heart may be drawn to the right and backward when the right lung and pleura are contracted:—

Mary I., twenty-three years old, entered the medical side of the Boston City Hospital July 8, 1886, service of the late Dr. E. J. Forster. Diagnosis: pulmonary tuberculosis.

She had night sweats; pain in the right side; temperature 104; respiration 32; pulse 144; heart negative.

Lungs: dull throughout the right chest, especially above the third rib and the spine of scapula, where breathing is broncho-vesicular with numerous crackling râles and increased voice sounds; below clavicle and at spine of scapula, small areas of cavernous respiration and bubbling râles with bronchophony. In lower half of right chest, crackling râles, but not so numerous as above.

In 1890 she entered the surgical side of the City Hospital, and Dr. Post removed a fibro-sarcoma from the right side of the neck, behind the sternocleidomastoid muscle. It was dissected out, and found by Dr. Henry Sears to consist of a mass of dense white tissue with fibrous tissue structure in places, and was very cellular. She was discharged September 22.

In 1898 she returned to the hospital (March 30), and was in the service of Dr. Bowditch. Diagnosis: pulmonary fibrosis. Hæmaturia.

Hemorrhage from the lungs eight years ago. Since then considerable yellowish and greenish expectoration night and morning.

No tubercle bacilli found in sputum in four examinations. The malposition of the heart thought to be due to the probable fibrosis of right lung.

May 28. *Examination with Screen* (see Fig. 172). — I found the heart was chiefly on the right side of the sternum. The whole right side was dark, and no outlines whatsoever could be followed there. When the patient lay on her back there was seen a nearly vertical, somewhat curved, line about 3.7 centimetres to the left of the sternum. As the patient turned to the left, this outline moved toward the right

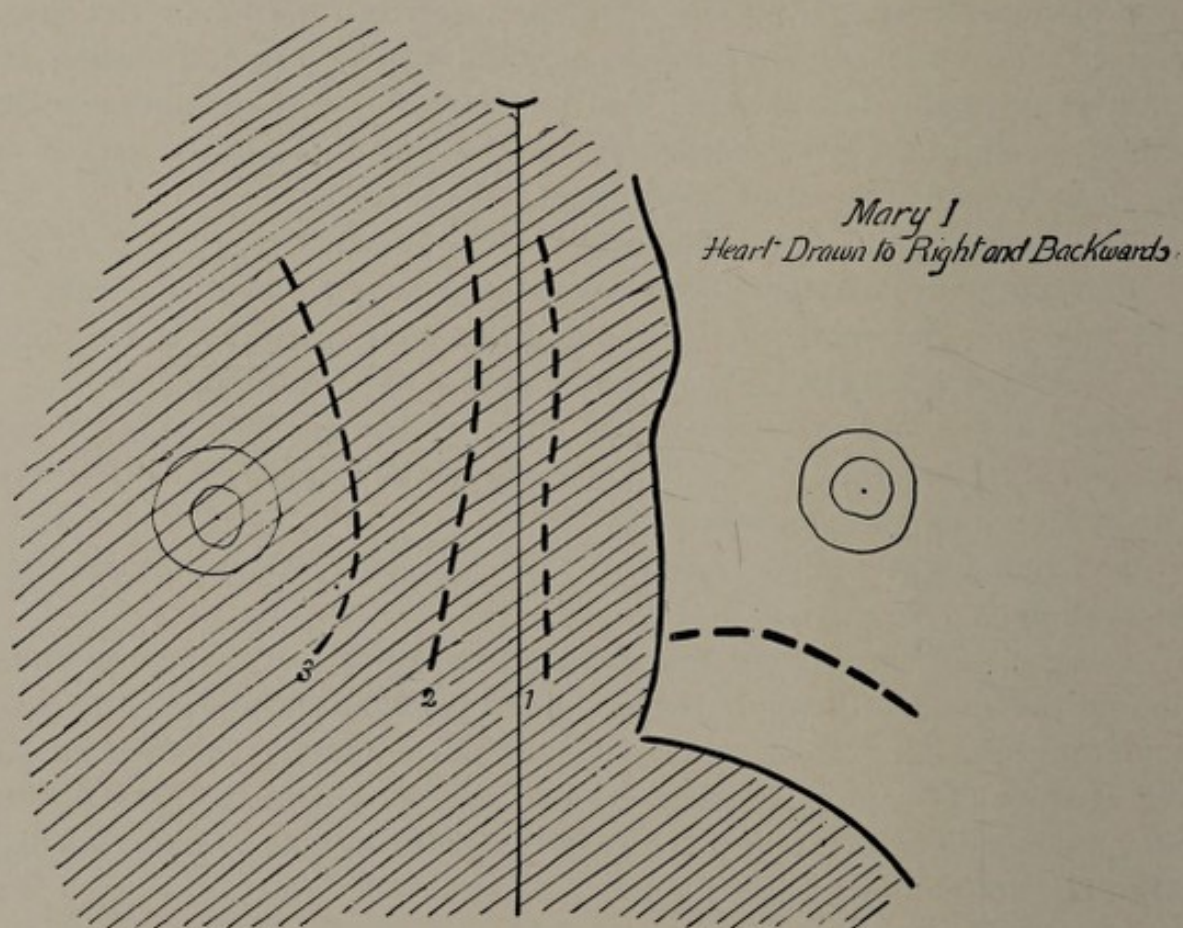


FIG. 172. Mary I. Cut of tracing made with screen on front of chest. (Cut one-third life size.) Pulmonary fibrosis. Heart drawn to the right and backward. The full line indicates limit of dark area with patient lying flat on her back. When she turned to the left, the limit of the dark area moved to the broken line marked 1; by turning still more, to the broken line marked 2; and by further turning, the outline was as shown at 3, thus showing that the heart was drawn away from the sternum. In other words, when she had turned sufficiently, the whole of the thorax to her left of line 3 was clear and to her right of it was dark.

nipple, and as she turned more and more, came nearly to it, and assumed a curve resembling somewhat the left border of the heart. (See 1, 2, and 3 in cut.) These appearances would indicate that the heart had not only been drawn to the right, but had also been drawn back from the anterior wall of the chest.

This patient had had pulmonary fibrosis, and the heart has probably been drawn to the right by the contraction of the lung and pleura.

May 31. Discharged relieved.

Displacement of Heart by Pericardial or Pleuritic Adhesions.—D. F. W., forty-two years old; entered the hospital December, 1898. Service of Dr. G. B. Shattuck. Diagnosis: emphysema and displaced heart.

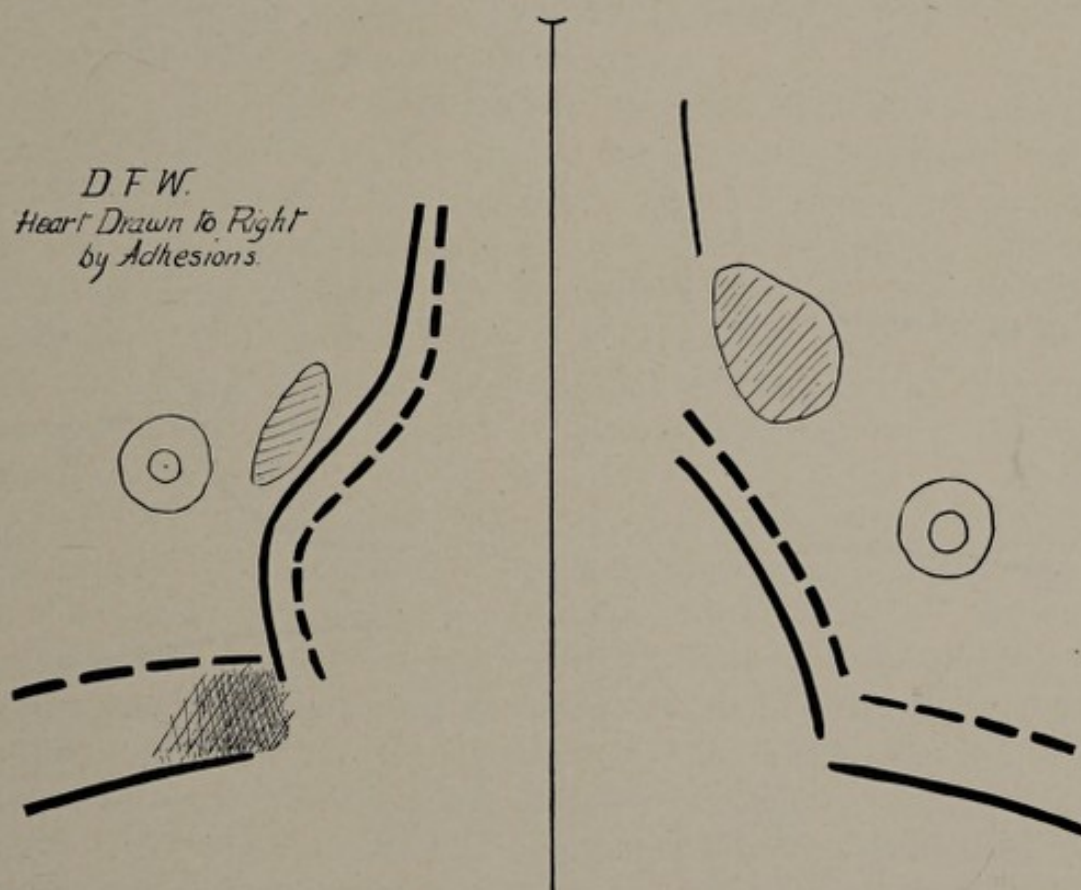


FIG. 173. D. F. W. X-ray tracing (one-third life size). Heart drawn to the right. Full lines indicate the position of heart and diaphragm in full inspiration; broken lines in expiration. This movement is exceptional, as usually the right side of the heart in full inspiration would not move in this way.

The question of an aneurism or a new growth in the chest was also considered.

X-Ray Examination with Screen.—I found the heart was farther to the right than normal during quiet breathing, and was drawn about 1 centimetre farther still to the right during deep inspiration. In the angle made by the right border of the heart and the upper border of the diaphragm, a darkened area was seen during full inspiration. This examination showed conclusively that there was no aneurism.

My interpretation of the appearances seen on the screen was as fol-

lows: The heart was drawn to the right by adhesions, and the darkened area on the right side of the heart was perhaps the shadow of thickened tissue, by means of which this organ was pulled out of its normal

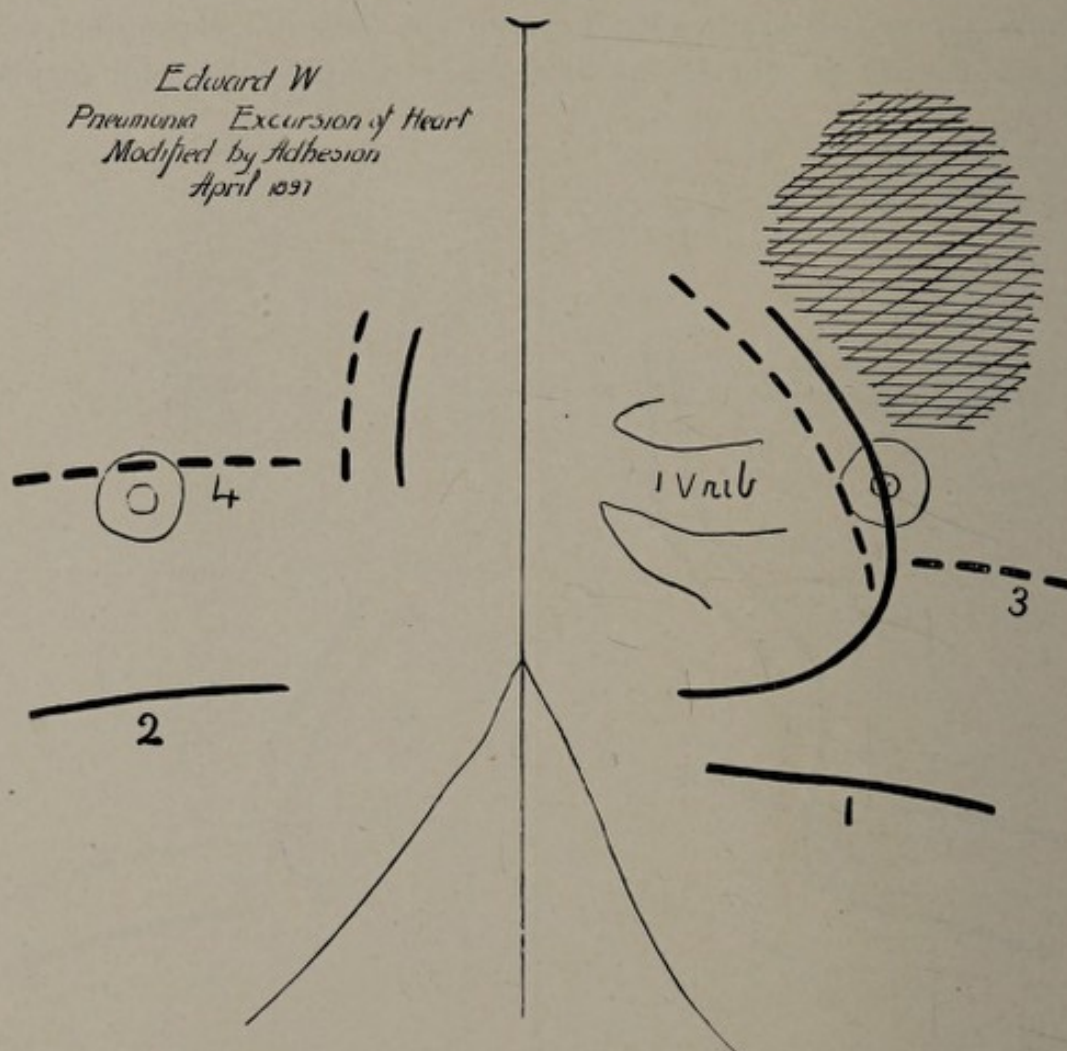


FIG. 174. Edward W. April, 1897. Convalescent from pneumonia on left side. Slight signs of tuberculosis at right side. Full lines show outline of heart and diaphragm in deep inspiration; broken lines in expiration. Heart is drawn to the left in full inspiration, instead of to the right, as usual. In the beginning of expiration the diaphragm moves up on the left side first (1), then on the right side (2), and reaches the position of expiration on the left side at (3), before the diaphragm arrives on the right side at (4); the order being 1, 2, 3, 4. The heart tips back into the position of expiration (broken line) as soon as the left diaphragm lifts (at the beginning of expiration after a deep inspiration), and as though it were let go suddenly. The heart is evidently held and cannot descend in full inspiration. The right apex should be shaded, but the shading is omitted because it would interfere with the name and date. (Cut one-third life size.)

position when the diaphragm descended; that is, at each descent the heart was jerked to the right towards the end of inspiration.

Heart attached; Movements unusual during Full Inspiration. — Edward W. (see Fig. 174), twenty-two years old, entered my service at the

Boston City Hospital April 24, 1897, with pneumonia on the left side. He had a chill one week before entrance. Pain in the left side, more marked on deep inspiration; some cough; no expectoration; heart normal. Lungs: good resonance and respiration over right lung; some dulness at the left apex in the back, extending down 5 centimetres below the spine of scapula; breathing at apex prolonged, with a few fine, moist, and occasional crackling râles after cough; breathing in the middle of the left back was broncho-vesicular in character, and harsher than in right back; vocal and tactile fremitus slightly increased.

April 29. X-Ray Examination.—Darkened area extending outward and upward from the heart on the left side; shortened excursion of diaphragm on this side. This indicated an unresolved pneumonia. Over this dark pulmonic area râles and a pleuritic rub were heard, and the patient reported that for the past year and a half, when he coughed, it "caught" him there. Right apex somewhat darker than normal; excursion of diaphragm on right side higher and shorter than normal. These conditions suggested tuberculosis at the right apex. Tuberculin given; reaction.

June 2. Second X-Ray Examination.—The right apex was clearer than on April 29; excursion of the diaphragm on this side had increased, but it was still higher in position than normal. On the left side the darkened area was less marked, and the excursion of the diaphragm 6.25 centimetres. The heart moved much less than in health during deep inspiration, the left border moved outward and upward instead of downward and toward the median line, and the right border moved inward and toward the median line. The heart was evidently held, and did not descend during full inspiration, as usual, with the diaphragm; therefore its lower border was seen more completely than is possible in health.

Displacement of Heart simulating Enlargement by Percussion.—The width of the heart, as determined by percussion, is the horizontal distance between the right and left borders. X-ray examinations show that the axis of the heart in some patients is more inclined than in others, and therefore a width of this organ taken in a horizontal line might give too great measurement. A heart whose position has been changed may sometimes be mistaken for an enlarged heart. For example, when the diaphragm is a little higher than normal, the axis of the heart may also be more horizontal; as a result of this direction of the axis the left border of the heart is turned more toward the left, and this organ seems enlarged on the left side. This displacement of the heart may be mis-

interpreted by percussion, and a diagnosis of enlargement made where none exists. The following case illustrates the advantage of an X-ray examination when the heart is not in its usual place:—

This patient, fifty years old, was referred to me, as it was thought by his physician that he had cardiac disease. I found by percussion that the left border of the heart, as well as the apex beat, was outside of the nipple line; the right border was not clearly defined, but seemed to be in about the usual place.

The *X-ray examination* showed that the diaphragm on the left side moved 2.5 centimetres; on the right side, 3.7 centimetres. The heart was drawn to the left and upward. Upon inquiry I learned that he had had pneumonia and pleurisy forty-three years before. I then told him they had been on the left side, to which he replied in the affirmative. But for the X-ray examination I should have considered that the patient had an enlarged heart, but this examination showed that his heart was not enlarged but simply displaced.

In another case, in which by percussion the left border of the heart and the apex beat were outside the nipple line, the X-ray examination showed that the organ was neither enlarged nor displaced, as percussion and palpation led the physician to believe, but that its axis was unusually horizontal, and this brought the apex beat farther to the left than if the axis of the heart had had the usual inclination.

The following tracing illustrates this point, and shows that the axis of the heart may be so much more horizontal than in health that the apex beat is nearly in the nipple line, and if percussion gives dulness in a line above this point, the physician might be easily led to overestimate the size of the heart, as by this method he might not recognize the inclined position of its right border, whereas, as the tracing shows, he could obtain an accurate knowledge of the size and position of this organ by an X-ray examination (Fig. 175).

In this patient, the diaphragm was rather higher than usual in the thorax. The long axis of the heart was nearly horizontal. The heart was dilated. The outline of the right ventricle and right auricle could be plainly followed to the right of the sternum. During a forced deep inspiration, the heart was diminished in size both in its vertical and horizontal diameters. This suggested dilatation of the heart rather than hypertrophy.

This case shows that the axis of the heart may be so nearly horizontal as to give, to a physical examination, the signs of a heart

which is very much enlarged (the heart was enlarged in this case, but its horizontal position exaggerated this unduly), as will be readily seen by the tracing.

Chlorosis. — In cases of chlorosis, the heart may seem by percussion to be enlarged both to the right and left, and by a later examination, made after the patient has improved, to be more nearly normal in size; but this apparent decrease in size, as determined by percussion, is shown

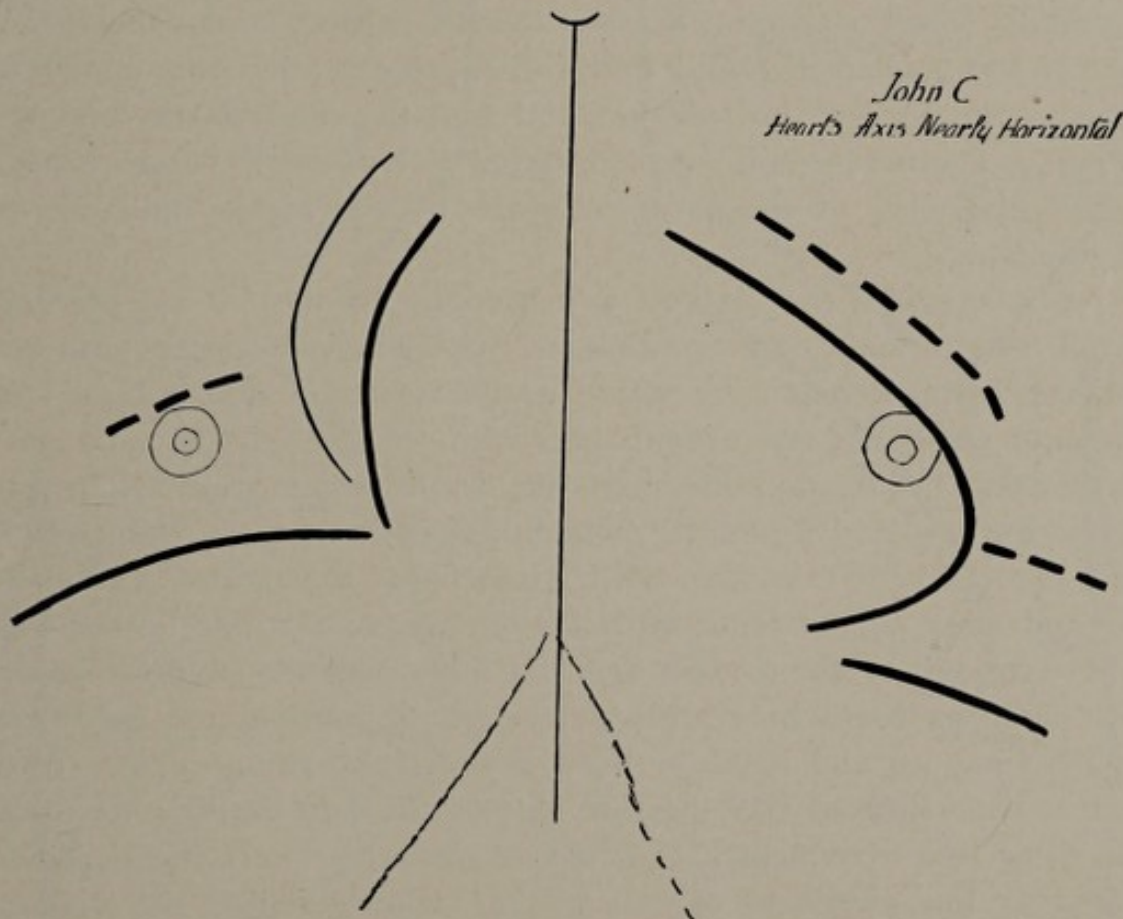


FIG. 175. John C. Cut of tracing made with screen on front of chest. (Cut one-third life size.) Full lines show position of heart during deep inspiration; broken lines, position during expiration. Heart's axis nearly horizontal.

by the fluorescent screen to be in reality due to the descent of the diaphragm, and the consequent change in the direction of the long axis of the heart; as in the cases given above, the heart has been displaced.

Anæmia. — In anæmia with constipation, the diaphragm would be higher than normal, thus tipping the heart and making it appear to have greater width. (See page 389.)

Unusual positions of the heart and transposition of this organ are

often easily recognized by an X-ray examination, when by other methods their recognition would be uncertain or difficult.

A Case of Apparent Dextrocardia. This case illustrates the advantages which fluoroscopic examinations have over those with a radiograph or the usual physical examination.

A. B., a patient of Dr. —, had been carefully examined by two excellent physicians, and the diagnosis of dextrocardia was made after a thorough physical examination. A radiograph of the heart was also made, which showed a sharply defined cardiac border much to the right of the median line, and that the heart extended only a short distance to the left of the sternum, and that this outline was not at all defined. The radiograph was considered to lend confirmatory evidence to the diagnosis of dextrocardia made by the history and physical examination.

At this stage, the patient was brought to me by his physician, that I might make an examination with the fluoroscope, in order that my outlines might be used in the report of the case. I saw him only once, but the examination with the screen was sufficient to demonstrate clearly that his heart was simply drawn to the right, probably as the result of a pleurisy, which he had had on the right side five years previously. The right border was far to the right of the median line, and close to the front wall of the thorax; the left border was a little to the left of the median line, but some distance from the anterior chest wall, as could be readily determined by examining the patient while sitting up and looking through the chest at an angle. In this position the whole of the anterior part of the left thoracic cavity was seen to be free from heart. The above conditions were readily demonstrated to the physician of the patient, who accepted the diagnosis without hesitation as complete and final.

SECTION V

OTHER ABNORMAL CONDITIONS OF THE HEART

Pulsations. — The pulsations of the heart may be followed in cases of irregular action, as in myocarditis; and it may be seen that they do not correspond to the pulsations at the wrist, that is, there are sometimes incomplete pulsations of the heart which do not give an impulse at the radial artery.

Pulsations of the Heart in Cardiac Disease shown by X-Ray Examination.—In cases of marked insufficiency of either the aortic or mitral valve, or both, the excursion of the left border of the heart,

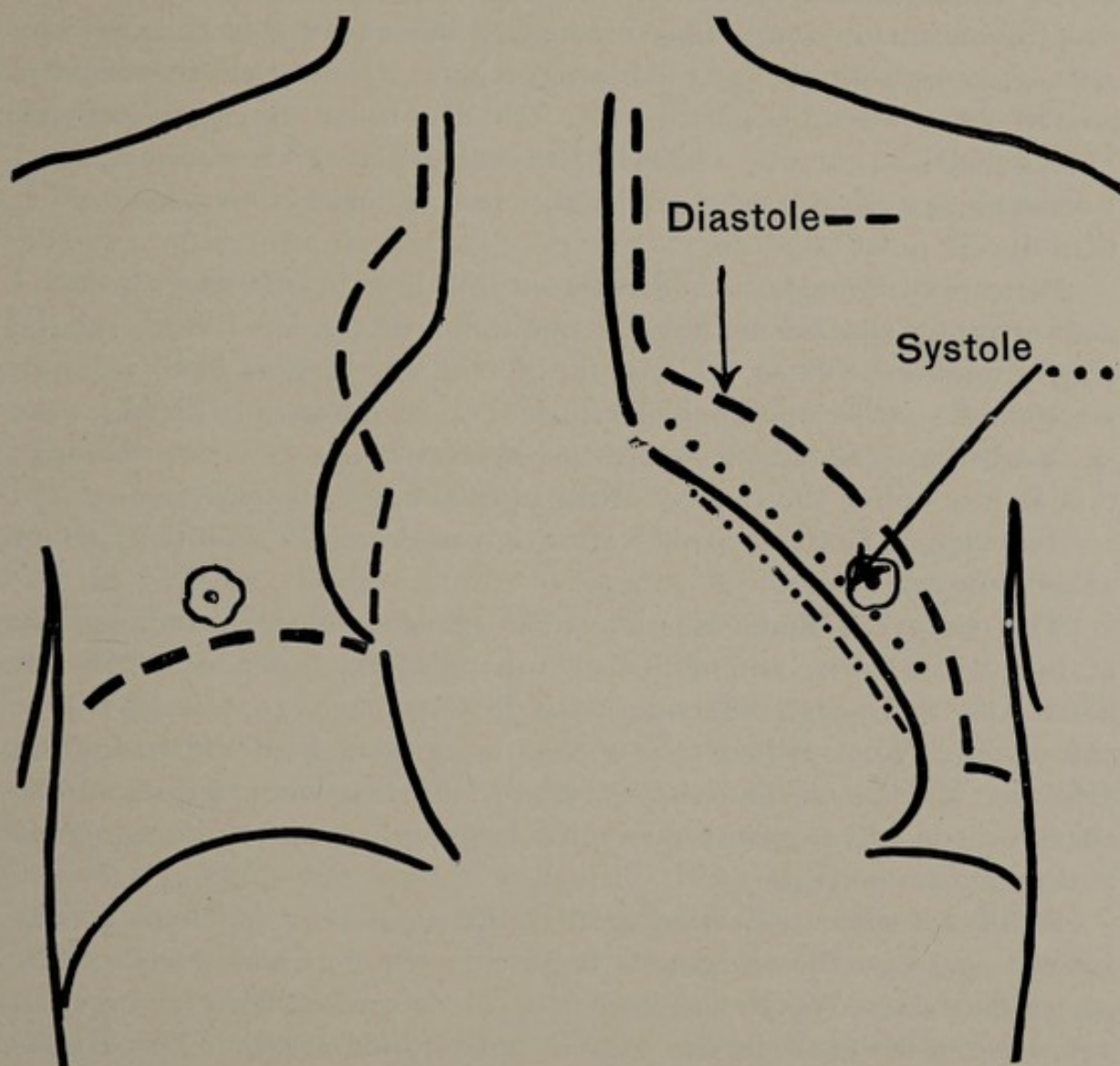


FIG. 176. John D. Aortic insufficiency.

Diagram of heart in a patient with aortic insufficiency. Compare with Fig. 157, normal movements. Diastole and systole during *ordinary* respiration are indicated by the arrows pointing to the broken and the dotted lines respectively. The line made up of dashes and dots shows where the left border of the heart is in systole during deep inspiration. When a full breath is taken the diastolic excursion is less than in ordinary breathing. The movements of the heart could be followed in this patient unusually well.

between systole and diastole, is much greater than under normal conditions. Not only is the to and fro excursion greater, but the length of the heart's border which is seen to move is much longer. (See Fig. 176, John D.)

Slight dilatations of the aorta may be seen in aortic insufficiency, and the pulsations of this artery may be observed.

An X-ray examination also shows that in some cases the movement of the heart between systole and diastole is much diminished during a deep forced inspiration. This diminished movement may be caused by a lessened regurgitation of the blood, or it may show that the heart is dilated rather than hypertrophied. I have found by means of the X-rays that some hearts, which by the ordinary methods of examination I considered to be dilated, were smaller in size during forced inspiration than during quiet breathing.

Pericardial Effusion. — When the cardiac area is enlarged, we should note carefully whether or not the pulsations of the left border can be clearly followed. If so, we have to do with an enlarged heart; if not, we should consider pericardial effusion. The outline of the dark area is also to be considered; in pericardial effusion its shape is rounded; that is, it is unlike the shadow of the normal heart.

The signs which pericardial effusion present differ with the amount of the effusion.

The larger amounts of pericardial effusion increase the shadow of the cardiac area and obliterate the pulsating outlines of the left border of the heart, and the triangle (see page 259) is of course obliterated. The cardiac area should be studied with the patient in different positions. The shadow of the effusion when traced on the chest wall is an excellent guide for tapping the pericardium, should that operation be required.

Small Effusion. — In pericarditis with small effusion it should be remembered that the effusion is largely in the dependent part of the pericardial sac. We should endeavor to determine what changes, if any, have taken place in the cardiac outline, and whether this outline is modified by a change in the position of the patient. The patient should therefore be examined in different positions.

Sitting Position; Tube behind Patient and Screen on Front of Chest; Deep Inspiration. — In this position the border of the left diaphragm would not be followed so far towards the median line, if there was pericardial effusion, as in health, and if the patient were inclined to one side or the other the cardiac outline might be modified.

Sitting Position; Light going through from Side to Side; Deep Inspiration. — The lower and posterior border of the heart should be determined, so far as possible; if the outline of the triangular area

formed by this portion of the heart (see pages 258 to 259) is not changed, there is probably not much, if any, pericardial effusion present.

Recumbent Position; Deep Inspiration. — An examination should also be made with the patient lying on his back, and also on his right and left sides, and with the light going through the body horizontally, the tube being on a level with the heart, to determine whether or not in these positions there is any modification of the outline of the heart.

The outlines of the heart and the effusion should be drawn during both inspiration and expiration.

Mobility of the Heart. — Hoffmann (Verhandlungen des Congresses für Innere Medicin, 1898) has found that the hearts in four cases of paroxysmal tachycardia, which but for this condition were normal, were surprisingly movable; the first moved 6 centimetres, the second 5.2 centimetres, the third 6.7 centimetres, and the fourth 5.3 centimetres. These observations are of much interest.

Hoffmann also found that the heart moved to the left surprisingly little in children; in ten persons in the first and second decades it did not move more than 1.2 centimetres; in grown persons there was a movement of 2 to 7 centimetres.

Murmurs. Auscultation and X-Ray Examinations. — These two methods of examination used together may enable the physician to determine with unusual exactness the site of the murmur on the heart, if auscultation is done after the outline of this organ has been traced on the chest. Second, it may enable him to recognize that the disappearance of a murmur due to the enlargement of the auriculo-ventricular ring is coincident with the diminution of the size of the heart. Third, it may enable him to recognize that murmurs which are present when the heart is pushed out of place disappear when the pressure is relieved, as for example in some cases of pregnancy.

Other conditions of the heart present abnormal appearances or outlines when examined by the fluorescent screen. (See Fig. 179 and Appendix.)

Persistence of the Ductus Arteriosus Botalli. — Zinn (*Deutsche Med. Wochenschrift*, No. 8, Supplement, pp. 41-42, 1898) gives a detailed account of a case in which the diagnosis of "Persistence of the Ductus Arteriosus Botalli" was supported by an X-ray examination.

The writer states that the interest of the case lay particularly in the fact that the widening of the pulmonary artery established by percussion could be recognized on the screen and in the radiograph.

SECTION VI

EFFECT OF TREATMENT WATCHED BY X-RAY EXAMINATIONS

The size of the heart may vary greatly from the normal, and become much enlarged, and yet resume a smaller size after rest in bed and digitalis, and this decrease in size may be observed by X-ray examinations.

Name *Ella H.* Age *12* Date *March 22. 1897.*
 Address _____ Occupation _____ Vol. *419* Page *248*
 Diagnosis *Endocarditis*

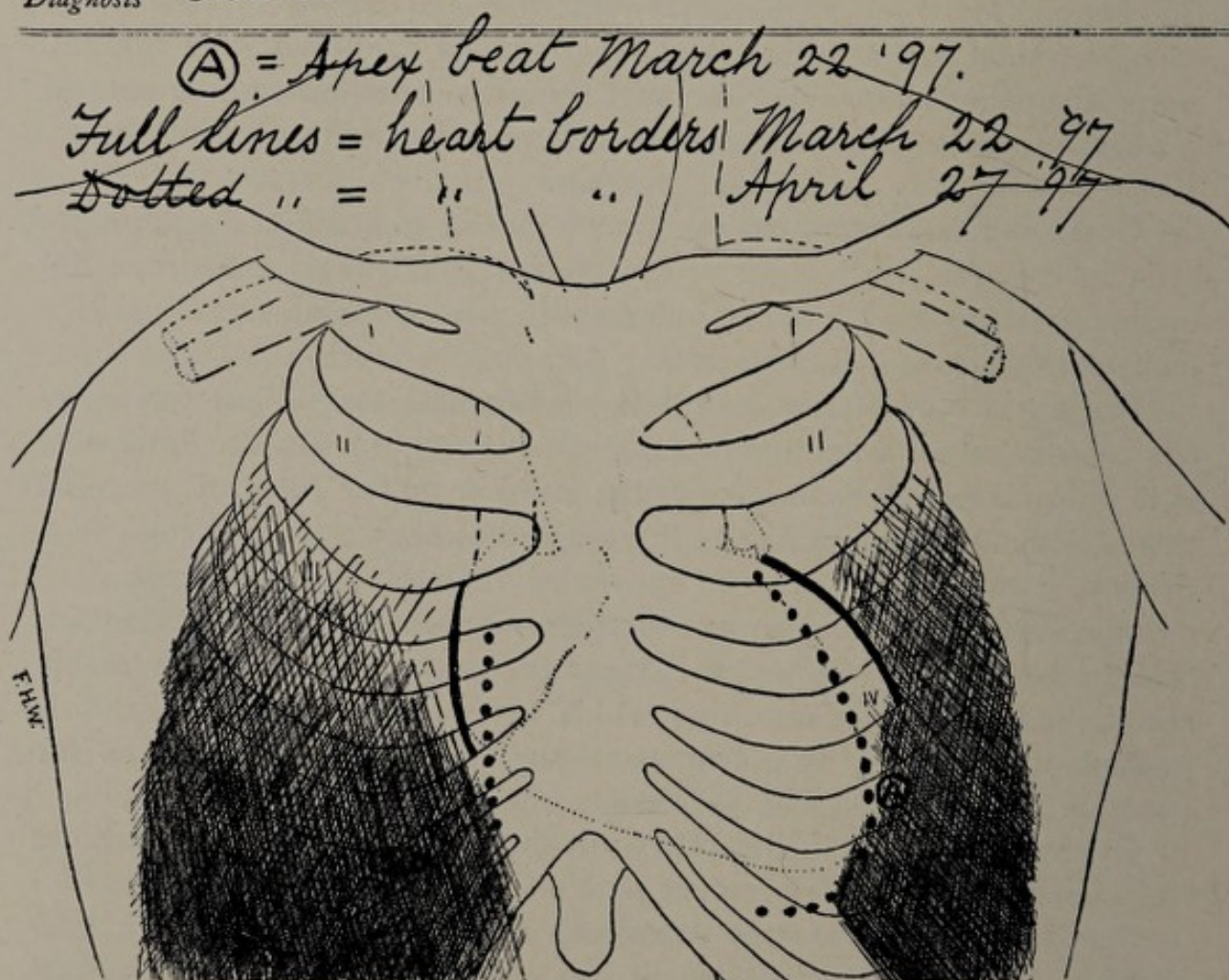


FIG. 177. Ella H. First X-ray examination. (Cut one-third life size.) Both lungs dark except in upper portions. Heart enlarged.

Progress of Improvement in Heart watched by X-Ray Examinations during Treatment. — Fortunately, in many forms of cardiac disease we are able to benefit the patient very much by suitable treatment. The

improvement is indicated on the screen in two ways: first, the size of the heart which has become enlarged is seen to diminish; and, second, the lungs gain in transparency as the heart's action becomes stronger and the congestion or œdema is lessened.

Name *Ella H.* Age *12* Date _____
 Address _____ Occupation _____ Vol. _____ Page _____
 Diagnosis *April 27 '97.*

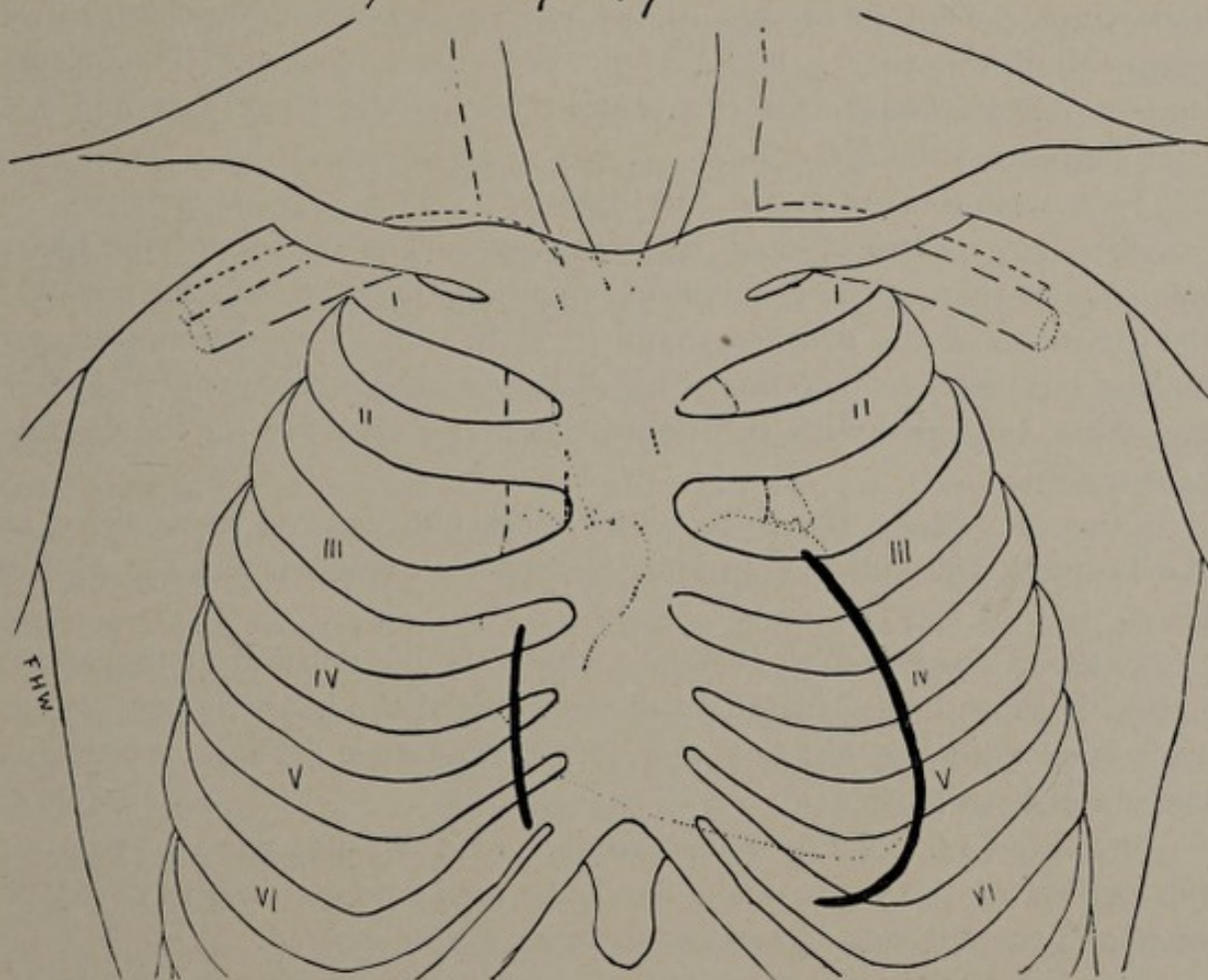


FIG. 178. Ella H. Third X-ray examination. (Cut one-third life size.) Lungs now clear. Excursion of diaphragm (lines not given) can be well seen on both sides. Heart smaller in size than on March 22.

The following cases illustrate this point:—

CASE I. Ella H., twelve years old, entered my service at the Boston City Hospital March 22, 1897. Diagnosis: endocarditis following rheumatism. Patient complained of dyspnœa and orthopnœa.

March 22. X-Ray Examination.—The outlines of the diaphragm could not be seen, and the outlines of the ribs were indistinct below the

second rib. These conditions showed marked œdema of the lungs or hydrothorax on both sides.

Physical Signs. — Dulness to percussion, respiratory murmur very much diminished, and absence of vocal fremitus on both sides in the lower portion of the thorax. There was a systolic murmur at the apex, transmitted to axilla, also a presystolic roll.

April 3. Second X-Ray Examination. — The size of the heart was the same as on March 24, but the front and back portions of the ribs were seen in both chests, and also the outline of the diaphragm on both sides. That is to say, in the twelve days since the last X-ray examination, the thorax had become very much clearer. The excursion of the diaphragm was 2.5 centimetres on the right side and 1.5 centimetres on the left side.

Treatment. — Rest in bed and digitalis.

April 27. Third X-Ray Examination. — The outline of the heart was smaller than at the previous examination, that is, nearer the normal; the excursion of the diaphragm on the right side was 5 centimetres and on the left side, 2.5 centimetres. A very marked improvement in her breathing coincided with the improvement as observed on the fluorescent screen.

CASE II. Mary H., thirty-eight years old, entered my service at the hospital December 13, 1898. Diagnosis: valvular disease of the heart.

Physical Examination. — There was a double murmur at the apex; pulmonic second accentuated; and the width of the heart by percussion, on a level with the nipples, was 17.5 centimetres. There was slight œdema of both legs.

December 14. X-Ray Examination. — Both lungs were very dark; the outline of the heart could barely be seen; no diaphragm could be seen, and the outlines of most of the ribs were obscured.

January 3, 1899. Second X-ray examination after rest and treatment with digitalis. The lungs were much clearer, and the excursion of the diaphragm on each side could be readily followed.

Hoffmann (Verhandlungen des Congresses für Innere Medicin, 1898) found by means of the X-rays that in some cases of mitral insufficiency the width of the heart was 18 or even 20 cm., and that in one case the width was diminished from 18 to 16 cm. after the use of digitalis, but later returned to 17.2. His X-ray examinations also showed that in normal men, from twenty to forty years of age, the width of

the heart varied from 14 to 15 cm., but in older persons the width was usually greater.

Avoidance of too Early Cessation of Treatment. — The condition of the patient may be so improved that further treatment seems unnecessary, but if the X-ray examinations show that the lower portion of the lung is still dark, the further use of digitalis is indicated; the remedy has not done all the good of which it is capable, if continued. The following case illustrates this point: —

Bessie N., twenty-nine years old, entered my service at the hospital March 27, 1897. Diagnosis: dilated heart and disease of the mitral valve.

History. — Had dyspnœa for seven months; pain in the præcordial region and over the left scapula; no œdema; marked orthopnœa.

Physical Examination. — Heart's area enlarged to the right; apex in the fifth space, 8.7 centimetres from mid-sternum; action regular; loud presystolic murmur at apex, with thrill. Examination of lungs negative.

This patient had rest and digitalis, and about one week later had improved so much that I considered the question of her transfer to the Convalescent Home; but did not send her, as an *X-ray examination* made at this time showed that the chest was dark throughout, except in the upper portion, where the ribs could be dimly seen. Two weeks later another *X-ray examination* showed improvement, but the outlines of the diaphragm, the heart, and the ribs, could only be seen during deep inspiration, and even then dimly. This indicated that a longer stay in the hospital would be beneficial. Without the X-ray examination she would have been discharged while she still needed hospital care.

Enlarged Hearts with Murmur. — It is probable that a murmur may sometimes be due to the failure of the valves to close on account of the inefficiency of the muscular walls of the heart, but it may disappear as the heart diminishes in size after rest and other suitable treatment. An X-ray examination may enable the physician to watch the heart and to observe that it has become reduced in size when the murmur is no longer heard.

Warning of Patient's Serious Condition given by X-Ray Examination. — Bridget O'D., fifty-five years old, entered my service at the hospital March 7, 1898. Diagnosis: myocarditis.

March 7. X-Ray Examination. — The pulmonary areas were so dark that the outlines of the heart could be seen only very dimly, and

the only diaphragm outline seen was that on the right side and during full inspiration. The heart was much enlarged to the right. The condition shown by this examination was a warning to put the patient on the list of those very dangerously ill. She died suddenly on March 13.

Timely Warning of Disease. — X-ray examinations of the heart warn the physician, in cardiac as well as renal diseases, of the serious condition that his patient is approaching, and point out to him the necessity for the timely use of remedies to supplement the insufficient action of the heart. Want of clearness, especially in the lower portion of the lung, will indicate early that suitable treatment is required.

Mr. S., fifty-eight years old, was sent to me from out of town for consultation and X-ray examination. His physician wrote to me as follows, "Patient suffering from some form of thoracic disease, probably an emphysematous condition with some complications."

History. — Asthma; marked dyspnoea on exertion; a rapid and irregular heart.

X-Ray Examination. — Both pulmonary areas so much darker than in health that it was far more difficult than usual to determine the size of the heart. The heart seemed enlarged. I advised that he should be taken back to his home, which was some miles from Boston, with extreme care, and be put to bed. I also advised suitably large doses of digitalis, and that its effects should be carefully watched.

Two weeks later his physician wrote me as follows: "The patient grew steadily worse and took to his bed the day after our visit to you. Every symptom was very grave, to say the least. Heart failure was expected at any time, and many pulsations of the heart were lost at the wrist. Respiration of the worst character. Delirium continuous. After a week, the patient improved. The lungs cleared up wonderfully well, and the heart and pulse came together. Orthopnoea had disappeared."

A later report from this physician stated that the patient had resumed his business.

The X-ray examination was undoubtedly of service in this case, giving immediate and unequivocal evidence of the conditions present, and imparting to me convictions as to the treatment that should be pursued, and that this treatment should be carried out courageously.

Want of Efficient Pulmonary Circulation shown by X-Ray Examinations. — (See Fig. 179.) The X-rays may be useful in indicating how much increase in density there may be in the lungs, due to passive congestion, or to œdema, without either giving rise to well-marked signs by

auscultation and percussion. In certain diseases or conditions of the valves of the heart the pulmonary circulation may be so much obstructed that the lungs are found radioscopically to be much darkened, even more so than the diagram represents. This should warn us to take suitable care. In X-ray examinations we have a new, useful, and delicate means

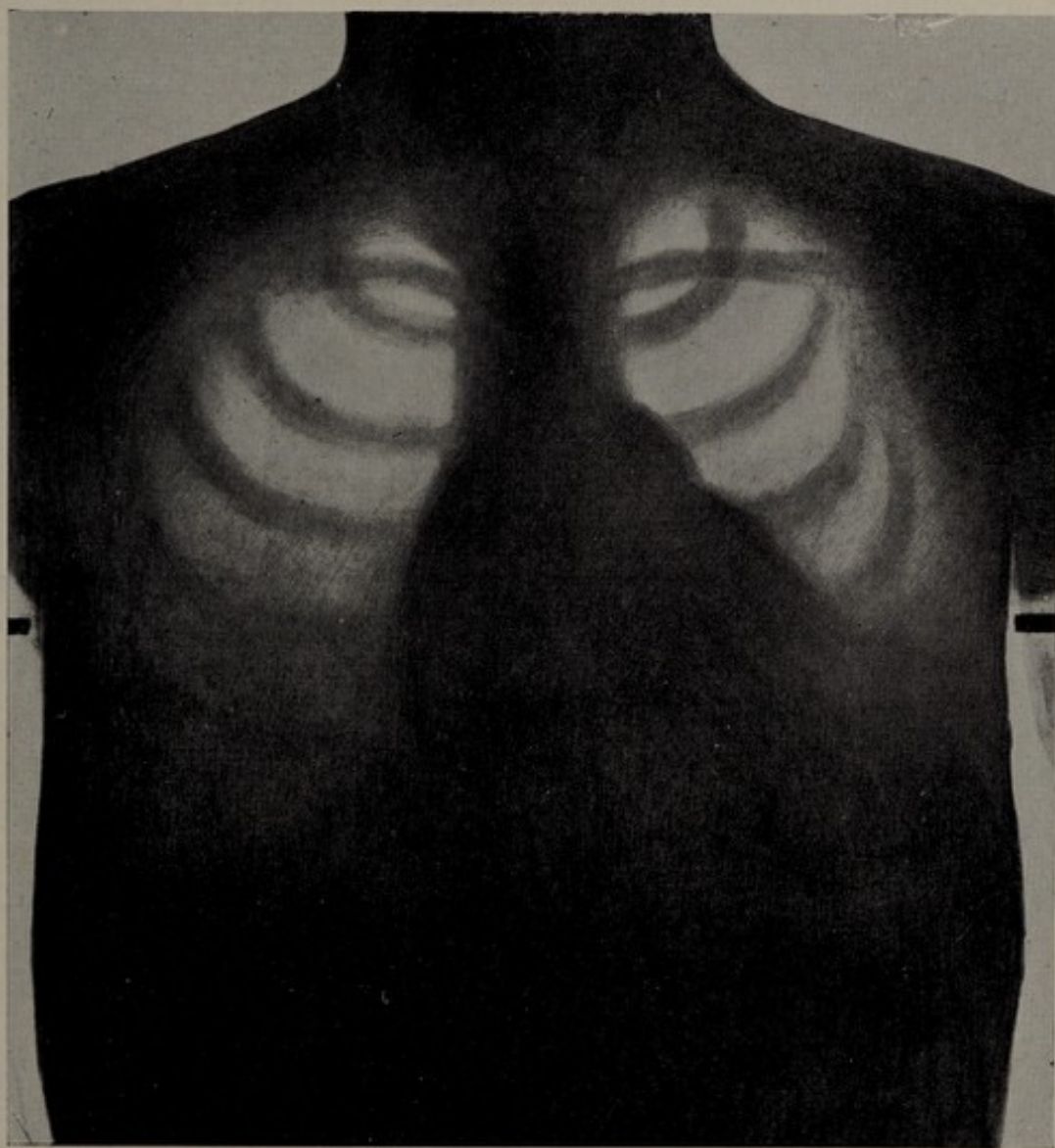


FIG. 179. Diagram of passive congestion of the lungs from valvular disease.

In valvular disease I have seen much darker lungs than the diagram indicates become clear, and the dyspnoea cease after treatment by digitalis.

of recognizing changes in the pulmonary circulation, due to abnormal conditions of the lungs, heart, or kidneys.

Alcoholics. — I have observed in a number of cases that the lungs of patients addicted to the use of alcohol were less bright throughout than normal, and in a few that there was a marked contrast between

the pulmonary area above the position of the diaphragm in expiration and the portion seen between the two positions of the diaphragm in full inspiration and expiration, this latter portion being much brighter than that above the expiratory diaphragm line. The lack of brightness in the lungs may be due to a pulmonary congestion, which would make these organs appear darker on the screen than in health; or there may be some other explanation of this condition.

In one patient, who was thirty-four years old, and had been drinking to excess for two weeks, and had been exposed to cold in the month of March, the excursion of the diaphragm on the right side was 7.5 centimetres, and on the left 7 centimetres; above the point reached by the diaphragm during expiration, on both sides, the lungs were uniformly denser than normal, so dense that the ribs were scarcely visible, but below this point, during full inspiration, the pulmonary area was bright on both sides. The right side of the heart was much enlarged. This patient had no physical signs by auscultation and percussion except that the note by percussion was less clear than in health. The increase in the size of the heart was not found by percussion.

Passive Congestion shown to be Absent by X-Ray Examination.— On the other hand, we may be assured that there is no passive congestion in the lungs in some cases of cardiac disease in which we suspect this condition, if an X-ray examination shows normal brightness of the pulmonary areas.

Louis C., twenty-six years old, a patient of Dr. Horace D. Arnold, came to the medical out-patient department of the Boston City Hospital on March 5, 1898, complaining of gastric symptoms and palpitation, with pain in the cardiac region.

Physical examination at this time gave a mitral systolic murmur at the apex in the nipple line.

On January 7, 1899, his symptoms were more marked. Apex in the sixth space in the nipple line; both presystolic and systolic murmurs present.

February 11. The signs and symptoms continued. It was a question whether or not there was a passive congestion of the lungs.

February 14, 1899. I found by *X-ray examination* that this condition was not present, as the lungs were perfectly clear.

Precautionary and Preventive X-Ray Examinations.— The following case illustrates the advantage of such examinations:—

Wm. A. H., twenty-nine years old. This patient, having joined a

party which was bound for the Klondike, came to see me as a precautionary measure to learn whether or not he was sound in body.

I found that he had a much enlarged heart, and that he was wholly unfit for packing over the steep trail beyond Skaguay, for example (the railway had not then been built), and for undertaking life in such a country.

Many middle-aged men of large affairs and great energy doubtless overtax their hearts in various ways. As a consequence, they are obliged to retire from active work before many years; or the end comes suddenly. It would be better if more persons in our country would follow the custom of some of my patients, and go to a physician to be examined once a year. This custom is more useful, even, than formerly, for by means of X-ray examinations we are able to give earlier warning of some diseases of the chest than has hitherto been possible.

CHAPTER XI

THORACIC ANEURISMS

Appearances seen on the Fluorescent Screen and by X-Ray Photograph in Aneurisms.—The appearances vary greatly and depend on the size and position of the aneurism.

A small aneurism of the descending arch of the aorta casts a shadow to the left of the sternum and above the heart, and by localization would be found to be in the posterior rather than the anterior part of the chest. (See Fig. 180.)

An aneurism of the ascending aorta would usually cast a shadow to the right of the sternum, and by localization would be found nearer the anterior than the posterior chest wall.

A large aneurism casts a shadow on both sides of the sternum; the heart is often seen to be more or less displaced, or enlarged.

Difficulty of Diagnosis by Ordinary Methods; Need of X-Ray Examinations.—The diagnosis of an aneurism is often difficult and sometimes impossible by the ordinary methods. Aneurisms are not infrequently overlooked in their early stages, the time when there is the best opportunity for prolonging life; or, if recognized, their extent is not appreciated; or their presence is suspected when they do not exist. Therefore, in order to get as accurate a knowledge as possible of the condition of the thoracic cavity, the chest should be examined by means of the fluorescent screen, both in front and behind, and from side to side. An X-ray photograph may also be of service. Pulsations can be seen only by means of the screen. If the walls of the aneurism are thick and the sac is filled with a dense clot, there may be no pulsation. (See case of D., page 327.) On the other hand it is, I suppose, possible for a dense body near the normal aorta to have a movement imparted to it by the pulsations of that blood vessel.

Method of Examination by the X-Rays.—The spinal column should be examined to see if there is any displacement of the vertebræ which

might push the aorta to one side; for if through disease in the vertebræ or some neighboring part the descending aorta is pushed a little to the left, this condition might be confounded with an aneurism, if this possibility were not in mind and this region carefully examined. If there

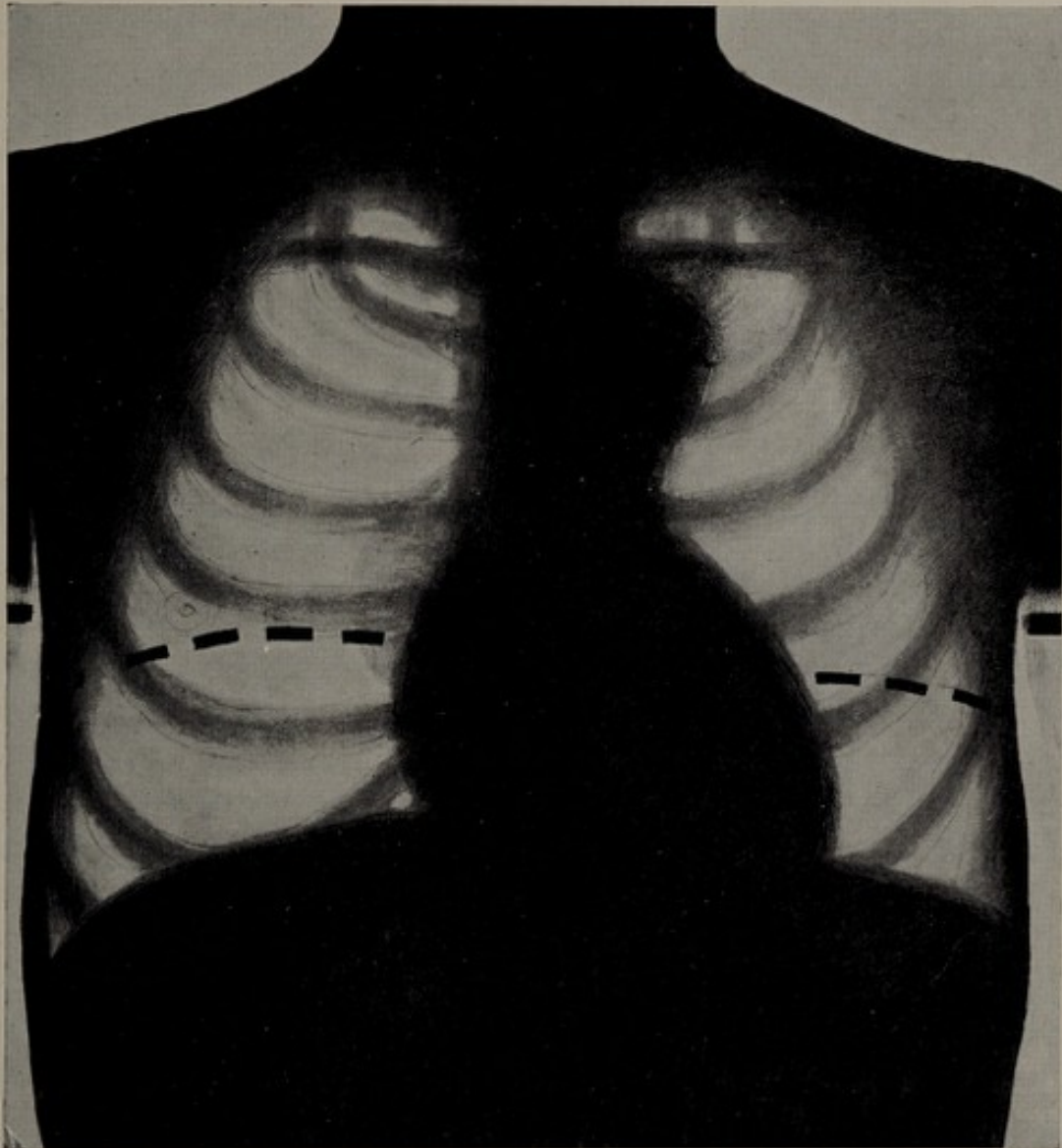


FIG. 180. Diagram of an aneurism of the descending aorta. Full inspiration. The aneurism would often be higher in the chest than is shown in this diagram. A dilatation of the ascending arch of the aorta would usually cast a shadow on the right side of the sternum. Broken lines show position of diaphragm in expiration. The heavy lines under the axillæ indicate the level of the nipples.

is disease of the spine, producing displacement of the aorta, a careful X-ray examination of the line of the vertebræ would reveal the cause of the unusual position of this artery.

Moreover, in some healthy individuals the aorta is more prominent than in others. I have examined some persons in whom there was no

trace of aneurismal dilatation, but in whom the outline and even the pulsation of the descending arch of the aorta could be followed.

If any departure from the normal outlines is found in this portion of the thorax, the physician should determine whether or not the abnormal outline is due to something which is nearer the front or the back of the chest. This point may be ascertained by making two examinations of the patient, one with the fluorescent screen on the front, and the other with the screen on the back of the chest; or the screen may be in a constant position and the patient may be examined with the tube in two different positions, about 60 centimetres apart. (See Chapter III, page 81.) The outlines seen on the screen should be traced on the skin, or celluloid covering the screen. (See Chapter III, pages 77-81, for directions for making and recording the observations made.) An X-ray photograph should also be taken, as stated above.

Further, we may be assisted to distinguish between new growths in the thorax and an aneurism. For this purpose a careful determination of the position of the outlines, not only laterally but antero-posteriorly, is important. If, for example, when examining the chest, a small shadow is seen on the fluorescent screen in the neighborhood of the descending arch of the aorta on the left of the sternum, the physician must determine whether it is cast by something situated in the front or back of the chest. As a rule, an aneurism of the ascending portion of the aorta will be found nearer the front of the chest than the back; whereas aneurisms of the descending aorta in the early stages would be found nearer the posterior portion of the chest than the anterior. If pulsation of the outline is seen, we probably have to do with an aneurism, though it is possible that a movement might be given to a new growth situated over the aorta. Whether or not this variation from the normal is due to a new growth or to an aneurism cannot always, of course, be determined by the X-rays alone. They furnish only one way, though a very valuable way, of studying this region.

Other Means of Diagnosis. — The history of the case should also be carefully considered; the patient's age; the symptoms, and their duration; for while in some cases the diagnosis of an aneurism can be made with much certainty with the aid of the X-rays, it may in others be difficult to recognize the cause of the abnormal outline found by means of the fluorescent screen.

Early Diagnosis Possible by X-Rays. — In general, it may be said that aneurisms of the thoracic aorta may be seen by the X-rays before

there are physical signs. Furthermore, where it is desirable to be sure that no thoracic aneurism exists, the X-ray examination can render much service. There are patients who have troublesome symptoms, or signs such as dyspnœa, paralysis of the left vocal cord, pain in the chest, and dulness to percussion over an area which might easily be the site of an aneurism; these symptoms may give the physician much anxiety if he is led to consider that they are due to this cause. For example, in a patient in whom Dr. G. A. Leland found paralysis of the left vocal cord, my X-ray examination showed no aneurism. Later, Dr. Leland informed me that the paralysis of the cord had disappeared. In these cases it is a satisfaction to the patient and to the physician to be able to exclude the presence of an aortic aneurism, and we may be quite sure that no aneurism is present if the X-rays give normal outlines in the thoracic cavity when careful examination of the patient in various positions has been made, including of course the triangular space behind and below the heart. Herein lies one of the advantages of this method of examination. It may give us better assurance of the absence of an aneurism of the aorta in suspected cases than any other evidence at our command.

Cases of aneurism may give physical signs suggestive of tuberculosis, neuralgia, or œsophageal stricture. The cases given below illustrate some of these points.

In a series of 41 cases I examined 37 because an aneurism was suspected and 4 to determine the size of the heart. Of these 41, 16 gave normal outlines in the region where an aneurism had been suspected; 6 had more or less dilatation of some portion of the aortic arch, and 19 had typical aneurisms. Seventeen of these aneurisms had their seat in the aortic arch. The seventeenth case had also a second aneurism of the innominate artery; the eighteenth case had two aneurisms, one in the innominate and another in the subclavian artery; the nineteenth had an aneurism in the subclavian artery. In 9 of these 19 cases there were no physical signs of aneurism.

Aneurism suggesting Pulmonary Tuberculosis. — CASE I. M. J., a man aged fifty-nine years, brought to me October, 1896, by Dr. M. P. Smithwick, illustrates the increased accuracy in diagnosis that an X-ray examination may afford. The great size of the sac seen on the fluorescent screen suggested early rupture, and therefore a frank statement of the case was made to the patient and gratefully received by him, as he was thus given an opportunity for a much-needed arrangement of business affairs.

Family History. — Father died of consumption at seventy-two years of age. It was usual for the males of the paternal branch of the family to develop this disease after fifty-nine years. Mother died of apoplexy. The patient, his family, and his physician did not doubt that he was following the family tradition and developing tuberculosis. It was not surprising that the mistake should be made, when we compare the clinical picture of hæmoptysis and cough with the physical examination, which gave râles at the left apex. The husky voice led one to suspect laryngeal tuberculosis.

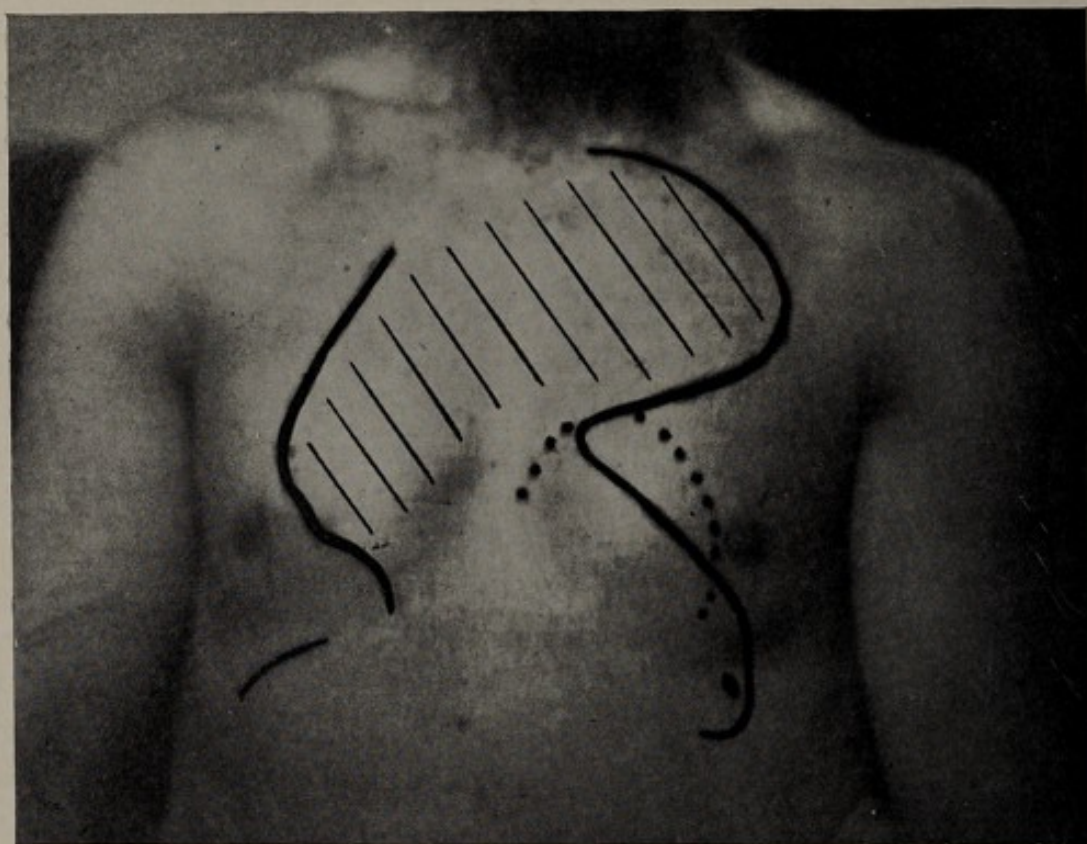


FIG. 181. Case I. M. J. Reproduction of photograph of X-ray outlines drawn on chest. X-ray examination showed a large thoracic aneurism. Family history and symptoms suggested tuberculosis. Dotted line, cardiac area as determined by percussion, full line inside as found by X-rays.

Previous History. — Always "short-winded." About four years ago he suddenly became unconscious for about a minute. There was no warning, and recovery was immediate. About June 15, 1896, he began to be hoarse and grew rapidly worse, and had some cough. About this time, while running after some colts, he had marked dyspnœa. This symptom increased, although he could walk a distance if careful. On July 15 he first raised a little blood, rather dark in color, and this occurred from time to time afterward, especially after talking. Four or five

times after October 1 he had short and sharp attacks of pain that started in the "pit of the stomach" and radiated to left shoulder and down left arm to elbow. There was numbness of the left arm associated with this pain.

Physical Examination. — The voice is shrill and husky. Examination of the larynx by Dr. Leland shows the left cord paralyzed and fixed in median line. The arteries are quite resistant and nodular, and somewhat tortuous. The heart area is decidedly diminished, action is regular and fairly strong. Apex beat in sixth interspace apparently outside of the nipple. The aortic first sound is rough; second sound is ringing and valvular. Lungs: resonance somewhat exaggerated. Over upper left chest, resonance, respiratory murmur, vocal fremitus, and voice sounds somewhat exaggerated, especially in front. At left apex and to second rib in front are numerous fine moist râles. A faint pulsation is to be felt by pressing the chest between the two hands. It seems most marked at the junction of the second rib with the sternum.

X-ray examination with screen made October, 1896, showed that the patient had a large thoracic aneurism, as indicated in Fig. 181. Some weeks later, after returning from a drive, death occurred suddenly. There was profuse arterial hemorrhage from the mouth. Failure to observe necessary precautions may have hastened the end.

Aneurism of Aorta, with Perforation into Œsophagus; Aneurism and Size of Heart as determined by X-Ray Examination confirmed at Autopsy. — This case should remind us that an aneurism ought to be excluded before we dilate a supposed œsophageal stricture.

CASE II. E. H. was admitted to the service of Dr. George G. Sears at the Boston City Hospital June 13, 1898. Diagnosis: aneurism of the aorta. He was brought to me for X-ray examination June 17th. The following history was given: family history was negative. Past history: neither syphilis nor rheumatism; alcohol in moderation.

Present Illness. — Slight pain began in cardiac region five months ago; a month later it was felt in front of right chest; and two weeks later just to right of spinal column at level of lower angle of scapula; it was a dull ache and has persisted and increased in these three places; cough increases the pain but full inspiration does not; on swallowing, pain begins at level of thyroid and extends along the spine to lower dorsal region; solids are regurgitated occasionally; meat causes severe pain unless finely minced; no cough or palpitation; dyspnœa and hoarseness for three weeks.

Physical Examination.—Left vocal cord partially paralyzed; pulmonary resonance good, being slightly exaggerated over right front; respiration harsh and wheezy; on full inspiration sounds much prolonged on right side; cardiac area extends from mid-sternum to nipple line; sounds normal; apex in fifth interspace; pulsations seen over greater part of sternum; radial pulse regular, good strength and volume; no œdema of extremities; urine normal. Diagnosis of aneurism of aorta.

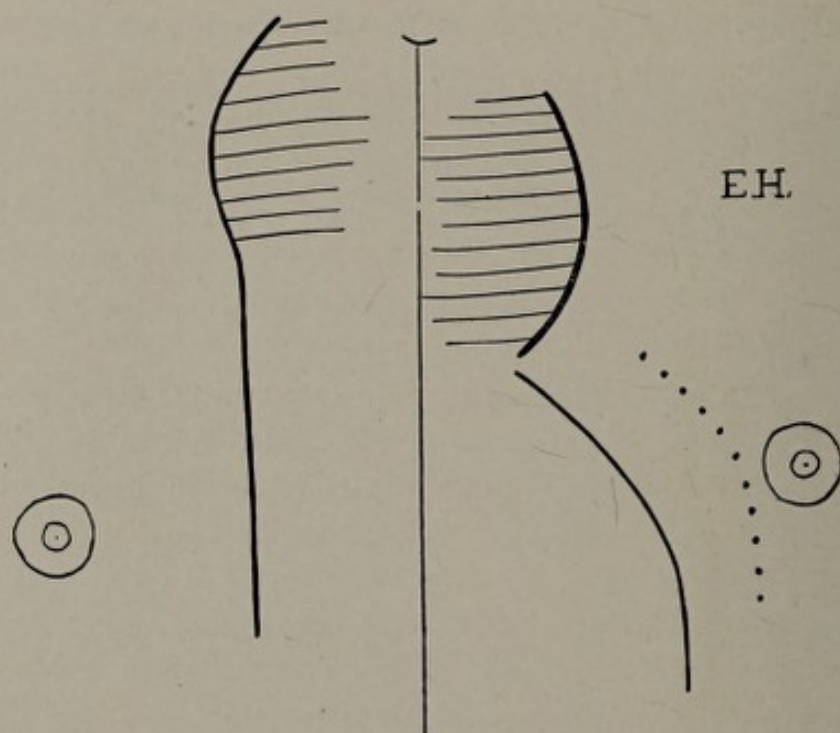


FIG. 182. Case II. E. H. Tracing of aneurism of aorta. Aneurism and size of heart seen by X-rays confirmed at autopsy. (Cut ¹ one-third original size.)

X-Ray Examination.—Figure 182 gives the outline of the aneurism seen on the fluorescent screen, as well as the left border of the heart, which border was much nearer the median line than Dr. Sears and I had placed it by percussion. The X-ray examination showed that the heart was smaller than normal, and this fact was confirmed by the autopsy.

Three weeks after admission patient raised a pint of dark blood. Two days later felt unable to swallow solids or liquids, and after two more days the stools were tarry. Died. A post-mortem examination

¹ The cuts of the aneurisms are reproductions of the tracings made by means of the fluorescent screen. I have not attempted to give reproductions of X-ray photographs, as such reproductions are so often unsatisfactory.

was made by Dr. F. B. Mallory, and I quote a part of the record. "Intestines contain dark material. In posterior wall of transverse arch of aorta, 3 millimetres below beginning of left subclavian artery, is an opening 12×18 millimetres. This opening is directly connected with a reddish-gray clot projecting through anterior wall of œsophagus by an opening 4×5 centimetres, with thin, retracted, dark greenish edges. Lower border of œsophageal perforation is on level with bifurcation of trachea. The opening communicates with a thin-walled cavity $4 \times 7 \times 8$ centimetres, filled with dark clotted blood in laminæ. Intima of aorta everywhere thickened. Many elevated yellowish plaques. No areas of softening nor calcification. Weight of heart 270 grammes. Valves and cavities normal. Some fatty degeneration of muscle microscopically. Lungs very œdematous."

"*Anatomical Diagnosis.* — General arterio-sclerosis. Aneurism of aorta with perforation into œsophagus."

The shadow of the aneurism was a little larger than the aneurism itself seen after death, but during life the sac may have been distended, and therefore larger than it was at the autopsy.

Subclavian Aneurism; X-Ray Examination before Operation to exclude Extension below Clavicle. The Result of this Examination confirmed by Autopsy. — Before ligating the subclavian, carotid, or innominate arteries for aneurism, it is manifestly desirable to know the extent of the aneurism, and whether or not there is also an aneurism of the aorta. In the following case the innominate artery was ligated by Dr. George W. Gay, and the case was reported by him in the *Boston Medical and Surgical Journal*, July 22, 1897.

CASE III. A. McC., widow, thirty-nine years of age.

To determine the lower boundary of the aneurism and to ascertain if the aortic arch were involved, Dr. Gay referred the case to me for X-ray examination, with diagnosis of fusiform aneurism of the innominate, subclavian, and carotid arteries.

X-ray examination with screen showed the outline of the portion of the aneurism above the clavicle, and demonstrated that there was no extension of the aneurism below the clavicle, and that the lungs were normal. The X-ray examination was confirmed by the autopsy.

Diagnosis of Aneurism confirmed by X-Ray Examination.

CASE IV. C. S., a patient in my service at the Boston City Hospital, a house painter, thirty-six years old, had a well-defined aneurism of the aorta, but no history of dyspnoea.

History. — Syphilis eighteen years ago; well until eight months ago, when dull pain with occasional paroxysms of sharp pain began in front of chest, in left arm to the elbow, and later shot up left side of back of neck and head. The pain has been constant from the beginning, and nine weeks ago became so excruciating that he was compelled to cease working. No weakness or tenderness of the arm; hoarse five or six weeks; no dyspnœa; constipated; appetite poor.

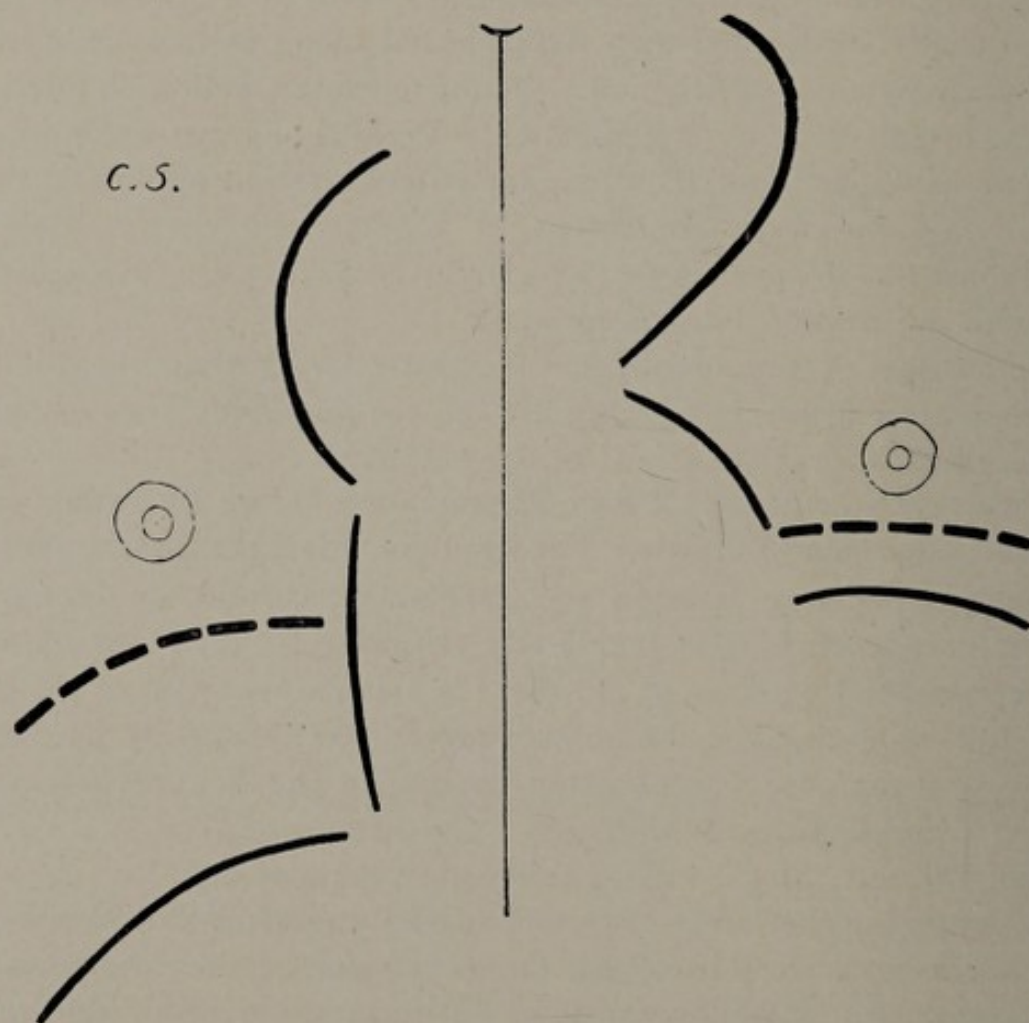


FIG. 183. Case IV. C. S. Cut of X-ray tracing. The greater portion of the aneurism is to the left of the sternum, though it also extends to the right side. The excursion of the diaphragm on the left side is much less than on the right. (Cut one-third life size.)

Physical Examination. — Well developed and nourished; voice high-pitched; pupils equal and reactions normal; no paralysis of ocular muscles; neither wrist nor toe drop; grasp normal; lead line present. Tracheal tug; radial pulses alike; cardiac area and sounds normal except in second interspace to left of sternum, where first sound is prolonged and second sound slightly accentuated; at apex of left lung in

front, to third rib, and behind to spine of scapula, vocal resonance and fremitus are diminished; no râles; on full inspiration right side of the chest is the more expansive. Laryngoscopic examination by Dr. Leland showed right vocal cord normal, left paralyzed.

X-ray examination by me showed a well-defined dark area in upper left chest, extending out from the aorta and expanding with every heart-beat. The excursion of the diaphragm on the left side was much diminished as compared with the right.

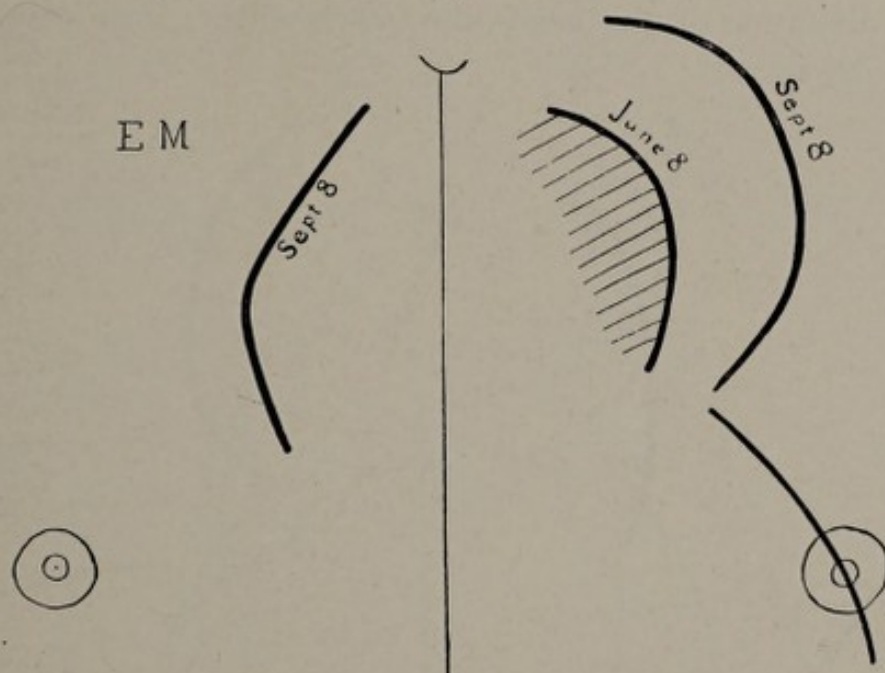


FIG. 184. Case V. E. M. Cut of X-ray tracing. June 8, first X-ray examination. Small aneurism indicated by full line enclosing shaded area. September 8, second X-ray examination. Increase of aneurism indicated by full lines marked "Sept. 8." (Cut one-third original size.)

Aneurism suggesting Intercostal Neuralgia; suspected Aneurism confirmed by X-Ray Examination. These Examinations enable us to determine whether an Aneurism is or is not increasing.

CASE V. E. M., thirty-three years of age, referred to me by Dr. J. J. Putnam for X-ray examination with reference to aneurism. Patient had suffered with what appeared to be severe intercostal neuralgia for which an operation had been done. The pain was in his left arm, left side, and below the ribs. It had been severe for two months, sometimes by day, but especially at night. There was a history of syphilis.

X-ray examination made June 8, 1897, showed a small aneurism of the descending portion of the aortic arch, which is indicated in the tracing (Fig. 184) by the shaded lines of the inner outline marked

June 8. A second X-ray examination made September 8, 1897, gave the outline marked in the tracing September 8, which demonstrated that the aneurism was increasing. Later the physical signs of aneurism became well marked, the pulsation being easily palpable, and finally the aneurism ruptured.

Extent of Aneurism determined only by X-Ray Examination. — The following case illustrates well how definitely we may outline an aneurism in the chest by means of the X-rays, and shows that a considerable amount of dilatation of the descending arch of the aorta may give rise to no physical signs.

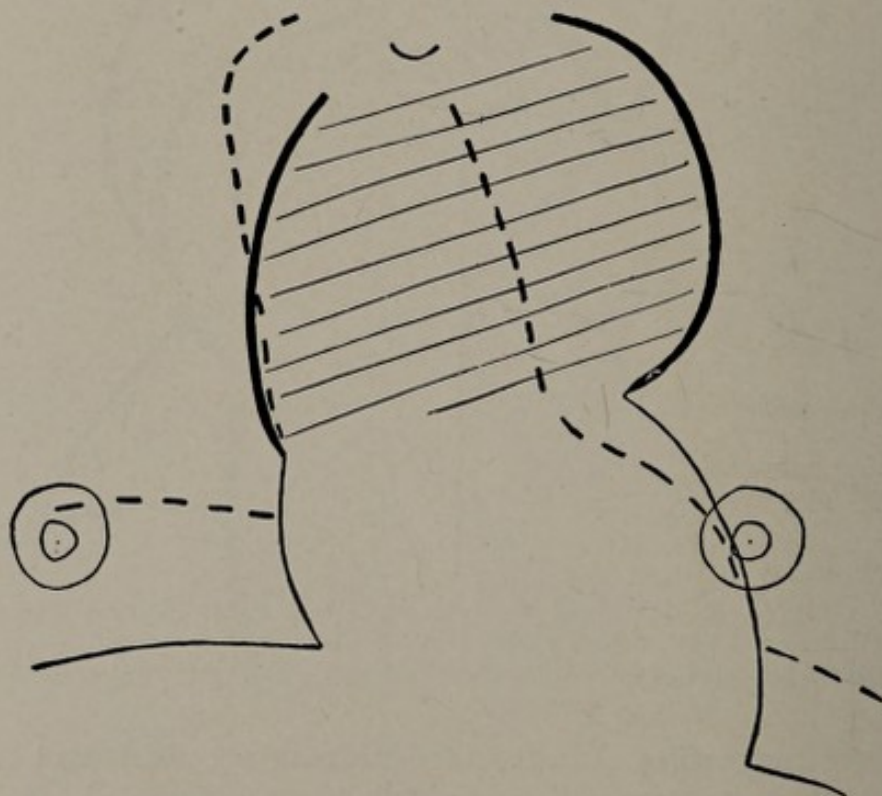


FIG. 185. Case VI. Aneurism of aorta in James L., thirty-three years old. Broken line shows outline of aneurism by percussion. Full line shows X-ray outline of aneurism and heart. The part of the aneurism to the left of the sternum was not indicated by percussion. The horizontal line near the nipples shows position of diaphragm in expiration (broken line) and in full inspiration (full line) by X-ray examination. (Cut one-third life size.)

CASE VI. James L., thirty-three years old.

This patient was under the care of Dr. J. L. Morse, and the diagnosis of thoracic aneurism was made by the usual methods, but its extent was revealed only when he was brought to me for an X-ray examination, as until that was made the dilatation of the aorta to the left of the sternum was unrecognized, and could not have been recognized by ordinary physical examination.

Diagnosis of Aortic Aneurism by X-Ray Examination confirmed by Autopsy. Position of Left Border of Heart obtained by X-Ray Examination confirmed at Autopsy.

CASE VII. A man forty-five years old was brought to me for examination, from the out-patient department, by Dr. Arnold, on February 18, 1899, with diagnosis of probable aneurism of the innominate artery and possible aneurism of the aorta.

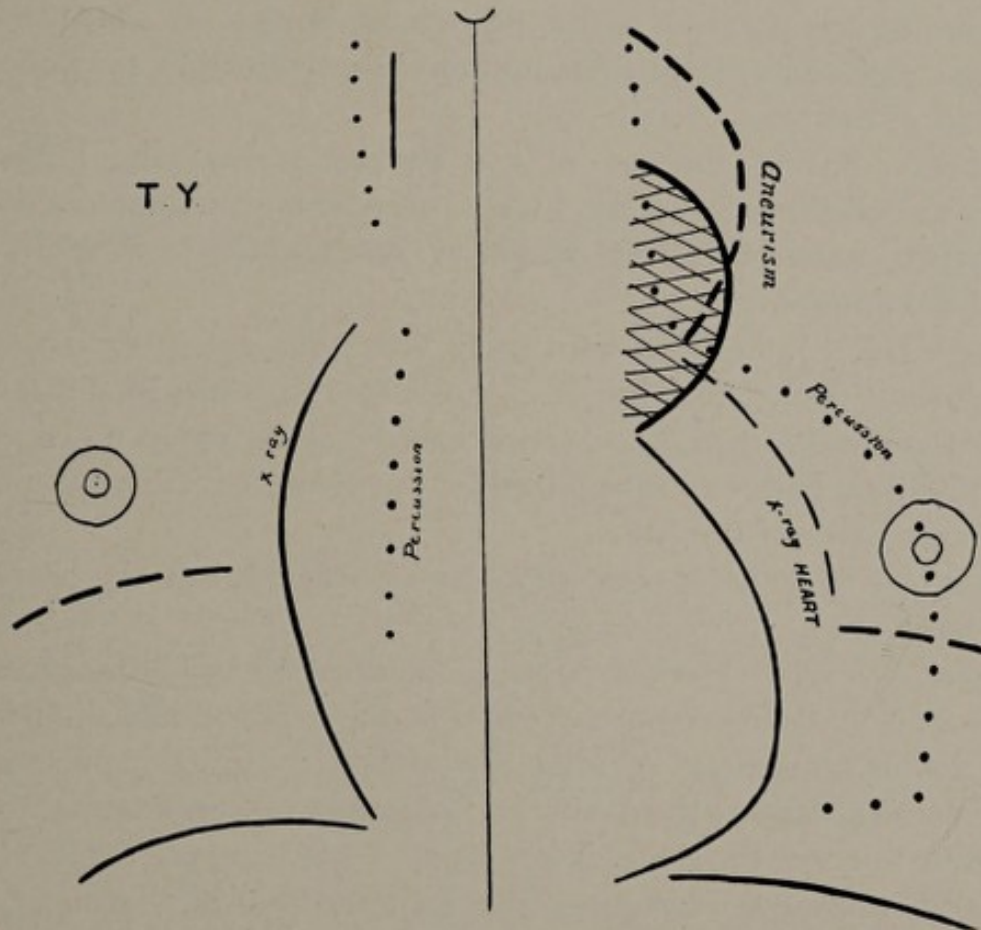


FIG. 186. Case VII. The full and broken curved lines indicate the outlines of the aneurism and the heart in inspiration and expiration respectively as determined by X-ray examination; the dotted lines, the outlines as determined by percussion. The autopsy confirmed the correctness of the X-ray examination. The full and broken parallel lines indicate the position of the diaphragm in inspiration and expiration. (Cut one-third life size.)

The X-ray examination made February 18 revealed a small aneurism of the descending portion of the aortic arch, which gave no signs by auscultation and percussion, even after the X-ray examination.

On February 23 the patient was found on the street unconscious, was brought into my service at the hospital, and a few moments later died. No cause of death was discovered by Dr. Pearce at the post-mortem, but the autopsy showed a small aneurism of the descending

portion of the aortic arch corresponding to the outline drawn at the X-ray examination, likewise an aneurismal dilatation of the innominate artery, neither of which had ruptured.

It will be seen by comparing the X-ray lines with the dotted lines, which represent the outlines found by percussion, that we failed to recognize any dulness over the site of the aneurism, and even after I had *seen* its outline on the fluorescent screen we could not detect it by percussion. *Further*, by following the dotted line which indicates the left border of the heart as found by percussion, we see that it is incorrect when compared with the same border as determined by the fluorescent screen and at the autopsy.

Another point of interest in this patient is that the lungs were found to be normal both by the X-ray and post-mortem examinations.

Aneurism unsuspected by Physical Examination; determined by X-Ray Examination.

CASE VIII. J. McC., a man forty years old, referred to me from the out-patient department by Dr. Arnold, March, 1899, illustrates some cases of the class in which aneurism could not be made out on physical examination, and was recognized in the X-ray examination made to determine the size of the heart.

History. — Syphilis eleven years ago; rheumatism six years ago; alcohol habitually.

Present Illness. — Marked dyspnoea on exertion and at times vertigo; very nervous and sleeps poorly; pain at times in the left shoulder and breast; visible pulsations of all large arteries; capillary pulse; heart dulness begins below third rib and extends 2 centimetres to right of sternum; apex in sixth interspace, 3 centimetres outside nipple line; double murmurs over aortic area; similar murmurs at apex, which are transmitted toward axilla; diastolic murmur heard over epigastrium and systolic over large areas in back; diffuse visible pulsation over cardiac area.

X-ray examination revealed with unusual clearness a small aneurism of the descending arch of the aorta, and its pulsations were easily seen on the screen. Two examinations were made, with an interval of three weeks between them, and the outline of the aneurism was readily observed; most clearly when the fluorescent screen was placed on the patient's back, over the upper part of the left scapula. Dr. John W. Bartol kindly brought the patient to me on April 15 and June 3, 1899. We found no change from the previous X-ray examination.

Aneurism unrecognized by Auscultation and Percussion seen by an X-Ray Examination.

CASE IX. E. D., a neurasthenic woman, forty-two years old, referred to me from the nervous out-patient department of the Boston City Hospital by Dr. P. C. Knapp, after the throat department had reported to him complete paralysis of the left recurrent laryngeal nerve. It is interesting to note that the hoarseness, which led to suspicion of aneurism, had made no impression on the patient, because she had been somewhat hoarse since early school days. Patient has suffered from nervousness for three years; lately easily tired, emotional,

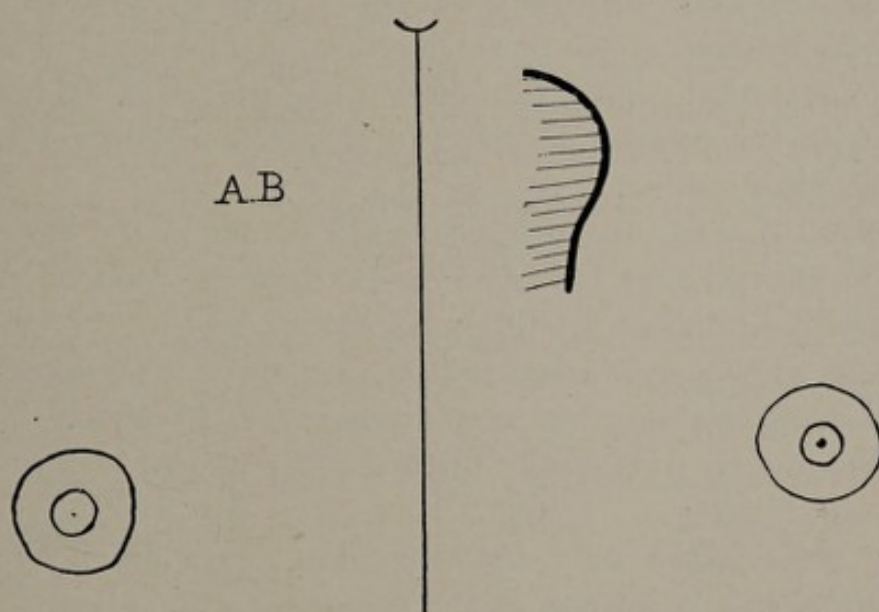


FIG. 187. Case X. A. B. Cut of X-ray tracing. Aneurism of descending portion of aortic arch, recognized only by X-ray examination. Full line partially enclosing shaded area indicates aneurism.

and depressed. Hoarseness has increased since she has become emotional. Some dyspnoea recently.

Physical Examination. — Auscultation and percussion gave no signs of aneurism.

X-ray examination with screen revealed a small aneurism of the aorta.

Aneurism recognized only by an X-Ray Examination.

CASE X. A. B., referred to Dr. Leland for oesophageal stricture, and sent by him to me for an X-ray examination in March, 1898.

History. — In twenty-two years of married life her only pregnancy resulted in a miscarriage. Patient was said to have a stricture about 2 centimetres below the upper end of the oesophagus, and another about

opposite the second rib. During the past summer her family physician had passed an œsophageal bougie every third day. Shortly before coming to me this treatment had been omitted and she felt no worse.

Physical examination gave no sign of thoracic aneurism.

X-ray examination revealed what was probably a small aneurism of the descending portion of the aortic arch. Its outline was plain whether viewed from front or behind.

This case suggests the advisability of an X-ray examination before dilatation for œsophageal constriction in some cases.

Aneurism suspected on account of Hoarseness, but there was no Paralysis of the Left Recurrent Laryngeal Nerve; X-Rays showed no Aneurism was Present. — As is well known, hoarseness may be the first, and for a long time the only, sign of thoracic aneurism. This symptom was present in the following case, and it was therefore referred to me for an X-ray examination.

CASE XI. B. D., forty-five years old, came to the throat department of the Boston City Hospital on January 17, 1900, to consult Dr. Leland, to whom he gave the following history:—

Six weeks previously he first noticed a marked hoarseness of voice, and that a considerable effort was necessary to phonate. There were no other symptoms. His family history and personal history were both negative.

Careful *examination with the fluorescent screen* did not reveal anything abnormal in any portion of the thoracic aorta.

Subsequent examination of the larynx by Dr. Leland showed the arytenoid on the right side to be absolutely immobile, both in respiration and phonation; the *right* vocal cord was also involved. Pupils equal; no glands demonstrable; no physical signs or symptoms of aneurism.

On subsequent inquiry in June, 1900, the patient reported that his voice was completely restored.

CASE XII. **Tentative Diagnosis of Thoracic Aneurism.** — The hospital record in the case of O. D. is given below, and my X-ray examination follows:—

Thomas O. D., thirty-three years of age. Patient of Dr. Metcalf of Winthrop, Mass.

Family History. — Father and one brother died of cramps. Three sisters and mother living.

Past History. — Never been sick before December, 1899, when he complained of hoarseness. Admitted to military hospital. Diagnosis:

perichondritis; not relieved. Was readmitted, April 20, 1900, complaining of constant cough in addition to his hoarseness. Discharged May 13, improved. No tubercle bacilli found; no loss of weight; no physical examination recorded.

Last admission, June 9. Loss in weight 25 pounds since June 9. Normal weight 190 pounds.

Present History. — Still complains of hoarseness with violent cough. Uvula much relaxed; was amputated. Temperature on admission 102° , which next day fell to normal. Has had an occasional night sweat.

Physical Examination. — Examination of chest showed a displacement of the heart to the right. Apex beat not felt, but was loudest in fifth interspace, 1.25 centimetres to left of right nipple. Percussion of cardiac area showed dulness to right of sternum; left lung dull throughout. Breathing diminished, but not absent. Loud râles over upper left back. Vocal and tactile fremitus both absent over entire left lung. Expectoration profuse for a few days, apparently pure pus. Microscopic examination for tubercle bacilli negative; test with tuberculin negative.

Since admission, expectoration has practically ceased. Heart remains displaced to right of sternum; dulness over left lung still persistent; bronchial râles much diminished and often absent; breathing still diminished, but present; vocal fremitus still much diminished; tactile fremitus also diminished, but present, with the exception of left front, where it is practically absent.

Pain in right shoulder behind, going down to elbow and hand at times. Tactile fremitus increased over right chest, upper half.

A definite diagnosis was not made, but another physician, who saw him in consultation, was inclined to think it was tuberculosis.

My X-ray examination, given below, inclined me to the diagnosis of aneurism, but there was so unusual a history that I desired to watch the patient still further before making a definite diagnosis. This, however, could not be done, as the patient left the State.

X-Ray Examination with Screen. — The full line, marked *A*, in the tracing, is an outline of the aneurism, this portion of which the X-rays showed to be nearer the posterior than the anterior chest wall; this outline does not move even in deep inspiration. The full and broken lines, marked *B* and *C* respectively, outline the aneurism on the right in inspiration and expiration, and the X-rays showed that this portion was nearer the front than the back of the thorax. All the full

lines in the tracing indicate the outlines seen during a deep inspiration, and the broken lines those seen in expiration. Contrary to the usual rule in health, the heart in deep inspiration moved downward and to the left instead of downward and to the right. Further, when the heart moved toward the right in expiration, the added portion of the outline *A*, indicated in the tracing by a broken line, was brought into view. That is to say, the heart lies in front of the aneurism, and is

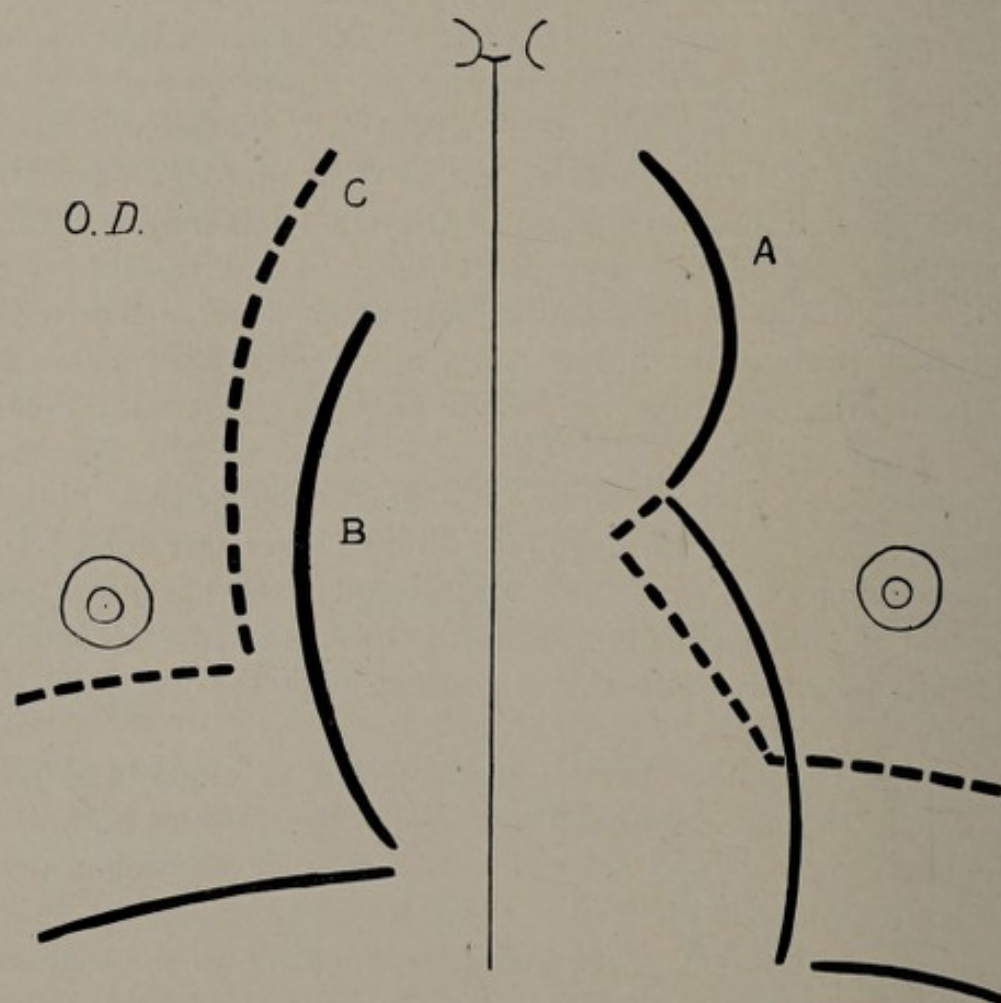


FIG. 188. Case XII. O. D. Cut of tracing made with screen on front of chest. X-ray examination shows the outlines of what proved to be an aneurism, and that it was nearer the back than the front of the chest. (Cut one-third life size.)

drawn upward and to the right in expiration, but is pulled out of this abnormal position by the descent of the diaphragm.

The subsequent history, obtained some time later, was as follows: On September 13, 1900, the patient went to a baseball game; on his return home he coughed up a quantity of blood, and died in a few minutes.

Information obtained at Autopsies of Cases of Aneurism in Regard to Heart confirmed by X-Rays. — The cases of aneurism that I have exam-

ined have afforded several opportunities to confirm by autopsy the correctness of the position of the left border of the heart as determined by X-ray examination, and to show that that obtained by percussion was incorrect. The following case and Case VII are illustrative :—

Aneurism of Ascending Aorta ; Enlarged Heart ; X-Ray and Percussion Lines compared ; X-Ray Outlines confirmed by Autopsy.

CASE XIII. D. This patient was seen by Dr. Arnold in the outpatient department and sent to the hospital ; he entered my service and

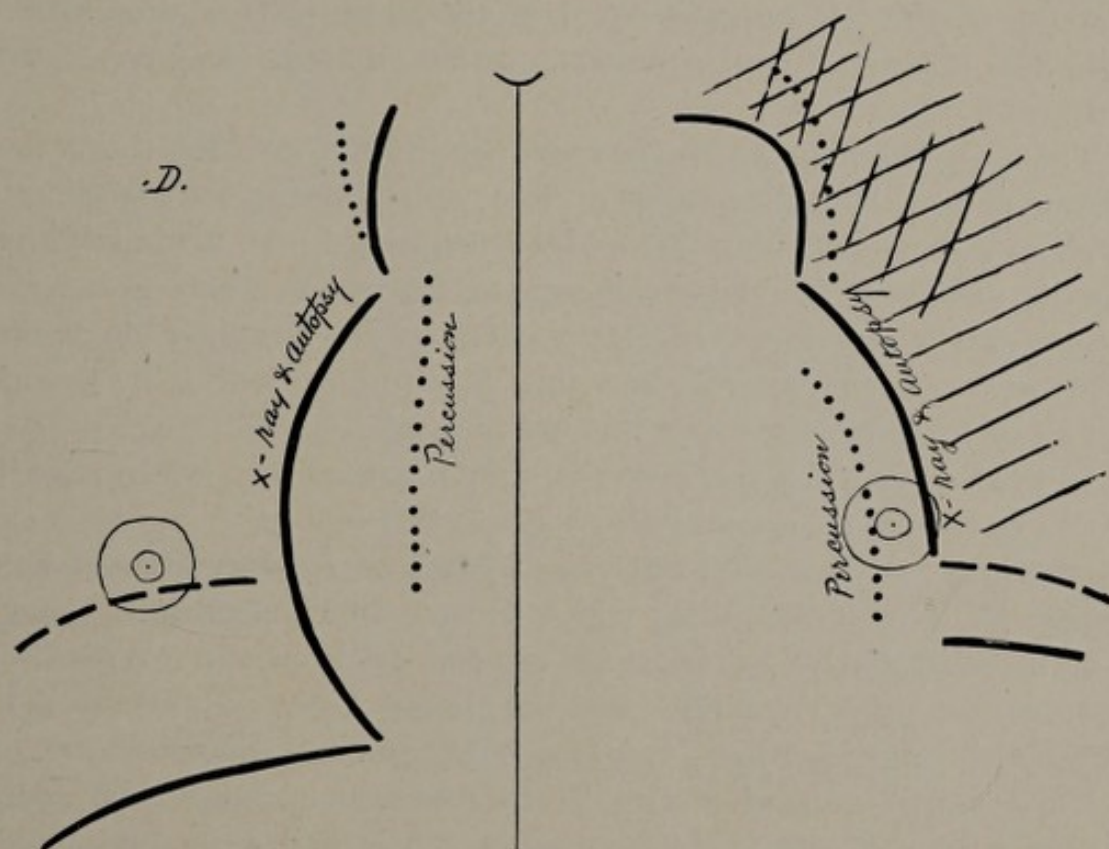


FIG. 189. Case XIII. D. Aneurism of the ascending aorta without pulsation. X-ray and percussion lines compared. X-ray lines confirmed at autopsy ; also the density of the lung that was determined by X-ray examination. (Cut one-third life size.)

was examined carefully, both by the usual physical examination and radioscopically, and the outlines of the heart and of the aneurism, as determined by each method, were compared. The following cut gives a reduced copy of the outlines as determined by the X-rays and by percussion ; the full lines indicate the former, the dotted lines the latter.

At the autopsy, which took place a few days later, and at which I was present, the correctness of the X-ray outlines was confirmed. The position of the right and left borders of the heart and of the aneurism

was determined by Dr. Mallory, by measurements taken directly after the removal of the sternum and the opening of the pericardium. The tracing of the outlines made at the X-ray examination was in my hand, and it was found that these outlines agreed with Dr. Mallory's measurements. Four millimetres above the cusp of the aortic valve there was an opening 2×2.75 centimetres in the anterior surface of the aorta, rather to the left side. This communicated with a sac having very thick walls, which was filled with a dense clot. The aneurism was unruptured. There was marked fatty degeneration of the heart. The condition of the left lung as noted at the X-ray examination was also confirmed, it being found somewhat denser than normal, especially at its upper portion.

This case is one in which the aneurism did not threaten the patient's life, as shown by the autopsy. The dense tissue surrounding the aneurism and its sac being filled with a firm, hard clot, made it unlikely that the aneurism would have increased further in size. X-ray examinations made at intervals in such cases would demonstrate that the aneurism was not increasing, and that interference with it by the introduction of wires or horse hair was not indicated.

If the conditions were reversed, and the aneurism was increasing, the X-ray examination would also indicate this fact.

Importance of Fluorescent Screen and Careful Interpretation of X-Ray Photograph. — The difficulties which present themselves in the diagnosis of thoracic aneurisms, where X-ray examinations are not used, or if used are not properly interpreted, is illustrated very well by a case published in the *American Journal of the Medical Sciences* in 1900.

This woman presented herself at a hospital in June, 1898, seeking treatment, as she said, for an *aneurism*. She had a tumor extending through the upper portion of the sternum. The tumor was soft and elastic, and pulsated with every heart beat, the pulsation being slightly expansile, and causing the apex of the tumor to rock slightly from side to side. . . . Below this tumor, at the level of the third and fourth costal cartilages, was a second pulsating mass, larger, flatter, and less inflamed than the other. This mass was in the median line, and covered an area as large as the palm of the hand. The upper tumor broke on the third day, and a small quantity of bloody puriform material escaped, reducing the size of the mass at least one-third. The lower swelling was opened and material like that from the upper mass was evacuated. She improved and was sent to a convalescent

home, returning to the out-patient department some weeks later. Three physicians who had seen the patient agreed that there was no aneurism present. An X-ray photograph was taken at this time, but no indication of an aneurism was observed on the radiograph.

On the evening of September 15 she went to bed feeling as usual. At midnight she got up. There was the sound of a gush and a cry. Her husband found her dead in a pool of blood issuing from her chest.

Her physician's frank comment is as follows:—

"The accompanying radiographs should have prevented the mistake in diagnosis. But I am ashamed to say that none of those who saw her took a sufficiently intelligent interest in them to see their significance until it was too late.

"We looked at them solely for evidence as to perforation of the sternum. Finding no gap in the sternum shadow, the false inference was drawn that no such perforation was present. But we should have known that the position of the spinal column is such that perforations of the sternum, even of considerable size, do not show on a radiographic plate.

"It is perfectly easy now to see that there is a tumor in the region of the aortic arch, and to distinguish the heart and the liver below. But somehow, this did not force itself upon us at that time. The moral obviously is that we should know more about the interpretation of radiographic plates."

I refer to this case because the question is put forcibly and clearly. If we desire to secure the advantages which the X-ray examinations afford in cases of aneurism, we must not only take pains to get good radiographs, but we must also teach ourselves how to interpret them. Further, if this patient had been examined with the fluorescent screen, a good apparatus being used, instead of by means of a photographic plate, the aneurism could not have been overlooked.

Recently I have seen in consultation a few patients, where a diagnosis of thoracic aneurism, based on an X-ray examination, had been made by the examining physicians, in whom I found a perfectly normal thorax by X-ray examination. And further, I have had my attention directed to cases in which a diagnosis of an aneurism was made by the attending physicians, but no aneurism was found at the autopsy. These occurrences have led me to go over my own cases carefully with reference to their subsequent history, and in no case, so far as I can ascertain, has any patient in whom I have found no aneurism by X-ray

examination proved later to have one. On the other hand, all the cases in which I have made the definite diagnosis of aneurism by X-ray examination, and in which I have been able to get the subsequent history, have either died of what was undoubtedly the rupture of an aneurism; or, if death ensued from some other disease, and a post-mortem was made, an aneurism has been found corresponding in position and size to that found by my X-ray examination. The partial exception to this statement is the case of Mr. C., given in the chapter on New Growths. The cause of death was a mass of glands below the sternum, which gave rise to outlines very similar to some aneurisms. I saw the patient only once. The examination was not as complete as I desired, and I found it difficult to decide whether the appearances were due to a new growth or to an aneurism, but inclined to the latter diagnosis. As stated in the chapter on New Growths, I expected to see the patient again, get history, and make a further examination. But the expectation was not fulfilled.

I do not mean to suggest that I might not find it impossible to make a definite diagnosis in some cases, but I believe this would now occur infrequently.

In conclusion, X-ray examinations should be made both with the fluorescent screen and the X-ray photograph. Normal outlines in the upper part of the chest give us the best assurance that an aneurism of the aorta is not present, though symptoms may obtain which lead the physician to suspect it. On the other hand, if an aneurism be present, its outline will be demonstrated by the X-ray examination. An outline suggestive of aneurism may be due to other causes, as a new growth, for example. But confusion of this kind is not common, and we can in most cases convince ourselves by a careful examination whether or not it is an aneurism which casts the shadow. X-ray examinations enable us to determine the extent of an aneurism much more accurately than the usual physical examination, and to detect its existence at a much earlier stage. Successive X-ray examinations enable us to determine whether or not it is increasing.

To make a definite diagnosis of aneurism by the usual physical examination we may be obliged to wait for the development of marked signs, and this delays treatment. On the other hand, if the physician begins treatment because the signs are suspicious, he runs the risk of subjecting his patient to an unnecessary regimen. The advantages of an X-ray examination when compared with the usual physical examina-

tion are evident. A definite diagnosis can be made in most cases before there are physical signs. Treatment can therefore be begun at an earlier and more hopeful stage, can be planned more intelligently, as the knowledge of the position and extent of the aneurism is more accurate, and its results can be better estimated because we can more accurately measure any change in size. In cases like that of D., page 327, the physical signs, not only the X-ray signs, would be found early because of the position of the aneurism, which was directly under the sternum. The X-ray examination should of course be considered in connection with the history and all other evidence when making a diagnosis.

An operation should not be performed on an aneurism near the thoracic aorta until the latter artery has been examined by the X-rays, for if an aortic aneurism exists, operation would be inadvisable.

CHAPTER XII

NEW GROWTHS. ENLARGED GLANDS. ABSCESS AND GANGRENE OF LUNG

NEW growths in the bone may as a rule be easily recognized by the X-rays, as for example an osteosarcoma or an exostosis, but as these growths will be considered under the surgical uses of the rays, we need not discuss them here, but will take up directly those that occur in the thorax.

A new growth in the lung usually casts a marked shadow, and in the latter stages may fill up most of one side of the chest and thus render this side completely dark on the fluorescent screen. If, however, the new growth is recognized in its early stage, the shadow cast may be slight. In many cases an X-ray examination makes it evident without much question that we have to deal with a new growth, although in some at least its presence was unsuspected by the usual methods. There are other cases in which the disease has advanced so far before the patients are examined by the X-rays as to involve a large part or the whole of one lung, and in such cases the appearances seen on the screen may well at first sight call to mind pleurisy with large effusion or an unresolved pneumonia. There are still other cases in which a new growth, under certain conditions, may simulate a thoracic aneurism. Therefore, if the interpretation of the appearances seen on the screen is not perfectly plain, the patient should be examined with the X-rays going through the body from different directions; and in certain cases an X-ray photograph should be taken.

Likewise it must be remembered that the X-ray examination is only one method, and that its results are to be considered in connection with the history of the patient, his present condition, and the evidence obtained by other means of physical examination; but I have no doubt that, as we learn better how to make and how to interpret X-ray examinations, they will aid us to make a more definite and an earlier diagnosis, when it is a question of a new growth, than has hitherto been possible.

On the other hand, when a patient has been examined by the ordi-

nary methods, and the case does not *seem* to be obscure, although the symptoms observed are not wholly characteristic of those produced by a new growth, or the diagnostic picture obtained is incomplete, an X-ray examination should be made for confirmation or refutation of the diagnosis.

The points just touched upon can be most clearly appreciated by the history of a few cases and the accompanying cuts.

The first case illustrates the method of locating a new growth:—

Daniel M., thirty-nine years old, came to the out-patient department of the Boston City Hospital on January 26, 1899, and was under the care of Dr. John L. Ames.

History.—On January 9 the patient raised a little dark blood. Had some diarrhœa and passed two spoonfuls of dark blood. He weighed 165 pounds.

Present Illness.—The general appearance of the patient was good. The physical examination showed, at the right back, beginning about the middle of the scapula, an area of dulness about the size of the palm of the hand, which did not extend to the base of the lung. Over this area the respiratory and vocal sounds were somewhat diminished. The fremitus was about the same on both sides. There were no râles. At the right apex in front there was no dulness, but respiration was broncho-vesicular in character. Expiration was prolonged and harsh.

On January 28, 1899, the patient was sent to me for an *X-ray examination* with reference to early pulmonary tuberculosis. The radioscopic examination showed in the right chest a dark and sharply defined area with a rounded outline, about 15 centimetres high and 12 centimetres wide. There was a space of about 2.5 centimetres between the lower border of the dark area and the diaphragm during deep inspiration, and during expiration the curve of the diaphragm overlapped the lower portion of the dark area in such a way as to indicate that during this period of the respiratory movement the lower portion of the mass intervened between the dome of the diaphragm and the posterior wall of the chest. I then examined the thorax from different points of view in order to determine the exact position of this dark area, and I found it was situated nearer the back than the front of the chest. This position was demonstrated in several ways, and the following description and cuts show the method pursued, and that accurate information can be obtained in some cases by the fluorescent screen.

Method of Examination. — (See also Chapter III, pages 81–86.) When the patient was lying on his face, and the screen was placed on his back and the tube below him, the outline of the dark area was more sharply defined than when the respective positions of the screen and tube were reversed, which showed that the dark area was nearer the posterior than the anterior wall of the chest.

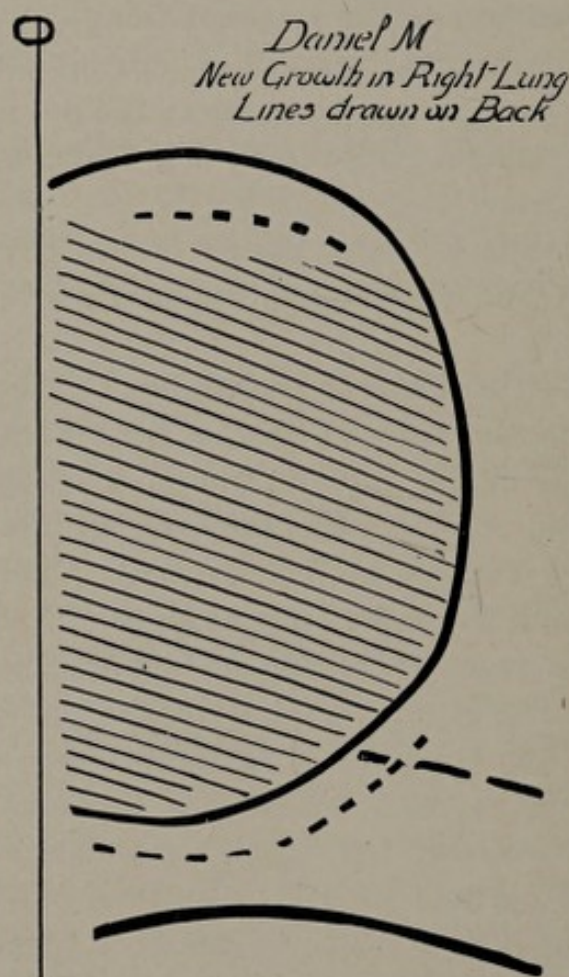


FIG. 190. Daniel M. Cut of tracing made with patient lying on his face, the screen on his back, and the tube below the stretcher. The shaded area indicates the dark mass; the full line enclosing it, its outline and position during expiration; the dotted lines, its outline and position during full inspiration; the full line in the lower part of cut and the broken line parallel to it, the position of the diaphragm in full inspiration and expiration respectively.

This cut includes only the right back; the median line is shown, and at its upper end the spinous process of the seventh cervical vertebra is indicated. (Cut one-third life size.)

Second, when the screen was on the front of the chest, and the tube behind the patient, the shadow moved through a greater distance during deep inspiration than when the respective positions of the screen and tube were reversed; which again showed that the darkened area was nearer the posterior than the anterior wall of the chest. Further, with the screen on the front of the chest the shadow of the lower edge

of the mass moved a greater distance in full inspiration than the upper edge; which showed that the lower edge was nearer the posterior part of the chest wall than the upper edge. In full inspiration the shadow of the lower edge moved 2.5 centimetres, and that of the upper edge a little less.

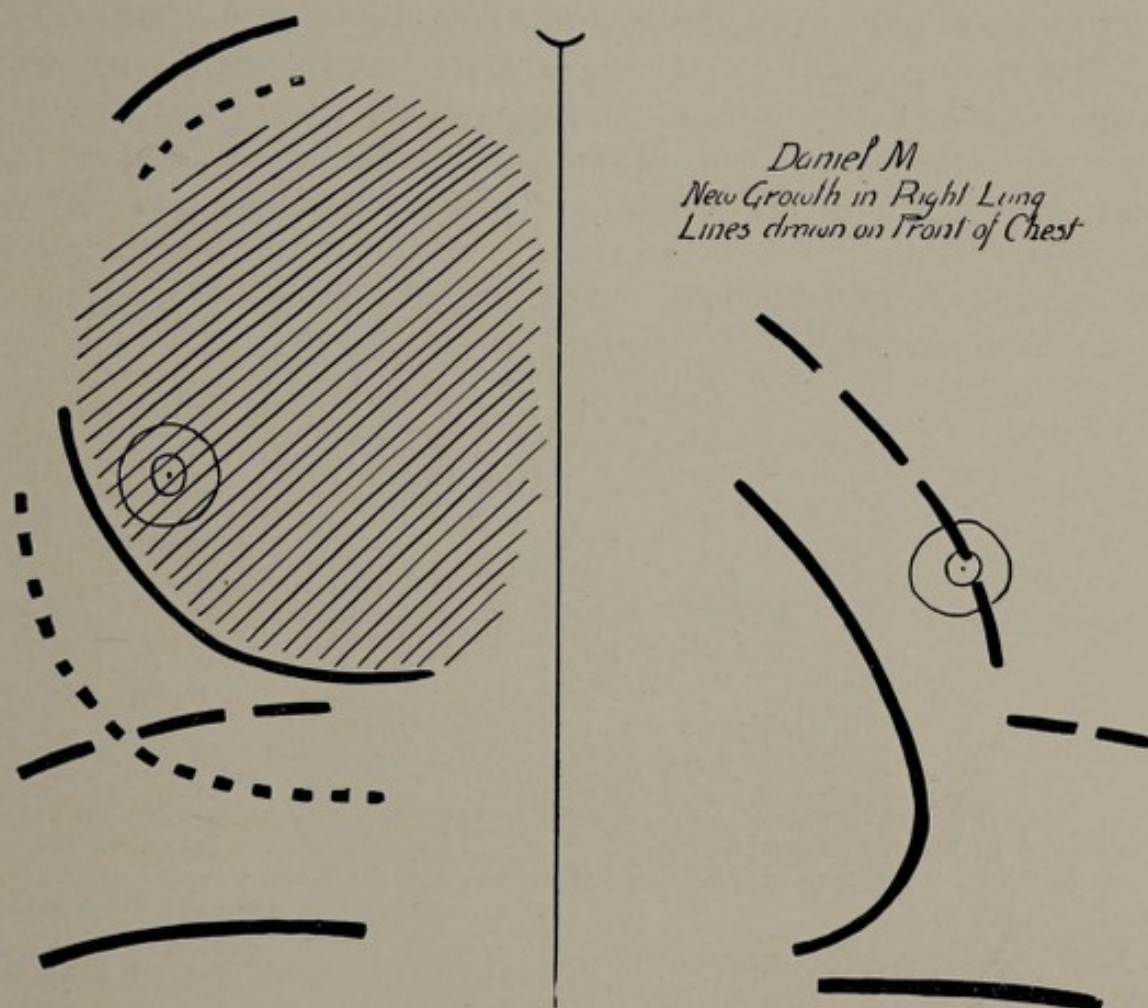
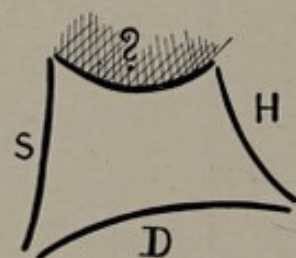


FIG. 191. Daniel M. Cut of tracing made with patient lying on his back, the screen on the front of his chest, and the tube below the stretcher. Shaded area indicates the new growth; the full curved line above and below it, its outline and position in expiration; the dotted lines, in full inspiration. The other full lines indicate the outline and position of the heart and diaphragm in full inspiration; the broken lines, in expiration. (Cut one-third life size.)

By comparison with Fig. 190, it will be seen that the shadow of the lower border of the dark mass move farther when the screen is on the front of the chest than when it was on the back. As the distance of the tube from the screen was the same in both cases, it is evident that the mass casting the shadow was nearer the screen when it was on the back than when it was on the front of the chest.

Third, when the tube was placed somewhat behind and to the right of the patient, so that the X-rays fell upon the chest at a point between the axillary lines (screen on front), the front of the chest was clear; which again showed that the shadow seen was not due to a mass in the front of the chest.

Several X-ray examinations were made of this patient, but the accompanying tracings represent the appearances seen on the fluorescent screen at one of these examinations only. In Fig. 191 the outline of the heart and diaphragm is indicated by a full line in deep inspiration, and by a broken line in expiration; and the outline of the new growth by a full line in expiration and a dotted line during inspiration. The first tracing (see Fig. 190) is copied from the lines which were drawn on the back of the chest, the patient lying on his face (the oval at the top of the median line indicates the position of the spinous process of the seventh cervical vertebra); the second (see Fig. 191) from the lines drawn on the front of the chest; and the third, a small tracing (see Fig. 192), from the lines drawn on the right side of the chest during a deep inspiration.



*Daniel M.
Lines drawn on Right Side
during Full Inspiration*

FIG. 192. Daniel M. Cut of tracing made from patient with the screen on his right side and the tube opposite the left side, showing the outline of the bright area seen when he was examined in this position during full inspiration. In health this area has the shape of a spherical triangle (see Chapter X, on Heart, page 259). In this patient the limit of the upper part of the bright area was formed by the dark mass; the lower limit of this area corresponded to that found in health. D represents the line of the diaphragm in full inspiration; H, the lower and posterior border of the heart; S, the parts just anterior to the spine; ?, the lower border of the growth.

When the patient was examined in the latter position, that is to say, with the light going through the body from side to side, and the fluorescent screen on the right side, instead of the usual spherical triangle (see Fig. 158 in chapter on Heart) outlined by the diaphragm below, the heart in front and above, and posteriorly by what I have called the "spine," although strictly speaking the shadow is not cast by the spine itself, but rather by what lies in front of it, I found a figure defined by four curved sides, the convex side of all four lines being inward. The lowest of these curves is a portion of the diaphragm, the anterior one the lower posterior border of the heart, the posterior one the spine, and the upper one a portion of the new growth.

The reader must imagine the patient with all these lines drawn on his skin (they are, of course, readily removed with a little alcohol), in order to appreciate how the examinations made from different sides confirmed each other, and gave an exact indication of the size, position, and movement of the dark mass.

The X-ray photograph (Fig. 193) was taken somewhat later than the tracings; it shows the rounded border of the dark new growth, and below the growth the lighter pulmonary area crossed by the ribs on both the anterior and posterior wall of the chest; likewise in its lower portion the outline of the diaphragm and the liver. I have had only a

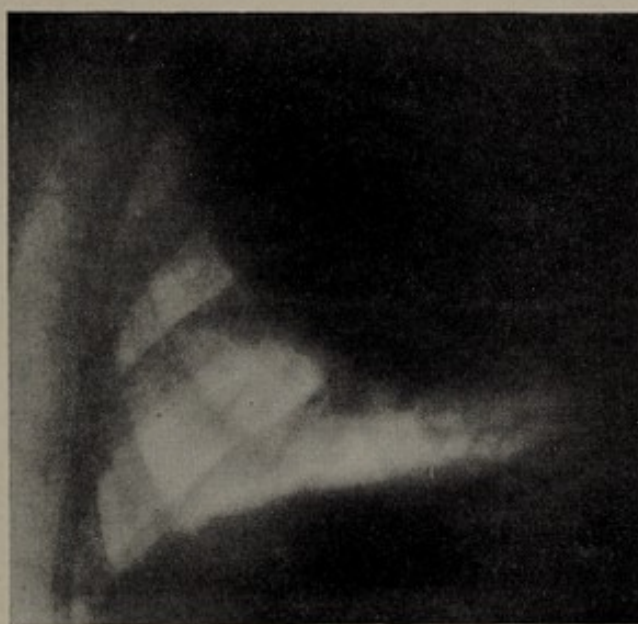

FIG. 193. Daniel M. Radiograph taken with plate on front of chest and tube behind the back. The curved outline of the dark mass above the light area corresponds to the outline seen on the fluorescent screen (Fig. 192, page 336). Below the light area, which is crossed by the ribs on front and back of thorax, is seen a portion of the diaphragm. (About one-third size of original.)

portion of the outline of the new growth reproduced in the cut, for if the whole had been included a greater reduction of scale would have been necessary than was advisable.

The striking features of this case are, first, the fact that so large a mass in the thorax should give such slight physical signs; and, second, the readiness with which its outlines, position, and movement could be followed on the fluorescent screen.

The well-defined, rounded outline of the mass suggested an aneurism, but an aneurism of this extent would be accompanied by some well-marked changes in the heart, and these were not present; also the position of the heart would be lower down in the chest, whereas there

was only a slight displacement of this organ to the left. Therefore the diagnosis suggested by the first appearances would not be borne out by the other observations.

The three tracings and radiograph are given to show how we may determine, not only the size, but the position, of a new growth in the chest more exactly by an X-ray examination than by other methods.

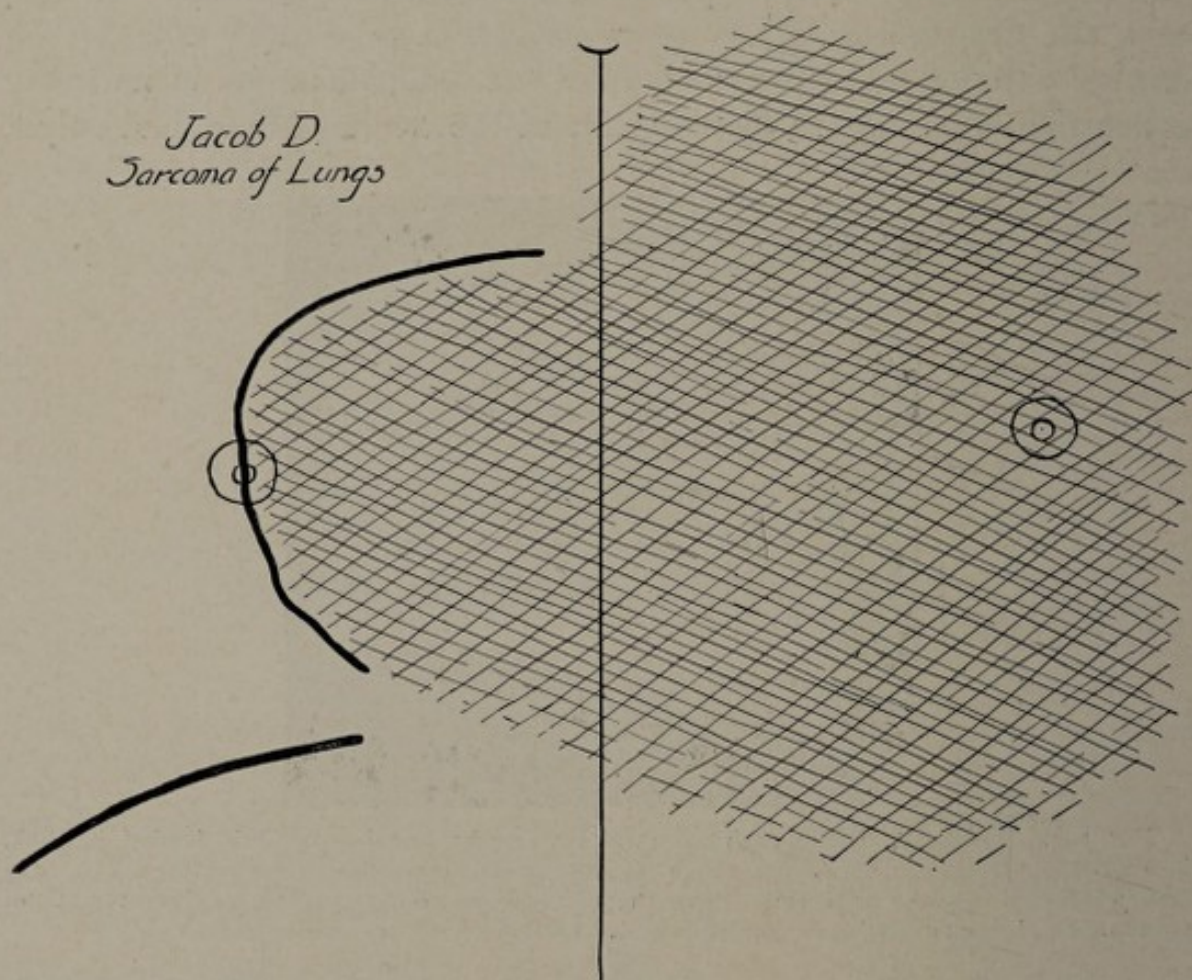


FIG. 194. Jacob D. Cut of tracing made with screen on front of chest. New growth in left lung extending to right lung. (One-third life size.)

Diagnosis of New Growth made by Aid of X-Rays confirmed by Autopsy.—Jacob D., twenty-five years old, entered the Boston City Hospital August 3, 1898. A patient of Dr. G. G. Sears.

History.—Began to cough two days before entrance. Soreness across lower chest. Chest enlarged for three weeks. Reclining in bed, especially on the left side, caused coughing. Expecterated whitish material. Coughed up dark blood "a long time ago." Had lost considerable flesh.

August 5. Left chest aspirated, and thirty-eight ounces of bloody fluid withdrawn.

August 8. It was noticed that the whole chest pulsated, and when the patient was aspirated again on this day the needle seemed firmly held and had a distinct impulse with each pulsation of the heart.

Dr. Sears kindly allowed me to examine the patient with the X-rays, and the result is given below:—

X-ray examination with the screen, made on August 10, showed that the whole of the left chest was uniformly dark, and that a part of the right chest was also dark as far as the right nipple. (See Fig. 194.) The darkened area in the neighborhood of the right nipple was evidently not a displaced heart; I thought it was probably due to a new growth. The reason for this conclusion was as follows: the apex beat of the heart was felt in the fifth interspace, just inside the nipple, therefore the outline seen to the right of the sternum could not well be the border of the heart. The age of the patient, the presence of bloody fluid in the chest, the failure to find bacilli, and the loss in flesh, taken in connection with the X-ray examination, all pointed toward a new growth. This diagnosis was confirmed by finding a part of a spindle-cell sarcoma in a small amount of material which was withdrawn from the chest on the end of a needle August 15; and subsequently by the autopsy. The latter showed that the tumor had evidently arisen from the mediastinal lymph-glands; that the left lung was studded with soft, projecting, round tumor nodules; and that similar ones were also present in the right lung.

Tumors in Chest; Results obtained by X-Ray Examination and Auscultation and Percussion compared.—The following case is given to show the advantage of comparing the results obtained by auscultation and percussion with those obtained by an X-ray examination:—

H. Leo¹ cites the case of a boy ten years old, an abstract of which is as follows:—

In June the right leg was amputated above the knee on account of sarcoma. Recovered. In July he had a dry cough. In August complained of pain in the left side and back. In September there was sudden difficulty in breathing, high degree of dyspnœa, great weakness, accentuated heart activity, and pain in the chest. These symptoms continued, and on October 7 the patient died.

¹"Nachweis eines Osteosarkoms der Lungen durch Roentgenstrahlen," *Berlin. klin. Wochenschr.*, April 18, 1898, 349-350.

The day before his death an X-ray examination showed a diffuse shadow over the left side, with an irregular boundary touching the heart shadow; a small bright zone outside of this boundary; and a shadow on the right side which was much darker than the diffuse shadow on the left and almost corresponded to the heart in darkness. This dark oval shadow showed a clearly defined boundary. The extent of the shadows far exceeded the extent of the dulness as determined by the physical examination. Percussion had only given a dulness on the left side, reaching downward from the spine of the scapula to its lower point, and forward to the axillary line, and still forward to the right, from the clavicle down to the third rib, but indicated that the lungs were otherwise normal, and only by the X-ray examination was the seat of the trouble ascertained.

A post-mortem examination a day later corroborated the X-ray indications.

Tumors in Head. — Although this section is devoted to the thorax, it may be said here, for want of a more convenient place, that tumors in the brain with our present apparatus and inexperience must necessarily offer a good deal of difficulty to detection by the rays. One case,¹ however, has been reported, where the skull was remarkably thin, in which the size and position of the tumor was recognized during life, and the observations were confirmed at the post-mortem examination.

Differential Diagnosis. — The following case shows how the appearances seen on the fluorescent screen in a new growth on the one hand, and a pleurisy with large effusion on the other, may differ from or resemble each other: —

George D., thirty-nine years old, entered the hospital March 23, 1899. In the service of Dr. C. F. Withington.

Diagnosis. — Pleurisy with effusion.

March 24. Patient aspirated and 70 ounces of blood-tinged fluid withdrawn.

March 26. Flatness from two inches below spine of scapula on right side.

March 27. Aspirated again and 44 ounces of bloody fluid withdrawn. Flatness just below angle of scapula. Rising toward spine of scapula there was a dull area where the breathing was diminished.

¹ "Cerebellar Tumor about the Size of a Lemon recognized Clinically, demonstrated by the X-Ray and proved by Autopsy," by Archibald Church, M.D., *American Journal Medical Sciences*, February, 1899, page 125.

March 30. No tubercle bacilli found.

April 5, 1899. Discharged relieved.

October 24, 1899. Reëntered the hospital and was placed in my service. Meanwhile the disease had evidently progressed.

Diagnosis. — New growth.

History. — Seven weeks before entrance had sharp pain in the right chest, worse on deep inspiration; slight dyspnœa; no cough, chills, or fever. At work until ten days previous to entrance. Right chest had been tapped seven times, no fluid obtained. Had lost eight pounds in four months.

Physical Examination. — Heart: right border indeterminable on account of dulness in the right chest. Left border 12.5 centimetres to left of median line. Apex in fifth space in the nipple line. No murmurs. Lungs: left chest moved more than right in respiration. Marked bulging of lower right chest, as low as costal margin. Dulness on right, beginning at third rib in front and spine of scapula behind, and increasing to flatness at right base. Respiratory sounds diminished over this area. Tactile fremitus diminished. Fine crackling and medium moist râles in back, over dull area. Tactile fremitus increased over upper right front. Liver: bulging in hepatic region. Lower border 3.5 fingers below costal margin in the nipple line.

On *October 25* the *X-ray examination with the screen* showed that the whole of the right chest was dark throughout, as well as much of the upper portion of the left chest. The only outlines visible were those of the left diaphragm and a portion of the left and lower border of the heart. This X-ray examination at first suggested pleurisy with effusion, but a more careful consideration of the appearances on the screen showed that they might be due to another cause.

Let us study the cut (Fig. 195) a moment and see how the X-ray signs reproduced there should be interpreted. The darkened right side suggests pleurisy with effusion, and the shaded left apex pulmonary tuberculosis; but, given a large pleuritic effusion, as the right side taken by itself indicates, we should expect to find the heart more displaced to the left than is the case. Further, in a pleurisy with large effusion on the right side, the left lung and pleura being normal, the diaphragm on the left side would be seen lower in the chest than in health, because it would have been pushed down by the organs of the right side that were displaced to the left by fluid; whereas in this respect the cut shows a normal diaphragm on the left side. If this cut is compared with the

diagram of pleurisy with effusion (Fig. 128 in the chapter on Pleurisy), the points of difference in the two illustrations will be noted and the matter will be made clearer. In Fig. 128 we see the *much*-displaced heart and the lowered diaphragm that are characteristic of pleurisy with large effusion; but these signs are wanting in the cut we are considering.

Let us now take up the history and physical signs. Thoracentesis in March, 1899, had shown the presence of some bloody fluid in the

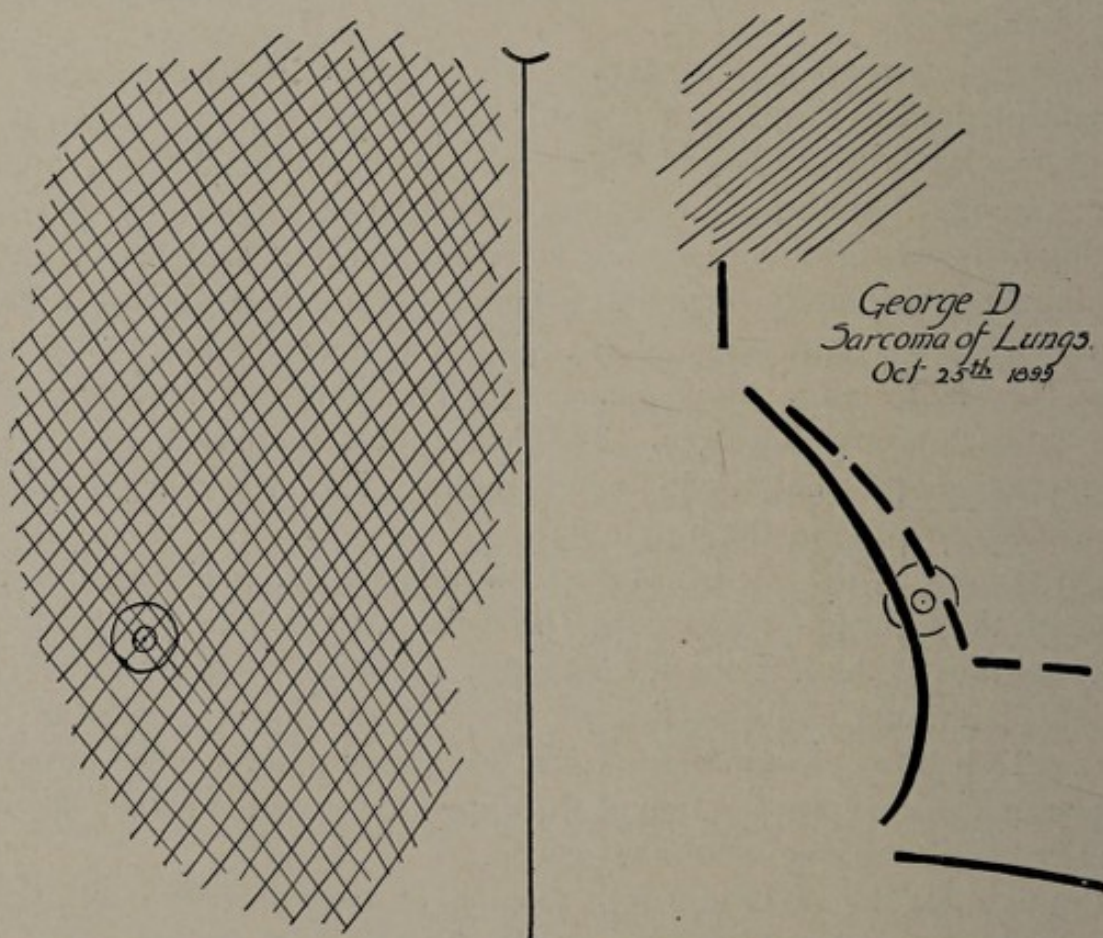


FIG. 195. George D. Cut of tracing made with screen on front of chest. New growth in right lung and at apex of left lung. (Cut one-third life size.)

thorax, but when the chest was tapped in October, no fluid was withdrawn. The physical signs indicated to a large extent pleurisy with much effusion, but the history and appearances suggested a different explanation. Therefore, taking the X-ray examination in connection with these two latter facts, the diagnosis of a new growth seemed the more probable one. Of course the diaphragm might be lowered on the left side by a large new growth in the right chest as well as by a

large quantity of liquid there, but when we find the diaphragm normal on the left side and a dark area on the right, we may well suspect that this appearance in the lung is due to something other than pleurisy with large effusion.

On October 31 I asked Dr. John C. Munro to see the patient in consultation, and the next day he was transferred to the surgical side of the hospital. On November 3 Dr. Munro operated, and several small masses were removed for examination. The pathological diagnosis was spindle-cell sarcoma. On November 8 he operated again and removed as much of the new growth as seemed wise. On November 27 another operation was done at the request of the patient, which he bore very well. In April, 1900, the patient again returned to the surgical side of the hospital, and it was evident that the disease had progressed.

X-Ray Appearances of an Extensive New Growth and an Interstitial Fibrous Pneumonia compared. — The comparison of the cut (Fig. 195, George D.) of a new growth, with the diagram of pleurisy with large effusion (see Fig. 128, chapter on Pleurisy) has shown us how the appearances seen on the screen may differ in these two diseases, and, therefore, how the X-rays may aid us in making a differential diagnosis when used in connection with other methods. Now let us compare the cut of a new growth (George D.) and an interstitial fibrous pneumonia (Fig. 196, Richard S.), and see how the appearances seen on the screen in these two diseases resemble each other.

Richard S., forty-one years old, entered my service at the Boston City Hospital October 16, 1899.

History. — Pneumonia two years ago. Rheumatism in muscles of back from time to time for past three years. Always fairly well and strong excepting this. For past one and one-half years had had dyspnoea on exertion.

Present Illness. — Well up to ten days ago, when taken with chills. Pain throughout back and chest. Dyspnoea with cough. Dyspnoea increased in severity with some orthopnoea. Has vomited every day since second day of attack, and complains of sharp pain over præcordia. Much expectoration with cough, whitish and frothy in character. No rusty sputa.

Physical Examination. — Lungs: percussion note over right front and upper right back slightly higher-pitched than left; respiratory sounds increased on right, diminished over left. Dulness over lower half of left back, with bronchial breathing in areas, and bronchophony,

also medium and fine crackling râles. Tactile fremitus absent in left back. Sibilant and sonorous râles throughout upper left back.

October 18. No tubercle bacilli found in sputa.

October 30. *X-Ray Examination with Screen* (see Fig. 196). — Heart is found not displaced to right. Left chest dark throughout, but rather lighter below than above. Outline of left diaphragm not

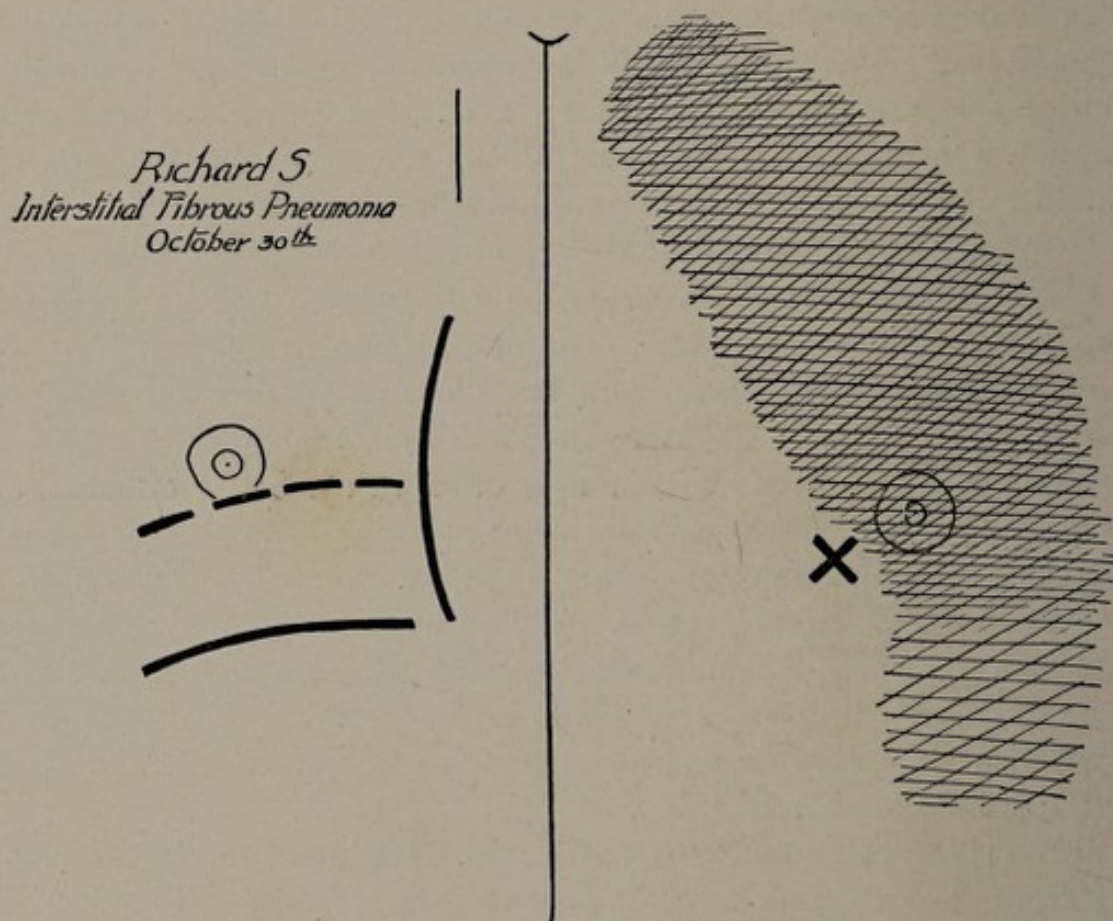


FIG. 196. Richard S. Cut of tracing made with screen on front of chest. Interstitial fibrous pneumonia. Left chest dark throughout, but darker in upper than lower part. Apex beat felt at X. This darkened area does not indicate pleurisy with large effusion, as the heart is not sufficiently displaced; likewise the upper part of the chest is darker than the lower, which would not be the case in pleurisy with effusion. (Cut one-third life size.)

seen. Left border of heart barely seen, but this faint outline is not given in the cut. Apex beat shown in the cut by a cross.

Patient died November 25.

The autopsy showed that the left pleural cavity was obliterated and the whole left lung was dense. Small cavity in the base filled with blood. Diagnosis: "Interstitial fibrous pneumonia. Purulent bronchitis."

New Growth in Chest Wall.—The following case shows how an X-ray examination may be used to indicate that a new growth in the chest wall does not extend to the lung:—

Martin F., entered the hospital July 7, 1898, suffering from typhoid fever. Patient of Dr. E. M. Buckingham.

There was a circular prominence on his chest, 6 centimetres in diameter, lying between the right nipple and the heart. (See Fig. 197.)

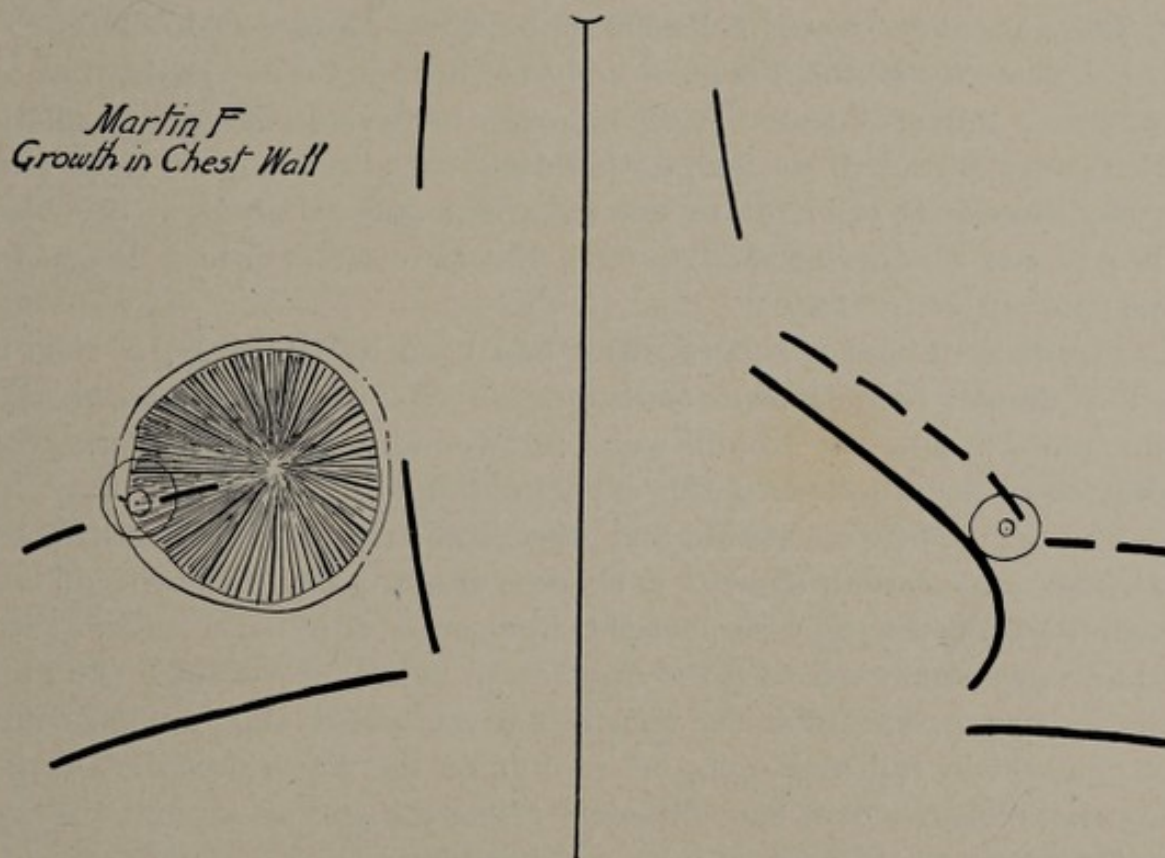


FIG. 197. Martin F. The shaded area on the right chest represents the size and position of an indurated mass which was prominent when the chest was inspected and cast some shadow on the screen. The outline of the diaphragm and heart are X-ray outlines. (Cut one-third life size.)

It was important to know whether the cause of this prominence was connected in any way with the thoracic cavity.

X-Ray Examination with Screen.—I therefore examined the patient with the X-rays, first, while he was lying on his back, and saw a darkened area on the screen corresponding to the prominence on the chest, but found that the new growth was probably limited to the chest wall, for the outlines of the lungs, the movement of the diaphragm, and the outline of the right border of the heart did not give evidence that the new growth extended inward. I then examined the patient lying first

on one side and then on the other, and it was evident in these positions that the growth did not extend inward, as the lung was clear behind it.

The cut (see Fig. 197, Martin F.) given differs from the others in this chapter, inasmuch as the lines marking the new growth are intended to represent what was seen on the outside of the chest, and not the shadow thrown on the fluorescent screen; but the full and broken black lines are the lines of the heart and diaphragm seen on the screen.

The patient recovered from his typhoid fever and was discharged.

Echinococcus of the Lung. — Levy-Dorn and Zadek¹ state that according to different statistics, from seven to twelve per cent of all the echinococci appear in the lungs, most frequently in the lower right lobe, as the disease is often of secondary origin and arises from the liver. They report a very instructive case, the abstract of which is as follows: —

The patient was a robust man; had been a butcher. In 1897 he had dyspnoea, hæmoptyses, expectoration of pus sometimes streaked with blood; tubercle bacilli were not found. In November, 1898, echinococci were found in the expectoration.

The signs by percussion and auscultation were not decisive, but an *X-ray examination* showed a shadow about 5 centimetres long and 4 centimetres broad, with a light interior and a dark edge. This shadow was connected with the diaphragm by a short streak. The diaphragm was pulled up at the junction of this streak or band, and could not contract in full inspiration as well as on the left side. In the left lung there was an oval black shadow about the size of a plum. These shadows were found to have a central position.

The conclusions from the X-ray examination were as follows: The patient had two separate areas of echinococci, one in the right and one in the left lung. Their central position explained the negative result of percussion. As the middle portion of the area in the right lung was light, it was probable that the echinococci were discharged from that side and that the cavity had become filled with air, but were still present in the left lung as indicated by the dark area.

Malignant Disease of the Abdomen; Question of Extension into Thorax. — The X-ray examination may, in malignant disease of the abdomen, assist in determining whether or not the disease has extended to the thoracic cavity.

¹ *Berlin. klin. Wochenschr.*, May 15, 1899, p. 431.

B. B., a patient of Dr. Munro, had cancer of the liver, and the physical signs suggested a possible extension of the disease to the lungs.

My *X-ray examination with the screen*, however, showed that the lungs were perfectly clear. The physical signs which indicated extension into the thorax also improved, so that the disease probably had not reached the thoracic cavity. This case and a tracing are given in Chapter XIV, page 376.

A Bunch of Enlarged Glands simulating the Outline produced by an Aneurism when examined from One Direction. — In some instances new growths under the upper part of the sternum simulate a thoracic aneurism. It is therefore important to examine the dark area seen on the screen during both inspiration and expiration, and carefully observe its outline. If there is no pulsation of the outline seen, the shadow may or may not be due to an aneurism. If there is pulsation and the outline increases in size, the dark area is probably caused by an aneurism. If there is pulsation which produces displacement, but does not enlarge the outline, the dark area is more apt to be a new growth than an aneurism.

The following case is chosen to show how a bunch of enlarged glands may give outlines on the fluorescent screen that simulate those produced by an aneurism; also to show the importance of examining the chest from different directions in order to locate exactly the object producing the shadow cast on the screen; and, third, to show the importance of considering other indications of disease besides the appearances seen on the screen.

Mr. C., forty years of age, was referred to me by Dr. John W. Farlow for an *X-ray examination*. He had complained of pressure which was sometimes felt in the upper portion of the thorax. He had paralysis of the vocal cord, dyspnoea, etc. Some of these symptoms suggested an aneurism, but other signs characteristic of the disease were wanting.

X-Ray Examination with Screen. — I examined the patient with the fluorescent screen, and found that there was a dark area in the neighborhood of the aorta, as indicated in the cut (Fig. 198, Mr. C.), but there was no pulsation of these abnormal outlines; that there was obstruction to expiration; that the lungs were dilated to their fullest extent; that the diaphragm was low down in the chest, nearly as far as the costal border, and moved very little in expiration.

Judging by the appearances on the screen, it was difficult to decide

whether we had to do with an aneurism or a new growth, but I finally inclined to the former view, though I did not make this diagnosis; the case was puzzling, and the outlines seen on the screen, though in some respects similar, yet differed from any other case of aneurism of the aorta that I had examined with the X-rays. I expected, however, to see the patient again, get history, and take an X-ray photograph; but was disappointed in this expectation. Where the appearances are unusual at least two radiosopic examinations should be made.

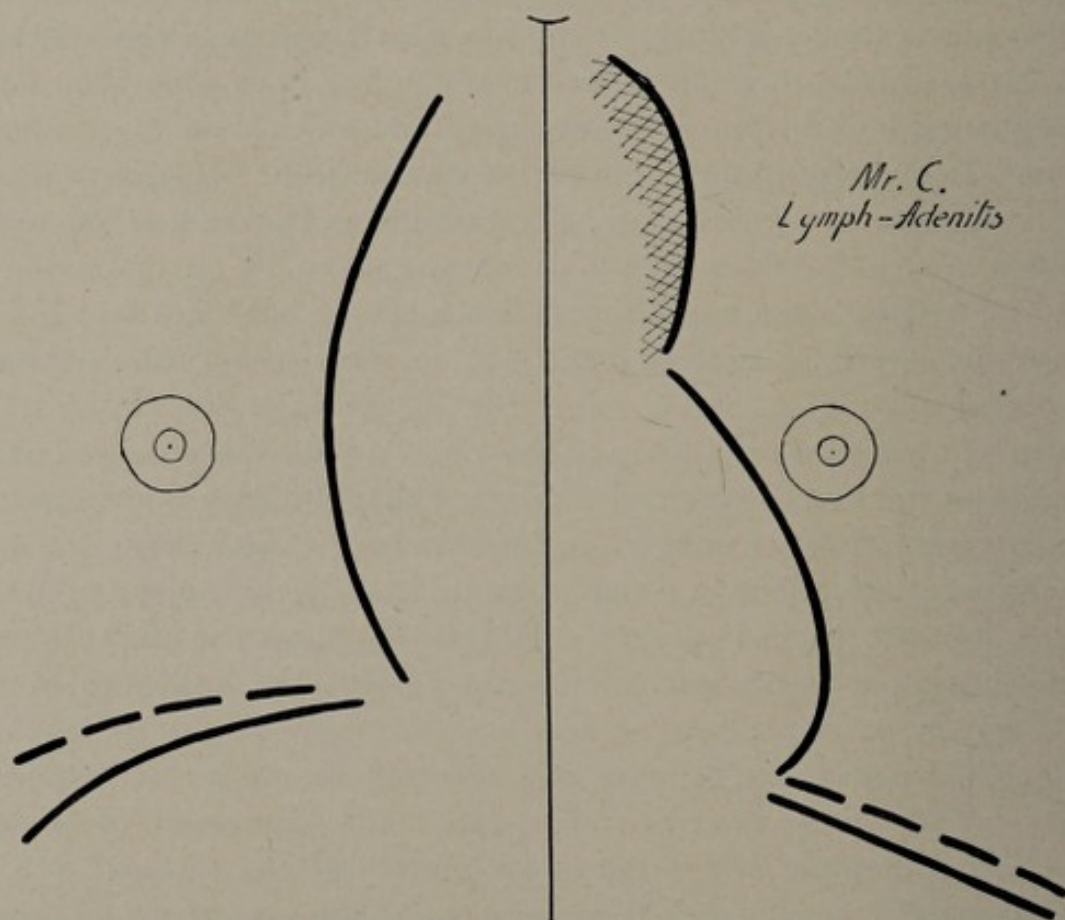


FIG. 198. Mr. C. Cut of tracing made with screen on front of chest. Patient with lymph-adenitis casting a shadow beside the upper part of the sternum. Lungs much distended, diaphragm low down, and but little movement in respiration. Tracheal obstruction. (Cut one-third life size.)

The patient died on May 10, 1899, and no aneurism was found. An account of the case was given in an article by Dr. Classen which was published in the *Albany Medical Annals*, and I quote the portion of the autopsy record relating to the aorta. The autopsy was made by Dr. Lartigau:—

“*Aorta*.—Shows no apparent dilatation at any point. The circumference of the thoracic aorta is 5.5 centimetres; the circumference of

the abdominal aorta is 5 centimetres. The intima is markedly irregular, the irregularity being due to various-sized areas of elevated fatty atheroma. Behind the trachea, at a point on a level with the aortic arch, and situated more to the left of the median line, is a bunch of enlarged glands about the size of a small orange. The individual glands vary in size from a pea to those having a diameter of 3 centimetres. They are firm in consistency, and are on section deeply pigmented in the central portions, less so in the peripheries, which are apparently congested. The central pigmented portions are black. Now and then on the sectional gland small pin-point to pin-head sized discrete hemorrhages are apparent. The individual glands are bound together by old firm bands of connective tissue."

In this patient the absence of pulsation in the outlines seen on the screen, and the obstruction to expiration on both sides, were opposed to the diagnosis of a small aneurism. In other patients I have observed this incomplete expiration and depressed diaphragm in one or in both lungs where there was obstruction of the air passage of one or both of these organs, due to some other cause than an aneurism. I recall one case in which there was obstruction of the left bronchus due to a well-marked aneurism, and in which the diaphragm also was depressed and had little movement.

Enlarged Bronchial Glands; Disease extending into Lungs. — An X-ray examination may be of value in the early stage of this disease, when no other method will serve; and successive examinations would enable us to determine whether or not the disease is progressing. The following case indicates that we may get signs that the disease originating in the bronchial glands has extended into the lung earlier by an X-ray examination than by other methods:—

Mrs. S., thirty years old. Patient of Dr. John C. Munro. Entered the hospital August 15, 1899.

An enlarged gland about the size of a cherry, just posterior to the submaxillary gland, and another on the left side of the neck, about the level of the sternocleidomastoid muscle, about the size of a pigeon's egg, were removed by Dr. Munro. They were found to be carcinomatous in character. On September 18 she reentered the hospital with a recurrence beneath the submaxillary scar, and a new enlargement of glands above the clavicle, which was operated upon by Dr. Munro. On November 6 he removed two small enlarged glands from the subclavian triangle on the left side of the neck; on January 4, 1900, he

removed several small enlarged glands from the superior carotid triangle and from the subclavian triangle on the left side of the neck. The patient made a good recovery from all these operations.

On March 9 the patient again reëntered the hospital and was examined by Dr. Bowditch. His record is as follows: "Lack of per-

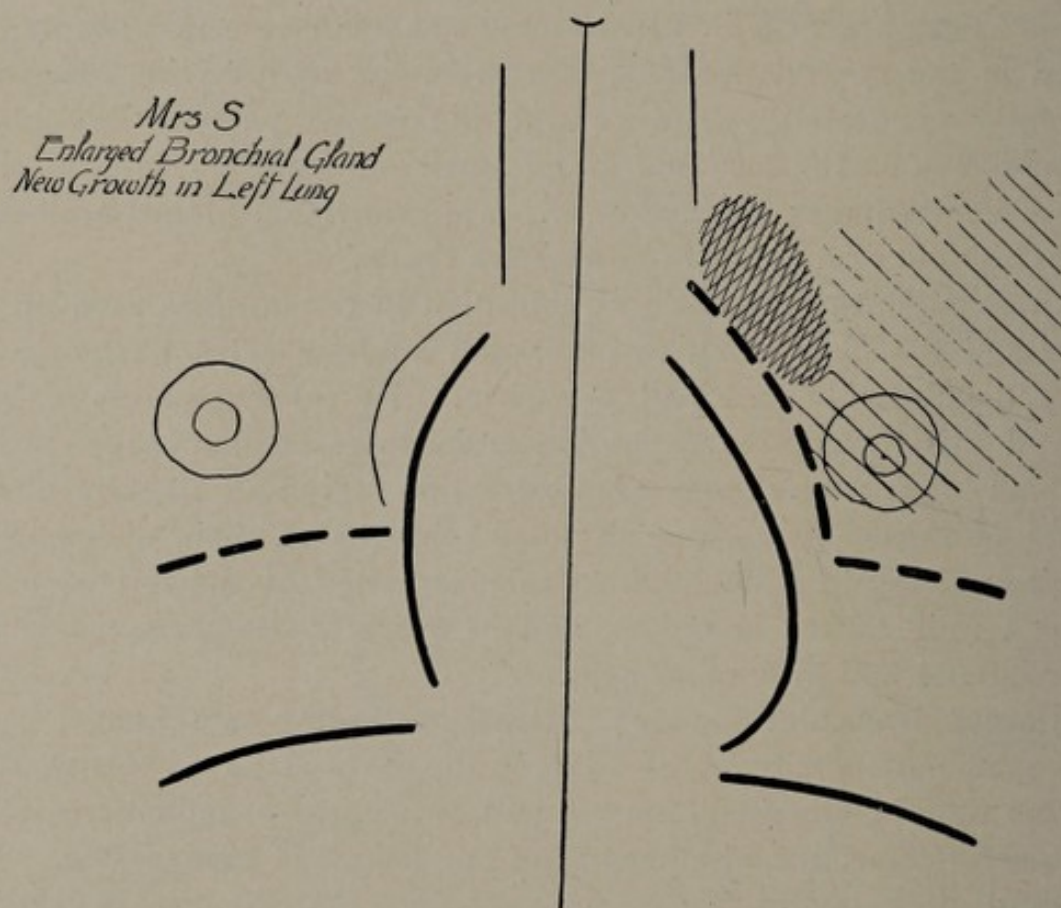


FIG. 199. Mrs. S. Cut of tracing made with screen on front of chest. Carcinomatous bronchial glands; extension of disease into left lung, suggested by darkened area over and outside of left nipple. (Cut one-third life size.)

cussion note at both apices; respiration at left apex in front bronchovesicular; no râles heard. There is a question of incipient disease at apices. Sputum examination recommended."

On March 9 I made an *X-ray examination with screen*, and found a darkened area on the left side of the chest just above the heart and stretching outward toward the left. The portion of this area just above the heart was darker than its outward portion, as indicated in the tracing. (See Fig. 199.)

In the early part of April I suggested to her physician, Dr. Metcalf, another X-ray examination, but she was already too weak to come

to Boston. She died in the following June from her pulmonary trouble. There was no autopsy.

Abscess and Gangrene of Lung.—The more exact location of an abscess in the lung, or of a circumscribed gangrenous area, than has hitherto always been possible, will doubtless assist the surgeon when he operates on these cases. The following case shows that we may locate the exact position of an abscess in the lungs by means of an X-ray examination:—

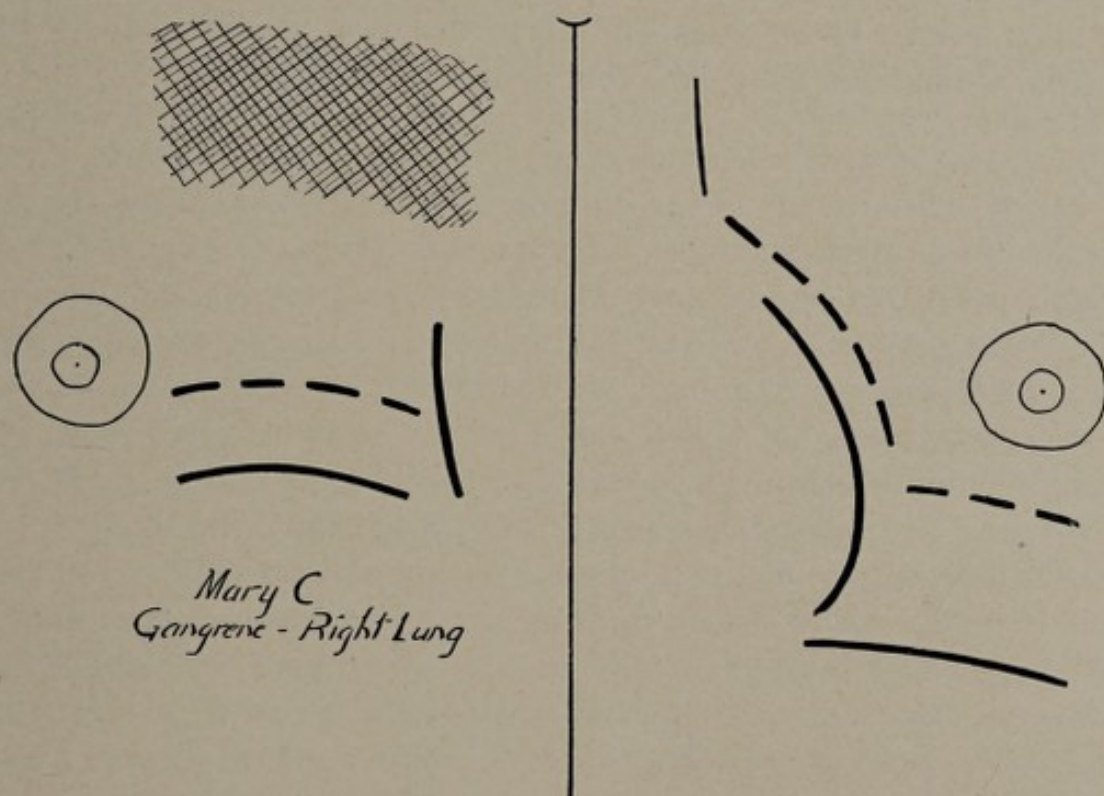


FIG. 200. Mary C. Cut of tracing made with screen on front of chest. Gangrene of right lung. Excursion of diaphragm shortened on right side. (Cut one-third life size.)

Mary C., twenty-four years old, entered the hospital April 13, 1898. Patient of Dr. V. Y. Bowditch.

Diagnosis.—Abscess or gangrene of lung.

History.—Had severe pain in the right chest for three weeks. For two weeks, cough and expectoration, large in quantity and very offensive; losing flesh and strength rapidly; breath very foul.

April 13. Physical Examination.—Heart's area normal; slight systolic murmur over pulmonary area. Lungs: slight dulness at the right apex, down as far as the third rib in front and the spine of scapula behind; slight dulness to a less degree in the left apex;

moist crackling râles in both apices, without any marked change in respiratory murmur. A few râles heard extending down right back as far as the angle of the scapula.

April 15. Patient seen in consultation with Dr. George H. Monks, who advised examination by X-rays, and, therefore, I examined her with the fluorescent screen and found a well-defined dark area at the right apex, and that the excursion of the diaphragm was shortened on that side and shortened from below. (See Fig. 200.)

April 18. Operation done by Dr. Monks, who opened near the right apex into an area corresponding to the dark shadow seen in Fig. 200, from which escaped a very foul odor and some pus.

CHAPTER XIII

CONCLUSION OF THORAX

BROADLY speaking, it may be said that a darkened apex naturally suggests beginning pulmonary tuberculosis; a darkened area in the middle of the lung, pneumonia; and a darkened area in the lower portion, a pleurisy with effusion or an empyema: for it is well known that the first two areas are the frequent sites of tuberculosis and pneumonia, respectively, and the fluids present in pleurisy and empyema naturally darken the lowest part of the chest. There are, of course, many exceptions to this, as when a patient is convalescing from pneumonia at the apex there may be appearances which would simulate those found in early tuberculosis, namely, a darkened apex and a shortened excursion of the diaphragm; but the history of a recent pneumonia, and a second examination after an interval of a week or so, showing an improvement in these signs, would point out their probable cause. If it is a question whether the lung is involved, or whether there is fluid in the pleural sac, it should be borne in mind that in the latter case there is more apt to be a change in the position of the neighboring organs, which is seen on the screen, and also that the appearances on the screen are more likely to vary when the patient is examined in different positions. The X-rays assist the practitioner to recognize an encapsulated and an interlobar fluid; to differentiate an empyema from a multiple abscess of the liver. Atelectasis and syphilis produce conditions in the lungs that may be observed on the fluorescent screen.

An abnormal condition of the heart may be recognized by its outlines, its size, by its displacement, by watching the character of its movements during the respiratory tests, and also by observing the change in outline of this organ produced by the pulsations during systole and diastole. The X-rays assist the practitioner to differentiate between an enlarged heart and a pericardial effusion, and between a pericardial effusion and an encapsulated empyema, and to recognize adhesions which

limit the change in the position of the heart between expiration and deep inspiration.

An aneurism is suggested if a darkened area is seen in either side of the sternum above the heart. The changes seen taking place in the thorax as a new growth increases, by means of X-ray examinations made at intervals, are suggestive. A new growth may simulate for a time other abnormal conditions.

Acute and Chronic Processes compared. — In general, I may say that the appearances seen on the screen in acute processes would vary after an interval of a week or so, whereas those due to chronic conditions would not so vary in this length of time. Hence the practical importance of two examinations, for this reason as well as for others.

Association of an Acute and Chronic Process. — An acute and chronic process may obtain in the thorax at the same time; for example, a pleurisy with effusion may be associated with a tuberculosis of the lung on the same or on different sides of the chest, or a patient may be suffering from a pneumonia in one lung and a tubercular process in the other; in this case improvement would be seen on the screen in one lung, while the signs in the other lung would remain stationary or increase; or emphysema and tuberculosis may occur together.

Association of Two Acute Diseases. — Two acute diseases may be found in the same patient at the same time, for example, empyema and pneumonia.

It is obvious that more experience is required to interpret the appearances seen on the screen, if more than one disease is present; or if it is a question whether or not certain of the signs seen are the results of a disease which occurred some years previously,—an old and quiescent tuberculosis, or adhesions from a former pleurisy with or without a pneumonia, for example.

X-Ray Examination of the Whole Chest, not of One Organ Alone. — It is likewise evident that, in making an examination of the thorax, the condition of one organ must not be studied alone, but in connection with the other outlines in the chest. That is to say, the position of the heart, for instance, should be noted in connection with the appearances in the lungs, and those in the lungs with the heart. If, for example, we find that during full inspiration the heart is drawn toward the side of the chest, any suspicions that have been aroused concerning the lung may be strengthened. On the other hand, if both lungs are darkened at their bases in valvular disease, it is a sign of failure in compensation;

or, if in renal disease, it is a sign of serious import. Without citing further examples, I think it is clear that the practitioner must not only consider the appearances observed by the X-rays in connection with other signs and symptoms, but that he must also consider the X-ray examination of one organ in connection with that of another.

X-Ray Examinations made by Trained Physicians, preferably Specialists of Thoracic Diseases. — The conclusion naturally follows that the medical use of the X-rays must be in the hands of trained physicians, and that they must learn to make and interpret these examinations, just as they have learned the use of other methods of examination, as, for instance, auscultation and percussion. This statement may be still further limited by adding that this method of examining the chest is one which should be used chiefly by those who make a specialty of thoracic diseases, just as the ophthalmoscope is most valuable to those who are specialists in diseases of the eye. Nevertheless, all medical schools should teach the method of X-ray examination in connection with auscultation and percussion, even though the student should never have the opportunity to use this new method himself when he becomes a practitioner; for the use of these examinations will teach the student to interpret better the signs given by the former methods and to understand their limitations. It has been said that the "X-rays are a most effective method of showing how great a rôle the imagination may play when using auscultation and percussion."

X-Ray Examination Part of Physical Examination. — An X-ray apparatus intelligently used gives the physician the not infrequent satisfaction of making a definite diagnosis when it would not otherwise be done, or of basing his opinion and advice on clearer perceptions of the conditions present than would otherwise be possible. In some cases it may or may not add anything to the information obtained by other methods; but the ability to make the usual physical examination of the chest, and then look at the problem, by means of an X-ray examination, from another standpoint, and thus consider the question anew, and by its means confirm or disprove the first opinion, is a gain that will not be questioned by any physician who is familiar with diseases of the chest, and has informed himself in the use of the X-rays. The ordinary physical examination is not complete without an X-ray examination. The latter should be used as a part of the former.

Need of X-Ray Apparatus by Physicians. — I am not infrequently asked by physicians whether or not it would be wise for them to pur-

chase an X-ray outfit. The foregoing pages will enable any one who reads them to answer this question for himself. It is evident that time is required for the practitioner to train himself in the use of the apparatus and in making examinations of the chest. There are also pitfalls into which those inexperienced in this method may fall; for example, a physician inexperienced in X-ray examinations may tell his patient, on the evidence thus obtained, that he has some serious or fatal disease of the chest which does not exist, when a physician who thoroughly understood the method could assure the patient that the supposed condition was not present. These mistakes should not condemn the use of the X-rays, but rather indicate the importance of carefully observing and interpreting the appearances seen.

The study of X-ray examinations in diseases of the chest has been pursued by many; among those who have contributed to its advancement, the names of Bouchard, Beclere, Benedikt, Grunmach, Ziemssen and Rieder, and Weinberger are especially noteworthy.

CHAPTER XIV

X-RAY EXAMINATION OF THE ŒSOPHAGUS, ABDOMEN, AND PELVIS

ŒSOPHAGUS

X-RAY examinations of the alimentary canal have presented greater difficulties than those of other parts of the body, because in its natural state it is not easily distinguished from the other soft parts surrounding it; but the size and position of portions of it may be determined by artificial means.

Œsophagus. — A metallic sound may be passed through the œsophagus and thus its outline may be made visible on the fluorescent screen; or a soft rubber tube closed at its inner end may be passed into the œsophagus and then filled, more or less, as desired, with mercury or lead shot. The dark shadow cast by the metal enables the physician to determine the position of the œsophagus.

Stricture of the Œsophagus. — A stricture probably could not be recognized by the X-rays unaided, but if a rubber tube filled with shot or mercury were inserted, as described above, and the point watched on the screen to which the metal descended, the rays would show the position of the stricture. Also, an X-ray examination might enable the practitioner to distinguish between an obstruction due to stricture or to pressure from outside, for in the latter case the œsophagus might be displaced. If this displacement were caused by a new growth, its recognition might lead to the recognition of the latter by directing attention to this part of the radiograph and negative. (The negative should be carefully studied, as stated in Chapter III, page 96.)

Diverticulum. — A diverticulum may be recognized if its position is a favorable one, by means of the following method. Bismuth is mixed with the food, and when the patient has eaten the mixture his throat is watched on the screen. If the bismuth lodges in the diverticulum, the position of the latter may be pointed out in some instances. Or a rubber tube filled with shot or mercury may be inserted. If the

sound finds the opening, the position of the diverticulum may be seen on the screen.

ABDOMEN

The advances in certainty and ease of diagnosis to which we are assisted by the X-rays in diseases of the thorax are very obvious, but their use in studying diseases in the abdominal cavity has not progressed so far because of the natural difficulties which beset the practitioner when making observations by means of the X-rays in this region; but I think sufficient has been done to show they can be of assistance to us, and that their aid in this field is capable of further development.

In the thoracic cavity we distinguish the outlines of the heart by their contrast with the lighter lungs, but in the abdominal cavity, under ordinary conditions, such contrast does not prevail; it may be produced, however, by artificial means.

Introduction of Air or Gas into Organs. — First, air or gas may be introduced into the hollow organs, and thus their position may be made clearer than before by the presence of the light areas thus produced on the screen. For instance, air may be pumped into the large bowel, and the outline of the sigmoid flexure and the descending colon may be easily followed. Not only does this procedure enable the practitioner to follow the position occupied by this portion of the large intestine, but he can thus more readily detect abnormal conditions in neighboring parts of the abdominal cavity; for example, some pathological conditions in or about the left kidney; or if the stomach, instead of the bowel, has been distended, some conditions about the pancreas, an organ which has been quite inaccessible to methods of physical examination.

Introduction of Air or Gas to displace Organs. — Second, air or gas may be used to displace the parts near the special organ we wish to examine; for example, the outline of the spleen may be followed more fully by filling the stomach and lower bowel with air or some gas; by this means the lower portion of the spleen is surrounded by a medium through which the X-rays pass easily, and light areas are brought near the denser spleen, and contrast is thus produced. Gas is also under certain conditions present naturally in the intestines, and under these circumstances, of course, contrast obtains.

Use of Bismuth. — Some substance, such as bismuth, opaque to the rays, may be introduced into the hollow organs.

Let us now consider the various organs of the abdomen separately, beginning with the stomach.

STOMACH

Methods for observing the Stomach. — Various methods have been devised to determine the size, shape, and position of the stomach by means of the X-rays. First, a rubber tube provided with spiral wire¹ may be inserted into the stomach, — Lindermann determined the position of a stomach by this means. This flexible sound adapts itself to the wall of this organ and its outline may be followed on the screen. Second, gas may be pumped into the stomach, or the patient may be given a Seidlitz powder, each of the two powders being mixed with a tumbler of water and taken separately. The dense organs surrounding the stomach are thus somewhat displaced, and the area of the latter organ appears light on the screen, as the rays pass readily through the space occupied by the gas. This method would answer to determine the size of the stomach in a general way, but would not, I think, be as accurate as the method about to be described. Third, some substance opaque to the X-rays, such as an emulsion of subnitrate or metallic bismuth, may be poured into the stomach through a stomach tube; or powdered subnitrate or metallic bismuth may be mixed with the food — the latter is more opaque to the rays than the former — and the size, shape, and position of this organ watched on the screen. I have not tried all of the various methods alluded to, but have found the one which I have used, namely, the mixture of subnitrate of bismuth with food, quite satisfactory. My first observations were made four years ago with this salt, the use of which would naturally suggest itself to any one who was seeking a substance opaque to the rays and harmless to the patient. If the practitioner does not wish the bismuth to pass on into the intestines, the stomach may be freed from it by means of the stomach tube after the observations on the stomach have been made. Subnitrate of bismuth has been used in making these examinations, and, so far as I am aware, no untoward results have been caused by its use; it is non-irritating and non-poisonous, and a large or small percentage of it may be used, as desired; a preparation must be employed that is free from any trace of arsenic and that is perfectly pure.

It is an advantage in examining the stomach, or any other of the organs below the diaphragm, to have the bowels empty; therefore certain preparations for an examination of the stomach are necessary.

¹ Lindermann, *Deutsche Med. Wochenschr.*, 1897, No. 17, p. 266.

First, a good movement of the patient's bowels should be secured on the day before, and on the morning on which the observations are to be made, in order to diminish the obstruction to the rays and allow the bismuth to be seen as clearly as possible.

Second, the stomach should be free from food.

Third, an ounce of subnitrate of bismuth, well mixed with food, such as bread and milk, should be given to the patient when everything is ready for the examination. The food should be stirred from time to time while the meal is being taken, or perhaps better, some of the bismuth which has settled in the bottom of the bowl may be dipped up with each spoonful.

The further procedure may be noted in the description given of the cases observed.

Two or three years ago Dr. W. B. Cannon, then a student of the Harvard Medical School, who had made some excellent observations on the digestion of cats,¹ assisted me in some observations on the stomachs of two children, the elder of whom, James W., was ten, and the younger, M. W., was seven years of age. As a rule the children were lying on their backs on the canvas stretcher already described; the target of the vacuum tube was 45 to 60 centimetres from the under surface of the body at a point under the umbilicus; and the fluorescent screen was placed over the abdomen. The outlines observed were traced by one or other of the methods already detailed, that is to say, either on the thin sheet of glass or celluloid which covered the screen, by means of a lithographer's pencil, or directly on the skin by means of a clinical pencil, and then copied on to tracing cloth for permanent record. After the first tracings were made the glass or celluloid was washed and used again, or the skin was washed with alcohol and thus made ready for another tracing, according to the method adopted.

The results of our observations fall naturally into three divisions: first, the position of the stomach and the difference of position obtaining between the standing and the prone positions; second, the movements of the stomach in respiration; and third, the changes in the shape of the stomach during digestion.

Position of Stomach when standing and lying down.—Saturday, September 23, 1899, James W., ten years of age, was examined with the X-rays during digestion. He finished eating a pint of milk into

¹ "The Movements of the Stomach studied by Means of the Roentgen Rays," *American Journal of Physiology*, Vol. I, May 1, 1898.

which bread had been broken and with which nearly an ounce of subnitrate of bismuth had been mixed at 2.56 P.M. The tube in this case was 53 centimetres from the boy's back. A coin, which cast a shadow on the screen, was placed over the umbilicus to mark the position of the latter. At 3.30 P.M., the lower border of the stomach was on a line




FIG. 201. Cut of tracing made by means of the fluorescent screen from a girl seven years old, showing the outline of the stomach one hour after a meal of bread and milk containing subnitrate of bismuth. The full horizontal line is at the level of the iliac crests; the full lines at right angles to it are the outlines of the body; the other full lines indicate the position of portions of the diaphragm, heart, and stomach during full inspiration. Broken lines show position in expiration. (Cut one-half its original size.)

This cut I published in the Transactions of the American Climatological Association, 1898.

with the umbilicus; at 5 P.M., 1.5 centimetres above this point. During this time the boy was lying on his back.

He was then examined, at the latter hour, when standing, and in this position the lower border of the stomach was 1.5 centimetres below the umbilicus; that is to say, with the change of position in the boy, there

was a difference of 3 centimetres in the position of the lower border of the stomach.

Movement of the Stomach during Respiration.—The preceding tracing shows the outline of the stomach of M. W., a girl seven years old, during inspiration and expiration, one hour after a meal of bread and milk mixed with $\frac{1}{4}$ ounce of subnitrate of bismuth had been taken. The full horizontal line at the bottom of the cut is on a level with the iliac crests; the other full lines at right angles to it are the outlines of the body; the full lines give the position of the stomach, heart, and diaphragm in full inspiration; and the broken lines show their position in expiration. The tracing is one-half the original size.

The four following tracings are taken from James W., and show the size and position of the stomach during the process of digestion; that is, at 3.30, 4.20, about 7.40 and 9.05 P.M. The patient when all these trac-

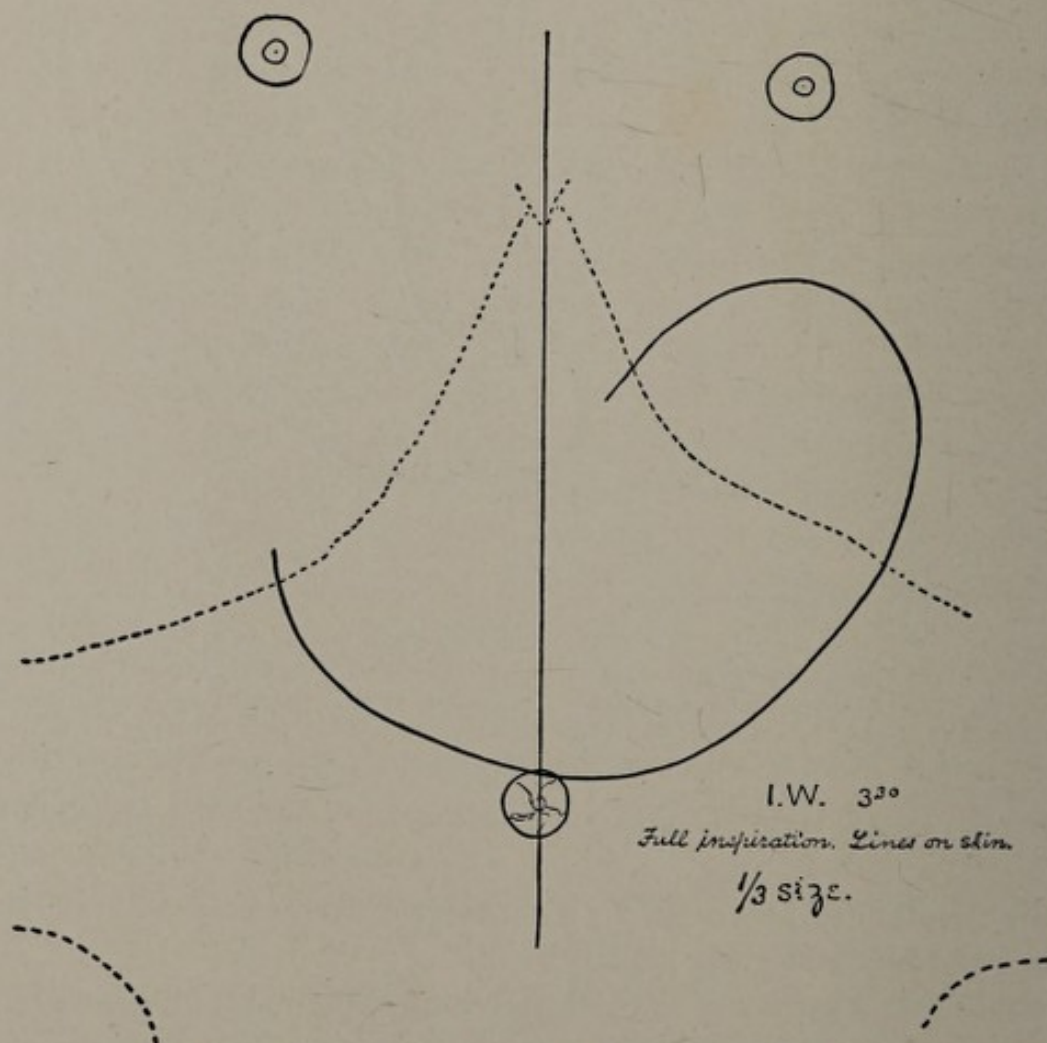


FIG. 202. James W. Cut of X-ray tracing. 3.30 P.M. In order to show the position of the nipples, the costal borders, and the iliac crests, this tracing was reduced to one-third its original size.

ings were made was lying on his back on the stretcher. In the last three tracings the broken line shows the position of the stomach in expiration and the full line in deep inspiration.

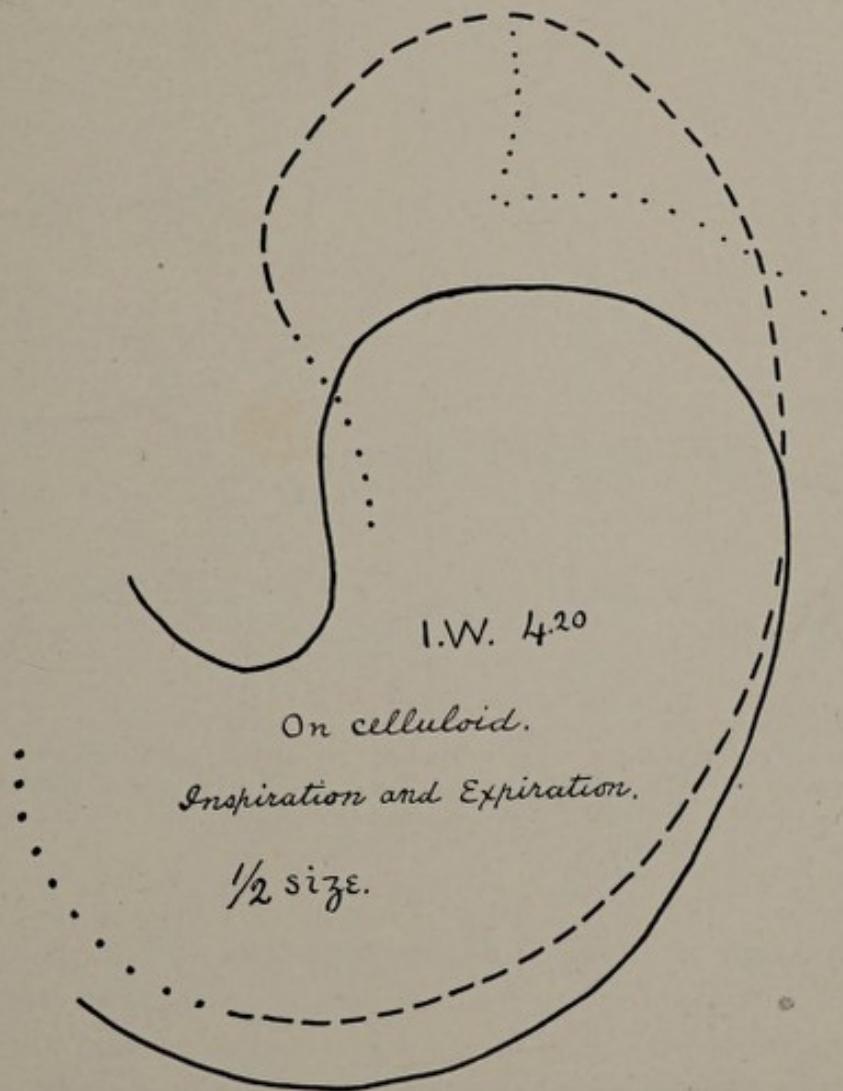


FIG. 203. James W. Cut of X-ray tracing. 4.20 P.M. Broken line shows size and position of stomach in expiration; full line, in deep inspiration.

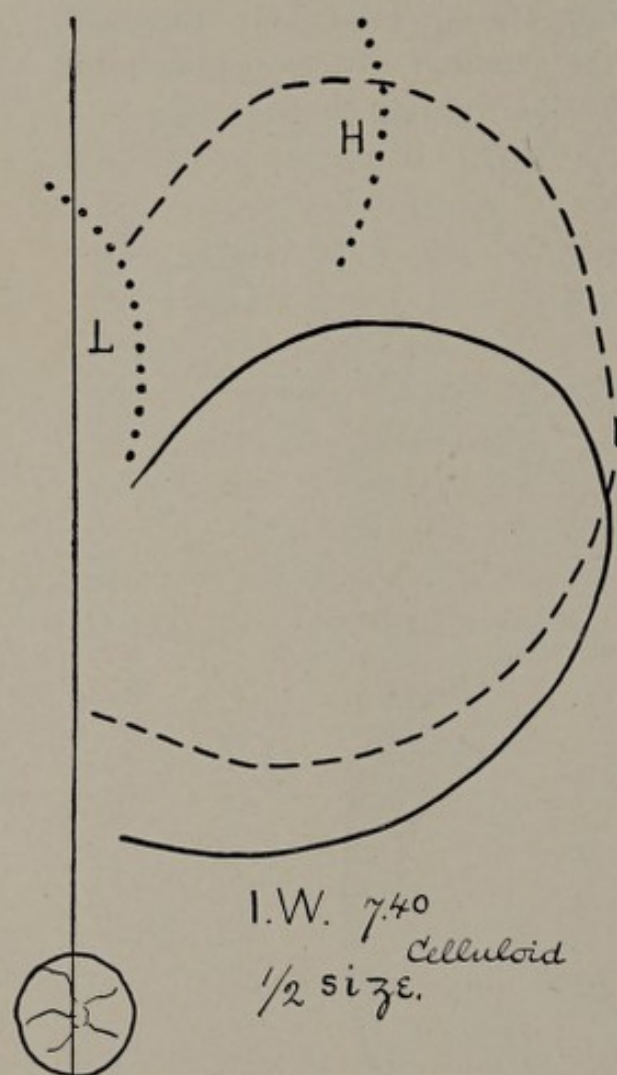


FIG. 204. James W. Cut of X-ray tracing made on celluloid. 7.40 P.M. Broken line shows size and position of stomach in expiration; full line, in deep inspiration.

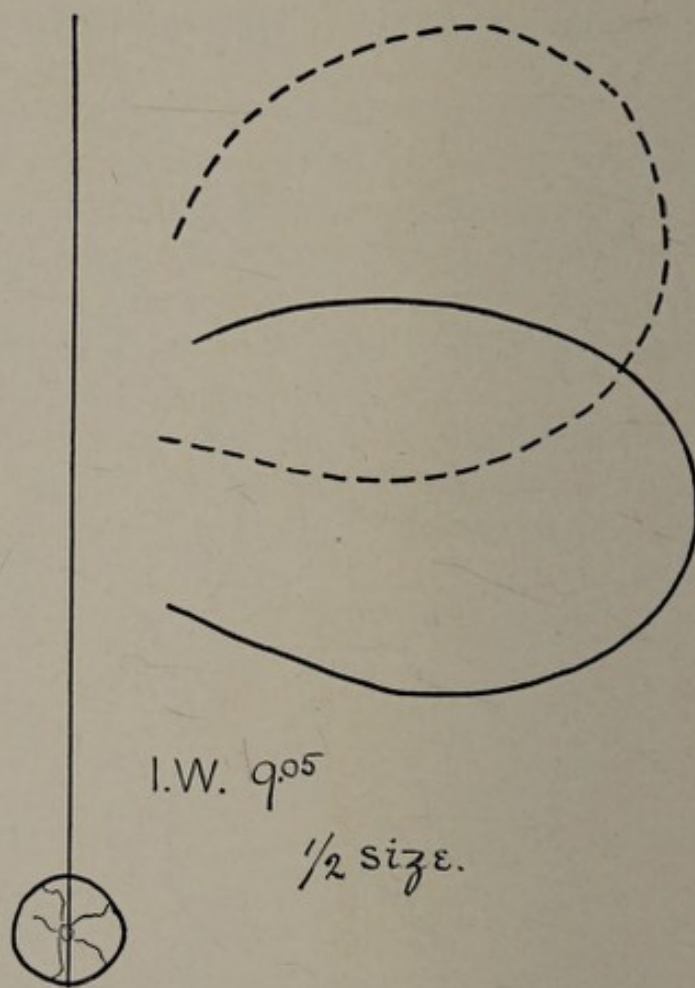


FIG. 205. James W. Cut of X-ray tracing. 9.05 P.M. Broken line shows size and position of stomach in expiration; full line, in deep inspiration.

Changes in Shape of Stomach during Digestion. — This point is illustrated by the following tracings from M. W., taken at intervals during a period of $4\frac{1}{2}$ hours. The child finished her meal of bread and milk at 12 noon. In the first four tracings the pyloric region is represented by a dotted line because that portion of the stomach could not be seen distinctly. The change in size and shape of the stomach as digestion progressed are indicated in the tracings given below. It will be seen that the upper border of the stomach did not alter so much in position as did the lower border.

A third child, K. A., five years of age, was recovering from typhoid fever when I examined his stomach with the X-rays. The procedure

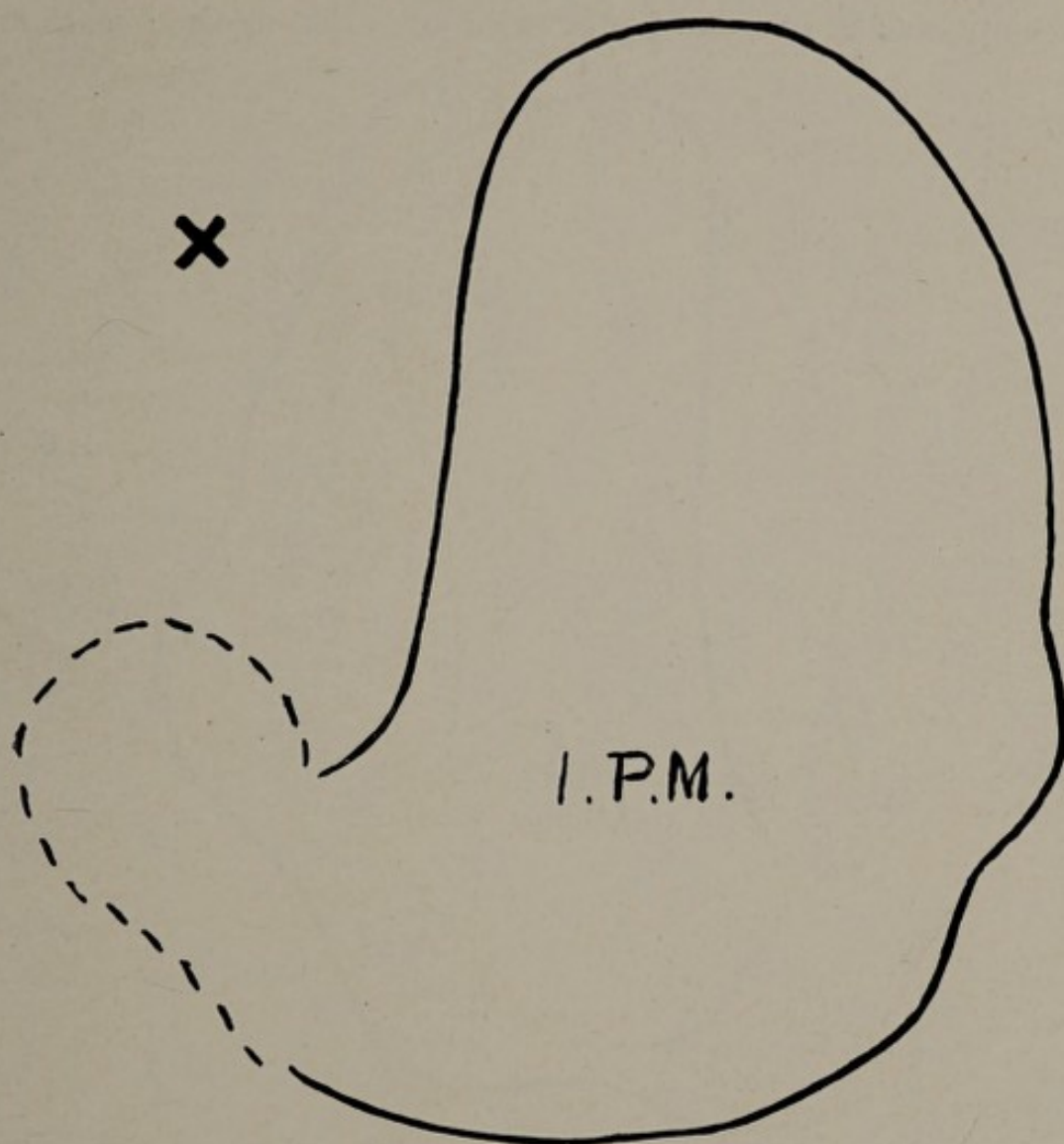


FIG. 206. M. W. In this and the following six tracings, which are full size, the horizontal line at the bottom of the cuts represents the position of a metal rod which was placed on the abdomen on a level with the superior iliac crests.

Where two tracings are given in one cut, they are intended to indicate the alternating positions of the outline.

The vacuum tube was under the X indicated in this first tracing, made at 1 P.M.

was as follows: He was given 2 drachms of castor oil on one day, in order to empty the bowels, and the bowels moved that day and again the

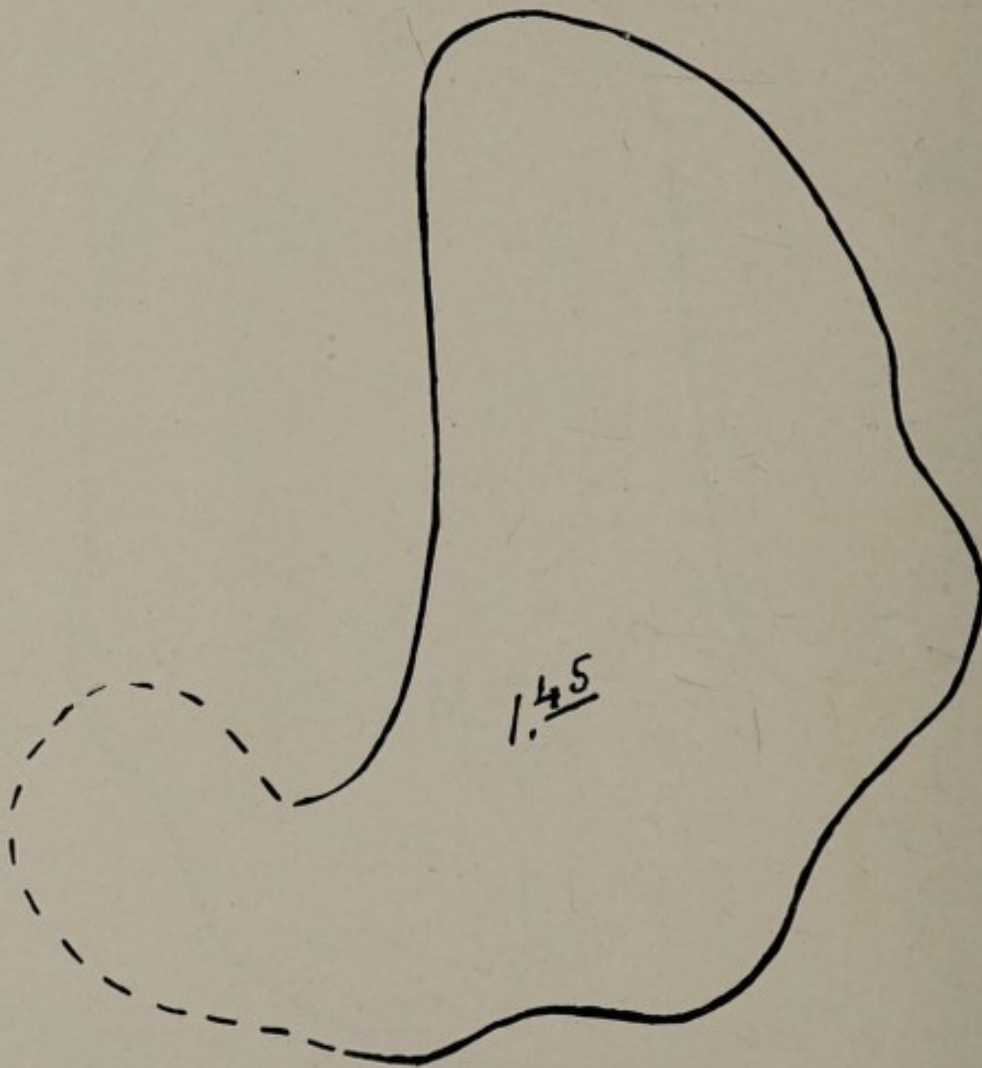


FIG. 207. M. W. Full size.

next morning. At 11 A.M. on the latter day he ate a bowl of bread and milk mixed with 6 drachms of subnitrate of bismuth. He was then examined by means of the fluorescent screen, and photographs were

taken at intervals of one or two hours for several hours after the meal, the plate being placed on the front of the body. The radiograph, taken

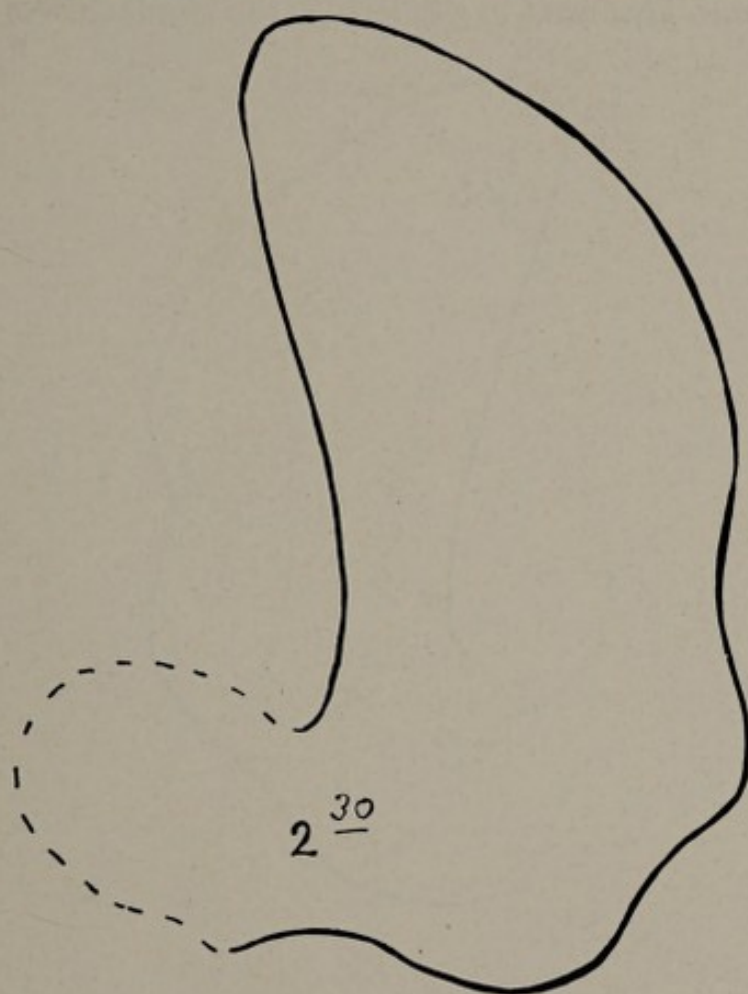


FIG. 208. M. W. Full size.

$3\frac{1}{2}$ hours after the meal, showed that the area of the stomach was dark and its outline was best defined at its greater curvature, but this outline was still better defined on the fluorescent screen because the stomach

moves during respiration and therefore its outlines are blurred on the radiograph. The vertebræ which were directly behind the stomach could not be seen. The area to the left of the stomach was free from

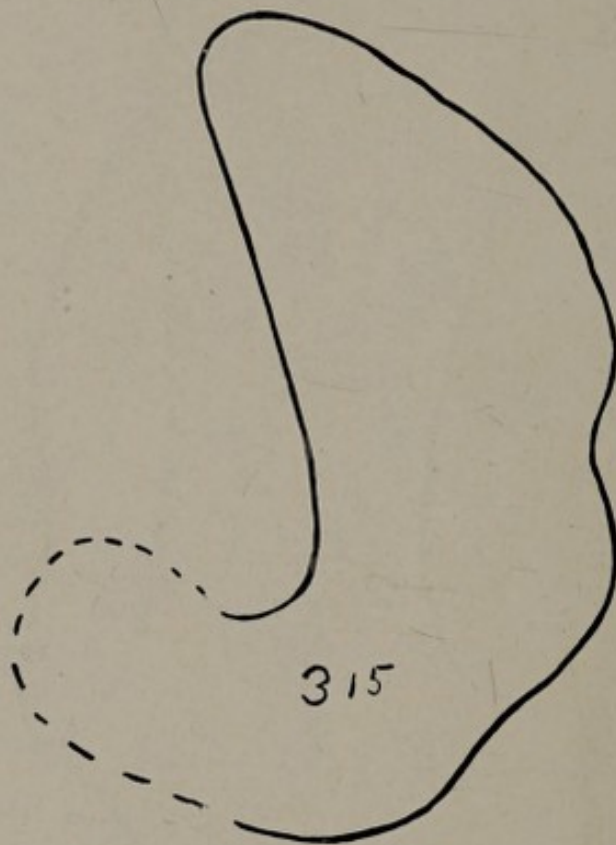

FIG. 209. M. W. Full size.

bismuth and showed as a light place on the radiograph. A coin was placed directly over the umbilicus as a point of reference, and its shadow could be seen in the radiograph.

The next radiograph showed that the bismuth had been widely distributed through the abdominal cavity, and that it had gone down into the pelvis to some extent. The image of the coin was almost obscured.

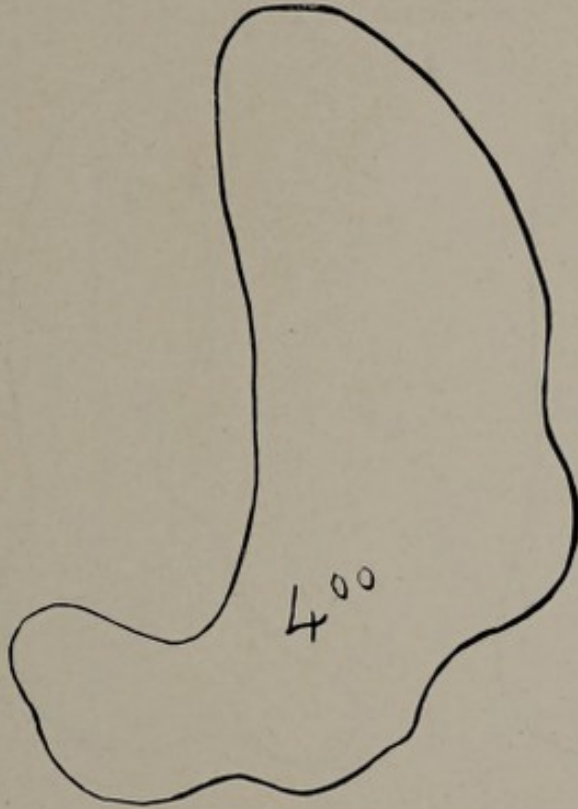


FIG. 210. M. W. Full size.

The last radiograph, made $5\frac{1}{2}$ hours after the meal, showed that there was no food in the stomach, and that the great mass of it was on the

left side, low down, and had reached the region of the left iliac fossa. The parts which had been dark were now nearly as clearly defined as normal, notably the vertebræ behind the stomach. The next morning the dejections had the color characteristic of bismuth.

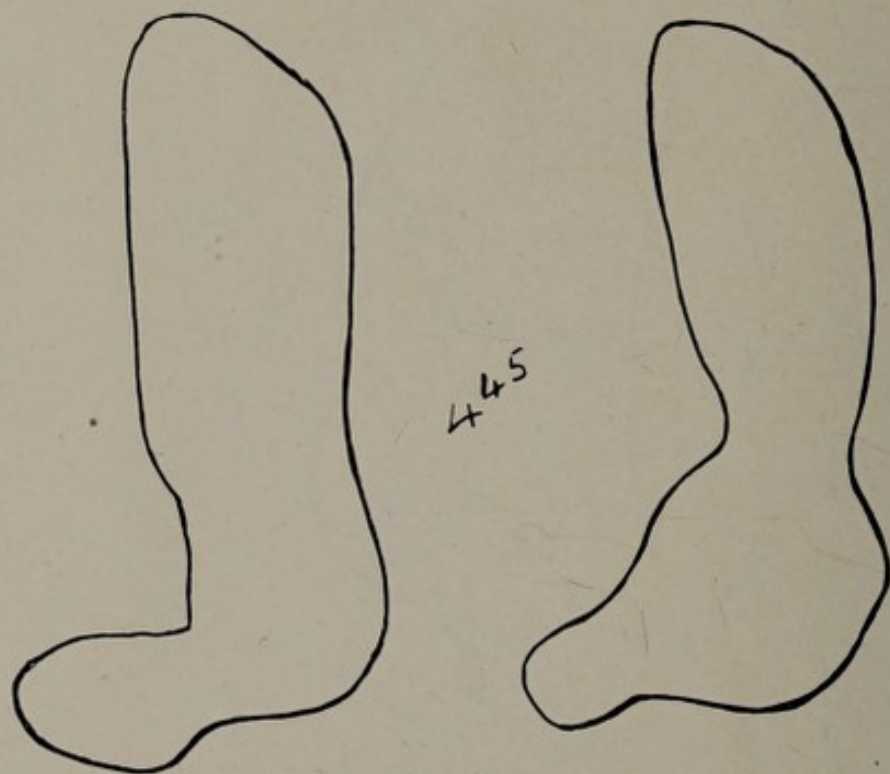


FIG. 211. M. W. Full size.

This experiment suggested that the food is passed through the intestines at a somewhat rapid rate; that the contents of the alimentary canal pause in the stomach and in the large intestine, but that elsewhere

there is continuous movement. It is possible that there was a trace of castor oil left in the system, which quickened the passage of the food, or the fact that the bowels had been recently emptied might have made it move more rapidly than it would have done under normal conditions ;

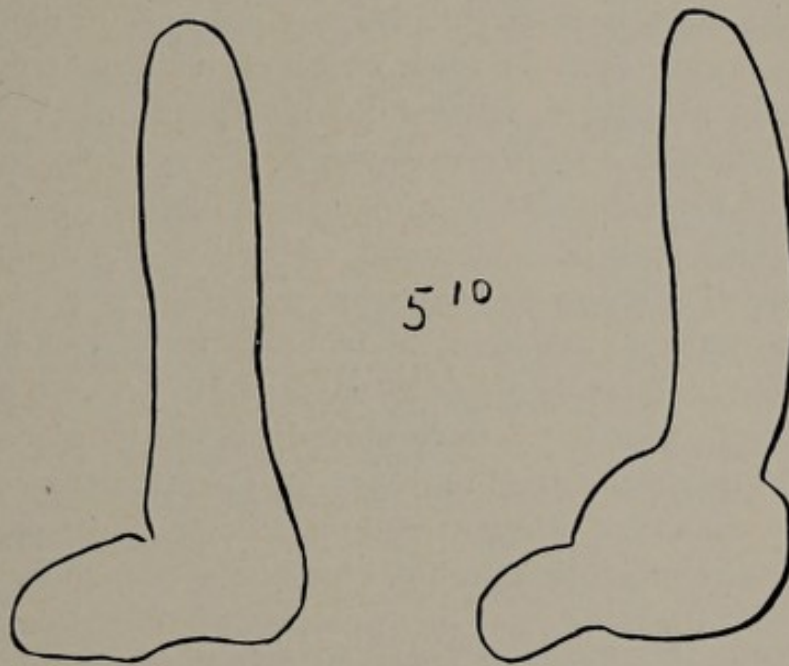


FIG. 212. M. W. Full size.

or still other factors may have contributed to its quick movement. The experiment indicates that the X-rays afford an excellent means for studying some points relating to the physiology of digestion.

Thus we see that if bismuth is given as described above, an outline

of part of the stomach, its position in inspiration and expiration, and some peculiarities of shape may be noted; likewise that its changes in size during the process of digestion may be observed; further, the respective rapidity with which digestion proceeds in different individuals may be watched. After the various characteristics belonging to the stomach in health have been established, the presence of abnormal conditions of this organ, such as some cases of malignant disease, will perhaps be more readily recognized than at present. The constant presence of a darkened area in the stomach, for example, may suggest the thickening of its walls due to a malignant disease; some displacements or adhesions may be recognized, as well as hour-glass contractions, or an unusual delay of the digestive process.

X-ray photographs do not show the movement of the stomach which takes place from expiration to deep inspiration. The photographic plate, or the screen, whichever is employed, should be placed over the abdomen, not on the back, when an X-ray examination is made.

These observations are preliminary in character, and merely suggest some of the ways in which this problem may be approached.

Physiology of Digestion. — The process of digestion has been observed carefully and independently by W. B. Cannon¹ in the stomachs of cats, and by Roux and Balthazard² in the stomachs of frogs, dogs, and men. Bismuth was used as a means of defining the limits of this organ. The peristaltic movements were followed and the diminution in size observed as digestion went on. These observers found that the stomach divided itself physiologically into two parts; that the larger cardiac area serves as a reservoir for food, and the smaller lower area, by its strong peristaltic movements, serves to force the food into the duodenum. The experiments showed further, that these regular peristaltic movements ceased if the animal were disturbed (Cannon), and it seems probable that the same effect might be produced in human beings if the nervous system were profoundly affected during the digestive process.

Roux and Balthazard also found that as a rule, in dogs and men, the liquids with which they experimented began to be evacuated from the stomach into the duodenum only two or three minutes after they had

¹"The Movements of the Stomach studied by Means of the Roentgen Rays," *American Journal of Physiology*, Vol. I, May 1, 1898.

²*Comptes rendus de la soc. de biologie*, 1897, 10 S, iv, pp. 567-569, 704-706, 785-787, and *Archives de physiologie*, 1898, 5 S, x, pp. 85-94.

entered the stomach; whereas certain solids remained in the stomach for a long time, and that the pylorus remained closed so that nothing could pass into the duodenum.

Digestive Tract observed by Means of Capsules. — Boas and Levy-Dorn¹ gave a patient capsules covered with celluloid, to prevent them from dissolving, and filled with bismuth to make them obstructive to the X-rays, and then watched their progress through the digestive tract by means of the fluorescent screen. The capsules were 2.25 centimetres long, 1.25 centimetres thick, and weighed 12 grammes. In cases of slight stomach trouble the capsule was usually found in the cecum at the end of twenty-four hours; if the pyloric orifice was much contracted the capsule lay for days in the stomach. The writers think this method a valuable one for discovering the presence of a contracted opening, and for distinguishing this condition from dilatation of the stomach. If there is no contraction present the capsule passes off naturally.

The size and position of the cardiac end of the stomach can be determined by sounds with metallic tips; the metal enables the observer to recognize the position of the cardiac orifice because of the obstruction it offers to the X-rays.

LIVER

The outline of the upper and lower border and of the left lobe of the liver may be followed in children by means of the X-rays, and also in many adults under suitable conditions; but as a rule, although the upper border of the liver of adults can be determined with certainty on the fluorescent screen, the lower border can generally be better determined by the usual methods. Enlargements of the liver, or changes in its outline, if they affect the diaphragm, may be recognized by the rays, but the observer should be very careful in his interpretation of the appearances seen on the screen. Echinococci of the liver sometimes escape into the thoracic cavity, and may there be recognized by means of the X-rays, and thus the attention of the practitioner be directed to the correct diagnosis. (See Chapter XII on New Growths.)

SPLEEN

The lower border of the spleen can be most easily recognized by distending the large intestine with air, as in this way the neighboring

¹"Zur Diagnostik von Magen u. Darmkrankheiten mittels Roentgenstr.," *Deutsche Med. Wochenschr.*, January 13, 1898, p. 18.

organs are displaced and this border is therefore brought into contrast with the light area produced by the air. The upper border, where it lies against the diaphragm, can be determined for all practical purposes by determining the position of that portion of the diaphragm.

The spleen of children can be seen very well on the screen, and the motion its shadow describes during a full inspiration shows that it not only descends with the diaphragm, but that its anterior border moves more than its posterior border, and that the spleen is turned about its long axis; on the screen it has the appearance of turning a somersault.

KIDNEYS

An X-ray examination may be of service in renal diseases by showing the size and position of the kidneys, especially that of the left one, as this is more easily photographed than the right, because a large part of the outline of the latter is very much obscured by the superimposed liver; second, by indicating the serious nature of the renal disease by appearances in the lungs; and third, by pointing out renal calculi. This latter point will be especially considered in the chapter on Calculi.

Renal Disease. — The X-rays indicate the presence of œdema of the lungs in renal disease by showing that the bases of these organs are darkened on the fluorescent screen, before it is recognized by a physical examination. They also show that the outlines of the other organs in the thorax are sometimes very ill defined in this disease. Therefore by X-ray examination of the lungs in renal disease we may sometimes get an indication of the serious condition of the patient. The following cases will illustrate this point: —

CASE I. E. C., forty-seven years old. September, 1896. Chronic diffuse nephritis. For three months this patient suffered from dyspnœa, which steadily increased. My X-ray examination showed the chest to be uniformly dark throughout, except at the apices, where the first and second ribs could be fairly well made out. The outlines of the diaphragm and of the heart could not be seen. The appearances by X-ray examination suggested œdema of the lungs, but the record of the physical examination made by her physician on the following day, with this in view, did not disclose this condition. This patient suffered from increasing dyspnœa and orthopnœa, and died one week later.

CASE II. A. B., fifty years old, came to me for consultation. He was known to have a chronic renal disease. X-ray examination showed the lungs to be much less clear than in health. Although he attended

regularly to his business, and there had been no recent symptoms to cause unusual anxiety to him or to his physician, nevertheless, on the evidence of an X-ray examination, I warned him that it would be wise for him to put his affairs, which involved large business interests, in order. About three months later he died.

It will thus be seen that the X-rays may be of service in examinations of the kidneys, directly, as first stated, and indirectly, by pointing out more emphatically than other methods of examination an abnormal condition of the lungs, thus giving warning which would enable the physician to afford relief by suitable treatment, or, where this cannot be done, to put the patient on his guard in relation to his affairs.

ASCITES

In ascites, when the patient is lying on his back and the rays pass through him from side to side, the abdomen may be seen to be divided into an upper, lighter area, and a lower, dark area, the upper border of the lower area being a horizontal line, the level of the ascitic fluid. This line remains level even when the patient changes his position. By pushing the side of the abdomen quickly the line of fluid may be disturbed. Above the fluid the abdominal cavity is not uniformly lighter, but the moving shadows crossing it suggest that the intestines are changing their direction.

Ascitic fluid or gas in the abdomen or a new growth may push up the diaphragm and make its outline abnormal. The excursion of the diaphragm may also be limited.

NEW GROWTHS

New growths in the abdomen are not easily recognized by an X-ray examination. We may get some suggestion of their presence if they affect the outline of the diaphragm. Or if the growth is well marked and dense, it may cast a shadow on the fluorescent screen or be seen in the negative. New growths near the diaphragm (for example, affecting the liver) may push up the diaphragm on this side or change its outline. That is, during expiration the diaphragm may go up into the thoracic cavity with a sharper curve than in health. Or, during full inspiration the outline of the diaphragm may not have its usual curve, and its outline may be less regular than normal, as if it wrapped itself about something of abnormal shape. Also the presence of any unusual mass just below

the diaphragm may affect the position of the heart (see chapter on Heart), for example, and the long axis of this organ may be made more horizontal than usual.

Carcinoma of the Stomach. — In one case of carcinoma of the stomach I noticed that the median end of the diaphragm on the right side did not have as long an excursion on its inner half as on its outer half, and that its outline was changed in a way to suggest that some obstruction underneath it prevented its descent to as low a point as usual.

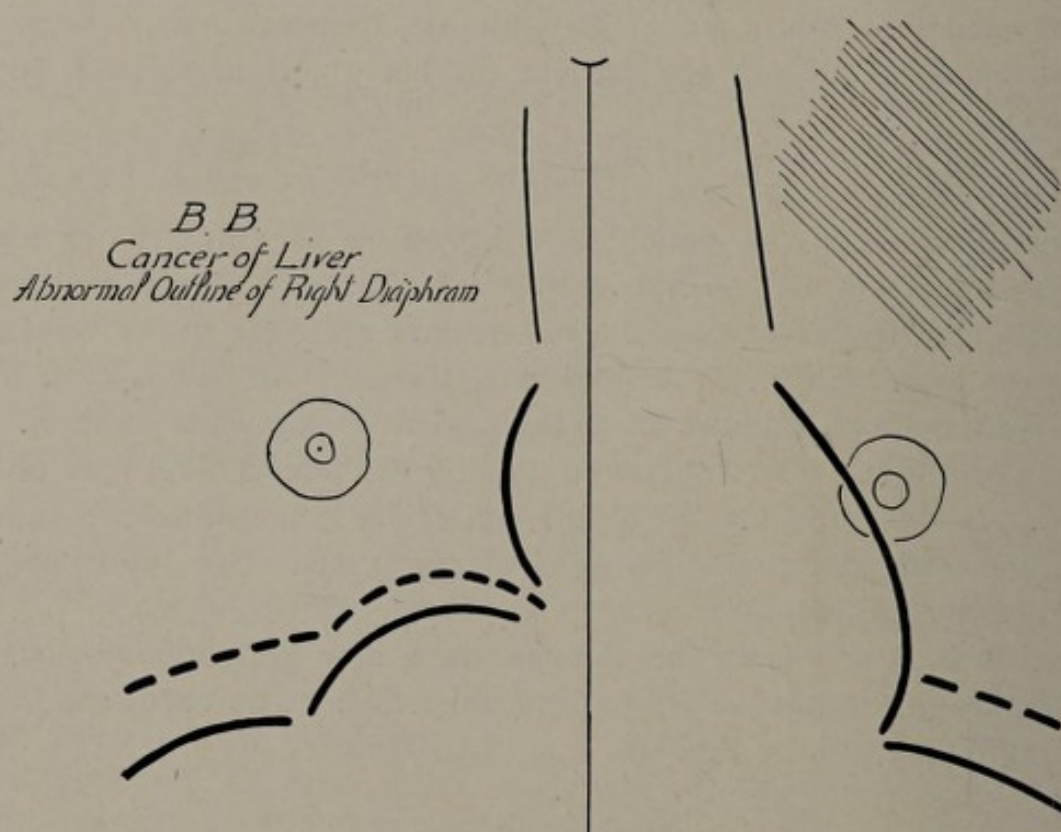


FIG. 213. B. B. Cancer of liver. Cut of X-ray tracing. Auscultation and percussion indicated to the physician of the patient extension of the disease into the thoracic cavity. My X-ray examination showed no evidence of this extension. Broken line and full line below it show abnormal outline of diaphragm in expiration and inspiration respectively. (Cut one-third life size.)

While it is far more difficult to recognize a new growth in the abdominal cavity, by an X-ray examination, than when it is situated in the thorax, yet there are cases in which we may be guided by this method in determining whether or not the disease in the former region has extended above the diaphragm. For example:—

Carcinoma of the Liver. — Bernard B., thirty-nine years old; patient of one of my colleagues; was suffering from carcinoma of the liver. The examination by auscultation and percussion indicated to his physician

that the disease had extended into the thoracic cavity. By *X-ray examination*, however, I found no evidence of such extension; the lung was clear in this region. This case is also referred to in the chapter on New Growths.

Cancer of the Pylorus.—I examined the following case with the X-rays, with the result noted below:—

Ruth A. G., forty years old, entered the hospital March 10, 1898. Diagnosis: cancer of the pylorus.

A hard, resistant mass, oval in shape, 7.5 centimetres long by 5 centimetres wide, its middle point about 5 centimetres to the right of the umbilicus, could be easily felt. The stomach was distended on account of this obstruction, and this distension was obvious both to the eye and to the hand.

An examination with the fluoroscope showed an area darker than normal over the site of the mass above described, but nothing was gained by the X-ray examination that was not more easily got by other methods.

Any conditions which give rise to marked contrasts in density would offer some opportunity for X-ray examination. I recall among others a patient whom I was examining with the fluorescent screen, whose abdomen was much distended by gas. When he was lying on his back with the light going through the abdomen from side to side, the picture on the screen was made up of two areas, the lower of which was dark and the upper light. As I watched the screen, I saw a dark mass about the size of a closed hand appear from time to time above the dark area on the screen, and move across the light upper half of the picture, and then disappear again, moving from the end of the screen, near the back of the pelvis, toward the front of the abdomen. This mass seemed to be undoubtedly connected with the intestine, but my experience in this direction was too limited to go farther than this. Abdominal section by the surgeon showed the object to be a mass of malignant disease connected with the intestine.

Phantom Tumors.—Patients with phantom tumors should always be examined by the X-rays, whenever practicable, with the light going through the abdomen from side to side as well as antero-posteriorly, for if the apparent tumor is caused by gas, a bright area would be seen on the screen, and the presence of a dense tumor would be precluded.

New growths in the abdomen may be recognized by means of X-ray examination, but, as a rule, at so advanced a stage that their presence

has already been made probable by other means of investigation. But as progress is made in methods of examination for this part of the body, much more may be done than is at present practicable.

The question of the treatment of carcinoma by the X-rays is discussed in the chapter on the Therapeutic Uses of the X-Rays.

INTESTINES (See also Appendix)

Insoluble capsules containing opaque substances may be given to the patient, as we have just seen, and their passage through the intestines watched. It is, however, not possible to determine exactly in which part of the small intestines the capsules may be, as the folds lie so much over one another.

To determine by means of such capsules whether or not a stricture is present in some part of the intestines would hardly be a wise procedure, since the capsule might plug the opening, and thus cause serious trouble, unless preparation had been made for operation. In this case the capsule might help the surgeon to find the site of the stricture.

The large intestine may be injected with fluid containing an opaque substance like subnitrate of bismuth, and its outline and position studied. I think, however, that we should remember that any liquid which is opaque to the rays must be heavy, and that the risk of putting into the large intestine such a weight as might be dangerous to its integrity should not be taken.

Another method for determining the position of the large intestine is — after the bowels have been emptied by a mild cathartic — to inject air into the intestine, and thus distend it. Its position is then recognized on the fluorescent screen by the light area.

A sigmoid flexure and a descending colon which are distended with gas may show their position and sacculated outline with surprising distinctness in a radiograph.

PELVIS

It may be of importance to know the size of the pelvic inlet and to be able to determine whether it is narrower than normal on account of malformation of the pelvis or of bony changes; and this information can now be obtained by the X-rays.

Bouchacourt¹ states that the photograph can show now almost with

¹ "De la radiographie du bassin de la femme adulte," *L'Obstet.*, Paris, 1900, v, pp. 20-34.

certainty whether there is or is not a deformity of the pelvis; whether it is symmetrical or unsymmetrical; and finally, what the cause of the deformity is.

Method for taking a Photograph of the Pelvis. — When the size of the brim of the pelvis is desired, the patient may rest on the plate in a sitting position, leaning somewhat backwards; the tube in this case is placed above and in front of her; or the patient may be on her back with the thighs drawn up and the plate under the tuberosities of the ischii, and as nearly as possible in a plane at right angles to the axis of the pelvis. The tube is placed above the patient in a line with the pelvic axis.

Trendelenburg Position. — Freund¹ found that the Trendelenburg position was a convenient one for photographing the pelvis, as in this position the vascular intestinal coils, etc., fall toward the diaphragm, and therefore the X-rays have freer passage.

Sacrum. — When a photograph of the sacrum is desired it is best to place the patient in a prone position, with the plate under her and the tube above her.

Measurement of Transverse Diameter of the Pelvis. — In order to determine the transverse diameter of the superior brim of the pelvis, I have devised the following method by which the two halves of the pelvis are taken separately but on the same photographic plate. The patient lies on her back on the stretcher, with the plate over the abdomen and the inlet of the pelvis about parallel with the plate. When the right side of the pelvis is being taken, the left half of the plate is shielded by a sheet of lead placed under the plate. The tube is placed by means of a plumb-line as nearly as possible directly under the right border of the superior brim of the pelvis, in the line of the pelvic axis, 3 centimetres to the right of the median line. If the tube is at least 60 centimetres from the plate, and as nearly as possible just above the point the position of which we wish to determine, the error in the photograph will not be great. After the first exposure has been made and the left side of the pelvis is to be photographed, the sheet of lead is moved so as to cover the right half of the plate, and the tube is placed immediately over the left edge of the superior outlet of the pelvis, 3 centimetres to the left of the median line, its proper position being obtained, as before, by means of the plumb-line; the

¹ Report of paper read before the Society for the Diffusion of Scientific Knowledge in Vienna. *British Medical Journal*, 1899, Vol. II, Epitome, p. 85.

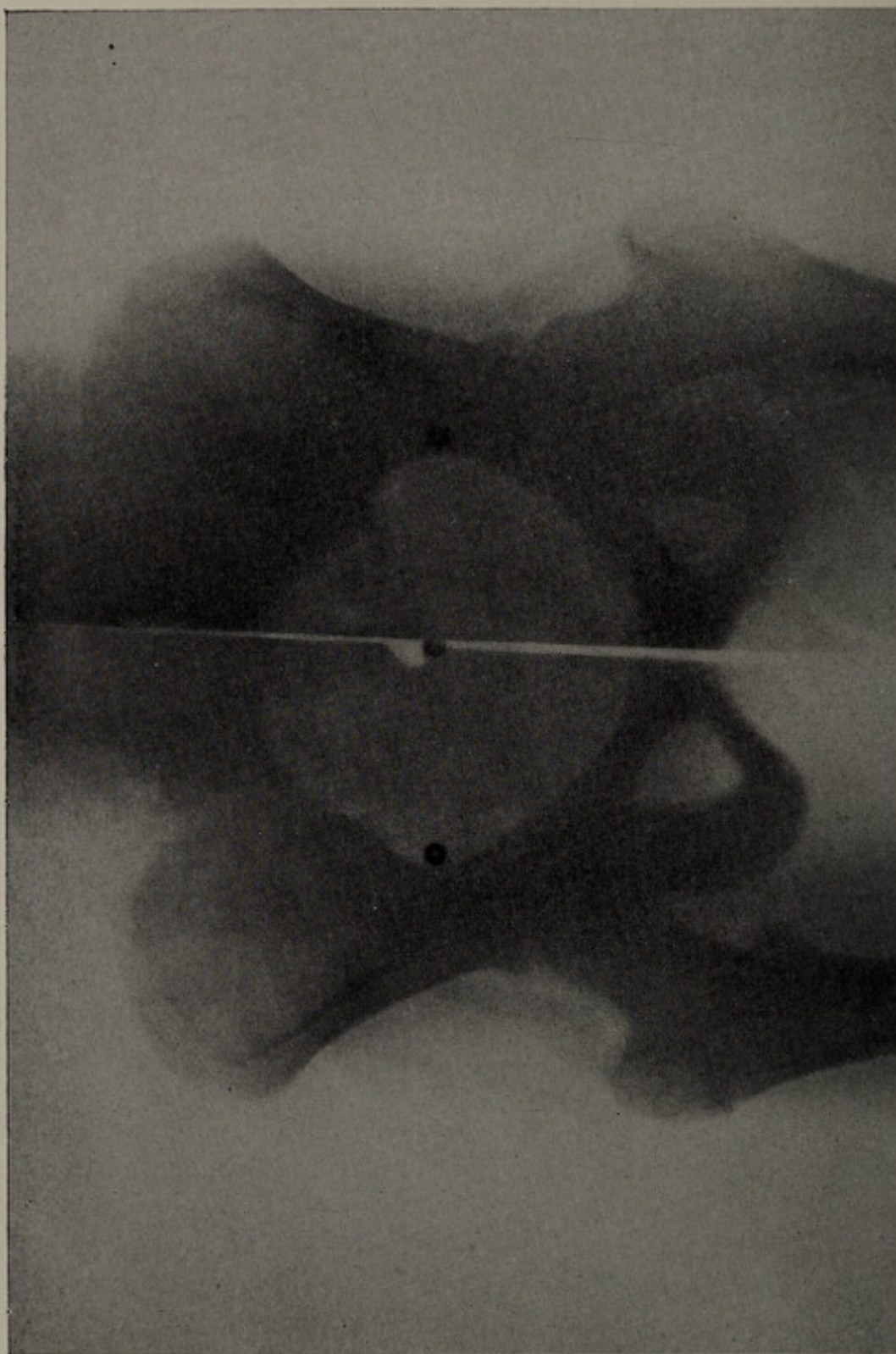


FIG. 214. Pelvis taken on one plate, but each side exposed separately in order that the tube may be so placed that the rays will fall vertically on the part exposed, and thus exaggeration in size may be avoided.

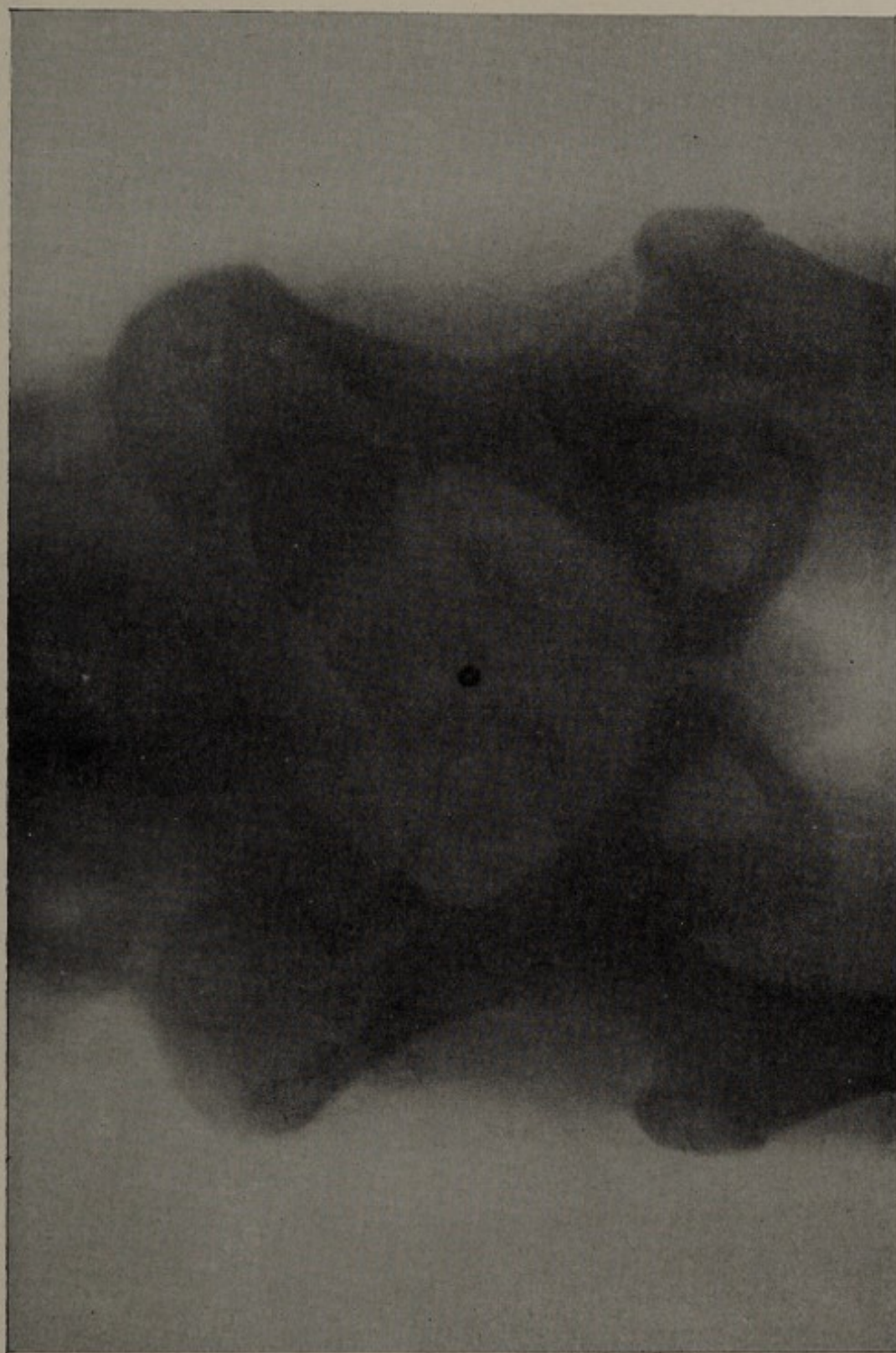


FIG. 215. The same pelvis as taken in Fig. 214, but radiographed at one exposure; consequent exaggeration in diameter of brim (1.5 centimetres) due to the position of the tube with regard to the brim and the plate.

photographic plate is not disturbed. An exposure is then made of this part, and thus a photograph of the two sides of the brim of the pelvis is obtained. (See Fig. 214.) By this method the error due to the slanting direction of the rays falling on the pelvic brim and the plate when only one exposure is made for both sides, is avoided, and no calculation is necessary to estimate the amount of exaggeration as in the latter case. Figure 215 illustrates the error resulting when only one exposure is made. Figures 214 and 215 are cuts of the same pelvis, but there is a difference between their widths of 1.5 centimetres. The correct width is that obtained from Fig. 214.

Gravid Uterus.—Some observers, notably Dr. Edward P. Davis, have succeeded in taking an X-ray photograph of a gravid uterus; and one case at least has been reported¹ in which the X-rays confirmed the diagnosis of extra-uterine pregnancy, the X-ray photograph showing a foetus 5 or 6 months old.

Drs. Varnier and Pinaud² have studied the gravid uterus in dead and living women by means of the rays. In one patient who died of pulmonary congestion, the photographic plate showed the outline of the uterus, and within it the vertebral column of the foetus. In another who died of eclampsia when the foetus was 7 months old, the right border of the uterus was pressed toward the left and the head of the foetus was presented at the superior strait.

They also made X-ray photographs of the gravid uterus in sixteen living women; seven had been pregnant from 2 to $4\frac{1}{2}$ months, and nine from 5 to $7\frac{1}{2}$ months. The conclusions drawn from these cases were as follows: The maternal pelvis can be completely seen up to $4\frac{1}{2}$ months, and more clearly the earlier the photograph is taken: but of the uterus and its contents no trace is perceived. These latter are traversed with such ease by the rays that they do not interfere with the study of the pelvis. After 5 months the uterus and its contents form on the negative a veil, as it were, which is badly defined and without definite contour, but which conceals the posterior wall of the pelvis and the vertebral column. In two cases a pale silhouette of the foetal head could be dimly divined in the pelvic area.

In a second series of seven cases examined from April 23 to October 20, 1898, the same results (that is to say, negative) were obtained

¹ Turbert, *Lancet*, London, 1898, June 5, p. 1782.

² "Radiographie de l'uterus gravide," *Ann. de Gynec. et d'Obstet.*, Paris, 1899, li, pp. 278-289.

whether the foetus was alive or dead. Two of these patients had been pregnant from 2 to 3 months, and five from 5 to 8 months.

In the living patient the head of the foetus can be photographed at the opening of the pelvis as well at 6½ months as at the approach of full term, and the size of the foetus, its orientation, and the amount of flexion and engagement, can be estimated. In such photographs, taken with the patient in the reclining posture, neither the vertebral column nor the limbs of the foetus are seen.

Drs. Varnier and Pinaud are still prosecuting their study of the gravid uterus.

Determination as to whether a Fœtus has or has not breathed.—X-ray examinations may be of service to determine whether a child has or has not breathed. Walsham found the lungs opaque in a foetus which had not breathed.

CHAPTER XV

CHILDREN. CALCIFICATION OF TISSUES. ANÆMIA. PHYSIOLOGY

CHILDREN

THE X-rays afford excellent opportunity for examining children and infants. Their smaller size makes them especially suitable for this method of investigation. All parts of infants and children are far more readily accessible than those of adults, not only the thoracic cavity, but also the abdomen and the head. We see easily the outlines in the thoracic cavity, and we can follow the outline of the liver, spleen, and left kidney, the last particularly when the patient lies on the face with the fluorescent screen on the back. All the joints, especially the shoulder and hip joints, are far more easily photographed than those of the adult. In examining the thorax, indeed, care must be taken to avoid too much light, for the organs in the chest of a young child are so easily traversed by the rays that if the light is too strong the border of the heart, for instance, would not be well defined because the edges would be penetrated by the rays, and, therefore, the shadow of the heart cast on the screen would be smaller than the heart itself.

I think there can be no question as to the value of X-ray examinations in diseases of children. While the difficulties to be overcome on the part of the physician are great, the inconvenience to the patient is slight, in fact is reduced to a minimum. Children may lie down on the comfortable stretcher and be allowed to go to sleep, as they often do. They may then be examined with the fluorescent screen, or an X-ray photograph may be taken without disturbing them. Or, if the child objects to lying down, he may be held in his mother's arms in a suitable position. It is not always necessary to remove the clothing.

The X-ray examination is an excellent means of supplementing other methods of examination in children, and deserves careful, patient, and thorough study. It has already proved to be of service in surgical cases, such as in diseases involving the bones; for example, in the recognition of hip disease or other tuberculous conditions, malformations,

displacements, fractures, delayed union of epiphyses, rickets; and I am convinced that those who choose to cultivate this field on the medical side will find their patience well rewarded. For instance, in some cases of pneumonia, especially in the early stages, we cannot detect the presence of pneumonic areas in infants and children, nor in adults, as has been shown, by the usual methods; in these cases a doubtful diagnosis may be made more certain by an X-ray examination. See chapter on Pneumonia, Clara B., page 184.

Again, in young patients with symptoms which suggest tuberculous meningitis, it may be desirable to have a careful X-ray examination of the lungs, with a view to determining whether or not tuberculous foci exist there.

It is unnecessary to give special directions for making X-ray examinations of children, as the same general rules hold for them as for adults. Especial care should be taken, however, when a child is to be examined, that everything is in readiness, in order that the examination may be completed in a few moments, before he has had time to get restless.

Children may be examined with a smaller and less expensive apparatus than is required for adults, and I think, eventually, in hospitals for children and infants, an X-ray examination will be made in many cases a part of the routine.

CALCIFICATION OF THE TISSUES

It has been stated in the first chapter that the permeability of a substance depends partly upon its chemical composition, and it is evident from the data there given that when the salts of calcium are found in the soft tissues they would be less easily traversed by the rays, and if the situation is a favorable one for taking a radiograph, this change in composition would be very evident. In the pleuræ, in the lungs, and in the arteries we find calcification which can frequently be recognized. The slight amount of calcification which would show on a radiograph of the arteries of the extremities would not be apparent if it were in the ascending aorta, but well-marked calcification of portions of the aorta can be seen on the negative and even on the fluorescent screen; a dark area due to marked calcification of the ascending aorta, for example, may cast a shadow.

I have observed a darkened area on the fluorescent screen over the site of what was shown to be, soon after, by a *post-mortem* examination, a marked calcification of the aorta. It has been stated that it is possible

to recognize, by an X-ray examination, calcification of the coronary arteries, but this seems to me at present impracticable.

If a radiograph of the aorta in its early portion is desired, the plate should be placed on the front of the chest; when of other portions of the aorta it is better to place the plate on the patient's back.

The two following cuts illustrate the appearances seen when calcification of the tissues has taken place: —

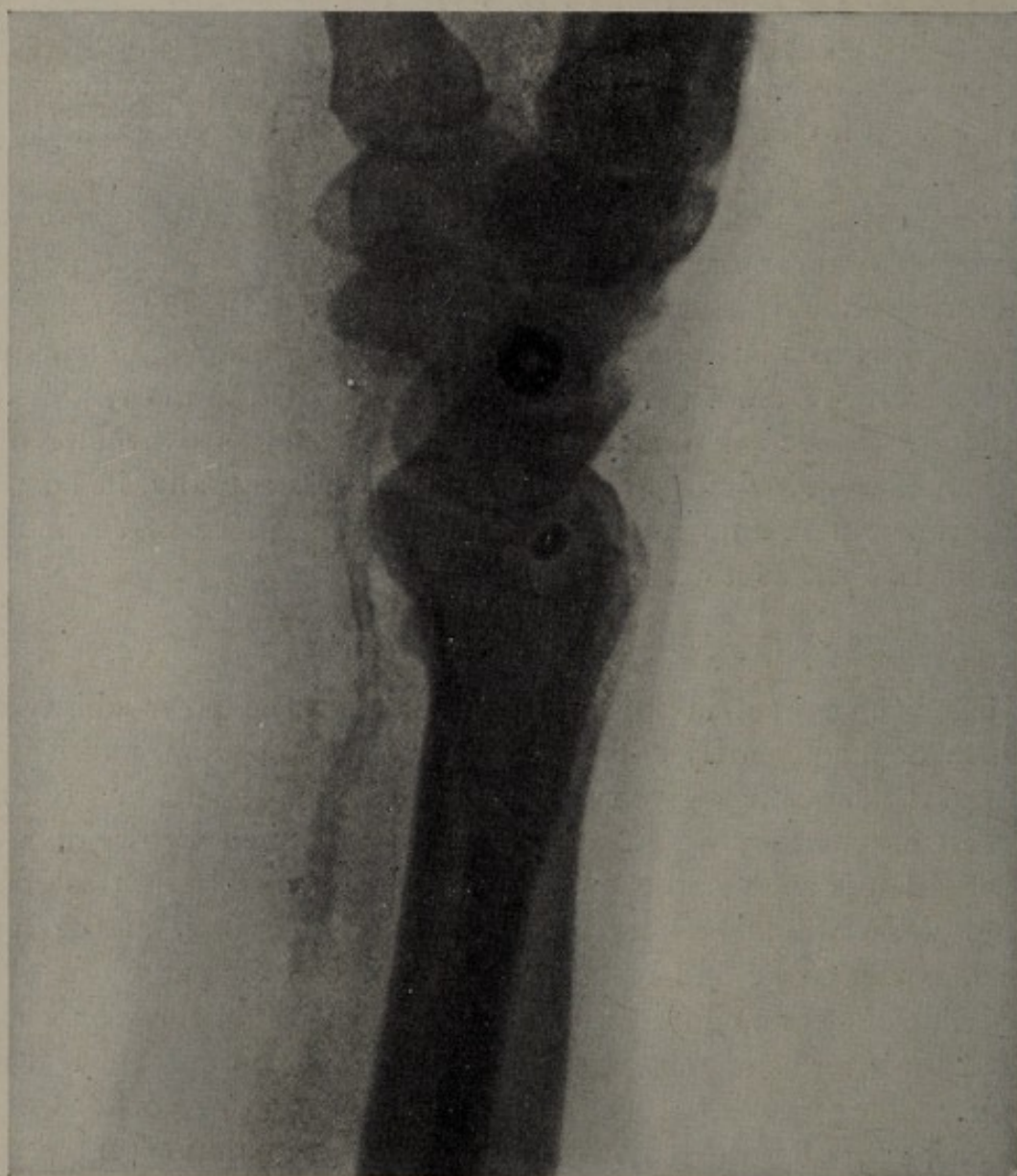


FIG. 216. Calcification of radial artery in a man thirty-seven years old.

Normal Blood Vessels. — Normal blood vessels cannot be so easily recognized as when they are calcified, but it is quite possible to recognize in individuals, both young and old, normal arteries by means of

X-ray photographs; for example, the dorsalis pedis, the popliteal artery, or the brachial artery and its division into the ulnar and radial arteries. I have radiographs of normal arteries in the extremities taken

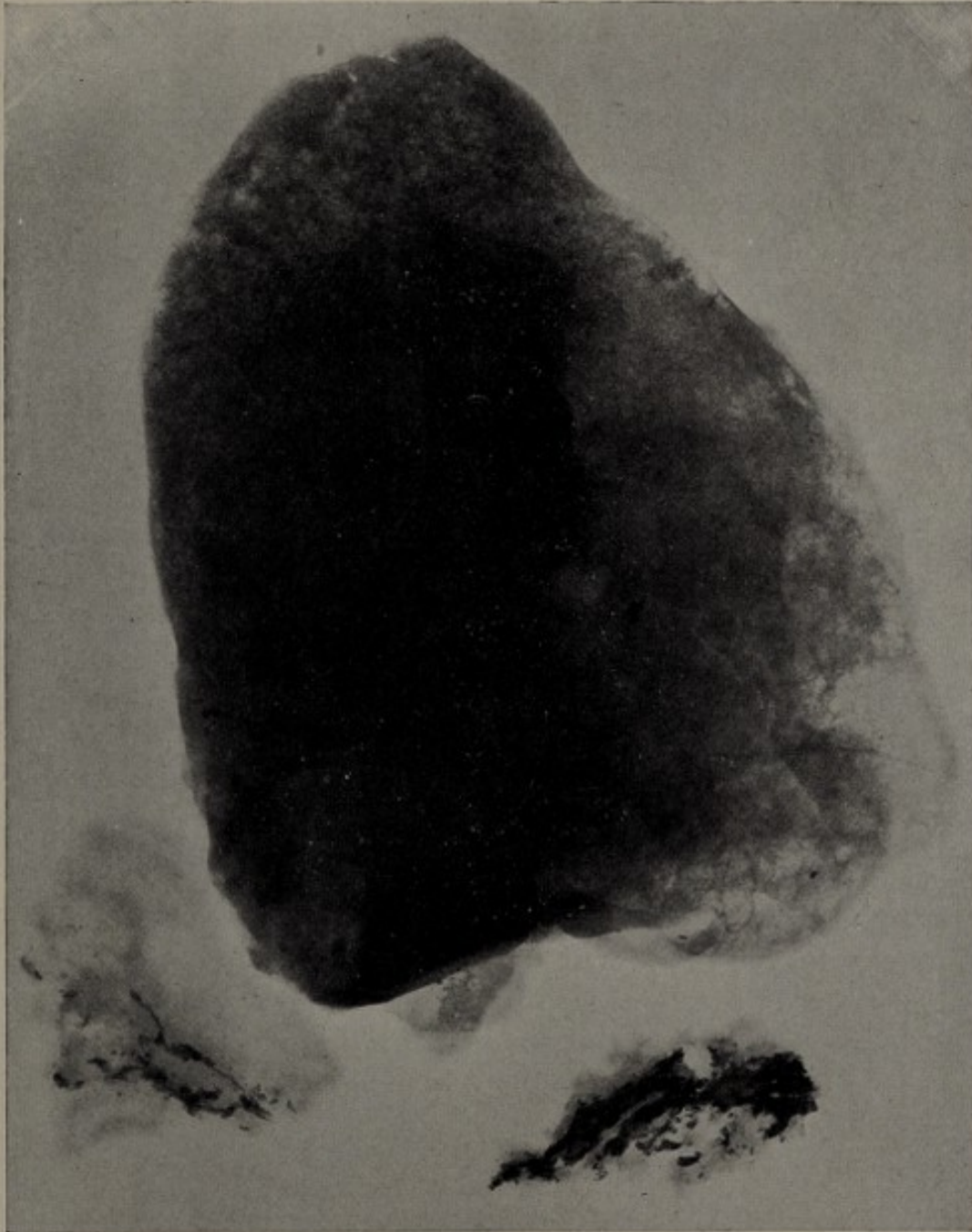


FIG. 217. Calcified pleura and tuberculous lung taken from autopsy.

in 1896, and also radiographs showing the outlines of the thoracic aorta, both the ascending and descending portion, and the superior vena cava. The right border of the latter and of the ascending aorta can be followed in the radiograph for a considerable distance.

ANÆMIA

I have examined eleven cases of anæmia in young women, by the X-rays, and in six of these found no marked departure from the normal by this method. In five of them the appearances varied from the normal.

In one of these the upper portion of the left lung was darker than normal and the excursion of the diaphragm was shorter on this side than on the other side. Four days later the excursion of the diaphragm had increased and the darkened area in the upper portion of the left lung was less marked. Ten days after the first examination the darkened area in the left lung had disappeared, and the excursion of the diaphragm was greater than on the right side.

In the second case the excursion of the diaphragm was limited on both sides ; in this patient only one examination was made.

In the third patient the excursion of the diaphragm on each side was only 2 centimetres. Eleven days later it had increased to 5 centimetres.

The fourth patient entered the hospital with a diagnosis of debility and pregnancy. The X-ray examination showed that the whole of the left lung was darker than normal and the excursion of the diaphragm could not be made out ; on the right side the excursion of the diaphragm was only 2 centimetres, and the upper portion of the right lung as far as the third rib was darker than normal. These appearances seemed to indicate pulmonary tuberculosis, but the patient had a normal temperature and did not react to tuberculin. Twenty-seven days later the appearances in the chest had improved very much. The excursion of the diaphragm on the right side was 7 centimetres, on the left side 4.7 centimetres, and only a slight shading of the upper part of the left lung remained. This case shows the importance of a second X-ray examination made after an interval of time.

In the fifth patient, the excursion of the diaphragm during deep inspiration was less than normal and the heart was smaller than normal.

Small Hearts. — In four out of seven patients suffering from anæmia that I examined with the X-rays I found the heart was smaller than normal. The ability to recognize with certainty this condition may be of much service to the patient in both treatment and prognosis.

Error possible as to Width of Heart by Ordinary Methods. — In anæmia with constipation we may be deceived by the ordinary methods

as to the size of the heart; it may seem wider than normal if the diaphragm is higher up in the chest than in health. After suitable treatment, in such cases, with laxatives and iron, the width of the heart by the usual examination seems to be diminished, but the X-rays show that the size of this organ has not altered, but that the supposed enlargement was due to the fact that the axis of the heart was more horizontal than normal on account of the higher position of the diaphragm. (See chapter on the Heart, pages 287, 288, and 297.)

Pernicious Anæmia.—In three cases the excursion of the diaphragm was much less than in health. In one of them an X-ray photograph was made of both legs. The tibiæ did not show an outline indicating the medullary cavity, although this was quite evident in both fibulæ. This photograph was taken in order to see if any changes in the bone marrow could be observed.

PHYSIOLOGY

In physiology, problems relating to the voice, digestion, and respiration have been studied by means of the X-rays, and Imbert and Bertin-Sans¹ consider that they are of great value in the study of articular movement.

The movements of the stomach during digestion have been discussed in the chapter on the Abdomen, but a few words in regard to Scheier's² investigations concerning the voice and larynx are in place here.

Physiology of the Voice and Speech.—Dr. Max Scheier has watched on the screen the motions made by the soft palate while the person observed was speaking; he noticed that the palate rose to different heights according to the vowels uttered; least when "a" was pronounced, a little higher with "e," and so on with each successive vowel in order, rising highest with "i"; the shape also of the palate varied according to the vowels spoken. If consonants, with the exception of the semivowels and the resonants, were pronounced, the palate rose even higher than with "i," but when "m," "n," and "ng" were uttered it hardly moved. If the vowels were spoken in a nasal tone it rose only a little; if the tone of the voice were high it rose more than when the tone was deep; likewise it rose higher if the vowels were uttered in a loud tone of voice than when softly spoken.

¹ *Compt. rend. Acad. d. Sc., Paris*, May 4, 1896, p. 997.

² "Weitere Mittheilungen über die Anwendung der Roentgenstrahlen in der Rhino- und Laryngologie," *Fortschritte a. d. Geb. d. Roentgenstr.*, B. I, 1897-1898.

Effect of Excessive Exercise on the Heart. — T. Schott (*Berlin. klin. Wochenschrift*, May, 1897) gives X-ray photographs of the hearts of children from twelve to fourteen years of age that had been acutely dilated by wrestling with each other until they were out of breath. The photographs show a widening of the heart, chiefly in the region of the left ventricle, which had taken on a special form.

Schott, in a later article (*Verhandlungen des Congresses für Innere Medicin*, April 11-14, 1899), shows by pulse tracings and tracings made of the heart before and after exercise, that excessive exercise makes the pulse faster, less regular, and less full, and that it enlarges the heart. Several of these tests were made on individuals after they had ridden rapidly several kilometres on a wheel.

CHAPTER XVI

THERAPEUTIC USES OF THE X-RAYS

THE accounts given in the medical journals of the therapeutic uses of the X-rays in diseases of the skin have seemed to many practitioners beyond belief. It is surely marvellous that certain skin affections can be relieved by exposure to the X-rays, without producing inflammation or causing inconvenience to the patient; but sufficient evidence has now been accumulated to show that in certain fields the X-rays have therapeutic properties. In some of the early cases inflammation and dermatitis were produced, and even more serious injuries, but it has now been demonstrated that these results are unnecessary if proper care is exercised. In order to show the good results that may be obtained, as well as the care that should be taken and the dangers to be avoided, I have selected a few cases which will be given later to illustrate certain points that should be borne in mind when using the X-rays as a therapeutic measure.

In 1897 Freund¹ published the results of two series of experiments in the treatment of hypertrichosis with the X-rays. In one, depilation was produced after an aggregate exposure of twenty hours, without causing any noteworthy inflammation; in the other, a dermatitis which took on the character of a necrosis was set up after an aggregate exposure of forty-four hours. This production of inflammation in the deeper layers of the skin, and breaking up of the tissues, suggested the use of the X-rays to Schiff as a therapeutic agent in the treatment of lupus, and two cases which he thus treated are given in detail in the *Archiv für Derm. u. Syph.*, B. 42, 1898. In one case, that of a girl fourteen years old, who had suffered with this disease since she was three years of age, the lupus tract extended on the dorsal side of the arm from the metatarso-phalangeal joints of the left hand to within a hand's breadth of the elbow joint. The patient was protected by a sheet of lead where treatment was not desired, and the tube was placed at a distance of 15-20 centimetres, in such a position that the X-rays fell directly upon

¹ *Wiener Med. Wochenschr.*, 1897, and with Schiff, 1898, No. 22, p. 1058.

a portion of the lupus tract. As a control, when the part of the arm near the elbow was being treated, the tube was placed opposite the inner side, and under these circumstances the X-rays did not sufficiently penetrate the parts to affect the lupus.

Before further considering the use of the X-rays in this disease I think it will be instructive to take up briefly their action on the skin.

Normal and Abnormal Skin. — Albers-Schönberg¹ states that, on the whole, the action of the X-rays on the normal and abnormal skin is similar. After a shorter or longer time the skin becomes slightly yellow, then slightly red; this light red becomes darker, and in many people a slight irritation and pricking occur, which is followed by a burning sensation that in sensitive persons grows into pain. In some cases, with this increasing redness comes a slightly œdematous swelling of the skin. If the skin continues to be exposed to the X-rays it takes on an ever darker color, and excoriation appears which in a few days spreads over the whole of the X-rayed portion of the skin, which then looks as if it had been burned. In a number of cases, provided the X-rays were no longer applied, the skin healed from the edge toward the centre. The tendency to heal varied. If excoriation had followed upon the œdematous condition of the skin, the healing was very slow. The new skin that formed was of a delicate rose color and very thin, and it was months before it took on the character of the normal skin. Albers-Schönberg has not himself seen injuries going any deeper into the skin than to the rete malphigii. He has observed, like others, the cumulative action of the X-rays on the skin.

In cases in which hyperæmia appeared, as well as sometimes in other cases, a peculiar displacement of the pigment occurred in the X-rayed spot. The centre and the greater part outside of it became perfectly white and pigmentless, but scattered over it were single pigment spots resembling freckles, some of which were as large as beans, while the edge corresponding to the outline of the mask was colored of a strong yellowish brown. This displacement of the pigment lasted a long time, often for months, and then gradually the skin became normal in color again. Hahn and Albers-Schönberg state that it is important to recognize this discoloration, as the scattered spots of pigment do not disappear under glass pressure, and in a case of lupus, therefore, might be mistaken for new nodules or the remains of old ones.

¹ "Über die Behandlung des Lupus und des chronischen Ekzems mit Roentgenstrahlen," *Fortschritte a. d. Geb. d. Roentgenstr.*, B. II.

Finger Nails. — Hahn and Albers-Schönberg also observed that the finger nails were affected by the X-rays; they became thin and brittle on the edge and were bent like claws. The conditions set up suggested to them that here, as in the case of temporary alopecia, there was also a disturbance in the nutrition of the parts.

Mode of Action of the X-Rays. — Schiff thinks that the violent inflammation produced in lupus is sufficient to injure the life conditions of the micro-organisms, and, therefore, their continuance; Kümmell,¹ that a specific effect is not produced on the lupus by the X-rays, but rather, perhaps, an electro-chemical (Jankau) or tropho-neurotic (Barthélemy) influence lies at the bottom of their work; Gocht,² that while the artificially non-infectious and harmless inflammation which reaches to the subcutaneous tissue is going on, an annihilation of the tubercle bacilli and healing take place. In harmony with this idea are, he thinks, observations made on cases of lupus in which erysipelas occurred, and following this disease the inflammatory process came to a standstill, and the skin quickly formed over the lupus patches; Albers-Schönberg³ suggests that possibly the X-rays have a direct effect on tuberculous tissue, an effect which may be aided by a hyperæmia; but he thinks that we are unwarranted in ascribing a healing influence to the acute dermatitis, because in some of his cases of lupus the nodules dried up and disappeared without dermatitis. My experience has been similar in so far that I have found it unnecessary to excite dermatitis when treating cases of lupus.

Apparatus. — The writers, when reporting the following cases, have given certain details concerning the apparatus used, that is to say, the number of volts, and amperes, and sometimes also the spark-length of the induction coil and the number of interruptions per minute; but more exact information is needed in order to determine the amount of X-rays produced in the tube of one practitioner as compared with that of another. The efficiency of different coils varies very much.

The resistance of the tube is a cardinal factor to be considered. There is no wholly satisfactory way known at present of measuring the intensity and quality of the light obtained by one physician with one

¹ "Die Behandlung des Lupus mit Roentgenstrahlen und mit konzentrierten Licht," *Beilage zur Centralblatt für Chirurgie*, 1898, No. 26, pp. 52-63.

² "Therapeutische Verwendung der Roentgenstrahlen," *Fortschritte a. d. Geb. d. Roentgenstr.*, B. I, 1897-1898.

³ *Fortschritte a. d. Geb. d. Roentgenstr.*, B. I, 1897-1898, p. 75.

apparatus, as compared with that obtained by another with a different apparatus.

It seems advisable to call attention to the inadequacy of the data given by various writers, as otherwise it might appear incomprehensible that the same results do not follow when apparently the same quality of apparatus is used.

Freund¹ states that when the X-rays are employed for treatment and not for purposes of diagnosis, with 12 volts not more than 1.5 amperes should be used; that the spark-length of the coil should not exceed 30 centimetres, and that the interruptions should vary between 800 to 1000 per minute. I may say, on the other hand, that I have used a current of 1.5 to 2 amperes at 220 volts, and a coil with a spark-length of 75 centimetres, in treating lupus, without exciting dermatitis, much less excoriation and gangrene.

LUPUS VULGARIS

Illustrative Cases. — The two following cases were treated by Kümmell² and show good results without any harmful effects except for a slight reaction in the second case which required an interruption in the treatment. Kümmell placed his tube at first at a distance of from 10–6 centimetres, but as a very violent reaction appeared after a relatively short time he later increased this distance to 40 centimetres, diminishing it gradually, if no reaction appeared, to 20 centimetres. The sittings were never over half an hour long, and generally were one-quarter hour twice a day. He lays stress on the importance of knowing exactly the intensity of the light.

CASE I. Mrs. D., twenty-eight years old. Lupus of the nose for ten years; under medical treatment five years. The whole nose was covered with nodules, ulcerations, and scabs, and the nostril was partly destroyed. Treatment with the X-rays was begun on November 28, 1897, and two sittings daily of one-quarter hour each were given. January 13, 1898, the ulcerations had cicatrized, the scabs had fallen off, and the nodules had disappeared; but the nose was still red. The patient was then discharged from the hospital and came to it only for treatment. The redness of the skin began to abate.

CASE II. Mrs. K., fifty-six years old. Tuberculosis. Lupus of the nose for fifteen years. The end and left side of the nose as well as

¹ *Weiner Med. Presse*, No. 31, 1899.

² *Beilage zur Centralblatt für Chirurgie*, No. 26, 1898, pp. 52–63.

the left side of the cheek was infiltrated and covered with numerous nodules and ulcerations. Treatment with X-rays given; slight reaction; pause of a few days; complete recovery after three months' treatment; the traces of the disease scarcely to be seen.

Comparison of X-Ray and Other Treatment in One Case reported by Kümmell.

CASE I. Extensive lupus over the whole face, on the forehead, and reaching down to the right shoulder. To show the effect of different treatments one side was treated with the rays, the other by Dr. Hollander with hot air cauterization, and both sides healed; but on the cauterized side of the face the lupus nodules reappeared and ectropion followed on account of the contraction of the scar.

Kümmell continued the treatment in his cases until the scabs had fallen off, the ulcers were healed, and the nodules had mostly disappeared. He considered his recoveries as only provisional, as the time elapsed was too short to speak of permanent results.

Insulation. — Kümmell insulated some of his patients by placing them in chairs, under the legs of which glass was put, in order to hasten treatment that was often slow in its effects, but later gave up this procedure because of the very quick and unaccountably strong reaction which often took place. Gocht insulated some of his patients in like manner. He mentions no ill effects.

Mode of Healing. — The process of healing in lupus cases was observed by Kümmell to proceed in the following way as a rule: cleansing of the ulcers; cicatrization; drying up and falling off of the scabs; peeling of the skin; decrease in the size of the nodules; disappearance of the redness; formation of a white scar without any contraction. Kümmell thinks the essential point of this method consists in the fact that the scar formed is more like the normal skin than can be obtained with any other method, and this result outweighs the long duration of the treatment. He also thinks that the healing is the surer the more the injury to the skin is avoided.

Schiff's¹ experience as to the process of healing, after the treatment of his first two cases, is, like Kümmell's, instructive, and gives a little different picture of what goes on in the skin: —

1. A general phlogistic reaction;
2. Specific reaction of the lupus tissue to the X-rays, as shown by the fact that lupus nodules not visible before the treatment were manifest afterward;

¹ *Archiv für Derm. u. Syph.*, B. 42, 1898.

3. Loosening and falling off of nodules, following the exposure ;
4. Subsidence of the swelling of the lymph glands in the lupus tract ;
5. The torpid ulcers seemed to be changed into active granulations by the X-rays.

Dermatitis produced by Exposure to an Excited Vacuum Tube in the Lupus Tract may be slow in Healing.—Albers-Schönberg¹ reports a case which shows how long a time may be necessary to heal a dermatitis produced by exposure to an excited vacuum tube. The left cheek only of this patient was treated by the X-rays sixteen times in two months. After two sittings a redness appeared, which after sixteen sittings increased, and was followed by an excoriation. This dermatitis showed extraordinarily little tendency to heal, and after 130 days was not yet well, but presented an excoriated spot 2.5 centimetres long by 2 centimetres broad.

Long Duration of Treatment.—Albers-Schönberg reports a case in which the treatment with the X-rays was continued for a period of eight months, with intervals of many weeks. One hundred and fifty-one sittings in all were given. He attributes the long duration of treatment in this case to the fact that the patient was one of the first to be treated and the tubes used were too weak and too old.

In nine cases reported by him the current was 30 volts and 4-5 amperes. The tube was at a distance of 10-25 centimetres and its resistance was 15 centimetres.

Dermatitis diminished Susceptibility of Skin.—Albers-Schönberg noticed in his cases of lupus in which dermatitis occurred that after a complete recovery from the dermatitis the skin on further exposure to the X-rays was much less susceptible to them. The reaction appeared, generally speaking, more slowly, and was of a milder form than at first. Gassmann and Schenkel observed this point likewise.

X-Rays in Combination with Unna's Salve.—The following case reported by Hahn and Albers-Schönberg² is of interest as indicating the effect of supplementing the X-ray treatment with the use of salve :—

CASE I. B., eleven years old. Lupus. Sixty sittings in five months. Improvement rapid. The spot least improved was unfavorably placed with regard to the X-rays, so that it was not exposed to so intense a light as the remainder of the tract. This spot was treated with Unna's green salve with good result. The X-rays were then applied again, after which the nodules healed quickly. The boy had no dermatitis, not

¹ *Fortschritte a. d. Geb. d. Roentgenstr.*, B. II, 1898-1899, p. 27.

² *Münchener Med. Wochenschr.*, March 6, 1900.

even a passing redness or sensation of pain. Hahn and Albers-Schönberg attribute this good result to the use of the vaseline dressing, and state in reply to the objection that might be made of an individual idiosyncrasy in this case, that in all the cases in which they used vaseline the inclination to hyperæmia and reaction was diminished.

Dr. A. Everett Smith¹ has reported a case which is of interest, as the desired result was accomplished so much more quickly than in some of those already cited.

Frank N., about eighty years old. Lupus patch on face which extended from the left side of nose over the bridge to the right side of nose, and involved the inner canthus of right eye and the inner third of the lids, together with the bulbar conjunctiva. There was never much pain; it bled occasionally, and disfigured him much. His general health and family history were good.

Sittings were given him about every fifth day for twenty minutes at a time, the diseased surface being placed about 5 centimetres from the light. He received in all twelve treatments. No medicine whatever was allowed. He was using applications of vaseline at first, but that was stopped. "Marked improvement commenced after the second treatment, and was not interrupted until the sore was completely and entirely healed. After the second treatment healthy granulations appeared, and healing was remarkably speedy. There was no burning from the light or other unpleasant symptoms complained of, except a slight headache and a decided 'crawling sensation' in the sore after the first two treatments." The cicatrix produced a slight ectropion, but vision was normal. All parts healed perfectly, and a healthy cicatrix formed.

Recurrence of Lupus. — Albers-Schönberg reports the following cases in which there was a recurrence: —

CASE I. Miss K., thirty-six years old. Duration of disease about eleven years; always under medical care.

Treated by X-rays sixty-eight times. The patient lived out of town, so that the treatment was carried on at long intervals. The right cheek was first exposed to the rays, and excoriation appeared after twenty-seven sittings. The dermatitis healed quickly. Soon after the latter had been cured the lupus again appeared on the same cheek, but was got rid of after from five to six sittings. The left cheek showed excoriation after twelve sittings, but healed quickly. The parts affected by

¹ "Lupus Vulgaris of Fifteen Years' Standing successfully treated and cured by Exposure to X-Rays," *Philadelphia Medical Journal*, December 1, 1900, pp. 1058-1059.

the lupus were replaced by healthy skin. The affection of the mucous membrane of the nose was much diminished, but not completely healed. Three months afterward there was a recurrence in the shape of seven nodules on each cheek; some ulceration and crusts. The nodules dried up after thirteen sittings. This case when last reported¹ had been free from anything suspicious for six months.

Albers-Schönberg and Hahn call attention to the fact that the recurrence healed quickly, and that in the spots previously exposed to the X-rays the nodules developed more slowly and less vigorously. They also quote a case in which the lupus appeared in a new spot three months after the original lupus tract had been successfully treated, but suggest that this fact speaks favorably for rather than against X-ray treatment.

CASE II. A. K., boy thirteen years old. Duration of disease about four years.

This patient was given twenty-eight sittings with the X-rays during three months. A reaction set in after the second sitting, but there was no excoriation. The process of healing advanced by gradual drying up of the nodules.

Two months and a half later the lupus returned in the nostril and at the end of the nose. The treatment with the X-rays was repeated, and at the time the case was reported the patient had again recovered.

Gassmann and Schenkel report that in two of their cases the lupus recurred; in the first case, seven months after; and in the second, six months after the cessation of the treatment.

Jutassy² states that nearly fifty cases of lupus treated by means of the X-rays by Kümmell, Freund, etc., have been published, and that of the older cases about fifty per cent have had a recurrence; but that there are cases reported by Schiff, Gocht, Kümmell, and Albers-Schönberg, which were treated two years ago, and have had no recurrence. Albers-Schönberg³ states that cases of Kümmell and Gocht have been free from a return since January, March, and July, 1897, and two of his own since January, 1898.

Susceptibility of the Patient. — It has been stated that the susceptibility of persons to the action of the X-rays differs; therefore, the first sittings must be cautiously given to test the individual idiosyncrasy.

¹ *Münchener Med. Wochenschr.*, February 27, 1900.

² *Fortschritte a. d. Geb. d. Roentgenstr.*, 1900, Bd. III, H. 3, p. 119.

³ *Ibid.*, 1898-1899, Bd. II, p. 24.

The practitioner should begin with "small doses," as one observer puts it. It seems to me however that the condition of the tube and of the apparatus is a stronger factor than the patient.

Cumulative Action of the X-Rays. — The action of the X-rays, according to various observers, is cumulative, and therefore special care must be taken in using the treatment. Dermatitis can be avoided if the necessary caution is exercised. Albers-Schönberg states that the first sign of a reaction is a slight irritation or heat; if the sittings under these conditions are continued, the part where the reaction has appeared reddens; the sittings should then be stopped until the redness disappears, and there is no longer heat or irritation. By means of these pauses the cumulative action will be avoided, but if the sittings are continued, dermatitis, excoriation, gangrene, etc., will follow.

Method of Treatment. — The patient must be protected from an excited vacuum tube not only in the immediate neighborhood of the diseased tract, but elsewhere, or dermatitis and loss of hair may follow. Some practitioners use sheets of lead, others, cardboard covered with tinfoil, for this purpose.

Protection by Shield. — A shield is fastened over the portion of the body to be treated, by means of a strip of bandage, for instance, passed around the body above and below the point where the disease is located. The shield should not be held by the patient. If the surface is uneven, a piece of cork may be slipped under the bandage when it is necessary to press the shield against the skin. The shield is made of cardboard — or, better, of blotting-paper, which can be adapted to uneven surfaces — covered with four thicknesses of tinfoil, and extends at least 5 centimetres in every direction beyond the diseased tract, in order that the neighborhood of the tract may be protected from the rays. The blotting-paper and the tinfoil may be held together by surgeons' plaster. A hole is cut in the shield corresponding in size to the part to be treated. The tinfoil should never be allowed to come in contact with the skin, and the blotting-paper should not be allowed to get moist, as it then becomes a conductor of electricity, and a current passing through it may irritate the skin under it.

The shield may be made in the following way: A hole is first cut in the blotting-paper corresponding in size, no larger, to the part to be treated; then the tinfoil is fastened to it by means of the plaster, next the foil is cut in lines radiating from the centre of the opening in the blotting-paper and these pointed pieces are folded back.

Mask. — For the face I use a mask, made of gauze and pressed into the shape of a face, such as may be purchased at theatrical supply stores. This mask of course does not obstruct the rays. I cover it with tinfoil except over the diseased area, and cut one or several small holes in the portion of the mask lying over the part to be treated, in order to recognize the size of the area. It is better not to make this

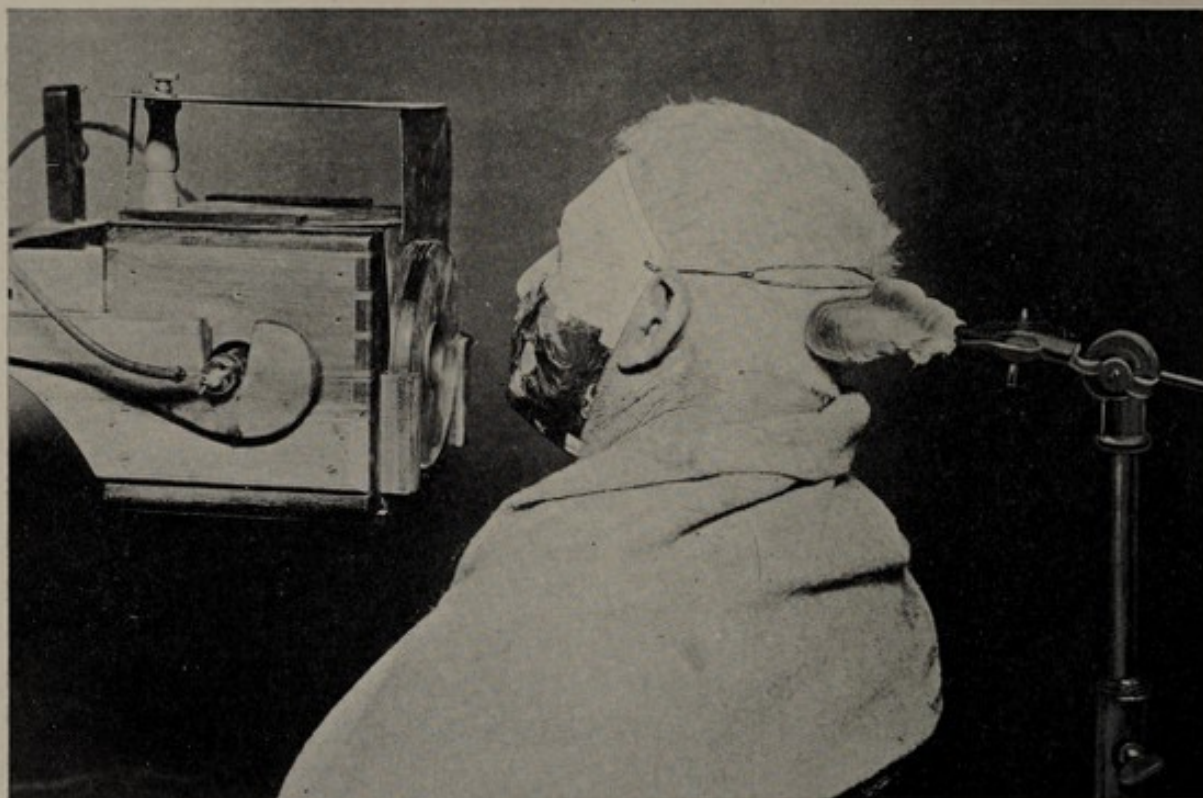


FIG. 218 shows the method of treating areas of lupus, or cancer of the face, with the patient seated in front of the tube. The box containing the vacuum tube is seen on the left. On the front of the box is a diaphragm of sheet lead, and outside of it is a thin sheet of aluminum in which there is no opening, and which projects above the front of the box and is grounded; outside of these two sheets is a circular diaphragm of glass. The opening in the glass diaphragm shown in the cut is rather too large for this patient. The patient has on a mask which is covered in its lower portion with tinfoil, and in the centre of the latter is cut an opening somewhat larger than the area to be treated. An opening has also been cut in the mask, somewhat smaller than that of the tinfoil; in order that the tinfoil may not touch the face. A mask painted with white lead may be used instead of the tinfoil mask. The head of the patient is steadied by means of a photographer's stand, that is shown on the right of the cut.

hole of the same size as that of the diseased tract, if this is a large one, because the mask, if so cut, would not keep in place as well. It is held on the head by means of a bandage, in the same way as the shield just described or better by an elastic with spring-clips at each end.

Protection by a Box. — The tube is enclosed in a box, coated on the inside with lead paint as devised by Rollins (see Chapter II), in the side of which a circular opening is cut about 5 centimetres in diameter, and

this diameter can be made smaller when desired by a diaphragm of heavy sheet lead which is covered with a diaphragm of plate glass; this acts as a diaphragm and also prevents the patient from getting a slight spark from the lead plate. By means of diaphragms of different sizes the aperture through which the X-rays can pass is increased or diminished according to the size of the part to be treated, and therefore the cone of rays will only fall on the diseased part and the tinfoil of the shield immediately surrounding it. As stated in Chapter II, the diameter of the cone of rays when it reaches the body is broader than at the aperture; this fact must be taken into consideration in choosing the opening to be used for a given part. The need of protecting other parts of the body than the immediate neighborhood of the diseased spot is illustrated by cases that have been reported in the medical journals, and this box, with its adjustable diaphragm, is a simple way of obtaining the desired protection, and obviates the need of many different shields suited to different parts of the body, such as would otherwise be necessary.

Apparatus. — In my office I have used a coil; the current was from .5 to 2 amperes at 220 volts. The resistance of the tube was from 1 millimetre to about 1 centimetre. At the hospital I used my large static machine, described in Chapter II, and for therapeutic purposes I prefer it to a coil. The patient was placed from 10 to 15 centimetres from the target.

As already stated, these data as to the apparatus and the distance of the tube from the patient are insufficient for purposes of comparison, and I give them to emphasize the fact, for the above current can be used without exciting dermatitis.

If the tube is near, the action is quicker and more intense, as the intensity of the light varies inversely as the square of the distance. New tubes of low resistance, that is to say, from less than a millimetre to about 1 centimetre, are thought to be better for therapeutic purposes.

Length and Frequency of Sitzings. — The length and frequency of the sittings must depend: first, upon the resistance of the tube; second, upon its distance; third, upon the power of the exciter used; and fourth, upon the susceptibility of the patient and whether a delicate part of the skin is to be treated. Knowledge of the apparatus and experience and judgment are necessary to use this treatment. Each case must be treated according to its special needs and the apparatus employed, therefore only general rules can be given. By some practitioners the

treatment in lupus is given daily except for the pauses made necessary by the condition of the skin. Albers-Schönberg suggests that on the first and second days the sittings should not exceed ten minutes, in order that the susceptibility of the patient may be tested. If the skin remains normal, he increases the sittings to half an hour, but makes that

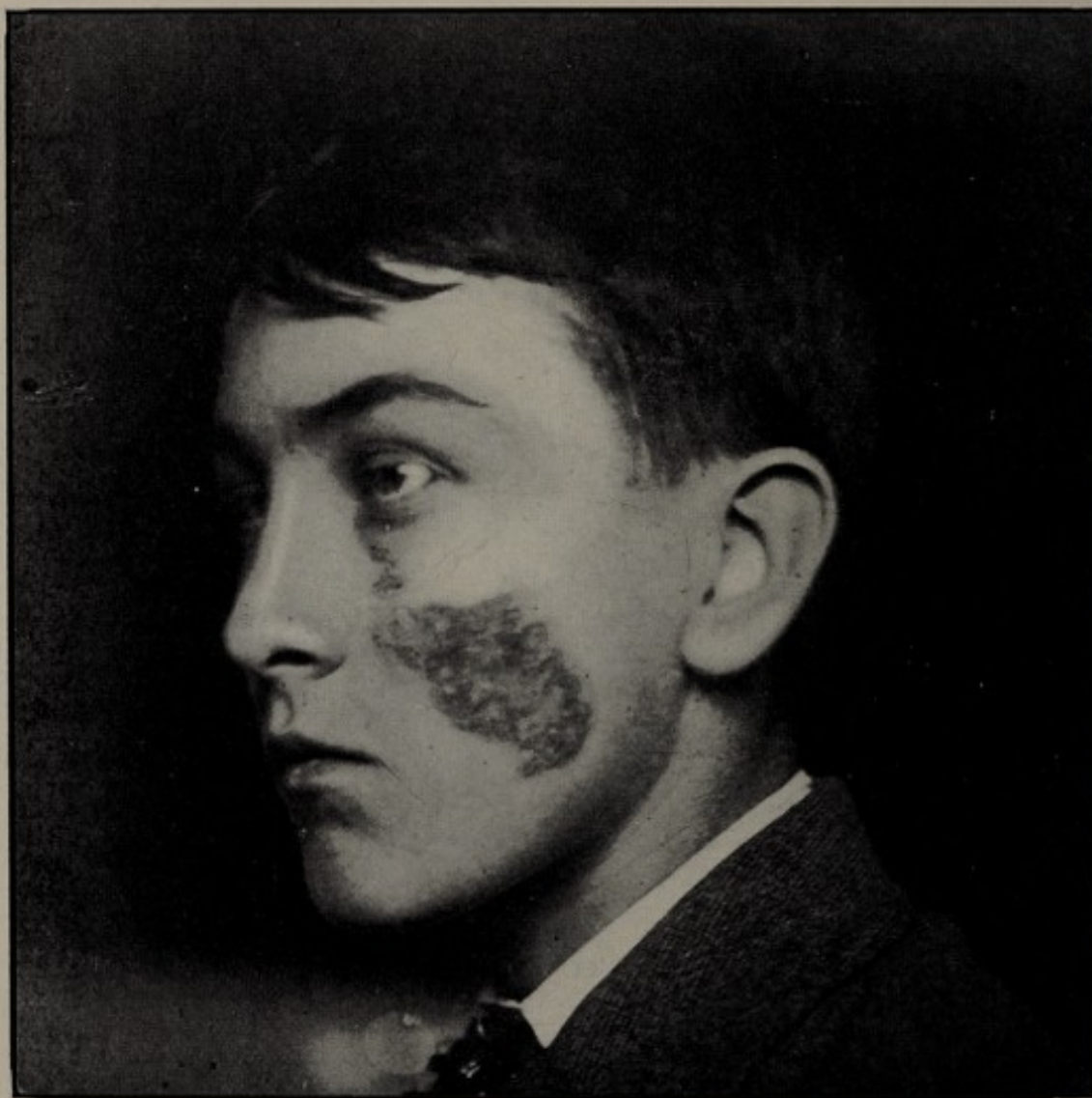

FIG. 219. Lupus. Before treatment by the X-rays.

time the maximum. Freund¹ thinks it is wise to pause for two or three weeks after the first two sittings, in order to avoid any immoderate reaction that might arise from some idiosyncrasy of the patient. He advises that the sittings should then be given daily and that their length should be at first five minutes, later ten, and eventually twenty minutes.

¹ *Wiener Med. Presse*, No. 31, 1899.

My suggestion is that in the beginning the sittings should not be given oftener than twice a week, because the ill effects, if any are produced, follow so slowly, often one or two weeks after the exposure; and that they should not as a rule exceed ten minutes. If there is the slightest indication of irritation the sittings should be suspended. The recovery




FIG. 220. Lupus. After treatment by the X-rays.

is not hastened by pushing the treatment too energetically, for if a dermatitis is produced the sittings must be temporarily abandoned. My experience is that it is quite possible to carry out the treatment successfully without causing any inconvenience, and certainly no severe irritation.

The two preceding cuts are taken from photographs of a patient treated by me with the X-rays: one was made before treatment and the other after.

The two following cuts (see Figs. 221 and 222) indicate the condition of a young woman, suffering with lupus, at the beginning of treatment and after improvement was well begun. A final cut after still further improvement had taken place cannot be given as the patient went away so that I could not get a photograph.

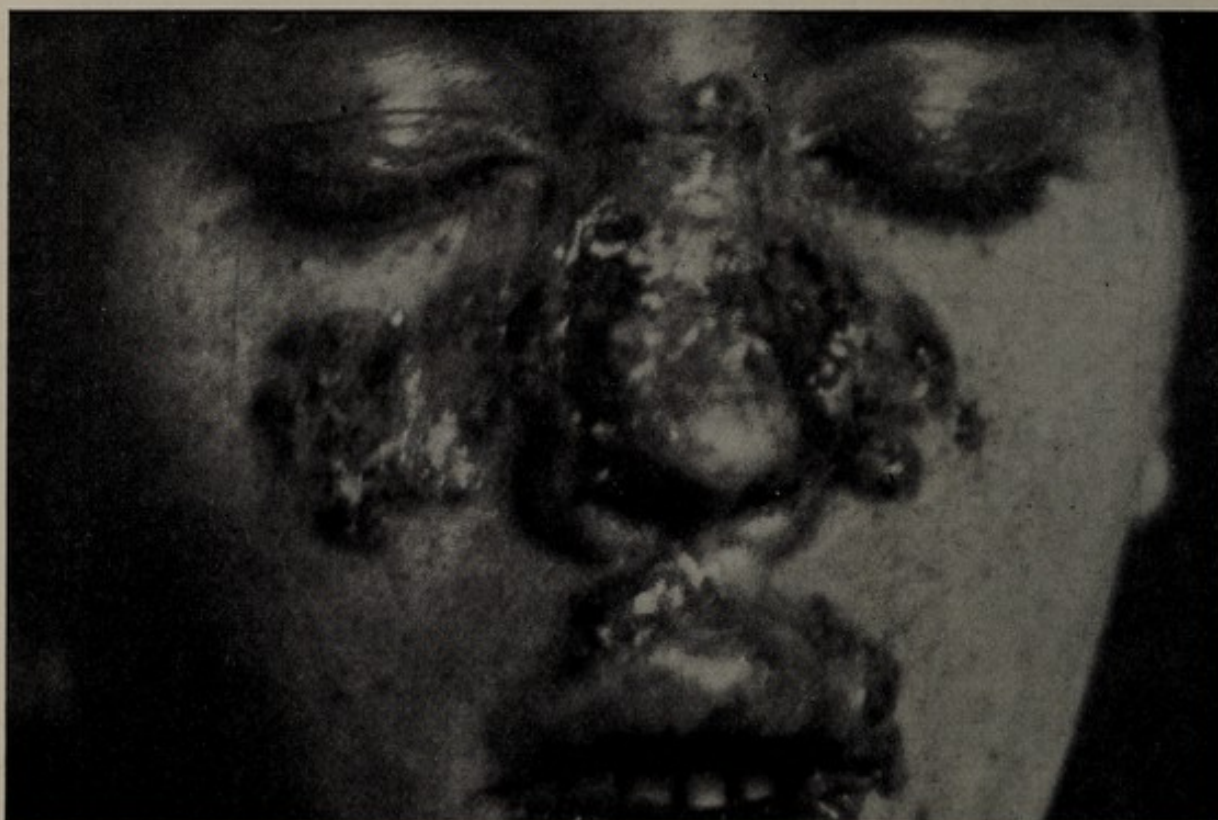

FIG. 221. Lupus vulgaris before treatment.

In this case the patient at first had much pain, the face was swelled and the surface was moistened in parts by a constant discharge of pus or serum. During the course of the treatment the pain and swelling subsided and the affected area became dry and painless.

LUPUS ERYTHEMATOSUS

Schiff¹ reports a case of lupus erythematosus which he treated successfully with the X-rays.

The patient was a woman, and had suffered from the disease for seven years. In July, 1898, when treatment was begun, the process

¹ *Fortschritte a. d. Geb. d. Roentgenstr.*, Bd. II, pp. 135-137.

had affected both cheeks, ran up on the nose, and also appeared between the eyebrows and in one ear.

The left cheek only was treated by the rays; the right cheek was left untouched as a control and for the purpose of comparison. On September 5 treatment was stopped and the condition of the face was as follows: The infiltrations on the left cheek had disappeared; the skin, except for some pigmentation which was gradually disappearing, was smooth and nearly approached the normal. The side of the face

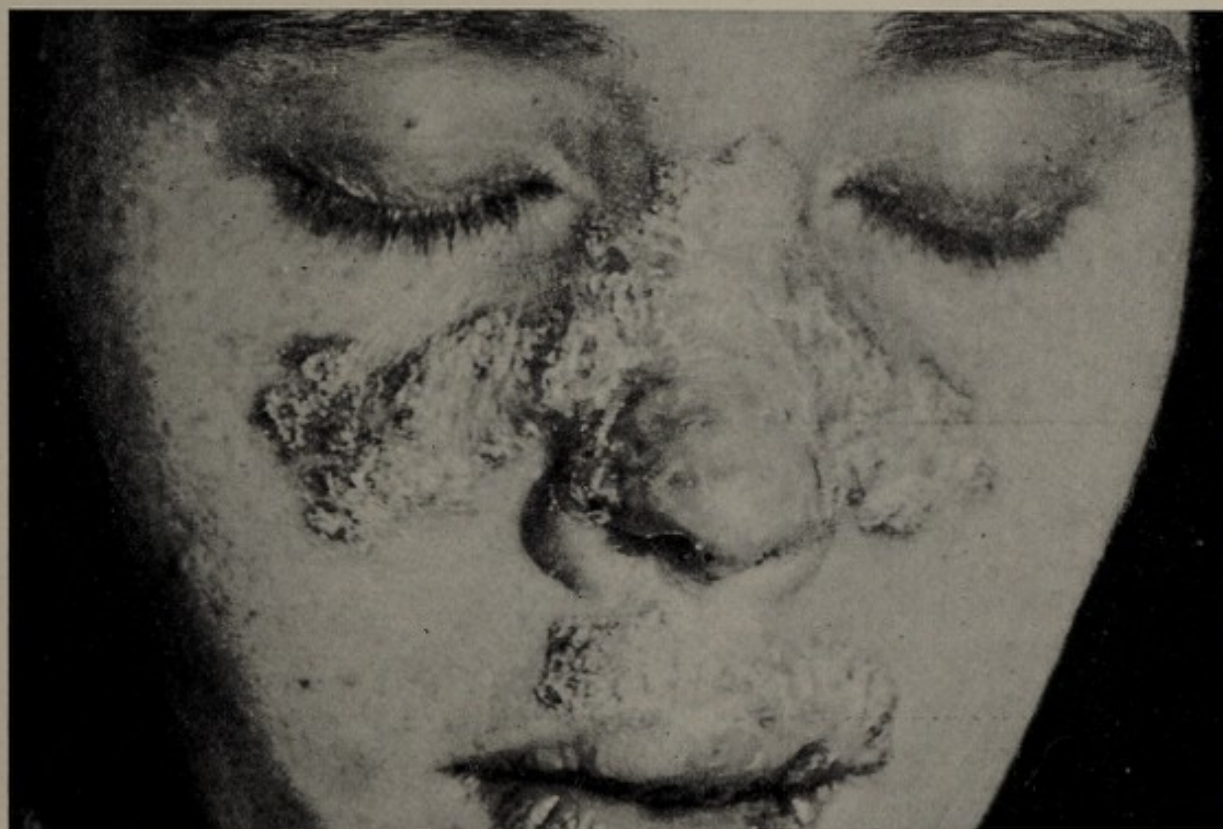

FIG. 222. Lupus vulgaris after partial treatment.

that had not been exposed to the action of the rays remained in its original condition.

As a rule, during the treatment, new vacuum tubes were used which gave out a very intense light. The tube was about 10 centimetres distant from the cheek and each sitting lasted on an average from ten to fifteen minutes.

Jutassy¹ reports the following case:—

CASE I. Lupus erythematoses nasi et faciei. Man, twenty-eight years old. Duration of disease 8 years; had been treated without result

¹ *Fortschritte a. d. Geb. d. Roentgenstr.*, Bd. III, H. 3, p. 120.

and the disease spread after the use of Paquelin's cautery, and the lupus was disseminated. This case was treated by the X-rays from October 4 to October 10, 1898. The sittings, amounting in all to $5\frac{1}{2}$ hours, were arranged in such a way that the lesion on the face, which was in the form of a butterfly, had longer treatments than the lesion on the bridge of the nose. In the beginning of November the crusts came off in large thick laminæ, but a small strip under the eye-lids and on the bridge of the nose, that had been covered by the lead mask, remained. The patient was again exposed to the rays from the 14th to the 29th of November — six sittings, in all 3 hours — so that the outer rays fell on the spots that were already free. The remaining crusts then came off, and since that time, nearly ten months, the face has been for the most part free. A recurrence took place in March, 1899, on the bridge of the nose and on the right half of the face in some places, of the size of a bean, but did not spread further. Jutassy states that the present results justify the prognosis that the healing obtained by the employment of this new therapeutic remedy will be radical.

LUPUS SIMULATING SYPHILIS

The following cases are of interest as showing the non-effect of the X-rays in these cases :—

CASE I. Kümmell reports the case of a boy suffering from a disease in which the diagnosis was lupus. He was given X-ray treatment, but as he did not improve the sittings were stopped. The disease proved to be syphilis, and under specific treatment the boy recovered.

CASE II. Gocht reports the case of a man thirty-nine years old who had had syphilis six years previously. Increasing redness of the nose during four months. Treated with the X-rays for more than a month without result. It was probably not a case of lupus vulgaris, but one of constitutional syphilitic affection.

Hahn and Albers-Schönberg¹ cite the following case as one in which the X-rays decided the differential diagnosis.

CASE III. Mr. P. There was a large ulcer on the left side of the nose, which was declared by a pathological anatomist and by a specialist to be of tuberculous origin. Hahn and Albers-Schönberg hesitated as to the diagnosis of lupus, although syphilitic infection was denied. By request of the patient's physician X-ray treatment was given, but

¹ *Münchener Med. Wochenschr.*, March 13, 1900.

no change was produced by eight sittings. The physician then gave specific treatment and the ulcer was completely cured within fourteen days. The patient then remembered an infection of some years previous.

Concentrated Sunlight and Electric Arc Light.—Finsen has used concentrated sunlight and electric arc light in the treatment of lupus. Kümmell thinks the disadvantage of this method as compared with the X-rays is the fact that with the first two only a small part can be treated at one time, whereas with the X-rays the whole tract can be treated at once. Kümmell also thinks it might be practical eventually to combine the two methods; that the large lupus tracts might be treated with the X-rays, and that when single nodules only remain the concentrated light of Finsen's apparatus might be used. Freund likewise states that Finsen's method takes a great deal of time, particularly with persons who have a strongly pigmented skin, because the pigment hinders the action of the light in the deeper layers.

ECZEMA

Hahn¹ reports two cases of eczema treated by the use of the X-rays:—

CASE I. Mrs. W. had suffered for four years from chronic eczema in both legs, which had resisted all possible therapeutic remedies. The spot on the right leg was as large as the palm of the hand. The eczema was cured by subjecting the diseased parts to the action of the X-rays twelve times. The treatment was given daily, with the exception of Sundays and of those days when the patient was prevented from coming. It lasted from twenty to twenty-five minutes, and the tube was placed at a distance of about 30 to 40 centimetres from the patient.

Later report:² Nine months afterward, slight recurrence on one leg, but the other remained well.

CASE II. Mrs. W. had had eczema for two years in both legs. On the outside of the right leg there was an area about 12 centimetres long by 6–7 centimetres broad, and on both sides of the left leg there was a patch the size of the palm of the hand. In this case also all therapeutic measures had been tried without result. The right leg was subjected to the action of the X-rays four times, and then a reaction took place, which showed itself as a redness on the spot itself and in

¹ "Durch Roentgenstrahlen geheiltes chronisches Ekzem," *Fortschritte a. d. Geb. d. Roentgenstr.*, Bd. II, pp. 16–18.

² *Münchener Med. Wochenschr.*, March 6, 1900.

the immediate neighborhood; but this redness yielded in three days on the application of bandages wet with lead water. The X-rays were then again applied to the right and also to the left leg, and the eczema was cured. Each individual treatment in this case was of the same duration as in Case I, and the tube was at the same distance from the patient.

Later report.¹ Slight recurrence six months afterward on the left leg, which yielded to treatment with salve.

Hahn also gives a case of chronic eczema treated by Albers-Schönberg with the X-rays, which finally involved the whole back of the hand and which had been treated without result. The treatment with the X-rays began on February 9, and was given daily for half an hour. On February 11 there was a slight reaction. On March 28 the hand was completely well. On April 19 a few eczematous pustules the size of the head of a pin appeared on the back of the hand, which made the diagnosis of chronic eczema certain.

The two following cases of Albers-Schönberg increase the evidence already adduced in this direction as to the beneficial effect of the X-rays in cases of eczema:—

CASE I. Chronic impetiginous eczema of the head. Boy five years old; had been treated for four years without result. The whole face, the head where the hair grew, and the neck were changed into a surface covered with scabs and crusts with exudation; the face was bloated, the eyelids swollen. To demonstrate the action of the X-rays the face, head, and neck were covered with a tinfoil mask, out of which was cut an oval hole 9 × 5 centimetres in size, and a portion of the cheek only was thus left exposed. After a treatment of about twenty minutes the part of the cheek exposed presented a changed appearance; it was dry and remained dry. After a few more sittings a lively peeling of the epidermis set in on the part treated. The rest of the face and head and neck were then systematically treated, with equally quick and good results. The exudation ceased and no more scabs formed. The dry skin began to peel off, islands of normal skin arose and increased in size. After thirty treatments the child showed traces only of the eczema. The bloating of the face had completely disappeared, and the general condition was good. The recovery, when the case was reported, was going on well.

I find a case given by Albers-Schönberg and Hahn in a later article,²

¹ *Münchener Med. Wochenschr.*, March 6, 1900.

² *Ibid.*

which seems to be a further report of this same case. After a month the eczema appeared on the throat, but the head and face remained almost entirely well. The sittings were then renewed, but only a transient improvement took place. Later, the boy had a treatment of sulphur baths and vaseline, and was completely cured; after five months the eczema returned again, but was again (when reported) improving under treatment.

CASE II. Child. Extensive impetiginous eczema of the face and head. Duration of disease six weeks.

Ten to twelve X-ray sittings were given and no reaction was produced. The face healed quicker than the head under the hair. The hair came out, but in about a month had grown again. Child completely well a year later.

The prominent characteristic during the healing process of these two cases was the extraordinary quickness with which the X-rays worked. Albers-Schönberg characterizes the effect as follows: (1) cessation of the exudation; (2) drying up of the skin; (3) peeling.

Jutassy¹ reports the following case, which is instructive as a warning, because the treatment was continued longer than proved to be necessary, and a dermatitis was set up:—

Eczema chronicum manus. Man twenty-nine years old. On the back of both his hands. Disease of seven years' duration. Treated medically without result. X-ray treatment given from July 25 to August 3, 1898, eight sittings, the whole time amounting in all to two and a half hours, after which upon the intact skin reddish brown erythema appeared, and the lesions arising from the eczema came off. On the metacarpo-phalangeal joint of the hand only, a large crust the size of the palm of a child's hand remained, therefore this portion was X-rayed again on August 8. It proved, however, to be superfluous, for a purulent dermatitis set in, and while the skin of the left hand and the other part of the right hand got well in a few days, the complication took about a month to heal, and a smooth white scar was left. Since then, thirteen months, there has been no recurrence.

The most striking case of the usefulness of the X-rays in the treatment of acute eczema which I have had, is the following:—

CASE I. B. J. A man fifty years old, who had suffered from this disease every winter for several years past, and who formerly required to be treated some weeks or months before he obtained relief. This

¹ *Fortschritte a. d. Geb. d. Roentgenstr.*, Bd. III, H. 3, p. 120.

year, on the 19th of the month, he came to see me and stated that the night before he had had intense itching and redness of the skin on the outer part of the left upper arm, and that he had waked in the night to find his night-dress saturated with exudation from this area. When I saw him there was a red area 15 centimetres long and 10 centimetres wide, which was rough but not moist. The intense itching of this area was extremely hard to bear.

I made a single exposure of the diseased tract to the X-rays, with the exception of a small portion that was excluded as a control, at three o'clock, P.M., for ten minutes, the target of the vacuum tube being at a distance of 10 centimetres from the skin. In the evening the itching had decreased, and on the following morning there was no itching and absolutely no discomfort over the part which had been exposed to the X-rays.

On the 21st of the month, forty-eight hours after the first exposure to the X-rays, the skin was still rough, but there was no pain and no itching. The small portion of the eczematous area which had purposely not been exposed to the rays was, however, still red, swollen, and itching, and this was now subjected to the X-rays for eight minutes; likewise a reddened area on the inside of the left arm, which itched somewhat, for six minutes.

On the 23rd of the month there was a slight redness and irritation on the inner side of the left arm, and this tract was, therefore, exposed to the X-rays for ten minutes. On the 26th of the month the patient returned to state to me that he had been perfectly well since the treatment, and there had not been the slightest itching. The area first affected, on the outer part of the arm, which was 15 centimetres long and 10 centimetres wide, was still rough, but gave him no discomfort whatsoever.

CASE II. X. Y. had chronic eczema of the back, neck, and arms, with much itching in some portions, especially about the elbows. He had been treated six weeks by the usual method. I tried to relieve him by means of the X-rays. After the first exposure the patient thought the itching was much diminished, but it returned on the second day, and further daily exposures to the X-rays for several days did not give him any relief. It is not improbable that, if I had then known better how to use the X-rays in this disease, I might have been able to help him. Possibly the parts treated by the X-rays healed subsequently under ointments more rapidly than they might otherwise have done; but I am not satisfied that the X-rays were of any advantage to this patient.

Hahn and Albers-Schönberg¹ draw the following conclusions from fourteen cases of eczema:—

In eczema with exudation, the latter dried up after from one to four sittings, and remained dry. In eczema with itching, the latter ceased often permanently after one sitting. In dry eczema the influence of the X-rays was also favorable; on an average, after the fourth sitting a striking change appeared; the spots that had looked as if they were dead took on a fresher appearance; the surface became smooth, though somewhat red, and the crusts did not form again.

Small tracts of eczema were cured after a few sittings and did not need further treatment; if the eczema was more extensive a longer course of treatment was necessary; but in all cases, even the most obstinate, they obtained a good result. In cases of recurrence the X-rays were not so effective; more sittings were necessary; the disease did not react so promptly. On the other hand, medical treatment, which had been absolutely useless before the employment of the X-rays, produced its proper results after the sittings and completed the cure that had been initiated by the rays. The following case is illustrative:—

CASE I. Miss M. Eczema with itching and fissures on both hands. Duration of disease one year; constantly under treatment.

Three sittings with the X-rays. After the first sitting of twenty minutes' duration the itching disappeared. Six months later a recurrence. The itching was again stopped after one treatment. Great improvement in the disease after the tenth treatment. For reasons personal to the patient the X-ray sittings were abandoned, and salve was applied with good result, although before the use of the X-rays it had been employed without effect.

The conclusions arrived at by Hahn and Albers-Schönberg² after the treatment of twenty cases of lupus, one of favus, and two of psoriasis vulgaris, in addition to the fourteen cases of eczema mentioned above, are also of special interest:—

1. The X-rays work surely and favorably in lupus and other skin diseases.
2. They cure absolutely the eczema which accompanies lupus, and the thickening resembling elephantiasis arising from the same, and therefore are adapted to the treatment of surfaces and deeper parts.
3. Recurrences are not excluded by this method any more than by any other method.
4. The X-ray treatment does not exclude other methods, but rather supplements them, or may be combined with them.

¹ *Münchener Med. Wochenschr.*, March 6 and 13, 1900.

² *Ibid.*, March 13, 1900.

5. What is true of lupus is also true of eczema and of other skin diseases, which, however, need further study.
6. By appropriate treatment and technical skill, dermatitis, excoriation, gangrene, etc., can be avoided.

NÆVUS FLAMMEUS OR VASCULOSUS

The following case, reported by Jutassy,¹ is of such interest that I give it in some detail:—

J. E., twenty-two years old; cabinet-maker; congenital teleangiectasia or nævus vasculosus or flammeus faciei.

The process affected almost the whole right half of the face. The teleangiectasia did not rise above the level of the skin on the forehead, but on the cheek and nose livid growths from the size of hempseed to that of beans could be seen, so that the teleangiectasia was combined with angioma.

The color varied from the color of cinnabar to dark purple; the edges and the whole of the forehead that was involved was lighter than the centre of the nævus; the nose and the skin about the eye appeared particularly livid. The patient was of middle height, well developed, and healthy. The hair of his beard and mustache was weak and strikingly scanty on the affected parts.

The treatment was begun in October, 1897, but only a small part was treated at first as an experiment. The head and neck were protected by a thick piece of lead in which a hole 3 by 4 centimetres was cut. Thus not only a portion of the nævus was exposed, but also a healthy piece of skin 3 to 4 millimetres broad, as a control experiment.

From October 6 to 12, 1897, the patient was exposed in all four and a half hours to the X-rays, in eight sittings, and then a slight hyperæmia showed itself on the healthy skin, which in the course of ten days became dark brown in color and the nævus became dark red. At the end of October the epidermis came off in small scales, and by the use of oxide of zinc salve the slight dermatitis was healed entirely by November 10.

The nævus part of the skin that had been subjected to the X-rays was essentially paler, and showed a marked contrast between its color and that of the nævus to which the X-rays had not been applied, so that the experiment was considered a success.

¹ *Fortschritte a. d. Geb. d. Roentgenstr.*, B. II, 1898, pp. 213-216.

Jutassy then produced a more severe dermatitis. The X-rays were applied from November 20 to 30, and to prevent the hair of the head and beard, and the eyebrows and eyelashes, from falling out, a lead mask was put on which left the cheek, nose, and forehead uncovered. The nævus was so exposed to the rays in eleven sittings that the centre of the light alternately touched the cheek, then the nose, and lastly the forehead; so that the cheek and forehead were subjected to intense light for from five to ten hours, and the nose four hours; altogether the face was exposed to the light fourteen hours, until the normal portion of the face that was left unprotected by the lead, for a control, showed an erythema. The dermatitis developed until December 10, and gave all the characteristic features of an inflammation. The patient complained of trouble in the bones of his face at the articulation of his jaw. In the next two weeks an eczematous excoriation was visible, which later passed into a pustular eruption. The epidermis largely scaled off and the corium lay exposed.

On December 25, the patient went to St. Roch's Hospital, where he was treated first daily, then every two days, and later, every three days, with boric-vaseline. The new skin formed tolerably quickly toward the centre. On January 10, 1898, the skin of the nose was completely healed. At the beginning of February, 1898, the inflammatory process had entirely disappeared. The nævus, except in the protected parts, that is, in the neighborhood of the eye, the upper lip, and the skin of the head under the hair, had disappeared; there was no trace of angioma. Over the part that had been exposed to the X-rays was a soft smooth scar, rose-red in places, but which scarcely differed from the normal skin. On the edge, only, was the yellowish brown hyperpigmentation marked. Where the head and beard were unprotected by the lead a little hair fell out.

Nearly a year and a half after the treatment was given the skin of the forehead and nose could scarcely be distinguished from the normal skin. The cheek where the livid spots had been showed still a rose-red color. The hyperpigmentation was essentially diminished by medical treatment, but did not entirely disappear, therefore Jutassy thinks the pigment was probably not in the outer skin, but in the upper layer of the cutis. The new skin was thin and susceptible to changes in the temperature. In winter it had a deeper shade of rose-red, whereas in warm weather it almost disappeared. Two photographs of the patient are given, one before and one after treatment.

SYCOSIS AND FAVUS

Freund and Schiff,¹ in treating sycosis and favus by the X-rays, were guided by the idea that by removing the hair, which they looked upon as a foreign body, they would eliminate every exciting cause of inflammation in the outer follicular tissues, the cutis, and the papillæ. And in fact after the removal of the hair they saw no new pustules form in the cases of sycosis; the secretion and crust formation ceased completely. They also noticed that, before the removal of the hair, the appearances due to acute inflammation were much less prominent, and the most striking inflammatory infiltrations in the neighborhood of the parts of the beard that were affected grew more level with the surface and disappeared. At this stage the hair that was pulled out showed dry roots without any bulbous swelling, whereas before the roots were surrounded by a glossy infiltrated sheath. At the same time the subjective troubles of tension and heat, from which the patient had suffered, yielded.

When treating the favus they proceeded very energetically. All the hair on the head, whether affected apparently with favus or not, was exposed to the X-rays, and the treatment was not stopped until the skull was completely deprived of hair. This was done with the idea of destroying any hidden parasites by which, eventually, the neighboring parts might be affected. The repeated treatment was not intended to prevent the hair of the head, or of the beard from growing again, and it did not.

Freund and Schiff state that with the methods of treatment carried on by them no dermatitis occurred. As soon as any redness appeared which deviated in the slightest degree from the redness due to the hyperæmia already present, the treatment was stopped. After from seven to eleven sittings the hair was loosened and fell out, or was easily pulled out by the fingers. The redness, together with all other indications of disease, disappeared in the course of the next ten to twelve days.

The method was as follows: The apparatus used was a Ruhmkorff coil with a spark-length of 30 centimetres. It was excited by means of six storage cells (12 volts). The resistance of the tube never exceeded 10 to 15 centimetres. The interruptions did not follow so quickly upon

¹ "Weitere Anwendungsgebiete der Radiotherapie," *Fortschritte a. d. Geb. d. Roentgenstr.*, Bd. III, H. 3, pp. 109-110.

one another but that a flickering of the light could be plainly seen. The tube at first was at a distance of 15 centimetres from the part treated, but the distance was gradually reduced to 5 centimetres. The sittings, which at first lasted only five minutes, were increased to fifteen minutes. The healthy skin in the neighborhood of the parts treated was protected by sheets of pasteboard covered with lead .5 millimetre thick.

CASE I. F. S., twenty-six years old. Sycosis of the beard. Duration of disease four years. On both cheeks where the hair was growing were numerous nodules and pustules, pierced by a hair and often surrounded by a scab. The roots of the hair were swelled with purulent matter. The upper lip was free from disease. The treatment was begun on April 18, 1899. On April 25 the hair was loosened and came out when slightly pulled. Slight hyperæmia. After another week all reaction disappeared. The spots that had been affected by sycosis were smooth and white.

CASE II. J. H., *eczema chronicum barbæ*, *blepharitis bilateralis*. Duration of disease over fifteen months. When the crusts came off there were diffuse moist areas.

Treatment was begun on the left side, May 18, 1899, and after eleven sittings the hair fell out. After five sittings the exudation had completely ceased. The blepharitis disappeared at the same time as the sycosis. A slight erythema appeared and disappeared after six days. June 7 treatment was begun on the right side, and was brought to a close on June 19. October 2 the patient had a thick, full black beard again, which was in a perfectly healthy condition.

CASE III. J. H., twenty-eight years old. Sycosis of the upper lip and chin. Duration of disease six months. A photograph of the patient is given before treatment, which was begun on February 28, 1899, another after the conclusion of the treatment on March 17, 1899. In the second picture the mustache was gone, and the face looked smooth. On September 4, the mustache had grown out again. On the chin were isolated inflamed follicles, but after three sittings these were again normal.

CASE IV. J. H., ten-year-old schoolboy. *Favus scutularis capillitii* of seven years' duration. On April 8, 1899, treatment was begun on the left half of the back part of the head. The hair fell out April 22. Then treatment was begun on the skull in the region of the forehead, and was brought to an end on May 5. At last the right half of the back of the head was treated. The whole treatment ended May 26.

After the treatment was over, the use of carbolanolin salve was prescribed for fourteen days. October 2 the skin on the head was perfectly healthy and the hair that had come out had been replaced by a new growth.

Sycosis Non-Parasitaria. — Gassmann and Schenkel¹ report the following case: —

CASE I. G. B., thirty-six years old. Entered the hospital November 22, 1897. Disease of thirteen years' duration. Had been treated medically but with no, or only transient, result.

X-ray treatment was begun on April 12, 1898, and was given daily for twenty minutes, with the tube at a distance of 20 centimetres. After the ninth sitting the treatment was stopped on account of dermatitis.

The folliculitis disappeared, and a hairless and comparatively normal skin remained.

December 6. The patient wrote that the parts treated had not changed, but had remained smooth and healed.

HYPERTRICHOSIS

Healthy but Superfluous Hair. — Jutassy² has treated forty-four cases of hypertrichosis with the X-rays. In these cases he endeavored to produce a reaction that would lead directly to depilation, and he also tried the method which Schiff and Freund pursue, that is, by the accumulation of many slight inflammations to produce a chronic inflammation, and thus a chronic degeneration of the papillæ. He states that the production of a lasting alopecia was brought about without any noteworthy reaction. His observations taught him the need of proceeding cautiously.

Jutassy states that the reaction appears in young people more quickly and more completely than with middle-aged persons. With old people he had had no experience. The skin of blondes reacts more quickly and more vehemently than that of brunettes; strong, well-developed hair comes out in proportion easier than the lanugo hair. The reaction is greatest where the centre of the light falls; therefore, the vertical rays are the most efficient. The intensity of the reaction corresponds to the intensity of the light used, the distance of the tube, and the length of exposure.

¹ "Ein Beitrag zur Behandlung der Hautkrankheiten mittelst Roentgenstrahlen," *Fortschritte a. d. Geb. d. Roentgenstr.*, B. II.

² *Fortschritte a. d. Geb. d. Roentgenstr.*, B. II, pp. 194-195; B. III, H. 3, p. 119.

I give one case reported by Jutassy:—

CASE I. Hypertrichosis totalis faciei et colli. Woman twenty-five years old. The cheek, chin, and neck were covered with close, coarse, black hair, but there was not much on the upper lip. The face was treated by the rays from the 3d to the 14th of November, 1898; ten sittings being given, three and a half hours in all. December 2 with the complete removal of the hair, a brownish red erythema set in. The patient went away with the understanding that as soon as the erythema disappeared she would return for further treatment. The erythema disappeared in the beginning of the new year, 1899, but the patient did not come back until February, and then there was a slight recurrence, but only about the corners of the mouth, and that to a much less degree. X-ray treatment was repeated on February 5, 6, 7, — one and a half hours in all, — after which an erythema showed itself and this time more quickly. After the removal of the hair a recurrence took place, but only in the neighborhood of the left corner of the mouth, and the hair was slight in quantity, so that another repetition of the treatment seemed superfluous, the more so as these few hairs could be removed easily in half an hour by electrolysis.

Freund states that treatment should be stopped when the skin appears of a light red or brown color, and the hair seems loose. According to his experience this occurs in hypertrichosis after 17–25 sittings; in sycosis and favus in 7–13 sittings. Hypertrichosis needs, he thinks, a second course of treatment, consisting of 3–5 short daily sittings, which should be given after an interval of eight weeks. If this second course of treatment is omitted, the hair usually returns in about two and one half months, as generally the first treatment does not suffice.

LYMPHOMATA COLLI

Gocht¹ reports the following case:—

CASE I. A man forty-six years old had been operated on repeatedly, and the last time the wound had not healed well, as the beard kept up a continual irritation. To get rid of this hair he was given daily treatment with the X-rays. The sittings began on April 23, and on June 8 the hair on the chin and neck had all disappeared, and the wound had closed smoothly and well. After two months and a half no hair had grown out, though the skin was more delicate than before. It was otherwise normal. The removal of the hair gave the desired relief.

¹ *Fortschritte a. d. Geb. d. Roentgenstr.*, B. I, p. 17.

PSORIASIS

Albers-Schönberg states that in this disease it has been observed that the scales can be easily pulled off without bleeding, after four sittings, and adds that if this is the case an interval between the sittings is indicated, for the skin that is affected with psoriasis is inclined to excoriation when subjected to the X-rays.

ACNE

Acne vulgaris.¹ — Jutassy observes that he and others have remarked the cure of acne vulgaris in cases where the skin was treated by the X-rays for some other reason than the acne.

Acne rosaceæ.¹ — Jutassy also reports that he is experimenting in his laboratory with acne rosaceæ, and states that Schiff and Freund think that the use of the X-rays is indicated in obstinate acne and comedones.

TUBERCULOSIS

Pulmonary Tuberculosis. — Hahn² reports that a patient suffering from chronic pulmonary tuberculosis was exposed by Rieder to the X-rays, but with no encouraging results.

Dollinger³ states that Bergonie and Mongour report two cases of acute phthisis in individuals who were in bad condition owing to poor nourishment and the excessive use of alcohol. The result was negative. In a case of lingering pulmonary tuberculosis the treatment produced very slight results; in a second case there was a rapid improvement in the general condition and the strength and appetite increased, but the local process remained unchanged; a third case improved generally and locally during the first month of treatment, and then severe digestive disturbances appeared.

Dr. Sinapius, in August, 1897, published a pamphlet in which he gives an account of his use of the X-rays in the treatment of pulmonary tuberculosis. He cites a number of cases in which he states that excellent results have been obtained, but the diagnosis was not established in these cases and his statements are not convincing.

Laryngeal Tuberculosis. — The successful treatment of lupus by the X-rays should lead us to try them in laryngeal tuberculosis.

¹ *Fortschritte a. d. Geb. d. Roentgenstr.*, B. III, H. 3, p. 119

² *Ibid.*, B. III, H. 1, p. 36.

³ *Ibid.*, B. II, pp. 72-73.

Tuberculous Elbow-joint and Wrist. — Southgate Leigh gives a case of a tuberculous elbow-joint, which is reported by Werner,¹ that was exposed to the X-rays for two hours from two to three times a week. After twelve hours' exposure the inflammation had disappeared, and the patient had been free from recurrence for eighteen months when reported upon.

Dollinger² states that Kirmisson reports a case of a tuberculous wrist which was much improved by daily sittings of ten minutes' duration, for two and a half months, and was cured completely by elastic compression following the X-ray treatment.

A Case of Tuberculosis in a Wound caused by a Burn.³ — Dr. Ivar Bagge, of Göteborg, Sweden, reports a case of a man, J. B., forty-seven years of age, who had always been healthy and had no tuberculous history. When J. B. was thirty years old he burned the left back and front of his chest with boiling water. He went to no physician, but tried to heal the wound himself, and meanwhile he worked often in a family in which two of the members were suffering from tuberculosis. The wound healed for the most part with scars, but the unhealed parts were covered with granulations and crusts; these never healed completely during the seventeen years; they dried up and then opened again, suppurated and increased. Finally the wounds became so bad that the patient could not work, and therefore in August, 1899, he went to the hospital for treatment, and remained there almost five months. During this time he took a cold in his head, and he had a habit of putting his fingers into his nose, and likewise of picking off the crusts from the wounds on his chest. Shortly after he recovered from the cold a wound appeared in the mucous membrane of the right nostril. The nostril swelled up, and an elevation the size of a bean could be seen on the right side of the nose. This elevation soon ulcerated and the new wound increased in size. The upper lip became affected and the trouble spread to the right cheek. As these wounds resisted the energetic treatment applied in the hospital, the patient was sent, in January, 1900, to Dr. Bagge, who applied the X-rays with the result that the wounds on the front and on the back were healed in the course of three weeks, and the bandage could be taken off.

Dr. Bagge states that the striking point in this case is the fact that

¹ *Fortschritte a. d. Geb. d. Roentgenstr.*, B. III, H. 3, pp. 122-123.

² *Ibid.*, B. II, p. 72.

³ *Ibid.*, B. III, H. 6, p. 218.

the X-ray treatment that was applied only to the front of the chest likewise healed the larger ulcerations that were on the back, as well as those under the axilla, as quickly as those below the clavicle. This is only one case, and the good results may have been due to some other cause than the X-ray treatment. Dr. Bagge mentions, in connection with this case, two cases that he treated of lupus of the hard palate, with ulcerations. The mucous membrane of this palate was healed, although the rays had passed both through the soft and hard parts of the face.

TRIGEMINAL NEURALGIA

Gocht¹ reports the case of a man seventy-six years old, who had suffered from trigeminal neuralgia of the right side for from ten to eleven years, and the pain came on daily with such severity that large doses of morphine had been used for years. The patient went to Dr. Gocht for surgical treatment, but instead was treated daily for half an hour with the X-rays, as an experiment. From the second day on the patient had no more pain and required no more morphine. On the sixth day he had a very slight attack. He was then obliged to go away, but a week later returned. The attacks had not returned, but the right cheek had reddened, and the hair upon it, as well as upon the upper lip and chin, had almost entirely come out. Somewhat later the pain returned, but to what extent is not known.

NEW GROWTHS

For some time past attempts have been made to treat various forms of new growths by means of the X-rays, and recently it has become a recognized method of treatment for external forms in the hands of those who have learned something of its use in this field; among external forms I include those of the breast, and of any part which is easily accessible from the exterior, such as portions of the tongue, the larynx, and the cervix uteri, if the disease is in a very early stage.

When more is known about the physics of the radiation from the vacuum tube, we may be able to separate the beneficent from the harmful radiation and thus be enabled to bring the deep-seated cancers within reach of this method without risk of burning the patient. It now seems as if the radiation from a vacuum tube had separate and

¹ "Therapeutische Verwendung der Roentgenstrahlen," *Fortschritte a. d. Geb. d. Roentgenstr.*, B. I.

distinct actions. First, prompt relief from pain takes place, second, the process of repair begins to be evident, and third, if the treatment has been pushed vigorously, dermatitis may follow.

I will refer briefly to some of the early attempts to treat carcinoma by means of the X-rays, and then take up at more length the subject of the treatment of external new growths.

Carcinoma of the Breast. — Gocht¹ reports the two following cases of cancer of the breast; first that of a woman fifty-four years old. She was treated daily for six days, and felt better subjectively, and the pain almost entirely disappeared. On the seventh day she had a sudden rise in temperature, and erysipelas developed, which spread over the back and breast and the whole right arm. A few days afterward there was profuse bleeding from the ulcerating carcinoma, which was followed not long after by death.

Second a patient forty-six years old, where the cancer had been operated on several times, the last time being in 1896. Treatment with the X-rays was begun in November, 1896. The pain subsided quickly, but when the sittings were stopped because the apparatus was out of order for about twelve days, returned, so that morphine was again necessary. As soon, however, as the sittings were renewed, the morphine was again omitted. In January and February, 1897, the cancer increased, and in the middle of the latter month the patient was no longer able to be carried to the X-ray room. The pain returned and morphine was again used. The patient died February 26, 1897.

Carcinoma of the Stomach. — Despeignes² has treated a patient with a carcinoma of the stomach by the X-rays. The sittings were given twice a day for half an hour, with the result that a week later the pain had diminished, the tumor had considerably decreased in size, the yellow color of the skin had almost disappeared, and emaciation made no further progress.

External Forms of Cancer. — Johnson and Merrill, in an excellent paper in the *Philadelphia Medical Journal* for December 8 and 15, 1900, give the results of their use of the X-rays in carcinoma and describe carefully six cases. They arrive at the conclusion that to produce a curative effect a so-called X-ray burn must be set up; and they state that the static machine and smaller coils are not applicable for the use of the X rays in this disease.

¹ *Fortschritte a. d. Geb. d. Roentgenstr.*, B. I., p. 16.

² *La Semaine Medicale*, No. 37, 1896, p. cxlvi.

They select a tube of low resistance, "but before using it on a patient its burning time is determined. This is very important, for we have found that, of two equally soft tubes operated on the same current, one may produce a burn in three minutes, while with the other an exposure of thirty minutes may be necessary to effect the same result. . . ."

"It is our object to produce a mild inflammation and pigmentation in and about the diseased tissue, gradually increasing its severity, until we have a burn of such depth that it will require six weeks to heal on

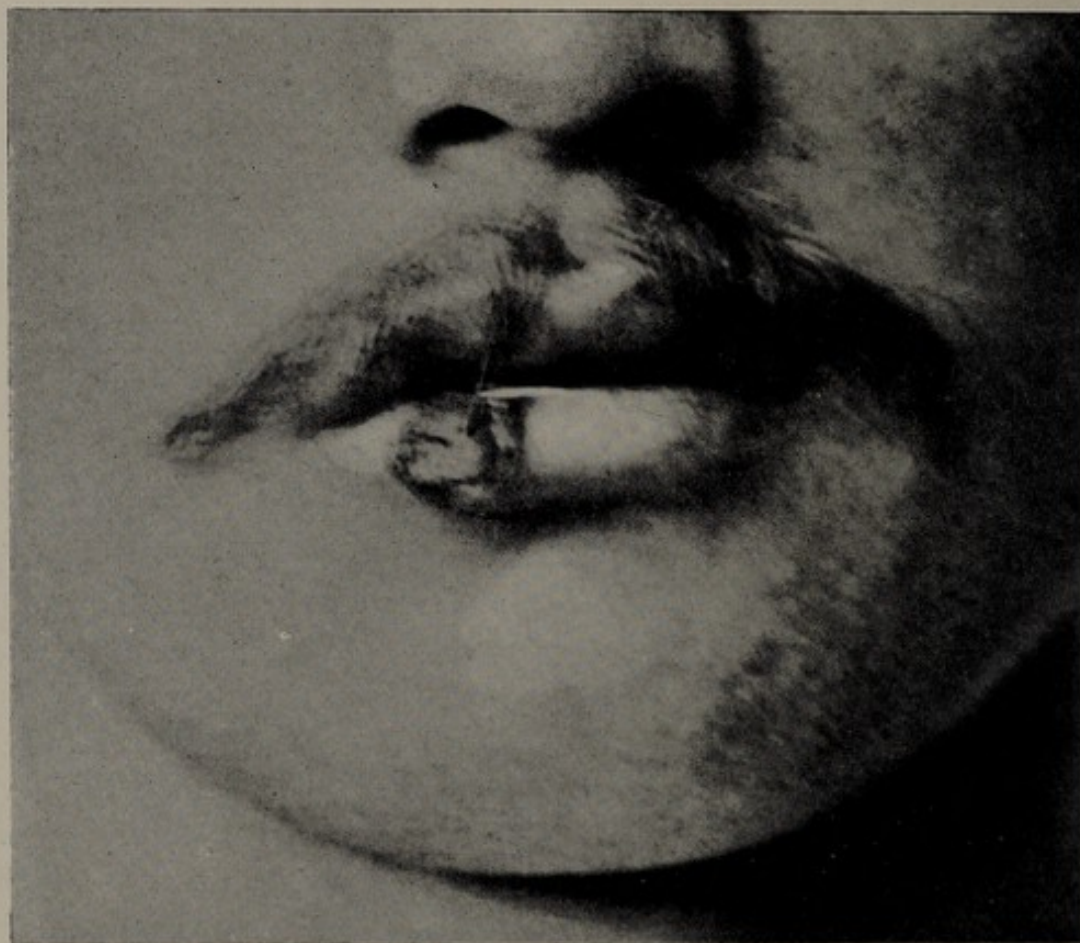


FIG. 223. H. N. Epidermoid cancer of the lip before treatment with the X-rays. Front view.

the normal skin. The treatment is then suspended for a month, and if a complete cure is not in prospect at the end of this time, the process is continued over those parts which still resist."

It is well known that cancer, especially of the face, may yield, not only to surgical interference, but also to the effect of caustics, which are not infrequently used to treat it; and if relief is given only by the burning action of a vacuum tube, there are other methods of cauterizing a diseased part which are much simpler. Until this caustic action

is excluded, it is not demonstrated that we have a therapeutic agent that is novel in its action for the treatment of face cancer.

My own experience¹ in using the X-rays for the treatment of cancer differs from the above and has demonstrated to me that in certain forms of cancer, the pain, odor, discharge, and growth disappear, and that this can be brought about without pain or inconvenience, or a burn.

Many of my cases have been treated with a vacuum tube that was

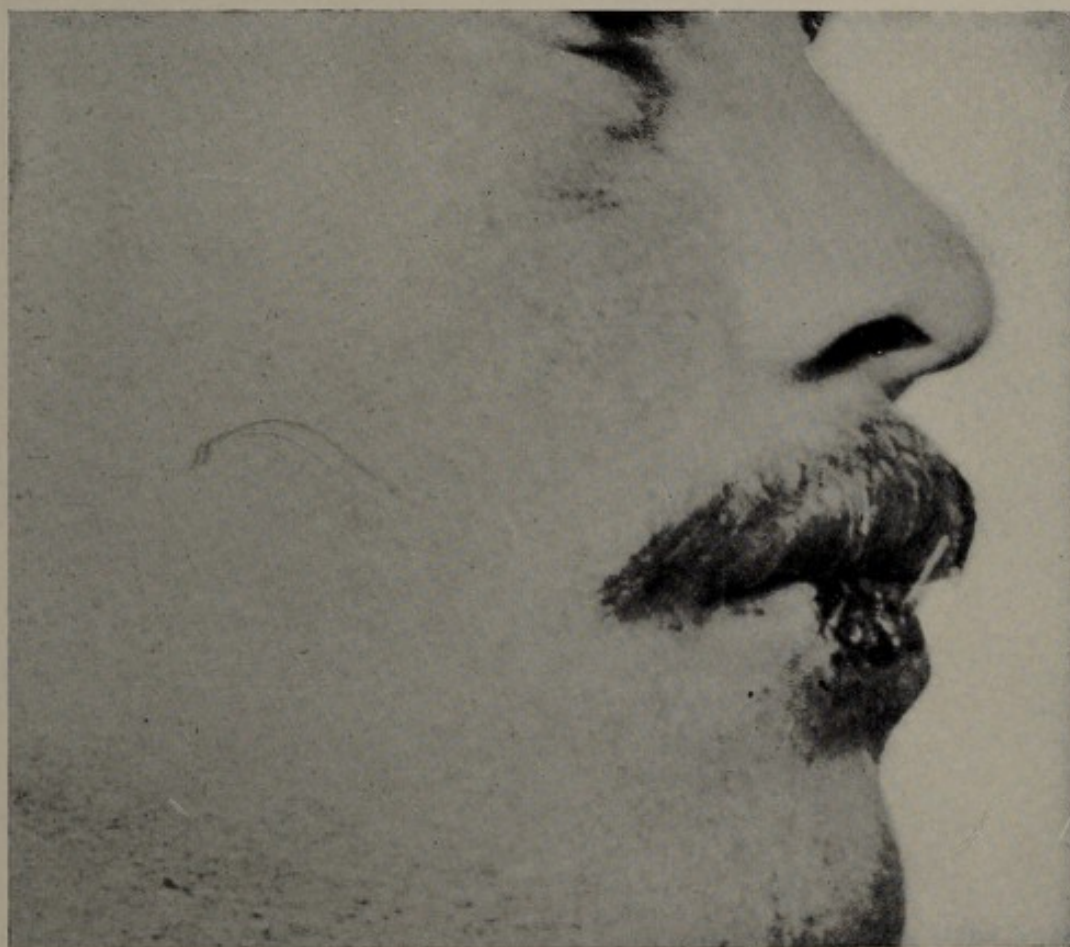


FIG. 224. H. N. Epidermoid cancer of the lip before treatment with the X-rays. Side view.

excited by a static machine. As examples of the good effect of this treatment, I will cite the following cases:—

CASE I. H. N., a young man twenty-five years old, who had been a patient of Dr. H. L. Burrell, and by him was kindly transferred to my service, gave the following history: He had always been well and strong. Three months ago he noticed a small crusted sore on the right side of the lower lip, which he thought was a coldsore. It, however,

¹ "Note on the Treatment of Epidermoid Cancer by the Roentgen Rays," *Boston Medical and Surgical Journal*, January 17 and April 4, 1901.

kept up a constant scabbing, and slowly grew larger. There was no attendant pain, but it had grown "fairly rapidly" during the past two weeks. The patient came to the hospital for operation.

A small bit of the growth was removed and submitted to Professor Mallory, assistant pathologist at the Boston City Hospital, for examination. He reported that the growth was an epidermoid cancer. The

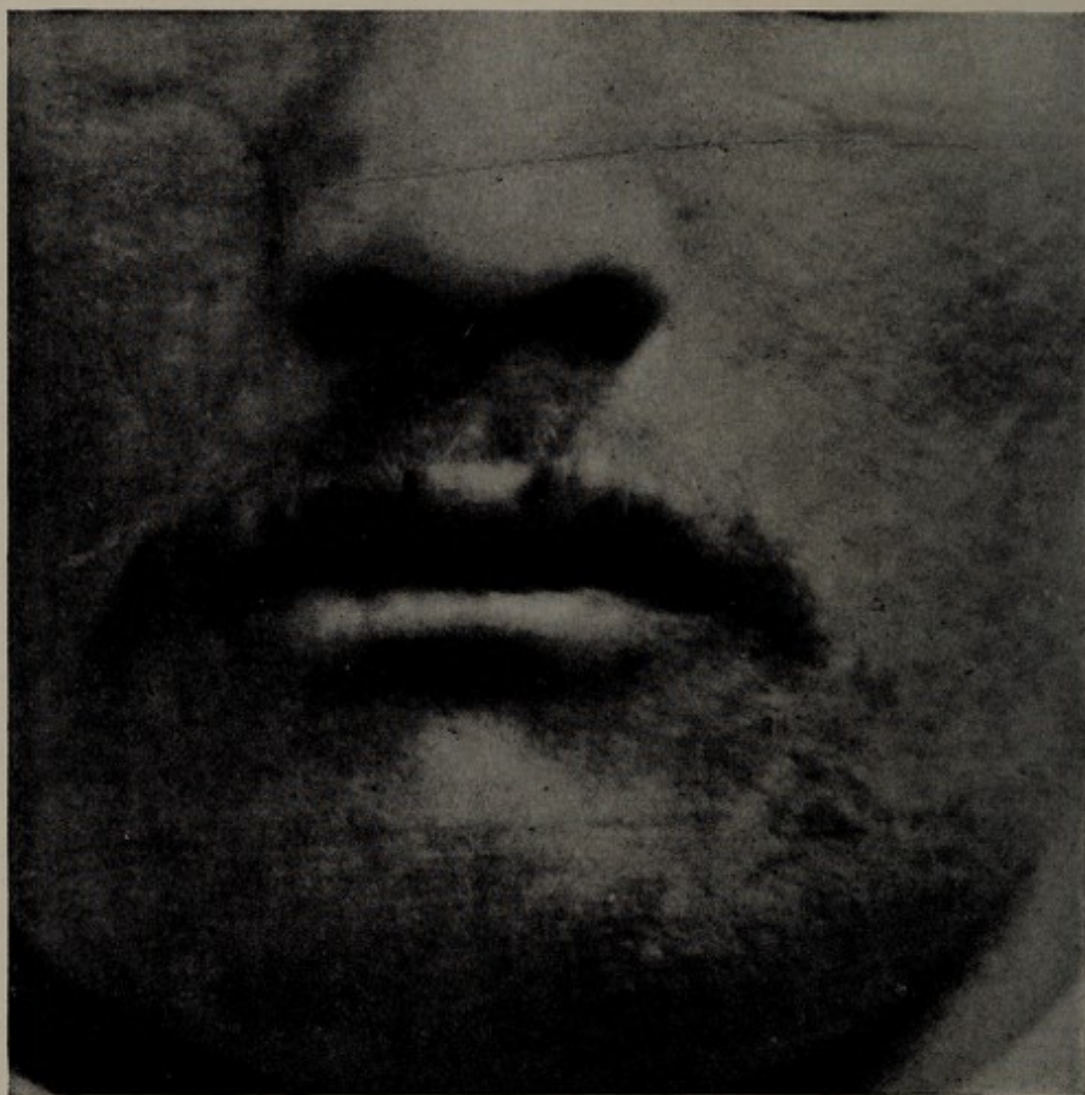


FIG. 225. H. N. After treatment with the X-rays. Front view.

lesion on the right half of the lower lip was 1.5 centimetres long and about 1 centimetre wide; it was crusted and indurated. A small gland was felt under the inferior maxilla, just to the right of the symphysis. Recently the patient had complained of some pain in the lower lip near and around the lesion.

The first exposure to the X-rays was of seven minutes' dura-

tion, and the patient was placed about 12 centimetres from the target of the tube. The resistance of the tube was equivalent to 1.5 centimetres of air. During the ensuing week daily exposures of five minutes' duration each were made. All the parts except

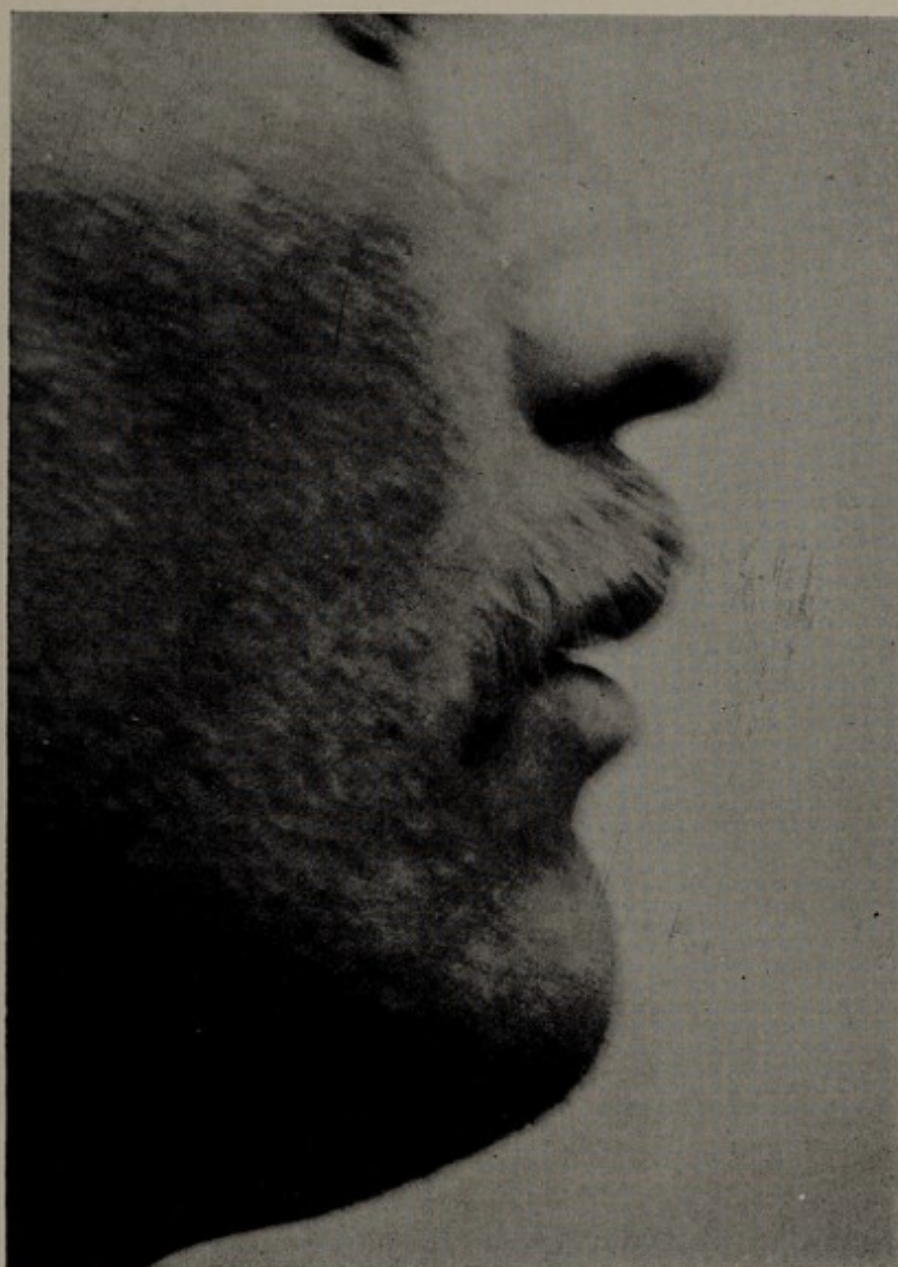


FIG. 226. H. N. After treatment with the X-rays. Side view.

those immediately around the growth were carefully protected by means of a shield made of tinfoil laid over blotting-paper, as described in the treatment of lupus. At the end of this time the crust came off, leaving a clean base, and the induration had apparently diminished. From this time the treatment was about two minutes daily.

On the eleventh day from the beginning of the treatment the cancer was smaller, the induration was much less, and cicatricial tissue was forming, especially on the right side of the growth. The opening in the protective shield was then found to be much too large, and a shield with a smaller hole was made and substituted for it. On the thirteenth day the induration had disappeared. On the eighteenth day the lip showed marked improvement, though it had not been as rapid during the past few days as during the first week, therefore the length of the

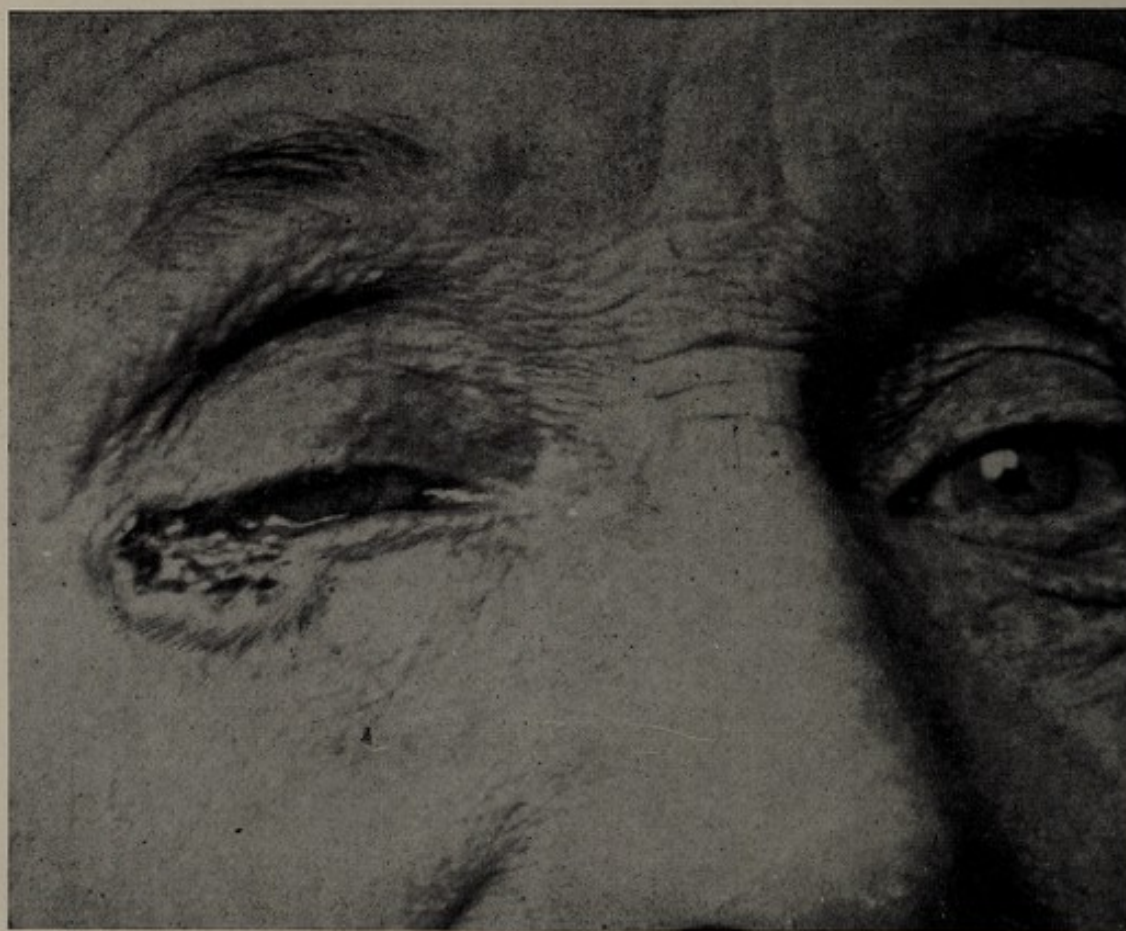


FIG. 227. J. C. Epidermoid cancer before treatment.

exposures was increased during the next ten days to five minutes daily. From that time the healing made such good progress that the time of treatment was reduced to one minute, and the distance of the tube from the patient was increased to about 20 centimetres. The part was kept clean by means of a solution of peroxide of hydrogen, which the patient applied several times a day. The treatment by the X-rays continued in all for about five weeks, but the latter part of the time it was almost nominal. I wished to keep the patient under observation until

complete healing had taken place and be ready to resume it should improvement cease. There has been no recurrence after more than a year.

Presumably with this patient healing would have taken place more rapidly had the treatment been a little more energetic. Four photographs (see Figs. 223 to 226), two of which show the appearances before the treatment was begun, and two views taken after healing had occurred, speak for themselves. The enlarged gland could not be felt after treatment.

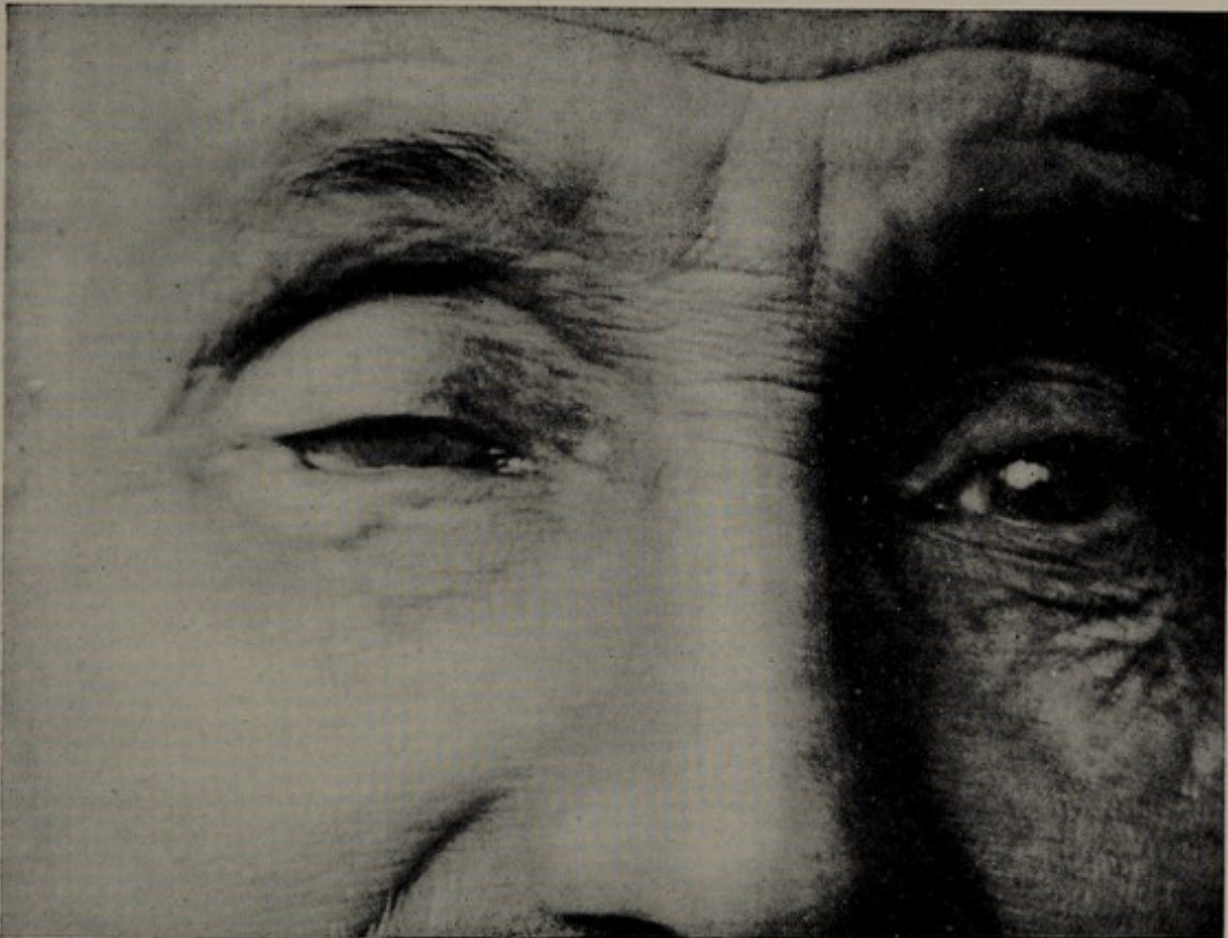

FIG. 228. J. C. Epidermoid cancer during treatment.

New growths attacking the lid of the eye cannot well be treated surgically without removing a considerable part, or perhaps the whole, of the lid. This would require a plastic operation also. By means of the X-rays I have found it practicable to treat the disease, even when extending to the edge of the lid, without any irritation extending to the eye in consequence of this treatment; and the treatment can be carried on without interfering in any way with the usefulness of the patient's sight, or with his work.

CASE II. J. C., sixty-nine years of age; carpenter. Sent to me by Dr. Wadsworth. Twenty years ago a small pimple started on the outer canthus of the right eye, but practically did not increase in size for a great many years. Four or five years ago it was burnt with acid. Dur-

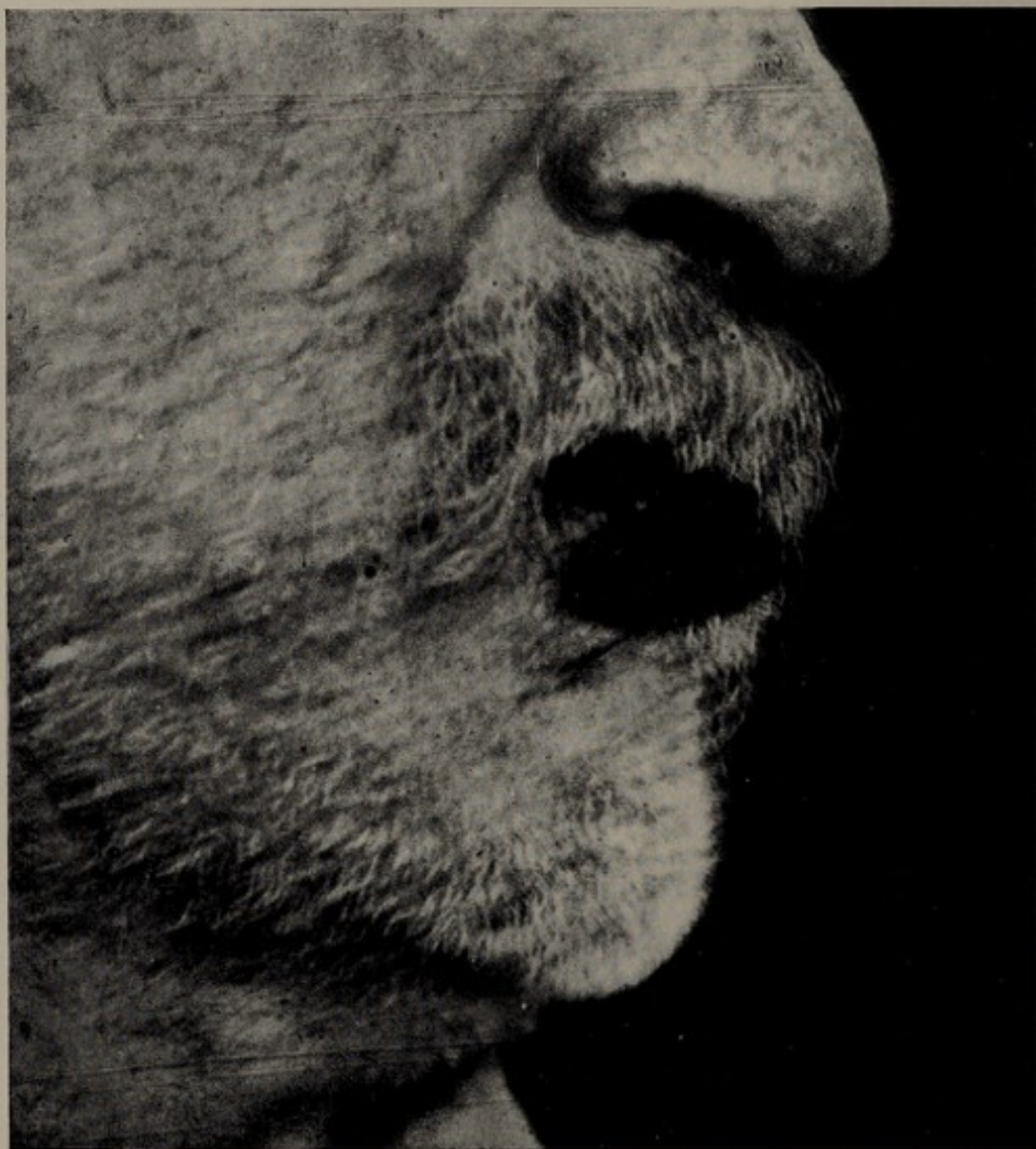


FIG. 229. B. F. Epithelioma. Side view before treatment.

ing the past six months it began to grow rapidly, and ulcerated in the centre. There was no pain but some itching.

Physical Examination. — An area on lower lid of right eye 2 centimetres long by .5 wide. There was some ulceration in the centre, and a well-defined lower edge raised above the surface of the skin, which was indurated. (See page 426.)

Dr. Mallory examined a specimen of the growth, and found it to be an epidermoid cancer.

I exposed this patient to the X-rays, the face being suitably protected and the eyelids closed, about five minutes every other day for about four weeks. The slow improvement that took place was soon noticeable by a slight reddening and softening of the edges of the induration. The treatment was then omitted for two weeks, owing to necessary absence on my part. On my return I found the improvement, which had gone on during this time, very striking. The raised indurated ridge

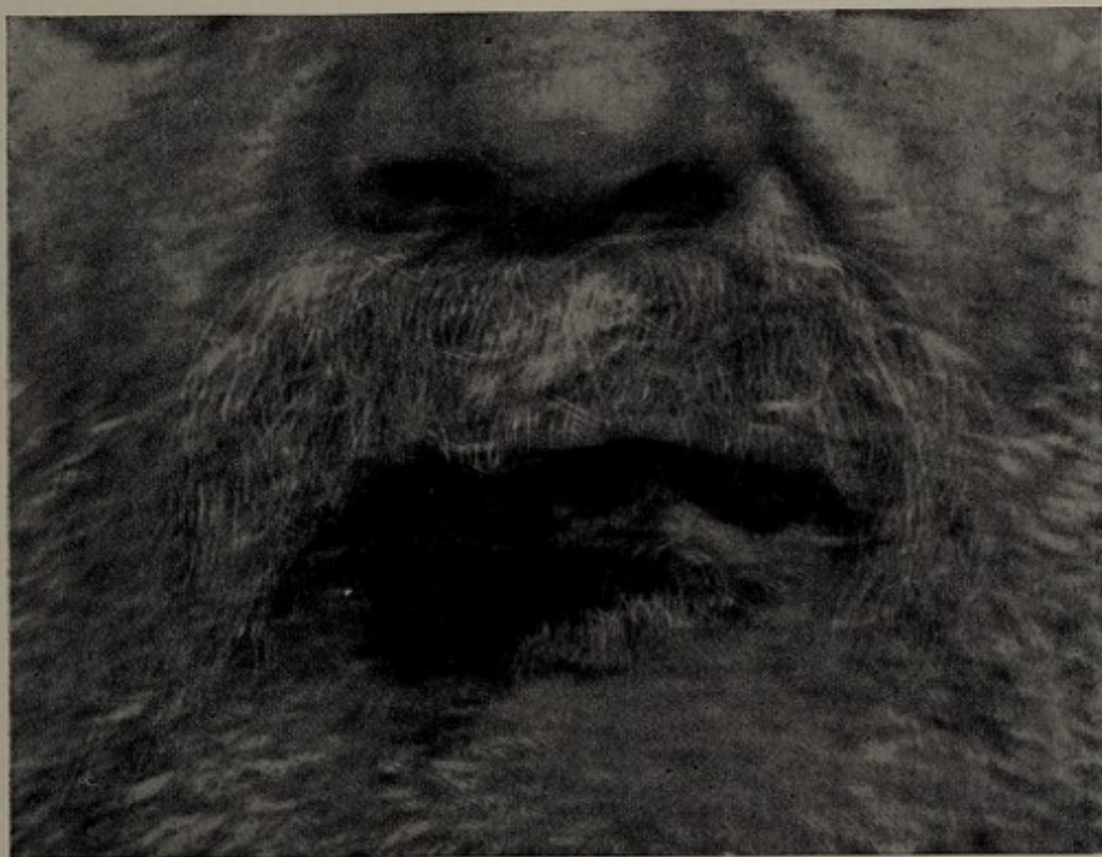


FIG. 230. B. F. Front view before treatment.

had disappeared, though the induration lying under the part which was ulcerated still remained; the ulcerated area was not then more than a third its original size, and the skin about the growth was slightly puckered, having drawn together as the growth diminished. The especially interesting feature in this case is that it continued to improve during cessation of treatment. I have observed this same characteristic in other cases.

CASE III. B. F., a man fifty years of age. Patient referred to me by Dr. Burrell. The microscopic examination, made in the pathological

laboratory of the Boston City Hospital by Dr. Mallory, showed that the patient had an epithelioma of the lip. The growth, which was of four years' duration, included nearly the whole of the lower lip, which was between two and three times as thick as normal. The whole lip was indurated, and had an ulcerated surface that was at times covered by a dark crust. The odor was foul, penetrating, and unbearable.

Treatment. — Exposures of about five minutes were made daily, except Sundays, with the lip at a distance of from 12 to 15 centimetres from the target of the tube. The tube had a resistance of about 1 centi-

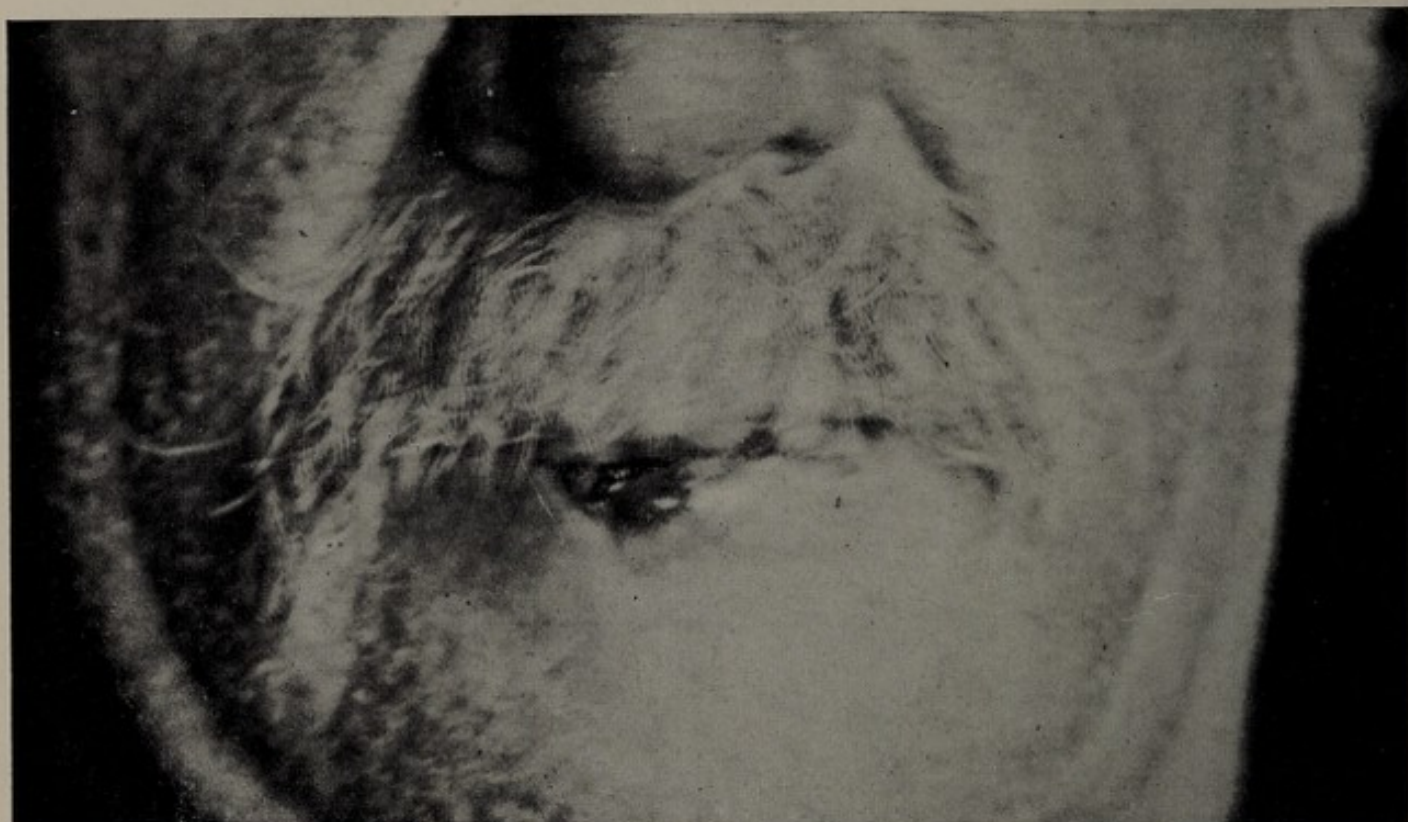

FIG. 231. B. F. After about six weeks treatment.

metre. After six exposures the odor had ceased, and here was less induration. The hair on the lower lip, which was exposed during treatment to the X-rays, was at no time loosened. Unsuccessful attempts were made from time to time to pull it out with the forceps.

The first two cuts (see Figs. 229 and 230) were taken before treatment. The third photograph (see Fig. 231) is a front view taken about six weeks after the beginning of the treatment. The lip was then soft and pliable throughout, except for a small crust; in the centre of the lip there was a furrow. The fourth view (see Fig. 232) was taken some weeks later than Fig. 231. Healing was perfect and the scar slight.

It is difficult to estimate the necessary duration of treatment in this case, as it was interrupted.

CASE IV. Among the cases I have found instructive is the following:—

D. K., a man seventy-three years old. Referred to me by Dr. M. F. Gavin. Diagnosis: a typical epithelioma of the hand.




FIG. 232. B. F. About a month later than preceding figure.

History.—Five months previous to my seeing this patient, as he drew his hand out of his pocket he tore off a small wart. An ulcer then formed, which grew rapidly. At the time of his entrance to the hospital, the ulcerated surface was 7.5 centimetres long and 4 centimetres wide and was surrounded by an edge raised in parts 1 centimetre above the surface of the skin, and this edge was firmly indurated; the whole mass presented a cauliflower-like appearance. (See Figs. 233 and 234.) Dr. Mallory reported as follows:—

"The growth shows a typical, rapidly growing epidermoid carcinoma containing many epithelial pearls. Mitotic figures are numerous. The

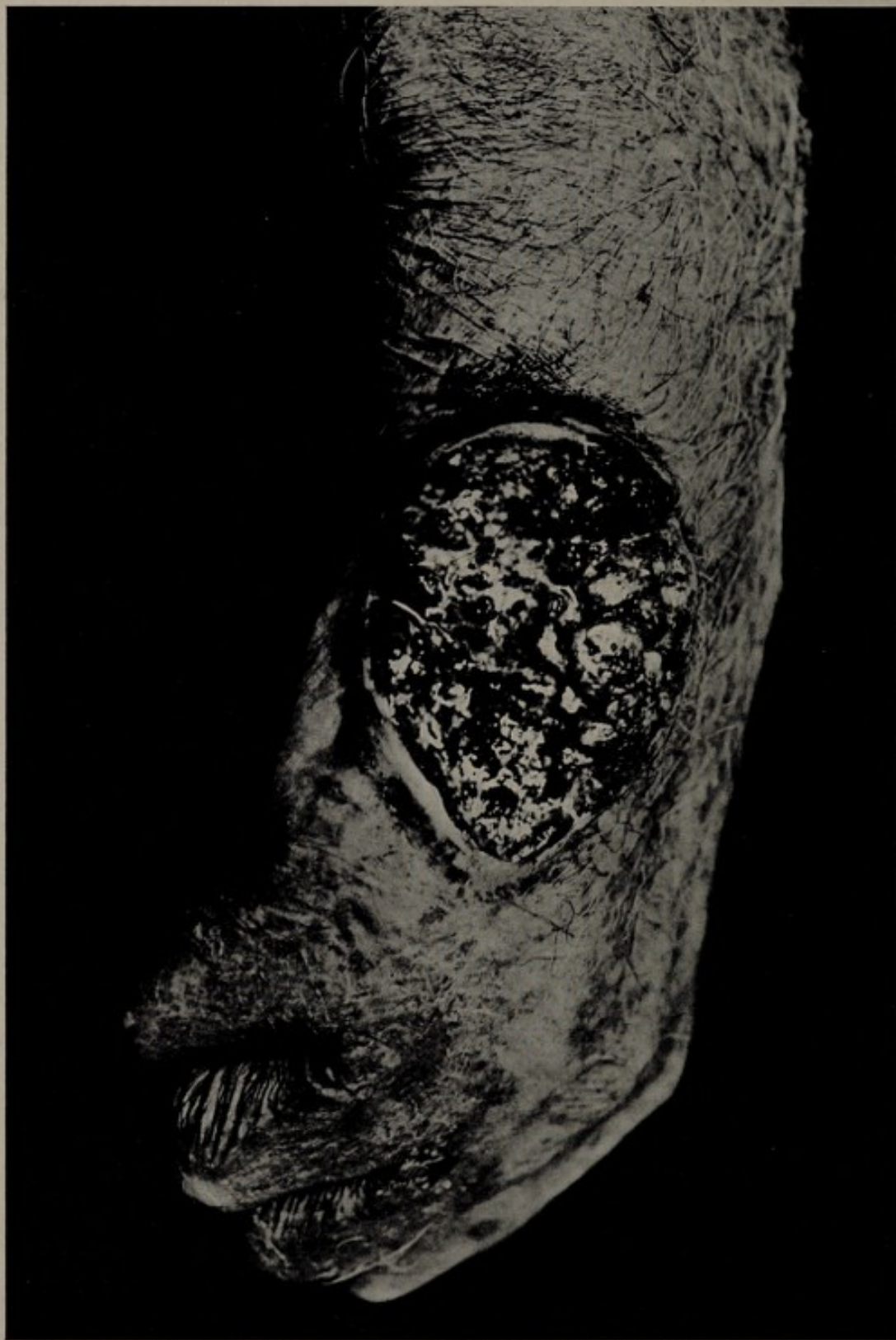

FIG. 233. D. K. Epidermoid cancer of hand. Near the beginning of treatment.

surface of the growth is ulcerated; the underlying tissue is infiltrated with many polynuclear leucocytes. The carcinoma extends out at the edge for some distance in the corium underneath the normal epidermis." (See Fig. 235, page 434.)

Treatment. — Daily exposures were made — usually of five or ten minutes, sometimes of twenty minutes' duration — with the hand at a distance of 15 centimetres from the target of the tube. Improvement began in about one week, at which time the two photographs, of which



FIG. 234. D. K. Epidermoid cancer of hand. Side view of Fig. 233.

cuts are shown, were taken. This improvement continued, and after eight weeks the ulcer had become smoother on its surface, and was but 6 centimetres long by 3.5 centimetres wide, and the induration was largely gone. (See Fig. 236, page 435.) At this time I had a thin specimen taken, reaching down to the full depth of the growth and from the centre of the ulcerated area to well beyond the edge of the growth into the healthy skin, and this was sent to the pathological laboratory, where it was examined at my request. I give Dr. Mallory's report, and also the comments made by him and Dr. Councilman: —

"The ulcerated area left after treatment with X-rays shows no evidence of carcinoma except at the edge near and beneath the epidermis, where a few small islands of epithelial cells, some of which are dividing by mitosis, are present. The central portion of the ulcerated area is

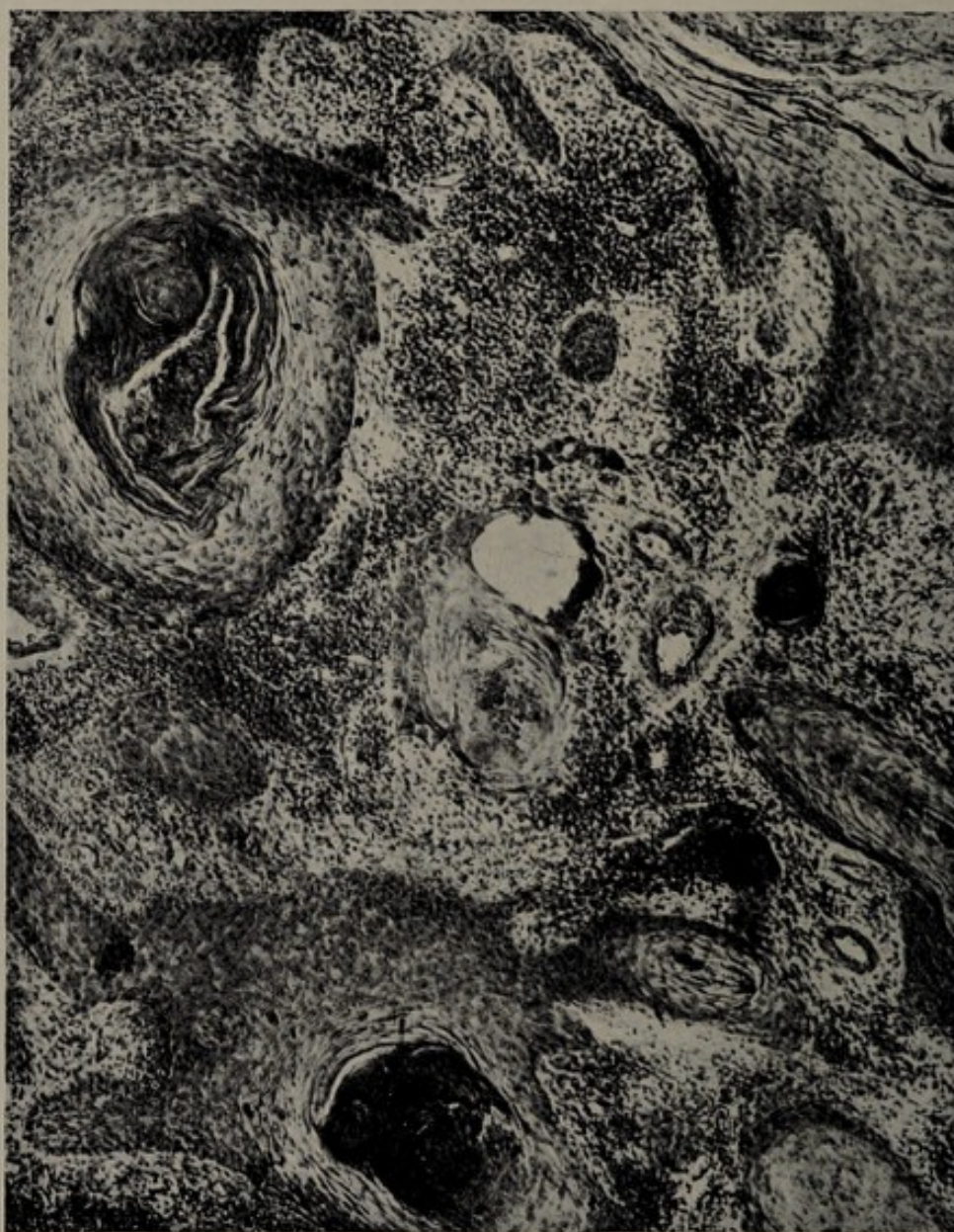

FIG. 235. A portion of a section through the carcinoma before treatment with the X-ray. Magnified approximately 77 diameters. The masses of squamous epithelial cells and the interstitial tissue crowded with small round cells are shown.

entirely free of any carcinomatous growth. The base of the ulcer is composed of rather dense fibrous tissue, in which are the remains of epithelial pearls often surrounded by young connective tissue cells and giant cells. Toward the surface is granulation tissue infiltrated with

numerous polynuclear leucocytes. The surface is covered with more or less fibrin containing leucocytes in its meshes. The reaction on the part of the connective tissue to the necrotic growth is surprisingly slight." (See Figs. 237 and 238.)

Dr. J. H. Wright kindly had made for me in the Pathological Laboratory of the Massachusetts General Hospital the excellent microphotographs from which Figs. 235, 237, and 238 were made.

The fact that near the edges of the ulcer there were still a few small islands of epithelial cells may be accounted for in perhaps two ways:

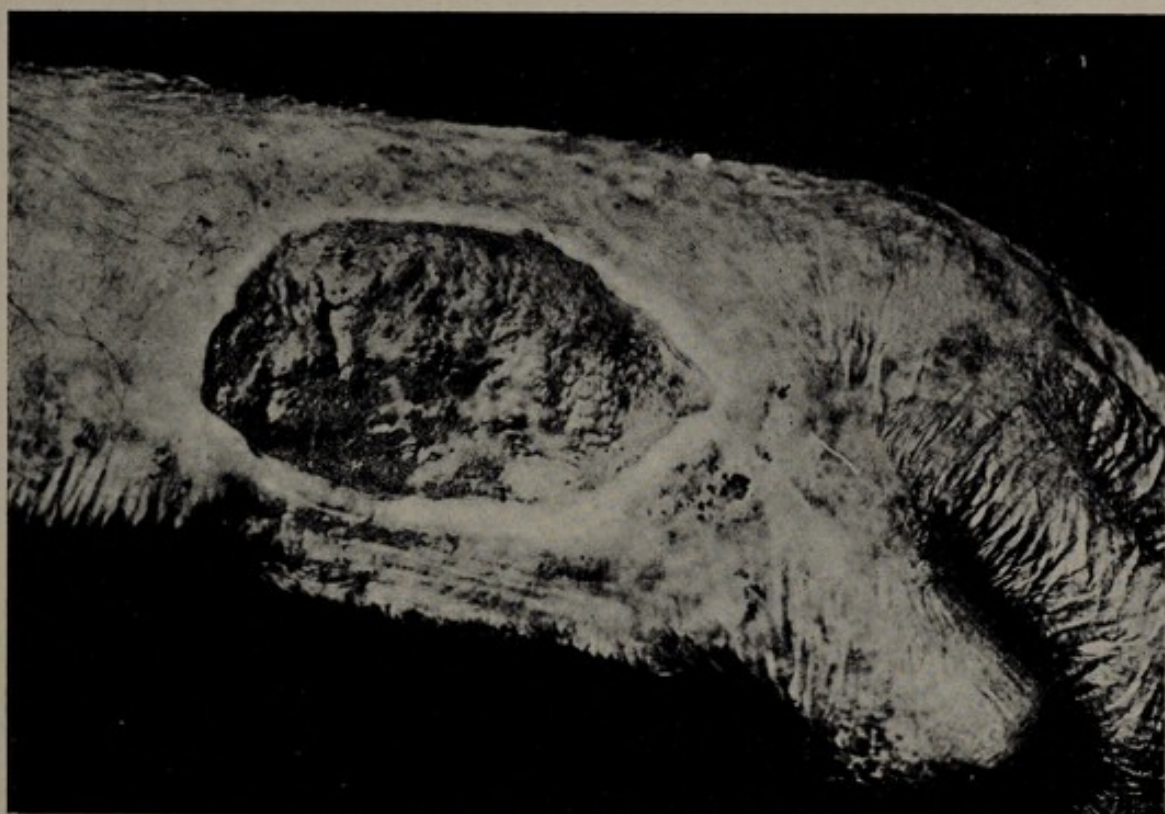

FIG. 236. D. K. Epidermoid cancer after some treatment by the X-rays, and as it appeared when the second specimen was taken for microscopic examination. (See Figs. 237 and 238.)

First, this portion of the growth, where the edges were much raised, was thicker than the other portions; and second, the edges may have been more or less protected by the lead shield which was used to prevent the rays from striking the healthy skin near the cancer. If this latter supposition is correct, it shows that it is of the first importance to expose an area of apparently healthy tissue around the growth, as well as to expose the growth itself to the X-rays. In fact this should always be done. It is not improbable that some of the early cases of cancer treated by this method will recur, because this apparently healthy tissue has not been

fully treated. But if this recurrence takes place, it should not discourage us from using this method of treatment, but only be regarded, for the present at least, as showing that it has not been efficiently carried out.

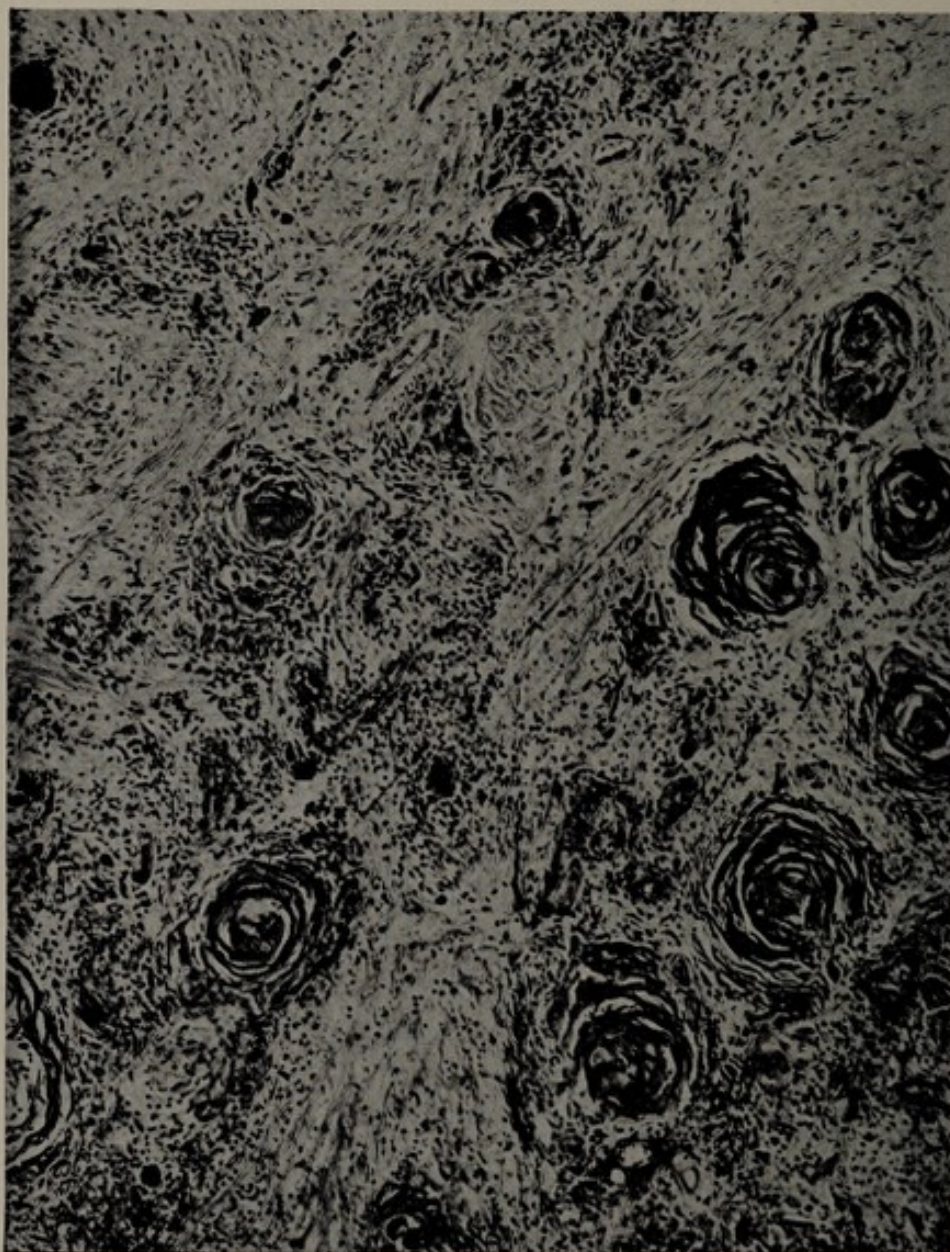


FIG. 237. A portion of the section through the centre of the carcinomatous ulcer after treatment with the X-rays. Magnified approximately 77 diameters. The small groups of necrotic squamous epithelial cells and the granulation tissue in which they are imbedded are shown.

Two important points, which Dr. Councilman and Dr. Mallory notice, are that the central portion of the ulcerated area was entirely free from carcinomatous growth, and furthermore, as Dr. Mallory states in his report, the reaction on the part of the connective tissue to

the necrotic growth was surprisingly slight. It would seem that the X-rays have a selective action.

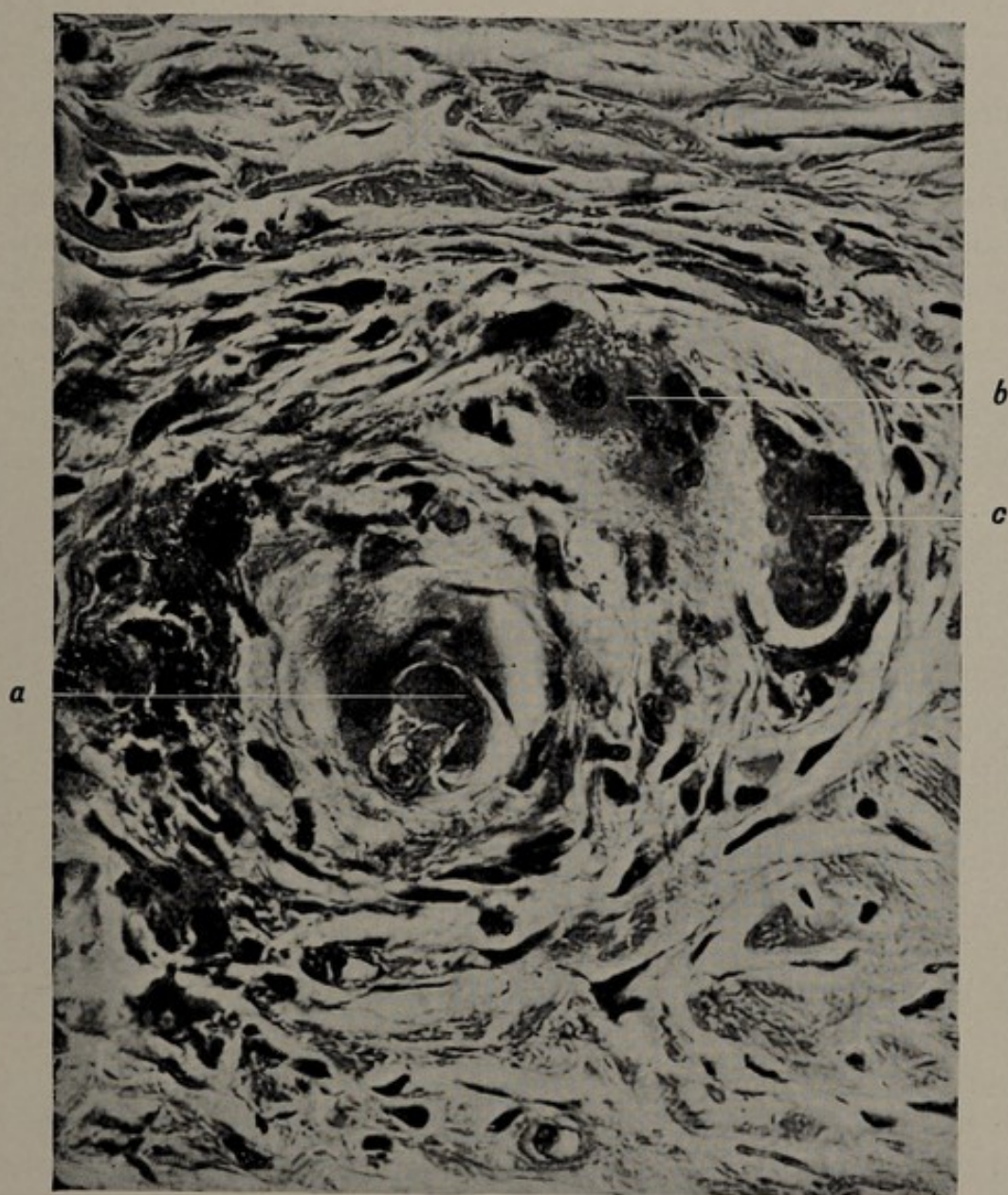


FIG. 238. A portion of the section through the centre of the carcinomatous ulcer after treatment with the X-rays. Near the centre of the figure is a small group of necrotic squamous epithelial cells *a*. Around this are seen new formed connective tissue cells, and above and to the right are two multi-nucleated giant cells *b* and *c*. The group of necrotic epithelial cells thus produces the same reaction on the part of the surrounding tissue as a foreign body does. Magnified approximately 500 diameters.

RODENT ULCER

Stenbeck,¹ of Stockholm, reports the following case of rodent ulcer:—

¹ "Ein Fall von Hautkrebs, geheilt durch Behandlung mit Röntgenstrahlen," *Mittheilungen aus den Grenzgebieten der Medicin und Chirurgie*, VI, 1900, pp. 347-349.

Christina A., seventy-two years of age. The patient had two confluent ulcers on the nose; the upper, on the bridge, having an average width of 1.5 centimetres, and the lower, on the nostril, a somewhat greater width. The glands were not swollen. The ulcer had been treated with salves and hot iron.

Stenbeck gave the patient treatment with the X-rays; at first the sittings were ten to twelve minutes long, with the tube at a distance of 15 to 20 centimetres. After four sittings there was a reaction, and after eight to ten sittings pus formed, which, however, soon diminished in amount. After about thirty-five sittings the cleansing of the ulcers began; they became smoother, and a new, thin, but smooth skin formed from the edges inward. After this process had begun, and the ulcers showed signs of healing, the sittings were increased to fifteen minutes, with the tube at a distance of 10 centimetres. A slight reaction ensued, but the new skin was not thrown off; the reaction soon passed, and complete healing followed.

Stenbeck states that the ulcer was not examined microscopically, as the patient was unwilling, but that this diagnosis was made by several physicians, and the course of the disease and the characteristic appearances observed, demonstrated that it was a typical case of skin cancer (rodent ulcer).

Dr. Stenbeck also states that Dr. Sjögren reported a case of rodent ulcer that was not yet healed, at the same medical meeting, held December 19, 1899, in which the above case was given.

In "A Preliminary Communication on the Treatment of Rodent Ulcer by the X-Rays,"¹ Dr. James H. Sequeira reports twelve cases treated by this means.

The first of these twelve cases was sent to Dr. Sequeira to be treated by the Finsen method, but as the patient could not bear the pressure of the apparatus which is used to render the parts under treatment anæmic, Dr. Sequeira applied the X-rays instead, having already had some experience of the value of these rays in the treatment of lupus. Of these twelve cases, eight are still under treatment, and four are under observation, the ulcers having healed.

"In no instance has there been a disappointing result. The treatment is painless, and nothing further is required but to cover the part with a simple antiseptic dressing. It is, of course, too early to say anything as to the permanence of the cures in these cases, but I hope

¹ *British Medical Journal*, February 9, 1901, pp. 332-334.

to be able to make a further communication upon the subject with particular reference to the histological changes. The immediate result is all that can be wished for, and I feel justified in recommending the use of the X-rays, at least in the cases in which complete removal by the knife is impracticable."

From among my cases of rodent ulcer I will choose two as examples of the excellent results which this method of treatment gives.

CASE I. J. H., a man seventy years old. Referred to me by Dr. M. F. Gavin. The growth—a small specimen from which was examined microscopically by Dr. Mallory, and found to be a carcinoma of the rodent ulcer type—began fifteen years ago. There was a red

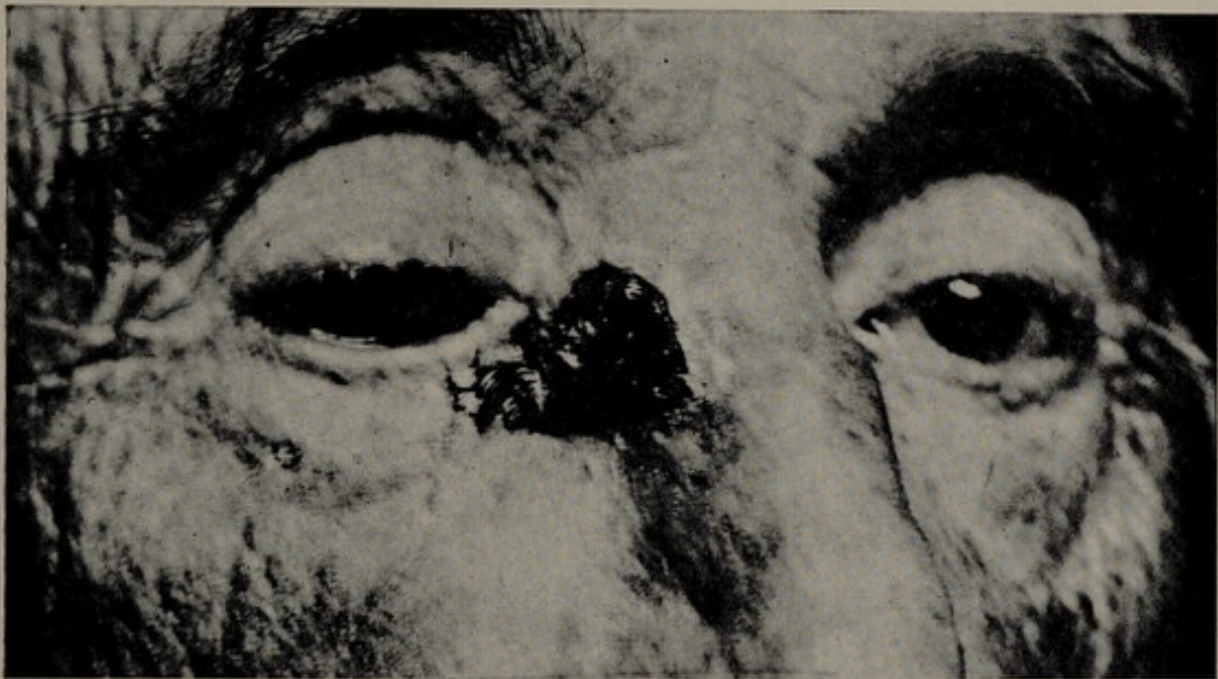

FIG. 239. J. H. Rodent ulcer before treatment by the X-rays.

and somewhat swollen annular area, about 1 centimetre wide, surrounding the ulcer.

The exposures were made at a distance of 12 centimetres from the target, and were from three to five minutes' duration daily, except Sundays during the first four weeks. Twenty-four hours after the first exposure, which lasted five minutes, a shrinking and slight puckering of the swollen ring around the ulcer was noticed. After three exposures, of three minutes each, the redness and swelling of this ring had diminished. After six exposures, there was likewise, by measurement, a slight diminution in the size of the ulcer.

The order of healing seems to be as follows: the ulcer heals up

from the bottom, and then afterward closes over. This closing in of the surface, though delayed at the beginning, takes place rapidly after it is fairly under way. The total duration of the treatment in this patient was nearly six weeks. During the last two weeks it was applied for only one minute a day, and probably this was unnecessary.

CASE II. A. B., a man fifty-five years of age. Referred to me by Dr. David W. Cheever. Rodent ulcer of about thirty years' duration. Five operations had been done, in one of which one of the eyes had been removed. His experienced surgeon finally decided that further operation was impossible, and referred the patient to me. The growth

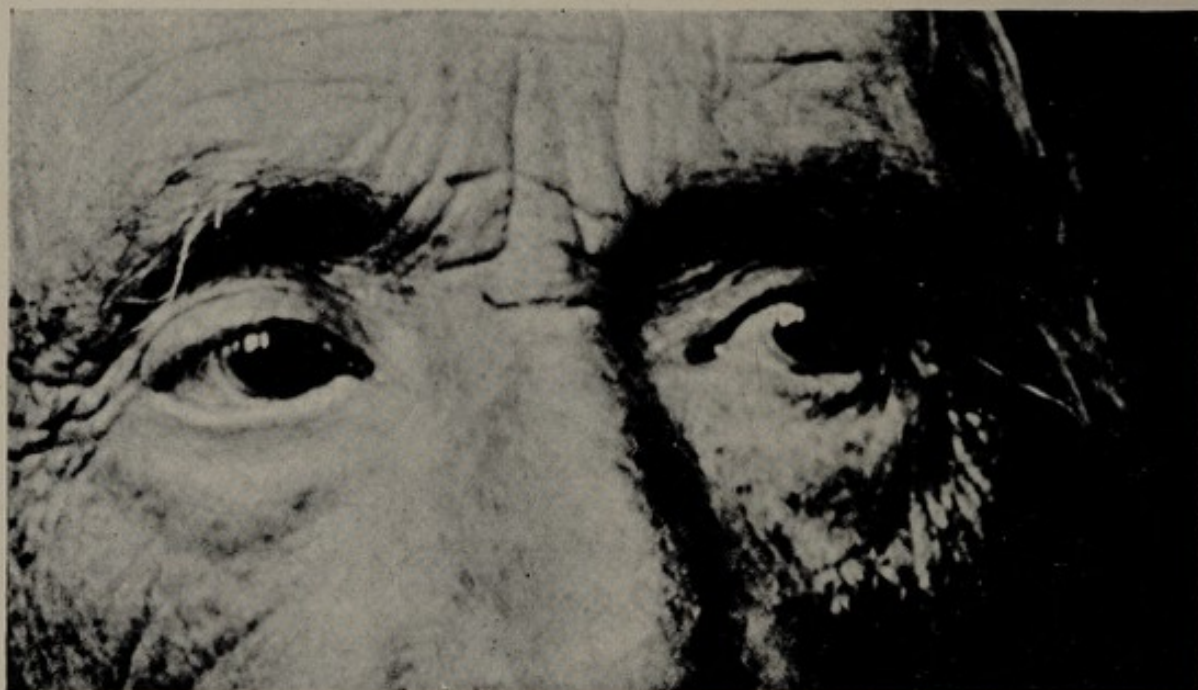

FIG. 240. J. H. Rodent ulcer after treatment.

involved the whole of the orbit, the eyebrow, and the side of the nose, and extended below the orbit on to the cheek, an area of 7×8 cms. It has healed over under treatment by the X-rays.

Some of the growths I have treated were typical epitheliomas; others were of the rodent ulcer type; still others were ulcers that were indurated and had persisted for months, or in some cases for years; clinically these were epitheliomas, but when a specimen was examined under the microscope they did not present the appearances typical of epithelioma, and were reported by Dr. Mallory either as chronic inflammatory tissue or plasmoma. It is noteworthy that all of these cases, however, yielded to treatment by the X-rays.

The exposure of external growths, with the target at a distance of 10-15 centimetres, to the X-rays for a few minutes (usually five to ten) two or three times a week, for several weeks, is in general what is required, or daily exposures may be made for several days, and repeated after an interval of a few days. Where the growth is more extensive, a longer time than this may be necessary. On the other hand, in very early cases, fewer exposures may suffice.

I have been unable to get statistics on a large scale that will show the distribution of cancer in various parts of the body, but as an example I have taken the cases admitted to the Boston City Hospital for a series of years—I have not included those received at the outpatient department—and have placed them in two groups, namely, external and internal cases, as shown in the following table. I have classed as internal, cases which may be accessible, such as some cases of the tongue and larynx, for example. The cases are likewise divided into two groups, namely, cancers and carcinomas, as they are thus classed in the records of the hospital.

The table is intended merely to give some indication of the proportion of cases which might be amenable to treatment by the X-rays in a very early stage of the disease.

It is desirable, of course, to begin this treatment at as early a moment as possible, in order to avoid the chance of metastases, and also to shorten the duration of treatment. It may be that from the surgical standpoint many would advise operative measures in early cases, but I think we have now got far enough in the use of the X-rays to justify their employment in the early stages also, in order that we may teach the community that these growths may be healed by a harmless and painless method; and when this fact is realized we will hope that few of them will be allowed to advance to serious dimensions through delay and fear of the knife. In deciding whether the X-rays should be used, or an operation done, it is to be remembered that improvement, under the first method of treatment if properly carried out, may be looked for within two or three weeks; therefore, a trial of the X-rays does not require much delay.

Of course it will be urged that to carry out this method requires a good deal of time. It is only fair to suggest that with more experience the duration of treatment will probably be lessened. I find already that I have learned to carry it out with fewer exposures than I gave at the beginning.

It will also be stated that these growths may return. This criticism

now remains to study the method carefully with the view of finding out the best modes of procedure, and of determining its limitations. This is a question of time and careful observation.

Where the X-rays are used for purposes of examination, there is now no risk of any burn or inconvenience to the patient; but where they are used for therapeutic purposes, it is at present necessary to have the tube very near him; and there is, therefore, greater risk of setting up an X-ray burn than there is when the rays are used for purposes of diagnosis. But if proper care is exercised, I do not think that it is necessary to cause a burn; in none of my cases of external growths has one occurred.

This subject is still so new that all opinions about it must necessarily be tentative. The special points that my experience thus far suggests may be thus summarized:—

1. This treatment is adapted to external new growths which have not great depth, though they may cover much surface.
2. The treatment causes no pain.
3. There need be no delay on account of dread of the knife.
4. Pain and odor are relieved.
5. Healing follows without causing a burn.
6. The results from a cosmetic standpoint are excellent.
7. Treatment can be carried on without the work in which the patient is engaged being given up.
8. Signs of improvement may be seen within two or three weeks.
9. In the larger forms of external growths an operation might first be done to remove the growth so far as possible, and then the X-rays may be applied.

The disadvantages are:—

1. The apparatus is expensive and difficult to use properly, and with its present capacity the X-rays do not exert their full action through a great thickness of tissue.
2. The treatment may have to be continued for some time.

A therapeutic measure cannot, of course, point out the cause of a disease; but it may throw suggestive light upon it. For example, in the radiation from a vacuum tube, good results are produced in a disease where the cause is known to be due to a microscopic organism; for instance, tuberculosis of the skin, or lupus, yields more or less well to the action of this agent; but syphilitic growths, it is said, do not yield readily to this method of treatment. The clinical picture which healing

cancers present is quite suggestive. Their response to treatment in certain cases is immediate, sometimes within two or three days; and, further, in some of the cases improvement continues for a time after the exposures have been stopped. These facts, taken together with the microscopic appearances after treatment, suggest that cancer is produced by some living cause; and also that the radiation from a vacuum tube — probably the X-rays — interferes with its life.

INTERNAL FORMS OF CANCER

As yet we have only begun the use of this new therapeutic agent, and there is much to be learned, both on the side of the physics of the X-rays and on that of an intelligent application of them. Therefore until I have had still further experience with these forms, I prefer not to discuss this side of the subject. I am about to try a 75 cm. (30 inch) coil in these cases.

RODENT ULCER TREATED BY FINSSEN'S LIGHT TREATMENT

Drs. Morris and Dore,¹ in a paper on "Finsse's Light Treatment of Lupus and Rodent Ulcer," point out the conditions which are favorable, and those which are unfavorable, for this treatment. I refer to it here, as the question may arise as to whether this treatment, or that of the X-rays, is to be preferred. It seems probable that in most, if not in all, cases, the treatment by the X-rays will replace that of Finsen.

"UNFAVORABLE CONDITIONS FOR FINSSEN'S METHOD

"A. Those which hinder the penetration of the light, and so prevent a good reaction: —

1. *Scarring*, especially from scraping, when the cicatricial tissue is, as a rule, very dense.
2. *Pigmentation*, which intercepts the ultra-violet rays.
3. *Great vascularity*, because it is more difficult to express the blood from the part, and unless the tissues be made anæmic the rays will not penetrate.
4. *Great depth below the surface*, with which may be included: (A) Thickness and induration of the nodules; (B) surrounding inflammation and induration; (C) confluence of the nodules.

"B. Difficulties of position: —

1. *On the skin*; for example, when the disease is situated near the eye special compressors have to be used, and it is sometimes difficult to adapt even these to the surface to be treated, or on the eyelid, when it is impossible to apply adequate pressure.

¹ "Remarks on Finsen's Light Treatment of Lupus and Rodent Ulcer," *British Medical Journal*, February 9, 1901, pp. 326-332.

2. *On the mucous membrane* ; the interior of the nose and mouth is inaccessible, with the exception of the gums and lips, which can be treated, the latter by eversion. (In these cases the combination of X-rays with Finsen's treatment has been found most successful.)

"C. Extent of the disease : —

"As only a small area can be treated each day, very extensive cases are unfavorable, both from the long duration of the treatment and the fact that while one part is being treated the disease may be spreading in another.

"FAVORABLE CONDITIONS

"Conversely, cases are favorable where the disease is limited to a small area, is superficial, is not spreading, and has not undergone previous treatment, especially operative."

THE X-RAYS AS AN ANALGESIC

Werner¹ reports on two cases which Southgate Leigh presented before the Seaboard Medical Association. The first was a youth who had been shot in the thigh. A bad swelling appeared at the knee, and was so painful that the slightest movement was impossible. The physician who took a radiograph of the thigh had so poor an apparatus that the patient was exposed four hours to the rays. On the following day he was free from pain, and on the third day could walk.

Another case was that of a patient suffering from gallstones. The X-rays were used for diagnostic purposes. The stone was not found, but the patient was free from pain and had no further gallstone colic.

ARTICULAR RHEUMATISM

Schmid-Monnard² gives a short report of an article by Sokolow on the cure of articular rheumatism in children by the X-rays. Sokolow treated four cases with good results. The children were covered with a woollen cloth and exposed to the X-rays for ten to twenty minutes. The tube was at a distance of 50-60 centimetres. The first case was a girl of nine years who was suffering with pain and swelling in the right and left wrist, finger, and knee. The pain disappeared after the second sitting. The second was a girl fourteen years old who had violent pain and swelling in the knees, which disappeared after the first sitting. The third was a girl of three years of age who had violent pain and swelling in the knees, which diminished after the third sitting. After

¹ *Fortschritte a. d. Geb. d. Roentgenstr.*, B. III, H. 3, pp. 122-123.

² *Ibid.*, B. I, p. 209.

four days the swelling was reduced 3 centimetres in circumference. The last case was a girl of thirteen years who had suffered from chronic rheumatism and heart disease for five years. The disease grew worse; the pain was violent; there was swelling, and the knee was bent at an angle of 45° . After each application of the X-rays the leg could be straightened more; the pain diminished, and disappeared after the fourth sitting.

Immelmann¹ reports on an article by Stenbeck (of Sweden) regarding the treatment of articular rheumatism with the X-rays. Fifty-two patients in all were exposed to the rays; forty per cent were much improved; forty per cent felt subjectively better; and twenty per cent gave an entirely negative result.

Summary of Directions concerning Apparatus and Length and Frequency of Sitting. — It is evident that experience in using the X-ray apparatus is essential before an attempt is made to employ the X-rays for treatment. There are two sets of precautions, which should be taken when using these rays as a therapeutic agent: first, those relating to the apparatus; and second, those relating to the patient. The exact resistance of the tube should be known, as it is stated that tubes of low resistance are more efficient for treatment than those of high resistance. The tube should be enclosed in a box of such a character as to protect the patient by permitting the rays to issue only in the desired direction, and a grounded aluminum screen should be interposed between the tube and the patient. The patient should further be protected by a shield made of blotting-paper and tinfoil or, for the face, a mask of gauze or paper painted with white lead.

The time of the exposure, the distance of the tube from the patient, and the frequency of the exposures must be determined for each individual, each disease, and each apparatus. In general it is well that the target should be placed at a distance from the patient of from 15 to 20 centimetres, and that the exposures should last from five to twenty minutes, and should be given two or three times a week. If at any time redness or bronzing of the skin takes place, the exposure should be suspended until these effects have disappeared; for if the exposures are continued under these circumstances, serious injury may result. The ill effects, if any occur, may not appear for a week or more after exposure.

No substances such as oxide of zinc, iodoform, or aristol should be

¹ *Fortschritte a. d. Geb. d. Roentgenstr.*, B. II, p. 227.

used in local applications while this treatment is carried on, as they obstruct the passage of the X-rays and vitiate their effect.

CHANGES PRODUCED IN THE SKIN BY EXPOSURE TO AN EXCITED VACUUM TUBE, AND THEIR CAUSES

Jutassy¹ states that short and weak exposures cause hyperæmia and erythema; long and intense exposures produce ulcers; the effect does not show itself at once but after a shorter or longer time. The X-ray dermatitis heals tolerably quickly and leaves a fine, smooth scar, except when ulcers penetrating deep down into the cutis are produced, which easily cause necrosis, and heal with great difficulty, and in this respect are like torpid specific ulcers. This necrosis is differentiated from other necroses, according to the investigation of Gassmann, in that it also disturbs the structure of the blood vessels. Unna, who had the opportunity of examining the human skin suffering from dermatitis erythematosa produced by exposure to an excited vacuum tube found such changes that he concluded the X-rays attacked the most resistant tissues of the skin, and by this means he explained the long continuing cumulative action observed.

Jutassy also touches upon other histological changes, namely, the atrophy of the sweat and sebaceous glands, as well as the papillæ of the hair (Kibby and Jutassy) and the obliteration of the capillaries (Gassmann and Jutassy), and adds that Destot explains the pathological changes in a tropho-neurotic way; Kaposi seeks a reason for them in the paresis of the blood vessels; and Bordier, in the disturbance of the nutrition of the tissues, because he found that under the action of the X-rays the osmosis in the tissues of animals as well as of plants was delayed.

CAUSE OF THE SO-CALLED X-RAY BURN

H. D. Hawks (*Electrical Review*, August 12, 1896) reported that he had severely burned himself with the X-rays.

W. M. Stine (in the *Electrical Review* for November 18, 1896) stated that the burns consequent on an exposure of the body to an excited vacuum tube were not due to the X-rays, but to the ultra-violet light coming from the tube.

Elihu Thomson (*Electrical Review* for November 25, 1896) gave it

¹ *Fortschritte a. d. Geb. d. Roentgenstr.*, B. III, H. 3, pp. 118-119.

as his opinion that the effects produced were not electrostatic in their origin, as had been suggested, but were due to the chemical activity of the Roentgen rays.

Tesla (*Electrical Review*, December 2, 1896) wrote that the burns were not due to Roentgen rays, but to ozone that was generated on the skin, and possibly to a small extent to nitrous acid. He therefore interposed a screen made of aluminum wire, that was connected with the ground, between the tube and the person, and no burns occurred. Before he took this precaution one of his assistants had been burned.

Rollins (*Electrical Review*, January 5, 1898) exposed his hand to a tube the resistance of which was so high that no current could be forced through it with the generator used, and therefore no X-rays were produced; yet the hand was burned. This experiment showed that the so-called X-ray burns could be produced by electricity, but did not show that they could not also be caused by the X-rays.

Trowbridge (*American Journal of Science*, 1898, page 129) stated that the "so-called X-ray burn is due to an electrification — a discharge at the surface of the skin — and this electrification may or may not be accompanied by X-rays." Trowbridge exposed his hand to the brush discharge of a generator, with the result that a typical X-ray burn was produced.

Elihu Thomson (*American X-Ray Journal*, November, 1898) stated that burns were produced by the X-rays, and chiefly by those rays that are produced by a "soft tube"; that is, one of low resistance.

BACTERIA

EFFECT OF X-RAYS ON BACTERIA

Mink. *Typhoid bacillus*. — Gocht¹ reports that Mink, starting with the fact that daylight, sunlight, and electric arc light weakened and injured bacteria growing in culture media, exposed typhoid bacilli on an agar plate to the X-rays for half an hour without any injurious effect; he then exposed them for thirty-five minutes and without any noteworthy result; but fewer colonies grew on the portion of the plate exposed to the rays. Later reports from Mink show that he exposed typhoid bacilli to the X-rays for eight consecutive hours without any injurious effects worth mentioning.

¹ *Fortschritte a. d. Geb. d. Roentgenstr.*, B. I, 1897-1898, p. 34.

Von Wolfender and Forbes Ross¹ report experiments with the *bacillus prodigiosus*. The cultures were grown on potato and carried on to the fifth generation. The coil used had a spark-length of 18 inches; voltage 16; amperage 8 to 10. The exposure to the rays was fifty or sixty minutes, and the test tube was placed at a distance of 6 inches from the vacuum tube. The writers state that a single exposure increased the growth markedly; further exposure stimulated the growth so as to deprive the bacilli of their power to form pigment when subjected to warmth, but this power was recovered when subjected to cold, and a larger amount of pigment was formed than originally, but it was slightly different in color; up to the fifth generation the result of an hour's exposure was to produce an exuberant growth. The writers observed changes in the protococcus.

The natural comment upon one experiment is that the glass of the test tube, if thick, would obstruct the passage of the X-rays.

Beck and Schultz.—**Rieder**² reports that Beck and Schultz have experimented with *color-producing bacteria*. The bacteria were planted in agar on Petri dishes. The induction coil used had a spark-length of 12 centimetres, the tube was at a distance of 25 centimetres, and the bacteria were exposed for from twenty minutes to two and a half hours to the X-rays. Twenty-four hours after the exposure all the bacteria used in the experiment had grown well, however, and there was no difference to be seen in the color produced by these and those that were protected from the rays by sheets of lead.

Berton has made experiments with bouillon cultures of *diphtheria bacilli* and exposed them to the X-rays sixteen, thirty-two, and sixty-four hours respectively. After each exposure two guinea pigs were inoculated with the culture that had been subjected to the rays, and two other guinea pigs, as a control, with the ordinary bouillon culture of diphtheria. Both sets of guinea pigs died quickly.

Sabrazès and Rivièrè experimented with the *bacillus prodigiosus*. The tube was placed at a distance of 15 centimetres, and, in order to exclude the light rays, the dishes were covered with black paper. The exposure lasted one hour a day for twenty days, and produced no effect on the bacilli as to color, morphological properties, or growth. These investigators also experimented with the X-rays on leucocytes and with

¹ "A Preliminary Note on the Action of Roentgen Rays upon the Growth and Activity of Bacteria and Microorganisms," *Lancet*, 1898, p. 1752.

² *Münchener Med. Wochenschr.*, 1898.

the heart of a frog, but could see no effect upon either although the exposure lasted over one hour.

J. Brunton Blaikie obtained the same negative results in his experiments with cultures of *tubercle bacilli* and with guinea pigs inoculated with diphtheria toxine after an eight hours' exposure to the X-rays.

Rieder. — In the following described experiments with various bacteria, Rieder used a voltohm induction coil with a spark-length of 30 centimetres and three hundred interruptions per minute. The cultures, on an average, were placed at the distance of 10 centimetres from the target, in order that they might be exposed to a direct and close action of the rays.

The cultures were placed in Petri dishes that were covered during the exposures with a piece of lead, out of the centre of which a hole had been cut. The exposures lasted from forty-five minutes to three hours. In some cases the hole in the centre of the lead was covered with black paper that was impervious to daylight, in order that the X-rayed part might show unmistakably the effect of the Roentgen rays on the bacteria. The action of the X-rays proved to be the same whether or not the hole was covered with this paper.

Cholera Vibriones. — The cultures of cholera vibriones were exposed to the X-rays for forty-five minutes and were then put into an oven that was heated to 37° C. When the dishes were taken out and their contents examined macroscopically and microscopically, it was found that the centre of the dish corresponding to the hole was free from colonies, whereas between the circumference of the hole and that of the dish there were very numerous colonies. The culture medium in this case was agar.

Bacterium Coli. — With these bacteria gelatine was used as a culture medium, and the cultures were exposed about an hour and then placed in the oven after an interval of thirty-six hours, with the result that there were many fewer colonies in the part of the dishes under the hole than the portion under the lead.

Staphylococcus Pyogenes Aureus. — The same positive result was obtained in this case by means of a short exposure, the culture medium used being gelatine.

Staphylococcus Pyogenes. — In this experiment the time of exposure was only about forty minutes, and the result, although positive, was not so striking as in the other cases. The culture medium used was agar.

Diphtheria Bacillus. — Blood serum cultures of diphtheria bacilli were exposed for nearly an hour to the X-rays and then placed in an oven heated to 37° C. After remaining there for almost two days only a few colonies were to be seen in the centre of the dish open to the rays, whereas under the lead they were very numerous.

Typhoid Bacillus. — These bacilli were grown on agar plates; the part of the dish exposed to the X-rays was almost free from colonies, but they grew very close to the circular opening, forming a white ring.

These experiments showed that these bacteria, when grown in agar, blood serum, or gelatine, were killed by the X-rays when exposed to them for about an hour. In other words, bacteria outside of the body, but living in suitable media, can be deprived tolerably quickly by the X-rays of capacity for further development. Rieder adds that it is not necessary to kill the bacteria inside the human body, but that to check their development will probably be sufficient, for the natural guardian of the organism, namely the blood, with its strong bactericidal action, can complete the destruction of the pathogenic germs.

Effects of X-Rays on Developed Colonies. — Rieder then experimented with developed colonies, and found in the case of the cholera colonies that the bacteria were killed after an exposure of two hours, but the gelatine cultures of bacterium coli which had been in the oven twenty-four hours, before the exposure of an hour to the rays, showed colonies in the exposed part of the dish which on the average were as large in size as those on the protected part, although fewer in number; which seemed to indicate that, though the rays could prevent the development of new colonies in this case, they could not stop those already existing.

Tubercle Bacilli Cultures. — Eight dishes containing a solution of extract of beef, glycerine, and pepton were sterilized and spread with a thin layer of a fresh bouillon culture of tubercle bacilli; four of these dishes were then exposed to the X-rays for over an hour, after which exposure they and the unexposed dishes were placed in an oven heated to 37° C. A week later, in the unexposed dishes there was a luxuriant growth of tubercle bacilli; in three of the exposed dishes the growth was diminished, and in the fourth there was scarcely any growth to be seen.

The striking point in these experiments is the directly opposite results reached by Rieder from those obtained by other investigators. Rieder ascribes this difference to the difference in the apparatus.

EFFECT OF CONCENTRATED LIGHT ON BACTERIA

Kümmell¹ reports two parallel series of experiments made by Finsen with concentrated blue light and the direct arc light, the source of light being 75 centimetres distant, on cultures of micrococcus prodigiosus, bacterium coli, typhoid bacilli, etc. The concentrated light diminished the power of growth in one to one-half hours, and killed the bacilli in eight to nine hours, whereas the concentrated blue light diminished their capacity for development in four to five minutes, and killed the bacilli in fifteen to twenty minutes.

EFFECT OF X-RAYS ON ANIMALS INOCULATED WITH BACTERIA

Rieder,² following his experiments with the X-rays on bacteria cultures, made a series of experiments regarding the action of these rays on various animals, namely, mice, rabbits, and guinea pigs. The animals were inoculated with virulent streptococci, staphylococci, etc., and then exposed immediately to the X-rays. The results were negative. Rieder then injected animals with tubercle bacilli with results which differed little from those of Mühsam (see below). The tuberculous disease of the internal organs generally developed later in the X-rayed animals than in the control animals; the local tuberculosis was delayed and in many cases also the general infection; nevertheless the animals died.

Kratzenstein³ reports on Mühsam's experiments with twenty-six guinea pigs that were inoculated with tuberculosis; his observations led him to the conclusion that the X-rays are not in a position to arrest general tuberculosis, but can modify the local disease. With a few exceptions the X-rayed animals survived the control guinea pigs, and at dissection showed that the disease was not so extensive.

Lortet and Genoud. — Took eight guinea pigs of equal weight and size, and injected into the right inguinal region a fluid mixed with the powdered spleen of a very tuberculous guinea pig. Two days later three of these guinea pigs were exposed at the point of injection to the X-rays for an hour a day for two months, with the result that they kept well, gained in weight, had no ulcers, and the inguinal glands were hard and of normal size. The remaining five guinea pigs grew thin,

¹ *Centralblatt für Chirurgie*, April, 1898.

² *Fortschritte a. d. Geb. d. Roentgenstr.*, B. III, H. I, 1899, p. 36.

³ *Ibid.*, B. II, 1898-1899, p. 47.

developed ulcers at the point of injection, and the inguinal glands became soft and spongy.

Fiorentine and Linaschi injected guinea pigs in the intraperitoneal region with a culture of virulent *tubercle bacilli*. The tube was at a distance of 10–20 centimetres, and so placed that the rays penetrated the inoculated part. The X-rayed animals, when dissected, showed many fewer tuberculous nodules than the control guinea pigs, and in a second set of experiments the tuberculous nodules had disappeared altogether, in the neighborhood of the injection, in the X-rayed animals.

CHIEF THERAPEUTIC USES OF THE X-RAYS

The X-rays as a therapeutic agent may be used to relieve pain and itching in certain diseases, to remove hair for cosmetic reasons, to treat sycosis and favus; to remove a birthmark, and, what is most important, to cause external new growths to heal. These rays are also serviceable in lupus — especially lupus vulgaris, and in some cases of eczema and acne.

The mode of action of the X-rays when they give relief from pain offers an inviting field for physiological study.

For further discussion of therapeutic uses, see Appendix.

CHAPTER XVII

INTRODUCTION TO SURGERY

THE X-rays were used in surgery, first, to detect certain foreign bodies, such as bullets; and second, to recognize fractures. With the progress of time each of these applications of the rays has been carried out more carefully, foreign bodies are more exactly located, and fractures are studied with more thoroughness. The impression prevails among some surgeons that the two applications just mentioned are still the only ways in which the X-ray examinations assist in surgery; but this impression is a mistaken one, for the method has extended beyond these limits, and includes: first, the large subject of diseases of the bone, as, for example, tuberculosis of the bone, rickets, tumors and abscesses of the bone, sub-periosteal abscess, osteosarcoma, osteomyelitis, the study of the bone during the process of repair, etc.; second, congenital malformations; third, the specialties of dental and orthopedic surgery; fourth, the detection of calculi. This method has shown itself of service likewise to the embryologist and the anatomist in the study of the development of the skeleton¹ from the earliest stages, and in the study of the normal joints.² An exact knowledge of the latter is also of especial benefit to the surgeon.

The surgical use of the X-rays is then in a stage of natural development. It is evident that the profession appreciate the fact that we now have for surgical purposes a method of examination which is harmless, and useful as a basis for diagnosis, treatment, and prognosis, and one that may save needless operations. The criticisms which were made of it in the early days, and the shortcomings of which it was accused, were

¹ "Atlas der normalen u. pathologischen Anatomie in typ. Roentgenbildern," Lambertz, Lucas Grafe & Sillem, Hamburg, 1900.

² E. A. Codman, M.D., "Experiments on the Application of the Roentgen Rays to the Study of Anatomy," *Journal of Experimental Medicine*, 1898, pp. 383-392; and Eugene R. Corson, M.D., "An X-Ray Study of the Normal Movements of the Carpal Bones of the Wrist," *Proceedings of the Ass'n Am. Anat.*, December, 1898, pp. 67-92.

due largely to the difficulties of carrying it out, and especially to the want of familiarity with radiographs, and consequently, as was natural, an inability to read and interpret what they showed. This new method should of course be used in connection with other methods of examination.

Size of Apparatus.—Since the extremities are more easily penetrated by the rays than the trunk, a less powerful exciter for the vacuum tube than is necessary for the physician will answer for a great deal of surgical work. Foreign bodies are very apt to be found in the extremities, as needles, bits of glass, etc., get into the hands and feet more frequently than into other portions of the body. Second, an examination of the records of 8361 cases of fractures admitted to the Boston City Hospital during fifteen years, exclusive of those treated in the out-patient department, demonstrates that fifty-four per cent at least could have been examined with a machine of moderate power; and that out of 1537 fractures treated during two years at the out-patient department, sixty-nine per cent could have been examined also with a machine of this size. (See Table, page 456.)

These statistics in regard to fractures, together with the fact already mentioned that a larger proportion of foreign bodies are found in the extremities than in the trunk, indicate that in all probability more than one-half of the surgical cases could be examined with a comparatively small and inexpensive machine. By this I do not mean to suggest that, when possible, the surgeon should not have the best apparatus, but I do wish to indicate that good work can be accomplished with inexpensive apparatus, although, of course, the latter would have its limitations.

Radiograph and Fluorescent Screen.—The radiograph is better adapted to the surgeon than the physician, as most of the former's work is done on the extremities, whereas the physician deals more largely with the thorax; in the extremities the parts are at rest; in the trunk, as a rule, they are in motion. But, as will be seen later, the fluorescent screen is also helpful to the surgeon in connection with the radiograph.

Knowledge of Normal Bones and Joints; Interpretation of X-Ray Photographs.—Before the surgeon attempts to interpret X-ray photographs of abnormal bones or joints, he should familiarize himself with the appearances of the bones and joints of healthy persons of various ages; otherwise he may not infrequently be led into error. For

instance, an epiphyseal line in a child may be mistaken for a fracture. Likewise, when considering a given photograph, he should always have at hand a history of the case.

TABLE (See page 455)

8361 CASES OF FRACTURES TREATED IN THE WARDS OF THE BOSTON CITY HOSPITAL
IN FIFTEEN YEARS PREVIOUS TO JULY, 1897

| <i>A</i> | | <i>B</i> | |
|--|------|---|------|
| 4504 cases could have been examined with a machine of moderate power. | | 3857 cases needed a more powerful machine. | |
| HAND — | | FACIAL BONES | |
| Fingers | 275 | Jaw | 202 |
| Thumb | 53 | Nasal bones | 124 |
| Metacarpal | 65 | Zygoma | 6 |
| Carpal | 1 | SKULL | 564 |
| Wrist | 10 | RIBS | 587 |
| Colles | 314 | STERNUM | 14 |
| FOREARM — | | SPINE | 159 |
| Both bones | 193 | COCCYX | 6 |
| Radius | 120 | PELVIS | 89 |
| Ulna | 70 | HUMERUS | 65 |
| ELBOW | 96 | Shaft | 313 |
| LEG — | | At elbow joint | 103 |
| Both bones | 1349 | Head | 6 |
| Fibula | 820 | Anatomical neck | 62 |
| Tibia | 396 | Surgical neck | 48 |
| Potts | 304 | CLAVICLE | 232 |
| ANKLE | 9 | SCAPULA | 51 |
| FOOT — | | FEMUR | 60 |
| Astragalus | 41 | Neck | 349 |
| Metatarsal | 143 | Shaft | 616 |
| Os calcis | 45 | Impacted | 11 |
| Tarsus | 27 | At knee | 18 |
| Toe | 167 | KNEE | 150 |
| Cuboid | 1 | | |
| Cuneiform | 1 | | |
| Phalanges | 4 | | |
| | 4504 | | 3857 |

A series of X-ray photographs of the skeleton, and especially of all the joints of healthy individuals, would be very helpful in every hospital

for comparison with corresponding parts in the X-ray photograph of any given patient.¹

Radiographs are sometimes accused of being deceptive, but very frequently they seem to be deceptive because the surgeon has not learned to interpret them.

Value of Negative. — The art of reading the negative made by means of the X-rays is one which deserves careful study especially on the part of the surgeon as the negative often shows, particularly one of calculi, more than the print. (See Chapter III, page 96.) It also saves delay, although if Velox paper is used, the time necessary to make a print is short.

Two or More Negatives made. — If the negative presents only a faint shadow its import may be variously interpreted; therefore two negatives at least should be made and carefully compared, and unless the appearances seen in one confirm those observed in the other, a third should be made; no doubtful appearance that lacks confirmation should be used as a basis for diagnosis.

Further, X-ray negatives or photographs may be misleading because the relative position of the part to be photographed, the plate, and the tube are not such as to give the best answers to the questions in the mind of the surgeon.

Stereoscopic pictures aid in making simpler the interpretation of some of the conditions present, those about the elbow and ankle joints especially. This point will be further discussed in succeeding chapters. Professors Trowbridge, Elihu Thomson, and Girdwood directed attention to the method some years ago.

Comparison of Well and Affected Bone. — In disease of the bone the immediate comparison of the well and the affected part is often advantageous, and to this end it is desirable, if we suspect disease of the bones of one leg, for example, to take a picture of both legs on one plate.

Importance of Two Views. — Two radiographs of a given injury or foreign body are often necessary for diagnosis. This point will be discussed in more detail in the succeeding chapters.

Importance of Good Negatives. — In the early days of the X-rays the surgeon was obliged to accept pictures such as should not be received to-day, and although much may be suggested by an indifferent

¹ Since this was written, I find that Dr. R. Jedlicka has made radiographs of the elbow joint; Drs. G. Kratzenstein and W. Scheffer, of the wrist and shoulder joints. *Fortschritte a. d. Geb. d. Roentgenstr.*, Ergänzungsheft 4, 1900.

negative, in many fractures, for example, much more can be learned from a good one, and X-ray photographs of the bones should be carefully made with a good apparatus in order to get as perfect outlines and details as possible. When X-ray examinations are made with reference to, or on account of, a suspicion of a diseased condition of the bone, nothing short of the best can be considered in estimating the capabilities of this method. In many cases, in order that the photographer may do his work in the best way, it must be done under the direction of the surgeon. Many things that would be overlooked in a poor radiograph show distinctly in a good one, and it takes but little more time to obtain a good picture than to make a blurred and unsatisfactory one.

Swelling about a Fracture and Swollen Joints. — When there is considerable swelling about a fracture, or if the joints are much swollen, it is more difficult to obtain a satisfactory picture than when there is no swelling, for two reasons: first, the plate must be farther from the bone in the former case; and, second, the thicker the soft parts are the more obstruction do they offer to the rays. For example, a bone which is 2.5 centimetres in diameter at the wrist, and is covered by soft parts having a thickness of 1.25 centimetres, would show a marked contrast to the soft tissue in an X-ray photograph; but if such a part were swollen so that the soft tissues were 3.7 centimetres in thickness, the difference between the amount of rays absorbed by the bones and the tissue would make the contrast between the two less pronounced. In such cases as the above, or when photographing the hip, better results may be looked for when a tube is used that has a low resistance, and when the plate is given a long exposure, than when the contrary method as to tubes and exposure is employed. For soft tissues, tubes with low resistance should be used, because greater differentiation is obtained by them. If the parts are thick much energy must be sent through the tube.

Bones and Soft Tissues. — When a radiograph is desired of the bones and soft tissues, the exposure cannot always be readily adapted for both conditions, because to show the one requires a longer exposure and a tube of different resistance than the other. The length of the exposure, as in ordinary photographs, must be adapted to the amount of light which the plate receives from the desired object.

Sinus. — The extent of a sinus may be recognized by means of the X-rays, by injecting into it a paste made of subnitrate of bismuth; the paste should be thin enough to flow easily. It may be injected through a piston syringe.

CHAPTER XVIII

DEVELOPMENT OF THE SKELETON. CONGENITAL MALFORMATIONS. FRONTAL CAVITIES. MUSCLE

DEVELOPMENT OF THE SKELETON

THE following cut is given to show how well the osseous portions of the skeleton may be seen even during foetal life; but since the development of the skeleton has been studied and discussed with great care, and beautiful reproductions of X-ray photographs made by Dr. Lambertz,¹ it is superfluous to do more than refer the reader to his work on this subject.

Epiphysis. — The X-rays are of assistance in pointing out delayed union of the epiphyses, and when we are familiar with the appearances

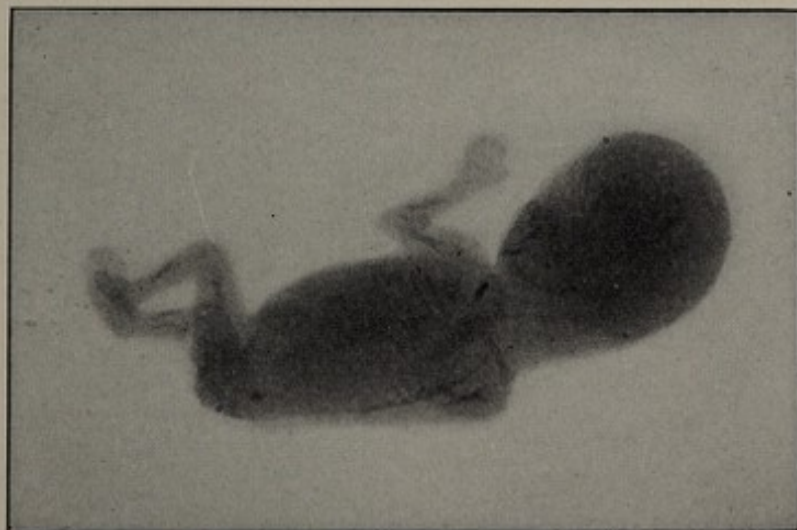

FIG. 241. Foetus. (Size of original.)

to be expected of the epiphyses at different ages, that is to say, when we have made a physiological scale, we may find that we have gained a method of estimating the general condition of younger patients in regard to their development.

¹"Atlas der normalen u. path. Anat. in typ. Roentgenbildern," Lucas Grafe & Sillem, Hamburg, 1900.

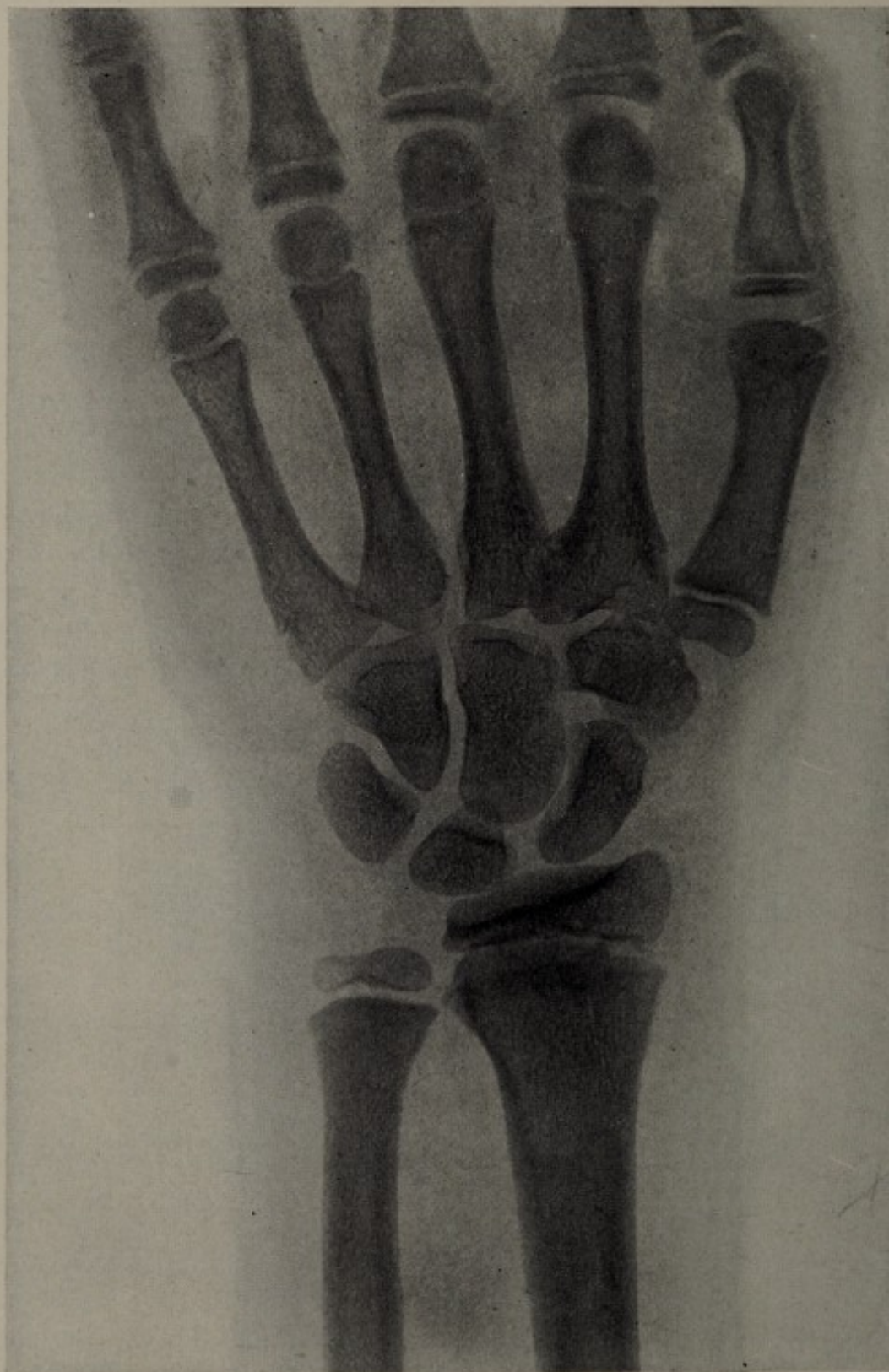


FIG. 242. A. P. Boy about fourteen years old. Epiphysis of radius.

The preceding cut shows how clearly the epiphyses may be seen in a boy about fourteen years of age. The patient, A. P., was examined at the out-patient department of the Boston City Hospital.

Epiphyseal Lesions in Children. — Hitherto our knowledge of epiphyseal lesions has only been approximately correct, but accurate information can now be obtained by the X-rays. Poland¹ showed, as early as 1896, the importance of obtaining X-ray photographs of certain forms of recent complicated injuries to the epiphyses in children, and cited a case of a boy seventeen years old, where the X-ray photograph confirmed the diagnosis of a lesion in the distal end of the metacarpal bone. His book, entitled "Traumatic Separation of the Epiphyses," is of value to any one who desires to make himself familiar with this subject.

Corson has also written an excellent article on the study of the normal membral epiphyses at the thirteenth year.²

Disturbance of the Development of the Bones in Cretinism. — Hofmeister³ has published an interesting and instructive article on this subject, in which he reports at some length the case of a girl four years old who appeared like a child of a year and a half old only. She could not speak, but cried continually. The thyroid gland could not be felt. The extremities were myxomatous and very much thickened.

The X-ray photographs showed that the bones, although normal in shape, were strikingly small for the age of the child. In almost all the long bones the diaphysis only was seen; of the epiphysis either nothing, or small centres of ossification only, could be observed. The child improved strikingly when given thyroid extract.

Robert von Wyss⁴ has made an interesting investigation of the development of the skeleton in cretins and cretinoids, and compared it with that of the normal individual. He examined by means of the X-rays 30 abnormal persons, 24 of whom ranged from 7 to 20 years of age, and 6 from 23 to 55 years of age. In connection with the data obtained from radiographs of the elbow, hand, knee, etc., he gives the personal history so far as he has been able to obtain it, and in 7 cases belonging to two families, the family history.

¹ "Skiagraphy as an Aid to the Diagnosis of Epiphyseal Lesions of Childhood," *British Medical Journal*, London, 1896, Vol. I, p. 620.

² *Annals of Surgery*, 1900, pp. 621-647.

³ "Über Störungen des Knochenwachstums bei Cretinismus," *Fortschritte auf dem Gebiete der Roentgenstrahlen*, 1897-1898, pp. 4-12.

⁴ "Beitrag zur Kenntnis der Entwicklung des Skelettes von Kretinen und Kretinoiden," *Fortschritte a. d. Geb. d. Roentgenstr.*, B. III, 1899-1900.

From a careful investigation of the subject he draws the following conclusions : —

1. That there is no hint, in the cretins and cretinoids observed, of premature ossification, or synostosis (he mentions that premature synostosis has been taught for forty years).

2. That there is a delay in the ossification of the cartilaginous parts of the skeleton, in the cretins and cretinoids who are at the age of development or a little older only, as shown by the late development of the centres of ossification and the delayed union of the epiphyses.

3. The delay in the process of ossification as compared with the normal individual is of a few years' duration only, as a rule, judging by the macroscopic investigation and the X-ray examination; only exceptionally is an abnormal condition to be found in this respect after the age of twenty-five.

4. The bones of the hand are the latest to ossify.

Ossification of the Cartilage of the Larynx. — Scheier,¹ in his study of the larynx by means of the X-rays, found in all the cases he examined that the ossification began at the end of the second decade. He considers that this ossification must be looked upon as a normal process that begins when other portions of the skeleton have concluded their growth. He also found that the ossification advanced from point to point in a tolerably regular manner, and its line of advance was different in men and women.

CONGENITAL MALFORMATIONS

It is not infrequently difficult for the surgeon to decide from the data obtained by the ordinary methods of examination whether or not he should attempt to improve the condition of the patient. The X-rays afford the surgeon a means of determining the exact condition of the bones, and, if an operation seems desirable, assist him to plan the best method of procedure. The following illustrations show how readily the distribution of the bony portion of the hand can be made out : —

Deficiency and Arrested Development of Bones. — Dr. Lane² reports two cases of deficiency of the shaft of the ulna, treated successfully by the insertion of a rabbit's femur. He gives an X-ray photograph illustrative of the operation.

¹ *Fortschritte a. d. Geb. d. Roentgenstr.*, B. I, 1897-1898, p. 64.

² *Trans. Clin. Soc.*, London, Vol. XXXII, 1899, p. 44.

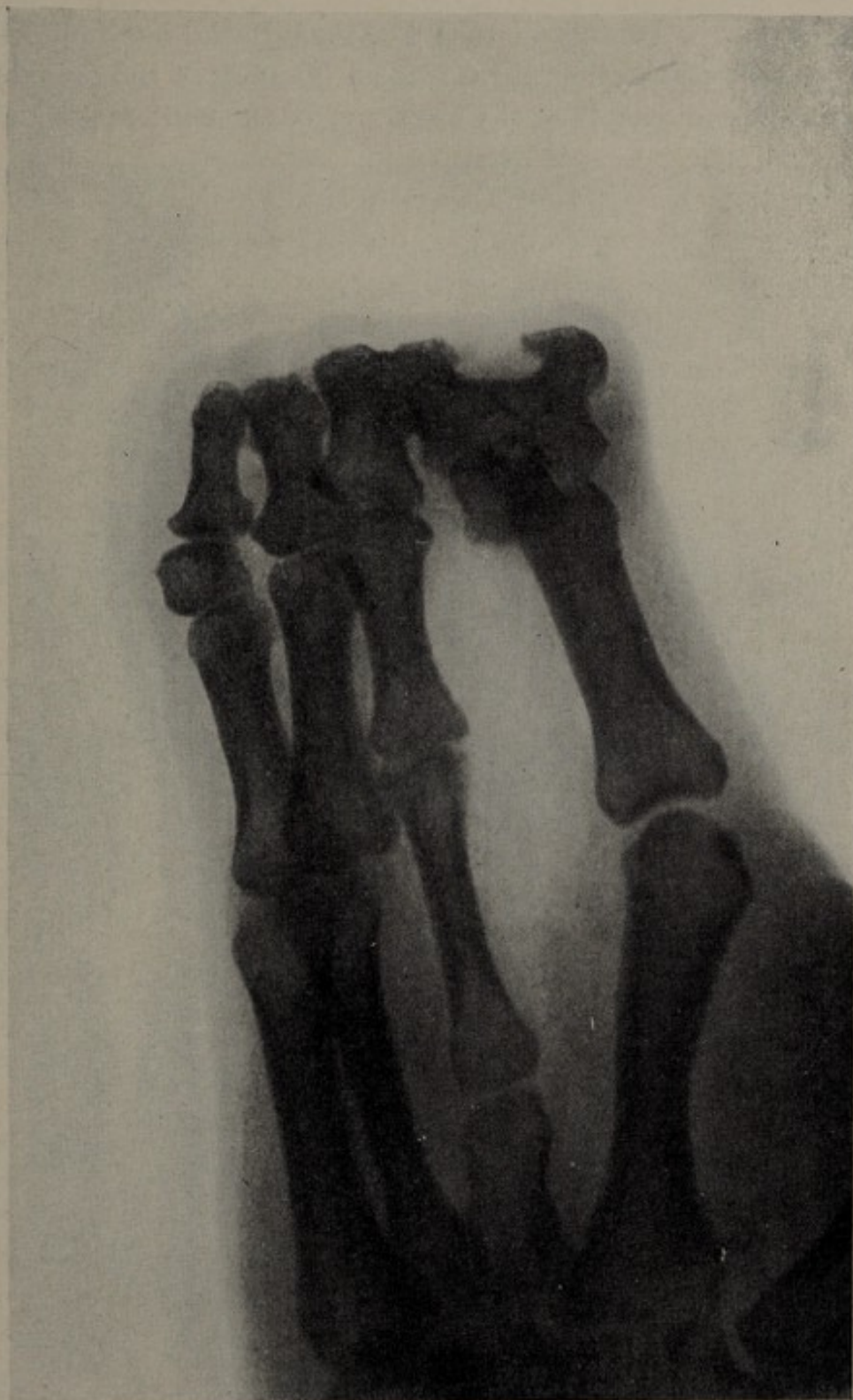

FIG. 243. Congenital malformation of hand.

Dr. Schorstein¹ reports a case of congenital absence of both clavicles, and Dr. Alfred G. Levy,² a case of arrested development of the third and fourth ribs. These cases are illustrated by radiographs.

¹ *Lancet*, January 7, 1899, p. 10.

² *British Medical Journal*, May 13, 1899, p. 1150.

Spina Bifida. — In this disease Dr. Carl Beck¹ has found that the radiograph showed whether there was an opening in the spinal column and gave some indications of the character of the contents of the sac.

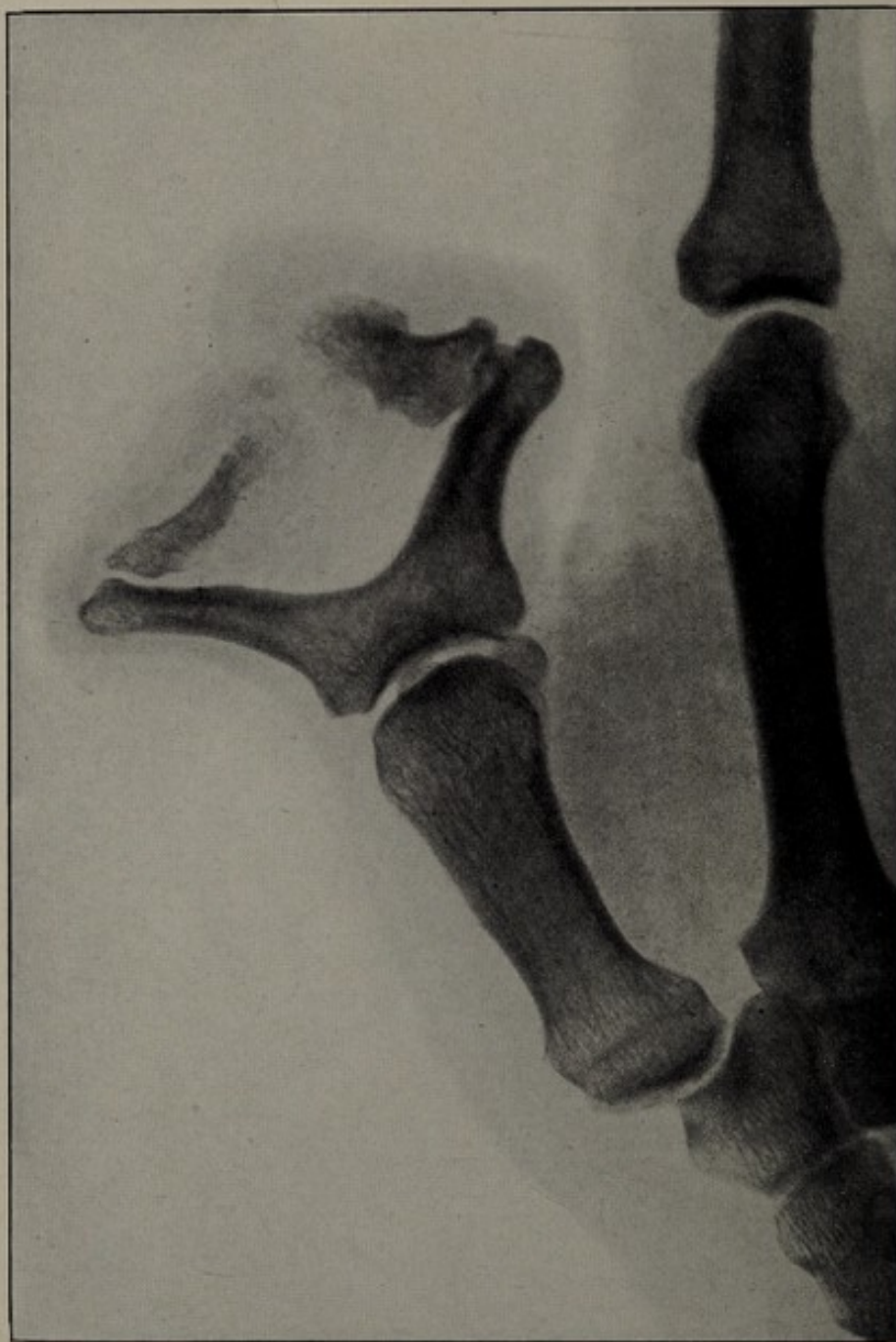


FIG. 244. Congenital malformation of right thumb. Man twenty-five years old. Patient of Dr. Cushing.

Examination of Frontal Cavities by the Aid of the X-Rays. — Scheier² indicates the usefulness of the X-rays in this direction. For-

¹ *New York Medical Record*, August 13, 1898, p. 231.

² *Fortschritte a. d. Geb. d. Roentgenstr.*, B. I, 1897-1898.

merly the only means of judging whether or not the sound reached the sinus frontalis was the direction it had taken and the distance it had entered. Now, by means of the X-rays, its entrance or failure to enter can be definitely settled. In some cases in which Scheier used the sound, the X-rays showed that it had reached the cavity easily, and its shadow could be watched on the screen as it was moved about. In other cases the X-rays showed that the sound had not reached the frontal cavity as Scheier had thought from the direction it had taken and the distance it had entered. He found the screen gave clearer pictures than the negative, and the negative than the print.

Spiess¹ has also done some work in this direction, and considers that all danger is excluded because the movements of the instrument can be watched on the fluorescent screen. He also thinks that by means of improved instruments, on which he is working, the frontal cavities can be brought into better communication with the nose, and all the sinuses can be thoroughly scraped. He considers that with better instruments the rhinologist can treat cases of empyema of the frontal cavities in its severest form, that have been formerly referred to the surgeon. Further, he believes that with the use of the X-rays the practitioner can hardly be deceived as to whether or not a frontal cavity exists. The part should be examined from both the right and left sides with the screen, and if the question is not clear an X-ray photograph should be taken with the face in profile, and also with the light going through from the back of the head to the face.

MUSCLE

Myositis Ossificans Traumatica. — Frederick Eve² reports a case in which the X-ray photograph showed a mass in front of the femur that had an ill-defined outline. This osseous mass was removed by operation, and the patient did well. Dr. Eve remarks that the diagnosis would have been impossible without the X-ray photograph and exploration.

X-ray examinations may be of use in myositis ossificans progressiva.

Myositis Ossificans. — Dr. de la Camp³ reports a case of so-called myositis ossificans, of which Virchow published an account in the *Berliner klin. Wochenschr.*, No. 32, 1894. The patient during the previous

¹ *Ibid.*

² Trans. Clin. Soc., London, 1899, xxxii, p. 232.

³ *Fortschritte a. d. Geb. d. Roentgenstr.*, B. I, pp. 179-180.

four years had had no further marked attacks of ossification, nor had his condition been essentially influenced, so that clinically he remained the same. Virchow, in discussing the case, considered that it was an exostosis luxurians rather than a myositis ossificans; that the ossification did not so much have its origin in the muscles, as that (to use Virchow's expression) the skeleton had a contagious effect upon its surroundings. The X-ray photograph, states Dr. de la Camp, confirms this view, and shows that the most marked ossification was in the thorax where the muscles and skeleton come in contact with each other.

Remy and Contremoulin¹ report that by the aid of chemical preparations the muscles, ligaments, and tendons of dead bodies, both of men and frogs, could be seen in the radiograph. This method would be useful in showing the anatomical relations of soft part.

¹ *Electrical Review*, New York, April 14, 1897.

CHAPTER XIX

FRACTURES AND DISLOCATIONS

THE X-rays provide a more accurate and detailed picture of a fracture than can be had in any other way. In some cases, as will be seen presently, the diagnosis of fracture can be made only after an X-ray examination; in other cases, which simulate a fracture, the X-rays show that none exists. In severe sprains, where the foot, for instance, is much swollen, it may be difficult without the rays to know whether or not a fracture is present. Further, the X-rays make unnecessary or curtail the painful examination of a swollen and sensitive part, and it is not improbable that the excellent views of the fractured bones which may now be obtained will lead to improved methods of treatment.

Drs. Ross and Wilbert,¹ in a careful study of 500² fractures, have shown the value of the X-rays in the diagnosis and during treatment of these injuries. The article is illustrated by outlines of various fractures, and by a diagram showing the frequency with which fractures occur in different bones. The interesting fact is pointed out that of these cases 349 were fractures of some portion of the upper extremity, and 151 of the lower. Fractures of one or more phalanges were found in 21 cases, and of one or more metacarpal bones in 51 cases. It is also suggested that these fractures, as well as those of the metacarpal bones, were probably not recognized in the past, even when of quite an extensive nature. In many of the metacarpal cases patients did not apply for treatment until two to ten days after the accident; pain, especially when trying to use the hand, was severe. The writers also show that injuries of the lower articulating surface of the humerus are more common in children than in adults, and they state that when the

¹ "Five Hundred Cases of Fractures of the Extremities verified by Radiographs," *Philadelphia Monthly Medical Journal*, June, 1899.

² Since this was written Drs. Ross and Wilbert have reported on a second series of five hundred cases which were verified by radiographs, *Philadelphia Medical Journal*, 1900, VI, 1241-1244.

long bones are broken at or near the middle, the line of fracture is apt to be more transverse than oblique.

C. T. Dent¹ states that the X-rays have modified existing views as to the nature of fractures. First, they are nearly always more or less oblique; and, second, longitudinal splitting has occurred more often than has been realized. He likewise points out that the X-rays enable the surgeon to watch the process of union in oblique fractures, and that they render aid by indicating to him how long a rigid apparatus should be worn.

I will not attempt, in the space at my disposal, to discuss the whole subject of X-ray examinations of fractures in detail, as books are now written on radiographic examinations of the fracture of one portion of a single bone; for example, works by Dr. E. Gallois of Lyons, and Dr. Fernand Picard of Paris, on fractures of the lower end of the radius; but will present a few cases of fractures, the radiographs of which were made chiefly at the Boston City Hospital, to illustrate the ways in which the X-rays assist in this field.

Method of Examination by the X-Rays. — The methods of examination have been considered in Chapter III, but will be further discussed here and illustrated by X-ray photographs.

Examination with Fluorescent Screen. — Before taking a photograph of a dislocation or a fracture it is well to examine the given part first with the fluorescent screen, in order to see in which direction the view is likely to be the most instructive. The screen may show the fracture when the photograph does not, but such a case is rare. After the examination has been made with the fluorescent screen, the photographic plate can be put over the part to be radiographed and the exposure made without moving the patient.

Examination with the Radiograph. — The radiograph gives the surgeon a good basis for proper treatment, and puts him in a position to determine what is most judicious for the individual case. X-ray examinations not only enable the surgeon to aid the special patient, but to become a better practitioner because the habit of thinking out a new problem is encouraged.

The following case illustrates the importance of X-ray examinations, and shows also that in some instances radiographs are essential — that we cannot rely upon the fluorescent screen. The case also shows that

¹ "The Value of Skiagraphy in Surgical Cases," *Practitioner*, London, 1898, LX, pp. 123-136.

it is well to have the plate rather larger than would be necessary to cover the supposed site of the injury.

T. D. fell a few feet from a staging and injured his right foot. He went directly to a hospital and was carefully examined by the usual methods. No injuries were found. He was then examined with the fluoroscope, and no injuries were detected. No radiograph was made. The patient remained three days in the hospital, and was then discharged with his foot in a plaster cast. A day or two later he returned to the out-patient department of the hospital, and this time a radiograph was taken. The plate used was large enough to include the lower portion of the tibia and fibula as well as the foot, and the radiograph showed (see Fig. 245) a fracture of both bones of the right leg.

Importance of Radiograph from Two Points of View. — Sometimes one photograph will answer, but it is best to take two from different points of view. It is quite possible, as just shown, that a fracture may escape observation by the fluorescent screen, or even with a single X-ray photograph, but if two pictures of the bone are taken, the chance of not finding a fracture, if one exists, is very small. Suppose one of the long bones to have been fractured, with no displacement, but simply a crack through the bone. If a view is taken looking through the crack of the fracture, it will be easily recognized on a photographic plate. If, however, the view is taken at right angles to this, the fracture may escape detection even by an X-ray photograph. When there is a fracture without displacement it is as a rule not recognized by an examination with the fluorescent screen.

Stereoscopic Pictures. — For the location of many fractures of the bones — this statement applies particularly to the joints — and of the position of foreign bodies, a so-called stereoscopic view is very satisfactory. In order to get a good view of many surgical injuries or diseases of the bones two pictures must be taken from different points of view, as already suggested, but the relation of the parts will often be still more clearly indicated if these two views are stereoscopic ones. To carry out this method of examination the tube must be moved, after the first exposure has been made, a distance of 6.2 centimetres, and a second photograph taken, the patient remaining in the same position during the two exposures. After the negatives have been developed the photographs must be mounted stereoscopically. They are then looked at with the stereoscope, or, with practice, with the eyes alone. Now that we have a reflecting stereoscope it is no longer necessary to

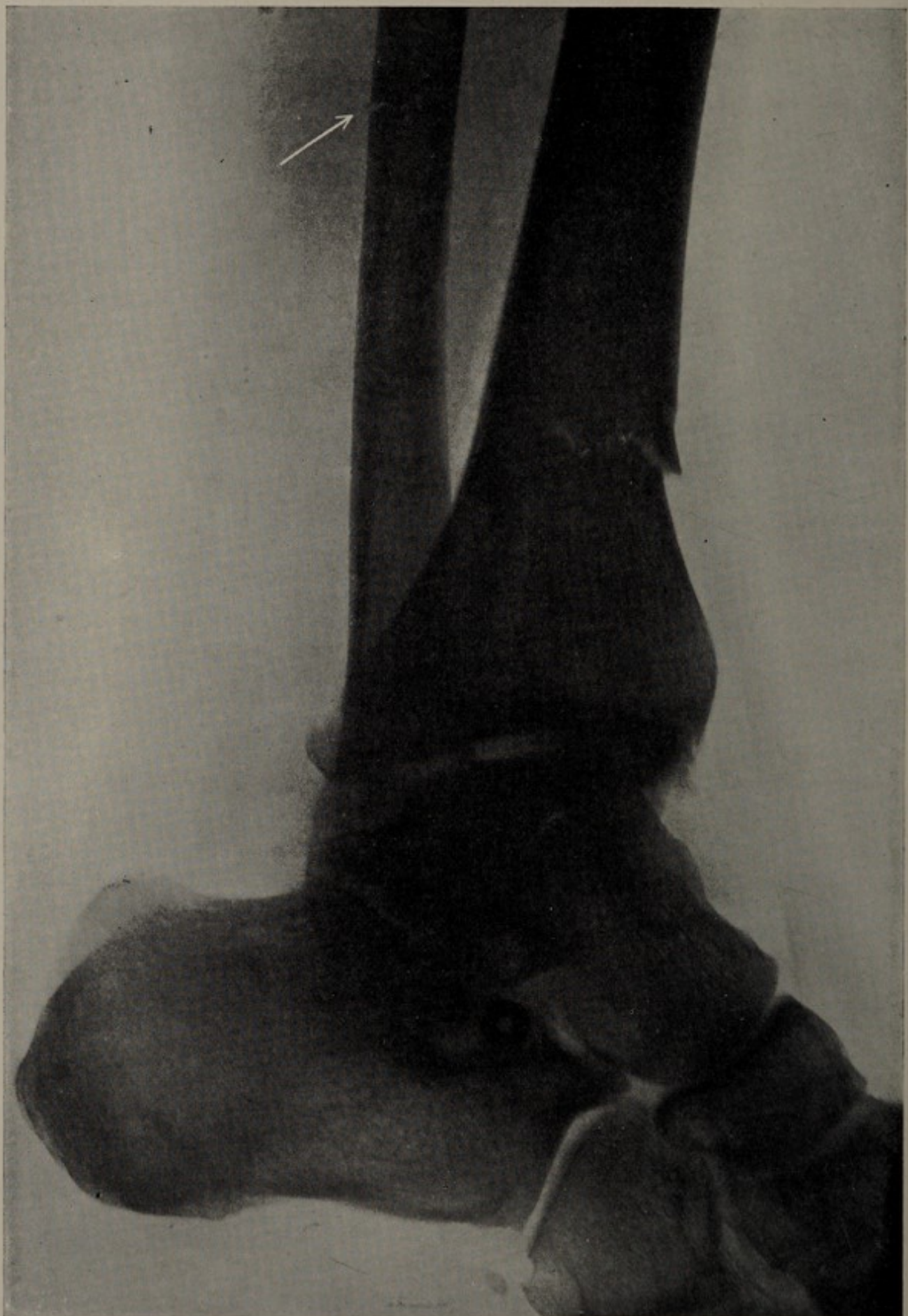

FIG. 245. T. D. Fractures recognized only by radiograph.

reduce the pictures in order to make them fit into a small stereoscope. Professor Girdwood has suggested and used the reflecting stereoscope successfully.

The following cut shows a modification of the Wheatstone stereoscope. The radiographs are held in sliding frames, and the observer so places his eyes that the reflection of each picture is seen in each of the two mirrors in the middle of the apparatus.




FIG. 246.

Errors to be avoided. — Two errors are not uncommon when making X-ray examinations of bones. The first occurs only in patients where the epiphyseal line is still present; this line has been mistaken for a fracture, hence the importance of familiarity on the part of the surgeon with the characteristics of the bones of persons of different ages (see Chapter XVII, Introduction to Surgery, page 455); the other is due to the reliance placed upon one photograph for the determination of the presence or absence of a fracture. Two photographs should be taken, as above stated, to avoid this error, the direction of the light when the first view is taken being at right angles to its direction when the second photograph is made.

Advantages of Permeable Splints and Dressings. — Wooden splints and cotton dressings are preferable to plaster, and to dressings that




FIG. 247. Radiograph of:

Soft rubber drainage tube.

Silver wire.

Going from left to right, the needles are threaded with catgut, horsehair, silkworm gut, iron-dyed silk, and silk, respectively.

Tin.

Plaster-of-paris bandage 6 mm. thick.

Aluminum four times as thick as the tin.

Wooden splint 3 mm. thick.

Mill board 6 mm. thick.

Iodoform bandage.

Starch bandage.

Rubber plaster.

Corrosive cotton.

Cotton.

obstruct the rays, whether an X-ray photograph is to be taken or an examination made with the fluorescent screen, because they allow the surgeon to see the position of the parts, and learn whether it has been properly set without removing the splints, and to watch the process of repair going on. The preceding cut illustrates the various degrees of obstruction offered to the X-rays by different kinds of splints and dressings, and by buckles, pins, etc.

The following cut (Fig. 248, fracture of both bones of the leg) shows the effect of iodoform in a picture, and that it might easily be mistaken for a foreign body (see Chapter III, page 86). It is so opaque that in this case it obscures one of the fractures.

Position of Patient. — It is an advantage, generally speaking, to have the patient lying on the stretcher when a photograph of a fracture is taken. The position is a comfortable one, and enables the patient to keep the given part at rest.

EXAMINATION OF SPECIAL BONES OF THE BODY, ILLUSTRATED BY RADIOGRAPHS

These radiographs largely explain themselves; they and the notes appended indicate or demonstrate such points as the following: that X-ray examinations make a more exact diagnosis possible; they may show the absence of a fracture where by the ordinary methods one was thought to be present, or the presence of a fracture that had been overlooked by the ordinary methods — this fact is especially the case in fractures of the phalanges and metacarpal bones; if there is a fracture, they show its site and character, and whether or not the parts are in good position; that the X-rays are useful in showing us cases of fracture where there is much swelling and where palpation is difficult; that an old callus may be seen, but not a recent callus, or that the latter can be seen only indistinctly; that it is an advantage to compare the well and injured extremity on the same plate; that thin parts are more easily radiographed than thick parts; that it is important to take radiographs of a fracture from two points of view; that a record of the position of the tube with reference to the plate is necessary (see Chapter III, page 87), and of the relative position of the plate and the part to be photographed.

When these radiographs were taken, the tube was 70 centimetres from the plate, and, as a rule, opposite the fracture. I do not give cuts

of stereoscopic pictures, as they do not lend themselves readily to demonstration without a stereoscope.

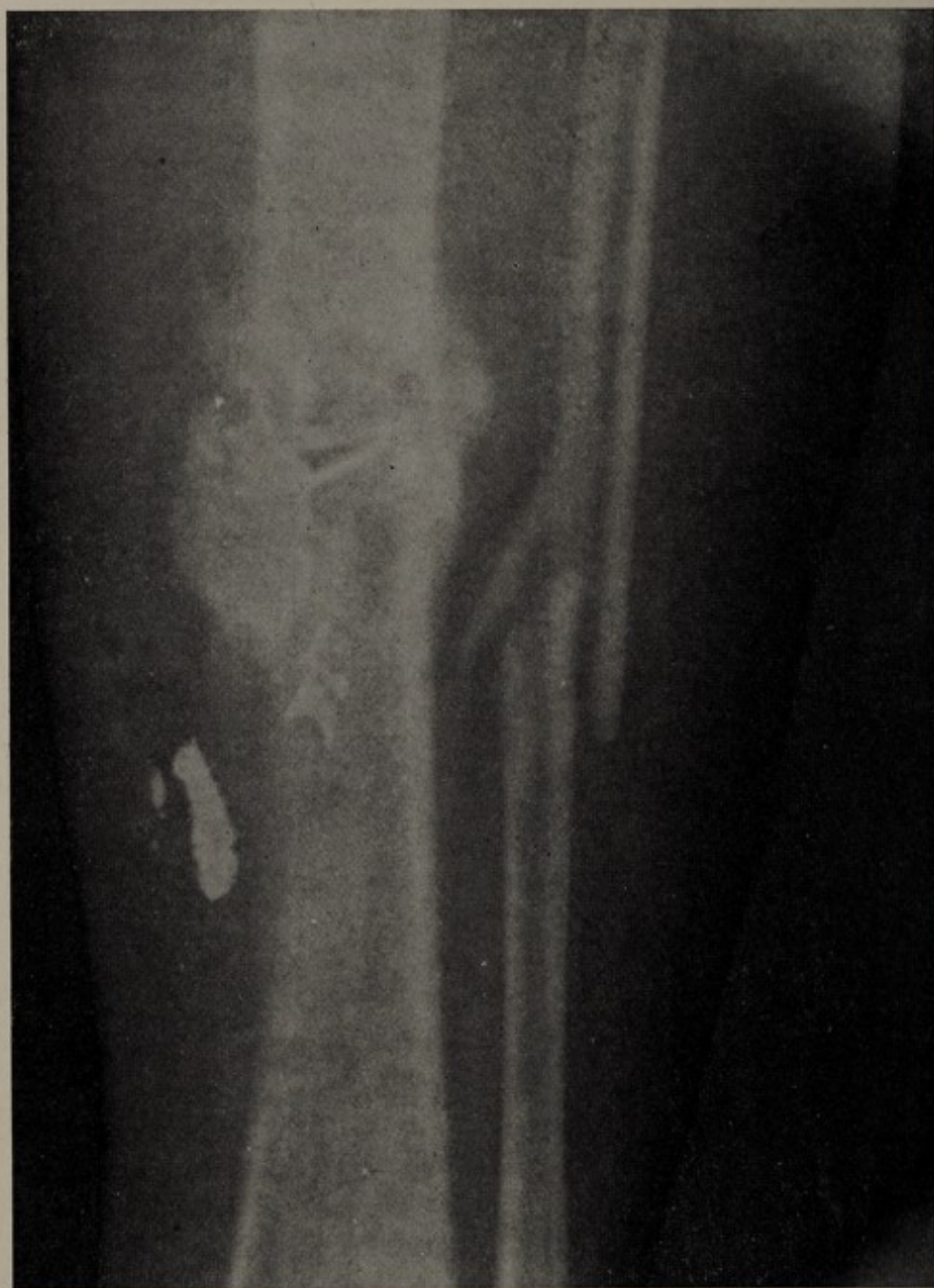

FIG. 248. The light foreign bodies at left of cut, resembling pieces of metal, are pieces of iodoform. Both bones of the leg have been fractured, but the fracture of the tibia is obscured by the iodoform. (This radiograph was taken on bromide paper, which was then coated with oil, and silver prints were made from it. In this cut the parts that would be dark in a print made from an ordinary glass negative are light; the iodoform obstructs the X-rays and casts a shadow as does lead.)

Skull. — If a fracture of the skull has occurred, or is suspected, it is well first to examine the head carefully with the fluorescent screen, and to follow so far as may be possible the outline of the interior as well as the exterior of the bones of the cranium, as this examination may enable the practitioner to select the best point of view from which to take the photograph. By "point of view" I mean the best position both for the vacuum tube and the photographic plate with reference to the part of which a photograph is desired. If the fluorescent screen gives no hint, two or more photographs must be taken so that the part may be viewed from different directions. The base is now inaccessible.

Much ingenuity may be exercised in devising suitable methods for obtaining photographs of special parts of bones of the face. For example, if a picture is desired of some portion of the jaw, or of the teeth, it is an advantage to put the photographic plate inside the mouth, in contact with the part to be photographed, according to the method devised by Dr. Rollins (see chapter on Dental Surgery, page 606). To make this arrangement practicable the film used must be stiffened by a backing of wood or cardboard and wrapped in light-proof paper, and the whole must be covered with a water-tight cloth. The size of the film must be adapted to the part of which a picture is desired. By this method the photograph may be taken without including the bones on the other side of the face, as would be necessary were the film on the outside of the cheek and the tube opposite the other cheek, and thus the picture is free from undesired and confusing images.

Spine. — In photographing the spine it is generally best to make separate pictures of the cervical and dorsal vertebræ, and perhaps also of the lumbar vertebræ. A good photograph of several of the first-mentioned vertebræ may be obtained when the plate is put on the side of the neck with the light opposite to it on the other side. (See Fig. 68.) The outlines of this portion of the spine can also be seen very well on the fluorescent screen. When a photograph is desired of the dorsal and lumbar vertebræ, the best position for the plate is under the back, the patient being in a prone position on the stretcher. In this connection the following case reported by Noble Smith¹ is interesting, as it shows the usefulness of the X-rays in injuries to the spine. The patient fell eighty feet, and some weeks after the fall suffered from pain and stiffness of the neck. An examination showed an angular bend between the fifth and sixth cervical vertebræ, and an X-ray photograph

¹ *Medical Press and Circular*, London, 1900, N. S. LXIX, p. 240.

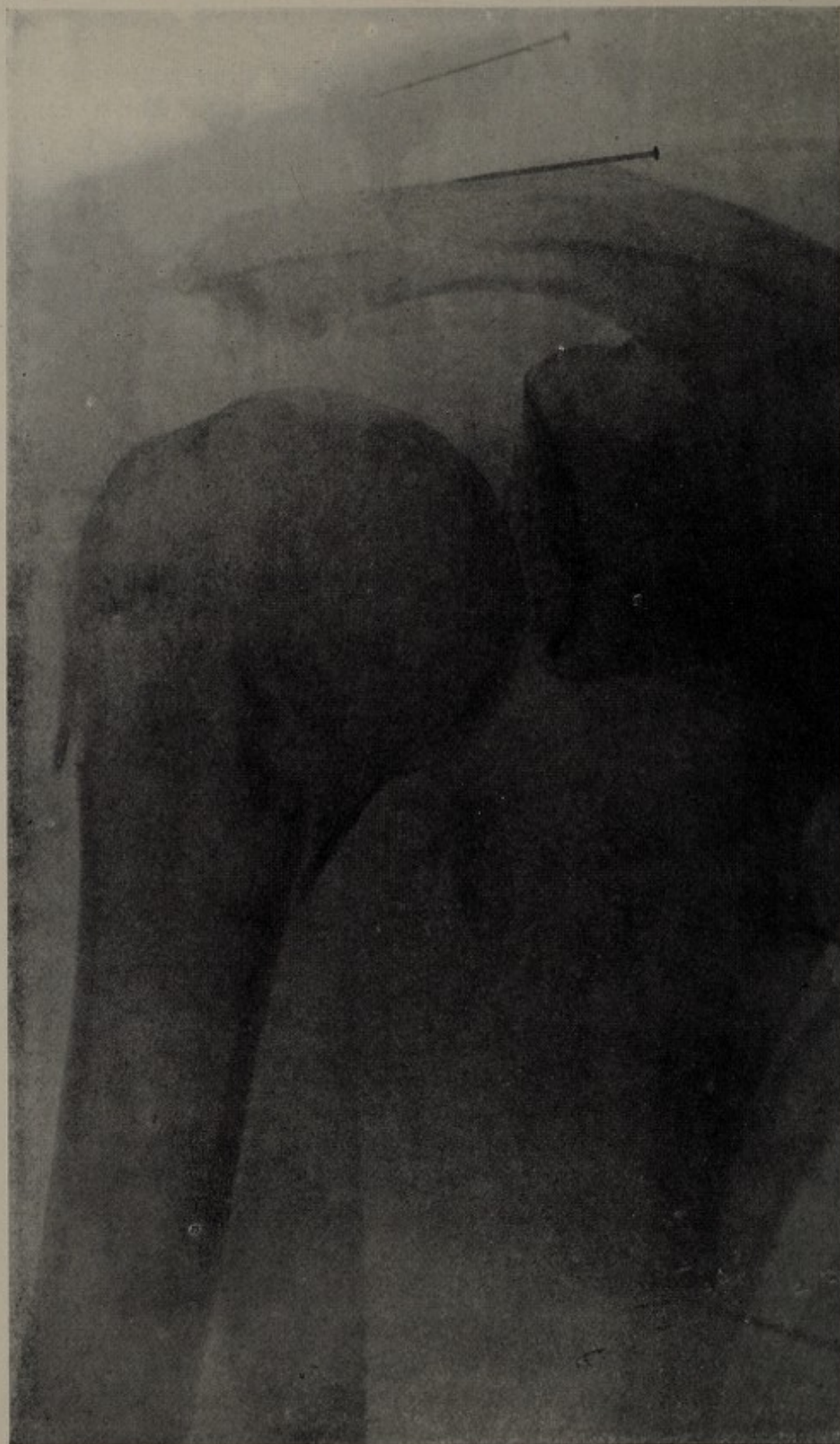

FIG. 249. Patient of Dr. Lothrop. Fracture of surgical neck of right humerus just below tuberosities. Radiograph shows site and character of the fracture. The radiograph was taken outside of the bandages after the fracture was put up.

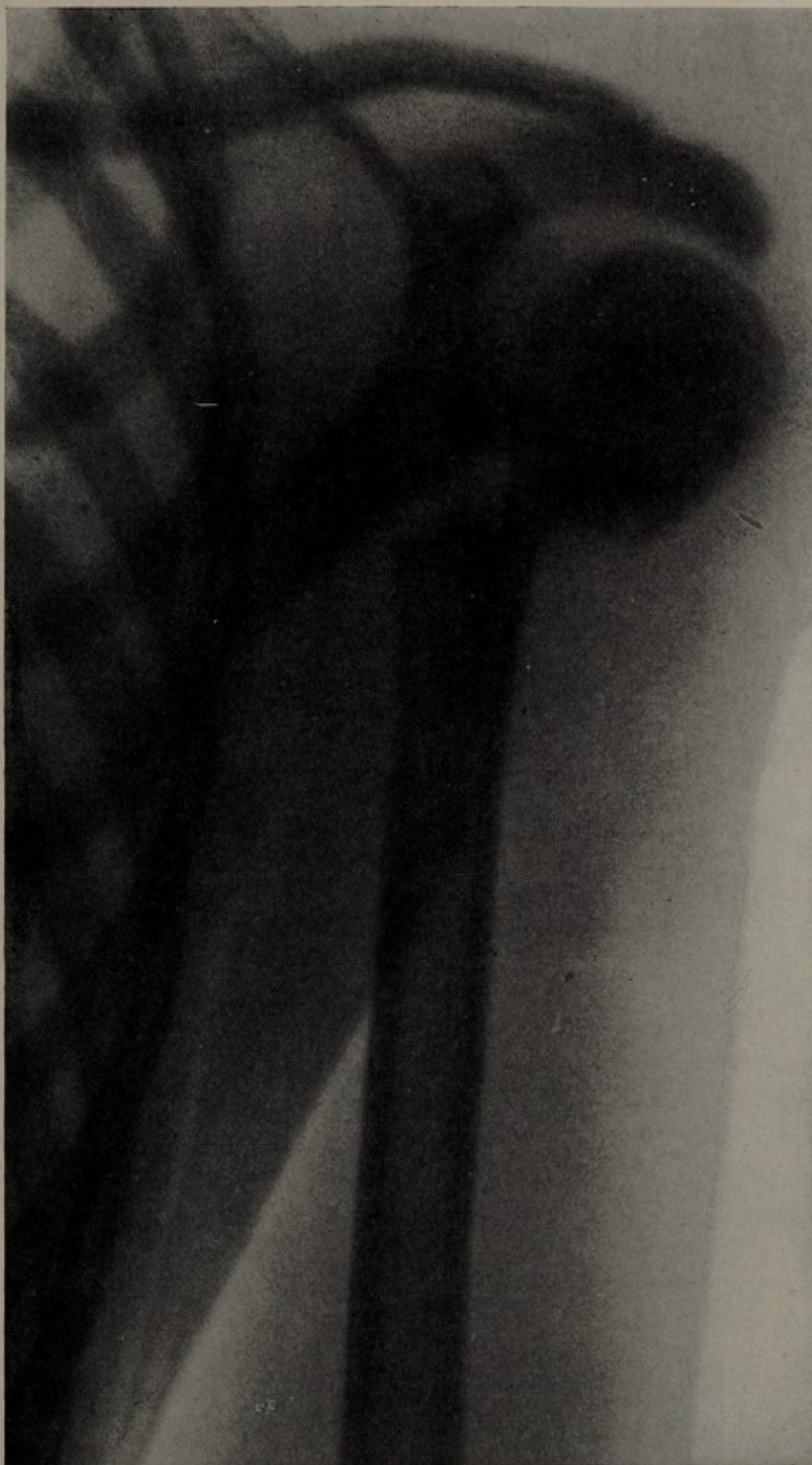

FIG. 250. Fracture of surgical neck of the right humerus of a girl nine years old.

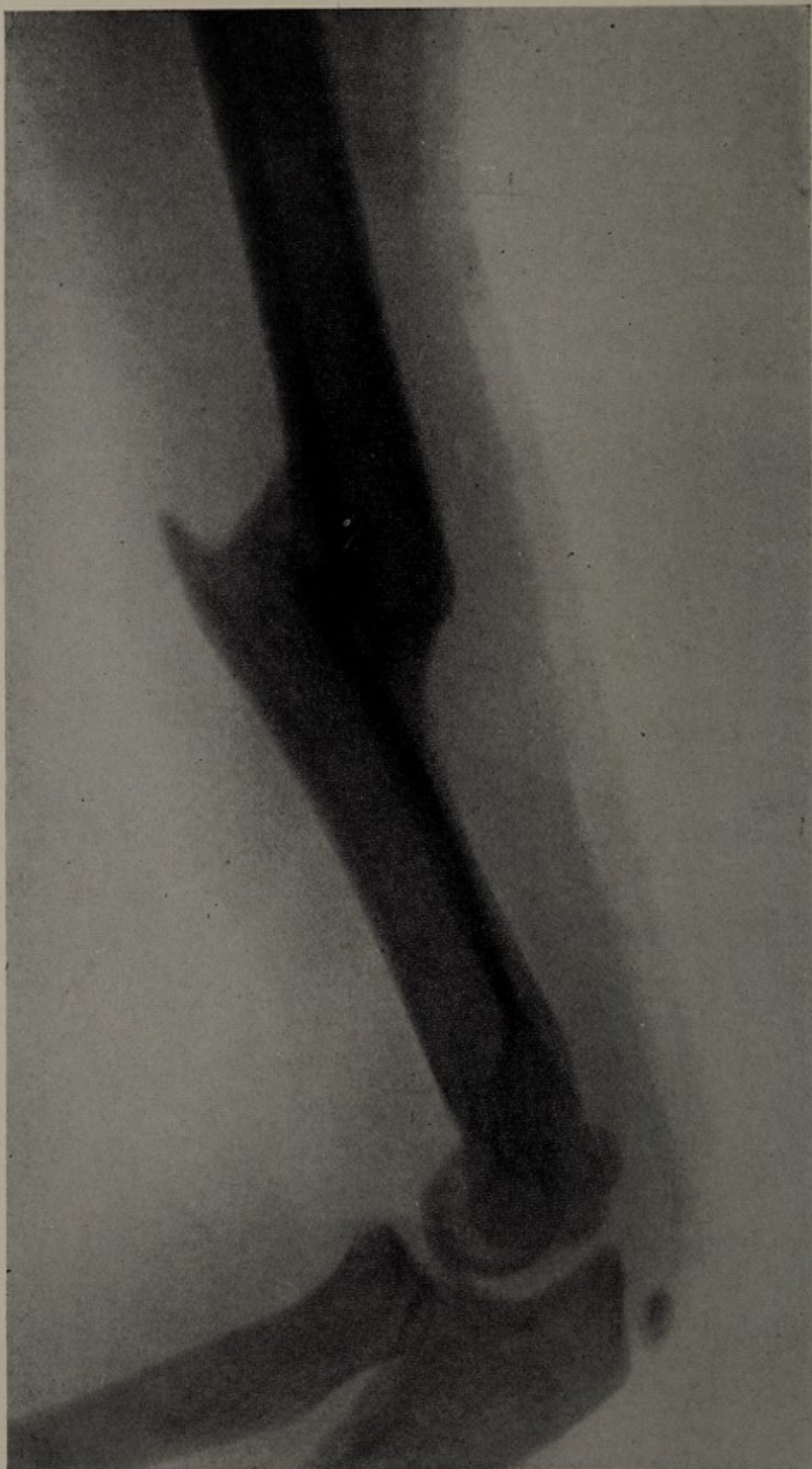


FIG. 251. Healed fracture of lower third of humerus in a girl ten years old. Callus shows clearly.

clearly indicated a partial displacement between them. The patient was placed under ether and firm extension made upon the head. Some

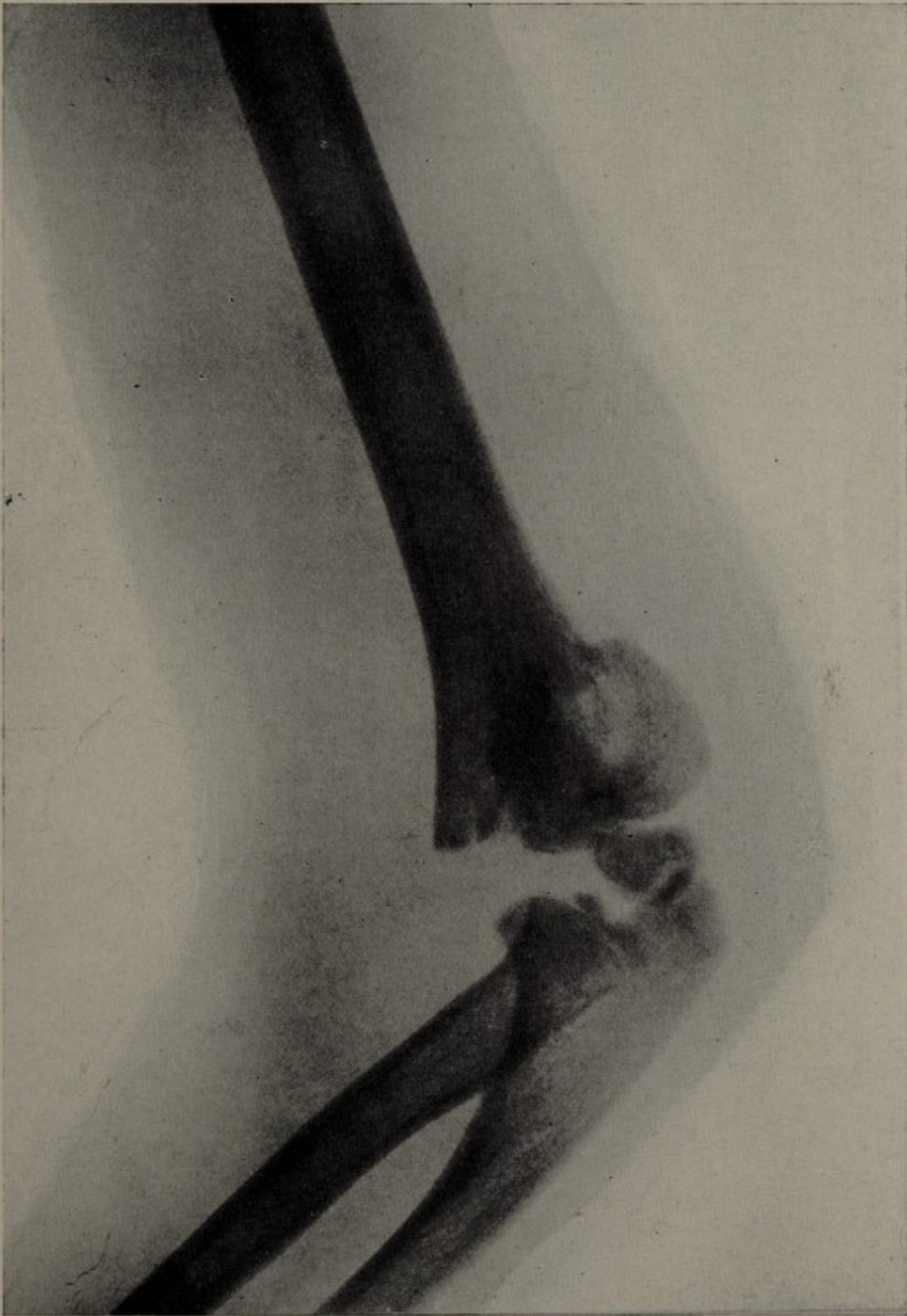


FIG. 252. Patient of Dr. John C. Munro. Fracture of lower end of humerus and olecranon.

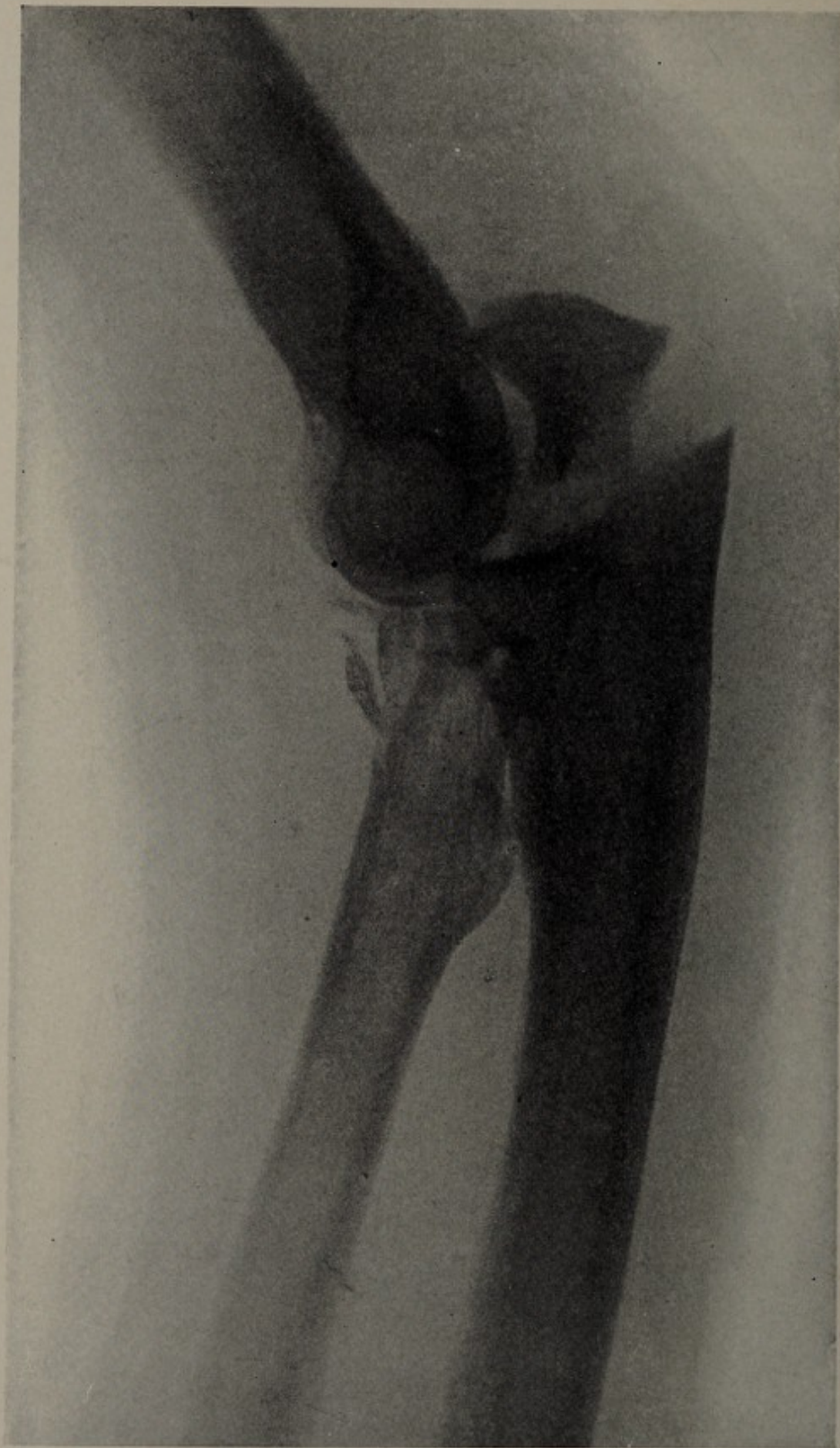


FIG. 253. Patient of Dr. Paul Thorndike. Fracture of olecranon and head of ulna of a man seventy-six years old. Crepitus; effusion into the joint; motion at elbow caused extreme pain. X-ray photograph taken a week after the accident.

adhesions gave way, and after more force was applied, a slight gliding movement was felt in the neck, and it was then found that the vertebræ occupied their natural straight position. Since this operation the patient has remained perfectly well.

Shoulder. — X-ray photographs are of great service in determining the exact site of a fracture of the humerus, especially when it occurs

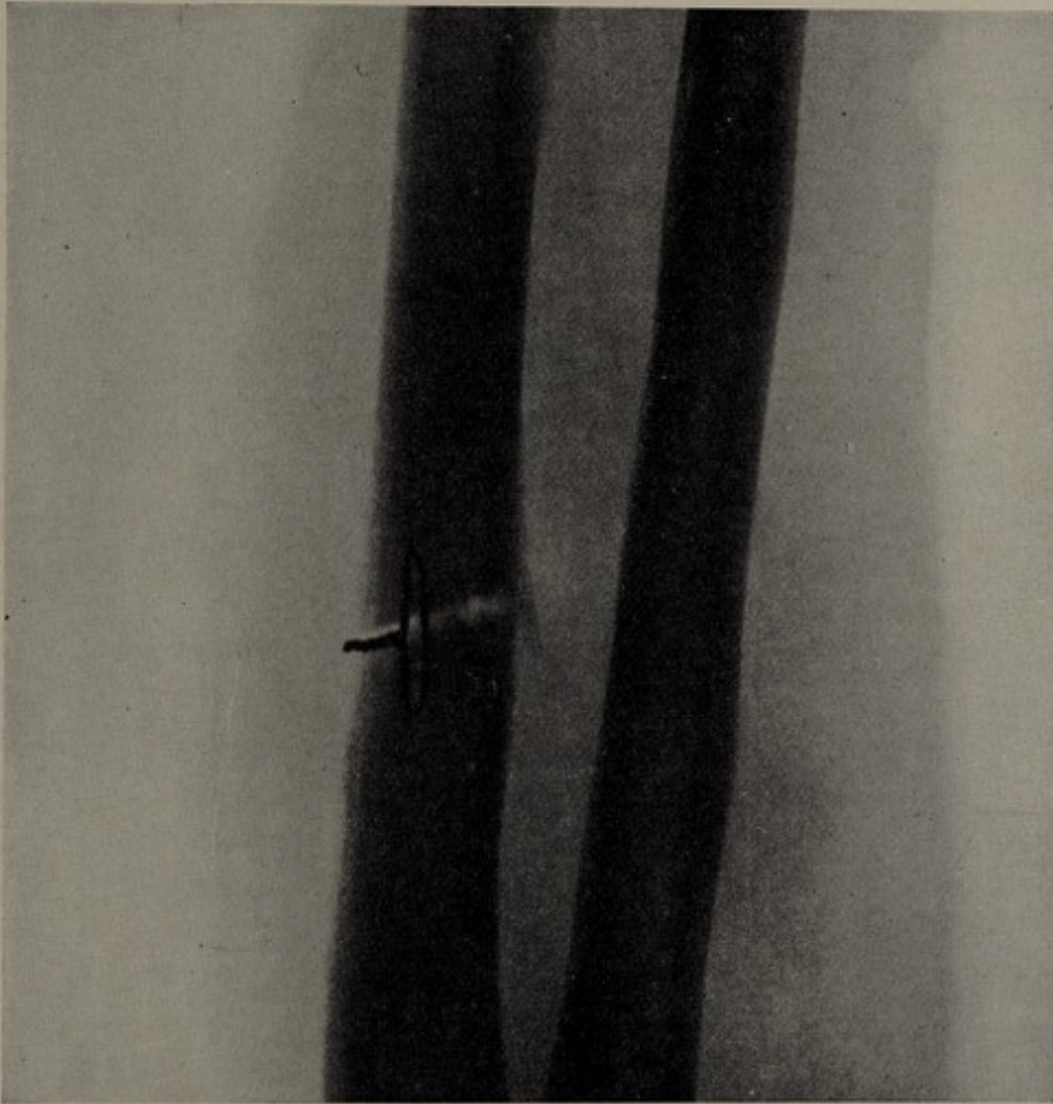


FIG. 254. Fracture of ulna caused by a circular saw; ends of ulna approximated by silver wire. Patient of Dr. Post.

near the joint of the shoulder. Two photographs of this fracture are frequently necessary in order to obtain all the information desired; one should be taken with the plate on the front, and the other with the plate on the back, of the shoulder. The shoulder is often so enveloped in the dressing or splint that the plate cannot be brought near the bone, and in such a case the tube must be placed at a greater distance from

the patient than would otherwise be desirable, in order to avoid distortion and to obtain good definition. In photographing the parts about the shoulder joint, including the shoulder itself and the clavicle, it is usually best to put the plate nearest the part of which a picture is

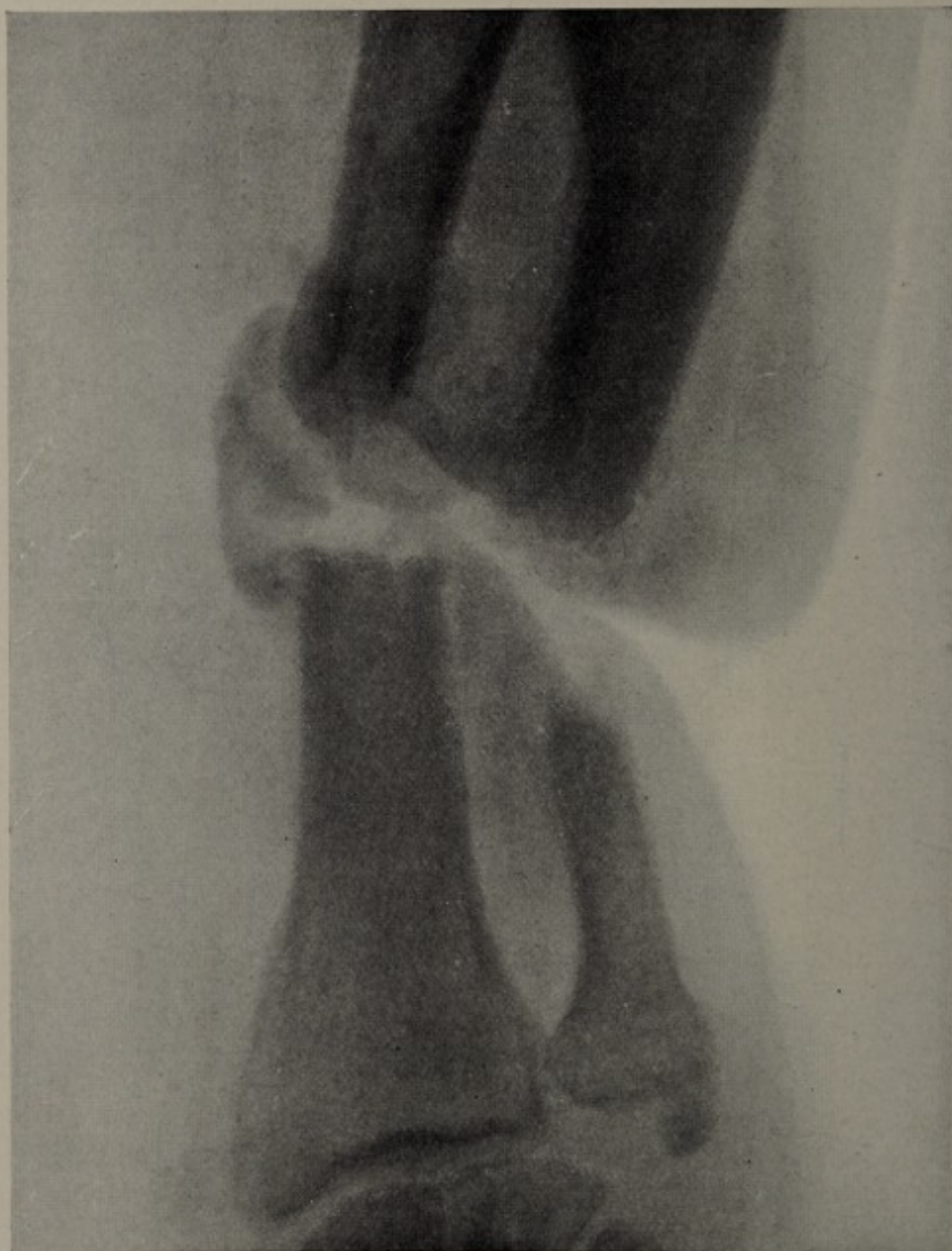


FIG. 255. Ununited fracture and necrosis of the bone. J. W., twenty-five years old. Fell from a house at a height of about forty feet, October 26, 1899, and injured his left arm. The radius was found on examination to be fractured at about the middle, and there was a backward dislocation of the elbow. December 18, necrosis of bone for about 3.5 centimetres. The X-ray photograph from which this cut was made was taken March 28, 1900.

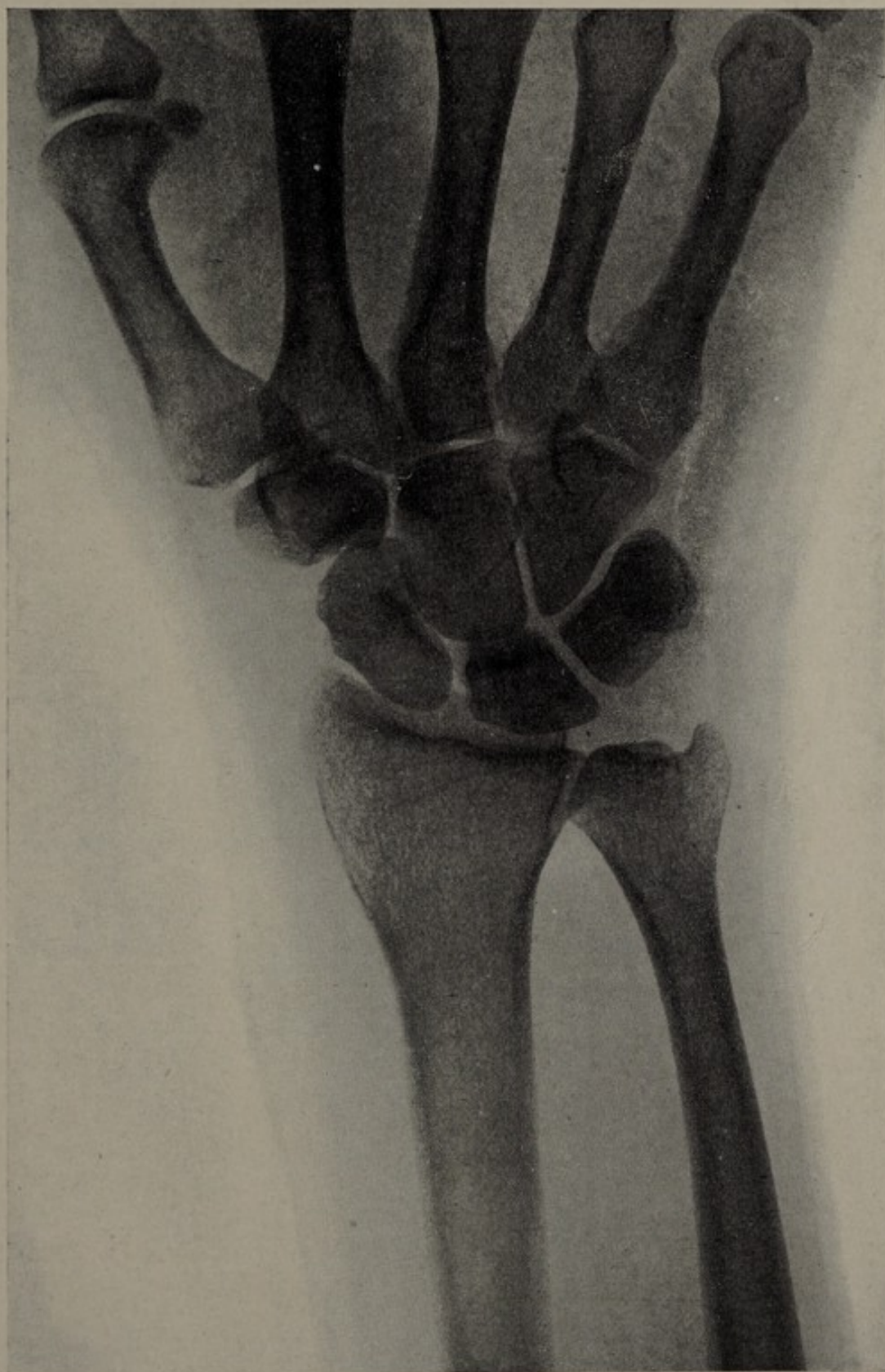


FIG. 256. Supposed fracture of radius; radiograph indicates that none exists.

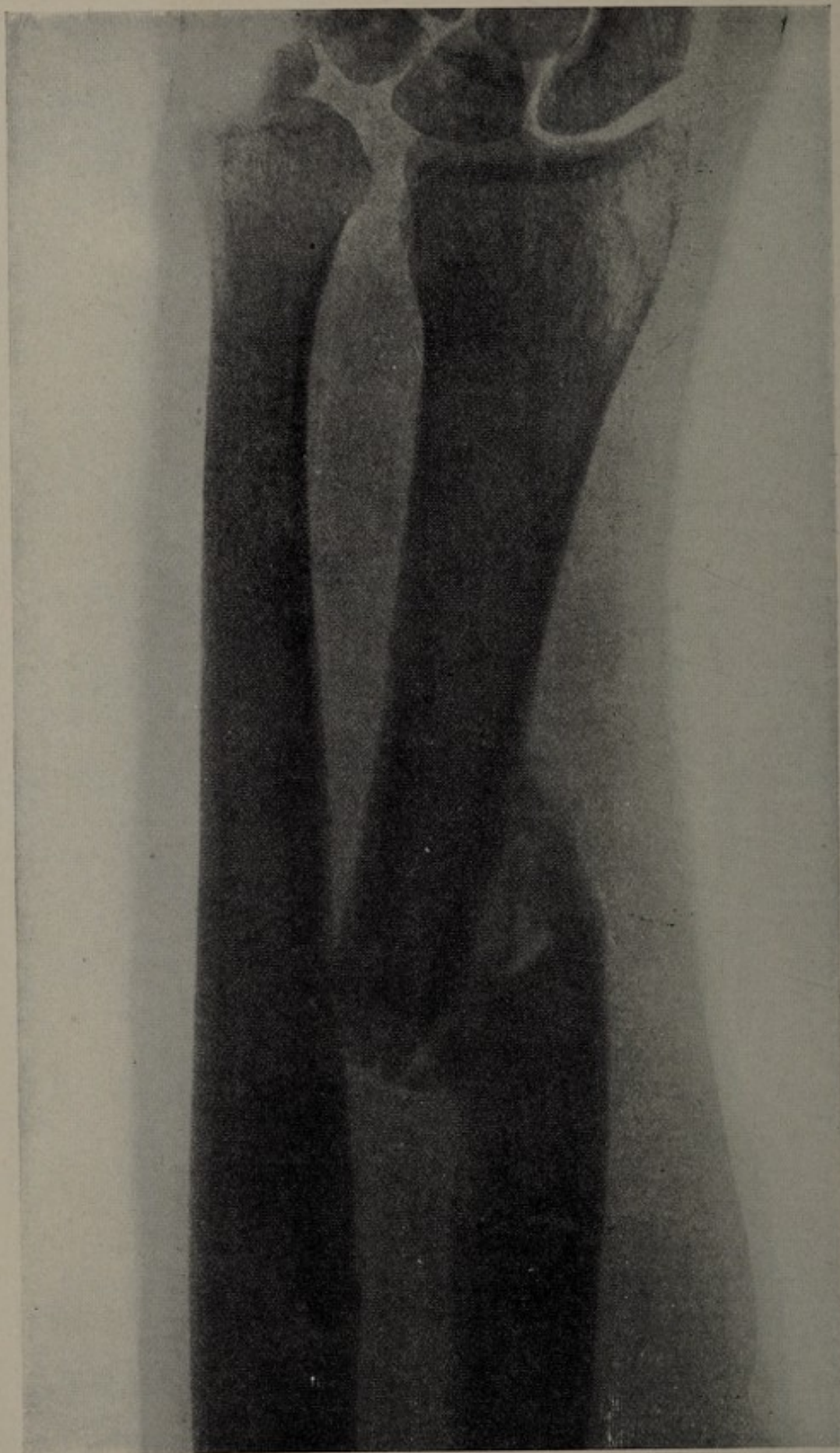


FIG. 257. Simon D. Patient of Dr. Monks. Healed fracture of left radius before operation.

desired, and to place the tube on the opposite side, at a considerable distance from the patient, in order to get good definition and avoid the distortion mentioned above.

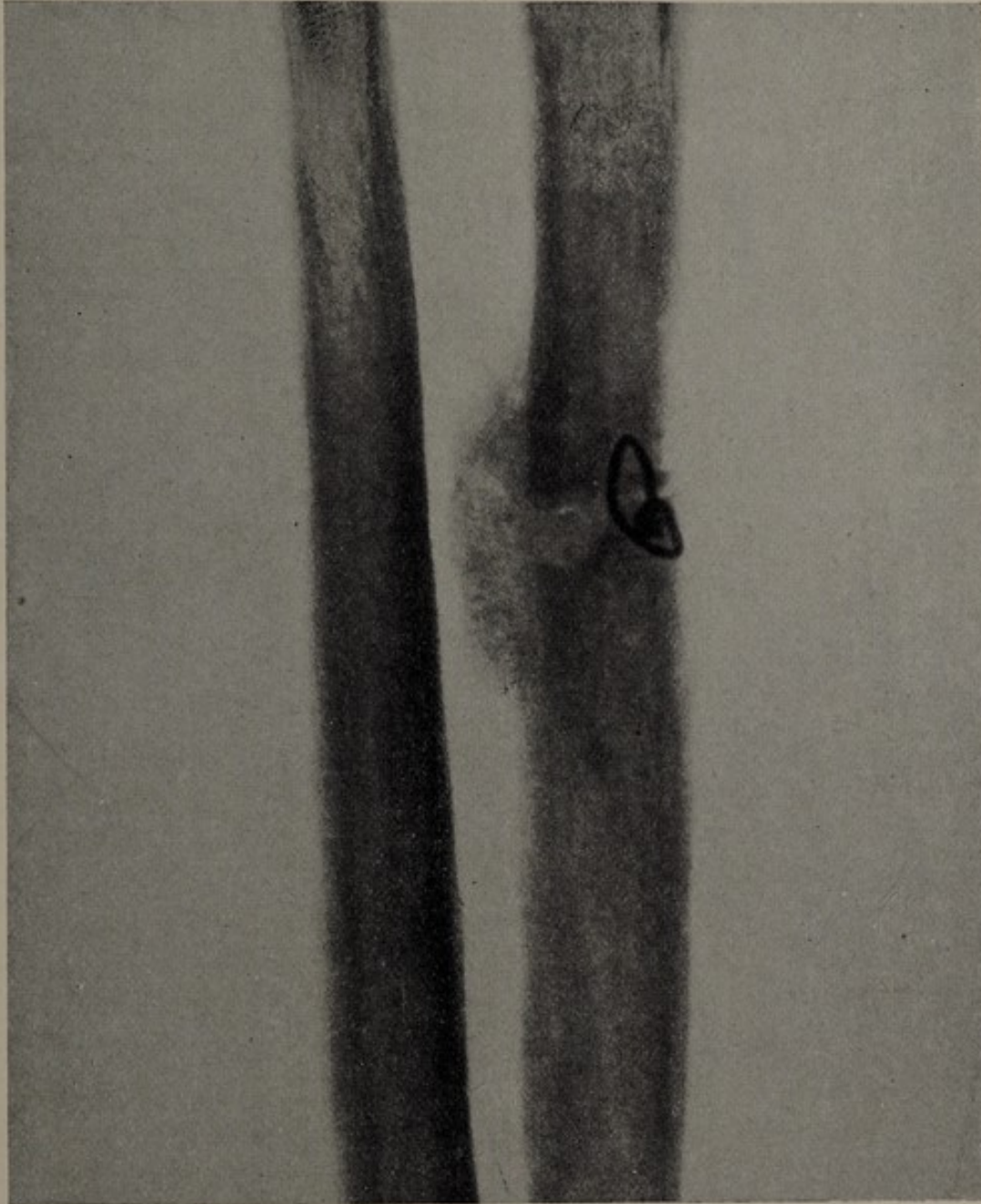


FIG. 258. Simon D. Patient of Dr. Monks. Taken two months after operation; shows callus.

Elbow. — The elbow-joint is somewhat complicated, and it is often difficult to interpret X-ray photographs of fractures of this joint. As a rule, therefore, two pictures at least are necessary, one taken from an antero-posterior and one from a lateral point of view. The stereoscopic

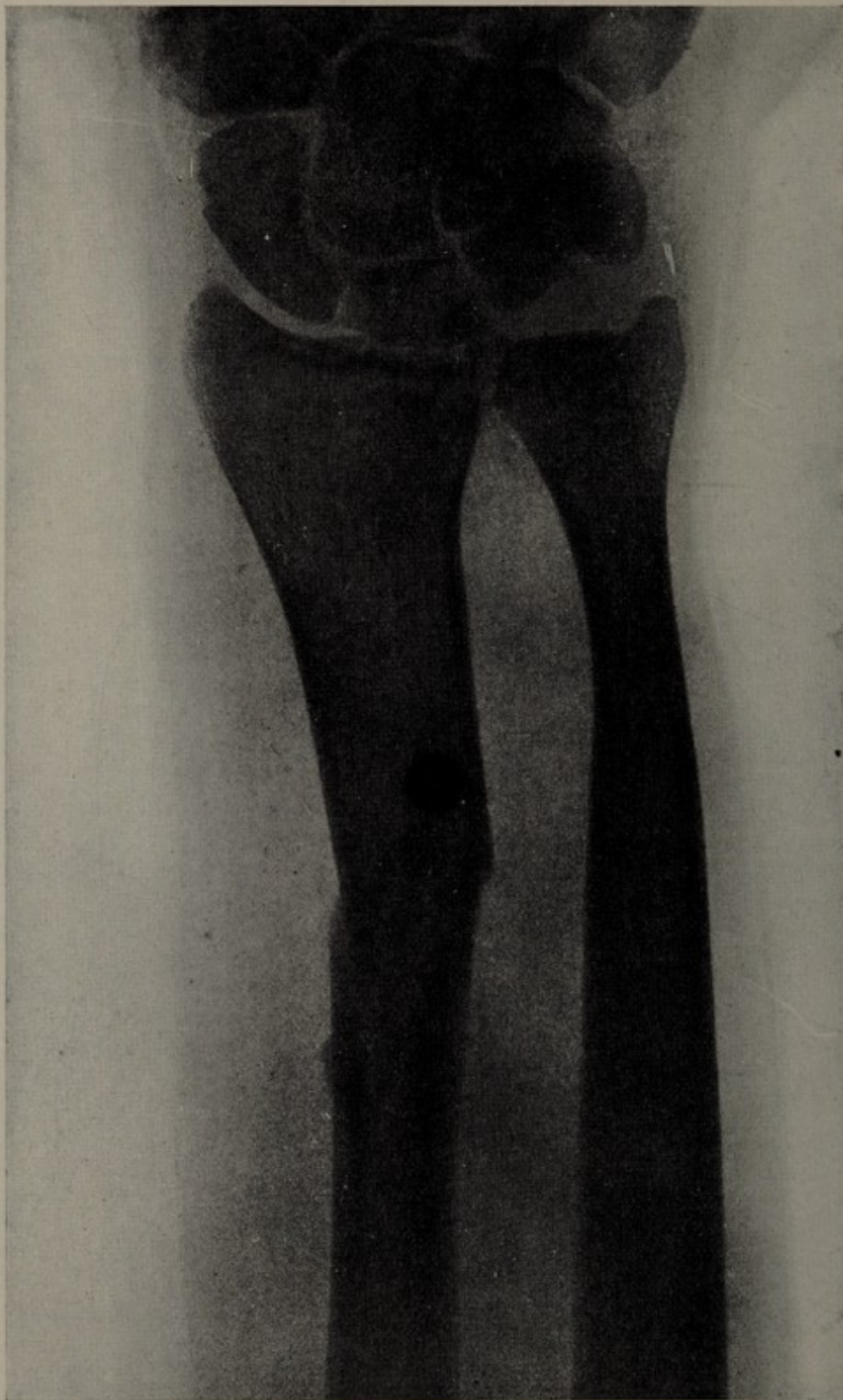


FIG. 259. Frederick F., twenty-five years old; carpenter. Entered hospital November 23, 1900. Patient of Dr. George H. Monks. Open fracture of the radius. The right forearm at its distal end presents an open, extensive, comminuted fracture. December 7th, position by inspection and by X-rays good. Antero-posterior view.

The small metal washer indicates the point opposite which the target of the vacuum tube was placed. The tube was at a distance of 70 centimetres.

method is also of assistance here. If the elbow is surrounded by a thick bandage, or if it cannot be straightened, it is difficult to get a plate of

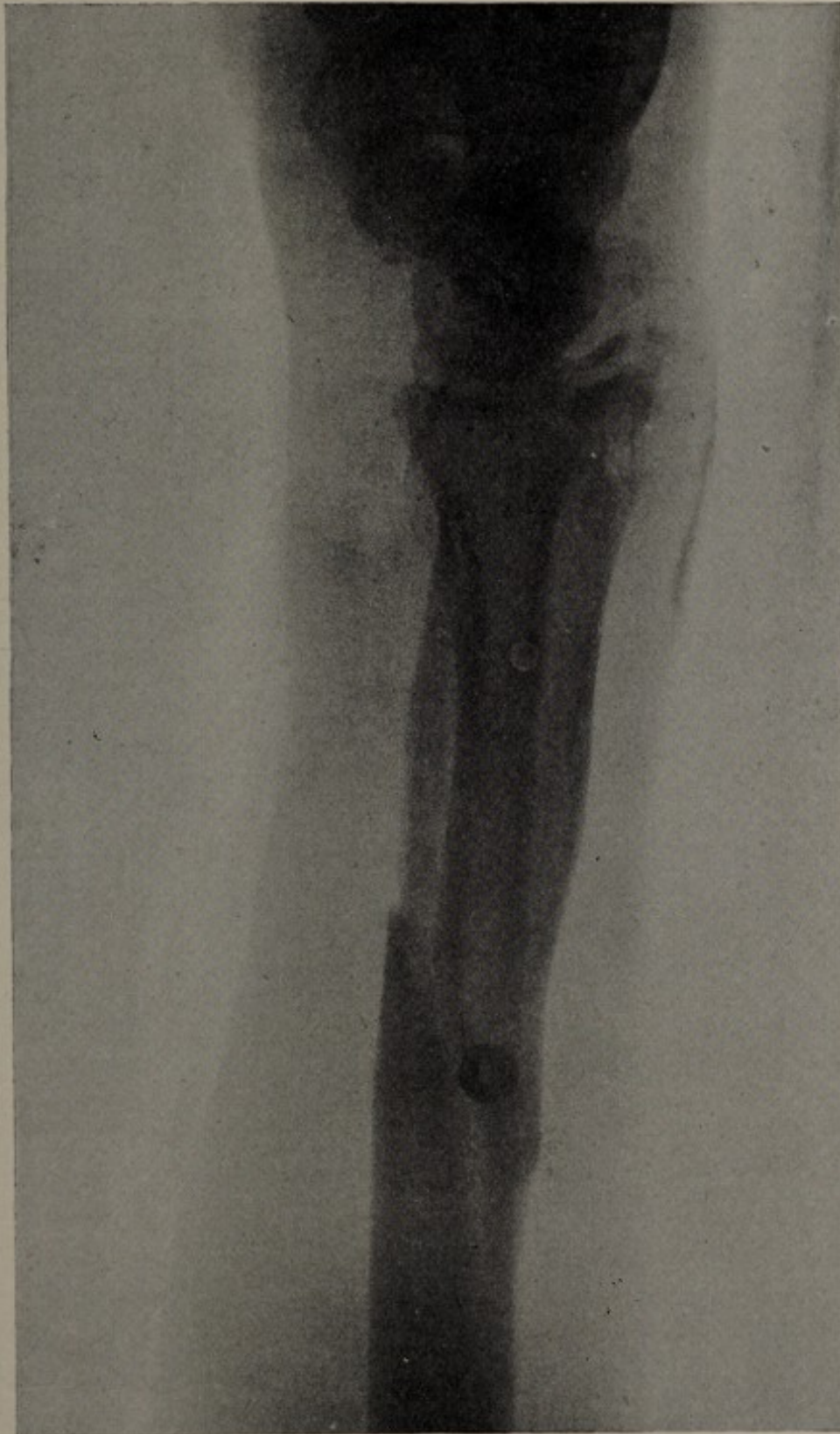


FIG. 260. Frederick F. Lateral view.

ordinary size near enough to the inside of the elbow to get a good picture; therefore in such a case rather a small plate should be used. The tube should be at a considerable distance, about 70 centimetres away, as when a shoulder is taken, and for the same reason.

Radius, Ulna, and Wrist. — Two photographs should be taken of an arm fractured near the wrist, or of a fractured wrist; one from an anteroposterior and the other from a lateral point of view; a stereoscopic picture of the wrist joint and the end of the radius is often instructive.

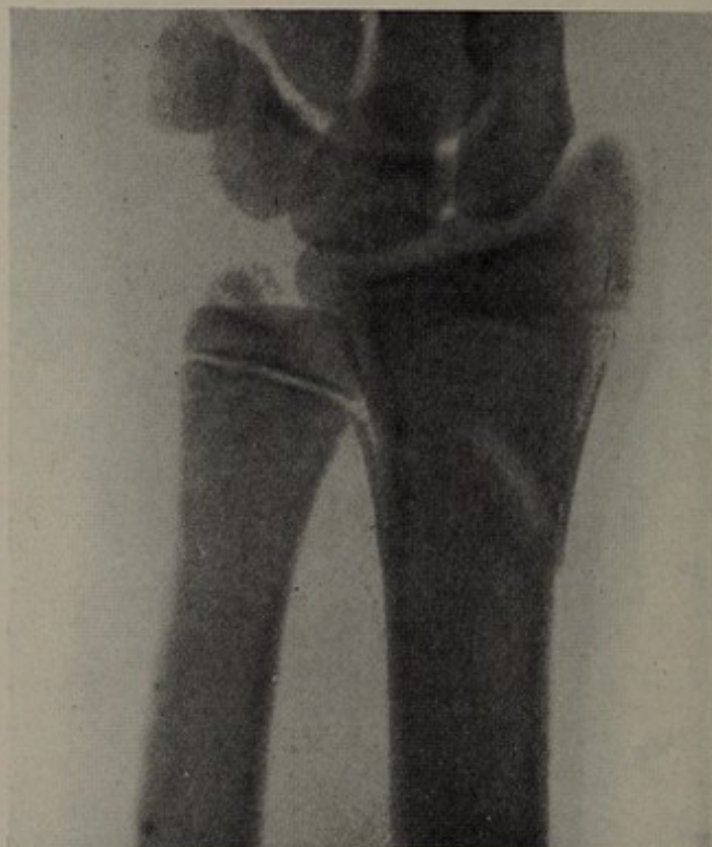

FIG. 261. James C., age not given in records. Out-patient department of the Boston City Hospital. Diagnosis, sprained wrist. X-ray photograph showed fracture of radius 2.5 centimetres above the articular surface.

There is no fracture of the ulna; the line seen on the ulna is the epiphyseal line. Such lines have been mistaken for fractures.

Supposed Fracture of Radius. — The cut (see Fig. 256) shows no fracture of the radius, and probably none exists, where by the ordinary methods a fracture was thought to be present.

Radiographs as a Guide to Treatment. — Simon D., twenty-seven years old, entered the hospital April 18, 1899, patient of Dr. Monks. The patient fractured his left radius and both femurs by falling about forty feet in an elevator. About two months and a half later the

X-ray photograph was taken, which showed bowing of the radius and supination limited over two-thirds. The end of the left radius had grown to the ulna. (See page 484.)

To improve rotation an operation was performed by Dr. Monks on the radius. An incision was made over the site of the fracture and the

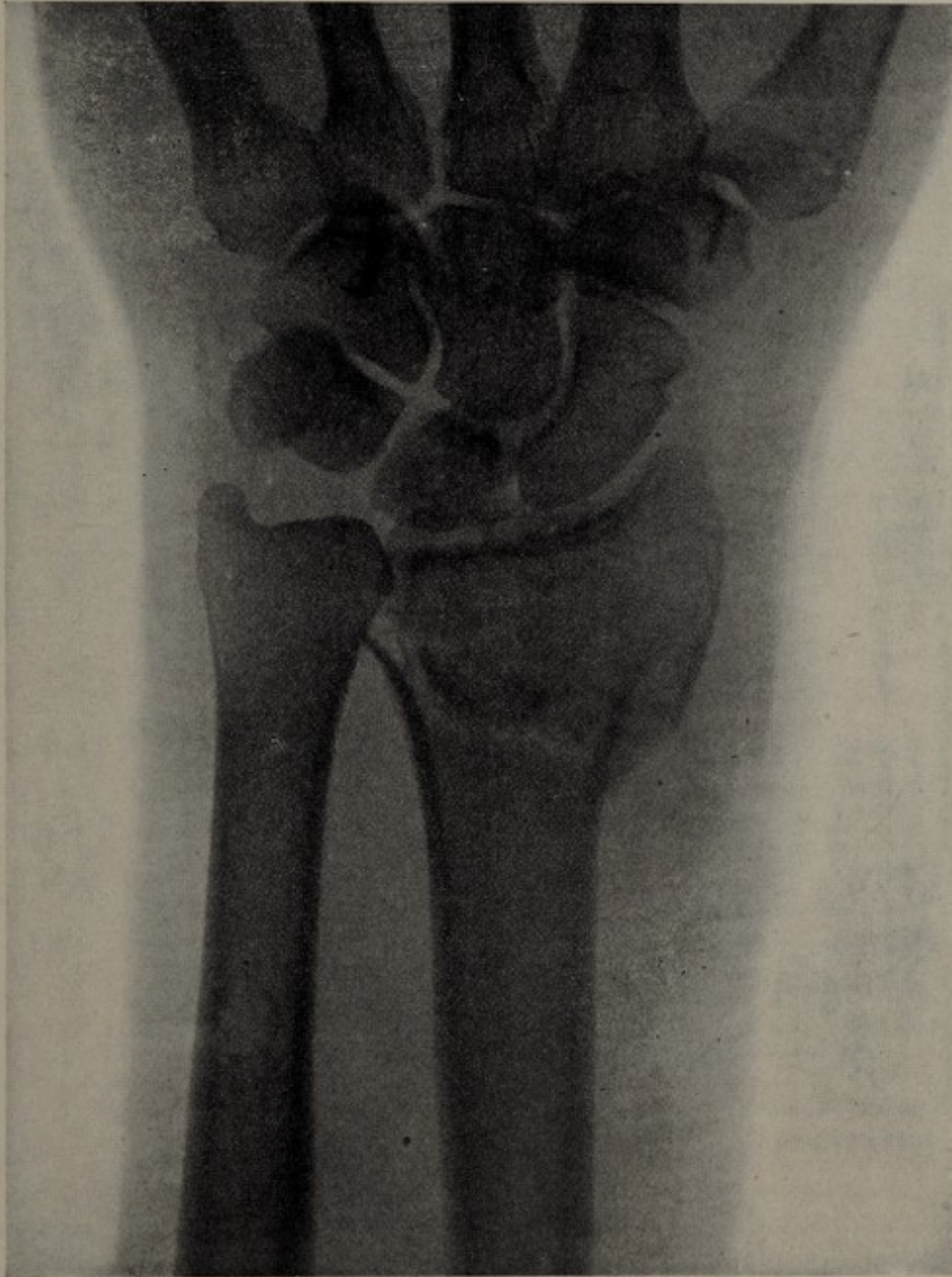


FIG. 262. Left colles fracture. Patient of Dr. J. B. Blake. Two views of a fracture of the wrist should always be taken — one from front to back and the other from side to side — and this is now done as a matter of routine at the Boston City Hospital.

old callus was divided with a chisel. Adhesions with the ulna were broken away, and the smallest possible piece was sawed off of each end of the radius to square them. The ends of the radius were then drilled and wired with silver wire, as seen in the radiograph, taken about two months after this operation was done. (See Fig. 258.)

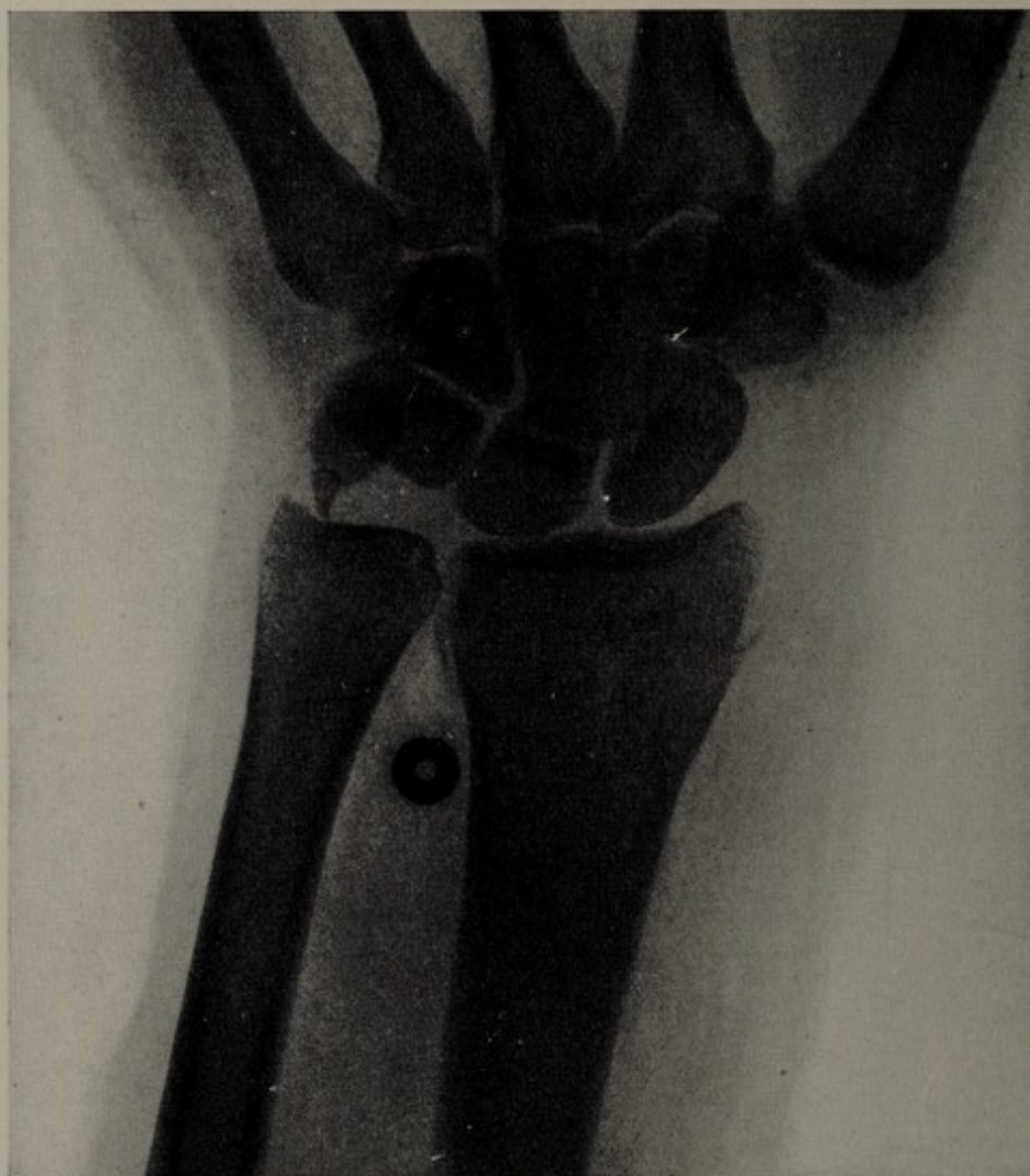


FIG. 263. Gertrude F., twenty-three years old. Entered hospital November 8, 1900. Patient of Dr. Monks. Diagnosis: fracture of left radius. Fell down a flight of stairs, injuring both wrists; under ether; crepitus; abnormal mobility. Radiograph also shows fracture of the tip of the styloid process of the ulna. Antero-posterior view.

New and Old Callus about a Fracture.—A callus which has formed recently about a fracture does not show in an X-ray photograph, but later, when inorganic salts are present, it gives a well-marked outline. The cases (see Figs. 258 and 283) are illustrative.

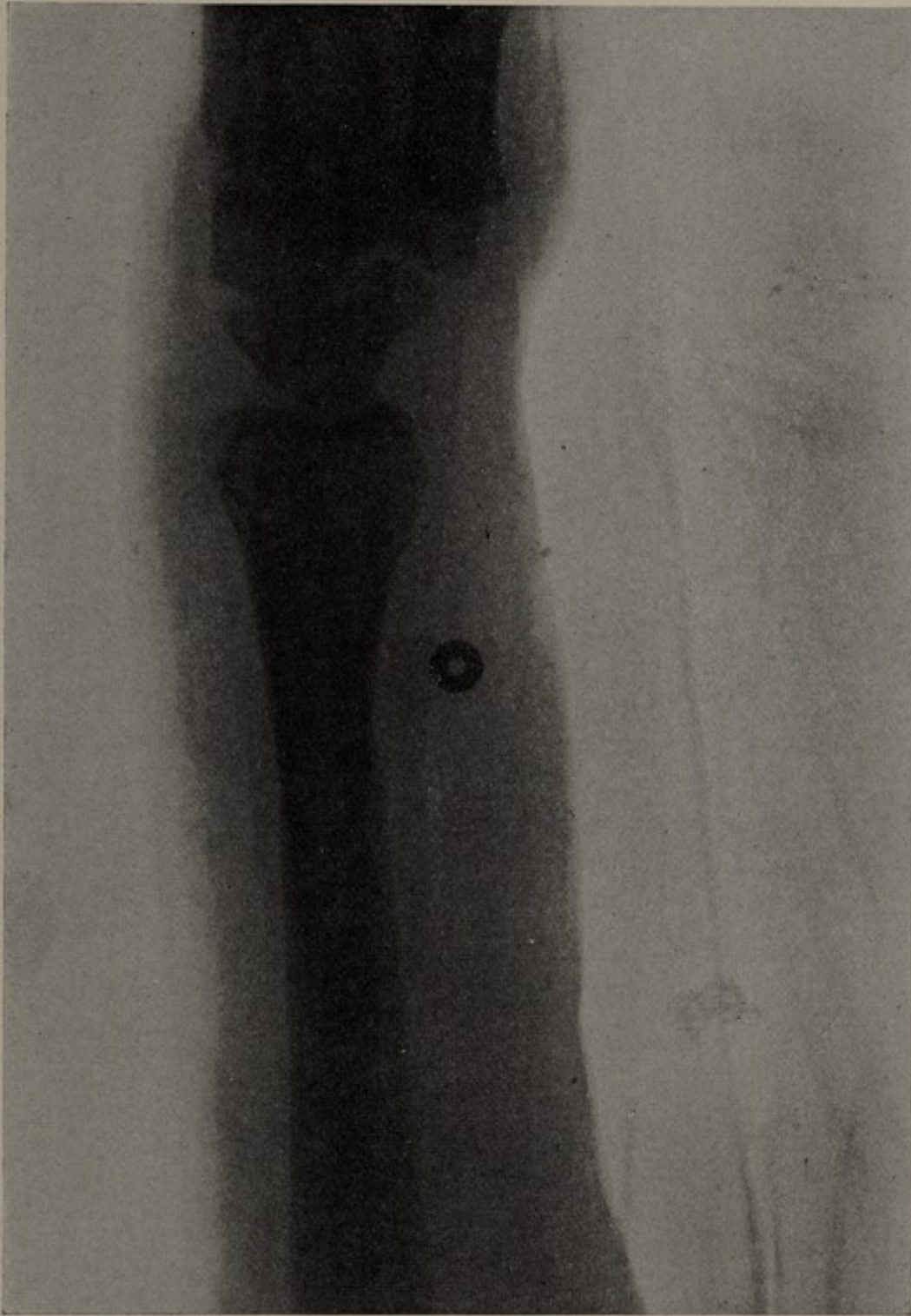


FIG. 264. Gertrude F. Fracture of the left radius and the tip of the styloid process of the ulna.
Lateral view.

Fracture of Phalanges and Metacarpal Bones liable to be overlooked without X-Rays. — These fractures are apt to be overlooked by the ordinary methods, as already indicated on page 467, but are seen by the X-rays.

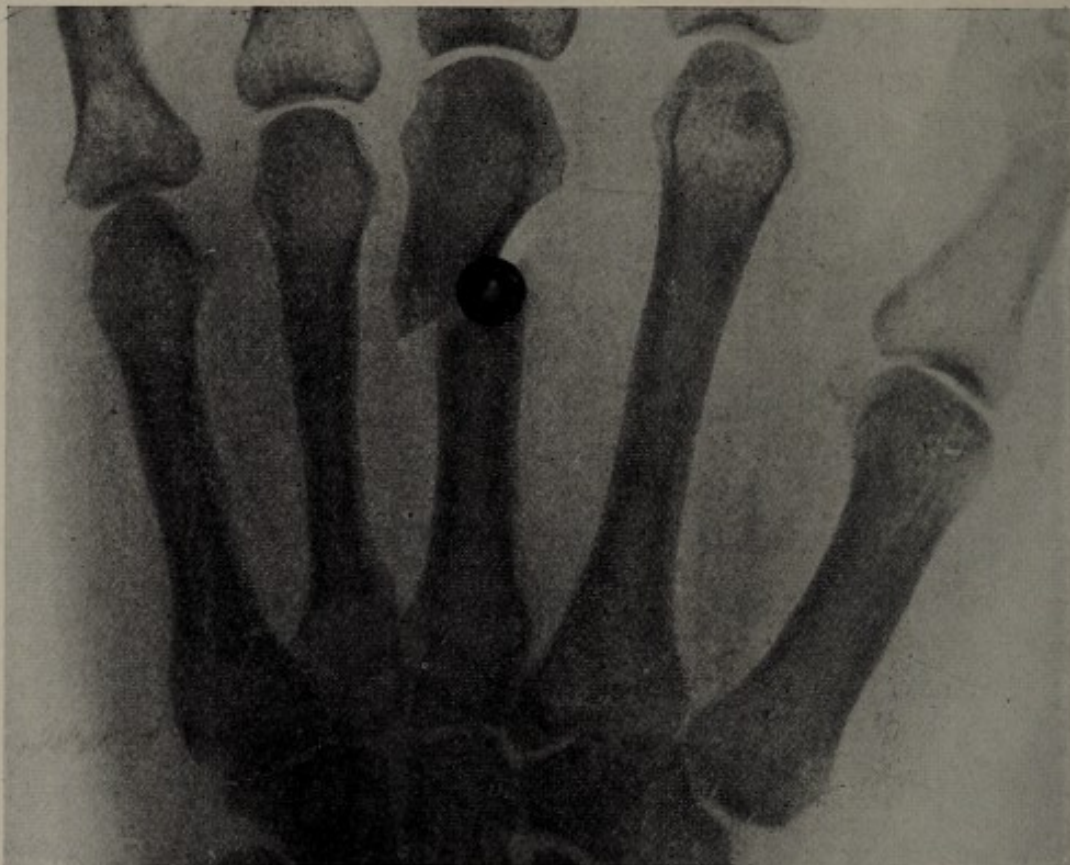

FIG. 265. Mrs. H. Fracture of third metacarpal bone. Antero-posterior view.

The preceding and the three following cuts (and the next case given, "Stave of the Thumb") show how easily this overlooking may occur:—

The So-called "Stave of the Thumb" Fracture.—Beatson¹ reports the case of a surgeon who had fallen, during rough weather, on a steamer, and thought he had merely bruised his thumb severely; but the recovery was so slow that sixteen days after the accident he consulted the reporter of this case. Beatson thought he could detect some crepitus, and an X-ray photograph confirmed the existence of a fracture at the base of the metacarpal bone. The leading feature of this fracture Beatson describes as the "inability to oppose the thumb to the index finger." This inability interfered with the use of the hand in many ways. An X-ray photograph taken two and a half weeks after treatment showed satisfactory results, and later all disablement disappeared. Beatson concludes by recommending that all "sprains of the right thumb" be X-rayed, for otherwise a fracture may be overlooked.

Pelvis.—This part of the skeleton is taken up in the chapter on the Abdomen.

¹ *British Medical Journal*, May 5, 1900.

Hip. — There are special difficulties to be encountered in obtaining an X-ray photograph of a hip-joint, particularly in stout patients; first, because the difference in the amount of rays absorbed by the thick tissues surrounding the bone and the bone itself is not so great as in the more superficial joints, and therefore the bone does not stand out as well in the photograph as is the case when the joints lie nearer the surface; second, because the bone is at a considerable distance from the

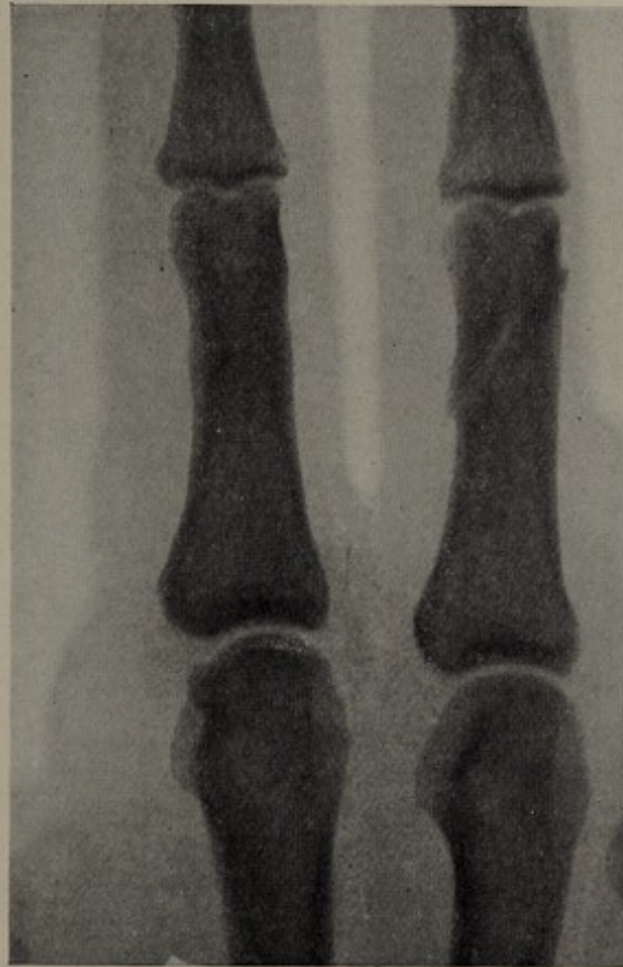

FIG. 266. Fracture of phalanx of second finger of right hand; no displacement; little mobility. Corresponding phalanx of first finger shown for comparison.

plate; third, if the hip-joint is tuberculous the contrast between the bone and the soft tissues is not so good as when the joint is normal, unless the patient is very much emaciated, because a tuberculous bone is more transparent to the rays than a normal bone, and therefore the tuberculous bone and the soft tissues are more nearly alike in regard to the obstruction they offer to the rays.

In photographing a fractured hip it is often well to place the patient

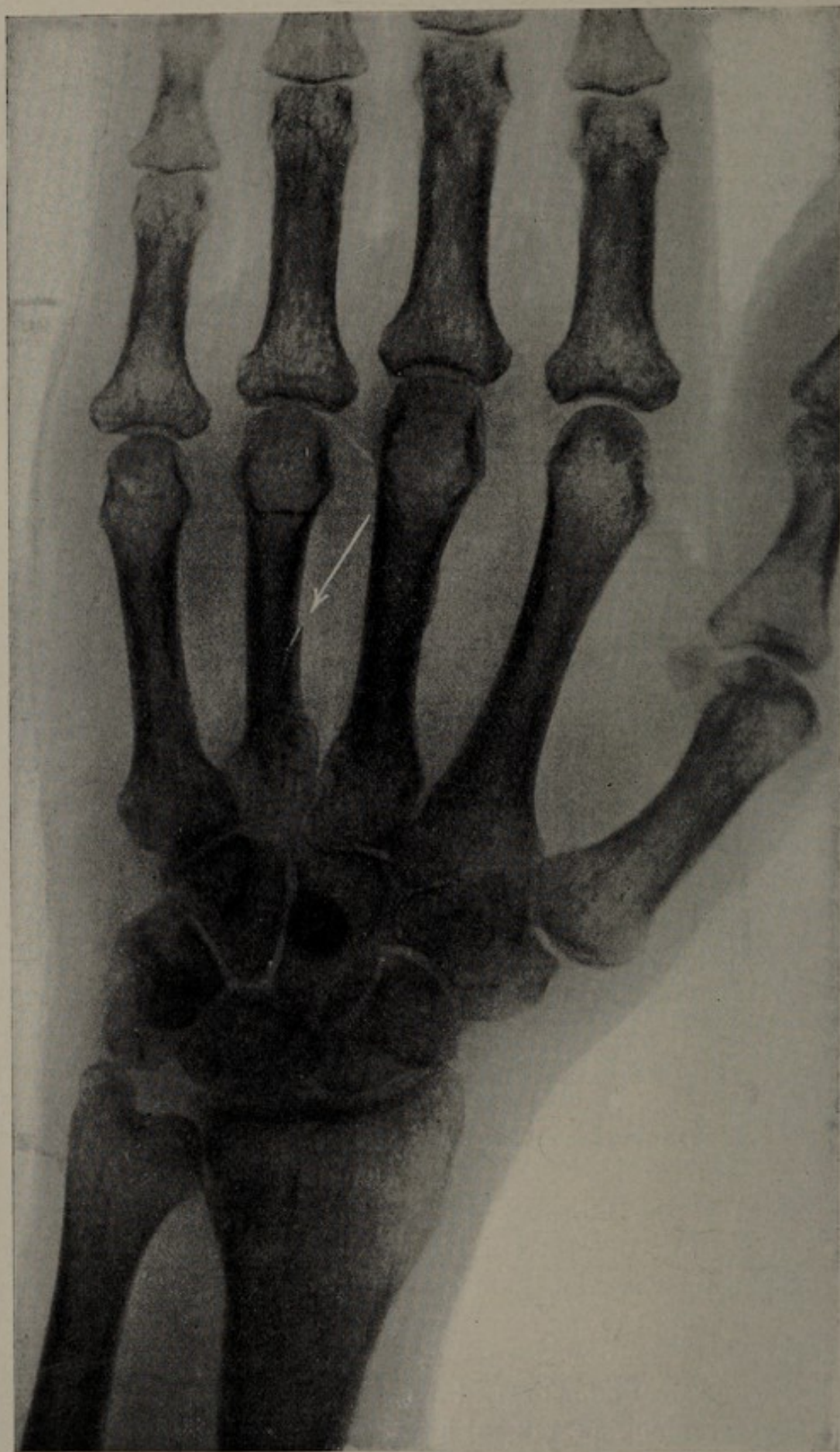

FIG. 267. Fracture of fourth metacarpal bone of left hand, indicated by arrow.

on his back and the tube underneath him, not in the median line, but under the point it is desired to photograph. If the patient is thin, the plate is placed to advantage over the front of the hip; but if stout, it is better to put it under the patient because the large abdomen makes it difficult to get the plate as near the front of the hip as is desirable; or

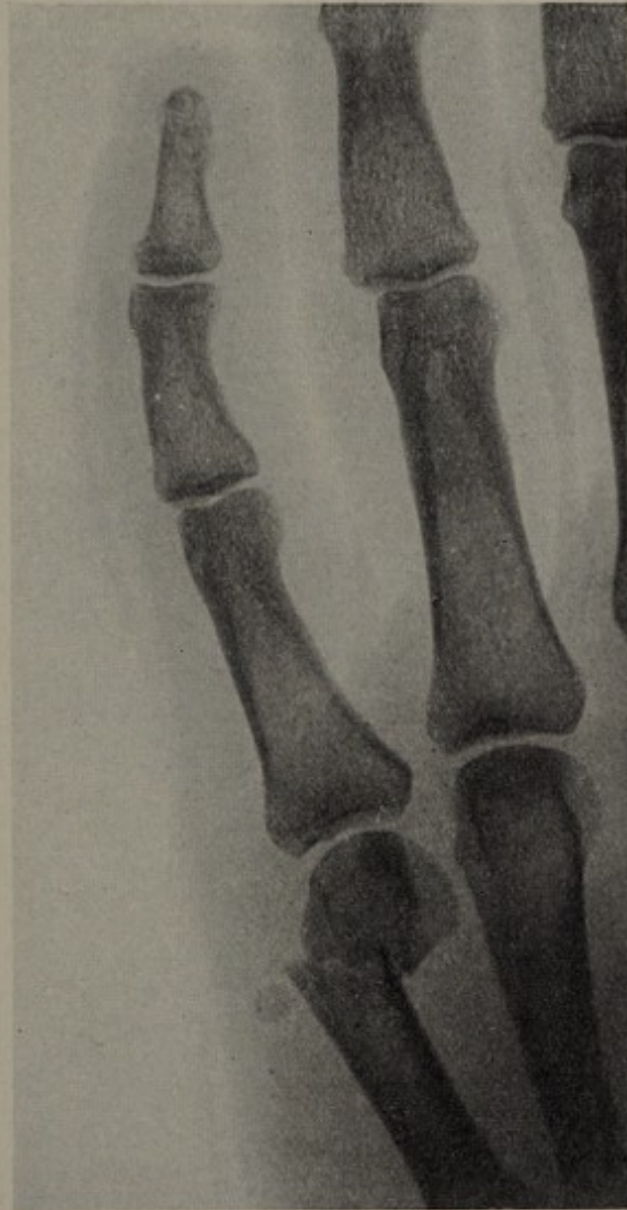


FIG. 268. Fracture of fifth metacarpal of hand. Patient of Dr. F. B. Lund.

the hips and the femurs may be placed in the same position and the tube be put opposite the median line, as this arrangement gives an opportunity of comparing one hip with another.

Thigh. — In fractures of the femur, or upper and lower part of the tibia and fibula, two photographs are necessary, as in the case of the

elbow-joint, one taken from an antero-posterior, and one from a lateral, point of view.

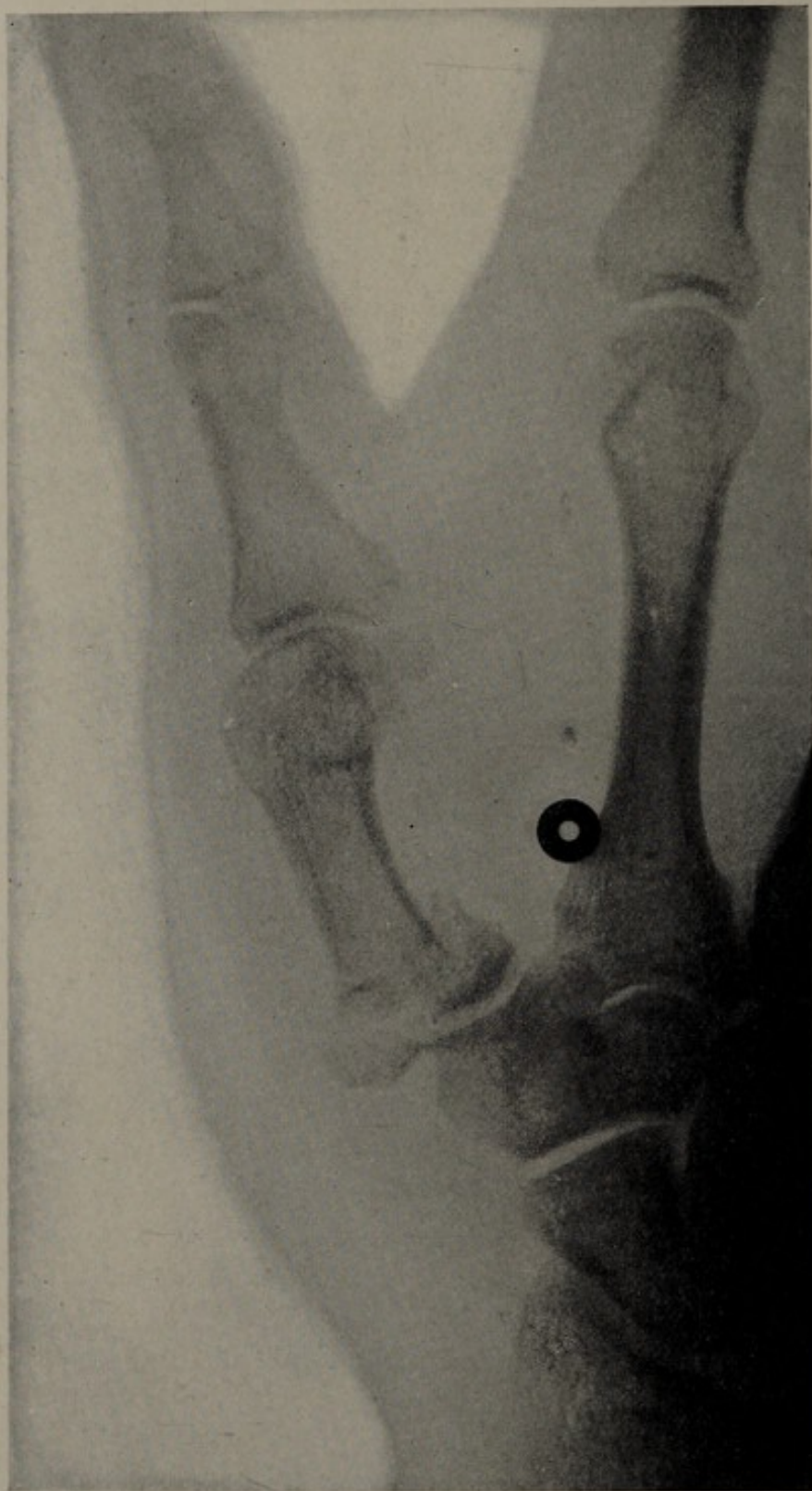


FIG. 269. J. W. Fracture of thumb.

Importance of Two Views. — The following case shows the advantage of taking two views of a fracture. The first radiograph was made from a lateral point of view and showed no fracture (see Fig. 270); the second radiograph was taken from an antero-posterior direction and showed fracture. (See Fig. 271.)

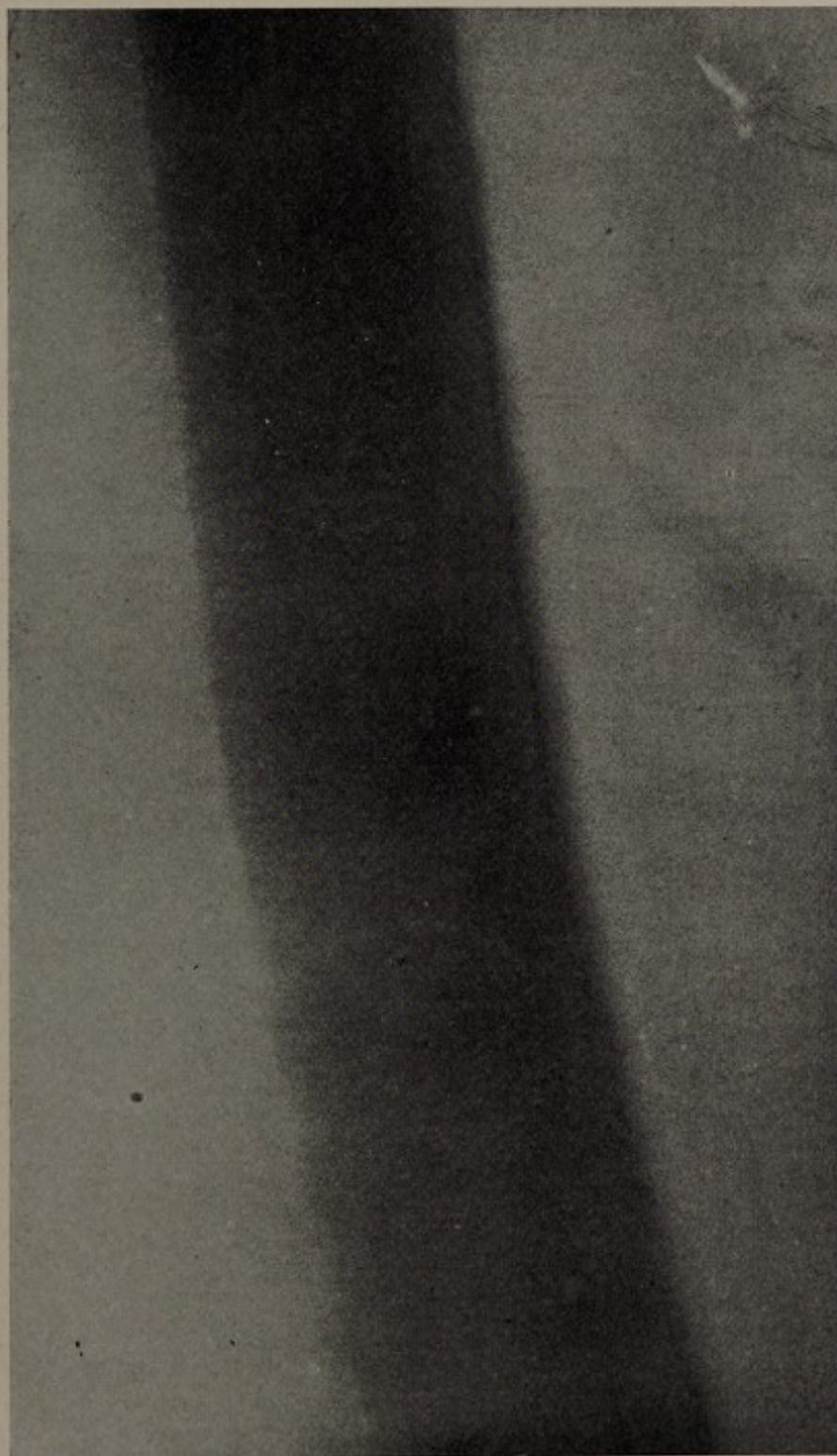

FIG. 270. Fracture of left femur. Lateral view; no fracture shown. Patient of Dr. M. F. Gavin.

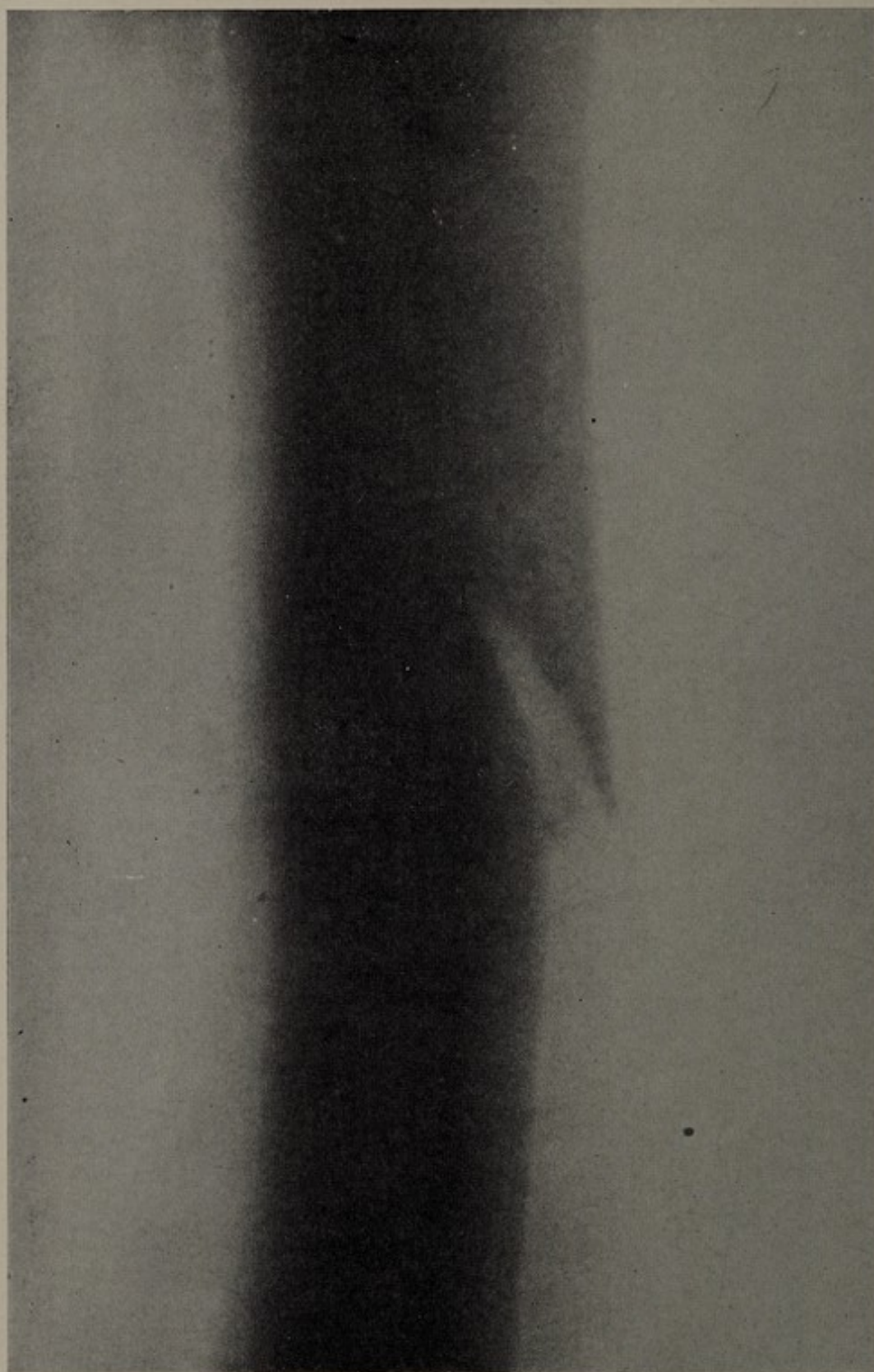

FIG. 271. Fracture of left femur, antero-posterior view; fracture shown. Patient of Dr. Gavin.

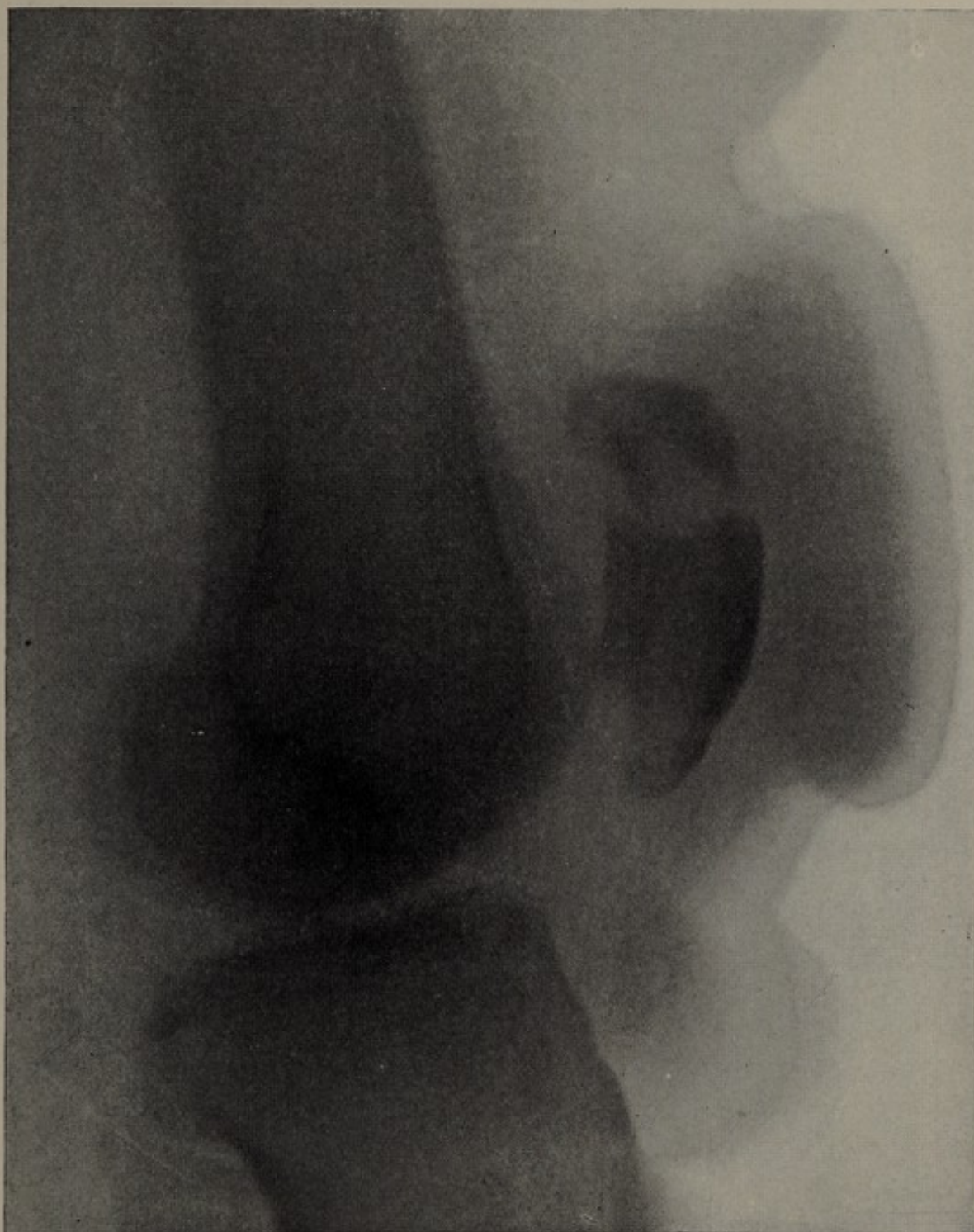


FIG. 272. Patient of Dr. W. P. Bolles. Fracture of patella of a man fifty-four years old. X-ray photograph taken the following day. The cut shows the position after the bandage had been applied to the approximate parts. The depression of the flesh above and below the patella shows the position of the bandage.

Knee. — When a photograph of the knee is desired, two views are better than one. In nearly all cases, if only one picture is made, it is best to put the plate either on the inside or outside of the knee rather than under or above it.

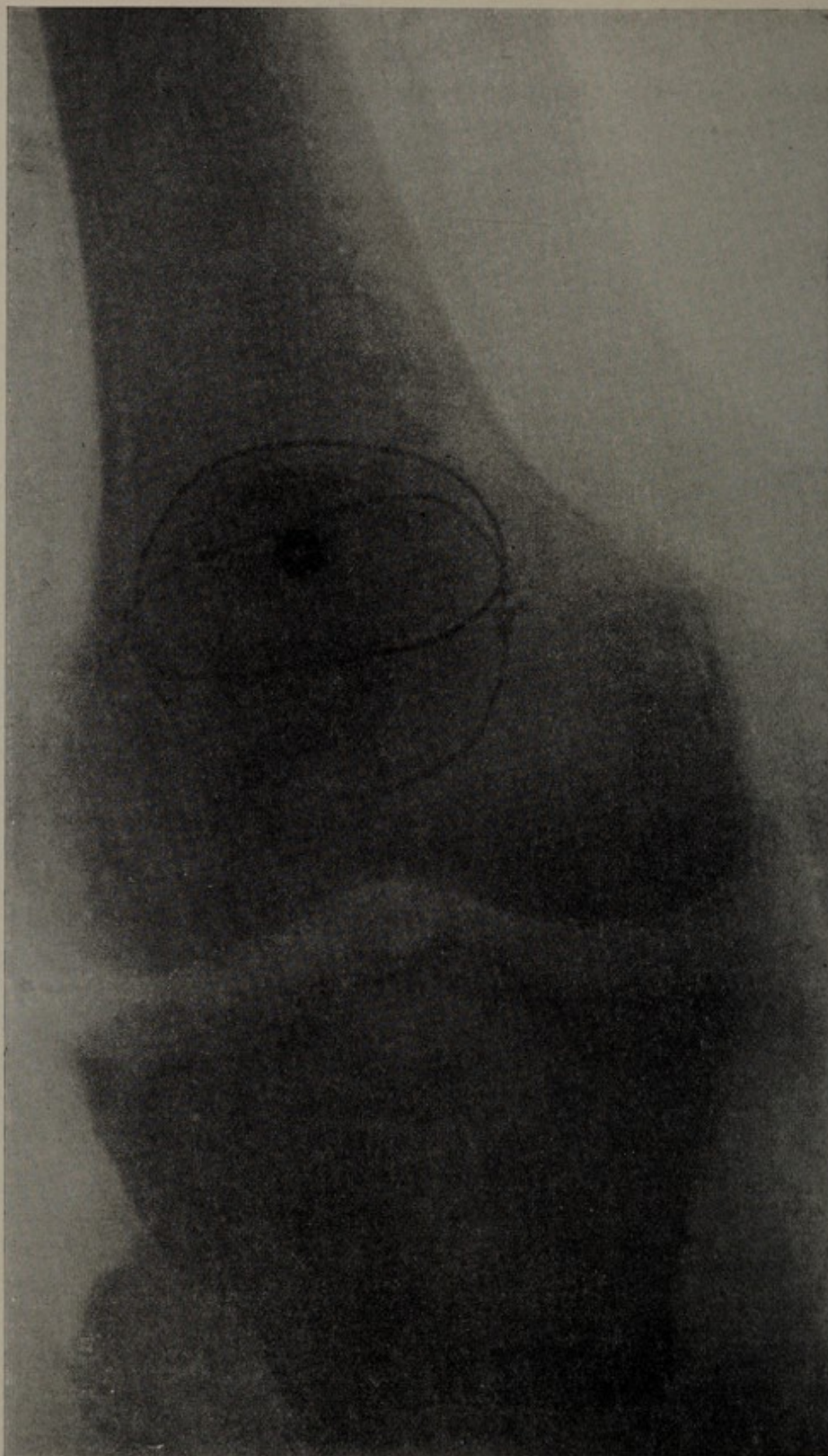


FIG. 273. Fracture of patella; front view; plate over patella; bones wired by Dr. F. S. Watson's method.

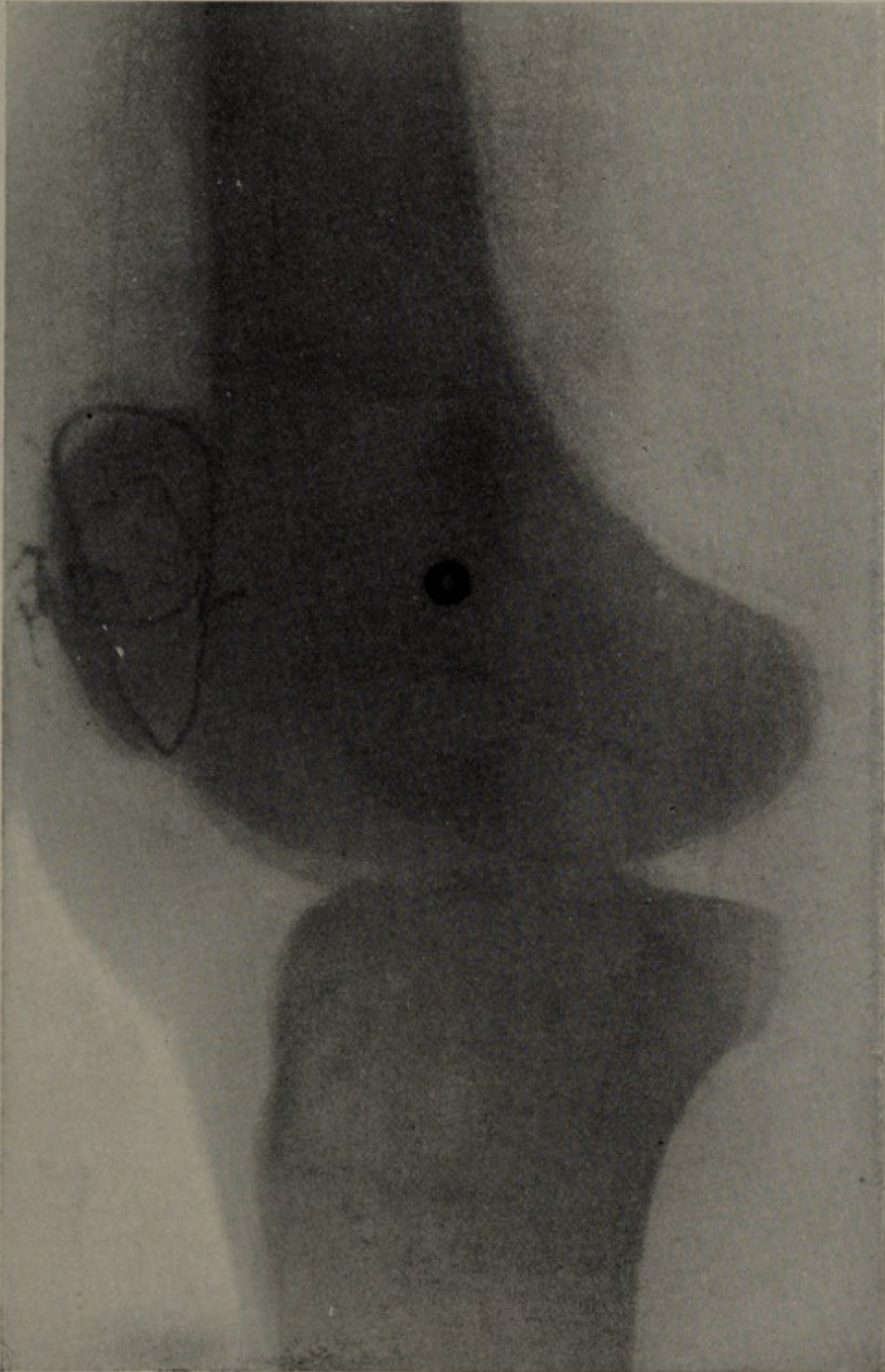


FIG. 274. Fracture of patella; side view. Patient of Dr. F. S. Watson.

Leg and Ankle. — In fractures of the bones of the leg an antero-posterior view is usually the better, but of the ankle a side view is the

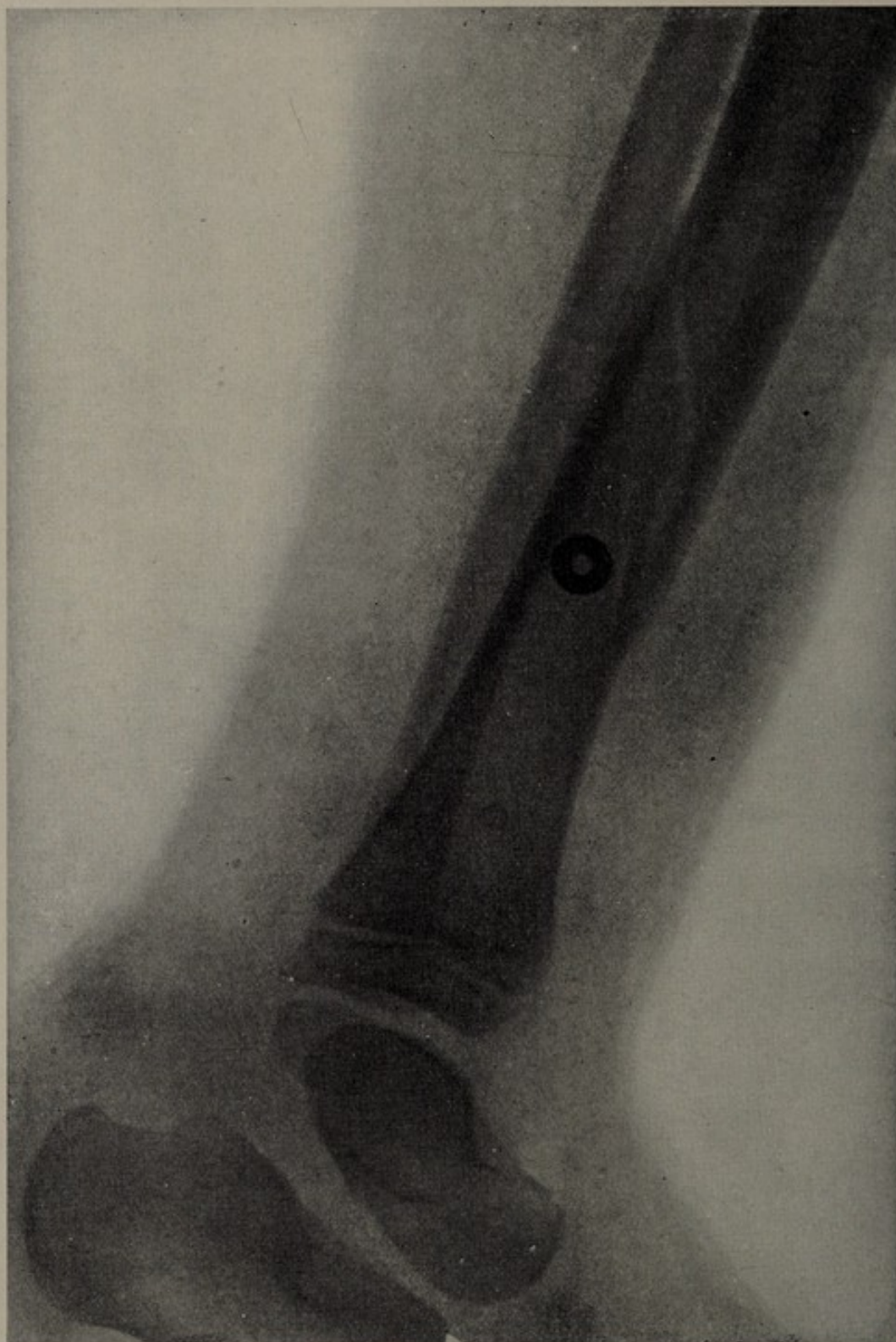


FIG. 275. John S., five years old. Patient of Dr. Munro. November 13, 1900, tripped over stick in room and was afterwards unable to stand. Sent to the hospital on the same day. Left leg at junction of middle and lower third presents a deformity; considerable swelling; no crepitus; very sensitive to touch. X-rays showed a fracture of the tibia; fibula intact. Radiographs taken on day of entrance, November 13, 1900. Plate placed on inside of leg. Tube was opposite metal washer. This case shows the importance of two views.

better, and easier to take. Two views of the ankle and leg, an anteroposterior and a lateral one, as in the case of the elbow, will often reveal

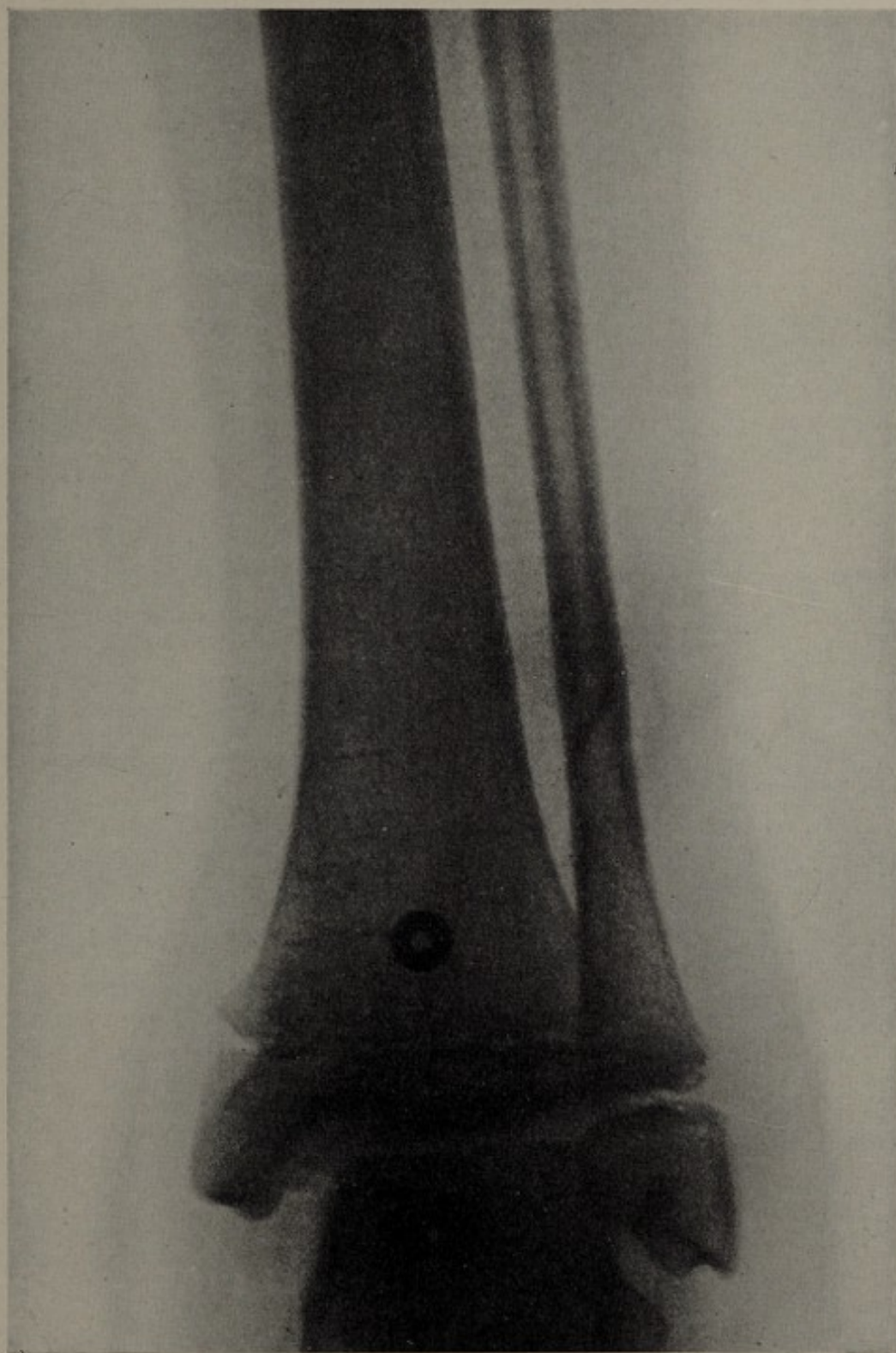


FIG. 276. John S. Plate placed on front of leg. This view does not show fracture, but it is clearly seen in the lateral view (see preceding figure).

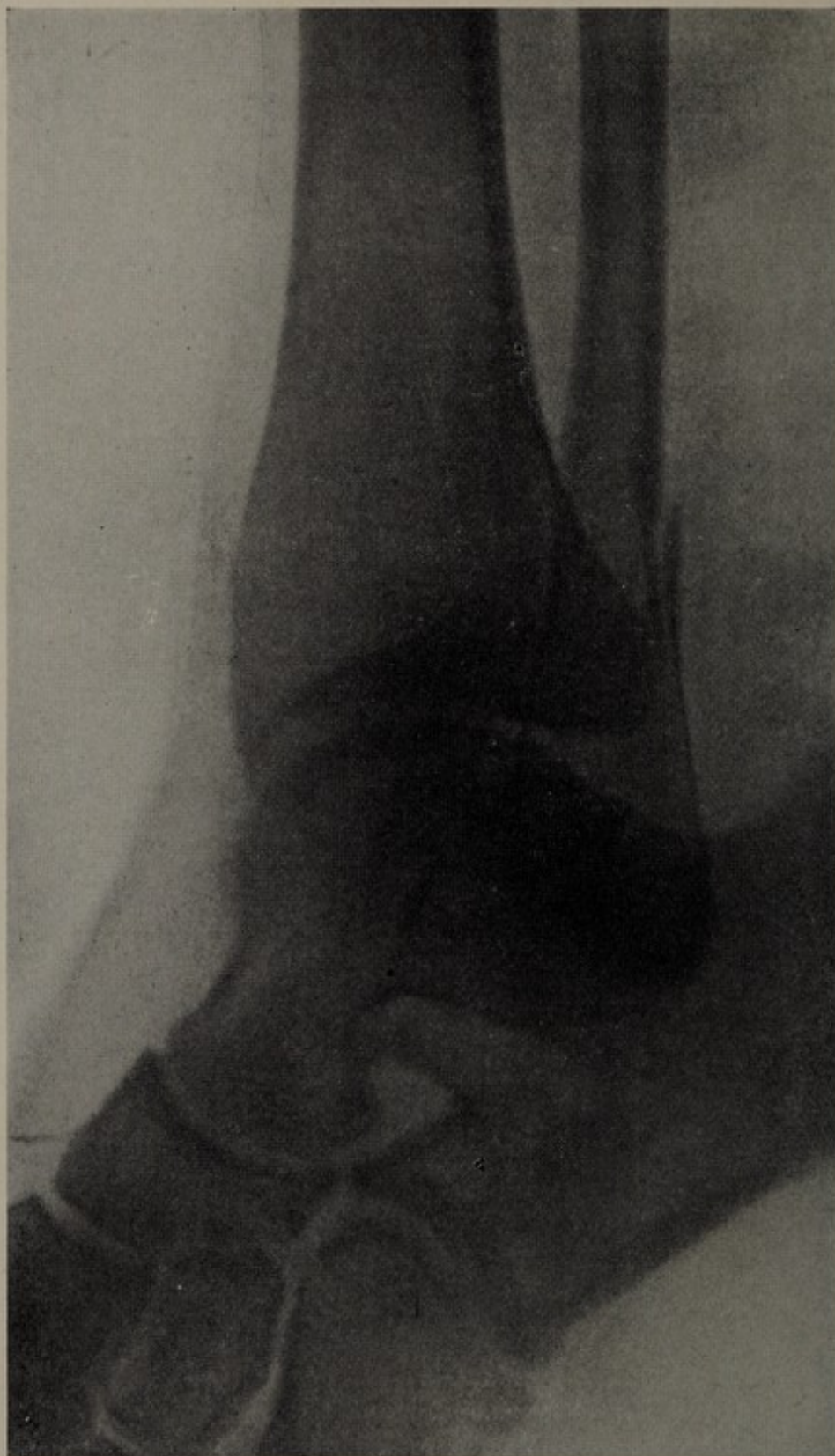

FIG. 277. Patient of Dr. Cushing. Fracture of lower end of fibula. In this case, of a woman thirty years old, the left ankle was much swollen, and there was also much swelling of the leg and foot; tenderness began 6 centimetres above the tip of the external malleolus. Careful examination by the usual methods was not possible on account of œdema and swelling. Two X-ray photographs were taken. The one from the antero-posterior view showed no fracture; the lateral view showed fracture.

more clearly the exact condition of the bones than can be obtained in any other way. Stereoscopic pictures are also excellent.

Importance of Two Views. — The following case (like John S., Figs. 275, 276) illustrates the importance of two views: —

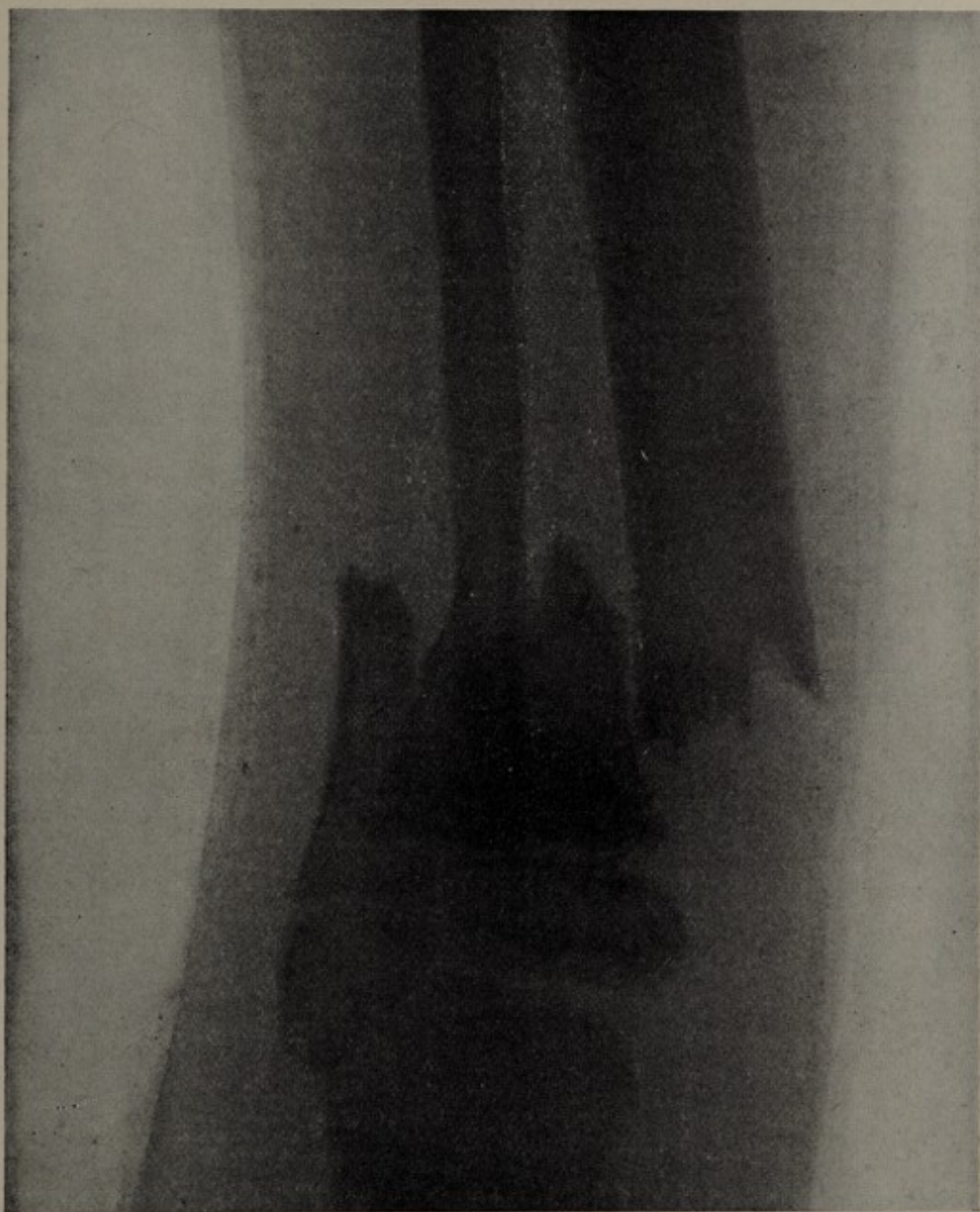


FIG. 278. William A. Fracture of both bones of the leg. Antero-posterior view.

William A., nine years old, a patient of Dr. H. W. Cushing, attempted to climb on to a truck; caught his foot between the spokes of the

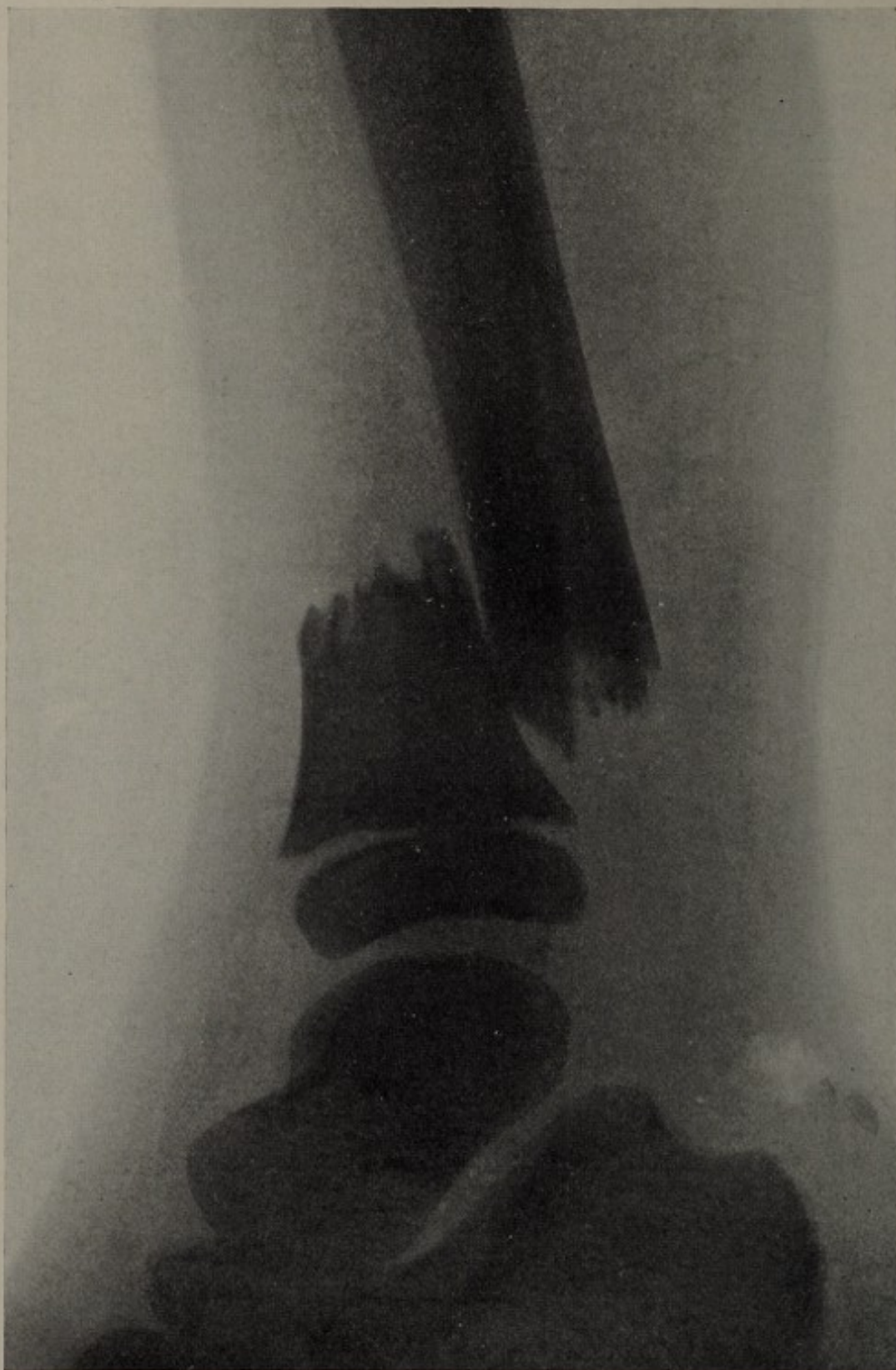


FIG. 279. William A. Lateral view.

wheel, and injured his right leg. There was apparently an oblique fracture of both bones of the leg. About ten days later two X-ray pictures

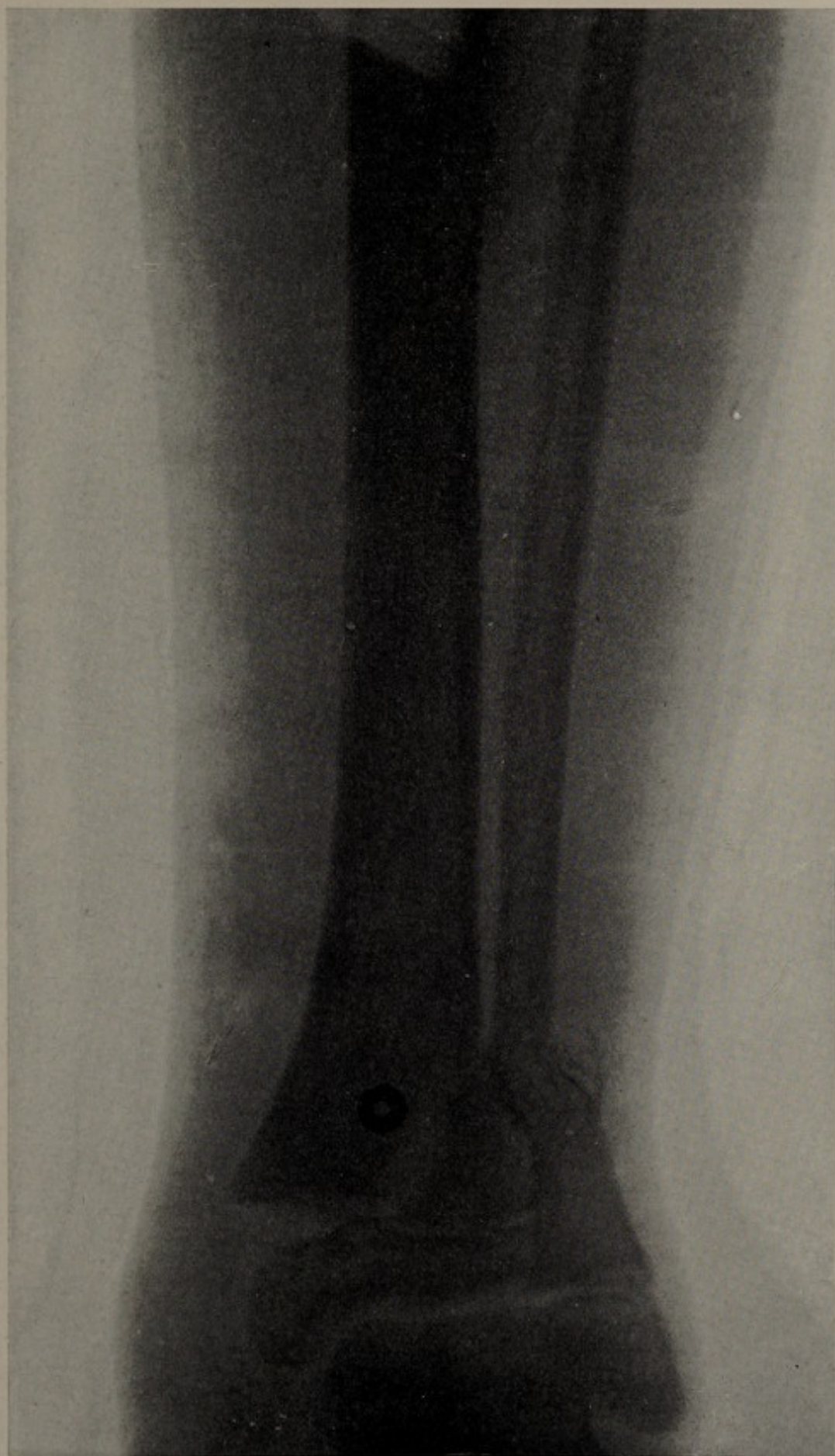


FIG. 280. John C., ten years old. Patient of Dr. W. P. Bolles. While coasting ran into curbing, injuring left leg. Two radiographs are given, which show a separation of the epiphysis at the lower end of the tibia, and the fibrous fracture of the fibula. Antero-posterior view.

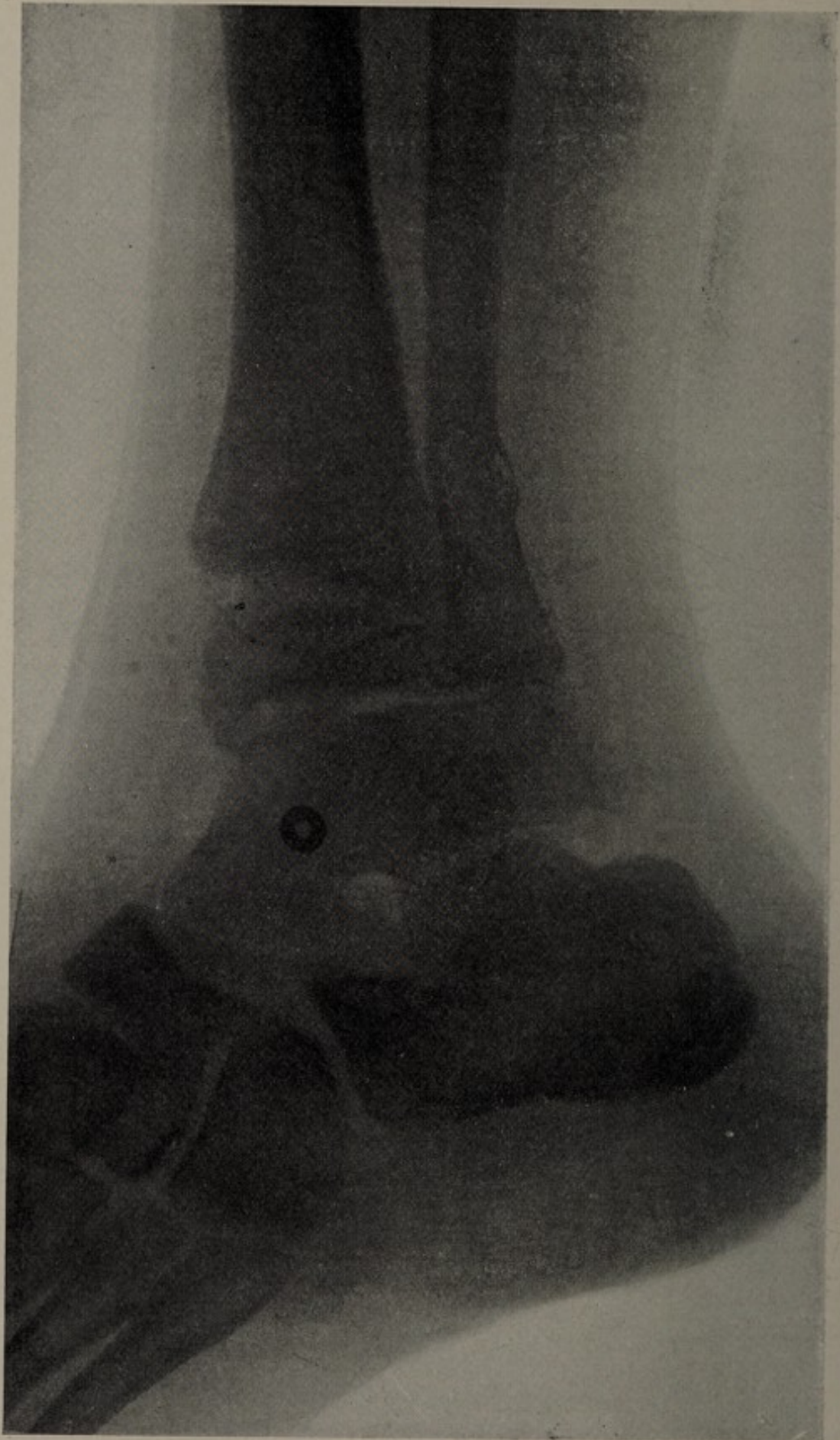


FIG. 281. John C. Lateral view.

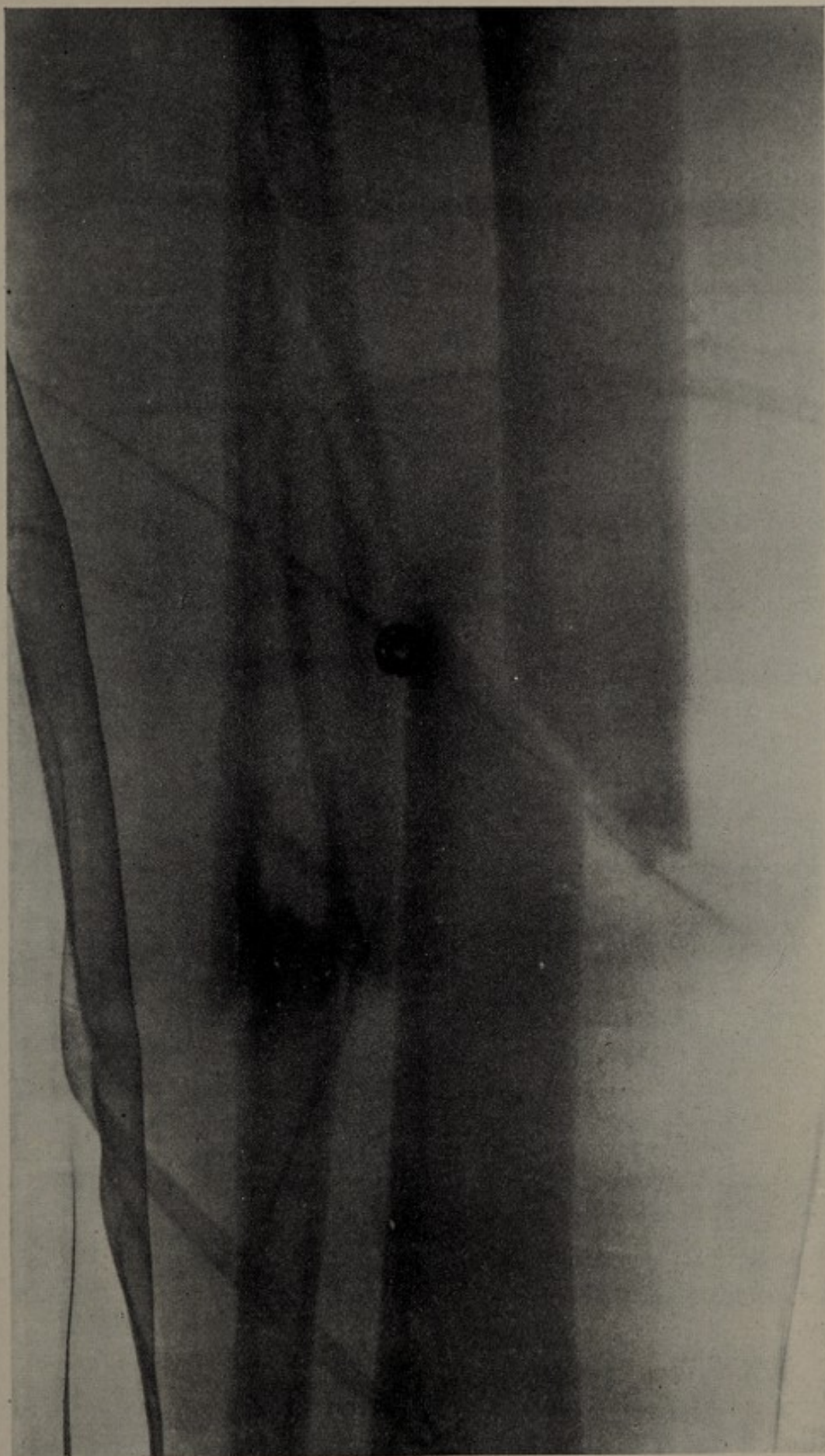


FIG. 282. James H. G., thirty-nine years old. Entered hospital November 30, 1900. Patient of Dr. Munro. The patient was thrown from his seat while driving a team and fractured both bones in the middle third of the right leg on November 30, 1900. Swelling and crepitus. Radiograph made December 1, 1900, which shows the fracture taken after the splints and bandages had been put on.

were taken, one from an antero-posterior, and the other from a lateral point of view. In the former view especially the fracture of both bones of the leg is clearly seen.

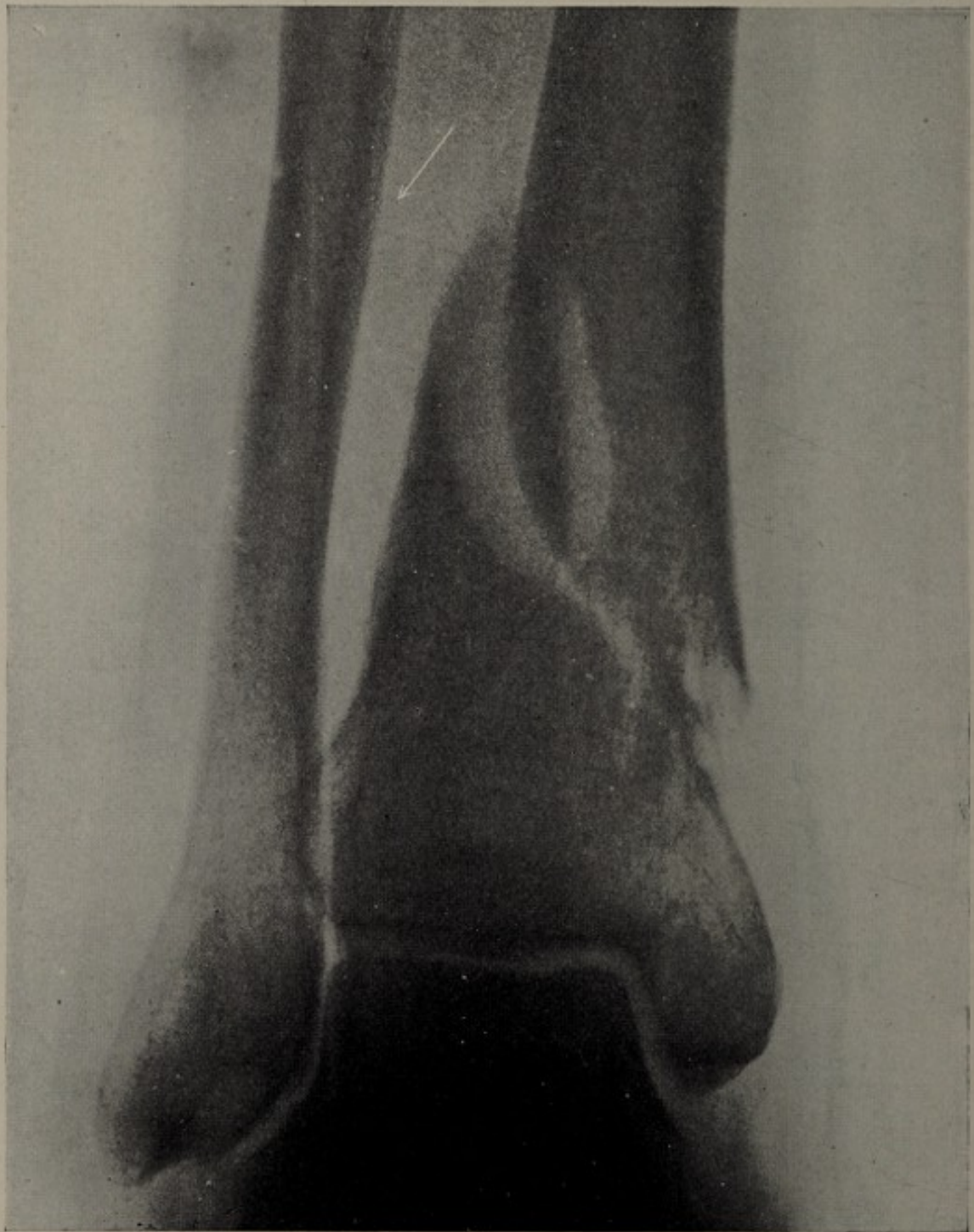


FIG. 283. J. F. S. Fracture of lower end of tibia and longitudinal split in fibula. Patient of Dr. Watson. Callus felt distinctly, but did not show in the radiograph.

**Fracture of Lower End of Tibia and Longitudinal Split in Fibula ;
New Callus not shown by X-Rays. — J. F. S., a man forty-five years old,**

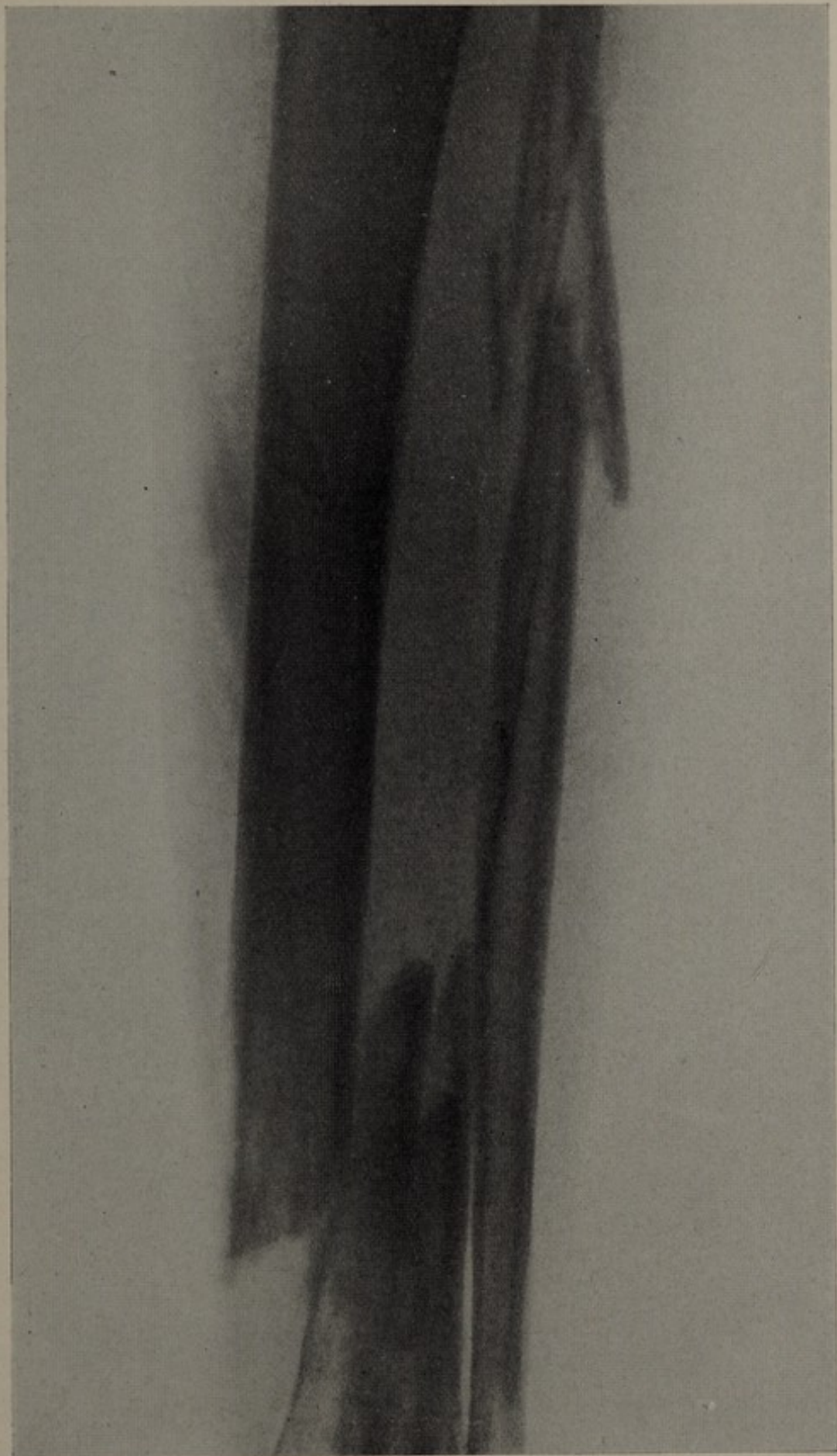

FIG. 284. Michael M., sixty-one years old. Entered the Boston City Hospital January 11, 1899. Patient of Dr. Watson. While walking along the street, slipped on the ice and fell to the ground. The left leg showed, 5 centimetres above the internal malleolus, an oblique fracture of the tibia. The left fibula appeared also to be broken. Radiograph taken March 25, 1899, showed clearly a fracture of both tibia and fibula. The patient was discharged with good union April 26.

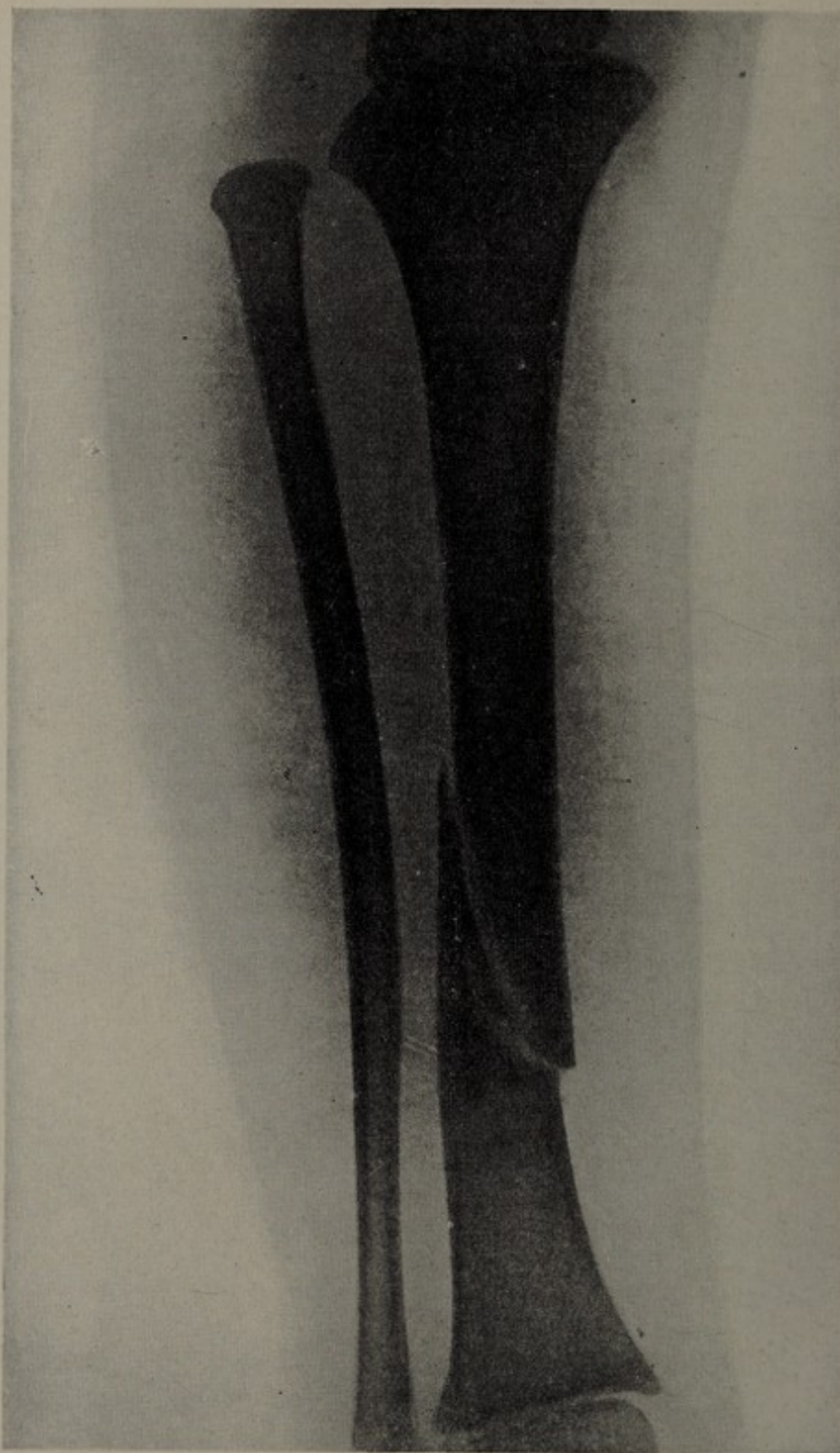


FIG. 285. Patient of Dr. Cushing. Fracture of tibia and apparently of fibula, that of the fibula being slightly higher than that of the tibia. An X-ray photograph was taken from an antero-posterior point of view, which showed the fracture of the tibia, and that there was probably no fracture of the fibula. The injured leg shown in this cut was taken on the same plate with the uninjured leg. The patient was a boy three and a half years old, who fell about twenty feet from a second-story window.

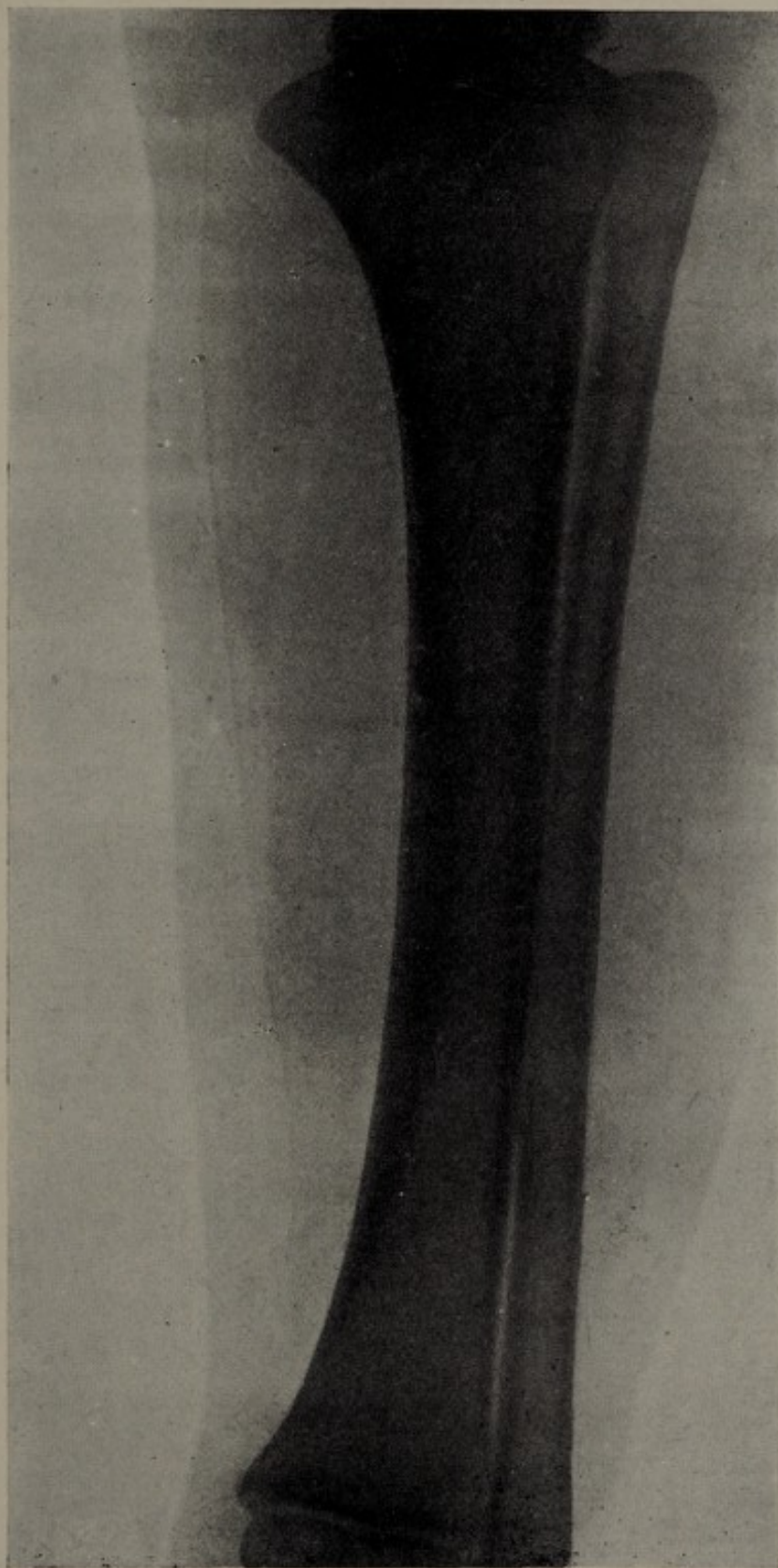


FIG. 286. Uninjured leg. Taken on same plate with the injured leg shown in preceding cut.

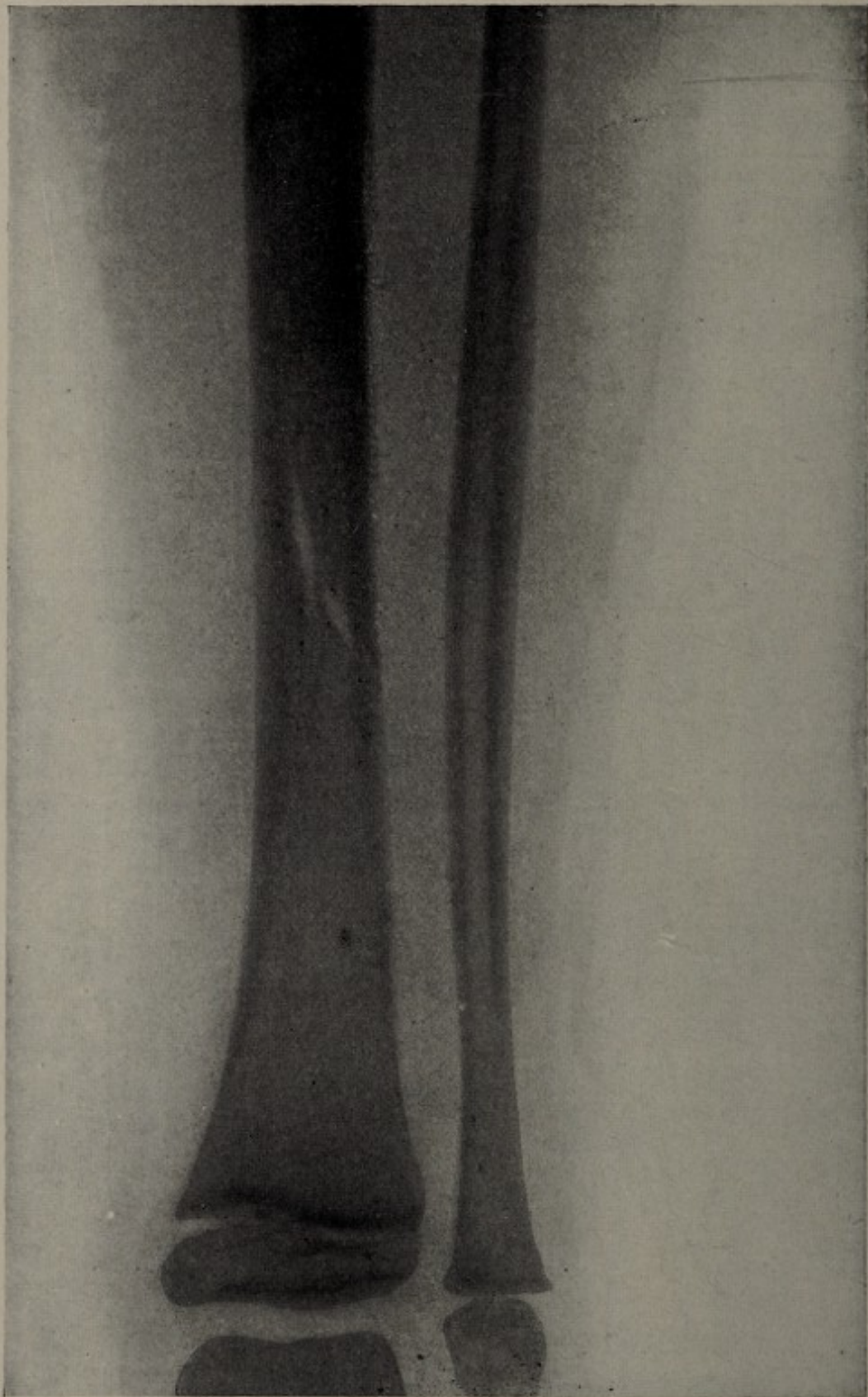


FIG. 287. Fracture of the tibia of a boy six years old. A wheel passed over the left leg. Patient of Dr. J. C. Munro. Taken on same plate with following figure.

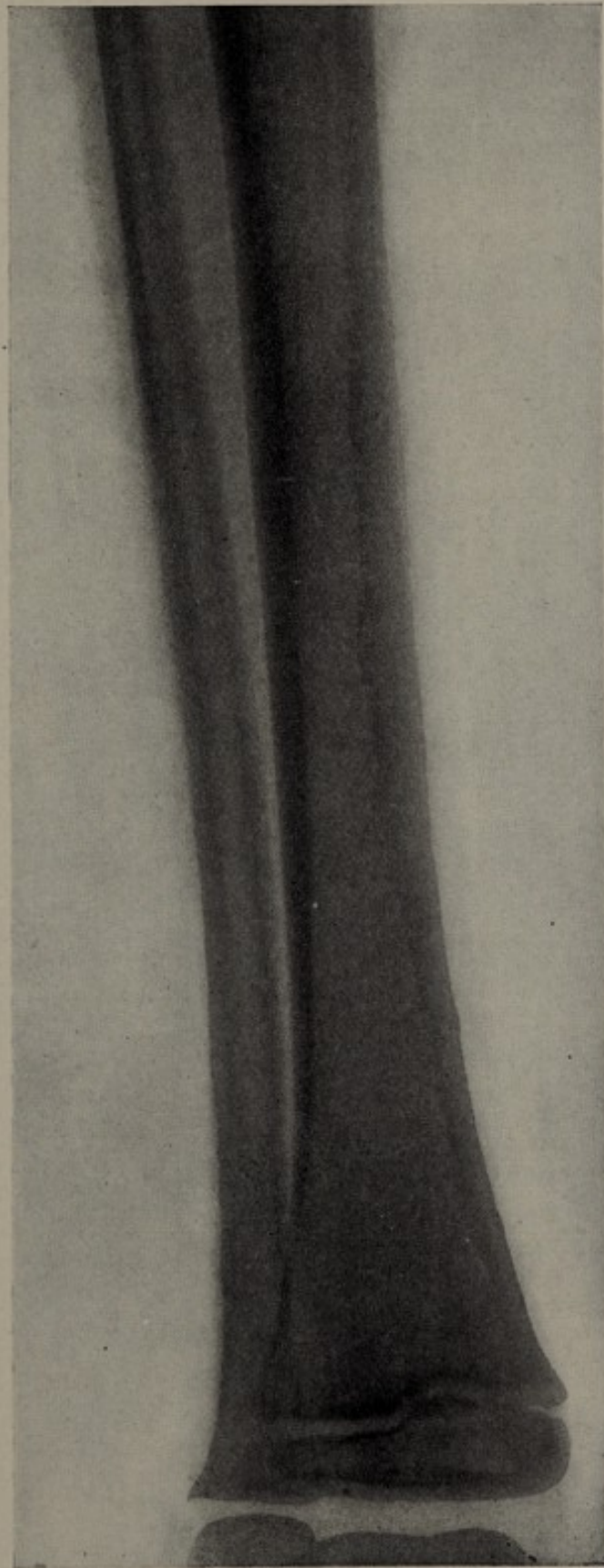


FIG. 288. Boy six years old. Uninjured leg. Taken on same plate with preceding figure.

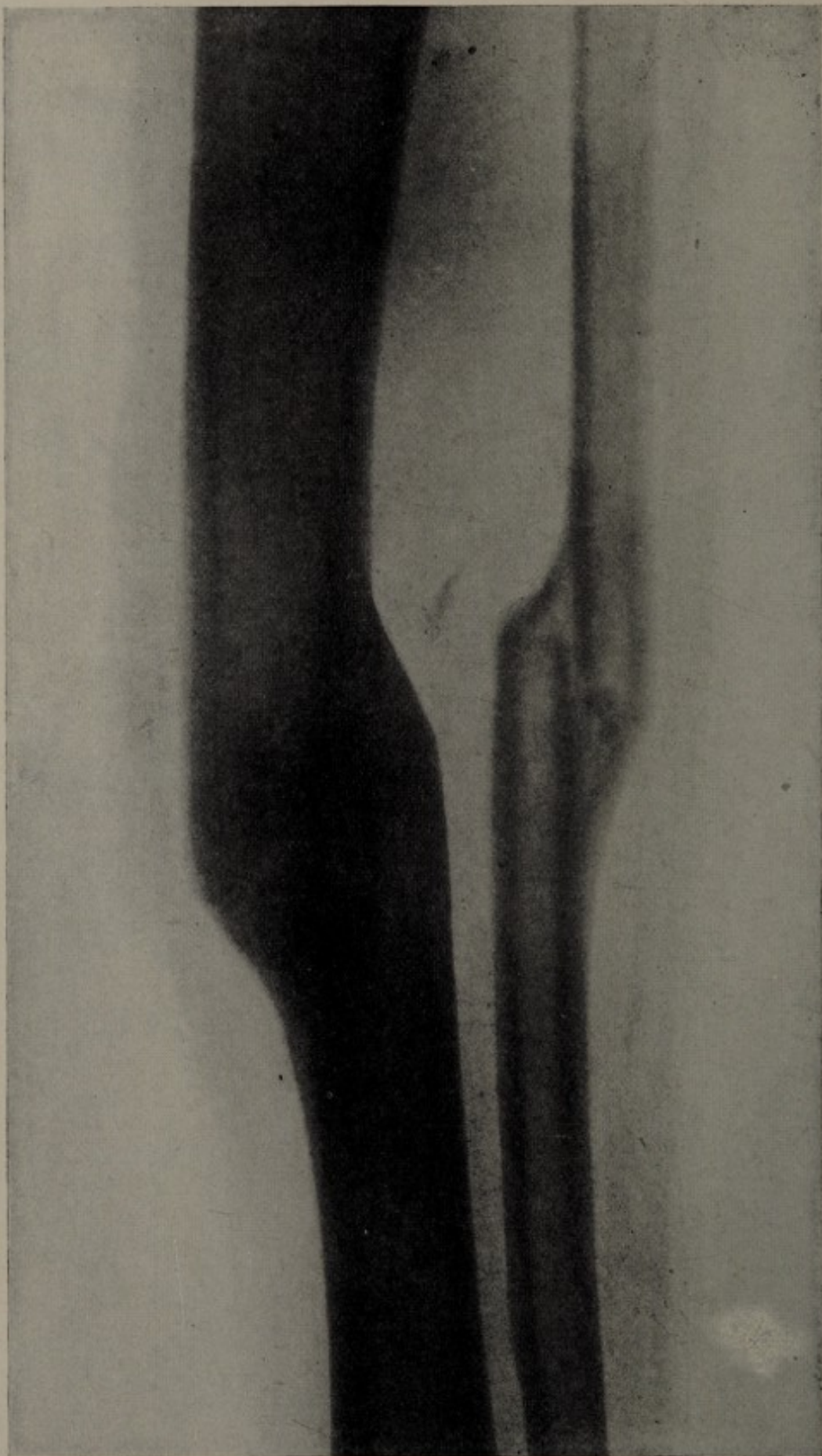


FIG. 289. Patient of Dr. M. F. Gavin. Fracture of both bones of the leg and callus. Two years later patient fractured both bones of the other leg. (See Fig. 290.) These cuts are made from a large negative on which both legs were radiographed together.

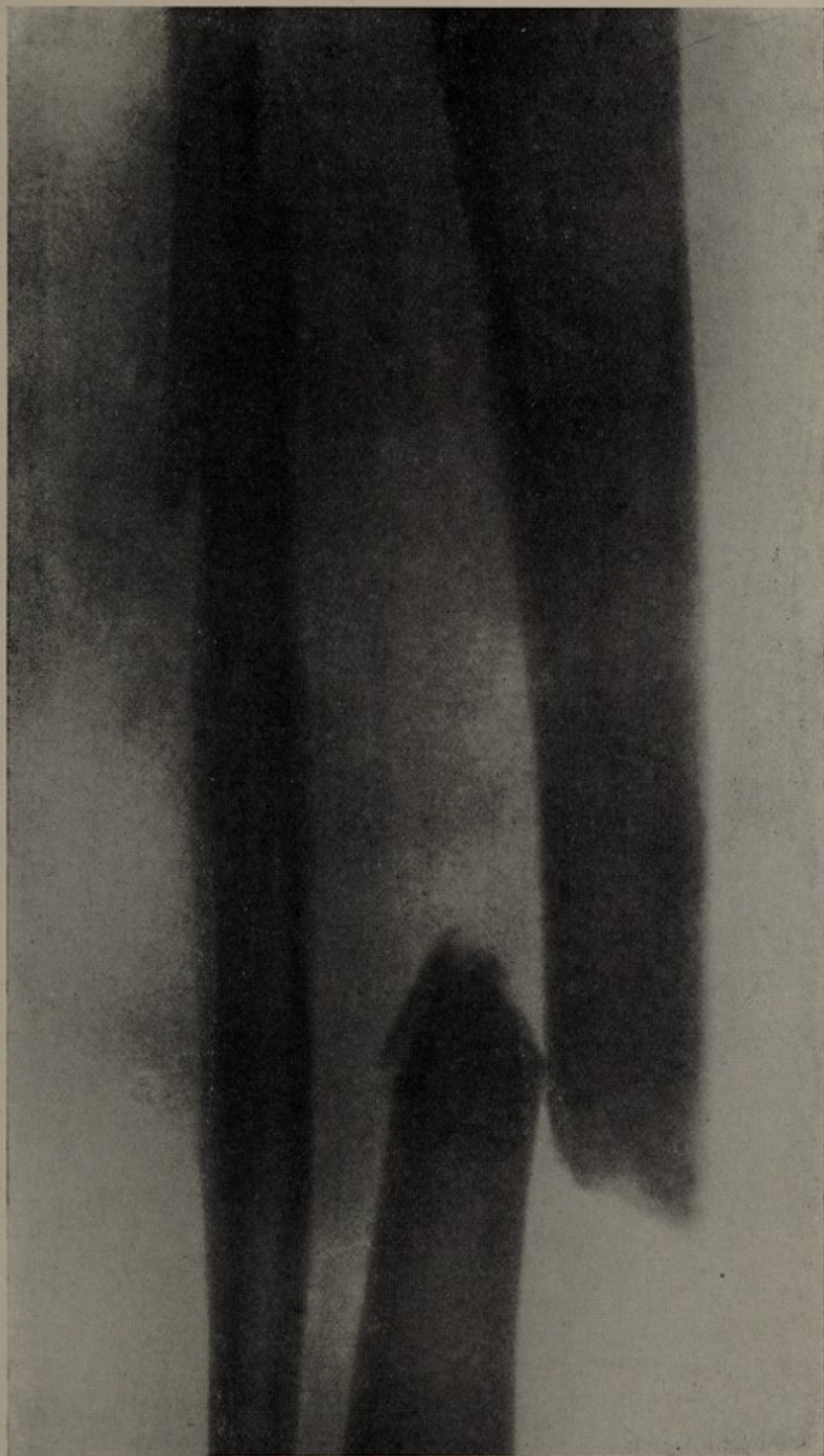

FIG. 290. Patient of Dr. Gavin. Fracture of both bones of leg. Recent fracture; details of fibula less clearly seen than in that of the other leg, although both legs were taken on the same plate. One illustrates how clearly the bones show when the soft tissues are in normal condition, and the other how much less clear they appear when the tissues about them are inflamed.

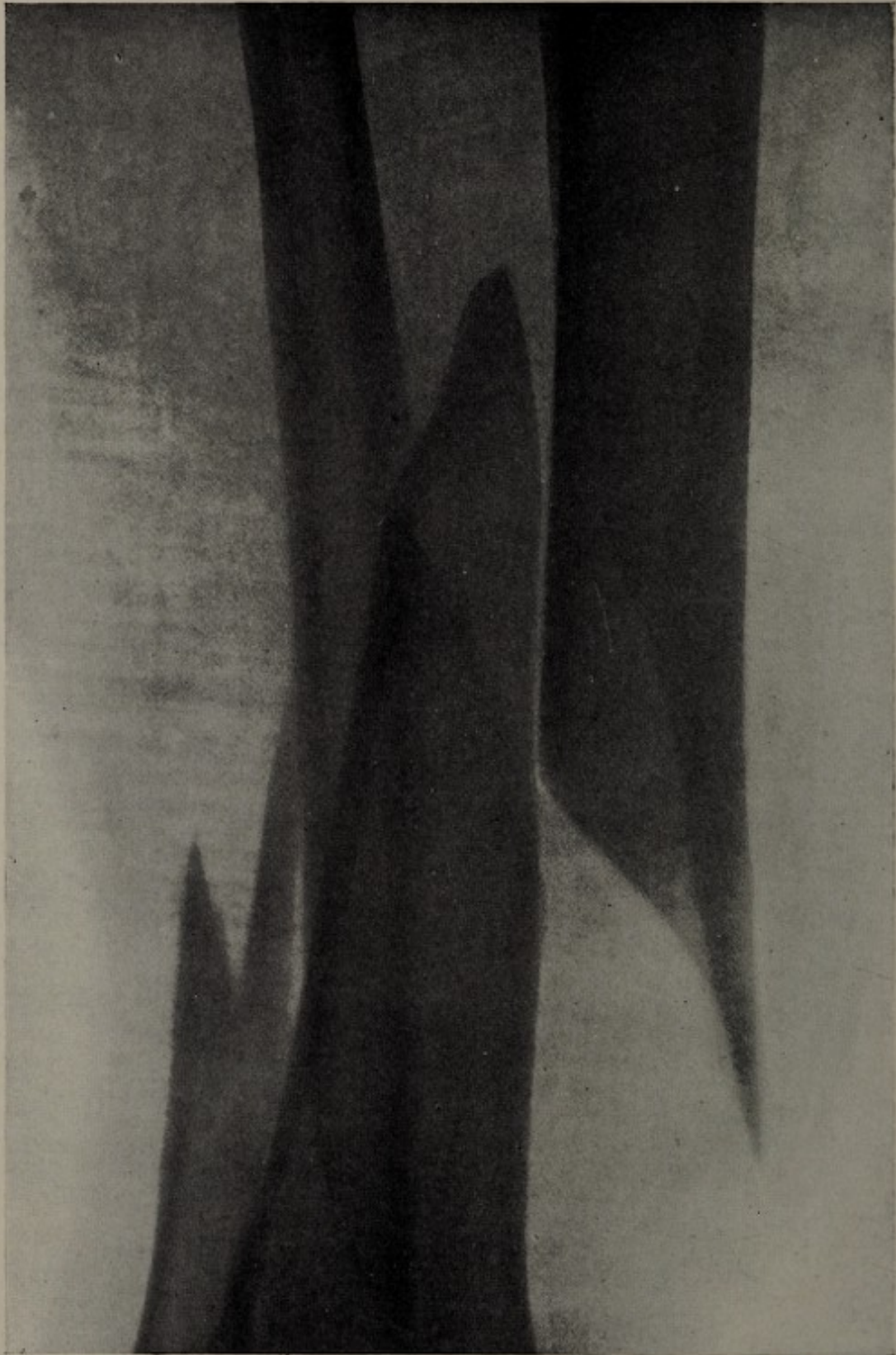


FIG. 291. Patient of Dr. Bolles. Fracture of both bones of the leg. William T., thirty-two years old, while dancing at a theatre, twisted his right foot, heard the bone snap, and fell on the stage. The X-ray photograph was taken six days later. This cut shows well the character of a fracture due to torsion.

entered the hospital December 16, 1899. Patient of Dr. Watson. On this day a bale weighing two hundred pounds fell on the outer side of his leg. There was considerable swelling and crepitus. On January

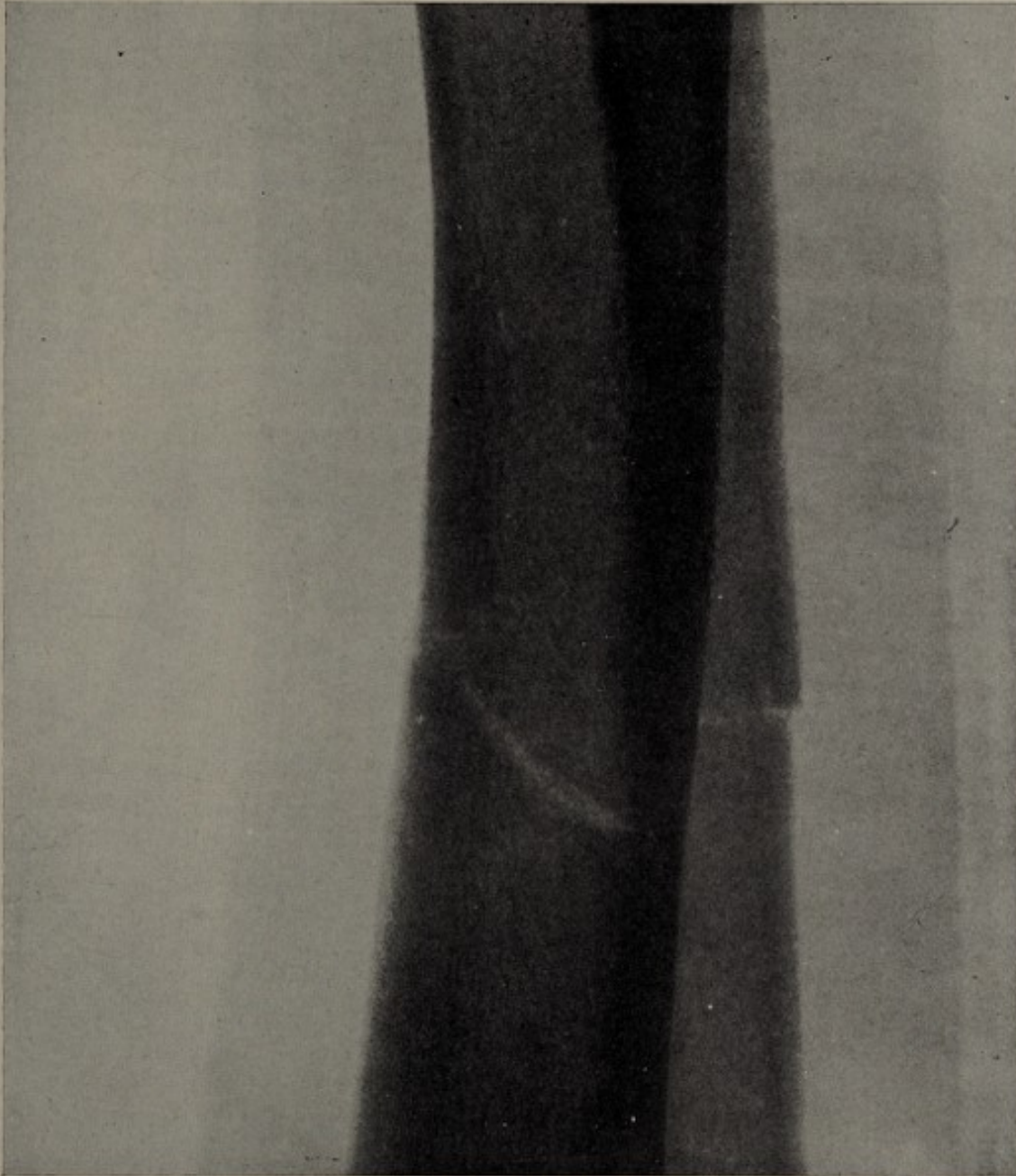


FIG. 292. Patient of Dr. Cushing. Fracture of both bones of the leg of a man twenty years old, who was kicked by a horse. X-ray photograph was taken three days after the accident. No callus to be seen. The character of a fracture caused by a heavy, sharp blow is seen in this cut. Compare with preceding cut, of a fracture caused by torsion.

13, 1900, a large callus was felt. An X-ray photograph (Fig. 283) was taken on this day, which showed no trace of the callus, although it was apparent to the touch. Compare the cut (Fig. 283) with Fig. 258, which shows an old callus.



FIG. 293. Fracture of tibia and fibula of a boy seven years old. Wheel of cart passed over his leg. Patient of Dr. Bolles. The photograph from which this cut was made was taken from a lateral point of view. The one taken from the antero-posterior point of view is not shown.

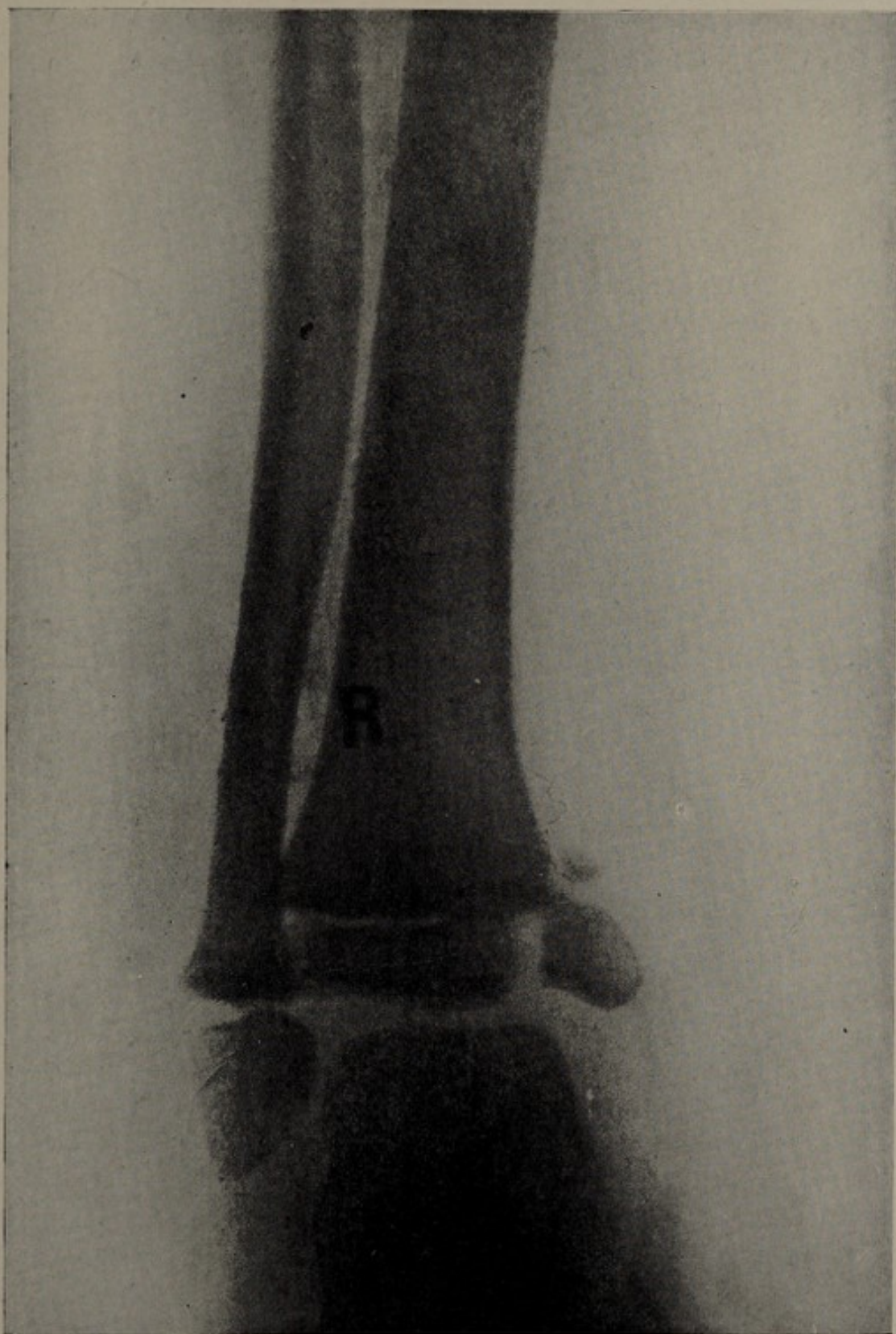


FIG. 294. Fracture of epiphysis. *R* indicates the point opposite which the light was placed and that it was the right leg.

Absence of Fracture indicated by X-Rays; Fracture by Ordinary Methods. — The cut (Fig. 285) shows that there was a fracture of the tibia, but probably none of the fibula, as had been supposed before the radiograph was made. Cuts 285 and 286 illustrate the method of taking well and injured leg on same plate, for comparison: —

Bowed Leg mistaken for Fracture. — Noble Smith¹ cites a case of a child two and a half years old who was thought to have bowed legs. He noticed, however, that only one leg was affected, and that the inner malleolus was higher than natural, and that the child felt pain if the limb were touched. He therefore took a radiograph, which showed a fracture of the tibia 4 centimetres above the ankle-joint. The bone was cut down upon and straightened, and the child made a good recovery.

Advantage of comparing Injured and Uninjured Leg. — Cuts 287 and 288 also show the advantage of taking a picture of both legs in order to compare the injured and uninjured one: —

Tarsus. — For examining the bones of the tarsus the tube must be placed according to the special bones that it is desired to photograph.

X-Rays show Cause of Chronic Swelling of Foot. — The chronic swelling of the foot which arises from slight sudden blows, from a rifle butt, for instance, has heretofore been looked upon as due to an inflamed condition of the soft parts, tendons, joints, etc.; but Freund² states that the X-rays show it is really due to the fracture of one of the metatarsal bones.

There is a saying that "a bad sprain is worse than a broken bone," but a new light is thrown on this adage by X-ray examinations, as they show that fractures may be present when they are not recognized by the older methods, and therefore that the inflammation and pain which they produce are attributed to other causes. The saying, with our present knowledge, should for some cases be amended.

Foot. — The metatarsal bones and phalanges are often most easily photographed with the plate placed on the floor, the patient then resting his foot lightly upon the plate; the tube, of course, is placed above the foot in such a way that the rays may fall upon it vertically; in this position the tube is brought so near the knee or thigh of the patient that the latter should be screened from it by a box thickly coated with white lead as already described.

¹ *Medical Press and Circular*, London, March 7, 1900, p. 240.

² *British Medical Journal*, 1899, II, Epitome, p. 85.

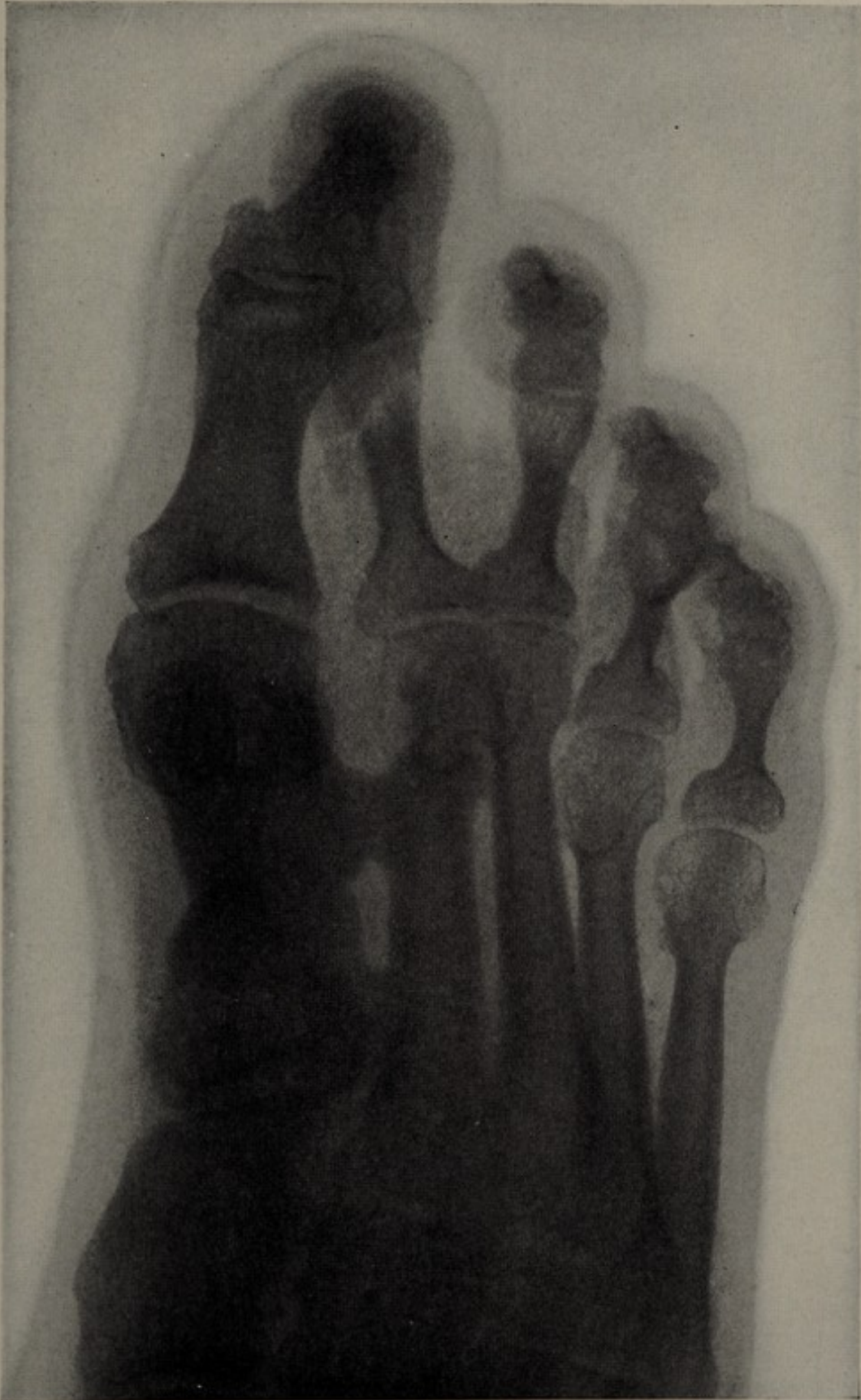

FIG. 295. Injury to foot. Injury occurred about a year before the X-ray photograph was taken. Patient, a man about thirty years old. Testimony as to whether or not there was an injury of the foot was required in a distant city. (Compare with next figure.)

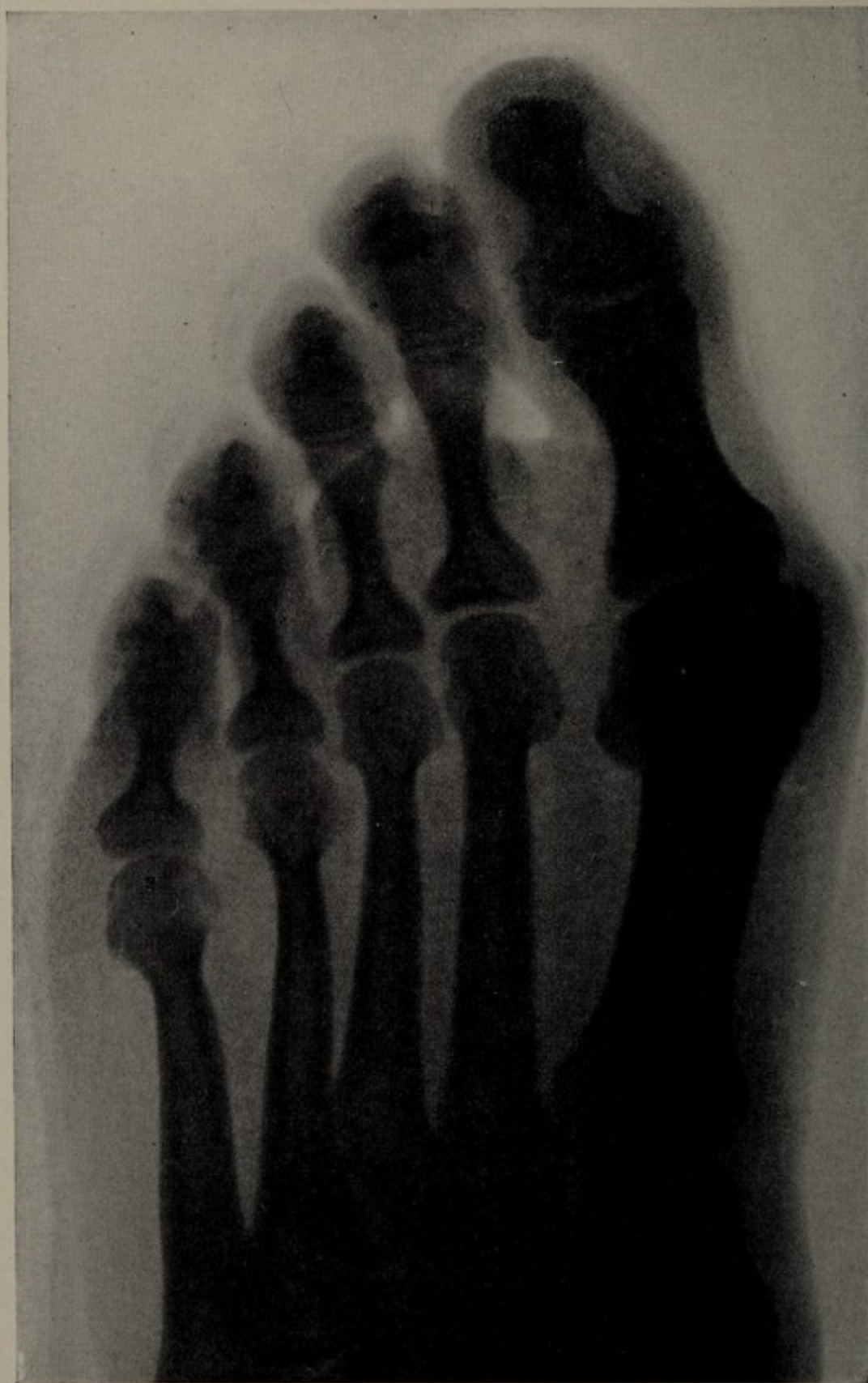

FIG. 296. Uninjured foot. (Compare with preceding figure.)

Advantage of comparing Injured and Uninjured Foot. — Cuts 295 and 296 show the advantage of taking a photograph of both the injured and uninjured foot.

Fractures of Phalanges of Great Toe and Fracture of First Phalanx of Second Toe. — Alfred W., twenty years old, patient of Dr. H. W. Cushing, caught his right foot between the elevator and the floor above, and was brought directly to the hospital. There was some ecchymosis and

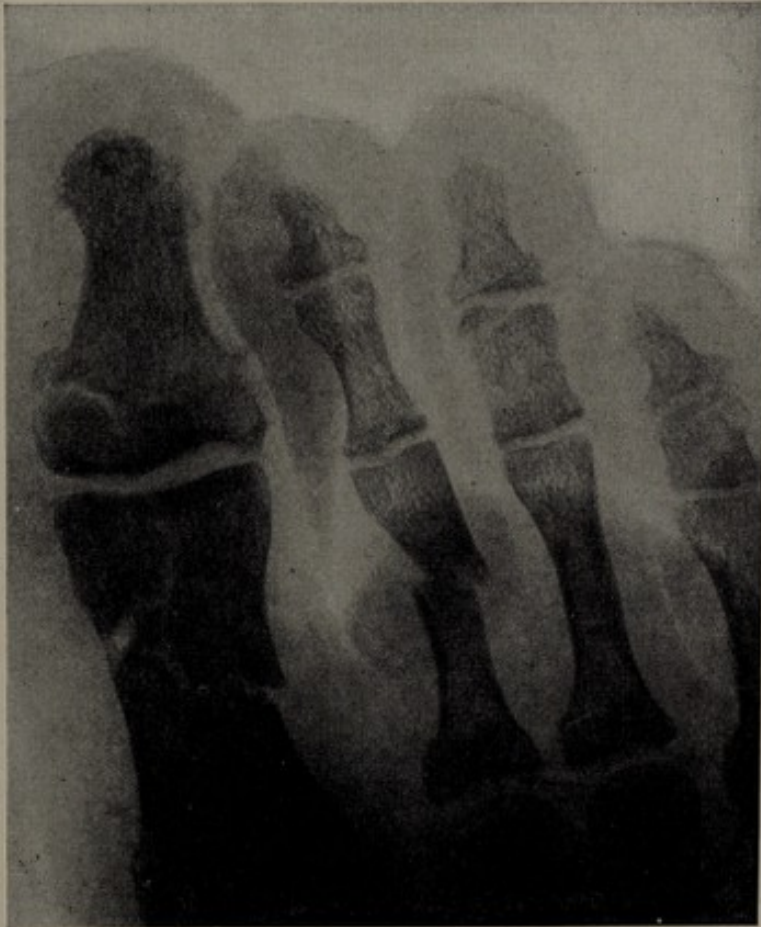

FIG. 297. Fractures of phalanges of great toe and fracture of first phalanx of second toe. Two of these fractures were unsuspected before the radiograph was made.

swelling across the entire metatarsal region and base of toes, but no fracture of metatarsals was made out. There was bony crepitus and pain in phalanx of great toe. The X-ray photograph showed fractures of the phalanges of great toe and of the phalanx of second toe. The second fracture of the great toe and the fracture of the second toe were not suspected by the ordinary methods. The uninjured foot was taken by the side of the injured foot and on the same plate for purposes of comparison, but is not shown.

DISLOCATIONS

In certain cases it is difficult to distinguish between a dislocation and a fracture; radiographs indicate clearly the conditions which are present. The following cuts (Figs. 298, 299, 300, 301, and 302) are illustrative of dislocations.

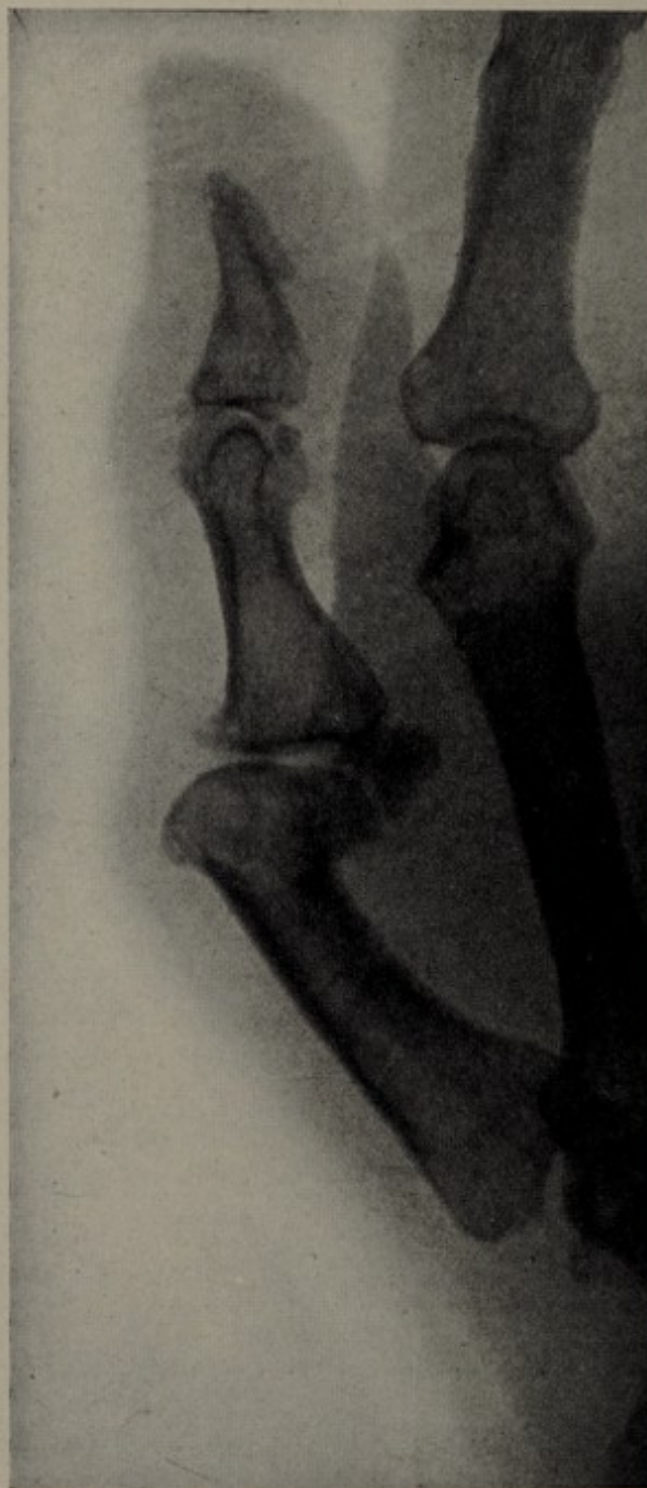

FIG. 298. Dislocation of thumb. Old injury to hand. Patient of Dr. Blake.

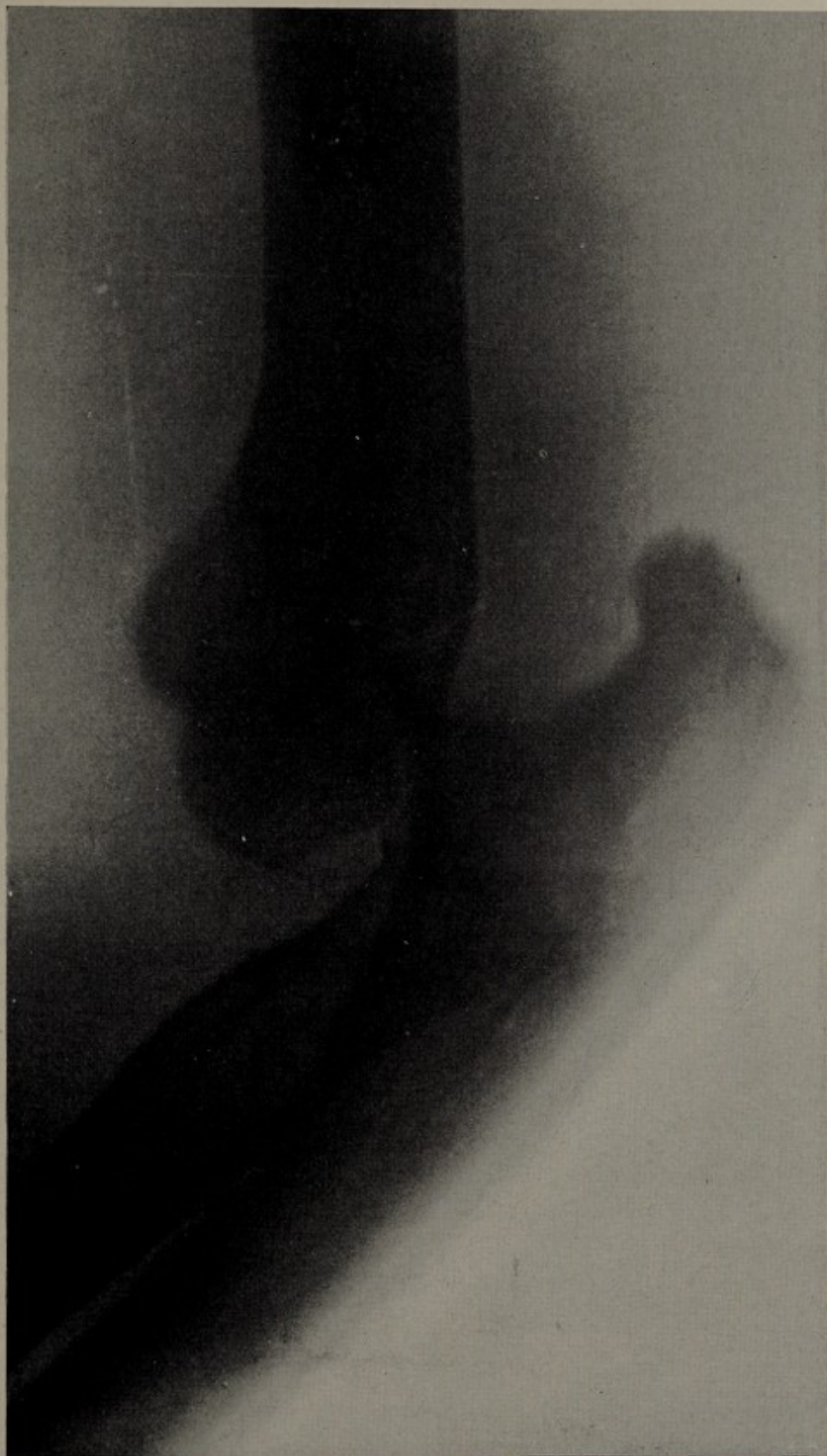

FIG. 299. Dislocation of both bones of forearm backward. Patient of Dr. Edwin W. Dwight.

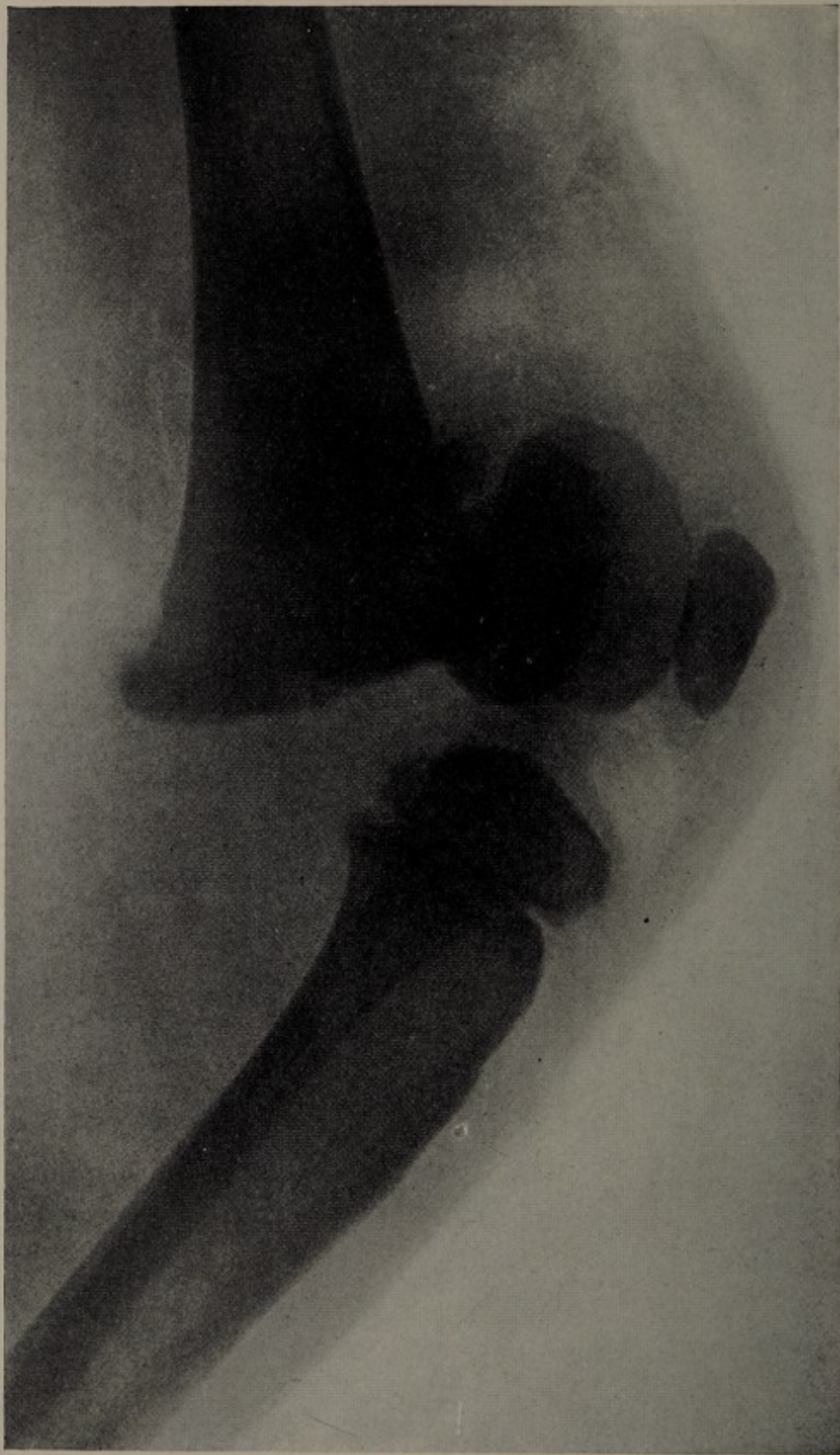


FIG. 300. Hugh C. Dislocation and separation of epiphysis of lower end of left femur in a boy seven years old. When the X-ray photograph was taken (June 16, 1899), the plate was put on the outside of the left knee.

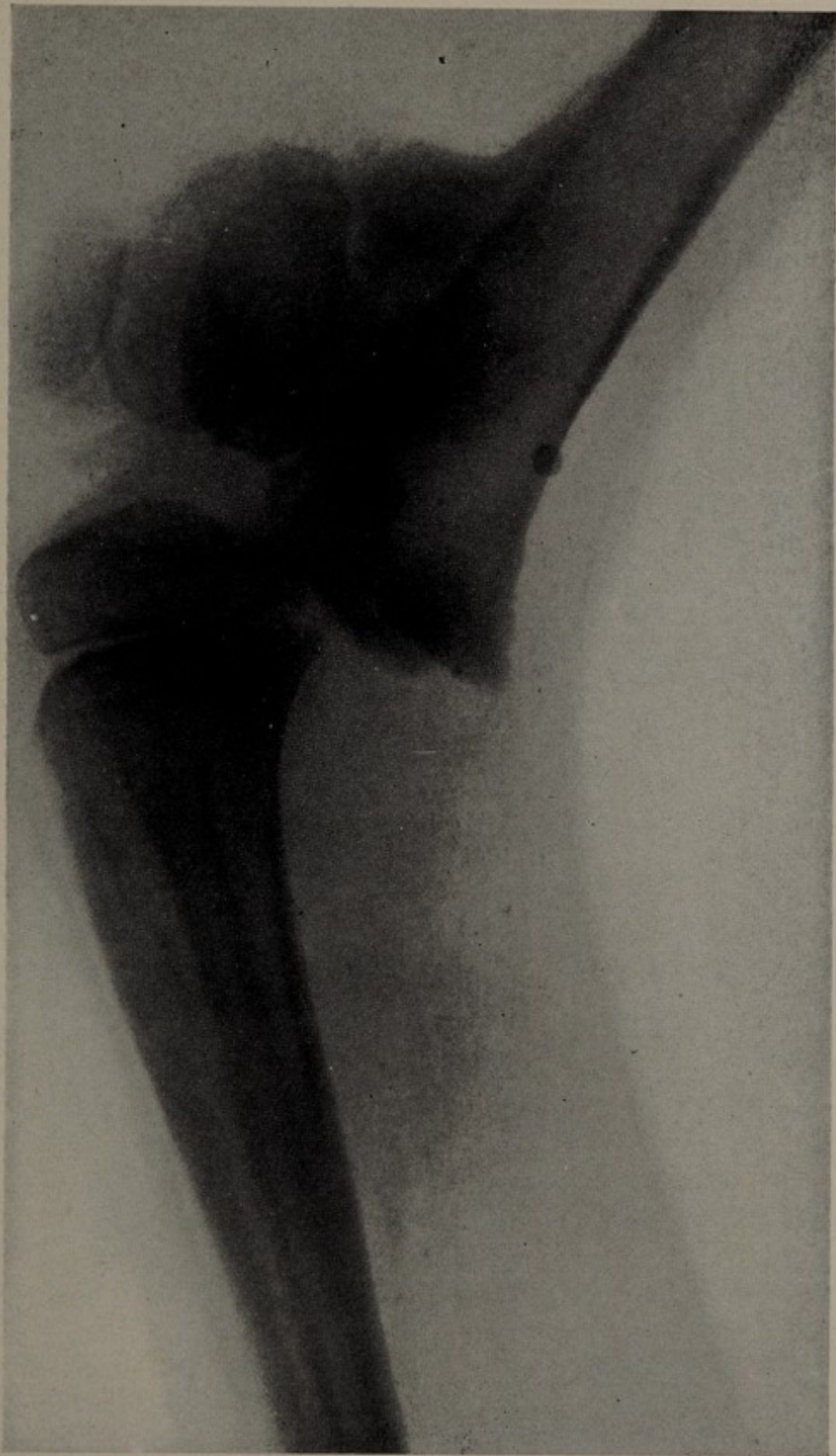


FIG. 301. Hugh C. Cut of X-ray photograph taken nearly three months later.
2 M

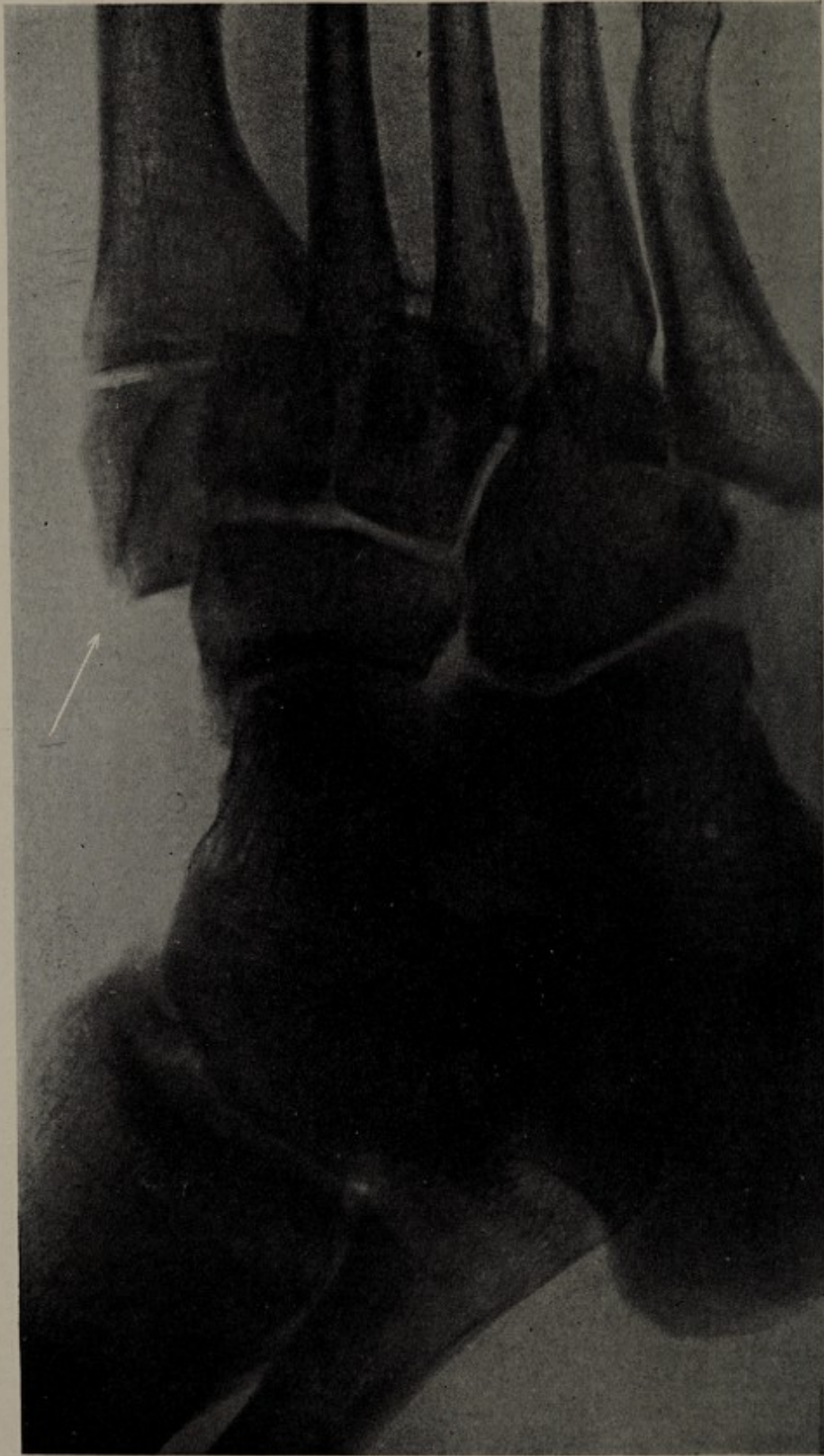

FIG. 302. Philip M., thirty-five years old. Subdislocation of metatarsus. Patient of Dr. H. L. Burrell and Dr. Gavin. Patient was on one knee at work, with the sole of the right foot uppermost. This foot was run over by a heavy team. Marked prominence inward and upward of first metatarsal bone.

CHAPTER XX

FOREIGN BODIES

It is frequently necessary or desirable to know whether a foreign body is present or not in the human body, and if it is, to learn its exact location in order to remove it, or to determine whether or not its removal should be attempted. The X-rays can show us those substances whose shadows present a contrast to the shadows of the surrounding tissues, and therefore objects, such as bullets or other pieces of metal or glass, admit, as a rule, of precise localization, whereas a splinter of wood or the shell of a nut could not be seen or only under very favorable conditions. But in the case of metallic objects, we have a probe which is exact, clean, and painless. Moreover, it will determine the position of a bullet, for example, after the most careful search by all other methods has failed to reveal its location.

Methods of Localization. — Various methods have been devised for the localization of foreign bodies, some of which have already been described (see Chapter III, page 81, and Chapters XI and XII), and we will now consider others: first, a method which is carried out by means of the fluorescent screen; and second, those which are carried out by means of X-ray photographs.

First Method; by Fluorescent Screen. Part moved and examined from Two Directions. — The following description of the manner in which this method is carried out I quote from an article which I published in January, 1897:—

“Everything being now in readiness, the fluoroscope is placed directly on the thigh (let us suppose the bullet is there), and the examination is begun. After looking a moment the spark-gap may be changed a little in order to increase or diminish the light, as by means of this variation more can be seen, certain things showing better in a bright light and others in a less brilliant one. With a bullet it is generally well to use a considerable amount of light. After the fluoroscope has been moved about a little, the shadow of the bullet is found, and the spark-gap may again be changed, in order to

get as clear a shadow as possible. The physician, while still looking through the fluoroscope, then makes, with the pencil already described, a mark over the place where the bullet seems to be, and directly under the fluoroscope; he then makes a corresponding mark on the side of the thigh nearest the Crookes tube, over the shadow of the bullet, and draws 1 and 1 by the side of each of these two marks. Then, while still looking through the fluoroscope, the Crookes tube should be moved horizontally a few inches to and fro in order to learn how deeply the bullet is imbedded, for if the shadow of the bullet moves considerably in the fluoroscope, the bullet is some distance away. If it moves very little, it must be near the fluoroscope and the surface of the skin. If far from the surface, its shadow will, of course, be ill defined; if near, it will be very sharply defined. Next, the patient should be turned so as to allow the physician to look through the thigh in a direction about at right angles to that first taken, and, as before, a mark should be made with the pencil over the place where the bullet seems to be, both when the point of the pencil is held directly under the fluoroscope and on the side of the thigh nearest the Crookes tube. These points should be marked 2 and 2, and the bullet will be found at the point where the line from 1 to 1 intersects that from 2 to 2. I have used this method for locating bullets in different parts of the extremities, and in the neck, thorax, back, and abdomen, and usually the situation of the bullet is readily determined by this means. The first bullet I located in this way was in April, 1896."

It is well to go over the marks indicating the position of a foreign body with nitrate of silver, so that they will not come off when the part is washed with an antiseptic; the stains caused by the former may be removed, when desired, by painting them with tincture of iodine. The iodine may in turn be removed by dilute ammonia water. Since nitrate of silver is a caustic, it should be diluted, as a precaution, with some less caustic substance, nitrate of potash, for example. The ordinary diluted lunar caustic consists of equal parts of nitrate of silver and nitrate of potassium. This substance is too strong, and I have had a crayon made which has a smaller proportion of nitrate of silver, in order to obtain a pencil suitable for marking on the skin. The crayon should be moistened when it is to be used.

The above method of locating a foreign body applies to all such as can be seen on the fluorescent screen, but some cannot be thus recognized, and in this case the radiograph must be employed.

Second Method ; by X-Ray Photograph. Stereoscopic Pictures. — Dr. G. P. Girdwood¹ has devised an excellent method of locating a foreign body by means of stereoscopic radiographs. Dr. Mackenzie Davidson² has also worked out a similar method which differs in certain particulars from that of Dr. Girdwood.

Localizers. — A number of forms of apparatus have been made for the purpose of localization, among which the following deserve special mention : —

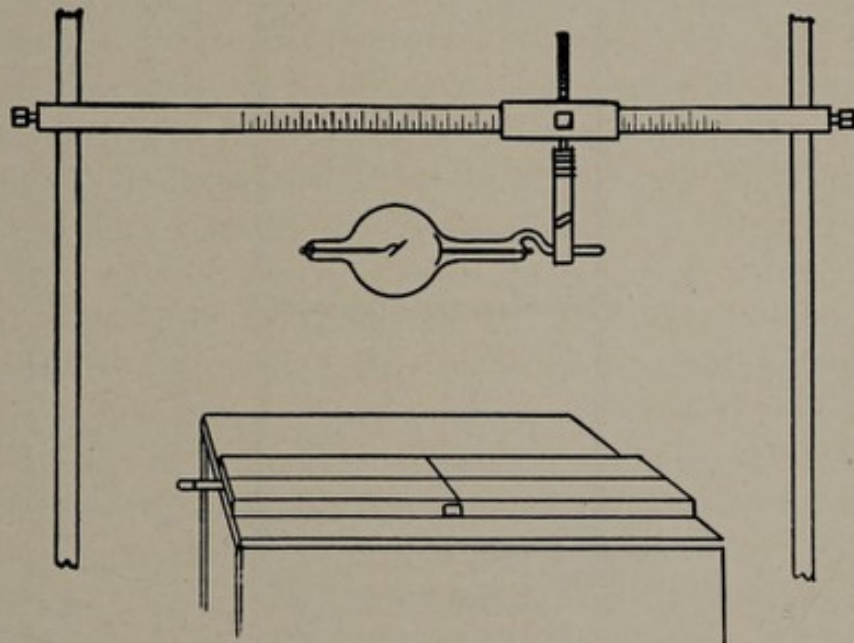


FIG. 303. Mackenzie Davidson exposur. The photographic plate is placed beneath the crossed wires on the board. The wires are inked and leave marks on the skin of the part, and the image of the wires appears on the negative. This gives lines for localization. The tube is suspended vertically above the transverse wire and equidistant at each exposure from a point vertically above where the wires cross.

Fig. 303 and Fig. 304, and descriptions, are taken from "The Use of the Roentgen Ray in the War with Spain," by Captain W. C. Borden.

Mackenzie Davidson has devised a very ingenious apparatus for locating a foreign body. The following account is quoted from an article³ by him and Dr. Hedley : —

"Two wires at right angles to each other are placed upon the photographic plate, film, or paper. The Crookes tube is then placed with its anode at a measured distance from the plate and exactly perpendicular to where the wires cross. The tube is fixed in a holder which slides

¹ "Stereoskiagraphy," *Montreal Medical Journal*, 1899, p. 193.

² *British Medical Journal*, December 3, 1898, p. 1669.

³ "A Method of Precise Localization and Measurement by Means of Roentgen Rays," by J. M. Davidson and W. S. Hedley, *Lancet*, October 16, 1897, p. 1001.

in one plane. Further, one of the cross wires must be in exactly the same plane as that in which the tube is to be displaced. The wires being painted over with some pigment, the part to be photographed is placed on the plate and carries with it a mark of the cross wires. The tube is then displaced to a measured distance to one side of the perpendicular, and an exposure given, then to a corresponding point on the other side of the perpendicular, and another similar exposure given. The

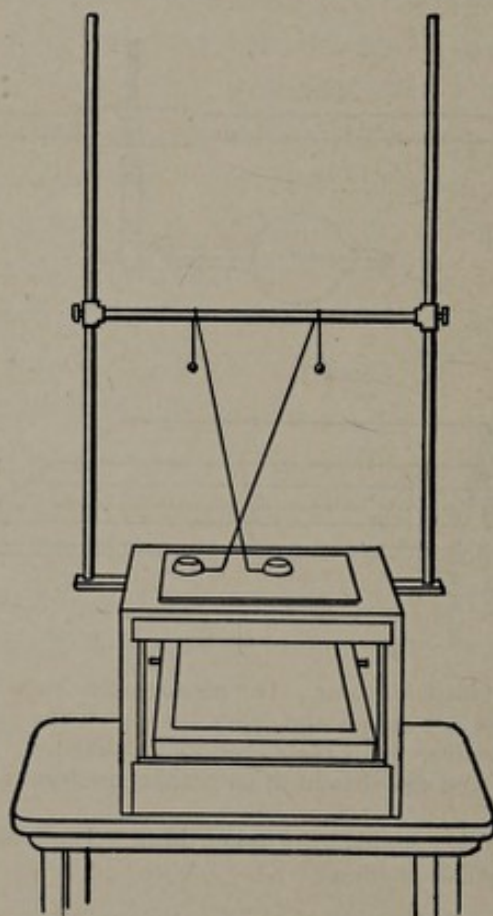


FIG. 304. Mackenzie Davidson localizer. The negative is placed on the glass plate in the same position relative to the two points on the crossbar that it occupied relative to the anode when the exposure was made. Weighted threads are then stretched from corresponding points on the image to the points on the crossbar, and their point of crossing indicates the position which the lodged missile occupied relative to the plate when the exposure was made.

resulting negative shows double images from the two different points of view. A further precaution is necessary, viz., to mark one quadrant of the plate and the corresponding quadrant on the patient's skin.

"The negative having been developed, fixed, and slightly washed, is at once placed on a horizontal stage illuminated from below by a suitable reflector (an arrangement similar to a retoucher's desk). The negative may be placed with the gelatin surface upward, or downward

if the glass is not too thick. In the case of celluloid films it is most convenient to place them downward. The negative is adjusted so that a perpendicular dropped from a notch in a horizontal scale falls upon the point where the shadows of the wires cross. On each side of it another notch is made at the exact distance and height that the anode of the Crookes tube occupies in the two exposures. A fine silk thread is then passed through each lateral notch, and a small lead counterweight is attached to one end of each thread, while the other is passed through the end of a fine needle. The needle is weighted with lead so that its eye lies flat on the surface of the negative. In short, these two silk threads represent the path of the X-rays, so that if each needle be carefully placed upon a corresponding point in each shadow, it follows that the point where these threads cross marks the position occupied by the corresponding part of the actual object. Further, its distance can be measured perpendicularly from three planes—from the horizontal which gives its depth, and from the two planes represented by the shadows of the cross wires. By measuring any other desired corresponding points the precise size, position, and direction of the object can be determined, and remembering that the cross wires have left their mark on the patient's skin, we can at once from these data give the surgeon all the information he can possibly desire. . . . Dr. Hedley suggested that instead of displacing the tube, two tubes be used and a simultaneous exposure given."

Harrison's Apparatus.—Harrison,¹ following the idea described by Davidson in the *British Medical Journal*, January 1, 1898, has devised a localizer which he considers rather simpler. His description is as follows:—

"The stand of my focus tube is 7 inches wide and about 18 inches long, and I fix the tube so that its centre is 7 inches above the board. The tube can be moved to either side, and a point is marked on the extreme edge of the board on each side, directly under its centre. These points are joined by a straight line, and a line is drawn at right angles through the centre of the first line. The sensitive plate should be so placed that its centre coincides with this point. A photograph is taken with the tube over each of the lateral points in succession on the same plate, and the distances of the images of the foreign body from the sides of the board must be accurately measured.

"I now draw on a board a square of 7 inches and divide one side

¹ *British Medical Journal*, February 12, 1898.

into a scale. On this scale I mark the distances of the images of the object from the sides of the board, with two pins. I also fasten two pins at the two opposite corners of the board. Two threads are now fastened to these pins and passed round the pins on the scale. Their point of intersection will show the position of the object."

Harrison has made a modification of his apparatus so that the whole object, or as many points as are desired, can be localized, and if the subject examined is bigger than the hand, a larger square than the one described can be made. His description of this modified apparatus¹ is as follows:—

"A 7-inch square is drawn on a board, and its centre accurately marked; at the ends of a line drawn through the centre, perpendicular to two of the sides, two upright rods are fixed (for convenience of carriage these can be made to take in and out); at a height of 7 inches on each of these pillars a hook or loop is placed.

"Take the case of a needle in the hand. A double photograph of the hand and needle is taken with the light alternately right and left. A tracing of this photograph is then taken on the sensitive side, marking distinctly the ends of the needle. This tracing is then placed so that its centre coincides with the centre of the square; pins are then stuck slantingly through the tracing into the board at the ends of the needle. Cross threads are carried from the pins to the loops, and kept stretched by small weights. Where these threads intersect will show the position of the needle relatively to the sensitive plate which is represented by the tracing."

Grossman's Method for localizing a Foreign Body in the Eye.—Karl Grossman,² in localizing a foreign body in the eye, utilizes the eye itself for the purpose of obtaining the necessary parallax of the shadow; the vacuum tube, the head of the patient, and the photographic plate retain their relative position to each other unchanged. Grossman describes his method as follows:—

"Either one or two pairs of skiagrams are taken. The first pair is obtained by making the patient look (*a*) downward, (*b*) upward, in the same plane, the X-rays coming from the other side of the face and somewhat in front of the face. If the foreign body be in the eyeball, the shadow has moved from (*a*) to (*b*) as follows:—

¹ *British Medical Journal*, April 2, 1898, pp. 882-883.

² "Localization of Foreign Bodies in the Eye by X-Rays," *Liverpool Medico-Chir. Journal*, January, 1899, pp. 359-361.

| | |
|-----------|------------------------------------|
| Upward, | if in the anterior half hemisphere |
| Downward, | " " " posterior " " |
| Forward, | " " " inferior " " |
| Backward, | " " " superior " " |

the axis of these four half-hemispheres being at the same time the axis of rotation for the upward movement.

"If the shadow has not moved, the foreign body might still be in the eyeball, viz. at any point on the axis of rotation. In this case the second pair of skiagrams would become necessary, the patient, this time, having to look at a point (*c*) temporalward, (*d*) nasalward, in the horizontal plane. A movement of the shadow from (*c*) to (*d*) would mean the presence of a foreign body in the eye, viz. in the temporal hemisphere if forward; in the nasal hemisphere if backward.

"It may be mentioned that the relative position of the tube, head, and plate need only remain the same for the two exposures of each pair; viz. for (*a*) and (*b*) on the one hand, and for (*c*) and (*d*) on the other, but may be a different one for each pair of skiagrams.

"In order to give landmarks of orientation to the skiagrams, thin lead wire or narrow strips of lead foil were applied in various ways; if necessary, they can be placed in the conjunctival sac."

Dr. Sweet's¹ Apparatus. — The apparatus is fixed to the patient's head, and by knowing the distance of one of the balls of the indicator from the centre of the cornea and the distance between the two balls the position of the metal in the eye may be determined.

Dr. Sweet² has employed the rays for diagnostic purposes in thirty-five cases of injury to the eyes. In thirteen cases there was shown to be no foreign body in or near the eye. In the remaining twenty-two a foreign body was found either in the eyeball or the orbit, the localization being verified in sixteen cases by magnetic extraction, or by enucleation, and in two cases by the ophthalmoscope. Three cases were gunshot injuries and no operation was performed for the removal of the shot; while one patient did not reappear after the radiographs were made.

Dr. Sweet considers that these cases show an accuracy in the determination of the situation of foreign bodies in the eye by the use of the Roentgen rays, that he believes is not equalled by any other means. If

¹ "The Value and Method of determining the Precise Location of Pieces of Metal in the Eye by Means of the Roentgen Rays," *Archives Ophth.*, New York, November 27, 1898, pp. 377-399.

² "Locating Foreign Bodies in the Eye; Results of Two Years' Work with the Roentgen Rays," *Philadelphia Medical Journal*, October 14, 1899, pp. 718-719.

the examination is negative, both the surgeon and the patient are reassured. If the radiograph indicates that a foreign body is in the eye, an attempt to remove it may be made before a firm exudate has formed about it. To wait until the inflammation has subsided, in the hope of determining the situation of the metal by the ophthalmoscope, consumes valuable time and menaces the safety not only of the injured but of the sound eye.

Piece of Copper in the Eye. — One of the first cases, so far as I am aware, in which the X-rays helped to indicate the presence of a foreign body in the eye, was that of a patient who was brought to me in June, 1896, by my brother, Dr. Charles H. Williams. Messrs. Charles L. Norton, R. R. Lawrence, and myself examined this patient in the Rogers Laboratory of Physics of the Massachusetts Institute of Technology.

The patient, M. M., seventeen years old, was brought by Doctor Shurtliff of Somerset to Doctor Williams on June 5, 1896. His description of the case is as follows:¹—

"The day before he had placed a Flobert rifle cartridge in a vise and hammered it; the cartridge exploded, and a piece struck his left eye. Examination showed no injury to the eyelids, but a vertical cut extended two-thirds across the cornea, the anterior chamber was empty, and the pupil was filled with a mass of opaque lens substance. Under atropine there was some adhesion between the iris and lens capsule, and no view could be had of the interior of the eye on account of the opacity of the lens. There was very little redness of the sclera, and no complaint of pain. Light projection was fairly good upward, inward, and outward, but uncertain downward; fingers could not be counted.

"It was hard to decide whether this injury was caused by a piece of cartridge which had struck the eye and then rebounded, or whether the metal had lodged within the eye. No use could be made of the electromagnet for diagnosis and removal, as the metal was probably copper. . . ."

The patient was laid on the table with his injured eye close to the plate holder, and the vacuum tube so placed that the rays passed partly across the bridge of the nose, and partly through the thin nasal and orbital bones to the injured eye, and so on to the plate. After ten

¹"A Case of Extraction of a Bit of Copper from the Vitreous, where X-Rays helped to locate the Metal," by Dr. Charles H. Williams. *Boston Medical and Surgical Journal*, August 13, 1896.

minutes' exposure the developed plate showed what appeared to be a foreign body a little back of the centre of the eyeball. A second X-ray photograph with the tube in a different position showed no foreign body. It may be that this exposure was not suitable, or that the thin metal strip, which was found later was turned edgewise to the light, thus giving a less marked impression on the plate.

Dr. Charles H. Williams operated and removed a thin, nearly straight piece of copper, 6 millimetres long by 3 millimetres wide, and of the thickness of the cartridge shell.

Bullet in Head. — An interesting case of the localization of a bullet by the X-rays is given by R. C. Lucas.¹ The patient was a child ten years old, who was shot in the back of the head. There was a circular wound over the upper part of the occipital bone, about 6 millimetres in diameter, rather to the right of the median line. A radiograph showed that the bullet had separated into two pieces, one of which was lying near the hole in the skull, and the other about 4–5 centimetres farther on. After the foreign bodies were removed the improvement was marked.

Bullet in Head. — K. W., 30 years old, entered the surgical side of the Boston City Hospital November 23, 1899. Service of Dr. Munro. Four years ago the patient was shot through the right side of the face, but did not suffer much from the injury until three weeks ago. At times since then her jaws have seemed to set tightly, and there was swelling on the right side of the face, accompanied with much pain. About 1.25 centimetres anterior to the lobe of the ear on this side was a small scar. There was a slight tenderness about this region on pressure, also over right temporal region. On November 28, with the aid of two X-ray photographs, Dr. Munro removed the bullet, which was found 2.5 centimetres from the surface, imbedded in fat tissue close to the temporal bone. The patient was discharged well.

Foreign Body in Œsophagus. — The following cut shows the condition of a girl 13 years old, who was brought to me for an X-ray examination. On December 26, 1898, she had swallowed a fifty-cent piece; subsequent to this vomiting occurred if anything stuck in her throat when eating. Liquids were swallowed without difficulty. I examined her with the fluorescent screen, and located the position of the coin as follows: opposite second rib in front and fourth dorsal vertebra behind; in front, from 6 to 12.5 millimetres to right of median line; behind, a

¹ "Localization of Bullets by X-Rays," *British Medical Journal*, October 21, 1899, p. 1064.

little to right of median line. A radiograph, from which this cut was made, was also taken. (See Fig. 305.)

Dr. J. F. Baldwin¹ describes the case of a child who without any assignable cause had symptoms of croup with inability to swallow. About a month later the child was very much emaciated. Dr. Baldwin advised an X-ray examination, which showed a button in the œsophagus, about five centimetres above the stomach.

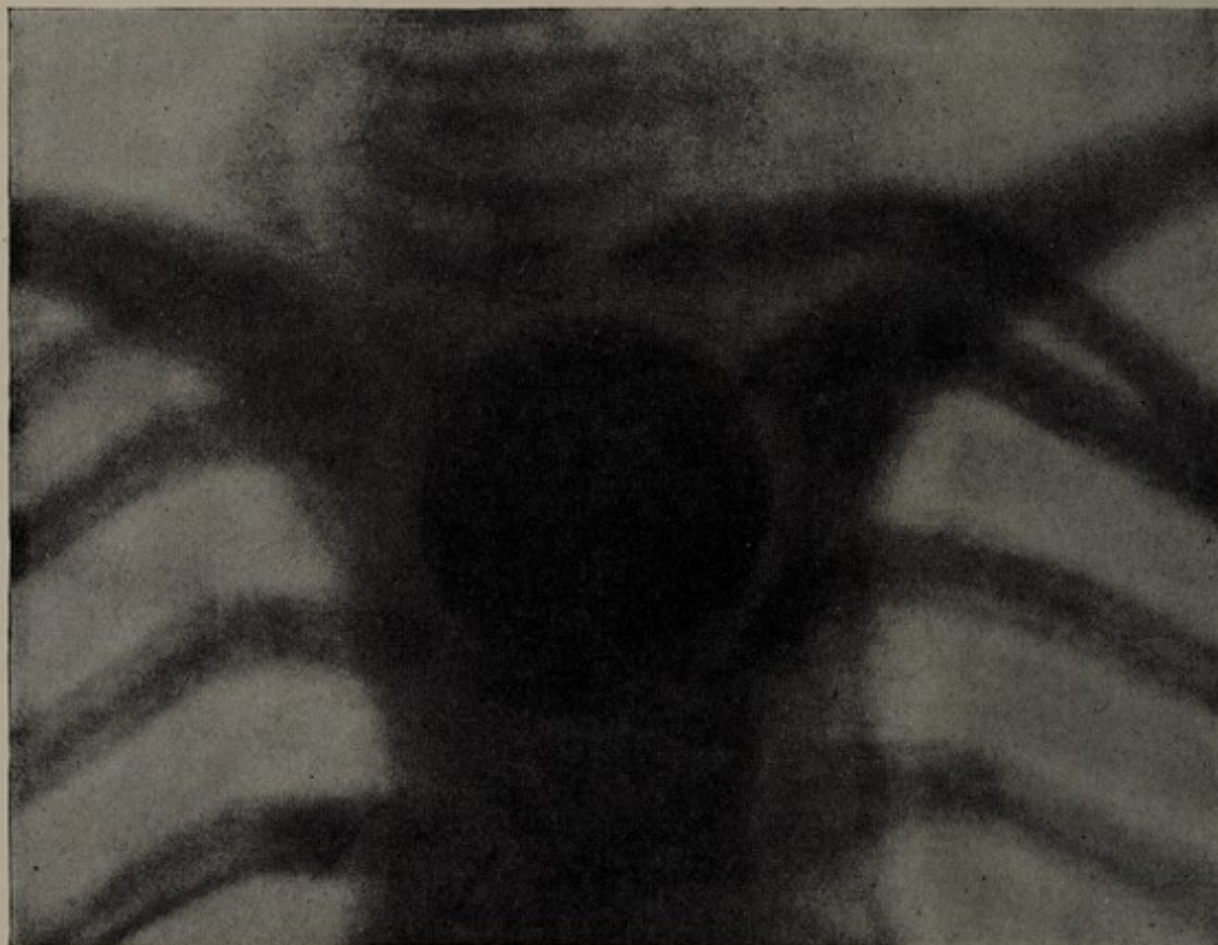


FIG. 305. Half dollar in œsophagus.

Piece of Steel in Arm found only by X-Rays. — A piece of steel entered the right arm of a man twenty years old. An unsuccessful attempt was made to find the steel; the arm became much swollen and the patient came to the out-patient department of the Boston City Hospital in September, 1899, where another unsuccessful attempt was made under cocaine to find the foreign body. Two X-ray photographs were then taken (see Figs. 307, 308) and the steel was removed under ether.

¹ *Columbus Medical Journal*, February, 1900, p. 73.

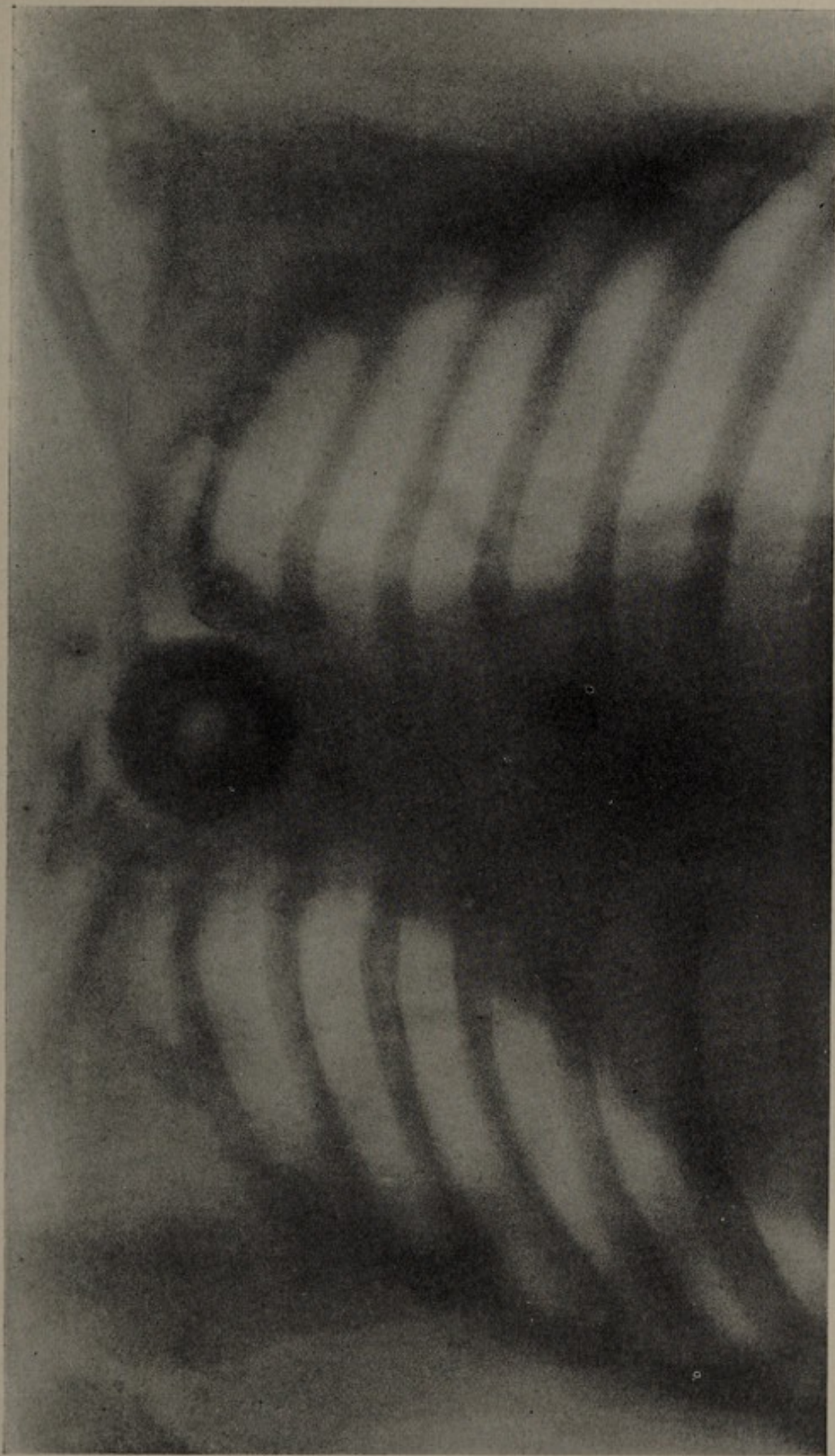


FIG. 306. Whistle in oesophagus; a flat tin whistle with a hole in its centre. Removed by operation.

This case illustrates the advantage of taking two photographs, each from a different point of view, as two views give the surgeon more exact knowledge of the position of the object than one alone could do, and

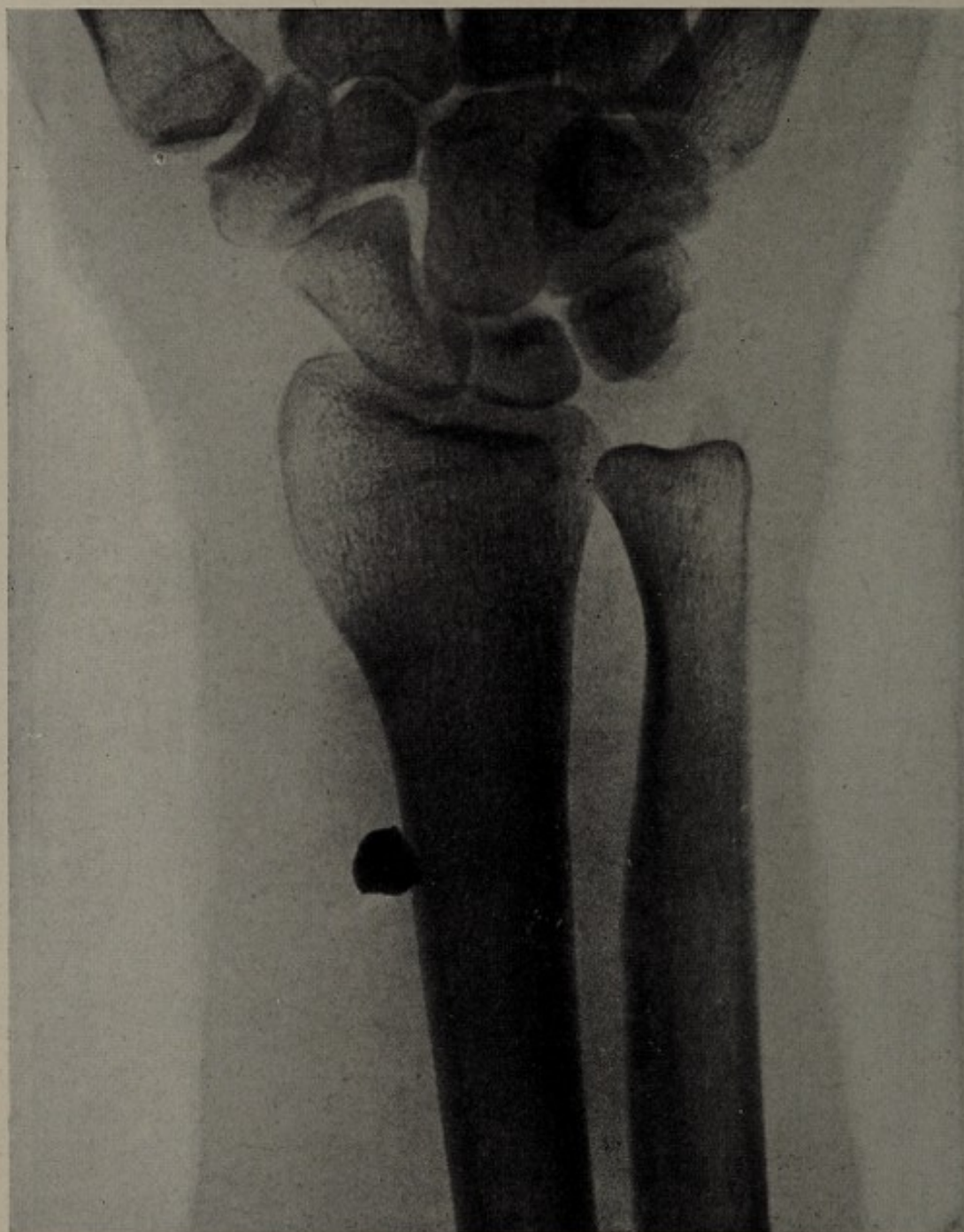


FIG. 307. Piece of steel in arm. Found only after radiographs were made. Antero-posterior view.

thus assist him in operating. Likewise this case shows the usefulness of X-ray examinations in locating foreign bodies, for it will be noticed that two examinations without the use of the X-rays failed to find this

foreign body, although it was of considerable size and in a part easy of access.

Importance of Two Views; Needle in Os Calcis. — This case is instructive because it shows the need in most cases of two X-ray photographs,

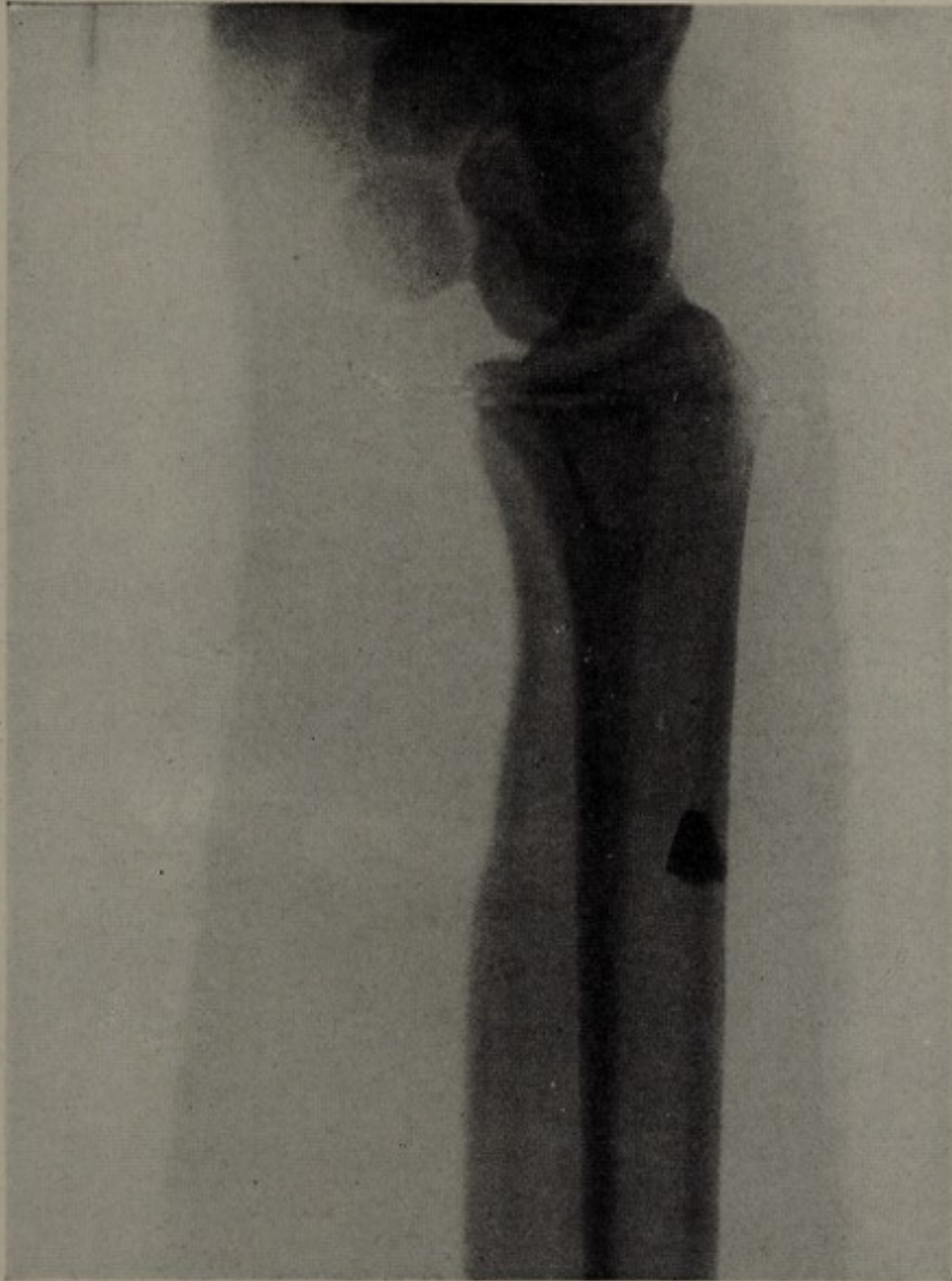

FIG. 308. Piece of steel in right arm. Lateral view. (See also Fig. 307.)

each taken from a different point of view. One only was made of this case at first (see Fig. 309), and the needle was then sought for carefully under ether for more than an hour without success. The second X-ray picture was made from an antero-posterior direction and showed that the piece of needle was in the middle of the os calcis. If the precaution

had been taken to make either a stereoscopic picture or two views, one from a lateral and the other from an antero-posterior point of view, the first long search would have been avoided.

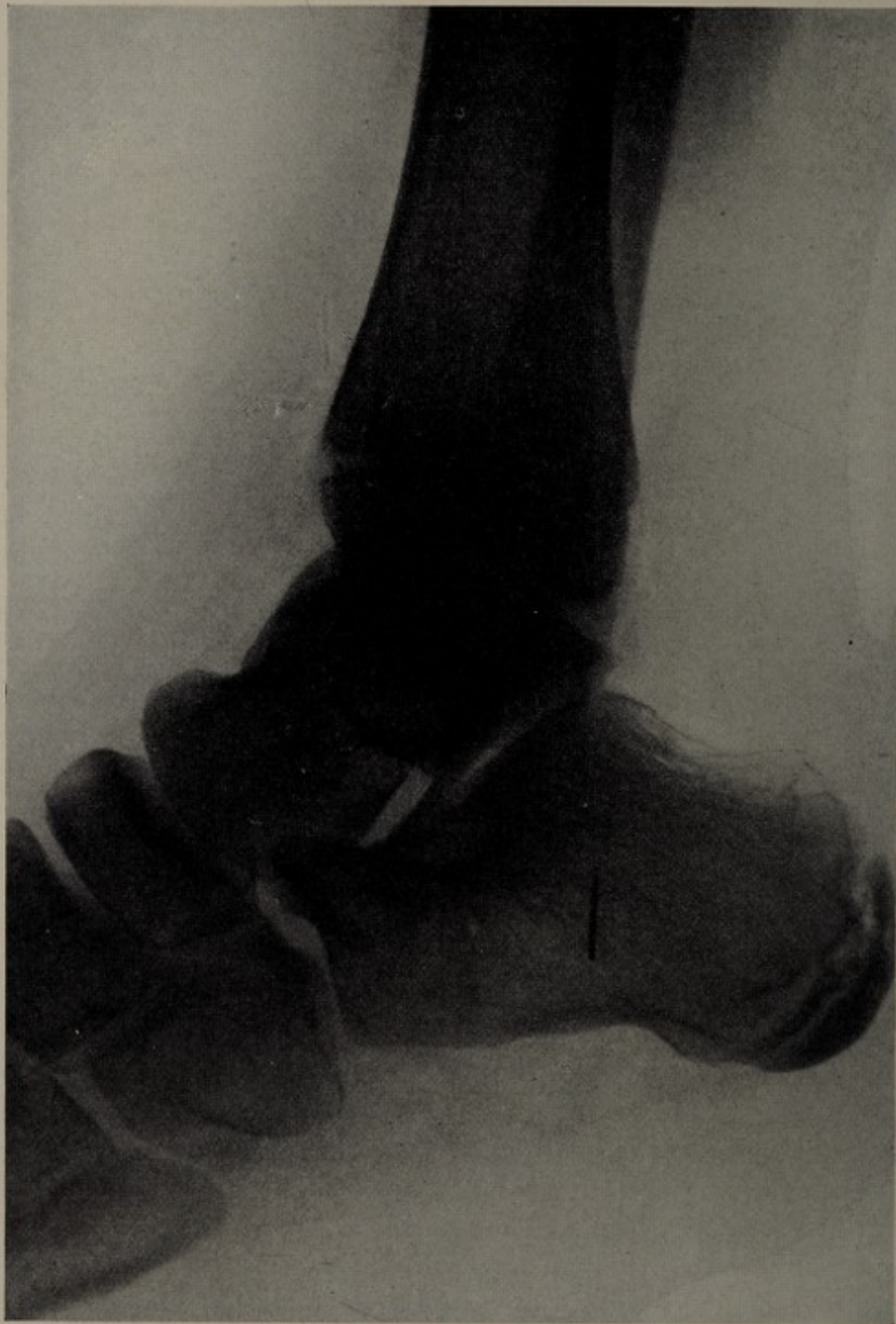


FIG. 309. Needle in middle of os calcis.

Precautions to be taken in Regard to Needles. — A needle should be cut out directly after it has been located by the X-ray examination, for

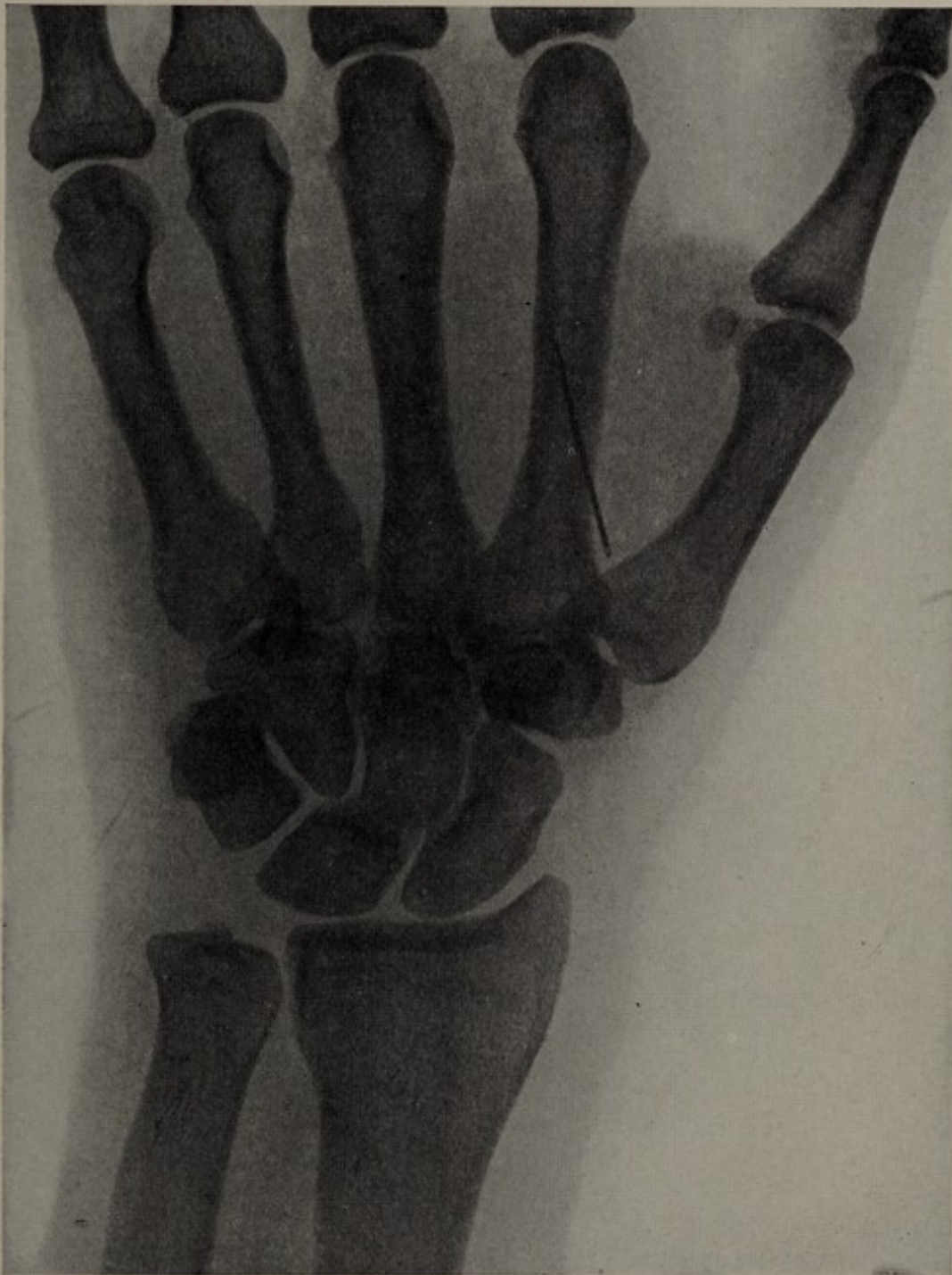

FIG. 310. Needle in hand. The eye of the needle can be seen. Patient of Dr. J. B. Blake.

if there is delay it may change its position. For example, a young woman was examined at the hospital with the fluorescent screen, and a needle found in her right hand between the carpal ends of the second and third

metacarpal bones. The next day two negatives showed that the needle had moved to a point over the wrist. About two weeks later it was found between the first and second metacarpal bones, about opposite

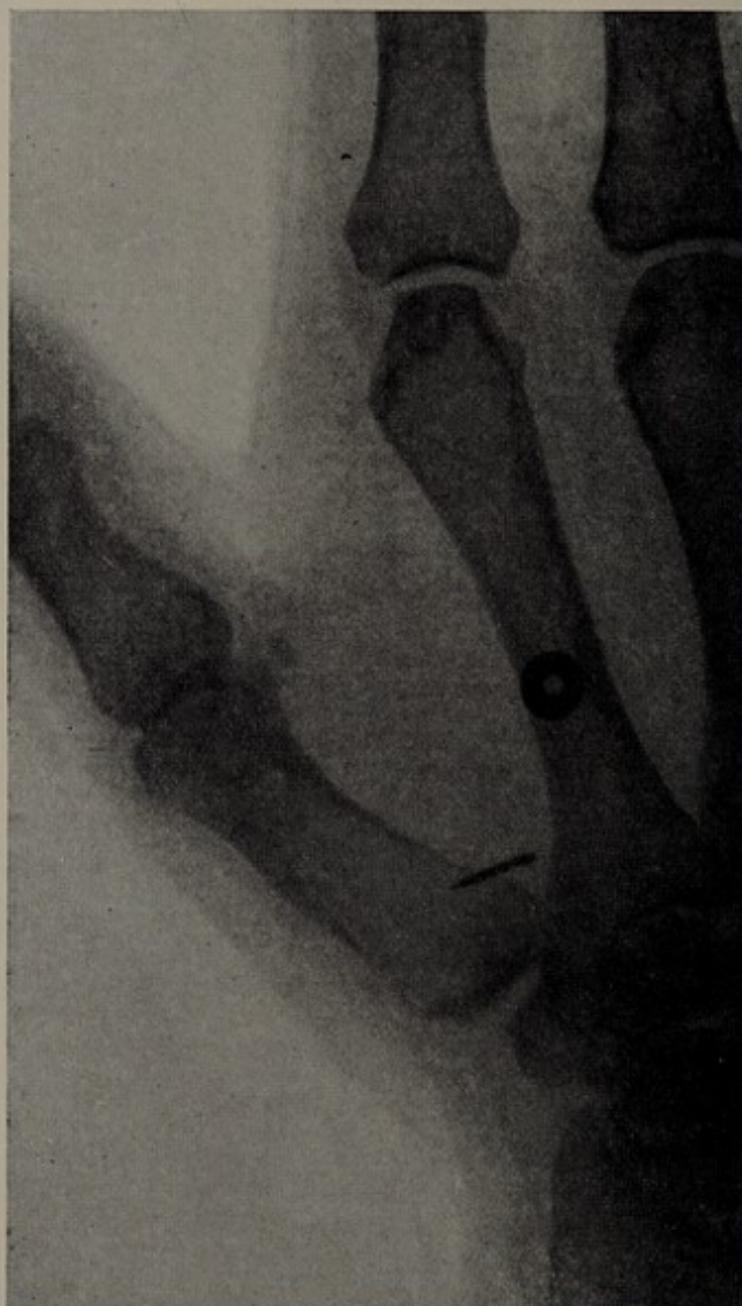


FIG. 311. Needle in hand; antero-posterior view. (See following figure.) The tube was 70 centimetres distant and directly opposite the metal washer.

the middle of the first metacarpal. Twenty-four hours later an operation was performed, but the needle was not found.

Forster and Hugi¹ give a detailed account of experiments made to

¹ *Fortschritte a. d. Geb. d. Roentgenstr.*, B. I, pp. 170-179.

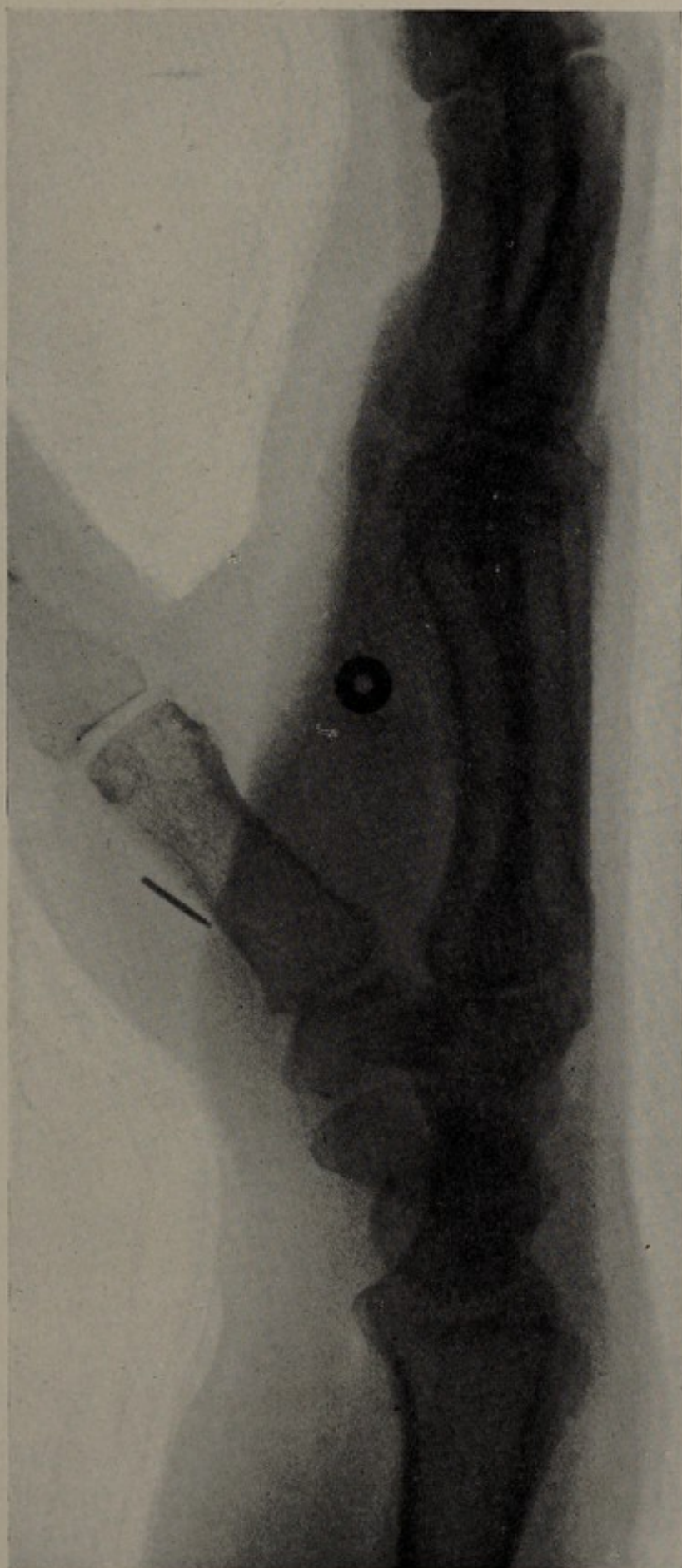


FIG. 312. Needle in hand; lateral view. (See preceding figure.)

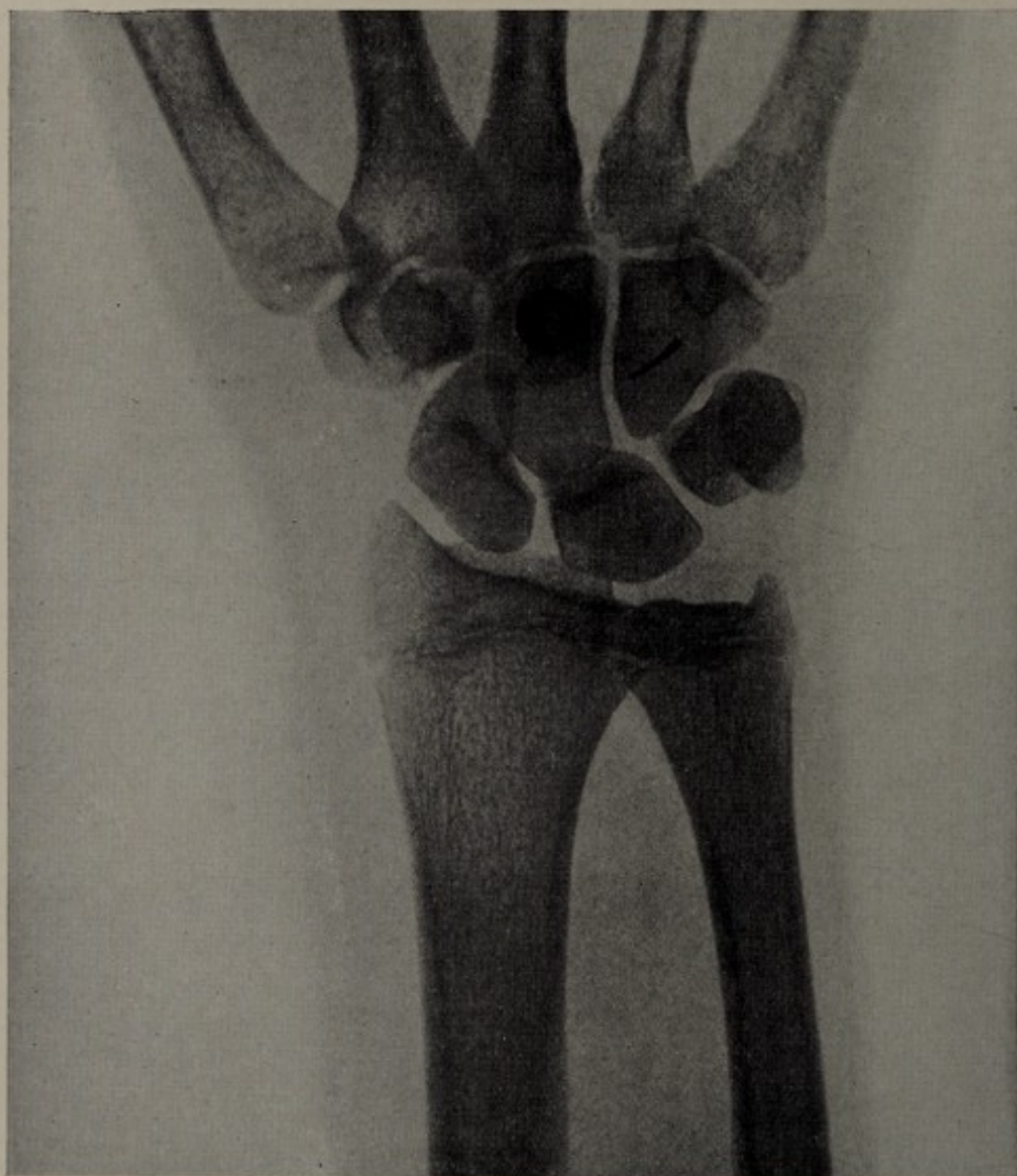


FIG. 313. Needle in wrist; antero-posterior view. (See also following figure.)

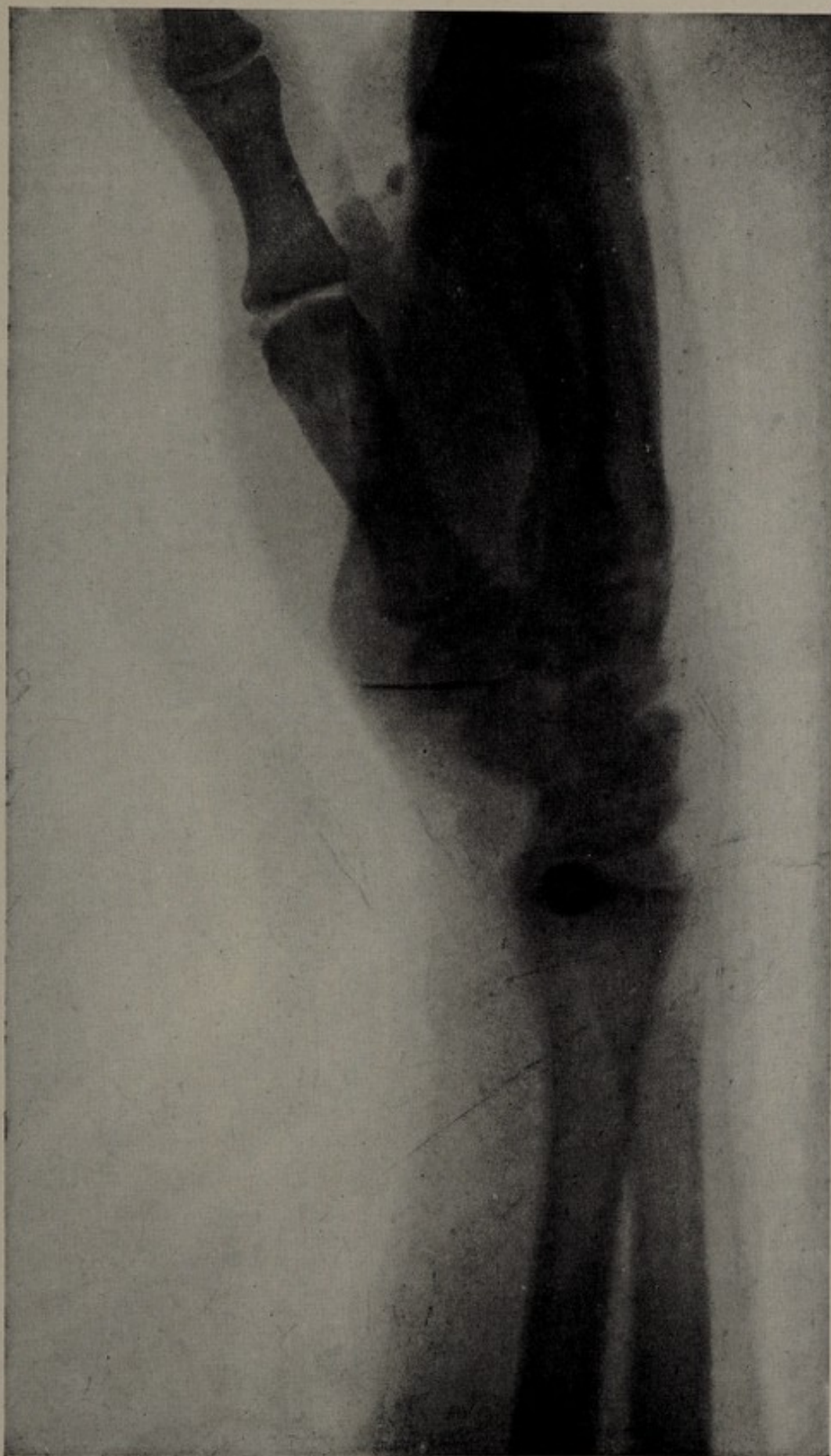


FIG. 314. Needle in wrist; lateral view. From same patient as shown in preceding figure.

determine how small a piece of metal could be seen in a radiograph. They used four fragments of needles of known weight and size, and attached them firmly to various parts of the human body, and then radiographed them. The summary of their experiments is as follows :

1. An iron foreign body in the hand ; weight 1 milligramme. The exposure was ten seconds, and the tube was at a distance of 20 centimetres from the photographic plate.
2. Iron foreign body in the forearm ; weight 1 milligramme. Exposure thirty seconds ; distance of tube 30 centimetres.

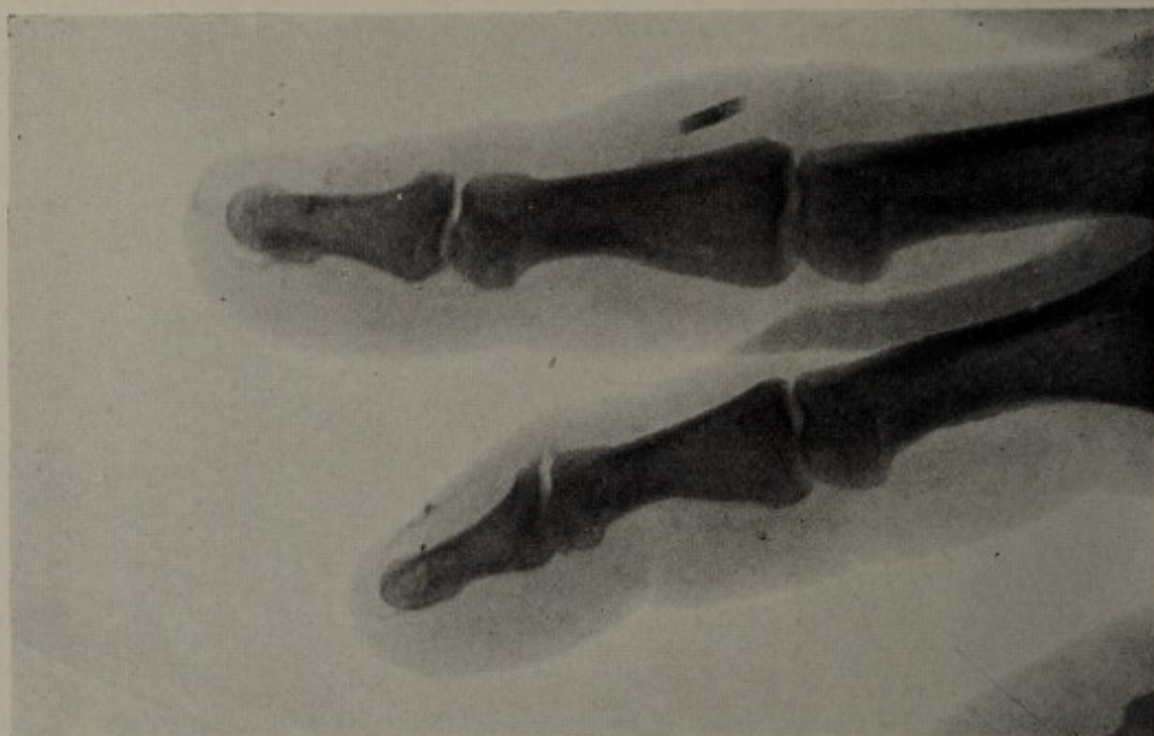

FIG. 315. This cut shows a piece of glass in the upper finger. Patient of Dr. Lund.

3. Iron foreign body in the upper arm ; weight 1 milligramme. Exposure thirty seconds ; distance of tube 30 centimetres.
4. Iron foreign body in the foot ; same weight as above. Exposure one to two minutes ; distance of tube as above.
5. Iron foreign body in the knee ; weight 4 milligrammes. Exposure five minutes ; distance of tube 40 centimetres.
6. Iron foreign body in the thigh ; weight 1 milligramme. Exposure five minutes ; distance of tube 40 centimetres ; but it could be seen only when the image of the needle fell on the muscle and was not in the shadow of the femur.
7. Iron foreign body in the shoulder ; weight 1 milligramme. Exposure five minutes ; distance of tube 40 centimetres.
8. Iron foreign body in the thorax of children four to twelve years old ; weight 1 milligramme. Exposure five minutes ; distance of tube 40 centimetres, unless the body was hidden by the sternum or backbone.
9. Iron foreign body in the abdomen of children four to twelve years old ; weight 4 milligrammes. Exposure ten minutes ; distance of tube 40 centimetres.

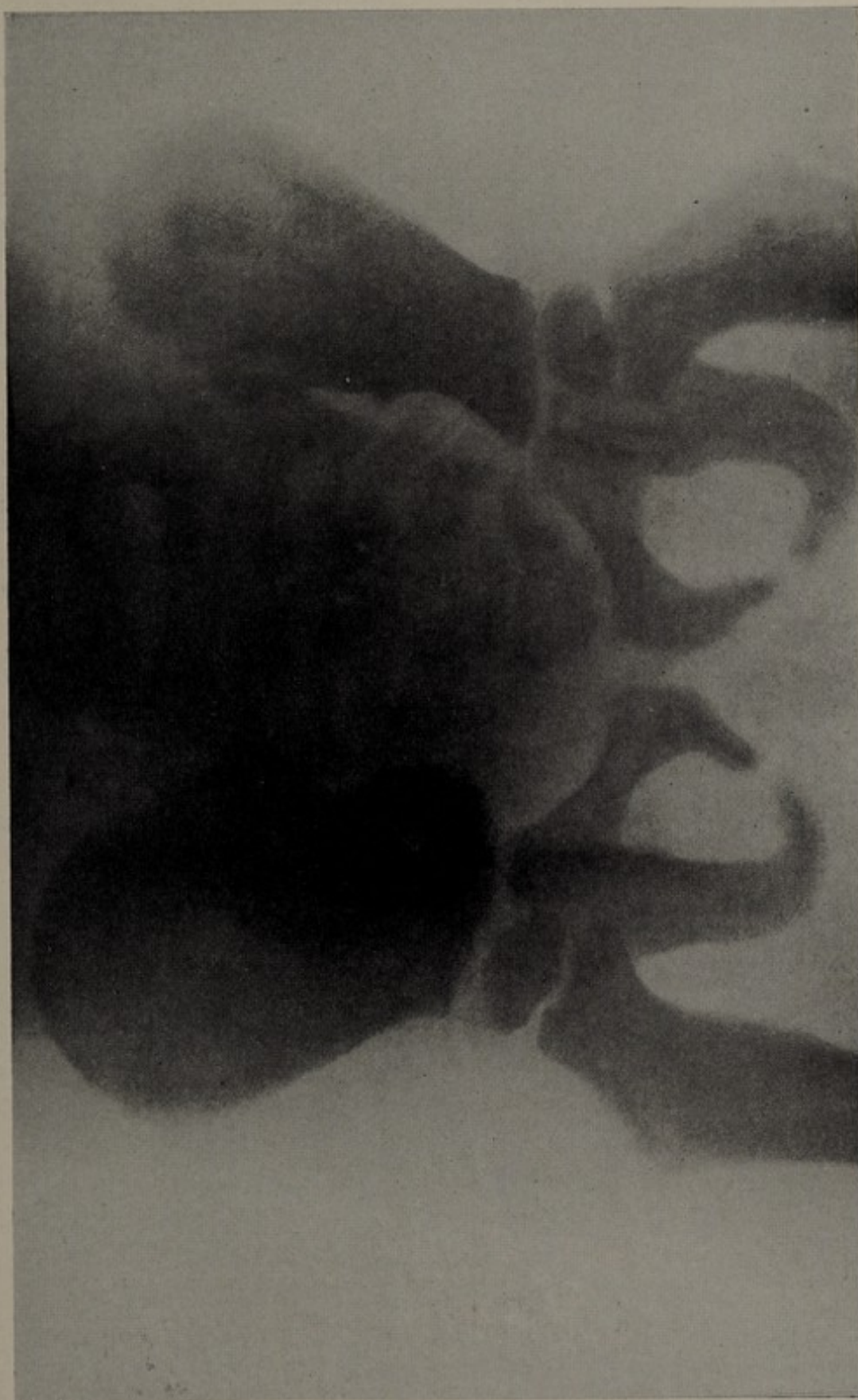

FIG. 316. Flat tin whistle, with hole in centre, in pelvis of boy. Passed by natural channels later.

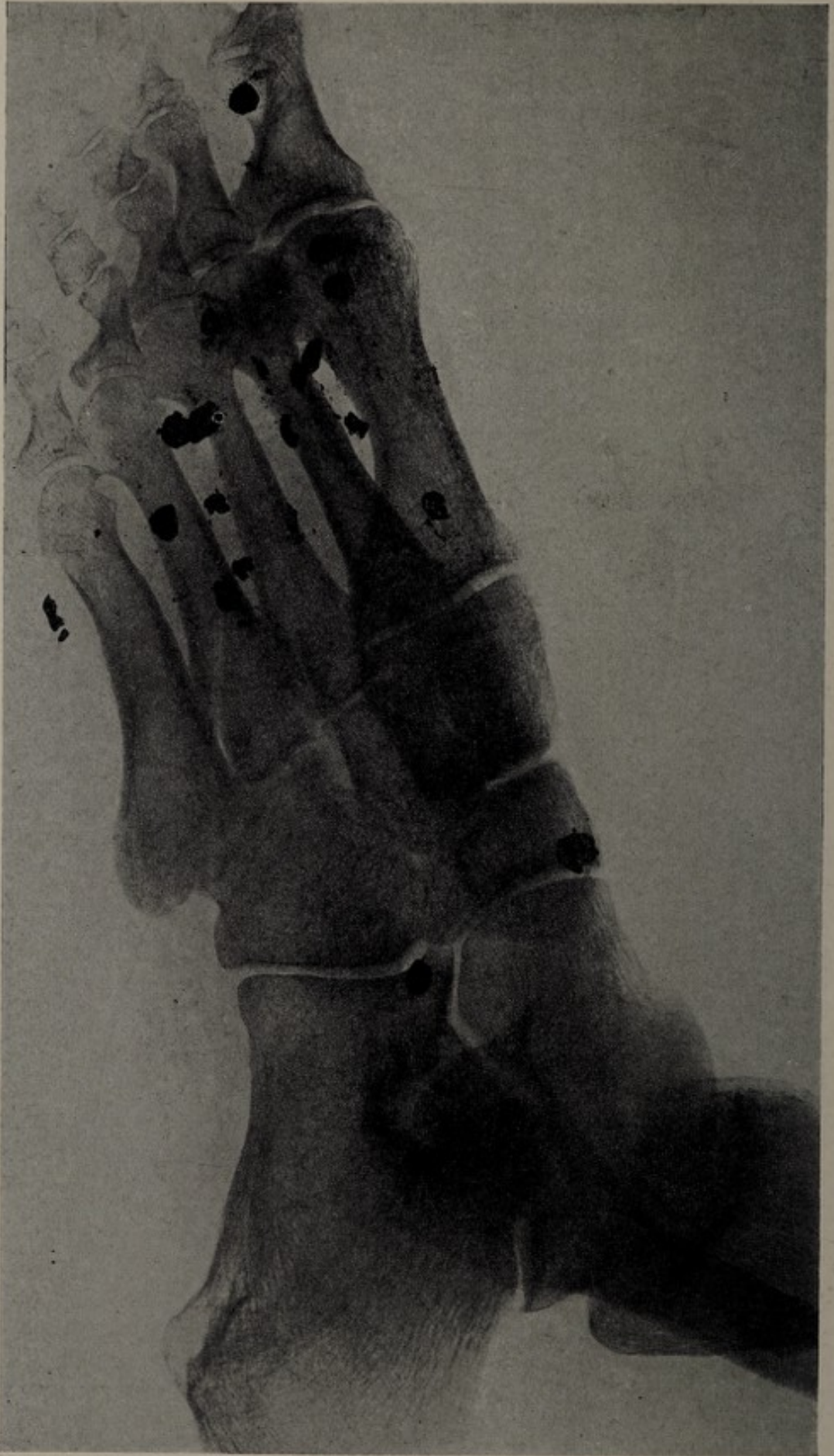


FIG. 317. Shot in a man's foot. The shot have been there many years and occasion him no trouble.

CHAPTER XXI

X-RAYS IN MILITARY SURGERY

It may be said that the principles which govern the use of the X-rays in this field are the same as those which obtain under the conditions in which an apparatus that has its independent source of electricity is used; therefore only a few words are necessary on this subject.

The X-rays have been employed in military surgery with success. It has been well said by Dr. Haughton that "The X-rays have furnished the army surgeon with a probe which is painless; which is exact; and, most important of all, which is aseptic."

Dr. Abbott and Mr. Symons¹ believe that the X-rays will be of great use in future wars, but not at the actual front. They found that a screen saved much time because the question of depth was so easily approximately solved by its aid. The X-rays not only assisted them to localize bullets, but also indicated other sources of irritation, namely, pieces of dirt and sequestra, and thus proved useful guides to a secondary operation.

Surgeon Major Beevor,² M. B., Army Medical Staff, on the contrary, considers that every civilized nation should have an X-ray apparatus not only at base hospitals, but wherever soldiers are fighting. The apparatus used during operations on the frontier of India was a ten-inch spark coil with a primary battery. If the roads are not good, he thinks that a portable apparatus should not weigh more than eighty to one hundred pounds, so that it can be slung from a pole and be carried by two men. One difficulty encountered with the apparatus was the melting of the wax, by the hot sun, that insulated the wire of the secondary coil, but this trouble was overcome by the use of a mixture of paraffin wax and

¹ "Surgery in the Græco-Turkish War," *Lancet*, London, January 14, 1899, p. 80.

² Report of Address made before the Royal United Service Institution, *British Medical Journal*, May 28, 1898, p. 1408.

resin which did not melt under 150° F. A covering of felt protected the coil from the sun, rain, snow, and frost.

Major Battersby¹ states that the ordinary methods were insufficient to demonstrate the position of the bullet in the tissues, or to show that a bullet was not present, in twenty-one men out of one hundred and twenty who were wounded at the battle of Omdurman and carried into the hospital. In twenty of these cases the diagnosis was reached by means of the X-rays; in the twenty-first case the patient was too feeble to bear the examination.

Major Battersby found that the fluorescent screen was advantageous in that any part of the body could be examined without delay, but it was most useful at night, because no dark room was available and the hood employed was not sufficient to keep out the intense sunlight. He likewise found that when plates are used in warm countries an alum bath is necessary because the water which is used in the developing solution and to wash the plate is always warm. He used a bicycle to charge the storage battery; but thought in the Soudan a static machine was the ideal apparatus.

Edward Loison² suggests the use of Eastman paper of bromide of silver, or films, in military surgery for taking X-ray photographs, in order to avoid the risk run of breaking the plates, if these are used. Glass plates, too, are heavy to carry; still, he thinks them the best.

Captain W. C. Borden,³ Assistant Surgeon in the United States army, expresses the following opinion in regard to the need of an X-ray apparatus in military surgery, and the place where it should be kept:—

"The use of the Roentgen ray has marked a distinct advance in military surgery.

"It has favored conservatism and promoted the aseptic healing of bullet wounds made by lodged missiles, in that it has done away with the necessity for the exploration of wounds by probes or other means, and by this has obviated the dangers of infection and additional traumatism in this class of injuries.

"In gunshot fractures it has been of great scientific value by showing the character of the bone lesions, the form of fracture, and the

¹ *British Medical Journal*, January 14, 1899, p. 112.

² *Arch. de Med. et Pharm. Milit.*, Paris, 1899, Vol. 33, p. 435.

³ "The Use of the Roentgen Ray by the Medical Department of the United States Army in the War with Spain."

amount of bone comminution produced by the small caliber and other bullets — conditions which could not have been otherwise determined in the living body.

“In the treatment of these traumatisms it has been of great value in determining the course of treatment to be pursued, as its use, together with the course of the cases under treatment, has shown that aseptic or septic condition of the wound is of far greater importance than the amount of bone comminution. This is illustrated by those cases of extensive bone comminution which, when connected with aseptic wounds, progress to favorable termination with a minimum of immediate and remote ill effects; while those cases in which the bone traumatism is slight, if complicated by infection of the wound, are much more difficult to treat and serious in their result. . . .

“The many cases of lodged bullets in which the bullets were left undisturbed until the patients reached a general hospital or hospital ship, where the missiles were located by the Roentgen ray and removed under aseptic technic with complete safety to the patient and rapid recovery, prove the non-necessity for the use of Roentgen ray apparatus in field or other advanced hospitals. Even where the bullet can be readily located without the use of the Roentgen ray, the experience of the late war and the opinion of numerous authorities lead to the conclusion that the zeal of the surgeon should not cause him to remove the missile at the field hospital except in special cases. Infection is almost sure to occur from the almost absolute impossibility of obtaining asepsis under conditions which are present at the front, and the recovery of the patient is delayed and the functions of the wounded part likely to be impaired in consequence of the suppuration which will follow.”

CHAPTER XXII

DISEASES OF THE BONES AND OF THE JOINTS

THE change in chemical composition accompanying pathological processes is obvious in certain diseases of the bones and of the joints by the aid of the fluorescent screen, but far more so by that of X-ray photographs, and a careful study of good radiographs will do much to make our conception of these diseases clearer. More exact diagnosis can be made in some cases by means of the X-rays, and in other cases a definite diagnosis cannot be made without them.

The following table will serve to place before the eye of the reader some of the conditions in which X-ray examinations are of service:—

| | | |
|--------------|--|---|
| BONES. | { PERIOSTITIS. | |
| | { OSTEITIS. Spina ventosa. | |
| | { OSTEITIS DEFORMANS. (Affects both bone and periosteum.) | |
| | { OSTEOMYELITIS. Abscess, Necrosis, Sequestra. | |
| | { REGENERATION OF BONE AFTER OPERATION. CALLOUS FORMATION. | |
| | { TUBERCULOSIS. (Nearly always begins in epiphyses ; sometimes in joints.) | |
| | { SYPHILIS. | |
| | { RICKETS. Coxa vara. | |
| | { ACROMEGALIA. | |
| NEW GROWTHS. | { CHRONIC PULMONARY OSTEOARTHROPATHY. | |
| | { | OSTEOMA. (Exostoses.) |
| | | CHONDROMA. |
| | | OSTEOCHONDROMA. |
| | | OSTEOSARCOMA. |
| | | CHONDROSARCOMA. |
| | | CANCER. (Rare.) |
| | { Differentiation of bony from other tumors. | |
| JOINTS. | { TUBERCULOSIS. | |
| | { COXITIS. | |
| | { SYPHILIS. | |
| | { ARTHRITIS DEFORMANS. | Rheumatoid arthritis. (Atrophy of bone and all joint structures.) |
| | | Osteo-arthritis. (Hypertrophy of bone and cartilages.) |
| | | Charcots. |
| | { RHEUMATISM, acute. | |
| | { DEPOSITS ABOUT JOINTS, including urate of soda or lime salts. | |
| | { LOOSE CARTILAGE. | |

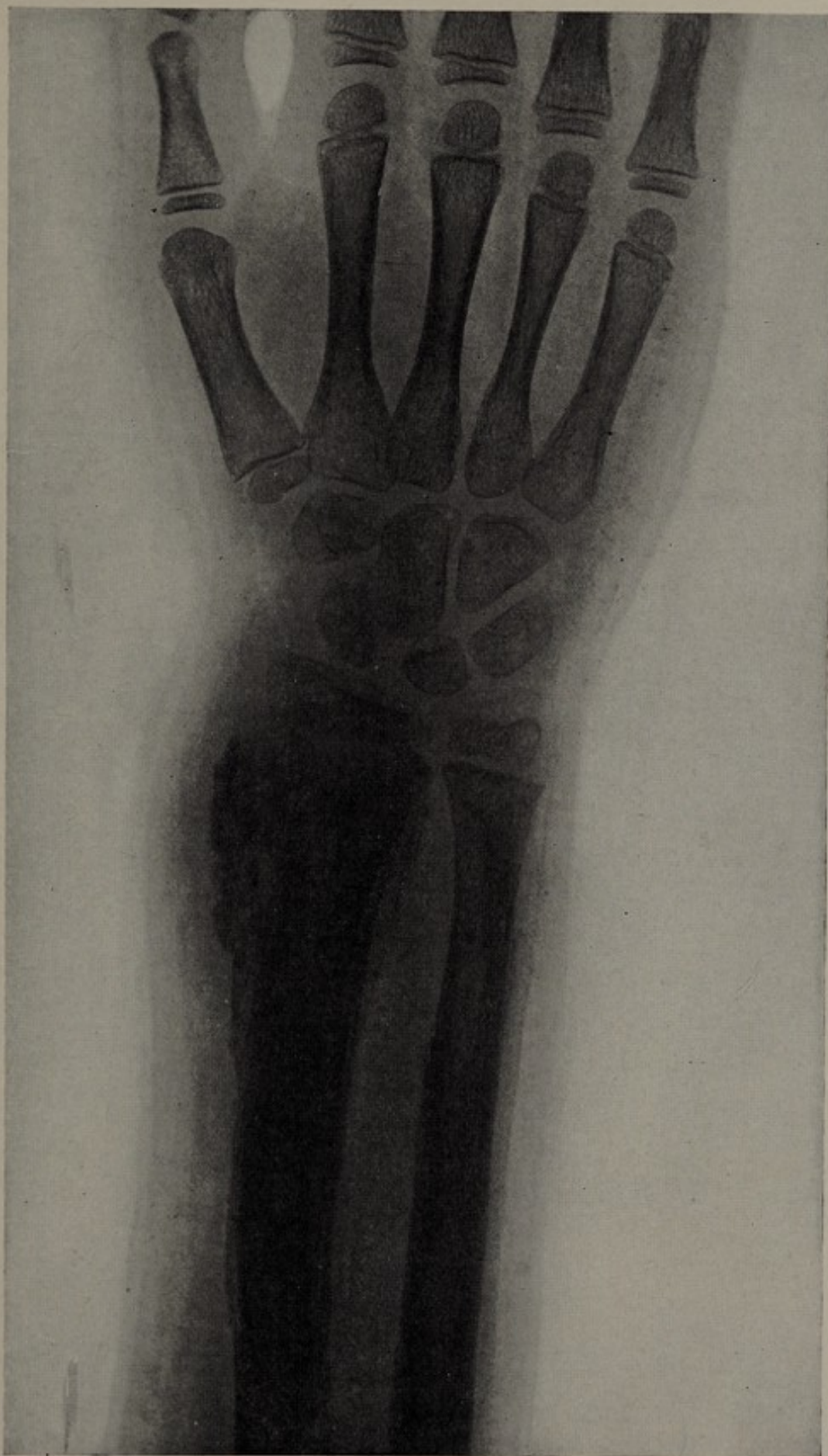


FIG. 318. Acute periostitis of the radius.

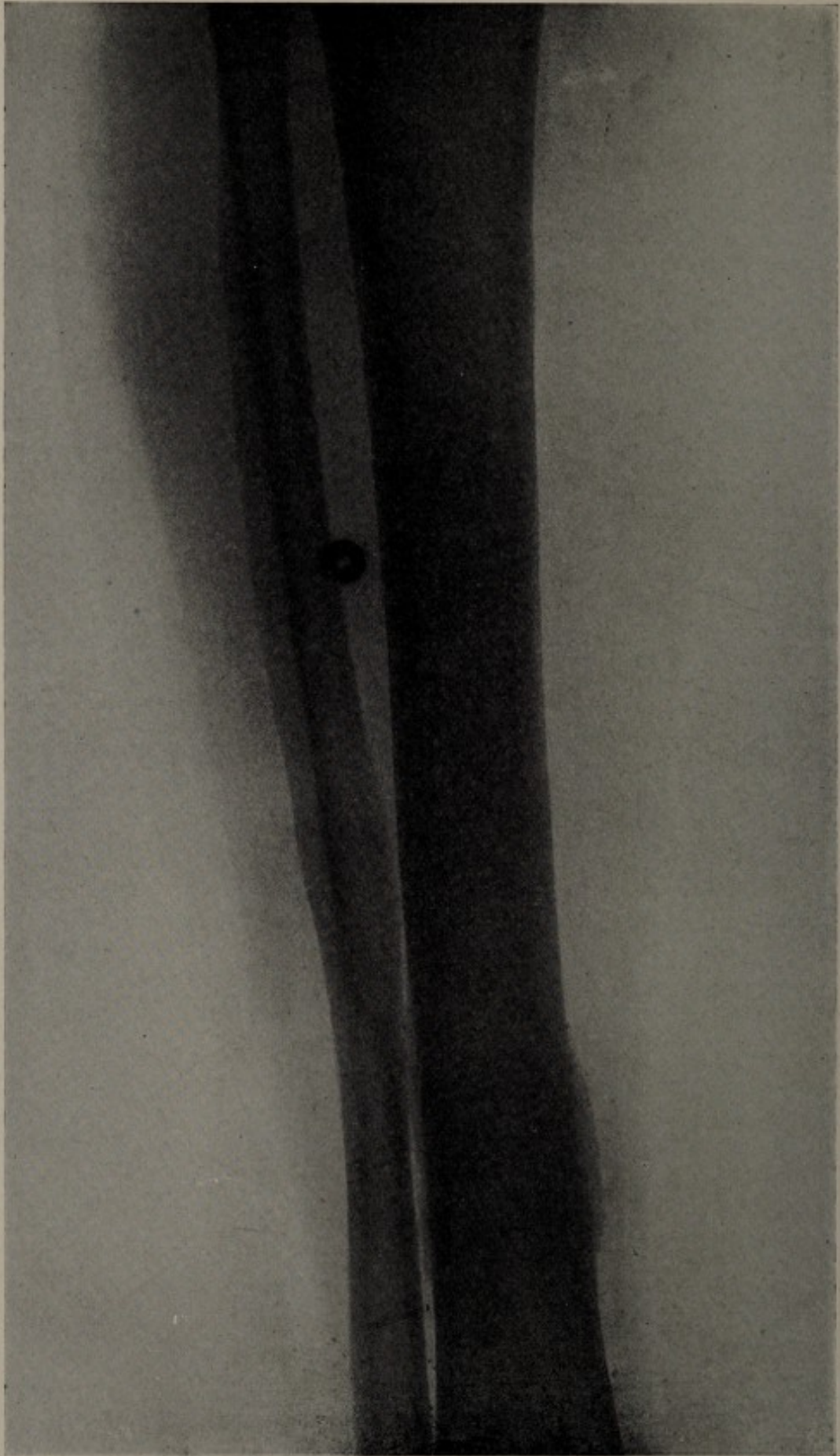


FIG. 319. Augusta G., forty-five years old. Chronic periostitis of the fibula and of a small portion of the tibia.

DISEASES OF THE BONES

Methods of Examination. — The general directions already given for examination of the bones when fractured largely apply in the following diseases. It is well to place the healthy and diseased bone on the same plate and photograph them thus, for purposes of comparison. The best results can be obtained if a new tube that has a low resistance is used.

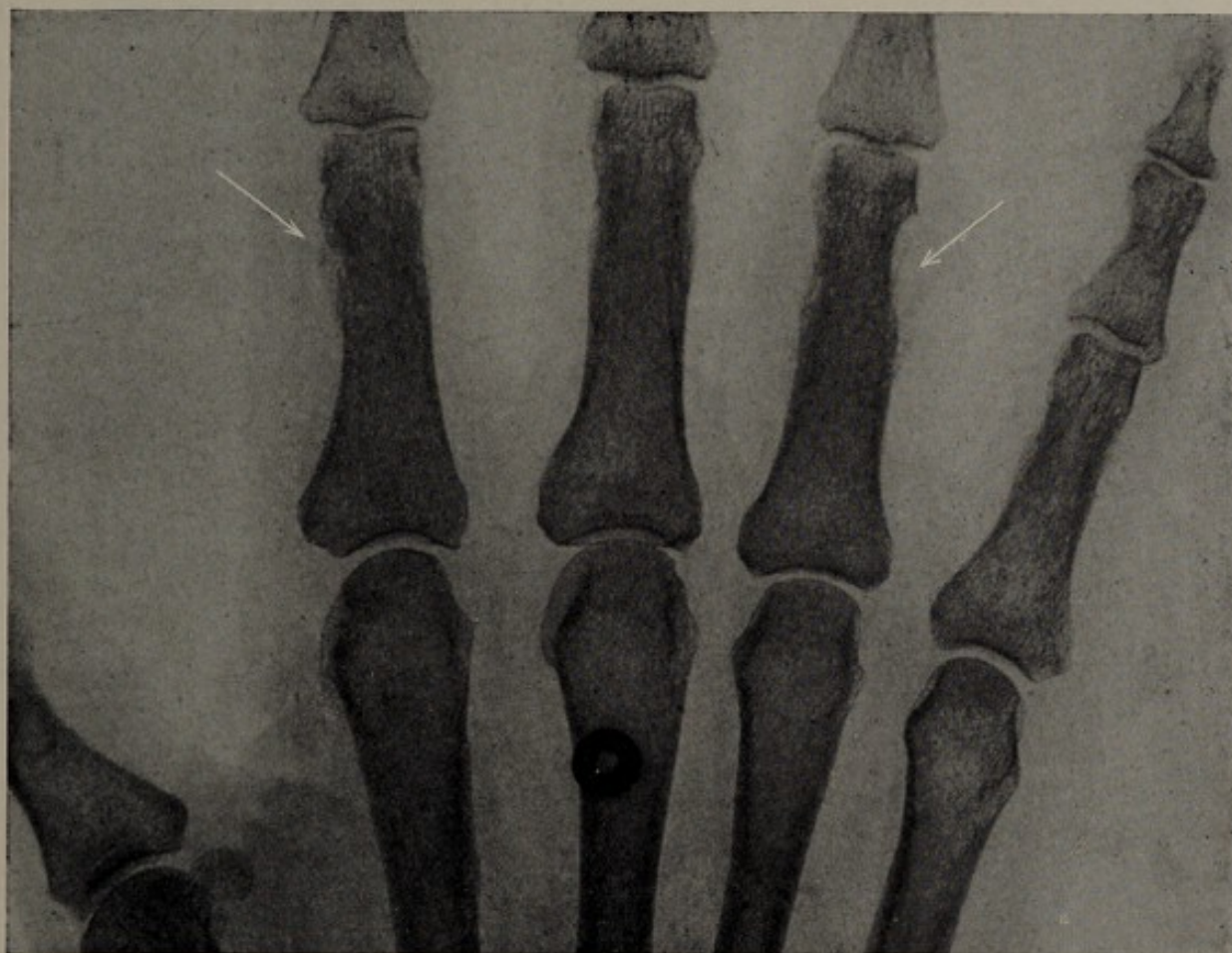


FIG. 320. Augusta G., forty-five years of age. From same patient as Fig. 319. Shows loss of bone substance in phalanges.

The special difficulties lie in so arranging the apparatus as to obtain the best differentiation, and in the correct reading of the radiograph, particularly in cases where the disease is beginning and only a small focus is affected. The changes in the outline and thickness of the bones, of the periosteum, in the cancellated structure of the bones, in the amount of rays absorbed by the tissues, should all be carefully studied in the radiographs. A well-made radiograph may be defined as one which shows the details of the bones, and also of the soft parts, such as skin,

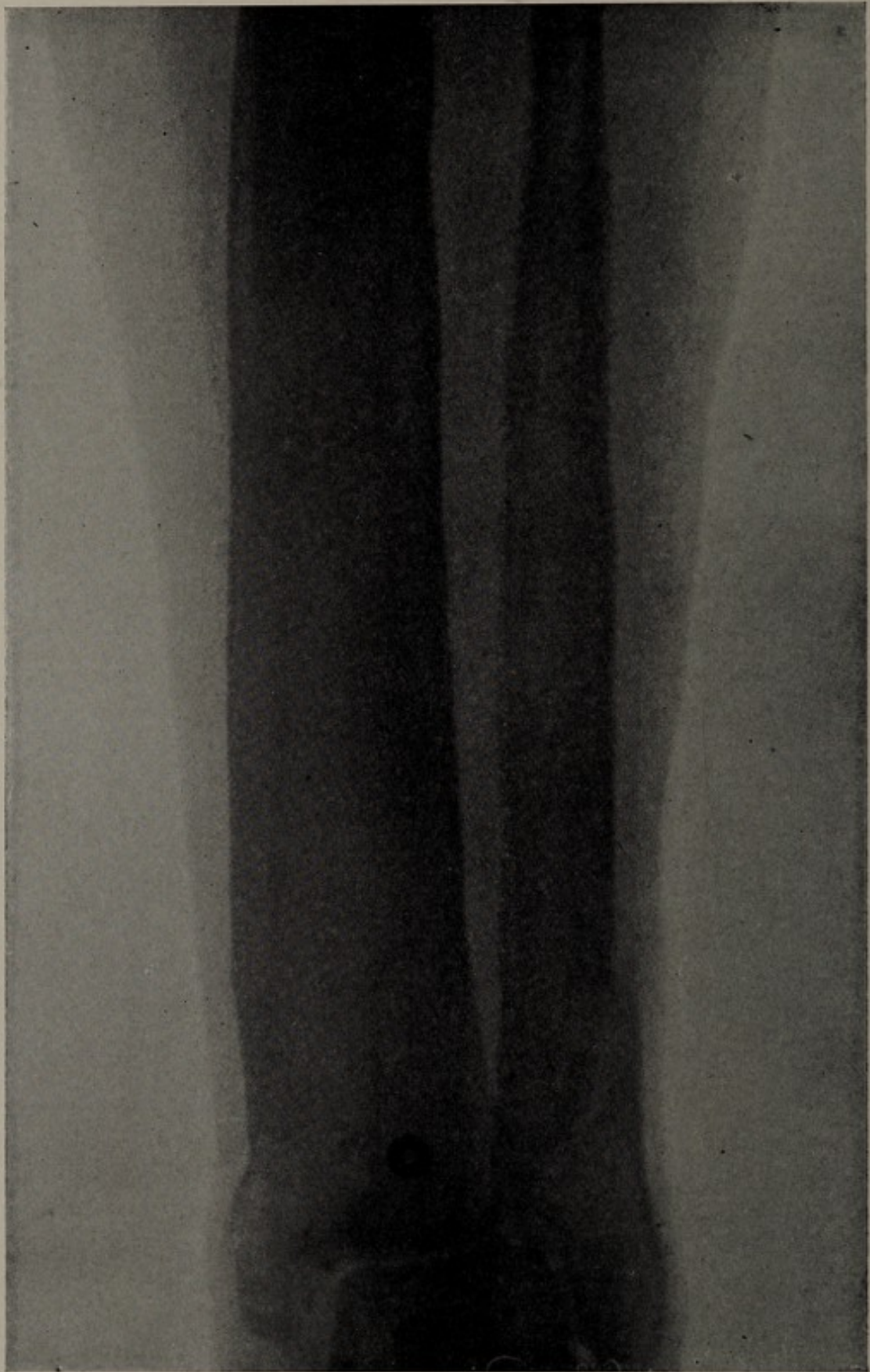


FIG. 321. Osteitis of tibia and fibula. Fracture of fibula.

fatty tissues, muscles, tendons, and in some cases normal arteries, with surprising clearness. I regret that the beautiful detail shown by them cannot always be reproduced by any method that it is practicable



FIG. 322. Z. Osteomyelitis, with necrosis of lower jaw. Patient of Dr. E. H. Nichols, out-patient department, Boston City Hospital.

to use in a book ; but the half-tones given here indicate in part what the negatives show.

Spina Ventosa. — Feilchenfeld¹ reports on a typical case of spina-ventosa of the right forefinger in a boy eight years of age. The X-ray photograph showed the swelling of the soft parts, a very slight thickening of the bone, and two quite small carious foci at the base of the phalanx. The writer notes the importance of this case because it shows the possibility of early diagnosis at a time when a small diseased place in the bone could not otherwise be located.

Regeneration of the Bones after Operation. — The following cases are illustrative : —

Ollier² describes the case of a girl fifteen years old who had suffered from suppurative osteomyelitis of the tibia, with invasion of the articulations of the astragalus and persistent suppuration of tarsus. In October, 1889, he removed a piece of the tibia 28 centimetres long, which included the whole of the epiphysis with its malleolus, and he also completely removed the astragalus. The fibula, although attacked by osteitis, was simply abraded, but as it was longer than the tibia and made the foot turn inward, Ollier cut out the external malleolus. May 1, 1897, a radiograph was taken which showed that the new tibia was almost as long as, and thicker than, the normal one in a large part of its extent ; its exterior surface was slightly irregular ; the darkness of the shadow indicated compact tissue ; its malleolus was very clearly marked. The astragalus was indicated in the radiograph by an osseous mass insignificant in size. The patient can dance without fatigue and walk a distance of from 10 to 12 kilometres.

Ollier reports a second case of a patient sixteen years old on whom he had operated five years before. The radiograph showed that new bone had formed.

Dr. H. W. Cushing³ gives radiographs and an instructive account of a case of acute osteomyelitis in a boy sixteen years of age upon whom he operated successfully. Two years after the removal of the left tibia the patient was well and strong, and walked unaided and with-

¹ *Berlin klin. Wochenschr.*, May, 1896, p. 403.

² "Démonstration par les rayons de Roentgen de la régénération osseuse chez l'homme a la suite des opérations chirurgicales," *Compt. rend. Acad. d. Sc.*, Paris, 1897, CXXIV, pp. 1070-1074.

³ "A Method of Treatment for the Restoration of Entire Tibiæ Necrotic from Acute Osteomyelitis," *Annals of Surgery*, August, 1899.

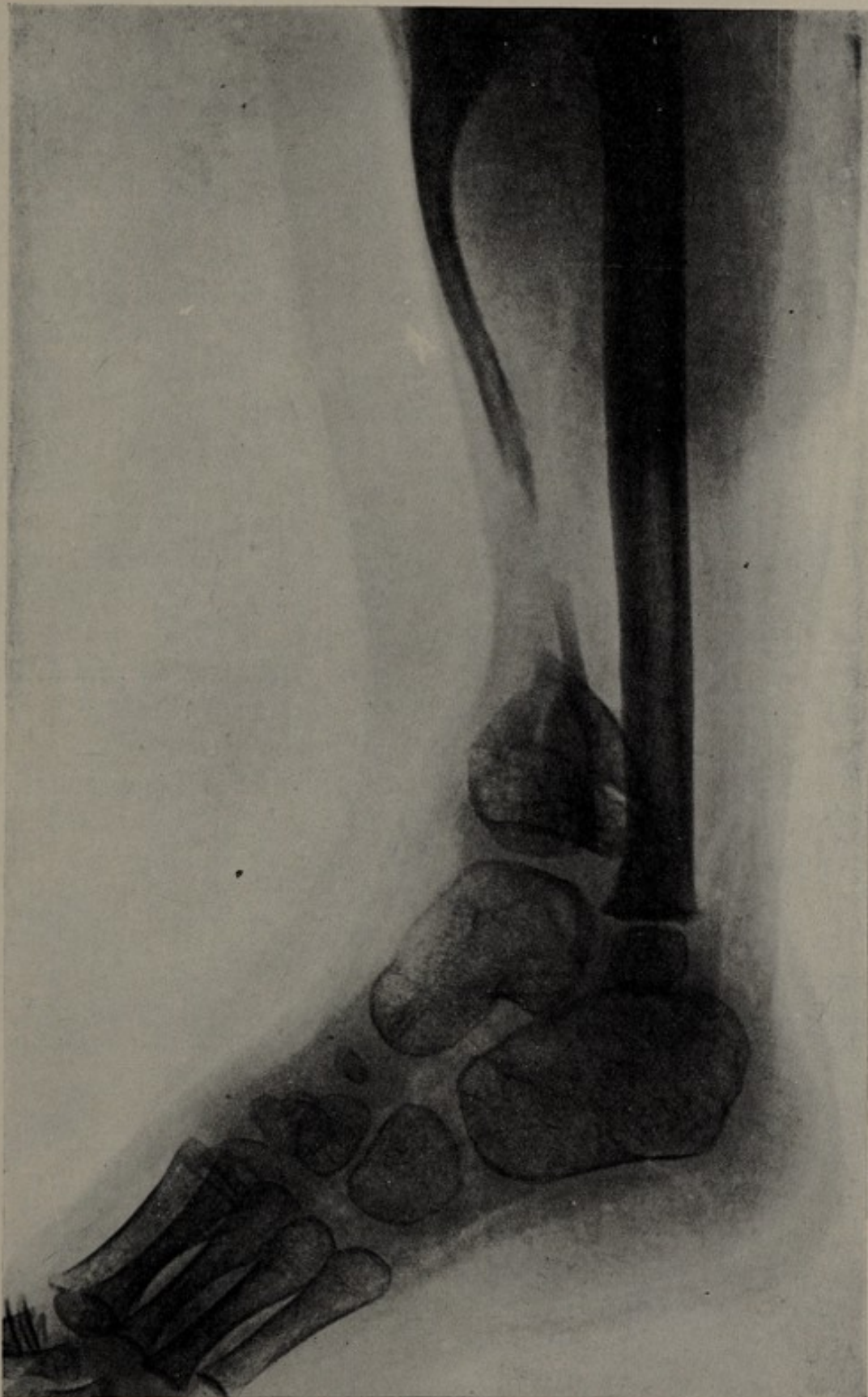


FIG. 323. Alexander S. Service of Dr. H. W. Cushing. Osteomyelitis of the tibia. Lateral view. It will be noticed that the bones of the foot were outlined with unusual clearness in the radiograph from which this half-tone was made, — there has been no retouching, — and that they are more permeable than normal to the X-rays.

out difficulty. The radiograph showed the bone to be intact, with a distinct cortex and a medullary cavity. A part of the shaft just above the malleolus and of the epiphysis was lighter than elsewhere; the process of repair was delayed there, and probably the calcification was less in amount. Dr. Cushing concludes that the shaft of the bone is more easily restored than the epiphysis. The reader is referred to the original article for details and suggestions in regard to treatment.

Osteomyelitis of the Tibia. — Alexander S., four years old, entered the hospital June 5, 1899. Service of Dr. H. W. Cushing. Three days before he had fallen on a stove and injured his left leg. He had a temperature of $103\frac{1}{2}$ and a pulse of 110. On June 6 operation was performed and a considerable amount of dark brown pus escaped from the incision along the lower and inner side of the tibia. The entire periosteum of the shaft of the tibia was dissected away. The cavity left then filled with purulent fluid. The shaft of the tibia was excised below the tuberosity and above the malleolus.

One year later the radiographs (see Figs. 323, 324), one taken from a lateral and the other from an antero-posterior point of view, were made, which show that bone formation had taken place: —

Osteomyelitis. Mary P., seven years old; entered the hospital November 13, 1900; patient of Dr. Munro. Two weeks ago fell down stairs, bruising leg, which began to swell rapidly; much pain and constitutional symptoms. The patient is anæmic. The left leg presents a marked enlargement. X-rays showed involvement of the periosteum at the upper portion of the tibia (see Fig. 325).

Operation by Dr. Munro on November 13, cavity curetted out. January 1, 1901, a second operation; periosteum split down about 10 centimetres. For 7.5 centimetres the periosteum was lined with a crackling, rough, new bone 3 to 4 millimetres thick, ending below in normal periosteum. The periosteum with its new bone was peeled from the shaft and the shaft sawn through just below the beginning of the normal periosteum, and the fragment was removed. A rough necrotic fragment about 12.5 millimetres in diameter was removed from the epiphyseal end, and the epiphysis curetted wherever the bone seemed diseased. The edge of the periosteum was sutured with catgut, and the leg compressed laterally so that the periosteum fell together more or less closely. A temporary drain was placed at the upper end, the skin below being sutured. X-ray photograph taken January 17, 1901.

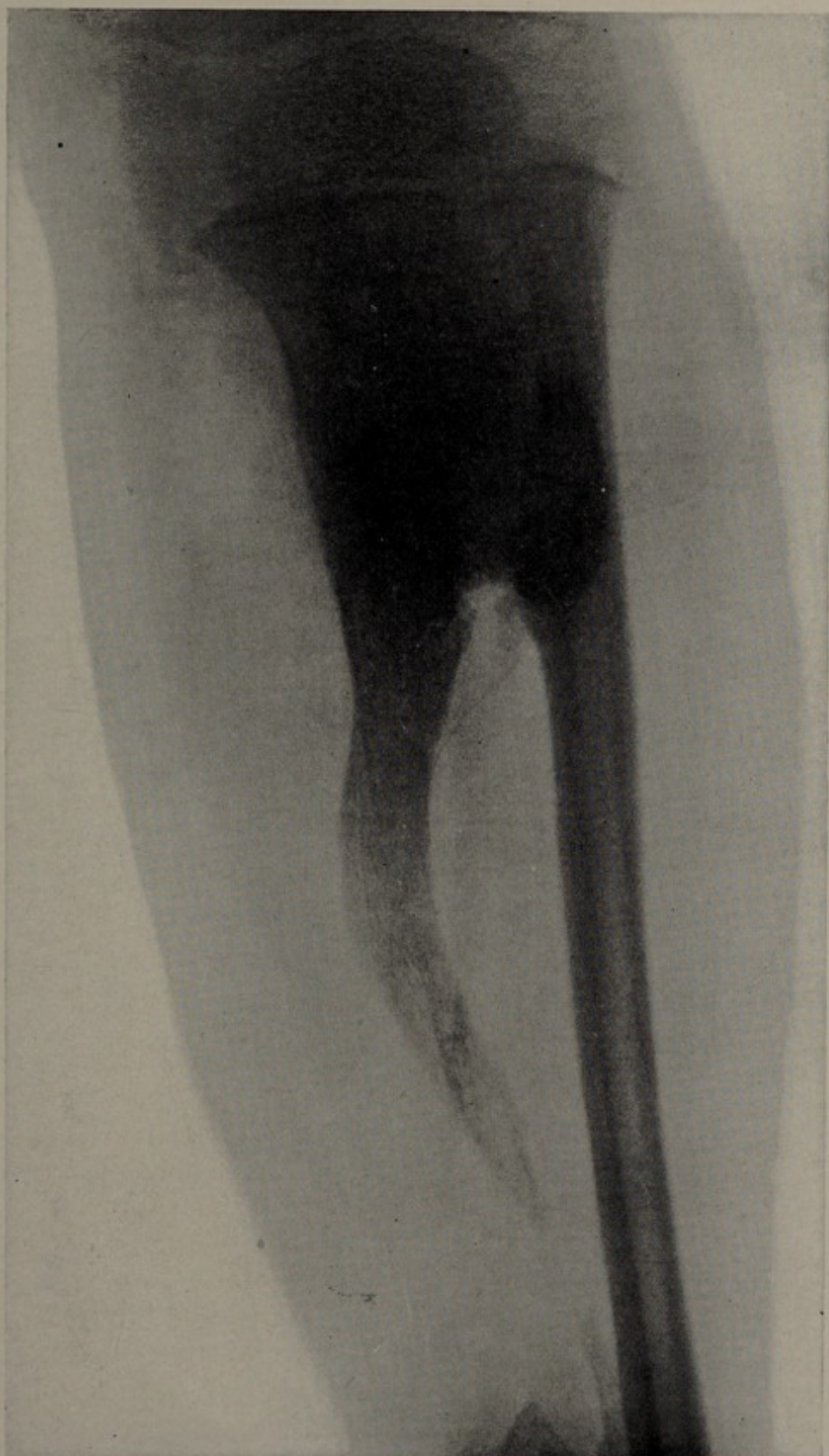


FIG. 324. Alexander S. Osteomyelitis of the tibia. Antero-posterior view.

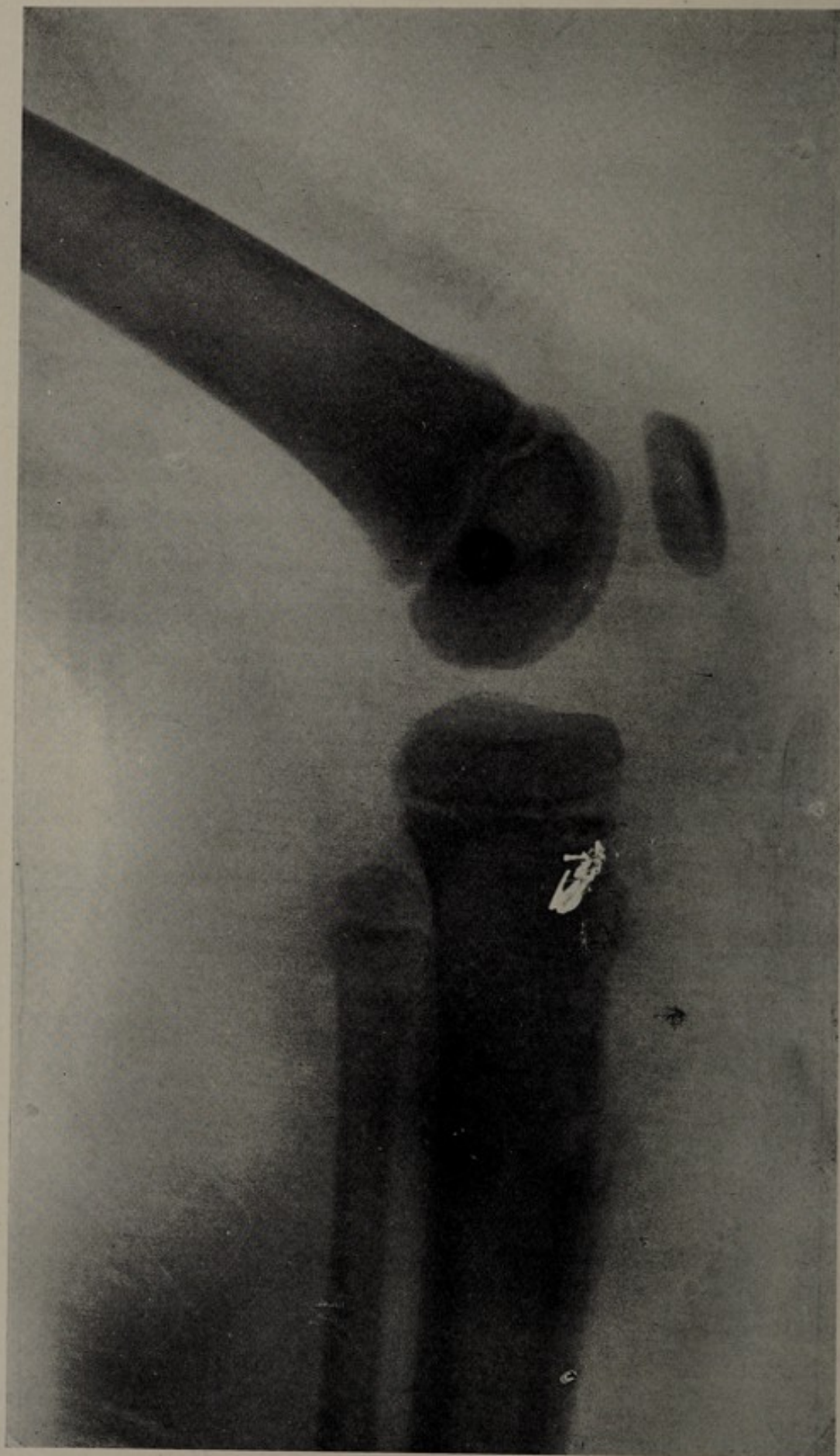


FIG. 325. Mary P. Osteomyelitis. Before operation. The white spot seen in the upper part of the diseased area is caused by an injury to the negative.

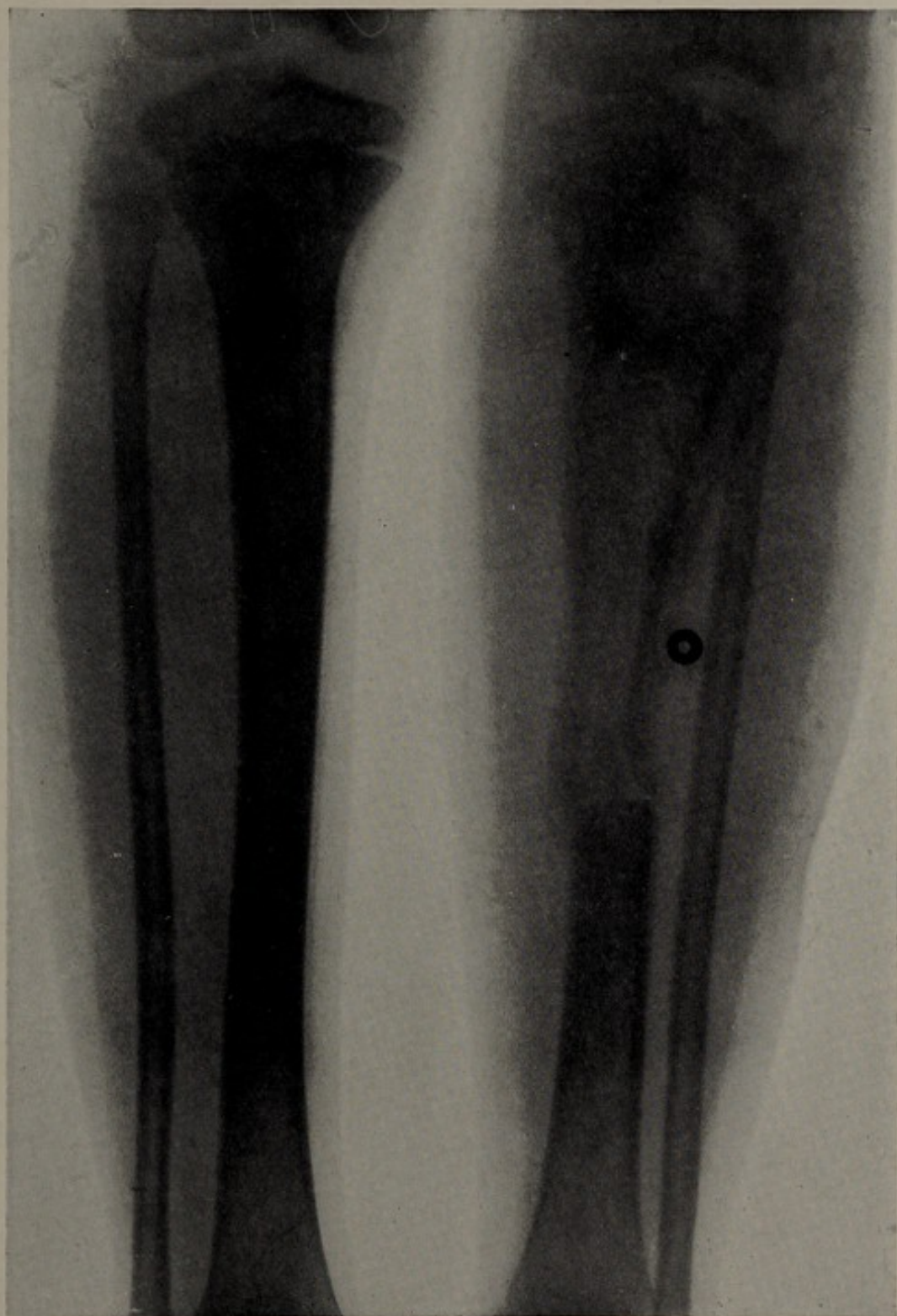


FIG. 326. Mary P., seven years old. Osteomyelitis of tibia. Well and diseased leg compared. Antero-posterior view. Radiograph taken January 17, 1901, after operation.

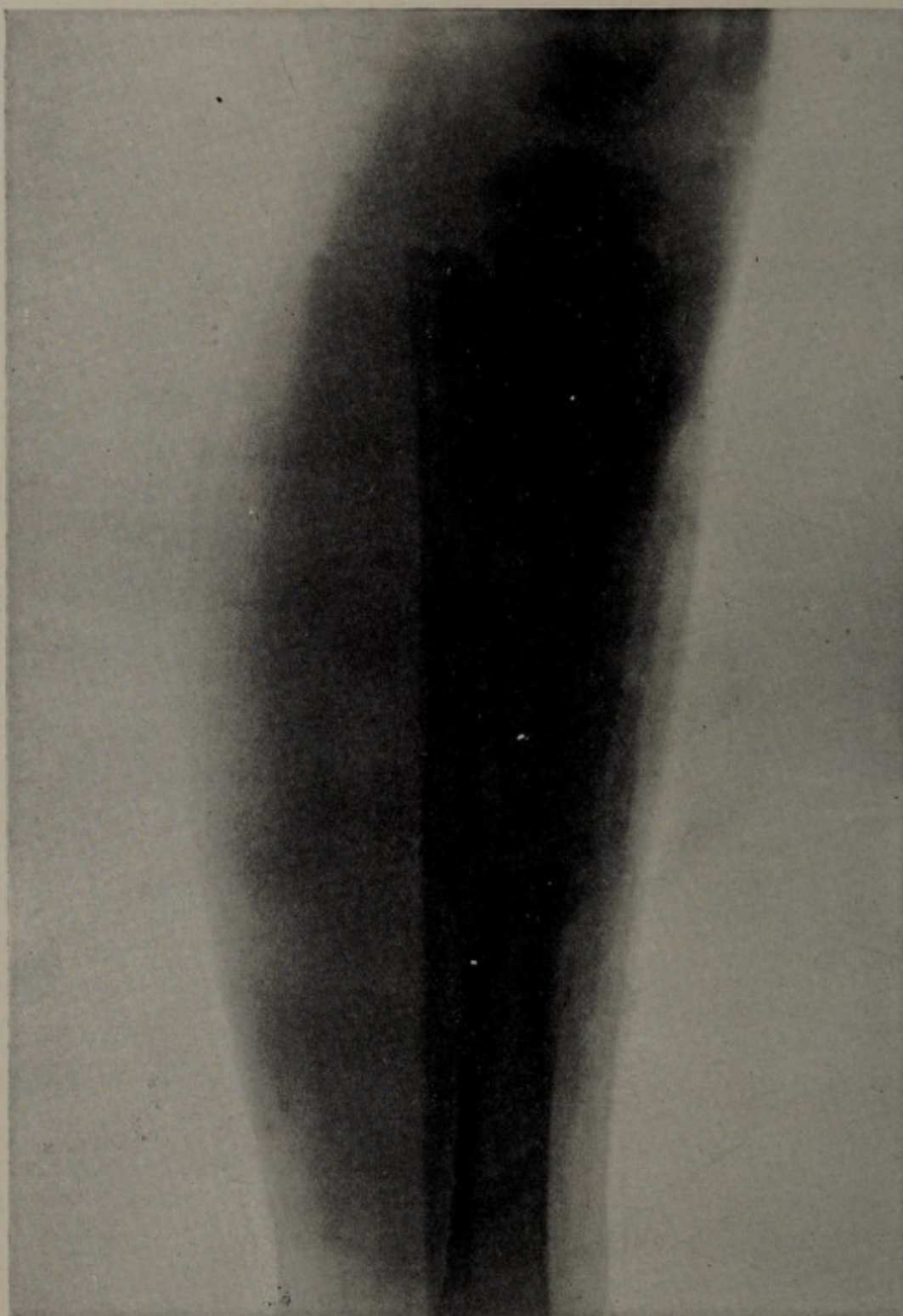


FIG. 327. Mary P. Osteomyelitis of tibia. Lateral view. Radiograph taken January 17, 1901, after operation.

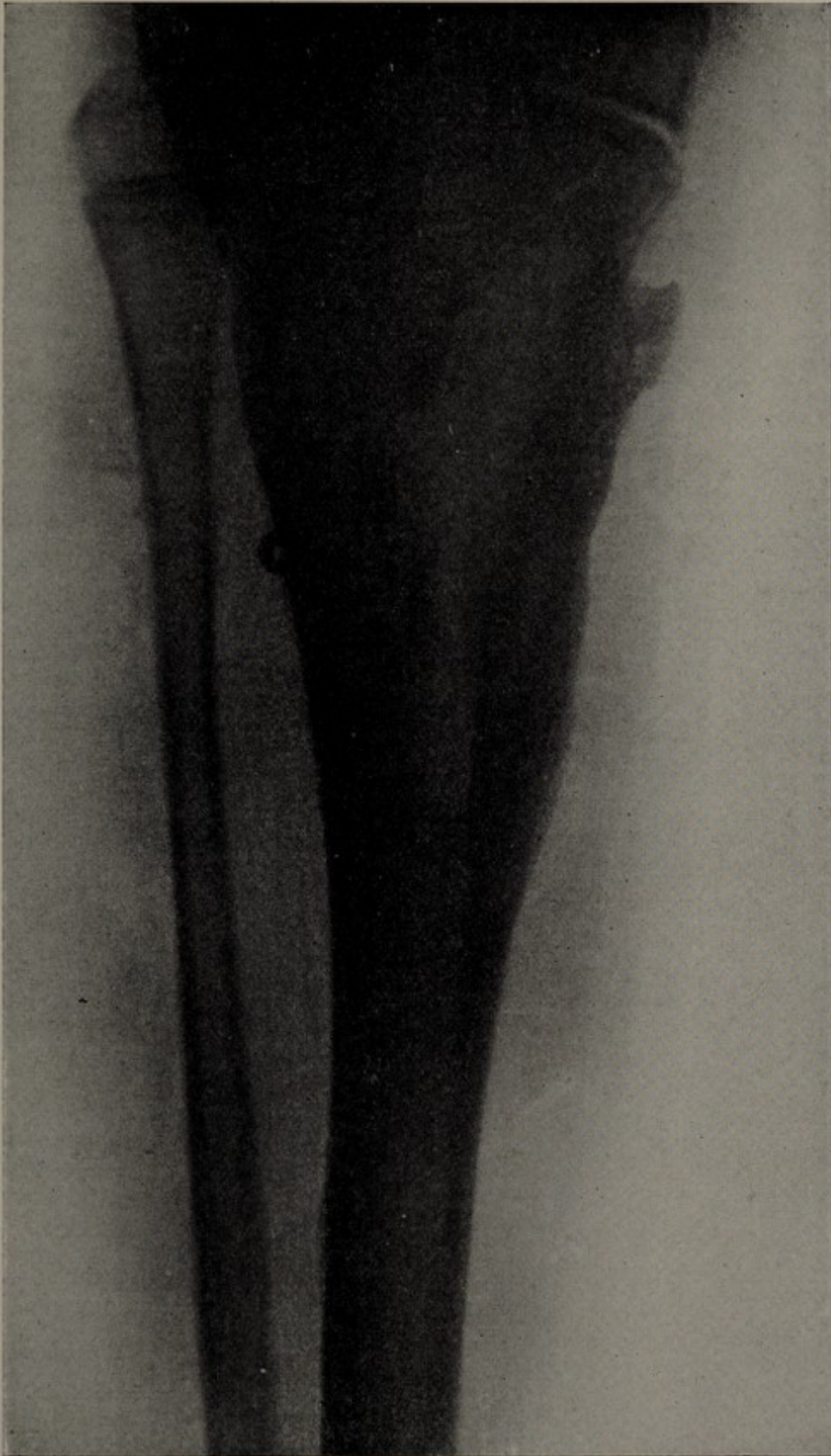

FIG. 328. H. T. S., fourteen years old. Entered the hospital February 7, 1901. Osteomyelitis of the tibia. Antero-posterior view. Operation done February 15, by Dr. Paul Thorndike. Incision over fluctuation into extensive abscess. Was in the hospital in October, 1900, with osteomyelitis.

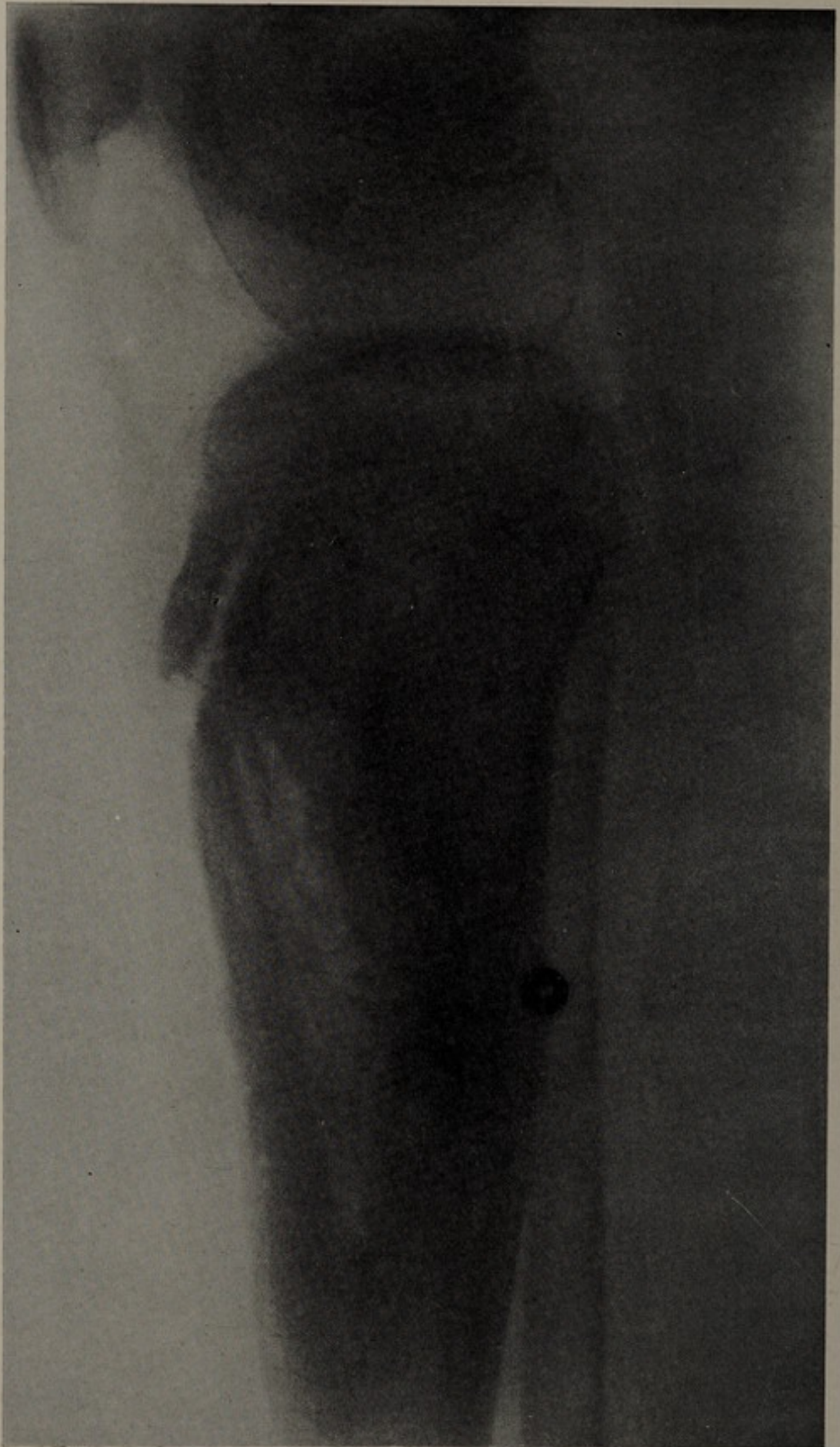


FIG. 329. H. T. S. Osteomyelitis of the tibia. Lateral view.

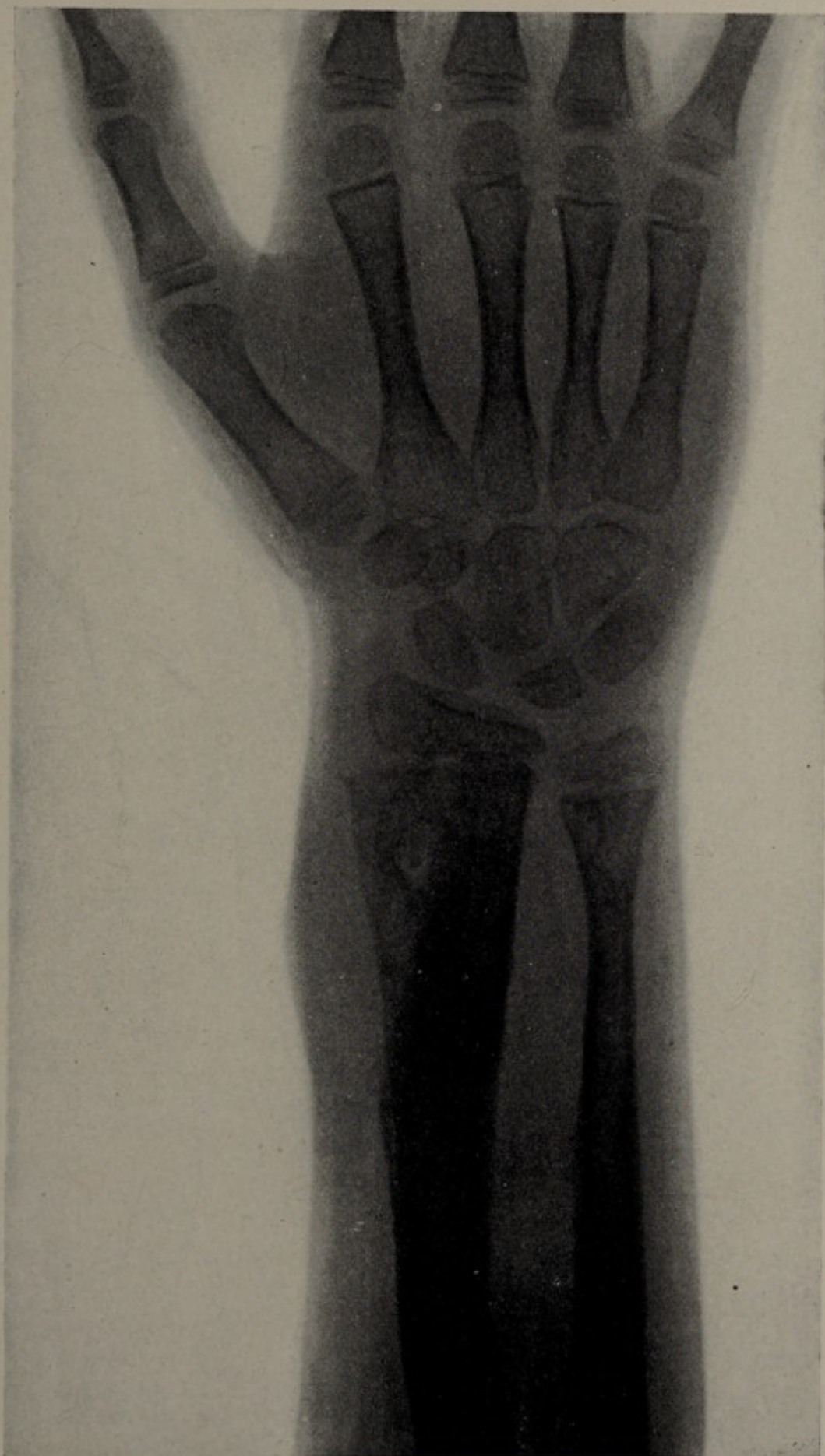

FIG. 330. Delora A. S., eight years old. Entered hospital January 21, 1901. Patient of Dr. Bolles. Osteomyelitis of radius. Incision made in fluctuating swelling over the head of the radius and a considerable amount of pus evacuated. X-ray photographs made on January 22, 1901. Antero-posterior view.

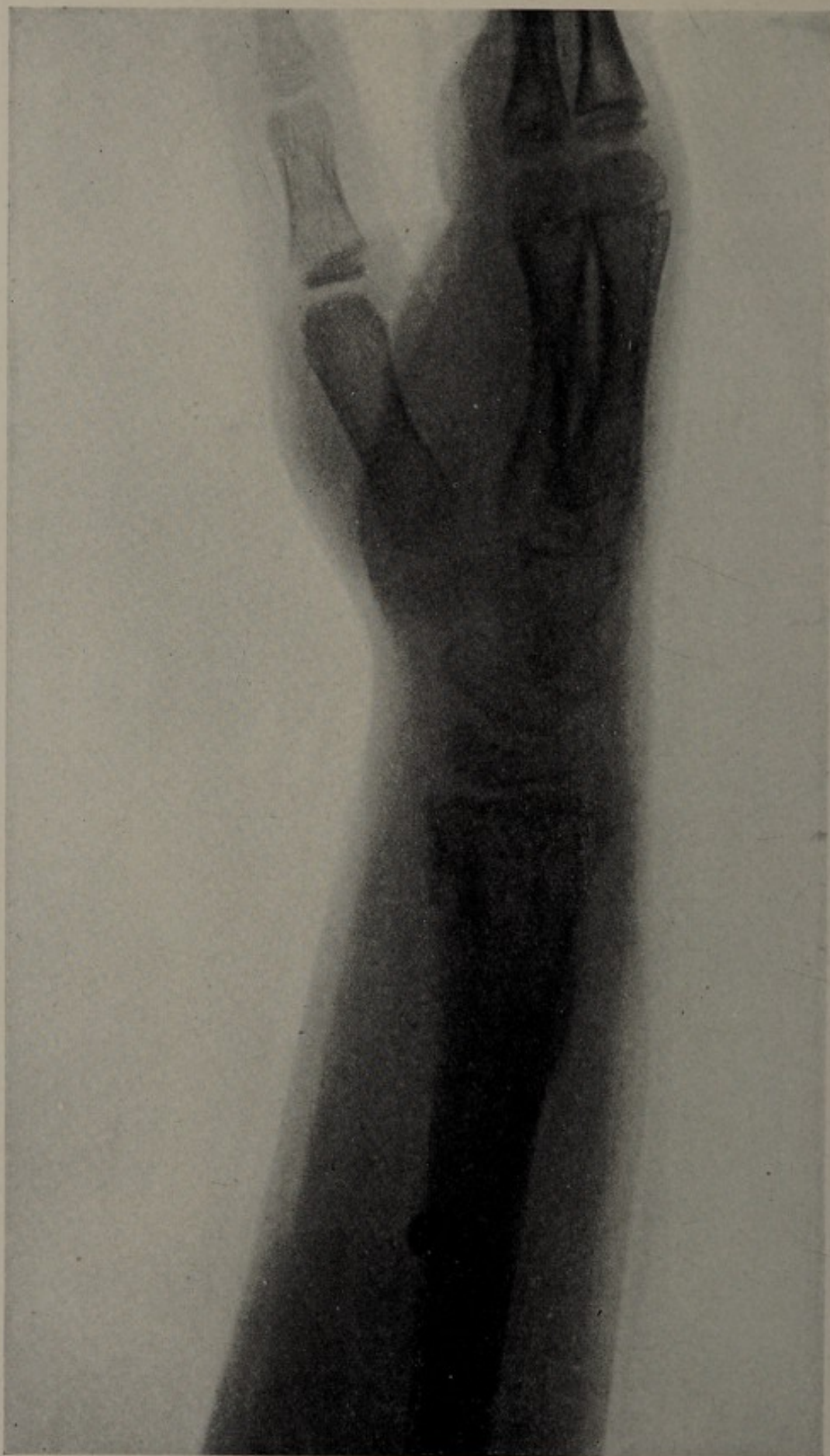

FIG. 331. Delora A. S. Osteomyelitis of radius. Lateral view.

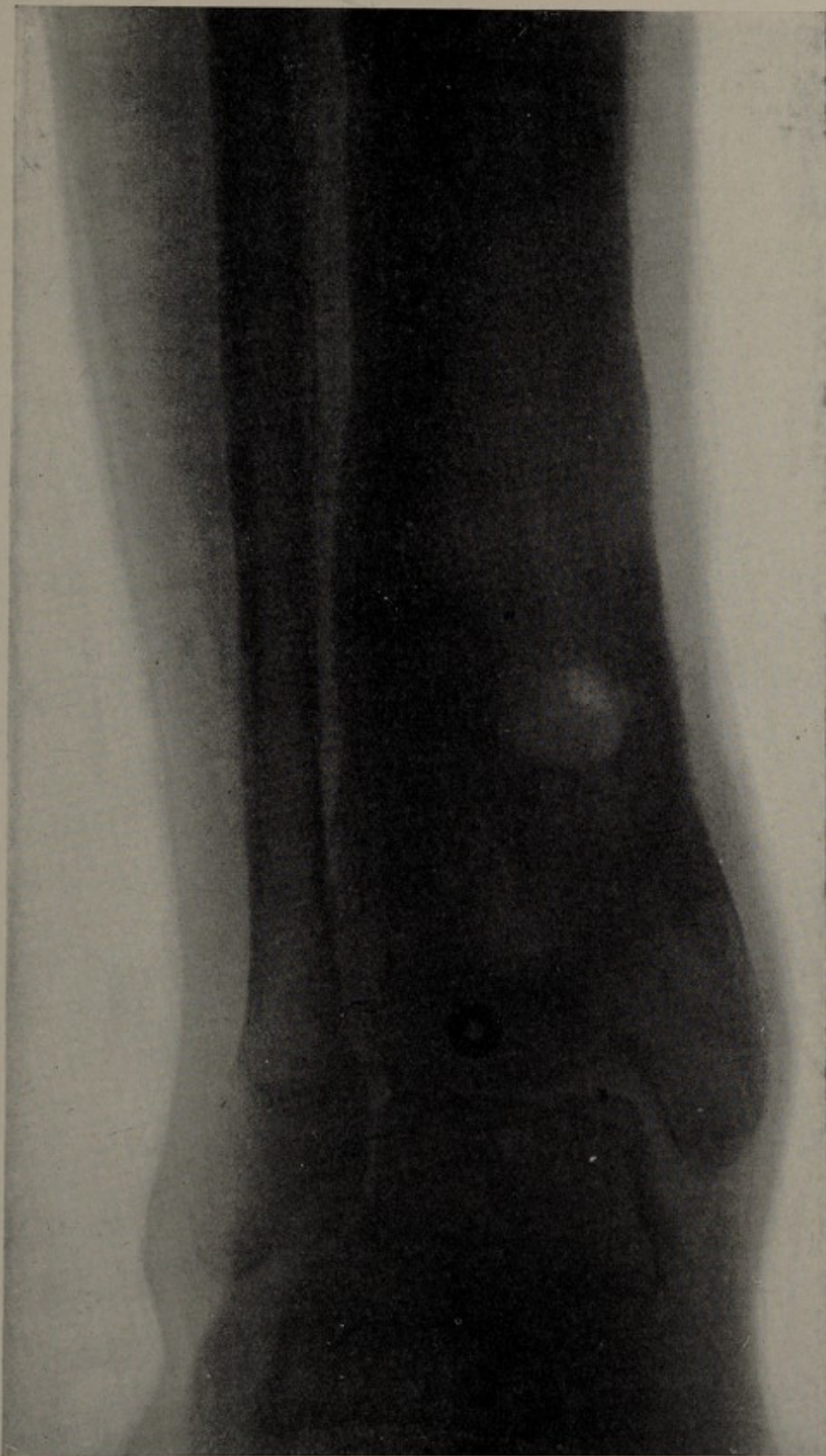

FIG. 332. Roy H., fifteen years old. Osteomyelitis; abscess; thickened tibia. Radiograph taken January 5, 1901. Antero-posterior view. Operation done by Dr. Burrell, January 21, 1901. Sinus enlarged; no dead bone.

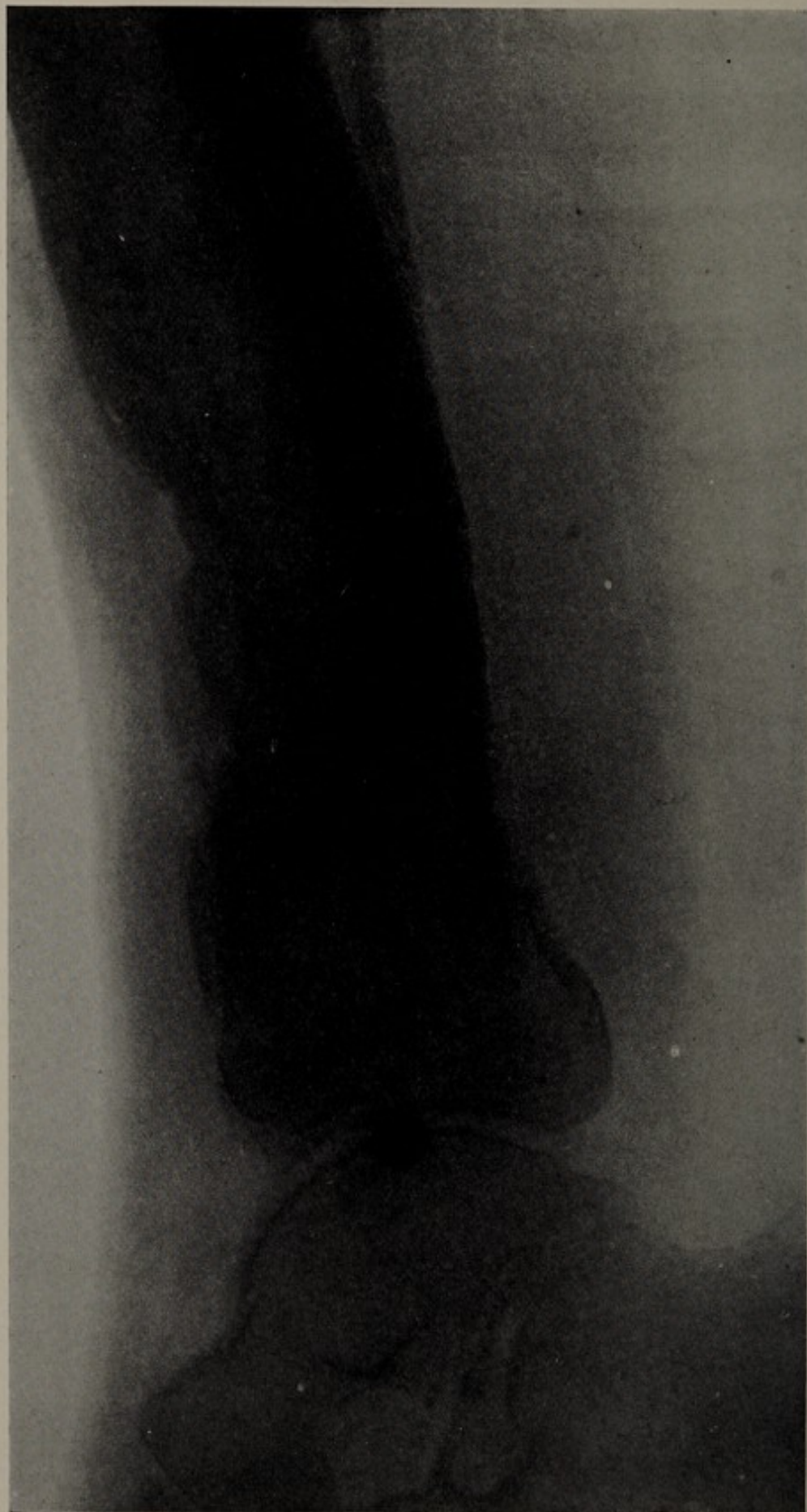


FIG. 333. Roy H. Lateral view. Radiograph taken January 5, 1901.

Tuberculosis of the Bones.—Tuberculous bones, in many cases at least, are lighter than normal ones. The outlines of tuberculous joints, and especially the ends of the bones near them, are less defined than normal. The cause of the lighter shadow appears to be the result of a diminished amount of inorganic salts in the diseased bones. This subject, tuberculosis of the bones, will be further discussed under joints.

Syphilitic Disease.—Reference will be made to the use of the X-rays in this disease under joints.

Rickets.—This disease affects the bones during development. The proliferation of the cartilage cells leads to an enlargement of the epiphyses, and the cartilage is lacking in its normal amount of calcareous matter. The X-rays show that in rickets the bones are less dense than normal and that their shape is altered. A comparison of the following analysis¹ of the bones of a healthy child two months old, with that of rachitic bones, is instructive, and indicates why the normal and the rachitic bones differ in the shadows they produce on the screen or in the photograph:—

| | HEALTHY CHILD. | | | RACHITIC BONES. | |
|--------------------------|----------------|-------|--------|-----------------|----------|
| | TIBIA. | ULNA. | FEMUR. | TIBIA. | HUMERUS. |
| Inorganic matter | 62.3 | 64 | 20.6 | 33.6 | 18.8 |
| Organic matter | 34.68 | 35.9 | 79.4 | 66.3 | 81 |
| Calcium phosphate . . . | 57 | 56 | 14.7 | 26.9 | 15.6 |
| Magnesium | 1 | 1 | 0.8 | 0.8 | |
| Calcium carbonate . . . | 6 | 6 | 3 | 4.8 | 2.66 |
| Soluble salt | 0.7 | 1.6 | 1 | 1 | 0.6 |
| Ossein | 33 | 34.9 | 72 | 60 | 81 |
| Fats | 0.8 | 1 | 7 | 6 | |

The following cut was made from an X-ray photograph of the foot of a child four years old, and shows the rachitic bones, the muscles, and the adipose tissue:—

Coxa Vara.—Muirhead Little² sums up his article on this subject by saying that coxa vara in adolescence may be produced by the action

¹ Hallburton's Physiology.

² "Remarks on Coxa Vara," *British Medical Journal*, November 5, 1898, pp. 1394-1395.

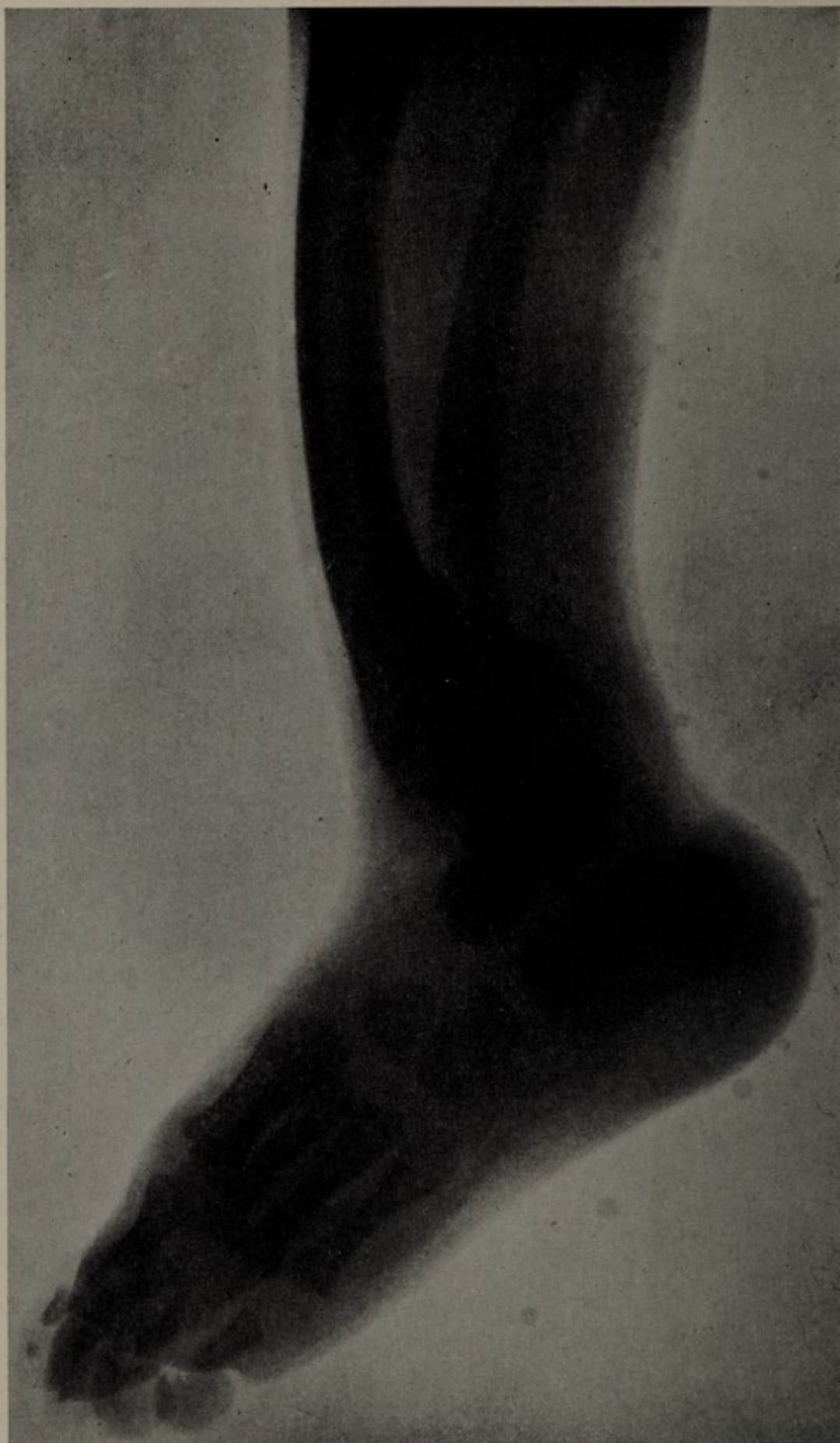


FIG. 334. Rickets. Foot. From a colored child four years old (1896).



FIG. 335. Coxa vara. Patient of Dr. E. H. Nichols.

of gravity on bones softened by any disease; that when present in children it is due to rickets; that some cases of apparent coxa vara are in reality curvature of the upper part of the diaphysis of the femur; others are cases of dislocation of the hip; and still others, greenstick fracture of the cervix femoris. The X-rays afford, he thinks, the surest means of diagnosis that we at present possess, and should always be employed. He reports a case in which the diagnosis of coxa vara had been made, but in which the radiograph showed that both hips were dislocated.

Changes in Neck of Femur. — R. J. Godlee¹ reports three cases of shortening and eversion of the lower extremity depending upon changes in the neck of the femur, in order to suggest that some of the cases described as coxa vara may be of a different nature. Excellent illustrative radiographs, made by Mackenzie Davidson, are given in the article. Godlee believes that two of these cases were the result of tuberculous changes taking place in the distal side of the epiphysis of the head of the bone, and he thought that in one of these two some change had also occurred in the hip-joint itself.

Acromegalia. — X-ray photographs have been of some service in this disease by pointing out changes in the bones.

Murray² reports two cases in which X-ray photographs showed an increased thickness of the shaft of each of the phalanges of the hand, the absence of osseous union between the phalanges and the epiphyses, and a great increase in the bulk of the soft structure of the hands, and in one case, of the feet. Murray suggests that the union of the epiphyses may have been arrested by some other cause than the acromegalia.

Oudin and Barthélemy have also reported on the use of the X-rays in acromegalia.

New Growths. — New growths which in any way interfere with the bony structure, as, for example, a growth which might cause disintegration of the spinal column, may be recognized indirectly by an X-ray examination; that is, the changes in the bones could be recognized by an X-ray photograph, but the cause of the change would be decided by means of other signs and symptoms.

New growths which are formed in the soft tissues, such as carcinoma and sarcoma, have already been referred to in connection with the

¹ Trans. Clin. Soc., London, XXXII, pp. 244-247.

² "Acromegaly with Goitre, and Exophthalmic Goitre," *Edinburgh Medical Journal*, February, 1897, pp. 170-174.

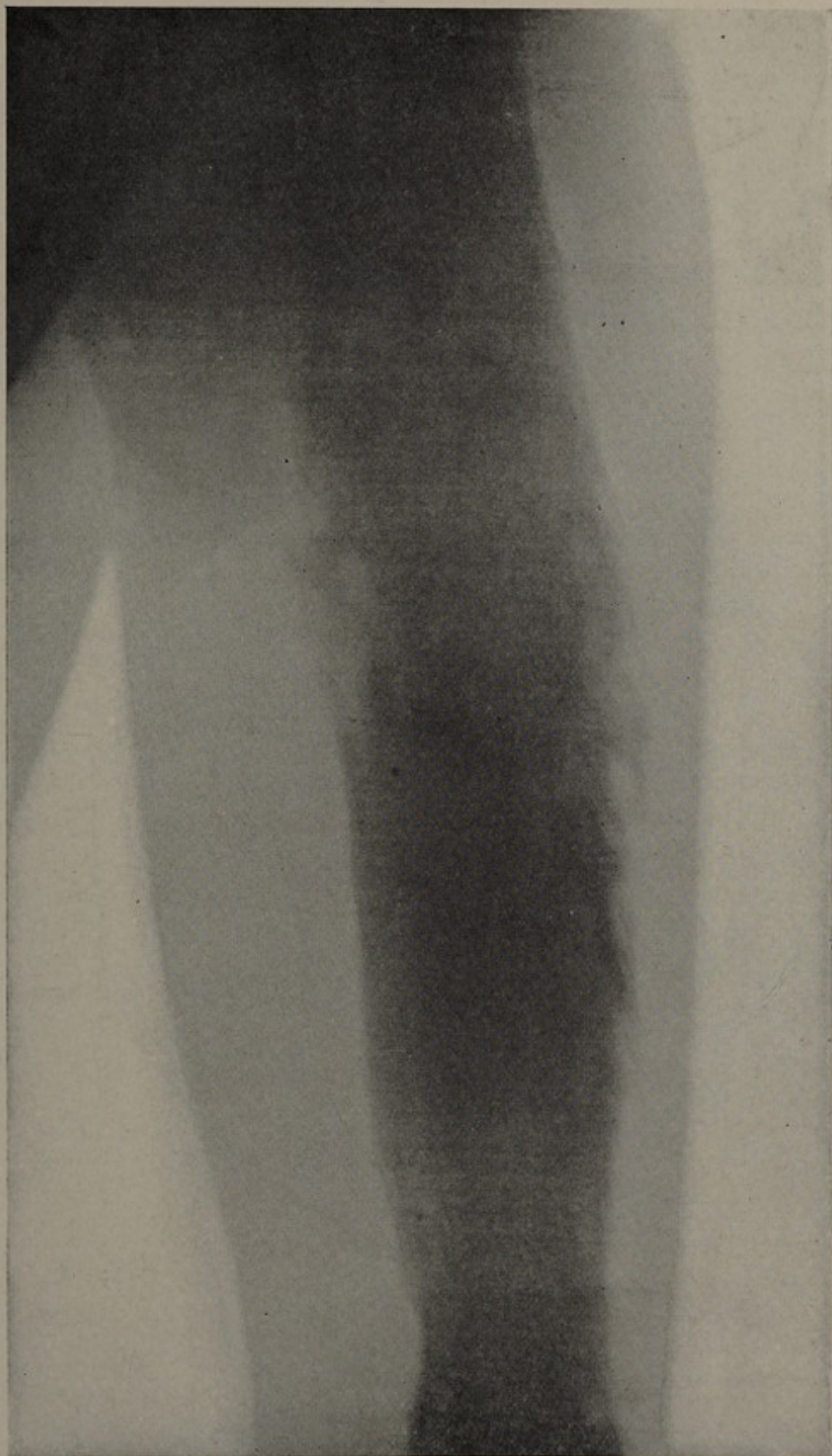


FIG. 336. Osteosarcoma of humerus. Patient of Dr. Bolles in 1896. The fluorescent screen and radiograph showed great enlargement of humerus and shaggy outline. The patient was lying on his back when the radiograph was taken, with the tube above him and a little inside the humerus; that is, toward the median line of the body. Dr. Bolles considered that this was an osteosarcoma of the humerus.




FIG. 337. Photograph of knee. Mary K., fourteen years old. See radiograph, Fig. 338.

medical uses of the X-rays. Some of these may affect the bones in their neighborhood.

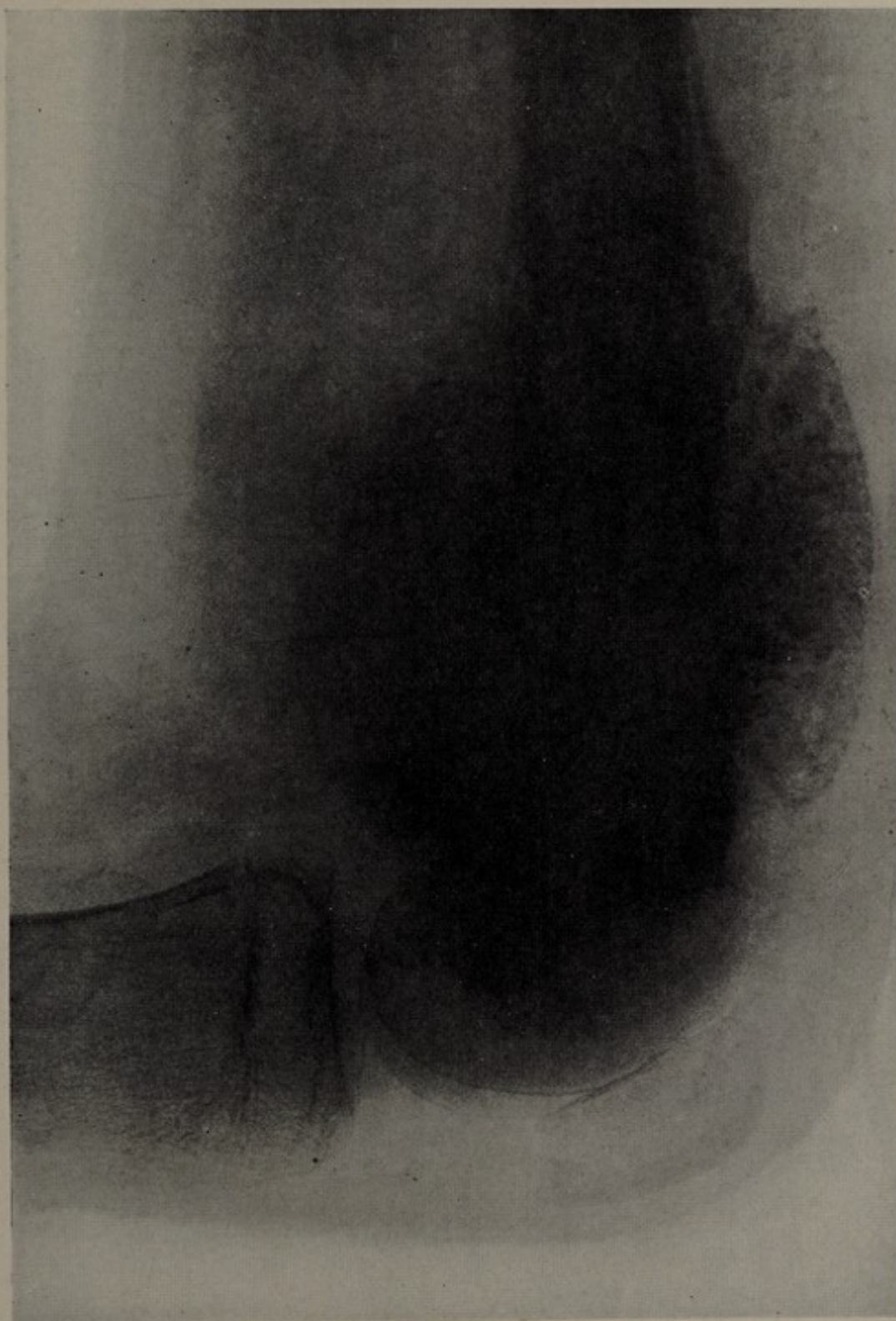

FIG. 338. Mary K., fourteen years old. Chondrosarcoma of lower end of femur. Service of Dr. H. W. Cushing. Radiograph taken before operation.

Differentiation of Bony from other Tumors. — X-ray photographs, as well as the fluorescent screen, assist in differentiating hard tumors which are made up of bony material from those which are not. I recall, for

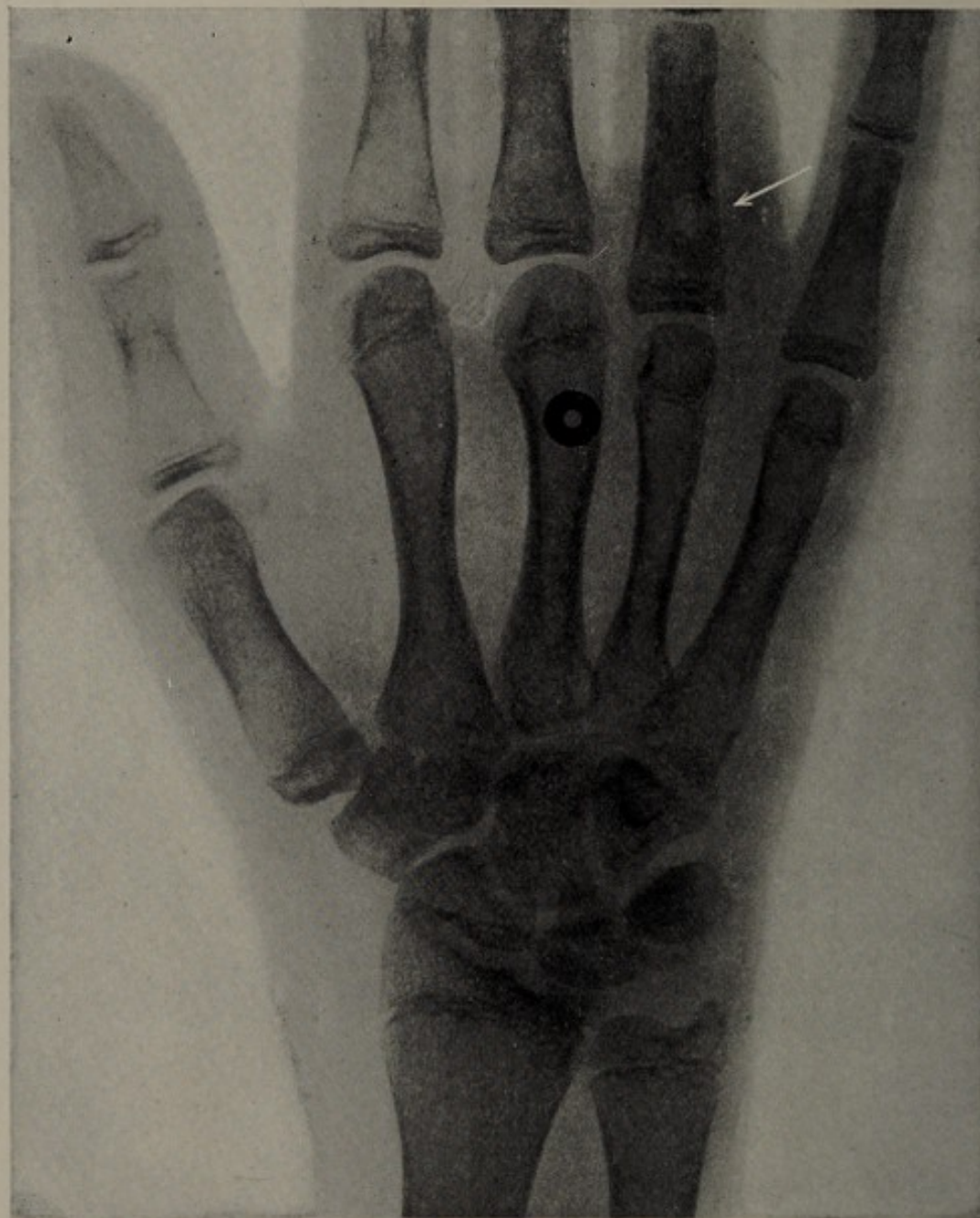

FIG. 339. Mary K. Antero-posterior view. Disease beginning in phalanx of third finger; spot indicated by arrow.

example, a dense, firm tumor of the thigh which seemed to be connected with the femur. While looking through the fluoroscope, with the fingers pressed against this hard growth, it could be readily observed that the fingers did not come within 3.5 centimetres of the femur; that is to

say, though the tumor was firm and dense, it did not contain any considerable portion of mineral salts.

Chondrosarcoma. — Mary K., fourteen years old, entered the hospital April 10, 1900. Service of Dr. H. W. Cushing. Six months before

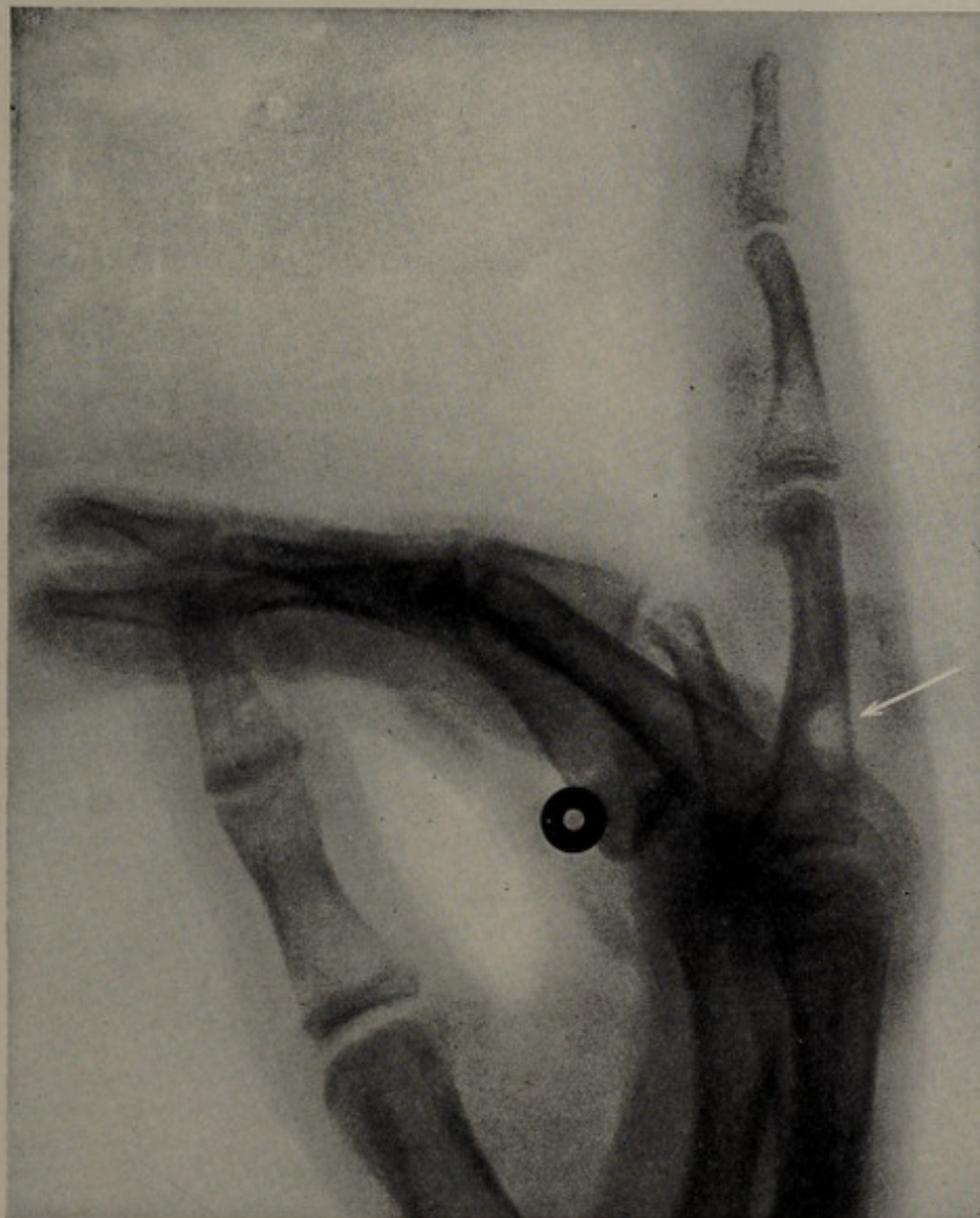


FIG. 340. Mary K. Lateral view.

entrance, without suffering any injury, or without any apparent cause, she had felt pain in the left knee, which was aggravated by walking. About the lower part of the thigh swelling was soon noticed, which increased; pain constant and dull in character. Figure 338 shows the outlines of the bones of the knee delicately pencilled (they are not re-

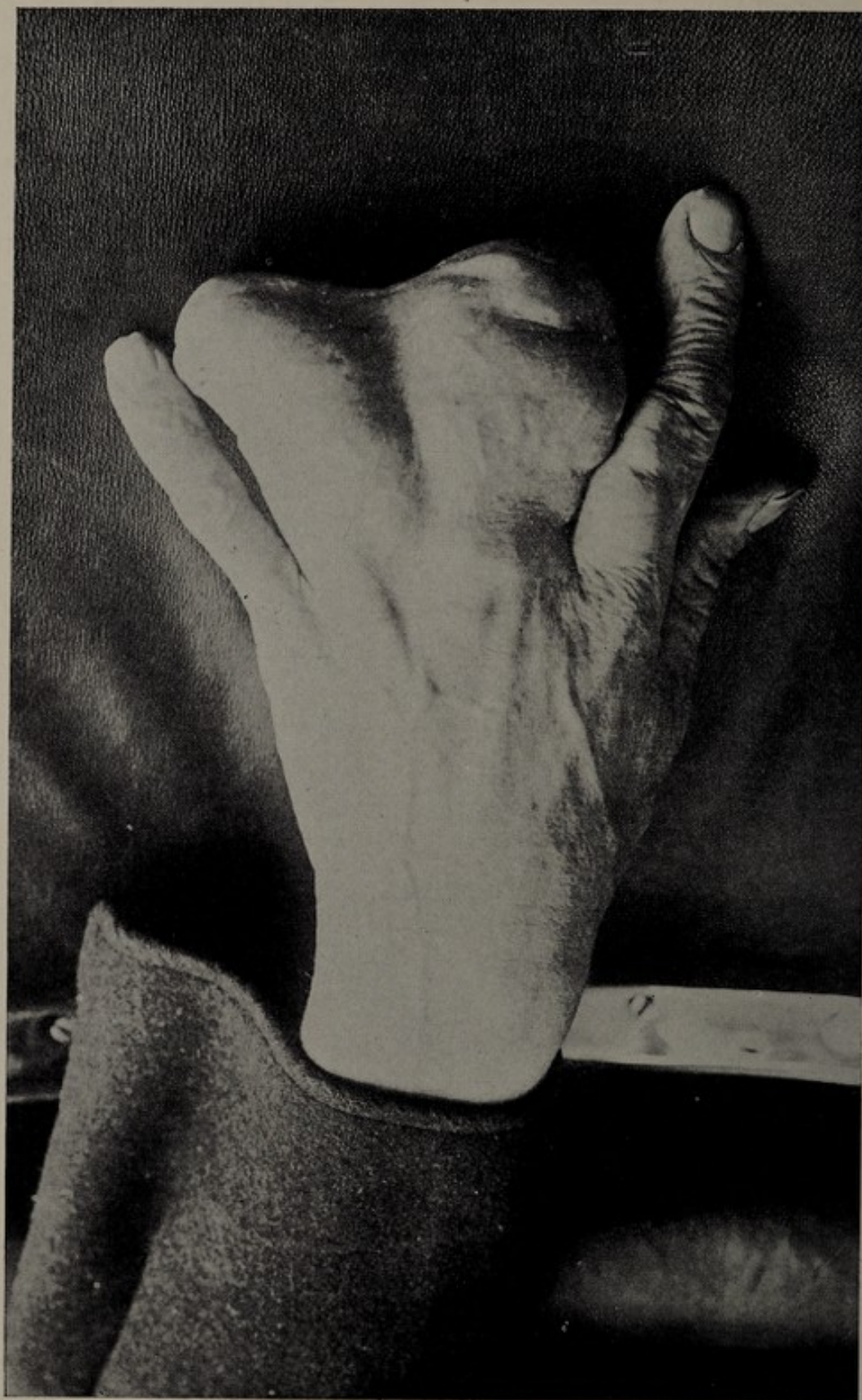

FIG. 341. A. B. Ordinary photograph of the hand of a man sixty-seven years of age. (See Fig. 342.)

touched), and that the interior of the lower end of the femur, the site of the disease, is very dark, but just above this point that the bone is lighter than normal. The outline and structure of the diseased area can be easily

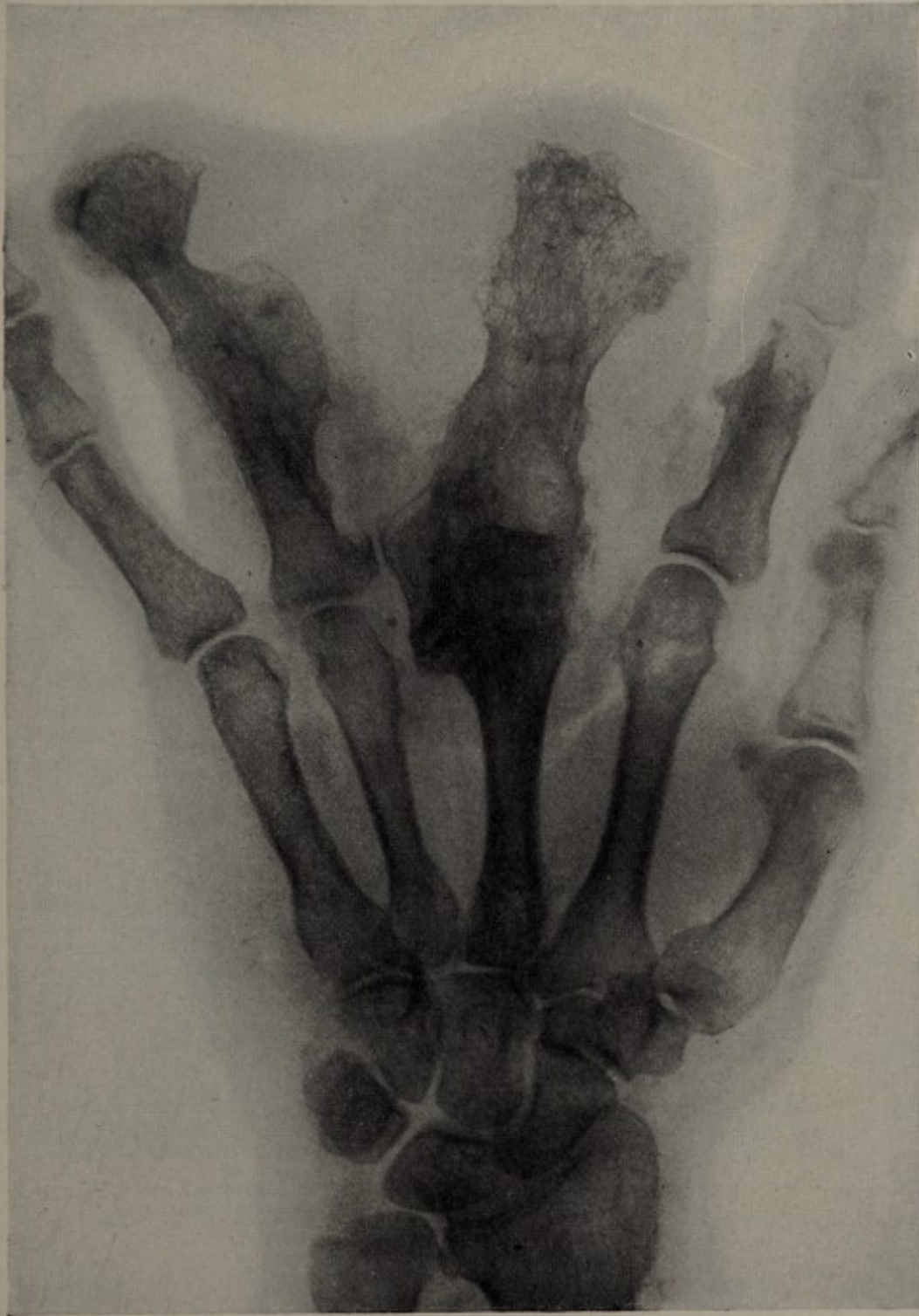

FIG. 342. A. B. Tumor involving fingers of the left hand of a man sixty-seven years old. The tumor had existed for many years, but was increasing slowly in size. It was probably congenital. This patient was in the service of Dr. Cushing. (Compare with Fig. 341.)

followed in the negative, as well as the outlines of the muscles and tendons. Amputation of the upper fourth of thigh, April 20, 1900.

Mary K. November 21, 1900. Ring finger of right hand has been

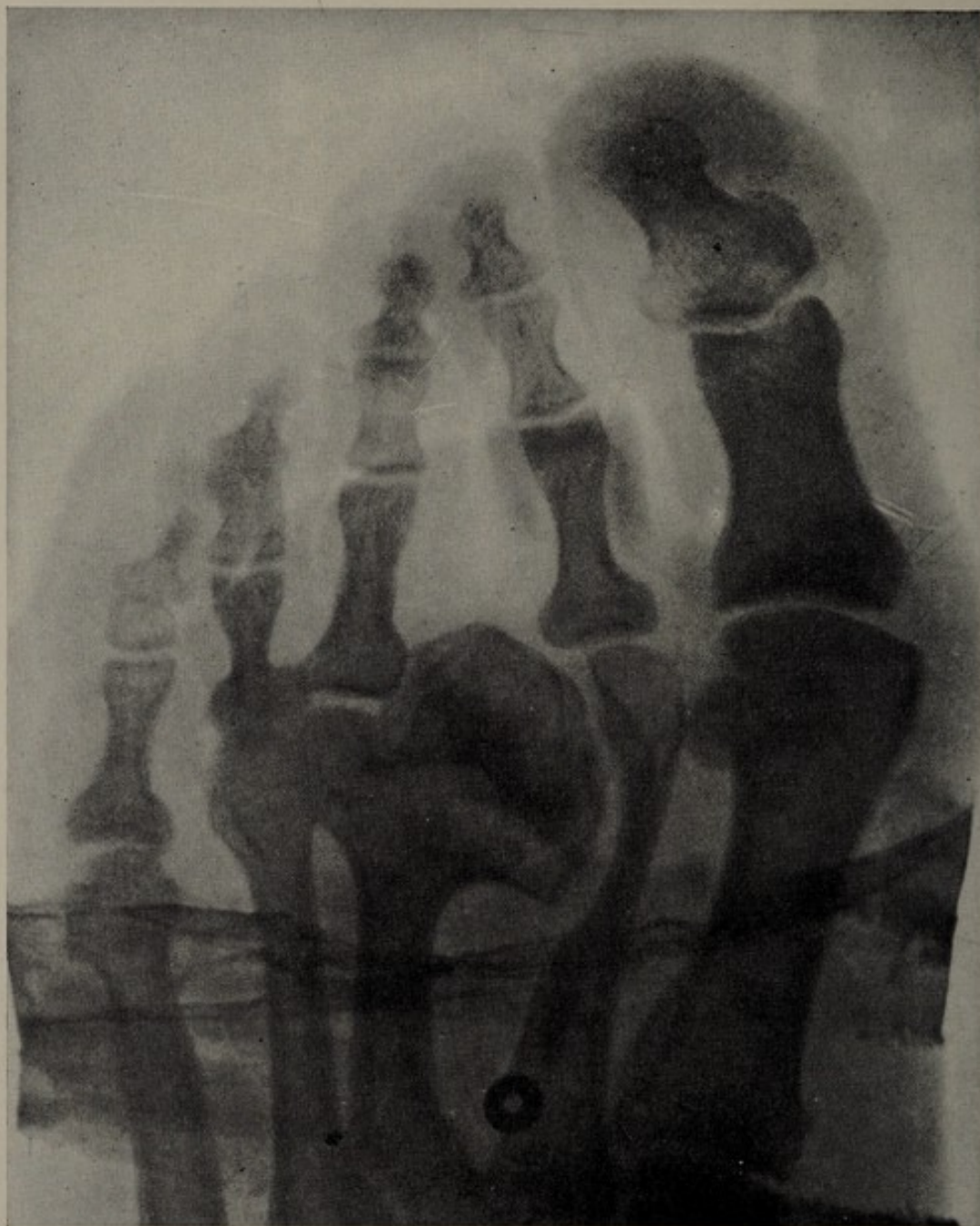

FIG. 343. Jacob I. Exostosis. Cut also shows effect of this growth on the next metatarsal. Radiograph taken through bandage.

inflamed, swollen, and tender. Fluctuation detected to-day; to be opened; wearing a splint.

November 22. Under anæsthetic; incision made over fluctuation and pus evacuated.

November 26. Culture showed the infection to be one of staphylococcus.

December 1. Incision of finger nearly healed. Discharged to Convalescent Home.

Metastatic Carcinoma. — Benedikt¹ describes a case of a patient who had had the right kidney removed on account of a cancer, by Gussenhauer. Three and a half years afterward sciatica set in, first on the right side and later on both sides. This pain was considered as a new illness, entirely unconnected with the former cancer. But in spite of the treatment given the pain increased in severity. A radiograph was then taken, which showed that the last lumbar vertebra was almost entirely destroyed. The diagnosis of metastatic carcinoma was thus assured. Benedikt emphasizes the value of the X-rays in aiding the physician to an early diagnosis in these diseases of the vertebræ, and states that they present no marked symptoms for a long time, but if taken in the early stage can be more successfully treated.

JOINTS AND CARTILAGES

Methods of Examination. — The joints in the hands and feet, wrists and ankles, are most easily photographed, because they are small and lie near the surface, so that the bones can be brought close to the plate; other joints present special difficulties on account of their size, position, or surroundings. In the study of the joints the tube should be directly above or underneath the joint to be photographed, that is, opposite the interarticular space, in order to show as much as possible of the outlines of both bones; further, the diseased joint should be compared, when possible, with a normal one in the same individual. Further directions for examining joints have been given in the chapter on Fractures, and special methods for special joints will readily suggest themselves to the practitioner. These tissues can be examined with the best results if a new tube that has a low resistance is used.

Tuberculosis of Foot. — Leslie E. P., eighteen years old, entered the hospital May 26, 1899. Service of Dr. H. W. Cushing.

Diagnosis: tuberculosis of the foot.

History. — Four months before lameness began in left ankle, possibly after slight "sprains." No swelling noticed. Lameness increased in next two months. Two months ago it was put up in plaster-of-paris.

¹ *Wiener klin. Wochenschrift*, June 8, 1899, p. 639.

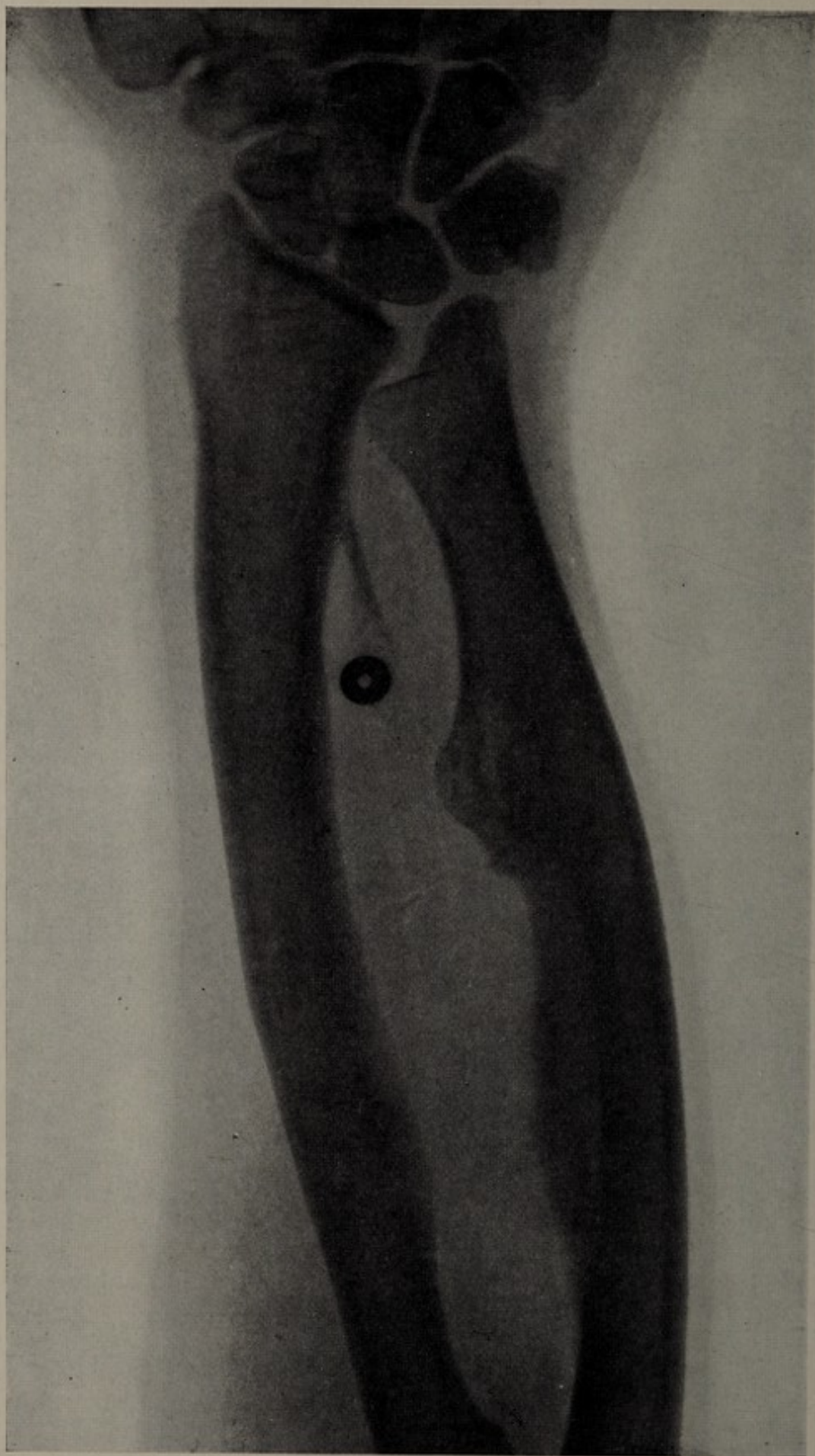


FIG. 344. Salvator C., twenty-three years old. Typhoid. Entered hospital September 20, 1900. Entered my service October 1. Arm examined with the above result. Antero-posterior view. Exostosis of ulna and radius.

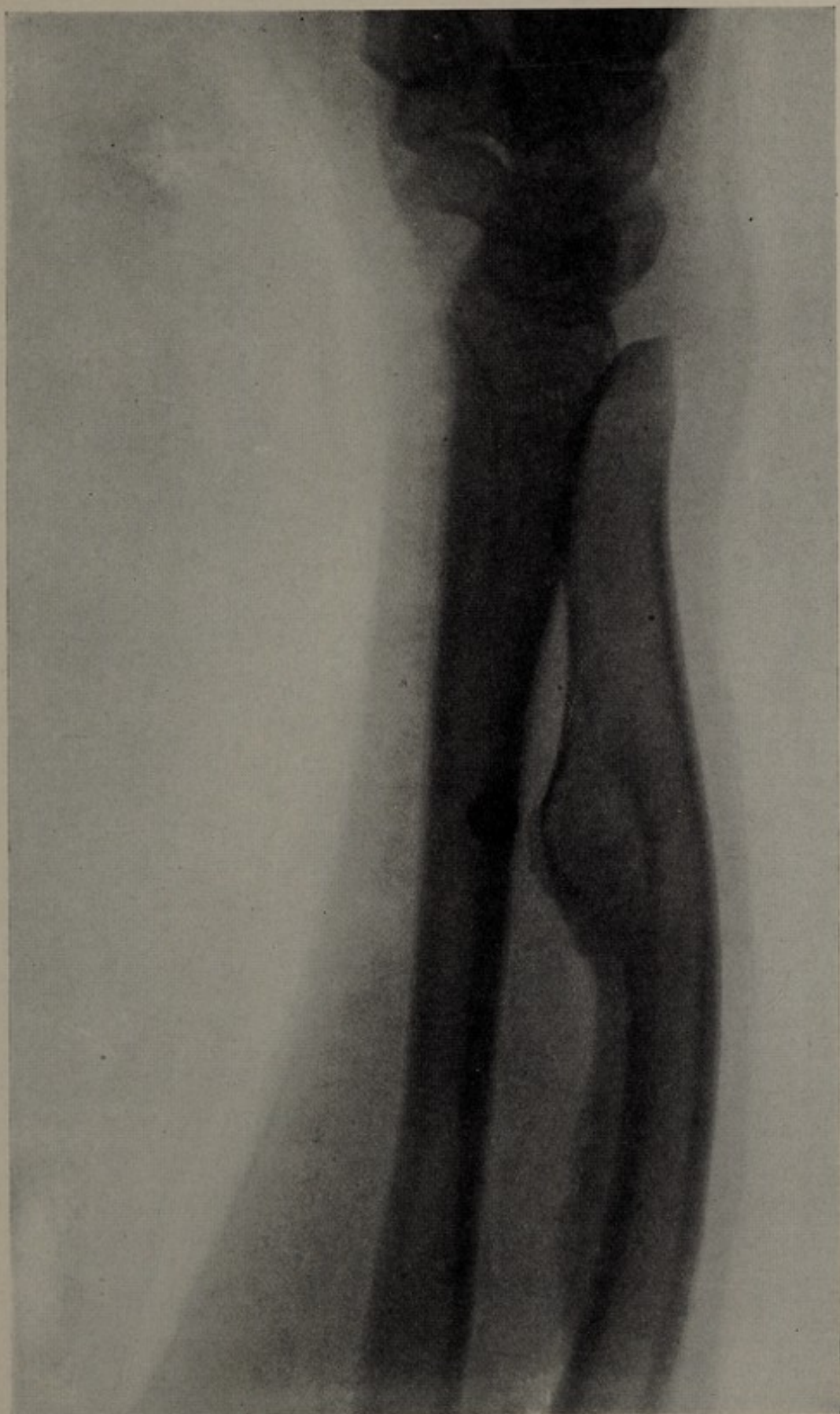


FIG. 345. Salvator C. Lateral view. (See also Fig. 344.)

About this time the patient had severe pain for three days. Œdema about ankle; no discharge.

The following X-ray photographs were taken on March 27, 1900.

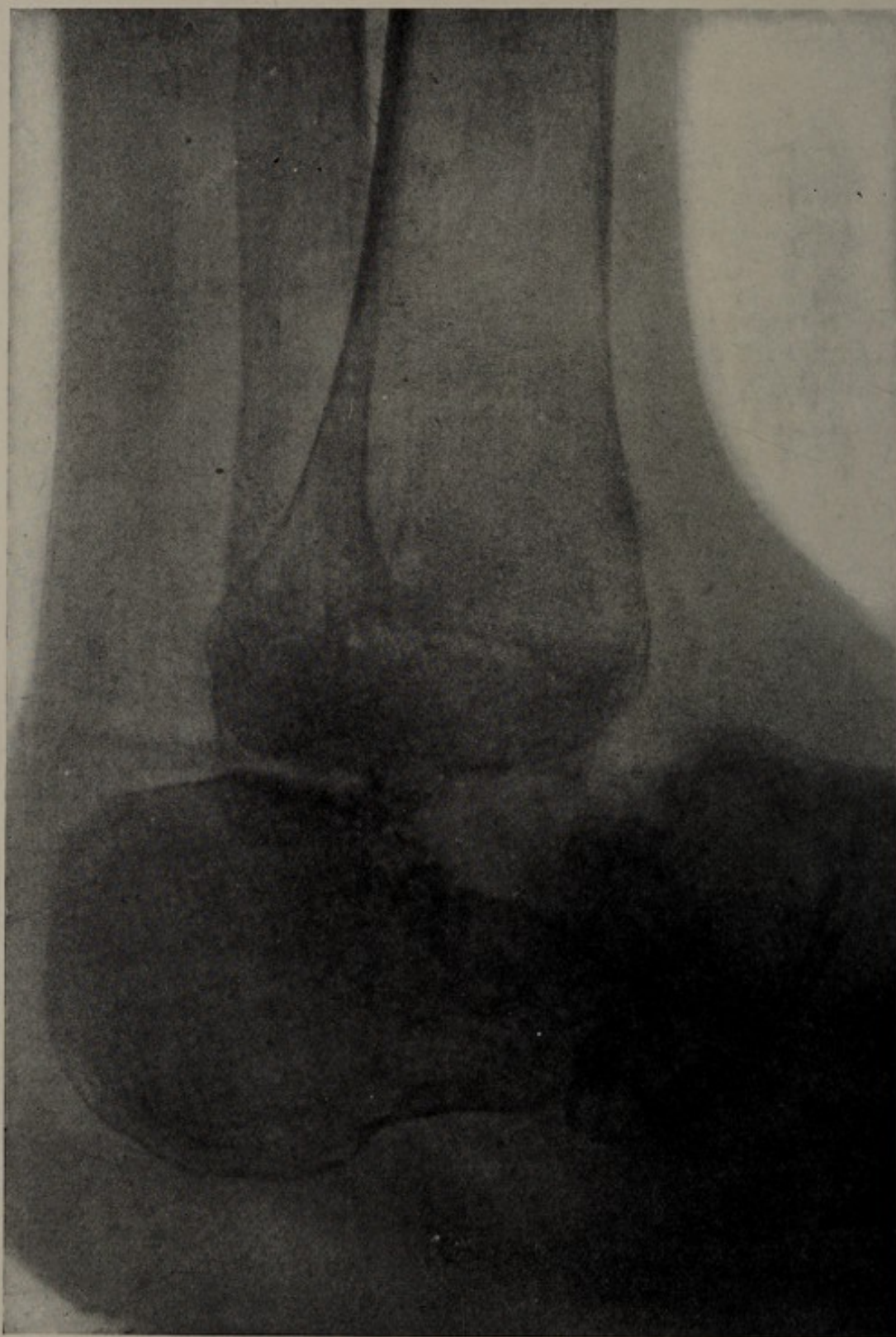


FIG. 346. Leslie E. P. March 27, 1900. Tuberculosis of ankle.

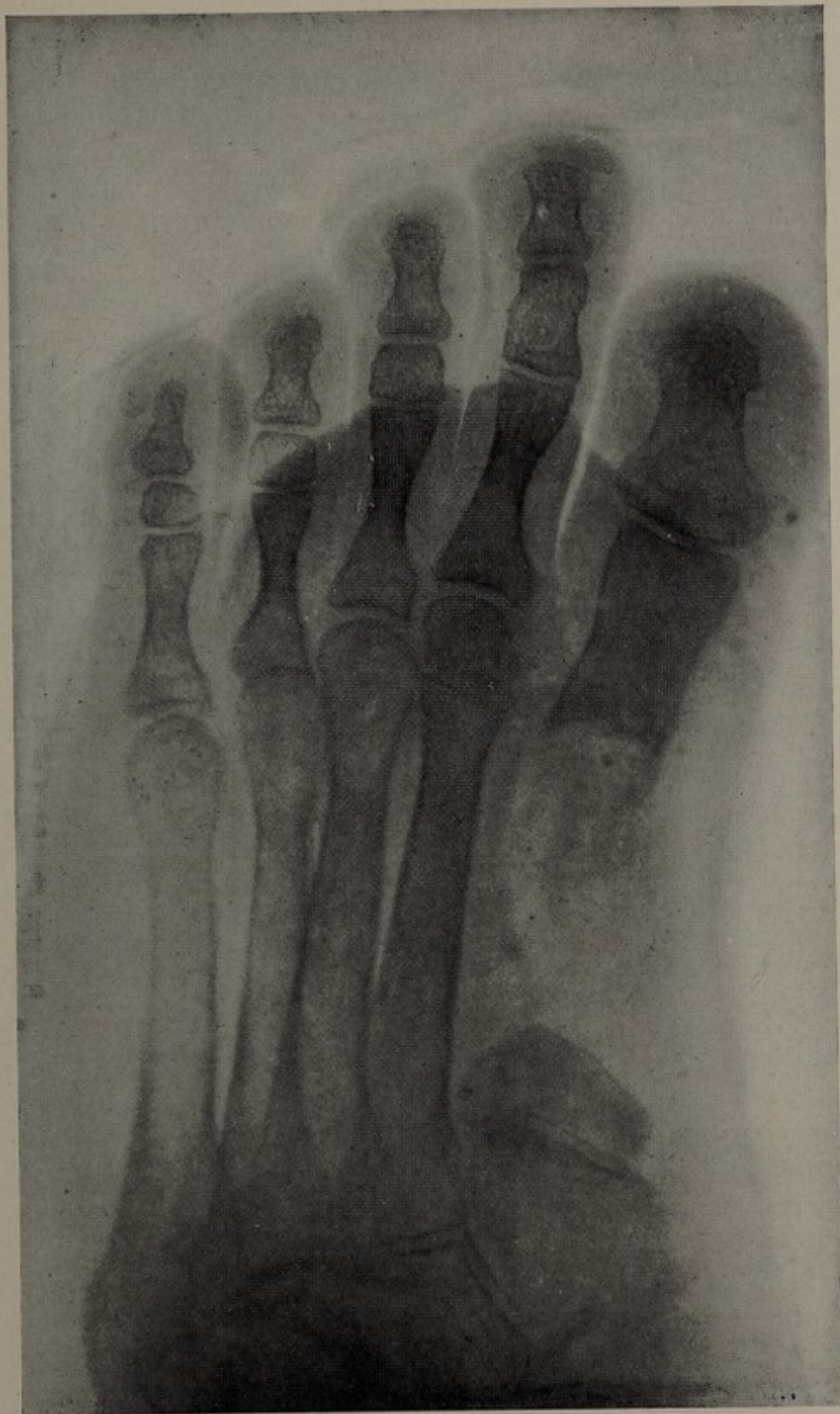

FIG. 347. Leslie E. P. Tuberculosis of foot. Another view.

Many accounts of the usefulness of the X-rays in tuberculosis of the bones have been published, among which the following may be mentioned as further illustrating this point:—

Lannelongue, Barthélemy, and Oudin¹ report a case of tuberculosis of the first and second phalanx of the middle finger of the left hand in

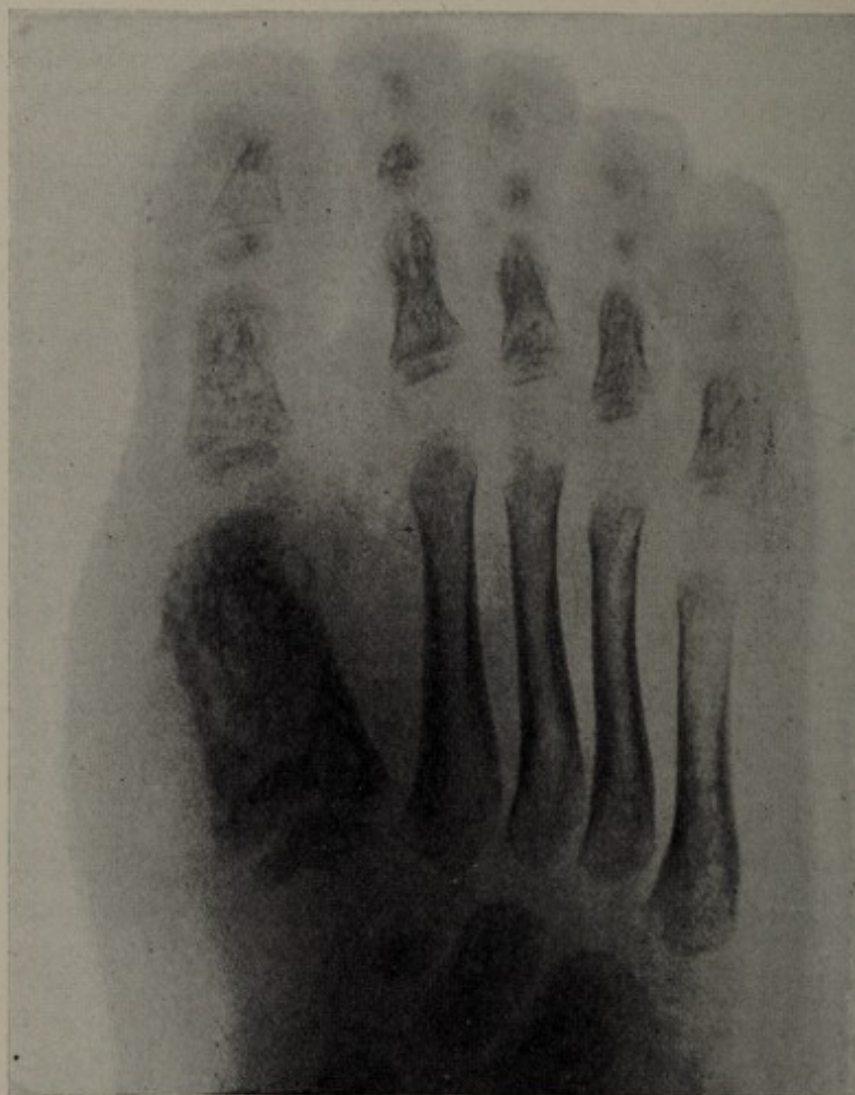

FIG. 348. M. J., child. Tuberculosis of the foot. The disease is chiefly in the first metatarsal and phalanges. X-ray photograph taken April 11, 1900.

which the X-rays confirmed the diagnosis. The radiograph showed that a portion of the second phalanx was lighter than normal, which indicated a rarefying osteitis, and that the space occupied by the cartilages of this articulation was greater than that of the other analogous joints, which indicated that the articulation was somewhat affected, as

¹ "De l'utilité des photographies par les rayons X dans la pathologie humaine," *Compt. rend. Acad. d. Sc.*, Paris, 1896, pp. 159-160.

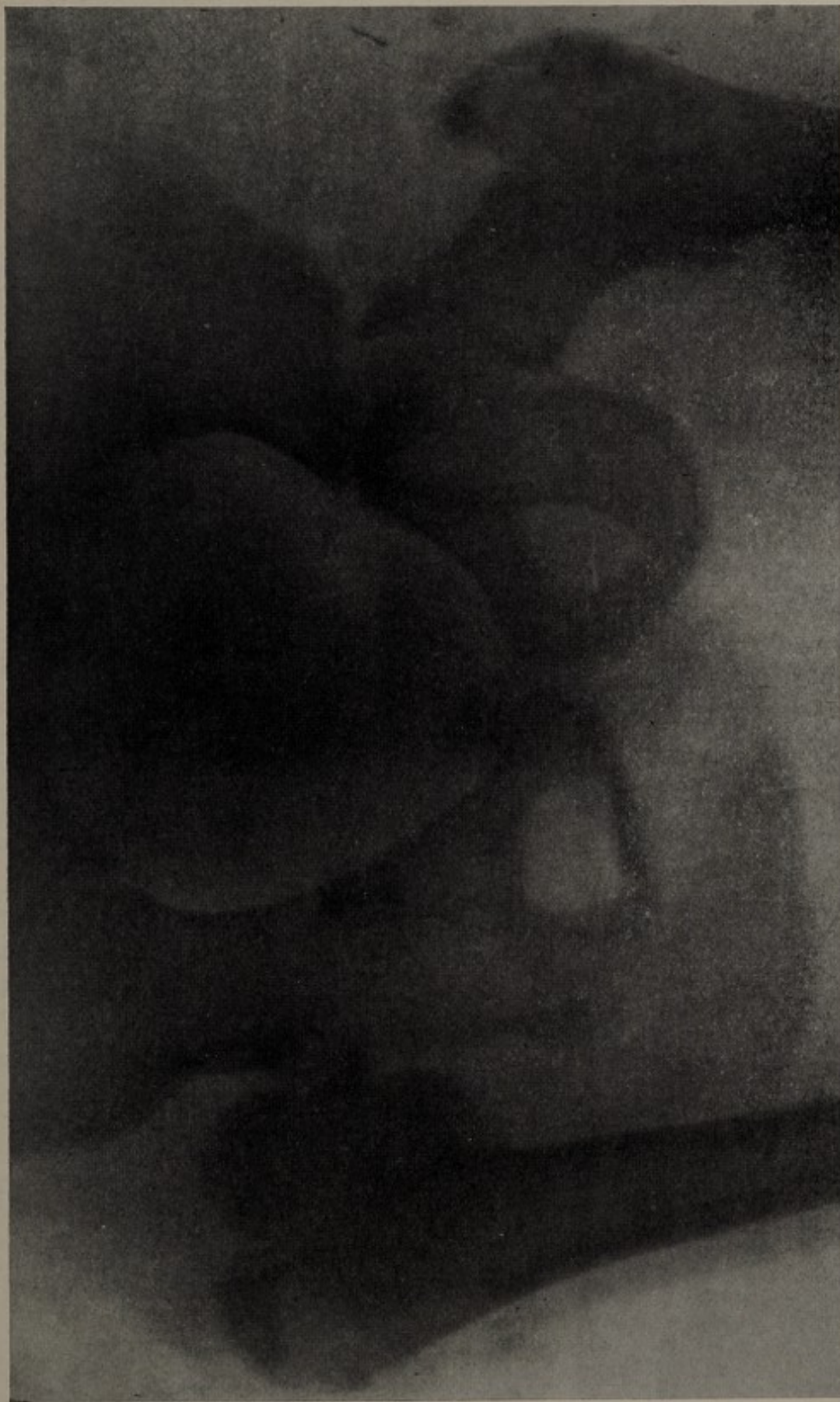

FIG. 349. Old tuberculosis of hip. William A., fourteen years of age, entered my service at the hospital with typhoid fever. Has had hip disease, with shortening of the right leg, since he was a little boy.

they had supposed. Dr. De F. Willard¹ reports on three series of radiographs (taken by Professor A. W. Goodspeed) of tuberculous knees. In the case in the second series the patient was twenty years old and had suffered from the tuberculous process for ten years. Radiographs were taken from four different points of view. The limb was fixed in a straight position, and great erosion of the tibia and femur had taken place; therefore no attempt was made to restore motion for fear a further destructive process might be set up. Dr. Willard states that the value of the X-rays for diagnosis and as a guide to treatment was well illustrated by this series of radiographs, as well as by the first series which he described. Levy-Dorn² states that cases have been reported in which small tuberculous foci on the spinal column of children have been observed in radiographs. A. Oschmann³ has written an excellent article on the operative treatment of tuberculous elbow-joints, that is well illustrated by radiographs, to which the reader is referred.

Tubercular Osteitis. — Oudin and Barthélemy⁴ report on a radiograph in which areas of tubercular osteitis could be plainly determined in spite of the swelling and suppuration of the surrounding soft parts.

Coxitis. — Redard⁵ discusses the value of the X-rays in coxitis, and states that they indicate in the very beginning of the disease the changes that have taken place; they assist the observer, by showing the condition of the bones, to distinguish coxitis from osteomyelitis and from different kinds of arthritis. In many cases the radiographs demonstrate that the coxitis has delayed the ossification of the upper epiphysis of the femur.

Caries of the Spine. — Noble Smith,⁶ in 1896, reported two cases, with illustrative radiographs, in which he had used the X-rays for purposes of diagnosis. In one case the symptoms had been attributed to hysteria, but as they increased rapidly the patient was seen by another physician, and Noble Smith was consulted. The latter believed that there was caries of the cervical vertebræ. Later a radiograph was taken

¹ "Roentgen Ray Skiagraphs," Trans. Orthop. Assn., Philadelphia, 1896, p. 275.

² "Zur Kritik und Ausgestaltung des Roentgenverfahrens," *Deutsche Medicinische Wochenschrift*, December 9, 1897.

³ "Über die operative Behandlung des tuberculösen Ellenbogengelenkes und ihre Endresultate," *Arch. f. klin. Chir.*, Berlin, 1899, LX, pp. 177-245.

⁴ *La France Médicale*, December, 1896, p. 807.

⁵ Reported in *Klinisch-therap. Wochenschr.*, 1898, XXXIV, p. 1230.

⁶ "The Diagnosis of Spinal Caries by the Roentgen Process," *British Medical Journal*, June 6, 1896.

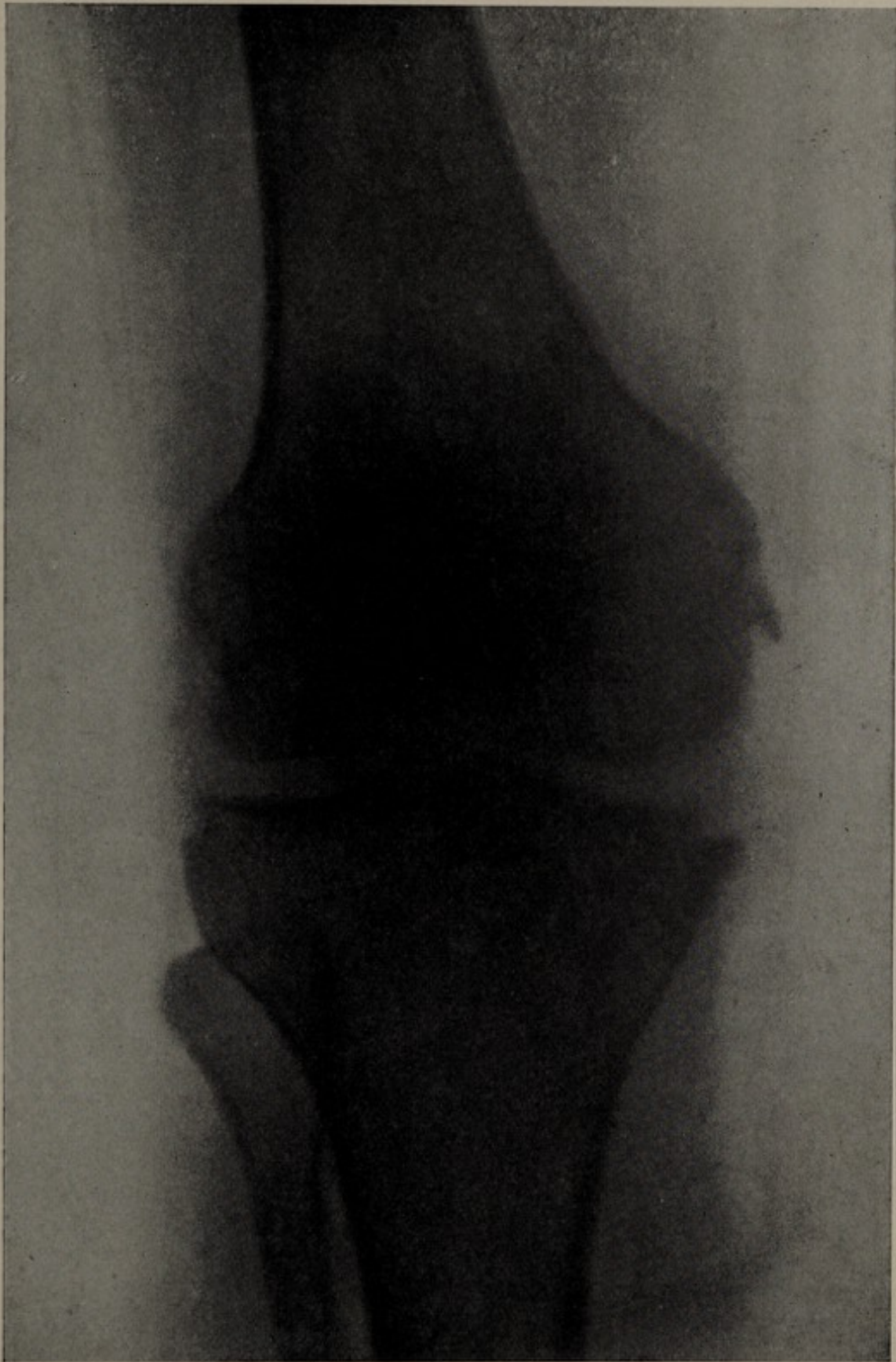


FIG. 350. Delia F. Service of Dr. Post. Disease of the bones and joint, probably tuberculosis. Antero-posterior view. The inner trochanter of the femur and the same side of the tibia are involved. By comparing the inner half of the articulating surface with the outer half, it will be seen that the former is less well defined than the latter.

which showed the cervical vertebræ, from the second to the seventh inclusive. The appearance of the bone demonstrated the severity of the disease which had existed, and the amount of repair that had taken place. The radiograph cleared up all doubt as to the nature of the case, and also indicated the line for treatment.

Oudin and Barthélemy¹ have also shown how useful the X-rays are in indicating the extent of Pott's disease in children.

Syphilitic Diseases. — Hahn² has published an instructive account of the work he has done in studying syphilitic diseases by means of the X-rays.

In one case the X-ray photograph (taken by Dr. Albers-Schönberg) showed that the tumors on the forearm were not connected in any way with the bones, but were completely isolated, and each single tumor could be made out on the picture.

In a second case the X-ray photograph showed distinctly the thickening of the tibia. The patient was suffering from an osteosclerosis.

In still another case there was a bony tumor of the humerus, and the patient could only extend his arm to an angle of 150 degrees. Anti-syphilitic treatment was instituted, and the X-ray photograph showed the reduction of the tumor, and that the arm could be moved through a greater angle.

A fourth case was that of a syphilitic knee-joint. The tumor was almost as big as the head of a man, and appeared to be a new growth. The X-ray examination showed that the bone itself was only indirectly affected, but that a periosteal deposit nearly 1 centimetre thick had formed on the bone, beginning about 10 centimetres above the knee joint, and extending downward to the condylus internus. The outline of the internal condyle was uneven, and its shadow was less dark than that of the external condyle. The X-ray photograph also indicated a large exudate which had pressed the patella outward. Another radiograph taken during treatment showed improvement in all these appearances.

Hahn,³ in a report of Roentgen ray work, gives a case, described by Stamm, of a boy a year old. Stamm ascribed the multiple thickening of the different long bones to syphilitic disease of the epiphyseal cartilage, but the X-ray photograph showed nothing abnormal in the bones; the structure was plainly to be seen.

¹ *La France Médicale*, December, 1896, p. 807.

² *Fortschritte a. d. Geb. d. Roentgentstr.*, B. II, pp. 132-135.

³ *Ibid.*, p. 190.

Albers-Schönberg¹ reports on four pictures of syphilitic disease of the joints showed by Katzenstein; one of syphilitic dactylitis and three of diseases of knee-joints.

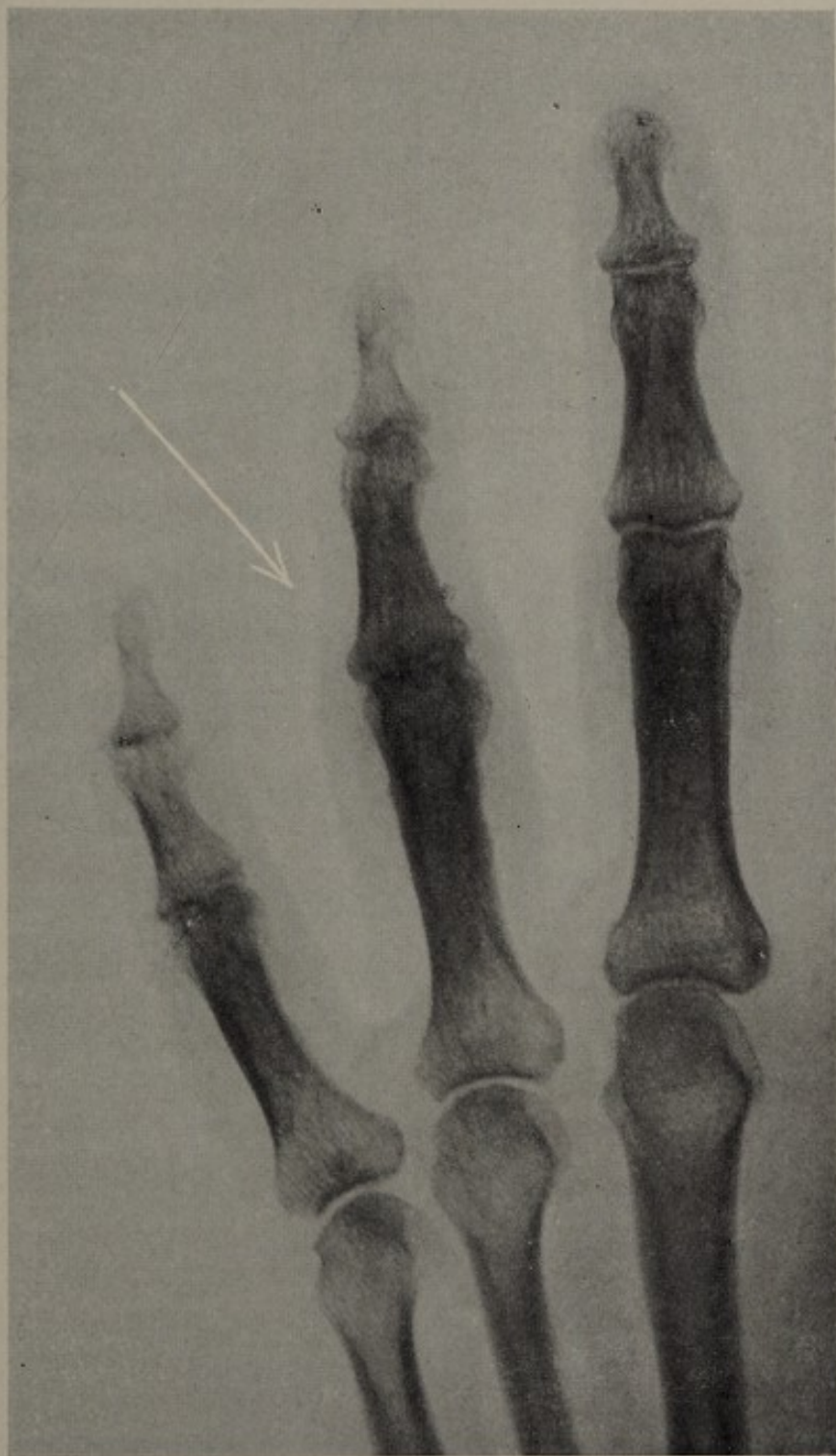


FIG. 351. Rheumatoid arthritis of third finger joint indicated by arrow. The space between the phalanges is not as clear as it is in the corresponding joint of the middle finger.

¹ *Fortschritte a. d. Geb. d. Roentgenstr.*, B. III, p. 35.

Rheumatoid Arthritis. — The preceding radiograph shows the appearances seen in this disease.

Osteo-arthritis of the large joint of the great toe. This caused much pain unless boots adapted to the foot were worn. (See Fig. 353.)

Cartilage. — In most radiographs of the joints we find a space between the ends of the bones under normal conditions, but when the articular cartilage has been thinned, or is absent, the bones are not thus separated. Articular cartilage has a composition between the soft and hard tissues, represented by muscle on the one hand and bone on the other, and we should, therefore, in conditions involving the cartilage, take more than one radiograph, and make one of the exposures with a view to getting a picture of the cartilage, or of determining its altered condition or absence. These tissues can be examined with the best results if a new tube that has a low resistance is used.

Hyaline Cartilage. — The shadow of this cartilage may vary, as in age it may become calcified or ossified.

Loose Cartilage. — Loose cartilages are generally of hard fibrous or partly bony tissue. They show in the radiograph, but not as distinctly as bone (Fig. 352).

Cartilages affected by Gout. — In this disease crystalline urates (sodic urate) are deposited in the cartilage and elsewhere, and they may be seen in the radiograph outside the joint.

In some cases the sodium urate, acting as a foreign body, may set up an inflammation, and become infiltrated with calcium phosphate, as tuberculous matter often is; calcium urate may also be found; the composition of the cartilage being thus changed, it would show even more clearly in the radiograph.

Flat Foot. — (See Fig. 354.) B. H., eighteen years old. Service of Dr. Bolles. This patient had had pain in the sole of his right foot for about two months, after standing or walking for some time. He had had no injury, and was otherwise well. An operation was performed, and he was discharged relieved.

Bony and Fibrous Ankylosis. — Osseous ankylosis can be distinguished from fibrous ankylosis by means of the X-rays; the radiograph shows in the former that the interarticular space is obliterated.

Osseous Ankylosis. — Mr. Sidney Rowland¹ inserts in his report to the *British Medical Journal* the following case of osseous ankylosis

¹ "Report on the Application of the New Photography to Medicine and Surgery," by Sidney Rowland, *British Medical Journal*, 1896, Vol. I, pp. 496-497.

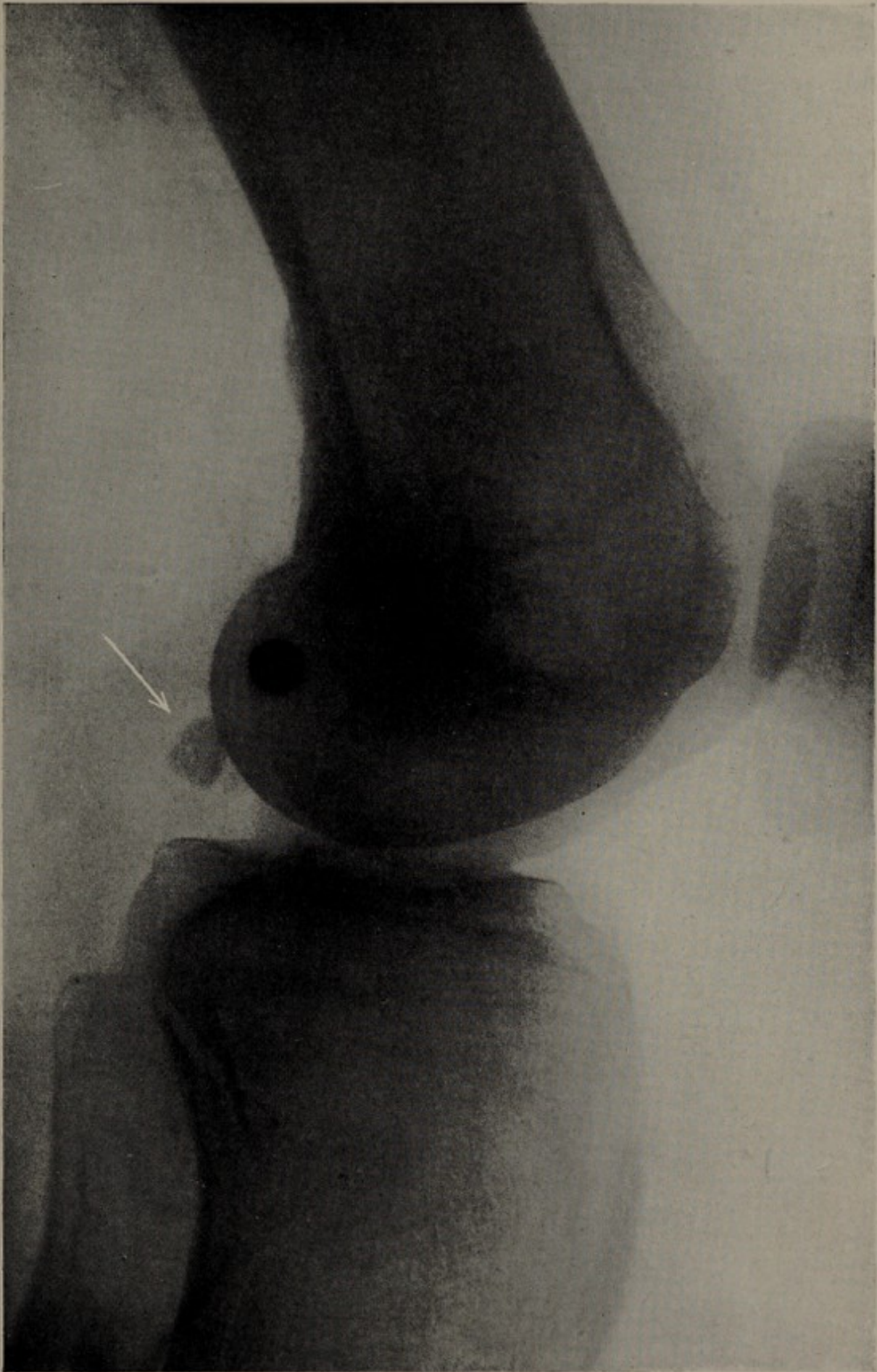


FIG. 352. Loose cartilage in knee-joint.

which was treated by Dr. B. L. Abrahams, and of which Mr. Sidney Rowland took the radiographs:—

The patient, V. F., a youth of nineteen, injured his right little finger while attempting to catch a cricket ball. As a result of this accident,

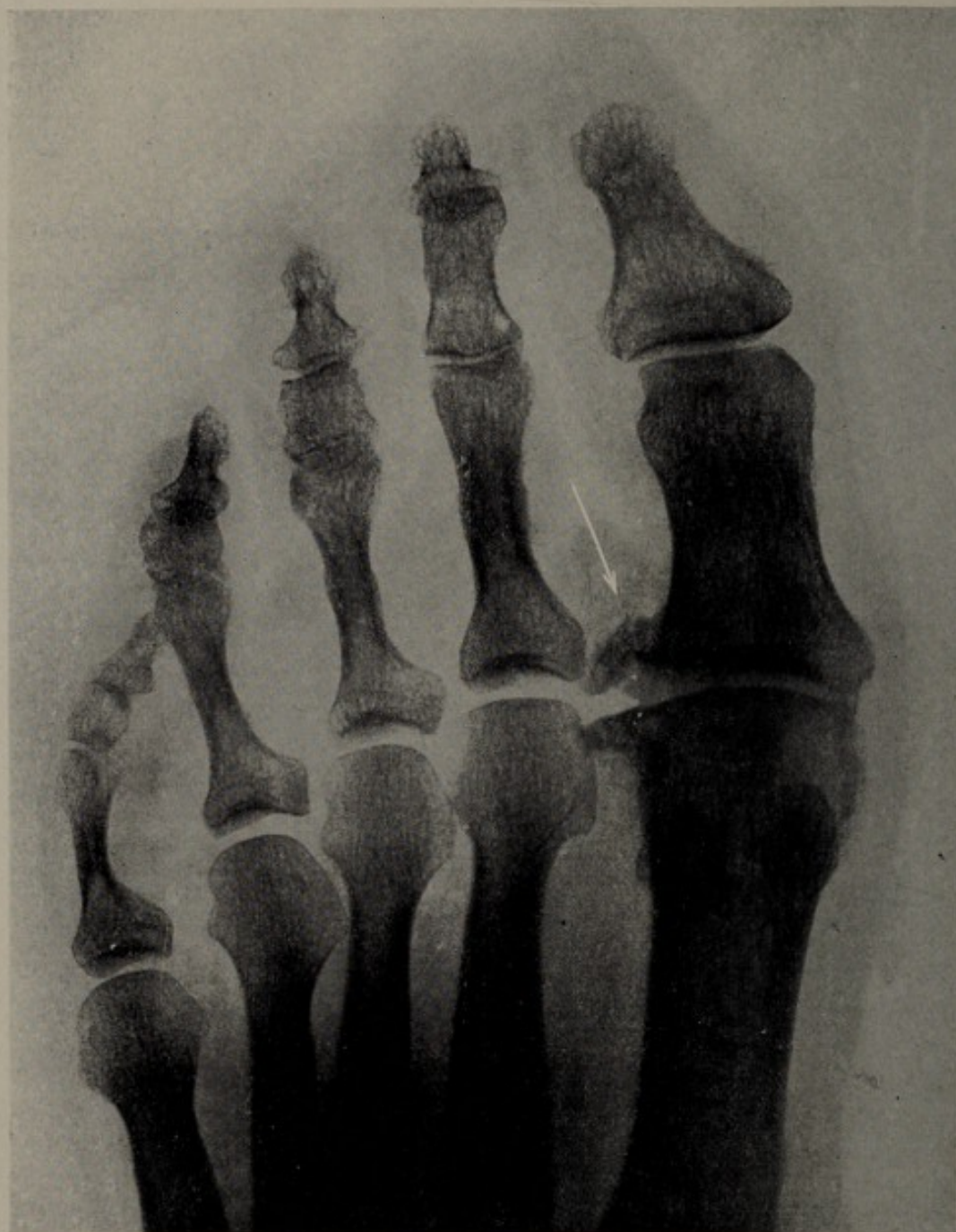

FIG. 353. Osteo-arthritis of great toe joint.

the last joint of this finger was bent at a slight angle, and was fixed in this position, allowing neither flexion nor extension. This condition prevented the patient from completely closing his fist, and any force

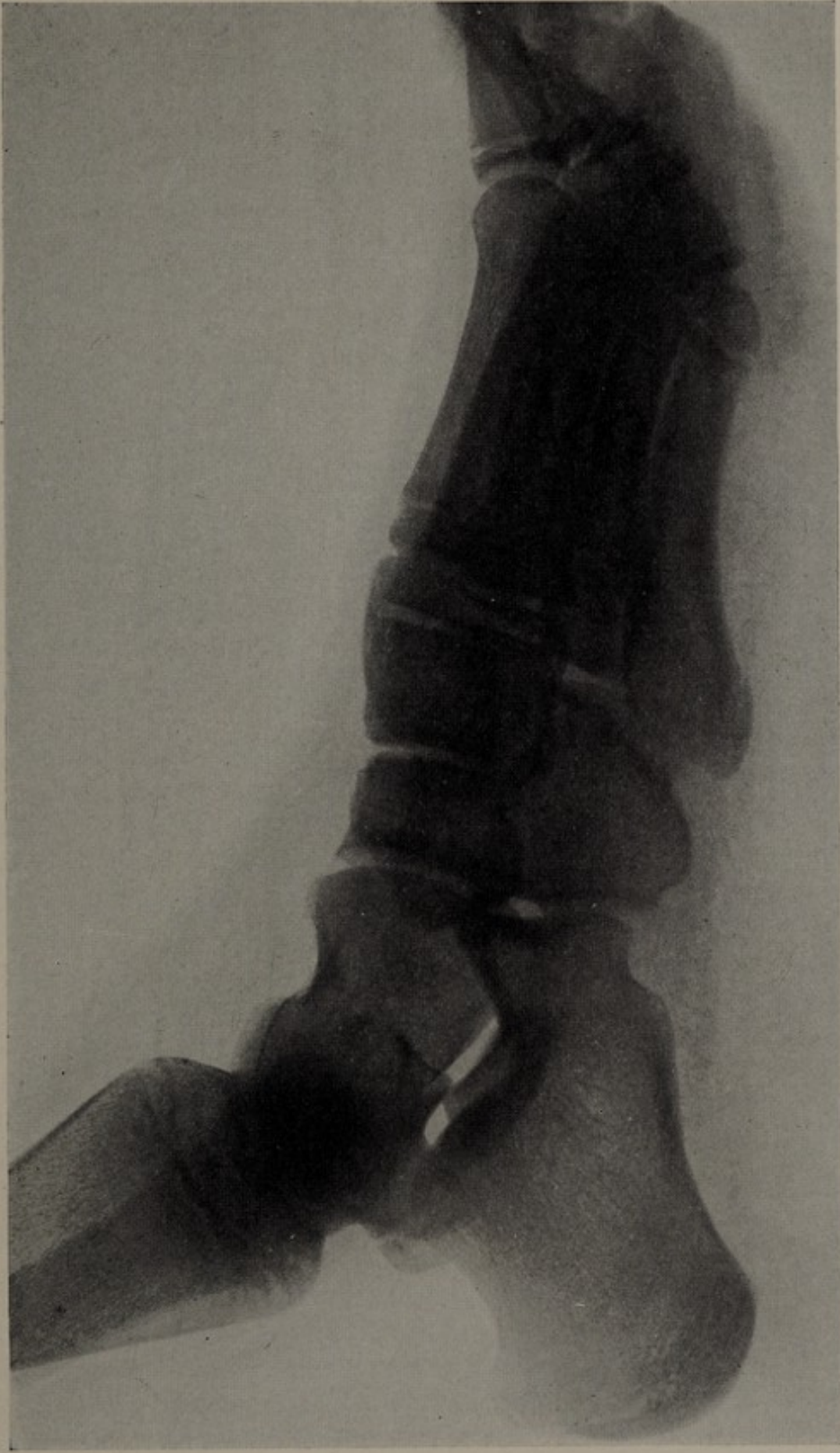

FIG. 354. Flat foot. Patient of Dr. Bolles.

transmitted through the bones of the finger caused great pain. He was treated at the out-patient department of a hospital in London for some little time, and was then told that the phalanges had been fractured, that the joint was firmly ossified, and that, to obtain relief, amputation of the phalanx was necessary. The patient then went to Mr. Rowland, who made a radiograph of the finger, and he and Dr. Abrahams concluded that the two last phalanges were connected by a bridge of bone which had been thrown out, owing to the traumatic inflammation of the joint. Dr. Abrahams broke the bridge, and a radiograph taken after the operation showed that the two phalanges were no longer connected. In this case the X-rays indicated the line of treatment by showing that the ankylosis was only partial, not total.

It is evident that the X-rays afford a means of recognizing chemical changes that have taken place in the body. We should therefore use every effort to study with the greatest care any conditions or diseases involving such a change, for a knowledge of it will aid us in making a diagnosis, and possibly enable us to anticipate the subsequent changes which are physical in character.

The X-rays will continue to become of more value for examining diseases of the bones and joints as the apparatus improves, because with better apparatus will come greater possibilities in the way of differentiation; their value in these diseases will also increase as the practitioner learns to interpret better what the radiograph presents.

CHAPTER XXIII

DENTAL SURGERY

FOR the successful use of the X-rays in dentistry, sharp definition in negatives is necessary, and differentiation is required between tissues that do not differ very much in the obstruction they offer to the passage of the X-rays. The roots of the teeth are only a little less permeable to the rays than the surrounding bone, and therefore it is difficult to get a clear picture of their ends.

SUITABLE APPARATUS

Generator. — The A. W. L. Universal coil with the Heinze interrupter is a good apparatus for taking photographs of the teeth. The current obtained is unidirectional and steady, and steadiness of the radiant area is essential when taking photographs of such small objects.

Tube. *Sharp Definition.* — To insure good definition the cathode stream must be sharply focussed on the target, as this secures a small radiant area from which the X-rays arise. A suitable tube for X-ray work is shown in Fig. 26, page 36. The stems of the anode and cathode are bare and of sufficient size to stand hard use without being bent out of line. The cathode is drop-forged to an exact curvature and the concave face is perfectly smooth; defects in this surface alter the cathode stream and thus make the radiant area of the target larger, with the result that the definition of the picture is not so sharp. The target is of platinum alloyed with iridium; the stem is hollow and cooled artificially (see Chapter II, page 35), and therefore the cathode stream can be sharply focussed on its face without danger of melting the metal. The angle is 56° instead of 45° , and thus the apparent radiant area is made smaller in its longest diameter and approaches more nearly to a circular form.

Resistance. — For good differentiation between tissues that are not very different in permeability the tube must have a low resistance. Methods for lowering the resistance when it has become too high, and

obtaining again the proper quality of light, have been stated in Chapter II, page 44. The following cut (see Fig. 355) shows the oven there mentioned. It has asbestos ends *CC*, through which pass the terminals *DD*. It is heated by the burners *HH*, the effect of the heat on the tube, which is supported by asbestos slabs *AA*, being observed through a transradiable door. The heat liberates the gas from the glass walls of the tube. But all methods of lowering the resistance are temporary.

Rollins believes that one cause of the rise in the resistance of a tube is due to a diminished supply of gas particles in the terminals, and




FIG. 355. Oven for heating tube, thereby liberating gas from its walls and lowering its resistance.

that it is a necessary result of use. He therefore considers that to reduce this resistance some method should be devised to restore these gases to the terminals.

Tube-holder and Diaphragm.—In addition to a suitable apparatus and tube for producing a small and steady radiant area, it is essential for obtaining the best definition to so enclose the tube that no X-rays can escape except the smallest cone that will cover the area to be photographed. Figure 42, Chapter II, page 52, shows a suitable tube-holder with cover removed, and Fig. 356 shows the cover and diaphragm in place.

Screen.—While taking radiographs of the teeth it is, of course, important to avoid danger of burns; an aluminum screen, grounded, as



FIG. 356. Apparatus in position for photographing upper front teeth.

suggested by Tesla, should therefore be used (see Chapter II, page 58). A good form of screen for dental photography is shown in Fig. 356. It consists of a framework of wood sliding on the tube-

holder. To this is attached a disk of tin 43 centimetres in diameter, in the middle of which is a square hole 10 centimetres in diameter. Three sides of the square surrounding the hole are grooved, and in these grooves slides a sheet of aluminum or a screen of aluminum wire. The latter is the more convenient, as it allows the ordinary light as well as the X-rays to pass on to the patient, and shows to the eye the area covered by the cone of X-rays escaping from the tube-holder.

Position of Patient. — Figure 356 shows the general arrangement of the apparatus for taking a photograph of the upper front teeth.

Position of Plate or Film. — Glass plates are less useful than films for photographing the teeth. The method in general use in this country was devised by Dr. Rollins in 1896. It consists in placing inside the mouth the sensitive films, which have previously been enclosed in




FIG. 357. Films for photographing teeth. To be placed inside the mouth. Method devised by Dr. Rollins in 1896.

a thin bag of black soft rubber or black waterproof paper, to exclude light and moisture, and in putting the tube opposite the same jaw as the films and about 28 centimetres distant from them. Several films, each one separated by a thin sheet of foil, are used, because in this way each negative has a slightly different exposure. The film-holder is shown in Fig. 357.

For some cases the metal film-holder shown in Fig. 358 is desirable.

Length of Exposure. — The length of exposure depends upon the amount of light, and varies from a few seconds to several minutes, according to the form of apparatus used.

The main uses of the X-rays in dentistry are as follows: —

1. To obtain information about unerupted teeth.
2. To find the position of roots before regulating, or for bridge work.
3. To recognize pulpless teeth.




FIG. 358. Metal film-holder.

4. To determine the presence, cause, and extent of alveolar abscess.
5. To discover the extent of alveolar absorption in chronic loosening of the teeth.
6. To detect fractures of roots caused by blows or falls.
7. To find whether a root canal has been filled.
8. To find fluid in the antrum.

1. **Unerupted Teeth.** — The X-rays give us information in regard to unerupted teeth not easily obtained in any other way. This information may be desired for the following purposes:—

(a) *Absence or Presence of Permanent Teeth.* — The most frequent need is to determine whether or not there is a permanent tooth in the jaw, in those cases in which a temporary tooth is retained beyond the normal age. If such a tooth is found, and is of normal shape, and in a position to erupt, the temporary tooth should be removed; if the permanent tooth is deep in the jaw, the following method devised by Dr. Rollins should be employed. This method consists in cutting down with one of his tubular knives until the tooth is reached; a mechanical appliance is then adjusted which prevents the neighboring teeth from closing up the gap made by the removal of the temporary tooth, and at the same time exerts traction upon the unerupted tooth.

(b) *Neuralgia.* — Another important use of the X-rays in this direction is the detection of unerupted teeth that are causing neuralgia. It is not uncommon for teeth, particularly lower third molars,

to be imbedded in the jaw in such a position that they cannot come through, and therefore become the seat of obstinate pain. The treatment in such cases is to remove the given tooth; or, if this removal involves too serious an operation, to remove the tooth which prevents the eruption. Dr. Rollins has found that teeth which the X-rays show to be lying at right angles to their normal position, will turn through an angle of 90 degrees, erupt in proper position, and then advance into the space left free by extraction until they fill it; a process to which he has given the name of "progression in teeth."

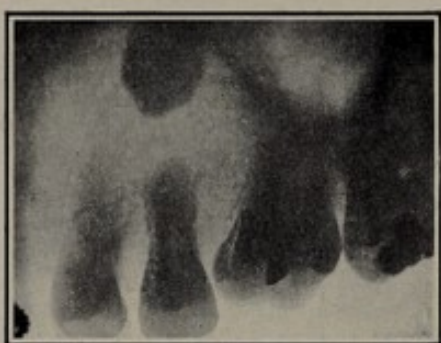

FIG. 359. Patient of Dr. Clapp. Age twenty-one; male. Shows unerupted cuspid very high up and over second bicuspid. Also portion of antrum.

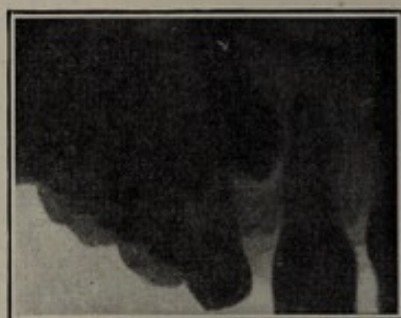

FIG. 360. Patient of Dr. Clapp. Shows unerupted cuspid, but no trace of lateral. Temporary cuspid in place.

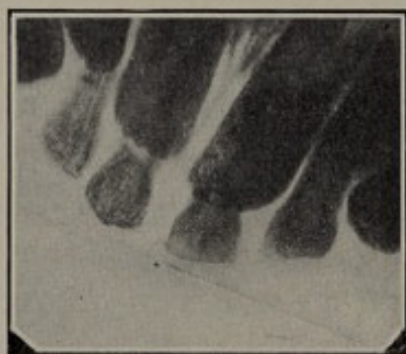

FIG. 361. Patient of Dr. Price. Radiograph of the superior front teeth of a boy eight years of age. His mother and grandmother had lacked the permanent laterals, and it was feared he would also, and steps were being taken to prevent the first being shed, when the radiograph was taken, which shows clearly that the boy will get his permanent laterals.

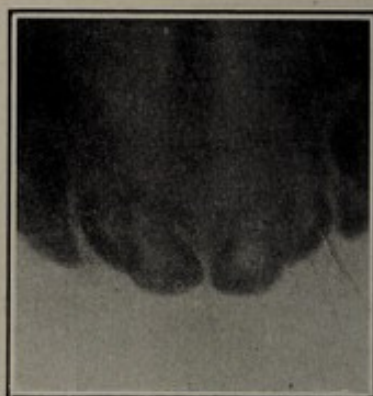

FIG. 362. Patient of Dr. Price. Shows the superior arch, in which no teeth have been erupted, of a boy fourteen months of age. Not only are all the teeth of the temporary set shown in the negative of the radiograph, but the negative also shows that the central incisors of the permanent set are forming and that the crypts are started for the permanent laterals, which teeth his father has never had.

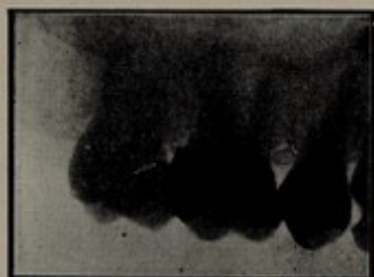


FIG. 363. Patient of Dr. Clapp. Shows the structure of the bone, the floor, and considerable portion of the antrum. It was taken to ascertain if there was an impacted third molar, none having ever erupted.

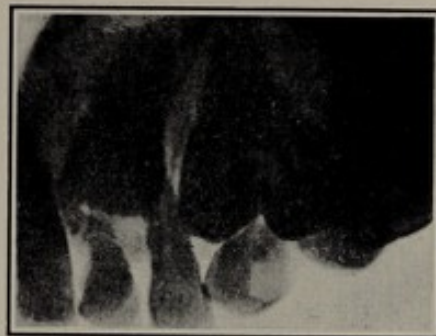


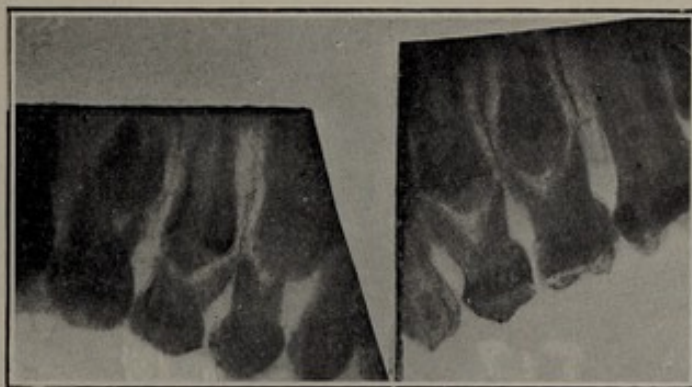
FIG. 364. Patient of Dr. Clapp. (Age fifteen.) Left superior temporary central and cuspid still in place. Taken to ascertain if the permanent central was in the jaw. X-ray photograph shows it, and also that the apex of root is still unformed.

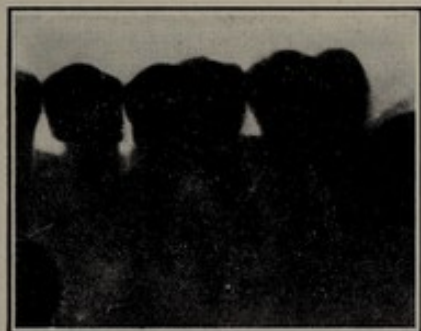

FIG. 365. Patient of Dr. Clapp. Shows crown of unerupted third inferior molar completely within the jaw. Alveolar and gum line shown in cut.

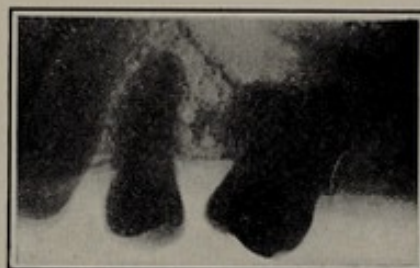

FIG. 366. Patient of Dr. Clapp. (Fifteen seconds' exposure.) Taken to ascertain if a root of the first molar remained unerupted. Shown to impinge on root of second molar. (Superior.)



FIGS. 367, 368. Patient of Dr. Price. Show both sides of the superior arch of a girl of twelve years of age, who has retarded dentition. They show very clearly the relation of the temporary molars to the bicuspid which are forming above them.

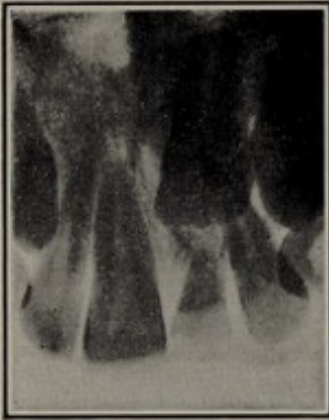
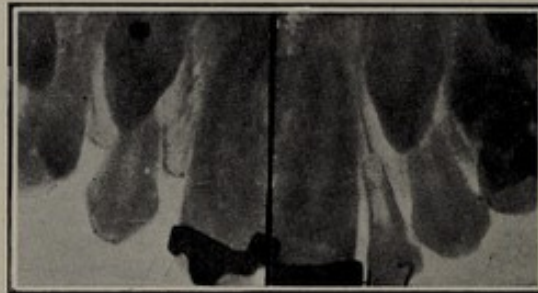
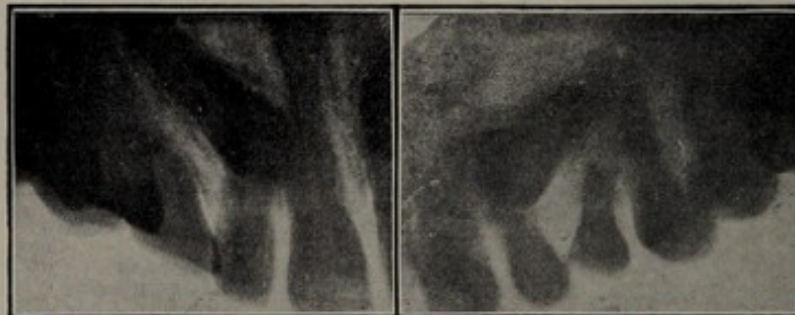
FIG. 369. Patient of Dr. Clapp; girl, aged thirteen. Shows temporary left lateral. The permanent central, with apex unformed, is within the jaw above the temporary central. Shows, also, portion of nasal cavity.



FIG. 370. Patient of Dr. Price. Shows a case of delayed dentition. A girl at seventeen years of age still has her temporary cuspid, with no indication that the permanent has ever formed. The radiograph shows it to be imbedded against the central at an angle of about forty-five degrees. It is now being placed in its proper position. The gold of a crown is conspicuously shown on the next tooth.



FIGS. 371, 372. Patient of Dr. Price. Show the front part of the superior arch of a boy at fourteen years of age. He has still his temporary cuspids and the right temporary lateral. The centrals have been regulated. Clearly the boy is never to have his permanent laterals, but will in time get his permanent cuspids.



FIGS. 373, 374. Patient of Dr. Clapp. Woman, age twenty-three. Temporary cuspids in place, with the unerupted permanent ones lying nearly horizontally within the jaw.

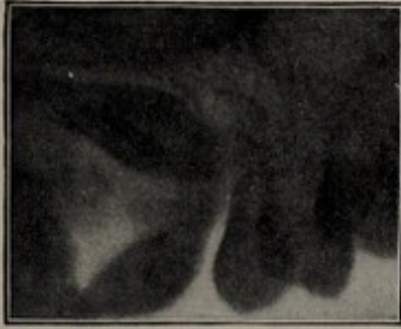

FIG. 375. Patient of Dr. Clapp. Girl, age about fourteen. Shows deformed left lateral and the left central imbedded and horizontal in the jaw.



FIG. 376. Patient of Dr. Clapp. Malplaced inferior third molar.

2. **Position of Roots.**—(See Fig. 377.) (*a*) Before regulating teeth it is often desirable to know, not only the position of their roots, but also to what extent they are closed. If the apex of the root is not fully formed, the teeth can be regulated more rapidly without danger of destroying the pulp. The X-rays often give valuable information in regard to some tooth which it is desired to move; this process is not

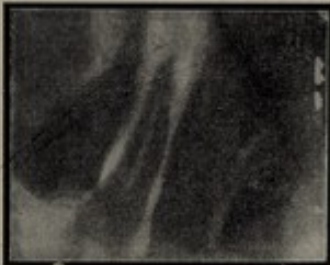


FIG. 377. Patient of Dr. Clapp. Shows curved root of lateral, demonstrating why there was difficulty in rotating it.



FIG. 378. A piece of bridge work in position, resting on cuspid and lateral roots. The picture was taken to ascertain the probable strength of the lateral root. It is shown to be very short and with but slight alveolar attachment.

infrequently impracticable owing to some malformation of the root, but before the discovery of the X-rays time was sometimes lost in vain attempts to bring such a tooth into place. (*b*) A knowledge of the position of the roots is desirable for bridge work. (See Fig. 378.)

3. **Diagnosis of Pulpless Teeth.**—The pulp chamber in a pulpless tooth shows more clearly on the negative than the living pulp, but this diagnosis can usually be made with ease without the use of the X-rays.

4. **Alveolar Abscess.** — The death of the pulp is often followed by an abscess. This abscess is usually due to imperfect manipulation, but as the roots are small and irregular it is not always possible to fill them to the ends. As a result, an abscess may develop. The X-rays would show the extent of this abscess.

Broken Instrument. — (See Figs. 382, 383.) In preparing the roots for filling, instruments are frequently broken without the knowledge of the dentist, or if he is aware of the fact and attempts their removal, they may be forced through the ends of the roots. The X-rays show that such conditions are frequent, and indicate, first, the importance of using untempered instruments made of piano wire for all work on root canals; and, second, the position of the piece of instrument if the accident has occurred, and thus enable the operator to take suitable measures.

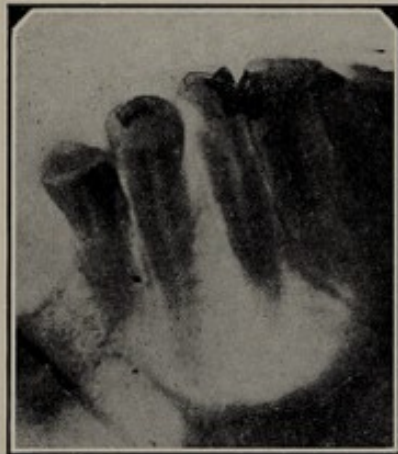

FIG. 379. Patient of Dr. Price. Shows an abscess of eight years' standing. It has formed at the apex of the superior lateral incisor, and has developed a cavity in the bone as large as a hickory nut.

Origin of Abscess. — It is not always easy to determine the point of origin of the abscess, for sometimes an alveolar abscess does not appear to take the shortest path to the surface. The X-rays make it possible to determine its origin and in consequence make the treatment more simple. With the information given by the X-rays this incision

can be made directly over the abscess, and thus the least loss of tissue possible is involved.



FIG. 380. Patient of Dr. Price. Shows the extent of an abscess of the lower jaw which has half cut the jaw in two.

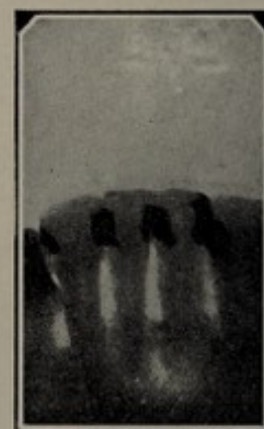
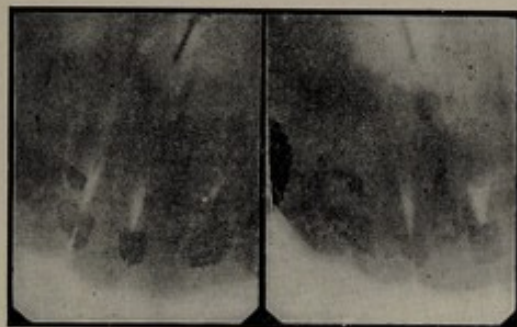


FIG. 381. Patient of Dr. Price. Shows the appearance of the early stage of an abscess at the apex of a root.



FIGS. 382, 383. Patient of Dr. Clapp. Broken instrument in the jaw. The instrument was forced through the central, and remained in the jaw a year, causing serious abscess. These two cuts show the great liability to error in diagnosis from X-ray pictures unless two views are taken. One of the cuts represents the instrument as protruding from the apex of the central; the other, that it lies between the central and lateral. The latter was the true position.

5. **Extent of Alveolar Absorption.** — The X-rays are not necessary to show the presence of alveolar absorption, which is sadly evident and impossible of cure, but it is of interest to know the extent of the loss. Dr. Rollins has shown by means of the X-rays an absorption of the edge of the alveoli in mouths where there was no outward sign of the disease.

6. **Fractured Roots.** — (See Fig. 384.) It has been impossible by the older methods to make a diagnosis of a fracture of the upper end of a root, and therefore impossible to learn whether or not such fractures would heal. It has been customary to believe that dentine had no power of repair. Dr. Clapp, however, has observed by the X-rays a fracture which did not show in subsequent negatives, and although he does not consider such evidence conclusive, it is nevertheless interesting.

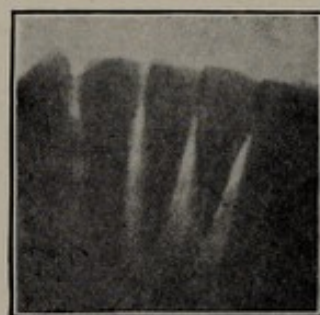

FIG. 384. Patient of Dr. Clapp. Shows lower incisor broken near apex by blow from a polo mallet.

7. **Root Canal filled or not.** — It is often desirable to know, without removing a filling, whether or not a root canal has been filled, and this information can be furnished by the X-rays even when the filling is not of metal, for the oxide of zinc used in the non-metallic fillings is less permeable by the rays than the dentine.

8. **Fluid in the Antrum.** — Fluid can be seen in the antrum by ordinary light, therefore, although the X-rays can be used, to determine the presence or absence of this fluid, they are not likely to supersede the present method.

Interpretation of X-Ray Pictures. — It is easy, as already stated, to draw incorrect inferences from X-ray negatives. Figures 382 and 383,

made from the same case, illustrate this fact: in Fig. 382 the broken steel instrument appears to project from the end, in Fig. 383 from the side, of the root.

Further, unless care is taken to place the light and the plate in proper relation, distortion will occur and very erroneous conclusions may be drawn. By practice alone can accurate results be obtained. In a general way it may be said that it is desirable to keep the plane of the film perpendicular to the central rays and parallel with the long axis of the teeth to be photographed.

I am indebted to Dr. Dwight M. Clapp of Boston and to Dr. Weston A. Price of Cleveland for the radiographs from which the cuts of the teeth were made.

I am also indebted to Dr. Rollins for his kindness in obtaining these radiographs and providing the cuts; likewise, for the material contained in this chapter, and for the cuts marked with his name in this chapter and in Chapters II and XXIV.

Dr. Rollins was among the first to appreciate the importance of Roentgen's discovery to medicine, and his genius for devising new forms of apparatus has already been illustrated in the chapter on X-ray equipment. His contributions to a better knowledge of the physics of the cathode rays, the progenitors of the X-rays, are well known.

CHAPTER XXIV

CALCULI

THE ease with which calculi can be recognized by the X-rays depends upon their size and chemical composition. The importance of this latter factor is illustrated by an experiment which I made in 1896.

Before trying to take X-ray photographs¹ of calculi in the body, I placed several different kinds, together with other objects, on a photographic plate, and added to these a cup of water as a standard of comparison. The result is seen in Fig. 385. It will be readily appreciated, from a glance at this illustration, that calculi similar in size will be recognized more or less easily according to the amount of inorganic salts contained in them, as those made up largely of organic matter cast a much fainter shadow than those consisting mostly of inorganic substances.

The difficulty of recognizing calculi made up of pure uric acid is further illustrated by the following test:—

I took a kidney which had been hardened in formalin and which contained uric acid calculi and small cysts, and, placing it on a photographic plate, exposed it to the X-rays. After the plate was developed there was no trace of the small uric acid calculi or of the full cysts, but the outline of the cavities which had been made by cutting open and emptying some of the cysts could be seen on the plate. The calculi were from 3 to 6 millimetres in diameter, and the cysts varied from about 12 to 15 millimetres in diameter.

Thus, in the kidneys, bladder, or gall bladder, we may expect to detect calculi by the rays when they contain inorganic matter, that is, mineral substances, such as the salts of calcium; but if they are made up wholly

¹ When such X-ray photographs are made it is well to include a receptacle holding a measured depth of water, as shown in the cut, otherwise the comparison may be misleading; for by using a short exposure we may easily make a negative which would suggest that the objects photographed were not easily penetrated.

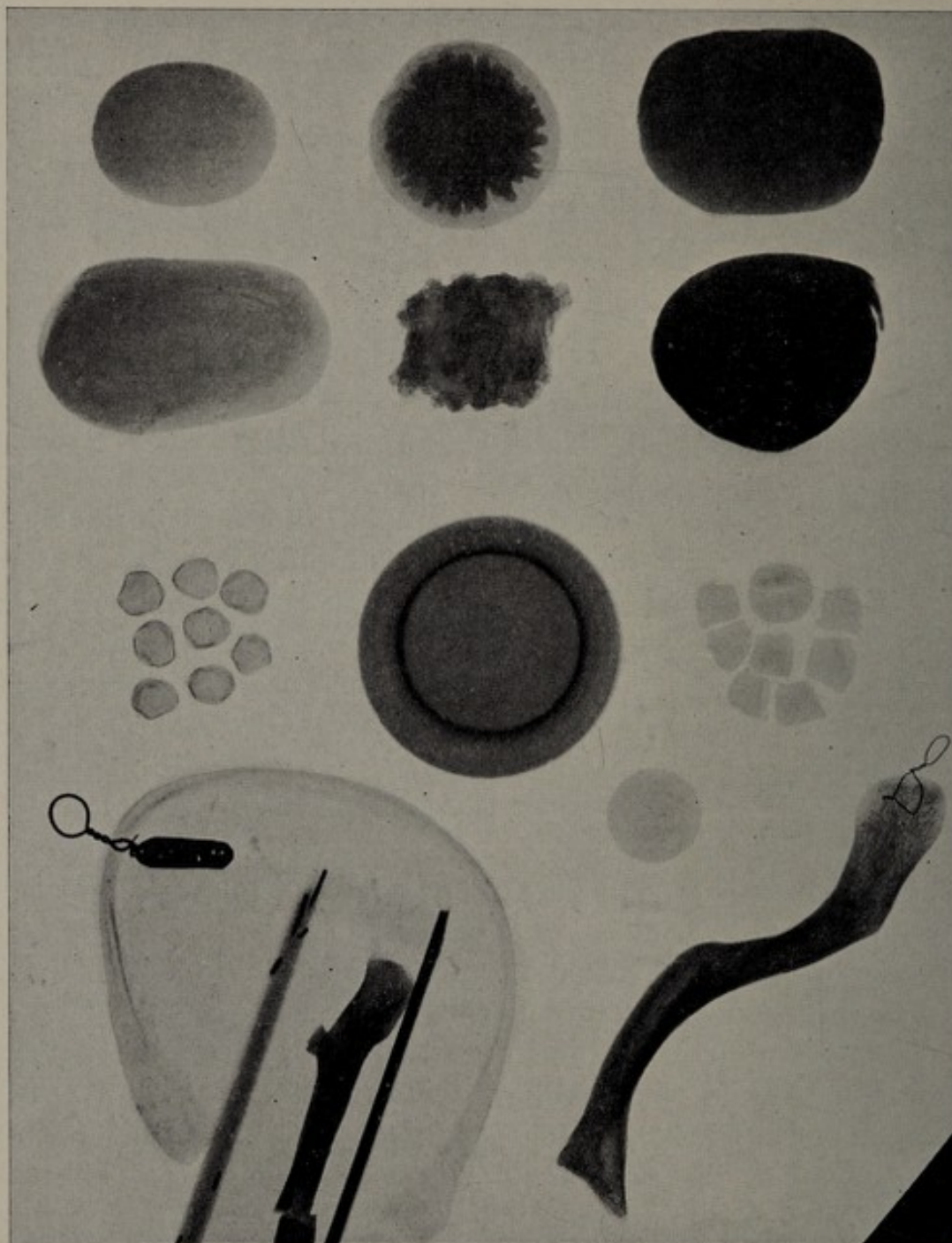


FIG. 385. Experiment made in 1896. The two upper rows of objects in this radiograph are calculi. The two calculi on the left are composed of uric acid and urates; those on the right, of phosphates; and the two in the middle, of oxalate of calcium and uric acid, the upper one of these last two having an outside coating of urates. In the centre of the picture is a round aluminum cup, containing water, 2.5 centimetres in depth, and on either side of this cup is a group of gall stones, and to the right and below the cup a single large gall stone is seen indistinctly. In the left-hand lower corner is a decalcified bone, bent into the shape of Π , with a lead tag attached by a copper wire. The decalcified bone surrounds an incinerated bone, which is lying on a piece of cotton wool in a wooden box with a glass side. In the right-hand lower corner is a dry bone; in the extreme right-hand corner is a triangular piece of lead. The picture is reduced to one-third of its original size.

of organic matter I think they can be photographed only with difficulty, because stones made up of uric acid are penetrated by the rays about as easily as the soft tissues of the body.

Ringel¹ stated that oxalates, urates, and phosphates stood in the order named as regards the obstruction they offered to the passage of the X-rays, oxalates being the most opaque. On further investigation, however, he found that the uric acid stone he had photographed contained traces of oxalate of calcium, and that a pure uric acid stone was more transparent than the phosphatic, that is, the most transparent of all the three substances.

He thought that phosphatic calculi were the most common, that is to say, in his collection he has three oxalate stones, three uric acid, and eleven phosphatic stones. Other observers, however, find the uric acid or urates to be the most common form. It is possible, therefore, that the conditions of the place in which the patient resides determine to some extent the composition of the calculi.

Appearances seen on the X-Ray Photograph. — The following cut is illustrative (see Fig. 386).

Methods of Examination for Kidneys and Ureters. — The apparatus must be good and the tube one that will differentiate as much as possible between the tissues. The patient's bowels should be thoroughly emptied, and no meal should be taken for some hours previous to the examination. When the patient has been thus prepared he should be placed flat on his back on the canvas stretcher, with the plate supported under the stretcher, as shown in Fig. 72. The photographic plate used should be sensitive and fresh, and be so placed as to include the last four or five ribs, both kidneys (as both may contain calculi), and the whole pelvis, as the calculus may be in the ureters. Two or three negatives should be taken for the sake of greater certainty. Good negatives are those which show the outline of the soft tissues, such as the kidneys and muscles.

Helen A. L., twenty-two years of age. Entered the hospital November 5, 1900. Under Dr. Lund's care. Diagnosis: renal calculi.

At the age of ten she had pain in the right lumbar region after getting tired. Five or six years ago had first attack of severe pain in right lumbar region. Pain came on suddenly. No change noted in urine; since then three or four similar attacks. Has had occasionally a drag-

¹ "Zur Diagnose der Nephrolithiasis durch Roentgenbilder," *Arch. f. klin. Chir.*, Berlin, 1899, LIX, pp. 167-174.

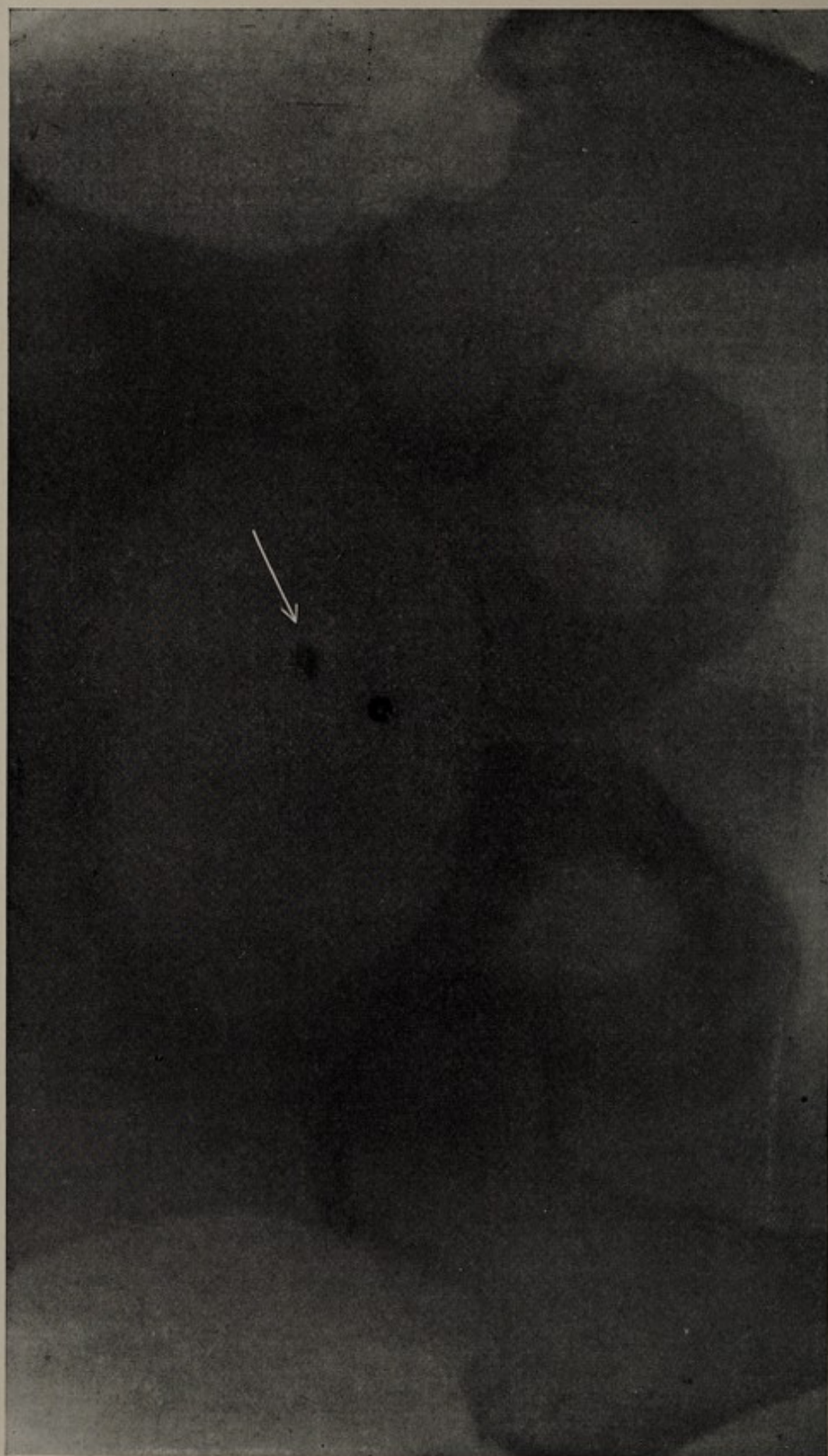


FIG. 386. This cut shows a small vesical calculus, and was made from a radiograph taken at the Boston City Hospital. The patient refused to be operated on, as the pain from which he had been suffering diminished. The small copper washer below the calculus shows the point opposite which the target of the tube was placed.

ging pain in the same region while lying on the left side. Last attack two years ago; present attack three weeks ago.

November 9. Examination of urine showed little trace of albumen; considerable pus; a few blood globules; no crystalline elements and no positive evidence of chronic pyelitis.

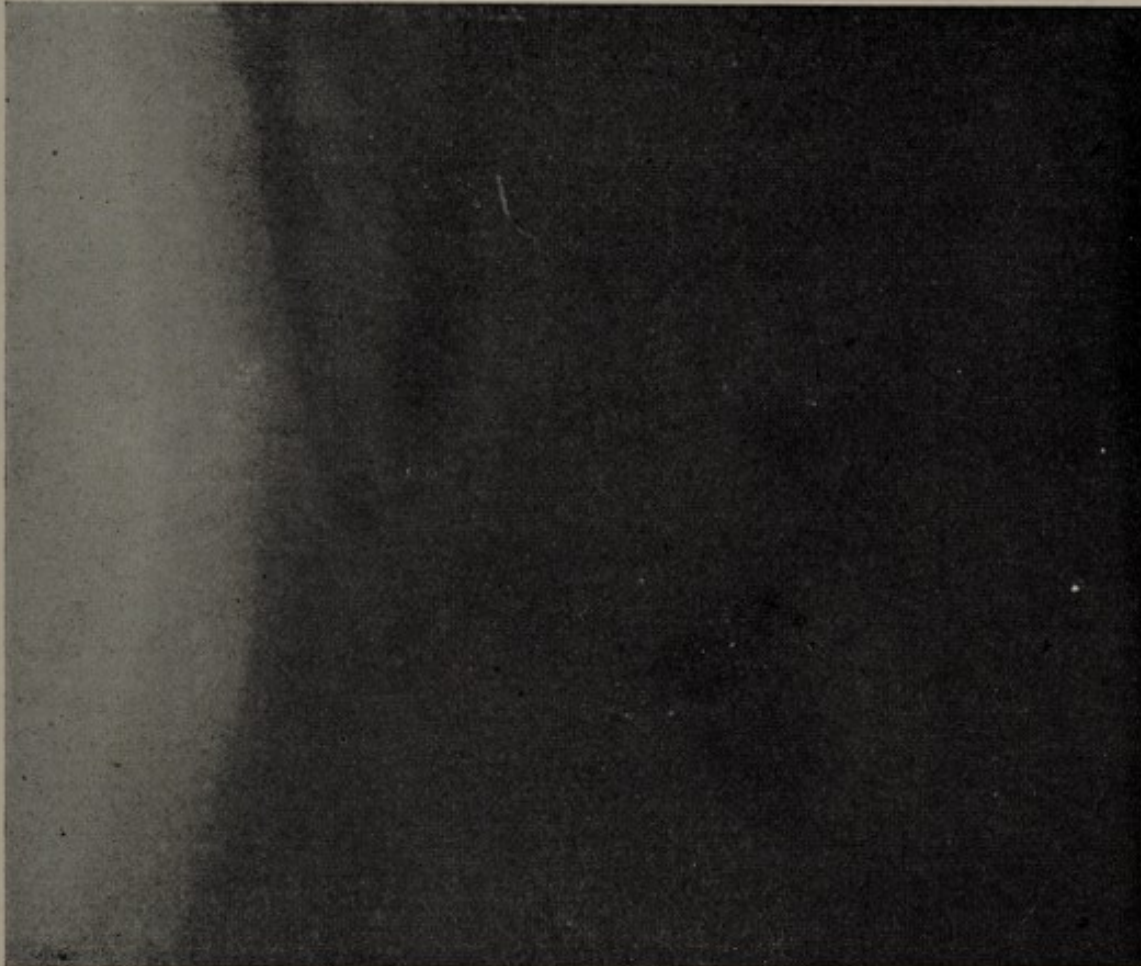


FIG. 387. On the left is seen the outline of the side of the body, and about 1 centimetre from it the outline of the muscles. The group of dark areas to the right of the centre and below the middle of the cut indicate the calculi. On the negative they are much more readily made out, but it has not been possible to reproduce them satisfactorily. Six or seven stones were counted on the negative before, ten were found after operation; composition, uric acid and urates coated with calcic phosphate.

X-ray examination on November 9 showed stones in right kidney; six or seven could be made out on the negative. See Fig. 387.

November 10. Operation done. Kidney found low down in lumbar region; cortex split along convex border and a number of stones removed from calices, pelvis, and infundibula. As little secreting kidney remained, it was removed. The patient made a good recovery. Discharged December 15. See also Figs. 388 and 389.

Comparison of X-Ray Negatives and Radiographs. — The negatives should be carefully examined, — we must not be satisfied with the appear-

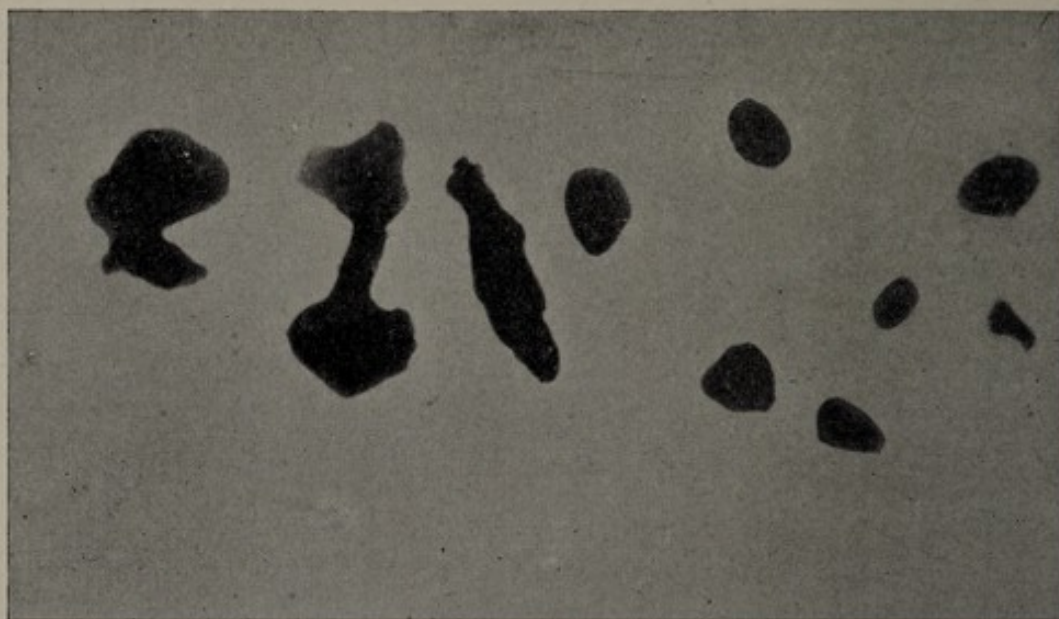


FIG. 388. Shows a radiograph of the calculi after they had been removed from the kidney.

ances seen on the radiograph, — as often the dry negative will reveal clearly what the print at most suggests. Further, some things may be seen during the development of the plate, which are not apparent later.

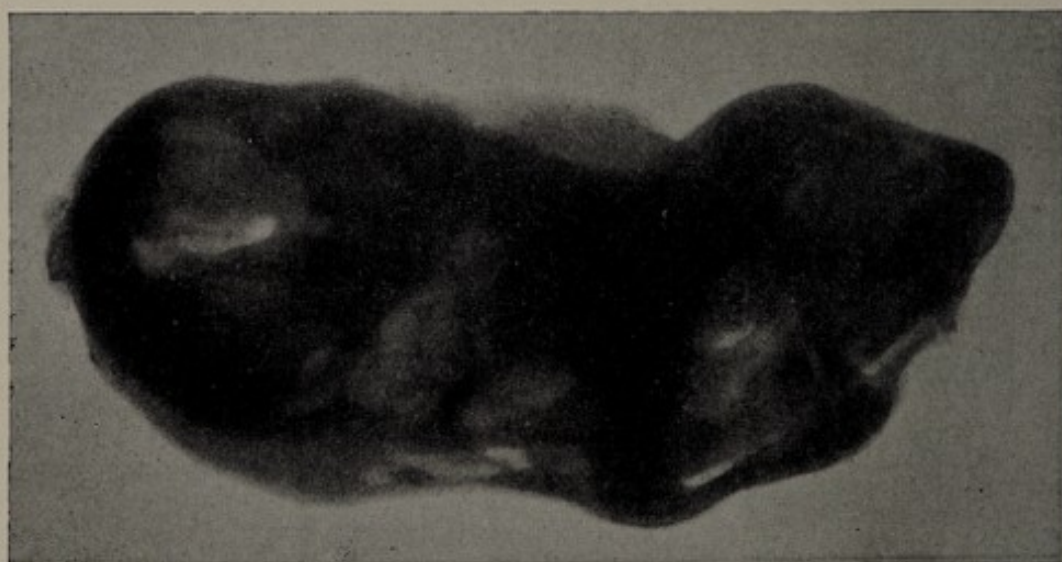

FIG. 389. Radiograph of the kidney after removal.

Comparison of X-Ray Negative and Fluorescent Screen. — The fluorescent screen is not so satisfactory as X-ray negatives in making exami-

nations for calculi, and should not be employed for this purpose, for, unless the stones are large and made up of oxalate or phosphate of calcium, they would not be detected on the fluorescent screen.

Fenwick's Method of Examination of Kidney outside the Body.—Fenwick¹ has examined the kidney with the fluorescent screen after it has been taken out from the patient's loin. This procedure, as he states, would not always be possible, as in some patients the blood vessels are too short to permit of it; further, this method might entail delay, for if the surgeon who took out the kidney should also make the X-ray examination, he would be obliged to remain in a darkened room for ten minutes before he could use the fluorescent screen properly, as it would be entirely useless to give any weight to the results of an X-ray examination unless the observer's eyes were in a proper condition for seeing.

Method of Examination for Bladder; Photograph taken outside of Bladder.—It is desirable to so place the patient when he is examined that the plate should be as near as possible to the calculus. He should therefore lie on his face on the stretcher; the tube should be placed above him and the plate under him, as this position would bring the calculus nearer the plate than any other, unless he is stout, or the calculus is not free in the bladder. In either of these cases he should lie on his back with the plate under him. The operator cannot determine whether or not the calculus is free in the bladder, and therefore if the patient is thin, and the results are not satisfactory when the radiograph was taken with the patient lying on his face, a second X-ray photograph should be taken when he is lying on his back. The size of the calculus is shown on the radiograph, and sometimes its composition is indicated by its shape, as in the mulberry calculus for instance.

The bladder is of course more accessible to other means of examination than many other parts.

Instrument for Photographing Calculi in the Bladder.—The following cut shows an instrument Rollins devised in 1896 for photographing a calculus in the bladder. It consists of an aluminum tube 22.5 centimetres long and 2.5 centimetres wide, which is closed with a solid piece of metal at one end, while to the other is fitted a handle which screws on (see *HH*, Fig. 390). *FC* is a thin piece of metal with grooved edges which holds several photographic films or pieces of bromide paper that should be about as wide as the tube and about half its length.

¹ *British Medical Journal*, 1897, p. 1075; *International Medical Annual*, 1898, p. 338.

Direction for its Use. — The instrument should be got ready for use in a dark room. To put the films in place the sliding piece *FS* is removed from *FC*, and the films are slid into the grooves and pushed to

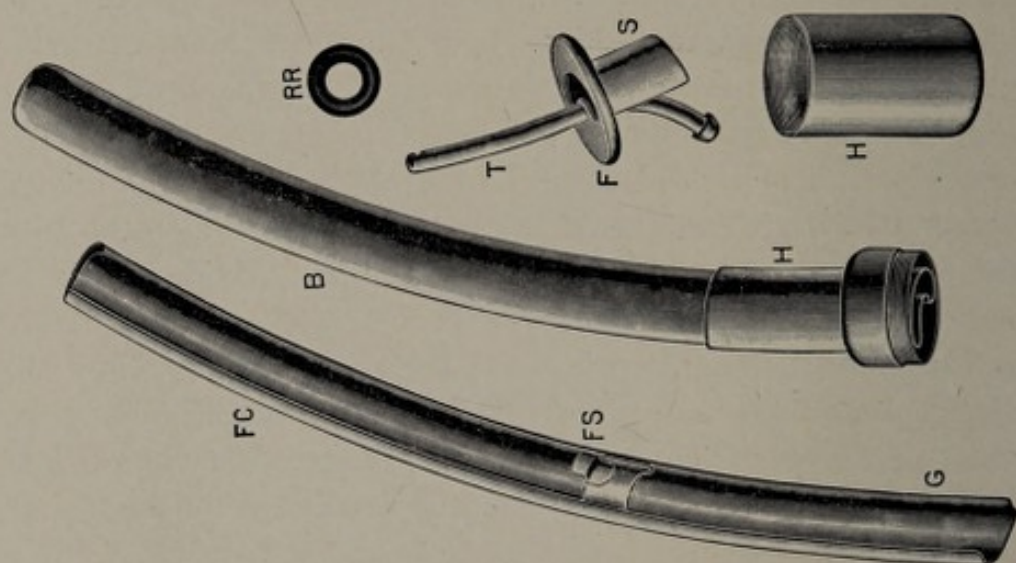


FIG. 390. Instrument for photographing a calculus in the bladder. (Rollins.)

the end as far as they will go. *FS* is then put back to hold the films in place, and the tube is then pushed inside of *HB*, and the round handle *H* screwed on.

The patient is placed on his back and the tube above the bladder; the instrument with the convex side up is then inserted into the rectum and held in such a position that the films are brought just below the bladder. After a proper exposure the instrument is taken out and the films are developed. In the two cases in which I have used this instrument nothing was found on the films; calculi were present, however, and were removed, but proved on analysis to be made up of uric acid.

This instrument may also be passed into the vagina and a photograph may then be taken of the bladder.

I give below an account of the majority of cases thus far reported, at this writing, in which the recognition of calculi by the X-rays was confirmed by operation or by autopsy, because it is instructive to note the amount of successful work done in this direction, and the composition of the stones of which the X-rays have given evidence; and I desire at the same time to direct special attention to Dr. Leonard's and Dr. Abbe's articles on the use of the X-rays in this field, as they have devoted themselves most zealously to this subject.

The following case is the first in which the X-rays were successfully employed to point out a calculus:—

CASE I. Dr. MacIntyre of Glasgow (*Lancet*, London, July 11, 1896). Calculus found by X-rays in one patient. Diagnosis confirmed by operation.

CASE II. Swain (*Bristol Medico-Chirurgical Journal*, 1897, p. 1). Patient: male, twenty-seven years old. Composition of calculus: oxalate of calcium. Size: $1\frac{1}{8} \times \frac{7}{8} \times \frac{5}{8}$ inches. Weight: 148 grains. Symptoms: transient hæmaturia, pain. In urine, pus cells.

CASE III. Görl (*Münch. Med. Wochenschr.*, April 5, 1898) reported at a meeting of a German medical society, December 2, 1897, the finding of a hard stone by the X-rays, of the size of a plum, which was removed by operation.

CASE IV. Thyne (*Australasian Medical Gazette*, October 20, 1897, p. 502). Patient: female. Composition of calculus: oxalate of lime, with a coating of phosphate of lime. Weight: 275 grains. Symptoms: renal colic and vomiting. In urine, pus.

CASE V. Taylor and Fripp (*Trans. Clin. Soc.*, London, 1897–1898, pp. 200–202) report a case in which a renal calculus was detected by an X-ray photograph and successfully removed. The patient was a man twenty-six years old. Several X-ray photographs were taken without detection of any opacity in either loin. An incision was then made to explore the right lumbar region, but the kidney could not be found. Three days later another X-ray photograph was taken, in which a definite though not well-defined opacity was evident. It was thought to be a stone, though it was very high up, above the twelfth rib. The wound was reopened, and the stone was discovered and removed. The calculus was made up of alternate layers of uric acid and phosphate, weighed half an ounce, and was $1\frac{3}{8}$ inches long, $\frac{3}{4}$ inch wide and $\frac{5}{8}$ inch thick. Examination of the urine showed only slight traces of blood on three days out of thirty-eight. The fact that several X-ray photographs were made before the stone was detected is a special point of interest in this case.

CASE VI. Bevan (*Chicago Medical Recorder*, March, 1898). Patient: male, thirty years old. Large stone. Composition not given.

CASE VII. McArthur (*Chicago Medical Recorder*, February, 1898) reports the case of a patient supposed to be suffering from pyelitis, who had previously had a stone removed from one kidney. The X-rays

showed a stone in the other kidney, which was removed. The stone was phosphatic and measured $\frac{3}{4}$ inch by $\frac{1}{2}$ inch.

CASE VIII. Lauenstein (*Deutsche Zeitschrift f. Chirurgie*, No. 50, 1898-1899, p. 195). Patient: male, forty-seven years old. Composition of calculus, carbonate of calcium, oxalate of calcium, and uric acid. Size: $2\frac{1}{4} \times 1\frac{3}{4} \times 1$ centimetre. Weight: 8 grammes. The shadow seen on the plate was 2 by 3 centimetres, and was 3 centimetres distant from the border of the twelfth rib, 4 centimetres from the body of the vertebræ, and 8 centimetres from the spinous processes. The evidence obtained by the X-rays enabled Lauenstein to make an incision in the kidney just large enough to extract the stone, which was of the size indicated in the radiograph.

CASE IX. Dr. C. A. Morton (*Lancet*, London, 1898, Vol. I, p. 1534) reports a case of a patient twelve years old, where the stone was detected in the kidney by means of an X-ray photograph after the subsidence of all symptoms. He had had, during previous attacks, severe pain in the left loin, frequent passage of urine, and hæmaturia. When admitted to the hospital there was no sensitiveness to pressure over the kidney. The bladder was sounded with negative result. Pain in the left loin; vomiting, but no hæmaturia; muscles over the kidney became rigid during attacks of pain. He apparently recovered, so that he could run and jump without pain. The only distress was along the urethra after micturition. An X-ray photograph showed a shadow over the twelfth rib, and operation discovered a typical oxalate of calcium stone, which was $\frac{1}{2} \times \frac{3}{4}$ inch in size. The patient recovered.

CASE X. Dr. Herman (*Wien. klin. Wochenschr.*, 1899, Vol. VIII, p. 190) cites a patient thirty-nine years old, in whom clinical examination showed all the symptoms of a stone in the bladder, but its existence could not be corroborated by an instrument. X-ray examination showed repeatedly the existence of two stones, one the size of a walnut and the other the size of a hazelnut. They were removed by operation.

CASE XI. Dr. Herman also reports the following case (*Wien. klin. Wochenschr.*, 1899, Vol. VIII, p. 190): A patient twenty-six years old, from whom a stone the size of a hazelnut was removed, was examined by the X-rays because the wound showed no tendency to heal after several weeks. The Roentgen picture showed, about 10 centimetres to the left of the spinal column, three indistinct shadows; the largest the size of a pea, the smallest the size of a lentil. The large shadow of the kidney lay outward from the shadows of the stones. After the removal of the

stones the correctness of the size of the shadows noted in the radiograph was corroborated by the stones.

CASE XII. Alsberg (*Münch. Med. Wochenschr.*, December 20, 1898) reports the case of a man thirty-four years old; a shipbuilder, large, powerful, and well-nourished, who entered the hospital in June, 1898. He had suffered for ten years with pain in the right side, below the arch of the ribs. He attributed this to a blow from a mast. In 1893 he went to the hospital. Nothing unusual was found and massage was without effect. He left the hospital after several weeks, unrelieved. After this he had constant pain, and finally was obliged to walk in a bent position. Another physical examination showed nothing except tenderness over the right kidney. The urine was clear and without albumen, and the microscopic examination negative.

A Roentgen photograph showed, about 4 centimetres to the right of the spinal column, a sharply defined uniform shadow. This shadow was $3\frac{1}{2}$ centimetres long and $2\frac{1}{4}$ centimetres broad. $1\frac{1}{2}$ centimetres below and outward from this shadow was seen a second, 1 centimetre in diameter, round, but with indefinite borders. An operation found the stones just as shown in the Roentgen picture, the smaller one being made up of little stones about the size of peas. The large stone was very hard, dark brown in color, $\frac{1}{2}$ centimetre thick, and made up of oxalate of calcium. It weighed 8 grammes. The smaller stones together weighed 2 grammes and were made up of oxalates. In this case it was possible to make a certain diagnosis by means of the X-rays, and the carrying out of the operation was made easy, as the stones were so accurately located that it was not necessary to search for them.

CASES XIII, XIV, XV, AND XVI. Mackenzie Davidson (*Archives of the Roentgen Ray*, May, 1899) reports four cases in which a diagnosis of renal calculi was made by the X-rays and confirmed by operation. One case was that of a boy eighteen years old. The stone was made up of uric acid with a thin crust of oxalate of calcium; size: $2 \times 1\frac{6}{10}$ inches.

CASES XVII AND XVIII. Wagner (*Centralblatt f. Chirurgie*, No. 8, 1899) reports two cases. *First case* that of a girl ten years old. Radiograph showed four stones, one large and three small. They were made up of phosphate of potassium and magnesium, with a trace of ammonium phosphate. The *second case* was that of a woman thirty-eight years old. A stone the size of a walnut was discovered in the pelvis of the kidney. This was verified by autopsy.

CASE XIX. McBurney of New York reported at a meeting of the Practitioners' Association, in 1898, the successful removal of a calculus $\frac{3}{4}$ inch in diameter, which had been found by means of the X-rays.

CASE XX. Longard (*Deutsche Med. Wochenschr.*, No. 4, 1898) reports a case in which his X-ray photograph showed that there were four stones in the bladder, and this diagnosis was confirmed by operation. The X-ray photograph also showed the presence of a fifth stone which was not found in the bladder, but in the ureter behind the bladder, at a second operation.

CASE XXI. G. Julliard (*Fortschritte a. d. Gebiete d. Roentgenstrahlen*, B. II). Patient: male, thirty-four years of age. The presence of a calculus was demonstrated by the metallic sound. An X-ray photograph was afterward made which gave a very clear shadow of the calculus, its place, its shape, and its size. After operation the stone was measured. Its length was 25 millimetres, and its greatest width 15 millimetres. It weighed 4 grammes. It was made up of calcic oxalate and a trace of ammonium magnesium phosphate.

CASES XXII AND XXIII. Abbe of New York (*Annals of Surgery*, August, 1899) reports two cases. The first was that of a man twenty-seven years old. Composition of calculus, oxalate of calcium and urates. Size: $\frac{1}{2}$ inch in diameter. Symptoms: hæmaturia and pain. The second case was that of a woman twenty-eight years old. Composition of calculus, oxalate of lime. Size: $\frac{1}{2}$ inch in its longest measurement. Symptoms: renal colic. The shadow was seen between the eleventh and twelfth ribs $1\frac{1}{2}$ inches from the vertebral edge.

CASES XXIV, XXV, AND XXVI. Albarran (*Annales des Maladies des Organes Genito-Urinaires*, pp. 673-687, 1899). Patient: a man twenty-eight years of age. By process of elimination Albarran arrived at the conclusion that the patient had renal calculi. An X-ray photograph was then taken which showed on the left side, 9 centimetres from the median line, a very clear shadow which was partially hidden by the eleventh rib. It was of irregular form and resembled a reversed "L." Its greatest length and breadth was 5 centimetres. On the right side were three small shadows, the largest of which was not as big as a nut. The first was below the eleventh rib; the second between the eleventh and twelfth ribs; and the third below the twelfth rib, near its end. The operation on the left side confirmed the diagnosis made by the X-ray photograph. Albarran also cites the two following cases reported by Müller and Braatz:—

Müller. — The radiograph gave positive information which was confirmed by operation. The calculus was made up of carbonate of lime with traces of uric and oxalic acid.

Braatz. — The radiograph gave a clear picture of a renal calculus which was confirmed by operation. The stone was oxalic in composition.

CASE XXVII. Rutherford Morrison (*British Medical Journal*, November 18, 1899). Calculus removed by operation owing to the evidence obtained from the patient's symptoms and the X-rays. The stone was the size of a filbert and was made up of oxalate of lime.

In the *Annals of Surgery*, August, 1899, Dr. Leonard, who has had the largest experience in this field, gives fifty-nine cases which he had personally examined by the X-rays, and in eight of these the evidence obtained by the X-rays was confirmed by operation. I quote below these latter eight cases:—

"CASE I. — March 15, 1898. Mr. C. S. W., referred by Dr. Edward Martin. His symptoms were sufficiently pronounced to lead to a diagnosis of calculus. This diagnosis was confirmed by the skiagraph, with the additional detail that two calculi were present, and giving their position. This facilitated their removal, as the smaller calculus was encysted, and was only found by measurements derived from the skiagraph. They were uric acid calculi, weighing 32 grains and 10 grains.

"CASE 6. — May 17, 1898. Mr. H. A. L., referred by Dr. J. William White. Had had attacks of renal colic at frequent intervals, and had passed previously a small mulberry calculus. Two months ago the passage of gravel ceased, and the paroxysms of pain increased in frequency and intensity. Urine was acid; sp. gr. 1032. No blood, no pus, heavy deposits of uric acid gravel. The skiagraph showed the presence of a calculus, which was found encysted in the superior calyx, and was covered with urates. It weighed 21 grains.

"CASE 8. — Mrs. A. D. K., referred by Dr. J. William White. In this patient calculi were present in both kidneys. The right kidney was operated upon and the calculus removed. The patient recovered from the operation, but the kidney was too nearly disorganized to maintain its function. The post-mortem examination showed the skiagraphic diagnosis to be correct, and that the three calculi in the left kidney had destroyed it totally, although no symptoms had ever been referred to that side or that kidney. The calculus removed weighed 4 drachms 10 grains.

"CASE 11. — November 19, 1898. Mr. C. S., referred by Drs. Mitchell and Martin. This patient had had marked but indefinite symp-

toms of renal calculus, extending over a period of twelve years. Although examined on numerous occasions by prominent surgeons, the diagnosis had never been established, while exploratory nephrotomy had only been once suggested. The symptoms at this time were more marked but were still indefinite. The skiagraph showed a large hydro-nephrotic kidney, with one large and two small calculi. Every detail was subsequently confirmed by the operation. The kidney was sacculated and enlarged, and the three calculi were removed. The patient recovered completely. In this case, as in others where multiple calculi were shown, the value of such detail was demonstrated in making the operation complete.

"CASE 12. — November 29, 1898. Mr. J. H., referred by Dr. James Tyson. He has had indefinite lumbar pain for six years; has had slight traces of blood in urine, but had never passed a calculus. The only symptoms were lumbar pain, a trace of pus, and some albumen. The skiagraphs showed a small calculus. Dr. White performed an exploratory nephrotomy, but was unable to palpate the calculus or touch it with a needle in the apparently healthy kidney. The incision into the kidney disclosed the correctness of the diagnosis, as an oxalate calculus was removed that weighed twelve grains.

"CASE 17. — December 6, 1898. Mr. W. W., referred by Dr. J. William White. He had had frequent attacks of acute pain in the lumbar region, but not characteristic of renal colic. Just before the examination he had had pain with chill and sweating, with a lingering pain through back and limbs. The urine was normal in odor and color, no albumen, no sugar, acid in reaction; the microscope showed a few pus-cells, occasional red cells, some epithelium, but no casts. The skiagraph showed the presence of a calculus, which was removed by operation and weighed 17 grains. It was composed of phosphates and oxalates.

"CASE 24. — March 7, 1899. Mr. A. D. C., referred by Dr. W. W. Keen. The patient's symptoms were sufficiently typical to make the diagnosis of calculous disease probable. The skiagraphs made it positive. The oxalic acid calculus was subsequently removed and weighed 48 grains.

"CASE 53. — October 24, 1899. J. J. M., referred by Dr. A. J. Downes. This patient had passed calculi on three occasions. The last was passed five years ago, since which time he had been free from symptoms until nine months ago, when an abscess formed in the lumbar region and was opened. The patient was, however, so weak

that a more serious operation was not advisable. The sinus was reopened three months ago, but the physical condition still contraindicated extensive exploration. The urine has contained a slight trace of pus from time to time and some red blood corpuscles. The skiagraph showed a large calculus in the left lumbar region opposite the inter-vertebral cartilage of the second and third lumbar vertebræ. At the subsequent nephrolithotomy it was found that the shadow of the calculus had been cast by a mass of amorphous urates and phosphates contained in a crystalline shell that filled the pelvis of the kidney. This mass broke up readily under the finger, and contained minute uric acid calculi. The detection of a calculus of such character leaves no doubt of the accuracy and efficiency of this method, and its value in negative diagnosis."

So far as I have been able to gather from the literature accessible to me, of cases published at the time these were collected, there have been thirty-five cases where a diagnosis of the presence of renal calculi by means of a radiograph was confirmed by operation. In fourteen cases the composition was not given. In all the others they were either made up in part or in whole of oxalate or phosphate of calcium, except one of Dr. Leonard's, in which there were calculi of uric acid weighing 10 and 32 grains respectively; and the case on pages 617, 619, 620, in which the calculi were made up of uric acid and urates coated with calcic phosphate.

In the present stage of this study, it is probable that a larger proportion of successful cases would have been reported than of unsuccessful ones, and it is also probable that out of the considerable number of unsuccessful cases which had symptoms of a calculus, some of them may have been made up of uric acid, and were not recognized by the X-ray examination. When we consider that in most countries the uric acid calculi are the most common of all, and that out of the twenty-one cases given where the composition is stated, only one is put down as pure uric acid, it would seem probable that either the method is not yet carried out by most observers as carefully as it will be in the future, when it has been perfected, or that pure uric acid calculi will always remain, on account of their having about the same power of absorption of the X-rays as the soft tissues of the body, the most difficult to detect, to say the least.

It is to be remembered, of course, that in a considerable proportion of these cases the diagnosis was probable without the X-ray examination.

Various authors have reported the removal of renal calculi by operation after failures to find them by X-ray photograph.

Gall Stones. — Gall stones cannot be easily recognized as yet by the X-rays, because they are generally composed of organic matter, and therefore do not cast much, if any more, shadow than the surrounding soft parts; but if they should contain salts of calcium, they would be more easily detected. The fact that the plate can be brought near the gall bladder is an advantage, and enables the observer to obtain a better photograph than when the plate is at a distance. Some observers have, however, reported a few cases where they were satisfied that they had recognized gall stones in X-ray photographs, and their diagnosis was confirmed by operation.

Dr. Carl Beck (*New York Medical Journal*, January 20, 1900) has made ninety-seven radiographs of twenty-eight cases of suspected cholelithiasis, in nineteen of which the presence of biliary calculi was ascertained by operation. In only two of these nineteen cases was he able to obtain shadows on the plates, and they were so slight that he would not have relied upon them for diagnosis. In several of the cases examined, he made from six to ten exposures, varying the position of the plate and the length of the exposure.

Dr. Beck's study of this difficult problem has recently resulted in unusual success, and at a meeting of the Academy of Medicine of New York held in January, 1901, he showed good radiographs of gall stones.

Dr. Leonard, in an excellent paper read at the same meeting, stated that about one-half of the calculi are found in the ureters and the other half in the kidneys, exclusive of those found in the bladder and gall bladder.

Absence of Calculus not definitely determined by the X-Rays. — In many cases where the symptoms point to a diagnosis of a calculus, but it is a question whether or not one is present, I think its absence would not be definitely demonstrated by lack of evidence of it in the X-ray photograph.

Determination of Presence of Calculus. — On the other hand, if evidence is obtained by at least two X-ray negatives of the presence of a calculus, whether in the kidneys, ureter, or bladder, even though the ordinary indications are indefinite, this evidence is conclusive; the presence and position of the stones can be accurately demonstrated.

Conclusions. — The presence of calculi containing inorganic matter, such as mineral salts, may be detected by X-ray photographs. If the

apparatus and technique are very good, Dr. Leonard's experience is that calculi made up of pure uric acid can also be found. The X-ray examinations give definite and positive information as to the location, and, within certain limits, as to the number and the size of the calculi. They show in which organ the stone is present; which kidney or which ureter is affected; and often whether there is one stone or several. The operation is therefore simplified, and the surgeon is less likely to overlook a given calculus when several are present. The presence of calculi may be detected early by means of the X-rays, also when they have been quiescent for some time and give rise to only slight or indefinite symptoms. Further, there is no danger attending this method of examination, and no discomfort.

Calculi can be more easily detected in young or thin patients than in stout or adult persons. Thickness is one of the obstructions offered to the passage of the rays, as we have seen in Chapter I, and in youth the soft tissues seem to be more permeable by the rays than in adult life. But the composition of the calculus has more influence than the size or age of the patient. That is to say, a calculus made up of oxalate of calcium would be far more easily detected in a stout person than a calculus of urates in a thin patient.

New Method of Diagnosis.—The X-rays then contribute one more means of diagnosis, and in cases where a calculus is suspected in the urinary tract, an X-ray examination should be made.

Difficulty of Diagnosis of Calculus by Ordinary Methods.—It is well recognized that there are many difficulties in the way of a definite diagnosis of calculi in the urinary tract. For example, there are various symptoms which suggest strongly the presence of renal calculi; on the other hand, there are cases of renal calculus which are unsuspected because the symptoms observed may be referred to another cause.

Direct and Indirect Use of X-Rays.—X-ray photographs will not only be a means of pointing out calculi directly, as indicated, but eventually will also prove of service by pointing them out indirectly, for they will instruct the profession more exactly in regard to the symptoms which calculi produce. That is to say, the X-rays, by giving more definite information than hitherto of a calculus in the kidney, for example, will enable the physician to associate characteristic groups of symptoms with its presence, that he is not now able to connect definitely with the disease. In this way the X-rays will increase the

possibility of making a tentative diagnosis without an X-ray examination, and more cases will be recognized. The X-ray examination would then follow for more definite information.

The work done by surgeons in this field is a triumph of careful and persistent endeavor over many obstacles, and those who have demonstrated the possibilities of the X-rays in this direction deserve the appreciation and gratitude of the profession.

CHAPTER XXV

USEFULNESS OF X-RAY EXAMINATIONS TO LIFE INSURANCE COMPANIES. MEDICO-LEGAL USES OF THE X-RAYS

THE foregoing pages show the usefulness of these examinations in life insurance cases, but it may be of service to call attention to one or two points already discussed.

The organs to be considered by life insurance examiners in the physical examination of candidates are chiefly the kidneys, the lungs, and the heart. Two of these organs — the lungs and the heart — are especially open to inspection by the X-rays, and if it is desirable to put the candidate to the least possible trouble he can be thus examined without removing the clothing. In the lungs, for instance, old foci of tuberculosis give rise to abnormal appearances, which can be seen on the fluorescent screen, and yet which might be overlooked by auscultation and percussion, if not near the surface of these organs. It is important for the insurance company to know if such foci exist, because they are a source of danger. Emphysema of the lungs is best recognized by the X-rays; the effects of old pleuritic adhesions may sometimes be seen by this new method of examination, and thoracic aneurisms may be detected in an early stage.

The size and position of the heart can be determined with greater certainty and exactness by the X-rays than by the older methods. Some companies will now accept as risks persons who have certain heart murmurs, but no company would knowingly accept a man who had an enlarged heart, and if this organ is enlarged as the result, for example, of a valvular lesion, or of arterio-sclerosis, renal disease, or a fatty muscle, the X-ray examination not only shows it, but shows it with certainty and precision.

There is, I think, no single method of physical examination of the thorax that gives more trustworthy and complete evidence of the normal or abnormal condition of the organs in this part of the body than an examination with the fluorescent screen, when properly carried out.

From the standpoint of the life insurance company it is not always so much a question of what the disease is as whether there is or is not an abnormal condition in the chest. This method of examination should of course always be made by a physician who is experienced in its use.

Medico-Legal Uses of Radiographs. — There is, I think, no question that radiographs will eventually be admitted as evidence by the courts, and that they can make some doubtful points perfectly clear. Obviously, evil results would be produced if this kind of evidence were employed in any other than an intelligent way. Before the radiograph is admitted, it should be shown that it has been taken by a person trained to this kind of work. The position of the part, of the plate, and of the tube should be accurately determined and stated. (See Chapter III, especially pages 64 to 66 and 86-87.) The point on the plate opposite which the tube was placed should be indicated on the radiograph by a metal letter, as shown on page 521.

In cases of fracture, for example, two views should be taken, for the reason given in a preceding chapter (page 469). The kind of fracture shown in the radiograph might give some indication of the force which caused it, and this knowledge might sometime be useful from a medico-legal standpoint. For instance, there would be a difference of character in the fracture produced by a direct and heavy blow, as from the kick of a horse, and in that produced by torsion. (See Figs. 291 and 292.)

In fractures it is of the first importance to distinguish between the functional and the anatomical results. It is already recognized that a perfectly useful limb may not look well in the radiograph, and as it is the desire of both the surgeon and the patient to have as serviceable a member as possible, this test rather than the anatomical one, as shown by the radiograph, should be followed. No covering, other than a sheet, should be allowed over the part of which a radiograph is to be taken, especially if it is a question of a foreign body, as there might be objects opaque to the rays in the clothing.

Radiographs should be read not only by a surgeon, but by a surgeon who is trained in reading them. In cases of poisoning we do not expect the jury to interpret all the tests which the chemist has made, but the latter can make the meaning of these tests clear to the jury.

APPENDIX

As more and more hospitals will have an X-ray department, a few words in regard to the development of the one at the Boston City Hospital may be of service. In 1896 the Trustees, who have shown much interest in this method of examination, kindly placed a room at my disposal, in which I set up my apparatus and made examinations with the fluorescent screen and by means of radiographs for more than two years, and in which I have also taught something of this method of examination to students in connection with exercises in clinical medicine.

In 1898 Mr. Ernest Fewkes was appointed to do the radiographic and photographic work of the hospital. Mr. Fewkes had no knowledge of X-ray work when he was appointed, but his twelve years' experience as a photographer and his marked mechanical ability were strong recommendations. I taught him how to use the apparatus and to take radiographs, and gave much time to this part of the work for more than another year, and still supervise it. The X-ray photographs which have been reproduced in the preceding pages were made for the most part by Mr. Fewkes. The medical work with the fluorescent screen I have thus far done myself, and any physician whose interest lies in diseases of the chest will find it advantageous to learn how to use it, just as the laryngologist has found it necessary to learn to use the laryngoscope, and the ophthalmologist the ophthalmoscope.

At the Boston City Hospital three different requisition blanks are used, — one when a radiograph is desired, another when it is desired to make an examination with the fluorescent screen, and still a third when an ordinary photograph is wanted. These are filled out by the house officer and signed by the visiting physician or surgeon. These blanks are then sent to Mr. Fewkes, and an appointment is made for the patient to go to the X-ray room. The blank gives the name of the patient, the ward and bed number; also the volume and page of the medical or surgical record. The negatives are seen by the surgeon, or the physician,

as the case may be, and a print of each is inserted in the record book as a part of the record of the patient. When an examination with the fluorescent screen has been made, a memorandum of it, and a tracing if desired, is inserted in the record book.

A portable apparatus might be used at the bedside, but where the method of examination employed at the Boston City Hospital is followed, there are few patients who cannot easily be taken to the X-ray room on a stretcher, examined upon it, and then be brought back to their beds. (See page 27.)

The time has come when every large hospital should make proper provision for X-ray work; by this I mean provide opportunity for having X-ray photographs taken for the surgical side of the hospital, and for the making of fluoroscopic examinations and for the therapeutic uses of the X-rays. These needs demand more than one X-ray apparatus; and suitable rooms, including a developing room and dressing and waiting rooms for the patients. For the treatment of skin diseases and new growths and the other therapeutic uses of the X-rays, the apparatus can be so arranged as to excite more than one tube and thus time and expense can be saved. The cost of the building and the necessary appliances means an outlay of thousands of dollars; and the running expenses would, of course, be considerable.

X-RAY EQUIPMENT

The question of the best form of X-ray apparatus is still an unsettled one, the ideal apparatus is yet to be devised. During the past six years I have had four static machines, each larger and better than its predecessor, and five coils, each one successively larger than the other. I have likewise had the temporary use of still other apparatus from different manufacturers, and I have also talked with many medical men from other parts of the country when they were visiting the X-ray room at the Boston City Hospital, or at my office, and have learned from them what they have seen in other places, as well as profited by my own visits to others. The result of these inquiries and of my own experience may be in part summed up as follows:—

Generator.—The requisites for the best work are a generator of abundant power, provided with adjustable multiple spark-gaps (see pages 16 and 17) and good tubes with regulators. If the generator is wanting in power, it will not be able to excite a tube of high resistance;

and although it can excite one of low resistance, the amount of light generated will not be great, therefore the need of a powerful generator is evident. With it an efficient amount of light can be obtained, and by suitably adjusting the regulator of a well-made tube the desired quality can be produced.

Static Machine.—Moisture is the great drawback of the static machine; an efficient one is more expensive than a coil, and photographic plates need a longer exposure than when a very large coil is used; but it gives a steadier light than a coil, and therefore is excellent for fluoroscopic work; tubes ranging over wider limits of resistance can be used on it and they last longer; it is independent of an electric main.

A static machine with eight revolving plates of plate glass about 100 to 125 centimetres (40 to 50 inches) in diameter, and so well built that it can be safely run at a speed of 400 revolutions per minute, is suitable for office use. It should be narrow enough to be carried through a door, and should be put in as dry and warm a place as possible. An arrangement devised by Mr. E. E. Fewkes of the Boston City Hospital is the simplest one I have seen for withdrawing moisture from the case. This device should make it possible to use the machine nearly, if not quite, every day in the year, except in damp climates. The machine should have adjustable multiple spark-gaps. While such a machine might not be capable of taking X-ray photographs as quickly as a large coil (that is a coil of 61 centimetres, 24 inches), their quality would be equally good except of the more difficult parts, such as the hip and the spine; but the necessity for photographing these parts is infrequent in daily practice. An intensifying screen might be of some assistance when using a static machine in these latter cases, but the pictures would not be so clear.

Coils.—For photographic work, a coil with a simple form of interrupter, such as the hammer, run by a low voltage current, such as may be obtained from a storage battery, has from the beginning yielded and continues to yield good results. The excellent pictures taken by Professor Goodspeed some years ago were made by such a coil with a mechanical interrupter. When currents of high voltage are used a suitable interrupter (see pages 20–23) is difficult to find. The electrolytic interrupter, especially the form devised by Wehnelt, was considered a decided advance over its predecessors, as with it a large amount of energy could be sent through the tube; but I have found the one devised by Heinze and referred to on page 22 (this is superior to the one devised by Heinze

and figured on page 21) more satisfactory than any other electrolytic interrupter. The disadvantages of electrolytic interrupters are: that if the apparatus is constantly used, the platinum wire of the interrupter wears rapidly and the amount of the current which passes through the tube diminishes—the wire, however, can then be slid down a little further; it is difficult to get tubes adjusted to this form of interrupter on very large coils, and the tubes do not last as long as when used on some other form of exciter. These coils do not give as steady a light as the static machine, but they have the advantage of taking photographs more quickly.

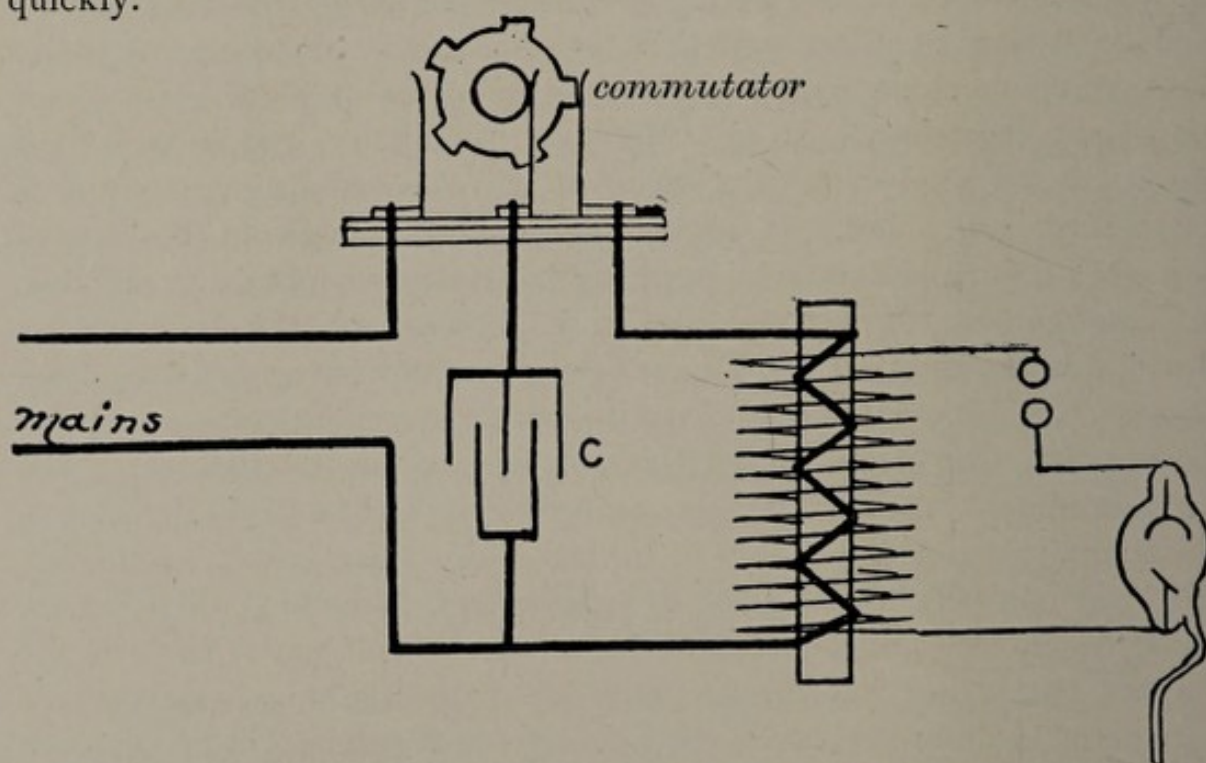


FIG. 391. Norton and Lawrence apparatus. This cut is taken from the *Electrical Engineer*, March 24, 1897. The direct current of 220 volts is taken from the street main; by means of the commutator the condensers (*C*) are charged with this current and then discharged through the primary of the coil.

The form of coil which, so far as I know, gives the steadiest light and is the one best adapted to fluoroscopic work is that devised by Norton and Lawrence, and described on pages 26–27. The interruptions are made in the current of the primary by means of a commutator. The tubes do not wear as rapidly as when an electrolytic interrupter is used, and the only part of the apparatus requiring attention is the commutator. A simple way of overcoming this difficulty is to have three wheels, and when one is worn to slip on another while the first is being repaired. This form of coil, which is still in the experimental stage, requires a large condenser, which adds very much to its cost. (See Fig. 391.)

Portable apparatus. — A good form of apparatus which is as portable as a trunk is a 40-centimetre (16-inch) Ritchie coil, with a hammer interrupter, that is run by a current of 8 volts from a storage battery.

Static Machine compared with Coils: *for fluoroscopic examinations of the chest: comparative value of fluorescent screen and X-ray photograph for chest examinations.* — My experience teaches me that static machines are far superior to coils for fluoroscopic examinations of the chest, because they give a perfectly steady light of excellent character, whereas that from a coil is, as a rule, unsteady. Only those who have used a large static machine for these examinations can appreciate what a value this method has. Examinations of the chest with the fluorescent screen satisfy the needs of the practitioner more fully than those with the X-ray photograph (see pages 99, 120, 169–170, 270, 328, 334–337), therefore a static machine is far better for examining the chest. Fluoroscopic examinations should of course be recorded as described on pages 77 to 81, and as shown in Figs. 79, 82, 83, 153, 168, 169, etc.

TABLE SHOWING SOME OF THE RESPECTIVE ADVANTAGES AND DISADVANTAGES OF STATIC MACHINE AND COIL

| STATIC MACHINE | | COIL | |
|--|---|---|---|
| Advantages | Disadvantages | Advantages | Disadvantages |
| Perfectly steady light. | Very susceptible to moisture. | Not affected by moisture. | Light is unsteady. |
| Tubes of lower resistance (except with large coils) and ranging over wider limits of resistance can be used. | Longer exposure needed for photographic work. | Shorter exposure for photographic work. | Range of resistance for tubes narrow and tubes do not last as long. |
| Light excellent for fluoroscopic work. | Large one is more expensive than coil. | More powerful for amount of money expended. | As a rule, ill adapted to fluoroscopic work. |
| Independent of electric main. | | Occupies smaller space. | Interrupter wears. |

In short, moisture is the chief source of trouble with static machines, the interrupter with coils.

The practitioner uses the X-rays for three kinds of work: (1) photographic, (2) fluoroscopic, and (3) therapeutic; the coil has the advantages of shorter exposures for the first, but is not adapted to the second; the static machine is the best for the second, and either can be used for the third. The static machine and the A. W. L. coil may be used where it is desired to employ electrotherapeutic treatment.

The practitioner must be guided, in his choice of an apparatus, by the kind of work he chiefly desires to do; by the climate, and by the source of electrical supply; that is whether or not an electric main is at hand. If one is available whether it affords a direct or an alternating current; if the former, of what voltage?

Intensifying Screens.—Intensifying screens have been used with brilliant success for taking instantaneous photographs of the chest, especially by Ziemsson and Rieder;¹ the second and third parts of their book, which have just reached me, are even more commendable than the first part: but much time and expense are necessary to carry out this photographic method, and therefore it is less adapted to the needs of daily practice than the fluoroscopic examination; moreover, for the practitioner's purpose, the information they afford is often not as full; but both methods have indispensable fields of usefulness.

Tubes of high resistance are most suitable when intensifying screens are used, yet a tube of low resistance is necessary when it is desired to differentiate between the tissues; but the light from such tubes may have too little penetration to produce instantaneous pictures even when an intensifying screen is used: hence slight increase of density in tuberculosis, for instance, may not be so well detected by photographs taken in such a way, as by those made with a tube of low resistance without an intensifying screen and given a longer exposure, especially if these photographs are taken while a full breath is held as they should be. (See page 250.)

Stereoscopic Fluoroscope.—Mackenzie Davidson was, I believe, the first to devise and use the stereoscopic fluoroscope. Recently Eugene W. Caldwell has employed a most ingenious form of stereo-fluoroscopic apparatus which he has fully described in the *Electrical Review* for November 16, 1901.

Tube and Regulator.—The automatic regulator shown in Fig. 38, page 45, is an efficient one, and especially useful for therapeutic work. When a light of great penetration is desired, comparatively little of which would be absorbed on the surface of the body, such a light as is

¹ *Die Roentgenographie in der inneren Medicin.* Wiesbaden. Published by J. F. Bergmann.

shown in the tube marked 2, Fig. 39, page 48, the movable rod of the regulator should be drawn out until the distance between its right-hand end, as seen in Fig. 38, and the cross is considerable. When a light of less penetration is desired, most of which would be absorbed before passing through the hand, the distance between the right-hand end of the rod, as seen in Fig. 38, and the cross should be comparatively short. On my large static machine at the Boston City Hospital I use a resistance of 2 to 3 millimetres, about $\frac{1}{8}$ inch.

Tubes having a regulator for varying their resistance are better if they have targets that can be moved nearer to or farther from the cathode, because the focus of the cathode stream varies with the resistance of the tube; therefore, to keep the target in the focus of this stream, it must be adjustable. (See Fig. 38, page 45.)

TIMES OF EXPOSURE FOR X-RAY PHOTOGRAPHS

I did not give a table of times of exposure for taking X-ray photographs of various parts of the body in the first edition because different forms of X-ray apparatus vary greatly in strength; and, as no one table would apply to all of these, it seemed better to let each observer determine this time by experiment with his own apparatus. But experience has shown me that some table, though imperfect, is better than none; I believe, too, that the strength of the apparatus used is becoming greater and more nearly alike than formerly. I therefore insert the following table, which may be of service when an apparatus of considerable power is used and a tube of low resistance, that gives a good light; that is to say, when the light is of such a quality that it does not diminish much in brilliancy on the fluorescent screen when the hand is examined at a distance of 153 centimetres (5 feet) from the tube as compared with that seen when the hand is examined at a distance of 54 centimetres (18 inches) from the tube:—

| | | |
|-----------------|-----------------------------------|--|
| Hands, feet | about 2 minutes | Tube 66 centimetres (26 inches) from plate. Resistance of tube 2 to 3 millimetres, about $\frac{1}{8}$ inch. See also note on fluorometer, page 681. |
| Forearm, ankle | about 3 to 4 minutes | |
| Elbow, leg, arm | about 4 minutes | |
| Knee, thigh | about 4 to 5 minutes | |
| Chest | about 4 to 5 minutes | |
| Shoulder | about 5 minutes | |
| Head | about 5 minutes | |
| Kidney | about $4\frac{1}{2}$ to 7 minutes | |
| Hip | about 5 to 8 minutes | |

Thinner parts require, of course, less exposure than thicker and denser parts. With the thicker parts too long an exposure causes fogging, perhaps by diffusion of the light through the tissues; for example, if an exposure of six minutes is right for a hip, ten minutes' exposure would give a fogged plate. Diaphragms over the part and on the opposite side from the plate are an aid in preventing fogging which occurs more readily with tubes of high than with those of low resistance.

HEAD AND NECK

With the better forms of apparatus now at our disposal, and with greater experience, more can be learned from X-ray photographs of nearly all parts of the head and neck than has been possible in the past.

THE THORAX

EMPHYSEMA

In one case of emphysema that I have seen lately, the heart was pushed so far forward that the whole of its posterior border could be followed when the light went through the chest from side to side; and it was pushed so strongly against the anterior wall of the chest that its lateral borders could be perfectly defined by percussion.

PNEUMOHYDROTHORAX

The following case shows that all the usual physical signs of pneumohydrothorax may not be present in some cases.

A. B., 50 years of age. Diagnosis pulmonary tuberculosis; pleurisy with effusion; two litres of fluid withdrawn from the chest. A few days later he was examined with some other patients who had pleurisy with effusion in order to compare the fluoroscopic signs seen in his chest with those observed in the chest of these latter patients. To my surprise, I found the X-rays showed that A. B. had a pneumohydrothorax, but careful physical examination made on the same and on the following days failed to give succussion or the coin sound. The front of the chest, however, below the level of the nipple when the patient was in a sitting position, was flat to percussion, but the same area gave good resonance when the patient was in a prone position.

PLEURISY WITH EFFUSION. DARKENED AREA IN THE LOWER PART OF THE THORAX

The fluoroscope shows that there may be pleurisy with a very small effusion in the outer and lower portion of the chest, obscuring a part of

the outer end of the diaphragm, and at the same time a friction rub may be heard above the site of the effusion.

The direction of the line indicating the upper portion of the shadow cast by moderate amounts of pleuritic effusion varies with the quantity of fluid present in the chest.

Sitting position. — When the amount of effusion is moderate, the line is more nearly vertical than when the chest is nearly full of fluid.

The following cut shows how fluoroscopic examinations may assist in distinguishing between fluid in the pleural sac and an increased density in the lung.

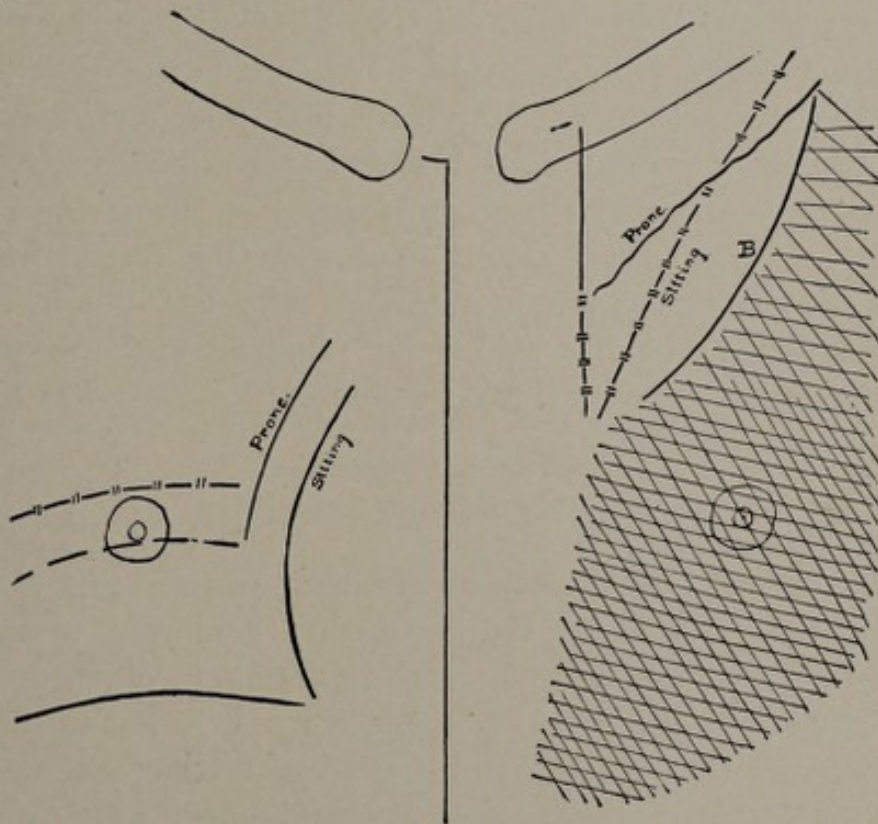


FIG. 392. — Pleurisy with effusion on left side.

The full line marked "prone" on the left side and the full vertical line parallel with the line of the sternum indicate about the limits of the light area seen on the fluorescent screen when the patient was lying on his back; the line marked "sitting" and the vertical line of the same character, the limits of the light area when the patient was sitting and facing the observer squarely. The position of the light with reference to the patient was the same in both these examinations; that is, behind the patient, 70 centimetres from the screen and opposite the point where the median line crosses the fourth rib.

The line marked *B* and the whole of the vertical line indicate the limits of the light area when the patient was sitting with his left shoulder turned a little toward the observer, who was in front of the patient in all three cases.

The heart line marked "prone" shows the position of the right border of the heart when the patient is lying down, and the one marked "sitting" the place of this border when the patient is in that position. In both these cases the tube was behind the patient, 70 centimetres distant from the fluorescent screen, and opposite the point where the median line crosses the fourth rib.

It is not always easy to distinguish by physical signs between a liver that is higher than normal, and some effusion on the right side of the chest, but this distinction is readily made by a fluoroscopic examination.

When the lower portion of the chest is slightly darkened, it is well to consider the possibility of inflammation just below the diaphragm. For instance, in one case I saw a shadow on the screen in the lower portion of the thoracic cavity in a patient who had pus in one of her kidneys, and after the pus had been removed and the patient had recovered from the operation, this portion of the chest was found to be perfectly clear.

HEART

One way in which fluoroscopic examinations assist auscultation is in determining the position of the heart with reference to the anterior thoracic wall both in inspiration and expiration. When, for example, the lower portion of the heart is farther from the chest wall than usual, we may find that the murmurs are heard less distinctly than we should expect below the line where the heart and chest wall separate. By determining the exact position of the heart in the thorax, both when seen in the fluoroscope with the light going through from back to front, and also with the light going through from side to side, the reason why the heart sounds are transmitted more distinctly in one place on the chest wall than in another is made clear. The fluoroscope shows that in one case the heart is near the chest wall, and in the other that it is farther away.

Fluoroscopic examinations in cardiac disease also show that some of the outlines of the ventricles, auricles, pulmonary artery, or venæ cavæ vary from the normal as would be expected. (See, for example, Fig. 179, page 307.)

ABDOMEN

INTESTINES

Dr. W. B. Cannon¹ has made interesting and instructive observations on the movement of the food through the intestines by watching the process of digestion in this portion of the digestive tract of cats, and he has found that the antiperistalsis in the large intestine may force a nutrient enema into the small intestine. The food used in these experiments was mixed with subnitrate of bismuth in the proportion of one-tenth to one-third of its weight. Canned salmon, which is much liked by cats, was generally used. Dr. Cannon found that the constrictions going on in the small intestine caused the food to divide into segments, with the result that it was mixed with the digestive juices and then brought into contact with the absorbing mechanism; these constrictions also emptied the venous and lymphatic radicles of their contents by compression of the intestinal wall; peristalsis was usually combined with segmentation, that is, as the food moved on constrictions occurred which separated one end from the main body, but this separation was only momentary, for the two masses were soon united again, and the combined material was pushed onward until another constriction repeated the process described; the ilioæcal valve was competent for food entering the colon from the ileum; the usual movement of the transverse and ascending colon and cæcum was an antiperistalsis; the food, after being brought into a closed sac, was thoroughly mixed by constrictions running toward the cæcum and again subjected to absorbing walls without interfering with the process going on in the small intestine; when the new food entered the large intestine a strong contraction took place along the cæcum and ascending colon which pushed some of the food onward; this contraction was followed by antiperistaltic waves; as the material accumulated in the transverse colon tonic constrictions appeared which carried it into the descending colon, leaving the transverse and ascending portions free for the antiperistaltic waves, and then it was carried out of the lower descending colon by peristalsis and the pressure of the abdominal muscles; the remainder of the material was then spread into the emptied tract and this tract was again cleared. Dr. Cannon states that his observations have given no evidence of antiperistalsis in the small intestine, but that the antiperistalsis of the large intestine, as

¹ "The Movement of the Intestines Studied by the Roentgen Rays," *American Journal of Physiology*, Vol. VI, January 1, 1902, No. V.

already stated, may force a considerable amount of a large nutrient enema into the small intestine, and the segmentation of this enema would have the same results as if the enema had passed normally through the stomach. The movement of both the large and small intestine ceased if the cats were frightened, distressed, or angry; but these movements continued during sleep.

THERAPEUTIC USES OF THE X-RAYS

Further experience with the X-rays as a therapeutic agent both in this country and in Europe has confirmed their value in this field of medicine and demonstrates that they have in this direction a wide range of usefulness and that the subject is worthy of careful study; but doubtless untoward results will follow their use in inexperienced hands which may bring the method temporarily into disfavor.

Apparatus. — The apparatus required is either a good-sized static machine or a coil. It has been stated that static machines would not answer the purpose, and that the therapeutic uses of the X-rays could only be carried out when a coil was used to excite the vacuum tube; but either will answer. I use the static machine described on pages 9 to 17 at the hospital, and a coil at my office. There is, I think, an advantage in using the larger forms of apparatus for the larger new growths, but much smaller forms will answer for the smaller and superficial growths, although the time of exposure and the distance of the tube should not be the same in the one case as in the other. All forms of X-ray apparatus should have adjustable multiple spark-gaps (see pages 16, 17, and 26) by means of which the light may be regulated.

Resistance of Tube. — The next important consideration is the choice of a suitable tube, and the following facts throw some light on the subject. Frida Hansmann¹ has shown that the rays from a tube of low resistance reduce a larger amount of the silver salt in a photographic film than those from a tube of high resistance, that is, probably more rays from a tube of the former character are stopped by the film and exert their action there than from a tube of the latter kind. Further, the picture of a hand on the fluorescent screen suggests that all the rays coming from a tube of low resistance are absorbed by even so thin a part of the body as the hand; whereas the picture of a hand made by a

¹ "Beziehungen zwischen der chemischen Wirkung der aus einer Röntgenrohre austretenden Strahlung zur Wirkung des Lichtes auf dieselbe Bromsilbergelatine," *Fortschritte a. d. Geb. der Roentgenstr.*, B. V, H. 2, pp. 89-115.

tube of high resistance indicates that only a small proportion of the rays are absorbed, the portion of the screen under the hand being nearly as light as elsewhere.

The above considerations suggest that tubes of low resistance should be used for treating superficial lesions, because much of the light from such tubes is absorbed in or near the surface; but tubes of high resistance for deep-seated lesions, as the light from such tubes does not exert so large a proportion of its action upon the surface.

Tube Holder.—The tube should be placed in a tube holder, the inside of which is painted with many coats of white lead as suggested by Rollins (see pages 50 and 400), which obstructs the passage of the rays so that they can find an exit only where special provision has been made for them. Fig. 393 shows the coil, stretcher, and tube holder and Fig. 394 the tube holder in relation to the patient when he is being treated in a prone position. The top of the box has a circular opening 5 (better 10) centimetres in diameter, that is covered by a piece of plate glass 15 millimetres thick. Through this glass and the opening in the bottom of the box the physician can look down, and get a view of the area to be treated, and see that the target of the tube is in proper relation to it. After the tube has been arranged so that the rays will fall on the diseased part, a thin aluminum screen is slipped in to cover this lower opening, and is then grounded. There is also an opening in the back, that is covered with a sheet of plate glass, and another in the front of the box, so that when the patient is treated in a sitting position, the physician can look through the box from back to front and see as before that the target is in the exact position desired. The opening in the box next the patient, whether he is treated in a prone or in a sitting position, is covered by a diaphragm made of sheet lead, of a suitable size, which limits the size of the cone of rays issuing from the box so that it covers a spot a little larger than the diseased area. The rays are limited exactly to the area desired by placing over it a sheet of pure tin (or a mask may be used as shown on page 400), 1 or 2 millimetres thick, which has an opening in it corresponding in size and shape to the area to be treated. As the diseased area heals, another piece of the sheet tin is used with a suitably smaller opening.

Method of Treatment.—Before exposing the diseased part to the X-rays, the patient should be placed in a comfortable position. If the disease is superficial, the tube, enclosed in the tube holder, should be brought to within 15 or 20 centimetres (6 or 8 inches) of this part.

Some ingenuity must often be exercised in exposing new growths, in cavities such as the mouth for instance. In treating a growth in this position, I have found the glass speculum, employed as shown in Fig. 395, useful.



FIG. 393. — Cut showing X-ray apparatus and stretcher with tube holder above stretcher. To place the tube holder below the patient the inner side of the stretcher must be lifted up; the holder, which is supported by a counterpoise, may then be slid down to any desired height above the floor.

Time of Exposure; General Rule.—The diseased area should be given an exposure of five minutes for the first few sittings, and this time may be gradually increased to twenty minutes or even more, and the exposures may be given two or three times a week. But, as stated on page 446, the time of exposure, the frequency of the exposures, and

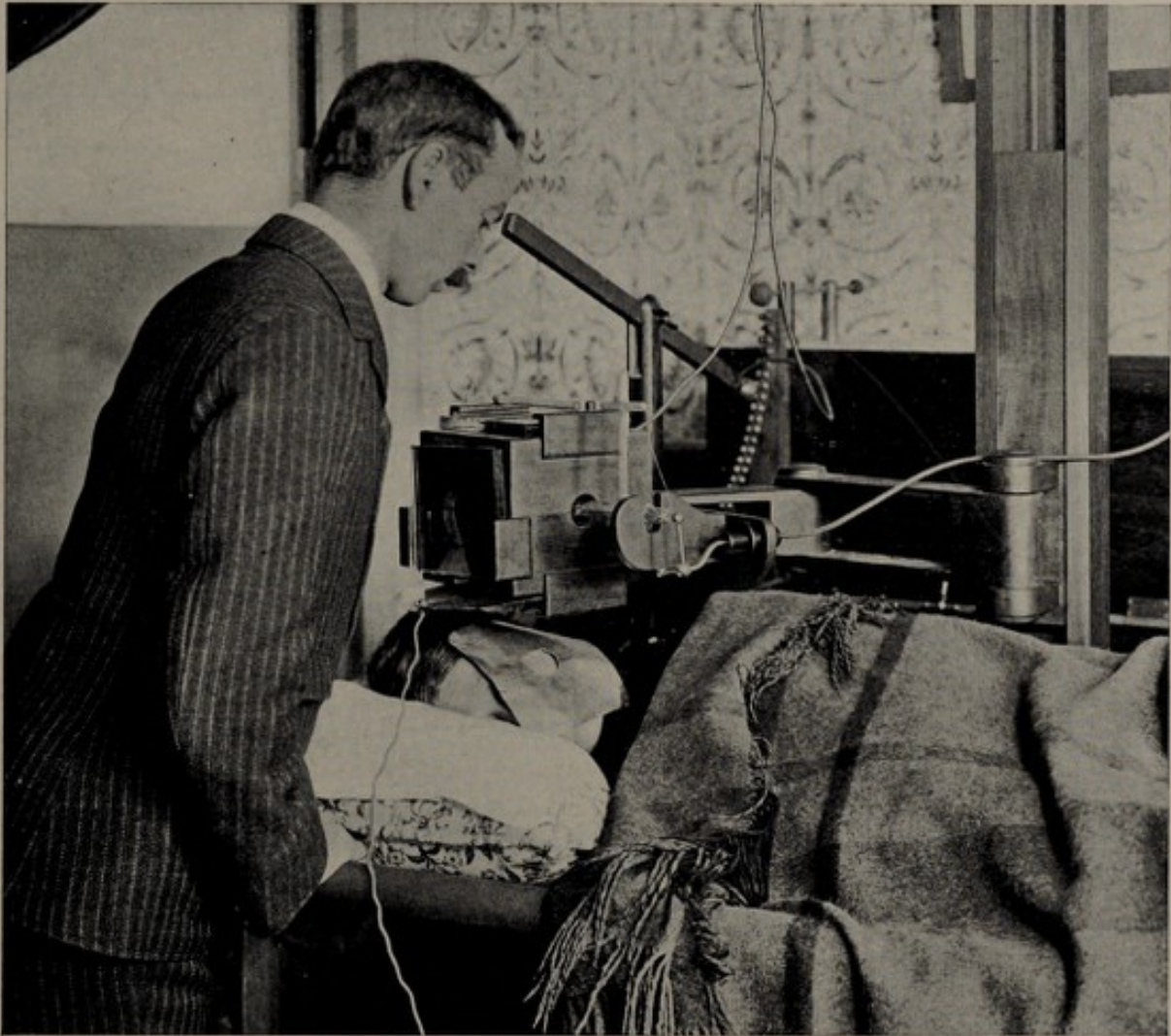


FIG. 394.—Cut showing position of tube in relation to patient when he is treated in a prone position. The sheet tin placed over the face to protect the healthy parts from the X-rays has been pushed forward a little to show the opening in it. The aluminum screen has been slipped in and grounded, but the physician is represented as if he were looking through the box to ascertain whether or not the target is in the proper position with regard to the diseased area.

the distance of the tube from the patient, must be determined for each individual, each disease, and each apparatus.

Exposures given by Physicians.—There has been a tendency to put non-medical men in charge of X-ray work, but at the present stage these rays can be most satisfactorily used as a therapeutic measure under the immediate charge of a physician who understands how to use

the apparatus, or better, by the physician himself. It appears to be a simple matter in a hospital, for example, to send a patient to the non-medical man, who has charge of the static machine or the coil, with the direction that the diseased area be exposed to the X-rays; but this man knows nothing of the medical side of the question, and can only succeed

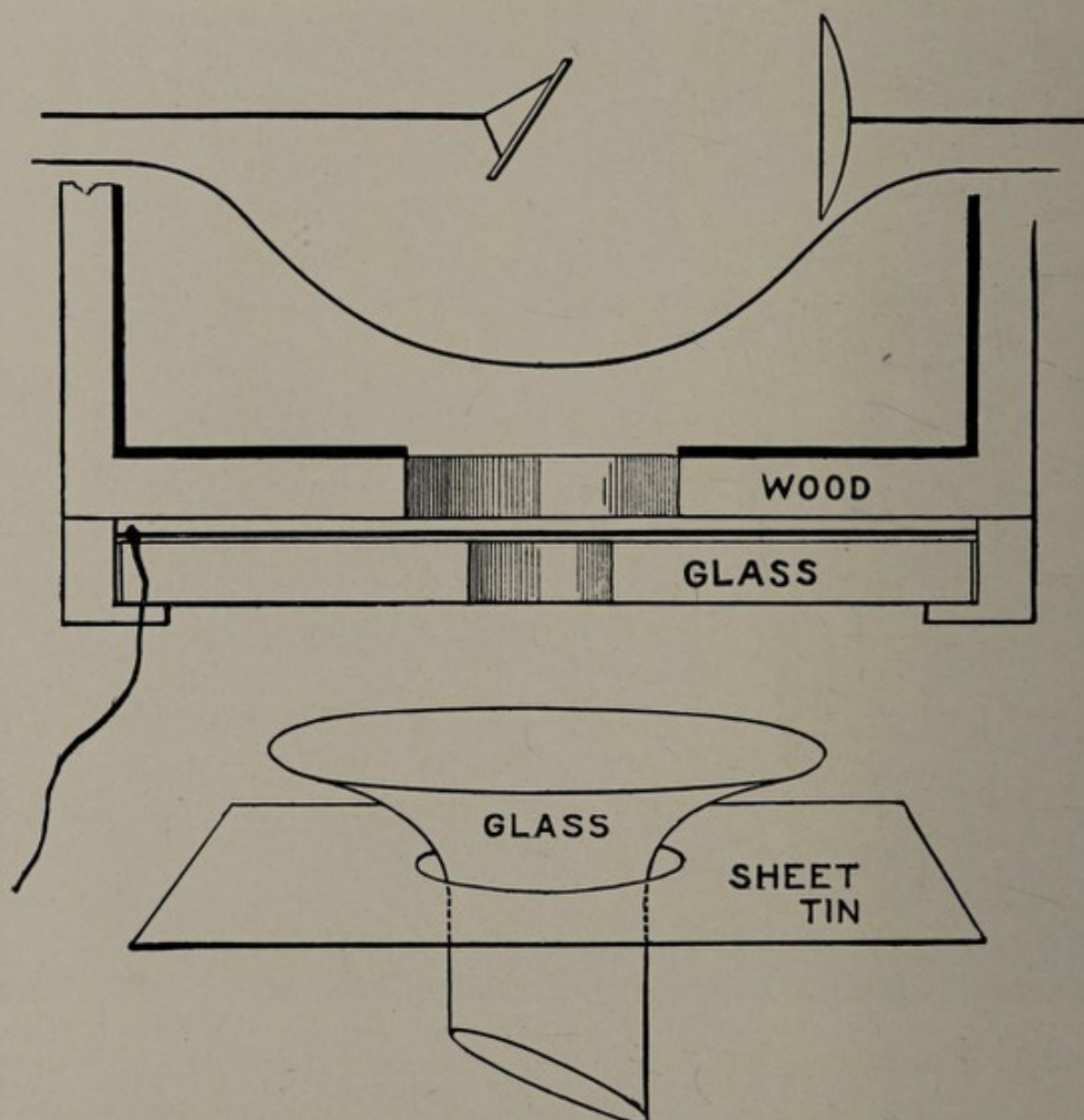


FIG. 395. — Glass speculum to be used for treating cancer of the tongue. The flaring edge of the speculum shields the parts under it, and the sheet of pure tin is a further protection. The section of the tube holder and the tube are shown above the speculum. A glass diaphragm only may be used in the lower part of the tube holder, as shown in the cut, or an additional one of sheet lead may be placed above it. The aluminum screen shown in the cut and grounded by a wire is four times too thick.

imperfectly in his attempts to use the X-rays as a remedy, or he may do harm with them. These rays are a powerful form of energy, and must be used carefully and understandingly, especially when employed as a therapeutic measure.

LUPUS VULGARIS

Time and experience have made it still more clear that it is not necessary to excite dermatitis when treating this disease by the X-rays, and that, if any inflammation appears, treatment should be suspended until it has subsided; that this treatment has the advantage of benefiting some patients without resort to painful operations, that no pain is necessary, and that the scars produced are better than those resulting from other methods of treatment. Dr. Thurston Holland¹ recommends that the X-rays should be used before any other method is adopted, not only in bad cases of long continuance, but more especially in cases that are in an early stage. Schiff,² on the contrary, considers extirpation and transplantation the ideal method for circumscribed, accessible, little foci, and that the X-rays should be used for the extensive, deeply ulcerated processes that attack the mucous membrane and inaccessible parts, and are looked upon as inoperable.

Holland reports two cases of lupus vulgaris of five years' duration that had been scraped and cauterized before treatment by the X-rays, that are of interest. The ulcerated lupus patch in the first case, involving the lobe of the left ear and extending from there to the left side of the chin, was given seventeen exposures of fifteen minutes each; there was a slight recurrence after a lapse of nearly two years, and six more exposures of ten minutes each were given. The ulcerated lupus patch in the second case, a little larger than a halfpenny, was given six exposures of ten minutes each. Dr. Holland used a tube of high resistance in both of these cases.

Dr. Clarence A. Greenleaf³ believes that cases which have not been subjected to surgical treatment recover rapidly on exposure to the X-rays, but that if they have received the former treatment before that by X-rays, recovery is slow in proportion to the amount of this previous surgical interference. In one case which he reports, where there had been no surgical treatment, good results were obtained in twelve exposures to the X-rays. He points out the importance of hygienic surroundings and the good general condition of the patient to the ultimate result.

¹ "The Treatment of Lupus by the X-Rays," *Liverpool Medico-Chirurgical Journal*, March, 1901, pp. 87-92.

² "Der Gegenwärtige Stand der Roentgen-Therapie," *Klinisch-therapeutische Wochenschrift*, 1901, No. 27, July 7, pp. 883-887.

³ "The Therapeutic Value of the X-Ray in Lupus Vulgaris," *Buffalo Medical Journal*, October, 1901, pp. 189-193.

LUPUS ERYTHEMATOSUS

Two more cases of lupus erythematosus, in addition to those given in the body of the book, may be of interest as strengthening the evidence of the good effect of treatment by the X-rays in this disease.

Dr. Richard F. Woods¹ reports the following case, that had been increasing for four years, but was cured by five exposures to the X-rays of ten minutes each, given twice a week :—

M. D., thirty-two years of age. The patient noticed a small pimple on her face which increased in size, bled quite freely at times, and caused some pain. Two years previous to treatment by the X-rays, the patient had applied various ointments and taken medicine internally without obtaining good results. July 12, 1901, the growth, about the size of a half dollar, was slightly raised, of a bright reddish color, and its centre was partially covered with scales; the mouths of the sebaceous glands were somewhat altered, and the follicular orifices were enlarged and filled with hardened sebaceous matter.

The improvement was remarkable after the second exposure to the X-rays, and went on so rapidly that a sixth treatment was found unnecessary.

Dr. James Startin² reports a well-marked case of butterfly lupus erythematosus extending over the bridge of the nose on to both cheeks in a woman thirty years of age. Dr. Startin used at first various applications—salicylic collodion, etc.—with some good results, but progress was slow. He then applied the X-rays at intervals of three days; the results were good; after six applications cicatrization had taken place.

CHRONIC ECZEMA

Sjögren and Sederholm³ report that the majority of ten cases of chronic eczema treated by them with the X-rays were completely healed. In one case, in which the skin was remarkably dry and rough, the improvement was temporary only; but in two other similar cases the improvement remained. The results were most striking in cases in which there were dry infiltrations and thickening, and partially wet

¹ "A Case of Lupus Erythematosus cured by the X-Rays," *American Journal of Medical Sciences*, September, 1901, pp. 834-836.

² "On X-Rays in the Treatment of Lupus and Rodent Ulcer," *The Lancet*, July 20, 1901, pp. 144-145.

³ "Beitrag zur therapeutischen Verwertung der Roentgenstrahlen," *Fortschritte a. d. Geb. der Roentgenstr.*, B. IV, H. 4, pp. 157-159.

patches. Sjögren and Sederholm state that the good results obtained in this disease seemed permanent, but it is yet too soon to say there will not be a recurrence.

SYCOSIS HYPHOGENES

Dr. Hugo Zechmeister¹ reports a case of sycosis hypogogenes of more than two years' duration treated by the X-rays. The treatment was stopped for four days because the skin looked tense and reddened, but was then resumed. At this time healing was going on well, when a new pustule appeared; nine days later, however, healing was complete, and after three months there was no recurrence.

Zechmeister states that Gassmann and Schenkel's cases of sycosis show no recurrence after a lapse of a year.

PSORIASIS

Dr. Startin² reports a case of psoriasis that came under his care in March, 1900. The patient was a woman twenty-one years of age, who had psoriasis of the legs, arms, and body. Dr. Startin first treated her with tonics, arsenic, and tarry preparations, until she was tolerably well, except for one patch on the leg about 6 inches long and 3 inches wide. This patch he treated with the X-rays, giving the patient seven exposures at intervals of about three days, with the result that the whole skin was healthy about a fortnight after the last sitting. Dr. Startin states that in the treatment of skin diseases he generally gives four or five exposures of ten to fifteen minutes on consecutive days with the target at a distance of 5 inches. Dr. Startin remarks that whether the X-rays injure the micro-organisms, or whether phagocytosis is stimulated, is still a vexed question.

Hahn³ reports that this disease is favorably influenced by the X-rays. The scales fall off after the first four to six treatments without the bleeding characteristic of patches of psoriasis appearing. The cases had not been under observation long enough to say whether or not there would be a recurrence.

Sjögren and Sederholm⁴ (Stockholm) state that, according to their experience, the X-rays are of little value in cases of psoriasis.

¹ *Monatshefte für praktische Dermatologie*, April 1, 1901, B. XXXII, No. 7, pp. 329-336.

² "On X-Rays in the Treatment of Rodent Ulcer," *The Lancet*, July 20, 1901, pp. 144-145.

³ *Fortschritte a. d. Geb. der Roentgenstr.*, B. IV, H. 2, pp. 95-96.

⁴ "Beitrag zur therapeutischen Verwertung der Roentgenstrahlen," *Fortschritte a. d. Geb. der Roentgenstr.*, B. IV, H. 4, pp. 145-170.

In the following instance the results have been thus far satisfactory :

A. B. Psoriasis of forty years' duration. When this patient came to me for treatment by the X-rays nearly the whole of the front, back, and sides of the body were affected. Five exposures of twenty

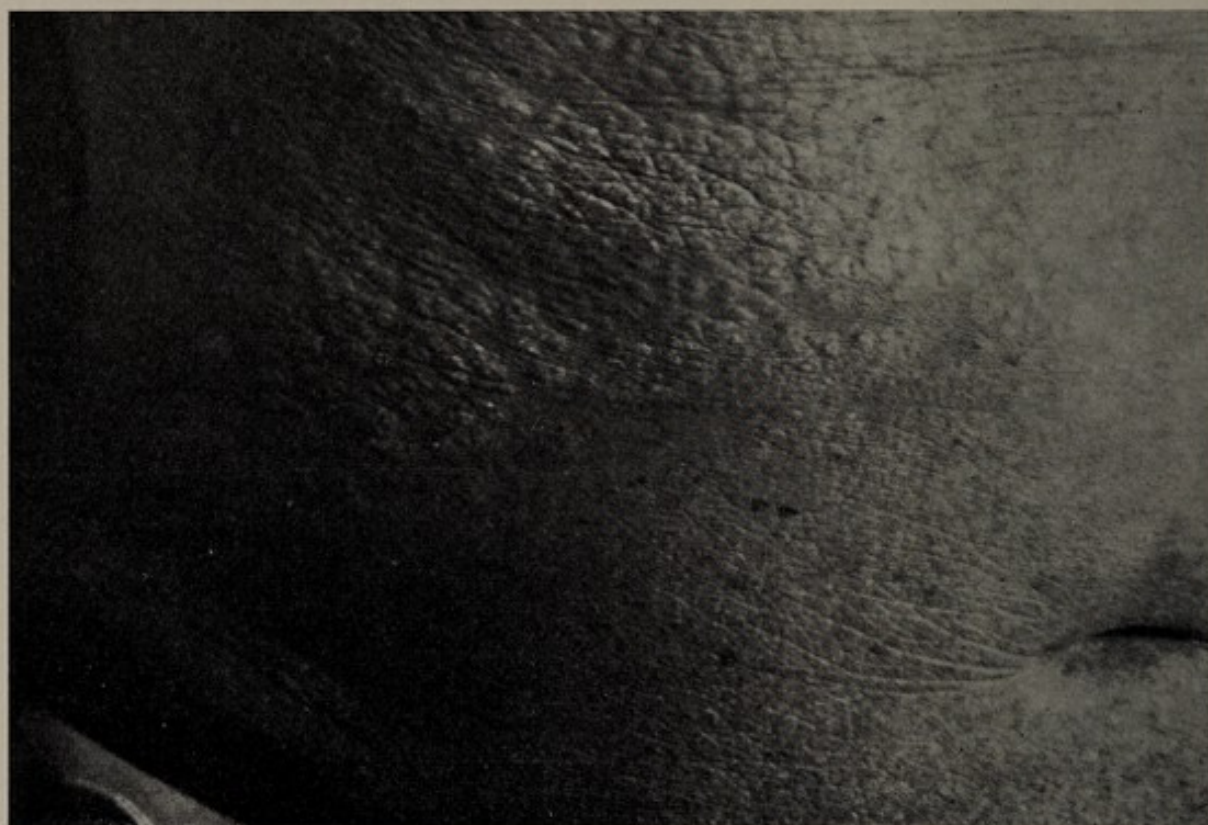


FIG. 396. — A. B. Psoriasis of 40 years' duration. The umbilicus is seen near the lower right-hand corner of the cut. The upper half of the cut shows the rough, dry, scaly psoriasis before treatment by the X-rays; the lower part, an area which had been of the same character, but which became soft, smooth, and almost like the normal skin, except in color, after five exposures to the X-rays of twenty minutes each.

minutes each caused marked improvement in the area treated; the skin became soft and smooth although still remaining of a reddish color for a few days. Fig. 396 shows in its upper part a portion of the untreated area, and in its lower part the area that had been given five exposures.

ACNE VULGARIS AND ACNE ROSACEÆ

Dr. Gautier¹ (Paris) reports that in fifteen cases of acne vulgaris and acne rosaceæ the advantages of X-ray treatment have been very great. He recommends a daily sitting of five or six minutes' duration

¹ "Traitement de l'acne et de la couperose par les rayons-x," *Comptes-rendus du XII Congrès International de Médecine*, Moscou, August, 1897, pp. 385-386.

with the tube at a distance of 30 centimetres, and a current of 6 amperes and 18 to 20 volts. The good effect in these cases became obvious after the sixth sitting; the skin peeled, the acne grew paler, the vessels were less apparent. Later, white ribbonlike masses were seen to appear between the nodules and the patches of acne rosaceæ.

Dr. Pakhitonov¹ (Paris) reports a case of a woman twenty-three years of age who had suffered from acne vulgaris since she was thirteen years old. She improved under treatment, but was not completely cured. Dr. Pakhitonov sent her to Dr. Gautier for baths, which soothed the general irritation, but the patches persisted. They finally decided to use the X-ray treatment, and after twelve exposures the patches were completely blanched.

Hahn² reports two cases of acne rosaceæ in which he obtained excellent results. The redness of the nose and of the contiguous parts disappeared, and months had elapsed, when this report was made, without a recurrence.

LEPROSY, ELEPHANTIASIS, PRURITUS ANI AND VULVÆ, AND WARTS

Leprosy. — Dr. Sequeira³ reports one case of nodulated leprosy of the skin that has shown marked improvement, the hard masses softening and becoming flat.

Elephantiasis. — Sorel and Soret report favorable results with this disease.

Pruritus Ani and Vulvæ. — Sjögren and Sederholm⁴ observed that the itching in these diseases was favorably influenced by the X-rays, and healing took place if no great change of this part of the skin had been produced by the original disease, and if the cause of the itching was cured.

Warts. — They also found the X-rays useful in the treatment of warts.

NEW GROWTHS

Experience has shown that there is a great variety of new growths in which healing has followed the use of the X-rays. Since I wrote the chapter on the therapeutic uses of the X-rays, I have been constantly

¹ "L'Acne et les rayons-x," Comptes-rendus du XII Congrès International de Médecine, Moscou, August, 1897, pp. 382-385.

² *Fortschritte a. d. Geb. der Roentgenstr.*, B. IV, H. 2, pp. 95-96.

³ *British Medical Journal*, September 28, 1901, p. 851.

⁴ "Beitrag zur therapeutischen Verwertung der Roentgenstrahlen," *Fortschritte a. d. Geb. der Roentgenstr.*, B. IV, H. 4, pp. 145-170.

using them as a therapeutic agent, more especially in the treatment of various forms of cancer; and thus far I have not found any kind of new growth, which was favorably situated, that did not yield to these rays to some extent. A microscopical diagnosis has been made for me in all my cases, generally by Dr. Councilman and Dr. Mallory, of the Boston City Hospital, except in those of recurrence after operation, or in any case in which the excision of a piece of the new growth would seem to be detrimental to the patient. The cases in which a specimen has not been examined under the microscope have been, as a rule, so typical clinically as to leave little doubt as to the diagnosis. My cases include epithelioma, rodent ulcer, carcinoma, flat-celled carcinoma, papilloma, spindle-celled sarcoma, keratosis, new growths that looked clinically like epithelioma, but which the microscope showed to be chronic inflammatory tissue, or ulcerations and necrosis, or plasmoma, and an affection of the skin that resembled an epithelioma, but proved to be tuberculosis.

The situations of the growths in my cases include all parts of the face, and the ear, tongue, jaw, neck, larynx, arm, hand, and breast, as well as deeper parts.

The readiness with which these new growths yield to the X-rays varies; it is a striking fact that, while the rays act on all forms, so far as I have observed, more readily than on healthy tissue, it is also noteworthy that they distinguish between the new growths. Rapidly growing and ulcerating epitheliomas are affected very quickly; arrest of the spreading and improvement may take place after a single exposure of only a few minutes (I have had two patients in which a small growth healed after two such exposures); on the other hand, a rodent ulcer requires, for its size, a longer exposure, and the results follow more slowly. But the site of the growth at present is the important element, although both must be considered.

Method of Treatment. — The general rules for using the X-rays as a therapeutic agent have been given on pages 646–650, but a few more special directions may be of assistance.

Time of Exposure. — The slowly growing tumors may show only slight results after exposures of from fifteen to twenty-five minutes; whereas actively growing ones, where there is much cell proliferation, must be exposed with great caution; five minutes or less may be all that is desirable at first. A too energetic use of the X-rays may have the effect of stimulating some new growths, as an operation seems to do in some cases. (See page 666.)

There are certain indications that guide the practitioner in carrying out this treatment. Itching, prickling, a drawing sensation, or sometimes a slight irritation or reaction, appearing in a new growth a day or two after the exposure, are favorable signs.

If we are dealing with an epithelioma which has almost wholly replaced the normal tissues, we cannot expect to get rid of it without causing the tumor to break down and ulcerate. That is to say, under exposure to the X-rays these cells are killed, act as a foreign body, and come off. The sound tissues, however, are not affected by this exposure, and in places only partly invaded by a new growth this breaking down and coming away does not necessarily occur; the new growth simply disappears.

If we are treating a rodent ulcer, which is a more obstinate growth to deal with than an epithelioma, the exposure may be of such length as to cause a slight reaction, redness, and swelling. An exposure that will cause a reaction in a diseased part may not produce it in a recently healed area. But, as already stated, the sound tissues should not be subjected to the action of the rays, but the opening in the sheet of lead or pure tin, used to protect the healthy parts surrounding the diseased area, should be made smaller as healing takes place.

In treating new growths the parts in which the neighboring glands are situated should be exposed to the rays as a precaution.

EXTERNAL NEW GROWTHS

The new growths which lie near the surface may be included with the external cases, and these cases may be divided into three groups.

First Group: Early Cases, and Cases of Slow Growth.—It seems probable that most cases belonging to the external class can be made to disappear by means of the X-rays if the treatment is begun early or if they are of slow growth; some forms, as already stated, yield more rapidly than others, the quickly growing ones more rapidly than those of slow growth. Thus far every case of external new growth that has come under my care early has healed or is improving under treatment; but, of course, all these latter cases may not recover.

Illustrative Cases

CASE I.—Alfred T., thirty years of age. Patient of Dr. F. E. Cheney. Microscopical diagnosis, epidermoid cancer of the lower lid. History: The growth began as a small sore under the lid in September, 1900; in May, 1901, the growth was about half as large as a pea; in July, 1901, the lower lid was gone and the growth was rapidly extending

on the cheek. When the patient was sent to me for treatment by the X-rays, the growth was five by two by one and one-half centimetres in extent.

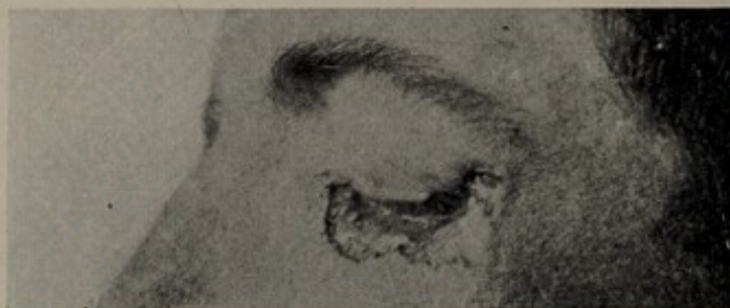

FIG. 397. — Alfred T. Microscopical diagnosis, epidermoid cancer of the lower lid. Before treatment by the X-rays.

X-Ray Exposures. — The first exposure was of fifteen minutes' duration; after an interval of four days a second of twenty minutes was given, and on the two following days two exposures of twelve minutes each were given. Improvement was noticeable after the second exposure. During the following four weeks, exposures of about five minutes each were made daily, except on Sundays, and during the next three weeks every other day except on Sundays. At this time the second photograph (see Fig. 398) was taken.

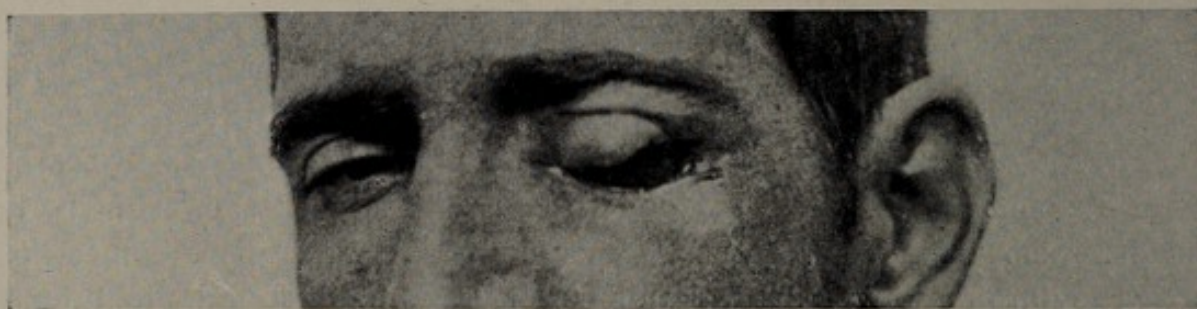


FIG. 398. — After treatment by the X-rays, but before healing was fully accomplished. There is some oedema of the upper lid which followed an incision made in its outer end in order to free it and enable me to reach the growth there more easily. The ulceration on the cheek healed completely, leaving but a slight scar.

CASE II. Thomas H. G., sixty years of age. Microscopical diagnosis by Dr. Mallory of the Boston City Hospital, epidermoid carcinoma. Growth of seven to eight years duration. In July, 1901, when the patient was referred to me by Dr. M. F. Gavin, there was an ulcerated surface on the right temple, as shown in Fig. 399.

X-Ray Exposures. — Five exposures of ten minutes each were given on consecutive days, and were followed by exposures of three minutes

each for two days. The treatment was then stopped for two weeks; at the end of this time healing had taken place over half the original area.

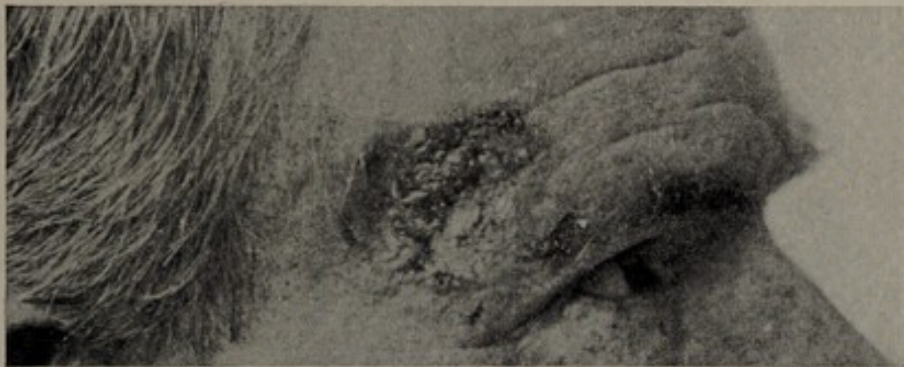

FIG. 399. Thomas H. G. Microscopical diagnosis, epidermoid carcinoma. Before treatment by the X-rays.

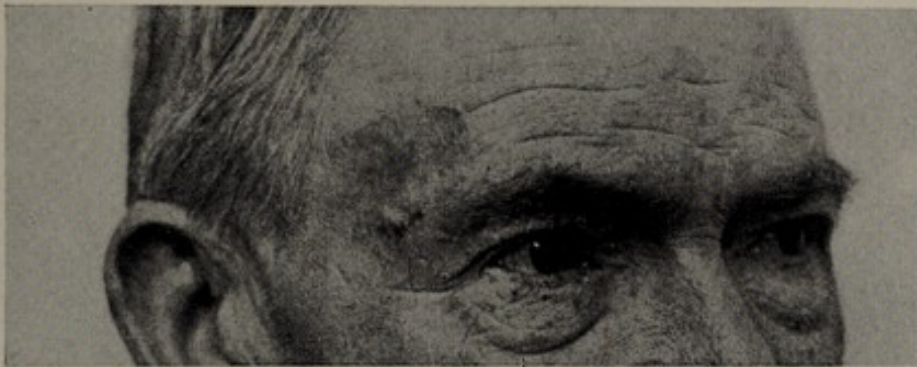

FIG. 400. Thomas H. G. After treatment by the X-rays.

The exposures were then resumed, and were given once a week for five weeks, and were of three minutes' duration. At the end of this time complete healing had taken place.




FIG. 401. John M. D. Clinical diagnosis, epithelioma. Before treatment. Steady improvement has followed the use of the X-rays.

CASE III. John M. D., seventy-five years of age. The clinical diagnosis in this case was epithelioma of the nose, which was of six

years' duration. I have given this patient six exposures of five or ten minutes each, and he is improving rapidly. The photograph from which Fig. 401 was made was taken before treatment by the X-rays.

CASE IV. Mrs. S., forty years of age. Clinical diagnosis, epithelioma of cheek. This growth began five years ago as a small pimple and has grown much more rapidly during the past year than at first.

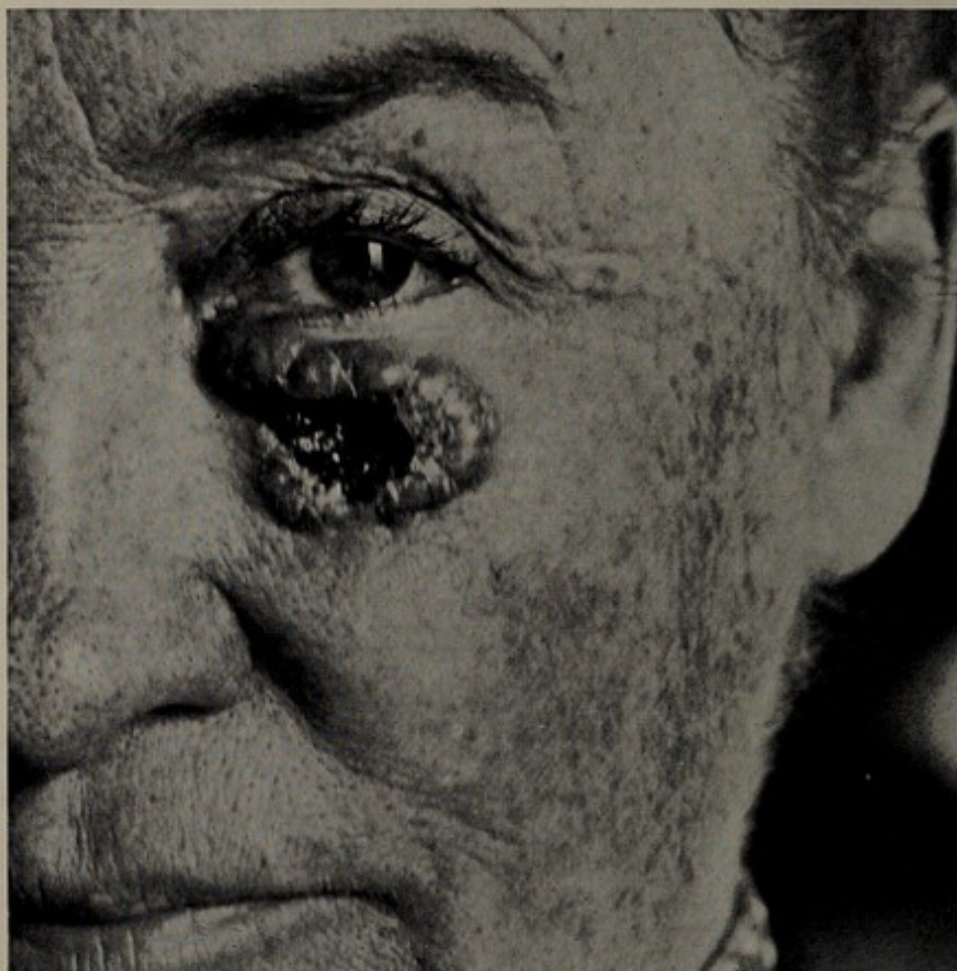

FIG. 402. Mrs. S. Clinical diagnosis, epithelioma of cheek. Photograph taken after two exposures of ten minutes each to the X-rays.

The photograph was taken after two exposures of ten minutes each had been made, and when the edges of the cavity had begun to contract as a result of the exposures. The patient is improving rapidly, and after six more exposures of five minutes each, given twice a week, the growth is only half the size it was when this treatment was begun.

Epithelioma of the Eyebrow. CASE V. This patient, fifty years of age, had had a wart for several years over one eye. Eight or nine months before coming to me, she noticed a change. The growth increased, and when I began to treat it there was an oval ulceration $1\frac{1}{4}$

by $1\frac{1}{2}$ centimetres in size on an indurated base. This healed after exposure to the X-rays, leaving only a slight hollow scar.

Epithelioma of the Tongue.—Dr. James Startin¹ reports a very favorable result in a case of ulcerating epithelioma of the tongue after nine exposures to the X-rays.

SARCOMA

Dr. William Allen Pusey² reports a case of sarcoma, in which the X-rays were applied with success.

The patient was a man twenty-four years of age, who in February, 1901, noticed a small hard swelling, the size of a filbert, below the angle of the jaw, on the *left* side of the neck, which gradually increased in size. In May, 1901, he observed a similar hard swelling, of the size of a filbert, on the right side of the neck, about an inch below the mastoid process, which increased rapidly in size. Ten weeks later the condition was as follows: a hard movable swelling the size of a hen's egg just below the angle of the jaw on the left side, which was not tender or painful; another hard mass under the upper third of the sternocleidomastoid muscle on the left side, and still another very hard mass, the size of a man's fist, on the right side of the neck, below the ear and mastoid process; neither of these two latter masses was freely movable, tender, or painful. The clinical diagnosis of sarcoma was made by Dr. Ochsner, and the diagnosis of small, round-cell sarcoma by Dr. Zeit after a microscopical examination. Dr. Ochsner removed the tumors on the *left* side; the patient made a speedy recovery and was sent to Dr. Pusey on September 2 for a month's treatment by the X-rays as a preliminary to a second operation. Twenty-one exposures, varying in length from ten to fifteen minutes each, were given to the *right* side of the neck between September 2 and 27, with a tube of high resistance which gave a weak light; the tube was placed at a distance of 5 centimetres from the surface treated. On September 17 slight erythema appeared; by September 27 there was pronounced dermatitis, which increased for the following six days and then rapidly disappeared, and by October 12 was almost well. The tumor decreased in size during the first ten days of treatment by the X-rays, and on October 11 there was no trace of the disease left except a small painless gland not larger than the kernel

¹ *The Lancet*, November 16, 1901, p. 1375.

² "Cases of Sarcoma and of Hodgkin's Disease treated by Exposures to X-Rays: A Preliminary Report," *Journal of the American Medical Association*, January 18, 1902.

of an almond. On December 7 the patient reported that his neck seemed to be in as good a condition as it ever was, and that the gland appeared to be about half as large as the kernel of an almond. This report was repeated on January 12, 1902, and the patient added that since September he had gained 12 pounds. Dr. Pusey states that there is no doubt that the tumor on the right side, which was treated by the X-rays alone, was of the same character as that on the left side.

The following case of tuberculosis of the foot, which resembled an epithelioma, is instructive.

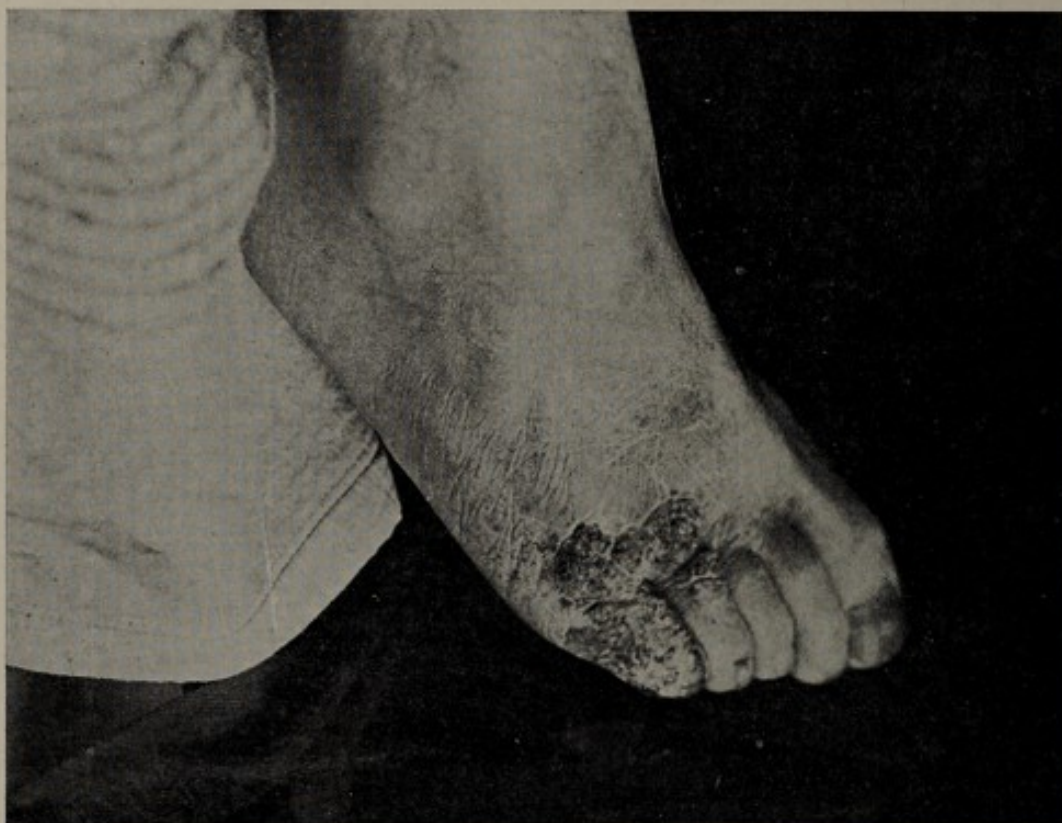

FIG. 403. Daniel K. Tuberculosis of foot which had the appearance of an epithelioma. Before treatment.

Daniel K., forty-three years of age. Microscopical diagnosis by Dr. Mallory of tuberculosis of the foot. History: In July, 1898, this patient bruised his foot, but it was well again in two or three days. In February, 1901, the foot became painful; in June, 1901, a growth appeared of a papillomatous nature, which increased slowly and was accompanied by pain. Later the growth increased rapidly, and the pain ceased.

X-Ray Exposures. — After seven exposures of ten to fifteen minutes each, the pain, which had returned before the exposures were begun, subsided, and in the outside of the foot there was an itching sensation.

After three more exposures of five to ten minutes each, the growth had disappeared from the fourth toe. The patient is still under treatment.

Second Group. — The next group of external cases to be considered includes those patients who for some reason have delayed consulting a physician until the growth has attained some size, when treatment by the X-rays may be a slow one. In these cases there is at present a choice between an operation and the X-rays, and there has as yet been too little experience to show in which cases to choose the one and in which the other; but this experience is being rapidly gained. I will presently take up one way in which it seems to me this question may be approached.

Third Group. — The third group to be discussed consists of inoperable cases and those in which the patient declines operation. The amelioration that has followed the use of the X-rays in treating some new growths which are inoperable justifies us in using this method in these cases. The relief from pain in some instances, namely on the night following the day during which an exposure had been made, brings forth grateful comment from patients; and even in this group cases will be found, I think, that may be healed by the X-rays, — rodent ulcers, for example, that have been operated on more than once, and that have finally reached a stage where further operation is impracticable. In any case some good may be accomplished by giving relief from symptoms and affording hope and consolation to the patient. While operation may be advised in certain cases rather than the X-rays, there need be no hesitation about using them, with due precaution against accident, where they are the only chance. The experience gained in treating this third group will eventually assist the practitioner to decide which cases of the second group should be assigned to operation and which to the X-rays.

Inoperable Cases. — The results obtained in the large and inoperable cases have been in marked contrast to those obtained in cases of the first group; some cancers of the tongue, for instance, that I have treated were in places difficult of access or advanced; they improved so far as they could be reached, but eventually became worse. One case of a cancer near the tip of the tongue was, however, a very favorable one; the patient came to me early and there was marked improvement after two, three, and four exposures; he was then persuaded by an astrologer to put himself under the care of an irregular practitioner, a friend of the astrologer.

The following histories and cuts illustrate a part of my experience in inoperable cases.

CASE I. Alex. J., fifty years of age. Entered the Boston City Hospital January 22, 1902. Microscopical diagnosis, epidermoid cancer.

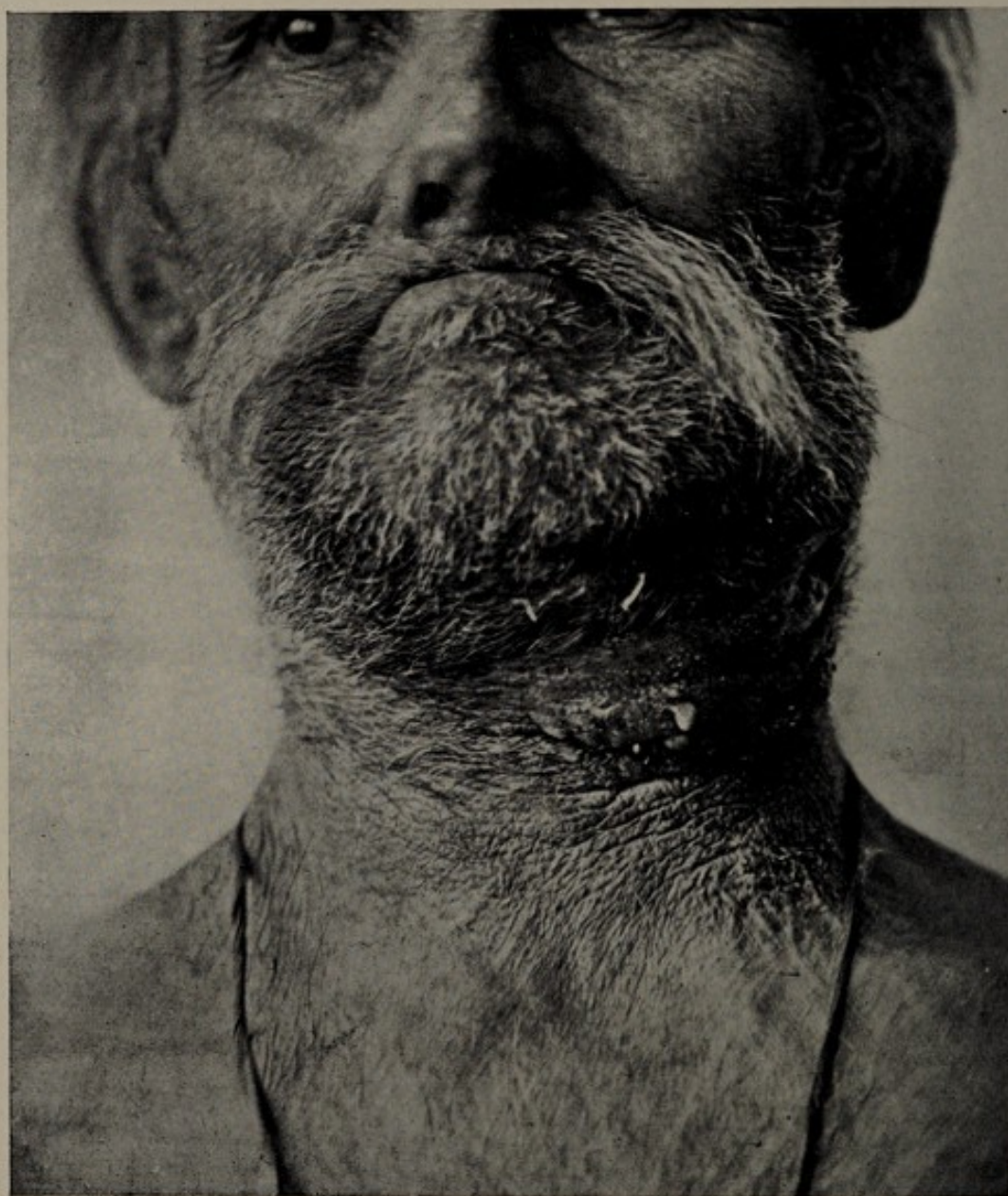


FIG. 404. Alex. J. Microscopical diagnosis, epidermoid cancer. Before treatment.

History: Four years ago this patient was operated on in England for carcinoma of the upper lip. Six months ago the neck began to swell; three weeks before entrance the part became painful, but there was no difficulty in eating or swallowing; on entrance there were several sinuses and a discharging ulcer; the case was inoperable.

X-Ray Exposures. — After fourteen exposures varying from ten to thirty minutes each, and given three times a week, it was evident that he was not permanently improving, although externally the growth had

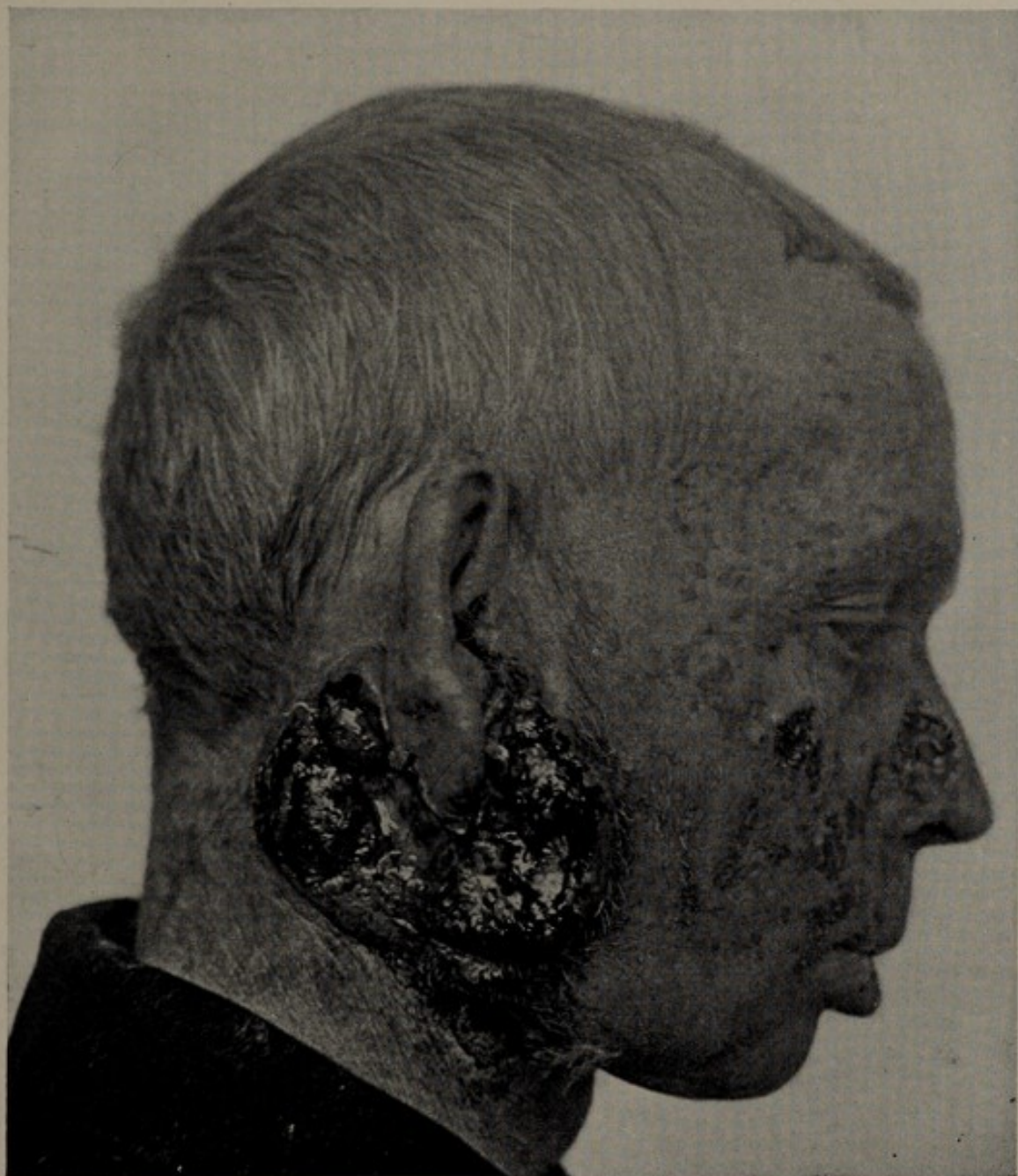

FIG. 405. Dennis R. Microscopical diagnosis, carcinoma. Before treatment.

diminished in size and the pain was relieved after each exposure. He developed difficulty in swallowing, and the growth was evidently extending to deeper parts, and I therefore suspended treatment by the X-rays, as it did not seem likely to be of any permanent avail.

CASE II. Dennis R., fifty years of age. Referred to me by Dr. Bryant of Haverhill. Entered the Boston City Hospital February 17, 1902. Clinical diagnosis, carcinoma. History: Fifteen months ago a pimple appeared on the neck behind the ear. The patient scratched it, and it became sore and did not heal. In April, 1901, it was curetted at the Hale hospital in Haverhill.

When the patient came to me the edges were raised about 2.5 centimetres above the surrounding skin; the lower portion of the ear was a mass of new growth hanging over a deep crater of repulsive ulceration.

Treatment by X-Rays.—The patient has had fifteen exposures, given three times a week, two of fifteen minutes each and thirteen of thirty minutes each; the pain has been relieved and externally the parts have improved; but difficulty in swallowing developed after seven exposures, and there seemed to be little object in pursuing the treatment by the X-rays with the idea of giving permanent relief; nevertheless persistent treatment has been followed by improvement in these symptoms also; the raised edges are not so high, and on one side the edge is nearly on a level with the skin; the area of the growth is smaller, and thus far the improvement is marked. The patient is still under treatment.

In the cases which lie between the extremes of early new growths on the one hand and inoperable cases on the other, the choice of treatment will vary with the size, location, and character of the growth.

When a surgeon is doubtful in any given case which method to recommend, he must take into consideration the fact, before coming to a decision, that a short period of treatment will show whether or not improvement will take place under their use—epitheliomas will show improvement in about two weeks; and if the suggestion is made that an operation be first done and then that the X-rays be used, the important fact must be appreciated that in some cases at least the X-rays are at a disadvantage after an operation, as even a slight one stirs up an activity which the X-rays do not readily overcome.

Treatment after Operation.—The X-rays may be used to prevent recurrence, and this treatment should be begun as soon as the patient has recovered from the operation; the region in which neighboring glands are situated should also be exposed to the X-rays as well as the site of the disease.

The following cases illustrate the use of the X-rays in the treatment of recurrence after operation:—

CASE I. Arthur B., six years of age. Patient of Dr. Gardner of

Providence. In this case the microscopical diagnosis of spindle-celled sarcoma was made by Dr. Palmer, who reported that it was a very typical neoplasm. The patient was brought to me for treatment by the X-rays on account of a recurrence following an operation on his arm. (See Fig. 406.) He has had fourteen exposures of from twelve to twenty minutes each, twice a week, and the arm is now nearly

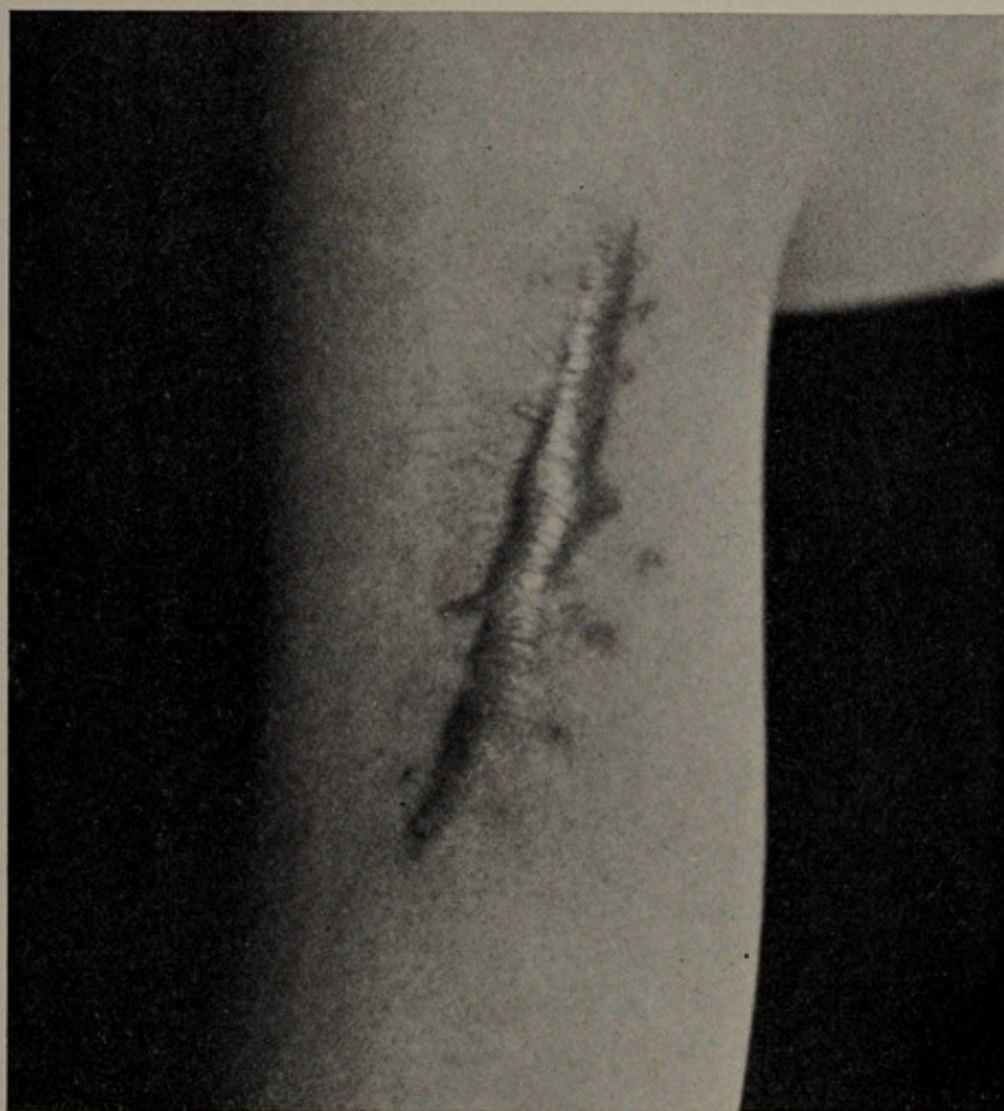

FIG. 406.—Arthur B. Microscopical diagnosis, spindle-celled sarcoma. Before treatment by the X-rays.

well. There is hardly any trace of induration, the swelling has subsided, and the color, which was red, is becoming like that of the surrounding skin.

The following case shows with what wonderful rapidity the good effects of the X-rays may appear under the most favorable conditions, and this fact should encourage patients to have any slight and suspicious

growth treated at the earliest moment, as then not only is success more assured, but also the number of visits required is comparatively few.

CASE II. Mrs. B., patient of Dr. H. L. Burrell. Epithelioma of face. Microscopical diagnosis by Dr. Mallory. History of epithelioma which began two years ago, on side of the face, arising from a scar caused by an injury. Dr. Burrell removed the growth a year ago, and did a plastic operation. Recently there was a recurrence. When the patient came to me there was some slight thickening of the horseshoe-shaped scar, on the left temple, the ends of which were 3 to 4 centimetres apart. At one end of the scar there was an ulceration 1 centimetre in diameter with raised and thickened edges.

X-Ray Exposures.—Three days after one exposure of fifteen minutes' duration the ulceration had crusted over, the raised edges were lower, and the growth had the appearance of healing rapidly. A second exposure of ten minutes was then made, and a few days later the growth had healed.

Epithelioma over the Zygoma.—The correspondent¹ of the *Medical Press* reports a case of recurring epithelioma over the zygoma which Schiff had treated with the X-rays. Healing was produced after twenty-seven sittings.

PAPILLOMA OF LARYNX

CASE. Henry S., seventy-eight years of age. This case was sent to me by Dr. Leland, who made a clinical diagnosis of papilloma of the larynx. History of three and one-half months' duration. The suffocative attacks were relieved by a few exposures to the X-rays, swallowing became easier, and the hoarseness was diminished. Dr. Leland's subsequent examination showed that the growth was much smaller. The patient is not well, but his improvement has been so unmistakable that there is good reason to hope that such cases may eventually be within the reach of the X-rays.

RODENT ULCERS

Dr. J. H. Sequeira² has treated forty-five cases of rodent ulcer since June, 1901, with the X-rays. The ulcers healed rapidly and large cavi-

¹ *Medical Press*, November 7, 1901. From our own correspondent in Vienna, November 23, 1901.

² *British Medical Journal*, September 28, 1901, p. 851.

ties filled up. He had difficulty with the hard, raised edge. Slight recurrence, which, however, was easily controlled, had been observed.

Cancer.—In his slight experience with cancer, the pain had been relieved and ulceration had dried up, but in some cases the tumors grew rapidly in spite of the rays.

Dr. George G. Stopford Taylor¹ reports the surprisingly good effects of the X-ray treatment upon the form of rodent ulcer that has a natural tendency to heal in one part while it spreads in another. He gives one case of multiple rodent ulcer of the left upper cheek and lower eyelid, which, after a series of twenty-minute exposures to the X-rays, amounting in all to four hours, showed no visible trace of the disease.

In other cases similarly situated, in which the periosteum was involved, the results had not been so satisfactory; the healing had broken down again.

In one case of inoperable rodent ulcer of the scalp in a man sixty-nine years of age, the surface almost healed over, then the epithelium was destroyed, and again and again restored on exposure to the rays. Dr. Taylor observed that the X-rays had the power to excite the temporary growth of epithelium on the surface of carcinomatous ulcers. He noticed this effect in two cases of epithelioma, and in a fatal case of pigmented carcinoma of the scalp. In this latter case, through the new sheet of epithelium, the pigmented tumor cells could be plainly seen.

Dr. Taylor considers the action of the X-rays to be that of a stimulant, and that they should be applied with such care that over-stimulation does not occur.

All my cases of rodent ulcer are slowly improving under treatment or have healed, with one exception. This one is that of an old woman who lived at a distance; she came a few times, and there was improvement, but she was too feeble to pursue the treatment. Eight of the cases which are improving have been under treatment for months; they do not yield readily and may not heal, but it is too soon to say what the outcome will be. Rodent ulcers require longer treatment as a rule than epitheliomas. The physician need have no hesitation in using the X-rays because the ulcer is extensive if it is superficial.

RECURRENCE

Some of my cases of new growth have been well for more than a year without any sign of recurrence. One in which slight recurrence has

¹ *British Medical Journal*, September 28, 1901, pp. 852-853.

taken place and which has yielded to a few more exposures, is instructive. This patient had an epithelioma of the lip, and was obliged to give up the treatment when the growth was perhaps three-fourths healed. He continued to improve after treatment was stopped, and in a few weeks there was no induration and no glands could be felt. Complete healing had apparently taken place. Some six months after, he returned to me with superficial ulceration about 1 centimetre in diameter, in part over the site of the former trouble. This return would suggest that, in order to prevent recurrence, the treatment should be thoroughly carried out in the beginning.

On the general question of a recurrence, which is so frequent after operation, only a partial answer can be given, as the X-rays have been used too short a time to determine this point; still, thus far, they promise well on this serious side of the matter. Should there be any sign of recurrence, treatment by the X-rays should and would be promptly and unhesitatingly resumed by the patient. Further, there is so much more to be learned in order to carry out this treatment in the best way, that, even if a recurrence occurred at the present time, it need not necessarily occur after the method has been perfected.

CANCERS OF THE BREAST

I believe the X-rays may render service in the treatment of certain forms of cancer of the breast. In these cases also the earlier the treatment is begun the better; some forms will be found to yield more readily than others, — the carcinomas more readily than the scirrhus variety, for example. Benign indurations may also be successfully treated.

I have had eleven cases of cancer of the breast, and most of these, even the ones in which the growth was so large as to involve the whole breast, show some improvement. The hard breast which was fixed to the chest wall has become movable, and, later, somewhat softer; growths reappearing in the scar following an operation have yielded, ceased to spread, shrunk up, and a crust has fallen off. Most of my cases are still under treatment.

CASE I. Mrs. J., sixty years of age. Clinical diagnosis, carcinoma of breast of three years' duration. The photograph from which the cut was made was taken after three exposures to the X-rays. After twenty exposures, of from ten to thirty minutes each, the im-

provement was great; the ulceration had healed, and the original induration, which is shown by the broken line, had mostly disappeared.

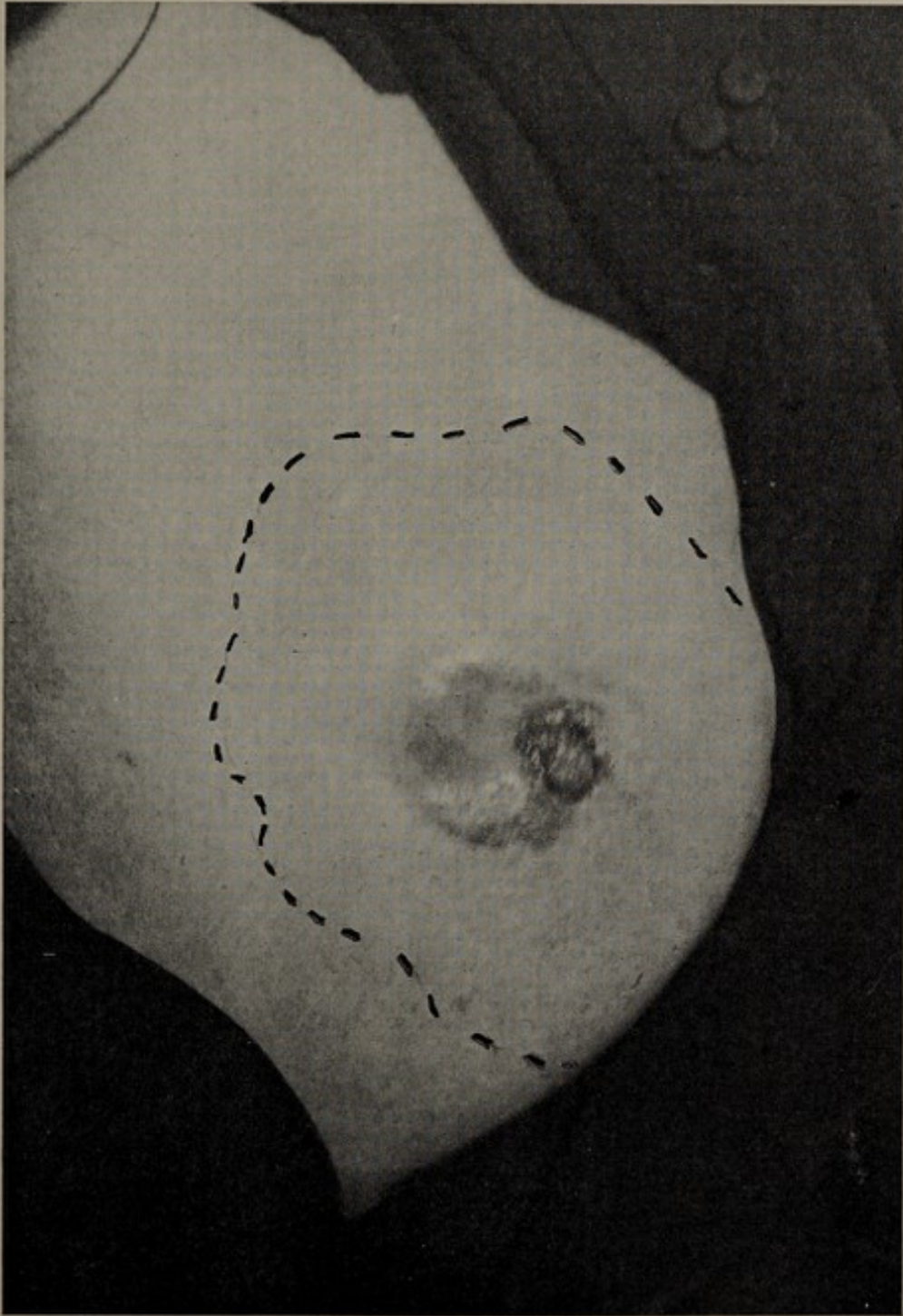


FIG. 407.—Mrs. J. Clinical diagnosis, carcinoma. Photograph taken after three exposures to the X-rays. The broken line shows the limit of the deep, hard, irregular mass. The area of offensive ulceration about the retracted nipple has already partially healed.

After twenty exposures all of the induration below the level of the nipple had disappeared, and most of that above and on either side of it. Improvement was so rapid that marked decrease in the size of the growth was obvious from week to week; after a few more exposures the breast seemed well.

INTERNAL FORMS OF CANCER

At present the practitioner is not justified in promising that the X-rays will cause deep-seated new growths to heal. The treatment may, however, afford relief in some cases, either after operation or where operation is not practicable. With more experience and improved apparatus, however, we have reason to hope that some at least of the internal new growths will come within reach of this method. Tubes of high resistance should be used in treating internal forms of cancer.

Rollins,¹ in order to learn whether or not the X-rays would affect cell growth in the interior of the body with a view to their effects in internal cancer, made a series of careful experiments on guinea pigs. To exclude any electrical effects, the guinea pigs were placed in a grounded Faraday chamber, — that is, in a closed metallic chamber that was hung by silken cords inside another metallic chamber. The walls of the two chambers that faced the tube were made of aluminum .26 millimetre thick, and the walls on the side away from the tube had windows of iron wire gauze in order that air might be admitted. The generator used in these experiments was a static machine with sixteen plates of plate glass, averaging 2 metres in diameter, and the speed was one hundred and twenty revolutions per minute. The resistance of the tube in certain of the experiments was 14 millimetres. The target was white-hot where the cathode stream struck it, and the remainder was red-hot. The tube was placed outside the Faraday chamber, and its target was 14 centimetres from the guinea pigs. The X-rays were obliged to go through two sheets of aluminum, before they could reach the animals, one of which was connected with the earth by means of a small metal wire; and yet loss of hair, paralysis, abortion, burns, or death could be produced, if the exposures were long enough, or death could be produced without causing a burn. As a control other guinea pigs were placed in the Faraday chamber, but were not exposed to the X-rays, and kept there for the same length of time as those that were so exposed. These guinea pigs remained well and produced young. Both classes of guinea pigs were kept in the same pen and received the same care and food. The following table, taken from the article published January 9, 1902, shows the method pursued in these experiments and some of the results obtained.

¹ *Boston Medical and Surgical Journal*, February 14 and 28, March 28, 1901, and January 9, 1902.

TABLE SHOWING EFFECTS OF X-LIGHT ON GUINEA PIGS

| No. 1. MALE, EXPOSED TO X-LIGHT IN FARADAY CHAMBER | | | | No. 2. FEMALE, EXPOSED TO X-LIGHT IN FARADAY CHAMBER | | | | No. 3. MALE, NOT EXPOSED, CONTROL | | | | No. 4. FEMALE, NOT EXPOSED, CONTROL | | | |
|--|-------------------|------------------------|---------------------------|--|-------------------|------------------------|---------------------------|-----------------------------------|-------------------|---|--------------------|-------------------------------------|-------------------|---|--|
| Day | Weight in Grammes | Length of Exposure, M. | Spark-Length of Tube, Mm. | Day | Weight in Grammes | Length of Exposure, M. | Spark-Length of Tube, Mm. | Day | Weight in Grammes | Length of Time in Faraday Chamber, Min. | | Day | Weight in Grammes | Length of Time in Faraday Chamber, Min. | |
| 1 | 1,078 | 15 | 14 | 1 | 746 | 15 | 14 | 1 | 931 | 15 | | 1 | 756 | 15 | |
| 2 | 1,033 | 15 | 14 | 2 | 740 | 15 | 14 | 2 | 931 | 15 | | 2 | 756 | 15 | |
| 3 | 1,045 | 15 | 14 | 3 | 755 | 15 | 14 | 3 | 926 | 15 | | 3 | 772 | 15 | |
| 4 | 1,047 | 15 | 14 | 4 | 755 | 15 | 14 | 4 | 926 | 15 | | 4 | 771 | 15 | |
| 5 | 1,012 | 15 | 14 | 5 | 751 | 15 | 14 | 5 | 930 | 15 | | 5 | 781 | 15 | |
| 6 | ? | 0 | .. | 6 | ? | 0 | .. | 6 | ? | 0 | | 6 | ? | 0 | |
| 7 | ? | 0 | .. | 7 | ? | 0 | .. | 7 | ? | 0 | | 7 | ? | 0 | |
| 8 | 1,001 | 15 | 14 | 8 | 758 | 15 | 14 | 8 | 930 | 15 | Hair losing gloss. | 8 | 792 | 15 | |
| 9 | ? | 0 | .. | 9 | ? | 0 | .. | 9 | ? | 0 | | 9 | ? | 0 | |
| 10 | ? | 0 | .. | 10 | ? | 0 | .. | 10 | ? | 0 | | 10 | ? | 0 | |
| 11 | 991 | 15 | 14 | 11 | 747 | 15 | 14 | 11 | 917 | 15 | | 11 | 804 | 15 | |
| 12 | 990 | 15 | 14 | 12 | 772 | 15 | 14 | 12 | 945 | 15 | | 12 | 830 | 15 | |
| 13 | 971 | 15 | 14 | 13 | 750 | 15 | 14 | 13 | 930 | 15 | | 13 | 823 | 15 | |
| 14 | 976 | 15 | 14 | 14 | 757 | 15 | 14 | 14 | 918 | 15 | | 14 | 827 | 15 | |
| 15 | 982 | 15 | 14 | 15 | 752 | 15 | 14 | 15 | 918 | 15 | | 15 | 827 | 15 | |
| 16 | 999 | 15 | 14 | 16 | 769 | 15 | 14 | 16 | 926 | 15 | | 16 | 852 | 15 | |
| 17 | 984 | 20 | 14 | 17 | 762 | 20 | 14 | 17 | 921 | 20 | | 17 | 841 | 20 | |
| 18 | 975 | 20 | 14 | 18 | 762 | 20 | 14 | 18 | 909 | 20 | | 18 | 850 | 20 | |
| 19 | 981 | 20 | 14 | 19 | 763 | 20 | 14 | 19 | 915 | 20 | | 19 | 860 | 20 | |
| 20 | ? | 0 | .. | 20 | ? | 0 | .. | 20 | ? | 0 | | 20 | ? | 0 | |
| 21 | 994 | 30 | 14 | 21 | 781 | 30 | 14 | 21 | 930 | 20 | | 21 | 893 | 20 | |
| 22 | 971 | 30 | 14 | 22 | 765 | 30 | 14 | 22 | 925 | 20 | | 22 | 886 | 20 | |
| 23 | 986 | 30 | 14 | 23 | 779 | 30 | 14 | 23 | 931 | 20 | | 23 | 906 | 20 | |
| 24 | 964 | 30 | 14 | 24 | 778 | 30 | 14 | 24 | 932 | 20 | | 24 | 908 | 20 | |
| 25 | 976 | 30 | 14 | 25 | 781 | 60 | 14 | 25 | 926 | 60 | | 25 | 923 | 60 | |
| 26 | 959 | 60 | 14 | 26 | 771 | 60 | 14 | 26 | 925 | 60 | | 26 | 917 | 60 | |
| 27 | ? | 0 | .. | 27 | ? | 0 | .. | 27 | ? | 0 | | 27 | ? | 0 | |
| 28 | 980 | 60 | 14 | 28 | 777 | 60 | 14 | 28 | 939 | 60 | | 28 | 941 | 60 | |
| 29 | 954 | 60 | 14 | 29 | 746 | 60 | 14 | 29 | 930 | 60 | | 29 | 925 | 60 | |
| 30 | 945 | 90 | 14 | 30 | 726 | 90 | 14 | 30 | 932 | 90 | | 30 | 941 | 90 | |
| 31 | 930 | 90 | 14 | 31 | 697 | 90 | 2 | 31 | 949 | 90 | | 31 | 956 | 90 | |
| 32 | 908 | 90 | 2 | 32 | 667 | 90 | 2 | 32 | 950 | 90 | | 32 | 943 | 90 | |
| 33 | 886 | 90 | 2 | 33 | 643 | 90 | 2 | 33 | 953 | 90 | | 33 | 956 | 90 | |
| 34 | ? | 0 | .. | 34 | ? | 0 | .. | 34 | ? | 90 | | 34 | ? | 90 | |

When the spark length was 2 mm., the target was 35 mm. from cathode. The exposures are given in minutes, length of spark-gap of tube in millimetres.

These experiments show that we must proceed with caution; burns can evidently be produced by exposure to an X-ray tube when no electricity is present, and the experiment made also by Rollins, and referred to on page 448, and reported in the *Electrical Review*, January 5, 1898, demonstrates that burns can be caused by electricity when no X-rays are present. Further, Rollins found that burns could be produced by the X-rays when tubes of either high or low resistance were used.

SUMMARY

Already most small external new growths can be successfully treated by the X-rays, and some external new growths of considerable size are within their reach. When the X-rays are used there is no dread of an operation to be contended with and no shock, and therefore patients will eventually go early to a practitioner, if they have a suspicious growth; the method is painless and the cosmetic results are unquestionably the best.

In addition to the curative action of the X-rays, they may be used to ameliorate the condition of patients in incurable cases.

There is the hope that some internal new growths may eventually come within the reach of this treatment.

The best way of avoiding the larger forms of external growths is by prevention; that is, by submitting all early new growths, whether they seem of a dangerous nature or not, to the X-rays. No harm can follow their use in proper hands, and much good will result from this course. So soon as it is widely known that there is a harmless, painless, and excellent way of treating early new growths, people will resort to this method without delay. It is now the duty of the profession to make this method known, at the same time warning patients of its present limitations.

TUBERCULOUS GLANDS

Enlarged cervical glands, even when of great size, respond surprisingly well to treatment by the X-rays; and of course no scar is left, as is the case after an operation.

TUBERCULOUS SINUSES

Tuberculous sinuses of the neck.—Dr. F. M. Briggs has had two cases of tuberculous sinuses of the neck that have been benefited by treatment with the X-rays, of which he has kindly given me notes.

The first was that of a boy about fourteen years of age who gave a history of long-standing freely suppurating cervical adenitis on both sides of the neck, and of eight months' treatment and operations at different hospitals. When Dr. Briggs first saw him he had a sinus opening on both sides of the neck, and fluid injected into the opening on one side issued from that of the other. Dr. Briggs referred the case to Dr. S. W. Allen for treatment by the X-rays. After six exposures the opening on one side had closed, and there was only a small amount of daily discharge from that on the other. The patient is still under treatment and improving.

The second case was that of a boy of about eight years of age who had had a daily discharge from a sinus on one side of the neck near the ear, for nineteen months, during which time he had been under constant treatment without avail. Dr. Briggs referred this case to Dr. C. C. Simmons, and after two exposures to the X-rays by him the sinus stopped discharging. The patient has reported once a week since the sinus has closed, and it has not reopened.

OLD ULCERATIONS

Sjögren and Sederholm¹ found that old ulcerations were favorably influenced by the X-rays, in that fresh granulations arose which were followed by healing.

Dr. Taylor² reports that "a further proof of the remediable effect of the rays in stimulating the growth of epithelium was afforded by the following case." A small boy had been burned on the left arm near the elbow joint. His arm had been neglected, and where any healing had taken place the scar was hard and fibrous, and contractions seemed probable. Dr. Taylor applied the X-rays, and the unhealed portions of the ulcer healed rapidly; there was a soft and flexible scar, and the child had a serviceable movement of the arm.

HODGKIN'S DISEASE

The X-rays seem likely to be of service in Hodgkin's disease; the following cases are illustrative:—

CASE I. John McC., twenty-one years of age, cook, entered the Boston City Hospital, November 16, 1901. Diagnosis, Hodgkin's disease.

¹ "Beitrag zur therapeutischen Verwertung der Roentgenstrahlen," *Fortschritte a. d. Geb. der Roentgenstr.*, B. IV, H. 4, pp. 145-170.

² *British Medical Journal*, September 28, 1901, pp. 852-853.

History. — Good health until a year ago, when he noticed a small hard lump in right posterior cervical gland 1 centimetre in diameter;

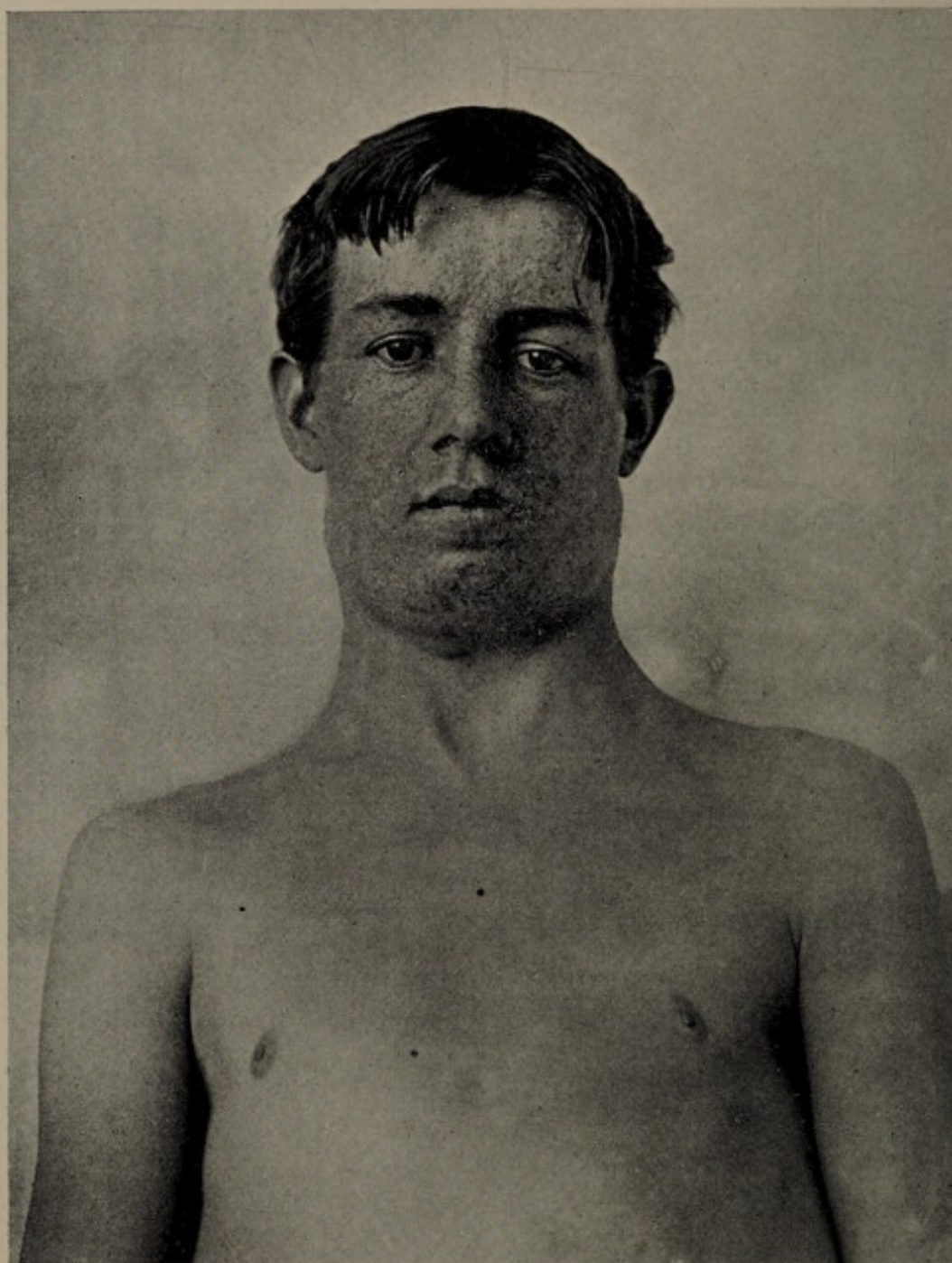


FIG. 408. — John McC. Hodgkin's disease. Photograph taken February 3, after one exposure, of ten minutes, of right cervical glands, given on February 1.

six months later the glands under the right jaw and below, in the neck, had increased in size. In September, 1901, he consulted a physician and was told that the tonsils were enlarged and as a consequence the

glands had enlarged. The tonsils were cut, but the glands rapidly grew larger, and soon the glands on the left side of the neck, in the axillæ,

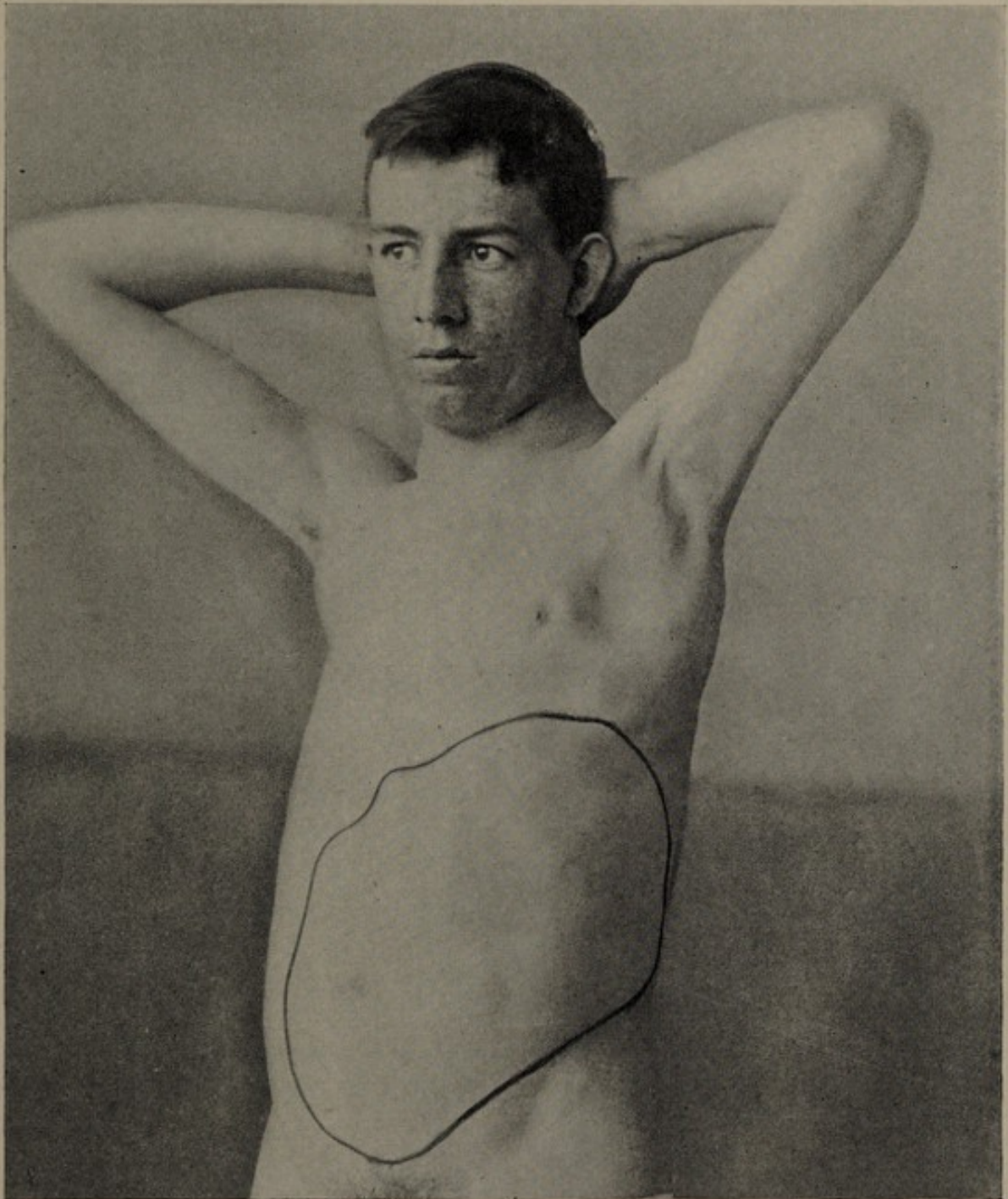


FIG. 409.—Hodgkin's disease. The black line shows the size of the spleen before treatment by the X-rays; after about eighteen exposures it was not more than one-fourth this size.

above the elbows, in the left groin, and the popliteal spaces also showed enlargement. The patient had worked continuously; always pale.

November 16. Physical Examination.—Enlarged glands as stated in history. Spleen greatly enlarged from sixth space to 16 centimetres below costal border for a width of 15 centimetres.

November 18. Blood Examination.—Red corpuscles, 5,472,000; white, 4400; hæmoglobin, 50 per cent.

Examination with the Fluorescent Screen.—Enlarged glands in mediastinum behind upper portion of heart.

November 29.

| | | | |
|---------------------------|---|----------------------------------|-----|
| Differential blood count: | { | Polymorpho-nuclear neutrophiles. | 69% |
| | | Lymphocytes | 30% |
| | | Eosinophiles | 1% |

February 1, 1902. X-ray treatment begun; right cervical glands exposed for ten minutes.

February 3. Glands on right side of the neck, which had been about as large as those on the left, much diminished in size. Photograph (see Fig. 408) taken, which shows the difference between the treated and the untreated sides.

Glands on left side of the neck exposed for ten minutes.

February 5. Marked improvement in glands on left side. Glands on this side exposed for fifteen minutes.




February 8. Glands on both sides are so much reduced in size that their enlargement is not very noticeable. Exposure of ten minutes to each side.

After this time the exposures were made three times a week for six weeks; the cervical, axillary, and left inguinal glands being exposed ten or fifteen minutes each at each exposure, and the spleen generally thirty minutes. The spleen is already much smaller, and all the glands which were thus exposed have become softer and most of them cannot be seen or felt. The unexposed glands have remained unchanged. The patient is still under treatment.

Dr. Pusey¹ reports two cases of Hodgkin's disease which he has under treatment by the X-rays.

The first was a boy four years of age. In August, 1901, Dr. Ochser made a diagnosis of Hodgkin's disease and removed the cervical glands on the right side. On September 11 he referred the case to Dr. Pusey for the treatment of the glands on the left side, which were as large as a fist, by the X-rays. After two months' treatment these glands were reduced to the size of an almond. From November, 1901,

¹ *Journal of the American Medical Association*, January 18, 1902.



In benign forms of induration of the breast, in tuberculous glands, in cervical adenitis, in Hodgkin's disease, in some forms of enlarged spleen, in some diseases of the thyroid gland, I have observed favorable results following the use of the X-rays, and this experience suggests that they may be of value in diseases of any accessible part of the glandular system. I am now pursuing further this general question of the use of the X-rays as a therapeutic agent in diseases involving glands, including the prostate gland.

up to the time the case was reported on by Dr. Pusey, the boy was given intermittent treatment by the X-rays.

The second patient was a man fifty years of age, who had an enlargement of the axillary and epitrochlear glands of the right side. The diagnosis of Hodgkin's disease was made by Dr. McArthur, and the patient was treated for some time with parenchymatous injections of arsenic, in spite of which the tumors steadily increased in size. On November 1, when the epitrochlear gland was almost as large as a goose egg and very hard, Dr. Pusey subjected it to the X-rays. Within a month it was about one-third its previous size, and when reported on was about as large as an olive and quite soft. Meanwhile the axillary gland, which was being treated with the arsenic injections, showed no change. On December 18, at Dr. McArthur's suggestion, Dr. Pusey began to make exposures of this gland, which was as large as a child's head and interfered with the motion of the arm, to the X-rays. Dr. Pusey reports that the patient thinks it softer and smaller, and says that he can now play billiards, which of late he had been unable to do.

EXOPHTHALMIC GOITRE

I am using the X-rays for treating Parry's or Graves' disease, and thus far with encouraging results. The glands have diminished in size, and the general condition of the patients has improved.

Mary D., twenty-six years of age. Right lobe of thyroid gland 2 by 4 centimetres, left lobe 5 by 8 centimetres. After five exposures of twenty minutes each, given at intervals of about four days, the right lobe was $1\frac{1}{2}$ by 2 centimetres, the left lobe $3\frac{1}{2}$ by 4 centimetres, and her general condition was much improved.

DISEASE OF CORNEA

Some months since I suggested to my friend, Dr. Walter B. Lancaster, the possibility of using the X-rays in the treatment of certain affections involving the cornea, and asked him if he would send me some cases. Dr. Lancaster kindly consented to do so, and some time later sent me two patients, but expressed himself as sceptical of any good result following the treatment. I exposed both these patients to the X-rays, and some improvement resulted in each case; but I will consider only one in detail, as the other was obliged to return to his home in Nova Scotia before a satisfactory number of exposures had been made.

CASE I. Charles F., forty-eight years of age. History of gonorrhoeal ophthalmia twenty months previously.

Condition when Treatment by the X-Rays was begun. — Dr. Lancaster found that in the left eye there was a semicircular, dense, flat leucoma in the lower half of the cornea, shading off gradually in the upper half, and leaving above the diseased portion a crescent of clear cornea 2–3 millimetres wide, and below it a strip $\frac{1}{2}$ –1 millimetre wide; that the pupil dilated but little with a mydriatic, on account of an extensive adhesion, so that vision was the same with and without atropine. The patient could count his fingers at a distance of 25 to 30 centimetres and stated that there had been no improvement in the eye for months.

Method of Treatment. — I raised the upper lid of the eye by sticking one end of a strip of surgeon's plaster to it and the other end to the forehead. I then suspended a disk of glass about 4 centimetres in diameter, in the centre of which there was a hole 3–4 millimetres in diameter, in front of the eye so that the opening came opposite the area I desired to expose to the X-rays. The disk was held by a thread which passed through its opening and was fastened to the surgeon's plaster on the forehead. The diaphragm used in the tube holder had an opening about $1\frac{1}{2}$ centimetres in diameter, and this opening was brought opposite the aperture in the disk and only 3 centimetres away from it. The exposures were made once a week for three months and twice a week for two months, lasting usually about ten minutes. It was necessary, of course, to proceed with great caution when exposing the eye to the X-rays.

At the end of this five months I sent the patient to see Dr. Lancaster, and he reported that the patient could count his fingers at a distance of 60 centimetres instead of 25–30 centimetres as before; that the greatest gain was in the appearance of the scar, which was smaller, smoother, and less dense than before. To eliminate error in this examination, the vision was tested without atropine and after atropine had been in the eye for twenty-four hours.

I have satisfied myself in other cases that it is quite possible to expose the conjunctiva to the X-rays for therapeutic purposes, and this patient shows that it is practicable to expose the cornea to them. I hope to have the opportunity of pursuing this study farther with Dr. Lancaster, for the number of cases in which vision is impaired or lost through a diseased cornea is large; there seems to be no danger in the method if it is carried out with extreme care, and it is possible that some

among the many patients suffering from disease of the cornea may be relieved. Rodent ulcer of the cornea, as well as others, would probably yield to such treatment.

Good results have followed the use of the X-rays in a considerable number of diseases; what proportion of cases of a given disease will be relieved time will determine; the method is still a new and undeveloped one. The physics of the rays are not yet fully understood, and their mode of action is unknown; the theory that they act as a germicide is hardly probable, unless we consider that all the diseases in which they seem to exert a good influence are due to micro-organisms. It seems probable that when we have learned how the X-rays act, we shall have made advances, the influence of which will be far reaching and not second in importance to the discovery of the X-rays themselves.

Fluorometer

To those who are making a study of the uses of the X-rays the value of a simple instrument for determining the amount of rays issuing from a given vacuum tube is obvious. There are several ways in which this measurement may be made; I have chosen the following, which depends upon the distance that a tungstate of calcium screen must be held from a given vacuum tube, in order that the illumination from it may equal that from a radio-active substance which has been measured by a standard source of light. The radio-active substance with which I experimented was radium (Curie) that was most kindly placed at my disposal by Dr. Rollins. I found that when a tungstate of calcium screen with the radium lying upon it was placed over a vacuum tube in a dark room and the X-rays allowed to strike it, the radium was less bright than the luminous screen; but that as the screen was moved farther away from the vacuum tube the brightness of the screen diminished until a point was reached at which the screen was less bright than the radium; that then by approaching the screen gradually nearer the vacuum tube a point was found at which the radium and the screen were about equally bright. I experimented with several vacuum tubes in this way and found that the distance at which the screen and the radium were about equally bright was different with different tubes; the limit of variation being between ten and forty-one centimetres; and the distance was constant for the same tube under the same conditions. I then made a simple instrument by means of which the distance from a vacuum tube at which the light from the radium and the screen are about equal in brightness could be determined and thus the amount of fluorescence produced on the screen by a given tube be measured. This instrument can also be used to test the quality of the tungstate of calcium screens. In both tests the radium is the constant; and in the latter test the amount of fluorescence produced by a given tube must first be determined in order that the quality of the screen may be the only unknown quantity. I have called this instrument a fluorometer (see Fig. 410).

To use this instrument as a standard of measurement the radio-active substance must be compared with a standard of light. Mr. R. R. Lawrence, Instructor of Electrical Engineering in the Massachusetts Institute of Technology, has kindly tested the

radio-active substance (radium) that I have used, and this test indicated that the light it gave out was equal to that from a white surface when illuminated by a standard candle at a distance of about five metres (sixteen feet). He thought that a more accurate determination might be made by using in the photometer a light more similar to that given out by the radium than was then at his disposal. As by means of a photometer the amount of light given off by the radium can be measured in terms of a known standard, so the amount of fluorescence produced on a tungstate of calcium screen by a given tube and the brightness of which a given screen is capable may both eventually be referred to the same standard.

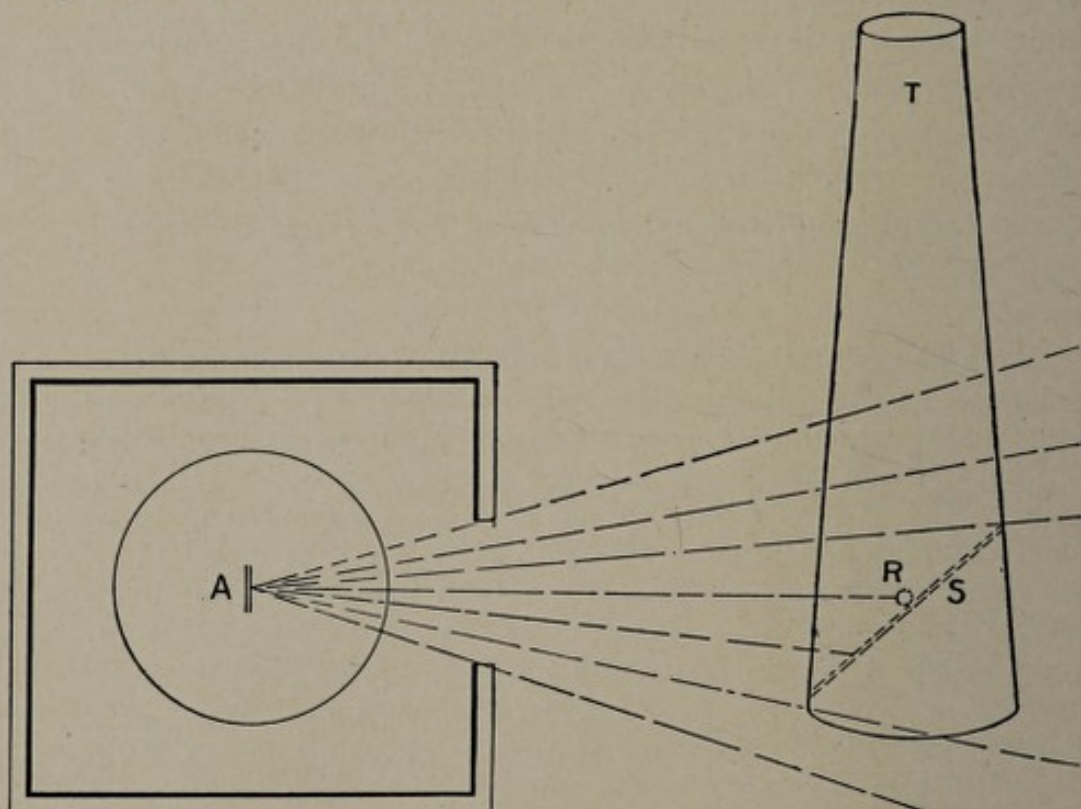


FIG. 410. Fluorometer. Instrument for determining the amount of fluorescence produced by different vacuum tubes on the tungstate of calcium screen, and also for determining the quality of different tungstate of calcium screens. The cut shows the section of a Rollins box, and of a vacuum tube, the anode of which is at *A*. The broken lines originating at *A* represent the cone of rays issuing from the box. At the right of the cut is shown a cardboard tube *T* the interior of which is black and in the lower end of which is a small oval screen *S* of tungstate of calcium; across this screen is fastened a sealed glass tube *R* eight centimetres long, containing some radium (Currie). This screen has been put at an angle in the tube in order that the instrument may be used without exposing the eye and the hand to the X-rays. To determine the amount of fluorescence produced on the tungstate of calcium screen by a given tube the room should be darkened; the tube *T* should be grasped near the top, and its opening, the rim of which is made soft by a covering of velvet, placed close to the eye; the tube *T* should be held at such a distance from the anode of the vacuum tube that the radium appears as a bright band on the less bright screen; then the cardboard tube should be brought gradually nearer the anode until a point is reached at which the amount of light from the radium *R* and the screen *S* is about equal (or the point when the band of light from the radium is just disappearing may be chosen). The distance between the radium and the anode should then be measured and noted. Vacuum tubes may thus be tested and the differences between them determined. By using a tube, the brilliancy of which has been thus determined, tungstate of calcium screens can also be thus tested and their different degrees of brightness measured. The brightness of the radium can be measured in terms of a known standard by a photometer, and then by means of a fluorometer the tube and the screen can be referred to the same standard.

INDEX

A

- Abbe, Dr., use of X-rays by, for recognition of calculi, 622, 626.
- Abbot, Dr., on use of X-rays in military surgery, 553.
- Abdomen, cases of cancer and of carcinoma of, at Boston City Hospital, 442.
- displacement of heart by distended, 286.
- malignant disease of, 346-347.
- new growths in, 375-378.
- X-rays in studying diseases of, 358.
- Abdominal muscles an assistance in expiration in emphysema, 197.
- Abscess, alveolar, 612.
- of liver, 353.
- of lung, 351-352.
- radiographs of, 573, 574.
- Absorption, law of, of X-rays, 2.
- Acne, 418, 453, 654-655.
- Acromegalia, 556, 578.
- Action, mode of, of X-rays, 393.
- Adhesions, displacement of heart by, 290-291, 293-294.
- See Pleuritic adhesions.
- Air, absorptive power of, 4.
- injection of, into intestines, 378.
- introduction of, into organs, 358.
- withdrawing, in pneumothorax, 237-238.
- Air passages, effects of obstruction of, 200, 201.
- obstruction of, due to enlarged glands, 349.
- Air resistance, character of vacuum tube should be defined by its, 46.
- Albarran, Dr., recognition of calculi by X-rays, 626-627.
- Albers-Schönberg, concerning therapeutic uses of X-rays, 392, 393, 396, 397-398, 399, 402, 406, 408-409, 411-412, 418.
- report of, on pictures of syphilitic diseases of joints, 597.
- Alcohol, intemperate use of, a cause of enlarged heart, 271.
- skin-tracings removed by, 79.
- Alcoholics, effect of, on appearance of lungs, 307-308.
- Alimentary canal, difficulties of X-ray examinations of, 357.
- Alopecia, Jutassy's production of a lasting, 416.
- Alsberg, Dr., recognition of calculus by X-rays, 625.
- Aluminum, radiograph of, 472.
- Aluminum screen, 47, 53-54.
- Anæmia, displacement of heart in, 297.
- examination of, by X-rays, 388.
- pernicious, 389.
- symptom of tuberculosis, 117, 120, 162.
- Analgesic, X-rays as an, 445, 663.
- Anatomy, use of X-rays in, 454.
- Aneurisms, 310-331.
- aortic, operations inadvisable when present, 331.
- appearances seen on screen in, 310.
- changes in outline of heart due to, 262.
- difference of X-ray and percussion determinations of left heart border in cases of, 276, 278.
- effect of pressure of, on bronchus, 200, 349.
- enlarged heart caused by, 271.
- illustration of difficulty of correct diagnosis of thoracic, 328-329.
- obstruction of bronchus due to, 349.
- subclavian, 317.
- thoracic, new growth may simulate, 332.
- Animals inoculated with bacteria, effect of X-rays on, 452.
- Ankle, cases of fractures of, at Boston City Hospital, 456.
- photographing fractures of, 501-505.
- time of exposure for photographing, 641.
- tuberculosis of, radiograph of, 590.
- Ankylosis, X-rays of use in examining, 598.
- Anode, of vacuum tubes, 34.
- and target united, 35-36.
- Antrum, cases of cancer of, at Boston City Hospital, 442.
- Anus, case of cancer of, at Boston City Hospital, 442.
- Aorta, aneurism of, 310, 312-313, 322-324.
- appearance of, on screen, 100.
- dilatation of, in aortic insufficiency, 300.
- dilatation of, recognized by X-ray examination, 320.
- Aortic arch, tumor in region of, 329.
- Aortic insufficiency, excursion of heart in, 299.
- Apex beat of heart, 252-253.

- Apparatus, X-ray, 8-58, 636-641.
 for examining children, 385.
 in India, 553.
 for locating foreign bodies, 533-538.
 for photographing teeth, 603-606.
 precautions concerning, in therapeutic uses of X-rays, 446-447.
 size of, in surgery, 455.
 in therapeutic uses of X-rays, 393-394, 401, 646.
 for treating cancer, 421-423.
- Appendicitis confounded with pneumonia, 192.
- Arc light, Finsen's experiments with, and bacteria, 452.
 in treatment of lupus, 407.
 in treatment of rodent ulcer, 444.
- Army, use of X-rays in the, 553-555.
- Arteries, X-ray photographs of, 386-387.
- Arterio-sclerosis, 317.
 as cause of enlarged heart, 271.
 inferred from enlarged heart, 283.
- Artery, pulmonary, appearance of, on fluorescent screen, 100.
- Arthritis, of joints, X-ray examinations of service in, 556.
 of finger-joints, radiograph of, 597.
- Articular rheumatism, 445, 446.
- Ascites, 375.
- Ascitic fluid and water, experiment with, 6.
- Association of an acute and chronic process, 354.
- Astragalus, case of removal of, 562.
- Atelectasis may be observed on fluorescent screen, 353.
- Atomic weight of elements of human body, 2-3.
- Atrophy of bone and joint structures, X-ray examinations of service in, 556.
- Auricle, right, appearance of, on screen, 100, 252.
 enlarged in emphysema, 193.
- Auscultation, examination by, in carcinoma of liver, 376-377.
 in examining chest, 109.
 in examining heart and lungs, 162.
 for murmurs of heart, 301.
 pneumonia in early stages may give no signs by, 183.
 in cases of tumors in chest, 339-340.
 more definite signs by X-rays than by, 149.
 X-ray examinations should be taught in connection with, 355.
- Autopsy, confirmation of X-ray determinations by, in cases of—
 aneurism, 326-328.
 broncho-pneumonia, 192.
 calculi, 622.
 new growths, 338-339.
 pleurisy, 216-217.
 tumor of head, 340.
- A. W. L. universal coil, 28-31, 63, 640.
 in photographing teeth, 603.
- Axilla, cases of cancer and of carcinoma of, at Boston City Hospital, 442.
- Axis of heart, inclination of, 247-248, 286, 295, 297.
- ### B
- Back, case of healing of ulcerations on, after rays had traversed body, 419-420.
- Bacteria, effect of X-rays on, 448-453.
- Bacterium coli, X-ray experiments with, 450.
- Bagge, Dr. Ivar, case of tuberculosis in a wound reported by, 419-420.
- Baldwin, J. F., localization of button in œsophagus by, 540.
- Balthazard, Dr., observation of digestive process by, 372-373.
- Bandages, radiographs of, 472.
- Barker, G. F., 1, 2.
- Barthélemy, on mode of action of X-rays in treatment of lupus, 393.
 on use of X-rays in—
 acromegalia, 578.
 Pott's disease in children, 596.
 tubercular osteitis, 594.
 tuberculosis of bones, 592.
- Bassuel on heart in systole, 254-255.
- Battersby, Major, on use of X-rays in military surgery, 554.
- Beard, removal of, in lymphomata colli, 417.
 sycosis of the, 415.
- Beatson, Dr., report of case of "stave of thumb" fracture by, 492.
- Beck, experiments of, with color-producing bacteria and X-rays, 449.
 use of radiograph in spina bifida by, 464.
 use of radiograph to detect gall stones by, 630.
- Beclere, Dr., 356.
- Becquerel rays and X-rays, theory concerning, 1.
- Beavor, Surgeon Major, on use of X-rays in military surgery, 553.
- Benedikt, Dr., 356.
 on value of X-rays in diagnosis of diseases of vertebræ, 587.
- Bergonie, Dr., cases of acute phthisis reported by, 418.
- Bertin-Sans, Dr., on study of articular movement by X-rays, 389.
- Berton, Dr., experiments of, with diphtheria bacilli and X-rays, 449.
- Bevan, Dr., recognition of calculus by X-rays, 623.
- Bicycle used to charge storage battery, 554.
- Birth-mark, therapeutic use of X-rays for removing, 453.
- Bismuth, for recognizing diverticulum, 357.
 injected into sinus in empyema, 241.
 introduction of, into hollow organs, 358.
 for observing intestines, 378, 645.
 for recognizing sinus, 458.
 for observing stomach, 359, 362, 366, 369-370, 373.

- Bladder, calculi in, 615.
cases of cancer and of carcinoma of, at Boston City Hospital, 442.
method of examination for, 621.
- Blaikie, J. Brunton, experiments of, with bacteria and X-rays, 450.
- Blanks for X-ray records, 79-80.
- Blondes, skin of, reacts most quickly to X-rays, 416.
- Blood, specific gravity of, and water, experiment with, 6-7.
- Blood vessels, normal, X-ray photographs of, 386-387.
- Boas, Dr., fluorescent screen used by, to observe digestive tract, 373.
- Body, constituents of the, 3, 5.
locating foreign substances in, 81-86. *See* Foreign bodies.
photographing different parts of, 88-96, 641.
- Bone, comminution by bullets, shown by X-rays, 554-555.
comparison of well and affected, 457.
decalcified, radiograph of, 616.
diseases of, 556-587.
disturbance of development of, in cretinism, 461.
new growths in, 332.
opacity of, to X-rays, 2.
use of X-rays in diseases of, 454.
- Bones, of forearm, radiograph of dislocation of both, 527.
of leg, radiographs of fractures of, 505, 506, 509, 516-519.
long exposure for details of, 96.
metacarpal, fracture of, 491-492, 494.
metatarsal, photographing, 522.
regeneration of, after operation, 562.
tuberculosis of, 575.
- Borden, Captain, on use of X-rays in military surgery, 554.
- Borders of heart, method of determining, with X-rays, 247.
- Bordier, Dr., on changes produced in skin by exposure to excited vacuum tube, 447.
- Boston City Hospital, cases of cancers and of carcinomas at, 441-442.
cases of fractures treated at, 455, 456.
- Bouchacourt, Dr., on use of X-ray photograph in study of pelvis, 378-379.
- Bouchard, Dr., 356.
- Bowed leg, fracture mistaken for, 522.
- Bowels should be empty in examining organs below diaphragm, 359-360.
- Box for vacuum tube, 50-55, 400-401, 446.
- Braatz, Dr., recognition of calculus by X-rays, 627.
- Brain, tumors in, difficulty of detection by X-rays, 340.
- Break, Spottiswoode's electrolytic, 20.
- Breast, cancers of the, 420, 670-671.
carcinoma of, treatment of, by X-rays, 421, 670-671.
cases of cancer and of carcinoma of, at Boston City Hospital, 442.
- Breathing, effect of, on position of heart, 247-248.
See Respiration.
- Brightness, of lungs in X-ray examination, 100.
comparative, of lungs in tuberculosis, 119.
- Bromide paper for X-ray pictures, 57, 554.
- Bronchial glands, hypertrophied, in pulmonary tuberculosis, 119.
- Bronchitis, 200-201.
excursion of diaphragm in, 198.
and tuberculosis, 124, 140, 141-142.
- Broncho-pneumonia, shadow in cases of, 192.
- Bronchus, obstruction of, due to aneurism, 349.
- Brunettes, skin of, reacts less quickly to X-rays, 416.
- Bullets, localization of, by X-rays, 531-532, 539.
See Surgery, military.
- Burn, cause of so-called X-ray, 447-448.
curative effect of X-ray, 421-422.
- Burns avoidable in therapeutic use of X-rays, 443.
- Butterfly lupus erythematosus, cases of, 405-406, 652.
- C
- Calcification, of pleuritic membrane, 233.
of tissues, 385-387.
- Calcium, atomic weight of, 3, 4.
phosphate of, radiograph of, 5.
triphosphate of, in human body, 3.
- Calculi, 4, 615-632.
radiographs of, 616, 619, 620.
- Calculus, vesical, radiograph of, 618.
- Caldwell, Eugene W., stereo-fluoroscopic apparatus employed by, 640.
- Callus, new and old, about a fracture, 490.
radiograph of, 516.
- Cancer, cases of, at Boston City Hospital for a series of years, 441-442.
epidermoid, 423, 657-658, 664-665.
external forms of, 421, 657-661.
inoperable cases of, 440, 663.
internal forms of, 672.
of hand, 431-437.
of liver, 347.
of pylorus, 377.
of tongue, 663.
- Cancers of the breast, 420, 670-671.
- Cannon, Dr. W. B., observations of process of digestion by, 360, 372, 645-646.
- Capsules, digestive tract observed by means of, 373.
- Carbon, atomic weight of, 3.
- Carbonate of calcium, radiograph of, 5.
- Carbonate of magnesium, radiograph of, 5.
- Carbonate of sodium, radiograph of, 5.

- Carcinoma, 578, 581.
 cases of, at Boston City Hospital for a series of years, 441-442.
 of the breast, 421, 670-671.
 epidermoid, 658-659.
 of the liver, 376-377.
 metastatic, 587.
 of the stomach, 376, 421.
- Cardiac disease, 299.
- Cardiac enlargement, 271.
- Caries of spine, 594, 596.
- Carotid artery, ligating, in aneurism, 317.
- Cartilage, cricoid, photographing the, 89.
 loose, of joints, X-ray examinations in, 556.
 radiograph of, 599.
- Catgut, radiograph of needle threaded with, 472.
- Cathode of vacuum tubes, 34.
- Cats, Dr. Cannon's observations of stomachs and intestines of, 360, 372, 645-646.
- Cauterization, hot air, for lupus, 395.
- Cautery, Paquelin's, spread of lupus after use of, 406.
- Celluloid, capsules of, for observing digestive tract, 373.
 use of, for recording fluorescent screen appearances, 77.
- Cervix femoris, greenstick fracture of, 578.
- Cheek, epithelioma of, 660.
- Chemical composition to be considered in using X-rays, 7.
- Chest, X-ray examinations of, 71, 74, 100, 102, 354-355.
 dimensions of, determine excursion of diaphragm, 108.
 fluorescent screen best for examinations of, 109, 639.
 foreign bodies in, locating, 86.
 in hydrothorax, appearance of, on screen, 234.
 in pleurisy, appearances in, 202-204.
 in pneumothorax, appearances in, 234.
 time of exposure for photographing the, 641.
 tracings on the, 79.
- Chest wall, new growth in, 345-346.
- Children, articular rheumatism in, relieved by X-rays, 445-446.
 epiphyseal lesions in, 461.
 injuries of humerus common in, 467.
 observations of spleen of, 374.
 observations of stomachs of, 360-372.
 outline of liver in, 373.
 Pott's disease in, 596.
 small leftward movement of heart in, 301.
 tuberculous foci on spinal column of, 594.
 X-ray examination of, 384-385.
- Chloride of calcium, risk of drying static machine with, 14.
- Chloride of potassium, radiograph of, 5.
- Chloride of sodium, radiograph of, 5.
- Chlorine, atomic weight of, 3.
- Chlorosis, displacement of heart in, 297.
- Cholelithiasis, radiographs of cases of, 630.
- Cholera vibriones, experiments with cultures of, 450.
- Chondroma, X-ray examinations of service in, 556.
- Chondrosarcoma, 556, 583, 585.
 of femur, radiograph of, 581.
 photograph of, 580.
- Church, Dr. Archibald, report of, concerning tumor in head, 340.
- Clapp, Dr. Dwight M., radiographs of teeth by, 608, 609, 610, 611, 613, 614.
- Classen, Dr., account by, of case of enlarged glands simulating the outline produced by aneurism, 348-349.
- Clavicles, appearance of, on fluorescent screen in emphysema, 193.
 fractures of, at Boston City Hospital, 456.
 normal outlines of, on screen, 102-103.
 position of plate in photographing, 482.
 radiograph of, 104.
- Clitoris, case of cancer of, at Boston City Hospital, 442.
- Cloth easily penetrated by rays, 59.
- Clothing, removal of, in medico-legal cases, 86.
- Coccyx, fractures of, at Boston City Hospital, 456.
- Codman, E. A., on X-ray study of anatomy, 454.
- Coils, static machine compared with, 639-640.
- Colds bordering on pneumonia, 192.
- Colon, descending, method of following outline of, 358.
- Colonies, bacterial, effects of X-rays on developed, 451.
- Comedones, 418.
- Comparison, of static machine and coils, 639-640.
 between X-ray photographs and screen examinations. *See* Fluorescent screen examinations.
 of X-ray with percussion and auscultation determinations. *See* Auscultation, Percussion.
- Condenser for static machine, 19.
- Congestion, how detected, 103.
 passive, of lungs, 307.
 pulmonary, lack of brightness in lungs due to, 308.
 shadows on fluorescent screen in, 158, 201.
- Consonants, shape of palate in pronouncing the, 389.
- Constipation, displacement of heart in anæmia with, 297-298.
 size of heart in anæmia with, 388-389.
- Contraction, heart displaced by, 290-291.
- Contremoulin, Dr., report by, of radiographs of muscles of animals, 466.
- Copper, piece of, in eye, 538-539.
- Cornea, X-ray treatment of disease of, 679-680, 681.

- Corson, Eugene R., references to articles by, 454, 461.
 Cotton, dressings, 86.
 radiograph of, 472.
 Cough, morning, an indication of tuberculosis, 140.
 Councilman, Dr. W. T., 164, 272, 433-435, 436, 656.
 Coxa vara, 575, 578.
 radiograph of, 577.
 Coxitis, value of X-rays in, 594.
 Crayons for skin-tracings, 77-78.
 Cretinism, disturbance of development of bones in, 461.
 Cretins, development of skeleton in, 461-462.
 Cricoid cartilage, photographing the, 89.
 Crookes, construction of vacuum tube by, 34.
 Cures, of diphtheria, increase in percentage of, 160.
 possibility of, in cases of pulmonary tuberculosis, 160.
 Curtain for hiding static machine, 93.
 Cushing, Dr. H. W., report by, of cases of regeneration of bones after operation, 562-564.

D

- Dactylitis, syphilitic, 597.
 Dampness, removal of, from plates, 14.
 Davidson, J. Mackenzie, apparatus for locating foreign bodies devised by, 533-535.
 radiographs by, 578.
 report by, of recognition of calculi by X-rays, 625.
 stereoscopic fluoroscope devised by, 640.
 Davis, Edward P., photograph of gravid uterus by, 382.
 De la Camp, Dr., report of case of myositis ossificans by, 465-466.
 Densitometer, 105-106.
 Density, contrasts in, offer opportunity for X-ray examination, 377.
 in lung, an obstruction in viewing heart, 247.
 in lungs, X-rays indicate increase in, 306-307.
 of lungs in pneumonia, 164-167.
 pulmonary, X-ray examination an aid in showing, 191.
 Dent, Dr. C. T., on use of X-rays in fractures, 468.
 Dental surgery, use of X-rays in, 603-614.
 Depilation produced by X-ray exposure, 391.
 Dermatitis produced by exposure to X-rays, 391, 409.
 avoided by caution, 399.
 time necessary to heal a, 396.
 unnecessary in treatment of lupus, 393, 651.
 Despeignes, Dr., X-ray treatment of carcinoma of stomach by, 421.
 Destot, Dr., 447.
 Development of X-ray picture, 57.
 Dextrocardia, case of apparent, 298.
 Diagnosis, in pneumonia made certain by use of X-rays, 183-186.
 more than one X-ray examination often necessary to determine, 191.
 of pulmonary tuberculosis, 120-122, 124.
 of pulpless teeth, 611.
 X-ray apparatus a help to a definite, 355.
 See Autopsy.
 Diagrams of X-ray appearances in chest in —
 aneurism, 311.
 aortic insufficiency, 299.
 emphysema of lungs, 104.
 health, full inspiration, 101.
 heart movements, normal, 254.
 passive congestion or œdema of lungs, 307.
 pleurisy with large effusion, 204.
 pleurisy with small effusion, 203.
 pneumohydrothorax, 242.
 pneumothorax, 235.
 pulmonary tuberculosis, 115.
 Diameter of heart, errors to be avoided in measuring, 263.
 relation of, to height of individual, 261.
 Diameter of pelvis, measurement of, 379.
 Diaphragm of body, appearance of, on screen, 100.
 depression of, due to aneurism, 349.
 displacement of, by ascitic fluid, 375.
 displacement of heart by, 286.
 effects of position of, in measuring heart, 269.
 heart rests on, during expiration, 247.
 limitation of movement of, in pneumonia, 171.
 outline of, in pleurisy with effusion, 202.
 pneumonia and unequal excursion of, 288-290.
 position of, in pneumohydrothorax, 245.
 position of, in pneumothorax, 234.
 See Excursion of diaphragm.
 Diaphragm for vacuum tube, 47, 49-50, 52, 60, 63, 95, 97, 604.
 Diaphysis of femur, curvature of, 578.
 Diastole, experiments on form of heart in, 253-257.
 Difference of X-ray and percussion determinations of left heart border, 276-279.
 Diffraction bands by X-rays, 1-2.
 Digestion, physiology of, X-rays a means for studying, 371-372, 645-646.
 size and position of stomach during, 361-372.
 Dilatation, aneurismal, of innominate artery, 322.
 of aorta recognized by X-ray examination, 320.
 of heart by exercise, 390.
 Diphtheria, increased percentage of cures in, 160.
 Diphtheria bacillus, X-ray experiments with, 449, 451.

- Disintegration of spinal column, 578.
 Dislocation of hips mistaken for coxa vara, 578.
 Dislocations, 526-530.
 Displacement of heart, 111, 167, 188, 204, 213, 234, 279, 283-298, 642.
 Distension, abdominal, effect of, on heart, 288.
 Diverticulum, method of recognizing, 357-358.
 Dogs, experiments with hearts of, 255-256.
 observations of digestion in stomachs of, 372.
 Dollinger, Dr., 418, 419.
 Dore, Dr., on Finsen's concentrated light treatment of lupus and rodent ulcer, 444-445.
 Dorsalis pedis artery, recognizing, by X-ray photographs, 387.
 Drainage tube, radiograph of, 472.
 Dressings, advantage of cotton, in taking radiographs, 86, 471, 473.
 Dried egg albumen, radiograph of, 5.
 Ductus arteriosus Botalli, persistence of the, 301.
 Dyspepsia a symptom of tuberculosis, 162.
 Dyspnoea, in case of aneurism of aorta, 315, 322.
 in case of emphysema, 195, 218.
 in case of enlarged glands, 347.
 in case of interstitial fibrous pneumonia, 343.
 possible cause of thoracic aneurism, 313.

E

- Ear, case of cancer of, at Boston City Hospital, 442.
 Eastman paper for use in military surgery, 554.
 Echinococcus, of lung, 346.
 of liver, 373.
 Eclampsia, photograph of uterus in, 382.
 Eczema, 407-411.
 Hahn and Albers-Schönberg's conclusions concerning X-ray treatment of, 411-412.
 treatment of, by X-rays, 407-412, 652-653.
 Elbow, fractures of, at Boston City Hospital, 456.
 time of exposure for photographing the, 641.
 Elbow-joint, photographing fracture of, 485-487.
 radiographs of, 457.
 tuberculous, treatment of, by X-rays, 419, 594.
 Electric current for induction coils, 8.
 Electrolytic break, Spottiswoode's, 20.
 Elements of human body, table of atomic weights of, 3.
 Elephantiasis, X-ray treatment of, 655.
 Embryology, use of X-rays in, 454.
 Emphysema, an aid in following pulsations of right auricle, 252.
 association of tuberculosis with, 140-141.
 displacement of heart by, 642.
 enlargement of heart due to, 272.
 heart drawn down in, 288.
 inferred from enlarged heart, 283.
 of the lungs, 193-200, 262, 633.
 Emphysema (*continued*) —
 lungs permeable by rays in, 262.
 pleurisy with effusion complicated with, 218.
 pulmonary, a hindrance in heart-examination by percussion, 198, 281.
 radiograph of case of, 199.
 tuberculosis symptoms disguised by, 124, 198, 199.
 Empyema, interlobar, 218.
 after pneumonia, 192.
 suggested by darkened lower lung, 353.
 with permanent opening, 241.
 X-rays an assistance in recognizing, 353.
 Enlargement of heart, 167, 188, 262.
 chief causes of, 271-272.
 Ensiform cartilage, 79.
 Epiphysis, absence of union of, 578.
 delayed union of, 459.
 dislocation and separation of, radiographs of, 528, 529.
 fracture of, radiograph of, 521.
 separation of, at lower end of tibia, radiograph of, 507, 508.
 Epithelioma, of hand, 431.
 of lip, 430, 670.
 Epitheliomas treated by X-rays, 440, 659-661.
 Equipment, X-ray, 8-58, 636-641. *See* Apparatus.
 Errors to be avoided in X-ray examination of bones, 471.
 Erysipelas, observation of cases of lupus with, 393.
 Erythema, in case of eczema of beard, 415.
 from short exposures, 447.
 after treatment for hypertrichosis, 417.
 Eve, Frederick, report of case of myositis ossificans traumatica by, 465.
 Examination, annual, recommended, 309.
 of bladder, 621.
 in diseases of bones, 559.
 of chest, 354-355.
 in emphysema, 194, 642.
 fluorescent screen. *See* Fluorescent screen examinations.
 in fractures, 468-525.
 of frontal cavities, 464-465.
 of heart, 263-270, 644.
 of joints and cartilages, 587.
 of kidneys, 374, 617.
 of lungs in pneumonia, 168.
 of pneumothorax, 234.
 of pneumohydro or pyothorax, 241-244.
 of new growths, 109.
 of new growths in thorax, 334-338.
 ordinary physical, incomplete without an X-ray examination, 355.
 in pleurisy with effusion, 205, 642-644.
 precautionary X-ray, 147.
 preliminary, with fluorescent screen, 99.
 of teeth, 606.
 of thoracic aneurisms, 310.

Examination (*continued*) —

- of thorax, 76-77, 642-644.
- in tuberculosis, 117-118.
- of ureters, 619.
- of X-ray negatives, 96.
- Examinations, comparison of X-ray, with percussion and auscultation, in —
 - diseases of heart, 272-283.
 - pleurisy with effusion, 213, 217.
 - pneumonia, 173, 183-186.
 - tuberculosis, 149-151.
 - tumors in chest, 339-343.
- X-ray, as supplement to palpation, 191.
- method of making X-ray, 59-99. *See* Fluorescent screen examinations.
- Excoriation of skin by X-rays, 392, 394.
- Excursion of diaphragm, affected by pleuritic adhesions, 229, 230.
- in anaemia, 388, 389.
- in aortic aneurism, 319.
- in bronchitic cases, 200.
- in emphysema of lungs, 193.
- in gangrene of lung, 351, 352.
- normal, 106.
- in pneumonia, 167, 288-290.
- in pulmonary tuberculosis, 111-115.
- shortened owing to a severe cold, 137.
- in tuberculosis, 288.
- Exercise, effect of excessive, on heart, 390.
- Exertion, pain in side after, 233.
- Exostosis, 556.
- luxurians, 466.
- radiograph of case of, 586.
- of ulna and radius, radiographs of, 588, 589.
- Expectoration in early stages of pulmonary tuberculosis, 121-122.
- Experience, essential in using X-ray apparatus, 446, 649-650.
- necessary for X-ray diagnosis, 356.
- Experiments, Forster and Hugi's, with radiographs, 546, 550.
- Ludwig and Hesse's, 253-257.
- Rollins', with guinea pigs, 672-674.
- Expiration, effect of, on appearance of lungs on screen, 100.
- incomplete, due to enlarged glands, 349.
- position of heart during, 247.
- See* Respiration.
- Exposure of plates, 62-64, 96-98, 641.
- in photographing bones and soft tissues, 96.
- in photographing lungs, 108.
- in photographing teeth, 606-607.
- table of times for, 641.
- Exudation, eczema with, 411.
- Eye, localizing foreign body in, 536-539.
- new growths on lid of, 427-429, 657-658.
- Eyes, adaptation of, to dark room, 75.
- method of deciding whether at fault, 103-106.
- necessity for training, in use of X-rays, 103.

F

- Face, cases of cancer and of carcinoma of, at Boston City Hospital, 442.
- photographing bones of, 475.
- Fats readily traversed by rays, 3.
- Favus, X-ray treatment for, 411-412.
- X-ray treatment for, Freund and Schiff's, 414-416.
- Feilchenfeld, Dr., report of case of spina ventosa by, 562.
- Femur, changes in neck of, 578.
- chondrosarcoma of, radiograph of, 581.
- coxitis delays ossification of, 594.
- curvature of, diaphysis of, 578.
- dislocation of, radiographs of, 528, 529.
- fracture of left, radiograph of, 497, 498.
- photographing fractures of, 495-496.
- Femurs, fractures of, at Boston City Hospital, 456.
- fracture of both, 488-490.
- Fenwick, Dr., method of, of examination of kidney outside the body, 621.
- Fever, lack of, in pneumonia in old patients, 185.
- Fewkes, E. E., 635, 637.
- Fibrosis, pulmonary, displacement of heart by, 291.
- Fibula, fractures of, radiographs of, 504, 507, 508, 511, 512, 520, 560.
- osteitis of, radiograph of, 560.
- periostitis of, radiographs of, 558, 559.
- split in, and fracture of tibia, radiograph of, 510.
- Films, development of, 57.
- Finger, glass in, radiograph of, 550.
- spina ventosa of, 562.
- diseased, radiographs of, 582, 583.
- tumor of, radiograph of, 585.
- Finger-nails, effect of X-rays on, 393.
- Fingers, fractures of, at Boston City Hospital, 456.
- photographing the, 98.
- Finsen's light treatment, for bacteria, 452.
- of lupus, 407.
- of rodent ulcer, 444-445.
- Fiorentine, Dr., experiments of, with X-rays and animals inoculated with bacteria, 453.
- Flesh, transparent to X-rays, 2.
- Fluid, in thorax, 353.
- pleuritic, 213, 230, 285-286, 643.
- serous, 205.
- Fluorescent screen, of assistance to surgeon in connection with radiograph, 455.
- importance of, in diagnosis of aneurism, 328.
- localization of foreign bodies by, 531-532.
- value in studying pulmonary tuberculosis, 111.
- Fluorescent screen appearances, in bronchitis, 200.
- in case of apparent dextrocardia, 298.
- in emphysema, 193, 642.
- in heart-examinations, 247, 262, 270, 285-288.

- Fluorescent screen appearances (*continued*) —
 in hydrothorax, 234.
 in pleurisy with effusion, 202-205, 642-644.
 in pneumothorax, 234.
 in pneumohydrothorax, 241, 243, 642.
 in pneumonia, 164-180.
- Fluorescent screen examinations, for calculi, 617.
 comparison between X-ray photographs and,
 in —
 early tuberculosis, 120.
 fractures, 99.
 heart-diseases, 270.
 localization of foreign bodies, 99, 554.
 pleurisy, 205.
 pneumonia, 169-173.
 study of thorax, 99.
 of heart, 247-253, 257-270.
 of œsophagus, 357.
 rules for, 74-77.
- Fluoride of calcium, radiograph of, 5.
- Fluorine, atomic weight of, 3.
- Fluorometer, 681-682.
- Fluoroscope, 56. *See* Fluorescent screen.
 stereoscopic, 640.
- Fœtus, determining size and position of, 382-383.
 photograph of, 459.
- Food, length of stay in stomach, 372-373.
 stomach should be free from, for examination,
 360.
 tracings of stomach containing, 361-371.
- Foot, cases of cancer and of carcinoma of, at
 Boston City Hospital, 442.
 chronic swelling of, 522.
 flat, 598, 601.
 fractures of, at Boston City Hospital, 456.
 method of photographing, 89, 522-525.
 radiographs of, 523, 524, 552.
 time of exposure for photographing, 641.
 tuberculosis of, 587, 591, 592, 662-663.
- Forearm, fractures of, at Boston City Hospital, 456.
 photographing the, 93, 641.
 radiograph of dislocation of both bones of,
 527.
 tumors on, X-ray examination of, 596.
- Foreign bodies, in air passages, 200.
 fluorescent screen sometimes best for studying,
 99, 455.
 localization of, 81-86, 454, 531-552.
 necessity for taking two views of, 98.
- Forster, account by, of experiments in detecting
 pieces of metal by radiographs, 546-550.
- Fracture, greenstick, of cervix femoris, 578.
 mistaken for bowed leg, 522.
 of ulna, 481.
- Fractures, in children, use of X-rays in, 384.
 necessity for taking two views of, 98.
 radiograph of, preferable to screen examina-
 tion, 99.
 radiographs of. *See* Radiographs of fractures.
- Fractures (*continued*) —
 records of cases at Boston City Hospital, 455,
 456.
 use of X-rays in gunshot, 554-555.
 X-rays used in studying, 454, 467-524.
- Frei, construction of vacuum tube by, 34.
- Freund, on apparatus for therapeutic uses, 394.
 on Finsen's concentrated light treatment, 407.
 on frequency of sittings, 402.
 on recurrence of lupus after X-ray treatment,
 398.
 on treatment of acne and comedones, 418.
 on treatment of hypertrichosis, 391, 417.
 on treatment of sycosis and favus, 414-416.
 on Trendelenburg position for photographing
 pelvis, 379.
 use of X-ray photography by, in fractures, 522.
- Fripp, Dr., recognition of calculus by X-rays, 623.
- Frog, experiments with X-rays on heart of, 449-
 450.
- Frogs, observations of digestion in stomachs of,
 372.
- Frontal cavities, X-rays an aid in examining,
 464-465.

G

- Gall bladder, calculi in, 615.
 cases of cancer of, at Boston City Hospital, 442.
- Gallois, E., work by, on X-ray treatment of frac-
 tures, 468.
- Gall stones, 445, 630.
 radiograph of, 616.
- Gangrene of lung, 351-352.
- Gas, introduction of, into hollow organs, 358.
 liberation of, from terminals and walls of vac-
 uum tube, 42-45.
 in pleuræ, effect on heart of, 285-286.
- Gases almost wholly transparent to rays, 4.
- Gassmann, on changes produced in skin by X-ray
 treatment, 396, 447.
 on recurrence of lupus, 398.
 treatment of sycosis by, 416, 653.
- Gautier, Dr., on treatment of acne by X-rays,
 654-655.
- Gelatin, radiograph of, 5.
- Genoud, experiments by, with X-rays and animals
 inoculated with bacteria, 452-453.
- Girdwood, G. P., method of locating foreign bodies
 devised by, 533.
 use of stereoscopic pictures by, 457, 471.
- Glands, enlarged, 347-351.
 tuberculous, 674.
- Glass, best material for plates of static machine,
 10.
 in finger, radiograph of, 550.
 obstacle to passage of rays, 40, 41.
 tracing outlines of heart on, 264.
 use of, for recording appearances, 77.
- Glycerine, radiograph of, 5.

- Gocht on therapeutic uses of X-rays, 393, 395, 398, 406, 417, 420, 421, 448.
- Godlee, R. J., reports of, on changes in neck of femur, 578.
- Goitre, exophthalmic, 679.
- Goodspeed, A. W., radiographs by, 594, 637.
- Görl, Dr., recognition of calculus by X-rays, 623.
- Gout, cartilages affected by, 598.
- Graves' disease, X-ray treatment of, 679.
- Gravid uterus, 382.
- Greenleaf, Dr. Clarence A., on therapeutic treatment of lupus vulgaris by X-rays, 651.
- Groin, cases of cancer and of carcinoma of, at Boston City Hospital, 442.
- Grossman's localizer of foreign bodies in eye, 536-537.
- Growths, localization of foreign, 81-86.
new, use of fluorescent screen in determining position of, 109. *See* New growths.
- Grunmach, Dr., 356.
- Guinea pigs inoculated with bacteria, effect of X-rays on, 452.
Rollins' experiments with, to ascertain effect of X-rays on cell growth, 672-674.
- Gussenbauer, Dr., 587.

H

- Hahn, on therapeutic uses of X-rays, 392, 393, 397, 398, 406, 407-409, 411-412, 418, 653, 655.
X-ray study of syphilitic diseases by, 596.
- Hair, removal of, in treating sycosis and favus, 414. *See* Hypertrichosis.
- Hand, cancer of, 431-433.
cases of cancer and of carcinoma of, at Boston City Hospital, 442.
congenital malformation of, 462, 463.
epithelioma of, 431-433.
fracture of, at Boston City Hospital, 456.
needle in, 545, 546, 547.
photograph of, 584.
photographing the, 93, 98, 641.
- Hansmann, Frida, on resistance of vacuum tube, 646.
- Harrison's localizer of foreign bodies, 535-536.
- Harvey, opinion of, on shape of heart in systole, 254.
- Haughton quoted concerning use of X-rays in military surgery, 553.
- Hawkes, H. D., on so-called X-ray burn, 447.
- Head, eczema of, treatment of, by X-rays, 408.
examination of, for fracture, 475.
position of plate and tube in photographing, 88.
time of exposure for photographing, 641.
tumors in, 340.
- Healing, process of, in lupus cases, 395-396.
- Heart, 247-309, 644.
appearance of, in emphysema, 193.
- Heart (*continued*) —
appearance of, on fluorescent screen, 100.
best time for measuring, 248-249, 253.
displacement of, 283-298.
in pleurisy, 204, 213, 291.
in pneumonia, 167, 188.
in pneumothorax, 234, 235.
in pulmonary tuberculosis, 111.
not recognized by percussion, 279.
examination of, by auscultation and percussion, 162, 282.
examination of, by X-rays, 247, 262, 270, 285, 288.
experiments by Ludwig and Hesse on form of, 253-257.
fatty, 271.
murmurs, 301, 305.
normal, 247-283.
overtaxing the, 309.
photographing the, 93-95, 270.
pleuritic adhesions shown by displacement of, 233.
position of, affected by new growths in abdomen, 375-376.
position of, in pulmonary tuberculosis, 119.
size of, 270-283.
size of, in anaemia, 388.
size and position best determined by X-rays, 633.
weights compared with widths, 273-275.
width of, in mitral insufficiency, 304.
width of normal, 260.
- Heart sounds, hearing the, 17, 93.
- Hearts of dogs, experiments with, 255-256.
- Hedley, W. S., account by, of method of locating foreign bodies, 533-535.
- Height of individual, width of heart in relation to, 261.
- Heinze electrolytic interrupter, 21, 22, 25, 637-638.
- Herman, Dr., recognition of calculi by X-rays, 624-625.
- Hesse, experiments by, on form of heart, 253-257.
- Hip, case of carcinoma of, at Boston City Hospital, 442.
disease, use of X-rays in, 384.
time of exposure for photographing the, 641.
tuberculosis of, radiograph of, 593.
- Hip-joint, photographing the, 493-495.
- Hips, dislocation of, mistaken for coxa vara, 578.
- Hoarseness, aneurism indicated by, 323, 324.
- Hodgkin's disease, X-ray treatment of, 675-679.
- Hoffmann, Dr., investigations by, on movements of the heart, 301, 304-305.
- Hofmeister, Dr., on disturbance of development of bones in cretinism, 461.
- Holder, for pencil in skin tracings, 77.
for vacuum tube, 47-55, 604, 605, 647.
- Holland, Dr. Thurston, on treatment of lupus by X-rays, 651.

Holtz influence machine, 8.
 necessity of case for, 14.
 Horsehair, radiograph of needle threaded with, 472.
 Hugi, account by, of experiments in detecting pieces of metal by radiographs, 546-550.
 Humerus, fractures of, radiographs of, 476-479.
 osteosarcoma of, radiograph of, 579.
 tumor of, use of X-rays in treating, 596.
 Hydrocele fluid and water, experiment with, 6.
 Hydrogen, atomic weight of, 3.
 Hydrothorax, 234.
 Hyndman, H. H. F., 1, 2.
 Hyoid bone, cut of, 88.
 photographing the, 89.
 Hyperæmia, in case of sycosis of beard, 415.
 caused by short exposures, 447.
 inclination to, diminished by vaseline, 397.
 Hypertrichosis, treatment of, by X-rays, 391, 416-417.
 Hypertrophy of bone and cartilages, 556.
 Hyposulphite of soda solution, for fixing negatives, 58.
 Hysteria, difference of X-ray and percussion determinations of heart border in cases of, 278.

I

Imbert, Dr., on study of articular movement by X-rays, 389.
 Immelman, Dr., 446.
 India, X-ray apparatus in, 553.
 Induction coils, 8, 19-31, 637-640.
 Inexperience, danger of, in X-ray examinations, 356, 649-650.
 Inflammation, condition of pleuræ following, 229.
 hair regarded by Freund and Schiff as a source of, 414.
 of skin by exposure to X-rays, 391.
 Influence machines, 8.
 Influenza accompanied by pneumonia, 191-192.
 Innominate artery, ligating the, in aneurism, 317.
 Inspiration, deep, best time for measuring heart, 248-249, 253.
 effect of, on appearance of lungs on screen, 100, 248.
 movement of heart during, 247-248.
 movement of heart during, in tuberculosis, 288.
See Respiration.
 Insulation, of patients under X-ray treatment, 395.
 of static machine, 10.
 Intensifying screens, 96, 120, 637, 640.
 Interpretation of X-ray pictures, importance of correct, 89, 356, 613-614, 634.
 Interrupters for coils, 20-22, 24, 637-638.
 Intestine, cases of cancer of, at Boston City Hospital, 442.
 methods of observing large, 358.

Intestines, 378.
 movement of food through, 370, 645-646.
 Iodide of potassium injected in empyema, 241.
 Iodine for removing skin-tracings, 532.
 Iodoform, bandage, radiograph of, 472.
 injected in empyema, 241.
 opacity of, to X-rays, 86, 473, 474.
 Iron, amount of, in blood, 6.
 atomic weight of, 3.
 Itching, eczema with, 411.

J

Jankau on mode of action of X-rays, 393.
 Jaw, cases of cancer and of carcinoma of, at Boston City Hospital, 442.
 fractures of, at Boston City Hospital, 456.
 necrosis of lower, radiograph of, 561.
 Jedlicka, R., radiographs by, 457 n.
 Johnson, Dr., on use of X-rays in carcinoma, 421-422.
 Joints, of children easily photographed, 387.
 diseases of the, 556, 583-602.
 method of examining, by X-rays, 587.
 radiographs of, 457.
 swollen, 458.
 Julliard, G., recognition of calculus by X-rays, 626.
 Jutassy, Dr., on changes produced in skin by exposure to excited vacuum tube, 447.
 on X-ray treatment of —
 acne, 418.
 eczema, 409.
 hypertrichosis, 416-417.
 lupus, 398, 405-406.
 nævus flammeus, 412-413.

K

Kaposi, Dr., on changes produced in skin by exposure to excited vacuum tube, 447.
 Katzenstein, radiographs by, 597.
 Kibby, on changes produced in skin by exposure to excited vacuum tube, 447.
 Kidney, photographing the, 641.
 radiograph of, 620.
 Kidneys, calculi in, 615.
 X-ray examinations of, 374, 617.
 Klondike adventurer with enlarged heart, 308-309.
 Knee, fractures of, at Boston City Hospital, 456.
 photograph of, 580.
 photographing the, 89, 499, 641.
 Knee-joint, loose cartilages in, radiograph of, 599.
 syphilitic diseases of, 596-597.
 Kratzenstein, G., 452, 457 n.
 Kümmell, on Finsen's light treatment, 407, 452.
 on X-ray treatment of lupus, 393, 394, 395, 398, 406.

L

- "La grippe," pneumonia with, 191-192.
 Lambertz, X-ray photographic work of, 459.
 Lane, Dr., report by, of cases of deficiency of bone, 462.
 Lannelongue, Dr., report by, of use of X-rays in a case of tuberculosis of bones, 592.
 Larynx, cases of cancer and of carcinoma of, at Boston City Hospital, 442.
 ossification of cartilage of, 462.
 papilloma of, 668.
 plates for photographing, 88.
 tuberculosis of the, 418.
 Lauenstein, Dr., recognition of calculus by X-rays, 624.
 Lawrence, R. R., 26-27, 538, 638, 681-682.
 Leather transparent to X-rays, 2.
 Leg, cases of cancer and of carcinoma of, at Boston City Hospital, 442.
 fractures of bones of, 501.
 fractures of both bones of, radiographs of, 505, 506, 509, 516-519.
 fracture of, mistaken for bowed, 522.
 fractured, taking radiograph of, 89, 91, 92.
 fractures of, at Boston City Hospital, 456.
 Legs, eczema in, 407-408.
 Leigh, Southgate, 419, 445.
 Leo, H., on case of tumor in chest, 339.
 Leonard, Dr., recognition of calculi by X-rays, 622, 627-629, 630, 631.
 Leprosy, X-ray treatment of, 655.
 Lesions, character of bone, shown by X-rays, 554-555.
 epiphyseal, 461.
 of tuberculosis, old, X-ray examination of value in, 124, 148-149.
 valvular, as cause of enlarged heart, 271, 283.
 Letters, brass, for identification of position of negative, 87, 634.
 Leucocytes, effect of X-rays on, 449-450.
 Leucocytosis, absence of, in some cases of influenza, 192.
 Level, use of a, in posing patient for heart-examination, 247.
 Levy, Alfred G., report by, of arrested development of ribs, 463.
 Levy-Dorn, on detection of small tuberculous foci by radiographs, 594.
 on echinococcus of the lung, 346.
 observation of digestive tract by, 373.
 study of heart by, 249, 261.
 Life insurance examinations, use of X-rays in, 633-634.
 Ligaments, length of exposure for, 96.
 Light, adjustment of static machine for varying, 16, 22.
 amount necessary for photograph and screen, 47.
 for developing X-ray pictures, 57-58.
 Light (*continued*) —
 method of testing quality of, 46, 646, 681-682.
 penetrating power of, 46.
 treatment, Finsen's concentrated, 407, 444-445, 452.
 Linaschi, experiments of, with X-rays and animals inoculated with bacteria, 453.
 Lindermann, method of, for observing stomach, 359.
 Lip, cases of cancer and of carcinoma of, at Boston City Hospital, 442.
 epithelioma of, 430.
 Liquids, length of stay of, in stomach, 372.
 Little, Muirhead, on coxa vara, 575, 578.
 Liver, cancer of, 347, 442.
 carcinoma of, 376-377, 442.
 displacement of, in pleurisy with effusion, 204.
 echinococcus of the lung arises from, 346.
 observation of, by X-rays, 373, 644.
 Localization of foreign bodies, methods of, 81-86, 531-538.
 Localizers of foreign bodies, 533-538.
 Location of static machine, 15.
 Lodge, arrangement of vacuum tube by, 35.
 Loison, Edward, suggestion by, of employment of Eastman paper in military use of X-ray photography, 554.
 Longard, Dr., recognition of calculi by X-rays, 626.
 Lortet, Dr., experiments of, with X-rays and animals inoculated with bacteria, 452-453.
 Lucas, R. C., report of case of localization of bullet by, 539.
 Ludwig, experiments by, on form of heart, 253-257.
 Lung, abscess of, 351-352.
 cases of cancer and of carcinoma of, at Boston City Hospital, 442.
 echinococcus of, 346.
 gangrene of, 351-352.
 new growth in, 332.
 Lungs, abnormal, 103, 160.
 apices of, comparison of, 75-76, 102.
 apices of, examination of, 102, 134-135.
 appearance of, on screen, 100.
 appearance of, on screen in early tuberculosis, 115.
 cavities in the, 157-158.
 clearness in, necessary to determine borders of heart, 247.
 crowding of, by diaphragm or abdomen, 288.
 emphysema of the, 193-200, 633, 642.
 examination of, by auscultation and percussion, 162.
 examination of, in pneumonia, 168.
 examination of, when tuberculosis is in some other portion of body, 147.
 œdema of, 158.
 œdema of, in renal diseases, 374-375.
 photographing the, 93-95.

Lungs (*continued*) —

- of pneumonia patient (cuts), 165, 166.
 - region usually affected in pneumonia, 167-168.
 - transparency of, to rays during deep inspiration, 248.
 - tuberculosis in, in cases of pleurisy, 222-229.
 - use of densitometer on, 106.
 - X-rays readily traverse, 100.
- Lupus, therapeutic use of X-rays in treatment of, 391, 394-407, 411-412, 420, 651-652.
- Lupus erythematosus, 404-406, 652.
- Lupus vulgaris, 394-395, 651.
- Lymphadenitis, 347-349.
- Lymph glands, case of tumor arising from mediastinal, 339.
- Lymphomata colli, 417.

M

- Macalister, Donald, quoted on form and mechanism of heart, 253-257.
- McArthur, Dr., recognition of calculus by X-rays, 623-624.
- McBurney, Dr., recognition of calculus by X-rays, 626.
- McIntyre, Dr., recognition of calculus by X-rays, 623.
- Magnesium, atomic weight of, 3.
- Magnesium ammonium phosphate, radiograph of, 5.
- Malformations, 463-465.
- in children, 384.
 - of pelvis, 378-379.
- Mallory, Dr., examination of new growths by, 424, 429, 430, 431-433, 434-435, 436-437, 439, 440, 656, 658, 668.
- Mask for face in lupus, 400, 446.
- Measles, bronchitis following, 201.
- Measurement of heart, 248-249, 253.
- faulty method of, 265-270.
- Medico-legal use of X-rays, 86, 633-634.
- Membrane, pleural, fluid enclosed in, 218.
- Men, average weight of heart in, 273-275.
- heart more to the right in, than in women, 260.
 - position of nipples of, 261.
- Meningitis, difference of X-ray and percussion determinations in cases of, 277.
- tuberculous, examination of patients with symptoms suggesting, 385.
- Merrill, Dr., on use of X-rays in carcinoma, 421-422.
- Metacarpal bones, fracture of, 467, 491-492.
- radiographs of fractures of, 492, 494, 495.
- Metal, experiments with radiographs of, 550.
- necessity of removing, in taking radiographs, 86.
- Metals, X-rays absorbed by, 2.
- Metatarsus, radiograph of subdislocation of, 530.
- Mice inoculated with bacteria, effect of X-rays on, 452.

- Milk sugar, radiograph of, 5.
- Mill board, radiograph of, 472.
- Mink, experiment of, with typhoid bacilli and X-rays, 448.
- Mitral insufficiency, width of heart in, 304.
- Mitral valve, excursion of heart in insufficiency of, 299.
- Mobility of heart, 301.
- Moisture on plates, precautions against, 14, 637.
- Mongour reports negative results with X-rays in phthisis, 418.
- Morning cough an indication of tuberculosis, 140.
- Morris, on Finsen's light treatment of lupus and rodent ulcer, 444-445.
- Morrison, Rutherford, recognition of calculus by X-rays, 627.
- Morton, Dr. C. A., recognition of calculus by X-rays, 624.
- Mottling of lung in X-ray photograph, 117.
- Mouth, cases of cancer of, at Boston City Hospital, 442.
- Movement of heart during respiration, 247-248.
- of stomach during respiration, 362-363.
- Mühsam, experiments of, with X-rays and animals inoculated with bacteria, 452.
- Müller, Dr., recognition of calculus by X-rays, 627.
- Munro, Dr. John C., use of X-ray photography in localization of bullet in head by, 539.
- Murmurs of heart, 301, 305.
- Murray, on use of X-rays in acromegalia, 578.
- Muscle, examination of, by X-rays, 465-466.
- length of exposure for, 96.
- Myocarditis, pulsations of heart in, 298.
- X-ray examination of, 305-306.
- Myositis ossificans, 465.

N

- Nævus flammeus, X-ray treatment for, 412-413.
- Nails, effect of X-rays on, 393.
- Neck, cases of cancer and of carcinoma of, at Boston City Hospital, 442.
- Necrosis of bone, radiograph of, 482.
- of lower jaw, radiograph of, 561.
- Needle, in hand, radiographs of, 545, 546, 547.
- in os calcis, 543-544.
- Needles, precautions concerning, 545-546.
- Negative, aids to interpretation of the, 87.
- method of examining, 96, 98.
 - necessity for more than one, 96.
 - relative usefulness of screen and, in examinations of thorax, 108.
 - value of, in surgery, 457.
- Negatives, X-ray, compared with photographs, 96.
- Nephritis, as cause of enlarged heart, 271-272.
- chronic diffuse, 374.
- Nervous system, effect of disturbance of, on digestion, 372.

- Neuralgia, aneurism suggesting intercostal, 319-320.
 caused by unerupted teeth, use of X-rays for, 607-608.
 suggested by cases of aneurism, 313.
 trigeminal, X-ray treatment for, 420.
- New growths, 332-347, 655-681.
 in abdomen, 375-378.
 changes in outline of heart due to, 262.
 obstruction of trachea by, 200.
 in thorax, distinguishing between, and aneurism, 312.
 treatment of, by X-rays, 420-444, 655-681.
 which interfere with bony structure, 578.
- Night sweats an indication of tuberculosis, 140.
- Nipples, variation in distance between, 261.
- Nitrate of silver for marking position of foreign bodies, 532.
- Nitrogen, atomic weight of, 3.
- Norton, Charles L., 26-27, 538.
- Norton and Lawrence apparatus, 26-27, 638.
- Nose, cases of cancer and carcinoma of, at Boston City Hospital, 442.
 epithelioma of, 659-660.
 lupus of, 394-395, 406-407.
- Nutshell, pneumonia caused by swallowing, 200.

O

- Observation, necessity of correct, of X-ray appearances, 99, 356.
- Edema of the lungs, 158, 307.
 in renal disease, 374.
- Esophagus, aneurism of aorta with perforation into, 315-317.
 cases of cancer of, at Boston City Hospital, 442.
 foreign bodies in, 539-541.
 method of rendering outline of, visible on fluorescent screen, 357.
 stricture of, 313, 315-317, 323-324, 357.
- Olecranon, radiograph of fracture of, 479, 480.
- Oleic acid, radiograph of, 5.
- Ollier, report by, of cases of regeneration of bones after operation, 562.
- Omentum, case of cancer and of carcinoma of, at Boston City Hospital, 442.
- Opening, permanent, empyema with, 241.
- Ophthalmoscope for verifying localization of foreign body, 537.
- Os calcis, needle in, 543-544.
- Oschmann, A., on the operative treatment of tuberculous elbow-joints, 594.
- Ossification, of cartilage of larynx, 462.
 of epiphysis of femur, coxitis delays, 594.
- Osteitis, of tibia and fibula, radiograph of, 560.
 tubercular, 594.
 X-ray examinations of service in, 556.
- Osteoarthropathy, X-ray examinations of service in chronic pulmonary, 556.
- Osteochondroma, X-ray examinations of service in, 556.
- Osteoma, X-ray examinations of service in, 556.
- Osteomyelitis, radiographs of, 561, 563, 565-574.
 of tibia, case of, 562.
 X-ray examinations of service in, 556.
- Osteosarcoma, 332, 556.
 of humerus, radiograph of, 579.
- Osteosclerosis, use of X-rays in, 596.
- Oudin, on use of X-rays in —
 acromegalia, 578.
 Pott's disease, 596.
 tuberculosis of bones, 592, 594.
- Ovary, case of cancer of, at Boston City Hospital, 442.
- Overwork, as cause of enlarged heart, 271.
 lessens power of resistance to tuberculosis, 159.
 relaxation of cardiac walls from, 270.
- Oxalic acid, radiograph of, 5.
- Oxygen, atomic weight of, 3.

P

- Page induction coil, 8, 22-23.
- Pakhitonov, Dr., report of, on case of acne vulgaris, 655.
- Palate, case of cancer of, at Boston City Hospital, 442.
 lupus of hard, 420.
 motions made by soft, in speaking, 389.
- Palmitic acid, radiograph of, 5.
- Palpation may supplement X-ray examination, 191.
- Pancreas, abnormal conditions about, detected, 358.
- Paper, for printing X-ray negatives, 57, 554.
 transparent to X-rays, 2.
- Papilloma of larynx, 668.
- Paralysis, of laryngeal nerve, 323.
 of vocal cord, 313, 315, 316.
- Parry's disease, X-ray treatment of, 679.
- Patella, radiographs of fracture of, 499, 500, 501.
- Pathological conditions indicated by width of heart, 261.
- Patient, data concerning, 81.
 position of, in X-ray examinations, 65-74.
See under Position.
 precautions relating to, in using X-rays for diagnosis, 58.
 for treatment, 446.
 support of, during X-ray examination, 59.
- Pelvis, 378-383.
 Bouchacourt on deformity of the, 378-379.
 case of cancer of, at Boston City Hospital, 442.
 fracture of, at Boston City Hospital, 456.
 radiograph of whistle in, 551.
- Pencil, radiographic, 77-79.
- Penetration, of cloth by rays, 59.
 of X-rays, property of, 2.
- Penis, cases of cancer and of carcinoma of, at Boston City Hospital, 442.

- Percussion, and X-ray determinations of left heart border, table of, 276-279.
 thickness of chest wall may mislead in, 198, 282.
 compared with X-ray examinations in cases of—
 aneurism, 312-313, 322-324.
 carcinoma of liver, 376-377.
 chlorosis, 297.
 displacement of heart, 295-296.
 fluid in chest, 213.
 heart diseases, 162, 266-267, 269, 272-275, 295-296.
 lung diseases, 162.
 pneumonia, 165-166, 183.
 tumors, 339-340.
 for chest-examination, 109.
 emphysema a hindrance to, 198.
 X-rays give more definite signs than, 149.
 X-ray examination should be taught in connection with, 355.
- Pericardial adhesions, as cause of enlarged heart, 271.
 displacement of heart by, 293-294. *See* Adhesions.
- Pericardial effusion, 300.
- Pericarditis, position for examining patient with, 300.
- Pericardium, effect of stretching, on heart-pulsations, 252.
 tapping, in case of effusion, 300.
- Perineum, case of cancer of, at Boston City Hospital, 442.
- Periostitis, of fibula, radiographs of, 558, 559.
 of radius, radiograph of, 557.
 X-ray examinations of service in, 556.
- Peristaltic movements in frogs, dogs, and men observed, 372.
- Phalanges, fractures of, 467, 491-492.
 photographing the, 522.
 radiograph showing loss of bone substance in, 559.
 tuberculosis of, 592.
- Phalanx, radiograph of fracture of, 493.
- Phantom tumors, 377.
- Pharynx, case of cancer of, at Boston City Hospital, 442.
- Phosphate of calcium, radiograph of, 5.
 Phosphate of sodium, radiograph of, 5.
 Phosphorus, atomic weight of, 3.
- Photographs, comparison of X-ray, and negatives, 96.
 comparison of X-ray, and screen examinations, 99, 120, 169-171, 205, 270.
 development of X-ray, 57.
 of heart, best made during deep inspiration, 270.
 importance of interpretation of X-ray, in aneurism, 328.
 interpretation of X-ray, in surgery, 455.
See Negative, Radiographs, Views.
- Photographs of—
 aneurism, X-ray outlines of, on chest, 314.
 carcinoma of breast after three exposures to the X-rays, 671.
 carcinoma of neck before treatment, 665.
 diaphragm, normal outlines of, on chest, 107.
 epidermoid cancer of eyelid before treatment, 426, 658.
 epidermoid cancer of eyelid during treatment, 427, 658.
 epidermoid cancer of lower lid before treatment, 658.
 epidermoid cancer of lower lid after treatment, 658.
 epidermoid cancer of lip before treatment, 422-423.
 epidermoid cancer of lip after treatment, 424-425.
 epidermoid cancer of hand before treatment, 432-433.
 epidermoid cancer of hand after partial treatment, 435.
 epidermoid cancer of hand, section of, before treatment, 434.
 epidermoid cancer of hand, section of, after partial treatment, 436-437.
 epidermoid cancer of neck before treatment, 664.
 epidermoid carcinoma of temple before treatment, 659.
 epidermoid carcinoma of temple after treatment, 659.
 epithelioma of cheek after two exposures to the X-rays, 660.
 epithelioma of lip before treatment, 428-429.
 epithelioma of lip after six weeks' treatment, 430.
 epithelioma of lip a month later still, 431.
 epithelioma of nose before treatment, 659.
 Hodgkin's disease after one exposure of right cervical glands, 676.
 Hodgkin's disease before exposure of spleen to X-rays, 677.
 lupus of cheek before treatment, 402.
 lupus of cheek after treatment, 403.
 lupus of face before treatment, 404.
 lupus of face after partial treatment, 405.
 method of applying treatment, 400.
 psoriasis after partial treatment by X-rays, 654.
 rodent ulcer of face before treatment, 439.
 rodent ulcer of face after treatment, 440.
 spindle-celled sarcoma before treatment by X-rays, 667.
 tuberculosis of foot before treatment, 662.
- Photography, dental, 603-614.
- Phthisis, diagnosis of, not made by X-rays only, 122-123.
 negative results in therapeutic treatment of, 418.

- Physicians, need of X-ray apparatus by, 355-356.
 use of X-rays must be by trained, 355, 649-650.
- Physiology, of digestion, 372.
 of voice and speech, 389.
- Picard, work by, on X-ray treatment of fractures, 468.
- Pigment in skin, a hindrance in treatment of lupus, 407.
- Pinaud, X-ray study of gravid uterus by, 382, 383.
- Pins, experiment in photographing, 64, 65, 67.
- Planté rheostatic machine, 8.
- Plaster, opacity of, to X-rays, 471-473.
- Plaster-of-paris bandage, radiograph of, 472.
- Plates, photographic, 56-57.
 identification of position of, 87.
 support of, by diaphragm, 95-96.
- Plates for static machine, 10, 637.
 cleaning, 15.
 method of holding, 10-13.
 removal of dampness from, 14.
 speed of, 14.
- Platino-cyanide of barium, 56.
- Pleuræ, adhesion of surfaces of the, 229-233.
 clearness in, necessary to determine borders of heart, 247.
- Pleural cavity, fluid and gas in, 285.
- Pleural sac, fluid in, in empyema detected by X-ray examination, 192.
- Pleurisy, diaphragmatic, 218.
 may disguise signs of tuberculosis, 124.
 displacement of heart caused by, 291.
 encysted, 216-217.
- Pleurisy with effusion, 202-233, 642-644.
 and emphysema, 195, 218.
 new growth in lung suggested by, 332, 340-341.
 and pneumonia, 218-221.
 or pneumonia, 186-191.
 and pulmonary tuberculosis, 222-229.
 relief by drawing fluid in cases of, 237.
 suggested by darkened lower lung, 353.
 tuberculosis associated with, 140, 142-143.
- Pleuritic adhesions, 229-233.
 expansion of lungs lessened by, 167.
 excursion of diaphragm limited by, 180.
 "stitch" in side associated with, 233.
- Pleuritic effusion, effect on position of heart of, 285.
 an obstruction to viewing heart, 247.
- Pleuritic fluid, experiments with, 6.
- Plumb-lines, 60, 66.
 indirect, 66, 69, 70.
- Pneumohydrothorax, 70-71, 213, 241, 642.
- Pneumonia, 103, 164-192.
 appendicitis confounded with, 192.
 colds bordering on, 192.
 darkened middle of lung suggests, 353.
 empyema overlooked after, 192.
 influenza accompanied by, 191-192.
- Pneumonia (*continued*) —
 interstitial fibrous, resemblance of, to new growth, 343-344.
 new growth in lung suggested by, 332.
 in old people, 185.
 outline on fluorescent screen, 173.
 pleurisy with effusion and, 218-221.
 pleurisy or, 186-191.
 and tuberculosis, 124.
 or tuberculosis, 191.
- Pneumopyothorax, 70-71, 241.
- Pneumothorax, 234.
- Poland, on epiphyseal lesions in children, 461.
- Polarization, property of, claimed for X-rays, 1.
- Position, of foreign object in body, locating, 81-86.
 of heart (normal), 247.
 of heart in women, 260.
 of needle in hand, change of, 545-546.
 of patient in examination for heart diseases, 247, 258, 263.
 of patient in examination of pericarditis, 300.
 of patient in examination of pleurisy, 205.
 of patient in examination of pneumohydrothorax, 70-71, 241, 244.
 of patient in photographing fracture, 473.
 of patient in photographing pelvis, 379.
 of patient in photographing sacrum, 379.
 of patient in X-ray examination, 59-74.
 of plates in examining patient, 88-97.
 of plate, identification of, 87.
 of plate, patient, and tube, necessity of knowing, 66, 67, 89.
 of plate, in photographing bones of face, 475.
 of plate, in photographing spine, 475.
 of plate, in photographing teeth, 606.
 of roots of teeth, 611.
 of stomach during digestion, 362-372.
 of vacuum tube and plate, 64-65.
- Potassium, atomic weight of, 3.
 chloride of, radiograph of, 5.
- Pott's disease, X-rays of value in showing extent of, 596.
- Pregnancy, extra-uterine, X-rays confirm diagnosis of, 382.
- Price, Dr. Weston A., radiographs of teeth by, 608, 609, 610, 612, 614.
- Process, of digestion, observing, 362-373, 645-646.
 of healing in lupus cases, 395-396.
 of ossification, 462, 594.
- Processes, acute and chronic, compared, 354.
- "Progression in teeth," 608.
- Prostate, cases of cancer and of carcinoma of, at Boston City Hospital, 442.
- Pruritus ani and vulvæ, X-ray treatment of, 655.
- Psoriasis, 418, 653-654.
- Psoriasis vulgaris, X-ray treatment for, 411-412.

- Pulmonary area, method of determining whether of normal brightness, 102.
- Pulmonary tuberculosis, 111-163.
 absence of result in exposing patient with, to X-rays, 418.
 aneurism suggesting, 313.
 most widespread of all diseases, 159.
 pleurisy with effusion and, 222-229.
See Tuberculosis.
- Pulsation, lack of, in aneurism, 310.
- Pulsations of heart, 249, 252.
 blur outlines of X-ray photographs, 270.
 in cardiac disease, 299.
- Pulse, state of, after exercise, 390.
- Pus, cup full of, under fluorescent screen, 205.
 and water, experiment with, 6.
- Pusey, Dr. William Allen, on case of sarcoma treated by X-rays, 661-662.
 on X-ray treatment of Hodgkin's disease, 678-679.
- Pyelitis, 623.
- Pylorus, cancer of, 377.

R

- Rabbits inoculated with bacteria, effect of X-rays on, 452.
- Radiographs, comparative merits of, and screen examinations. *See* Fluorescent screen examinations.
- better adapted to surgeon than to physician, 455.
- Forster and Hugi's experiments with, 546, 550.
- fractures recognized by, 469, 470.
- importance of, in fractures and dislocations, 468-469.
- light required for taking, 47.
- localization of foreign bodies by, 533-538.
- medico-legal uses of, 634.
- precautions necessary in taking, 86-87.
- Radiographs of—
 abscess, 573, 574.
 aluminum, 472.
 aorta, 250.
 arthritis of finger-joints, 597.
 blood, vulcanite cup containing, 7.
 calcified tissues, 386, 387.
 calculi, 616, 618, 619, 620.
 calluses, 485, 516.
 chondrosarcoma of femur, 581.
 clavicles and ribs, 104.
 constituents of the body, 5.
 cotton, 472.
 coxa vara, 577.
 decalcified bones, 616.
 disease of bones and joint, 595.
 dislocation of both bones of forearm, 527.
 dislocation and separation of epiphysis, 528, 529.
 emphysema, 199.
 exostosis, 586.

Radiographs of (*continued*) —

- exostosis of ulna and radius, 588, 589.
- finger, 582, 583.
- flat foot, 601.
- foot, 523, 524.
- foreign bodies in œsophagus, 540, 541.
- fractures of both bones of leg, 470, 505, 506, 509, 516, 517, 518, 519.
- fracture of epiphysis, 521.
- fractures of femurs, 497, 498.
- fractures of fibula, 504, 507, 508, 511, 520, 560.
- fracture of fifth metacarpal bone, 495.
- fracture of fourth metacarpal bone, 494.
- fractures of humerus, 476, 477, 478, 479.
- fractures of olecranon, 479, 480.
- fracture of patella, 499, 500, 501.
- fracture of phalanx, 493.
- fractures of radius, 483, 484, 486, 487, 488, 490, 491.
- fracture of third metacarpal bone, 492.
- fracture of thumb, 496.
- fractures of tibia, 502, 503, 510, 511, 514, 520.
- fracture of toes, 525.
- fracture due to torsion, 518.
- fracture of ulna, 481.
- gall stones, 616.
- glass in finger, 550.
- heart, 250, 251.
- hyoid bone, 88.
- iodoform bandage, 472.
- kidney, 620.
- loose cartilage in knee-joint, 599.
- lung, tuberculous, 112.
- malformation of hand, 463, 464.
- mill board, 472.
- necrosis of lower jaw, 561.
- needle in hand, 545, 546, 547.
- needle in os calcis, 544.
- needle in wrist, 548, 549.
- needles threaded with catgut, horsehair, iron-dyed silk, silkworm gut, and silk, 472.
- new growth in lung, 337.
- osteitis of tibia and fibula, 560.
- osteo-arthritis of great toe-joint, 600.
- osteomyelitis, 561, 565-573.
- osteosarcoma of humerus, 579.
- pelvis, 380, 381.
- periostitis of fibula, 558.
- periostitis of radius, 557.
- phalanges, showing loss of bone substance in, 559.
- pins, 65, 67.
- plaster-of-paris bandage, 472.
- rickets, 576.
- rubber drainage tube, 472.
- rubber plaster, 472.
- separation of epiphysis of tibia and fibrous fracture of fibula, 507, 508.
- shot in foot, 552.

Radiographs of (*continued*) —

- silver wire, 472.
 - split in fibula, 510.
 - staphylococcus infection, 582, 583.
 - steel in arm, 542, 543.
 - sub-dislocation of metatarsus, 530.
 - teeth, 608, 609, 610, 611, 612, 613.
 - thickened tibia, 573, 574.
 - tin, 472.
 - trachea, 88.
 - tuberculosis of ankle, 590.
 - tuberculosis of bones (probable), 595.
 - tuberculosis of foot, 591, 592.
 - tuberculosis of hip, 593.
 - tuberculous lung, 112.
 - tumor of finger, 585.
 - ununited fracture and necrosis, 482.
 - vertebræ, cervical, 90, 91.
 - vesical calculus, 618.
 - water, vulcanite cup containing, 7.
 - whistle in œsophagus, 541.
 - whistle in pelvis, 551.
 - wooden splint, 472.
- Radius, exostosis of, radiographs of, 588, 599.
- fracture of left, 488-490.
 - fractures of, radiographs of, 484, 486-488, 490, 491.
 - method of photographing fracture of, 488.
 - osteomyelitis of, radiograph of, 571, 572.
 - periostitis of, radiograph of, 557.
- Records, of appearances seen on fluorescent screen, 77, 99.
- of position of tube with reference to plate, 473.
 - of X-ray examinations of chest, 110.
- Recoveries from tuberculosis, percentage of, 160, 161.
- Rectum, cases of cancer and of carcinoma of, at Boston City Hospital, 442.
- Recurrence of lupus, 397-398.
- Redard, on value of X-rays in coxitis, 594.
- Refraction, property of, claimed for X-rays, 1.
- Regeneration of bones after operation, 562.
- Regurgitation of the blood, effect on heart pulsations, 300.
- Remy, report by, on radiographs of muscles of animals, 466.
- Renal disease inferred from, enlarged heart, 283.
- appearances in lungs, 307, 354.
- Renal diseases, 374-375. *See* Bladder, Kidneys, Ureters.
- value of X-ray examinations in, 306.
- Resistance of vacuum tubes, 42-43, 47-48.
- methods of changing, 44, 45.
- Respiration, in emphysema of the lungs, 193, 194.
- excursion of diaphragm in normal, 108.
 - experiment showing effect of, on appearance of lungs on screen, 100.
 - of fœtus, determination of, 383.
 - movement of stomach during, 362-364.

Respiration (*continued*) —

- in pleurisy with effusion, 203-204.
 - in X-ray examinations for tuberculosis, 118.
- Rheostat, 22.
- Rheumatism, acute articular, 127-129, 289.
- articular, treated by X-rays, 445-446.
 - association of tuberculosis and, 130.
 - of joints, X-ray examinations of service in, 556.
- Ribs, appearance of, on fluorescent screen, 100, 102, 103; in emphysema, 193.
- fractures of, at Boston City Hospital, 456.
 - radiograph of, 104.
- Rickets, 575.
- radiograph of case of, 576.
 - use of X-rays in recognition of, 385.
 - X-ray examinations of service in, 556.
- Rieder, reports by, on experiments with bacteria exposed to X-rays, 449, 450-451, 452.
- use of intensifying screen by, 640.
 - X-ray study of diseases of chest by, 120, 356, 418.
- Ringel, on comparative permeability of calculi by X-rays, 617.
- on photographing the hand, 93.
- Ritchie coil, 19, 23, 24, 25, 639.
- Rivière, experiments of, with bacteria and X-rays, 449-450.
- Rodent ulcers. *See* Ulcer.
- Roentgen, 1, 2, 34.
- Rollins, Dr. William, experiment of, with so-called X-ray burn, 448, 672-674.
- experiments by, with guinea pigs, to determine effect of X-rays on cell growth, 672-674.
 - invention and manipulation of X-ray apparatus by, 17, 18, 27, 28-31, 32, 34, 35, 36, 37, 38, 42, 44, 46, 50, 52, 54, 60, 262, 400, 475, 604, 606, 607, 608, 613, 621-622, 647.
 - value of work of, 614.
- Ross, Dr., on value of X-rays in cases of fracture, 467-468.
- Ross, Forbes, experiments of, with bacteria and X-rays, 449.
- Roux, observation of process of digestion by, 372.
- Rowland, arrangement of vacuum tube by, 35.
- Rowland, Sidney, report of, on case of osseous ankylosis, 598-602.
- Rubber plaster, radiograph of, 472.
- Ruhmkorff induction coil, 8, 22-25.

S

- Sabrazès, experiments of, with bacteria and X-rays, 449-450.
- Sacrum, position of patient in photographing, 379.
- Salve, carbolanolin, use of, after treatment for favus, 416.
- Unna's, in combination with X-rays, 396.
- Sarcoma, 578, 581, 661-662.
- spindle-celled, 343, 656, 666, 667.

- Saw, fracture of ulna caused by, 481.
 Sayen's vacuum tube, 44.
 Scapula, fractures of, at Boston City Hospital, 456.
 Scar, after treatment for lupus, 395.
 after treatment for *nævus flammeus*, 413.
 Scheffer, W., 457 n.
 Scheier, Max, investigations of, concerning voice and larynx, 389.
 study of ossification of cartilage of pharynx by, 462.
 use of X-rays in examination of frontal cavities by, 464-465.
 Schenkel, observations by, of use of X-rays in lupus, 396, 398, 416, 653.
 Schiff, on use of X-rays in acne, 418.
 on use of X-rays in lupus, 391, 395, 398, 404-405, 651.
 X-ray treatment of sycosis and favus by, 414-416.
 Schmid-Monnard, 445.
 Schorstein, report by, of case of congenital malformation, 463.
 Schott, T., photographs by, of hearts of children, 390.
 Schultz, experiments of, with color-producing bacteria and X-rays, 449.
 Screen, aluminum, 47, 53-54.
 platino-cyanide of barium, 56.
 tungstate of calcium, 55.
 See Fluorescent screen.
 Scrotum, case of cancer of, at Boston City Hospital, 442.
 Sederholm, on X-ray treatment of—
 chronic eczema, 652-653.
 old ulcerations, 675.
 pruritus ani and vulvæ, 655.
 psoriasis, 653.
 Seehear, 60, 262.
 Seidlitz powder, use of, in observing stomach, 359.
 Sequeira, James H., on X-ray treatment of rodent ulcer, 438-439, 668-669.
 Serous fluid and pus compared, 205.
 Shadow, X-ray picture a, 62.
 Shadow on fluorescent screen, of abnormal heart, 262.
 of abnormal portions of lungs, 103.
 in aneurism, 310.
 of apices of lungs, 118-119.
 of blood vessels and soft tissues in heart-examinations, 262.
 in cases of broncho-pneumonia, 192.
 of calcification of ascending aorta, 385.
 of foreign bodies, 531-532.
 of foreign substance in body, 81-85.
 of hypertrophied bronchial glands, 119.
 of interlobar fluid, 218.
 of lung in pneumonia, 164.
 of lung in pulmonary tuberculosis, 111.
 of metal pencil-holder, 77.
 Shadow (*continued*) —
 of new growth in lung, 332.
 of pericardial effusion, 300.
 in pulmonary congestion, 158, 201.
 of pus, 205.
 of serous fluid, 205.
 of spleen, 373-374.
 of sticking plaster, 86.
 Shadows, character of X-ray, 1-2.
 Shield for patient in X-ray treatment, 399-401, 425, 446, 647.
 Shot in foot, radiograph of, 552.
 Shoulder, cases of cancer of, at Boston City Hospital, 442.
 photographing the, 89, 641.
 X-ray photographs in fracture of, 481-485.
 Shoulder-joint, radiographs of, 457.
 Side, case of cancer in, at Boston City Hospital, 442.
 "stitch" in, 233.
 Sigmoid flexure, method of following outline of, 358.
 Silk, radiograph of needle threaded with, 472.
 Silkworm gut, radiograph of needle threaded with, 472.
 Sinapius on treatment of pulmonary tuberculosis by X-rays, 418.
 Sinus, radiograph of, 573-574.
 recognizing, by X-rays, 458.
 size of, recognized by X-rays, 241.
 Sinuses, tuberculous, 674-675.
 Siphon for withdrawing air in pneumothorax, 238.
 Sitings, length and frequency of, in lupus, 401-403.
 Sjögren, case of rodent ulcer reported by, 438.
 on X-ray treatment of—
 chronic eczema, 652-653.
 old ulcerations, 675.
 pruritus ani and vulvæ, 655.
 psoriasis, 653.
 Skeleton, development of the, 459-462.
 Skiagrams for localizing foreign body in eye, 536-537.
 Skin, affections relieved by exposure to X-rays, 391.
 cancer. *See* Ulcer, rodent.
 changes produced in, by different exposures, 447.
 diseases. *See* Eczema, Lupus.
 effect of X-rays on blondes' and brunettes', 416.
 normal and abnormal, 392.
 susceptibility of, diminished by dermatitis, 396.
 tracings on. *See* Skin-tracings.
 Skin-tracings, 77-80.
 in heart-examination, 248, 264.
 iodine for removing, 532.
 in observations of stomach, 360.
 Skull, fractures of, 456, 475.

- Smith, A. Everett, report by, of X-ray treatment of lupus vulgaris, 397.
- Smith, Noble, on use of X-ray photography in cases of injured spine, 475, 479, 481, 522, 594-596.
- Sodium, atomic weight of, 3.
radiographs of, 5.
- Sokolow on X-ray treatment of articular rheumatism in children, 445-446.
- Spark-gap, adjustable, 15, 16.
adjustable multiple, 16, 17, 26, 27, 47, 48, 637.
- Specialists, X-ray examinations preferably by, 355.
- Speculum, glass, for treating cancer of tongue, 650.
- Speech, physiology of, 389.
- Speed controller, 14, 93.
- Speed of plates, 14, 637.
- Spieß on use of X-rays in examination of frontal cavities, 465.
- Spina bifida, 464.
- Spinal column, examination of, 310-311.
tuberculosis foci on, 594.
- Spina ventosa, 562.
- Spine, caries of, 594, 596.
case of cancer of, at Boston City Hospital, 442.
fractures of, at Boston City Hospital, 456.
photographing the, 88, 94-97, 475-481.
position of plate and tube in examining, 88.
- Spleen, observations of, by X-rays, 358, 373-374.
- Splints, advantage of wooden, in taking radiographs, 86, 471, 473.
radiograph of wooden, 472.
- Spottiswoode electrolytic break, 20.
- Sprains, aid of X-rays in examining, 467.
- Stamm, use of X-rays by, in case of syphilitic disease, 596.
- Staphylococcus pyogenes, results of X-ray experiments with, 450.
- Starch bandage, radiograph of, 472.
- Startin, Dr. James, report of, concerning case of lupus erythematosus, 652.
on X-ray treatment of epithelioma of tongue, 661.
on X-ray treatment of psoriasis, 653.
- Static machine, 8-19, 637.
compared with coils, 639.
location of, 15.
for use in the country, 31-32.
See Apparatus.
- "Stave of the thumb" fracture, 492.
- Stearic acid, radiograph of, 5.
- Steel, localization of piece of, 540.
- Stenbeck, on X-ray treatment of articular rheumatism, 446.
on X-ray treatment of rodent ulcer, 437-438.
- Stereoscope, use of, in examining fractures, 457, 469-471.
use of, in interpreting elbow fractures, 485-487.
- Sternum, fractures of, at Boston City Hospital, 456.
- Sticking plaster, shadow cast by, 86.
- Stine, W. M., on so-called X-ray burn, 447.
- "Stitch" in side associated with pleuritic adhesions, 233.
- Stokes, G. G., 1.
- Stomach, carcinoma of the, 376, 421.
cases of cancer and of carcinoma of, at Boston City Hospital, 442.
length of stay of food in, 372-373.
methods for observing the, 359.
movement of, during respiration, 362-363.
- Stomachs, observations of cats', 360, 372.
observations of children's, 360-372.
observations of dogs', 372.
observations of frogs', 372.
- Stones in bladder and kidneys, 623-629.
- Stretchers, 59, 60, 61, 63, 76, 78, 92, 94, 95, 97, 648, 649.
- Stricture, œsophageal, 313, 323-324, 357.
- Subnitrate of bismuth injected in empyema, 241.
- Subnitrate, emulsion of, used for observing stomach, 359.
- Sulphate of sodium, radiograph of, 5.
- Sulphur, atomic weight of, 3.
baths in combination with X-ray treatment for eczema, 409.
radiograph of, 5.
- Sunlight, concentrated, for treating lupus, 407.
- Surgery, introduction to, 454-458.
dental, 603-614.
military, 553-555.
- Swain, Dr., recognition of calculus by X-rays, 623.
- Sweet, apparatus of, for treatment of injuries to the eye, 537-538.
- Swelling, of foot, X-rays show cause of, 522.
about fractures, 458.
of joints, 458.
- Sycosis, Freund and Schiff's treatment of, 414-416.
hyphogenes, 653.
non-parasitaria, 416.
- Symons, on use of X-rays in military surgery, 553.
- Synostosis, 462.
- Syphilis, 353, 406-407, 556, 596-597.
- Systole, form of heart in, 253-257.

T

- Table, of atomic weights of elements of human body, 3.
of cases of cancers and of carcinomas at Boston City Hospital for a series of years, 442.
of cases of fractures treated in Boston City Hospital for fifteen years, 456.
of diseases of bones and joints in which X-ray examinations are of service, 556.
of elements of bones of healthy child and of rachitic bones, 575.

Table (*continued*) —

- of heart weights compared with heart widths, 273.
- of times of exposure for taking X-ray photographs, 641.
- showing advantages and disadvantages of static machine and coil, 639.
- showing difference of X-ray and percussion determinations of left heart border, on level with nipple, during expiration in 155 cases, 276-279.
- showing effects of X-light on guinea pigs, 673.
- showing width of heart in relation to height of individual, 261.
- Tachycardia, mobility of heart in paroxysmal, 301.
- Tapping. *See* Pleurisy and Pneumothorax.
- Target of vacuum tubes, 32, 65-66.
 - faulty position of, 37.
 - position of, in heart examination, 247.
 - position of, to object examined, 65, 87.
 - united with anode, 35-36.
- Taylor, Dr., recognition of calculus by X-rays, 623.
- Taylor, Dr. George G. Stopford, on X-ray treatment of old ulcerations, 675.
 - on X-ray treatment of rodent ulcer, 669.
- Teeth, 603-614.
 - progression in, 608.
 - radiographs of, 608-613.
 - unerupted, 607.
- Teleangiectasia, congenital, 412-413.
- Tesla, screen for shielding patient recommended by, 47, 58, 91.
 - on so-called X-ray burn, 448.
- Tesla induction coil, 8.
- Testicle, cases of cancer of, at Boston City Hospital, 442.
- Therapeutic uses of X-rays, 391-453, 646-681.
- Thigh, method of photographing fractures of, 495-496.
 - time of exposure for photographing the, 641.
 - tumor of the, 582-583.
- Thomson, Elihu, 447-448, 457.
- Thomson coil, 8.
- Thomson's dynamo static machine, 8, 19.
- Thorax, 100-110, 642-644.
 - abnormal condition of, in pleuritic effusion, 205.
 - abnormal condition of, in empyema, 205.
 - aneurism of, new growth may simulate, 332.
 - case of cancer in, at Boston City Hospital, 442.
 - measuring density of, 105-106.
 - method of examining, illustration showing, 76.
 - new growths in, 332-352.
 - screen examination of, preferable to photograph, 99.
- Throat, cases of carcinoma of, at Boston City Hospital, 442.
- Thumb, fractures of, at Boston City Hospital, 456.
 - dislocation of, radiograph of, 526.
 - fracture of, radiograph of, 496.
- Thyne, Dr., recognition of calculus by X-rays, 623.
- Thyroid cartilage, photographing the, 89.
- Tibia, fractures of, radiographs of, 502, 503, 510-512, 514, 520.
 - osteitis of, radiograph of, 560.
 - osteomyelitis of, 562, 563, 565-570.
 - thickened, radiograph of, 573, 574.
 - thickening of the, 596.
- Time, for exposure of photographic plates, 62-64, 96-98, 606-607.
 - in which stomach retains food, 372-373.
 - length of, necessary to arrest tuberculosis, 160-161.
- Tin, radiograph of, 472.
- Tissues, calcification of, 385-387.
- Toepler-Holtz influence machine, 8.
- Toes, fractures of, 456, 525.
 - osteo-arthritis of joint of great, 598, 600.
- Tongue, cancer of, 663.
 - cases of cancer and of carcinoma of, at Boston City Hospital, 442.
- Tonsil, cases of cancer and of carcinoma of, at Boston City Hospital, 442.
- Torsion, radiograph of fracture due to, 518.
- Trachea, cut of, 88.
 - obstruction of, by new growth, 200.
- Tracheotomy to remove swallowed nutshell, 201.
- Tracing cloth, 79, 265.
- Tracings on skin. *See* Skin-tracings.
- Transparency of lungs during deep inspiration, 100, 248.
- Treatment, too early cessation of, in heart diseases, 305.
- Trendelenburg position for photographing pelvis, 379.
- Triangle-shaped area in heart examinations, 258, 259, 300, 336.
- Trowbridge, Professor John, 39-40, 448, 457.
- Trowbridge's directly connected system, 32.
- Tube holder, 47-55, 604, 605, 647.
- Tubercle bacilli, in sputa, 121.
 - test for, 121-122.
 - X-ray experiments with, 450-451.
- Tuberculin, 121-122.
- Tuberculosis, acute miliary, X-ray examination valuable in, 125, 157.
 - of ankle, radiograph of, 590.
 - association of, and acute articular rheumatism, 130.
 - association of, and some other disease, 140.
 - of the bones, 575.
 - displacement of heart in, 288.
 - distinguishing, from pneumonia, 191.
 - dyspepsia a symptom of, 162.
 - early definition of, 117.

Tuberculosis (continued) —

- early comparative value of screen and X-ray photograph in, 120.
- of foot, 587.
- of foot, radiograph of, 591, 592.
- of hip, radiograph of, 593.
- incipient pulmonary, 139-140.
- indicated by physical signs but not by X-rays, 143-147.
- laryngeal, treatment of, 418.
- of phalanges, 592.
- physical signs of, hidden by emphysema, 198.
- in pleurisy cases, detected by screen examinations, 222-229.
- pulmonary, 111-163.
- pulmonary, cases where X-ray examination is valuable, 124.
- pulmonary, most widespread of all diseases, 159.
- pulmonary, suggested by darkened apex of lung, 353.
- suggested by cases of aneurism, 313.
- suggested by pneumohydrothorax, 241.
- X-rays reported ineffective in therapeutic treatment of cases of pulmonary, 418.
- Tumor, of finger, radiograph of, 585.
- of humerus, use of X-rays in examining, 596.
- of stomach, treatment of, by X-rays, 421.
- Tumors, in chest, 339-343.
- differentiation of bony, from others, 582-583.
- enlargement of heart caused by, 271.
- on forearm, X-ray examination of, 596.
- phantom, 377.
- See New growths.
- Tungstate of calcium screen, 55-56, 681-682.
- Turbert, report by, on use of X-rays in gravid uterus, 382.
- Typhoid bacillus, X-ray experiments with, 448, 451.
- Typhoid fever, caution about food in, 288.
- new growth in patient with, 345.

U

- Ulcer, carcinomatous, 434-437.
- of cornea, 680.
- rodent, 437-443, 668-669.
- syphilitic, 406, 407.
- Ulcerations on back of chest healed by X-rays applied to front, 419-420.
- old, 675.
- Ulcers produced by long and intense exposure, 447.
- Ulna, deficiency of shaft of, 462.
- fracture of, 481.
- method of photographing fracture of, 488.
- and radius, exostosis of, radiograph of, 588, 589.
- Unna, on changes in skin from exposure to excited vacuum tube, 447.
- Unna's salve, X-rays in combination with, 396.
- Uranium, atomic weight of, 3.

- Ureters, method of examination for, 617.
- Uric acid, elements of, 3-4.
- Uterus, cases of cancer and of carcinoma of, at Boston City Hospital, 442.
- gravid, 382-383.

V

- Vacuum tube, 32, 34-41.
- distance of, from patient, for therapeutic purposes, 401.
- importance of resistance of, in therapeutic uses, 393-394, 646, 647.
- separate and distinct actions of radiation from, 420-421.
- shielding, from patient, 400-401, 647.
- Vacuum tube position, in examining the heart, 247, 263.
- in examining joints, 587.
- for examining patient in pericarditis, 300.
- in examining stomachs of children, 360.
- in photographing foot, 522.
- in photographing pelvis, 379.
- in photographing shoulder and elbow, 481, 488.
- relative to plate, 62-65.
- relative to patient, 88.
- in treating eczema of legs, 407.
- in treating lupus, 391-392.
- Vagina, case of cancer of, at Boston City Hospital, 442.
- Van Ziemssen, 120, 356.
- use of intensifying screen by, 640.
- Variation in appearance on screen in acute and chronic processes, 354.
- Varnier, X-ray study of gravid uterus by, 382, 383.
- Vaseline, X-rays in combination with, 396-397, 409, 413.
- Velox paper, 57, 457.
- Vena cava, superior, X-ray photograph of, 387.
- Ventricle, left, widening of, by exercise, 390.
- right, enlarged in emphysema, 193.
- right, pulsations of, during inspiration, 252.
- Ventricles, appearance of, on screen, 100.
- Vertebrae, caries of cervical, 594, 596.
- cervical, radiograph of, 90, 91.
- examination for displacement of, 310-311.
- photographing the, 475.
- value of X-rays in diseases of, 587.
- Vesalius, opinion of, on shape of heart in systole, 254.
- Views, importance of taking two, of fractures, 457, 469, 473, 485, 488, 495, 497, 499, 505-506, 510, 542-544, 634.
- interpretation of. See under Interpretation.
- Virchow, account by, of case of myositis ossificans, 465-466.
- Vocal cord, paralysis of, 313, 315, 316, 347.
- Voice, physiology of the, 389.

- Von Wolfender, experiments of, with bacteria and X-rays, 449.
- Voss influence machine, 8.
- Vowels, shape of palate in pronouncing the, 389.
- Vulva, cases of cancer of, at Boston City Hospital, 442.
- W
- Wagner, Dr., recognition of calculi by X-rays, 625.
- Walsham, Dr., X-ray examination by, of lungs of foetus, 383.
- War, use of X-rays in, 553-555.
- Warnings given by X-ray examinations, 305-309.
- Warts, X-ray treatment of, 655.
- Washer used for locating point on skin, 87.
- Water, and ascitic fluid, experiment with, 6. radiograph of, 5. sterilized, injected in empyema, 241.
- Wax, melting of, by sun, overcome, 553-554.
- Wehnelt's electrolytic interrupter, 20, 24, 637.
- Weinberger, Dr., 356.
- Werner, reports by, on therapeutic uses of X-rays, 419, 445.
- Wheatstone stereoscope, 471.
- Whistle in cesophagus, radiograph of, 541. in pelvis, radiograph of, 551.
- Width of heart, 260. errors to be avoided in measuring, 263.
- Wilbert, on use of X-rays in cases of fracture, 467-468.
- Willard, De F., report of, on radiographs of tuberculous knees, 594.
- Williams, Dr. Charles H., use of X-rays in locating foreign body in eye by, 538-539.
- Williams, Dr. Francis H., references to articles published by, 5, 49, 106 n., 111, 113, 142, 202, 222, 247, 249, 258, 260, 262, 423, 532.
- Wimshurst influence machine, 8.
- Women, average weight of heart of, 273-275. heart more to the left in, than in men, 260.
- Wood transparent to X-rays, 2.
- Woods, Dr. Richard F., report of, concerning case of lupus erythematosus, 652.
- Wright, J. H., 435.
- Wrist, fracture of, at Boston City Hospital, 456. method of photographing fracture of, 488. photographing the, 98. radiographs of needle in, 548, 549. tuberculous, treatment of, by X-rays, 419.
- Wrist-joint, radiographs of, 457.
- Wyss, Robert von, investigation of development of skeleton in cretins and cretinoids by, 461-462.
- X
- X-ray, apparatus, portable forms of, 27, 639. department at hospitals, 635, 636.
- X-rays, dental uses of, 603-614. medico-legal uses of, 634. military uses of, 553-555. mode of action of, 393. origin and nature of, 1. introduction to surgical uses of, 454-458. therapeutic uses of, 391-453, 646-681.
- X-ray tracings, 77-79, 126. transferred to blanks for record, 79-80, 174.
- X-ray tracings and records of appearances in—
 bronchitis, 201.
 cancer of liver, 376.
 chest (normal), 102, 107.
 heart, errors to be avoided in recording X-ray outlines, 266-268.
 displacement of, by diaphragm and distended abdomen, 287.
 displacement of, 289, 290, 292-294, 297.
 effect of treatment observed, 302-303.
 inaccuracy of percussion shown, 280-285.
 new growths, 324-336, 338, 342, 344-345, 348, 350-351.
 pleurisy with effusion, 206, 208, 210-212, 214-215, 217, 219, 221, 223-225, 226-227, 229, 231-232, 643.
 pneumonia, 169, 171, 172, 174, 176-179, 181, 182-184, 187, 189-190.
 pneumohydrothorax, 243, 245.
 pneumothorax, 236-239.
 pulmonary tuberculosis, 116, 126, 128, 131, 132, 133, 136, 137, 138, 150-154.
 pulmonary tuberculosis suspected by physical signs not indicated by X-rays, 145.
 stomach during digestion, 361-371.
 thoracic aneurisms, 316, 318-321, 323, 326-327.
- Z
- Zadek on echinococcus of the lung, 346.
- Zechmeister, Dr. Hugo, on treatment of sycosis hyphogenes by X-rays, 653.
- Zinn on persistence of ductus arteriosus Botalli, 301.



IMPERATIVE SURGERY

For the general practitioner, the specialist, and the recent graduate. By HOWARD LILIENTHAL, Attending Surgeon, Mt. Sinai Hospital, New York City, with numerous original illustrations from photographs and drawings. Cloth, Square 8vo, \$4.00, net. Half morocco, Square 8vo, \$5.00, net.

"Dr. Lilienthal has limited his work to what are ordinarily known as emergency operations; that is, to the description of the technics of surgical procedure in conditions which demand active and immediate surgical intervention. It is in this respect that his book is unique in surgical literature. . . .

"The chapters on abdominal surgery are especially complete, and, as we shall subsequently point out, are superbly illustrated. Under the description of each operation there is a full statement in detail of the after-treatment. This includes not only the care of the patient immediately following the operation, but his subsequent treatment, covering the time for removal of sutures and for change of dressings. The importance of this feature of the book is self-evident.

"The text throughout is marked by earnestness and thoroughness. There is no ambiguity of procedure; the reader is not left to choose any one of several methods. The choice is made for him, and this is done in a literary style which is exceptionally lucid and concise. The impression that is made by reading the book is one of complete subordination of the unessential to the necessary, of a mass of detail which is clearly set forth and as clearly elucidated, and, finally, of an epitome of an individual surgeon's experience in a branch of the art which, perhaps, is the widest in the saving of life.

"It is necessary to speak of the illustrations, which are not only numerous, but of a character rarely encountered in medical books. Many are made from photographs, others from drawings; but the distinguishing feature which characterizes them is their remarkable clearness. . . .

"It is scarcely too much to say that since Dr. Lilienthal's book fills an unoccupied place in surgical literature, and because it is altogether scientific and modern, it must prove one of the successful books of the year."—Extracts from an extended review in the *New York Medical Journal*, March 17, 1900.

A MANUAL OF SURGERY

By CHARLES STONHAM, F.R.C.S., Eng., Senior Surgeon to the Westminster Hospital; also Lecturer on Surgery and Clinical Surgery, and Teacher of Operative Surgery; Surgeon to the Poplar Hospital for Accidents; Examiner in Surgery, Society of Apothecaries, London, etc., etc. Fully illustrated. Three volumes. Cloth, 12mo, \$6.00, net. Vol. I, General Surgery. Vol. II, Injuries. Vol. III, Regional Surgery.

The work is notably *modern*, and as such much that is of historical interest merely has been purposely omitted, since it is undesirable to clog a work intended for immediate daily use with material which is out of date so far as actual practice is concerned and is readily accessible in printed works for those who would follow up the historic side of the subject.

No better aid can be found for the student or for the general practitioner who wishes to review the very latest of the new discoveries in both the theory and method of treating surgically pathological conditions.

THE MACMILLAN COMPANY

66 FIFTH AVENUE,

NEW YORK CITY

THE PRACTITIONER'S HANDBOOK OF TREATMENT; OR, THE PRINCIPLES OF THERAPEUTICS

By the late J. MILNER FOTHERGILL, M.D., M.R.C.P., Foreign Associate Fellow of the College of Physicians of Philadelphia. Fourth edition. 8vo. Cloth. \$5.00. Edited, and in great part rewritten, by WILLIAM MURRELL, M.D., F.R.C.P.

The enormous progress in all departments of medicine during the last ten years has necessitated a thorough revision of the work. Considerable additions have been made, but Dr. Fothergill's original design, and, above all, his characteristic style, have as far as possible been preserved.

In the Preface to the First Edition of this work, Dr. Milner Fothergill points out that it is not "an imperfect practice of physic, but an attempt of original character to explain the *rationale* of our therapeutic measures . . . and "is a work on medical tactics for the bedside rather than the examination table."

The *Lancet*, in its obituary notice of Dr. Fothergill, states that "in his profession he exhibited great natural skill in interpreting the indications for treatment of disease, and in many cases of difficulty he would clear up the lines of treatment with a hand that was felt to be masterly. . . . He always wrote what was instructive in a vivacious and interesting, oftentimes original and pungent, style."

INTRODUCTION TO THE OUTLINES OF THE PRINCIPLES OF DIFFERENTIAL DIAGNOSIS

With Clinical Memoranda, by FRED J. SMITH, Senior Pathologist to the London Hospital.
Ex. Cr. 8vo. \$2.00.

DIABETES MELITUS AND ITS TREATMENT

By R. T. WILLIAMSON, M.D. (Lond.), M.R.C.P., Medical Registrar, Manchester Royal Infirmary; Hon. Med. Officer, Pendleton Dispensary (Salford Royal Hospital); Assistant to the Professor of Medicine, Owens College, Manchester. With 18 illustrations (two colored). Royal 8vo. Cloth. \$4.50.

"The study of diabetes, which formed the basis of the author's discovery of the discoloration of methylene blue by blood taken from a diabetic subject, has made his name well known in connection with this disease. A contribution from his pen, in the form of a monograph upon diabetes, is bound to be interesting. In the work before us, we find a more thorough consideration of the subject than has yet appeared in the English language. The chapters devoted to symptomatology and complications are particularly full and thorough. The treatment of the disease is excellently handled, and closes the work in a thoroughly practical manner. The bibliography attached to each chapter and an appendix on diabetic dietetics add value to a work which in completeness and didactic worth is unexcelled." — *N. Y. Medical News*.

THE MACMILLAN COMPANY

66 FIFTH AVENUE,

NEW YORK CITY



