

An atlas of dental extractions : with notes on the causes and relief of dental pain designed for the use of medical students and practitioners / by C. Edward Wallis.

Contributors

Wallis, C. Edward 1868-1927.

Publication/Creation

London : Churchill, 1909.

Persistent URL

<https://wellcomecollection.org/works/d8yussr5>

License and attribution

This work has been identified as being free of known restrictions under copyright law, including all related and neighbouring rights and is being made available under the Creative Commons, Public Domain Mark.

You can copy, modify, distribute and perform the work, even for commercial purposes, without asking permission.

**wellcome
collection**

Wellcome Collection
183 Euston Road
London NW1 2BE UK
T +44 (0)20 7611 8722
E library@wellcomecollection.org
<https://wellcomecollection.org>

AN ATLAS OF
DENTAL EXTRACTIONS

C. E. WALLIS



24309


3/6 net



22500299842

Med

K49464



AN ATLAS OF
DENTAL EXTRACTIONS

WITH
NOTES ON THE CAUSES AND RELIEF
OF DENTAL PAIN

*DESIGNED FOR THE USE OF MEDICAL STUDENTS
AND PRACTITIONERS*

BY

C. EDWARD WALLIS, M.R.C.S., L.R.C.P., L.D.S.

ASSISTANT DENTAL SURGEON KING'S COLLEGE HOSPITAL;
ASSISTANT MEDICAL OFFICER (EDUCATION) LONDON COUNTY COUNCIL;
LATE DENTAL SURGEON VICTORIA HOSPITAL FOR CHILDREN,
CHELSEA, ETC.



LONDON
J. & A. CHURCHILL
7, GREAT MARLBOROUGH STREET
1909

FILE COPY
CLAUSE 343... LIMITED.
5 TO... W.1.

15400 24309

14 786 413

By the same Author.

THE CARE OF THE TEETH
IN
PUBLIC ELEMENTARY SCHOOLS

With Special Reference to what is being done in Germany.

WITH 6 ILLUSTRATIONS AND CHART, 1S. NET.

J. & A. CHURCHILL.

WELLCOME INSTITUTE LIBRARY	
Coll.	WelMOrnex
Coll.	
No.	WU

PREFACE.

THIS atlas and notes have been designed for the use of *medical* students and practitioners with the object of assisting them to perform such emergency dental operations as may be expected to occur in a country practice or on board ship where the services of a dental surgeon cannot be obtained.

A minimum number of dental appliances has been recommended and various means of improvising a dental chair have been shown.

I have to express my great indebtedness to Professor Underwood, Dr. Harold Austen, Mr. Norman Bennett, and Mr. G. K. Aubrey for many valuable suggestions, and also to Messrs. Allen & Hanburys for the loan of the blocks.

C. E. WALLIS.

38, QUEEN ANNE STREET;

June, 1909.

FILE COPY
GLAUB. J. J. & CO. LIMITED.
5 TO 12, BROAD ST., GOLDEN SQUARE, W.1.

LIST OF PLATES.

1. EXTRACTION OF UPPER INCISORS AND CANINES.
2. EXTRACTION OF LOWER INCISORS, LOWER CANINES, AND INCISOR AND CANINE ROOTS.
3. EXTRACTION OF RIGHT AND LEFT UPPER BICUSPIDS.
4. EXTRACTION OF RIGHT LOWER BICUSPIDS AND LOWER ROOTS ON THE RIGHT SIDE OF THE MOUTH.
5. EXTRACTION OF LEFT LOWER INCISORS, BICUSPIDS, AND ALL ROOTS ON LEFT SIDE OF MOUTH.
6. EXTRACTION OF RIGHT UPPER MOLARS.
7. EXTRACTION OF LEFT UPPER MOLARS.
8. EXTRACTION OF RIGHT LOWER MOLARS.
9. EXTRACTION OF LEFT LOWER MOLARS.
10. EXTRACTION OF UPPER AND LOWER ROOTS AND LOWER WISDOM TEETH.
11. THE USE OF THE ELEVATOR FOR EXTRACTING LOWER STUMPS AND LOWER WISDOM TEETH.



Digitized by the Internet Archive
in 2019 with funding from
Wellcome Library

THE CAUSES AND RELIEF OF DENTAL PAIN.

IN studying the causes of toothache one must bear in mind the various structures of which a tooth is composed, and the surrounding tissues with which it is in close relation. A tooth may be regarded as a hard, unyielding box, enclosing a highly sensitive and vascular pulp or "nerve" as it is commonly called.

The portion of tooth which is implanted in the jaw is more or less conical in shape and closely surrounded by its bony socket, which is therefore a hollow cone.

Between the root and the socket is a fibrous membrane known as the "dental periosteum," in which a capillary network ramifies for the nutrition of the socket and the external surface of the root; and through this membrane pass the blood-vessels that enter the pulp.

Irritation applied to any vascular tissue produces *hyperæmia*, which may be but transitory or pass into the condition of *inflammation* if the irritant be not speedily removed.

It is important, therefore, to distinguish *two different sources of the pain* of toothache according as the pulp or the dental periosteum is the part primarily affected, for on the correctness of diagnosis will depend the chance of successful treatment.

Inflammation of the pulp.—The hyperæmia of the

pulp occurring in this condition leads to swelling that causes a darting, shooting, or throbbing pain in the tooth, owing to the resistance offered by the unyielding wall of the pulp cavity to the expansion of the pulp tissue.

Heat or a lowered position of the head intensifies the throbbing, since either will still further increase the congestion.

As the dental periosteum is not involved, pain is not usually felt on the tooth being pressed or bitten into its socket.

Inflammation of the dental periosteum.—This membrane, on becoming inflamed, is thickened, and therefore raises the tooth in its socket; hence it appears lengthened and is bitten upon before its neighbours when the jaws are closed, pain being produced from the periosteum being squeezed between the two unyielding surfaces of tooth and socket.

The pain is of a dull, heavy, not throbbing character, not worse at night, and often relieved by heat and generally in early stages by pressure.

The tooth is tender to the slightest touch, and the gum surrounding it is swollen and feels velvety to the finger.

Irritation of the dental pulp.—If the irritation be long continued and slight, an increased formation of dentine may take place from stimulation of the odontoblasts.

Irritation of the dental pulp may arise from:

- (1) Caries with or without the presence of cavities.
- (2) Heat and cold; contact of sweet, sour, or acid substances.
- (3) Conduction of heat and cold through a metal filling.
- (4) Exposure of dentine from any cause producing loss of the enamel, such as friction from bands or dental plates, wearing down of teeth from excessive use.

Symptoms.—The symptoms depend upon the amount of hyperæmia; thus slight discomfort may follow on taking hot or cold fluids, the contact of cold air, etc.

The pain, however, is usually of a shooting or darting character and occurring at irregular intervals, sometimes brought on by heat or cold, especially cold, or by the contact of sweet, salt, or sour substances.

The tooth may also be tender to the slightest touch owing to an extension of the hyperæmia to the dental periosteum.

Treatment.—When the pain is due to the presence of a cavity in the tooth it must be thoroughly syringed with warm water, and into the cavity must be inserted a small pellet of cotton-wool that has been dipped in one of the following local anæsthetic substances (it is essential to squeeze the excess from the pellet, as it is undesirable for the medicament to overflow into the mouth):

Oil of cloves.

Eugenol.

Creosote.

Oil of cinnamon.

Strong liquefied carbolic acid.

Warm saturated solution of carbonate of soda.

Oil of peppermint.

Cocaine crystals, especially the crystals dissolved in glycerine 1 in 3.

Carbolised resin is a most convenient preparation for the purpose, as in addition to relieving pain it serves as a temporary stopping for two or three days until a dentist can be seen.

Formula for Carbolised Resin.

Resin	4 parts
Carbolic acid crystals	4 parts
Chloroform	3 parts

In cases in which owing to the loss of the enamel the dentine has become exposed and highly sensitive to heat and cold, relief can be obtained almost immediately by the application of solid nitrate of silver to the sensitive area; the most convenient plan is to fuse a little of the powdered salt on the end of a probe or hair-pin so as to form a bead, which can be readily applied to any part of the mouth.

When there is no visible cavity it is well to treat the pain on general constitutional principles with anti-neuralgic remedies, such as chloral hydrate, exalgin, antipyrin, gelsemium, phenacetin, and so forth. The application of iodine and aconite paint to the gums in the vicinity of the painful tooth frequently affords great relief by the counter-irritation and anodyne effect produced.

Iodine and Aconite Paint.

℞ Liquor iodi fortis } equal parts.
 Lin. aconiti }

To be applied to the gums on a small swab of cotton-wool not more than twice daily.

In severe and urgent cases it may be necessary to administer morphine hypodermically. In all cases, however, in which no cavity can be seen, the patient should be advised to consult a dentist, who may be able to find a dental cause not discoverable without the use of special dental appliances.

Acute inflammation of the pulp is usually the result of its exposure or infection by the advance of caries; it may, however, be produced by the fracture of a tooth due to a blow, the application of arsenious acid for destroying the pulp, or as an extension of inflammation from the dental periosteum.

If a section be made through a tooth the pulp of which is in a state of acute inflammation, the pulp tissue will

be seen to be bright red, whereas a healthy dental pulp is of a very pale pink colour.

Symptoms.—Pain, usually of a shooting character, brought on by food pressing against the exposed surface or by the application of heat or cold, and in its early stages characteristically intermittent.

The pain is *worse at night*, when the patient lies down and becomes warm in bed, increased congestion being thus produced; the pulp is squeezed against the hard, unyielding walls of the pulp cavity.

The pain may or may not be referred by the patient to the tooth really affected, a lower tooth being frequently indicated by the patient as the one in fault when the real source of pain is an upper one.

Referred dental pain, however, never crosses the median line.

Examples of referred pain.—Earache is frequently due to a carious molar tooth. Pain in the bicuspid or canine region may also be due to a carious wisdom tooth on the same side of the mouth.

Course.—If the acute inflammation of the pulp be allowed to run its course untreated, the pulp usually becomes strangulated at the apical foramen and its death results; death of the pulp, however, may not occur until a second or third attack.

Treatment.—The first indication is the relief of pain, and this may be accomplished by the same means as for the pain due to irritation of the pulp, namely, the insertion of a pellet of cotton-wool dipped in one of the following:

Oil of cloves, eugenol, creosote, oil of cinnamon, pure carbolic acid, oil of peppermint, a warm saturated solution of carbonate of soda, or crystals of cocaine; carbolised resin¹ is also useful for this purpose, and has the

¹ See "Formula for Carbolised Resin" on p. 3.

additional advantage of serving as a temporary stopping for three or four days.

Treatment.—If pain of a severe throbbing character has lasted for some time destruction of the dental pulp is usually advisable; this is effected by the application of some preparation containing not more than gr. $\frac{1}{16}$ arsenious acid to the exposed pulp, the preparation being carefully retained in position by gutta-percha or wool soaked in sandarac or mastic varnish. Arsenic should not as a general rule be applied to temporary teeth.

The process of "killing the pulp" should be in most cases a painless one; in the cases in which much pain ensues the cause is usually the application of too tight a dressing, which does not allow of the expansion of the pulp due to the congestion produced by the arsenic. The application of arsenic for this purpose should not be undertaken by anyone without special training, as it is frequently a matter of considerable difficulty, and may cause sloughing of the gums and necrosis of the alveolus if carelessly performed.

Chronic suppurative inflammation of the pulp usually arises from infection of the dental pulp that has been exposed by caries.

Symptoms.—Pain coming on at irregular intervals of a wandering neuralgic character, which the patient may not refer to a tooth at all; the presence of throbbing is not infrequent, and may assist in locating the source of the pain.

A paroxysm is often brought on by the sudden application of heat or cold, sweet or salt substances. The characteristic symptom of suppurative inflammation of the pulp is the production of great increase of pain on the application of heat.

The *tooth is not tender* unless the periosteum is involved and the *gum is not swollen*.

Treatment.—The application of local anæsthetics and sedatives on cotton-wool as for irritation of dental pulp ; opening the pulp chamber usually gives immediate relief, but is a procedure that can only be carried out with special dental instruments. General constitutional treatment must therefore be used to supplement local palliative applications until skilled dental treatment can be obtained.

Polypus of the pulp.—Sprouting granulation of the exposed surface of a chronically inflamed pulp may take place, the granulations growing till the carious cavity is completely filled by them, constituting what is known as *polypus of the pulp* ; a polypus of this kind is not usually very sensitive.

Treatment.—The polypus must be cut away and the pulp destroyed by arsenious acid.

Dental periostitis (periodontitis, pericementitis).—Inflammation of the fibrous and vascular membrane which lines the socket of a tooth and covers and nourishes the cementum is called variously “dental periostitis,” “periodontitis,” and “pericementitis.”

It may be general, involving the periosteum of all the teeth, or local, being in that case confined to the socket of one tooth only ; like inflammation elsewhere, it may be *acute* or *chronic*.

General inflammation of the dental periosteum is dependent on some constitutional condition, such as rheumatism, gout, tuberculosis, syphilis, or may be associated with one of the exanthematous fevers, the inhalation of the fumes of phosphorus as in match-makers, the administration of mercury.

Localised dental periostitis may be acute, frequently running on to *alveolar abscess*, or chronic, in which suppuration either does not occur at all or is restricted to the periosteum *near the margin of the socket*.

Acute localised dental periostitis.—*Causes:* (1) Inflammation spreading from a living inflamed pulp, through the apical foramen to the periosteum immediately surrounding it.

(2) Direct absorption by the periosteum of septic material from a putrefying pulp.

(3) Stopping an imperfectly sterilised tooth from which septic material is unable to escape, except through the apical foramen.

(4) Injury caused by a blow upon the tooth, injuring and perhaps leading to infection of the periosteum.

(5) The escape of arsenic from a dressing applied for the destruction of a dental pulp.

(6) Exposure and infection of the periosteum supervening in the condition known as pyorrhœa alveolaris (Riggs' disease).

Symptoms.—In the early stages the tooth or teeth may be merely tender and uncomfortable; later, however, owing to the swelling of the dental periosteum the affected teeth become raised, as well as loose and tender to the slightest touch.

The gums also become involved, since the dental periosteum is reflected outwards at the margin of the alveolus, and become swollen and deeply congested, presenting a velvety feeling when touched by the finger.

Sudden changes of temperature or weather will often bring on or accentuate an attack of dental periostitis in those subject to this affection.

When dental periostitis is produced by mercury or phosphorus, there is tenderness and loosening of the teeth, extreme congestion of the gums, which become spongy and readily bleed, together with great oral fœtor.

Ulceration with sloughing of the gums and necrosis of the jaw may ensue.

Ptyalism is especially marked in mercurial poisoning.

General treatment.—*Constitutional*: Remove the cause if possible, as in the case of mercury and phosphorus poisoning.

Treat general condition if gouty, rheumatic, tuberculous, or syphilitic.

Local.—Render the mouth as aseptic as possible by the use of mouth washes, of which sanitas combined with chlorate of potash lotion (gr. x to the ounce) is one of the best.

In cases in which one or more teeth are involved, counter-irritation applied by first drying a large area of the gums near the affected teeth and then painting it with *iodine and aconite paint* gives great relief.

Formula.

℞ Liquor iodi fortis } equal parts.
 Lin. aconiti }

This should not be applied more than twice or three times daily, as it tends to make the mucous membrane so sore that further applications become impossible.

The application of a capsicum plaster, which is a sort of diminutive mustard leaf, to the previously dried gum also gives great relief; it should be held over the root of the affected tooth with the finger until it adheres, and then allowed to remain until it falls off.

Chronic localised dental periostitis.—This condition must be treated in the same way as the above, by general constitutional treatment and by the application of the iodine and aconite paint night and morning, or if more convenient by the application of capsicum plasters.

Chronic suppurative dental periostitis—pyorrhœa alveolaris.—The pathology of this condition is very obscure; it is apparently due to a pyogenic infection.

Symptoms.—Those of suppuration of the dental periosteum, plus inflammation of the gums (gingivitis), accompanied by the formation of deep pockets, from which pus exudes round the necks of the teeth, leading to destruction of dental periosteum, absorption of the alveolus, and loosening of the teeth.

Treatment.—The treatment of this condition is exceedingly unsatisfactory; at the same time efforts must be made to minimise the suppuration by the use of antiseptic mouth-washes, such as chlorate of potash in combination with sanitas, permanganate of potash, etc.

Alveolar abscess.—An abscess arising from a tooth is known as an alveolar abscess or “gum-boil”; it is usually situated at the end of the root of a tooth.

Causes.—Extension of septic infection from the pulp or periosteum of a tooth.

Symptoms.—Those of dental periostitis much intensified, *e. g.* the tooth is raised and tender; the gums are swollen, deeply congested; pus frequently wells up at side of tooth.

Sulcus between cheek and tooth instead of being hollow is filled up by a globular or diffuse swelling.

Sometimes diffuse cellulitis of the face occurs, the whole cheek becoming swollen, tense, shining, very painful, and the eye closed if the abscess is connected with an upper tooth. The pus from an upper tooth may burrow into the antrum in the case of upper bicuspids (or molars), or be directed towards the palate (upper lateral incisor) either between the periosteum and the bone, when there will be great pain, or between the periosteum and the mucous membrane, when there will be but little pain, since the tissue in that situation is somewhat lax and therefore yields readily.

When an abscess is situated at the root of a lower

molar, particularly a lower wisdom tooth, *trismus* may occur from :

(1) Spasm of the masseter, which symptom will disappear under an anæsthetic.

(2) Inflammatory infiltration of the masseter, in which case the administration of an anæsthetic will simply enable the operator to apply the necessary force to open the jaw with a screw wedge or Mason's gag.

An abscess from a lower wisdom tooth sometimes points beneath the angle of the jaw, and an abscess connected with any lower tooth may burst either through the cheek or beneath the margin of the mandible.

The submaxillary lymphatic glands sometimes become infected, in which case they will be swollen and tender.

The submaxillary lymphatic glands in children are sometimes infected with tubercle, probably conveyed to the glands by carious teeth with exposed pulps.

Treatment of alveolar abscess.—When an alveolar abscess has already formed, great relief will usually be obtained by incising the abscess in the mouth.

In cases in which the abscess is very large and is threatening to burst outside the cheek, it is wise to apply a piece of gauze with flexible collodion over the thinned area of skin, and thus to minimise the danger of or prevent the occurrence of an external opening; at the same time efforts must be made to make the abscess point in the mouth, and this is best done by the application of a roasted dried fig or a dried fig squeezed dry from boiling water and held in the mouth over the abscess; it is often necessary to apply a succession of these fig poultices.

Poppy-head fomentation, made by boiling two ounces of bruised poppy-heads for ten minutes in a pint of

water and held in the mouth, often gives great relief and may shorten the course of the affection.

In severe cases of alveolar abscess extraction of the tooth is the only course open to the medical practitioner, and the sooner it is done the better for the patient; the old idea that it is necessary to wait till the inflammation has subsided is often disastrous to the patient, as it may lead to the formation of an external opening in the cheek and permanent scarring of the face.

An abscess arising from a lower wisdom tooth usually necessitates its extraction, this is often a matter of great difficulty, and can only be accomplished by using the elevator; it sometimes happens that it is impossible to reach the wisdom tooth, in which case it may be necessary to remove the second lower molar before dealing with the offending wisdom tooth.

Local anæsthesia in the extraction of teeth.—Though still to some extent on its trial, the hypodermic injection of certain anæsthetic solutions is in a considerable number of cases successful in enabling the extraction of teeth to be performed painlessly. At the same time it is essential for the operator to know exactly what he is injecting and the exact amount and purity of the active ingredient contained in his injection.

Nothing can be more dangerous than the injection of the much advertised proprietary local anæsthetics, most of which contain an indefinite amount of cocaine, and which within the writer's knowledge have over and over again produced serious results.

Cocaine is certainly to be avoided in all these preparations.

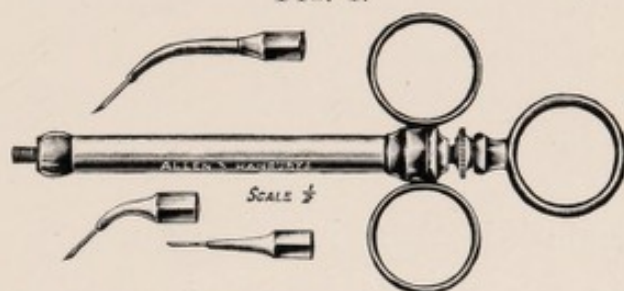
There are no absolutely reliable and satisfactory preparations for the purpose, though novocaine (which is a white soluble powder of definite chemical composition)

and injections containing eucaïne combined with adrenalin frequently do very well. Novocaine can be obtained either in the form of tablets to be dissolved in sterilised water so as to make a 1 to 2 per cent. solution, or as a 2 per cent. solution ready prepared for dental use; it is of the utmost importance that whatever solution is used must be freshly prepared and sterile.

For difficult extractions the 2 per cent. solution should be used; for simple extractions the 1 per cent. solution is sufficient.

A very satisfactory syringe is that designed by Dr. Dawson, of Dublin, as it is readily sterilisable, and more-

FIG. 1.



over, by reason of its "finger-rings," affords a perfect command over the barrel and piston.

Procedure.—(1) The patient's mouth should be thoroughly rinsed with sanitas and water or a permanganate of potash mouth-wash.

(2) A swab of cotton-wool soaked in 10 per cent. novocaine or cocaine (10 per cent.) solution is held by the patient over the part to be injected, so as to anæsthetise the mucous membrane to the prick of the needle.

(3) The syringe is next warmed and sterilised, and the needle should be boiled in a small test-tube before use.

(4) If novocaine is used the syringe should then be filled with 17 minims (1 c.c.) of the 1 or 2 per cent. solution according to the difficulty of the extraction, and then an

injection made of about 12 minims on the external and 4 minims on the internal side of the alveolus, the aim of the operator being to surround the tooth with a zone of anæsthesia, and for this purpose at least two punctures are necessary; the point of the syringe should be inserted about 3 mm. from the free edge of the gum adjacent to the tooth to be removed; the needle should be inserted quickly and the injection made very slowly, the syringe being held in position for some seconds after the requisite quantity has been injected. When the gum becomes blanched, and not till then, the anæsthesia may be regarded as complete.

Hypodermic Injection of Adrenalin and Eucaine.

R Beta-eucaine	gr. $\frac{1}{6}$
Adrenalin chloride	gr. $\frac{1}{2000}$
Aq. ad.	℥xvij.

To be freshly prepared or used from an "ampoule."

Hypodermic injections into the gums should not be made—

(1) In inflammatory or suppurative conditions of the mouth.

(2) In cases of alveolar abscess. In such cases the application of cotton-wool soaked in 10 per cent. novocaine for some five minutes will much alleviate the pain of a dental extraction.

The local anæsthesia that can be produced by freezing the gums with a spray of *ethyl chloride* is frequently very useful in the case of readily accessible single-rooted teeth, but it must be borne in mind that it has a great tendency to cause the teeth to become brittle owing apparently to the freezing of their "organic" matter, with the result that they may be very readily broken during the attempt at extraction and thus lead to much difficulty.

GENERAL NOTES ON EXTRACTION OF TEETH.

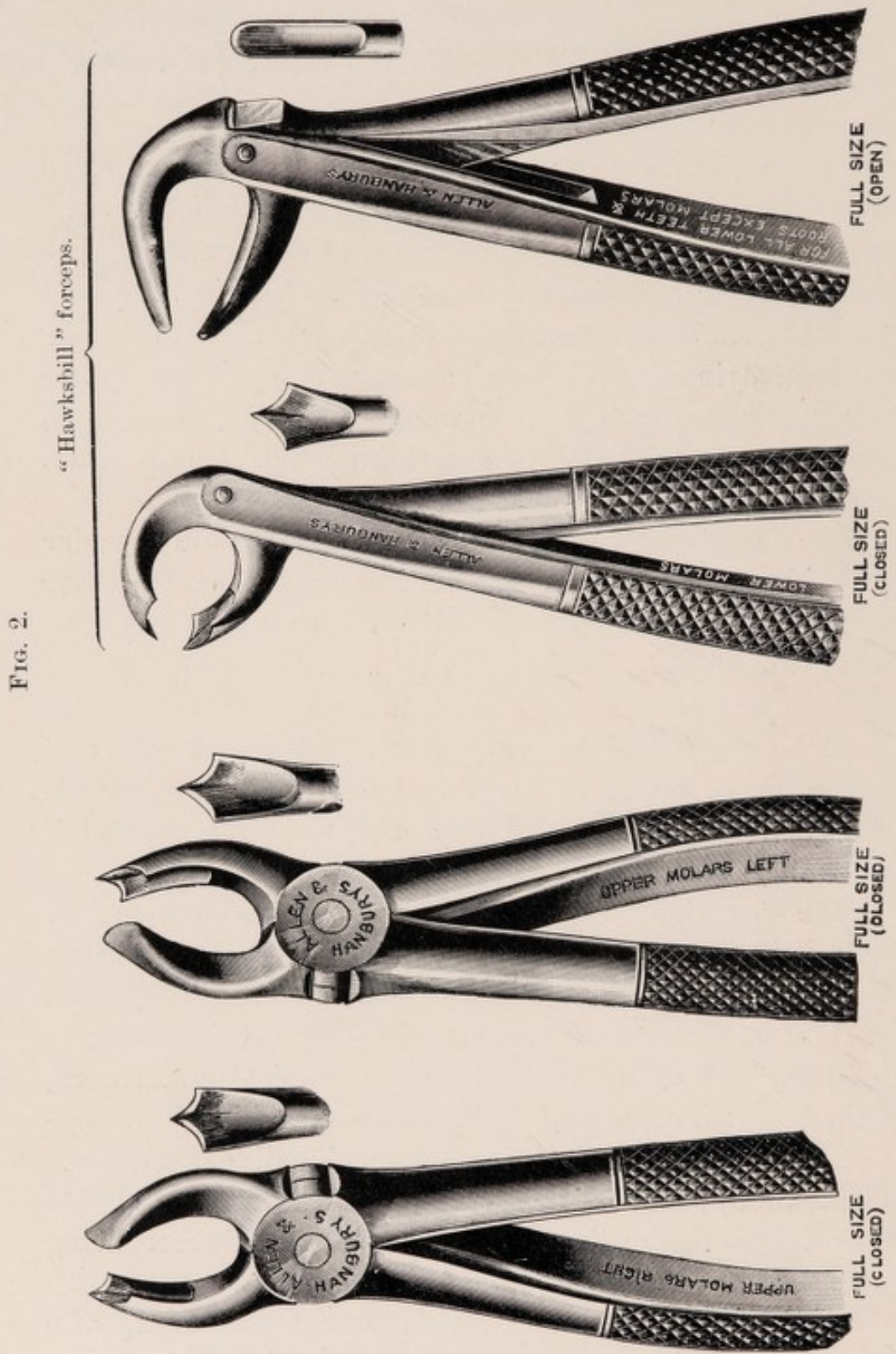
The minimum number of forceps that can be expected to deal with any ordinary case of extraction is five, and this number combined with a "fish-tail" elevator will be sufficient for practically every tooth. In Figs. 2 and 3 the patterns suggested are shown together with a pair of "conveying forceps" such as are very useful for applying medicaments on cotton-wool for the relief of pain, and also a dental probe for ascertaining the exact position and extent of carious cavities.

The use of so-called "straight" forceps for lower molar and bicuspid teeth is not recommended, as they are exceedingly difficult to use and do not provide nearly as much leverage as those of the so-called "hawkbill" pattern as shown here. The blades of all dental forceps must be *bevelled* so that they grasp the teeth on a flat and not a sharp edge, as is frequently the case with ill-designed forceps, which simply break the teeth instead of grasping them.

The "straight" elevator is not recommended, as not only is it difficult to use but is an exceedingly dangerous instrument in the hands of one unaccustomed to its use.

It is of the utmost importance that all instruments used for extracting teeth should be efficiently sterilised, either by boiling or else by prolonged soaking in a solution of carbolic acid (1 in 20) or biniodide of mercury (1 in 3000); it is also essential that the forceps should be clean in the ordinary sense of the word before being placed in the antiseptic lotion.

Inasmuch as few practitioners possess the luxury of a dental operating chair, a convenient substitute can be



"Hawksbill" forceps.

FIG. 2.

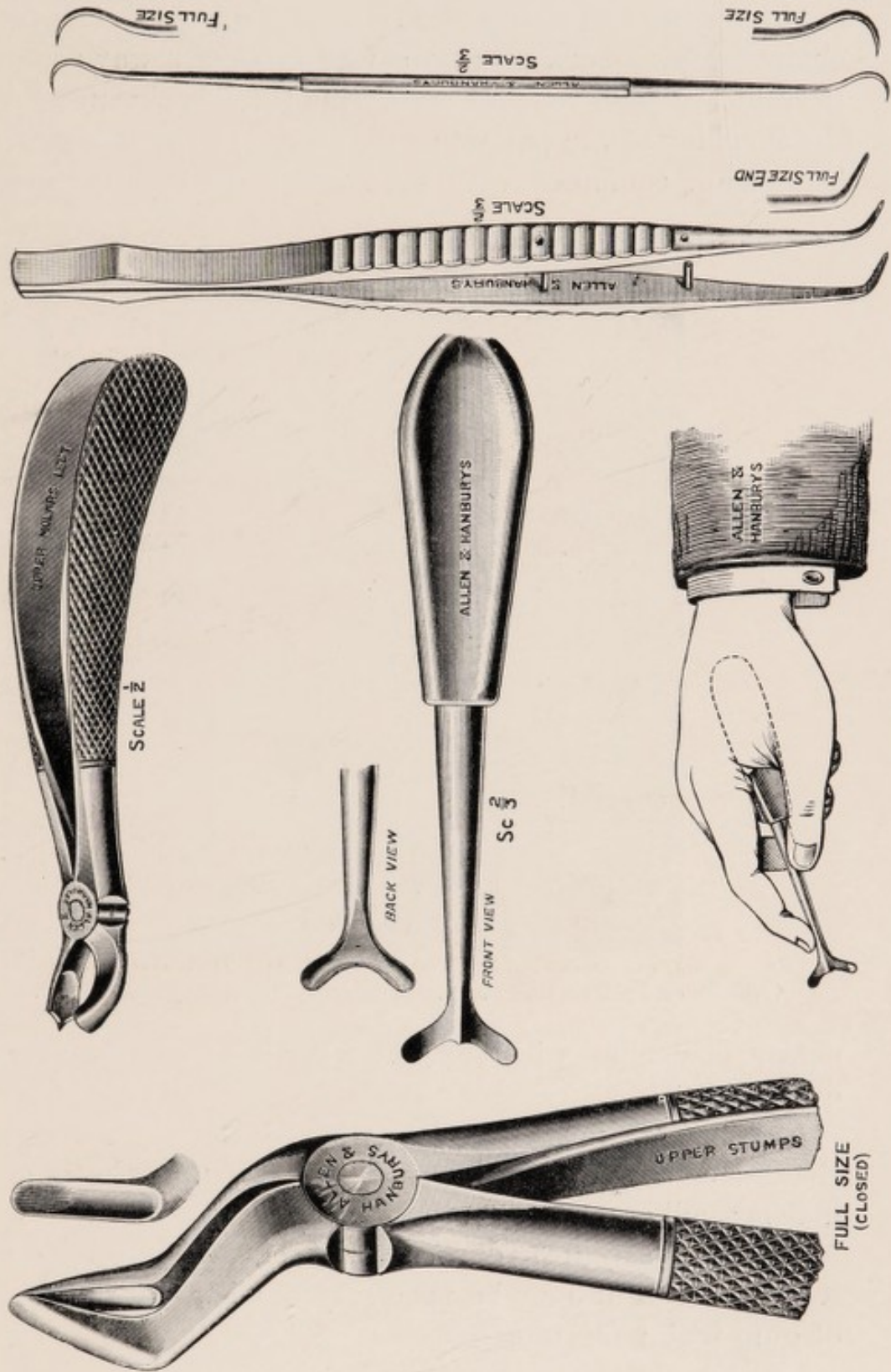
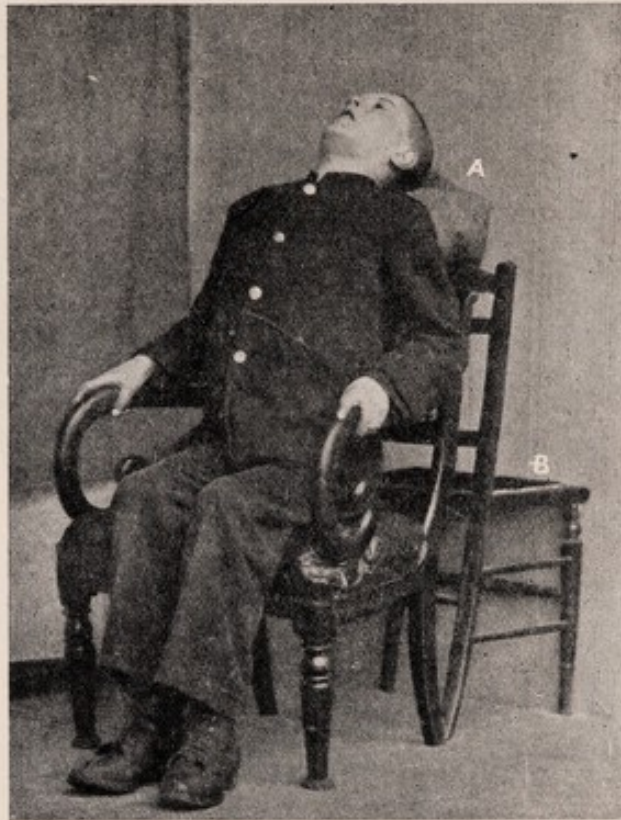

FIG. 3.

18 GENERAL NOTES ON EXTRACTION OF TEETH.

readily devised as shown in Fig. 4 by placing two strong chairs back to back against a wall in such a way as to prevent the chair in front from being tilted backwards by the flinching of the patient or the efforts of the operator. This plan, combined with such other positions as are



A. Cushion on back of chairs. B. Chair resting firmly against a wall.

shown in dealing with particular teeth, is sufficient for every case.

Special care must be taken when extracting a tooth that stands alone; it frequently happens that the gum is firmly adherent to a tooth of this kind and may therefore be seriously torn during the process of extraction; in such a case it may be necessary to cut away the tag of gum with a lancet or scissors.

THE EXTRACTION OF TEMPORARY TEETH.

ALL the temporary teeth except the molars have *one* root.

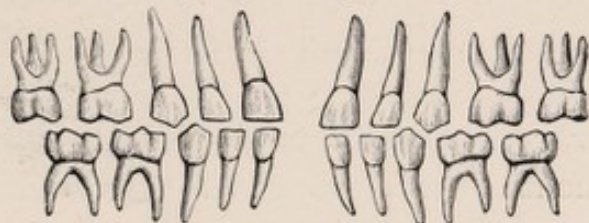There are *no* bicuspid in the temporary dentition.

The position of the temporary molars is occupied by the bicuspid in the permanent dentition.

The *bicuspid*s erupt between the roots of the "temporary molars," and therefore occupy their position when they are lost.

In extracting the temporary teeth the patient should be

FIG. 5.



The temporary teeth.

placed in the same position as for the corresponding permanent teeth.

General principles.—Grasp the crown of the tooth firmly in the forceps.

In the case of a temporary molar it is important to avoid pressing the forceps upwards or downwards to any appreciable extent for fear of removing the crown of an on-coming bicuspid which lies between its roots ready to take its place.

For *upper incisors or canines* use "straight" or bayonet root forceps.

For *upper molars* use right or left upper molar forceps or bayonet root forceps in cases where the crown is much broken down.

For *lower incisors or canines* use lower hawksbill root forceps; the same forceps can be used on either side of the mouth.

For *lower temporary molars* use lower hawksbill molar forceps or lower hawksbill root forceps.

Broken-down temporary teeth and roots can either be extracted with root forceps or prised out with the "fish tail" elevator, making use of an adjacent tooth as a fulcrum.

It is quite *unnecessary* to have special forceps for temporary teeth.

It is important to avoid extracting prematurely a *second temporary molar*; loss of this tooth may lead to a moving forward of the adjacent first permanent molar and consequent crowding and irregularity of the bicuspid teeth.

The *temporary canines* should also be retained until their permanent successors show signs of erupting; premature extraction of the temporary canines allows the bicuspid teeth to move forward and thus may lead to the deformity of projecting canine teeth.

Undue retention of the temporary teeth may, on the other hand, lead to irregularity of the permanent successors; in cases of doubt it may be well to postpone extraction until the advice of a dental surgeon can be obtained.

DENTITION TABLE.

The following table shows the order in which the milk teeth and permanent teeth appear, and the average age at their eruption. There are wide variations as to time, and great irregularity in the order of their appearance.

Milk teeth.—The first dentition begins at the sixth or

seventh month, and is completed by about the second year.

Central incisors . (1) lower, 6th month; (2) upper, 7th month.

Lateral incisors . (1) upper, 9th month; (2) lower, 10th month.

First molars . 12th month.

Canines . 18th month.

Second molars . 2nd year (often later).

The full primary dentition is 20 teeth; 10 in each jaw.

Permanent teeth :

First molars 6½ years

Lower central incisors . 7 „

Upper central incisors . 8 „

Lateral incisors 9 „

First bicuspid 10 „

Second bicuspid 11 „

Canines 12 „

Second molars 13 „

Third molars (wisdom) . 17 to 25 years,
or at any later period.

The full permanent dentition is 32 teeth; 16 in each jaw.

HÆMORRHAGE AFTER EXTRACTION: TREATMENT.

Local.—In slight cases it is sufficient for the patient to sit quiet with cold or iced water in his mouth; where ice cannot be obtained holding *very* hot water in the same way is often successful, especially if alum be dissolved therein.

It is not infrequent, however, that blood will continue to well up from the socket from which the tooth has

been removed; in such a case it is necessary to syringe the socket with ice-cold or very hot water or boric lotion and then to apply pressure to the bleeding point by firmly plugging the socket with cotton-wool or lint soaked in fresh adrenalin or other supra-renal gland preparation; the application of tannin, either as glycerine of tannin or on wool soaked in hazeline and powdered with tannin, answers in many cases. Perchloride of iron is a most unsatisfactory remedy, and should only be used as a last resource when nothing else is obtainable.

Constitutional.—It is not uncommon for an operator to be warned by the patient that excessive bleeding has previously followed the infliction of a cut or the extraction of a tooth. It has been shown that a large proportion of these cases are due to insufficient coagulability of the blood owing to an insufficiency of calcium salts; it is therefore wise in such cases to administer one of the drugs which are known to rapidly increase the coagulability of the blood.

Calcium lactate, calcium chloride, and magnesium carbonate have all been shown to produce this effect in a marked degree within the space of an hour or so; the salt selected should be administered in a single dose of ʒj the night before the proposed operation.

The best and most pleasant to take is calcium lactate, which may be administered in compressed tablets or in a draught such as the following:

R Calcii lactatis	ʒj.
Syrup	q.s.
Aq. ad.	ʒj.

Fiat haustus.—To be taken as a draught the night before the dental extraction takes place.

The effect of these salts appears to last about three to four days, so that in the event of dental extractions being performed on successive days a second dose is not called for.

PAIN AFTER EXTRACTION.

PAIN after the extraction of a tooth may be due to the lateral displacement of the alveolus which is brought about by the application of the forceps; this can be minimised by applying firmly a finger and thumb after the tooth has been removed and so restoring the alveolus to its former position.

Besides this, owing to the socket becoming septic either from the operator making use of unsterilised instruments or else operating in a mouth that is very foul, pain may continue in a tooth socket for a considerable time.

To avoid this every mouth, before operation, should be made as clean as possible by the use of tooth-powder and sanitas and permanganate of potassium mouth-washes, and after the extraction has taken place every effort must be made to keep the socket free from the remains of food and other decomposable matter. If, two or three days after the extraction, the patient complains of pain in the socket, the treatment is to keep it syringed out with sanitas and water.

A pledget of cotton-wool soaked in liquor potassæ and pure carbolic acid, equal parts, usually affords immediate relief from pain after the socket has been syringed out in this way.

INDEX.

- Aconite and iodine paint, 4
Acute inflammation of pulp, 4
Adrenalin and beta-eucaine injection,
14
Alveolar abscess, 10
Anæsthesia, local, 12
Anodyne applications, 3
Arsenic for dental pulp, 6
- Beta-eucaine, 14
Bicuspid, extraction of right and
left upper, plate 3
— — of right lower, plate 4
— — of left lower, plate 5
Biniodide of mercury, 15
- Calcium chloride, 22
— lactate, 22
Canines, extraction of upper, plate 1
— — of lower, plate 2
— temporary, premature extraction
of, 20
Carbolic acid, 3, 5
Carbolised resin, 3
Carbonate of magnesium, 22
Chair, operating, 18
Chloride of ethyl, 14
Chronic dental periostitis, 7
Chronic suppurative inflammation of
pulp, 6
Collodion, flexible, 11
- Dental periostitis, 7
Dentition table, 20
Destruction of dental pulp by arsenic,
6
- Earache, 5
Elevator, use of, plates 10, 11, and
page 15
Eruption of teeth, order of, 21
Ethyl chloride, 14
Eucaine, 14
Extraction, hæmorrhage after, 21
— pain after, 23
— of temporary teeth, 19, 20
— of permanent teeth (*see under
names of teeth*).
- Fig-poultice, 11
"Fish-tail" elevator, plate 10
Fomentations, poppy-head, 11
Forceps, 16, 17
- Gag, Mason's, 11
Gingivitis, 10
Glands, infection of, 11
Gum-boil, 10
- Hæmophilia, 21
Hæmorrhage after extraction, 21
Hawksbill forceps, 15
- Improvised operating chair, 18
Incisors, extraction of upper, plate 1

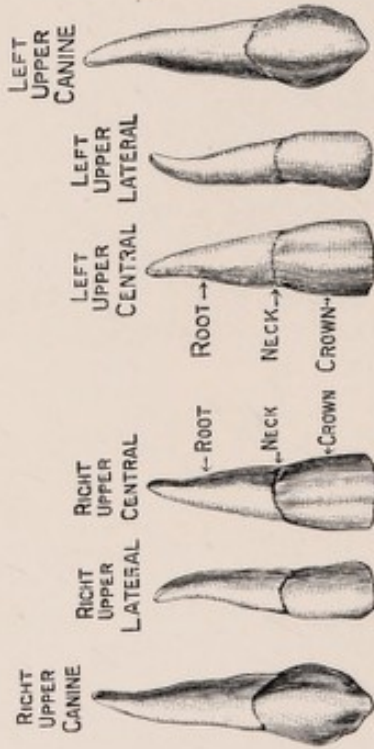
- Incisors, extraction of lower, plate 2
 Inflammation of the pulp, 1, 4
 Inflammation of dental periosteum, 2
 Instruments, sterilisation of, 15
 Iodine and aconite paint, 4
- Lactate of calcium in hæmophilia, 22
 Local anæsthesia, 12
- Mason's gag, 11
 Masseter, spasm of, 11
 Mercurial poisoning, 7
 Mercury, biniodide of, 15
 Molars, extraction of right upper, plate 6
 — — of left upper, plate 7
 — — of right lower, plate 8
 — — of left lower, plate 9
 — premature extraction of temporary, 20
- Novocaine, 12
- Operating chair, 18
- Pain after extraction, 23
 — referred, 5
 Perchloride of iron, 22
 Periostitis, dental, 7
 Phosphorus poisoning, 7
 Polypus of pulp, 7
- Poppy-head fomentations, 11
 Potassium chlorate, 9
 Ptyalism, 9
 Pulp, inflammation of, 4
 Pyorrhœa alveolaris, 8
- Referred pain, 5
 Resin, carbolised, 3
 Riggs' disease, 8
 Roots, extraction of, plates 10, 11
- Scarring of face, 11
 "Straight" forceps, 15 and plate 1
 Stumps, extraction of, plates 10, 11
 Suppurative inflammation of dental pulp, 6
 Syringe, Dawson's, 13
- Tannin in hæmorrhage, 22
 Teeth, order of eruption of, 21
 — permanent, plates 1-11
 — temporary, 19
 Temporary teeth, extraction of, 19
 — premature extraction of, 20
 — shapes, 19
 Trismus, 11
- Wisdom teeth, extraction of lower, plate 10
 — — of upper, plates 6, 7

PLATE 1.

EXTRACTION OF UPPER INCISORS AND CANINES.

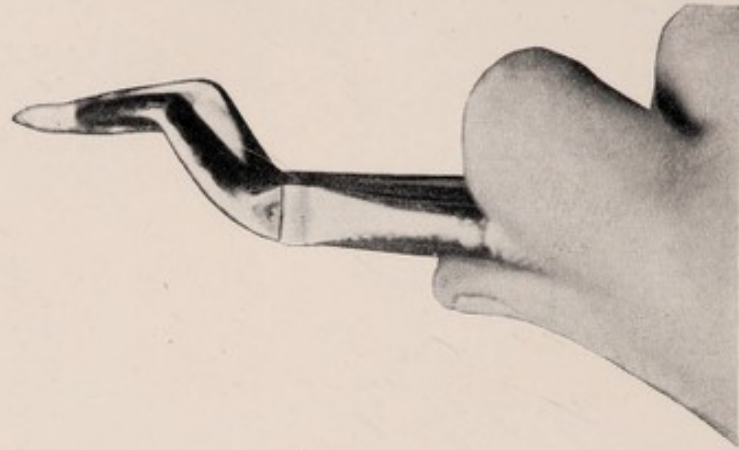
PLATE 1.

EXTRACTION OF UPPER INCISORS AND CANINES.




Incisor teeth have one root only.

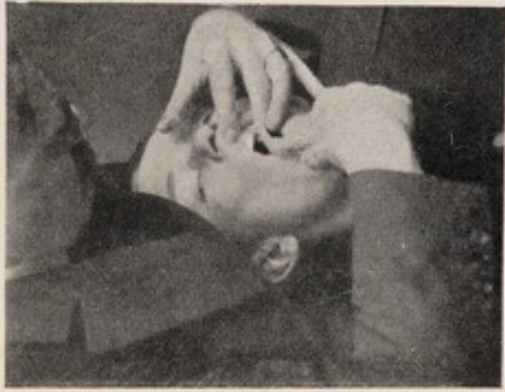Forceps to be used, either { Bayonet upper root forceps, or Straight upper root forceps.



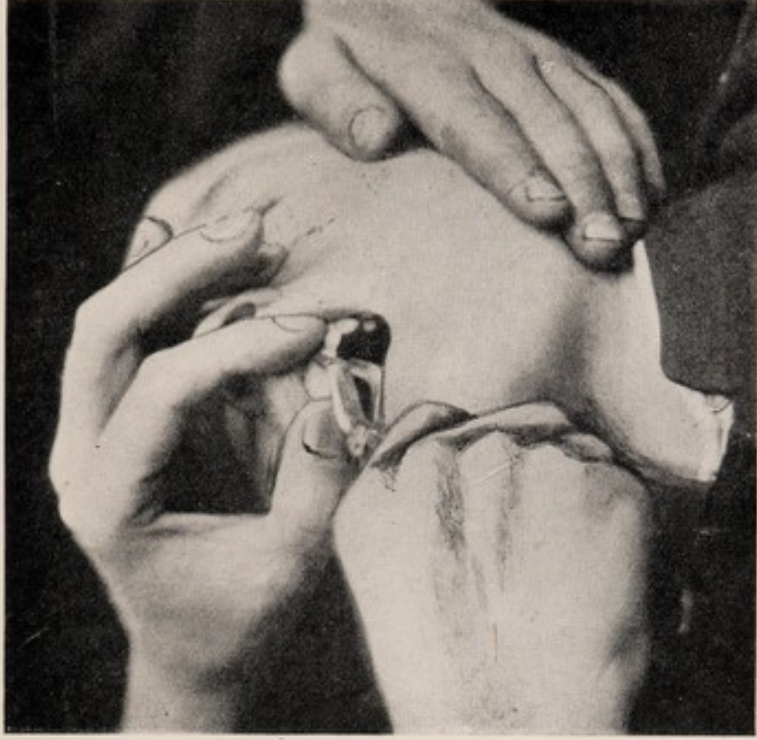"Bayonet" root forceps applied to an upper incisor tooth.



"Straight" upper root forceps.



Patient seated on a firm chair ; operator standing behind and to the right, with left side against a wall in order to avoid being pushed backwards.



Assistant standing behind with back against a wall, and supporting patient's head with his hands.

Application of Forceps :

Apply blades as in photos.

Press forcibly upwards between neck of tooth and surrounding gum.

Rock gently in order to loosen, and at the same time rotate forceps on the tooth in order to free it from its attachment.

When quite loose then withdraw the tooth.

After extraction press the alveolus together antero-posteriorly with a finger and thumb. It is specially important in the case of front teeth not to fracture the alveolus.

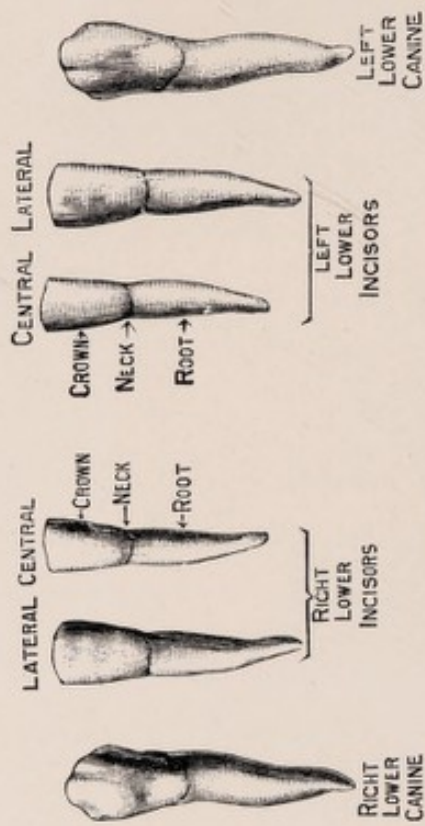
PLATE 2.

EXTRACTION OF LOWER CANINES, ALL LOWER INCISORS,
AND INCISOR AND CANINE ROOTS.

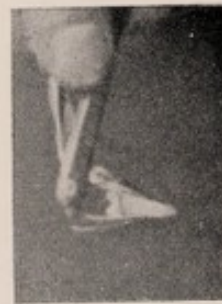PLATE 2.

EXTRACTION OF LOWER CANINES, ALL LOWER INCISORS, AND INCISOR AND CANINE ROOTS.

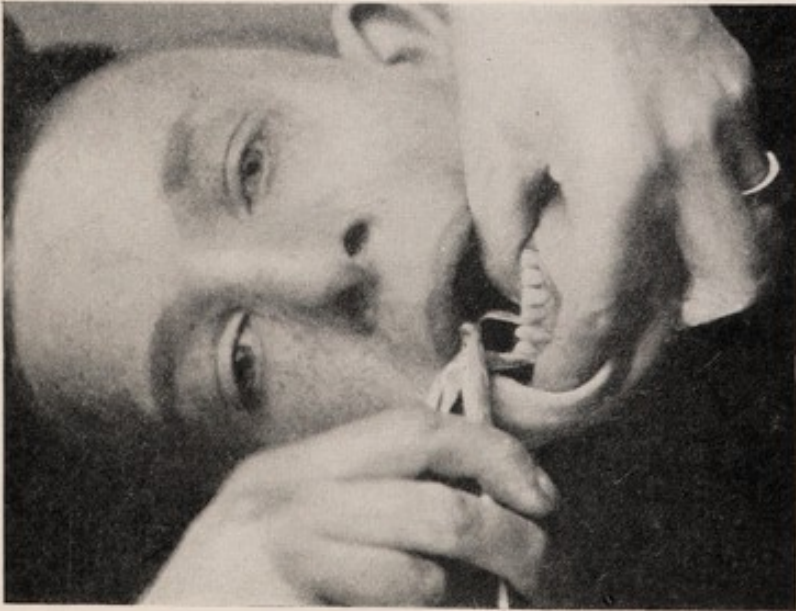N.B.—All lower incisors and canines are single-rooted teeth.



Forceps to be used, Lower "Hawksbill" root forceps; the same pair is used for both sides of the mouth.



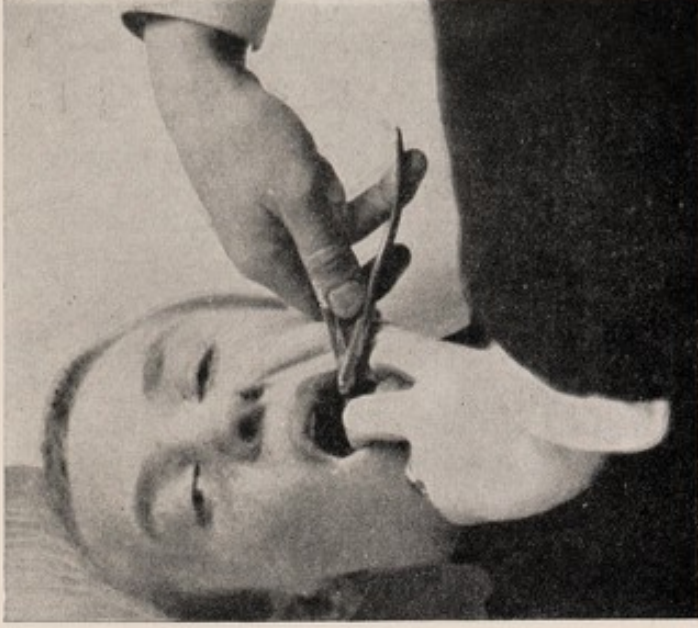
Forceps grasping tooth.



Operator standing behind with back against a wall.



Patient's head in a corner.



Head resting in corner.

Application of Forceps:

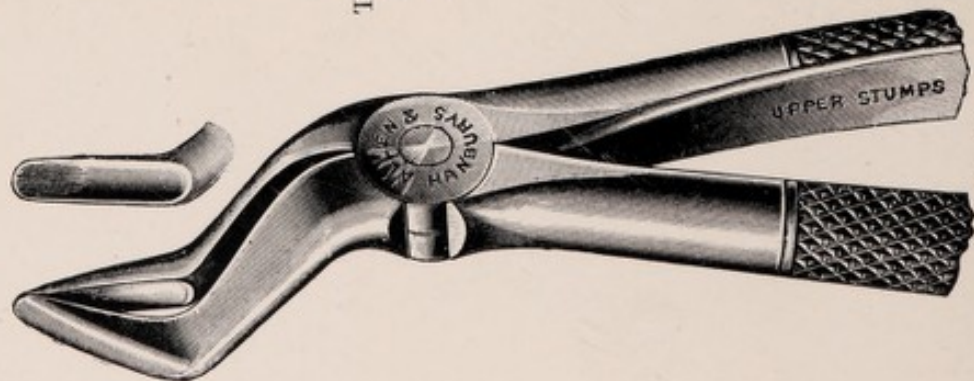
Apply forceps carefully between the neck of the tooth and the surrounding gum. Press down forcibly, rocking the tooth slightly inwards and outwards at the same time. When *quite loose* withdraw the tooth from its socket. After extraction press the alveolus together with a finger and thumb.

PLATE 3.

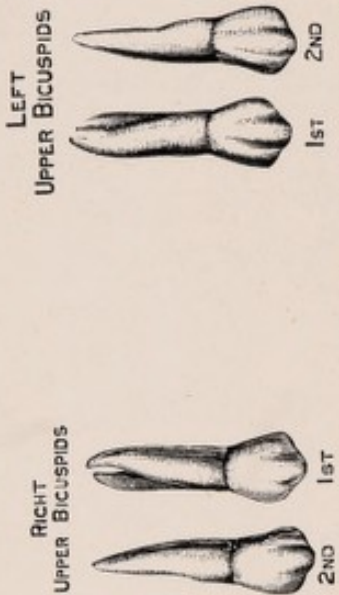
EXTRACTION OF RIGHT AND LEFT UPPER BICUSPIDS.

PLATE 3.

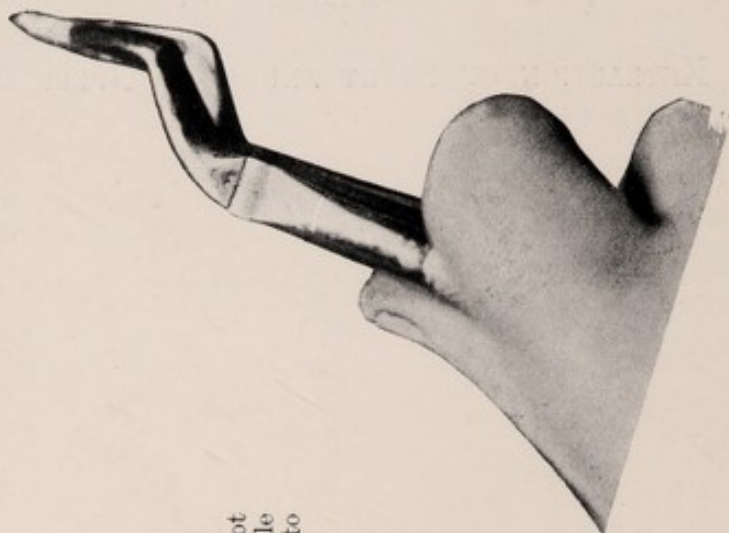EXTRACTION OF RIGHT AND LEFT UPPER BICUSPIDS.



FULL SIZE
(CLOSED)

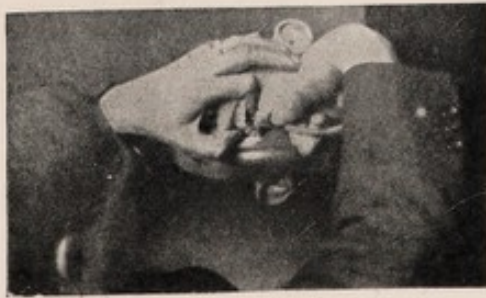

The first upper bicuspid has frequently a bifurcated root as seen here; it is therefore important to use as little lateral movement as possible in extraction in order to avoid fracture




Bayonet root forceps applied to upper bicuspid tooth.

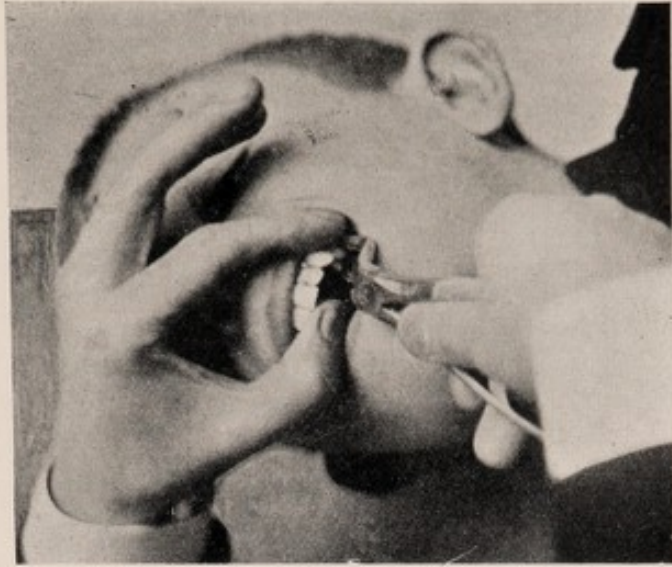Forceps to be used. Bayonet root forceps, the same pair are used for both sides of the mouth.



Patient's head resting on cushion placed over back of two chairs. Operator standing in front and to the right of patient.



Improvised dental chair.



Patient's head in corner of room.

Application of Forceps :

Apply blade carefully as in the photos.

Press forcibly upwards between the neck of the tooth and the surrounding gums.

Rock gently in order to loosen the tooth from its attachments, especially in an outward direction, owing to the outer alveolar plate being thinner than the inner.

When *quite loose* then withdraw the tooth.

After extraction press the walls of the alveolus together.

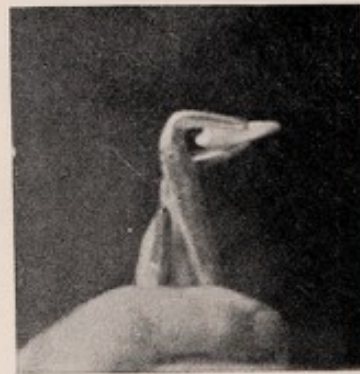
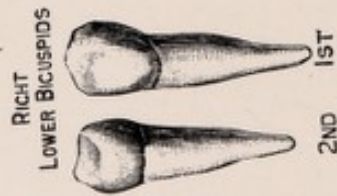


PLATE 4.

EXTRACTION OF RIGHT LOWER BICUSPIDS AND LOWER
ROOTS ON THE RIGHT SIDE OF THE MOUTH.

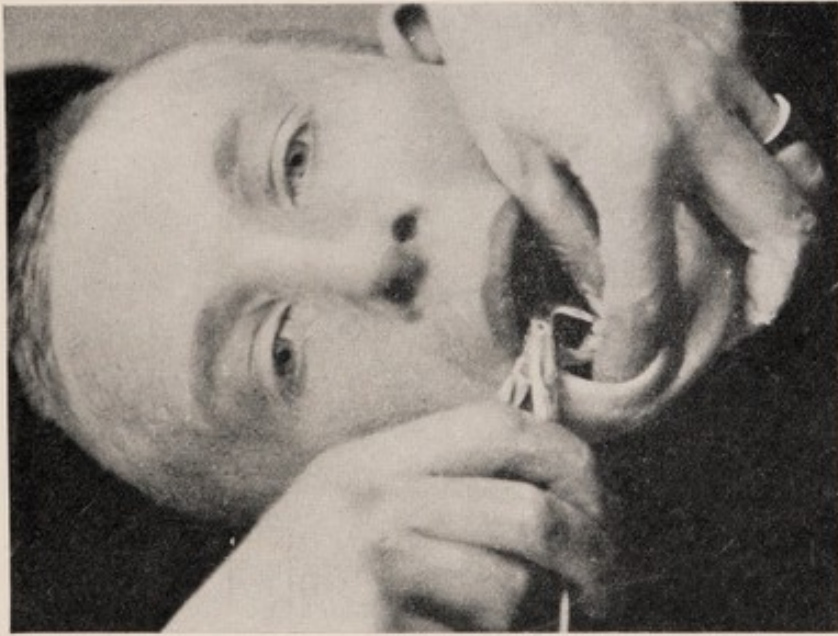PLATE 4.

EXTRACTION OF RIGHT LOWER BICUSPIDS AND LOWER ROOTS ON THE RIGHT SIDE OF THE MOUTH.



Forceps to be used, Lower "hawkbill" root forceps; the same pair are used for both sides of the mouth.

Forceps holding a lower right bicuspid, showing the importance of thoroughly pressing down the blades between the neck of the tooth and the surrounding gum in order to grasp as much of the tooth as possible.



Operator standing behind with back against a wall.



Operator standing with his back against a wall.
Operator sitting on firm chair with back against the wall. Patient seated on floor between knees of operator.



Application of Forceps :

- Apply forceps carefully between neck of tooth and surrounding gum.
- Press down forcibly, rocking the tooth slightly inwards and outwards at the same time.
- When quite loose withdraw the tooth from its socket.
- After extraction press the walls of the alveolus together.




PLATE 5.

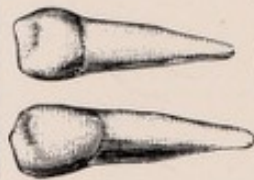
EXTRACTION OF LEFT LOWER INCISORS, BICUSPIDS, AND
ALL ROOTS ON LEFT SIDE OF MOUTH.

PLATE 5.

EXTRACTION OF LEFT LOWER INCISORS, BICUSPIDS, AND ALL ROOTS ON LEFT SIDE OF MOUTH.

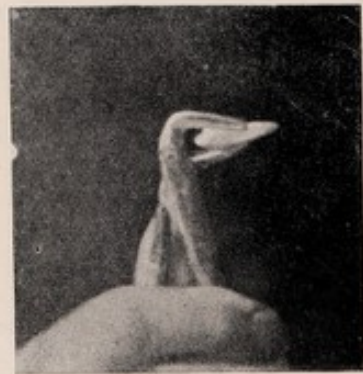N.B.—Lower incisors being single-rooted are extracted with the same forceps as bicuspid.

LEFT
LOWER BICUSPIDS



1ST 2ND

Side view of left lower bicuspid.



Showing method of applying forceps to lower bicuspid.

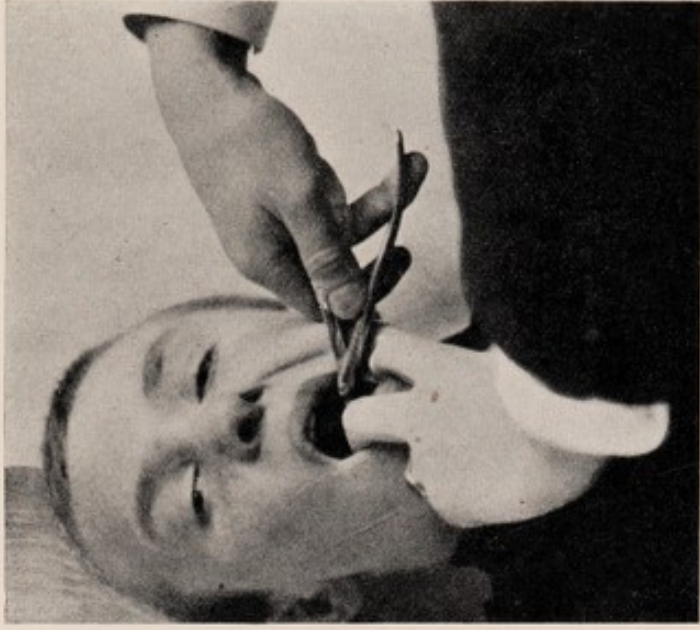


FULL SIZE
(OPEN)

Lower "hawkbill" root forceps; the same pair are used for both sides of the mouth.



Head of patient resting against corner of room
with cushion behind head if necessary.



Patient's head resting against a corner or else
supported against the chest of an assistant.

Application of Forceps :

Apply forceps carefully between neck of tooth and the surrounding gum.
Press forcibly downwards, rocking the tooth slightly inwards and outwards at the same time.
When quite loose withdraw the tooth from its socket.
After extraction press the walls of the alveolus together.




PLATE 6.

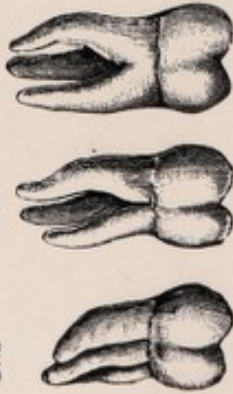EXTRACTION OF RIGHT UPPER MOLARS.

PLATE 6.

EXTRACTION OF RIGHT UPPER MOLARS.


SIDE VIEW

RIGHT UPPER MOLARS
3RD 2ND 1ST



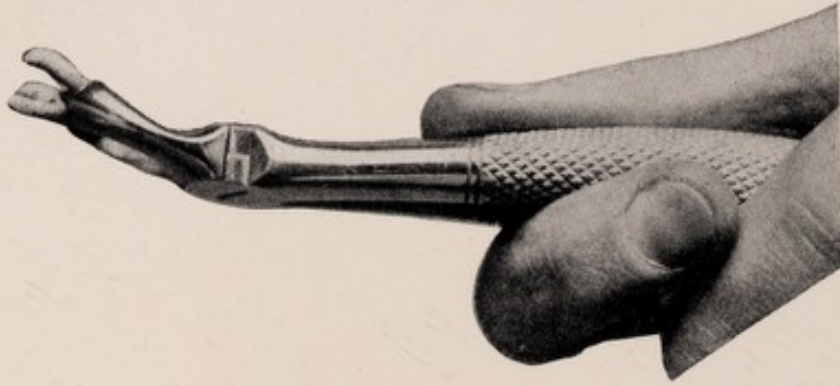
WISDOM TOOTH

Upper first and second molars have three roots, two external (buccal) and one internal (palatine). The wisdom tooth when normal has three roots like the first and second molars, but frequently these are fused together, and consequently to extract an upper wisdom tooth it is usually best to use upper bayonet root forceps.

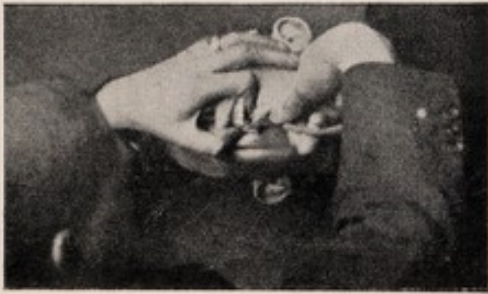

FULL SIZE
(CLOSED)

Right upper molar forceps; the outer (buccal) blade has two grooves to fit over the two buccal roots; the point fits between the two buccal roots and therefore serves to indicate to which side the forceps belong.



Forceps applied to right upper molar.



Head resting on back of chair. The position of the operator is the same as for right upper bicuspids, viz. in front and to the right of patient.



Improvised dental chair—back chair resting against wall.

Application of Forceps:

Apply the blades of the forceps carefully so that they can be pressed upwards between the tooth and its surrounding gum.

Press forcibly upwards.

Rock tooth slightly inwards and outwards until loose.

Withdraw in an outward direction, that is to say, in the direction of the large palatine root.

After extraction press the walls of the alveolus together.




PLATE 7.

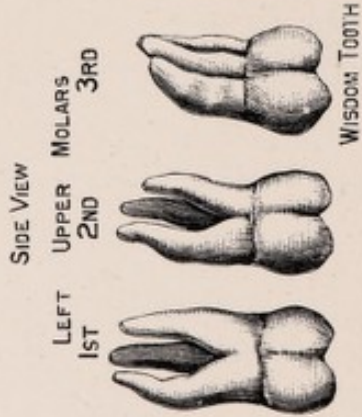
EXTRACTION OF LEFT UPPER MOLARS.

PLATE 7.
EXTRACTION OF LEFT UPPER MOLARS.

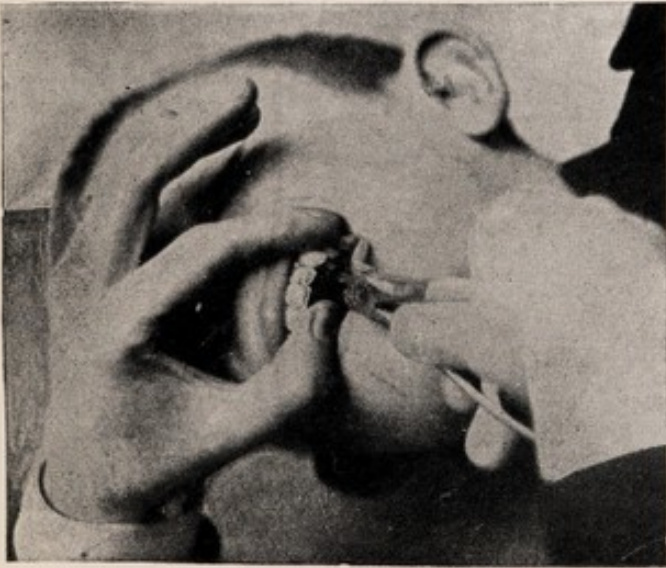

Mode of grasping a left upper molar.

Forceps to be used. The outer blade has two grooves to fit over the two buccal roots; the point fits between the two buccal roots, and serves to indicate for which side the forceps are to be used.



The first and second upper molars have three roots (two buccal, one large palatine); third upper molar (wisdom tooth) has, *when normal*, three roots like the first and second, but frequently these are found irregular in shape or fused together, for which reason it is advisable to extract them with upper bayonet root forceps.



Position of patient as for *left upper bicuspids*: (1) With head resting against a pillow placed against corner of room; (2) or on a firm chair with high back, against which the head rests on a cushion; (3) seated on one of two chairs placed back to back, the second chair resting against wall, with operator's left foot resting on it to steady it.



Improved dental chair.

Application of Forceps:

Apply the blades of the forceps carefully so that they can be pressed upwards between the tooth and its surrounding gum.

Press forcibly upwards.

Rock tooth slightly inwards and outwards till loose.

Withdraw in an outward direction; that is to say, in the direction of the large palatine root. After extraction press the walls of the alveolus together.

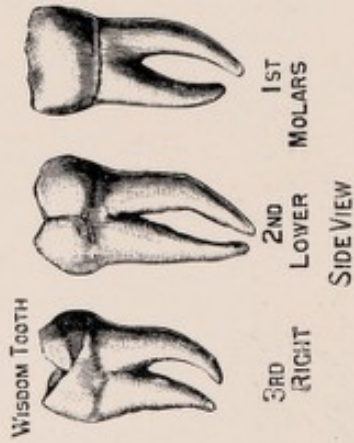


PLATE 8.

EXTRACTION OF RIGHT LOWER MOLARS.

PLATE 8.

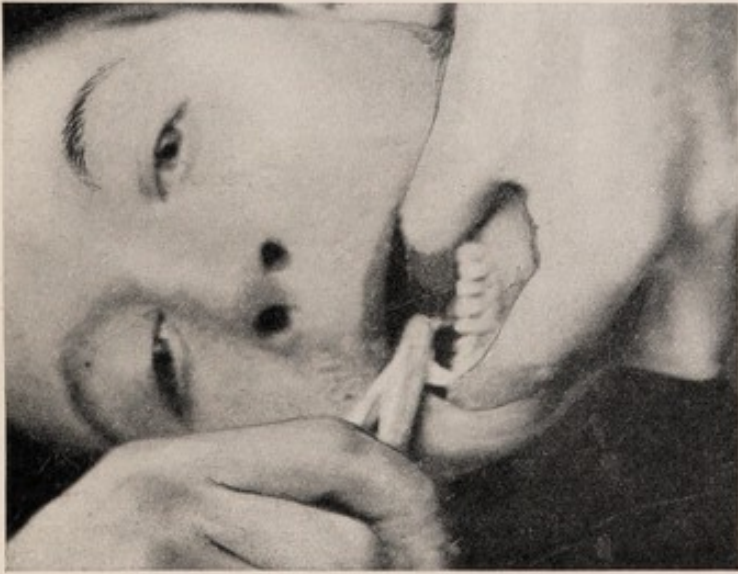EXTRACTION OF RIGHT LOWER MOLARS.



Lower "hawkbill" molar forceps. The same pair are used for both sides of the mouth. Note that each blade has two grooves to fit over the anterior and posterior roots respectively; the point between these grooves fits in between the two roots, as shown in diagram.



Showing method of applying forceps to a right lower molar.



Operator standing behind with back against a wall.



Operator's back to rest against a wall.



Back of chair to rest against a wall.

Application of Forceps :

Apply forceps carefully between neck of tooth and surrounding gum.

Press forcibly downwards, rocking the tooth slightly inwards and outwards at the same time.

When quite loose withdraw the tooth from its socket.

After extraction press the walls of the alveolus together.

When a lower molar is broken away nearly level with the gum it is frequently necessary to extract it with lower "hawkbill" root forceps applied to each root separately ; in this way frequently both roots may be extracted at the same time.

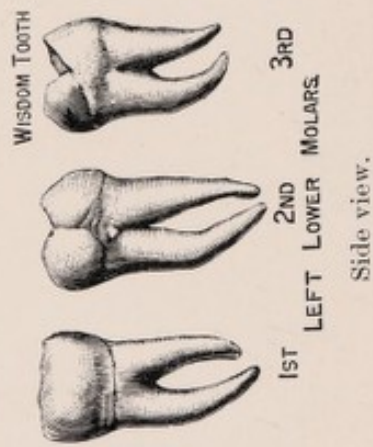
The "fish-tail" elevator is also very useful for extracting lower roots, using an adjacent tooth as a fulcrum (*vide* use of "fish-tail" elevator on plates 10 and 11).

PLATE 9.

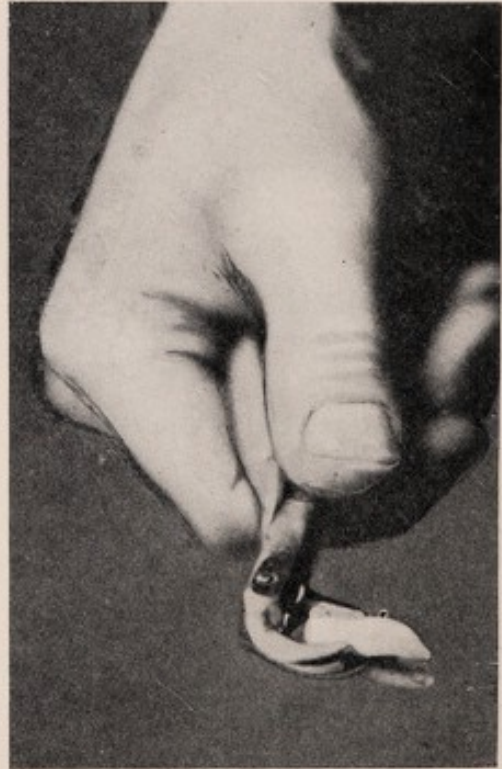EXTRACTION OF LEFT LOWER MOLARS.

PLATE 9.

EXTRACTION OF LEFT LOWER MOLARS.



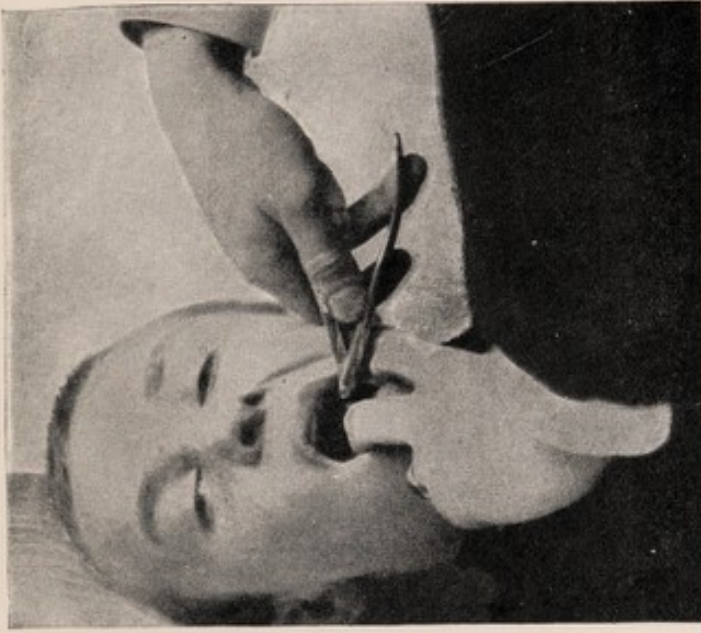Lower "hawkbill" molar forceps; the same pair is used for both sides of mouth.



Forceps grasping lower molar tooth.



Patient's head resting against corner of room.



Patient's head resting against corner of room or firmly supported by an assistant standing behind.



Improvised dental chair.

Application of Forceps :

Apply forceps carefully between neck of tooth and surrounding gum.

Press forcibly downwards, rocking the tooth slightly inwards and outwards at the same time.

When quite loose withdraw the tooth from its socket.

After extraction press the walls of the alveolus together.

When a lower molar is broken away nearly level with the gum it is frequently necessary to extract it with lower "hawkbill" root forceps applied to each root separately; in this way frequently both roots may be removed at the same time.

The "fish-tail elevator" is also very useful for extracting lower roots, making use of the tooth in front or behind as a fulcrum. See use of fish-tail elevator on plates 10 and 11.

PLATE 10.

EXTRACTION OF UPPER AND LOWER ROOTS AND LOWER
WISDOM TEETH.

PLATE 10.

EXTRACTION OF UPPER AND LOWER ROOTS AND LOWER WISDOM TEETH.

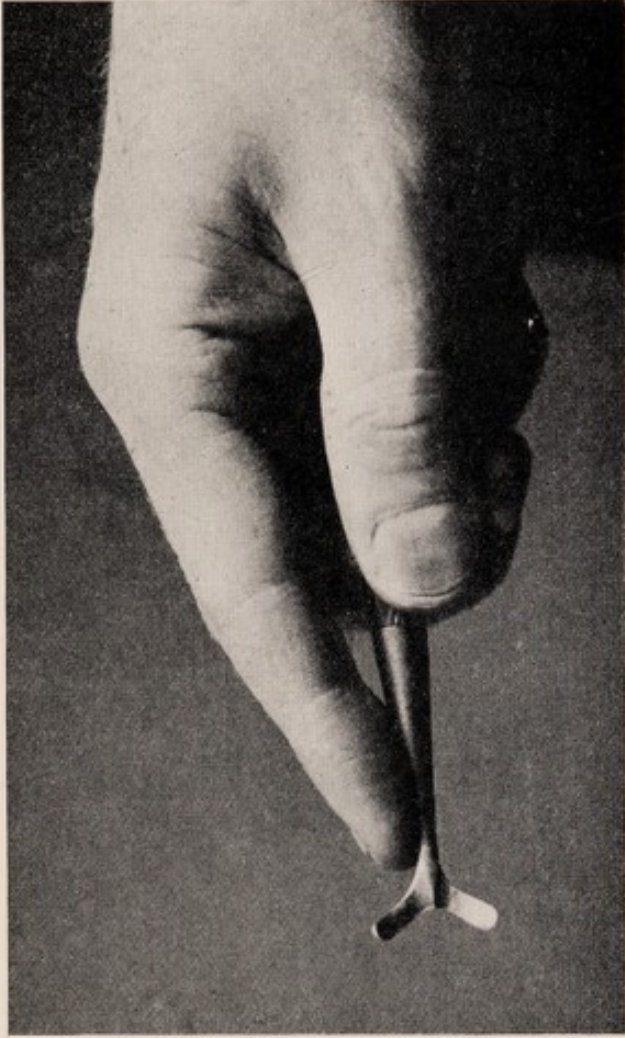
When the crown of a tooth has disappeared and little or nothing remains but its root or roots, it is usual to extract these either by the use of upper bayonet forceps in the case of upper roots or by the use of lower hawkbill forceps in the case of lower roots.

In both the cases the patient is put in the same position as for the extraction of the corresponding complete tooth.

In applying either of these instruments it is essential to open the blades just so far as will embrace the whole circumference of the root and not the mere projecting portion that may show through the gums; the forceps are then pressed forcibly upwards or downwards as the case may be, and the root, being rocked, becomes loose and can be withdrawn. It is useful to bear in mind that the width of the root to be extracted is usually that of its neighbours, though some of it may be covered by overlapping gum.

In extracting roots it is of the utmost importance to see that each root is out of the mouth before proceeding to extract another; most serious results may follow the entrance of a root into the trachea.

The Use of the Elevator.—The instrument here shown, designed by the author, is known as “the fish-tail” elevator, and differs from others of the curved variety in having a double-ended blade, so that it combines the advantages of the ordinary right and left curved elevators as usually made.



Position of Patient.—As for the removal of lower molar teeth, or seated on improvised dental chair as shown on plate 6.

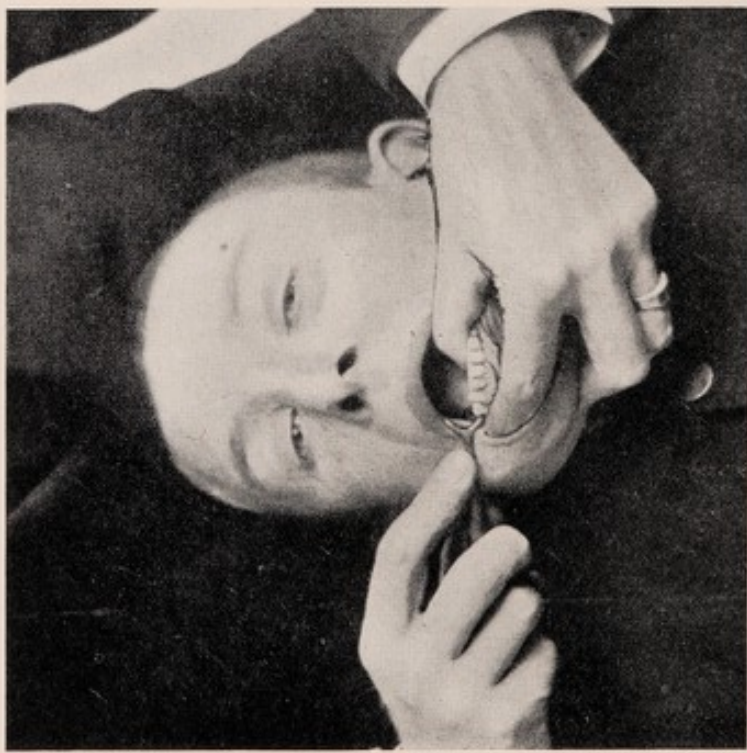


PLATE 11.

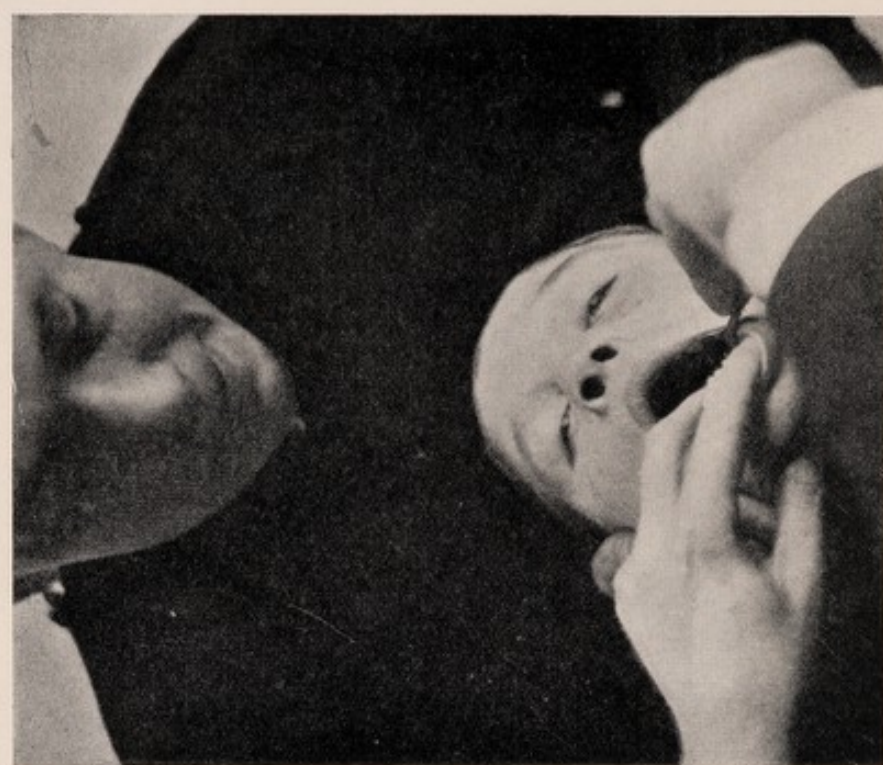
THE USE OF THE ELEVATOR FOR EXTRACTING LOWER
STUMPS AND LOWER WISDOM TEETH.

PLATE 11.

THE USE OF THE ELEVATOR FOR EXTRACTING LOWER STUMPS AND LOWER WISDOM TEETH.



Operator standing behind with his back against a wall; patient seated on a firm chair.




Assistant standing behind supporting head, with his back against a wall, operator standing in front of patient.

TO USE THE ELEVATOR: GENERAL PRINCIPLES.

Press whichever blade is to be used forcibly downwards and inwards on the outer side of the alveolus between the anterior or posterior edge of the socket and the tooth or root to be extracted, using an adjacent tooth as a fulcrum; it is important in all cases to support the fulcrum with a finger or thumb, as it may happen that the tooth used for this purpose may become loosened instead of the one to be extracted.

LOWER WISDOM TEETH.

As it is frequently difficult to extract lower wisdom teeth with forceps, owing to the backward curve in their root or a broken-down condition of the crown, it may become necessary to make use of the elevator, the second lower molar, when present, being used as a fulcrum to enable the remains of the wisdom tooth to be "prised" out, as in above photograph.



No. 4.

J. & A. CHURCHILL

**Recent
Works**
for
Students
and
Practitioners
of
Medicine.



LONDON:
7, Great Marlborough Street.

MAY, 1909.

INDEX.

PAGE

- 2 Anatomy. Physiology.
- 3 Materia Medica. Pharmacy.
- 4 Hygiene. Bacteriology.
- 5 Pathology. Psychology. Dictionaries.
- 6 Medicine.
- 7 Medicine.
- 8 Surgery.
- 9 Surgery. Anæsthetics.
- 10 Neurology. Urinary Disorders.
- 11 Midwifery. Gynæcology. Medical Jurisprudence.
- 12 Ophthalmology.
- 13 Otology. Pædiatrics. Dentistry.
- 14 Tropical Diseases. Dermatology.
- 15 Chemistry. Physics.
- 16 Microscopy. Miscellaneous.

FREE ON . . .
APPLICATION.

- 1. Complete Catalogue.
- 2. Catalogue of Science Books.

Anatomy



Physiology

A Treatise on Human Anatomy. By various Authors.

Edited by HENRY MORRIS, M.A., F.R.C.S., President of the Royal College of Surgeons, England; Consulting Surgeon to the Middlesex Hospital, and J. PLAYFAIR McMURRICH, A.M., Ph.D., Professor of Anatomy, University of Toronto. Fourth Edition. With 1025 Engravings, of which 319 are printed in 3 or 4 colours. 30s. net. Also issued in 5 parts. Parts I, II, and III, 8s. net each; and Parts IV and V, 5s. net each.

Anatomical Terminology, with Special Refer-

ence to the B.N.A. By LLEWELLYS F. BARKER, M.D., Professor of Medicine, Johns Hopkins University, Baltimore. With Illustrations and 2 Coloured Plates. 5s. net.

A Manual of Practical Anatomy. By the late Pro-

fessor ALFRED W. HUGHES, M.B., M.C. Edin., Professor of Anatomy, King's College, London. Edited and completed by ARTHUR KEITH, M.D., Lecturer on Anatomy, London Hospital Medical College. In three parts, Part I, 10s. 6d. Part II, 8s. 6d. Part III, 10s. 6d.

Heath's Practical Anatomy: a Manual of Dis-

sections. Edited by J. E. LANE, F.R.C.S., Surgeon and Lecturer on Anatomy at St. Mary's Hospital. Ninth Edition. 321 Engravings. 12s. 6d.

Clinical Applied Anatomy; or, The Anatomy of

Medicine and Surgery. By CHARLES R. BOX, M.D., F.R.C.P. Lond., Physician to Out-patients, St. Thomas's Hospital, and W. McADAM ECCLES, M.S. Lond., F.R.C.S. Eng., Assistant Surgeon, St. Bartholomew's Hospital. Illustrated by 45 Plates, of which 12 are coloured, and 6 Figures in the Text. 12s. 6d. net.

Essentials of Surface Anatomy. By CHARLES R.

WHITTAKER, L.R.C.S., L.R.C.P., etc., Demonstrator of Anatomy, Surgeons' Hall, Edinburgh. 2s. 6d. net.

Text-Book of Anatomy for Nurses. By ELIZABETH

R. BUNDY, M.D., Member of the Medical Staff of the Woman's Hospital of Philadelphia. With a Glossary and 191 Illustrations, 34 of which are printed in colours. 7s. 6d. net.

Human Osteology. By LUTHER HOLDEN. Eighth Edition.

Edited by CHARLES STEWART, F.R.S., and ROBERT W. REID, M.D., F.R.C.S. 59 Lithographic Plates and 74 Engravings. 16s. Landmarks, Medical and Surgical. Fourth Edition. 3s. 6d.

Elements of Human Physiology. By ERNEST H.

STARLING, M.D., F.R.C.P., F.R.S., Jodrell Professor of Physiology in University College, London. Eighth Edition. 323 Illustrations. 12s. 6d. net.

Practical Physiological Chemistry. By PHILIP B.

HAWK, M.S., Ph.D., Professor of Physiological Chemistry in the University of Illinois. Second Edition. With Coloured Plates and 126 Figures. 16s. net.

The Cell as the Unit of Life, and other Lectures

delivered at the Royal Institution, London, 1899-1902: an Introduction to Biology. By the late ALLAN MACFADYEN, M.D., B.Sc., Fullerian Professor of Physiology, Royal Institution, London. Edited by R. TANNER HEWLETT, M.D., F.R.C.P., D.P.H., Professor of General Pathology and Bacteriology, King's College, London. 7s. 6d. net.

The Functional Inertia of Living Matter: a

Contribution to the Physiological Theory of Life. By DAVID FRASER HARRIS, M.D., C.M., B.Sc. (Lond.), F.R.S.E., Lecturer on Physiology and Normal Histology in the University of St. Andrews. 12 Illustrations. 5s. net.

Materia Medica *℞* Pharmacy

A Text-Book of Materia Medica for Students of Medicine. By C. R. MARSHALL, M.D., Professor of Materia Medica and Therapeutics in the University of St Andrews. 127 Illustrations. 10s. 6d. net.
BY THE SAME AUTHOR.

A Manual of Prescribing for Students and Practitioners of Medicine. 5s. net.

Materia Medica, Pharmacy, Pharmacology, and Therapeutics. By W. HALE WHITE, M.D., F.R.C.P., Physician to, and Lecturer on Medicine at, Guy's Hospital. Tenth Edition. 6s. 6d. net.

Southall's Organic Materia Medica. By JOHN BARCLAY, B.Sc.Lond. Seventh Edition. Revised by ERNEST W. MASON. 7s. 6d. net.

A Text-Book of Materia Medica. By HENRY G. GREENISH, F.I.C., F.L.S., Professor of Pharmaceutics to the Pharmaceutical Society. Second Edition. 269 Illustrations. 15s. net.

BY THE SAME AUTHOR.

The Microscopical Examination of Foods and Drugs, in the Entire, Crushed, and Powdered States. 168 Illustrations. 10s. 6d. net.

ALSO, WITH EUGENE COLLIN,

An Anatomical Atlas of Vegetable Powders. 138 Illustrations. 12s. 6d. net.

Practical Pharmacy. By E. W. LUCAS, F.I.C., F.C.S. Second Edition. 224 Illustrations. 12s. 6d. net.

BY THE SAME AUTHOR.

The Book of Prescriptions (Beasley) with an Index of Diseases and Remedies. Rewritten by E. W. LUCAS, F.I.C., F.C.S. Ninth Edition. 6s. net.

The Book of Receipts: containing a Veterinary Materia Medica, a Pharmaceutical Formulary, a Photographic Formulary, a Synopsis of Practical Methods employed in the Examination of Urine, Milk, Potable Waters, Sputum, etc., together with numerous Chemical and other Tables. (The Eleventh Edition of Beasley's Book.) With 10 Plates. 7s. 6d. net.

First Lines in Dispensing. With 93 Illustrations. 3s. 6d. net.

The National Standard Dispensatory. By H. A. HARE, B.Sc., M.D., and others. 478 Illustrations. 31s. 6d. net.

Medical and Pharmaceutical Latin for Students of Pharmacy and Medicine. By REGINALD R. BENNETT, Pharmacist and Teacher of Pharmacy at University College Hospital, London. 6s. net.

A Companion to the British Pharmacopœia. By PETER WYATT SQUIRE, F.L.S., F.C.S. Eighteenth Edition. 14s. net. Pocket Edition, 7s. 6d. net.

The Pharmaceutical Formulary: a Synopsis of the British and Foreign Pharmacopœias. By HENRY BEASLEY. Twelfth Edition by J. OLDHAM BRAITHWAITE. 6s. 6d.

Tuson's Veterinary Pharmacopœia. Sixth Edition. Edited by JAMES BAYNE, F.C.S. 7s. 6d. net.

Year-Book of Pharmacy. Annually, 10s.

Hygiene Bacteriology

The Theory and Practice of Hygiene. (NOTTER and FIRTH.) By R. H. FIRTH, Lt.-Col. R.A.M.C., F.R.C.S., Officer in Charge of the School of Army Sanitation, Aldershot. Third Edition. 22 Plates (some of which are in colours) and 200 other Illustrations. 21s. net.

BY THE SAME AUTHOR.

Military Hygiene: a Manual of Sanitation for Soldiers. With 40 Illustrations. 3s. 6d. net.

Manual of Hygiene. By W. H. HAMER, M.D., Lecturer on Public Health, St. Bartholomew's Hospital; Assistant Medical Officer of Health of the County of London. 93 Illustrations. 12s. 6d. net.

A Handbook of Hygiene and Sanitary Science. By GEO. WILSON, M.A., M.D., Medical Officer of Health for Mid-Warwickshire. Eighth Edition. Illustrated. 12s. 6d.

Lessons on Elementary Hygiene and Sanitation, with Special Reference to the Tropics. By W. T. PROUT, C.M.G., M.B., C.M.(Edin.), Hon. Lecturer School of Tropical Medicine, Liverpool. Second Edition. With 60 Illustrations. 2s. 6d. net.

The Effects of Borax and Boric Acid on the Human System. Third Treatise. With Diagrams. By Dr. OSCAR LIEBREICH. 5s. net.

A Simple Method of Water Analysis. By JOHN C. THRESH, M.D.Vic., D.Sc.Lond. Sixth Edition. 2s. 6d. net.

BY THE SAME AUTHOR.

The Examination of Waters and Water Supplies. 19 Plates and 11 Figures in the Text. 14s. net.

ALSO, WITH ARTHUR E. PORTER, M.D., M.A.CANTAB.

Preservatives in Food and Food Examination. 8 Plates. 14s. net.

Foods and their Adulteration. By HARVEY W. WILEY, M.D., Ph.D. With 11 Coloured Plates and 86 other Illustrations. 21s. net.

A Manual of Bacteriology, Clinical and Applied. By R. TANNER HEWLETT, M.D., Professor of General Pathology and Bacteriology in King's College, London. Third Edition. 24 Plates and 72 Figures in the Text. 10s. 6d. net.

BY THE SAME AUTHOR.

Serum Therapy, Bacterial Therapeutics, and Vaccines. 20 Figures. 5s. net.

Clinical Diagnostic Bacteriology, including Serum- and Cyto-diagnosis. By ALFRED C. COLES, M.D., D.Sc., F.R.S.E. 2 Coloured Plates. 8s. net.

A Text-Book of Bacteriology. By G. M. STERNBERG, M.D. Second Edition. 9 Plates and 198 Figures in the Text. 26s.

Lessons in Disinfection and Sterilisation. By F. W. ANDREWES, M.D., F.R.C.P., Lecturer on Pathology, St. Bartholomew's Hospital. Second Edition. 31 Illustrations. 3s. 6d. net.

Pathology Psychology Dictionaries

Pathology, General and Special, for Students

of Medicine. By R. TANNER HEWLETT, M.D., F.R.C.P., D.P.H., Professor of General Pathology and Bacteriology in King's College, London. 31 Plates and 13 Illustrations in Text. Second Edition. 10s. 6d. net.

A Manual of General or Experimental Pathology,

for Students and Practitioners. By W. S. LAZARUS-BARLOW, M.D., F.R.C.P., Director of the Cancer Research Laboratories, Middlesex Hospital, Second Edition. 21s. net.

BY THE SAME AUTHOR.

The Elements of Pathological Anatomy and Histology for Students. 24s. net.

Surgical Pathology and Morbid Anatomy. See page 8.

The Pathologist's Handbook: a Manual for the

Post-mortem Room. By T. N. KELYNACK, M.D. 126 Illustrations. Pegasus, 4s. 6d.

Psychological Medicine. By MAURICE CRAIG, M.A., M.D., F.R.C.P., Physician and Lecturer on Mental Diseases, Guy's Hospital. 22 Plates. 12s. 6d. net.

Mental Diseases: Clinical Lectures. By T. S. CLOUSTON, M.D., F.R.C.P. Edin., Lecturer on Mental Diseases in the University of Edinburgh. Sixth Edition. 30 Plates. 14s. net.

The Force of Mind; or, the Mental Factor in Medicine. By ALFRED T. SCHOFIELD, M.D., Hon. Physician to Friedenheim Hospital. Third Edition. 5s. net.

BY THE SAME AUTHOR.

Unconscious Therapeutics; or, The Personality of the Physician. Second Edition. 5s. net.

ALSO

The Management of a Nerve Patient. 5s. net.

The Journal of Mental Science. Published Quarterly, by Authority of the Medico-Psychological Association. 5s. net.

Dictionary of Medical Terms: English, French, German. Edited by PAUL BLASCHKE. 8s. net.

Dictionary of Medical Conversation; English- German, 4s. net. German-English, 4s. net.

A German-English Dictionary of Terms used in Medicine and the Allied Sciences. By HUGO LANG, B.A., and BERTRAM ABRAHAMS, M.B., B.Sc., F.R.C.P. 15s. net.

Dunglison's Dictionary of Medical Science. By THOMAS L. STEDMAN, M.D. Twenty-third Edition. 577 Illustrations, including 84 page-plates. 34s. net.

A Medical Vocabulary. By R. G. MAINE, M.D., LL.D. Seventh Edition, by W. W. WAGSTAFFE, B.A., F.R.C.S., and G. D. PARKER, M.B. 12s. 6d.

Medicine

A Text-Book of Medicine. Begun by the late C. HILTON FAGGE, M.D.; completed and re-written by P. H. PYE-SMITH, M.D., F.R.S. Fourth Edition. 2 vols. 42s.

Manual of the Practice of Medicine. By FREDERICK TAYLOR, M.D., F.R.C.P., Consulting Physician to, and Lecturer on Medicine at, Guy's Hospital. Eighth Edition. 8 Skiagram Plates and 45 Illustrations. 16s. net. **Some Disorders of the Spleen.** 3s. net.

A System of Clinical Medicine for Practitioners and Students. By THOS. D. SAVILL, M.D., M.R.C.P., in 2 vols. 4 Coloured Plates, and 286 Figures in the Text. Vol. I: Local Diseases and Pyrexial Disorders, 12s. 6d. net; Vol. II: Diseases of the Skin, the Nervous System, etc., 8s. 6d. net.

A Short Practice of Medicine. By ROBERT A. FLEMING, M.A., M.D., F.R.C.P.E., F.R.S.E., Lecturer on Practice of Medicine, School of the Royal Colleges, Edinburgh; Assistant Physician, Royal Infirmary, Edinburgh. Illustrated, partly in colour. 10s. 6d. net.

The Practice of Medicine. By M. CHARTERIS, M.D. Professor of Therapeutics and Materia Medica in the University of Glasgow. Ninth Edition. Edited by F. J. CHARTERIS, M.D., Ch.B. Illustrated. 9s. 6d. net.

Student's Guide to Medical Diagnosis. By SAMUEL FENWICK, M.D., F.R.C.P., and W. SOLTAU FENWICK, M.D., B.S. Ninth Edition. 139 Engravings. 9s.

A Dictionary of Medical Treatment for Students and Junior Practitioners. By ARTHUR LATHAM, M.D. Oxon., F.R.C.P. Lond., Physician and Lecturer on Medicine at St. George's Hospital. 6s. 6d. net.

Text-Book of Medical Treatment (Diseases and Symptoms). By NESTOR I. C. TIRARD, M.D., F.R.C.P., Professor of the Principles and Practice of Medicine, King's College, London. 15s.

A Manual of Family Medicine and Hygiene for India. Published under the Authority of the Government of India. By SIR WILLIAM J. MOORE, K.C.I.E., M.D. Seventh Edition edited by Major J. H. TULL WALSH, I.M.S. 70 Engravings. 6s. net.

Waring's Bazaar Medicines of India. By Lt.-Col. C. P. LUKIS, I.M.S., Principal of the Medical College, Calcutta. Sixth Edition. 6s. net.

The Blood: how to Examine and Diagnose its Diseases. By ALFRED C. COLES, M.D., D.Sc., F.R.S. Edin. Third Edition. 7 Coloured Plates. 10s. 6d. net.

Lectures on Medicine to Nurses. By HERBERT E. CUFF, M.D., F.R.C.S., late Medical Superintendent, North-Eastern Fever Hospital, London. Fifth Edition. 29 Illustrations. 3s. 6d. net.

How to Examine the Chest. By SAMUEL WEST, M.D., F.R.C.P., Physician to St. Bartholomew's Hospital. Third Edition. 46 Engravings. 5s.

Medicine

Ulcer of the Stomach and Duodenum. By SAMUEL FENWICK, M.D., F.R.C.P., and W. SOLTAU FENWICK, M.D., B.S. 55 Illustrations. 10s. 6d.

BY THE SAME AUTHORS.

Cancer and other Tumours of the Stomach. 70 Illustrations. 10s. 6d.

On Carbohydrate Metabolism, with an Appendix on the Assimilation of Carbohydrate into Proteid and Fat, followed by the Fundamental Principles and the Treatment of Diabetes dialectically discussed. By FREDERICK W. PAVY, M.D., LL.D., F.R.S., F.R.C.P., Consulting Physician to Guy's Hospital. With 8 Plates. 6s. net.

The Schott Methods of the Treatment of Chronic Diseases of the Heart, with an account of the Nauheim Baths, and of the Therapeutic Exercises. By W. BEZLY THORNE, M.D., M.R.C.P. Fifth Edition. Illustrated. 5s. net.

The Clinical Examination of Urine, with an Atlas of Urinary Deposits. By LINDLEY SCOTT, M.A., M.D. 41 original Plates (mostly in colours). 15s. net.

Urine Examination made easy. By T. CARRUTHERS, M.B., Ch.B. 1s. 6d. net.

Rational Organotherapy, with Reference to Urosemiology. Translated from the Russian Text by Professor Dr. A. VON POEHL, Professor PRINCE J. VON TARCHANOFF, Dr. ALF VON POEHL, and Dr. P. WACHS. Vol. I. 7s. 6d. net.

On Gallstones, or Cholelithiasis. By E. M. BROCKBANK, M.D.Vict., M.R.C.P.Lond., Honorary Physician to the Ancoats Hospital, Manchester. 7s.

Obstinate Hiccough: the Physiology, Pathology, and Treatment. By L. F. B. KNUTHSEN, M.D.Edin. 6s.

On Syphonage and Hydraulic Pressure in the Large Intestine, with their Bearing upon the Treatment of Constipation, Appendicitis, etc. By RALPH WINNINGTON LEFTWICH, M.D. 3s. net.

Uric Acid as a Factor in the Causation of Disease. By ALEXANDER HAIG, M.D., F.R.C.P., Physician to the Metropolitan Hospital. Seventh Edition. 75 Illustrations. 14s. net. **Uric Acid, an Epitome of the Subject.** Second Edition. 2s. 6d. net. **Diet and Food considered in relation to Strength and Power of Endurance, Training, and Athletics.** Sixth Edition. 2s. net.

Surgery

The Operations of Surgery. By W. H. A. JACOBSON, M.Ch.Oxon., F.R.C.S., Consulting Surgeon Guy's Hospital, and R. P. ROWLANDS, M.S.Lond., F.R.C.S., Assistant Surgeon, Guy's Hospital. Fifth Edition. 2 vols. 777 Illustrations. 42s. net.

Surgery: its Theory and Practice. By WILLIAM J. WALSHAM, F.R.C.S., Surgeon to St. Bartholomew's Hospital. Ninth Edition, by W. G. SPENCER, F.R.C.S., Surgeon to the Westminster Hospital. 620 Engravings (including 24 Skiagrams). 18s. net.

Surgical Pathology and Morbid Anatomy. By ANTHONY A. BOWLBY, F.R.C.S., Surgeon to St. Bartholomew's Hospital, assisted by F. W. ANDREWES, M.D., Lecturer on Pathology, St. Bartholomew's Hospital. Fifth Edition. 196 Engravings. 10s. 6d. net.

A Manual of Surgical Diagnosis. By JAMES BERRY, B.S.Lond., F.R.C.S., Surgeon to, and Lecturer on Surgery at, the Royal Free Hospital. 6s. net.

A Synopsis of Surgery. By R. F. TOBIN, Surgeon to St. Vincent's Hospital, Dublin. Second Edition. Interleaved, leather binding. 6s. 6d.

Ovariectomy and Abdominal Surgery. By HARRISON CRIPPS, F.R.C.S., Surgical Staff, St. Bartholomew's Hospital. Numerous Plates. 25s.

BY THE SAME AUTHOR.

On Diseases of the Rectum and Anus, including the Fifth Edition of the Jacksonian Prize Essay on Cancer. Third Edition. With 13 Plates and 34 Illustrations. 10s. 6d. net.

ALSO

Cancer of the Rectum, especially considered with regard to its Surgical Treatment. Jacksonian Prize Essay. Fifth Edition. With 13 Plates and several Engravings. 5s. net.

Diseases of the Rectum, Anus, and Sigmoid Colon. By F. SWINFORD EDWARDS, F.R.C.S., Senior Surgeon to St. Mark's Hospital for Fistula and other Diseases of the Rectum. Third Edition. 102 Illustrations. 10s. 6d. net.

A Manual of Minor Surgery and Bandaging. Fourteenth Edition of Heath's. By BILTON POLLARD, F.R.C.S., Surgeon to University College Hospital. About 250 Engravings. 7s. 6d. net.

BY THE SAME AUTHOR.

Injuries and Diseases of the Jaws. Fourth Edition. Edited by HENRY PERCY DEAN, M.S., F.R.C.S., Assistant Surgeon to the London Hospital. 187 Wood Engravings. 14s.

ALSO

Clinical Lectures on Surgical Subjects delivered at University College Hospital. First Series, 6s.; Second Series, 6s.

An Essay on the General Principles of the Treatment of Spinal Curvatures. By R. HEATHER BIGG. Illustrated by Photographs and Sketches. 5s. net.

Surgery Anæsthetics

The Surgery of the Alimentary Canal. By ALFRED ERNEST MAYLARD, M.B.Lond. and B.S., Senior Surgeon to the Victoria Infirmary, Glasgow. 27 Swantype Plates and 89 Figures in the Text. 25s.

BY THE SAME AUTHOR.

A Student's Handbook of the Surgery of the Alimentary Canal. 97 Illustrations. 8s. 6d.

ALSO

Abdominal Pain : its Causes and Clinical Significance. Second Edition. 7s. 6d. net.

ALSO

Abdominal Tuberculosis. 57 Illustrations. 12s. 6d. net.

Clinical Essays and Lectures. By HOWARD MARSH, F.R.C.S., Professor of Surgery in the University of Cambridge. 26 Illustrations. 7s. 6d.

Hare-lip and Cleft Palate. By R. W. MURRAY, F.R.C.S., Surgeon, David Lewis Northern Hospital. 25 Illustrations. 3s.

BY THE SAME AUTHOR.

Hernia, its Cause and Treatment. 27 Illustrations. 4s. 6d. net.

Modern Bullet-Wounds and Modern Treatment, with Special Regard to Long Bones and Joints, Field Appliances and First Aid. By Major F. SMITH, D.S.O., R.A.M.C. 3s. net.

Surgical Emergencies. By PAUL SWAIN, F.R.C.S., Surgeon to the South Devon and East Cornwall Hospital. Fifth Edition. 149 Engravings. 6s.

Chloroform: a Manual for Students and Practitioners. By EDWARD LAWRIE, M.B.Edin., Lieut.-Col. I.M.S., Residency Surgeon, Hyderabad. Illustrated. 5s. net.

Neurology Urinary Disorders

Paralysis and other Nervous Diseases in Childhood and Early Life. By JAMES TAYLOR, M.D., F.R.C.P., Physician National Hospital for Paralysed and Epileptic, Queen Square. 74 Illustrations. 12s. 6d. net.

A Manual of Diseases of the Nervous System.

By SIR WILLIAM R. GOWERS, M.D., F.R.S.

VOL. I.—Nerves and Spinal Cord. Third Edition, by the Author and JAMES TAYLOR, M.D., F.R.C.P. 192 Engravings. 15s.

BY THE SAME AUTHOR.

Subjective Sensations of Sight and Sound, Abiotrophy, and other Lectures on Diseases of the Nervous System. 18 Illustrations. 6s. net.

ALSO

Epilepsy and Other Chronic Convulsive Diseases. their Causes, Symptoms, and Treatment. Second Edition. 10s. 6d.

ALSO

The Borderland of Epilepsy, Faints, Vagal Attacks, Vertigo, Migraine, Sleep Symptoms, and their Treatment. 4s. 6d. net.

Text-Book of Nervous Diseases and Psychiatry.

By CHARLES L. DANA, A.M., M.D., LL.D., Professor of Nervous Diseases in Cornell University Medical College. Seventh Edition. With 3 Plates and 261 Text-figures. 25s. net.

Selected Papers on Stone, Prostate, and other

Urinary Disorders. By REGINALD HARRISON, F.R.C.S., Surgeon to St. Peter's Hospital. 15 Illustrations. 5s.

A Handbook of Clinical Cystoscopy. By E. HURRY FENWICK, F.R.C.S., Surgeon to the London Hospital. 31 Plates and 144 Figures in the Text. 18s. net.

BY THE SAME AUTHOR.

Atlas of Electric Cystoscopy. 34 Coloured Plates. 21s. net.

ALSO

The Value of Radiography in the Diagnosis and Treatment of Urinary Stone. With 80 Plates. 10s. 6d. net.

ALSO

Obscure Diseases of the Urethra. 63 Illustrations. 6s. 6d.

ALSO

Obscure Diseases of the Kidney, the Value of Ureteric Meatoscopy in their Diagnosis and Treatment. 14 Plates and 43 Figures in the Text. 6s. 6d.

ALSO

Operative and Inoperative Tumours of the Urinary Bladder. 39 Illustrations. 5s. net.

ALSO

Tumours of the Urinary Bladder. Fasc. I. 5s. net.

ALSO

Ulceration of the Bladder, Simple, Tuberculous, and Malignant: a Clinical Study. Illustrated. 5s.

Midwifery Gynæcology

Medical Jurisprudence

Manual of Midwifery, including all that is likely

to be required by Students and Practitioners. By ALFRED L. GALABIN, M.A., M.D., F.R.C.P., Consulting Obstetric Physician to Guy's Hospital. Sixth Edition. 329 Engravings. 14s. net.

Manual of Midwifery. By T. W. EDEN, M.D.,

C.M.Edin., F.R.C.P.Lond., Obstetric Physician and Lecturer on Practical Midwifery, Charing Cross Hospital. Second Edition. 42 Plates and 234 Illustrations in the Text. 12s. 6d. net.

A Short Practice of Midwifery, embodying the

Treatment adopted in the Rotunda Hospital, Dublin. By HENRY JELLETT, M.D., B.A.O.Dub., Gynæcologist and Obstetrical Physician, Dr. Steevens' Hospital. Fifth Edition. 200 Illustrations. 10s. 6d. net.

BY THE SAME AUTHOR.

A Short Practice of Midwifery for Nurses, with

a Glossary of the Medical Terms used in the Book, and the Regulations of the C.M.B. Third Edition. 6 Coloured Plates and 164 Illustrations. 6s. 6d. net.

A Manual for Midwives. By C. J. N. LONGRIDGE,

M.D., M.R.C.P., F.R.C.S., Examiner Central Midwives' Board. 3 Plates and 47 Illustrations. 3s. 6d. net.

A Short Manual for Monthly Nurses. By CHARLES

J. CULLINGWORTH, M.D., F.R.C.P., Obstetric Physician to St. Thomas's Hospital. Sixth Edition. 1s. 6d. net.

Diseases of Women. By ALFRED L. GALABIN, M.A.,

M.D., F.R.C.P., Consulting Obstetric Physician to Guy's Hospital. Sixth Edition. 284 Engravings. 16s. net.

A Short Practice of Gynæcology. By HENRY JELLETT,

M.D., B.A.O.Dub., Gynæcologist and Obstetrical Physician to Dr. Steevens' Hospital. Third Edition. 310 Illustrations. 12s. 6d. net.

Outlines of Gynæcological Pathology and Morbid

Anatomy. By C. HUBERT ROBERTS, M.D.Lond., Physician to the Samaritan Free Hospital for Women. 151 Illustrations. 21s.

Lectures on Medical Jurisprudence and Toxi-

cology. By FRED. J. SMITH, M.D., F.R.C.P., F.R.C.S.Eng., Physician to, and Lecturer on Forensic Medicine and Toxicology at, the London Hospital. Second Edition. 8s. 6d. net.

Medical Jurisprudence: its Principles and Prac-

tice. By ALFRED S. TAYLOR, M.D., F.R.C.P., F.R.S. Fifth Edition, by FRED. J. SMITH, M.D., F.R.C.P., Lecturer on Medicine at the London Hospital. 2 vols. 39 Engravings. 36s. net.

Ophthalmology

Nettleship's Diseases of the Eye. Sixth Edition.
Revised and Edited by W. T. HOLMES SPICER, M.B., F.R.C.S., Ophthalmic Surgeon to St. Bartholomew's Hospital. 161 Engravings. 8s. 6d.

Medical Ophthalmoscopy: A Manual and Atlas.
Fourth Edition. By SIR W. R. GOWERS, M.D., F.R.S., and MARCUS GUNN, M.B., F.R.C.S., Surgeon to the Royal London Ophthalmic Hospital. Auto-type Plates and Woodcuts. 14s. net.

Manual of Ophthalmic Surgery and Medicine.
By W. H. H. JESSOP, M.A., F.R.C.S., Senior Ophthalmic Surgeon to St. Bartholomew's Hospital. Second Edition. 8 Plates and 155 other Illustrations. 9s. 6d. net.

Refraction of the Eye: a Manual for Students.
By GUSTAVUS HARTRIDGE, F.R.C.S., Surgeon to the Royal Westminster Ophthalmic Hospital. Fourteenth Edition. 109 Illustrations, also Test-types, etc. 5s. net.

BY THE SAME AUTHOR.

The Ophthalmoscope: a Manual for Students.
Fifth Edition. 68 Illustrations and 4 Plates. 4s. net.

Diseases of the Eye: a Manual for Students and Practitioners. By J. HERBERT PARSONS, D.Sc., M.B., B.S., F.R.C.S., Assistant Ophthalmic Surgeon, University College Hospital; Assistant Surgeon, Royal London (Moorfields) Ophthalmic Hospital. 308 Illustrations and 15 Plates. 10s. 6d. net.

BY THE SAME AUTHOR.

Elementary Ophthalmic Optics, including Ophthalmoscopy and Retinoscopy. 66 Illustrations. 6s. 6d.

Royal London Ophthalmic Hospital Reports.
By the Medical and Surgical Staff. Vol. XVII, Part III. 5s. net.

Ophthalmological Society of the United Kingdom. Transactions. Vol. XXVIII. 12s. 6d. net. Also in Three Fasciculi at 4s. net each.

Otology ∩ Pædiatrics ∩ Dentistry

The Labyrinth of Animals, including Mammals, Birds, Reptiles, and Amphibians. By ALBERT A. GRAY, M.D.(Glas.), F.R.S.E., Surgeon for Diseases of the Ear to the Victoria Infirmary, Glasgow. Vol. I, with 31 Stereoscopic Plates. 21s. net (including Stereoscope). Vol. II, with 45 Stereoscopic Plates, 25s. net.

Some Points in the Surgical Anatomy of the Temporal Bone from Birth to Adult Life. By ARTHUR H. CHEATLE, F.R.C.S., Aural Surgeon to King's College Hospital. 112 Illustrations. 5s. net.

Diseases of the Ear, including the Anatomy and Physiology of the Organ, together with the Treatment of the Affections of the Nose and Pharynx. By T. MARK HOVELL, Senior Aural Surgeon to the London Hospital. Second Edition. 128 Engravings. 21s.

The Diseases of Children. By JAMES F. GOODHART, M.D., F.R.C.P., and G. F. STILL, M.D., F.R.C.P., Professor of the Diseases of Children, King's College. Eighth Edition. 12s. 6d. net.

The Wasting Diseases of Infants and Children. By EUSTACE SMITH, M.D., F.R.C.P., Physician to the King of the Belgians, and to the East London Hospital for Children. Sixth Edition. 6s.

On the Natural and Artificial Methods of Feeding Infants and Young Children. By EDMUND CAUTLEY, M.D., Physician to the Belgrave Hospital for Children. Second Edition. 7s. 6d.

Your Child's Health: Medical Notes for Mothers and Teachers, School Nurses and Health Visitors. By JOHN GRIMSHAW, M.D., B.S.(Lond.). 2s. 6d. net. **Health Talks about Children.** 1s. net. **Eye-strain and Eyesight.** 1s. net.

Dental Anatomy, Human and Comparative: a Manual. By CHARLES S. TOMES, M.A., F.R.S. Sixth Edition. 286 Engravings. 12s. 6d. net.

BY THE SAME AUTHOR.

A System of Dental Surgery. By Sir JOHN TOMES, F.R.S. Revised by C. S. TOMES, M.A., F.R.S., and WALTER S. NOWELL, M.A.Oxon. Fifth Edition. 318 Engravings. 15s. net.

Practical Treatise on Mechanical Dentistry. By JOSEPH RICHARDSON, M.D., D.D.S. Seventh Edition, revised and edited by GEORGE W. WARREN, D.D.S. 690 Engravings. 22s.

Decay in Teeth: an Investigation into its Cause and Prevention. By J. SIM WALLACE, M.D., D.Sc., L.D.S.R.C.S. Second Edition. 5s.

A Manual of Dental Metallurgy. By ERNEST A. SMITH, Assay Office, Sheffield. Second Edition. 38 Illustrations. 6s. 6d.

Dental Materia Medica, Pharmacology, and Therapeutics. By CHARLES W. GLASSINGTON, M.R.C.S., L.D.S.Edin.; Senior Dental Surgeon, Westminster Hospital. 6s.

Tropical Diseases & Dermatology

Waring's Bazaar Medicines of India. See page 6.

The Malarial Fevers of British Malaya. By HAMILTON WRIGHT, M.D. (MCGILL), Director of the Institute for Medical Research, Federated Malay States. Map and Charts. 3s. net.

BY THE SAME AUTHOR.

The Etiology and Pathology of Beri-Beri. With Map and Charts. 3s. net.

Studies from Institute for Medical Research, Federated Malay States. Vol. III. 10s. net.

Beri-Beri: its Symptoms and Symptomatic Treatment. By PERCY N. GERRARD, M.D., District Surgeon, Federated Malay States Civil Service. 2s. 6d. net. Extracts from the above, 1s. 6d. net.

Report on the Prevention of Malaria in Mauritius. By RONALD ROSS, D.P.H., F.R.C.S., F.R.S., Professor of Tropical Medicine, University of Liverpool. With 25 Illustrations. 5s. net.

On the Causes and Continuance of Plague in Hong Kong, with Suggestions as to Remedial Measures; a Report presented to the Secretary of State for the Colonies. By W. J. SIMPSON, M.D., F.R.C.P. Numerous Charts and Diagrams. 10s. net.

On the Outbreak of Yellow Fever in British Honduras in 1905, together with an Account of the Distribution of the *Stegomyia fasciata* in Belize, and the Measures necessary to Stamp Out or Prevent the Occurrence of Yellow Fever; a Report presented to the Government of that Colony. By RUBEK BOYCE, M.B., F.R.S. Illustrated with numerous Plates and Plans. 3s. 6d. net.

A Handbook on Leprosy. By S. P. IMPEY, M.D., late Chief and Medical Superintendent, Robben Island Leper and Lunatic Asylums, Cape Colony. 38 Plates. 12s.

A Manual of Diseases of the Skin, with an Analysis of 20,000 Consecutive Cases and a Formulary. By DUNCAN E. BULKLEY, M.D., New York. Fourth Edition. 6s. 6d.

Skin Diseases of Children. By GEO. H. FOX, M.D., Clinical Professor of Diseases of the Skin, College of Physicians and Surgeons, New York. 12 Photogravure and Chromographic Plates and 60 Illustrations in the Text. 12s. 6d.

On Maternal Syphilis, including the Presence and Recognition of Syphilitic Pelvic Disease in Women. By JOHN A. SHAW-MACKENZIE, M.D. Coloured Plates. 10s. 6d.

The Diagnosis and Treatment of Syphilis. By TOM ROBINSON, M.D.St. And., Physician to the Western Skin Hospital. Second Edition. 3s. 6d.

BY THE SAME AUTHOR.

The Diagnosis and Treatment of Eczema. Second Edition. 3s. 6d.

Chemistry

Physics

Chemistry, Inorganic and Organic. By CHARLES L. BLOXAM. Ninth Edition, by J. M. THOMSON, F.R.S., Professor of Chemistry in King's College, London, and A. G. BLOXAM, F.I.C. 284 Engravings. 18s. net.

The Elements of Chemistry. By M. M. PATTISON MUIR, M.A., Fellow of Caius College, Cambridge. Illustrated. 10s. 6d. net.

The Analyst's Laboratory Companion: a Collection of Tables and Data for Chemists and Students. By A. E. JOHNSON, B.Sc., F.I.C. Third Edition. 6s. 6d. net.

Commercial Organic Analysis: a Treatise on the Properties, Modes of Assaying, Proximate Analytical Examination, etc., of Organic Chemicals and Products used in the Arts, Manufactures, etc. In 8 vols. By A. H. ALLEN, F.I.C. £6 16s. [Prospectus on application.]

Volumetric Analysis; or, the Quantitative Estimation of Chemical Substances by Measure. By FRANCIS SUTTON, F.C.S., F.I.C. Ninth Edition. 121 Engravings. 20s. net.

A Manual of Chemistry, Theoretical and Practical. By WILLIAM A. TILDEN, D.Sc., F.R.S., Professor of Chemistry in the Royal College of Science, London. 2 Plates and 143 Woodcuts. 10s.

Valentin's Practical Chemistry. By Dr. W. R. HODGKINSON, F.R.S.E., Professor of Chemistry and Physics in the Ordnance College, Woolwich. Tenth Edition. 14 Plates and 83 Figures in the Text. 10s. net.

A Handbook of Physics and Chemistry for the Conjoint Board. By H. E. CORBIN, B.Sc.Lond., and A. M. STEWART, B.Sc.Lond. Third Edition. 165 Illustrations. 6s. 6d. net.

A Treatise on Physics. By ANDREW GRAY, LL.D., F.R.S., Professor of Natural Philosophy in the University of Glasgow. Vol. I. Dynamics and Properties of Matter. 350 Illustrations. 15s.

Qualitative Analysis and Practical Chemistry. By FRANK CLOWES, D.Sc.Lond., Emeritus Professor of Chemistry in the University Coll., Nottingham. Eighth Edition. 101 Engravings. 7s. 6d. net.

Quantitative Analysis. By FRANK CLOWES, D.Sc.Lond., and J. B. COLEMAN, A.R.C.Sci. Dub.; Professor of Chemistry, South-West London Polytechnic. Seventh Edition. 125 Engravings. 10s.

BY THE SAME AUTHORS.

Elementary Practical Chemistry.

Part I. Fifth Edition. General Chemistry. 75 Engravings. 2s. 6d. net.

Part II. Sixth Edition. Analytical Chemistry. 20 Engravings. 3s. 6d. net.

Introduction to Chemical Analysis. By HUGH C. H. CANDY, B.A., B.Sc., F.I.C., Lecturer on Chemistry in the London Hospital Medical College, Analyst to the London Hospital. 3s. 6d. net.

Researches on the Affinities of the Elements and on the Causes of the Chemical Similarity or Dissimilarity of Elements and Compounds. By GEOFFREY MARTIN, B.Sc. Lond. Illustrated. 16s. net.

Microscopy ✎ Miscellaneous

The Microscope and its Revelations. By the late WILLIAM B. CARPENTER, C.B., M.D., LL.D., F.R.S. Eighth Edition, by the Rev. W. H. DALLINGER, LL.D., F.R.S. 23 Plates and more than 800 Wood Engravings. 28s. Half-Calf 32s.; or, in two vols, sold separately, cloth, 14s. each.

Vol. I. The Microscope and its Accessories.

Vol. II. The Microscope, its Revelations.

The Microtome's Vade-Mecum: a Handbook of the Methods of Microscopic Anatomy. By ARTHUR BOLLES LEE. Sixth Edition. 15s. net.

The Quarterly Journal of Microscopical Science.

Edited by Sir RAY LANKESTER, K.C.B., M.A., D.Sc., LL.D., F.R.S. Each Number, 10s. net.

Manual of Botany, in two Vols. By J. REYNOLDS GREEN, Sc.D., M.A., F.R.S., late Professor of Botany to the Pharmaceutical Society.

Vol. I. Morphology and Anatomy. Third Edition. 778 Engravings. 7s. 6d.

Vol. II. Classification and Physiology. Second Edition. 466 Engravings. 10s.

BY THE SAME AUTHOR.

An Introduction to Vegetable Physiology. Second Edition. 182 Illustrations. 10s. 6d. net.

Plant Anatomy from the Standpoint of the Development and Functions of the Tissues and Handbook of Micro-Technic. By WILLIAM CHASE STEVENS, Professor of Botany in the University of Kansas. 136 Illustrations. 10s. 6d. net.

Therapeutic Electricity and Practical Muscle Testing. By W. S. HEDLEY, M.D., in charge of the Electro-therapeutic Department of the London Hospital. 110 Illustrations. 8s. 6d.

A Manual for Hospital Nurses and others engaged in attending on the Sick. By EDWARD J. DOMVILLE, L.R.C.P.Lond., M.R.C.S.Eng., Surgeon to the Royal Devon and Exeter Hospital. Ninth Edition. 1s. 6d. net.

Nursing, General, Medical, and Surgical, with an Appendix on Sickroom Cookery and Dictionary of Medical Terms. By WILFRED J. HADLEY, M.D., F.R.C.P., Physician to the London Hospital. Second Edition. 3s. 6d. net.

St. Thomas's Hospital Reports. By the Medical and Surgical Staff. Vol. XXXV. New Series. 8s. 6d. net.

Guy's Hospital Reports. By the Medical and Surgical Staff. Vol. XLVII. Third Series. 10s. 6d. net.

LONDON

J. & A. CHURCHILL

7 GREAT MARLBOROUGH STREET

