

Roentgenologic studies of Egyptian and Peruvian mummies / by Roy L. Moodie ... 76 plates in photogravure, chiefly from roentgenograms prepared in the Division of roentgenology of Field museum.

Contributors

Moodie, Roy Lee, 1880-1934.

Publication/Creation

Chicago, 1931.

Persistent URL

<https://wellcomecollection.org/works/wh9r9khp>

License and attribution

This work has been identified as being free of known restrictions under copyright law, including all related and neighbouring rights and is being made available under the Creative Commons, Public Domain Mark.

You can copy, modify, distribute and perform the work, even for commercial purposes, without asking permission.



Wellcome Collection
183 Euston Road
London NW1 2BE UK
T +44 (0)20 7611 8722
E library@wellcomecollection.org
<https://wellcomecollection.org>

FOLIO 4

BC (Folios)



ACCESSION NUMBER

PRESS MARK



22101228532

X 18785

FIELD MUSEUM OF NATURAL HISTORY

FOUNDED BY MARSHALL FIELD, 1893

ANTHROPOLOGY, MEMOIRS

VOLUME III

ROENTGENOLOGIC STUDIES
OF
EGYPTIAN AND PERUVIAN MUMMIES

BY

ROY L. MOODIE

PALEOPATHOLOGIST TO THE WELLCOME HISTORICAL MUSEUM, LONDON

76 Plates in Photogravure Chiefly from Roentgenograms
Prepared in the Division of Roentgenology of Field Museum

BERTHOLD LAUFER
CURATOR OF ANTHROPOLOGY
EDITOR



CHICAGO, U. S. A.
1931

91

64839

Gallies

BC (Folios)



CONTENTS

	PAGE
List of Plates	5
Editor's Note	9
Preface	11
Introduction	13
Development of Roentgenologic Study of Mummies	15
Bibliography	16
North American Mummies	17
Bibliography	18
Review of Mummification in Egypt and Its Relation to the Interpretation of Roentgenograms	19
Mummification of Infants in Ancient Egypt	19
Mummification in Pre-Columbian Peru	19
Detailed Report and Pathologic Interpretation of Roentgenograms of Egyptian Mummies	20
Detailed Report and Pathologic Interpretation of Roentgenograms not Illustrated	25
Summary	26
Arthritides	26
Arteriosclerosis	26
Oral Diseases	26
Diseases of the Soft Tissues	27
Detailed Report and Pathologic Interpretation of Roentgenograms of Peruvian Mummies	28
Detailed Report and Pathologic Interpretation of Roentgenograms not Illustrated	38
Summary	45
Pre-Columbian Pediatrics	45
Infant Mummification in Pre-Columbian Peru	46
Arthritides	46
Arteriosclerosis	47
Oral Diseases	47
Caries	47
Calculus	47
Fistulae	47
Pyorrhea Alveolaris	48
Impaction	48
Injuries	49
Tumors	49
Trepanning	49
Report on Ancient Trepanned Peruvian Skulls in Field Museum of Natural History by Frank E. Wood	49
Uta	51

	PAGE
Nasal Disturbances	51
Otosclerosis and Deafness	52
Otitis Media	52
Mastoiditis	52
Syphilis	52
Appendix: Mummified Animals of Egypt and Peru	53
Introduction	53
Mummified Fauna	53
Technique of Embalming	54
Cost and Purpose of Mummification	55
Imitation Mummies	55
Mummified Anthropoids and Their Diseases	56
Other Mummified Mammals	56
Mummified Avifauna	57
Mummified Reptiles	58
Mummified Fish	59
Mollusks	59
Summary	59
Detailed Report and Roentgenologic Interpretation of Egyptian Animal Mummies	60
Notes on Peruvian Animal Mummies	63
Bibliography of Animal Mummies	63
Index	65

LIST OF PLATES

- I. Montana Blackfoot Indian. North American tree burial.
- II. Woman from Predynastic Burial, Egypt. Head and trunk.
- III. Same Woman as Plate II. 1. Right mastoid. 2. Hand and wrist.
- IV. Same Woman as Plate II. Vertebral column showing lesions.
- V. Same Woman as Plate II. Lumbar vertebrae, sacrum, and coccyx.
- VI. Same Woman as Plate II. Ossification in anterior longitudinal ligament.
- VII. Poker Spine of an Eskimo.
- VIII. Torso of Mummy, Egypt. Long shadow may indicate liver.
- IX. Mummy, Egypt. Detail showing genu valgum.
- X. Girl with Curvature of Spine, Roman Period, Egypt.
- XI. Boy with Curvature of Spine, Roman Period, Egypt. Brother of girl in preceding plate.
- XII. Unwrapped Mummy of Infant, Egypt.
- XIII. Unwrapped Mummy of Child, Egypt.
- XIV. Mummy of Child in Coffin, Egypt.
- XVa. Mummy of Boy Twelve Years Old, Egypt.
- XVb. Lower Limbs of Boy in Preceding Plate.
- XVI. Child Mummies, Roman Period, Egypt. 1. Boy. 2. His sister.
- XVII. Head of Mummy, Young Woman, Egypt.
- XVIII. Mummy Head with Cartonnage, Egypt.
- XIX. Mummy Head and Neck, Egypt.
- XX. Mummy Head of Woman Showing Painted Mask, Egypt.
- XXI. Archaeological Map of West Coast of South America by Charles W. Mead.
- XXII. Mummy of Child, Peru.
- XXIII. Heads of Mummies, Peru. 1. Hydrocephalus in infant. 2. Mastoid and adjoining injury in adult.
- XXIV. Skulls, Peru. 1. Impacted lower right, third molar. 2. Pyorrhea and salivary calculus. 3. Edentulous palate. 4. Effects of soft tumor on palate.
- XXV. Parts of Skulls of Mummies, Peru. 1-2. Pyorrhea. 3. Pyorrhea and caries.
- XXVI. Skulls, Peru. 1. Mace injury. 2. Trepanning.
- XXVII. Skulls, Peru. 1. Mace injury. 2. Trepanning.
- XXVIII. Skulls, Peru. 1. Caries. 2. Antral fistula. 3. Calculus.
- XXIX. Skull, Peru. 1. Photograph showing lesion in skull. 2. Roentgenogram.
- XXX. Mushroom Head of Femur, Mummy, Peru. 1-2. Different views of same.
- XXXI. Arthritis Deformans, Mummy, Peru. 1. Pelvis. 2. Femur.

- XXXII. Arthritis Deformans, Mummy, Peru. 1. Pelvis. 2-3. Femur.
- XXXIII. Cranial Tumor on Skull, Peru.
- XXXIV. Eskimo and Prehistoric Peruvian Skulls. 1. Syphilitic lesions in Eskimo skull. 2. Osteoporosis in prehistoric Peruvian skull.
- XXXV. Skulls, Peru. 1-3. External auditory passages.
- XXXVI. Skulls, Peru. 1. Small osteoma. 2-3. Auditory passages, right and left.
- XXXVII. Skulls, Peru. 1-3. Ear disturbances.
- XXXVIII. Skulls, Peru. 1. Ear disturbance. 2. Mastoid. 3. Nasal disturbance.
- XXXIX. Skull, Peru. 1. Sclerotic temporal bone. 2-3. Diseased mastoids in same skull.
- XL. Mummy of Infant, Peru.
- XLI. Mummy of Infant, Peru. Skeleton incomplete.
- XLII. Mummy of Infant, Peru.
- XLIII. Mummy of Infant, Peru.
- XLIV. Mummy of Child, Peru.
- XLV. Mummy of Child, Peru.
- XLVI. Mummy of Child, Peru.
- XLVII. Mummy of Infant, Peru.
- XLVIII. Mummy of New-Born Infant, Peru.
- XLIX. Mummy of Infant, Peru.
- L. Mummy of Infant, Peru.
- LI. Mummy of Child, Peru.
- LII. Mummy of Child, Peru.
- LIII. Mummies, Peru. Adult, youth, and infant included in same package.
- LIV. Photographs of Mummy Head, Peru. 1. Front. 2. Profile.
- LV. Roentgenograms of Head in Preceding Plate. 1. Anterior. 2. Lateral.
- LVI. Sketch of Peruvian Grave. After Eaton.
- LVII. Typical Mummy Packages, Peru.
- LVIII. Typical Mummy Packages, Peru.
- LIX. Deformed Skulls of Incas, Peru. Showing trepanning.
- LX. Skull of Adult, Peru. 1. Showing large trepanning. 2. Detail of Fig. 1 with evidences of infection and slight healing.
- LXI. Skull of Child, Peru. 1. Showing unusual cranial lesion and osteoporosis. 2. Detail of Fig. 1.
- LXII. Skulls of Adults, Peru. 1. Showing trepanning in state of advanced healing. 2. Showing healed, depressed area due to injury or trepanning.
- LXIII. Mummified Baboon Skull, Egypt. Drawing.
- LXIV. Diseased Bones of Mummified Baboon, Egypt. Drawing.
- LXV. Mummies of Animals, Egypt (Photographs). 1. Baby crocodile. 2. Imitation mummy of a kitten; no skeleton in package. 3. Imitation mummy of a gazelle; only horns in package.

- LXVI. Mummy of a Cat, Egypt. 1. Photograph. 2. Roentgenogram showing complete skeleton.
- LXVII. Mummy of a Cat, Egypt. 1. Photograph. 2. Roentgenogram showing complete skeleton.
- LXVIII. Imitation Mummy of an Unidentified Animal (Cat?), Egypt. 1. Photograph. 2. Roentgenogram showing skull only.
- LXIX. Imitation Mummy of a Small Animal, Egypt. 1. Photograph. 2. Roentgenogram revealing absence of skeleton.
- LXX. Roentgenograms of Mummified Birds, Egypt. 1. Kite. 2. Falcon.
- LXXI. Imitation Mummy of a Bird, Egypt. 1. Photograph. 2. Roentgenogram revealing unidentified bones.
- LXXII. Photograph of Mummy of a Goose, Egypt.
- LXXIII. Roentgenogram of a Goose Shown in Preceding Plate.
- LXXIV. Mummy of a Hawk, Egypt. 1. Photograph. 2. Roentgenogram.
- LXXV. Mummy of a Raptorial Bird, Egypt. 1. Photograph. 2. Roentgenogram.
- LXXVI. Mummy of a Vulture, Egypt. 1. Photograph. 2. Roentgenogram.

EDITOR'S NOTE

In 1925 Mr. E. C. Jerman of the Victor X-Ray Corporation of Chicago volunteered his services to the Museum and took a number of X-ray photographs of Egyptian and Peruvian mummies in the Museum's collections. Thirty-two subjects were made by him with such gratifying and convincing results that at my suggestion a Division of Roentgenology was established in the Museum in 1926. Mr. Stanley Field, President of the institution, manifested deep interest in this novel phase of museum work and generously presented the institution with a complete X-ray equipment especially adapted for museum purposes. Special quarters for housing this equipment were laid out, and now include an operating room, a dark room, and an office. In founding this division the Museum has taken the lead in a novel line of museum practice and technique, making an invaluable addition to methods of research which bid fair to yield important results in archaeological and biological investigations.

Miss Anna Reginalda Bolan, formerly assistant professor of roentgenology and photography at the University of Illinois, was appointed Roentgenologist in charge of this division. The work of the Division of Roentgenology was favorably received by both radiologists and the general public. A number of radiographs were exhibited at the Nebraska State Fair of 1927 and at two scientific conventions held in Chicago during the same year, with demonstrations of the work done in the Division, and attracted wide attention.

During the last years many experiments were conducted with a view to perfecting the technique and have resulted in producing films of greater clarity and brilliancy.

Professor Roy L. Moodie does not require an introduction to the scientific public. He is well known for his numerous contributions to our knowledge of the diseases of ancient times, as evidenced by his books "The Antiquity of Disease" and "Palaeopathology—an Introduction to the Study of Ancient Evidences of Disease," as well as by the long series of monographs forming his "Studies in Paleodontology."

He was professor of anatomy at the University of Illinois College of Medicine, 1914-18, professor of anatomy and research librarian with the University of Illinois at Chicago, 1924-28, and has been professor of paleodontology at the College of Dentistry of the University of Southern California since 1928. He also holds the rank of paleopathologist with the Wellcome Historical Museum of London.

The study presented by him in this volume of the pathological conditions found in ancient Egyptian and Peruvian mummies as revealed by roentgenograms prepared in Field Museum will be warmly welcomed by pathologists, students of the history of medicine, radiologists, and archaeologists.

I wish to thank Miss Bolan and Miss Lillian A. Ross for their assistance in seeing the manuscript through the press.

PREFACE

The purpose of this monograph is to add to our knowledge of mummification through an interpretation of roentgenograms of the collection of unopened mummy packs at Field Museum of Natural History. The roentgenologic results of this examination are of the highest quality, as may be seen from the numerous plates which represent only that material which is the property of Field Museum. During the course of this study, which has extended over many months, comparative observations have been made on materials preserved in several other museums. I am thus under obligation to the officials of the American Museum of Natural History, the United States National Museum, the Army Medical Museum, the San Diego Museum, and the Museum of Anthropology of the University of California in San Francisco.

It is well known that mummification was practised extensively in ancient Egypt and to a more limited extent in pre-Columbian Peru. A single mummified body of a North American Indian is in the collections of Field Museum. Mummies of sacred animals and of man represent the Egyptians. Unfortunately, the data accompanying the Egyptian mummies are exceedingly meager, so that we cannot assign any of them to a definite time in Egyptian chronology. There are more than sixty mummy packs from Peru, including a large number of children. Locality data for the Peruvian mummies are exact, and are very helpful. It seems probable that some of the mummies are post-Columbian, especially those of children.

Particular emphasis is placed on the search for evidences of disease and injury. Careful accounts of the various phases of paleopathology are given in text and plates. I have been aided in this study by L. C. Kinney, a roentgenologist of San Diego, California. He has also made for me a large number of roentgenograms showing the pathologic conditions in the Hrdlicka Peruvian collection of the San Diego Museum, many of which have been used to illustrate a number of my "Studies in Paleopathology," published in the *Annals of Medical History*, and "Studies in Paleodontology," published in the *Pacific Dental Gazette*.

Many noted anthropologists have been consulted about various matters during the course of this study. I am thus under obligation to G. Elliot Smith of London for advice concerning the Egyptian mummies. Claude Gaillard of the Lyons (France) Museum of Natural History has aided by advice, by the gift of literature, and by a roentgenogram of a sacred bundle containing snakes. A. L. Kroeber of the University of California and E. W. Gifford of the Museum of Anthropology at San Francisco have given literature, advice, and a set of roentgenograms of Peruvian mummies. Herbert U. Williams of the University of Buffalo has sent literature, and many others have contributed materially to whatever success the work may have.

Members of the staff of Field Museum have been uniformly courteous and helpful throughout the long period of time the work has been in preparation. I wish to express special thanks to Miss Anna Reginalda Bolan for valuable assistance in this work. The ideals of excellence maintained by the Museum cannot be commended too highly.

ROY L. MOODIE

SANTA MONICA, CALIFORNIA
January, 1931

INTRODUCTION

Our knowledge of diseases in ancient time has been widened by the application of the Roentgen ray to the study of unopened mummy packs. A striking advance is made, especially among Peruvian material, in the possibility of studying entire skeletons. Our previous studies on pre-Columbian Peruvians have been largely restricted to consideration of isolated skeletal parts.

Roentgenologic study of unopened mummy packs has its limitations. In all mummy packs there are many obscuring features, such as the use of dense materials in embalming among the Egyptians, and the inclusion of objects of metal, ears of maize, pottery, beads, shells and other trinkets, and the presence of clumps of sand and small gravel in mummy packages from both Egypt and Peru. Slight surface lesions, osteoporosis, and in many cases trepannings, traumatic injuries, and even linear fractures pass unobserved in a Roentgen examination of unopened mummy packs, on account of the superimposition of materials denser than the involved areas through which the shadows are made.

We feel, however, that the advance in our knowledge of disease in ancient times more than compensates for the disadvantages incurred in such a study. Roentgenology supplements all other methods of learning of physical troubles in early times.

One great advantage in the present study is the possibility of observing the condition of many Peruvian child mummies ranging from those of premature delivery up to the age of puberty. The collections of child mummies in Field Museum are adequate to give a good cross section of the physical condition of the children of ancient Peru, in so far as the skeletal parts are concerned. We learn that there is none of the bony manifestations of rickets to be seen among the mummies of twenty-nine children less than fourteen years of age, from pre-Columbian Peru. A trace of the disease was found among the ancient Egyptians. Like syphilis, rickets apparently is a modern disease. (See also Annual Report of Field Museum for the year 1930, p. 419.)

It is impressive to note the high percentage of disease and injury among the fifty-three mummy packs studied. Among the pre-Columbian Peruvian mummies, the incidence of disease and injury is 10.52 per cent. Among the Egyptian mummies studied the enormous figure of 40 per cent is deduced as the incidence of disease and injury, based on fifteen mummies. While among the twenty-nine pre-Columbian children from Peru the incidence is low, yet we are unable in most cases to determine the diseases of the teeth, as well as of all soft parts.

A determination of the incidence of disease and injury of the skeletal parts of the Pleistocene saber-tooth reveals a much lower percentage, in no case over 7 per cent. This determination, however, is based on a count of about one thousand skeletons. Undoubtedly a much lower percentage would result if we could base our count on a larger series of ancient mummies. Our statistics are further vitiated by the failure of the Roentgen ray to reveal certain lesions of childhood which we know from dry skulls were prevalent among pre-Columbian children.

It is of great importance to our knowledge of disease in ancient times to develop the field by further study of additional mummy packs by the roentgenologic method.

The roentgenograms chosen illustrate representative conditions found in unopened mummy packs. To the roentgenograms of the pre-Columbian Peruvians especially have been added a number of explanatory photographs of prehistoric lesions found on material preserved in San Diego Museum. The reader is referred to the volume by Mark Armand Ruffer, "Studies in the Paleopathology of Egypt," for information regarding pathologic conditions found in ancient Egyptian mummies.

Attention has been called by Weston Price ("Capabilities and Limitations of the Roentgen Rays," in "Dental Infections—Oral and Systemic," I, chap. 1, pp. 35-54) to the limitation of the X-rays in demonstrating *all* lesions, especially those which are slight, or covered by more or less dense tissue. The interpretation of roentgenograms of dry bones and mummies offers further difficulties on account of the absence of shadow-casting fluids, and of all soft parts. The roentgenological appearance of mummies is quite different from that of a living body. Other difficulties are found in the intrusions of foreign bodies into the wrappings of the mummies, both intentional and unintentional.

The most commonly found obstructions (Plate XXII) are clumps of sand and small gravels which have drifted into the wrappings of both Egyptian and Peruvian mummies during their many centuries of interment. The shadows cast by these materials are very confusing, although fortunately such objects are more often restricted to the periphery of the mummy pack. Objects of gold, silver, copper, pottery, ears of maize, shell beads, and many other things wrapped with the body confuse the passage of the rays.

The Roentgen rays fail to reveal lesions due to trepannings (Plate XXIX), club injuries, sling shot wounds, and even linear fractures. Many of the Peruvian mummies had the skull trepanned (Plate XXVII) extensively, yet I have been unable, in an examination of the many roentgenograms of mummy packs at Field Museum, to determine the presence of a single trepanning. This failure is explained in part by the conditions met with in a pre-Columbian male skull (No. 288, San Diego Museum) from Cinco Cerros, Peru (Plate XXIX), which had been trepanned in the frontal bone above the left orbit, possibly for the relief of a sinus headache, yet the X-rays show no evidence of the cutting, and the sinuses are clear and very large.

Only one skull in Field Museum (Cat. No. 168806, roentgenograms A122, A123, Field Museum) shows clearly a cranial lesion due to a blow from a star-shaped mace (Plates LIV, LV), yet such lesions were fairly common.

The various embalming materials used in Egypt offer some resistance to the passage of the X-rays, as in the case of the Egyptian mummy No. 105215 (Plate XIX) where most of the skeleton is obscured by embalming materials. A hypertrophic spleen (Plate VIII), indicating malaria, is suggested by the shadow on the right side of Egyptian mummy No. 30021, but the appearance may be due to the insertion into the abdomen of a parcel of intestines, wrapped in linen, smeared with pitch, with sand adherent.

I have introduced a number of illustrations to show many lesions which are not evident in ordinary X-ray examinations, but require treatment not possible with mummy packs. Such pictures are shown on Plates XXIV, XXVI, XXVIII, XXIX, XXXIV-XXXVIII. It will be evident that X-ray examinations of mummy packs are incomplete in establishing the presence of all lesions.

ROENTGENOLOGIC STUDIES OF EGYPTIAN AND PERUVIAN MUMMIES

DEVELOPMENT OF ROENTGENOLOGIC STUDY OF MUMMIES

An historical account is given here of the use of the Roentgen rays in the study of mummies. The chronological review of literature is not for the purpose of establishing priority for anyone, but to show the development of the subject.

The writers most prominent in this field are: Arthur Baessler and George F. Eaton on Peruvian material; Marcel Baudouin on neolithic material found in France; Victor Lortet, Claude Gaillard, G. Elliot Smith and Warren R. Dawson on ancient Egyptian mummified lower vertebrates and man; H. J. Means on ancient American mound-builders; Henry Snure on Pleistocene vertebrates, and Roy L. Moodie on ancient vertebrates and pre-Columbian Peruvians.

The writings of Lortet and Gaillard on the splendid collections from ancient Egypt in the Natural History Museum at Lyons, France, contain the earliest reference to the use of the Roentgen rays in a study of the contents of unopened mummy packs (1903-9). No special comment was made in their work on the importance of the Roentgen rays in such investigations. It must be noted, however, that these authors were chiefly concerned with the taxonomic relations of the mummified fauna of ancient Egypt. Incidentally, they picture a few osseous lesions.

Baessler's folio, comprising fifteen plates with explanations, gives four roentgenograms of mummy packs from ancient Peruvian cemeteries. The roentgenograms in this publication show little more than the situation of the enclosed skeletons and the posture of the extremities. The small size of the pictures precludes any determination of the skeletal structure.

Smith in his studies on ancient Egyptian mummy packs realized the importance of the X-rays, but was seldom able to employ them. In the "Catalogue of the Royal Mummies of Egypt in the Cairo Museum" (1912), Preface (p. iii), he writes: "In the case of many of the mummies, especially those in the best state of preservation, there was singularly little that an anatomist could do, provided of course that he refrained from damaging the body. In such mummies as those of Ramses III, for instance, the anatomist can add little to what any one can see for himself by looking at the body encased in its resinous carapace. Examination with the aid of X-rays would, no doubt, have provided much additional information (and I hope that this will be done at some future time) but I was unable to get such investigations carried out, except in the case of the mummy of Tuthmosis IV."

Smith writes (p. 94, footnote, under heading, "The Mummy Supposed to Be That of Tuthmosis I"): "There is then abundant evidence for placing this mummy in the series between those of Ahmosis I and Tuthmosis II, and it is particularly unfortunate that we are unable . . . to add the testimony of the mummy of Amenothos I to the discussion. Perhaps M. Maspero at some future time may give his consent to the use of X-rays, and obtain a skiagram of the mummy of Amenothos I, which would show the positions of the arms, without disturbing the wrappings and the garlands that now hide them from view."

On page 44 Smith writes (under the heading, "The Mummy of Tuthmosis IV"): "Other parts of the body were examined by means of the Roentgen rays, i.e., to determine the age of the individual."

Smith and F. Wood-Jones did not employ X-rays in their investigations of what proved to be the most extensive study of paleopathology ever made, i.e., the examination of thousands of bodies in the archaeological survey of Nubia.

Smith and Dawson, in "Egyptian Mummies," have referred to the use of roentgenograms. They write (p. 94, footnote), "This mummy [Tuthmosis IV] is the only one so far that has been examined with X-rays."

Eaton (1916) employed the Roentgen rays to explain pathologic conditions seen in crania and limb bones obtained from burials in the Peruvian highlands, in connection with the deserted city of Machu Picchu.

Among the voluminous writings of Baudouin, Croix-de-Vie (Vendée), France, are a few articles devoted to the use of the Roentgen rays in the interpretation of osseous lesions found in neolithic skeletons. His contributions are brief, but written with a full appreciation of the subject.

André Rouillon (1923) has reviewed the work of Baudouin, advancing the subject somewhat by his own discoveries.

Snure (1924) attempted to study the nature of the pathologic lesions seen in the Pleistocene fauna of Rancho la Brea. His determination of pathologic lesions in the mucosa sini frontali is a mistake. The shadows which appear in the frontal sinus of the sloth (*Nothrotherium*) are due to granite pebbles, which are found throughout the skull.

Means (1925) studied, in an incidental way, certain lesions found on skeletal remains from the old Indian mounds of Ohio. His illustrations are splendid, and his brief determinations seem logical.

My own work (Moodie, 1923, 1926, 1927) has so far been only a series of trials to determine the value of the employment of roentgenograms in the study of fossil and other ancient material. If the specimens are penetrable by the Roentgen rays, the results are valuable, but in petrified and infiltrated objects the use of the Roentgen rays is not warranted by the results. Attempts to secure serviceable roentgenograms of the huge skulls of *Myiodon*, a Pleistocene edentate, have so far failed because of the amount of material to be penetrated.

BIBLIOGRAPHY

- BAESSLER, ARTHUR.—1906. *Peruanische Mumien. Untersuchungen mit X-Strahlen*. Plates I-XV. Georg Reimer, Berlin.
- BAUDOUIN, MARCEL.—1921. Étude radiographique de trois métatarsiens de l'âge de la pierre polie, atteints d'ostéo-arthrite chronique. *L'Avenir Médical*, Lyon, XVIII, No. 4, pp. 87-88, 1 radiograph.
1923. Radiographiques d'os humains pathologiques de la pierre polie. *Comptes rendus de l'Académie des Sciences*, Paris.
1924. Études de quelques radiographies d'os d'âge de la pierre polie. *La Semaine Dentaire*, VI, No. 37.
- EATON, GEORGE F.—1916. The Collection of Osteological Material from Machu Picchu (Peru). *Memoirs Conn. Acad. Arts and Sciences*, V, pp. 1-96, plates I-XXXIX.
- X-rays of adult female skull, showing a healed lesion on the right parietal eminence; pathological limb bones.

LORTET and GAILLARD.—1903-1909. La faune momifiée de l'ancienne Égypte. Archives du Muséum d'Histoire Naturelle de Lyon, VIII-X, figs. 92-95.

In IX, p. 29: diseased conditions in apes. X, fig. 37, p. 42: syphilitic (?) skull of young woman. Roentgenograms, fig. 103, p. 36, 2nd series. Fig. 216, p. 301: mummy pack of snakes.

MEANS, H. J.—1925. A Roentgenological Study of the Skeletal Remains of the Prehistoric Mound-Builder Indians of Ohio. Amer. Jour. of Roentgenology and Radium Therapy, XIII, 359-367.

Six plates of unusually excellent radiographs of diseased skeletal remains.

MOODIE, ROY L.—1923. Paleopathology. Urbana.

Summary of work done up to that date.

1926. Studies in Paleopathology, XVIII. Tumors of the Head among Pre-Columbian Peruvians.

Annals of Medical History, VIII, No. 4, pp. 394-412, 15 figs.

X-rays of several tumors.

1926. Studies in Paleopathology, XIX. Pleistocene Examples of Traumatic Osteomyelitis. Same, VIII, No. 4, pp. 413-418, 4 figs., December.

X-rays of lesions.

1927. Studies in Paleopathology, XX. Vertebral Lesions Resembling Myositis Ossificans Progressiva in a Sabre-tooth, Pleistocene of California; Compared with Certain Ossifications in the Dinosaurs. Same, IX, No. 1, pp. 91-102, 11 figs.

X-rays of lesions.

1927. Studies in Paleopathology, XXI. Injuries to the Head among pre-Columbian Peruvians. Same, IX, No. 3, pp. 298-328, 65 figs., September.

X-ray interpretations of lesions.

ROUILLON, ANDRÉ.—1923. Lésions osseuses préhistoriques de la Vendée (France). Thèse pour le doctorat en médecine (Faculté de Médecine de Paris), pp. 1-260, 86 text figs., 10 plates, some of which are radiographs.

SMITH, G. ELLIOT.—1912. The Royal Mummies. Catalogue général des antiquités égyptiennes du Musée du Caire, pp. 1-118, plates I-CII.

Discusses the value of the X-ray in determining obscure anatomical facts.

1924 (with Warren R. Dawson). Egyptian Mummies. New York.

Refers to the value of the X-ray in a study of mummies at p. 94 (footnote, p. 115; pp. 118, 121).

1926. The Diversions of an Anatomist in Egypt. Cambridge University Medical Society Magazine.

On page 36 refers to the use of the X-ray to determine the age of the pharaoh Thothmes IV.

1927. Tutankhamen and the Discovery of his Tomb, with 25 illus. and maps. London.

X-ray referred to on pp. 86, 127, 129.

SNURE, HENRY.—1924. A Roentgen-Ray Study of the La Brea (California) Fossils. Amer. Jour. of Roentgenology and Radium Therapy, New York, XI, pp. 351-354. Figs.

NORTH AMERICAN MUMMIES

No great cult of mummification has been developed in the North American continent comparable to that of Egypt or Peru. While evidence of attempts to preserve the bodies of the dead is forthcoming from most regions in North America, it does not seem that the methods employed were at all elaborate.

The practice of preserving the bodies of the dead was in vogue among the inhabitants of the Aleutian Islands and the Kadiak Archipelago at the time of their discovery, and probably had been the custom among them for centuries. We find nothing of it on the mainland (W. H. Dall).

The body was prepared by making an opening in the pelvic region and removing all the internal organs. The cavity was then filled with dry grass, and the body placed in running water. This in a short time removed most of the fatty portions, leaving only the skin and muscular tissues. The knees were then brought up to the chin, and the whole body secured as compactly as possible by cords. The bones of the arms were sometimes broken to facilitate the process of compression. In this posture the remains were dried. When thoroughly dried, the body was wrapped in skins and matting (Dall).

Mummy bundles have been found on the Mexican plateau, the body bound in a contracted position within a network of ropes. False heads and masks were commonly used.

In the great southwestern area of the United States, mummies were common in the form of desiccated bodies. The limbs were folded, and the bodies were wrapped in blankets, mats, etc., and tied with fiber ropes. A considerable number of such "natural mummies" has been recorded in the southwestern area.

In Basket-Maker caves of northeastern Arizona bodies wrapped in blankets and woven cloths have been found.

In the Mammoth Cave, Kentucky, the body of a woman in a remarkable state of preservation, with features discernible, was discovered.

The evidences show a deliberate intention to preserve the mortal remains in order that thereby the immortality of the body might be secured, a notion that is intimately associated everywhere with the practices of mummification.

PLATE I

Field Museum Cat. No. 51701.

Roentgenograms: A167, upper part; A169, lower part.

Source: Medicine Lodge, Blackfoot Reserve, Montana.

Age: four years, six months.

Sex: female.

Body extended and clothed; cotton jacket and buckskin trousers and moccasins, also two bead necklaces. An example of tree burial.

Skeleton free from any defect; in excellent state of preservation. A most remarkable child.

BIBLIOGRAPHY

The following list is merely introductory:

DALL, W. H.—1875. Alaskan Mummies. *American Naturalist*, IX, pp. 433-440. Also in the *Indian Miscellany*, 1877, pp. 344-351.

GODDARD, PLINY E.—1921. Indians of the Southwest. *American Museum of Natural History*, Handbook Series, No. 2, second edition.

Disposal of dead, p. 52, with picture of mummy wrapped in cotton robe.

GUERNSEY and KIDDER.—1921. Basket-Maker Caves of Northeastern Arizona. *Papers of the Peabody Mus. of American Archaeology and Ethnology*, Harvard Univ., VIII, No. 2.

JAMES, EDWIN OLIVER.—1928. Cremation and the Preservation of the Dead in North America. *American Anthropologist*, XXX, 1928, pp. 214-242.

With extensive bibliography.

LOUD, LLEWELLYN L. and HARRINGTON, M. R.—1929. Lovelock Cave. *Univ. Calif. Publ. in Amer. Archaeol. and Ethnol.*, XXV, No. 1.

Mummies, p. 31, plates VIII-XI.

REVIEW OF MUMMIFICATION IN EGYPT AND ITS RELATION TO THE INTERPRETATION OF ROENTGENOGRAMS

Our knowledge of the various processes of preparing the dead in ancient Egypt and Nubia is fairly complete and accurate. The factor involved which interests us here is the condition in which the body was left at mummification.

It is not known whether the neolithic dwellers in Egypt cremated their dead or not. There is too little evidence.

The earliest method of preservation was burial, in an extended position, in the hot dry sand of the desert; and doubtless many were left on the surface to the jackals, which also exhumed many of the burials. In an unwrapped, extended position, some of the internal organs might reveal certain pathological conditions. Calculi—renal, hepatic, or otherwise—should be revealed by dense shadows. Hypertrophic calcified cirrhosis of the liver would be revealed. Hypertrophic conditions of the spleen, whether malarial or leucemic, might be expected to show. All vascular calcifications up to arteriosclerosis would show, since some of the larger arteries are known to have been converted into tubes of bone.

At the time when the technique of embalming was at its height all internal organs, and even the muscles were removed. This condition would hinder the search for evidences of disease among the softer tissues.

The method of arranging the body in an embryonic or folded position would be followed by difficult roentgenologic interpretation, because of overlapping shadows.

The activity, through thousands of years, of vandals in mutilating the mummies, exchanging burials, and mixing the burial arrangements, and the attempts at repairing the effects of vandalism by the priestly devotees, all have their due influence on the confusion of roentgenologic evidence.

In common with the Peruvian mummy packs, the ancient Egyptian packs are infiltrated with sand, small gravel, and ceremonial objects, as well as having, at times, a mass of embalming materials to interfere. The details of the effects of these various factors on our roentgenologic findings are given in another section of this monograph.

MUMMIFICATION OF INFANTS IN ANCIENT EGYPT

There are only scant references in literature to even the occurrence of infant mummies. Thus G. Elliot Smith¹ refers to the mummy of Queen Mäkeri, who died in child-bed, and figures an unwrapped bundle which possibly contains the body of her baby. He also refers to the mummy of Prince Sipaari, a child of five or six years. F. Wood-Jones² discusses briefly the burial of infants. The field of prehistoric pediatrics in Egypt is practically untouched.

MUMMIFICATION IN PRE-COLUMBIAN PERU

So far the literature has indicated that mummification in prehistoric Peru was a natural process, a matter of sun-drying, wrapping, and interment in the dry

¹The Royal Mummies, Queen Mäkeri and Her Baby, p. 98, plate LXXIV; Prince Sipaari, pp. 22, 24, plate XIX.

²F. Wood-Jones and G. Elliot Smith, *Archaeological Survey of Nubia*, 1907, p. 217.

sands of the coastal deserts and in caves, rock shelters, and in huacas (small mortuaries) among the mountainous districts. Comments by Garcilasso de la Vega as to this matter are hardly of scientific value, yet his statements are largely confirmed by the conditions found. L. Reutter¹ has reviewed the subject.

Careful scrutiny of the many roentgenograms of prehistoric Peruvian mummies in Field Museum adds nothing to our present knowledge of embalming methods. No lumps of resin, pitch or other embalming materials, such as we frequently meet with in ancient Egyptian mummies, obscure the picture of any of the bodily parts. Clumps of small gravel and sand are retained within the wrappings of both Egyptian and Peruvian mummies which often obscure important details. Numerous small pieces of pottery, ears of maize, metal objects, and ornaments of shell are frequently included in the mummy packs of pre-Columbian Peruvians, but I have seen nothing to lead me to think that any of the opaque materials were used in embalming. In a few Peruvian mummies traces of viscera are seen, but there is never any evidence of disarrangement.

Recently statements have been published that complete evisceration was extensively practised among the population whose bodies are found mummified at Parakas in Peru. Not only was evisceration done, but the heavier muscle masses were removed, and the remains cured by "smoking." No anatomical evidence has yet been given, and we are still uncertain as to just how evisceration was done or what disposition was made of the viscera.

The burial mounds at Parakas and their contents are briefly discussed by A. Hyatt Verrill, "Mummy Mining in Peru" (*Art and Archaeology*, XXIX, April, 1930, pp. 171-180, with 16 figs.); see also his chapters XIV and XV, "The Incans and pre-Incans," in his "Old Civilizations of the New World," 1929, pp. 277-358; and Julio C. Tello, "Antiguo Peru: Primera Epoca," Lima, 1929, pp. 1-183, illustrated.

There is abundant evidence to show that bodies were often imperfectly dried before being wrapped. The commonest indication of this is seen in the disorganized, slumped, and mixed condition of the ribs and vertebrae, pointing to extensive putrefaction (Plates XLI-XLIII).

DETAILED REPORT AND PATHOLOGIC INTERPRETATION OF ROENTGENOGRAMS OF EGYPTIAN MUMMIES

PLATE II

Field Museum Cat. No. 31736.

Roentgenogram: A229.

Source: Egypt; predynastic era.

Age: adult.

Sex: female.

Predynastic female, Egyptian mummy. A much bowed, decrepit, senile, but not necessarily old individual, crippled by disease to the point of total incapacity.

Pyorrhea had robbed her of most of her teeth. Arteriosclerosis is evident throughout the field, especially around the scapula. Spondylitis deformans had consolidated the vertebral column. The ribs are fixed by osseous bands.

¹L'embaumement dans le Nouveau Monde et particulièrement chez les Incas, 1912, pp. 142-144; in his *De l'embaumement avant et après Jésus-Christ*, Paris, 1912.

PLATE III

Fig. 1: Same woman as Plate II.

Roentgenogram: A229.

Right mastoid of predynastic Egyptian female showing air-cells of the mixed pneumatic type, indicating a healed infection. A defect in the cranial wall above.

Fig. 2: Same woman as Plate II.

Roentgenogram: A029.

Hand and wrist of same individual showing arteriosclerosis in the contorted interosseous artery.

PLATE IV

Same woman as Plate II.

Roentgenogram: A031.

Part of the vertebral column, lower thoracics, showing the lipping of lesions of spondylitis deformans.

PLATE V

Same woman as Plate II.

Roentgenogram: A235.

The lumbar vertebrae, sacrum, and coccyx of same predynastic female, showing the condition of part of the acetabulum. The zygapophysial regions are firmly ankylosed.

PLATE VI

Same woman as Plate II.

Roentgenogram: A233.

View opposite to that shown in Plate II. Running along the anterior surface of the vertebral column may be seen the partly ossified, longitudinal ligament, fixing the vertebrae in their bowed condition.

SUMMARY OF PLATES II-VI

Field Museum Cat. No. 31736.

Predynastic Egyptian mummy.

Roentgenograms: PD1, PD3, A229, A231, A233, A235, A237, A239.

Age: adult.

Sex: female.

Examination of head shows:

Mastoid, left, of the pneumatic mixed cell type. Cortex evidently very thin. Large posterior cells clear anteriorly, showing a cloudy granulation indicating osteosclerosis due to healed infection. Pituitary fossa large, but not abnormal. Vault normal. Frontal sinus very small, but normal. Other sinuses clear of trouble. Maxilla completely edentulous; mandible with five anterior teeth, all others lost. Possible cause: absorptive osteitis.

Examination of torso and limbs:

Cervical vertebrae normal. Thoracic vertebrae with a strong kyphosis. Spinous processes on mid-dorsal vertebrae indicate spondylitis deformans, i.e., ossifications in ventral longitudinal ligament. Further evidence of this condition is seen in lumbar region. Articular surfaces of vertebral arches evidently partly coalesced by partial ossification of ligaments. Sacrum and pelvis normal. Ribs

normal with indications of associated arteriosclerosis in bodies of ribs. Scapulae normal; arteriosclerosis of blood vessels on ventral surface of right scapula. Bones of arms normal, with arteriosclerosis of radial (?) artery near left wrist. Sternum and leg bones normal. Acetabulum normal and well developed. Ligaments in lumbar region sclerosed, indicating senile changes.

PLATE VII

San Diego Museum Cat. No. 557.

Source: St. Lawrence Island, Ales Hrdlicka, collector.

Age: adult.

Sex: undetermined.

A "poker spine" of an Eskimo. This condition, known as spondylitis deformans, is due to the ossification of the longitudinal vertebral ligaments. Why the ligaments should ossify is not known. This pathological condition has a wide geographical and geological range. It occurs in the Comanchian dinosaurs, among Tertiary mammals, among Pleistocene mammals and reptiles. It is common in ancient man. The condition has been ascribed to many things, but the etiology is doubtful. The ancient Egyptians offer numerous examples of spondylitis deformans, but it is rarely found among the pre-Columbian Peruvians.

PLATE VIII

Field Museum Cat. No. 30021.

Roentgenograms: A207, A211, A219, A221, A225, A227.

Source: Egypt.

Age: adult.

Sex: female.

Body extended with arms folded over chest. Head obscured by plaster mask. Apparently only a few teeth present in the lower jaw. Large mass casting shadow in right side of abdomen may be hypertrophied spleen, indicating malaria, or it may be a package of intestines rolled, pitch-encrusted, and inserted into the abdomen.

PLATE IX

Field Museum Cat. No. 105214.

Roentgenograms: A302, A304, A306, A308, A310.

Source: Egypt.

Age: adult.

Sex: male.

Head obscured by a mass of pitch; body extended, with arms crossed over chest. Details of thorax and abdomen obscured by embalming materials. Knock-kneed condition exists with femora distinctly bowed. This condition possibly indicates rickets in childhood. If this is rickets, it is the first example known from ancient Egypt.¹ Chronic arthritis of the hips doubtless produced the shambling gait of this old man. It is of interest to note the association of rheumatic effects and the edentulous condition of the jaws.

PLATE X

Field Museum Cat. No. 30004 (sister of 30003. See Plate XI).

Roentgenograms: A184, A186, A188.

¹ Wood-Jones and Smith were unable to prove the existence of rickets in ancient Egypt.

Source: Egypt.

Age: about twelve or fourteen years.

Sex: female.

Mummy of a young girl, showing lateral curvature of spine. Identical condition exists in her brother (Plate XI). There are no evidences of disease, and while improper posture may account for the curvatures, yet other factors, such as rough handling, must be considered. Elements are obscured by cowry shells over the orbits, beads and metal objects over the thorax, with gravel, clumps of pitch and sand distributed throughout the entire wrappings.

PLATE XI

Field Museum Cat. No. 30003 (see also Plate X).

Roentgenograms: A197, A199, A201.

Source: Egypt.

Age: ten or twelve years.

Sex: male.

Vertebral column exhibiting lateral curvature, pronounced to the right. No evidences of accompanying disease. Pads of rough, heavy, painted cloth in wrappings obscure some of the details. The prominent knees are those of a child ten to twelve years old, but other joints are too obscure for identification.

PLATE XII

Field Museum Cat. No. 111469.

Roentgenogram: A497.

Source: Egypt.

Age: infant.

Sex: undetermined.

Unwrapped infant mummy of Egypt. No evidences of disease.

PLATE XIII

Field Museum Cat. No. 111522.

Roentgenograms: A517, A518.

Source: Egypt.

Age: child.

Sex: undetermined.

Unwrapped child mummy of Egypt. No evidences of disease.

PLATE XIV

Field Museum Cat. No. 30025.

Roentgenograms: A0100, A0101.

Source: Egypt.

Age: seven years, six months.

Sex: male.

Mummy of boy named Padi Amon, from Egypt. Arms entirely removed, legs broken at mid-thigh, and lower parts of femora removed, feet badly cramped, presumably so that the body could be placed in a coffin that was much too small for the individual.

PLATE XV *a* and *b*

Field Museum Cat. No. 30017.

Roentgenograms: A0127, A0128, A0129, A0130.

Source: Egypt.

Age: twelve years.

Sex: male.

Unwrapped mummy of a boy, Egypt.

No evidences of disease; cause of death cannot be determined. Skeletal parts all healthy; teeth normal. Body extended; wrappings removed. Some of the body tissues are obscured by small clumps of sand. Faint evidences of position of viscera, but not definite enough for positive determination. Muscles of legs well shown.

PLATE XVI

Fig. 1: Field Museum Cat. No. 30003.

Fig. 2: Field Museum Cat. No. 30004.

Photograph: 59106.

See Plates X and XI for data.

Complete roentgenographic illustration of brother and sister, details of which are shown in Plates X and XI.

PLATE XVII

Field Museum Cat. No. 30009.

Roentgenograms: A260, A264, A266, A268, A270, A272, A274.

Source: Egypt.

Age: adult.

Sex: female.

Body fully extended, with arms crossed over chest, hands on shoulders.

Head and neck dislocated from trunk, seventh cervical vertebra free. Full set of teeth; normal. Mastoid slightly sclerosed. Adventitious bone in pelvic region. No evidences of disease or injury. Roentgenogram shows head and neck dislocated.

PLATE XVIII

Field Museum Cat. No. 111520.

Roentgenogram: A510.

Source: Egypt.

Age: adult.

Sex: undetermined.

Egyptian mummy head with mask.

PLATE XIX

Field Museum Cat. No. 105215.

Roentgenogram: A302.

Source: Egypt.

Age: adult.

Sex: male.

Egyptian mummy. Pitch and heavy wrappings obscuring head and neck, illustrating limitations of roentgenography of wrapped mummy packs.

PLATE XX

Field Museum Cat. No. 30007.

Roentgenograms: A252, A254, A256, A258.

Source: Egypt.

Age: about twenty-five years.

Sex: female. (In legend of Plate XX, *for man read woman.*)

Head with mask. Arms crossed over chest with hands on shoulders.

A powerful skeleton. No evidences of disease. Frontal sinuses unusually large. Mastoid filled with large air-cells, but they do not indicate disease.

DETAILED REPORT AND PATHOLOGIC INTERPRETATION
OF ROENTGENOGRAMS NOT ILLUSTRATED

Field Museum Cat. No. 30000.

Roentgenograms: A312, A314, A316, A318, A320, A322.

Source: Egypt.

Age: about thirty-five years.

Sex: female.

Mummy and case of a lady named Dje Mukesankh.

Huge masses of sand-encrusted pitch prevent adequate examination of all parts. Areas shown, apparently free from disease, except that the teeth of the maxilla have been lost by pyorrhea. This condition seems to be present also in the molar region of the lower jaw.

Field Museum Cat. No. 30010.

Roentgenograms: A276, A278, A280, A282, A284, A287.

Source: Egypt.

Age: adult.

Sex: male.

Man named Pu Nefer.

Powerful frame extended, with arms crossed over chest. Head with mask. Neck dislocated below seventh cervical vertebra. Details of head obscure. No evidence of diseases or injury in thorax or abdomen. Details obscured by embalming materials. Soft tissue visible on legs.

Field Museum Cat. No. 30011.

Roentgenograms: A288, A290, A294, A296, A298.

Source: Egypt.

Age: adult.

Sex: female.

Mummy of a woman named Men.

Head normal, so far as can be determined. Legs strong and healthy.

Torso and arms not included in package. Cavity normally occupied by these parts has been packed with leaves and straw (?). Head suspended by board reaching from neck to pelvic region.

Field Museum Cat. No. 30018.

Roentgenograms: A191, A193, A195.

Source: Egypt.

Age: about ten years.
Sex: male.
Boy of the Roman period, Egypt.
No evidences of disease apparent.

Field Museum Cat. No. 30023.
Roentgenograms: A242, A244, A246, A248, A250.
Source: Egypt.
Age: adult.
Sex: undetermined.

Body extended, with hands spread over pelvis. Femora articulating in acetabulum, but shifted. Skeleton much disarranged.

No evidences of pre-mortem injury or of disease, in the parts available for study. Most of the skeleton obscured by embalming materials.

SUMMARY

ARTHRITIDES

Manifestations of joint diseases are very common in ancient Egyptian mummies. The various aspects of arthritis, as revealed in the dry tissues of early Egyptians, have been thoroughly covered by the work of Smith and Wood-Jones,¹ and Ruffer.² Little is to be added to what we already know from an examination of the Egyptian mummies X-rayed in Field Museum.

A female mummy dating from predynastic times shows many evidences of disease. Arthritis held many of her joints rigid (Plates II, IV-VI), and the vertebral column was sharply flexed forward. She was a much-bowed, decrepit, senile, but not necessarily old individual. Spondylitis deformans is evident.

An example of traumatic arthritis is exhibited in Plate IX. The shambling gait of this old man was doubtless due to luxation and torsion of the left leg.

ARTERIOSCLEROSIS

Hardening of the arteries was very prevalent in ancient Egypt. Its details may be found in the volume of Ruffer's Collected Essays.

Definite evidences of this disease are shown (Plate III, Fig. 2) in the predynastic female. The arteries so afflicted are usually tortuous (Ruffer's accounts give all the histological details). Sclerosed arteries are evident over the scapula and ribs, but especially in the interosseous artery of the forearm. Here the blood vessel resembles a piece of heavy wire badly kinked.

ORAL DISEASES

The most obvious indication of oral disease in Egyptian mummies is the absorptive osteitis resulting from pyorrhea (Plate II). This disease is the common lot of man, both ancient and modern. It is the most ancient, most prevalent, and most widely distributed of all oral afflictions. It occurs among fossil mammals

¹Report on the Human Remains, The Archaeological Survey of Nubia, 2 vols., folio, 1907, pp. 1-375, plates I-XLIX, and numerous text-figures. Additional material is to be found in the bulletins of the Archaeological Survey of Nubia by the same authors.

²Studies in the Palaeopathology of Egypt, 1921, University of Chicago Press. This book contains several papers discussing various aspects of arthritides.

and among all ancient and modern races of man. Among the ancient inhabitants of Peru and Hawaii the incidence of this disease was very high.¹

The majority of the Egyptian mummies examined in Field Museum by the Roentgen ray exhibit the heads so obscured by masses of pitch or sand-coated tar, by masks, head-dresses, or ornaments, that proper interpretation of the condition of the teeth cannot be made. Only here and there are glimpses of the dental series to be had. We are not able to add anything of note to the discussions by Ruffer,² who has written extensively on this subject.

DISEASES OF THE SOFT TISSUES

The only way in which disease of the soft parts may be recognized is by the calcification of areas undergoing degeneration, or by the excessive hypertrophy of organs. The oblong shadow seen on the left side of the body (Plate VIII) of a female mummy may be an hypertrophied liver due to disease, or it may be a linen-wrapped package of intestines, dipped in tar and inserted into the abdomen. Microscopic examination is the only sure way of identification.

No calculi either of gall-bladder, urinary bladder or kidney have been identified in these roentgenograms, although special search has been made for them.

The body of a twelve-year-old boy (Plate XV *a* and *b*) shows faint evidences of hypertrophic, calcified viscera but the evidence is not clear.

None of the above suggestions indicates new occurrences, since all have been discussed by Smith, Wood-Jones, and Ruffer.

¹G. G. MacCurdy, Human Skeletal Remains from the Highlands of Peru, *Amer. Journ. Physical Anthropology*, VI, 1923, pp. 218-329, plates I-XLIX. H. G. Chappel, Jaws and Teeth of Ancient Hawaiians, *Memoirs Bernice P. Bishop Museum*, IX, 1927, pp. 251-268, plates XLII-XLV.

²See his Collected Essays, Studies in the Palaeopathology of Egypt.

DETAILED REPORT AND PATHOLOGIC INTERPRETATION OF ROENTGENOGRAMS OF PERUVIAN MUMMIES

PLATE XXI

Archaeological map of west coast of South America.

PLATE XXII

Field Museum Cat. No. 183681.

Roentgenograms: A356, A357.

Source: Ancon, Peru. G. A. Dorsey, collector.

Age: five or six years.

Sex: undetermined.

Body wrapped in striped cloth. Disintegration has taken place and parts of skeleton are missing. Teeth nearly all erupted, some dropped out and mingled with bones of thorax. Legs flexed over abdomen. Inclusions of maize, gourds, pottery, and implements.

No evidences of disease or injury.

PLATE XXIII

Fig. 1: Field Museum Cat. No. 191863.

Roentgenograms: A362, A363, A364.

Source: Ancon, Peru.

Age: three or four years (joints too obscure to be certain).

Sex: undetermined.

Mummy of child, well wrapped in cloth and tied with fiber rope. Bunch of orange feathers at head. Numerous small pieces of pottery in mummy pack. Head indicates hydrocephalus.

Skeletal parts obscured by the many extrinsic objects, but no obvious evidences of disease or injury are present (see Plate LVIII, Fig. 2).

Fig. 2: Field Museum Cat. No. 168806.

Roentgenogram: A112.

Source: Lower Chillón Valley, Peru. A. L. Kroeber, collector.

Age: adult.

Sex: male.

Pre-Columbian, Peruvian mummy head, unwrapped. Perforated silver disks on cheeks. Roentgenogram shows mastoid and adjoining mace injury resulting in a considerable loss of skull material.

PLATE XXIV

Fig. 1: Field Museum Cat. No. 168806.

Roentgenogram: A122 (see Plate XXIII, Fig. 2).

Record of impaction in prehistoric times.

Fig. 2: San Diego Museum Cat. No. 206.

Source: Huarochiri, Peru.

Age: adult.

Sex: male.

Pyorrhea and salivary calculus.

Fig. 3: San Diego Museum Cat. No. 8.

Source: Cinco Cerros, Peru. Ales Hrdlicka, collector.

Age: adult.

Sex: male.

A prehistoric male skull showing total loss of teeth from the palate, probably due to pyorrhea. On the right of the picture is a large antral fistula draining a sinus infection which doubtless developed from an apical, perforating abscess. Such openings are difficult to determine in a general Roentgen examination of an unopened mummy pack, and, though common, they fail to show. The absence of teeth can usually be detected, but this depends on an accidental clear field. Roentgenograms of the mastoids usually show many details. In this specimen the mastoid on the right was diseased.

Fig. 4: San Diego Museum Cat. No. 157.

Source: Chavina, Peru.

Age: adult.

Sex: female.

Pressure atrophy in palate, due to soft tumor in the maxillary antrum.

PLATE XXV

Fig. 1: Field Museum Cat. No. 168816.

Roentgenogram: A133.

Source: Cemetery A, Marquez, Lower Chillon Valley, Peru. A. L. Kroeber, collector.

Age: three individuals: adult, youth, and infant.

Sex: one male; two undetermined.

In this unusual Peruvian mummy pack, the roentgenogram revealed an entire adult skeleton and two additional skulls, one a youth, the other an infant.

The skull pictured here is of the adult, showing loss of a few teeth, and roots of others exposed by alveolar absorption due to pyorrhea (see also Plates XXVIII, Figs. 2-3; LIII).

Fig. 2: Field Museum Cat. No. 183874.

Roentgenogram: A51.

Source: Peru.

Age: adult.

Sex: undetermined.

Pyorrhea caused the loss of most of the teeth in this individual. The roots of the remaining teeth are largely exposed. The superior alveoli are all absorbed.

Fig. 3: Field Museum Cat. No. 191860.

Source: Ancon, Peru.

Roentgenograms: A104, A106, A108, A109.

Age: adult, about twenty-five years old.

Sex: female, as suggested by the slender bones and pelvis.

Pyorrhea resulted in the loss of many teeth and the exposure of the roots of others. A small apical abscess is evident in one of the upper cuspids.

Pneumatic mastoid of the large cell type. Outer skull wall thin. The mastoid is clear and shows no evidences of disease, such as sclerosis or absorption.

No other pathologic changes evident.

PLATE XXVI

Fig. 1: San Diego Museum Cat. No. 5.

Source: Cinco Cerros, Peru. Ales Hrdlicka, collector.

Age: adult.

Sex: male.

A much battered male, prehistoric skull obtained from the ruins of an ancient fortress at Cinco Cerros, Peru. The individual was probably a soldier.

The left side of the skull shows sling shot injuries on the occiput, a huge opening due to a blow from a star-shaped mace, and the arch has been broken by a blow from a club. None of these injuries shows clearly in a roentgenogram. Huge openings, at times, cast uncertain shadows on a roentgenogram taken of an unopened mummy pack.

Fig. 2: San Diego Museum Cat. No. 257.

Source: Cinco Cerros, Peru. Ales Hrdlicka, collector.

Age: adult.

Sex: female.

A prehistoric female skull from the ruins of an ancient fortress at Cinco Cerros, Peru, showing a large trepan opening involving the right frontal and parietal. The unhealed edges indicate that the operation was fatal. Such openings do not show at all, or but very poorly, in roentgenograms of unopened mummy packs. The majority of the prehistoric Peruvian mummies in Field Museum come from Ancon, a coastal site which, like other similar areas, has yielded few examples of trepanning. The procedure seems to have been more common in the highlands. I have elsewhere suggested the possibility of the surgical act of trepanning being regarded as a military measure.

PLATE XXVII

Fig. 1: San Diego Museum Cat. No. 6.

Source: Lomas, Peru.

Age: adult.

Sex: male.

A pre-Columbian Peruvian skull showing in the roentgenogram distinct evidences of a severe mace injury.

Fig. 2: San Diego Museum Cat. No. 285.

Source: Cinco Cerros, Peru.

Age: adult.

Sex: male.

Skull showing evidences of an anterior and posterior trepanned area.

PLATE XXVIII

Fig. 1: San Diego Museum Cat. No. 197.

Source: Collungo, Peru.

Age: adult.

Sex: male.

Mandible of a pre-Columbian male, showing two carious teeth on the right. The swelling on the left ascending ramus is due to a tumor.

Fig. 2: San Diego Museum Cat. No. 324.

Source: Pachacamac, Peru.

Age: adult.

Sex: female.

An unusually large fistulous opening is to be seen on the right of the picture, opening directly into the maxillary sinus. This skull exhibits another large fistula in one orbit due to an abscess in the frontal sinus, derived doubtless from this antral abscess.

Fig. 3: San Diego Museum Cat. No. 174.

Source: Cajamarquilla, Peru.

Age: adult.

Sex: male.

Excessive deposits of salivary calculus on the teeth. Dentists are familiar with such accumulations today. The relation of this deposit to pyorrhea is evident on examination of the plate.

PLATE XXIX

San Diego Museum Cat. No. 288.

Photograph and roentgenogram.

Source: Cinco Cerros, Peru. Ales Hrdlicka, collector.

Age: adult.

Sex: male.

A concrete example of the failure of a roentgenogram to show a serious osseous lesion. This skull had been trepanned immediately above the left orbit, possibly to relieve sinus headache, due to a slight infection in the frontal sinuses. The roentgenogram shows not a trace of this operation, and the sinuses are clear.

PLATE XXX

Field Museum Cat. No. 168816.

Roentgenograms: A140, A138 (see Plates XXV, Fig. 1; LIII).

The roentgenological appearance, from two angles, in an ancient, unopened Peruvian mummy pack. Mushroom head of the femur designated as arthritis deformans. Etiology is uncertain. Articular surfaces of limb bones are eroded, due either to post-mortem decay or disease (tuberculosis).

PLATE XXXI

Fig. 1: San Diego Museum Cat. No. 51.

Source: Huacho, Peru. Ales Hrdlicka, collector.

Age: adult.

Sex: female.

Lesion of arthritis deformans in pelvis of ancient Peruvian mummy.

Fig. 2: San Diego Museum Cat. No. 60.

Source: Chan-Chan, Peru. Ales Hrdlicka, collector.

Age: adult.

Sex: male.

Mushroom head of femur showing same condition. This plate more fully explains the conditions seen in Plate XXX. The etiology of this lesion is unknown.

PLATE XXXII

Fig. 1: San Diego Museum Cat. No. 51.

Source: Huacho, Peru.

Age: adult.

Sex: female.

Roentgenologic appearance of pelvis shown in Plate XXXI, Fig. 1.

Figs. 2-3: San Diego Museum Cat. No. 60.

Source: Chan-Chan, Peru.

Age: adult.

Sex: male.

Femur showing mushroom head (see Plate XXXI, Fig. 2). The disturbances in the architecture of the bones are evident.

PLATE XXXIII

San Diego Museum Cat. No. 158.

Source: Chavina, Peru.

Age: adult.

Sex: female.

Roentgenogram of a small, female skull of a pre-Columbian Indian, showing hair-like trabeculae of the epicranial tumor; an hyperostosis cranii.

PLATE XXXIV

Fig. 1: San Diego Museum Cat. No. 319.

Source: St. Lawrence Island. Ales Hrdlicka, collector.

Age: adult.

Sex: undetermined.

Syphilitic lesions of the cranium of an Eskimo. Such lesions have never been seen in prehistoric American skulls.

Fig. 2: San Diego Museum Cat. No. 154.

Source: Collungo, Peru. Ales Hrdlicka, collector.

Age: youth.

Sex: male.

Posterior aspect of a prehistoric Peruvian adolescent male, showing the healed lesions of osteoporosis, due to a nutritional disease of childhood.

PLATE XXXV

San Diego Museum Cat. Nos. 423, 429, 440.

Source: Peru.

Age: adult.

Sex: undetermined.

Photographs, enlarged, of the left external auditory meatus in three prehistoric Peruvian skulls, showing the nature of the dense aural exostoses, which in the middle and lower figures have nearly closed the meatus. Such conditions are fairly common in Peruvian skulls, but rarely are such small lesions detected in a general roentgenogram of an unwrapped mummy pack.

PLATE XXXVI

Fig. 1: San Diego Museum Cat. No. 6.

Source: Lomas, Peru.

Age: adult.

Sex: male.

A small, ivory-like osteoma on the posterior wall of the left auditory meatus of prehistoric Peruvian skull.

Figs. 2-3: San Diego Museum Cat. No. 333.

Source: Chicama, Peru.

Age: adult.

Sex: undetermined.

Photographs, enlarged, of the right and left auditory passages of skull, showing aural exostoses in both ears. It is probable that this individual was totally deaf.

PLATE XXXVII

San Diego Museum Cat. Nos. 122, 262, 978.

Source: Peru.

Age: adult.

Sex: undetermined.

Auditory passages of three prehistoric Peruvian skulls showing effects of a chronic discharge of infective material (pus) and indicating a long-standing otitis media, in each case.

PLATE XXXVIII

Fig. 1: San Diego Museum Cat. No. 122.

Source: Collungo, Peru.

Age: adult.

Sex: undetermined.

Results of an intracranial abscess of the middle ear of a prehistoric Peruvian.

Fig. 2: San Diego Museum Cat. No. 441.

Source: Chicama, Peru.

Age: adult.

Sex: undetermined.

Vertical section of a diseased mastoid.

Fig. 3: San Diego Museum Cat. No. 101.

Source: Chicama, Peru.

Age: adult.

Sex: undetermined.

Disease of the alveoli associated with nasal disturbances, in a prehistoric Peruvian skull, showing an hypertrophied and deflected nasal septum.

PLATE XXXIX

Fig. 1: San Diego Museum Cat. No. 86.

Source: Chavina, Peru.

Age: adult.

Sex: undetermined.

Roentgenogram, from above, of sclerotic temporal bones of an ancient Peruvian.

Figs. 2-3: San Diego Museum Cat. No. 347.

Source: Chilca, Peru.

Age: adult.

Sex: undetermined.

Roentgenograms of both diseased mastoids of a prehistoric Peruvian.

PLATE XL

Field Museum Cat. No. 183932.

Roentgenograms: A130, A131.

Source: grave thirty-two miles northwest of Lima.

Age: possibly new-born, two or three months post partum.

Sex: undetermined.

Prehistoric (?) Peruvian infant mummy.

Normal Peruvian infant well preserved. Skull uncrushed, and parts all associated.

There are no evidences of disease.

PLATE XLI

Field Museum Cat. No. 183875.

Roentgenogram: A112.

Source: Ancon, Peru.

Age: four months (?).

Sex: undetermined.

Incomplete skeleton of infant from ancient Peru. String of beads at left, undoubtedly fish vertebrae. A glass (?) bead to right. Mummy package is round; no anatomical association of parts.

No evidence of disease can be detected.

PLATE XLII

Field Museum Cat. No. 183939.

Roentgenograms: A360, A361.

Source: Ancon, Peru.

Age: infant, full term, possibly a week old.

Sex: undetermined.

Mummy of infant wrapped with cloth and bound with fiber rope. Several small ears of maize. Small piece of metal in mouth.

No evidence of disease.

PLATE XLIII

Field Museum Cat. No. 183932.

Roentgenograms: A339, A340.

Source: Ancon, Peru. G. A. Dorsey, collector.

Age: two or three years.

Sex: undetermined.

Mummy of a child; body extended, wrapped with cloth and tied with nets and cord. Skull slightly crushed. Skeleton fairly well arranged with slight disturbances in orientation. Irregular fragments of metal in each hand and in mouth. Small metal rods at each shoulder.

No evidences of disease or injury.

PLATE XLIV

Field Museum Cat. No. 183911.

Roentgenograms: A365, A366, A367.

Source: Ancon, Peru.

Age: three or four years.

Sex: undetermined.

Mummy of child, wrapped in several layers of cloth. Cloth tattered and torn. Parts of skeleton lost. Deciduous teeth all present. Small ears of maize and metal objects in mummy pack.

No evidence of disease.

PLATE XLV

Field Museum Cat. No. 191853.

Roentgenograms: A384, A385.

Age: seven or eight years.

Sex: undetermined.

Body wrapped in coarse cloth. Three small ears of maize and other unidentified objects included in package. Deciduous teeth erupted and some have fallen out; four of them in thorax. Skeletal parts only slightly disarranged post mortem. Extended position, legs crossed. In unusually good preservation.

Careful inspection reveals no obvious osseous changes due to disease or injury.

PLATE XLVI

Field Museum Cat. No. 183937.

Roentgenograms: A357, A358.

Source: Ancon, Peru. G. A. Dorsey, collector.

Age: one to two years.

Sex: undetermined.

Mummy of child, wrapped in cloth and bound with bark cord. Gourd bowl over face. Body badly crushed and skeleton scattered and disintegrated.

No evidences of disease or injury.

PLATE XLVII

Field Museum Cat. No. 183934.

Roentgenogram: A335.

Age: new-born.

Sex: undetermined.

Very small mummy of full-term baby wrapped and tied with coarsely woven cloth. Bones disintegrated and scattered. Head crushed.

No evidences of disease or injury.

PLATE XLVIII

Field Museum Cat. No. 183859.

Roentgenograms: A117, A119.

Source: Ancon, Peru.

Age: new-born.

Sex: cannot be determined.

This mummy of an infant found wrapped in cloth and covered with rush mat, tied with closely woven bands or ribbons. Another mat of rushes placed over first. Skull crushed and skeletal elements scattered.

No evidence of disease.

PLATE XLIX

Field Museum Cat. No. 183892.

Roentgenogram: A128.

Source: Ancon, Peru.

Age: possibly three months.

Sex: undetermined.

Small child less than one year of age, skull crushed, bones disintegrated.

No evidence of disease.

PLATE L

Field Museum Cat. No. 191856.

Roentgenogram: A392.

Source: Ancon, Peru.

Age: infant about one year.

Sex: undetermined.

Body wrapped in thin cloth, fastened by sewing. Condition very good. Skull crushed. Teeth partly erupted.

No evidences of disease or injury.

PLATE LI

Field Museum Cat. No. 183921.

Roentgenograms: A343, A345.

Source: Ancon, Peru. G. A. Dorsey, collector.

Age: about three years.

Sex: undetermined.

Skeleton complete. No evidences of disease or injury.

PLATE LII

Field Museum Cat. No. 183679.

Roentgenograms: A360, A361.

Source: Ancon, Peru. G. A. Dorsey, collector.

Age: about six years.

Sex: undetermined.

Skeleton disarranged and partly disintegrated.

No evidences of disease or injury.

PLATE LIII

Field Museum Cat. No. 168816.

Roentgenogram: A136 (see Plates XXV, Fig. 1; XXX).

Age: adult, youth, and infant.

Sex: undetermined.

Entire adult skeleton with skulls of youth and infant in one package.

PLATE LIV

Field Museum Cat. No. 168806.

Source: Lower Chillon Valley, Peru. A. L. Kroeber, collector.

Age: adult.

Sex: male.

Fig. 1: Front view of pre-Columbian Peruvian mummy head, wrappings removed. Note regularity in lower teeth and the twisted upper cuspid with diastema.

Fig. 2: Left lateral aspect of same skull, showing mass of black hair, condition of skin and pad of wool over nose.

PLATE LV

Field Museum Cat. No. 168806.

Roentgenograms: A123, A122.

Roentgenologic illustration of head in Plate LIV.

Fig. 1: Frontal sinuses unequal but free from infection. Roots of teeth firmly embedded.

Fig. 2: Left lateral aspect of same skull. Huge mace injury in occiput. Mastoid air-cells large. Third molars impacted.

PLATE LVI

Sketch of a Peruvian grave, with body folded. In a small chamber at the rear of a large natural cave formed by a group of irregular boulders. In the highlands of Peru at Machu Picchu.

After Eaton, who figures two roentgenograms of the diseased skull.

PLATE LVII

Figs. 1-2: Field Museum Cat. No. 191861.

Photograph: 58492.

Typical Peruvian mummy packs.

PLATE LVIII

Figs. 1-2: Field Museum Cat. Nos. 3522, 103711.

Photographs: 58493, 58489.

Peruvian mummy packs.

PLATE LIX

Fig. 1: Field Museum Cat. No. 40235.

Photograph: 68687.

Deformed adult skull of Inca, showing trepannings.

Fig. 2: Field Museum Cat. No. 40221.

Photograph: 68682.

Source: Huaracundo, Peru. G. A. Dorsey, collector.

Deformed adult skull of Inca, showing trepanning.

PLATE LX

Fig. 1: Field Museum Cat. No. 40307.

Photograph: 68685.

Adult skull showing large trepanning.

Fig. 2: Field Museum Cat. No. 40307.

Photograph: 68678.

Detail of Fig. 1, showing evidences of infection and slight healing.

PLATE LXI

Fig. 1: Field Museum Cat. No. 40208.

Photograph: 68679.

Source: Ancon, Peru. G. A. Dorsey, collector.

Skull of child; unusual lesion in area of osteoporosis.

Fig. 2: Detail of Fig. 1.

PLATE LXII

Fig. 1: Field Museum Cat. No. 40222.

Source: Huaracundo, Peru. G. A. Dorsey, collector.

Adult skull showing trepanning in state of advanced healing.

Fig. 2: Field Museum Cat. No. 40203.

Source: Ancon, Peru. G. A. Dorsey, collector.

Healed, depressed area due to injury or trepanning.

DETAILED REPORT AND PATHOLOGIC INTERPRETATION OF ROENTGENOGRAMS NOT ILLUSTRATED

Field Museum Cat. No. 183680.

Roentgenograms: A364, A365.

Source: Ancon, Peru. G. A. Dorsey, collector.

Age: seven or eight years.

Sex: undetermined.

Body wrapped in coarse cloth, ends tied and bound with rope. Much disintegration, and parts of skeleton obscured by clumps of sand in the wrappings. Teeth (deciduous) dropped out and scattered.

No evidences of disease or injury.

Field Museum Cat. No. 183677.

Roentgenograms: A358, A359.

Source: Ancon, Peru. G. A. Dorsey, collector.

Age: infant.

Sex: undetermined.

Skeleton crushed, flattened, and parts of bony structure obscured by vast numbers of small sand clots. Body wrapped in cloth, bound with plaited rope. No evidences of disease or injury.

Field Museum Cat. No. 191801.

Roentgenograms: A376, A377, A378, A379, A380, A381.

Source: prehistoric, Ancon, Peru. G. A. Dorsey, collector.

Age: fifty to sixty years.

Sex: male.

Large adult mummy, wrapped in cloth and bound with rope. In same grave were found six small mummies, all in extended position.

Skull shows sutures nearly closed; mastoid with large air cells, thin cortex. Edentulous palate; the few remaining anterior mandibular teeth exposed by pyorrhea. Cervical series normal but with recent break. Vertebral column with flexure to left. Anatomical arrangement of extremities disturbed. No further evidences of pathology.

Field Museum Cat. No. 191838.

Roentgenogram: A388.

Source: Ancon, Peru. G. A. Dorsey, collector.

Age: infant, a few weeks old.

Sex: undetermined.

Body wrapped in cloth and bound with loosely twisted rope. Bones scattered and partly disintegrated. Small bones of hands and feet lacking.

No evidences of disease or injury.

Field Museum Cat. No. 191857.

Roentgenograms: A393, A394.

Source: Ancon, Peru. G. A. Dorsey, collector.

Age: new-born, or a few weeks old.

Sex: undetermined.

Infant wrapped in coarse cloth, fastened by sewing and bound with rope. Body badly crushed; thorax and abdomen partly disintegrated. Ears of maize included in wrappings.

No evidences of disease or injury.

Field Museum Cat. No. 191854.

Roentgenogram: A389.

Source: Ancon, Peru.

Age: premature.

Sex: undetermined.

Small infant mummy wrapped in coarse cloth, fastened by tying with rope. Ends bound with bands of cloth. Body and skeleton badly disintegrated.

No evidences of disease or injury.

Field Museum Cat. No. 191837.

Roentgenograms: A386, A387.

Source: Ancon, Peru. G. A. Dorsey, collector.

Age: first year.

Sex: undetermined.

Mummy of child wrapped in coarse cloth and bound with fiber rope. Skeleton disintegrated, crushed, and distorted. Cranium missing. Adult left ungual pes phalange included in package.

No evidences of disease or injury.

Field Museum Cat. No. 183860.

Roentgenograms: A88, A89, A92, A93, A95.

Source: Ancon, Peru.

Age: about thirty-seven.

Sex: male.

Large mummy in flat position, wrapped in cloth bound with rope. Unusual position for Peruvian mummy.

Lipping of the edges of the mid-dorsals indicates incipient spondylitis deformans. Shoulders show no pathology. Both mastoids diseased and hypertrophied, indicating a middle ear infection. Absorptive alveolar osteitis in mandible and maxilla, resulting in the loss of nearly all teeth in the maxilla and most of the lower molars. Arms, legs, pelvis, and lumbar region show no evidences of either disease or injury.

Field Museum Cat. No. 183799.

Roentgenograms: A113, A115.

Source: Ancon, Peru.

Age: about five years.

Sex: female.

A113 shows the head; necklace of Olivella shells.

A115 shows the body. Joints not clear enough to make definite determination of age.

There are no evidences of disease or injury.

Field Museum Cat. No. 191855.

Roentgenogram: A390.

Source: Ancon, Peru. G. A. Dorsey, collector.

Age: premature.

Sex: undetermined.

Very small infant wrapped in coarse cloth. Body folded and disintegrated.

No evidences of disease or injury.

Field Museum Cat. No. 183895.

Roentgenograms: A67, A69, A72, A73.

Source: Ancon, Peru.

Age: about forty years.

Sex: male.

Skeleton normal; no evidence of disease or injury.

Field Museum Cat. No. 5805.

Roentgenograms: A63, A65.

Source: Chancay, Peru. G. A. Dorsey, collector.

Age: youth of twelve or thirteen years, based on state of growth of knee.

Sex: undetermined.

Head and upper half of trunk show no disease. Skull artificially deformed. Leg bones show disintegrated condition of ends often seen in tuberculous arthritis, but in this case doubtless due to decay.

Field Museum Cat. No. 183911.

Roentgenograms: A433, A434, A435, A436, A437.

Age: adult and new-born babe.

Sex: female.

Sand and gravel in wrappings, also beads, pottery, shells, and irregular pieces of metal. Package contains adult female and new-born babe. Possibly mother and infant died in child-bed. Bones indistinct on account of heavy wrappings. Spine fractured post-mortem; ribs distorted.

No obvious evidences of disease or injury.

Field Museum Cat. No. 191839.

Roentgenograms: A489, A490, A491, A492.

Head, limb bones, vertebrae, and ribs badly scattered and indistinct. Sand and gravel in wrappings. Ends of long bones disintegrated.

Impossible to identify either disease or injury.

Field Museum Cat. No. 191778.

Roentgenograms: A367, A368, A369, A370, A371, A372, A373, A374, A375.

Source: Ancon, Peru. G. A. Dorsey, collector.

Age: twelve or thirteen years.

Sex: uncertain, possibly female.

Heavy wrappings. Bones of entire skeleton disarticulated and partly disintegrated. Skull brachycephalic; teeth scattered, one incisor and one deciduous molar showing evidences of caries. Part of mandible swollen. Epiphyses loose and scattered; legs folded; arms in unusual position, elbows on level with top of head. Left femur slightly curved anteriorly, in a manner that suggests a nutritional disturbance. Otherwise bones all normal.

A finger ring on each hand, an unusual finding, possibly indicating Spanish influence. Seashells (clam) and ears of maize enclosed in wrappings. According to Dall, the clam may have formed an important item of the diet of ancient Peruvians.

Field Museum Cat. No. 191862.

Roentgenograms: A60, A61.

Source: Ancon, Peru.

Age: youth.

Sex: undetermined.

Skull and limb bones exhibit no indication of disease. Erosion on ends of limb bones due doubtless to decay in a moist burial. The few teeth visible in good condition. Skull normal, though artificially deformed. Limb bones, vertebrae, and ribs showing evidences of disintegration. Skeletal parts dislocated as if the mummy pack had been roughly handled after disintegration of the flesh. Two pieces of pottery included in mummy pack.

Field Museum Cat. No. 191851.

Roentgenograms: A419, A420, A421, A422, A423, A424, A425, A426.

Age: adult.

Sex: male.

Body in sitting posture, heavily wrapped with coarse, striped cloth and bound with fiber rope. Metal (?) band about 0.5 x 5 inches, perforated at each end, included in package. Also, inclusions of several small opaque packages about 1 x 4 inches. Skeleton scattered and disintegrated, bony architecture indistinct due to overlapping of parts and heavy wrapping.

No obvious pathological evidences.

Field Museum Cat. No. 191858.

Roentgenograms: A382, A383.

Age: three or four years.

Sex: undetermined.

Heavy wrapping. Skeleton badly scattered, disarticulated and disintegrated. Cause of death not apparent. Head normal. Bones too indistinct to show architecture.

No apparent evidences of disease or injury.

Field Museum Cat. No. 183678.

Roentgenograms: A362, A363.

Source: Ancon, Peru.

Age: about eighteen months.

Sex: undetermined.

Skeleton unusually well preserved, with little distortion. Skull crushed.

No evidences of disease or injury.

Field Museum Cat. No. 183912.

Roentgenograms: A350, A351, A352.

Source: Ancon, Peru. G. A. Dorsey, collector.

Age: two and one-half or three years.

Sex: undetermined.

Skeleton of body shows the customary confused state commonly seen in infant mummies of Peru. Skeleton apparently normal.

Field Museum Cat. No. 183913.

Roentgenograms: A374, A375.

Source: Ancon, Peru. G. A. Dorsey, collector.

Age: about fourteen years.

Sex: undetermined.

Mummy of child wrapped in cloth, dog-hide, and straw matting, and tied with fiber rope. Skull healthy, but asymmetrical. Teeth normal and in place. Quantities of sand in wrappings obscure skeletal details.

No evidences of disease or injury.

Field Museum Cat. No. 183919.

Roentgenograms: A331, A332.

Source: Ancon, Peru. G. A. Dorsey, collector.

Age: possibly six months.

Sex: undetermined.

Baby mummy, unwrapped, fragmentary. Skein of thread about neck; ankles bound.

No evidences of disease or injury.

Field Museum Cat. No. 183923.

Roentgenograms: A326, A327.

Source: Ancon, Peru. G. A. Dorsey, collector.

Age: uncertain, possibly three years.

Sex: undetermined.

Bones badly scattered and disintegrated. Body wrapped in coarse cloth and bound with fiber rope.

No pathologic evidences.

Field Museum Cat. No. 183927.

Roentgenograms: A376, A378.

Age: about seven years.

Sex: undetermined.

Mummy wrapped in cloth and bound with bark rope. Pottery and ears of maize included in package. Skeleton disintegrated.

No evidences of disease or injury.

Field Museum Cat. No. 183928.

Roentgenograms: A368, A370, A371, A372.

Source: Ancon, Peru. G. A. Dorsey, collector.

Age: about ten years.

Sex: undetermined.

Mummy of child wrapped in cloth of coarse material. Bones disintegrated especially at the ends. Skull normal. Teeth all intact. Right lower third molar unerupted.

No evidences of disease or injury.

Field Museum Cat. No. 183933.

Roentgenograms: A347, A348.

Source: Ancon, Peru. G. A. Dorsey, collector.

Age: about two years.

Sex: undetermined.

Skeletal elements disarranged. Not one epiphysis in place. Two small pots contained in package.

No evidence of disease.

Field Museum Cat. No. 183935.

Roentgenograms: A379, A380.

Source: Ancon, Peru. G. A. Dorsey, collector.

Age: uncertain, possibly eight years.

Sex: undetermined.

Mummy wrapped in cloth tied with fiber and bark rope. Coca leaves over face. Skeleton disintegrated, bones scattered.

No apparent evidences of pathology.

Field Museum Cat. No. 183938.

Roentgenograms: A341, A342.

Source: Ancon, Peru. G. A. Dorsey, collector.

Age: new-born.

Sex: undetermined.

Mummy wrapped in cloth and bound with fiber-bark rope.

No evidences of disease or injury.

Field Museum Cat. No. 168446.

Roentgenogram: A033.

Source: Excavation E, Cemetery A, Marquez (in gully in desert at north end of valley, near beach), Lower Chillón Valley, Peru. A. L. Kroeber, collector.

Age: child, not possible to determine accurately on account of scattered, broken and macerated condition of the bones.

Sex: undetermined.

No pathologic changes evident.

Field Museum Cat. No. 168505.

Roentgenogram: A037.

Source: Upper Chillón Valley, Marquez, Peru. A. L. Kroeber, collector.

Age: about two years.

Sex: undetermined.

Entire body macerated. No pathologic changes evident.

Field Museum Cat. No. 168530.

Roentgenogram: A040.

Source: Excavation F, Upper Chillón Valley, Marquez, Peru. A. L. Kroeber, collector.

Age: about two years, joints not clear enough to determine exactly.

Sex: undetermined.

No pathologic changes evident.

Field Museum Cat. No. 168541.

Roentgenograms: A043, A044.

Source: Excavation F, Upper Chillón Valley, Marquez, Peru (in gully in desert at north end of valley, near beach). A. L. Kroeber, collector.

Age: child.

Sex: undetermined.

No pathologic changes.

Field Museum Cat. No. 168555.

Roentgenogram: A036.

Source: Excavation F, Lower Chillón Valley, Marquez, Peru. A. L. Kroeber, collector.

Age: new-born, apparently full term babe.

Sex: undetermined.

No pathologic changes evident.

Field Museum Cat. No. 168588.

Roentgenograms: A041, A042.

Source: Excavation F, Lower Cemetery A, Marquez (in gully in desert at north end of valley, near beach), Lower Chillón Valley, Peru. A. L. Kroeber, collector.

Age: child.

Sex: undetermined.

No pathologic changes evident.

Field Museum Cat. No. 168594.

Roentgenograms: A034, A035.

Source: Lower Chillón Valley, Marquez, Peru. A. L. Kroeber, collector.

Age: between three and four years.

Sex: undetermined.

No pathologic changes evident.

Field Museum Cat. No. 168598.

Roentgenogram: A039.

Source: Excavation F, Marquez, Lower Chillón Valley, Peru. A. L. Kroeber, collector.

Age: three years, indicated by epiphyses of long bones.

Sex: undetermined.

Complete skeleton in good preservation.

No pathologic changes evident.

Field Museum Cat. No. 171303.

Roentgenograms: A77, A79, A80, A82.

Source: Location A, Cahuachi, Valley of Nazca, Peru. A. L. Kroeber, collector.

Age: adult.

Sex: possibly male.

Body well preserved, head missing.

No pathologic changes evident.

SUMMARY

PRE-COLUMBIAN PEDIATRICS

There is a great prevalence of infant mummies in the pre-Columbian Peruvian collections at Field Museum, most of which are either full-term or less than two years of age. The cause of death is in no case definitely indicated by the roentgenograms of these numerous infant bodies. The high rate of infant mortality, apparent from the large number of small mummies, was doubtless due to negligence, or improper diet and unfavorable environment.

The great percentage of the diseases of childhood would make no impress on the skeleton, or on the soft tissues either, but we are surprised to find no traces whatever of rickets. Elliot Smith and Wood-Jones found no traces of rachitic conditions among the ancient Egyptians and early Nubians.

An obscure disease, probably of nutritional origin, the effects of which are commonly called osteoporosis, was prevalent in pre-Columbian Peru, as we know from the skulls of many children and its healed lesions in the adult, for the condition is restricted to children. Osteoporosis (Plate XXXIV, Fig. 2) is

evident always as bilaterally symmetrical lesions, in the roof of the orbit, in the parietals and occipitals, externally and internally. Such lesions, however, are not recorded by the Roentgen rays, and we cannot say from our examination of the roentgenograms whether or not lesions of osteoporosis are prevalent among Peruvian infants. Not only are the lesions not evident in the wrapped mummies where the wrappings, other parts of the body, and opaque inclusions cast confusing shadows, but a roentgenologic examination of an unwrapped, dry skull, perforated with the osteoporotic patches, does not show them. I have previously¹ reviewed the factors involved in osteoporosis or *cribra cranii*, and am presenting here a photograph (Plate XXXIV, Fig. 2) of the posterior aspect of a prehistoric adolescent male, from Collungo, Peru, showing the paired, healed, external lesions of osteoporosis.

Hydrocephalus is suggested by certain of the heads of the pre-Columbian Peruvian infant mummies, but the head is so often crushed flat, with the cranial bones scattered and distorted, that one can not say definitely that any one of them is hydrocephalic. The condition is thought to be that shown in Plate XXIII, Fig. 1, but this interpretation is to be regarded as merely suggestive, rather than a definite diagnosis.

INFANT MUMMIFICATION IN PRE-COLUMBIAN PERU

There are no evidences to show that all of the bodies of pre-Columbian infants in Peru received any special attention, and no attempt at embalming was noted. Some of the infants received careful attention and were sun-dried, wrapped, and interred with all evidences of respect for the dead. The majority of these children received scant attention, and were hastily and carelessly wrapped in coarse cloth and clumsily bound with rough cord. Doubtless in rocky places the small bodies, thus prepared, were thrust into deep crevices, caverns, or rock shelters, and forgotten.

Roentgenologic examination of such infant mummy packs shows, usually, that the skeleton is badly confused and disarranged, indicating haste in burial. As in other and older mummy packs, the inclusion of clumps of sand, small gravel, pieces of pottery, food, ornaments, etc., interferes with the passage of the Roentgen rays and obscures some of the regions. Often the wrappings themselves obscure the skeletal parts. Reference may be made here to the previous discussion of mummification in pre-Columbian Peru.

ARTHRITIDES

Arthritic lesions of any kind are rare among the pre-Columbian Peruvians. Attention has been called to certain arthritic lesions in the mandibular articulation² in an ancient Andean, and several observations have been made on the mushroom head of the femur, but lesions of *spondylitis deformans*, so prevalent in ancient Egypt, are seldom seen among pre-Columbian Peruvians. Hrdlicka³ (pp. 62-69) appends some statistical data on pathologic conditions of the skulls (278) and bones (humeri, 650; radii, 287; pelvic bones, 724; sacra, 199; vertebrae, 822, etc.) examined in 1913 in the Chicama Valley, which reveal the presence of numerous arthritic lesions.

¹Roy L. Moodie, *Paleopathology, Symmetric Osteoporosis of the Skull*, 1923, pp. 398-400.

²Roy L. Moodie, *Studies in Paleodontology*, IX. Definite Association of Rheumatic Lesions with Diseases of the Teeth in an Ancient Peruvian, *Pacific Dental Gazette*, XXXVI, 1928, pp. 757-759, 2 figs.

³A. Hrdlicka, *Anthropological Work in Peru in 1913, with Notes on the Pathology of the Ancient Peruvians*, *Smithsonian Misc. Collections*, LXI, No. 18, 1914, p. 59, plates I-XXVI.

Among the roentgenograms of unopened Peruvian mummy packs arthritis of the hip joint is revealed (Plates XXX-XXXII) in rare cases. This condition has thus far been that of the mushroom head of the femur and the destruction of the acetabulum into a broad, shallow pan. The condition is rare elsewhere in ancient times, but from the abundant evidences of this arthritis the disease was fairly common in Peru.

ARTERIOSCLEROSIS

Lesions of arteriosclerosis, so common among the ancient Egyptians,¹ are quite rare among the pre-Columbian Peruvians so far studied. Williams² has recorded the only evidence of arterial change seen in Peruvian mummies, basing his observations on material furnished by Field Museum. He says, "The artery wall at this point showed granules and masses that blackened with nitrate of silver, while the adherent mass within the artery became intensely black. Without doubt, the conditions were arteriosclerosis, which showed calcification, and a calcified thrombus."

No gross lesions of arteriosclerosis are known, and none is revealed in the scores of roentgenograms examined.

ORAL DISEASES

CARIES

Cavity formation was not particularly prevalent among the pre-Columbian people of Peru. An inspection of carious openings in the crowns and sides of the teeth shows that these lesions do not differ particularly from the caries of today (Plate XXVIII, Fig. 1). The entire subject, as it relates to ancient Peru, has been discussed³ in a manner sufficiently complete to show its low prevalence in ancient times.

In the study of the roentgenograms of unopened mummy packs I have been able (Plate XXV, Fig. 3) to identify few examples of caries because of numerous difficulties, especially the intervention of many different objects producing obscurity of the teeth.

CALCULUS

Tartar formation was prevalent in ancient Peru and doubtless to this factor may be ascribed the exceedingly common pyorrhea which resulted in the loss of so many teeth. Plates XXIV, Fig. 2, and XXVIII, Fig. 3, show maxillary teeth with huge accumulations of calculus.

Teeth showing effects of pyorrhea (periodontoclasia) are common among the roentgenograms of unwrapped mummies, and by close inspection tartar can be recognized as slight shadows around the roots of some of the teeth afflicted by pyorrhea.

FISTULAE

Fistulae always indicate abscess formations of the various types. A commonly seen fistula (Plate XXVIII, Fig. 2) is one that represents an apical dento-

¹ Marc Armand Ruffer, On Arterial Lesions Found in Egyptian Mummies, *Journ. Pathology and Bacteriology*, XV, 1911.

² Herbert U. Williams, Gross and Microscopic Anatomy of Two Peruvian Mummies, *Archives Path. and Lab. Med.*, IV, 1927, p. 4, fig. 1.

³ Roy L. Moodie, Studies in Paleodontology, VIII. Dental Caries in Pre-Columbian Peru, *Pacific Dental Gazette*, XXXVI, 1928, pp. 669-674, 3 figs.

alveolar type which has broken through the thin floor of the maxillary sinus¹ from which infection spreads by way of the paranasal sinuses into the orbit and into the ear.

PYORRHEA ALVEOLARIS

An absorptive, alveolar osteitis is responsible for great changes in the teeth of ancient Peruvians. Loss of teeth was very common, and numerous edentulous palates occur not only among the many dry skulls preserved in museums, but also among the unopened mummy packs, as revealed by this study. A high percentage of the ancient population lost their teeth at an early age, before forty at least. Part of this loss is to be attributed to alveolar abscesses, but the greater part was due to that complex series of changes commonly called pyorrhea alveolaris. This is not the place to discuss the etiology of this common disease, and we will only note here its relation to the presence of salivary calculus which is often found in excess on ancient Peruvian teeth.² Other than this we can only record its prevalence.

There may be some relation between dental disease and the prevailing habit of chewing coca leaves mixed with lime, which has been common in Peru for centuries. Cocaine, as well as producing a general bodily disturbance, would deaden pain, relieve fatigue, and slow down circulation, but I am unable to point out any definite relation between coca chewing and oral infection.

In the general roentgenograms no detailed observations on a series of dentitions are possible. Pyorrhea is suggested in Plates XXIV, Fig. 2; XXV, Figs. 1-3; XXVIII, Figs. 2, 3.

IMPACTION

Details of dental pathology in roentgenograms have often been obscured because of the impossibility of securing adequate views of a selected dental area in a head attached to the body, or the face is obscured by wrappings which could not be removed; by clumps of sand and small gravel within the wrappings; by artifacts buried with the dead; by ears of maize or by parts of the skeleton in those bodies where disintegration of all supporting tissues had resulted in a skeletal disarticulation. Among the Egyptian mummies this difficulty is intensified by masses of pitch or tar, by masks, by head-gear and by the mineral paints used on the coffins.

Plates LIV, Figs. 1, 2, and LV, therefore, offer an exceptional opportunity not only to study the features of an ancient Peruvian, but to show in detail the dental conditions, especially to call attention to the rare example of impaction of the mandibular third molars. Two other examples of such an impaction in ancient Peruvians have been seen, but none offers such definite evidence as the present isolated head. It was found, quite accidentally, in loose earth which had already been dug over, by A. L. Kroeber, who was in Peru on an expedition undertaken on behalf of Field Museum.

The impacted molars show nothing new, but are figured here as a record of impaction in prehistoric times. Such cases are rare, indicating that impacted molars occur more frequently at the present time than in the prehistoric ages.

¹Roy L. Moodie, *Studies in Paleodontology*, XI. Antral Fistulae in the Palates of Pre-Columbian Peruvians, *Pacific Dental Gazette*, XXXVI, 1928, pp. 762-766, 4 figs.

²Roy L. Moodie, *Studies in Paleodontology*, VII. Excessive Deposits of Salivary Calculus on the Teeth of Pre-Columbian Peruvians, *Pacific Dental Gazette*, XXXIX, 1931, No. 1, pp. 24-29, 4 figs.

A point of interest is in the huge mace injury to the left occiput here clearly shown (Plate LV). Frequently such injuries are not evident in roentgenograms. The mastoid air-cells are large, but apparently not diseased.

INJURIES

No fractures of limb bones are revealed by the roentgenograms of the pre-Columbian mummies examined. However, a number of fractures of the limbs are represented in the San Diego Museum. It has been stated that the prehistoric Peruvians were capable of reducing luxations and setting fractures, but I know of no justification for this.

Injuries to the head have been described.¹ Sling shot wounds were the commonest injuries in ancient Peru but the Roentgen rays rarely reveal such lesions in wrapped specimens. A mace injury is shown in Plate XXIII, Fig. 2, and further details are shown in Plates XXVI, Fig. 1; XXVII, Fig. 1.

TUMORS

Neoplasms of many kinds are common among the pre-Columbian Peruvians² (Plate XXXIII). However, none has been recognized in this series of roentgenograms of unopened mummy packs. An interesting tumor, often seen, has been called hyperostosis cranii, due to the presence of an endocranial tumor of the dural membrane.³ Surface osteomae of ivory-like consistency are commonly seen on skulls and mandibles. These are benign and never attain uncomfortable dimensions.

TREPANNING

Nothing is added to our already extensive knowledge of prehistoric trepanning by an examination of the roentgenograms of pre-Columbian mummy packs. As related in another section of this report, trepanned openings are not always visible on roentgenograms (Plate XXIX, Fig. 2). Under proper arrangements, in unwrapped specimens trepanned openings do show (Plate XXVI, Fig. 2; XXVII, Fig. 2), but these studies add nothing to our present knowledge. Such evidences are rare among the Peruvian mummies in Field Museum because the majority of their mummies are derived from the coastal area where trepanning was seldom practised.

REPORT ON TREPANNED ANCIENT PERUVIAN SKULLS IN FIELD MUSEUM OF NATURAL HISTORY

BY

FRANK E. WOOD

PLATE LIX

Fig. 1: Field Museum Cat. No. 40235.

Photograph: 68687.

Source: Cuzco, Peru.

Age: adult.

Sex: undetermined.

¹ Roy L. Moodie, Studies in Paleopathology, XXI. Injuries to the Head among Pre-Columbian Peruvians, *Annals of Medical History*, IX, 1927, pp. 298-328, figs. 1-22.

² Roy L. Moodie, Studies in Paleopathology, XXIII. Surgery in Pre-Columbian Peru, *Annals of Medical History*, N. S., I, No. 6, 1929, pp. 698-728, 20 figs.

³ Roy L. Moodie, Studies in Paleopathology, XVIII. Tumors of the Head among Pre-Columbian Peruvians, *Annals of Medical History*, VIII, No. 4, 1926, pp. 394-412, 15 figs.

Skull shows Aymara deformation, with a depression just back of the bregma and a shallower one across the forehead. An area 40 x 20 mm in the superior right corner of the frontal bone appears to have suffered from injury or infection of the scalp.

There have been two trepanations close together in the left parietal. The two occupy most of an area of 45 x 30 mm in the superior anterior corner, the longer axis extending from within 10 mm of the sagittal suture and making an angle of 30 degrees with the coronal one. The two openings are separated by a narrow bar 8 mm wide. The posterior opening is a rectangular ellipse with diameters 23 mm and 16 mm long, the outline being comparatively regular. The anterior opening is elliptical, with diameters 26 mm and 17 mm long. The longer diameters of the two openings are nearly parallel. The posterior margin of the anterior opening is slightly incurved. It would seem that the operator made the posterior trepan first, then modified the outline of the later anterior one to avoid breaking through the narrow bar between the two openings. The sides of the incisions are perpendicular or nearly so. A few faint striae around the margin may be tool marks. The inner table of the bone projects into the opening around considerable of the margin. There is a suggestion of a slight infection in the upper one-third of the separating bar and also at the lower posterior corner of the anterior opening. Apparently both openings healed ultimately. The skull is about 6 mm thick in that section and shows no pathologic features.

Fig. 2: Field Museum Cat. No. 40221.

Photograph: 68682.

Source: Cuzco, Peru.

Age: adult.

Sex: undetermined.

This skull shows Aymara deformation, the bandage groove crossing the middle of the forehead and just above the inion. The cranial sutures are much fused and obliterated. There is a shallow depression, possibly a scar, about 15 mm in diameter on the coronal suture, 25 mm to the left of the bregma.

The result of the trepanation is a large, irregular opening on the right side. The longest diameters of the opening at right angles are 40 mm and 35 mm. Most of the opening would be included in a rectangle 30 x 25 mm. The lower border of such an area would be about 15 mm above the pterion; one-fourth of the area lies in the parietal and three-fourths in the frontal. The margin is irregular and thin, but had healed perfectly. The large size and irregular shape of the trepan would seem to indicate a comminuted fracture as the occasion for the trepanning. In any case the operation was performed by scraping, the bevel on the lower side being 15 mm wide.

PLATE LXII

Fig. 1: Field Museum Cat. No. 40222.

Source: Cuzco, Peru.

This skull is dolichocranial, with an index of 73.2. Deformation has caused flattening and depression of the forehead and probably the prominent parietal bosses. The cranial walls are heavy. The trepanation removed the lambdoidal corner of the right parietal involving both sagittal and lambdoidal sutures in that region. The opening is nearly circular, the upper border being somewhat flattened. The diameter is about 20 mm. The cranial wall is about 7 mm thick in the adjoin-

ing area, and the margin of the opening is beveled outward from 10 mm to 15 mm. Healing was perfect with complete closure of the medullary cavity. There are signs of another operation in the left parietal near the summit of the parietal dome. A circular area about 30 mm in diameter, with its center 45 mm from the sagittal suture and 65 mm from the lambdoidal one, has been scraped flat. In the center of this area there is a depression about 7 mm in diameter. It is very rough and irregular on both sides and bottom, and may have been caused by a blow with some sharp-pointed implement, or by disease. The wound seems to have healed, and secondary growth of bone has nearly covered the cancellous tissue and left a single, small rounded spicule rising from the side of the depression. Shown just to the right of the point of the arrow. In any case the flattened area was undoubtedly produced by scraping.

Fig. 2: Field Museum Cat. No. 40203.

Source: Ancon, Peru.

This skull shows slight occipito-frontal flattening. Cephalic index 89.1.

There are slight traces of osteoporosis symmetrically arranged on the base of the skull. The trepan was in the left parietal 75 mm from the coronal suture and 62 mm from the sagittal one. The present appearance is that of a funnel-shaped cavity sunk to the inner table of the bone. The outer rim is a poorly defined angular ellipse with diameters 12 mm and 25 mm. The bottom is only 3 x 5 mm. There are three small openings through the inner table. These may be foramina, though these were rare in this region in other skulls examined. The porous layer shown in the figure represents the medullary layer. Around the mouth of the opening there is a zone where the thickness of the skull increases from 6 mm to 12 mm. The walls of the funnel are smooth, and healing seems to have been perfect. We venture the following possible history of this case. There was a lesion of some kind, possibly a penetration of the outer table by some blunt-pointed instrument and treatment of the wound by incomplete trepanation.

The appearance of the opening suggests that, in the operation, the anterior wall was made by a straight or slightly curved cut, perpendicular to the surface, while the posterior wall was produced by two cuts somewhat beveled and meeting at an obtuse angle. These cuts were carried through to the inner plate.

UTA

A phase of the disease leishmaniosis, due to blood parasites, is called uta. Its antiquity in Peru is very great if we may judge from its pictorial representation on ancient pieces of pottery. The disease usually manifests itself in unsightly erosions around the mouth and nose. It occasionally attacks the nasal cartilages and even the bones, so that one may detect its ravages in a profile view of the head of a mummy. From the appearances in certain skulls and from their pottery it has been assumed that primitive surgeons at times attempted to arrest the progress of the disease by amputating the diseased parts.

NASAL DISTURBANCES

Pathologic conditions in the nose and paranasal sinuses are of great importance in connection with the teeth, eyes, and ears. I have described elsewhere the pathway of an infection originating in an upper apical abscess which ruptured into the maxillary antrum, thence to the nose and frontal sinuses, from which an abscess had developed into the orbit. Through the Eustachian tube, the ears

and mastoids were involved. These conditions are considered at some length by Burton.¹ His study is based on the collections of pre-Columbian Peruvian skeletons preserved in San Diego Museum.

Close examination of favorable roentgenograms of unopened mummy packs reveals nasal disturbances of the turbinates, especially, but none is sufficiently clear to attempt a diagnosis.

OTOSCLEROSIS AND DEAFNESS

I have attempted, so far without success, to identify, in the many roentgenograms of temporal bones available to me, some evidence of a thickening in the walls of the cochlea or of the osseous auditory passages. By inspection, one can determine a thickening in the walls of the meatus. This condition is commonly associated with aural exostoses. These neoplasms often take the form of smooth, solid osteomata. Several may occur together and close the auditory passage, thus causing deafness. Such manifestations are fairly common among ancient Peruvians.

A number of factors were effective in causing deafness in pre-Columbian Peru, other than otosclerosis. A brief discussion of these will suffice since the determinations were made on material other than mummy packs.

Aural exostoses (small osteomata) were a frequent cause of partial or complete deafness among the pre-Columbian Peruvians (Plates XXXV, XXXVI). The nature of these strange growths is that of a benign tumor of limited development. Their origin is doubtless due to local irritation, either of infection or mechanical disturbances such as might ensue from the finger nails or other stiff objects used to free the passage of cerumen. The growths are solid and ivory-like, and are often associated with sclerosis in the walls of the auditory passage (Plate XXXVI) producing bilateral deafness by occlusion of the passages.

OTITIS MEDIA

Otitis media occurred among the pre-Columbian Peruvians as may be seen in Plate XXXVII, where the external auditory meatus is greatly enlarged by the discharge of pus. Otitis media may take the form of an intracranial abscess (Plate XXXVIII, Figs. 1, 2).

MASTOIDITIS

Mastoiditis² of any severity was of infrequent occurrence, and only one example of abscess of the mastoid has been seen, although mastoid infections (Plates XXXVIII, Fig. 2; XXXIX, Figs. 2, 3) have frequently been detected.

SYPHILIS

Prehistoric evidences of syphilis are still wanting, although numerous claims have been made. Fuller study of the lesions has, in each suspected case, resulted in an adverse opinion. The subject has frequently been discussed,³ and the present study of prehistoric Egyptian and Peruvian mummies has added nothing to our knowledge of the subject. Syphilitic lesions in a modern Eskimo skull from St. Lawrence Island are shown in Plate XXXIV, Fig. 1.

¹ Frank A. Burton, Some Considerations on Prehistoric Aural, Nasal, Sinus Pathology and Surgery, *El Palacio Press*, 1927, pp. 1-38, figs. 1-17.

² Roy L. Moodie, Mastoiditis in Prehistoric Peru, *Annals of Medical History*, IX, 1927, p. 357, 1 fig.

³ Roy L. Moodie, Studies in Paleodontology, V. The Teeth and Palate in an Adult, Syphilitic Eskimo, with a Consideration of Systemic Disease, *Pacific Dental Gazette*, XXXVI, No. 9, 1928, pp. 525-539, 12 figs.

APPENDIX: MUMMIFIED ANIMALS OF EGYPT AND PERU

INTRODUCTION

Field Museum possesses a collection of unopened mummy packs of the animal fauna of ancient Egypt. The various specimens, regrettably, have no definite locality labels, so it is not possible to date them accurately. Their intrinsic interest, however, is very great, as the knowledge of such objects is not widely disseminated. No discussion of the mummified fauna of ancient Egypt exists in English, leaving it impossible for those not especially trained in foreign literature to gain access to this interesting field. Nothing of importance has been added to the subject within the past twenty years. Although roentgenograms of unopened mummy packages were made almost two score years ago, yet those made at Field Museum are of such high quality that all previous efforts are surpassed. These pictures show so clearly the osteological features that one may be fairly sure of specific identification. A new and interesting interpretation of the imitation or "false" mummy packs is given. Methods of embalming, as applied to animals, are discussed.

MUMMIFIED FAUNA

The species of animals included within the mummified fauna of ancient Egypt are very numerous, the approximate number of forms, so far as known, being given under each subheading. The animals mummified and possibly considered as sacred ranged from the bovines and apes downward through the many other groups of vertebrates, including such mammals as various carnivores, insectivores, and rodents. Of birds there were great numbers of individuals and more than three dozen species. The long-billed ibis was perhaps the most numerous of all. Reptiles are represented by crocodiles, lizards, and snakes, including the king cobra. There are no amphibians known in the fauna, but fishes are abundantly preserved in large packages, consisting of great numbers of specially treated individuals. Most astonishingly, there are many species of mollusks preserved.

Lortet was of the opinion that practically all vertebrate animals of ancient Egypt were preserved. From this viewpoint a study of the mummies becomes a paleozoological problem, enabling us to reconstruct the fauna of a few thousands of years ago almost perfectly, if Lortet's opinion is correct. Certainly the prepared mummy packs show a vast range of materials. Yet one misses a few forms which were excluded possibly on account of their bulk. The camel was known to the Egyptians of the first dynasty; the ostrich, the hippopotamus, the ass, and the elephant were known at an early date, but to embalm any of these would have been an appalling task. The bull, apparently, was the largest mummified animal.

An approximate digest of the mummified fauna of ancient Egypt, as compiled from the writings of Lortet and Gaillard, reveals the following forms, reaching the astonishing total of ninety-seven species, eighty of which are vertebrates: two species of apes; dog; fox; jackal; wild cat; domestic cat; two insectivores; two rodents; African bull; antelope; two gazelles; two sheep; goat; two deer; thirty-eight species of birds; crocodile; lizard; serpents; fourteen species of fish; seventeen mollusks. Amphibians are unknown as mummies, but a *Rana*, a *Hyla*, and a large toad are represented in faience and serpentine, as are also the lion, pig, and rabbit, none of which was found mummified.

Numerous insects were known and are represented in various ways, but none of them was preserved in mummified packs, as would readily have been possible.

The scaraboid beetles were especial favorites, and the flea, fly, grasshopper, hornet, locust, praying mantis, and scorpion were well known.

The turtle was the emblem of death and darkness to the ancient Egyptians, and, although represented in stone, it formed no part of the mummified fauna.

Two species or varieties of cats were held sacred in ancient Egypt, and mummified cats are abundant. Figures of the animal occur in bronze, faience, lapis, porphyry, gold, silver, wood, etc. The mummified cats shown (Plates LXVI, LXVII) are probably the domesticated, smaller variety, *Felis maniculata* var. *domestica*. Kittens, half-grown and adult individuals, are met with. The viscera were removed and placed in canopic jars, the fore limbs folded along the body and the hind limbs drawn up under the pelvis. The body was placed in a natron bath, after which it was dried. The wrappings on some of the mummified cats were elaborately interwoven and decorated.

TECHNIQUE OF EMBALMING

There is no reason to believe that the methods of preparation of animal mummies differed in any outstanding manner from those employed for humans, save possibly that of evisceration. The viscera were all removed from the human bodies, save in the earliest method of simply interring the body in dry, hot sand. Evisceration was doubtless practised on all of the mummified animals, excepting in the case of the smaller ones, where a slit in the abdominal wall was probably made to allow the entrance of the salt solution. Periods of immersing and drying secured all essential results. Injections were unknown. If they had been understood, the viscera would have been left intact. Every anatomist knows the unsatisfactory, tedious task of preserving a "cut" from the post-mortem room. Small animals the size of mice were prepared in a packet containing many individuals, the package being dipped in pitch to protect the contents.

The viscera of the various animals, after removal and soaking for a period of some days or weeks in the natron bath were placed in funereal or canopic jars and sealed with pitch or plaster. The flesh was doubtless removed in some cases. Some of the small cat mummies show that the viscera and flesh were removed, the fore legs folded down the body, the hind legs drawn up against the pelvis, the ribs drawn down along the backbone, and the whole wrapped in linen. Many of the birds were preserved—feathers, viscera, and flesh—by dipping in pitch after the natron bath, and were wrapped singly or in groups of as many as forty individuals.

The most important embalming medium was the natron, niter, or salt bath, which consists of an aqueous solution of common salt, sulphate and carbonate of sodium, in varying proportions. In this bath the bodies were kept immersed for a varying interval, depending on the size and condition of the animal. The source of the natron supply is not known, but this must have been mined in some of the numerous salt lake beds found in various deserts not far from Egypt. Dry salt was also used in quantities.¹

The oils, gums, spices, and resins used were apparently all of vegetable origin, mineral oils being unknown. The pitch, so lavishly used in the preparation of bird mummies by dipping the bodies into the pitch and by sealing the jars in which the sacred ibises were placed, was all derived from conifers, and was largely imported. Cedar oil, a powerful preservative, was used in quantities

¹M. A. Ruffer, The Use of Natron and Salt by the Ancient Egyptians, *Cairo Sci. Jour.*, IX, 1918, pp. 34-53.

especially on the viscera, the body cavity, in humans at least, being filled with cloth soaked in oils or resins.

Warren R. Dawson¹ has written the most recent account of the practice of mummification.

COST AND PURPOSE OF MUMMIFICATION

Animals, especially birds, were preserved in the ancient Egyptian tombs for two purposes: one of them for food for the departed, and the other for religious reasons. Preservation of bird hearts shows us that the ancient Egyptians were as fond of "giblets" as we are; or this may have been a religious observance.

The preparation of the various animal bodies differed in time consumed and in costliness. Many packages were handsomely prepared, decorated, and treated with great care. Such is the condition of the thousands of sacred ibises.

A single bull required two hundred yards of linen, half a yard wide. Crocodiles and other slender animals required braces of palm-leaf ribs. Costly sarcophagi were cut from stone or wood with an image of the animal on top of the casket. Wooden coffins and embalming materials must have run the cost of the preparation of animal mummies to an excessive degree. It is not known to me whether the state government, religious organizations, or individuals paid the cost. Certainly the extensive practice of mummification of bodies, both human and animal, must have been a great drain on the national resources, especially since many of the products used in preparation were imported.

The purpose of mummification was, at its base, religious, but it is difficult to conceive of the continuation of such an expensive program as a result of religious enthusiasm. The embalmers themselves were doubtless numerous enough to encourage embalming as a source of income, enjoyed by them over a period of many centuries. Even in ancient times it seems probable that the embalmers belonged to a guild or organization of their own; a union, active even as late as the Graeco-Roman period.

IMITATION MUMMIES

Anyone who has to do with the preservation of large animal and human bodies in tanks of solution can appreciate how in clearing out a natron tank, now and then, the ancient Egyptian embalmers found in odd corners an isolated head, or fragments of skin or limbs. Since it was contrary to their religious belief to allow incomplete animals to start on their way to eternal life, they probably perfected the notion of making false packages containing a few feathers, fragments of skin, a tangled lot of limb bones, a head, or indistinguishable parts. To Osiris, apparently, they relegated the job of straightening things out "over there" (Plates LXVIII, LXIX, LXXI).

Another suggestion in explanation of the numerous false mummy packages, is that the embalmers, paid by the number of packs they turned out, now and then faked a few. I believe, however, that the first explanation is more adequate.

Imitation human mummies are discussed by Smith and Dawson. Ruffer also has described the subterfuges of the ancient embalmers. To rectify their carelessness in losing a part of the body through disintegration, they replaced the lost part by any available object, such as substituting a piece of pottery for a lost hand.

Field Museum possesses a few false mummies, some of which are illustrated (Plates LXVIII, LXIX, LXXI). There are false mummies representing the

¹ Making a Mummy, *Journal of Egyptian Archaeology*, XIII, p. 40.

domestic cat and a kitten; one with a cat's head only. A package of mixed bones (Plate LXXI) may be regarded as a false mummy. Anserine birds are represented by other packages.

An instructive example of another type of false mummy is seen in the mummy of a woman named Men (Field Museum Cat. No. 30011), of which the five roentgenograms show that the neck, arms, thorax, abdomen, and pelvis are missing. The head is connected with the pelvic region by a board. Apparently the original wrapping is still intact, precluding any acts of vandalism.

MUMMIFIED ANTHROPOIDS AND THEIR DISEASES

The dog-faced baboon, *Papio hamadryas*, was the ape most venerated in ancient times by the Egyptians, and the relics of this animal are abundant. The representations take the form of mummies, carvings in hard stone, in faience and by skeletons. Lortet and Gaillard give voluminous discussions of the remains of this animal. Some of them must have been kept captive in the temples, since Poncet has described and figured skeletal parts of this ape which were so diseased that the individuals, crippled as they were by spondylitis deformans, rickets, etc., could not have escaped the leopards, their greatest enemy, had they been wild on the hills (Plates LXIII, LXIV).

A second anthropoid species, *Papio anubis*, was mummified, and the monkeys are doubtfully represented by a pack in the Lyons (France) Natural History Museum, the roentgenogram of which, as published by Lortet and Gaillard, indicates a *Cercopithecus*.

I have already reviewed the evidences of disease in chapter XIII of my Paleopathology,¹ represented in the mummified apes which were found in ancient Egyptian tombs.

A skull of a baboon (Plate LXIII), *Papio hamadryas*, shows in the symmetric hypertrophy of the cranial bones the condition often seen in human skulls due to Paget's disease, more generally known as osteitis deformans, leontiasis, and often confused with acromegaly.²

An intense periostitis, due to an injury, is evident on the proximal ends of a radius and ulna. Poncet regards this as the site of a sarcoma.

OTHER MUMMIFIED MAMMALS

The bull was so important in the mythology of ancient Egypt that its mummified remains are abundant. It was the oldest and most important animal cult in Egypt. Although of different races the animal species was *Bos africanus*, the animals preserved being largely males. Mummies, elaborately prepared, are found at Sakkara, Abusir, and at other places. The costliness of the preparation of these bovine mummies was very great, as shown by Spiegelberg in his study of the Apis bull.

An antelope, the bubal hartebeest (*Bubalis boselaphus*), a native of the larger part of northern Africa, was mummified, but its remains are rare.

Two species of gazelles, *Gazella dorca* and *G. isabella*, recently abundant in the wilder districts of Algeria, Tunis, and Tripoli, were preserved at Kom-Mereh as mummies.

¹ Rickets (Plate LXIV, Figs. 1-3) is evidenced in a set of limb bones markedly curved, indicating cardinal symptoms of this disease.

² Spondylitis deformans is evident in a series of ankylosed lumbar vertebrae, representing the dog-faced baboon. This disease was extremely prevalent among the ancient Egyptians.

Well-prepared mummies of sheep and goats, apparently domesticated, represent three or more species.

An unusual package obtained at Sakkara contained a stag and a crocodile, an association difficult to explain.

Two varieties of cats, a large feral form (*Felis maniculata*) and a small domesticated variety, were extensively mummified. Field Museum possesses several unopened mummy packs, containing either complete bodies of the domesticated cat, or a head, or scraps of skin. The larger feral cat is not represented in the Museum's collection. In Plate LXVIII the mummy of an unidentified animal (cat?) is shown; the roentgenogram reveals only a skull. Plate LXIX illustrates the imitation mummy of a small animal; the roentgenogram reveals the absence of a skeleton.

The number of mummies of cats is extremely large, preserved in tombs at different localities. Many of the cat mummies are elaborately prepared and decorated. Sacred to Bast, cats are represented in bronze and wood. Two roentgenograms of the domesticated variety are shown in Plates LXVI, LXVII.

Jackals were infrequently mummified.

Mummified remains of dogs from Assiout and other places represent four domesticated varieties. A fox was also included in the mummified fauna.

Shrews were regarded as symbols of darkness, and these tiny, insect-eating mammals less than two inches long, of two species, were mummified, often being preserved in packages which were placed in a sarcophagus of stone or wood, on the top of which was a model of the animal.

The rodents were represented by a striped mouse and a rat.

Lortet and Gaillard list the following species of mammals as being members of the mummified animal fauna:

Papio hamadryas, dog-faced baboon; *P. anubis*, ape; *Cercopithecus*, monkey; *Canis familiaris*, domestic dog; *C. aureus*, fox (?), jackal; *Felis maniculata*, large wild cat; *F. maniculata* var. *domestica*, domestic cat; *Crocidura gigantea*, shrew; *C. religiosa*, shrew; *Acomys cahirinus*, striped mouse; *Mus alexandrinus*, rat; *Bos africanus*, bull; *Bubalis buselaphus*, antelope; *Gazella dorcas*, gazelle; *G. isabella*, gazelle; *Ovis longipes* var. *palaeoaegyptica*; *O. platyura* var. *aegyptiaca*; *Ammotragus tragelaphus*; *Hircus mambricus*; *H. thebaicus*.

MUMMIFIED AVIFAUNA

The birds are the most abundant of all the mummified animals of ancient Egypt, both in numbers of individuals and in the number of species, of which there are about forty so far recognized. These forms are the kites, hawks, eagles, owls and falcons, representing the raptorial birds; the wading birds, represented by the ibis; and the anserine forms, including the geese. Raptorial birds predominate in the mummified fauna. Perching birds are not represented, but the grouse are present, as are also the blue rollers. The study of Lortet and Gaillard was made on more than one thousand mummies of birds. These fall into two important groups—those of the ibis and those of the raptorial birds.

The commonest mummified bird is the Egyptian kite (Plate LXX, Fig. 1), of which immense numbers were preserved either singly or in bundles of twenty to forty birds. Field Museum possesses examples of this bird. I have identified the species as *Milvus aegyptius*, conspecific with the scavenging kite of the present time, which one may see perched on the flat roofs of houses, or on trees near the

villages, waiting for refuse. It is not known how the ancient Egyptians captured so many of these birds, but it would have been an easy matter to trap them. Plate LXX, Fig. 1, a mummified kite, shows the common method of preserving single birds. The birds were uniformly dipped in pitch and wrapped. There is a second species of *Milvus* present in the fauna, *M. regalis*. At the present time the species is found throughout Africa and in Madagascar, extending into southeastern Europe, Greece and Dalmatia. Mummies of the kite are found in Egypt at Roda, Gizeh, Kom Ombo, and other necropolises.

Hawks of several species were mummified, but I am unable to determine, definitely, the species represented in the Museum collections. Of three described species of *Buteo* the hawk shown is probably *B. ferox* (Plate LXXIV).

The anserine bird shown in the roentgenogram (Plate LXXV) may be a goose (*Anser albifrons*). This bird, carefully plucked and prepared, was often preserved in the ancient tombs as a food offering. The bird was also represented in colored drawings on the walls of tombs. The roentgenogram of the bird is exceptionally perfect and shows all osteologic details.

The vulture probably is represented in the Museum collections by two fairly perfect mummies, of which one is shown in Plate LXXVI. A false mummy which is illustrated in Plate LXXI apparently consists of odd bones of the vulture. These mummy packages contain only a single bird, never numbers as in the case of smaller birds. The mummified species was the black and white form so abundant in Egypt during the time of the Pharaohs, taken to Italy by the Romans, and living wild throughout the greater part of Africa.

Mummies of the ibis have been recovered from tombs at a number of localities, and the mummification of this bird was followed from the twentieth dynasty to the Grecian epoch. The long beak was turned down along the breastbone, and, after dipping in pitch, the body was covered with several layers of cloth. The exterior was left unadorned, or elaborately decorated, and either kept as packages or put into jars which were closed with pitch. It seems probable that a bird as large as the ibis was eviscerated, but there is no definite evidence bearing on this point, unless it is given by Savingy, whose writings I have not seen. The roentgenograms show no visceral shadows.

Another ibis-like bird, *Plegadis falcinellus*, was also mummified, but it is rare. Lortet and Gaillard had only four incomplete specimens.

The following species of birds are recognized by Lortet and Gaillard as representing the mummified avifauna of Egypt:

Milvus aegyptius, *M. regalis*, *Pernis apivorus*, *Elanus caeruleus*, *Haliaetus albicillus*, *Buteo desertorum*, *Buteo ferox*, *Buteo vulgaris*, *Circaetus gallicus*, *Aquila imperialis*, *Aquila maculata*, *Aquila pennata*, *Falco feldeggii*, *Falco babylonicus*, *Falco barbarus*, *Falco subbuteo*, *Hierofalco saker*, *Cerchneis tinnunculus*, *Cerchneis cenchris*, *Accipiter nisus*, *Milvax gabar*, *Circus cyaneus*, *Circus aeruginosus*, *Circus macrourus*, *Circus pygargus*, *Pandion haliaetus*, *Bubo escalaphus*, *Scops aldrovandi*, *Asio otus*, *Asio brachyotus*, *Strix flammea*, *Ibis aethiopica*, *Plegadis falcinellus*, *Cuculus canorus*, *Coracias garrula*, *Hirundo rustica*, *Oedipnemon oedipnemon*, *Pteroclorus senegallus*.

MUMMIFIED REPTILES

Field Museum possesses a small mummy of a very young crocodile, whose skeleton is visible in spots between the abundant lumps of sand-coated pitch. The specimen is too imperfect to produce a good roentgenogram for publication,

but the diagnosis is correct, and the species is doubtless the *Crocodilus niloticus*, an animal held sacred throughout Egypt and kept tame in Lake Moeris, where the animals were fed regularly and even adorned with jewels (Plate LXV, Fig. 1). The reptile is known now only in the upper reaches of the Nile and as far south as Madagascar.

In the process of mummification large crocodiles, after soaking in the natron bath, were wrapped in cloth, the slender body being supported by long sticks, the ribs of palm leaves often being used for this purpose.

Lizards are represented in the ancient fauna by a single species. The large monitor (*Varanus*) was not included in the mummified fauna.

Serpents were fairly common in ancient Egypt, and they were preserved in mummy packs, several together. Lortet and Gaillard published a roentgenogram of such a package. The king cobra has been recognized in the mummified serpents, but the subject is incompletely studied. In view of the importance of the worship of the serpent to the ancient Egyptians our knowledge of ancient snakes is all too brief.

MUMMIFIED FISH

No mummified fish are contained in Field Museum collections. Although the piscine fauna of the Nile is fairly extensive and probably has been for a long time, and although a variety of fish forms is represented in Egyptian mythology, yet only the Nile perch (*Lates niloticus*) was held sacred and embalmed in great numbers. At certain villages in Egypt, notably Esne or Latopolis, as the Greeks called it, a veritable cult of the worship of this fish developed. At this locality prodigious numbers of mummified fish of the above species have been found, some of them measuring a meter or more in length, and so perfectly are they preserved that the iridescence of the eyeballs and scales is retained.

Lydekker speaks of this fish as "monster," alluding to its fierce voraciousness. Whether this trait was admired by the worshippers of the fish is not known.

MOLLUSKS

While the molluscan species recorded by Lortet and Gaillard may justly be regarded as members of the mummified fauna of ancient Egypt, yet there is no reason to believe that these shellfish were regarded as sacred. The seventeen species recorded represent ten marine gastropods, two fresh-water gastropods and five marine lamellibranchs, all in a condition of semi-fossilization, and the rich coloring is largely lost. The species are all of local origin, being found either in the Nile, the Mediterranean, or the Red Sea. They are all species that are living today.

SUMMARY

Although there are about one hundred species of animals in the mummified fauna of Egypt, yet not all of them were sacred, and some animals which were held sacred were not mummified. The reason for this distinction is difficult to understand. What was the basis of choice in embalming animals for mummification, and hence for eternal life? The underlying purpose of mummification was religious, and this obtained for both humans and animals, but at the present time we cannot understand the multitudes of change in thought and custom, as mirrored in the practice of mummification which developed at an early period in Egypt, waxed strong and waned. Today the whole of that civilization which

demanded mummification is in ruins. From those ruins we must slowly reconstruct the ancient life.

DETAILED REPORT AND ROENTGENOLOGIC INTERPRETATION OF EGYPTIAN ANIMAL MUMMIES

PLATE LXIII

Source: Egypt. Lortet and Gaillard.

Dorsal aspect of a mummified baboon skull showing symmetric hypertrophy doubtless due to Paget's disease, osteitis deformans.

PLATE LXIV

Source: Egypt. Lortet and Gaillard.

Figs. 1-2: Left femur and tibia of a baboon, *Papio hamadryas*, showing what is regarded by Professor Poncet as the results of rachitic deformation. This is one of the oldest examples of rickets.

Fig. 3: Right humerus of same species, showing rickets.

Fig. 4: Portion of the lumbar region of the vertebral column of a mummified baboon, showing typical lesions of spondylitis deformans.

PLATE LXV

Fig. 1: Field Museum Cat. No. 30037.

Roentgenograms: A463, A465.

Photograph: 69817.

Source: Egypt.

Mummy of a young crocodile.

Fig. 2: Field Museum Cat. No. 30034.

Roentgenogram: A465.

Photograph: 69817.

Source: Egypt.

Imitation mummy of a kitten.

Fig. 3: Field Museum Cat. No. 111509.

Roentgenograms: A498, A500.

Photograph: 69819.

Source: Egypt.

Imitation mummy of mammal, possibly a gazelle as identified by horns protruding from head of package. No other skeletal material enclosed.

PLATE LXVI

Field Museum Cat. No. 30031.

Fig. 1: Photograph: 69816.

Fig. 2: Roentgenogram: A469, showing complete skeleton.

Source: Egypt.

Mummy of a cat. Well-preserved specimen.

PLATE LXVII

Field Museum Cat. No. 30033.

Fig. 1: Photograph: 69816.

Fig. 2: Roentgenogram: A470, showing complete skeleton.

Source: Egypt.

Mummy of a cat. Well-preserved specimen.

PLATE LXVIII

Field Museum Cat. No. 30029.

Fig. 1: Photograph: 69816.

Fig. 2: Roentgenogram: A460.

Source: Egypt.

Imitation mummy of a cat. Package contains no skeletal material except a skull which has been identified as *Felis maniculata* var. *domestica*.

PLATE LXIX

Field Museum Cat. No. 30035.

Fig. 1: Photograph: 69816.

Fig. 2: Roentgenogram: A465.

Source: Egypt.

A package containing no skeleton, made to represent an animal mummy. The roentgenogram suggests the possible inclusion of a few fragments of skin.

PLATE LXX

Fig. 1: Field Museum Cat. No. 30030.

Roentgenogram: A467.

Source: Egypt.

Mummy of a kite.

Fig. 2: Field Museum Cat. No. 30039.

Roentgenogram: A474.

Source: Egypt.

Mummy of a falcon.

PLATE LXXI

Field Museum Cat. No. 30043.

Fig. 1: Photograph: 69820.

Fig. 2: Roentgenogram: A475.

Source: Egypt.

Imitation mummy of a bird. The ancient embalmers were careful not to lose a scrap of bone, feathers, skin or flesh of the animals undergoing mummification, so that all individuals might be complete for eternal life. This false mummy package contains isolated, fragmentary bones of some large bird.

PLATE LXXII

Field Museum Cat. No. 111508.

Photograph: 69818 (see also Plate LXXIII).

Source: Egypt.

Mummy of a goose.

The duck was apparently not among the sacred animals of ancient Egypt, but the goose shown in this photograph was painted and engraved on many ancient monuments of the Nile Valley. Prepared geese, well plucked as if for roasting, are found in ancient tombs of royalty, in one case placed in a wooden sarcophagus. Mummified geese are not commonly found, so the present example is unusual. The bird here shown may have been the widely distributed species *Anser albifrons*, since this is the common species of the region. The dark masses in the pelvis and to the right of the feet are sand-encrusted pitch, or the former may indicate food material still in the viscera.

PLATE LXXIII

Same specimen as Plate LXXII.

Roentgenogram: A509.

PLATE LXXIV

Field Museum Cat. No. 30045.

Fig. 1: Photograph: 69815.

Fig. 2: Roentgenogram: A482.

Source: Egypt.

Mummy of a hawk.

The hawk was the type and symbol of the oldest of all the gods of Egypt, Heru-ur, whose counterpart at a later period was the hawk-headed god, Horus, who was the son of Isis, and hawk worship was universal throughout Egypt in predynastic times.

Several species of hawks and falcons were mummified in ancient times, and they rank next to the kites in abundance and are found in the same necropolises. The hawk shown here is probably *Buteo ferox*. The roentgenogram shows the common method of folding the wings and legs during the processes of embalming.

PLATE LXXV

Fig. 1: Field Museum Cat. No. 111516.

Photograph: 69815 (see Plate LXXVI).

Source: Egypt.

Large, strong-winged, raptorial bird, in good state of preservation.

Fig. 2: Roentgenogram of same: A483.

PLATE LXXVI

Field Museum Cat. No. 111516.

Fig. 1: Field Museum Cat. No. 30038.

Photograph: 69815.

Source: Egypt.

A large vulture.

Fig. 2: Roentgenograms: A527, A528.

Source: Egypt.

Large, raptorial bird, possibly a vulture. The absence of shadows in the abdominal region would indicate evisceration before the natron bath. Relations of bones of legs and feet can be seen, with digits closely appressed. The tip of the tail was broken in handling; having been immersed in pitch, the feathers have become brittle after centuries in the tomb. The shadows alongside the body are due to bandages.

NOTES ON PERUVIAN ANIMAL MUMMIES

Field Museum possesses no mammal or bird mummies from Peru, and the impression prevails that the practice of mummifying animals was restricted to Egypt. It is thought that the ancient Peruvians, of whatever epoch, did not embalm either animal or human bodies, but mummified the humans by sun-drying and took no pains with animal bodies. This subject has never been adequately studied, and much remains to be learned about the practice of mummification in early times in Peru.

Under date of April 9, 1930, writing from Lima, Peru, A. Hyatt Verrill reports, "... nearly all the mammals and many of the birds of Peru have been found mummied with the human bodies. Macaws, parrots, dogs, cats (domesticated wild species), viscachas, guinea-pigs, herons, flamingos, doves, ducks, hawks, and countless others—even including llamas, vicunas, and alpacas, are known from the ancient graves of Peru. Many of these, too, were as carefully preserved and wrapped to form miniature mummy bundles as were the human bodies. I have the mummy of a dog which I took from a grave at Pachacamac which is not only wrapped, but enclosed in a specially constructed basketry case."

The parrot is depicted by Rivero and Tschudi and the species shown is regarded as probably *Ara militaris*, as suggested by Dr. Alexander Wetmore from an inspection of the color plate. This determination, however, could only be verified by handling the specimen.

Professor A. Nehring has discussed, briefly, the nature of the Inca dog, whose skeletons are found in ancient burials as recorded by Reiss and Stübel. Eaton gives further information on the dog and discusses the remains of guinea-pigs.

BIBLIOGRAPHY OF ANIMAL MUMMIES

A. EGYPTIAN ANIMALS

BUDGE, SIR E. A. WALLIS.—1925. Figures of Animals, Birds, and Reptiles, Sacred to the Gods. In his book: *The Mummy. A Handbook of Egyptian Funerary Archeology*, pp. 385–388.

KNIGHT, ALFRED E.—1915. Sacred Animals. In *Amentet—an Account of the Gods. Amulets & Scarabs of the Ancient Egyptians*, pp. 137–177.

LORTET, L. C. and GAILLARD, C.—1903–1909. *La fauna momifiée de l'ancienne Egypte. Archives du Muséum d'Hist. Nat. de Lyon*, IX–X.

Introduction: Chiens et chacals; chats; insectivores; rongeurs; bovides; race et origine des boeufs de l'ancienne Egypte; antilopes; moutons; mouflon à manchettes; chèvres; oiseaux; reptiles; poissons; mollusques; singes; chats; offrandes funéraires; natron antiseptique; etc.

LYDEKKER, RICHARD.—*Wild Life of the World. III: Africa.*

MOODIE, ROY L.—1923. *Paleopathology. Chap. xiii.*

Rickets in ancient Egypt, p. 397, plate LXXXVII. Lesions in the mummified animals of Egypt, p. 410.

- PELLEGRIN, JACQUES.—1900. Radiographie appliquée à la détermination de momies de poissons. *Bull. Mus. d'Hist. Nat. Paris*, VI, pp. 175–176.
- PONCET, A.—1908. Déformations osseuses pathologiques, pp. 26–32, illus. *Archives du Muséum d'Hist. Nat. de Lyon*, in "La fauna momifiée de l'ancienne Egypte."
- RUFFER, MARC ARMAND.—1912. Notes on Two Egyptian Mummies Dating from the Persian Occupation of Egypt. In *Studies in the Palaeopathology of Egypt*, 1923, pp. 127–138. Imitation mummy shown in plate XXXVIII.
- SAVIGNY, J. C.—1805. *Histoire naturelle et mythologique de l'Ibis*. Paris.
- SMITH, G. ELLIOT and DAWSON, W. R.—1924. Egyptian Texts Relating to Embalming, in *Egyptian Mummies*, chap. III, pp. 45–56, illus. Embalming according to Herodotus and later authors in chap. IV.
- SPIEGELBERG.—1920. Study of the Apis Bull's Embalming. *Aegyptische Zeitschrift*, LVI, 1 ff.
- PETTIGREW, TH. J.—1834. A History of Egyptian Mummies and an Account of the Worship and Embalming of the Sacred Animals by Egyptians, with remarks on the funeral ceremonies of different nations and observations on the mummies of the Canary Islands, of the ancient Peruvians, Burman priests, etc., London.

B. PERUVIAN ANIMALS

- EATON, GEORGE F.—1916. The Collection of Osteological Material from Machu Picchu. *Memoirs Connecticut Acad. Arts and Sciences*, New Haven, V, pp. 1–96. 39 plates. Dog: pp. 65, 107.
- NEHRING, A.—The Inca Dog. In Reiss and Stübel, *The Necropolis of Ancon*, III, plates CXVII–CXIX.
- RIVERO, MARIANO EDWARD and VON TSCHUDI, JOHN JAMES.—1851–54. *Peruvian Antiquities*, translated into English from the original Spanish by Francis L. Hawks. Human mummies shown in plates I–VIa. Parrot in plate VI.

INDEX

- Abscesses, dental, 29, 47
 Aleutian Islands, mummies of, 17
 Ancon, Peru, site of an ancient necropolis, 28, 29, 39
 Animal mummies, of Egypt, 53; of Peru, 63
 Ankylosis, 21
 Apes, rickets and osteitis deformans in, 56
 Arteriosclerosis, hardening of the arteries, 20; in Egypt, 22; in Peru, 47
 Artery, interosseous, in Egyptian, 21
 Arthritides, diseases of the joints, 26, 46
 Auditory meatus, 32, 33
 Aural exostoses, small tumors in ears, 32
 Avifauna, mummified in Egypt, 57
 Aymara deformation in Peru, 50

 Baboon, mummified, diseased, 56, 60
 Baby, crocodile, 58, 60
 Baby, human, see Infants
 Baby of Queen Mäkeri, 19
 Baessler, Arthur, 15
 Bark rope, in binding mummy packs, 35
 Basket-Maker caves, natural mummies in, 18
 Baudouin, Marcel, 16
 Blackfoot Indian child, 18
 Bull, sacred in Egypt, embalming of, 56
 Burials, extended, 19; folded, 19; tree, 18
 Button osteomae on skulls, 33

 Calculi, absence from mummies, 27
 Calculus, salivary on teeth, 47
 Canopic jars, 54
 Caries difficult to detect in mummies, 47
 Cats, embalmed in Egypt, 57
 Caves, Basket-Maker, 18; Mammoth, mummy in, 18
 Cedar oil, 54
 Cobra, in mummified fauna of Egypt, 53, 59
 Coca leaves in child burial, 43
 Cocaine, 48
 Coccyx, freedom from disease, 21
 Crocodiles, worship and mummification in Egypt, 59, 60

 Dall, W. H., on North American mummies, 17
 Dawson, Warren R., 16, 55
 Deafness, due to obstruction of passages, 52
 Dje Mukesankh, 25
 Dog, Inca, 63

 Eaton, George F., on ancient Peruvians, 16
 Embalming, technique of, 54
 Eskimo, diseases of on St. Lawrence Island, 22, 32

 Falcon, mummified in Egypt, 61
 Fish, mummified in Egypt, 59
 Fistula, antral, 31
 Fractures, treatment of in Peru, 49

 Gaillard, Claude, on mummified fauna of Egypt, 57
 Goose, mummified in Egypt, 62
 Gourds in pre-Columbian Peruvian burials, 28, 35

 Hawk, mummified in Egypt, 58, 62
 Hrdlicka, A., on pre-Columbian diseases in Peru, 46
 Hydrocephalus, in Peruvian infant, 28, 46
Hyla in Egypt, 53
 Hyperostosis cranii in Peru, 32

 Ibis, sacred, mummified in Egypt, 58
 Imitation or false mummies, 55
 Impactions, dental, 37, 48
 Infants, 19, 23, 34, 46
 Injuries to head, club, 30; mace, 30, 49
 Insectivores in mummified fauna of Egypt, 53
 Insects in Egypt, 53

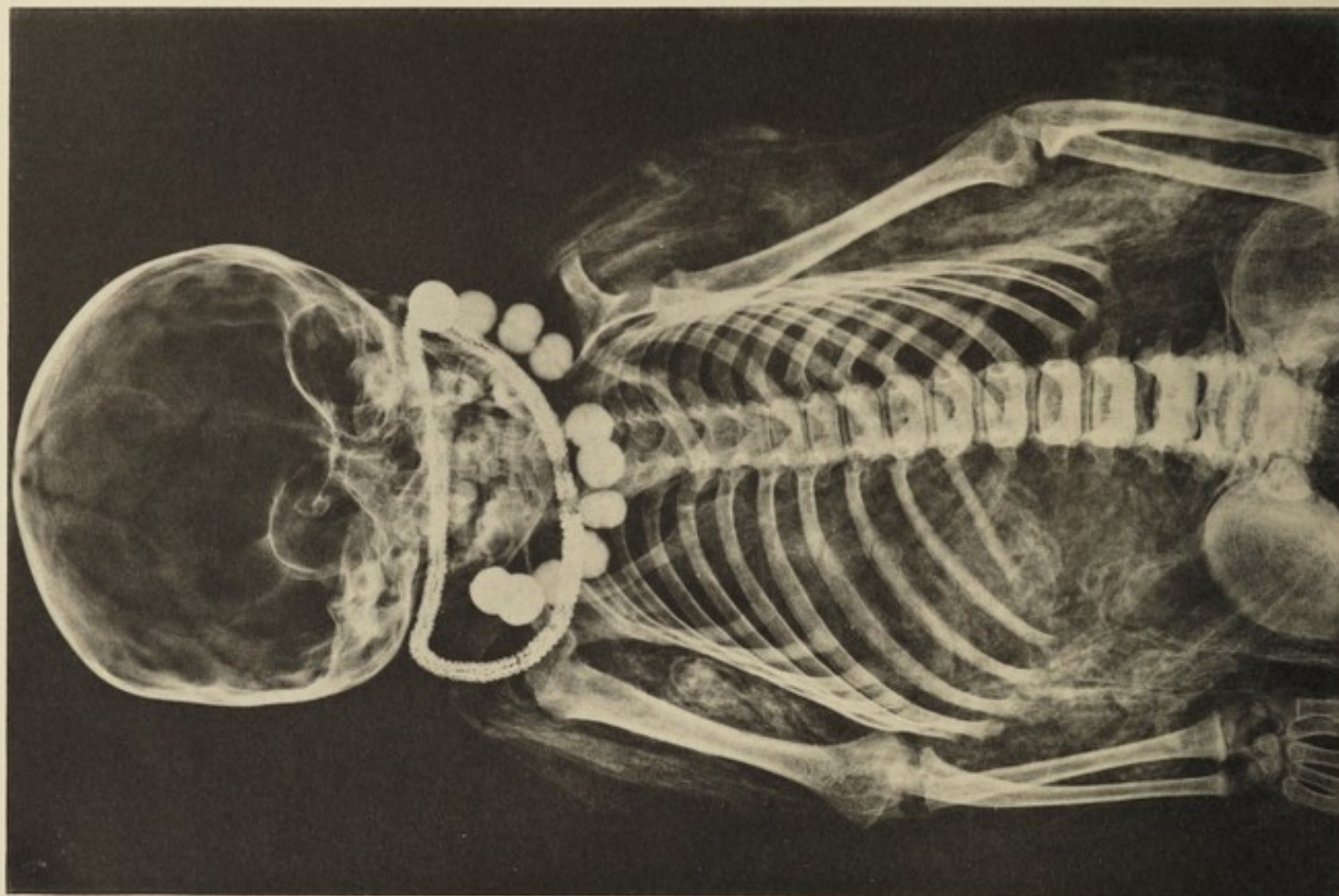 Jackals, 57
 Joints, diseases of, 26

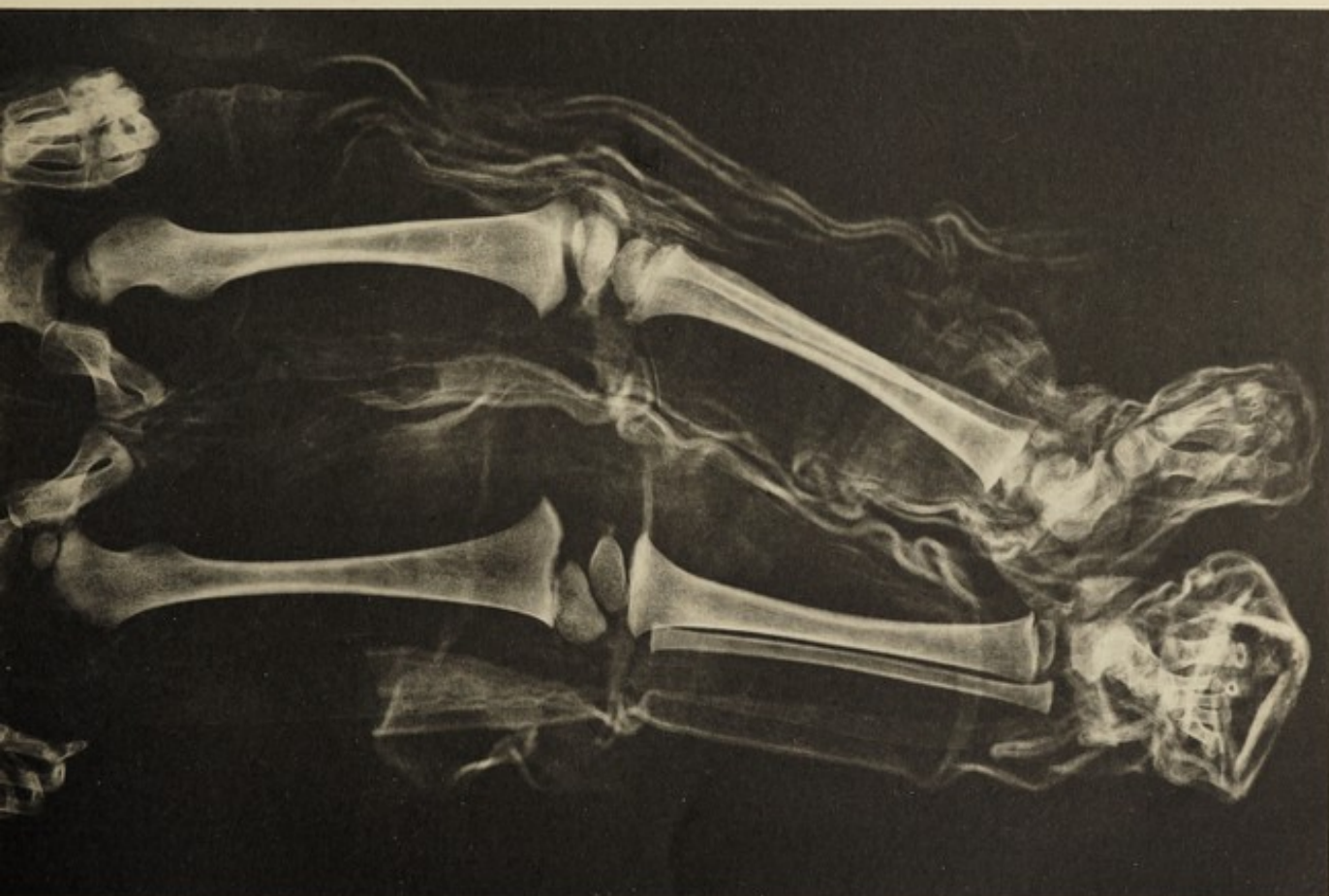 Kadiak Archipelago, mummies in, 17
 Kite, mummified raptorial bird, 57, 61
 Knock-knees, 22
 Kyphosis in mummy, 21

 Latopolis, the town of the perch worship, 59
 Leishmaniosis, uta, 51
 Leontiasis, same as osteitis deformans or Paget's disease, 56, 60
 Ligaments, ossification of, 21
 Linen, use of in embalming, 55
 Liver, diseases of, 27
 Lizards, mummified in Egypt, 59
 Lortet, Victor, authority on mummified fauna of Egypt, 53, 60

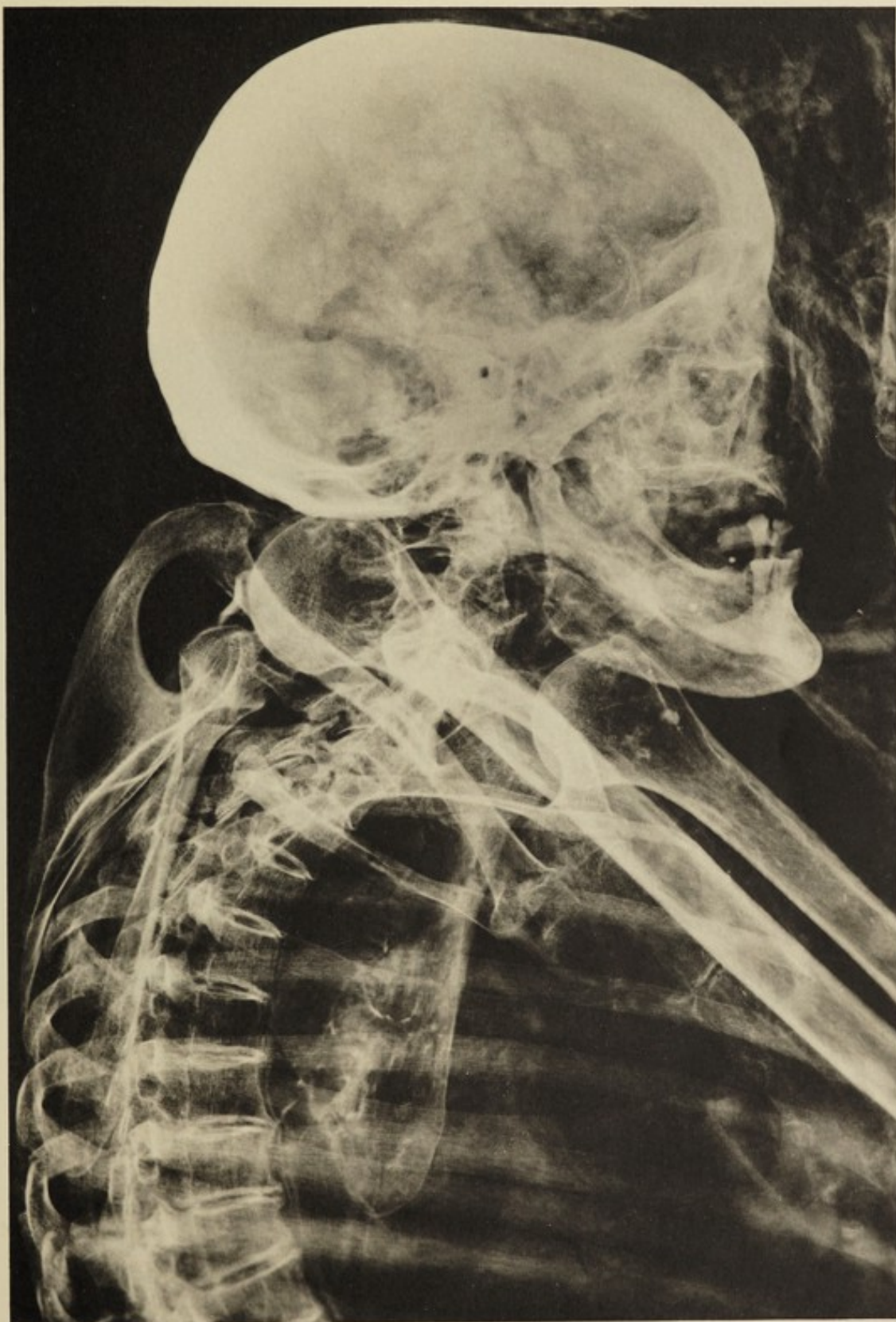 MacCurdy, G. G., 27
 Mace injury, 30
 Machu Picchu, lost city in the Andes, 16
 Maize, ears of in ancient Peruvian mummy packs, 34, 35
 Mäkeri, Queen, 19
 Mammals, mummified in ancient Egypt, 53, 56
 Mastoiditis, in ancient Peru, 34, 52
 Mastoids, condition of in Peru, 33, 34
 Means, H. J., on mound-builders, 16
 Men, an Egyptian woman of this name, 25
 Metal, in mummy packs from Peru, 34, 35
 Mollusks in ancient Egyptian fauna, 59
 Mummies, animal in Egypt, 53; animal in Peru, 63; human, in Egypt and Peru, 20; North American, 17; Peruvian, 28

- Mummification, cost of for animals, 55; in Egypt, 19; of infants, 19; in Peru, 19
 Mushroom head of femur, 31, 32
Myiodon, skull of, 16
- Nasal septum, diseases of in Peru, 33
 Natron, 54
 Nehring, A., on Peruvian animals, 63
 Neoplasms, see Tumors
 Niter, 54
Nothotherium, X-ray of skull of, 16
- Oils, used in embalming, 54
 Olivella shells in mummy packs, 40
 Oral diseases, 26
 Osteitis, absorptive, see Pyorrhea
 Osteitis deformans, 56, 60
 Osteoma, auditory, 33
 Osteoporosis, in Peruvian children, 32, 38
 Otitis media, 33, 52
 Otosclerosis, 52
- Paget's disease, 56, 60
Papio anubis, 56
 Parakas, Peru, mummy mining in, 20
 Pedi Amon, an ancient Egyptian youth, 23
 Pediatrics, pre-Columbian, 45
 Perch, a Nile fish in mummified fauna, 59
 Pitch, used in embalming in Egypt, 24
 Pituitary fossa, 21
 Poker spine in Eskimo, 22
 Poncet, on diseases of apes, 56
 Pottery included in mummy packs, 28
 Pyorrhea alveolaris, 20, 26, 48
- Ramses III, 15
Rana, a frog in ancient Egypt, 53
 Reptiles, mummified in Egypt, 58
- Resins, 54
 Reutter, L., on embalming, 20
 Rickets, doubtful evidence of, 13, 22
 Rope, bark, 35; fiber, used in tying mummy packs, 34, 42
 Rouillon, André, 16
 Ruffer, M. A., 26
- Salt, used in embalming in Egypt, 54
 Serpents, mummified in bundles, 59
 Sinuses, frontal, 31; maxillary, 31
 Smith, G. Elliot, on Egyptian mummies, 15
 Snure, Henry, on X-rays of sloth, 16
 Spine, vertebral, curvature of, 23; poker, 22
 Spondylitis deformans, 21, 22
 Syphilis, absence of in ancient times, 52
- Tartar formation, 47
 Teeth, diseases of, 47
 Tello, Julio C., 20
 Toad in Egypt, 53
 Trepanation, double, in Peru, 37, 50
 Trepanning in Peru, 49
 Tumors, 29, 32, 49
 Turtle, 54
 Tutmosis I and IV, 15
- Uta, a phase of leishmaniosis, 51
- Vandalism, 19, 56
 Verrill, A. Hyatt, 63
 Vulture, 62, 63
- Williams, Herbert U., 47
 Wood, Frank E., 49
 Wood-Jones, F., 16

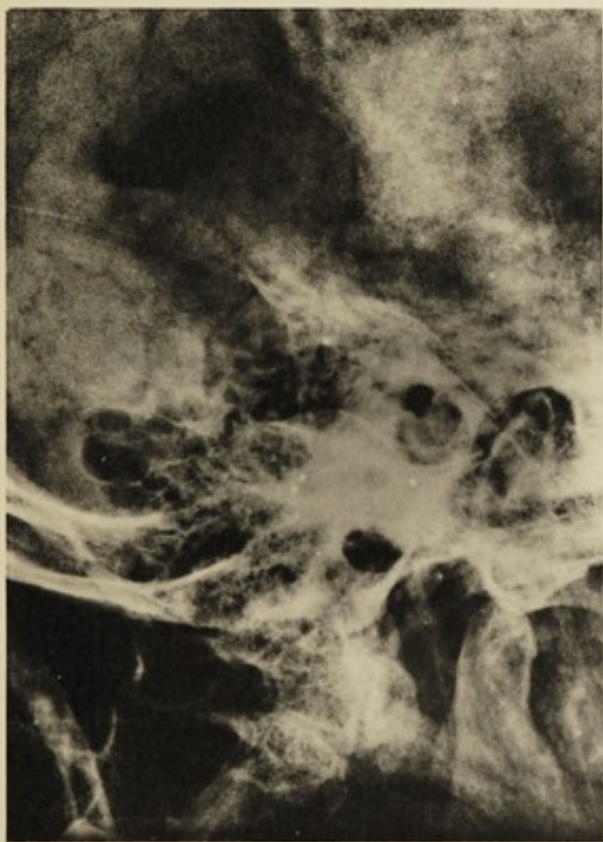



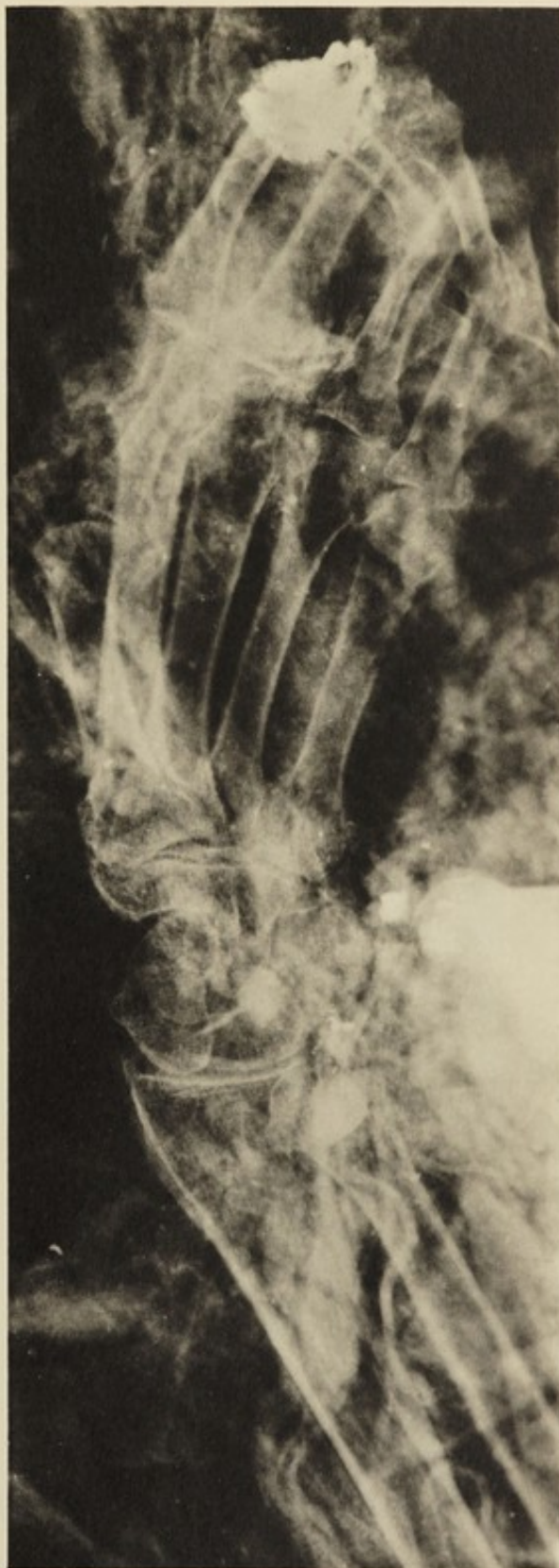MONTANA BLACKFOOT INDIAN
North American tree burial



WOMAN FROM PREDYNASTIC BURIAL, EGYPT
Head and trunk

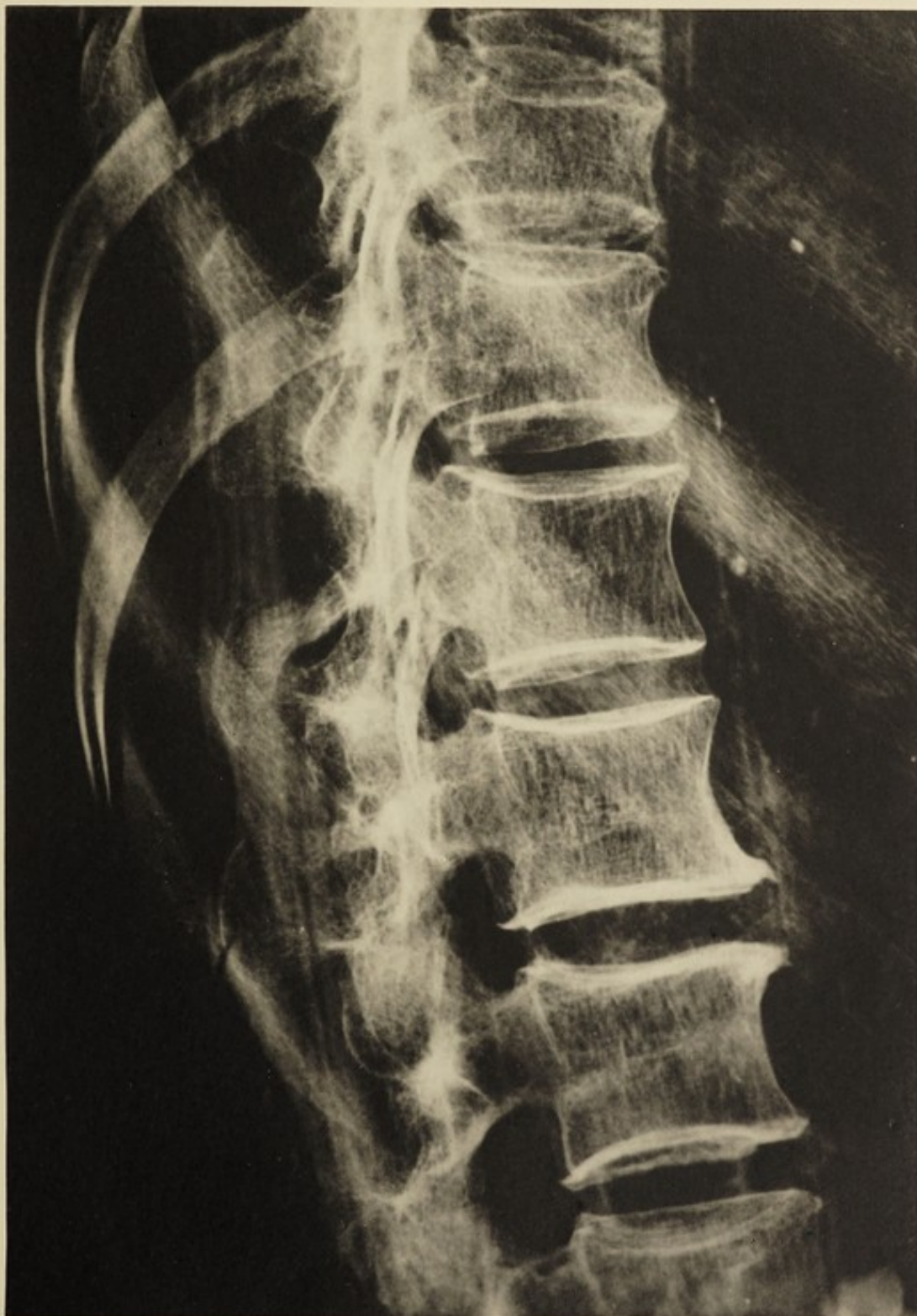

1

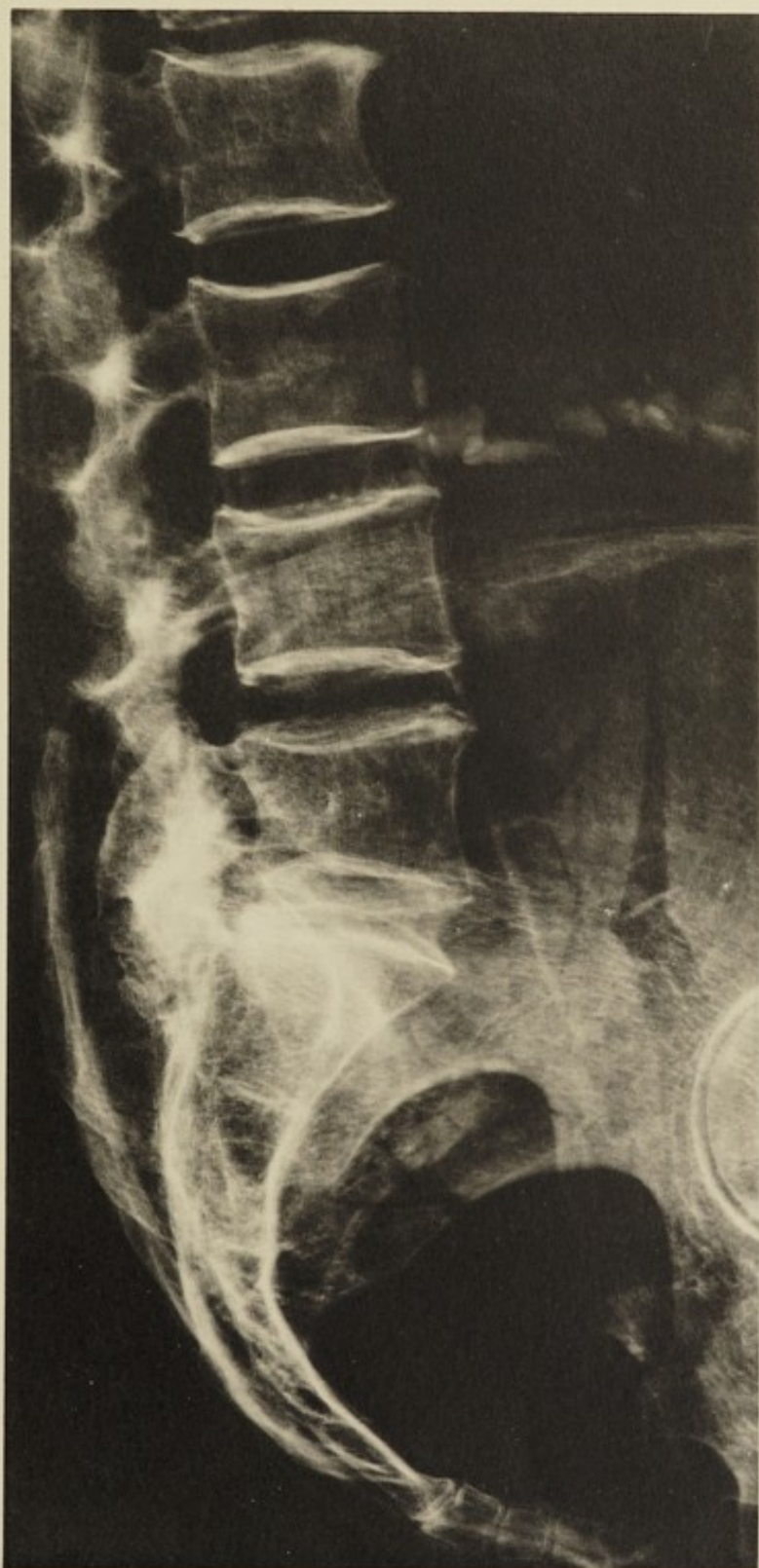


2

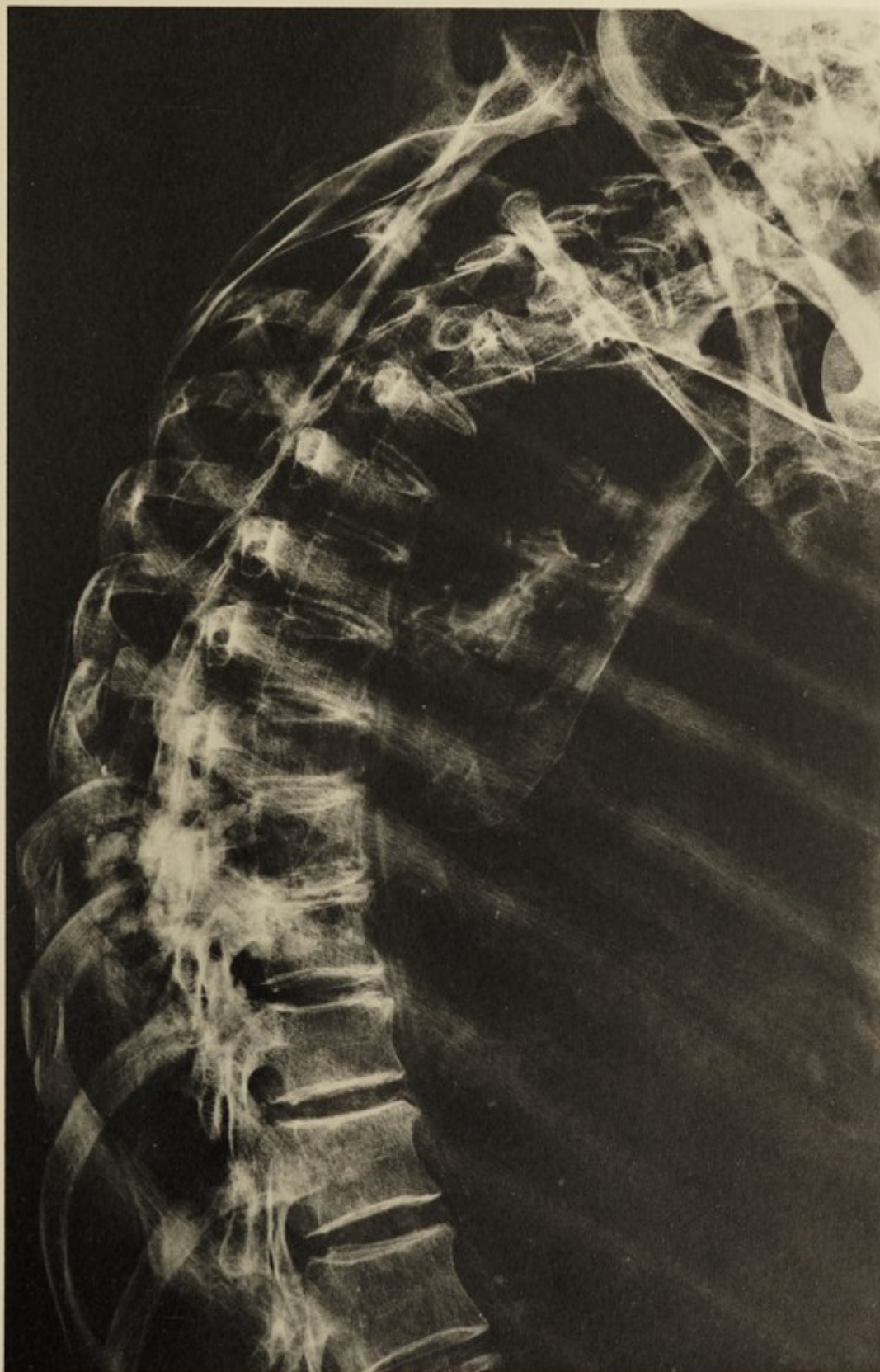SAME WOMAN AS PLATE II
1. Right mastoid. 2. Hand and wrist



SAME WOMAN AS PLATE II
Vertebral column showing lesions



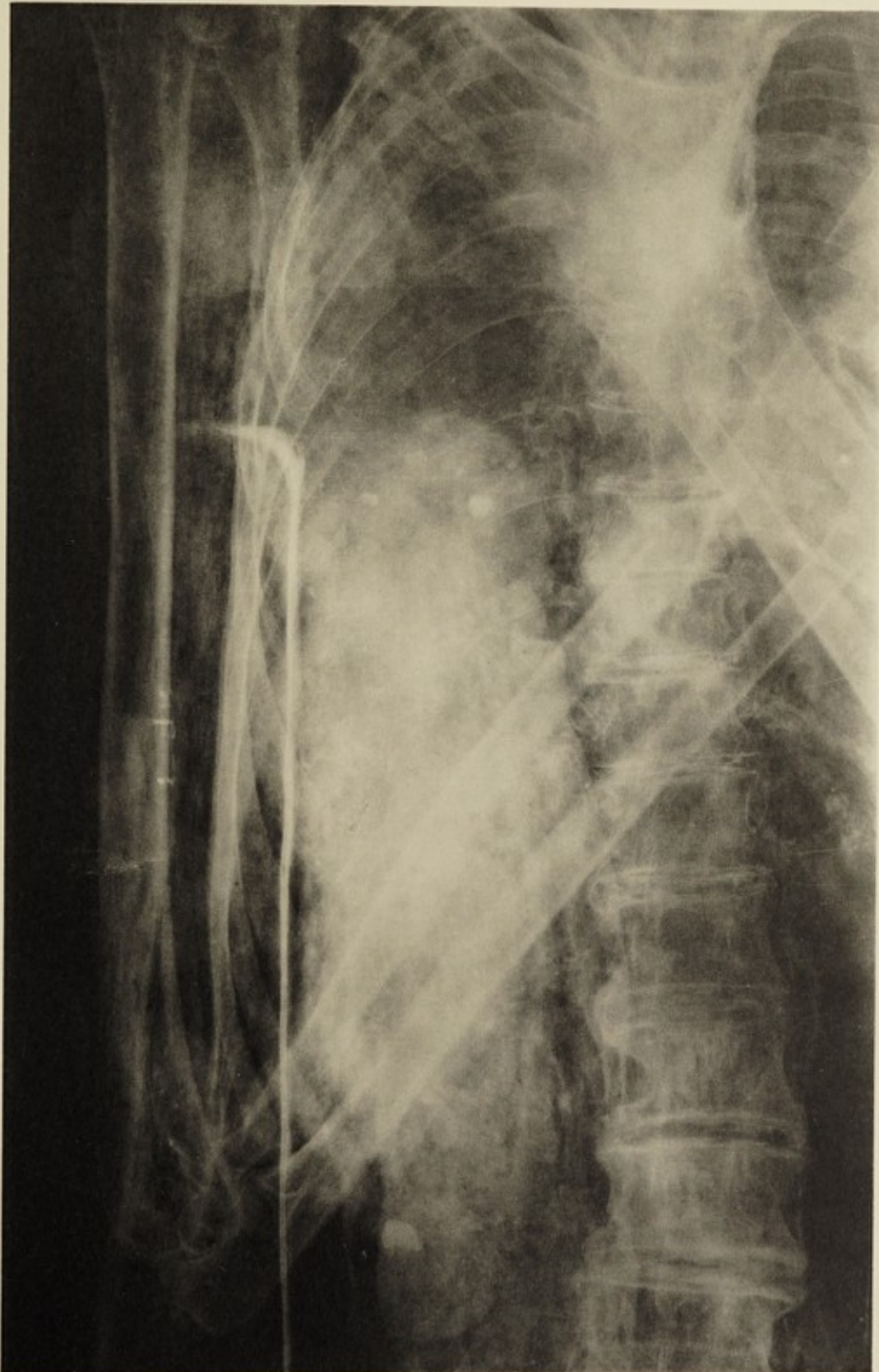
SAME WOMAN AS PLATE II
Lumbar vertebrae, sacrum, and coccyx



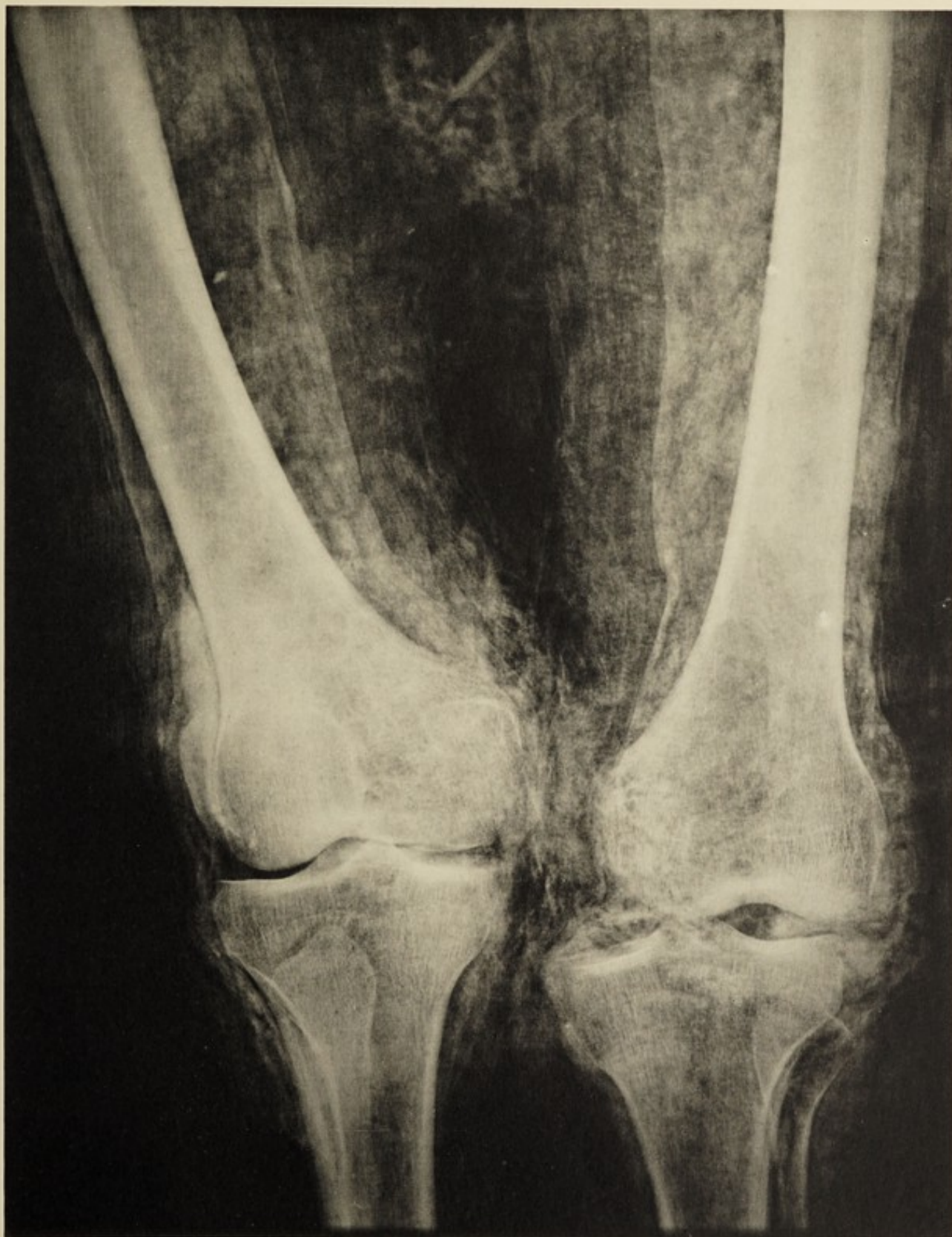SAME WOMAN AS PLATE II
Ossification in anterior longitudinal ligament



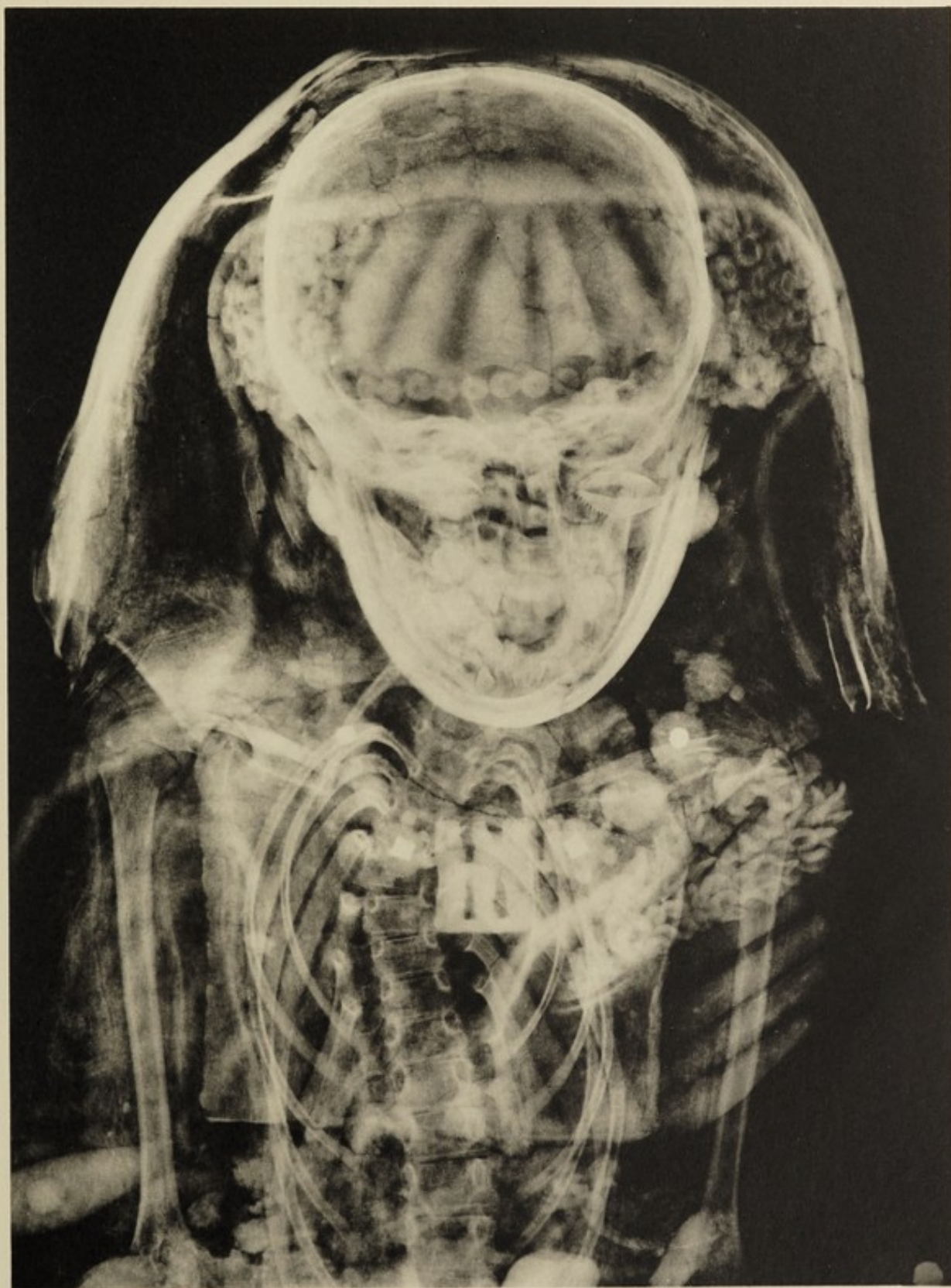POKER SPINE OF AN ESKIMO



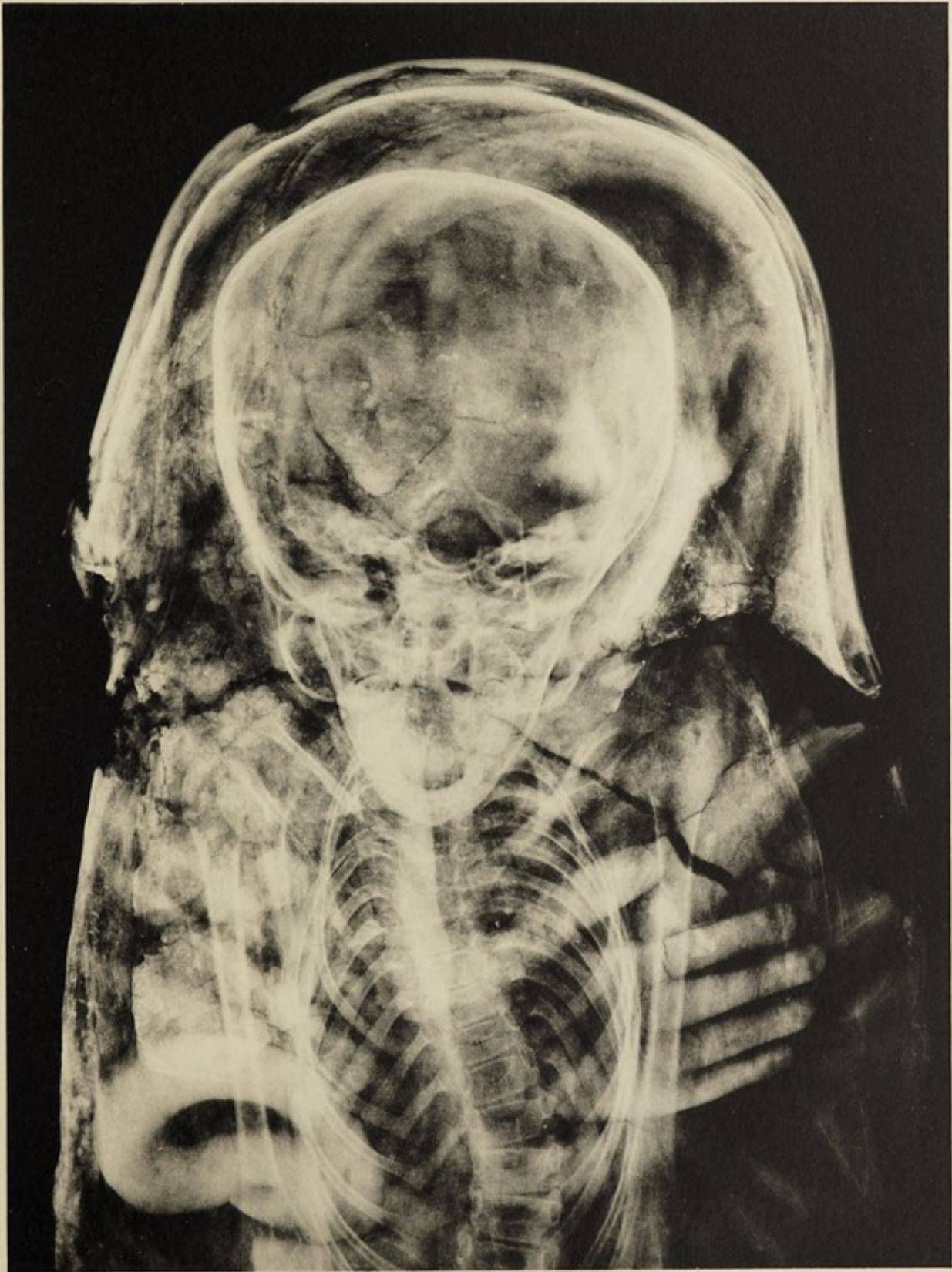TORSO OF MUMMY, EGYPT
Long shadow may indicate liver



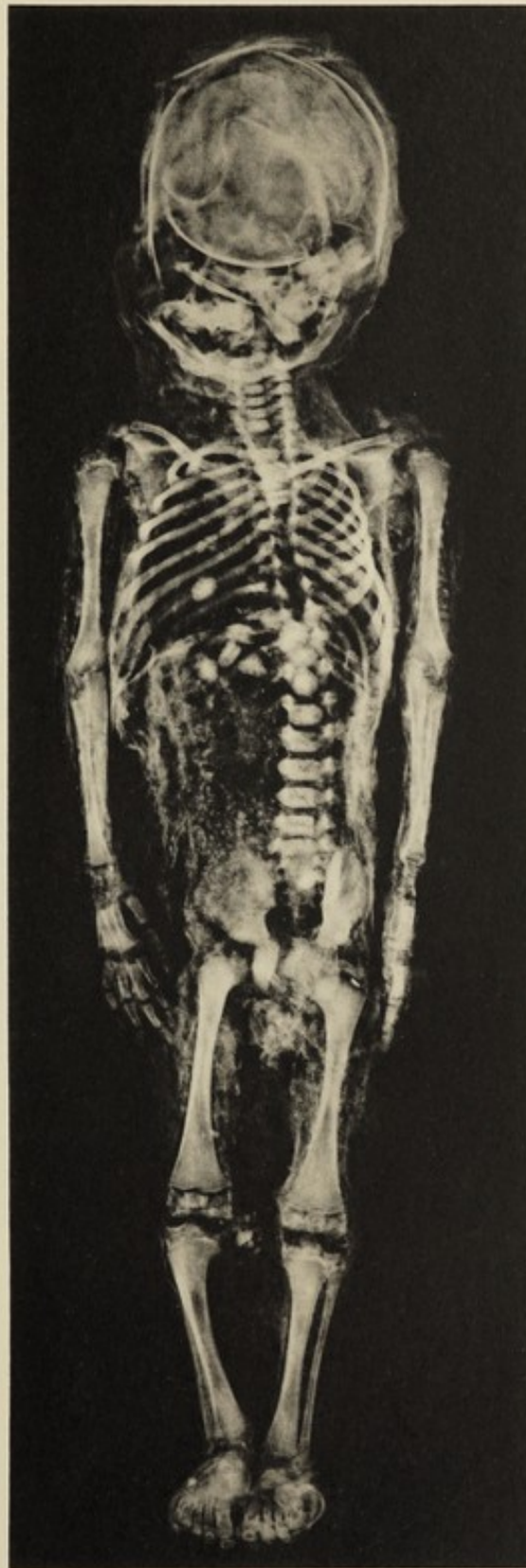
MUMMY, EGYPT
Detail showing genu valgum



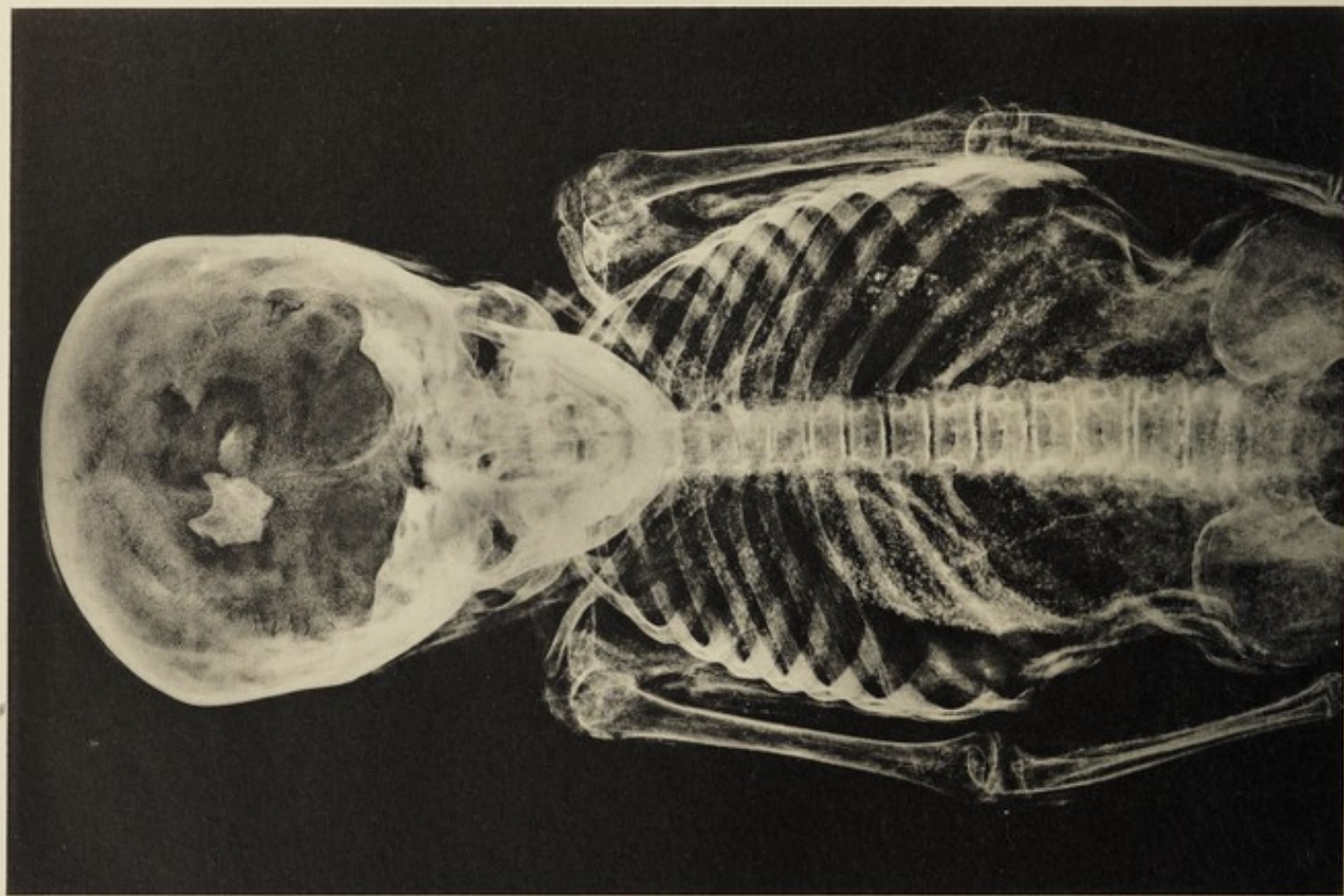
GIRL WITH CURVATURE OF SPINE, ROMAN PERIOD, EGYPT

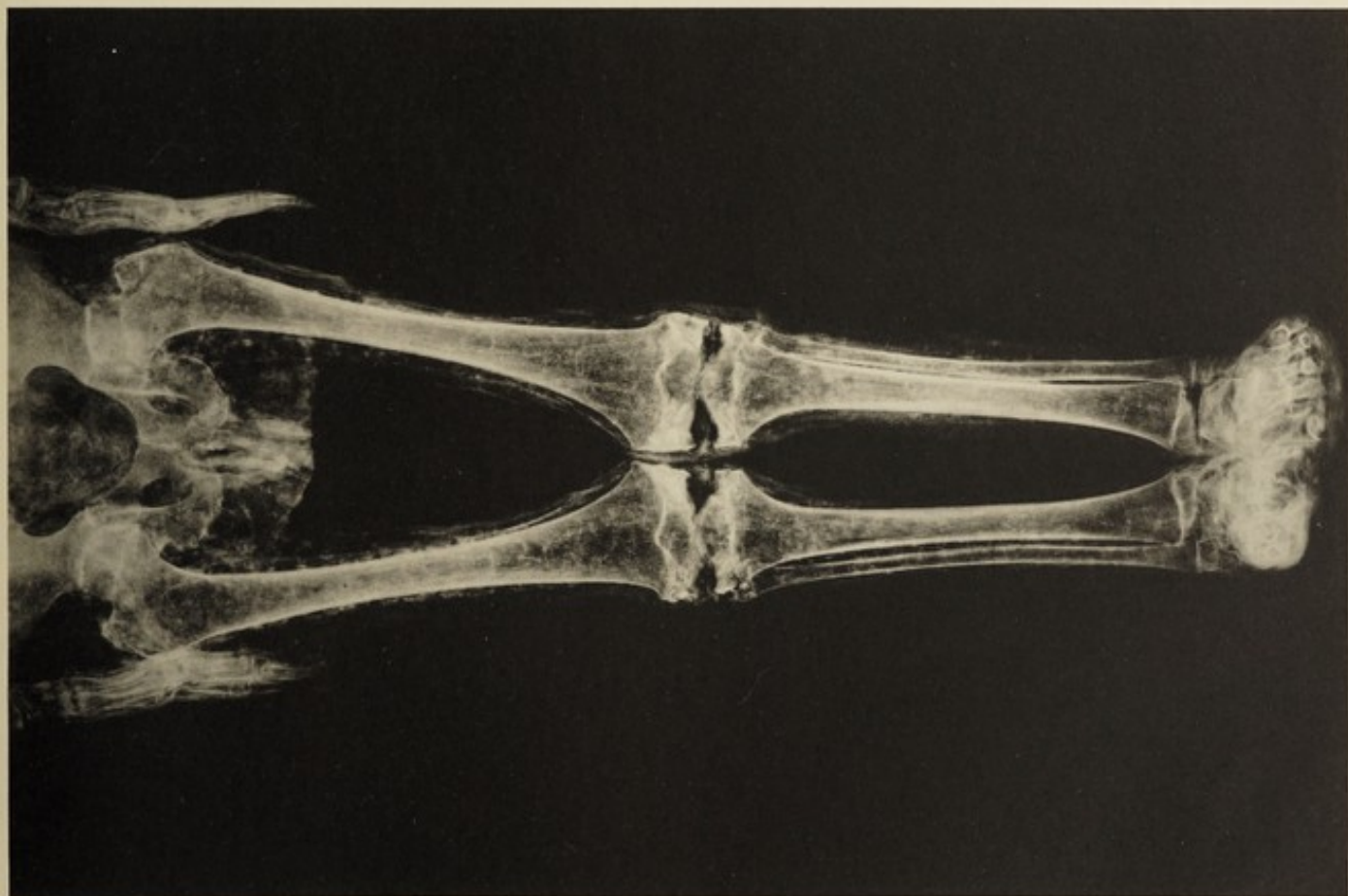


BOY WITH CURVATURE OF SPINE, ROMAN PERIOD, EGYPT
Brother of girl in preceding Plate

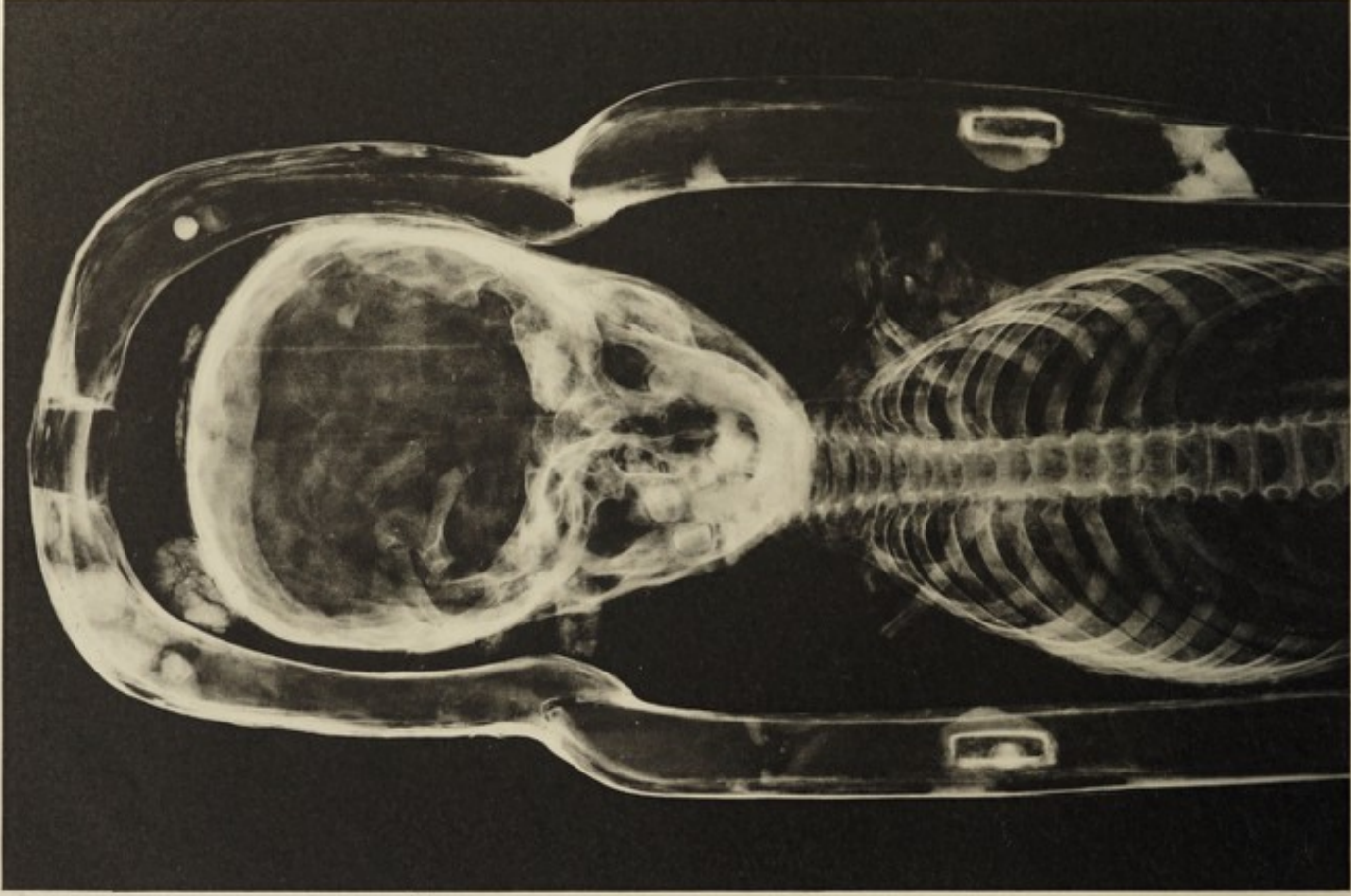


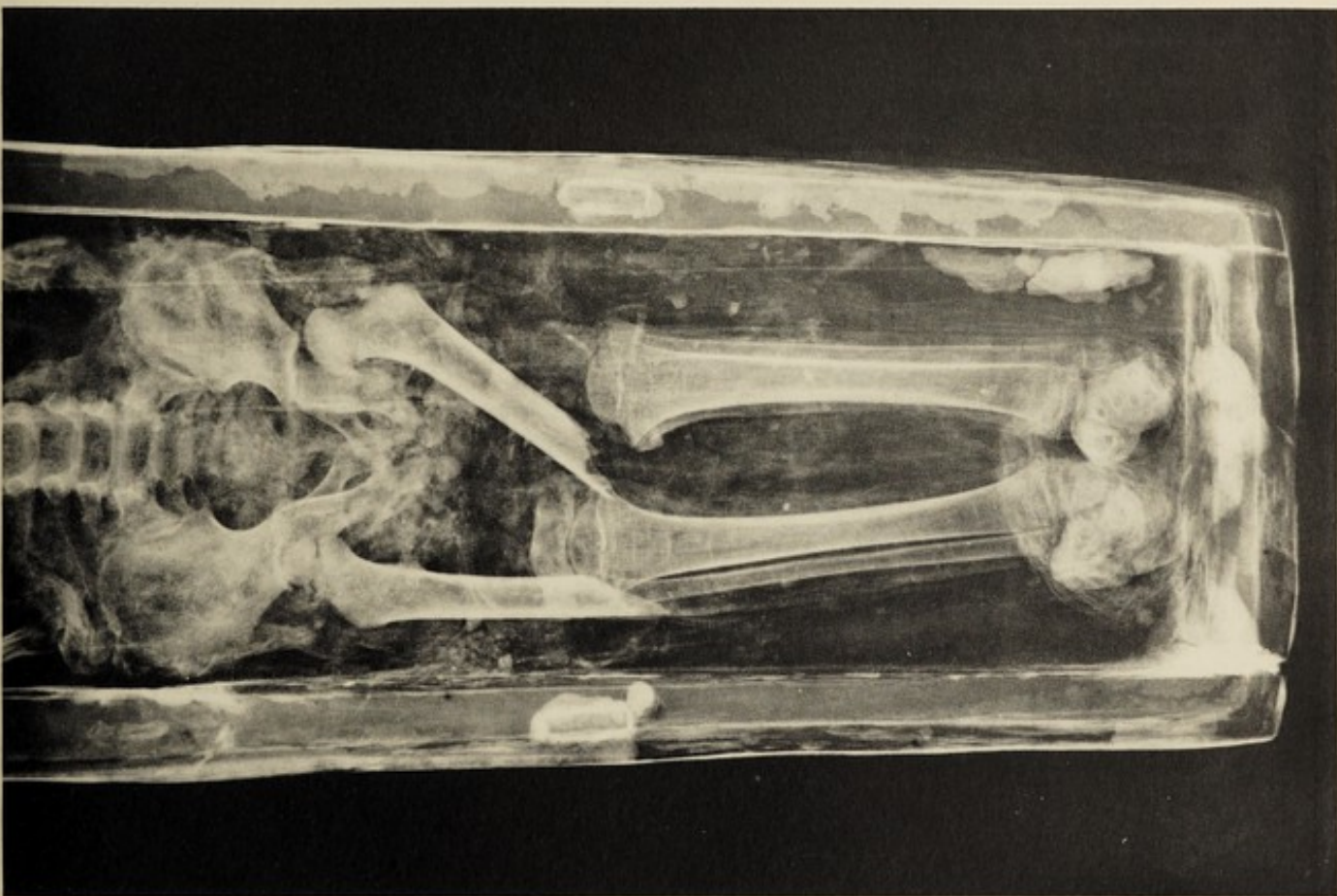
UNWRAPPED MUMMY OF INFANT, EGYPT



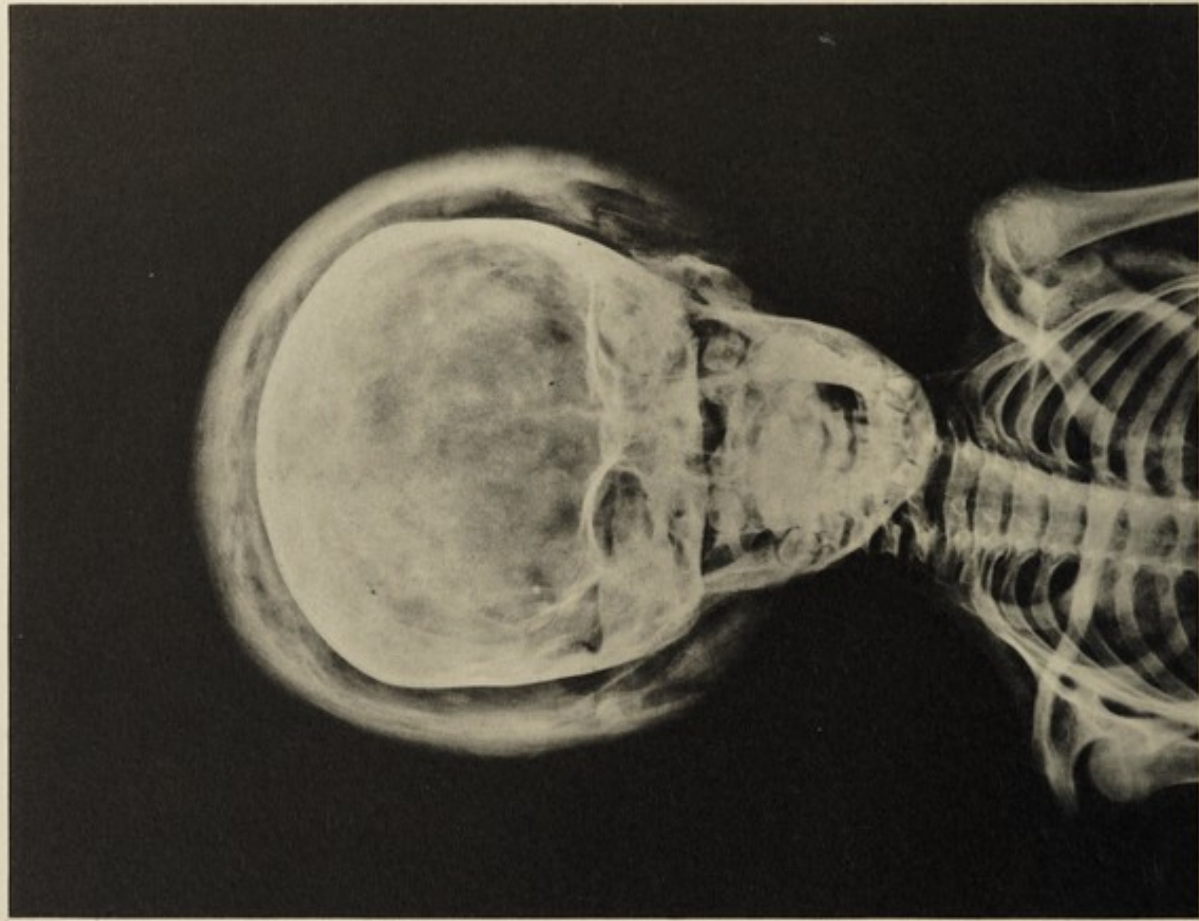


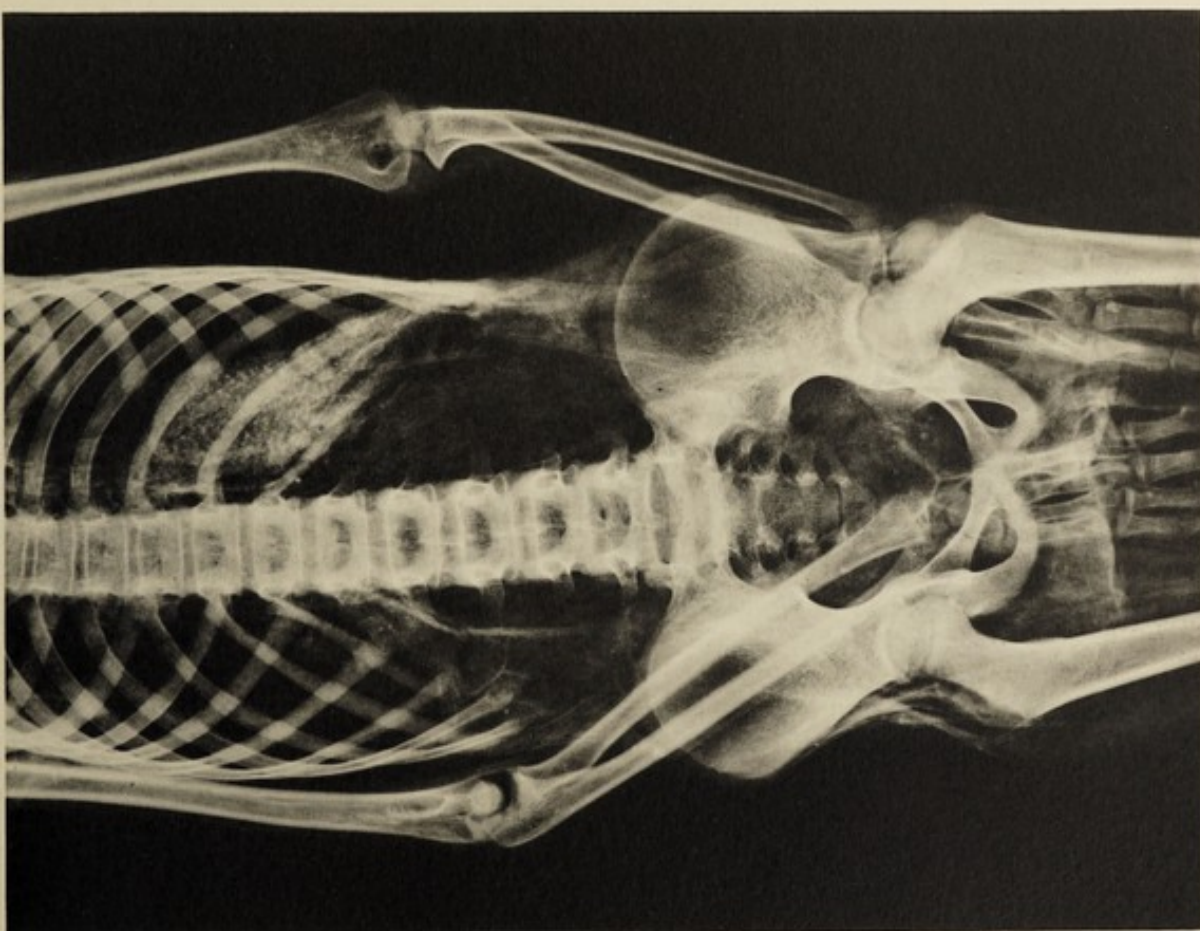
UNWRAPPED MUMMY OF CHILD, EGYPT



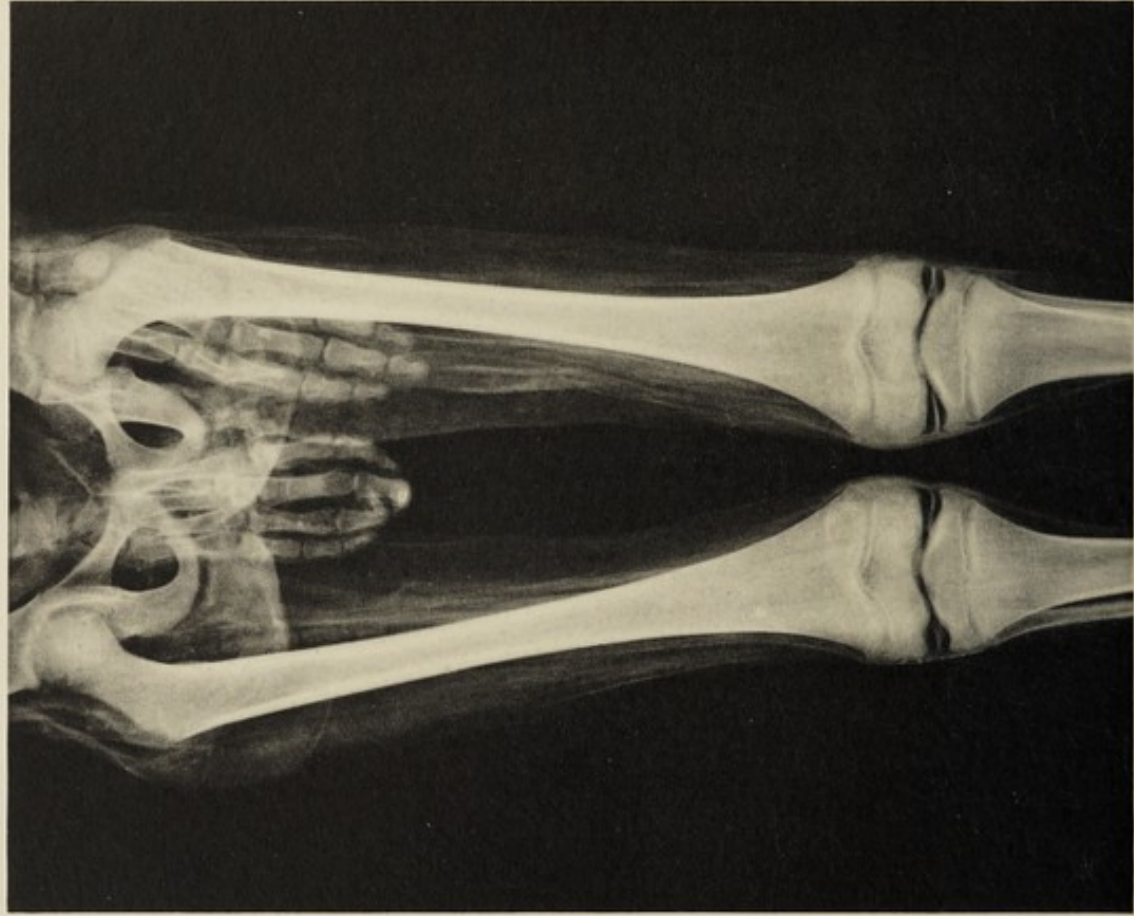


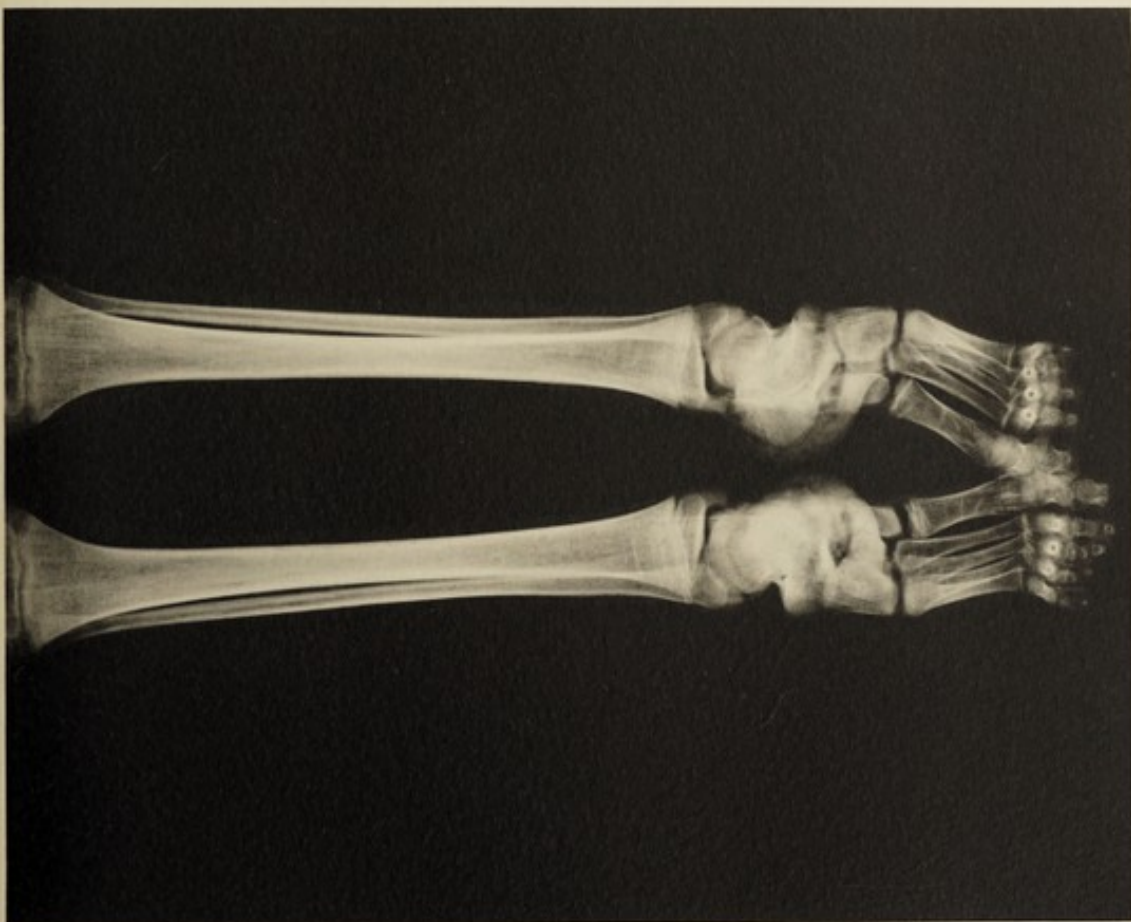
MUMMY OF CHILD IN COFFIN, EGYPT
Roentgenogram reveals absence of arms and parts of femora





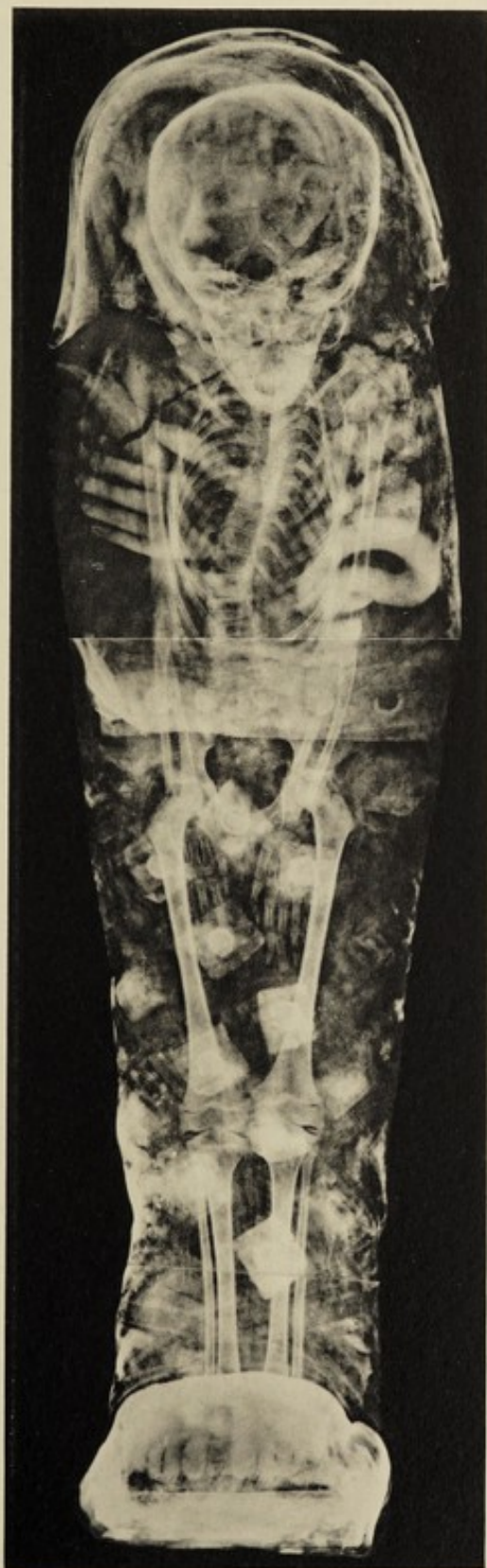MUMMY OF BOY TWELVE YEARS OLD, EGYPT
Head and torso. Wrapping removed except from head



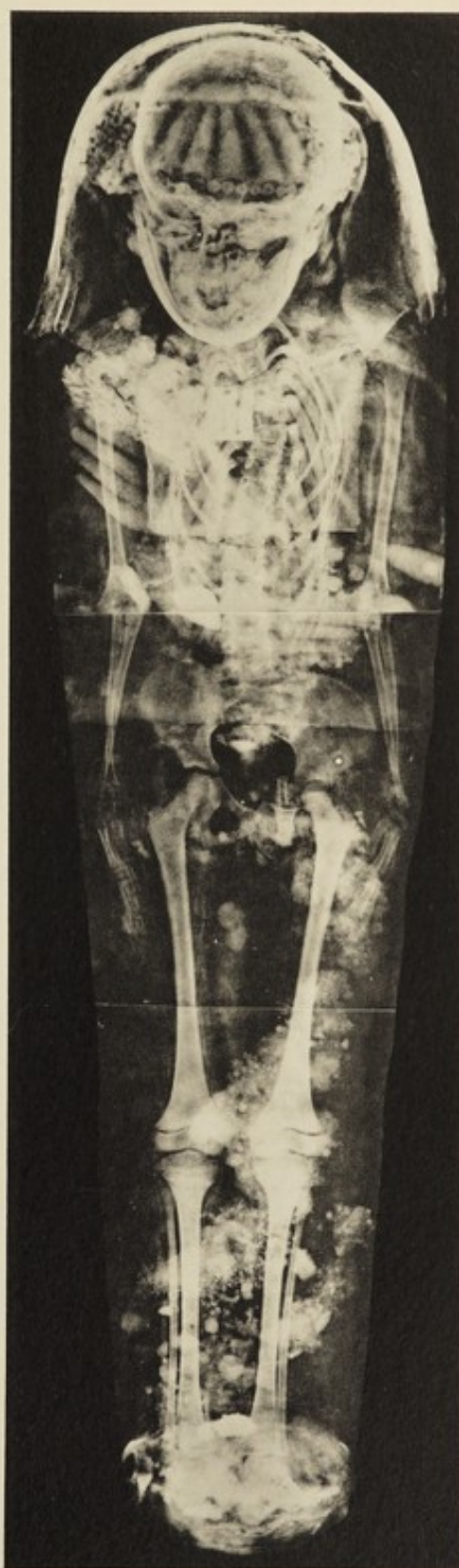


LOWER LIMBS OF BOY IN PRECEDING PLATE

Body in excellent state of preservation



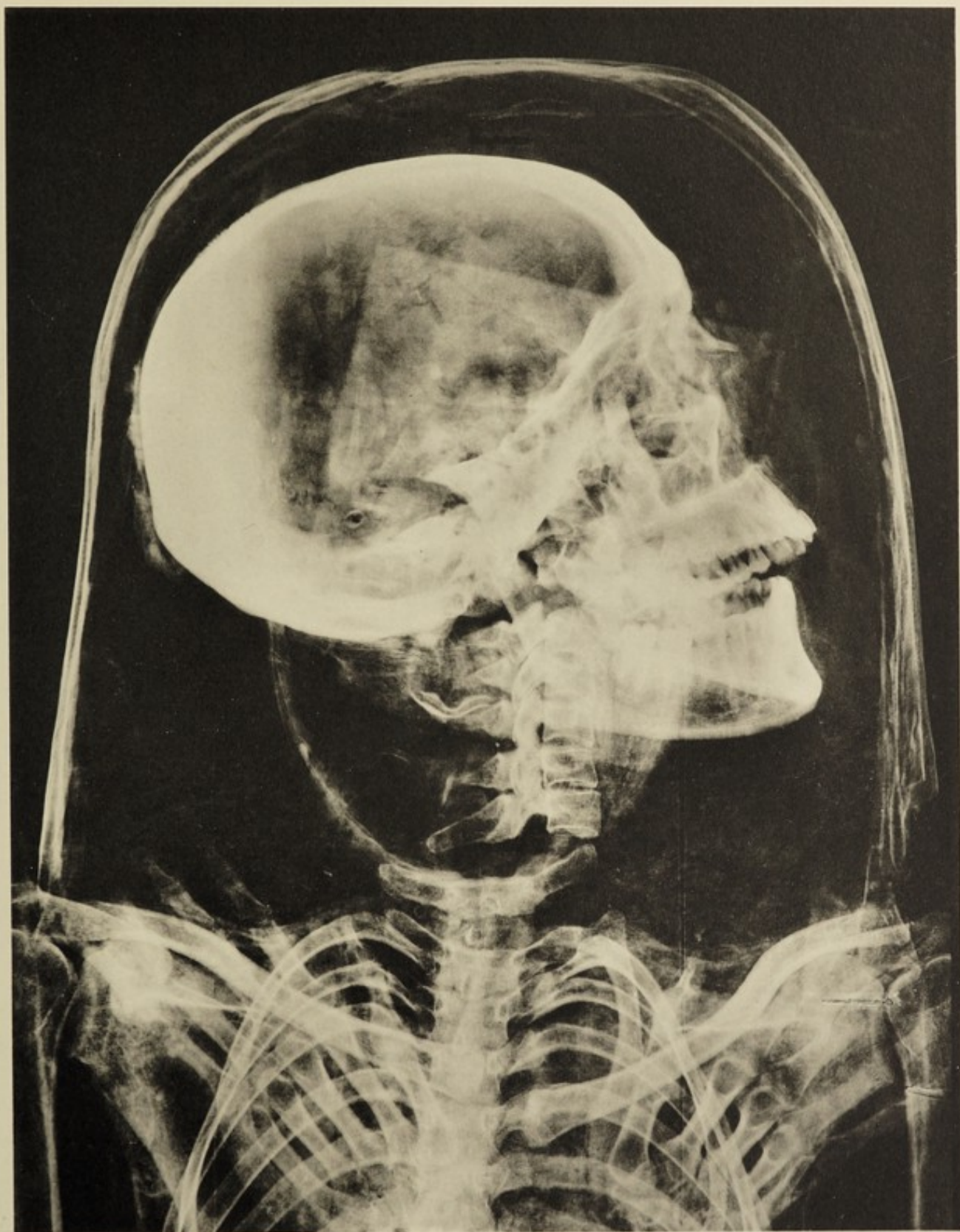
1



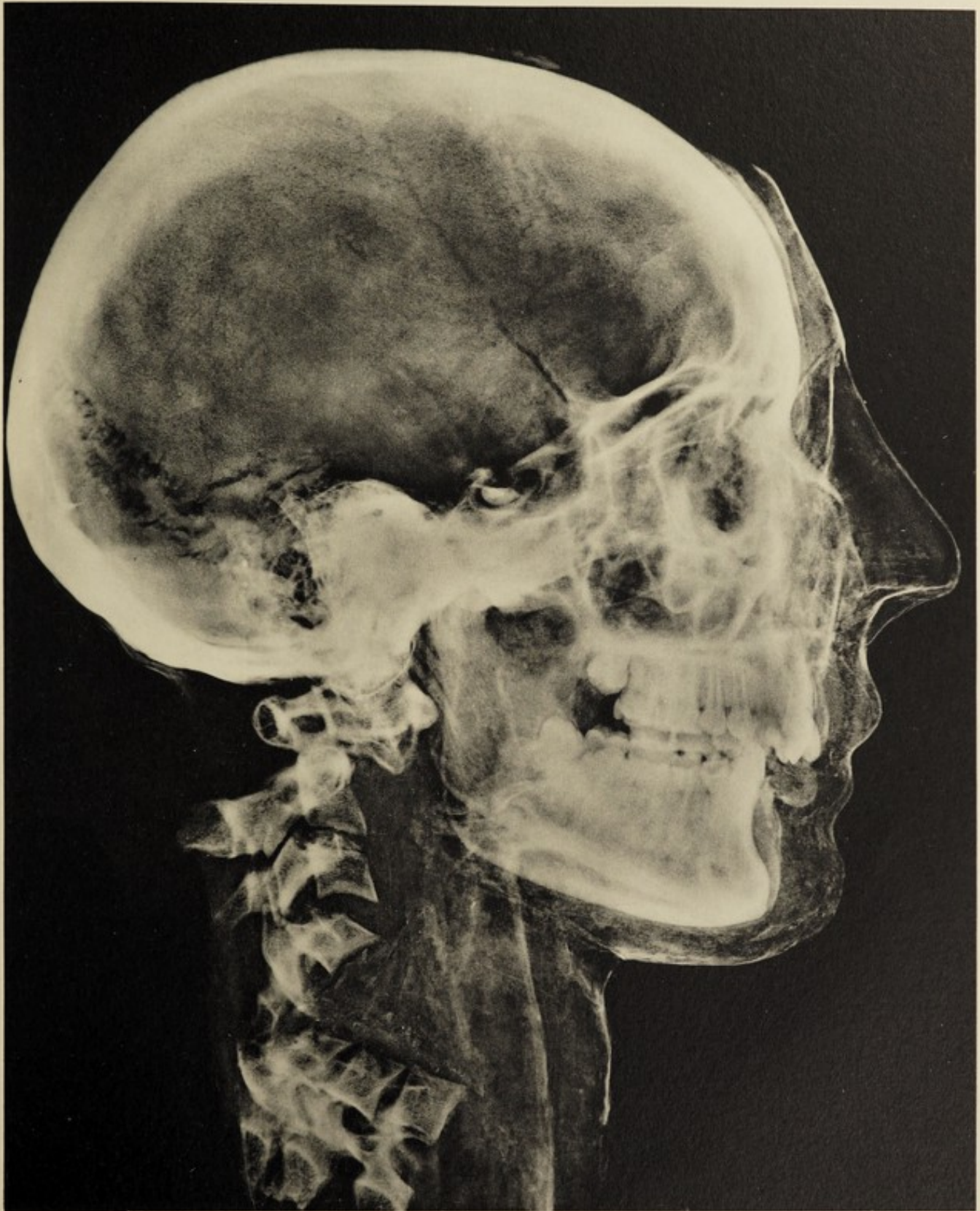2

CHILD MUMMIES, ROMAN PERIOD, EGYPT

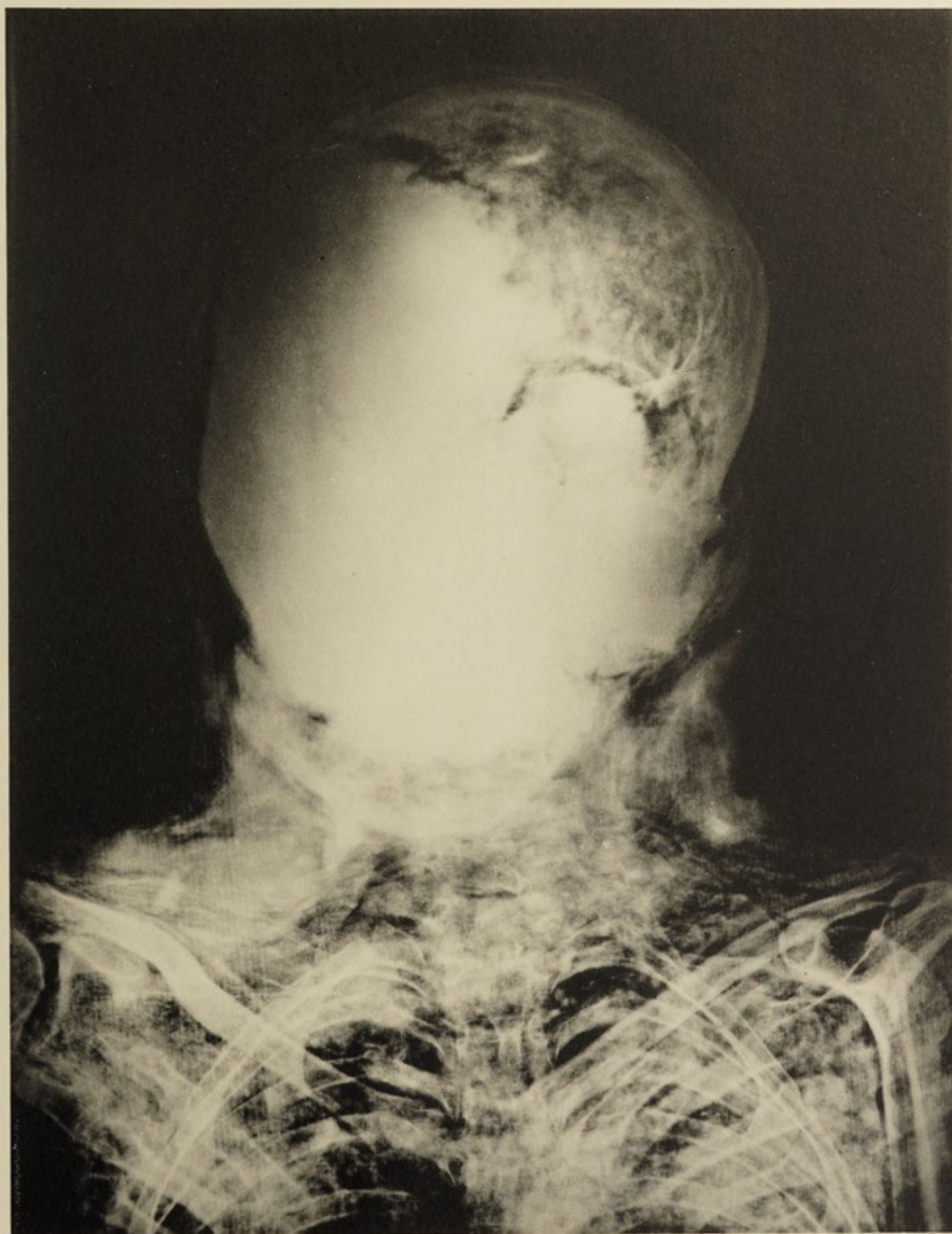1. Boy. 2. His sister



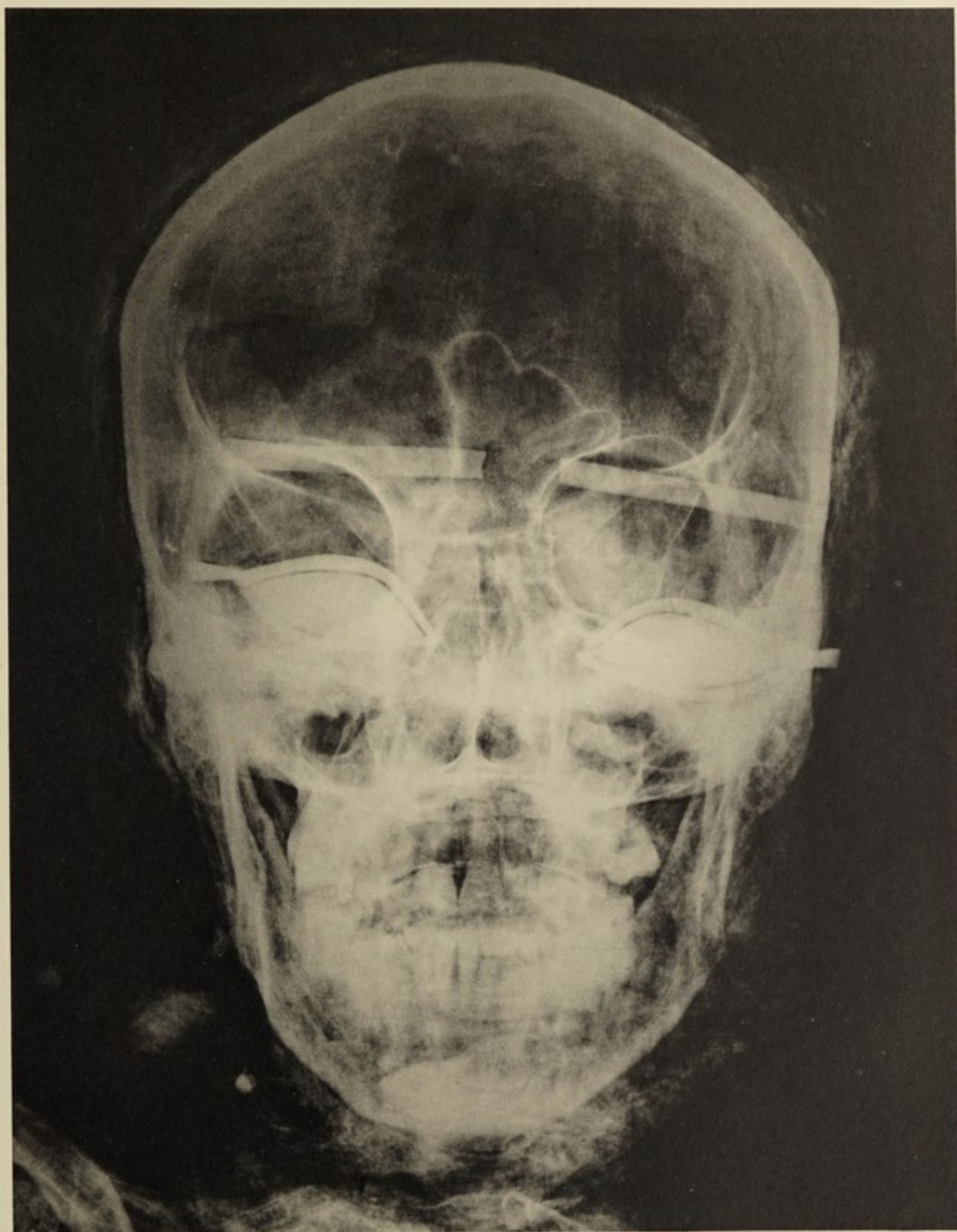
HEAD OF MUMMY, YOUNG WOMAN, EGYPT
The complete mummy is in the Museum's collection



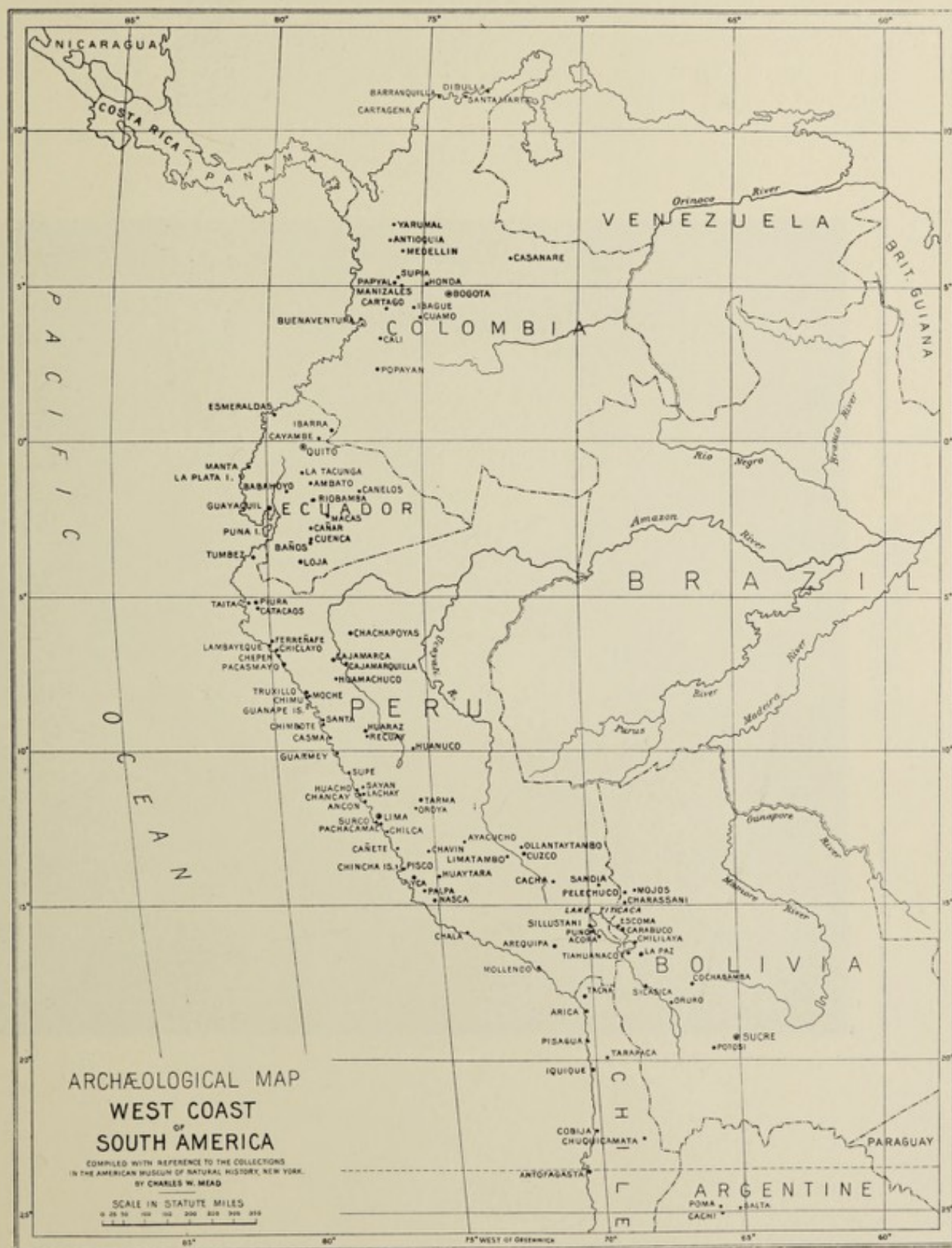
MUMMY HEAD WITH CARTONNAGE, EGYPT

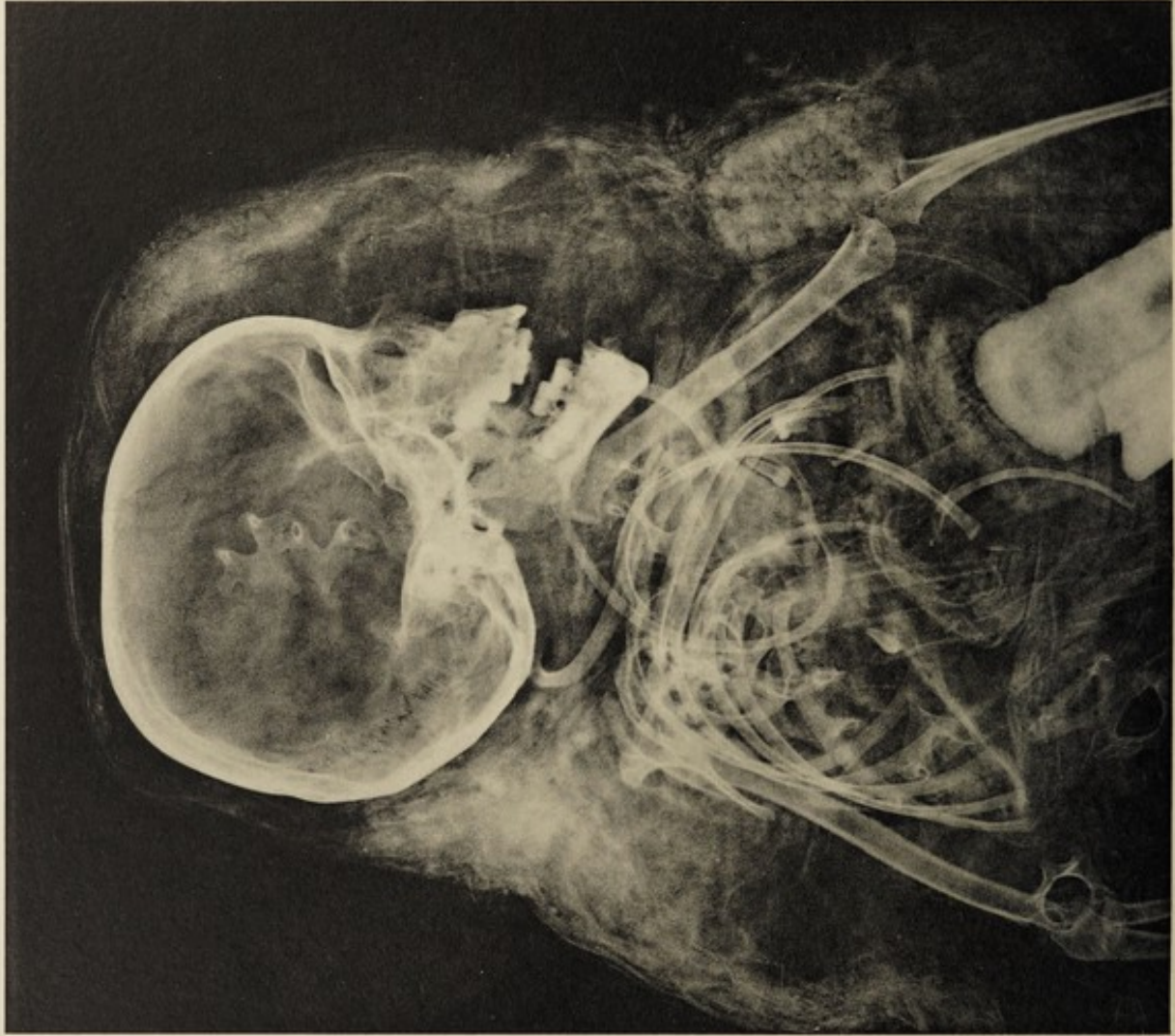


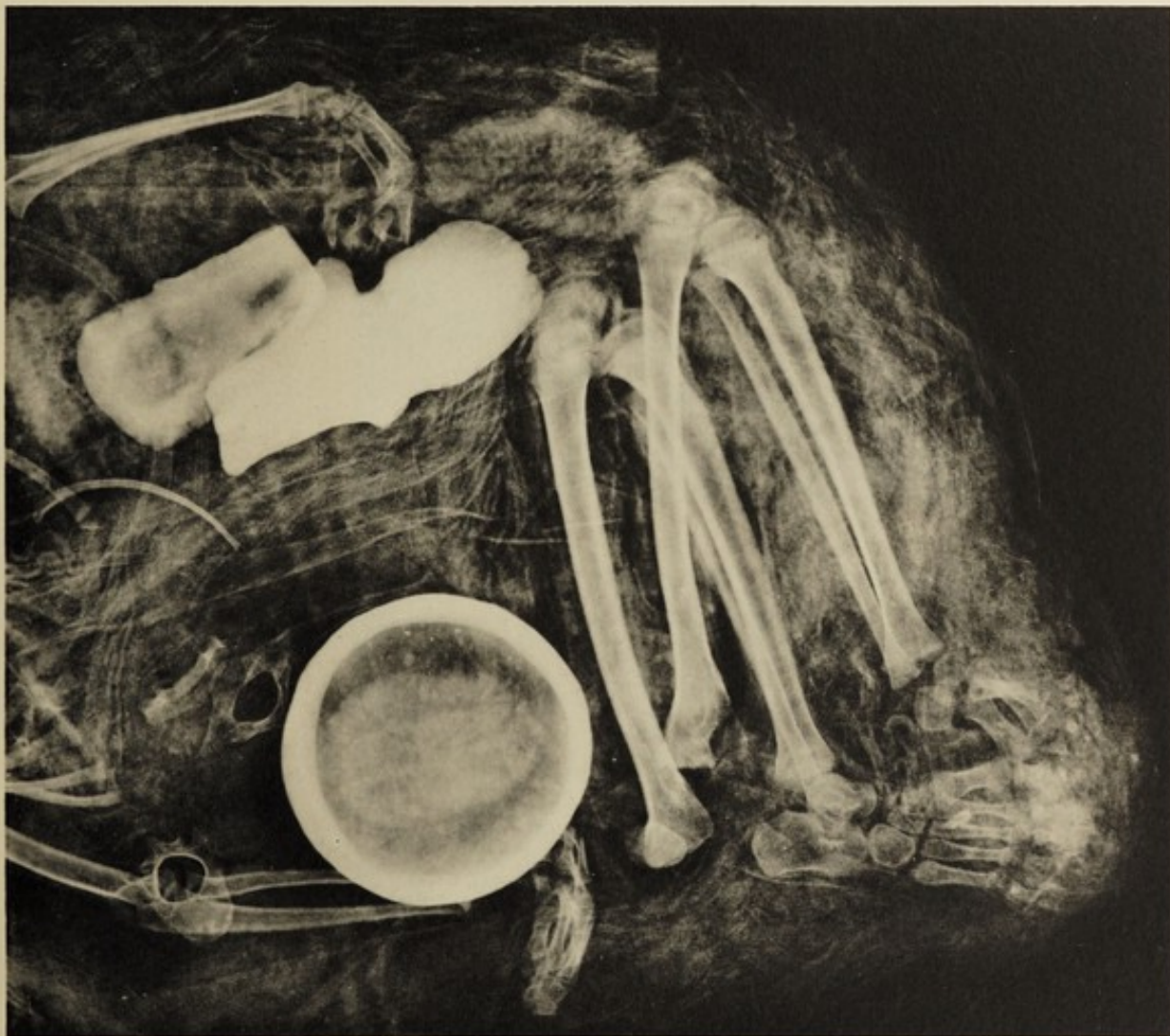MUMMY HEAD AND NECK, EGYPT
Anatomical detail obscured by pitch in wrappings



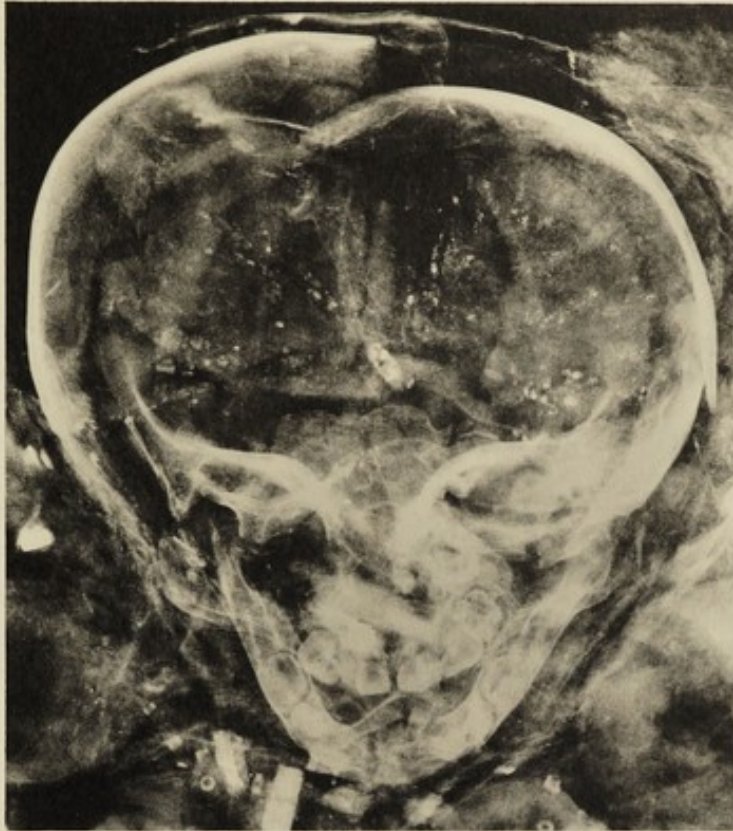MUMMY HEAD OF MAN SHOWING PAINTED MASK, EGYPT



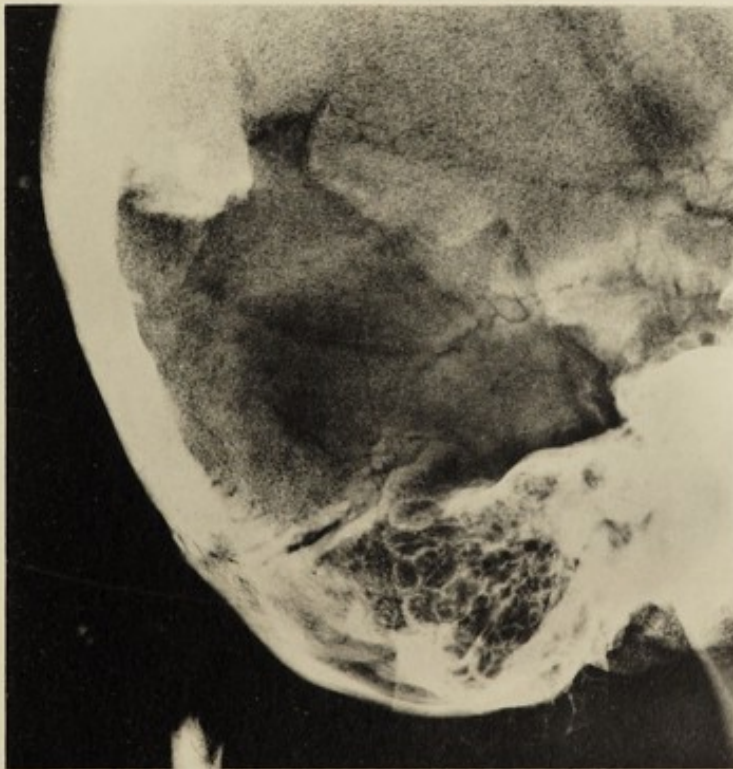




MUMMY OF CHILD, PERU
Pottery, trinkets and maize in package



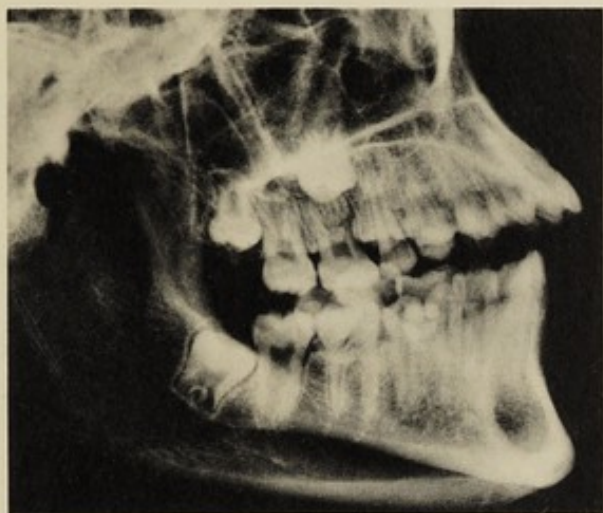1



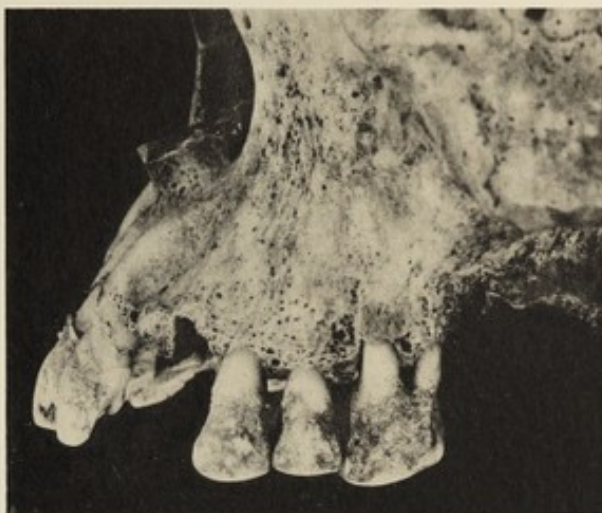2

HEADS OF MUMMIES, PERU

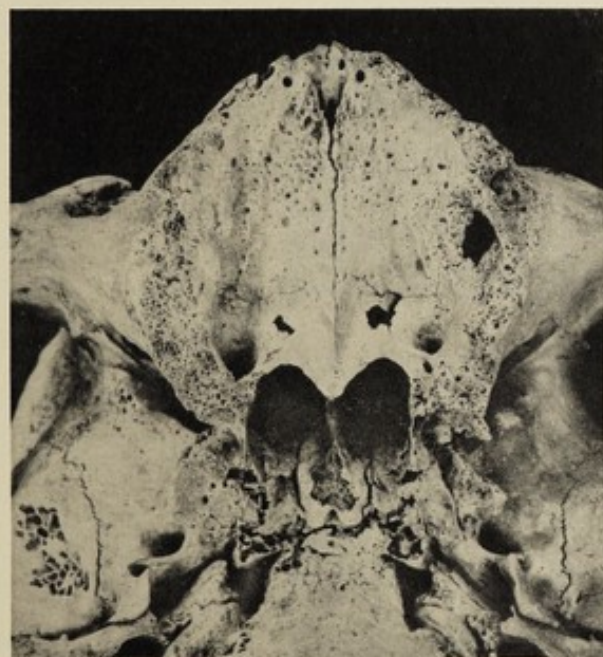1. Hydrocephalus in infant. 2. Mastoid and adjoining injury in adult



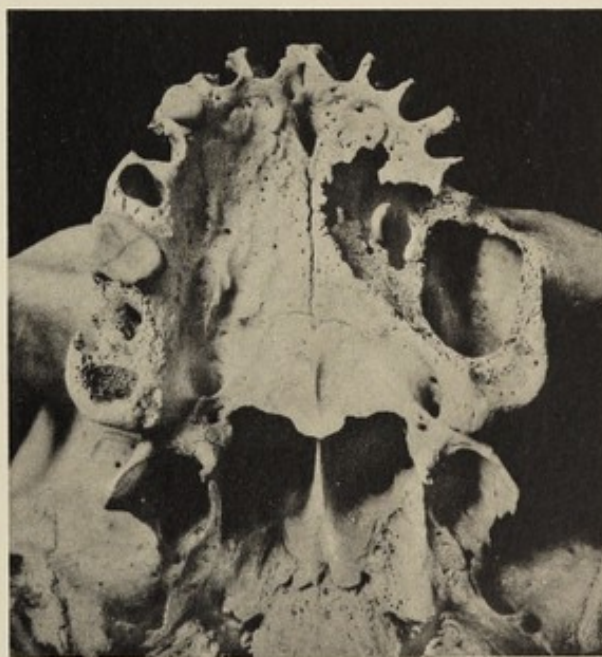
1



2



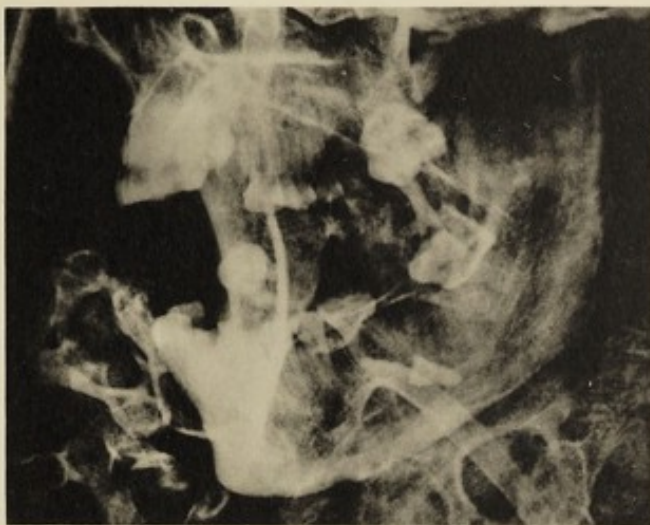3



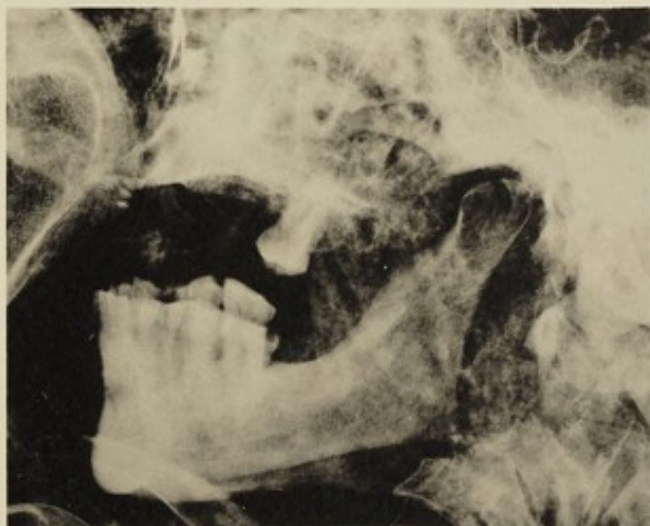4

SKULLS, PERU

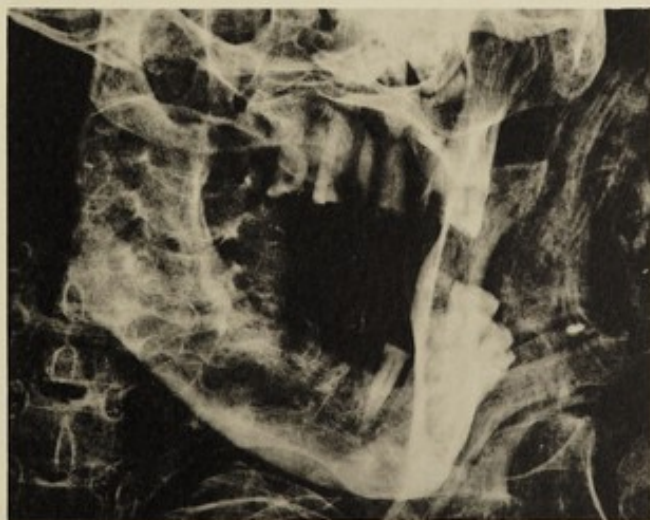
1. Impacted lower right, third molar. 2. Pyorrhea and salivary calculus. 3. Edentulous palate. 4. Effects of soft tumor on palate



1



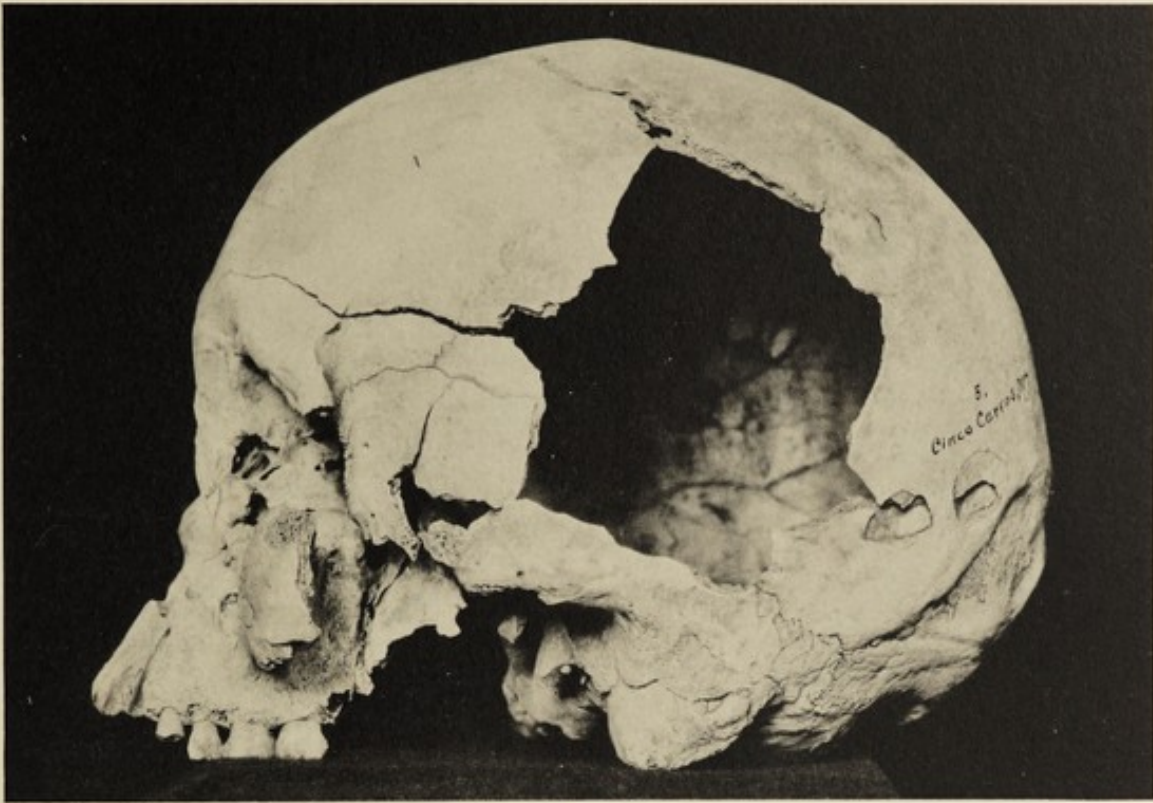2



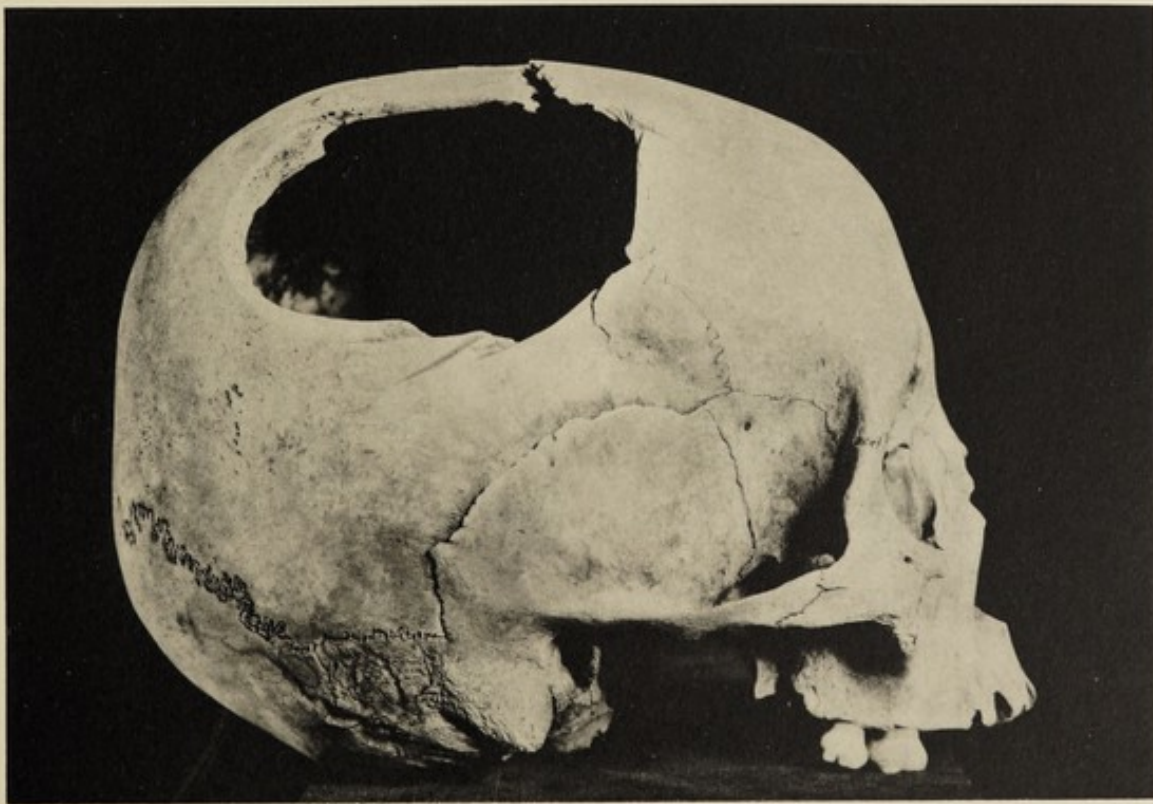3

PARTS OF SKULLS OF MUMMIES, PERU

1-2. Pyorrhea. 3. Pyorrhea and caries



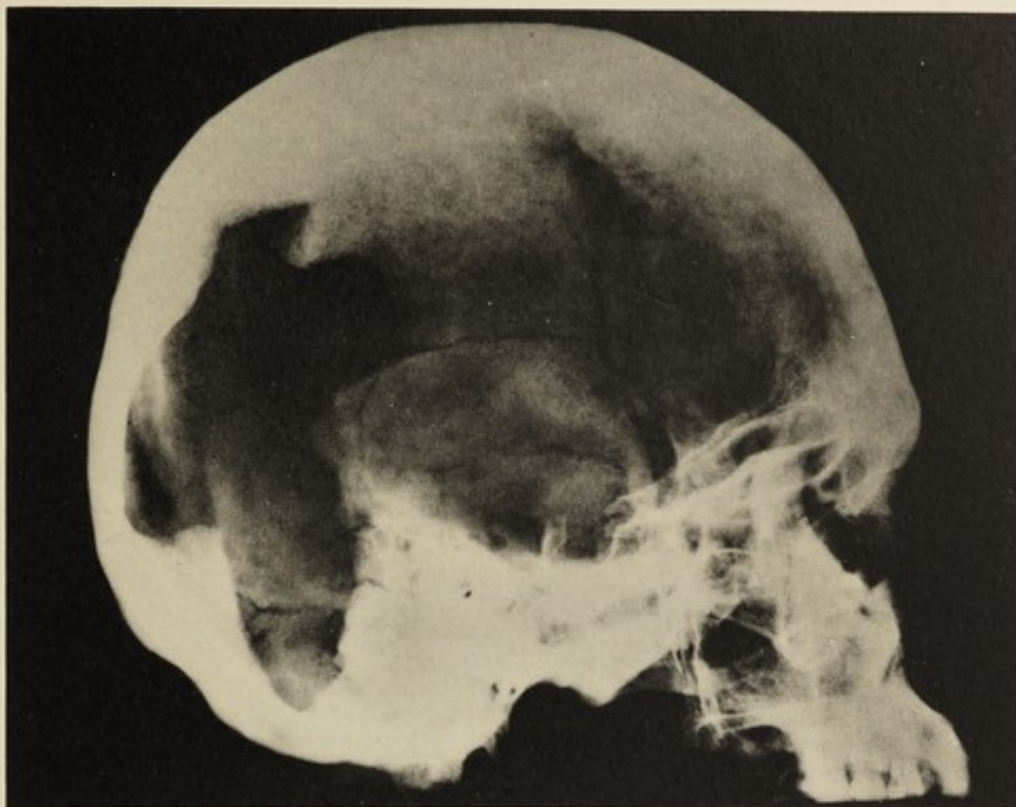
1



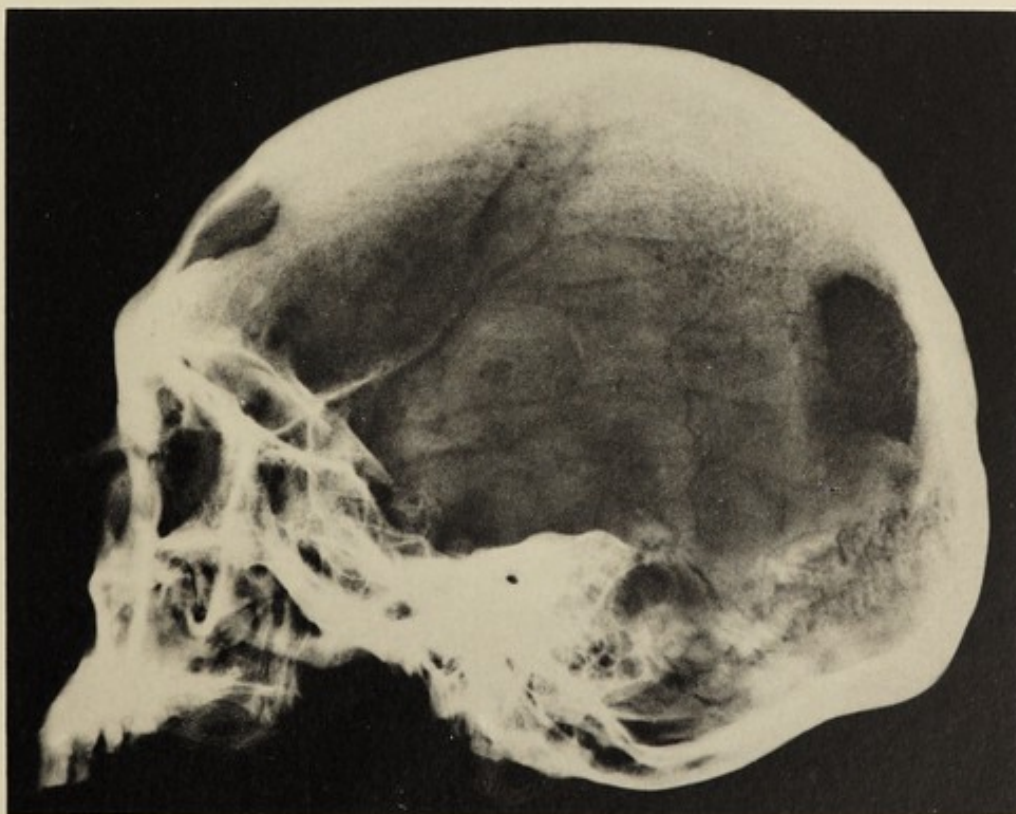
2

SKULLS, PERU

1. Mace injury. 2. Trepanning



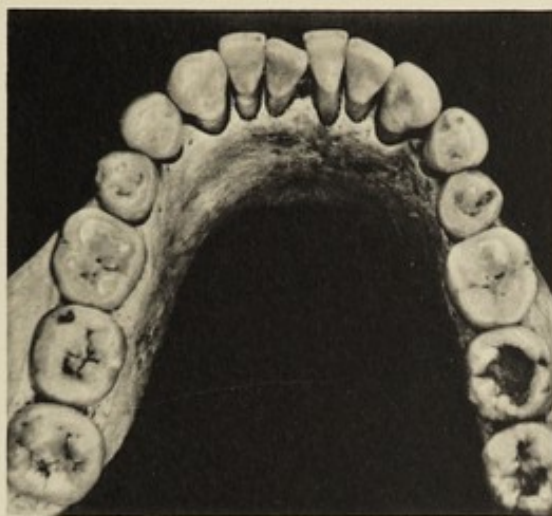1



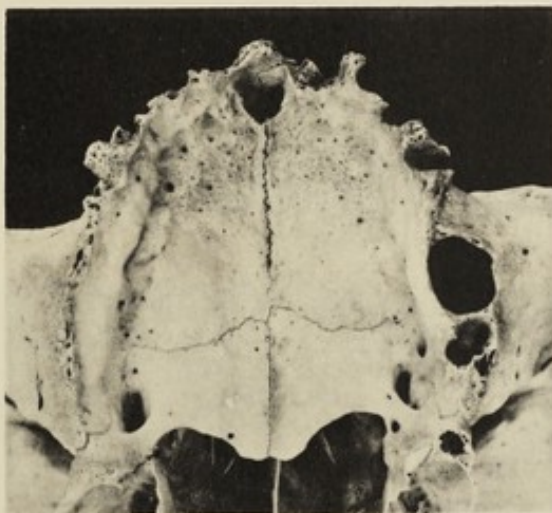
2

SKULLS, PERU

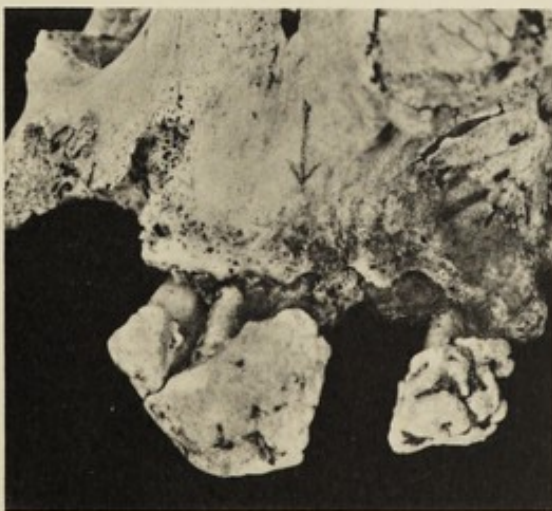
1. Mace injury. 2. Trepanning



1



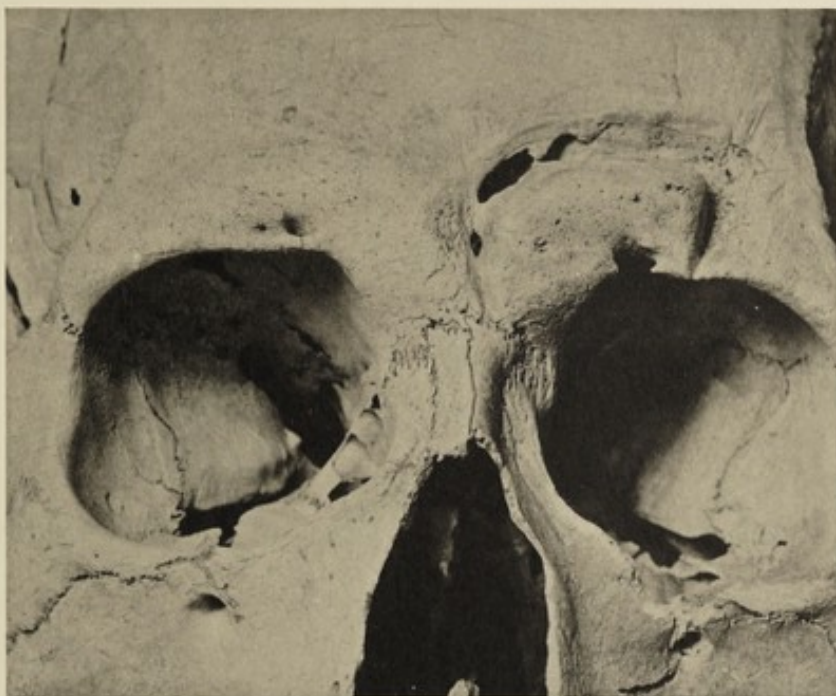2



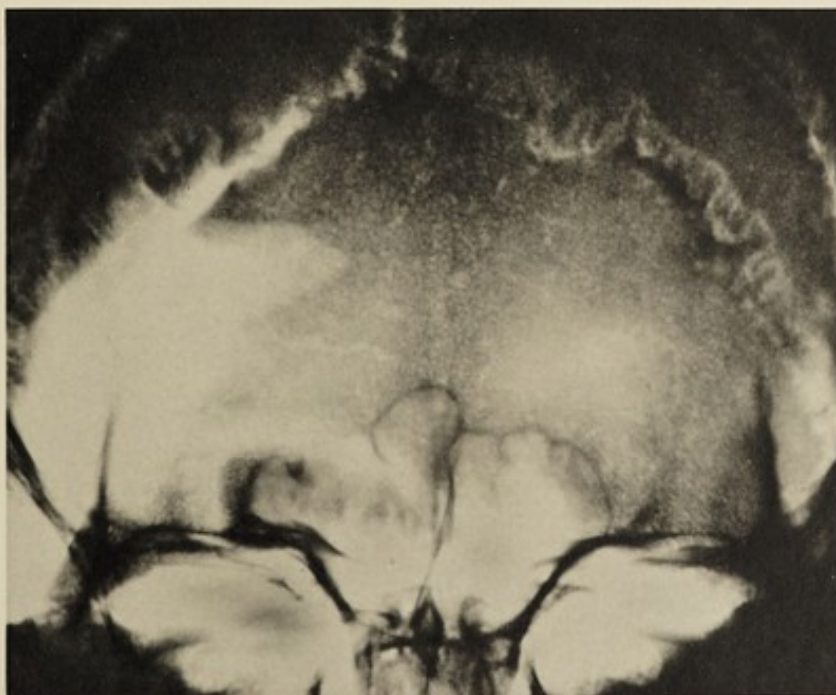
3

SKULLS, PERU

1. Caries. 2. Antral fistula. 3. Calculus



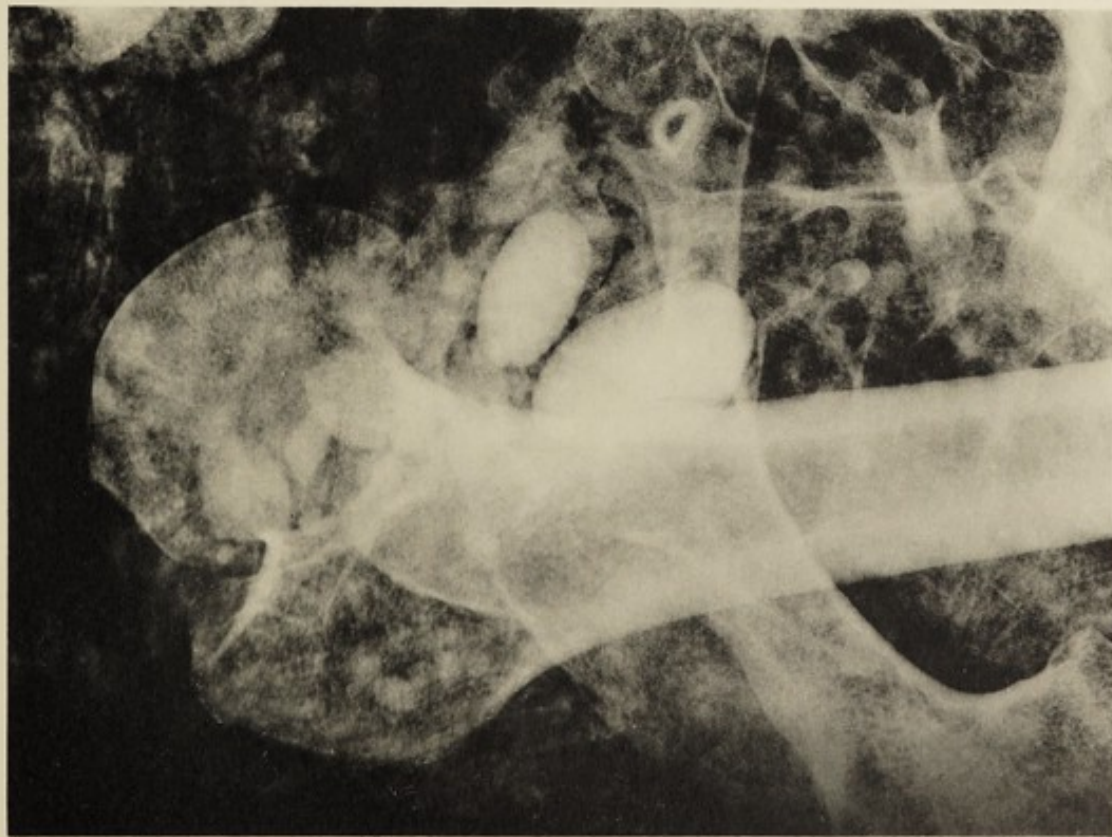
1



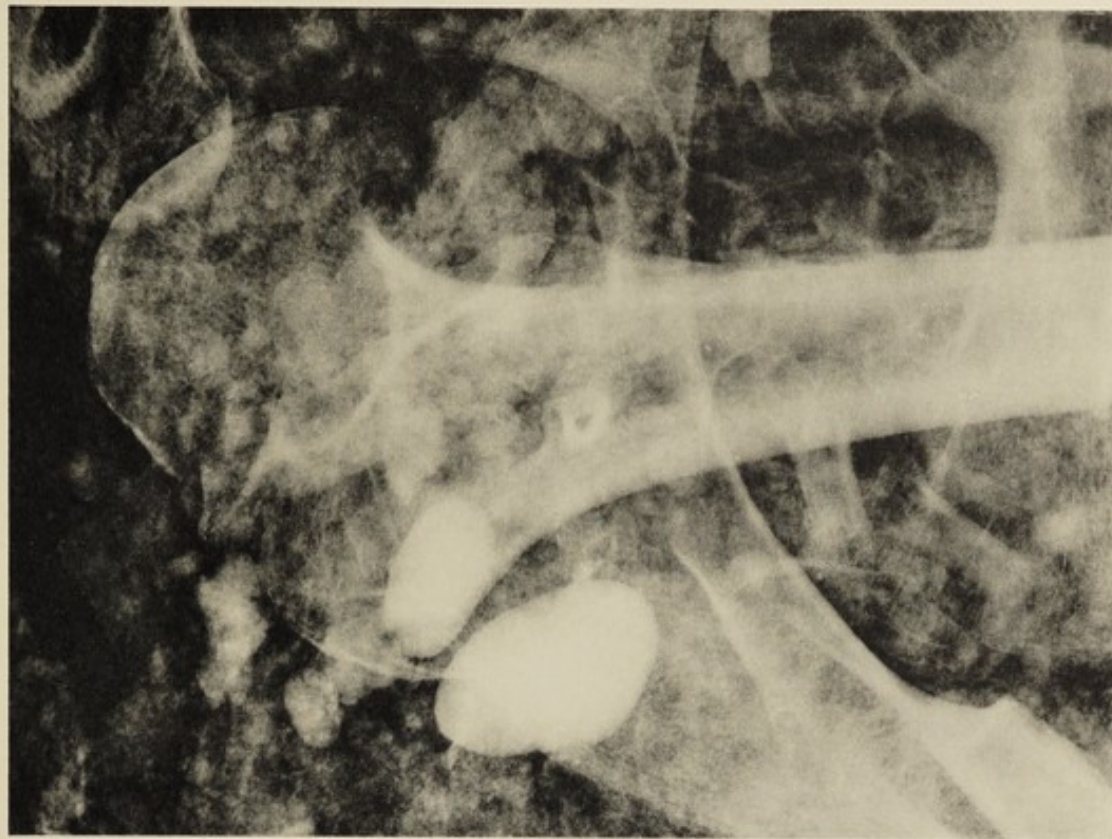
2

SKULL, PERU

1. Photograph showing lesion in skull. 2. Roentgenogram



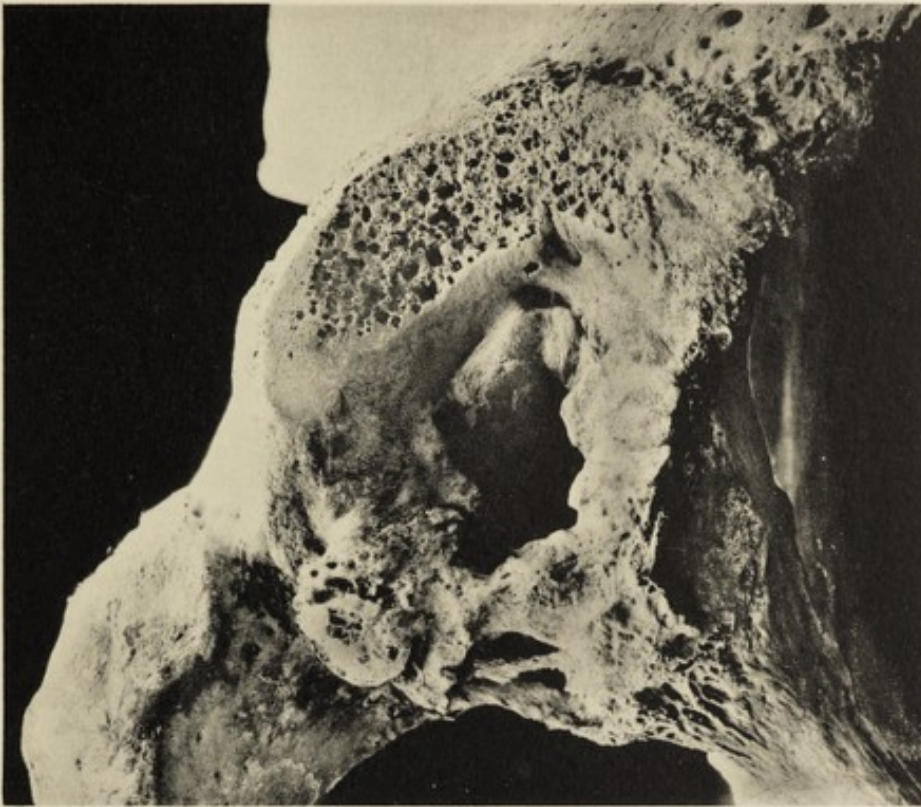1



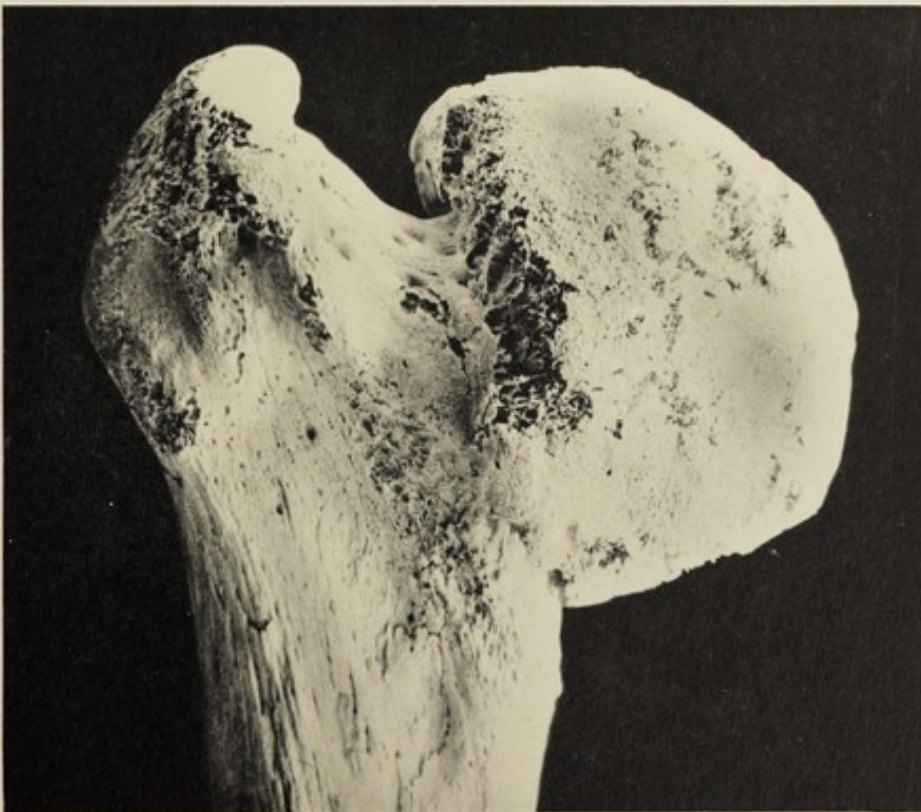2

MUSHROOM HEAD OF FEMUR, MUMMY, PERU

1-2. Different views of same



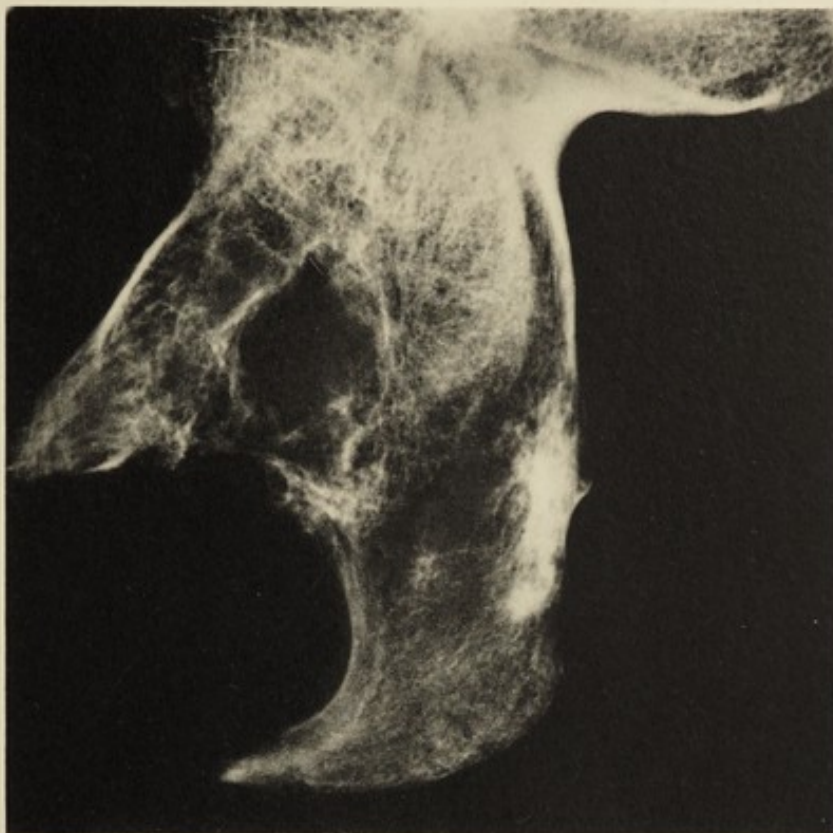1



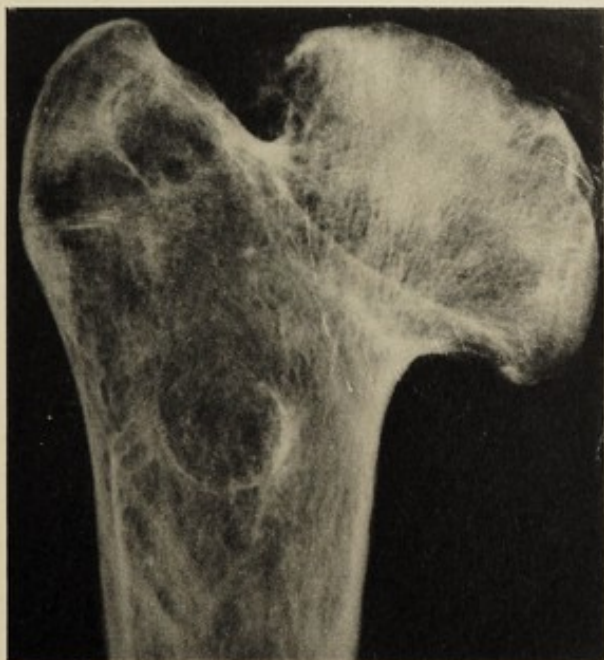
2

ARTHRITIS DEFORMANS, MUMMY, PERU

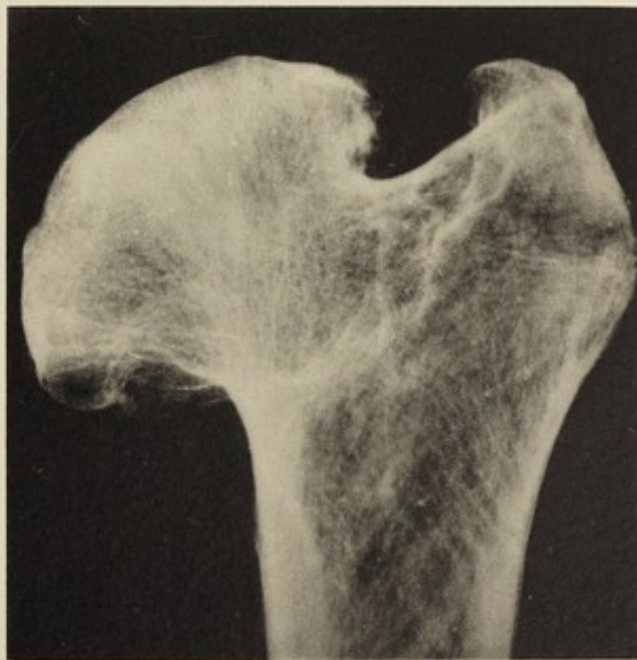1. Pelvis. 2. Femur



1



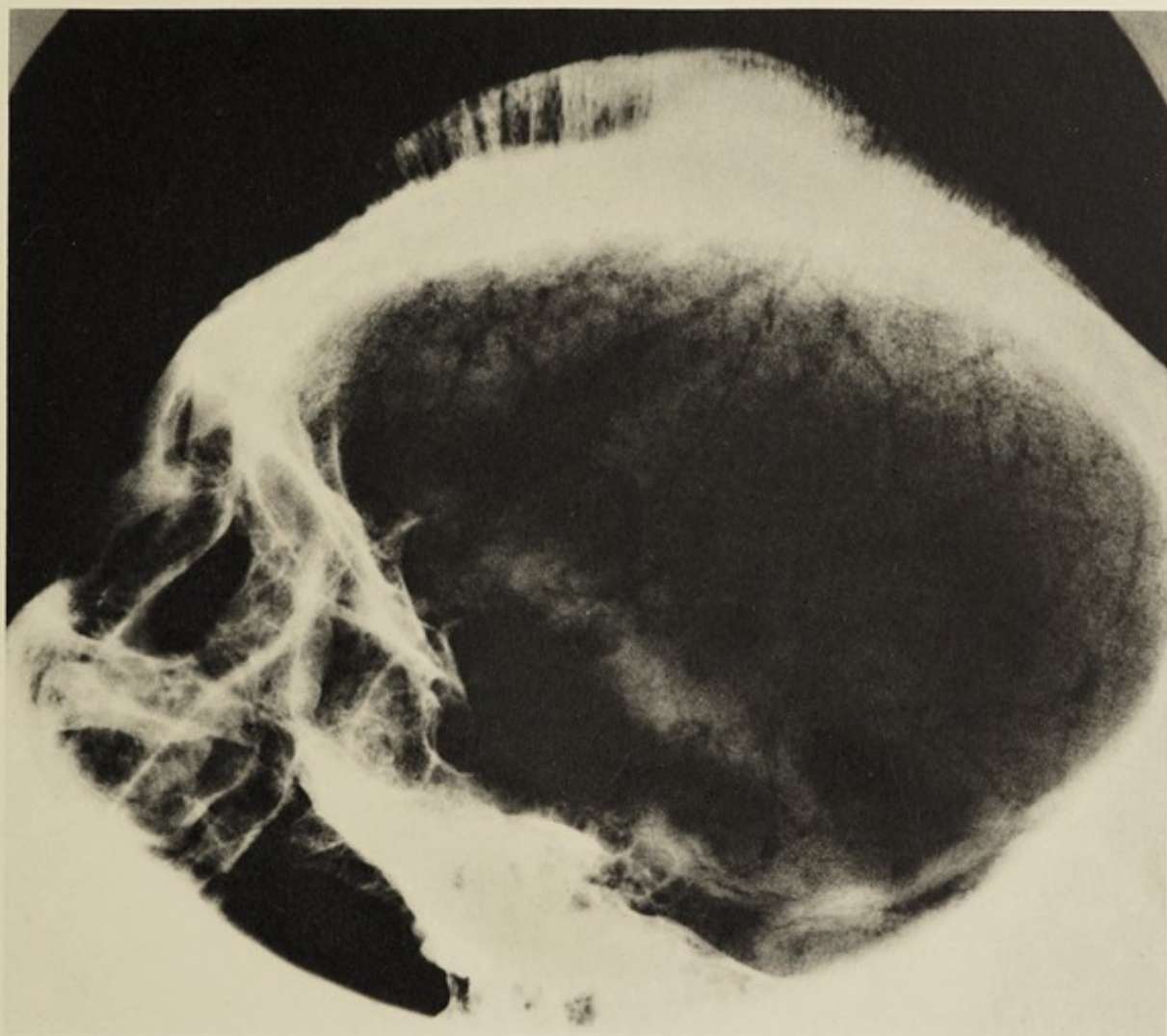2



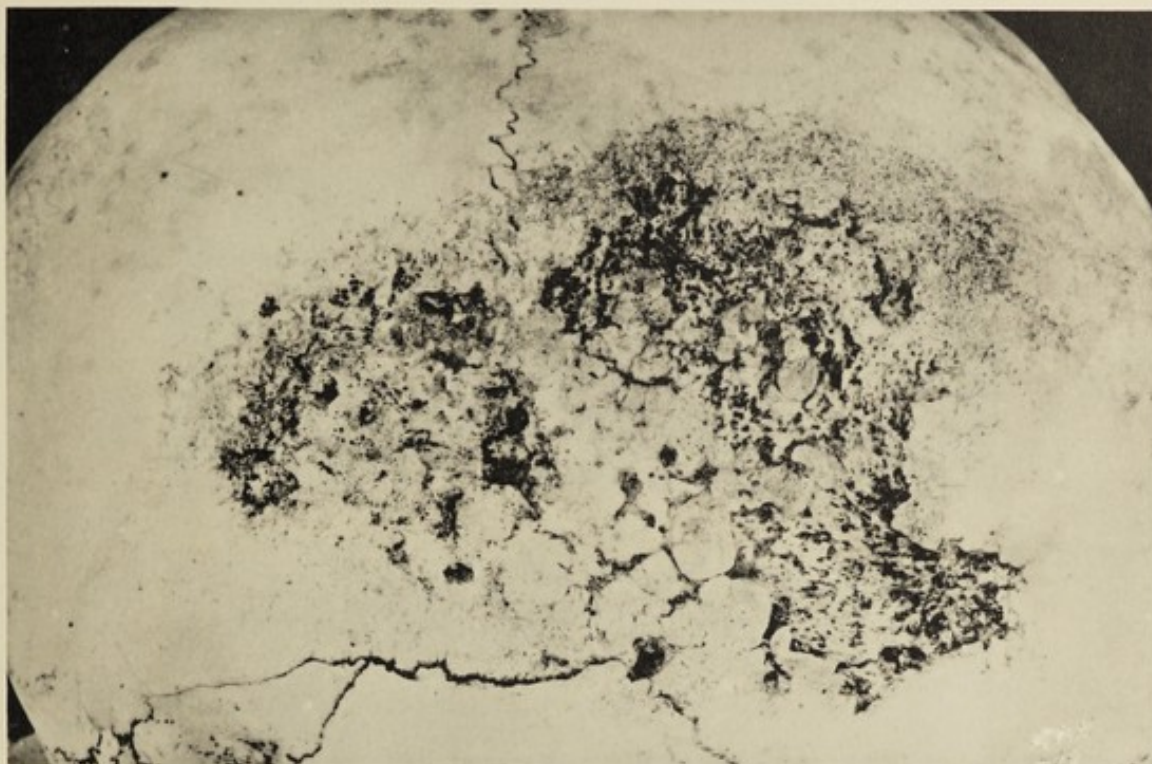
3

ARTHRITIS DEFORMANS, MUMMY, PERU .

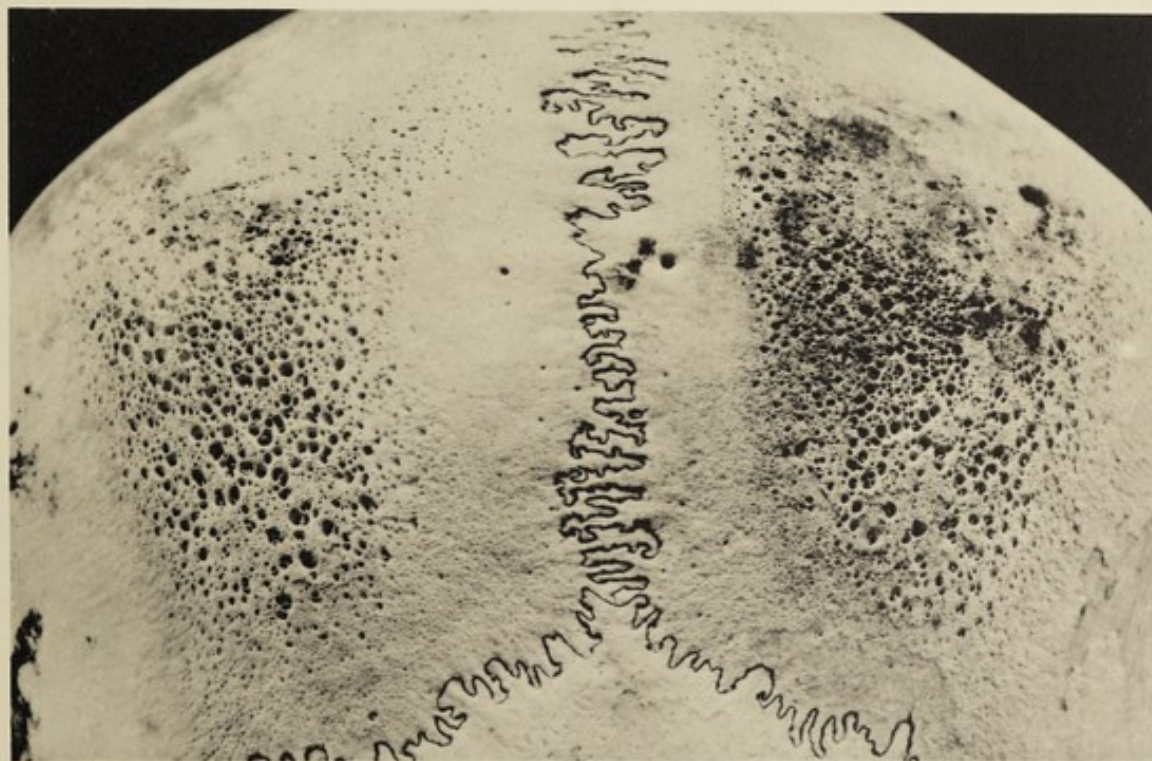
1. Pelvis. 2-3. Femur



CRANIAL TUMOR ON SKULL, PERU



1

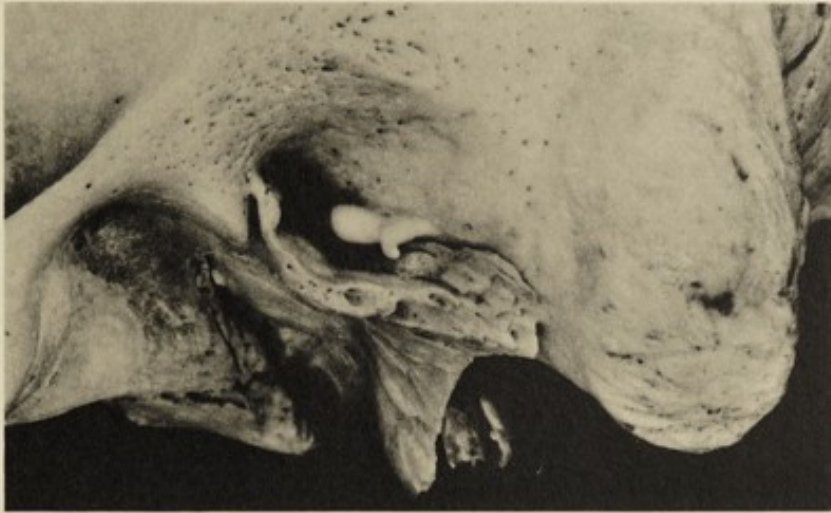

2

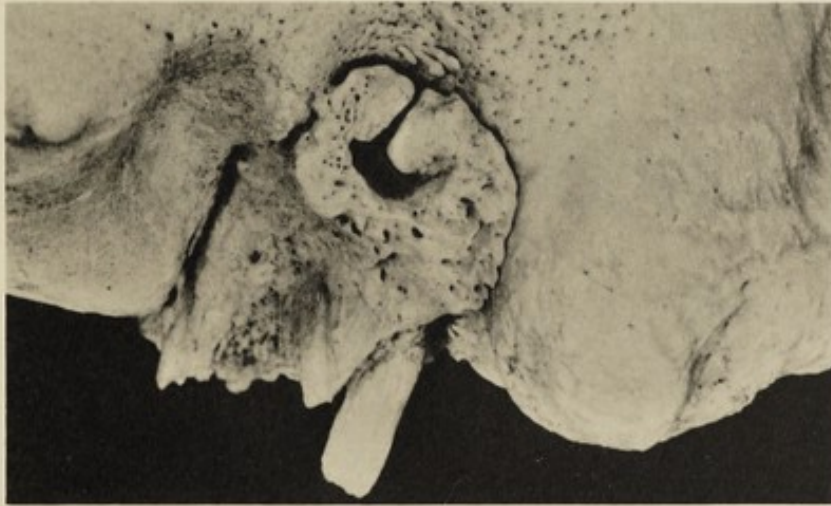ESKIMO AND PREHISTORIC PERUVIAN SKULLS

Syphilitic lesions in Eskimo skull. 2. Osteoporosis in prehistoric Peruvian skull

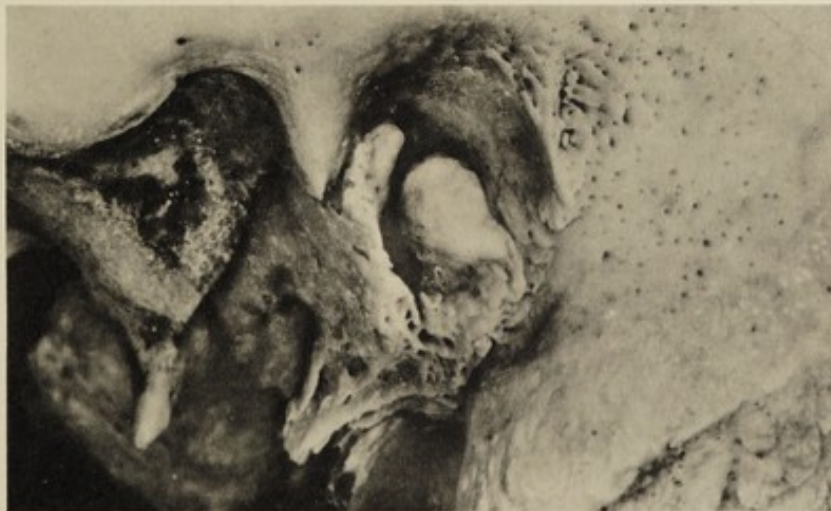1
su A 52
(modern)



1



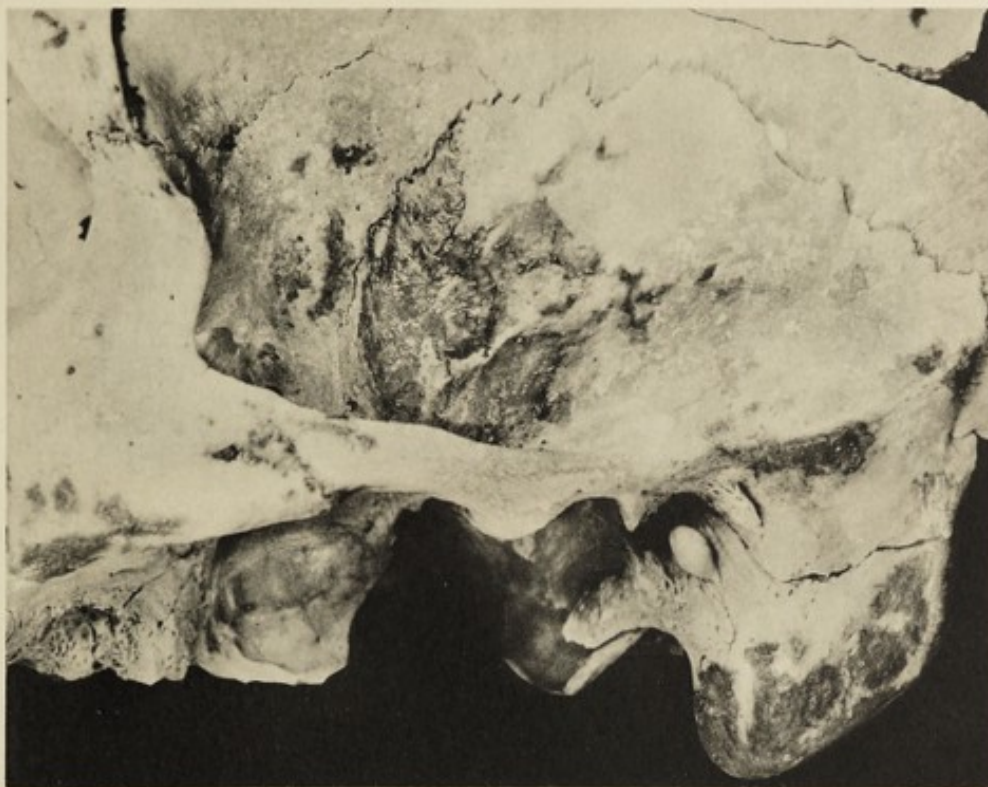2



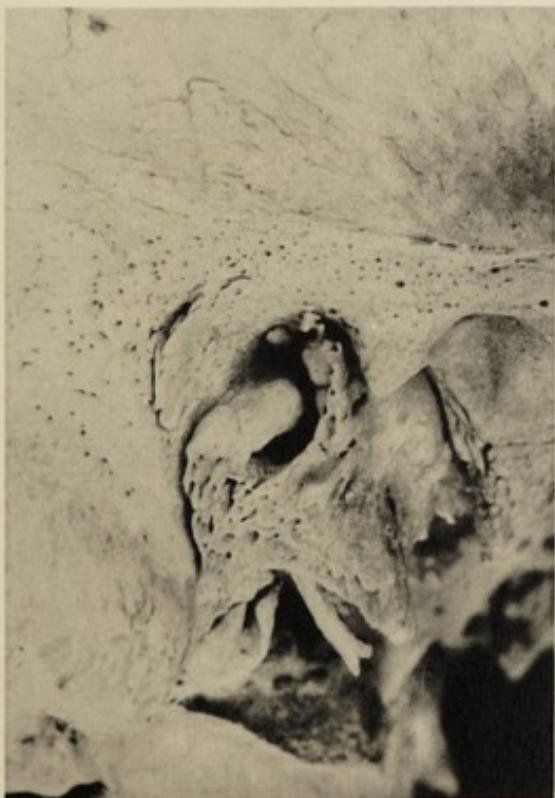3

SKULLS, PERU

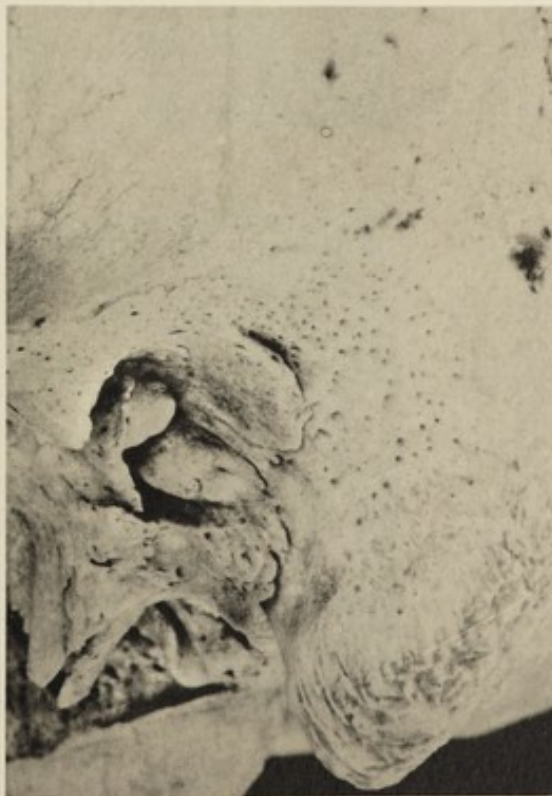1-3. External auditory passages



1



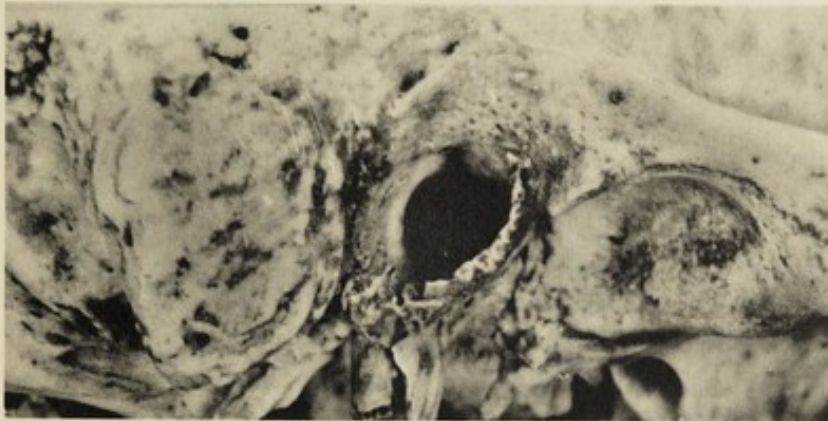2



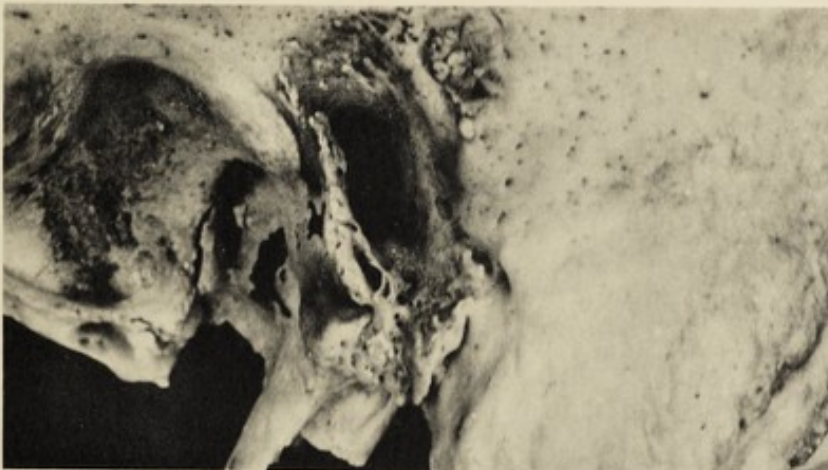3

SKULLS, PERU

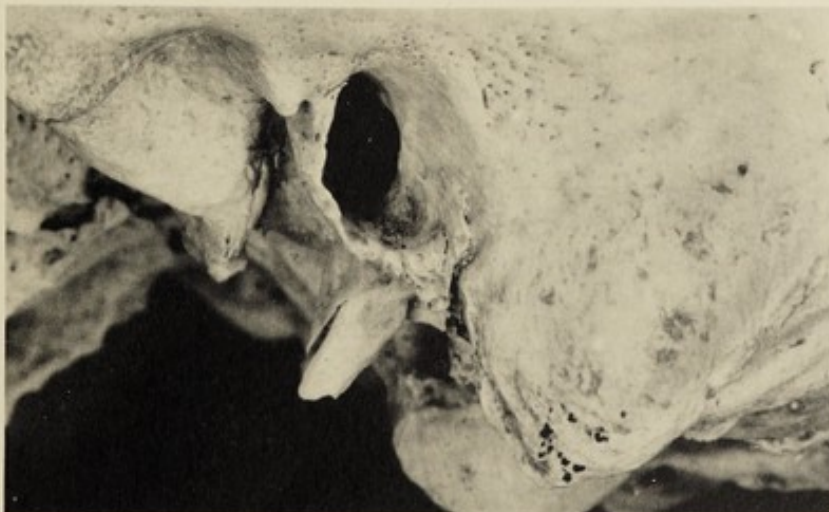1. Small osteoma. 2-3. Auditory passages, right and left



1

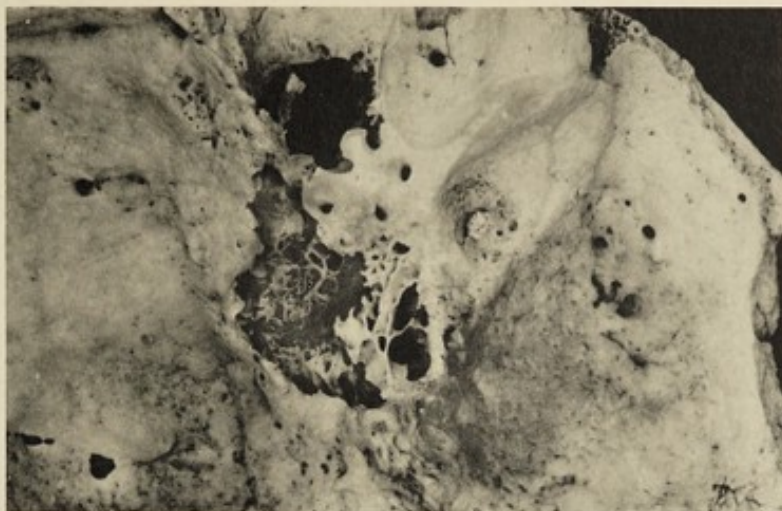


2

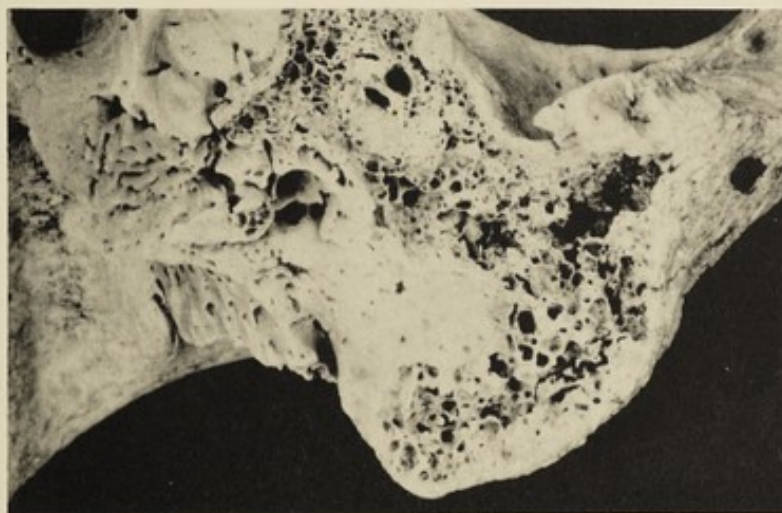

3

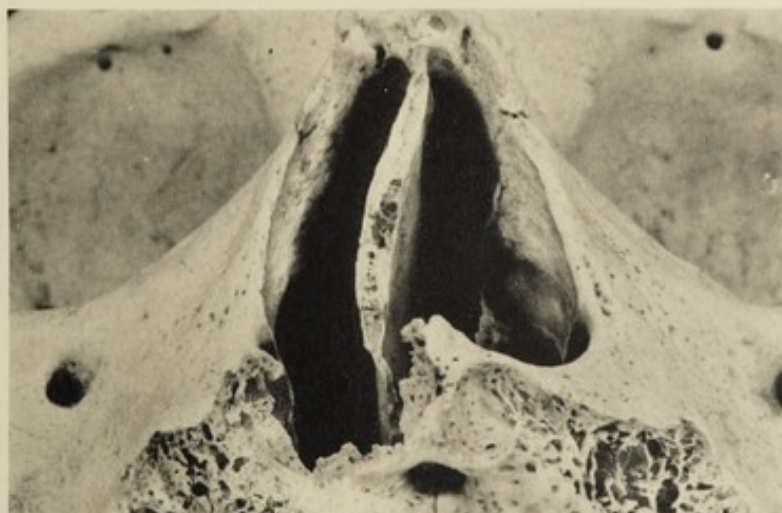
SKULLS, PERU
1-3. Ear disturbances



1



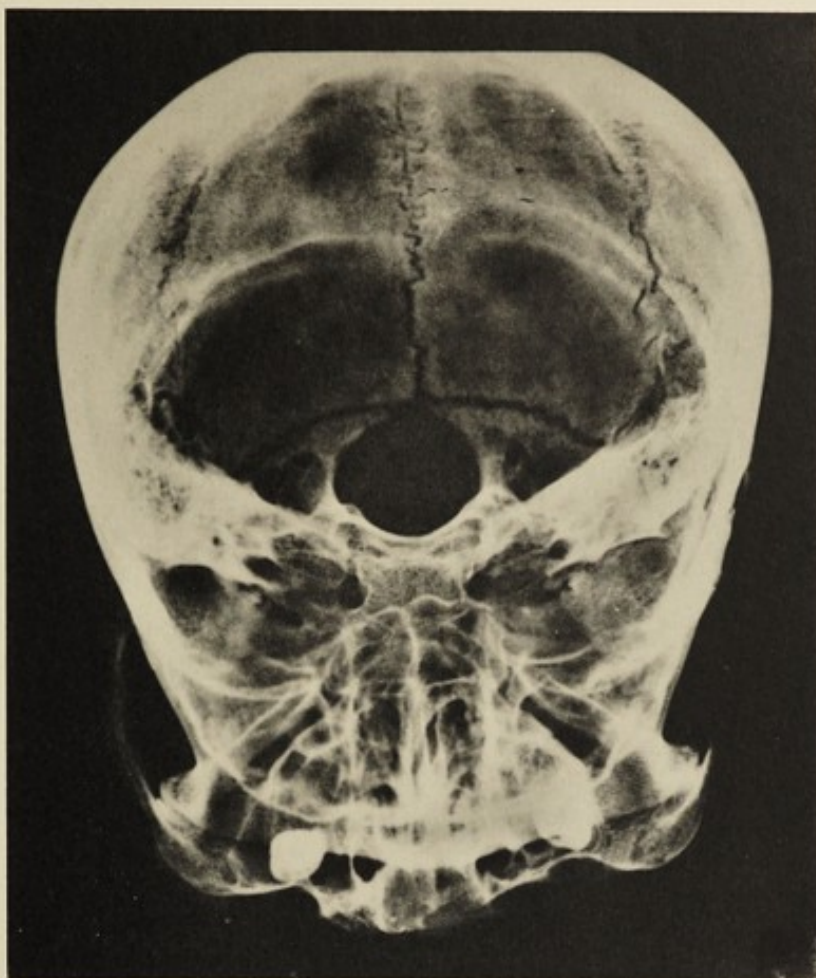2



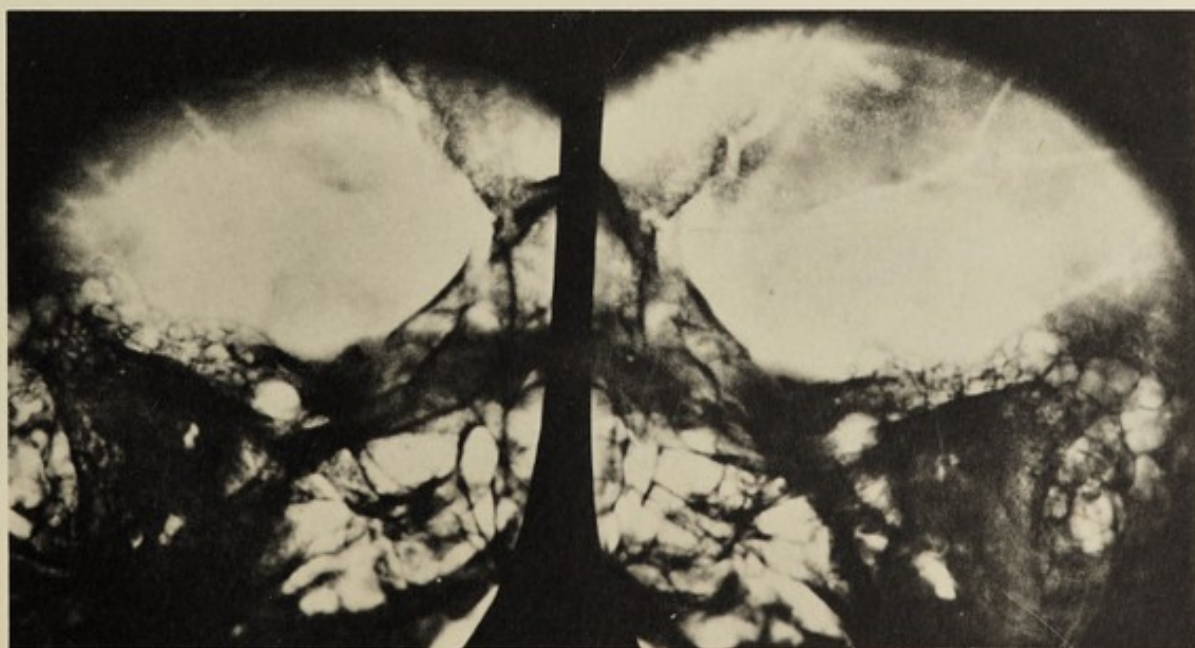3

SKULLS, PERU

1. Ear disturbance. 2. Mastoid. 3. Nasal disturbance



1

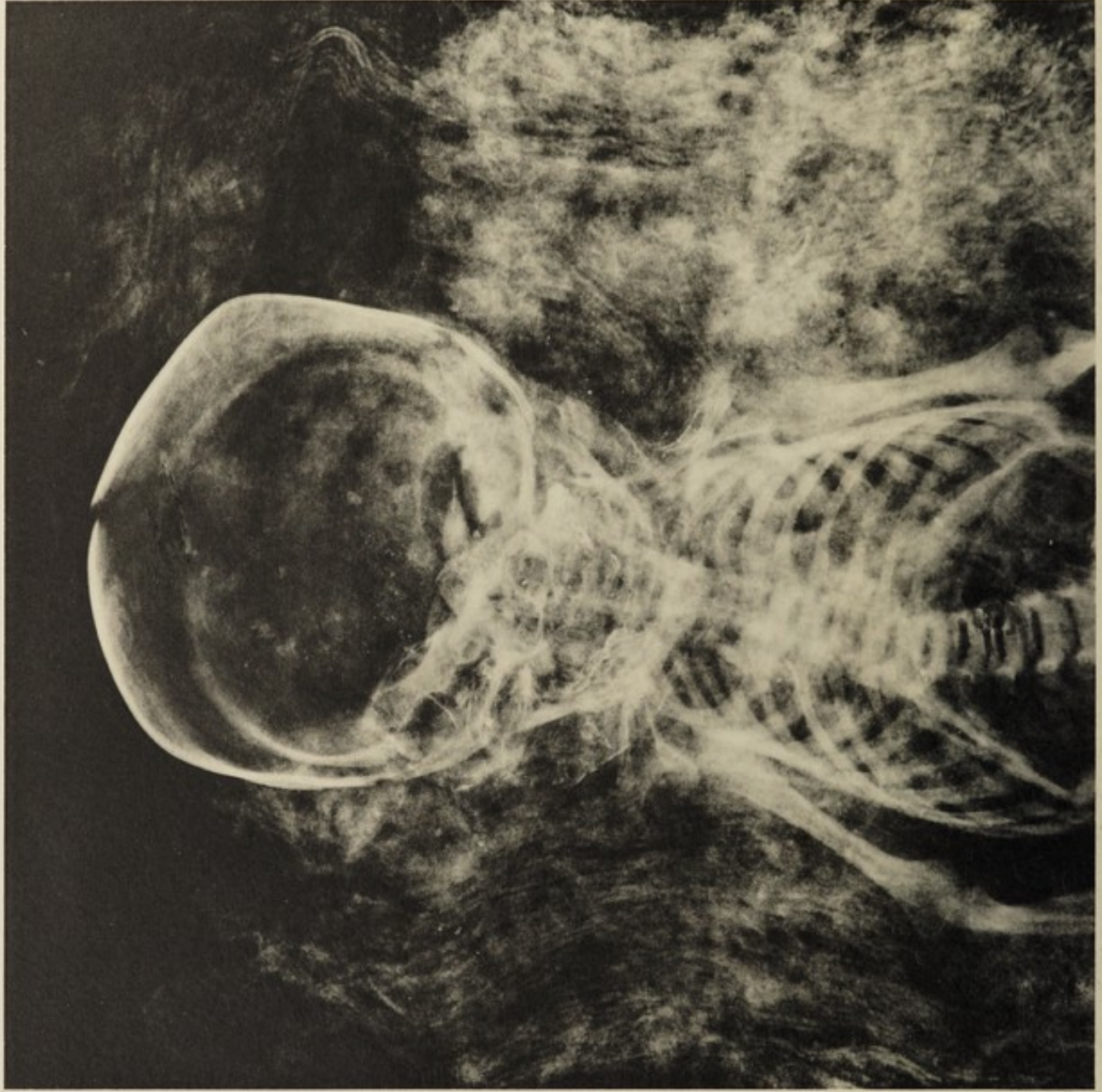


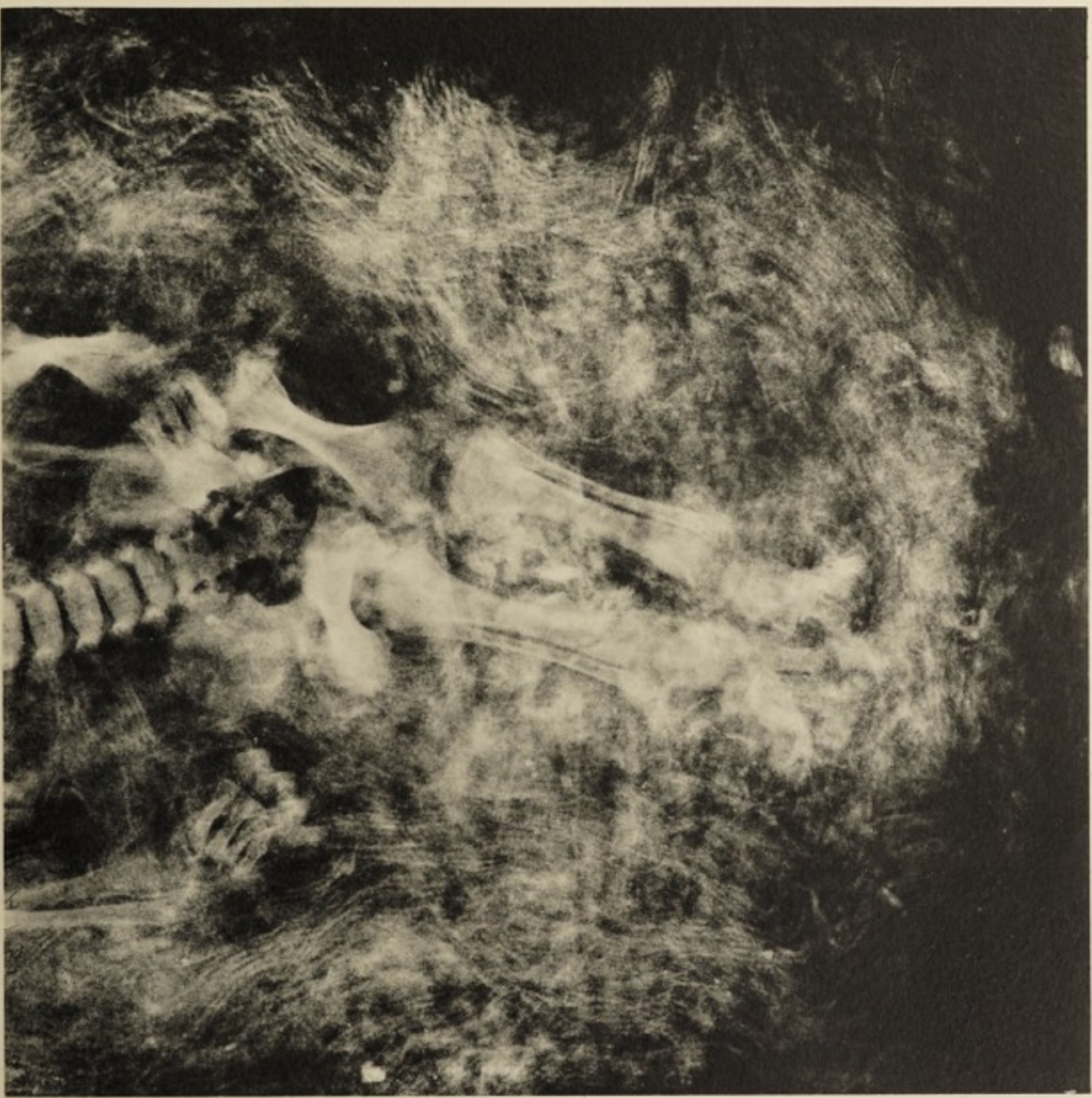2

3

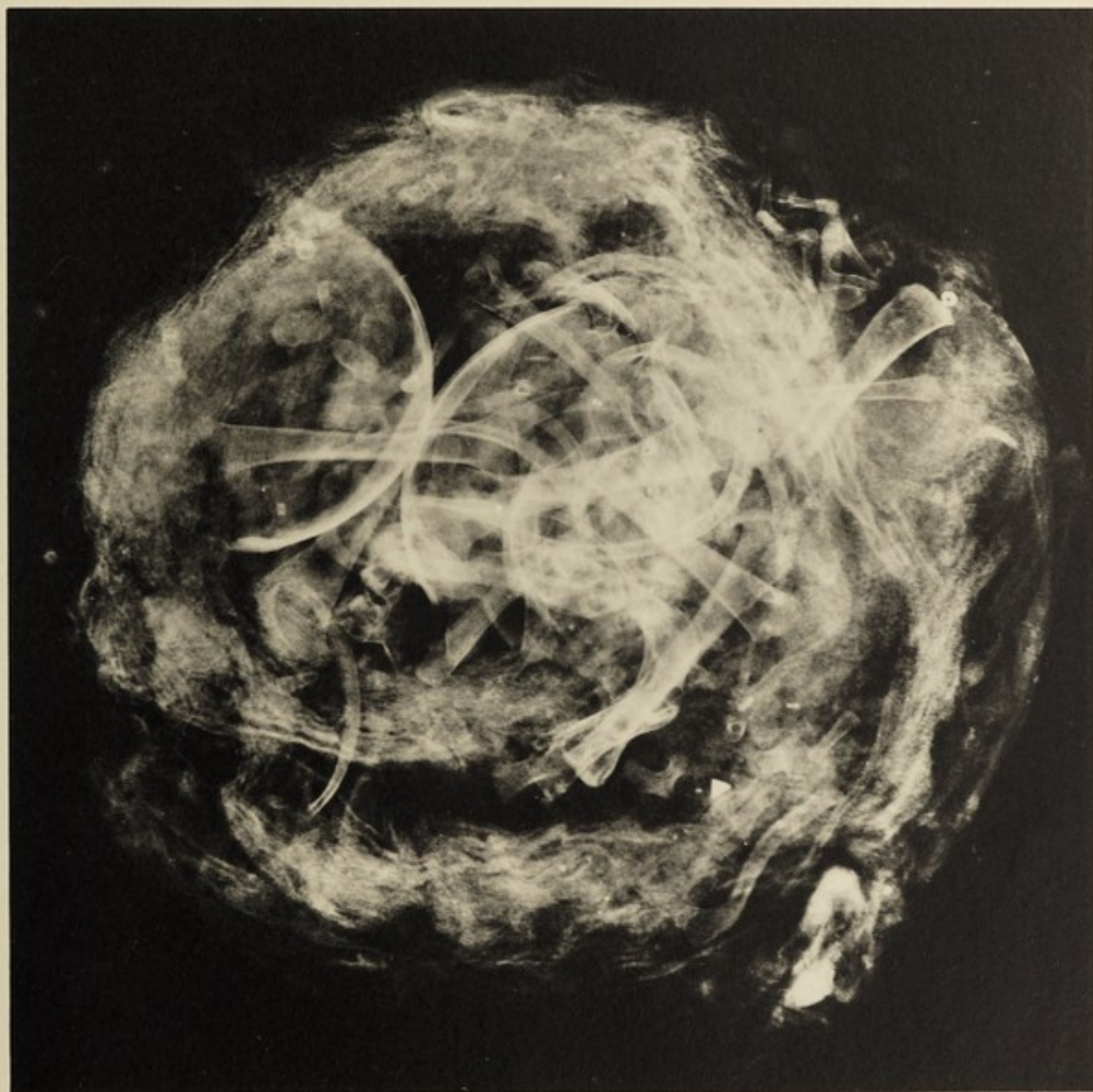SKULL, PERU

1. Sclerotic temporal bone. 2-3. Diseased mastoids in same skull

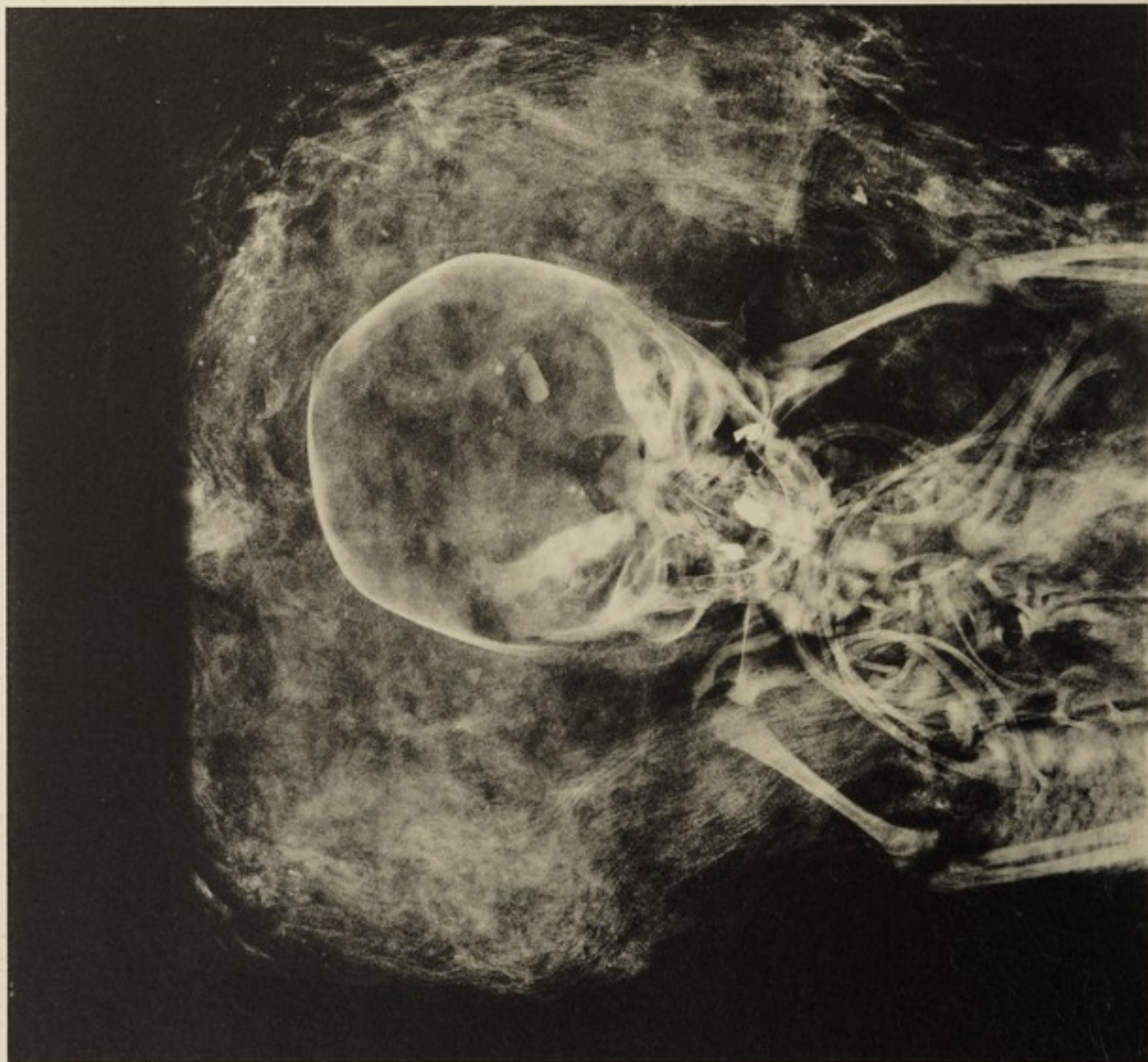


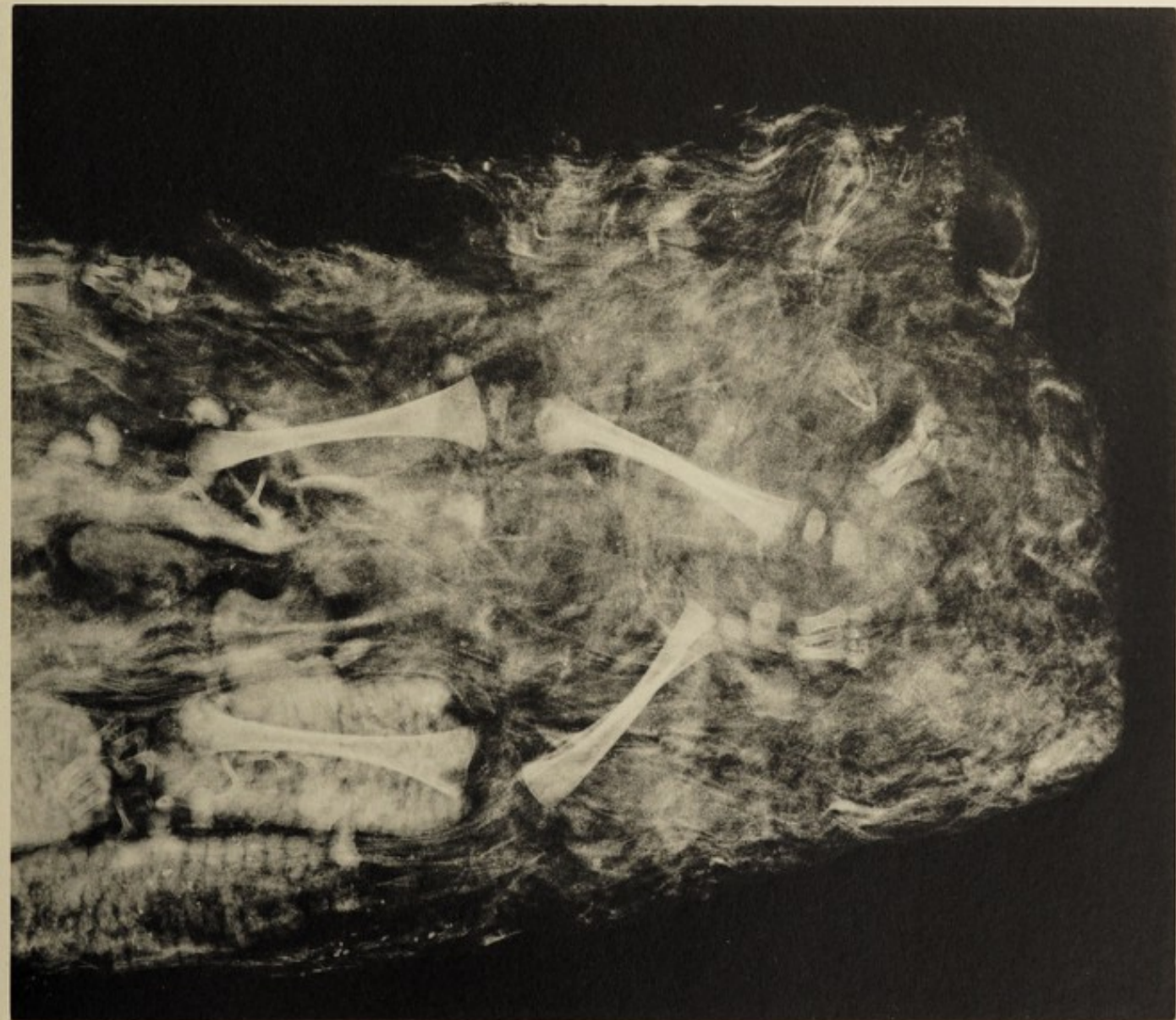

MUMMY OF INFANT, PERU

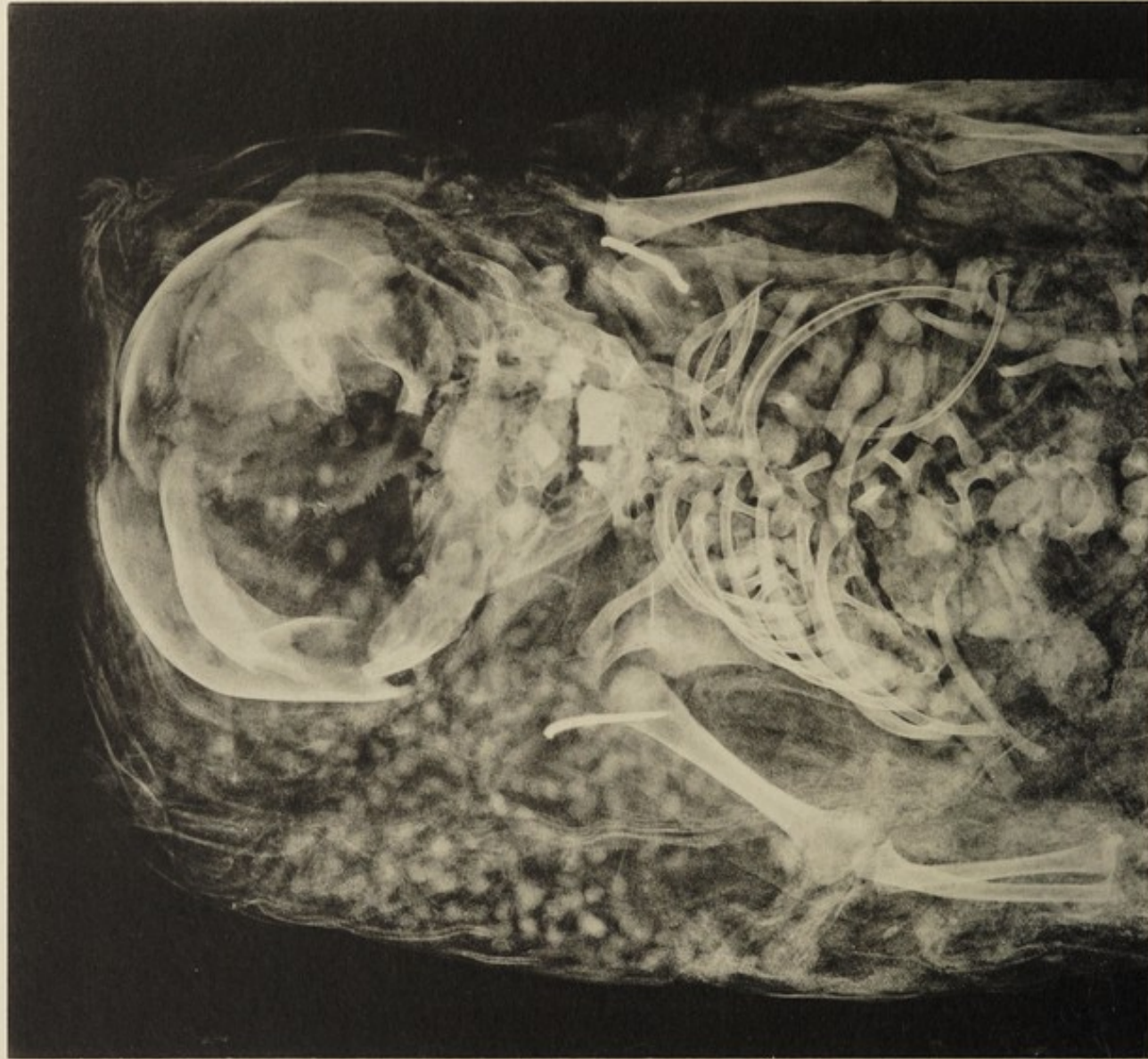

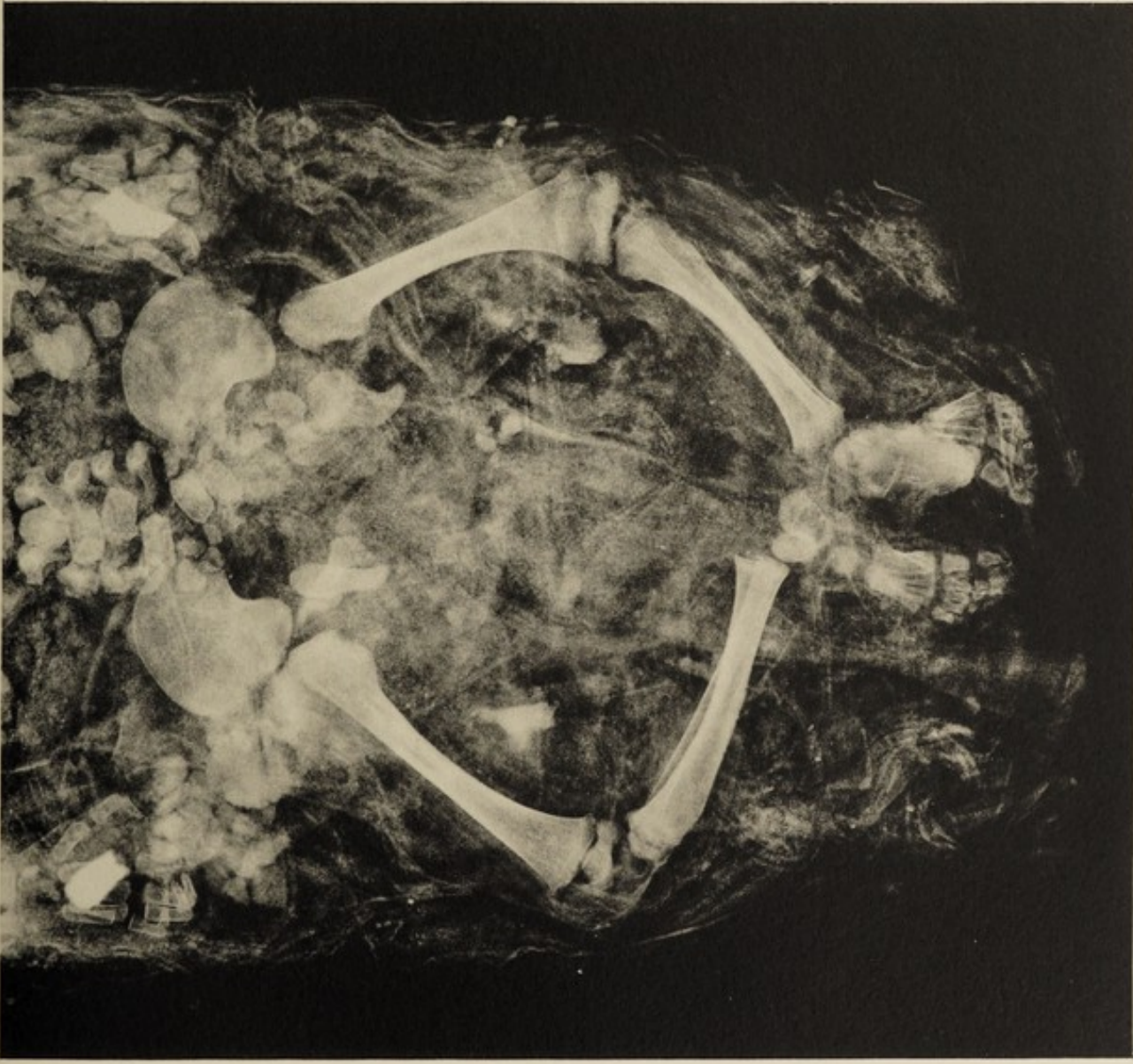
MUMMY OF INFANT, PERU
Skeleton incomplete



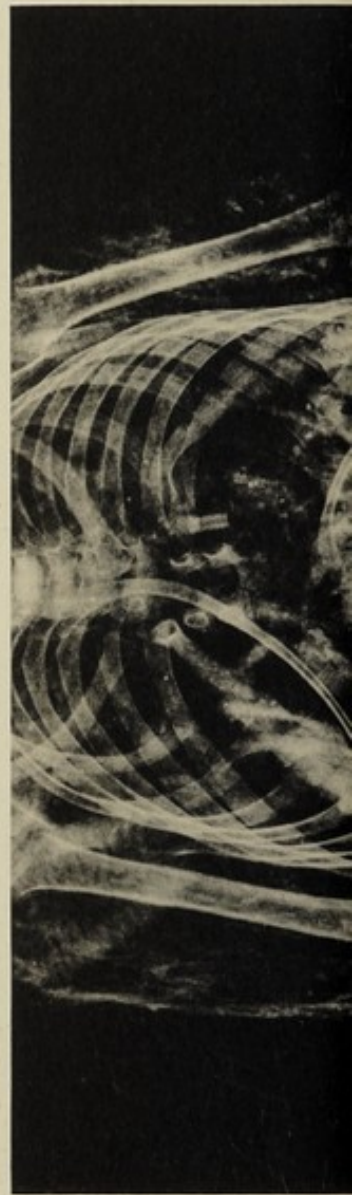
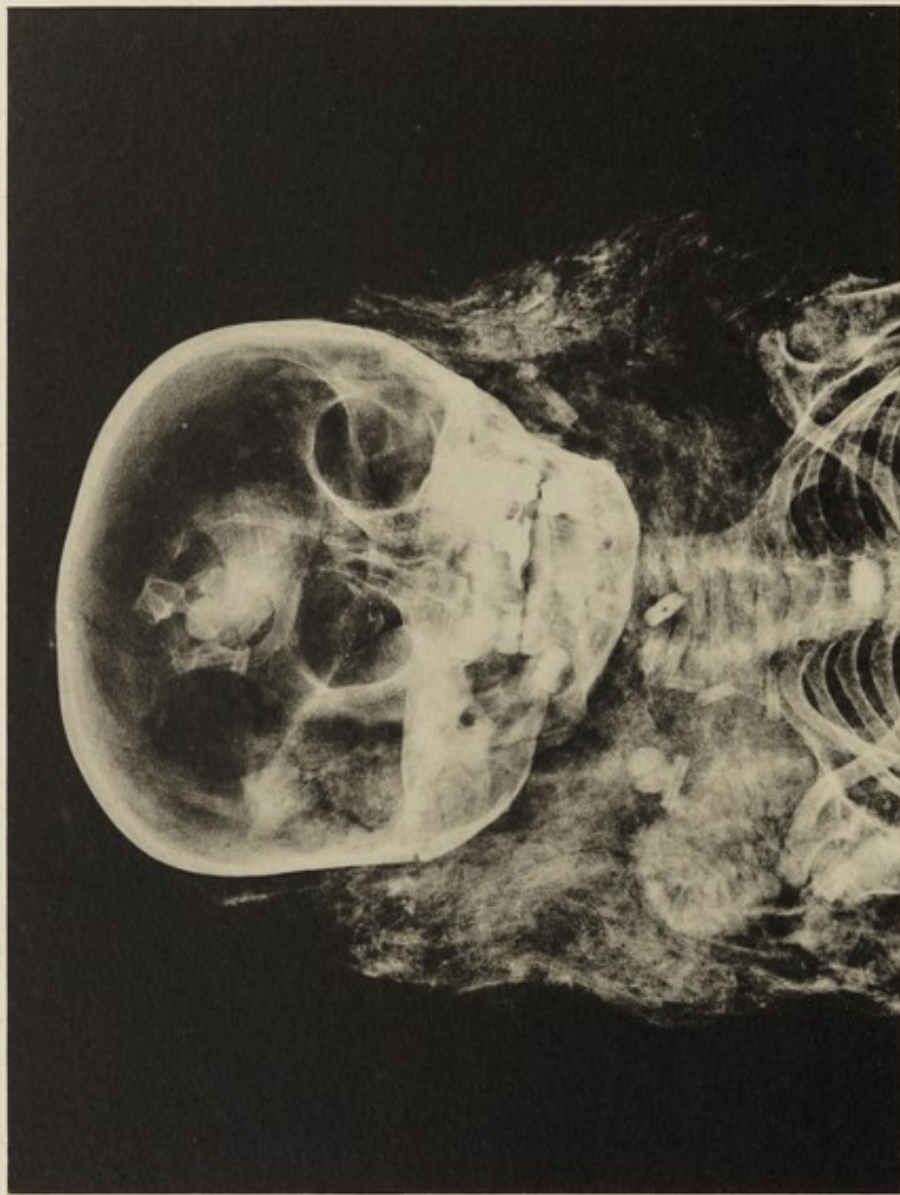


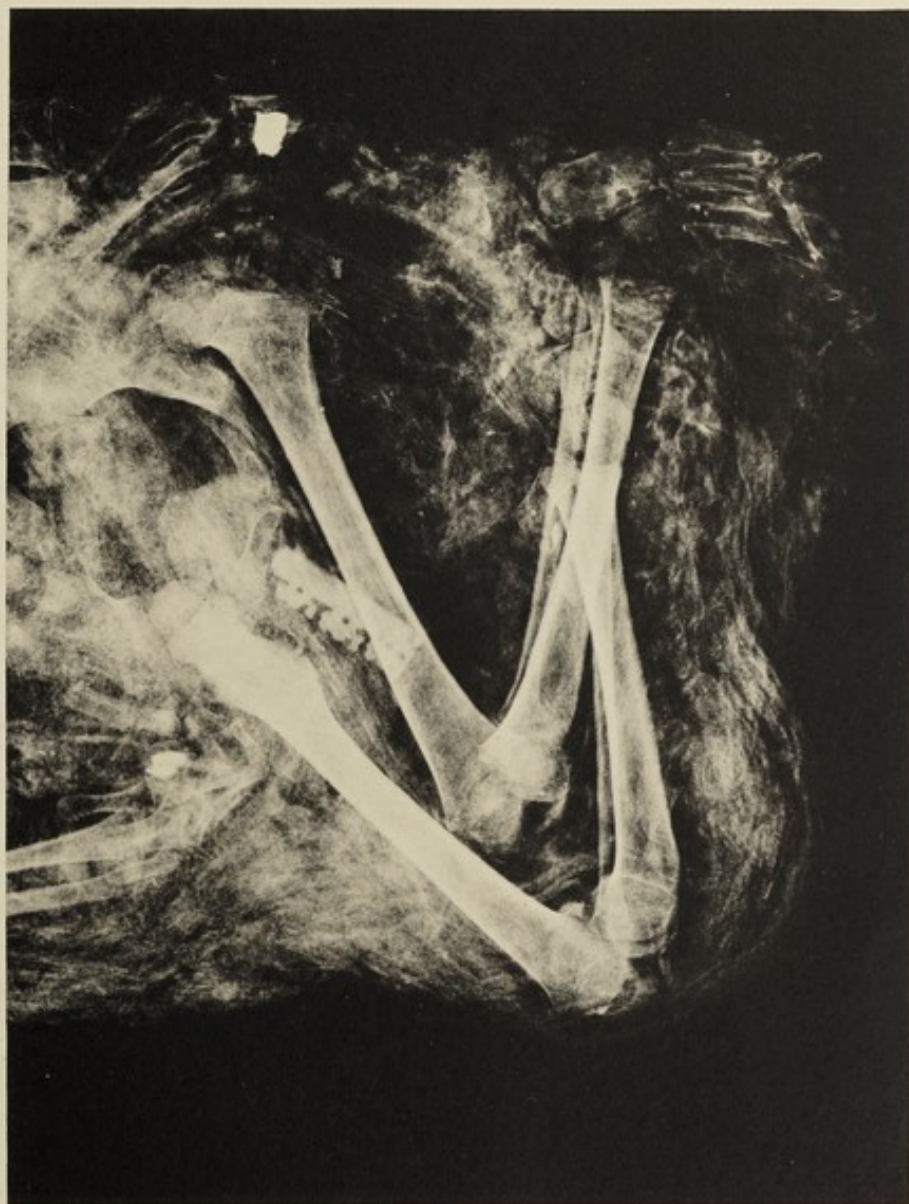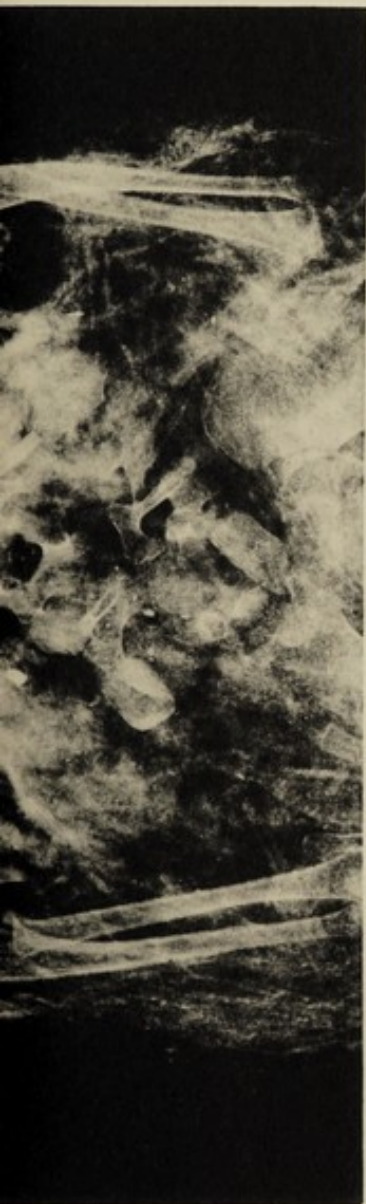
MUMMY OF INFANT, PERU. SKELETON INCOMPLETE
Pieces of metal in mouth and ears of maize in package





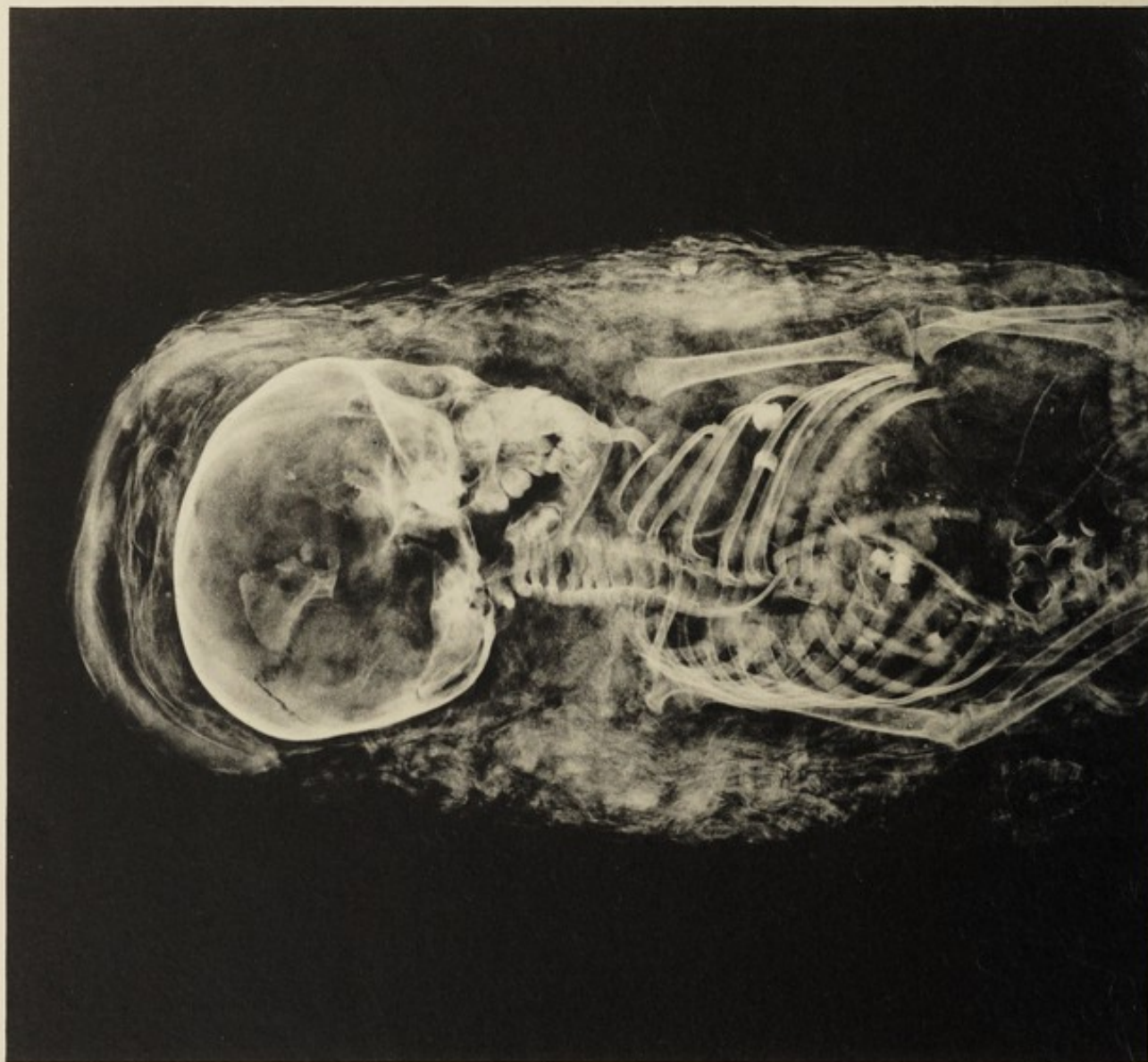MUMMY OF INFANT, PERU
Pieces of metal in mouth and hands and at each shoulder

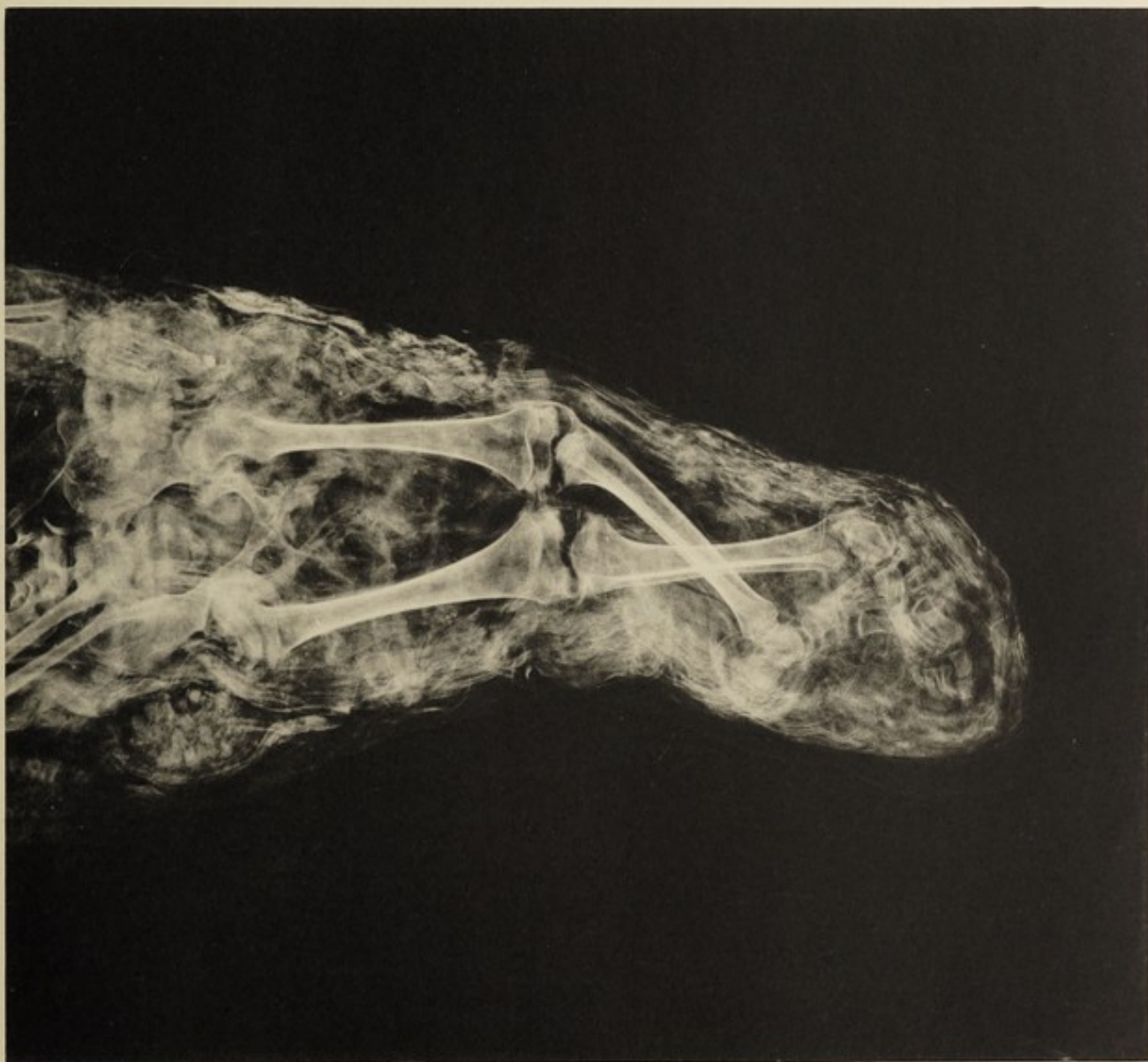



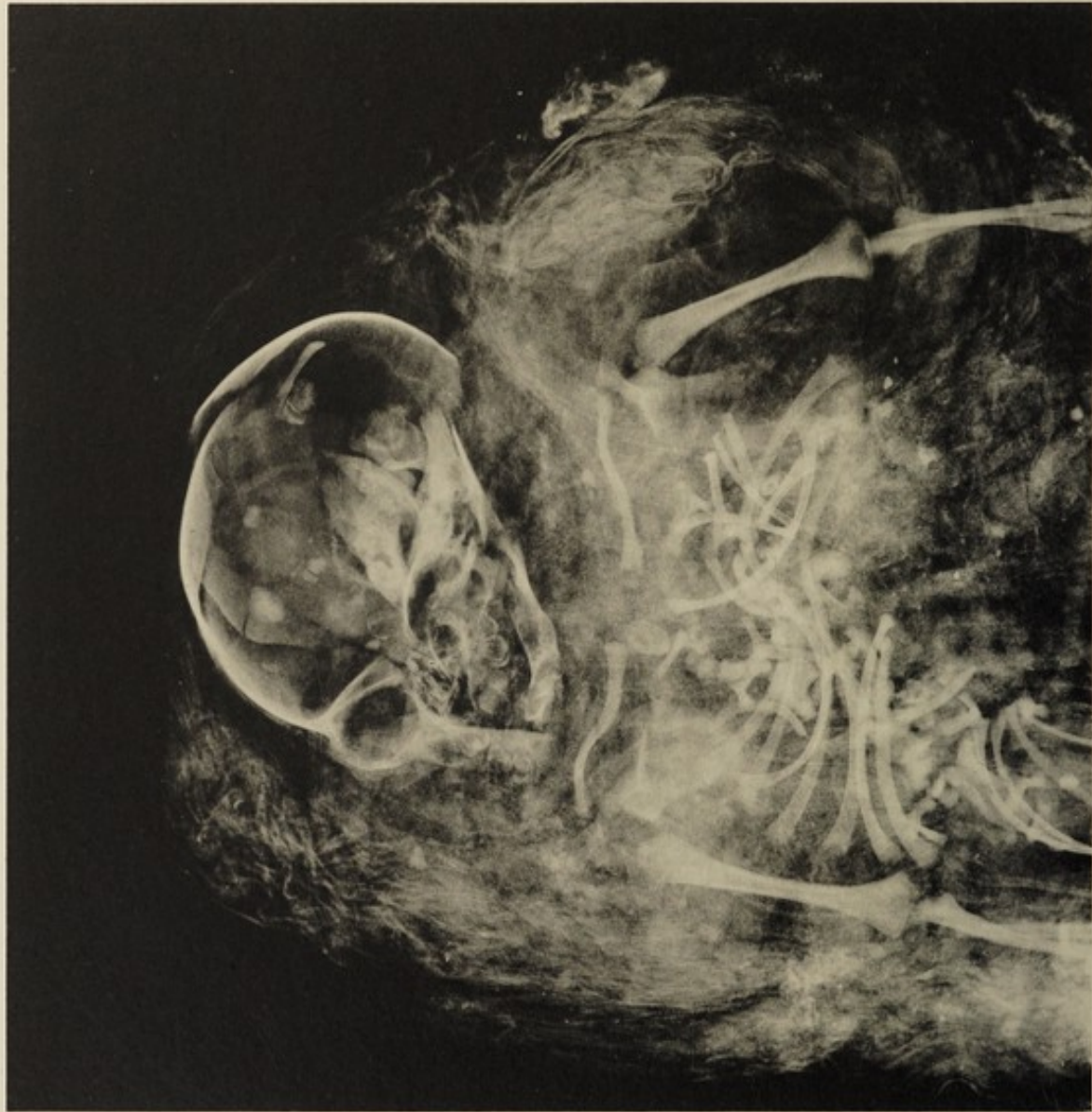MUMMY OF CHILD, PERU

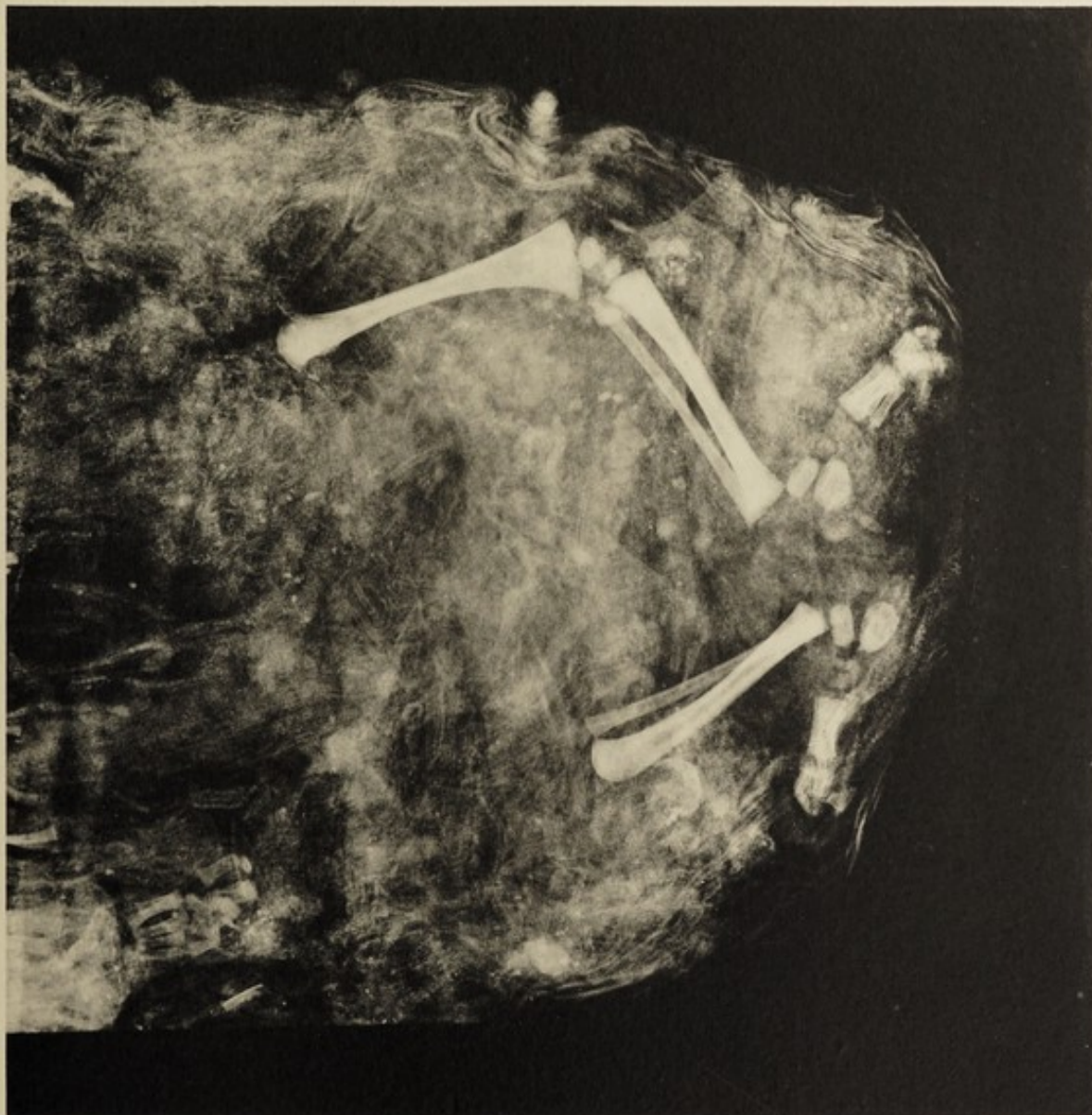Small ears of maize, beads, fragments of metal and piece of carved bone in package



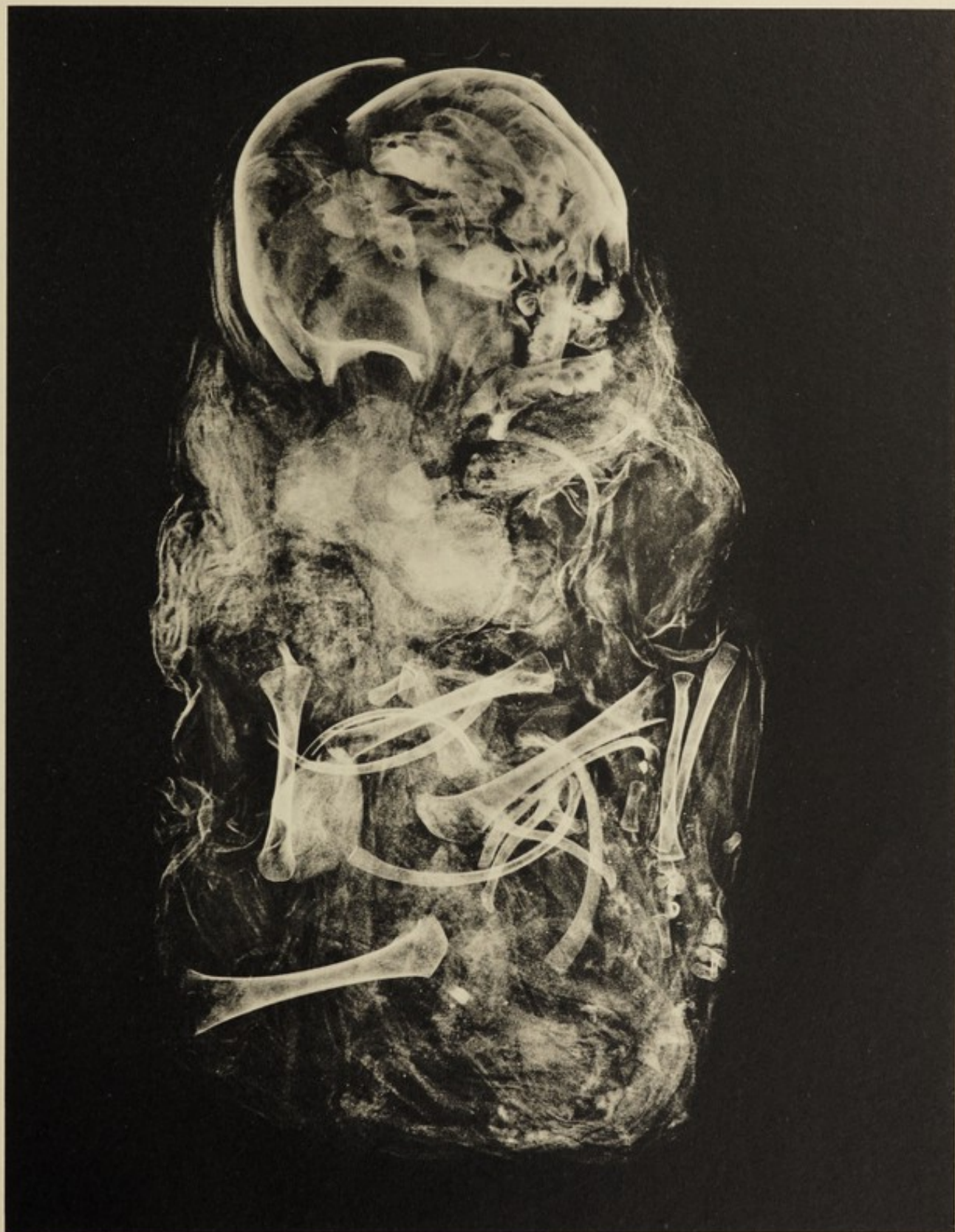

MUMMY OF CHILD, PERU

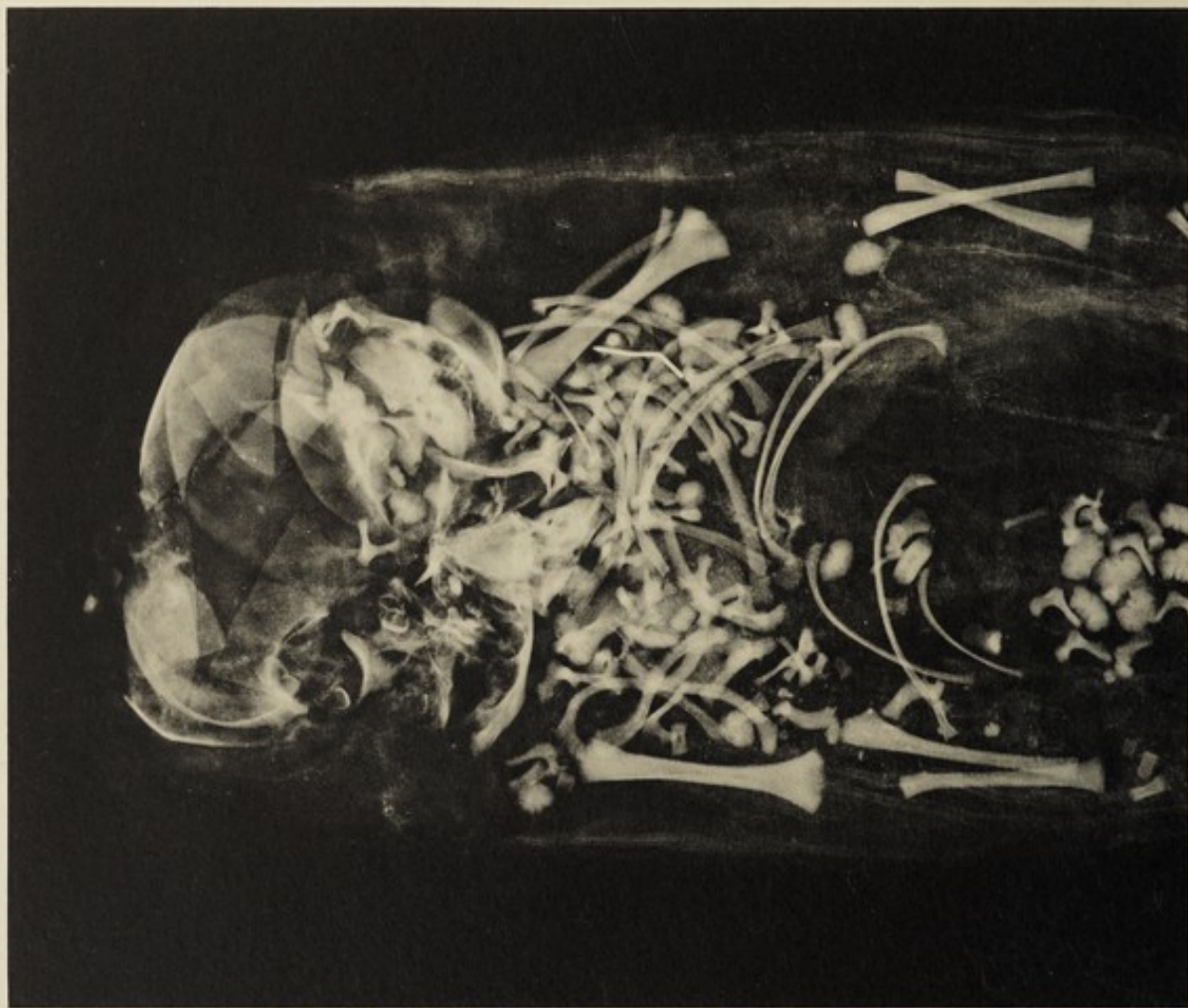


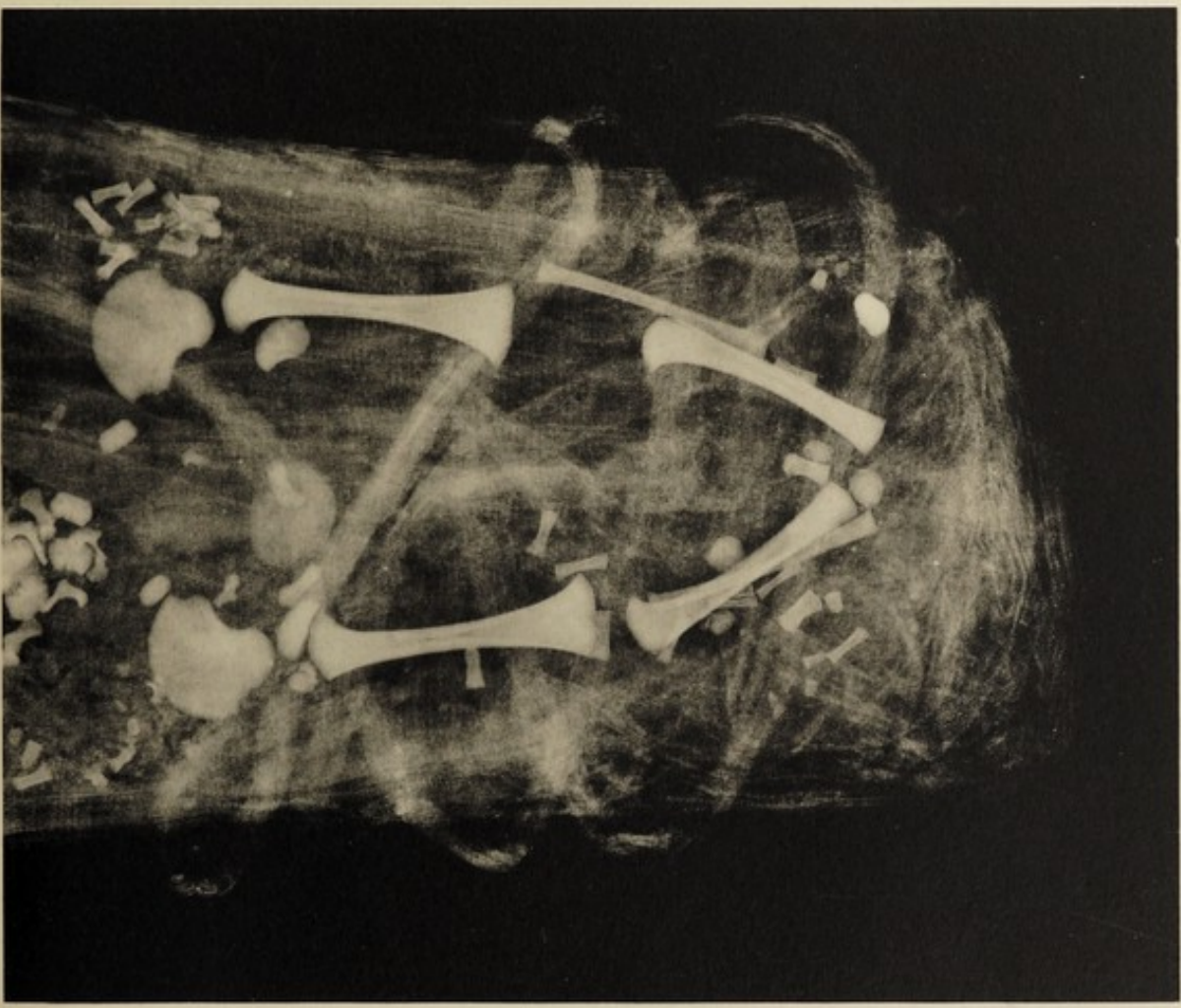


MUMMY OF CHILD, PERU
Skeleton incomplete

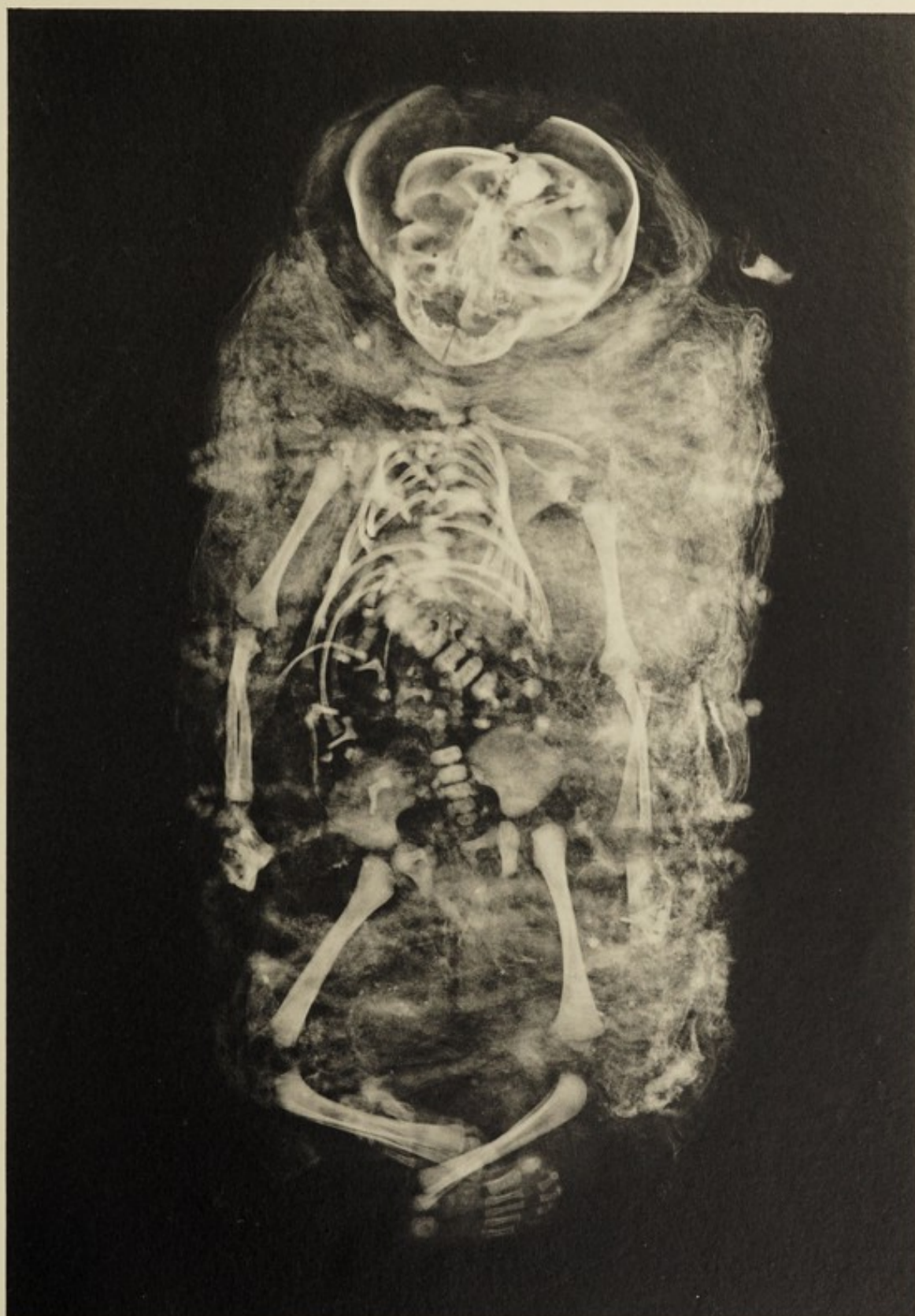

MUMMY OF INFANT, PERU
Wrapped in cloth and covered with rush mat

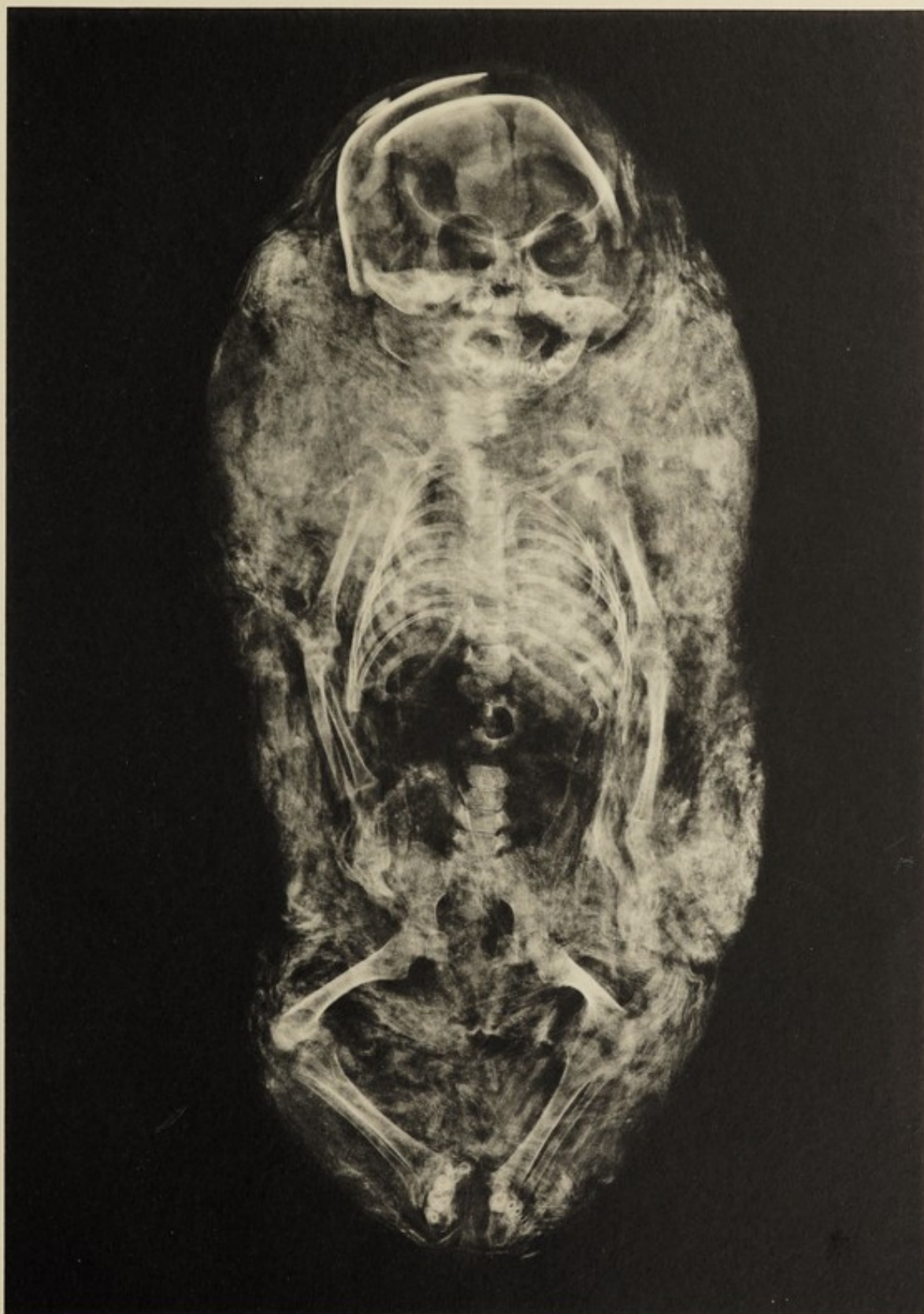



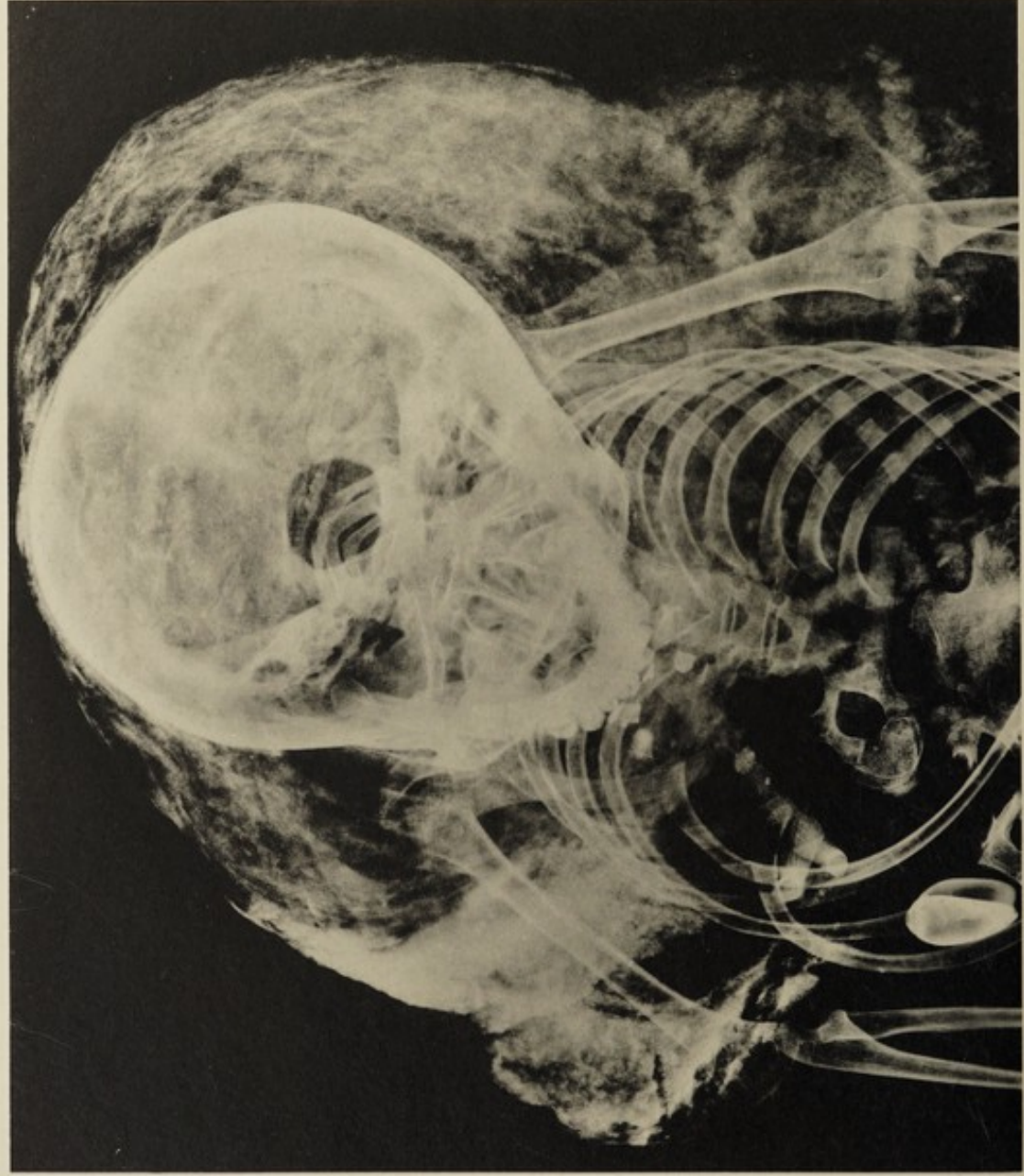
MUMMY OF NEW-BORN INFANT, PERU

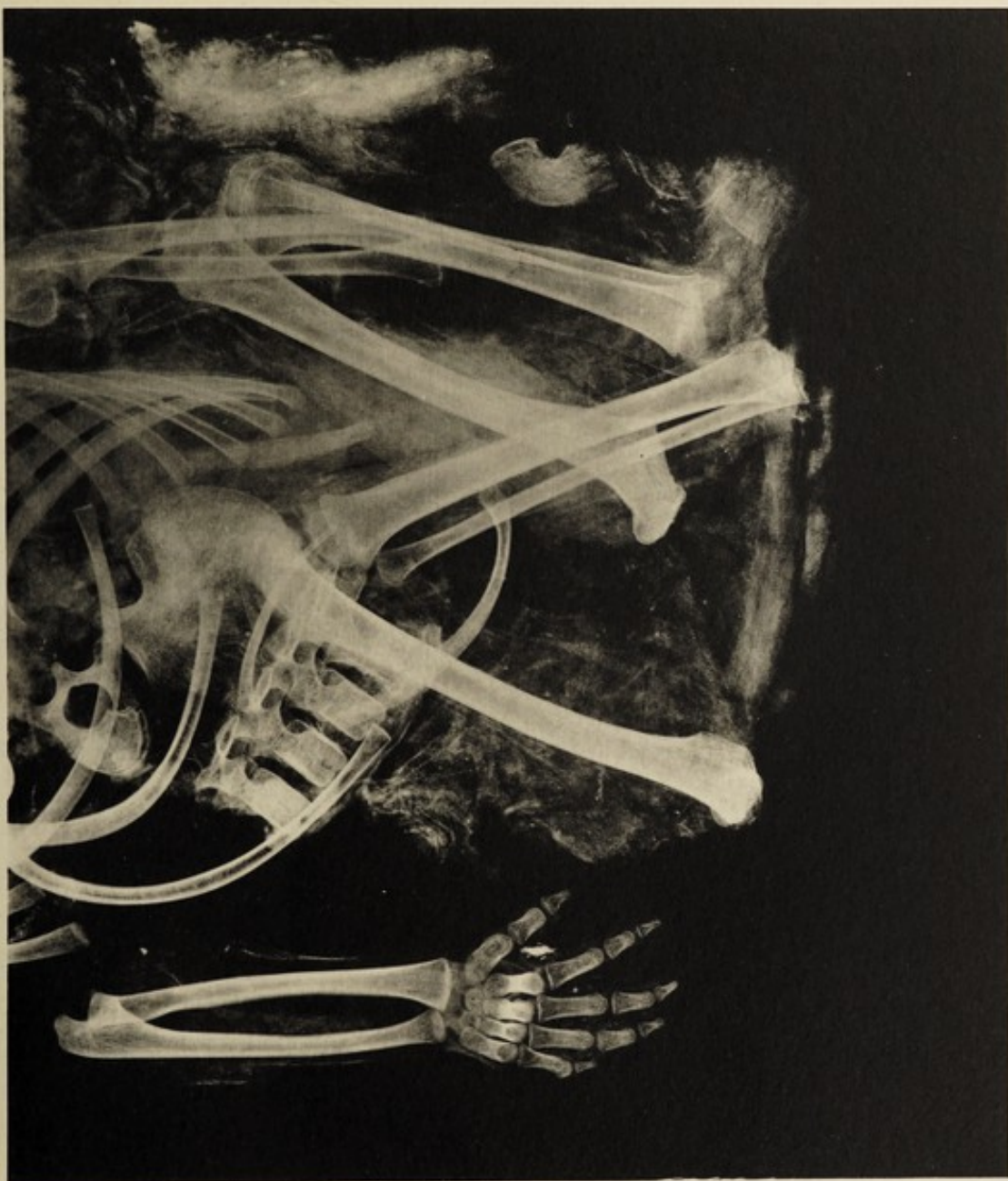

MUMMY OF INFANT, PERU

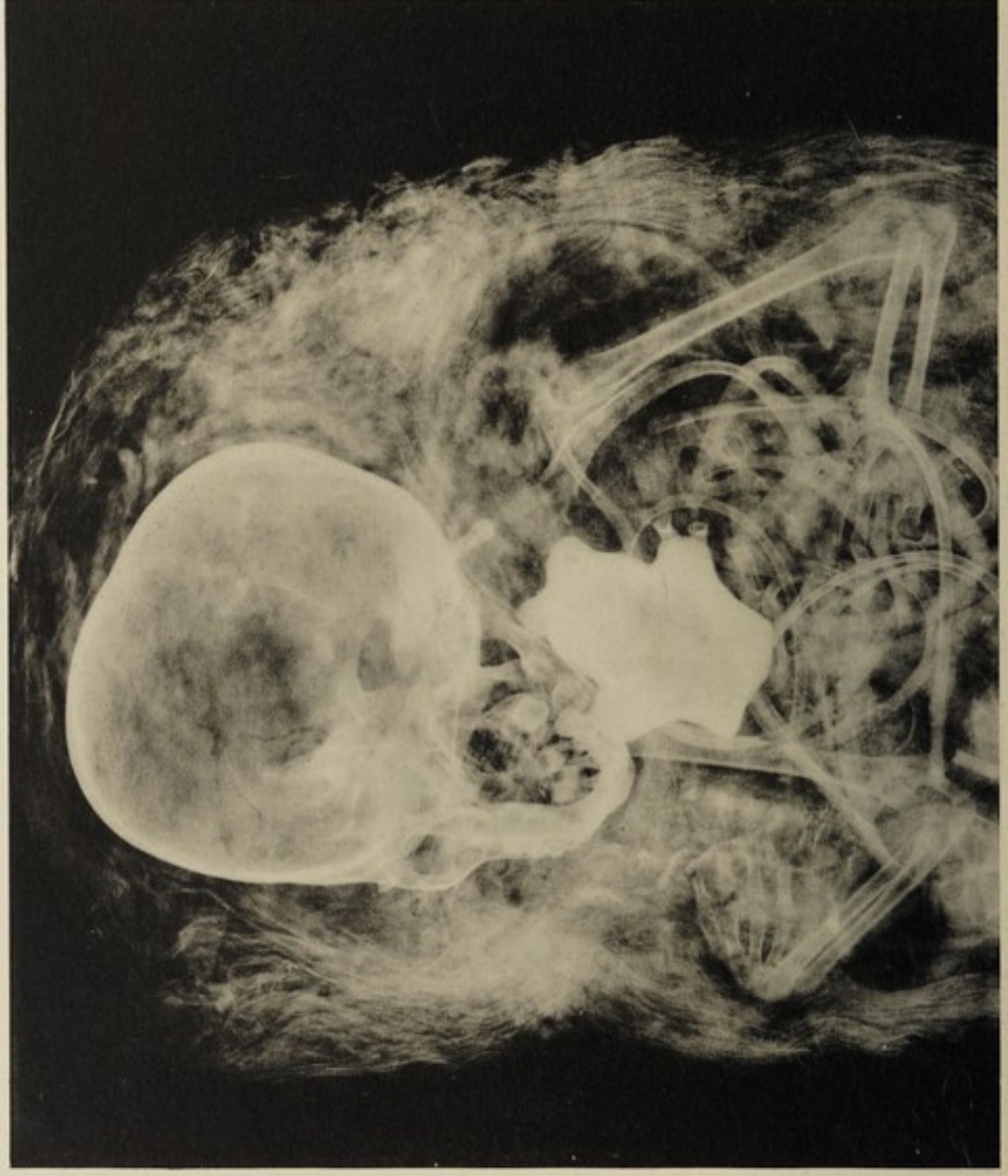


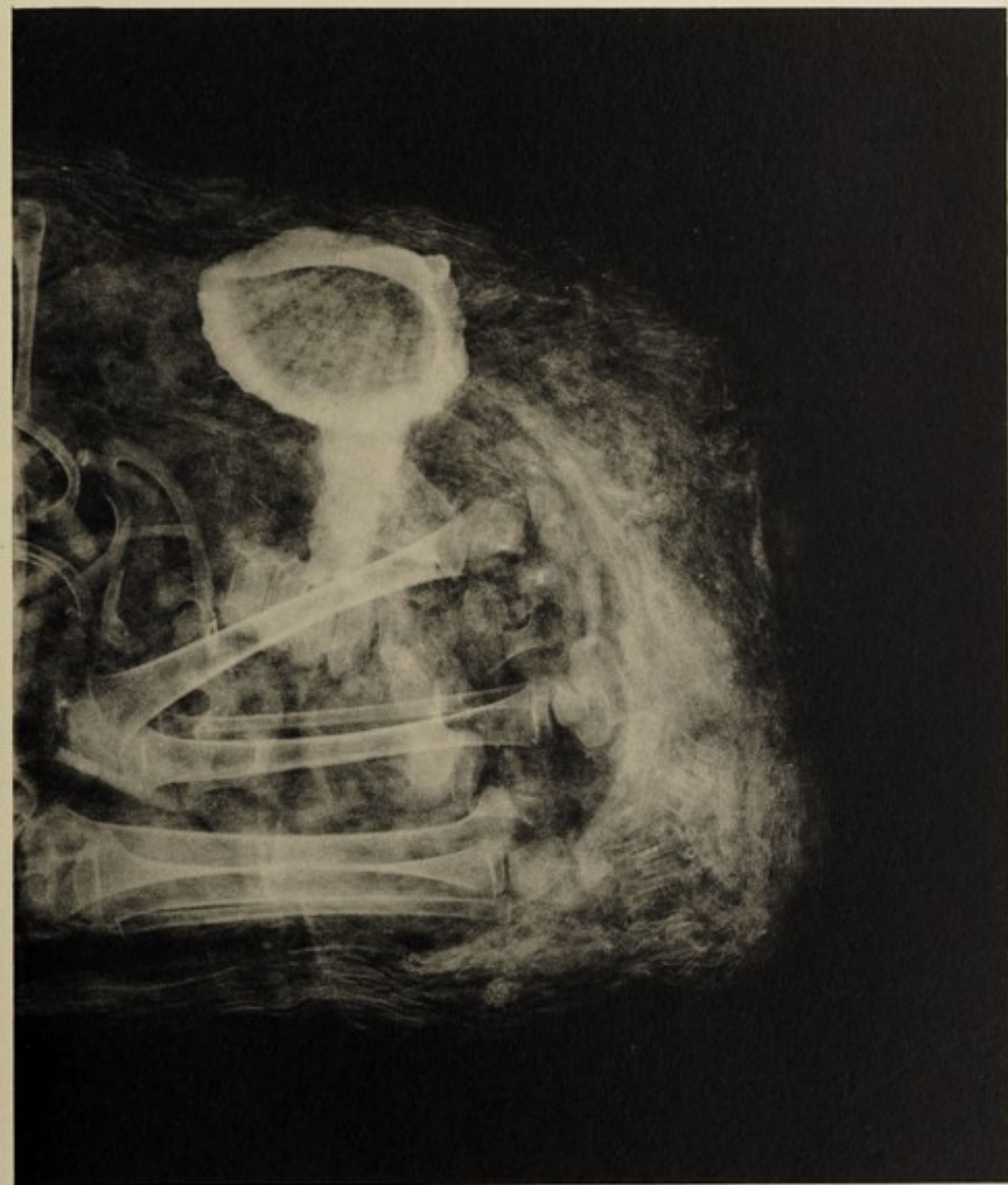
MUMMY OF INFANT, PERU



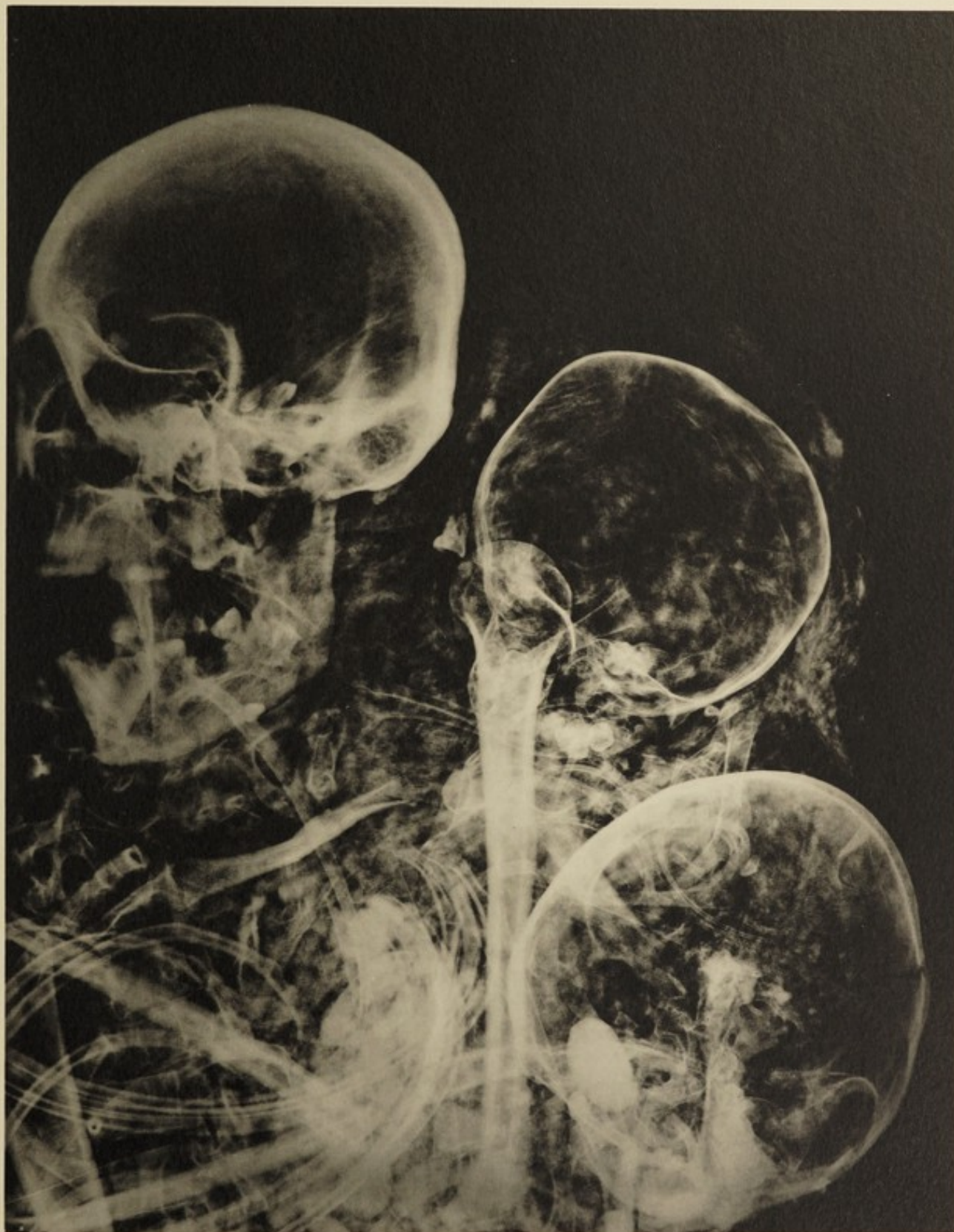

MUMMY OF CHILD, PERU
Wrappings tattered and torn



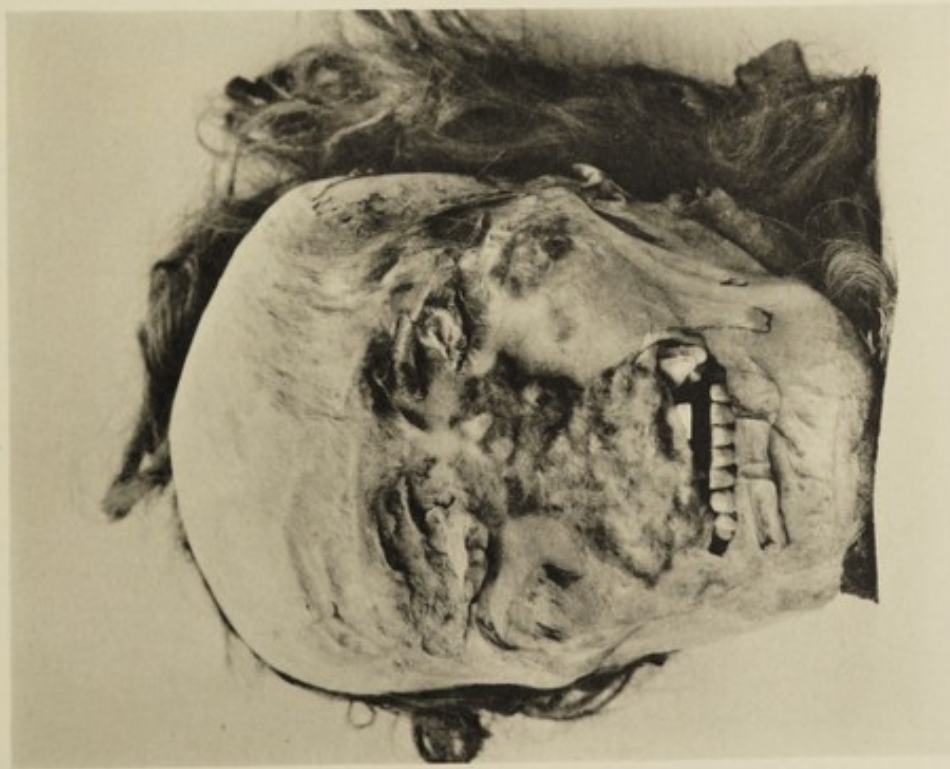

MUMMY OF CHILD, PERU
Shells included in package

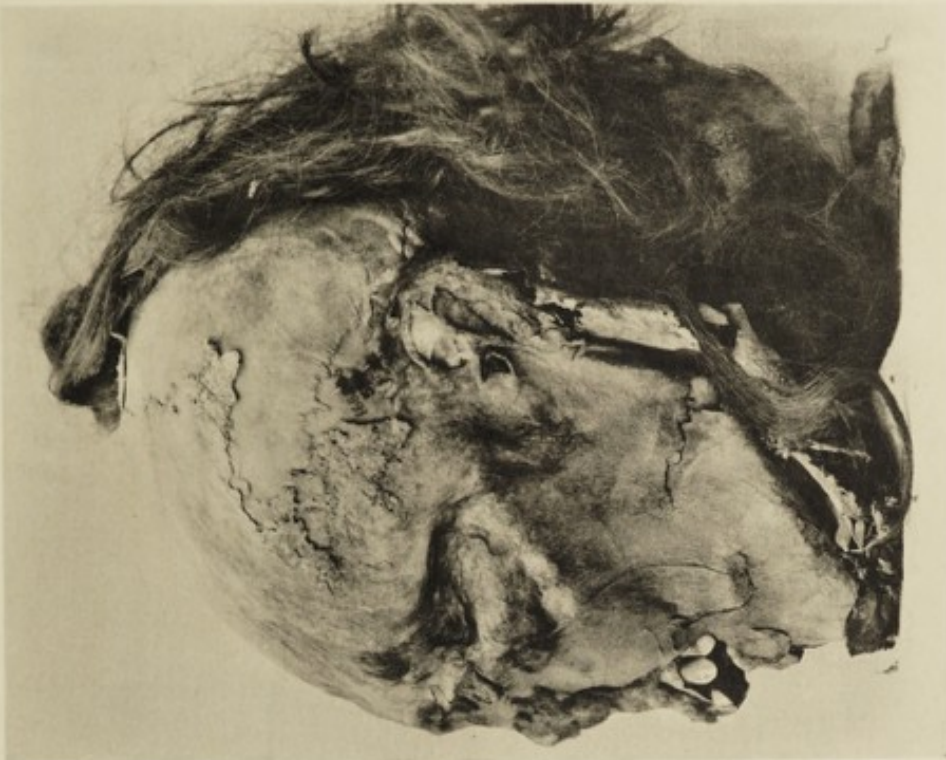

MUMMIES, PERU

Adult, youth, and infant included in same package

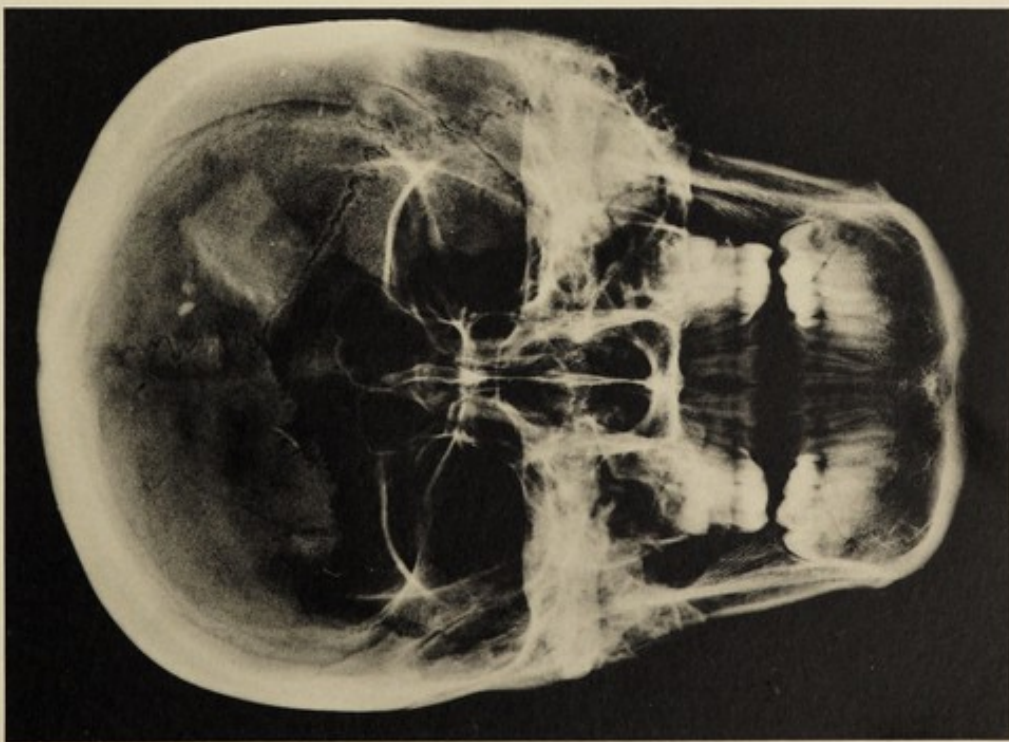


1

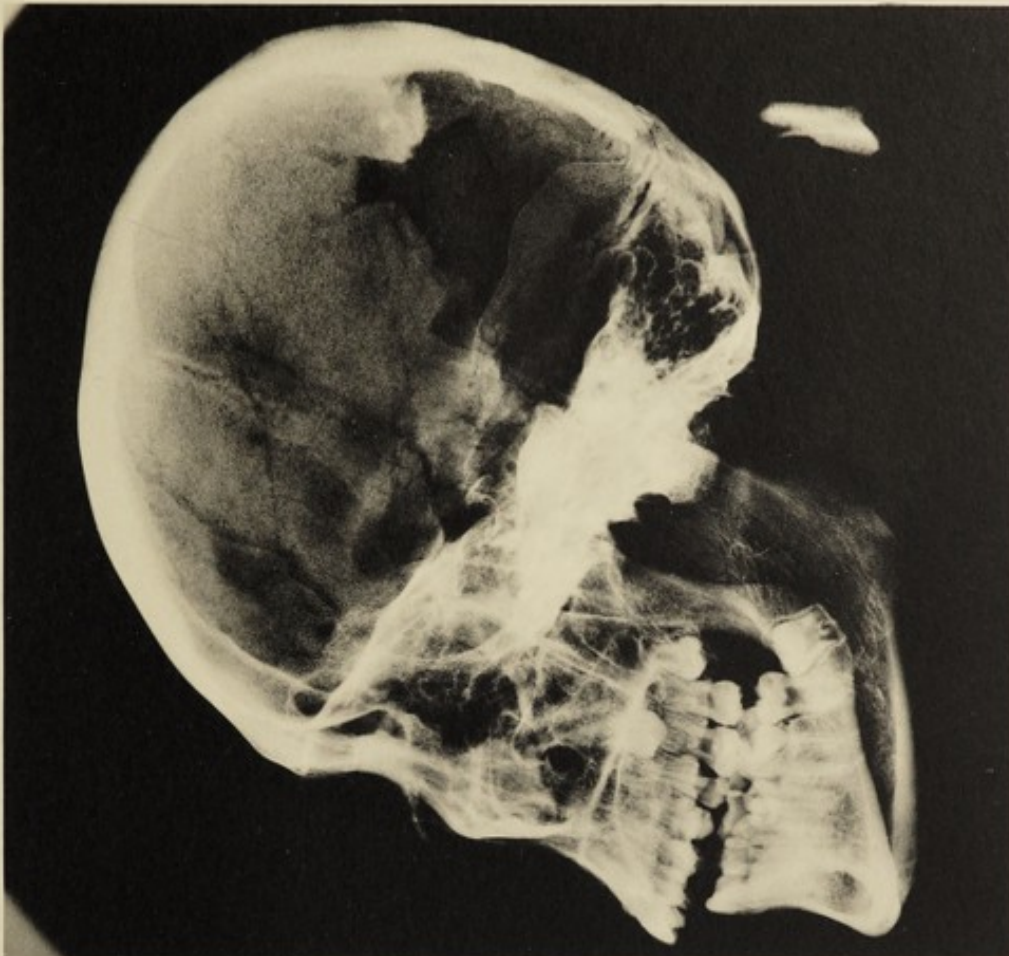

2

PHOTOGRAPHS OF MUMMY HEAD, PERU
1. Front. 2. Profile

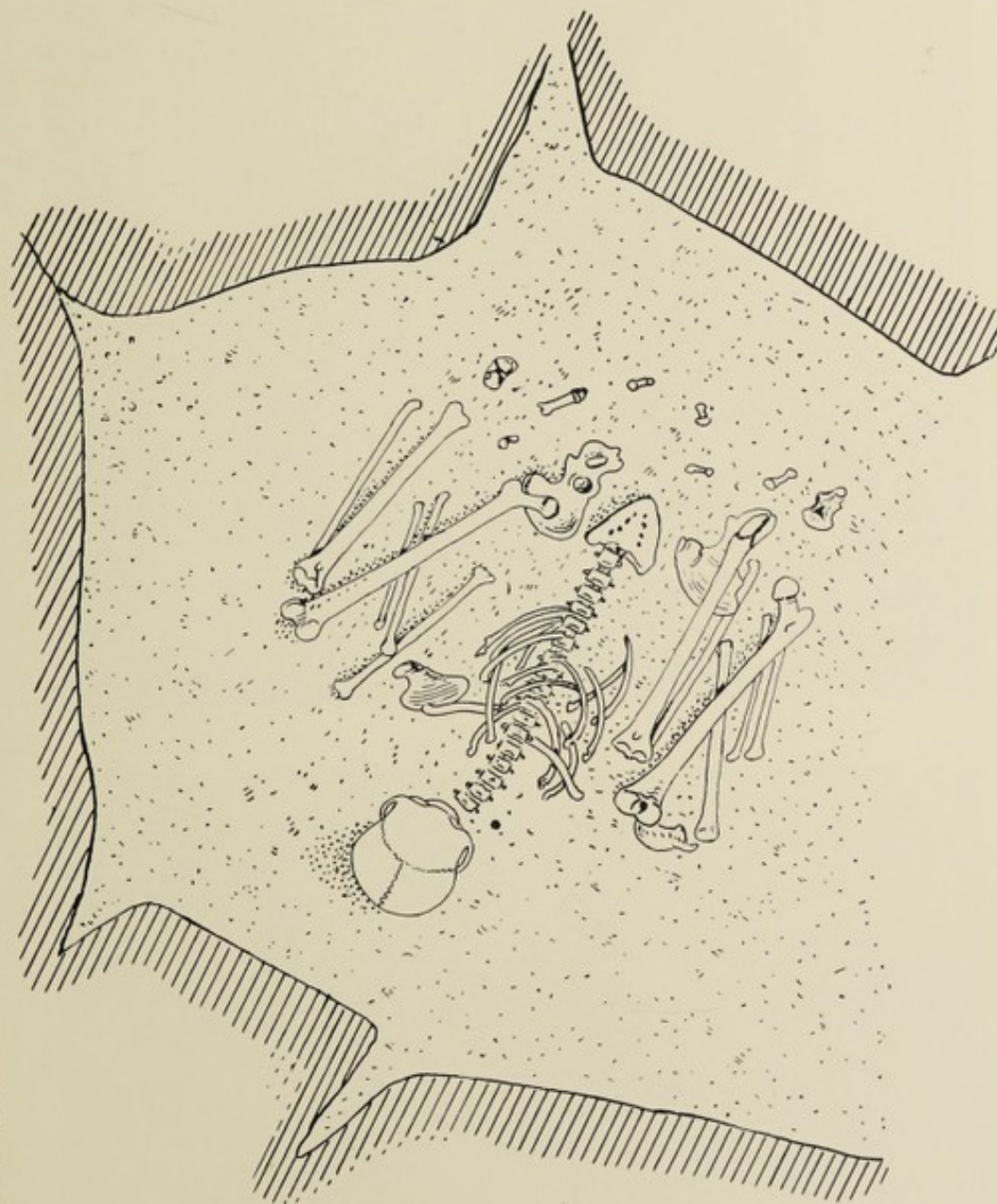


1

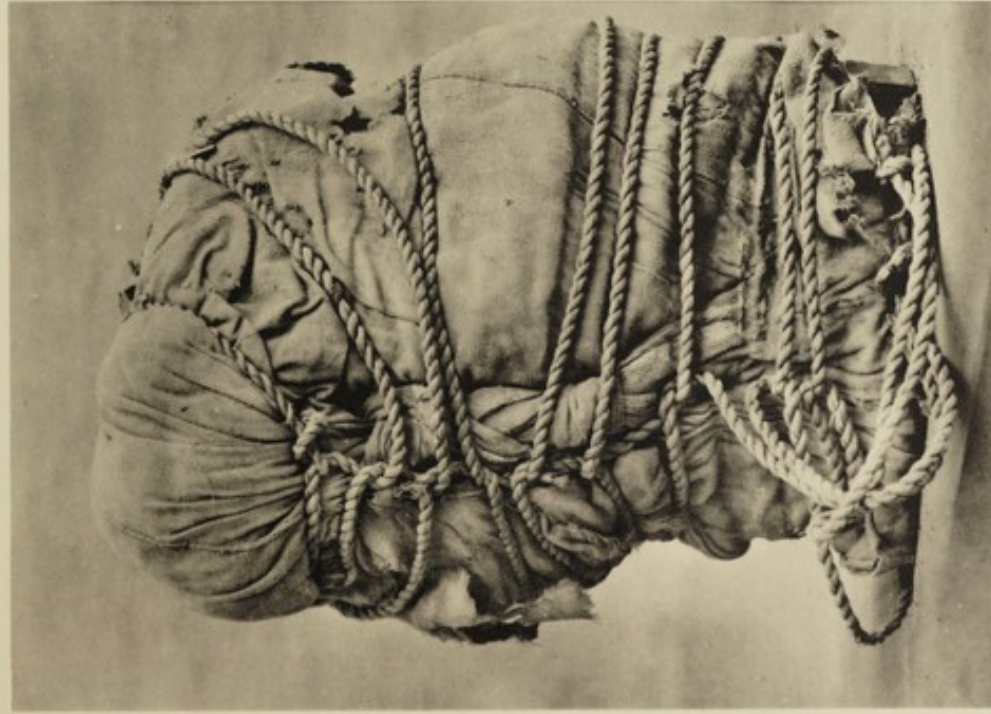


2

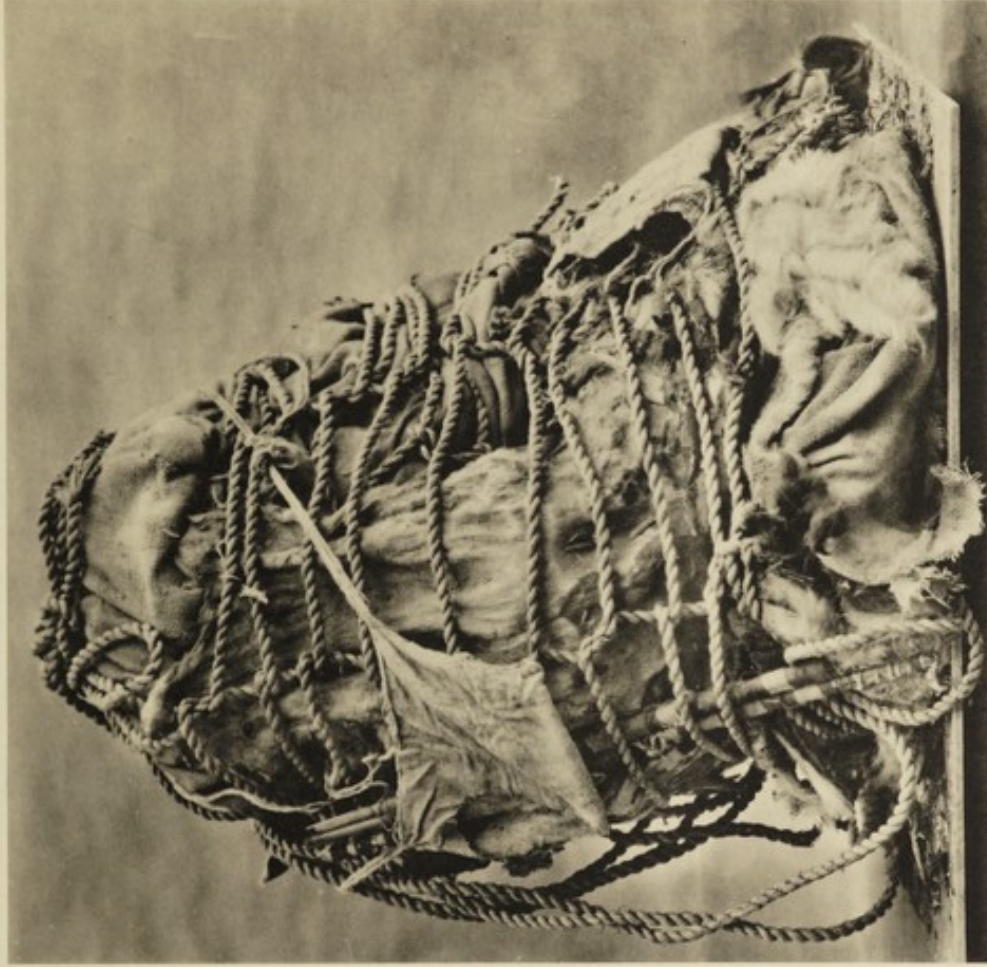
ROENTGENOGRAMS OF HEAD IN PRECEDING PLATE
1. Anterior, 2. Lateral



SKETCH OF PERUVIAN GRAVE
After Eaton

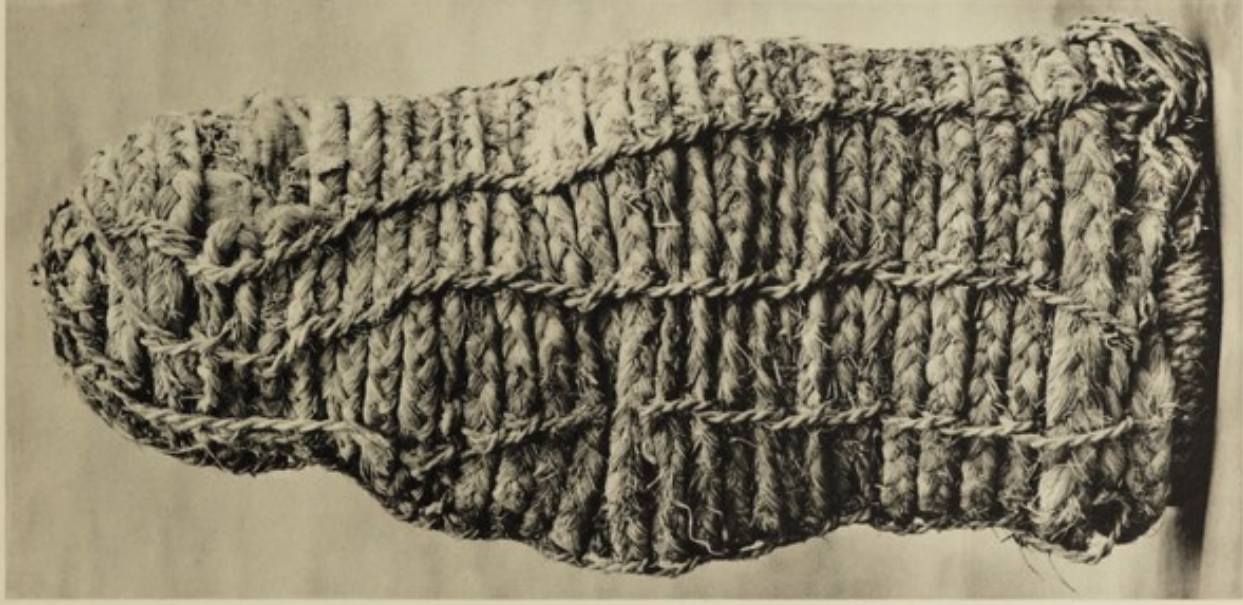


1

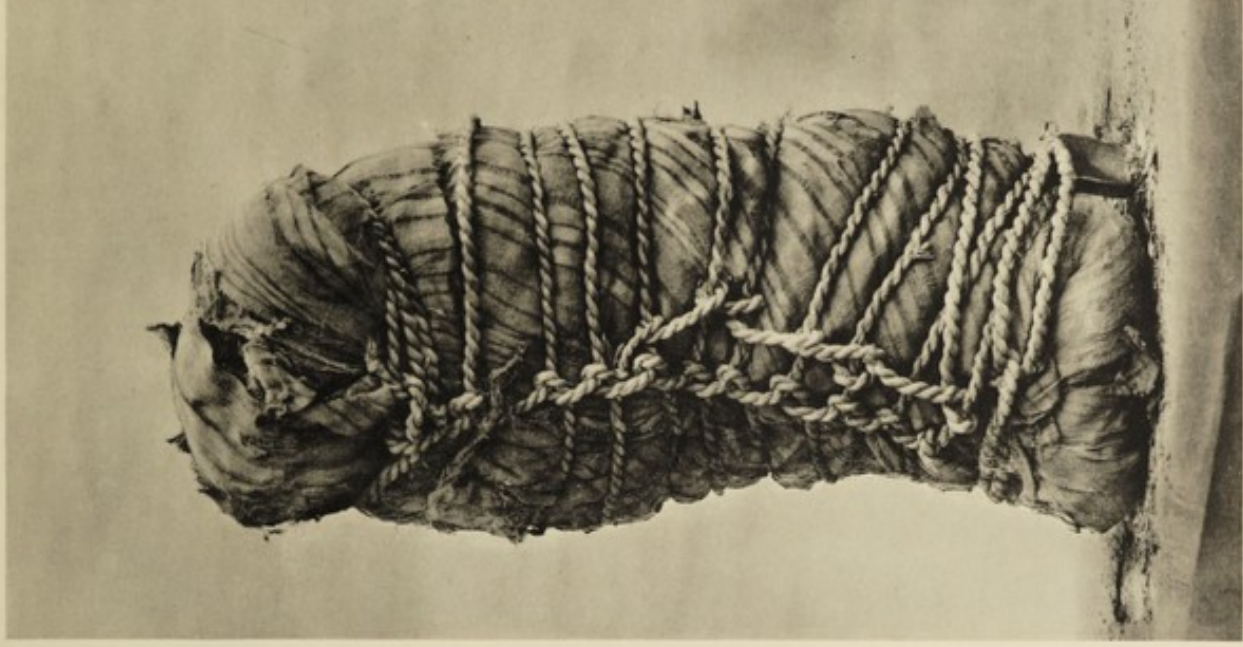

2

TYPICAL MUMMY PACKAGES, PERU

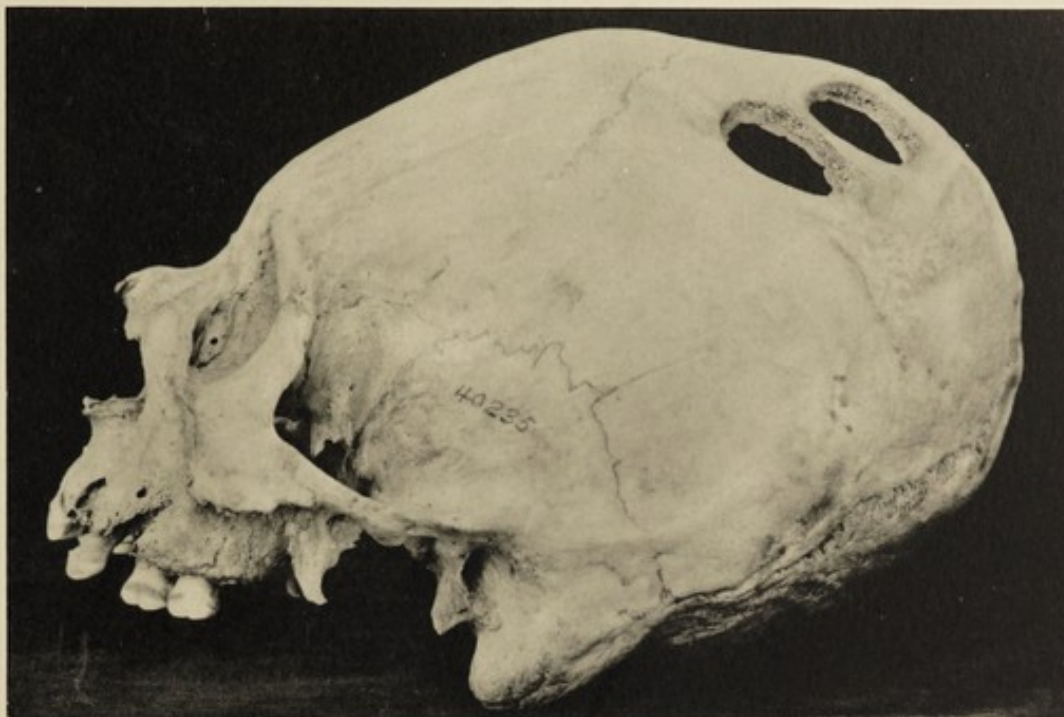


1

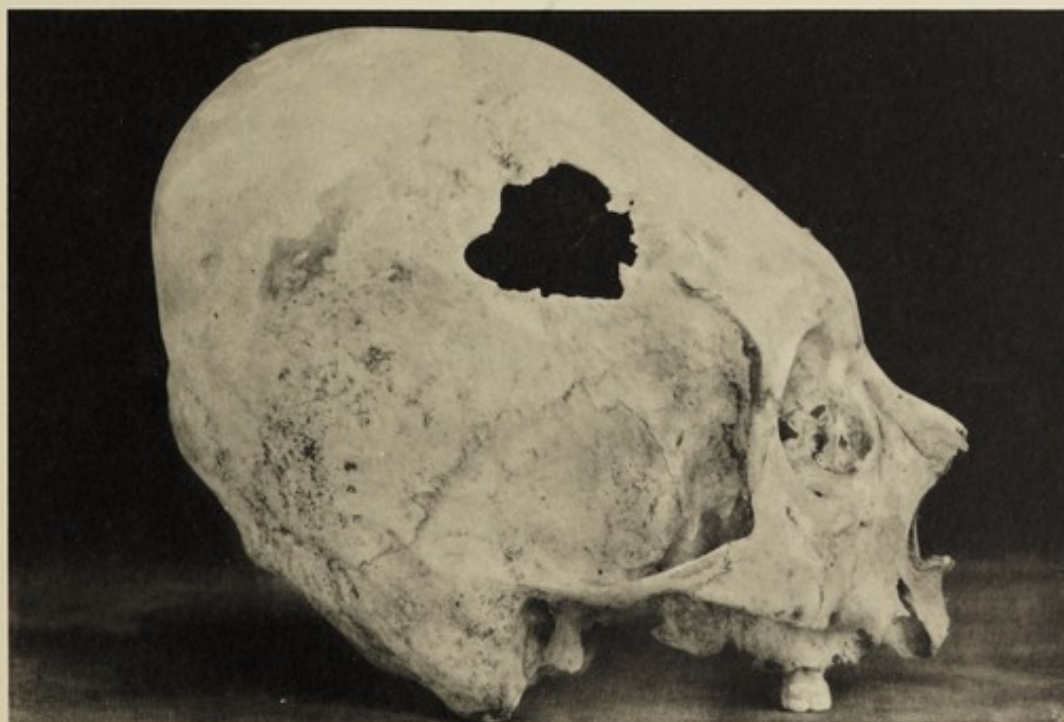


2

TYPICAL MUMMY PACKAGES, PERU

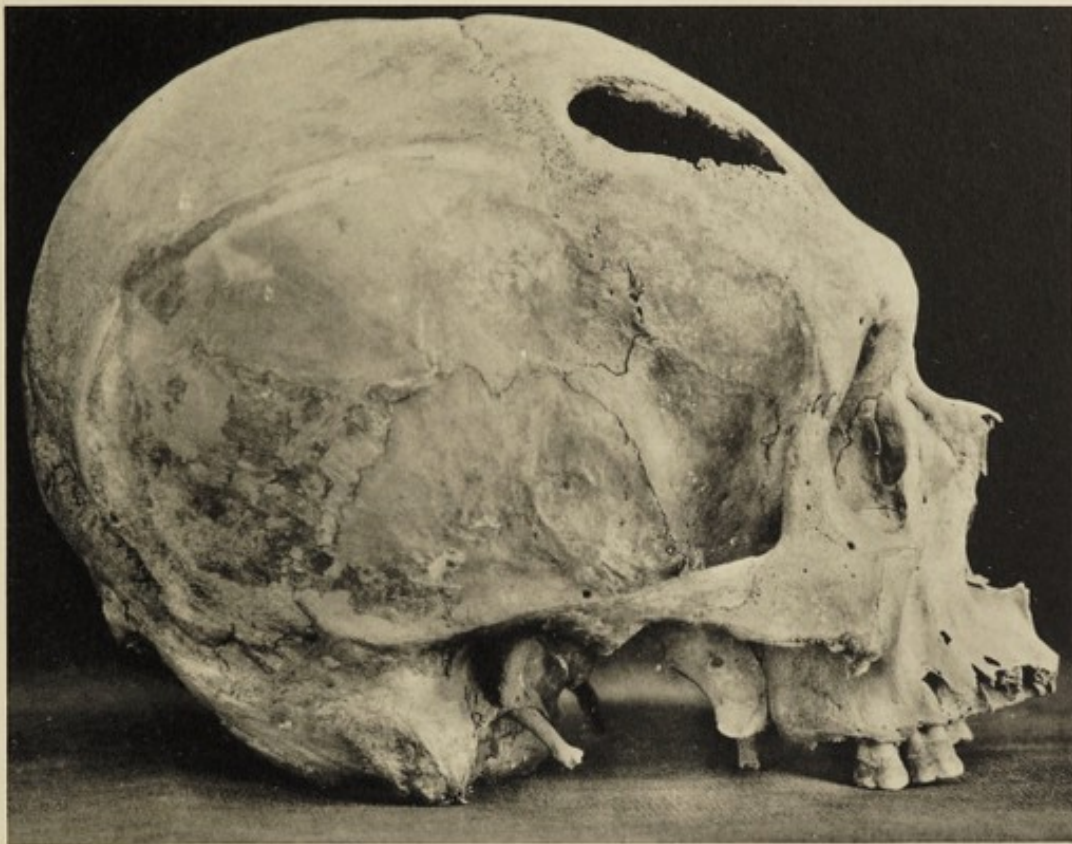


1

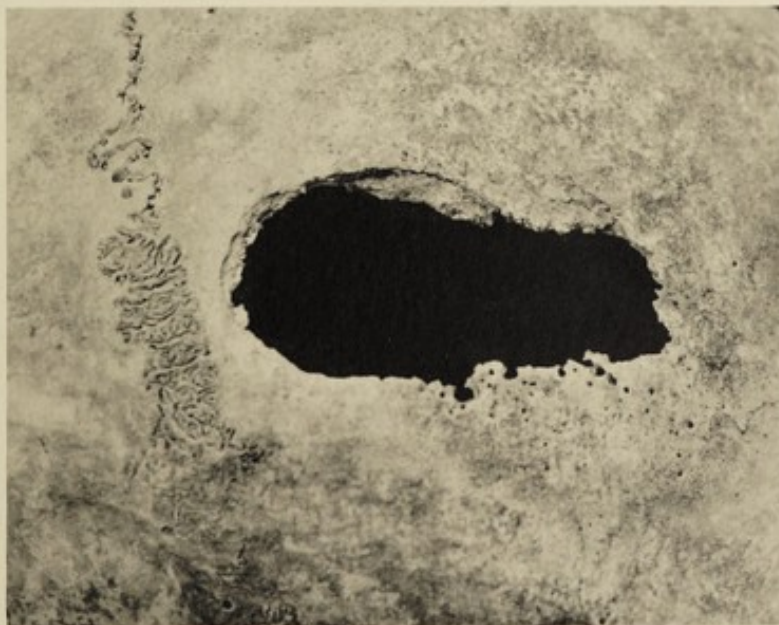


2

DEFORMED SKULLS OF INCAS, PERU
Showing trepanning



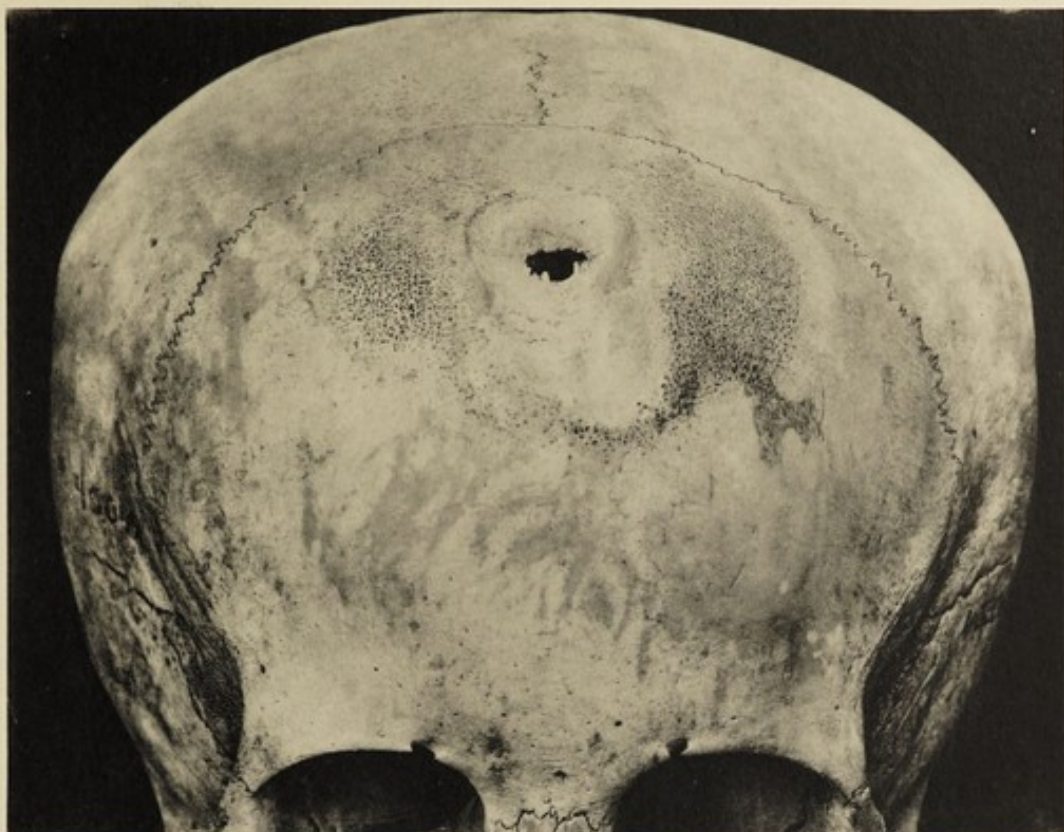
1



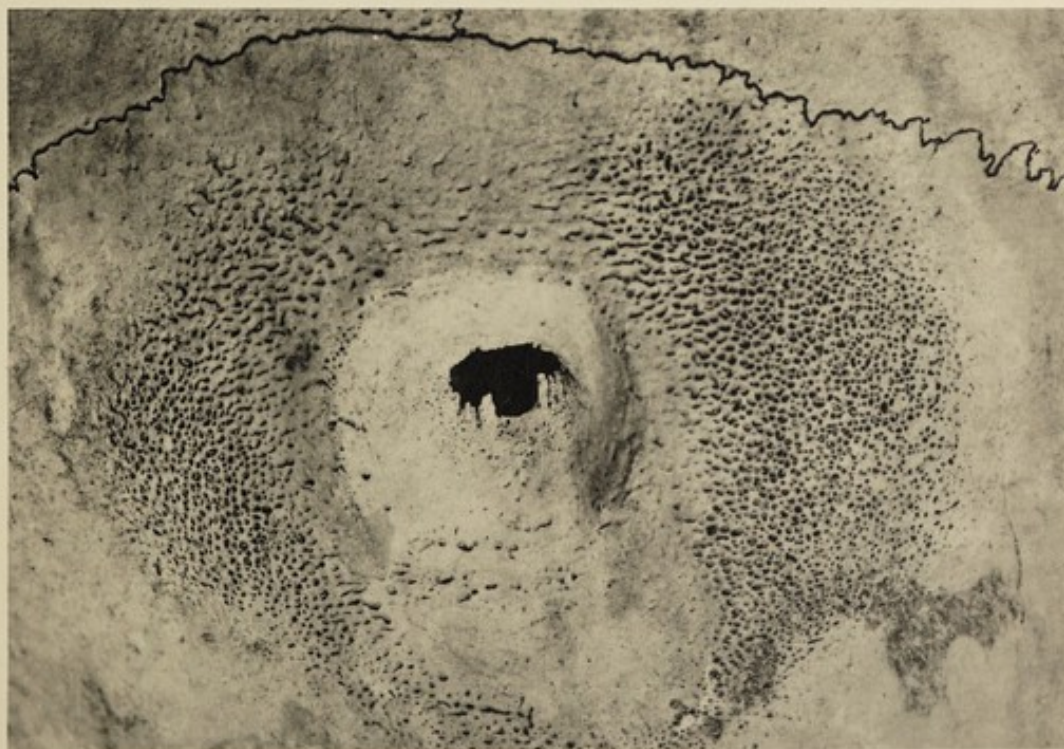
2

SKULL OF ADULT, PERU

1. Showing large trepanning. 2. Detail of Fig. 1 with evidences of infection and slight healing



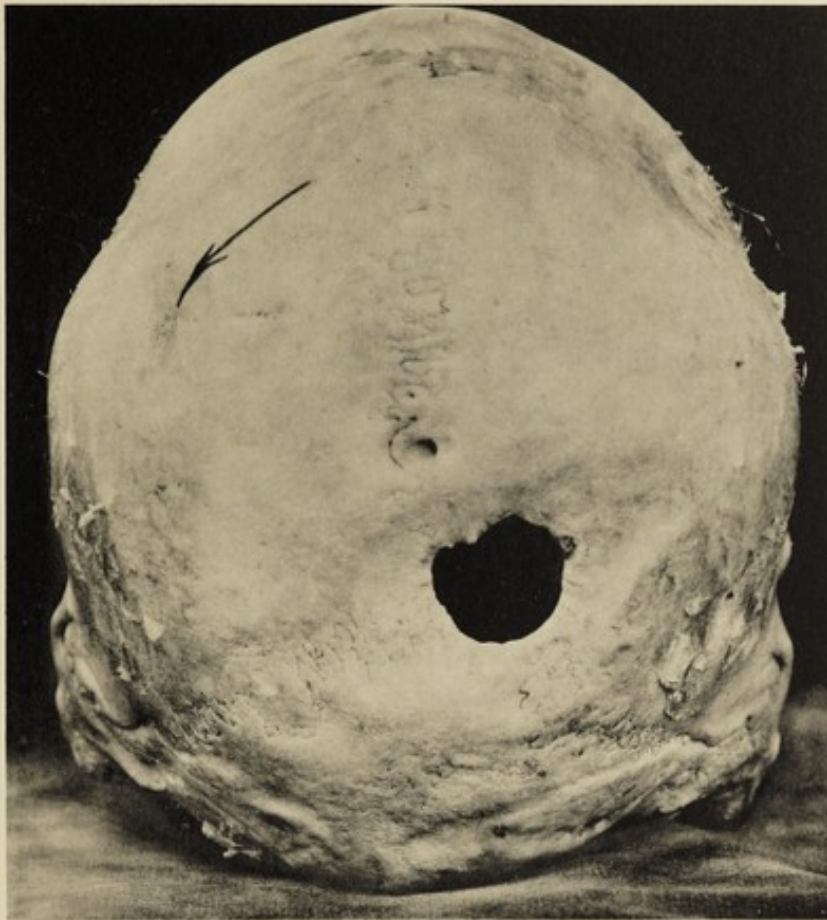
1



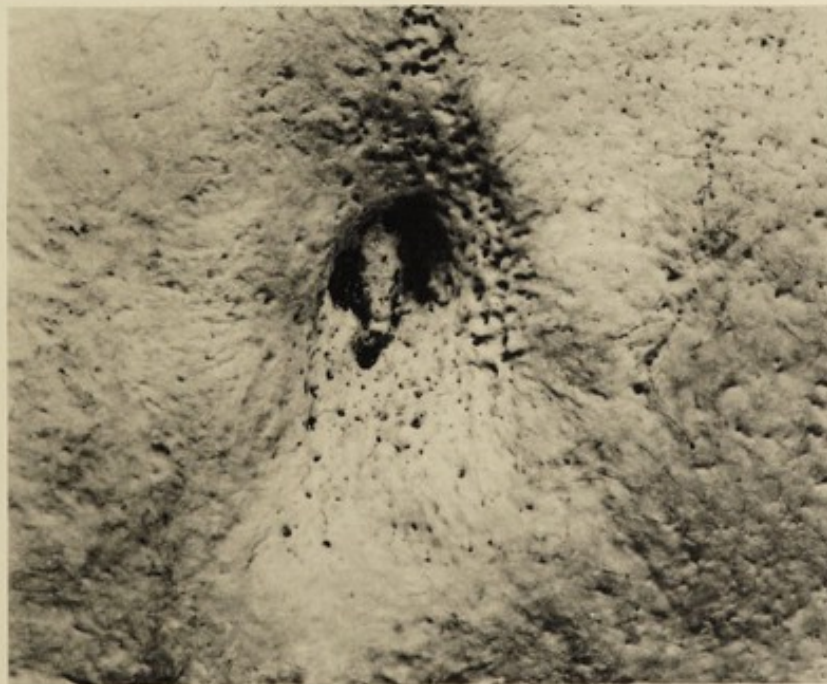2

SKULL OF CHILD, PERU

1. Showing unusual cranial lesion and osteoporosis. 2. Detail of Fig. 1



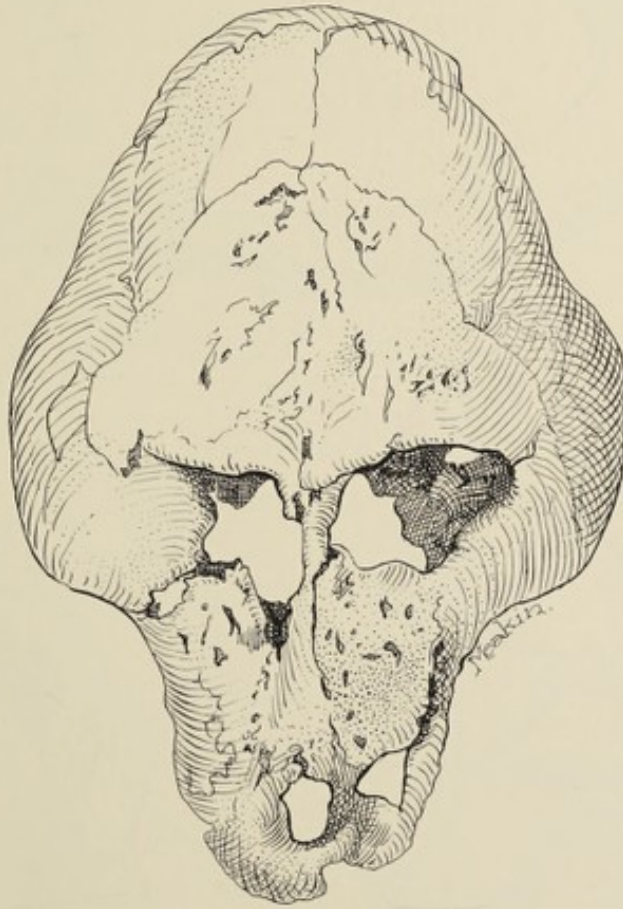
1



2

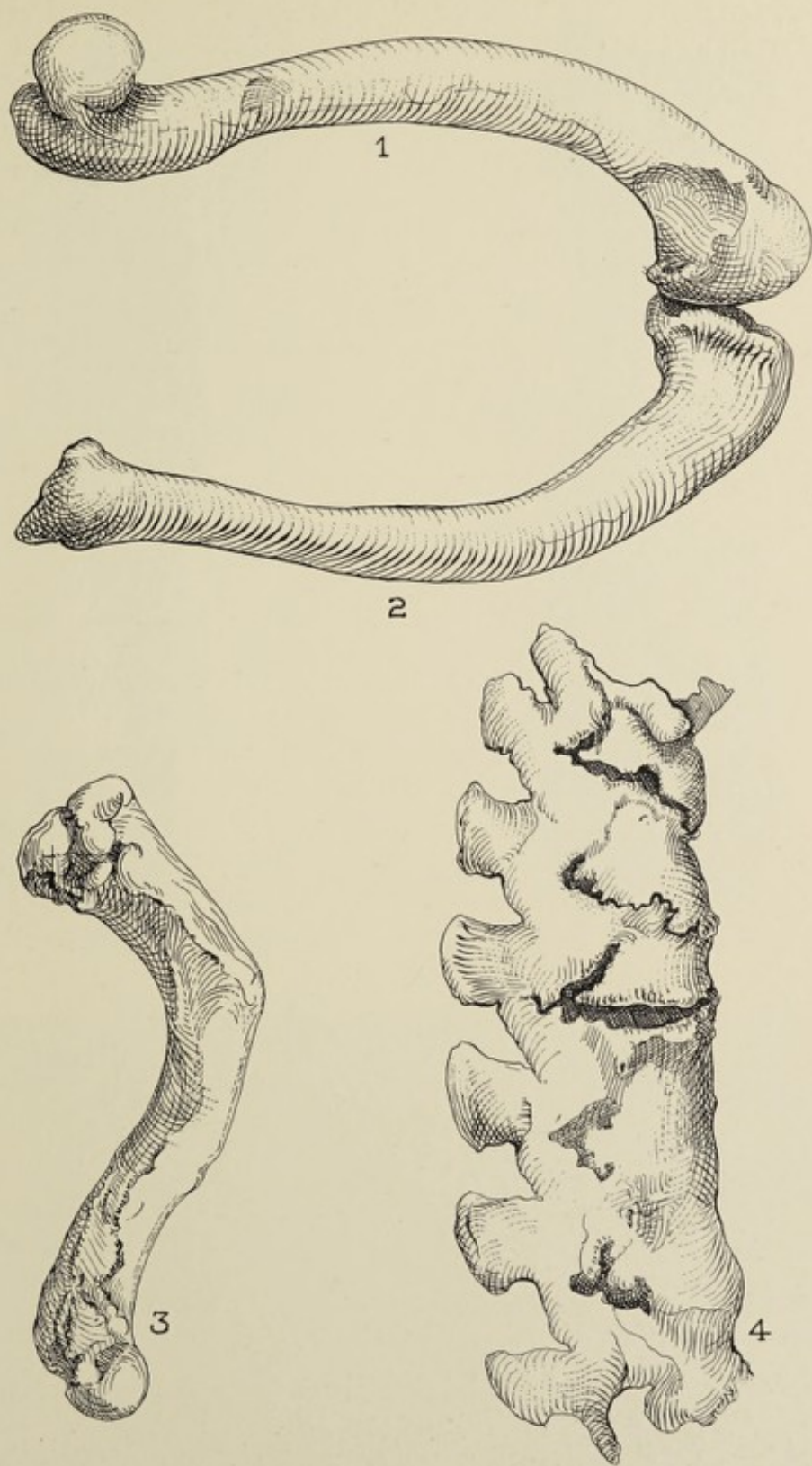
SKULLS OF ADULTS, PERU

1. Showing trepanning in state of advanced healing. 2. Showing healed, depressed area due to injury or trepanning




MUMMIFIED BABOON SKULL, EGYPT

Drawing



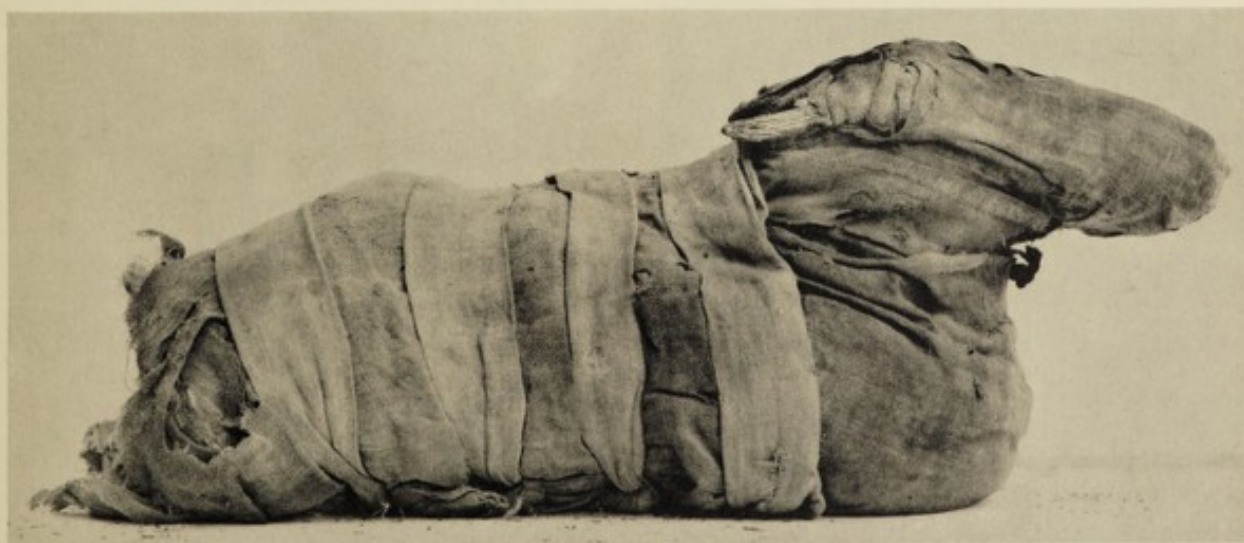DISEASED BONES OF MUMMIFIED BABOON, EGYPT
Drawing



1



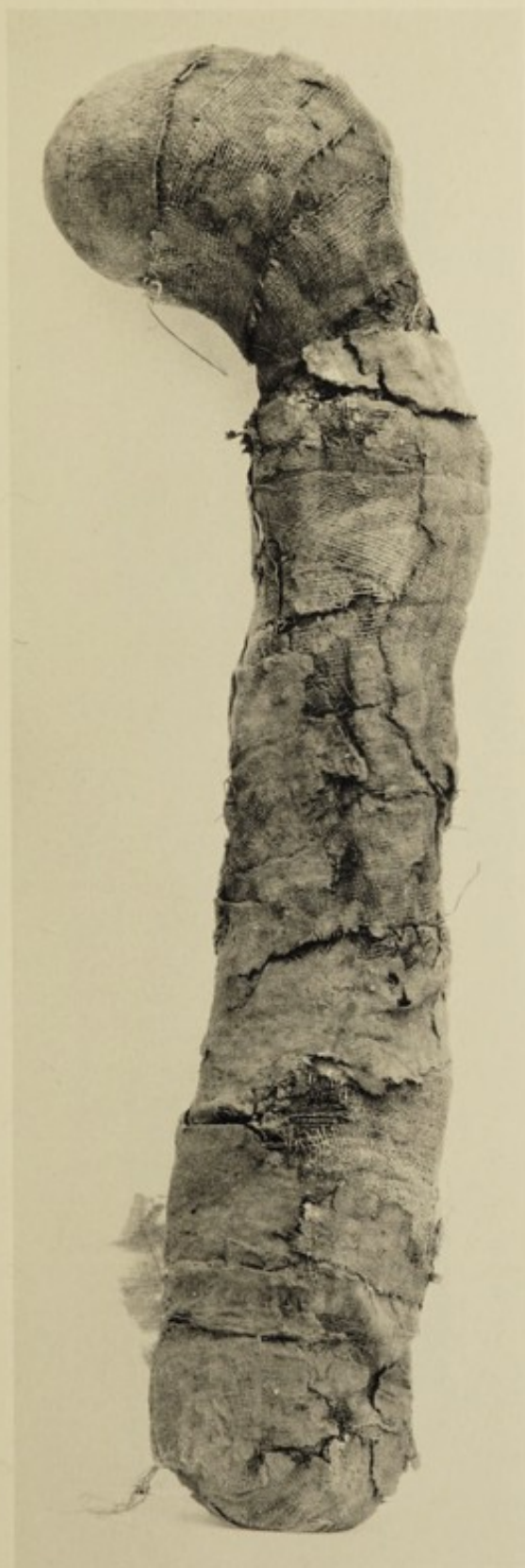2



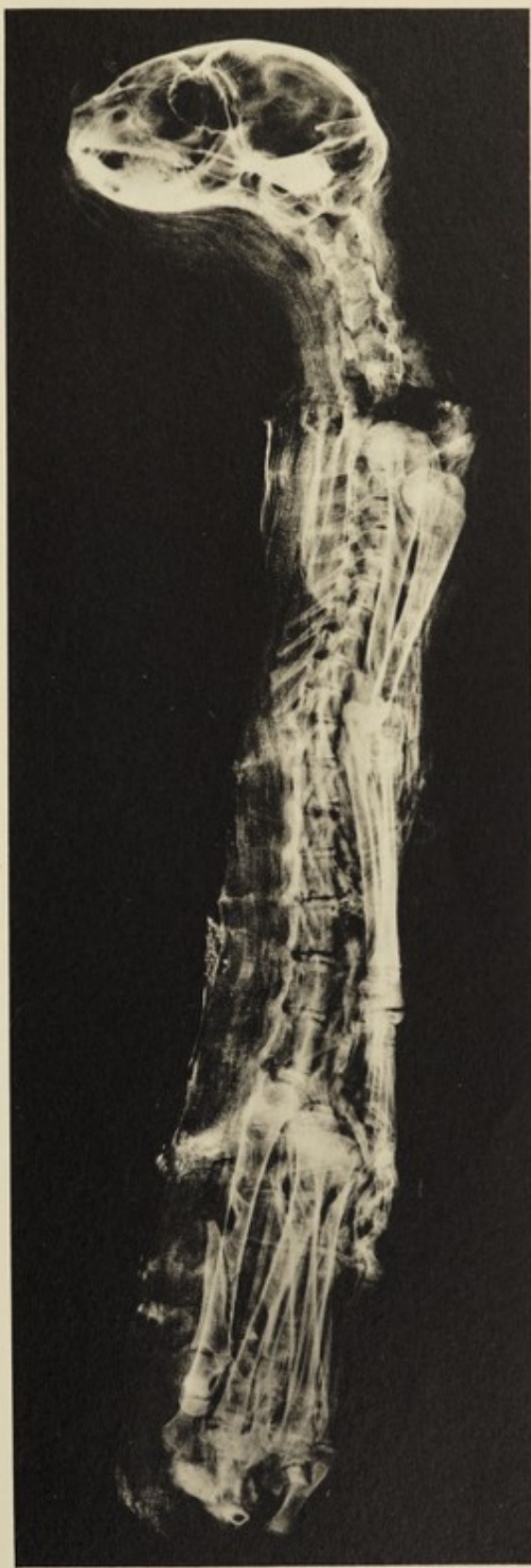3

MUMMIES OF ANIMALS, EGYPT (Photographs)

1. Baby crocodile. 2. Imitation mummy of a kitten; no skeleton in package. 3. Imitation mummy of a gazelle; only horns in package



1



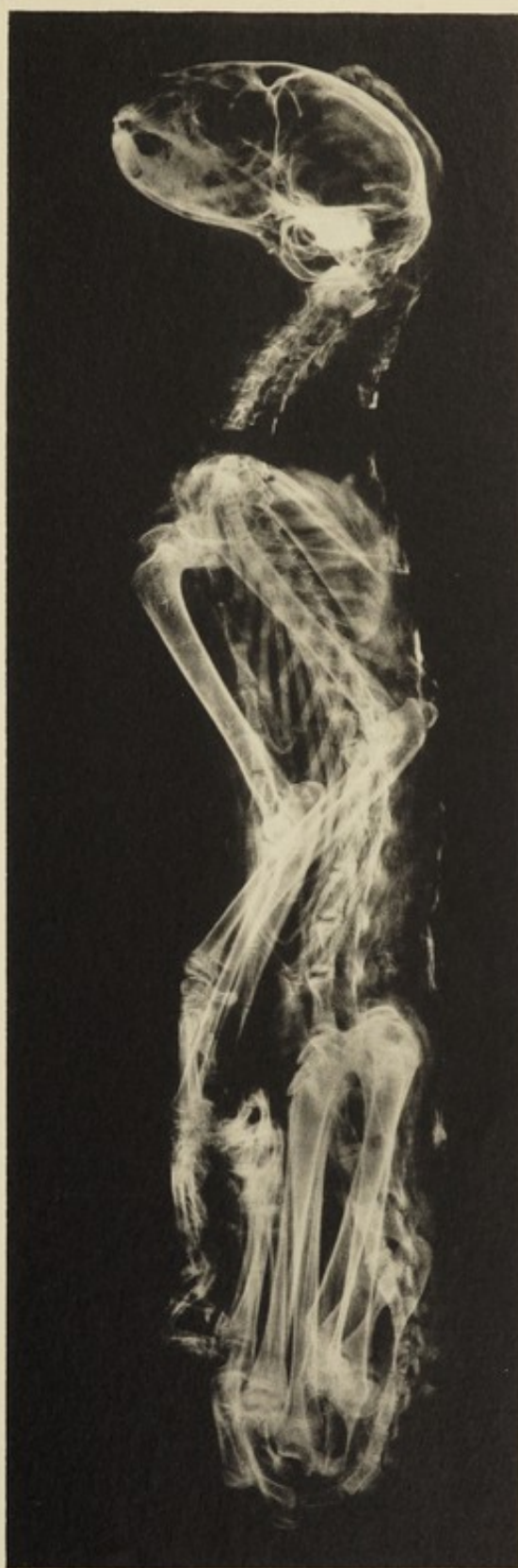2

MUMMY OF A CAT, EGYPT

1. Photograph. 2. Roentgenogram showing complete skeleton



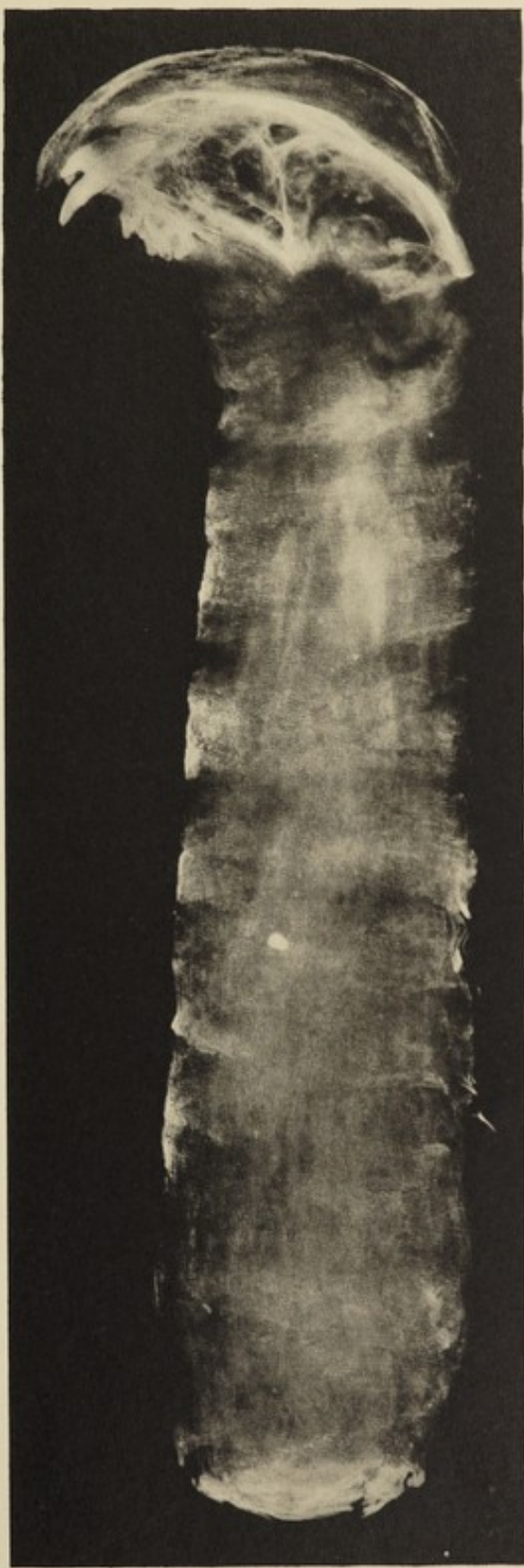1



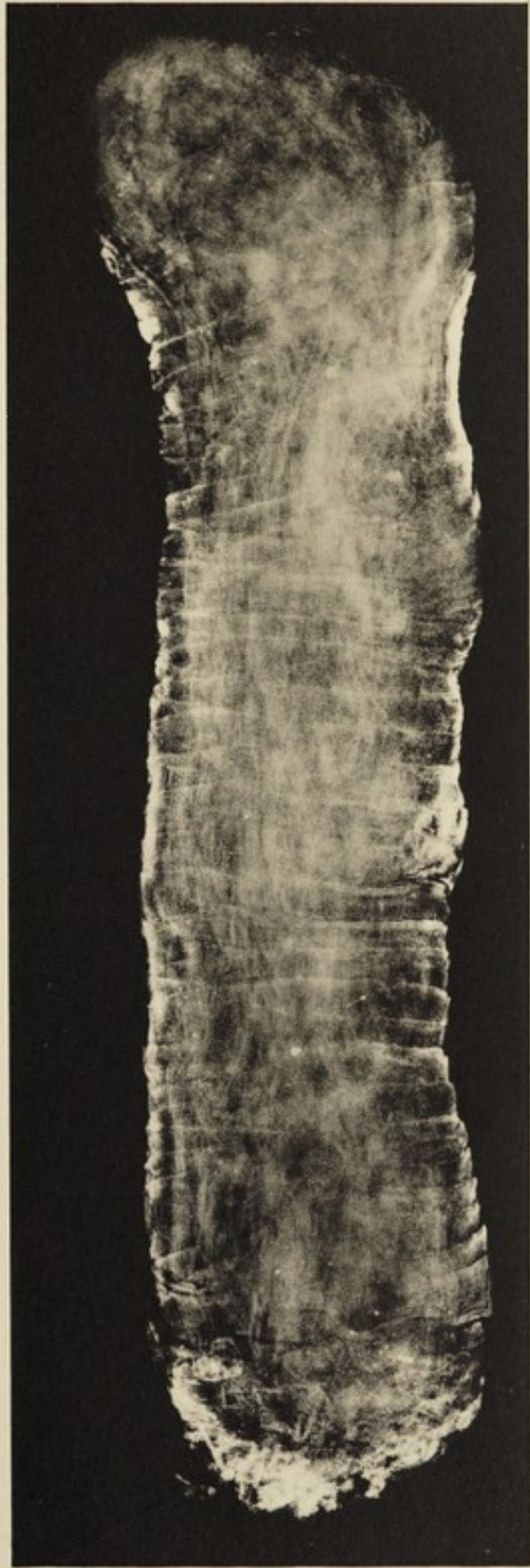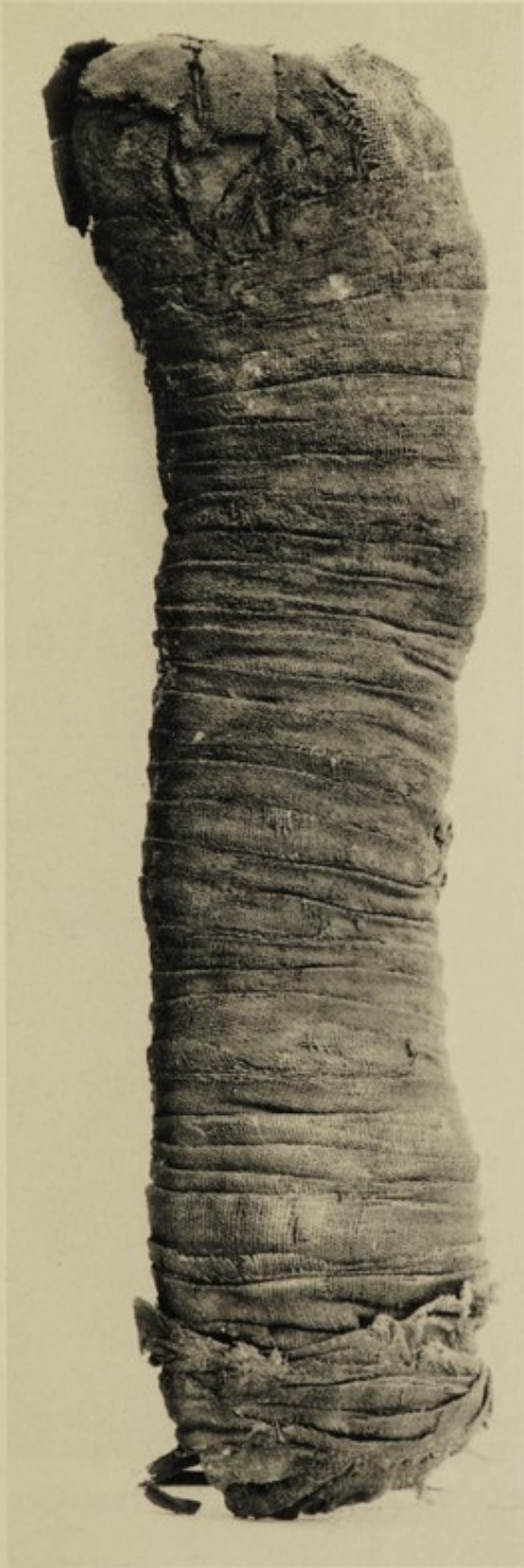2

MUMMY OF A CAT, EGYPT

1. Photograph. 2. Roentgenogram showing complete skeleton



1
2
IMITATION MUMMY OF AN UNIDENTIFIED ANIMAL (CAT), EGYPT
1. Photograph. 2. Roentgenogram showing skull only

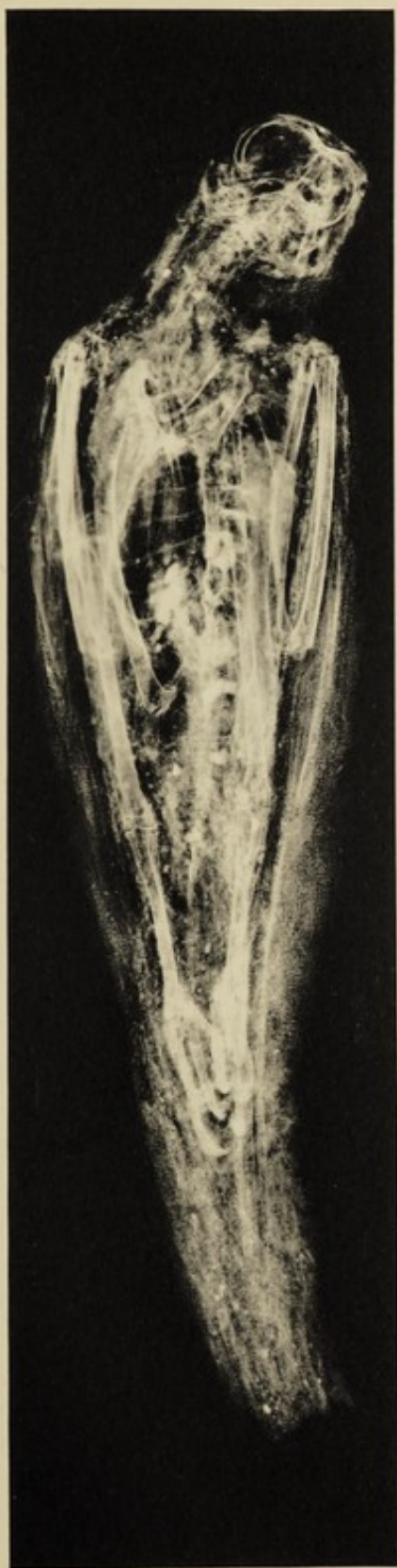

1

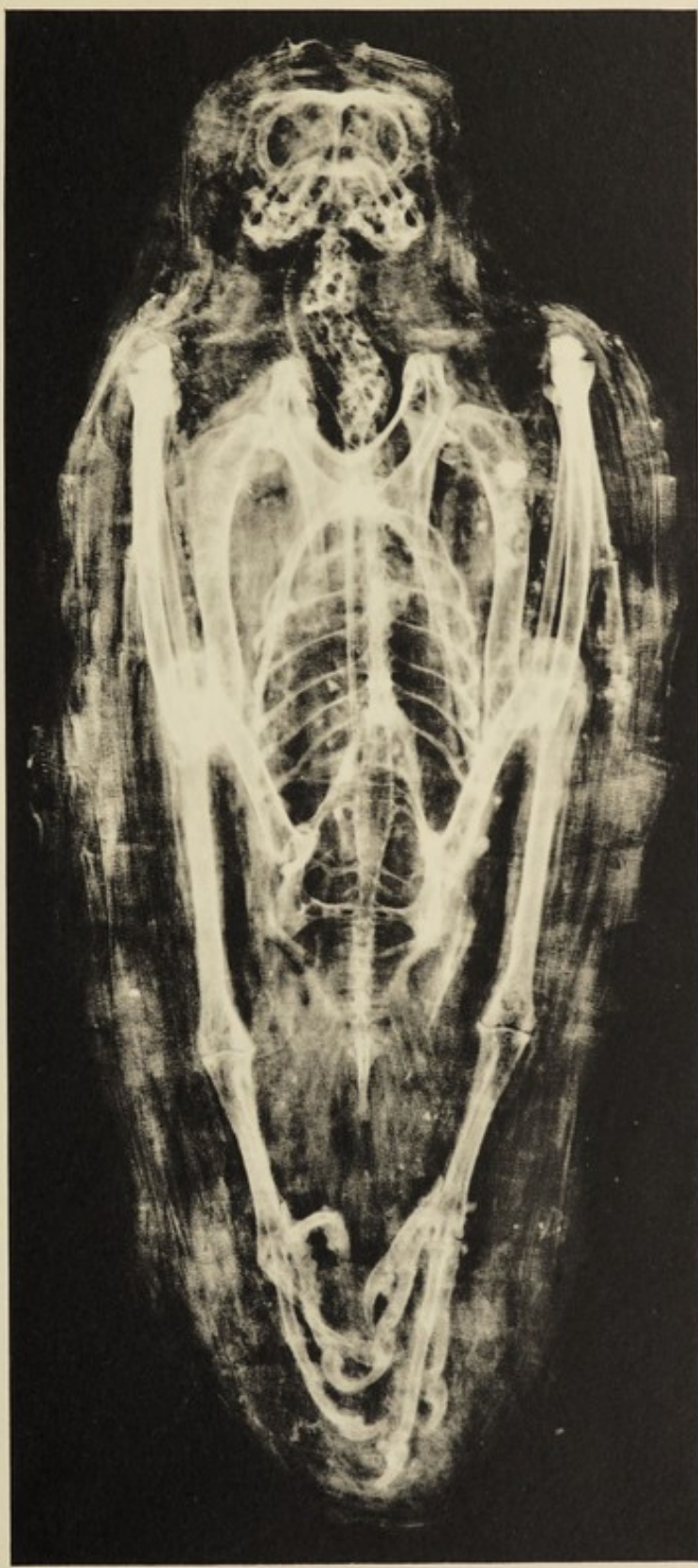2

IMITATION MUMMY OF A SMALL ANIMAL, EGYPT

1. Photograph. 2. Roentgenogram revealing absence of skeleton

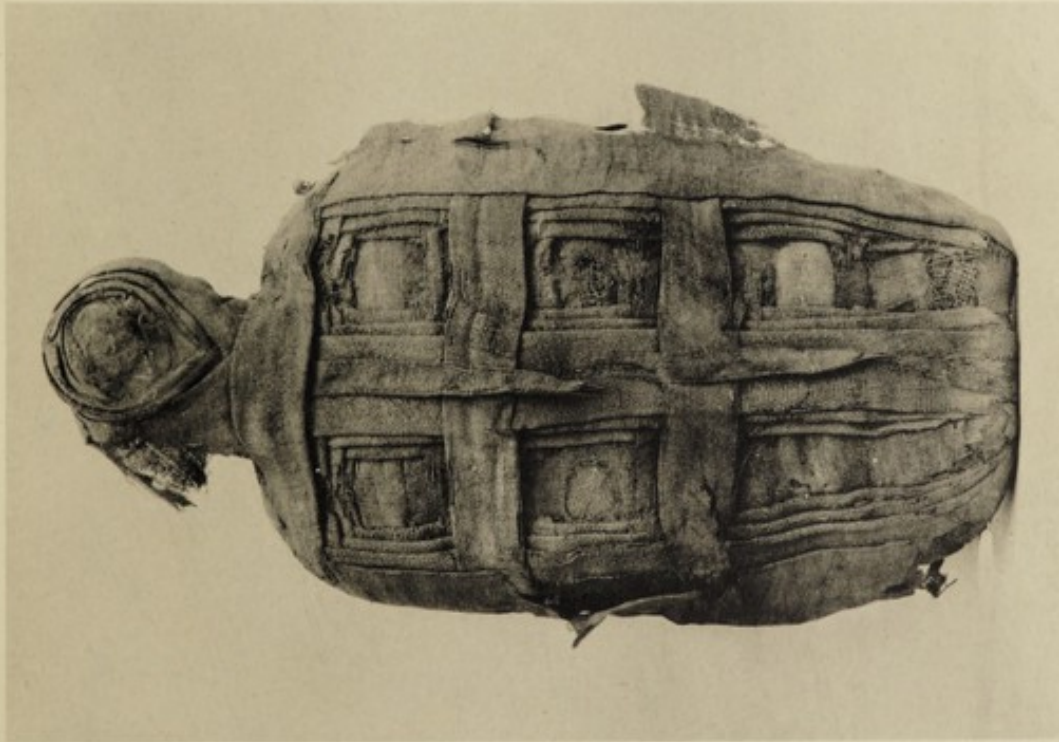


1

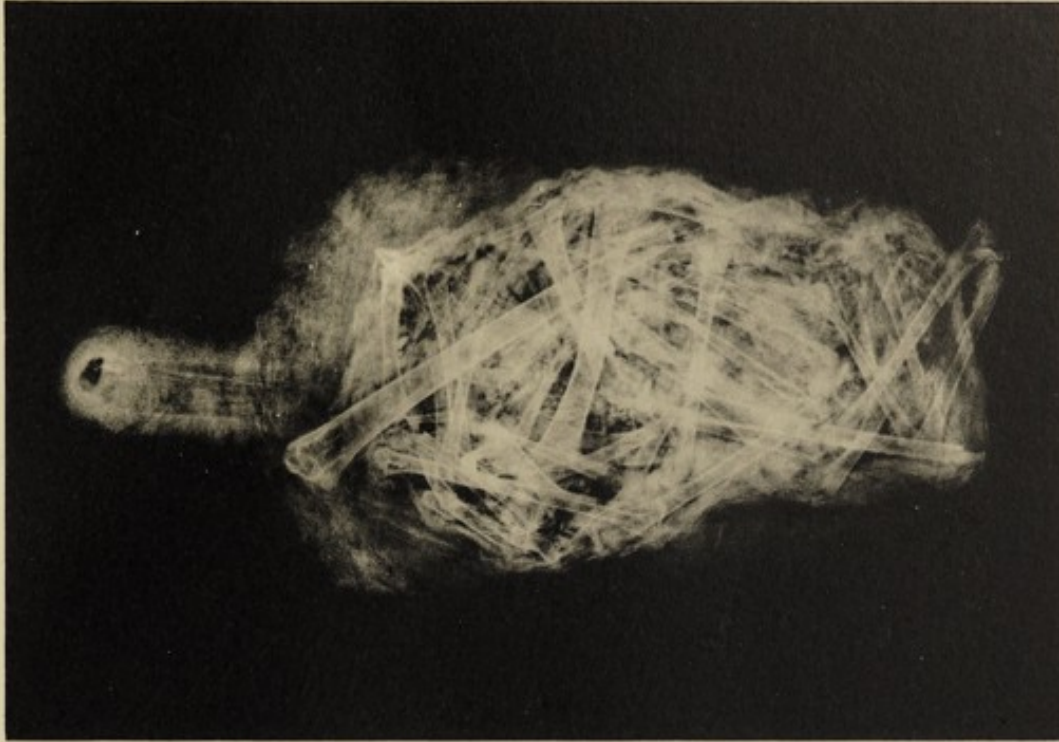


2

ROENTGENOGRAMS OF MUMMIFIED BIRDS, EGYPT
1. Kite. 2. Falcon



1

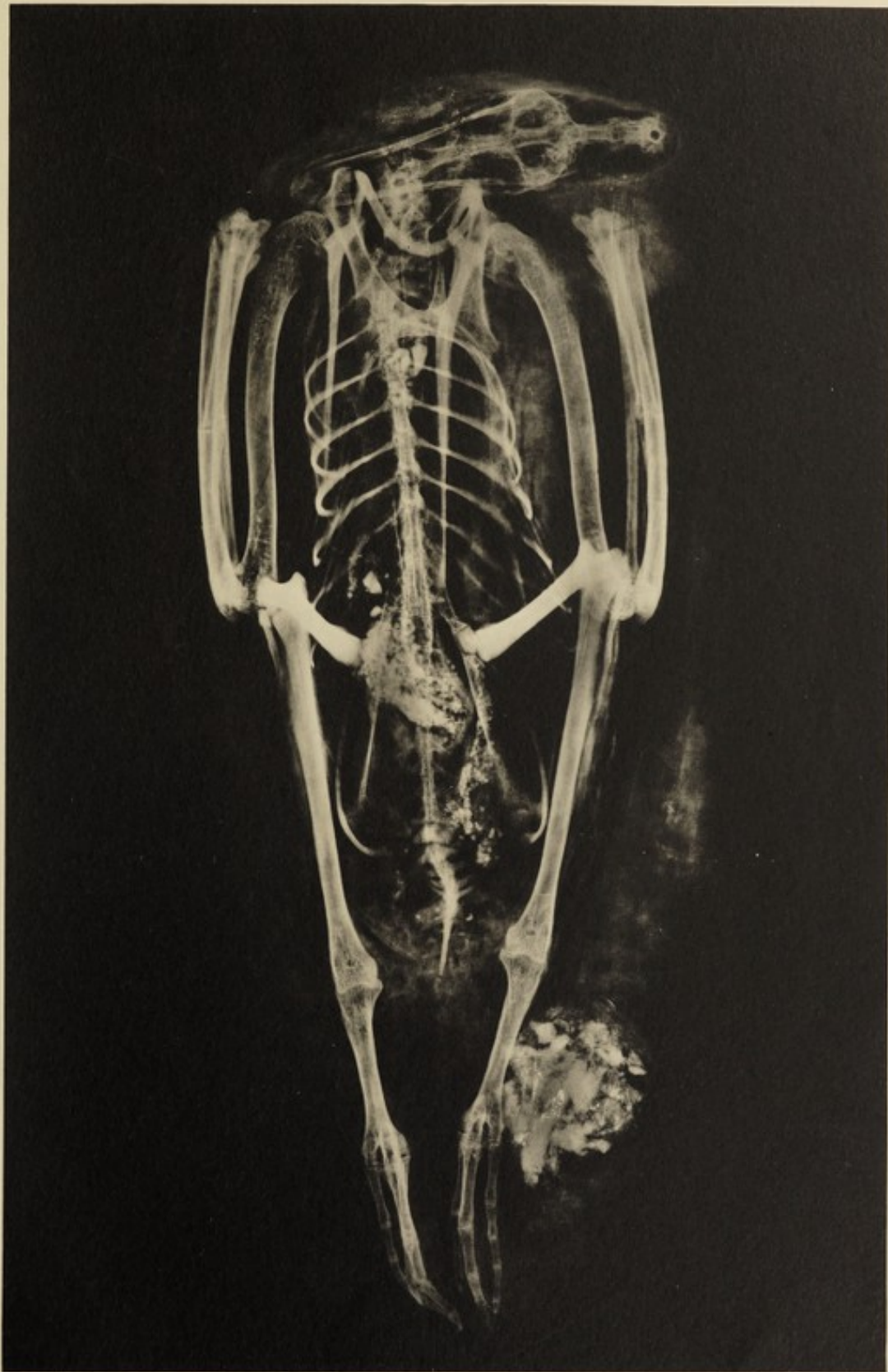

2

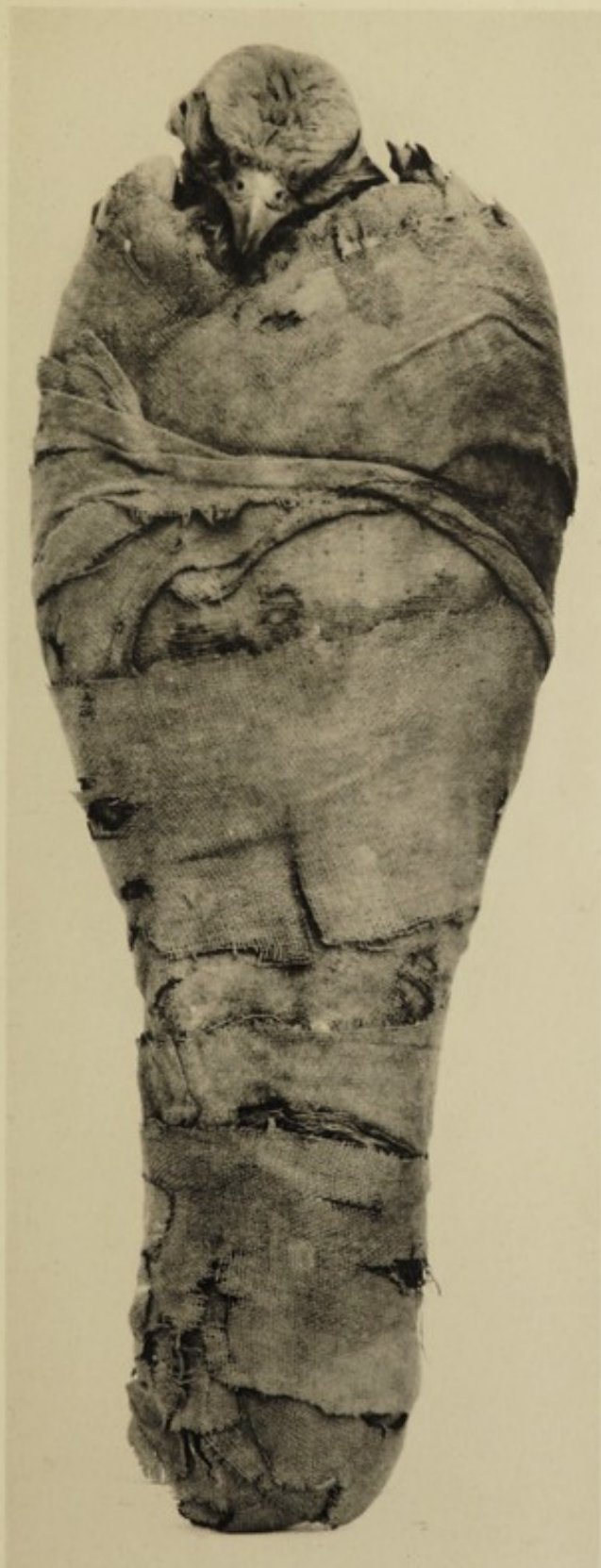IMITATION MUMMY OF A BIRD, EGYPT
1. Photograph. 2. Roentgenogram revealing unidentified bones



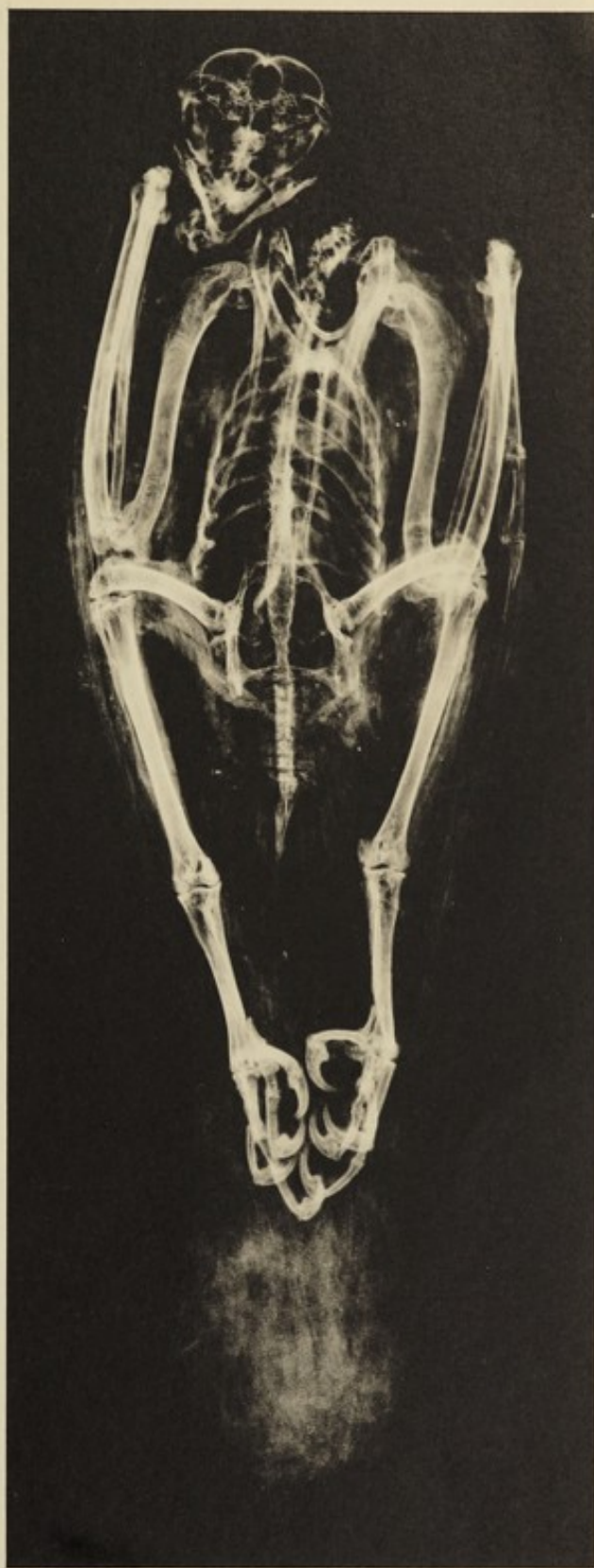PHOTOGRAPH OF MUMMY OF A GOOSE, EGYPT



ROENTGENOGRAM OF A GOOSE SHOWN IN PRECEDING PLATE



1



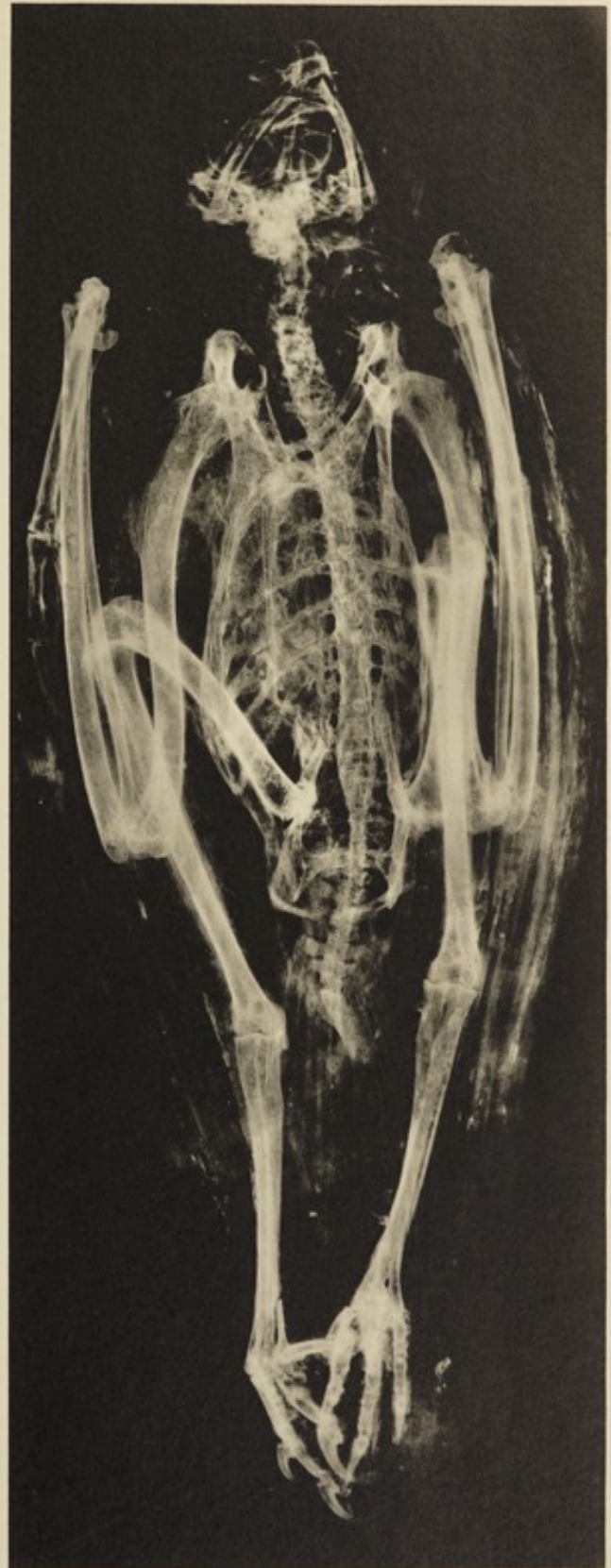2

MUMMY OF A HAWK, EGYPT

1. Photograph. 2. Roentgenogram



1



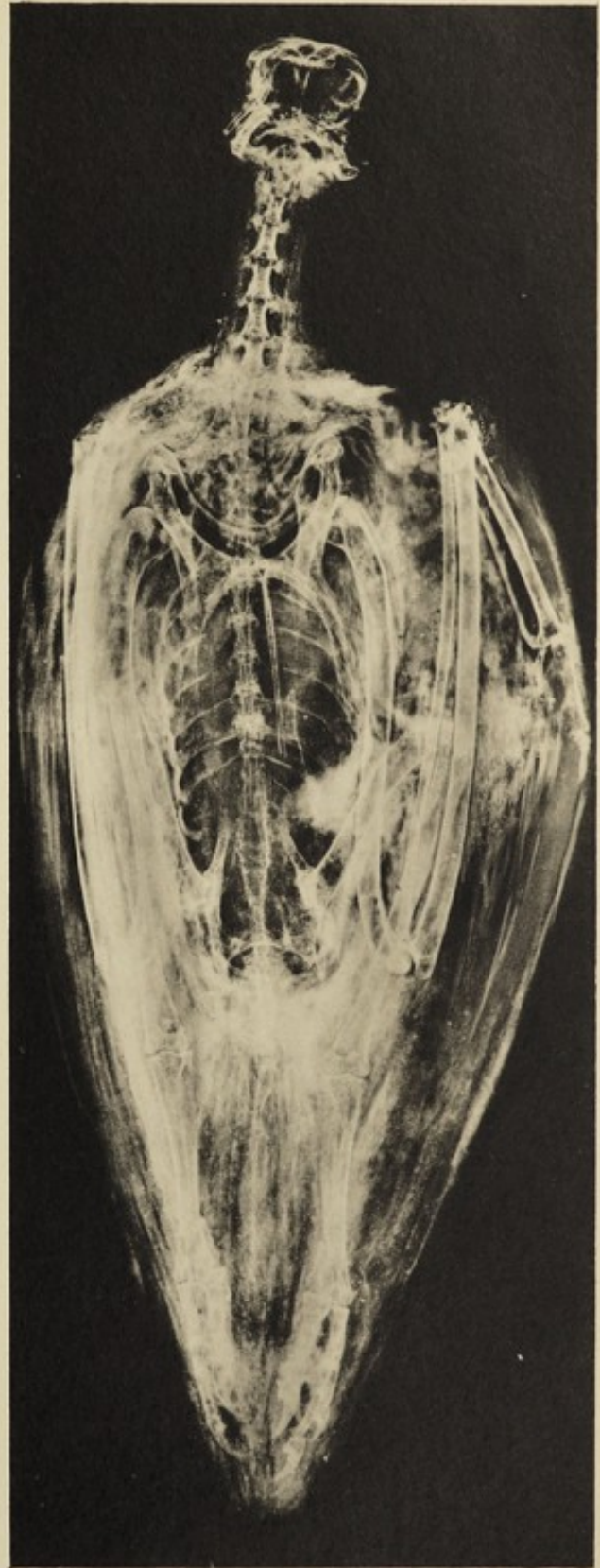
2

MUMMY OF A RAPTORIAL BIRD, EGYPT

1. Photograph. 2. Roentgenogram



1



2

MUMMY OF A VULTURE, EGYPT
1. Photograph. 2. Roentgenogram

$\frac{44}{44}$ Wellcome ②
Slip 48.

