

**Relation of lesions of the small intestine to disorders of the stomach and cap as observed roentgenologically / by Lewis Gregory Cole, M.D.,
Professor of Roentgenology in Cornell University Medical College.**

Contributors

Cole, Lewis Gregory, 1874-1954

Publication/Creation

Philadelphia : Lea & Febiger, 1914.

Persistent URL

<https://wellcomecollection.org/works/hrghw9vp>



Wellcome Collection
183 Euston Road
London NW1 2BE UK
T +44 (0)20 7611 8722
E library@wellcomecollection.org
<https://wellcomecollection.org>

11
12


*Relation of Lesions of the Small Intestine
to Disorders of the Stomach and Cap
as Observed Roentgenologically*

BY

LEWIS GREGORY COLE, M.D.

PROFESSOR OF ROENTGENOLOGY IN CORNELL UNIVERSITY MEDICAL COLLEGE

FROM THE
AMERICAN JOURNAL OF THE MEDICAL SCIENCES
July, 1914, No. 1, vol. cxlviii, p. 92



RELATION OF LESIONS OF THE SMALL INTESTINE TO DISORDERS OF THE STOMACH AND CAP AS OBSERVED ROENTGENOLOGICALLY.

By LEWIS GREGORY COLE, M.D.,

PROFESSOR OF ROENTGENOLOGY IN CORNELL UNIVERSITY MEDICAL COLLEGE.

CONTENTS

Clinical recognition of the relation between lesions of the small intestine and gastric symptoms	1
Terminology	2
Thesis	2
Technique of complete gastro-intestinal examination	2
Combined fluoroscopic and serial roentgenographic examination of the stomach	3
Examination of ileocecal region	3
Examination of gall-bladder	4
Examination of colon	4
Value of complete gastro-intestinal examination	4
Erroneous methods of determining gastro-intestinal motor efficiency	4
Previous communications of author concerning roentgenology of stomach and cap	6
Usual findings in the duodenum	7
Usual findings in the jejunum	8
Usual findings in the ileum	8
Physiology of the small intestine as observed roentgenographically	8
Motor phenomena of the duodenum	8
Motor phenomena of the jejunum	8
Roentgenologic appearance of small intestine partly due to consistency of contents	8
Unusual findings observed in the small intestine illuminate many obscure functional gastro-intestinal lesions	9
Spasm of the pars pylorica	10
Spasm of the pyloric sphincter	11
Spasm of the cap	12
Resemblance of roentgenographic appearance of spasm of the cap to cicatricial contraction from postpyloric ulcer	13
Permanent changes in the pars pylorica resulting from spasm	14
Permanent changes in the pyloric sphincter resulting from spasm	14
Permanent changes in the cap resulting from spasm	15
Inhibition of duodenal peristalsis a cause of retention in stomach and cap	15
Dangers of prolonged retention in the cap	16
Ileal dilatation a cause of inhibition of duodenal peristalsis	18
Causes of ileal stasis and dilatation	19
Colonic stasis	20
Membranes and veils	22
Kinks in the terminal portion of the ileum	22
Insufficiency of the ileocecal valve	24
Chronic appendicitis	26
Diagnostic value of roentgenology	27

THE relation of lesions of the small intestine to disorders of the stomach has been recognized for many years by clinicians, most notably perhaps in the vomiting, pain, and tenderness referred to

the right hypochondrium in cases of appendicitis, and in the gastric symptoms manifested by acute intestinal obstruction. Mayo has compared the stomach to a fire-alarm box, and has called attention to the futility of trying to extinguish the fire by squirting water on the alarm box. In a recent article read before the American Roentgen Ray Association,¹ Crane quoted Mayo's simile, and cited instances in which he also had observed gastro-intestinal symptoms with roentgenological evidence of a lesion at some distant point. In this communication I shall try to show that the roentgenologist can detect the first sign of smoke, and after searching farther, can usually find the location of the fire itself.

TERMINOLOGY. Before entering upon any discussion an explanatory word should be said concerning terminology. While the roentgenological findings of the gastro-intestinal tract differ in every individual, I have come to recognize certain findings as usual and others as unusual. In this communication the term *usual* will be applied to those findings which are most common, that is to say, normal, so far as I have been able to determine, and the term *unusual* will be applied to uncommon roentgenographic findings, which are associated with symptoms.

THESIS. As a working basis it will be necessary to describe the physiology of the duodenum, jejunum, and ileum as observed roentgenologically, and to compare the unusual findings with the usual findings. It will be seen that certain phenomena in the small intestine are frequently accompanied by peculiar manifestations in the stomach and cap. These gastric manifestations, viz., primary and secondary evidences of spasm and their opposites, atony or lack of peristalsis of the pylorus, pyloric sphincter and cap, must next be described. Upon this foundation we shall build up the superstructure which is the main subject of this communication—that ileal stasis, and particularly ileal dilatation, are directly related to and responsible for certain spasms and even organic lesions of the pylorus, pyloric sphincter, and cap. In conclusion, we shall estimate the value of the roentgenological evidence for determining in each individual case whether or not surgical procedure is indicated, or what other method of treatment is advisable.

TECHNIQUE. In order to obtain the findings upon which our observations are based, an extensive routine examination of the entire gastro-intestinal tract is essential. Although the technique employed is being elaborated continually, a brief description of the present method may be of interest.

About 11 P.M., or ten hours before the roentgenographic examination, the patient takes bismuth or barium suspended in buttermilk, in conjunction with a meal of meat, potatoes, and bread. At 9 o'clock the next morning he presents himself for

examination. A roentgenogram of the whole abdomen is made to determine how far the meal taken the night before has progressed. This information can usually be obtained from the fluoroscopic examination, which is made simultaneously; but if any doubt exists the plate should be developed immediately in order to ascertain with certainty whether or not the ileum is empty. If food still remains in the ileum the same examination is repeated bi-hourly until the ileum is completely evacuated, then the patient takes bismuth or barium suspended in buttermilk. After the passage of the ingesta through the esophagus has been observed fluoroscopically the stomach is examined by combined fluoroscopy and serial roentgenography.

SERIAL ROENTGENOGRAPHY OF THE STOMACH. Twelve roentgenograms are made in the prone posture, four to six in the lateral direction, two posteriorly, and twelve with the patient erect, after which the patient at once eats a meal of meat, potatoes, and bread. Two hours later another series of six to twelve roentgenograms is made, two of them stereoscopic roentgenograms of the entire gastro-intestinal tract. As this series often gives the most valuable information, we are therefore increasing the number of exposures made at this time. If further details concerning the progress of gastric digestion seem desirable, another series of roentgenograms is made four hours after ingestion. A pair of stereoroentgenograms is invariably taken six hours after the bismuth meal. If at this time the fluoroscope reveals an appreciable gastric retention, five or six roentgenograms of the stomach are made.

EXAMINATION OF ILEOCECAL REGION. As the condition of filling in the ileocecal region is of prime diagnostic importance at this time, two small stereoroentgenograms (8 x 10 inches) are made of this portion of the tract, and if marked stasis or any other unusual finding is observed fluoroscopically, six to eight small roentgenograms of this region are made. Two hours later, *i. e.*, eight hours after ingestion, one plain roentgenogram or a pair of stereoroentgenograms is made. This completes the examination for that day. At nine o'clock the next morning, *i. e.*, twenty-four hours after the ingestion of bismuth and buttermilk, another roentgenogram is obtained. If there is evidence of colonic stasis or constipation a roentgenogram is made every twenty-four hours until the colon is evacuated. In case the patient habitually depends upon a cathartic, it should be allowed as usual, but an active purgative is undesirable.

After the examination just described there remains to be made an examination of the gall-bladder for possible calculi, and also an examination of the colon, while mechanically distended, for the purpose of discovering any spasmodic or organic lesions not detected when the bismuth passed through from above.

The night before this examination an active cathartic is adminis-

tered. If this is not effective the patient takes a saline cathartic early in the morning, but on no account an enema, as this might be retained and dilute the bismuth clyster, which is used to distend the colon.

EXAMINATION OF GALL-BLADDER. Before the colon is examined, roentgenograms are made over the gall-bladder region, as biliary calculi can be detected in at least 50 per cent. of the cases when they are present.²

EXAMINATION OF THE COLON. A clyster of bismuth or barium, mucilage of acacia, and hot water (barium sulphate $\mathfrak{z}\text{v}$, mucilage of acacia $\mathfrak{z}\text{xij}$, hot water q. s., $\mathfrak{z}\text{xxx}$) is now administered and retained by the patient while a pair of stereoroentgenograms of the colon are made. It is a wise procedure to make a third plain roentgenogram or another pair of stereoroentgenograms, because it is sometimes difficult to differentiate between spasms and organic lesions in a single pair of stereoroentgenograms.

The gastro-intestinal tract has now been completely examined by successive series of roentgenograms made immediately after the bismuth meal, and at intervals thereafter of two hours, four hours, six hours, eight hours, ten hours, twelve and fourteen hours, twenty-four hours (if necessary), forty-eight hours, and seventy-two hours, and by one or more pairs of stereoroentgenograms of the colon, made after a bismuth clyster has been administered.

Such a series of roentgenograms, viewed upon a light box, where they may be studied individually and collectively, gives a wealth of information. By carefully studying the findings in one region and comparing them with the findings in other portions of the tract it is often possible to unravel the most complicated cases.

VALUE OF COMPLETE GASTRO-INTESTINAL EXAMINATION. A study of about 300 such cases, showing the stomach, small intestine, and colon at various intervals after the ingestion of food, has revealed a great variety of significant findings, a correlation of which leads me to the publication of this preliminary report.

ERRONEOUS METHODS OF DETERMINING GASTRO-INTESTINAL MOTOR EFFICIENCY. Many of the previous roentgenological observations on ileal stasis have been unreliable, because the bismuth has been mixed with or suspended in unsuitable mediums, and because the period required for ileal evacuation has been reckoned from the time when the bismuth was administered, instead of being reckoned from the time when the last trace of it left the stomach.

² Case, The X-ray Examination of the Liver and Gall-bladder, Arch. of Roent. Ray, September, 1913; Roentgenoscopy of the Liver and Biliary Passages, with Special Reference to Gall-stones, Jour. Amer. Med. Assoc., September 20, 1913. Cole, Roentgenographic Diagnosis of Gall-stones and Cholecystitis, Surg., Gyn., and Obst., February, 1914, vol. xviii, No. 2. Pfahler, Die Roentgenstrahlen als Hilfsmittel bei der Gallensteindiagnose, Fort. a. d. Geb. d. Roent., April, 1911, N.H., xvi, B. 5, pp. 335-337. Gastric and Duodenal Adhesions in the Gall-bladder Region and Their Diagnosis by the Roentgen Ray, Jour. Amer. Med. Assoc., June 17, 1911, vol. lvi, No. 24, pp. 1777-1779.

Other conditions, such as recent catharsis, which so often precedes a gastro-intestinal examination, undoubtedly affect the motor phenomena.

In a previous communication³ I have already shown the fallacy of testing the gastric motor efficiency by administering bismuth suspended in fluid or mixed with cereal, and the same is true for intestinal motor efficiency. If the test is to be of value the stomach and intestines must be called upon to evacuate such a meal as is normally imposed upon them. Therefore the true test of gastro-intestinal motor efficiency is made by administering bismuth or barium, suspended in fluid, preferably buttermilk, *in conjunction with* a Riegel meal of meat, potatoes, and bread.

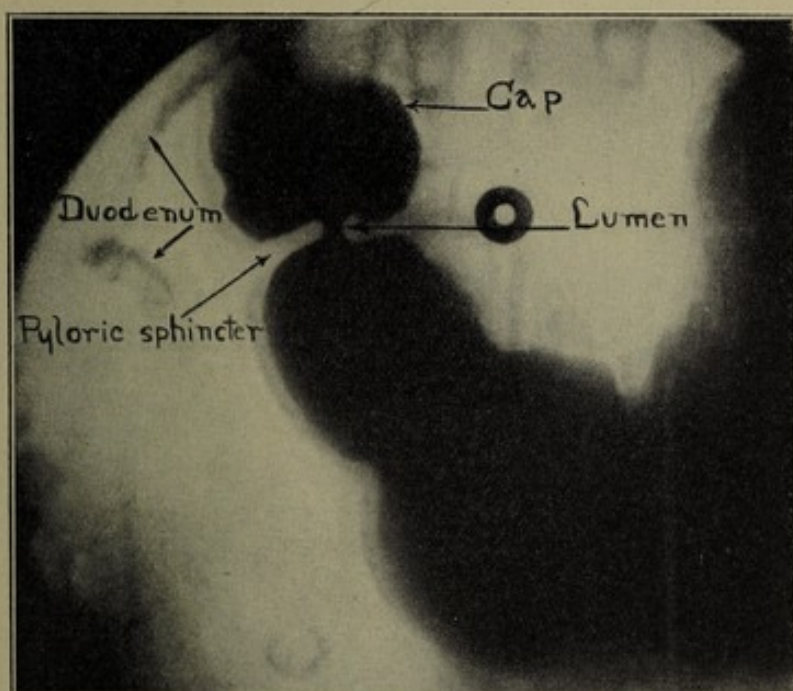


FIG. 1.—Normal cap (pilleus ventriculi).

An even more fertile source of error is dating the period of ileal retention from the time of ingestion. For instance, if the stomach is high and of the cow-horn type, especially if a condition of diminished acidity or achylia exists, evacuation will be accomplished very rapidly, perhaps in two hours, whereas many a stomach, presenting no organic obstruction, requires six hours for complete evacuation. Suppose now that in both cases the ileum is just evacuated ten hours after ingestion. According to the old method of reckoning, both cases present the same degree of ileal stasis, although, as a matter of fact, one case presents an eight-

³ Die Diagnose der Boesartigen und Gutartigen Magen—und Duodenal-Laesionen und ihre Unterscheidung durch Serien-Roentgen-Aufnahmen, Zeitschrift f. klinische Medizin, Berlin, 1914, 79, B. H., 5 u. 6.

hour while the other presents only a four-hour ileal retention. The time required for bismuth impregnated food to pass through the small intestine may be corroborated by reckoning the speed with which the next succeeding meal, not impregnated with bismuth, displaces that previously ingested, or mixes with it at the cecum.

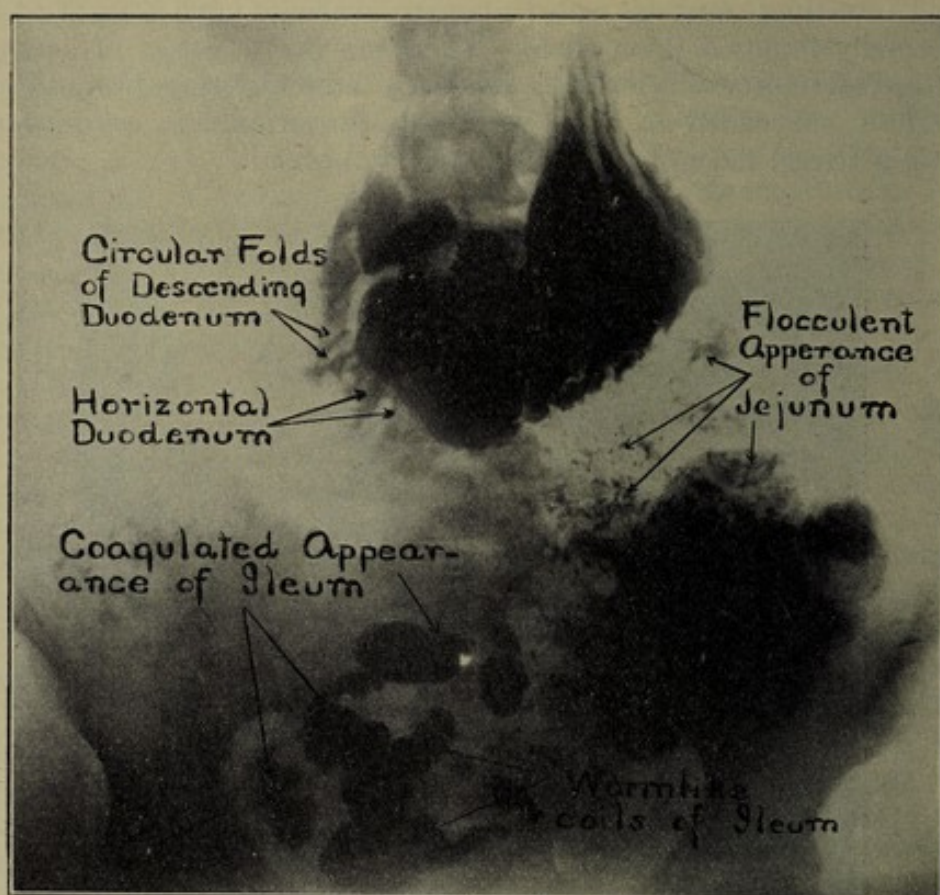


FIG. 2.—Usual roentgenographical appearance of cap, duodenum, jejunum, and ileum.

KNOWLEDGE OF ROENTGENOLOGY OF THE STOMACH AND CAP AN ESSENTIAL TO AN UNDERSTANDING OF THIS COMMUNICATION. In previous communications, which are, in a way, introductory chapters to the present work, the physiological characteristics and motor phenomena of the pyloric sphincter and pilorus ventriculi (cap)⁴ as observed roentgenographically have been described. In fact this information constitutes the *sine qua non* of roentgenological diagnosis of the gastro-intestinal tract. It has been shown that the region previously termed the first or ascending portion of the duodenum is not the duodenum in any sense, but is actually the

⁴ Arch. of Roent. Ray, December, 1911, p. 242; Amer. Quart. of Roent., March, 1912, vol. iii, No. 4, p. 1. Arch of Roent. Ray, October, 1912, No. 147, p. 172; Jour. Amer. Med. Assoc., November 30, 1912, vol. lix, p. 1947.

cap of the stomach (pilleus ventriculi) (Fig. 1). Its anatomy and physiology as observed roentgenologically and the lesions to which it is subject have been described.⁵ Therefore in this communication we may begin with the descending portion of the duodenum.

USUAL FINDINGS IN THE DUODENUM. Embryologically the descending and not the ascending duodenum is the proximal end of the midgut. Anatomically it exhibits small, irregular, circular folds, particularly on its posterior aspect. It descends at an acute

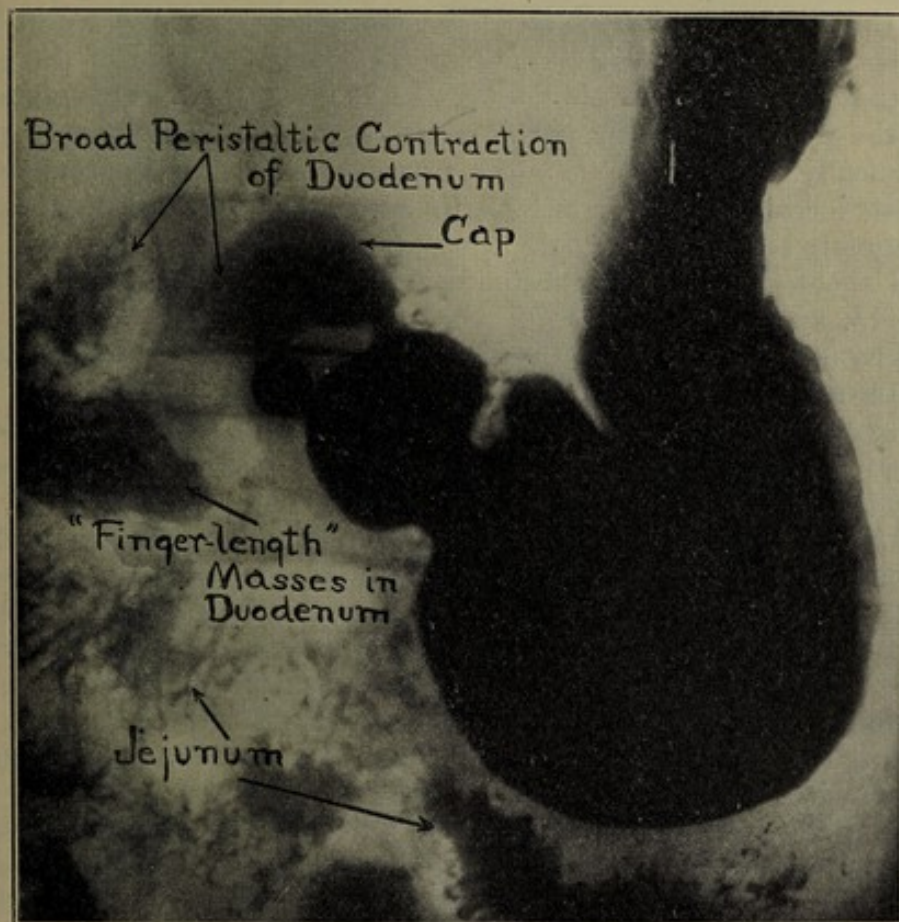


FIG. 3.—Withdrawal of chyme from cap by broad propulsive peristalsis of duodenum.

angle from the top of the cap, and in conjunction with the horizontal portion, fits around the head of the pancreas, occupying a fixed position. As it frequently passes down behind the stomach it may be obscured by the pars pylorica, except where it extends above and below the stomach. It can be identified by its shape, and position and the ring-like appearance of its circular contractions (Figs. 1, 2, and 3). Its motor phenomena are a broad, rapid, periodical, propulsive peristalsis and a churning or mixing motion of the circular folds.

⁵ Arch. of Roent. Ray, April, 1912, No. 141, p. 425; Jour. Amer. Med. Assoc., September 6, 1913, vol. lxi, No. 10, p. 762.

USUAL FINDINGS OF THE JEJUNUM. From the horizontal duodenum the ingesta pass into the jejunum in the upper left quadrant of the abdomen, where they are broken up into finely comminuted particles. Roentgenographically these fragments present the flocculent appearance which distinguishes the jejunum from the rest of the small intestine (Figs. 2 and 3).

USUAL FINDINGS OF THE ILEUM. As the chyme reaches the centre of the small intestine and occupies the ileum it begins to form into coagulated masses. Upon reaching the terminal portion of the ileum these coagulated masses collect in long, worm-like coils, and as they near the cecum they fill the lumen of the gut, so that frequently one can identify several continuous convolutions of the ileum, especially if the roentgenograms are studied stereoscopically. The ileum, therefore, is recognized roentgenographically by its location in the right lower quadrant of the abdomen and the coagulated appearance of the contents in its upper portion (Fig. 2), and the well-defined worm-like coils in its lower portion (Figs. 2, 10, 15, and 16).

PHYSIOLOGY OF THE SMALL INTESTINE AS OBSERVED ROENTGENOGRAPHICALLY. The characteristic roentgenographic findings by which the various portions of the small intestine may be thus identified are the result of certain physiological phenomena, expressed roentgenologically in terms of motor activity.

MOTOR PHENOMENA OF THE DUODENUM. The descending duodenum obtains the ingesta by means of broad peristaltic contractions (Fig. 3), which withdraw the chyme from the reservoir cap, where it collects after being expelled through the pyloric sphincter during the systole of each gastric cycle. Duodenal peristalsis occurs periodically, but not coincidentally with or at the same rate, as gastric peristalsis. The chyme is thus propelled through the duodenum in the finger-like masses described by Holzkecht (Fig. 3). During the early stage of digestion this process takes place very rapidly, because the contents of the cap are only slightly acid and mostly fluid, having been expelled through a more or less tightly contracted sphincter.

MOTOR PHENOMENA OF THE JEJUNUM. Roentgenographic observations have proved that the name jejunum was well chosen by the ancients from their postmortem investigations, for the peristalsis of this portion of the tract is so rapid that the jejunal lumen is seldom seen dilated or even filled.

MOTOR PHENOMENA OF THE ILEUM. The ileum retains the food longer than any other portion of the small intestine. It lodges here temporarily, after being passed rapidly through the cap, duodenum, and jejunum.

ROENTGENOLOGIC APPEARANCE OF SMALL INTESTINE PARTLY DUE TO CONSISTENCY OF CONTENTS. The flocculent appearance of the jejunum, coagulated appearance of the upper ileum, and worm-like coils of the lower ileum are probably caused, in part

at least, by the consistency of the contents as well as by the peristalsis characteristic of each region. When a clyster passes back through an incomplete ileocecal valve, filling the ileum and even distending the jejunum, the roentgenological findings peculiar to different portions of the small intestine do not present.

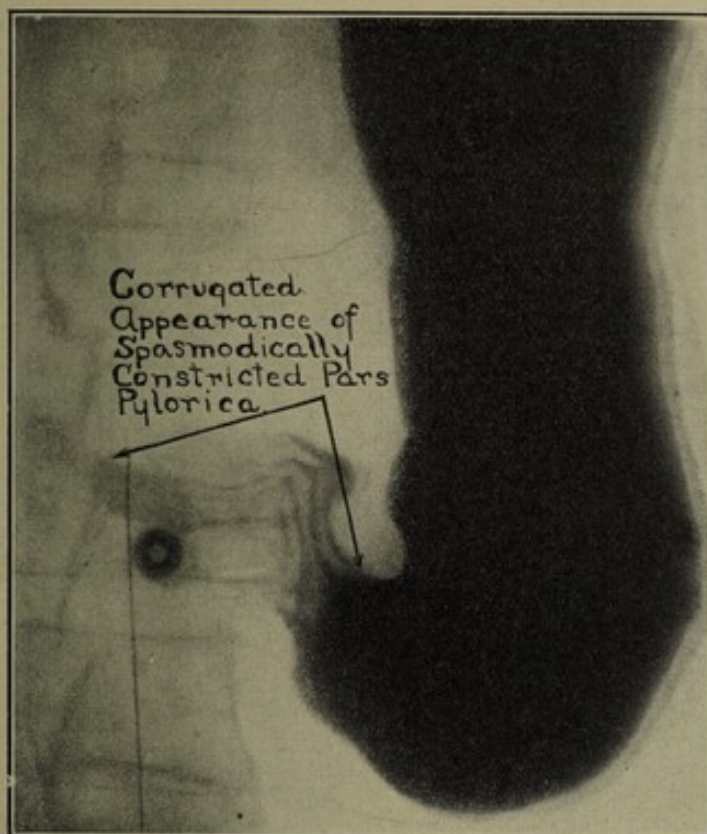


FIG. 4, a.—Spasmodic constriction of pars pylorica.

UNUSUAL FINDINGS OBSERVED IN THE SMALL INTESTINE ILLUMINATE MANY OBSCURE FUNCTIONAL GASTRO-INTESTINAL LESIONS. Variations from the above-described motor phenomena of the small intestine cause unusual roentgenographical findings, which illuminate, I believe, many of the obscure functional and even organic disorders of the gastro-intestinal tract. A description of all of the roentgenological findings associated with functional gastric derangements would form an extensive communication in itself. In this paper we can only enumerate and briefly describe those usually associated with lesions of the ileocecal region. Such functional gastric disorders present the following roentgenological findings:

- | | | |
|---|---|----------------------------|
| 1. Spasms of | { | (a) the pars pylorica. |
| | | (b) the pyloric sphincter. |
| | | (c) the cap. |
| 2. Results of spasms, indicated by permanent changes in | { | (a) the pars pylorica. |
| | | (b) the pyloric sphincter. |
| | | (c) the cap. |
| 3. Gastric retention without pylorospasm. | | |

SPASMS OF THE PARS PYLORICA, PYLORIC SPHINCTER, AND CAP. There are two ways of ascertaining that the pars pylorica, pyloric sphincter, or cap is subject to spasmodic contraction. The spasm itself may be registered on some or all of the roentgenograms of the series in the very act of occluding the lumen. Or only the results of the spasm may be visible in a permanent diminution of the lumen, caused by constant or spasmodic contraction of the muscular coat.

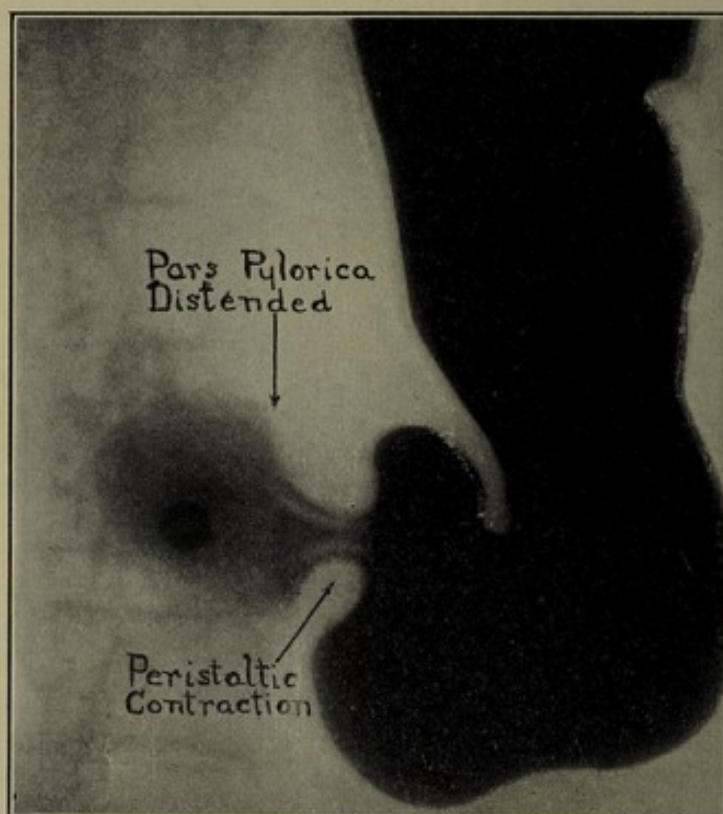


FIG. 4, *b*.—Relaxation of spasm illustrated in Fig. 4, *a*.

SPASM OF THE PARS PYLORICA. The roentgenographical picture of spasmodic contraction of the pars pylorica shows that portion of the gastric lumen reduced in size out of all proportion to the dimensions of the pars media and pars cardiaca. The whole or only the pyloric end of the region may be distorted. The mucosa and submucosa, normally ribbed by shallow rugæ, are puckered into deep folds, which give the lumen a corrugated appearance (Fig. 4, *a*). These furrows may run transversely or obliquely. The roentgenogram which presents these phenomena may be followed by one showing a perfectly smooth, well-distended contour of the same region, indicating that the spasm has relaxed its grip temporarily (Fig. 4, *b*). Sometimes the spasm occurs only at a certain stage of digestion, and is absent in all the roentgenograms made before and after this interval.

SPASM OF THE PYLORIC SPHINCTER. The presence of a spasmodic constriction of the pyloric sphincter may be inferred from the

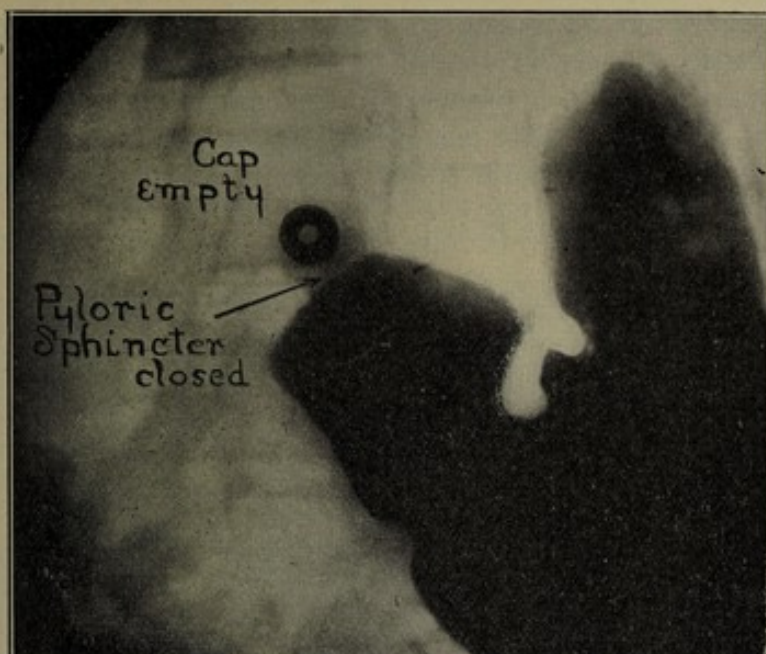


FIG. 5, a.—Spasmodic constriction of pyloric sphincter.

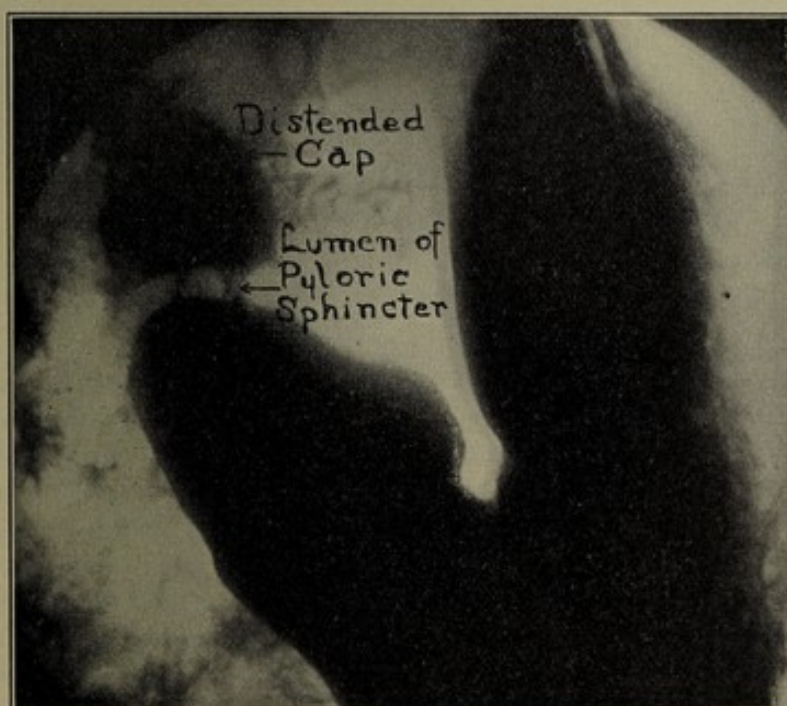


FIG. 5, b.—Relaxation of spasm illustrated in Fig. 5, a.

absence of bismuth in the lumen of the sphincter and cap, provided the bismuth is seen passing freely from the stomach into the cap

in roentgenograms made previously and subsequently (Fig. 5, *a* and 5, *b*). If the cap is quickly evacuated by duodenal peristalsis, its outlines will remain indistinct or invisible until a relaxation of the pyloric sphincter opens the passage from the pars pylorica through which the cap is resupplied with contents.

In spite of Kreuzfuch's reports to the contrary, my observations have been that the gastric peristalsis may be just as active while a spasm involves the pyloric sphincter as it is when the sphincter is functioning normally.

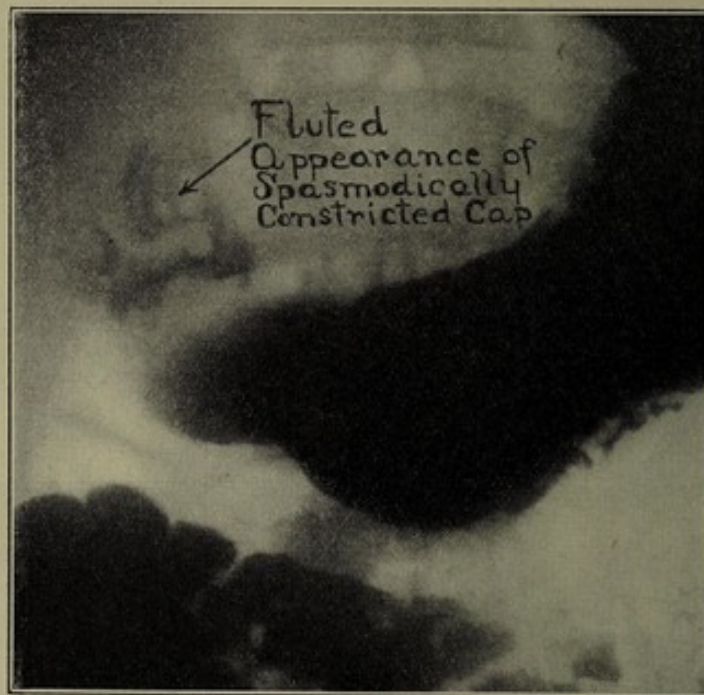

FIG. 6.—Spasmodic constriction of cap, caused by chronic appendicitis. Proved by operation.

SPASM OF THE CAP. Constriction of the cap from spasmodic contraction presents roentgenographical evidence similar to that caused by a spasm of the colon. The cap has the appearance of having been twisted or wrung empty of its contents, only a suggestion of its bismuth impregnated contents being visible, caught or entangled under the constricting folds. As a result the distorted lumen casts a corrugated or fluted shadow on the roentgenograms (Fig. 6). An interesting case of this kind, presenting definite symptoms of ulcer of the cap, was referred to me from a hospital for the sake of increasing the number of my postpyloric ulcer cases. The clinical history was so typical that I economized by making only about half the usual number of roentgenograms. Even this limited series proved enough to justify a negative diagnosis of chronic indurated duodenal ulcer, that is, an ulcer indicating

surgical procedure. Most of the roentgenograms showed definite graphic evidence of a spasm of the cap. In two instances, however, a fully distended well-defined cap presented a perfectly normal picture. I therefore reported that the lesion was spasmodic rather than organic, although the spasm might possibly be caused by a superficial postpyloric ulcer. This negative report delayed operation for the duodenal ulcer, which had been diagnosed by other means. Two days later the patient's symptoms culminated in a definite attack of acute appendicitis, for which an emergency operation was performed. The clinical diagnosis of duodenal

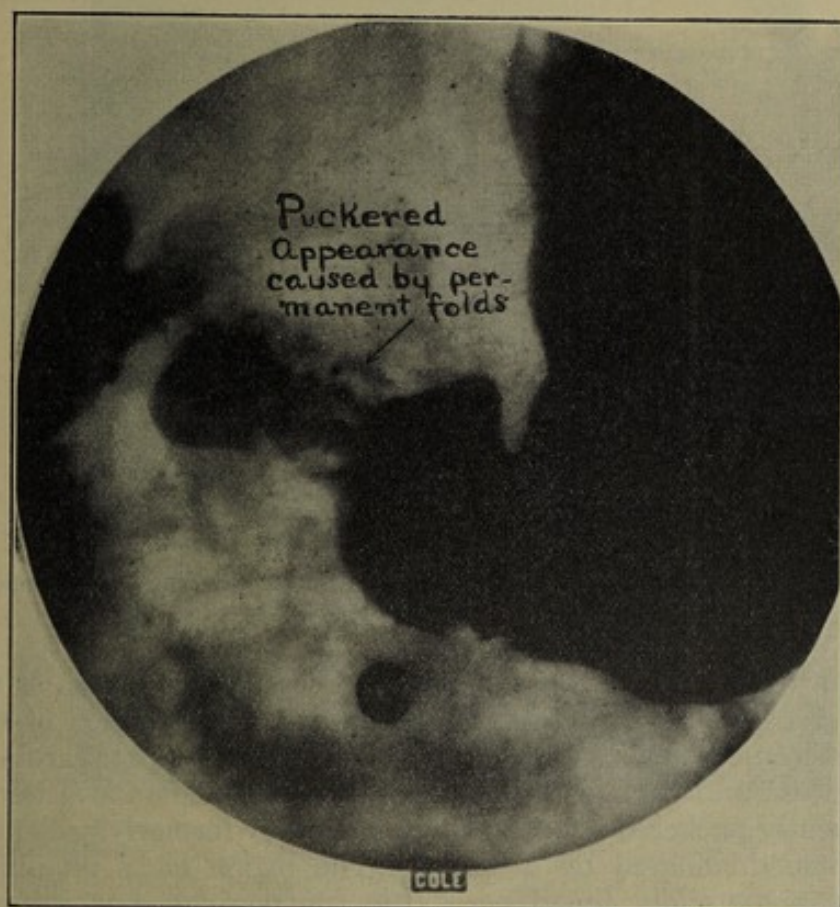


FIG. 7.—Permanent changes in gastric wall, resulting from long-continued spasm of pars pylorica. Proved by operation.

ulcer had been made so positively, and the history had been so definite that I permitted myself to dispense with a complete gastrointestinal examination, and allowed a preconceived theory to distract my mind from considering a lesion of the right iliac fossa as the origin of the spasm, although in several previous cases I had recognized a similar interrelation. The moral of this is, "Don't let a perfectly typical history of some condition deter you from making a complete examination."

PERMANENT CHANGES IN THE PARS PYLORICA, PYLORIC SPHINCTER, AND CAP. All of the findings described thus far have been direct evidence of the spasm itself. Let us now consider the roentgenological findings of those permanent changes which result from long-continued spasms of the pars pylorica, pyloric sphincter, and cap.

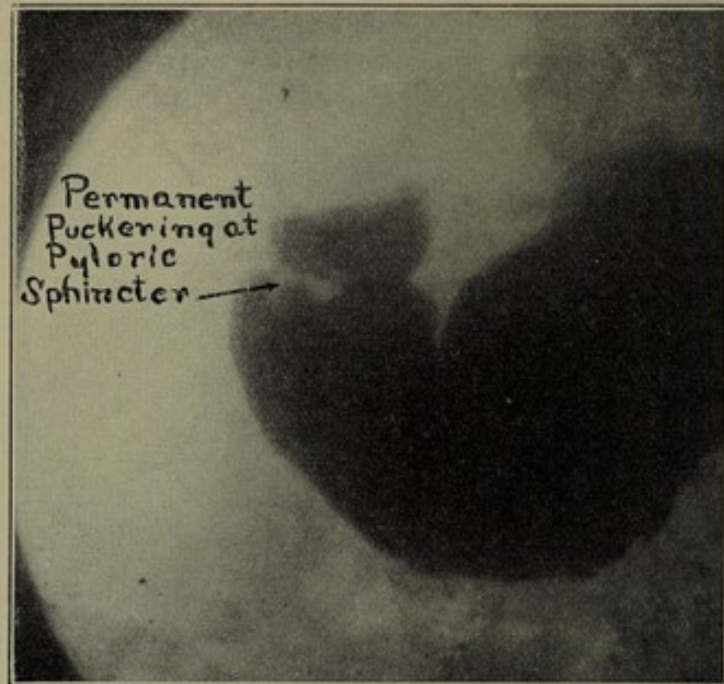


FIG. 8.—Permanent changes in pyloric sphincter, caused by constant spasmodic constriction, a reflex from chronic appendicitis. Proved by operation.

Frequent spasm of the pars pylorica causes a contraction of the muscular coat, and a consequent diminution of the lumen of this region as compared with lumen of the pars media and pars cardiaca. The mucosa and submucosa heap up into deep folds and attain a permanently puckered appearance, such as they formerly presented only when dominated by a spasm. The region lacks pliability, presenting unusually broad peristaltic contractions, but exhibits a regular systole and diastole (Fig. 7).

The result of spasm of the pyloric sphincter is not quite so characteristic. It may be described as a puckering resembling the folds near a purse string that had been tightly drawn, and is most prominent during the stage of diastole, when the adjacent tissue is completely relaxed (Fig. 8). The sphincter may be thicker than normal, but at some stage of digestion its lumen should be distinctly shown.

The roentgenological findings of permanent changes resulting from spasm of the cap are so similar to those of postpyloric ulcer that the two conditions are sometimes difficult to differentiate.

Such a case is illustrated in Fig. 9. Roentgenographically the cap had the appearance of being cicatricially contracted by an ulcerative process, and the lesion was diagnosed as postpyloric ulcer. Operation revealed chronic appendicitis and redness and swelling of the cap near the pylorus without any evidence of ulceration, obviously the result of constant reflex spasmodic contraction from the diseased appendix.

GASTRIC RETENTION WITHOUT PYLOROSPASM. Having discussed overactivity of the muscularis as a functional lesion of the pars pylorica, pyloric sphincter and cap, let us now consider lack of activity of these same muscular tissues.

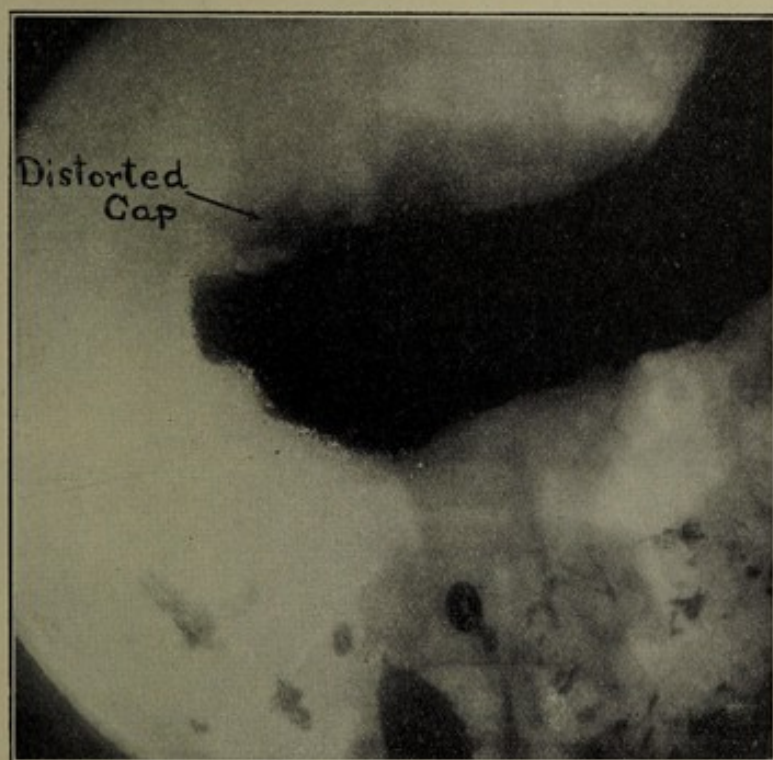

FIG. 9.—Permanent changes in cap, resulting from long-continued spasm, a reflex from chronic appendicitis. Resembles the roentgenographical appearance of cicatricial contraction from postpyloric ulcer.

Although lack of tonicity is undoubtedly a functional disorder of the stomach, and as such is related to our subject, yet it is not caused by a lesion at some distant point, so far as we know, and should therefore be omitted here.

RETENTION IN STOMACH AND CAP DUE TO INHIBITION OF DUODENAL PERISTALSIS. Retention in the stomach and cap longer than the normal time required for digestion is a roentgenological finding of the utmost significance. As digestion progresses there often ensues a diminution or complete inhibition of propulsive duodenal peristalsis and evacuation of the cap is suspended temporarily (Fig. 10). At the same time gastric peristalsis may still

continue and even increase its propulsive power, owing to the diminished bulk which it is gripping. Thus the cap, being rapidly filled from the stomach and not evacuated by the duodenal peristalsis, distends during the later stages of digestion to fuller proportions than before (Fig. 10). Sometimes the force of gastric peristalsis is sufficient to expel the chyme through the cap into the descending and horizontal duodenum, but so long as the jejunum remains empty, it is obvious that duodenojejunal peristalsis has stopped functioning. It is the absence of this agent for sucking

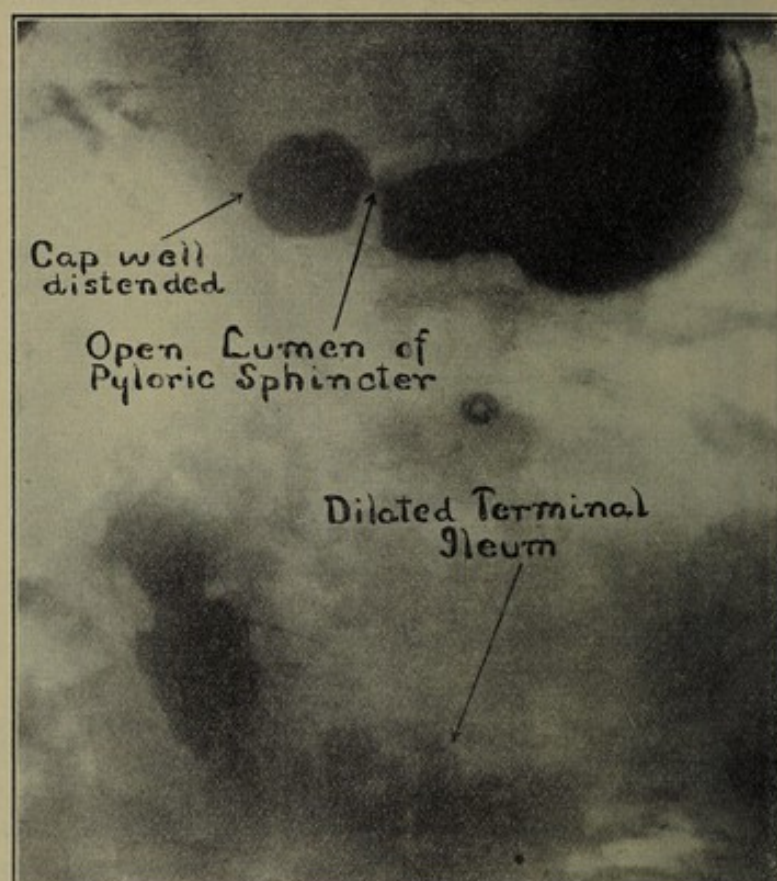


FIG. 10.—Dilatation of terminal ileum, causing inhibition of duodenal peristalsis and resultant gastric and cap retention.

the food from the cap and propelling it through the duodenum, which explains the gastric and cap retention in many instances, for it cannot be contended that there is any organic or functional disturbance of the stomach or cap, since the chyme courses through them freely, nor is it tenable to suppose that any organic obstruction exists in the duodenum or jejunum, as the chyme rapidly traversed this region at an earlier stage of digestion.

DANGERS OF PROLONGED RETENTION IN THE CAP. Retention in the cap is often the harbinger of organic lesions of the right hypochondrium. It may cause conditions favorable for the

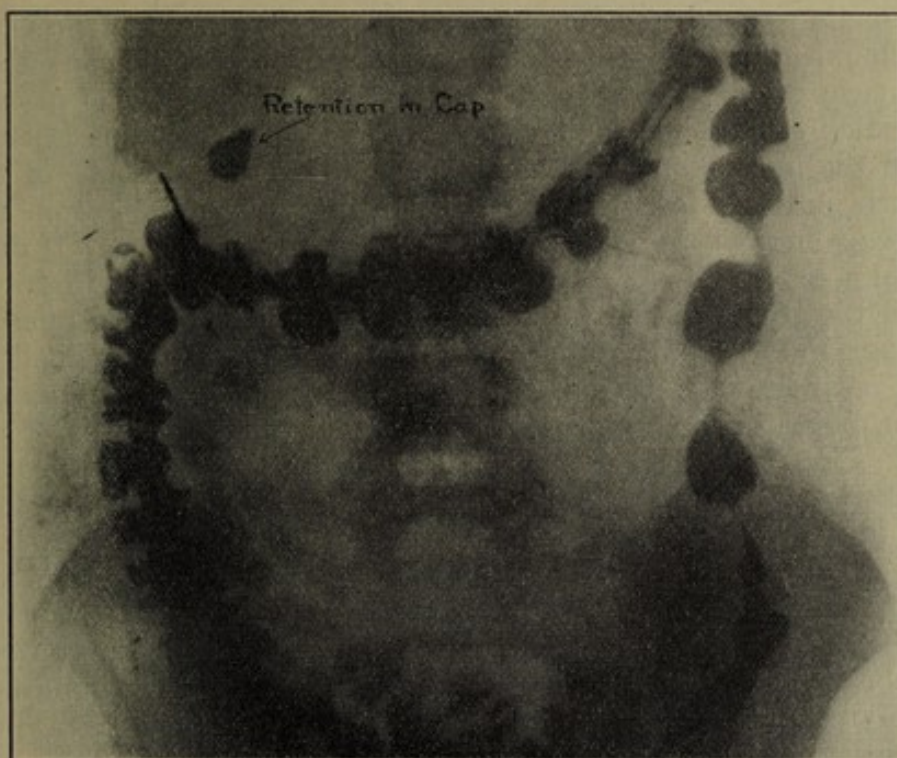


FIG. 11.—Prolonged retention in cap after evacuation of stomach, duodenum, and jejunum.

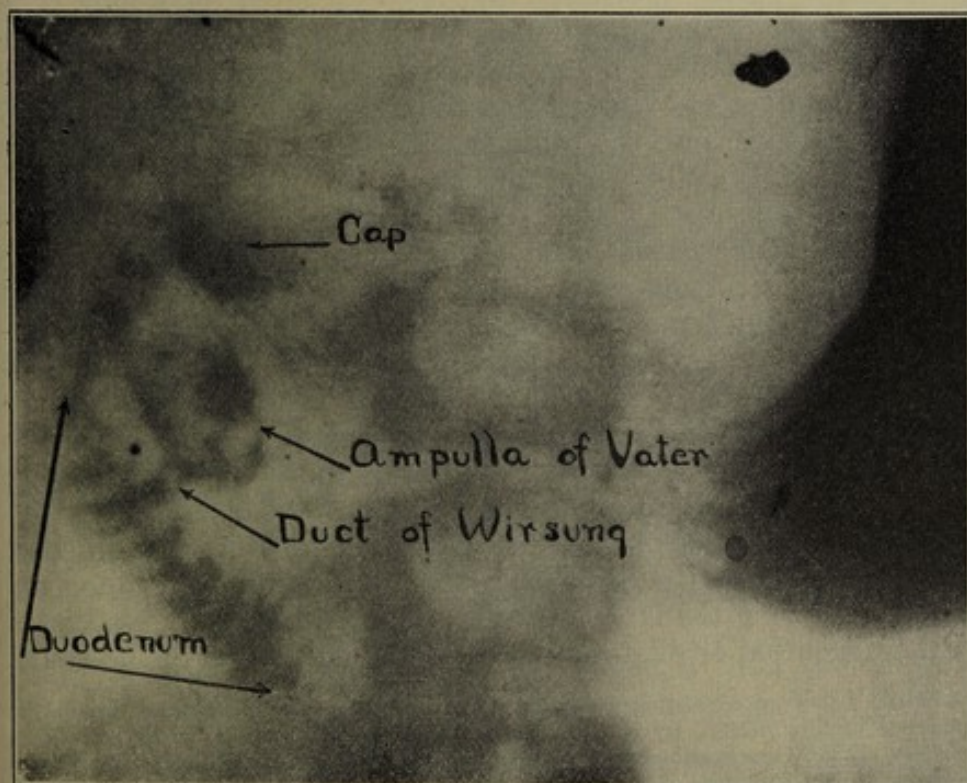


FIG. 12.—Distention of duct of Wirsung and ampulla of Vater by bismuth ingesta.

production of postpyloric ulcer. As has been stated in previous communications the cap has the function of a reservoir or second stomach, where it is probable that the finishing touches of proteid digestion are applied to the small amount of chyme thus isolated from the bulk of food in the stomach. That the strength of the gastric juices is intensified in the cap may be inferred from the presence here of the glands of Brunner and Lieberkuhn. If duodenal peristalsis ceases after most of the chyme has been withdrawn from the stomach, and an appreciable amount of chyme remains in the cap for a much longer period of time than usual (Fig. 11), is it not reasonable to suppose that this chyme becomes hyperacid from oversaturation with the juices of the secretory glands of the cap? For if it is imprisoned in the cap without being diluted by weaker chyme from the stomach or neutralized by alkaline solutions administered for this purpose an excess of acid must result. Is it not likely, therefore, that a prolongation of this condition will destroy the muscular coat, particularly if the mucosa has been bruised or broken by solid particles of food or by instrumentation? If this supposition be correct, any condition which diminishes, paralyzes, or inhibits duodenojejunal peristalsis will be a predisposing cause of postpyloric ulcer.

It is also important to note the far-reaching results of dilatation of the descending and horizontal duodenum, which may be filled by an active gastric peristalsis and not evacuated for a long time in consequence of the inhibition of duodenal peristalsis. The over-distended lumen offers no resistance to the expulsion of chyme through the duct of Wirsung into the ampulla of Vater (Fig. 12), and perhaps even into the common or cystic duct. This indicates a direct source of gall-bladder infection.⁶

ILEAL DILATATION A CAUSE OF INHIBITION OF DUODENAL PERISTALSIS. Ileal stasis has been the all-absorbing problem of late among clinicians and surgeons interested in gastro-intestinal lesions. Although roentgenological evidence has played an important role in the diagnosis of this condition, interpretation of the findings has been influenced in many instances by the preconceived theory which the surgeon or practitioner was trying to prove. Case's roentgenological studies of the ileocecal region are an exception to this rather general rule.⁷

Careful observation of the entire gastro-intestinal tract at different periods after ingestion has shown that the inhibition of duodenal peristalsis during the later stages of digestion is usually associated with a distention or dilatation of the terminal portion of the ileum.

⁶ A like duodenal dilatation may also be caused by an organic obstruction at the duodenojejunal junction, by pressure from the mesentery vessels, or by adhesions.

⁷ Case, X-ray Observations on Colonic Peristalsis and Antiperistalsis, with Special Reference to the Function of the Ileocolic Valve, Read before International Congress, London, August, 1913; X-ray Studies of the Ileocecal Region and the Appendix, Amer. Quart. of Roent., November, 1912, p. 77.

It has been noted that as the chyme accumulates in and distends the ileum, duodenal peristalsis diminishes. The replete ileum, no longer a hungry gut, apparently exerts its influence to prevent overfilling by cutting off the supply from above. The connecting link between the gastroduodenal and ileocecal regions may be a chemical reflex. I suspect that when the ileum becomes replete it curtails through a reflex the amount of bile and pancreatic secretions, so that the alkalinity of the duodenal juices is not sufficiently strong to neutralize the acid or hyperacid chyme expelled from the stomach and rendered more acid by the secretions of the cap. Hence there ensues a cessation of the alternating alkaline and acid reactions of the descending duodenum, the exciting cause for the propulsive duodenal peristalsis, which normally evacuates the cap and propels the food through the duodenum and jejunum.⁸ This theory presupposes some such chemical influence as the reflex described by Cannon, Marbeau, and Mehring, except that it controls the propulsive duodenal peristalsis instead of the pyloric sphincter. I have observed time and time again that if after the contents of the stomach and cap have remained stationary for some time the ileum be partly evacuated a rehabilitation of duodenal peristalsis will be established forthwith and food may be seen leaving the cap and passing forward through the jejunum.

When gastric achylia exists it may be that this reflex is materially altered, as the chyme is neutral or only slightly acid, and can be rendered alkaline by the duodenal secretions with great rapidity. This would account for the rapid evacuation of the stomach in some cases of gastric cancer.

Having demonstrated that gastroduodenal retention may be caused by the inhibition of duodenal peristalsis, and having associated this inhibition with a surfeited ileum, one next seeks to discover why the ileum does not rid itself of an oversupply by passing it forward into the cecum.

Roentgenological evidence indicates that ileal stasis or rather ileal dilatation may be caused by

1. Incomplete evacuation or fecal impaction in the cecum and ascending colon.
2. Various types of membranes and veils involving the colon and terminal cecum.
3. Kinks of the terminal portion of the ileum.
4. Insufficiency of the ileocecal valve.
5. Chronic appendicitis (primary or secondarily from adhesions, either before or after its removal).

All of these conditions may be recognized and differentiated from each other with a remarkable degree of accuracy by a thorough

⁸ If I have delved further into the causes of these roentgenological findings than my experience as a physiologist will justify, perhaps my suppositions may stimulate some physiologist to prove or disprove these theories.

roentgenological examination, preferably in conjunction with a serial roentgenographical examination of the stomach and duodenum.

The symptoms of ileal stasis are rather varied because sometimes the symptoms of the cause prevail, and sometimes the symptoms of the effect prevail, particularly those referable to the stomach and cap. These symptoms will be considered under the discussion of each cause.

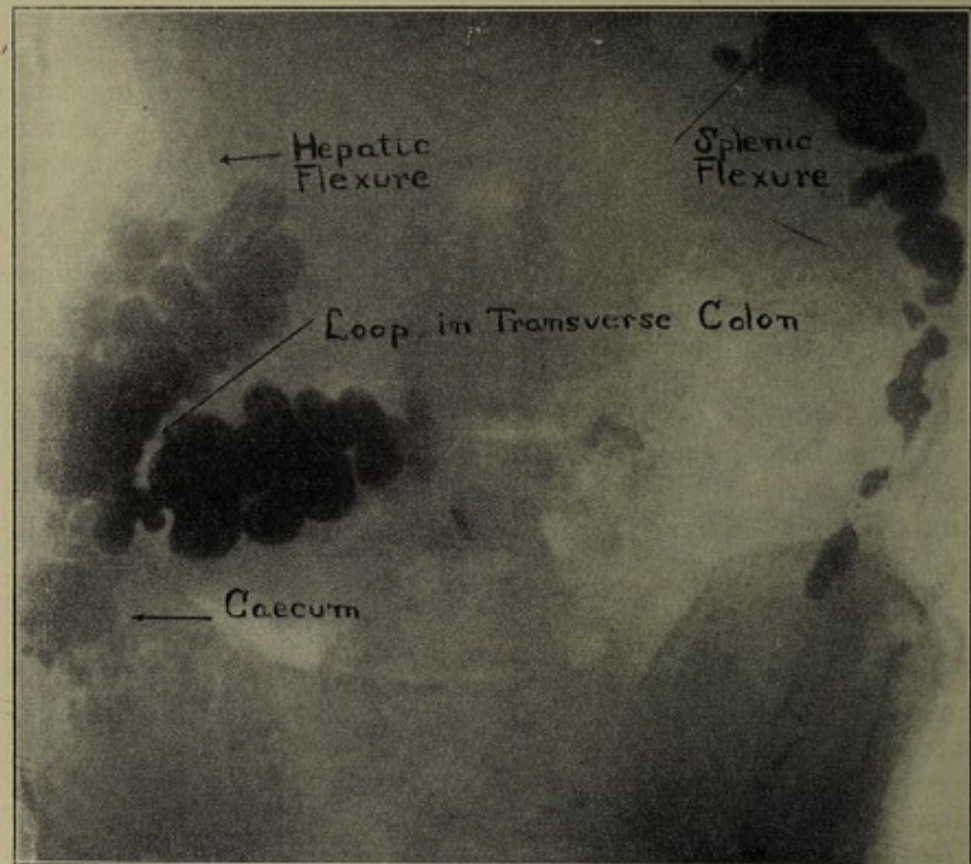


FIG. 13.—Stasis in cecum seventy-eight hours after ingestion.

COLONIC STASIS. Colonic stasis is perhaps the most common cause of ileal stasis. Since the time when man dispensed with forefeet and assumed the erect posture it has been uphill work for the ascending colon to evacuate itself. Overdistention of the cecum and ascending colon constitutes a large proportion of colonic stasis. The dilatation and atony of this region is partly compensated for by the active peristalsis of the terminal portion of the ileum. In proof of this, bismuth impregnated feces will be observed in the cecum much longer after a bismuth meal followed by a period of fasting than after a bismuth meal followed by the ingestion of food or possibly water. If the stasis (or constipation) in the ascending colon is persistent, unusual energy is demanded

from the peristalsis of the terminal ileum. When its strength is not sufficient to break the blockade, delayed evacuation results, accompanied by a chain of symptoms, perhaps referable directly to the exciting cause, "cecal constipation," or perhaps referred to the stomach and cap, as suggested earlier in this article. To overcome this obstruction, bismuth impregnated chyme may be

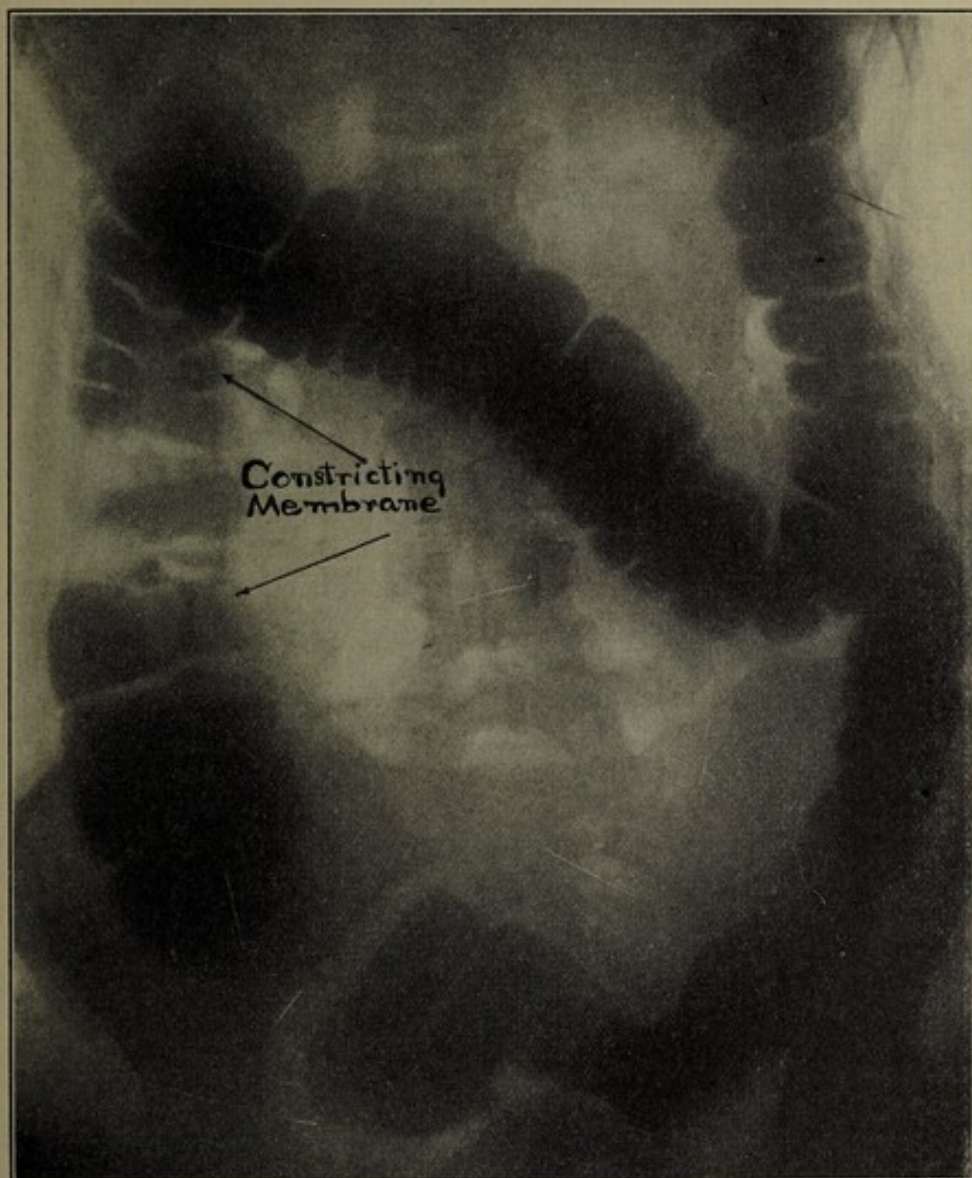


FIG. 14.—Pericolonic veil, involving ascending colon. Proved by operation.

seen frequently, forcing its way up through the fecal accumulations in the cecum and ascending colon, or the next meal succeeding the bismuth meal may be observed working up through the ascending colon (Fig. 13). If in such cases the cecum and ascending colon can be evacuated by properly applied manipulation, massage or even catharsis, previous to the ingestion of more food, stasis

of food in the terminal ileum will thus be diminished, and often the gastric or duodenal symptoms referred to the right hypochondrium will be relieved. Moreover, lesions in this region of a much more serious character may perhaps be prevented.

MEMBRANES AND VEILS. The various types of veils and membranes involving the cecum, ascending, and first portion of the transverse colon undoubtedly cause an ileal stasis, either directly by affecting the colon or terminal ileum, or indirectly by the associated constipation which blocks ileal evacuation. These lesions may be diagnosed with a great degree of certainty by roentgenography, preferably combined with roentgenoscopy. The drawing up of the cecum, the irregular filling defects in the colon, and particularly the "double-barrel shotgun" appearance of the ascending and first portion of the transverse colon, referred to by George, are very characteristic roentgenological findings (Fig. 14). Such conditions are undoubtedly important factors in the cause of obscure symptoms referred to the stomach and cap, particularly those associated with hyperchlorhydria, and should be searched for when the right hypochondrium fails to reveal the seat of the trouble. Sometimes the direct symptoms of constipation are so severe that the presence of gastroduodenal symptoms is entirely overlooked.

I fear that the treatment of these conditions is not so simple as some surgeons would lead us to think. One group of surgeons will split these membranes, remove the veils, and watch the colon pop out of its cage, believing that the patient is freed from symptoms forever. Unfortunately they are likely to return, renewed by the conditions which originally caused them, or by the trauma of manipulation from surgical procedure. In other cases where there is atony and dilatation, some surgeons attempt to reduce the size of the colon and hold it in position by artificially producing the conditions which the aforementioned group of surgeons try to destroy. The most successful method of surgical treatment for such cases could be determined by postoperative roentgenological investigations in conjunction with careful clinical observations.

KINKS IN THE TERMINAL PORTION OF THE ILEUM. Kinks in the terminal portion of the ileum, either with or without mobile cecum, undoubtedly do occur and cause the group of symptoms described by Lane and recognized by others. But these kinks are a rare rather than frequent cause of iliac stasis. I was told by Dr. Jordan, who has made roentgenological examinations of many of Mr. Lane's cases, that the roentgenological finding on which he bases the diagnosis of kinks of the terminal portion of the ileum is immobility of this region to palpation under fluoroscopic examination, and that the presence or absence of ileal stasis is not so important a factor. On several occasions I have been able to recognize kinks of the terminal ileum with dilatation of the proximal ileum, and

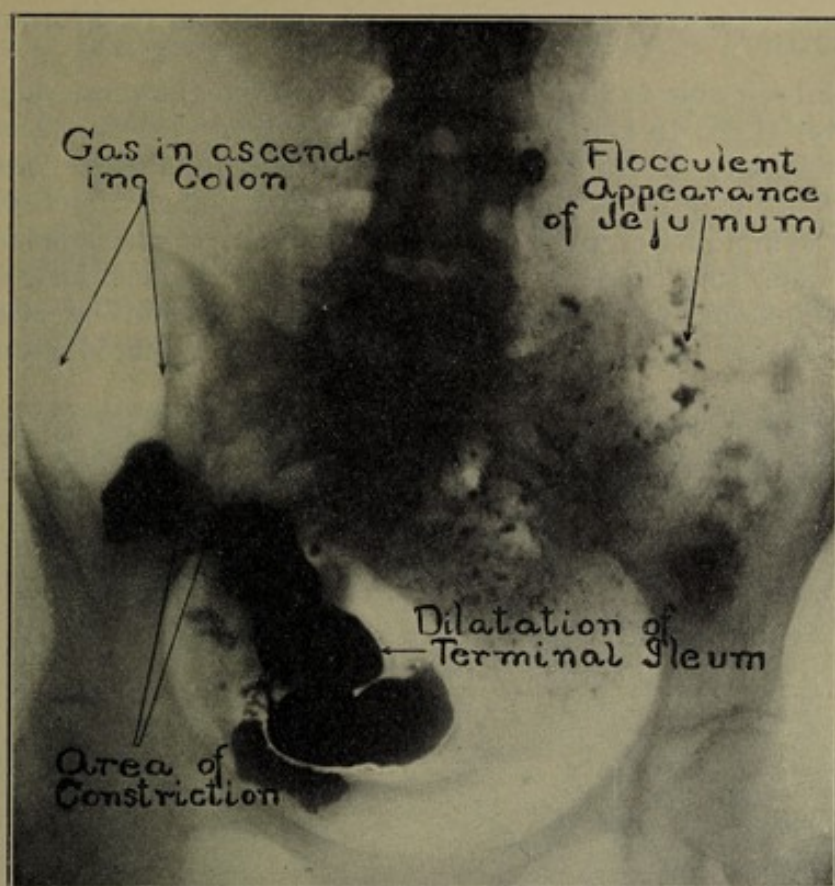


FIG. 15.—Lane's kink. Proved by operation.

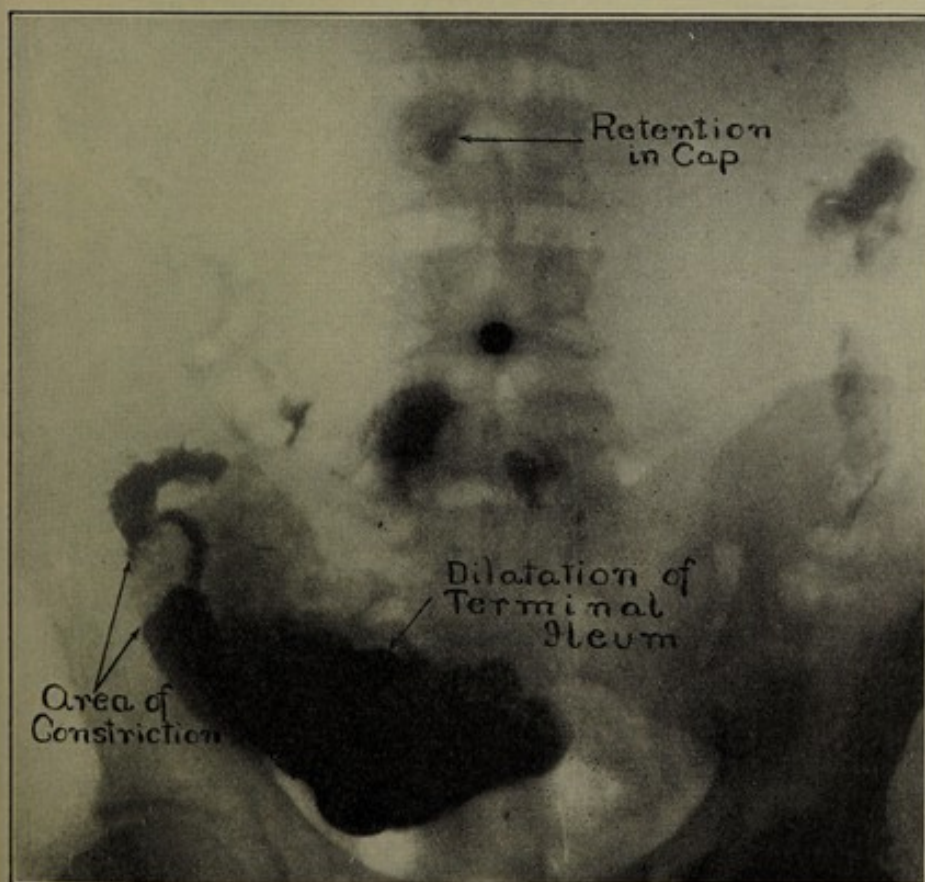


FIG. 16.—Lane's kink.

I have been able to demonstrate them to even the most skeptical observer (Figs. 15 and 16). When a kink really exists and causes ileal stasis and dilatation, especially if it is associated with symptoms surgery for its relief is undoubtedly indicated. The frequency with which symptoms of these lesions are referred to the stomach or duodenum, sometimes associated with organic lesions, viz., ulcers and adhesions, as described by Mr. Lane, should be strongly emphasized. But that iliac kinks and the associated group of

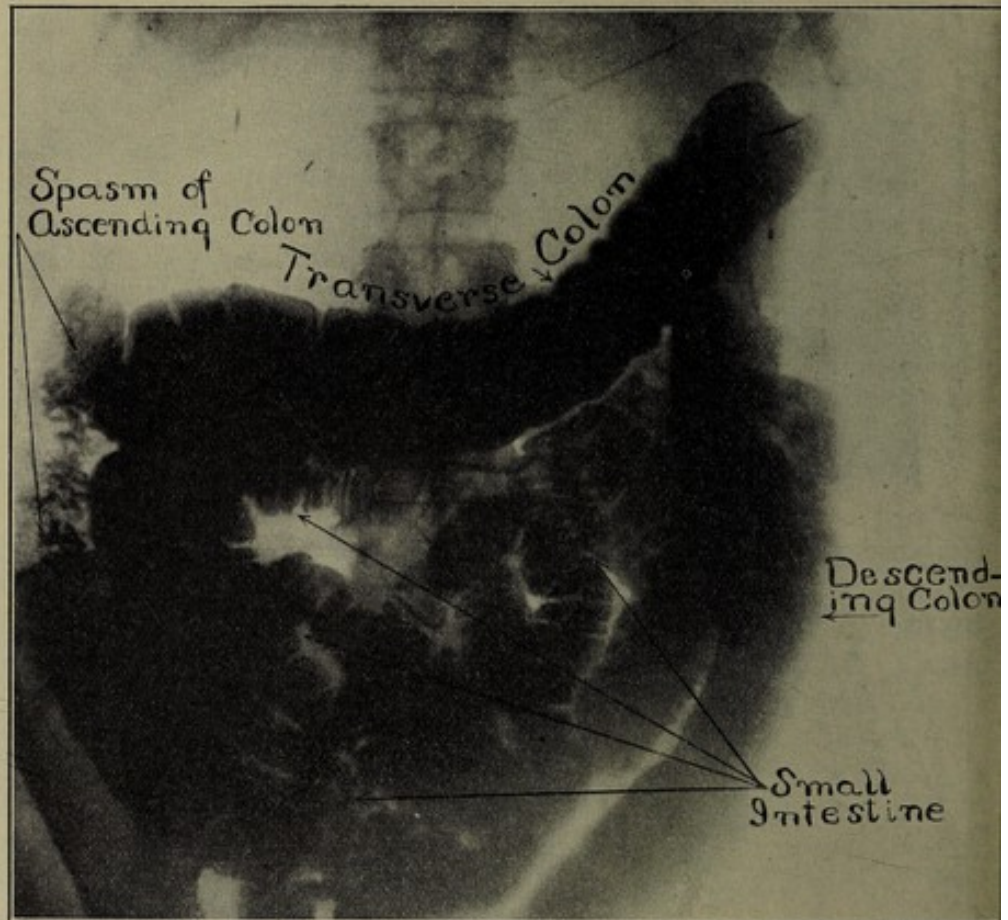


FIG. 17.—Distention of small intestine, caused by the passage of a bismuth clyster through an incompetent ileocecal valve.

symptoms and pathology occur with anything like the frequency that some observers would lead us to think, or that ileal stasis is caused solely or largely by kinks of the terminal portion of the ileum, is doubtful, as evidenced by the roentgenological findings. Therefore, operative procedure intended for the relief of kinks in the terminal portion of the ileum will not cure all cases of ileal stasis nor relieve their associated symptoms. Furthermore, if the stasis is not caused by a kink, operative procedure may aggravate the symptoms.

INSUFFICIENCY OF THE ILEOCECAL VALVE. Insufficiency of the ileocecal valve is a condition which I first recognized in 1902

(Figs. 17 and 18). Out of the cases examined since that time I have observed about 200 cases of this irregularity, and have used every effort to arouse the interest of surgeons and practitioners in the subject without success. Even now in cases where the clyster passes all the way to the duodenum, and the patients present marked abdominal symptoms, surgeons and practitioners refuse to attribute any significance to this finding. I find that the only way I can

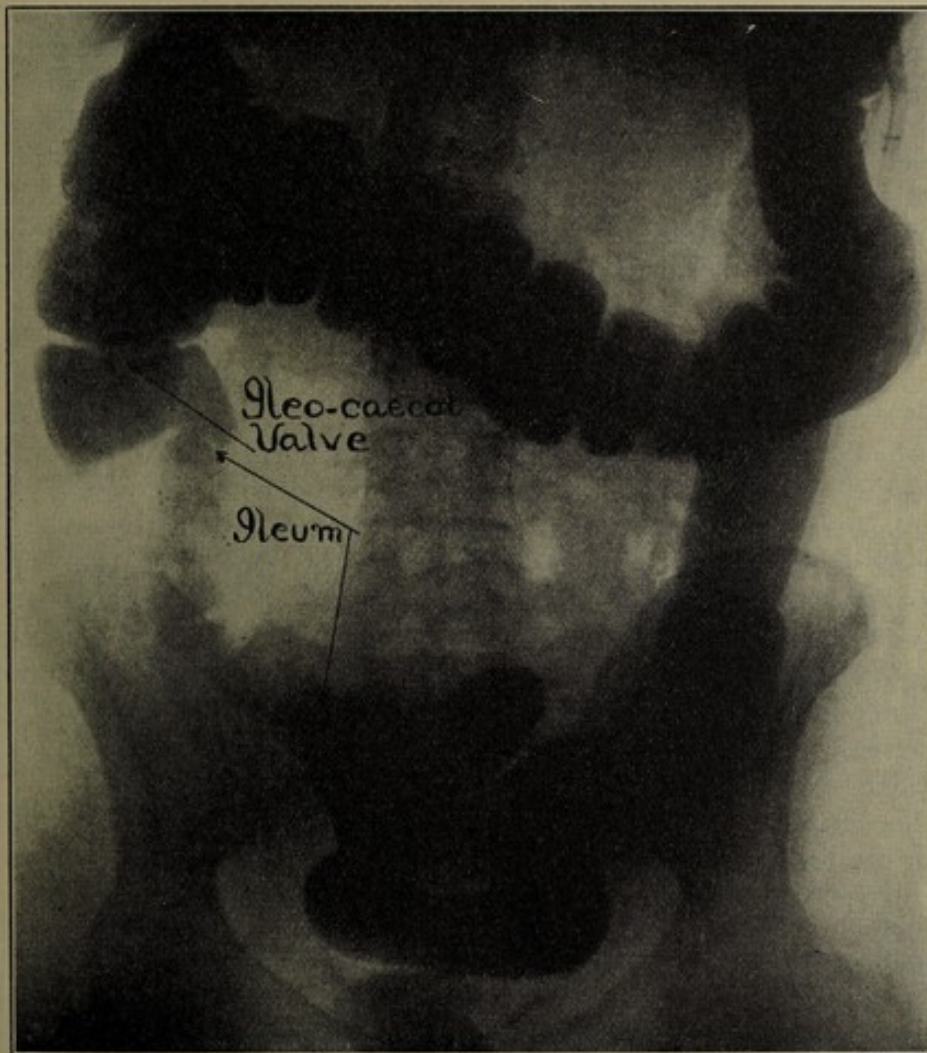


FIG. 18.—Distention of small intestine, caused by the passage of a bismuth clyster through an incompetent ileocecal valve.

interest them is to ask if they would expect symptoms if they fed their patients feces removed from the colon. I have failed to report this group of cases, at first because the question of tuberculosis occupied my attention, and later because my efforts were concentrated on gastroduodenal lesions. Kraus, Schwartz, Holzknecht, and more recently Groedel and Dietlan, have reported roentgenographical observations of ileocecal insufficiency. Case

has published an article, and on several occasions demonstrated slides, showing the frequency with which this lesion manifests itself. Its clinical aspects have been described by Kellogg,⁹ who has recently devised an operation for repairing an incompetent valve, and a method of constructing an artificial one, which will undoubtedly create a great interest in the whole subject.

Some of my cases of ileocecal insufficiency, particularly the first ones that I recognized as such, where the bismuth had passed a long distance up the small intestine, were associated with periodical attacks of nausea, vomiting, fever, prostration and headache, and with cramping abdominal pain, especially marked in the right quadrant of the abdomen. This is the group of symptoms which has been attributed to a variety of causes, such as bilious attack, migraine, auto-intoxication, and frequently appendicitis. In some cases if the symptoms were sufficiently indefinite the patient was permitted to retain his appendix, at least temporarily, in case it had not already been removed.

Reflecting on the roentgenological evidence, it occurred to me that this group of obscure symptoms was very likely due to the influx of large quantities of feces, loaded with bacteria and their products, from the colon, where they are normal, into the small intestine, which is relatively sterile compared with the colon. To increase my confidence in this theory, I found that the severity of the symptoms was proportionate to the length of the small intestine which the cecal contents traversed. Many cases were observed, presenting a mild degree of insufficiency, and the accompanying symptoms were only slight, or if acute, the attacks occurred at long intervals. Kellogg and Case have already referred to the iliac stasis, caused by or associated with this lesion, and my experience corroborates their observations.

The importance of ileocecal insufficiency justifies a communication limited to that subject alone, but it is impossible to consider it further in this communication, where it has been introduced merely as one of the potent factors in ileal stasis, and consequently in spasmodic and organic lesions of the stomach and cap.


CHRONIC APPENDICITIS. The roentgenological findings of chronic appendicitis are of immense diagnostic importance. The appendix, partially or completely filled, has occasionally been found by many roentgenologists, and reported at meetings or perhaps exhibited as a monstrosity. But Case and George deserve the credit of observing the appendix roentgenographically often enough to justify them in drawing conclusions as to the significance of its roentgenological appearance. Case states that the appendix may be shown in about 50 per cent. of the cases by milking the bismuth into its lumen. George maintains that he can show an appendix

⁹ Kellogg, *Surgery of the Ileocecal Valve*, Surg., Gyn., and Obst., November, 1913; *Incompetency of Ileocecal Valve*, Med. Record, New York, June 21, 1913.

in eight cases out of ten, if it has not been removed. He finds that the appendix of a child is readily filled by manipulation, but so rapidly evacuated that it is difficult to roentgenograph it. It is doubtful if the mere filling of the appendix is of pathological significance. But as Case has already declared, much information may be derived by examining it roentgenographically. It is possible to determine its size, shape, and position, the presence or absence of areas of constriction or permanent kinks, and whether or not it is adherent to adjoining viscera. A persistent fleck of bismuth, remaining therein for several days, is an important finding, indicating incomplete evacuation. If this phenomenon is accompanied by spasmodic constriction of the cap or pars pylorica, and the stomach, small intestine, and colon show no evidences of an organic lesion, there can be little doubt that the symptoms are due to chronic appendicitis. Even when the appendix is not visible to corroborate one's suspicions, the cause of the spasm may often be attributed to the appendix with considerable certainty, especially if the entire gastro-intestinal tract presents an otherwise perfectly normal appearance (Figs. 6 and 9).

DIAGNOSTIC VALUE OF ROENTGENOLOGY. It may be contended from a scientific stand-point that some of these deductions regarding the association of one lesion with another are not sufficiently proved. This may be true, but all inferences aside, the bare facts definitely shown by the roentgenological findings are sufficient to keep the scientific investigator busy for the next decade proving or disproving their association with each other. If our observations be correct, and we have a wealth of material to prove that they are correct, how vast is the field of functional gastro-intestinal disturbances thus opened up, whereon roentgenology is destined to throw the light which will reveal obscure lesions that have hitherto escaped detection by other methods of examination.

When the first alarm is sounded this search light should be put in action, lest, as Mayo warns, we deluge the alarm box and ignore the flames. If the roentgenologist is given an opportunity to make a complete examination, he can determine with a reasonable degree of certainty whether a torrent of surgical procedure is needed to extinguish the fire, or perhaps he may find that the chemical engine of hygiene, correct diet, and medication is sufficient. All of the lesions, with the exception of chronic appendicitis, may be diagnosed as accurately by a thorough roentgenological examination as by the old-fashioned exploratory laparotomy. Moreover, the roentgenological diagnosis can be made without loss of time or strength to the patient, and indicates whether medical or mechanical treatment will suffice or that surgical procedure is necessary.



THE AMERICAN ART MUSEUM OF THE CITY OF NEW YORK

FOUNDED BY THE CITY OF NEW YORK
IN 1880

THE AMERICAN ART MUSEUM OF THE CITY OF NEW YORK
IS A DEPARTMENT OF THE CITY OF NEW YORK

THE AMERICAN ART MUSEUM OF THE CITY OF NEW YORK
IS A DEPARTMENT OF THE CITY OF NEW YORK

THE AMERICAN ART MUSEUM OF THE CITY OF NEW YORK
IS A DEPARTMENT OF THE CITY OF NEW YORK

THE AMERICAN ART MUSEUM OF THE CITY OF NEW YORK
IS A DEPARTMENT OF THE CITY OF NEW YORK

THE AMERICAN ART MUSEUM OF THE CITY OF NEW YORK
IS A DEPARTMENT OF THE CITY OF NEW YORK

THE AMERICAN ART MUSEUM OF THE CITY OF NEW YORK
IS A DEPARTMENT OF THE CITY OF NEW YORK

THE AMERICAN ART MUSEUM OF THE CITY OF NEW YORK
IS A DEPARTMENT OF THE CITY OF NEW YORK

THE AMERICAN ART MUSEUM OF THE CITY OF NEW YORK
IS A DEPARTMENT OF THE CITY OF NEW YORK

THE AMERICAN ART MUSEUM OF THE CITY OF NEW YORK
IS A DEPARTMENT OF THE CITY OF NEW YORK

THE AMERICAN ART MUSEUM OF THE CITY OF NEW YORK
IS A DEPARTMENT OF THE CITY OF NEW YORK

THE AMERICAN ART MUSEUM OF THE CITY OF NEW YORK
IS A DEPARTMENT OF THE CITY OF NEW YORK

THE AMERICAN ART MUSEUM OF THE CITY OF NEW YORK
IS A DEPARTMENT OF THE CITY OF NEW YORK

THE AMERICAN ART MUSEUM OF THE CITY OF NEW YORK
IS A DEPARTMENT OF THE CITY OF NEW YORK

THE AMERICAN ART MUSEUM OF THE CITY OF NEW YORK
IS A DEPARTMENT OF THE CITY OF NEW YORK

THE AMERICAN ART MUSEUM OF THE CITY OF NEW YORK
IS A DEPARTMENT OF THE CITY OF NEW YORK

THE AMERICAN ART MUSEUM OF THE CITY OF NEW YORK
IS A DEPARTMENT OF THE CITY OF NEW YORK

THE AMERICAN JOURNAL OF THE MEDICAL SCIENCES

Edited by GEORGE MORRIS PIERSOL, M.D. Monthly. Illustrated. 1920 p
yearly. Price, \$5.00 per annum.

THE AMERICAN JOURNAL OF THE MEDICAL SCIENCES, founded in 1820
long been recognized as the leading medical journal of the English-speaking race. It
the first it sought the epoch-making papers, and becoming recognized as their me
it has, in turn, been sought by those who have had discoveries or real advances in
art and science of medicine to announce in its Department of Original Articles. In
1914 *The American Journal* will still further develop a feature that has proved
useful and popular, namely, a series of Special Articles, written by prearrangement
men of the highest authority, and covering present-day topics of the greatest im
tance and interest. These articles are designed to be clinical and practical, and to pr
important advances and the latest knowledge clearly and concisely, with particular refe
to application in daily work. The Department of Book Reviews will continue to con
critical and discriminating estimates of important new books, as well as briefer notices of
of less importance and of new editions. The Department of Progress of Medical Sci
under the charge of recognized specialists, will continue to summarize the actual advanc
the art and science of medicine appearing in the leading medical periodicals of the world.

PROGRESSIVE MEDICINE

A QUARTERLY DIGEST OF ADVANCES, DISCOVERIES AND IMPROVEMENTS
IN THE MEDICAL AND SURGICAL SCIENCES, COVERING THE ENTIRE DOMAIN
OF MEDICINE. Edited by HOBART AMORY HARE, M.D., Professor of Therapeutics
in Jefferson Medical College, Philadelphia; Physician to the Jefferson Medical College
Hospital, etc. Assisted by LEIGHTON F. APPLEMAN, M.D., Instructor in Therapeutics,
Jefferson Medical College, Philadelphia. In four octavo volumes, containing 1200 pages
amply illustrated. Annual subscription price, in heavy paper covers, \$6.00, *net*; in
binding, \$9.00, *net*. Carriage paid to any address.

PROGRESSIVE MEDICINE is the story of the progress, discoveries and improvement
in the various branches of the medical and surgical sciences, and is published four
a year, in March, June, September and December. The matter presented is the dig
essence of the entire medical literature of the world published during the previous
months, modified, explained and criticised in the light of the personal experience of the
tributor. By this method useless information is discarded and only that which is valuable
really helpful to the practitioner is retained. Practicality and thoroughness are the contri
features. The contributors are authorities in their respective lines, and their experien
private and hospital practice enables them to choose unerringly that which their br
workers require. Every article is original, the veritable product of the author whose
it bears. The style is narrative in form, hence easy to read. The interpretation of the
stated is given and their bearing upon the whole subject under consideration is clearly
simply indicated.

COMBINATION RATES

THE AMERICAN JOURNAL OF THE MEDICAL SCIENCES	per annum, \$5
PROGRESSIVE MEDICINE (heavy paper covers)	" 6
PROGRESSIVE MEDICINE (cloth binding)	" 9
PROGRESSIVE MEDICINE (paper covers) and the AMERICAN JOURNAL	" 10

PHILADELPHIA
706-8-10 Sansom St.

LEA & FEBIGER

NEW YORK
2 West 45th