

**A description of the mode of using the forceps invented by Mr Fay for the extraction and excision of teeth.**

**Contributors**

Fay, Cyrus.

**Publication/Creation**

[London] : [publisher not identified], [1826?]

**Persistent URL**

<https://wellcomecollection.org/works/dckwrdy7>


**License and attribution**

This work has been identified as being free of known restrictions under copyright law, including all related and neighbouring rights and is being made available under the Creative Commons, Public Domain Mark.

You can copy, modify, distribute and perform the work, even for commercial purposes, without asking permission.

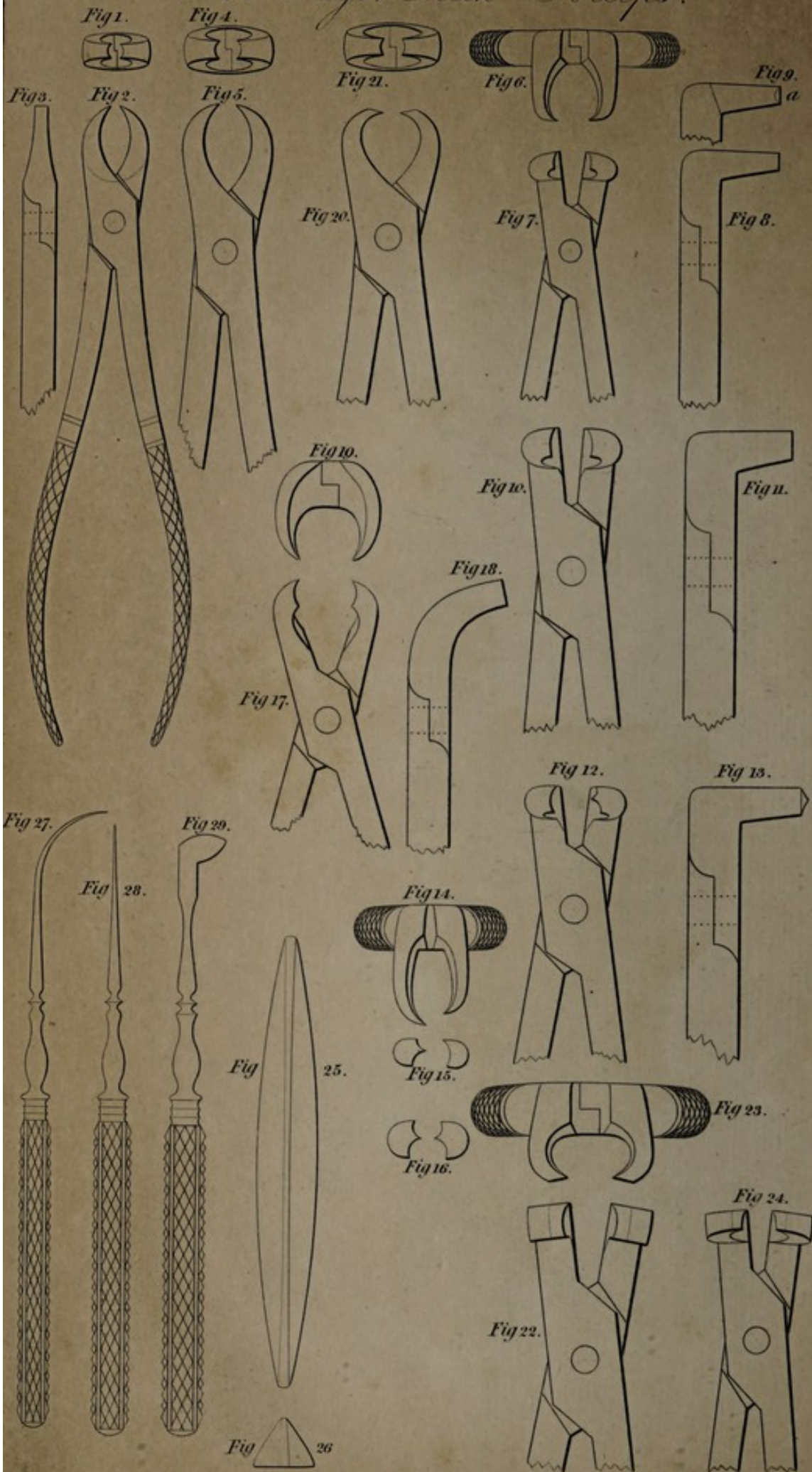


Wellcome Collection  
183 Euston Road  
London NW1 2BE UK  
T +44 (0)20 7611 8722  
E [library@wellcomecollection.org](mailto:library@wellcomecollection.org)  
<https://wellcomecollection.org>



# *Mr. Fay's Teeth Forceps.*

Plate 7.



Drawn by Cornelius Varley.

Engraved by J.B. Taylor.

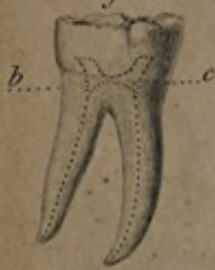

*Faint, illegible text at the top of the page, possibly a title or header.*



*Mr. C. Fay's Teeth Forceps.*

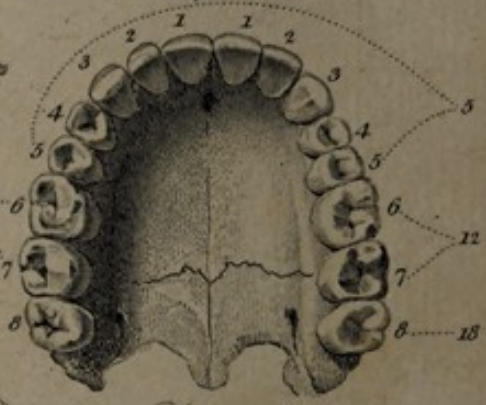
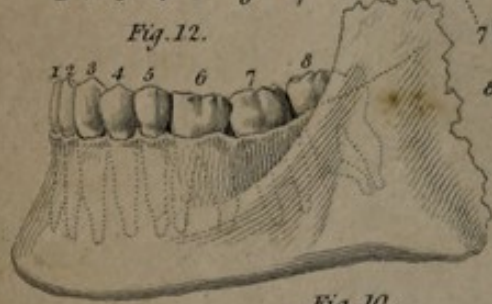*Fig. 13.*



*Fig. 8.*



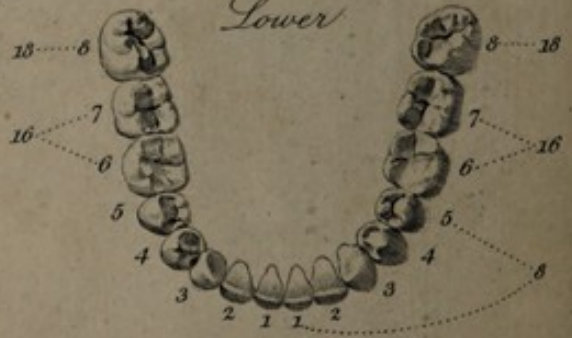
*Fig. 12.*



*Upper*

*Fig. 11.*

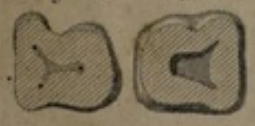
*Fig. 10.*




*Lower*

*Fig. 14.*

*Fig. 15.*



*Fig. 9.*



*Drawn by C. Farley.*

*Engraved by W. Kelsall.*



13

A

DESCRIPTION

OF THE MODE OF USING

THE FORCEPS

INVENTED BY MR. FAY

FOR THE

**Extraction and Excision of Teeth.**

EXTRACTED FROM THE FORTY-FOURTH VOLUME OF THE  
TRANSACTIONS OF THE SOCIETY OF ARTS.

LONDON:

PRINTED BY T. AND J. B. FLINDELL,  
67, ST. MARTIN'S-LANE.

1827.

18

THE FOLIO  
No. 100  
SOCIETY

INVENTED BY MR. FAY

FOR THE

EXTRACTION AND EXTENSION OF CORDS.

EXTRACTED FROM THE FORTY-FIFTH VOLUME OF THE  
TRANSACTIONS OF THE SOCIETY OF ARTS.

LONDON:

PRINTED BY J. AND J. W. KIMBLE.

1837



## IMPROVED FORCEPS FOR THE USE OF DENTISTS AND OTHERS.

---

*The LARGE SILVER MEDAL was this session presented to Mr. C. FAY, 7, Sackville-street, Piccadilly, for his improved Forceps for the use of Dentists. The following communication was received from him on the subject, and a set of the Forceps has been placed in the Society's repository.*

SIR,

HAVING early in my professional career felt the greatest inconvenience from the imperfections of the instruments usually employed for the extraction of teeth, I was induced to prepare others more accurately adapted to their figure. From an attentive consideration of their structure, I was soon convinced that the *neck of the tooth* was the only part on which the necessary force could be applied with the greatest safety and advantage. Now as the teeth do not all present the same configuration, it follows that the figure of their necks must also vary; of this fact every anatomist must be convinced. I state nothing new when I say that there are certain teeth formed very much alike, both in the upper and lower jaw, and that of the teeth thus similar to each other there are various classes,



but that each class retains the same peculiarity of figure in all ages, and under all circumstances. Having stated thus much, which I think necessary in order to prepare you for what follows, I beg leave to say, that I have invented *a set of instruments accurately, because anatomically*, suited to these several classes of teeth, a desideratum, as I believe, never before accomplished. These instruments are forceps, corresponding in number to the different classes of teeth, and suited to the same classes on the right side, and on the left, in the upper and in the lower jaw, amounting to six in number; but as it is necessary to have two sizes of three of these, the number of extracting forceps is nine, and by referring to the plate, it will be seen with what precision the forceps may be applied to the proper tooth. Thus I found myself in possession of a set of instruments answering the required end, because correctly adapted to the varied form of the parts to which they are intended to be applied.

The next point was to determine *how the power* thus possessed *should be directed*. The line of least resistance is that which coincides the nearest with the average direction of the axes of the roots; consequently the power should be applied more or less perpendicularly to the jawbone.

I do not pretend to say that I am the first person to attempt the perpendicular extraction of teeth, but I hope to show to the Society that I have accomplished that object with the simplest, the safest, and the easiest means.

The advantages which I consider these forceps to possess over all others, are briefly these:

1st. They may, as before stated, be accurately applied to the necks of the several classes of teeth; they are made



to fit the necks only, never making the least pressure on the enamel or body of the teeth, and consequently may be used without any danger of breaking a carious tooth in the attempt to extract it.

2d. They never can slip when once accurately applied on the necks of the teeth, a great practical benefit.

3d. No cutting of the gum, or any other preparatory measure, is necessary, as the edges of the blades of the forceps may be at once brought upon the necks of the teeth.

4th. A provision is made by the beaked form of the extremities of the blades of the forceps designed for the extraction of the teeth having more than one root, by which means the forceps may be steadily fixed on the remains of a decayed tooth, even when the edges of such teeth are below the level of the gums. To which may be added, that they enable the operator to extract the teeth in the perpendicular direction with a less amount of force than any other instruments.

The manner of using the right-angled forceps is shortly this. The forceps having been carefully applied on the neck of the tooth to be removed, the operator is to put a small bit of any light wood across the jaw, of a thickness sufficient to occupy the space between the joint of the forceps and the anterior teeth, then steadily seizing the handles of the instrument, he is to make a gentle semirotatory motion at the same time that he is pressing the handles of the instrument downwards. This motion separates more easily the vessels and membranes connecting the roots to their sockets, and surrounding the neck of the tooth; for, be it remembered, the soft parts, and not the hard, present the greatest resistance to the removal of the teeth. It might



be supposed that the pressure of the piece of wood on the anterior teeth, in loosening the diseased one, would produce pain; on the contrary, it is not felt, because the action and re-action are exactly equal between the pressure on the jaw and the resistance of the tooth.

There are other forceps which I beg leave also to submit to the examination of the Society, for a purpose distinct from that for which the instruments already described are designed, and before describing them, I will briefly state what they are intended to accomplish.

In the centre of every tooth is a little cavity, in which is expanded a nervous pulp forming the principal seat of sensation in that organ; and the nerves pass through the roots of the tooth by very minute passages into this cavity where they are spread out. The base of this cavity is situated a little above the level of the neck of the tooth, and it struck me, that when caries had extended so far as to expose the nervous matter contained in it to the various agencies from which in the healthy state of the parts it is protected, it would be easy to remove that part of the tooth, the seat of the pain, and thus allow the sound living roots to remain in their sockets undisturbed, to support the adjoining teeth: as it is a notorious fact, that the entire removal of one tooth, however easily performed, causes the adjoining ones to become prematurely loose, and ultimately to fall out, in consequence principally of the absorption of the alveolar process. Minutely to describe how this happens would occupy too much space, and I mention it merely as a well known fact, to show the value of allowing the healthy roots of a tooth to remain. This operation I have called the *operation of excision*, and I recommend it as a most valuable substitute for the extraction of teeth



in the majority of cases of caries, but by no means to supersede it altogether, as there are very many cases requiring the entire extraction of the teeth, when disease has proceeded beyond a certain point; as, for example, beyond the common cavity which I have cursorily described; or when the jaw itself is diseased.

The instruments employed by me in this operation are forceps accurately fitted, like those for extraction, to the necks of the teeth, but having fine, well-tempered, cutting edges; these edges must be carefully applied on the necks of the teeth, as close to the gums as possible, taking care to keep the edges parallel to the edges of the gums, which are to be depressed a little with the inferior surface of the blades of the forceps, so as to bring the cutting edges fairly beneath the enamel, which, in the adult, is the criterion of being below the common cavity of the tooth. Then with a gradual application of pressure on the handles of the forceps, the tooth is in an instant snapped off at the neck, and the common cavity, the seat of the pain, is thus removed, leaving the patient a painless, bony surface for mastication, a firm prop for the support of the adjoining teeth, and a basis for an artificial tooth if it should be required. I may mention here a fact never before noticed; namely, that the openings by which the minute canals terminate in the common cavity become, soon after the excision of the crown, *plugged up with bony matter*, which thus affords a permanent protection to the interior of the stump, and presents a continuous and firm surface for after life. In addition to these advantages, the operation is performed, even on the largest teeth, in a moment, and consequently at a *great saving of suffering*, which should be the grand object of all sound surgery.



The following letters from professional gentlemen, many of whom speak from their own personal experience, render any farther observations on my part wholly unnecessary.

I am, Sir,

*A. Aikin, Esq.*

&c. &c. &c.

*Secretary, &c. &c.*

C. FAY.

---

CASES.

SIR,

London, Sept. 7, 1826.

In reply to your letter of this morning's date, I have great pleasure in stating, that since the operation which you performed on my tooth I have never experienced the slightest pain, either in that part of the tooth which you suffered to remain in its alveolar socket, or in any of the parts contiguous to it, although for four months previous to the excision of the crown of the tooth I found it impossible to masticate on that side.

With regard to the operation of excision, as performed by you, I have no hesitation in stating that it appears to me to be a very great improvement in that branch of the profession which is connected with the surgery of the teeth.

I am, Sir,

&c. &c. &c.

*C. Fay, Esq.*

J. W. GULLIFER, M. D.



32, Middleton-street, Wilmington-square,

February 7, 1826.

In confirmation of Mr. Fay's new method of operating on the teeth in particular cases, by the excision of the crown or body of the tooth, instead of extraction, I am happy to bear testimony of its complete success in my own person. Since having undergone the operation (upwards of a twelvemonth) I have not experienced any particular uneasiness in the remaining stump, or surrounding gum; and I fully concur in the general approval of the practice of excision in the place of extraction, in all cases where the tooth has not become carious below the margin of the alveolar process, or where there is no reason to suppose a collection of matter at the root of the tooth.

In such cases as render extraction absolutely necessary, I must do Mr. Fay the justice also to declare, that his improved forceps for the extraction of teeth are the best adapted instruments yet offered to the medical public for that purpose.

WILLIAM BRADLEY,

*M. R. C. S. London.*

4, Chapel-street, Bedford-row,

DEAR SIR,

Nov. 7, 1826.

I am happy in having an opportunity of giving my testimony to the superior method adopted by you of operating upon the teeth. As to the plan of excision, I can only repeat the assurance I gave you at the time of operating, viz. that I was instantly relieved from the most distressing toothache, without experiencing, during the operation, more pain than the slightest scratch of a pin would have



given. Three months have now elapsed, and I have not felt the least inconvenience from the stump.

I have lately examined the stump of a tooth you excised for a medical gentleman (Mr. Wade, of the Westminster Dispensary), which afforded me a practical proof of the justness of your statement of the growth of bony matter over the foramina through which the nerves proceed to the common cavity of the tooth. It is not more than six weeks since you cut off Mr. W.'s tooth, and it would be impossible now to introduce the point of the finest needle into the stump which now remains.

I am sure, when the operation of extraction is necessary, the excellence of your plan cannot be doubted; any man of the smallest ingenuity, who will examine your instruments, must at once admit this.

I am, Sir,  
&c. &c. &c.  
ROBERT DAVEY,  
*C. Fay, Esq.* *M. R. C. S. London.*

179, Piccadilly, Aug. 23, 1826.

I have seen Mr. Fay cut off a molar tooth of the right side, for a medical friend of mine.

The operation, which is entirely new in this country, was instantaneously performed, and the pain, previously very great, was immediately removed.

I have visited my friend several times since, who declares he has had no uneasiness from the time of the operation.

ROBERT WAKE,  
*M. R. C. S. London.*



DEAR SIR, Berners-street, Feb. 15, 1826.

I have minutely examined your instruments for the teeth, and consider them very superior to all others of the kind, and well worthy the attention of the profession.

Your new and effectual mode of operating by excision has been fully evidenced to me in two of my domestics, on whose teeth you operated satisfactorily.

I am, Sir,

&c. &c. &c.

*C. Fay, Esq.*

JOHN FAITHORN, M. D.

No. 9, Gerard-street, Soho,

Aug. 21, 1826.

I have much pleasure in bearing testimony to Mr. Fay's improved method of operating on the teeth, his forceps for extraction appearing to me superior to any before invented. Of the new operation by excision I can speak with much confidence, having submitted to it myself, and seen it practised in several other instances.

A lady, for whom Mr. Fay excised four teeth, and whom he afterwards supplied with artificial ones twelve months since, expresses herself highly satisfied, having experienced no inconvenience beyond a slight tenderness in the gums for about a week, the stumps proving a great support to the artificial teeth.

Of the advantages of excision over extraction there can be little doubt; that is, when the disease does not extend beyond the body of the tooth, the neck being the only place at which excision can be practised with success, as the excised part must include the common cavity.



The stump of the tooth which Mr. Fay cut for me remained slightly tender for about ten days; and on examining it about three weeks afterwards, I found the small cavities, giving passage to the nervous twigs, had become obliterated, by a deposit of bony matter.

The operation of excision, if dexterously performed, that is, if it be done steadily, without moving the tooth in its socket, of course including the common cavity, is scarcely to be felt, as evidenced in a gentleman on whom Mr. Fay operated in my presence a few days since, and who was only aware of the operation having been performed by the cessation of the pain in his tooth.

By excision, the sockets of the sound teeth are not deprived of their accustomed support, whilst the form of the jaw is much less injured than in extraction.

R. WADE,

*Member of the College of Surgeons.*

No. 46, Lincoln's Inn-fields,

Sept. 21, 1826.

After a careful examination and consideration of the instruments and the operations of Mr. Fay, I have great pleasure in stating my conviction of their utility. The mode of extracting the teeth appears to me to be more safe and certain than that which I have seen practised; and the proposal of removing the crown of a tooth is ingenious and, I believe, novel.

JOSEPH HENRY GREEN.



No. 5, New North-street,

August 20, 1826.

SIR,

I have carefully examined the forceps employed by you for the extraction of the teeth, and have no hesitation in saying that they are superior to any I have seen used for that purpose; first, because they are accurately adapted to the shape of the teeth individually, and bear only on their necks; secondly, because they allow the teeth to be removed in the direction of their sockets, with greater safety and less power than with any other instruments.

Of your operation of excision I can speak with much confidence; the anatomy of the teeth fully warrants it, and experience has shown that it is very superior to extraction. I have seen you operate on six persons at different times, and I heard them assure you that the operation gave no pain, and that they were perfectly satisfied with the result. Three of these persons I have seen several times since, and they have assured me that they have experienced no inconvenience from the operation.

I am so satisfied respecting its consequences that I would have it performed on myself if circumstances required.

In answer to your inquiry respecting the originality of this procedure, I beg leave to say that I never heard or read of any such operation before you explained it to me. I have examined the principal collections of surgical instruments in Europe, but I never found any forceps like yours for the extraction of teeth; and I think that the operation of excision, for the reasons you have stated, deserves to be ranked among the improvements of modern surgery.

EDWARD JOHN SPRY.

*C. Fay, Esq.*



*Explanation of the Figures of Mr. Fay's Teeth Forceps.  
Plates VII. and VIII.*

Plate VII. figs. 1, 2, and 3, end and side views of a small straight forceps, for the extraction of any of the single-fanged teeth in the upper jaw, whether temporary or permanent.

Figs. 4 and 5 represent similar views of a forceps, for the same purpose, of a larger size.

Figs. 6, 7, and 8, end, front, and side views of a right angled forceps, for the extraction of the single fanged teeth in the lower jaw.

Fig. 9, is an inside view of one of the beaks of this forceps, to show the depth of the grooved surface which lays hold of the tooth; this contrivance obtains in all the forceps for extraction, and is intended to prevent the fracture of the tooth by the pressure of the instrument, an accident which would be sure to happen if an acute margin were opposed to the tooth.

Figs. 10 and 11, a front and a side view of a similarly shaped forceps of a larger size, which may be used for the extraction of the same teeth as the former in the adult, or of the molar teeth in either jaw, if the tooth to be removed is not decayed below the neck.

Figs. 12, 13, and 14, front, side, and end views of the single hooked forceps, for extracting the two anterior molar teeth of the upper jaw on the left side.

Fig. 15, end view of the left single hooked forceps, for the extraction of the same teeth on the right side (see figs. 9 and 10, plate VIII.)

Fig. 16, a front view of the double hooked forceps for the extraction of the two anterior molar teeth on both sides



of the lower jaw. The manner in which this instrument embraces the neck and upper part of the fangs of the teeth mentioned, is shown in fig. 8, plate VIII. This instrument is intended more particularly for the extraction of these teeth when decayed more or less below the level of the gums, and to obviate the risk of breaking them, by insinuating the hooks of the instrument below the neck, between the roots of the tooth. The same may be said of the single-hooked forceps for the extraction of the molar teeth of the upper jaw.

Figs. 17, 18, 19, front, side, and end views of the hawkbill forceps, for the extraction of the third molar or wise teeth of both jaws.

Figs. 20 and 21, side and end views of the straight *cutting* forceps, for excising the crowns of the single-fanged teeth, especially in the upper jaw.

Figs. 22 and 23, front and end views of a right-angled cutting forceps, for excising any of the molar teeth either in the upper or lower jaw.

Fig. 24, front view of a right-angled cutting forceps, for excising the single-fanged teeth of the lower jaw, or the bicuspid of the upper.

Figs. 25 and 26, the outline and section of one of the pieces of wood used as a fulcrum in the extraction of the teeth in the manner described.

Fig. 27, Examining tenaculum.

Fig. 28, Stilette.

Fig. 29, Gum lancet.

Plate VIII. figs. 9 and 10, represent the manner in which the molar teeth of the right side in the upper jaw are taken hold of by the single-hooked forceps, shown in fig. 15, plate VII. The hook entering between the two



exterior roots, while the plain beak embraces the single internal root.

Fig. 11, the teeth of the upper and lower jaws, opposite to each of which the numbers of the forceps, in plate VII, are attached by dotted lines, to show the teeth designed to be extracted with each forceps.

Fig. 12, a side view of the jaws, the direction and situation of the fangs of the teeth being shown by dotted lines.

Fig. 13, one of the lower molar teeth of the right side, in which the figure of the internal cavity is shown by dotted lines; the dotted line *b c*, passing through the base of the cavity. Excision must be performed immediately below this line.

Figs. 14 and 15, represent the appearance of an excised molar tooth a little above the line just mentioned. The crown is turned upward, to show the size of the cavity; and the base of it, in fig. 14, shows the minuteness of the orifices through which the nervous twigs pass. These orifices become obliterated by a deposit of bony matter.

[As the Committee was obliged, from want of room, to give insertion only to a few of the cases submitted to them, and to curtail the communication addressed to the Secretary to its present abbreviated form, Mr. Fay has been induced to prepare a little work, containing his opinions on certain practical points of dental surgery, which will soon be ready for publication.]



