

A descriptive catalogue of a very extensive and capital collection of anatomical preparations : original casts of the gravid uterus, accurately moulded from nature, coloured anatomical drawings, and natural history; forming the entire and genuine museum of an eminent professor of anatomy, who has declined teaching ... which will be sold by auction, by Mr. Hutchins, at his rooms, in King-Street and Hart-Street, Covent-Garden, on Monday, December the 10th, 1787, and the twelve following evenings (Sundays excepted), at six o'clock.

Contributors

Hutchins, Mr. active 1779-1789.

Publication/Creation

[London] : [Hutchins], [1787]

Persistent URL

<https://wellcomecollection.org/works/jxwqpg7e>

License and attribution

This work has been identified as being free of known restrictions under copyright law, including all related and neighbouring rights and is being made available under the Creative Commons, Public Domain Mark.

You can copy, modify, distribute and perform the work, even for commercial purposes, without asking permission.



Wellcome Collection
183 Euston Road
London NW1 2BE UK
T +44 (0)20 7611 8722
E library@wellcomecollection.org
<https://wellcomecollection.org>

A
D E S C R I P T I V E
C A T A L O G U E

O F A

Very Extensive and Capital COLLECTION

O F

ANATOMICAL PREPARATIONS, &c. &c.

To be Sold by AUCTION,

On *Monday* the 10th of *December* 1787, and 12
following Evenings.

Price 1s.

C O N D I T I O N S

O F S A L E,

A S U S U A L.

Not in Russell (other
Hutchins sales at nos.
123, 128). Included in
ESTC but with no
attribution.

Baillie was only at the start
of his career in 1787 and
continued to teach for
many years. Surely the
obvious candidate is John
Sheldon who gave up at
about this time for reasons
unknown and went to
Greenland in 1788.

cf. Proc RSM 1959, 52,

231-8

HJS 14/2/86

~~ATKINSON, E~~ GAUOT, A.

Elementary treatise on
physics, experimental and applied

2nd ed -

London: H. Baillière.

1866

(transl. fr. Gaucot's 'Elements de physique')

~~GAUOT~~

(have other eds.)


603

It would appear
that this is John
Hunter's collection
The date would be
compatible

The reference to
Sheldons ^{would on the} Lymphatics
refers to Hunter &
to Hewson (the late)
whereas the Catalogue
is one of a living
anatomist's collection
The catalogue contains
references to Miss
Stones' drawings
& she is the artist
of the Specimen in
Sheldons book Plate
2. but not of the
other figures on
the plate

At Vordelen
22.ii.29
—

Re
MST
260.2



Digitized by the Internet Archive
in 2019 with funding from
Wellcome Library

It is probable that this is a catalogue of Matthew Baillie's collection .He was appointed physician to St George's Hospital in 1787, the year of the sale. It cannot be the catalogue of John Hunter's whodied in 1793 and whose collection was bought by a parliamentary grant of 15000 pounds in 1799=

H.R.S.

It is probable that this
is a catalogue of Matthew
Baillie's collection. He
was appointed physician
to St George's Hospital
in 1787, the year of the
sale. It cannot be the
catalogue of John Hunter's
whodied in 1793 and whose
collection was bought by
a parliamentary grant of
15000 pounds in 1792.

A
DESCRIPTIVE
CANTALOGUE
Of a very Extensive and Capital
COLLECTION
OF
ANATOMICAL PREPARATIONS,
ORIGINAL CASTS OF THE GRAVID UTERUS,
accurately moulded from Nature;
COLOURED ANATOMICAL DRAWINGS,
AND
NATURAL HISTORY;
Forming the Entire and Genuine MUSEUM
OF AN
Eminent Professor of ANATOMY,
Who has declined Teaching.

*This Collection has been the Work of many Years extensive
Practice and close Application to this Study.*

Which will be Sold by AUCTION,
By MR. HUTCHINS,
At his ROOMS, in King-Street and Hart-Street,
Covent-Garden,

On MONDAY, December the 10th, 1787, and the Twelve
following Evenings (*Sundays excepted*), at Six o'Clock.

The Whole will be on View on FRIDAY the 7th and
SATURDAY the 8th Instant.

CATALOGUES (at One Shilling each) may be had of Mr. HUTCHINS,
N^o 41, King-Street, Covent-Garden: Who fixes a Valuation on
Noblemen's and Gentlemen's Effects of all Sorts, in Town or Coun-
try; and the Value, if required, immediately given for the same.



First Night's Sale,

Monday, December 10th 1787.

ANATOMICAL PREPARATIONS.

D R I E D B O N E S .

- 1 **F**OUR sections of adult heads
- 2 Four ditto ditto
- 3 Two sections of human *crania*
- 4 Two arches of *crania*, one very remarkable for the spinal process of *os frontis*
- 5 Two ditto, both remarkable for prints of *glandulæ Pacchioni*, and one for two remarkable impressions on *os frontis*
- 6 Three arches of *crania*, one from a young subject, for sutures
- 7 Three ditto, one from a rickety subject, and one with *ossa wormiana*
- 8 Two *bases* of *crania*, and one arch of ditto
- 9 Two *bases* of ditto, and one arch of ditto
- 10 A scull and lower jaw, and a *basis*
- 11 Two sculls and lower jaws

A.

12 Two

- 12 Two skulls and two lower jaws
- 13 Two ditto and two ditto
- 14 A very old skull, in which the alveolar processes have been absorbed
- 15 Two *bases* of *crania*, and three sections
- 16 Separated bones of the *pelvis*, and large cylindrical bones of the lower extremity (9 in number)
- 17 Skull of the porpoise with the lower jaw
- 18 Separated bones of the *pelvis*; two *scapulae*, and large cylindrical bones of the superior extremity; and a hand with the natural ligaments
- 19 The skeleton of a bird, and *ossa innominata* of a quadruped
- 20 The bones of the *pelvis* separated, and large cylindrical bones of the inferior extremities

PREPARATIONS IN SPIRITS.

- 21 A *polypus*, or specimen of coagulable lymph, from the cavity of the right ventricle of the human heart
- 22 A beautiful specimen of a ramified polypus, from the pulmonary artery of the human subject
- 23 A portion of the *allantois*, with its termination, from the foetal calf
- 24 A beautiful specimen of the cuticle of the human *fetus* or *podotheca*, inverted
- 25 A ditto of the foot, not inverted
- 26 A preparation of the Schneiderian membrane, or membrane which forms the organ of smell, minutely injected, in which the opening

- ing of the Eustachian tube towards the *fauces* is preserved
- 27 A section of the organ of smell in the human subject; shewing several of the sinusses, and remarkable for a perforation in the *septum nasi*
- 28 A specimen of three lacteals injected with quicksilver, on the human small intestine and mesentery, dried, and preserved in oil of turpentine
- 29 Cuticle from the thumb of the human subject, to shew the structure and connection of the nail
- 30 Lamellated coagulable lymph, from an aneurism in the human subject
- 31 The femoral artery opened with an aneurismal *sacculus*
- 32 Two—one of coagulable lymph from the pulmonary artery of the human subject; the other a portion of the human *aorta*, with an ossification of the internal coat
- 33 A most beautiful and very minute and successful injection of the *villi* of the foot in a young subject; the cuticle is removed
- 34 A beautiful specimen of coagulable lymph, from the pulmonary artery of the human subject
- 35 Two—a portion of an aneurismal cyst opened, from the arch of the human *aorta*—and a preparation of lamellated coagulable lymph, from an aneurism
- 36 A preparation of the hand of a young subject, minutely injected with quicksilver, and preserved in oil of turpentine
- 37 A foot of a young subject, minutely injected
- 38 A cyst from the liver of a dropical subject

- 39 A *volvulus*, or *intus susceptio*, from the human
ileon
- 40 A lacteal injected with quicksilver, on the hu-
man small intestine
- 41 Injected skin of the human lips, with ulcera-
tions
- 42 A preparation of a portion of the human blad-
der, shewing the beginning of the *urethra*,
and the *caput gallinaginis*, with two bristles
inserted in the orifices of the seminal ducts
- 43 A very large lymphatic, injected with quick-
silver, on the human spermatic cord
- 44 Skin of a Black, minutely injected and dissected
- 45 The *corpus glandulosum Peyerii*, or *ventriculus suc-
centuriatus*, of a common cock, injected
- 46 Two—one a preparation of injected skin, from
a small-pox subject; the other a prepara-
tion of *cuticle* and *rete mucosum* of a negro
- 47 A transverse section of the *proboscis* of an ele-
phant
- 48 A preparation of *villi* of the skin of the hu-
man thumb, minutely injected
- 49 The tongue of the *phoca* or seal, remarkable
for having the *apex* bifid, and for its large
papillæ
- 50 A lymphatic vessel injected with quicksilver,
on the human diaphragm
- 51 A most beautiful preparation of the human
skin, very minutely injected, and preserved
in oil of turpentine
- 52 Two—a specimen of coagulable lymph, from
the pulmonary artery; and a specimen of
injected skin, with a dead portion which is
separating from the adjacent living parts
- 53 Two—a preparation of the human eye, shew-
ing the *membrana conjunctiva*; and a prepa-
ration

ration of the orifices of *glandulae Meimbomii*,
on the *tarsus*

- 54 A very curious specimen of the cuticle and *rete mucosum* of the negro, from the sole of the foot, which demonstrates that the *rete mucosum* thickens in the same proportion that the cuticle does
- 55 A nose injected, shewing the orifices of the sebaceous glands in the skin
- 56 A beautiful specimen of coagulable lymph, which was thrown out from the exhalant vessels in a subject who died of *empyema*
- 57 Two—the tongue of a monkey, injected; and a preparation of injected skin
- 58 The internal villose coat of the human gall-bladder, minutely injected
- 59 A portion of the intestine and mesentery of a porpoise, minutely injected, with a lacteal injected with quicksilver
- 60 A preparation of *villi* of the small intestine of a dog, with *glandulae aggregatae*
- 61 A preparation of gravid *uterus*, injected, from the cat; the surface where the *placenta* adhered is evident
- 62 The large conglomerated lacrymal gland of the turtle
- 63 *Os hyoides*, *larynx*, and thyroid gland, of the human subject, with the *epiglottis*; the thyroid gland is diseased with *bronchocele*
- 64 A tongue, with tonsil glands, *epiglottis*, &c. minutely injected from a young adult human subject
- 65 A portion of the stomach of the *torpedo*, or numb fish, with the lacteals injected with quicksilver
- 66 Three circular vessels filled with quicksilver,
with


with which the lacteals frequently seem to communicate in the ass

- 67 Villi of the skin of the lips, minutely injected
- 68 Human *vesiculæ seminales* opened, to shew their internal cellular structure
- 69 A portion of the human stomach and *duodenum* injected, and opened to shew the valve called *pylorus*
- 70 Two—one a preparation of the humours of the human eye; the other a preparation of the *iris* and crystalline *lens* of a cat
- 71 The tongue and *rima glottidis* of a swan
- 72 The tongue of a young human subject, minutely injected
- 73 A remarkable tumor extirpated from the skin of the thigh—It was of the cancerous fungous kind
- 74 A preparation of the *choroid* coat of the eye, minutely injected with quicksilver, and preserved in oil of turpentine
- 75 Two—a preparation of coagulable lymph from the pulmonary artery, and a portion of a cyst from a diseased liver
- 76 A human eye from a young subject, minutely injected, and divided by a transverse section—Shews the *choroid* coat and ciliary processes
- 77 A perpendicular section of a human eye—Shews the *arteria centralis* of the optic nerve, the *tunica sclerotica*, *cornea*, and form of the globe of the human eye
- 78 Four different sections of the eyes of white rabbits, in which there is no *pigmentum nigrum*—The blood in these animals appears to supply the want of it
- 79 A human tonsil gland, minutely injected

- 80 Two—a very minute injection of the kidney of a *fœtus*, demonstrating the cortical and tubular substance; and a preparation of the human *testis*—The tubes are exposed, and partly unravelled
- 81 A human spleen from a young subject, with a small appendage
- 82 A human abortion
- 83 Two—the villose coat of the human gall bladder; and a preparation of the *placenta* and membranes of a cat
- 84 An ulcerated human spleen
- 85 A schirrous tumor from the human breast, curiously diseased
- 86 The *ovarium* of a hen
- 87 Two—a schirrous human *pancreas*, and the *renal capsulæ* of the horse, in sections
- 88 A section of the *penis* of a horse—There is only one *corpus cavernosum*; a bougie is inserted in the *urethra*
- 89 A portion of the human *funis umbilicalis* with a knot in it
- 90 A portion of the strong muscular stomach of the *raja*, or skate fish
- 91 Two preparations of ulcerated small intestines, from a human subject who died of the dysentery, one is injected
- 92 Two—a preparation of skin, with a wart; the cuticle is separated; and a preparation of skin from a small-pox subject, injected
- 93 A foetal pigeon near the time of hatching—The yolk was just going to be drawn into the cavity of the *abdomen*
- 94 A specimen of human *colon*, much ulcerated, from a dysenteric subject
- 95 A gall bladder, opened, much enlarged and thickened,

- thickened, from a subject affected with jaundice and gall-stone cholic
- 96 A portion of the *membrana chorion* from the cow, which is studded with bodies apparently glandular
- 97 The *dura mater* of the human subject, taken from one hemisphere of the human brain, injected for arteries and veins
- 98 A preparation of the *pia mater*, minutely injected, with its processes and *tomentum cerebri*
- 99 The curious conglomerated kidney of the porpoise
- 100 The beautiful villose surface of the foot of the horse, minutely injected, the hoof being removed—This appears to serve principally for the formation of the horn, or hoof
- 101 The skeleton of an ass, remarkably well articulated, with the case containing it

End of the First Night's Sale.



Second Night's Sale,

Tuesday, December the 11th, 1787.

DRIED BONES.

- 102 **T**HREE sections of *crania*
- 103 Two *bases cranii*, and two arches; one
basis very remarkable for anterior cli-
 noid processes and frontal sinusses
- 104 A human skull bisected, with lower jaw
- 105 Two *bases cranii*, and two arches
- 106 Two ditto, and two ditto
- 107 Three *crania*, with lower jaws
- 108 Three ditto, with lower jaws
- 109 Four ditto
- 110 Four arches of *crania*
- 111 Three ditto, and seventeen odd bones and sec-
 tions of *crania*
- 112 Bones of the *pelvis*, separate; and bones of
 the arm and fore arm, with interosseous and
 other natural ligaments
- 113 A skeleton of a stork
- 114 Separated bones of the *pelvis*, and large cy-
 lindrical bones of the inferior extremities
- 115 A superior extremity injected, for arteries
- 116 A ditto, for ditto

- 117 An inferior extremity injected, for arteries
- 118 A ditto ditto, for ditto
- 119 A head injected and prepared, for arteries
- 120 A ditto, for ditto
- 121 A trunk, with the heart, and large vessels on the spine, in the cavity of the *thorax* and *abdomen*, injected
- 122 A preparation of the *aorta*, *vena azygos*, *cava*, and thoracic duct, injected
- 123 A preparation to shew the heart in *situ naturali*, and the *vena portarum* injected
- 124 A preparation of the human heart, and large vessels, injected and prepared, with a glass bell
- 125 Two specimens of corroded kidneys, with the arteries and veins
- 126 A ditto, very beautiful
- 127 An adult arm, for arteries and veins
- 128 A ditto; for ditto
- 129 A head injected, for arteries and veins
- 130 A section of the head prepared, for arteries
- 131 A preparation of a portion of the human *penis*, with the *glans* injected with quicksilver—There has been an ulcer on the *glans*
- 132 A portion of the stomach and *duodenum* of a turtle, minutely injected
- 133 A section of the lungs, from a patient who died of consumption—The air cells are so obstructed with *pus*, that the lungs sank in water
- 134 Stomach of a lobster—The teeth, which are placed in the stomach of this animal, are seen
- 135 A wind egg, or egg hatched without the shell
- 136 A foetal kitten in the membranes, with the *placenta* injected from the mother

137 Two,

- 137 Two—a portion of liver, with a cyst containing an hydatid ; and a portion of the stomach of a cow, to shew the two different kinds of villose processes
- 138 A very curious diseased preparation from the thigh of an old adult subject—The femoral artery is opened, which was about to ossify, and the vein is contracted into a solid cord
- 139 A preparation of the human *penis*, to demonstrate the *lacunæ* of the *urethra*—Bristles are inserted in the *lacunæ*
- 140 A transverse section near the *basis* of the *proboscis* of the elephant
- 141 A longitudinal section of ditto
- 142 A preparation of the *glans penis*, to demonstrate the *glandulæ odoriferæ Tysoni*, which are very evident in this specimen
- 143 A *chirotheca* inverted ; shewing the nails to be processes of the cuticle.—In this specimen the *rete mucosum* is separated complete with the cuticle ; the colour is darker than the cuticle ; the line of separation between them is easily distinguished on the upper part of the preparation. This is a very rare kind of specimen, from a *fœtus* of nine months
- 144 A preparation of the foot of an ass, to shew the villose processes from which the hoof is formed
- 145 The tongue and *larynx* of the turtle, injected ; a bougie is inserted in the *rima glottidis*
- 146 A very curious and remarkable specimen from the *colon* of the human subject ; upon the villose coat are seen a great number of fungous ulcerated excrescences, from a subject who died of dysentery

- 147 A deception—a drawing of the lacteals, by Miss Stone, immersed in oil of turpentine
- 148 A loculated kidney from the human subject; the cells were filled with *pus*
- 149 The integuments of the lobster separated
- 150 A most beautiful specimen of the Schneide-
rian membrane, or organ of smell, most
minutely injected; the frontal *sinus* is seen,
one of the posterior nares, and the *uvula*
- 151 A most beautiful specimen of the kidney of a
cat; the veins which run on the external
superficies of the kidney, which distinguish
the class called *Felis*, are minutely injected
with blue; the coat of the kidney is sepa-
rated
- 152 A specimen of cuticle from the heel of the
human subject
- 153 A very curious specimen of the human cuti-
cle from the ball of the great toe; the *rete*
mucosum is likewise separated; the prints of
the villose processes are evident
- 154 *Basis* of the human tongue, with the *epiglottis*
injected—The different *foramina cæca* are
very large in this preparation.
- 155 A very curious specimen of the *rete mucosum*
in a white subject
- 156 A most beautiful specimen of the human
tongue, for the *papillæ*
- 157 A specimen of the human adult tongue, and
a portion of the under lip, to shew the ori-
fices of the *glandulæ submaxillares*
- 158 A section of the human tongue, with the sub-
maxillary and sublingual glands; a white
bristle is inserted in the orifice of the duct
of the submaxillary gland, and several
black bristles are placed in the ducts of the
sublingual


- 159 Two—a preparation of coagulable lymph; and a preparation of vessels and cells, which communicated with the lacteals in an ass, injected with quicksilver
- 160 A most beautiful and very minutely injected specimen of the lacteal on the great intestine of the turtle, filled with quicksilver, dried, and preserved in oil of turpentine
- 161 A very curious and new kind of specimen of the *ampullæ lacteæ Lieberkühni*, filled with the natural chyle, from the *ileon* of the human subject: for a particular description of this specimen, see Mr. *Sheldon's* work of the Absorbent System, and *Lieberkühn's* Treatise, by the same author
- 162 An enlarged *nympha*, extirpated from a human female subject
- 163 A most beautiful specimen of the newly-discovered cells and excretory ducts of the human prostate gland and *vesiculæ seminales*, injected with quicksilver
- 164 The excretory duct of the human *pancreas*, injected and dissected
- 165 A most beautiful and very minutely injected specimen of the *villi* of the human lips, from a female subject; the cuticle is removed
- 166 Lymphatic vessels injected with quicksilver, on the broad ligament of the human gravid *uterus*
- 167 A specimen of the bards, from the *cetus mysticetus Linnæi*, or Greenland whale, to shew the structure of whalebone
- 168 Specimens of *tæniæ cucurbitinæ*, or gourd-seed worms, found in the *cæcum* of a horse
- 169 A specimen of cuticle and *rete mucosum*, with the nails inverted, from the human *fœtus* at nine months

- 170 A specimen from the human heel, of the supposed vessels of perspiration, as described by Dr. Hunter, in the Medical Commentaries, and by the late Dr. Monro
- 171 A preparation of the human eye, to shew the choroid coat, *iris*, and insertion of the optic nerve
- 172 Four opake chrystalline *lenses*, with thickened and opake *capsulae*, from the cataractous eyes of horses
- 173 A very curious specimen of calcareous concretions, found in the fat over the anterior surface of the *tibia*
- 174 Two preparations of eyes—the injected specimen, for the *iris* and ciliary processes, is from the human subject; the other, for the *iris* and chrystalline *lens*, from the dog
- 175 A most beautiful and minutely injected specimen of the *venae vorticosae* of the human eye: they are situated on the choroid coat
- 176 A very rare specimen of the *membrana pupillaris*, discovered by Wachendorf in the human eye, injected
- 177 Sections of the eye of a cock, to shew the *marfupium nigrum*
- 178 Two—one, the human eye, to shew the double choroid coats; the other a chrystalline *lens*, from the *squalus carcharis*, or dog-fish
- 179 Two—the chrystalline *lens* of an ox, with the *capsule* injected; and a section of the eye of a turtle injected
- 180 A most beautiful and successful separation of the cuticle and *rete mucosum*, in the African, with the true skin, which is white
- 181 Two sections of the human eye, injected, to shew the vessels on the choroid coat, *plexus ciliaris*, *pigmentum nigrum*, and anterior chamber

- 182 A most beautiful and very minutely injected specimen of the tongue, *fauces*, and *uvula*, of a young subject
- 183 Two—shew the late discovered membrane of Monsieur Demours and Descemet, called *membrana humoris aquei*, which appears to be of a horny nature in the hare and horse; it is found lining the inside of the *cornea*
- 184 Two preparations of the human eye—one shews the coats upon the optic nerve, with the passage of the *arteria centralis Zinnii* in the optic nerve; the other is a transverse section, for the *retina*
- 185 Two—one contains two specimens of *teniae*, or tape worms, from a cat; the other, some curious specimens of worms, from the *cæcum* of the horse
- 186 An ulcerated *cæcum*, with its appendix, from a subject who died with dysentery
- 187 A very beautiful specimen of the *placenta*, injected, with the membranes and *fœtus* of a kitten at the full time: the uterine portion or cells of the *placenta* are injected, the foetal vessels are seen ramifying uninjected on the surface of the *placenta*
- 188 Lacteal *villi* of the turbot, minutely injected, on the internal coat of the intestine
- 189 A most beautiful and very minutely injected stomach and *meso-gastrion* of the turtle, for the lacteals, filled with quicksilver
- 190 A preparation of the *ileon* of the human subject, with the *ampullulae Lieberkubnii* loaded with chyle
- 191 A portion of the small intestine in the elephant, the *valvulae conniventes* are very remarkable
- 192 A specimen from the human small intestine, of arteries and lacteals injected

- 193 An hydatid worm and its cyst
- 194 A very curious specimen of a large kidney stone, polished, with a great variety of *nuclei*
- 195 An *intus susceptio*, or *volvulus*, opened
- 196 A beautiful specimen of bot worms, adhering to the villose surface of the stomach of the horse
- 197 Lacteals injected on the great intestine of the turtle
- 198 A curious specimen from a child born with an imperforated *rectum*—the operation was performed—a bougie is passed into the part that was perforated
- 199 A most beautiful and very minutely injected specimen of the villose coat of the stomach of the human *fœtus*, with the *œsophagus*
- 200 Lymphatics injected with quicksilver, on the superficies of the spleen of the calf

End of the Second Night's Sale.



Third Night's Sale,

Wednesday, December the 12th, 1787.

D R I E D B O N E S.

- 201 VARIOUS ribs, two clavicles, and various epiphyses from the larger cylindrical human bones
- 202 An *anchylosed human female pelvis*
- 203 Various bones of the superior and inferior extremities, some are rickety
- 204 Various *ossa innominata*, ten in number
- 205 Two *ossa innominata*, two *scapulæ*, a clavicle, *os brachii*, *ulna*, and *radius*
- 206 Two *ossa innominata*, two *ossa femorum*, two *tibiæ*, and two ditto from a rickety subject
- 207 Two *ossa innominata*, two *ossa femorum*, and two ditto rickety
- 208 Two curious specimens of the *os femoris*, from a rickety subject
- 209 Two ditto ditto of the *tibia*, which contain very little ossific matter
- 210 Two thigh-bones for *epiphyses*, and two diseased ditto

- 211 A very curious old distorted female skeleton, prepared by the natural method
- 212 Two *ossa innominata*, two *ossa femorum*, two young ditto for *epiphyses*, and two *ossa brachii*

WET PREPARATIONS.

- 213 An *ovarium* from the gravid *uterus* of the sow, to demonstrate the *corpora lutea* in a multiparous animal
- 214 Two ditto, with the arteries and veins minutely injected, from the gravid *uterus* of a cat
- 215 A portion of the human gravid *uterus* at nine months, minutely injected, both arteries and veins, with the *membrana decidua uterina* separated
- 216 Two—two transverse sections of the abdominal portion of the *aorta*, from an aneurismal subject, which had a very muscular appearance; and a preparation to shew the villose coat of the human gall bladder
- 217 A preparation, minutely injected, to shew the cylindrical *villi* on the internal coat of the small intestine of a Hen; remarkable likewise for the want of *valvulae conniventes*
- 218 The *uterus*, and a portion of the *vagina*, with the Fallopian tubes and *ovaria*, most minutely injected, in a *fetus* of nine months. The vascularity of the *os tincae* is very remarkable
- 219 Two—a *specimen* of the human spleen from a young human subject; and a transverse section of the human eye
- 220 Two—1. a preparation of young bot worms, on the internal coat of the stomach of a horse; the horny cuticular coat which covers half the stomach of this animal, and the
line

- line of separation between it and the villose coat, are evident in this *specimen*;—
2. are worms found in a lacteal gland in an afs
- 221 Two—1. the *gordius filiformis Linnæi*;—2. are impregnated *ova*, from the *sepia*, or cuttle-fish
- 222 A very beautiful *specimen* of a *tania*, or tape worm, complete; *it was expelled by Madame Nouffer's medicine*
- 223 A portion of *ileon*, with an ulcer that has eroded the villose and muscular coats, from a dysenteric subject, injected
- 224 A *specimen* from the human subject, of a double pancreatic duct
- 225 A preparation of small intestine from the turtle, to demonstrate lacteals, injected with quicksilver on the villose coat. The arteries are injected with red, and the veins with black
- 226 A foetal kidney and renal *capsula* in the *fœtus*, minutely injected
- 227 A portion of gravid *uterus*, to which the *placenta* adhered, injected, both arteries and veins; arteries red, veins black; remarkably thick
- 228 A portion of the liver of the lobster; it consists of *tubuli*, and is similar to the *tubuli testis*; these tubes are injected with black from the *ductus hepaticus*
- 229 A diseased spleen; in the upper part of the preparation, the glandular flesh has lost its spongy appearance
- 230 A lacteal injected with quicksilver, on the mesentery of an elephant
- 231 The villose coat of the stomach, in the human *fœtus* of nine months, minutely injected

- 232 A large lymphatic vessel and gland, taken from the neck of a living dog, and immersed in spirits; it is full of the natural lymph, which is coagulated by the spirit; the cells of the gland are evident, and distended likewise with the lymph
- 233 A diseased prostate gland from the human subject
- 234 A *lumbricus teres*, or round worm, from the human subject, dissected
- 235 A most beautiful and minutely injected *specimen* of the *villi* of the *glans penis*
- 236 A most beautiful *specimen* of a portion of small intestine of the turtle, for the arteries, veins, and lacteals; the arteries red, veins yellow; and the lacteals are injected with quicksilver, most minutely, and are very distinct and turgid
- 237 Two foetal frogs, in two bottles
- 238 Is a very elegant and curious *specimen*, to demonstrate the vascularity of bone, and the elastic ligaments which are placed between the spinal processes of the spine; it shews likewise the transit of many of the dorsal nerves at their proper *foramina*, and the entrances of the posterior branches of the intercostal arteries at the same *foramina*
- 239 Two—one is a portion of the *uterus* of a cow, which shews the remains of the maternal portion of the *placenta*, a considerable time after delivery; and a foetal spleen, minutely injected
- 240 A beautiful preparation of the lacteals injected with quicksilver, on the stomach and *mesogastrium* of a large turtle, with the blood-vessels injected
- 241 A very fine *specimen* of a very large *lumbricus teres*,

teres, or round worm, from the human subject

242 A specimen of the human colon opened in a young scrophulous subject, and injected minutely—It shews the *glandulae solitariae Peyerii*

243 A similar preparation from the same subject, injected, to shew the *glandulae aggregatae Peyerii* in the ileon

244 Two—1. the *sternum* of a human *fœtus* at seven months; the ossifications are taken out;—2. is a preparation of cellular network of vessels, supposed to belong to the lacteals in the small intestine of the ass, injected with quicksilver

245 A mouse opened; in the liver an hydatid, which contained a tape worm, which is partly drawn out from the cyst

246 Two—1. *tenia hydatiginea*, from the liver of the sheep;—2. is a portion of a large cylindrical bone from the human subject—a vessel is seen injected, passing from the inside outwards

247 A portion of *ileon*, from a human subject who died of dysentery—The ulcer has eroded the three coats of the intestines, so as to make a perforation; in consequence of which, a part of the *fæces* was found in the cavity of the *abdomen*

248 An aneurism, from the human subject; it is situated on the lower part of the abdominal portion of the *aorta*, near the bifurcation—The upper part of the *aorta* in this preparation is ossified

249 A specimen of a gravid ovo-viviparous animal, —the *chamæleon*

250 A very curious specimen of long cylindrical worms, found in the *trachea* of an ass

251 Two

- 251 Two—1. villose coat of the small intestine of a dog; the animal was fed with milk previous to killing him; a ligature was made on the vessels of the mesentery; the parts were put into rectified spirit, to destroy the irritability, and the *villi* were found full, and as much erected as if the arteries and veins had been injected;—2. is a portion of the human *funis umbilicalis*, to shew the contorsion made by the arteries
- 252 A very beautiful *specimen* of the *os frontis* of a young human subject, most minutely injected; the earth is extracted, to render the bone transparent
- 253 A section of the *glans penis*, and part of the *corpora cavernosa*, to shew their cellular structure
- 254 A section of a schirrous liver, from a human subject
- 255 A most beautiful and very minutely injected *specimen* of a parietal bone of a *fetus* of nine months
- 256 Diseased ulcerated *colon*, from a human subject who died of dysentery
- 257 A diseased *uterus*, with an incipient *polypus* arising from the internal surface of the *uterus*
- 258 An aneurism, from the thoracic portion of the *aorta descendens* of the human subject; it is of the mixt species
- 259 An human stomach, with a large ulcer which has eroded the coats on both sides of it; found in an adult subject, who died soon after recovering from the natural small pox
- 260 A most beautiful *specimen* of lacteals, minutely injected with quicksilver, on the *mesocolon* of the turtle; the veins are injected with black

- 261 The lower part of the *ileon*, which has a schirrous appearance, from a dysenteric subject
- 262 A very curious *specimen* of an ulcerated bladder and *urethra*, with strictures
- 263 A diseased bladder and *urethra*
- 264 A monstrous chicken
- 265 The lower part of the spine and *os sacrum*, from a *fœtus* of nine months
- 266 A very beautiful and rare *specimen* of the *tubuli testis* of the human subject, injected with quicksilver, and dissected
- 267 A foetal sheep in its membranes
- 268 Two—1. a portion of tape worm, from the human subject ;—2. round worms found in the *œsophagus* of a dog
- 269 A beautiful *specimen* of incipient ulceration on the villose coat of the *ileon* of the human subject, minutely injected
- 270 The villose coat of the turbot, minutely injected ; the *villi* are large and flat, and resemble the microscopic appearance of the human *villi*
- 271 Two—1. a foetal *tibia*, with the *periosteum* separated ;—2. a portion of cyst evacuated from an abscess of the liver
- 272 The semilunar or moveable cartilages of the knee joint of the human subject
- 273 A foetal *uterus*, with a portion of the *vagina* opened, to shew the *os uteri*
- 274 Two—1. a schirrous lymphatic gland extirpated from the neck of a human subject ;—2. spleen of a dog, minutely injected
- 275 Two—1. is an hydatid, from the liver ;—2. is a portion of small intestine of a turtle, minutely injected—The *valvulae conniventes*, in this animal, run in the longitudinal direction

- 276 The curious reticulated villose coat of the *duodenum* of the turtle
- 277 A most beautiful *specimen* of the villose coat of the *cæcum cum appendice*, and lower part of the *ileon*, in a human *fœtus* of nine months, most minutely injected—The glandular structure of the *ileon* is very evident
- 278 Hydatids from the kidney, voided with the urine, from the human subject
- 279 Two *ovaria* taken from a sow at heat; they are full of *vesiculæ*, which are the *ova* visible at this period; and these contain a fluid, in which, according to Mr. Buffon, are found the same *animalculæ* as are seen in the male *semen*
- 280 A portion of the human liver, so minutely injected that no interstices can be seen between the vessels with the naked eye
- 281 The human eye injected, both arteries and veins—The optic arteries are seen running on the outside of the optic nerves, piercing the *tunica sclerotica*, and distributed on the choroid coat; the *venæ vorticosæ Zinnii* are injected with yellow, and very distinct—It is a most beautiful and rare *specimen*
- 282 Two fœtal kidneys minutely injected and macerated
- 283 A *specimen* of the small intestine of the human subject, with arteries, veins, and lacteals injected
- 284 A longitudinal section of the kidney of an ass, minutely injected, both arteries, veins, and excretory ducts
- 285 A preparation of *foramen ovale*, found open in a human adult subject—A bougie is placed in the *foramen*
- 286 A curious *specimen* of ossification in the human liver

- 287 A very curious *specimen* of a cluster of *ampullæ lacteæ*, filled with natural chyle, in the human subject
- 288 A very remarkable worm, found in the *ductus communis cholidochus* of an elephant
- 289 A most beautiful and most minutely injected *colon* of the human *fœtus*, in which the *glandulæ solitariae Peyer*i are very evident
- 290 One hundred and ten gall stones found in the gall bladder of a human subject
- 291 A human lacteal and gland injected with quicksilver, in the human subject
- 292 The knee joint, from a young human subject, minutely injected, to shew the ossification of the *patella*
- 293 Two—1. a foetal *sternum* injected, for ossification;—2. is the first stomach of a foetal calf
- 294 Two—1. a foetal kidney, minutely injected; shews the cortical and tubular substance;—2. is a portion of small intestine, from the porpoise; the arteries are injected with red, and the lacteals with quicksilver
- 295 Calcareous concretions found in the substance of the *cæcum* of the horse
- 296 Two—1. *glandulæ aggregatæ*, seen in the small intestine of an als;—2. is a worm of the *gordius* kind, found in a trout stream
- 297 Two—1. a tumor extirpated from some part of the human body;—2. a *specimen* of ulcerated small intestine, from a human dysenteric subject
- 298 A very curious and rare *specimen* of a distinct false aneurism in the *aorta* of an horse, near its origin, from the left ventricle—This disease produced sudden death in the animal

- 299 Ulcerated *cæcum*, from a human dysenteric subject
- 300 Lymphatics arising from the human kidney, injected with quicksilver—A very rare specimen, and very difficult to find and inject

End of the Third Night's Sale.



Fourth Night's Sale,

Thursday, December the 13th, 1787.

- 301 **A** *Basis cranii*, with the cavity filled with
plaister of Paris, and *dura mater* injected;
and a perpendicular section of the *cranium*
- 302 Two heads, with the arteries injected
- 303 A curious preparation of the foot and ankle
joint, in which the ligaments of the foot,
and insertions of the different tendons are
carefully and accurately dissected—a very
useful preparation
- 304 An *anchylosis* of five lumbar *vertebræ* in the
spine of an horse
- 305 A foetal *cranium*, from a subject affected with
hydrocephalus externus
- 306 A scull of a *fœtus* of seven months, the *ca-*
vitas cranii is filled with wax, and the jaws
are dissected, to shew the rudiments of the
first set of teeth
- 307 A section of a bisected head, injected and
dissected for arteries; the frontal *sinus* is
seen, which is remarkably large in this sub-
ject; there is a corresponding projecting
part in the *occiput*

- 308 A preparation to shew the falciform process of the *dura mater*, in a young subject, and the *tentorium*, and first set of teeth, twenty in number, complete

D R I E D B O N E S.

- 309 The natural skeleton of the spine and *thorax* of a young subject, complete
 310 The natural skeleton of a young rickety subject, complete
 311 A section of an adult *cranium*, to demonstrate several of the *sinusses*
 312 Adult separated bones of the *pelvis*
 313 A very curious trunk, from an adult rickety subject; the bones are remarkably soft
 314 A foetal human *cranium*, nine months
 315 A dried preparation of *scapula*, *clavicula*, and a portion of the *os brachii*, of the adult human subject, with the ligaments which are placed around the shoulder joint, accurately dissected
 316 *Scapula*, *os brachii*, *radius*, and *ulna*
 317 Ditto
 318 A very beautiful *specimen* of a bleached bone of a quadruped
 319 Three *Crania*—*deer*, *cat*, and *turtle*
 320 A very curious distorted adult spine, from a human rickety subject

D R I E D I N J E C T E D P R E P A R A T I O N S.

- 321 An arm of a young human subject, for the arteries
 322 An adult ditto, for the arteries

- 323 A ditto, ditto
- 324 A ditto, ditto
- 325 Superior extremity of an African, injected and dissected, for arteries and veins; it is remarkable that there was no superficial palmar arch of arteries
- 326 A superior extremity, most minutely injected and dissected, for the arteries, particularly for the *anastomoses* around the elbow joint
- 327 A *lusus naturæ*, a superior extremity, for arteries, with an high division and very remarkable large and unusual anastomosing branch, just below the elbow joint
- 328 A superior extremity, for arteries and veins
- 329 A very fine *specimen* of the lower extremity, injected, and most accurately and minutely dissected, for arteries; it is free from animal oil: the branches of the internal iliac arteries are traced, as well as all the different ramifications of the external iliac arteries, with the femoral and popliteal, anterior and posterior tibial, and interosseous arteries
- 330 A very neat *specimen* of the spine and part of the ribs of a human adult subject, with the trunk of the *aorta*, *vena azygos*, and thoracic duct, injected. There is a remarkable bulbous appearance in the duct near its termination, in the angle where the lymphatics of the superior extremity on that side, and those of the neck have terminated; some of these trunks are seen entering the bulb
- 331 A trunk of a young human subject, with the heart and large vessels injected, and prepared in *situ naturali*; the diaphragm is likewise preserved

- 332 The heart and *aorta*, from an aneurismal subject
- 333 A very fine *specimen* of an adult human arm, very minutely injected, and accurately dissected, for the arteries
- 334 A superior extremity, for arteries—a *lusus naturæ*
- 335 A section of a bisected adult head, for the arteries
- 336 A ditto, very beautiful and accurately dissected
- 337 An hernial sac filled with plaster of Paris: the *testis* & *tunica vaginalis* is dried, and adhering to the lower part of the preparation
- 338 The heart of an afs injected, the right ventricle is opened
- 339 The *aorta descendens* traced in a dog
- 340 Two—1. foot of an afs, with the blood-vessels dissected—2. the *larynx* and *os hyoides* of a large turtle

WET PREPARATIONS, IN SPIRITS.

- 341 A very beautiful and distinct *specimen* of the *glandulæ aggregatæ Peyerii*, in the small intestine of the afs, injected minutely—no *valvulæ conniventes* in this animal
- 342 Kidney of the cat, with the veins injected with quicksilver
- 343 The curious fulcated spleen of the *phoca*, or *sea-calf*; arteries injected with red, veins yellow
- 344 Hand of a monkey, minutely injected, for the *villi*, or *organ of touch*
- 345 Foot of the afs, the hoof is separated

- 346 *Intestinum ileon* of the human adult subject,
minutely injected
- 347 An impregnated *ovum*, with the beautiful *fimbriae* of the Fallopian tube, in the viper
- 348 A very beautiful *specimen* of the *villi* of the
skin, or organ of touch, minutely injected
- 349 *Specimen* of a multiparous gravid *uterus*, in a
mouse
- 350 *Ovaria* of a gravid frog, with the long and
curiously contorted *tubae Fallopiæ*, and
other *viscera*
- 351 Kidnies and testicles of a male eagle
- 352 Tendon of the *masseter* muscle of a monkey
unravelled
- 353 A lacteal of the first order, injected with
quicksilver, in the human subject, with a
lacteal gland
- 354 The diaphragm of a *fetus* of nine months,
minutely injected
- 355 The lower jaw of a human *fetus*, at nine
months, minutely injected
- 356 The *abdomen* and *thorax* of an owl opened,
and the *viscera* exposed, to demonstrate
that in the carnivorous birds there is no
gizzard, but a membranous stomach
- 357 The *pancreas*, or *appendiculæ duodenales* of a
spinous fish (the cod); the numerous ducts
opening into the intestines are seen
- 358 A cylindrical bone of the human subject in-
jected, to shew its vascularity—The earth
is extracted, and the bone is rendered
transparent
- 359 A portion of the upper part of the intestine
ileon, to shew the *valvulae conniventes* of the
villose coat
- 360 A portion of the *membrana decidua* injected,
arteries red, veins black, in the sow; dried
and

and rendered transparent, in oil of turpentine

- 361 A varicose *lacteal*, injected with quicksilver, in the human subject
- 362 A very curious *specimen* of a sacculated human bladder, from a subject afflicted with the stone
- 363 A portion of human *ileon*, containing three *volvuli*, which are marked by the black bristles
- 364 A longitudinal section of an human adult kidney, minutely injected, to demonstrate the cortical and glandular substance
- 365 A human adult tongue injected, with the tonsil glands, *epiglottis*, and ligaments of the organ of the voice
- 366 A most beautiful *specimen* of an adult human *pancreas*, with its excretory duct, injected with black, and dissected—Through the whole length of the gland the termination of the duct is seen, where the black bristles are inserted, and the *ductus communis* is laid open
- 367 Is a *lusus naturæ*, a very large and uncommon *diverticulum*, communicating with the human *ileon*, with a scrophulous mesenteric gland opened
- 368 A curious *specimen* of ulcerated *colon*, from a human subject who died of dysentery
- 369 The valves of the heart in a horse, with the *carneæ columnæ* and *cordæ tendineæ*
- 370 A very beautiful and rare *specimen* of *ampullæ lacteæ*, with a cluster of them, in one part of the preparation distended with the natural chyle, in a human subject
- 371 A *hernia*, from the human subject; it is a *bubonocèle*—the sac contains *epiploon*
- 372 Is a ditto

- 373 *Colon* and *cæcum*, with its *appendix*, injected minutely, with several ulcerations, one of which has perforated the *cæcum*, from an adult human subject who died of the dysentery
- 374 An human double spleen, with arteries and veins injected
- 375 A contracted and diseased gall bladder, from the human subject, with the cystic and common ducts opened, which are very much enlarged
- 376 A portion of human adult spleen, with a part ossified
- 377 A very curious *specimen* taken from the carotid artery of a horse that was bled to death; the artery was found very much contracted, which is seen in the upper portion; on opening an adjacent portion, equally contracted with that before described, it contracted to the dimensions seen in the lower portion; which proves that the contraction did not arise from elasticity, but from muscular power
- 378 A perpendicular section of the kidney of a dog, injected minutely; it is a *specimen* of the simple kidney, and shews the great vascularity of the cortical substance; and the contrary in the tubular substance
- 379 A valve of the human heart ulcerated and ossified; the ulceration seems to depend on the pressure of the ossific or cretaceous matter on the adjacent parts
- 380 A very curious *specimen* of the gall bladder and *ductus cysticus* of the human subject: the gall bladder contains several *calculi*; one of these obstructs the passage from the *ductus cysticus* into the gall bladder; owing to
E
this

this obstruction, no bile could pass from the liver into the gall bladder; and the gall bladder was found contracted, almost without cavity, and contained a small quantity of *mucus*; which proves, contrary to the opinion of Professor Albinus, that the gall bladder is a receptacle, and does not secrete the bile it contains; for, was the opinion of Professor Albinus just, the gall bladder should in this case have been distended with bile

- 381 The cock sparrow at the breeding season; the *testes* are seen, which are now very large. If the animal is examined when not breeding, they are so small as to be found with difficulty
- 382 A portion of *tibia* injected, from a young subject, with the superior articular surface and femilunar cartilages
- 383 A section of a diseased human kidney, with a large hydatid
- 384 The human adult stomach opened, to shew the *rugæ* on the villose coat, which depend on the contraction of the muscular coat, and are not permanent
- 385 A portion of large intestine, from the turtle, with lacteals injected, in oil of turpentine
- 386 A portion of human *colon*, with ulcerations from dysentery
- 387 A portion of the human liver, from a subject who died with a large abscess in this part
- 388 A portion of the human adult stomach, with part of the *intestinum duodenum*, and *pylorus*—There is a glandular appearance in some parts of this preparation
- 389 A very curious *specimen* of a very large double human kidney, with double *pelvies* and
ureters,

- ureters*, injected with yellow—The *pelves* and *ureters* did not communicate, and the kidney was single upon the other side of the subject—The bladder had three openings, formed by the *ureters*
- 390 A diseased spleen, from a human adult subject, with the coat thickened, cartilaginous, and ossified in some parts
- 391 A schirrous *testis*, with the *tunica albuginea* and *vaginalis* adhering at most parts; cut through to shew the diseased *tubuli*
- 392 Is a very curious schirrous breast, opened to shew the diseased internal structure
- 393 A kidney and renal *capsula*, taken from a *fetus* at nine months, born without the brain—The small size of the renal *capsula* is remarkable. In all the *fatuses* born without brain, that were examined by the late Mr. Hewson, a similar appearance was remarked; from which observations he was inclined to believe that the renal *capsula* belonged, or had some particular connection with, the nervous system
- 394 Two—a human lacteal, injected with quicksilver, in the human subject; and a portion of the coat of a dropical *ovarium*, from the human subject, much thickened
- 395 A diseased gall bladder, containing a large *calculus*, from the human adult subject
- 396 A portion of the human diaphragm perforated by a fractured rib which was driven into the cavity of the *thorax*—This became the cause of death
- 397 A very curious *specimen* of a portion of dropical *ovarium*, of the human subject; the water is contained in small cells, and has somewhat of a honeycombed appearance—

This preparation shews the vesiculated structure of the *ovarium* ; for these are supposed to be the natural vesicles enlarged and diseased

398 A curious *specimen* of schirrous *uterus*, from the human subject

399 A curious *specimen* of the ulcerated cancerous *uterus*

400 A *specimen* of imperforated *rectum*, from a human *fœtus* of nine months—There was an *anus*, and between the *anus* and termination of the *rectum*, which formed the apex of a cone, a hard callous substance was interposed ; so that the push made by the *feces* in the *rectum* could not be felt *per anum* ; and it was not perforated, although many attempts were made by skilful surgeons

End of the Fourth Night's Sale.



Fifth Night's Sale,

Friday, December 14th, 1787.

DRY PREPARATIONS.

- 401 **V**ARIOUS separate bones of the hands and feet
- 402 Human separate *vertebræ*, some diseased; and a preparation of the crucial and other ligaments of the knee joint, with the semilunar cartilages, in a human subject, accurately dissected and dried
- 403 A human scull with the lower jaw prepared, to shew the falciform and lateral processes of the *dura mater*
- 404 A human female *pelvis*, prepared by the natural method, with *caries* in the *os sacrum*, owing to the pressure of a tumor on that part
- 405 A ditto, with a fracture of the *os pubis*, which occasioned the death of the subject
- 406 A very neat *specimen* of a male *pelvis*, prepared by the natural method
- 407 *Aorta*, with the spine and part of the ribs of a porpoise
- 408 Three arches of *crania*, for sutures, &c. one has

has the arteries of the scalp injected and prepared

- 409 A preparation of the *aorta*, *vena magna intercostalis* injected, and thoracic duct with its termination in the angle, prepared upon the spine, with a portion of the ribs, in the human subject
- 410 A human scull, with the lower jaw, a section
- 411 A human scull, with the lower jaw
- 412 A very old ditto, the futures are beginning to vanish
- 413 An ossified *aorta*, injected, from the human subject
- 414 An incurvated *aorta*, from the spine of a distorted subject, injected
- 415 A portion of the spine and ribs, from a rickety subject, an adult; several of the ribs are fractured; there is very little earthy matter in these bones
- 416 A very curious distorted trunk, from a rickety subject, with double incurvation
- 417 The *pelvis* of the ostrich
- 418 Part of the scull of the *trichechus walrus*, or *sea-morse*, with the tusks and some of the grinders
- 419 A tusk of the rare and lately discovered *sus aethiopicum*, described by Dr. Pallas
- 420 A tusk of the *walrus*, or *sea-morse*
- 421 A tusk of the *hippopotamus*, or *river-horse*, from the Nile, in Egypt
- 422 A specimen of bone from the whale, dug out of the earth—it is in a fossil state
- 423 A very neat specimen of the *thorax*, with the natural cartilages and *sternum*
- 424 A very curious and uncommon distortion of the trunk, from rickets; with a remarkable *lusus* in the sixth rib on the right side

- 425 Two diseased *ossa femorum*, and ditto *tibiæ*, from the *lues venerea*
- 426 A female adult skeleton, imperfect
- 427 Three diseased *tibiæ*, owing to *lues venerea*
- 428 The bones of a very large turtle, separated, very white
- 429 A superior extremity of an adult human subject, injected, for arteries; in which there is a remarkable high division of the brachial artery

WET PREPARATIONS.

- 430 A very curious and minutely injected *specimen* of the skin of the hand and arm of the human subject, to demonstrate its great vascularity
- 431 The villose coat, and part of the muscular coat of the *cæcum*, with its *appendix*, and lower portion of the *ileon*, which came *per anum* from a dysenteric subject; and what is very remarkable, the patient recovered
- 432 A *bubonocèle*, containing *epiploon*, from the human subject
- 433 A schirrous *uterus*, from the human subject; the cavity of the *uterus* is obliterated; the *os tincæ*, by which the upper section is suspended, is in a state of cancerous ulceration
- 434 Two—the larger one contains a cyst taken from the shoulder of a lady, which contained a transparent fluid; and a cyst, with a solid body, which is preserved in the small bottle
- 435 Part of the hand of a human subject, who fell from the top of a house, and pitched with his hand on the point of an iron rail; the

the weight of his body, with the force of his fall, separated the hand, and tore the tendons from their connections with the bones

- 436 A very beautiful *specimen* of an *hernia* in the human subject; it is a *bubonocoele*; it contains small intestine; the hernial sac consists of several layers, which can be seen on the cut edges of the sac: a portion of the abdominal muscles, with the ring, is left; and the *testis* in the *tunica vaginalis* is seen, forming a separate cavity below the hernial sac
- 437 A very large diseased spleen, with the arteries injected. Such are sometimes found in subjects labouring under long continued intermittent fevers, and are frequently called ague cakes, by practitioners
- 438 A very remarkable *specimen*—the *uterus*, with a portion of the *vagina* in a human subject; who died of dysentery, with large ulcerations on the internal surface of the *rectum*; —the internal surface of the *vagina* is ulcerated in a very remarkable manner, and this appears to be owing to a sympathy between the vessels of the *rectum* and *vagina*, which arise from the same trunks
- 439 An imperforated *anus* and *rectum*, from a human *fœtus* of nine months, similar to the one before described: it could not be perforated, although attempts were made by several skilful surgeons
- 440 A portion of the lower part of the *ileon*, from a dysenteric subject, with the peritoneal coat bare at one part; the ulcer that has been situated upon this part of the intestine is now healed; it is injected

- 441 The human kidney dissected, with the *pelvis* and *ureter* injected with red
- 442 A curious diseased loculated kidney, with inflammatory exudations of lymph, and a stone in the *pelvis*
- 443 A section of a kidney from an ass, with the *tubuli uriniferi* of *Bellini* injected from the ureter with red
- 444 The *branchiæ*, or gills of a fish, injected
- 445 The *ventriculus succenturiatus seu corpus glandulosum Peyer*, injected
- 446 A portion of *pia mater*, of a human *fœtus*, minutely injected
- 447 The brain and part of the spinal marrow of a very large cod
- 448 A section of a human urinary *calculus*, polished, to shew the concentric *laminæ*
- 449 A ditto, has formerly been rough, or what is called a mulberry stone
- 450 A section of a human urinary *calculus*
- 451 The *pia mater* of the human *fœtus*, from one hemisphere of the brain, injected and prepared
- 452 The Schneiderian membrane, with the *crista galli*, and cribriform plate of the ethmoid bone, with the olfactory nerves traced through the cribriform plate to the membrane
- 453 An *intus susceptio* in the *ileon* of a human adult subject
- 454 A portion of the human *cerebrum*, minutely injected
- 455 The air cells in the lungs of the human *fœtus*, minutely injected with quicksilver
- 456 A curious facculated bladder; bristles are introduced in the openings of the *ureters*

- 457 Two *specimens* of ulcerated intestines, from dysenteric subjects, injected
- 458 A portion of the brain of the human subject, minutely injected
- 459 A section of a large gall-stone, from the human subject
- 460 A great number of biliary *calculi*, found in the gall-bladder of a human subject
- 461 Part of the coats of the *cæcum*, *colon*, lower portion of the *ileon*, and *appendix*, which has sloughed, and was voided *per anum*, in a human dysenteric subject
- 462 The swimming bladder, with a bristle introduced into the opening of the duct that leads from the bladder into the stomach in a pike
- 463 The *fungus* of the *dura mater*, that sometimes arises from that part after the operation of the trepan
- 464 The spinal marrow from a child born without brain—there appears to be very little nervous substance in it
- 465 A portion of ulcerated *colon* from a dysenteric subject
- 466 A *lusus naturæ*, a very curious distribution of the ascending branches of the *aorta*, in a young human subject: the first ascending branch is the right carotid artery; the next is the left carotid; the next is the left subclavian; and the last is the right subclavian artery, which arises from the back part of the *aorta*, and passes obliquely behind the *aspera arteria* and *œsophagus*, in its passage to the right arm
- 467 Air cells injected with quicksilver, in the lungs of a dog
- 468 A portion of the lungs of a turtle, injected for arteries,

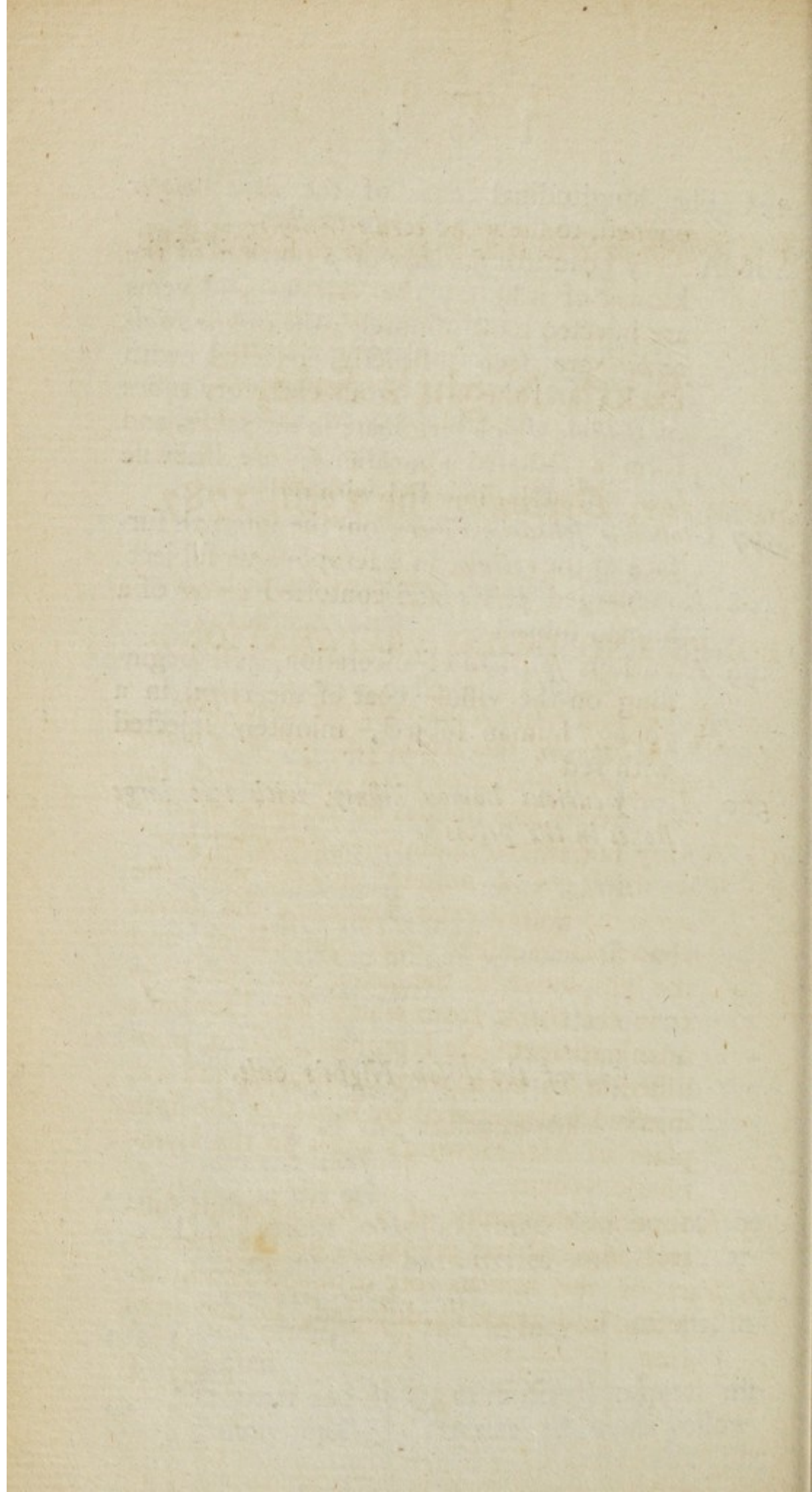
- arteries, and the air cells, which are very large in this animal, are distinctly seen
- 469 A human foetal kidney, with the renal *capsula*, minutely injected
- 470 Six very curious gall-stones from the human subject
- 471 A bladder, with four *ureters* opening into it.—N. B. Bristles are inserted in the opening of the *ureters*—one has fallen out
- 472 The swimming bladder, with the duct passing from it into the stomach, in a dace
- 473 A cyst found distended with a fluid in the anterior lobes of the brain of a giddy sheep. This had no doubt produced the disease; it was not in the ventricles
- 474 A portion of the human *cerebellum*, minutely injected
- 475 A very beautiful preparation, and most minutely injected, of the gills of the lump-fish, with the trunk of the gill artery preserved
- 476 One hundred and twenty biliary *calculi*, from the gall-bladder of a human subject
- 477 A most beautiful and most minutely injected and matchless preparation of the air cells, in the lungs of a turtle
- 478 The *larynx*, and contiguous parts, taken from a subject who cut his throat
- 479 A diseased loculated kidney, from the human subject
- 480 A portion of the *dura mater* of the human subject, minutely injected; to shew the distribution of the *arteriae duræ matris*
- 481 Calcareous concretions in the coats of the *intestinum cæcum* of a horse
- 482 The curious conglomerated kidney of a *phoca*,

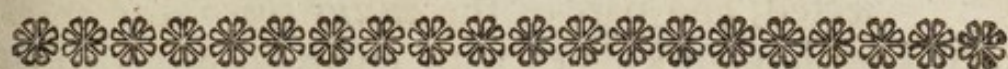or *sea-calf*, minutely injected for arteries and veins. The veins running on the external *superficies* of the kidney, are very remarkable in this animal

- 483 The gills of a cod-fish, minutely injected
- 484 Part of the lungs of a young human subject, who died of consumption; an abscess is seen in the lungs, with a large blood-vessel passing through the cavity of the abscess
- 485 The curious conglomerated kidney of the porpoise
- 486 Biliary *calculi* from the human subject, of an uncommon colour
- 487 A portion of small intestine, with four distinct ulcers, from a dysenteric subject
- 488 The heart of a large turtle, minutely injected, with its two large auricles, and three large vessels seen arising from the heart; it is remarkable, that in this animal, the coronary vessels pass to the internal surface of the *pericardium*, to supply it with blood: this is seen in the preparation
- 489 A portion of the human *jejunum*, to shew the *valvulae conniventes*
- 490 The swimming bladder, with the opening of the duct leading into the stomach, in a carp; the lower bristle is inserted in the opening of the *ductus communis cholidochus* into the intestine
- 491 Ditto, in the eel
- 492 The curious conglomerated kidney of the otter, injected for arteries and veins; arteries red, veins black
- 493 *Tubuli uriniferi*, in the kidney of an ass, injected
- 494 The heart and lungs of a foetal puppy, minutely injected; arteries red, veins yellow
- 495 The

- 495 The longitudinal *sinus* of the *dura mater* opened, to shew the *cordæ Willisii*
- 496 A very beautiful *specimen* of a portion of the kidney of a horse; the arteries and veins are injected most minutely; the *cryptæ Malpighii* are seen distinctly, injected with black; and the uriniferous excretory tubes of *Bellini*, which terminate in the *pelvis*, and form a radiated appearance, are likewise seen distinctly, injected with red
- 497 *Glandulæ solitariae Peyeri*, on the internal surface of the *rectum*, in a scrophulous subject
- 498 An enlarged *pelvis* and contorted *ureter* of a human subject
- 499 A curious *specimen* of ulceration, just beginning on the villose coat of the *colon*, in a young human subject, minutely injected with red
- 500 A very curious human kidney, with two large stones in the *pelvis*

End of the Fifth Night's Sale.





Sixth Night's Sale,

Saturday, December the 15th, 1787.

BONES AND DRIED PREPARATIONS.

- 501 **A** Human adult scull, with the lower jaw
- 502 **A** *basis* of the scull, with the *dura mater*
filled with plaster of paris and injected, for
the arteries and sinusses of the *dura mater*
- 503 A very fine human scull, with the lower jaw
- 504 The trunk of a human subject, with the
aorta and *vena cava* superior; the *ductus*
thoracicus is filled with quicksilver, and
the lymphatics in the *pelvis* are injected—
It is the trunk from which Mr. Hewson's
terminations of the lymphatic system, pub-
lished in his work, were delineated, and was
injected and prepared by him; see the sixth
plate of Mr. Hewson's work on the Lym-
phatic System
- 505 A superior extremity of a human adult sub-
ject, injected and prepared, for the arteries
- 506 Part of the human fore arm and hand, in-
jected and carefully dissected, for the arte-
ries

507 A

- 507 A monkey injected, for the arteries and veins
 508 Part of the human spine, with the *aorta* injected, and part of the *ductus thoracicus*
 509 Two human kidneys with enlarged *pelves* and *ureters*, injected with yellow
 510 The gills of a cod-fish, with the gill artery injected with yellow, and the veins coming from the gills with red: these veins collected form the *aorta* of the fish—This specimen is useful for explaining the circulation of the blood in fishes

WET PREPARATIONS.

- 511 Two beautiful specimens in one bottle, the *valves* of the *aorta* and pulmonary artery in the human subject—The *corpora sesamoidea Aurantii* are distinctly seen
 512 A coil of human intestine, most minutely injected, from a young subject
 513 A very beautiful specimen of a human impregnated ovum, at a very early period; the *membrana chorion* is opened and spread out—Shews the *corpusculum album seu vesicula umbilicalis*
 514 A very beautiful specimen of a human foetal stomach, injected and rendered transparent, to shew the ramifications of the arteries
 515 A transverse section of the arm of a young human subject, to prove that the red colour of the muscles depends upon the blood—The muscles are now white, owing to the arm of this subject having been injected with water to expel the blood
 516 An artery from the leg of a human subject who has undergone the operation of amputation. At the lower part of the artery, immediately

immediately above the part where the ligature was applied, and the last lateral branch, a plug of coagulable lymph is seen, where the blood was at rest: this plug has become vascular, owing to vessels shooting from the internal coat of the artery into it, which are injected in this preparation—an instance of the formation of a solid from a fluid, and of its organization

517 A curious diseased human kidney, with enlarged and thickened *ureter*, owing to pressure made upon the lower part of the *ureter* by a large and dropfical *ovarium*. From the pressure made by the urine retained in the *pelvis* of the kidney, a great part of the cortical substance is removed

518 A beautiful and most minutely injected *specimen* of an early-impregnated *ovum*, with the *placenta* and membranes compleat, from the gravid *uterus* of the cat.—The *fœtus* is in the center, inclosed with the *membrana amnion*. The space between the outside of the *amnion* and internal surface of the transparent *chorion*, which lines the inside of the *membrana decidua*, or opake *chorion*, is evident. The opake *chorion*, the external surface of which is in contact with the internal surface of the zone-like *placenta* of this animal, is most minutely injected, as well as the *placenta* itself, from the blood-vessels of the *uterus* of the mother; the arteries with red and the veins with black injection. The *placenta* is divided into lobes.—This cannot be seen in this animal at the latter periods of utero-gestation

519 A human *ovum*, at a very early period, with the *membrana decidua uterina* compleat

- 520 A portion of human small intestine, from a young subject, minutely and distinctly injected, and rendered transparent
- 521 A beautiful injected front view of the *viscera* of the thoracic and abdominal cavities, in a human *fœtus* of seven months—Shews the descent of the *testes*, *gubernacula*, &c. &c.
- 522 The lower part of the spine, with the *pelvis*, from a human *fœtus* of nine months, which laboured under a *spina bifida*. The bony bridge and spinal processes of the sacral *vertebræ* are wanting, and a round hole is seen at this part which communicated with the cavity of the tumor. The whole of the *os coccygis* is likewise wanting
- 523 Spine of a human *fœtus* at nine months, with the bony bridge removed, to shew the *medulla spinalis*, with the coat formed by the *dura mater*, and termination of the *medulla* in the *cauda equina*
- 524 A portion of small intestine, from the adult human subject, injected; the arteries with red, the veins with yellow; and three lacteals of the first order are injected with quicksilver with their glands, whose cellular structure is evident
- 525 The *corpora cavernosa* of the human *penis* laid open, to expose the curious *pectenlike septum*, forming the communication between the *corpora cavernosa*
- 526 The male and female frog, killed and prepared *in coitu*—Upon the internal surface of the thumb of the male is a curious substance, found only at this time, to prevent the female slipping from his grasp
- 527 A very large *lumbricus teres*, or round worm, from the human subject

- 528 A portion of mesentery and small intestine of an elephant, with a lacteal injected with quicksilver—Very remarkable for the small size of the lacteal
- 529 A human abortion at the latter end of the fourth month, with the *funis umbilicalis*, and a portion of the intestines not yet drawn into the *abdomen*
- 530 The human gall-bladder, with the *ductus cysticus* and *ductus hepaticus*—The lymphatics upon its coats are injected with quicksilver
- 531 The human gall-bladder, with the *ductus cysticus* and *hepaticus*; remarkable for having two openings from the pancreatic duct; the large one pointed out by a white bristle being introduced near the red bougie, which is inserted in the orifice of the *ductus communis*. The orifice of the supernumerary duct is marked by the two white bristles
- 532 The contents of the impregnated *ovaria* of a female frog, of the common size
- 533 A portion of the stomach of the horse; a great part of the internal surface is entirely covered by the *oestri equini* (bot worms) adhering to it
- 534 A curious species of *tenia*, from the small intestine of a cat
- 535 Part of the human *vas deferens*, and the whole of the *epididymis*, injected with quicksilver
- 536 A preparation of *cancer scroti*, from the human subject
- 537 Adhesions between the human lungs and pleura, formed by exudations of the coagulable lymph of the blood in a pleuritic subject

- 538 Caries of the *corpora vertebrarum* of the spine, which produced incurvation, pressure upon the spinal marrow, *paralysis* in the lower extremities, and death
- 539 A very curious and remarkable *specimen* of dropfical *ovarium*; it contains two large cysts; the upper one is opened, the coat of which is very thick; the under one is very thin—The Fallopian tube and *fimbriæ* may be seen in one part of the preparation; it is injected
- 540 A very remarkable *specimen* of worms, of the cylindrical form, found in the trunk of the *vena portarum* of an afs—Ruysch found similar ones in the mesenteric artery of the horse
- 541 Contains a great number of opake chrystalline *lenses* from the cataractous eyes of horses—In many of these *specimens* the capsule of the *lens* is thickened and opake, as well as the *lens*; and in some of them the substance of the *lens* is ossified
- 542 A beautiful *specimen* of lymphatics of the human gall bladder, injected with quicksilver
- 543 A section of a human dropfical *ovarium*; shews the cells which contained the water
- 544 The curious conglomerated kidney of the *phoca*, or *sea calf*, minutely injected, the arteries with red, and the veins with black
- 545 A perpendicular section of part of the human gravid *uterus*, with a portion of the *placenta* adhering—The sinusses of the *uterus* are distinctly seen; and the maternal or uterine cells of the *placenta* are injected by the black composition which was thrown into the veins of the *uterus*

- 546 The eye of the *cete mysticetus*, or *Greenland whale*, divided by a transverse section ; remarkable for the great thickness and curious texture of the *tunica sclerotica*—The *retina* is seen, and the *tapetum* of a white colour, on the internal surface of the *posterior* portion of the choroid coat
- 547 Two bardsers of the *cete mysticetus*, to shew the structure of whalebone, which consists of hairlike filaments ; these compose layers, and these constitute the barder—It is a species of horny cuticle found in the palate of this animal
- 548 A portion of human small intestine with the mesentery, with five human lacteals and two glands, injected with quicksilver
- 549 Part of the choroid coat and *iris* of the *cete mysticetus*—The pupil is closed, and the vessels of the choroid coat are distinctly seen without injection
- 550 The human bladder of a young subject, minutely injected—There are no *villi* on the mucoſe coat—bristles are inserted in the *ureters*
- 551 An impregnated *ovum* from the gravid *uterus* of a cat, at an early period of utero-gestation—The blood-vessels of the *uterus* were injected, the arteries with red, the veins with black. The cells of the *placenta* are seen injected, with the different membranes and *fœtus*
- 552 A preparation of a portion of the human spine, taken from the loins, to shew the intervertebral substance and transverse ligamentous fibres connecting the bodies of the *vertebræ*
- 553 A human foetal stomach, very minutely injected

- 554 A *cotyledon*, from the gravid *uterus* of a cow, injected from the *fœtus*; shews the maternal and foetal portions of the *placenta* distinctly
- 555 A gravid frog, injected
- 556 A female frog, injected minutely; shews the long and tortuous *tubæ Fallopianæ*, and the *ovaria* after the exclusion of the *ova*
- 557 *Tuba Fallopiana*, with the *fimbriæ*, from a human gravid *uterus*—The *ovarium* is opened, in which the *corpus luteum* is seen; the opening of the *tuba Fallopiana*, at the *fimbriæ*, is likewise very perceptible
- 558 A scrophulous hip joint, from a young subject
- 559 A portion of gravid *uterus*, taken at the ninth month; the four membranes are separated and turned down—The preparation is minutely and distinctly injected, the arteries with red, the veins with black; the *uterus* has a curious laminated appearance. The membranes, which are separated and turned down, lay in the following order, reckoning from above downwards:—The *membrana decidua uterina*, which is injected—the *membrana decidua fœtina, seu caducea, seu chorion opaca*—the *membrana chorion transparenens*—the *membrana amnion*
- 560 The bladder of a cat, minutely injected, and rendered transparent
- 561 A human kidney, with double *pelves* and *ureters*
- 562 The human eyelids, with bristles introduced into the *puncta lacrymalia*
- 563 The *uterus* with part of the *vagina* of a young human subject, with the bladder opened, bristles introduced into the *ureters*, with the *ovaria* and *tubæ Fallopianæ*—The *rugæ* in the

- the *vagina* and *uterus* are very distinct and beautiful
- 564 The cellular or reticular substance of the *scrotum* of a young human subject prepared, it is injected and rendered transparent
- 565 A portion of the *injected gravid uterus* of a bitch; shews the internal surface, and part where the *zone placenta* was attached
- 566 A foetal *scapula*, with its different *epiphyses*
- 567 A curious double or horse-shoe kidney, from the human *fœtus*
- 568 A kidney of a cat, most minutely injected; shews the veins that run on its external surface; the *capsule* of the kidney is separated
- 569 A bleak-fish, with the large *tenia* or tape worm, which was found in the cavity of the *abdomen* of this fish
- 570 A male frog. This animal was injected alive, by the muscular power of the heart driving on the injection: there is an appearance of *cryptæ* in the liver. It is a very beautiful *specimen*; the black scabrous *apparatus* on the thumbs, described in Lot 526, is very evident
- 571 Hair with animal oil, and something like *membrana decidua*, found in the *ovaria* of a human subject; supposed to be a false conception
- 572 An enlarged human *clitoris*, which was extirpated by the knife, successfully
- 573 The human adult *testis* opened, to shew the different sets of *tubuli seminiferi*
- 574 The spine of the gar-fish, remarkable for the bones being of a green colour

- 575 Part of the spine, *os innominatum*, and bones of the lower extremity, in a very young human *fœtus*, shewing ossification
- 576 The *puncta lacrymalia*, *caruncula lacrymalis*, and excretory ducts of the lacrymal gland of an ox
- 577 The eye of the *phoca*, or *sea-calf*, minutely injected, divided in the direction of its short axis; shews the curious *processus ciliaris*, the white *tapetum*, and *retina*
- 578 The human kidney, with the *pelvis* and *ureter*, injected and dissected
- 579 The whole of the intestinal canal of a skate opened, to shew the curious spiral *valvula connivens*
- 580 The lower portion of the *gastrocnemius muscle*, with the *tendo Achillis*, of an adult human subject, minutely injected
- 581 A human kidney, with double *pelves* and *ureters*, injected
- 582 The human *palpebræ*, with the *tunica conjunctiva*, injected minutely
- 583 A portion of *aorta*, taken adjacent to the heart of a turtle; shews the elastic and muscular coat of the artery; the last is reticulated
- 584 *Scapula* and large cylindrical bones of the superior extremity of a human *fœtus* of seven months, shewing ossification
- 585 A transverse section of the human *corpora cavernosa*, and *corpus spongiosum*, of the *penis*
- 586 A schirrous tumour of the human adult liver
- 587 A portion of the human *penis*, with the *glans*; the *urethra* opens at the root of the *frænum præputii*

- 588 The abdominal portion of the human *aorta*, with an aneurism of the mixt kind situated at the origin of the large *azygos* trunks
- 589 The *aorta ascendens* of a human adult subject, with the ascending branches, from an aneurismal subject; the internal coat is ossified in many parts; the valves are preserved, and the muscular and elastic coats are exceedingly tender and distractile, and are separated
- 590 Spine of a human *fœtus* at seven months, to shew the progress of ossification in the *corpora vertebrarum*; the arch and processes are removed
- 591 The *scrotum* and *penis* of an African who died with the small-pox
- 592 The diaphragm of a cat, minutely injected, and rendered transparent
- 593 The valves of the heart, with the *cordæ tendineæ*, and *carneæ columnæ*
- 594 The internal jugular vein of an horse inverted, to shew the valves
- 595 A *polypus uteri*, from the human subject; it was extracted by ligature
- 596 A hen opened, to shew the *ovarium* and *oviductus*
- 597 A cock opened, to shew the large *testes* and *vasa deferentia*—Bristles are put into their terminations in the *cloaca*
- 598 *Placenta* of a cat, minutely injected from the *uterus*; the foetal vessels are seen uninjected on its internal surface
- 599 The lymphatics of the lungs of a turtle, minutely injected with quicksilver

600 The lungs of the turtle dissected, to shew the ramifications of the *aspera arteria*, and large size of the air cells in this amphibious animal; the pulmonary artery is likewise injected, and the *trachea* becomes membranous, when it enters the lungs

End of the Sixth Night's Sale,



Seventh Night's Sale,

Monday, December the 17th, 1787.

ANATOMICAL PREPARATIONS.

- 601 **T**WO dried human *placentæ*, injected
 602 Two ditto
 603 A human double *placenta*, injected, from
 twins; the arteries are injected with red,
 and the veins with yellow: there was no
 communication between the vessels of the
 two *placentæ*
 604 The trunk of a human monstrous *fætus*, dried.
 There is a perforation in the diaphragm,
 through which part of the liver and small
 intestines have protruded into the cavity of
 the *thorax*
 605 A *hernia*—a *bubonocèle*, with the prolapsed in-
 testine
 606 The lungs of a turtle injected and prepared, to
 shew the large air cells in this animal
 607 The trunk of a swan injected and prepared
 608 The heart of a very large turtle injected and
 prepared;

prepared; the coronary arteries are injected with quicksilver—with the glass bell and stand

- 609 Eleven preparations of the human ear, to demonstrate the different parts of the internal organ of hearing
- 610 A very beautiful corroded preparation of the vessels of the human kidney; the emulgent artery is injected with yellow, the vein with red, and the *ureter* and *pelvis* with green—with the stand and glass bell
- 611 Another ditto; the arteries are injected with red, the vein with green, and the *ureter* with yellow—with a glass bell and stand
- 612 The heart of the *phoca*, or *sea-calf*, injected, with its different vessels, and prepared, with the glass case containing it. The form of the heart and auricles is very remarkable, and the *foramen ovale* appears to be open, for the yellow wax has passed from one auricle into the other
- 613 Six preparations of the human internal ear, with the bony circle of the *tympanum of infants*, and the *ossicula auditus*—with a glass bell and two stands
- 614 The heart and lungs of a young human subject injected—with the stand
- 615 An inferior extremity of a human adult subject, injected, and very minutely and carefully dissected, for the arteries and veins
- 616 A very beautiful preparation of the aortic system, traced in a female adult subject
- 617 A very large young subject, with the arteries and veins injected, dissected and prepared
- 618 A human heart injected and corroded, from a young subject—with a glass bell and stand
- 619 A ditto, from an adult human subject

- 620 A very beautiful preparation of the human heart, with all the large vessels arising from it
- 621 A corroded kidney, with double *pelves* and *ureters*.—The artery is injected with red, the vein with green, and the *ureters* with yellow
- 622 A preparation of the human adult heart injected; the pulmonary artery is removed, to shew the manner in which the *aorta* arises from the left ventricle; the right ventricle is opened to shew the communication between the auricle and ventricle
- 623 A most beautiful corroded preparation of the human heart, injected with red and green; and four preparations, very neatly dissected, of the elbow, wrist, and two ankle joints—with the stand and glass bell
- 624 A very beautiful set of separated bones of the head, from the human subject, very white and beautiful—with the glass case containing them
- 625 A skeleton of a domestic fowl—with the case
- 626 A very large tusk of the *sea morse*, or *walrus*
- 627 A very curious injected preparation from a subject with a distorted spine; it consists of part of the *aorta* and *vena cava inferior*, with the emulgent vessels injected. The *pelvis* of one kidney is as large as the bladder in some subjects, and globular; it was found distended with urine; it is remarkable that the *ureter* is not enlarged, which it generally is when the *pelvis* is enlarged; the *pelvis* was not thickened in its coats, but had become rather thinner from the distension; the reverse is most commonly observed in enlarged *pelves* and *ureters*

- 628 A skeleton of a rat, prepared by the *Dermestes lardarii* *Linnaei*—with the glass case containing it
- 629 A black glass case, containing fifteen dried preparations, *viz.* two preparations of the *aspera arteria*, injected and dissected from the lungs. Eleven different specimens of ossified arteries; in some of these the arteries are so much ossified, as to become mere bony tubes—some specimens of *vasa vasorum*—and a vein of the human subject, prepared to shew the valves
- 630 A very beautiful bust from a thin adult subject, in which the arteries are very distinctly injected and dissected; the ascending branches of the *aorta* are traced, with the thoracic portion of the *aorta descendens*, and the intercostals: there is a *lusus naturæ* in the intercostal artery, that passes over the tenth rib on the right side

WET PREPARATIONS.

- 631 Two—1. the *cæcum* of a rabbit, to shew its glandular structure in this animal;—2. are two portions of the femoral vein, plugged up by coagulable lymph, from an old human subject, supposed to have been much afflicted with the cramp
- 632 A *lumbricus teres*, from an horse, a very large one. The remarkable *apparatus* found at one end of the *lumbrici*, can be seen in this *specimen* with the naked eye
- 633 A portion of human *ileon*, from an adult, who died with dysentery.—There are two ulcers on the villose coat; the superior one has perforated

perforated the intestine. If this preparation is held between the light and the eye, the lacteals, which run in the longitudinal direction of the intestine, can be seen. For a particular description of this *specimen*, see Mr. Sheldon's work on the Absorbent System, plate 2.

- 634 Two—1. is a preparation of the human skin, injected;—2. is a portion of the small intestine of an elephant injected. There are no *valvulae conniventes* in this animal; instead of these, the intestine has permanent *rugae*, as seen in the *specimen*
- 635 The iliac artery, from an aneurismal subject. The muscular coat is evident
- 636 Contains several *specimens* of arterial and venous trunks of the turtle, to shew the muscularity of the arteries and veins, which is very evident in this animal; one *specimen* is injected
- 637 Two—1. a portion of intestine, minutely injected;—2. a preparation of the human eye
- 638 Two—1. a large cyst in the human lungs;—2. the buff or coagulable lymph, from the blood of a person labouring under pleurisy
- 639 Two—1. a section of the eye of an ox, injected; shews the oval pupil in this animal, the ciliary processes, and *iris*;—2. a scirrhous tumor which was extirpated from the human breast
- 640 A portion of small intestine of a turtle, minutely injected, to shew the curious *valvulae conniventes*, which run longitudinally in this animal

641 The

- 641 The kidney of a young human subject, minutely injected, for arteries and veins—The *stellulae Verheyeni* are very evident in this preparation; these are branches of the veins so called, found on the external surface of the kidney
- 642 Three sections of cataractous eyes of horses—It is remarkable that the eye of this animal loses its globular form in long-continued cataracts
- 643 Two—1. a portion of adult human liver, minutely injected;—2. a foetal *tibia* and *fibula*, injected
- 644 Is a very curious diseased *specimen* from the cataractous eye of an horse; the optic nerve is degenerated into a filament, and is adhering to the posterior part of the capsule of the chrystalline *lens*
- 645 Two preparations of the human adult eye—1. shews that the membrane *iris* consists of two coats; the internal choroid coat is separated from the ciliary processes in this *specimen*, and is seen in N° 2. adhering to the anterior surface of the vitreous humour around the chrystalline *lens*—It appears from this, that the *corona ciliaris*, as it is called, which is seen in N° 2. is nothing more than part of the internal choroid coat separated from the internal surface of the ciliary processes
- 646 A very curious *specimen*; contains a new-formed membrane, made by an exudation of coagulable lymph from inflammation—Vessels are seen injected, passing into and through this membrane
- 647 A very curious and minutely injected *specimen* of the eye of the *phoca*, or *seal*, divided by a transverse

a transverse section. In the upper portion the *cornea* is raised, to shew the curious reticulated anterior surface of the *iris*, which is black in this animal; the ciliary processes are remarkable large, and most beautifully injected. In the lower portion the optic nerve is seen, with a curious *plexus* of optic arteries upon it, on the inside the *tapetum* and *retina*.

648 The eye of the *squalus cacharias* *Linnaei*, or dog-fish, divided by a transverse section; the *tunica sclerotica* is cartilaginous;—the two choroid coats are seen; the internal is very remarkable, and contains a *pigmentum argentinum*

649 Is a ditto, with the globular chrystalline *lens*

650 Two—1. is a fœtal kidney, with the renal *capsula* minutely injected; the internal substance of the kidney is seen, and the renal *capsula*: in the kidney the tubular substance is seen in the different mamillary portions;—2. is a kidney from a human *fœtus* born without brain, to shew the small size of the renal *capsulae* in such instances

651 Two—1. is a preparation of the knee joint in a human *fœtus* at nine months, minutely injected;—2. are the ribs of a human *fœtus* at nine months, with the intercostal muscles injected and rendered transparent

652 Two—1. is the abdominal *viscera* of a male frog, compleat and minutely injected; in the upper part of the bottle are contained the *vesiculæ seminales*, *testes*, and *omentum*;—2. are two sections from the muscular *aorta* of a turtle; the lower one is injected

- 653 A longitudinal section of the eye of a Greenland whale, with the curious sclerotic and choroid coats, optic nerve, and *retina*
- 654 The eye of a calf, with the blood-vessels in the choroid coat and *retina* injected with quick silver
- 655 Two—1. is a *lumbricus teres*, from the human subject;—2. is a section of the eye of a dog with the *iris* exposed, and chrystalline lens in its natural situation
- 656 *Tibia* of the *fetus*, minutely injected, and rendered transparent
- 657 Two—1. is a portion of the membranous *placenta* of a mare, injected minutely; arteries red, veins yellow;—2. is the renal *capsule* of an adult subject, injected minutely, and opened, to shew that the substance has similar appearance to the substance of the brain
- 658 Two preparations of the human eye; one shews the lateral insertion of the *arteria centralis Zinnii*
- 659 Two—1. is a *specimen* of small intestines adhering together, owing to inflammatory exudation of coagulable lymph, from a subject who died of *peritonitis*;—2. is a *specimen* of thickened *pleura* from inflammation
- 660 Two—1. is a *placenta*, from the human subject, at an early period of utero-gestation, unravelled, to shew the foetal portion;—2. is a preparation of the small intestine with ulcerations, from a dysenteric subject
- 661 Two—1. is a portion of the membranous *placenta* of the mare, injected, both arteries and veins;—2. are carious bones from a finger

- 662 Two—1. is the *ovarium*, with the *corpus luteum*, from the *gravid uterus* of a cow;—
2. contains portions of the human *membrana decidua*
- 663 Two—1. is a preparation of the human skin, minutely injected;—2. is the cartilaginous portion of the *septum nasi*
- 664 Two—1. is a portion of small intestine, from the human subject, with part of a lacteal trunk distended with the chyle;—2. is a cluster of scrophulous glands, extirpated with success from the carotid artery, near the posterior angle of the lower jaw
- 665 Two—1. a portion of human small intestine, with a lacteal trunk opened, to shew the valves;—2. is a portion of human *ileon* injected, to shew the *glandulae aggregatae Peyerii*
- 666 A human *uterus* opened; the cavity was obliterated at two places, marked by the bristles; this is one of the mechanical causes which produces barrenness
- 667 A portion of the body of the thigh-bone; the *cancelli* are removed by absorption, and a curious *septum* is formed within the medullary canal. It is probable that this alteration has taken place after the operation of amputation, as the *periosteum* appears to be thickened and ossifying near one of the edges of the preparation
- 668 Two—1. is a portion of the *intestinum caecum*, from the horse, containing two worms of a very curious species, which, when first found, were of a red colour, and bore through the villose coat into the substance of the intestine;—2. is a portion of liver, with a supernumerary lobe

669 Two—1. a *lumbricus teres*, from the human subject;—2. a preparation of the human eye, to shew the *retina*

670 Two—1. a portion of human intestine, taken from the lower part of the *ileon*;—2. specimens of hydatids

671 A curious loculated and ulcerated kidney taken from a subject who had the *testis* on the same side extirpated with a cancer—is probable that the disease may have been communicated to the kidney by the lymphatic vessels, as the lymphatic vessels of the *testis*, in their terminations, join those of the kidney

672 Is a very beautiful and minutely injected front view of the *viscera*, in a human *fœtus* of seven months

673 A very beautiful specimen of the lymphatic vessels of the human *testis*, injected with quicksilver; with the *vas deferens* and *epidymis* likewise injected with quicksilver

674 Two specimens of ulcerated intestines, from dysenteric subjects;—1. is from the small intestine, and is injected minutely;—2. from the large intestine

675 Two—1. is a portion of dropical *ovarium* from the human subject;—2. are foetal ribs, at nine months, to shew that they are completely ossified

676 Is a very curious specimen of diseased gland *Peyeri* in the small intestine of a human subject, minutely injected—A cluster of *glandulae aggregatae* are seen, which appear to be obstructed, as well as several of *glandulae solitariae*, which are likewise seen in this specimen; which proves, contrary

the opinion of many eminent anatomists, that the *glandulae solitariae* are situated in the small as well as in the large intestines

677 Two preparations, in two bottles, of an aneurism of the mixt species, from the human subject; it is situated upon the *arcus aortae*, and burst into the *cavities pericardii*, and produced sudden death. The artery is ossified in several parts; the rupture is seen in N° 1. There are two *sacculi*. The opening from the *aorta* into the left carotid artery is obliterated, and the valves of the artery are preserved. N° 2. contains the other section.—A quantity of lamellated coagulable lymph is seen in both sections, where the blood has been at rest

678 Two—1. is a portion of a schirrous human breast;—2. is a portion of ulcerated *colon*, from a dysenteric subject

679 Two—1. is a portion of the cribiform membrane, *decidua uterina*;—2. is a portion of the human *tibia*, with the *medulla* injected

680 Two—1. a human kidney with small hydatids;—2. a scrophulous lymphatic gland, minutely injected. The parts which are diseased appear to have their cells obstructed with a curd-like substance, and the gland has lost its vascularity in these parts

681 Two—1. a part of the stomach of an ass, with the horny cuticular portion, and part of the villose coat; it has been eroded by the *oestri*, or bot worms;—2. a kidney, with small renal *capsula*, from a human monster born without brain, at the ninth month

682 Is a very curious diseased preparation, from boy of twelve years of age. It consists a portion of the root, and part of the *arcus*

aortæ. The valves of the *aorta* are ossified; a circumstance seldom found in young subjects. There is an appearance of ulceration on the inside of the arch of the *aorta*; and on the outside, opposite the ulceration, the artery is dilating, and forming an aneurismal *sacculus*

- 683 Two—1. is a curious diseased calculous human kidney; it contains several *calculi*; the whole of the cortical and tubular substance is removed by absorption; there was not the least appearance of *pus*, or ulceration;—
2. is a part of the *aorta*, with the curious ossified and contracted emulgent artery belonging to this kidney
- 684 Is a perpendicular section of the head, neck, and part of the body of the *os brachii* of a human subject—There was an abscess in the internal part of the head and neck of the bone, and the earthy matter was removed at this part. This must have occasioned dislocation; and is an instance of dislocation arising from internal cause
- 685 A foetal puppy, at the full time, in its membranes, with the zone-like *placenta* and part of the *uterus*, injected from the vessels of the mother
- 686 Two—1. is the zone-like *placenta* of a foetal puppy, unraveiled;—2. is the diaphragm of a human *fetus*, minutely injected
- 687 Two—1. of the *cornua uteri* of a cat, opened, minutely injected; shewing the internal surface and parts where the *placenta* adhered;—
2. are two foetal frogs
- 688 Is a preparation of the human gravid *uterus*, injected. The sinusses of the *uterus* are seen upon the cut edge; the *tubæ Fallopianæ*,
fimbriæ,

fimbriæ, and *ovaria* are preserved; the *ovarium* on one side is opened, to shew the *calyx* from which the *fœtus* came, and the surrounding *corpus luteum*

689 A preparation of the thoracic viscera of a *fœtus* of seven months, minutely injected

690 A preparation, shewing the descent of the *testes* in a *fœtus*, at the latter end of the seventh month

691 A portion of human gravid *uterus*, with part of the *placenta*, very minutely injected, both arteries and veins, shewing the cells belonging to the maternal or uterine portion of the *placenta*

692 A portion of the human gravid *uterus* at the full time, with part of the *placenta* adhering; the cells filled with black injection; part of the spermatic vessels are left, and the spongy chorion is seen adhering to the internal surface of the *uterus*

693 A human *uterus*, now somewhat contracted, taken from a subject who died soon after delivery

694 Is a human deficient monstrous *fœtus* at nine months, born without brain; the kidneys and renal *capsulæ* are left; the last are very small, as has been before noticed

695 A large portion of human gravid *uterus*, with part of the *placenta*, injected minutely, the arteries with red, the veins with black; several of the sinusses are seen on the outside of the *uterus*, and upon its cut edges; the maternal cells are very minutely injected, and the *funis umbilicalis* and *fœtus* are preserved

696 Is a very curious preparation from the human gravid

gravid *uterus* at the seventh month; it was supposed to have been a case of superfœtation. It is a twin case. In the bottom of the bottle is seen a *placenta*, which belonged to a *fœtus* of seven months, of which the woman was delivered; this is injected, both arteries and veins, and a portion of the *funis umbilicalis* is left—above this *placenta* an *ovum* is seen opened, which contained the small *fœtus*, which is preserved with the withered *funis umbilicalis*—the cribriform appearance of the *membrana decidua* is evident on the outside of the *ovum*. To explain this case, without having recourse to superfœtation, we may suppose that the woman conceived twins, and that one was blighted at an early period

697 Is a preparation of the human *hymen* from an adult

698 Is a case of *prolapsus vaginae*, that could not be returned, cured by an operation: the large tumour, contained in two bottles, consisted of a part of the anterior portion of the human *vagina*; the *meatus urinarius* was drawn out upon it, which was raised from this tumour by dissection, and returned to its proper situation: the tumour was removed by the knife, and the patient was cured: it had been of several years standing

699 Is a most curious ulcerated bladder and *urethra*, with *fistula* in *perinæo*, from an adult human subject

700 Is a most beautiful specimen of a human *uterus*, taken from a subject who died soon after delivery; it is minutely injected, the
arteries

arteries with red, the veins with black. The *tubæ Fallopianæ* and *ovaria* are preserved. It is divided by a perpendicular section, to shew the *os tincæ*, and its internal structure; it is contracted a little, and the surface where the *placenta* adhered, and from which the lochial discharge is thrown off, is evident


End of the Seventh Night's Sale.

arteries with red the veins with black
The red arteries and veins are
found. It is divided by a perpendicular
line to show the arteries and veins
The red arteries are connected by
the red veins where the arteries are
found where the local changes are
found.

English Light and Salt

The English Light and Salt is a
very good and useful medicine
for the cure of the following
diseases.

1. The English Light and Salt is a
very good and useful medicine
for the cure of the following
diseases.
2. The English Light and Salt is a
very good and useful medicine
for the cure of the following
diseases.
3. The English Light and Salt is a
very good and useful medicine
for the cure of the following
diseases.
4. The English Light and Salt is a
very good and useful medicine
for the cure of the following
diseases.
5. The English Light and Salt is a
very good and useful medicine
for the cure of the following
diseases.
6. The English Light and Salt is a
very good and useful medicine
for the cure of the following
diseases.
7. The English Light and Salt is a
very good and useful medicine
for the cure of the following
diseases.
8. The English Light and Salt is a
very good and useful medicine
for the cure of the following
diseases.
9. The English Light and Salt is a
very good and useful medicine
for the cure of the following
diseases.
10. The English Light and Salt is a
very good and useful medicine
for the cure of the following
diseases.



Eighth Night's Sale,

Tuesday, December the 18th, 1787.

701 **T**WO — a transverse section of the human foetal lungs, minutely injected; and a portion of the lungs of a turtle injected, shewing the large air cells of the lungs in this animal

702 The sciatic nerve of the human subject unravelled

703 The *saccus æreus* of the shad-fish, with the duct that passes from the bottom of the stomach into the *saccus æreus*.—Note, a bristle is inserted at the opening of the duct in the stomach, through the duct, into the *saccus æreus*

704 The gills of the cod-fish, minutely injected, with the trunk of the gill artery

705 A portion of the human *dura mater*, from an adult, where it covers the superior edge of the falciform process, to shew the *glandulae Pacchioni*, which are remarkably large and evident in this subject

706 Air cells of the lungs, injected with quick-silver, in a water-rat

707 A portion of adult human lungs, from a subject who laboured under *phtisis pulmonalis*, and died suddenly, after vomiting a considerable quantity of blood.—The cavity of an abscess is seen in the preparation, and over the black bristle a large ruptured blood vessel, from which the blood was poured out

708 A remarkable ossification of the membrane *pleura*, of the human subject.—Note, it was taken from that part of the *pleura* that lines the ribs and intercostal muscles

709 The half of a thigh-bone of a pig coloured by feeding the animal with madder; it demonstrates the manner in which the cylindrical bones grow—that there is not an equal increase of bulk in every part of these bones. Where the bone is red, the ossific matter was depositing, and the bone growing in consequence of this deposition.—There are two places, one on the upper part of the body of the bone, the other on the lower part, that are not tinged with the madder, and prove that the bone was not growing in these parts

710 A diseased spinal marrow, with the *cauda equina*, from a human *fetus* of nine months, which had the *hydrocephalus externus*.—The spinal marrow seems to contain very little nervous matter

711 The curious conglomerated kidney, with the *ovarium*, from a turtle.—The external surface of the kidney resembles the brain of the human subject

712 The *intestinum rectum* of a human subject opened, to shew the ulcerated internal surface, owing to the dysentery

713 The

- 713 The kidney of an afs divided by a perpendicular section—the *tubuli uriniferi* of Bellini, are very minutely injected
- 714 A very curious diseased loculated kidney, from the human subject, with enlarged and thickened *ureter*. This disease arose in consequence of pressure made upon the lower part of the *ureter*, by a large drop-fical *ovarium*
- 715 A small urinary human *calculus*, and three sections of human urinary *calculi*; one is very remarkable, it appears to consist of two *calculi*, which have afterwards united
- 716 Two sections of a human biliary *calculus*
- 717 The hip-joint, with the *ligamentum teres* and capsular ligament prepared, in a human adult subject
- 718 The *villi* of the human gall-bladder, minutely injected, in the *fœtus*
- 719 A metatarsal bone, and the three *phalanges* of a toe, divided by a perpendicular section, in a young human subject, to shew the *epiphyses*
- 720 Two—1. part of a human thigh-bone prepared, to demonstrate that the *periosteum* is double in some places;—2. is a portion of a cyst from a liver abscess; it seems to be formed of the coagulable lymph of the blood
- 721 A very curious carious human *radius*
- 722 The kidney of a young human subject, minutely injected; the arteries with red, the veins with black.—Note, the *cryptæ Malpighianæ* are very evident in this preparation
- 723 The organ of hearing in the cod-fish; an *ossiculus auditus* is seen of a remarkable shape,

shape, and the three semicircular canals are formed in cartilage; the nerve called *chor-da tympani* is evident.—This preparation was made by the late Mr. Hewson, F. R. S. very many years ago

724 A beautiful *specimen* of the longitudinal *valvulae conniventes* in the turtle, most minutely injected

725 A very curious diseased bladder, from a male adult human subject, very remarkable for the fungous excrescences arising from its internal surface. Bristles are passed into the openings of the *ureters*

726 The *sternum* and clavicles of the silk fowl of Africa, to shew the remarkable black *periosteum*

727 The elbow joint of a young human subject, minutely injected; near the outer edge of the sigmoid surface of the *ulna*, follicles are seen, which give some reason for supposing these to be synovial glands

728 The knee joint prepared, with its different ligaments, in a young human subject, minutely injected

729 The hip-joint of a young human subject, injected, shewing the *ligamentum teres*

730 A foetal human *sternum*, with the cartilages of the ribs, and *cartilago ensiformis*, to demonstrate ossification

731 A portion of the human *dura mater*, from an adult subject.—A bougie is passed into the longitudinal *sinus*, which is ruptured, and a great quantity of blood was found between the internal surface of the *cranium* and *dura mater*: this is therefore a case of sanguineous apoplexy, or *hæmorrhagia cerebri*, which might have been relieved, and possibly

possibly cured, by the application of the trepan

- 732 A portion of human lungs with abscesses, taken from a young consumptive subject; several large vessels are passing through the cavity of the abscess, which are marked by bristles, whose coats are not yet eroded
- 733 A curious ossified and otherwise diseased portion of a human *aorta*, from an adult who was aneurismal—the two outer coats of the artery were exceeding tender and easily separated. From this and similar observations it appears, that two properties, found in sound arteries, are defective in aneurismal subjects; *viz.* elasticity and muscular power
- 734 The coat of the human spleen in an ossified state
- 735 The knee-joint of a young human subject, most minutely injected, shewing the vascularity of the ligaments, and ossification of the *patella*
- 736 A portion of the liver, with the gall ducts and bladder, in an eagle
- 737 A curious human kidney, containing eight *calculi*
- 738 The heart and *pericardium* of a human adult subject, who died of inflammation of these parts, and the consequent extravasation of coagulable lymph from the external surface of the heart and internal surface of the *pericardium*
- 739 A very curious *aneurisma mixta*, from an adult human subject, in two bottles. N^o 1. contains the *aorta ascendens*, and thoracic portion of the *aorta descendens*. The *aorta* is taken from its origin at the left ventricle—
a large

a large *sacculus* is seen extending from the origin of the *aorta* through the whole of the arch of the *aorta*, and into the trunk of the right carotid and subclavian arteries; this sac pressed against the inside of the *sternum*, and produced *caries* in this bone. The upper part of the thoracic portion of the *aorta descendens* formed the sac seen in the bottom of the preparation, which pressed upon the left side of the spine and several of the ribs. Part of the *vertebræ* are removed, and some portions of the adjacent ribs; still there is no appearance of what is called *caries* in this part: the fact is, the earthy part of the bone has been absorbed, owing to the *stimulus* given by the pressure and pulsation of the tumour, without producing any deposition of *pus* or ulceration. Part of the aneurismal cavity is situated where the substance of several of the bones formerly was, as is seen in N° 2.

- 740 The ancle joint of a young human subject, most minutely injected, for the synovial membrane

DRIED PREPARATIONS.

- 741 The horned *uterus* of the cow, injected, for arteries; with the *os tincæ* and part of the *vagina*
- 742 The fore leg of an ass, injected and dissected, shewing arteries
- 743 The human scalp of a young subject, minutely injected, shewing the ramifications and *anastomoses* of the frontal, temporal, and occipital arteries.—Note, it must be held between a strong light and the eye, to see the vascularity

- 744 A *hernia*, a *bubonocoele*, from the human subject. The hernial sac is distended with plaster of paris; the cavity of the *tunica vaginalis*, with brown wax; the *vas deferens* is injected with quicksilver
- 745 An incurvated *aorta*, from a subject with crooked spine. It is ossified in some places
- 746 The *vulva*, *vagina*, *anus*, and *rectum*, with the bladder opened, and the *meatus urinarius* of an adult female subject—A very useful preparation
- 747 The *aorta* traced in the *thorax*, neck, and head of a dog
- 748 A preparation of the heart in *situ naturali* and *vena portarum*, with the *aorta* and *vena cava ascendens* and *descendens*, injected and carefully dissected, in a young human subject, with the diaphragm and lungs
- 749 The *uterus*, with part of the bladder and *rectum*, injected, in an adult human subject
- 750 The *spine* and part of the *ribs*, with *aorta*, *vena cava superior*, and *vena magna intercostalis*, with a double *ductus thoracicus*
- 751 A very curious preparation of a *hernia* dried, from the human subject. The spermatic vessels are injected; and it is remarkable, that the *vas deferens*, which is filled with quicksilver, is very near the anterior surface of the tumour, and separated from the artery and vein
- 752 A very beautiful injected specimen of a human heart, with a great length of vessels preserved with it, with a stand and glass bell
- 753 The *penis* of a stone-horse, injected and prepared. It is remarkable, that this animal has only one *corpus cavernosum*

- 754 A superior extremity of the human subject, injected, shewing the arteries.—Note, the palmar arches, and their different *anastomoses*, are distinctly seen in this preparation
- 755 A young subject, injected and prepared, shewing the arteries
- 756 A young subject, injected and prepared, shewing the arteries and veins. The *vena portarum* is injected and preserved—A very neat specimen
- 757 A superior extremity of an adult human subject, injected and prepared, for arteries
- 758 A very curious ossified *aorta*, from the human subject, injected
- 759 Part of the *aorta* and the trunk of the pulmonary artery injected, to demonstrate the valves at their origins from the ventricles of the heart
- 760 A preparation of the thoracic duct, with *aorta*, *superior cava*, and *vena magna intercostalis*, injected, with the spine and part of the ribs, in an adult human subject

WET PREPARATIONS.

- 761 Two portions of human small intestine, from a young subject, minutely injected
- 762 The *patella*, with its ligament, minutely injected, in the human subject
- 763 Sections of bones of the great toe of the human subject, for *epiphyses*
- 764 Foetal human *ossa innominata*, at the seventh month
- 765 A foetal human *os femoris*, at the ninth month, with its *epiphyses*

- 766 A foetal human *os femoris*, at the seventh month, with the *os innominatum* and *ligamentum teres*
- 767 The human eye-lids, with bristles passed into the *puncta lacrymalia* through the *canaliculi lacrymales*, and into the *ductus communis*
- 768 A foetal human liver, at seven months, minutely injected
- 769 A foetal pigeon, with the membranes
- 770 A very beautiful *specimen*, and most minutely injected, of the human knee joint; shewing the ossification of the *patella*, now far advanced
- 771 Superior extremity of the *tibia*, divided by three transverse sections, to shew the progress of ossification in an *epiphysis*
- 772 The black *ingluvies*, or crop, of the African silk fowl
- 773 The *tunica cornea* of the Greenland whale, separated into eight *laminæ*; a fibrous texture may likewise be perceived in the *laminæ*
- 774 Two sections of the human adult eye, to prove that the choroid coat is a double membrane;—the *iris* is dissected in the upper section, and on the side the *processus ciliaris* is seen, &c.
- 775 Two—1. is the *œsophagus* of a turtle;—2. is the cuticular coat of the same, separated
- 776 The upper jaw with the palate of a human *fœtus*, at nine months; very remarkable in having two *incisors* cut
- 777 Two—1. is the *tarsus*, carefully dissected, from the upper lid of the human eye;—2. is a preparation of the human adult eye, shewing the *retina* and *pigmentum nigrum*
- 778 A portion of small intestine, from the *æsi*, to shew a cluster of *glandulæ aggregatæ Peyerii*,
L 2
minutely

minutely injected, and remarkable for having no *valvulae conniventes*

- 779 Two—1. valves of the *aorta* and pulmonary artery ;—2. the human *glans penis*, with a *cicatrix*, the consequence of ulceration
- 780 A portion of human liver, from a subject who died with a large liver abscess. It appears to be a *congeries* of vessels belonging to that gland, the surrounding solid having been removed by ulceration
- 781 A very beautiful preparation of the *valvulae semilunares* of the *aorta* and pulmonary artery in the human subject
- 782 Two—1. part of the spleen of a fish, with curious formed *teniae* adhering to it ;—2. is a diseased lacteal gland of an ass, containing two or three worms in the lower part, of a cylindrical form
- 783 A very curious *specimen* of a tape-worm, or *tænia*, compleat
- 784 Two—1. is a portion of the great intestine of a turtle, with lacteals injected with quick-silver ;—2. is an hydatid from the liver
- 785 Two preparations from the horse, shewing the *carneæ columnæ* in this animal, which pass from the internal surfaces of the ventricles of the heart through their cavities
- 786 Two—1. is an human impregnated *ovum*, at an early period, with the *fætus* ;—2. is a portion of small intestine of a dog, with the cylindrical *villi*, and a cluster of *glandulae aggregatae Peyeri*
- 787 Two—1. shews the curious *glandulae aggregatae Peyeri* in the fox ;—2. the *os brachii* of a common cat, to demonstrate a character found in all the animals of the cat kind ; viz. that the brachial artery passes through the

the *os brachii* before it reaches the elbow joint

788 Two—1. is a preparation of the broad ligament and *ovarium* of a human subject; the *ovarium* is opened, and the whole is injected;—2. a portion of the femoral artery ossified

789 The stomach of a human *fœtus*, at nine months, minutely injected

790 A large quantity of *lumbrici teretes*, found in the *intestinum ileon* of a boy about twelve years of age

791 Two—1. is a portion of thickened *pleura* from inflammation, from the human subject;—2. is the stomach of a foetal puppy, injected

792 Is a beautiful and very rare specimen of a human impregnated ovum, at the sixth week. The shaggy vessels, forming penicilli on the outer surface of the transparent chorion, are very distinct. There is an opaque spot at one part, where the placenta was about to be formed

793 Two—1. is a human adult uterus, opened, to shew its cavity and the *os tincae*; a polypus is beginning from the upper part of its internal surface;—2. is the intervertebral substance from between several of the *vertebræ dorsi*

794 The eye-lids, with the *tunica conjunctiva* minutely injected, from an adult human subject

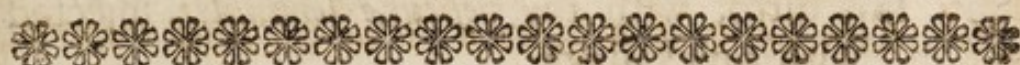795 A foetal human kidney, with the renal *capsula*, most minutely injected

796 The spermatic artery injected with quicksilver, and the *testis* of a young bull. The artery forms what is called *corpus pyramidale*

797 A

- 797 A portion of human gravid *uterus*, of a prodigious thickness, injected ; arteries red, veins black ; the *placenta* adhered to its internal surface
- 798 The spine of a human *fœtus* at nine months, with *spina bifida* ; a great number of the *vertebræ* want the arch and spinal process
- 799 *Oestri equini*, or bot worms, adhering to the internal surface of the stomach of a horse
- 800 Is a very extraordinary large cylindrical worm, found within the substance of the kidney in a dog. It was of a blood-red colour when first taken out.—It was found by Mr. Grant, the surgeon, when apprentice to Mr. Ranby at Chelsea College

End of the Eighth Night's Sale.



Ninth Night's Sale,

Wednesday, December 19th, 1787.

DRIED PREPARATIONS.

- 801 **T**HE human bladder of a male adult subject, with the *vesiculæ seminales*, injected; shewing likewise the insertion of the *ureters* in the bladder
- 802 Two—a ditto, with the *vesiculæ seminales*, injected with quicksilver, shewing that the *vesiculæ seminales* are formed by the *vas deferens*; and the bladder of a dog, with the *vasa deferentia*, injected with quicksilver. There are no *vesiculæ seminales* in this animal
- 803 Three—a portion of the bladder of a horse, with the *vasa deferentia*, *vesiculæ seminales*, and *ureters*, injected; and two bladders, one from an adult female subject, and one from a young subject, injected
- 804 The *vesiculæ seminales*, with the *vasa deferentia*, *ureters*, and cells of the prostate gland, injected with quicksilver, in a horse

805 The

- 805 The human bladder, with the *vesiculæ seminales* and *ureters*, injected
- 806 Is a ditto, with the *vesiculæ seminales*, injected with quicksilver
- 807 Five—a preparation of the human bladder, to shew the oblique insertions of the *ureters*;—a very large human *vesicula seminalis*;—the horned *uterus* of a cat;—the bladder injected, with the long *meatus urinarius* in a cat;—and the *testes*, *vasa deferentia*, and *vesiculæ seminales*, of a hedge-hog; these *vesiculæ seminales* were filled by injecting the *vasa deferentia*
- 808 Two pair of *vesiculæ seminales*, from the human subject; one pair is opened, shewing their internal cellular structure
- 809 Two pair ditto
- 810 Three—an enlarged *ureter* and *pelvis* injected, from the human subject;—the spermatic artery of the *testis* of a young bull, injected with quicksilver;—and the thoracic duct, with the *receptaculum chyli* and lacteal trunks terminating, in the human subject
- 811 Several specimens of large lacteal trunks, from the *cæcum* of a horse
- 812 A very curious diseased preparation of the human kidney, injected, with the large blood-vessels. No part of the kidney was left on one side but the enlarged and thickened *pelvis*, which is filled with yellow wax. The opposite kidney, which is preserved, was not diseased
- 813 Is a human kidney; with an enlarged *pelvis* and *ureter*
- 814 Is a ditto
- 815 Is a ditto, very much enlarged

- 816 A kidney, with two emulgent arteries, and an enlarged *pelvis* and *ureter*
- 817 The human gall-bladder, with the ducts injected; and two ditto, from the human subject, one has the arteries and veins injected
- 818 Two—one is a very curious specimen of ossifications in the liver of an horse; it looks very like lymphatics loaded with cretaceous matter. The small specimen is taken from the liver of a sheep
- 819 Specimens of intestines; the arteries are injected with red, the veins with yellow
- 820 Three preparations of the human *penis*, injected; one shews the *corpora cavernosa penis*;—another, the *crura penis* and *corpus bulbosum*, with their attachment to the *os pubis* and *ligamentum suspensorium penis*;—the small one is a transverse section; shews the *corpora cavernosa*, *vena magna*, and passage of the *urethra* through the *corpus spongiosum*
- 821 A preparation of the human adult *penis* injected, with the *os pubis* and *ligamentum suspensorium*
- 822 Are two models of the human *penis*
- 823 A curious distorted human *penis*, and another ditto, both injected
- 824 Is the curious *penis* of a dog, with the large bulb and *glans*, and the *musculus retractor penis*
- 825 Two—the bladder and *vesiculæ seminales* of a monkey, injected with quicksilver;—and a preparation of the *pelvis* of a *fœtus*, at nine months, with its contents, to shew the descent of the *testis*, &c.
- 826 Two—a preparation of the human spleen, with the artery injected with red, the vein

with yellow; the artery is remarkably tortuous, and is ossified;—the other is the *testis* of an horse, with the blood-vessels injected

827 Seven specimens of human small intestines, with the arteries and veins injected; and a preparation of the human *cæcum*, part of the *colon*, and *ileon*, injected

828 A preparation of the human gall-bladder, with the different ducts injected; the opening into the *intestinum duodenum* is preserved

829 Is a ditto, with the pancreatic duct

830 Three preparations of the heart of the human *fœtus*, injected; two with the *lungs*

831 Four—a preparation of the thoracic duct in a young subject;—the *sternum* of a bird, with a curious convolution in the *aspera arteria*;—and two preparations, shewing the air cells in a turtle, injected

832 A heart of a cat, with the lungs injected;—a ditto, without the lungs;—and a preparation of the human *vesiculæ seminales*, injected with quicksilver

833 A preparation of the human heart injected; and the heart of a dog injected

834 Valves of the *aorta* and pulmonary artery

835 Four specimens of the arteries and veins injected, upon the human small intestines; the arteries are injected with red, the veins with yellow

836 Five—two specimens of intestine, from the elephant;—part of the *aspera arteria* of a horse;—the *cæcum* of a calf, injected;—and the valve of the *colon*, &c. injected, in a young human subject

837 The contents of the *pelvis* of a male *fœtus*; the bladder is situated entirely within the cavity

cavity of the *abdomen*; at this period part of the *rectum* alone fills the cavity of the *pelvis*;—the femoral artery and *arteria profunda* of a human adult subject, injected;—three preparations of human intestines injected;—and a portion of small intestine injected, from the elephant

838 Six—the bladder of the turtle, with the *rectum*; the bladder opens into the *rectum* in this animal;—two portions of small intestine, and one transverse section of the large intestine of the elephant;—a portion of human intestine, with two lacteals filled with coarse injection;—and the valves of the *aorta*

839 The stomach of a dog;—the bladder of a human *fœtus*, minutely injected;—a portion of human small intestine, minutely injected, both arteries and veins;—and the *cæcum* of a seal, injected

840 Nine specimens of injected intestines, from the human subject; some from the seal

841 Three—a *lusus naturæ*, the muscle called *biceps cubiti*, with three heads, from a human subject;—a preparation of the knee joint, from the human *fœtus*;—and the *ileon*, *colon*, and *appendix* in the *fœtus*, shewing that there is no *cæcum* in the *fœtus*

842 Three—valves of the *aorta* and pulmonary artery;—and valves of the *aorta* ossified, from the human subject

843 Four specimens—part of the *aorta* and *ductus thoracicus* of an horse, injected;—subclavian and jugular veins, with a double termination of the thoracic duct, in the human subject;—part of the *funis umbilicalis*, with a

curious contortion of the artery;—and a portion of human *aorta* ossified

844 Part of the *aorta* and *ductus thoracicus* of an horse, injected;—subclavian and jugular vein, with a double termination of the thoracic duct, in the human subject;—the gall-bladder of a dog, remarkable for several small hepatic ducts, terminating in the cystic duct;—and a bifid gall-bladder from a cat

845 Three—a preparation of the *aorta* and *vena cava* of an adult human female subject, shewing the origin of the spermatic arteries and veins, with the kidneys and emulgent vessels; the bladder is laid open, and the *vagina* and *rectum*;—the stomach of a human adult subject;—and the stomach of a large cod-fish: the substance of the stomach is perforated by worms

846 Two preparations of the lacteals of the horse, injected with quicksilver on the small intestine and mesentery

847 Three—a preparation of the lacteals in the turtle, with the arteries and veins injected;—a portion of small intestine of an elephant;—and a portion of human small intestine, with a lacteal injected, which runs longitudinally on the intestine near four inches

848 Three—two specimens of lacteals injected with quicksilver, on the small intestine of an ass;—and lacteals injected with quicksilver, on the stomach of the *torpedo*, or numb-fish

849 Three—1. the stomach of a seal, injected, with the arteries and veins;—and two preparations of human intestine, with the arteries and veins injected

850 The curious spiral *valvula connivens* in the skate-

- skate-fish; the large *œsophagus* and mixt stomach of a bird of the loon kind;—and a preparation of the valve of the *colon*, with a very long *appendix*
- 851 Three—the stomach, transverse arch of the *colon*, *duodenum* with the *pylorus*, and spleen, injected for the arteries;—the lower portion of the *ileon*, the *cæcum*, and *appendix*;—and a preparation of the tongue of a porpoise, with the *larynx* and *os hyoides*
- 852 An adult stomach of the human subject, with the arteries injected; and a preparation to shew the valve of the *colon*, with the arteries injected
- 853 The stomach of a pig inflated; there is a valve where the *œsophagus* enters the stomach in this animal, and in another part of the stomach behind the *œsophagus*; and a portion of human *ileon*, with a *diverticulum*
- 854 The human adult heart dried hollow, shewing its internal structure, with the large vessels of the heart—very difficult to prepare
- 856 Five—a curious bifid gall-bladder found in a cat;—a human stomach from a young subject, minutely injected;—a portion of small intestine of a *fetus*, with the arteries injected with black;—a portion of large intestine of a turtle, injected, arteries, veins, and lacteals;—and a vein of a horse, with a valve, prepared
- 857 Three hair-balls from the stomach of a cow; one is covered with calcareous matter
- 858 A curious *calculus* from the *cæcum* of a horse; and a section of ditto
- 859 A very curious globular *calculus* from the *cæcum* of a horse
- 860 Fifty casts of *calculi* in plaster of Paris, most of them from the horse

D I S E A S E D B O N E S.

- 861 Ulceration with *caries* of the human spine : the disease is situated in the bodies of the eleventh and twelfth dorsal and first lumbar *vertebræ* ; this produced pressure upon the spinal marrow, *paralysis* of the lower extremities, and death.—It is a subject from which one of Mr. Pott's plates was engraved. See Mr. Pott's work on *Paralysis* of the lower extremities, &c.
- 862 A similar disease in the bodies of the 3d and 4th dorsal *vertebræ*. This is likewise figured in Mr. Pott's work
- 863 Is a ditto, which is delineated in Mr. Pott's work
- 864 Is a most beautiful *specimen* of this kind, situated nearly in the middle of the back
- 865 A case of ulceration, with *caries* of several of the bodies of the lower dorsal *vertebræ* and ribs, from the pressure of an aneurismal tumour
- 866 The spine of a human subject, with a double incurvation from the rickets
- 867 Is a specimen of incurvation of the spine, from *caries* of the bodies of the eleventh, twelfth, and first lumbar *vertebræ* ; and is figured in Mr. Pott's work
- 868 Is a similar diseased spine, from a young scrophulous subject
- 869 Nine preparations from the human spine ; some are diseased
- 870 A *caries* of the spine, which produced the angular humped back, similar to those before described ; and three luxuriant *vertebræ*
- 871 Two curious rickety *ossa femorum*, from human subjects

- 872 A curious rickety *os femoris, tibia,* and *fibula*, articulated, and very much incurvated
- 873 *Tibia* and *fibula*, with bony granulations, forming what are called bone-spavins, from the horse
- 874 A diseased human *tibia*
- 875 An incurvated *os femoris* and *tibia*, and a diseased *tibia* and *fibula*, all from human subjects
- 876 Three diseased *ossa femorum*; one is very deformed from the rickets
- 877 A very crooked *os femoris*, from a human subject; and a diseased *os femoris*
- 878 A crooked *os femoris* and *tibia*, from rickets
- 879 Two crooked *ossa femorum*, from rickets
- 880 Is a very curious crooked specimen of the *os femoris*, from the human subject, owing to rickets; and a diseased *os femoris, tibia,* and *radius*
- 881 Five—three specimens of bony granulations of the human *tibia*;—and two diseased human ribs
- 882 A curious diseased *spina ventosa* and *anchylosis*, in the foot of a horse
- 883 A curious distorted *tibia* and *fibula*, from an adult human subject, owing to rickets
- 884 Two specimens of bone-splints or bone-spavins, from the horse
- 885 Is a very distorted *os femoris*, from the human subject, owing to rickets; and a bony excrescence from a horse
- 886 Four—*ossa parietalia*, and part of the *os occipitis*, with the lower jaw, from a monkey who died of *scrophula*;—the *tibia* from a stump;—and a curious diseased thigh-bone, with an *exostosis*
- 887 A tooth of the *cete physter macrocephalus*, or spermaceti whale

- 888 A tusk from the newly-discovered *sus æthiopicum*, described by Dr. Pallas
- 889 The tooth of the *physter macrocephalus*, divided by a longitudinal section
- 890 A tooth from the same animal
- 891 A ditto from the same, and a transverse section of a tooth of this animal, in which concentric layers are seen, which shews us how the teeth are formed
- 892 Seven specimens of tusks from the wild-boar
- 893 Three teeth—two from the *physter*, or spermaceti whale;—and one from the rhinoceros, or else from *trichechus rosmarus*, or *walrus*—if from the last, it is a molar tooth
- 894 A tooth of the elephant prepared and polished, to shew the curious distribution of the enamel in this animal
- 895 Two—a tooth of the elephant prepared, for the enamel, by a longitudinal and transverse section, polished
- 896 The grinding surface or *basis*, and the enamel, prepared, in the tooth of an elephant
- 897 The grinder of that scarce animal the *sus æthiopicum*, prepared, to shew the enamel
- 898 A transverse section of a tusk of an elephant, polished, to shew its curious internal structure;—and two grinder-teeth of horses, prepared, shewing the enamel
- 899 One *incisor*, and two sections of molar teeth of the horse, prepared, shewing the enamel
- 900 Four beautiful sections of molar teeth of the horse, prepared, shewing the distribution of the enamel

End of the Ninth Night's Sale.



Tenth Night's Sale,

Thursday, December 20th, 1787.

DRIED BONES.

- 901 **A**N *os femoris*, from a dropfical subject, divided by a perpendicular section, shewing the *cancelli* and internal structure of the bone
- 902 The *tibia*, from a dropfical subject, prepared in a similar manner
- 903 The *os brachii*, prepared by a longitudinal section
- 904 Six—two sections of the *os femoris*, and four from the *tibiae* of the human subject, shewing their internal structure
- 905 The *os femoris* of an ostrich, divided by a longitudinal section, shewing the air cells which are found in the bones of birds—the thimble-like *foramina* by which the air enters the bone are evident
- 906 Two—half of the thigh-bone of a pig, which is of a red colour, from feeding the animal with madder;—and the tooth of the hippopotamus, or river-horse of the Nile, with the enamel, prepared

- 907 Two very large *cuspidati*, from a lion
- 908 Five—a tusk or *cuspidatus* from the lower jaw of the *sus æthiopicus*;—a grinder of the horse, prepared, for enamel, by dying the tooth; the enamel will not take the dye;—and three preparations of teeth of the horse, shewing the enamel
- 909 Four—two transverse sections of molar teeth of the horse, prepared, shewing the enamel;—an *incisor*, and a section of ditto, from the horse
- 910 The jaws of a fish—it is supposed to be the *hystrix*, it is remarkable that there is only one tooth in each jaw, which are formed by the jaw-bones being covered with enamel, where the alveolar processes are placed in other animals

WET PREPARATIONS.

- 911 Two—1. is a portion of the human *placenta* unravelled, shewing the foetal vessels;—2. is the horned *uterus*, and part of the *vagina*, of a young sow; this is cut out, in spaying the young sows, with impunity; and in the old ones the *ovaria* are removed—it was taken out by a sow-gelder from the living animal
- 912 A portion of human gravid *uterus*, at the full time, with part of the Fallopian tube; a bristle is inserted in the Fallopian tube, to shew the opening of the tube into the *fundus uteri*: it is injected, and the *membrana decidua uterina* is separated in some parts from the internal surface of the *uterus*
- 913 Two—1. is a portion of the *aorta*, from the human subject, with the internal coat of the artery

artery separated, shewing that ossification in arteries begins in or under the internal coat;—2. is a portion of stomach or intestine, from what animal is unknown, with the villose coat separated—There is a very remarkable appearance in the villose coat of this preparation.

914 Is a portion of human gravid *uterus*, at the full time, injected, shewing the arteries and veins on the cut edges, and on its internal surface the contorted exhalent *anguillulae arteriarum* of Roederer

915 Two—1. is part of the *chorion* from the gravid *uterus* of a sow, injected, and rendered transparent; the arteries are injected with red, the veins with black;—2. a cyst from the liver, containing an hydatid

916 The double *saccus aereus*, or swimming bladder, in a carp, with the muscles preserved, and the duct which communicates with the cavity of the stomach: by the compression of this *saccus aereus* the animal is rendered heavier relative to the water, and *vice versa*

917 Three—1. is a portion of the gravid *uterus* of the cow, taken some time after delivery; it proves that the maternal portions of the *placenta* remain in the *uterus* in this animal;—2. part of a *tenia*, or tape-worm, from the human subject;—3. part of the *aspera arteria* and *larynx* of a *fetus*, injected and opened, to shew the ligaments of the organ of the voice

918 Two—1. is a curious hydatid worm, called *bulba globosa*, found in cysts in various animals, especially sheep; this species was taken from the liver of a sheep;—2. contains a portion of the liver with the cyst

919 Is a very beautiful specimen of an impregnated human *ovum*, at an early period of utero-gestation. The *fœtus* is seen with the *funis umbilicalis* in the cavity of the *amnion*, and the four membranes which form the *involucra* of the *fœtus* are now very evident; these lie in the following order, reckoning from within outwards:—

1. *Membrana amnion*,
2. ————— *chorion transparens*,
3. ————— *decidua fœtina*, seu *reflexa Hunteri*
4. ————— *decidua uterina*; the two last form the opaque *chorion* in the latter period of utero-gestation

920 A preparation of the lymphatics of the *testis* injected with quicksilver from the *tunica albuginea*, shewing their course upon the spermatic process

921 Two—1. is the villose coat of the *intestinum rectum* of the cat, minutely injected;—2. is the *cæcum* of the dog, to shew the large and numerous mucous glands

922 Two—1. the human *ovarium* and Fallopian tube, with a bristle introduced into the orifice, at the *fimbriæ*;—2. is a fœtal lamb

923 A human *fœtus* at seven months, with the *placenta* and *funis umbilicalis*

924 The *membrana chorion opaca*, with the *amnion* minutely injected, arteries red, veins black, from the sow

925 A very beautiful and most minutely injected specimen of the lacteals, with the curious cellular structure of the lacteals, between the villose and muscular coats of the turtle, filled with quicksilver

926 The *fœtus* of a negro. It is remarkable that
the

the *fetus* of the African, when born, is white—it is more hairy than the *fetus* of the European

927 Two—1. are human bones prepared by an intense heat, to shew the pores which are occupied by the vessels of the bone;—2. are worms of the species called *gordius filiformis*

928 The horned *uterus* of a bitch, with several fungous excrescences which grew from the internal surface of the *vagina*

929 The head and chest of a human monster, born without the brain; the spinal marrow and nine pair of nerves were found upon dissection, which proves that the nerves are not elongations of the brain, but original formed parts

930 A diseased knee joint, from an adult human subject who was afflicted with *fungus articularum* or white swelling

931 A foetal calf, with its membranes and *membrana allantois*

932 A preparation from the adult human subject, with a large ulcer in the *urethra*, which produced a *fistula in perinæo* and death. The prostate gland is preserved, with the *vesiculæ seminales*, *vasa deferentia*, and *ureters*; the *vesiculæ seminales* are distended with the semen which they contained

933 A human monster born without brain

934 A very curious deficient human monster without brain; it is a *monoculus*—it has a kind of proboscis instead of the nose

935 A beautiful preparation of the lungs of the turtle, to shew the ramifications of the *aspera arteria* and the air cells; the pulmonary artery is injected

935 A

936 A *uterus* and dropfical *ovarium* from the human fubject; the *uterus* has been fo much extended by the enlargement of the *ovarium*, as to obliterate the *os tincæ*

937 A preparation of the *uterus*, *vagina*, *tubæ Fallopiæ*, and *ovaria*; a large cancerous ulcer has destroyed the anterior portion of the *vagina*, and fome hydatids are feen fixed to the tubes near the *fimbriæ*; and the *uterus* is opened to fhew its internal cavity and the *os tincæ*

938 Is a difeafed bladder, *urethra*, and *penis*, from an adult human fubject; there is a ftricture in the posterior part of the fpongiouf portion of the *urethra*, where the fuperior briftles are placed, and nothing would pafs through this part but a fmall piece of catgut; the urine got out, where the briftles are feen on the outside of the *urethra*, into the interftices of the cellular membrane of the *fcrotum*, was diffufed, which induced inflammation, mortification, and death. The patient would not confent to an operation; and fome inftruments lately difcovered were not known at that time. The bladder was much thickened, and contracted

939 The head and cheft of a monfter born without brain

940 A human gravid *uterus*, with the bladder and *inteftinum rectum*, from an adult fubject;—a cancer has eroded the *os tincæ*, has destroyed part of the bladder and *rectum*, and has made a communication amongft their different cavities

DISEASED BONES.

- 941 Two—part of a human *pelvis*, with an *anchylo-
losis* in the sacro-iliac joint;—and a portion
of spine, with several anchylosed ribs and
vertebræ
- 942 Six anchylosed dorsal *vertebræ* of a horse,
with *exostosis*
- 943 Two—an *anchylo-
losis* at the sacro-iliac joint in
the human *pelvis*;—and anchylosed *verte-
bræ* and *os sacrum*
- 944 1.—Four anchylosed human *vertebræ*, shew-
ing that *anchylo-
losis* may take place during
the existence of the inter-vertebral substance,
by the ossific granulations shooting over the
anterior surface of the inter-vertebral sub-
stance;—2. an *anchylo-
losis* between the su-
perior extremities of the *tibia* and *fibula*,
where they form the lateral joint near the
knee
- 945 An *anchylo-
losis* between the *tibia* and *fibula*, near
their lower extremities. This has probably
arisen from a fracture of the *fibula*, which
has been driven in by the injudicious use of
tight bandage, which has produced the *an-
chylo-
losis*
- 946 An *anchylo-
losis* between the *os brachii* and *ulna*,
at the elbow joint.—In this specimen we
may observe a wasting of the *os brachii*, and
alteration of form in the *condyles*
- 947 An *anchylo-
losis* of the *os brachii*, *radius*, and *ulna*,
at the elbow joint: the *condyles* and spines
of the *os brachii* are very much altered
- 948 Four anchylosed lumbar *vertebræ* of an horse,
with an *exostosis*

949 A very curious *anchylosis* of six human dorsal *vertebræ*

950 Two—five anchylosed human *vertebræ*;—and part of the bones of the foot anchylosed in a horse

951 Two—a cast of compleat *anchylosis* in the knee joint;—and two anchylosed *vertebræ* from the human subject

952 Two—1. a rib of a horse, with two fractures and ossific granulations;—2. a portion of diseased *os femoris* from a stump

953 Two—1. a curious *lusus naturæ* in a human rib;—2. a portion of carious human thigh-bone, from a subject, with *fungus articu-
lorum*

954 The knee joint from an adult human subject, with *fungus articu-
lorum*

955 The hip joint of a human subject, with *caries* and a partial *anchylosis*

956 A curious *os brachii* and *ulna*, from a young human strumous subject, with a partial *an-
chylosis*.—The body of the *ulna* is very much wasted

957 Three specimens of diseased bones from *fun-
gus articu-
lorum*

958 A portion of a curious diseased *tibia*, which is remarkable for the increased vascularity, and alteration with respect to absorption, that has taken place in this specimen previous to the throwing off the exfoliated portion

959 A portion of human *os femoris* from a stump.—In this specimen we may observe bony granulations from the vessels of the *periost-
teum*, near the part where amputation was performed. The effects produced by the absorption of the earth on the outside of the bone

bone is evident; there is a groove, formed by the absorption of the earth, between the dead portion of bone near the part amputated and the once adjacent living part. It looks as if the whole portion was an exfoliation, owing to a compound fracture, and that the surgeon by mistake had performed an amputation below this fracture, and that this portion has been exfoliated afterwards

960 *A very curious specimen*—an ulceration and caries of the *os femoris*, from an abscess in the internal cavity of the bone

961 Two exfoliations of bone from the human *tibia*;—and five specimens of exfoliations from the human *cranium*; shewing the scabrous surfaces from which the ossific matter has been absorbed, between the living and dead parts of the bone

962 Is a case of *necrosis tibiæ*; a curious large internal exfoliation of part of the body of the human *tibia*: it was locked by the adjacent bony granulations, which have been formed by the surrounding *periosteum*

963 Is one of the most extraordinary diseases of bone that is on record.—It is a case of *necrosis tibiæ*, from the human subject; the whole of the body of the *tibia*, from disease, has lost its life; the superior and inferior extremities of the bone have continued in their living state.—The dead bone seems to have stimulated the vessels of the adjacent living *periosteum*, which contains the vessels whose branches supply the bone with nourishment, and deposit the ossific matter. These vessels have thrown out ossific matter on the outside of the dead *tibia*, which has served as a mould to the matter deposited

by the *periosteum* : this has united with the extremities of the bone ; and it is probable, if this case had been rightly understood, and the dead *tibia* removed, which was locked by the adjacent osseous matter, (which might have been effected by a transverse section of the dead *tibia*, which was completely exfoliated) the internal cavity would have been filled by bony matter, and a new *tibia* formed ; and amputation, which was performed in this case, might have been avoided, and the limb saved.—Vide *Troja de Regeneratione Ossium*

- 964 Is the arch of a human *cranium*.—The subject from whom it was removed had a fracture of the *cranium*. The trepan was applied, and a portion of fractured bone was removed from this part : the place where the bone was removed is supplied by a membrane. He recovered from the operation
- 965 A human *cranium*, with two venereal ulcerations in the *os frontis*
- 966 A ditto, with venereal *caries* or ulceration
- 967 The arch of the *cranium* from a human subject. He underwent the operation of the trepan, and recovered. Some time after his recovery he was salivated for the *lues venerea* ; when the salivation took place, the parts which had been perfectly healed a considerable time before, were removed, and the part went into a state of ulceration ; which proves that new-formed parts are weak, from being more disposed to be removed by ulceration
- 968 A human adult *cranium* with *corona veneris*, from *lues venerea*
- 969 Two casts of arches of *crania*, with venereal *caries*

970 A very remarkable specimen of a thigh-bone, from a subject with confirmed *lues venerea*, in three sections. The bone is much enlarged, the internal cavity of the bone is filled up by osseous matter, and the marrow has been removed by absorption. There is very little appearance of *cancelli*, and the bone is much enlarged. This proves that venereal nodes affect the internal as well as the external parts of bone

971 Two specimens, containing five pieces;—one is an enlarged *os femoris*, from a subject with *lues venerea*, divided by three transverse sections;—the other is a portion of *tibia*, with a venereal node on its external surface, divided by a transverse section, to shew that the internal part is not diseased in this specimen, and that the disease has begun in the *periosteum*

972 Is a curious diseased *carpus*, *metacarpus*, and fingers, from *lues venerea*

973 Two thigh-bones with venereal nodes, from the human subject. The vessels of the *periosteum* have deposited the ossific matter forming the nodes, and the pores for the vessels of the bone are much enlarged, and is a proof that the bones, in these venereal cases, become more organized

974 The *tibiae* and *fibulae* from the same subject, very much diseased

975 Five—the large cylindrical bones of the superior extremity and *scapula*, very much diseased with venereal *caries* or ulceration

976 Ditto

977 A curious diseased arch of the *cranium*, affected with venereal ulceration or *caries* in five different places: both tables of the *cranium*

are perforated in several places.—An exfoliation was going on in one part, and a groove may be perceived between the dark discoloured part of the bone, which was dead, and would have been soon cast off by the adjacent living parts, if the patient had survived. The groove forms a line of separation between the once living and dead part of the bone, in which the ossific matter has been absorbed, and in this way a separation is effected between the living and dead parts, as has been first asserted by Mr. John Hunter

978 The *patella* and seventeen bones of the hand, from the same subject, with venereal ulceration

979 Three—a fractured human thigh-bone, united by *callus*;—a diseased human *tibia*, from a subject, from *lues venerea*;—and a *clavicle* affected with venereal *caries*

980 Two curious specimens of fractured human thigh-bones, from the human subject, united by *callus*

981 A curious oblique fracture of the human thigh-bone, united by *callus*

982 A fracture of the human *tibia*, united by *callus*

983 A curious oblique fracture of the human *tibia*

984 Two fractured human *tibiæ*, united by *callus*

985 A fractured *tibia* and *fibula*, from the human subject;—and a fractured *radius*, united by *callus*

986 An oblique fracture in the body of the *os femoris*, united by *callus*

987 Is

987 Is a very curious distorted specimen of the human thigh-bone, from fracture. It is united by a double *callus*; the bones lap over each other for full three inches, by which means the limb has been shortened: and this is the case in all the other specimens; which has been owing to the absurd and injudicious custom of laying the leg and thigh of subjects who have fractured the thigh-bone in the extended posture; which method is still used by some practitioners, and is contrary to all anatomical principles. By this absurd method of treating fractures of the thigh, the subjects from which these thigh-bones were taken, have been all lamed, by the limb on the fractured side being shortened, and otherwise distorted, as may be seen in the different specimens.—Vide *Mr. Pott's Observations on Fractures in general*

988 A very distorted fractured human thigh-bone, united by *callus*. The limb of the subject has been placed in the extended position, and proves fully the force of the preceding observation

989 Two—a fractured *tibia* and *os brachii*, both united by *callus*

990 A longitudinal section of a fractured human *tibia*, which has been badly set, united by *callus*;—and a fractured human *fibula*, united by *callus*

991 A fractured *tibia* and *fibula*, from the human subject, united by *callus*

992 A ditto

993 A fracture of the neck of the thigh-bone, united by *callus*

994 A curious fracture of the neck of the human *os brachii*,

brachii, united by *callus*. The motion of the arm has been much impeded, in consequence of which the bone is wasted

995 A very curious specimen of fracture in the head and neck of the human *os femoris*, united by *callus*. One part of the head is polished, owing to attrition, from the head of the bone becoming too large for the cotyloid cavity of the *os innominatum*

996 Two fractured human *tibiæ*, united by *callus*


997 Four specimens of fractured human bones.—A fractured *tibia*, united by *callus*;—a fractured *radius*, united by *callus*;—a fractured rib, united by *callus*;—and a fractured *tibia* not united

998 Two—the fractured rib of an horse, united by *callus*;—and a cast of a compound fracture of the human *os brachii*, from a gunshot wound, with the *callus*

999 A distorted human *os femoris*, and two sections of a fractured human *fibula*, united by *callus*

1000 A most beautiful preparation of the arteries and veins in a human busto, very accurately dissected, and free from animal oil—with the stand and glass case.—It is very seldom that the veins can be so minutely injected.

End of the Tenth Night's Sale.



Eleventh Night's Sale,

Friday, December the 21st, 1787.

- 1001 **T**HIRTEEN, a variety of *sterna* from the human subject
- 1002 Various diseased human *vertebræ* from a distorted subject, and an *os sacrum*
- 1003 Twenty-four various cervical, dorsal, and lumbar *vertebræ*, from the human subject
- 1004 The seven cervical *vertebræ*, and various diseased *vertebræ*, from the human subject
- 1005 Two portions of horn from a deer, in a fossil state, found in the bed of the river Rodon; a curious horn from an antelope; and part of the tusk of an elephant
- 1006 Part of the tooth of a narwal, or sea-unicorn; at each end of the tooth the enamel may be seen;—and the secondary tooth of a narwal
- 1007 A set of separated bones of the human *cranium*; the *os frontis*, *sphenoides*, and *ethmoides*, are not separated—shewing the relative situation of the ethmoid bone
- 1008 A complete set of separated bones of the human *cranium*
- 1009 Part of a bisected human head; with the eyeball,

ball, and the six muscles of the eye, dissected

1010 *Clavicula, scapula, os brachii, radius, and ulna*, from the human subject

1011 A portion of bone from a whale, shewing the internal cellular structure

1012 The skull of a porpoise

1013 A very large *cranium* of the *trichechus rosmarus Linnæi*, or sea-morse

1014 A very large molar tooth from the elephant. The structure of this tooth answers the purpose of a third dentition in this long-lived animal

1015 Two tusks of a young elephant

1016 The *tympanum auris* of the *cete mysticetus*, or Greenland whale

1017 A large tusk of the *sus æthiopicum*

1018 Two tusks with part of the *cranium* of ditto, with the curious snout bones

1019 Three curious horns from different animals

1020 The bone from the nose of the *rhinoceros*

1021 Two dorsal *vertebræ*, from a very large and old elephant

1022 Two ditto

1023 Two ditto, and one lumbar *vertebræ*, from the elephant

1024 The *tibia* and *fibula* of a very large elephant

1025 The *os femoris* of ditto

1026 The skull of an unknown animal from the Musquito shore; it has no incisive teeth

1027 The skull, *pelvis*, and other bones, unarticulated, of a young female elephant

1028 A skeleton of a seal, imperfect

1029 The skeleton of an old lioness

1030 The

- 1030 The *cranium* of a young *trichechus rosmarus*,
or *walrus*
- 1031 The *caput osseum* of the *babyrussa*
- 1032 A curious diseased *os femoris*, and a *tibia*
and *fibula*, from *lues venerea*
- 1033 A very curious diseased *fibula*, and a dis-
eased *os femoris*, from *lues venerea*
- 1034 An *os femoris* and *tibia* with venereal nodes
- 1035 An *os femoris* and *tibia*, both diseased from
lues venerea
- 1036 Two diseased *ossa femorum*, from *lues venerea*
- 1037 Four ditto, from ditto
- 1038 Two *ossa brachiorum*, from ditto
- 1039 A *spina ventosa* in the lower extremity of a
human *os femoris*
- 1040 A diseased *tibia* and *fibula*, from the human
subject, from the *lues venerea*

CASTS IN PLAISTER OF HUMAN GRAVID UTERI.

- 1041 A set of casts of gravid *uteri*, from a subject
who died at the ninth month, moulded and
accurately coloured from nature.—N° 1,
shews the gravid *uterus* in *situ naturali*, and
the adjacent *viscera*; the sinusses of the
uterus may be seen, and large vessels going
to the *uterus*.—N° 2, shews the *fœtus* in *situ*
naturali.—N° 3, shews the situation of the
placenta, and its attachment to the *uterus*.
In this cast, and N° 2, the large sinusses of
the *uterus* and arteries may be seen on the
cut edges of the *uterus*; the *aorta descen-*
dens, *vena cava inferior*, and kidneys, are
likewise seen in this cast

- 1042 A cast of a human gravid *uterus*, in *situ naturali*, from a different subject, at the ninth month; the obliquity of the *uterus* is very remarkable in this cast
- 1043 A cast of a curious double *uterus* and *vagina*, one of the *uteri* was gravid. There were two Fallopian tubes, two *ovariae*, *os tinctæ* was double, and a *septum* in the *vagina*, with a perforation in it, and two complete sphincter muscles—All these circumstances may be seen in the cast. It is described in the Philosophical Transactions,
- 1044 Three casts of gravid *uteri* at the ninth month, from a human subject; shewing every thing respecting the *uterus*, *fatus*, and *placenta*, that can be demonstrated by casts
- 1045 A cast from the human gravid *uterus*, in the beginning of the seventh month; the *uterus* has been injected and dissected, to shew the distribution of the larger blood vessels.
- 1046 A cast of a true human *mola*, or false conception
- 1047 A cast of the muscles of the arm and hand, from a very muscular subject
- 1048 A cast of the hand of Mr. O'Burne, the Irish giant
- 1049 A cast from a large human dropical *ovarium*
- 1050 Three casts of the human hand
- 1051 A cast of a varicose aneurism in the arm of the human subject
- 1052 A two-foot anatomical figure of the external muscles of the human subject, in plaister of Paris
- 1053 A ditto, by Roubilliac
- 1054 Two small ditto—one wants the arms

- 1055 A small cast of the muscles, in fine plaister of Paris, and accurately repaired—with the glass cover and stand
- 1056 A cast of a beautiful female trunk
- 1057 A cast of a diseased human leg and thigh, from a female subject, owing to *elephantiasis*
- 1058 A phantom, made upon a human skeleton, for teaching the application of bandages
- 1059 A cast of a *spina ventosa* in the superior extremity of the *tibia* of a human subject
- 1060 A cast of an *exostosis*, or enlargement of the *condyles* of the human thigh-bone: it was not a *spina ventosa*: the bony mass was solid and very heavy

DISEASED BONES, FROM HUMAN SUBJECTS.

- 1061 Two *tibiae*, and two *fibulae*, diseased from *lues venerea*
- 1062 Two *fibulae*, ditto, and a *tibia* with a large venereal node
- 1063 A diseased *tibia*, and two portions of ditto, from the *lues venerea*
- 1064 A diseased *os femoris*, a portion of ditto with a node, and a curious diseased *fibula*, owing to the *lues venerea*
- 1065 A diseased *fibula* and a *tibia* with an incipient *necrosis*
- 1066 Two *tibiae*, one with a node; and two portions of *fibulae*, diseased from the *lues venerea*
- 1067 Two *ossa brachiorum*, and an *ulna* and *radius*, much diseased from the *lues venerea*
- 1068 Two *ulnae*, shewing the alterations produced in these bones by confirmed *lues*
- 1069 A distorted *tibia*, from the rickets

- 1070 Three *tibiæ*, with venereal nodes
- 1071 An enlarged *radius* and *ulna*, from a subject with *lues*
- 1072 Two *tibiæ*, and two *fibulæ*, very much diseased from the *lues*
- 1073 A *tibia* with a very large venereal node, and a diseased *fibula* from *lues*
- 1074 A distorted *tibia*, from a rickety subject
- 1075 A *tibia* much enlarged from venereal nodes, and a *fibula* diseased from *lues*
- 1076 Three diseased *tibiæ* from the *lues venerea*
- 1077 A diseased *tibia*, and two *fibulæ* ditto, from *lues*
- 1078 Four diseased *tibiæ*, some much enlarged from *lues*
- 1079 A very distorted *os femoris*, from a subject with rickets
- 1080 Two thigh-bones, and two *fibulæ*, diseased from *lues*
- 1081 A distorted *tibia*, from a subject with rickets
- 1082 Ditto *tibia* and *fibula*, from ditto
- 1083 Three *tibiæ*, diseased from *lues*
- 1084 Three ditto, ditto
- 1085 Two *fibulæ* much distorted, and a ditto *radius*, from a subject with rickets
- 1086 A very curious and much distorted *os femoris*, owing to rickets
- 1087 Three *tibiæ*, much enlarged and otherwise diseased, from *lues*
- 1088 Two sections of diseased *tibiæ*, with bony granulations; and a portion of a curious diseased *ulna*, from a scrophulous subject
- 1089 A diseased *tibia*, and two *fibulæ* ditto, from *lues*
- 1090 A very curious and much distorted *tibia*, owing to rickets

NATURAL COMPARATIVE SKELETONS.


- 1091 A skeleton of a mouse compleat, made by the *dermestes lardarii* Linnæi, in a glass case
- 1092 A ditto of a rat in a case, prepared by the same insects
- 1093 A natural skeleton of a frog, prepared by dissection
- 1094 A ditto of a rat, prepared by the *dermestes*
- 1095 The skeleton of a large male frog, prepared by dissection, in a circular glass case
- 1096 Two skeletons of moles, prepared by the *dermestes*—with the glass case
- 1097 A very beautiful skeleton of a rat, prepared by the *dermestes*, with the glass case
- 1098 A skeleton of a hedge-hog, prepared by the *dermestes*—with the glass case
- 1099 A natural skeleton of a human *fœtus* in the eighth month—with the glass case
- 1100 A very beautiful skeleton of the *lemur macauco* Linnæi—with the glass case

D R I E D B O N E S, &c.

- 1101 *Scapula, clavícula,* and large cylindrical bones of the superior extremity of the human subject
- 1102 Ditto
- 1103 *Os sacrum, innominatum, femoris, tibia,* and *fibula*
- 1104 A ditto
- 1105 The bones of the superior extremity connected, and some odd bones from ditto
- 1106 The

- 1106 The first rib, and three other ribs, from a very large elephant
 1107 The first rib, and two ditto, from ditto
 1108 Four arches of human *crania*, shewing the futures, tables, &c.
 1109 A very curious arch of a human *cranium*, with a remarkable projection of the *os occipitis*; and the *cranium* of a turtle
 1110 The *ileon* and *colon* of a turtle, injected, arteries red, veins yellow; and two human *placentæ*, with the *funes umbilicales*, injected

End of the Eleventh Night's Sale.



Twelfth Night's Sale,
Saturday, December the 22d, 1787.

DRIED PREPARATIONS:

- 1111 **T**WO human *placentæ*, with the *funes*,
injected
- 1112 Three ditto, injected
- 1113 Two *funes umbilicales*, and two portions of
ditto, with very large arteries
- 1114 Two preparations of the human internal
thoracic arteries; and the *rectum* of the
human subject distended with wax
- 1115 The human *aorta* distended with plaister of
Paris, shewing the valves; and the caro-
tid artery of an horse—It was increased
one third in length by injecting it, and in
the same proportion in width
- 1116 A section of a bisected *cranium*, and lower
jaw of a human subject
- 1117 A section of the human *cranium*, with the
processes of the *dura mater* and maxillary
sinusses, &c.
- 1118 A set of very white and beautiful separated
bones of the *cranium* and face, from the
human subject—and a glass bell and
stand

- 1119 A beautiful natural skeleton of a parroquet, with a glass bell and stand
- 1120 A very curious and remarkable *cranium*, from the human subject: a suture passes, in the transverse direction, through the *os occipitis*, and there is a large *os wormianum* where the sagittal and frontal futures meet

78 DISEASED BONES.

- 1121 A diseased *clavicle*, *os brachii*, *ulna*, and first bone of the *sternum*, owing to the *lues venerea*
- 1122 A *tibia* with a venereal node, and two diseased *fibulae* from the *lues*
- 1123 A distorted *tibia* and *fibula*, owing to the rickets
- 1124 A distorted *tibia* owing to the rickets, and two diseased *tibiae* from *lues*
- 1125 A distorted *os femoris* and *tibia*, from the rickets
- 1126 A distorted *os femoris*, *tibia*, and *fibula*, from the rickets
- 1127 A ditto *tibia* and *fibula*, from ditto
- 1128 Two distorted *ossa femorum* from the rickets
- 1129 Three *tibiae* very much enlarged, with the venereal nodes
- 1130 A distorted *tibia* from the rickets—a fractured *tibia* united by *callus*—and a diseased *tibia* from the *lues*
- 1131 Three diseased human ribs
- 1132 A curious *lusus naturæ*, a bone uniting two human ribs:—there was a compleat joint and capsular ligament at each extremity of the supernumerary bone
- 1133 An *os brachii* and *scapula* with *caries*, in the

the joint of the shoulder, which must have produced dislocation

1134 A portion of diseased *tibia*, and two ditto, both diseased; one has the medullary artery injected;—and a portion of *os brachii* diseased from the *lues*

1135 A *tibia* and *fibula*; the superior articular surface of the *tibia* is diseased, owing to *fungus articularum*;—a cast of an *anchylosis* of the knee joint;—and a diseased *fibula*

1136 A very curious diseased arch of the human *cranium*, from a subject of forty years of age, who died from *hydrocephalus externus*; the ossific matter has been absorbed in several parts of the parietal bones, and a great quantity has been deposited in the central portions of these bones, so as to produce a considerable thickness in these parts, whilst these bones are diaphanous in other places. This remarkable change in the parietal bones seems to have taken place from the pressure made by the water

1137 Another diseased arch of the human *cranium*, equally remarkable.—On the external surface, on the summit of the frontal suture, an eminence may be perceived, and the bone has a purulent hue at this part; on the internal surface, opposite this eminence, a hole is seen in the inner table of the bone, which leads into the *diploe*; this cavity was filled with blood from a rupture of the longitudinal sinus, this produced apoplexy and death; upon dissection blood was found extravasated between the *dura mater* and internal surface

of the *cranium*. The removal of the ossific matter of the bone has been owing to the pressure made by the blood. The elevation of the external table must be accounted for by supposing the earth to have been totally absorbed in this part at one time, and earthy matter having been again deposited, nature had made every effort to save the patient, tending to evacuate the blood; and, had the case been understood, the life of the patient would most probably have been saved by the application of the trepan

1138 A cast of a varicose aneurism in the human arm; and a cast from the arch of a *cranium* much diseased from the *lues*

1139 A cast of the muscles and tendons of the human foot

1140 Two small anatomical figures of the human muscles, in plaister

1141 *A compleat set of casts of gravid uteri moulded and coloured from nature, similar to those described in the eleventh night's sale*

1142 A coloured cast of the muscles of an adult human subject, of the natural size

1143 Three specimens of fossil bones in their *matrix*, from the rock of Gibraltar, and another fossil from ditto

1144 Thirty-two specimens of fossil bones, from ditto

INTESTINAL CONCRETIONS AND CALCULI.

1145 Two hair balls from the stomach of the cow

1146 A ditto, covered with calcareous matter

1147 A

- 1147 A *calculus* from the *intestinum cæcum* of a horse; and a section of a ditto
- 1148 A globular *calculus*, from the *cæcum* of a horse
- 1149 A ditto, shewing the internal structure
- 1150 A curious veined *calculus*, from the *cæcum* of a horse
- 1151 A curious elliptical *calculus*, from the *cæcum* of a horse. Its external surface is eroded from the intestinal juices, or from absorption
- 1152 A large *calculus*, from the *cæcum* of a horse
- 1153 A large dark-coloured globular ditto, from ditto
- 1154 A transverse section of a large tusk of the *trichechus walrus*, or sea-morse, shewing its curious internal structure
- 1155 One half of the lower jaw of a large crocodile, with a box containing a number of teeth of the crocodile. Two things are very remarkable in these specimens;—viz. The lower jaw of this animal is formed by six ossifications; two futures are evident in the specimen; and the teeth are formed one within the other
- 1156 Two portions of human diseased *tibiæ* from *fungus articularum*; and two portions of *ossa brachiorum*, diseased, one by scrophula, the other most probably from a gun-shot wound
- 1157 A portion of a diseased *os femoris*; and a portion of diseased *tibia* from *fungus articularum*
- 1158 A diseased *os femoris*; a portion of ditto, diseased from *fungus articularum*; and three anchylosed human *vertebræ*

- 1159 The prepared skin of a lioness; and ditto of a monkey, from Sumatra
- 1160 The trunk of a turtle, with the curious double *aortæ*, *vena cava superior*, *vena portarum*, and thoracic duct, injected
- 1161 A ditto
- 1162 A very curious *cranium*, with the lower jaw of an horse. The molar teeth on the left side, both in the upper and lower jaws, are four times longer than those on the right side; the upper teeth on the left side lap over the under ones, and prevented the lateral motion of the jaw, so necessary to this animal in grinding its food. A grinding surface has been formed on the inside of the upper teeth, and outside of the under ones, by attrition; and one tooth in the lower jaw is locked in a curious manner by the two adjacent teeth
- 1163 The *caput osseum* of a beaver
- 1164 A bisected *cranium*, and five sections of the *cranium*
- 1165 The *cranium* and lower jaw of a seal; the ethmoid bone is very remarkable;—and a preparation of the muscles of the human eye
- 1166 *Crania* of a cat, a pig, a turtle, and of an animal of the marmot kind; and the *pelvis* of a turtle
- 1167 Two preparations from the upper jaw of the human subject, to shew the secondary teeth; a portion of the lower jaw, with *caries*; and the *tympanum* of a large quadruped
- 1168 *Cranium* of a cat; the upper jaw of a young human subject, with the second set of teeth; a curious fractured bone of a bird, united

- united by *callus*; and the diseased *radius* and *ulna* of a hare
- 1169 The *caput osseum* of a greyhound bisected, shewing the organ of smell in this animal; and part of a bone of a whale
- 1170 A cast of a gravid *uterus* at nine months, with the adjacent *viscera*. The obliquity of the *uterus* is very remarkable
- 1171 A cast of a human *mola*, or false conception
- 1172 Two casts of distorted *ossa brachiorum*; and a cast of a fractured *os brachii*, from a gunshot wound
- 1173 Two casts of the human gravid *uterus*, at the full time
- 1174 A young subject, with the nerves very minutely dissected; and a section of the head of an adult human subject, with the nerves that are contained in the orbit accurately dissected, and the eye-ball and muscles of the eye preserved in spirits in a cask, with a cover
- 1175 A preparation of the vessels of the lungs of a young human subject, corroded—with the glass bell and stand
- 1176 A corroded kidney, with an enlarged *pelvis*—with the glass bell and stand
- 1177 The heart of a turtle, injected—with a pedestal and glass bell
- 1178 Two human *placentæ*, injected, from twins
- 1179 A preparation of the human ear, shewing the *musculus longus* and *brevis Mallei*, with the *membrana tympani* and *Malleus*: the situation of the *laxator tympani Valsalvæ* is marked by red paint in the *meatus auditorius externus*;—a foetal *os temporis*, with the *membrana tympani*;—and a section of the human mastoid process, shewing the cells

- cells which communicate with the *cavitas tympani*
- 1180 A preparation of the human stomach, minutely injected, the arteries red, and the veins yellow—with the glass case
- 1181 A preparation of the ligaments of the joint of the shoulder; a cast of a fractured *os brachii*; and a section of the *os calcis* of the human subject
- 1182 Five dried preparations of the human *larynx* and *os hyoides*
- 1183 A fish of the triquetter kind; a bader of a small whale; the *caput asseum* of an albitros; and two *crania* of quadrupeds
- 1184 Various human *vertebræ*, *os innominatum*, *os sacrum*, and *os femoris*
- 1186 *Scapula*, *os brachii*, *ulna*, and *radius* of the human subject
- 1187 Ditto
- 1188 Three *scapulæ*, and separated bones of the *pelvis*
- 1189 A diseased *os brachii* and *clavicula*
- 1190 A carious *patella* from *fungus articularum*; a section of the *os calcis*; a preparation of the internal ear, with a bristle passed through the passage of the *aquæduclus Fallopii*; and three bones for making preparations of the internal ear
- 1191 Five human *patellæ*, two are diseased; and two anchylosed human *vertebræ*, from a distorted spine
- 1192 Ten various human *ossa innominata*
- 1193 The lower jaw of a very young human subject, injected and prepared, shewing the first set of teeth
- 1194 The *cranium* of a human *fœtus*, at the seventh month; and a section of a *cranium*, with a remarkable long styloform process

- 1195 Five human *patellæ*, and a portion of *os femoris*, with a small *exostosis* within the cavity of the joint.—This preparation explains one cause of the loose bodies sometimes found in the knee joint
- 1196 Nine various *epiphyses*, from the large cylindrical bones of the human subject
- 1197 A fractured rib united by *callus*, and three distorted ribs; and a variety of ribs for study
- 1198 A human heart dried hollow, to shew its internal structure
- 1199 A beautiful preparation of the human spine of a *fœtus*, in spirits
- 1200 A large wet preparation of the lacteals, injected with quicksilver, on the intestine and mesentery of a turtle; with the arteries and veins likewise injected

End of the Twelfth Night's Sale.



Thirteenth Night's Sale,

Monday, December the 24th, 1787.

- 1201 **A** Set of separated bones of the human
cranium
- 1202 A set of ditto. The ethmoid bone is want-
ing
- 1203 Two *ossa temporum*, two *ossa maxillaria*, *os*
frontis, and two *ossa parietalia*
- 1204 Four *ossa maxillaria superiora*, for making
preparations of the second set of teeth
- 1205 Part of the *cranium* of the *fœtus*, shewing the
ossicula auditus, and six *ossa temporum* of the
human subject, for making preparations of
the ear
- 1206 Two *ossa maxillaria* of a young subject, for
making preparations of the teeth, and four
ditto, from *fœtussus*; and a variety of flat
bones of the *fœtus*
- 1207 A lower jaw of the human subject, with a
complete set of teeth, and various cylin-
drical bones from the superior extremity

R

1208 **A**

- 1208 A very curious specimen of the lower jaw, from a subject who chewed tobacco;—on the left side, near the three last grinders, a cavity is formed, by absorption of the bone, from the stimulus given by the pressure of the quid
- 1209 Seven lower jaws, and six sections of the lower jaw, from the human subject; two *ossa maxillaria superiora*, and four sections of the *ossa maxillaria superiora*, from the human subject
- 1210 Six lower jaws, from the human subject, and a section, shewing the maxillary sinusses
- 1211 Various human *vertebræ*, and various separated bones of the human hand and foot
- 1212 Two fractured *radii*, united by *callus*; and two cylindrical bones of a bird, shewing the *foramina* where the air enters the bones
- 1213 A curious diseased *os temporis*, from a human subject. Pressure was made upon the seventh pair of nerves, at and in its passage in the bone, by matter or a tumour, which has caused the absorption of the ossific matter at this part, and produced deafness; a remarkable eminence is seen on the internal surface of the *os petrosum*, and the mastoid process is divided, shewing the cells;—and a curious diseased human *patella*, from attrition
- 1214 A curious diseased human rib; it has been fractured; the *callus* appears to have been formed, and from some unknown cause it seems to have been absorbed, producing the separation of the once united portions;—and part of a *fibula*, from a stump, and two sections

sections of the human *tibia*, with the medullary artery injected.

- 1215 A portion of the jaws, with the incisor teeth of a horse; a section of the human *cranium*; and three various *epiphyses* from the cylindrical bones of the human subject
- 1216 A preparation of the heart and liver of a *fœtus*, shewing the umbilical vein injected, and *ductus venosus*; and a preparation, shewing the *ossa turbinata*, *cellulæ mastoideæ*, *tubæ eustachina*, and *maxillary sinus*, in the human subject
- 1217 A great variety of human teeth, and some from other animals
- 1218 An exfoliation from the human lower jaw;—the *meatus auditorius*, *cavitas tympani*, and *labyrinthus auris*, filled with tin for corrosion;—and a section of the human *penis*
- 1219 Various curious diseased bones of the head, from a scrophulous monkey;—a section of a diseased *tibia*;—two petrous portions of *ossa temporum*, from the *fœtus*;—mesenteric glands, full of calcareous matter;—a fractured rib of an animal, united by *callus*;—and the lower jaw of a *fœtus*
- 1220 A dog, with the blood-vessels injected;—and the neck and head of a dog injected. In these animals a puncture was made in the *arteria carotidea communis* of each, on the left side, and a fine needle was passed through the edges of the wound; an orbicular suture was made under the needle, to save the cavity of the artery at this place, instead of tying above and below the puncture, as in the operation of the aneurism; the artery is obliterated for the space of

three inches near the puncture, and the circulation was carried on by the anastomosing branches. — See Mr. Lambert's Paper on this subject in the London Medical Observations and Enquiries

1221 A curious diseased *os frontis* of a monkey who died from scrophula; an ossified artery from the human subject; and some curious diseased nails, from an old human subject

1222 Four specimens of ossified arteries, injected; and two preparations of human intestine with the arteries and veins injected

1223 A curious and very rare specimen of an ossified vein from the human subject; and a *diverticulum*, from ditto

1224 The trunk, head, and neck of an injected silk fowl, shewing many other parts of a black colour besides the *periosteum*

1225 A preparation of *ileon*, from a human subject who died with dysentery: the lacteals can be seen by holding this preparation between the light and the eye

1226 A preparation of the human liver, from a young human subject, with the lymphatics injected with quicksilver

1227 The trumpet fish

1228 A snake, unknown

1229 A section of a curious animal of the gelatinous kind, of twenty feet in length, taken out of the sea in an East India voyage

1230 A large chameleon, preserved in spirits

1231 A glass vessel and cover, containing a human monster born without lungs, and a part of the abdominal *parietes* wanting, injected

1232 A magazine, containing a seven months human

human *fœtus*, and a human *uterus*, for dissection

ANATOMICAL DRAWINGS, OF THE
SIZE OF NATURE,

BY MISS STONE.

- 1233 A drawing of the grinder, with the curious disposition of the enamel, in the *ſus æthiopicum*; and a ditto of ditto, with the enamel prepared
- 1234 Three—a drawing of an hydatid worm, and the cyſt which contained it, and a delineation of two different ſpecies of *teniæ*
- 1235 A drawing of a human *cranium*, remarkable for *offa triquetra*; and the diviſion of the *os occipitis* by a ſupernumerary future
- 1236 Two—a ditto of a ſacculated human bladder, and a ditto of two anchyloſed human *vertebræ*
- 1237 A ditto of a curious *necroſis tibiæ*
- 1238 Two—a ditto of an *exoſtoſis* in the foot of a horſe;—and a ditto of two anchyloſed human ribs
- 1239 Two ditto—one, of the gall bladder full of *calculi*;—and a ditto of the ſuperficial veins of the kidney of a cat, injected with quick-ſilver
- 1240 Two beautiful drawings of the *venæ vorticoſæ* and arteries of the human eye, and the *plexus ciliaris* in the eye of a turtle
- 1241 Two ditto of the enamel in the grinders of the elephant

1242 Two

- 1242 Two—one, of the arteries and veins of the human intestine ;—and one, of tendinous fibres unravelled
- 1243 Two ditto, of the excretory ducts of the human *testis*, injected with quicksilver
- 1244 Three ditto ; two, of excretory ducts of *testis*, injected with quicksilver, one of them with *vasa aberrantia* ;—and one with lymphatics of the *testis*
- 1245 Five drawings of natural history, from the island of Barbadoes
- 1246 Seven ditto, of enamel in the teeth of horses
- 1247 Two ditto, of lacteals, arteries, and veins of the human subject
- 1248 Two ditto, *vesiculæ seminales* in a *fœtus* at nine months, injected with quicksilver ;—and the cells of the prostate gland of the adult human subject, minutely injected with quicksilver.—See *De Graaf*.
- 1249 Four drawings of ulcerated intestines, from human subjects who have died from the dysentery
- 1250 Four drawings of tortoises and turtles
- 1251 A beautiful drawing of the arteries, veins, and lacteals of the turtle
- 1252 Three—one, of the thoracic duct of a turtle ;—a ditto of lymphatics on the diaphragm ;—and a ditto of a lacteal on the human intestine
- 1253 Two—one, of lymphatics on the human lungs ;—and one, of the air cells injected with quicksilver in the lungs of a dog
- 1254 A very beautiful drawing of a *lusus naturæ*—a horse-shoe kidney from the human *fœtus*, with the renal *capsula*
- 1255 Two views of a *calculus*, taken from the middle

middle portion of the *ureter* of the human subject

- 1256 Two—one, of the *arteriæ duræ matris*;—and another of the arteries and veins of the human intestine
- 1257 A drawing of the gall bladder and ducts, and the pancreatic duct of the human subject;—and a ditto of a bifid gall bladder, found in a cat
- 1258 A curious fleshy tumour, adhering to the *pylorus* of the human subject: it produced sickness at stomach, and other disagreeable symptoms
- 1259 Two—one, of the lacteals in an ass;—and a ditto in the turtle, with the arteries and veins injected
- 1260 Two—one, of an enlarged human *pelvis* and *ureter*;—and a ditto of the human spleen, with a very tortuous and ossified artery
- 1261 A very beautiful preparation of the arteries, veins, and lacteals, injected, in a turtle—in a gilt frame
- 1262 Two—one, of the large *granadilla*;—and one from the *contrayerva* plant of Jamaica
- 1263 Two—one, of a calculous kidney;—and a ditto of a curious disease of the kidney
- 1264 Two—one, of a distinct false aneurism in a horse;—and a ditto of an ossification in the liver of a horse
- 1265 Two—a drawing of a human monster, born without brain;—and another, shewing the descent of the *testes*, by Mr. Patterson
- 1266 A beautiful coloured drawing of an aloetic plant, by Miss Stone
- 1267 Three—one, of a distorted puppy, with a want of the palate;—a ditto of an human *intus susceptio*;—and a ditto of a *hernia*
- 1268 Two

- 1268 Two—of diseased lungs with abscesses, and large blood-vessels in their cavities not eroded
- 1269 Eight drawings of plants from the island of *Jamaica*
- 1270 A lacteal, injected with quicksilver, in an ass;—and two, of diseased and anchylosed human ribs
- 1271 A diagram to explain the structure of the human eye
- 1272 Three drawings of *Medusæ*
- 1273 Mr. Hewson's microscopic view of the red vesicles of the blood in various animals
- 1274 Two—one, a *lusus* of the ascending branches of the *aorta*;—and one, of the human *cæcum* and *appendix*
- 1275 One, of the human gall bladder and ducts, injected, with their termination in the *duodenum*
- 1276 A very beautiful drawing of the arteries, veins, and three lacteals, injected with quicksilver, with their glands
- 1277 Two—the lymphatics on the stomach of the *torpedo*, injected with quicksilver; and one, of the integuments of an African
- 1278 A very beautiful drawing of a corroded kidney of the human subject, with double *pelves* and *ureters*
- 1279 A beautiful drawing of lacteals in the human subject
- 1280 Two of shells of turtle
- 1281 A drawing of a *squalus pristis*
- 1282 A ditto of the human thoracic duct
- 1283 A ditto, with three magnified views of the human *iris*, by Mr. Birnie
- 1284 A drawing, containing several views of the *mysticetus*, or Greenland whale
- 1285 A beau-

- 1285 A beautiful drawing, by Rymfdyk, of the blood-vessels of the human gravid *uterus*
- 1286 A ditto of lacteals, injected with quicksilver, in the ass
- 1287 A ditto of a *hernia*
- 1288 A ditto of *anchylosed vertebrae* in the spine of a horse
- 1289 One, two views of a curious *acarus*, with two microscopic views of ditto
- 1290 A frame with three preparations of human intestine injected
- 1291 A picture, in oil colours, of a bird from Jamaica
- 1292 Three ditto, in oil colours; one of several parasitical plants; and two ditto of flowers; both from Jamaica
- 1293 A drawing of a double human monster
- 1294 Two ditto, one of an incurvated *aorta*, of the human subject; and one of an ossified *aorta*
- 1295 Two ditto of ossifications of the human *aorta*
- 1296 A ditto of the human thoracic duct with a double termination
- 1297 A ditto of the arteries of the arm, with a *lusus naturæ*
- 1298 A drawing of a curious human monster
- 1299 Two botanical drawings; one, of the Guernsey lilly; the other, of a monstrous melon thistle
- 1300 A beautiful drawing of the human thoracic duct, &c.
- 1301 A ditto of ditto, with the termination
- 1302 Two, of a large human aneurism
- 1303 A ditto of an aneurism on the arch of the human *aorta*
- 1304 Three ditto of natural history
- 1305 Two

- 1305 Two beautiful coloured drawings of the
lacerta sexlineata
- 1306 Two ditto—one, a microscopic view of a
curious *acarus*; and one, of the head of the
squalus zygena
- 1307 Two ditto; one, of the curious *valvula con-*
nivens of the skate; and one, of an imper-
forated *rectum*, described in a former part
of this catalogue
- 1308 Four coloured plates, from Mr. Hewson's
Lymphatic System
- 1309 Four—one, of a dolphin; one, of a bird, the
puffin; one, of a marine worm; and one, of
a curious worm, with a microscopic view of
part of the same animal
- 1310 Three ditto—one, of a human kidney, with
double *pelvis* and *ureter*; one, of the cellular
net-work of vessels on the intestine of an ass;
and one, of the tooth of the hippopotamus,
prepared, shewing the enamel
- 1311 A ditto of a human monster born without
brain, with a fissured palate
- 1312 A ditto of a human monster born with one
eye, and a *proboscis* where the nose is gene-
rally placed
- 1313 A ditto, of two kidneys with enlarged *pelves*
and *ureters*
- 1314 A ditto, of arteries, veins, and lacteals on
the intestine and mesentery of a turtle
- 1315 Four drawings of a very curious diseased
human skull
- 1316 Two ditto—one, of the enamel in the ele-
phant; and one, of the shell of a beautiful
tortoise
- 1317 Nine prints of the skeleton and muscles of
the human subject, in frames
- 1318 A large mahogany anatomical case with
glass

glass door, and a press with folding doors underneath

1319 A ditto, ditto

1320 A very large double mahogany anatomical cabinet, with sliding glass doors

1321 A mahogany chest of drawers for holding anatomical preparations

1322 A ditto

1323 Sundry tables and stools for anatomical purposes

1324 Ditto

1325 Sundry shelves

1326 A small mahogany cabinet, with drawers

1327 A ditto

1328 A ditto

F I N I S.

right door, and a pair with folding doors
underneath
1319 A. Case, and
1320 A. Very large double mahogany anatomical
cabinet, with India glass doors
1321 A. Mahogany chest of drawers for holding
anatomical preparations
1322 A. Case
1323 A. Mahogany table and stools for anatomical pur-
poses
1324 A. Case
1325 A. Mahogany cabinet
1326 A. Mahogany cabinet, with drawers
1327 A. Case
1328 A. Case