

**An operation for epithelioma of the lower eyelid / by Freeland Fergus.**

**Contributors**

Fergus, A. Freeland 1858-1932.

**Publication/Creation**

[Place of publication not identified] : [publisher not identified], [between 1900 and 1909?]

**Persistent URL**

<https://wellcomecollection.org/works/txd2eaq2>



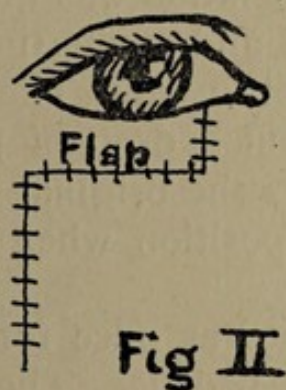
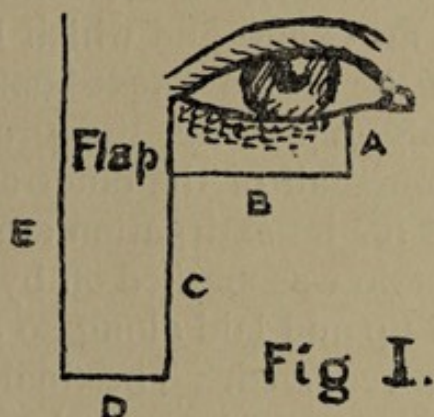
Wellcome Collection  
183 Euston Road  
London NW1 2BE UK  
T +44 (0)20 7611 8722  
E [library@wellcomecollection.org](mailto:library@wellcomecollection.org)  
<https://wellcomecollection.org>

2

## AN OPERATION FOR EPITHELIOMA OF THE LOWER EYELID.

By FREELAND FERGUS, M.D., Glasgow.

A case of epithelioma involving the outer half of the lower eyelid recently came under my notice for treatment. There was no great ulceration but to the extent above indicated there was a well marked infiltration of the skin. A portion of the tissue was removed and examined by



Dr. Mackie, at that time of the Pathological Institute of the Western Infirmary, now attached to the Pathological Department of the Middlesex Hospital. He was clearly of opinion that the growth was epithelioma. Under these circumstances it became imperative to remove and that completely almost the entire lower eyelid.

The amount of structure which required removal



was unusually large and the difficulty of replacing the excised structure did not seem to me to be met by any of the procedures mentioned in the ordinary text-books. The only method of blepharoplasty which seemed to me likely to give an adequate result was the well known one of Dieffenbach. That operation, however, while it gives a satisfactory new eyelid, leaves a large naked surface to be covered over either by granulation or by skin grafts.

Under these circumstances I determined to try a flap operation which to me is new and which I have not found described in any of the ordinary text-books.

Figure 1. roughly represents the growth, occupying rather more than one-half of the outer aspect of the lid. The incisions used for its extirpation are indicated by A and B. A flap of skin was marked off by the incisions C, D and E dissected up and laid along so as to replace the lid which had been removed. The final result is shown in Figure II. The skin was loose and no difficulty whatever was experienced in approximating the edges of the space denuded by the removal of the flap. For some days before the operation was undertaken the parts were carefully prepared and at the time of operation, tincture of iodine was freely used. The parts healed by immediate union without a drop of pus. The word flap in Figure I. indicates the original position of the skin and in Figure II. its position when the operation was completed.

Union took place at once for the flap had a broad, highly vascular pedicle. The small cross lines in Figure II. indicate the sutures employed.

Unfortunately this operation cannot be used for men as the flap was so long that it would have involved the hairy part of the face. Not long ago, I had to remove a large portion of the lower eyelid from a man, and in that case the flap was cut from the forehead right above the nose very much after the method recommended by Exner.



That case also did well, but the pedicle of the flap required much more twisting which caused the epithelial layer of the flap although not the *cutis vera* to slough.

The pedicle also had to be removed afterwards. The final result however was all that could be desired.

In the case of a man I might cut the flap straight upwards from the neighbourhood of the outer canthus when the growth is at the outer part of the lid. For all cases occurring at the inner aspect I believe Exner's method to be eminently satisfactory. It has given good results in my hands.

