

**Malignant disease of conjunctiva / by Freeland Fergus.**

**Contributors**

Fergus, A. Freeland 1858-1932.

**Publication/Creation**

[Place of publication not identified] : [publisher not identified], [1905?]  
(London : Adlard.)

**Persistent URL**

<https://wellcomecollection.org/works/xwfhmjjy>



Wellcome Collection  
183 Euston Road  
London NW1 2BE UK  
T +44 (0)20 7611 8722  
E [library@wellcomecollection.org](mailto:library@wellcomecollection.org)  
<https://wellcomecollection.org>

*Malignant disease of conjunctiva.*

By FREELAND FERGUS, M.D.

Case of A. B—, æt. 9 years.

The case which I wish to record seems to me to be of special interest, both on account of its essential rarity and of its extraordinary malignancy.

The patient, a girl, æt. 9 years, was sent to my clinic by Dr. Hill, of Carlisle, and was admitted on November 24th, 1903. On examining her, I found that the conjunctiva of the right eye presented an appearance the like of which I had never seen before. The bulbar conjunctiva was covered, especially at its lower and inner aspects, with sprouting vegetations not at all unlike those which are seen in some cases of severe spring catarrh. They were soft to the touch, pale in colour, and were covered by a frothy mucous discharge. At no part was the limbus corneæ involved, nor was the palpebral conjunctiva. The history which I got was that the condition began about six months before the patient was sent to me.

At this stage I inclined to the opinion that I was dealing with one of the rarer forms of conjunctivitis, and the water-colour sketch, carefully executed by Mr. John Henderson, shows that there was some ground for such a view. A difficulty at once arose, however, when an attempt was made to classify it along with any well-defined form of conjunctivitis.

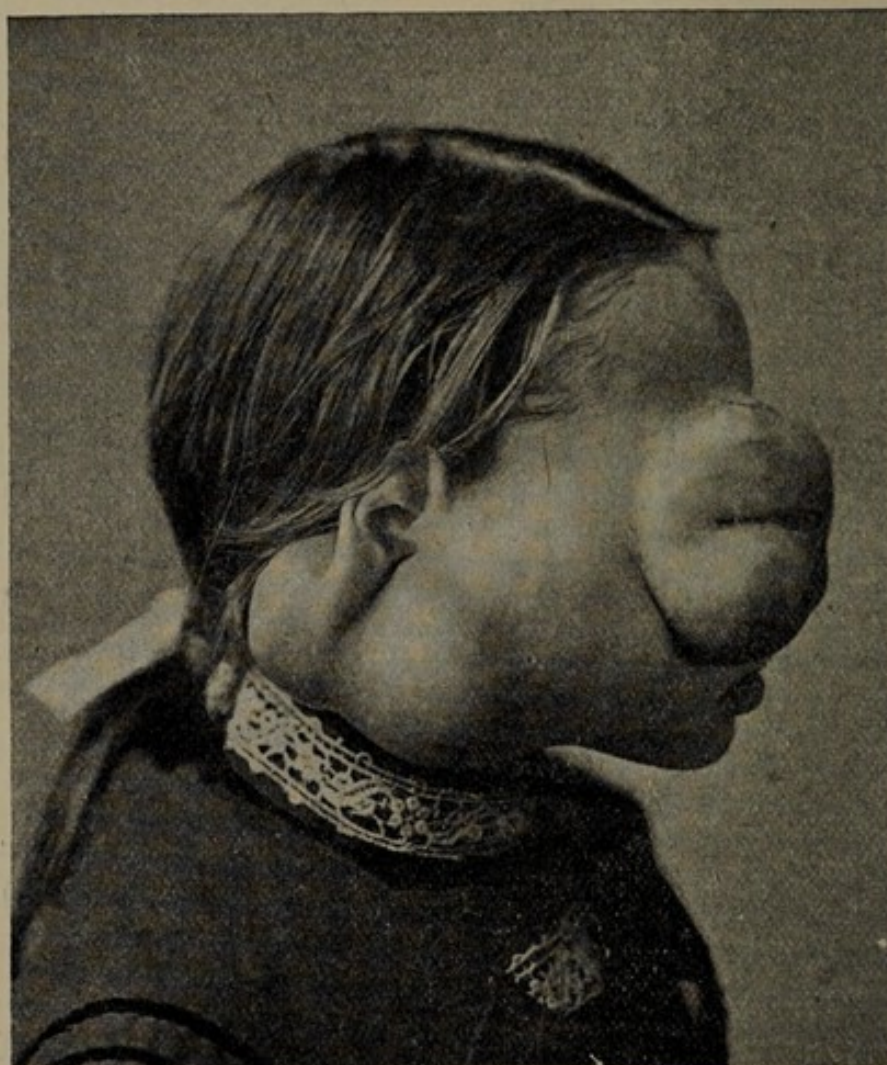
The freedom of the limbus from any complication almost



certainly precluded the idea of spring catarrh, while on the other hand the appearances did not at all correspond with the classical descriptions of Parinaud's disease.

The patient was kept under observation for about a month, undergoing various forms of local treatment, which were of no avail. Towards the end of December (on the 23rd) a large portion of the diseased tissue was carefully

FIG. 1.



excised. The malady did not seem at that time to extend back into the orbit; there was no exophthalmos, and the vision was  $\frac{6}{9}$  of Snellen's scale. A portion of the tissue removed was sent to a pathologist, whose report was indefinite and did not in the least clear up the diagnosis. The case was evidently one of unusual difficulty.

On January 13th, 1904, the remainder of the growth



was removed, and a month afterwards the patient went home. There was still fair vision in the eye and there was no sign of extension into the orbit.

On March 8th, 1904, the patient returned to the eye infirmary, and the following is an epitome of the notes made of her case by the House Surgeon.

The tumour has recurred. It presents to the inner side of the eyeball and appears to affect the bulbar and palpebral conjunctiva. The movements of the ball, which is displaced outwards, are limited, and the mass which projects forwards separates the lids somewhat. It is pale, soft, and œdematous, and the surface is irregular. The patient is free from pain and there are no enlarged glands. Vision =  $\frac{6}{60}$ .

At this period I was seized with influenza, and the care of the patient passed into the hands of my colleague, Dr. Lewis McMillan. Just before leaving duty I removed two portions of the tumour; one of these I sent to Mr. Devereux Marshall, who kindly examined it and sent me an extremely interesting report. He, perhaps, will be good enough to favour the Society with an account of his observations. The other portion was sent to Professor Muir, of the Pathological Department of the University of Glasgow.

The following is Professor Muir's report :

PATHOLOGICAL DEPARTMENT,

WESTERN INFIRMARY,

*March 16th, 1904.*

"The tumour consists of masses of cellular connective tissue which are pushing up the conjunctival epithelium in a papillomatous manner, the epithelium being at places thinned, especially over the depressions, and at others somewhat thickened. In the central parts of the masses are fairly numerous and thin-walled vessels, many of which are surrounded by a fibrous or somewhat myxomatous tissue. The peripheral parts (*i. e.*, under the epithe-



lium) are almost entirely cellular, the cells being spindle-shaped or somewhat irregular in form ; amongst them are thin-walled vessels and a delicate fibrillar substance. While in general plan of structure the growth corresponds rather with a simple papillomatous tumour, yet it is difficult to reconcile the highly cellular character with this view of the condition, and I very much fear that it will prove to be really of sarcomatous nature."

Both reports with which I was favoured agreed as to the malignancy of the growth, and indeed by this time the clinical history as well as the naked-eye appearances could leave no reasonable doubt as to the correctness of that opinion. Dr. McMillan, therefore, on March 21st, dissected out the entire contents of the orbit. A thoroughly clean sweep was made of the whole thing, and the patient returned to Carlisle on April 14th. She came back to the infirmary on May 23rd, and it was then found that the orbital cavity was filled with tumour mass and that the preauricular gland had become involved. It was also observed that at times the patient was drowsy, and as I had reason to believe that there was an extension of the growth into the cranial cavity, I determined to let matters alone. The patient therefore returned to Carlisle and was under Dr. Hill's care until her death, in October.

Dr. Sedgwick, of Carlisle, made an autopsy and sent certain portions of tissue to me. These were examined by Dr. Inglis Pollock. [Lantern slides made from his preparations were exhibited.]

I think the only diagnosis possible is that of leucosarcoma, and the starting-point of the malady would seem to have been the ocular conjunctiva.

The following is Dr. Sedgwick's report :

#### NOTES ON AUTOPSY, OCTOBER 14TH, 1904.

Body of girl, æt. 12 years. Rigor mortis present in legs only. No post-mortem discoloration. Attached to the right side of the head is an enormous tumour, larger



in extent than the head. The tumour apparently arises from the right orbit and the preauricular region. Viewed anteriorly, it has two "lobes," the upper of which is about five inches above the orbit, presenting an ulcerated surface. The lower lobe extends outwards two inches beyond the point of the right shoulder, and its extremity is also ulcerated. The body of the tumour is smooth, soft, rounded, and pale, and presents no veins on its surface. Viewed laterally, the tumour has apparently three lobes, there being a posterior lobe, very smooth, soft, and semi-translucent.

This tumour tore open during manipulation and revealed a jelly-like interior.

There were no glands to be felt anywhere in the body.

*Chest.*—No glands felt in the mediastina.

*Pleura.*—Normal.

*Lungs.*—Both lungs showed marked basal œdema. No traces of secondary deposit.

*Heart and pericardium.*—Normal.

*Abdomen.*—No fluid in the peritoneal cavity. No glands felt.

*Liver.*—Normal. No trace of secondary deposit.

*Spleen.*—Normal.

*Kidneys.*—Normal.

*Pelvic organs.*—Normal.

After removal of the skull-cap the tumour was found to have involved the whole of the right anterior fossa, the bone of which was practically absorbed, there being a little thin egg-shell bone to the outer and posterior quadrant of the fossa. There were two large outgrowths of tumour, one of which lay above and posterior to the right supra-orbital fissure, and the second towards the middle line, apparently finding its way through the cribriform plate and pushing the falx cerebri nearly an inch to the left of the middle line.

In the middle fossa on the right side was a continuation of the same growth, extending an inch outward and to the right; the whole of the lesser right wing of the sphenoid together with the sella turcica were in process of absorp-



tion by the growth, the sella turcica being replaced by a soft pulpy and gritty mass. The meninges of the base of the brain were not apparently involved, and the brain itself showed no deposit either by extension or metastasis. There was softening of the inferior frontal lobes, and the olfactory bulbs were soft and flattened. The optic chiasma was much softened and flattened from above downwards.

The ventricles of the brain were distended. The tumour also involved the right palatal bone, bulging into the mouth, while the right posterior naso-pharynx was completely plugged by growth.

The cephalic tumour was observed clinically to arise from a preauricular gland or glands, and the orbital cavity (the eye having been removed); notwithstanding the phenomenally rapid growth of the tumour, and the involvement of big venous sinuses (*e. g.*, the cavernous sinus), the rest of the body remained free from metastasis, there being no cervical gland enlargement.

*(January 26th, 1905.)*