

Tortuosity of the aorta / by Joseph Sailer and G.E. Pfahler.

Contributors

Sailer, Joseph, 1867-1928.

Pfahler, George E. 1874-1957.

Publication/Creation

[Place of publication not identified] : [publisher not identified], [1903?]

Persistent URL

<https://wellcomecollection.org/works/xuewcrc2>




Wellcome Collection
183 Euston Road
London NW1 2BE UK
T +44 (0)20 7611 8722
E library@wellcomecollection.org
<https://wellcomecollection.org>

SUPPLIERS OF
G. E. PFAHLER, M. D.,
1409 SPRUCE ST.

Tortuosity of the Aorta.

BY
JOSEPH SAILER, M.D.,
AND
G. E. PFAHLER, M.D.,
OF PHILADELPHIA.

FROM
THE AMERICAN JOURNAL OF THE MEDICAL SCIENCES,
OCTOBER, 1903.



Digitized by the Internet Archive
in 2019 with funding from
Wellcome Library

<https://archive.org/details/b3060414x>

TORTUOSITY OF THE AORTA.

BY JOSEPH SAILER, M.D.,

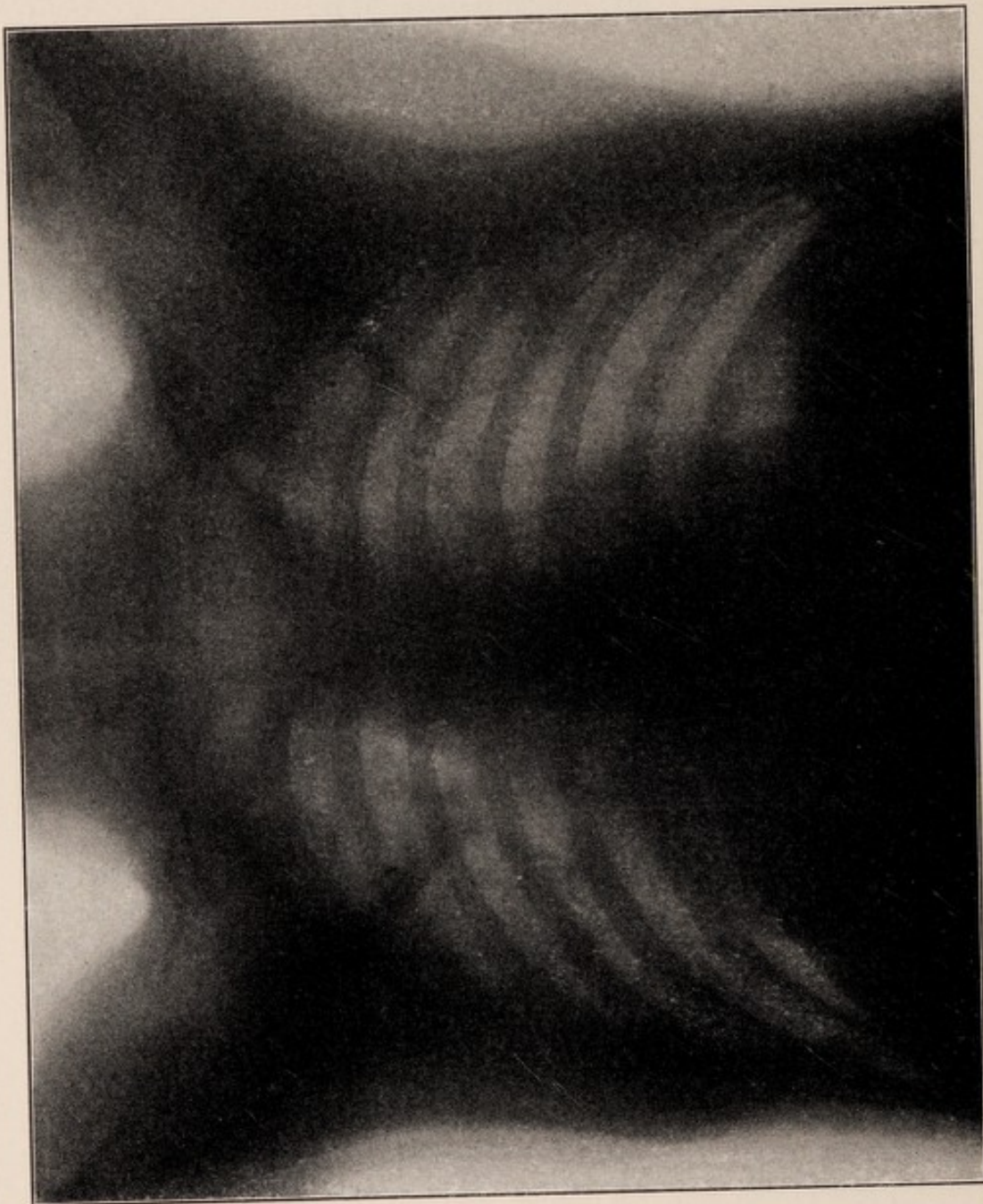AND

G. E. PFAHLER, M.D.,
OF PHILADELPHIA.

IN the course of a series of studies upon lesions of the aorta, which consisted of careful clinical examinations combined with fluoroscopic and radiographic examinations, we were surprised at the frequency with which some of the lesser signs of aortic aneurism were present. Among these were inequality of the radial pulses, suprasternal pulsation, tracheal tugging, accentuation of the aortic second sound, and brassy cough. Not infrequently the patients complained of certain other symptoms, particularly dyspnœa, anginoid attacks, and localized pains. In many cases aneurism was undoubtedly present, either causing characteristic pressure symptoms or being manifest as an external expansile pulsation. In a number of cases, however, we observed with the fluoroscope an expansion in the shadow of the aorta at the level of the fifth or sixth dorsal vertebra, extending from one-half to two inches to the left. This, we supposed, represented an aneurismal dilatation of the aorta at this point. Upon all cases that died effort was made to obtain autopsies, sometimes successfully; and we discovered that in the majority of cases in which this skiagraphic picture was observed no dilatation of the aorta was present, nor did sections through the wall of the aorta at this point indicate that there was any diminution of the muscular layer, such as might have accounted for dilatation under pressure of the blood current. In the second autopsy careful dissection showed that at this point the aorta made a bend to the left, not very unlike the tortuosity that is observed frequently in cases of atheroma of the peripheral arteries. Altogether we have records of eighteen cases with skiagraphs in which this combination occurred, and of these four have been examined post-mortem, all with similar results. It seems not unlikely, therefore, that among subjects of arterial sclerosis this tortuosity of the aorta, giving rise to some of the signs of aneurism of the arch, is relatively a common process. There is no reason to suppose that tortuosity of the arch of the aorta differs in any way from tortuosity of the other arteries of the body. In all probability it is produced by a loss of

elasticity, a gradual elongation and dilatation of the bloodvessel as a result of this loss, and the fact that at certain points in its course the artery is fixed, so that between these points compensation for elongation is only accomplished by bending. It would seem as if in the aorta this compensation could be attained by increase in the height of the

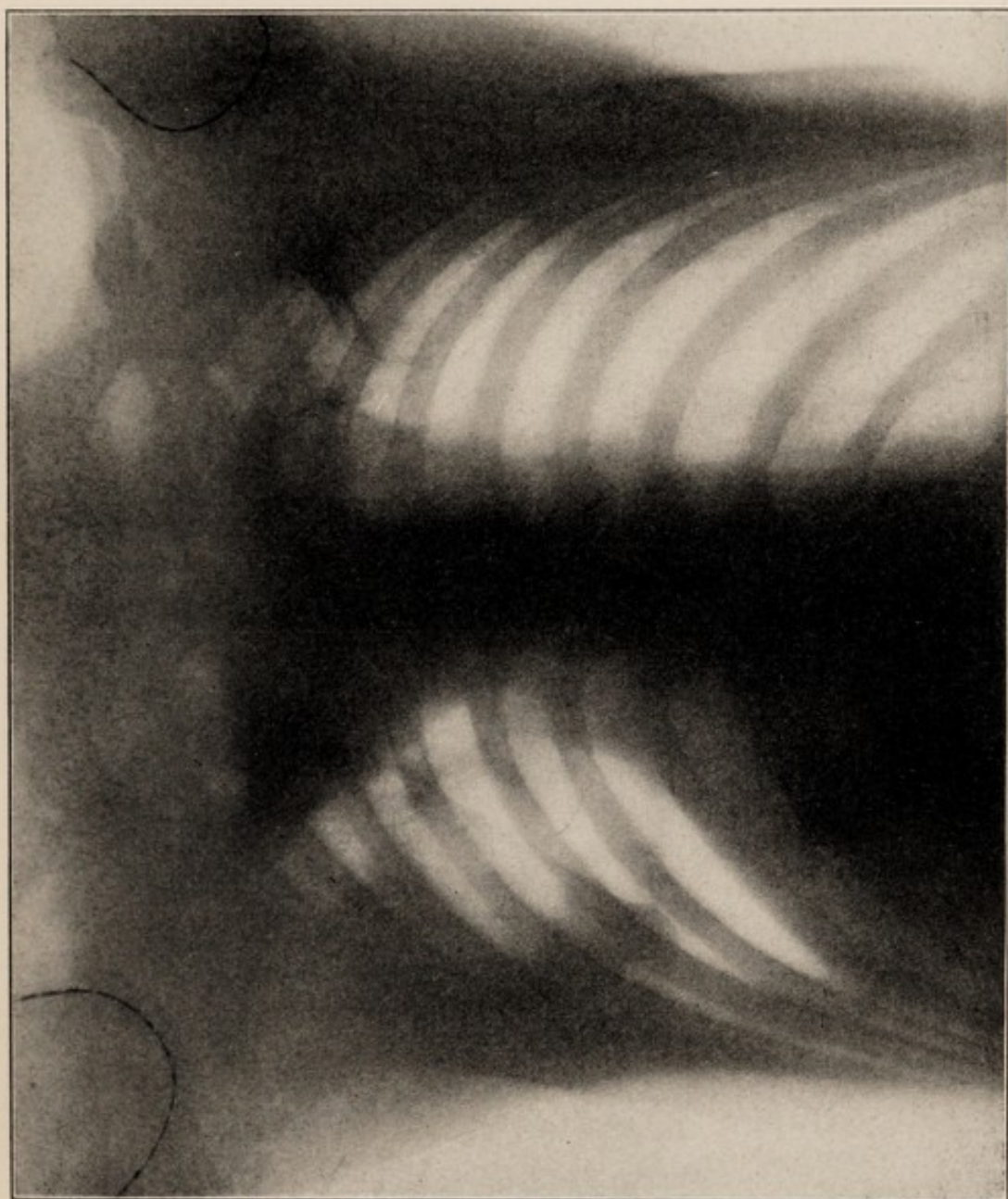FIG. 1.



Normal chest. No bulging in the shadow of the aorta at the junction of the transverse and descending portion.

arch. The arch of the aorta is practically fixed at two points: the aortic orifice of the left ventricle, and the point where it reaches the vertebral column at the level of the fifth dorsal vertebra. The position of the attachment to the heart can only vary when the heart itself is moved; the attachment to the vertebra is not quite so firm and is made

by connective tissue and by the intercostal arteries. Nevertheless, it is sufficiently firm to prevent extension downward, in which it is aided by the large vessels arising from the arch. The extension upward of the arch is hindered by the closeness of the manubrium to the bodies of the vertebra and the fact that the space between them contains the

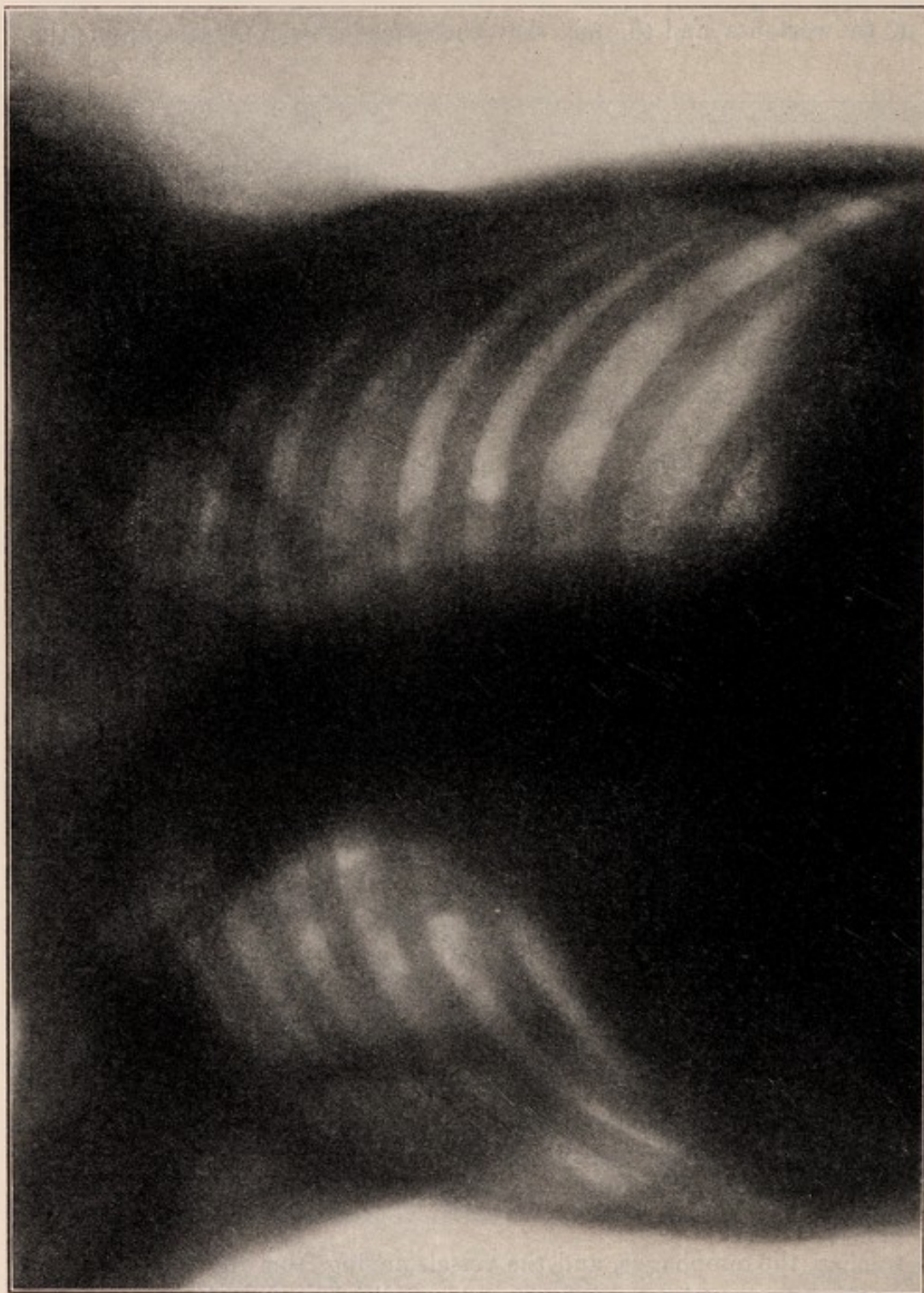

Tortuosity of the aorta. The dark shadow of the spinal column may be seen in the central portion of the skiagraph. The shadow of the aorta extends upward about one inch to the right of the spinal column, and at the left makes a sharp bend about two inches to the left, then curves inward and downward, where it joins the shadow of the heart.

trachea, the œsophagus, and the vessels arising from the arch. That a certain amount of extension upward usually does occur is evidenced by the frequency of suprasternal pulsation, but this extension can only be moderate, and the elongation of the aorta, exposed as it is to the full force of the contraction of the left ventricle, in all probability must be

frequently so great that it cannot be compensated entirely by this movement; therefore it is obliged to deviate laterally, in which direction it meets little to resist it except the compressible upper lobe of the

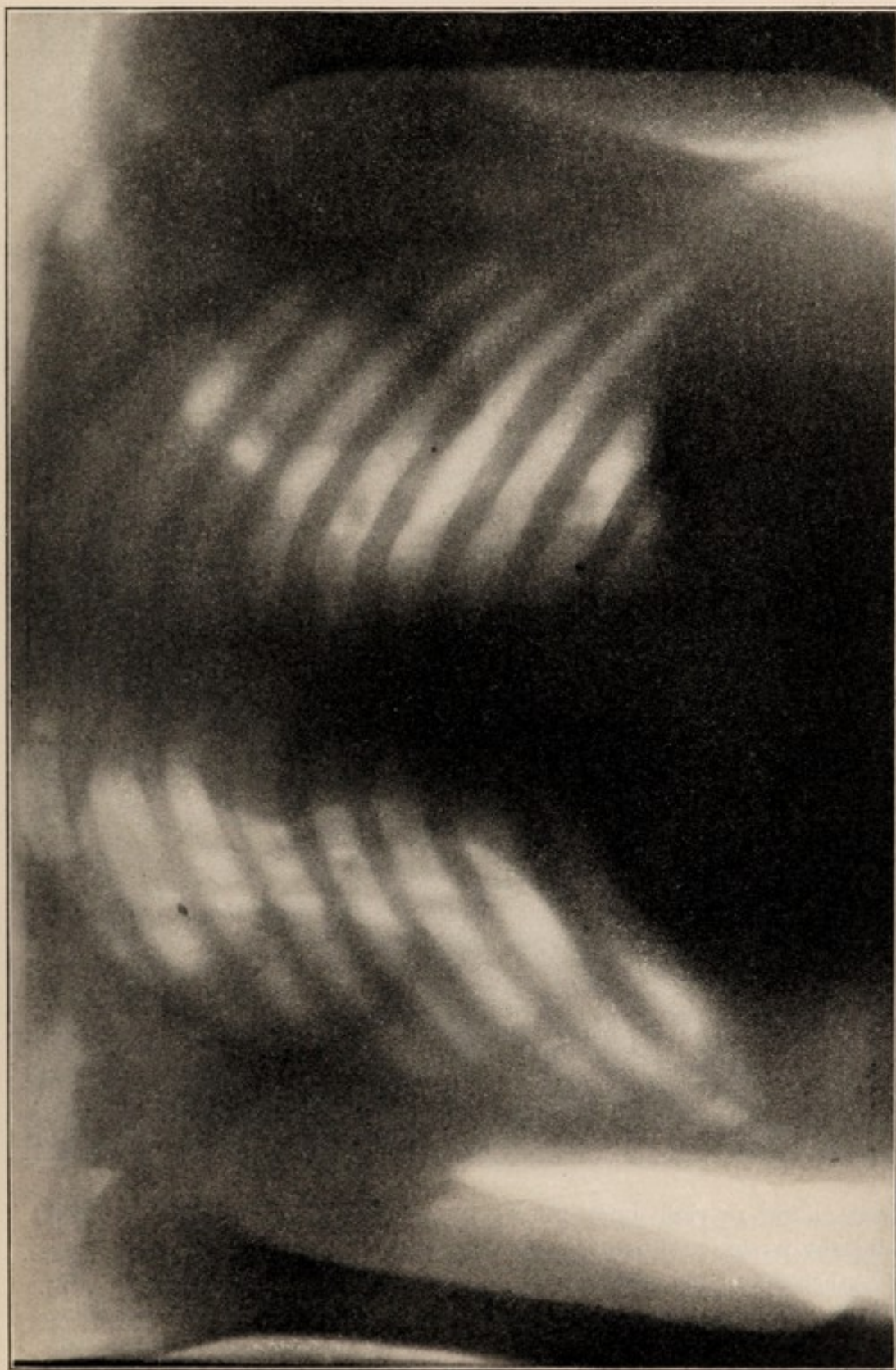
FIG. 3.



Tortuosity of the aorta, shown by the projection in the shadow at the left portion of the arch.

left lung. As a result of this, the descending portion, before it reaches the vertebral column, becomes separated further than normally from it, so that it produces a slight bending at the point where they join, and

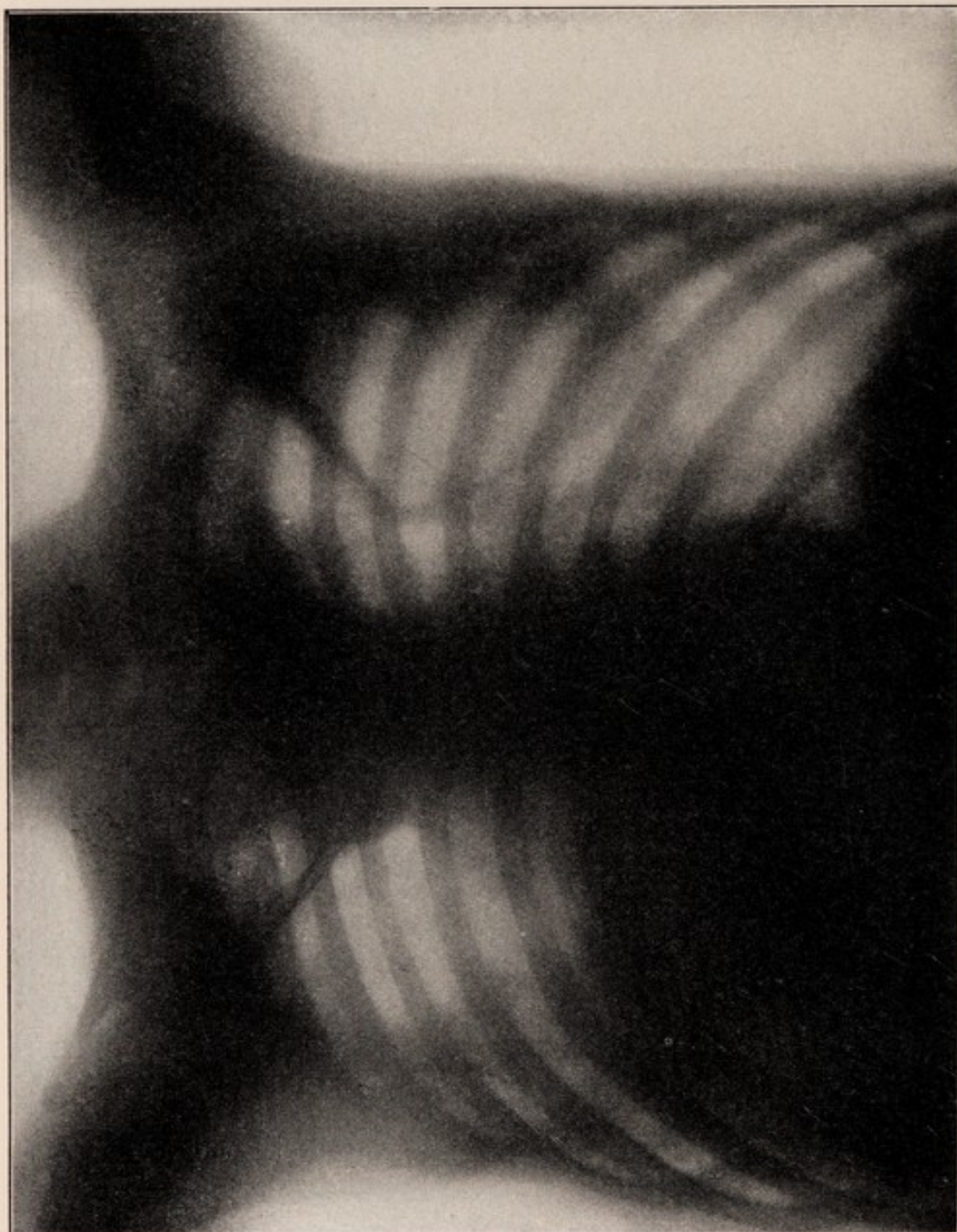
this bend is the tortuosity that we have observed in our skiagrams. The examinations of the aorta in old persons have convinced us that this tortuosity is by no means uncommon, even in patients who have



Tortuosity of the aorta and aneurism of the innominate artery. The shadow of the aorta may be seen extending upward to the right of the spinal column, where it is continuous with the shadow of the innominate aneurism; then a bulging is seen at the left portion of the arch, which is indicative of the tortuosity.

not necessarily had clinical symptoms that attracted attention. If at an autopsy or a dissection, after the removal of the sternum, the left lung is carefully dissected away without disturbing the position of the

FIG. 5.

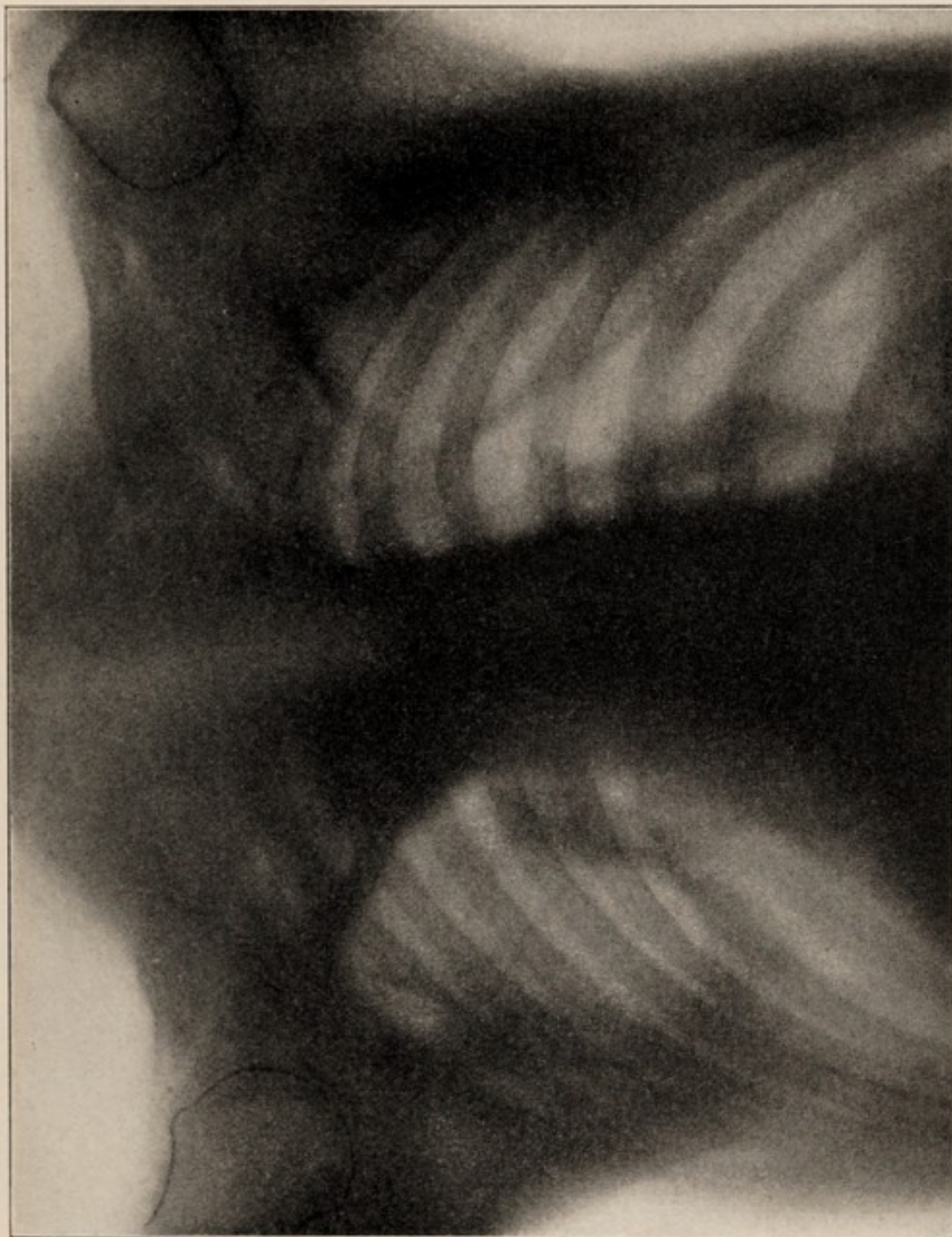

Tortuosity of the aorta, shown by the projection in the shadow at the left portion of the arch.

heart, aorta, or right lung, the whole arch of the aorta is then exposed and any irregularity readily demonstrated.

Atheroma of the aorta has received considerable attention from clinicians. The physical signs that it is supposed to cause, however, have been, as a rule, limited to an impairment of the resonant note over the

upper portion of the sternum, which may extend slightly to either side of its border, and is due to dilatation of the first portion of the aorta; a systolic murmur, heard best over the manubrium and transmitted into the vessels of the neck, and occasionally—it is stated—heard also at the

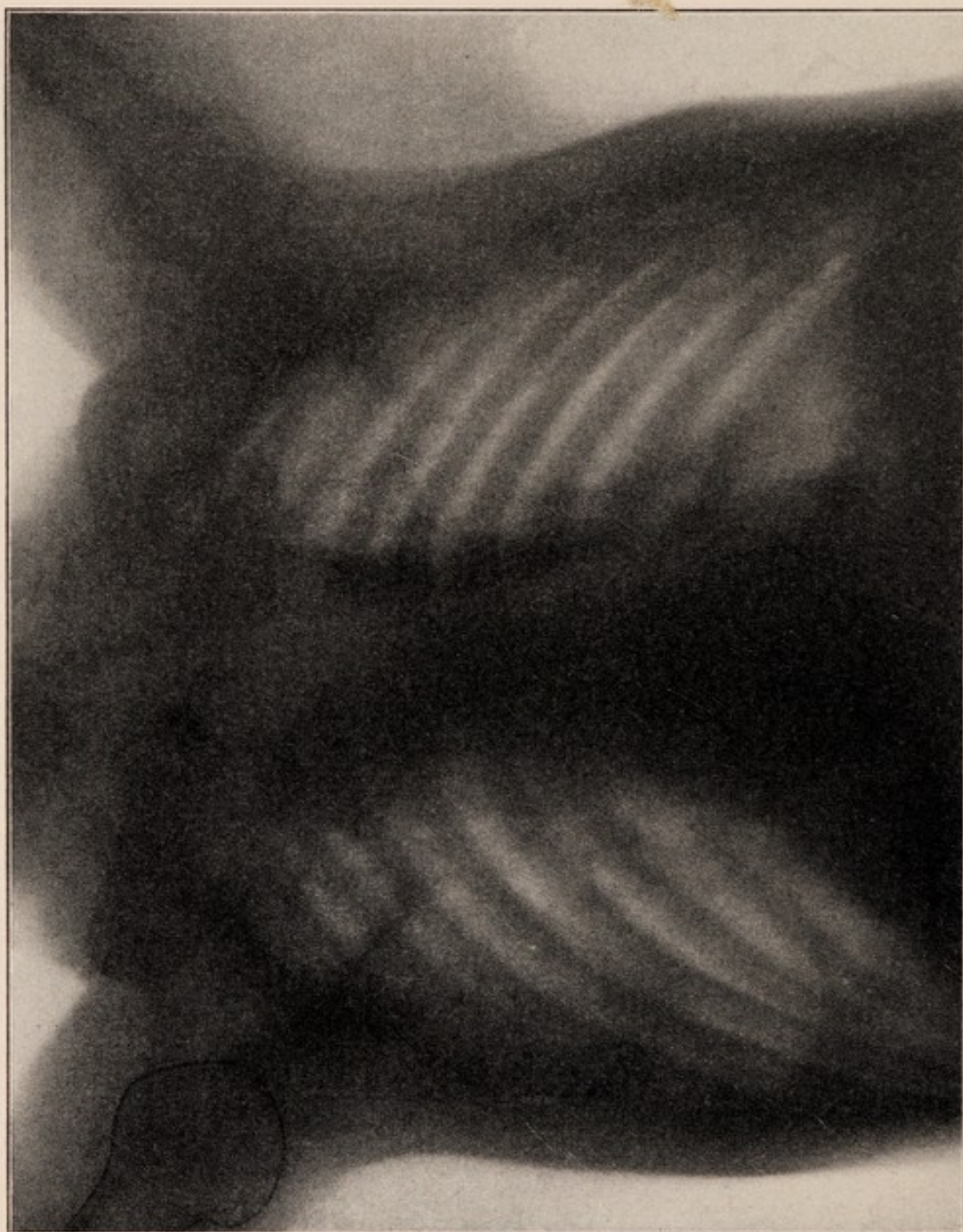

Tortuosity of the aorta. This is shown by the marked bulging of the shadow at the junction of the transverse and descending portions of the arch of the aorta.

apex; and sometimes a double murmur, due less to the atheromatous condition than to the insufficiency of the aortic valves, which is secondary to it. Sansom¹ mentions the fact that sometimes the arch of the aorta is elevated, causing elevation of the left subclavian and the innominate,

and rendering these arteries more susceptible to palpation, so that it is easy to produce a thrill in them on pressure; and occasionally the thrill occurs spontaneously. The symptoms of atheroma are pain,

FIG. 7.



Tortuosity of the aorta. This is indicated by an increase of about one inch in the shadow of the aorta at the junction of the transverse and descending portions.

dyspnœa, and sometimes anginoid attacks. We have been unable to find any reference to inequality of the pulses, tracheal tugging, inequality of the pupils, and suprasternal pulsation. There is some difference of opinion as to whether the second aortic sound is invariably accentuated or not. It does not appear to have been recorded that typical

aneurismal cough may occur as a result of an atheromatous condition without aneurismal dilatation.

The investigators, who employed the fluoroscope or skiagrams for the

FIG. 8.



Tortuosity of the aorta, indicated by the bulging of the shadow at the left portion of the arch.

purpose of studying changes in the aorta, were early impressed by the fact that although aneurism was occasionally overlooked, it was more frequently diagnosed when it did not exist. In 1897 Levy-Dorne² stated

that the early stages of aneurism were more common than had hitherto been supposed, and that the prognosis of commencing aneurism appeared to be not so unfavorable, especially as only a few had any tendency to enlarge. His pictures illustrate the small pulsating projections to the left of the sternum. Gocht,³ a year later, thought that by means of the Röntgen ray it was possible for the clinician to determine the presence of aneurism in cases in which doubtful symptoms were present. In opposition to this, Dumstrey and Metzner⁴ recommend considerable caution in the diagnosis of aneurism by means of the Röntgen rays, especially when there are no physical symptoms. They thought that mediastinal tumors might give rise to the same picture. Holzknecht⁵ was the first to show that pulsating hemispherical shadows just above the heart are not always aneurisms. He argued that this idea was based upon the supposition that the thoracic aorta was always situated in the median line, and that the arch lies in the shadow of the sternum. This is true only of the ascending portion of the arch, and as the transverse and descending portions lie practically in the same plane, they are projected as a pulsating, band-like shadow, intensely dark and with a free end. It may be seen during life, although he agrees with Weinberger⁶ that it rarely projects considerably to the left. This projection has also been observed and described by Immelmann.⁷ Holzknecht later discussed the subject more thoroughly in his textbook. In this he stated that aneurism of the arch theoretically was usually seen to the right of the sternum in sagittal pictures. Dilatation gives rise to a shadow seen on either side of the sternum, and is readily confused with aneurism. The differential diagnosis can be made by the fact that there are no pressure symptoms and no tendency of the shadow to enlarge. Simple dislocation of the aorta usually appears just to the left of the spinal column, and the pulsating shadow sometimes extends as much as six inches to the left of the left border of the sternum, forming, in fact, a pulsating shadow much larger than that projected by aneurism of the arch. In cases in which the heart is elevated the natural bending of the heart to the left is increased. In forty-six cases that he observed in which this shadow was present only six proved ultimately to be cases of aneurism. Holzknecht has undoubtedly seen and correctly interpreted the picture to which we call attention; but he classifies all these conditions as dislocation of the aorta, and fails to recognize that there is usually an actual elongation of the vessel, and that, in addition to the thrusting of the arch to one side, there is also a condition of tortuosity.

The following are the abridged notes of the cases that we observed :

CASE I. — P. H., aged thirty-eight years, a negro hostler. Had syphilis at the age of fifteen years. Eighteen months before death he received a blow over the right clavicle, and later noticed pulsation in the right side of the neck, followed by pain, cough, and paroxysms of dyspnoea.

Physical Examination. The pupils were equal. The right radial pulse was absent; the left radial pulse was small. The right carotid pulse was absent, and the left carotid pulse and its branches pulsated vigorously. There was pulsation of the prominent sternal end of the right clavicle, due to a mass beneath in which there was neither thrill nor murmur. The right external jugular vein was distended. The area of cardiac dulness was normal. The aortic second sound was accentuated. A diagnosis of innominate aneurism was made, but it was difficult to explain why the left radial pulse was so weak. The fluoroscope showed a pulsating tumor in the region of the innominate, and a prominence to the left of the descending aorta that had expansile pulsation. At the autopsy there was found aneurism of the innominate artery and atheroma and tortuosity of the arch of the aorta.

CASE II.—W. B., white, aged sixty-nine years, a printer. Had been an inmate of an insane asylum. There was no history of rheumatism; he denied syphilis; he had smallpox at thirty-nine years. He complained of dyspnoea on exertion, pain, and cough. He also was maniacal.

Physical Examination. The left subclavian artery and its branches pulsated more weakly than the corresponding arteries to the right. The carotids were equal. There was distinct downward tracheal tugging and suprasternal pulsation. The left ventricle was dilated, and there was a systolic murmur transmitted into the vessels of the neck. The fluoroscope showed a prominence to the left of the aorta, which had expansile pulsation. At the autopsy there was atheroma of the aorta with tortuosity of the descending portion. There was no aneurism and no dilatation.

CASE III.—J. H., white, aged fifty-seven years, machinist. He denied rheumatism and syphilis, but had had heart trouble for ten years. He complained of pain in the precordial region and dyspnoea.

Physical Examination. There was a receding pulse, with Traube's and Durosiez's signs. There was suprasternal pulsation and doubtful tracheal tugging. The left ventricle was considerably enlarged. There was the double murmur of aortic regurgitation. There was no accentuation of the aortic second sound. The X-ray showed the characteristic pulsating prominence to the left of the aorta. A diagnosis was made of insufficiency of the aortic valves, dilatation of the aorta, and tortuosity.

CASE IV.—J. L., white, aged ninety-seven years, shoemaker. He denied syphilis and rheumatism. He suffered from dyspnoea on exertion; he had no cough and no pain.

Physical Examination. The arteries of the distribution of the left subclavian pulsated more freely than those of the right. The carotids were equal. There was suprasternal pulsation and slight tracheal tugging. The percussion note over the base of the sternum was impaired. There was general atheroma. The fluoroscope showed a pulsating mass to the right of the descending arch of the aorta. At the autopsy the aorta was found to be tortuous, and there was no aneurism and no dilatation.

CASE V.—N. McC., white, aged seventy-three years, stone-mason. Had had rheumatism and used alcohol to excess. He complained of dyspnoea on exertion and had a cough that was slightly metallic.

Physical Examination. The carotid and radial pulses were equal. There was distinct suprasternal pulsation and tracheal tugging. There was impaired resonance over the manubrium, and the second aortic sound was accentuated. The fluoroscope showed an abnormally broad aortic arch and pulsating prominence to the left of the descending arch.

CASE VI.—W. S., white, aged twenty-four years, a barber. He gave a history of rheumatism, and admitted alcohol in moderation, but denied syphilis. He had no dyspnoea and no pain. He had a hoarse but not metallic cough. The radial and carotid pulses were equal; there was distinct tracheal tugging; there was impaired resonance over the manubrium, and a faint systolic murmur heard over the base and transmitted into the vessels of the neck. There was no thrill. The fluoroscope showed a pulsating prominence to the left of the descending portion of the arch of the aorta.

CASE VII.—A. T., a laborer, had had rheumatism. He admitted alcohol in moderation, but denied syphilis. There was dyspnoea upon exertion and precordial pain, but no cough.

Physical Examination. The left radial pulse was smaller than the right. There was no tracheal tugging and no suprasternal pulsation. The fluoroscope showed a pulsating projection to the left of the descending portion of the arch of the aorta.

CASE VIII.—J. W., aged forty-three years, a negro laborer. Many of his family had heart disease. He had acute articular rheumatism at twenty-five years. On admission he had dyspnoea increased by exertion, cough and expectoration, and pain in the chest and epigastrium.

Physical Examination. The left radial was smaller than the right and seemed slightly retarded. The arteries were atheromatous. The heart was enlarged; there was a systolic musical murmur transmitted into the vessels of the neck, which subsequently showed a double murmur. There was slight tracheal tugging; a thrill was readily produced by pressure upon the subclavians and occasionally was spontaneous. The fluoroscope confirmed the great enlargement of the heart, the increased breadth of the arch of the aorta, and also showed a projection to the left of the descending portion of the arch that had expansile pulsation. At the autopsy obliterative pericarditis was found, with hypertrophy of the heart, atheroma and marked dilatation, and tortuosity of the aorta at the junction of the arch and the vertebral column.

CASE IX.—H. W., white, aged sixty-eight years, a carpenter. He suffered from dyspnoea on exertion and gave a doubtful history of paralytic stroke.

Physical Examination. The left radial pulse was smaller than the right. The carotids were equal; the left pupil was slightly dilated. The heart was enlarged; there was a double murmur over the base; suprasternal pulsation and distinct tracheal tugging. Percussion resonance over the manubrium was impaired. The fluoroscope showed a pulsating projection to the left of the descending portion of the arch.

CASE X.—W. S., white, aged seventy years, a laborer. Had had rheumatism, but denied syphilis. He complained of severe cough, which was distinctly metallic in character.

Physical Examination. The left radial pulse was smaller than the right. There was distinct tracheal tugging; impaired resonance over the manubrium. The fluoroscope showed a distinct bulging to the left

of the descending portion of the arch of the aorta which had expansile pulsation.

CASE XI.—S. McH., white, aged fifty-one years, a carpenter. Admitted syphilitic infection. At forty-three years had right hemiplegia.

Physical Examination. The pupils were equal; the carotids and radial pulses were equal. There was tracheal tugging and a faint suprasternal pulsation. The heart was not enlarged. The second aortic sound was not accentuated, but the first sound was loud. There was impaired resonance over the manubrium, and the patient had a hoarse, aneurismal cough, which had lasted seven years. The fluoroscope showed increased width of the arch of the aorta, and a projection to the left of the descending portion of the arch which had expansile pulsation.

CASE XII.—M. O., white, female, a domestic. She had been conscious of heart disease for two years.

Physical Examination. Pupils were equal; the right radial pulse was slightly weaker than the left. There was expansile pulsation in the lower portion of the neck, which was apparently due to an atheromatous anomalous vessel. There was no tracheal tugging and no thrill. The heart was enlarged to the right and left. There was a systolic murmur transmitted into the vessels of the neck. The aortic second sound was greatly accentuated, and the pulmonic second was reduplicated. The percussion note over the manubrium was impaired. The patient had dyspnoea, but no pain and no cough. The fluoroscope showed dilatation of the ascending portion of the arch of the aorta that had expansile pulsation.

CASE XIII.—T. M., white, aged thirty-six years, laborer. He had had malaria, rheumatism, and syphilis, and admitted excessive indulgence in alcohol. For about two years he had had boring pain in the left chest, located usually in the sixth interspace, either just beneath the angle of the scapula or in the nipple line. It was worse after exertion and the sixth rib was tender.

Physical Examination. Pulsation in the left subclavian, brachial, and radial arteries could not be felt. In the right subclavian, brachial, and radial arteries it was strong. The carotids were equal. There was a systolic murmur, heard best at the apex. The aortic second sound was greatly accentuated. There was slight paralysis of the left vocal cord (Dr. Gleason). The fluoroscope showed a distinct prominence of the descending portion of the arch, which had expansile pulsation. There was no dilatation of the aorta in any part. The patient is still alive, and the signs have not changed in eighteen months. It seems not impossible that in this case we are dealing with an actual aneurism, although the fluoroscopic picture is the same as that in the other cases.

CASE XIV.—R. W., white, aged forty-four years, a knife-grinder. He had had psoriasis for twenty years, and had used alcohol and tobacco to excess. He denied venereal disease. One year ago he had erysipelas.

Physical Examination. The pupils were equal; the left brachial and radial arteries pulsated more weakly than the right. The carotid pulses were equal. The heart was not enlarged. The aortic second sound was accentuated; there was no suprasternal pulsation, but distinct tracheal tugging. The fluoroscope showed increase in the width

of the arch of the aorta, and a projection to the left of the descending portion which had expansile pulsation.

CASE XV.—M. B., white, female, domestic, aged seventy years. Had had rheumatism for many years. Had dyspnoea upon exertion, and had complained for twenty years of pain in the left side of the chest. There was a cough, which was not metallic in character.

Physical Examination. The radial pulses were equal; there was an anomalous vessel crossing the anterior portion of the neck, which was atheromatous. There was no tracheal tugging. The heart was slightly enlarged, and there was a double murmur over the base, the systolic element being transmitted into the vessels of the neck. The fluoroscope showed dilatation of the ascending portion and a projection to the left of the descending portion of the arch of the aorta which had expansile pulsation.

CASE XVI.—J. T., white, aged sixty-one years, broom-maker. Had malaria at sixty-six years; pleurisy at forty-five years; several attacks of asthma. He denied syphilis. He complained of cough and moderate expectoration.

Physical Examination. The right carotid and subclavian arteries and their branches pulsated more vigorously than the corresponding vessels on the left. There was no tracheal tugging, but a powerful suprasternal pulsation. The heart was slightly enlarged. There was a systolic murmur transmitted into the vessels of the neck, and the aortic second sound was accentuated. The fluoroscope showed dilatation of the ascending portion of the arch of the aorta and distinct prominence of the descending portion of the arch, with expansile pulsation.

CASE XVII.—P. D., white, stone-cutter. Had used alcohol to excess; he never had rheumatism, and denied syphilis. There was moderate dyspnoea, pain in the region of the heart, and a cough which was not metallic in character.

Physical Examination. The pupils were equal and of the Argyll-Robertson type. The right pupil was smaller than the left. The carotid and radial pulses were equal. There was a thrill in the vessels of the neck upon pressure. There was suprasternal pulsation and distinct tracheal tugging. The heart was slightly enlarged to the left; there was a soft systolic murmur at the apex and base, and a harsh systolic murmur at the base. There was also a harsh systolic murmur in the vessels of the neck. The aortic second sound was not accentuated. The fluoroscope showed dilatation of the ascending portion of the arch of the aorta, and a projection to the left of the descending portion which had expansile pulsation.

CASE XVIII.—C. H., white, female, domestic, aged eighteen years. Patient had recently had acute articular rheumatism.

Physical Examination. The carotids and radials were equal. There was suprasternal pulsation, but no tracheal tugging. The heart was not enlarged; the second aortic sound was greatly accentuated. The fluoroscope showed that the ascending portion of the arch was increased three-fourths of an inch in width, and to the left of the descending portion there was a shadow that had expansile pulsation.

In summarizing these cases we find that the inequality of the pulses was present in ten and not present in eight cases; that in nine of the ten cases pulsation was more vigorous on the right than on the left

side. Inequality of the pupils was present in three cases; in one of these there was reason to believe that it was due to some nervous condition, as the pupils showed the Argyll-Robertson phenomenon. Suprasternal pulsation was present in twelve cases and absent in six. Tracheal tugging of distinct downward character was present in eleven and absent in seven cases. A systolic thrill was felt in the vessels of the neck, either with or without slight pressure, in nine cases, and it could not be elicited in nine cases. A systolic murmur usually transmitted into the vessels of the neck was present in eleven cases, but was not heard in seven cases. Twelve of the cases had dyspnoea; in one of these there were physical signs of emphysema and chronic bronchitis; in the others it was probably due to the cardiac condition. Many of these patients were old, and nearly all of them had atheromatous arteries. Precordial pain was present in seven cases and was not complained of in eleven cases. In many of the cases complications in the form of valvular heart disease were present. In one case there was actually an aneurism of the innominate artery. The degree of atheroma and the age of the patient also modified the symptoms, and the extent of the tortuosity must vary considerably in different cases.

It is difficult from this study to give a clear picture of the symptomatology of the condition of atheroma of the aorta leading to tortuosity of the descending portion of the arch. It may at least be said that in those conditions in which atheroma and tortuosity exist, certain of the physical signs, particularly tracheal tug and inequality of the radial pulses, which have been supposed to be strongly suggestive of aneurism, are not uncommon, and that they are associated with other signs and symptoms, such as murmur, thrill, suprasternal pulsation, inequality of the pupils, accentuation of the aortic second sound, that are also found in aneurism of the arch. Probably it would be justifiable to suspect tortuosity in cases in which there is inequality of the radial pulses, slight tracheal tugging, dyspnoea, and in which the symptoms are stationary for a considerable period of time and the fluoroscope shows a projection to the left of the descending portion of the arch of the aorta that has expansile pulsation.

REFERENCES.

1. Sansom. *Diseases of the Heart*. London.
2. Levy-Dorne. *Congress f. innere Medicin*, Berlin, 1897, p. 316.
3. Gocht. *Lehrbuch der Röntgenuntersuchung*, Stuttgart, 1898, p. 199.
4. Dumstrey and Metzner. *Fortschritte auf dem Gebiete der Röntgenstrahlen*, vol. i.
5. Holzknecht. *Wiener klin. Woch.*, 1900, No. 10.
6. Weinberger. *Atlas der Radiographie der Brustorgane*, Vienna, 1901.
7. Immelmann. *Röntgen Atlas des Normalen Menschlichen Körpers*, Berlin, 1900.


The first part of the history of the United States of America is the period from the discovery of the continent by Christopher Columbus in 1492 to the establishment of the first permanent settlements. This period is characterized by the exploration of the continent by Spanish, French, and English explorers, and the establishment of the first permanent settlements by the English in 1607.

The second part of the history of the United States of America is the period from the establishment of the first permanent settlements to the American Revolution in 1776. This period is characterized by the growth of the colonies, the struggle for independence from Britain, and the establishment of the United States as a new nation.

The third part of the history of the United States of America is the period from the American Revolution to the Civil War in 1861. This period is characterized by the expansion of the United States, the struggle for slavery, and the establishment of the United States as a federal republic.

The fourth part of the history of the United States of America is the period from the Civil War to the present. This period is characterized by the Reconstruction era, the Gilded Age, the Progressive Era, and the modern era.

The fifth part of the history of the United States of America is the period from the present to the future. This period is characterized by the challenges of the future, such as climate change, nuclear war, and the rise of artificial intelligence.



LEA'S PERIODICALS

The Medical News—Weekly.

A weekly medical newspaper is indispensable to those who would keep always posted to date on the incessant advances of practical medicine. **THE NEWS** answers every need. Its many departments cover all avenues of information and present a comprehensive knowledge of progress in every line. Weekly, illustrated, 2496 quarto pages of reading matter per year. Price, \$4.00.

The American Journal—Monthly.

A monthly medical magazine, covering the entire science, and therefore helpful to every practitioner. Its **ORIGINAL ARTICLES** represent the experience of the most progressive medical men, its **REVIEWS** keep readers discriminatingly posted on the best literature, and the department of **PROGRESS** is an authoritative and instructive summary of advances thoroughly digested from the leading medical periodicals of the world. Monthly, illustrated, 2304 pages of reading matter per year. Price, \$5.00.

Progressive Medicine—Quarterly.

PROGRESSIVE MEDICINE consists of original matter written by authorities in their respective departments, who give in an interesting narrative form a clear statement of the world's advances in every branch. Issued every three months it brings to the reader at frequent intervals fresh knowledge ready for application. Quarterly, illustrated, 1600 to 2000 pages per year. Price, \$10.00, for the four volumes in cloth binding:

The Pocket Formulary for 1903.

THE MEDICAL NEWS FORMULARY contains about 1700 prescriptions representing the latest and best therapeutics. Arranged alphabetically under headings of the various diseases for quick reference. Full annotations, directions and details. A most useful wallet-sized volume leather bound, with pocket and pencil. \$1.50, *net*.

The Visiting List for 1903.

THE MEDICAL NEWS VISITING LIST contains 32 pages of data needed by every practitioner and blanks for recording all details of practice, both clinical and financial. In four styles: **WEEKLY**, dated for 30 patients, **MONTHLY**, undated, for 120 patients per month, **PERPETUAL**, undated, for 30 patients weekly, and **SIXTY PATIENTS**, undated and without the preliminary data, for those requiring specially large record books. Price, \$1.25. Thumb Index, 25 cents extra.

Special Combinations.

These unrivalled periodicals and practical aids and conveniences are offered in combination on reduced and easy terms. Sample reductions are given below and rates will be quoted on any other combinations on application. Orders in excess of \$4.00 can be divided into convenient instalments, concerning which address the Publishers.

	Alone.	In Combination.	
Per Annum.			
American Journal of the Medical Sciences,	\$5.00	\$8.00	\$16.00
Medical News,	4.00		
Progressive Medicine,	10.00	1.25	\$16.75
Medical News Visiting List,	1.25		
Medical News Formulary,	1.50 net,		
In all \$21.75 for \$17 00			

LEA BROTHERS & CO., Publishers,

111 FIFTH AVENUE, NEW YORK.

706, 708 & 710 SANSON ST., PHILADELPHIA.