

A case of unilateral uterus with a solitary kidney having two ureters : exhibited at the Aberdeen, Banff, and Kincardine Branch of the British Medical Association, 5th February, 1879, and at the Obstetrical Society of London, 5th March, 1879 / by Francis Ogston, jun.

Contributors

Ogston, Francis, Jr., 1846-1917.

Publication/Creation

Aberdeen : A. King, 1879.

Persistent URL

<https://wellcomecollection.org/works/qy7wvbfr>

License and attribution

This work has been identified as being free of known restrictions under copyright law, including all related and neighbouring rights and is being made available under the Creative Commons, Public Domain Mark.

You can copy, modify, distribute and perform the work, even for commercial purposes, without asking permission.



Wellcome Collection
183 Euston Road
London NW1 2BE UK
T +44 (0)20 7611 8722
E library@wellcomecollection.org
<https://wellcomecollection.org>

NOTE.—Dr. Wilson's case, opposite, is given as cured, on the strength of a report from her attendant, Dr. Mitchell of Rayne. On the 19th of July, 1879, Dr. Mitchell informed me that he had been mistaken in reporting her as cured to Dr. Wilson, and that she has been, on the contrary, incontinent ever since the operation.

ALEX. OGSTON.

NOTE.—Dr. Wilson's case, opposite, is given as cured, on the strength of a report from her attendant, Dr. Mitchell of Rayne. On the 19th of July, 1879, Dr. Mitchell informed me that he had been mistaken in reporting her as cured to Dr. Wilson, and that she has been, on the contrary, incontinent ever since the operation.

ALEX. OGSTON.

THE
LIBRARY OF THE
MUSEUM OF COMPARATIVE ZOOLOGY
AND ANATOMY
HARVARD UNIVERSITY
CAMBRIDGE, MASSACHUSETTS
U.S.A.

H. J.

A CASE
OF
UNILATERAL UTERUS

WITH A
SOLITARY KIDNEY HAVING TWO URETERS;

EXHIBITED AT THE
*Aberdeen, Banff, and Kincardine Branch of the British Medical
Association, 5th February, 1879.*


AND AT THE
Obstetrical Society of London, 5th March, 1879.


BY
FRANCIS OGSTON, JUN., M.D.,

LECTURER ON TOXICOLOGY, AND ASSISTANT TO THE PROFESSOR OF MEDICAL
JURISPRUDENCE IN THE UNIVERSITY OF ABERDEEN.

ABERDEEN: A. KING & COMPANY.

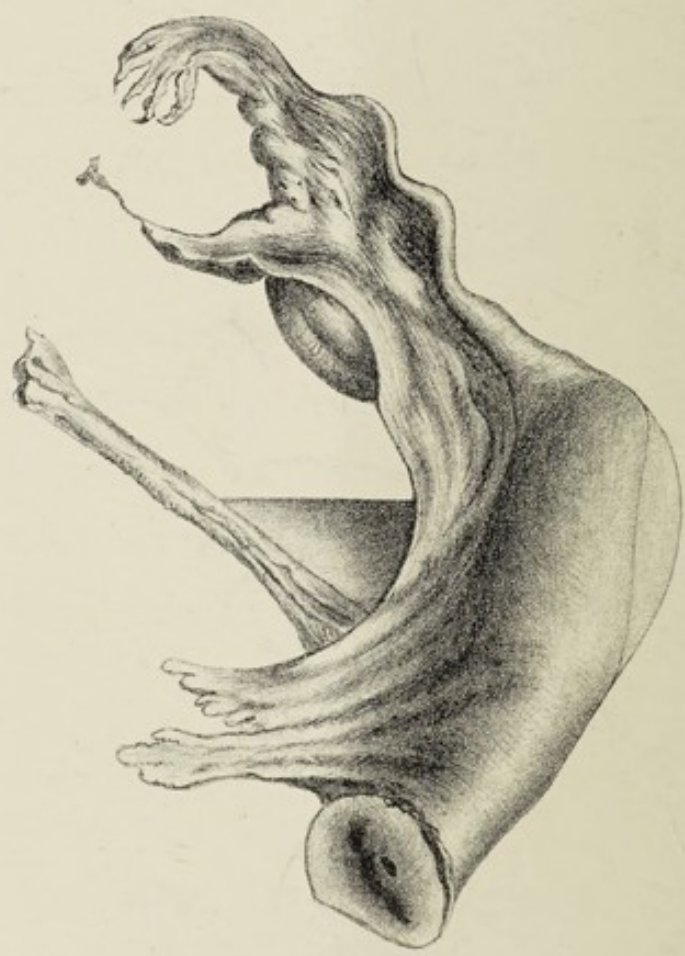1879.





Digitized by the Internet Archive
in 2019 with funding from
Wellcome Library

<https://archive.org/details/b30575199>



DESCRIPTION ACCOMPANYING PREPARATIONS.

The UTERUS had only its right half developed ; its left half, left fallopian tube, left ovary, and left broad ligament being wanting.

The RIGHT KIDNEY had two ureters, the upper, which was imperforate, opening into a cyst with bony plates in its walls, and terminating in the usual position to the *left* side of the bladder ; the *right* (lower) ureter running the usual course.

The kidney lay completely on the right side of the spinal column.

The LEFT KIDNEY was absent.

The LEFT SUPRA-RENAL CAPSULE was found at the position it usually occupies ; the *right* one at the upper end of the double kidney.

The body otherwise, the pelvis, and the external genitals were normally developed.

LIBRARY OF THE
UNIVERSITY OF TORONTO

1

1827