

**Two cases of calcareous infiltration of the muscular fibre of the heart / by Joseph Coats.**

**Contributors**

Coats, Joseph, 1846-1899.

**Publication/Creation**

[Place of publication not identified] : [publisher not identified], [1872]  
(Glasgow : Dunn and Wright.)

**Persistent URL**

<https://wellcomecollection.org/works/uc8mp8m3>

**License and attribution**

This work has been identified as being free of known restrictions under copyright law, including all related and neighbouring rights and is being made available under the Creative Commons, Public Domain Mark.

You can copy, modify, distribute and perform the work, even for commercial purposes, without asking permission.



Wellcome Collection  
183 Euston Road  
London NW1 2BE UK  
T +44 (0)20 7611 8722  
E [library@wellcomecollection.org](mailto:library@wellcomecollection.org)  
<https://wellcomecollection.org>

---

TWO CASES  
OF  
CALCAREOUS INFILTRATION  
OF THE  
MUSCULAR FIBRE OF THE HEART.

BY  
JOSEPH COATS, M.D.,

LECTURER ON PATHOLOGY IN GLASGOW UNIVERSITY, AND PATHOLOGIST TO THE GLASGOW  
ROYAL INFIRMARY.

---

---

REPRINTED FROM "THE GLASGOW MEDICAL JOURNAL," AUGUST, 1872.

---



TWO CASES  
OF  
CALCAREOUS INFILTRATION  
OF THE  
MUSCULAR FIBRE OF THE HEART.

---

THESE two cases, of what appears to be a very rare affection of the heart, will be found to differ very considerably both as to their clinical history and the appearance of the affected heart-tissue.

CASE I. was that of a man admitted to the fever wards of Glasgow Royal Infirmary in a dying condition. He died shortly after admission, and no history of his illness could be obtained. At the *sectio cadaveris*, it was observed that the entire surface of the trunk and limbs was dotted with hæmorrhagic points. The right tibia was much thickened, and the skin over it was the seat of two ulcers, which were situated in the centre of a large cicatrix, occupying nearly the entire shin surface of the tibia. The body was spare, but not remarkably emaciated. In addition to the lesion in the heart about to be described, the internal organs presented the following conditions:—The lungs presented old adhesions, with evidences of considerable bronchitis and emphysema; the liver contained five or six deposits of a pearly white colour, and about the diameter of a horse bean, which were situated superficially, but penetrated into the substance of the liver, replacing a corresponding portion of



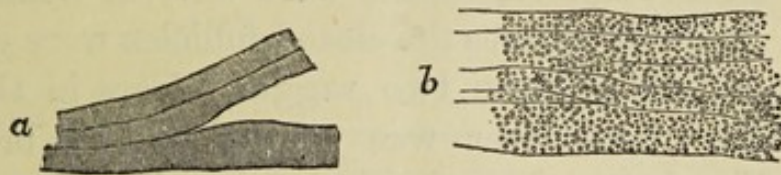
the hepatic tissue; the kidneys were normal in size, but considerably hyperæmic; the spleen was normal; the brain was perfectly normal.

Turning now to the heart, it was found that the pericardium contained about two ounces of fluid, without any fibrinous exudation. On making a section of the wall of the left ventricle, a condition was observed, which, in dictating the pathological report, was described as "an extreme state of fatty degeneration." Under the impression that it was fatty degeneration, certain peculiarities in its distribution were noted. It did not occur in patches, producing the usual mottled appearance chiefly of the internal layers of the muscular substance, but, on the contrary, the external layers were those affected, and the lesion involved homogeneously, a distinct thickness of the myocardium. At the apex of the left ventricle, about two-thirds of the thickness of the wall was seen to be involved, and from this, upwards, the affection extended gradually to a less and less depth, ceasing entirely a short distance from the base. But in every part it was the external layers which were affected, the disease not penetrating to the internal surface of the heart. The affection was confined to the left ventricle. The sub-pericardial fat on the surface of the heart was noted to be rather less than normal. The valves were normal.

The affected portion of the heart was examined microscopically, in the fresh state, immediately after the inspection. With a low power, it was observed that the muscular fibre in the affected region was extremely opaque, presenting in this respect very much the appearance of extreme fatty degeneration, but it was noted that the degenerated part passed much more abruptly into the normal than is usually the case in fatty degeneration. The accompanying wood-cut shows the appearance presented by the affected part (*b*) when examined with a high power, contrasted with a small portion of the tissue from a normal part of the same heart (*a*). With the higher power it was found that the opaque appearance observed with the low power depended indeed on the



presence of granules within the muscular fibres, but that these were larger and of a much more regular size and appearance than fat granules; and further, that at the margins of the



affected part, there was not any appearance of transition to the normal, and in particular no aggregation of granules round the nucleus such as is seen in the earlier stage of fatty degeneration. At the same time there could be no doubt, and this is abundantly evident from a glance at the wood-cut, that the tissue affected was the muscular fibres, the shape, general outline and direction being preserved. To a portion of tissue so affected, a drop of hydrochloric acid was then added, allowing it to penetrate gradually beneath the cover-glass, while the object was observed with a low power. As the acid reached the tissue and gradually penetrated its substance, it was observed that the opaque appearance described above, completely disappeared, fading away before the advancing stream of acid, *but without any evolution of gas*. The tissue, cleared up in this manner, was then examined with the high power, and it was seen that the transverse striæ had been restored, and that, except a certain degree of paleness from the action of the hydrochloric acid, the muscular tissue could not be distinguished from the normal. At a later period it was observed that the appearances described above were not destroyed either by steeping in distilled waters or by maceration in alcohol, and that therefore the substance deposited is insoluble in these media.

CASE II. was also from the fever wards of the Royal Infirmary. The case was primarily one of relapsing fever, complicated by suppuration of both parotid glands. There was also paralysis of the left lower limb. At the *sectio*, there was found, besides the parotid abscesses, evidence of the



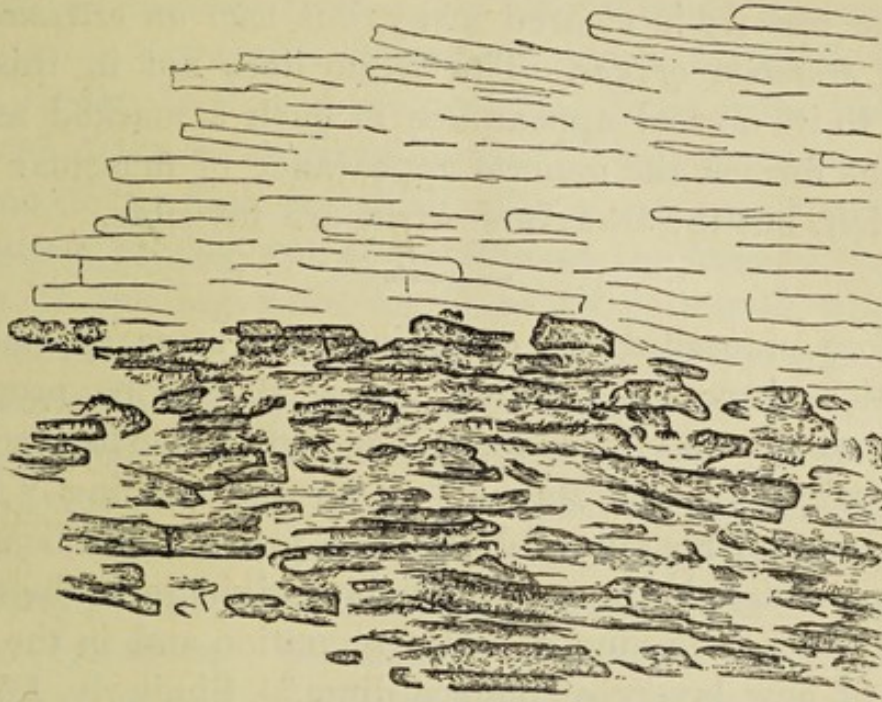
presence of pyæmia. In the lungs and kidneys there were numerous metastatic abscesses, those in the kidneys presenting the usual elongated form, perpendicular to the surface. In the spleen, there were several defined dark patches. In the intestines the closed follicles were generally enlarged, and there were two ragged ulcers in the caput cœcum coli. The liver was normal. The brain was normal. No obstruction of either femoral artery could be discovered.

The pericardium contained about two ounces of turbid fluid, and the surface of the heart presented several fibrinous flakes. The heart was normal in size. In the wall of the left ventricle, numerous pale gritty deposits were found, and these were arranged more or less in patches, of which the distribution was noted as follows:—On the anterior surface of the left ventricle are two patches situated just to the left of the septum, the one about the size of a sixpenny piece, and the other about half that size. Viewed from the surface, they are somewhat streaked in a direction from left to right, and from base to apex; and on cutting into them they are seen to extend in the form of white gritty deposits into the wall of the ventricle with an irregular margin, replacing the external layers of the muscular tissue to the depth of about a line. Above these, and still on the anterior surface of the left ventricle, there are two elongated streaks passing in a direction parallel to the streaks on the two patches; and on cutting into these they present the appearance of aggregations of solid cylinders. The posterior surface of the left ventricle is more irregularly streaked, but the streaks all lie in the same general direction, namely, from left to right and from base to apex. This surface is much more generally affected, but there is no aggregation into patches, and on section it is seen that only the most superficial layers of the muscular tissue are affected. The walls of the right ventricle are perfectly free from any such affection.

The microscopic examination of this case, as seen in the accompanying woodcuts, shows that while here also there

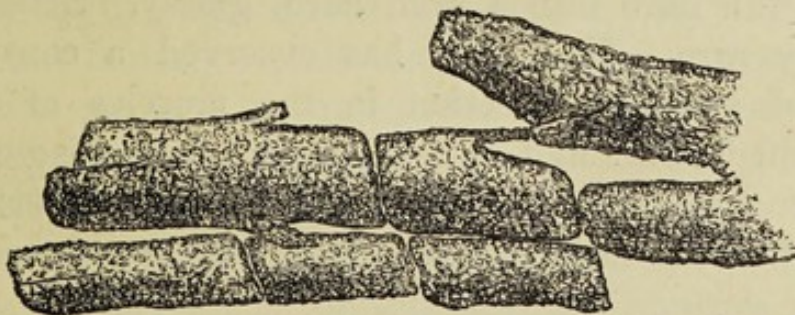


is a deposition of calcareous salts in the muscular fibres of the heart, some differences exist as compared with the other.



Section from heart of Case II., with low power, showing contrast of normal and diseased muscular tissue.

The deposition here is not in such a minutely granular form as in the other case, the tissue in the parts affected being converted more into solid opaque, somewhat crystalline cylinders, which have the same thickness as the muscular fibres, and at the margins of the affected part are seen to lie parallel to these. In some cases, these solid cylinders have sustained a transverse fracture, and even with a low



Affected muscular fibre of the heart in Case II., with high power.

power, they present an appearance quite different from that of fatty degeneration, and here, as well as in the first case,



the transition from the affected to the sound tissue is somewhat abrupt. When treated with hydrochloric acid in the same way as in the first case, a solution also takes place, and the opacity is cleared away, but *with an extremely well marked evolution of gas*. The tissue does not in this case return to its normal appearance in such a marked manner as in the former, the general appearance of muscular fibres being left, but the transverse striæ are invisible.

---

Before proceeding to enter into the more special considerations involved in these cases, it will be proper to inquire whether a similar lesion has been hitherto described. Rokitsansky,\* in his "Manual" under the heading "Anomalous Osseous Substance," describes a formation of bony concretions, which, he says, "invariably originate in the fibroid tissue, which is produced by inflammation and in the deposition of new layers of endocardium." Similarly, Förster† mentions the formation of concretions or so-called ossification, as occurring especially in the valves of the left heart, as a result of degeneration of inflammatory products. In the muscular substance of the heart, calcification occurs most frequently in old encapsuled abscesses, and also in fibrous masses, which form after inflammation of the fleshy walls. But, in his later "Lehrbuch der pathologischen Anatomie," Rokitsansky, under diseases of muscle remarks, "a proper ossification, that is, an ossification of the muscular fibre, following on a previous transformation of the same, which converts the fibre into a stiff, hard, glassy, brittle rod, is extremely rare. H. Meyer has observed a considerable degree of such an affection in the muscles of the leg (Zeitschrift für rat. Med. I., 1851), and I have also observed it in several places in the muscular tissue of a hypertrophied heart, which were distinguished by their pale colour."‡

\* Rokitsansky's Manual of Pathological Anatomy, translated by the Sydenham Society. Vol. IV., p. 209.

† Förster's Handbuch der pathologischen Anatomie. 2nd edition, 1863. Bd. II., p. 676.

‡ Lehrbuch d., path. Anat. II., p. 230.



Förster\* also refers to these two cases in treating of diseases of muscle.

On turning to the former of these papers, as abstracted in Canstatt's Jahresbericht, I find a condition of the muscles of the lower extremity described, which seems in every respect similar to that of the muscular fibres of the heart in the *second* of the cases given above. The case was one of gangrene of the foot, for which, after a continued period of suppuration, the leg was amputated at the knee. Several muscles of the leg were found to be yellowish white in colour, but fibrous in appearance. It is stated also, that they splintered longitudinally like asbestos, and it is to be remarked, that the altered structure in the heart under consideration also presented a remarkable resemblance to asbestos. On microscopic examination, the affected muscles were found to be formed of partly homogeneous and partly granular cylinders. On adding hydrochloric acid, there was a development of gas, and the cylinders returned to the appearance of muscular fibre. The tendons were, to some extent, similarly impregnated. The essential characters of the change which the muscular fibre had undergone in this, and in my second case, seem to be identical, and a certain amount of resemblance might be traced also in the circumstances under which the lesion occurred.

The case observed by Rokitansky, seems to have been very similar also to the second case described in this paper. In a summary of his paper, contained in Schmidt's Jahrbücher, very little more is given concerning this case than appears in the passage quoted above from his "Lehrbuch," but it is particularly noted that the affection occurred in patches, was confined to the left ventricle, and the patches were mostly situated near the apex. The other particulars of the case are not mentioned.

Turning now to the first case recorded above, I do not find, either in English or foreign medical literature, any description of a similar lesion. The only case at all similar to it, of which I am aware, is one shown to me by Dr Köster, in

\* l. c., p. 1016.



Würzburg, in the summer of 1870, and not yet, so far as I am aware, published by him. Here, as in my case, the impregnation of lime salts was in a minutely granular form, and the salts were dissolved on the addition of hydrochloric acid, without the evolution of gas.

It is not uncommon to meet with cases which have a superficial resemblance to those related above, cases, that is to say, of calcification, or so called ossification of the heart. But when these cases are examined, it is always found that the impregnation of lime salts is not into the muscular substance proper, but into some of the other tissues of the heart. The remarks from the works of Rokitsky and Förster, quoted above, express this with sufficient clearness, and the same fact is also distinctly laid down in the following words of Dr Hope\*—"In all these cases the disappearance of the muscular fibre is referable to atrophy, resulting from compression by the encroachment of the new productions."—"All these transformations are generally results of pericarditis or endocarditis." And, with the exception of the cases already mentioned, I have found no deviation from this rule.

When we come to consider what may be the causes of the conditions found in these cases, very great difficulties present themselves. In the first case, it is noted that no history of the disease could be obtained; the patient was admitted in a dying condition, and no details of his illness were forthcoming. Looking to the *post-mortem* appearances, we find that these were evidences of old-standing bronchitis and emphysema, while the deposits in the liver, and the condition of the right tibia suggest the inquiry as to the existence of the syphilitic taint. In respect to the other case, the fact already referred to, of its occurrence in a case of pyæmia, is worthy of remembrance in connection with the causation, especially considering that in Meyer's case, a similar lesion occurred in the muscles of the leg, in a case of gangrene and prolonged suppuration. The actual con-

\* On the Diseases of the Heart and Great Vessels, by Dr Hope. 1849. p. 330.



nection of the two conditions, however, it might be difficult to make out.

In these cases, it is impossible to say what effect the condition of the heart under consideration may have had on the action of that organ during life, but it is possible to conceive that the results of such a lesion might be very distinct, and even serious. The diseased muscular fibres can hardly have possessed their normal power of contraction, and, in addition, their rigidity would oppose a serious obstacle to the contraction of the heart, which would require to be overcome by the remaining healthy fibres. Then again, the danger of rupture of the heart in cases where this lesion exists readily suggests itself, the rigid cylinders would not offer the same resistance as the normal tissue, would be apt to undergo laceration, especially where such an extent of the thickness of the ventricle near the apex is involved, as in the first case described above.

To summarise the facts observed in these cases, it is to be noted that we have here two instances of a very rare lesion, these two cases, however, presenting very marked differences. In *Case I.*, the lime salts have been deposited in the muscular fibre in the form of minute round granules, the appearance produced considerably resembling, both to the naked eye and microscopically, that of fatty degeneration. The salt here deposited was not the carbonate, but probably entirely the phosphate of lime. This occurred in a case of chronic bronchitis and emphysema, with a possible syphilitic taint. In *Case II.*, the lime salt, which consisted in great part of the carbonate of lime (effervescing with an acid), was deposited more homogeneously, converting the fibres into rigid cylinders, having a considerably crystalline texture. This occurred in a patient who died of pyæmia.\*

\* Portions of these hearts have been placed in the hands of Mr John Ferguson, of Glasgow University, for analysis; and his report will appear in a future number of the *Journal*.



section of the two conditions, however, it is difficult to make any.

In these cases it is important to say what effect the position of the heart has on the circulation. The action of that organ is not the same, but it is possible to conceive that the results of such a change might be very distinct and even serious. The disease, however, does not necessarily possess that special power of contraction, and in addition, the heart would oppose a serious obstacle to the contraction of the left ventricle, which would tend to be overcome by the remaining healthy tissue. Then again, the danger of rupture of the heart in cases where this lesion exists tends to be less, the rigid condition would not offer the same resistance as the normal tissue, would be apt to enlarge, especially where such an extent of the thickness of the ventricle has been involved, as in the first case described above.

To summarize the facts observed in these cases it is to be noted that we have here two instances of a very rare lesion, three cases, however, presenting very marked differences. In Case 1, the heart valve has been deposited in the muscular fibre in the form of minute round granules. The appearance produced is entirely resembling that of the united eye and not at all like that of fatty degeneration. The salt here deposited was not the carbonate, but probably entirely the phosphate of lime. This occurred in a case of chronic bronchitis and emphysema, with a possible syphilitic taint. In Case 2, the lesion, which consisted in great part of the contents of the (collapsing with an end) was deposited from being generally converting the tissue into rigid cylinders having a considerably irregular texture. This occurred in a patient who died of pyæmia.

\* Portions of these hearts have been placed in the hands of Mr. John of the University of London, and the report will appear in a future number of the Journal.