

On the local effects of crude paraffin / by Alex. Ogston.

Contributors

Ogston, Alexander, 1844-1929.

Publication/Creation

[Place of publication not identified] : [publisher not identified], [1871]
(Edinburgh : Oliver and Boyd.)

Persistent URL

<https://wellcomecollection.org/works/bwbkg9dm>

License and attribution

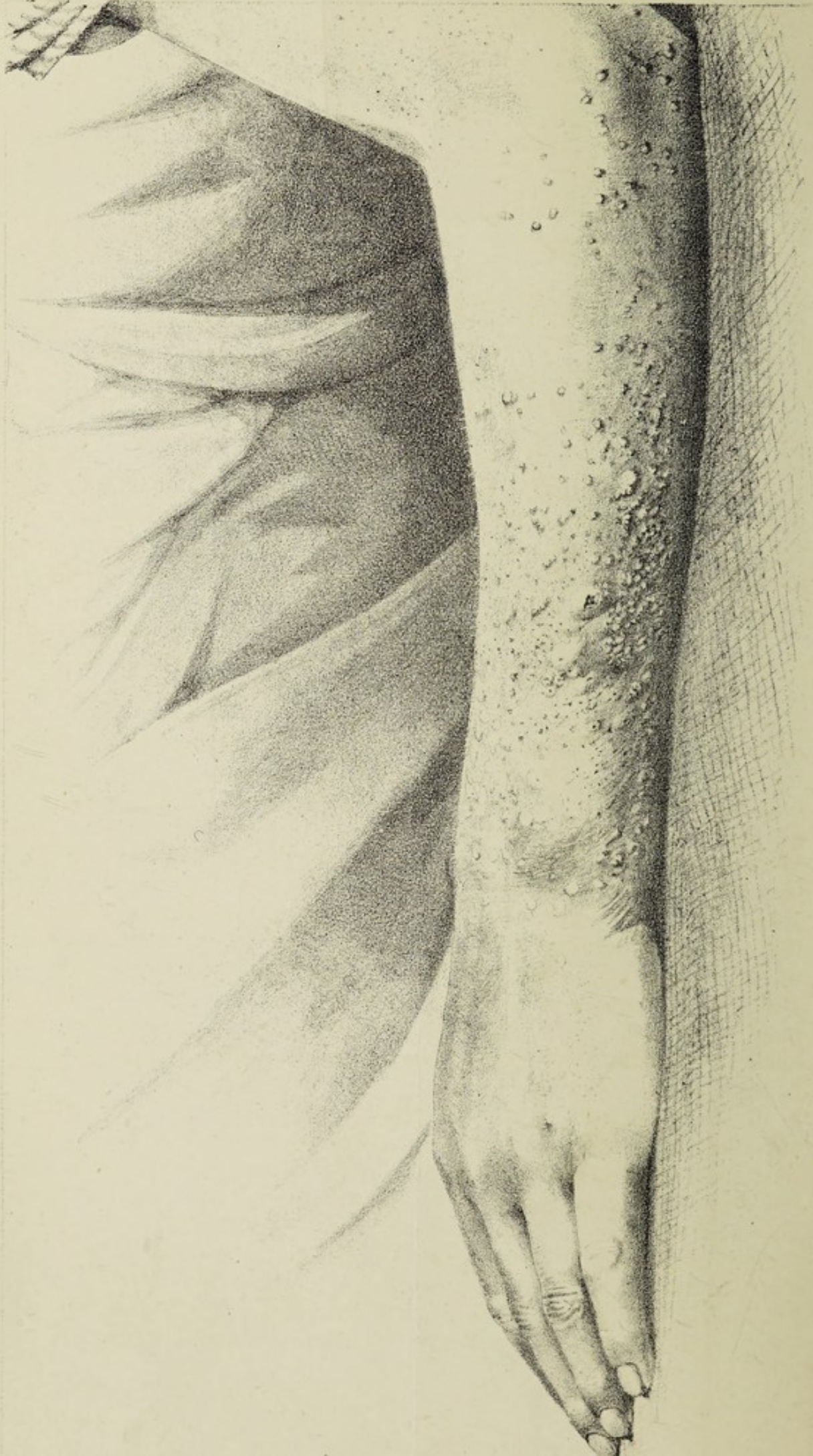
This work has been identified as being free of known restrictions under copyright law, including all related and neighbouring rights and is being made available under the Creative Commons, Public Domain Mark.

You can copy, modify, distribute and perform the work, even for commercial purposes, without asking permission.



Wellcome Collection
183 Euston Road
London NW1 2BE UK
T +44 (0)20 7611 8722
E library@wellcomecollection.org
<https://wellcomecollection.org>





with Alex. Ogston

Compliments

LOCAL EFFECTS OF CRUDE PARAFFIN.

By ALEX. OGSTON, M.D., ABERDEEN.

(Reprinted from the *Edinburgh Medical Journal* for December 1871.)

THE Messrs Miller's Chemical Works at Aberdeen have afforded the opportunity for collecting the following information concerning the appearances produced on the skin of those engaged in the manufacture of paraffin, which seems of sufficient interest to warrant being recorded:—

The workmen engaged in this manufacture have the skin over portions of their bodies, more especially of the hands and arms, but also of the feet and legs, brought daily for many hours at a time into contact with the paraffin shale, and with the oily matters mixed up with it, the result being an eruption of nodules and pimples on the skin so exposed, speedily breaking out on those who are for the first time engaged in it, lasting for a few weeks or months, and then generally diminishing or disappearing. In a few exceptional individuals the eruption does not disappear, but, assuming a chronic character, produces so marked and prolonged an affection of the skin that the general health becomes impaired, and the cessation of this employment becomes a necessity. The appearances differ in the two classes of cases, acute and chronic, and, while the essential alterations in the skin remain the same, the presence of inflammatory action in the acute, and its absence in the chronic forms, leads to a marked distinction between the two, and admits of their being separately described.

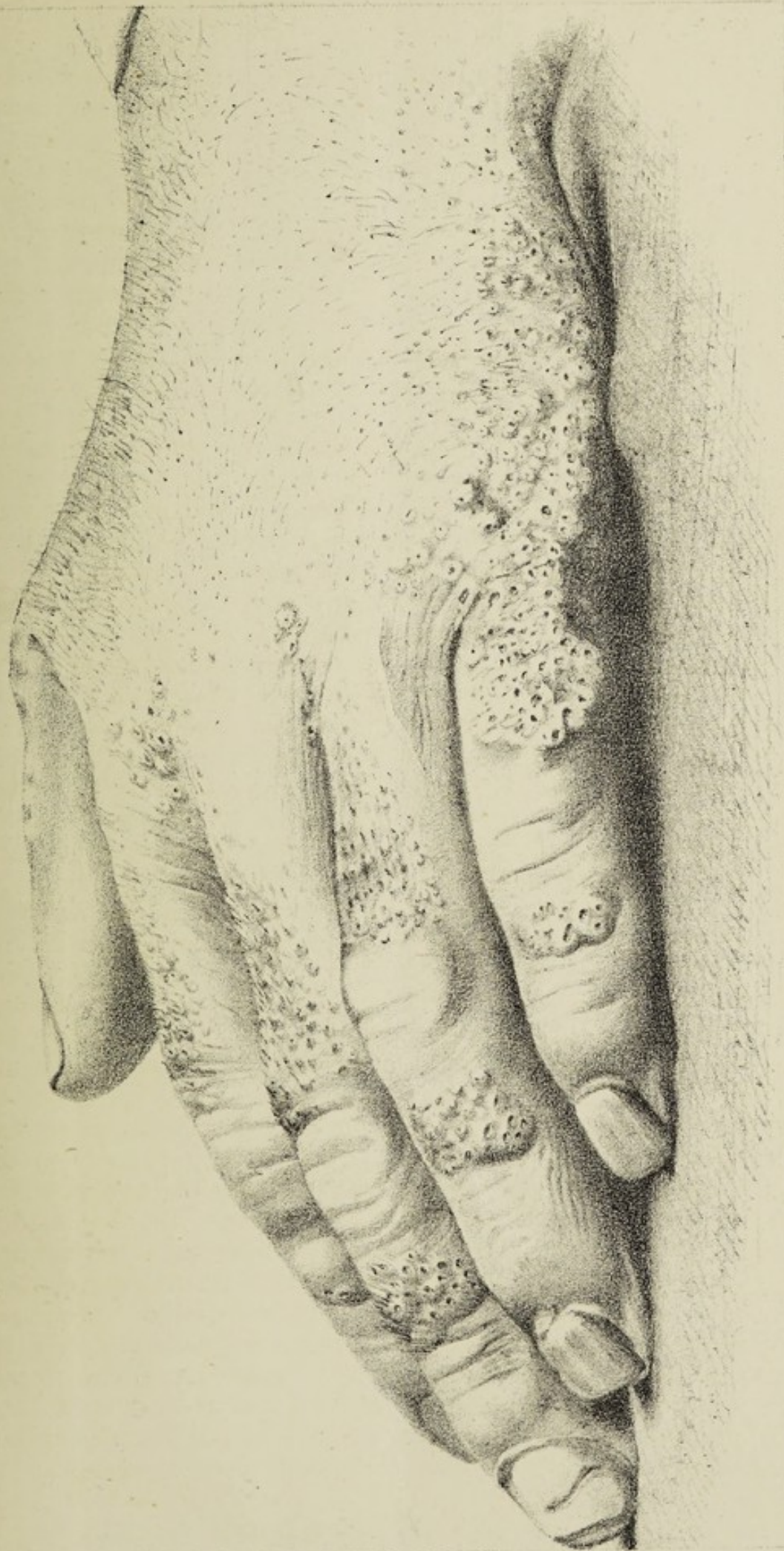
▶ In the *acute* form of the eruption, which soon appears in those exposed to the influences of crude paraffin, the skin of the hands, wrists, arms, feet, and legs becomes covered with a rash of bright red nodules, closely approximate to each other, and usually largest and most numerous on the wrists, or wherever the dress tightly embraces the skin; the dorsal aspects of the parts being most severely affected, and the palms of the hands and soles of the feet enjoying a complete immunity. Similar nodules arise, though to a less extent, on the face, neck, and other parts of the body to which the oily matters find access.

On examining minutely the skin of those affected in this way,

the following are the leading peculiarities of the eruption:—The bright red nodules, hard to the touch, tender on pressure, varying little in size, which is about equal to that of a grain of barley, are of a rounded form, and consist each of a single hair-follicle with the parts immediately surrounding it, which are inflamed, indurated, and reddened. The hair emerges from the very summit of the nodule, and the orifice of the hair-follicle is much enlarged and easily visible to the naked eye as an aperture of a magnitude similar to that of a pin-hole in a card. The dilatation extends to the deeper part of the follicle, which forms the kernel of the inflamed knot, the retention of its contents evidently contributing to the inflammatory induration around. The gaping mouth of the follicle exhibits masses of cast-off epithelial scales, dry and friable instead of greasy and tenacious; the nodule has little of the tendency to run on to suppuration observable in an ordinary *comedo*, and its contents cannot be squeezed out. On the contrary, the redness and induration, after remaining for some little time, gradually diminish, and finally disappear, leaving the hair-follicle enlarged, and its mouth gaping so as to exhibit the retained epithelial masses, these latter being rendered more distinct by continued retention and accumulation of dirt. In fact, the *acute* form of the eruption consists of successive crops of these nodules, which are thus at the same time seen in all stages of their growth, full development, and subsidence; while the skin between them, studded with the black gaping mouths of such follicles as have already passed through or are about to undergo the process, retains, contrary to what is observed in the chronic form of the malady, its natural pliancy and elasticity.

In all paraffin-workers patency and enlargement of the hair-follicles continue to some extent so long as they are engaged in this manufacture, and the black dots in the skin of their hands and face strike the eye of the observer at once; men with dark complexions and strong hair being especially deformed in this way, while fair complexions and light or reddish hair escape comparatively unaffected.

A few exceptional individuals, with swarthy complexions and hairy skins, suffer so much from an exaggerated patency of the follicles that they are compelled to quit their occupation and seek a more suitable calling. When the disease assumes this *chronic* form it exhibits the following characteristics:—The backs of the feet and toes, the dorsum of the hand, and the backs of the fingers between, but not over, the joints, exhibit a peculiar honeycombed appearance of the skin, which is elevated, thickened, and inelastic, so as to prevent or render difficult and painful the flexion of the fingers and hand. These elevated honeycombed patches are of natural colour, and not inflamed (except where an isolated papule exhibits the appearance described under the acute form), but consist of densely-grouped arrays of hair-follicles, with the indurated cutis between and around them, the follicles packed with dry brittle



Keith & Gibb,

CHRONIC EFFECTS OF CRUDE PARAFFIN.

Lithog^s. Aberdeen.



Digitized by the Internet Archive
in 2019 with funding from
Wellcome Library

accumulations of epithelial scales, so extensive as to be easily visible through the dilated mouths of the follicles, these latter being large enough to admit the extremity of an ordinary probe. The hairs themselves have disappeared from these patches, having probably become atrophic from the pressure of the epidermic masses, while cracks and bleeding fissures traverse the indurated parts, and in rare instances a follicular abscess gives variety to the picture. The knuckles of the fingers and toes, the palms of the hands, and the soles of the feet, remain unaffected by the disease. In the subjects of the chronic malady the complexion is pale and the tongue foul, while the loss of flesh betrays the effects of the sleepless nights caused by the constant irritation and pain of the skin of the affected extremities.

The *modus operandi* of the crude paraffin in producing these results seems to be as follows:—The oily matters in the shale, called “blae oil,” when separated, are both penetrating in their properties and irritating to the skin; and, coming continually in contact with the epidermis, soak into the hair-follicles, where they create an irritation soon leading to induration and increased exfoliation of epithelial scales. This exfoliation is not counterbalanced by increased expulsion of the scales, owing doubtless partly to the large quantities cast off, and partly to the usual fatty and lubricating substances mixed up with them being dissolved out and removed by the “blae oil,” thus leaving the brittle epidermic masses plugging the follicles, and increasing the inflammatory irritation. (The palms of the hands, soles of the feet, and knuckles of the fingers and toes—places supplied with sweat-glands but no hair-follicles—escape the irritation, from the watery contents of the sudariparous pores presenting an obstacle to the ingress of the oil.) After a time the hairs on the most exposed parts become atrophic and fall out, but the continued retention of the epithelial masses keeps up the process in the follicles and the induration of the surrounding skin.

The workmen are in the habit of employing “shale spirit” to wash the affected parts, whether with any beneficial effect is, I think, doubtful.

