

## **Observations on clinical medicine / by J. Warburton Begbie.**

### **Contributors**

Begbie, James Warburton, 1826-1876.

### **Publication/Creation**

[Place of publication not identified] : [publisher not identified], [1864]  
[(Edinburgh) : [Oliver and Boyd.]]

### **Persistent URL**

<https://wellcomecollection.org/works/ukeepbcug>

### **License and attribution**

This work has been identified as being free of known restrictions under copyright law, including all related and neighbouring rights and is being made available under the Creative Commons, Public Domain Mark.

You can copy, modify, distribute and perform the work, even for commercial purposes, without asking permission.



Wellcome Collection  
183 Euston Road  
London NW1 2BE UK  
T +44 (0)20 7611 8722  
E [library@wellcomecollection.org](mailto:library@wellcomecollection.org)  
<https://wellcomecollection.org>

716

# OBSERVATIONS

IN

## CLINICAL MEDICINE.

BY J. Warburton Begbie, M.D.,

Physician to the Royal Infirmary.

---

*Reprinted from the Edinburgh Medical Journal, March 1864.*

---

### *Favus (Tinea Favosa)—its Treatment by Depilation.*

THIS interesting form of cutaneous affection, the truly parasitic nature of which is now generally admitted, has been of frequent occurrence in the hospital wards during the whole period of my service as physician. I have nothing to add to the accurate as well as detailed accounts of the disease which are to be found in the writings of such authors as Devergie, Hebra, and Bazin, on the Continent, and of Mr Erasmus Wilson and Dr M'Call Anderson, in our own country. The experience I have had of Favus has convinced me of its intimate connexion with filthiness of the head and body, of its ready communicability when favoured by the pre-existence of dirtiness, the predisposing cause of most importance, in the person exposed; and, lastly, of its eminently satisfactory treatment by one plan, and by that one plan only. I contrast, very favourably for the process of depilation, the different means for the cure of Favus affecting the scalp, which have been formerly witnessed, at various times, and in various places—and likewise employed by myself; and now, having obtained results so completely satisfactory, by the employment of depilation,—practised very nearly as M. Bazin has recommended it, I have relinquished all other expedients for effecting the removal of this frequently loathsome disease, and can confidently recommend depilation as a most efficient remedy. Coupled with the depilatory process, however, must be, first of all, the thorough cleansing of the scalp, and then the employment of what are likewise styled *parasiticide*



remedies, or still more strictly in relation to Favus, a disease dependent on the existence of a plant or vegetable-like parasite—*phyticides*. Of these a solution of the corrosive sublimate (one or two grains to the ounce of water, with the addition of a little alcohol or hydrochlorate of ammonia), the oleum juniperi pyrolignicum (huile de cade of the French), and the subsulphate of mercury (turpeth mineral), in the proportion of a scruple or half a drachm to the ounce of prepared lard, are the chief; and so long as the act of depilation is in progress, the diligent use of one or other of these parasite destroyers is to be enjoined. I have found the empyreumatic oil of juniper to be most serviceable; and from the year 1850, when I first saw it in use in the St Louis Hospital at Paris, have been constantly in the habit of employing it in the treatment of the parasitic, as well as of the scaly, affections of the skin. The precise plan pursued in the treatment of all the cases of Favus recently under my care, is as follows. On reception, the patient has at once a hot bath, and both head and body are as thoroughly as possible cleansed, with the aid of soft soap; the hair of the head is then cut to the level of the Favus crusts, and, as Bazin has directed,<sup>1</sup> the oil of juniper (before mentioned) is applied by means of a thick camel-hair brush. On the succeeding day, poultices of potato-starch are placed over the head, and diligently continued till the complete separation of the crusts is effected. This done, the juniper oil is re-applied; and on the day following, the process of depilation commenced. While this is continued, the daily use of one or other of the phyticide applications is being made. Care should always be taken that the depilation is complete, and that it is persevered in until the growth of healthy-looking hairs over all parts of the scalp is observed. Thus the treatment may require *many weeks* for its thorough execution; but when it is held in remembrance that the cure effected is radical, its lengthened duration may well be tolerated.

The following, one of the most recent examples of Favus under my care, in which the trunk as well as the scalp was affected, will serve as a further illustration of the treatment now described:—

E. S.,<sup>2</sup> æt. 17, single, living in her sister's house at M., near Edinburgh, admitted into Ward XV., Royal Infirmary, in November 1863, suffering from well-marked Favus of the head and upper part of the back, which she says has existed since infancy. By the application of poultices, and by washing with black-soap, her head has frequently become so clean as to lead her friends to believe that they had effected her relief from this offensive complaint; but in seven or eight days the scalp had again become covered with yellow crusts, emitting the peculiar and characteristic odour. The patient has on several occasions been under medical

<sup>1</sup> Leçons Théoriques et Cliniques sur les Affections Cutanées Parasitaires. Professées par le Docteur Bazin. Paris, 1858. (See page 138.)

<sup>2</sup> Reported by Mr S. E. Roberts, clinical clerk.



treatment, but with a like result. She has always been well clothed and properly fed, taking animal food three or four times a-week. She has no other ailment, and has always enjoyed good health. Till within the last two years the disease was confined to the head; but about that period a similar eruption began to show itself on the upper part of the back, and has since then extended over both shoulders. At present the scalp is almost entirely covered with dirty yellow crusts, and over it several patches of baldness exist. The eruption on the back possesses a brighter yellow colour than that on the head, extending on the left side from the top of the shoulder to the waist, and, transversely, from about the angles of the ribs to the spine; the denser crusts being situated over the scapular region. The patient complains of much itching and uneasiness in the parts affected, but of no pain. The head and back having been carefully washed, while the hair was closely clipped on the former, the juniper oil was applied, and thereafter the removal of the crusts effected by poultices of potato-starch. This done, depilation was commenced, and at the same time the use of the following lotion, for both the head and back:—℞ Hydrargyri Sublimati Corrosivi, gr.xij., Ammoniae hydrochloratis, ℥i., Aquæ fontis, ℥vj.—*Solve.* The first depilation in this case was completed in about three weeks; it has been continued till nearly the present time (13th February), so as to effect the removal of all the unhealthy-looking hairs which have re-appeared. Latterly, the following application, which I can strongly recommend as a phyticide, has been employed for the head, instead of the corrosive-sublimate lotion:—℞ Saponis Mollis, ℥ij., Olei Juniperi Pyrolignici, Spiritus Rectificati, Glycerinæ, ā ā, ℥iv.—*M.* The patient still remains in hospital; but the appearance of both head and back is eminently satisfactory, while the hair over the former is now appearing in a healthy and vigorous condition. I see no reason to doubt that in this case, as in many previous examples, the recovery will prove complete and lasting.

*Herpes Circinatus (Tinea Circinata) with Favus.*

The association of Tinea Circinata, a parasitic affection frequently styled ringworm of the body,—to distinguish it from Tinea (Herpes) Tonsurans, ringworm of the scalp,—with Favus, has been noticed, more particularly by Hebra, who has delineated the two eruptions as occurring at the same time in the same subject.<sup>1</sup> The case I am about to relate appears to me of interest—*firstly*, as an example of the co-existence of two affections supposed by Bazin and others to be dependent on the presence of separate and distinct vegetable parasites. In Favus it is the well-known Achorion Schoenleinii, in Tinea Circinata the Trichophyton Tonsurans, which is met with.

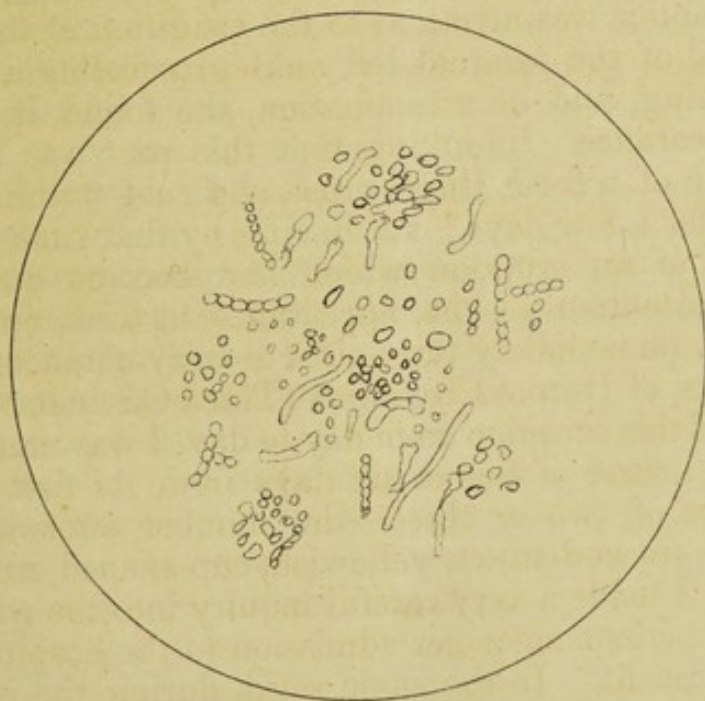
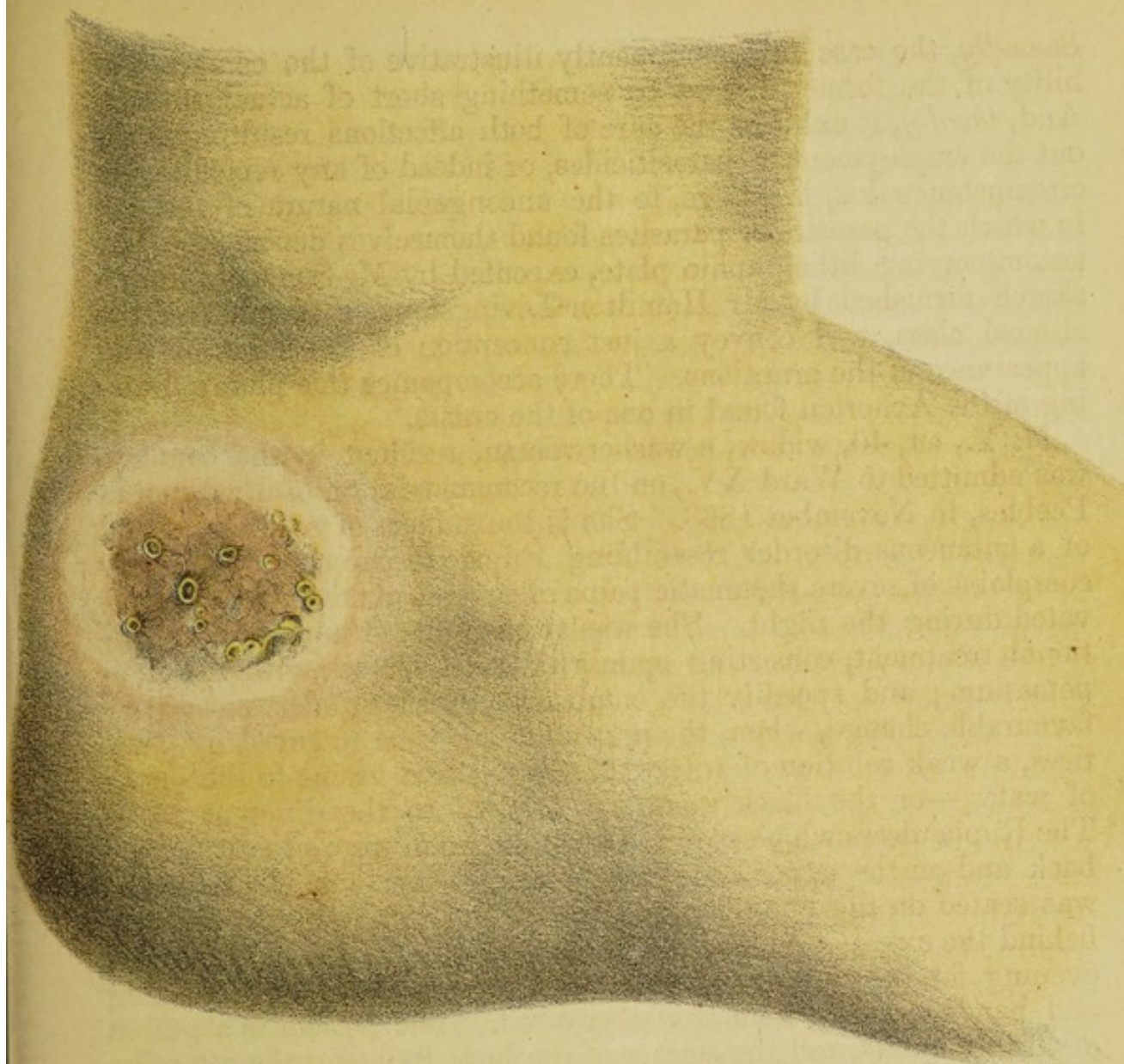
<sup>1</sup> See a plate in Hebra's Atlas of Cutaneous Diseases. To be found also in the earliest fasciculus, issued by the New Sydenham Society.




*Secondly*, the case is pre-eminently illustrative of the communicability of the former disease by something short of actual contact. And, *thirdly*, it exhibits the cure of both affections resulting without the employment of parasiticides, or indeed of any remedies,—a circumstance due, I believe, to the uncongenial nature of the soil in which the parasite or parasites found themselves deposited. The accompanying lithographic plate, executed by Mr Schenck, from a sketch furnished by Mr Hamilton Livingstone, a member of the clinical class, will convey a just conception of the situation and appearance of the eruptions. There accompanies this plate a drawing of the Achorion found in one of the crusts.

M. Y., æt. 40, widow, a washerwoman, resident in the country, was admitted to Ward XV., on the recommendation of Dr Junor of Peebles, in November 1863. She is the subject of sore throat and of a cutaneous disorder resembling *Rupia Prominens*, but chiefly complains of severe rheumatic pains of several joints, greatly aggravated during the night. She was at once placed under a constitutional treatment, consisting mainly of cod-liver oil, with iodide of potassium; and speedily the cutaneous disorder underwent a very favourable change, when, the crusts having been removed by poultices, a weak solution of nitrate of silver—five grains to the ounce of water,—or the black wash was applied to the different sores. The *Rupia* ulcers which required most attention were situated on the back and on the upper and lower extremities. One, in particular, was seated on the outer side of the ankle of left foot, immediately behind the external malleolus. This foot she exposed morning and evening for the purpose of dressing the sore, removing a stocking and bandage with which it was covered. The patient is a person of cleanly habits, and the surface of the body indicates the attention which she has paid to ablution. About the middle of December, the patient's notice was attracted to the condition of the skin in the neighbourhood of the internal left ankle, by feeling a considerable degree of itching, and on examination, she found it red and inflamed in appearance. Thinking that this part was about to become the seat of a fresh *Rupia* crust, she said nothing about the circumstance for a few days; but having by that time observed the circular form of an eruption which had become developed, she directed my attention to the appearance at visit on the 23d of December. I immediately recognised a very characteristic circle, or rather circles, of *Herpes Circinatus* (*Tinea Circinata*). Watching the progress of this eruption from day to day, I was much interested to find, in the course of five or six days from its first recognition, the appearance of two or three—the number afterwards reached seven or eight—most distinct, yellowish, cup-shaped crusts of favus. At this period I made a very careful inquiry into the whole circumstances of the patient since her admission to the hospital, and with the following result. In the same ward, during the entire period of her occupation of a bed, there had been two well-marked cases










of Favus,—one of these being that of the patient E. S., already briefly detailed in this report, the other that of a little girl, J. M'N., æt. 8, who had laboured under the disease, affecting the head only, since her second year. This little patient, it was distinctly ascertained, was frequently in the habit of visiting the woman M. Y.; and it is conjectured, with, I think, every show of probability, that while so engaged, some of the sporules of the Achorion may have fallen from her head upon the foot of M. Y., which she had at the time exposed, for the purpose of cleaning the sore on its external surface, and of applying to it the lotion of nitrate of silver. The precise relation of the Tinea Circinata to the Favus may be difficult of explanation, but the intimate co-existence of these two parasitic disorders is one of the most interesting features in this very illustrative case. The parasite existing in the former affection is believed to be identical with that found in Tinea (Herpes) Tonsurans—ringworm of the head,—and in Sycosis (Mentagra)—ringworm of the beard—the so-called Trichophyton Tonsurans. The microscopic differences between the Achorion and the Trichophyton are, however, confessedly not very remarkable. The former is composed of sporules, empty tubes (the mycelium), and tubes filled with sporules; the latter is characterized by the presence of spores, with very few if any tubes. It is, however, consistent with my own observation, that in the examination of some Favus crusts, sporules alone are to be detected, just as Mr Erasmus Wilson states that mycelium is sometimes to be found in the trichophyton.<sup>1</sup> Hence, probably, it results that so competent an authority as Hebra reduces the number of cutaneous fungi to one, conceiving the differences in the microscopical characters of the four usually recognised parasites—the achorion, the trichophyton, the microsporon furfur, and the microsporon Audouini—to be determined by the peculiarity in structure of the part of the skin which is their seat. However this may be, I had no difficulty, in the present instance, in detecting the Achorion, presenting the appearance of well-marked oval and round sporules, with very few tubes, in the small yellow crusts which appeared on the surface of the erythematous patch lying within the distinct vesicular circles of Herpes. And so, likewise, when the usual desquamative change had succeeded the earlier appearance of the Tinea Circinata, in the cuticular scales gently removed for microscopic examination by means of a blunt instrument, I observed numerous sporules, but neither empty nor filled tubes—precisely the same appearance as I have frequently seen before, and last witnessed in a case of ringworm which occurred this week in the hospital. The limitation of the two affections in this case to a very small surface of the skin—their appearance on no other part of the body separately—the immediate succession of the Favus crusts to

<sup>1</sup> On the Phytopathology of the Skin, and Nosophytodermata, the so-called Parasitic Affections of the Skin.—*British and Foreign Medico-Chirurgical Review*, January 1864.



the annular eruption of Herpes—the exposure of the patient herself to the contagion (or communication short of actual contact) of Favus, but not, so far as can be ascertained, to that of ringworm—and finally, the joint and complete disappearance of the two eruptions, all traces of which have now vanished—exhibit, I think it must be admitted, a very intimate connexion between the two disorders in this particular instance. As an evidence of the communicability of Favus, the case, indeed, is one of very great value. It is also valuable, as showing that even that intractable disorder (well named *Tinea*) may come to a spontaneous termination. Essentially it is a disease of the hair-follicles. Developed in the situation in which it occurred in this case, the fungus speedily dies, as it were, a natural death. The same remark applies to Herpes Circinatus, which not unfrequently requires no decided treatment.





Digitized by the Internet Archive  
in 2019 with funding from  
Wellcome Library

<https://archive.org/details/b30566381>



