

Elephantiasis Arabum of the right inferior extremity : successfully treated by ligature of the femoral artery / by J.M. Carnochan.

Contributors

Carnochan, J. M. 1817-1887.

Publication/Creation

New York : J.F. Trow, 1852.

Persistent URL

<https://wellcomecollection.org/works/gq726q8v>


License and attribution

This work has been identified as being free of known restrictions under copyright law, including all related and neighbouring rights and is being made available under the Creative Commons, Public Domain Mark.

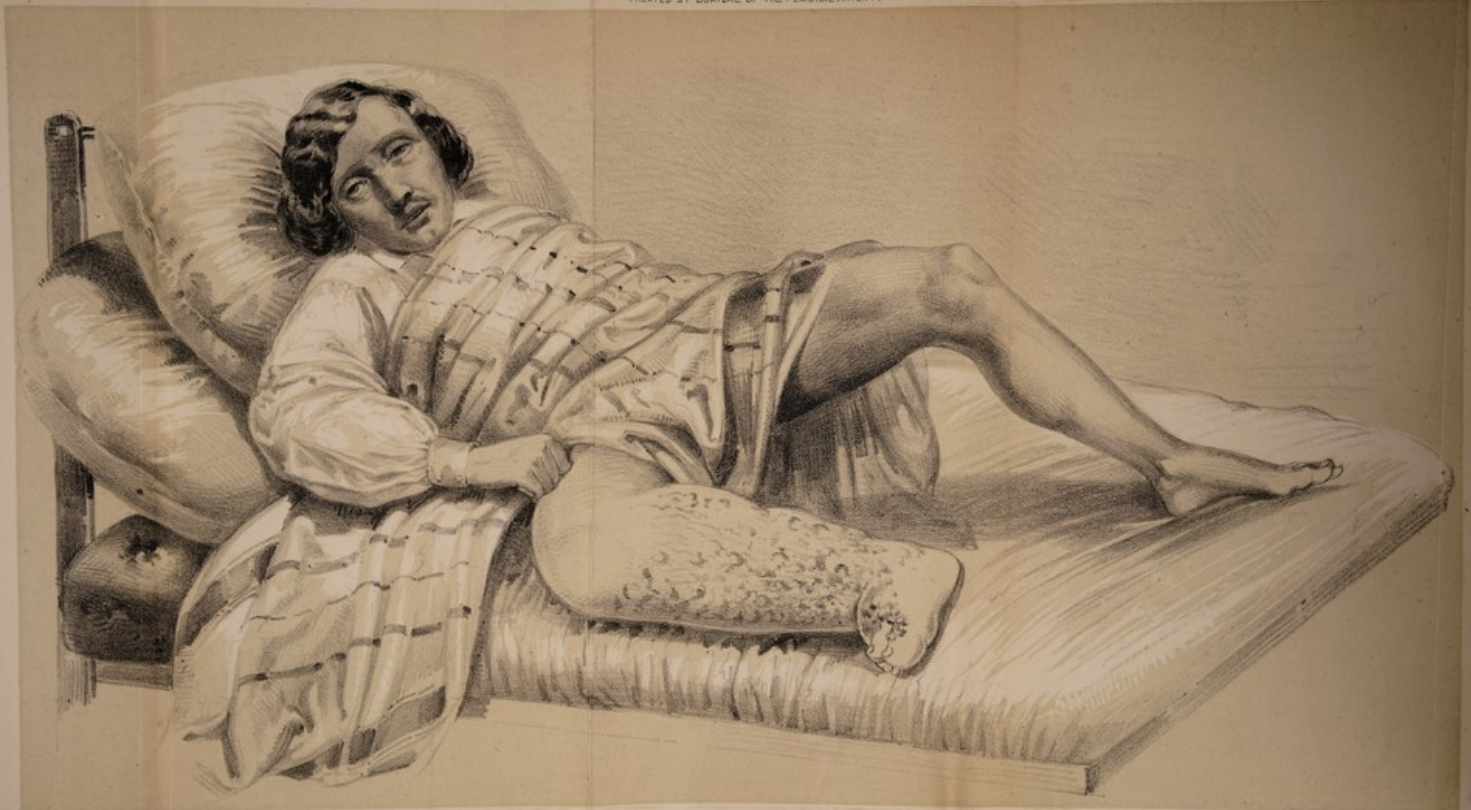You can copy, modify, distribute and perform the work, even for commercial purposes, without asking permission.



Wellcome Collection
183 Euston Road
London NW1 2BE UK
T +44 (0)20 7611 8722
E library@wellcomecollection.org
<https://wellcomecollection.org>



OF CARNOCHAN'S CASE OF ELEPHANTIASIS ARABUM.
TREATED BY LIGATURE OF THE FEMORAL ARTERY.



ENGRAVED BY W. H. HAYES

LITH. BY G. H. HALL, NEW YORK.

21
ELEPHANTIASIS ARABUM

OF THE

RIGHT INFERIOR EXTREMITY :

SUCCESSFULLY TREATED

By Ligature of the Femoral Artery.

BY

J. M. CARNOCHAN, M. D.,

PROFESSOR OF THE PRINCIPLES AND OPERATIONS OF SURGERY IN THE NEW-YORK MEDICAL
COLLEGE; SURGEON TO THE STATE EMIGRANTS' HOSPITAL; OPHTHALMIC SURGEON
TO THE SAME INSTITUTION, ETC.

With a Plate.

~~~~~  
[From the New-York Journal of Medicine. September, 1852.]  
~~~~~

NEW-YORK:
JOHN F. TROW, PRINTER, 49 ANN STREET.

1852.

THE UNIVERSITY OF CHICAGO

THE UNIVERSITY OF CHICAGO

SUCCESSFULLY TREATED

Signature of the Principal Author

J. M. GARZOCAN, M. D.

1881

NEW YORK

HOWE, PRINTER, 23 ANN STREET

1881

Dedicated

TO THE PRESIDENT AND MEMBERS

OF THE

HONORABLE BOARD OF COMMISSIONERS OF EMIGRATION,

IN

NEW - YORK.

BY THEIR OBEDIENT SERVANT,

J. M. CARNOCHAN.

President of the Board.

Hon. GULIAN C. VERPLANCK.

Members.

CYRUS CURTISS,
GREGORY DILLON,
CHAS. H. MARSHALL,
J. C. ZIMMERMAN,
Hon. AMBROSE C. KINGSLAND,
Hon. CONKLIN BRUSH,
GEORGE W. BLUNT,
ELIAS HICKS,
JAMES KELLY.

Vice President.

JAMES L. MORRIS,

Digitized by the Internet Archive
in 2019 with funding from
Wellcome Library

ELEPHANTIASIS ARABUM
OF THE
RIGHT INFERIOR EXTREMITY,
SUCCESSFULLY TREATED
BY LIGATURE OF THE FEMORAL ARTERY.

Elephantiasis Arabum, so called in contradistinction to *Elephantiasis Græcorum*, because its history was first described by Arabian authors, is a malady, the etiology and pathology of which are not definitively understood at the present day. The treatment also remains uncertain; and when the disease has existed for any length of time, it is generally looked upon as irremediable by any other means than amputation of the tissues, or of the member involved. This malady is not confined in its attacks to any particular part of the body; the vulva, the scrotum, and the inferior extremities are, however, the principal seats of the disease. When affecting the lower extremity, its peculiar form, which is somewhat like the clumsy appearance of the elephant's leg, suggested the name of *Elephantiasis*.

Elephantiasis of the Arabs is said to be uncommon in Europe, and as respects this country, I am not aware of its occurrence endemically, in any part of it. Insulated cases, however, certainly do present themselves. Within the last three years, five marked cases have come under my observation; of these, in two instances, the malady showed itself in

the scrotum, and, in the other three, the seat of the disease was in the inferior extremity. Four of these cases became developed in persons residing in different parts of the United States, one in New-York, one in Florida, one in Virginia, and one in the State of Pennsylvania; the other case occurred in a patient who was a native of Ireland, and who imported the disease with him. These patients were all adult males, and the circumstances preceding the development of the disease in each case, were generally dissimilar; thus, in the cases where the inferior extremity was affected, the disease in one became manifested after an attack of paludal fever; in another also, after a febrile attack; and in the third, after the individual had been working for some time at an occupation requiring him to stand for hours with his legs immersed in water. In one of the two cases where the scrotum and integuments of the penis were affected, the elephantiasis was preceded by a scrotal hernia, and by an attack of syphilis, while the other was associated with, and preceded by, a large hydrocele of the tunica vaginalis testis.

Climate cannot be said to have exerted any influence, as the cases occurred in different localities. The accounts, however, related of this malady, will not allow us to doubt that it is met with in certain latitudes and localities, more frequently than in others. In the West Indies, some parts of Asia, and among the Arabs, it is found to exist endemically; but, although this fact is established, and points to the influence of climate, what that influence is, and how it operates, remains unaccounted for, with any degree of certainty. The enlargement of the thyroid gland, which occurs in certain parts of Europe and North America, is ascribed to the drinking of snow water, and of water impregnated with calcareous or earthy particles; while in the equatorial or tropical regions, the prevalence of elephantiasis is attributed to the alternations of heat and cold. But these speculations, resting as they do upon no positive data, are extremely vague, and thus, both as regards the more frequent occurrence in certain localities, and as regards the difficulty of accounting for the influence of climate, elephantiasis and bronchocele, both hypertrophic conditions of the tissues, appear to have some analogy to each other.

The production of the disease has also been attributed to the obliteration of the veins of the member affected, and likewise to chronic inflammation, commencing at the dermoid structure, and extending, by contiguity of tissue, to the subcutaneous layers; but again, it must be remarked, that no fixed invariableness of antecedence has been observed. One fact which may have some bearing upon the etiology of elephantiasis, and to which I shall again presently allude, has been generally overlooked. I refer to the morbid condition and dilatation of the principal arterial trunk of the member affected. The disease has also been supposed to arise from frequent attacks of erysipelas; and as another cause, from sub-inflammation of the absorbent vessels and lymphatic glands.

Elephantiasis, as in two of the cases which came under my observation, is sometimes rapid in its accession or invasion, and, when occupying an extensive surface, the constitution participates in the local affection. The skin assumes no erysipelatous hue; the subcutaneous tissues become engorged, tumified, and tense; the course of the lymphatics, if the seat of the malady be on a limb, is marked by nodulated cords; and the glands of the groin or of the axilla may also become affected and enlarged; these various symptoms being ushered in by a deep-seated and violent pain in the region of the disease.

If the disease, after the acute stage, do not recede, the intumescence remains, although the other symptoms may subside for a time. Exacerbations recur at intervals varying in duration, and the enlargement of the tissues increases, until the structures invaded remain, as it were, stationary in their abnormal condition, imparting to the hand, when examined, a harsh, dense, pachydermatous sensation, and presenting to the eye, in the most characteristic form of the disease, a rough, scaly, dusky-looking mass of deformity, well represented in the accompanying illustration.

If the disease progress no farther than has just been described, the enlargement of a limb, or of the scrotum, remains an insufferable encumbrance; while, in the uninterrupted

progress of the disease, fœtid and incurable ulcerations may occur, abscesses may take place among the morbid tissues, and the internal organs may become deranged. The prognosis, consequently, must be unfavorable, when the disease has existed for some time, and assumed its characteristic, chronic and intractable form.

In the early stages of the disease, it is possible that it may be confounded, especially in females, in whom the subcutaneous strata are usually thicker than in males, with diffuse and deep-seated inflammation of the cellular tissue, or with œdema or anasarca. The history and progress of the disease, the sensation imparted, upon examination, by the tumor, and the peculiar local traits, generally suffice to enable the practitioner to discriminate, without much difficulty, between elephantiasis and the other diseases just named.

It would appear from the different accounts given of this disease, that the whole of the tissues of a member may become ultimately implicated. Some are primarily affected, while others, such as the bones, are probably not involved in the morbid degeneration, until the disease has been of long standing. The tissues primarily affected would seem to be the vascular; and the pain, redness, and hardness met with in the first stage of the disease, in the course of the lymphatic vessels, together with the appearances of the veins, upon autopsy, as mentioned by Bouillaud and others, evince with sufficient certainty a pathologic condition of the vessels. The arteries also participate in the disease, and very probably at an early stage of its invasion.

The skin generally shows early participation in the malady; most commonly the development of the initiatory stage is accompanied by some form of cutaneous affection, such as eczema, erysipelas, lichen, or ulceration. These affections occur, however, so frequently without any of the hard and bulky intumescence characteristic of elephantiasis being manifested as a sequent, that it is reasonable to suppose they are accompaniments merely of disease of the deeper-seated tissues, especially of the vascular tissues upon which, in reality, the elephantiasis depends. The different strata of the skin are hypertrophied to a

considerable degree, the epidermis presenting a series of dusky, hard, superimposed scales. This condition of the epidermis, however, is not always present, especially when the scrotum is the seat of the disease. The subcutaneous adipo-cellular layer is blended with the dermoid tissue, so as to form a hard, dense, and lardaceous mass of irregular thickness; the sub-aponeurotic and intermuscular cellular tissue becomes also changed and hypertrophied; the muscles, also, are in the progress of the disease perverted, becoming softened and less deeply colored than in their normal condition, sometimes being converted into fatty tissue, at others into an indurated formation, and even, at times, exhibiting deposits of bony material; the nerves are sometimes found to be increased in size; the bones are sometimes found unaltered, and sometimes are found increased in size; and, lastly, the interosseous ligament is at times found ossified. Lesions of the internal organs are not so frequently found to accompany elephantiasis *Ara-
bum* as the other form, known as elephantiasis *Græcorum*; still, diseases of the internal viscera are seen as complications of the former, when the malady has existed for a long period.

In its initiatory stage, the treatment of elephantiasis, regarded as a *phlegmasia*, should be conducted upon antiphlogistic principles; thus bleeding, emollient applications, tepid baths, and the vapor *douche*, are recommended and resorted to. In the more chronic stages of the malady, compression, combined with scarifications and local bleeding, are said to be useful. Iodine frictions and the vapor *douche* appear to merit most attention, having, upon good authority, been used advantageously in cases of genuine elephantiasis.

When the disease has resisted every rational curative method, and when the part attacked has attained a size which, by reason of the weight of the mass, renders it an unmanageable encumbrance, as happens in elephantiasis of the scrotum and of the inferior extremities, amputation is advised and practised as the only alternative. But this extreme resort is not usually attended with success, the disease generally returning upon some other member with all its original inveteracy and obstinacy.

In the following case which came under my management, I resorted to a method of treatment which, as far as I know, is entirely novel, and which, both for this reason and because it terminated in the perfect restoration of the diseased and cumbrous limb to its normal condition and functions, I have thought deserving of publicity.

The annexed drawing of the limb of the patient, taken from nature, gives an accurate representation of the disease.

CASE.—Charles Roller, of lymphatic temperament, and short stature, æt. 27, born in Aix-la-Chapelle—occupation, merchant, left his home in December, 1849, landed in New-York in February 1851, went thence to Connecticut, where for eight months he worked in a factory, standing during his hours of labor; thence went to Virginia, where he worked on a farm for about six months, at the expiration of which period he was taken with fever, of an intermittent character. Up to that time, he had always been in good health.

During the fever, the inguinal glands on the right side became swollen and painful; the swelling and pain extending in the course of the femoral vessels as far as the knee. The pain was followed by swelling and redness of the thigh down to the knee. From the knee, the pain and swelling continued to extend downwards as far as the toes; being, at this time confined chiefly to the portions of the limb along the course of the saphena vein, and also of the posterior tibial vessels. The redness and tumefaction here, as in the thigh, was preceded by deep-seated pain. The tumefaction of the limb continued to increase; while, at the same time, febrile exacerbations occurred at intervals, varying from two to six days. After a period of about six weeks from the commencement of the disease, the fever entirely disappeared, and by this time, also, the pain and redness had entirely ceased; the limb, however, remaining hard, swollen and rough, and presenting, in a marked degree, the peculiar characteristics of elephantiasis Arabum, in the chronic period of the disease. From this time forward, the hardness and intumescence gradually increased, and the limb became so cumbersome, that the patient was obliged to give

up all business, and confine himself chiefly to a recumbent posture. In this condition, the patient left Virginia for the purpose of seeking medical relief at the New-York Emigrants' Hospital, into which he was admitted the fifteenth of January, 1851. The appearance of the patient upon entering the Hospital was somewhat emaciated. He had no febrile symptoms, and the chief difficulty, under which he labored, arose from the enlarged and hypertrophied condition of the right inferior extremity.

The limb was enlarged from the toes to within a short distance below Poupart's ligament. The thigh, although enlarged, was not much indurated; while, from a short distance above the patella, downwards, the limb presented a dense, hypertrophied, hard, scaly, shapeless mass, the appearance of which will be best apprehended by referring to the accompanying plate.

The morbid condition of the tissues pervaded the foot and toes, there presenting groups of tuberculated growths. The circumference of the limb around the ankle, was nearly as large as that of the calf; measuring fifteen and one-half inches, while the circumference of the calf measured nineteen and one half inches.

The patient was put under treatment upon entering the Hospital. The recumbent posture was enjoined, and for some time various discutient lotions were used. Bandaging was resorted to, with frictions of ungu. Potass. Iodid; the Iodide of Potassium being also prescribed internally.

At times, also, the limb was painted with strong tincture of Iodine; local and general baths were used, regular bandaging of the limb, from the toes upward, being the while carefully observed.

This plan of treatment was perseveringly adhered to from the fifteenth of January to the twenty-second of March, a period of a little over two months, without any amelioration. Having thus tried, without success, the method of treatment most approved of, I proposed to place a ligature upon the femoral artery, with a view of changing the morbid condition of the structures supplied by the branches of this arterial trunk. A

consultation was held, and my proposition was acceded to as preferable to amputation, the usual alternative resorted to in this stage and extent of the disease. Accordingly, on the twenty-second of March 1851, I secured the femoral artery, a short distance below the origin of the *arteria profunda*. Upon exposing the femoral artery, this arterial tube was found to be changed, so as to present an appearance somewhat like the color of the aorta of the ox, and to be larger than the common iliac of the human subject. In consequence of this appearance of the artery, after some hesitation, I applied the ligature, preferring to do this, rather than to expose the external iliac, of the soundness of which I could not be certain.

The ligature came away from the femoral artery on the eleventh day, accompanied by secondary hemorrhage, the occurrence of which I had expected as probable. For the purpose of arresting the hemorrhage, the *external* iliac artery was secured by ligature, by Dr. A. E. Hosack, who happened to be on duty at the time in the Hospital. The external iliac was found to be about the size of the brachial artery. This, for a time, apparently had some influence upon the hemorrhage; but on the following day, bleeding was again renewed from the orifice, in the femoral artery, with as much profusion as ever.

The hemorrhage was now restrained by the prompt application of a tourniquet, on the *cardiac* side of the bleeding orifice, by the house surgeons, Drs. Thompson and A. K. Smith.

This even failed to stop permanently the hemorrhage, and the blood recommenced oozing copiously at intervals. The patient was now sinking fast, and the ligature of the common iliac, or amputation at the hip-joint, appeared to be the only resources left. But the hemorrhage now being evidently reflux, it was suggested to apply the tourniquet, so as to produce compression on the *distal* side of the bleeding orifice: this was done, and was followed by a complete cessation of the bleeding.

From this time, (April fourth, 1851), the house surgeon kept an instructive record of the case, which record I have now before me. For several days, the pulse ranged from 115 to 108: the dressings were carefully attended to, and light diet prescribed. On the twelfth, the leg was found to be con-

siderably reduced in size, and the ligature of the external iliac, came away. On the seventeenth, brandy and quinine, with good nourishment, were ordered. On May the first, finding the leg still more reduced and the lower wound healed, I ordered tincture of iodine to be painted on the leg, and the bandage to be continued; I also ordered a solution of chloride of soda to be used as a wash on the upper wound, which continued to discharge freely.

The patient now went on gradually improving in strength and appearance, and left the Hospital in the latter part of June, completely cured of his malady. At this date, sixteen months after the ligature of the femoral artery, the patient is in robust health, and presents no indications that the disease will return.

Faint, illegible text, likely bleed-through from the reverse side of the page. The text is mirrored and difficult to decipher.

