To
Dr. Dyce
with the Author's
Kind regards.

CONTRIBUTIONS

TO

THE PATHOLOGY OF MORBID GROWTHS.

CONTRIBUTIONS

TO

THE PATHOLOGY OF MORBID GROWTHS.

BY

CHARLES MURCHISON, M.D., L.R.C.S.E.,

EX-PRESIDENT OF THE ROYAL MEDICAL SOCIETY,
MEMBER OF THE PHYSIOLOGICAL AND BOTANICAL SOCIETIES, AND RESIDENT PHYSICIAN
IN THE ROYAL INFIRMARY, OF EDINBURGH.

ILLUSTRATED BY NUMEROUS ENGRAVINGS, COPIED FROM NATURE AND DRAWN ON
WOOD BY THE AUTHOR.

EDINBURGH: SUTHERLAND AND KNOX.
LONDON: SIMPKIN, MARSHALL, & CO.

MDCCCLII.

[FROM THE MONTHLY JOURNAL OF MEDICAL SCIENCE.]

MURRAY AND GIBB, PRINTERS, EDINBURGH.

CONTRIBUTIONS

TO

THE PATHOLOGY OF MORBID GROWTHS.

THAT the study of the nature and structure of morbid growths is one of very great importance cannot for a moment be doubted, when we consider the numberless cases in which these affections, in one form or another, come under the notice of the surgeon and medical practitioner, and the vast amount of anxiety, misery, and pain, too frequently terminating only in death, which they inflict on the human race.

Till a very recent date our ideas as to the pathology of morbid growths were very vague and obscure. Within the last few years, however, great light has been thrown on the subject by the attention which has been paid to the investigation of the minute structure of all tissues, both healthy and morbid. By this a step has certainly been taken in the proper direction; for, as Dr Baillie, the eminent pathologist, has truly remarked, "A knowledge of morbid structure does not lead with certainty to the knowledge of morbid action, although the one is the effect of the other; yet surely it lays the most solid foundation for prosecuting such inquiries with success."

Much, however, still remains to be done, before our knowledge of the structure of morbid growths can be regarded as in any degree perfect; and this perfection, in my opinion, will be best obtained by the possession of numerous cases of such tumours, presenting any peculiarity in their minute structure, accurately and carefully described, along with illustrative drawings.

It is with this object in view, that I have resolved to lay before the profession the present series of observations, which I intend to continue, from time to time, according as examples shall present themselves for examination. I may remark, that many of the cases to be described were contained in an "Inaugural Dissertation," to which the Medical Faculty of the University of Edinburgh awarded a gold medal in August 1851.

These cases, I trust, will be regarded as a contribution to the series of facts, by means of which we will ultimately be enabled to arrive at a more correct knowledge of the pathological nature of tumours, than we at present possess, and as, therefore, of infinitely more value than any number of theories on a subject in regard to which facts are still wanting on which to build these. Dr Abercrombie has most truly remarked, that "recorded observations must form the only basis on which can be founded any legitimate principles in medical science."

The description of each of the following cases has been divided into three parts; the first giving a short *history* of the morbid growth, with the appearance presented by it before its removal from the body, in all cases in which this has been possible; the second, describing its appearance and *structure*, as seen by the naked eye, and with the assistance of the microscope; and the third, containing a few general *remarks* on the nature and peculiarities of the case in question. The histological description of each case is illustrated by woodcuts, after drawings sketched by myself from nature. These drawings have always been made to resemble as closely as possible the natural appearances presented by the morbid tissues.

The microscopic observations have been conducted with a compound microscope, manufactured by Messrs Smith and Beck, of London, and most of them with an object-glass of one quarter of an inch focus.

I may add, that in every case the morbid structure has been subjected to examination within thirty-six hours after its removal from the body.

Case I.—*Cancerous Tumour of Lower Jaw—Removal of Symphysis of Jaw—Return of the Disease in the Neck—Death.*

History.—William M——, æt. 51, a labourer, was admitted into the Royal Infirmary on November 4th, 1850, under the care of Mr Syme. He stated that he had always enjoyed good health until ten months before admission, when, from a violent concussion in a railway carriage, his lower jaw received a severe blow from another man's head. Two of the incisor teeth were knocked out, and three others of the front teeth so loosened, that it was afterwards necessary to remove them. A few days after the accident, a swelling, attended with great pain, made its appearance in the hollow beneath the tongue. After some days this swelling was lanced by a surgeon, and about a tablespoonful of a dark bloody matter evacuated. This gave great relief to the pain; but in a short time a swelling re-appeared in the same place, which in a few days burst, discharging a thick purulent matter. This ulcerated opening had never closed up. Soon after, a firm swelling began to appear in the gums of the missing teeth, and gradually increased, projecting

backwards to the space beneath the tongue. On the patient's admission, the four incisor and the right canine teeth of his lower jaw were wanting. In the angle of the jaw beneath the tongue a tumour was seen, forming a prominence about the size of a plum. This tumour was immoveably attached to the jaw, appearing to take its origin from the empty alveoli. The consistence of the tumour was not firm, so that it retained an impression made with the finger on its surface. On its upper surface was an irregular ulcerated surface, about the size of a sixpence, presenting a dirty grayish aspect, and throwing off a very fetid discharge. The jaw, for about two inches on either side of the symphysis, was felt to be considerably thickened, this thickened condition extending as far as its lower margin. The man stated that he had never had much pain in the tumour, but its situation, and the fetid nature of the discharge, made him anxious to have it removed. It had already been burned with various caustics, without any beneficial result. There was no enlargement of any of the cervical glands, and, with the exception of the tumour, the patient seemed in the enjoyment of perfect health.

On the 16th of November, after the administration of chloroform, Mr Syme removed the symphysis of the lower jaw, with nearly two inches of the horizontal ramus on either side. A longitudinal incision was first made in the mesial line, through the lower lip and chin, down to the bone. The two flaps of soft parts were then dissected from off the bone, and division of the latter effected by means of the saw and bone-pliers. The tongue was tied forward to prevent its slipping back. After the removal of the bone, the edges of the soft parts were brought together again, by means of twisted and common sutures. On the 18th, the thread by which the tongue was held forwards became loose, yet the patient could swallow, and had no difficulty in controlling its motions. On the 20th, the sutures were removed, and the edges of the wound were found to have all united by the first intention. On the 9th of December, the man was dismissed from the hospital. For some days before, he had been walking in the open air. The divided ends of the lower jaw were covered with granulations, were quite in their natural position, and could be moved freely up and down. The man could articulate, eat, and drink, but could not protrude his tongue from his mouth. At that time there was no sign of any return of the disease.

Nothing more was heard of this man for some months; but, in the following summer, his wife came to the hospital, and stated that soon after her husband returned home, swellings appeared in various parts of the neck—increased in size with considerable rapidity, and were the seat of great pain, and that in May death put an end to his sufferings.

Examination of the Tumour after its Removal.—The tumour after removal was found to be of about the size of a dried fig, firmly at-

tached to the alveolar processes of the jaw bone, and projecting backwards, so as to fill up the angle formed by the junction of the two horizontal rami. It was of soft consistence, retaining an impression made with the finger; and there was a patch of ulceration, about the size of a sixpence, presenting an irregular surface and edges, of a dirty grayish colour, and emitting a very fetid discharge, in the epithelial membrane covering its upper surface. When the tumour was cut into, the cut surface was of a grayish-pink colour, and yielded, on scraping or squeezing it, a quantity of a thick dirty pinkish fluid. Its consistence was more or less elastic, but varied at different parts; generally speaking, it was firmer near its attachment to the bone than on its free surface; at one or two places, and particularly at the left extremity of its attachment to the bone, there were a few drops of a thick dirty reddish-brown puriform fluid. It contained no osseous spicula or bony matter in its interior. After dissecting the tumour from off the bone, no trace of the alveoli could be seen in the latter; but, on the upper margin of the jaw, there was a large cup-shaped cavity, bounded before and behind by the anterior and posterior laminæ of the bone, which were here far more widely separated than in the natural condition of the parts, fully four-fifths of an inch intervening between them at one part. This cavity extended downwards to within a third of an inch of the lower margin of the jaw. To the bottom and sides of this cavity, which presented a rough uneven surface, the morbid structure under consideration had been attached.

A drop of the fluid obtained from a freshly made section of the tumour was treated with a little water, placed between two glass slides, and examined under a microscope, with a magnifying power of about 250 diameters linear. It was found to contain the following elementary bodies. (Fig. 1.) In the first place, there were nucleated

Fig. 1.

A drop of the fluid obtained from a fresh section of the tumour forming the subject of Ca L., treated with diluted acetic acid.

cells of various sizes and in all stages of development; the largest had a diameter of fully $\frac{1}{300}$th of an inch; they were for the most part of

a rounded or oval form; some, however, had a pyriform, an elongated, or an irregular outline. A few of the cell walls were perfectly transparent; most of them, however, presented a very finely granular aspect. The addition of a drop of very diluted acetic acid dispelled this granular appearance; acid a little stronger dissolved them altogether, leaving the nuclei unaffected. These nuclei were mostly round or oval, with an average diameter of $\frac{1}{1600}$th of an inch, and contained in their interior one or more nucleoli. The number of these nuclei in each cell varied greatly; some of the cells were loaded with them, very many contained two nuclei set side by side, while in others there was only one; one cell was seen with two nuclei, each of which seemed to be splitting up into two others. Several large mother cells were seen with one or more nucleated cells in their interior, the spaces between the different cell walls often containing several nuclei and fine granular matter. Floating among these cells were numbers of naked nuclei, similar to those already described as existing in the cells. Some of these seemed to have, as it were, a transparent membrane rising from one of their surfaces. There were also a few compound granular corpuscles, or cells loaded with small globules of oil, but these were not numerous. Some of t e large nucleated cells were observed containing a number of oil globules between the nucleus and cell wall, and there were others in which nothing but oily and albuminous granules could be detected, no nucleus being visible even after the addition of acetic acid. The above elements were mixed up with a quantity of granular and molecular matter, a few oil globules, and several scales of cholesterine. The reddish-brown puriform fluid contained a large amount of granular and molecular matter, and its cells were more irregular and broken down. The fluid taken from near the attachment of

Fig. 2.

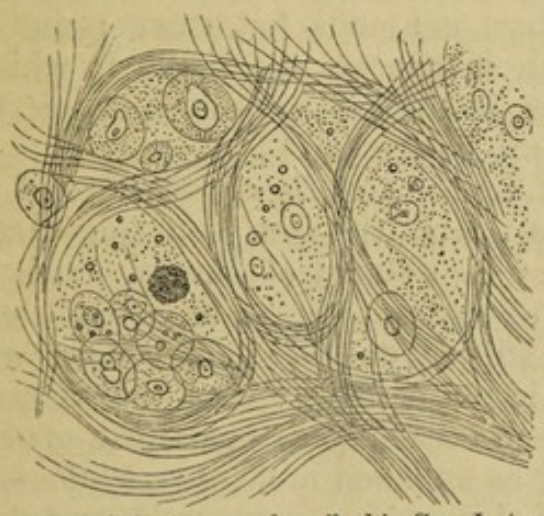

The edge of a thin section of the tumour described in Case I., treated with acetic acid.

the tumour to the bone contained a quantity of mineral granular matter, dissolved by nitric acid, with the emission of small bubbles

of gas. A thin section was made, with a double-bladed knife, of the firmest portion of the tumour; and this, when treated with acetic acid, and examined under the microscope, presented an interlacing network of very delicate filaments, in the meshes of which were imbedded the cells and other structures already described. At one or two places the filaments seemed disposed in concentric circles, as represented in Fig. 2.

Remarks.—From the description which has been given of this tumour, and from the history of the case subsequent to the operation, no one, I think, will be inclined to doubt its cancerous nature. As an example of cancer in bone, it is of considerable interest, from the fact, that as yet we possess but few cases of cancer attacking this tissue, in which the structure of the morbid deposit has been carefully examined and recorded. Dr Bennett, in his "Observations on Cancerous and Cancroid Growths," (pp. 98, 100), has recorded two cases of cancer of bone, one in which the cancer existed in the phalanges of the fingers and toes, and resembled somewhat the structure of the tumour above described; and another of cancer of the sternum and ribs, in which the cellular element does not seem to have reached such a high stage of development. Lebert, in his recent work entitled "Traité des Maladies Cancereuses," mentions his having met with thirty-five cases of primitive cancer of bone, but he has given no detailed description of these cases, nor representations of their elementary structure.

The cells in this case of cancer presented, in a marked degree, the characteristics which have been attributed by Lebert, Bennett, and other authors, to the cancer cell; and such a case as this would tend to establish the doctrine of the former author as to the pathognomonic specificity of the cancer cell. If this doctrine were confirmed by observation in all cases, the study of morbid growths would be very much simplified: unfortunately, however, it is not. In future observations I shall endeavour to prove that no such specificity, as Lebert contends for, exists; and that every form of cell is met with in cancer, the tissue in which the cancerous deposit takes place, in some instances, seeming to exercise an influence over the form of the cell.

The presence of filamentous tissue in a case of cancer of bone is not without interest, from the fact, that some authors have considered it a necessary constituent of cancer. It is true, that, in the majority of cases of cancer, fibrous tissue does exist in greater or less quantity, yet still we do occasionally meet with specimens in which no trace of it can be detected, so that its presence cannot be said to be absolutely necessary to constitute cancer. Cases illustrative of this will be adduced in a future communication.

The presence of cholesterine, compound granular corpuscles, and a large quantity of albuminous and oily granules floating among the cellular elements, would seem to indicate that a process of disintegration was going on in the morbid tissue.

The absence of bony spicula in the substance of the tumour, and the fact of a large quantity of calcareous granules being detected along its line of attachment to the bone, confirms a statement made by Lebert, in reference to a distinguishing character between cancer of the periosteum and cancer in the interior of bone. The former, he says, gives rise to a sort of hypertrophy of the bone, numerous osseous spicula being developed in its substance, whereas the latter gradually destroys and removes the surrounding bony tissue.[1]

As to the mode of origin of this tumour, the patient attributed its growth entirely to the blow he had received on the jaw; and the fact of its taking its origin from the part which before the accident had been occupied by the teeth, renders this the more probable. Blows and other injuries we know to be frequent causes of the origin of all forms of tumours; and Dupuytren has recorded the particulars of a case very similar to the above, in which he removed the symphysis of the lower jaw, on account of a tumour, whose origin was attributed to a blow received on the chin three months previous to the operation. This tumour he designates osteo-sarcomatous, but from its description it seems to have been not unlike the one we have been describing. The operation was temporarily successful; but, as in the above case, the man died six months afterwards from a return of the disease.[2]

CASE II.—*Fibro-Nucleated Tumour in Mammary Region—Excision —Recovery.*

History.—On the 7th of December 1850, Mr Syme excised a small tumour from the mammary region of a middle aged married lady. It was situated immediately underneath the integuments, two or three inches above and to the outside of the right nipple. It appeared to be of about the size and shape of a large pea, and had been growing for several months. It may be mentioned, that the lady was liable to the growth of encysted tumours in the scalp.

An incision was made through the integuments down upon the tumour, which was then grasped with a hook, and dissected out. The wound healed by the first intention.

Description of the Tumour after its Removal.—It was of about the size of a French bean, and of firm consistence. On section, it presented a grayish-white colour, and glistening surface. It contained no milky juice; but on scraping the surface of the section, a slight quantity of a watery fluid was collected on the edge of the knife, which microscopic examination showed to contain rounded and elliptical bodies like nuclei, having an average diameter of $\frac{1}{2400}$th

[1] Op. cit., p. 732.

[2] Dupuytren on the Diseases and Injuries of Bone, translated by the Sydenham Society, p. 416.

of an inch. (Fig. 3.) These bodies were transparent, but presented a well-marked outline, and most of them contained in their interior one, two, or more rounded granules. They were seen either

Fig 3.

Fig. 4.

Fig. 3 —Nuclei, etc., found in the fluid obtained by scraping the surface of a fresh section of the tumour.
Fig. 4.—A thin section of the tumour made with a Valentin's knife, treated with acetic acid.

isolated or adhering by their edges in small masses. The action of acetic acid seemed to produce little or no change upon them. Along with these bodies was a small quantity of fine granular matter. A thin section of the tumour, made with a Valentin's knife, treated with acetic acid, and compressed between two glass plates, was found to consist of a stroma of white fibrous tissue, interspersed through the filaments of which were a number of the nuclear bodies above described, the whole presenting an appearance similar to what is represented in the accompanying figure. (Fig. 4.)

Remarks.—This interesting tumour, consisting of nuclei interspersed through a stroma of white fibrous tissue, would seem to belong to that class of morbid growths which Professor Bennett has recently described under the name of fibro-nucleated tumours. Professor Bennett, in his "Observations on Cancerous and Cancroid Growths," records three examples of this form of tumour; one occurring in the thigh (Ob. XXXIV.), another in the parotid gland (Ob. XXXVII.), and a third in the soft parts of the upper arm (Ob. XLVII.). The structure of these tumours, as ascertained by microscopic observation, presented a very close resemblance to what has just been described. But though I have denominated this tumour by the term fibro-nucleated, from its intimate resemblance to the tumours described under that name by Professor Bennett, it is not without considerable doubts as to the propriety of separating the so-called *fibro-nucleated* tumours into a class distinct from that of *fibrous* tumours. Naked nuclei interspersed among the fibres are present in greater or less quantity in most fibrous tumours; and, indeed, Vogel remarks:—"In none but mature and perfectly-formed tumours are nuclei ever absent."[1] It is true, one may form a dis-

[1] Vogel's Path. Anat., translated by Day, p. 216.

tinction between tumours which consist of fibrous tissue formed by the splitting up of the walls of nucleated cells, the nuclei of which may remain imbedded among the filaments, or may ultimately disappear, and those which are formed by nuclei and nuclear fibres without the intervention of cells; and this I believe is the distinction which Professor Bennett draws between fibrous and fibro-nucleated growths. Now, nuclei may form fibrous tissue in one of two ways. The nuclei may elongate, and become themselves transformed into fibres; the fibres developed in this way, however, are of the yellow elastic variety,[1] while the fibres of all the fibro-nucleated tumours described by Professor Bennett, and examined by myself, belong to the white variety, and must have been developed by the other process,—viz., by the nuclei elongating and splitting up a surrounding hyaline substance into delicate parallel filaments. But, in the case of a tissue, composed of white fibres with interspersed nuclei, it would in most cases be very difficult, if not impossible, to determine whether the nuclei are those of cells whose walls have become elongated and split up into fibres, or whether they are nuclei which have split up into filaments a previously hyaline matrix. The absence of all vestiges of cells in the latter case is not a sufficient ground of distinction, for even in ordinary fibrous tumours, all traces of the original cell structure may have quite disappeared; and, indeed, in the same tumour, we may have at one part a tissue consisting entirely of filaments and nuclei, *without* any cells; and at other parts, of nucleated cells becoming transformed into fibres. Cases illustrative of this will be recorded in a future communication. Dr Bennett himself allows that there are transition varieties between the fibro-nucleated and true fibrous tumours. Thus, of the four cases recorded in Obs. XXII., XXIII., XXIV., and XLIII., he states that they were probably instances of the fibro-nucleated tumour, although in them the nuclei seemed to have passed here and there into fibro-plastic bodies, "exhibiting a transition stage between the fibro-nucleated and the purely fibrous cancroid growths."—P. 178.

For my own part, I am inclined to consider the distinction which has been drawn between fibrous and fibro-nucleated tumours as in a great measure arbitrary; and that the latter are only a variety, or, perhaps, more correctly speaking, a particular stage, in the development of the former. The subject, however, well deserves further investigation, as does also the mode of development of fibrous tissue generally.

[1] This view, as to the development of yellow elastic fibrous tissue, was first promulgated by Henle, and is the one generally adopted by physiologists. I may mention, however, that some recent investigations of Mr James Drummond, of Edinburgh, on the Development of the Ligamentum Nuchæ, throw some doubt on Henle's view, and would seem to render it probable that cells, as well as nuclei, take part in the development of yellow elastic fibres.

CASE III.—*Fibro-Nucleated Tumour of the Soft Palate—Excision—Cure.*

History.—Catherine B——, æt. 25, a servant, was admitted into the Royal Infirmary, under the care of Mr Syme, on the 21st of January 1851, on account of a tumour of the soft palate, situated between the uvula and left tonsil. The mucous membrane at this point was seen to be slightly prominent, and very red and vascular. This tumour had been growing for twelve months. When first observed, it was a mere pimple; but latterly it had increased considerably in size, and on admission was felt to be of about the size of a cherry. It was at times the seat of considerable uneasiness. On January 24th a hook was inserted into the mucous membrane over the tumour, and then cut out so as to expose the surface of the latter. The hook was then inserted into the tumour itself, which was dissected out. With the exception of a considerable hemorrhage from the wound some days after the operation, it healed without any bad symptoms.

Examination of the Tumour after its removal.—It was of about the size of a small "marble." Its form was almost globular, but slightly longer in one direction than the other. It was of firm consistence. When a section was made through its centre, the cut surface was smooth, and of a dirty whitish colour. No milky juice exuded on squeezing; but, on scraping the surface of the section, a small drop of a watery slightly viscid fluid was collected on the knife's edge. On placing this under the microscope there were detected in it numerous minute bodies, which seemed to be of the nature of nuclei. (Fig. 5.) These were for the most part of a

Fig. 5. Fig. 6.

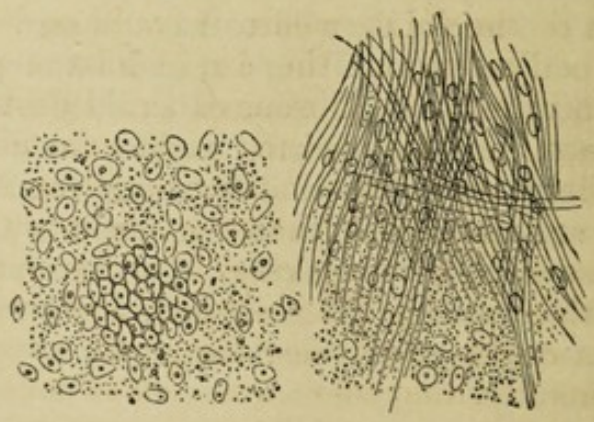

Fig. 5.—Appearance presented under the microscope by a drop of the fluid, obtained by scraping the surface of a fresh section of the tumour.
Fig. 6.—The edge of a thin section of the same tumour.

rounded form; a few were elliptical, or even still more elongated. Their average diameter measured about $\frac{1}{2800}$th of an inch. They were of a grayish colour, and but little affected by the action of

acetic acid. Each contained in its interior one or more minute rounded granules. These bodies were seen either isolated or adhering by their edges in small masses. Along with them was a considerable quantity of albuminous molecular matter. On making a thin section with a double-bladed knife of the solid portion of the tumour, washing it well with water, and then adding to it a drop of acetic acid, it presented under the microscope an appearance similar to that shown in Fig. 6,—a fine fibrous tissue, with nuclear bodies, like those just described, interspersed among the filaments.

Through the whole substance of the tumour, there was a pretty dense network of capillary blood-vessels.

Remarks.—In structure, this tumour bore a very close resemblance to the one last described, differing only in the nuclei being of smaller size, and of a more rounded form. Like the preceding, it evidently belonged to Professor Bennett's class of fibro-nucleated growths, concerning which we have already treated (see Remarks on Case II). The peculiarity of its situation, which is a rare one for any form of growth, added additional interest to it.

CASE IV.—*Osseo-Cartilaginous Body in the Knee-Joint—Excision —Death.*

History.—On the 7th of September 1848, M—— D——, æt. 19, a female servant, was admitted into the Royal Infirmary, under the care of Mr Syme, with symptoms of a moveable body in her left knee-joint, which had commenced seven months before admission. She complained of fits of the most agonising pain in the joint, generally supervening quite suddenly, especially whenever she attempted to walk, so that she was obliged to give up her situation. The body was quite moveable, but was generally situated at the inner part of the joint, where it could be felt through the soft parts, apparently of about the size of a large pea. Mr Syme made various attempts first to remove the body by subcutaneous incision of the synovial membrane; and, this failing, he endeavoured to make its position fixed, by transfixing it with a needle, and retaining it so transfixed for three weeks at a time. All these means failing, however, to afford relief, Mr Syme not having then adopted the mode of operating he has since had recourse to, on the 23d of December made a direct incision down upon the body, and removed it. Next morning there was violent inflammation in the knee, accompanied with general febrile symptoms. This resisted all the means employed to check it; the joint swelled, the whole limb became œdematous, the inflammatory fever gradually passed into irritative fever and hectic, and the patient expired on the 29th of February 1849.

Mr Syme presented me with the loose body on the day on which he removed it; and the following description, with the drawings,

formed part of a communication read by me before the Edinburgh Royal Medical Society, March 30, 1849.

Examination of the Body after its removal.—It was two-thirds of an inch in length and one-third of an inch in breadth at its broadest end. It was of a somewhat pyramidal form, having three sides gradually tapering to a point at one extremity, and truncated at the opposite, as is represented in the annexed woodcuts. (Figs. 7 and 9.)

Its external surface was smooth and glistening, like that of an articular cartilage, and to all appearances was covered by a thin membrane, which originally had been a reflexion of the synovial membrane of the knee-joint. I was not able, however, to effect a separation of this membrane from the subjacent texture. Attached to a slight depression in the middle of one of the triangular surfaces of the body, was a small shred of membrane, by means of which it had probably at one period been connected to one of the various surfaces entering into the formation of the joint. A transverse section of the body showed that two distinct structures entered into its composition, one of these resembling cartilage the other bone. The former did not completely envelope the latter, but was only laid on, as it were, on one side of it. (See Fig. 8.) There

Fig. 7. Fig. 8. Fig. 9.

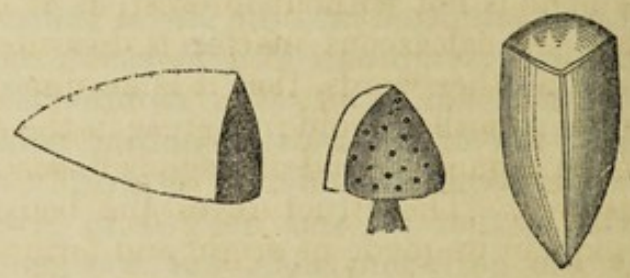

Figures 7 and 9 show the pyramidal shape of the body. The drawings are somewhat larger than the natural size.

Fig. 8 represents a transverse section of the body, showing the position of the cartilage upon one side of the bony matter, and the shred of membrane attached to another surface.

appeared to be a distinct line of separation between the two. The cartilaginous substance, which to the naked eye closely resembled articular cartilage, was found on microscopic examination to be composed of a transparent slightly granular matrix, in which were imbedded nucleated cells, exactly similar to the elongated cells met with in the costal cartilages. (Fig. 10.) But the most interesting structure was that of the bony matter, which possessed Haversian canals, concentric lamellæ, lacunæ, and canaliculi, in all respects resembling those met with in true bone, except that the canaliculi were not so distinctly marked. The presence of Haversian canals in the bony matter necessarily implied the existence, at one time, of blood-vessels. (Fig. 11.)

Fig. 10.

Fig. 11.

Fig. 10.—A thin section of the cartilaginous substance, showing nucleated cells imbedded in a granular matrix.

Fig. 11 represents a portion of a thin slice of the bony matter, with the Haversian canals, lacunæ, and canaliculi. The last have been represented as too distinct.

Remarks.—Loose bodies have been found within the capsules of all the large joints of the limbs, with the exception of that of the hip. They have also been found within the capsules of the articulations of the lower jaw, but by far their most common site is that of the one just described within the capsule of the knee-joint. The structure of these bodies varies; sometimes they consist entirely of a substance like cartilage, at other times there is a bony nucleus in the centre of the cartilaginous mass; while at other times, as in the above case, bony matter constitutes the greater part of their bulk. The fact of the bony matter in this case presenting the structure of true bone is not without interest, as it has been generally believed that the calcareous matter is deposited in an amorphous manner, or, in other words, that it is an unorganised formation, deposited from a mother liquid; whereas in the above case the bony matter was an organised and analogous formation, deposited from a cyto-blastema. The structure of the body may to some extent serve to explain its mode of origin and formation. Various opinions have been entertained as to the manner in which these bodies originate. Some, as Munro,[1] have maintained that they were pieces of cartilage, broken off from the articulating surfaces of the joint. Bichât thought they were portions of the synovial membrane transformed into cartilage. Sander[2] regarded them as "precipitates from the synovia;" and Richerand[3] has described them as partly *inorganic* concretions of the synovia, and partly *organic* formations springing from the synovial membrane. Hunter[4] supposed that they were extravasations of blood, which had become organised into a structure resembling that of the part to which they were connected. Lænnec[5] believed that these bodies were

[1] Medical Essays and Observations of Edin., vol. iv., p. 244.

[2] Dic. des Sciences Médicales, iv., p. 127.

[3] Nosographie Chirurgicale, ii., 349.

[4] Transac. of Society for Improvement of Medical and Surgical Knowledge, vol. i., p. 229.

[5] Chelius' System of Surgery, translated by South, vol. ii., p. 707.

formed on the outer surface of the synovial membrane, and gradually forced their way into the cavity of the joint, the synovial membrane covering them yielding and forming a pedicle by which they are attached. The theory of Lænnec which has been last mentioned is the one which, in my opinion, approaches most nearly to the truth; for it explains in a satisfactory manner the structure of the body above described, as will appear from the following considerations:—

1. This body, like all others found in the joints, presented externally a smooth serous-like surface, exactly like that of the synovial membrane.

2. Bodies, similar to the above, are often found, not loose in the cavity of the joints, but attached by a pedicle to some part or other of the synovial membrane; and in the above case, though the body was quite free, the remains of the pedicle by which it had been attached might still be made out.

3. The true bony structure described above could only have been developed in one of two ways. It may have originated from a proper ossifying point, as when temporary cartilage is converted into bone. This, however, seems far from probable, and I think that the only other feasible explanation of its presence is, that it originated as an abnormal growth,—a small exostosis, so to speak, of one of the articulating surfaces entering into the formation of the joint, which in the progress of its growth pushed before it the cartilage and synovial membrane, till at last it was only attached by a membranous pedicle of the latter, and ultimately, from the rupture of this pedicle, it became quite free in the cavity of the joint. The peculiar position of the cartilage on one side only of the body seems to favour this view. Of course, this mode of formation will not be applicable to those bodies which may be found attached to portions of the synovial membrane not covering the articulating surfaces, but it would be interesting to ascertain if these ever contain the structure of true bone. I am not aware of this having been detected in any such case, and I should be inclined to doubt if it ever exists.

CASE V.—*Ulcerated Congenital Cartilaginous Tumour (Enchondroma) of Middle Finger—Amputation of Finger—Recovery.*

History.—P—— S——, æt. 12, a fisherman's son, from Shetland, was admitted into the Royal Infirmary on the 21st of October 1851, on account of a large tumour in the proximal phalanx of the middle finger of the left hand. This tumour was of a globular form, and of about the size of an orange, projecting principally on the dorsal aspect of the phalanx. The patient stated that this tumour had existed at the period of his birth, but that its growth had latterly greatly increased in rapidity. About three weeks before admission, a small pustule formed on the skin covering

the more prominent part of the tumour. After a few days this "broke," leaving an ulcerated surface, which rapidly extended, until at the time of admission it was considerably larger than a penny-piece. The surface of this sore presented a dirty grayish aspect. There was but little discharge, and no blood had escaped from it. The consistence of the tumour was firm, with here and there a peculiar elasticity, especially near the ulcerated part. The tumour was firmly attached to the proximal phalanx, and seemed to spring from its substance. The two distal phalanges, as also the corresponding metacarpal bone, were quite uninvolved. Through the skin covering the tumour might be seen a network of large veins. The patient had never complained of any pain in the tumour, even when it was pressed upon with considerable firmness. He had no other swelling in any part of his body, and was in the enjoyment of excellent health.

On the day after admission, chloroform was administered to the patient, and the finger with the tumour was amputated at the metacarpo-phalangeal joint in the ordinary manner. Five arteries required to be tied. The edges of the wound were kept in apposition by tying together the fore and ring fingers, and by compresses of lint.

No untoward symptom supervened upon the operation, and by the end of three weeks the wound had perfectly healed, and the patient was dismissed cured.

Examination of Tumour after removal.— Its weight was 5 oz. avoirdupois. No difficulty was experienced in removing the integuments from the surface of the tumour, which then exhibited a smooth glistening aspect, as if it had been enveloped in a serous cyst. It appeared to take its origin from the dorso-ulnar aspect of the phalangeal bone, which was considerably distorted from its normal shape, being concave towards the aspect of the tumour, and convex in the opposite direction. The extensor and flexor tendons were correspondingly distorted in their course. On cutting into the tumour, it was found to extend into the central medullary cavity of the bone. The external bony laminæ were expanded over a considerable portion of its surface, gradually becoming thinner and thinner towards its more prominent part, where there was only a thin fibrous sheath, and at the ulcerated part even this was wanting. At several points, chiefly in the neighbourhood of the expanded osseous laminæ, this enveloping sheath presented a density and structure not unlike those of articular cartilage. From this external envelope a number of ramifying septa passed inwards through the substance of the tumour, dividing it into numerous polygonal compartments, of about the size of small peas. Like the external envelope, the structure of these septa was partly fibrous and partly cartilaginous; and in many of them there was calcareous matter, especially near the attachment of the tumour to the bone; in the medullary cavity of the phalanx, the proper substance

of the tumour was contained in little cavities hollowed out in the texture of the bone. These septa pervading the tumour were very vascular, so much so, that at some parts they appeared to the naked eye like red lines. The compartments formed by these septa were filled with a substance of a light pinkish colour, translucent lustre, and of the consistence of a firm jelly. The substance of the tumour gradually became softer in the direction of the ulcerated surface, and for about one-fifth of an inch beneath the surface of the ulcer its colour was a dirty yellow.

A minute particle of the translucent substance from the centre of the tumour was compressed between two glass plates, and examined with the microscope, with a power magnifying about 250 diameters linear. It was then seen to consist of transparent nucleated cells, imbedded in a structureless hyaline matrix. A few of these cells are represented in Fig. 12. They were of very

Fig. 12.

Fig. 12.—Nucleated cells, composing the gelatinous substance.

various forms, as round, elliptical, pyriform, and fusiform, while a few were caudate, having one or more long filamentous processes passing from one of their extremities. Several of these cells were observed with a diameter of $\frac{1}{450}$th, but their average diameter did not exceed $\frac{1}{800}$th, of an inch. Each cell contained in its interior a single, rounded, opaque nucleus, from $\frac{1}{2500}$th to $\frac{1}{3000}$th of an inch in diameter. Diluted acetic acid rendered the cell walls somewhat more transparent, but produced no change on the nuclei. A particle of the yellowish softened portion of the tumour was found to contain cells similar to the above, but exhibiting an irregular shrivelled outline, pus corpuscles, oily globules, and a large quantity of granular matter. (Fig. 13). The structure of the gristly portions of the external envelope and the septa resembled precisely that of the translucent interior, with this exception, that the containing matrix exhibited a finely granular, in place of hyaline, aspect.

Fig. 13.

Fig. 13.—Nucleated cells, pus corpuscles, oil globules, and granular matter, obtained from the softened portion of the tumour.

Remarks.—This tumour was a good example of that class of morbid growths which, from Müller, have received the name of *Enchondromata*,[1] occurring, too, in a situation in which these tumours are not unfrequently met with. It consisted essentially of two parts—a firm membranous interlacement, some parts of which were of a cartilaginous or osseous texture, arranged so as to form areolar spaces, which enclosed the other constituent of the tumour, —a translucent gelatinous substance, consisting of nucleated cells, imbedded in a hyaline matrix. The tumour seemed to have taken its origin in the medullary cavity of the bone, and in its growth to have gradually expanded the osseous laminæ over its surface, found its way through these, and at length, from the great tension consequent on its size, produced ulceration of the super-imposed integuments, this ulceration with softening extending to the proper substance of the tumour. The fact of the tumour being congenital is not without interest. The nuclei of the cells found in the above described tumour underwent little or no change from the action of diluted acetic acid. In this respect they afforded a striking contrast to the nuclei of cells described by Professor Bennett as existing in an enchondroma of the humerus, which, on being treated with acetic acid, became so pale that nothing but their outline was discernible.[2]

Case VI.—*Atheromatous Cyst on the Back—Tapped—Injected with Iodine—Recovery.*

History.—Mr ——, a gentleman, upwards of sixty years of age, consulted Mr Syme, in the beginning of November 1850, in reference to an immense tumour on his back, so large, that when he was dressed it gave his back the appearance of being very much bent forwards.

[1] On the Nature and Structural Characteristics of Cancer. By J. Müller. P. 96.

[2] Op. cit., p. 110.

This tumour had been gradually increasing in size for the long period of forty-six years, though with much greater rapidity during the twelve months previous to the patient's application to Mr Syme. Mr M—— attributed its origin to a severe strain in the lower part of his back, which he received while playing at the game of "leap frog." The tumour was of a somewhat circular outline, but its margin was not very well defined; it covered almost the whole posterior lumbar region, extending from the sacrum almost as far as the lower angles of the scapulæ. Its surface was convex, with a few irregular depressions and elevations; it was far more prominent at the lower than at the upper part. The whole tumour had a distinctly fluctuating feel, and, on tapping, an impulse was distinctly conveyed from one side to the other.

A small trocar was plunged into the most dependent part of the tumour; a few drops of a thick yellowish fluid escaped through the canula, and, after introducing a probe, about two fluid ounces more came away; its consistence, however, was so thick that no more would flow through the canula. This was, therefore, withdrawn, and with a probe-pointed bistoury an incision, half an inch long, was made into the tumour. Through the opening thus made the contents of the cyst were slowly evacuated. The walls of the cyst were at first allowed to collapse of themselves, but when they were nearly emptied, pressure was employed in such a manner as to exclude the entrance of air. A pad of lint was placed over the wound, and a broad bandage round the loins.

After some days there was a slight re-accumulation of fluid in the cavity. This was drawn off, and two fluid drachms of pure tincture of iodine injected; and after some days more a whole fluid ounce of the tincture was thrown in. This produced considerable redistention of the cavity, but remarkably little disturbance of the system. The swelling, after some time, began to diminish, and there now remains only a slight fulness in the region of the tumour.

Examination of the Contents of the Cyst.—These, when measured, were found to amount to 140 fluid ounces. In colour and consistence, the fluid very closely resembled ordinary pus; but, on close inspection, it presented a very remarkable appearance, from there being suspended in it an immense number of translucent gelatinous-looking bodies, varying in size from that of a cherry to that of a millet-seed, or less. A drop of the fluid, when subjected to microscopic examination, was found to consist of globules, of an oily nature, with a large quantity of scales of cholesterine. (Fig 14.) The latter were remarkable for their great size, some single scales measuring $\frac{1}{120}$th of an inch. Here and there might be seen a few pus corpuscles ($\frac{1}{3000}$th of an inch), exhibiting, after treatment with acetic acid, a two or three-lobed nucleus. There was also a considerable number of compound granular corpuscles. One of the

small gelatinous-looking bodies, when examined with a low magnifying power, was seen to possess a distinct external cyst, containing a quantity of molecules and granules, of an oily nature, which escaped on rupturing the cyst by pressure. The cyst itself appeared quite structureless. In one or two of them there was something like a fine fibrous structure, an appearance, however, which careful

Fig. 14.

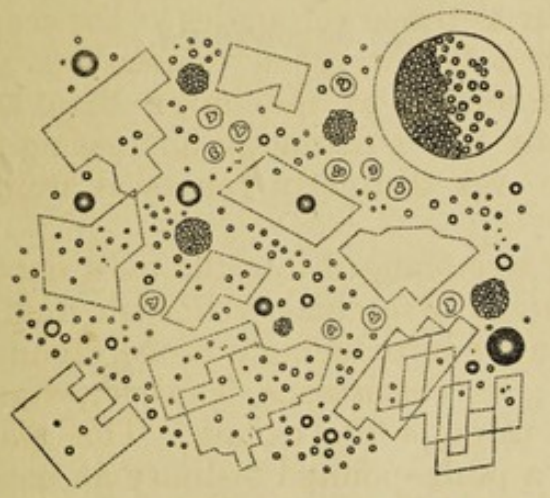

Fig. 14.—Cholesterine, oil globules, compound granular and pus corpuscles, found in a drop of the fluid. Along with these is represented, at the upper and right hand corner, one of the peculiar cysts described in the text, not nearly so highly magnified as the other elements of the fluid.

examination showed to be owing to creasings of the cyst when ruptured and evacuated of its contents. The cysts disappeared under the action of strong acetic acid, allowing the oily matter to escape.

Remarks.—The above is a good example of a cystic tumour with atheromatous contents, resembling in some respects the class of tumours designated by Müller by the term Cholesteotoma, but certainly not agreeing in every particular with the characters he assigns to this class. Thus Müller, in his description of it, says:—" Its consistence more resembles lard than fat, and it presents on section a lustre not unlike mother-of-pearl. Its chief peculiarity is, that the fat *cells* composing it are arranged in concentric laminæ, separable from one another," etc.[1] This tumour is rather referable to the class of true encysted tumours, the cyst in this instance containing a large quantity of oily matter and cholesterine. Professor Bennett[2] has described cysts containing such contents as the cholesteotoma of Müller. The above extract, however, from the translation of Müller's work, is sufficient to show that the tumour alluded to by that author is of a very different nature.

The transparent cysts, containing oily matter, found in this encysted tumour were very peculiar, and, so far as I am aware, have

[1] On the Nature and Structural Characteristics of Cancer. By J. Müller. Translated by Dr West.

[2] Op. cit., p 105.

not before been met with, or at all events described. In appearance they were not unlike some forms of hydatids, but the nature of their contents seems to forbid their being regarded in this light. The existence of the pus corpuscles renders it probable that the walls of the cyst had taken on an inflammatory action. Independently of its peculiar contents, this tumour is well worthy of notice from the lengthened duration of its growth, and the immense size which it attained.

(*To be continued.*)