

[Notes and illustrations of three cases of facial surgery / William Keith].

Contributors

Keith, William, 1802 or 1803-1871.

Publication/Creation

[Place of publication not identified] : [publisher not identified], [1841]

Persistent URL

<https://wellcomecollection.org/works/zfd6pkrk>

License and attribution


This work has been identified as being free of known restrictions under copyright law, including all related and neighbouring rights and is being made available under the Creative Commons, Public Domain Mark.

You can copy, modify, distribute and perform the work, even for commercial purposes, without asking permission.



Wellcome Collection
183 Euston Road
London NW1 2BE UK
T +44 (0)20 7611 8722
E library@wellcomecollection.org
<https://wellcomecollection.org>

Case of James Scott.




1841 April 20th

Donald M. Kenzie Weaver, aged Seventeen. Had lost his nose by the ulceration, called Lupus. The flap was lifted from the forehead, and the Columna, to divide the Nostrils, taken as a slip from the middle of the upper lip. The Cure is complete at this date.

Thomas Leslie Laddler, aged Twentyfour. Presents a fair specimen of squinting, cured by the new operation. The second view of his face taken four months after the operation is intended to shew its permanency. no offering is seen of the eye, either to turn outwards or inwards

Alexander Shiach aged Twelve. After having had a tooth extracted for what he supposed toothache the Jaw became locked by the formation of a hard tumour presenting the appearance shown in figure 2nd. On the removal of the portion of Carious bone sketched beneath the figures by an incision in the Gum; the swelling gradually subsided the motions of the jaw and the power of mastication were soon perfectly recovered and the face resumed its natural look as in Figure 5th.





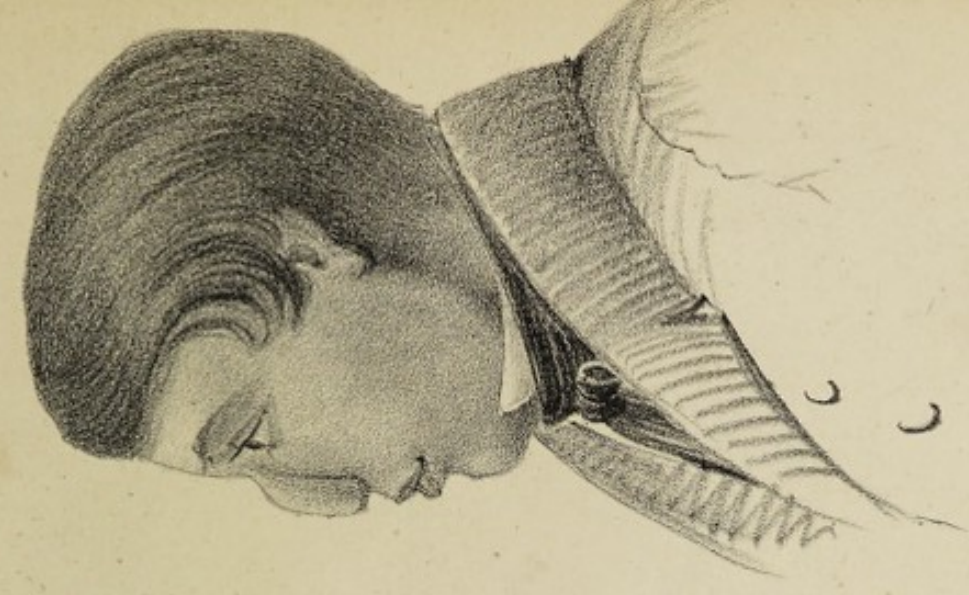Appearance of Donald MacKenzie's face
previous to operation.

(THE EFFECT OF LUPUS.)




Front view of face at this date,
March 1st 1841.

J. Henderson, Lithog.



Side view of the same.






Thomas Leslie, Cured August 17th 1840.




Appearance March 1st 1841.

Misses'son Lithg. Allo.




Digitized by the Internet Archive
in 2019 with funding from
Wellcome Library

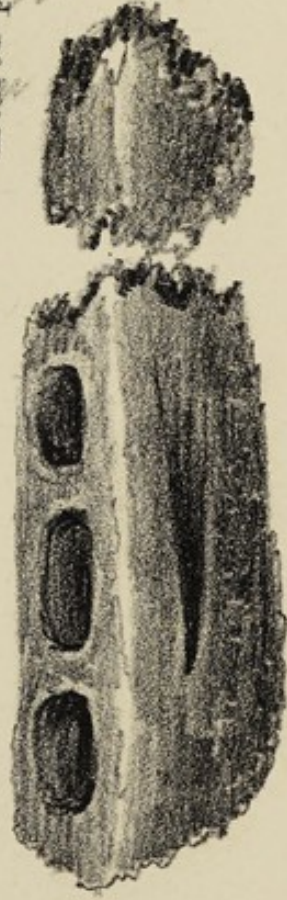
<https://archive.org/details/b30559261>



Appearance after the Cure.



Appearance before removal of the diseased portion of the jaw.



Size and appearance of the portion removed.

