

Anormal nutrition in the human articular cartilages, with experimental researches on the lower animals / by P. Redfern.

Contributors

Redfern, Peter, 1821-1912.

Publication/Creation

Edinburgh : Sutherland and Knox, 1850.

Persistent URL

<https://wellcomecollection.org/works/qqjpzum9>


License and attribution

This work has been identified as being free of known restrictions under copyright law, including all related and neighbouring rights and is being made available under the Creative Commons, Public Domain Mark.

You can copy, modify, distribute and perform the work, even for commercial purposes, without asking permission.



Wellcome Collection
183 Euston Road
London NW1 2BE UK
T +44 (0)20 7611 8722
E library@wellcomecollection.org
<https://wellcomecollection.org>



46407

ANORMAL NUTRITION
IN THE
HUMAN ARTICULAR CARTILAGES,
WITH
EXPERIMENTAL RESEARCHES ON THE LOWER
ANIMALS.

BY

P. REDFERN, M.D., LONDON,

MEMBER OF THE ROYAL COLLEGE OF SURGEONS IN ENGLAND; LECTURER ON ANATOMY AND PHYSIOLOGY,
AND ON HISTOLOGY; AND EXAMINER AT THE UNIVERSITY AND KING'S COLLEGE, ABERDEEN;
MEMBER OF THE COUNCIL OF THE ROYAL MEDICO-CHIRURGICAL SOCIETY OF
ABERDEEN; MEMBER OF THE ABERDEEN PHILOSOPHICAL SOCIETY;
LATE MEMBER OF THE COUNCIL OF THE PARISIAN
MEDICAL SOCIETY, ETC.

EDINBURGH: SUTHERLAND AND KNOX.
LONDON: SIMPKIN, MARSHALL & CO.

MDCCCL.



[FROM THE MONTHLY JOURNAL OF THE MEDICAL SCIENCES.]

MURRAY AND GIBB, PRINTERS, EDINBURGH

ANORMAL NUTRITION

IN

ARTICULAR CARTILAGES.

SINCE the discovery of the structure and functions of nucleated cells in plants and animals, by Schleiden and Schwann, it has become very important to determine with precision what part the blood-vessels perform in the functions of nutrition, growth, reproduction, secretion, and the production of such heterologous structures as cancer, tubercle, &c. In many of these processes there cannot be a doubt that, whilst blood-vessels are more or less necessary, the most important part is played by nucleated cells, which become the agents in the formation of tissues, whether homologous or heterologous, as well as the really efficient organs for the extraction of different substances from the blood, and for effecting various changes in them as they pass through the cell and become influenced by its development.

Perhaps there is no tissue in the body which affords a better opportunity for the examination of many of the changes which nucleated cells undergo, in the different periods of their existence, than that of cartilage; for in it changes are continually going on during the whole of life, such as take place at certain periods only in other textures. Moreover, these changes in the articular cartilages in man, are effected without any more direct communication with blood-vessels than exists upon their surfaces; for it is only when such cartilages exceed a certain thickness, about $\frac{1}{8}$ th of an inch, that they are permeated by canals which contain blood-vessels, as occurs in the larger mammals. The passage of vessels through the sub-

stance of this tissue will be seen to be very different, at least in degree, from that complete irrigation of the textures usually styled vascular, for yet a large portion of the substance of the cartilage is very far removed from any vessel containing blood. Now, as it has never been shown that cartilage, under any circumstances whatever, becomes vascular, it is clear that it is in the best possible position amongst the textures for the investigation of those processes which are continually going on without the immediate agency of blood-vessels, and take place, properly speaking, in the texture itself.

It is stated by Professor Alison, that the essential peculiarity of inflammation is a peculiar perversion of nutrition or of secretion; and in Professor Bennett's admirable work on Inflammation as a process of anormal nutrition, it is plainly demonstrated, that all the changes which take place in the matters exuded in inflammation are alone referable to the general plan by which the nutrition of healthy textures is effected, and that thus softening, induration, hypertrophy, ulceration, &c., are produced.

That changes, which may be equally referred to an anormal nutrition of the texture, take place in the diseases to which articular cartilages are so liable, appears plain from the nature of the changes that occur in them in such cases, and which I shall endeavour to describe and illustrate, as they appeared to me during lengthened examinations of a number of cases, the particulars of which will be afterwards detailed.

It is said that inflammation, ulceration, softening, hypertrophy, atrophy, and ossification, are the diseases to which cartilages are liable. Of the existence of inflammation in them, there is perhaps no other evidence than that furnished by ulceration, which is unquestionably the most important of all the affections of this texture, and is generally believed to be the climax of the most severe affections of the joints. Whether atrophy occurs, except as the result of such changes as take place in ulceration, is yet doubtful; whilst ossification appears to be confined to the cartilages of the larynx, the costal cartilages, and the fibro-cartilages found uniting the bones at the synchondroses.

The most important views of the nature and progress of ulceration in cartilages may now be briefly stated, that it may be seen whether or not they are consistent with the changes which microscopic observations reveal in the textures.

Sir B. Brodie saw very plainly that nutritive changes take place in cartilages, and concluded that they contain blood-vessels. He argued, 1st, that there are instances in which vessels extend into the cartilage from diseased bones; 2d, that, notwithstanding the great amount of friction to which many cartilages are exposed, no change takes place in them, and yet the enamel of the teeth wears away in old age; 3d, that the structure of cartilage becomes changed in disease in such a way as to indicate that new matter is deposited and the old

absorbed,—changes which Sir B. Brodie believed to require the existence of vessels in the interior of the cartilage for their accomplishment. This author, in the third edition of his very valuable work on Diseases of the Joints, states his belief, that ulceration or absorption of articular cartilages may take place from the action of their own vessels, and that ulceration may arise from:—"1st, Disease originating in the neighbouring soft parts, especially inflammation of the synovial membrane; 2dly, it may depend on a morbid condition of the cartilage itself; or, 3dly, on a chronic inflammation of the surface or substance of the bone with which it is connected; 4thly, it may be the result of a peculiar alteration in the condition of the cancellous structure of the bones, which is met with in young scrofulous persons." In his additional notes on ulceration of articular cartilages, Sir B. Brodie states, that he has not been able to satisfy himself as to the exact nature of the ulceration resulting from inflammation of the synovial membrane; and then, referring to cases of inflammation of the synovial membrane, in which ulceration begins in the centre of the cartilage, he states that of such cases neither Mr Key's hypothesis, nor any other, affords any reasonable explanation. Of the degeneration of cartilage into fibrous structure, he remarks: "I have no doubt that it often exists where it is never followed by ulceration; but I am also well assured that, in many other instances, it precedes, and, in fact, forms the first stage of the disease."

Mr Key¹ describes three forms of ulceration of articular cartilages accompanying respectively acute or chronic inflammation of the joint, or strumous disease of the bone, as well as "that in which the structure appears to undergo a change in its organisation, independent of foreign agency." In three of these conditions, he says, "the cartilage is not absorbed *per se*, but through the agency of a structure, probably evolved for the special purpose of completing that process;" and the fourth is "the result of disorganisation of texture."

Mr Key² states:—"The absence of all action in the cartilage, and a total want of vascularity in those parts where ulceration appears to be most active, were the circumstances that first led me to look for some agent in the work of ulceration." This statement occurs in speaking of ulceration caused by inflammation of the synovial membrane from wounds. Mr Key believes that the highly vascular membrane which covers the cartilages of such joints causes ulceration to take place in them, and that it progresses in proportion to the amount of the inflammation and the vascularity of the newly-formed membrane. And yet, in his further remarks³ on ulceration resulting from inflammation caused by wounds, the same author adds:—"In these cases the cartilage is found often to be extensively de-

¹ Medico-Chirurgical Transactions, vols. xviii. and xix.

² Ibid, vol. xviii. p. 235.

³ Ibid, vol. xviii. p. 148.

stroyed, and the bone laid bare, without any appearance of a membrane for the purpose of absorption." But he distinguishes between absorption and ulceration as two modes, by either of which cartilage may be removed:¹—"In some parts may be seen the membrane adhering to the cartilage or to the denuded bone, in various degrees of activity or vascularity, according as its office is completed or in progress; and in others, a total loss of the cartilage may be observed without the development of a membrane. It is not unusual for one half of a knee-joint to be losing its cartilage by absorption, while, by a process of inflammation subsequently excited, the other is in a state of active ulceration."

Regarding the removal of the cartilages of old people, Mr Key says:²—"I am unable to offer any very conclusive evidence as to the exact nature of the process in all such cases; but I believe it will be found to be analogous to the processes which I have previously described." He remarks on the fibrous degeneration:³—"It appears to me to be an action altogether different from absorption, and analogous to the softening of the intervertebral substance." Again:⁴—"It is a disease of a peculiar character, and differing in many respects from the ordinary affections of joints that end in the destruction of the cartilage."

Mr Mayo⁵ believes Key's views to be at variance with the facts revealed by dissection, and states that "there are three distinct forms of ulceration, or three varieties of ulcerative disease, which, although they may be occasionally combined, are oftener met with separately." These are—rapid and clean excavation on the surface, with inflammation of the synovial membrane; chronic ulceration on the surface, with fibrous or brush-like projections, and inflammation of the synovial membrane; and ulceration on the deep surface, with inflammation of the bone and synovial membrane, and, in some instances, "with sensible vascularity of the cartilage itself." He reports several cases of ulcerated cartilages, in which, he says, they were evidently vascular. These, however, are of no value in deciding the question regarding vascularity, as in no case was the minute structure examined; and Mr Liston says, that the preparations to which Mr Mayo refers, exhibit nothing at all satisfactory on the subject.

Mr Liston believed that he had injected vessels passing from the bone into the substance of diseased cartilage; but Professor Goodsir has plainly shown,⁶ that there is every reason to believe that such vessels ramify in a new texture occupying the place from which the cartilage has been removed by absorption. Moreover, Mr Liston himself says,⁷ that in such cases ulceration may be proceeding from

¹ Medico-Chirurgical Transactions, vol. xix. p. 243.

² Ibid, vol. xix. p. 149.

³ Ibid, vol. xix. p. 135.

⁴ Ibid, vol. xviii. p. 241.

⁵ Ibid, vol. xix. p. 49.

⁶ Anatomical and Pathological Observations.

⁷ Medico-Chirurgical Transactions, vol. xxiii. p. 95.

the free surface, that "the cartilage is often previously swollen and softened," and that "more than one form of the ulcerative process may sometimes be observed in the same articulation."

Mr Toynbee states :¹—"The investigations of Sir B. Brodie, Mr Mayo, and more recently of Mr Liston, leave no doubt, that in some diseases to which articular cartilage is subject, blood-vessels are distributed throughout its substance." He speaks also of researches which he has made upon "those morbid states of articular cartilage, in which blood-vessels are prolonged into its substance, and upon the manner in which the vessels are introduced into it."

Henle says, that cartilage is neither liable to inflammation nor hypertrophy, and that atrophy depends on a want of nutrition from diminished vascularity of the neighbouring textures. He and Mandl² agree in the view that the changes to which cartilages are subject in diseased joints, depend on maceration in the pus, altered synovia, &c. M. Richet, Prosector to the Faculty of Medicine of Paris, takes a similar view,³ and even says, that portions of cartilage are not unfrequently met with, in joints in a very advanced stage of disorganisation, *retaining all the chemical and physical characters*. He proposes that the terms inflammation and ulceration of cartilage should be rejected, and replaced by the phrases, softening, wearing, "usure," and erosion; and shows that cartilage may be softened, reduced to a fibrous state, or even totally disappear in joints, which certainly cannot be called healthy, but which sometimes present little or no symptoms of derangement during life. M. Richet's reviewer⁴ in 1846 says: "It is indisputable that cartilage is frequently removed by the action of the adjacent tissues, *without itself having any active participation in the process*."

Professor Goodsir attributes the removal of texture in ordinary ulceration to the formation of nucleated cells, which take up, during their growth, the materials of which the surrounding parts are composed. Speaking of ulceration of articular cartilages,⁵ he describes a gelatinous or a false membrane on the surface, both consisting of nucleated particles, intermixed in scrofulous disease with tubercular granular matter, and in simple inflammation with fibres and blood-vessels. He was the first to point out that the cells of the cartilage "become larger, rounded or oviform, and instead of two or three nucleated cells in their interior, contain a mass of them. At the very edge of the ulcerated cartilage the cellular contents of the enlarged cartilage corpuscles communicate with the diseased membrane by openings more or less extended. If a portion of the false membrane

¹ Philosophical Transactions, 1841, Part I., p. 172.

² Mandl—Manuel d'Anatomie Générale, p. 381.

³ Recherches pour servir à l'Histoire des Tumeurs Blanches. (Annales de la Chirurg. Française et Étrangère, Mai, Juin, 1844.)

⁴ British and Foreign Medical Review, vol. xxi. p. 136.

⁵ Anatomical and Pathological Observations.

be gradually torn off the cartilage, the latter will appear rough and honey-combed. Into each depression on its surface a nipple-like projection of the false membrane penetrates." Mr Goodsir points out that the cartilage may be attacked upon its attached surface in a similar manner, a vascular and false membrane being, in that case, formed between it and the bone, a layer of nucleated cells always existing between the loops of capillaries and the ulcerated surface. He adds:—"The cartilage, where it is not covered by the false membrane, is unchanged in structure."

Mr South believes firmly in the truth of Wilson and Key's notion of the deposit of a new and vascular substance upon the synovial membrane being the usual cause of ulceration of cartilage, and that the cause is not in the cartilage itself. In support of this view, he quotes largely from Mr Goodsir's observations, in pages 17 to 19 of Mr G.'s work before-named.

Mr Rainey states that the absorption of cartilage is preceded by conversion of its nuclei into drops of oil, which are sufficiently characteristic, and capable of being removed by the addition of ether. The intercellular substance is also converted into granules of oil, arranged in irregular lines running in all directions, grooving and excavating the cartilage.

In Guy's Hospital Reports for October 1848, Mr Birkett recorded the examination of a diseased knee-joint, and maintained "that the destruction of articular cartilage depends chiefly upon a diseased state of the capillary vessels of the bone, whereby its nutrition is suspended, and that then disintegration simply, and not ulceration, takes place. That this disintegration is mainly attributable to a metamorphosis or conversion, first of the nuclei, and then of the intercellular or hyaline substance, into fat." Mr Birkett believes bone to be analogous to the true skin, and cartilage to epithelium;¹ and states, in opposition to all other observers, that the cells of articular cartilage, near to the bone, have no regular arrangement.

Such is the nature of this very instructive process as it has appeared to others. Without further remarks, I shall now proceed to give the results of other examinations, and endeavour to show that the facts are capable of being reconciled with a true physiology.

OBSERVATION I.—Disease of Cartilage of the Knee-Joint without Symptoms—Severe comminuted and complicated Fracture of the Bones of the Leg—Amputation—Death from Exhaustion.

Charles Clarke, æt. 42, labourer, admitted into the Aberdeen Royal Infirmary, December 16, 1848, under Dr Kerr, for a severe comminuted fracture of both bones of the leg, extending into the knee-joint, and produced by the fall-

¹ M. Richet in 1844 made a similar statement as to the analogy in structure and mode of nutrition of cartilage and epidermis, nails, &c.

ing of a metal roof upon him. Has always been a stout healthy man, though of intemperate habits. Ten or twelve years ago he injured his ankle on a stone before his door, but it is not known whether he fell. He was confined to the house at this time for three weeks, and was attended by Dr C. of this town, who does not recollect the occurrence. Five years ago, when at his usual work, at the gas-works, he was much hurt and scalded about the head and shoulders by the bursting of a boiler, but his knee was not injured. He completely recovered from these injuries, and was in good health, at his work, at the period of occurrence of the accident which caused his admission. He never suffered from lameness, or made any complaint regarding his knee.

Amputation was performed in the thigh—the posterior flap sloughed, and the patient died from exhaustion on January 3, 1849. The body and sound limb were not examined.

On opening the knee-joint of the amputated limb, a quantity of blood was found, which had evidently escaped from vessels lacerated by a fracture separating the articular surfaces of the tibia. After washing away the blood, the surface of the cartilage on the upper part of the internal condyle of the femur, was found considerably elevated, reddish in colour, and presenting a covering of fibres attached at one end to cartilage, apparently healthy, and projecting into the joint by the other. This was over an extent of surface which could be covered with a sixpence, whilst at a little distance, and directly upon the trochlear surface of the femur, one-fourth of an inch distant from the edge of the cartilage, an irregular excavation was found, of the size of a split pea. The edges of this excavation were loose, and overhung its bottom, the deepest part being covered with a thin layer of apparently healthy cartilage, and the whole exposed surface reddish in colour, and split into fibres as in the spot before-named. The internal portion of the articular surface of the patella, and the central part of the vertical ridge separating this from the external part, were covered with cartilage in a similar state of disease. Here, however, there was neither excavation nor elevation of the diseased part; but, as in the other two diseased spots, the greater part of the disease was separated from the edge of the cartilage by a distance of one-fourth of an inch, occupied by the last-named substance in a perfectly normal state.

Microscopic Examination.—Portions of cartilage removed from the attached surface, in the regions affected by disease, and elsewhere, present a series of elongated cells, containing nuclei or other cells, placed vertically to the surfaces of the cartilage, and varying in length from $\frac{1}{900}$ th to $\frac{1}{1300}$ th of an inch. These cells, and the hyaline substance in which they lie, differ in no respect of structure from perfectly healthy cartilage.

Sections taken vertically at the diseased parts, show healthy cartilage at the part near to the bone, but, on proceeding towards the free surface, numerous rounded, oblong, or oval cells are found, varying in length from $\frac{1}{100}$ th to $\frac{1}{600}$ th of an inch, and in breadth from $\frac{1}{220}$ th to $\frac{1}{1000}$ th of an inch. The smaller ones contain three or four irregularly rounded or oblong corpuscles, and many of the larger ones sixty or eighty similar bodies. These corpuscular nuclei vary in diameter from $\frac{1}{2000}$ th to $\frac{1}{5000}$ th of an inch, and the larger ones contain small nucleoli. At the same part the intercellular substance is split into large bands, which, on arriving at the surface, are sub-divided into others, varying in breadth from $\frac{1}{500}$ th to $\frac{1}{3300}$ th of an inch, and all possessing the glistening and granular appearance of other parts of the hyaline substance—(Fig. I.) The cells above described are found in the substance of the larger bands into which the intercellular substance has been split; in some places their walls are indistinct; in others altogether imperceptible, the nuclei in the last-named places being spread out in the texture, and either preserving the size and appearance which those within the cells present, or they are enlarged and seen to consist of a cell wall, containing a nucleus—(Fig. II.) The whole texture at the diseased parts is of a reddish brown colour, and considerably darker than healthy cartilage.

Fig. I.



Fig. II.

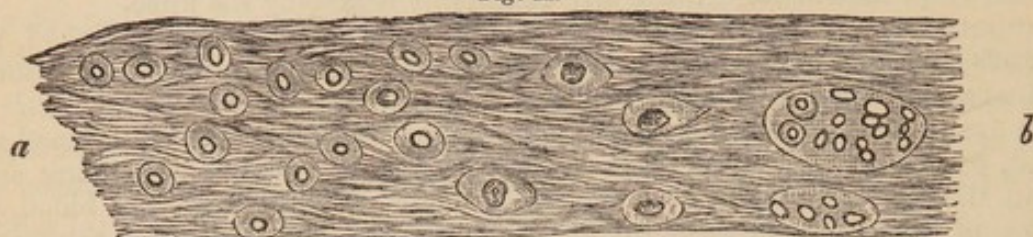

Fig. I.—Portion of a vertical section through the diseased part; a, bands and fibres projecting into the joint; beyond b, the cartilage is healthy.

Fig. II.—Portion of a similar section; a, free surface. This band contains the original cells broken up into masses, or new cells, each one of which has its nucleus.

Remarks.—The disease, which had proceeded in this case to the destruction of parts of the cartilage through the greater extent of its thickness, without giving rise to any symptoms, commenced on the surface, at parts considerably removed from the edge, and progressed without the assistance of blood-vessels in the cartilage, or a newly formed membrane. It is evidently similar to that which was described by Sir B. Brodie, and adduced by him as a proof that ulceration of cartilage is caused by vessels passing into its substance, and referred to by Mr South, under the head of “self-ulceration of cartilage.” The real characters of this disease, as shown by a microscopical examination, have not yet been made known, so far as I am aware. They consist in the gradual enlargement and rounding of the cells, which become filled with a multitude of corpuscles, which, on the bursting of the cells, are discharged into the texture, and removed from it by changes to be afterwards shown. The hyaline substance splits into bands and fibres, and is subsequently disintegrated and removed from the part. It will be afterwards shown whether these changes indicate a disease of a peculiar character, and altogether distinct from ordinary ulceration of cartilage, as is believed by Sir B. Brodie, South, and Key.

OBSERVATION II.—*Diabetes—Death from Diarrhoea—Extensive disease of the Cartilages of the Left Knee-Joint without Symptoms.*

A. R., æt. 38, labourer, admitted into the Aberdeen Royal Infirmary, December 5, 1848, under Dr Kilgour, for diabetes, the first indication of which he noticed during the previous summer. On admission, has every appearance of having been a strong and healthy man—is emaciated, complains of great thirst, and frequent micturition. Urine, 13lbs, sp. gr., 1·040, gives every indication of the existence of a large quantity of sugar on the addition of yeast, the sulphate of copper test, and on microscopic examination.¹ During the treat-

¹ A full account of the symptoms, the progress of the case, and its treatment, is to be found in the hospital reports, but is here omitted as not being connected with the disease of the cartilages.

ment, the urine became much less in quantity, and of sp. gr. 1.025, but diarrhoea came on with extreme prostration, and he died on December 22, and was removed to the dissecting rooms, where the disease of the cartilages was discovered.

This patient walked perfectly well on his admission into the hospital, and made no complaint whatever of his knee. He stated that in his usual occupation of building dry stone walls he had been much exposed to cold and wet. About ten weeks previously, he fell into a quarry thirty feet deep, and "injured his thigh and shoulder, which confined him to bed for a short time, but he was able to go about during his recovery; and, within a fortnight, to leave Fife-shire (where the accident happened) for home."

Examination of Left Shoulder.—The scapula presents two vertical fractures, one separating the glenoid cavity, and the coracoid process from the body, the other removing the acromion and a portion of the spine. The fragments are only slightly displaced, and very firm union has taken place. On the same side, five ribs below the first show a united fracture about the middle of each. The first rib, the humerus and clavicle, show no trace of injury, but both clavicles were removed with difficulty at their sternal ends, owing to dense fibrous tissue around the articulations.

Examination of Left Knee-Joint.—The femur has its surface covered with healthy cartilage throughout. The central part of the external glenoid cavity of the tibia is evidently raised over an extent of surface equal in size to a small horse-bean. The swelling is highly elastic, and fluctuates indistinctly. It has no abrasion of any kind on the surface, but close to its edge, at the part looking towards the central and posterior part of the joint, there is a fissure extending backwards and inwards for one-fourth of an inch. The fissure is also oblique in relation to the surface, for, in passing down towards the bone, it inclines from before backwards and outwards. It lodges a fibrous mass, which is adherent to the posterior lip of the fissure, and projects one-tenth of an inch beyond the surface. At its ends, the fissure appears limited, but from the anterior one, an indistinct depression leads forwards for two lines, bounding the raised part, and appearing like a trace of a healed fissure.

Two sections were carried through the external condyle of the tibia, from before backwards, perpendicularly to the surface of the cartilage, one passing through the centre of the raised portion, the other by the internal side of the fissure. These sections removed a portion of bone and cartilage, half-an-inch broad, of which the lateral surfaces are delineated in Figs. III. and IV. On both these sections the bone presents an even and perfectly distinct plate of compact tissue, from one-tenth to one-fifteenth of an inch in thickness, where it is in contact with the cartilage. The first section (Fig. III.), shows the car-

Fig. III.

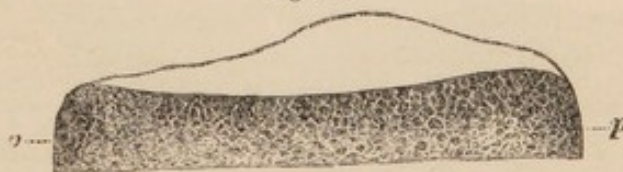


Fig. IV.

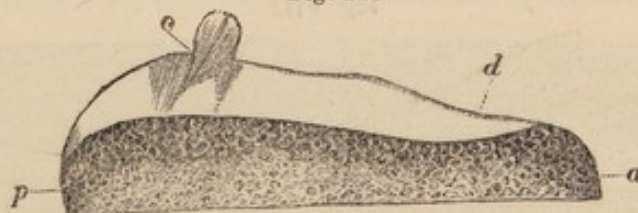


Fig. III.—Appearance of the cartilage and bone on a section through the centre of the elevation on the external glenoid cavity of the left tibia; a, anterior, p, posterior, edge.

Fig. IV.—Appearance of a section parallel to the former, and half an inch internal to it; a, anterior, p, posterior, edge; c, tuft of fibrous tissue projecting from the fissure.

tilage to be four-fifteenths of an inch thick at the raised part, and thinned off towards the edges, as represented in the figure, which is of the normal size. The other section, represented of the normal size in Fig. IV., shows the cartilage to be one-fifth of an inch thick at the most prominent part, and a quantity of fibrous tissue projecting one-eighth of an inch from the fissure.

The cartilage covering the internal glenoid cavity appears a little roughened, but it is found to be healthy. A section was also made through this condyle and its cartilage, from before backwards, and the appearance of the section is represented in Fig. V.

Fig. V.




Fig. V.—Section carried through the centre of the internal glenoid surface, from before backwards; a, anterior edge.

Microscopic Examination.—The tuft, projecting from the fissure, consists of a multitude of large and small bands of hyaline substance, and of a mass of beautifully waved fibres, precisely like those of the lateral ligaments of the knee. These bands and fibres are attached to the cartilage at one end, and are free at the other. There are all degrees of this splitting into the waved fibres, many of the large bands being granular and hyaline at their attached ends, then indistinctly striated, and at their free ends a mass of pure fibrous tissue. The largest bands are about $\frac{1}{280}$ th of an inch broad. Interspersed amongst the fibres and bands, are a number of beautifully rounded or oblong cells, generally in groups of three or four, containing nuclei of different sizes, situated eccentrically. The cells vary in length from $\frac{1}{1000}$ th to $\frac{1}{500}$ th of an inch, and in breadth from $\frac{1}{1250}$ th to $\frac{1}{830}$ th of an inch. The nuclei contain a number of irregular, elongated, and bright granules, the largest of which are $\frac{1}{5000}$ th of an inch, whilst many are not larger than $\frac{1}{15000}$ th of an inch in diameter (Fig. VI.)

In some places there are patches of fibrous tissue of $\frac{1}{20}$ th of an inch in extent, throughout which the cells, which are mixed with the fibres, are very uniform in size, measuring $\frac{1}{2000}$ th of an inch by $\frac{1}{3300}$ th, irregular, with thin and indistinct walls, and containing granular bodies similar to those just named, as belonging to nuclei, but of larger size. (Fig. VII.)

The bottom of the fissure does not reach the bone, but is separated from it by a thin layer of perfectly healthy cartilage. Owing to its oblique direction, sections can be obtained through the whole thickness of the cartilage, and having

Fig. VI.

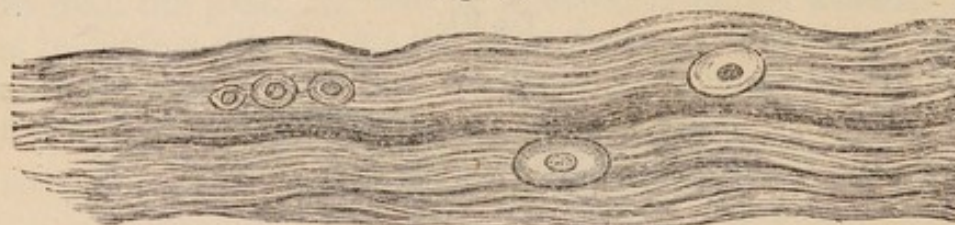

Fig. VII.

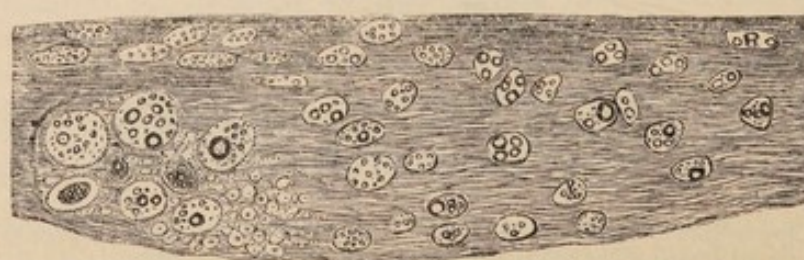

Fig. VI.—Striated band, with cells interspersed, removed from the tuft of fibrous tissue shown in Fig. IV., c.

Fig. VII.—Fibrous tissue, with small irregular cells, containing large bright granules.

the fissure passing through them. Proceeding from the surface of such sections, the cells parallel to it are found but little changed in their characters, except in the immediate neighbourhood of the fissure; lower down, there are—1st, large rounded or oblong cells, containing large nuclei; 2d, rounded patches of cells, which measure $\frac{1}{100}$ th of an inch by $\frac{1}{1700}$ th, and contain nuclei or granules, the patches being $\frac{1}{200}$ th of an inch long, by $\frac{1}{700}$ th broad; 3d, small cells spread out in the texture, which has now, in the vicinity of the fissure, become distinctly split into bands and fibres, though nearer the surface it is granular and hyaline. Proceeding upwards from the bone, similar changes are seen, the lowest cells being in perpendicular groups, then enlarged and distended with small cells or corpuscles; whilst, nearer to the fissure, these are found mixed with the texture. The intercellular substance, also, is hyaline and mottled near the bone, then striated, and, at the fissure, split into bands and fibres as on its opposite side.

Wherever the small cells or nuclei, which measure from $\frac{1}{1400}$ th to $\frac{1}{3500}$ th of an inch in diameter, are set free, and do not present their usual irregular outline, with their glistening and homogeneous appearance, they contain the irregular granules shown in the cells in Fig. VII., and, in that case, are almost always found in a dark and indistinct fibrous texture, which becomes so much darker and shrivelled, on being subjected to the action of a very weak solution of creasote, that the cells can then be seen with great difficulty.

On examining the general structure of the part not evidently thickened, as at Fig. IV., *d*, the horizontal arrangement of cells at the surface, and of vertical ones in the deeper part, are as distinct as in the most healthy cartilage, the cells themselves, and the hyaline substance, being also quite healthy. Even in the elevated parts, no change is noticed for some distance, except that the cells become less numerous and less regularly arranged in the tissue; a few are rounded or oblong, and increased in size, so as to measure $\frac{1}{500}$ th by $\frac{1}{770}$ th of an inch.

Left Patella.—Externally this bone is of the usual shape and size, but its articular surface is convex from above downwards, especially on the central ridge, and to the outer side of this; passing from without inwards, it is at first straight and then excessively convex, as shown in Fig. VIII., representing the appearance of a section carried horizontally through the middle, on the upper half.

Fig. VIII.

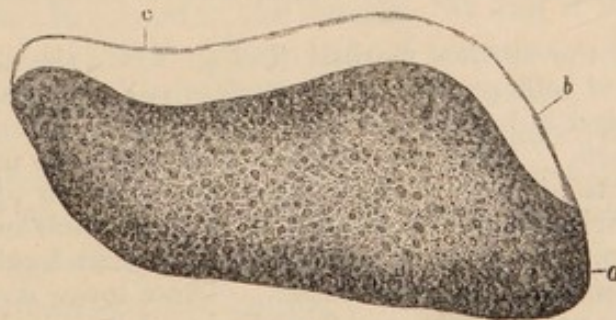


Fig. VIII.—Horizontal section through the centre of the patella, shown on the upper half; *a*, internal edge; *b*, soft and spongy part; at *c*, the cartilage is soft and spongy in the middle of its thickness.

The cartilage has a granular appearance on the surface, especially on its external half; and, on being placed in water, a number of short fibres float from it and give it a villous appearance. The whole surface has a finely striated appearance from above downwards.

Microscopic Examination.—The processes projecting into the interior of the joint, consist of bands of fine fibres, separated from each other at their free extremities, and only recognisable, as formed of hyaline substance, by tracing them to their attachment to the cartilage. Small elongated nuclei are visible amongst the fibres, and running in the same direction—(Fig. IX.) There are

also small cells to be found in some of the bands. Large masses, of a rounded form, and highly glistening character, are to be found loose amongst the fibres, attached to them at their extremities, or stuck upon them in different parts of their course, and forming a part of their substance—(Fig. X.) These bodies,

Fig. IX.

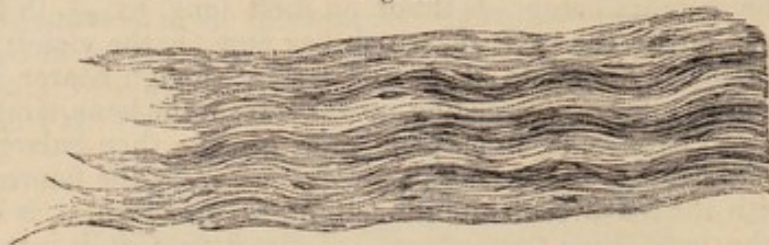


Fig. X.

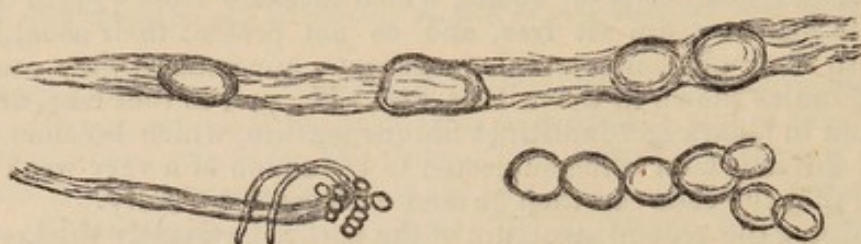


Fig. IX.—Fibrous band projecting from the surface of the patella.

Fig. X.—Glistening bodies found loose and upon fibres which have no ordinary cells amongst them.

when loose, have very much the appearance of starch globules without the hilus. They are of considerable consistence, and appear of the same density throughout. From their connection with the bands, their glistening character, and the absence of any save small and irregular cartilage cells where these bodies are found, it is tolerably certain that they are cartilage cells which have undergone this remarkable change in structure, and most probably one quite as great in their chemical characters. Lying amongst these loose bands and fibres, are a number of perfect octohedral crystals, completely insoluble in strong acetic acid. The side of the largest of these measures $\frac{1}{340}$ th of an inch, of the others $\frac{1}{1700}$ th, and many are so small as to be recognised as crystals only with difficulty.

At the point of the section marked *b*, Fig. VIII., the texture is soft and spongy, the layer of cells parallel to the surface still remains, but its cells are considerably enlarged in both length and width, measuring on an average $\frac{1}{710}$ th by $\frac{1}{1420}$ th of an inch. A few are rounded, and these are much larger, measuring from $\frac{1}{300}$ th to $\frac{1}{400}$ th of an inch long, and $\frac{1}{400}$ th to $\frac{1}{700}$ th broad. The cells nearest the surface have lost almost all trace of their nuclei, and are evidently breaking up. They lie in a highly transparent hyaline substance, separated at some distance from each other. Those lower down contain nuclei or corpuscles of the usual forms, and these lie in a denser and granular texture, reddish-brown in colour, and darker than the healthy intercellular substance.—(See Figs. XI. and XII.) In the deeper parts, the texture is more healthy, the cells being of the usual form, and arranged in groups perpendicular to the surface, except where the intercellular substance is softened, and indistinctly fibrous; for, in all such places, the cells are much enlarged, and contain a number of smaller ones, of which the nuclei are the most prominent objects.

Near to the edge, on the opposite side, precisely similar changes have taken place, but the affection of the superficial cells has not proceeded so far. At the point marked *c*, Fig. VIII., the interior of the cartilage is soft and pulpy. The intercellular substance is indistinctly fibrous,—the cells are of large size, and many have discharged their contents (cells or nuclei), which are found mixed with the fibres. This change reaches the bone, but is most marked in the

middle of the thickness of the cartilage. The part of the surface which corresponds to it, is granular and reddened, and is at all points far distant from the edge of the cartilage.

Fig. XI.

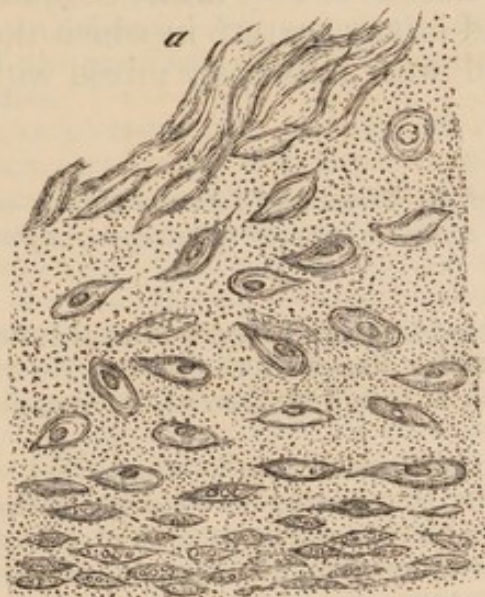
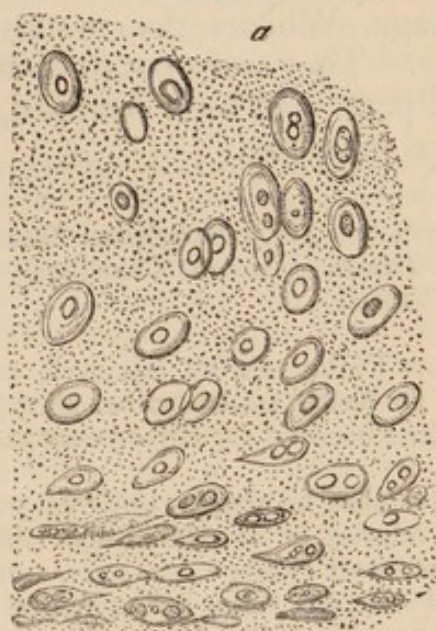

Fig. XII.



Figs. XI. and XII.—Vertical sections of cartilage from the surface of the patella; a, free surface.

Remarks.—This was the case of a man, who, though walking about without any lameness, up to a fortnight previous to his death, had considerable disease of the cartilages of the patella and left tibia, involving, in some parts, nearly the whole thickness of the structure. There can be no doubt, therefore, that disease may go on to the complete removal of portions of articular cartilage in the centre of a joint, without any symptoms whatever; and it is probable that the whole of the cartilage might be so removed, were it not that other structures generally become involved in the disease. When it is considered that cartilage belongs to the simplest class of textures,—that its functions are mechanical ones—and that it is not furnished with nerves, these facts are not so surprising as they would otherwise appear. The fact of the existence of actual disease, in the two cases now related, is certain, from the changed condition of the structure. In the enlargement and crowding of the cells with corpuscles, and the splitting of the hyaline substance into bands, this case resembles the former, but here, fibrous tissue, in some parts absolutely incapable of being distinguished from that of ligaments, was formed by the splitting of the hyaline bands, whilst the nuclei of many of the cells were destroyed by being converted into granules. These granules were not affected by acetic acid, by the copious application of liquor potassæ for four hours, nor could they be seen to undergo any change on the addition of ether. In cells further advanced in disease, there are large globules of oil, but the granules are irregular in their outline, though like oil in other respects. Probably they constitute one stage in the conversion of nuclei into oil. In most parts the disease appears to

have commenced on the surface, but at *c*, (Fig. VIII.), both the cells and the hyaline substance in the deeper parts were considerably changed, whilst there was scarcely any affection of the surface, showing plainly that the disease may commence in any part of the cartilage. Whence the crystals of oxalate of lime arose, it is difficult to say. They were not to be found in any texture in which the diseased parts had been wrapped, and were intimately mixed with the fibrous processes.

OBSERVATION III.—*Scrofulous Disease of the Wrist and adjacent Joints—extensive Disease of all the Cartilages, and complete removal of many—Amputation—Phthisis.*

James Finlay, æt. 19, labourer, admitted into the Aberdeen Royal Infirmary under Dr Keith, on December 26th, 1843, for disease of the wrist. He has resided in Aberdeen for three years past—is of thin and spare habit—complexion pallid.

States that he always enjoyed good health until lately—that eight weeks before admission he injured his right wrist by swinging between two casks, and felt pain in it at the time. He continued at his work, as a shop porter, for some weeks, his wrist being at first a little swollen, and then so painful as to oblige him to give up his work. At this time, the pain was deeply seated—of an aching character, and always worst at night; in the morning the wrist felt stiff. Two or three weeks after the injury he placed his arm in a sling, and used poultices, without relief. When five weeks had elapsed, he applied to Dr Laing as an out-patient of the hospital. At this time there was a swelling on the anterior and inner aspect of the wrist, which, on being opened, discharged two or three table spoonsful of pus and blood; another opening was made lower down, but scarcely any pus escaped from it. These openings continued to discharge until his admission, the fluid becoming gradually more serous. A week previous to his admission, a small abscess, on the back of the carpus, burst, and discharged some pus and blood. His father is a stout and healthy man, but he knows nothing of his mother or other relatives.

On admission, there are the three openings above-named, leading to extensive sinuses; and from the posterior one, portions of rough bone are felt. The whole wrist is much swollen, and white in colour—the hand swollen and almost useless.

A week after admission, Dr Keith removed parts of the unciform and fifth metacarpal bones. Erysipelas came on, and extended to the axilla. It was stopped by the application of nitrate of silver, and in a week or ten days, abscesses formed on the outside of the limb near the shoulder and elbow, as well as in the palm. These were opened, and discharged a large quantity of matter. Emaciation and hectic supervened, and, in consequence, the arm was amputated near the wrist, on March 3d. The wound healed tolerably well—the ligatures separating within ten days, and his health improved very much; but since leaving the hospital he has suffered severely from an affection of the chest, which has all the characters of phthisis.

Examination of the Hand.—All the tissues about the wrist-joint are infiltrated with a gelatinous effusion, through which the sinuses run in different directions. On opening the wrist-joint, the bones are found to adhere so firmly in many places, that the few isolated patches of cartilage which remain tear off portions of bone and lie on the opposite surface. Where there is no cartilage, the bones are rough and bare. The adjacent surfaces of the radius and ulna are in the same state, but the lower part of the surface of the ulna is covered with cartilage over a great part of its extent. The bones are tolerably firm, and resist attempts to pass needles, or the points of forceps, into them.

In the articulation between the rows of carpal bones scarcely any cartilage remains, and the bones are more or less firmly united. Part of the head of the os magnum has broken away and adheres to the scaphoid.

The bones in the upper row separate readily, and are still covered with cartilage on their opposed surfaces; those in the lower row also separate easily; the cartilage of their opposed surfaces is removed, and in its place there is a soft fibrinous mass. The carpal end of the fifth metacarpal bone, and the lower part of the unciform, have been removed, and a mass of granulations covers their ends.

The carpo-metacarpal articulations open easily. The articular surface of the trapezium for the metacarpal bone is covered with cartilage, and appears healthy. Scarcely a trace of cartilage exists on any other bone, but the articular surfaces are covered with a soft granular exudation. The metacarpal bones are bare where they are opposed to each other, except the adjacent sides of the third and fourth, which are covered with cartilage. The inter-articular ligaments are entire and still very firm.

Microscopic Examination.—The cartilage on the lower articular surface of the radius (Fig. XIII.) presents a series of rounded cells $\frac{1}{1700}$ th to $\frac{1}{1400}$ th of an inch in diameter, which lie in rounded clusters of the diameter of about $\frac{1}{700}$ th of an inch, and are in some places bound together by a mother cell; in others, they are much further apart. They contain a number of irregular granules of various sizes, as represented below. In other places, there are large rounded patches, $\frac{1}{230}$ th of an inch long and $\frac{1}{280}$ th broad, granular in appearance, and presenting traces of former nuclei. There are all sizes of the patches below the measurements given. Besides these, there are rounded cells of the sizes of the patches, containing a number of irregular and glistening corpuscles measuring $\frac{1}{2360}$ th to $\frac{1}{1420}$ th of an inch. Some of these corpuscles contain a number of granules. Many of the sections taken from these parts present a remarkably beautiful appearance, showing, at one part, small rounded cells with granules in their interior; further on, similar cells, considerably enlarged, but still containing a few small granules; and, nearer to the surface, a further enlargement occurs—the granules disappear—the cells become mottled, and many are seen to have burst and discharged their contents. These changes are shown in the section represented in Fig. XIV.

Fig. XIII.

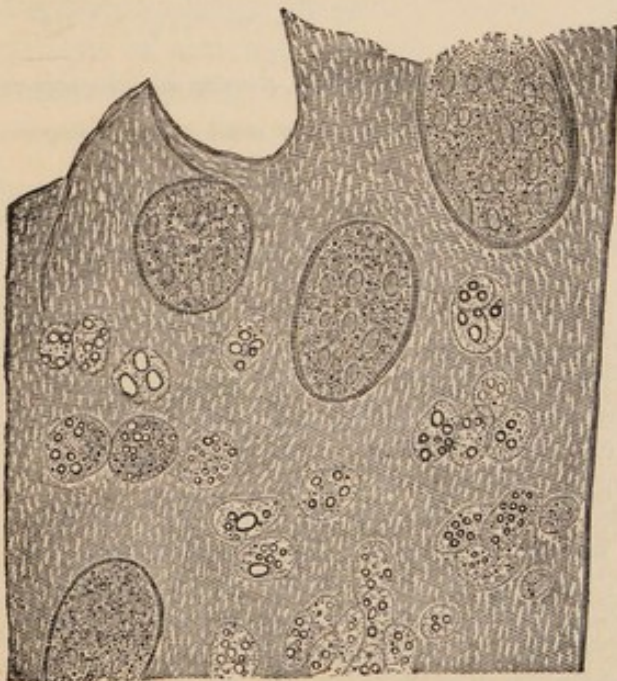
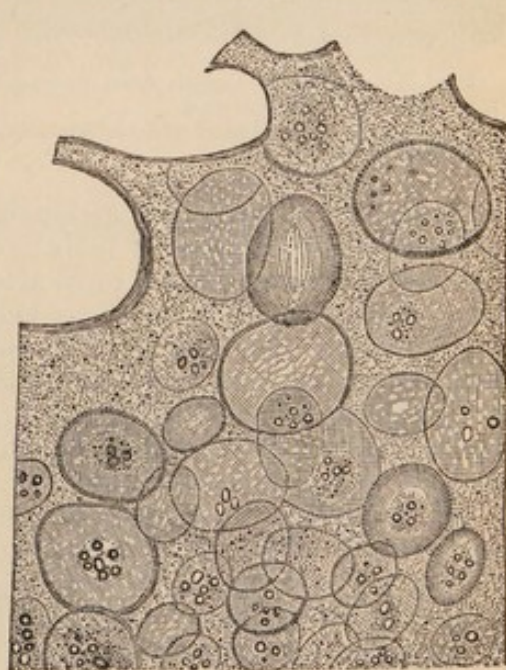


Fig. XIV.



Figs. XIII. and XIV.—Oblique sections of cartilage from the radius and semilunar bones, showing, Fig. XIII., clusters of cells, with granules and granular patches; in Fig. XIV., the distension of the cells, and the destruction of their granules as they come to the surface.

A small patch of cartilage on the radial surface of the semilunar bone, presents, in the middle of its thickness, a number of cells which are evidently breaking up. Their average size is $\frac{1}{300}$ th of an inch by $\frac{1}{550}$ th. They are full of glistening and slightly granular corpuscles, which are rounded, oblong, or semilunar in their shape. On the surface, there is a finely mottled hyaline substance, full of corpuscles, like those in the cells, but larger in size, measuring from $\frac{1}{2500}$ th to $\frac{1}{1400}$ th of an inch in diameter. These are so large and closely applied to each other in some parts, as to give to the texture the appearance of a portion of temporary cartilage. At the part of this cartilage which is applied upon the bone, there are a number of nucleated cells spread out in a granular substance, as shown in Fig. XV. These are probably produced by the development of the corpuscles before-named into perfect cells.

Sections taken vertically from the cartilage on the cuneiform surface of the semilunar bone, show at the deepest parts (Fig. XVI.) irregular cells, having

Fig. XV.

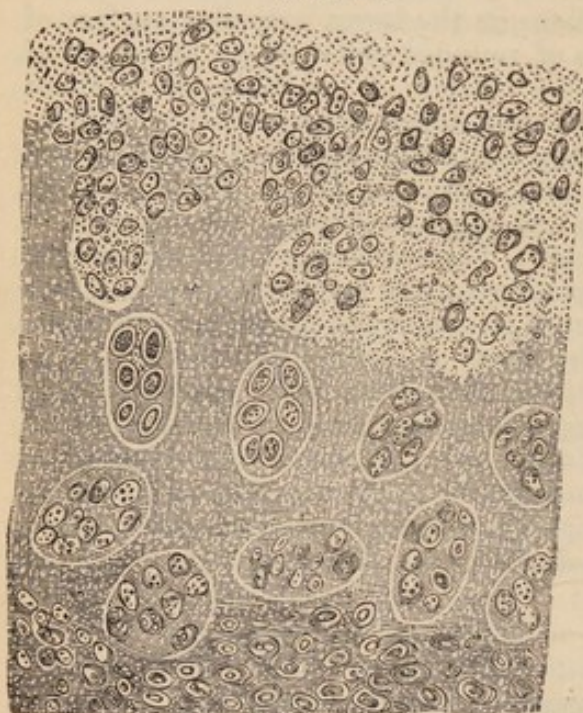

Fig. XVI.

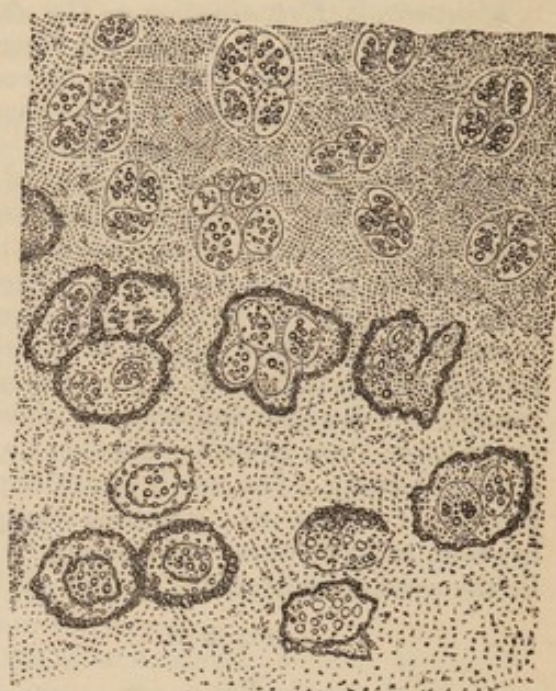

Fig. XV.—Vertical section from the radial surface of the semilunar bone, showing the cells nearest to the bone at the lower part.

Fig. XVI.—Deepest part of a vertical section from the cuneiform surface of semilunar, showing the cells with thickened walls.

large granular nuclei, and measuring about $\frac{1}{400}$ th of an inch in diameter. The walls of these cells and of their nuclei are much thickened, and will not allow the light to pass through until after the action of hydro-chloric acid. In the middle of the sections there are cells or clusters of cells, of sizes from $\frac{1}{700}$ th to $\frac{1}{1400}$ th of an inch, containing irregular and differently sized granules in some places, and the ordinary corpuscular nuclei in others. On the surface, the cells are distended, and contain a few granules in a cluster in their centre, and some are opened up by bursting. Such cells measure as much as $\frac{1}{230}$ th of an inch in their greatest diameter, and are represented in Fig. XIV.

At the anterior and posterior limits of the radial surface of the ulna there are portions of cartilage, the hyaline substance of which is converted into dark fibrous tissue, mixed with cells $\frac{1}{1400}$ th of an inch in diameter, each containing four or five granules. Sections may be obtained having fibrous tissue and granular cells at one part; at another, similar cells almost free from granules, and lying in unchanged hyaline substance; and again, such cells in groups, as in Fig. XV.

Every other articular surface was examined with the greatest care, and similar changes were found to have taken place in every one. The soft lymph,

covering the end of the fifth metacarpal bone and of the unciform, is full of remarkably beautiful fusiform nucleated cells and blood-vessels. The fibrinous-looking mass covering many of the surfaces from which the cartilage has been removed, consists of fusiform cells splitting up into fibres, and plastic cells (Bennett). Where the mass is more distinctly fibrous, it is mixed with corpuscles, which are precisely similar to those found in other parts, as contents of cartilage cells. It may be noticed, that though the surface of the trapezium for the first metacarpal bone appears healthy to the naked eye, the cells on the surface are opened out, as is represented in Fig. XI. They are very large, some contain granules, and others are empty or contain a shrivelled nucleus. The deep cells of such parts are enlarged and full of the usual corpuscles.

Remarks.—This disease was the result of injury occurring in a scrofulous constitution. Large portions of the articular cartilages of all the joints about the wrist were removed, and ankylosis had commenced, but the removal of the limb was necessary to save the patient's life after the attack of erysipelas. The microscopic examination showed that the cartilage had suffered from similar changes to those in the former cases, though, in this case, they had been more rapid in their progress. The appearances of sections, in many parts, exhibit such remarkable changes in the characters of the cells in different periods of their existence, as to prevent their recognition without tracing them from one stage to another. In very few places was the hyaline substance converted into fibres, owing, probably, to the rapid molecular disintegration going on in it and in the cells. On one articular surface, the disease was evidently going on in both the superficial and deep parts at the same time. The corpuscles set free and enlarged, give to the texture the appearance of temporary cartilage, and when this is considered, together with the fact of the thickening of the deep cells, it is important to inquire whether the calcareous matter in ankylosis may not be occasionally deposited in portions of articular cartilage so changed, as it is in the primary formation of bone.

OBSERVATION IV.—*Old Disease and Ankylosis of the Bones of left Tarsus—Extensive Disease of the Cartilages of both Knee-Joints—no Disease in the Hip or Ankle Joints—Death from Fever.*

The patient, A. F., æt. 68, died of fever in the Royal Infirmary on February 14, 1849, and was brought to the anatomical rooms. The body was that of a strong muscular man—the second toe of the left foot had been removed by operation. His history has been collected from his former medical attendant, and from persons who have known him for fifteen or twenty years.

He was employed as a shop porter, and when so engaged, ten or twelve years ago, he thrust a nail into the plantar surface of the left foot, by treading on part of an old cask; suppuration and caries followed; he was confined to the house for twelve months; the second toe and portions of several other bones of the foot were removed, and the wound healed up. Not being able to carry on his usual occupation, he sat at a stall and sold fruit for some time, and then resumed his occupation as a common porter, and continued it until four days previous to his death. He was generally known, partly from his dissolute ha-

bits, and from his peculiar gait; for, in walking, he made little use of his knees, but threw the whole weight of his body alternately on the lower extremities, making progression by a sort of rocking motion from side to side. This peculiarity occurred after the injury to his foot, but did not interfere with his occupation, for he could carry very heavy burdens. He never suffered from recognised disease of the knee-joints, nor was he ever known to complain of them.

Examination of Right Knee-Joint.—The patella is of the usual shape, and its articular surface is covered with cartilage throughout. This presents a granular and velvety appearance over a large slightly depressed patch in the centre. The cartilage nearest to the circumference and one-fourth of an inch in breadth all round, is of the usual density, but is split by grooves running towards the centre. In different parts there are fibrous processes hanging loosely from the surface, and of one-eighth to one-fourth of an inch in length. A horizontal section was made through the middle of the bone. The cartilage is one-tenth of an inch thick at the most prominent part of the section, and one-seventh at the middle of the surface for the external condyle. The parts next to the bone, and the bone itself, appear healthy.

Right Femur.—The cartilage on the trochlear surface is velvety and soft in the centre;—for one-fourth to three-fourths of an inch at the circumference it is dense, white, and split on the surface by grooves passing towards the centre. Where the trochlear surface joins the external condyloid one, the surface is remarkably irregular; in some places elevated, in others depressed, the cartilage being dense and white in patches—then flocculent, soft, and covered by a multitude of projecting fibrous processes. The depressed parts have a puckered appearance at their margins, the bone being covered at the bottom by fibrous and translucent tissue. Further down, and directly on the lower and posterior part of the surface of the external condyle, is a large and irregular patch of $1\frac{1}{4}$ th inch in extent from before backwards, and from one-fourth to one-half of an inch in different places from side to side. On this patch, the bone is thinly covered by translucent fibrous tissue. The patch is separated from the edge of the surface by apparently healthy cartilage of one-fourth of an inch in extent on the outside, and somewhat less on the inside; behind, it runs within one-eighth of an inch of the edge of the surface, and is separated from it by cartilage which is velvety and granular on the surface. On making a section from before backwards, passing through the trochlear surface and the depressed patch on the external condyle, the bone presents a perfectly smooth edge at every point, except in front of the patch on the condyle, where it is raised $\frac{1}{30}$ th of an inch for an extent of one-fifth of an inch from before backwards. The cartilage is $\frac{1}{10}$ th of an inch thick on the trochlear surface, and becomes gradually thinner on passing to the junction with the condyloid surface, where for more than one inch it is only $\frac{1}{30}$ th of an inch thick. It then regains its thickness for half an inch immediately in front of the raised portion of bone, and for one-fourth of an inch behind it; whilst on the remaining part of the section, corresponding to the bottom of the depressed patch, there is only a thin membrane.

Proceeding backwards from the trochlea on the surface of the internal condyle, the junction of the two presents similar irregularities and fibrous processes, on the surface, to those on the opposite side. At one of such points the bone is raised, and it is bare at the apex of a small projection of one-eighth of an inch in diameter; posteriorly, the cartilage has a smooth and nearly healthy appearance, except on the outer edge of the condyloid surface, where it is granular and flocculent; and behind there is a large patch, on which the cartilage is rough, white, and presents a number of fibrous processes hanging loosely into the joint. On making a section from before backwards, through the left half of the trochlear surface and left condyle, the cartilage on the former appears healthy, and is one-tenth of an inch thick; at the junction of the two, and over a space of one-third of an inch from before backwards, the bone is

raised above the level of the cartilage in a circular spot, and is bare or covered with a thin membrane; behind this, the cartilage is at first thin, but gradually increases in thickness, until at about the middle of the condyloid surface it is $\frac{1}{15}$ th of an inch thick, again becoming thinner in proceeding backwards.

Right Tibia.—The cartilage of the internal glenoid cavity is apparently healthy behind, but soft and velvety in front. One-fourth of an inch distant from its anterior part, there is a spot of the size of a split pea, in the centre of which the bone is bare, the cartilage adjacent presenting a number of fibrous processes. The cartilage on the external glenoid surface appears healthy, except in front and internally, near the attachment of the anterior extremity of the semilunar cartilage, where the surface is raised about $\frac{1}{15}$ th of an inch over a rounded spot of the size of a split pea; and again, at the posterior part, where there is a depression which would hold half a split pea. At the bottom of this, there is a semi-transparent membrane with a puckered appearance on the surface; near this spot, there is a slight velvety appearance on the cartilage, as well as on the semilunar cartilage. Near the depression, there are three distinct fissures, each of about half an inch in length, and with a stellate arrangement.

The semilunar cartilages are flocculent on their thin edges, and the external one is of like character on its surface, at the part corresponding to the depression. In other parts their surfaces appear healthy.

Microscopic Examination.—The fibrous processes on the patella, one-eighth to one-fourth of an inch long, consist of large and small, flat, and glistening bands, which are split up at their edges and free extremities into fibres of different sizes. Some of the bands are finely striated, many have large masses of hyaline substance interrupting their continuity, or stuck upon them, as represented in Fig. X. At different distances on the bands, there are perfectly regular oblong cells of different sizes, usually $\frac{1}{710}$ th of an inch by $\frac{1}{900}$ th. They contain a small finely granular nucleus, or a larger and more distinctly granular one. The cells are in considerable quantity only at those parts where the bands show but little tendency to split; where there is a distinct splitting, the cells are far apart, appearing to be destroyed by the splitting, or converted into the glistening masses on the fibres. At all the deep parts of the section, the cells and hyaline substance are healthy; but, on advancing towards the surface, the cells become rounded, much enlarged, and filled with corpuscles, which are discharged upon the surface or mixed with the tissue. At the free edge, the hyaline substance breaks up into bands and fibres at a very definite point, and there are found in the bands the large nucleated cells before-named and figured in Fig. VI., or nucleoli spread out in the tissue, and amongst the fibres a multitude of small, elongated granular cells, as shown in Fig. VII. The dense and white portions at the circumference show traces of the superficial cells opened out; but, in most parts, the cartilage is converted into fibrous tissue, of which the fibres run horizontally. All stages of this transition can be seen in different parts; whilst in all, there is a notched and very definite margin to the less changed hyaline substance, the notches being the result of the opening of cells on the surface.—(Fig. XVII.)

On the femur, the projecting processes are of similar characters to those on the patella; many containing large and bright nucleated cells; others are striated and split at their edges and free extremities into fibres undistinguishable from ordinary fibrous tissue. Such bands contain numerous corpuscles in many places. These measure $\frac{1}{2300}$ th by $\frac{1}{3500}$ th of an inch. They are granular in some places; in others, surrounded by an indistinct cell wall, and they are not to be found where a complete conversion into fibres has taken place.

The cartilage, exposed by both sections through the articular surface of the femur, is healthy in one or two small spots only; in other parts, the deep cells are enlarged, measuring, in many places, $\frac{1}{280}$ th by $\frac{1}{330}$ th of an inch, and still nearer the surface, $\frac{1}{200}$ th by $\frac{1}{250}$ th of an inch. They are full of corpuscles. Similar corpuscles are seen in patches, in other parts, as shown in Fig. XV.

The horizontal layer of cells is very thick in some situations; its cells are so much enlarged as to measure $\frac{1}{220}$ th of an inch long, by $\frac{1}{1660}$ th broad;—they contain a central granular nucleus, and some are granular throughout;—at the surface, they can be seen bursting and forming a granular and fibrous mass, in which nuclei can be found elongating. (See Fig. XVIII.) In other parts, indeed

Fig. XVII.

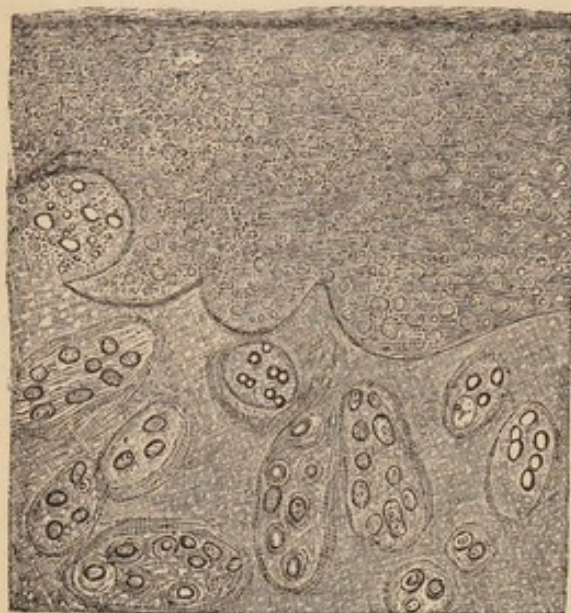

Fig. XVIII.

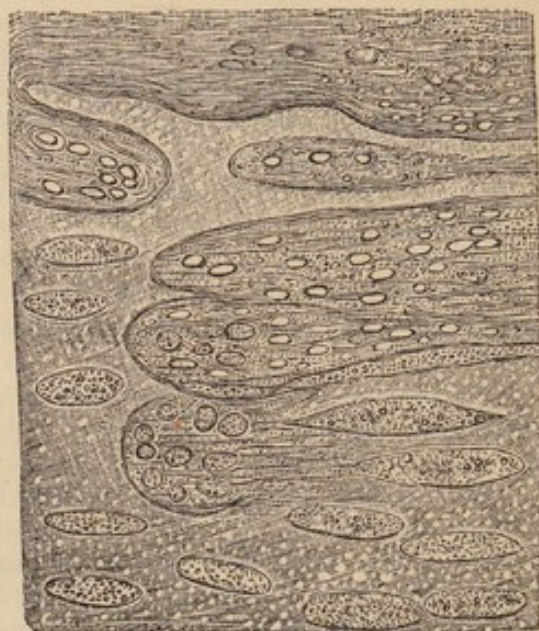

Fig. XVII.—Vertical section near the circumference of the right patella, showing the notches produced by the bursting of cells, and the fibrous and granular mass on the free surface.

Fig. XVIII.—Vertical section of the cartilage of the femur, showing the superficial cells enlarged, granular, and bursting. The upper part of the figure shows the granular and fibrous mass on the surface.

over a large portion of the surface, some of the cells, usually lying horizontally, exist; but the surface is covered with a fringe of fibres $\frac{1}{300}$ th of an inch long, which is evidently the result of the splitting of hyaline substance. The thin semi-transparent membrane, covering the bottom of the depressions before de-

Fig. XIX.

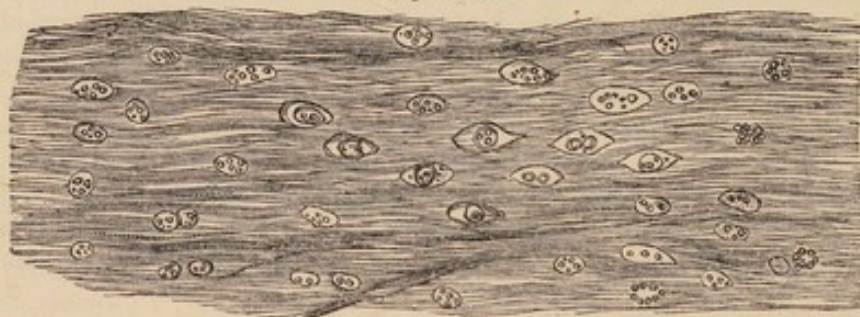
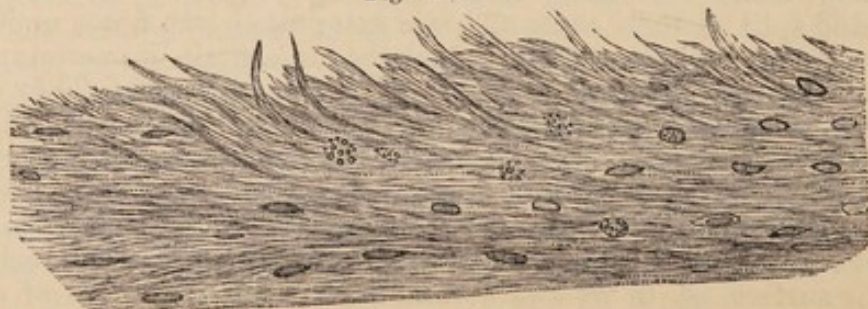


Fig. XX.



Figs. XIX. and XX.—Projecting processes from the patella and femur.

scribed, consists of dark fibrous tissue, the fibres of which run horizontally, and yet form a short fringe on the surface by their loose extremities. Acetic acid renders the fibres transparent, and brings out a series of nuclei, running in the direction of the fibres, as shown in Fig. XXI. and XXII. Where this tissue joins with the cartilage, the discharged corpuscles of its cells can be seen, in all stages of elongation, to become mixed with the fibres, or actually converted into them. The elongation can be observed in almost every preparation (Fig. XXIII.); and there seems the best reason for believing that the nuclei are the changed corpuscles of the cells. The raised portions of bone present nothing remarkable.

Fig. XXI.

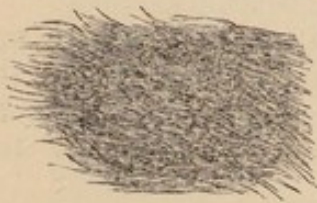


Fig. XXII.



Fig. XXIII.



Fig. XXI.—Fibrous tissue from the surface of the cartilage.

Fig. XXII.—The same, acted on by acetic acid.

Fig. XXIII.—Fibrous mass, with corpuscles elongating from the surface of the left femur.

The horizontal layer of cells, from the central part of the internal glenoid surface of the tibia, has been removed, and the surface presents a number of excessively transparent hyaline bands of all sizes, projecting free into the cavity. Where these are attached to the hyaline substance, there are elongated, open spaces, indicating the original position of cells which have caused the splitting.—(Fig. XXIV.) Still deeper, are large nucleated cells, or cells crowded with corpuscles; whilst, near to the bone, the cells are of their usual form and size, and the hyaline substance is healthy. Near the edges of the surface, and where the cartilage is still dense, the horizontal layer of cells is still to be seen, but its most superficial cells are enlarged and separated at a considerably increased distance from each other (Fig. XXV.), the deeper parts being healthy. The cartilage around the spot of bone which is bare, is split in the usual way into fibres and hyaline bands.

Fig. XXIV.

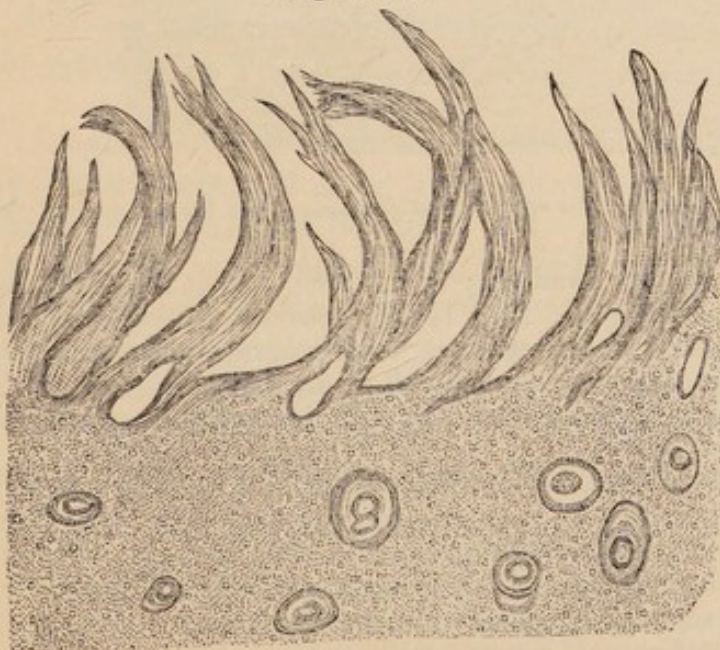


Fig. XXV.

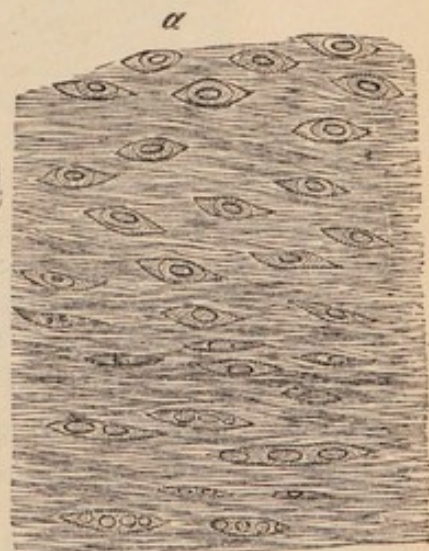


Fig. XXIV.—Vertical section from the cartilage of the central part of the internal glenoid cavity of the tibia, showing the splitting into fibres on the surface.

Fig. XXV.—Changes in the superficial cells near the edge of the internal glenoid cavity; a, free surface.

The cartilage of the external glenoid cavity presents, in different parts, the various appearances before described. On the edges of the fissures, there is a loose fibrous mass, the cells in the neighbourhood being filled with corpuscles, and some of them $\frac{1}{100}$ th of an inch in diameter. The raised portion, in front, is covered by a thin fibrous membrane, and under this are several small masses of dense calcareous matter, in the very substance of the cartilage. Below these, the cartilage is but little changed. The calcareous matter dissolves slowly, and with effervescence, in acetic acid. The solution gives no precipitate with ammonia, nor with ammonia and sulphate of magnesia, but when solution of oxalate of ammonia is added, a dense white precipitate of octohedral crystals immediately takes place. The crystals are insoluble in acetic acid, and have all the characters of oxalate of lime. The substance consists of carbonate of lime.

The flocculent appearance of the semilunar cartilages is produced by fibres and bands, which cannot be distinguished from those obtained from the proper cartilages—(Fig XXVI). Like the latter, these contain, at some distance from their free extremities, rounded nucleated cells—(Fig. XXVII). In many

Fig. XXVI.

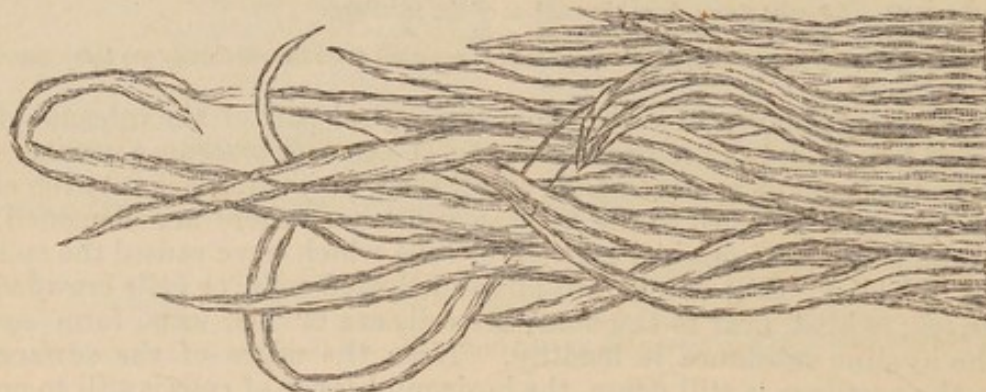
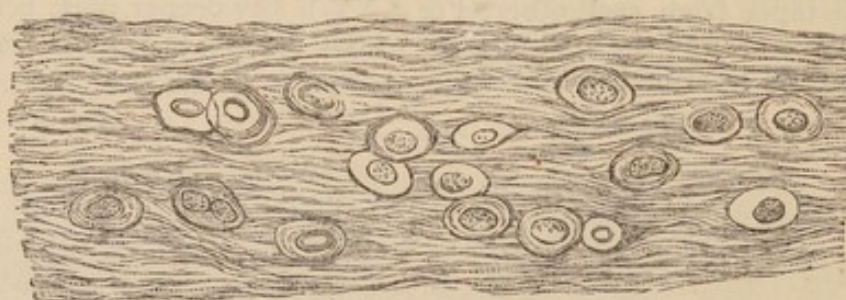


Fig. XXVII.



Figs. XXVI. and XXVII.—Two portions of the same fibrous projection from the free edge of the semilunar cartilage, where it is flocculent.

parts, the walls of such cells become gradually indistinct; and, at last, nothing but their nuclei can be observed (Fig. XXVIII.), these being spread out in the tissue. The deeper and more external parts consist of an intricate interlacement of fibres, with an occasional nucleated cell or a corpuscle.

Many of the fibrous processes present masses of hyaline substance attached to them, as in Fig. X.

Examination of the Left Knee-Joint.—The cartilage of the patella is velvety and soft on the surface, owing to fibrous processes such as have been described. Amongst them are numbers of the octohedral crystals before-named. The superficial and deep cells have undergone the usual enlargement, and then present a granular nucleus, or a series of corpuscles, in their interior.

The articular surface of the femur is covered with cartilage throughout. On the external condyle this is but little changed; on the internal one, the cartilage is slightly velvety, and on its external part, there is an abraded and vel-

Fig. XXVIII.

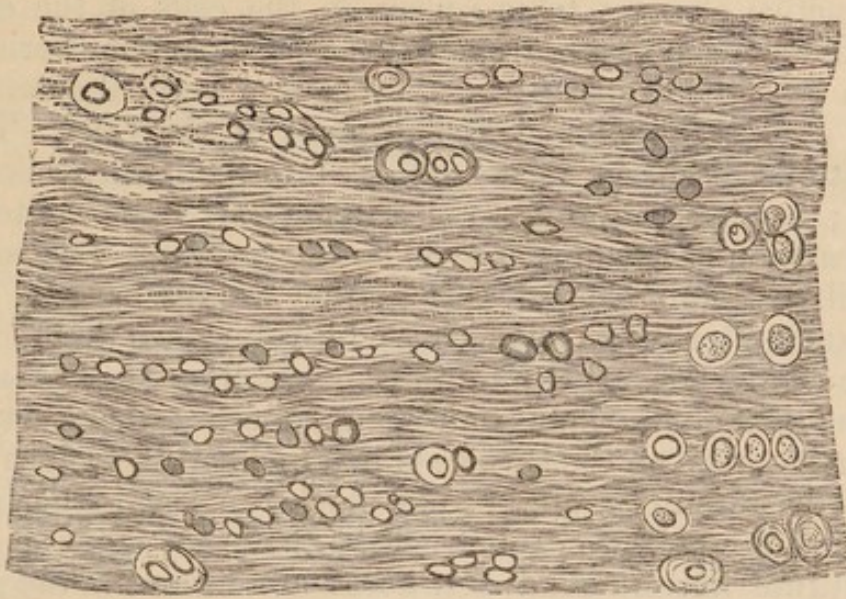


Fig. XXVIII.—Section of the semilunar cartilage near the internal edge, deeper than the fibrous processes.

vetty patch, three-fourths of an inch long and one-third broad. The trochlear surface has a similar patch above and outside. The changes of the cells, and the splitting of the hyaline substance, are of the usual kinds in all the diseased parts.

The external glenoid cavity of the tibia presents a large oblong patch of velvety cartilage internally and posteriorly; but this does not extend to the edge;—the other parts are healthy. The diseased portion has lost its superficial cells; the deeper ones are enlarged, distended, and some have discharged their corpuscles into the fibrous mass on the surface, whilst the parts next to the bone are healthy. On all parts of this surface there are octohedral crystals, insoluble in acetic acid; and here and there a rhombic and imperfect crystal, soluble in the same acid. The cartilage of the internal glenoid cavity is healthy near the circumference, but similarly diseased to the external one at the central part.

The semilunar cartilages have in a few places undergone similar changes to the opposite ones.¹

Remarks.—This was an instance of extensive disease on every articular surface of both knee-joints, occurring in an individual who carried the heaviest burdens, without inconvenience, up to four days previous to his death. The disease affected every cartilage in the right knee-joint to a greater extent than those in the left one, owing probably to more weight having been thrown upon the limb of that side, as the result of the previous disease of the left foot. Everywhere the disease commenced on the surface, and at the central parts of the cartilages. On all the surfaces, the hyaline substance

¹ I have to express my warmest thanks to the medical officers of the Royal Infirmary for their kindness in affording me every facility in the examination of the cases under their care on all occasions. It is right to state that I alone am responsible for the selection and statement of the facts.

was split into bands and fibres, one cause of which appears to have been the active changes taking place in the cells of the cartilage. The free fibres, when formed from the superficial parts, lie horizontally; but when from the deeper parts, they have a vertical arrangement, evidently due to the normal arrangement of the cells. That the cells burst and discharge their contents into the tissue, there can be no doubt; but it is not quite so clear what part these contents take in the formation of the fibrous mass on the surface. The corpuscles of the cells certainly elongate before they are discharged, and to a greater extent afterwards; but, as it is positively shown that the hyaline substance can be converted into fibres as small as those of white fibrous tissue, without the immediate agency of cells; that part, at least, of the fibrous tissue on the surface of diseased cartilages is so formed; and that the corpuscles appear like nuclei in the tissue, after the action of acetic acid, we cannot believe that they actually elongate and constitute fibres. And yet, fibres are formed in the granular mass, without the development of other and new cells.

OBSERVATION V.—Extensive Disease of the Bones of the Left Tarsus; Complete Destruction of some of the Articular Cartilages of the Foot, and Partial Disease of all the Rest; Amputation; Recovery.

Alexander Johnston, æt. 41, farm-labourer, admitted into the Aberdeen Royal Infirmary, under Dr Keith, on March 20, 1849. Is considerably emaciated—complexion and irides light. States that he has always enjoyed good health, and lived regularly. About twenty years ago, a horse trod upon his left foot, and rendered him lame for some days, but he continued his work and was soon well. Two years ago, he noticed pain on the inner side of the left foot, which he ascribed to a sprain, and as it went off in a few days, he took little notice of it, and continued his work. About twelve months ago, he first felt pain on the outer side of the left tarsus, limited to a space about the size of a shilling; the pain being at times dull, at others lancinating, and not regularly worse in the night than day;—he continued at his work for a month, when he gave it up, and since then he has never resumed it. He says the pained part was somewhat swollen; it was lanced by a surgeon, and blood alone escaped from the wound. It was again lanced, five months after the commencement, and pus then escaped:—at this time the pain was constant, but he could walk about. In December of the same year, an opening was made into a swelling which had formed on the inner side, and he says ten or twelve ounces of pus escaped.

On admission, the foot was considerably swollen, and there were two fistulous openings on the inner side, and several on the outer side, of the tarsus. Amputation was performed in the lower third of the leg, on March 31st, whilst the patient was under the influence of chloroform. Erysipelas took place in the stump two or three days afterwards—leeches were applied—suppuration occurred, and openings were made. At present (April 10) he is going on well, and his health has improved considerably.

Examination of the Foot.—The soft tissues are matted together, and the ligaments are softened and reduced to a pulpy mass, or altogether removed.

Astragalus.—The articular surfaces for the tibia and fibula are covered with cartilage, which is apparently healthy, except at the edges of the upper and external surfaces, where it is reddened and abraded. The surfaces for the os

calcis and scaphoid show parts covered with cartilage, which appears healthy—others with cartilage which is riddled with openings, exposing the bone; or, with patches of diseased cartilage here and there,—and others, which present a rough and bare surface of bone. The bone is soft and spongy, and its head is the part most diseased.

Os Calcis.—The surfaces for the astragalus are similar to those to which they are opposed, but the parts from which the cartilage has been removed are covered with a soft and closely adhering gelatinous mass. The surface for the cuboid presents an opening, as large as the point of the little finger, leading to a large cavity in the anterior part of the bone, containing a reddish gelatinous mass, in which are spicula of bone. The posterior part of the bone is dense, and appears healthy.

Cuboid.—The posterior surface is covered with the soft pulpy mass, and it presents an opening, which is of the size of a small pea, and leads into the softened and spongy substance of the bone. The cartilage of the anterior surface is entire in the centre, but reddened and abraded at the edges. A few patches remain on the internal surfaces, which are separated from the scaphoid and external cuneiform bones by the gelatinous mass.

The scaphoid bone is rough and bare on its non-articular surfaces, and the articular ones in front are covered with cartilage, which is abraded at the ridges separating them,—the surface behind presents no cartilage, at two reddish and irregular spots, where it is covered with a soft and vascular membrane. The bone appears but little changed.

The cuneiform bones are all bare, soft, and spongy, below and in front. Their articular surfaces are covered with cartilage, which appears healthy.

The metatarsal bones appear healthy at their tarsal extremities, except the first and second, which are carious below and behind. The shafts are healthy, and the heads are covered with cartilage, which is very thin at the plantar edge of the surfaces in all the bones, whilst the head of the first is denuded of cartilage in several parts, especially at the lower edge. The cartilages of the phalanges appear healthy.

Microscopic Examination.—The soft-reddish mass, covering the bones, is composed of fibres, fusiform cells, and plastic cells, with a few irregular, rounded, and nucleated cells up to $\frac{1}{1700}$ th of an inch in diameter (Fig. XXIX.) ; or, of a molecular mass, containing a few shrivelled granular cells, and granules of oil. The soft mass in the interior of the diseased bones is granular, and contains primitive filaments and plastic cells (Bennett)—(Fig. XXXI.) When acetic acid is added to the fibres, it partially dissolves them and leaves a granular mass. It causes contraction of the plastic cells, and shows their granules more plainly—(Fig. XXX.)

Fig. XXIX.

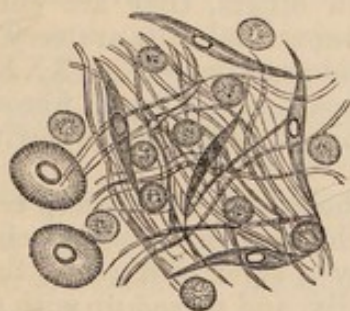

Fig. XXX.

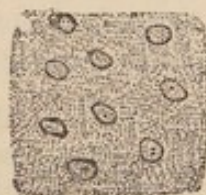

Fig. XXXI.

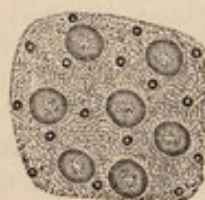

Fig. XXIX.—Fibres, with fusiform, plastic, and nucleated cells in the soft mass covering the diseased bones.

Fig. XXX.—The fibres and plastic cells after the action of acetic acid.

Fig. XXXI.—Molecules, fatty granules, and plastic cells, from the interior of the diseased bones.

The cartilage on the surface of the astragalus for the tibia is healthy, except at the edges: all the other cartilages are affected with disease of similar charac-

ters on all the surfaces. The cartilages of the phalanges are all diseased, though they appear healthy to the naked eye. In many places a distinct but thin membrane may be removed from the surface of the cartilage. This consists of horizontal or vertical fibres, mixed up with corpuscles discharged from cells, and in all stages of elongation. The hyaline substance on the surface, or in the deeper parts, may be seen in different preparations to become striated, and then split into fibres, the arrangement of which is horizontal or vertical, according to the original direction of the cells of the tissue. In every part, this change in the hyaline substance is associated with the enlargement of the cells, and the discharge of their corpuscles. Both changes are shown in Figs. XXXII. and XXXIII., taken from sections of the cartilage on the heads of the metatarsal bones.

Fig. XXXII.

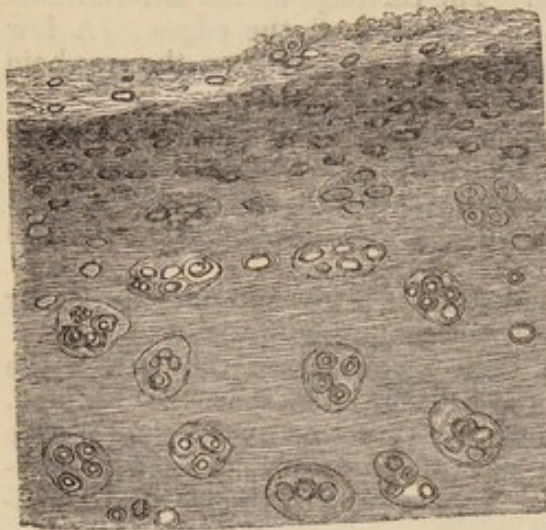
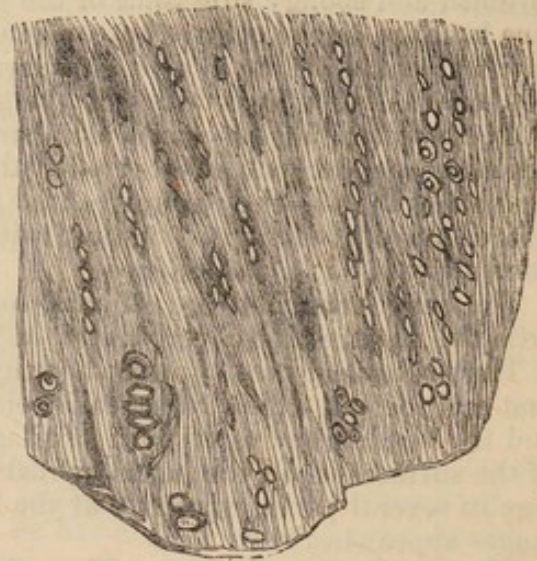


Fig. XXXIII.



Figs. XXXII. and XXXIII.—Vertical sections of cartilage from the heads of the metatarsal bones, showing the changes in the cells and hyaline substance in the superficial and deep parts.

Sections, taken from the tarsal end of the fifth metatarsal bone, show the superficial cells to be granular, and very much enlarged, many being $\frac{1}{230}$ th, and a few $\frac{1}{140}$ th of an inch long, resembling those in Fig. XVIII. The deeper cells measure on an average $\frac{1}{350}$ th by $\frac{1}{400}$ th of an inch. They are filled with corpuscles, closely packed together, and a few contain cells as well.

The posterior surface of the third cuneiform bone is so much diseased, that its cartilage is almost as loose as if stretched across a cavity, and yet the deep cells are but little changed in many places; in others, they are enlarged, rounded, and filled with corpuscles or cells. The superficial cells are very much elongated, and many contain large fat globules and granules—(Fig. XXXIV.) ; in some places the cells have opened on the surface, and this has a fibrous and nucleated covering, which presents nipple-like processes filling the cavities of the cells which have burst.

The cartilage on the anterior surface of the cuboid bone has its deep cells enlarged, rounded, and full of cells or corpuscles, the superficial cells being absent in many places, and their place supplied by a layer of fibres, $\frac{1}{80}$ th of an inch thick, these fibres being arranged horizontally, and mixed up with nuclei, measuring $\frac{1}{1770}$ th by $\frac{1}{7100}$ th of an inch—(Fig. XXXV.) Where the superficial cells remain, they are elongated and granular, or they are seen opening on the surface. In one place alone are the deep cells finely granular and distended, as if about to burst, whilst the superficial ones are but little changed, and have no membrane covering them.

The other articular surfaces were carefully examined, and similar changes were found in their cartilages. Notwithstanding the bones of the second

row of the tarsus are so spongy as to cut like cheese, the disease in the cartilage appears to have gone on to the greatest extent on the surface.

Fig. XXXIV.

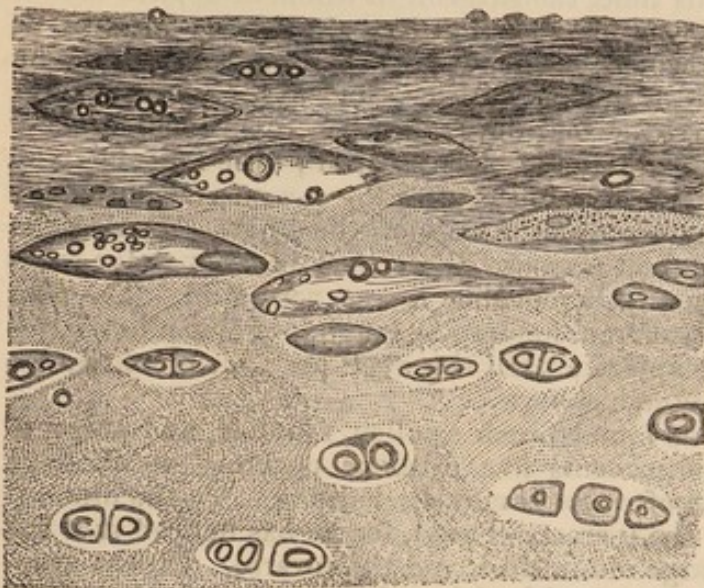


Fig. XXXV.

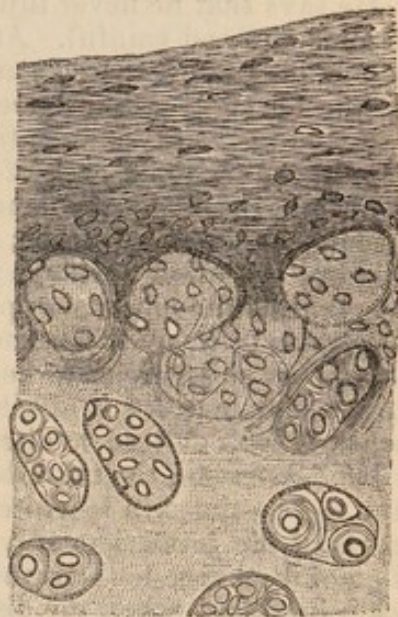


Fig. XXXIV.—Vertical section of loose cartilage on the posterior surface of the third cuneiform bone, showing the superficial cells enlarged, and containing fat globules and granules.

Fig. XXXV.—Vertical section of the cartilage on the anterior surface of the cuboid bone, showing the enlargement and bursting of the deep cells, and the fibro-nucleated membrane, with its nipple-like processes on the surface.

Remarks.—There seems good reason to believe that this disease commenced in the bones of the second tarsal row,—that it involved the cartilages and the other bones in its progress,—and that it was of long standing. The changes in the structure of the cartilage were of a similar character to those described in the foregoing observations, whilst the occasional conversion of the nuclei into fatty granules and globules was perfectly shown. It is remarkable that so many of the cartilages should have been attacked on their free surface, whilst they covered bones so seriously diseased. The formation of the fibro-nucleated covering of the diseased cartilage was shown to take place by an actual conversion of the texture of the cartilage into it, whilst it was as evident that the membrane was not present until the changes, which are essential for ulceration or rapid absorption, had actually taken place; and, therefore, that the membrane was rather the result than the cause of these processes. Not the slightest attempt at ankylosis had taken place, for the disease continued extending in the bones after the destruction of their articular surfaces and cartilages, and was obviously of such a nature that it could not have been cured without the occurrence of a very material change in the nutrition of the diseased parts.

OBSERVATION VI.—*Scrofulous Disease of the Elbow-Joint; Ulceration and complete removal of large portions of the Articular Cartilages; Partial Ankylosis; Erysipelas; Amputation; Recovery.*

Wm. Howitt, æt. 23, farm-labourer, admitted into the Aberdeen Royal Infirmary, under Dr Keith, on March 19, 1849, for disease of the elbow-joint.

Complexion light—irides blue—has always enjoyed good health. States that his brother had sores about his ankle for some time, when sixteen or eighteen years of age, but that he is now quite well.

He says that he never injured his elbow, but, three years ago, he noticed it become stiff and painful. At this time, the surgeon to whom he applied lanced it behind, and evacuated some blood mixed with pus;—he carried his arm in a sling for eight or nine weeks, when the elbow got so much better that he resumed his work, and continued it until a week previous to his admission, except at four periods, each of three or four days' duration. On each of these occasions, the elbow was lanced, and pus and blood escaped;—the first time, the opening was made in front; and twelve months after the commencement of the disease, the other openings were made at the sides of the elbow. During the whole time the elbow was painful on pressure, there were occasional lancinating pains in it, and for some time each morning it was very stiff. The pain was never so severe as to keep him from holding a plough, or doing other farming work; nor did it affect his appetite until the week previous to admission, when he was obliged to discontinue his work.

On admission, the left elbow is found much swollen, rounded, and pulpy to the feel;—the skin is white, and presents five fistulous openings at different parts of the joint, but only one of these is now discharging. To the diminution of discharge he attributes the increase of pain, for he has noticed that the pain increased when the discharge diminished, and the reverse. On the evening of the third day after admission, he felt sick and generally unwell, and on the following day, the elbow was affected with erysipelas, which speedily extended to the shoulder. A blister was applied on the outside of the upper part of the arm, and the erysipelas at once stopped, and did not return. Suppuration, however, took place some days afterwards, and two or three ounces of pus were evacuated by an incision in the lower part of the arm;—the abscess healed rapidly. Amputation was performed under the influence of chloroform on the 14th of April. The hemorrhage was troublesome at the time, and recurred, though a great number of ligatures had been applied. After the operation, he went on very well, and on the 10th of April the wound had healed by the first intention, except at a few small spots. He was dismissed cured on May 14, 1849.

Examination of the Limb.—The elbow is much swollen and rounded,—the numerous sinuses communicate with the joint on both sides. On cutting through the soft tissues, and especially the parts immediately under the skin, they are found infiltrated with a gelatinous substance;—the ends of the bones adhere, and at last yield with a noise as of some part giving way;—this is found to be the posterior part of the external condyle of the humerus, which adhered to the ulna, and has torn off a portion of bone from it. The trochlear surface of the humerus is covered with cartilage, both in front and behind,—the other parts are destitute of it, and are covered by a spongy fibrinous mass of a reddish colour, the mass and the bone below it being highly vascular. The ulna presents similar appearances. It has no cartilage except on the ridge separating the two surfaces of the olecranon and on the smaller sigmoid cavity;—in most other parts, the bone is rough and bare, and, in the remaining ones, covered by a firm fibrinous and reddish mass. The radius has diseased cartilage on the surface around its head, and on the adjacent part of its humeral surface; the other part of this surface is bare, or covered with a dense fibrous mass which has particles of bone adhering to it that have been torn from the humerus.

Microscopic Examination.—The fibrous substance is the same in every part, and consists of an indistinct granular mass, or of fully formed fibrous tissue with waved fibres, amongst which are patches of cartilage cells, which are very transparent, slightly granular, and evidently the discharged contents of larger cells.—(Fig. XXXVI.) On adding acetic acid to these structures, the fibres are rendered transparent, or converted into a granular mass, and the whole tissue is found studded with beautiful and elongated nuclei.—(Fig. XXXVII.)

Where the cartilage appears to be wholly absent and replaced by a fibrous mass, its corpuscles are yet to be found; in some places, mixed up abundantly with a hyaline and softened mass; in others, amongst fibres, granules, fusiform

Fig. XXXVI.

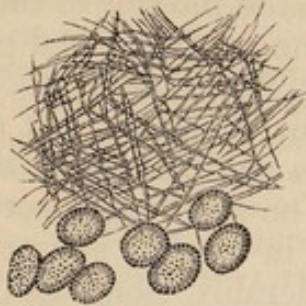

Fig. XXXVII.



Fig. XXXVI.—Fibrous tissue and scattered cells from the soft mass on the articular surfaces.
 Fig. XXXVII.—The same fibrous tissue, after the action of acetic acid.

cells, and spicula of bone. The last-named elements constitute the soft, red-dish, and vascular mass found on many parts uniting the opposed bones. The texture of the bone at such places is exceedingly soft, and has no defined surface, but its cells appear to be opened up, and spicula are found projecting into the soft mass, so that it is scarcely possible to obtain any portion of the fibrous mass from the surface without spicula. The vessels appear to spring from the bone. They render the mass excessively vascular, but wherever the cartilage cells remain in a hyaline substance, no vessels ramify amongst them, though the part is of a brownish-red colour, as in case No. I., where there were no blood-vessels except at a great distance. In some parts, the fusiform cells are very numerous, and amongst them are nucleated cells of different sizes, rounded, irregular, or caudate, and blood corpuscles.

Sections from the thickest portions of the cartilage of the humerus, ulna, and radius, show cells near to the bone, of nearly healthy character; but in the greater number of places, even these cells are enlarged, rounded, and contain corpuscles, of which the mean size is $\frac{1}{5400}$ th by $\frac{1}{2300}$ th of an inch, the cells themselves measuring $\frac{1}{230}$ th by $\frac{1}{400}$ th of an inch. On approaching the surface, the enlarged cells are seen to burst and discharge their corpuscles, which are found in a finely granular gelatinous mass. Many of the corpuscles are seen considerably elongated, and others become gradually lost in the fibrous tissue found in many parts on the surface. In a few places the hyaline substance is split into bands and fibres on the surface, as was more perfectly seen in case IV.—(Fig. XXXVIII.)

Fig. XXXVIII.

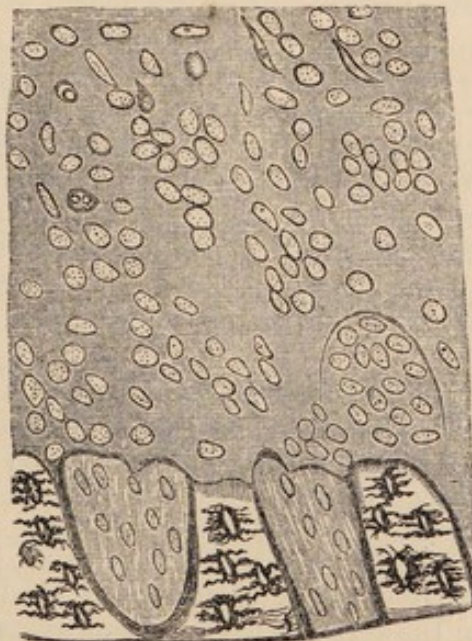


Fig. XXXVIII.—Vertical section of the cartilage of the humerus, showing the changes in the cells and the elongation of the corpuscles.

Remarks.—This was a chronic disease in a scrofulous constitution, and it destroyed the whole of the tissues in the interior of the joint, with but little suffering. The affection of the cartilages had gone on to the removal of the whole superficial layer of cells, whilst the deeper ones were shown to be undergoing the usual changes, but to have suffered to a less extent, so that there can be little doubt that the disease commenced on the free surface. The discharged corpuscles of the cells were seen lying on the surface in hyaline substance, or among a mass of fibres; they were considerably elongated, and at many parts appeared to have become transformed into fibres. When the fibrous tissue was acted upon by acetic acid, a number of nuclei were seen, which appeared to be the remains of the elongated corpuscles. These bodies could not have been inactive in the formation of the fibrous tissue, and they may have been concerned in this process in one or both of two ways—viz., by elongating into fibres, or by causing the hyaline substance to split into fibres, as in the cases before related, and as very evidently took place, in some parts, in the present instance. The fusiform cells appeared to have grown in the usual way in the blastema, formed of newly exuded matters and the disintegrated substance of the diseased cartilage. The fibrous tissue, found where the cartilage had been destroyed, was becoming perfectly organised; whilst the texture of the bone was opened out, and spicula were shooting into the fibrous mass for the purpose of consolidating the union between the bones. It is a matter of extreme interest and importance to ascertain in what way the new bone in ankylosis is really formed; and in connection with the subject, I may refer to the elevations of the surface of the bone, in Observation IV., which appeared to have taken place at those parts from which the cartilage had been removed by former ulceration, or a chronic process of the same character.

OBSERVATION VII.—*Cancer of the Liver, Brain, Kidney, and of every other Organ except the Heart; Cancerous Deposits in the Right Psoas Muscle, on the transverse processes of the Lumbar Vertebrae, and on the Right Ilium and Femur; Disease of the Cartilages of all the articulating processes of the Lumbar and several of the Dorsal Vertebrae—of the Fibro-Cartilage of the Right Sacra-Iliac Synchondrosis—of the Cartilages of the Right Hip and Knee-Joint,—of both Elbow-joints, and of the Carpal Articulations;—Tubercle and Cicatrices at the Apices of both Lungs;—Granular Degeneration of both Kidneys; Epileptic Convulsions; Partial Paralysis; Death.*

This was the case of a widow, æt. 48, who had a son before marriage, but no children since that time. She was stout and healthy up to January 1849, and gained her livelihood by carrying large baskets of fish to the country, and by selling dulse (*Rhodomenia Palmata*), which she herself pulled, standing in a considerable depth of water. When she went to the country, she was generally away from home for two or three days at a time; but she lived regularly, and was never known to have taken spirits of any kind. In January she began to complain of pains in the right hypochondriac, epigastric, and in the lumbar regions, with œdema of the lower extremities. Her complexion became sallow,—the symptoms above-named continued to increase in intensity,—she had

a distinct epileptic fit on April 18th, and another imperfect one on the 26th, in which she died. A complete account of her symptoms, and of the characters of the cancerous and other disease, will be given in another paper.

In the post-mortem examination, made in the dissecting-room, corresponding portions of the ventral and dorsal aspects of the right ilium, half-an-inch distant from the anterior superior spinous process, were found uncovered by periosteum, over a space as large as a half-crown piece. On these spots there were cancerous deposits as large as the halves of a large walnut, by the sides of which there were numerous small nodules on the bone; whilst, under the deposits, the bone was rough but presented a plane surface. Behind the trochanter major of the right femur, a similar deposit was found, lying also on rough bone, not covered by periosteum. In all these parts, the deposits of cancerous matter appeared to have taken place in the substance of the periosteum, or between it and the bone, and their histological characters were those of the larger masses found in the different organs.

In the substance of the right psoas muscle is another extensive and elongated deposit, lying upon the transverse processes, and the sides of the bodies of the second and third lumbar vertebræ, which are not covered by periosteum at the parts named. The right articulating processes of the second, third, and fourth lumbar vertebræ are considerably enlarged, but their texture is dense, with the exception of the upper articulating process of the second, which is infiltrated with the yellowish deposit, whilst its transverse process is nearly destroyed at its middle, and broke off during the examination.

The cartilage on every articular process of the lumbar vertebræ, and those of most of the dorsal ones, is diseased. The right articular surfaces of the 2d, 3d, and 4th lumbar have scarcely any cartilage left upon them, the bone being bare and rough, or covered by reddish velvety patches of diseased cartilage. The cartilage of the other processes appears affected most seriously at the edge of every surface, where it is reddish and velvety or flocculent. The cartilages on the articular facettes of the bodies and transverse processes of the dorsal vertebræ are similarly diseased, but to a less extent as we proceed upwards in the column.

Microscopic Examination shows the superficial cells absent from most parts, and granular where they still remain. In many places the cells are as much enlarged and rounded as in Obs. I. and IV. They contain a number of other cells, each of which has several bright granules in its interior. In some places the cells have burst and discharged their contained cells on the surface or into the tissue. The hyaline substance, in the velvety parts, presents a mass of fibres and bands free on the surface.

The bones separate very easily at the right sacro-iliac synchondrosis, and the fibro-cartilage joining them contains very large elongated cells, crowded with others which are granular; or they contain small patches of granules, indicating the original position of their contained cells or nuclei. Most of such cells lie in clusters, and are placed vertically to the surfaces of the bones. They lie in an indistinctly fibrous intercellular substance, which is highly transparent. —(Fig. XXXIX.)

On the head of the right femur, and at the bottom of the acetabulum, near the attachment of the round ligament, the cartilage is fibrous, velvety, and reddened. On being examined, its hyaline substance is found converted into bands and fibres, whilst the cells are very much enlarged and crowded with corpuscles or cells, which are granular.

Right Knee-Joint.—The cartilage of the patella is velvety and rough in the centre, but denser and smooth near the circumference; that of the femur, at the inner edge of the junction of the inner condyle with the trochlea, is depressed and velvety; but apparently healthy in other parts. The cartilage of the external glenoid cavity of the tibia is soft and velvety in the centre, but dense and apparently more healthy at the circumference.

Microscopic Examination shows that the velvety parts of these cartilages have healthy cells and hyaline substance in the deep parts; at the surface, the

Fig. XXXIX.

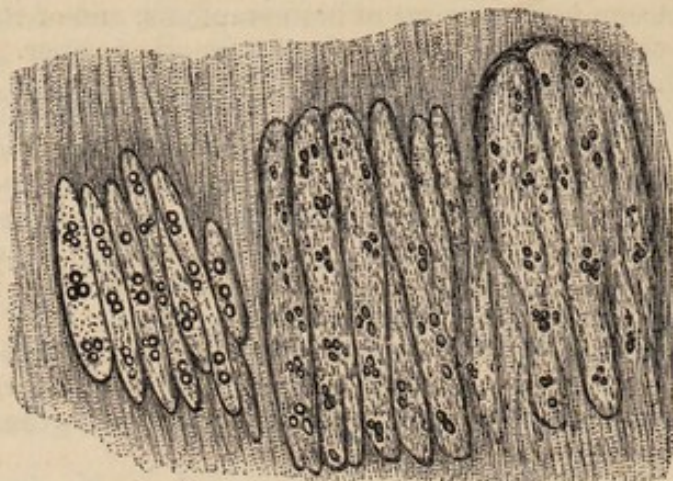


Fig. XXXIX.—Portions of fibro-cartilage from the right sacro-iliac synchondrosis.

hyaline substance is split into bands and fibres in the usual way, whilst all the cells contain granules, collected together into small patches, which occupy the normal position of the nuclei. These granules are found in all the cells, whether belonging to the superficial or deep layers. In many places, all the cells of the superficial layers are completely removed.

Upper Extremities.—The cartilage, on the ridge separating the small head of the humerus from the surface for the ulna, presents, in both limbs, a linear excavation running from before backwards. The cartilage on the larger sigmoid cavity of both ulnæ is divided into two parts by a thin band of membrane, which passes across at the junction of the olecranon with the shaft, and is the only substance which covers the bone at that part. On examining the structure of the cartilage near the excavations on the humeri, it is found converted into fibrous tissue on the surface, whilst a thin layer of cartilage is applied to the surface of the bone. The membranous band on the ulnæ is of a fibro-nucleated character, similar to that covering the bone in the depressions on the femur in Obs. IV.

Several patches of cartilage on the bones of the carpus present similar diseased appearances to those before described in the other surfaces. In the joints of which no mention has been made, the cartilages are healthy.

Remarks.—Owing to the co-existence of the disease of the cartilages, in this case, with the general cancerous affection, it is of great importance to ascertain whether the former was produced by the latter affection. The characters of the disease in the cartilages were not affected by the cancerous disease, for they were precisely those which are found in all similar states of disease without cancer. There was no deposit of cancerous matter in the cartilages, nor any degeneration of them other than is usual, especially in old persons. And yet the greater extent of disease on the surfaces of the lumbar than of the dorsal vertebræ appears connected with the great amount of cancerous affection of the abdomen, and it was probably the result of the increased activity of the circulation, which we may suppose to be necessary for the deposit of large masses of cancer, tubercle, or other exudations. It is to be noticed, that on all the articulating processes of the vertebræ, the disease commenced at the edges of the cartilages, whilst it was found in the centre of the surfaces alone, on the right patella and tibia.

OBSERVATION VIII.—*Gelatinous Degeneration of the Tissues of the Tarsus and Ankle; commencing disease of the Cartilages; Amputation; Recovery.*

George Prosser, æt. 9, a schoolboy, admitted into the Aberdeen Royal Infirmary, under Dr Keith, on April 24, 1849. He is remarkably intelligent—complexion light—irides grey. His father is a stout healthy man; but his mother is of a scrofulous diathesis.

He suffered from an affection of the chest, with pleuritic effusion, about a year ago, but recovered tolerably well. A short time before Christmas 1848, he complained of pain in the region of the right ankle, but no swelling or other positive mark of disease was noticed until about a month afterwards, when the ankle was evidently swollen. It was still painful, especially on moving. For three months after the commencement of the disease, he continued to walk to school as before; but, at the end of this time, he could not wear his shoe; and before admission, the pain got so much worse as to prevent him from walking.

On admission, considerable swelling exists about the right ankle-joint. He has pain in it equally bad during the day as in the night. This frequently occurs in paroxysms without any evident cause, and is so severe as to make him cry aloud. It is also produced by any movement of the joint. He cannot walk, and he was carried to the hospital.

An opening was made, three weeks after his admission, on the outside of the ankle-joint, and a small quantity of pus escaped. This relieved the pain very considerably; the wound did not heal, and fungous granulations protruded shortly after from an ulcer of the size of a half-crown piece, occupying the position of the opening. The patient became emaciated, hectic came on, and amputation in the lower third of the leg was performed on June 9th. The stump healed rapidly, and his general health improved from the day of the operation.

Examination of the Foot.—Considerable swelling exists in the region of the tarsus, extending back as far as the ankle. In front of the external malleolus is an ulcer of the size of a half-crown piece, with fungous granulations protruding. The skin on the inner side is healthy, but appears thinned. The tissues surrounding the ankle and tarsal articulations are converted into a reddish-brown gelatinous mass, mostly at the parts close to the bones; but this change does not extend in any considerable amount to the tarso-metatarsal articulation. There are no effusions in any of the articulations; and the cartilages, on a superficial inspection, appear healthy. When examined more minutely, those of the ankle-joint, and of the articular surfaces of the first row of tarsal bones, appear slightly reddened in some places, and at their edges are covered, for an extent of a line or more, by a highly vascular and pulpy membrane (synovial), which is less distinctly seen on the scaphoid and cuboid bones, and does not exist on those further in front, at least in the same vascular and pulpy state. All the bones of the tarsus are softened, and cut like cheese.

Microscopic Examination.—The pulpy membrane is full of loops of capillaries, amongst which are numerous fusiform corpuscles and plastic cells, or granular ones, precisely like the latter. The pulpy mass outside the joints has a similar structure. The cartilages are all affected in the same manner. In the most diseased parts, the superficial cells are rounded and enlarged to two or three times their usual size. They contain dark granules, and are displaced so much from their horizontal direction, that many lie obliquely or vertically in the finely granular hyaline mass, which separates them very considerably from each other. The deeper cells of these parts are granular, but not perceptibly changed in size or position.

In the parts least diseased, the cells of the surface are broader than usual, but scarcely as long as healthy cells ;—they are separated from each other, and contain no evident nucleus, but appear finely mottled. The central parts of most of the surfaces are nearly healthy.

Remarks.—This was a case in which there were many symptoms which are usually believed to indicate the existence of serious diseases in the articular cartilages, and yet the affection of these textures was so slight, as to be found only after a very careful examination. There were the usual appearances produced by the gelatinous disease of the synovial membrane, and the texture of the bones of the tarsus was opened out, so that they were all very much softened. The affection of the cartilages had evidently commenced at the circumference of their free surfaces, for all the deep parts were quite healthy. That the disease in the cartilages should commence at the parts just named is not surprising, when it is considered that, in adult articular cartilage, these parts are very freely supplied with blood, being covered with a distinct reflection of the synovial membrane, and the *circulus articuli vasculosus* of Dr William Hunter. The vessels on the surface of the cartilage, at the parts named, become distended with blood ; an anormal nutrition is going on in all the parts surrounding the joint, and this process may be expected to extend to the cartilages, as it was found to have done in the present instance. If articular cartilages are chiefly nourished by the vessels of the bone, as is believed by Mr Toynbee, it is very singular that they are not more frequently attacked by disease on their attached surface, especially in cases where there is extensive disease in the bones.

OBSERVATION IX.—*Disease of nearly the whole Articular Cartilages in the Body, with Porcellanous Formations in a few spots ; Fracture of the Neck of the left Femur eighteen months before Death ; excessive Softening of the Bones of the left Lower Extremity ; Incomplete Paralysis ; Death from Exhaustion.*

J. N., female, æt. 60, hawker. Was in the habit of drinking whisky for seven years before death ; had three children, but was never married. Stated that since the year 1846 she had suffered much from headache and giddiness, and that in the end of that year she fell down whilst washing clothes. In falling she cut her forehead, but knew nothing of the accident for some time, when, on recovering from insensibility, she found that she had been bled, and that active purgatives had been given to her. About the end of the year 1847 she fractured the neck of her left femur in leaping out of a cart, and was removed to the hospital, and placed under the charge of Dr Keith. She recovered from this accident, and walked about tolerably well on crutches until the end of March 1849, when she began to complain of pains and numbness in the right arm and leg, and the right side of the body. From the time of the fracture, she had also pain in the left hip-joint during movements of the limb. After the end of March she never left her bed, and appeared to be sinking gradually. Wine was ordered by her medical attendant, and continued until her death. The bowels were habitually constipated. Complete retention of urine took place, requiring the introduction of the catheter on the 27th of May, and every

day afterwards up to her death. The urine became exceedingly offensive: it was thick, of a reddish-brown colour, and was believed at times to contain blood. On the 4th of June, the patient was removed to the poor's house, where she continued to sink, and died on June 10th.

Post-mortem Examination, made in the dissecting rooms. The body is considerably emaciated; numerous white lines on the skin of the abdomen indicate previous distension; the left lower extremity is two and a-half inches shorter than the other; it rotates and moves in every other direction more freely than natural; the greater trochanter appears to project considerably, and is found much higher than usual, and not more than three inches distant from the anterior superior spinous process of the ilium.

Head and Spine.—The membranes and substance of the brain externally appear healthy. On making sections of the right corpus striatum, an elongated reddened spot is seen of three-fourths of an inch in extent from before backwards. The structure of this part appeared perfectly healthy on microscopic examination. The spinal cord was exposed by removing the lamellæ of the vertebræ, and when the dura mater was slit open posteriorly, both the membranes and the cord appeared healthy, except that three small calcareous plates were found on different parts of the arachnoid at the lower part of the dorsal region. On removing the cord and membranes from the vertebral canal, a yellowish-white curdy deposit of an inch and a-half in length and half an inch in breadth, was found lying between the dura mater and the posterior part of the bodies of the 2d and 3d cervical vertebræ. Part of the deposit was evidently in the substance of the dura mater, though it could not be seen from the inner surface, whilst anteriorly it was lodged in the substance of the periosteum, which had completely given place to it, in the position of the body of the 3d vertebra, allowing it to rest on the bone. Microscopic examination—not made, however, until a considerable time after death,¹—showed the curdy matter to consist of a multitude of irregularly rounded, oblong, or triangular granular cells, measuring from $\frac{1}{2000}$ th to $\frac{1}{3500}$ th of an inch, lying in a sort of blastema, and associated with a number of small loose granules. Acetic acid produced no change in these structures, besides rendering the cells very slightly more transparent.

Chest.—Both lungs are firmly attached to the walls of the chest in every part by old pleural adhesions. At the apices of the lungs there are slight puckering. Heart and pericardium healthy.

Abdomen.—All the organs are perfectly healthy, except the mucous membrane of the bladder, which is covered by a thick brownish layer of mucus. It is also softened and covered by a multitude of small and irregular ulcerations. Six or eight ounces of thick brownish and excessively fetid urine were found in it.

Left Lower Extremity.—*Hip-Joint*.—All the muscles in the neighbourhood, and especially the glutei and the pectineus, are much atrophied. The fibres of the gluteus medius and minimus are considerably shortened. The capsular ligament is much thickened, but complete. Above the joint, the cotyloid ligament is almost wholly destroyed, and the capsular ligament is attached to the periosteum half-an-inch beyond the edge of the cavity; below, it is attached quite close to the trochanter minor and the psoas; and behind, it is blended with the external rotator muscles at their insertion. At all these points, the original capsule appears to have been detached or destroyed, a large portion of the present capsular attachments being apparently formed by effusions of lymph,

¹ The body had been injected with a strong solution of arsenite of potash;—the nervous matter of the cord was softened, but the curdy matter did not appear to be decomposed. On several occasions I have purposely examined tubercular and cancerous deposits under similar circumstances, and found their structural characters well preserved in the parts not exposed.

which have become converted into dense fibrous tissue. On opening the capsule, the head is found to be separated from the bone, and lying in the acetabulum, presenting, towards the neck, a flattened but rough surface, the margins of which correspond precisely to the edge of the cartilaginous surface. The neck cannot be said to exist, having been almost wholly removed by absorption. Between the inter-trochanteric lines there is an extremely irregular surface directed towards the head. From this surface and its margins, several dense fibrous bands pass to be attached to the capsule near the head, and one or two to the irregular surface on the head itself. In the substance of these bands are several loose portions of bone, which appear to have been separated at the time of the accident. On withdrawing the head from the acetabulum, to which it is attached in the usual way by the round ligament, the latter brings away with it a dense white membrane, which covers the whole surface of the cartilage, and is reflected from it to the ligament. Where the membrane has been torn off, the bone at the bottom of the acetabulum is left rough and bare, and where the membrane has been withdrawn from the surface of the cartilage, the latter is roughened. At the upper part of the acetabulum, the cartilage, covered by the membrane, presents several depressions and irregularities, and similar appearances are seen also at the lower part near to the edge of the cartilage. In the latter position there is one part, where the bone appears to be covered merely by a thin membrane, of the characters of the one described on the depressed patches on the condyles of the femur in Obs. IV.

A thin fibrous membrane covers the fractured surface of the head of the femur, and is continuous with a denser membrane, which can be traced over the whole cartilaginous surface to the round ligament. The membrane and round ligament can be readily stript off, and they expose bare bone near the attachment of the ligament, and at the very edge of the articular surface; but, on the remaining parts, a layer of cartilage, of considerable density and granular on the surface, is found. A brownish-red patch, three-fourths of an inch long and half-an-inch broad, immediately above the round ligament, presents a very thin layer of cartilage, which at one spot is quite yellow; whilst another patch of half-an-inch in diameter, below the ligament, has an extremely thin covering of reddish-brown cartilage. The bone, under these two patches, and at the irregular one near the round ligament, from which the cartilage has been altogether removed, has its texture completely opened out and softened, being in some parts a mere shell, which breaks down readily under the fingers.

Knee-Joint.—The cartilage of the femur presents a deep depression, elongated from before backwards, on the inner condyle, near its junction with the trochlea. Over a space of the size of a shilling, on the centre of the trochlear surface, there is a patch of fibres, many of which project half to three-fourths of an inch beyond the surface. The cartilage of the external glenoid surface of the tibia is depressed in the centre, and furnished with projecting fibres, and that of the internal surface is slightly fibrous in the centre, but the cartilage of both surfaces is nearly healthy under the semilunar cartilages. The cartilage of the patella has a large and irregularly depressed patch in the centre, running towards the internal edge of the bone. Its whole surface appears thinly covered with fibres, and, in some places, is rough and granular.

The cartilages of the ankle-joint, and of the articulations of the foot, appear healthy; but a few are thinned at their edges, and the bones at such parts are excessively soft.

The shaft of the femur of this side has a very large medullary canal, and very little compact tissue; its lower end is considerably softened. The whole of the tibia consists of soft spongy substance, which admits of its being crushed in the hand or twisted in any direction. The fibula is similarly changed, and can be twisted round the fingers very readily. All the bones of the foot can be crushed between the finger and thumb with the greatest ease. The cancelli of these bones contain an unusual quantity of oil.

Right Lower Extremity.—The neck of the right femur is attached to the shaft at an angle of 125° . A section through the head, neck, and shaft, shows a lamina of dense bone, nearly one-fourth of an inch thick, at the lower part of the neck, supporting it. The shaft consists of a thin shell of bone, leaving a large medullary canal, in which there are only a few slender spiculæ.

Hip.—The cartilage of the head of the femur is rough and velvety around and below the attachment of the round ligament. It terminates at the edge of the surface by a very irregular line, where it is much thinner, and runs towards the bone, which is nearly bare. The cartilage of the acetabulum is thinned at the edges, but otherwise appears healthy.

Knee.—The cartilage of the femur is soft and velvety on the centre of the trochlear surface, and at an elongated spot near the inner edge of the inner condyle. The latter spot is an inch-and-a-half long, by one-fourth of an inch broad, and presents a number of loose fibres projecting from it for three-fourths of an inch. At the posterior part of the external condyle, there is a depressed spot of the size of half a split pea, where the bone appears covered by a very thin layer of membrane or cartilage. The cartilages on the glenoid surfaces of the tibia are very soft and spongy, where they are not covered by the semilunar cartilages. The external surface is much more diseased than the internal, and it has long fibrous processes projecting from it. The lower surface of the external semilunar cartilage is covered with fibrous processes near its free edge at about the middle of its length. The lower three-fourths of the cartilage of the patella is soft and velvety; the upper part is dense, but presents three small depressions of considerable depth.

Ankle and Foot.—On the edge of the anterior articulating surface of the astragalus, there is an elongated depression one-fourth of an inch long, where the bone is bare. The other cartilages of these parts appear healthy. The bones present their usual firmness, and contrast remarkably with those of the opposite limb.

Microscopic Examination.—Left Hip-Joint.—The fibrous membrane covering the surface of the cartilage of the femur and acetabulum, consists of fibres which run for the most part horizontally, but in some places interlace with each other. In the acetabulum, distinct cells, $\frac{1}{700}$ th of an inch in their greatest diameter, are seen amongst the fibres. These cells are beautifully rounded or oblong, and contain patches of granules in their centre. In many parts, as on the centre of the surface on the femur, a number of the cells of the superficial layers of the cartilage are seen to be mixed with the fibres, these cells being in different stages of degeneration. On the addition of acetic acid the fibres swell and become excessively transparent, a number of elongated granular nuclei, or elongated patches of dark granules, becoming visible at the same time. On examining the part of the membrane in contact with the cartilage, it is evidently seen to be formed of the superficial layers of that tissue, the cells becoming granular, and constituting the nuclear bodies which appear on the action of acetic acid. Distinct nipple-shaped processes of the membrane are seen lodged within the notches produced by the evacuation of the contents of the diseased cartilage cells.

The superficial layer of cells is only found in some parts. Its cells exhibit all stages of the changes represented in Figs. XI., XII., XIII., XXV., and XXXIV. In different parts they are found slightly swollen, and have their usual arrangement—still more enlarged and disposed irregularly—or they are seen to be so much swollen as to be irregularly rounded, constituting large granular or molecular patches or cavities. Their contents are the usual nuclei increased in number, small corpuscles, dark granules, or a molecular mass. The deep cells are similarly changed. When they measure $\frac{1}{200}$ th of an inch in diameter, scarcely any trace of nuclei can be seen, and the cells contain dark granules and molecular matter. The hyaline substance near to the surface has indistinct fibres running in the direction of the superficial cells; whilst, in the

deeper parts, it is dark and molecular, or indistinctly fibrous, the fibres running perpendicularly to the surface.

The yellow spot on the cartilage of the head of the femur is found to be owing to the existence of a quantity of oil in the substance of the tissue ; but no fatty matter exists within the cells, though they are much enlarged. In some places, where the cartilage is not more than $\frac{1}{45}$ th of an inch thick, the superficial cells are not all removed, and yet no progressive enlargement of the deep cells is observed on passing down to the bone, as it is on passing towards the free surface at parts where that constitutes the principal or sole point of absorption. On examining the edge of the cartilage at the margin of the surfaces, and near to the attachment of the round ligament, after stripping off the fibrous membrane from it, the hyaline substance is found to be converted into distinct interlacing fibres, amongst which are numbers of cells or corpuscles, the whole tissue at these parts being almost precisely similar to fibro-cartilage.

The microscopic appearances in the diseased parts of the other cartilages of these extremities are similar to those above-named. Where there is a fibrous membrane on the surface, or where fibrous processes project from it, these consist of bands or fibres running in different directions according to the position of the cells where the fibres are formed. Amongst the fibres are a few cartilage cells, or granular patches indicating their former existence, and always seen after the action of acetic acid. The mode of junction of the fibrous layer, found on the surface, with the cartilage, and the changes which are seen to have taken place in the superficial and deep cells are precisely similar to those which have been already described in the cartilages of the left femur and acetabulum.

Upper Extremities.—The cartilage covering the heads of both humeri presents whitish patches, as if there were a deposit of dense matter immediately below the surface. The cartilage of the glenoid cavities is healthy.

Elbow-Joint.—The cartilage on the lower articular surfaces of the humeri is reddened and velvety on the small head and the adjacent ridge,—that on the right humerus presents an abraded spot on the trochlear surface, and an elongated but deep notch, $\frac{1}{4}$ th of an inch long, and $\frac{1}{12}$ th broad, at the anterior part of the ridge, separating the trochlear surface from the small head. The cartilage on the heads of the radii is reddened and velvety or fibrous, especially at the edge of the humeral surface, and at the part near to the ulna, where nearly the whole thickness of the layer is diseased. The cartilage on the ulna is slightly reddened and velvety. On each side, it is divided into two parts by an irregular membranous band passing across at the junction of the olecranon with the shaft. At this point, the bone appears almost bare, except at the radial end of the band on the left ulna, where there is still a layer of cartilage.

Wrist-Joints.—The left wrist-joint is healthy. In the right one the cartilages covering the lower surfaces of the radius and ulna, are converted into fibres at their margins, whilst their central parts are covered by a thin membrane.

Right-Hand.—Many parts of the cartilages of the bones in the lower carpal row are reddened, velvety, and abraded. The semilunar surface of the unciform, and the unciform surface of the fourth metacarpal bone, present irregular spots, where the bone is completely bare, smooth, and covered with porcellaneous deposit.

Left-Hand.—The cartilage on the lower surface of the scaphoid, and on the semilunar surface of the unciform bone, is removed on each for an extent of $\frac{1}{6}$ th of an inch. The exposed bone is perfectly smooth and porcellaneous, and the edge of the surrounding cartilage is loose and velvety. The surface of the trapezoid for the trapezium is in the same state. Several other cartilages of the carpal bones are reddened and velvety, and especially the cartilages in the carpo-metacarpal articulation of the thumb.

Microscopic Examination.—On examining vertical sections of the cartilage of the heads of the humeri, passing through the white spots, these are found to be

produced by a deposit of dark-brown granules in the intercellular substance of the superficial layers of the cartilage, the cells of the same parts being slightly enlarged and granular—(Fig. XL.) On the addition of acetic, or the stronger

Fig. XL.

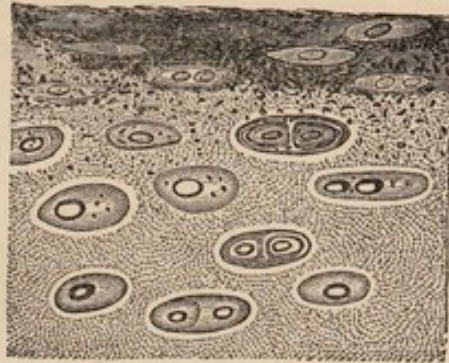


Fig. XL.—Vertical section of the superficial layers of cartilage from the head of the right humerus having the whitish deposit between the cells.

acids, to such sections, the dark-brown deposit gradually disappears, passing through different shades of brown and yellow. A slight effervescence takes place at the same time, but the bubbles appear to proceed from all parts of the cartilage, and certainly not in greater number from the dark deposit than from other parts. On neutralising the acid solutions thus obtained, and adding a solution of oxalate of ammonia, a copious and immediate deposit of crystals of oxalate of lime takes place. Similar indications of the existence of a smaller quantity of lime are given by acting upon other portions of the same cartilages, in which there is no deposit in the superficial parts.

All the velvety parts of these cartilages present the usual bands or fibres into which the hyaline substance has been split, the horizontal or vertical arrangement of these depending on their position in regard to the superficial or deep cells. Where the cells of the superficial layers exist, they are enlarged, especially in breadth, separated from each other, and granular. The deeper cells measure, in many places, $\frac{1}{200}$ th of an inch in their long diameter, and one which appears ready to burst, measures $\frac{1}{140}$ th of an inch. Their contents are, a number of beautifully spherical cells, which measure $\frac{1}{1400}$ th of an inch, and contain round and bright granules—(Fig. XLI.) ; whilst, in some places, the cells contain corpuscles of the ordinary irregular form.

Fig. XLI.

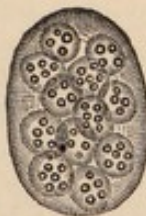

Fig. XLI.—Large cells, containing smaller granular ones, found in many cartilages.

Where the cartilage is covered by a membrane, this consists of interlaced fibres, amongst which are nuclei in all stages of elongation, patches of granules, and a few cartilage cells. The membrane presents rounded notches, where it is adapted to the surface of the cartilage. The membrane covering the ulna, at the junction of the olecranon with the shaft, contains a number of small bodies like osseous lacunæ, which appear surrounded by a cell wall, as if formed by the calcification of cartilage cells.

Overhanging and bordering the parts which are becoming porcellanous, the hyaline substance of the cartilage is split into bands and fibres, amongst which

are large cells of the characters of that delineated in Fig. XLI. ; or, a number of smaller cells are found amongst fibres which interlace with each other, composing a tissue which is almost precisely similar to fibro-cartilage in its structural characters.

Remarks.—Without any symptoms which could be supposed to indicate diseased action in the joints in this case, almost every articular cartilage in the body became seriously affected, and parts of several were almost wholly destroyed. The nature of the disease in every joint was similar to that before detailed in Obs. I., II., IV., and VII. On many of the cartilaginous surfaces there was a dense fibrous membrane, which was evidently produced by splitting of the hyaline substance of the cartilage into fibres, and by changes in the cells, which had reduced them to granular nuclei or isolated patches of dark granules. In the elbow-joint an apparent conversion of cartilage cells into osseous lacunæ, by calcification of their walls, was observed. The softening of the bones of the left lower extremity, independently of those of other parts, was very remarkable, and might possibly have been produced by diminished nutrition of the whole of the parts of this extremity since the occurrence of the fracture.

The nature of the disease which led to the death of the patient cannot be made out very positively. The symptoms were those usually produced by cerebral congestions or chronic lesions of the nervous centres, and with them must be considered the deposit in the upper part of the vertebral canal. This deposit had every appearance of tubercle ; but it was not found until too late a period to allow of its nature being very positively stated by microscopic examination. The ulceration of the bladder probably hastened the fatal termination, and may have arisen from the retention of urine, as there was no disease of the other parts of the urinary tract.

OBSERVATION X.—Gelatinous Degeneration of the Synovial Membrane of the Ankle and Tarsal Articulations—Loosening and Destruction of the Cartilages—Softening of the Bones—Anchylosis of the Astragalus and Os Calcis—Amputation—Recovery.

David Wood, æt. 25, farm-servant, admitted into the Aberdeen Royal Infirmary on April 11, 1849, under Dr Pirrie, for disease of the left ankle. He is tall and thin ; complexion and hair light.

States that he was confined to bed for rather more than a week, from an attack of scarlet fever, in the beginning of November 1848. In the beginning of the year 1849, his feet became uneasy on walking ; and about the second week of February his left ankle first became the seat of greater stiffness and uneasiness than other parts, inducing him to walk on the outer part of the foot rather than on the sole. This slight uneasiness in the ankle gradually increased, and the toes became unusually stiff and extended. After two or three weeks, he observed a swelling on the outer side, which gradually extended round the joint, with increase of pain. The pain was but little felt when sitting quietly, but it was very severe in walking, obliging him to give up work a month previous to his admission, and of late destroying his rest in bed. He applied a few leeches to the joint a short time since, but with little or no benefit.

On admission, there is a considerable, hard, and but slightly elastic swelling of the joint, very prominent over both malleoli, and at these parts of a red colour. The foot is immoveably fixed at right angles with the leg, the tendons of the muscles in the anterior tibial region being excessively tense. There is very considerable gnawing pain in the whole articulation, increased by pressure, or by attempting to walk, and generally alleviated, or temporarily removed, by rest. In bed, however, the joint is usually uneasy, and at times so painful as to disturb his sleep.

Perfect rest was enjoined—leeches were applied with some relief—cooling lotions were used and afterwards poultices. Matter formed successively on the inner and outer sides of the ankle-joint, and when evacuated by incisions in these situations, it was found to be of an unhealthy serofulous appearance. These evacuations gave temporary relief, but the openings closed, and the pain soon became as bad as before. He was put upon a course of iodide of potassium and cod-liver oil, but the ankle did not improve, and towards the end of May the pain became exceedingly severe, his rest was much disturbed, and he became feverish. Anodyne draughts and febrifuge medicines were administered, and soothed him considerably, but no amendment took place in the ankle. The constitution was much affected by the irritation and confinement, which he appeared unlikely to be able to bear much longer, and therefore amputation was resolved on, and performed in the lower third of the leg, on June 16, 1849. A severe attack of erysipelas came on in the stump; but on July 21 the wound was nearly healed.

Examination of the Foot.—Fistulous openings in front and behind the lower tibio-peroneal articulation lead to bare bone upon the lower end of the fibula and adjacent part of the tibia. All the sub-cutaneous tissues about the ankle and tarsus are infiltrated with a soft, brownish, gelatinous mass, and the parts of the synovial membranes which cover the ligaments form very thick, brown, soft, and pulpy masses.

The ankle-joint contains a quantity of pus. The cartilage of the lower extremity of the tibia is smooth, and white on the surface; in many places it is not more than half a line in thickness, and over the whole surface it separates very readily from the bone, bringing with it small osseous spiculæ. The surface of the bone is highly vascular, and the part immediately in contact with the cartilage is softened; but at the distance of a line it appears more healthy. The contiguous non-articular parts of the tibia and fibula present rough bone, covered only with the brownish gelatinous substance. The cartilage of the fibula is reddened and pulpy over half its surface, and it is readily detached from the bone. The greater part of the upper articulating surfaces of the astragalus is covered with white and dense cartilage; but, in many places, it is reddened, pulpy, loose from the bone, and even perforated, so that the bone can be felt bare through the openings in the cartilage.

The inter-osseous ligament between the astragalus and os calcis is almost completely destroyed. What remains of it consists of softened fibres, which can be readily picked away with forceps, whilst firm ossific union has taken place at those parts from which it has been removed by disease. The cartilages of the anterior and posterior articular facettes, between the above-named bones, are $\frac{1}{16}$ th of an inch thick, and applied close to each other, without union. They appear healthy, except at the portions immediately in contact with the ossified parts, where they are somewhat gelatinous and transparent.

The cartilages on parts of all the surfaces in the articulation between the two rows of tarsal bones are reddened, thinned, and capable of being easily torn from the bones. Those situated further forwards in the foot appear healthy on the surface; but, under all, except those of the phalanges, the bone is considerably softened in its texture. All the bones of the tarsus, and the extremities of the metatarsal bones, cut readily with a knife, and the tarsal

ones, near many of their articulating surfaces, can be broken down with the fingers.

Microscopic Examination.—The reddish-brown gelatinous mass contains a number of fusiform and nucleated cells; a few exudation corpuscles, only partially filled with granules; and a large number of spherical, finely granular and indistinctly nucleated cells, varying in size from $\frac{1}{2300}$ th to $\frac{1}{1400}$ th of an inch. On the action of acetic acid, these cells show a distinct, rounded, and granular nucleus, measuring in all the cells about $\frac{1}{3500}$ th of an inch. All the structures named as components of the gelatinous mass lie in a finely granular blastema.

The cartilages of the ankle-joint have no trace of the horizontal layer of cells on the surface, but this presents a number of free fibres, $\frac{1}{350}$ th of an inch long, projecting into the joint, and formed of hyaline substance. At the attachment of the bands and fibres to the hyaline substance it is finely molecular, and excessively transparent. The same molecular, disintegrated, hyaline substance is seen on the deep surface; but on this there are neither bands nor fibres. In the centre of the cartilage the cells are of the usual size, but their nuclei are extremely irregular in form; nearer the free surface the nuclei are seen in all stages of conversion into granules, whilst the cells are rounded, and, instead of lying in groups, are separated at equal distances from each other. Several of these cells have a finely mottled appearance, as if the granules had been converted into molecules. (See the large molecular patches in Fig. XIII.) Near the deep surface the cells are but little changed, whilst directly upon it they are molecular, and apparently undergoing the same process of disintegration as the hyaline substance. On adding acetic acid to these cartilages, the hyaline substance becomes very transparent, but the granules are in no way affected.

In the articulations further on in the foot, similar changes have taken place to a less extent. On the posterior surfaces of the scaphoid and cuboid bones, the superficial cells are swollen and granular, as well as separated from each other at a greater distance than in the natural state. On the cuboid the superficial cells measure $\frac{1}{850}$ th by $\frac{1}{1500}$ th of an inch, and contain irregular or rounded granules, very much like oil, and measuring $\frac{1}{3500}$ th of an inch when of the largest size, whilst there are all sizes below this. The deeper cells are quite healthy.

The anterior surfaces of the cuboid and scaphoid bones present similar changes in their superficial cells, but only in some places, and to a slight extent. The adjacent surfaces of the cuneiform bones are considerably softened, and their cartilages are more diseased; the cells are swollen and granular, and the hyaline substance is broken down and molecular, or is distinctly fibrous. The cartilages applied close to each other in the anchylosed articulation have their superficial cells crowded with eight or ten corpuscular nuclei in each. They are $\frac{1}{470}$ th of an inch long, and separated from each other. The usual clusters of deep cells are only seen in a few parts, for the cells have in most places separated from each other, and have become swollen and rounded. Near the anchylosed part the cells are further changed, and the majority of them measure $\frac{1}{470}$ th by $\frac{1}{580}$ th of an inch, and are crowded with corpuscles. Many of the smaller cells are perfectly spherical, and present a nucleus without evident boundaries, as it appears to be only a denser portion of the gelatinous contents of the cell. In all these parts the hyaline substance is finely mottled. The portion of the cartilage exactly in apposition with the anchylosed part of the bones has its hyaline substance converted into perfect fibres, interlacing in every direction, and forming spaces of $\frac{1}{470}$ th of an inch in diameter, which are occupied by dilated cells, or by clusters of corpuscles which have evidently belonged to single cells. In other parts the corpuscles are quite free, and lie in hyaline substance, or perfect fibrous tissue formed from it. They measure from $\frac{1}{2300}$ th to $\frac{1}{3500}$ th of an inch in their long diameter, and but little less transversely.

Remarks.—At the period of amputation, the bones, and other structures entering into the composition of the articulations, were all seriously diseased. Except in the case of the cartilages, it is not easy to point out what course the diseased action was taking, nor is it possible to state with certainty in what tissue it commenced. The bones had their articular lamina almost wholly destroyed by softening and opening out of the texture; and thus the attachment of the cartilages was loosened. Beyond their articular surfaces, several of the bones were not so much diseased, but the tarsal ones were softened throughout. All the cartilages were in a much more advanced stage of disease on their free surfaces than elsewhere; and those in which the disease was just commencing showed this at the same part, notwithstanding that the bones under them were completely softened. The disease in the synovial membranes and soft tissues had the characters of the gelatinous disease of authors. I am disposed to regard the disease as one of anormal nutrition, depending on a constitutional cause, but manifesting itself at a particular part. It is not unlikely that all the textures suffer at once, but that the effects of the disease are first manifested in some cases in the softer tissues, and in others in the bones; but little pain being produced until the last-named texture becomes seriously involved. If the disease is a general one, it is at once explained why local treatment, especially in hospitals, so uniformly fails, and occasionally proves injurious, whilst the administration of Ol. Jecoris Aselli and good diet, in a pure atmosphere, is at times attended with the most satisfactory result.

OBSERVATION XI.—*Disease of the Articular Ends of the Bones, and of the Cartilages of the Knee-Joint—Gelatinous Degeneration of the Synovial Membrane—Amputation.*

James Jackson, æt. 34, of scrofulous diathesis, admitted into the Aberdeen Royal Infirmary on March 17, 1849, under Dr Pirrie, complaining of pain, swelling, and stiffness in his right knee.

States that whilst at work, two years and a-half ago, he gave his knee a violent twist, after which it was painful for a few days, and then got quite well. About eighteen months ago he first felt deeply-seated and gnawing pain, generally confined to one spot below the patella, but occasionally affecting both sides of the knee. The pain was most severe when he was warm in bed, and was of the same character as it has maintained throughout. For eight or nine months the knee has felt stiff; but no swelling was noticed about the joint, to the best of his recollection, until four or five months after the commencement of the pain. Twelve months ago he began to use a liniment, and continued its application for six weeks. On the 23d of April 1848, he first applied to a medical practitioner. His knee was blistered, and various ointments were applied until about five weeks before his admission, but without benefit.

On admission, the joint is considerably swollen, especially on the lateral parts above the articulation, where the swelling is soft and yielding; but it is hard in other parts. There is great stiffness of the joint, owing to the swelling, which is increased by standing or walking, and diminished by rest in bed. Severe, and nearly constant, gnawing pain exists below the patella, and is increased on pressure. Pain of a similar character is also occasionally felt on the outer, and less frequently on the inner, side of the joint, being worst in

bed, and on beginning to walk; whilst, after walking a little distance, it is less perceived. Severe pain is also excited by any sudden shock applied to the foot, as in making a false step.

March 20.—Eight ounces of blood to be drawn from the knee by cupping, and one grain of proto-iodide of mercury to be taken night and morning.

March 27.—Scott's dressings of compound mercurial ointment were applied to-day.

April 4.—The pain has almost left the knee. A short splint is applied behind the joint, to secure perfect immobility. To continue the pills.

April 26.—On removing the dressings, the swelling is seen to be less than at any other period since its commencement; the pain is very slight, and has only been felt at intervals since the application of the dressings.

April 28.—A small blister to be applied below the knee, on the inner side, and to be dressed with mercurial ointment.

May 6.—To discontinue the pills. The mouth has not been affected.

May 8.—A slight swelling, with fluctuation, exists on the inner side of the lig. patellæ. On making a small puncture into it, a little pus escaped; the opening was carefully closed, and absolute rest enjoined.

May 10.—Three drachms of scrofulous pus were evacuated to-day, by a small incision made on the inner side of the patella, and afterwards closed.

May 24.—Has been using a lotion of spirit and acetate of ammonia, and taking the syrup of iodide of iron. More pus had accumulated, and it has been evacuated as before. A portion of the head of the tibia can be felt bare with the probe.

June 5.—To have cod-liver oil, instead of the syrup.

June 12.—To-day the pus has escaped from an opening spontaneously made. Poultices to be applied.

June 16.—Excruciating pain in the knee, on the slightest motion, has gradually come on of late. The patient is much thinner and paler than when admitted. As there appears to be no prospect of a cure, amputation has been resolved on.

June 23.—Chloroform was administered to-day, and the limb amputated above the knee.¹

Examination of the Limb.—Considerable swelling exists about the knee-joint. It is round and pulpy, and the skin over it is white. All the sub-cutaneous tissues in the neighbourhood of the joint are infiltrated with a yellowish gelatinous substance; and, on opening it, a quantity of brownish purulent fluid is found.

The articular surfaces of the femur and tibia are covered with white and dense cartilage, which is smooth on its free surface, and can be very easily detached from the bones, tearing away small spiculæ with it. The edges of the surfaces are overlapped to the extent of one-eighth of an inch all round, and to that of half an inch at the junction of the trochlear and condyloid surfaces of the femur, by a highly vascular and soft membrane, continuous with the synovial membrane covering the ligaments. Under the thickened or newly-formed membrane, the surface of the cartilage appears abraded and uneven. The edges of the cartilages of the tibia are grooved half-way through their thickness, and rough upon their surface where the internal edge of the semilunar cartilage is applied upon them. The last-named cartilages themselves are soft and pulpy, and overlapped by the vascular membrane.

The internal part of the articular surface of the patella is destitute of cartilage over a rounded spot of half-an-inch in diameter, which has bare and smooth bone at its bottom. The cartilage of the lower half of the surface is thin, rough, and covered by the pulpy and vascular membrane an eighth of an

¹ The history and symptoms of the disease, up to the period of amputation, in this case, and in that recorded in Obs. X., have been abstracted from a report, kindly furnished me by Dr Pirrie.

inch thick. On the upper half of the surface there is tolerably smooth and thick cartilage, which is split by vertical fissures near the junction of the upper and lower halves. Here the superficial layers of the upper part of the cartilage overlap the granular surface of that of the lower half to an extent of one-sixth of an inch, so that they present a distinct and irregular fringe, running across the bone.

On cutting through the head of the tibia, its texture is found to be opened out and much softened, so that it can be readily broken down with the fingers. The articular end of the femur is also softened to a less extent, whilst the patella presents a much denser texture and a more firmly adhering cartilage.

Microscopic Examination.—The vascular membrane on the free surface of the cartilages, and the pulpy vascular mass between them and the bone, are of the same structure. Both consist of a mass of fusiform cells and blood-vessels, with a few exudation and plastic cells intermixed; whilst in a few parts there are perfect fibres. All these structures exhibit their usual reactions with acetic acid. The deepest part of the membrane on the surface contains, amongst its other structures, a granular mass, and a series of corpuscles, which appear to have been discharged from cartilage cells, and changed in their characters. Under the membrane the surface of the cartilage presents a number of very large cells, which are open on one side towards the fibro-nucleated and granular mass, and closed on the other. By this arrangement the surface of the cartilage presents notches, and the pulpy membrane a series of nipple-shaped processes which are lodged within them.

The inter-cellular substance, near the edge of the surfaces, consists of perfect fibres, whilst the cells measure $\frac{1}{140}$ th of an inch long, and are crowded with distinctly granular corpuscles, measuring $\frac{1}{2300}$ th by $\frac{1}{3500}$ th of an inch.

Except at the very edge of the surfaces, the superficial cells remain. In the centre they are elongated, and full of granules, like oil; nearer the edges they are very much swollen, and present a molecular or granular mass in their interior. Many of such cells measure $\frac{1}{470}$ th by $\frac{1}{700}$ th of an inch.

The deeper cells are much less changed. They are somewhat enlarged, and their contained corpuscular nuclei are granular. Those at the deepest part have undergone scarcely any change, even on the surface which is so easily detached from the bone. The edges of sections passing through this surface show a number of notches; but it does not appear that these have any connection with the changes in the cells. The hyaline substance, through the whole thickness of the cartilage, is darker and more mottled than natural; whilst in many parts a filamentary arrangement of the molecules may be seen, similar to that described by Leidy in healthy cartilages, but much more evident than it.

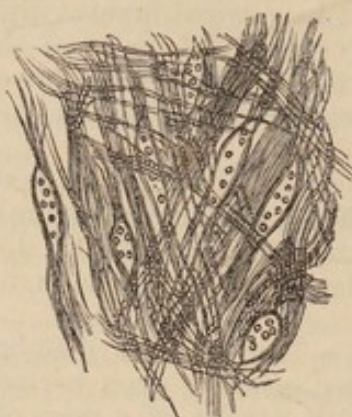In some parts the corpuscles are set free from their cells, and lie in the tissue; in others the walls of the corpuscles cannot be seen, and small patches of granules indicate their position.

The cartilages of the tibia present the appearances above-named. Where they are grooved under the semilunar cartilages their cells are all swollen, very large, granular, and presenting the appearances represented in Figs. XIII. and XIV.

The semilunar cartilages consist of a mass of fibres, interlaced in every direction, and have amongst them a number of loose granular corpuscles, many of which are as distinctly fusiform and splitting into fibres as the fusiform cells of granulations.—(Fig. XLII.)

Patella.—The superficial cells are removed from every part. Where the cartilage is dense, the cells are much enlarged, rounded, filled with corpuscles, and they lie in hyaline substance, which is darker and more granular than usual. A few of the deep cells have calcareous matter in their walls. In many places the cartilage is softened, and consists of a mass of fibres, mixed with clusters of granules, with granular corpuscles, or with large dilated granular

Fig. XLII.

Fig. XLII.—*Fusiform cells splitting into fibres from the semilunar cartilages.*

cells. These softened parts are almost precisely similar in structure to those described in Obs. II., in the cartilage of the tibia.

Remarks.—At the period of amputation, the articular ends of the bones, the cartilages, and the synovial membrane, were all seriously diseased. The history of the case, and the character of the symptoms, would lead to the belief that the disease commenced in the tibia, and then extended to the other structures—to which view there is nothing to oppose in the anatomical characters of the diseased parts. The loosening of the attachment of the cartilage to the bones was apparently similar to that described in several cases by Mr Mayo, whilst there can be no doubt that the pulpy and vascular membrane overlapping the edges of the cartilages was a similar one to that which Mr Key believes to be the cause of ulceration. The disease was undoubtedly in a more advanced stage at those parts of the cartilage which were overlapped by the pulpy membrane, or the semilunar cartilages, than in others, which indicates simply that the cartilages so diseased derived their supply of nutritive material from the blood circulating near them in the membrane named, and not that the membrane in itself possesses any peculiar virtue by which it is enabled to act upon the cartilage, and cause its removal. The tolerably healthy appearance of the deep cells, where the cartilage could be separated from the bone by the slightest force, is opposed to the view that these textures derive their nutritive fluid principally from the dilated vessels of the bone. Lastly, it is not to be forgotten that the superficial cells of the cartilage were diseased in every part—that no evident membrane could be seen on the central parts of the surfaces—and that the deeper parts of the cartilages were least affected by the disease: circumstances which appear to point to the synovial fluid as possibly concerned in the supply of nutritive matter to the cartilages, both in health and disease.

OBSERVATION XII.—*General Disease of the Articular Cartilages—Death from Fever.*

The disease was found in this case in a female (J. A.), æt. 60, who died of fever in the Royal Infirmary of Aberdeen, on the 26th of May 1849. She had

been married, and had had several children. Other particulars of her history could not be obtained; for, when brought to the infirmary, two days previous to her death, she was in a state of insensibility, from which she never recovered.

The body was that of a well-developed female. In the post-mortem examination, made in the dissecting-rooms, there were no traces of disease in any of the organs, except in the existence of cicatrices and puckerings in the apices of the lungs, and old but not extensive adhesions of the pleuræ. The fibres of both recti muscles of the abdomen were torn, a little below the umbilicus, on both sides, and diffused clots of blood were found in the same positions. There was also some sero-sanguineous effusion in the sub-cutaneous cellular tissue over the ruptured part of the right rectus, this muscle being torn to a greater extent than the left one. No evidence of contusion existed on the skin.

Examination of the Joints.—Shoulders.—The cartilage covering both glenoid cavities was healthy; but the dark deposit, described on the head of the humerus in Obs. IX., was found here, also, in small quantity, in the superficial layers of the cartilage of both humeri.

Elbow-Joints.—The whole of the cartilages are of a rose-pink colour, especially where their surfaces are soft and velvety. The cartilage on the lower end of the humerus of both sides is soft and velvety on the anterior surface of the small head, and on the ridge separating this from the pulley-like surface for the ulna. The cartilage on the head of the radius on both sides is soft and velvety on the whole surface opposed to the humerus, and especially for one-sixth of an inch around the cup-shaped cavity. The cartilage of the ulna, on both sides, is soft and velvety, or flocculent, near the centre, and is divided into two parts by a band, one-eighth of an inch in breadth, which runs across at the junction of the olecranon with the shaft. At this part the bone is covered by a thin uneven membrane, except at a small spot, on the left side, where it is bare, and at another on the outer part of the band on the right side, where the cartilage still remains.

The cartilages of all the other joints of these limbs are healthy in structure; but some of the cartilaginous surfaces on the carpal bones are reddened near their edges.

Hip-Joints.—The cartilage on the head of the right femur is abraded near the edges of the surface. At the attachment of the round ligament there is a spot, of an inch in diameter, where the cartilage is reddened, velvety, and fissured—the fissures radiating from the ligament. A large portion of the surface nearer the circumference is whitish and mottled, as if there were some deposit in the superficial parts. Several velvety portions of cartilage are also found near the circumference of the acetabulum. Similar appearances occur in the left hip-joint, the cartilage of the acetabulum, and the round ligament of this side, being of a bright yellow colour.

The other joints of the lower limbs are healthy, except the tarso-metatarsal articulations, the cartilages of which have some deposit in their superficial parts.

Microscopic Examination.—All the parts which are velvety and flocculent to the naked eye have their hyaline substance split into large bands, and these again into smaller ones. Where the cartilage is soft and pulpy, its hyaline substance is indistinctly fibrous and molecular; in a few places it is converted into fibres, which are arranged, in relation to the cells, like the fibres of fibro-cartilages. There are but few parts of any of the diseased cartilaginous surfaces which are quite healthy. Over the greater part of each, the superficial cells are enlarged, and somewhat rounded; containing, in some places, their usual nuclei; in others, the nuclei contain dark granules, or their former position is merely indicated by small patches of granules. The deeper cells in many parts are enlarged, rounded, crowded with granular corpuscles, or with similar ones without granules. These cells are of all sizes, up to $\frac{1}{120}$ th of an inch. Many of the largest appear molecular, and are similar to those before represented in Fig. XIII.

The whitish mottled spots on the heads of the thigh bones, and in other parts, are precisely similar to those described on the humerus, in Obs.

IX. The superficial cells of such parts are enlarged, rounded, and contain globules of oil of different sizes. They lie in a dark brown granular substance, which, on being acted on by acetic or the stronger acids, loses its colour, passing through different shades of brown and reddish-brown to yellow, the colour in one stage being precisely the reddish-brown colour assumed by the inter-cellular substance in many of the former cases of fibrous degeneration. Some of this dark deposit was found in the cartilages of the right elbow-joint, where it could not be observed with the naked eye.

The cartilage of the ulnæ, near the line separating the olecranon from the shaft, presents a number of beautiful hyaline bands on the surfaces, and in the deeper parts rounded cells of larger size than in any of the foregoing cases: many measure $\frac{1}{100}$ th by $\frac{1}{120}$ th of an inch, and a few are considerably larger. Some of the cells are seen to be breaking up, each of the numerous contained corpuscles appropriating to itself a part of the gelatinous contents of the cell, so as to complete itself, and constitute another nucleated cell:—others contain small patches of molecular or granular matter, which are the only indications of the previous existence of the nuclei or corpuscles.

In the examination of the yellow parts of the cartilage of the left acetabulum, the whole colouring matter is found within the cells, giving to the texture a very beautiful appearance.

Remarks.—This case was so similar to that recorded in Obs. IX., and some of the former ones, that scarcely any remark is necessary. The disease was general, and possessed of the usual pathological characters.

OBSERVATION XIII.—*Complete Destruction of the Cartilages, Ligaments, and Synovial Membrane of the Knee-Joint—Exudation, with Vegetable Productions in the Pharynx, Œsophagus, and upper part of the Larynx—Death.*

This patient, a female, æt. 22, was admitted into the Aberdeen Royal Infirmary, under Dr Laing, in May 1849, for disease of the knee-joint. I did not see her during life, but was enabled, by the kindness of Dr Laing, to collect the few following facts from his case-book, and the account given by himself, the dresser, &c. :—

The patient had previously suffered from disease of the elbow-joint, but she stated, on admission, that it gave her no trouble, notwithstanding that considerable grating of the ends of the bones took place on motion of the joint. One ankle-joint had also given her uneasiness. The disease in the knee-joint had existed fifteen months. When admitted, this joint gave her considerable pain, especially on motion; it was swollen and rounded; the skin was perfectly entire, and had been so from the commencement of the disease; the leg was unusually moveable at the joint, and required support by pillows, to prevent its bending laterally upon the thigh. The disease appeared to progress gradually; the pain continued, very severe; the leg became more moveable laterally at the knee, but the skin remained entire throughout; and not the slightest tendency to the formation of an abscess was observed. After about six weeks from the time of admission, she complained of being very unwell; in two days from this time she had severe rigors, with difficulty of breathing and deglutition; and death took place within twenty-four hours of the occurrence of the last-mentioned symptoms.

Post-mortem Examination.—(Thirty-six hours after death.)—The lower lobes of both lungs are intensely congested, and calcareous concretions, apparently occupying the bronchi, and of a branched form, are found in two or three places. A greyish-white curdy mass of exudation is found covering the whole of the pharynx, and three or four inches of the upper part of the œsophagus. It can be readily detached from the mucous membrane, which is slightly reddened, and it extends to the margins of the glottis, covering the aryteno-epiglottidean folds. In the interior of the larynx a thin and more

transparent lymph is found in small quantity. The organs in the chest and abdomen, which have not been named, are healthy. Head not examined.

Knee.—On opening the joint, five or six ounces of thick and dark-brown pus escaped. The sub-cutaneous tissues are gelatinous,—the lateral ligaments are completely destroyed, and the crucial ones are considerably diseased. All the surfaces of the bones entering into the formation of the joint are of a dirty-brown colour, and appear rough and completely bare. On more careful examination, a few small and thin patches of cartilage are found on the femur, whilst every other portion of cartilage, and the semilunar cartilages, have disappeared. The texture of the bones is opened out, but they cannot be crushed between the fingers.

The elbow and ankle joints not examined.

Microscopic Examination.—The cells immediately on the surface of the patches of cartilage are very large, rounded, and molecular, opening on the surface; those situated deeper are less changed in shape and size, but they contain a number of dark granules in lieu of their nuclei. The hyaline substance presents an indistinct and mottled appearance.

The lymph substance found in the larynx is a granular mass, with which primitive filaments (Bennett) and epithelial scales are intermixed; that in the œsophagus and pharynx contains a mass of epithelium, with granular matter and vegetable productions, such as are found in ordinary aphthæ, but with stronger stems and larger sporules. The vegetations form at least half the bulk of the pharyngeal exudation.

Remarks.—One peculiarity in this case was the complete destruction of every texture in the knee-joint, and probably, also, of the cartilages in that of the elbow, with less suffering and constitutional affection than happens in many cases where there is only very slight destruction of tissues. The brown degeneration had gone on in the knee until five or six ounces of dirty brown pus were formed, and yet there was no approach of the matter to the surface in any part,—but slight emaciation had resulted,—and there is reason to believe that had the knee-joint been the only diseased part, recovery might have taken place after amputation.

The fatal disease in the pharynx, œsophagus, and upper part of the larynx, was of an aphthous nature, the greater part of the exudation being composed of the usual vegetations. There is no reason to believe that it had existed more than three days previous to death, but whether it resulted from the disturbance caused by the diseased joints, or arose altogether independently of that cause, there does not appear to be sufficient evidence to decide.

Before proceeding with the subject of disease in articular cartilages, it is necessary to notice their position amongst the tissues, and their mechanical and vital properties in the healthy state. They are formed of a texture, which, in the purest state in which we see it, consists of a mass of nucleated cells, similar in every respect to those of the cellular textures in plants. Other forms of cartilage have their cells spread out in a granular or fibrous mass, called the hyaline or inter-cellular substance of cartilage. The cells, in every form, are capable of producing others, so that, whilst the old cells are constantly disappearing, others are growing to supply their places;

and thus the tissue is continually undergoing important nutritive changes, by which its functions are preserved to the latest periods of existence. Its powers of absorption are very great, and there can be little doubt that, by these, articular cartilages receive a sufficient amount of nutritive material from the blood which circulates in the vessels of the bone or synovial membrane.

In the Philosophical Transactions for 1841, Mr Toynbee pointed out that the blood-vessels of the bone, near a cartilaginous surface, present certain convolutions, dilatations, plexuses, and other peculiarities, well adapted for the reception of blood, from which the liquor sanguinis may be separated by exudation, for the purpose of nourishing the cartilage. He showed, also, that these vessels are separated from the cartilage by "a lamella of bone, composed of two sets of osseous layers; the one, dense and thick, is continuous with the vertical fibres of the cancelli; the other, delicate and thin, principally composed of osseous corpuscles, is situated at right angles to the latter, and fills up the interspaces of the vertical fibres." Mr T. believes that articular cartilage is chiefly nourished by exudations from the above-named blood-vessels, the arrangement of which, with the absence of any other means of nutrition, have led him to this conclusion. He points to the existence of a number of osseous lacunæ, without other openings or canals, in the articular lamella of the bones; and to a series of minute canals, situated in the deeper parts of the cartilage, and leading towards the free surface, as means whereby the passage of nutritious fluid from the blood-vessels of the bone into the substance of the cartilage may be facilitated. In the fibro-cartilages, Mr T. states, that the blood-vessels uniformly terminate within the boundaries of the fibrous tissue, without passing into the part formed of cartilage. He regards the fibrous portion of fibro-cartilage as formed from the cells of the cartilaginous part, having found that, in the foetus of three and seven months, the external part of the inter-vertebral substance contains cells elongating into fibres, whilst up to adult age, the changes in it consist in the encroachment of the fibrous portion upon the cartilaginous. It may be noticed here, that Mr T. also maintains that, during the whole of life, articular cartilages gradually become thinner by being converted into bone.

Dr Leidy¹ has different views regarding the structure and mode of nutrition of articular cartilages. He describes the cartilage corpuscles as solid nucleolo-nucleated cells lying in groups. The contents of the cells are a translucent, homogeneous, or minutely granular substance, with a central mass of distinctly coarser and darker granules, in which a transparent, round, or oval nucleus can be seen, coloured brown by the application of tincture of iodine. He has described and figured the cartilage matrix, as a substance made up of filaments

¹ American Journal of Medical Sciences, April 1849.

$\frac{1}{25000}$ th of an inch in diameter, composed of a single row of granules. These filaments are arranged horizontally at the free surface, but vertically in the deeper parts of the tissue. To this arrangement of the filaments, he attributes the horizontal and vertical arrangement of the cells, which, he says, in being developed amongst fibres, will necessarily extend in the direction in which there is least resistance, in the line of direction of the filaments,—and also the direction taken by fractures in different parts of the thickness of the cartilage. He regards the intra-cellular substance as originating in the exercise of the vital activity of the cells, which accumulate and fix around and within themselves certain matters which they derive from the surrounding nutritive fluids, as happens in the case of many zooid plants,—the cells themselves multiplying by division into masses which ultimately become cells like the former. Dr L. believes articular cartilage to be nourished by fluids poured out from the blood on its attached surface, and by the *circulus vasculosus* at its circumference, but especially by the synovial fluid, which is rich in albumen, the substance from which he regards it as certain that the tissue of cartilage is formed. Henle noticed the probability of the occurrence of this third mode of nutrition many years ago, but it is difficult to conceive that the synovial fluid should serve the purpose of nourishing the tissue, the free surface of which, there can be no doubt, it is intended to lubricate. Again, the synovial fluid is deficient in potash, magnesia, and sulphuric acid, which are found in cartilages; and, moreover, the costal and many other cartilages are certainly not nourished by it. The filamentary arrangement of the molecules of the healthy inter-cellular substance is important, as it is shown, by the preceding observations, that, in the most frequent changes to which articular cartilages are liable under the influence of increased or anormal nutrition, the hyaline substance on the surface splits into bands and fibres parallel to it; whilst, in the deeper parts, these are always arranged more or less vertically.¹

It was noticed by Mandl that the nuclei of fibro-cartilage more frequently contain fatty matter than those of true cartilages; and Henle remarks that whenever fibres become developed in the inter-cellular substance of certain cartilages, the nuclei of their cells become converted, in great part, into fat, as if the two processes were connected with each other, whilst the cytoblasts never contain fat in those cartilages which do not become fibrous. The latter author also adds, that whilst fibres are frequently found, in advanced life, in those cartilages which have a tendency to ossify, he has never seen

¹ I am indebted to my friend, Dr W. T. Gairdner, for the opportunity of perusing Dr Leidy's paper after the first part of these observations was in the hands of the Editors. The splitting of the hyaline substance, so manifest in the first observation, was the subject of a paper read before the Medico-Chirurgical Society of Aberdeen, on the 4th of January last.

a trace of fibre in those which do not ossify, as the articular cartilages and those of the nose.

So far as I am aware, the actual conversion of the hyaline substance of articular cartilage into fibres, in disease, has not been previously demonstrated, though the external appearances of such cartilages are sufficient to lead to a suspicion of its occurrence. In many of the states of disease which have been described in the preceding observations, the fusion of the walls of old cells with the intercellular substance, and the division of the gelatinous cell-contents into as many pieces as there are corpuscles or nuclei in the interior, were seen to take place much more evidently than they ever are in the healthy state, proving that this is one very important mode in which new cells are formed and the old ones removed from the tissue.

The most important uses of articular cartilages are mechanical. They constitute a beautifully smooth and highly elastic covering for the ends of the bones, thus facilitating motion, and decomposing a large portion of the forces, which would have produced repeated fractures, had they been applied directly to the bones. But, as these textures are subjected to great friction, they would wear away gradually, but for the constancy of their nutritive changes, which are sufficient to prevent this, as is shown in the fact that the cartilages are not thinner in individuals, or in particular limbs that are almost unceasingly employed, than in others; and that, though the cartilages are a little thinner in old than in young persons, the difference has never been shown to result from friction, nor to exceed in amount similar changes known to take place in other textures as age advances. Again, the elasticity of most, if not of all substances, is impaired by constant use, in which we see an additional necessity for the constantly recurring changes in articular cartilages. The fact being certain, that important nutritive changes do constantly take place in these textures, it is surely inconsistent with true pathology to conclude that they are not likewise subject to anormal nutritive changes, similar to those from which all other textures are known to suffer. And yet, the argument can have no weight without the support of numerous and well-ascertained facts.

Mr Birkett,¹ following out Richet's view, has endeavoured to show that bone and cartilage in their relations to each other are similar to true skin and cuticle. To prove this, however, appears to me to require some explanation—why the cells of cartilage should so readily produce others, when no single epithelial cell can perform a similar function;—why articular cartilage is never reproduced, whilst cuticle and epithelium are replaced more readily than any other tissues in the body;—why, when there is a very obvious chemical difference in the deep and superficial layers of cuticle, no such difference can be shown in the parts of articular cartilage;—and why the deep cells of cartilage are arranged in perpendicular

¹ Guy's Hospital Reports, October 1848.

columns, and the superficial ones horizontally to the surface, if they merely constitute a simple epithelial layer.

It is important to notice that no nerves enter into cartilages, and that nothing is known of their existence in fibro-cartilages, in which we might have expected to have found them, in connection with the fibres. Such structures are not sensitive, as has been shown by numerous observations and experiments, and yet it is generally believed that, in disease, they cause such acute pain as exhausts the patient.

I shall proceed to notice the affections to which articular cartilages are liable under the heads of Morbid Anatomy, Chemistry, Pathology, Diagnosis, and Treatment.

Morbid Anatomy.—Hypertrophy, or an actual increase in the substance of the cartilage, occurs occasionally, without any obvious change in the texture, though it is generally accompanied with a soft, spongy, and decidedly diseased condition. The elevation described as occurring in Case No. II., on the external articular surface of the left tibia, took place without any very material change in structure; whilst the thickening of the cartilage of the patella in the same joint evidently arose from softening and positive disease.

Softening is generally very evident to the naked eye. The texture of the part so diseased is pulpy, and resembles a portion of soft fibro-cartilage. For microscopic examination, sections are difficult to be obtained, and the part requires slight separation with needles,—the hyaline substance is dark and indistinctly granular or fibrous,—the cells are enlarged, and contain a number of other cells or nuclei;—in many parts, the dark fibrous mass, contains corpuscles or small cells, which appear to have been set free by the bursting of larger ones.

Atrophy is seen in old people, in whom it is found affecting a whole surface or particular parts. If affecting particular parts, there are generally traces of the former existence of other disease; but when it is thinner than usual over the whole surface, its structure appears healthy.

Ulceration is found involving whole surfaces, the cartilage being soft, velvety, and abraded;—more frequently, such changes are found in the central parts of the cartilages alone, the circumferential part being white, dense, and generally split by numerous small fissures;—or a small spot of the size of a split pea may be the only part affected, and may present an irregularly rounded and excavated spot, the margins of which are fringed by a multitude of projecting bands and fibres, the deepest part being also covered with similar processes. Again, limited depressions occasionally exist, and appear as smooth as if portions of cartilage had been scooped out:—in more active forms of disease, the cartilage is removed very rapidly; and, on examination, a few patches here and there may be the only traces of its former existence. Such patches are generally reddened;

—their surface, though not perfectly smooth, may yet be glistening, and their general appearance is often such as might lead to the impression, that they are portions of tolerably healthy cartilage, which have been left after the absorption of the other parts. The whole surfaces entering into the formation of a joint, or particular parts of the same, are not unfrequently found covered with fibrous and projecting fringes in advanced life. These are best seen on immersing the surface in water, when the fibrous processes float out, and may be carefully examined. They are of all sizes and lengths, attached at one end to the surface of the cartilage, and free at the other. They are found most frequently on the cartilages of the patella and trochlear surface of the femur, the substance of these cartilages, at the same time, being apparently healthy, as far as can be ascertained by the naked eye.

The process thus spoken of as ulceration may commence at any part of the cartilage,—on either of its surfaces, or in its very substance, though its favourite seat is the free surface, from which it gradually extends to the deeper parts, destroying them as it meets with them, and, at last, leaving the bone completely bare.

Whatever external appearance the disease presents, the structural changes are found to be similar, in all cases, on a microscopic examination. These consist of changes in the structure and arrangement of the cells, and of others in the hyaline or inter-cellular substance. In very active forms of disease, the changes in the inter-cellular substance are little observed, owing to its rapid disintegration, or to its absorption into the cells; whilst, in chronic cases, the splitting of the hyaline substance gives to the surface a character so peculiar and well-marked, that, after repeated microscopic examinations, it is possible to state, on a simple inspection, what changes the structure will be found to have undergone, when more minutely examined.

The first changes which can be noticed in the cells are their enlargement and irregular arrangement in the tissue. Some of the cells, in the foregoing observations, were found to measure $\frac{1}{100}$ th of an inch in their long diameter, and others were five or six times their usual size, over large portions of many diseased surfaces. They become rounded, oval, or oblong, and very generally isolated and irregularly distributed, instead of being elongated and found in groups which form columns in the deeper parts. If only slightly enlarged, their nuclei remain in small number, and are irregular;—if considerably enlarged, their contents differ entirely from those of healthy cells, and consist of a mass of corpuscles, which are irregularly rounded, oblong or triangular, glistening on the surface, and varying in diameter from $\frac{1}{2000}$ th to $\frac{1}{5000}$ th of an inch, the larger ones being finely granular, or containing a small nucleolus—(Fig. I.) On tracing sections, containing such cells, towards the surface or diseased part, the cell-walls become indistinct,—patches of corpuscles are met with without cell-walls enclosing them, and the corpuscles

are found at length freely mixed with the tissue.—(Fig. XV.) These changes are best marked in the deep cells, though they occur also in the superficial ones. The cells of the free surface enlarge and become much further separated from each other, losing their regularity of arrangement. Their nuclei generally disappear, and the whole cell often becomes finely granular, and is reduced to a mere shred of membrane, which is gradually lost.—(Figs. XI., XII., and XXV.) In some places the diseased cells enclose others, of about $\frac{1}{1400}$ th of an inch in diameter, which are shortly released by the bursting of the containing cells. These smaller cells are full of dark and irregular granules, $\frac{1}{15000}$ th to $\frac{1}{5000}$ th of an inch in diameter.—(Figs. XIII. and XIV.) They are often found mixed with fibrous tissue, to which they give a dark and indistinct character, as they become gradually lost amongst its fibres.—(Fig. VII.) The diseased cells, nuclei, or corpuscles, contain granules under many other circumstances. Indeed, the granules appear of all intermediate sizes up to $\frac{1}{2000}$ th of an inch, when they are evidently formed of drops of oil, into which the nuclei have probably been converted.

When the disease advances with great rapidity, scarcely any changes can be seen but those in the cells. These become rapidly distended,—thin nuclei are converted into granules, and the cells afterwards form a number of cavities in the tissue, the walls of which appear finely mottled—(Figs. XIII. and XIV.)—or the cells burst upon the surface, causing it to present a series of cavities; and, having discharged their contents, these enter into the formation of a fibro-nucleated membrane, with nipple-like processes which fill up the opened cells.—(Figs. XVII., XVIII., and XXXV.)

The alterations in the hyaline substance consist of a splitting into bands and fibres of all sizes, the smallest fibres being indistinguishable from those of white fibrous tissue. The bands constitute the processes projecting into the joint, loose at one end, and attached to the cartilage at the other. This change was noticed in all the preceding observations. It is not so often seen in acute as in chronic cases, probably because, in the former, the rapid enlargement of the cells destroys the hyaline substance before it has time to break up into bands and fibres; whilst, in the chronic disease, the structure is not always wholly removed, but converted into the fibrous membrane which covers the bone when ulcers have healed. Wherever the surface presents the velvety appearance, this is found to be due to the splitting of the hyaline substance into fibres and bands. Amongst these, rounded gelatinous masses are at times found, and they are occasionally stuck upon the striated bands, and interrupt their continuity. They have every appearance of being the changed contents of cartilage cells.—(Fig. X). The smaller bands are very transparent, and contain no traces of nuclei or cells,—the larger ones have, within them, all the forms of cells and nuclei, which are found deeper in the texture, the most advanced stages of disease in the cells being always found at the part split into fibres. In the parts

wholly converted into small fibres, traces of the nuclei cells can generally be seen—(Figs. IX., XIX., XX., and XXVIII.), or there are small granular cells, as in Fig. VII. Where the bands are connected with the cartilage, enlarged cells or cavities are occasionally found (Fig. XXIV.) in a position which indicates that they are concerned in causing the splitting; and it is to be noticed, that when the hyaline substance of the original surface of the cartilage splits, its bands and fibres lie horizontally, but when that of the deeper parts undergoes a like change, the bands and fibres are always vertical to the surface, the difference being evidently owing to the normal arrangement of the cells of these parts, whether the cells are or are not the immediate cause of the splitting.

The membrane covering the bone at the bottom of old ulcerations which have healed, and that which covers the free surface of cartilages in a chronic state of disease, are of the same character, the latter being only of more recent formation. They consist of dark and very small fibres running horizontally, no nuclei being seen in the parts of old formation until after the action of acetic acid—(Figs. XXI. and XXII.); whilst in other and more recently formed parts, the nuclei are very distinct—(Fig. XXIII.), and in still more recent ones, there is an indistinctly granular and fibrous mass, full of the corpuscles discharged by the bursting of cartilage cells, and in various stages of elongation.—(Figs. XVII. and XVIII.)

As long as the cartilage is the only tissue affected, no other structures are found than those which have been named, and no pus is formed. But, whenever the bone or synovial membrane becomes diseased, these parts throw out the usual exudation, in which new structures grow. Upon the synovial membrane, the exudation becomes organised into lymph or converted into pus, or it may be mixed with tubercular granular matter if it be in a scrofulous individual; in the tissue of the bone, plastic and fusiform cells and primitive filaments are formed in the exuded matters. In all such cases, the new elements just named appear, and have a few changed cartilage cells mixed amongst them.—(Fig. XXIX.)

Disease affecting the articular fibro-cartilages is of a character precisely similar to that before named, whether the changes in the cells or in the fibrous mass be considered.—(See Figs. XXVI., XXVII., and XXVIII.)

Chemistry.—During the occurrence of the above-named morphological changes, there are doubtless many important chemical ones. Thus, the fibres (Figs. VI. and IX.) formed from the hyaline substance, are at first rendered transparent, and then almost wholly dissolved, by the action of acetic acid, as is the case with white fibrous tissue, which is known to consist of gelatin, but cartilages contain chondrin. Now, when the complete conversion into fibres has not taken place, and granular cells are mixed with indistinct fibres, acetic acid has less effect in producing transparency and solution, the actual chemical composition of the part probably chang-

ing in a direct ratio with the changes of structure. Similar chemical and morphological changes are found to advance side by side in the conversion of fibrin into pyin, and this into gelatin, during the formation of white fibrous tissue from coagulated blood-plasma. The gelatinous masses, stuck upon the bands in some places, and loose in others, are also the changed contents of cartilage cells. In many places, the nuclei of cells appear to be resolved into fat; and it is curious to notice, that, in the greater number of places where granular cells are found, these are of the size of the compound granular or exudation cells found in diseased states of other tissues; and yet they are not newly formed cells, but those of cartilage changed in character. Another well-marked chemical action is shown in Observation IV., in the deposition of a number of masses of carbonate of lime in the very substance of the cartilage; and should it prove that the crystals of oxalate of lime, found on the surface in this case, and in Observation II., were formed during life, the mode of production of the oxalic acid will constitute a very interesting and important object of research.

Pathology.—The essential nature of all the known diseases of articular cartilages, is shown by the preceding observations to be a change in the nutrition of their texture. That any one of these is produced mechanically cannot for a moment be maintained, after a careful examination of the texture of the diseased part. Even the fringed and flocculent appearance of cartilages in chronic disease, is always associated with marked changes in the cells and hyaline substance. And yet it is possible, that, in Observation IV., the greater amount of pressure thrown on one lower extremity than the other, was connected with the more extensive disease in the right knee-joint. That the disease depends on actions going on in the cartilage, and proper to it, is proved by its frequent occurrence without a vestige of disease in the synovial membrane or bone; and that all the changes go on independently of any peculiar action in the blood-vessels, is shown by the appearance of the disease on the surface, in by far the greater number of cases, and at parts far removed from the vessels of the bone, or of the synovial or other membrane. Many authors get rid of the “fibrous degeneration of the cartilage,” by assigning to it a nature altogether different from that of other processes in the same texture. That it differs thus, is the opinion of Mr Key, who was the first to maintain that ulceration of articular cartilages results from the absorbing action of a membrane produced on its surface: yet Mr K. does not hesitate to state boldly, that after inflammation caused by wounds, the cartilage is often found to be extensively destroyed and the bone laid bare, without any appearance of a membrane for the purpose of absorption. Yes, it is certain, that in many, if not in the majority, of cases of ulceration of cartilages, the process commences without the presence of any membrane whatever; whilst, on the other hand, there can be little doubt that cartilages are very frequently covered by a thickened

synovial, or a newly-formed vascular membrane, without an ulceration resulting.

That these processes do not *depend* on the conversion of the nuclei and hyaline substance into fat, is shown by such changes being only occasional ones, the whole substance of the cartilage being very frequently destroyed, without the production of fatty granules in a single cell. They can only be referred to an anormal nutrition of the texture, by which the cells become inordinately and imperfectly developed, and the hyaline substance is split into bands and fibres. It will be seen that these statements require to be received as ultimate facts, and that, however inexplicable the nature of the process may appear beyond this, an anormal state of the nutrition of the part gives us as perfect an explanation of the formation of the diseased textures before named, as healthy nutrition does of the manner in which the texture is preserved in its normal state.

The causes of disease in articular cartilages, may be either local or general. At times, the cartilages of a great number of joints are found affected in the same individual; whilst, in others, a particular part of one cartilage in a single joint may be the only diseased spot. Injuries, as a blow or fall, may be the exciting causes, as well as a constitutional disposition to disease, the latter being the cause where a great number of joints are affected at the same time. Again, in many cases, the disease is secondary, and is the result of acute or chronic inflammation of the synovial membrane or bone, by which the circulation in these parts is accelerated, and their nutritive processes disordered. Should an anormal exudation take place, as in scrofulous inflammations and tubercular deposits, its ingredients become mixed with the products of the disease in the cartilages.

The disease may be acute or chronic. When acute, the changes in the cells are at times the only ones which can be observed, and the whole cartilages of a joint may be removed with extreme rapidity. In two cases, Mr Mayo saw the articular cartilages of the ankle completely removed within a month after an injury; and after the lapse of two months, in another case, he found that the cartilages had disappeared, and that the bones were joined by semi-transparent and organised lymph from $\frac{1}{6}$ th to $\frac{1}{4}$ th of an inch in thickness. Mr Lawrence,¹ relates the case of a patient, who died of phlebitis after blood-letting, in which he believes that complete destruction of the articular cartilages of the femur and tibia took place in four days. When the disease is chronic, it may last for years without producing any symptoms whatever; or, it may be the cause of the crackling and grating sometimes noticed in the joints of old people. In Observations I., II. and IV., the patients died of other affections without knowing that disease existed in the joints; and, in the last-named one, the nature of the changes was such, as to render it very probable that disease had existed for years, and had been cured, in

¹ Lectures on Surgery; *Lancet*, 1829 and 1830, Vol. ii.

many places, by the formation of the thin and translucent membrane covering the bone.

Now, if it be true, that disease having the same essential structural characters in all cases, at times goes on to the complete destruction of the texture, without the patient or his attendant being aware of its existence; and in others, causes such violent pain and hectic irritation in the system as to require amputation, the fact is of extreme importance, as, so far as I know, no similar occurrence takes place in any other texture whatever.

I shall not presume to deny, that uncomplicated disease of articular cartilages produces excessive pain, since this is stated very positively on the high authority of Sir B. Brodie, and by most surgical writers. And yet, on looking over the numerous cases which have been related by Sir B. Brodie and other authors, I find but few which will aid in the determination of the question. Uncomplicated disease of cartilage is of very rare occurrence, if we exclude the cases of fibrous degeneration; and carefully collected reports of numerous cases, with histological examinations, are necessary to establish a fact so decidedly at variance with everything we know of disease and its characters in other textures. This will appear more evident from the following considerations:—

1st. Nerves have never been found in cartilages, and there is not the slightest reason for believing that they contain any, for they give no evidence of sensibility in man or in animals on being exposed or sliced away. The cuticle, enamel, and the substance of the brain, are in a similar position. They contain no nerves, and give no indications of sensibility, when parts are removed, or otherwise destroyed. Moreover, it is well known to every pathologist, that an immense portion of the whole bulk of the cerebrum may be utterly destroyed by disease, without a single recognised symptom or other mark of the existence of the lesion. Hence the value of pain.

2nd. It is certain that disease of cartilages may go on for years, and even be cured by the efforts of nature, without the knowledge of the patient, and that the essential characters of such disease are similar to those of other diseases of the same tissue, which are supposed to be the cause of excessive and exhausting pain.

3rd. The symptoms supposed to indicate disease in the cartilages are so closely allied to those produced by affections of the bones, that a positive diagnosis is very difficult to make until the bone becomes exposed, and then the symptoms are, at least, as easily attributable to the disease in the bone as to that in the cartilage. Indeed, M. Richet, in the work before named, when entirely ignorant of the real nature of the changes which take place in diseased articular cartilages, gives several good anatomical and other reasons why the symptoms supposed to arise from disease in them should be referred to the bones.

4th. Pus has never been shown to be formed from the substance of diseased articular cartilages, nor from effusions into their texture.

At the time when pus is formed in joints, the pain becomes very severe, though there may have been but little previously, the very formation of pus indicating that other textures than the cartilage are affected, and that the pain proceeds from the disease in them.

After ulceration has gone on for a considerable time, the part may be healed without any evident exudation. The structure which is formed, is precisely of the same character as the fibro-nucleated membrane found on the surface of cartilages in a chronic state of disease, and it is probably formed in a similar way to the latter, by such a new arrangement of the particles of the cartilage as converts it into fibrous tissue.

Diagnosis.—Little remains to be said on this head. It has been shown, that in cases of chronic disease affecting every cartilage in both knee-joints, there may not be a single indication of disease. It is generally believed, that ulceration of cartilages is indicated by pains, which are at first slight, and afterwards become excessively severe,—which affect a particular spot, deep in a joint, as well as remote parts of the limb, becoming more severe during the night, and always unattended by swelling for four or five weeks, or even for many months. These pains are always increased by motion of the joint and pressure of the articulating surfaces against each other. At last, the suffering becomes most excruciating, and is accompanied by painful spasms and startings of the limb during sleep; the patient's health and spirits fail, and amputation alone can save his life. Sir B. Brodie lays great stress on the character of the pains, and the exhaustion produced by them; on their gradual increase in intensity, and on the occurrence of pains in remote parts of the limb;—on the absence of swelling for a long time, and then on its peculiar character. But the symptoms of disease extending in the bone are so nearly similar, that it is doubtful if all the characters taken together will enable an accomplished surgeon to distinguish the two. It is not at all surprising that, when ulceration has laid the bone bare at a particular part, the symptoms should be so much aggravated, and pus formed, for this is just what we should expect from disease in the bone.

Treatment.—Without a correct diagnosis, the treatment must be empirical, to a certain extent; and directed to the relief of particular symptoms. All the diseases of cartilages result from a local or general disorder of the nutritive processes:—in the former case, there may be no indications of disease; and, in the latter, the bone and synovial membrane are either implicated from the first, or become so subsequently, and the treatment must vary accordingly. Sir B. Brodie places great reliance on caustic issues, and states, that they are of greater service in cases where the cartilages are ulcerated than in other diseases of the joints. When the disease is of a scrofulous or tubercular character, there can be no doubt that more benefit is to be expected from constitutional than from local treatment. For all such cases, the *Ol. Jecoris Aselli* is especially indicated, and local

counter-irritation should be used at the same time, at a greater or less distance from the joint, according to the activity of the disease. It is very obvious that, whenever the cartilages of a joint have lost their smooth surfaces, perfect rest is essential for a cure; and it should be secured by bandaging, according to Mr Scott's plan, or by splints, &c. This is equally essential when ankylosis is expected; for nothing can be conceived so likely to produce destructive irritation as the moving of two roughened and highly sensitive surfaces of bone upon each other; nor is anything so likely to prevent the organisation of the lymph, which may be expected to be poured out in this stage of the disease.

Finally, I may state the following as the conclusions which appear to be warrantable from the foregoing considerations:—

1st, That the whole of the known forms of disease in articular cartilages are connected with changes in the texture, which are essentially similar to each other.

2nd, That during the progress of these changes, the cells of the cartilage become enlarged, rounded, and filled with corpuscles, in lieu of healthy cells; bursting subsequently, and discharging their contents into the texture on the surface; whilst the hyaline substance splits into bands and fibres, the changed hyaline substance and the discharged corpuscles of the cells, afterwards forming, in many cases, a fibro-nucleated membrane on the surface of the diseased cartilage.

3rd, That these changes are alone referable to an anormal nutrition as their immediate cause, and, in no case, to mechanical or chemical actions, such as attrition or digestion in a diseased secretion.

4th, That most extensive disease may be going on in many joints at the same time, and may proceed to destroy the whole thickness of the cartilage in particular parts, without the patient's knowledge, and whilst he is engaged in an active occupation.

5th, That the disease commences most frequently upon the free surface; but it may proceed from the bone to affect the attached surface, or it may take place in the middle of the thickness of the cartilage.

6th, That it is, at least, very doubtful if the symptoms which are believed to indicate the existence of ulceration of articular cartilages, are not really dependent on a morbid change in the bone.

7th, That disease of the whole thickness of an articular cartilage, at particular parts, admits of a natural cure, by the formation of a fibro-nucleated membrane from the substance of the cartilage, without the occurrence of any new exudation.

EXPERIMENTAL RESEARCHES

ON THE

LOWER ANIMALS.

OPPORTUNITIES for examining uncomplicated disease of the human articular cartilages in early life being so rare, that it is difficult for any one to obtain such a number as may enable him to determine with precision the nature of such changes, it becomes necessary to resort to the lower animals to ascertain whether similar affections occur in them;—whether or not such lesions can be induced artificially, and if so, what is their real nature, progress, and mode of termination. In undertaking such a task, it is not to be forgotten, that facts can only be made apparent on certain conditions, viz. that each individual observation be made with the utmost care and faithfulness, and that the observations be sufficiently numerous. Bearing these things in mind, I commenced a series of experiments on the cartilages of the lower animals, in the early part of January 1849, immediately after my attention had been arrested by a remarkable case of disease, and before I knew anything of the real nature of many of the changes which I have since witnessed. These experiments were continued during the whole year, and were nearly ninety in number. The progress of each one was carefully watched and recorded from day to day; and on the death of the animal, a lengthened microscopical examination of every texture, in the neighbourhood of the parts operated upon, was made, and the changes of structure were figured and described. The results of like operations were found precisely similar, in animals of the same species, in all cases in which some accidental occurrence had not taken place, such as the supervention of acute inflammation in the joints, pressure on the articular surfaces resulting from dislocations, &c.; and consequently it is unnecessary to give in this place the whole particulars of each experiment.

The effects of the irritation produced in the *costal cartilages* of

dogs, by the insertion of a *seton*, were ascertained and recorded in twenty-nine instances, in twenty-one of which the seton had been inserted a different number of days before death, the period of time varying from one to fifty-two days. In the remaining eight instances, the setons were inserted at four of the same periods before death as the others above-named. The setons consisted of strong silk, which was passed through the middle of each cartilage by a curved needle, the external surface having been previously laid bare by an incision through the skin and subjacent muscles. The ends of the silk were tied close upon the cartilage, to secure them from removal, and the external wound was carefully sewn up.

The wounds always healed by the first intention when not again interfered with; a copious effusion of lymph took place under the skin, and was an inch in its thickness in places where more than one operation had been performed. Absorption of the portion of cartilage included in the silk took place in three days, and solution of continuity in the whole cartilage in four days, the silk escaping by the wound when this did not heal immediately; and, in other instances, it remained close to the divided cartilage, enclosed in a cyst of fibrous tissue containing a sero-purulent fluid. On the fifth and sixth days, the ends of the cartilage at the seat of operation were found separated to the extent of one-eighth of an inch; on the eighth and tenth days, they were a fourth of an inch apart; and after the twenty-eighth day, they were generally three-eighths of an inch distant from each other, though in two instances they were found much nearer. The ends presented different appearances: in about half the instances, both were rounded or pointed; in two cases, the sternal end was concave, and the costal one convex; and in the rest, one or both of the ends were flattened, concave, rounded, or pointed, these differences in no way corresponding to the length of time which had elapsed from the period of operation. In every case, both ends were slightly reddened, and softer than natural; they were connected behind by a portion of thickened perichondrium; and, in some cases, by a half cylinder of that membrane, so that no doubt can exist that the space between the ends was the result of a removal of the texture of the cartilage, rather than of separation of the ends by mechanical means. This interspace was occupied by a reddish-yellow, soft, and granular mass, which, on being examined at different periods up to the twenty-fourth day, was found to contain large numbers of spherical, finely-granular cells, $\frac{1}{3500}$ th to $\frac{1}{2300}$ th of an inch in diameter, leaving one bright nucleus, $\frac{1}{5000}$ th of an inch in diameter, after the action of acetic acid. The mass also contained primitive filaments (Bennett) with fusiform and exudation cells, the latter having but few granules in their interior. It will be seen that these are the ordinary constituents of an inflammatory effusion in which cellular growths are taking place, and, as such, they are not to be confounded with the cells in the diseased ends of the cartilages and in their immediate neighbourhood, which will be afterwards described.

It has been already noticed that the portion of perichondrium connecting the ends of each cartilage divided by disease was considerably thickened. The thickening was believed to exist even on the first and second days after the passage of the silk, and it was quite obvious on the third day, the membrane afterwards becoming four or five times its usual thickness. The extent of the thickened part was from one-fourth to half an inch along both ends of the cartilage, but beyond this, the perichondrium retained its healthy characters. In every case, the first changes which took place in the structure of the cartilage were those in its perichondrial layers, and the extent of these changes was invariably limited to the part covered by thickened perichondrium, the actual amount of change of structure in the cartilage being always in a direct ratio with that of the thickening of the membrane just named.

That the changes of structure of any part may be properly appreciated at their very commencement, it is essential that every appearance and character of the healthy texture be thoroughly known; and, indeed, without such an acquaintance with a particular texture on the part of others, it is almost impossible to convey to them any idea of its morbid anatomy and pathology. There can be no question that the only certain method of recognising slight disease in any texture, is to compare it with a portion of healthy tissue removed from the same individual under precisely similar circumstances; and therefore Fig. XLIII., which represents healthy tissue, has been inserted, that the characters of the diseased textures may be more readily understood.

The section which the figure just named represents, was removed vertically from the costal cartilage of the dog in the direction of its length, the upper part of the figure showing the structure of the perichondrium and of the perichondrial layers of the cartilage. The perichondrium consists of a dense mass of fibres, which run in the direction of the cartilage for the most part, and present the characters of ordinary fibrous tissues, the greater number of the fibres being those of white fibrous tissue, which are at once rendered transparent, and then destroyed, by the action of acetic acid, and the remainder consisting of nucleolar or elastic fibres lying amongst the former, and not in any way changed by the acid. The nucleolar fibres are found interspersed irregularly amongst those of the white fibrous tissue, their arrangement being precisely that which is noticed in other fibrous membranes. On examining the deepest part of the perichondrium, in section with the cartilage, no line of demarcation can be seen between them, for amongst the fibres of the perichondrium a few of the cells of the superficial layers of the cartilage can be seen; whilst, deeper than this, is a mass of cells which are separated from each other mainly by hyaline substance containing a few fibres. The action of acetic acid on such parts neither affects the cells of the cartilage, which are here very much elongated, and scarcely to be distinguished from fibres, nor the nuclear fibres of the perichondrium,

as has been before stated. It becomes a question, therefore, whether there be any real perichondrial membrane perfectly distinct from the transformed superficial layers of the cartilage? or whether, as there is a great difference in the external part of the perichondrium and the deepest perichondrial layers of the cartilage, the former texture derives its origin from the latter by nutritive changes which affect the cartilage during the whole of life? The solution of this question is of the utmost importance in physiology and pathology, as it affects the general inquiry, whether textures are as distinct from each other as they are usually considered? and whether any one texture is capable of being absolutely transformed into another, which has hitherto been considered perfectly distinct. If, however, it can be shown that the structure of articular cartilages, in which Henle states that he has never been able to find a fibre, is readily convertible into fibrous tissue; and if articular cartilages, generally believed by physiologists to be incapable of ossification, can be demonstrated in different stages of calcification through their entire thickness, a great part of the difficulty in believing in the possibility of conversion of cellular cartilage into fibrous perichondrium will be removed. The transformation of articular cartilages into fibrous membrane in the human subject has been already shown in the foregoing pages, and the strongest confirmation of the statements previously made on this head will now be given, in the fact, that whenever the articular or other cartilages of animals are subjected to considerable injury, the process of conversion of the adjacent uninjured cartilage into fibrous texture commences instantly to heal up the breach. Moreover, the connection of the superficial layers of the cartilage with the formation of the perichondrial fibrous tissue, is much more evidently shown in disease, when the texture of the cartilage becomes opened out, and the relation of its elements to the fibres of the perichondrium can be more satisfactorily examined.

The characters of the healthy costal cartilage of the dog are as follows:—Immediately under the perichondrium it consists of numbers of elongated cells, which lie so closely applied to each other, that the whole texture appears to be made up of them, or a few fibres may be seen in some places between the cells; a little deeper, similar cells, a little greater in width, lie, further separated from each other in a hyaline substance; whilst still deeper in the cartilage, the cells are yet further separated, much larger, rounded, and arranged in groups imbedded in hyaline substance. The average size of the superficial cells is $\frac{1}{1400}$ th of an inch long, by $\frac{1}{7000}$ th or $\frac{1}{5000}$ th broad, and some of them contain a small nucleus or a few indistinct granules, whilst in many, neither nucleus nor granules can be perceived—(Fig. XLIII.) The cells in the deeper parts are very large, always containing a distinct nucleus, and occasionally a nucleolus. They are of various sizes, the largest being in the deepest parts, and very generally changed by the occurrence of ossification in the centre of the cartilage, even in very young animals.

On the third day after the passage of a seton through the cartilage, the portion which had been included in the silk had disappeared, and the exposed surface was rough and soft. The perichondrium in the immediate neighbourhood was evidently thickened, and the superficial cells of the cartilage were increased in width, separated from each other, and each contained from three or five to twelve or sixteen highly refracting granules, $\frac{1}{5000}$ th of an inch in diameter. In some places the walls of the cells were not visible, and patches of granules indicated their former existence; in others, patches of granules, which could not at first be seen, were shown to exist after the granular mass had been rendered transparent by acetic acid. The walls of the deeper cells, on the surface of absorption, were indistinct, their nuclei were dividing into a series of large bright granules, which filled up the clear space that formerly existed between the nucleus and cell-wall; and some cells were seen to have discharged their contents into a granular mass which lay on the surface.

On the fourth, fifth, and sixth days, the changes above named were all better marked. The superficial cells on the fifth day are shown in Fig. XLIV. They measured $\frac{1}{1400}$ th of an inch by $\frac{1}{2000}$ th, though, at a very slight distance in the same cartilage, the width of the superficial cells was not greater than $\frac{1}{7000}$ th of an inch. On the ends of the cartilage, after six days, there was a fibro-granular mass, in which the discharged corpuscles of the cartilage cells were distinctly seen after the addition of acetic acid. These bodies could also be separated from the end of the cartilage by pressure, for their connecting hyaline substance was very soft, and allowed the corpuscles to be pressed from it and examined loose on the field of the microscope. No action was exerted on them by acetic acid.

Fig. XLIII.

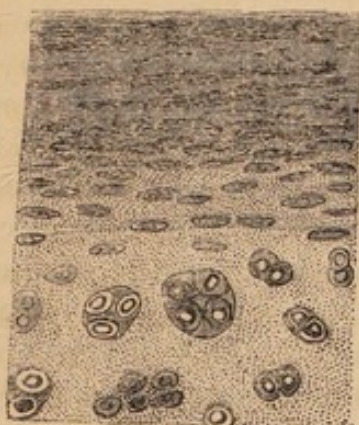

Fig. XLIV.

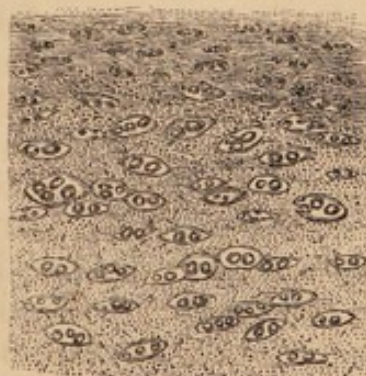


Fig. XLIII.—Section showing the perichondrial layer of cells in the healthy costal cartilage of the dog.

Fig. XLIV.—Perichondrial layer of cells of the costal cartilage of the same dog, changed by the insertion of a seton five days before death.

The further changes in the structure of the ends of the cartilages were so similar when examined at numerous periods up to the fifty-

second day, that they may be described by reference to a few observations.

On the fortieth day, a dense fibrous mass, on the thoracic surface of the ends of the cartilage, constituted the walls of a cyst, which contained the silk with the knots upon it perfectly entire. Complete solution of continuity of the cartilage had taken place, and its softened ends were separated to much less than the usual distance, the interspace being occupied by a fibrous mass. A portion of perichondrium connected the ends, and this membrane was three times its usual thickness for one-fourth of an inch in extent upon both. No change in the structure of the cartilage could be seen beyond the distance of half-an-inch from the solution of continuity. At that point, the thickening of the perichondrium commenced, and the cells under it were considerably increased in width, and apparently shrivelled or irregular on their surface. Further on, the changes were much more marked, the cells measuring $\frac{1}{2000}$ th of an inch in width, and having a swollen appearance. Many had a perfectly smooth surface, and no appearance of granules or a nucleus in their interior; others were wrinkled or contained numerous granules. In the deeper parts of the superficial layers of the cartilage, the cells lay in a perfectly hyaline substance; but those near the perichondrium had indistinct fibres amongst them, and, in fact, gradually mixed with the perichondrial fibres until they could no longer be recognised. The deeper cells had indistinct walls near the end of the cartilage; and in the place of nuclei of the ordinary kind, they contained numerous bodies much smaller than nuclei, and refracting the light as highly as oil. A little further on, these were discharged from the cells into softened hyaline substance, and irregularly disseminated through it, measuring from $\frac{1}{1400}$ th to $\frac{1}{3500}$ th of an inch in their greater diameter. They were round, oblong, triangular, or considerably elongated; in some places, apparently shrivelled; and in others, they contained small but very evident granules. At the point where the large cells discharged their corpuscles into the hyaline mass, their walls constituted a notched line in the tissue, the notches being filled by the hyaline and corpuscular mass—(Fig. XLV.) A little beyond the line just named, as well as in the perichondrial layers close to the surface of absorption, the hyaline substance became less transparent, fibres began to appear between the corpuscles, and the latter were less distinctly seen—(Fig. XLVI.) Then many of the corpuscles became very much elongated, and lay amongst a mass of fibres, whilst others, which remained rounded and of very small size, gradually disappeared amongst similar fibres.

The structure of the mass between the ends of the cartilage was very similar to the textures just named. It consisted, near the cartilage, of hyaline substance, containing a mass of corpuscles disseminated in it; and, at a little distance, of a fibrous mass, containing similar corpuscles, elongating so as very evidently to constitute the nuclear fibres of the fully-formed fibrous tissue. Every stage of the

formation of these fibres from the corpuscles was examined in one or other of the cartilages operated on; for, even when the corpuscles

Fig. XLV.

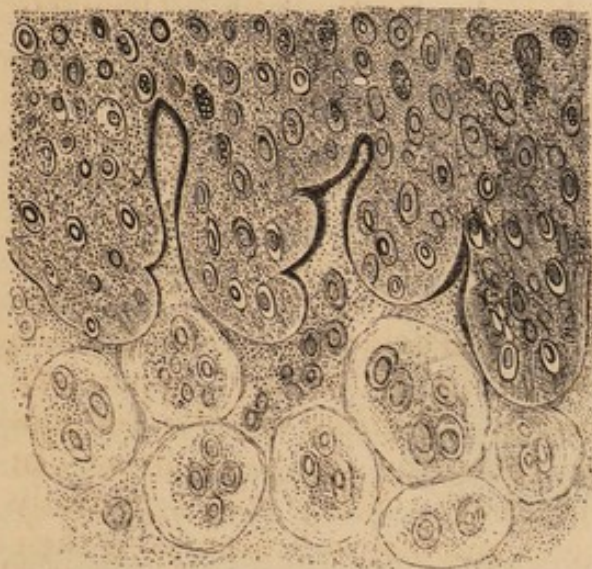

Fig. XLVI.




Fig. XLV.—Section of the costal cartilage of the dog, showing the discharge of the corpuscles of the cells, resulting from the passage of a seton thirty-four days before death.

Fig. XLVI.—Section showing the first appearance of fibres in the hyaline substance between the changed and granular cells of the perichondrial layers of the costal cartilage of the dog, after the passage of a seton forty days before death.

seemed to have wholly disappeared amongst the fibres, they could be brought into view by the action of acetic acid, and then appeared as represented in Fig. XLVII., or much more elongated, and con-

Fig. XLVII.



Fig. XLVII.—The appearance of the fibro-nucleated mass, after the action of acetic acid.

stituting fibres. Reference to the formation of fibrous tissue from the substance of human articular cartilages, shows the process to be precisely similar in them. (See Figs. XXI., XXII., and XXIII., also Figs. XXXVI., XXXVII., and XXXVIII.) And again, a similar but less evident change appears to take place in the healthy state of the superficial layers of the costal cartilages, at their junction with the perichondrium.

In one case, thirty-two days after the insertion of the silk, a tumour was found upon the posterior and upper part of the cartilage, and projected from it an eighth of an inch. It cut like cartilage or enchondroma, and appeared to the naked eye like cartilage with which bands of fibre were intermixed, being also covered externally

by a sort of capsule of fibrous tissue. Thin sections were translucent, consisting of fibres which were far apart, and enclosed amongst them a mass of elongated triangular or irregular corpuscles or cells, which were finely granular or nucleated. The corpuscles measured, on an average, $\frac{1}{1400}$ th by $\frac{1}{2000}$ th of an inch in diameter. Besides the cells and fibres, there existed an evident matrix, composed of hyaline substance—(Fig. XLVIII.)

Fig. XLVIII.

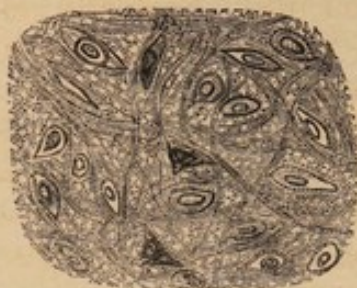


Fig. XLVIII.—Section of a tumour formed upon the costal cartilage of the dog, and resulting from the passage of a seton thirty-two days before death.

In another instance, forty-four days after the insertion of the silk, a quantity of calcareous matter was found amongst the fibrous tissue between the ends of the cartilage, and was composed in some parts of open spaces, surrounded by calcareous, branching arms, as in the cancellated texture of bone. Distinct osseous lacunæ, and discharged corpuscles of cartilage cells, were likewise found in different places; and, on tracing them towards each other, the lacunæ were seen to be formed by the calcification of the walls of cartilage cells, as distinctly as the spaces in the interior of the cells, constituting the hard parts of vegetables, can be traced in their formation from secondary deposits.

The *ensiform cartilage* took on precisely the same changes as the costal, in an instance in which a seton was passed through it, in the dog, forty-four days before death.

The results of the passage of a seton, in four instances, through the *cartilage of the nasal septum*, were also almost precisely similar to those following the same operation on costal cartilages. On the first and second days afterwards, no change could be seen in rabbits. After seven days, in the dog, the perichondrium near the opening was slightly thickened, and the cells under it were larger and rounder than natural. On the edges of the opening, the deeper cells were also decidedly changed in their characters and arrangement. They formed less distinct groups than those at a little distance, being more regularly disseminated through the texture; they appeared shrivelled, and contained bright granules, like globules of oil, $\frac{1}{5000}$ th of an inch in diameter. A granular and indistinctly fibrous mass was found on the edge of the opening, lying in contact with hyaline substance, which was softened, and in many places fib-

rillated, or even fibrous, where it joined with the granular mass. The splitting of the hyaline substance was much more distinct after forty-four days, in another instance, also in the dog. In this case, it took place at a well-marked line, and the corpuscles, set free from cells at a little distance, were mixed with the fibres, and became gradually lost amongst them. The cartilage cells, at $\frac{1}{50}$ th of an inch distant from the point of splitting of the hyaline substance, contained distinct granules, and each appeared to have appropriated a portion of the surrounding hyaline substance to itself, so that the whole appeared converted into a perfectly cellular mass. The largest cells measured $\frac{1}{470}$ th of an inch in their long diameter; and their corpuscles, when set free, varied in length from $\frac{1}{2300}$ th to $\frac{1}{1500}$ th of an inch, and in breadth from $\frac{1}{3500}$ th to $\frac{1}{2300}$ th of an inch.

No change could be seen on the first and second days, after setons had been passed through the *cartilages of the ear* in rabbits; but on the forty-fourth day after one had been passed in the dog, a calcareous mass, full of osseous lacunæ, was found on the edge of the opening, where, also, the proper texture of the fibro-cartilage gave place to fibrous tissue, though no change could be seen to have taken place in the cells.

Division was practised on the costal cartilages of the dog in six instances, and the parts were examined in three cases, after six days; in two, after fifty-two days; and in the other, after fifty-six days. *After six days*, slight swelling was found at the point of division and for a sixth of an inch on either side, and was produced by soft, reddish lymph, which also extended into the fissure produced by the division, and was full of fusiform cells. The perichondrium was thickened, for a little distance from the point of division, in every instance, and the superficial cells were rounded and granular, as they were after the passage of the setons. No change could be seen in the deep cells at this period. *After fifty-two and fifty-six days*, the sternal end was found above the costal, overlaying it to the extent of one-fourth or three-eighths of an inch; and both ends were slightly reddened and soft. The perichondrium was thickened near the ends, and the cells below it were rounded and granular as usual. At this period, the deep cells were bursting and discharging their corpuscles into the hyaline substance, or upon the cut surface; the corpuscles, in the latter case, becoming much elongated, and mixed with a fibro-granular mass.

Ligatures were tightly applied to the costal cartilages in twelve instances in rabbits, and in five others in dogs, at periods varying from one to forty-eight days before the parts were examined.

On the first and second days, no change could be seen in rabbits, except that a small portion of cartilage appeared deficient under the ligature; but in the dog, two days after the application of a ligature, considerable destruction of the cartilage was found to have taken place for $\frac{1}{12}$ th of an inch in the direction of its length, whilst the ligature remained and enclosed a thin lamina of cartilage. The

surrounding soft tissues were detached from the cartilage, having been separated by inflammatory effusion. The thin portion of cartilage remaining in the ligature consisted of cells, which contained a number of small nuclei, apparently formed by irregular division of the ordinary ones; the surface of the same part presented a number of hyaline bands, $\frac{1}{280}$ th of an inch long, and precisely similar to those before described in the chronic disease of human articular cartilages. The perichondrial cells were changed in a very marked degree. They were broader than healthy cells, swollen, and contained from two to six or eight very bright granules; being also so much rounded and separated from each other as to require tracing up to the perichondrium to be recognised.—(Fig. XLIX.)

Fig. XLIX.



Fig. XLIX.—Changes induced in the perichondrial cells of the costal cartilage of the dog in two days, by the application of a ligature.

In the dog, on the fourth day, complete solution of continuity of the cartilage had taken place, and yet its central part was ossified. At one part, the perichondrium was evidently thickened, and the superficial cells were enlarged, granular, and irregularly distributed in the texture; where the perichondrium was not obviously thickened, the superficial cells were unchanged. When examined after a ligature had been applied thirty-nine days, the costal end of the divided cartilage was found lower than the sternal one, and overlaid by it for an extent of $\frac{1}{8}$ th of an inch. The ends were rounded and slightly softened, and the cells near to them were breaking up, and, in a few places, crowded with corpuscles, which, at a very definite line further on, were free in the hyaline substance. These corpuscles, when of the largest size, measured $\frac{1}{2300}$ th of an inch—the greater number being much smaller. Further on, they were either much elongated, or reduced to mere rows of granules, and mixed with fibrous tissue, apparently formed by splitting of the hyaline substance of the cartilage. The perichondrium was only slightly thickened; but near the free ends of the cartilage, its superficial cells were considerably enlarged, granular, and separated from each other,

the most external mixing with the fibres of the perichondrium, as if they were to constitute the nuclear fibres of that membrane when fully developed.

In a number of instances in which *ligatures* had been applied in rabbits *for thirty-three days, or longer*, to costal cartilages which were ossified in the centre, complete solution of continuity had taken place; the ligature remained on one end of the cartilage, and, together with both ends, was enclosed in a yellowish-white curdy mass, constituting tumours from the size of a horse-bean to that of a small walnut, consisting of irregularly-rounded granular cells, which varied in size from $\frac{1}{3500}$ th to $\frac{1}{2300}$ th of an inch, becoming shrivelled, and then displaying a large nucleus, or two or three granules, on the action of acetic acid. Destruction of the cartilage, which covered the central ossified part of each, had taken place on both ends to the extent of $\frac{1}{6}$ th of an inch; and on the surface of absorption, the cells had broken up and discharged their corpuscles into the hyaline substance, which, in some places, could be seen becoming fibrous at the same time as the corpuscles were elongating. In a few places, the fibrous mass was so fully formed as to prevent the corpuscles from being seen until after the action of acetic acid, which at once revealed their existence. The calcified part of each cartilage included in the ligature, presented a number of cells, in the walls of which calcareous matter had become deposited, giving to the texture an appearance very different from that of the part further on, in which spiculæ of bone were seen in their usual arrangement.

The results of operations on the *cartilages* of fourteen of the *largest joints* of dogs and rabbits show how little such textures are disposed to take on diseased actions;—that when disease is excited in them, it has no tendency to involve more of the cartilage than that which is immediately in the neighbourhood of the injured part, nor yet to extend to the other textures of the joint; and again, that whether the cartilage be injured by the knife, by actual cautery, or by the application of strong acids or alkalies, abnormal nutritive changes are excited in the surrounding parts, so that they soon give rise to fibrous texture, which heals up the breach.

I have found that simple exposure of the interior of the largest joints of the lower animals, for a limited time, is unattended with the production of disease; and, indeed, it would appear that in man, the danger resulting from simple exposure of serous and synovial membranes by incised wounds, with clean instruments, has been very much over-rated. In dogs and rabbits, simple incisions in the articular cartilages, and even the application of actual cautery to them, excited, in many cases, no inflammatory action whatever, or merely slight swelling of the joint for a few days; unless when a dislocation, as of the patella, was the result, or when both knee-joints of the same animal had been operated on at the same time. The lameness produced by such operations, especially in young animals, disappeared in a week or fortnight; but, when dislocation resulted,

more serious disease in the joint invariably occurred. The action of chemical substances could not be strictly limited to the cartilages, and acute inflammation, with copious effusions of lymph, took place in the interior of the joints to which they were applied.

The effects of *incision* of the *articular cartilages* of dogs were ascertained in eleven instances in which the process was not interfered with by any accidental occurrence. The incisions were made in the cartilage of the patella, and were directed obliquely from below upwards, so as to produce small wedge-shaped flaps, which were left attached by their bases. No change of structure was visible in three cases examined on the seventh day after operation. The rest were examined at different periods between the thirty-seventh and the forty-ninth day after the incisions had been made, and all presented precisely similar changes of structure, further advanced on the forty-ninth day than at periods before that time. In no case could any change be observed by the naked eye; for the position of each incision was merely indicated by the slightest transverse and curvi-linear depression where it had been made. At the thirty-seventh day, the surface of the cartilage was perfectly even, and the flaps were so firmly adherent to the cut surface below them, that sections were made with the greatest ease through the adjacent cut surfaces, and preparations were preserved with these surfaces still attached. The changes of structure were most marked at the free edges of the flaps, and on the cut surfaces, also for a slight distance in the superficial cells. On examining vertical sections through the flaps and cut surfaces, the cells at the base of the flaps were found arranged precisely as in healthy cartilages, the deep ones measuring $\frac{1}{2350}$ th to $\frac{1}{3500}$ th of an inch, accumulated in vertical groups of three or four—the group measuring $\frac{1}{700}$ th of an inch by $\frac{1}{2300}$ th. Passing onwards towards the free edge of each flap, the deep cells became granular, apparently from division of their nuclei into granules; and, in some cases, a similar change could be seen in the superficial cells of the flap. On the cut surfaces, and at the free edge of each flap, the cells were very large, round, or oblong in shape, and they measured from $\frac{1}{1400}$ th to $\frac{1}{330}$ th of an inch in their greater diameter, and from $\frac{1}{1400}$ th to $\frac{1}{540}$ th in the lesser. The greater number were oblong, but many were spherical, and all were crowded with irregular corpuscles, measuring from $\frac{1}{3500}$ th to $\frac{1}{2000}$ th of an inch. The inter-cellular substance was hyaline, and in a few places indistinctly fibrous. The cells were irregularly arranged in it, and thus contrasted remarkably with the vertical groups in the deep cells of healthy parts. Many of the large round cells, on the cut surfaces, projected considerably, and they no doubt discharged their corpuscles into the fibro-nucleated mass connecting the surfaces; for, on examination, the mass was found to be very transparent, occasionally containing imperfect fibres, and always studded with irregular corpuscles, differing from those within the cells, in being smaller and more irregular. The changes observed in the superficial layers of the cartilage were,—slight enlargement of the

cells, especially in width, with the production of granules in their interior, the inter-cellular substance becoming indistinctly fibrous or granular, so as partly to conceal the cells.—(Fig. L.)

Fig. L.

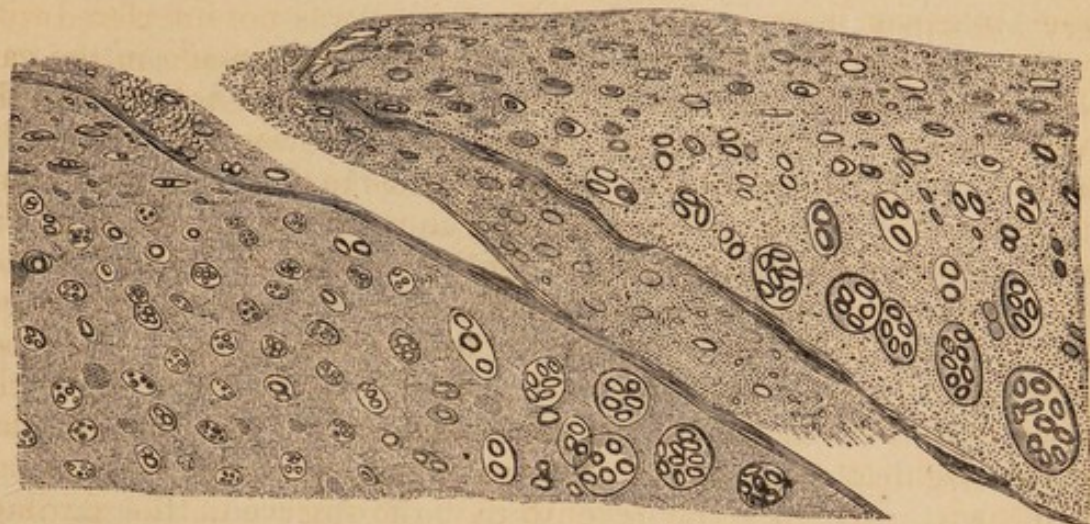


Fig. L.—Appearance of the cartilage of the patella of the dog on the edges of an incision, made forty-nine days before death.

In an instance in which the patella was dislocated outwards, and had the middle of its posterior surface firmly pressed upon the edge of the articular surface of the condyle of the femur during flexion, a small flap, made by incision, was found directed upwards, and lay in such a position as to make pressure upon another flap, situated higher up, causing its entire removal. The structure of the flap which was turned up was changed in a similar way to that of those before described. The whole upper part of the cartilage was loosened at its attachment to the bone. Its cells were indistinct in some parts, having become very granular, or reduced to mere patches of granules, which lay in a fibrous or hyaline matrix, the hyaline substance having become converted into fibres, whilst the cells were reduced to small patches of granules.

In another instance, the patella was dislocated internally, and the external half of its articular surface, which moved on the condyle during flexion and extension, presented a perfectly smooth and polished surface on a level with the other parts of the cartilage. This surface rung like bone on being struck with a knife; but, on being examined, still presented the usual arrangement of superficial and deep cells of cartilage, in a few places; whilst, in others, the cells of the whole thickness of the cartilage were distinctly calcified, explaining why this part of the surface was not depressed, as it would have been if the cartilage had been removed so as to have exposed the bone. The deep cells still retained their columnar arrangement even when completely calcified. On the surface of the uncalcified parts of the cartilage, large rounded cells existed, measuring in some places, $\frac{1}{470}$ th of an inch, and crowded with finely granular cor-

puscles. A similar calcification of the cells of the cartilage of the patella of the rabbit was noticed, after incision and inflammation of the joint resulting from this and the application of actual cautery to the cartilage of the femur. As the cartilage became calcified, the texture assumed the appearance of some forms of fibro-cartilage, with very indistinct fibres.

The changes produced by the application of *actual cautery* to a limited space on the cartilage of the femur or patella, so as to destroy it through nearly its whole thickness, were ascertained in dogs and rabbits in ten instances. It was found that inflammation by no means necessarily took place when the cauterised spot did not exceed one-eighth of an inch in its greatest diameter, and when dislocation did not result; but that when the application was made to a more extensive surface, even superficially, a considerable quantity of lymph was thrown out by inflammation, and was mixed with the elements of the diseased cartilages. The cases in which neither inflammation nor displacement occurred, were those in which the changes in the texture of the cartilage were best observed, though these were essentially similar, in all the cases, in animals of the same species.

No change of texture could be distinctly seen on the most careful examination made on the 2nd and 7th days after the application of the cautery; but a marked change was found at periods between the 37th and 98th days, and was always of the same character. Thus, *on the 39th and 49th days*, the cartilage presented a reddened and depressed spot at the point of application of the cautery; and, for the distance of a line around that part, it was slightly diminished in its thickness. Beyond this, every part of the texture appeared perfectly healthy, and consisted of a series of superficial cells, parallel to the surface, measuring $\frac{1}{1700}$ th of an inch by $\frac{1}{7000}$ th, and rarely containing a distinct nucleus or granule;—also of deep cells, arranged in vertical groups, as usual, these groups measuring $\frac{1}{700}$ th by $\frac{1}{2300}$ th of an inch, and lying in hyaline substance, like the cells of the surface. On proceeding in the examination, from the healthy towards the cauterised part, the deep cells were further separated, and constituted rounded groups rather than vertical columns; nearer still, the cells in the rounded groups became separated, enlarged, and regularly disseminated through the hyaline matrix; whilst, where the cartilage was diminished in thickness, the superficial cells were no longer seen, and the deeper ones were very much enlarged, rounded, or oblong, and crowded with corpuscles. The largest measured $\frac{1}{230}$ th by $\frac{1}{250}$ th of an inch, and the average size of their contained corpuscles was $\frac{1}{3500}$ th of an inch. The cells of largest size were found at an abrupt line, which constituted the margin of the surface to which the cautery had been applied; those seen on passing away from this point gradually diminishing in size.—(Fig. LI.) Beyond the largest cells, in the other direction, was a mass of corpuscles lying in a hyaline matrix, which, at a little distance, presented

traces of fibres; whilst perfect fibres, densely interwoven, constituted a fibrous membrane at the bottom of the cauterised spot. In the fibrous membrane, no further traces of corpuscles could be

Fig. LI.

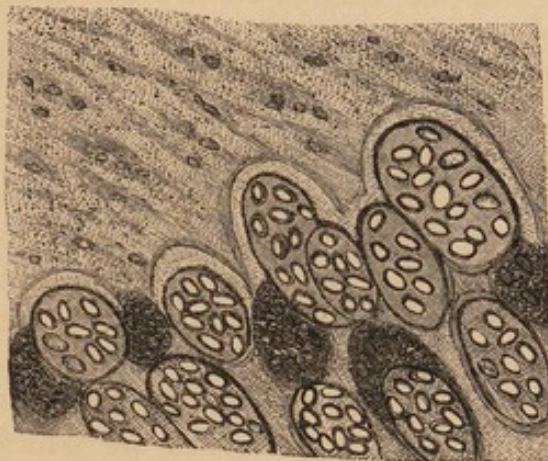


Fig. LI.—Shows the cartilage of the femoral trochlear on the edge of a spot to which actual cauterity was applied forty-nine days before death.

seen than small patches of granules; and, in many preparations, these were not visible without the action of acetic acid. Between the part consisting of perfect fibres, and that composed of corpuscles discharged into a hyaline matrix, the corpuscles were found gradually becoming smaller and elongated, like nuclei of fibres; or granular, shrivelled, and at last reduced to mere clusters of granules. The texture of the bone under the cartilage thus changed, was dense and apparently healthy.

In cases where inflammation had taken place, the cauterised and the neighbouring parts were covered with a dense fibrous mass, which could be stripped from the bone with forceps. The structure of the superficial and deep portions of this mass was very different, the superficial part consisting of fibrous tissue, with nuclei, elongated in the direction of the fibres, and brought into view by the addition of acetic acid; and the deeper ones having nuclei interspersed amongst fibres, and lying at right angles, or obliquely, in relation to each other, capable also of being traced in all stages of their formation, from the discharged corpuscles of cartilage cells.¹

In a knee-joint, in which internal dislocation of the patella became permanent, a dimple-like depression on the external part of the cartilage of the inner glenoid cavity of the tibia, indicated the point on which the condyle of the femur had rested. The superficial cells of this part were spherical, $\frac{1}{1200}$ th of an inch in diameter, and con-

¹ It is difficult to convey an accurate idea of the difference in appearance of the fibres and nuclei of the fibrous tissue, which was the product of inflammation, and of that which resulted from changes in the texture of the cartilage, notwithstanding that a few examinations of both, with the attention directed to the nuclei, readily serves to distinguish them.

tained three or four finely granular corpuscles, whilst the superficial cells of all the surrounding parts presented the usual horizontal arrangement.—(Fig. LII.)

Fig. LII.

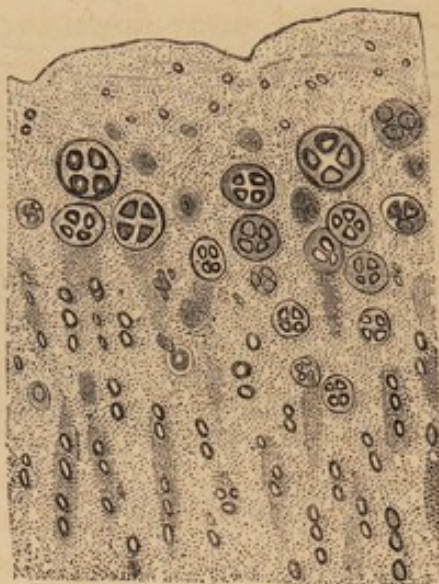


Fig. LII.—Cartilage of the internal glenoid cavity of the tibia, at a dimple like depression, on which the condyle of the femur rested, showing the large cells on the free surface.

In another case, the patella remained dislocated internally, and the cartilage of both glenoid cavities was considerably changed, without any other apparent cause than the unequal pressure made upon the surfaces. The cartilage of the external cavity was softened; its superficial parts were granular, and their cells largely developed and loosened, as shown in Figs. XI. and XII. These cells measured $\frac{1}{1000}$ th by $\frac{1}{1700}$ th of an inch, and contained imperfect corpuscles. The deeper parts appeared mottled, but their cells were unchanged. The cartilage of the internal glenoid cavity was absent over about half the surface in front and internally, as well as under the semi-lunar cartilages. Where it existed, the superficial cells were removed, and bands and fibres, formed of hyaline substance, projected from the surface for $\frac{1}{700}$ th of an inch. The cells in the deepest parts lay in vertical columns, in hyaline substance, which was mottled and indistinct, and those placed more superficially, were enlarged, and measured from $\frac{1}{1400}$ th to $\frac{1}{700}$ th of an inch. They contained corpuscles, and were irregularly distributed in the texture.

After actual cautery had been applied, for upwards of forty days, to the central part of the cartilages of the knee-joints of rabbits, similar changes to those detailed above were found; but in many parts the surface retained its level, and became calcareous, owing to deposition of calcareous matter in the walls of the cells and in their nuclei, converting them into bodies precisely like osseous lacunæ. This calcification could be observed in all stages; taking place, in some parts, where the arrangement of the cells had become irregular, and

in others, where they still formed columns arranged vertically. It will be recollected that a similar formation of lacunæ from cartilage cells was before shown to take place in the costal cartilages, and in the fibro-cartilage of the ear.

In two cases, in which central portions of the articular cartilages of the knee-joint had been cut away down to the bone, 140 days before death, precisely the same changes as are detailed above, took place in the adjacent parts, the only difference being, that many of the corpuscles which had been set free had become enlarged, and occupied spaces between the fibres, so as to give the texture the characters of fibro-cartilage.

Intense inflammation, with effusion of lymph, was the result of the temporary application of *hydrochloric acid*, *liquor potassæ*, or *liquor ammoniæ*, to the cartilages of the knee-joints of rabbits. The cartilage, in different places, underwent all the before-mentioned changes, being completely calcified in many parts; whilst, in others, there were various stages of production of granules in the cells, or reduction of the cells or nuclei to patches of granules found amongst fibres. In some places, the cells were large, and crowded with corpuscles;—in others, the corpuscles were interspersed amongst fibres, and were undergoing the usual conversion into nuclei;—and many parts consisted of cells lying in a very dark inter-cellular substance, which obstructed the passage of the light, even in very thin sections. Such parts were instantly rendered transparent by the action of acetic acid; the acetic solution thus obtained, giving, after neutralisation by ammonia, and the addition of oxalate of ammonia, numbers of beautifully octohedral crystals insoluble in acetic acid, and evidently those of oxalate of lime. It thus appears that the darkening of the hyaline substance is owing to the deposition of calcareous salts. In the cases just noticed, the application of the fluid was intended to be confined to the cartilages of the patella and femur, but a small quantity ran into the joints, apparently in consequence of which the superficial cells of the posterior part of the femoral condyles, and those of the cartilages of the tibia, were very much enlarged, widely separated, and connected only by a gelatinous and hyaline substance, from which the cells escaped readily by pressure. To the naked eye, these parts presented no trace of disease.

With a view to ascertain the mode of extension of disease from the bone to articular cartilage, I passed a thick brass wire, in two instances, in the dog, under the trochlear surface of the femur, at the distance of half-a-line from the cartilage; but, on examination of the parts, at periods of nineteen and thirty-four days afterwards, no change could be seen in the cartilage, except that its superficial cells in the neighbourhood of the part, were enlarged and granular. It is very probable, however, that this was the result of inflammation in the synovial membrane, as the deeper parts of the cartilage were certainly unchanged in structure, in both instances. After thirty-four

days, the bone in contact with the wire was softened; and, in both cases, the whole lower end of the femur was highly vascular. Considerable lameness followed both these operations, and continued for a week or ten days, after which it could scarcely be perceived, unless during unusual movements of the limbs.

From what has preceded, it is obvious that anormal nutritive changes can be induced in the cartilages of the lower animals, with considerable facility, by irritations of various kinds—such as the making of incisions into them, the insertion of setons, the application of ligatures, actual cautery, acids or alkalies:—again, they occur as the result of inflammation in the synovial membrane, which leads to the supply of nutritious fluid to the cartilage in increased quantity, and of anormal composition;—and, further, they result from unequal pressure upon articular surfaces, and appear to arise when the pressure is diminished, as well as when it is increased.¹ When changes are induced in the costal, articular, or nasal cartilages, by any cause whatever, they are essentially similar in all cases, and affect both the cells and inter-cellular substance. The cells become enlarged, rounded, or oblong, and irregularly arranged; their nuclei giving place to a multitude of corpuscles, or to a series of granules. The walls of the cells next become identified with the hyaline substance, when the corpuscles are set free, and begin to undergo other changes, elongating and becoming very evidently converted into the nuclear fibres of fibrous tissue, or reduced to small patches of granules, which may only become visible on acting upon the fibrous mass by acetic acid. During the enlargement of the cells, and especially at the period of discharge of their contents, the hyaline matrix becomes softened, and allows the corpuscles to be freely moved in it, or pressed out altogether; whilst, at a subsequent period, fibres appear in the interspaces of the corpuscles, and take on the characters of those of the white fibrous tissue. In this way, both elements of the cartilage are concerned in the formation of the fibrous membrane, which is destined to heal the breach in the tissue, for the hyaline substance is converted into the white fibres, and the corpuscles of the cells into nuclear or elastic fibres.—Or, an altogether different result may take place, especially in the case of articular cartilages, the whole thickness being converted into a calcareous mass; the cartilage cells becoming lacunæ, and calcareous matter being also deposited in the intercellular substance, rendering it dark and incapable of transmitting the light, the surface all the while remaining perfectly smooth and on its former level.

A very important feature in the changes induced in healthy cartilages by injuries, is their decided tendency to go on to a perfect cure, by the formation of a dense fibrous membrane, or a smooth

¹ The disadvantages of maintaining joints in one position, for lengthened periods, have long been familiar to surgeons.

calcareous lamina; for in no case do they extend further into the healthy cartilage surrounding an injured spot, than appears necessary for the formation of sufficient fibrous texture to constitute the cicatrix.

The early period at which changes occurred after great irritations, when compared with their very tardy development when mere incisions had been made in the cartilages, is of great consequence, showing that the changes are dependent on the activity of the nutritive process. It will be remembered that the enlarged and granular state of the superficial cells of costal cartilages was very manifest on the second day after the application of a ligature, and on the third day after the passage of a seton; whilst no change could be seen on the surfaces of incisions after seven days; and, even after forty-nine days, such parts presented very trifling changes when compared with those which had been subjected to more serious irritation.¹ Yet, as these changes were precisely similar to those which occurred under other circumstances, and went on to the formation of perfect fibrous tissue, there is no longer any reason to doubt that incisions, fractures, or other lesions of articular cartilages, are capable of complete cure by the production of fibrous tissue from the substance of the adjacent uninjured cartilage, on the establishment of an anormal nutritive process.

The general result of these researches, appears in the strongest manner confirmatory of the conclusions previously drawn from the examination of the human articular cartilages, and to be of importance in demonstrating:—

1st. That the changes of structure which result from the most varied injuries, are of similar characters in all cartilages.

2nd. That these changes invariably affect both the cells and inter-cellular substance.

3rd. That the only explanation of the nature of such changes which can be given is, that they depend upon an increased and anormal nutrition of the texture.

4th. That uncomplicated lesions of cartilage, especially such as have been artificially induced in the lower animals, manifest a very decided tendency to spontaneous cure by the production of fibrous tissue, or by calcification of the whole cartilage left after the injury.

¹ The slight extent of the changes induced in cartilages by division, and the length of time taken up in their completion, have probably given rise to many of the statements that divided or fractured articular cartilages never unite; whilst the same opinion appears to have been adopted by other observers on entirely different grounds. Thus, Dr Leidy, in his excellent paper on articular cartilages, in the "American Journal of Medical Sciences" for April 1849, says:—As well almost might the two opposed surfaces of articular cartilage unite in a joint in which there is little motion, as for the two broken edges of one to do so.

5th. That the fibrous tissue, which heals up breaches in the texture of cartilage, contains both the white and yellow fibrous elements, the former being produced by an actual conversion of the hyaline substance into it, and the latter by elongation of the discharged corpuscles of diseased cells into nuclear fibres.

6th. That diseased action arising from circumscribed destruction of the articular cartilages of the lower animals, evinces no tendency to extend to the remaining parts of these textures, nor to involve other structures, and lead to serious disease of the joint.