

On a remarkable diminution of the medulla oblongata and adjacent portion of the spinal marrow. Consequent upon gradual spontaneous luxation of the Processus dentatus and ankylosis at the upper part of the spine, yet unattended by any symptom of paralysis / by P.D. Handyside.

Contributors

Handyside, P. D. 1808-1881.

Publication/Creation

[Place of publication not identified] : [publisher not identified], [1840]
(Edinburgh : J. Stark.)

Persistent URL

<https://wellcomecollection.org/works/xzbjavtz>

License and attribution

This work has been identified as being free of known restrictions under copyright law, including all related and neighbouring rights and is being made available under the Creative Commons, Public Domain Mark.

You can copy, modify, distribute and perform the work, even for commercial purposes, without asking permission.



Wellcome Collection
183 Euston Road
London NW1 2BE UK
T +44 (0)20 7611 8722
E library@wellcomecollection.org
<https://wellcomecollection.org>

ON A REMARKABLE

DIMINUTION OF THE MEDULLA OBLONGATA,

AND ADJACENT PORTION OF THE
SPINAL MARROW,



CONSEQUENT UPON GRADUAL SPONTANEOUS
LUXATION OF THE PROCESSUS DENTATUS, AND
ANKYLOSIS AT THE UPPER PART OF THE SPINE,
YET UNATTENDED BY ANY SYMPTOM OF PARALYSIS.

BY

P. D. HANDYSIDE, M. D., F. R. S. E.,

Lecturer on Anatomy and Physiology, and Surgeon to the Royal Dispensary.

[WITH AN ENGRAVING.]

(Read before the Medico-Chirurgical Society.)

(From the Edin. Med. and Surg. Journal, No. 143.)

WILLIAM CRAIGIE, a working-cutler by trade, suffered at the age of 22 years, under a protracted attack of rheumatic fever, and was in consequence confined to bed for about seven weeks. During much of that time he was so debilitated as to be unable to turn his head or body, and lay almost constantly upon his left side. On recovery from this illness there was evident ankylosis between the occiput, atlas, and adjoining vertebræ, his head being bent immoveably forwards, and slightly to the right side. Nevertheless, he was able soon to return to his accustomed employment, and, indeed, he performed equally well the more severe and laborious operations at his forge, and the nicer and more delicate manipulations of a surgical instrument-maker, at which department of his trade he was unusually dexterous.

Four years previous to his death, he suffered under a severe bronchitic attack. After repeated invasions of this complaint, to which the severity of his occupation, with the alternations of temperature which he was frequently called upon to endure, in a great

degree exposed him, he was at length carried off, after a day of continued bodily fatigue, by a very sudden and rapid attack of asphyxia. Thus, at the age of 32 years, terminated a case of what
* was found, upon dissection, to be advanced vesicular bronchitis.

Sectio.—Upon examining the upper part of the spine, the occipital bone, as was anticipated, is found firmly ankylosed to the atlas. These two bones are immoveably united in three places.* This ankylosis serves to connect the condyloid processes, and the posterior fourth of the *foramen magnum* of the occipital bone, with the corresponding surfaces of the atlas; and the circumstance of the head of this individual being retained immoveably in a direction downwards and forwards to the right side, is explained by the circumstance of the right inferior articular surface of the atlas being dislocated downwards and forwards over the corresponding articular surface of the axis, and retained in this false position by a strong bony union.

The displacement between the atlas and axis is such that the anterior portion of the ring of the former bone projects forwards, downwards, and to the right side, from the corresponding portion of the body of the latter, to the extent of nine lines. The extremity of the right transverse process of the atlas projects seven-eighths of an inch forwards, and lies on the same horizontal plane with the extremity of the right transverse process of the axis; while the left transverse process of the atlas projects a quarter of an inch in front of the corresponding one of the axis, and is raised one inch above it. Again, the space which intervenes between the posterior surface of the odontoid process of the axis, and the anterior surface of the posterior segment of the atlas, for the lodgement of the lower part of the *medulla oblongata*, is reduced, in the mesian plane, to two lines; while to the right side of the mesian line, where, indeed, the *medulla oblongata* lay, this space does not exceed three lines and two-thirds in its antero-posterior diameter.

The synovial membrane of the atlanto-odontoid articulation is wanting, owing to the separation of these surfaces and their relative position being so much altered and deranged. However, the intervening space which has resulted from this distortion is occupied by a very strong fibro-cartilaginous band, of a cuboid shape, six lines in length by five lines in breadth. In the entire length of this dense texture, lie imbedded four vertical laminæ of bone, which at their extremities are connected to, and serve to retain immovable, what were formerly the two opposite articular surfaces. The transverse ligament of the atlas is altogether wanting, but the tubercles which served formerly for the attachment of that ligament are connected by soft fibro-cellular tissue to the intervening fibro-cartilaginous band already noticed. The *ligamentum subflavum*, extending between the atlas and axis, is absent, excepting in the

* See Plate, where the upper surface of the atlas and axis is faithfully represented, after the occipital bone had been forcibly detached from the atlas with the cutting pliers.

mesian line, where an elongated narrow band, remarkably dense, firm, and resisting in texture, though retaining none of its original elasticity, is stretched obliquely between these two bones, in a situation where they are apart from each other to the distance of one inch and three-eighths.

The articulations intervening between the second, third, fourth, and fifth vertebræ of the neck are not very free in their movements, owing to the deposition of calcareous matter in the fibro-cartilages covering their surfaces. An approximation to ankylosis is sufficiently manifested in this condition of the parts.

The membranes and vessels of the *medulla oblongata* and cervical portion of the spinal marrow were natural.

The *medulla oblongata* itself appeared natural, with the exception of a considerable alteration in the antero-posterior diameter of its lower portion, which, from the unusually contracted limits of the spinal canal at its upper part, was reduced to only three lines in thickness. It was also remarkably altered in its position, for it rested obliquely on the basilar portion of the occipital bone, while its lower portion was placed altogether to the right side of the odontoid process of the axis and of the arch of the atlas in a circumscribed space, the antero-posterior diameter of which, as already remarked, did not exceed three lines and two-thirds, and the transverse diameter of which measured only six lines.

The nerves arising from the *medulla oblongata* were of their natural size, consistence, and colour, and so likewise were the cervical nerves.

No paralysis, or even any remote indication of the existence of that state, or of any other affection of the nervous system, presented itself in any part of the body.

The foregoing case serves to illustrate well the very considerable amount of pressure and torsion which the *medulla oblongata* and upper part of the spinal marrow may be brought gradually to sustain, without the production of the slightest inconvenience; although these important and essential parts of the nervous system, being subjected suddenly to even a moderate amount of pressure, produces an interruption, which, if maintained, may terminate speedily in a total cessation of the vital functions of the body.

Professor Rust of Vienna, who gives the best account of this morbid condition, observes, that the pressure on the spinal cord, which the luxation of the occiput upon the atlas must produce, is not fatal, because it occurs gradually.* He refers to a specimen of luxation and ankylosis at the upper part of the spine, contained in the Anatomical Museum at the Jardin des Plantes at Paris, in which the vertebral canal had been so considerably contracted that a common quill could not be introduced into the opening. The patient survived, however, long enough for ankylosis to be effected†.

* *Arthrokakologie*, 1817, p. 32, (quoted by Mr Lawrence.)

† *Hist. Natur. Gén. et Partic. avec la description du Cabinet du Roi*, Tom. iii. p. 99.

4 Dr Handyside on *Diminution of the Medulla Oblongata, &c.*

Mr Lawrence, in his very valuable paper on Dislocations of the Vertebrae,* narrates a case in many respects very similar to that which I have described. The *processus dentatus* was so completely dislocated from the atlas and occiput, as to intercept about one-third of the spinal canal, yet without producing any paralytic affection. Mr Lawrence adduces from Reil's Archives† a parallel instance, in which the vertebral canal at the *foramen magnum* was diminished by one-half, and that too without a paralytic symptom.

Caries of the atlas and axis, accompanied by gradual spontaneous dislocation of the *processus dentatus*, is, among other pathognomonic signs, characterized by the entire absence of paralysis, which, according to Professor Syme,‡ is a very constant mark of the existence of this very interesting and important disease. The case which I have here detailed is worthy of notice, as presenting the peculiarity just noticed; while, at the same time, the history, symptoms, and necroscopic appearances of caries fail to be traced in it.


In the museum at Guy's Hospital, London, are some preparations illustrative of ankylosis and exostosis of the cervical vertebrae. But in all of these cases, as well as in many others which are recorded, paralysis had resulted. Dr Hodgkin, the author of the catalogue of that valuable collection, describes the preparations marked Nos. 1011 and 1012, as exhibiting the *processus dentatus* so much enlarged as to have occasioned paralysis. In No. 1012, a preparation taken from the body of a patient who had been under the care of Dr Bright, partial paralysis, both of the upper and lower extremities, had been produced by an exostosis arising from the *processus dentatus*.

* London Medico-Chirurgical Transactions, Vol. xiii. p. 400.

† Archiv für die Physiologie, Vol. iv. p. 407.

‡ Vol. xlv. of this Journal, pp. 8 and 9.

EDINBURGH, 10, SHANDWICK PLACE,
February 20, 1840.



Digitized by the Internet Archive
in 2018 with funding from
Wellcome Library

<https://archive.org/details/b30381915>

PLATE I.

Sternoptix Celebes.

Br. Or. 4
Br. R. 5
D. 1/10
A. 2/13
C. 18+18
P. 10
V. 1/7

Fig. 1.
(Nat. Size)




Fig. 2.
(Nat. Size)

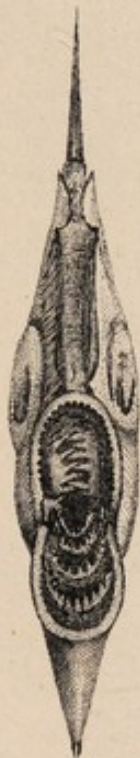

Fig. 3.
(Nat. Size)

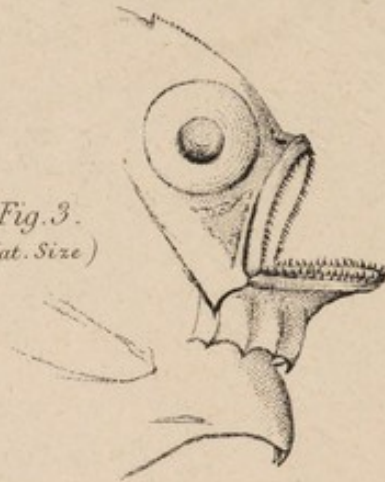


Fig. 4.



PLATE II.

Sternoptix Celebes, (one half larger than nature)

Fig. 1.

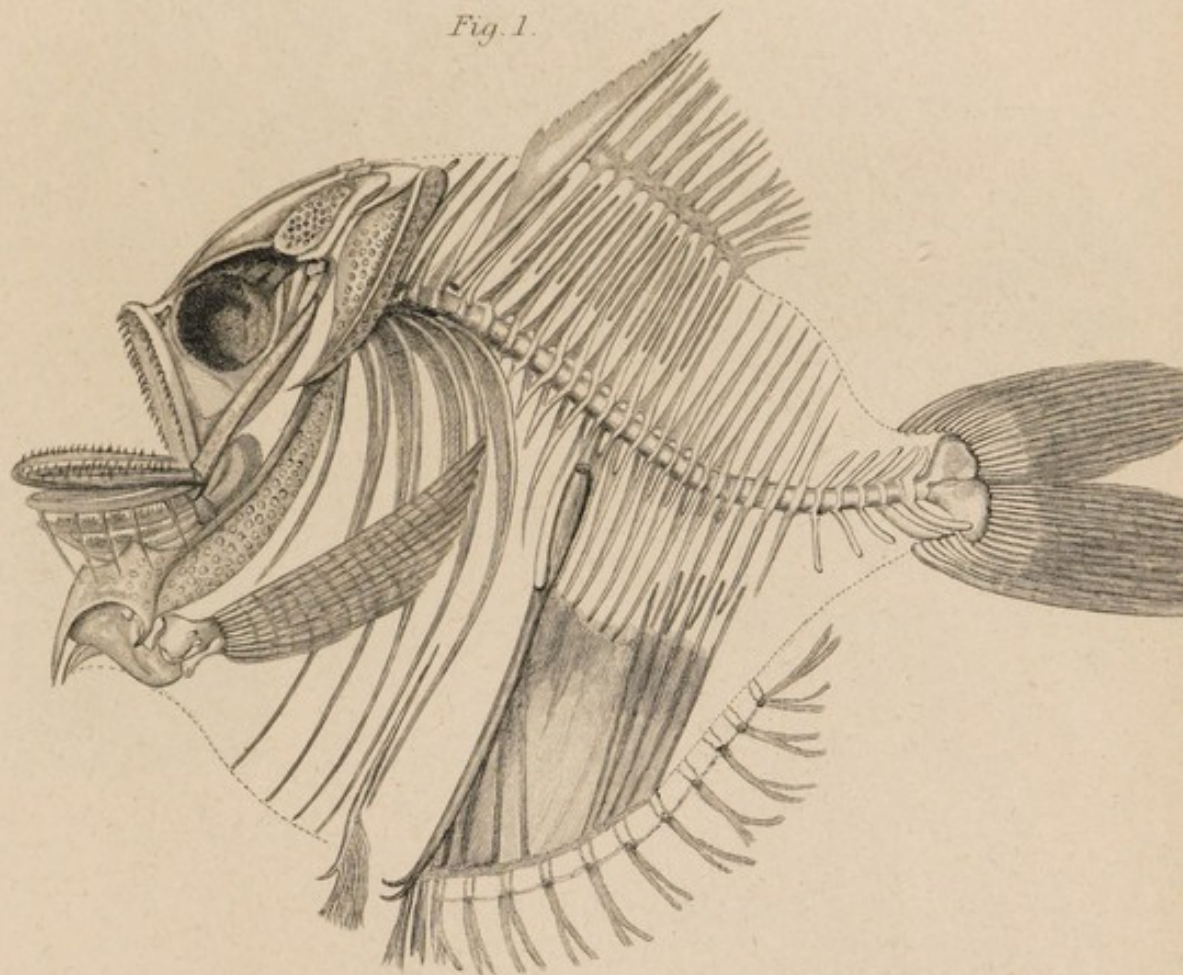
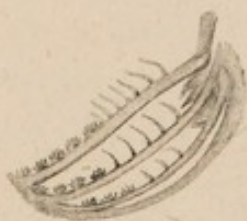
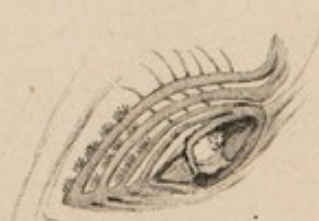
Fig. 2.



Lateral View

Fig. 3.



View of the Connexions Inferiorly & Superiorly

of the Left Branchial Arches & Palatine Teeth
(the Branchiae being removed .)

