

Observations on aneurism of the abdominal aorta / [Alexander Monro].

Contributors

Monro, Alexander, 1773-1859.

Publication/Creation

Edinburgh : Printed by P. Neill, 1827.

Persistent URL

<https://wellcomecollection.org/works/ahaj8g43>

License and attribution

This work has been identified as being free of known restrictions under copyright law, including all related and neighbouring rights and is being made available under the Creative Commons, Public Domain Mark.

You can copy, modify, distribute and perform the work, even for commercial purposes, without asking permission.



Wellcome Collection
183 Euston Road
London NW1 2BE UK
T +44 (0)20 7611 8722
E library@wellcomecollection.org
<https://wellcomecollection.org>

37138/p

852444

OBSERVATIONS
ON
ANEURISM
OF THE
ABDOMINAL AORTA.

BY
ALEXANDER MONRO, M. D., F. R. S. E.
PROFESSOR OF ANATOMY AND SURGERY IN THE UNIVERSITY OF EDIN-
BURGH, AND PRESIDENT OF THE ROYAL COLLEGE
OF PHYSICIANS, &C. &C.

EDINBURGH:
PRINTED BY P. NEILL.
1827.



PRELIMINARY OBSERVATIONS, &c.

NOTWITHSTANDING the little reliance which M. Foderé, and a few others, place in the knowledge which may be gained from the dissection of morbid bodies, I am disposed to think that most medical men entertain a different opinion, and concur with Dr Sandifort, who has remarked, “*Et quis denique vel ipsius Hippocratis aurea scripta attento volvens animo, non animadvertit sæpius summum hunc naturæ observatorem, longe plures sanaturum fuisse morbos, si cultri ope illorum inquirere causas ipse fuisset concessum. Revera enim in permultis casibus, causa morbi inventa, inventam etiam esse sanationem, et plurimos ab hostili morborum insultu esse liberatos.*”

The importance of the study of morbid anatomy, to the accurate knowledge of physic and surgery, must be obvious even to the cursory and inexperienced inquirer. It may indeed be represented as one of the primary foundations of medical science, for, without an intimate acquaintance with the morbid changes that take place in the human frame, as the causes or the effects of disease, the practice of physic and surgery can be directed only by ill-founded hypotheses, or blind empiricism.

The inspection of morbid bodies not only explains the cause of the progressive advancement of organic diseases towards their fatal termination, but also the manner in which such organic

derangements are sometimes arrested in their progress, or sometimes are entirely removed. Several striking illustrations of the above observations might be adduced. One or two are, however, sufficient for the purpose.

When blood has been extravasated within the substance of the brain, the red part of it is in some instances absorbed, and a clear fluid remains, which is contained in a distinct sac, and, after a time, this fluid is also absorbed, which is followed by an accretion of the opposite sides of the sac.

There are also several well authenticated instances upon record, in which ulcers of the intestines have been cured by an effort of nature.—The filling up of the bloodvessels by coagulable lymph, is one of the most striking examples of the efforts of nature, in preventing death from being occasioned by the loss of blood. This takes place in the vessels of the body, that have been divided by a wound. Thus the bleeding, which otherwise might have taken place from these, is prevented; and, owing to the same cause, a mortified is separated from a living part of the body without a loss of blood. By the same process, aneurisms of the larger branches of the arteries of the extremities of the body have been cured spontaneously. To the list of organic disorders which have been cured by an effort of nature, may be added an instance which lately fell under my observation, in which an aneurism of the abdominal aorta was filled up by coagulable lymph, owing to an obstruction of that artery above the seat of the disease.

Under the impression that such an important case cannot fail to be highly interesting to the medical world at large, and, in an especial manner, to Sir Astley Cooper, as bearing the strongest evidence of the propriety of his attempt to save the life of an individual, who was in the most imminent danger of immediate death, from the rupture of an aneurism of the abdominal aorta, I have been led to publish the annexed statement, together with a few observations on aneurism of the abdominal aorta, in which that formidable disease had followed its more usual course.

CASE OF ANEURISM OF THE ABDOMINAL AORTA,
ACCOMPANIED BY AN OBSTRUCTION OF THAT
VESSEL.

THE patient, a middle aged man, and well limbed, had, in consequence of exposure to cold, been seized with pain in his side, difficulty of breathing, cough, followed by expectoration, quick pulse, and the other symptoms of phthisis pulmonalis.

Notwithstanding all the remedies that were employed, the disease made rapid progress, and proved fatal in the course of four months.

It merits particular notice, that this man had no degree of weakness, numbness, or palsy in his limbs, and could walk about until a day or two before his death.

As the patient's death was owing to phthisis, the thorax was opened in the usual manner, by raising the sternum: the lungs presented the same morbid appearances as are usually detected in cases of tubercular phthisis, and the heart was in its natural state. After the contents of the thorax had been examined, the parietes of the abdomen were freely divided, so as to expose all the abdominal bowels, all of which were also in a healthy state.

Upon turning over the convolutions of the smaller intestines, a distinctly circumscribed tumour, rather more than three inches in breadth, and about two inches and three quarters in height, was observed lying upon the second and third lumbar vertebrae, which, upon a more minute investigation, proved to be connected with the descending abdominal aorta. This tumour was considerably flattened; and adhered very firmly to the second and third lumbar vertebrae, which were partially absorbed; and, when compressed, it felt somewhat hard, and evidently was filled by a quantity of clotted blood.

Upon cutting through the sac, it was found to be much thicker than the coats of any sound artery; and it did not seem to be composed of distinct layers, nor was there any deposition

of bone in any part of it; and in appearance it very much resembled thick white leather, which had been steeped for a considerable time in water. (Vide Engraving.)

The abdominal aorta entered into the very middle of the sac, (Vide Engraving) which was situated at the division of the aorta, into the two great iliac arteries; and I am disposed to think, that it was formed by the uniform expansion of the coats of that artery; and their unnatural thickness was probably owing to the addition of a quantity of compact cellular substance.

The aneurismal tumour was filled by portions of coagulable lymph, which were not disposed in parallel layers of an equal thickness, as in the greater number of aneurisms: but of short and unconnected portions of coagulable lymph, which crossed each other in different directions, so as to form a confused and irregular mass, which, on being pressed between the fingers, was evidently mixed with a gritty substance like sand.

After the removal of the sac, I carefully examined its inner surface, but could not discover any appearance of a rupture of the inner coats of the aorta.

The coeliac, superior mesenteric, renal, inferior mesenteric and lumbar arteries, were not larger than usual. A very correct idea as to the size of the intercostal and epigastric arteries could not be formed, as they had been divided in cutting through the parietes of the thorax and abdomen.

The portion of the artery which is immediately above the aneurismal tumour is evidently contracted, and was impervious; and, in that place the coats of the artery were to the touch firmer, and also whiter, than usual. Above this contracted portion, a conical shaped plug, of a firm nature, was placed*, with the smaller extremity undermost. This plug was of a deep red colour, and seemed to be composed of a solid mass of coagulable lymph, intermixed with the red globules of the blood. It was an inch and one-eighth long, about an inch broad at its basis, and was fixed by thin laminae of coagulable lymph to the sides of the aorta †.

* See Engravings, letter A.

† See Engravings, letter D.

This mass of coagulable lymph filled and completely obstructed the passage of the blood through the aorta.

As this plug adhered intimately to each side of the vessel by thin and dense layers of coagulable lymph, it appears to me that it was not formed *in articulo mortis*, but some time before death, and probably by an inflammatory action of the vasa vasorum of the coats of the aorta.

From the vicinity of the aneurismal tumour to the lumbar vertebræ, the vessels proper to these bones must have been much irritated; but they did not, as in the greater number of instances, in which an aneurism is seated in the immediate vicinity of a bone, secrete bony matter. A considerable portion of the second and third lumbar vertebræ was absorbed.

REMARKS.

AN obstruction of the abdominal aorta seems to me to be occasioned by two very different causes: it is an *original malformation*, or it is occasioned by a *disease in the coats of the artery, and a consequent deposition of layers of coagulable lymph within it.*

The case of obstructed thoracic aorta, which has been so ably described by my colleague Dr Graham, is of the former description; the coats of the thoracic aorta were *not thickened*, nor otherwise diseased, and the obstruction was similar to that which would have been occasioned by a ligature passed around that great artery. I have seen two instances, in which the arch of the aorta was contracted in different places, so that it somewhat resembled the arch of the colon, and in these instances there was no great degree of thickening of the coats of that great artery. In the instance of obstructed aorta, which fell under the observation of Dr Goodison, and also in that which I met with, the coats of the abdominal aorta were much thickened, the stricture was of considerable breadth, and coagulable lymph was found within the obstructed vessel. I have subjoined an ex-

tract from Dr Goodison's own description of the singular case above alluded to.

“ I found the aorta to be obliterated from the origin of the inferior mesenteric artery downwards, for the remainder of its length ; together with the greater part of the iliacs, on each sides, —the cavity of that on the left side being obliterated to its bifurcation into external and internal, and that on the right to more than one-half of the length of the common iliac.

“ The artery lay close, and was firmly attached to the spine. It had precisely the appearance of the trachea ; being rendered flat upon its posterior surface, but preserving anteriorly its circular, or convex form.

“ The iliac veins were so intimately connected with the arteries, as to cause considerable difficulty in their removal.

“ There was a large quantity of gelatino-cartilaginous matter surrounding that part of the aorta and vena cava, together with the portions of the iliac arteries and veins which were included in the disease.

“ The external appearance of the artery at first led me to think that an enlargement of its cavity existed ; but this was not the case at the time of the examination, whatever might have been its state formerly. This appearance was owing to the formation of the case of bone externally, and to the formation of gelatino-cartilaginous matter internally.

“ The bony sheath incased the artery for the space of about two inches, and was filled with a firm fleshy substance, which had the appearance of the muscular fibre of the heart. The substance was prolonged upwards, beyond the bony sheath, and adhered firmly to the coat of the artery.

“ The coats of the artery, at the diseased part, were separated, and the internal coat, having become the medium for the deposition of the ossific matter, had been literally converted into bone.”

Mr Crampton observes, “ By cutting longitudinally through the diseased portion of the artery, and turning out the condensed coagulum with which it was filled, I was enabled to ascertain the real nature of the changes which the vessel had undergone previous to its obliteration.

“ The internal coat, covered with steatomatous and earthy concretions, completely lined the cavity of the dilated portion of the artery ; the dilatation itself consists of three irregular pouches, which proceeded from the anterior and lateral surface of the vessel. It is obvious, therefore, that the disease commenced with dilatation of the artery, in consequence of a previously diseased and weakened state of its coats ; that the coats had suffered neither ulceration or rupture was evident, since (when the coagulum was detached) the internal membrane was found smooth and unbroken, and its surface presented precisely the same diseased appearances which were found on the internal coat of the aorta, immediately above and below the dilatation*.”

In the case which presented itself to me, there was an aneurism of considerable size at the division of the aorta into its two great iliac arteries. The aorta was impervious for the space of an inch and half above the tumour, and there was a plug of coagulable lymph above the impervious portion of the artery. (Vide engraving.)

The constricted portion of the aorta above the aneurismal sac, bore a striking resemblance to the permanent organic stricture of the gullet, intestines or urethra ; and it seems to me to be not improbable, that the temporary constriction of the aorta had paved the way for the permanent organic stricture of that artery.

The coagulation of the blood within the bloodvessels of a living animal, is one of the most beautiful resources of nature for preventing the loss of blood ; and it takes place from various causes, within the arteries of the body.

I had occasion to meet with one instance in which the arm had been torn off, and what was very remarkable, not above a couple of ounces of blood were lost. The patient's body had at the moment the arm was torn off been very much injured, and he died in the course of three days, from a violent inflammation of the chest. At the post-mortem examination, the torn axillary artery and corresponding vein were found to have been filled with coagulable lymph.

* Vide Dublin Hospital Reports, vol. ii.

In the same manner, in cases of abscess of the lungs, the bloodvessels in the vicinity of the seat of the disease are found filled by coagulable lymph; and many other similar instances might be enumerated, did the occasion require it.

With regard to aneurisms, it may be remarked, that a coagulum is very rarely formed until the sac has attained a very considerable bulk; and it takes place, in the first instance, in that part of the sac in which the blood is out of the direct current of circulation; hence, a spontaneous cure will be more readily accomplished in those instances, in which a large sac communicates by a narrow neck, with an artery which is not enlarged, than in such aneurisms as are of an oval or rounded form, and are occasioned by the uniform expansion of all the coats of an artery, and in which the artery enters into the middle of the sac, as in the annexed engraving. In some aneurisms of the arch of the aorta, which I have examined, there were a number of layers of coagulable lymph within the aorta; so that though the diseased portion of the aorta was externally of much greater bulk than is natural, the channel for the flow of blood was considerably contracted. But in the case which has been described by Dr Goodison, and also in that which I met with, the coagulum filled up the whole cavity, and completely obstructed the vessel. In some instances, the cause of this complete filling up of an artery is quite obvious,—it is the result of pressure. Thus, I had occasion to meet with an instance of aneurism in the arch of the aorta, in which the left arteria innominata was slightly thickened; the left carotid artery was completely obstructed by a regularly organized lymph; and the vein common to the left subclavian and left internal jugular vein, was converted, for the space of two inches, into a ligamentous chord.

In the case of aneurism of the abdominal aorta which occurred to me, the formation of the plug, and obliteration of that artery above the aneurism, had probably occasioned its cure.

In the greater number of aneurisms no coagulum is formed, excepting within the aneurismal sac, notwithstanding which, a spontaneous cure sometimes has taken place.

In short, whenever there exists a greater disposition in the blood to coagulate, than in the artery to expand, a coagulum will fill up the enlarged artery, and a spontaneous cure sometimes follows.

It may further be observed, that the obliteration of certain arteries and veins takes place, even when there is no reason to suppose the coats of these arteries and veins to be in a morbid state. This happens when it is no longer necessary for the due performance of certain functions in the animal economy, that the blood should follow a particular course. Thus the ductus arteriosus, and umbilical arteries and vein, become obstructed in a short time after birth ; and, in proportion as the ductus arteriosus is contracted, the branches of the pulmonary artery become so much enlarged, as to be capable of admitting the whole blood which is sent to them by the contraction of the anterior ventricle of the heart.

The arteries within the abdomen, like those of the other parts of the body, are liable to aneurism, and this morbid state is sometimes partial, but on other occasions general.

The partial enlargement is most frequent at the division of the aorta into its two great branches, the common iliac arteries, the free course of the blood downwards being, to a certain extent, resisted by the angle at which these iliac arteries are sent off from the parent trunk.

An aneurismal diathesis sometimes prevails at the same time in the different arteries within the abdomen, of which a remarkable instance has been recorded by my uncle Dr Donald Monro. He has observed : “ As this man died so suddenly, his body was opened the second day after his death, when several aneurisms were found in the cavity of the abdomen.

“ The superior mesenteric artery, just as it arose from the aorta, was dilated for above the length of an inch and a half, and was near an inch in diameter in the middle of the aneurismal sac, and was filled with a firm coagulum. The left emulgent artery was dilated at its beginning to the size of a filbert nut ; and the inferior mesenteric artery was beginning to be dilated just as it arose from the aorta.” And, as in the case related by

Sir A. Cooper, an aneurism in the abdominal aorta sometimes occurs in the same individual as an external aneurism.

The size of aneurisms in the abdominal aorta is extremely various, and, in general, they expand to a considerable extent*.

In the case of aneurism of the abdominal aorta, accompanied by an obstruction of that artery, the tumour had attained but a small bulk. This, perhaps, was owing to the tumour having been, as it were, strapped down by the inferior mesenteric artery, which adhered very intimately to its coats, and passed over the front of it; which artery, it may be remarked, was probably highly irritated by the tumour, for its internal coats were of a deep red colour, and the outer coat seemed to my eye to have been somewhat thickened.

Aneurisms of the abdominal aorta have sometimes attained so large a bulk as to fill the greater share of the abdomen, and have also compressed, to a certain degree, the bowels of the chest, so as to occasion difficult breathing.

My uncle Dr Donald Monro has published a very detailed account of an aneurism of this description, which, on account of its very particular nature and termination, merits the notice of the reader, and therefore I have subjoined an extract from that remarkable case:—

“ We observed, that the left side of the cavity of the abdomen was filled with one large black tumour, which, on examining, proved to be the cellular membranes behind the peritoneum, which covered the kidney, filled with blood. On cutting through the peritoneum, and these membranes, we found the kidney sound below, which we removed; and then laid the aorta bare from its coming out of the heart, till near its division into the two iliacs, which brought into view a large aneurismal sac, which extended from the diaphragm to the os pubis.

* De Haen has made mention of an exception to the above remark. An aneurism of the aorta protruded between the second and third ribs, and the external tumour, instead of increasing in bulk, suddenly disappeared, and was not perceptible for above a month before the patient's death. Upon dissection the arch of the aorta was found very much enlarged.

“ The upper part of this aneurismal sac was formed by a dilatation of the coats of the left side of the aorta, which at first view seemed to be dilated from where this vessel first passes through the diaphragm, till some way below where the emulgent artery of the right side goes off to the kidney ; though it afterwards appeared that the dilatation began much lower, about an inch above the rise of the coeliac artery, and extended no further than just below where the right emulgent goes off. The distended coats of the artery extended upwards and downwards, and towards the left side ; so that this part of the sac which seemed to be formed by them was full four inches long, and three inches broad, though the length of the aorta which was dilated, was but two inches in all.

“ The lower part of the sac was larger than the upper, and extended as far down as the os pubis ; and its coats seemed to be made up of the peritoneum and cellular membranes ; and it appeared as if this part of the sac had been recently formed by the coats of the true original aneurismal tumour giving way at the lower part, and allowing the blood to pass into and distend the cellular membranes behind the peritoneum, and to raise and push it forwards. Perhaps the coats of the true aneurism began to give way at the time the patient complained of the sensation of a stream of cold water running down into the lower part of the left side of the belly.

“ In dissecting off the membranes, to have a more distinct view of the whole tumour, I accidentally tore part of the sac, where its coats seemed to be formed of the peritoneum and cellular membranes, and there came out a quantity of clotted blood. I then introduced my finger through this aperture, and found that the upper part of the sac was filled with a firm fibrous coagulum, which afterwards, when it was taken out, appeared to be exactly similar to what is always found in aneurisms which have been of any standing ; but the lower part was filled only with recent coagulated blood. The aneurismal sac adhered firmly to some of the vertebræ, and to the lower ribs ; and these bones were become carious, and formed part of the sides of the sac.

“ I then had the aneurismal sac cut out of the body, and, in dissecting it away, I observed that it adhered very firmly to the last dorsal and the first and second lumbar vertebræ; and that the pulsation of the blood had worn away part of the aneurismal sac, where it adhered to those bones, and that they were bare and carious on the left side of their bodies; that a number of small osseous spines had grown out every where from the carious parts; that the cartilage between the first and second lumbar vertebræ was worn away for near half an inch deep on the fore and left side; and that the lower side of the last rib was bare and carious.

“ I next examined that part of the sac which had formed the large tumour on the back, and found, that the force of the blood had driven the sides of the dilated artery backwards, quite through the muscles of the back, till it had reached the skin.

“ The hollow which remained, after the aorta, with the aneurismal sac, and fibrous coagulum, were taken out of the body, appeared to be about three-fourths of as exact a spherical figure, of three inches and a quarter diameter, as if it had been formed by a turning wheel. It reached from the lowermost rib to the spine of the ileum.

“ On examining the inside of the fore part of the aneurismal sac (the only part which could be taken out entire), I observed that the aorta had not begun to be dilated for near an inch lower than it had appeared to be on the outside; that the artery had returned to its natural size again, immediately below where the right emulgent artery takes its rise from the aorta; and that there were a number of osseous concretions spread on the internal surface of the sac round the lower orifice where the aorta returned to its natural size, and went out of the sac.

“ And, on examining the fibrous bloody concretion, which filled the upper and back part of the aneurismal cyst, I found that there was a hollow or furrow on the fore part, through which the blood could pass freely from the upper part of the descending aorta to the lower, to be distributed through the lower extremities, which was certainly the cause why the pulse

continued regular, and without intermission during the whole course of this tedious and troublesome disorder."

Through the kindness of the late Dr Rutherford, I am enabled to make an important addition to the history of aneurism of the abdominal aorta. The case was drawn up for my own gratification and instruction : and I have given it in the Doctor's own words.

"The abdomen being opened, the viscera, in general, appeared to be remarkably sound ; and, though the body was much emaciated, yet no inconsiderable quantity of fat was observed betwixt and under the membranes. The stomach, as well as the great arch of the colon, were much contracted. The solid viscera, viz. liver, spleen, and kidneys, were very pale. The liver was at first thought to be enlarged ; but this appearance probably arose from the right lobe being pressed forwards and towards the left side, by a prominence of the part behind. The gall-bladder was flaccid, but contained a quantity of turbid pale brown or yellow bile. The pancreas was rather larger than common ; the spleen was of natural size and shape, but, like the liver, was protruded, the parts behind being also unusually prominent. For the same reason, the kidneys also projected farther into the cavity of the abdomen than is commonly to be observed. They were of a natural shape, but considerably smaller, especially the right one, than common. The parts that were so prominent at the back part of the abdomen were nowise discoloured ; and, unless by their prominence, gave no indication of their being in a morbid state.

"The cartilages of the ribs were partly ossified, so that they could not be divided without the aid of a saw. When they, with the sternum, were raised, the parts within the thorax exhibited a natural appearance. But presently it was found that there had been an effusion of a vast quantity of blood into the right cavity of the thorax. Hence a continued mass of coagulum was spread over the surface of the lower and middle lobes of the lungs, insinuated into the fissures betwixt the lobes, and accumulated abundantly behind the lungs, and over the surface of the diaphragm. Besides, many pounds of red serum were contained in the same cavity. In the left cavity of the thorax

there was only a small quantity of clear serum. The lungs, as to texture, were in general perfectly sound, only a few very hard roundish tubercles, not much larger than garden peas, were felt in them, immediately below their surface, and a few bands of cellular substance connected them, in certain points, particularly the right lobes, and to the tendon of the diaphragm. The pericardium was nowise diseased; it contained a little yellowish serum. The heart was pale and uncommonly small. Both the heart itself, and the large vessels proceeding from it, were quite empty of blood.

“ All the effused matter being removed from the right cavity, and the lungs raised, the diaphragm was discovered to be much diseased, protruded far into the thorax, greatly thickened, of a very deep red or purple colour, with a large ragged perforation in the most prominent part, through which the blood had issued into the right cavity of the thorax. Through this perforation was a communication with a very large and irregular preternatural cavity situate behind the posterior parietes of the abdomen. This, on the right side, was situate behind the right lobe of the liver, or upper part of the right kidney. By further examination, it was found to extend across the spine, then expanding, run downwards, so as to form a large oblong pouch, corresponding in situation and extent to the external tumour that had been observed on the left side of the spine. This great cavity was filled with coagulated blood, and such was its capacity, that it contained betwixt three and four pounds. Within, where the cavity crossed the spine, the bones were bare, rough, and greatly eroded, the interosseous cartilages projecting far beyond the wasted bodies of the vertebræ, (I believe the last dorsal and two first lumbar). It was not difficult now to trace the source of the extravasated blood. All the great bloodvessels within the thorax, and in the upper part of the abdomen, were in appearance perfectly sound, and of a natural size. But about the first and second lumbar vertebræ, the aorta was found to have con- creted most firmly with the anterior parietes of the cavity; and searching from within the cavity, it was found, that in this place the coats of the artery were completely eroded and de-

stroyed, so as to afford a large and free passage or opening, estimated at an inch and a half in length, from the artery into the cavity."

Other aneurisms of the abdominal aorta project backwards at the side of the spine, and sometimes attain a most enormous size. I have had occasion to see an instance, in which the aneurismal tumour in the back was at least eighteen inches in circumference, and so very heavy, that the patient could not turn himself in bed without aid; and, in the following instance, the tumour had attained a still larger size.

On the 28th September 1823, I was called to see A B, a stout man, 36 years of age, who had a tumour of a globular form, and three feet in circumference, on the right side, which extended from the ribs to the anterior spine of the os ilium. This tumour had a distinct pulsation, which was synchronous with that of the heart. It was so heavy that he could not turn himself in bed without aid, and was obliged to lie always on his side. The surface of the tumour was sphacelated, and a good deal of serum issued from it at different times for several days. The centre of the tumour communicated a distinct pulsation, but it was hard to the touch in its circumference.

The patient suffered acute pain in the back and loins, which extended down to the right thigh, scrotum and inferior extremities, which latter were œdematous. He was occasionally sick, but his appetite upon the whole was tolerably good.

I was informed that, three years ago, in putting some straw upon a cart, he had strained, or racked, as he called it, his back, which created very acute pain at the moment, which lasted for three or four days. He was at length somewhat relieved by bleeding, but the pain never left him, and he was supposed to labour under a disease of his stomach or liver, his appetite and digestion being, after a time, very much impaired. His pulse was not affected.

Last April, a tumour, about the size of a hen's egg, appeared on the right side below the ribs, and which had a distinct pulsation. This tumour increased rapidly in size, and created much uneasiness, so that he was obliged to take very large

doses of laudanum. The patient at length died, and without the tumour bursting externally or internally, seemingly quite exhausted by his very acute suffering.

DISSECTION.—The lungs were œdematous,—the heart in all respects sound ; but the aorta was a little larger than usual ; and before passing between the crura of the diaphragm, it was evidently expanded. On tracing the enlarged aorta, it adhered to the diaphragm ; pushed forwards and downwards the right lobule of the liver and right kidney, the enlargement having existed between the place above mentioned, and the renal arteries. The tumour extended backwards first to the left side, and then, as far as the pelvis, to the right side. The large sac seemed to be formed out of the coats of the arteries, to which a quantity of condensed cellular substance was added, and the muscles of the back were in part sphacelated, and five or six of the dorsal vertebræ were partially absorbed. The splanchnic nerve adhered intimately to the left portion of the sac ; hence the great pain and derangement in digestion ; and the nerve seemed to my eye to be somewhat larger than usual. The patient had had occasional difficulty in voiding his urine : but no mechanical obstruction was found in the bladder, and the coats of the ureters were somewhat thickened.

It was remarkable in this case, that the greater part of the blood in this great sac had not coagulated.

The sac itself was inflamed on its inner side, and lined by a thin layer of coagulated blood. In this case the inner coat of the aorta was redder than usual.

OF THE COATS OF THE ANEURISMAL SAC.

IN the case of obstructed aorta, I did not dissect the coats of the aneurismal sac, lest I should thereby have injured the appearance of so rare a specimen ; and, besides, it did not seem to be necessary, as my Father has already investigated this part

of anatomy with much attention. In a paper on aneurism, which was published in vol. 3d of the Literary and Physical Essays of this place, the following description has been given of the dissection of an aneurismal sac, in a letter from my grandfather to his son Dr D. Monro. “ The aneurismal sacs you sent me to Edinburgh were dissected by your brother in my presence. The appearances were the following :—The external loose cellular, and the cellulo-membranous, coats being dissected away carefully, the circular fibrous, commonly called muscular, coat, was evidently seen continued on all the three small sacs in every part of them, but was thicker there than in the sound part of the artery ; and, in the most enlarged part of the sacs, an extraneous substance, resembling a soft steatomatous matter, was intermixed with the muscular fibres. The cellular substance lining the inside of the muscular coat was considerably thicker than natural, and had much the same appearance of an extraneous substance filling its cells. The internal membrane of the artery adhered so firmly to these cells, that it could not be separated, but seemed thicker than in a sound state. Though the circular fibres could be observed at the sides of the incision made into the fore part of the sac of the left ham, as represented in your figure ; yet, as the dissection was continued backwards towards the most distended part, these muscular fibres became less observable, and could not be traced. Whether this apparent defect of them here was owing to a much greater proportion of the extraneous substance above mentioned, or to their having been destroyed by the great distention, is difficult to determine. The internal cellular coat of this sac was considerably thicker than in the smaller ones, but of the same texture. The most internal membrane was in a thickened adhering state. In the part of the great sac of the right ham which came to Edinburgh, no circular fibres could be seen, and the structure was otherwise much the same as that now described of the back part of the sac in the left ham.”

Professor Scarpa, one of the most justly celebrated anatomists in Europe, has also given a very distinct and beautiful representation of the proper fibrous or muscular coat, as he calls

it, in a case of an aneurism of the thoracic aorta, which is represented in Fig. 1. of his Tav. IX.; and as may be seen in Plate I. of Mr Wishart's translation of Scarpa on Aneurism; but I never could distinguish these fibres when that artery is in a healthy condition; and besides, it may be added, that, in aneurisms of the extremities, the muscular fibres of the coats of an aneurism are, on account of their greater size, much more apparent than in an aneurism of the abdominal aorta.

The late Mr Wilson of London, whose skill and accuracy as an anatomist have been universally acknowledged, has observed, "In the true aneurism, at the beginning of the disease, the coats of the artery are not ruptured; on the contrary, they are often increased in thickness before they become morbidly dilated; and, in general, the alteration in structure appears to begin in the inner and muscular coats*."

It may be proper to add, that my assistant Mr Mackenzie, who has lately paid much attention to the structure of aneurismal arteries, has assured me, that, in such diseased arteries, he has observed the muscular structure much more distinctly than in those arteries which are in a sound state.

Aneurisms of the abdominal aorta generally prove fatal before they burst, by the derangement which they occasion in the functions of the abdominal bowels, but sometimes they burst into the abdomen, or even into the thorax, as in the cases described by Dr Rutherford; and they generally have occasioned the absorption of the contiguous vertebræ.

* Lectures on the Vascular System, London 1819.

OF THE NEW CHANNEL BY WHICH THE BLOOD FLOWS TO THE
BOWELS OF THE PELVIS, AND TO THE INFERIOR EXTREMI-
TIES, WHEN THE ABDOMINAL AORTA IS IMPERVIOUS.

THE case which fell under my notice, affords a striking example of the circulation being carried on, when none of the blood reached the bowels of the pelvis or inferior extremities, by the medium of the trunk of the aorta; and also, that the blood may be diverted from its usual channel, without a derangement of the functions of that part of the body which is usually supplied by the aorta.

The blood probably reached the pelvis and inferior extremities of the body by different channels; a part of it, by the anastomosis between the internal mammary and epigastric arteries, another part of it by the medium of the anastomoses between the phrenic, lumbar, ileo-lumbar, and circumflex arteries, and by the anastomoses between the ascending branches of the gluteal and lumbar arteries; and I conceive that but a small part of the blood found its way downwards by the anastomoses between the internal mammary and epigastric arteries; as there must be a considerable impediment to the free flow of blood by that channel, for the usual current of the blood is then reversed,—for, instead of the blood rising upwards towards the internal mammary artery, as in the natural circulation, it must have descended through the epigastric artery towards the inferior extremities, by which the natural course of the blood is reversed.

If aneurism in the abdominal aorta be seated between the origin of the superior and inferior mesenteric arteries, I am led to suppose, from a preparation in my Museum, in which a ligature had been thrown around the descending aorta of a living dog, and, from the consequent enlargement of the anastomosing branch between the superior and inferior mesenteric arteries, and also by the result of the following experiment, made upon a dead body, that a considerable portion of the blood flows downwards by that channel.

I divided the abdominal aorta; one pipe was fixed into the upper portion, and another into the lower portion of that vessel.

A coloured injection was thrown into the uppermost pipe with force, and in the course of a minute a considerable portion of the injection flowed out at the mouth of the pipe, which had been inserted into the lower portion of the abdominal aorta ; and I found that the arteries of both inferior extremities had been completely filled by the injection.

From this experiment, it appears to me to be a legitimate conclusion, that if, in this case, where there had been no previous obstruction in the aorta, and no enlargement of the anastomosing branches, the injection had passed readily from the upper to the under part of the body, by the medium of the anastomosing branches of the superior and inferior mesenteric arteries, the thinner fluid, the blood, would certainly also have passed by the same unusual route, if the aorta were obstructed, in consequence of disease. When the lateral branches sent off from an artery are large and numerous, as at the elbow and knee joints, it might have been expected that the blood would still flow to the hand or foot, though the main trunk be obstructed ; but when there is a greater disproportion between the size of the obstructed artery and the lateral anastomosing branches through which the blood must afterwards pass, as in the obstructed aorta, there is reason to be apprehensive of a deficiency in the necessary supply of blood to the parts beyond the seat of the obstruction ; yet that did not take place in this case, for the limbs of the patient were not, in the slightest degree, paralytic or shrunk ; nor was there any symptom which, during the life of the patient, led to a suspicion of the existence of any disease in the arterial system.

My friend Professor Graham has described an instance of an obstruction of the thoracic aorta. The blood, in this instance, had been impelled with great force into the great left subclavian artery, and also into its branches the internal mammary and superior intercostal arteries, which occasioned a considerable enlargement of these vessels. The blood, therefore, reached the inferior extremities chiefly through the medium of the inosculation between the superior intercostal and mammary arteries, with the three arteries arising beyond the seat of the obstruction of the aorta.

The blood followed a similar course in the instance of contracted aorta which fell under the notice of Mr Paris.* The enlargement of the thoracic arteries was so remarkable as to be evident before the body was opened ; and, upon dissection, the arteria innominata and left subclavian arteries were found enlarged to twice their usual size, and also the internal mammary, phrenic, and transverse arteries of the neck.

But the case now under consideration is of an opposite description ; for the arteries in the more immediate vicinity of the tumour, viz. the lumbar, mesenteric, and cœliac arteries, were *not* enlarged beyond the usual standard ; which extraordinary fact perhaps admits of explanation, on the idea, that, as the obstruction had probably been of considerable duration, hence the collateral anastomosing arteries, which had previously been enlarged, had, as in cases of external aneurism, regained nearly their natural caliber.

OF THE SYMPTOMS.

THE greater number of aneurisms of the abdominal aorta at their commencement, derange the functions of the alimentary canal, and of the urinary organs, and induce diarrhea, and sometimes suppression of urine ; and, when they have attained a large bulk, they occasion great difficulty in breathing, by impeding the descent of the diaphragm, and are so heavy as to prevent the patient turning in bed without aid.

Considering the vicinity of the tumour to the hypogastric plexus of nerves, which includes two-thirds of the aorta, and considering likewise the state of the second and third lumbar vertebra, and the pressure made upon the vena cava inferior, it is remarkable, that there were no symptoms of the disease during life, no degree of weakness or swelling of the limbs, nor derangement as to the functions of the bowels of the pelvis, in the case of obstructed aorta, which fell under my notice.

In the case of an aneurism of the arch of the aorta, when the tumour, in consequence of the absorption of a portion of the

* Desault's Parisian Journal.

sternum has become external, the gradual cessation of the pulsation in the tumour indicates the gradual and progressive formation of layers of lymph within it.

When the sac of a large abdominal aneurism has attained a great size, it generally contains, at its more prominent part, more or less of coagulated blood; hence, when it projects backwards, pulsation is not very obvious, and it has been mistaken for a lumbar abscess. I attended a patient afflicted by a large aneurism, which was seated in the loins, and was informed by the friends of the patient, that a medical gentleman, supposing the tumour to be an abscess, had proposed to push his lancet into it, in order, as he said, to let out the matter.

OF THE SPONTANEOUS CURE OF ANEURISM.

MANY instances are to be found in the records of physic and surgery, in which aneurisms proper to the arteries of the extremities of the body have been removed by an effort of nature in the following manner :

The aneurismal sac is filled up by a number of layers of coagulable lymph, by which the artery is rendered impervious; these layers of lymph are afterwards absorbed, and the opposite sides of the artery grow together.

Considering that the blood is driven into the abdominal aorta, by the powerful contraction of the posterior ventricle of the heart, it is not to be expected that this artery should be frequently obstructed by coagulable lymph, unless the tumour, as in one in the Museum of the University, be placed at the side of the aorta.

MEDICAL TREATMENT.

THE filling up of aneurismal tumours, by coagulable lymph, has been occasionally brought about by diminishing the impetus and velocity of the blood which flows to the seat of the disease, by the repeated detraction of blood, by low diet, rest,

or by the use of the foxglove ; and, it may be remarked, that even when the disease is seated in the arch of the aorta, into which the blood is driven with great force from the left ventricle of the heart, the aneurism is in part filled, in some instances, by layers of coagulable lymph.

I have had occasion to meet with two such instances, in which very large aneurisms of the aorta were partially filled up by layers of coagulable lymph.

In the first of these, a part of the breast-bone, and a part of three of the upper ribs, had been absorbed. The tumour protruded externally, and measured fifteen inches in circumference, and at first it pulsated uniformly over its whole surface. The pulsation, however, became gradually less distinct, and at length ceased. The patient died in the course of eighteen months, from phthisis pulmonalis, and upon dissection I found the greater part of the aneurism filled by layers of lymph.

In the other case, the aneurismal tumour was as large as a child's head. This patient laboured under excessive difficulty in breathing, his face, and the point of his nose, became much swollen, so that he resembled a monkey. This symptom, according to Aretæus, strongly marks the difficulty with which the blood passes through the lungs.

His difficulty of breathing increased to a most distressing extent before death. Upon dissection, eight pounds of water were found within the chest, and there was a very large tumour connected with the arch of the aorta, which was completely filled by layers of coagulable lymph. Neither of the above patients died from a rupture of the arch of the aorta. The large aneurism, by pressing upon and irritating the lungs, occasioned phthisis, and in the latter, by preventing the free flow of blood through the lungs, had occasioned an effusion of water within the chest, which proved the more immediate cause of death. But, in the instance of obstructed aorta, a complete plug of coagulable lymph was formed within the abdominal aorta, though the patient walked about, and had not been restricted to very low diet before death.

SURGICAL TREATMENT.

NATURE, in the case of obstructed aorta, has pointed out the most efficacious means of curing aneurisms, which the surgeon should imitate, by passing his ligature around the vessel above the seat of the disease.

To those who are conversant with the history of scientific surgery, the valuable observations of Sir A. Cooper on different aneurisms, and on the improved mode of treating those of the carotid and inguinal arteries, and of the abdominal aorta, which have been introduced by that distinguished surgeon, are familiar. The case of obstructed aorta, which has been above described, cannot fail to be read with peculiar interest by the medical world at large, and by Sir Astley in particular. Nature had in this instance produced the same effects as the ligature which Sir Astley had thrown around the abdominal aorta, and has pointed out the accuracy of those principles, and the propriety of his attempt to save the life of one, who was weltering in his blood, and in the most imminent risk of immediate dissolution.

Combining together the results of the experiments of Sir A. Cooper upon dogs, (and which, it may be remarked, have been attended with similar results in the hands of others), and the cases which have fallen under the notice of Dr Goodison and of myself, there can be no doubt as to the safety and expediency, in certain cases, of throwing a ligature around the abdominal aorta.

To Mr Tyrrell we are indebted for the following account of the manner in which Sir A. Cooper performed the operation.

“ The patient’s shoulders were slightly elevated by pillows, in order to relax, as much as possible, the abdominal muscles; for I expected that a protrusion of intestines would produce embarrassment in the operation, and was gratified to find that this was prevented by their empty state, in consequence of the involuntary evacuation of the *fæces*. I then made an incision,

* *Vide* Sir A. Cooper’s Lectures on Surgery, London, 1825.

three inches long, into the linea alba, giving it a slight curve, to avoid the umbilicus; one inch and a half was above, and the remainder below the navel. Having divided the linea alba, I made a small aperture into the peritoneum, and introduced my finger into the abdomen; and then with a probe-pointed bistoury enlarged the opening into the peritoneum to nearly the same extent as that of the external wound. During the progress of the operation, only one small convolution of intestine projected beyond the wound.

“ Having made a sufficient opening to admit my finger into the abdomen, I passed it between the intestines to the spine, and felt the aorta greatly enlarged, and beating with excessive force. By means of my finger nail, I scratched through the peritoneum on the left side of the aorta, and then gradually passed my finger between the aorta and spine, and again penetrated the peritoneum, on the right side of the aorta.

“ I had now my finger under the artery, and by its side I conveyed the blunt aneurismal needle, armed with a single ligature behind it; and Mr Key drew the ligature from the eye of the needle to the external wound, when the needle was withdrawn.

“ The next circumstance, which required considerable care, was the exclusion of the intestine from the ligature, the ends of which were brought together at the wound, and the finger was carried down between them, so as to remove every portion of the intestine from between the threads; the ligature was then tied, and its ends were left hanging out of the wound.

“ During the operation the fæces passed involuntarily, and the patient's pulse, both immediately and for an hour after the operation, was 144 in a minute. I applied my hand to his right thigh, immediately after the operation, and he said that I touched his foot, so that the sensibility of the leg was very imperfect.

“ The omentum was drawn behind the opening as far as the ligature would admit, so as to facilitate adhesion; and the edges of the wound were brought together by means of a quilled suture and adhesive plaster.

“ He remained very comfortable until the following evening, when he vomited, and his fæces passed off involuntarily. 27th, Seven o'clock A. M. had passed a restless night, and had vomited at intervals; pulse 104, weak and small; pain in his head; great anxiety of countenance; very restless, and his urine dribbled from him. He gradually sunk, and died at eighteen minutes after one o'clock, having survived the operation forty hours.

“ *Dissection.*—No peritoneal inflammation but at the edges of the wound, which were glued together by adhesive matter, excepting at the part at which the ligature protruded. The thread had been passed around the aorta, about three quarters of an inch above its bifurcation, and rather more than an inch below the part at which the duodenum crosses the artery; it had not included any portion of omentum or intestine. Upon carefully cutting open the aorta, a clot, of more than an inch in length, was found to have sealed the vessel above the ligature; below the bifurcation, another, an inch in extent, occupied the right iliac artery; and the left was closed by a third, which reached as far as the aneurism: all were gratified to observe the artery so completely shut in forty hours. The aneurismal sac, which was of a most enormous size, reached from the common iliac artery to below Poupart's ligament, and extended to the outer part of the thigh. The artery was deficient from the upper to the lower part of the sac, which was filled with an immense quantity of coagulum*.”

The peculiarities of the above case probably induced Sir A. Cooper to adopt the above method of operating. It appears to me that the aorta is more accessible from behind.

I found, upon trial on a dead body, that a ligature might be readily passed around the aorta, after pressing to one side the kidney, by cutting down upon that vessel from behind, on the

* “ In an operation which I lately performed of tying the external iliac artery much above Poupart's ligament, I think I could with little difficulty have reached the aorta, by turning up the peritoneum without dividing it; and should I again wish to put a ligature on the aorta, I should prefer this method to the one I have before adopted.”

left side of the spine. My son made a similar experiment upon a ram, and passed a ligature around the artery, opposite to the third lumbar vertebra. The blood still continued to flow to the extremities, for there was no diminution of heat of the hinder limbs, and the animal retained the feeling and power of moving them, so that none of the nerves had been included in the ligature. It may be added, that, after the death of the animal, there was no appearance of peritonæal inflammation.

INFERENCES.

From what has been above stated regarding obstruction of the abdominal aorta, it follows ;

1st, That an aneurism of the abdominal aorta is sometimes cured, by an effort of nature, by an obstruction of that vessel above the seat of the disease.

2d, That an aneurism of the abdominal aorta, accompanied by an obstruction of that vessel, is not invariably characterized during life by any one pathognomonic symptom, even when there is reason to conclude that the disease had been of some duration.

3d, That an aneurism of the abdominal aorta does not prove invariably fatal, as that vessel has been sometimes completely obstructed by a plug of coagulable lymph ; notwithstanding which the blood still flowed to the lower parts of the body.

4th, That a ligature may be passed around the abdominal aorta, with the prospect of saving life, when the aneurism is seated in that part of the aorta which intervenes between the origin of the superior and inferior mesenteric arteries, and also when the aneurism occurs at the division of the aorta into the great iliac arteries.

5th, That, during the passing a ligature around the abdominal aorta, great caution is requisite, lest a part of the hypogastric plexus of the nerves which surrounds two thirds of that vessel, be included in it, which would undoubtedly bring on an incurable

palsy of the inferior extremities, and materially derange the functions of the bowels of the pelvis.

Lastly, that, upon consulting the records of physic and surgery, it will be found, that our knowledge of the nature and treatment of aneurism has arrived gradually at its present state of perfection, in consequence of the investigations, experiments, and operations, that have taken place chiefly in this country ; and, it may be added, that the cases of obstructed aorta which have been above described, render complete the history of aneurism.

EXPLANATION OF PLATE.

THIS engraving is of the same size as nature, and gives a back view of the aorta of an adult male.

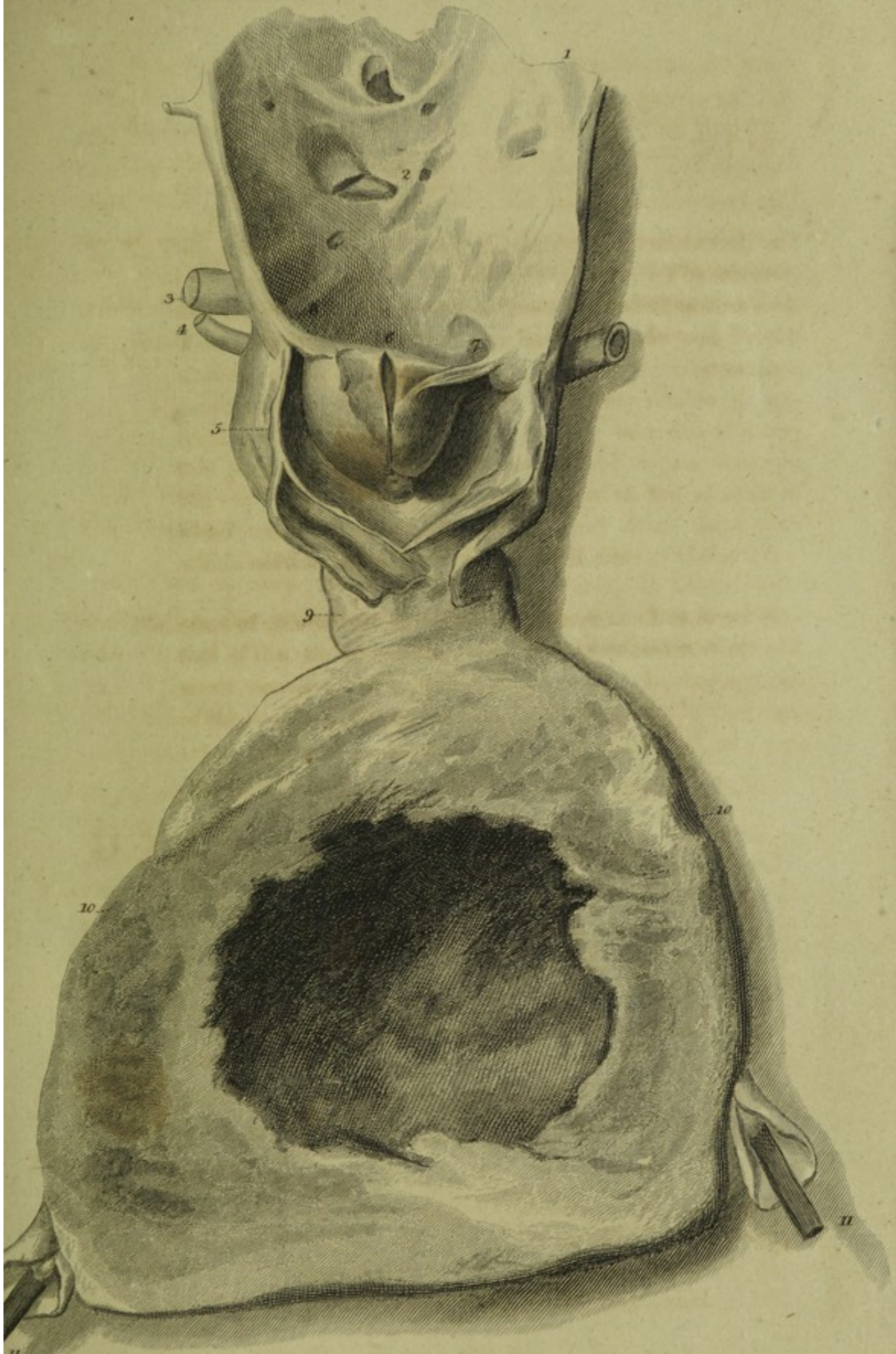
- I. Points out the abdominal aorta, which was opened from behind.
- II. Points out the origin of the superior mesenteric artery, which is not larger than that vessel is in its sound state ; an observation which may be extended to one of the lumbar arteries, which is referred to by No. IV.
- V. Points out the plug which filled the aorta. It is composed of a very solid mass of coagulable lymph, with which there were a number of the red globules of the blood intermixed, which gave it a deep-red colour.
- VI. Refers to a cut which was made into the plug, in order to discover its nature.
- VII. VIII. Point out two thin masses of coagulable lymph, by which the conical-shaped plug was firmly fixed to the side of the aorta ; and the engraving also exhibits the separation of the component coats of the aorta, which spontaneously took place after the artery had been opened.

At No. IX. the abdominal artery felt hard and like a solid cord, and it was found impossible to pass even the smallest probe through it down to the aneurismal sac marked by

X. X. This portion of the vessel was considerably contracted, and was whiter than any other part of the aorta. The aneurismal sac is represented after its contents had been removed. The aneurismal sac appears to have been formed by the uniform expansion of the coats of the aorta; whereas, according to Sennertus and Scarpa, an artery retains its natural size, and its coats are ruptured or corroded at a certain place, and seem included within, and to pass through, the sac, which is formed in consequence of the effusion of blood under the cellular sheath, or any other membrane which covers the ruptured or corroded coats of the artery.

The coats of this sac are of unusual thickness. The inner surface of the sac is irregular, owing to the adhesion of several small portions of coagulable lymph to it. In consequence of the pressure of the aneurism upon two of the lumbar vertebrae, these were found to have been absorbed to a certain extent.

XI. XI. Point out probes put into the common iliac arteries, which, in this case, were considerably contracted.



M^cInnis del.

W. Miller Sc.

