

## **Clinical electrocardiography / by Sir Thomas Lewis.**

### **Contributors**

Lewis, Thomas, Sir, 1881-1945.

### **Publication/Creation**

London : Shaw, 1924.

### **Persistent URL**

<https://wellcomecollection.org/works/nhzq5gww>

### **License and attribution**

Conditions of use: it is possible this item is protected by copyright and/or related rights. You are free to use this item in any way that is permitted by the copyright and related rights legislation that applies to your use. For other uses you need to obtain permission from the rights-holder(s).



Wellcome Collection  
183 Euston Road  
London NW1 2BE UK  
T +44 (0)20 7611 8722  
E [library@wellcomecollection.org](mailto:library@wellcomecollection.org)  
<https://wellcomecollection.org>



CLINICAL  
ELECTROCARDIOGRAPHY.  
THOMAS LEWIS.

THIRD EDITION





# CLINICAL ELECTROCARDIOGRAPHY

BY

SIR THOMAS LEWIS,

M.D., F.R.S., D.Sc., F.R.C.P., C.B.E.,

*Honorary Consulting Physician to the Ministry of Pensions ; Physician of the  
Staff of the Medical Research Committee ; Physician and Lecturer  
on Cardiac Pathology, University College Hospital ; Consulting  
Physician, City of London Hospital.*

---

Third Edition.

---

LONDON :

SHAW & SONS LTD., 7 & 8, FETTER LANE, E.C.4,  
Printers and Publishers.

---

1924.



BY THE SAME AUTHOR.

"The Mechanism of the Heart Beat."

"The Mechanism and Graphic Registration  
of the Heart Beat."

"Clinical Disorders of the Heart Beat."

"Lectures on the Heart."

"The Soldier's Heart and the Effort Syndrome."

## PREFACE.

**I**N republishing an account of clinical electrocardiography, I do so from conviction that this method of examination is essential to the modern study of heart disease. When some fourteen years ago I commenced to study disorders of the heart with the aid of the "string galvanometer" the method was in its early infancy; although it was regarded at that time as full of promise, yet its scope, in helping to perfect our knowledge of heart disease, could not then be foreseen. Electrocardiography has taken us far, having filled great gaps in our knowledge of these maladies; for it is a means of directly examining the all-essential heart muscle.

Cases of structural heart disease are few in which an electric examination is superfluous, and in a large percentage of cases the records modify, more or less profoundly, our conceptions of the malady which we treat.



Electrocardiography has developed ; it has grown along technical lines ; it has embraced a terminology of its own, the inevitable result of progress in a new direction.

In *Clinical Disorders of the Heart Beat* I have attempted to collect the simple bedside signs of disordered heart action and to narrate their influence upon prognosis and treatment in a manner palatable to pure clinicians. The present chapters supplement that book. They are intended to serve as an introduction to students of electrocardiography and as a guide to practitioners and hospital physicians in understanding curves which may be taken by others from patients in their charge. They describe in outline the most precise method which we possess, when we attempt to identify the many forms of disordered heart action. It frequently happens that other graphic methods fail to analyse these disturbances ; electrocardiography is the last court of appeal, and its judgment is practically speaking infallible. There are types of heart action upon

which other methods are nearly, if not quite, silent ; knowledge of these conditions is in the almost exclusive possession of electrocardiography. Finally, the electric curves have revealed a number of new signs, associated with abnormal distribution of the muscular masses in the heart, or with abnormalities in the course taken by the excitation wave in the heart.

In writing of *Clinical Electrocardiography* I confine myself to common varieties of disorder and to electric signs which are frequently to be observed. I do not submit the evidences for my conclusions in this handbook, seeing that these evidences are fully set forth in my larger treatise, *The Mechanism and Graphic Registration of the Heart Beat*.

T. L.

*November, 1923.*





Digitized by the Internet Archive  
in 2018 with funding from  
Wellcome Library

# CONTENTS.

---

|  | PAGE |
|--|------|
| CHAPTER I.   |      |
| THE ELECTROCARDIOGRAPHIC METHOD ... ..                             | 1    |
| <i>Connection of patient</i> ... ..                                | 5    |
| <i>The compensatory circuit</i> ... ..                             | 7    |
| <i>The standardiser</i> ... ..                                     | 7    |
| <i>The method of obtaining standardised electrocardiograms</i> ... | 7    |
| <i>Checking the accuracy of standardised curves</i> ... ..         | 9    |
| <i>Testing certain properties of the string</i> ... ..             | 11   |
| <i>Accessories...</i> ... ..                                       | 13   |
| CHAPTER II.  |      |
| THE PHYSIOLOGICAL ELECTROCARDIOGRAM ... ..                         | 14   |
| <i>The physiological auricular complex</i> ... ..                  | 18   |
| <i>The physiological ventricular complex</i> ... ..                | 18   |
| CHAPTER III.   |      |
| RHYTHMIC BUT ANOMALOUS ELECTROCARDIOGRAMS ... ..                   | 24   |
| <i>The constitution of the ventricular complex</i> ... ..          | 25   |
| <i>Aberrant beats</i> ... ..                                       | 28   |
| <i>Preponderance of left or right ventricle</i> ... ..             | 31   |
| <i>Inversion of "T"</i> ... ..                                     | 36   |
| CHAPTER IV.  |      |
| AURICULO-VENTRICULAR HEART-BLOCK, ETC. ... ..                      | 37   |
| <i>Partial heart-block</i> ... ..                                  | 37   |
| <i>Complete heart-block</i> ... ..                                 | 44   |
| <i>Slow action of the ventricle</i> ... ..                         | 48   |



| CHAPTER V.  |     |     |     |     |     |     | PAGE |
|---|-----|-----|-----|-----|-----|-----|------|
| PREMATURE CONTRACTIONS OR EXTRASYSTOLES                         | ... | ... | ... | ... | ... | ... | 53   |
| <i>Premature contractions of ventricular origin</i>             | ... | ... | ... | ... | ... | ... | 53   |
| <i>Premature contractions of auricular origin</i>               | ... | ... | ... | ... | ... | ... | 60   |
| <i>Premature contractions arising in the junctional tissues</i> | ... | ... | ... | ... | ... | ... | 66   |
| CHAPTER VI.   |     |     |     |     |     |     |      |
| SIMPLE PAROXYSMAL TACHYCARDIA                                   | ... | ... | ... | ... | ... | ... | 68   |
| <i>Dislocation of the pacemaker</i>                             | ... | ... | ... | ... | ... | ... | 75   |
| CHAPTER VII.  |     |     |     |     |     |     |      |
| AURICULAR FLUTTER   | ... | ... | ... | ... | ... | ... | 77   |
| <i>The electrocardiograms</i>                                   | ... | ... | ... | ... | ... | ... | 78   |
| CHAPTER VIII.   |     |     |     |     |     |     |      |
| AURICULAR FIBRILLATION  | ... | ... | ... | ... | ... | ... | 87   |
| CHAPTER IX.   |     |     |     |     |     |     |      |
| SINUS DISTURBANCES AND ALTERNATION                              | ... | ... | ... | ... | ... | ... | 101  |
| <i>Respiratory arrhythmia and allied irregularities</i>         | ... | ... | ... | ... | ... | ... | 101  |
| <i>Sino-auricular heart-block</i>                               | ... | ... | ... | ... | ... | ... | 103  |
| <i>Alternation of the heart</i>                                 | ... | ... | ... | ... | ... | ... | 103  |
| CHAPTER X.  |     |     |     |     |     |     |      |
| SPECIAL CONDITIONS  | ... | ... | ... | ... | ... | ... | 106  |
| <i>Electrocardiograms in valve lesions</i>                      | ... | ... | ... | ... | ... | ... | 106  |
| <i>Mitral stenosis</i>  | ... | ... | ... | ... | ... | ... | 108  |
| <i>Aortic disease</i>   | ... | ... | ... | ... | ... | ... | 111  |
| <i>Mitral regurgitation</i>                                     | ... | ... | ... | ... | ... | ... | 113  |
| <i>Congenital heart affections</i>                              | ... | ... | ... | ... | ... | ... | 113  |
| <i>Renal diseases and high blood-pressure</i>                   | ... | ... | ... | ... | ... | ... | 116  |
| <i>Exophthalmic goitre</i>                                      | ... | ... | ... | ... | ... | ... | 117  |

## CHAPTER I.

## THE ELECTROCARDIOGRAPHIC METHOD.

That electric currents are developed in the heart at each contraction of this organ was demonstrated in the middle of the nineteenth century. Modern electrocardiography is the outcome of this discovery. The currents are small, yet modern instruments are sufficiently sensitive to record them with facility. It is unnecessary that the heart should be exposed ; the currents will deflect a suitable galvanometer when the latter is connected to the limbs of the human subject, as Waller first showed. It is the study of the direction, time relations and magnitude of these currents which constitutes modern electrocardiography.

The instrument which is described in the present chapter is known as the "string galvanometer," the invention of Einthoven, a Dutch physiologist. It consists essentially of a powerful electro-magnet, the poles of which are closely approximated (Fig. 1); and of an extremely delicate conducting fibre of silvered quartz or glass which is stretched in the narrow gap between the two magnetic poles. If minute currents are led through this fibre, as it lies in the magnetic field, the fibre moves across the gap in response to the tested current in a plane at right angles to the lines of magnetic force. The magnified shadow of the fibre



is vertical and is projected by means of an optical system and powerful light on to the horizontal slit of a camera ; the shadow moves at right angles to and across the slit and the movements are photographed upon a sensitive plate which travels behind the slit. I do not propose to describe the detailed construction of the galvanometer itself or of

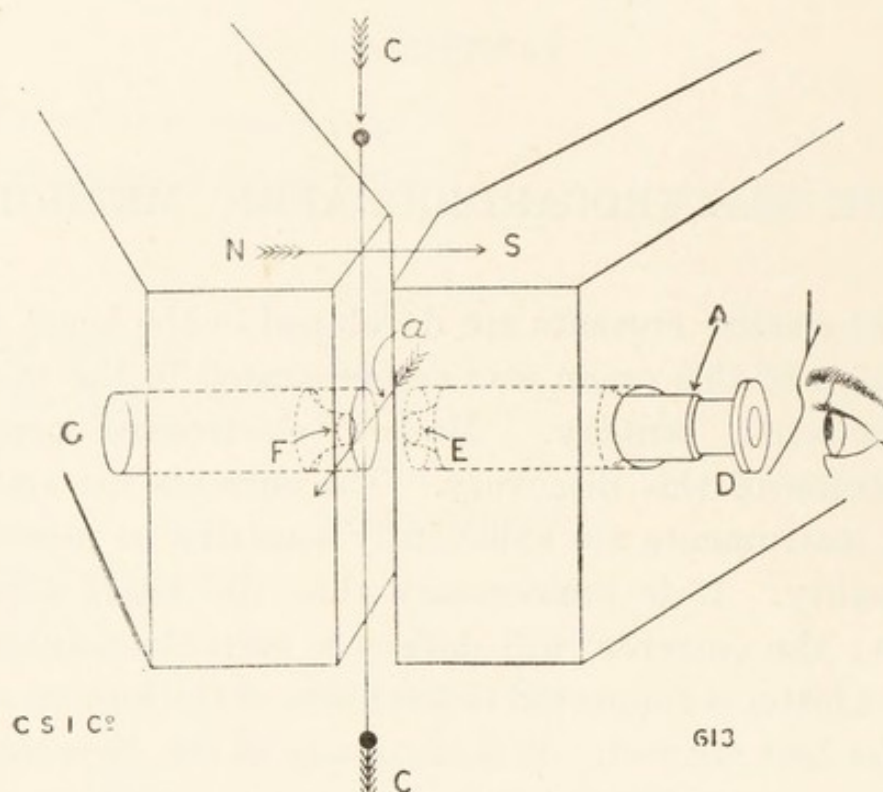


Fig. 1. A diagram illustrating the construction of the string galvanometer. The poles of the magnet (*N*, *S*) are seen in outline ; the recording fibre (*CC*) lies vertically between them ; its movements may be observed through a microscope (*D*). The movements of the string are in a plane parallel to the faces of the magnetic poles, as indicated by the central arrow. *F* is a condenser.

the accessory apparatus which it is necessary to employ in obtaining human electrocardiograms. Many different installations are now sold and some are specially arranged for clinical purposes. The galvanometer illustrated in Fig. 2 is perhaps the most serviceable of any, and is to be recommended for the simplicity of its construction and the ease with which it is kept in order and manipulated. The






Fig. 2. The string galvanometer as modelled by the Cambridge and Paul Scientific Instrument Company. The coils of the magnet (*B, B*) are seen in the background; they are supplied with current through the four terminals (*M, N*); the poles of the magnet (*A, A*) are in the foreground. The magnet is pierced by microscope (*G*) and condenser (*D, D*). The string is encased in a carrier (*E*), which is suspended from above upon two knife edge rests (*K, K*) and hangs between the magnetic poles. The string tension is adjusted by means of the milled screw (*J*); the position of the carrier in the field is altered by an adjustment at *F*. The tested current is led to the instrument through the two terminals *O* and *P*.

adjustments are simple and consist of mill-headed screws which level the instrument, centre the fibre in the field, increase or decrease its tension, and focus its shadow upon the camera. Those who desire a more detailed account of the apparatus may refer to the special descriptions issued



by its makers, or to my book, *The Mechanism and Graphic Registration of the Heart Beat*; but familiarity with galvanometric outfits can be gained best by handling the instruments.

The galvanometer is connected to the patient through some special form of switchboard. Students of electrocardiography utilise switchboards of different patterns, more

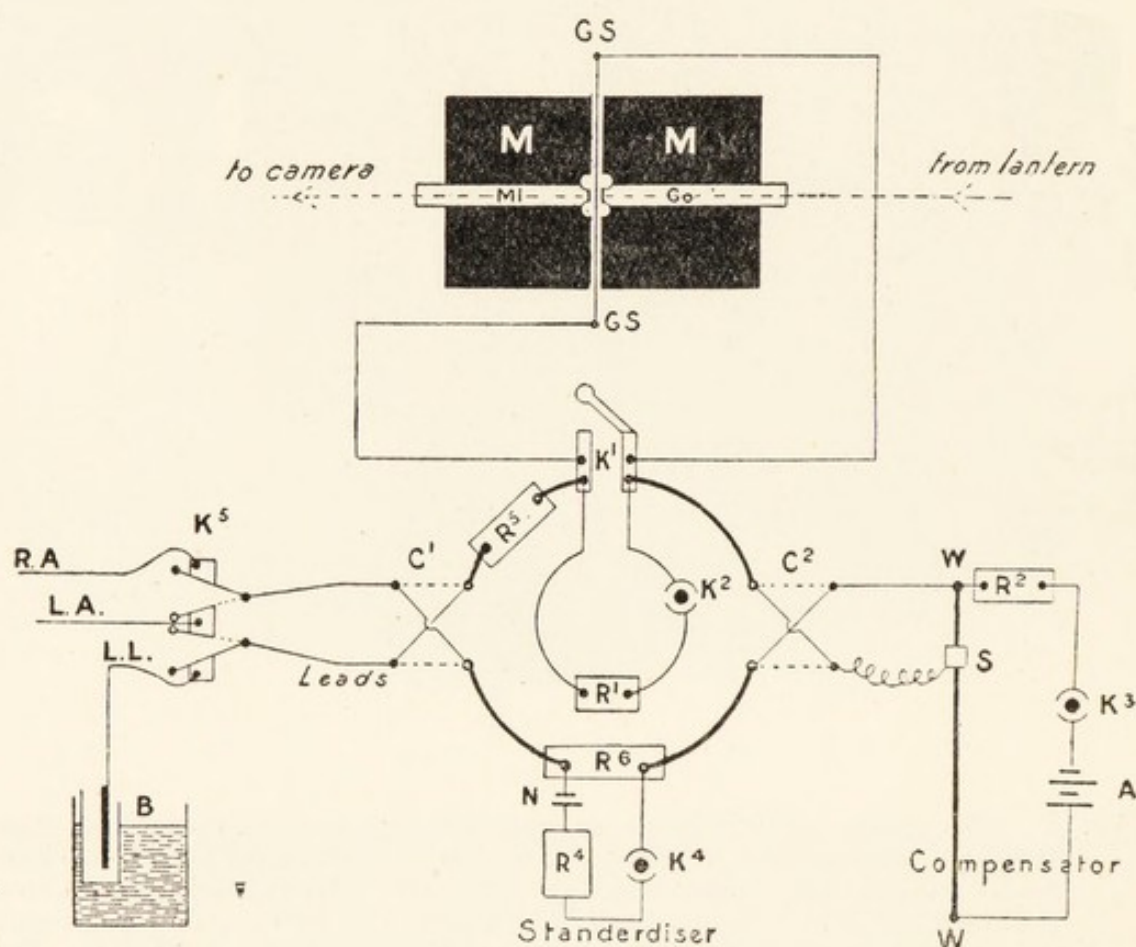


Fig. 3. A switchboard arranged as a group of simple circuits and connected to the galvanometer.

or less complicated; those supplied for clinical use are arranged to insure speedy and accurate work; the actual switches are therefore few in number but the wiring is intricate. I propose to describe a scheme which may be drawn as a group of simple circuits. This scheme, though serviceable, is no longer in clinical use, because the number of the keys

makes the manipulation of the board relatively slow. But I retain it as an illustration because its circuits and their use are easy to understand and because more complex boards are arranged on similar principles.

Fig. 3 is a diagram of the apparatus and its connections. The string of the galvanometer ( $GS$ ) is connected to a key ( $K^1$ ) which closes the string circuit. The closure of this key brings the string to rest and safeguards it from damage. The same key communicates with two circuits, the inner and outer circles of the diagram; the former is a shunt, containing a resistance and key ( $R^1$  and  $K^2$ ), so arranged that when closed it carries the greater part of the tested current, thus preserving the string from mishap. It is used when a current of unknown strength is thrown into the string circuit. The outer circle represents the main circuit; it is broken at three points; (1) at  $K^1$  where it joins the string circuit, (2) at  $C^1$ , by a commutator, where it connects to the patient, and (3) at  $C^2$ , by a commutator, where it connects to the compensator. It contains also a dial resistance ( $R^5$ ) and the standardiser. The separate parts of the apparatus may be described briefly and in rotation.

*Connection of patient.* One wire which runs from the commutator  $C^1$  to the key  $K^5$  may be connected at will to the right arm ( $R. A.$ ) or left arm ( $L. A.$ ) by means of the special key; the second or parallel wire may be connected to the left arm or left leg ( $L. L.$ ) by the same key.\* The actual contacts are made when the limbs are immersed in salt water,† and through porous pots containing zinc sulphate (Fig. 3  $B$  and Fig. 4). The key ( $K^5$ ) is arranged so that the two main wires may have the following paired connections.

\* The wires which connect to the limbs may be of any length; the patient who is observed may be in a separate building.

† The water should be warm and pieces of cotton wool may be added to form a bath of porridge-like consistency. By these means disturbing movements of hands and water are diminished.






Fig. 4. Photograph of a subject as connected for observation. The two arms and the left leg are used, and curves are taken from the three leads which are represented by arrows in the figure. The zinc sulphate is placed in the outer vessels of the electrodes shown in this figure.

|                | <i>Limbs connected.</i> |     |       |  |
|----------------|-------------------------|-----|-------|--|
| Lead I .. ..   | R. A.                   | and | L. A. |  |
| Lead II .. ..  | R. A.                   | and | L. L. |  |
| Lead III .. .. | L. A.                   | and | L. L. |  |

These are the connections which are employed in routine observation.



*The compensating circuit.* This is shown to the right in Fig. 3 ; and consists of an accumulator (  $A$  ), key (  $K^3$  ), suitable resistance (  $R^2 = 19$  ohms ) and slide wire (  $W$   $W = 1$  ohm ). It is used to bring the string shadow to zero when the patient is connected to the galvanometer ; it serves to neutralise the current derived from the skin, generally referred to as the " skin current," and is fitted with a commutator,  $C^2$ , which reverses the direction of the compensating current.

*The standardiser* is formed by a similar circuit to that of the compensator, consisting of a battery, suitable resistances (  $R^4$  and  $R^6$  ) and key (  $K^4$  ). It throws an E.M.F. of 3 millivolts into the main circuit, and is used to standardise the string excursion, so that all electrocardiograms may be comparable one with another.

The dial resistance  $R^5$  serves many purposes ; amongst others, the measurement of the resistance of the string or of the patient's body.

*The method of obtaining standardised electrocardiograms.*

Standardised electrocardiograms are obtained in the following manner.

1. With the compensating and standardising circuits open, but with the shunt (  $K^2$  ) closed and the patient in circuit (  $K^5$  connecting to  $R. A.$  and  $L. A.$ , the first lead).  $K^1$  is opened. The string shadow immediately takes up a new position, as a result of skin current flowing into the galvanometer, and shows minute electrocardiograms (Fig. 5a).

2.  $K^3$  is closed and a compensating current, or current to balance the skin current, is introduced which brings the string shadow to zero once again (Fig. 5b).

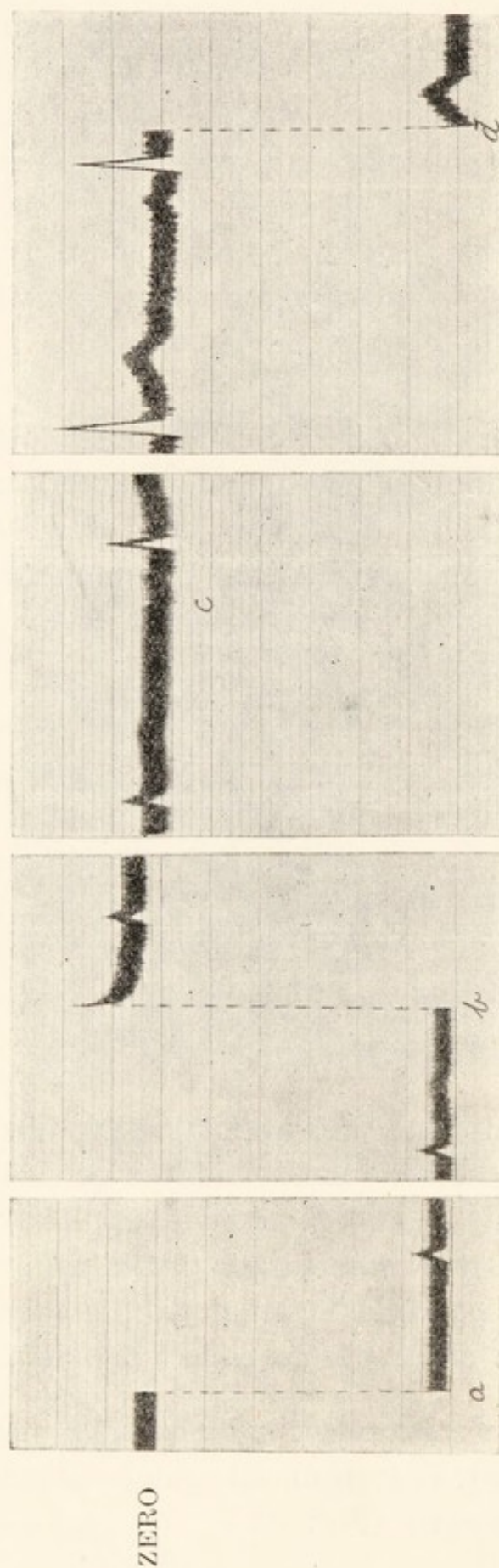


Fig. 5. Portions of a continuous curve, illustrating the steps taken in obtaining a standardised electrocardiogram.

This and all other curves used as illustrations read from left to right. The string is at first still. At *a* the main key ( $K^1$  of Fig. 3) is opened; the string is deflected in response to "skin current" and shows minute electrocardiograms. This current is compensated and the string brought back to "zero" by throwing a current of opposite direction into circuit (*b*). At *c*, the shunt  $K^2$  is removed, the string moves a little from the zero and the electrocardiogram increases in amplitude. The string tension is then adjusted until a potential of 3 millivolts deflects the whole curve through 3 centimetres (*d*). The curve is then a standard one and the photograph may be taken, while the string is moving in the region of the original zero line.



3. The shunt ( $K^2$ ) is opened and the string moves again\* showing larger electrocardiograms (Fig. 5c), because the whole current is now allowed to flow through the string.

4. If the string shadow has moved much to one side, it is again brought to zero by means of the compensator.

5. The standardising circuit is now made (introducing 3 millivolts) and broken repeatedly until, by adjusting the string tension, the whole curve is deflected through 3 centimetres (Fig. 5d). Tightening the string reduces and slackening it increases the sensitiveness of the instrument.

6. A curve is taken from the first lead.

7. The process is repeated in the case of leads *II* and *III*. The curves obtained have the correct amplitude and a value of 3 millivolts to each 3 centimetres of excursion, or 1 millivolt to the centimetre of excursion.

For convenience of measurement, a screen, of millimetre lines, is placed immediately in front of the photographic plate. The light, falling through the screen, is intercepted by these lines and the film is ruled as the photograph is taken (Fig. 5).

Though the steps taken in producing standardised electrocardiograms may seem complicated and tedious in the description, yet in practice they become simple ; with modern apparatus a series of curves from the three leads should be obtained from a single subject within a few moments.

#### *Checking the accuracy of standardised curves.*

The accuracy of an electrocardiogram from a given subject may be checked in a simple fashion by increasing

---

\* In Fig. 5c this movement is very small.



the resistance in the main circuit. When a curve has been

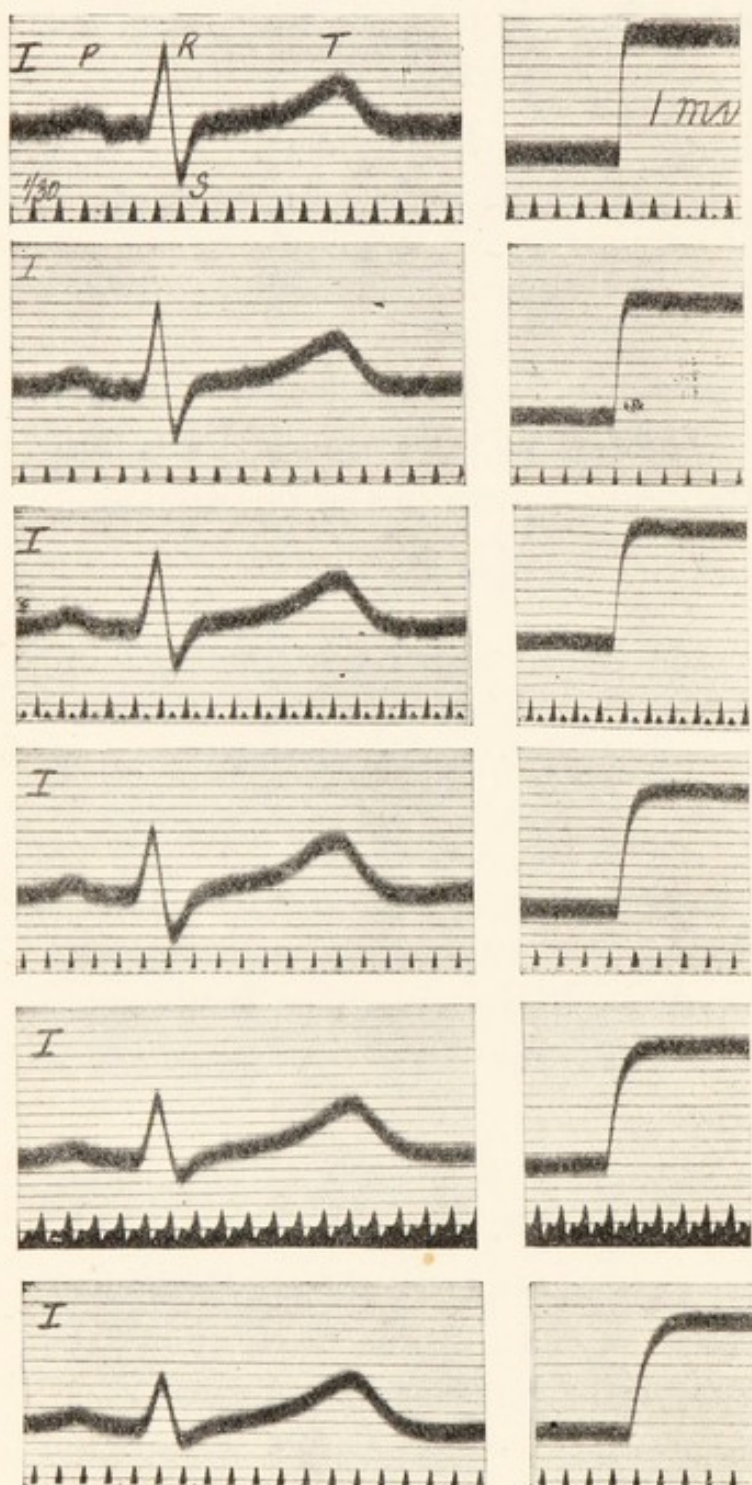


Fig. 6. Six electrocardiograms from lead *I* and from a single subject, and the six corresponding deflections in response to a test current. Illustrating the distortion of curves when the string tension is too slack. As the string is slackened beyond a certain limit and the deflection time (the time of a response to an E.M.F. of 1 millivolt over an excursion of 1 centimetre) increases, *R* and *S* are materially reduced in amplitude. Time-marker in thirtieths of a second in this and all other figures, unless otherwise stated.

\* The string resistance may be measured by obtaining a deflection of 6 centimetres with 3 millivolts, and by placing such a resistance in series with the string as halves its excursion; i.e., reduce it to 3 centimetres. The resistance of the string and the added quantity are then equal.

taken in the usual manner, a large resistance is placed in series with the string and patient by altering the dial resistance ( $R^5$ ). As a rule it is convenient to throw in a resistance which is approximately equivalent to that of the string itself.\* With this resistance in circuit the same procedure is followed, the tension of the string being suitably decreased, so as to give the original excursion of 3 centimetres to 3 millivolts. The second curve, the one taken with the added resistance in series, should be similar in every respect to the original one. This procedure is recommended as an occasional test; it is not necessary as a routine.



*Testing certain properties of the string.*

If standard curves of correct outline are to be obtained, the response of the fibre to simple current changes must carefully be examined from time to time ; for the excursion and shape of an electrocardiogram may be modified by the properties of the string. Supposing that an E.M.F. of 1 millivolt is thrown into circuit (the patient being disconnected) and that the tension of the fibre is arranged so that it gives an excursion of 1 centimetre ; the curve obtained has an outline similar to those shown to the right hand of Fig. 6. The string moves when the current enters it and eventually takes up a position 1 centimetre away. But in arriving at the new position it describes a curve. The characters of this curve are important. Fig. 6 shows six electrocardiograms from the same subject, and six responses to an E.M.F. of 1 millivolt. The curves differ because they were taken with different resistances in circuit, and consequently with different string tensions.\* From above downwards the added resistance was increased and the string was therefore slackened. All the curves were taken with the string at such a tension that 1 millivolt gave 1 centimetre of excursion (see deflections to right of strips).

In the first place, the movement of the string in response to 1 millivolt should be "dead beat" ; that is to say, there should be no over-shooting ; over-shooting tends to produce distortion of the electrocardiograms by increasing the amplitude of the initial deflections. Over-shooting is shown in Fig. 5 (at *b*) at a stage when the tension of the fibre was too great. In the second place, the movement should be of sufficient rapidity. The slacker the string, the more slowly

---

\* Adding resistance to the main circuit decreases the sensitiveness of the instrument and the string must be slackened to compensate this decrease if a constant excursion is to be maintained.



does it come to rest in its new position ; the deflection times for the six strips of Fig. 6 are 0.013, 0.023, 0.028, 0.045, 0.060 and 0.070 second, respectively, from *A* to *F*. Now the initial electric changes which result from the heart beat are rapid, and if the quickest movement of which the string is capable is too slow to follow these changes, an accurate electrocardiogram is not obtained. Undue slackness of the string distorts the curve and this distortion is well illustrated by the series of curves shown to the left in Fig. 6. As the string is slackened, a stage is reached when the steepest deflections (*R*, *S*) are shortened and their upstrokes and downstrokes are rendered more oblique ; once distortion appears, further slackening exaggerates it ; so that, as in the last strips of Fig. 6, certain deflections (such as *S* and *R*) tend to disappear. The electrocardiograms of the first two strips are exactly alike, these electrocardiograms are accurate ; the first change, a decrease in the amplitude of *R* and *S* in the third strip, is seen when the deflection time of the string is increased to 0.028 second.

For routine work the instrument and string should be tuned, so that while on the one hand there is no overshooting, on the other hand the deflection time does not exceed 0.02 second. The best strings for electrocardiographic work are those which fulfil these conditions over a considerable range of string tension. Intending students of electrocardiography are strongly advised to satisfy themselves fully of the adequacy in these respects of any instrument with which they propose to work. It is also necessary that the resistance of the string should be large compared with the resistance of the body, so that small variations of the latter do not appreciably affect the result. Strings having resistances of about 5,000 ohms are suitable.



*Accessories.*

The electrocardiogram is taken simultaneously with a time signal ; a tuning fork or other vibrator which casts its shadow on the camera slit suffices for this purpose, and such a device was used in obtaining the figures for this book. To-day it is customary to use a toothed wheel, rotating at a constant and controlled speed. Such a time-marker momentarily obliterates the whole of the light falling on the slit and rules vertical lines at regular intervals across the plate (see Fig. 84).

Simultaneous curves from the pulse (Fig. 62) or jugular vein may be obtained by allowing the levers of suitable recording devices to cast their shadows upon the camera slit.

## CHAPTER II.

---

### THE PHYSIOLOGICAL ELECTROCARDIOGRAM.

The normal electrocardiogram consists of a series of deflections, some of which are rapid and of short duration, while others are slow and of longer duration. They have been named in a purely empirical fashion, *P*, *Q*, *R*, *S* and *T*. The electrocardiogram opens with a blunt summit *P*, which occupies presystole, and is due to the contraction process in the two auricles (Figs. 7 and 8). Following upon this deflection the string shadow either maintains the zero position or dips somewhat. I speak of these portions of the electrocardiogram as the "auricular complex"; this complex begins with the upstroke of *P* and terminates at the opening of the "ventricular complex." The latter varies in the number of its component deflections; in its full form it comprises *Q*, a small dip, *R*, a tall spike, *S*, a steep valley of variable depth, and *T*, a broad blunt summit. The period occupied by all these deflections is approximately that of the ventricular systole with which they are associated. The earliest sign of contraction which can be recorded by other means from the ventricle occurs a little after the commencement of *R*, and usually during its upstroke. The contraction ends where *T* passes into the horizontal line of diastole, or within a few hundredths of a second of this point. These relations are indicated in Fig. 8, which is a simultaneous record of the electric changes and the apical heart sounds.






Fig. 7. An electrocardiogram from a normal subject, showing the auricular summit (*P*) and the ventricular deflections (*Q*, *R*, *S* and *T*).

In this and the remaining figures, the lead is marked in the upper left hand corner of the figure; the time, at the bottom, is in thirtieths of a second, the distances between the parallel horizontal lines represent tenths of a millivolt.

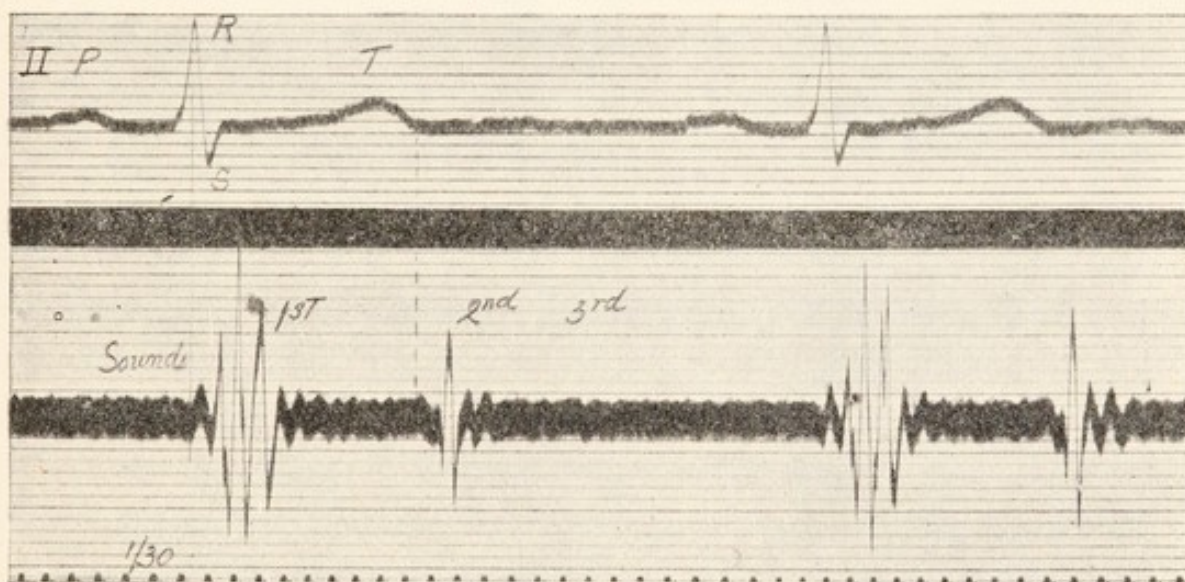


Fig. 8. Simultaneous electrocardiograms and heart sound curve from a normal subject. The figure shows the time-relations of the electrocardiogram to the beginnings of the 1st and 2nd heart sounds. All points on any vertical line are simultaneous.

Thus, the curves provide us with clear indications of the systoles of auricles and of ventricles, and enable us to establish, within very small limits of error, the time-relations of contraction in upper and lower chambers of any given heart.

The initial ventricular deflections (*Q R S*, or *R, S*, as the case may be) correspond to the spread of the excitation wave in the ventricle. This excitation wave is associated

with the wave of contraction. For the purposes of this book the wave of excitation and of contraction may be regarded as simultaneous and as following identical paths; they are now regarded as part and parcel of one process. The duration of the initial deflections may be taken as a measure of the time during which all parts of the ventricle are becoming active. The final deflection (*T*) is produced by subsidence of the ventricular activity, and finishes at the time when all parts of the ventricle first become quiescent.

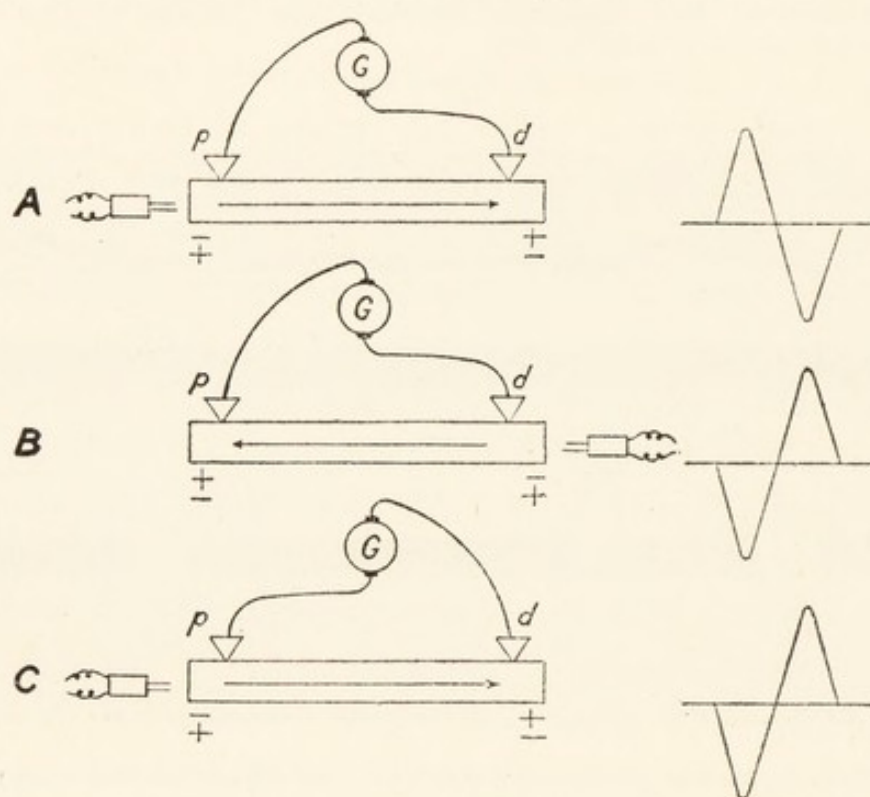


Fig. 9. A diagram illustrating the theory of electric curves. It represents a strip of muscle connected to the galvanometer and stimulated to contract from one or other end. The deflections, which are shown to the right, vary in direction according to the point at which the contraction originates and with the relation of the muscle to the electrodes.

Supposing that we take a simple strip of muscle, the fibres of which are parallel, and connect its two ends, which we will term proximal (*p*) and distal (*d*), to the galvanometer. If this strip is stimulated by a single induction shock, say at its proximal end (Fig. 9 *A*), then a wave of contraction flows



from *p* to *d*. When the muscle at *p* becomes active, it also becomes relatively negative to *d*, as shown by the swing of the galvanometric recorder; the swing is in a definite and known direction, it is the same as that given when *p* is replaced by the zinc terminal of a copper-zinc couple. But the wave passes to *d* and as it reaches this point it subsides at *p*. The distal end becomes active while the proximal end is resuming the quiescent state; as an accompaniment of this change, *d* becomes relatively negative to *p*, and the swing of the recorder is reversed. Thus the whole electric effect consists of two deflections which are in opposite directions, a simple *diphasic* effect. Now if the stimulus is applied at the distal end (Fig. 9*B*) the direction of contraction is reversed; in these circumstances *d* first shows relative negativity and later *p*; a diphasic effect is still obtained, but the directions of swing are the reverse of those seen when the contraction travels from *p* to *d*. It will be evident that the recorded curve will also show reversed phases if, stimulation being at the proximal end, the connections to the galvanometer are reversed (Fig. 9*C*).

The meaning of individual deflections in the electrocardiogram is necessarily a complicated matter; though understood in great part, they cannot be explained in any detail in this handbook. I shall be content to formulate the chief conclusions reached but will defer these until the next chapter. Meanwhile certain fundamental principles emerge from our simple experiment. The shape of the electric curve is controlled (1) by the path which the excitation wave takes through the tested muscle, and (2) by the lie of this muscle in relation to the leading off electrodes. *If the wave pursues an abnormal course through the heart, it will yield an abnormal electrocardiogram. If the points of contact, which the instrument makes in the body, are altered, the curve will alter correspondingly.*



Now it is known that all normal human hearts yield from a given lead, electrocardiograms which conform to a type. Although the curves taken from no two subjects are exactly alike, yet by experience we learn the limits of variation which are compatible with health.

*The physiological auricular complex.* *P*, the auricular representative, is found as a summit\* in all normal and young adult subjects and in all leads; it is small and rarely exceeds 2 scale divisions in amplitude; it is followed by a short line which is horizontal or dipping. Amongst the variations in form, which *P* presents in the normal subject, is occasional bifurcation (Fig. 10). *Auricular complexes*

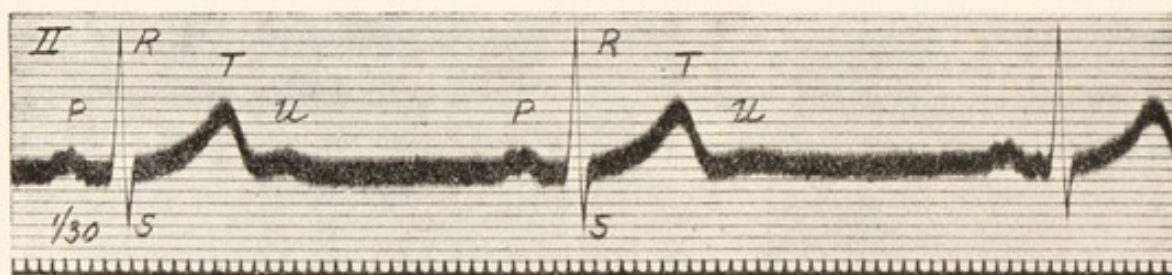


Fig. 10. A normal electrocardiogram, showing a divided *P* summit; a prominent *U* summit occurs at the beginning of diastole.

*of these forms are known to express the origin of the heart beat at the normal site of impulse formation and the passage of the wave through the auricular tissue along normal paths.*

*The physiological ventricular complex.* The variations which are found in the type of the physiological ventricular complex are many. *R* and *T* are always present; *Q* and *S* are often absent. All the deflections vary in amplitude and in shape, and in certain leads *T* may vary in its direction.

\* *P* and *R* are upward movements when the galvanometric connections are so arranged that if the right arm contact is replaced by the zinc terminal of a copper-zinc couple, and the left leg contact is replaced by the copper terminal, an upward deflection results.



The *QRS* group of deflections is quick, having in normal subjects a total duration of no more than one-tenth of a second. The presence of a *QRS* group of rapid deflections, followed by a slow blunt *T* deflection, indicates that the ventricular contraction has been propagated from normal points. *It has been awakened by impulses which have traversed the auriculo-ventricular bundle, its main divisions and their arborisations.*

Certain variations in the form and amplitude of individual deflections require closer description, and it will be necessary to refer to the leads from which the curves are taken. We may confine ourselves to those features which are of clinical importance.

Curves from the three leads of a normal subject are shown in Fig. 11. It will be noticed that in all *R* is prominent, but that it is most prominent in lead *II*, and that *T* is directed upwards. On the other hand *Q* and *S* are inconstant in the leads. This series of curves may be regarded as of average type. In a series of over 50 young adult subjects the greatest variations presented by serial leads are depicted in Figs. 12 and 13. The importance of these extreme electrocardiograms will be better appreciated when we deal with pathological curves in the next chapter. At present it should be noticed that in Fig. 12 *R* is inconspicuous in lead *I* and most prominent in lead *III*, while *S* is most conspicuous in lead *I*. Precisely the reverse relations are shown in Fig. 13, where *R* is most prominent in lead *I* and inconspicuous in lead *III*, while *S* is deepest in lead *III*. These variations in amplitude in part result from preponderance of the musculature in right (Fig. 12) and left (Fig. 13) ventricles respectively, and are extreme examples of the pictures which may be found in apparently healthy subjects.

Normal electrocardiograms occasionally exhibit notching of *R* or *S* (Fig. 13); and in lead *III* bizarre types of initial



deflections (the *QRS* group) are not uncommon ; examples are shown in Fig. 14.

*T* is always upright in young and healthy individuals in lead *II* and under normal conditions, but it is often inverted in lead *III* and may show partial inversion in lead *I*. Inversion in lead *III* is generally associated with the bizarre *QRS*

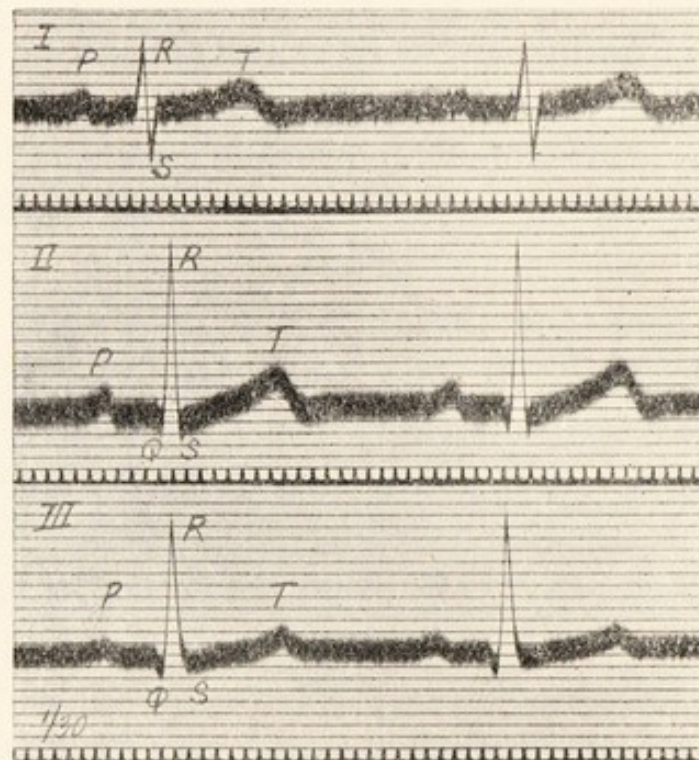


Fig. 11. Electrocardiograms from the three leads in a normal subject. To illustrate the change in the type of curve with change of lead. Note that *R* is tallest in lead *II*.

group to which reference has been made already (Fig. 14), but may occur with the usual form of initial deflections (Fig. 12).

An additional deflection *U* is not uncommon and is occasionally prominent (Fig. 10). This deflection is related to the early events of diastole, but beyond this is not understood.

Standard curves from the same subject are almost identical in form and amplitude from time to time. The constancy is such, and the variations in distinct subjects are



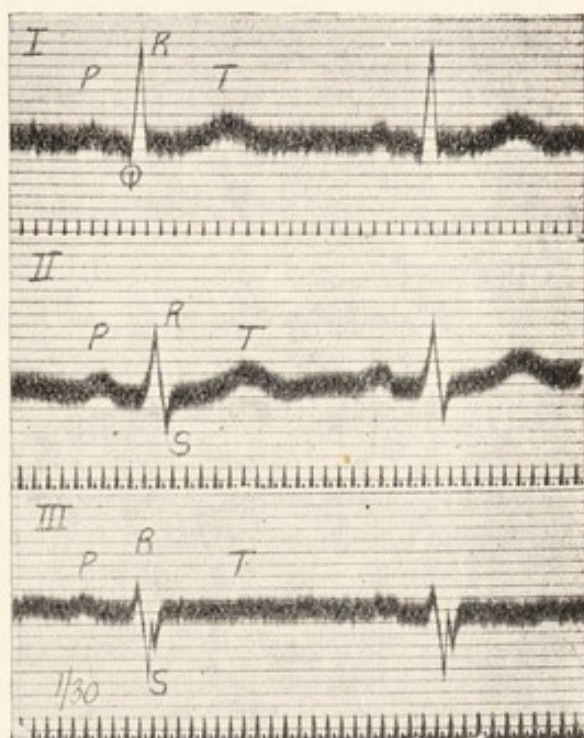
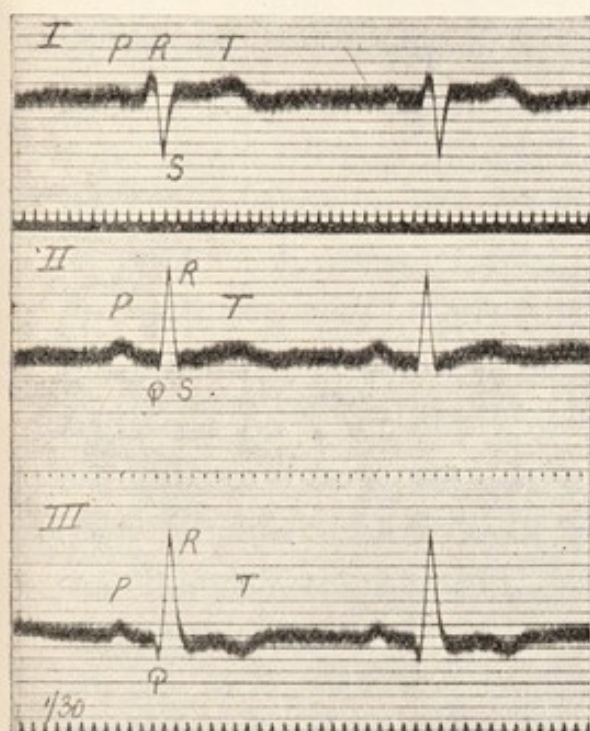


Fig. 12. Normal electrocardiograms, showing the tallest *R* in lead *III* and the shortest *R* and deepest *S* in lead *I*. For comparison with Fig. 21.

Fig. 13. Normal electrocardiograms, showing the tallest *R* in lead *I* and the shortest *R* and deepest *S* in lead *III*. For comparison with Fig. 20.

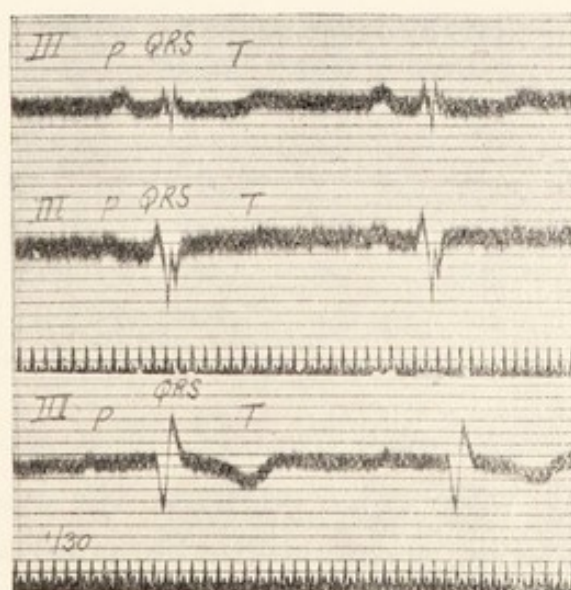


Fig. 14. Normal curves taken from lead *III* in three different subjects. Illustrating the curious initial deflections which are sometimes seen in this lead. They are often associated with inversion of *T*.

sufficiently definite, that electrocardiograms might well be used to identify the individual. Considerable changes in the heights or directions of deflections in electrocardiograms, taken from time to time and under similar conditions, do not occur in health and rarely occur in chronic disease. An observed change is significant of altered function.

A certain familiarity with the limits between which the amplitudes of deflections vary in health is useful ; it is gained by experience. Some idea of their value may be obtained from a series of curves taken from a number of active students. There were in all 59 individuals from whom curves were taken. The limits of amplitude for the several deflections are given in the accompanying table, which includes measurements

|                  |     | <i>P</i> | <i>Q</i> | <i>R</i> | <i>S</i> | <i>T</i> | <i>U</i> |
|------------------|-----|----------|----------|----------|----------|----------|----------|
| <i>Lead I.</i>   |     |          |          |          |          |          |          |
| Minimum          | ... | Trace    | 0        | 1.5      | 0        | —0.5     | 0        |
| Average ...      | ... | 0.52     | 0.51     | 5.16     | 2.06     | 1.93     | 0.10     |
| Maximum          | ... | 1        | 2.0      | 12.0     | 6.0      | 5.5      | Trace    |
| <i>Lead II.</i>  |     |          |          |          |          |          |          |
| Minimum          | ... | Trace    | 0        | 4.0      | 0        | Trace    | 0        |
| Average ...      | ... | 1.16     | 0.73     | 10.32    | 2.23     | 2.46     | 0.16     |
| Maximum          | ... | 1.7      | 2.5      | 16.5     | 4.5      | 5.0      | 0.8      |
| <i>Lead III.</i> |     |          |          |          |          |          |          |
| Minimum          | ... | Trace    | 0        | 2.0      | 0        | —2.0     | 0        |
| Average ...      | ... | 0.81     | 0.86     | 6.61     | 1.73     | 0.61     | 0.06     |
| Maximum          | ... | 1.5      | 2.5      | 14.0     | 4.0      | 3.0      | 0.3      |

from 52 subjects. The measurements from seven subjects are not given ; they were rejected from the normal series for various reasons. Six manifested abnormal signs upon the ordinary physical examination, and, of these, *four* gave electrocardiographic curves which diverged notably from those of the selected series. Only one student in whom no



other physical signs were obtainable presented divergent electrocardiograms. Two subjects who gave normal electrocardiograms were found to have, the one a tricuspid murmur, the other a slight extension of the left limit of heart dulness. These facts speak for themselves ; if in any subject electrocardiograms which show notable divergence from what is regarded as normal are obtained, it is probable that the heart is abnormal. But, on the contrary, if the electrocardiograms are normal in form, it does not follow that the heart is normal.

Electrocardiographic curves are modified by age ; the chief change is a decrease in the amplitude of *T* as the subject becomes older. They are also influenced by displacement of the heart, such as occurs in different postures, or with deep breathing or where there is an accumulation of fluid in a pleural sac. They are modified by exercise, notably by an increase in the amplitude of *T*. But these factors materially influence the interpretation of pathological curves in exceptional cases only.

## CHAPTER III.

---

### RHYTHMIC BUT ANOMALOUS ELECTRO-CARDIOGRAMS.

In the last chapter it was shown that electric curves are controlled by the direction which the excitation wave takes in the muscle yielding the record. Clearly to appreciate this principle and to apply it constantly is the basis of electrocardiography. If the heart beat starts in an abnormal focus or if a wave, propagated from the normal focus, subsequently deviates from its accustomed paths, an anomalous electrocardiogram is the result. The systoles of auricle or of ventricle may be classified according to the forms of electric curves which they produce.

Now, in the natural heart beat, the wave is propagated over auricle to ventricle ; the stimulus is conveyed from the first chamber to the last through the auriculo-ventricular bundle ; thence it spreads through the two main divisions of this bundle and is distributed to the right and left ventricle through the arborisations and basketworks of Purkinje cells. In these circumstances the systole which follows yields an electrocardiogram conforming to a recognised type ; the familiar deflections, *Q*, *R*, *S* and *T* are produced. This type of electrocardiogram is only seen when the systole to



which it corresponds is provoked by an impulse arising above the division of the *A-V* bundle—an impulse which I distinguish as *supraventricular*—and it is limited to responses of the ventricle to supraventricular impulses which descend all the normal channels. Thus, if the ventricle responds to an impulse generated in its own walls, the electrocardiogram is abnormal. (See Chapter V. on *Premature Contractions*.) The curve is also abnormal if a supraventricular impulse is distributed to the ventricle in an unusual manner, as may happen. For in the first instance and in the second, the course which the resultant wave takes in the ventricular walls deviates from the normal.

*The constitution of the ventricular complex.*

When a supraventricular impulse (for example, the normal impulse), on passing to the ventricles, enters the normal field of reception, it reaches the two ventricles simultaneously. Each ventricle possesses a complete and separate system of distributing fibres (see Fig. 15, top diagram). Each ventricle yields its own electric currents and each, while beating normally, yields a distinctive curve. Up to a point the forms of the curves distinguishing the normal systole of right and left ventricles, respectively, are known to us. It is for the student of electrocardiography to become thoroughly familiar with these types. In Fig. 15 is a diagram of the ventricles, seen in section, and of the auriculo-ventricular bundle and its ventricular connections. The septum of the ventricles forms a saddle across which the dividing bundle sits astride. If the right division of the bundle is transected below its origin (as at *B*<sup>1</sup>) the normal impulse no longer travels through it, but passes solely through the left stem. The distribution of the impulse is faulty, but it is only faulty in so far as the right ventricle is concerned; it is distributed to the left chamber in a perfectly normal fashion. The

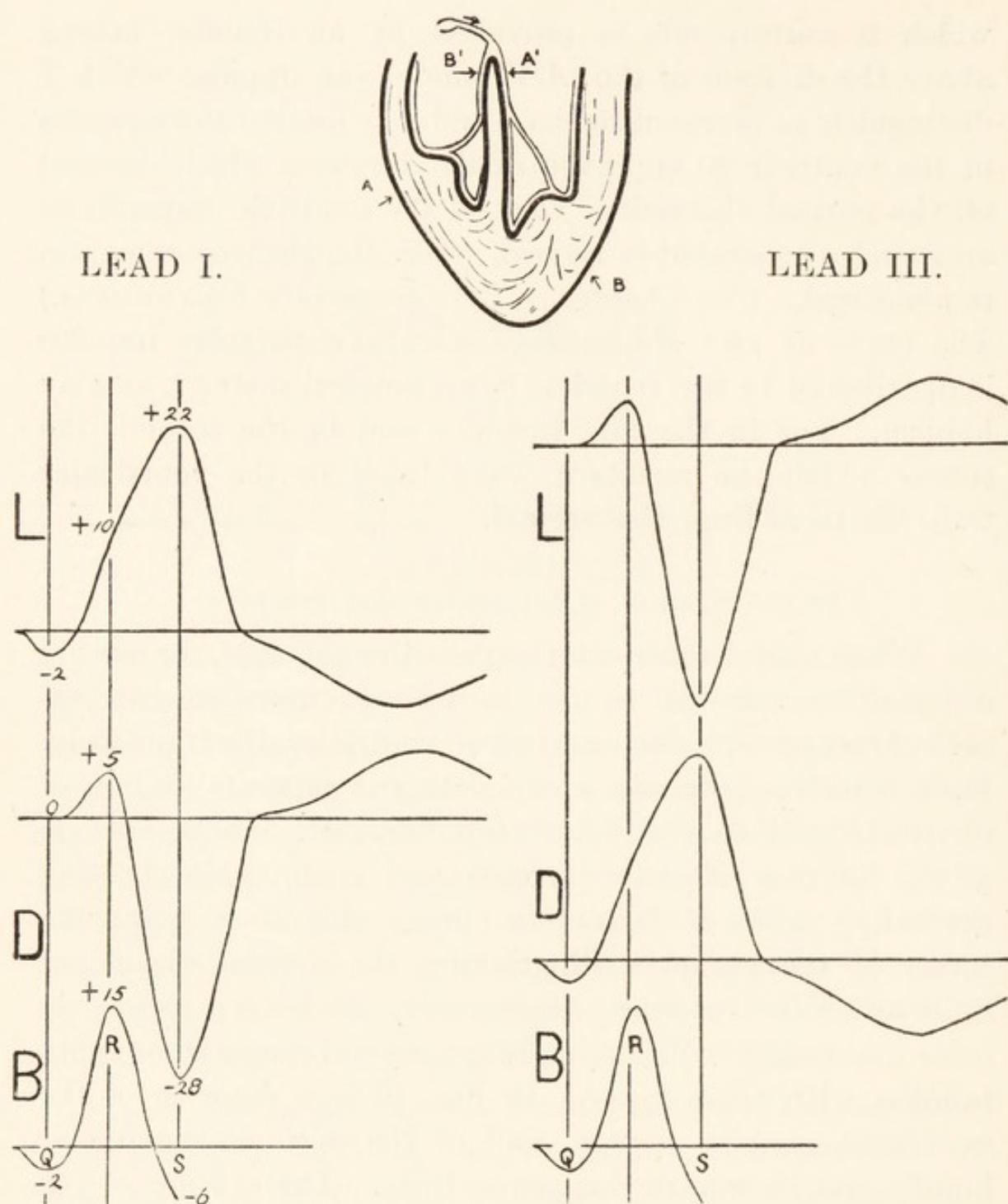


Fig. 15. A diagram of the ventricles seen in section and of the auriculo-ventricular bundle and its branches.

A lesion of the bundle division at  $A'$  forces the natural impulse to descend solely through the right division, the supply of the right ventricle. The corresponding electrocardiograms are characteristic, and are not dissimilar in form to those obtained by stimulating the right ventricle at  $A$ . A lesion of the right bundle division at  $B'$  confines the descending impulse to the path of the left division. The corresponding curves are characteristic and are not dissimilar in form to those obtained by stimulating the left ventricle at  $B$ .

Below the diagram are two series of curves, arranged vertically and corresponding to leads  $I$  and  $III$ . The top curve in each series is the *levogram*, obtained when the right bundle division is damaged; the middle curve in each series is the *dextrogram*, obtained when the left bundle division is damaged. The bottom curves represent the initial phases of the normal electrocardiogram and the diagram is arranged to show that these initial phases are the algebraic product of the levogram and dextrogram. In the series from lead  $I$  have inserted the amplitudes of the curves where they cross the common vertical lines, marking them as  $+$  or  $-$  quantities according as the deflection is up or down. Thus  $Q (-2)$  is the result of a similar dip  $(-2)$  in the levogram;  $R (15)$  is the product of the small spike  $(5)$  in the dextrogram and of the rising levogram  $(10)$ .



curves which this partial distribution yields are shown in the diagram (*L L*), and these curves in their initial phases (while the excitation is confined to the left ventricle) represent the currents *normally* formed in the left ventricle. In lead *I* the curve comprises a small downward phase, a large upward phase and a final and sustained downward phase. In lead *III* the curve comprises a small upward, a large downward and a final and sustained upward phase. Because these curves correspond in their initial phases to the natural systole of the left ventricle, I call them *levograms*. If, on the other hand, the left bundle division is divided the impulse is conveyed solely to the right ventricle ; but this distribution, in so far as it affects the right ventricle, is again normal. The corresponding curves, which I term *dextrograms*, are shown in the diagram (*D D*). The curve of lead *I* comprises a small upward phase, a large downward phase and a final upward phase ; in lead *III* it comprises a small downward phase, a large upward phase and a final downward phase.

Now the levogram and dextrogram are not only of intrinsic clinical importance, but they also show us how the normal electrocardiogram is constituted. I have indicated that in so far as their initial phases are concerned they represent the normal events in the left and right ventricle respectively. Each ventricle forms its own currents and it is the combination of the two effects which constitutes the normal curve. In the left hand series of curves of Fig. 15 the levogram and dextrogram of lead *I* are diagrammatised. Summate the initial phases of these two curves—add them together algebraically—and the result is the initial phases *Q*, *R* and *S* of the normal heart beat. A similar summation of the levogram and dextrogram in lead *III* will yield the normal curve in lead *III*. Study of this diagram will show that in human electrocardiograms :—



*In lead I "Q" is a left ventricular event.*

*"R" is mainly a left ventricular event.*

*"S" is a right ventricular event.*

*While in lead III "Q" is a right ventricular event.*

*"R" is mainly a right ventricular event.*

*"S" is a left ventricular event.*

That these conclusions are important will become clear when the curves corresponding to hypertrophy of the ventricles are described.

### *Aberrant beats.*

I term those beats of the ventricle *aberrant* which, propagated from supraventricular impulses, are distributed in a partial or faulty fashion; these aberrant beats are frequently discovered in clinical electrocardiograms. Just as the functions of the main stem of the *A-V* bundle are often defective in the human subject (see Chapter IV.), so also are those of its individual branches. The types of electrocardiogram representing deficient conduction in the main divisions of the bundle are illustrated by actual examples in Figs. 16 and 17 (and have been in part described in reference to Fig. 15). The natural auriculo-ventricular sequence is maintained, that is to say, each ventricular beat is preceded by an auricular one; the ventricular complexes are alone abnormal. The common features of the ventricular curves are the exaggerated amplitude of excursion, an amplitude often much greater than that of the curves chosen for illustration, and the prolongation of the initial phases. The deflections which replace the usual *QRS* group (initial deflections) have a total duration exceeding a tenth of a second and comprise more than a third of the whole complex. When the *right* branch is at fault the first chief deflection is a broad summit  $R^1$  in lead *I*, a deep and broad depression



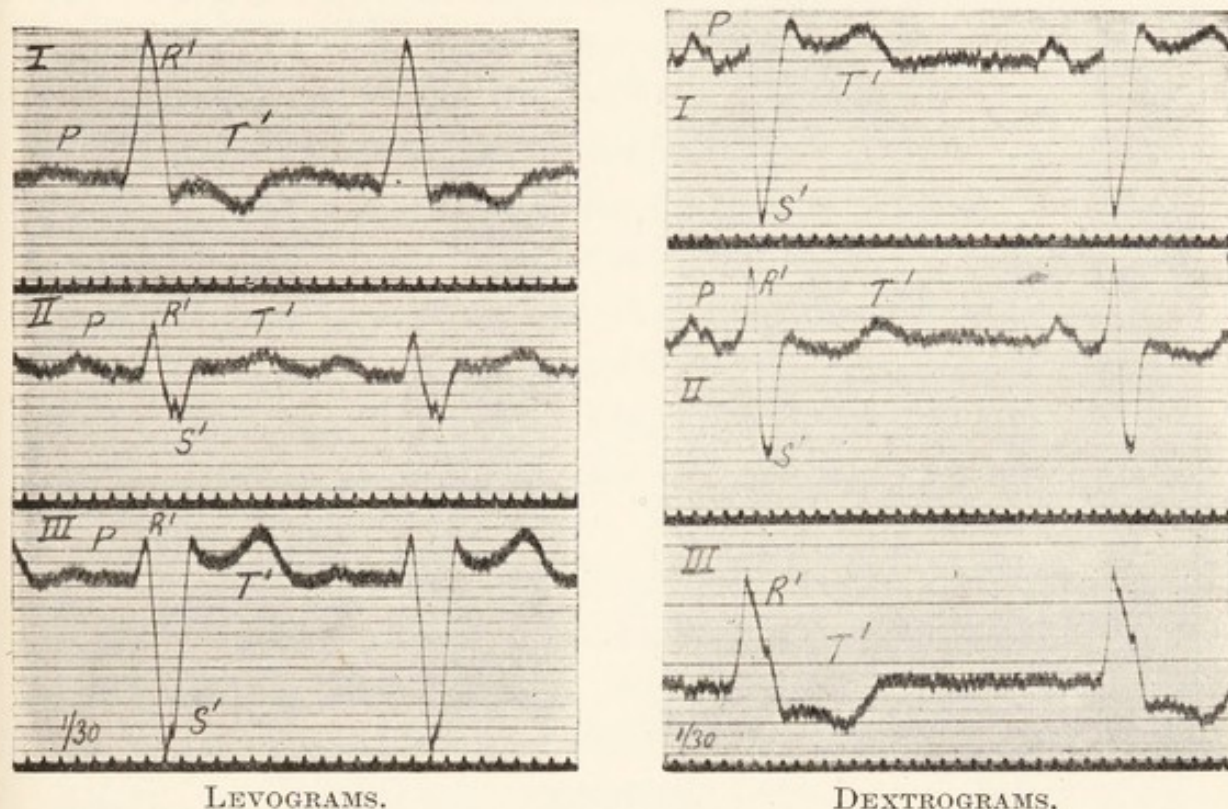


Fig. 16. Curves from the three leads, evidencing functional defect of the right division of the auriculo-ventricular bundle. Note the long duration of the initial phases and the large amplitude in leads *I* and *III*.

Fig. 17. Curves from the three leads, evidencing functional defect of the left division of the auriculo-ventricular bundle. The directions of the deflections are the reverse of those of the last figure, in leads *I* and *III*.

$S^1$  in lead *III* (Fig. 16). Each of these phases is followed by a sustained and very prominent phase  $T^1$  which is of opposite sign to the first chief deflection in the same lead; it is directed down in lead *I* and up in lead *III*. When the left branch is at fault the pictures are reversed (Fig. 17). A deep depression  $S^1$  is followed by an upright and prominent  $T^1$  in lead *I*; a broad summit  $R^1$  is followed by a downward directed  $T^1$  in lead *III*. In addition to these deflections, a dip ( $Q^1$ ) may appear to a variable extent in lead *I* of the levogram and in lead *III* of the dextrogram, while a diminutive summit  $R^1$  may open the events in lead *III* of the levogram and in lead *I* of the



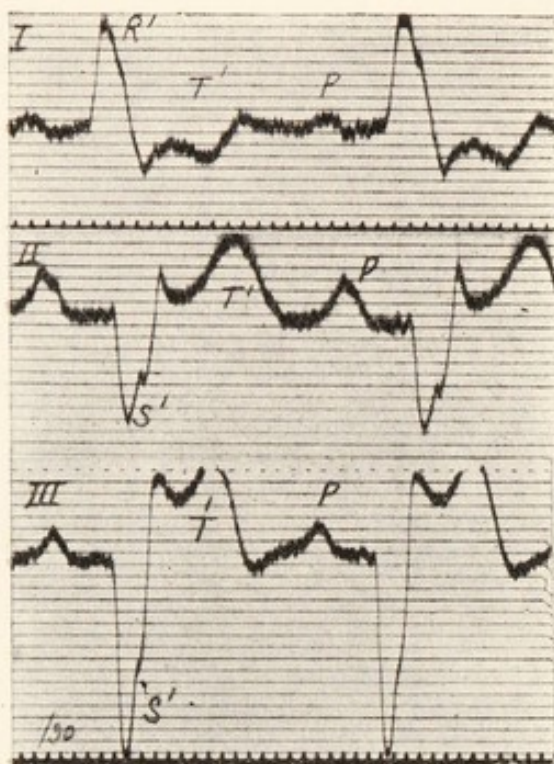


Fig. 18.

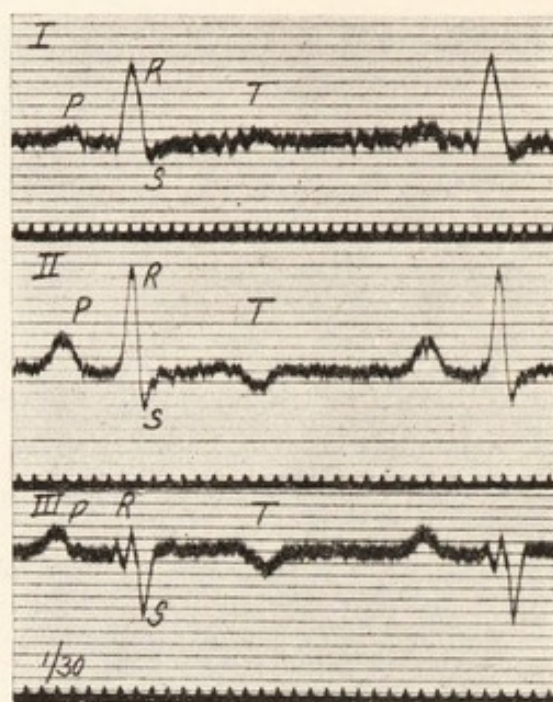


Fig. 19.

Fig. 18. Curves taken from the three leads in a case of aortic disease during a febrile attack. They show defective conduction along the right division of the auriculo-ventricular bundle (see Fig. 16).

Fig. 19. Curves from the same patient, taken a day later and during the subsidence of the fever. The ventricular portions of the curves have changed profoundly; there is now no evidence of bundle defect, but rather of preponderance of the left ventricle.

dextrogram. The curves of lead *II* are often similar to those of lead *III* in lesions of the right division, but in lesions of neither division are they so characteristic as in leads *I* and *III*.

The value of these electrocardiograms as signs of disease is great, for damage of the bundle divisions is to be identified by them, and by them only. A reduplication of the first heart sound is a frequent but inconstant association. The pathology of the lesions is similar to that of auriculo-ventricular heart-block, which is frequently coincident. As a permanent condition, damage of a bundle branch speaks for a lesion in this situation, though the latter is usually but a local expression of widespread mischief in more silent areas.



As a temporary condition it results from an acute or subacute process, an invasion of the myocardium by an infective agent or poison. Such was the probable explanation in the case from which Figs. 18 and 19 were taken. Admitted to hospital he was found to have an aortic lesion; the temperature was  $100^{\circ}$ , but there were no other clinical signs of infection. The electrocardiograms (Fig. 18) showed deficient conduction in the right branch of the bundle, a deficiency which passed away as the fever subsided (Fig. 19). The electrocardiogram provided the sole evidence of an acute myocardial involvement.

That the sign, as a persistent sign, is not infrequent in heart cases we know; as a transient sign it is probably more frequent than we suspect. The right division is much the commoner to be affected, probably because it runs a much longer course as an isolated strand. Curiously, a defect of this division is often associated with aortic disease. The death rate amongst patients who exhibit it is extraordinarily high.

*Preponderance of left or right ventricle.*

Before discussing the electrocardiograms associated with hypertrophy of the ventricles it will be convenient to particularise in respect of terms. Normally the separated ventricles when weighed show a certain mass relation to each other; the left ventricle in the average weighs approximately 1.8 times as much as the right. In instances of hypertrophy of the heart it is usual to discover an increase in the weight of both ventricles, pure unilateral hypertrophy as a manifestation of disease being rare; but although there is this bilateral hypertrophy, one ventricle is often involved to a greater extent than the other and the normal weight ratio between the two ventricles is then disturbed. When the heart is enlarged, such an altered ratio of weights changes the electrocardiogram to the forms now to be described.



To indicate a relative increase in the weight of a given heart chamber, I use the term preponderance of that chamber. We shall be dealing with instances of actual hypertrophy, confined may be to one chamber, but more usually affecting the two chambers unequally. Speaking of hypertrophy, there are certain preliminary considerations which I would impress upon my reader. While purely mechanical influences undoubtedly change the distribution of the mass of ventricular muscle, yet hypertrophy often exists where there is no reason to suspect antecedent alterations of the fluid pressures in the chambers, and where the degree of hypertrophy in a given chamber cannot legitimately be ascribed to an increase in the burden which that chamber may be supposed to have borne. Unquestionably there are causes of ventricular hypertrophy, and of massive hypertrophy, which are still unknown to us; I would even go so far as to say that the chief cause of hypertrophy is still unknown, and that we are unaware of the extent to which such unrecognised factors may be responsible for the hypertrophy associated with valvular disease. If in a case of enlarged heart electrocardiograms are sometimes obtained which point to preponderance of one chamber, while the clinical signs display a valve lesion usually associated with hypertrophy of the other chamber, the electrocardiographic signs are not to be discarded on that account. Providing that the heart is not materially displaced, the interpretation of the electric curves here given may still be accepted. If hypertrophy of the left ventricle is anticipated from the valve lesion and yet the curves of right preponderance are obtained, then the right ventricle is also hypertrophied and to an even greater extent than the left. Or if in instances of hypertrophy of the heart the curves show no sign of left or of right preponderance, then both ventricles participate more or less equally in the enlargement.



The electrocardiograms associated with *preponderance of the left ventricle* are curves in which there is a predominance of the levogram; they are illustrated by Fig. 20. The amplitude of *R* is greatest in lead *I* and is least in lead *III*; *S* is greatest in lead *III* and is inconspicuous in lead *I*; *Q* is most prominent in lead *I*. Reference to Fig. 15 will show why this should be, for the deflections which are

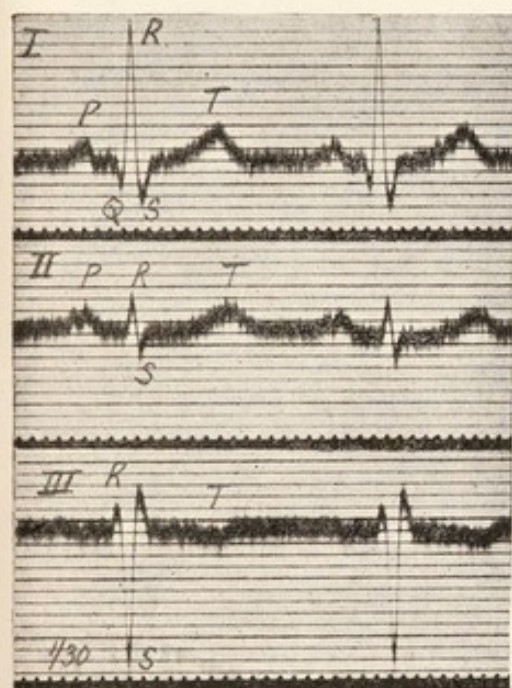


Fig. 20.

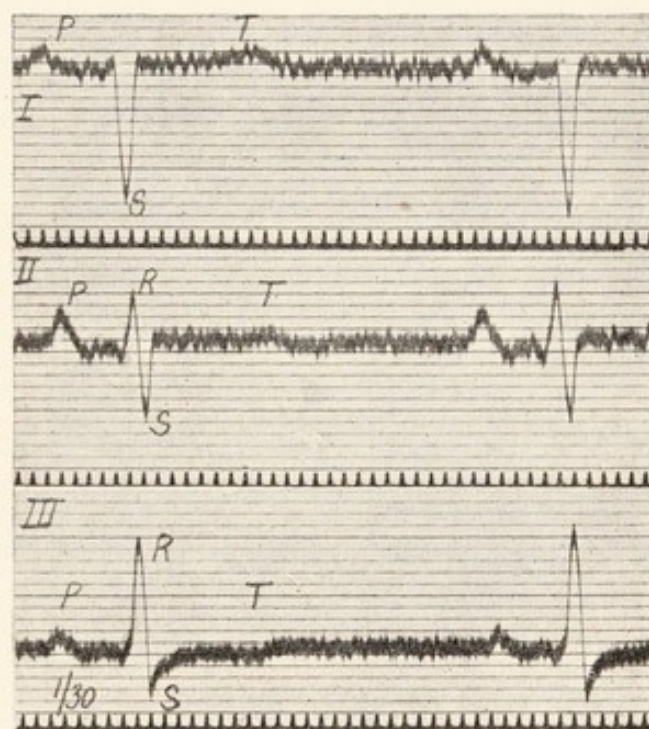


Fig. 21.

Fig. 20. Curves from the three leads in a case of aortic disease showing preponderance of the left ventricle. *R* is tallest in lead *I* and shortest in lead *III*, while *S* is deepest in lead *III*.

Fig. 21. Curves from the three leads showing preponderance of the right ventricle. Note that there is but a trace of *R* in lead *I* and that *S* is very deep; also that *R* is tallest in lead *III*, while *S* is small.

exaggerated in left ventricular preponderance are the deflections derived entirely or in chief part from the levogram (see Table on page 28). As is to be expected, the curves of left preponderance are to be seen most frequently in association with heightened blood pressure, aortic disease, and in the senile heart. In *preponderance of the right ventricle* (Fig. 21) the dextrogram predominates, *S* is exaggerated in



lead *I* and is shortest in lead *III*, *R* has its greatest amplitude in lead *III* and is inconspicuous or absent in lead *I*, *Q* is most in evidence in lead *III*. The deflections which are exaggerated are those derived from the dextrogram. The curves of right preponderance are obtained in an exaggerated form from cases of congenital pulmonary

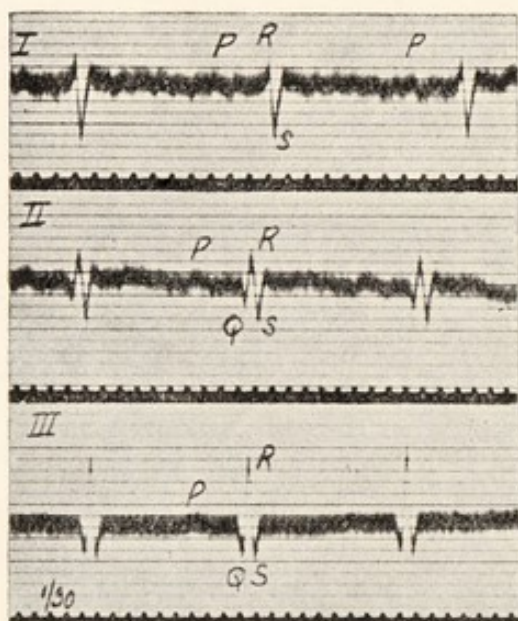


Fig. 22.

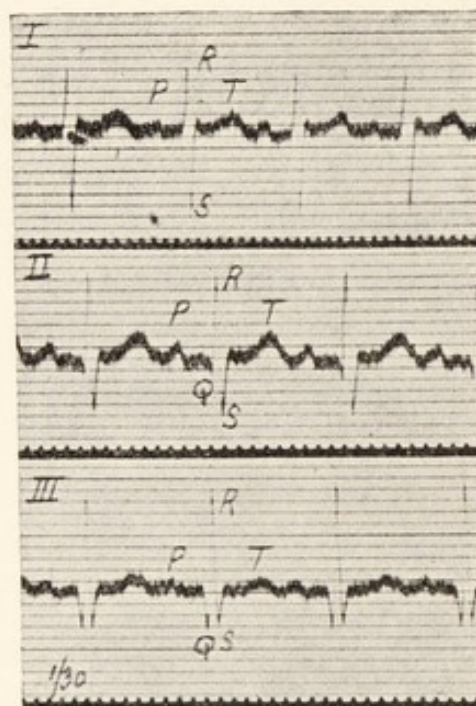


Fig. 23.

Fig. 22. Curves from a child two hours after birth. The relative heights and depths of the peaks is such as is expected where there is preponderance of the right ventricular muscle.

Fig. 23. Curves from the same child, but six weeks later. The right-sided preponderance is not evidenced by these curves to nearly the same extent.

stenosis and they are obtained in nearly all uncomplicated cases of advanced mitral stenosis. The constancy with which they are obtained from the new-born child (Figs. 22 and 23) is most notable, for in the new-born child the right ventricle is as heavy as the left; that is to say, the right ventricle preponderates, as judged by the condition in adults. In children the adult types of electrocardiogram become



established between the ends of the second and third month of extrauterine life ; it is at the same period that the normal weight-ratio between right and left ventricles becomes established.

Between the curves of ventricular preponderance and the curves corresponding to lesions of the *A-V* bundle divisions there are naturally many points of similarity ; there are differences also. The directions of the chief initial phases are the same in the two groups ; but in instances of the ventricular hypertrophy, the *duration* of the initial deflections is in the average much less ; it does not usually reach a tenth of a second and does not comprise as much as a third of the whole complex. In exceptional instances of preponderance, however, where one ventricle is enormously increased as compared to the other, the initial deflections of the corresponding electrocardiograms are prolonged and then they may be indistinguishable from those seen in lesions of the bundle divisions. In such cases the distinguishing feature is discovered in the direction of the final deflections. In lesions of the bundle divisions, the final deflection  $T^1$  in leads *I* and *III* is always of opposite sign to the chief initial deflection and is of unusual amplitude ; in cases of preponderance this rule does not hold good, moreover the final deflections *T* are not more pronounced in amplitude than are they in health. The two series of curves are well contrasted in Figs. 18 and 19, both series being taken from the same patient.

Recent observations by Dr. F. N. Wilson, of Ann Arbor, indicate that preponderance of one or other ventricle is not the only change in the heart which may produce curves of the types described. In view of his work it is inadvisable to interpret curves as displaying right or left ventricular preponderance in adults unless there are unmistakable clinical signs of cardiac enlargement.

*Inversion of "T."*

In young and healthy adults the final deflection *T* is always upright in lead *II*, almost always upright in lead *I*, but often inverted in lead *III*. Inversion of *T* in lead *II* may be provoked transiently by digitalis ; or by the ingestion of quantities of iced water, whereby the apical regions of the heart are cooled. As a persistent phenomenon it is seen from time to time in elderly subjects ; it is most commonly displayed by patients in whom there are abundant signs of grave myocardial disease (Figs. 19 and 96). Persisting, it is usually regarded as a sign of some prognostic consequence, being taken to indicate permanent myocardial damage. Although the death rate amongst groups of patients displaying it is heavy, sometimes it is found to persist for many years, while the health of the subject remains unchanged.



## CHAPTER IV.

---

### AURICULO-VENTRICULAR HEART-BLOCK, ETC.

#### *Partial heart-block.*

The chambers of the normal heart contract in orderly sequence ; each impulse is generated in the neighbourhood of the sino-auricular node. This is a special structure in the mammalian heart and situated at the opening of the superior vena cava. Because it controls the normal heart rhythm I term it the "pacemaker." The impulse, after leaving the node, courses through both auricles and, arriving at the auriculo-ventricular bundle, the specialised structure which unites auricles and ventricles, is transmitted to the ventricles and these respond to it. There is an appreciable delay in this transmission ; the auricle, as we know, contracts before the ventricle ; and the interval between the onsets of systole in auricle and ventricle indicates the length of this transmission time. The electrocardiogram measures this interval more accurately than any other method which we possess. The interval may be gauged as accurately in the human subject to-day as in an experiment upon an animal in which auricle and ventricle are laid bare. The measurement is taken from the commencement of *P*, the auricular summit, to the commencement of the ventricular complex ; as a rule *R* is used for the sake of uniformity, but *Q*, which is often the

first ventricular deflection, may be adopted if it is thought desirable. The *P-R* interval, as it is termed, varies in normal subjects between 0.12 and 0.18 second in length. Prolongation beyond 0.2 second is never found in healthy subjects under normal conditions. Such prolongation represents the first stage of heart-block. Fig. 24 illustrates the condition described; in it the *P-R* interval measures 0.32 second. The sole disturbance, as shown by the electrocardiogram, is

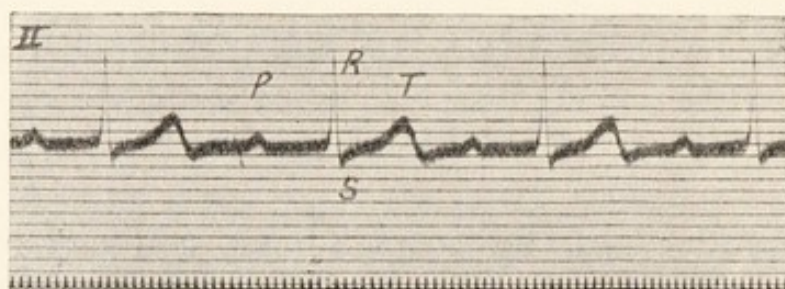


Fig. 24. An electrocardiogram from a case of subacute cystitis and a temporary affection of the heart, showing prolongation of the *P-R* interval to 0.32 second.

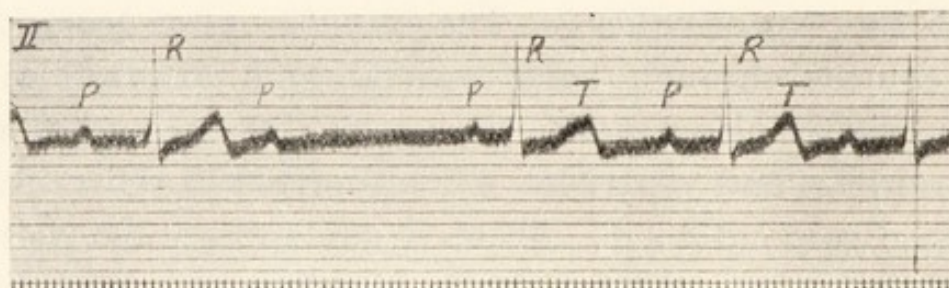


Fig. 25. From the same case, showing a single dropped beat.

an increase of the interval named; individual auricular and ventricular summits are of normal outline. The heart which manifests this change beats regularly.

The next phase in the progress of heart-block is termed the stage of "dropped beats," where, from time to time, an auricular systole provokes no ventricular response. The electrocardiograms show perfectly regular and normal auricular summits *P*, and most of them are followed by



ventricular complexes ; but here and there a ventricular complex is missed and the auricular peak stands isolated. This is one of the causes of so-called pulse "intermittence." A simple example of the condition is shown in Fig. 25 ; measurement will show that the auricular contractions are equidistant, while the intervals between the ventricular beats vary. An interval, of almost double the usual length, separates two of the ventricular contractions ; the long cycle is not exactly twice the length of the usual cycle, because, as the figure shows, the *P-R* interval which ends the long cycle is shorter than the remainder ; the ventricular beat which stands at the commencement of the restored rhythm has been moved a little to the left of its natural position, slightly shortening the cycle to the left of it and slightly widening the cycle to the right of it. All the remaining *P-R* intervals are of equal and increased length. This distribution of the ventricular beats is characteristic of their regularity. Figs. 27 and 28 exemplify the same phenomena. In Fig. 27 ventricular silences occur after each third or fourth auricular cycle. The analysis of such a curve is readily accomplished : consider the central group of three ventricular beats ; the first is preceded by an unmistakable auricular contraction ( $P^5$ ), for it lies in a long diastole. A similar auricular contraction ( $P^9$ ) is found at the end of the next long diastole. The remaining auricular contractions are discovered on attending closely to the shapes of the *T* waves.  $T^3$ ,  $T^4$  and  $T^5$  have different forms ; the first and last are split ;  $T^4$  is taller and more pointed. The *T* waves have different forms because *P* summits fall with them. If, in this curve, we take a distance of 6 time-marks from the commencement of an *R* summit and measure to the right, we always arrive at the apex of the corresponding *T* wave, for the length of systole is constant in the curve. That the remaining summits are



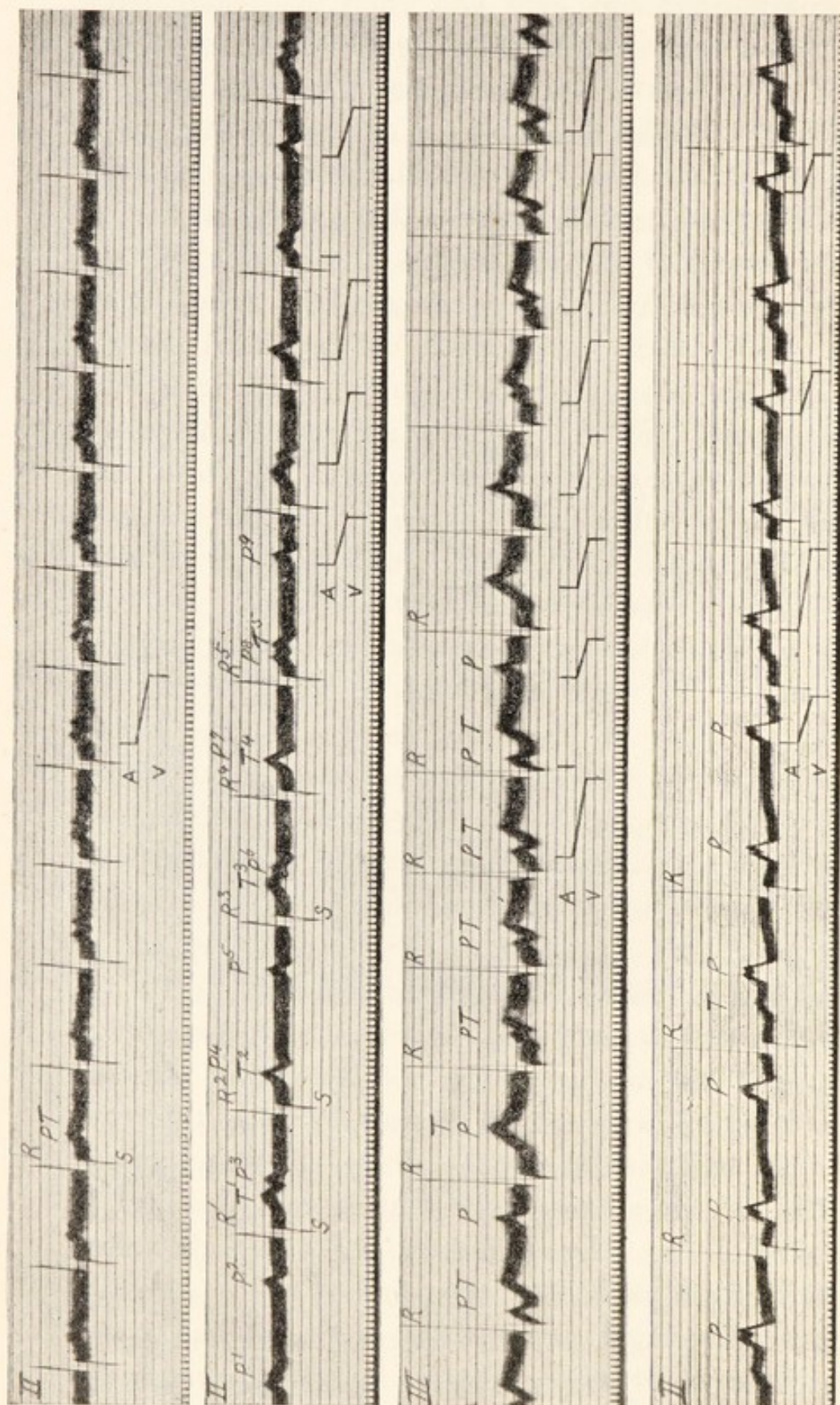


Fig. 26. An electrocardiogram showing prolongation of the  $P-R$  interval.  $P$  falls before the termination of  $T$  of the preceding ventricular cycle. From the same case as Fig. 27.

Fig. 27. Curve showing gradual prolongation of the  $P-R$  interval and the failure of response to each third or fourth auricular impulse. Partial heart-block of this grade is responsible for some instances of intermittent pulse.

Fig. 28. Curve showing gradual prolongation of the  $P-R$  interval, until  $P$  falls back to  $S$  of the preceding ventricular curve, with failure of response to each sixth or eighth auricular impulse.

Fig. 29. From a case of mitral stenosis (note the large and bifurcated  $P$  summit). Partial heart-block is present, the ratio of auricular to ventricular contractions being at first as 3 : 2, and later as 2 : 1.



auricular is proved by measuring the intervals between them ;  $P^5$  and  $P^6$  are separated by the same interval as  $P^8$  and  $P^9$ . The distance between  $P^6$  and  $P^3$  is exactly twice as great, and the intermediate point lies on the summit of  $T^4$ .  $T^4$  and  $P^7$  are blended ; the two summits superimpose accurately, whence the unusual amplitude of this peak. A perfectly regular series of auricular summits, therefore, is present in the curve ; on the other hand the ventricle beats irregularly. Yet the contractions in upper and lower chamber are related, for the events are repeated. The fifth auricular contraction ( $P^5$ ) yields the third ventricular response ( $R^3$ ) ; the succeeding auricular contractions ( $P^6$  and  $P^7$ ) also stimulate the ventricle ( $R^4$  and  $R^5$ ), but after progressively greater intervals ; the last auricular contraction of the group ( $P^8$ ), falling far back into ventricular systole as it does, stands isolated ; after the ventricular silence the events recur in precisely the same order. The shortening of the  $P$ - $R$  interval after the long diastole in this figure and in Fig. 25 results from rest and the consequent recovery of the conducting tissues ; subsequently, as impulse after impulse is transmitted, these tissues show greater and greater fatigue, until eventually a stimulus fails to pass. A beautiful example of similar events is portrayed in Fig. 28. The analysis proceeds along parallel lines to that just given and is portrayed by the diagram of auricular and ventricular contractions ruled upon the figure ; but the fatigue comes more slowly and only two ventricular silences are to be seen. Fig. 27 has a companion curve, namely Fig. 26. The two curves were taken from the same patient. Fig. 26 was obtained shortly after exercise ; it is noteworthy that all ventricular irregularity was abolished by this exercise, while the auricular rate was somewhat increased. The interpretation of this curve is not evident at first sight ;  $R$  and  $S$  are readily identified, but  $T$  seems double. The first of the twin peaks represents



an auricular systole in each cycle ; this is known by measurement of the interval between *R* and the summits in this figure and in Fig. 27. The relations are the same as those shown by *P*<sup>8</sup> and *T*<sup>5</sup> of the second figure. Thus the *P-R* interval throughout Fig. 27 shows great prolongation ; the auricular systoles do not fall in presystole or even in early diastole, but they coincide with the preceding ventricular systoles. In human electrocardiography it is almost always safe to assume that, if *T* shows bifurcation, it is complicated by an auricular complex ; and this general statement applies equally to individual *T*'s and to a series of *T*'s so deformed. Fig. 29 also shows partial heart-block. Here there is no difficulty in picking out the auricular contractions, for they have the form which they so commonly assume in mitral stenosis. In the earliest part of the figure the response to each third auricular beat fails ; in the last part of the figure what is known as 2 : 1 heart-block, in which alternate auricular impulses alone yield responses, is present. The figure demonstrates the same variation in *P-R* intervals which has been referred to in discussing other figures. A long diastole is followed by a short *P-R* interval and a short diastole by a long one, according to the preceding period of rest.

Partial heart-block is of much clinical importance, though it is not within the scope of the present book to discuss this standpoint. This has already been attempted in *Clinical Disorders of the Heart Beat*. As a permanent condition it tells us of chronic myocardial damage ; occurring in patients who complain of symptoms, such as fainting attacks, breathlessness or sternal pain, which may or may not be consequent upon cardiac mischief, it helps materially in arriving at a correct conclusion. As a temporary event, it speaks of an acute heart lesion or poisoning. It will be sufficient if I briefly relate the histories of the curves now presented. Figs. 24 and 25 were taken from a young boy



admitted to hospital for subacute cystitis, resulting from an infection by an organism of the *coli* group. While lying in bed for observation he developed an occasional irregularity of the pulse to which little significance was attached. When specially examined, the heart-block was discovered, and it became clear that the heart was invaded, either by the organism itself, or by the products of its digestion. Appropriate treatment, applied to the bladder, was followed not only by subsidence of the cystitis, but eventually by a restored cardiac action.

Figs. 26 and 27 were taken from a young girl who had experienced an attack of acute rheumatism a year before. The girl sought advice for pains in the neck and chest, and a slight irregularity of the pulse was noticed at her preliminary examination, while she lay quiet. The special examination revealed the disordered heart action which has been described. What was its significance? Partial heart-block appearing in cases of early rheumatic heart disease is one of our few reliable signs of invasion of the cardiac muscle. Chronic rheumatic heart disease, in its fully developed form, is not made in a day; an unhealthy aortic valve may suddenly collapse it is true, but thickened mitral cusps and hypertrophic degenerate muscle take years to develop. They develop, to my mind, as a result of repeated infections, often slight and passing unnoticed. It is along these lines that we may read the curves (Figs. 26 and 27); they evidence a slight but acute cardiac muscle lesion, a lesion which is but one step in the course of what may become a chronic and incurable malady. The picture is not an uncommon one, and often it is combined with a clear source of infection; the channel, maybe the throat, is found and sealed.

The electrocardiogram in this instance took us further; while the patient stood or gently exercised in the recumbent position, the pulse was regular (Fig. 26), and there was no



trace of diastolic murmur. Such was the condition when she was first seen. When the pulse was irregular a murmur was audible from time to time. The characteristic murmur of early stenosis of the mitral orifice was heard only when the heart's action was such that the auricular and ventricular systoles lay separate. When, as in Fig. 27, the contractions were simultaneous and the auricle forced no blood into the ventricle the murmur vanished. These electrocardiograms, therefore, not only explained the nature of the heart irregularity, its reaction to posture and exercise, which was at first so puzzling, but they prompted the search for the characteristic murmur during the irregular heart periods; finally, they told clearly of an acute invasion of the cardiac muscle, in a child, up and about and otherwise seemingly almost well.

The curve shown in Fig. 29 was taken from a case of mitral stenosis in which digitalis was being administered. This drug frequently produces heart-block and that which is shown in the illustration resulted from poisoning. The electrocardiogram demonstrated that the patient was fully under the influence of the drug.

#### *Complete heart-block.*

Partial heart-block is an unstable condition; it passes from one grade to another. In this it contrasts with complete heart-block which is the next disorder to be considered. We have seen that partial heart-block may be present while the ventricular action is regular (Fig. 24) or irregular, and while it is rapid (Fig. 26) or slow (end of Fig. 29). Complete heart-block is generally associated with a perfectly regular and slow ventricular action. The auricles beat at their usual rates and regularly, the ventricles also beat rhythmically, usually at a rate of about 30 per minute and quite independently of the auricles. The electrocardio-



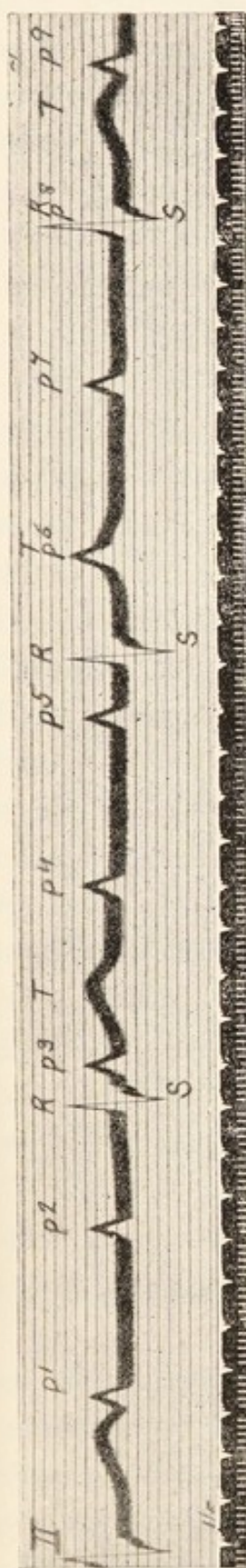


Fig. 30. A curve of complete heart-block, or dissociation of the auricular and ventricular rhythms. The auricles and the ventricles are beating regularly, but at the independent rates of 78 and 29, respectively. The time-marker shows fifths and thirtieths of a second. The exact algebraic summation of auricular and ventricular effects should be remarked.




Fig. 31. Showing complete heart-block in another case. The rates of auricle and ventricle are approximately 86 and 35, respectively. Note that each ventricular complex begins with  $Q$ , showing that the latter belongs to the ventricular systole.

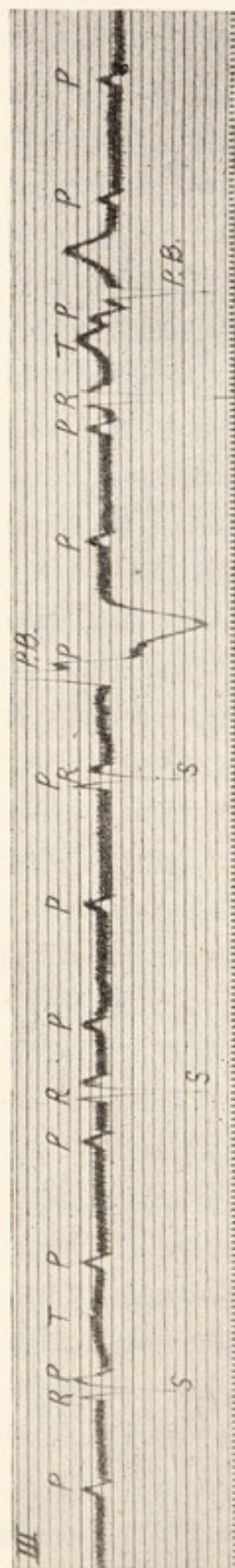


Fig. 32. From a case in which there was considerable enlargement of the heart towards the left side. The curve shows complete heart-block. The regular ventricular action is disturbed by two premature contractions (*P.B.*).



graphic curves portray the condition to perfection and immediately distinguish it from all other forms of slow ventricular action. Fig. 30 is an example; in this curve portions of four ventricular beats are represented at regular intervals; each consists of *R*, *S* and *T* deflections of normal form. During the diastoles evident *P* summits ( $P^1$ ,  $P^2$ ,  $P^4$ ,  $P^5$  and  $P^7$ ) appear. The remaining *P* summits fall with the ventricular systoles. One ( $P^3$ ) falls after *S*, another ( $P^6$ ) falls upon *T*. One ( $P^8$ ) is obscured by its coincidence with *R*. They occur equidistantly in the curve. Fig. 27 has already indicated the accuracy with which the auricular and ventricular electric effects superimpose when the systoles are simultaneous; it is in complete heart-block that this rule, the constancy of which will be again impressed from time to time, is so strikingly displayed. Several separate curves have been taken from the same patient and the separate ventricular complexes have been isolated and rearranged one above the other, not in the order in which they occurred, but in the order which displays the summation most clearly. The rearrangement is seen in Fig. 33. A single ventricular and two auricular complexes are shown in each curve of this figure. Traced from above downwards, the first auricular summits pass gradually into, through and beyond the opening phases of ventricular systole; the second auricular summits of the curves continue the tale, showing the passage over and clear of the broad summit *T*. In each instance, where it occurs, summation is accurate. The dissociation between the rhythms of the two chambers is thus paraded in unmistakable garb.

The electric curves of complete heart-block teach us more than that the heart is generating two distinct rhythms. The slower, or ventricular, rhythm is represented by curves of perfectly normal outline (Fig. 30). The contractions are awakened therefore through the normal channels. The



channels which carry the normal impulses from auricle to

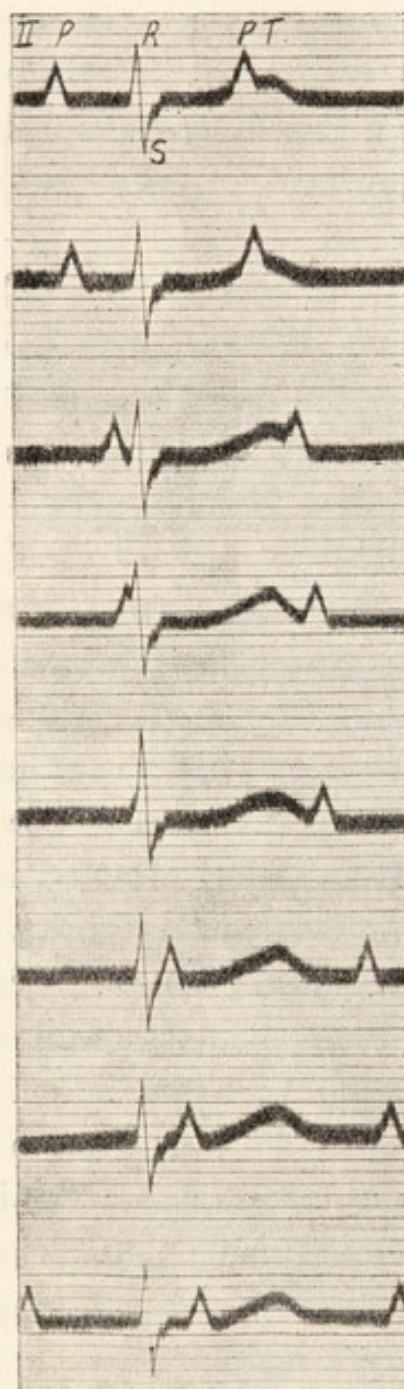


Fig. 33. A figure constructed from the electrocardiograms of the patient, whose curve is shown in Fig. 31. Single ventricular complexes have been re-arranged above each other so as to display their varying relation to the auricular complexes.

ventricle also convey the impulses of the independent ventricular rhythm. The impulses are of supraventricular origin. Yet these impulses do not arise in the auricle, which is contracting independently under the influence of the sino-auricular node. The new ventricular impulses arise in tissue lying between the bundle lesion and the division of the bundle into its right and left branches.

Fig. 31 demonstrates that *Q* is a ventricular effect. The curve is again one of complete heart-block, the auricular and ventricular rhythms being independent; *Q* is constantly associated with the ventricular and not with the auricular contraction; the same fact is established by Fig. 28.

In complete heart-block deviations of the ventricular complexes from the normal outlines are to be interpreted according to the usual rules, as they apply to hearts beating with the normal sequence of chamber contraction. Fig. 32 illustrates the third lead in a case of complete dissociation; the ventricular curves indicate preponderance of the left ventricle. The same figure is complicated by beats



of the ventricle which occur before the anticipated points. They are premature beats (*P.B.*) or extrasystoles, the nature of which will be described more fully in the next chapter. The auricular summits are traceable throughout the whole curve, whether they fall with the supraventricular or anomalous form of ventricular curve.

*Slow action of the ventricle.*

In partial heart-block when each second, third, or fourth auricular systole stimulates the ventricle, and when, too, the auricular rate is normal, the ventricular action is necessarily slow. The ventricular action is also slow, as has been seen, in complete heart-block.

It is necessary that slow ventricular rhythms of these types should be clearly distinguished from others in which the heart's action is different. To take the most familiar examples first, when the ventricle beats slowly in jaundiced patients or in those who are convalescent from acute infections, the retardation results from a similar slow action of the auricle. The rhythm of all chambers is slow, but the natural sequence of chamber beating is maintained. Such slowing results from high vagal tone, for the heart quickens in response to effort or such drugs as atropine ; the quickening is *gradual*. To the same class belongs the slow heart action of many healthy adults. All these true bradycardias exhibit an electrocardiographic picture similar to that shown in Fig. 34 ; each ventricular beat is preceded by a single auricular beat and both are of the normal type.

But there is another, rare and special form of slow action which involves the whole heart and in which chamber sequence is also undisturbed. On rare occasions patients are observed in whom the rate of the ventricle is persistently maintained at between 30 and 40 beats per minute while they rest. The hearts of which I speak react in a curious way to



exercise ; the acceleration is not gradual, there is an abrupt passage of slow into fast rate from one heart cycle to the next. The curve which is shown was taken from an athlete ; the rate of contraction, while at rest, was usually 36 per minute ; the first effect of exercise was an abrupt and approximate doubling of rate ; further acceleration was gradual ; similar events, though ordered reversely, were observed at the cessation of effort. This action of the heart will be spoken of again in a later chapter ; it belongs to a series of phenomena which are at present classed under the term "sino-auricular block."

When the auricular action is slow and the ventricle is starved of its full quotient of impulses, the last chamber frequently develops the same automatic action as is observed in complete heart-block ; so that although there is no fault in conduction, yet two impulse centres, auricular and ventricular respectively, are active and give rise to responses when opportunity offers. The auricular action is generally the dominant one, but if its rate falls below a certain point or if the automatic rate of impulse formation in the ventricle rises above the same point, then the last named chamber beats spontaneously. Generally this event is recognisable at once in electrocardiograms ; an example is shown in Fig. 35. In the first four cycles of this figure, the chambers are beating sequentially and slowly at a rate of 50 per minute. The fifth cycle shows a ventricular complex of the usual form, but this beat is not a response to an auricular contraction, the *P-R* interval is curtailed and there is partial coincidence of the chamber contractions. This coincidence is more pronounced in the last cycle of our illustration, where the *P-R* interval is minute. Now each ventricular complex is of normal outline ; so also is each auricular complex, so far as it is visible ; the ventricular beats are therefore all of supraventricular origin, while the auricular beats are all






Fig. 34. An electrocardiogram taken from an athlete while at rest, and showing a regular action of the whole heart at 36 per minute. With moderate exercise the rate suddenly doubled. The original slow action probably resulted from sino-auricular block.

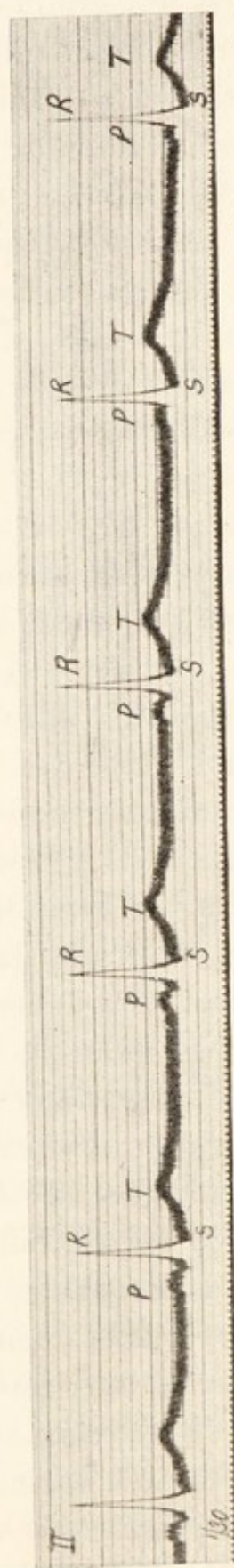


Fig. 35. A curve showing slow action of the whole heart, the rate being 50 per minute, with escape of the ventricle.

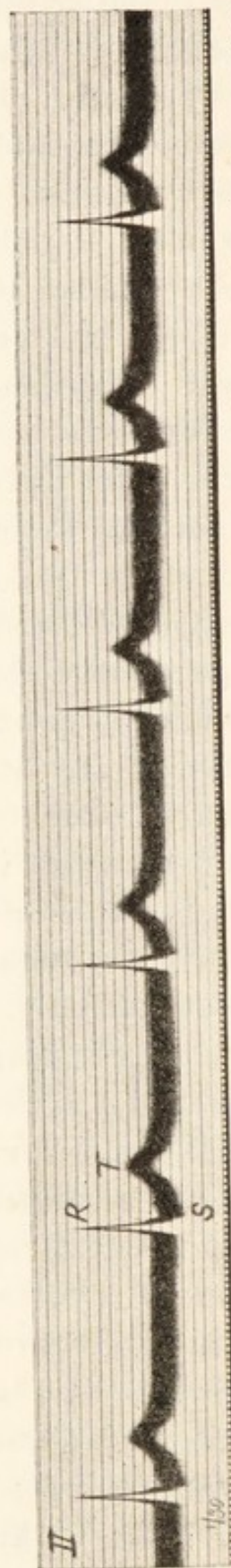


Fig. 36. A curve showing regular and slow action of the ventricle at 48 per minute. No trace of auricular complex is to be found and the line is perfectly smooth in diastole. These curves usually result from simultaneous contraction of auricle and ventricle (nodal rhythm).



derived from the natural pacemaker. Yet the ventricular beats originate in distinct ways; the first four are of supra-ventricular origin in virtue of their response to auricle; the last two are of supraventricular origin in virtue of the impulses formed in the junctional tissues, the usual site of ventricular automatism. When the ventricle originates a rhythm of its own it is this centre which is active; the ventricular beats are termed "escaped" ventricular contractions when they are isolated or in short groups. The bundle is not the only new centre which may come into play when the natural pacemaker is sluggish; other regions occasionally usurp the function of the natural pacemaker and capture the lead; that centre which produces successive impulses most rapidly is always responsible for the dominant rhythm. If the escape of the new centre is continued, the rhythm of the whole heart becomes controlled from that centre; that has happened in Fig. 36. This figure shows ventricular complexes only and a regular action at 48 per minute. The auricular representatives are not seen. Such electrocardiograms are found when auricle and ventricle contract simultaneously in response to impulses created in the neighbourhood of the auriculo-ventricular node; the mechanism is consequently termed "nodal rhythm." When the ventricle contracts in response to impulses derived from this centre, its electrical complexes are naturally of the supraventricular type. On the other hand, the auricular complexes are abnormal, for the auricular contraction wave is propagated in an abnormal direction. Having an abnormal form and falling at the same time as the ventricular contractions, they cannot as a rule be identified in the curve, which therefore shows ventricular beats only. Another form of "nodal rhythm" is shown in Fig. 63, where there is a simple shortening of *P-R* interval and an inversion of the auricular complex.

Escaped beats of the ventricle or auriculo-ventricular node are without clinical significance ; they are nearly always dependent upon relatively slow action of the natural pacemaker, and it is to this that attention should be directed. Yet it is important that they should be recognised when seen, and they are generally clear in electrocardiograms.



## CHAPTER V.

---

### PREMATURE CONTRACTIONS OR EXTRASYSTOLES.

Premature contractions, or extrasystoles, are responsible for the majority of those pulse disturbances which are included in the term "intermittence." They are abnormal contractions of the heart, which generally spring from some region of the musculature other than the normal pacemaker or sino-auricular node. I distinguish beats which arise from abnormal foci by the adjective *ectopic*. A premature beat is characterised by appearing before the expected natural beat, which would continue the regular rhythm of the heart. There are two chief classes of such beats—those which arise in the ventricle and those which arise in the auricle. Both forms are readily identified in electrocardiograms. A third type arises in the tissues which lie between auricle and ventricle.

#### *Premature contractions of ventricular origin.*

When the rhythm of the heart is disturbed by premature ventricular contractions (or ventricular extrasystoles), the disturbance of rhythm is as a rule limited to the ventricle; the auricle continues to contract at the expected instants. The premature ventricular beats are easily recognised. The electric complexes which represent them are known to be ventricular, because they are of the same duration as the normal ventricular complexes in the same subject; but they antecede and usually replace the regular responses of the ventricle, thereby disturbing the rhythmic action; their



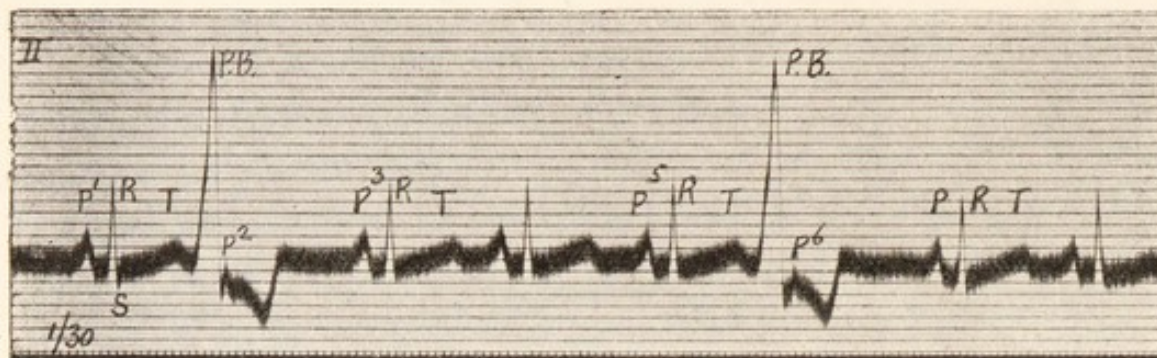


Fig. 37. An electrocardiogram showing two premature contractions, arising in the right ventricle. The curve shows two buried auricular complexes of normal outline. These premature contractions are responsible for the commonest forms of intermittent pulse (see Fig. 27).

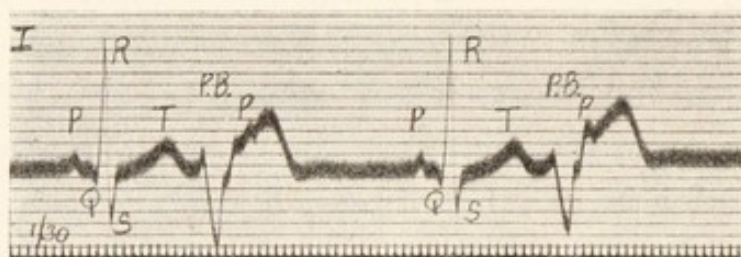


Fig. 38. Premature contractions arising in the ventricle, replacing the alternate normal ventricular beats and giving rise to one form of bigeminy of the ventricle and pulse. The figure illustrates the manner in which buried auricular complexes may be identified.

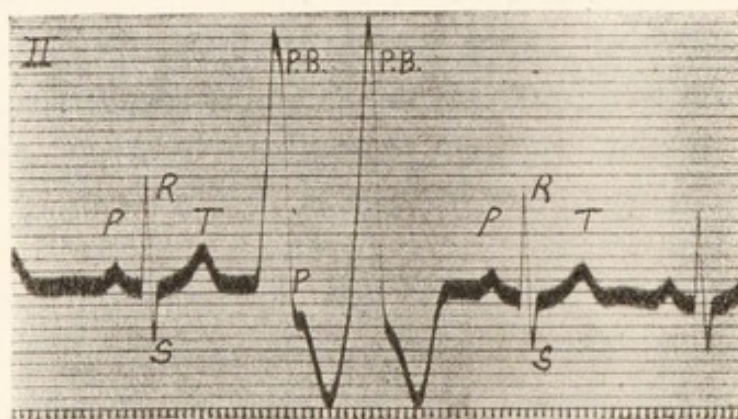


Fig. 39. Two premature contractions arising in the right ventricle. They occur together and replace a single normal ventricular contraction. The rhythmic auricular contraction falls with the first premature beat.

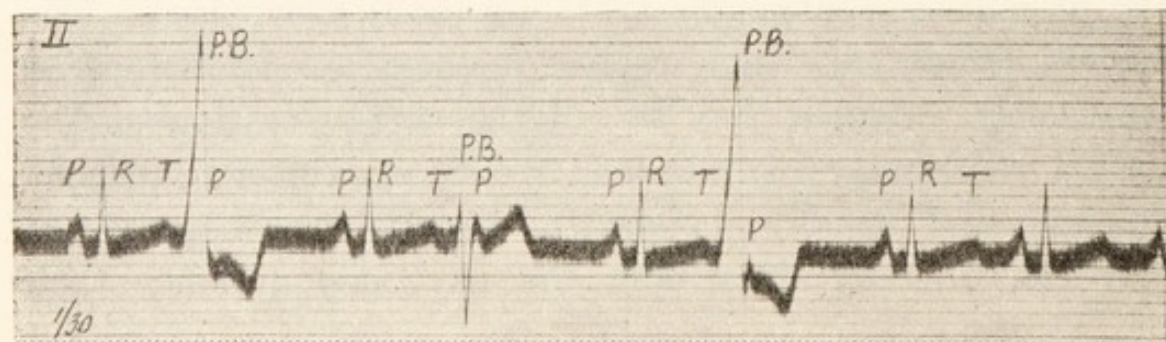


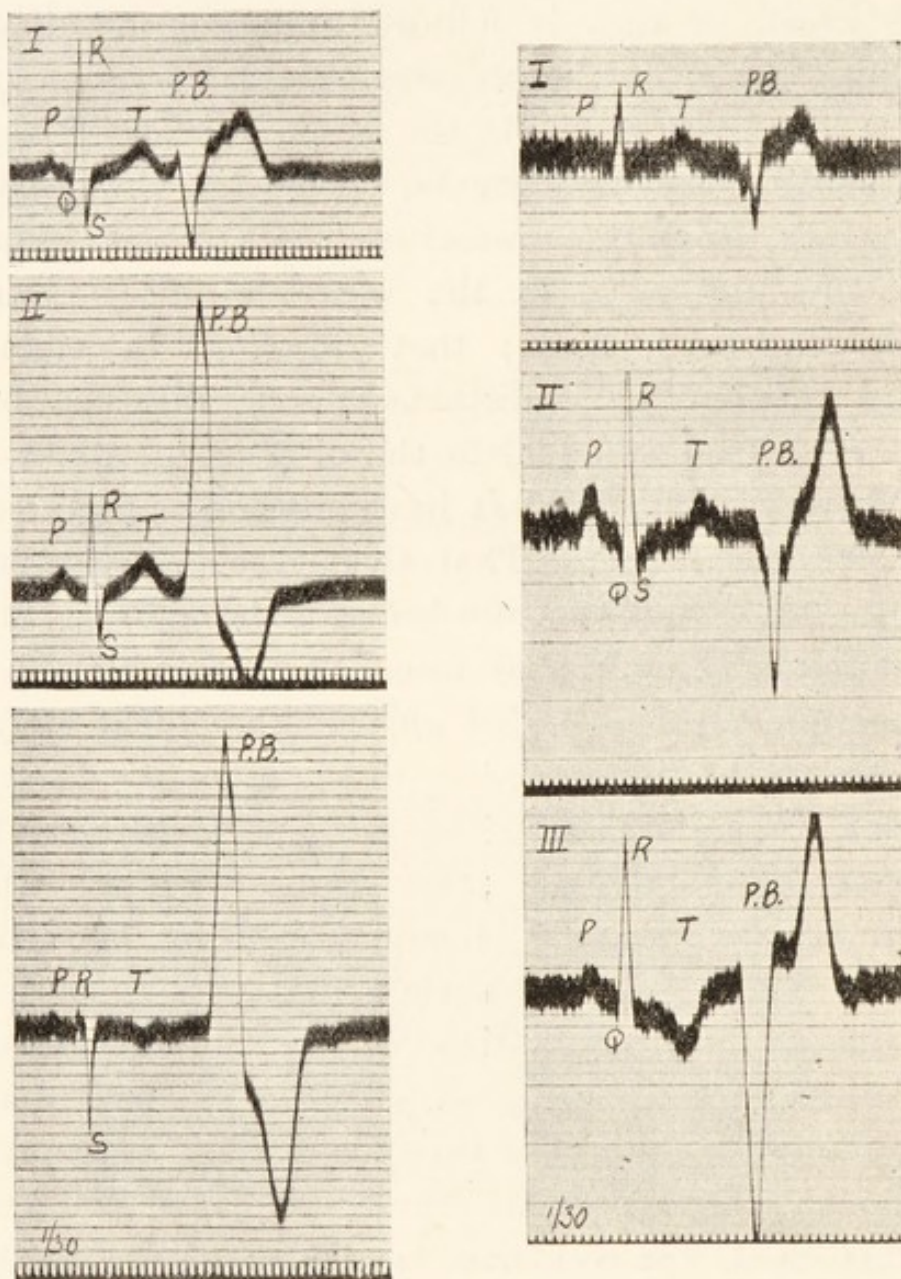
Fig. 40. Bigeminy of the ventricle, resulting from premature contractions of the ventricle. The premature beats arise from two separate foci.



form is anomalous. These points are illustrated by Fig. 37. The figure commences with a perfectly normal heart cycle ( $P$ ,  $R$  and  $T$ ); this is followed by a tall and pointed summit ( $P.B.$ ), which in turn is followed by a broad downward deflection. The total length of this anomalous complex is equal to that of  $R$  and  $T$  in the normal cycles. Succeeding the disturbance are three regular cycles and the disturbance is repeated. Now the premature beats of this figure are spontaneous and arise in the ventricle, for no auricular contractions precede them; they are *ectopic* in origin. The auricular rhythm is undisturbed; the distance between  $P^1$  and  $P^3$  is exactly equal to the distance between  $P^3$  and  $P^5$ . Where then is  $P^2$ ? It lies embedded in the complex of the premature beat. That this is so is ascertained by comparing the two premature beats of the figure; when the second occurs, the auricular rate has become a little slower and consequently the buried auricular complex ( $P^6$ ) lies a little more to the right, relative to the corresponding premature beat, than does  $P^2$ . The two premature beats give complexes of exactly the same form, the only difference between the two curves is engendered by the auricular complexes which fall with them; this difference is slight, and is due to the time relations of the several events. The buried auricular beats being recognised, the curve as a whole may be analysed fully. The auricular systoles are represented throughout; they occur in regular sequence. After each premature beat, the ventricle is silent; it is waiting for the next auricular impulse, to which it will respond. The long diastole which thus compensates for the prematurity of the abnormal ventricular contraction is spoken of as the "compensatory pause." All the auricular complexes of this figure are of normal type, for all have arisen at the pace-maker; all but two of the ventricular complexes are of normal type, for they have originated in impulses traversing the



normal paths. Two of the ventricular complexes are anomalous in outline, showing that the corresponding



Figs. 41 and 42. Figures illustrating the two chief types of premature contractions of ventricular origin as they are portrayed in the separate leads. Fig. 41 shows a premature beat which arises in the right ventricle Fig. 42 shows a premature beat arising in the left ventricle.

excitation waves ran abnormal courses; the course was abnormal because the starting point of the wave was abnormal.



Premature ventricular contractions in different subjects yield electric curves of very different forms independently of the lead from which the curves are derived. The pictures are also different in different leads in the same individual. In interpreting the curves, therefore, they may not be treated pictorially, each should be analysed in detail and upon the general lines which I have tried to summarise. Another curve is shown (Fig. 38) which illustrates the manner in which buried auricular contractions are discovered. The premature beats show two main deflections, one pointed and directed down and the other rounded and directed up. The shoulder of the rounded upstrokes is modified by a superimposed auricular representative (*P*) in each case, but it falls at slightly different points relative to the two premature beats. Two successive premature beats are shown in Fig. 39. They take the place of a single normal ventricular contraction. The single rhythmic auricular complex, which is buried, falls upon the downstroke of the first premature beat. If the two beats are compared, they will be found to differ chiefly in this respect. Premature beats from separate ventricular foci are shown in Fig. 40. Two are of the same form as those of Fig. 37; the third or central one consists of three deflections, a short spike, a deep and pointed depression and a rounded summit. The auricular contraction, which falls between the last two, is prominent and unmistakable.

There are two chief types of premature contractions of ventricular origin; one comes from the right ventricle (Fig. 41); the other comes from the left ventricle (Fig. 42; see Fig. 45 also). In any given case the shape of the electrical curves is usually very similar in leads *II* and *III*, but as a rule the direction of the deflections is reversed in lead *I* (Fig. 41), though this is not invariably the case (Fig. 42). The complexes of extrasystoles arising in the ventricles are not dissimilar to those seen in the lesions of the bundle



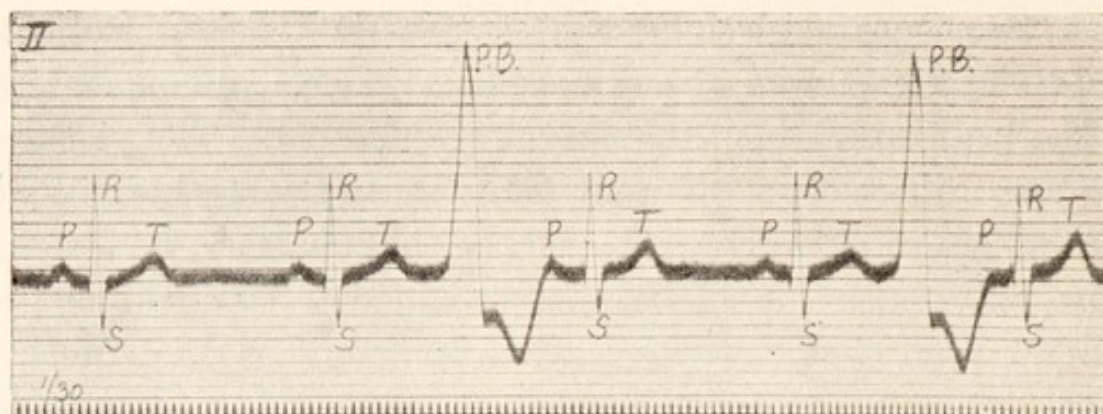


Fig. 43. Premature contractions arising in the right ventricle and interpolated between normal heart cycles.

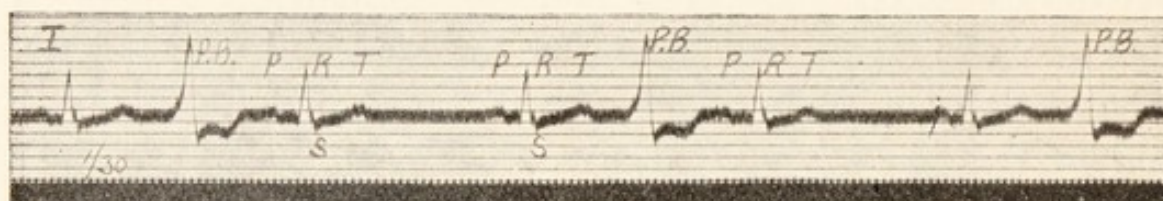


Fig. 44. Interpolated premature contractions of ventricular origin.

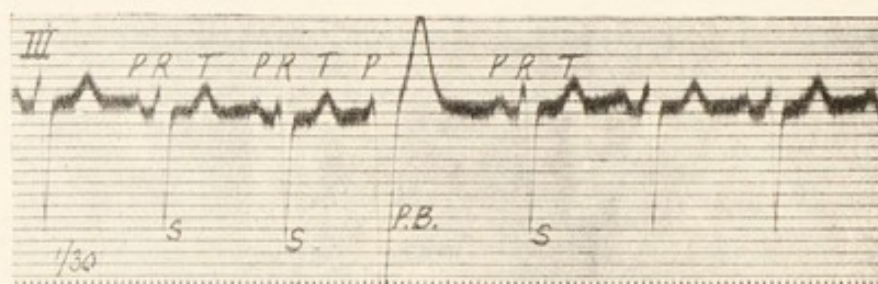


Fig. 45. Premature contraction arising in the left ventricle.

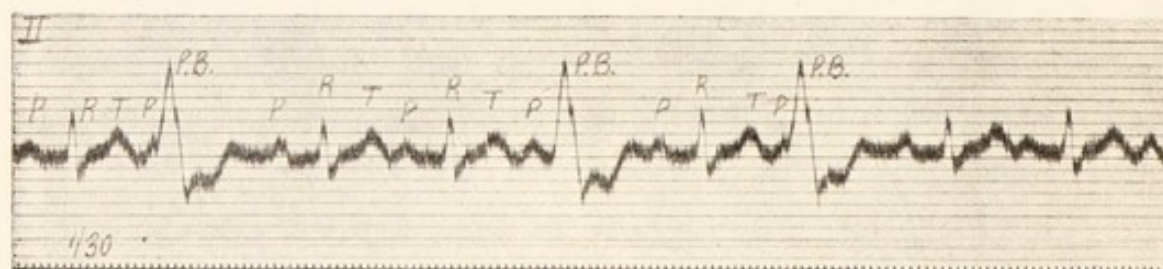


Fig. 46. Premature contractions arising in the ventricle, late in diastole. The auricular systole has begun, and in one instance is almost complete, before the extrasystole of the ventricle begins.

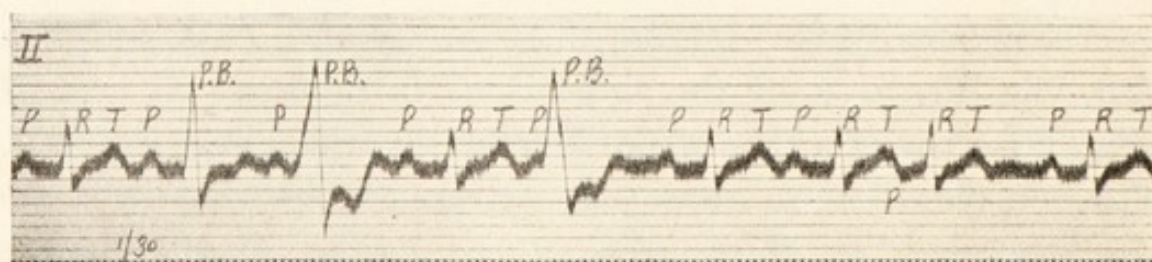


Fig. 47. From the same patient as Fig. 46, showing interference between two waves of contraction in the ventricle (see text). A premature contraction of auricular origin is seen towards the end of this figure.



divisions. In experiment stimulation of the right ventricle (Fig. 15 at *A*) yields curves similar to a lesion of the bundle branch at *A*<sup>1</sup>; that is natural since in both instances the wave is propagated from the same region of the heart. Similarly, stimulation of the left ventricle (Fig. 15, at *B*) yields curves which resemble those following a lesion of the bundle branch at *B*<sup>1</sup>.

Although premature contractions of ventricular origin are generally followed by "compensatory pauses," this only happens when the rhythmic auricular impulse finds the ventricle already in contraction. The ventricle is then "refractory" to stimulation. This is the reason why there is no response to buried auricular contractions, such as are seen in Figs. 37 and 38. But if the heart is beating slowly and the extrasystolic beats of the ventricle are very premature, the extra ventricular beat may have terminated before the next auricular impulse arrives, and this yields its usual response. In such circumstances the premature beat does not replace a normal ventricular event, but is an added phenomenon. Such beats are called "interpolated extrasystoles" (Figs. 43 and 44).

When a premature contraction falls very late in diastole, the disturbance of ventricular rhythm is slight, for it happens at an instant close to that at which a rhythmic beat is expected. The auricle may even contract before the premature beat of the ventricle begins, in which case there is an appreciable though shortened interval between the auricular beat and the premature one. The origin of the latter is nevertheless clearly shown by the shape of its electric complex. An example of this phenomenon is seen in Fig. 46. Supposing, however, that the premature beat comes so late that an auricular impulse is already well on its way to the ventricle, then two waves of contraction, one propagated from the normal source and the other propagated from the ventricular



source, travel over that chamber and meet somewhere in its walls. The electric complex of the ventricular contraction will then be of transitional form. Figs. 46 and 47 were taken from the same patient. A usual form of anomalous beat is seen in Fig. 46. Each of the three premature contractions of this figure produce similar electric curves; each falls late and after the auricular contraction has started. The first premature beat of Fig. 47 comes still later in diastole; the interval between it and the preceding auricular beat is just perceptibly less than the normal *P-R* interval. The resultant ventricular curve has a distinctive form, transitional between the normal and the abnormal electric complex. Such a contraction results when simultaneous but independent excitation waves meet in the ventricular walls.

*Premature contractions of auricular origin.*

When a new impulse arises in the auricle, the rhythm of both auricle and ventricle is disturbed. Usually the premature auricular contraction awakens a response in the ventricle. A simple example of the auricular extrasystole is shown in Fig. 48. The first and second cycles of the figure are normal, consisting of *P*, *Q*, *R*, *S* and *T* deflections. The third cycle is premature. Consider first the ventricular complex of this premature beat. It has a perfectly normal outline. The impulse responsible for it is known therefore to have travelled along the normal channels; that is to say, it has come down through the auriculo-ventricular bundle and its branches. It is a ventricular beat of supraventricular type (see page 25). When we search for the cause of this ventricular beat, we find it in an auricular contraction which precedes it. But this auricular beat is of abnormal type, the electric curve shows a depression and not a summit. To what is the inversion due? It results from the abnormal path which the excitation wave has taken in the auricle. The impulse,



starting the whole premature heart cycle, has been generated in an abnormal auricular focus, *i.e.*, in a region lying at a distance from the pacemaker. It has arisen from an *ectopic* centre and the wave has consequently passed through the auricle in a direction other than normal; but

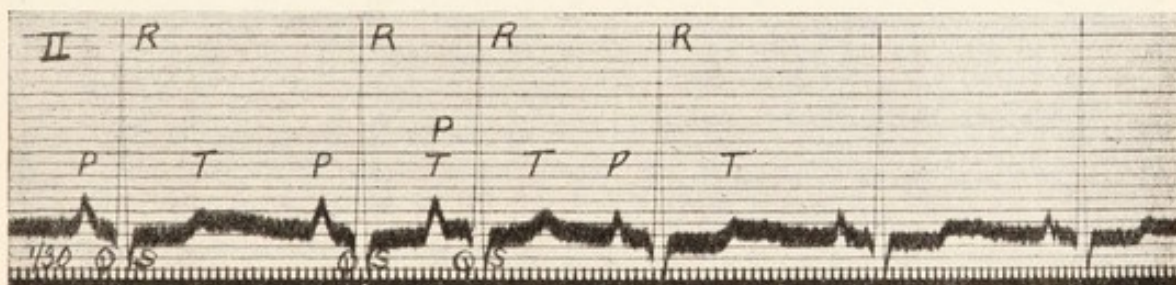
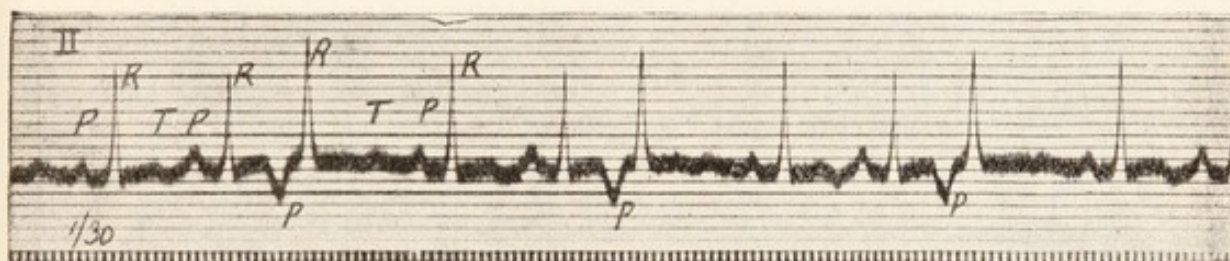
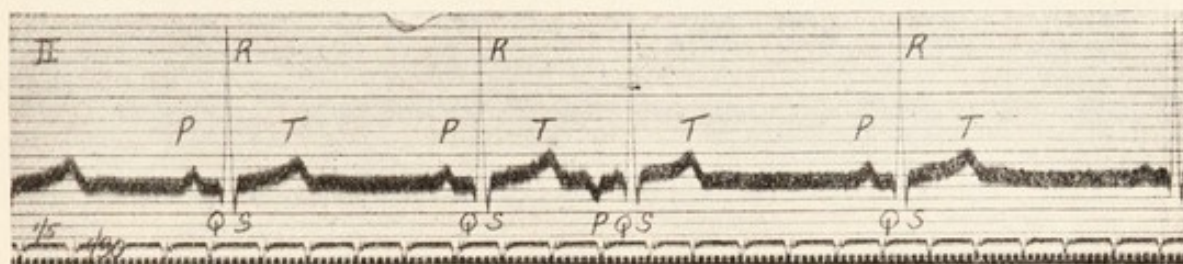


Fig. 48. A single premature contraction of auricular origin. The auricular complex is alone abnormal.

Fig. 49. Three isolated premature contractions, arising in the auricle. The corresponding auricular complexes are abnormal, and there is also slight distortion of the corresponding ventricular complexes (aberration).

Fig. 50. A single premature contraction, probably arising in the immediate neighbourhood of the sino-auricular node.

having arisen in the auricle, it travels to the ventricle along the only path open to it, namely, that constituted by the normal channels. Usually, the diastole which follows a premature auricular contraction is not compensatory; it is short of this, and consequently the fundamental rhythm of the



heart suffers disturbance. A rare example of premature auricular contractions, in which this diastole is almost if not quite compensatory, is shown in Fig. 49. The auricular

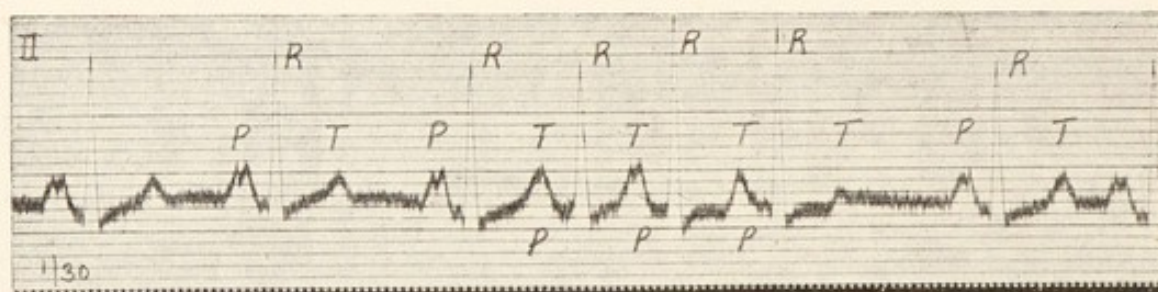
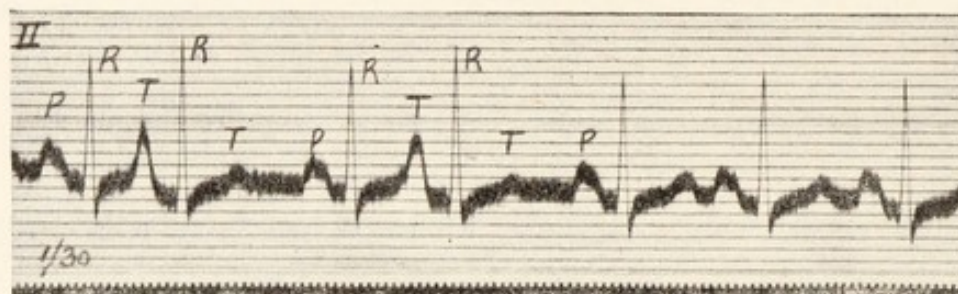
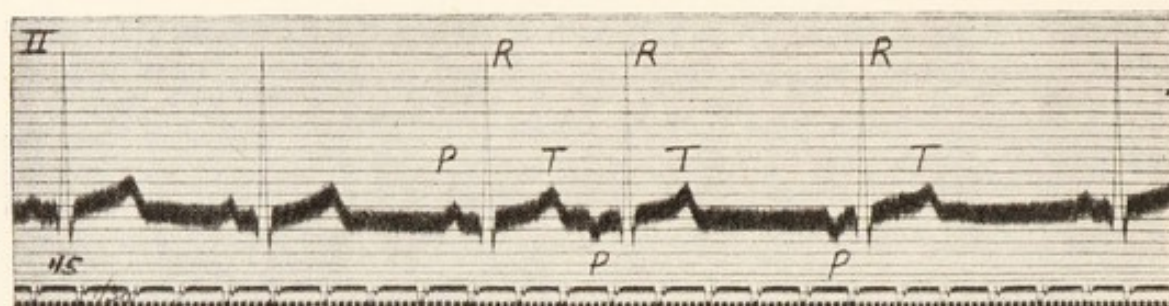


Fig. 51. A single premature contraction of auricular origin. The first beat after the pause originates in the same point as the premature one.

Fig. 52. Two isolated premature contractions of auricular origin. The premature auricular systole coincides with the preceding ventricular contraction; *P* and *T* are thus superimposed. Taken from a case of mitral stenosis.

Fig. 53. Three successive premature contractions of auricular origin. Taken from a case of mitral stenosis; note the split *P* summits in this and the preceding figure.

complexes are inverted in this figure, as in Fig. 48. When a premature beat arises in or near the sino-auricular node, then the whole premature electric complex is of normal form, as shown in Fig. 50; the *P* summits are similar throughout,



showing that the beats originate similarly ; moreover, the diastole which follows the premature beat is unduly shortened ; its length is either the same or somewhat shorter than that of the usual rhythmic beats.

On all but rare occasions the beat which follows a premature contraction is derived from the pacemaker ; the old heart rhythm is immediately restored (Fig. 48) ; but it sometimes happens that the first beat of the returning rhythm is also ectopic (Fig. 51) and springs from the same centre as the extrasystole. A not dissimilar disturbance, but of higher grade, is shown in Fig. 63.

When new impulses are created in the auricle, the premature auricular contraction may fall so early as to coincide with the preceding ventricular systole. *P* and *T* then fall together and summate. Summation of these summits is seen in Figs. 49 and 50, but is clearer in Fig. 52, where *P* and *T* are both prominent. The second and fourth beats of the last named figure are premature and arise at an ectopic auricular focus. The *P* summit of the premature beat coincides with the *T* summit of the preceding cycle and combines with it to form a tall blunt summit. Simple superimposition of *P* and *T* would not yield a united summit of the type depicted, for the rhythmic *P* is bifid in this case ; it is known, therefore, that the premature beats were ectopic in origin.

An example of premature auricular contractions, occurring in succession, is shown in Fig. 53. Each premature auricular complex coincides with a preceding *T* summit. All told, there are three of them.

While it is the general rule that the ventricular complex of a premature auricular contraction is of normal outline, yet its form often diverges ; it may diverge so conspicuously as to be mistaken for a beat of ventricular origin. The premature *R* summits of Figs. 49 and 52 are taller than those



of rhythmic beats ; but the difference in general outline is but slight. Examples of the chief forms of conspicuous divergence are illustrated in Fig. 54, which consists of four strips of curve taken from the same patient. In the first curve is a

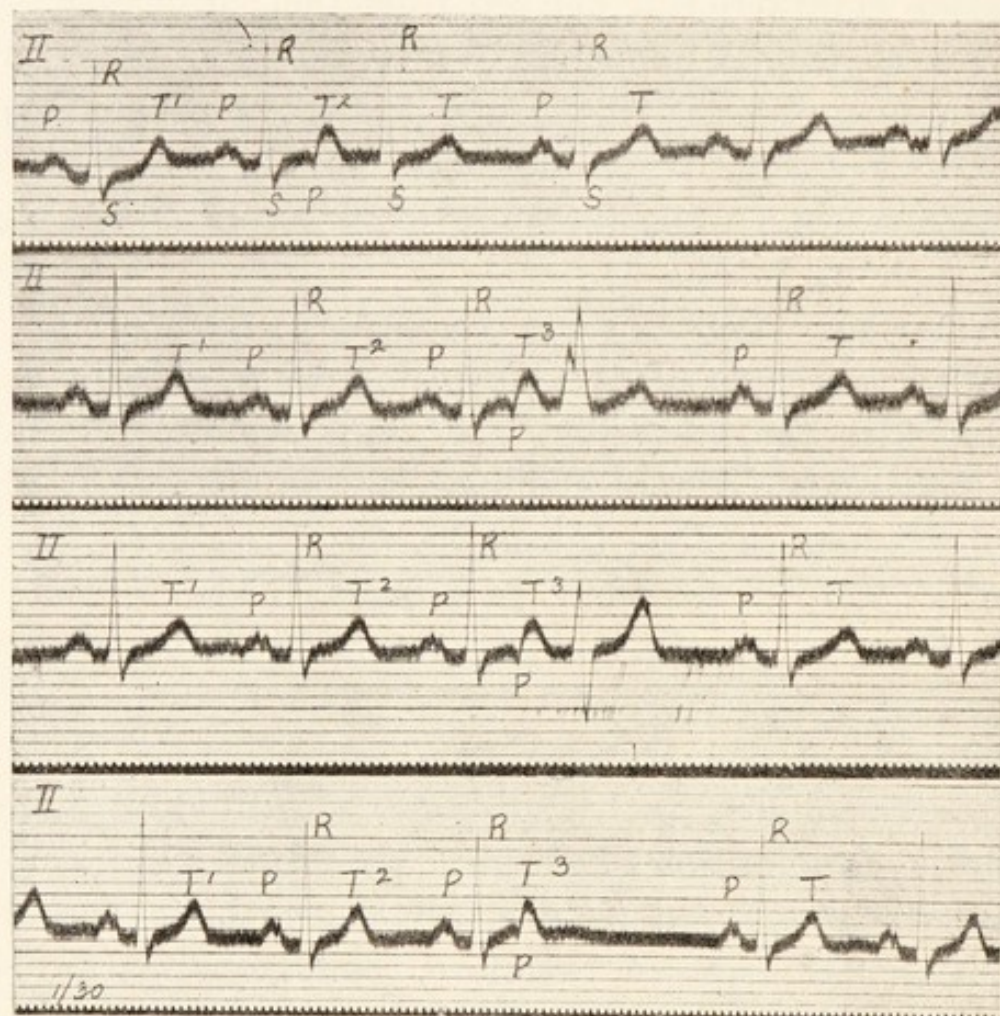


Fig. 54. Four curves from a single subject. Each shows a solitary premature auricular contraction. The premature auricular complex falls with the commencement of the preceding *T* and notches it. The corresponding ventricular complexes of the first three curves are of various forms ; the central curves illustrate a phenomenon which is described under the term "aberration." In the last curve the premature auricular contraction is blocked.

premature auricular contraction which conforms to the general rule ; all the ventricular complexes of this strip are similar ; the premature beat (the third in the curve) is evidently of supraventricular origin. The abnormal auricular complex



notches the upstroke of the preceding  $T$  summit; this is appreciated when  $T^1$  and  $T^2$  are compared; they have not the same shape, and the difference is due to an inverted  $P$  falling with  $T^2$ . The second and third curves show precisely similar events,  $T^3$  is notched by an abnormal auricular representative in both instances; but in these curves the premature auricular contractions give rise to ventricular beats of anomalous type. In the second curve the complex consists of two upwardly directed summits, the first of which is bifid; in the third curve upward and downward deflections of equal extent are followed by a rounded summit. Both the curious beats were of supraventricular origin, for each followed an

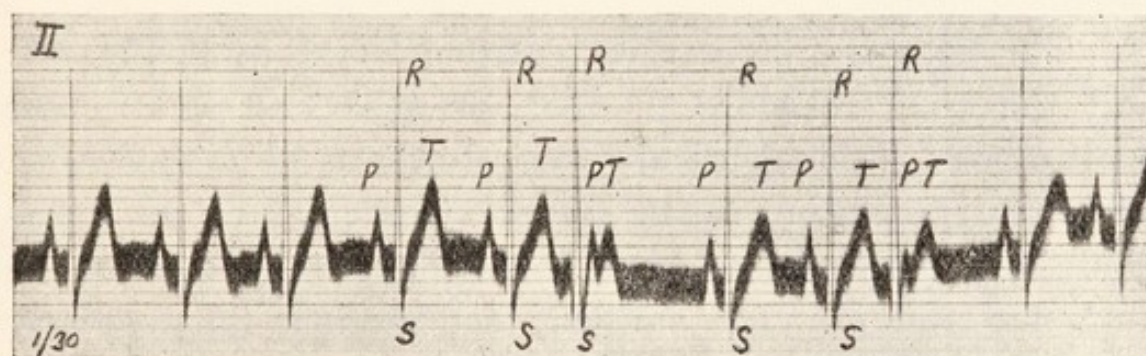


Fig. 55. Two premature contractions arising in the junctional tissues.

auricular systole which is to be detected in the curve; the abnormality of the ventricular curves is attributed to deficient conduction along certain tracts of the junctional tissues, whereby the auricular impulse has pursued an abnormal course in passing to the ventricle; the deficiency has been confined to the premature beats because the rest preceding these has been brief. These electric curves exemplify aberration (see page 28). Auricular extrasystoles, showing aberrant ventricular complexes, are almost confined to hearts in which conduction defects in the junctional tissues are demonstrable. The conduction intervals of the



premature beats are prolonged in the second and third curves of the present figure; and in the fourth or last curve a premature auricular contraction is blocked;  $T^3$  is again notched by an inverted  $P$ , but the auricular systole which the latter represents is not followed, as in the other curves, by a response of the ventricle. The last disturbance is often called a "blocked auricular extrasystole."

*Premature contractions arising in the junctional tissues.*

Although the majority of premature contractions arise in the auricle or in the ventricle, on occasion the conducting tissues, which unite these two chambers, appear to originate the disturbance.

There are two premature ventricular systoles in Fig. 55; and the time relations of the auricular and ventricular contractions in this figure are precisely the same as those seen when the premature beats are of ventricular origin. The pauses are compensatory, and there is no disturbance of the auricular rhythm. The auricular contractions fall regularly throughout the curve; each is represented by a normal  $P$  summit, though two of these summits are buried. The undisturbed auricular rhythm demonstrates that the premature beats have arisen below the auricle. Yet they have had their origin above the main division of the auriculo-ventricular bundle, for the ventricular complexes possess physiological outlines; the impulses have been supraventricular. The focus of disturbance, in such cases, is located in the auriculo-ventricular node or in the main stem of the bundle.

Premature contractions of any form are always easy to recognise in electrocardiograms; in other graphic records they often produce confusing pictures, and this is frequently the case when they appear in groups. The



characters of the pulse may closely resemble those which are associated with grave disturbances such as auricular fibrillation, flutter and alternation. Premature contractions are relatively benign, and as electrocardiography may be the only certain method of differentiating this irregularity from more serious disturbances, it is to be recommended as a final means to decide where there is doubt.

## CHAPTER VI.

---

### SIMPLE PAROXYSMAL TACHYCARDIA.

Electrocardiography has explained many of the phenomena of paroxysmal tachycardia. In the first place it has proved that these transient attacks of cardiac acceleration are not the result of simple disturbances of innervation as was at one time thought. If a heart accelerates in response to exercise, emotion, fever or other such cause,

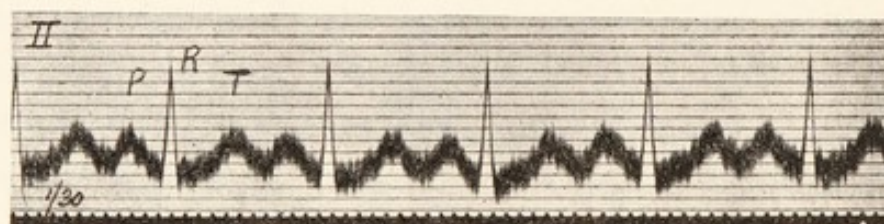


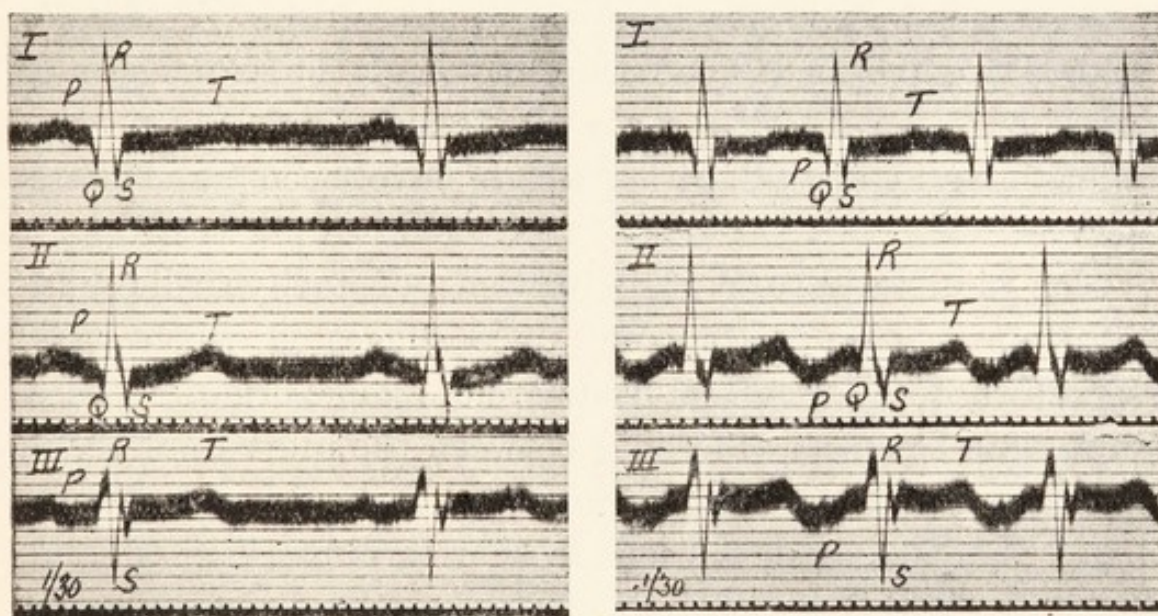
Fig. 56. An electrocardiogram from a case of exophthalmic goitre. The heart rate shown is 150 per minute. The curve indicates a simple acceleration of the normal rhythm.

then the electrocardiogram has in general a physiological outline. Auricular and ventricular complexes retain their shapes, except for minor changes which are the simple result of the increased heart rate. Fig. 56 was taken from a case of exophthalmic goitre, the ventricular rate being 150 per minute. The curve shows *P*, *R* and *T* summits; and these conform to the type of heart beat propagated from the natural pacemaker.

The curves of paroxysmal tachycardia are different; they show that the dominant centre of impulse formation has



moved at the onset of the attack, usually to some other part of the auricle. Figs. 57 and 58 are from a case of paroxysmal tachycardia; each figure shows the three leads. The first (Fig. 57) was taken while the heart action was natural, its rate being 81 per minute. The shapes of the auricular and ventricular complexes in these curves should be noticed and compared with those of Fig. 58, which depicts a paroxysm in which the heart rate was 146 per minute. It is seen that the ventricular complexes of the paroxysm retain their form and that they do so faithfully. Each ventricular



Figs. 57 and 58. Two sets of curves from a case of simple paroxysmal tachycardia. Fig. 57 was taken while the heart beat slowly; Fig. 58 while it beat rapidly. The curves demonstrate the supraventricular origin of the paroxysm. The inversion of *P* in leads *II* and *III* of Fig. 58 indicates that it arose in an ectopic auricular focus.

summit or depression of Fig. 57 is repeated in Fig. 58. The similarity extends even to the minutiae of the curves, even to the notch on the downstroke of *R* in lead *II* and the notch on the upstroke of *S* in lead *III*. The ventricular beats during the paroxysm were therefore of the same kind as those of the slow period; in both phases the impulses pursued the same course; that is to say, they travelled along the normal paths



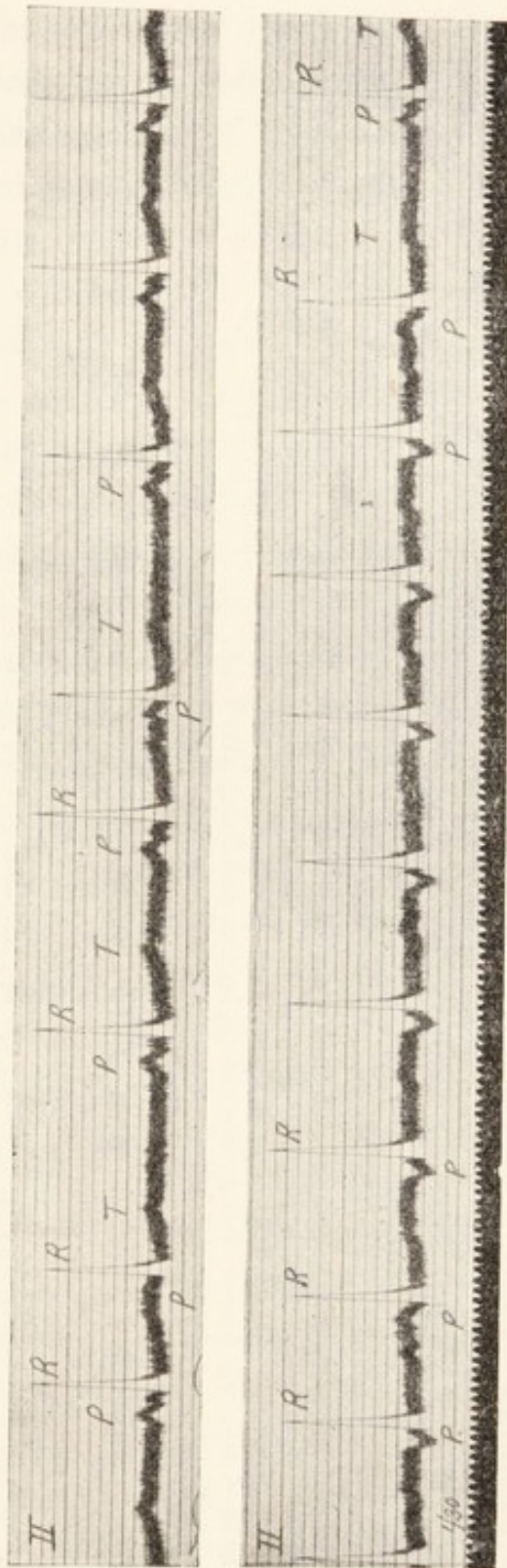
of the junctional tissues. The paroxysm was therefore of supraventricular origin. When we examine the auricular complexes in the two sets of curves, it is seen that while the *P* summits of the slow period are upright, those of the paroxysmal period are inverted in leads *II* and *III* and are also different in lead *I*. Such changes are significant, for they tell us that when the paroxysm comes, the natural pacemaker is no longer the dominant impulse centre, but that some new auricular focus has gained an enhanced activity and that the old centre is outpaced. Not infrequently such a conclusion as to the nature of the paroxysm can be maintained from its intrinsic beats alone. Yet it is always more justified when the curves of the two distinct phases of heart action can be taken, and when the similarities and dissimilarities which have been named are observed.

The similar nature of paroxysms of tachycardia and solitary premature beats is at once suggested when it is observed that the abnormal beats are of *ectopic* origin. There is in fact no essential difference between the individual beats of the one and the other. Premature beats are not always solitary ; they sometimes occur in short groups (Figs. 39 and 53) ; it is entirely a question of the length of these groups and the nature of our terminology as to whether we term such small groups successive premature beats or short paroxysms of tachycardia. In one and the same case, isolated beats, short groups and longer paroxysms may be found, and the electric curves usually show that all originate in the same focus (Fig. 59). Premature beats are characterised by the relatively short diastoles which precede them ; rapid impulse formation is expressed in the paroxysmal curves by the rate of the heart beat and by the prematurity of the first paroxysmal beat. That the two phenomena are essentially the same is also demonstrated by the manner in which



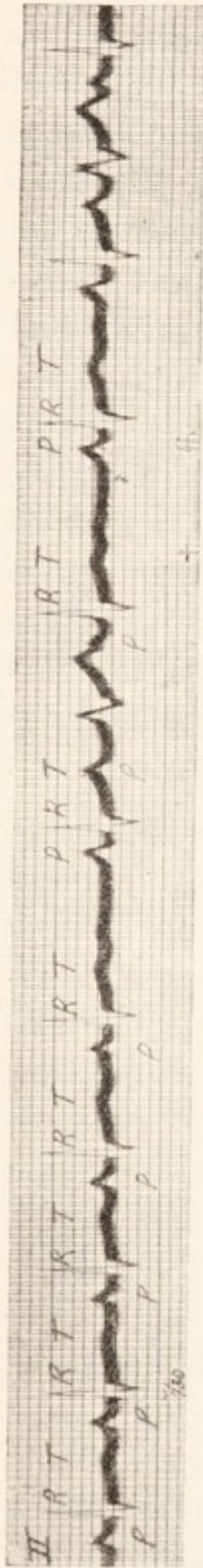

Fig. 59. The end of a paroxysm of tachycardia of auricular origin, and the commencement of the slow normal rhythm, interrupted by premature contractions. The last are auricular and two of them show ventricular complexes of aberrant type. The time marker in this curve rules vertical lines; a pair of lines occurs at each thirtieth of a second.



Figs. 60 and 61. Two curves from a case of simple paroxysmal tachycardia. Fig. 60 is from the period of slow and Fig. 61 is from the end of a period of rapid heart action. In Fig. 61 the first beat of the normal rhythm is shown at the very end of the curve. The curves show the ectopic origin of the paroxysm. Both slow and fast rhythms are interrupted by occasional premature beats having a common and auricular focus of origin.



each terminates. The solitary premature beat and the paroxysm are succeeded by a pause which in a single case

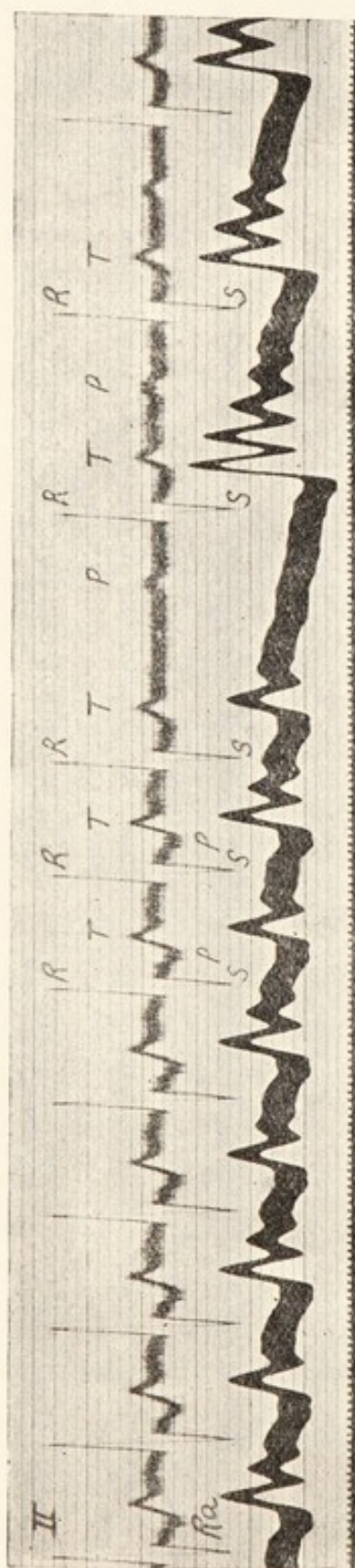


Fig. 62. The end of a simple paroxysm of tachycardia which arose in the auricle. There is delay in conduction during both slow and fast periods; during the latter the auricular contraction falls with the preceding ventricular systole. During the paroxysm the pulse shows alternation. The heights of *R* summits also alternate slightly, the *larger R* corresponding to the smaller pulse beat.

is of constant length, and there is an immediate return of the normal rhythm (Fig. 59). The change from one rhythm to the other in paroxysmal tachycardia is absolutely abrupt and in this way contrasts with the gradual slowing of a simple cardiac acceleration. Figs. 59, 61 and 62 are examples of curves which show the endings of paroxysms, and as these curves are published to illustrate special points they may be described in more detail.

In Fig. 59 the first five cycles are paroxysmal; these heart beats arise in a new auricular focus; this is ascertained by comparing the five paroxysmal beats with that which immediately succeeds them, the auricular summits are at first steep and small; with the return of the natural heart action they are larger and of a more customary form. The first normal cycle is succeeded by two premature contractions, each of which springs from the auricle and from the same focus as the paroxysmal



beats; the first premature beat has a ventricular complex of aberrant type (see Fig. 54, second curve and explanation). The diastole following the two premature beats has the same length as the diastole following the paroxysm. Then come two normal cycles and, after the last, two premature auricular contractions again occur. The figure clearly shows the associations between paroxysmal and premature beats which have been discussed.

In Figs. 60 and 61 are two curves from one case. The first exhibits a normal rhythm disturbed by two premature auricular beats. The *P* summits which are premature are smaller than those of the rhythmic cycles. The second shows a paroxysm of tachycardia in the same patient; the ventricular complexes are unaltered but the auricular ones are inverted. The second and last cycles of this paroxysm are premature and derived from the same source as those which are shown to disturb the normal rhythm in Fig. 60. A longer diastole terminates the paroxysm and the first beat of the returning normal rhythm is seen. Thus, in this patient, paroxysms of tachycardia, thrown in from an ectopic focus, disturb the normal rhythm; and both the paroxysms and the normal rhythm are interrupted by single premature contractions from a second ectopic focus.

Fig. 62 exhibits an electrocardiogram and radial pulse curve covering the end of a paroxysm of tachycardia and the beginning of the slow rhythm. The long post-paroxysmal diastole is well displayed and there is a little quickening of the heart rate at the beginning of the slow rhythm, a not unusual phenomenon. If the ventricular complexes of the slow and fast periods are compared, they will be found to be alike, except that at its commencement *T* goes deeper during the paroxysmal stage. This change in the shape of *T*, which is semi-inverted while the heart rate is fast, is not incompatible with acceleration alone. Had we simply the paroxysmal



curves, or even the curves of the slow and fast periods for comparison, then a complete analysis of the paroxysmal mechanism would not be feasible. The record of the transition from one form of heart action to the other provides us with the full data. If the last two cycles of the paroxysm are compared, it will be clear that *T* alters its shape; the semi-inversion is not present in the last paroxysmal cycle; it is due, in the other paroxysmal beats, to the superimposition of an inverted *P* upon *T*. The paroxysm has originated in a new auricular focus and each auricular systole has propagated a ventricular systole; the rate is fast (128 per minute) and the *P-R* interval is long (0.33 second); consequently each auricular contraction falls with the preceding ventricular contraction. The last ventricular beat is necessarily uncomplicated in this respect, for the auricular paroxysm has terminated before the ventricle responds to the last paroxysmal impulse. The paroxysm ends in the usual long diastole and the natural pacemaker re-establishes its control; but the prolongation of the *P-R* interval is maintained.

These illustrations show how valuable is a comparison of fast and slow periods in electrocardiograms. The curves of the paroxysmal phase are but rarely sufficient to provide a full analysis. The curves of both rapid and slow heart action are also insufficient at times; the curves which show the transition from fast to slow or from slow to fast are the most illuminating of all.

Paroxysms of tachycardia may also arise in one or other ventricle; in these circumstances the electric curves of individual beats are of the forms seen in Figs. 41 and 42. But tachycardia of ventricular origin is comparatively rare in records. An auricular origin is the general rule. It is probably because the ventricular disturbances are less compatible with life that they are so rarely recorded.



Similar attacks frequently originate in the junctional tissues, but the resultant curves are often obscure and difficult fully

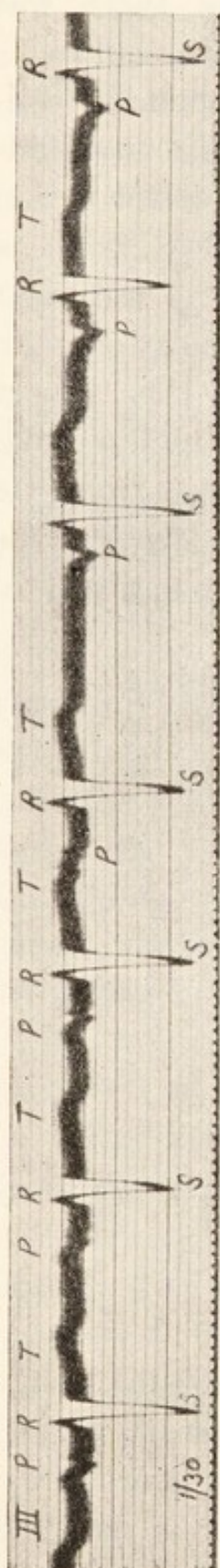


Fig. 63. From a patient who presented preponderance of the left ventricle. A regular rhythm of sinus origin is disturbed by a single premature beat arising in the auricle. A rhythm of ectopic origin follows this extra-systole; the *P-R* interval in these last three cycles is somewhat shortened; the new rhythm probably arose from the upper levels of the auriculo-ventricular node.

to elucidate. Where, as in Fig. 61, the *P-R* interval is slightly reduced and *P* is inverted, it is customary to locate the origin of the paroxysm in the upper part of the *A-V* node. In other and commoner instances of nodal paroxysms, *P* and *R* fall together and the former cannot then be deciphered.

The chief value of electrocardiographic records in tachycardia is in distinguishing between simple acceleration, simple paroxysmal tachycardia and a third condition which is described in the next chapter. The natural history of the three conditions and their reactions to treatment are essentially different. Rapid heart action of obscure origin is frequent; the electric method singles out those which are primarily of cardiac origin and distinguishes them from simple disturbances of innervation.

#### *Dislocation of the pacemaker.*

It may be profitable to contrast simple paroxysmal tachycardia with the disturbance of the heart's action which is shown in Fig. 63. This electrocardiogram opens with three cycles in which the heart beats

have been propagated from the natural pacemaker, as is evidenced by the shape of the complexes (*S* is deep because the curve was taken from a patient in whom there was a preponderance of the left ventricle; the curve is from lead *III*). The fourth beat is a premature contraction of auricular origin. The usual pause succeeds this disturbance, and subsequently rhythmic heart action is resumed. But the restored rhythm arises from a new focus, as is shown by the shape of the auricular complexes. There is little or no difference in the rate of the heart before and after the disturbance, and in this respect the curve contrasts with those of paroxysmal tachycardia. The ectopic rhythm is developed in this instance from the same type of impulses as is the normal rhythm; unlike the paroxysms of rapid heart action, it is not allied genetically to premature beats.



## CHAPTER VII.

---

### AURICULAR FLUTTER.

The term "auricular flutter" is used in this chapter to designate an acceleration of the auricle which, as has recently been demonstrated, is due to a peculiar condition, known as "circus movement" in the auricle. The disorder is not easy to diagnose by methods other than the electrocardiographic.

Circus movement is a continuous movement of the contraction wave around a ring of muscular tissue such as is provided by the mouths of the superior and inferior vena cava. Where circus movement has become established, there are no discrete impulses creating the separate beats of the heart, but each time that the wave completes the circuit of its chosen path, it spreads into the surrounding muscular tissue, which contracts in response. Thus, the revolving wave travelling in a ring of auricular tissue governs the movements of the whole auricle; and the auricular movements, as usual, govern the beating of the ventricle.

The usual rate at which the auricle contracts in flutter is approximately 300 per minute; in special circumstances it may be as low as 150, it may reach 360 per minute. The flutter comes abruptly and goes abruptly, as does a simple paroxysm of tachycardia. Rarely, flutter also occurs in short paroxysms, but in general it persists for months or years. In this and several other respects "flutter" is allied to another disorder, namely "auricular fibrillation," which is described in the next chapter.



The auricular rate is so rapid that the ventricle is rarely able to follow it; so it happens that most patients who exhibit flutter also demonstrate heart-block, the grade of which is generally such that only the alternate auricular impulses stimulate the ventricle. Most patients who are the subjects of flutter have an enhanced ventricular rate, but the ventricular rate is but half the auricular. On the other hand, the ventricular rate may be slow; any grade of block may be present.

*The electrocardiograms.*

The electrocardiograms are not difficult to recognise if carefully examined. It is often of advantage to have the

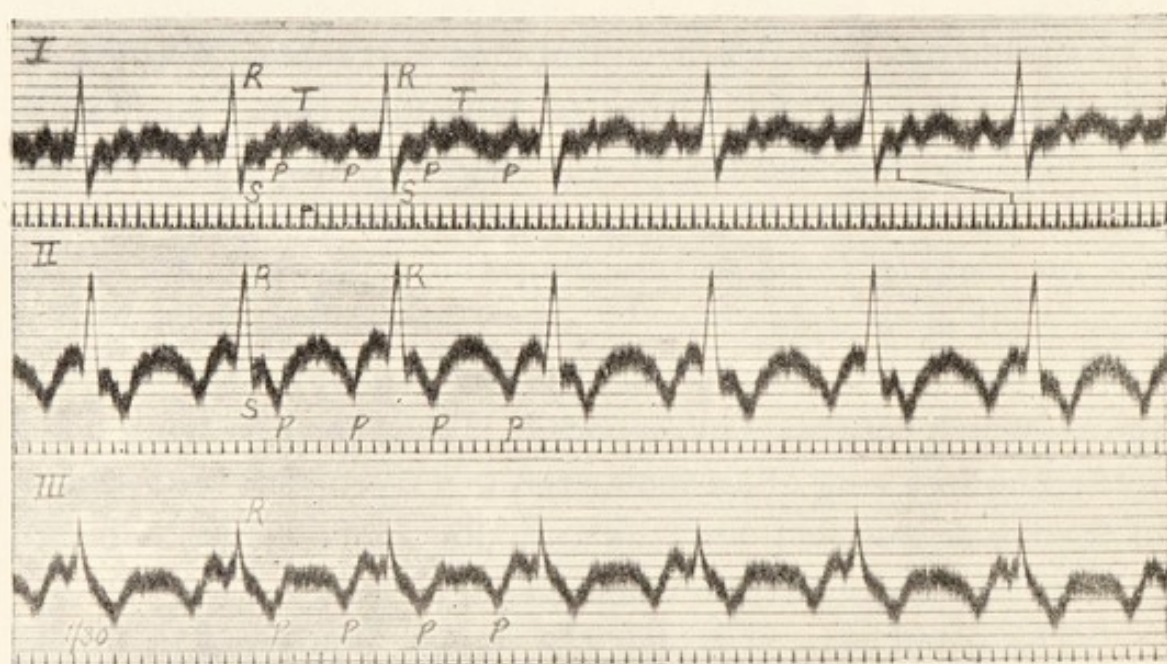


Fig. 64. Curves from the three leads in a case of auricular flutter. The auricular rate is 324, the ventricular rate is 162 per minute. In leads II and III the auricular complexes are contiguous.

curves from the three leads side by side, so that similar events may be compared in distinct leads. Fig. 64, which comprises all three leads, may be used to illustrate the chief points in the analysis. In lead II of this figure the most conspicuous peak is *R*; it is followed by a small depression *S*. These are

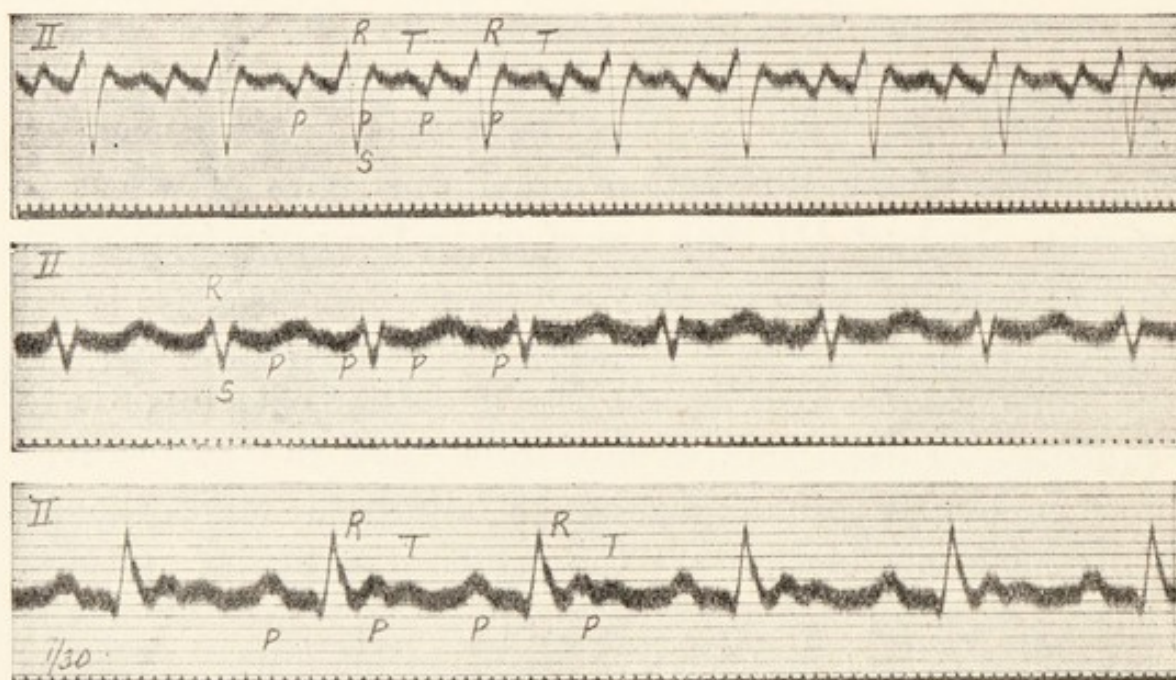


the only certain indications of ventricular systole. The remainder of the curve may be described as consisting of two V-shaped depressions, one of which might seem to correspond to an inverted *T*, the other to an inverted *P*. The two depressions have an almost exactly similar shape. Now this is not inconsistent with their representing an inverted *P* and *T*, for similarity of the two deflections is not uncommon. But it would be a strange coincidence if, with this similarity, *P* and *T* should be placed at exactly equal distances from each other throughout the whole curve. Moreover, even though *P* and *T* may resemble each other in a given lead, *they never do in all three leads*; yet in each of the curves of our illustration a uniform series of waves is present. In lead *III* they are of much the same form as in lead *II*; while in lead *I* they appear as small peaks. In all leads they lie at equal distances from adjacent summits of the same form; in all leads the deflections lie in orderly sequence. These facts demonstrate that the two waves have a similar origin; although alternate waves lie in ventricular diastole, all are the result of auricular systoles. Fig. 64 therefore shows 2:1 heart-block, the rate of the auricle being 324 and that of the ventricle 162. In leads *II* and *III* the real *T* is scarcely distinguishable, but in lead *I* it is clear, having a broad form and falling between two *P* summits.

The electric representatives of auricular contractions, when this chamber is in a state of flutter, are contiguous. In Fig. 64 this is clearest in lead *II*. For descriptive purposes, *P* may be said to commence in an upstroke and to be continued in a dome which ends at the foot of the succeeding upstroke. Each of these complete complexes in reality represents a complete movement of the contraction wave around its circuit in the auricle and, as there is no beginning or end to the movement, so there is no real beginning or end of the auricular



complex. As one upstroke precedes *R*, so the dome into which it continues runs through *R* and *S*. The next dome commences during the ventricular systole and runs on into ventricular diastole. Each auricular contraction partially coincides with a ventricular contraction and it is to this that many flutter curves owe their obscurity. Other examples of curves are shown in Figs. 65, 66 and 67. Fig. 65 shows the common type of auricular curve. The auricular contractions



Figs. 65, 66 and 67. Examples of auricular flutter curves. In each 2:1 heart-block is present. The auricular rates are approximately 330, 280 and 228, respectively; the ventricular rates, 165, 140 and 114, respectively.

are again twice as numerous as the ventricular. Each auricular complex may be described as commencing in an upstroke, but this upstroke is only clearly distinguished where it precedes *R*. It continues to a blunt summit and then the curve slopes away and becomes incorporated in the ventricular complex. The next upstroke coincides with the returning line of *S*; it comes to a point and slopes away again, but the gradual downstroke is interrupted by a small



*T* summit. Thus the auricular tracing as a whole is constituted by a zig-zag line of which the upstrokes are steep and the downstrokes are more gradual.

Fig. 66 exhibits a similar action. The ventricular complexes consist of *R* and *S* deflections. The auricular portion of the curve is traced as a uniform wavy line; one convexity falls midway between *R* summits, the other falls with *R*. The general and uniform undulation is visible though disguised; each convexity represents an auricular contraction; 2:1 heart-block is present. The rates of auricle and ventricle are 280 and 140, respectively. The analysis of Fig. 67 is easier, for here the *P*'s are more sharply defined. The auricular rate is 228 and the ventricular 114 per minute.

The analyses while 2:1 heart-block is present are difficult to those unfamiliar with the curves; sometimes they are almost impossible at this stage. The true nature of the condition is at once revealed when a higher grade of heart-block becomes established. The first curve of Fig. 72 is not very dissimilar to that of Fig. 66. The auricular line is a wavy one and there are two convexities to each ventricular systole; one falls midway between adjacent *R* summits, the other coincides with *R*; 2:1 heart-block is present, the rates being 300 and 150. The same patient demonstrated a higher grade of block upon another day; the auricular convexities then became clear, being less confused by ventricular summits; the curve is shown in the second strip of Fig. 72; 4:1 block is present, the rates being 300 and 75. (Similar electrocardiograms are shown in the first two curves of Fig. 73, the top curve of which should be compared with Fig. 65.) The same 4:1 ratio is shown in Fig. 68, a curve which has been taken at a faster speed and with a more sensitive string. This curve has been marked so as to reconstruct that portion of the auricular line which



is obliterated by *R* and *S*; the regular relation of four auricular convexities to a ventricular systole is made more apparent in this way.

The constant activity of the auricle may be demonstrated in another fashion. If the vagi are pressed upon in the neck, the ventricular beating is often checked; but the auricle continues to contract at its former rate (Fig. 69). The continuously wavy line, each convexity of which stands for an auricular beat, is thus strikingly displayed. It is to be emphasised again that each of the waves so traced corresponds




Fig. 68. From a case of flutter, showing 4:1 heart-block. Those portions of the auricular complexes which have been obscured by the initial phases of the ventricular complexes have been indicated by reconstructing the auricular oscillations. The standard for this curve is 1.5 centimetres to the millivolt.

to a complete revolution of the contraction wave in the auricle; the sinuous type of curve well displays the fact that the revolutions are continuous, uninterrupted and regular.

In the case of simple paroxysms of tachycardia, in which the fast rhythms are developed from some ectopic centre, nerve influences, such as are induced by exercise, emotion, posture or pressure upon the carotid sheath are practically without influence upon the rate at which the impulses are generated. The same statements apply also to flutter. That is so because in flutter, as in paroxysmal tachycardia, the natural pacemaker is out of action, and nerve control of rate, which is normally exerted through this pacemaker is largely or wholly lost. Figs. 69 and 70 were taken from the



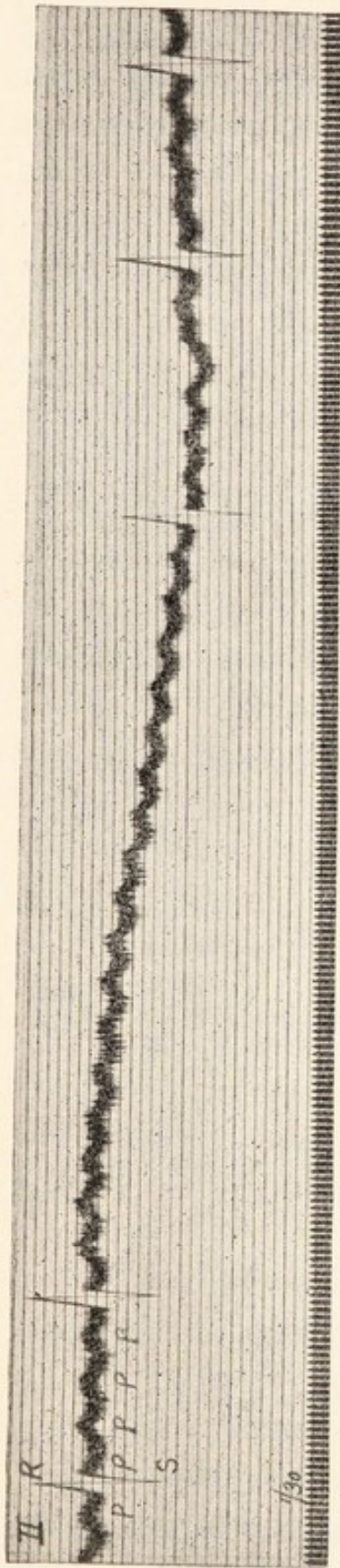


Fig. 69. From the same case, showing the effect of pressure on the right vagus during a period of 4 : 1 heart-block. The ventricle ceases to beat, the auricular action shows no abatement.




Fig. 70. From the same case after the heart's action had returned to the normal. Pressure on the vagus (right or left) now produced slowing of the whole heart. The left vagus was the one pressed upon in this instance.

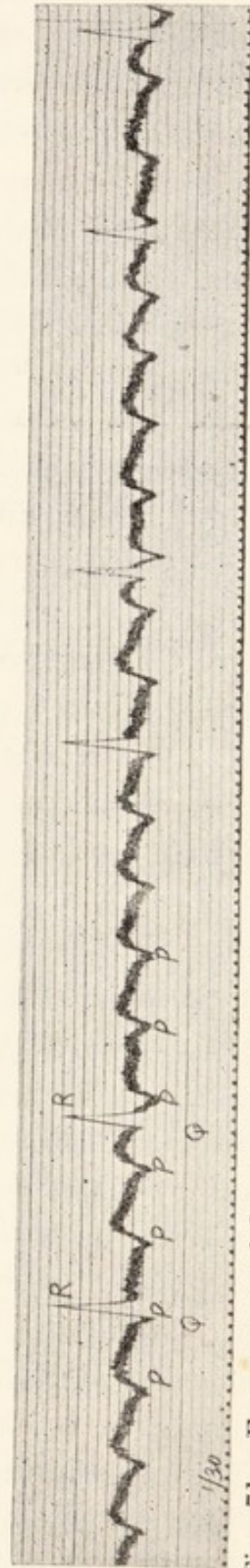


Fig. 71. From a case of flutter on digitalis, showing slow and irregular responses of the ventricle.



same patient and show the effects of pressure on the carotid sheath, during the flutter stage and during the stage of normal heart action. In both cases the vagus has been stimulated, as is shown in the one instance by ventricular standstill and in the other by slowing of the whole heart with a slight prolongation of the *P-R* interval. Both curves afford evidence of heart-block as a result of pressure, but the essential difference lies in the action upon the auricle. The flutter is uninfluenced (Fig. 69) ; the natural pacemaker reacts, the rate at which it builds up impulses being conspicuously decreased (Fig. 70).

Auricular flutter occurs for the most part in elderly subjects and in those in whom there are evidences of cardiac enlargement, myocardial degeneration, and symptoms of an exhausted reserve. When it develops, it throws a burden upon the heart proportioned to the increase of ventricular rate. When the heart muscle is degenerate and the rate rapid, dilatation, engorgement of the veins, enlargement of the liver and dropsy appear. On the other hand, when it develops in a heart whose muscle has considerable reserve, profound circulatory disturbances and embarrassment are not manifested ; but palpitation is common and a retrenchment of reserve power is noticeable in the response to effort. In this manner it disables even those in whom the heart muscle is strong. Fainting attacks are not uncommon in the condition, and are due to the ventricle suddenly responding to the full auricular rate.

Flutter may pass spontaneously into fibrillation, but more commonly the change is induced by digitalis administration. Digitalis and its allies are often very serviceable if given in full doses and the reaction is highly interesting. In my experience, the ventricular rate can always be reduced, so that 2 : 1 block gives place to heart-block of higher grade, Supposing that 2 : 1 heart-block is present originally, then



irregularity develops, and this is due to responses at irregular intervals (Fig. 71). Later, and if the drug is continued, the ventricle may become regular again, as a result of the development of 4 : 1 block (Figs. 72 and 73, 2nd curve of each). In

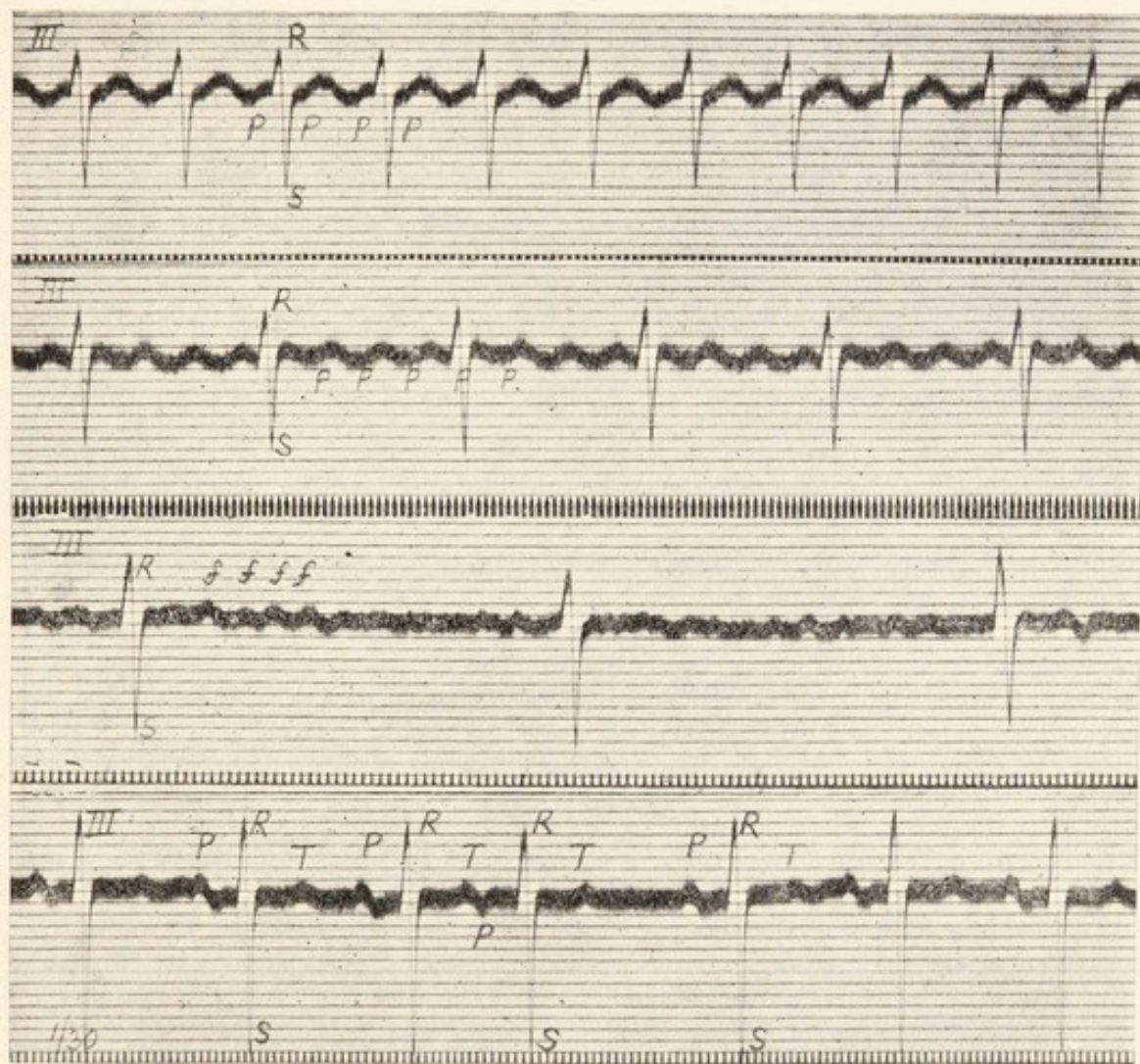


Fig. 72. Four curves from a case of long standing auricular flutter, showing the effects of treatment. The first curve shows an auricular rate of 300 and a ventricular rate of 150. In the second curve the auricular rate is maintained, but the ventricular rate has been halved (4 : 1 block is present) as a result of digitalis administration. In the third curve auricular fibrillation is seen and it is accompanied by a slow and irregular action of the ventricle. In the last curve the normal rhythm, interrupted by occasional premature contractions of auricular origin, has been restored.

these circumstances the ventricle may be beating at 75 while the auricles continue to beat at 300 per minute, and there may be no evidence, except the electrocardiographic, of the



rapid auricular beats. Finally, and in a large percentage of cases, I find that fibrillation of the auricles appears under the action of the drug (Figs. 72 and 73, 3rd curve of each); and further that, if the digitalis is withdrawn at this stage, the normal action of the heart is often restored (Figs. 72 and 73, 4th curve of each) and may persist. The treatment

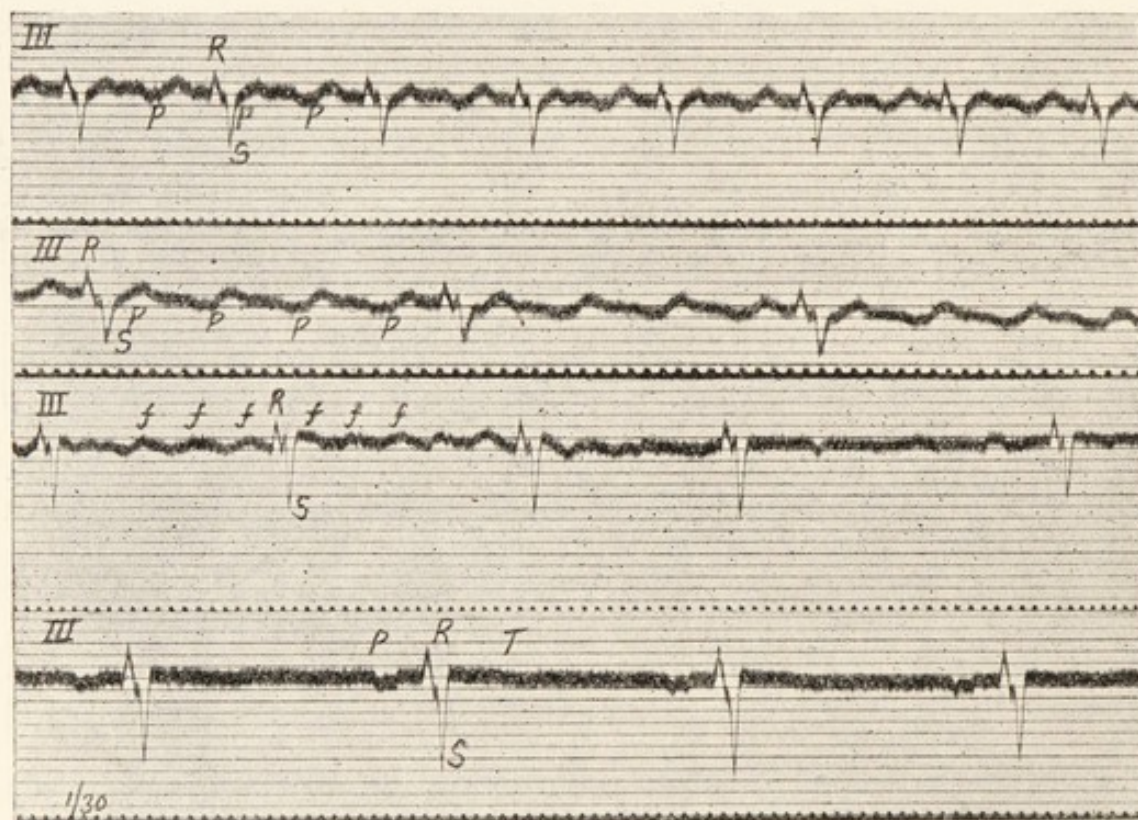


Fig. 73. A similar series of curves to that shown in Fig. 72. They show the effects of digitalis administration upon long standing auricular flutter. In the first curve the auricular rate is 320 and the ventricular rate is 160. In the second the rates are 324 and 81 (4 : 1 heart-block). In the third, the auricles are fibrillating and the ventricle is responding irregularly at an approximate rate of 79 per minute. In the last curve a regular and normal rhythm is re-established. The inversion of *P* in lead *III* is not significant of an ectopic origin of the heart beat in this instance.

of auricular flutter by digitalis is often most successful and brings with it much improvement of the patient's general condition. As the rapid ventricular rate subsides, cyanosis, engorgement, dropsy and other accompanying symptoms vanish quickly.



## CHAPTER VIII.

---

### AURICULAR FIBRILLATION.

Fibrillation of the auricle, as has recently been shown, is a variety of auricular flutter. In the flutter which I have already described, the movement of the wave as it circulates in the auricle is regular; that is to say, the same path is travelled over and over again in unvarying fashion. Consequently the beating of the auricle is regular, and the responses of the ventricle are arranged in relatively simple ratios. A circulating wave is also responsible for the condition termed fibrillation, but in this condition the path pursued is inconstant and the separate circuits are completed in varying times. Moreover the circuits are completed more rapidly than in simple flutter. The result is a much more disorderly movement of the auricle and a wholly irregularly response of the ventricle.

In fibrillation co-ordinate contraction has ceased in the auricles, the surface muscle of which exhibits constant minute twitching movements. The muscle, though extremely active, has relinquished its function of driving blood into the ventricles; the normal impulses which are transmitted to the ventricle are submerged and replaced by rapid impulses which are derived in a haphazard fashion from the irregularly and rapidly circulating wave in the auricle.

Our ability to recognise this disorder is a great asset because it is so frequent, because its effects are so profound,

and because its reactions to treatment are almost peculiarly its own. The electric curves of auricular fibrillation are characteristic and afford the only certain means of identifying it. It is recognised by two groups of signs; the first signs result from the changed functional state of the auricles, the second signs depend upon the character of the ventricular responses. We will consider the last first.

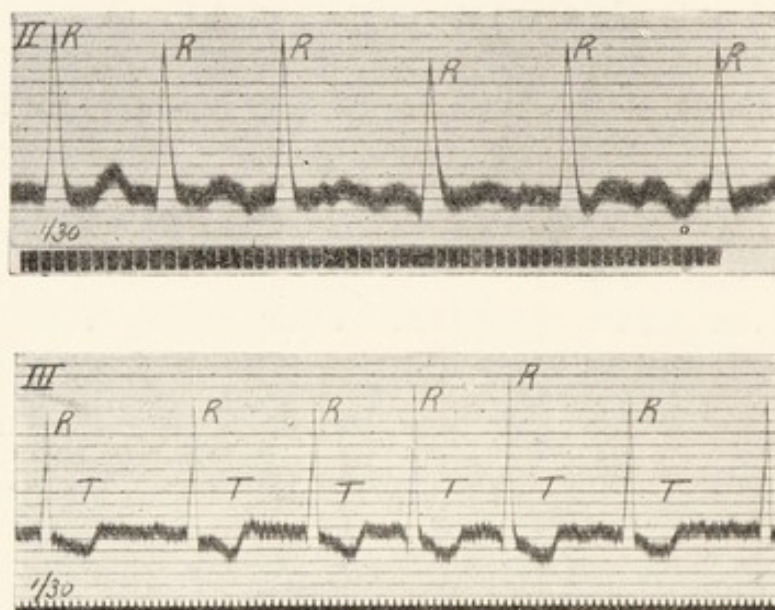


Fig. 74. A curve of auricular fibrillation showing rapid and irregular ventricular responses. The height of the peak *R* is variable and is not related to the length of the diastole which precedes it. The oscillations are obscured by the rapid ventricular action; that they are present is evident from the changing shape of those parts of the curve which unite adjacent *R* summits. There are no *P* summits.

Fig. 75. A curve of auricular fibrillation, showing rapid and irregular ventricular response, great variation in the height of *R*, and inversion of *T*. Fibrillation oscillations are only just visible; the very rapid and minute vibrations are from the body musculature. There are no *P* summits.

When the ventricle responds solely to a fibrillating auricle, its beats are necessarily of supraventricular origin; they consequently present the normal outlines in electric curves, *R* and *T*, or *Q*, *R*, *S* and *T* deflections are found. These ventricular complexes have all the same general outline though the heights of the *R* summits vary in many cases



from cycle to cycle. If the ventricular action is slow, then the *R* summits are almost constant in height, but when it is rapid (Figs. 74 and 75) the excursions vary, and there is then no relation between their heights and the diastoles which precede them; the individual complexes are placed at very irregular intervals.

The other group of signs is auricular. The *R* summits have no *P* summits before them, for, as there is no co-ordinate contraction of the auricle, so there is no presystolic auricular representative in the electric curve; but the quivering flesh of the auricle yields pronounced electric waves, oscillations which are clear in and characterise the majority of the curves. The type of oscillation deserves study; the average frequency is 450 per minute; so, if the ventricle beats at 75, there will be about six oscillations to each cycle, or if it beats at 110, there will be about four oscillations to each cycle. Only those oscillations which occupy diastole are easily distinguished; consequently, if the ventricle beats slowly, the oscillations are conspicuous; but if it beats fast, they may be difficult to distinguish. Each oscillation corresponds to a complete circus movement in the auricle, as in flutter; the difference being that the oscillations of fibrillation are more rapid than in flutter and irregular in length and form.

The oscillations of the first curve in Fig. 80 are very large, and it should be remarked that there is an attempt towards regular disposition, but the individual swings of the fibre *are never quite uniform as in flutter*. When *T* is prominent, as in this curve, it is deformed by oscillations which fall with it. The oscillations are continuous, but in one place (between the third and fourth *R* summits) the amplitude is diminished. This variation is always present, and if the mean amplitude is small, then the oscillations may vanish from place to place in the curves. In Fig. 81 (top curve) they are prominent at the beginning, but towards the end they are barely per-






Fig. 76. From a case of fibrillation under treatment with digitalis. It shows irregularity of the ventricle and inversion of *T*. The oscillations are small; *P* does not appear.




Fig. 77. From a case of fibrillation under treatment with digitalis. The ventricular action is irregular. The diastolic portion of the curve shows two series of oscillations, the one (*f.f.*) due to the fibrillations of the auricle, the other resulting from tremor; these last oscillations have a very high frequency.

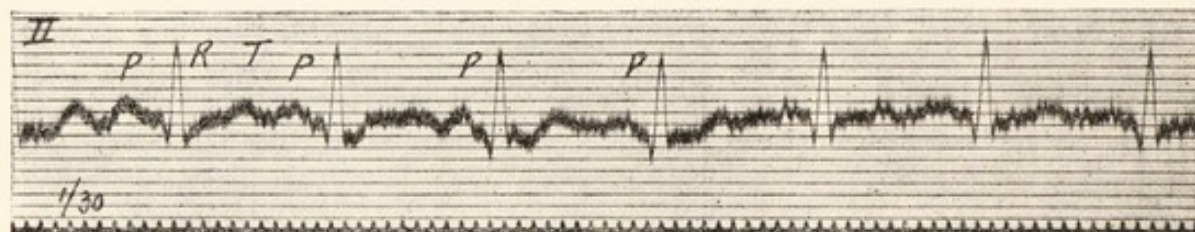


Fig. 78. From a case of exophthalmic goitre, showing a regular heart action. Each ventricular complex is preceded by a summit *P*, but the whole curve is disturbed by oscillations resulting from tremor of the somatic musculature.

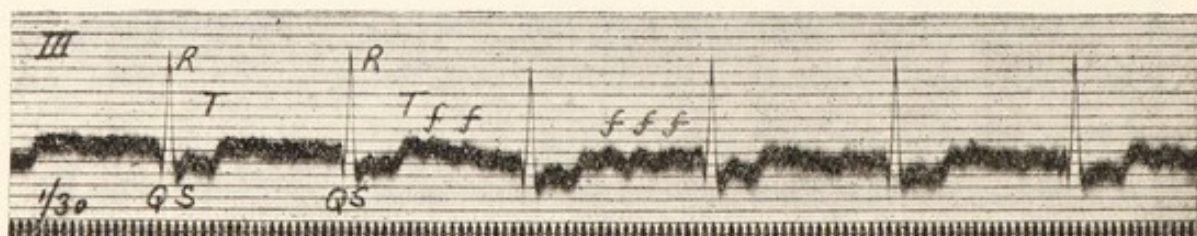


Fig. 79. From a case of auricular fibrillation, under treatment with digitalis. The fibrillation is evidenced by the oscillations *f.f.* and by the disappearance of *P* summits. The ventricular beats are placed regularly because complete heart-block was present. The rate is exceptional for a ventricular rhythm, being approximately 90 per minute.



ceptible. These changes in amplitude are due to gross change in the path taken by the circus movement. When the ventricle beats fast, as in Figs. 74 and 75, diastole is comparatively short and the oscillations are not clearly seen. Their presence is ascertained in such curves by scrutinising the lines which join the *R* summits; these lines are differently configured from cycle to cycle. The oscillations are in reality always continuous, but, as in flutter curves (Figs. 65 and 66), fast ventricular action may obscure them; in other instances, owing to change in the path taken by the wave the lead becomes temporary unsuitable and will not display them. They are especially prominent in cases of mitral stenosis (Figs. 80 and 94). In other conditions they are often small; Fig. 76 is an example of such a curve; this electrocardiogram should immediately suggest fibrillation, for the ventricular complexes are all of the supraventricular type, and quite irregularly spaced; furthermore, there are no *P* summits. There are deflections in Fig. 74 which at first suggest auricular contractions, but they are inconstant in form and position and should not mislead, being in reality individual and prominent oscillations which happen to fall in presystole. Fig. 77 shows another and distinct form of oscillation; it is of very high frequency and due to tremor of the somatic muscles; it is not to be ascribed to fibrillation, although the curve was actually from a case displaying this disorder. These minute vibrations are common in fibrillation cases, for the patients are often feeble or actually tremulous, but they may be present when no tremor is detected and may then confuse interpretations. It is wise to neglect them and to look to the general sweep of the curve. In Fig. 77 they are present throughout and distort the curve; it is from a fibrillation case, as may be seen immediately from the shape of the ventricular complexes, their arrangement and the absence of *P* summits; if the curve is regarded with the



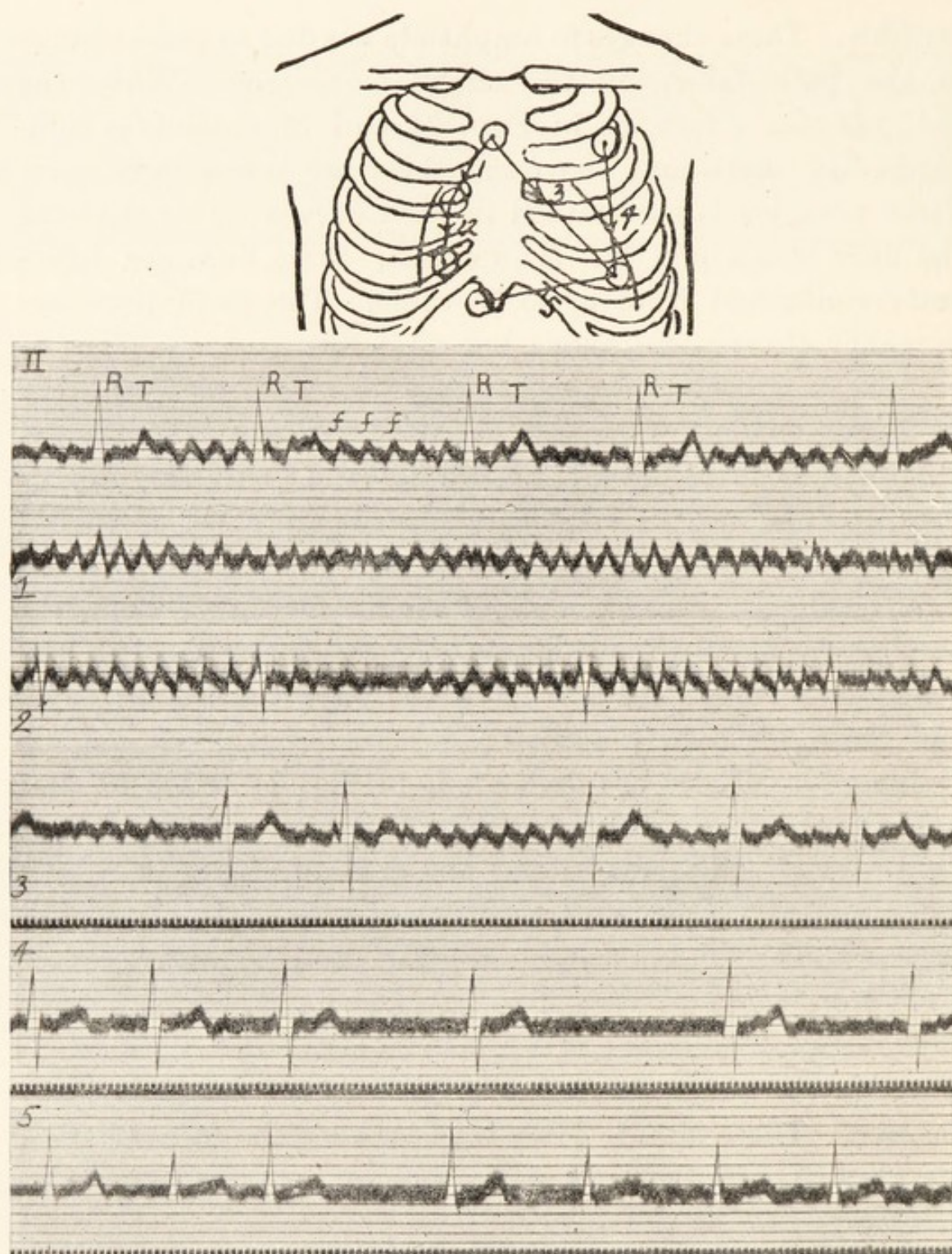


Fig. 80. A diagram of the chest wall showing the special leads (1 to 5) used in identifying the oscillations of auricular fibrillation; also six electrocardiograms. The first electrocardiogram is from lead *II*; it consists of irregularly placed ventricular complexes (*R, T*) and of large and continuous oscillations (*f.f.*). The remaining five curves are from the chest wall. 1 and 2 were taken from the area overlying the right auricle; in these leads the oscillations are maximal and the ventricular complexes are minimal. 3 was taken from an oblique lead covering the whole heart, and it shows both oscillations and ventricular complexes. 4 and 5 were taken from leads along the margins of the ventricles; they show but little sign of the oscillations. From a case of mitral stenosis.



eyelids almost closed, the fine tremor is no longer distinguished and the slower and inconspicuous oscillations of the fibrillating auricles then become clearer ; these are most prominent after the second ventricular beat and have the characteristic form. Fig. 78, a different type of curve, illustrates the same distinction ; it is from a case of exophthalmic goitre in which there was much tremor. The tremor oscillations are large and coarse, serrating the whole curve and obscuring *P* ; nevertheless *P* or some trace of it may be discovered in each cycle, despite the distortion ; it should be noted also that the ventricular beats are evenly distributed. The action of the heart from which this curve was taken was normal. Sometimes, when the somatic muscle tremor is coarse and the patient holds the limbs rigidly or unsteadily, the curves present difficulties and there may be doubt as to whether a given series of oscillations is of somatic or cardiac origin ; under these conditions special leads may profitably be adopted. Small metallic discs are fastened directly to the chest wall with a stiff paste of flour and salt. Convenient points of contact are depicted in the accompanying diagram which illustrates the method (Fig. 80). When fibrillation is present and the electrodes lie in the vicinity of the right auricle (leads 1 and 2 of the diagram) the oscillations are maximal, and there is but a trace of the ventricular beats. When they lie in the long axis of the heart (lead 3) both the oscillations and the ventricular complexes are conspicuous. Finally, when they lie along the left or right ventricular border (leads 4 and 5) the ventricular complexes are clear cut while the oscillations are small or absent. The corresponding electrocardiograms are shown below the diagram, the first curve of which is from the customary lead *II* (right arm to left leg). The special contacts analyse this axial lead, breaking it into its auricular and ventricular components. The oscillations of fibrillation are thus readily identified and



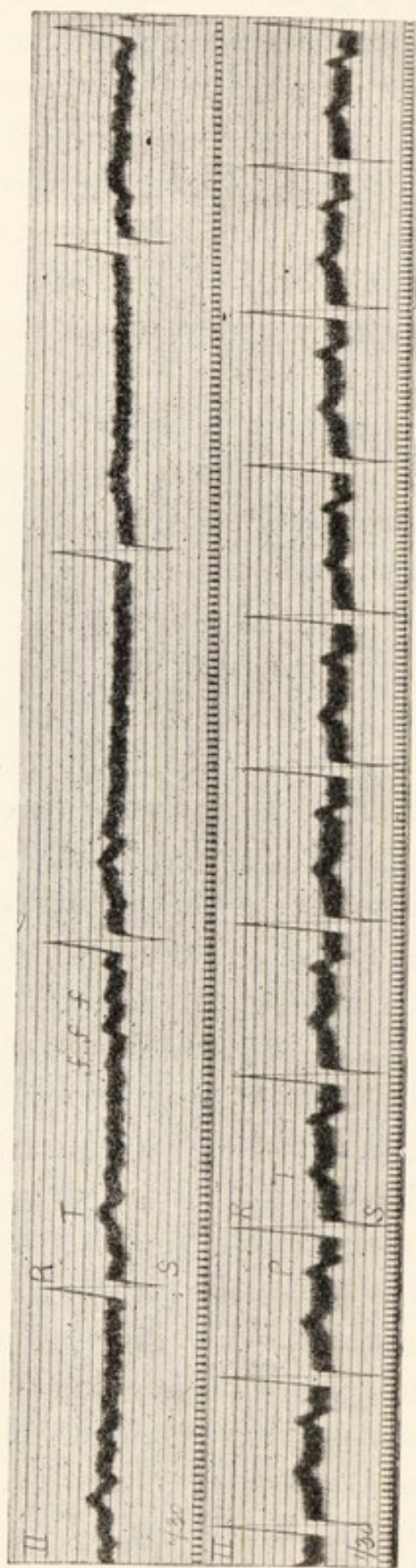


Fig. 81. Two curves from the same case; the upper one shows auricular fibrillation, the lower one displays the normal rhythm. In the first the ventricular action is irregular, there are no *P* summits and oscillations are conspicuous; the patient was under digitalis when this curve was taken and the action of the ventricle was slow consequently. In the second the action is regular, *P* is prominent and there are no oscillations. Note the similarity of the ventricular complexes in the two curves.



their auricular origin is clearly indicated. In tremulous subjects, oscillations are not seen in leads from the chest unless the muscles of the chest are visibly twitching.

The chief features of the electrocardiograms in fibrillation of the auricle are strikingly displayed when the curves of this condition and those showing the normal rhythm can be compared in one and the same case. Fibrillation, though usually a chronic and persistent disorder, occasionally occurs in short paroxysms or, as we have seen, terminates a period of auricular flutter. In such patients the comparison is possible. The curves of Fig. 81 were taken from the same patient within a few days of each other. The ventricular complexes are of the same type in both; in one they are distributed regularly and are preceded by the usual *P* summits (second curve); in the other the spacing is irregular, no *P* summits are discovered, and the whole base line exhibits the oscillations of fibrillation (first curve).

Two groups of signs have been insisted upon, namely, the auricular and ventricular, respectively. In the great majority of curves, the signs of both groups are found. We may now discuss the exceptional curves. It has been said that the oscillations may almost fail; absolute failure in all leads, from limbs or chest, does not occur. More important, from the standpoint of diagnosis, is the association of auricular fibrillation with *regular* action of the ventricle. This combination is also very infrequent, but occurs when the auricular impulses no longer control the ventricle; in other words, when the last-named chamber beats independently. Being exceptional, it serves to emphasise the rule, that while auricular fibrillation is present, the ventricular movements are disorderly. Fig. 79 illustrates the condition; it shows the usual type of oscillation, no auricular summits *P* are seen, but the ventricular beats have natural outlines and are in regular sequence. It is desirable to confirm the origin of the oscillations in these patients by means of the chest wall leads.



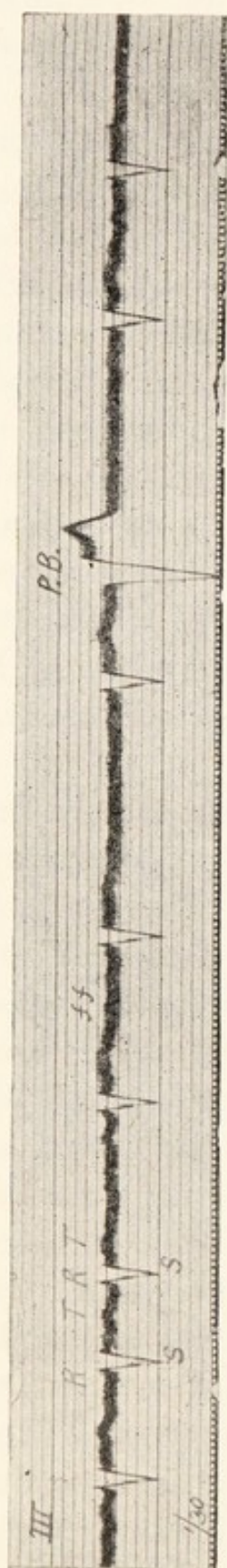


Fig. 82. From a case of auricular fibrillation. With a single exception, all the ventricular complexes are of the supraventricular type; the corresponding ventricular contractions are responses to the fibrillating auricle. The premature beat *P. B.* is of different origin, it comes from the left ventricle.




Fig. 83. From a case of auricular fibrillation on large doses of digitalis. It shows the coupling of ventricular beats which speaks of over-dosage. The first complex in each couple is of the supraventricular type; the second is of different form; these last contractions (*P. B.*) are premature and originate in the ventricle. The pauses succeeding the couples are of equal length; the drug had also produced complete heart-block in this instance,



Fibrillation is the acme of auricular disturbance, consequently it is never complicated by other perversions of auricular rhythm. But the heart which exhibits it may display any other type of disorder at the same time. Thus there may be heart-block. The responses of the ventricle to a fibrillating auricle are naturally rapid and approach 200 per minute. A slower ventricular action indicates heart-block, and the degree of heart-block is gauged by the degree of slowing. It is by producing high grades of partial heart-block and by assuaging the original rapidity of the ventricular beats that digitalis and its allies produce their most notable clinical effect. Figs. 76 and 77 were taken from patients fully under the influence of these drugs; the ventricular rates were 47 and 52 when the curves were taken; before treatment they had been rapid. Digitalis heart-block may be complete (Fig. 79 is an example) and when complete from this cause, the rate of the regular ventricle is relatively high. Heart-block resulting from bundle lesions produces slow ventricular action when the auricles fibrillate, and when complete, the ventricular rates are of the same order as those of uncomplicated heart-block. Thus, fibrillation may be accompanied by ventricular rates which range from 30 to 200, according to the conducting power of the auriculo-ventricular bundle.

The ventricular complexes in fibrillation are, as has been said, of the supraventricular type, but *T* may show inversion (Fig. 76) and the aberrant forms of beat, described on page 28, may occur, when one or other bundle branch is damaged. The comparative amplitudes of *R* and *S* in the three leads have the same significance as they have when the sequence is normal (see page 31 and Fig. 95).

Extrasystoles are seen from time to time; they spring from ventricular foci almost exclusively; they cannot originate in the auricle, but some appear to originate in the



junctional tissues. An example of this kind is given in Fig. 82; this curve was taken from lead *III* and the diminutive *R* and deep *S* represent the supraventricular type in this lead; a single anomalous contraction, a premature beat, is seen towards the end of the figure, and its form in the electric curve is that of a beat arising in the left ventricle. These premature beats are recorded most often in patients who are taking digitalis or an allied drug; appearing in these circumstances, they suggest relaxation of the treatment. When more frequent, they constitute urgent messages that the drug be discontinued; the condition is exemplified by Fig. 83; it is known as "digitalis coupling." Each ventricular complex of the supraventricular type (*R*, *T*) is followed at a close and constant interval by a complex of anomalous form. In this instance, the form is that of beats coming from the right ventricle. The ventricular rate is slow; there are no *P* summits, but there are small oscillations during the diastolic periods. The auricle is fibrillating. A continuation of digitalis, when this coupling has declared itself, is culpable; it is followed only too frequently by sudden and avoidable disaster.

The recently discovered remedy for fibrillation of the auricle, namely, quinidine, is an alkaloid having a very powerful action upon the heart. It is a drug which is to be given only in selected cases; but in these it is capable of restoring the normal rhythm in a very high percentage of instances. The details of treatment and the necessary precautions to be observed do not properly belong to this small treatise, which is intended primarily as an aid to the interpretation of records; they will be found in recent publications.\* But it is relevant to point out that the electrocardiograph is almost essential in following the progress

---

\* See Drury and Iliescu, *Brit. Med. Journ.*, 1921, ii, 511; and Lewis, *Amer. Journ. med. Sci.*, 1921, clxii, 781.

my book "Clinical Disorders of the Heart Beat".



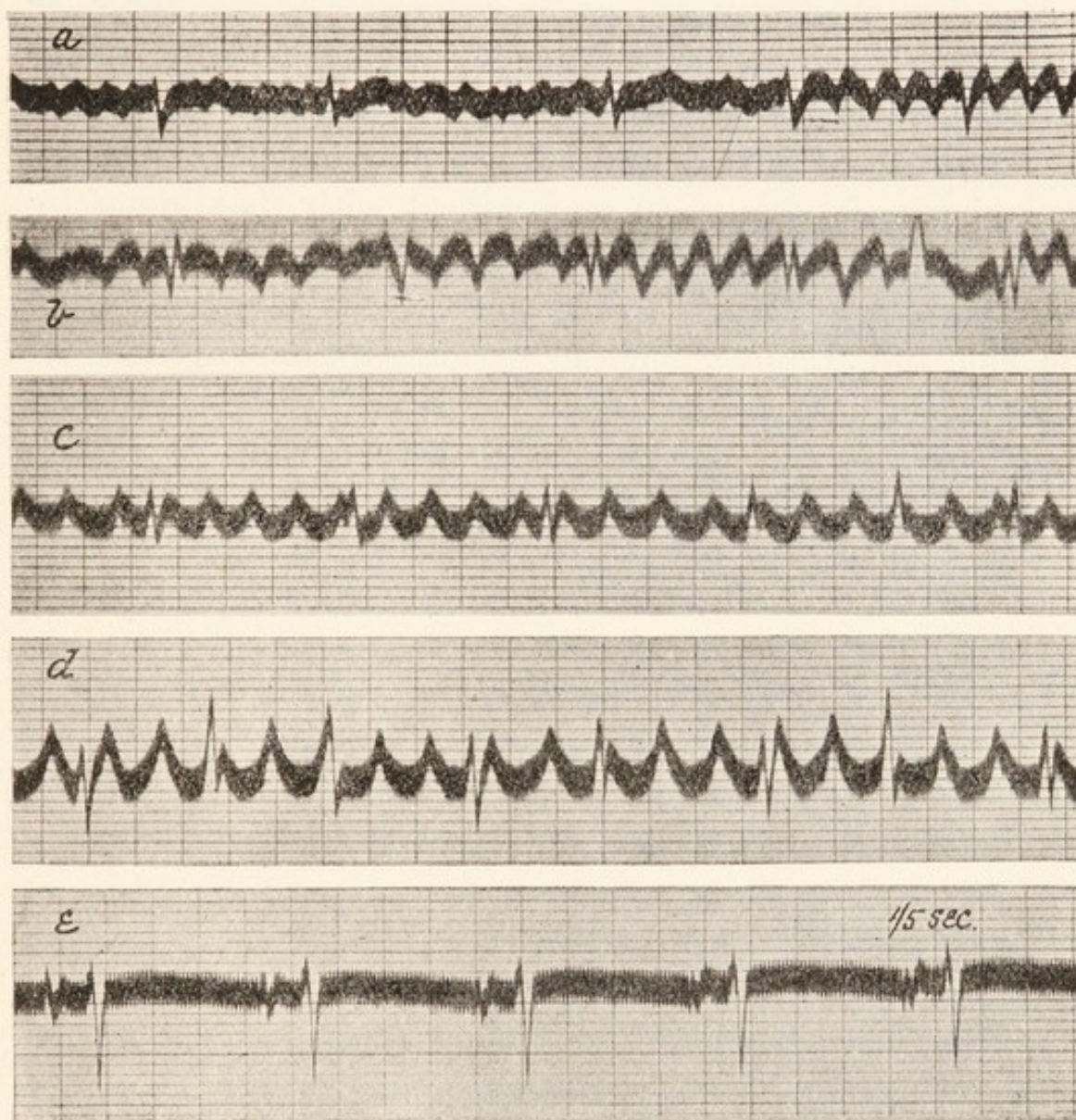


Fig. 84. Five curves taken from a pair of contacts arranged over the sternum in a case of auricular fibrillation. The time marker is in fifths of a second in all. (a) Before treatment; auricular oscillations at 450 per minute. (b) After 1 dose (approximately 5 grains) of quinidine, the oscillation rate has fallen to 350. (c) At the end of the first day's treatment, and after 3 doses of quinidine, the rate has fallen to 296. (d) At the end of the second day's treatment, and after 6 doses of quinidine, the rate has fallen to 247 and the oscillations have become almost regular. (e) Sixteen hours later, and after a final dose (the seventh) of quinidine, the normal rhythm has been resumed.



of such cases under treatment and briefly to state why that is so. The chief change seen is a slowing of the auricular oscillations ; the rate falls from its original level of 450 or thereabouts, to 300 or even 200 per minute, and the oscillations grow in amplitude and become more regular, until the final picture is similar to or identical with that given by simple flutter. The lowering of auricular rate, hardly to be detected except electrocardiographically, is premonitory to the final and abrupt change to normal rhythm ; whence its importance. Dosage is largely regulated by the speed and extent of the fall. Records are most conveniently taken by means of direct leads from the chest wall in the region of the right auricle and are illustrated by Fig. 84.



## CHAPTER IX.

---

### SINUS DISTURBANCES AND ALTERNATION.

#### *Respiratory arrhythmia and allied irregularities.*

Several closely related heart irregularities exist, which are due to variations in the rate at which the impulses are generated at the physiological pacemaker. A notable example is an irregularity of respiratory origin (Fig. 85) in which the heart beat gradually accelerates during the inspiratory phase and slows during the expiratory phase of respiration. In young subjects it is a normal phenomenon ; and during the earlier periods of life, allied irregularities, in which the whole heart participates but in which there is no constant relation to the acts of breathing, are observed (Fig. 86). These irregularities, often grouped under the term "sinus arrhythmia," are brought about by changes of vagal tone. In electrocardiograms they are readily recognised. Each beat of the heart is propagated from the natural pacemaker ; the electric curve is consequently formed of physiological complexes, in which the usual auricular and ventricular summits are seen. The disturbance is confined to irregular disposition of the beats ; the normal sequence of chamber contraction is retained.



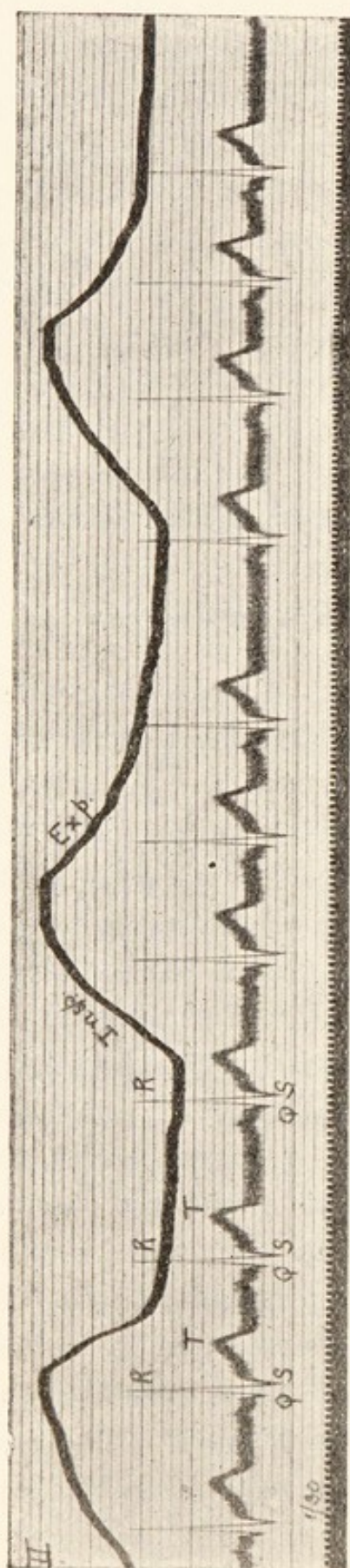


Fig. 85. Electrocardiogram and curve of respiration; showing a sinus arrhythmia. The heart quickens during the period when intrathoracic pressure is low. The whole heart is involved in the irregularity.

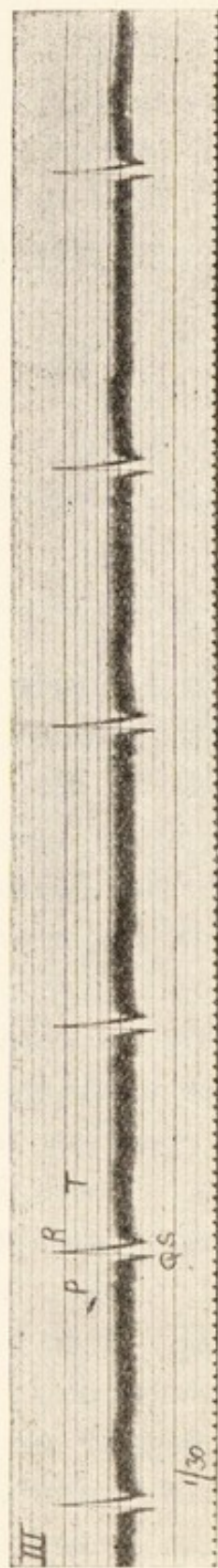


Fig. 86. A sinus irregularity, in which there was no relation to respiration. It was taken from a healthy child, a few hours after birth.



*Sino-auricular heart-block.*

Another though infrequent form of irregularity is related to those just considered. Provisionally it is termed "sino-auricular heart-block." This irregularity is but imperfectly understood and its significance, though apparently inconsiderable, is not fully known. In many patients it is of vagal origin; it is not uncommonly associated with auriculo-ventricular heart-block and, like the latter, may appear during digitalis administration. It generally manifests itself in one of two ways—by producing intermittences of the whole heart, or by leading to steep falls of heart rate. When a single heart beat is lost (as in Fig. 87), the length of the longest cycles is usually somewhat shorter than two cycles of the natural rhythm. When the heart rate falls, the passage from one rate to the other is abrupt; there is no transitional period (Fig. 88); although the slow rate may be almost exactly half the former rate (Fig. 88), yet more commonly halving of rate is hardly attained. Permanent slow action of the whole heart may be due to this disorder (Fig. 34) which supposedly is due to imperfect conduction between the natural pacemaker and the main mass of the auricular tissue; but whether this is the true explanation or not remains to be decided.

The electrocardiographic curve of each heart beat presents auricular and ventricular complexes of forms known to be associated with heart beats of normal origin.

*Alternation of the heart.*

When alternation of the heart is present, and is displaying itself in the arterial pulse, the electrocardiograms do not always show it. If the heart is beating slowly and alternation of the pulse is conspicuous, the several ventricular summits and depressions may be of uniform amplitude from beat to



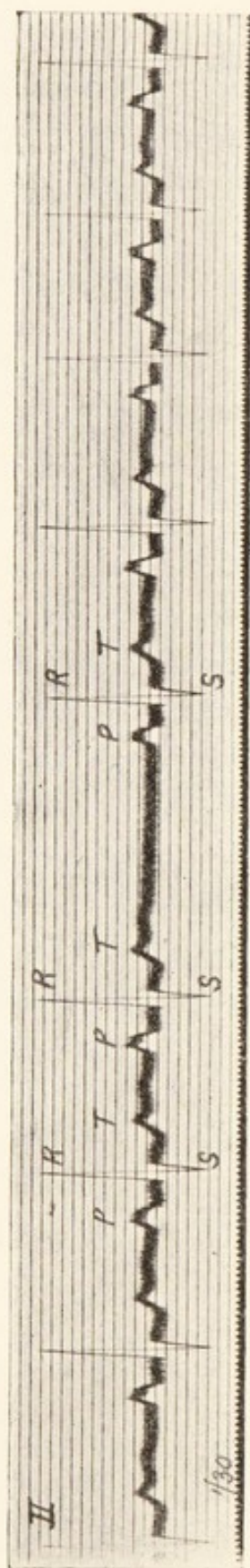


Fig. 87. "Sino-auricular block." An irregularity in which the whole heart is involved. A long pause interrupts what is otherwise an almost regular heart action. The long cycle is nearly, but not quite, twice the length of the short cycle. From a case of mitral stenosis (note the large split *P* summit). The irregularity resulted from digitalis.

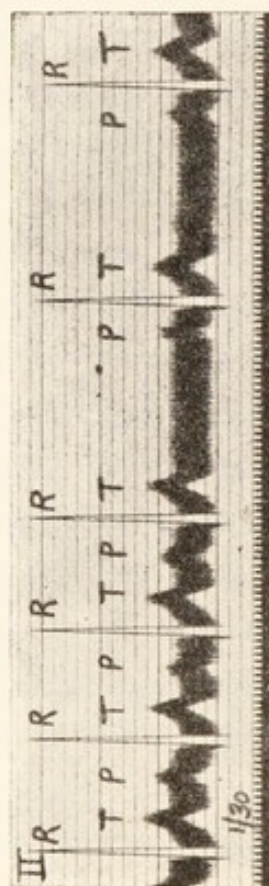


Fig. 88. "Sino-auricular block" in a case of exophthalmic goitre. The rate of the whole heart is suddenly and almost exactly halved. Note the prolongation of the *P-R* interval in the last cycle of the fast rhythm.



beat (Fig. 89); nevertheless alternation may be conspicuous in the electrocardiograms; it is seen to advantage in Fig. 63. In this figure it is increased after the premature contraction. When alternation accompanies paroxysms of tachycardia, traces of alternation in the amplitudes of *R* and *T* are usual. The left-hand portion of Fig. 62 serves as an illustration; the

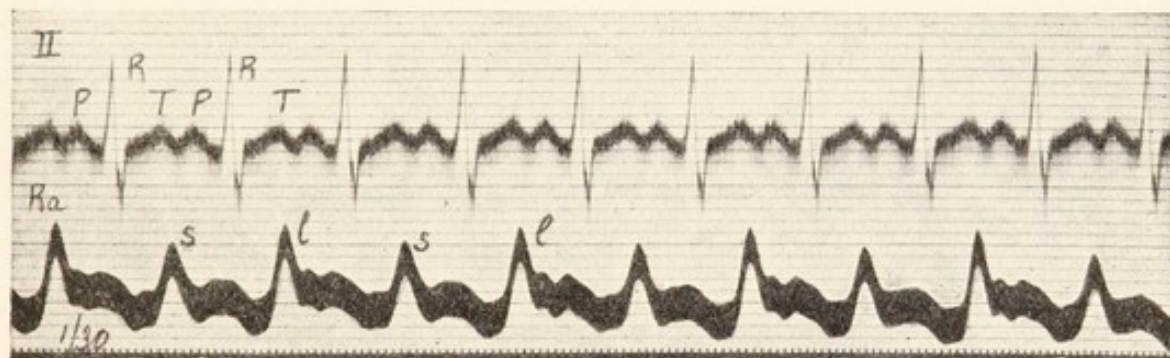


Fig. 89. Simultaneous electrocardiogram and arterial curve. The last shows conspicuous alternation, but in the electrocardiogram it is not perceptible (see Figs. 62 and 63).

alternation is confined to *R* and, though of minor degree, is quite distinct. Curiously enough, the alternation in electrocardiogram and pulse is not always parallel; while the small *R* summit may correspond to the small pulse beat, yet quite as frequently (as in Fig. 62) the large *R* corresponds to the small pulse beat. On occasion alternation of amplitude may be present in the electrocardiogram when the pulse fails to show it.



## CHAPTER X.

---

### SPECIAL CONDITIONS.

#### *Electrocardiograms in valve lesions.*

As a preliminary it should be stated emphatically that electrocardiography has little to do with valve lesions. The method is essentially one which investigates the muscle ; only, therefore, in so far as valve lesions affect the muscle do they influence the form of electric curves. Now the degree to which valve lesions upset the distribution of the mass of heart muscle is a question upon which we have no final evidence ; there is always the primary difficulty that anything which may have affected the valves may also have affected the contractile substance. The indiscriminate assignment of hypertrophy of this or that chamber to leakage at this or that valve as a causal agent cannot be too strongly deprecated. However boldly it may be asserted in a given case that left- or right-sided hypertrophy is the result of purely mechanical defects, the conclusion in the individual case is often impossible of proof. We know that free aortic leakage may consort with a light or heavy musculature ; we know that, produced under strictly aseptic conditions, reflux at this valve is generally followed by but relatively little muscle change ; again, some of the largest human hearts are found where no sign of valve defect or other mechanical disadvantage, to which cardiac embarrassment



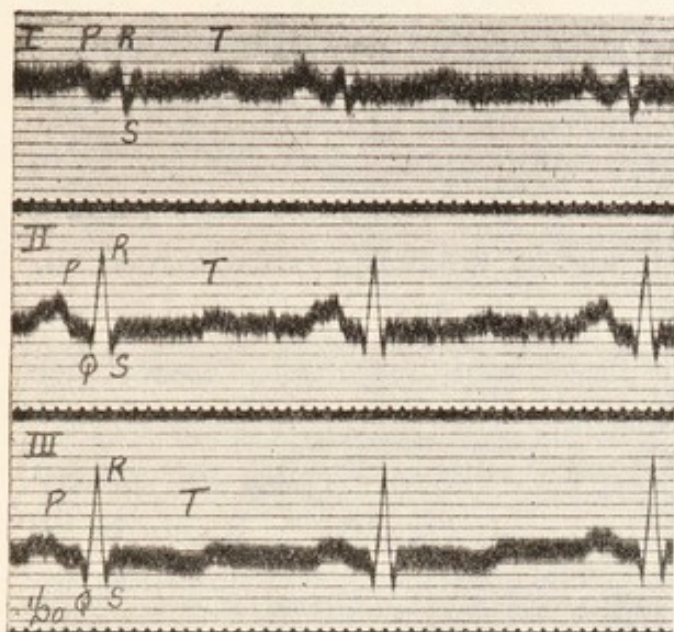
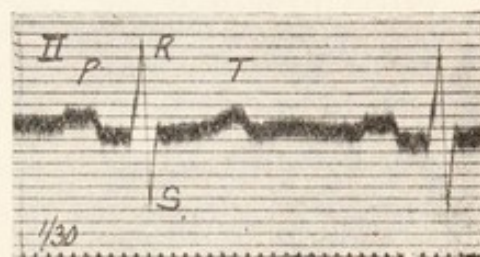
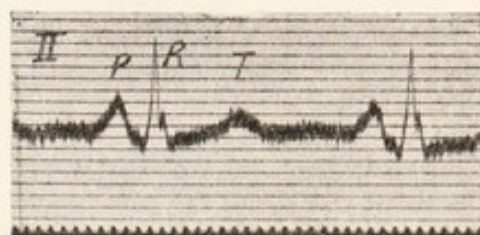


Fig. 90.



Figs. 91 and 92.

Fig. 90. From a case of mitral stenosis. The summit *P* is large, broad and notched in lead *II*. The initial ventricular peaks of lead *I* are small. *R* is tallest in lead *III*.

Fig. 91. From a case of mitral stenosis, showing a tall and pointed summit *P*.

Fig. 92. From a case of mitral stenosis, showing a broad and notched summit *P*.

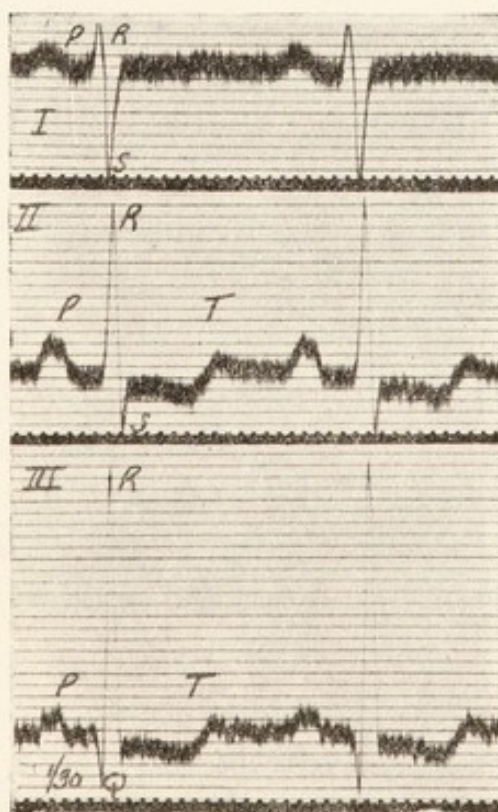


Fig. 93. From a case of mitral stenosis. The summit *P* is large, broad and notched in lead *II*. *R* is of least amplitude in lead *I* and of greatest amplitude in lead *III*; *S* is of greatest amplitude in lead *I*.



might be attributed, has ever been discovered. While alteration in the muscle as a sequel to pressure changes cannot be denied, yet it becomes increasingly clear that this hypothesis has in the past outstripped the facts. No question of cardiac pathology requires more critical revision to-day. Newer and more accurate methods of observation, untrammelled by tradition, are needed. These remarks are a necessary prelude to those which follow; for if we expect electrocardiograms which are held to depict preponderance of the right ventricle in all cases of mitral stenosis or those of preponderance of the left ventricle in all cases of aortic disease, our expectations will not be fulfilled. The sign of left preponderance may appear in mitral stenosis and that of right preponderance in aortic disease; and the reason for that which may be regarded as a discrepancy—but which in reality is not a discrepancy—is not obscure; the left ventricle *may* preponderate in mitral stenosis as the right *may* in aortic disease.

*Mitral stenosis.* The electrocardiograms of mitral stenosis are often so characteristic that the valve lesion may be diagnosed from these curves alone. The summit *P* has an exaggerated amplitude, amounting frequently to 2, 3 or even 4 scale divisions (Figs. 90, 91, and 92 and 93; and also Figs. 29, 52, 53 and 87); it is often broad, flattened and notched in the centre (Figs. 90, 92 and 93). The ventricular complexes are generally those associated with preponderance of the right muscle. Often this change is shown conspicuously (Fig. 93), *S* being exaggerated in lead *I* and *R* in lead *III*. Sometimes the change is less evident; small *R* and *S* deflections in lead *I* (Fig. 90) are not uncommon. When the auricles are fibrillating the curves associated with right preponderance remain (Fig. 95), and the exaggerated *P* summits are replaced by exceptionally large oscillations (Figs. 74, 79, 80 and 95). When new auricular rhythms, constituting paroxysms of



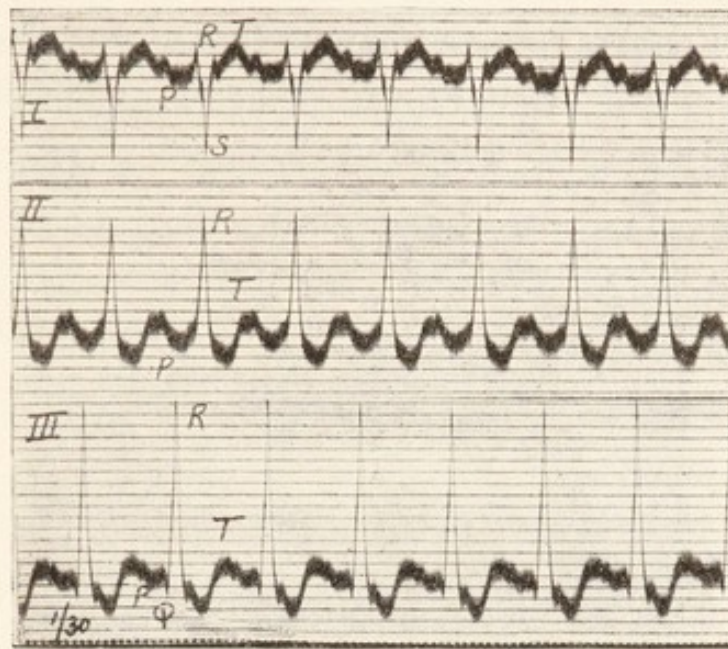


Fig. 94. From a paroxysm of tachycardia in a case of mitral stenosis. Preponderance of the right ventricle is indicated; the *P* summits are small because the paroxysm arose in an ectopic auricular focus.

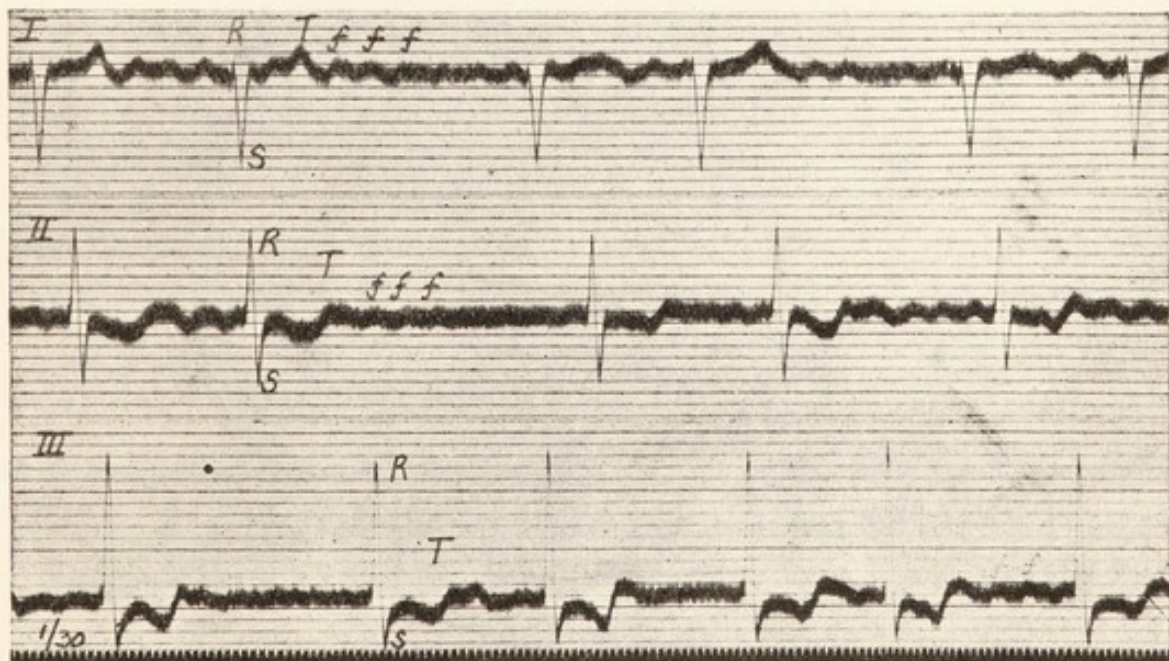


Fig. 95. From a case in which the auricles were fibrillating. Preponderance of the right ventricle is suggested by the ventricular complexes. The oscillations are prominent, as is usual in mitral stenosis.

The heart of this patient was subsequently obtained. Mitral stenosis was found. The left ventricle weighed 105 and the right ventricle 128 grammes.

tachycardia, occur in mitral stenosis, the ventricular peaks may suggest right preponderance, but the *P* summits no longer occur in their usual forms (Fig. 94). The signs I have described may lead to a correct diagnosis of mitral stenosis,

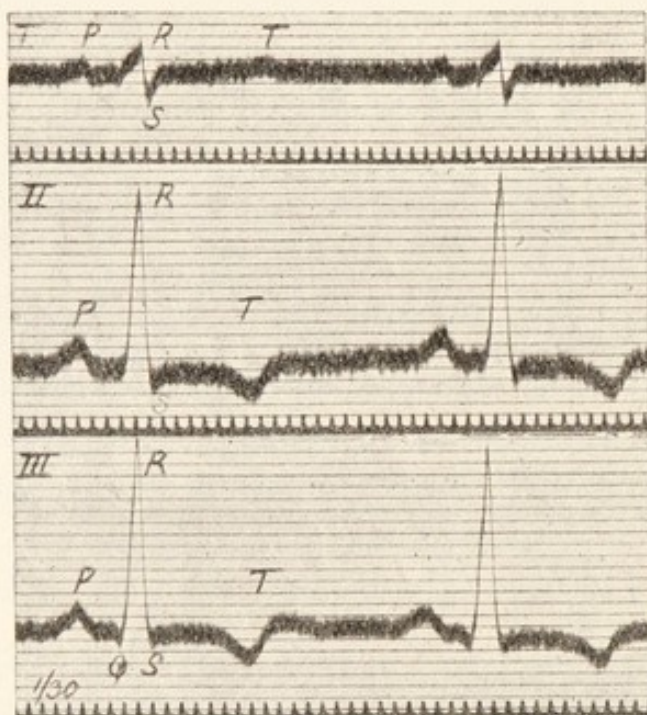


Fig. 96. From a patient in whom aortic regurgitation was present, showing inversion of *T* in lead *II*. The curve is exceptional because it speaks for preponderance of the *right* ventricle.

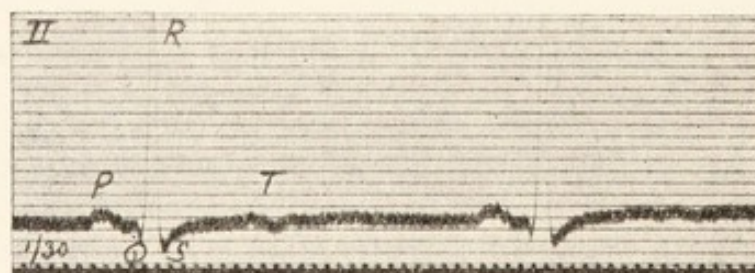


Fig. 97. From a case of aortic regurgitation, showing the flattening of *T* which is common in hearts which have this valve lesion.

which without the signs would be unrecognisable. Especially is this so when, the auricles being in fibrillation, the presystolic murmur fails or is replaced by a murmur falling in early



diastole. The records may be helpful also in differentiating diastolic murmurs of aortic, pulmonary and mitral origin (Steell's and Flint's murmur).

*Aortic disease.* The curves of aortic disease are varied in form; the uncomplicated valve lesion produces little or no alteration. In a dog in which free regurgitation was produced, the electrocardiograms, taken before and some forty days after operation, showed no appreciable change;

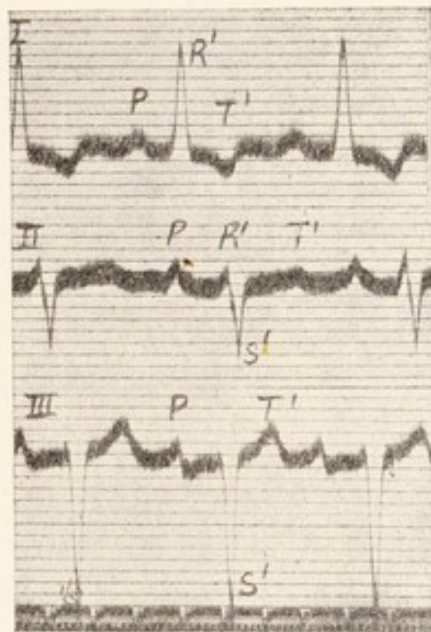


Fig. 98. From a patient in whom aortic regurgitation was present. It serves to emphasise the important distinctions between two series of curves, namely, those which are associated with left preponderance and those which indicate a deficiency of the right branch of the auriculo-ventricular bundle (see Chapter III.).

such slight change as was exhibited was unstable from day to day. It is true that left ventricular preponderance is often indicated in the curves of the human subject (Figs. 19 and 20), but it is not indicated with constancy in this condition, and the signs are encountered more frequently when aortic disease is absent. The picture of right preponderance is also compatible with lesions of this valve, though the association is exceptional (Fig. 96). A large excursion of *R* in lead *II* (Figs.

96 and 97), smallness of *T* (Fig. 97) or inversion of the same summit in lead *II* (Fig. 96) are quite common. The variability of the electrocardiograms in aortic disease harmonises with the findings at autopsy; these are equally variable. If the muscle of the separate ventricles is *weighed*, an increase in the weight of the left chamber is almost invariably found, but so also is an increase in the weight of the right chamber. The *relative* weights of the ventricles, which influences the

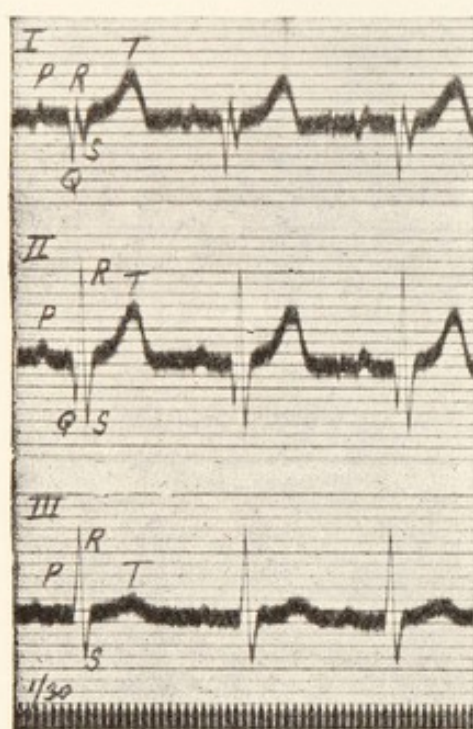


Fig. 99. From a case in which there was conspicuous displacement of the heart towards the right side.

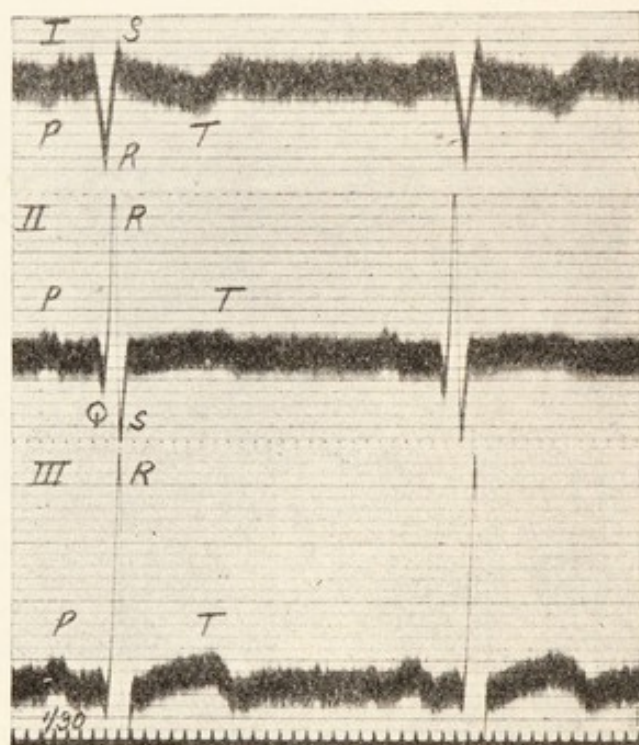


Fig. 100. The curves of a transposed heart. All the summits are inverted in lead *I*.

electrocardiogram, is normal in aortic disease almost as often as the natural ratio is disturbed by preponderance of the left ventricle.

The electrocardiograms which indicate deficient conduction through the right division of the bundle seem to be more than coincidentally frequent in aortic disease; occurring in aortic disease they may be misinterpreted. Fig. 98 serves



as an example. Now these curves were taken at a slow rate, and a cursory examination would suggest preponderance of the left ventricle. But the initial phases of the ventricular complexes are long, they together exceed a tenth of a second in duration. The direction of  $T^1$  in leads *I* and *III* and the notching of the downstroke of  $S^1$  in lead *II* all point

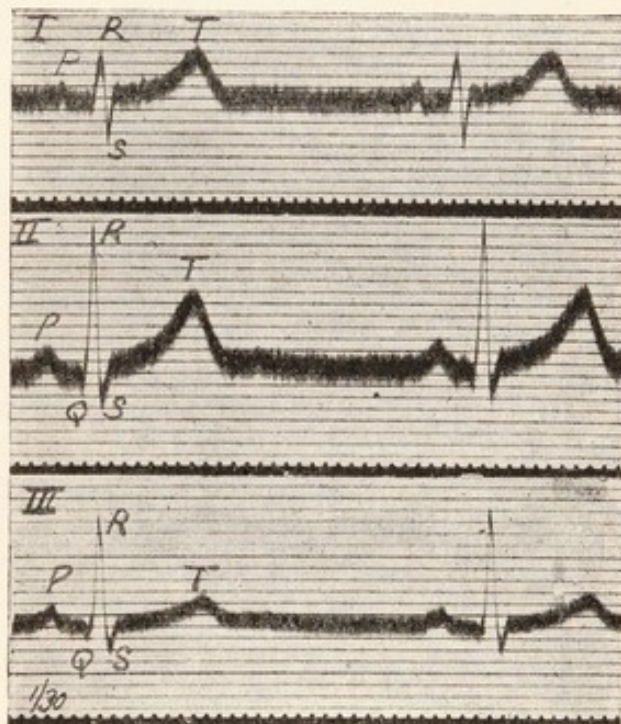
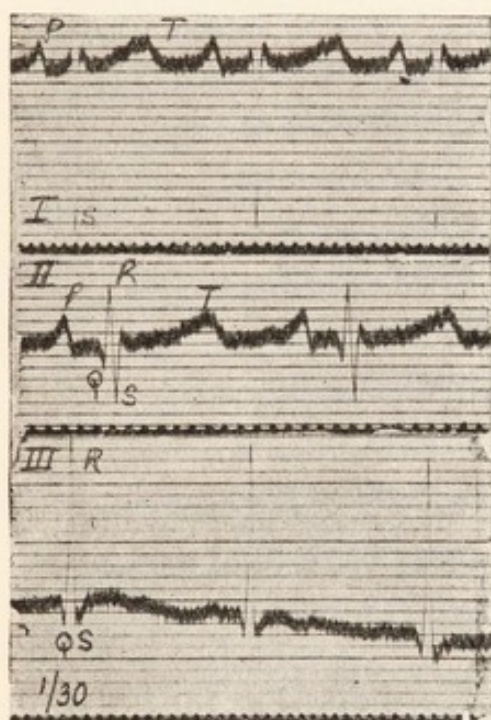


Fig. 101. From a patient in whom there were clear signs of congenital stenosis of the pulmonary artery. Right ventricular preponderance is indicated.

Fig. 102. From a patient who presented the signs of a patent ductus arteriosus. The curves are normal.

to a branch lesion (compare Figs. 18 and 19). A second example of the same defect in aortic disease has been given already in Fig. 18.

*Mitral regurgitation.* The curves show no constant characters.

*Congenital heart affections.* These curves are often of value. The electrocardiogram, when the heart is transposed, offers the most distinctive sign of the abnormality which we



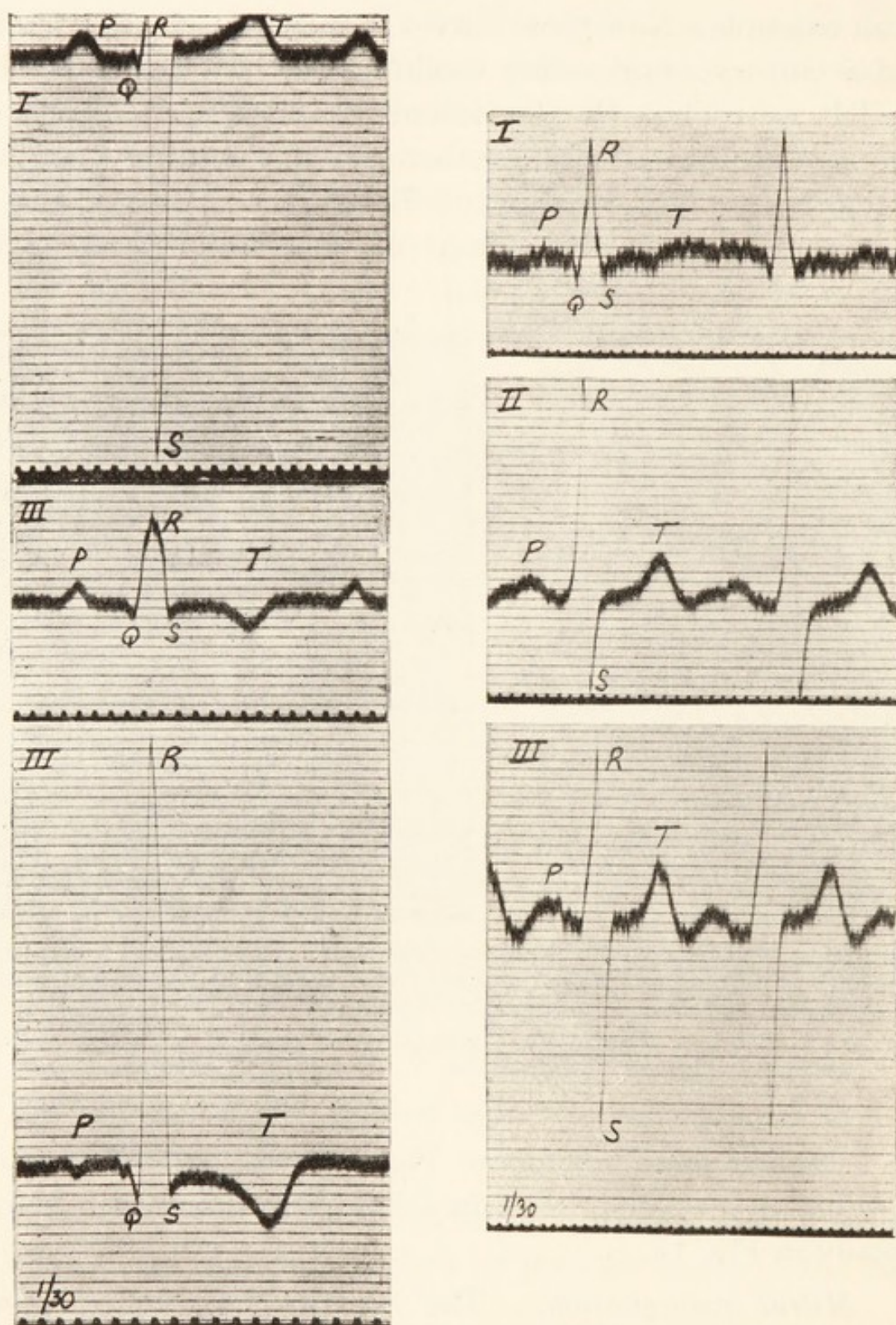


Fig. 103. From a child in whom there were signs of congenital pulmonary stenosis. Preponderance of the right ventricle is indicated in the curves. Note the exaggerated amplitude of excursion in leads *I* and *III*. The heart of this child was subsequently obtained; pulmonary stenosis was found; the left ventricle weighed 67 and the right ventricle 161 grammes. The middle curve is from lead *II* and not from lead *III*, as marked.

Fig. 104. From a lad with a greatly enlarged heart and congenital malformations. The chief signs were a systolic thrill, palpable over a wide area and maximal at the pulmonary cartilage; a systolic murmur, prolonged into and enforced in diastole, which was maximal in the same region; and a systolic apical murmur. The right carotid artery crossed the trachea. Note the increased excursion in leads *II* and *III*.



possess, not excepting the skiagram. All the summits of lead *I* are inverted (Fig. 100). A little consideration will make it clear how this change comes about. The lead is a symmetric one, being from the right arm to the left arm. A lead from the *left arm to the right* inverts the picture in the normal subject, and the left arm stands to the normal subject as does the right to the subject of transposition. But neither of the other leads is symmetric, and neither of the other leads shows inversion. For example, a lead from the right arm to the left leg in any subject gives almost precisely the same picture as does a lead from the right arm to the right leg. So it happens that a lead from the right arm to left leg (lead *II*) in a normal subject is almost equivalent to a lead from the left arm to the left leg (lead *III*) in the subject of transposition. In the subject of transposition, while *the curve from lead I is inverted, those of leads II and III replace each other*. The value of the transposition curves will be evident; displacement of the heart distorts electrocardiograms, but does not induce these changes. An example of extreme displacement is illustrated by Fig. 99. It was taken from a boy; the heart's impulse was found well to the right of the sternum, and no reason for displacement was apparent. The question of transposition arose, but the electrocardiograms denied the presence of this anomaly, as did also the skiagram; the chief distortion is in the opening ventricular events of lead *I*.

In those children in whom cardiac enlargement, cyanosis and harsh systolic thrills and murmurs, maximal over the pulmonary cartilage, are the chief diagnostic signs, the electrocardiograms generally indicate extreme degrees of right preponderance. These are instances of pulmonary stenosis. Fig. 101 exemplifies the curves of this condition; Fig. 103 is an exceptional example from a similar case and illustrates another feature of congenital heart curves, namely,



extreme amplitude of excursion. Exaggerated amplitude in several leads is in itself a valuable sign of congenital valve or septal defects. Another example, Fig. 104, shows this increase of excursion. Such curves are obtained, so far as I know, only when there is reason to believe that congenital malformation is present. It is impossible to speak at all fully of these electrocardiograms at the present time; we require more information regarding them, and especially a careful comparison with post-mortem material. If there is one congenital defect in which the electric curves should be normal, it is in uncomplicated patency of the ductus arteriosus. Fig. 102 was taken from a youth who exhibited a continuous harsh murmur over the pulmonary area. The heart was not enlarged, and though engaged in laborious work the patient had experienced no symptoms from childhood onwards. The curves present no abnormality.

*Renal diseases and high blood pressure.* The electrocardiograms of chronic renal disease are not distinctive. The curves may suggest preponderance of right or left ventricle, or the relative amplitudes of *R* and *S* in the several leads may be normal. However, curves of left preponderance are frequent in patients whose systolic blood pressure is high. These records are quite consistent with the ventricular weights in chronic renal disease; these weights show the ventricles to be equally hypertrophied in the average. Some of the hearts show preponderance of the left ventricle, notably those which have pumped against high arterial pressures; other hearts show right preponderance. The traditional teaching is that renal disease spells left hypertrophy; but this teaching is incomplete for, as often as not, right hypertrophy of equal degree may be shown by weighing the separated ventricles.



*Exophthalmic goitre.* It has been said that *T* is exaggerated in this condition. I have examined a number of such patients and, apart from the enhanced rate of beat and slight changes which may result therefrom, no definite alterations have been seen (see Figs. 56, 78 and 88) in the shape of the ventricular complex. Naturally irregularities of rhythm or changes in the form of curve, consequent upon hypertrophy, may be and frequently are associated with this disease from time to time.





# INDEX.





# INDEX.

---

|   |                  |
|---|------------------|
| ABERRANT CONTRACTIONS ... ..                        | 28, 65, 97 & 112 |
| <i>Aortic disease and</i> ... ..                    | 31 & 112         |
| ACCELERATED HEART ACTION ... ..                     | 68 & 77          |
| <i>In exophthalmic goitre</i> ... ..                | 68 & 117         |
| <i>In fever, with exercise, etc.</i> ... ..         | 68               |
| ACCESSORIES ... ..                                  | 13               |
| ACTIVITY AND NEGATIVITY ... ..                      | 17               |
| AGE (PHYSIOLOGICAL ELECTROCARDIOGRAM AND) ... ..    | 23               |
| ALTERNATION OF THE HEART ... ..                     | 103              |
| ALTERNATION OF THE PULSE ... ..                     | 103              |
| AMPLITUDE OF DEFLECTIONS ... ..                     | 22               |
| <i>In aortic disease</i> ... ..                     | 111              |
| <i>In bundle branch lesions</i> ... ..              | 28               |
| <i>In congenital disease</i> ... ..                 | 116              |
| <i>In hypertrophy</i> ... ..                        | 33               |
| <i>In mitral stenosis</i> ... ..                    | 108              |
| AORTIC DISEASE ... ..                               | 111              |
| <i>Aberrant impulses and</i> ... ..                 | 31 & 112         |
| <i>Hypertrophy and</i> ... ..                       | 33 & 108         |
| <i>R summit in</i> ... ..                           | 111              |
| <i>T summit in</i> ... ..                           | 112              |
| AURICULAR COMPLEX (SEE ALSO <i>P</i> SUMMIT) ... .. | 14 & 18          |
| AURICULAR FIBRILLATION ... ..                       | 87               |
| <i>Complete heart-block and</i> ... ..              | 97               |
| <i>Digitalis in</i> ... ..                          | 97 & 98          |
| <i>Heart-block and</i> ... ..                       | 97               |
| <i>Irregularity in</i> ... ..                       | 87               |
| <i>Mitral stenosis and</i> ... ..                   | 108              |
| <i>Nature of</i> ... ..                             | 87               |
| <i>Oscillations of (see Oscillations)</i> ... ..    | 89               |
| <i>Premature beats and</i> ... ..                   | 97               |
| <i>Quinidine in</i> ... ..                          | 98               |
| <i>Regular action of the ventricle and</i> ... ..   | 97               |
| <i>Transient</i> ... ..                             | 95               |

|   |     |     |     |     |     |     |                 |          |
|---|-----|-----|-----|-----|-----|-----|-----------------|----------|
| AURICULAR FLUTTER   | ... | ... | ... | ... | ... | ... | ...             | 77       |
| <i>Appearing under quinidine</i>                          | ... | ... | ... | ... | ... | ... | ...             | 100      |
| <i>Digitalis in</i>                                       | ... | ... | ... | ... | ... | ... | ...             | 84       |
| <i>Heart-block and</i>                                    | ... | ... | ... | ... | ... | ... | ...             | 78       |
| <i>Treatment of</i>                                       | ... | ... | ... | ... | ... | ... | ...             | 84       |
| AURICULO-VENTRICULAR BUNDLE                               | ... | ... | ... | ... | ... | ... | ...             | 19 & 25  |
| <i>Branches of</i>  | ... | ... | ... | ... | ... | ... | ...             | 25 & 28  |
| <i>Damage to branches of</i>                              | ... | ... | ... | ... | ... | ... | ...             | 28       |
| BLOOD PRESSURE RAISED                                     | ... | ... | ... | ... | ... | ... | ...             | 33 & 116 |
| BRADYCARDIA   | ... | ... | ... | ... | ... | ... | ...             | 48       |
| COMPENSATOR   | ... | ... | ... | ... | ... | ... | ...             | 7        |
| COMPENSATORY PAUSE  | ... | ... | ... | ... | ... | ... | ...             | 55       |
| COMPLETE HEART-BLOCK                                      | ... | ... | ... | ... | ... | ... | ...             | 44       |
| <i>Auricular fibrillation and</i>                         | ... | ... | ... | ... | ... | ... | ...             | 97       |
| COMPRESSION OF VAGUS                                      | ... | ... | ... | ... | ... | ... | ...             | 84       |
| CONGENITAL HEART AFFECTIONS                               | ... | ... | ... | ... | ... | ... | ...             | 113      |
| CONSTITUTION OF VENTRICULAR COMPLEX                       | ... | ... | ... | ... | ... | ... | ...             | 25       |
| DEFLECTION TIME   | ... | ... | ... | ... | ... | ... | ...             | 11       |
| DEXTROGRAM...   | ... | ... | ... | ... | ... | ... | ...             | 27       |
| DIGITALIS   |     |     |     |     |     |     |                 |          |
| <i>Fibrillation and</i>                                   | ... | ... | ... | ... | ... | ... | ...             | 97       |
| <i>Flutter and...</i>                                     | ... | ... | ... | ... | ... | ... | ...             | 84       |
| <i>Heart-block and</i>                                    | ... | ... | ... | ... | ... | ... | ...             | 44       |
| <i>Sino-auricular heart-block and</i>                     | ... | ... | ... | ... | ... | ... | ...             | 103      |
| DIPHASIC EFFECT   | ... | ... | ... | ... | ... | ... | ...             | 17       |
| DIRECTION OF CONTRACTION WAVE                             | ... | ... | ... | ... | ... | ... | ...             | 17       |
| "DROPPED" BEATS   | ... | ... | ... | ... | ... | ... | ...             | 38       |
| ECTOPIC BEATS   | ... | ... | ... | ... | ... | ... | 53, 55, 61 & 70 |          |
| ECTOPIC RHYTHM  | ... | ... | ... | ... | ... | ... | 70 & 76         |          |
| ELECTROCARDIOGRAMS (SEE PHYSIOLOGICAL ELECTROCARDIOGRAMS) |     |     |     |     |     |     |                 |          |
| ESCAPED CONTRACTIONS                                      | ... | ... | ... | ... | ... | ... | ...             | 51       |
| EXERCISE (INFLUENCE ON ELECTROCARDIOGRAMS)                | ... | ... |     |     |     |     | 23 & 68         |          |



## EXOPHTHALMIC GOITRE

|                                    |     |     |     |     |          |
|------------------------------------|-----|-----|-----|-----|----------|
| <i>Accelerated heart action in</i> | ... | ... | ... | ... | 68 & 117 |
| <i>T summit in</i>                 | ... | ... | ... | ... | 117      |

## EXTRASYSTOLES (SEE PREMATURE CONTRACTIONS)

|                |     |     |     |     |     |     |     |
|----------------|-----|-----|-----|-----|-----|-----|-----|
| FLINT'S MURMUR | ... | ... | ... | ... | ... | ... | 111 |
|----------------|-----|-----|-----|-----|-----|-----|-----|

|  |     |     |     |     |   |
|--|-----|-----|-----|-----|---|
| GALVANOMETER (SEE STRING GALVANOMETER) | ... | ... | ... | ... | 1 |
|--|-----|-----|-----|-----|---|

|                        |     |     |     |     |   |
|------------------------|-----|-----|-----|-----|---|
| GALVANOMETRIC CIRCUITS | ... | ... | ... | ... | 4 |
|------------------------|-----|-----|-----|-----|---|

|             |     |     |     |     |     |    |
|-------------|-----|-----|-----|-----|-----|----|
| HEART-BLOCK | ... | ... | ... | ... | ... | 37 |
|-------------|-----|-----|-----|-----|-----|----|

|                                   |     |     |     |     |    |
|-----------------------------------|-----|-----|-----|-----|----|
| <i>Auricular fibrillation and</i> | ... | ... | ... | ... | 97 |
|-----------------------------------|-----|-----|-----|-----|----|

|                              |     |     |     |     |    |
|------------------------------|-----|-----|-----|-----|----|
| <i>Auricular flutter and</i> | ... | ... | ... | ... | 78 |
|------------------------------|-----|-----|-----|-----|----|

|                 |     |     |     |     |    |
|-----------------|-----|-----|-----|-----|----|
| <i>Complete</i> | ... | ... | ... | ... | 44 |
|-----------------|-----|-----|-----|-----|----|

|                |     |     |     |     |    |
|----------------|-----|-----|-----|-----|----|
| <i>Partial</i> | ... | ... | ... | ... | 38 |
|----------------|-----|-----|-----|-----|----|

|                            |     |     |     |     |         |
|----------------------------|-----|-----|-----|-----|---------|
| <i>Premature beats and</i> | ... | ... | ... | ... | 48 & 66 |
|----------------------------|-----|-----|-----|-----|---------|

|                       |     |     |     |     |     |
|-----------------------|-----|-----|-----|-----|-----|
| <i>Sino-auricular</i> | ... | ... | ... | ... | 103 |
|-----------------------|-----|-----|-----|-----|-----|

|                     |     |     |     |     |          |
|---------------------|-----|-----|-----|-----|----------|
| HIGH BLOOD PRESSURE | ... | ... | ... | ... | 33 & 116 |
|---------------------|-----|-----|-----|-----|----------|

## HYPERTROPHY

|                           |     |     |     |     |          |
|---------------------------|-----|-----|-----|-----|----------|
| <i>Aortic disease and</i> | ... | ... | ... | ... | 33 & 108 |
|---------------------------|-----|-----|-----|-----|----------|

|                            |     |     |     |     |          |
|----------------------------|-----|-----|-----|-----|----------|
| <i>Mitral stenosis and</i> | ... | ... | ... | ... | 34 & 108 |
|----------------------------|-----|-----|-----|-----|----------|

|                                   |     |     |     |     |    |
|-----------------------------------|-----|-----|-----|-----|----|
| IMPULSES MEETING IN THE VENTRICLE | ... | ... | ... | ... | 60 |
|-----------------------------------|-----|-----|-----|-----|----|

|               |     |     |     |     |              |
|---------------|-----|-----|-----|-----|--------------|
| INTERMITTENCE | ... | ... | ... | ... | 39, 53 & 103 |
|---------------|-----|-----|-----|-----|--------------|

|                        |     |     |     |     |    |
|------------------------|-----|-----|-----|-----|----|
| " INTERPOLATED " BEATS | ... | ... | ... | ... | 59 |
|------------------------|-----|-----|-----|-----|----|

|       |     |     |     |     |   |
|-------|-----|-----|-----|-----|---|
| LEADS | ... | ... | ... | ... | 5 |
|-------|-----|-----|-----|-----|---|

|                |     |     |     |     |    |
|----------------|-----|-----|-----|-----|----|
| <i>Special</i> | ... | ... | ... | ... | 93 |
|----------------|-----|-----|-----|-----|----|

|                    |     |     |     |     |        |
|--------------------|-----|-----|-----|-----|--------|
| <i>Usual three</i> | ... | ... | ... | ... | 6 & 19 |
|--------------------|-----|-----|-----|-----|--------|

|          |     |     |     |     |    |
|----------|-----|-----|-----|-----|----|
| LEVOGRAM | ... | ... | ... | ... | 27 |
|----------|-----|-----|-----|-----|----|

|                     |     |     |     |     |    |
|---------------------|-----|-----|-----|-----|----|
| LIMITS OF AMPLITUDE | ... | ... | ... | ... | 22 |
|---------------------|-----|-----|-----|-----|----|

|                      |     |     |     |     |     |
|----------------------|-----|-----|-----|-----|-----|
| MITRAL REGURGITATION | ... | ... | ... | ... | 113 |
|----------------------|-----|-----|-----|-----|-----|

|                 |     |     |     |     |     |
|-----------------|-----|-----|-----|-----|-----|
| MITRAL STENOSIS | ... | ... | ... | ... | 108 |
|-----------------|-----|-----|-----|-----|-----|

|                                   |     |     |     |     |     |
|-----------------------------------|-----|-----|-----|-----|-----|
| <i>Auricular fibrillation and</i> | ... | ... | ... | ... | 108 |
|-----------------------------------|-----|-----|-----|-----|-----|

|                       |     |     |     |     |          |
|-----------------------|-----|-----|-----|-----|----------|
| <i>Hypertrophy in</i> | ... | ... | ... | ... | 34 & 108 |
|-----------------------|-----|-----|-----|-----|----------|

|                        |     |     |     |     |          |
|------------------------|-----|-----|-----|-----|----------|
| <i>Oscillations in</i> | ... | ... | ... | ... | 91 & 108 |
|------------------------|-----|-----|-----|-----|----------|

|                    |     |     |     |     |              |
|--------------------|-----|-----|-----|-----|--------------|
| <i>P summit in</i> | ... | ... | ... | ... | 40, 62 & 108 |
|--------------------|-----|-----|-----|-----|--------------|

|                                   |     |     |     |     |     |
|-----------------------------------|-----|-----|-----|-----|-----|
| <i>Paroxysmal tachycardia and</i> | ... | ... | ... | ... | 108 |
|-----------------------------------|-----|-----|-----|-----|-----|

|                                   |     |     |     |     |     |     |     |
|-----------------------------------|-----|-----|-----|-----|-----|-----|-----|
| NEGATIVITY AND ACTIVITY           | ... | ... | ... | ... | ... | ... | ... |
| NEWBORN CHILD                     | ... | ... | ... | ... | ... | ... | ... |
| NODAL RHYTHM                      | ... | ... | ... | ... | ... | ... | ... |
| OVERSHOOTING OF STRING            | ... | ... | ... | ... | ... | ... | ... |
| OSCILLATIONS                      |     |     |     |     |     |     |     |
| In fibrillation                   | ... | ... | ... | ... | ... | ... | ... |
| Character of                      | ... | ... | ... | ... | ... | ... | ... |
| Special leads to detect           | ... | ... | ... | ... | ... | ... | ... |
| Variations in amplitude of        | ... | ... | ... | ... | ... | ... | ... |
| OSCILLATIONS OF TREMOR            | ... | ... | ... | ... | ... | ... | ... |
| P SUMMIT                          | ... | ... | ... | ... | ... | ... | ... |
| Absence of                        | ... | ... | ... | ... | ... | ... | ... |
| Amplitude of                      | ... | ... | ... | ... | ... | ... | ... |
| Anomalous forms of                | ... | ... | ... | ... | ... | ... | ... |
| Bifurcation of                    | ... | ... | ... | ... | ... | ... | ... |
| Buried                            | ... | ... | ... | ... | ... | ... | ... |
| Contiguous                        | ... | ... | ... | ... | ... | ... | ... |
| In mitral stenosis                | ... | ... | ... | ... | ... | ... | ... |
| Meaning of...                     | ... | ... | ... | ... | ... | ... | ... |
| PACEMAKER                         | ... | ... | ... | ... | ... | ... | ... |
| Dislocation of                    | ... | ... | ... | ... | ... | ... | ... |
| PAROXYSMAL TACHYCARDIA            | ... | ... | ... | ... | ... | ... | ... |
| Mitral stenosis and               | ... | ... | ... | ... | ... | ... | ... |
| Simple form of                    | ... | ... | ... | ... | ... | ... | ... |
| Ventricular origin of             | ... | ... | ... | ... | ... | ... | ... |
| PARTIAL HEART-BLOCK               | ... | ... | ... | ... | ... | ... | ... |
| Clinical examples of              | ... | ... | ... | ... | ... | ... | ... |
| PATENT DUCTUS ARTERIOSUS          | ... | ... | ... | ... | ... | ... | ... |
| PHYSIOLOGICAL ELECTROCARDIOGRAM   | ... | ... | ... | ... | ... | ... | ... |
| Constancy of                      | ... | ... | ... | ... | ... | ... | ... |
| Influence of posture and exercise | ... | ... | ... | ... | ... | ... | ... |
| Time relations of                 | ... | ... | ... | ... | ... | ... | ... |
| POST-PAROXYSMAL PAUSE             | ... | ... | ... | ... | ... | ... | ... |
| P-R INTERVAL                      | ... | ... | ... | ... | ... | ... | ... |
| Prolongation of                   | ... | ... | ... | ... | ... | ... | ... |
| Shortening of                     | ... | ... | ... | ... | ... | ... | ... |
| Variation in                      | ... | ... | ... | ... | ... | ... | ... |



|  |               |
|--|---------------|
| PREMATURE CONTRACTIONS (EXTRASYSTOLES) ...     | 53            |
| <i>Auricular fibrillation and</i> ...          | 97            |
| <i>Auricular origin</i> ...                    | 60            |
| <i>Heart-block and</i> ...                     | 48 & 66       |
| <i>Sinus origin</i> ...                        | 62            |
| <i>Successive</i> ...                          | 57, 63 & 70   |
| <i>Ventricular origin</i> ...                  | 53            |
| PREMATURE VENTRICULAR CONTRACTIONS ...         | 53            |
| <i>Types of</i> ...                            | 57            |
| PROPERTIES OF THE STRING ...                   | 11            |
| PULMONARY STENOSIS (CONGENITAL) ...            | 34 & 115      |
| PULSUS ALTERNANS ...                           | 103           |
| Q DEPRESSION ...                               | 14, 28 & 47   |
| <i>Amplitude of</i> ...                        | 22            |
| <i>Nature of</i> ...                           | 14, 28 & 47   |
| <i>Quinidine in auricular fibrillation</i> ... | 98            |
| Q R S GROUP ...                                | 19 & 27       |
| <i>Bizarre type of</i> ...                     | 20            |
| <i>Length of</i> ...                           | 19 & 28       |
| QUINIDINE ...                                  | 98            |
| R SUMMIT ...                                   | 14 & 28       |
| <i>Amplitude in hypertrophy of</i> ...         | 33            |
| <i>Amplitude of</i> ...                        | 22            |
| <i>Aortic disease and</i> ...                  | 111           |
| <i>Bifurcation of (notching) of</i> ...        | 19            |
| <i>Increased amplitude of</i> ...              | 33, 111 & 116 |
| "REFRACTORY" STATE ...                         | 59            |
| RENAL DISEASE ...                              | 116           |
| RESPIRATORY ARRHYTHMIA ...                     | 101           |
| S DEPRESSION ...                               | 14 & 28       |
| <i>Amplitude in hypertrophy of</i> ...         | 33            |
| <i>Amplitude of</i> ...                        | 22            |
| <i>Bifurcation (notching) of</i> ...           | 19            |
| <i>Increased amplitude of</i> ...              | 33 & 116      |
| SINO-AURICULAR BLOCK ...                       | 49 & 103      |
| SINUS ARRHYTHMIA ...                           | 101           |

|  |     |     |     |     |     |     |                      |         |
|--|-----|-----|-----|-----|-----|-----|----------------------|---------|
| SINUS EXTRASYSTOLES  | ... | ... | ... | ... | ... | ... | ...                  | 62      |
| SINUS IRREGULARITIES   | ... | ... | ... | ... | ... | ... | ...                  | 101     |
| SKIN CURRENT   | ... | ... | ... | ... | ... | ... | ...                  | 7       |
| SLOW ACTION OF THE HEART   | ... | ... | ... | ... | ... | ... | 44, 48 &             | 103     |
| SPECIAL LEADS  | ... | ... | ... | ... | ... | ... | ...                  | 93      |
| STANDARDISER   | ... | ... | ... | ... | ... | ... | ...                  | 7       |
| STANDARDISED CURVES  | ... | ... | ... | ... | ... | ... | ...                  | 7 & 9   |
| STEELL'S MURMUR  | ... | ... | ... | ... | ... | ... | ...                  | 111     |
| STRING GALVANOMETER  | ... | ... | ... | ... | ... | ... | ...                  | 1       |
| STRING PROPERTIES  | ... | ... | ... | ... | ... | ... | ...                  | 11      |
| SUPERIMPOSED SUMMITS   | ... | ... | ... | ... | ... | ... | 41, 46, 55 &         | 63      |
| SUPRAVENTRICULAR IMPULSES  | ... | ... | ... | ... | ... | ... | 25, 26, 47, 51, 60 & | 88      |
| SWITCHBOARD  | ... | ... | ... | ... | ... | ... | ...                  | 4       |
| <i>T</i> SUMMIT  | ... | ... | ... | ... | ... | ... | ...                  | 14      |
| <i>Amplitude of</i>  | ... | ... | ... | ... | ... | ... | ...                  | 22      |
| <i>Aortic disease and</i>  | ... | ... | ... | ... | ... | ... | ...                  | 112     |
| <i>Exophthalmic goitre and</i>   | ... | ... | ... | ... | ... | ... | ...                  | 117     |
| <i>Increased amplitude of</i>  | ... | ... | ... | ... | ... | ... | 23 &                 | 117     |
| <i>Inversion of</i>  | ... | ... | ... | ... | ... | ... | 20, 36 &             | 97      |
| TESTING STRING   | ... | ... | ... | ... | ... | ... | ...                  | 11      |
| TRANSPOSITION OF HEART   | ... | ... | ... | ... | ... | ... | ...                  | 113     |
| <i>U</i> SUMMIT  | ... | ... | ... | ... | ... | ... | ...                  | 20      |
| <i>Amplitude of</i>  | ... | ... | ... | ... | ... | ... | ...                  | 22      |
| VAGAL COMPRESSION  | ... | ... | ... | ... | ... | ... | ...                  | 84      |
| VAGAL IRREGULARITIES   | ... | ... | ... | ... | ... | ... | ...                  | 101     |
| VALVE LESIONS  | ... | ... | ... | ... | ... | ... | ...                  | 106     |
| VENTRICULAR COMPLEX (SEE <i>Q</i> , <i>R</i> , <i>S</i> AND <i>T</i> ) | ... | ... | ... | ... | ... | ... | ...                  | 14 & 28 |
| <i>In the three leads</i>  | ... | ... | ... | ... | ... | ... | ...                  | 19      |
| <i>Meaning of...</i>   | ... | ... | ... | ... | ... | ... | ...                  | 18 & 28 |
| <i>Of anomalous forms</i>  | ... | ... | ... | ... | ... | ... | ...                  | 24 & 55 |
| <i>Physiological</i>   | ... | ... | ... | ... | ... | ... | ...                  | 18      |
| <i>Variations in</i>   | ... | ... | ... | ... | ... | ... | ...                  | 19      |



LONDON :

SHAW & SONS Ltd., FETTER LANE, E.C.4.















