

Gunshot injuries of bones / by Ernest W. Hey Groves.

Contributors

Groves, Ernest W. Hey 1872-1944.

Publication/Creation

[London] : H.Frowde : Hodder & Stoughton, 1915.

Persistent URL

<https://wellcomecollection.org/works/jzw2ftnc>

License and attribution

Conditions of use: it is possible this item is protected by copyright and/or related rights. You are free to use this item in any way that is permitted by the copyright and related rights legislation that applies to your use. For other uses you need to obtain permission from the rights-holder(s).

**wellcome
collection**

Wellcome Collection
183 Euston Road
London NW1 2BE UK
T +44 (0)20 7611 8722
E library@wellcomecollection.org
<https://wellcomecollection.org>

GUNSHOT INJURIES OF BONES

CAPT.
ERNEST W. HEY GROVES
R.A.M.C. (T.)

TRO
RAMC
Coll.
/GRO

OXFORD
WAR PRIMERS


~~15-c-24~~


ROYAL ARMY MEDICAL COLLEGE
No. *March 9th*
1916.
LIBRARY

28



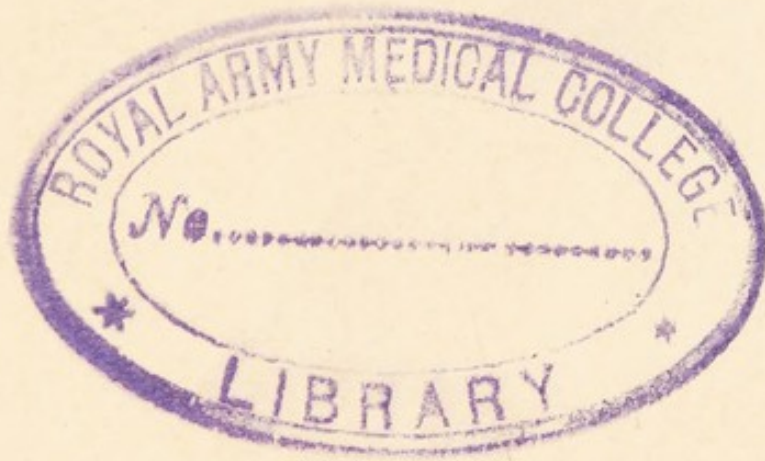22101939765





Digitized by the Internet Archive
in 2018 with funding from
Wellcome Library

<https://archive.org/details/b29932336>



GUNSHOT INJURIES OF
BONES

PUBLISHED BY THE JOINT COMMITTEE OF
HENRY FROWDE AND HODDER & STOUGHTON
AT THE OXFORD PRESS WAREHOUSE
FALCON SQUARE, LONDON, E.C.

OXFORD WAR PRIMERS

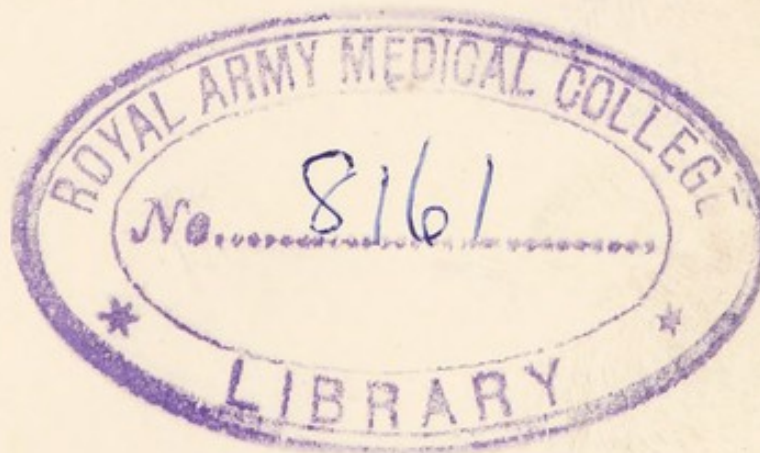
UNSHOT INJURIES OF BONES

BY

ERNEST W. HEY GROVES

M.D., M.S. (LOND.), F.R.C.S. (ENG.)

SRGEON TO THE BRISTOL GENERAL HOSPITAL; CONSULTING SURGEON
TO THE COSSHAM HOSPITAL; CAPTAIN R.A.M.C. (T.)



LONDON

HENRY FROWDE

HODDER & STOUGHTON

ORD UNIVERSITY PRESS

WARWICK SQUARE, E.C.

1915

PREFACE

THIS book has been written amidst the hurry and stress of active military service. Indeed the time necessary for its writing might never have been found, but for the leisure of a sea voyage necessitated by my transference to the Eastern theatre of war. Although the time has not yet come for the formulation of final conclusions about war wounds, it is fully ripe for the emphasis of certain general principles ; and as regards bone injuries, I have endeavoured to set these forth in broad outline which I trust will be of use to others.

I wish to thank Lieutenant T. H. Brown for his criticisms and suggestions of the MS., Mr. C. A. Joll for undertaking the proof-reading and selection of illustrations, and Messrs. John Wright & Sons for allowing me to fully draw upon the *British Journal of Surgery* and my forthcoming book on the *Modern Methods of Fracture Treatment* for the figures.

I have also to thank Miss Lucy Joll for most of the new diagrams.

CONTENTS

| | PAGE |
|---|------|
| CHAPTER I | |
| INTRODUCTION : PATHOLOGY : PHYSIOLOGY | 9 |
| CHAPTER II | |
| DIAGNOSIS | 19 |
| CHAPTER III | |
| SYMPTOMS AND REPAIR | 23 |
| CHAPTER IV | |
| REPAIR OF FRACTURES | 29 |
| CHAPTER V | |
| GENERAL PRINCIPLES OF TREATMENT | 34 |
| CHAPTER VI | |
| FRACTURES OF THE JAW AND UPPER LIMB | 68 |
| CHAPTER VII | |
| FRACTURES OF THE LOWER LIMB | 84 |
| CHAPTER VIII | |
| ON CERTAIN SPECIAL METHODS OF TREATING GUNSHOT FRACTURES | 106 |



GUNSHOT INJURIES OF BONES

CHAPTER I

INTRODUCTION: PHYSIOLOGY: PATHOLOGY

THE scope of the present articles is limited to a practical discussion of the severe gunshot injuries of the long bones, with especial view to establishing a satisfactory system for their treatment. It is not proposed to repeat or revise the ordinary text-book classification of the causes and varieties of fractures, these being taken for granted; neither is it advisable to deal with injuries of the skull, vertebræ, carpus, or tarsus, inasmuch as these are all dealt with elsewhere in connexion with the nervous system or joints.

Characteristic forms of Gunshot Injuries of Bone.—

These are in the majority of cases **open** (compound) fractures associated with an infected wound. The wound may be large, open, and lacerated, or it may be a mere puncture. In exceptional cases the fracture may be **closed** (simple), as when a limb is struck by a large fragment of low velocity.

A rifle bullet, or more rarely a shrapnel ball or shell fragment, may go right through a bone without

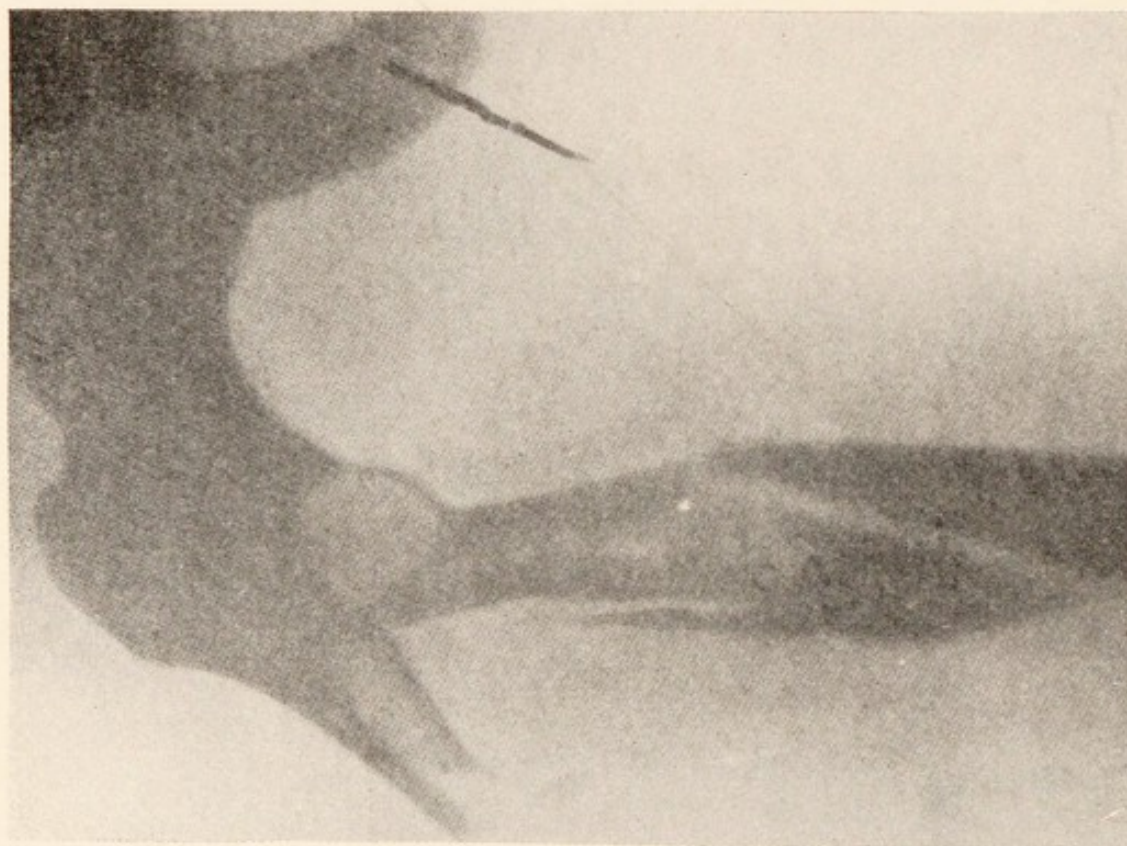


FIG. 2. COMMINUTED FRACTURE OF FEMUR.



FIG. 1. BULLET LODGED IN NECK OF FEMUR.

splintering it, this being most common at the expanded cancellous ends of the head of the humerus, the lower end of the femur, or the tarsus. Sometimes

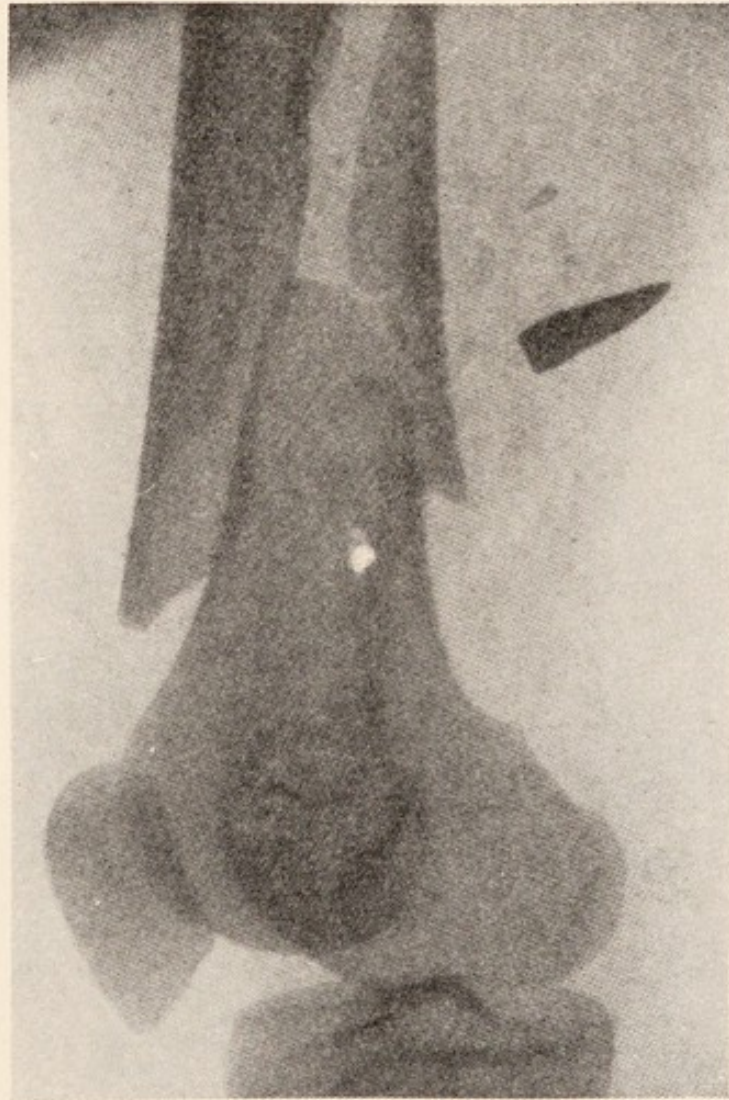


FIG. 3. COMMINUTED FRACTURE OF LOWER THIRD OF FEMUR.

a bullet lodges in the bone (see Fig. 1, upper end of femur), and the same may apply to a shell fragment.

Most frequently, however, the bone is shattered into many fragments, and this **comminuted** open septic fracture is the most typical and serious type of bone injury.

Not infrequently, however, a projectile of low

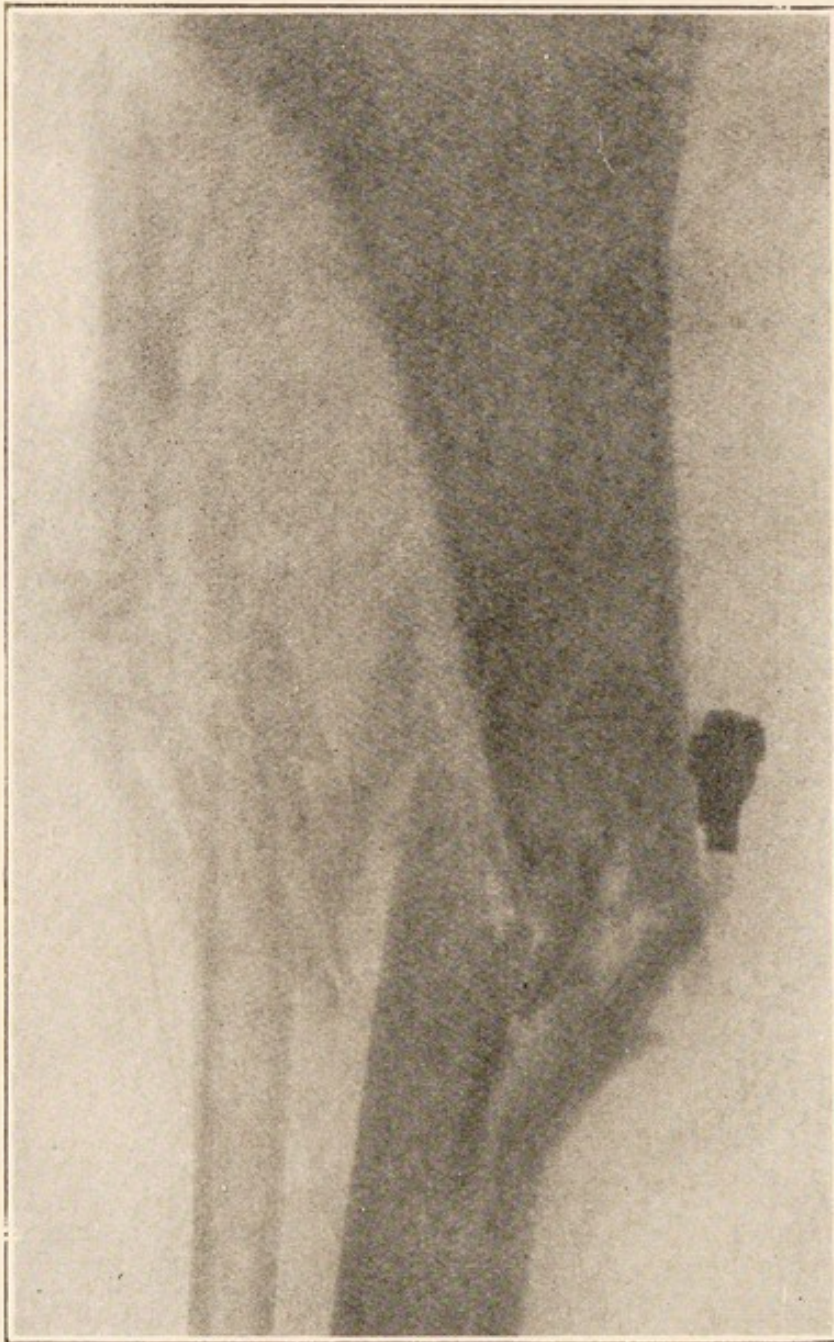


FIG. 4. COMMINUTED FRACTURE OF TIBIA AND FIBULA.
Shell fragment *in situ*.

velocity strikes the shaft of a bone and splits it as a **long oblique** fracture without causing much displacement.

Sometimes a comparatively simple type of fracture

may be associated with several long **fissures** of the shaft, which will be readily split open by any rough handling or injudicious attempts at open operations.

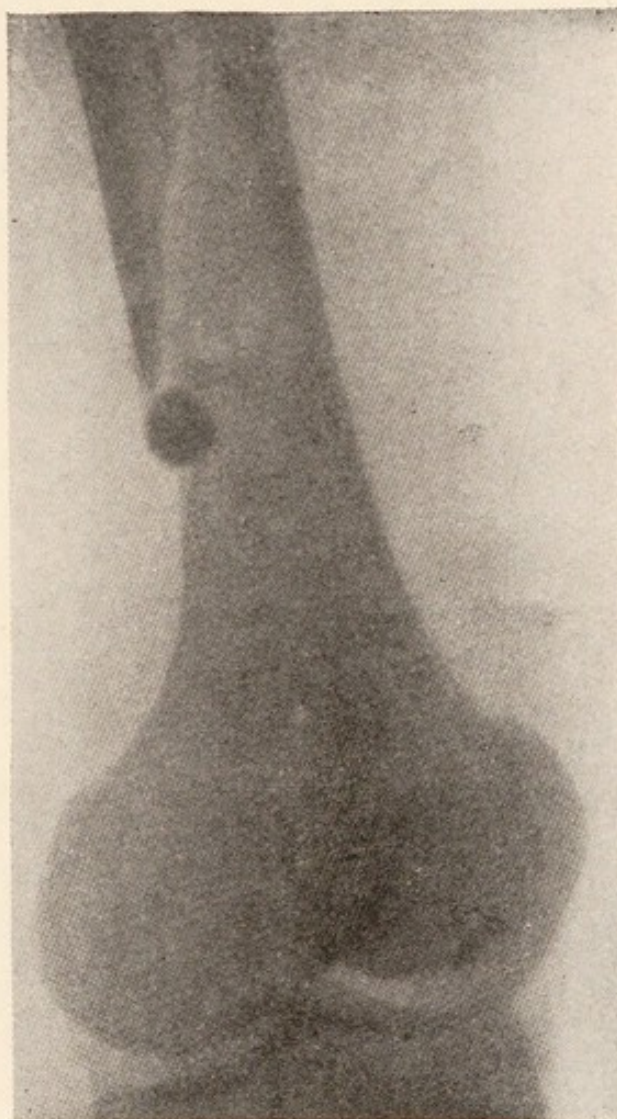


FIG. 5. OBLIQUE FRACTURE OF LOWER THIRD OF FEMUR.
Shrapnel bullet *in situ*.

PHYSIOLOGY

It is very necessary to bear in mind the essential facts relating to the blood-supply and vital characteristics of bone, because these certainly determine many of the special characters of bone tissue after injury.

Bone is simply connective tissue in which the intercellular tissue is calcified. The essential facts of growth and repair are much better understood by this relation, than by constructing a special bone physiology and pathology.

Like every other connective tissue, bone has three chief elements in its constitution, viz. (1) the essential tissue cells—the osteoblasts which in favourable conditions multiply and lay down new bone; (2) the blood and lymph vessels which are responsible for the nutrition of the bone cells; and (3) the intercellular tissue or secretion of the bone cells, which is really as much extracellular as the shell of a snail or the carapace of a turtle.

The essential for bone life and bone growth is the osteoblast. But the osteoblast is dependent upon the vascular tissue for its life and upon various vital stimuli for its activity in reproduction. And the vascular system is so walled in by the dense bone that it has much less capacity for adaptation to special conditions of irritation or infection than is the case with soft tissues.

Bone, like other compact tissues, has a capsule of common connective tissue, which acts as a containing or limiting membrane. This is the periosteum, which has usually been exalted into a quite undeserved eminence as the very matrix of the bone.

Periosteum never forms bone, though it greatly favours bone growth. These are the two facts which will serve to explain the apparent discrepancies of observation and endless discussion on the subject of

osteogenesis. On the surface of every dense bone open all the vascular channels. Upon this surface, protected by the vascular periosteum on the outer side and fed by the osteoplastic tissue beneath, rapid cellular changes can and do take place. Here it is that osteoblasts become collected in the natural growth of the young bone, in response to the stimulus of infection or injury. But whilst bone, quite apart from periosteum, contains all the tissues necessary for osteogenesis, it is very liable to interference with its blood-supply.




FIG. 6. DIAGRAM ILLUSTRATING THE RÔLE OF THE PERIOSTEUM IN BONE REGENERATION. In A a bit of bone surface covered by periosteum; the whole shaded area allows of vascularization. In B vascularization can only occur at the dots representing the open ends of the Haversian canals.

The rigid walls of the Haversian canals readily allow the channels to be blocked by inflammatory exudate, and if the vascular supply has been cut off, there is a very limited area by which fresh vascularization can take place.

But the periosteum with its loose connective-tissue mesh readily becomes vascularized by new capillaries and through these takes the blood into the underlying bone. Hence there is no contradiction in asserting that whilst bone without periosteum is the

matrix of new bone, yet periosteum is of the greatest possible assistance in osteogenesis, inasmuch as it acts as an intermediary between the osteoblast on the one hand and the vascular system on the other.

PATHOLOGY

It is only necessary to refer here to two points connected with the general pathology of bone injuries, viz. the relation of sepsis to repair on the one hand and to necrosis on the other.

Sepsis in relation to Bone Repair.—The reaction of a broken bone to septic infection varies very greatly. Sometimes a total necrosis takes place, at other times partial necrosis with great loss of substance, at other times an indefinite delay in healing with very little loss of tissue, and finally there may occur healing which is both rapid and excessive.

There are three chief factors which determine the nature of this tissue reaction to infection, viz. (1) the nature and severity of the infection; (2) the vascular supply of the injured bone; and (3) the drainage. When the infection is trivial, e.g. in case of a rifle-bullet wound or when the infected wound is promptly and efficiently opened and drained, gunshot injuries of the bones heal with astonishing rapidity. Whilst it is impossible in any particular case to predict whether a septic fracture is going to heal well and quickly or badly and slowly, yet we can be quite certain that it lies in our power very largely to determine which this issue is to be.

Sepsis in relation to Necrosis.—This is really the

same problem as the last, and determined by the same factors. But if the term necrosis is used to denote the death of a large part of the total thickness of a bone, it may be remarked that such necrosis is an extraordinarily rare result of gunshot wounds, and, further, that when it does occur, injudicious surgery has generally been a contributory factor.

Probably the immunity of the long bones from massive necrosis is due to their triple blood-supply from (1) the periosteum, (2) the nutrient vessels in the marrow, (3) the articular ends. But whether this is so or not, it is quite certain that any extensive operative exposure of the bones or drilling into the marrow cavity will quickly produce the necrosis which so rarely results from a mere gunshot injury.

The Reaction of the Soft Tissues.—The soft tissues need only here be considered in their direct relationship to the bone.

In the first place there is the actual primary muscle spasm caused by the injury. As far as the gunshot differs from a simple fracture, there are these chief points. Directly after the wound, and in proportion to its severity, the muscles are almost paralysed by the trauma, and at this period, which lasts for only one or two days, the limb may be restored to its proper length by the use of a minimum extension force. After this initial period, when general and local shock have passed off, the tissues react very strongly to all painful stimuli, and if the limb has not been immobilized, the shortening and deformity due to muscle spasm will be proportionately great.

In addition to the muscle contraction, there is the later factor of the scar tissue. This is laid down in great excess in comminuted and infected cases when healing begins. And this scar tissue, whether it is called callus or granulation tissue, will quickly contract and confirm or increase any existing deformity.

These points, which are of such fundamental importance in the treatment of gunshot bone injuries, may be summarized by saying that—

1. There is ample natural tendency for septic comminuted fractures to undergo repair, and that when infection has ceased to be aggressive, this repair is rather more rapid than in simple bone injuries.

2. This natural tendency to rapid repair may be aided by timely immobilization and extension, but may actually cause deformity if treatment is delayed, and it will be quite prevented by faulty treatment, whether this takes the form of taking out the living bits of bone which are essential for repair, or of operations which interfere with the blood-supply and spread the infection.

CHAPTER II

DIAGNOSIS

IN the great majority of gunshot fractures the nature of the injury is only too obvious. But nevertheless it is necessary to pay the greatest care to the examination of all these cases both for the recognition of foreign bodies, the detection of bone injuries unaccompanied by a loss of continuity, and in order to follow and control the various stages of repair. If the X-rays are important in the examination of simple fractures, they are even more so with gunshot bone injuries.

The necessity for X-rays in all limb injuries where the course and exit of the projectile is doubtful must then be first laid down quite definitely. The reasons for this are :

1. **The presence of large Fragments of Metal**, and especially of shell fragments, which may always be presumed to be the carriers of septic pieces of clothing.

2. **The actual embedding of Shell or Bullet Fragments in the Shafts of dense Bones.**—Cases are not uncommon of severe sepsis without obvious fracture, in which a mere enlargement of the wound with drainage would seem to be all the treatment needed, but which are proved on X-ray examination to have jagged shell splinters embedded in the bone with a

sort of casing of torn cloth. It is quite clear that such a septic focus should be recognized and removed at the very earliest possible moment.

3. The existence of extensive fissured Fractures without actual breach of continuity may be revealed, which will necessitate care in after-treatment in order to avoid bone displacement. I have seen this in all the long bones of the limbs, but whilst in those of the arm there is not much fear of subsequent displacement, such a disaster may easily occur if a man be allowed to walk on a splintered femur or tibia.

The importance of several views of the limbs, or at any rate two views in planes at right angles to each other, is generally accepted, and nothing but a shortage of personnel or material justifies the acceptance of a single picture of any important fracture.

It is often said that these cases are in such pain that they should not be disturbed by having more than one picture taken.

There are two valid answers to this objection. The first is that if the limb is properly put up, i.e. slung off the bed, any number of X-ray pictures may be taken without any disturbance whatever. And the other is that a purely side-to-side view, which is the one which often necessitates the limb being specially placed, is unnecessary, inasmuch as two pictures in planes at right angles can be taken both from the front.

In the diagram A represents the usual two planes in which limb skiagrams are taken, viz. purely antero-posterior and purely side-to-side. In B is

shown the better way of taking two right-angled views, which will avoid any moving of the limb.

The importance of having the Skiagrams taken with the Limb properly Supported and Orientated.—This work is sometimes spoiled by the slackness or the fads of the radiographer, who may think that his apparatus is of much more value than the patient's limb. Such a person will do all in his power to have the patient brought to the X-ray room instead of

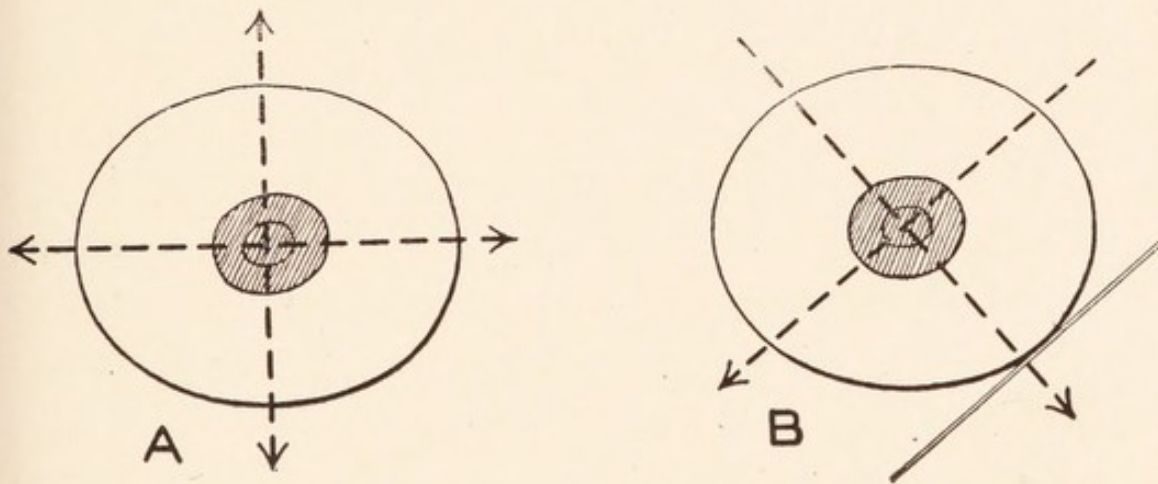


FIG. 7. A. THE USUAL PLANES FOR SKIAGRAMS.

B. THE BETTER WAY IN BAD CASES.

exerting himself to secure a portable apparatus and have the same taken to the patient.

Take the case of a fractured femur—in almost all such the X-rays are quite unnecessary for mere diagnosis, the fact of fracture being obvious to every one, including the patient. One of the main objects of the skiagram should be to estimate the relative position of the fragments and to indicate the line of treatment. This cannot be done unless the limb is put up and fixed by the apparatus which is

to be the main instrument in the treatment of the fracture. Put the limb up on its wire sling extension cradle, attach the 20 lb. weight, and then have the skiagrams taken. A system should also be adopted by which on the negative of every X-ray is indelibly written not only the name of the patient and the date, but the facts necessary for the correct orientation of the picture. Then, as the case proceeds, or treatment is modified, other pictures can be taken from a corresponding position to the first, and accurate information obtained as to progress.

CHAPTER III

SYMPTOMS AND REPAIR

ABOUT the immediate symptoms of gunshot injuries of bones not much need be said. Pain is present in a terrible degree. It is great in proportion to comminution, the amount of movement to which the patient is subjected, especially for dressings, and the degree of inflammation of the tissues.

It lasts, too, for a very long time, it may be for weeks or months, and this duration of the pain is simply dependent upon the failure to steady the limb in such a way that the broken fragments do not rub against one another whenever the patient is moved or the wound dressed.

I think it may be said, without any fear of exaggeration, that gunshot injuries of the bones are responsible for more pain than all the other casualties of war put together.

But it is necessary to consider shortly the more remote consequences in order that treatment may be intelligently directed towards averting the more serious of these.

Deformity from Overlapping.—This is probably the commonest type of malunion. It is more marked than in simple or closed fractures, partly because the soft tissues are so much torn and partly because the reflex spasm of the muscles is so great owing to the

pain associated with the frequent change of dressings in the methods of treatment commonly adopted.

It is more often seen after fractures of the femur and of both leg-bones than after upper limb injuries, because in the latter muscle tension is not so great, nor is treatment so inadequate. It ought not to be necessary to point out that this great overriding of the fragments ought to be prevented and not left for a late operation to cure. For not only is any secondary operation exceptionally difficult, owing to dense callus and scar formation, and muscle shortening; but the soldier who has already gone through the horrors of the battlefield, transport, and the pain associated with primary healing, will strongly object to facing another ordeal just at the time when he has counted upon convalescence. And yet this neglect of obvious primary deformity is only too often allowed, and is excused on the ground that in the first place the care of the septic wound was much more important than that of the fracture.

This argument would only be valid if the treatment of the wound and that of the fracture were essentially opposed to one another, and as this is not the case it falls utterly to the ground. Cases of gunshot fracture allowed to heal in positions of great deformity must be regarded, therefore, as evidence of ignorance or neglect, the latter being sometimes the inevitable result of administrative difficulties.

Deformity from Angulation.—This is not so common as the last, because it is more obvious, and even the ordinary wooden splints are usually capable of pre-

venting it. The most troublesome cases of angulation are those due to the loss of a part of the total thickness of the tibia whilst the fibula remains intact. The possibility of such an occurrence should ever be borne in mind, before removing any piece of loose bone prior to the formation of callus. That early and adequate extension is the only method necessary to prevent both these types of deformity is proved by the fact that they are both so rare after gunshot injuries of the humerus. In this case the patient is ambulant from the earliest possible date, and, whether treated by a splint or not, the natural position and weight of the arm serve to prevent any marked overlapping or angulation.

Non-union.—It is impossible to adequately discuss here the causes and varieties of non-union of fractures. After gunshot wounds it is not a common complication if we exclude those cases of merely delayed union associated with septic transverse fracture of the tibia.

It is difficult to draw a sharp line between non-union and delayed union. Both occur in the humerus and tibia much more frequently than in the other bones. There are two chief causes. In the first the soft parts, including the periosteum and muscle, are interposed between the fragments and serve to seal up the vascular pores of the fractured surfaces. This probably accounts for most cases of non-union of a fractured humerus. It can only be prevented by an early adequate extension. The extending force draws all the soft tissues into a straight tube and secures that the fractured surfaces shall become free.

But it is important to note that whilst extension can certainly prevent non-union, it can do nothing to cure it. If the broken surfaces have once become encased in a new connective-tissue limiting membrane, no mere pulling them apart will reopen their pores for callus exudation.

In the second place, the condition more commonly seen in the tibia, there seems to be from the outset a defect in callus production. This is always much more marked in the distal fragment, a fact which must be connected with the poorer blood-supply of this end of the bone. In such a case union is merely delayed, and, having secured proper wound healing, good alinement, and correct length, the limb may be fitted with removable splints and treated by ambulation, with confidence that union, though slow, will eventually come about. At any time, after the wound has soundly healed, bone union may be greatly hastened by exposing the ends and cutting through the eburnated surfaces by a drill or saw, so as to open up a communication between the vascular osteoblastic bone-tissue and the surface of the fracture (see Wildey, *Brit. Journ. of Surgery*, Jan. 1915).

Fibrous Union, or the Flail Limb.—Without doubt there will be many of these sad sequelæ of gunshot injuries after the present war. A long bone, e.g. the humerus or femur, is found to be comminuted, and being connected with a septic wound, it is assumed, often quite wrongly, that all loose fragments of bone are going to die, and they are therefore removed.

The large gap left is then bridged over by the

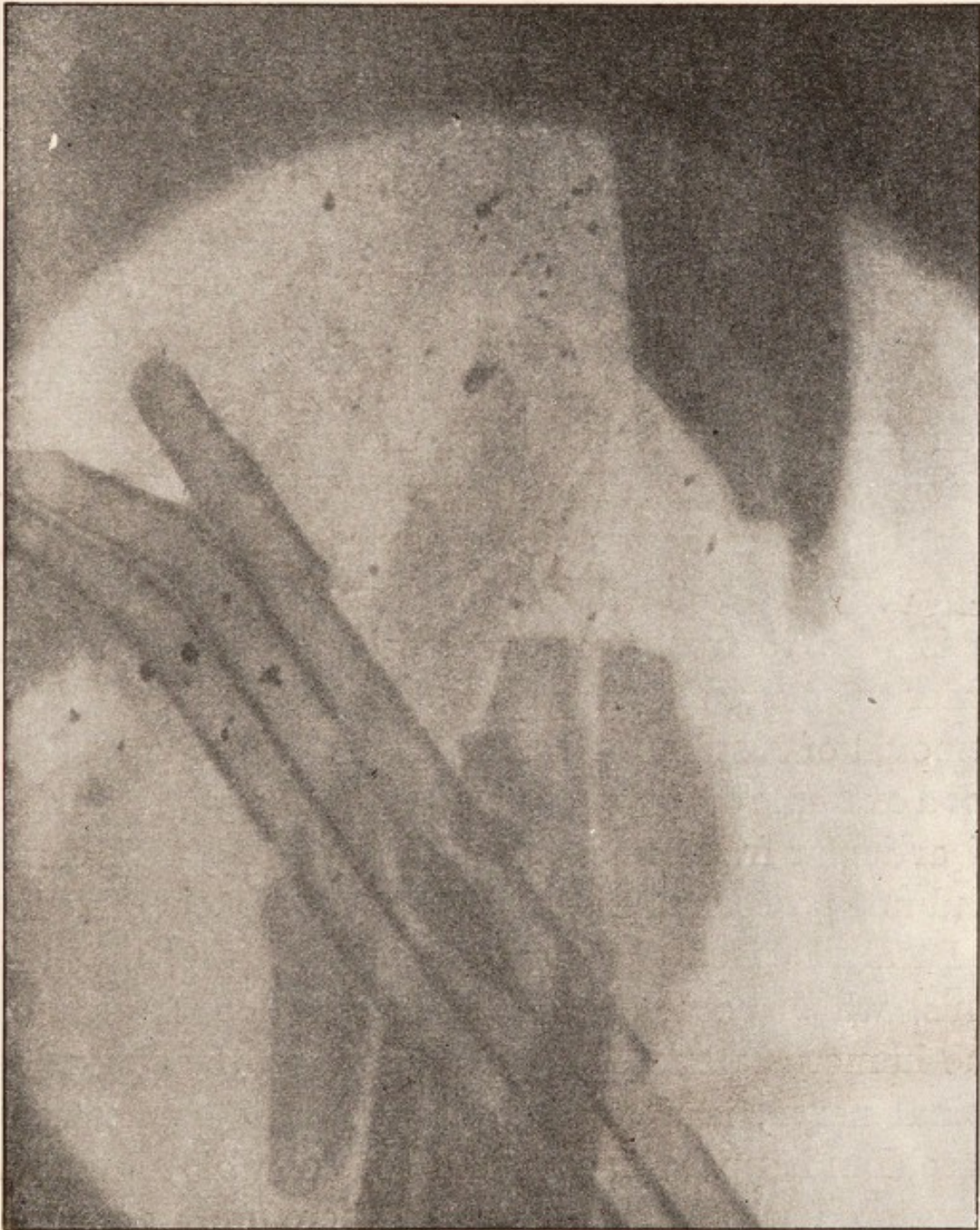

FIG. 8. MUCH COMMUNUTED FRACTURE OF FEMUR. Skiagram shows condition on admission. Three drainage-tubes *in situ*. Nearly all the fragments shown had to be removed later.

fibrous tissue and the periosteum remains what it ever has been, merely a connective-tissue structure,

falling over the distant remains of the shaft, but forming no new bone.

Such a limb is only a burden to its possessor, and he will be dependent upon the success of a late bone-grafting operation or the ingenuity of an instrument maker.

Secondary Changes in or near Joints.—When a comminuted fracture affects the articular end of a bone the conditions of repair and of subsequent function are quite different from those which obtain in lesions of the shaft. The danger here lies in the direction of callus excess and ankylosis of the joints, especially in the shoulder, elbow, and ankle; therefore it is wise to freely remove loose pieces of bone in order to ensure as far as possible a mobile joint. The removal of a splintered astragalus from the ankle is a good example of this type of procedure. Such removal of articular fragments ought to be undertaken early and not postponed until the joint has become fixed.

Paralysis from Secondary Nerve Involvement.—This, which occurs most commonly in fractures of the humerus where the callus involves the musculospinal nerve, is a most disappointing complication. It seldom happens except with considerable malunion associated with callus excess. Therefore, in general terms, the avoidance of late nerve implication must be by the avoidance of malunion. I am not prepared to say that it never occurs, but I certainly have never seen its occurrence in a case where adequate extension has been adopted from the outset.

CHAPTER IV

REPAIR OF FRACTURES

THE following scheme represents the main stages of bone repair :

I. **Blood-clot.**—This becomes infiltrated by leucocytes, connective-tissue cells, and osteoblasts, and permeated by capillary loops, to form

II. **Granulation Tissue or Procallus**, which in appearance and histologically is indistinguishable from granulation tissue elsewhere. The majority of the cells in it are osteoblastic. By their agency calcium salts are deposited in the intercellular tissue, and thus is formed—

III. **Callus** or calcified granulation tissue. This will be laid down where the original blood-clot was, but only at such distance from the actually broken bone surfaces as can be traversed by the osteoblasts.

III a. **Cartilage.**—In a large proportion of cases examined at a suitable stage the transformation of callus into bone can be seen to be preceded by a stage of cartilage. In animals this is very conspicuous. I am not aware that this has any practical importance, and therefore it is not necessary to dwell upon it.

IV. **Ossification of Callus.**—This, which is by far the slowest of all the processes, consists in a production of homogeneity between the soft callus and the hard

bone. The dense bone near the fracture becomes eaten into by cellular activity, shown to the naked eye by little pits filled with granulation tissue. This osteoporosis goes on rapidly in young bones and those near the vascular articular ends, and slowly in adult bones and in parts near the middle of the shaft. Its rapidity, in fact, seems to depend directly on blood-supply. Meanwhile the deposit of calcium is becoming denser in the callus, so that instead of a mere scattering of earthy salts, there is a lamellar deposit round all the blood-vessels and cellular tracts. Thus the hard bone becomes porous and the callus dense until a uniform spongy layer is formed of the same consistency. Then the process of rarefaction ceases and the whole mass becomes more solid by a deposit of bone lamellae in all its open spaces, until no channels are left except the Haversian canals. The outlying parts of callus and projecting spicules of bone, particularly on the convex side of a fracture, are gradually absorbed, whilst those which are subject to strain and stress, and especially the callus buttress on the concave side of a fracture, become more dense, until a stage is reached in which the bone-scar is thicker and harder than normal bone.

It is worth while to note the absolute uniformity of the general process of healing as it occurs in bones and in the soft tissues. The following important points may be emphasized :

1. The essential tissue of repair, granulation tissue or callus, is the product of the wounded structures. Thus callus is laid down by the broken bone surfaces, and

every piece of osseous tissue is a source of bone repair material. The quantity of callus depends upon—

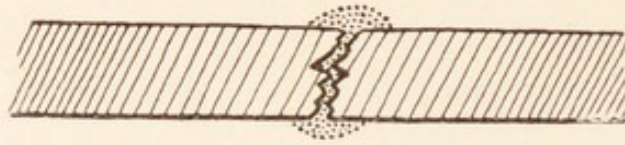
- (a) The vascularity of the injured bone.
- (b) The area of broken bone surface.
- (c) The presence of natural irritation, e. g. a certain degree of mobility or a well-resisted infection of a mild type.
- (d) The absence of destructive infection and its products.

2. Neither granulation tissue nor callus can be laid down at more than a very limited distance from its mother tissue. Thus a gap in a bone of more than a certain width will not be made good by callus. Either the bones will be drawn together until the callus cap of each fragment is in contact with the other or else there will remain a fibrous union.

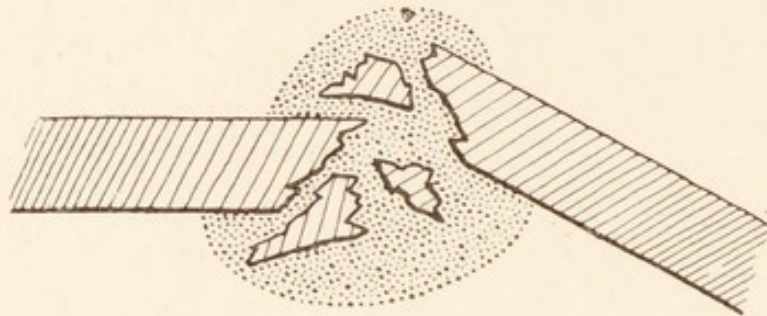
3. Ideal healing or a *restitutio ad integrum* is only possible when from the outset the broken bone surfaces are held in close apposition so that the gap between them is merely linear. This is the healing by first intention. Callus, then, has only to be laid down like cement between well-fitted stones.

4. When the broken surfaces are not placed end to end, healing is by granulation or callus excess, i. e. all the broken bits have to be welded into a mass of new tissue, which fills up the interstices, and which subsequently has to be reconstructed to meet the strains and stresses of the affected part of the skeleton.

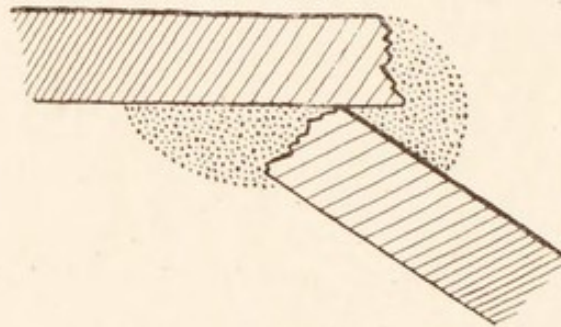
5. Healing may also take place by the union of granulating surfaces. That is to say, there exists a period of several weeks during which the misplaced



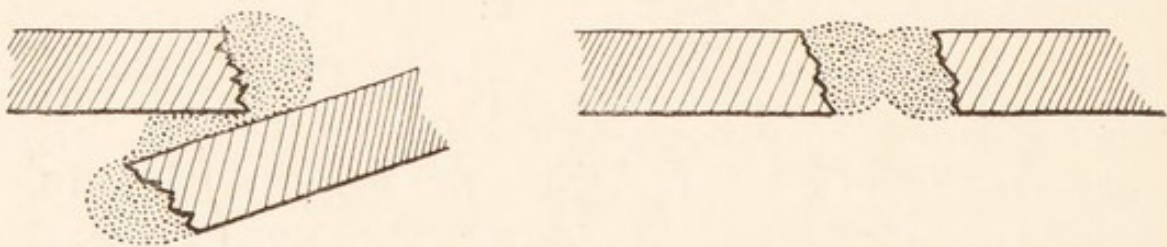
IDEAL HEALING 'BY FIRST INTENTION'.
The dotted area is granulation or callus tissue.



HEALING OF A COMMINUTED FRACTURE IN BAD POSITION.
'Healing by granulation' or callus excess.



HEALING OF AN UNCOMMUNUTED FRACTURE 'BY
GRANULATION' OR CALLUS EXCESS.



UNION OF A DISPLACED FRACTURE, RECTIFIED DURING
ACTIVE CALLUS GROWTH. 'Union of granulating
surfaces.'



NON-UNION AFTER LOSS OF SUBSTANCE
AND OSTEOSCLEROSIS.

FIG. 9. In these diagrams the closeness of the cross shading represents the density of the bone. The dotted areas represent callus.

ends of a bone are capped with callus, and in this period, if the displacement is corrected by appropriate extension, these callus caps brought into contact with each other will unite to restore bony continuity.

6. Healing in the sense of constructive repair ceases with cicatrization. Scar-tissue is avascular and comparatively acellular. Hence if bone union is delayed by any cause, e. g. excessive mobility, interposition of soft parts or mere mal-position beyond a certain period, the stage of granulation or callus production at the ends of the bone is succeeded by cicatrization or osteo-sclerosis and then little or no new bone formation can occur. The bone cells and their feeding vessels are locked up in dense avascular bone.

CHAPTER V

GENERAL PRINCIPLES OF TREATMENT

It is not perhaps sufficiently realized how new are the problems, or rather the conditions of the problem of the treatment of modern gunshot injuries. It is not so much that the nature of the injuries is different from what it used to be, but rather that modern aseptic or antiseptic surgery has arisen since the last great European war, and with it have developed greater possibilities and greater responsibilities in the conservative treatment of injured limbs than was ever thought of before. In the old days of 1870 an open comminuted fracture of the humerus or femur required immediate amputation. Practically no doubt or question existed about this, because any delay was followed by speedy death from wound sepsis.

But now all know that shattered limbs can be saved and even restored to functional usefulness. It is only necessary to provide free drainage and remove septic foreign bodies to prevent fresh infection, and to keep the main portions of the injured bone in correct position, and union of the bone with healing of the soft parts will follow.

Of course the treatment of open fractures has been successfully carried out ever since the days of Lister,

and indeed constituted what Lister himself regarded as one of the culminating triumphs of his discoveries. But the open fractures of civil life very rarely present the same degree of infection and comminution as is the rule in all the more serious gunshot injuries of this war. The former were potentially infected, but are brought for treatment before progressive infection has been established.

Therefore I repeat that the severe open comminuted fracture, to be treated without loss of life or limb, and treated so that transport can be undertaken without intolerable suffering, and treated not as a rare phenomenon, but as almost the commonest of the severe war injuries, is really a new problem in which all the factors which make for success or failure have to be most carefully thought out in order to devise an adequate solution. If this is not done several disasters may follow, and these disasters are so grave as to make one feel that the patients in whose cases they occur would have been much better off in the old days, and that for these men it would have been happier if Lister had never been born or his system and its developments perfected. It is not the fault of antiseptic surgery, but the lack of adaptation of suitable mechanical means to carry out the surgery which Listerism has made possible.

A brief reference to the evolution of abdominal surgery will make my meaning clear. Antiseptic surgery made it possible to open the abdomen and carry out various intraperitoneal operations with perfect safety. But this did not bring about the full

scope of modern abdominal surgery in a day or a year. For example, gastro-enterostomy, as it was at first performed with decalcified bone-plates, was such a lethal operation that it would have been better for its victims if they had lived before Lister, when no surgeon would have dared to open their abdomens. But this was simply because the technique of abdominal surgery had not been perfected, and it has taken years of pioneer work before gastro-enterostomy has become a simple and safe procedure.

So with fractures, we must first recognize the fact that if useful members are to be made out of shattered and infected limbs, it will be necessary to build up proper mechanical technique and, as has been the case with gastro-enterostomy, it will probably be found that progress lies in the direction of simplicity rather than in that of complication.

Fractures there always have been and splints without number to be applied to them, but here we have new conditions which demand new devices.

It has already been asserted that to ignore the novelty of the proposition and to attempt to solve it by old appliances is to risk the occurrence of disaster. To use a Scriptural phrase, it is to 'put new wine into old wine-skins'.

These disasters may be summarized as follows :

1. The patient will lose his life in the attempt to save the limb, either from acute or chronic sepsis or from some septic complication, e. g. secondary hæmorrhage.

2. The limb when saved will prove to be not worth

the saving owing to the final deformity, shortening, flail-like condition or destruction of the main joints.

3. The patient may suffer such intolerable agony during treatment, or his life be so endangered by sepsis or hæmorrhage, that it is necessary, after all, to amputate the limb, in which case not only has he endured unnecessary suffering and sickness, but he is debilitated as well as mutilated when the surgeon has done his work.

In discussing the general principles of treatment of gunshot fractures, I propose to first lay down what I conceive to be the main essentials to be aimed at, then to review the commonly accepted methods of fracture treatment, indicating how each fulfils or falls short of what we require, and lastly, to summarize the broad outlines of the methods which should be adopted.

One more prefatory remark is perhaps needed. Gunshot fractures include every type of bone injury: simple fissures; oblique or transverse uncomminuted breaks with an unbroken skin; fractures which are technically open or compound but in which the wound is made by a rifle bullet of high velocity which heals by first intention without infection; comminuted fractures with a large open wound and mild infection; and fractures like the last complicated by the presence of masses of septic cloth or jagged shell fragments and the most virulent infection.

All of these in which there is no wound or no infection can be treated upon ordinary lines which I have discussed and described fully in a recent work (*Modern*

Methods of Fracture Treatment: John Wright & Sons, Ltd., Bristol), and are not considered specially in the present article. In speaking of the particular problem of treatment of gunshot injuries of bones in the following pages, it must be understood that reference is made to fractures associated with wound infection.

The main essentials of Treatment to be secured.—

1. The limb must so be placed that the wound can be frequently dressed.

2. Immobilization must be effected in such a way that pain is reduced to a minimum and healing allowed to proceed, without interfering with wound treatment.

3. The infected wound must be treated thoroughly by the removal of foreign bodies and the provision of free and adequate drainage at the earliest possible moment. The wound must further be treated by frequently repeated or continuous methods which removed septic discharges and restore it to a healthy character.

4. The main fragments of the bone must be placed in correct position as regards alinement, rotation, and length until union has taken place.

5. Small fragments of bone must be left in their place when dealing with broken shafts. If the main fragments are properly placed and held, the small bits will usually come into sufficiently good line for practical purposes.

6. The correct placing of the limb and its fixation must be carried out directly after the first wound

toilet, so that proper bone union may be going on at the same time that the wound is being brought into a healthy condition, and healing of the soft parts is taking place. It is folly to first produce malunion and then have to correct it.

7. The uninjured parts of the limb must be maintained in health and functional usefulness, as far as this can be done without interfering with the union of the bone and the soft parts.

IMMOBILIZATION BY SPLINTS OR PLASTER OF PARIS.

The tying of the wounded limb to a stick may be perfectly good first-aid treatment, but it ought not to be the model and pattern for all subsequent procedures. And yet this is literally the case in many hospitals, and even hospitals where distinguished surgeons are in the very van of surgical progress in other branches of their art.

Wooden or Metal Splints.—The usual equipment of a military hospital for fractures consists in an assortment of long Listons, back and side leg-splints, various angled arm-splints, and a very few iron splints, e.g. Hodgen's or Macintyre's. But then, in addition to these simple things, are added a large number of plates, screws, and the implements wherewith to fix them.

The leg is tied on to one or more padded splints, of which the long Liston for the femur represents the most inadequate type. In fact I would go so far as

to say that the only thing that can be guaranteed as the result of the use of such a long splint for a bad gunshot fracture is a certain malunion, and this with the maximum of trouble to the nurse and pain to the patient.

It is dirty, uncomfortable, does not keep the patient or his leg really at rest, though it restricts him by many bandages ; it does not produce either extension or alignment, but effectually prevents both ; it makes the nursing of the case heavy in the extreme and the man's life a misery ; every time the bed-pan is used, patient and splint have to be lifted or rolled ; every time the dressing is done, the splint must be removed and then reapplied.

The dressing of the bad cases in the early stages requires four people and occupies from half an hour to forty minutes. One person does the actual dressing, one undoes and reapplies bandages, one holds the limb, and one holds the patient and tries to smother the shrieks with which he encourages the man in the next bed, who is awaiting his turn.

Wards containing many such cases tax the time, physical strength, and moral courage of the nursing staff, and they remain congested for weeks and months, whilst the fractured femurs drag on their painful weary course.

It seems to me to be unnecessary to discuss the pros and cons of this immobilization method in any detail. It has absolutely no merits except those of using material provided and following current textbook teaching.

Pillows and Sand-bags.—Many surgeons, seeing how futile it is to apply a method the essence of which is immobility—which has to be removed once or twice every day—have discarded all fixation apparatus, and they flex the knee over a pillow or lay it between sand-bags. They regard the wound infection as the main object of treatment and leave the broken bone and the patient's feelings to take care of themselves.

This is such a frank abandonment of the fracture problem that it need not detain us. It presents, however, an advance over the rigid wood splint, because it avoids a futile immobilization and the painful toil of constant putting on and off a useless burden. And further, for patient, nurse, and surgeon, there is not the danger of being deluded by the idea that the fracture is being treated, an idea which is engendered by the long splint called by a distinguished name and fixed in its place by artistic bandages.

Plaster of Paris.—This is probably the best of the immobilization methods, because it really does fulfil its professed purpose, viz. the fixation of the broken limb. With a very little practice and ingenuity in the incorporation of pieces of bent flat metal, so as to leave the wound free, it can give quite good results. But to accomplish this, much practice is required, and even then it needs both much time and the continuous supervision by those accustomed to its use. Apart from these difficulties of detail, it is open to several more serious objections. In the early stages of wound infection, when fresh incisions may be required at any moment, it is inapplicable, unless

applied in the form of a Croft's removable splint, which never has the same rigidity as a solid case. When the wound-discharges are at all profuse it is impossible to prevent the plaster-case from becoming horribly foul. For these two reasons it quite fails us in the early stages of the most severe cases, and any treatment of a gunshot fracture which only begins when the wound has wellnigh healed—is an evasion and not a solution of the essential problem. Another objection to plaster of paris is that it becomes loose when the limb shrinks, and this just at the period when cicatricial contraction is most liable to distort the fracture.

THE TREATMENT OF THE WOUND

The Mistake of doing too Little.—It is not a part of my task to discuss the general principles of infected wound treatment, but it is necessary to lay emphasis on these principles, lest it should be thought that in blaming others for neglecting the fracture in treating the wound, we are making the graver mistake of neglecting the wound in the treatment of the fracture.

There is not usually much difficulty in recognizing that the wound is infected. It speaks for itself in no uncertain language. But sometimes a doubt may arise—in those cases where the wound is neither large and stinking nor small and clean. Shell wounds, single wounds indicating that the projectile is still in the limb, and wounds which the X-ray proves to be

associated with foreign bodies, are all to be regarded as infected. It is well to remember that every piece of shell in a man's leg also means a piece of his trousers and a nidus of virulent infection.

Assuming, however, that there is an infected wound, the three essentials of treatment consist in early intervention, thorough intervention, and unremitting attention until healthy healing has begun. Early and thorough intervention imply an anæsthetic at the first arrival of the case at hospital. The wound must be freely enlarged, and supplemented by counter openings where necessary. In a badly infected limb the lymph tracts are filled with bacteria already, and there is no reason to hesitate in cutting apparently sound tissues, if this is necessary for drainage. The natural tendency is to make all incisions in a longitudinal direction with a view to preserving anatomical integrity. But in a muscular limb these longitudinal incisions become quickly closed by the tension of both muscle and fascia. It is often wiser, therefore, where anatomy will permit this to be done safely, to make **transverse or cruciform incisions**, dividing fascia quite freely and the great muscles through half of their thickness. For example, on the outside of the thigh, the ilio tibial band is cut across and the vastus externus and biceps are each freely incised transversely to their fibres. This will cause much less ultimate injury than a deeply spreading sepsis insufficiently drained. A wound of this character will naturally gape and go on gaping until healing takes place.

Foreign bodies are removed by forceps and then the interior of the wound is lightly scraped to clear out soft débris of clothing and bits of metal. On no account should bits of loose bone be taken out, and much less should they be dragged out by sequestrum forceps. This point will be referred to again later.

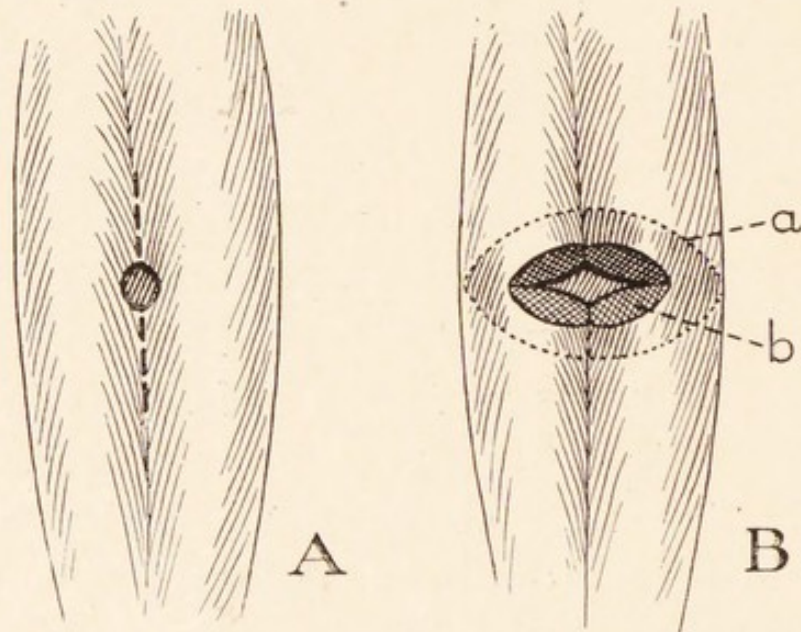


FIG. 10. DIAGRAM OF LONGITUDINAL AND TRANSVERSE DRAINAGE INCISIONS. In A the fascia has been split and the neighbouring muscles divided, there remains a hole which can only be kept open by a tube. In B the fascia is cut across at *a* and the two muscles half divided at *b*. The result is a naturally gaping wound which remains open whether a tube is in it or not. Even a large drainage tube becomes tightly nipped by the muscles whose fibres are intact, so that its lumen is closed.

The problem of drainage is not so important if transverse incisions have been made, and a large tube right through the limb is all that is required. I think that drainage is better effected by a loosely wound wire spiral than by a rubber tube, because the

former is cleaner and will not so quickly become blocked by lymph or nipped by pressure. But I am sure that a gaping incision and a correct position of the limb will make the other details of drainage unimportant.

In bad cases it is not enough to open, clean and drain the wound; it must be kept under constant irrigation. This is of course purely a mechanical process, carried out as well by sterile water as by any bactericidal agent. But it is easier to procure weak solutions of iodine or permanganate than sterilized water, and therefore these will be the fluids of choice. For several days the irrigation is kept up without intermission, then discontinued at night, and not finally stopped until the whole wound has been free from sloughs and pus.

Dressing and bandaging are only of the lightest possible character—a few strips of gauze, in the folds of which lies the nozzle of the irrigator, and a binder or many-tailed bandage which can be undone without movement of the limb. The bandage indeed is better altogether dispensed with in the acute phase, so that the air can penetrate freely the dressing.

A word of protest must here be urged against the too common practice of leaving a small infected wound alone, or of merely inserting into it a drainage tube. Local and constitutional evidence of grave infection may be absent, although bits of shell and scraps of cloth are still imprisoned in the tissues. If such a course is pursued, either extensive tracking of abscesses will occur or the case will drift on into

a chronic septic condition with rapid muscle wasting and general constitutional debility. It is a mistake to think that the mere making of a hole into the tissues and placing therein a drainage tube will secure evacuation of septic material. A large cavity full of toxins and septic débris exists, the walls of which are deeply sown with bacteria. This must first be cleared of its removable contents and then so opened up that it cannot lodge any further collection of secretion, and its every cranny made accessible to the air and to the mechanical cleansing of irrigation.

Not only has efficient wound treatment not begun until the deep tissues have been freely opened up, but whilst time is being wasted in applying dressings to the outer aperture, there is going on a steady tryptic digestive action in the interior of the limb which may first proclaim its activity by the occurrence of secondary hæmorrhage.

If it is futile merely to insert a tube into a small external shell wound, it is positively harmful to pack it with gauze. For this then acts as a plug, which tends still further to dam in secretion and to keep out the air.

THE EXTENSION TREATMENT OF FRACTURES

It may be safely said that every displaced fracture can only be restored to a correct position by extension. In the old methods of 'setting' a fracture, the limb is grasped and pulled upon; in the new way of open operation, the most essential step, before any plate

is affixed, is to seize the two fragments with forceps and pull them apart. Inasmuch as the chief element in producing displacement is the active and tonic contraction of the muscles pulling the two halves of the bone together, the chief element in treatment must be to overcome this contraction by an extension in the long axis of the limb.

Extension then must be the cardinal act of fracture treatment, whether we call it by this name or another and whether we use it alone or supplement it by subsidiary measures.

The problem is chiefly a mechanical one and must be considered from a mechanical point of view. It is the application of a definite force in a definite direction with a view to overcoming a definite resistance and bringing about a definite result. I use this reiteration advisedly because so many are content to deceive themselves by some sort of an extension which is left to act by magic and not by known mechanical laws. It is so common to see a 5-lb. weight tied to the end of a man's leg which is moreover bandaged to a long splint and half buried in the soft bed-clothes. One might almost as well tie a man's identity disk to the bottom of the bed or fix a lucky sixpence above it, as to expect a small weight so applied to do any good. *The Extension Force must be properly fixed to the Limb*, so as to exert an efficient pull upon the distal fragment.

In most gunshot wounds, treated in the early stages, this can be done by adhesive plaster. Broad strips of zinc oxide plaster ($2\frac{1}{2}$ inches wide) on stout

canvas are applied as high up as the wound in the injured part of the limb permits. These are affixed by circular turns of similar strapping of a narrower (1 inch) and thinner kind, the whole limb being covered in except the points over which the circular turns are omitted. Any bony prominences are protected by gauze or lint. The whole is covered by a firm roller-bandage. The object of using so much strapping and applying it in this manner is to distribute the pull as widely as possible over a large surface of the limb, to avoid isolated constricting bands, to prevent œdema, and to leave the joints free for early movements. If, owing to the size and position of the wounds, or to an unsoundness of the skin, or to the great force needed, this application by adhesive plaster is not possible, the attachment must be made directly to the lower fragment of bone, either by a transfixing pin or by the horseshoe screw clamps which will be described in detail later.

The amount of the Extension Force must be adequate to fully correct both angulation and overlapping. It is not a matter of giving a drug and trusting to a theory of therapeutics, but the use of one force to overcome another, and the force we use must be of such an amount and so applied as to do what we require of it. This can only be satisfactorily tested by X-ray examination. Measurements of muscular limbs are difficult to carry out with precision, and even then may give fallacious indication of reduction of deformity.

In the annexed diagram, for instance, an oblique

fracture is shown, in which the length of the bone has been restored without correcting lateral displacement and angulation.

In such a case over-extension must first be performed, so as to unlock the ends, after which they will readily fall into place. In the early period after injury (i. e. within one week) the following represent the usual amount of the extension force necessary to correct displacement: for a femur 20 lb., for a tibia and fibula 12 lb., for the arm bones 8 lb. But these are only rough guides, and the amount

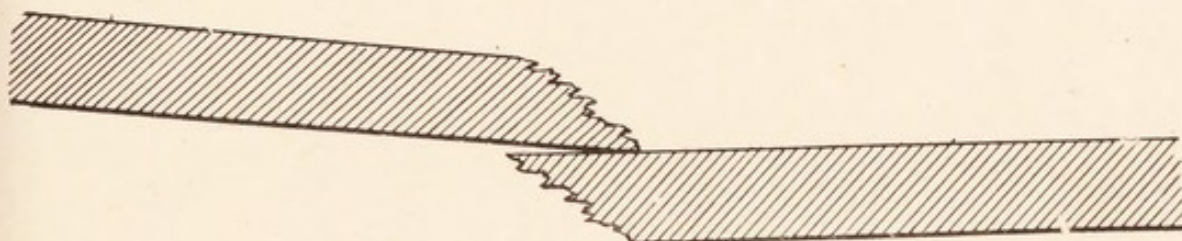


FIG. 11. To show that absence of shortening does not always mean correct alinement.

used in each case must be determined by its result. Bardenheuer used to employ up to 50 lb. for leg extension, but such a great weight is never necessary, and there are various objections to such a practice. The patient is caused considerable pain, the adhesive plaster may become dragged off and, most important of all, there is an injurious strain placed upon the ligaments of the joints below the fracture. If a 25 per cent. increase in the amounts suggested above (i. e. 25 lb. for a femur, 15 lb. for a tibia and 10 lb. for the arm bones) is not enough to fully unlock the overlapping, it is better to increase its efficiency by attaching it directly to the bone than by further increasing its amount.

The actual amount of effective extension force will depend upon various circumstances. Thus :

Conditions which make a large force necessary to produce effect.

Large bone.

Powerful muscles.

Pain causing muscle spasm. Constant moving which causes pain.

Extended position of limb which makes flexor muscles taut.

Long period since injury.

Resistance of bed upon which the limb lies or of splints to which it is bandaged.

Indirect or distant attachment of force.

Conditions which make a small force suffice.

Small bone ; weak muscles.

Absence of pain under influence of anæsthesia, narcotics, or certain kinds of light massage.

Immobility, which implies absence of pain and spasm.

Semi-flexed position of the joints by which the strong flexor groups of muscles are relaxed.

Commencement of treatment soon after the injury before inflammatory exudation or healing tissues are present.

Freedom of the limb from restricting bed, bandages or splints. This condition is usually obtained by free suspension of the limb in a sling.

Direct attachment of the extending force to the distal fragment.

Some of these conditions are beyond our control, but the majority are within it.

The extension force should be applied as soon as possible, whilst the patient is still under anæsthesia, the limb should be slung clear of all restricting

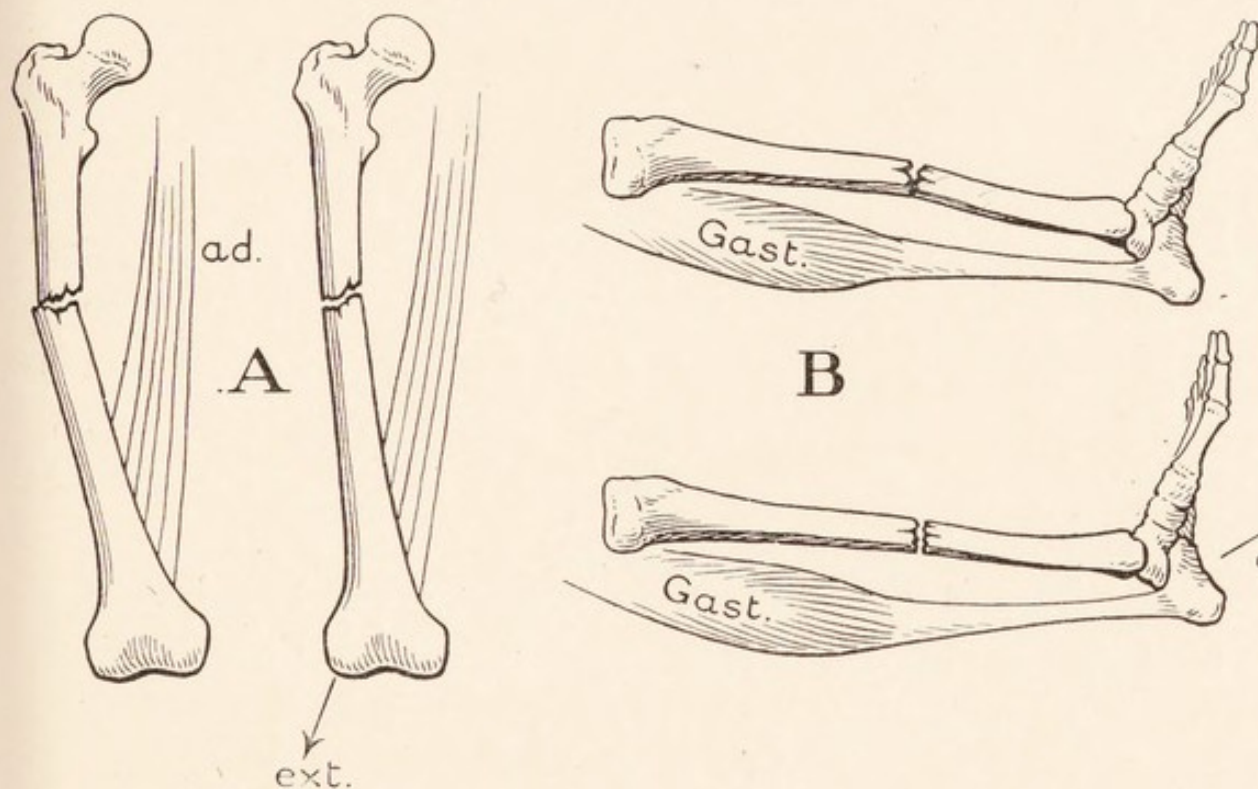


FIG. 12. DIAGRAM OF MANNER IN WHICH THE DIRECTION OF EXTENSION FORCE CAN BE MODIFIED SO AS TO CORRECT ANGLULATION. A. The femur, the lower fragment displaced inwards by the adductors (*ad.*); in the second figure an outward direction of the extending force (*ext.*) has corrected this. B. The tibia, the lower fragment displaced backwards by the gastrocneum (*gast.*) and this displacement corrected by giving a forward direction to extension.

obstacles to extension, placed in semi-flexion, fixed so that it need not be moved as a whole for days or weeks.

The Direction of the Extension.—If the extending force be of proper amount, properly applied, and the

limb is in correct position, it is usually unnecessary to employ any lateral or rotatory forces which greatly complicate treatment and mar the simplicity of the method. In certain parts, owing to the greater power of the muscles on one side of the limb than those of the other, there is always tendency to angulation, and this can easily be counteracted by suitably adjusting the direction of the extension. For example, in fractures of the shaft of the femur, especially those high up, the lower fragment is adducted, and extension should always be in an outward or abducted direction to counteract this. Similarly, in the lower leg, the calf muscles tend to pull back the lower fragment, with forward bowing of the shin. This is met by pulling forwards as well as downwards.

The Nature of the extending Force ; the Importance of Continuous Extension.—In the old method of 'setting a fracture', the limb was pulled away from the trunk, then fixed to a splint. We know that this is quite ineffectual by the evidence of the X-rays, but probably the failure is due more to gradual re-displacement than to inadequacy of the original 'setting'. The chief factor which causes and maintains displacement is a constant muscle-pull which gets stronger when the shock of the injury has passed away. Now a constant or mobile force can only be met and overcome by another constant mobile counter-force of greater power. It is not enough to pull the limb out to a correct length and then tie it to a splint by a fixed strap or bandage. Either the bandage slips or the strap becomes stretched or the patient moves the

limb in such a way as to slacken the extension. The extension force must be of the nature of a constant pull either by a weight acting over a pulley, or by a spring of steel or elastic. The weight has the great merit of continuing to act without change of force when the patient is moved; the spring has the merit of simplicity.

Applicability of Extension Methods to Gunshot Fracture.—Without doubt the extension principle, necessary in the treatment of all fractures, should be the dominant factor in dealing with gunshot injuries which present much displacement.

It has already been shown how the existence of an infected wound, which requires frequent attention, renders mere splint immobilization more than usually futile. And it will presently be urged that the same reason puts open operation out of the question.

Extension, adequate in amount, correct in direction and efficiently applied, remains thus as the one means of restoring the shattered bone to its normal shape and length.

The wound is left open for dressing or irrigation, the limb above the wound is free from constricting bandages, the joints can be exercised at an early period, and above all the treatment of the broken bone can be begun at the earliest moment and need not be delayed until the soft parts have healed.

TREATMENT BY 'MASSAGE' AND MOBILIZATION

This method, which unfortunately is so much misunderstood and therefore neglected, ought to have an

important place in the treatment of all fractures. But it was never intended or suggested that it should be the sole means of treatment of fracture presenting gross displacement. It is a method of quickly restoring health and function, first to the soft parts and then to the injured bone. It cannot either correct displacement or maintain a correct position. For gunshot injuries in which there is no displacement it is, therefore, the principal therapeutic measure, and for the others it is merely subsidiary.

It has just been stated that the manner and rationale of this method is misunderstood, and therefore it is necessary shortly to describe it, in order to avoid not only disappointment but also positive harm.

The mere term 'massage' is really unfortunate because it usually implies deep kneading as well as light stroking. It would be much better to call it hypnotism than massage, if it were not for the fact that the former term is so irredeemably associated with charlatanism. The essentials of 'massage' for recent fractures are :

1. Lightness of touch.
2. Regular monotonous application.
3. The abolition of pain, both local and general.
4. The abolition of muscle spasm.
5. The performance of painless movements of small amplitude by all the joints of the affected limb—the so-called 'internal massage'.

The light caressing Touch.—Fracture 'massage' is nothing more or less than producing a degree of anæsthesia by a series of light hypnotic passes. It is

the bringing about of a subtle nervous reflex by gently tickling the nerve-endings in the skin. It is not a mechanical rubbing of the tissues to squeeze on the lymph or blood flow.

The injured limb being suitably supported and exposed, the operator passes his hand along the most convenient surface from below upwards, barely touching the skin ; this is done slowly and evenly, and repeated with rhythmical monotony at the rate of about fifteen or twenty passes to the minute. After five minutes the pain ought to be less, after ten it should be gone, and in fifteen the patient is often asleep. At the same time the muscles become relaxed and the correction of displacement made easier. The actual site of the fracture is missed over by the stroking hand, so that there shall be no calling forth of pain stimuli. This séance is continued for twenty minutes each day.

The Movements.—On the third to the sixth day, according to the nature of the case, the limb is moved after about five minutes of the massage has been given. The movements are at first chiefly passive ; they are slow, of small amplitude, and must be absolutely painless. All the joints are exercised in this way, those distant from the fracture some days before those adjacent to it. Very soon the patient begins unconsciously to aid in these movements, and this, involving as it does muscular contraction, is just what is desired. Within the second or third week, after a simple fracture without displacement, all the joints can be moved painlessly

for their full amplitude, except perhaps those near to the site of injury, which take a little longer for full recovery. Unfortunately, however ideal may be this method for the speedy cure of slight fractures or the assistance of other measures adopted for severe ones, there are many practical difficulties which limit its use. In the rush of work which accompanies the intake of each fresh convoy, it is hard to get time or nurses to spend even an additional quarter of an hour over each fracture case. Very few ordinarily trained masseurs can be trusted to carry out the above method, simply because they feel it their duty to do more than 'the light caressing' stroke and gentle movement. They have been taught that *pétrissage* must follow *effleurage*, and so the good of the soothing caress is more than undone by the evil of the painful kneading.

At any rate there is one great principle taught by this method, which lessens rather than adds to our work. It is the advantage of a certain amount of mobility. The joints above and below the fracture should not be fixed more than is absolutely necessary, neither should the muscles be mummified by enswathing bandages. For example, in a fracture of the lower end of the humerus, the elbow should not be rigidly fixed. After the third day the joint is moved just so far as can be done without pain, perhaps three or four times, and this simple expedient will prevent it from stiffness.

Here, as about 'massage', great misconception exists. A common practice is first to wait for two weeks before

beginning movement and then to do forced movements. This can only do harm. A forced movement is painful, and pain means muscle spasm whilst force moves the fractured bones and tends to produce callus excess.

When for any reason a fracture has fully consolidated, with stiff joints and withered muscles, then of course the matter is different—deep massage and forced movements may be necessary. The latter even then are much best performed by the patient himself with the aid of some mechanical-exercise machine; but at the best recovery will be a slow and disappointing affair. Our object should be to prevent stiffness of the joints, and not first to allow it to occur and then to cure it.

OPERATIVE TREATMENT OF GUNSHOT FRACTURES

The Mistake of doing too Much

Closed Fractures or those with a healed Wound.—

In regard to those gunshot fractures in which there is no wound, or in which the wound has healed, the rôle of the open operation is very much that which it ought to play in the simple fractures of civil life. I have dealt with this subject at some length in the Hunterian lecture of 1914, and at still greater length in my forthcoming book on *Modern Methods of Fracture Treatment*, and I therefore do not think it is necessary to do more than briefly summarize the conclusions therein stated.

1. The first step is to get accurate anatomical

information as to the position of the fragments by the X-rays.

2. If no displacement exists, then 'massage' with movements constitute the procedure to be adopted.

3. If displacement is evident, then adequate extension is to be applied and further skiagrams taken after a few days.

4. If gross displacement still persists, the question of a more effectual extension method, e. g. that by single or double transfixion, must be considered. If applied, its results must again be tested by sight and not by faith.

5. If extension methods suitable to the case still leave displacement either of (*a*) length, (*b*) rotation, or (*c*) axial angulation, the case demands open operation.

6. Fractures of the leg bones demand operations more than those of the arm, that is to say we should require a higher standard of anatomical accuracy in the former than the latter before being content with non-operative measures.

7. Similarly, adults will require operation more than those whose bones are still growing, because the latter have a much greater capacity for restitution of form and function.

8. Fractures into the large joints with displacement usually require operation; in this category are included fracture of the patella and olecranon.

9. Old malunited fractures will always remain as the most important field for operative activity.

10. The more trouble a surgeon takes to master the

technique of extension methods, the fewer cases of recent fracture will remain for open operation.

11. A case of fracture in which anatomical accuracy of reposition can be attained by non-operative methods will be restored to functional activity more quickly by these than by operation.

12. No operation is satisfactory unless it achieves such mechanical efficiency that the bone is left by it as strong as it was before the fracture.

13. Any operative fixation which requires the limb to be splinted continuously for a long period afterwards is not worth carrying out.

14. Operative methods which satisfy the above criteria of mechanical efficiency are as follows :

- (a) Plates attached by transfixing bolts.
- (b) Curved plates fixed by converging 'metal-threaded' screws.
- (c) Wire encirclement, properly applied to oblique fractures and those of the olecranon and patella.
- (d) Nailing or bolting of detached fragments to the main bone.
- (e) Intramedullary pegging.

In applying the above principles to closed gunshot fractures a few remarks must be added. These all tend still further to limit the number of cases in which recourse must be made to operation.

The majority of gunshot fractures are comminuted, and this implies that alinement and extension is easy, healing is rapid, and operative fixation is difficult. Many apparently closed fractures, in which small wounds have healed, are potentially open, i.e. they

either have septic tracts running into them or septic foreign bodies which will cause a failure of healing even if they do not lead to disaster. The urgency of military surgery makes it undesirable ever to do a long or difficult operation requiring careful after-treatment by the operator, if a simpler method will suffice ; and lastly, there is much greater danger of serious septic infection of these cases than in civil practice, because of the frequency and virulence of other septic cases.

For all these reasons, I think it is quite plain that open operative methods cannot have a large share in the treatment of even closed gunshot fractures, and therefore I do not propose to devote any more space here to their consideration.

Open Fractures with an infected Wound.—It has always been a debatable question whether operations should be performed on open (compound) fractures. Results both good and bad have been obtained, the former being often published and the latter seldom. But it must be noted that the most eminent advocates of operative treatment of fractures, and more especially Lane, have always insisted that the more precise methods which involve plating, screwing, and the burying of foreign bodies in the tissues ought never to be undertaken except in an aseptic field. This view, founded on such obvious common sense, has been so widely accepted that it would hardly be necessary to do more than reiterate it when the case under consideration is a virulently infected gunshot wound. But circumstances have arisen which have induced

some surgeons to throw prudence to the winds, and not only to plate infected fractures but to belaud the method in order to make others follow their example.

It is necessary, therefore, most carefully to examine the problem with an open mind, for its issues are of overwhelming importance.

Arguments in favour of Operation.—It has already been observed that the amount of suffering which men with shattered limbs undergo is sometimes very great and prolonged. An agony is endured throughout the stage of transport, which is renewed at every dressing and dreaded more and more each day, an agony which quickly reduces the health and courage of the strongest patient and the energy of the bravest nurse. In the gaping wound is seen or felt the ends of the broken bone, and it soon becomes clear that the pain is largely caused by these jagged fragments grating against one another and against the inflamed tissues around. What humane surgeon, looking upon so much suffering associated with such a simple origin, does not long to seize the jarring bones and hold them still? The most obvious way of doing this, that suggests itself to a modern surgeon, is to screw on a plate. He realizes the need of mechanical strength and efficiency and uses a long heavy plate with many screws. The immediate result of this procedure is said to be most gratifying to surgeon, nurse, and patient, and there is no difficulty in believing this. The friction of the jagged fragments ceases, and with it the horrid pain and the dread of the next dressing. In fact the condition is so much improved that within a few days the

soldier can be sent home, instead of being kept for weary weeks and months blocking a bed urgently wanted for another fresh case.

This statement conveys all that can be said in favour of the operation, and it is a great deal, viz. immediate relief of pain, facility in dressing, lightening the work of nursing, and making early transport possible. In fact I think that it overstates the case, inasmuch as it ignores the possibility of difficulties, e. g. the splitting of a splintered bone, or complications, e. g. the occurrence of acute septicæmia. But for the sake of argument we will take the above description as a fair representation, and next inquire whether, even with this good start, the operation is likely to give results which justify its performance.

Arguments against Operation.—In order to get that immediate and complete fixation of the bone which is necessary to accomplish the first object of the operation, it is necessary to use very long, powerful plates, one writer speaking of 10-inch plates with eight screws as the instruments for securing a broken femur. Now the application of a plate of such size requires very extensive opening up of the soft tissues, in fact it involves slitting up the whole length of the limb. Perhaps if this wound be left open it may act as a good drain for the infected tissues, but it must necessitate in some cases the opening up of clean tissues to infection. When this long incision is made as I have seen it, along the inner surface of the tibia, the skin soon retracts and leaves the greater part of the shaft exposed to the air.

Even more important than the mere linear skin incision is the pulling aside of the soft parts and the turning aside the coverings of the bone in order to fully expose a surface sufficiently broad for the application of the plate. This more or less blunt dissection, however carefully done, must involve a damage to the tissues which makes them a ready soil for the development of the infective germs which are introduced into them. Unless the bone is really bared at least down to the periosteum the plate cannot be firmly screwed to it, and this baring requires a severance of the vascular tissues which enter its outer surface. Leaving a thick plate in the tissues involves the formation of many chinks and crannies filled with blood-clot in which the bacteria will flourish, so that the surface of the bone under and near the plate is partly devascularized and kept covered by septic blood-clot. The natural result of this will be that this area of bone will suffer necrosis.

A yet more dangerous step is still required, viz. the multiple boring of the shaft by six or eight holes, every one of which will infect the marrow cavity. So that it is not unfair to say that this manner of plating a fracture is bound to produce extensive septic infection of the medulla, and it will only be a happy accident if this does not result in osteomyelitis. Even if the septic process goes no further than the stage of local thrombosis, this will involve a serious interference with the blood-supply of the bone which has already been diminished from the outside.

However simple the fracture may seem to be, there are often fissures running up the shaft from the broken ends. When the holes are bored and the screws driven in, one of these fissures may be encountered, and by opening it up a further comminution is produced, and the operation may have to be abandoned.

If the above is a fair presentation of the case for and against operation, then it must be admitted that it is to be avoided, because it involves too great dangers of increase of sepsis and death of a large part of the bone.

Actual Results of Operations for infected Gunshot Fractures.—But theoretical and *a priori* reasoning is proverbially an unsatisfactory guide in practical matters, and it is necessary to inquire whether there are any facts which bear upon the final results of these operations. The story told by those who have performed them stops short at the point when the patient, eased of his pain and able to bear movement without discomfort, has been happily transported to England. But enough time has now elapsed for the concluding chapters to be written, and one would certainly think that it would have been possible to have obtained some further news of cases which, if successful, would indicate a fine instance of the value of bold surgery. But, as far as I know, nothing has been published about late results, and in the present stressful times it would be unfair to assume that there have been no successes. But certainly those who have the courage to practise these operations and have

taken the responsibility of advocating them, owe it to the profession to find out and tell us what have been their results.

On the other hand, there have been a number of cases in which just those disasters have occurred which we might have expected from *a priori* reasoning.

I have spoken with several surgeons who have received these cases after plating operations, and all have told of failure, or worse, and I have not been able to hear of a single success. Two examples will be enough. In one the fracture was of the femur, and in the other the tibia, and the latter specimen is in my possession and will be more fully described and figured in my new book. The history and result in both cases were so similar that one description will serve for both. The plate had been applied through a long incision which remained widely open. The man had derived great benefit at the time owing to the fixation of the bone and the consequent relief of pain. But this relief was only temporary, because after a few weeks the bare bone with its plate lying in a septic wound again became painful. This was due to the fact that the main part of the shaft had necrosed, and by a process of ulceration was gradually being cast off from the living bone above and below. As a consequence of this process mobility again was established, and at every dressing the inflamed and ulcerated bones were grating against one another. The evidences of sepsis also were more marked. Pus accumulated in the wound in greater quantity, whilst hectic fever, anæmia, and emaciation showed that

the patient was succumbing to toxic absorption. The limb therefore had to be amputated.

Advocates of plating septic fractures point out how well the screws hold in the bone. This is so, simply because the bone in which they hold is dead bone, not capable of tissue absorption.

The points for and against operation in septic cases may thus be summarized :

| <i>For.</i> | <i>Against.</i> |
|----------------------------------|--|
| Speedy relief of pain. | Extensive opening up of soft tissues to infection. |
| Making dressing easy. | Infection of bone-marrow by drilling. |
| Making early transport possible. | Liability to increase comminution. |
| | Danger of causing extensive necrosis. |
| | Ultimate loss of the limb. |

As I shall hope to show presently that it is possible to obtain in all cases immediate immobilization in a position which makes frequent dressing easy without disturbance, apart from open operation, I would conclude with a very earnest plea that the latter may be avoided, and the less dangerous and more effective extension methods more carefully studied and practised.

SUMMARY OF PRINCIPLES OF TREATMENT

The importance of the subject justifies me in closing this survey of general principles by the following summary of essentials :

1. Thorough initial wound-cleansing and drainage.
2. Immobilization without mummification.
3. Adequate extension in the correct direction.
4. Semi-flexion of the joints.
5. A position which gives free access to wound without disturbance.
6. Early movements of the joints.

CHAPTER VI

FRACTURES OF THE JAW AND UPPER LIMB

FRACTURES OF THE JAW

IN many ways fractures of the jaw stand apart from those of other bones, because they involve so many special factors and because the treatment is so largely a matter of dental surgery.

In regard to simple or closed fractures it is unnecessary to say much, because these are so exceptional as the result of gunshot injury. I confess that I have a great dislike of the numerous complicated devices, both intra- and extra-oral, which may have served their turn, but now may be relegated to the past.

The mouth must first be made as healthy as possible by the removal of carious teeth and tartar, and the jaws bandaged together until the internal wound has healed and the fracture is shut off from the mouth. Then the fracture is freely exposed by an incision below the line of the mandible and joined either by wire or by a moulded aluminium plate. If wire is used, then the following points should be noted. The fracture must be absolutely and accurately reduced before drilling or wiring. Two holes are made on each side of the break, and each corresponding pair of holes must be connected by a deep groove cut by a circular saw or chisel. In this groove

the wire will lie and become buried in callus. The mere cutting of the groove in itself will hasten callus union. The wire is placed by an introducer with the free ends sticking outwards. Each wire loop is then caught in the special wire-tightening forceps (see Fig.) and drawn absolutely taut before twisting. I always use tin-plated iron wire on account of its

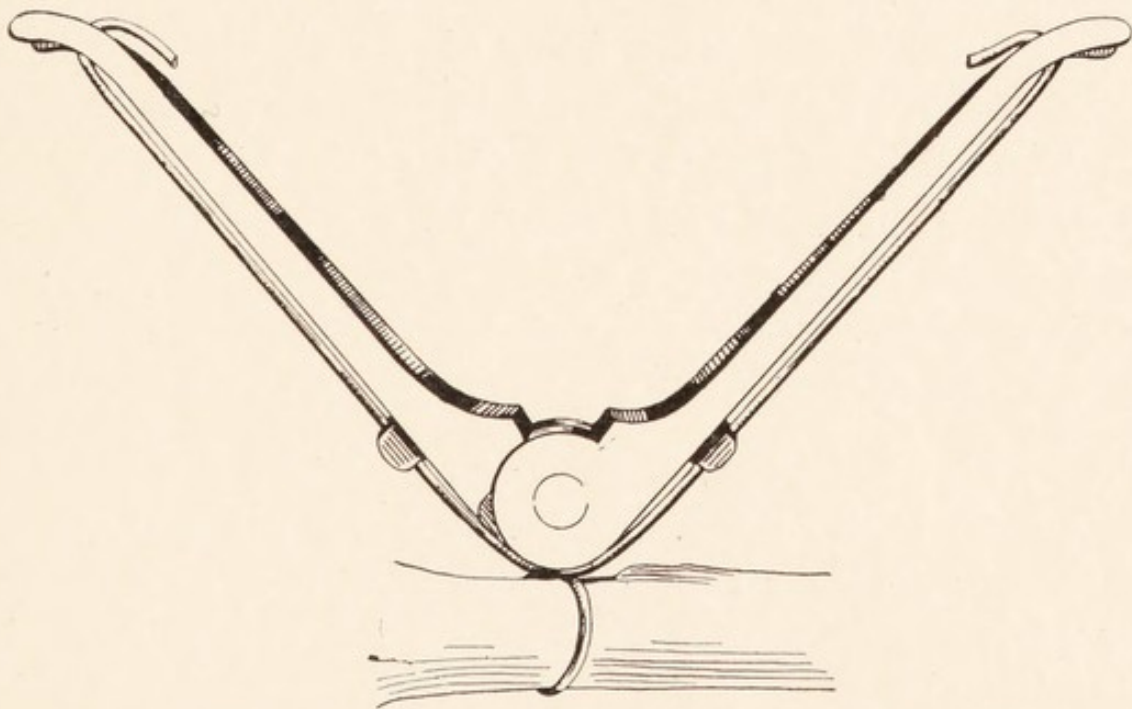


FIG. 13. THE AUTHOR'S WIRE-TIGHTENING FORCEPS.

cheapness and strength. The twisted ends are turned down into the grooves prepared for them, and union is now firm.

For union by a plate, a piece of $\frac{1}{8}$ inch aluminium sheet is cut so as to give a slightly curved plate 2 inches long and $\frac{5}{8}$ inch wide. The fracture is exposed and reduced, and then the malleable plate is fitted *inside* the body of the jaw and held there by forceps. The bone is drilled from without inwards, the drill passing on through the plate. The drill holes are

purposely not all in the same direction or in the same line. The four holes having been made, their outer ends are deeply counter-sunk. Bolts are then passed from within outwards and affixed by conical nuts screwed on to their outer projecting ends. The bolts are $\frac{1}{8}$ inch thick and made of plated iron, which can readily be cut off by a cutter flush with the outer surface of the bone.

Open Fractures with Loss of Substance.—If the patient has good teeth remaining firmly on each side of the splintered jaw, the case had best be treated by the dental surgeon, but I would urge that there should be a closer co-operation between the surgeon and the dentist than usually exists in the discussion and treatment of all doubtful cases. But it often happens that just where the dentist requires them there are no sound or firm teeth. These cases vary so much in their form and complications that it is impossible to do more than make some general suggestions as to surgical treatment.

Perhaps the commonest type is where the chin has been shot and a part of the symphysis either shattered or blown away. If the bone injury is ignored or its treatment postponed too long, there will develop an unsightly and disabling deformity from the falling together of the two halves of the jaw.

It is useless in such a case to attempt any treatment which involves a direct holding of the bone until the wound has taken on healthy conditions; on the other hand, it is a mistake to wait for complete healing, because then a dense cicatricial deformity will have

to be corrected. The right period is when the sloughs have come away and the wound is granulating. In this, as in other fractures, the appearance of granulation tissue in the soft parts corresponds with that of callus formation in the bone.

The Placing of a Transverse Strut.—As the tendency of deformity is the drawing together of the two halves of the jaw, the necessity for treatment consists in keeping these apart. This is done by passing a $\frac{1}{8}$ inch bolt right through from side to side, and fixing each end to the jaw. An incision about 1 inch long is made below each ramus, well behind the area of the wound. The skin is drawn up so as to expose the outer surface of the bone, and a hole is drilled right through from one side to the opposite by a drill 4 inches long. The drill is pierced by a hole at its cutting point, and this is used to withdraw a wire, which then acts as a guiding tractor for the bolt. The most important point in the drilling is that whilst it is being done, the two halves of the broken jaw must be held firmly against the upper jaws in correct position, because when once this line of drill has been made the jaw will be fixed by the bolt in the same position in which it was placed when pierced.

The bolt is $\frac{1}{8}$ inch thick and 4 inches long, with a screw thread cut in both ends. When it has been placed in position, a small plate with a threaded hole at one end is screwed on to each end. This plate is of iron, and can readily be bent. When each plate has been screwed up to the level of the bone, it is placed at right angles to the length of the jaw, with its free

end downwards. This is bent round the ramus and screwed to this by a metal threaded screw which runs in a direction at right angles to that of the bolt. The ends of the bolt are cut off and the skin incisions sutured.

Comminuted Fractures near the Angle of the Jaw with Displacement.—If the bone in the region of the



TRANSVERSE $\frac{1}{8}$ " BOLT FOR JAW FRACTURES, WITH EYELET FOR WIRE GUIDE.

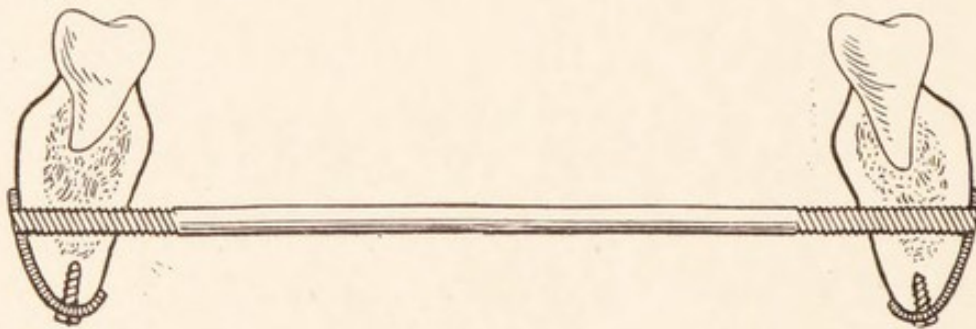


FIG. 14. DIAGRAMMATIC TRANSVERSE SECTION OF THE JAW SHOWING BOLT IN POSITION.

angle has been shattered, or even the lateral part of the ramus, and there are no teeth to which the dentist can attach a dental splint, the problem is rather difficult. After the wound has become healthy, a device on the principle of Lambotte's Fixateur may be applied outside the jaw in such a way that two screws hold on each side of the fracture. But the exact conditions which render this desirable are so rare that I do not think it worth while to describe it in detail. The case may also be treated by bandaging

the jaws together, so that the upper forms a splint for the lower, if the condition of the wound will allow it. Finally, when the wound is healed, there are a few cases where there has been great loss of substance in which bone-grafting may be undertaken, but I will reserve remarks on the technique of this procedure to a later chapter.

Fractures of the Clavicle.—Gunshot wounds of the clavicle are often associated with severe injuries of the underlying vessels and nerves. The bone is much splintered, and scraps of metal, cloth, and bone are deeply buried in the tissues. In such an injury the parts should be freely opened up and the infected wound treated with little or no regard for the bone lesion. If there is troublesome hæmorrhage, either early or late, the central portion of the clavicle should be freely removed or turned aside as a part of a musculo-cutaneous flap. As the entire bone can be taken away with little or no injury to the arm, this policy of sacrificing the bone if the deep tissues are endangered is fully justified. And similarly in comminuted fractures without obvious injury to vessels and nerves, it is well to take away loose fragments quite freely, because, whilst loss of bone is here of no consequence, there is real danger of callus excess causing late pressure upon the brachial plexus. During the treatment of the wound, the arm is kept in a sling, and at an early period is subjected to daily gentle massage and movements, particular care being taken to abduct and rotate the humerus.

Fractures without an infected Wound.—In these

there is the usual tendency for an overlapping of the fragments, owing to the pull of the pectoral and trapezius muscles. With the overlapping there is an angulation at the site of fracture, due to the weight of the arm pulling down the outer end.

There are many good ways of treating a fractured clavicle, and I will only describe the one which seems to me to be the simplest and most efficient. It is well known that if a patient with this injury be kept lying flat on his back in bed, union occurs in good position and with the least possible deformity. This gives the clue to the necessary treatment. Keep the shoulders back, supporting the weight of the arm, from angulating the outer fragment, and a good result will follow. When the shoulder is pulled backwards, the scapula slides round the thorax and a directly outward pull is given to the clavicle. Hence this is really an extension method obtained by a postural device. The best splint for this purpose is a thin flat piece of 'three-ply' wood, which requires no padding. It is placed behind the shoulders, and causes no discomfort when the patient is lying flat in bed. A broad padded leather strap passes round each shoulder and under the axilla, by which the limbs are drawn back against the splint into exactly the position they would occupy if the patient were lying in bed. A sling supports the elbow so as to take off the weight of the arm. When the patient is in bed the sling is removed, and every day 'massage' with movements is practised. After two to three weeks, union is firm enough to dispense with the splint.

FRACTURES OF THE HUMERUS

Upper End.—When the head of the bone and tuberosities are shattered, and an infected wound is present, there should be no delay or hesitation in opening up the parts quite freely. Whether the principal wound is anterior or posterior it should be enlarged and the corresponding edge of the deltoid retracted and cut through across its fibres if necessary for free drainage. In the anterior position the groove between the pectoral and deltoid is exposed and the adjacent edges of both are boldly incised. This, together with the retraction of the muscles, gives a free access to the head of the humerus, and there need be no hesitation in slitting up the capsule of the joint along the bicipital groove. Loose bits of bone had better be taken away in accordance with the above-mentioned principle that at the articular ends callus excess with ankylosis is the danger to be avoided, and not want of repair. In dangerously infected cases a free opening should be made right through from front to back and the arm put up in an abducted position with continuous irrigation continued until the wound becomes healthy.

Subsequently, abduction both by exercises and position is the chief point to be observed. The latter is obtained by keeping the arm at right angles to the chest for the whole period that he is in bed.

Shaft.—Gunshot fractures of the shaft of the humerus display marked comminution, but it is unusual to find any great displacement. This fact

is very suggestive. In a gunshot injury the great trauma causes a temporary paralysis of the muscles—when such an injury is in the upper arm the patient carries the limb in a position which ensures axial extension with semi-flexion of the joints from the

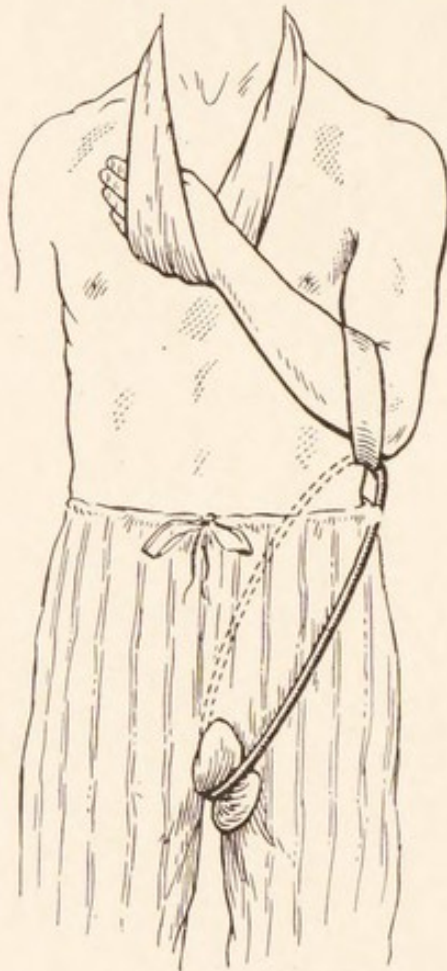

FIG. 15. METHOD OF TREATING FRACTURED HUMERUS BY EXTENSION WITHOUT SPLINT.

very outset, and therefore the position is made good from the very commencement.

Paralysis of the musculo-spiral nerve occurs very commonly, though it is generally only partial, as the result of contusion and not actual severance of the nerve. The existence of this complication makes it necessary to leave the forearm exposed for the

application of electrical treatment and the hand supported in dorsi-flexion in order to relieve the paralysed muscles from tension.

A very large number of gunshot fractures of the humerus are best treated without any splint at all, or with a mere protective splint incorporated in the

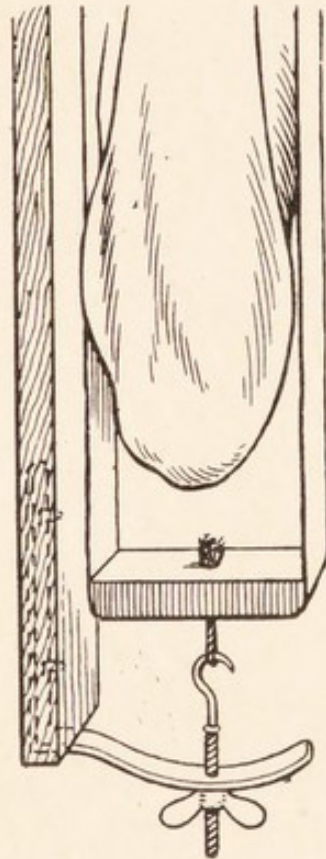


FIG. 16. MODIFIED BORCHGREVINK'S SPLINT FOR FRACTURED HUMERUS. The horseshoe-shaped axillary pad is not shown.

dressings. The natural extension caused by the weight of the forearm may be supplemented by attaching a weight or elastic band to the elbow by a band of webbing and supporting the hand only in a sling. This method is to be adopted in cases with such extensive wounds that there is not surface enough for the application of adhesive strapping. The elastic traction is kept up by a piece of stout drainage-

tube passed through the elbow-strap and round the perineum and outside the trousers or pyjamas. When, however, the wound allows of it, the simplest device is the extension splint shown in the figure, which is a pattern which I have modified from Borchgrevink's original model, first used in the late Balkan War.

Adhesive strapping is applied to the upper limb and attached to a little wooden piece below the elbow. The Y-shaped splint having been padded at the crutch is placed between the arm and the chest, and the extension stirrup is fixed to the projecting spring, which carries a fly-nut and screw by which the tension can be adjusted. The spring, when bent a right angle with the splint, gives 10 lb. extension, but usually less than this is sufficient. The hand is supported in a sling and the forearm and elbow-joint are massaged and gently moved each day from the very first.

No bandage is required to fix this splint, but a few loose turns may be used round both splint and arm to keep the dressing in place.

After 14 days the splint is taken off, and the remainder of the treatment consists in attention to the wound with movements of the joints.

FRACTURES OF THE LOWER END OF THE HUMERUS

Gunshot Wounds of the Elbow.—These injuries are associated with terrible pain and marked displacement. The latter usually takes the form of backward dislocation of the lower fragment of the humerus.

When the wound is explored, loose bits of bone

are to be removed and free drainage provided right through the elbow from side to side.

The splint which I have termed an antero-internal extension splint is especially designed for this type of injury. It is an internal angular splint on which the arm and forearm rest, the actual angle opposite the internal condyle of the elbow is cut away so that both surfaces of the joint are free for drainage.

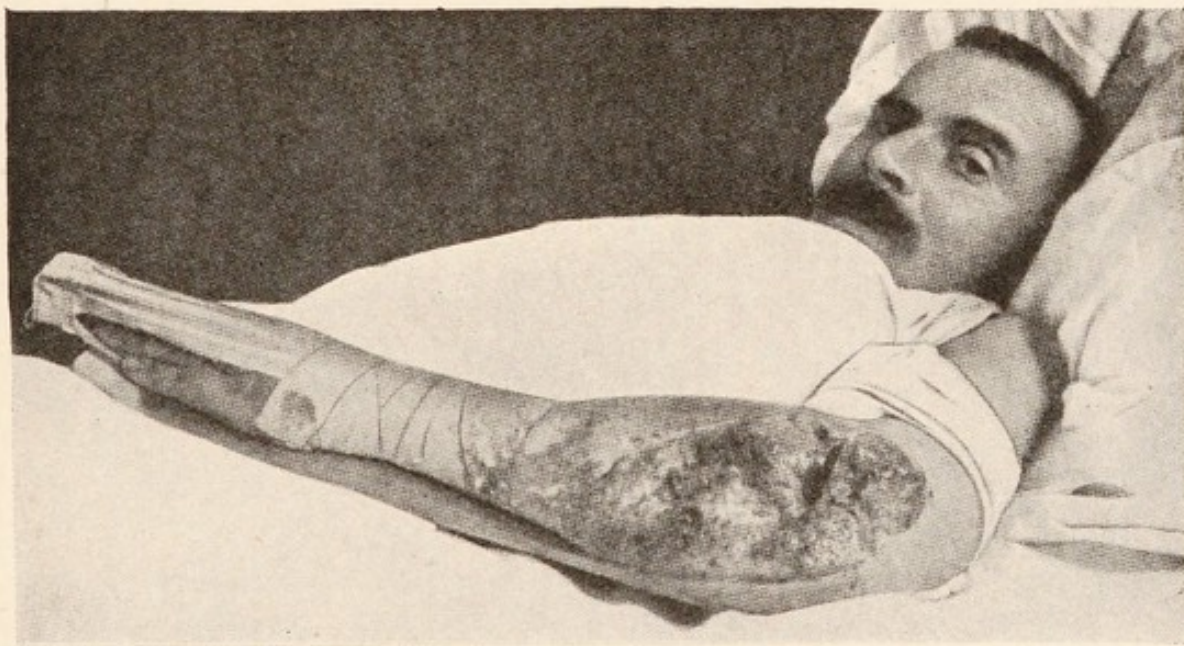


FIG. 17. THE ANTERO-INTERNAL SPLINT FOR FRACTURES NEAR ELBOW.

From the arm-piece a concave projection juts out which lies against the anterior or bicipital aspect of the upper arm and affords counter-extension.

A spring at the lower end of the splint provides for constant extension in the axis of the forearm. This is attached to the limb in the manner described below for forearm fractures. The outer end of the splint may be rested on a pillow and the inner on the patient's body, or the whole may be slung from above the bed.

FRACTURES OF THE FOREARM

It will be unnecessary to say much about those cases in which there is no displacement, which in general terms ought to be treated by the massage and mobilization method, neither is it necessary to differentiate between injuries in different parts of the bone. 'Take care of the joints, and the bones will take care of themselves' should be the guiding principle in all. One caution is necessary, and that is to avoid persistent pronation of the hand. To do this it is wise to use an anterior or posterior angular splint and keep the hand fully supinated. The anterior splint is, I think, the better, because it is smaller and lighter and requires less bandaging. The splint is removed daily for massage and movements.

Fractures with gross Displacement.—Any forearm-extension splint will serve to treat these cases, and the only object in having different patterns is to adapt the appliance to the position of the wounds, so that the latter may be left freely exposed for treatment. The anterior angular splint by its lightness and ready adaptability is that most suited for emergency work. It leaves the inner, outer, and extensor surfaces of the arm quite free. The posterior angular is much larger and heavier, and I should never use it unless it is necessary to leave the flexor surface uncovered. The antero-internal splint, already described for the elbow, is suitable for a bed-ridden patient, because it then affords a shelf on

which the shattered arm rests. The metal-frame splint has a broad surface against the biceps region and a metal band surrounding the forearm ; it leaves the whole surface of the latter free for dressing.

The simplest manner of attaching the extension force to the arm with any of these splints is to apply the longitudinal adhesive strips to the flexor and extensor surfaces of the forearm and take these right down along the front and back of the hand and fingers. But this leaves the hand in an uncomfortable position which will cause a troublesome stiffness

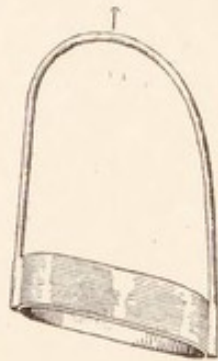

FIG. 18. SIMPLE WIRE FRAME FOR APPLYING EXTENSION TO HAND.

of the fingers. A better way, therefore, is to use a little metal-frame hand-piece, which can quickly be bent out of a single piece of stout wire. This consists of one oval which passes round the hand across the middle of the metacarpus and a stirrup at right angles to this which is of a size to surround the edges and tips of the four fingers. The adhesive strapping is attached to the encircling oval and the extension force to the horse-shoe loop. In this way the finger and thumb are left quite free and can be exercised at will throughout treatment. The arrangement

of the spring and the adjustment of the tension are just the same as in the humerus splint.

Fractures of the Metacarpals and Phalanges.—In most of these cases no special splinting is required. But on the other hand, great displacement may occur, which causes a hopeless stiffness and deformity if left untreated. It is quite worth while, therefore, to make some adequate provision to prevent this

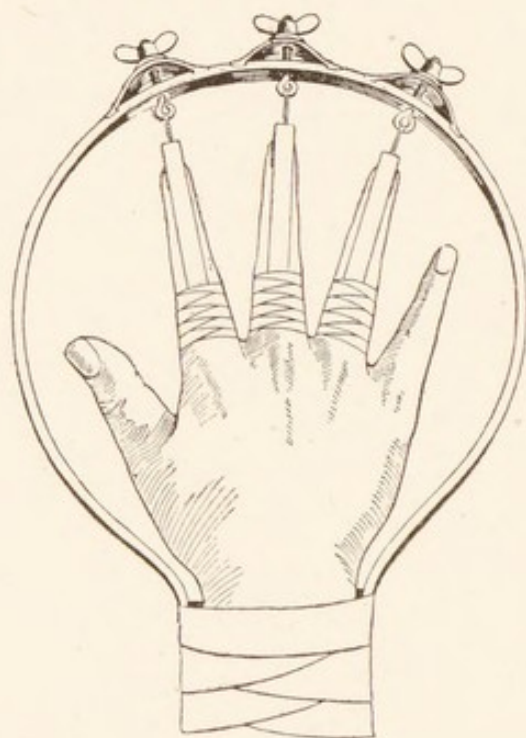


FIG. 19. FRAME TO PERMIT OF EXTENSION OF THUMB AND FINGERS.

deformity by an extension method which will not interfere with the treatment of the wounds.

The illustration explains a simple device for meeting these conditions. A wood splint is fixed to the forearm. To its edges is attached a metal band which is of a size and shape to encircle the periphery of the outstretched digits. Five holes in this metal

band afford traction-points for as many springs, which can be adjusted by screws. Each spring gives up to 3 lb. extension.

If, for example, the hand has been shattered and the three middle metacarpals comminuted, there are large wounds on the dorsal and palmar aspects. By keeping a constant pull on the three middle digits in the way shown in the figure, gross deformity is prevented, and whilst the hand is comfortably kept at rest, both aspects are free for frequent attention to the wounds.

CHAPTER VII

FRACTURES OF THE LOWER LIMB

Femur.—It will perhaps be most convenient to begin by discussing the treatment of fractures of the shaft of the femur, and having described the best types of apparatus for this the commonest injury, proceed to state what modifications are necessary for other fractures of the thigh.

Shaft of the Femur.—Objections to some splints in common use.

It has already been pointed out how the old type of splint falls so very far short of the requirements of ideal treatment of gunshot injuries. This applies, perhaps, with greater force to the splints for the femur than those for other parts. It is really with the gunshot injury of the thigh that the problem of adequate treatment alike of infected wound and of shattered bone reaches its most intricate form.

A simple long Liston Splint is perhaps the commonest device, which appeals to many because of its simplicity. They would say that in war time we cannot be encumbered with elaborate apparatus tedious of manufacture and troublesome to take about. Simplicity is of course a most desirable characteristic of treatment, but it is quite a fallacy to imagine that

by inadequate apparatus it is obtained. The splint may be simple but the treatment is long, arduous, and painful. I cannot believe that any one can be satisfied with the long Liston for gunshot wounds of the femur, and therefore I need not repeat the objections to its use, but point out a more desirable method.

Thomas's Knee-splint.—This splint is, when used for a broken thigh, an extension splint, and one which, to a limited degree, allows of postural treatment, i. e. correction of displacement by the direction of extension ; moreover, it leaves the limb uncovered by bandages for dressing. It has the advocacy of one of the most distinguished of orthopædic surgeons, Mr. Robert Jones. But in spite of all these things in its favour it seems to me to fall short of the ideals which we aim at. The extension is that of an inert band which lacks the constant character either of weight or spring. It ties the limb in an extended position, but it does not keep in action a constant extending force. It holds the main joints in a position of full extension which, by reason of the powerful flexor muscles, means one of maximum tension. And the rigid knee, which cannot be bent without undoing the extension, becomes fixed and painful. Although the back of the thigh is not covered by bandages, it cannot be readily got at, because this requires the leg to be lifted from the bed, and the lifting of a leg with a straight knee greatly increases the tension of the hamstring muscles, whilst the ring at the top of the splint does not readily allow of this movement. Therefore, unless the patient is

kept with the limb fully abducted over the side of the bed and the whole apparatus supported in this position, constant irrigation or frequent dressings without painful movement are impossible. This position of the leg right out of the bed takes up much space and renders it liable to be knocked by passers-by. Used merely as a transport splint the Thomas has some advantages, but the hard ring is very uncomfortable to lie upon when the leg is flat on the bed, and the patient will be always wriggling so as to ease his position.

I doubt very much whether effectual extension can be maintained by it, but if there is much tension on the leg the counter-pressure of the ring upon the man's perineum becomes very painful. It may be a good splint for the simple fractured femur of a child, but it does not meet the case of a shattered thigh in a powerful man, associated with a bad wound.

Hodgen's Wire Cradle Splint.—This, in my opinion, is without question the best of all the text-book patterns, and it embodies all the cardinal requirements for the treatment of gunshot fractures. In theory it is absolutely perfect, ensuring extension, semi-flexion of the joints, free access to the limb without disturbance. But in practice it is open to this objection, that it requires a good deal of experience, patience, and care for its correct adjustment. The limb is slung in a wire cradle to the bottom of which it is tied. Then the wire cradle is suspended by an oblique cord which both supports and extends it.

Thus the whole limb, from the hip downwards, is swinging in mid-air. Every manipulation of the wound and even the actions of passers-by tend to jar it, and one notices how a soldier whose leg is up in a Hodgen's splint anxiously watches each new comer

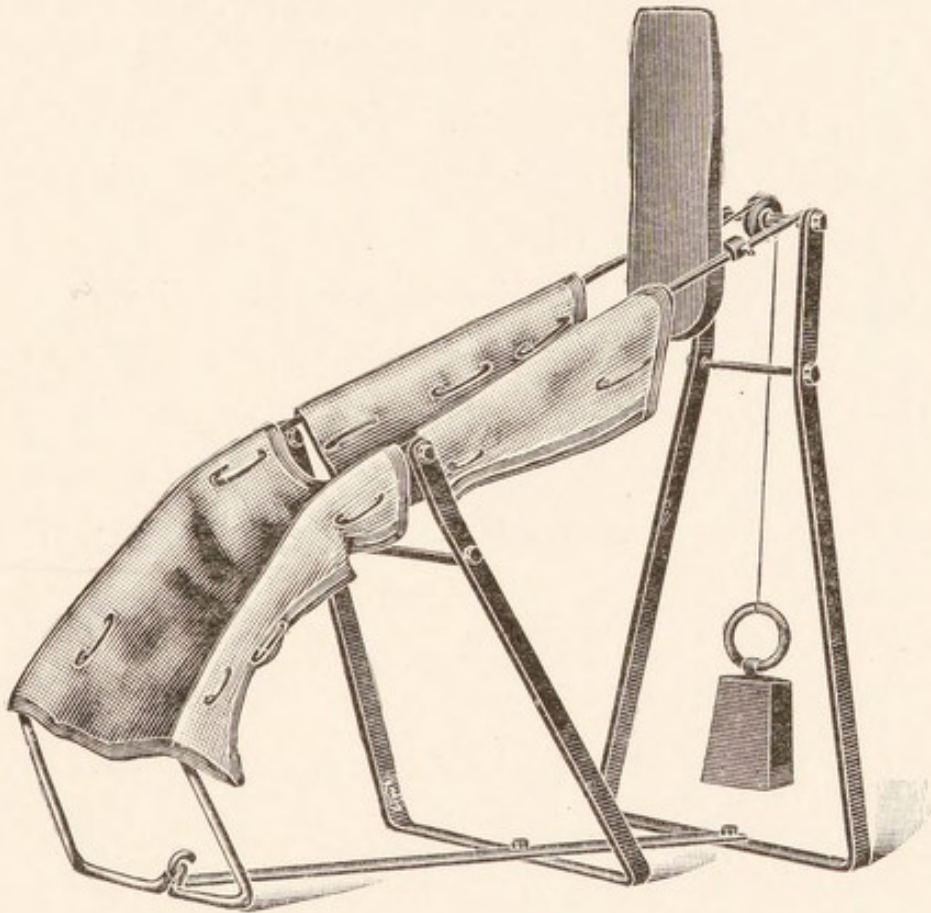


FIG. 20. WIRE CRADLE LEG-SPLINT WITH SLINGS IN POSITION.

lest he should hit against his bed and set his limb in movement.

Again, the mechanical extension is not so simple as it looks. Suspension and extension are both brought about through the pull of an oblique cord, and any change in suspension causes a corresponding change in extension.

A fixed Wire Cradle Splint.—If the wire frame of the Hodgen's splint is retained, but instead of being swung free is fixed, and the limb is extended inside the frame instead of with it, we have a perfectly simple splint which will serve for the treatment of the majority of cases of gunshot wounds of the femur.

The figure shows one form of this wire cradle splint, fixed up with its own stand. It will be noticed that the cross-pieces of this splint all lie beneath the limb instead of above it, like the upper cross-piece of a Hodgen. This enables the slings to be adjusted on the iron frame, and then the whole apparatus is placed beneath the leg, which is elevated above the bed in a position of semi-flexed hip and knee. (With a Hodgen only one end of the flannel slings can be fixed before adjustment, then the splint is put in front of the limb and the free ends of the slings fixed behind it.)

The leg below the knee is supported by a single sling made from a broad piece of calico. The thigh has three bands, each four inches wide, to make its cradle, so that one, two, or three of these can be removed at a time to expose the wounded area.

The same splint serves to support either right or left leg, but if there is a fracture high up, so that the upper part of the femur needs support, the outer bar can be prolonged four inches by an attached half-tube which slides upon it and makes the outer bar four inches longer than the inner, as is the case in a Hodgen's splint.

The whole apparatus has a broad base of support,

which rests on the bed, which should be made firm by the use of fracture-boards. A couple of sand-bags are placed inside the base in order to steady it.

Exactly the same cradle splint can be fixed to an upright board at the bottom of the bed instead of being supplied by its own metal frame. This makes

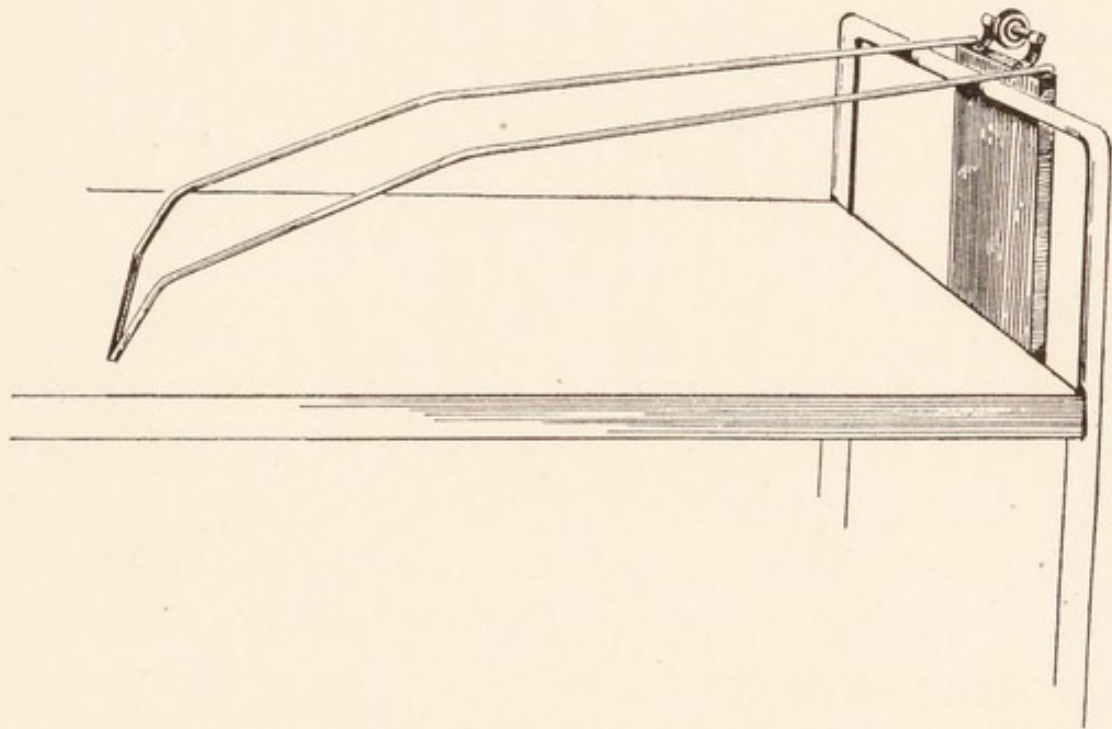


FIG. 21. WIRE-FRAME SPLINT FIXED TO UPRIGHT AT FOOT OF BED.

the thing much cheaper and better adapted for use in a large hospital.

At the lower end of the cradle splint is a cross-bar bearing a pulley wheel.

The usual adhesive plaster strapping is applied to the limb, the longitudinal pieces reaching up as high on the thigh as the wounds will allow. Overlapping circular strips fix the main pieces above the knee and the whole way between the tubercle of the tibia and

the instep; the anterior crest of the tibia and the malleoli being protected from pressure by pieces of gauze. The lower ends of the strapping are brought round a wooden sole which bears two outstanding metal projections. These just lie upon the wire bars of the cradle and serve to support the foot without restraining the movements of the ankle. This support makes it unnecessary to have any part of the sling beneath the heel or tendo Achilles, so that the great liability of these parts to pressure-sores is avoided. When all the adhesive plaster has been adjusted, the limb is firmly bandaged from the toes to the nearest possible point below the wounds in the thigh.

The extension weight of 20 lb. (at least) is attached to a hole in the iron cross-bar of the sole piece by a cord which runs over the pulley wheel. Counter-extension must be provided by raising the foot of the bed or by a perineal band round the opposite thigh and attached to the head of the bed.

The limb should always be put up in abduction, not only in order to prevent the common angulation produced by the pull of the adductors, but so as to make attention to the needs of defæcation easy. This abduction is obtained by placing the upper end of the splint in the middle of the bed and the lower at the extreme corner of the foot of the bed.

When the limb has been adjusted in this cradle splint, which is best done before the patient has recovered from the anæsthesia induced for the primary wound-treatment, it is left there day and night until bone-union is firm enough to allow of the leg being

moved. If the wound has been thoroughly and successfully treated, this period is about three to five weeks, consolidation being both rapid and firm.

In certain cases this method of extension will not suffice to obtain satisfactory distraction of the overlapping fragments. Such cases are those in which treatment of the fracture has been delayed and overlapping has become marked; and those in which the lower fragment is small, so that the adhesive plaster extension cannot get any purchase upon it except through the indirect pull of the ligaments of the knee. In such cases I do not think it is wise to increase the weight above 25 lb. It is better to transfix the lower fragment or hold it by the special horseshoe screw clamp which I have devised. The transfixion pin or clamp is then pulled upon by a cord which runs over a pulley at a higher level than the foot, and this is sufficiently explained by the illustration. In this way by directly pulling upon the lower fragment and by directing the pull in the axis of the thigh, a 20 lb. weight will be enough to distract the most obstinate displacement.

On the use of heavy Weights for Extension.—It is commonly objected that a 20 lb. weight extension will cause unbearable pain. This is, I think, only the case when it is wrongly applied.

Quite unnecessary pain may be caused in three ways. The adhesive plaster is put on badly so as only to grasp a small area of skin, which has thus to bear all the traction. Or the limb is not securely supported, so that whenever the dressing is done, the traction is

altered and every alteration in traction causes a re-adjustment of the muscles and bones with consequent friction. A small weight is put on at first and gradually increased. Here, again, every change means a fresh re-adjustment with resulting pain. It is much better to put the full 20 lb. on before anæsthesia is ended and then supplement the anæsthesia by a dose of morphia. The muscles once and for all are overcome, and no further pain is caused by the extension.

It is quite right and proper to reduce the amount of the extending weight when union has begun. Thus my usual practice is to maintain 20 lb. for 2 or 3 weeks, reduce to 15 lb. for one week and to 10 lb. for the remaining period.

To those who have never used transfixion extension, because they regard it as barbarous, it will come as a surprise how painless it is, involving as it does less weight, a firm hold on the bone, and no dragging upon the soft tissues.

Improvised Sling and Extension Methods. — If neither material, time, nor workmen are available to make special splints, quite good extension can be improvised by slinging the leg to a pole fixed above the bed in an inclined position, the lower end being higher than the upper so as to obtain an inclination of about 30 deg. The thigh is slung by one bandage and the leg below the knee by another. A curved gutter splint made of sheet metal, thick cardboard, or poroplastic and placed in the sling bandage beneath the fracture will make the apparatus much more comfortable and prevent sagging at the site of injury. (Illustration.)

Splints designed for Transport.—It is often a matter of vital urgency to be able to send cases of fractured femurs home from the base hospital as soon as the acute stage of wound-infection is over, but before union of the bone has occurred. To do this some sort

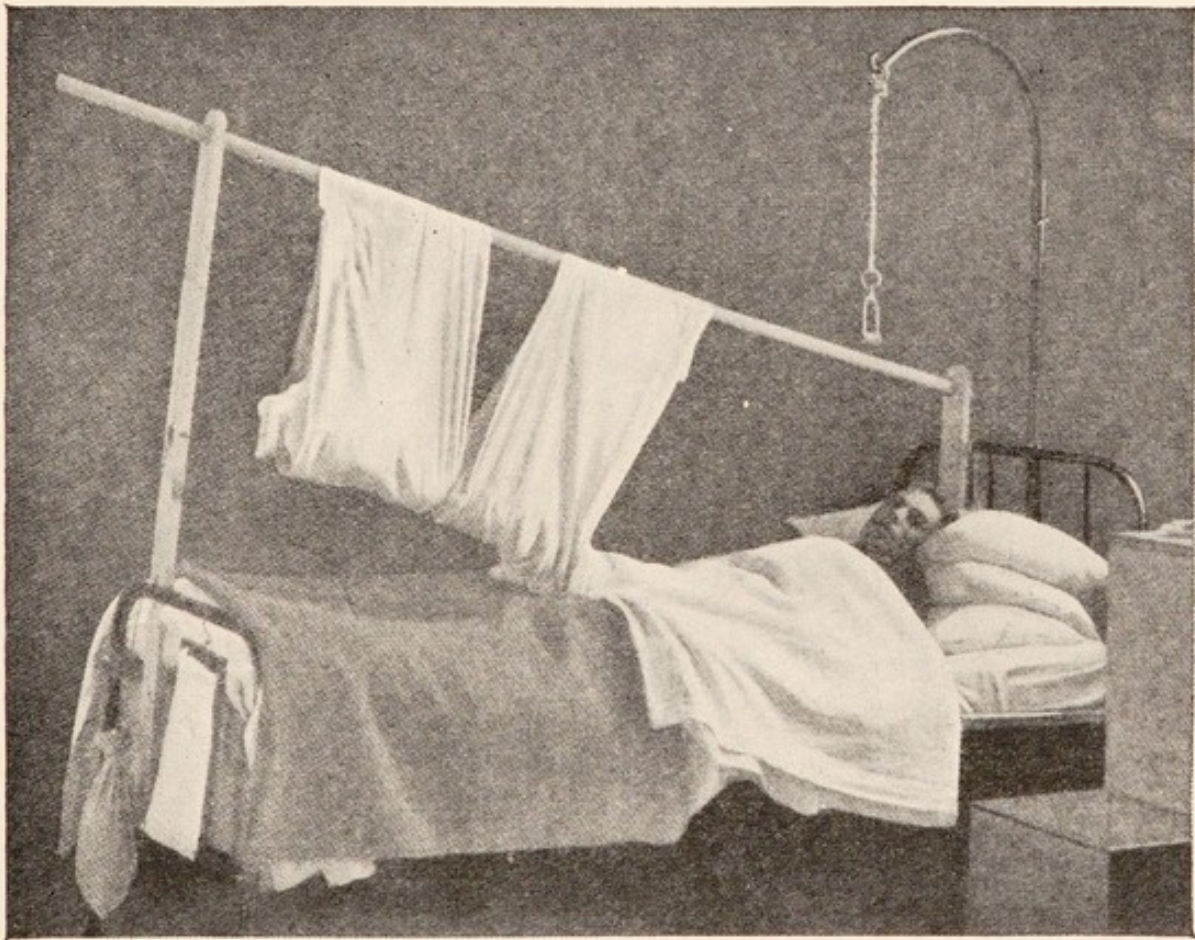


FIG. 22. A SIMPLE METHOD OF SUSPENSION AND EXTENSION OF THE LEG.

of modification of a Thomas's knee-splint is necessary. The drawbacks to the simple Thomas's splint may be obviated by a modification in which the long bars of the splint are bent at an angle of 135 deg. opposite the knee-joint, and the ring which encircles the thigh is

hinged to the leg-piece so as to permit flexion of the limb. The splint, which is made of $\frac{5}{16}$ steel wire, is supported by a strut at the knee, and the lower end is turned down so as to rest on the bed or stretcher.

This apparatus is made for a right or left leg in which the limb is slung, the joints are semi-flexed and this relieves much of the muscle tension in the thigh. The thigh is raised off the bed, and therefore the dressing can be done without disturbance. The sling under

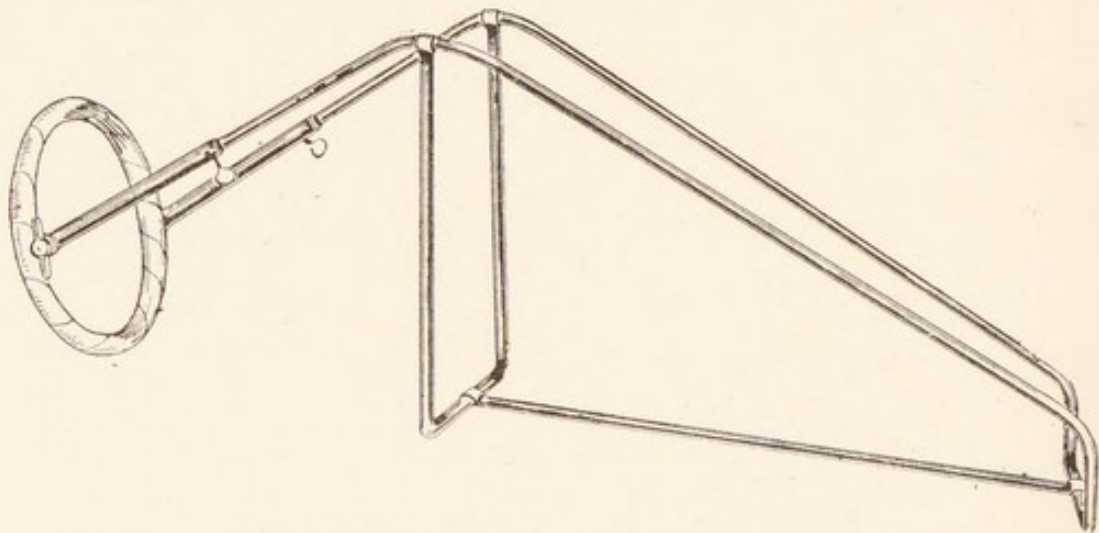


FIG. 23. MODIFIED THOMAS'S KNEE-SPLINT FOR TRANSPORT.

the calf tends to pull the leg up away from the hip, and therefore by reinforcing this by one broad strip of elastic bandage, a constant traction is maintained upon the thigh. The hinge between the ring and the leg-bars allows the former to adjust itself to the natural folds of the groin and buttock, whilst the raised position of the thigh obviates the discomfort of the patient lying upon the hard metal band. The limb should always be kept abducted, so that the counter-extension acting through the ring shall be equalized

between its outer and inner parts and not all be thrown upon the perineum.

Fractures high up in the Femur with Wounds in the Buttock or Groin.—For hospital treatment of these cases, the wire cradle splint already described answers quite well, if the extension-piece is fixed on to the outer bar so as to lengthen the outer part of the splint without bringing the inner part too close up to the

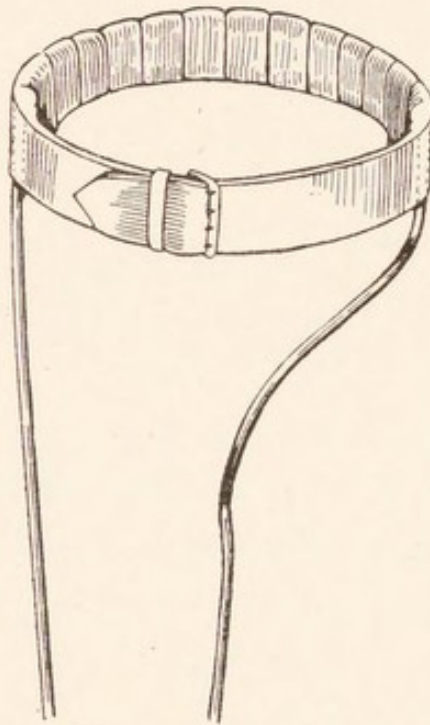


FIG. 24. UPPER END OF TRANSPORT-SPLINT IN CASES WHEN THERE ARE WOUNDS NEAR HIP OR BUTTOCK.

perineum. In this way the upper end of the femur can be slung. The wire cradle as a whole requires to be set at a higher angle so as to hold the leg up and expose the buttock for dressing or drainage. Full weight extension and full abduction are both particularly important to prevent a union in a position of coxa vara. **For Transport** of such a case, a special splint is necessary which whilst preserving the general

outline of the flexed Thomas's knee-splint, avoids encircling the wounded hip. This is accomplished by the use of a pelvic band, made of a semicircle of flat metal which lies behind and is attached to the body by a wide webbing strap in front. It is prevented from riding upwards by two perineal bands, the middle of each of which is sheathed in rubber. The outer bar of the splint fits into a slot in the metal part of the pelvic band just above the great trochanter; the inner leaves the inner aspect of the thigh, curves over the

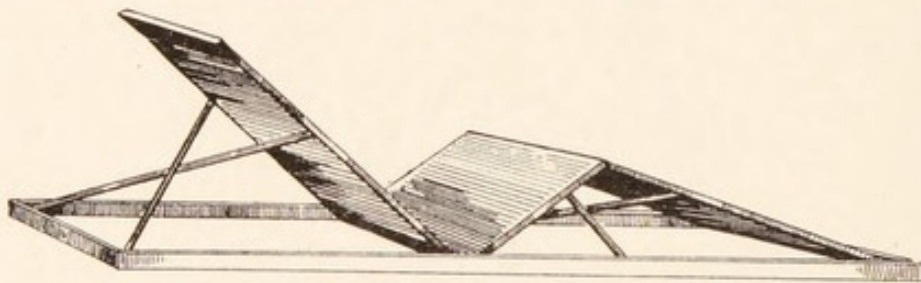


FIG. 25. STRETCHER-FRAME FOR TRANSPORT OF CASES OF FRACTURE OF BOTH FEMURS.

inguinal fold of the sound leg, and is attached on the opposite side of the pelvic band.

Double-fractured Femur.—These terrible injuries require some special apparatus for transport purposes, otherwise any prolonged journey will involve intolerable pain and any adequate wound-treatment cannot be done without an anæsthetic. A light wooden frame is made of material like that from which deck-chairs are constructed, and over this canvas is stretched. A reclining body-rest is thus formed of three planes, the upper is 3 feet long and supports the body at an inclination of 30 deg.; the middle one, inclined in an opposite direction, is 12 inches long and lies under the thighs; whilst the lower, of 18 inches, supports the legs.

There is no transverse bar at all in contact with either the body or legs. The section beneath the thighs has its canvas support as a double layer which folds round the two sides of the frame and laces at the side. It can be taken right away when the dressing has to be changed or the bed-pan used. The inclination of the body and the thighs allows for the latter being kept with a moderate degree of extension traction, by placing a pillow of suitable thickness under the upper part of the calves of the legs. The whole carrying-frame can be strapped on to a stretcher or laid in a cot or bunk.

FRACTURES OF THE PATELLA

These are seldom due directly to gunshot injuries, but as they occur frequently in military work, it is worth while to devote a few words to them.

The patella ought always to be sutured by a circular wire loop which just perforates the upper and lower margins of the bone. I use either a single loop of No. 16 iron wire or two loops of No. 18, the free ends of one loop being on the inner side, whilst those of the other are on the outer.

If the case be an old one in which the upper fragment is much retracted, this latter must be brought down, by freely dividing the adhesions of the patella fragment to the femur and by dissecting up the whole mass of the quadriceps muscle from the lower end of the thigh-bone until the two fragments can be brought together.

After this circular loop operation, no splint is required: 'massage' and movements are carried out

from the first, and the patient is allowed to walk in a week.

There are three wrong methods of operating upon a fractured patella in common vogue. One is the use of stout catgut to suture the aponeurosis over the front and at the sides of the bone. This will bear no strain until union has occurred, therefore the patient has to be kept with a rigidly splinted extended knee for four weeks, and very probably will end with a mere fibrous union. How can catgut hold against the pull of the quadriceps ?

Another is the one described in text-books as 'wiring the patella'. Silver-wire sutures are passed in a V-shaped manner through the two fragments and their ends twisted in front. This tilts the pieces of bone, leaving a gap next to the joint, it sharply bends the wire above and below, and it leaves the twisted ends of the wire just underneath the skin where they are liable to cause irritation. These sutures usually break, and hence the many recorded cases of recurrent fracture of the patella. A third method is that of putting on a Y-shaped plate with three screws. The screws never hold firmly in spongy bone, and therefore this method, like the catgut sutures, is really dependent upon an external splint taking off any possible strain until bone-union has occurred. It seems to me hardly worth while to do an elaborate internal suturing operation and then to depend upon an external splint which ensures the patient a stiff knee for months to come, and keeps him in hospital for weeks.

FRACTURES OF THE TIBIA AND FIBULA

Gunshot injuries of the bones of the leg present certain special features which differ from those of the closed fractures of civil life. Comminution is the rule and the long spiral fracture the exception. The superficial position of the tibia makes it easy for natural drainage to occur and therefore the acute stages of sepsis are soon overcome; but this same superficial position renders a chronic sepsis very common, and this often leads to the formation of a sinus which is very slow to heal.

Non-union of the tibia, or delayed union after gunshot wounds, is a complication which occurs more frequently in this bone than in all the other long bones together. The reason for this is, I think, to be found in the existence of chronic sepsis and a very avascular condition of the lower fragment. These conditions bring about a sclerotic condition of the fragments, especially the lower, which stops callus formation before union has occurred.

The existence of comminution renders replacement of the fracture easy by extension methods, if these are begun early. The liability to delayed union being due to a postponement of the healing process by sepsis, it requires that both wound and fracture should be put into the best conditions for healing at the earliest possible moment.

The Wire Cradle Splint described above for the thigh is perfectly suited for fracture below the knee, but it is unnecessarily bulky. A smaller splint which only

goes a short distance above the knee-joint is well suited both for hospital use and for transport.

In my earlier cases I used a metal-frame splint with a spring and screw extension, such as is shown in the illustration. But we found that in two respects improvement was desirable. The extended

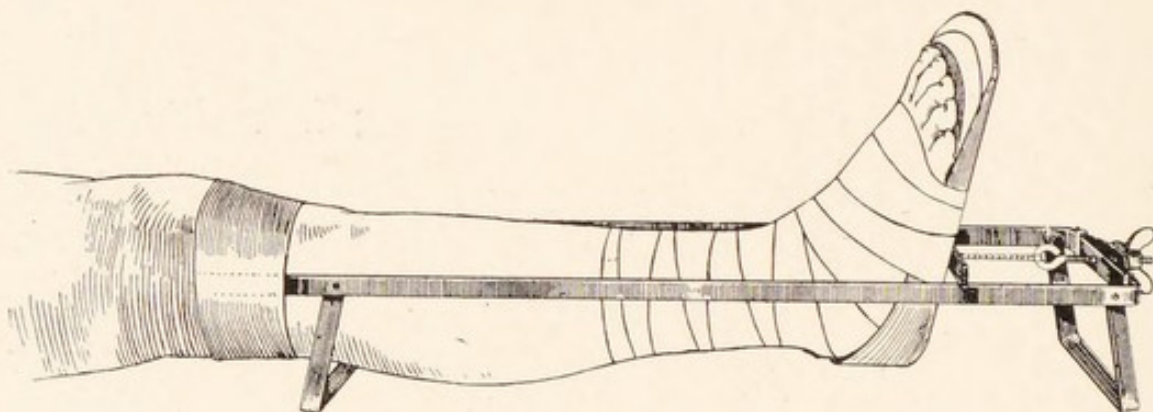


FIG. 26. AUTHOR'S EARLY-TYPE SPLINT FOR FRACTURE BELOW KNEE.

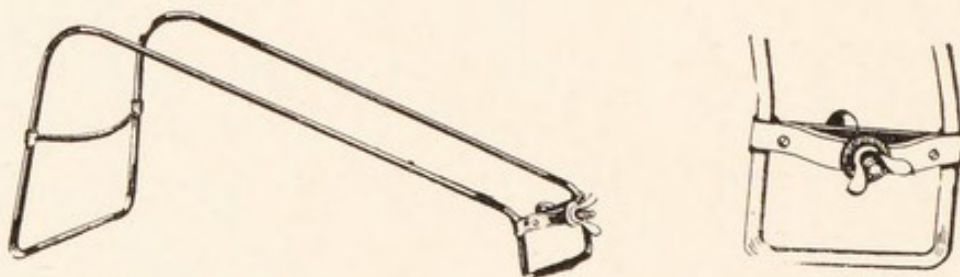


FIG. 27 A. WIRE-FRAME LEG-SPLINT FOR TIBIA. B. LOWER END WITH EXTENSION SPRING.

knee caused tension of the calf muscles, and a straight joint is much more likely to get stiff than one which is kept semi-flexed. Further, the adequate counter-extension requires the fixation of an encircling band below the knee, which is apt to slip up unless it is put on uncomfortably tightly.

The wire-frame splint in use now is like the bent Thomas's knee-splint cut short. The knee is held

semi-flexed, and across the broadly curved upper angle of the splint a transverse padded band holds the popliteal region of the thigh and affords counter-extension. The leg below the knee is inclined downwards so that gravity aids extension. The foot attached to a sole-piece with outstanding bars slides easily along the side-bars. The extension-spring and

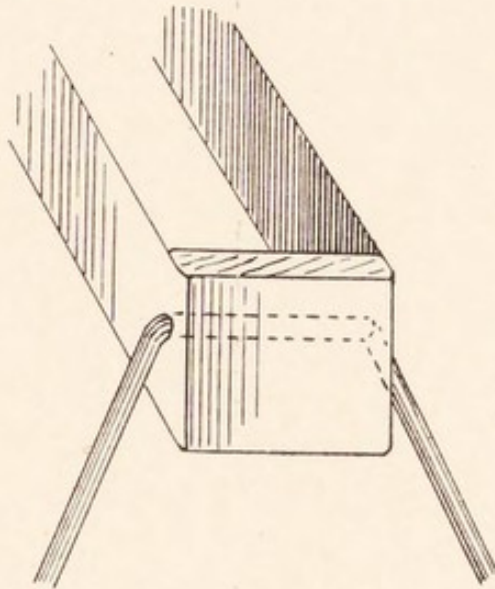


FIG. 28. DIAGRAM SHOWING THE MANNER OF ATTACHING A RUBBER TUBE TO EXTENSION STRAPPING. It is passed through holes in the long adhesive straps just above a wooden spreader. The free ends are tied to the lower bars of the splint where they are turned down. Plates applied must be long enough to pass round and cover the other side.

screw is exactly the same as that shown in the previous illustration. This splint can very quickly be made out of a piece of $\frac{1}{4}$ inch steel wire, and if the spring and screw are not at hand, a rubber drainage-tube can be substituted for these. In this way a cheap and light appliance is made which is equally efficient for transport and for extension treatment.

Fractures low down in the Leg-Bones. — Comminuted fractures just above the ankle present great difficulty in grasping the foot below the injury. For this difficulty I have three suggestions to offer. The first is to make a shoe for the foot, using the wooden piece with the outstanding bars as the sole. The upper of the shoe is made of wash-leather laced

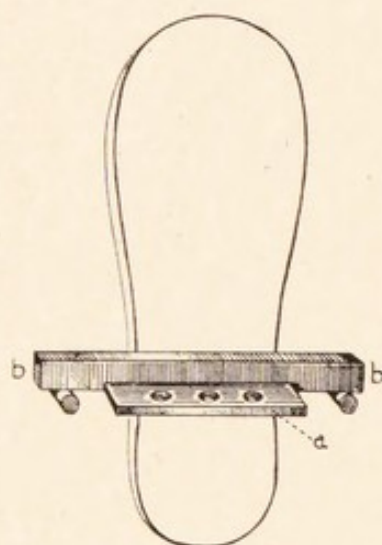


FIG. 29. LOWER ASPECT OF SOLE-PIECE showing the piece of angled iron, the outstanding flange of which (*a*) has three holes for attachment of the extension cord, so as to provide for a straight pull or one associated with a side twist of the foot. The projecting ends of the angled iron (*b*) run on the side bars of any of the wire cradle splints.

across the instep. The second, which mechanically is more efficient, is to use a transfixion pin, driven through the malleoli or os calcis, or a screw clamp (*vide infra*); and thirdly, a horseshoe clamp.

In all fractures of the leg-bones affecting their lower portions, the lateral position of the foot, i. e. as regards inversion or eversion, must be carefully guarded. A slightly inverted position is to be aimed

at so as to avoid the common tendency to talipes valgus.

This lateral traction to produce the correct degree of inversion is provided by having the extension attachment to the sole-piece, to one side or the other of the mid-line.

Incorrect Angle of Attachment of the Foot-Piece to the usual Back-Splint.—There is a feature common to nearly all the wooden back-splints and foot-pieces in ordinary use which requires alteration. This is the fixation of the foot piece at right angles to the leg portion. This is an unnatural and uncomfortable angle, as any one may convince himself by lying flat on a couch and pointing the toes straight upwards. This attitude causes great tension of the calf muscles. As a matter of fact it is almost impossible to keep the patient's foot in such a strained attitude, and what usually happens is that the toes rest against the front of the foot piece whilst the heel is an inch or more away, or this space is filled up with a pad. Not only does this give an insecure hold on the foot, but as a natural result it rests with all the weight of the lower part of the leg against the back of the heel—just the part which it is most important to guard against pressure. It is a most common thing to see the final recovery of a case of fracture of the leg-bones delayed by a large posterior pressure-sore at the heel. The foot-piece, if fixed to the back-splint, should always be inclined at an angle of 120 deg. to it. This will effectually relax the pull of the calf muscles upon the tendo Achilles, a relaxation

which is further ensured by bending the knee. And not only does this inclination of the foot-piece relieve the muscle tension, but it provides a real support for the sole of the foot, so that the leg rests upon this surface and not upon the back of the heel.

Movements of the Joints in Fractures treated by the various Wire Cradle Splints.—In all the wire cradle splints, whether those for the thigh or those for the leg, the limb simply lies upon a sling and the foot is supported by the projecting bars of the sole piece. When the time has come for exercising the joints, i. e. about one or two weeks after the injury, this can be done with great simplicity. The extension-cord is grasped below the foot and pulled upon with the same tension as has been used for treatment, the weight is lifted or the spring attachment is undone, and then, without relaxing the tension, the whole leg is lifted, slowly, gently, and for a small distance. This extends the knee and flexes the thigh. Only about ten of these slow movements need be done each day, and their amplitude is to be increased as this can be done without pain. The ankle-joint swings freely on a transverse axis all the time and is subjected to unconscious movements by the patient which may be supplemented by more systematic exercises if necessary.

FRACTURES OF THE FOOT

Gunshot injuries of the foot are either in the nature of perforating bullet-wounds without infection or displacement, or horribly shattered shell-wounds in

which there is much comminution and great sepsis. Only this latter group requires special treatment. The most important act of treatment consists in freely opening the wounds and cleansing them of contaminating foreign bodies. At the same time loose fragments are freely removed. It is only by a bold removal of pieces of bone or of several splintered tarsal bones, that free drainage can be secured and ankylosis prevented. Especially important is it to remove broken and displaced pieces of the astragalus. This procedure will clear the ankle-joint and preserve good movement. The os calcis and the first metatarsal bones stand in rather a different position from the other bones of the foot. They provide the chief base of support for the body in standing and the foramen is the point of attachment for the calf muscles. Therefore whilst any of the other bones may be freely sacrificed for the reasons above mentioned, these two should be carefully preserved and broken bits of them not taken away.

CHAPTER VIII

ON CERTAIN SPECIAL METHODS OF TREATING GUNSHOT FRACTURES

I HAVE endeavoured in the foregoing pages to present the broad principles of the treatment of gunshot fractures, laying emphasis on those methods which are of most value in dealing with a rush of cases under the strain and stress of war conditions. My great desire is to get those who have had but little special interest in bone surgery, to realize how much may be done by simple methods, and how wrong is the *laissez-aller* policy of letting shattered limbs go on to permanent deformity.

I now would add a short chapter on certain special methods, which are not intended to be of general application, but which may be necessitated by certain cases.

Extension by Transfixion Pins.— This method, which is associated with the names of Codavilla and of Steinman, is one of great mechanical power and of wide applicability. A steel pin is driven right through the lower fragment and serves as the point of application for the extension force. It provides great power, because the bone is directly held instead of only being pulled upon through the intermediation of the skin, fascia, muscles, and ligaments. Further,

it will allow of a much more powerful force being used than if the latter has to act through the skin, and the direction of the extension pull can be modified with great accuracy.

It is much easier and quicker of application than that of adhesive plaster, and once placed, the transfixion pin and extension cannot slip. But it involves the piercing of the bone, which to some people seems to be a far more serious matter than it really is. If the transfixion is done correctly it does not involve any appreciable risk, nor lead to any undesirable complications. It most certainly is not painful, i. e. the patient will suffer less pain when the fractured bone is transfixed and extended than when it is allowed mobility. Pain may be caused at first by the stretching of the soft parts, but e. g. 20 lb. pulling on a transfixion pin will cause less pain than the same weight attached to the skin, therefore the transfixion does not *per se* cause pain. It is true that when the method was first tried, cases were not uncommon in which sepsis round the transfixion holes occurred and led to long-persisting sinuses after the removal of the pin. But by the precautions to be mentioned in a moment, the risk of this sepsis is reduced to a minimum.

The method has its greatest value in the treatment of fractures with much overlapping in muscular limbs, where the case has been neglected and early malunion has begun. Again, in old cases of malunion it is of the utmost value as a substitute for more elaborate operations or as a preliminary to these. The malunion is broken down either by external force or

through an incision, and the latter is closed. Instead of tearing the soft parts which have become adaptively shortened, it is far better very often to place continuous extension on the bone by means of the transfixion pin.

Fractures of the femur, tibia and fibula and humerus may be treated by it, the indications in the first being very common, those in the last very rare, and those in the lower leg intermediate in frequency.

Technique.—The transfixion pins are steel rods of a thickness of $\frac{5}{32}$ in., $\frac{3}{16}$ in., or $\frac{1}{4}$ in., and of a length of 4 to 6 inches. But those which are 6 inches long and $\frac{3}{16}$ in. thick are of the most general use. The steel must be hard and highly tempered, so as to give a slight spring without bending. The best sites for transfixion are as follows: For the humerus, one inch above the epicondyles (a lower position is apt to pierce the olecranon fossa) rather in front of the supracondylar ridge on the inner side, and emerging behind the external ridge, so avoiding both ulnar and musculo-spiral nerves. For the femur, from the most prominent point of one condyle to that of the other. For the leg-bones, from a point on the internal malleolus two fingers above the tip, backwards and outwards to the external malleolus (a lower point is not permissible, otherwise the ankle-joint is in danger of being pierced). For the os calcis, a point one inch below the tip of the external malleolus. It has been suggested that the olecranon may be pierced for fractures at the lower end of the humerus, or the head of the tibia for those involving the condyles of

the femur. But both these are open to the serious objections that they immobilize the joint above just when it is important to leave it free, and that extension applied at these points can only act through the ligaments of the joint. It might be thought that the same arguments would forbid transfixion of the os calcis, but in the ankle the ligaments are so strong that they will suffer no harm, and in this joint there is no fear of any undue looseness, because the socket is so deep. The pin may be simply hammered through the bone, or inserted by a little T-shaped handle, but it is much more satisfactory to drill it in by a brace, the pin having a cutting drill-point at one end and a slot to fit the brace at the other.

The skin, having been prepared with iodine, is drawn up towards the body and nicked by the point of a knife at the site of entry. The pin is drilled through the bone, and its point cut down upon as it pushes out the skin (which is also drawn up) on the further side. In this way the elastic skin tightly fits round the pin, and there is no open wound at all. The points of puncture may be dressed with a morsel of gauze and mastisol, or by a pad of gauze and a bandage, or they may be left quite without dressing, being daily sprayed with weak iodine solution.

The pin having been inserted—and this is easily done in less than one minute under gas anæsthesia—its two ends are protected by screw-caps, the limb is slung in some sort of cradle splint, and the weight attached by a Y-cord to its projecting ends. It is left in place from two to four weeks, when ordinary

adhesive strapping extension may be substituted for it if union is not then sufficiently firm to dispense with extension.

Three points must be observed to avoid sepsis at the points of puncture. There must be no open wound, i. e. the skin must make a watertight junction with the pin. There must be no tension on the skin. It is to avoid this that the skin is pulled up before puncture. If, when transfixion has been done, a pull on the pin causes the appearance of a white bloodless tension area below it, it is better to make a longitudinal incision through this until tension is relieved and then to put in a stitch above the pin to close the opening. And thirdly, the pin must not be left in too long. Six weeks is the utmost limit, but I would prefer not to leave it longer than four if there is any sign of irritation round the pin-holes. Too long traction on the pin causes a sinus to occur from pressure absorption, and this may lead to troublesome sepsis in the depth of the bone.

Horseshoe Screw-clamps as a Substitute for Transfixion.—Some hesitation may be felt in driving a steel pin right through a large bone, especially in the presence of an infected wound in the close proximity to the point of transfixion. Again, in just those difficult cases where the fracture is situated at the lower end of the bone, in which only feeble traction can be made by means of adhesive strapping, and where direct transfixion is most valuable, there exists a splitting or actual comminution of the lower part of the bone. Thus the lower ends of the humerus, femur, tibia, and

fibula are very liable to be fissured into the joint. In such cases, a transfixion pin will do nothing to clamp the lateral pieces together, whilst it is very likely to further split the bone or separate the fragments. In neither the humerus nor the tibia and fibula can transfixion be applied lower than within one inch of the distal extremities of the bones. For

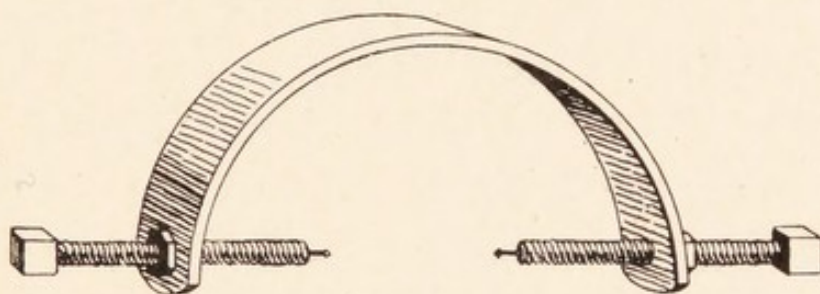


FIG. 30. HORSESHOE SCREW-CLAMP WITH 'POINTED' ENDS.

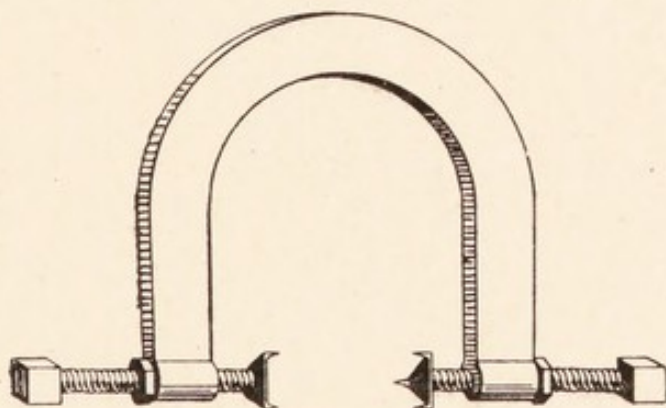


FIG. 31. HORSESHOE SCREW-CLAMP WITH TRIANGULAR POINTED ENDS.

such cases, and as an improvement on the transfixion method, I have designed and used with most gratifying results certain fixation apparatus which I would describe as 'horseshoe screw-clamps'. They are well explained by the figures. In all, there is a horseshoe-shaped piece of steel, into the ends of which stout screws are fitted. In one pattern the screws terminate in a point $\frac{1}{8}$ inch thick and $\frac{1}{8}$ inch long, with

a drill end. In the other pattern the screws terminate in a little three-pronged plate which loosely swivels on the end, so that the opposite plates can adapt themselves to the sloping sides of the bone and get a powerful hold without penetrating any distance into its substance.

These horseshoe screw-clamps can be applied under local anæsthesia, only small incisions being required. In the case of the humerus the screw-points take hold of the most prominent parts of the epicondyles ; in the femur they are applied to the condyles, and above the ankle they grasp the malleoli at the level of the joint. They are screwed in quite tightly, and in this position fixed by a locking nut. They take a very firm hold on the bone, but only by a grip of its surface, and at the same time they clamp together laterally separated fragments.

Double Transfixion.—It has been explained above how the great value of transfixion lies in the mechanical advantage of taking direct hold upon the lower fragment for purposes of extension. When this has been done we are still dependent upon the holding of the limb in a frame and pulling upon it with a weight.

But the principle can be further applied by transfixing both fragments of the broken bone and making direct extension of one transfixion bar away from the other. In this way we become masters of the situation, and obtain complete command over both ends of the bone, independently of any splint or weight.

I first discovered the value of this double transfixion apparatus when doing experimental work on

the fractures of cats.¹ Lambret of Paris had independently devised a similar appliance. But my earlier models, in common with that of Lambret, had this serious limitation, that the transfixion pins had to lie parallel to one another in the same plane.

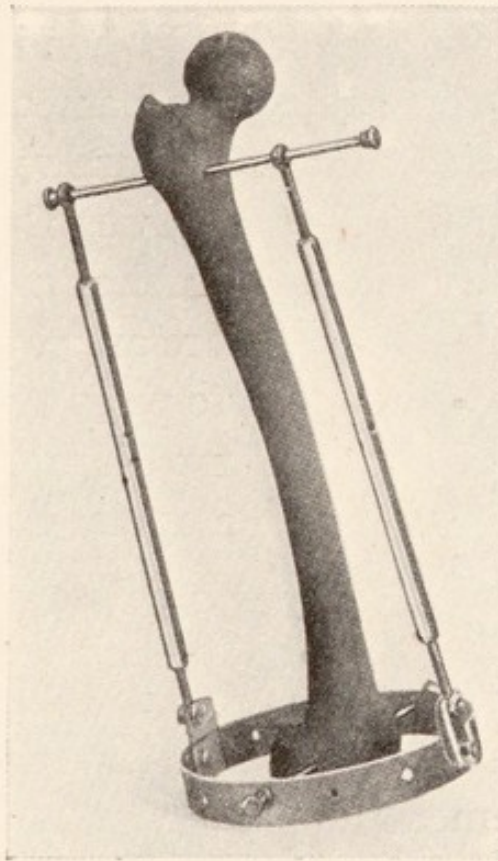


FIG. 32. AUTHOR'S DOUBLE TRANSFIXION APPARATUS APPLIED TO FRACTURED FEMUR.

But in my recent pattern of the double transfixion apparatus there is no such limitation, and the pins can lie in planes at right angles to one another or in any transverse diameter of the limb.

It is made in two sizes, one of which fits the humerus and the other the femur or tibia, but I do not think that there are many cases of fracture of the first-

¹ *British Journ. Surgery*, January 1914.

named bone which will require its use, and therefore I confine my present remarks to the femur and leg-bones.

The apparatus consists in two transfixion pins $\frac{3}{16}$ inch thick, and two longitudinal extension bars made of a tube into which screw rods $\frac{1}{4}$ inch thick threaded with reversed screws. The tube is perforated at its centre by holes for a lever, and when it is turned in one direction both the projecting bars are forced apart, whilst the reverse movement draws them together. One of the transfixion pins passes through two holes in a circular hoop of steel 6 inches in diameter $\frac{1}{8}$ inch thick and 1 inch wide. There are twelve holes in the hoop, arranged as six opposite pairs, so that the pin can lie in any one of six different diameters of the hoop. The extension bars fit by an eyelet-hole over the ends of one pin and by the other they take a bearing on the steel hoop by a joint which allows of a lateral movement through 30 deg. This point can be locked, When the apparatus is in position it permits of the following movements :

1. Direct Extension, by rotating the central tubes of the longitudinal bars in the same direction.

2. Tilting of the transfixion pins with consequent correction of angular deformity, by screwing one extension bar more than the other, or by screwing them in reverse directions. If the one pin which pierces the hoop lies at right angles to the plane of the extension bars, it can be tilted by pulling on one end in a distal and the other in a proximal direction.

3. Rotation of one transfixion pin in relation to the

other. This allows of rotatory displacement being corrected.

As regards the technique of the application of this apparatus to the thigh or lower leg, the general remarks made about transfixion apply here, but in the making of the punctures for the upper or counter

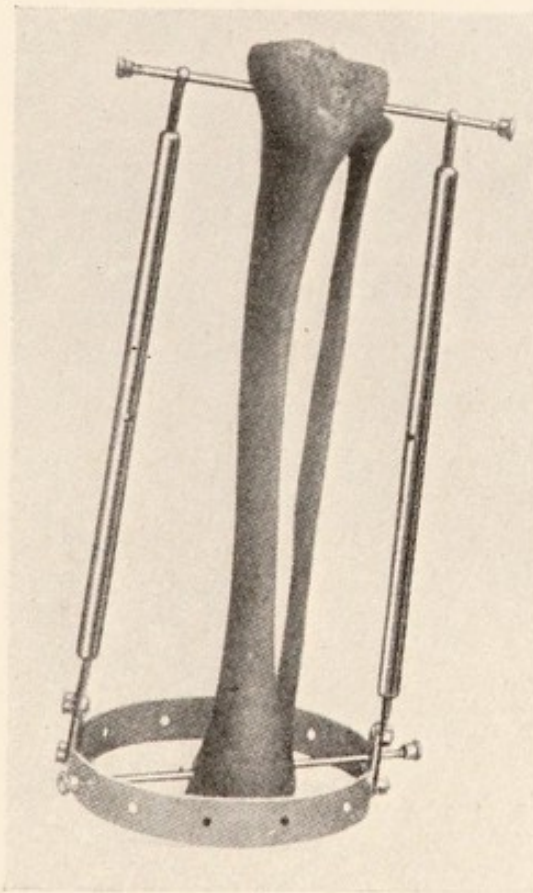


FIG. 33. DOUBLE TRANSFIXION APPARATUS APPLIED TO TIBIA AND FIBULA.

extension pin, the skin must be drawn downwards, whereas with the lower it is drawn upwards for the avoidance of tension.

In applying the upper pin to the femur a point is taken on the front of the thigh vertically below the anterior superior iliac spine and on a level with the lower border of the symphysis pubis. This is over

the base of the great trochanter. The pin is inserted backwards and outwards, so that its posterior end emerges behind the prominence of the trochanter and not at the back of the thigh.

The upper pin in the tibia should lie between the level of the lower border of the patella and the tuberosity of the tibia, in a transverse direction.

In each case the lower pin is in the position described above for simple transfixion.

The apparatus is applied under general anæsthesia ; the double transfixion, only occupying about $2\frac{1}{2}$ minutes, can be done under gas, but unless there is any contraindication ether is better, because this gives a fuller muscular relaxation and affords time for the adjustment of the hoop and extension bars.

Before the operation it is known by measurement or better by the X-rays exactly how much shortening exists. The longitudinal bars are twisted in their central tubular portions until this is fully corrected or until the transfixion pins show a marked bowing. Being made of higher tempered steel, they act as powerful springs, and within two days they will have straightened themselves, and further extension can be given by a few turns of the tubular screws, and so on at two-day intervals until the correct length of the bone has been gained.

The limb is slung up off the bed, so that the wounds can be dressed with the least disturbance. At the end of a week the patient with a fracture of the tibia and fibula can get up and the one with the fractured femur can be moved.

BONE-GRAFTING

Of late years there has been an increasing tendency to the use of living bone-grafts for the repair of fractures, and in the hands of Albee this method has had an extensive application.

When a piece of bone is transplanted into living tissues in another part of the body it may suffer one of the following fates :

1. True Vital Continuity.—It becomes rapidly vascularized and continues to live as a part of the surrounding bone.

2. Forms a mere Scaffolding.—It becomes slowly vascularized and in time penetrated by the invading tissue-cells of its environment, which slowly replace its substance by new bone.

3. Forms an Aseptic slowly absorbable Foreign Body.—It remains without vascular supply as an aseptic foreign body which is slowly absorbed by the surrounding living tissues.

4. Forms a Septic Foreign Body.—It becomes permeated by infective germs which not only kill its cells, but remain in its crevices and form a perpetual source of septic dissemination for the tissues in which it lies.

Much controversy has taken place about which of the three first-named processes is the normal method of action of a bone-graft, and it cannot be said that the matter is by any means settled. Exigencies of space forbid entering into this discussion here, and I can only state what I believe to be the practical conclusions.

True vital continuity of a bone-graft depends upon the osteoblasts receiving a sufficient blood-supply to prevent their death. This blood-supply can only be brought into the bone by capillary anastomosis through the narrow and tortuous Haversian canals. If this new circulation is not quickly established, none of the bone cells in the interior will survive, and the graft will only afford a scaffolding in the meshes of which outside bone cells enter to build up new bone. Therefore to get the quickest and best result we must affix the graft to its bed bone to bone by firm suturing so that new vascular loops can grow from one to the other without mechanical injury. Further, the graft should be covered with periosteum in order that the latter may provide a vascular plexus between the outside tissues and the Haversian canals of the graft.

If a graft is merely loosely laid in it cannot become vascularized, if constant movement occurs between it and its surroundings. The bone bed in which the graft lies is subjected to some degree of irritation and pours out cells, but before long this cellular proliferation ceases and sclerosis sets in. From this time onwards the graft can only remain as a loose foreign body.

This is the history of many of the cases of intramedullary pegging with bone-grafts for fractures, and accounts for the high degree of failures which the method has given.

A living bone peg tightly driven into a healthy medullary canal will certainly live and quickly unite

to its bed. With the same graft and same medullary canal, but with the one merely laid loosely in the other, union will not occur and the graft rather hinders than promotes healing.

Sepsis interferes with the success of bone-grafting in three ways. It kills the vital bone-cells of the graft, it converts the dead graft into a constant source of fresh infection, and if it does not cause necrosis of the bony bed it brings about a condition of sclerosis which prevents the outpouring of callus.

The following may be laid down as the conditions necessary for or favourable to successful bone-grafting.

1. Absence of sepsis.
2. Firm and close fixation of the graft to a living bone.
3. Abundant vascularity of the bone-bed.
4. An outside periosteal covering of the graft.

The Source of the Graft.—This should be taken from the patient himself; and though quite good results have followed using bone-tissues from corpses, this is never necessary in ordinary fracture work, but only in the replacing of articular ends of bones.

Three sources of the graft each present certain advantages. The upper two-thirds of the **fibula** has a complete periosteal covering, and if split it presents a good surface for new vascularization. It is not very strong, and its removal is more formidable than that of the other two bones to be mentioned. If used without splitting or taking off the periosteum, the latter will be an absolute bar to union between the graft and the bed. The anterior crest of the **tibia** is

on the whole the best graft material and that which is now used almost to the exclusion of other bones. It will provide both length and strength much superior to that of either ribs or fibula. It ought to be taken with one surface covered by periosteum, and be of sufficient depth to include the spongy interior marrow surface. This will become vascularized much more quickly than the dense outer portions.

The rib is a material which enjoys a sacred traditional reputation for creative properties, but in human hands it is not very good material. The eighth or ninth rib is best, and it should be removed with its outer covering of periosteum, the deep layer being left in place. It is better to cut into its dense inner table without fracturing it too much. Its special value is that it has a natural curve which makes it suitable for supplying defects in a curved bone like the lower jaw.

The Technique of Bone-grafting.—I think that because bone-grafting is to be used in the repair of a fracture, there is no reason for neglecting the ordinary maxims of mechanical efficiency of fixation, which I have insisted upon in speaking of the operative treatment of fractures. In fact mechanically efficient fixation is here of even more importance in placing a peg of living bone than a mere metal plate, because it is the condition necessary to produce direct vital continuity.

There are three ways in which a graft can be securely fixed to its bed of bone. (1) By driving the graft tightly into the medullary cavity of its bed;

(2) by making transverse drill-holes through both graft and bed, and suturing the two together by iron wire firmly twisted; and (3) by bolting the graft to its bed. The first two of these methods are the most generally applicable, and both are illustrated in the figure.

The Preparation of the Bed.—In many cases in which bone-grafting is required for the repair of old fractures, the bones are hard, eburnated, and sclerotic. It is absolutely necessary to cut away enough of this

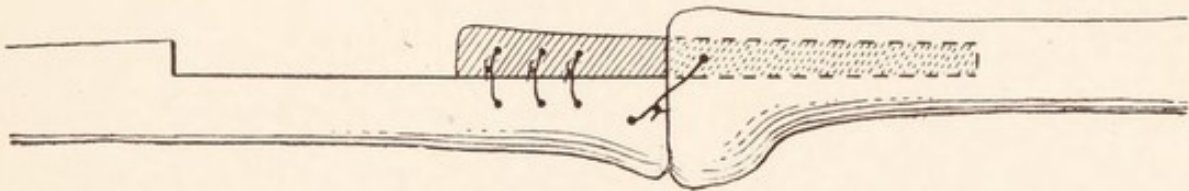


FIG. 34. Diagram from a case of resection of the knee in which a 6-inch graft has been cut from the tibia, its small end driven up into the femur, and its other part sutured by four wire sutures to the tibia.

tissue so as to expose a good surface of freshly cut vascular bone. Drilling and shallow saw-cuts may be employed as well to open up the surface to the interior cellular bone-tissues.

In a simple Ununited Fracture without loss of Substance the graft can be taken from the fragments. From each is cut a piece half the thickness of the shaft, the bit from one fragment is double the length of the other. These are then reversed, and the gap is then bridged over.

In this and other similar bone-grafting operations, after a sufficient number of wire sutures have been applied, a fine drill is used to piece both graft and bone-

bed at right angles to the long axis of the shaft by holes which will provide open channels for the growth of cells and vessels from the one piece of bone to the other.

In a Fracture with loss of Substance.—In those cases, unhappily too common, in which a part of the shaft has been shot away, lost by necrosis, or removed by ill-advised surgery, the limb may be rendered quite

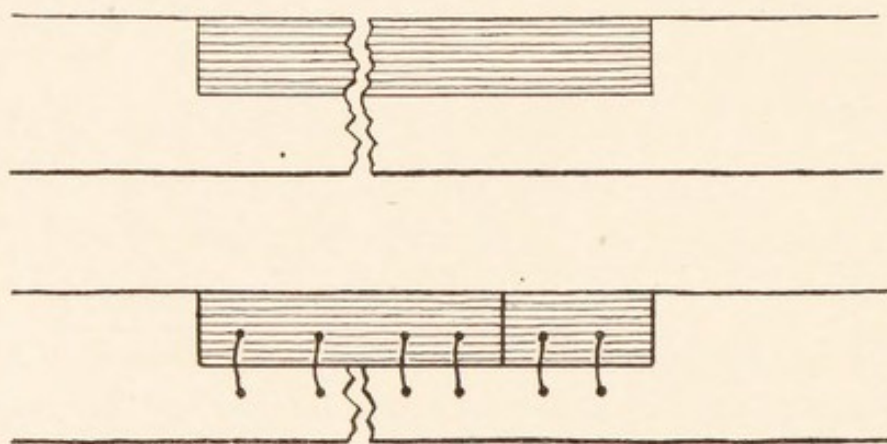


FIG. 35. DIAGRAM TO SHOW HOW GRAFT MAY BE TAKEN FROM FRACTURED BONES.

useless and flail-like. The only remedies for this, other than amputation, are a complicated and costly apparatus, which is an added burden to the weak limb, or a bone-grafting.


As the latter should not be attempted until the wound is very soundly healed, and the patient's general health restored, such a long time will have elapsed since the injury that there must be great shortening of the limb from cicatricial contraction.

In the case of the thigh, I would suggest that this shortening should be overcome by transfixion extension, carried out for one week by means of a single

pin through the condyles, and completed at the time of operation by transfixing the upper fragment and applying the screw extension apparatus which I have described above. This (the extension hoop and bars) ought not to be put on to the pins until the bone-ends have been cut, the graft prepared, and everything



BONE-ENDS SHOWING POSITION OF SAW CUTS.



GRAFT FROM TIBIA

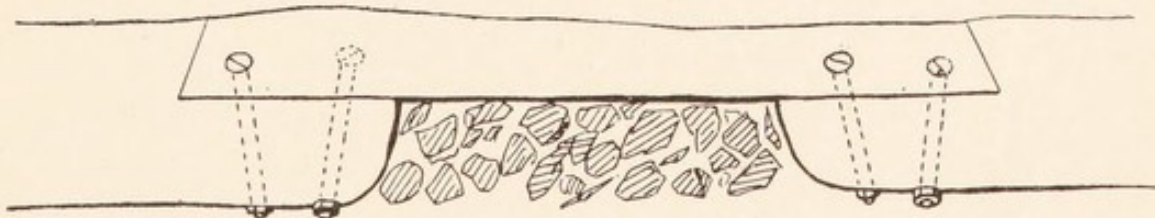


FIG. 36. FRAGMENTS DERIVED BY BREAKING UP THE BITS OF BONE TAKEN OUT FROM THE ENDS OF THE FRACTURE.

ready for adjustment. Then it is applied and the bones are pulled out to the desired length, and the apparatus is left in place for four weeks, acting as an absolutely efficient means of immobilization, which takes off the strain from the grafted fracture.

The illustration will make clear one method of fitting the graft, but many others will suggest themselves to the ingenuity of the surgeon. The success

of such an operation will depend as much upon the trouble which the surgeon takes to perfect his tools and his mastery of them, as upon the vitality of the patient.

It has become fashionable lately in doing bone-grafting to use soft absorbable ligatures to tie the graft in its place, catgut and kangaroo tendon being those chiefly in vogue. I think this is a great mistake, unless the graft is merely to fill up a gap in a solid bone. If there is to be strain and stress laid upon the union between the graft and its bed, then the soft ligature will allow slight movement and this will prevent vascular tissue from growing into the graft from its bed.

Properly placed wire sutures or bolts seldom give any trouble, and if rarely they have to be removed, they will then have done their work. It is the loosely placed wire or the screw whose functional grip soon loosens which have brought metallic fixation material into disrepute.

INDEX

- Angulation of fractured ends
a cause of deformity, 24.
- Arm, broken, treatment of, 75.
- Articular changes after fracture, 28.
- Bone, angulation of fractured ends, 24.
deformity after fracture, 23.
-grafting, 117.
gunshot wounds, varieties of, 9-13.
injuries, diagnosis of, 19 ;
effects on soft tissues, 17 ;
radiography in, 21 ;
skiagraphing of, 21.
non-union of, 25.
overlapping of fractured ends, 23.
pain after fracture, 23.
pathology of, 16.
physiology of, 13.
regeneration of, 15.
repair of, 16 ; effect of
necrosis on, 16 ; effect
of sepsis on, 16.
results of fracture, 23.
- Borchgrevink's splint for arm, 77.
- Broken leg, treatment of, 99.
- Broken thigh, 84.
- Callus, 29.
ossification of, 29.
- Closed fractures, operative treatment of, 57.
- Collar-bone, fractured, treatment of, 73.
- Compound fractures :
drainage in, 44.
dressing of wound in, 45.
operative treatment of, 60.
treatment of wound in, 42.
- Deformity after fracture, 23.
- Diagnosis of bone wounds, 19.
- Drainage in fracture, 44.
- Dressing of wound in fracture, 45.
- Elbow, fracture of, 78.
- Extension, method of applying, 90, 101.
by screw clamps, 110.
by transfixion pins, 106.
treatment of fractures, 46.
- Femur, double fracture of, 96.
fracture of, 84.
- Fibrous union after fracture, 26.
- Fibula, fracture of, 99.
- Fingers, fracture of, 82.
- Fissured fractures, 20.
- Flail limb after fracture, 26.
- Foot, fractures of, 104.
- Forceps for tightening wire, 69.
- Forearm, fracture of, 80.
- Fracture, articular changes after, 28.
closed, 9.
comminuted, 11.
compound, 9.
compound, treatment of wound in, 42.
deformity after, 23.

Fracture (*continued*)—
 diagnosis of, 19.
 drainage in, 44.
 essentials of treatment, 38.
 fibrous union after, 26.
 fissured, 12, 20.
 flail limb after, 28.
 immobilization of, 39.
 improvised extension in, 92.
 improvised sling in, 92.
 necrosis after, 16.
 nerve changes after, 28.
 non-union after, 24.
 oblique, 12.
 of clavicle, 73.
 of elbow, 78.
 of femur, 84.
 of femur, double, 96.
 of fibula, 99.
 of foot, 104.
 of forearm, 80.
 of humerus, 75.
 of jaw, 68.
 of knee-cap, 97.
 of metacarpals, 82.
 of patella, 97.
 of phalanges, 82.
 of tibia, 99.
 open, 9.
 open, treatment of wound
 in, 42.
 operative treatment of, 57.
 pain after, 23.
 paralysis after, 28.
 pathology of repair, 16.
 physiology of repair, 13.
 radiography in, 21.
 repair of, 29.
 secondary changes in joints
 after, 28.
 in nerves after, 28.
 sequelæ of, 23.
 simple, 9.
 treatment of, 34.
 by bone-grafting, 117.
 by double transfixion, 112.
 by extension, 46, 89.

Fracture (*continued*)—
 treatment of, by massage,
 53.
 by mobilization, 53.
 by pillows, 41.
 by plaster of Paris, 41.
 by sand-bags, 41.
 by screw-clamps, 110.
 by splints, 39, 84.
 by transfixion pins, 106.
 of wound in, 42.
 varieties of, 11.
 Gunshot fractures, see Frac-
 tures.
 wounds of bone, classifica-
 tion of, 9-13; diagnosis
 of, 19.
 Hey Groves's splint, 100.
 Hey Groves's wire-tightening
 forceps, 69.
 Hodgen's splint, 86.
 Humerus, fractured, 75.
 Immobilization of fractures,
 39.
 Inferior maxilla, treatment
 of fractured, 68.
 Jaw, fracture of, 68.
 Joints, changes after fracture,
 28.
 Knee-cap, fracture of, 97.
 Leg, fracture of, 99.
 Liston's splint, 39, 84.
 Mandible, treatment of frac-
 tured, 68.
 Massage, treatment of frac-
 tures by, 53.
 Metacarpal bone, fracture of,
 82.
 Mobilization, treatment of
 fractures by, 53.
 Muscul-spiral nerve, para-
 lysis of, 76.

- Necrosis in relation to sepsis, 16.
- Nerve changes after fracture, 28.
musculo-spiral, paralysis of, 76.
- Non-union after fracture, 25.
- Open fracture :
drainage in, 44.
dressing of wound in, 45.
operative treatment of, 60.
treatment of wound in, 42.
- Operative treatment of fractures, 57.
arguments for, 61, 66 ;
against, 62, 66.
results of, 64.
- Overlapping of fractured ends, a cause of deformity, 23.
- Pain after bone injuries, 23.
- Paralysis after fracture, 28.
of musculo-spiral nerve, 76.
- Patella, fracture of, 97.
- Pathology of bone, 15.
- Periosteum, uses of, 15.
- Phalanges, fracture of, 82.
- Physiology of bone, 13.
- Pillows, treatment of fractures by, 41.
- Plaster of Paris, treatment of fractures by, 41.
- Procallus, 29.
- Radiograms, methods of taking, 21.
- Radiography in bone injuries, 21.
- Repair of fractures, 29.
of septic fractures, 18.
- Sand-bags, treatment of fractures by, 41.
- Secondary changes
in joints after fracture, 28.
in nerves after fracture, 28.
- Sepsis, effect of, on repair of bone, 16.
- Simple fractures, operative treatment of, 57.
- Skiagrams, method of taking, 21.
- Sling, improvised, 92.
- Soft tissues, effects of bone injury on, 17.
- Splints, 39.
antero-internal, for elbow, 79.
Borchgrewink's, for arm, 77.
Hey Groves's, for broken leg, 100.
Hodgen's, 39, 86.
Liston's, 39, 84.
Thomas's knee, 85.
Thomas's, modified for transport, 94.
wire cradle, 88, 99.
for hand, 82.
for transport of wounded, 93.
- Thomas's knee-splint, 85.
- Tibia, fracture of, 99.
- Transport splints, 93.
- Treatment of broken fingers, 82.
of broken leg, 99.
of fracture, 34.
by bone-grafting, 117.
by double transfixion, 112.
by extension, 46, 89.
by improvised extension, 92 ; by improvised sling, 92.
by massage, 53.
by mobilization, 53.
by operation, 57.
by pillows, 41.

Treatment of fracture (*continued*)—

- by plaster of Paris, 41.
- by sand-bags, 41.
- by screw-clamps, 110.
- by splints, 39, 84.
- by transfixion pins, 106.
- of fractured clavicle, 73.
- of fractured collar-bone, 73.
- of fractured elbow, 79.
- of fractured femur, 84.
- of fractured femur, double, 96.
- of fractured fibula, 99.
- of fractured forearm, 80.
- of fractured foot, 104.
- of fractured humerus, 75.
- of fractured jaw, 68.
- of fractured leg, 99.
- of fractured metacarpals, 82.

Treatment (*continued*)—

- of fractured patella, 97.
 - of fractured phalanges, 82.
 - of fractured tibia, 99.
 - of musculo-spiral paralysis, 76.
 - of wound in fracture, 42.
- Upper arm, fracture of, 75.
- Weight, use of, in fracture, 91.
- Wire-tightening forceps, 69.
- Wound in fracture, dressing of, 45.
- treatment of, in fracture, 42.
- X-ray pictures in bone injuries, 21.

OXFORD WAR PRIMERS OF MEDICINE AND SURGERY

WOUNDS IN WAR: THEIR TREATMENT AND RESULTS.

D'ARCY POWER, M.B. (Oxon.), F.R.C.S. (Eng.), Lieutenant-Colonel R.A.M.C. (T.) 2s. 6d. net.

SURGERY OF THE HEAD.

L. BATHE RAWLING, M.B., B.C. (Cantab.), F.R.C.S. (Eng.), Major R.A.M.C. (T.) 3s. 6d. net.

INJURIES OF JOINTS.

ROBERT JONES, F.R.C.S. (Eng.), Major R.A.M.C. (T.) 3s. 6d. net.

GUNSHOT INJURIES OF BONES

E. W. HEY GROVES, F.R.C.S. (Eng.), Captain R.A.M.C. (T.) 3s. 6d. net.

INJURIES OF NERVES.

PURVES STEWART, M.D., F.R.C.P. (Lond.), Colonel R.A.M.C. (T.); ARTHUR H. EVANS, F.R.C.S. (Eng.), Captain R.A.M.C. (T.) 3s. 6d. net.

WOUNDS OF THE THORAX IN WAR.

J. KEOGH MURPHY, M.C. (Cantab.), F.R.C.S. 2s. 6d. net.

ABDOMINAL INJURIES.

Professor J. RUTHERFORD MORISON, F.R.C.S. (Eng.), Hon. Staff-Surgeon R.N.V.R. 2s. 6d. net.

INJURIES OF THE EYES, THROAT, NOSE, AND EARS.

A. MAITLAND RAMSAY, M.D. (Glas.), Major R.A.M.C. (T.); J. DUNDAS GRANT, M.D., F.R.C.S. (Eng.), late Major R.A.M.C. (Post Office Rifle Volunteers); H. LAWSON WHALE, M.D. (Camb.), F.R.C.S. (Eng.), Capt. R.A.M.C. (T.); C. ERNEST WEST, F.R.C.S. (Eng.), Captain R.A.M.C. (T.) 2s. 6d. net.

NERVE INJURIES AND SHOCK.

WILFRED HARRIS, M.D. (Cantab.), F.R.C.P. (Lond.), Captain R.A.M.C. (T.) 3s. 6d. net.

MEDICAL HINTS.


J. EDWARD SQUIRE, C.B., M.D., F.R.C.P. (Lond.), late Lieutenant-Colonel (Hon. Colonel) R.A.M.C. (V.) 2s. 6d. net.


THE STRETCHER BEARER: A Companion to the R.A.M.C. Training Book.

GEORGES M. DUPUY, M.D., Stretcher Bearer Ambulance Section (C), Norwood Co., Lambeth Battalion V.T.C. 2s. net.

CEREBRO-SPINAL FEVER.

THOMAS J. HORDER, B.Sc., M.D., F.R.C.P. (Lond.), Major R.A.M.C. 3s. 6d. net.





617.99

