

**The morphology and evolution of the apes and man / by Charles F. Sonntag
... with a foreword by Professor G. Elliot Smith.**

Contributors

Sonntag, Charles F. -1925.

Publication/Creation

London : J. Bale, Sons, & Danielsson, Ltd., 1924.

Persistent URL


<https://wellcomecollection.org/works/xmdhn85r>

License and attribution

Conditions of use: it is possible this item is protected by copyright and/or related rights. You are free to use this item in any way that is permitted by the copyright and related rights legislation that applies to your use. For other uses you need to obtain permission from the rights-holder(s).



Wellcome Collection
183 Euston Road
London NW1 2BE UK
T +44 (0)20 7611 8722
E library@wellcomecollection.org
<https://wellcomecollection.org>





ROYAL SOCIETY OF MEDICINE

FOUNDED 1805

INCORPORATED BY ROYAL CHARTER 1834

NEW CHARTER 1907

GIFT TO THE LIBRARY

PRESENTED BY

Dr. Leonard Williams

DATE January 1925



22102023387

Med
K7035

Digitized by the Internet Archive
in 2017 with funding from
Wellcome Library

<https://archive.org/details/b29821228>

THE
MORPHOLOGY AND EVOLUTION
OF
THE APES AND MAN

BY
CHARLES F. SONNTAG, M.D., CH.B., F.Z.S.

*Prosector to the Zoological Society of London, and Demonstrator
of Anatomy, University College*

WITH A FOREWORD BY
PROFESSOR G. ELLIOT SMITH, M.D., F.R.S.



London
JOHN BALE, SONS & DANIELSSON, LTD.
83-91, GREAT TITCHFIELD STREET, OXFORD STREET, W.1

29553

183 813

| | |
|-------------------------------|----------|
| WELLCOME INSTITUTE LIBRARY | |
| Coll. | we!MOmec |
| Call | |
| No. | QL |
| | |
| | |
| | |

FOREWORD.

IN virtue of his office as Prosector to the Zoological Society of London, Dr. Charles Sonntag has exceptional opportunities for original observation in comparative anatomy; and ever since he has occupied this position he has interpreted his duties in the most generous way as the patient and indefatigable collector of exact information, which in the *Proceedings of the Zoological Society* and in other ways he has promptly made available for others to use.

Some time ago I ventured to suggest to him that he could render an invaluable service to students and investigators if he would prepare and publish full accounts of the anatomy of the anthropoid apes based upon his personal observations, with such comparative and bibliographical notes as would make his report a standard work of reference for anthropologists and anatomists. This book represents the realization of that scheme.

Its importance depends upon the fact that it is an impartial and reliable statement of facts based upon direct observation and a laborious sifting of the voluminous mass of writings dealing with the Primates. It is a remarkable demonstration of Dr. Sonntag's patience and industry, and its special value to the student is its freedom from the bias which writers

intent upon the interpretation of evidence, rather than the collection of the evidence itself, are apt to introduce into their reports, however much they may strive to be impartial.

Hitherto there has been no book of reference giving complete information in Primate anatomy to which students of Anatomy or Anthropology could turn for enlightenment. A quarter of a century ago Sir Arthur Keith placed his colleagues under a deep debt of gratitude by compiling a bibliography and annotations upon the anatomy of the great Apes, which has been of the utmost service to workers in Anthropology ever since. In his book *Morphology and Anthropology* Dr. Duckworth, of Cambridge, has made a useful collection of data relating to the anatomy of the Primates; and scores of other writers have dealt with one or another branch of Simian anatomy, often in great detail. What especially was needed by students was a fuller summary of this mass of evidence compiled by someone with a first-hand knowledge of the facts.

In commending Dr. Sonntag's book to students perhaps I should explain that it is wholly his own work.

G. ELLIOT SMITH.

PREFACE.

THIS book is intended to serve as an introduction to Anthropology, for it deals with the first steps in that science, namely, the study of the relations of Man to the lower animals. It is based on observations made in the Anatomical Department and Ape House of the Zoological Society of London, and on the examination of specimens in the Museum of the Royal College of Surgeons of England, the Anatomical Museum of University College, and the British Museum of Natural History.

In a work such as this it is essential to include an analysis of the truly vast literature on the Apes, so that one can obtain an idea of the range of variation which each structure exhibits. More than seven hundred works have been consulted, and a selection has been made of books and papers which should be useful to research workers. Figures in heavy type after the names of authors in the text refer to the Bibliography.

I have to express my best thanks to Professor Elliot Smith for reading the proofs and writing an invaluable Foreword, to Sir Arthur Keith for the gift of parts of a Gorilla, and to Dr. A. Smith Woodward for permission to examine the specimens in the Department of Geology in the British Museum. I have also to express my thanks

to Dr. Doreen Stranger, Miss Kahan and Messrs. Awrounin, Henderson, Meneces, McCormick and Ogden, students in the Anatomy Department of University College, for their assistance in the work of dissection.

I am indebted to Professor Elliot Smith, Mr. R. I. Pocock, and the Publication Committee of the Zoological Society of London for permission to reproduce illustrations. Figures numbered 11, 12 and 19 to 57 are original, and were drawn under my supervision by my assistant, Mr. C. H. Hicks, to whom I express my thanks. Figure 5 is from a photograph by Mr. W. E. Le Gros Clark, F.R.C.S., and all other illustrations of living animals are from photographs by Mr. H. Bond of the Zoological Society.

C. F. SONNTAG.

Zoological Society of London,
October 25, 1923.

CONTENTS.

| | | | | | | |
|--------------|-----|-----|-----|-----|-----|------|
| | | | | | | PAGE |
| INTRODUCTION | ... | ... | ... | ... | ... | 1 |

Part I.—LEMURS, TARSIIUS AND MONKEYS.

| | | | | | |
|---------|----|-----------------------|--|-----|----|
| CHAPTER | I. | Lemurs and Tarsius... | ... | ... | 13 |
| | „ | II. | New World Monkeys or Platyrrhini | ... | 35 |
| | „ | III. | Old World Monkeys or Cercopithecidæ... | | 47 |

Part II.—THE ANTHROPOID APES.

| | | | | | |
|--------------|---|-----|-----|-----|-----|
| CHAPTER IV. | External Characters, Habits and Classi- | | | | |
| | fication ... | ... | ... | ... | 65 |
| „ V. | The Skeleton and Teeth | ... | ... | ... | 104 |
| „ VI. | The Joints ... | ... | ... | ... | 151 |
| „ VII. | The Muscular System | ... | ... | ... | 161 |
| „ VIII. | Organs of Digestion ... | ... | ... | ... | 209 |
| „ IX. | Organs of Circulation, Blood and Duct- | | | | |
| | less Glands ... | ... | ... | ... | 227 |
| „ X. | Organs of Respiration and Voice | ... | ... | ... | 257 |
| „ XI. | The Urinogenital Organs | ... | ... | ... | 264 |
| „ XII. | The Nervous System and Sense Organs | | | | 273 |
| „ XIII. | Evolution of the Primates | ... | ... | ... | 318 |
| BIBLIOGRAPHY | ... | ... | ... | ... | 333 |
| INDEX | ... | ... | ... | ... | 358 |



LIST OF ILLUSTRATIONS.

| FIG. | | PAGE |
|------|---|------|
| 1. | The Ruffed Lemur (<i>Lemur varius</i>) ... | 14 |
| 2. | The Slow Loris (<i>Nycticebus tardigradus</i>) ... | 14 |
| 3. | Demidoff's Galago (<i>Hemigalago demidoffi</i>) ... | 15 |
| 4. | The hand and foot of <i>Lemur macaco</i> ... | 16 |
| 5. | The Spectral Tarsier (<i>Tarsius spectrum</i>)... .. | 27 |
| 6. | The hand and foot of <i>Hemigalago</i> and <i>Tarsius</i> ... | 28 |
| 7. | The Brown Capuchin (<i>Cebus fatuellus</i>) ... | 36 |
| 8. | The hand and foot of <i>Ateles paniscus</i> ... | 37 |
| 9. | The Bonnet Macaque (<i>Macacus sinicus</i>)... .. | 48 |
| 10. | The Drill (<i>Mandrillus leucophaeus</i>) ... | 49 |
| 11. | The skulls of the lower Primates ... | 51 |
| 12. | The brains of the lower Primates ... | 59 |
| 13. | The Silvery Gibbon (<i>Hylobates leuciscus</i>) ... | 66 |
| 14. | Young Orang-Outans (<i>Simia satyrus</i>) ... | 76 |
| 15. | Adult Orang-Outan | 77 |
| 16. | The Chimpanzee (<i>Anthropopithecus troglodytes</i>) ... | 86 |
| 17. | Young Gorilla (<i>Gorilla gorilla</i>)... .. | 93 |
| 18. | Adult Gorilla | 94 |
| 19A. | The hand of the Bornean Gibbon and Orang-Outan | 95 |
| 19B. | The hand of the Chimpanzee and Gorilla ... | 96 |
| 20A. | The foot of the Bornean Gibbon and Orang-Outan | 97 |
| 20B. | The foot of the Chimpanzee and Gorilla... .. | 98 |
| 21. | Osteology of the Apes | 107 |
| 22. | The skull of the Orang-Outan | 111 |


LIST OF ILLUSTRATIONS

| FIG. | | PAGE |
|------|--|------|
| 23. | Skulls of young and adult Chimpanzees... | 118 |
| 24. | The skull of the Gorilla ... | 126 |
| 25. | Pelvis in Man and the Apes ... | 137 |
| 26. | The spinal and pelvic ligaments in the Chimpanzee | 152 |
| 27. | The facial muscles in the Chimpanzee ... | 162 |
| 28. | The ocular, orbital and nasal muscles in the Chimpanzee ... | 164 |
| 29. | The lips, cheeks and masticatory muscles in the Chimpanzee ... | 165 |
| 30. | The palatine and pterygoid muscles ... | 167 |
| 31. | The submaxillary region and omo-hyoid muscle ... | 169 |
| 32. | The cervical muscles in the Chimpanzee ... | 170 |
| 33. | The sacro-spinalis muscle in the Chimpanzee ... | 177 |
| 34. | The deep muscles of the back in the Chimpanzee... | 179 |
| 35. | Muscles and joints of the hand in the Chimpanzee | 188 |
| 36. | Muscles of the leg and the knee-joint in the Chimpanzee ... | 194 |
| 37. | The tongue of the Gorilla ... | 212 |
| 38. | The tongue of the Chimpanzee ... | 213 |
| 39. | The tongue of the Orang-Outan ... | 214 |
| 40. | The tongue of the Bornean Gibbon ... | 215 |
| 41. | The aorta and subclavian vessels in the Chimpanzee | 228 |
| 42. | Arteries of the head and neck in the Chimpanzee | 230 |
| 43. | The arteries of the upper extremity in the Chim- panzee ... | 235 |
| 44. | The abdominal and pelvic arteries in the Chimpanzee | 239 |
| 45. | Veins of the head, neck and thorax in the Chimpanzee | 247 |
| 46. | The portal vein in the Chimpanzee ... | 250 |
| 47. | The nasal meatuses and antrum of Highmore in the Chimpanzee ... | 258 |
| 48. | The internal organs of generation in the Chimpanzee | 266 |
| 49. | The external organs of generation in the Chimpanzee | 268 |

LIST OF ILLUSTRATIONS

xi

| FIG. | | PAGE |
|------|--|------|
| 50. | The brain in the Hoolock Gibbon and Orang-Outan | 286 |
| 51. | The brain in the Gorilla and Chimpanzee ... | 291 |
| 52. | The cervical and thoracic parts of the vagus and sympathetic nerves in the Chimpanzee ... | 295 |
| 53. | The abdominal parts of the vagus and sympathetic nerves in the Chimpanzee ... | 298 |
| 54. | The cervical plexus in the Chimpanzee ... | 300 |
| 55. | The brachial plexus in the Chimpanzee ... | 301 |
| 56. | The lumbar plexus in the Chimpanzee ... | 306 |
| 57. | The evolution of the Primates ... | 319 |



THE
MORPHOLOGY AND EVOLUTION OF
THE APES AND MAN.

INTRODUCTION.

Anthropology (Gr. *ἄνθρωπος*, man, and *λόγος*, a science) is the science which studies the relations of Man to the lower animals. It differs from **Ethnology** and **Ethnography**, which deal respectively with the characters and distribution of the races of mankind. When Anthropology is used in its widest sense, as a study of the natural history of Man, it includes all these branches of knowledge.*

The **aims of Anthropology** in its strictest sense were summarized by Huxley (87) as follows: "The question of questions for mankind—the problem which underlies all others, and is more deeply interesting than any other—is the ascertainment of the place which Man occupies in nature and of his relations to the universe of things. Whence our race has come; what are the limits of our power over nature, and of nature's power over us; to what goal are we tending—are the problems which

* The term Physical Anthropology, which is now in common use, includes the study of the relations of Man to the lower animals, and all aspects of the structure of the human races, particularly the measurements of the skulls.

present themselves anew and with undiminished interest to every man born into the world." An essential preliminary to the solution of these problems is a study of the biology of the Anthropoid Apes—the Gibbons, Orang-Outan, Chimpanzee and Gorilla.

Anatomy and Physiology.—The first requirement is an examination of the external characters and internal structure of the Apes, and this must be carried out with the thoroughness and minuteness which are employed in the study of human anatomy. The large series of data so obtained must then be submitted to a physiological analysis, in order that the significance of each group of characters can be understood. When that has been done the following conclusions can be made: The Anthropoid Apes resemble Man in a general way in form and structure, but they differ from him in several respects. Some of the differences are associated with diet and habits, particularly locomotion; others are dependent on the size and complexity of the brain; and others again are the outcome of different developmental processes.

Bio-Chemistry and Pathology. — Certain biochemical reactions, which are described on p. 255, have shown that there is a true blood-relationship between the Apes and Man; and pathological investigations have proved that they are liable to similar diseases, both contracted naturally and induced experimentally. So it is evident that their constitutions have much in common.

Psychology.—The psychologist will find much scope for his highly philosophical work in a study of the mentality of the Apes and Man, for they exhibit considerable differences in high function. Moreover, the

comparatively simple mentality of the Apes forms a foundation for the study of the complex activities of the human mind. In remote times the earliest true Men had probably simple minds, but the struggle for existence, which included defence, hunting, the building of homes and many other conditions led to a great development of the cerebral functions, and migrations brought them under the influence of varied climatic conditions, which influenced the central nervous system in no small degree.

Variations.—If several examples of each of the Apes are examined it will be found that many of the external characters and internal organs exhibit a considerable range of variation. And some parts vary more than others. So any attempt to define the characters of a species by the examination of one representative will be negatived by the examination of the next animal which comes to hand. In his article on the Gorilla (99) Keith says: "If the animals that make up the present race were superimposed muscle on muscle, artery on artery, brain-convolution on brain-convolution, the result would be, not the clear outline of a typical individual, but rather an amoeboid form, with a considerable amplitude of variation in certain well-defined directions . . . the lines of variation thrown out as pseudopodia may be regarded as feelers co-ordinating the race with its surroundings." Many of the variations depend on age, sex and the locality in which the particular animal is found; and it is certain that systematists have formed purely local races into distinct species. This is well seen in a study of the literature dealing with the Orang-Outan, for seventeen varieties have been men-

tioned by zoologists, whereas the Dutch settlers believe there is only one. The skull of this animal varies continually throughout life, and this may account for the differences in the external appearances upon which classifications are founded. It is therefore evident that the characters of a species can only be accurately defined after some hundreds of representatives have been examined.

Problems of Distribution.—The present-day Anthropoids are restricted to the dense forests in the tropical parts of Asia and Africa, but the discovery of the remains of extinct forms (e.g., *Dryopithecus*, *Pliopithecus*, *Palæopithecus*, &c.) in the rocks of France, Germany and Northern India shows that the distribution was formerly wider. We can assume that their extinction in these regions was probably due to climatic factors.

Endocrine Glands and Evolution.—Much light has been thrown on the relations between Man and the Apes by studies of the functions and diseases of the endocrine organs or ductless glands. And a study of these organs enables us to understand some of the agencies which have moulded the characters of the various human races. At a certain stage the foetuses of the Apes and Man have many characters in common, but the subsequent developmental changes, both intra-uterine and extra-uterine, proceed in different directions. In the Apes they are marked by a progressive increase in certain parts, such as the cutaneous pigmentation, hair, limbs, and facial skeleton. In Man, on the other hand, they are characterized by suppression, but the power to develop further lies dormant. The suppressive agents are the various ductless glands. When they are

diseased, or removed by experiment, the suppressive functions are withdrawn, the latent power reasserts itself, and Man assumes certain ape-like characters. If the pituitary body and suprarenal capsules are diseased simultaneously in the white races the skin becomes bronzed and hairy, the hands become large and clumsy, and the facial skeleton enlarges; the supra-orbital crests, zygomata and malar bones become prominent; and the maxillæ, mandible, or both together, exhibit prognathism. The teeth become widely spaced, and they are concealed by the lips which are very thick.

It may be asked how the ductless glands come to function differently in Man and the Apes. Bolk (311) believes that diet has played an important part. When Man's ancestors changed their diet from frugivorous to omnivorous or carnivorous, the functions of the glands changed, with the result that the body changed both somatically and physiologically. The whole processes of life and development became slowed in Man.

Classification.—At the summit of the Mammalian Class stand the Lemurs, Monkeys, Apes and Man, which comprise the Order Primates. Their relation to one another and to the other Mammals are shown in the following scheme:—

CLASS MAMMALIA.

Sub-class *PROTOTHERIA*.

Order *Monotremata*. Platypus, spiny ant-eater.

Sub-class *THERIA*.

Section A. *Metatheria*.

Order *Marsupialia*. Opossums, kangaroos, koala, &c.

Section B. *Eutheria*.

- Order I. *Insectivora*. Hedgehog, moles, shrews, &c.
 „ II. *Cheiroptera*. Bats.
 „ III. *Rodentia*. Rabbits, mice, squirrels, &c.
 „ IV. *Edentata*.
 Sloths, pangolins, armadillos, &c.
 „ V. *Cetacea*. Whales, porpoises, dolphins.
 „ VI. *Carnivora*. Cats, dogs, bears, seals, &c.
 „ VII. *Ungulata*. Sheep, cattle, goats, &c.
 „ VIII. *Sirenia*. Manatee, dugong.
 „ IX. *PRIMATES*.

- Sub-order I. *Lemuroidea*. Lemurs, lorises, aye-aye.
 „ II. *Tarsioidea*. Tarsier.
 „ III. *Anthropoidea*.

Section A. *Platyrrhini*.

- Family I. *Hapalidæ*. Marmosets.
 „ II. *Cebidæ*. Capuchins, howlers, &c.

Section B. *Catarrhini*.

- Family I. *Cercopithecidæ*.
 Macaques, baboons, langurs.
 „ II. *Simiidæ*. Gibbons, orang-outan,
 chimpanzee, gorilla.
 „ III. *Pithecanthropidæ* (?).
 Pithecanthropus (extinct).
 „ IV. *Hominidæ*. Man.

THE ORDER PRIMATES.

The animals composing the Order Primates vary considerably in size, some of the Marmosets and Galagos being diminutive, whereas the adult male Gorilla may exceed a fully-grown man in stature. With few exceptions they are adapted for an arboreal life.

The hallux and pollex are opposable to the other digits and the tail may be an important prehensile organ.

With the exception of Man all Primates have a covering of **hair**, and the direction of the hair slope presents features of interest from the phylogenetic point of view. Some species have tactile hairs or vibrissæ, which are also known as sinus hairs, from the presence of blood-sinuses round their enlarged root-bulbs. They gradually diminish from the lowest Primates up to the highest, and their gradual disappearance may be correlated with the increasing importance of the hand as a sensory organ.

The skin of the palms and soles has a more or less complete set of **pads**, which form part of the equipment for an arboreal life. In the lower Primates there are pads on the tips of the digits, over the heads of the metacarpals and metatarsals and on the proximal part of the palms and soles. In the Anthropoid Apes they are reduced to traces of the apical series. Besides these pads there may be small elevations of the epidermis.

The skin of the palms and soles is traversed by fine ridges, called **papillary ridges**, which are arranged in different ways in different Primates. They consist of thickenings of the epidermis over rows of dermic papillæ, and they lodge the orifices of the sweat glands. Their function is twofold—they help to make the grip secure; and they are sensory, for the dermic papillæ contain special sense organs. They become increasingly numerous from the lower Primates up to the highest, because of the progressive increase in the use of the hands as sensory organs. There is, therefore, an inverse ratio between the vibrissæ and papillary ridges.

Papillary ridges are also present on the gripping surfaces of prehensile tails.

The epidermis is thickened to form the **ischial callosities** in the Gibbons and Monkeys.

The **mammary glands** vary in position. In the Lorises and *Tarsius* there are both inguinal and pectoral mammæ; in the Aye-Aye (*Chiromys*) they are restricted to the groins; in *Hapalemur* they occur on the shoulders; and in all other Primates there are two pectoral mammæ. Phylogenetically the mammary glands are modified sebaceous glands. In some Primates there are also specially modified sebaceous glands which have an erotic function.

The **digits** of the hands and feet are usually five in number, but the thumb is absent in the Spider Monkeys (*Ateles*), and the index of the hand is a small stump in the Potto (*Perodicticus*). The relative lengths of the digits vary considerably.

The digits have **nails** or **claws**, but it is sometimes difficult to decide whether a particular structure is a nail or a claw. In the true Lemurs the index has a claw, but the other digits have nails; in *Tarsius* there are claws on the second and third digits of the foot; in *Chiromys* there are claws on all digits. Of the New World Monkeys the Marmosets have claws on all digits except the hallux: but the Cebidæ possess highly-arched claw-like structures. All Old World Primates have flat nails on all digits, but they are curved in some Gibbons. The digits also exhibit a variable amount of union by webs (syndactyly).

The **functions of the tail** are numerous. In *Tarsius* it is pressed against the tree trunks and acts as a

support; it may also act as an equipoise when the animal is performing its characteristic froglike leaps. It also acts as an equipoise in the Old World Mangabeys (*Cercocebus*), which are active jumpers; and it is an important prehensile organ in the New World Monkeys. The tail is a mere rudiment in the Baboons, and it is absent in the Anthropoid Apes and Man. In the Apes and Man the muscles of the tail have been transformed into the muscles of the pelvic floor, which plays an important part in supporting the abdominal viscera in the erect or semi-erect position.

The **eyes** are large in the Lemurs, *Tarsius* and Gibbons, but, as will be shown later, there are profound differences between the ocular apparatus in the Gibbons and that in the Lemurs and *Tarsius*. Large eyes are associated with nocturnal habits, and there appears to be an inverse ratio between the dimensions of the eyes and the size and bulk of the animal. Thus the eyes are small in the Chimpanzee and large in the Gibbons.

All Primates except Man and the Orang have a triangular process beneath the tongue for the openings of the ducts of the submaxillary glands; and some have an additional body, or **sublingua**, which is best marked in the Lemurs. The **stomach** is simple in all except the Langurs and Guerezas, and the entire large intestine has a well-marked **mesentery** in all Primates below the Anthropoid Apes; in the latter long stretches of the colon are bound down to the posterior abdominal wall, an arrangement which is associated with the erect or semi-erect attitude.

The **testes** descend into a scrotum, and the penis has

a bone in most Primates below Man. The **uterus** is usually simple, but the placentation varies.

The Order Primates is divisible into three sub-orders: Lemuroidea, for the Lemurs, Galagos, Lorises and Aye-Aye; the Tarsioidea for the Tarsiers; and the Anthro-poidea for the Monkeys, Apes and Man. This method of division accords better with the facts obtained from the study of comparative anatomy and palæontology than the inclusion of the Lemurs and Tarsius in a separate Order called the Prosimiæ. The word Prosimiæ is useful in descriptive work as indicating that particular features are found in the Lemurs and Tarsius, but not in the other Primates.

PART I.

LEMURS, TARSIIUS AND MONKEYS.

CHAPTER I.

LEMURS AND TARSIUS.

Sub-order LEMUROIDEA.

THE sub-order Lemuroidea includes the true Lemurs from Madagascar and the Comoro Isles (fig. 1), the Galagos from tropical East Africa (fig. 3), the Lorises of East India and Malaya (fig. 2), and the Aye-Aye from Madagascar. They are diversified in appearances, habits and diet, but arboreal forms predominate, and the vast majority are nocturnal. The diet consists of insects, eggs, nestlings or vegetable matters; the smaller species may be entirely insectivorous, whilst the "Sifakas" are purely vegetarian.

All species have a well-developed **furry coat**, whose colour may be extremely beautiful. The **eyes** are large, and in some cases highly coloured; but they often have a stupid blinking appearance during the day. The **ears** are large and prominent, and the elongated muzzle gives a bestial appearance to all species. The **tail** varies considerably, being long in the true Lemurs and absent in the Lorises; it is imperfectly prehensile, but it serves as a balancer when the animal is on the move.

Hands and Feet.*—The vast majority of species have pentadactyl hands and feet, but the index digit of the

* The hands and feet of many species have been figured by Pocock (171).



FIG. 1.—The Ruffed Lemur (*Lemur varius*).



FIG. 2.—The Slow Loris (*Nycticebus tardigradus*).

hand is reduced to a mere excrescence in the Potto (*Perodicticus*). All the digits of the hand are long and slender; they decrease in size in the order 4, 3, 5, 2, 1; and syndactyly is of the same extent as in Man in the true Lemurs, but more extensive in some other forms. The foot has four slender toes and a stout hallux, which can be abducted till it is at right angles to the middle line of the limb.



FIG. 3.—Demidoff's Galago (*Hemigalago demidoffi*).

All digits except the index of the foot are provided with **nails**, but that digit has a well-marked claw. The distal ends of the nails are convex, truncated or pointed. And the only exception to these conditions is the Aye-Aye (*Chiromys*), which has claws on all digits of the hands and feet (figs. 3 to 6).

The skin of the palms and soles has well-marked **pads**

(figs. 4 and 6), which can be arranged in three groups. Most distally lie the terminal digital pads, which give an expanded appearance to the ends of the digits. On the heads of the metacarpal bones lie the four intermediate or interdigital pads. And two pads over the proximal parts of the hands and feet constitute the third group. All pads may be quite separate, or there may be a variable amount of fusion between the pads of the intermediate

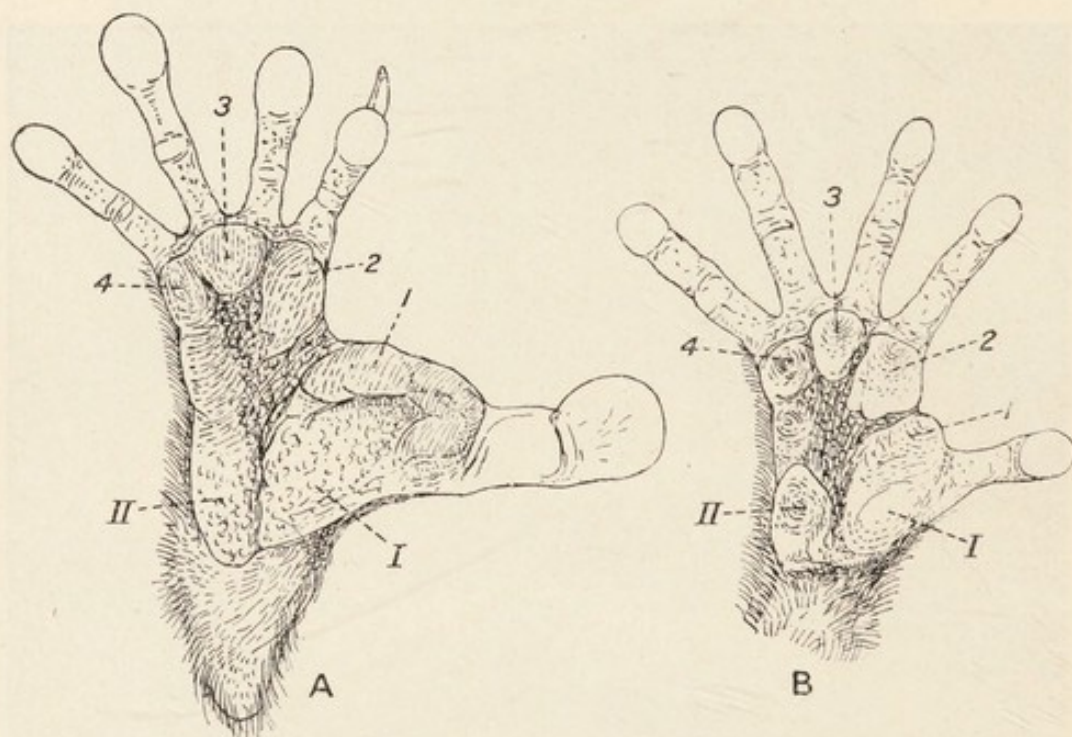


FIG. 4.—A, foot, and B, hand of *Lemur macaco*. $\times \frac{2}{3}$. 1-4, the intermediate pads; I, II, the proximal pads (Pocock).

and proximal groups, and between the individual pads in each group. But besides these pads the epidermis is nodulated.

The surfaces of the pads and other elevations are traversed by **papillary ridges**, on which may be seen the orifices of the ducts of sweat glands. The ridges are arranged in loops, concentric circles or oblique lines. When the characters of the papillary ridges are com-

pared with those in the higher Primates it will be found that the latter have a more extensive line system, with a consequently more acute tactile sense.

Vibrissæ.—Pocock points out that the most generalized arrangement is present in the Mouse Lemur (*Chirogaleus*). There are tufts above the eye (superciliary), round the mouth (mystacial), on the cheeks (genal), and below the chin (submental). All groups are present in *Chiromys*, and most species of *Lemur*. In the Galagos and Lorises the complement is less, the submental tuft suffering most. Carpal vibrissæ are absent in Asiatic and African Lemurs, but are present in the species from Madagascar.

Hair Slope.—The primitive hair-slope, which runs from the head backwards to the tail, is modified in the Lemurs. The hairs from the brow slant backwards and mingle with two streams passing upwards on the back of the neck. And the mid-dorsal line of the back forms a focus to which hairs are directed from the shoulders and the sides of the body. Hairs are directed downwards over the thighs, and the hairs on the arm and forearm converge towards the elbow-joint, as in the Apes. On the ventral aspect of the trunk the hairs form a spiral on each half of the abdominal wall; and Duckworth (50) regards it as characteristic of the Lemurs alone.

Peculiar Glands.—Special modified sebaceous glands have been found on the wrist and shoulder and round the anus. Their function is, however, not at all clear. Possibly they exert an erotic action.

Skeleton.—If the **skull** of any true Lemur (fig. 11) is compared with that of a Dog, it will be seen that in both the facial part is elongated to form a snout, the

occipital plane is perpendicular to the basicranial axis, and two globular swellings—the tympanic bullæ—project downwards from the basal aspect of the temporal bones. A great difference, however, will be seen in the orbito-temporal region; in the Dog the orbital cavity is not shut off in any way from the temporal fossa, but a **post-orbital bar**, formed by the frontal and malar bones, partially separates them in the Lemur. Within the orbit in the Lemur the ethmoid and lachrymal bones are separated by a union of the frontal and maxillary bones. No trace of the **nasal duct** appears within the orbit, but the orifice is seen on the face.

On the side of the skull the most important point to note is the union of the parietal and alisphenoid bones in the **pterion**.

The **glenoid cavity** for the reception of the condyle of the mandible is extremely shallow, but there is a well-marked post-glenoid tubercle. The jugular foramen is large, and the **internal carotid artery** passes into the skull through a foramen on the back of the tympanic bulla.

The **external auditory meatus** is shallow, whereas it is long in the Anthropoid Apes.

The foramen rotundum and **spheno-maxillary fissure** are confluent, and there is no canal in the alisphenoid for the internal maxillary artery as there is in the Dog.

The **bony palate** is long, and may be thickened behind. The turbinal region is complex; and the condyles of the mandible are level with the crowns of the molar teeth.

The **dental formula** is $I_2^2 C_1^1 PM_3^3 M_3^3$ in the true Lemurs. In the Indrisidæ it is reduced to $I_2^2 C_0^1 PM_2^2$

M $\frac{3}{3}$. Between the upper incisor teeth there is a well-marked gap in *Lemur*, but not in *Chiromys*. The lower canine tooth is like an incisor, and the first lower pre-molar resembles a canine tooth.

The **frontal bones** are frequently, but not always, separated by a persistent suture.

Vertebral Column.—When the column is examined as a whole it is seen that the tenth dorsal spine acts as a point towards which the other spinous processes converge; and it is known as the **anticlinal vertebra** or centre of motion. Such a condition is found in many mammals, but is absent in the Anthropoid Apes and Man. The whole curvature of the spine is also similar to that of other quadrupeds.

The spinal column in a true Lemur is composed of 7 cervical, 12 dorsal, 7 lumbar, 3 sacral and 27 caudal vertebræ, or 56 vertebræ in all. The spine of the axis is very large as in many lower mammals.

Pelvis.—The innominate bones are long and narrow, with small ischial tuberosities and a short symphysis pubis. The thyroid foramen is large, and the pelvic brim is nearly circular, as in Man, but not in the Apes.

The **sternum** is a long, narrow rod consisting of five pieces. The **clavicles** are well developed, and the **humerus** has a prominent pectoral crest; it is perforated by a foramen above the internal epicondyle as in the Carnivora.* The **radius and ulna** are not anchylosed. There is a sesamoid bone above the pisiform as in the Gibbon and some Chimpanzees; and a radial sesamoid

* This foramen transmits the median nerve, with or without the brachial artery in the Carnivora. It is sometimes present in Man.

bone is present in *Perodicticus* and *Chiromys*. The **carpus** has an os centrale.

The slender **femur** has a short, stout neck and three trochanters—the third trochanter being situated in the gluteal ridge. The upper end of the shaft is compressed antero-posteriorly, but the lower part is compressed transversely. The **tibia and fibula** are not fused distally as in *Tarsius*. The **entocuneiform** is rounded, and a saddle joint allows of free movements of the hallux. The **os calcis** is prominent and the tarsus is flat. The first metatarsal bone has a large tubercle for the tendon of the peroneus longus, thus suggesting that this muscle abducts the hallux (Duckworth).

The **Muscular System**.—The muscles have the same general arrangement as in Man, but they are disposed in a manner most suitable to the mode of life of the animal.

The *platysma* has an extensive origin from the mid-dorsal line of the neck, as in many Carnivora, and it sweeps forwards to blend with other muscles at the angle of the mouth. Beneath it there lies a sheet of muscle with transverse fibres known as the *sphincter colli*. These muscles, likewise the dorso-humeralis, are parts of the cutaneous musculature. The facial and auricular muscles are well marked.

The sternal and clavicular parts of the *sterno-mastoid* are slender, but the insertion into the occipital bone is extensive. The *trapezius* has no occipital origin as in the Gibbons, and the *rhomboides* is strong and extensive.

The *infra-hyoid muscles* are not peculiar, and the *digastric* muscle is really monogastric (Parson's second type); it runs from the occipital bone behind to the

deep surface of the mandible. In the higher Primates the conditions are more complex, there being posterior and anterior bellies.

The *deltoid* muscle is strong, but the *pectoralis major*, with which it is fused at its insertion into the pectoral crest on the humerus, is weaker than in many of the Primates. There is no clavicular origin of the *pectoralis major* as in the quadrupedal, terrestrial Baboons. The muscles arising from the scapular surfaces are not peculiar.

The fascial sheath of the *latissimus dorsi* gives rise to two slips, which unite to form the *dorso-epitrochlearis* muscle. This climbing muscle, which is inserted into the olecranon and fascia over the internal epicondyle, is present in all Primates except Man, in whom it is merely represented by some fascia. The *biceps* has a well-marked *lacertus fibrosus*, and the *coraco-brachialis* is double, the musculo-cutaneous nerve passing between the two parts.

The *muscles of the forearm* exhibit an early stage in the evolution of the flexors of Man. The *flexor sublimis* and *flexor profundus digitorum* exhibit some fusion, and the *flexor longus pollicis* is not separated from the deep flexor mass. The stages in the evolution of the human flexor muscles are described on p. 187. There is no *extensor brevis pollicis*.

The *gluteus maximus*, whose origin extends backwards from the posterior superior iliac spine, is thinner at its insertion into the femoral shaft.

The *biceps* has a single long head only, the short head being absent as in some lower Mammals. It is inserted into the deep fascia of the leg, no fibres going to the

head of the fibula. The *tibialis anticus* is large. The *soleus* arises from the fibula alone, as in the higher Apes; and the *tibialis posticus* has its origin restricted to the fibula as well.

The *plantaris*, contrary to the condition in the higher Apes, is large and its tendon ends in the plantar fascia. The latter sends slips to the digits, that to the hallux being strong; and the same condition is met with in the Chimpanzee.

The *flexor brevis digitorum* sends tendons to the four outer digits, but this is not always the case in the higher Apes. The tendons are perforated, as in the case of the flexor sublimis muscle, by tendons of the deep flexor muscles. The *flexor longus digitorum* and *flexor longus hallucis* send tendons to each of the five toes; so it is evident that the hallux receives two flexors, but the other digits each receive three. In the higher Apes the conditions are simpler.

The **Alimentary Canal**.—The **tongue** has a large sublingual plate, whose apex is divided into several denticles, which fit in between the lower incisor teeth; and it has been suggested that these act as natural toothbrushes. In *Chiromys* there is an apical hook, which keeps the space between the two rodent-like lower incisor teeth clear. In the higher Primates, the sublingua, which is a vestigial structure, is absent, or reduced to the state of plicæ fimbriatæ. The **palate** has well-marked transverse rugæ. The **stomach** is simple, the **duodenum** is large and the long cæcum has a tapering vermiform appendix. The **colon** has a pendent colic loop.

The **pancreas** is narrow, but is otherwise not peculiar.

The **liver** exhibits many primitive features. It resembles that of many quadrupeds in its tendency to form numerous little lobules. It has deep incisuræ for the œsophagus and duodenum. The left lateral lobe is large, the Spigelian lobe is small, and the caudate lobe is large in true Lemurs; the size of the caudate and Spigelian lobes varies in different species. The gall-bladder is sunk in a hollow, and there is a variable amount of contortion of its narrow end and of the common bile duct. The bare area between the liver and the diaphragm is marked.

The **Organs of Circulation**.—The cardiac apex is formed by both ventricles, whereas it is usually formed by the left ventricle in the higher Primates; in a Drill I observed it formed by the right ventricle (174). And the pericardium only adheres slightly to the diaphragm.

The **aortic arch** gives off the innominate and left subclavian arteries, and the former breaks up into the right subclavian and both common carotid arteries. This arrangement is frequent among lower Mammals, and in the Gibbons and Chimpanzees, but not in the Gorilla nor in Man. Between the heart and diaphragm there lies the fourth lobe of the right lung as in the Carnivora.

The **brachial artery** divides in the Lorises into an immense number of long parallel branches, constituting a form of rete mirabile. The **axillary artery** gives off a trunk which divides into the humeral circumflex, scapular circumflex, thoraco-dorsal and subscapular; and a somewhat similar condition in a Chimpanzee is shown in fig. 41. The **femoral artery** also breaks up into sheafs of vessels in the Lorises. This multiple subdivision of arteries is also met with in the Sloth, Whale,

and in the cerebral arteries of the Carnivora. No saphenous artery is present as in the Anthropoid Apes.

The **blood** does not give positive precipitin reactions with that of the higher Primates.

The **Organs of Respiration and Voice**.—The epiglottis projects up into the naso-pharynx, the so-called intranarial position. The ventricles of the larynx do not become prolonged into air sacs. In *Indris*, which is distinguished by its loud voice, and in *Lemur varius*, a laryngeal sac communicates with the larynx through an opening close to the cricoid cartilage (Milne Edwards and Otto). Muscular fibres form isolated bundles close to the thyro-arytenoid muscle (Duckworth). The tracheal cartilages are complete in many species, and in this respect the Lemurs differ from the higher Primates. The left lung has three lobes and the right one has four, of which one is termed the azygos lobe or lobus impar. Its relation to the heart has already been described.

Urogenital Organs.—The left **kidney** is lower than the right one, the reverse of the condition present in the higher Primates; and one papilla only is present. The **testes** descend into a scrotum and there is a cremaster muscle derived from the transversalis abdominis or internal oblique muscle. The **vesiculæ seminales** are absent in *Chiromys*; in other forms they open on the verumontanum (Weber). The **penis** has no corpus spongiosum in *Nycticebus*. But an os penis is present in all species; its extremity is bifid or spinulose.

The **uterus** is bicornuate, and the **urethra** traverses the clitoris for a variable distance.

The **Brain** (fig. 12):—Professor Elliot Smith (148) has pointed out that the brain in *Chiromys* is inter-

mediate in character between the brains of lower Mammals and those of the true Lemurs; and the brains in the Lemurs have genetic affinities to those of the Primates. His conclusions as to the place of the Lemurine brain are based on macroscopic and experimental observation.

The **cerebral hemispheres** are small. They cover only a small part of the cerebellum behind; and the large olfactory bulbs project from beneath the hemispheres anteriorly in Lemurs, but not in *Chiromys*. The **lateral ventricle** has no posterior horn.

The surface of each hemisphere has a few sulci in Lemurs, Galagos, Pottos and Lorises, but Weber (162) points out that it is richly convoluted in the large Indrisidæ. The **central sulcus** (C.S.) is absent or very small. There is a true **Sylvian fissure** (F.S.) as in the Primates; it varies in size, and it may run into the rhinal fissure below. In *Nycticebus*, as in many of the Cebidæ, the Sylvian fissure tends to pass into the intraparietal sulcus. In *Lemur* the frontal lobe has a well-marked sulcus rectus (S.R.), which corresponds to the inferior frontal sulcus of the higher Primates. The **parallel sulcus** (P.S.) does not arch over the upper end of the Sylvian fissure, but the Sylvian and parallel sulci are arched over by the lateral or **intraparietal sulcus** (I.-P.S.). The latter is free from the **transverse occipital** or post-lateral sulcus (P.-L.S.); but in the higher Primates the intraparietal sulcus frequently runs into the transverse occipital sulcus, which is concurrent with the simian sulcus.

On the mesial aspect of the hemisphere the **calcarine sulcus** is seen to be Y-shaped (Ca.S.), but part of the Y

may represent the parieto-occipital sulcus of the higher Primates. And the intercalary or **calloso-marginal sulcus** (C.-M.S.), is separate from it.

The **cerebellum** is mostly uncovered by the cerebral hemispheres. It is simple in character, and has well-marked flocculi.

The brains of the Lorises, Galagos and Pottos are even smoother than those of the true Lemurs, but the same general characters are present.

When the **cortical centres** are investigated it is seen how the visual areas in the occipital part of the brain are extensive.

The brain forms $\frac{1}{70}$ to $\frac{1}{60}$ of the body-weight in the true Lemurs, whereas it only forms $\frac{1}{100}$ of the body-weight in some of the Carnivora, which rank next to the Primates in the size of the brain.

Sub-order TARSIOIDEA (Fig. 5).

The Tarsiers are diminutive creatures inhabiting some of the Malay islands. They have immense eyes, pointed ears and a tufted tail; but the snout is reduced, thus bringing the eyes more to the front of the head than in the Lemurs. They have two curious habits—they can rotate their heads till they look directly backwards; and they leap from bough to bough in a frog-like manner in search of insects.

Hands and Feet (fig. 6).—The long, slender fingers and the short thumb are terminated by expanded pads, thus resembling the digits of the Geckos; and the intermediate and proximal pads are separate. The nails simulate claws. In the foot the toes and the large

hallux have large terminal pads, and there is considerable fusion of the plantar pads; the index and middle digits have true claws. The pads cover a relatively

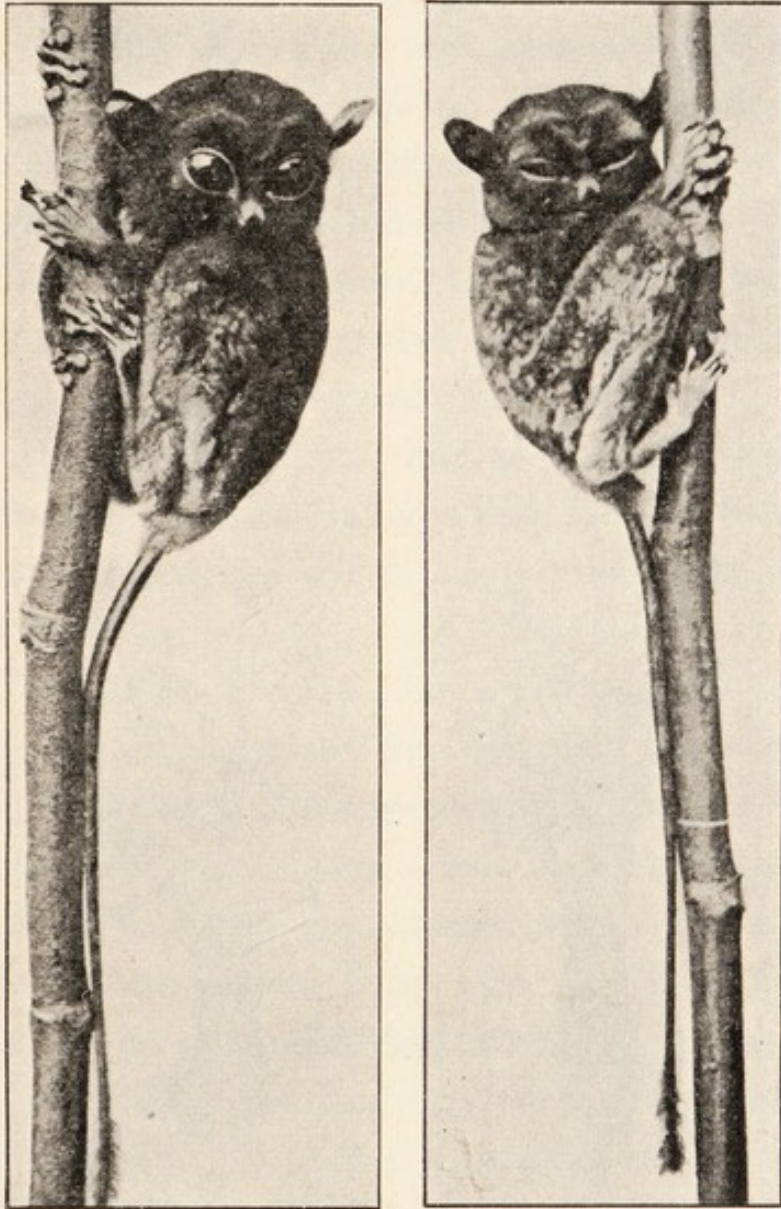


FIG. 5.—The Spectral Tarsier (*Tarsius spectrum*).

By permission of Professor Elliot Smith.

larger area of the palms and soles than in the Lemurs, and there are fewer small epidermal elevations. As all these elevations have papillary ridges the tactile area is greater in *Tarsius* than in the Lemurs. There are

also ridges on two naked areas on the tail. The increased tactile area is associated with ocular changes described below.

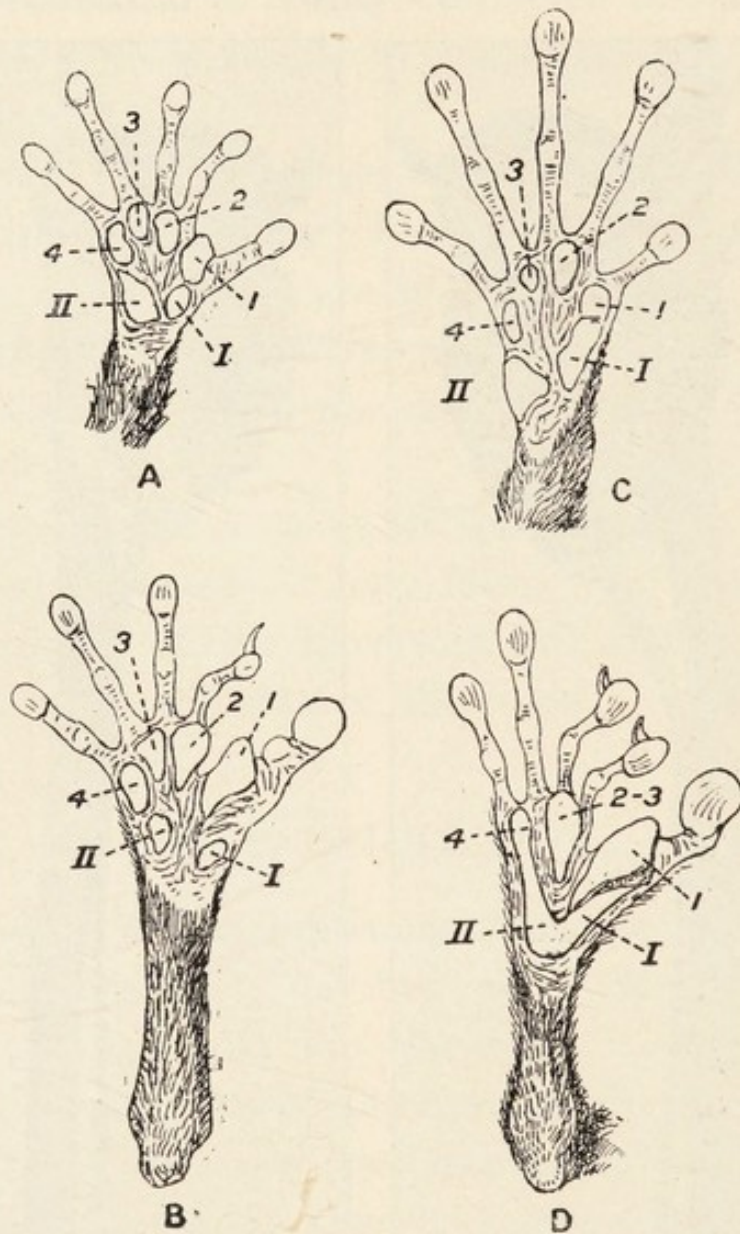


FIG. 6.—A, hand, and B, foot of *Hemigalago demidoffi*; nat. size. C, hand, and D, foot of *Tarsius*; nat. size. 1—4, intermediate pads; I, II, proximal pads (Pocock).

Vibrissæ.—The genal and submental vibrissæ are absent, as in the Lorises and Pottos; and the loss of these tufts is a derivative feature (Pocock). It indicates that these animals are more specialized than the

Mascarene Lemurs, which have the full complement (see page 17). Carpal vibrissæ are absent.

Hair Slope.—*Tarsius* differs from the Lemurs as follows: (1) The hairs on the head are directed forwards; (2) the hairs on the back diverge from the middle line; (3) the hairs on the forelimb all slope towards the manus; (4) there are spirals in the pectoral region but none on the abdomen.

Peculiar Glands.—These structures are absent. The **nipples** are four in number—two pectoral and two inguinal as in the Lorises and Galagos.

It is, therefore, evident that as regards the external characters the Lorises, Galagos and *Tarsius* have several points in common in which they differ from the Mascarene Lemurs.

Skull.—When viewed from the front the skull appears pyriform, with the narrow mandible below (fig. 11); and the broad upper part is formed mainly by the greatly expanded orbits. The latter are shut off from the temporal fossæ by post-orbital walls; and only a thin partition separates them from one another. The upper orifice of the **naso-lachrymal duct** lies on the face outside the orbit as in the Lemurs, both living and extinct.

The alisphenoid meets the parietal bone in the **pterion** as in the Lemurs and many higher Primates, and the former helps to complete the orbital wall.

The **glenoid fossa** is slightly deeper than in the Lemurs, and, as in them, there is a post-glenoid process. The tympanic bullæ are large, and there is a short, bony, external, auditory meatus. The **internal carotid artery** enters the skull through a foramen on the ventral surface of the bulla.

The **bony palate** differs from that in the Lemurs, and the foramen magnum is nearer to it than in them.

Of the foramina in the skull those for the **olfactory nerves** deserve special mention. In all Primates except *Tarsius* the olfactory filaments pass through the foramina in the cribriform plate of the ethmoid bone. In *Tarsius* there is no plate, and the olfactory nerve on each side passes through a single foramen as in Birds and in the Platypus (*Ornithorhynchus*).

Teeth.—The upper central incisors are not separated as in Lemurs; they are long and pointed, and they are much larger than the upper lateral incisors. The lower incisors constitute a pair of small cones (fig. 11). The upper canine teeth are smaller than the lower canines. The upper and lower molars are tricuspid, but the latter have an additional heel posteriorly. The dental formula is $I \frac{2}{1} C \frac{1}{1} PM \frac{3}{3} M \frac{3}{3}$.

The **sutures** disappear earlier than in the Lemurs.

Vertebral Column.—The forty-nine vertebræ composing the column are arranged as follows: C 7, D 13 or 14, L 6 or 5, S 5, C 18. The atlas is wide, and the axis is the only cervical vertebra with a distinct spinous process.

The **clavicles** are large, the **sternum** is narrow and the **scapula** is long and narrow. The **humerus** is large and has an epicondylar foramen. And the **carpus** possesses an os centrale; the unciform bone is large.

The **pelvis** is long and narrow, and the symphysis is limited to the pubis. The **tibia** and **fibula** are fused distally, and the **os calcis** and scaphoid are very long.

Muscular System.—The panniculus and *platysma myoides* are as in the Lemurs, but no *sphincter colli* is

present. The facial and auricular muscles, particularly the latter, are well marked.

The *sterno-mastoid* has no clavicular head of origin, and the *trapezius* merely reaches the occipital bone. The lower part of the trapezius forms a muscle known as the *depressor scapulæ*. A strip of muscle termed the *occipito-scapularis* is present beneath the trapezius. The pre-tracheal and most of the submental muscles are not peculiar, but the *digastric* muscle has two bellies in contradistinction to the monogastric form in the Lemurs. In Man the muscle has two separate bellies.

The *pectoral muscles* are much as in the Lemurs, but the *deltoid* muscle is not so extensive; it is divided into two parts as in some Marsupials. The *latissimus dorsi* gives off the dorso-epitrochlearis, but the latter arises from the muscle itself; in its origin the latter differs from that of the Lemurs.

The *muscles of the arm, forearm and manus* are much as in the Lemurs, but Duckworth (50) points out that the flexor longus pollicis is almost independent of the flexor profundus digitorum, though still receiving a slip from the flexor sublimis. In the separation of the flexor longus pollicis *Tarsius* resembles the higher Primates.

The lower limit of the insertion of the *gluteus maximus* is in the lower part of the thigh, a condition which resembles that in the Chimpanzee. The *biceps* has no femoral head, but the examination of many animals might show that this is variable as in the higher Apes.

The *vastus externus* is large as in the Lemurs, and the *tibialis anticus* is likewise greatly developed; but the *tibialis posticus* arises from both tibia and fibula. The *soleus* arises from the fibula alone as in the Lemurs and

many higher Primates. The *plantaris* ends in the plantar fascia.

Duckworth (50) after describing the muscles in the foot, points out that they are nearly identical with those in the Lemurs.

Alimentary Canal.—The **lips** have large sebaceous glands. The **tongue** has frenal lamellæ as in all Primates except Man and the Orang; but the sublingua is not specialized for tooth-cleaning as in the Lemurs. The **stomach** is simple, the **duodenum** is not so large as in Lemurs; and the large **cæcum** has no vermiform appendix. No pendent colic loop is present.

Organs of Circulation.—The **aortic arch** gives off its main branches as in Man, the Gorilla, and some Chimpanzees. The **internal carotid artery** enters the skull through an opening on the ventral aspect of the tympanic bulla. The **brachial artery** passes through the entepicondylar foramen as in some Carnivora (e.g., Racoons). The **saphenous** artery is present as in the Simiidæ.

Organs of Respiration.—The epiglottis is as in the Lemurs, and the tracheal rings are likewise complete. The lungs have many lobes; and one lobe of the right lung forms the lobus azygos.

Urogenital Organs.—The **kidneys** have several papillæ (Burmeister) as in Man and the Chimpanzee, a condition which is primitive in character. The **testes** are abdominal in position (Duckworth) and there is no **os penis**; in the absence of the os penis *Tarsius* resembles Man and differs from most other Primates. The **uterus** is bicornuate. The **labia** are well marked, and conceal the small clitoris and the orifices of the

urethra and vagina, which are close together. They resemble the labia in Man, and differ from those in the other Primates.

Brain.—It has been pointed out by Dubois (167) that the volume of the brain relatively to the size of the body is almost identical in *Tarsius* and *Nycticebus*. There are, however, important differences in the form and structure of the brain, and the following list contains the most important points:—

(1) The olfactory bulbs are relatively less than in the Lemurs, and relatively larger than in the higher Primates.

(2) The visual cortex is relatively larger than in the Lemurs, and less complex than in the higher Primates.

(3) The cerebral hemispheres are short and wide, they overlap the cerebellum more than in the Lemurs, and their surfaces merely show a small suprasylvian sulcus on each side.

(4) The association centres are much smaller than in the higher Primates.

(5) The corpus callosum is small.

(6) The cerebellum has large paraflocculi.

(7) The pons varolii is small and the trapezium is exposed.

Organs of Special Sense.—When the organs of special sense in the three Primate sub-orders are compared it is evident that *Tarsius* is intermediate between the Lemuroidea and Anthropeidea. In the first place the olfactory sense is poorer than in the Lemuroidea and better than in the Anthropeidea; and the reduction in the snout has allowed the eyes to come more to the front of the face, with the result that the visual fields overlap.

Consequently the loss of the olfactory sense leads on to the second point of difference—the visual apparatus in *Tarsius* is better developed than in the Lemurs, but poorer than in the Anthropeidea. The overlapping of the visual fields is associated with binocular vision and a great increase in the visual cortex. The Anthropeidea are more highly evolved, for they have maculæ luteæ and incomplete optic decussations, thus enabling them to focus objects on corresponding points on the retinae by moving their eyes alone. *Tarsius* has no maculæ and its optic decussation is complete, so it moves its head as a whole to see objects properly. In the third place the papillary ridges on the palms and soles are more extensive than in the Lemurs, but more restricted than in the higher Primates. Hence the acuteness of the tactile sense is also intermediate in *Tarsius*.

From a study of comparative anatomy one can conclude that *Tarsius* is in some ways more primitive and in other ways more specialized than the Lemurs; but on the whole the specializations are fewer and slighter. As Professor Elliot Smith (149) says: “*Tarsius*, however, although on a distinctly higher plane of Primate development, has managed to escape extinction with fewer and slighter specializations than the Lemurs. Hence it has retained a much more generalized and obviously primitive structure along with the germs of the features that are distinctive of monkeys.”

CHAPTER II.

THE NEW WORLD MONKEYS OR
PLATYRRHINI.

THE Platyrrhine Monkeys, so called on account of the wide partition separating their outwardly-directed nostrils, are diversified in form, structure and habits. But although they are more or less specialized, they all retain traces of their common ancestors. They also present characters which distinguish them sharply from the Old World Monkeys or Catarrhini. They are grouped in two families as follows:—

Family I. *Hapalidæ*. Marmosets (*Hapale*, *Midas*).

„ II. *Cebidæ*. Teetee (*Callicebus*), Douroucouli (*Aotus*), Howlers (*Alouatta*), Spider Monkeys (*Ateles* and *Brachyteles*), Sakis (*Pithecia*), Ouakaris (*Cacajao*), Capuchins (*Cebus*) and Squirrel Monkeys (*Saimiris*), Woolly Monkeys (*Lagothrix*).

They are never very large, but the Marmosets are diminutive.

All Platyrrhini are arboreal, and their progress among the trees may be assisted by a prehensile tail. They are vegetarian or insectivorous, and they will show discrimination in the selection of particular insects. Their disposition varies, some being bright and active,

whilst others are sullen; and their vocal powers vary from a sharp squeak to loud howlings, which have earned for their producers the popular name of "Howler Monkeys." Most species are natives of Brazil.

Nostrils and Septum Nasi (fig. 7).—Although the Hapalidæ and Cebidæ are all included in the Platyrrhine section the nasal septum is not always broad.




FIG. 7.—The Brown Capuchin (*Cebus fatuellus*).

H. O. Forbes has shown that the septum is comparatively narrow in *Aotus*, *Alouatta* and *Brachyteles*, and the nostrils are directed more forwards than in all other genera which have the typical broad septum and outwardly-directed nostrils. The nostrils are circular, slit-like or S-shaped. The septum and nostrils in the primitive *Douroucoulis* are like those of the Lemur-oidea, and different from those of all other Primates.

The **External Ears.**—Pocock (172) has shown that the auricles are useful for taxonomic purposes, and his paper should be referred to for details. In the Hapalidæ the pinna is very hairy, but it is more or less naked in the Cebidæ. Of the latter *Cebus* has an ear which can be regarded as typical. The tragus is

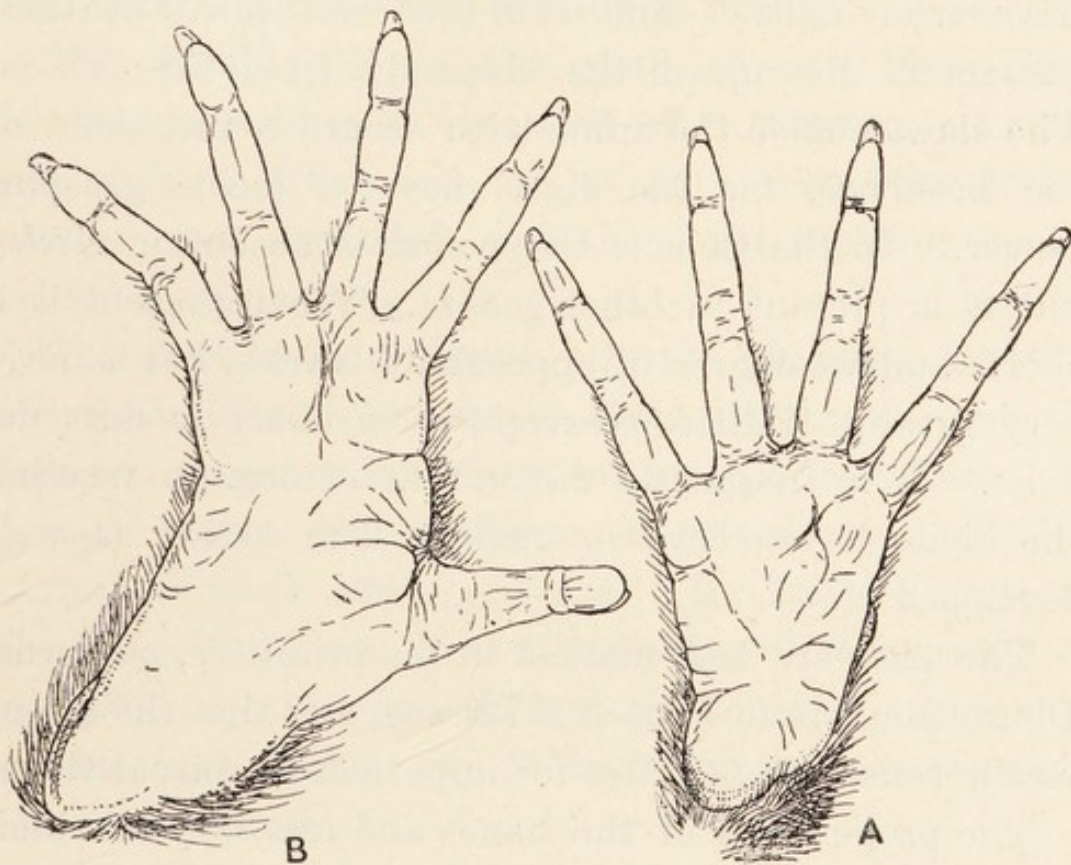


FIG. 8.—A, right hand of *Ateles paniscus*, from below ; B, right foot of the same. $\times \frac{1}{2}$. (Pocock.)

small, the antitragus is large and prominent and between them there is a well-marked incisura intertragica. There is also a deep notch between the antitragus in front and the antihelix behind ; and the latter is bifid above. The lower of the two divisions of the antihelix forms the supratragus. The upper part of the margin of the pinna is folded. No lobule is present.

The **head** is rounded, and devoid of a prominent snout.

Hands and feet (figs. 7 and 8).—The chief points of note regarding the hands and feet of the Hapalidæ are the shortness and non-opposability of the pollex, the variation in the amount of syndactyly, and the presence of strong claws on all digits except the halluxes, which have true nails. And the first and third of these characters distinguish the Hapalidæ from the Cebidæ. The claws enable the animals to secure a firm hold on the branches, for the digits have a feeble grasping power. In the Cebidæ the pollex is absent in *Ateles*, but it is present in other genera. When present it is short, and its degree of opposability varies, but is never very great. With few exceptions syndactyly does not exist. It is frequently difficult to determine whether the digits have claws or nails. The hallux is well developed.

The pads are best marked in the primitive, nocturnal Douroucoulis, and Pocock (172) suggests that the strong tactile sense compensates for imperfect nocturnal vision.

The proportions of the hands and feet vary considerably, and those of *Ateles* approach those of *Simia*; both animals use their hands in a hook-like manner.

The **Tail**.—All Platyrrhini have tails, but it is prehensile in only half of the total genera. It is prehensile in *Ateles*, *Brachyteles*, *Alouatta*, *Cebus* and *Lagothrix*; but it is not prehensile in the other Cebidæ nor in the Hapalidæ. When the tail is prehensile it exhibits variations in the degree of tactile sensibility.

Hair.—All Platyrrhini have a well-marked hairy covering and the fur varies in texture, feel and colour.

It is sometimes very beautifully coloured. The tail may be completely furry, or there may be naked areas of skin with papillary ridges. The hairs form a mane in the Lion Marmoset and a beard in the Howling Monkeys. They are implanted in groups of three, four or five.

No ischial callosities are present. The peri-anal skin has marked **odoriferous glands** in the Marmosets.

The **Skull**.—When the skull of any Platyrrhine Monkey is compared with that of a Mascarene Lemur two striking differences are at once seen—the cranial part is more expanded, and the facial skeleton is considerably reduced (fig. 11).

The skull varies in shape. In the Howling Monkeys the vertical depth is greater than the length; and the foramen magnum is situated on the flat back part. To a lesser extent this condition is present in *Callicebus*, *Aotus*, *Pithecia* and *Lagothrix*. In *Ateles*, *Cebus* and the Hapalidæ the skull is elongated, with a muzzle; the occipital region is convex, and the foramen magnum is on the basis cranii; so there is some resemblance to the human skull.

The **orbits** vary in size, and have their axes directed forwards and slightly outwards. They are shut off from the temporal fossa, only the speno-maxillary fissure being left of the wide communication which exists in the Lemurs. The **lachrymal orifice** is within the orbit. The interorbital width varies.

The **malar bones** have marked foramina for the passage of a nerve. The **anterior narial aperture** is oval or triangular. It is bounded by the premaxillæ and nasal bones.

The **top of the cranium** lies well above the supra-orbital margins; and on the side of the skull the parietal articulates with the malar bone, thus separating the frontal and alisphenoid.

The **tympanic annulus** is transversely short, and it is widely open laterally. It overlaps the tympanic bullæ, in the possession of which the Platyrrhini agree with the Lemuroidea and Tarsioidea, and differ from the Old World Monkeys and Apes. The **internal carotid artery** passes through a foramen between the annulus and bulla.

The **bony palate** is short, with a variable posterior nasal spine. The anterior palatine foramina are well-marked, but the posterior foramina are minute. The external pterygoid plates are large, but the internal plates are small, with variable hamular processes.

The width between the ascending rami of the **mandible** is greater than in the Lemurs as the result of the more capacious cranial cavity. The ramus ascendens is wide and deep, particularly in the Howling Monkeys with expanded hyoid bones. The coronoid process is recurved, and the symphysis menti slopes downwards and backwards.

In the interior of the skull the chief points to note are the extension of the cranial cavity, the petrosal has a **cerebellar fossa** of variable depth, and the tentorium is partly ossified. The posterior clinoid processes are well developed.

Teeth.—The dental formula is $I \frac{2}{2} C \frac{1}{1} PM \frac{3}{3} M \frac{2}{2}$ in the Hapalidæ, and $I \frac{2}{2} C \frac{1}{1} PM \frac{3}{3} M \frac{3}{3}$ in the Cebidæ, so, besides differences in the characters of the teeth there

are quantitative differences, the Cebidæ having an additional molar tooth on each side above and below.

In the Cebidæ the upper central incisors have chisel edges; they are larger than the upper lateral incisors, whose crowns are conical in the unworn condition. The lower incisors are slightly procumbent. The canine teeth are large and the lower ones pass up into diastemata between the upper incisors and canines. The incisor and canine teeth are not so specialized as those of the Lemuroidea. The three upper premolar teeth have two cusps lying antero-posteriorly, and they decrease in size in the order 1, 2, 3. The first lower premolar tooth is larger than the second and third, which are almost equal. It has one large and one small cusp; and the second and third lower premolars have more equal external and internal cusps. Gregory (507) points out that the three premolar teeth are remnants of an ancestral heritage of three teeth, and the number distinguishes the Platyrrhini from the Catarrhini.

Before proceeding to the consideration of the molar teeth it is necessary to refer to the terminology which is employed in the description of their cusps. The upper molar teeth have four cusps—two anterior and two posterior—and the lower teeth have a small postero-median cusp in addition. These cusps or tubercles have been named as follows (they are shown in fig. 11):—

Upper Molar Teeth—

Antero-external cusp*paracone* (PA).

Antero-internal cusp*protocone* (PR).

Postero-external cusp*metacone* (M).

Postero-internal cusp*hypocone* (HY).

Lower Molar Teeth—

Antero-external cusp*protoconid* (PRD).Antero-internal cusp*metaconid* (MD).Postero-external cusp*hypoconid* (HD).Postero-internal cusp*entoconid* (END).Postero-intermediate cusp....*hypoconulid* (HLD).

In *Cebus* the three upper molar teeth diminish in size in the order 1, 2, 3, and M3 is minute. The four cusps are present, and the protocones are connected to the metacones by oblique ridges in some species. The three lower molar teeth also diminish in the order 1, 2, 3. The hypocones are insignificant, especially on the degenerate third tooth. Faint ridges connect the paracones, protocones and metacones. In *Callicebus*, the most primitive Platyrrhine, the front of the protocones have sharp crests; and they are connected behind to the hypocones, which are really pseudohypocones. In *Aotus* the hypocones are well marked. In *Alouatta*, which is peculiar among the Platyrrhini for its leaf diet, the teeth are highly specialized.

In the Hapalidæ the third molar teeth have been lost. But the remaining ones have three low, rounded cusps, and the crowns themselves are rounded.

Vertebral Column.—The spinous processes of the dorso-lumbar vertebræ converge to a centre of motion, which varies in position, but is always in the lower dorsal region. The cervical vertebræ are seven in number in all species. The transverse processes have anterior ridges, or are triangular as in lower Mammalia, and the axis vertebra has a strong spinous process. The number of dorsal vertebræ and ribs is 13 or 14, of which 10 are sternal ribs. The lumbar vertebræ are 5 to 8 in number,

and the caudal vertebræ depend on the length of the tail. The sacrum is quadrangular, and the iliac bones are long and narrow, with a long pubic symphysis. The entire pelvis has a cylindrical appearance.

The **sternum** is narrow and composed of many parts, and the thorax is laterally compressed.

The **humerus** has an entepicondylar foramen for the passage and protection of the brachial artery and median nerve in all except *Brachyteles* (Weber). The **carpus** has an os centrale. The phalanges are long and incurved, being thus suitable for an arboreal life. But the pollex is only represented by the metacarpal bone in *Ateles*.

Alimentary Canal.—The **tongue** has no sublingua, but frenal lamellæ are present. The **stomach** is simple, but Vrolik (217) pointed out that there is a tendency to sacculation in *Ateles* and *Alouatta*, as in the Old World Semnopithecinae. The **colon** is long in the Douroucoulis and Marmosets, but it is short in other forms; and the cæcum is devoid of a vermiform appendix.

The **liver** is intermediate in character between those of the Lemuroidea on the one hand, and the Catarrhini on the other. The four lobes—right and left central and right and left lateral—vary in their relative proportions. Thus the four lobes are almost equal in *Ateles*, the lateral lobes are much larger than the central lobes in *Pithecia* and *Midas*, or there is a progressive diminution in the size of the lobes from right lateral to left lateral as in *Cebus*. The Spigelian and caudate lobes are well marked. And the gall-bladder is deeply recessed in the hepatic tissue.

The pancreatic and common bile ducts open together into the duodenum.

In many species the branches of the **aortic arch** are as in Man. Thus the arch gives off the left subclavian, left common carotid, and innominate arteries, the latter breaking up into the right subclavian and right common carotid arteries. The **heart** is more vertical than in the Anthropoid Apes and an azygos lobe of the right lung lies below it.

Respiratory and Vocal Organs.—No trace of air sacs communicating with the laryngeal ventricles exists, but other diverticula are present in some species. In *Midas rosalia*, according to Cuvier, a pouch communicates with the laryngeal cavity between the thyroid and cricoid cartilages; in *Ateles paniscus* there is a large membranous sac behind the cricoid cartilage; and in *Alouatta* the hyoid bone is expanded and ballooned to form a resonating chamber, which is protected by the extensive mandibular rami. The left lung has two or three lobes, and the right one has four, of which one is the azygos lobe.

Urogenital Organs.—The **kidneys** have many papillæ in *Ateles*, but one papilla only is present in each kidney in all other genera. And *Ateles* agrees with Man and the Chimpanzee in retaining the primitive condition of several papillæ.

The **penis** terminates in a glans of variable shape. In *Cebus* there is an os penis, but that structure is absent in *Ateles* and *Lagothrix*. A **scrotum** is present, but the communication with the abdominal cavity frequently remains open.

The **clitoris** varies in size, and reaches large proportions in *Ateles*; so that it may sometimes be mistaken for a penis. An os clitoridis may be present. The urethra does not traverse the clitoris.

The **Brain** (fig. 12c).—When the brain of a Platyrrhine monkey is compared with that of a Lemur it will be seen that it is more voluminous; and Professor Elliot Smith pointed out that the brain of *Pithecia* is more than three times as large as that of a Loris with the same weight of body (149). There are, however, well-marked affinities between them.

The **olfactory bulbs** are relatively smaller than in the Lemuroidea, and the **cerebrum** overlaps the cerebellum to a greater extent. In the Squirrel Monkeys (*Chrysothrix*) the extent to which the cerebrum overlaps the cerebellum is very great. According to Professor Elliot Smith (148) the overlapping in *Chrysothrix* is "unsurpassed even in Man."

The **central sulcus** (C.S.) is better marked in the Cebidæ than in the Lemuroidea; and the **Sylvian fissure** (L.S.) may be separate from the intraparietal sulcus (I-P.S.) as in the other Anthropomorphæ, or it may fuse with it as in many Lemuroidea. In the Hapalidæ a separate intraparietal sulcus may not exist. The **parallel sulcus** (P.S.) is well marked in the Cebidæ, but may be faint in the Hapalidæ.

The **inferior frontal sulcus** or sulcus rectus (S.R.) is present on many hemispheres, but the **inferior precentral sulcus** or sulcus arcuatus (P-C.S.) varies; it may be absent, it may curve round the sulcus rectus, or it may be united to the latter to form a radiating system as in *Lagothrix*.

On the mesial aspect of the hemisphere the **calcarine sulcus** (Ca.S.) is seen to be entire or bifid, and the single **calloso-marginal sulcus** (C-M.S.) stops short of the parieto-occipital sulcus (P-O.S.). The **collateral sulcus** may be single or multiple.

The **intraparietal sulcus** may be bifid posteriorly, the posterior limbs forming the transverse occipital sulcus (T.O.S.). The latter is situated behind the parieto-occipital sulcus and in front of the simian sulcus (S.S.); in many Anthropoid Apes the two latter are concurrent.

The **posterior rhinal fissure** is nearer the mesial surface than in the Lemuroidea.

The **cerebellum** is relatively larger transversely than in the Lemuroidea, and different brains exhibit varying degrees in the size of the flocculi and paraflocculi. The latter form the petrosal lobules. Owing to the increased bulk of the cerebellum the paraflocculi are reduced. The trapezium is concealed.

CHAPTER III.

THE OLD WORLD MONKEYS OR
CERCOPITHECIDÆ.

WITH the exception of those examples of the Barbary Ape which are carefully preserved on the Rock of Gibraltar, the Cercopithecidæ are inhabitants of Africa and Asia. Some are entirely arboreal, others are terrestrial, and others again are equally at home in the trees or on the ground. They may be purely vegetable feeders, or they may consume both fruits and insects; but the Baboons will kill lambs for the sake of the milk in their stomachs. Their minds as a rule are cunning, and they cannot be trusted to live in a docile manner in confinement, for they will bite severely when provoked. As regards the Baboons it may be stated that they are the only Mammals which thoroughly understand the value of combination for attack and for defence.

The family Cercopithecidæ is divided into the following sub-families and genera :—

Sub-family I. Cercopithecinae.

Genus *Cercopithecus*. Guenons.

„ *Macacus*. Macaques, Barbary Ape.

„ *Cynopithecus*. Black Ape.

„ *Theropithecus*. Gelada Baboon.

„ *Cynocephalus*. Baboons, Mandrill, Drill.

„ *Cercocebus*. Mangabeys.

Sub-family II. Semnopithecinae.

Genus *Semnopithecus*. Langurs.,, *Rhinopithecus*.,, *Nasalis*. Proboscis Monkey.,, *Colobus*. Guerezas.FIG. 9.—The Bonnet Macaque (*Macacus sinicus*).

These very diverse animals have been collectively termed “Cynomorpha,” or dog-like, but this term is really only applicable to the Baboons and a few others.

The body has a well-developed **hairy covering**, which varies in thickness, and in colour from dusky to bright.

In some species it is uniformly thick, but in others it is increased in certain parts; thus it forms a mane in the old male Gelada Baboon, and it forms a beard in *Cercopithecus barbatus*. In the Guerezas there is a mantle of long hairs on the back and shoulders.



FIG. 10.—The Drill (*Mandrillus leucophæus*).

The **skin** is dark in colour on the body, but it is frequently highly coloured on the face and buttocks. Bright pigmentation in these regions is most marked in the Mandrill and some Cercopitheques. The colour on the buttocks becomes very marked in the female at the menstrual periods.

In all Cercopithecidæ the epidermis is thickened to form **callosities** overlying the ischial tuberosities; and the latter form broad supporting platforms for the callosities in the Drill and Mandrill.

The **head** is rounded, and the nose is flattened, or prolonged to form a proboscis in *Nasalis*. The jaws exhibit a variable amount of **prognathism**; and the latter is most marked in the Cynocephali. The depth of the jaws below the orbits is greater than in the Cebidæ, but the top of the cranium is more elevated above the orbits in the latter. The **eyes** may be relatively large or small, and are dark in colour in the Cercopitheques. In some forms, particularly the Baboons and some Macaques, they appear wicked and cunning. The **nostrils** are separated by a narrow partition, except in the Guerezas, and are directed downwards. The ears are reduced.

Vibrissæ.—The increased acuteness of the tactile sense in the hands has been accompanied by a reduction in the vibrissæ. These hairs are only found in the supra-orbital, nasal and labial regions; for the genal and submental tufts are entirely absent.

Hair Slope.—Kidd has shown that the primitive condition is a general cranio-caudal slope of the hairs from the scalp right back to the tail, and downwards along the limbs. In the Cercopithecidæ the primitive arrangement is maintained, but there is a convergence of streams towards the elbows as in the Anthropoid Apes. No spirals are present on the chest or abdomen as in the Lemuroidea and Tarsioidea. But there is a spiral on the vertex of the head.

There are two pectoral **mammæ**.

Hands and Feet.—All Cercopithecidae have pentadactyl hands and feet. The palms and soles are hairless, and have traces of all primitive pads except the

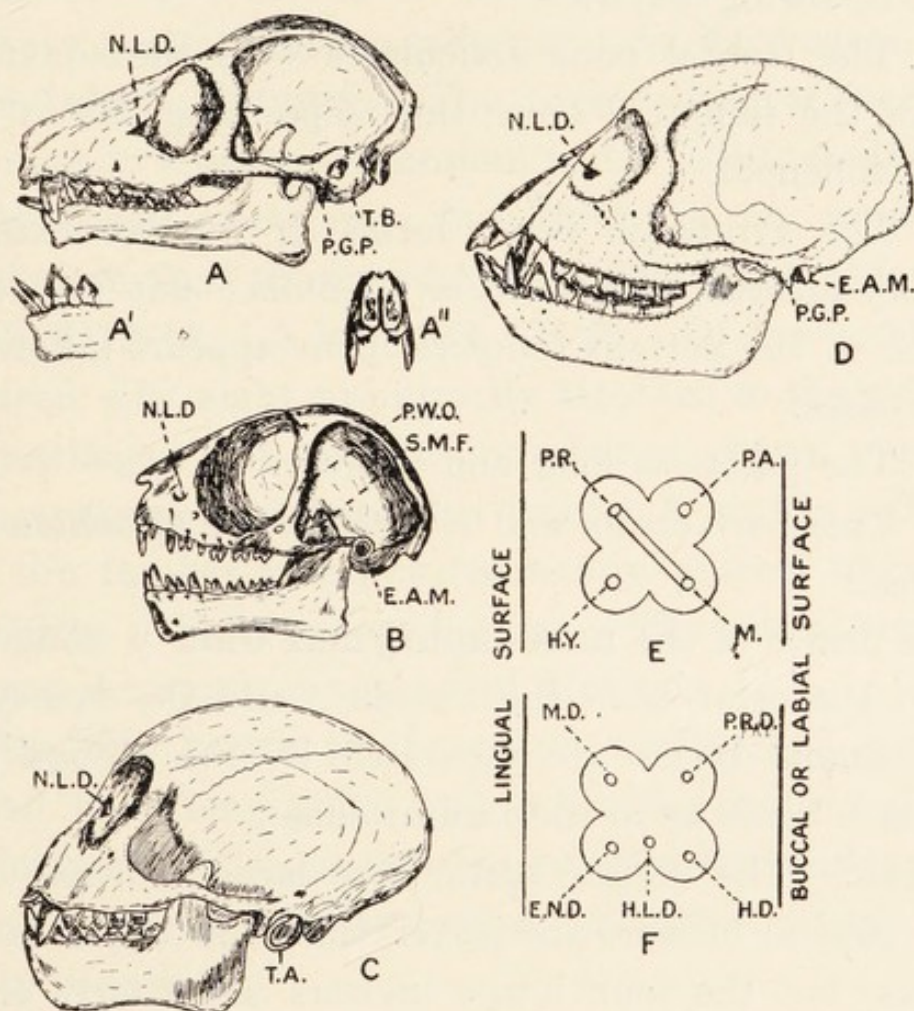


FIG. 11.—The skulls of the lower Primates. A, *Lemur macaco*; A', Mandible of *Lemur macaco* showing incisor, canine and first premolar teeth; A'', Front of skull of *Lemur* showing gap between the incisor teeth; B, *Tarsius spectrum*; C, *Cebus fatuellus*; D, *Macacus rhesus*; E, Cusps of upper molar teeth; F, Cusps of lower molar teeth; E.A.M., External auditory meatus; N.L.D., Nasolachrymal duct; P.G.P., Post-glenoid process; P.W.O., Posterior wall of orbit; S.M.F., Spheno-maxillary fissure; T.A., Tympanic annulus; T.B., Tympanic bulla. Letters on tooth cusps explained in text.

thenar pad of the proximal group. The entire surface is traversed by papillary ridges, so the tactile sense is very well developed. All fingers and toes have flat nails, and syndactyly is present in the Mangabeys.

The **Skull**.—The jaws exhibit prognathism, which varies in different genera, and is most marked in old animals. The skull differs from that in the Cebidæ in the following ways:—

(1) The frontal bone articulates with the squamous part of the temporal bone, thus separating the parietal and alisphenoid.

(2) The tympanic bone forms a tubular external auditory meatus, and there is no bulla; but the lower surface of the petrous temporal bone appears inflated in many cases.

(3) The palate is long and narrow.

(4) There are crests and ridges for the attachment of muscles.

The orifice of the **naso-lachrymal duct** is contained within the orbit as in the Cebidæ; and the lachrymal and ethmoid bones are separated by the frontal and maxillary bones as in the Lemuroidea.

Teeth.—The incisor teeth have large crowns. The upper central incisors are larger than the upper lateral incisors, but the four lower incisors are nearly equal. The canine teeth may be very long, and there are diastemata between the upper canines and upper lateral incisors.

The upper premolar teeth are almost equal in size. They have three fangs and two cusps, of which the outer is larger than the inner. Of the lower premolars the first is large, pointed and caniniform, the outer cusp being very large and sharp; the second lower premolar has subequal external and internal cusps. The lower premolars have two roots.

The upper molar teeth have four cusps connected by

transverse ridges, but no oblique ridges connect the metacones and protocones. The lower molars bear four cusps connected by transverse ridges, but no oblique ridges are present as in the upper molars; on their posterior parts there are talons or subsidiary cusps.

Vertebral Column.—The thoraco-lumbar vertebræ converge to a centre of motion, which is situated at the tenth dorsal vertebra; but there is no anti-clinal vertebra in the Anthropoid Apes. The vertebral formula is C7. D12-14. L5 to 7. S3. C3-26. Of the twelve to fourteen ribs eight are directly attached to the sternum by cartilages. A variable number of dorsal vertebræ have anapophyseal tubercles jutting from the pedicles; and the lumbar vertebræ frequently possess them too. The spine of the axis may be long. The caudal vertebræ possess chevron bones in tailed Monkeys.

The **iliac bones** are long and narrow, and are connected by a long pubic and ischiadic symphysis. The ischial tuberosities are everted, or form broad, flat plates for the support of the ischial callosities. The pelvic cavity is narrow.

The **sternum** is a narrow rod composed of six to eight sternobræ, and the manubrium is well marked. Vrolik (217) stated erroneously that there is no manubrium in the Mandrill.

The **clavicle** is straight at its sternal end, but the acromial end is concave forwards, with a large tubercle. The **scapula** is broad, with a small acromion process. The **humerus** has a prominent pectoral crest (outer lip of the bicipital groove) but no entepicondylar foramen. The **carpus** has an os centrale.

As in all Primates the **radius and ulna** can move on

one another in pronation and supination. And, as in most lower Primates, the carpus articulates with both radius and ulna. In the Simiidæ it only articulates with the radius.

The **femur** is long and slender, with a globular head and a large great trochanter. No third trochanter exists. The linea aspera is poor. The tibia and fibula are separate.

Muscular System.—As the muscular system in the Simian Catarrhini is fully described in Chapter VI, only a few special points are mentioned here.

The *cutaneous musculature* consists of the dermo-humeralis, platysma myoides and sphincter colli. It is thus equal to the musculature of the Lemurs, but it is more extensive than in the Simiidæ.

The *sterno-mastoid* has sternal and clavicular components in some forms, but the clavicular fascicle is absent in some species. The sterno-hyoid and sterno-thyroid muscles are not peculiar, and the omo-hyoid has no central tendon.

The *digastric muscle* belongs to Parson's first type. The anterior bellies are fused to form a fan-shaped muscle with a posterior tendinous arcade into which the tendons of the posterior bellies are inserted. It exhibits a variable amount of fusion with the subjacent mylo-hyoid muscle, from which it evolved by splitting (Gegenbaur).

The *pectoralis major* has no clavicular origin, but springs from the fascia over the rectus abdominis and from the sternum. The pectoralis minor is inserted into the fascia over the coracoid process or into the capsule of the shoulder-joint. The subclavius is very strong.

The *omo-trachelian* is as in the Simiidæ.

The *latissimus dorsi* has no costal or scapular origin, and gives off a well-marked dorso-epitrochlearis. The *rhomboid sheet* is undivided and the origin may reach the occiput. The *levator anguli scapulæ* and serratus magnus, which originate from the same muscular sheet, may be fused. The *deltoid* has a long clavicular origin, but the scapular muscles are not peculiar.

The *triceps*, especially the long head, is very powerful. The coraco-brachialis is double and the biceps has no lacertus fibrosus.

The *gluteal muscles* are not voluminous, and include the gluteus maximus, gluteus medius, gluteus minimus, and its derivative the scansorius. The tensor fasciæ femoris is present. The *biceps femoris* has no short (femoral) head.

The *adductor muscles* are well developed. The adductor magnus is composed of two parts between which the femoral vessels enter the popliteal region. In Man these parts are fused, and the femoral vessels pass through the "opening in the adductor magnus." Similar conditions are described in the Apes in Chapter VI.

The *soleus* has no fibular head as in the Lemuroidea and Simiidæ, and the *plantaris* ends in the plantar fascia.

The *flexor longus digitorum* supplies the four outer digits, and the *flexor longus hallucis* supplies the four inner digits. One head of the accessorius is present as in the Chimpanzee.

The *peroneus tertius* is absent.

The **Digestive Organs.**—The tongue has frenal lamellæ, but neither sublingua nor its remnants the plicæ fimbriatæ are present. The palate has well-developed rugæ.

The vestibule of the mouth has diverticula known as **cheek pouches** in all except the Langurs and Guerezas. Externally the buccinator and platysma cover the pouch on each side.

The **stomach** is a simple sac in those species which have cheek-pouches, but it is long and sacculated in the Langurs and Guerezas, which have no pouches. Possibly, as Owen suggested, the first compartment of the stomach replaces the pouches.

The **cæcum** is conical and devoid of a vermiform appendix. The **colon** is sacculated by longitudinal muscle bands, and it is freer than in the higher Simiidæ.

The parotid and submaxillary **salivary glands** are large, but the sublingual glands are small. The **pancreas** shows nothing peculiar, and its duct opens along with the common bile duct into the duodenum.

The **liver** varies in size and position. Thus it is very small and pushed up into the left hypochondrium by the large stomach in the Guerezas. In the Cercopithecinae it lies across the middle line, and it is well developed. There are no bare areas between it and the diaphragm. The degree of subdivision into lobes varies, and the component lobes vary in size in different genera. Thus the two central lobes are fused in the Baboons, but separate in the Guerezas; and the left lateral lobe is large in the former, but diminutive in the latter. Caudate and Spigelian lobes are both present. The gall-bladder is superficial in some species, but deeply recessed in others.

Organs of Circulation.—The long axis of the **heart** is more vertical than in the Simiidæ, and the azygos

lobe of the right lung lies between it and the diaphragm below and behind. The apex is to the left of the sternum, and is usually formed by the left ventricle. The pericardium is considerably adherent to the diaphragm.

The **aortic arch** may give off its main branches as in Man, or there may be only two trunks—a left subclavian and an innominate artery, which breaks up into the right subclavian and both common carotid arteries. Sometimes intercostal arteries arise from the aortic arch.

In the arm the most important points to note are the presence of an arterial trunk which gives rise to the **circumflex arteries**. In some species the anterior humeral circumflex artery arises directly from the axillary trunk. The **brachial artery** is superficial to the median nerve, and bifurcates into radial and ulnar arteries in the arm.

The **lingual and external maxillary arteries** arise by a common trunk—a condition which also exists in the Chimpanzee.

In the leg the **saphenous artery** runs from the femoral artery to the dorsum of the foot.

There is no saphenous opening, and the intra-thoracic part of the vena cava inferior is shorter than in lower Primates.

Organs of Respiration.—In many species there is an air-sac communicating with the larynx between the epiglottis and thyroid cartilage, or through an opening in the epiglottis.

The tracheal rings are incomplete behind.

The left lung has two or three lobes, and the right lung

has four, of which one is the azygos lobe. The latter is received within a sub-pericardiac pleural diverticulum.

Urogenital Organs.—In all species there is a single papilla in each **kidney**, and the right kidney is posterior to the left one.

The **penis** has a well-marked bone, whose characters are regarded as of taxonomic value by Pocock. The **prostate gland** is pyramidal with a small third lobe. The **vesiculæ seminales** are composed of tubes and lobules, but the latter predominate in the immense vesicles in the Drill. There may be one or two ejaculatory ducts. The testes lie in the inguinal canal, and the spermatozoa are large.

The **uterus** is simple, and the **vagina** is destitute of a hymen. **Labia majora** are absent, but the **clitoris** is large and penis-like; but it is not traversed by the urethra.

Copulation takes place in the dog-like position. During heat the female external organs and buttocks become turgid and reddened. Male animals are addicted to masturbation.

The **Brain** varies in complexity, but it is large. In a Common Macaque Monkey (fig. 12 D) the frontal lobes form a well-marked keel or rostrum along the inferior aspect of the great longitudinal fissure. The **central sulcus** (C.S.) has a slight inferior genu.

In front of the central sulcus there is a dimple representing the **superior precentral sulcus** (S.P.S.). The **inferior precentral sulcus** (I.P.S.) well merits the name "sulcus arcuatus," for it forms a bow round the inferior frontal sulcus (S.R.) or "sulcus rectus." On the inferior surface of the frontal lobe there is an H-shaped system of **orbital sulci**.

The **Sylvian fissure** (L.S.) begins in a vallecule on the inferior surface of the brain. It passes upwards and backwards to end in the **parallel sulcus** (P.S.). The latter is arched over by the diverging limbs of a Y-shaped

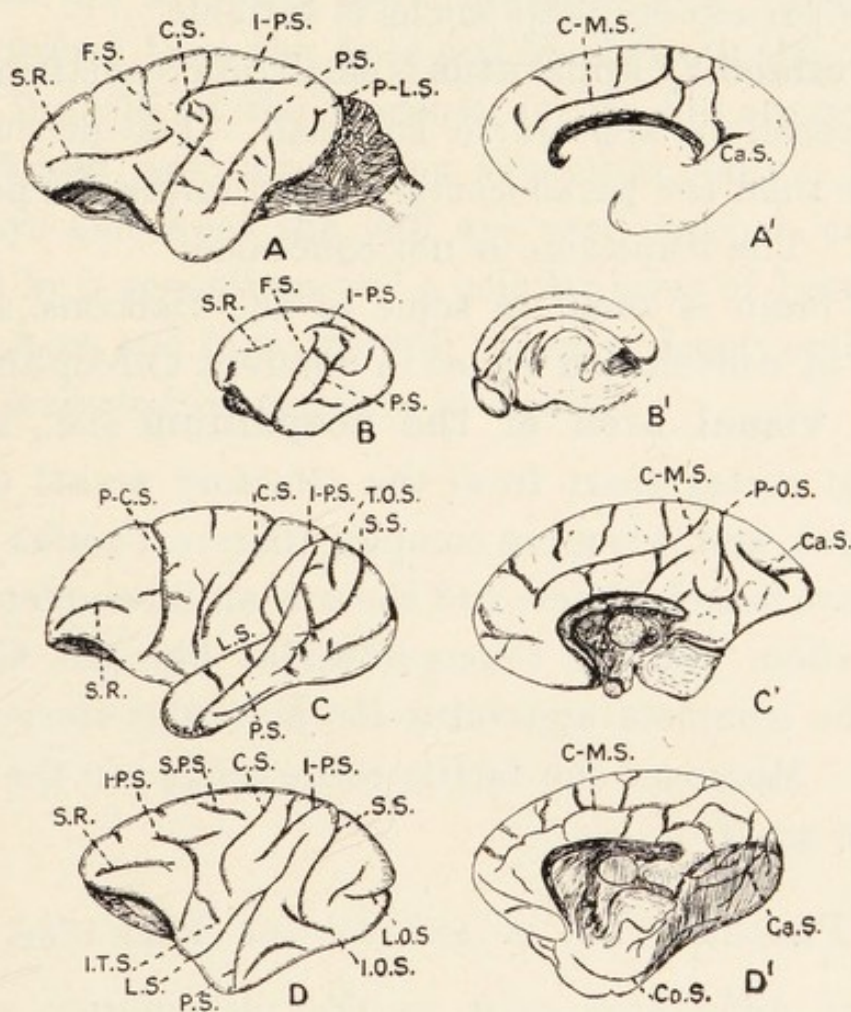


FIG. 12.—The brains of the lower Primates. The left-hand figures are the outer surfaces of the hemispheres, and the right-hand figures are the mesial surfaces. A.A', *Lemur macaco*; B.B', *Perodicticus potto*; C.C', *Cebus fatuellus*; D.D', *Macacus nemestrinus*. Letters explained in text.

system of sulci formed by the **intraparietal** (I-P.S.) and **simian** (S.S.) sulci. The **inferior occipital** (I.O.S.) and **lateral occipital** (L.O.S.) sulci are well marked.

The insula or **island of Reil** is concealed posteriorly, but anteriorly it passes forwards to the fronto-orbital

sulcus. Above the insula there lies a short inferior transverse sulcus (I.T.S.)

The **calcarine** (Ca.S.) and retro-calcarine sulci are continuous, and the **collateral sulcus** (Co.S.) is simple. The **calloso-marginal** (C-M.S.) sulcus is well marked, but the parieto-occipital sulcus is variable.

The **olfactory apparatus** is small (microsmatism), and the cerebellum appears to be small. The flocculus is smaller than the paraflocculus, which forms the petrosal lobule. The trapezium is not concealed.

The brain is small in some of the Baboons, and its degree of convolution varies in different Cercopithecidae.

The **visual area of the neopallium** (i.e., all the cerebral cortex apart from the olfactory areas) is well developed, and it is more complex than in *Tarsius*. The eyes have maculae luteae and there is an incomplete optic decussation. So the Cercopithecidae, like the Cebidae, have the complete apparatus for binocular stereoscopic vision. Moreover the tactile sense lodged in the hands is more acute.

PLACENTATION IN THE LOWER PRIMATES.

Great differences exist in the placentation of the Lower Primates, and it has been shown by Professor J. P. Hill (169), Hubrecht and others that the arrangements in *Tarsius* resemble those in Man and differ profoundly from those in the Lemurs. The chorion is vascularized through the body stalk in *Tarsius* and the Anthropoidea, whereas it is vascularized by way of the allantois in the Lemuroidea. The second great difference is seen in the nature of the placenta. In the Lemurs the yolk-sac placenta is a transitory structure, or it is

absent altogether ; and the permanent placenta is diffuse and non-deciduate. In *Tarsius* and the Anthropoidea there is not even a transient yolk-sac placenta ; and the permanent placenta forms a single or double disc. In *Tarsius* and in the Simiidæ and Man there is a single disc, but the Monkeys have frequently two. *Tarsius* is distinguished from the Apes and Monkeys in the characters of the villi on the placenta, for its villi are not very distinct and are covered by syncytium only. In the Monkeys and Apes the villi are very distinct, and are capped by a syncytium and a cellular layer of Langhans. In the Apes and Man the villi are more deeply embedded in the maternal tissues than in *Tarsius*.

PART II.
THE ANTHROPOID APES.

CHAPTER IV.

EXTERNAL CHARACTERS, HABITS AND CLASSIFICATION.

THE GIBBONS.

(Fig. 13.)

Configuration. — The Gibbons are the smallest Anthropoid Apes, the largest being only a little more than three feet long from the crown to the heels. They are also slenderly built, so the total mass of the body is small. The arms are longer in proportion to the length of the body than in all other Apes, and they touch the ground when the animals are fully erect; their span is very great, that in a Siamang three feet long being $5\frac{1}{2}$ feet. The forearm is longer than the arm, and the hand is longer than the foot as in the Chimpanzee; and the mode of life of these animals has earned the name of “Brachiators” for them. Weber (162) points out that the great length of the arms is a post-embryonal development. The tail is absent, and the small gluteal regions have callosities; in the possession of these structures the Gibbons resemble the Monkeys and differ from the other Apes.

Hand.—The hand is long and narrow. The skin of the palm is glabrous and pigmented; in the Siamang, Bornean and Hainan Gibbons it is black, but it is paler in the Hoolock Gibbon. The relative lengths of the

digits are as in the other Apes and Man; that is to say, the thumb is short, the middle finger is the longest, and the index and ring fingers are longer than the fifth finger. The digital formula expressing these relative lengths is $3 > 2 = 4 > 5 > 1$. The thumb and its metacarpal bone can be passively abducted till the latter is almost at right angles to the metacarpal bone of the index finger.



FIG. 13.—The Silvery Gibbon (*Hylobates leuciscus*).

The thumb is provided with a flat nail, but the other digits have nails highly arched transversely, or long claws projecting considerably beyond the fingers. In the Bornean Gibbon the second, third and fourth digits have arched nails, and the fifth digit alone can be said to possess a claw.

In the white-handed Gibbon the claw-like appearance

of the nails is marked on all digits. And in the Hoolock Gibbon the claws are of considerable length. Possibly these variations depend on age and sex rather than on species. The terminal phalanges exhibit well-marked pads, and the thenar and hypothenar eminences vary in prominence. No metacarpal pads are present.

The skin of the palm exhibits a number of grooves known as **flexure lines**, for they are situated in the areas where the hand bends in gripping. In all species there are transverse lines over the interphalangeal joints, and a curved line of more or less depth encircles the thenar area, which is submitted to considerable compression in the act of opposing the thumb. Many variations in the line pattern are seen in the palm, but it is highly improbable that these would be of value for purposes of classification. The Bornean and White-handed Gibbons (fig. 19A) have transverse lines, but the Hoolock Gibbon has longitudinal lines and several irregular little grooves.

The whole of the palm and fingers is traversed by fine ridges running in different directions; and these elevations, which are known as **papillary ridges**, are produced by thickening of the epidermis over rows of dermic papillæ. They are mainly sensory in function, but their roughness helps to make the grip of the hand secure. It will be seen in fig. 19 that longitudinal lines traverse the palm from the wrist to the roots of the fingers in all species. In the Bornean Gibbon there are loops on the thenar and hypothenar areas, but the Hoolock and white-handed species have no trace of these curves. The apical pads on the thumb and fingers are covered by ridges arranged in loops, and the skin of the remaining

phalanges is covered by oblique chains. When the ridges are examined through a powerful lens they exhibit the orifices of the ducts of sweat glands.

The back of the hand and fingers, except the terminal phalanges, is covered with white, grey or black hairs, but the colour is not specific.

In the Hoolock Gibbon, for example, it may be black or white. There are no traces of callosities on the backs of the penultimate phalanges as in higher Apes. When the sides of the fingers are examined it is seen how there is a very sharp line of demarcation between the hairy dorsum and the hairless palm.

The **foot**: Like the hand the foot is long and narrow, and its digits have the same relative lengths as the fingers; but the hallux is thicker than the toes. The skin of the sole is glabrous and pigmented, its colour being the same as that of the palm in each species. The primitive pads are represented, as in the hand, by globular expansions of the terminal phalanges, but the parts over the heads of the metacarpal bones are full. Flexure lines are situated over the interphalangeal joints, roots of the toes and sole, but these vary in different species, as shown in fig. 20. The papillary ridges are arranged much as in the hand. The dorsum of the foot and toes, except the terminal phalanges, is hairy. It is, therefore, evident that the external characters of the hand and foot have much in common.

The **head** is compressed and the crown is flattened; but the shape of the crown and the prominence of the supra-orbital crests are masked by a thick growth of hair (fig. 13). The position of the crests is indicated by long hairs, or by the anterior border of a band of white hairs,

which more or less completely surrounds the face in many species. The nose is flat, but well-marked, and the ears are more or less concealed in thick fur. The upper lip is short, and both lips are bulged forwards by the prognathous jaws. The eyes are bright, and the eyelashes are poorly developed. The neck is short.

The whole body has a thick covering of **hair**, but the hairs on the face are scanty. The colour varies at different ages, being fulvous or greyish in the first three years of life, but darker after that.

Pocock (223) points out that there is a considerable individual variation in the colour, and he states that the hue in a Hainan Gibbon altered concomitantly with the onset of menstruation. The skin is black. There are two pectoral mammæ.

Habits.*—The Gibbons are gentle, affectionate creatures, but there is evidence that they bite severely when they are irritated. They are also very timid, and the sight of an enemy makes them take refuge in flight.

Their **vocal powers** are considerable, and their penetrating cries are audible for miles. Dr. Salomon Müller, an observant and careful naturalist, in describing the voice of the Siamang said (87), "the voice is grave and penetrating, resembling the sounds gōek, gōek, gōek, gōek, gōek, ha ha ha ha haaaāāā, and may easily be heard at a distance of half a league." Martin (355) described the cry of the agile Gibbon as "overpowering and deafening in a room, and from its strength, well calculated for resounding through the vast forests." Pocock (223) contrasted the voices of the Hainan and

* Accounts of the habits are contained in papers 176, 180, 182, 210, 215, 223.

Hoolock Gibbons as follows: "The voice of our Hainan Gibbon is quite different from that of the Hoolock. It is a high-pitched trill all on the same note, and shriller even than the high note of the Hoolock's cry. It consists of about three to six distinct cries repeated in very rapid succession, suggesting almost production by vibration of the tongue, although, as a matter of fact, I believe the lips alone are instrumental in producing the effect. There is then a momentary pause, after which the cry is repeated. It may perhaps be represented in the following way: hōō hōō hōō hōō—hōō hōō hōō—hōō hōō hōō hōō hōō, &c. The Hoolock, on the contrary, cries as follows: hāh, hōō, hāh, hōō, hāh, hāh, hōō, hāh. The 'hōō' is on a lower note than the 'hāh,' with which the cry frequently ends. The ordinary expression of anger or remonstrance in the Hainan Gibbon is a prolonged and guttural grunt, repeated rapidly and often, and frequently interspersed with a kind of warble when the excitement rises."

In captivity Gibbons dip the backs of their hands and knuckles in the drinking troughs, and lick the fluid off the hairs; but it is incorrect to say, as Tickell (215) has, that some species scoop up the water. In their natural surroundings they can wipe rain-water off leaves, their long arms enabling them to reach much foliage; or they can descend to the sides of lakes and employ the methods which they exhibit in captivity. If they are observed from a distance in the jungle the females, with young ones clinging to their breasts, engaged in the process of hand-drinking, may appear to be washing the faces of their offspring.

Their **movements in the trees** are very graceful, and Martin has given the following account of the activities of a slender Gibbon, living in the Zoological Gardens of London, in 1840 : “ It is almost impossible to convey in words an idea of the quickness and graceful address of her movements : they may indeed be termed aerial, as she seems merely to touch in her progress the branches among which she exhibits her evolutions. In these feats her hands and arms are the sole organs of locomotion ; her body hanging as if suspended by a rope, sustained by one hand (the right, for example), she launches herself, by an energetic movement, to a distant branch, which she catches with her left hand ; but her hold is less than momentary : the impulse for the next launch is acquired : the branch then aimed at is attained by the right hand again, and quitted instantaneously and so on, in alternate succession. In this manner spaces of twelve and eighteen feet are cleared, with the greatest ease, and uninterruptedly, for hours together, without the slightest appearance of fatigue being manifested ; and it is evident that, if more space could be allowed, distances very greatly exceeding eighteen feet would be as easily cleared ; so that Duvauncel’s assertion that he has seen these animals launch themselves from one branch to another, forty feet asunder, startling as it is, may well be credited.

“ Sometimes, on seizing a branch in her progress, she will throw herself, by the power of one arm only, completely round it, making a revolution with such rapidity as to almost deceive the eye, and continue her progress with undiminished velocity. It is singular to observe how suddenly this Gibbon can stop, when the impetus

given by the rapidity and distance of her swinging leaps would seem to require a gradual abatement of her movements. In the very midst of her flight a branch is seized, the body raised, and she is seen, as if by magic, quietly seated on it, grasping it with her feet. As suddenly again she throws herself into action.

“The following facts will convey some notion of her dexterity and quickness. A live bird was let loose in her apartment; she marked its flight, made a long swing to a distant branch, caught the bird with one hand in her passage, and attained the branch with the other hand; her aim, both at the bird and the branch, being as successful as if one object had gained her attention.”

“On another occasion this animal swung herself from a perch, across a passage at least twelve feet wide, against a window which it was thought would be immediately broken: but not so; to the surprise of all, she caught the narrow framework between the panes with her hand, in an instant attained the proper impetus, and sprang back again to the cage she had left, a feat requiring not only strength, but the nicest precision.”

The progress of the Gibbons from branch to branch is carried out differently from that of the Monkeys. A Mangabey, for example, which has a long, non-prehensile tail, springs from branch to branch, using its hind limbs for propulsion and its tail for balancing. But the Gibbons employ their arms alone, the legs being tucked away close to the body, and out of the way of possible injury. The Orang-Outan, which is the most arboreal of the higher Apes, is not nearly so active as the Gibbons.

Considerable evidence has been collected to show that the Gibbons are the most bipedal of the Apes.

Bennett (176), in describing the habits of the Siamang, states: "He invariably walks in the erect posture when on a level surface; and then the arms either hang down, enabling him to assist himself with his knuckles; or what is more usual, he keeps his arms uplifted in nearly an erect position, with the hands pendent ready to seize a rope, and climb up on the approach of danger or on the obtrusion of strangers. He walks rather quick in the erect posture, with a waddling gait, and is soon run down if, whilst pursued, he has no opportunity of escaping by climbing. When he walks in the erect posture he turns the leg and foot outwards, which occasions him to have a waddling gait and to seem bow-legged." Sometimes they progress by leaps, rather than by placing one foot in front of the other. The whole of the narrow foot is placed on the ground and raised without elasticity of step.

Classification and Distribution.—The family Hylobatidæ includes two genera—*Symphalangus* and *Hylobates*. The former contains one animal, the Siamang, and the latter includes all other Gibbons.

The **Siamang** (*S. syndactylus*) is found in Sumatra. It is the largest Gibbon, and it is the only one possessing air-sacs communicating with the larynx. The fur is black and glistening, and its colour is not relieved by a circumfacial band of white hairs. The second and third toes are connected by a web for more than half their length, hence the name "syndactylus." The animals constituting the genus *Hylobates* are found in Further India, the Malay Archipelago, Hainan and Southern China. It is not known exactly how many species exist, and the multiplication of synonyms has led to much

confusion. There are, however, certain well-established species which can be recognized by their colour-markings, and possibly by the characters of their voices. Dahlborn (184) believed he could distinguish them by certain markings on the clavicles, but Keith (99) dissected several examples of each of a number of species and concluded that these had no taxonomic value.

In the **Hainan Gibbon** (*H. hainanus*), the face, palms, soles and ears are black, and there is no trace of a white circumfacial band. The hair on the body is soft, but devoid of woolliness. The head looks high, for the hairs on the vertex appear brushed upwards.

In all other species the hair on the crown is not porrect, and there is a varying degree of development of a white circumfacial band. In some species the hair on the wrists is grey or white. The circumfacial band is complete in the **White-handed Gibbon** (*H. lar*) from Burmah and the Malay Peninsula, the **Slender Gibbon** (*H. agilis*) from Malay and the **Siamese Gibbon** (*H. pileatus*). It is nearly complete in the **Bornean Gibbon** (*H. Muelleri*) and **Silvery Gibbon** (*H. leuciscus*). It is represented by a white supra-orbital strip in the **Hoolock Gibbon** (*H. hoolock*) from Further India; and it is reduced to a narrow submental strip in the **White-cheeked Gibbon** (*H. leucogenys*) of Siam. Sclater (209), Hermes (252), Bishop (87) and Pocock (223) have published illustrations showing the external characters of some of the above mentioned species.*

* Accounts of external characters of Gibbons are given in papers 176, 178, 179, 182, 183, 190, 198, 199, 200, 201, 203, 204, 207, 209, 210, 211-216, 220, 223.

THE ORANG-OUTAN (*Simia satyrus*).

(Figs. 14 and 15.)

Configuration.—The Orang differs markedly from the Gibbons, for it is heavy in build, ugly in appearance and sluggish in its habits. The largest males are a little more than 4 ft. in height from the crown to the heels, but its great bulk makes it appear much longer. The females are a few inches smaller. The girth of the body may be nearly two-thirds of its height in inches, and the massive head frequently exceeds a foot in width. The arms are very long, and their span, when they are extended at right angles to the trunk, exceeds the length of the body as in the Gibbons. Alfred Russel Wallace (293) states: "Five of this species, measured by me, varied only from 4 ft. 1 in. to 4 ft. 2 in. in height, from the heel to the crown of the head, the girth of the body from 3 ft. to 3 ft. 7½ in., and the extent of the outstretched arms from 7 ft. 2 in. to 7 ft. 6 in.; the width of the face from 10 to 13¼ in." Rollet, Blythe (231), Fick (247) and Brooke (234) give detailed measurements of a number of animals, and Huxley (87) records measurements made by Temminck, Schlegel, Müller, Humphrey and Spenser St. John. The abdomen is prominent, and the anus is more prominent than in Man.

The characters of the skull are continually changing throughout life, so that the facial appearances do not remain constant from maturity onwards. This fact was not known to many of the older writers, so that the data on which they based their specific distinctions are valueless. The brow is usually high and rounded, and may be hairy. The eyes are relatively close together, but

Fick (247), who made several very exact measurements, points out that the interpupillary distance is not much less than in Man. The nose is flattened, only the terminal part being prominent. The mouth is usually closed, and the thick lips are bulged forwards by the prognathous jaws. The chin is flat, and has a slight beard. The external ear is degenerate.




FIG. 14.—Young Orang-Outans (*Simia satyrus*).

The Orang differs from the other Apes in the possession of **cheek-pads**, which are well shown in fig. 15. Much attention has been paid to these structures, but we are as yet ignorant of their frequency and significance. They are semilunar or triangular blinker-like appendages which widen the face; and they may be so large that the external ears are concealed behind them. During life they are turgid, but they collapse somewhat after

death. Their basal parts are thick and fixed, but their peripheral parts are thinner and slightly mobile. They are composed of fat and connective tissue, and the skin which covers them is naked; Pöppig described a specimen in which the skin of the pads was hairy, but no other author has described such a condition. Their occurrence is independent of the age of the animal, and they are found in both the Bornean and Sumatran forms.




FIG. 15.—Adult Orang-Outan.

The **hand** is long and narrow, and traces of the primitive pads are only found on the terminal phalanges. The thenar and hypothenar eminences are small or absent. The digits have the same relative lengths as in the Gibbons, but the thumb is diminutive; all digits are provided with flat nails. The palm is glabrous and pigmented. The **flexure lines**, which are shown in

fig. 19, are not as numerous as those in the Gibbons and Chimpanzee, but more numerous and intricate than those in the Gorilla. The **papillary ridges** form loops on the terminal phalanges, over the head of the second metacarpal bone and on the thenar and hypothenar areas, which, however, are not elevated. On the rest of the palm, lines radiate from the carpus to the roots of the fingers. The first and second digits of the fingers have transverse ridges.

The back of the hand is rough, and it is covered with hairs to the distal extremities of the second phalanges of all the digits except the pollex. The hairs on the fingers are short and point distally, but those on the hand are long and directed proximally.

The **foot** is long and narrow. The digits are arranged as in the hand, and the hallux is diminutive; it is frequently, but not always, devoid of a nail. The plantar surface is glabrous, and the arrangement of the flexure lines (fig. 20) shows that the foot is a grasping organ. The dorsum is hairy down to the distal extremities of the penultimate phalanges. So it is evident that the external characters of the hand and foot have much in common.

The **umbilicus** is situated above the middle of the body as in Man, but it is farther from the symphysis pubis; in the Chimpanzee it is nearer the middle of the body, but it is below it in the Gorilla.

There are two insignificant pectoral **mammæ**, and even in lactation they are collapsed.

The **neck** is short, but the laryngeal air-sacs produce balloon-like swellings between the chin and the sternum.

Hair.—The whole body, with the exception of the

face, ears, palms and soles is covered with hair, which varies in length and colour in different animals, and in different parts of the body in each. It is, however, of some light or deep shade of reddish-brown. The colour and arrangement have been described by many authors, besides those given below in the footnote.* In the young animal the brow is more or less hairy (fig. 14), but the brow and its bounding cheek-pads are hairless in the adult (fig. 15). Keith [99] points out that the arrangement of the hair is due to the fact that, when the animal lies on its side, as it does in sleep, the hair acts the part of a natural thatch. On the neck and shoulders the hair is directed forwards and upwards towards the head; on the back it is directed downwards; on the pectoral extremity the hairs converge towards the elbow-joint, and those on the abdomen and legs point towards the ground. The hairs on the shoulders and the upper arms are the longest, and those on the brow, axillæ and ventral abdominal wall are the shortest. Also the hairs on the extensor aspect of the forearm are longer than those on the flexor surface.

When the hairs are examined microscopically it is seen how the cuticular scales have sinuous margins, which are quite unlike those of the other Anthropoids;

* The extremities have been described or figured by Abel (224), Alix (301), Barkow (302), Beddard (304), Camper (237), Fick (247), Fletcher (99), Harwood (251), Hepburn (83), Kollmann (346), Lucae (261), Trinchese (292), and Temminck (289).

The hairs have been described by Bolau (233), Chapman (238), Deniker (46), Hartmann (452), Martin (355), Wallace (293), Wenckstern (297) and others. Much information on the hairs of anthropological interest is contained in the work of Friedenthal (63A). The pattern of the cuticular scales on the hairs has been described by Duncan.

so this is a point of value for distinguishing the Orang from the Gibbons on the one hand, and from the African Simiidæ on the other.

The skin is brownish in colour, the hue varying considerably with age, sex and locality. It is, consequently, of little value for taxonomic purposes. Its intensity depends partly on climatic and partly on endocrine factors. It is never so dark as that in the Gibbons.

It is interesting to note that the two Asiatic Anthro-poids differ from one another in the characters of the hair and in the pigmentation of the skin; and the African Apes also differ from one another in these features. Moreover, the histological characters of the hairs of the former differ from those of the latter.

Habits.*—The Orang is the least interesting of the Apes. It lacks the grace and agility of the Gibbons, the intelligence of the Chimpanzee and the brutality of the Gorilla. It is both wild and shy, and although its strength is immense, it attempts to escape rather than defend itself when it is attacked by Man.

Its habits agree in many points with those of the Koala, Sloths and Lorises, for they are characterized by great sluggishness. If the animal is undisturbed it will remain in the same tree for several days. When seated among the branches it appears dull and apathetic; its back is arched, its head is bowed and its long arms either hold on to a branch or hang down by its sides. Like the Sloth it is very tenacious of life, and Wallace records that he found one still alive after a fall from a tree when "both legs had been broken, its hip-joints and the root of the

* Descriptions of the habits are contained in papers 250, 256, 268, 271, 282, 283, 293, 294.

spine shattered, and two bullets flattened in the neck and jaws." Specimens have also been found exhibiting healed fractures of the skull and limb bones.

The movements are slow and deliberate. It secures and tests the branches with its hands, after which it draws up both feet together; and it will even carry out these evolutions when it is hunted. During its progress it protects its feet, which appear to be very delicate, from injury. If it is pursued by Man its progress among the branches is never so fast that the hunter cannot keep pace with them.

During the day the Orang may be found in the top-most branches of tall trees, but as night approaches it descends to more sheltered parts and builds a nest; but it is incorrect to say that it constructs a hut. Small branches are laid crosswise to form a supporting framework, which is then covered by a thick bed of leaves. If the night is cold or windy or rainy it covers itself with leaves, taking particular care to cover its head. In captivity it will cover itself with straw or even with newspapers, if these are placed in its cage. It will also make supports in its cage, and I observed this being done very ingeniously in the Gardens of the Zoological Society of London. The animal in question, a young male, was lodged in a cage which had a rope hanging from the roof. The Orang clung to the rope by his left hand and both feet. With his right hand he made a loop, passed it through between the bars, turned it through a right angle and pulled it tight. In this way he made a perch for himself. If anyone displaced the rope he at once proceeded to remake his perch.

On the ground the Orang is a clumsy animal. He

moves on all fours in a laborious and shaky manner. His long arms raise the upper part of his trunk, and Huxley likens his gait to that of a very old man bent down by age, and making his way along by the help of a stick.

He walks on the outer borders of his feet and the inner edges of his hands. The upper surfaces of the toes and fingers rest on the ground, particularly by their proximal phalanges; and it will be seen later that this arrangement differs from that adopted by the quadrupedal Chimpanzee. The gait of the young animal can best be described as an awkward shuffle.

The long arms are useful for collecting the figs, leaves and young blossoms on which it subsists, but they are not used for hand-drinking, as are those of the Gibbons. The lips are used for drinking, and the lower one is made into a capacious trough for collecting rain water. If it is supplied with a pail of milk it will pour it into the trough so formed.

Dr. Salomon Müller, who carefully questioned many Dyak hunters, said: "According to the Dyaks, the only animal the Orang measures his strength with is the crocodile, who occasionally seizes him on his visits to the waterside. But they say that the Orang is more than a match for his enemy, and beats him to death, or rips up his throat by pulling the jaws asunder."

When the females are pregnant they may separate themselves from the others, and they may remain away till the young are born. The latter grow slowly and remain under care of their mothers for a considerable period. When the mothers are on the move the young ones cling to the hairs on their chests; and Wallace

(294) thinks that "the constant and powerful exercise of the limbs in the young animal, remaining as it does for many hours each day with the whole weight of its body supported by its four extremities from the body of its mother, must induce a development of the limbs, which can hardly take place in confinement."

When young animals are captured they can be tamed, and even taught to obey words of command. They are not very shy, and they appear to court human society.

They are, however, easily frightened, and one of the manifestations of fright is a disturbance of the balance of the ocular muscles. I observed the left eye directed upwards and inwards, and the right one downwards and inwards, when the small animal was frightened.

Distribution.—The Orang is only found in certain parts of the islands of Sumatra and Borneo; and there are problems connected with its distribution which have not been satisfactorily explained. Thus it occurs in two districts, twenty-five miles apart, but it is absent from the intervening country. Moreover it may be absent from one area, whose climate, trees, rivers and other conditions are similar to those in an area where it thrives well. It frequents dense, gloomy forests and mangrove swamps extending from the coast inland, and avoids mountains and places where the population is dense.

Many zoologists have recorded the presence of the Orang in various parts of Sumatra and Borneo, and it will be found, on a perusal of their works, that southwest Borneo and north Sumatra have provided most of the specimens. There is, moreover, evidence that the Sumatran variety has been found in Borneo, and no sharp distinction can be drawn between these forms.

Classification.—There is now a consensus of opinion that there is only one species of Orang, but there are local varieties. There is, however, considerable doubt as to the exact number of varieties. Various zoologists have made use of the characters of the skull and teeth, the colour of the hair, the presence or absence of cheek-pads and of nails on the great toe for purposes of classification; but all these characters vary with age and sex.

The skull never attains a fixed form, but it changes throughout the whole life period; and a series of photographs of the same animal from youth to old age would exhibit striking differences. Besides these osseous differences there are variations in the bulk of the muscles of mastication, which produce differences in the contour of the head. So it is evident that one cannot give any clear description of the actual local varieties, either in number or in characters; Brühl (235) and Dumortier (245, 246) have described the changes in the head and the characters of species.

Selenka (287) described six varieties in Borneo and two in Sumatra. Giglioli (447) considered that there are two species in Borneo, and Fitzinger (248) believed there are four species.*

It is now believed that Owen's Lesser Orang (*Simia morio*) was not a distinct species, but merely a young *Simia satyrus*.

* Abel (224), Hartmann (452), Hornaday (256), Mohnike (271), Müller (87), Rosenberg (279A), Schlegel and Müller (282), Selenka (287), Trinchese (292), Veth (292A), Wallace (293), Wenckstern (297), and others have recorded localities in which specimens were observed or shot.

THE CHIMPANZEES. (*Anthropopithecus*.)

(Fig. 16.)

Configuration.—The Chimpanzee is a powerful, heavily-built animal, but its bulk is not so great as that of the Orang or the Gorilla. The male may attain the length of five feet from the crown to the heels, but the female is smaller. The limbs are more nearly equal than in the other Apes. The forearm is longer than the arm, and the hand than the foot. The hand constitutes more than 25 per cent. of the upper extremity.

The **head** is compressed, with a flattened vertex. The supra-orbital crests are well marked, but are not so prominent as those in the Gorilla. The nose is flattened, and has a slight bridge; and it is encircled by a narrow groove in the upper lip. The lips are long and thick, and are bulged forwards by the prognathous jaws. The chin is receding. The neck is short.

The **skin of the face** is more or less pigmented, and the intensity of the colour varies at different ages; so it is not a character which can be relied on for taxonomic purposes.

The **external ear** is large, and stands out from the side of the head like a wind-sail. It is usually pale in colour. It is neither hairy, nor is it concealed by long tresses as in the Orang and Gorilla. It varies in character in different animals, and sometimes the two ears are different in the same animal. The margin of the ear is only folded in its upper part, and there is no trace of Darwin's tubercle. The tragus and antitragus are well marked, and are separated by a deep fossa. Superiorly the helix is continuous with the antihelix,

the fossa of the helix is shallow, and the fossa of the antihelix is deep. No lobule is present. The auricular cartilage is entire, with a thin margin.

The characters of the auricles and lips are usually very distinctive, and one can generally distinguish those of the Gorilla from those of the Chimpanzee. It occasionally happens, however, that it is difficult or even



FIG. 16.—The Chimpanzee (*Anthropopithecus troglodytes*).

impossible to tell whether a particular animal is a Gorilla or a Chimpanzee. Duckworth (324_A) describes such a specimen, and Keith (99) records a controversy about an animal named "Mafuka" in the Zoological Gardens of Dresden. Meyer and Bolau considered her to be a Chimpanzee, but Nissle and Hartmann thought she was a Gorilla. It is, therefore, evident that the external appearances of these Apes are not always distinctive:

and when any difficulty arises it is in connection with females.

The **hand** is long and narrow, and the small thumb only reaches as far as the metacarpo-phalangeal joint of the index finger. The palm is pale, smooth and hairless. The thenar and hypothenar eminences are small or absent, and pads are only present on the terminal phalanges. **Flexure lines** are well marked, but they are variable, as can be seen from a study of the illustrations published by Beddard (304), Gratiolet (330), Hepburn (82), Sperino (401) and others. The arrangements in a young male animal examined by myself are shown in fig. 19. It will be seen that there are well-marked lines on the interphalangeal joints; three transverse lines cross the palm, and the thenar and hypothenar areas are bounded by curved lines. Three longitudinal lines radiate into the palm from the junction of the thenar and hypothenar lines. The proximal parts of the digits, with the exception of the thumb, are webbed. The back of the hand and proximal parts of the first phalanges are hairy, and the hairs radiate in all directions from an area over the base of the metacarpal bone of the index finger. And the naked skin on the backs of the penultimate phalanges, which are used in locomotion, is thickened to form oval callosities.

The whole of the palmar aspect of the hand and fingers is covered with papillary ridges running in all directions; and their arrangement is shown by fine lines in fig. 19. They form loops on the terminal phalanges; on the middle phalanges they are transverse; and on the proximal phalanges they are oblique. The distal part of the palm is occupied by ridges in arches; and the more

proximal part of the palm, with the exception of the hypothenar eminence, has lines radiating laterally or antero-posteriorly. On the hypothenar eminence the lines form arches.

The **foot**, like the hand, is long and narrow, and its digits are arranged in the same way. Thus the hallux is short, and the middle digit is the longest. The basal line, as regards the action of the muscoli interossei, is drawn through the middle digit in both hand and foot, whereas it runs through the second digit in the foot in Man and the Gorilla. The toes, with the exception of the hallux, are also webbed in their proximal parts. The flexure lines are variable, but to a less extent than those on the hand. Their arrangement in the young male animal examined by me is shown in fig. 20; and it is more intricate than in animals described by some authors. It shows that the foot is a prehensile organ. The hallux has several deep lines. The hallucal lines are more pronounced than the pollical lines. The back of the foot is hairy, but the toes are hairless, and devoid of the callosities which are so pronounced on the fingers.

The hallux is thicker than the other digits, which vary in appearance in different animals. Thus I observed them to be long and slender in a young female, but they were more stumpy in a young male, which had almost the same dimensions of body.

As these animals were undoubted examples of *Anthropopithecus troglodytes*, and the characters of the female foot were similar to those of *Troglodytes calvus*, as described and figured by Beddard (304), no taxonomic value can be ascribed to these features.

Habits.—Those who have studied Chimpanzees in

their native haunts describe them as active, agile creatures. They run about on the ground in a quadrupedal manner, using their fore and hind limbs almost equally. They also jump off one foot which is used like a spring-board. In the trees they swing about as actively as some Gibbons. When the animal has been in captivity for a long time it develops stiffness of the joints, and its active movements are replaced by an awkward gait in which the body is dragged along, the forearms being used like crutches. It must be emphasized, therefore, that the mode of locomotion of an old menagerie specimen is quite unnatural.

Occasionally the Chimpanzee stands upright, and it is clearly seen at these times that the narrow sole is planted firmly on the ground, there being no plantar arch. It only remains erect for a very short period, for the mechanisms which allow Man to remain upright and be bipedal are poor or absent. Man's upright position is due to the following factors acting in harmony :—

- (1) The centre of gravity is low.
- (2) The ilio-femoral ligament is a strong band.
- (3) The structure of the knee-joint with its ligaments does not permit the thigh and leg to be rigidly locked.
- (4) The structure of the ankle-joint.
- (5) The muscular system is more divided and the muscles can co-operate to suit awkward attitudes.
- (6) The regulating powers of the central nervous system have reached a high degree of perfection.

These factors will receive detailed attention in subsequent chapters.

The arms are used as hook-like suspenders, for the diminutive thumb cannot convert the hand into a

grasping organ. The hallux, on the contrary, makes the foot a powerful grasping organ.

When the actions of the hand are closely watched, it is seen how the Chimpanzee employs the index and middle fingers together for most purposes.

It will be seen later that the anatomical differences between the human and anthropoid hand are not sufficient to explain the enormous differences in function. The reasons are to be found in the complexity of the brain and in the main uses to which the hand is put. In Man the hand is not used as an aid to progression, or as a support for the body, but it has been set free so as to act as the servant of his highly organized brain. The thumb has developed considerably and exceeds that of any Ape in size and in function. The other parts of his hand have not undergone such striking transformations, however, as the thumb.

It is frequently stated that the Chimpanzee is filthy in its habits, but many examples in captivity do not manifest this trait, nor any tendency to immoral behaviour.

There appears to me to be no doubt that the Chimpanzee is the most intelligent of the Anthropoid Apes, but there are individual differences in the degree of intelligence. Sally, the famous Chimpanzee belonging to the Zoological Society, had a higher degree of intelligence than her successors. Young animals have a good memory for faces, and they will remember a person who has injured them.*

Distribution.—Of all the Anthropoid Apes no single

* Accounts of the habits are contained in papers 303, 314, 324, 329, 344, 344, 355, 359, 363, 367, 383, 389, 398, 399.

species has such a wide distribution as the Chimpanzee. It is found in West and Central Equatorial Africa, from Gambia in the north to Angola in the south. Several specimens have been obtained from the neighbourhood of Lake Tanganyika, the Niam-Niam country and Uganda. The Uganda Chimpanzee has been given the specific name *Anthropopithecus schweinfurthi*.

Classification.—As the external characters of the Chimpanzee exhibit considerable variation with age, sex and locality, it is not surprising to discover, on consulting the literature dealing with taxonomy, that zoologists have invented specific names for mere varieties. And Trouessart has collected the various synonyms which have been applied to the two real species—the Common Chimpanzee (*Anthropopithecus troglodytes*) and the Bald-headed Chimpanzee (*A. calvus*).

(a) **The Common Chimpanzee** (*A. troglodytes* Linn).

Synonyms.—*A. sylvestris* (Tyson and Cowper); *A. niger* (E. Geoff); *A. leucoprymnus* (Less); *A. vellerosus* (Gray); *A. schweinfurthi* (Gigl); *A. aubryi* (Gratiolet et Alix).

(b) **The Bald-headed Chimpanzee** (*A. calvus*, Du Chaillu).

Synonyms.—*A. tschego* (Duvernoy); *A. kooloo-kamba* (Du Chaillu).

Some of these authors employed the old generic name *Troglodytes* instead of the modern *Anthropopithecus*.

Many fine illustrations of *A. troglodytes* have been published, and Bartlett (303) gives a fine plate representing *A. calvus*. He contrasts the external characters and habits of the two species. The face, hands and

feet in the Chimpanzee are white or of a pale flesh-colour; the same parts of the Bald-headed animal are black or brownish-black. . . . In the Chimpanzee the hair on the top of the head, and passing down from the centre (where it divides) to the sides of the face or cheeks, is tolerably long and full, forming what may be considered rather bushy whiskers; whereas in the Bald-headed animal the top and sides of the face and head are nearly naked, and there is no trace of a parting. The ears are particularly large in the Bald-headed animal; and the form of the head, the facial expression, the expanded nostrils and the great thickness of the lower lip, together with the more elevated skull, cannot fail to distinguish the Bald-headed Chimpanzee from the common variety.

THE GORILLA.

(Figs. 17 and 18.)

Configuration.—The Gorilla is the largest, strongest and most formidable of the Primates. The adult male may attain the length of 6 ft. from the crown to the heels, but the female is smaller, her length rarely exceeding $4\frac{1}{2}$ ft. The arms and chest are of great size, but the legs are insignificant in comparison. The hands reach below the knees when the animal is erect, and the span of the outstretched arms exceeds the length of the body.

The relative proportions of the segments of the arm are more like those in Man than are those of the other Apes. Thus the arm is longer than the forearm, whereas the reverse is the case in the Gibbons, Orang

and Chimpanzees. The hand is shorter than the foot as in Man and the Orang, but it is longer than the foot in the Gibbons and Chimpanzees.

The **head** is large and broad, with a receding brow and chin; and the ears, which are very human in




FIG. 17.—Young Gorilla (*Gorilla gorilla*).

appearance, are more or less concealed in the thick hair which clothes the sides of the head. The **supra-orbital crests** are very strongly developed, and overhang the deeply-set eyes like penthouses. The **nose** has a long bridge, and it is specially characterized by very thick

lateral folds, which pass into the short upper lip; and the nostrils are wide and patulous. The relative development of the nose and lips varies with age, as can be seen by comparing figs. 17 and 18, and with sex.



FIG. 18.—Adult Gorilla.

The lower part of the face is very prominent in the adult, because the **maxillæ** are prognathous, the mandible is very large, and the muscles of mastication are large and powerful. In the young animal the prognathism is less marked, and the lips are not bulged forwards to such an extent as those in the adult. As the

prognathism increases the general facial appearance alters. When the lips are retracted in life the huge canine teeth give the animal a very brutal appearance, which is intensified if it draws down the hairy crest, which runs along the sagittal line of the head.

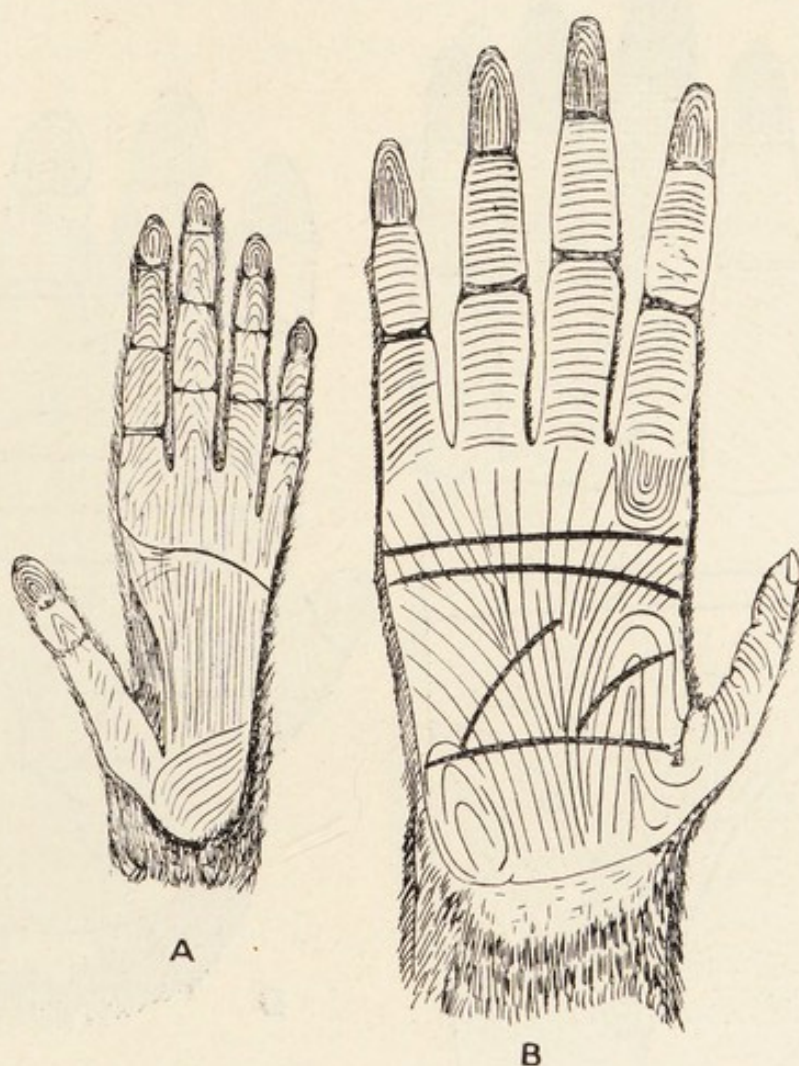


FIG. 19A.—The hand of the Bornean Gibbon (A) and Orang-Outan (B) showing the flexure grooves (thick lines) and papillary ridges (fine lines).

The **neck** is short, and the head is held more rigid than in the Chimpanzee. The thorax is short, wide and deep, and the abdomen protrudes as a large paunch.

The **hand** is relatively shorter and wider than in the other Apes, and the proportions of the palm approximate

to those in Man. The digital formula is as in other Apes, and the thumb is very small. The proximal parts of the digits are united by a web, and the terminal phalanges have flat nails. The primitive pads are

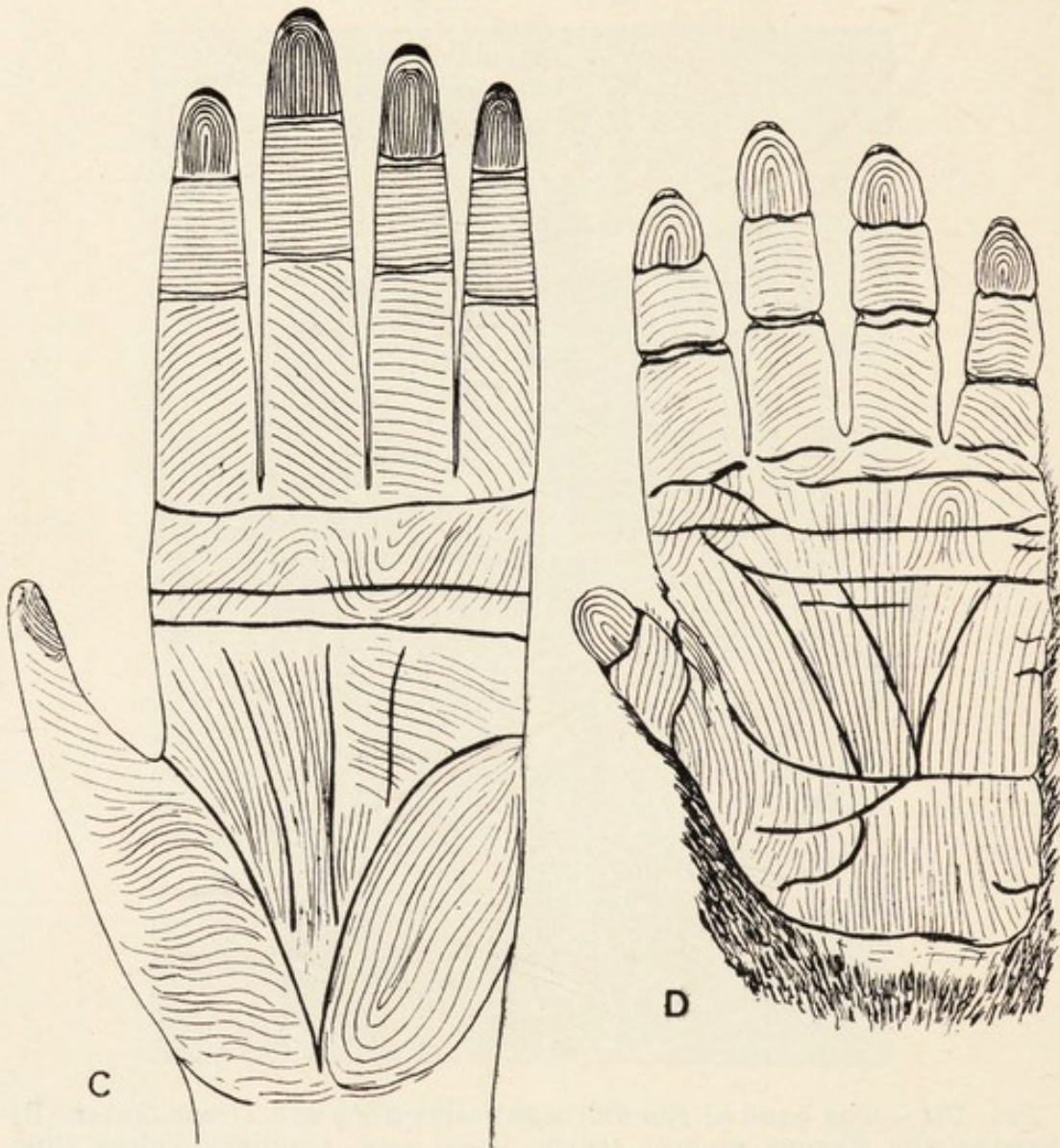


FIG. 19B.—The hand of the Chimpanzee (C) and Gorilla (D) showing the flexure grooves and papillary ridges.

reduced to those on the terminal phalanges. The palm is glabrous and pigmented, and is traversed by the usual flexure lines and papillary ridges. The **flexure lines** (fig. 19) are simpler than in many Apes; they consist

of horizontal grooves over the interphalangeal joints, and transverse grooves on the palm. On the palm the **papillary ridges** stream in three directions from the wrist. Some pass to the inner border, others run to the

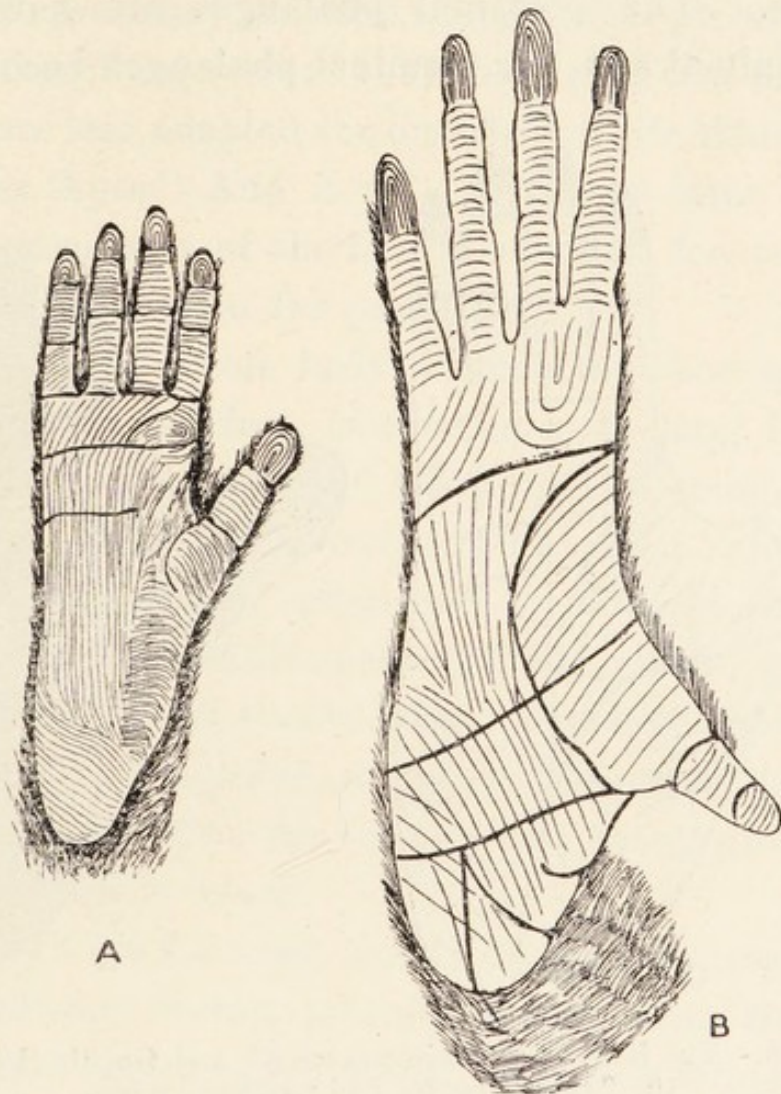


FIG. 20A.—The foot of the Bornean Gibbon (A) and Orang-Outan (B) showing the flexure grooves and papillary ridges.

outer border, and an intermediate series passes straight down to the roots of the middle and ring fingers. At the proximal ends of the clefts between the fingers there are groups of ridges forming concentric circles. The digits have oblique lines, and the apical pads have

systems of loops, which are more complex on the thumb than on the other digits.

The back of the hand is hairy. The back of the thumb is hairless, and the penultimate phalanges of the other digits, which have callous skin, are likewise devoid of hairs. The proximal phalanges are hairy in the young animal and the terminal phalanges become hairy

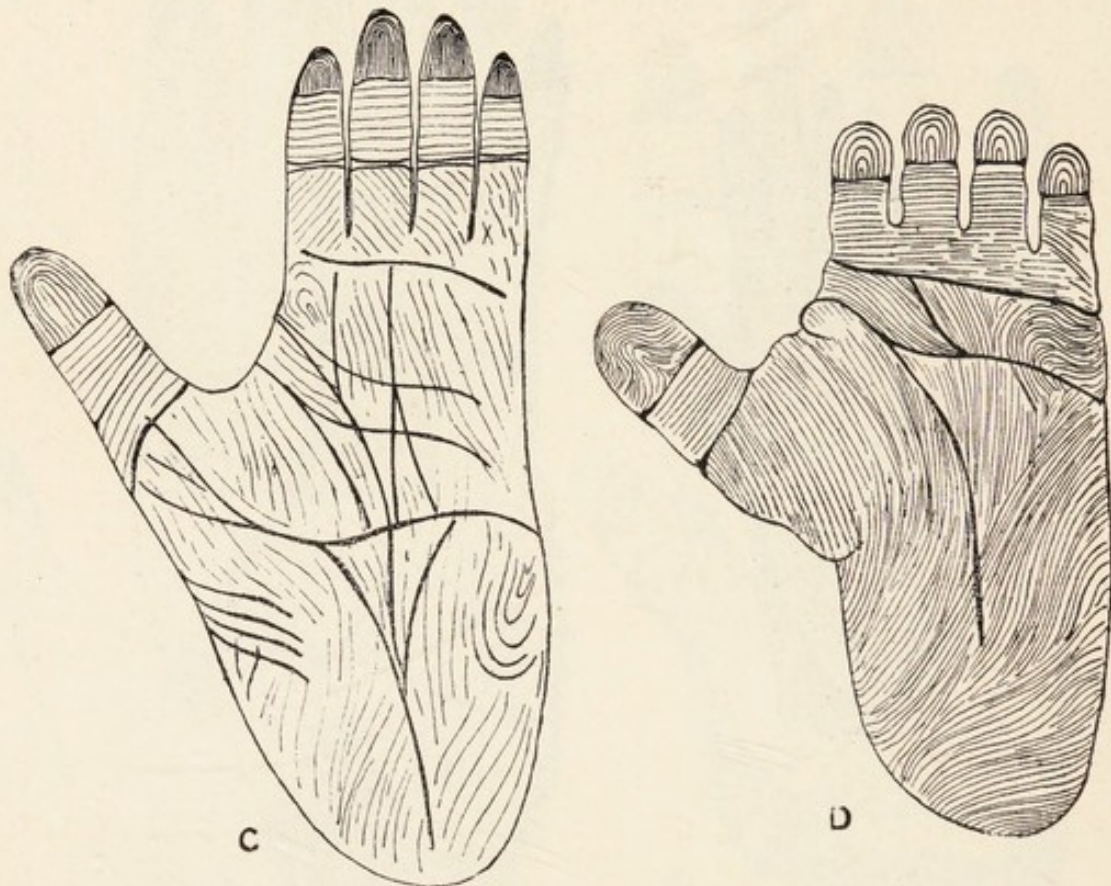


FIG. 20B.—The foot of the Chimpanzee (C) and Gorilla (D) showing the flexure grooves and papillary ridges.

in fully adult specimens. During progression the backs of the fingers are applied to the ground.

The **foot**, like the hand, approximates to that of Man in the relative proportions of length and width (fig. 20). The digital formula resembles that of the hand. The hallux is small, and the toes are greatly involved in a web. The primitive pads are slightly developed on the

terminal phalanges only, and the flexure lines are greatly reduced. The papillary ridges form three groups of parallel lines on the sole, and oblique or transverse lines on all the phalanges except the terminal ones, where they form loops. The back of the foot and the proximal phalanges are hairy, but the remainder is glabrous.

It is, therefore, evident that the hands and feet of the Gorilla are less adapted for an arboreal life than those of the other Apes. And it will be shown later that the internal structure of the foot is adapted for supporting purposes rather than for prehension.

Hairs.—The whole body, except the face and parts of the hands and feet, is covered with long hair of a black or rufous colour, and old animals become grizzled. Rothschild (485) points out that there is a rufous phase in all the subspecies recognized by him, so the colour of the hair exhibits dimorphism. He states, moreover, that "these rufous phases have been described respectively as distinct species or races" by other zoologists. Each hair is banded, the tip and root being grey, whilst the remainder is black.

The hairs on the scalp stream backwards towards the neck, and they form a prominent crest along the line of the sagittal suture. When the animal is enraged these hairs are strongly erected, and the crest is pulled downwards and forwards with the scalp. Two streams of hairs pass down on the side of the head and include the external ear between them. Sometimes these hairs are so thick that the ear is concealed. On the body the general direction of the hairs is downwards, but there are vortices over the clavicles and in the neighbourhood of the anterior superior iliac spines. The hairs on the

legs point downwards ; but those on the arms and fore-arms, which are of great length, converge towards the elbows. The arrangement of the hairs is well seen in figs. 17 and 18.

There are two pectoral **mammæ**, and the umbilicus is situated below the middle of the body.

Habits.*—The most reasonable account of the habits of the Gorilla is still the original account, published in 1847, by Savage and Wyman. After disproving several undoubted fables Savage says: "They are exceedingly ferocious, and always offensive in their habits, never running from Man, as does the Chimpanzee. They are objects of terror to the natives, and are never encountered by them except on the defensive. The few that have been captured were killed by elephant-hunters and native traders, as they came suddenly upon them while passing through the forests.

"It is said that when the male is first seen he gives a terrific yell, that resounds far and wide through the forest, something like kh—ah ! kh—ah ! prolonged and shrill. His enormous jaws are widely opened at each expiration, his under lip hangs down over the chin, and the hairy ridge and scalp are contracted upon the brow, presenting an aspect of indescribable ferocity. The females and young, at the first cry, quickly disappear."

The Gorilla approaches his enemy in a stooping, shuffling manner, but rises to his feet when about to attack. He uses his powerful arms and hands to disable or kill the hunter, or he may attempt to draw him towards his great teeth.

* Accounts of habits are contained in papers 429, 443, 445, 449, 458, 469, 483, 484, 487.

He makes a rude and simple nest, which is only occupied at night.

In captivity the young Gorilla usually manifests a sullen disposition, but that is not always the case. Occasionally it beats its chest, which resounds like a drum. Du Chaillu stated that the wild animal in the forests also thumped its chest till it resounded, but many disbelieved his statements. No adult animal has yet been captured alive and kept in captivity in any zoological gardens, and the number of young ones which have been on exhibition constitutes a very small series.

Distribution.—The actual limits of the area of distribution are not yet known, but the region in which it lives is small compared with the area inhabited by the Chimpanzee. It is found in the moist, forest region on the banks of the Gaboon and other rivers in West Africa. Specimens have been obtained at Lake Kivu. Its distribution is becoming more restricted, for it was seen in large numbers on the coast about the middle of last century. Keith (99) enumerates the writers who have recorded localities in which it has been killed. Barnes has obtained Gorillas at the altitude of 6,000-10,000 feet in the Kivu District.

Classification.—There appears to be only one species of Gorilla with several sub-species. Rothschild (485) recognizes the following varieties, which are distinguished by certain external and cranial characters:—

(1) **Gaboon Gorilla** (*Gorilla gorilla gorilla* Savage and Wyman):—Pelage dimorphic. Red phase does not differ on the body, but the whole crown becomes rufous. Occipital region narrow and triangular because the lambdoid crest has a sharp centre.

(2) **Cameroon Gorilla** (*Gorilla gorilla diehli* Matschie):—Rufous phase not so restricted; the red crown is not sharply defined and the body hairs are brownish, with some red hairs intermingled. Occipital region broad, and centre of lambdoid crest blunt.

(3) **Mountain Gorilla** (*Gorilla gorilla beringeri* Matschie):—Body stout and stocky. Hair intensely black. Large fleshy callosity on crest on the top of the head. Occipital region very broad and lambdoid crest absolutely flat.

As regards other sub-species which have been proposed (*G. jacobsi* and *G. manyema**) Rothschild points out that the material available is too scanty to warrant definite conclusions being drawn.

Pocock (80) has summarized our knowledge of the habits of the Anthropoid Apes as follows:—"The Gibbons are the most expert climbers and bipedal walkers, the least expert quadrupedal walkers. The Orangs rank second in climbing, third in quadrupedal and fourth and last in bipedal activity. The Gorillas take fourth place in climbing, second in bipedal and second in quadrupedal activity. The Chimpanzees stand third in climbing, third in bipedal and first in quadrupedal powers. . . . They have departed least from the primitive form." From a study of the anatomy of many examples of each Anthropoid, Keith (100) regards the Gorilla as more primitive in many ways than the Chimpanzee. He concludes that the Chimpanzee is a Gorilline derivative in which, with progressive brain development, there have been retrogressive changes in many organs; and

* Alix, E., et Bouvier, A. *Bull. Soc. Zool., France*, 1877, pp. 488-490.

the varieties are marked by the differences in the degree to which the changes have proceeded.

We shall see later that the best method of expressing the evolution of the African Simiidae on a genealogical tree is a Gorilline stem giving off *Anthropopithecus* high up, and the extinct Chimpanzee-like Ape *Palæopithecus* low down.

The external characters peculiar to Man are: (1) The nose has a depressed tip; (2) the upper lip has a median vertical groove or philtrum; (3) the lips have red margins, the whole of which are visible; (4) he has a chin; (5) the neck is long; (6) the distal palmar flexure grooves run obliquely instead of transversely across the palm; (7) the papillary ridges are more numerous and show absolute individual differences; (8) the foot is arched; (9) the hallux is never at the side of the sole; (10) the thumb is large, and the hand can enclose a sphere.

CHAPTER V.

THE SKELETON AND TEETH.

Section A. **The Skull.**

IN the preceding chapter we saw how many of the external characters, which are employed by systematists for taxonomic purposes, vary considerably with age, sex and environment; and many of the data which were formerly regarded as specific characters are now regarded, at best, as characteristic of sub-species. These remarks also apply, but with even greater force, to the skull; for no structure is so influenced by physiological agents acting from within, or by physical agents operating from without. By physical agencies I mean those impressions which the environment brings to bear on the surface of the body. It is, therefore, evident that the student should examine many skulls before he comes to definite conclusions as regards the cranial characters of each Anthropoid. Fortunately the skulls in our great Museums are provided with labels giving data of age, sex and the localities where they were found; so the student has ample material for thorough craniological investigations.

As **age** * advances the cranial and facial parts of the skull increase in size up to a point, but the latter continues to enlarge after the cranial part has stopped growing. In the Orang it keeps altering throughout

the whole life period. The result is that the jaws become increasingly prognathous, and the ridges, which give origin to the temporal muscles, gradually increase in size; in the Gorilla the enlargement of the crests reaches a maximum.

Sexual differences* are seen in the whole build of the skull, the size of the jaws and the degree of development of crests for the muscles of mastication. The female cranial cavity is always smaller than that of the male, the difference being least in the Gibbons and greatest in the Gorilla. The actual measurements are given later.

THE GIBBONS.†

Norma Verticalis.—The skull is ovoid in contour, and no prominent crests are present. But a well-marked line on each side marks the upper limit of the temporal muscle. The frontal bone may extend backwards to articulate with the occipital, but it usually articulates with the parietals by a curved coronal suture. The coronal and sagittal sutures usually meet; but the confluence is sometimes prevented by a lozenge-shaped Wormian bone. The vertex meets the plane of the occipital bone, which slopes downwards and forwards.

Norma Frontalis.—The **orbits** are capacious, and their borders are prominent. The upper margins form

* The age and sex differences in the skull have been described by Bischoff and others.

† Accounts of the skull in whole or in part have been written by Albrecht (4), Anderson (5), Bischoff (177), Duvernoy (53), Fry (188), Giebel (190), Hamy (451), Huxley (87), Keith (197), Regnault (380), Schlegel (282), Seydel (288), Waldeyer (218), Vrolik (217), de Blainville (20) and Deniker (44).

thickened crests which do not meet across the nose. The size of the cavities is dependent on the law which states that the volume of the eyes is inversely proportional to the bulk of the body. The **optic foramen** is round, and separated from the triangular anterior lacerate foramen. The **inferior orbital fissure** is wide and long. The os planum of the ethmoid bone is sometimes divided into two parts by a vertical suture. The **lachrymal hamulus** is rudimentary, and the bony bed for the lachrymal sac may be deep. The **naso-lachrymal duct** runs down to the nose through a well-marked canal.

The **anterior narial aperture** is ovoid, and is bounded below by the premaxillæ, laterally by the nasal processes of the maxillæ, and above by the flat, quadrate bone formed from the fused nasal bones. The **premaxillæ** do not extend upwards on the sides of the narial aperture to meet the nasal bones. No anterior nasal spine is present. On looking into the aperture one sees the turbinate bones and bony septum nasi very plainly.

The **infra-orbital foramina** consist of one prominent foramen placed on the maxillæ below the junction of the inner and middle thirds of the inferior margin of the orbit, and of two foramina on the malar bone. Through the former the infra-orbital branch of the maxillary division of the trigeminal nerve emerges.

No infra-orbital suture appears on the face. No supra-orbital foramen exists.

The most anterior part of the maxillæ, lying between the infra-orbital foramen and the anterior narial aperture, is expanded to form the long socket of the large

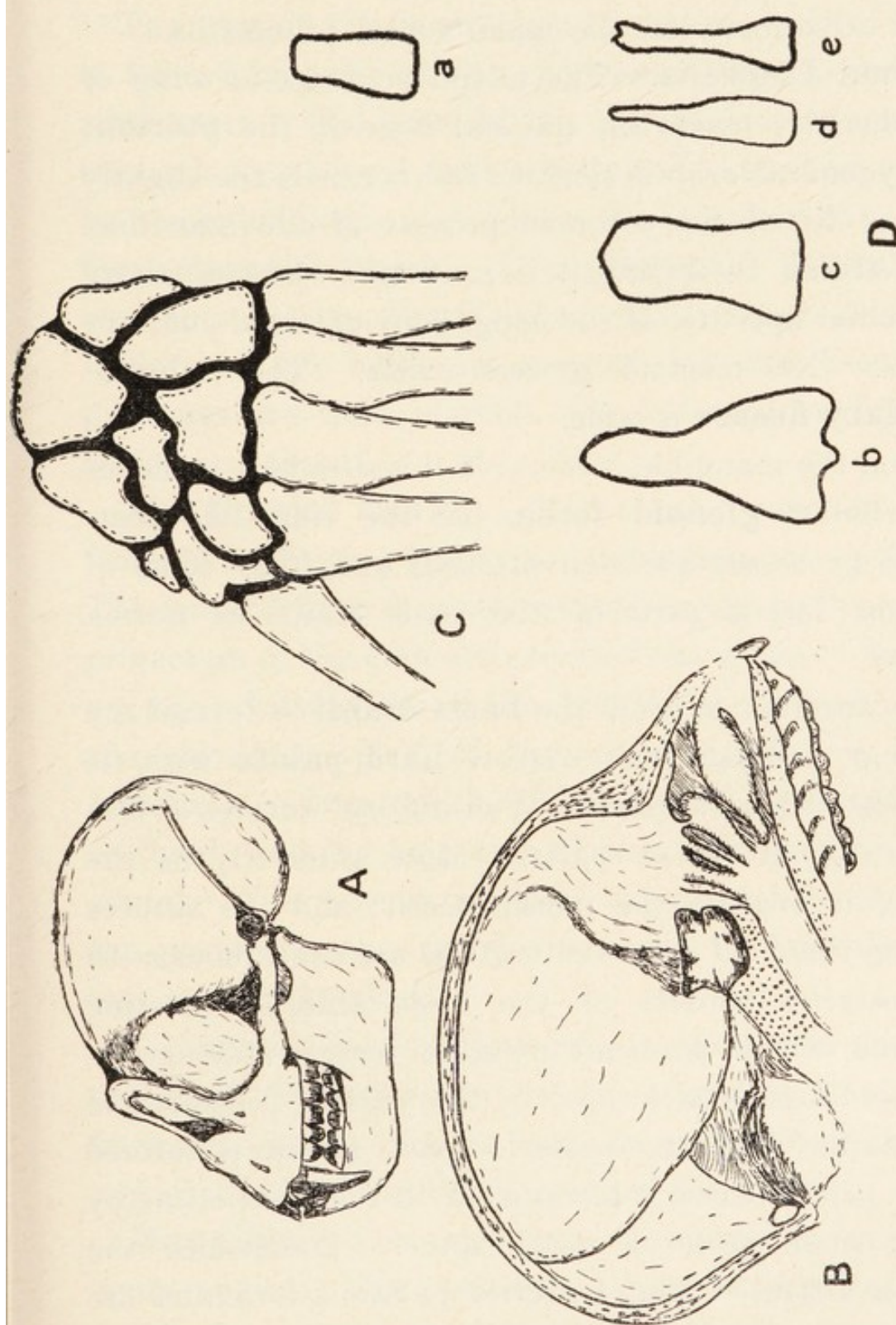


FIG. 21.—Osteology of the Apes. A, skull of the Bornean Gibbon; B, skull of the Bornean Gibbon on mesial section to show the turbinated bones; C, carpus of the Gibbon and Orang showing the os centrale; D, nasal bones of the Gibbon (a), Gorilla (b), Chimpanzee (c), and Orang (d, e). The carpus of the Chimpanzee and Gorilla is shown in fig. 35.

canine tooth. And slight ridges are produced by the fangs of the premolar and molar teeth. A well-marked suture exists between the maxilla and premaxilla.

Norma Lateralis.—The alisphenoid (great wing of the sphenoid) meets the parietal bone in the **pterion**. The zygomatic arch is slender, and conceals the slightly recurved tip of the coronoid process of the mandible. When traced backwards it is continued upwards above the circular aperture of the long, bony external auditory meatus. No mastoid process exists. The **sphenomaxillary fissure** is wide.

When the mandible is removed it is seen how it moves in a shallow **glenoid fossa**, but the ridge-like postglenoid processes are well marked, and form some of the most lateral parts of the basis cranii or norma basalis.

The anterior part of the **basis cranii** is formed by the long, comparatively narrow **hard palate** with its bounding dental arcade. Well-marked sutures divide the palate into three parts. Most anteriorly lie the premaxillæ bearing the incisor teeth; and the sutures marking them off from the maxillæ are continuous with the posterior borders of the large anterior palatine foramina, which transmit palatine vessels and nerves. The middle part is formed by the palatal processes of the maxillæ; and the posterior part, which is formed by the palate bones, is terminated in the middle line by a very small posterior nasal spine. Sometimes the spine is absent. The posterior palatine foramina are entirely on the palate bones, but they may be concealed by small bony shelves. The entire bony palate is curved from side to side. The horizontal plates of the

palate bone floor the quadrilateral posterior nares or choanæ.

The part of the basis cranii behind the palatal region is formed by parts of the sphenoid, temporal and occipital bones. The parts of the sphenoid visible are the strong basi-sphenoid, which is united to the basi-occiput by a marked horizontal suture, the presphenoid and the four pterygoid plates. The **pterygoid hamuli** are slender and sharp, and the pterygoid fossæ are wide.

No tympanic bullæ are present, but the Eustachian processes are well marked. Styloid and vaginal processes are absent.

The Cranial Cavity.—The cranial capacity varies from 76 to 90 c.c. ; and sexual differences are negligible. The anterior fossa is much reduced in size by the upward projection of the dome-like roofs of the orbits. So much are the orbital plates of the frontal bone bulged up that the cribriform plate of the ethmoid bone is at the bottom of a deep sulcus. The **clinoid processes** may be fused, and the long axis of the sella turcica is horizontal. The petrous temporal has a cerebellar pit, and the grooves for the lateral sinuses, particularly the right one, are well marked.

As regards the foramina it is important to note that the **foramen ovale** pierces the alisphenoid ; and the foramen magnum lies far back, being partly on the base and partly on the occipital plane of the skull.

Mandible.—The two halves are united in front at an acute angle. The posterior aspect of the symphysis menti has a fossa for the origin of the genial muscles. The symphysis is receding in the genus *Hylobates*, but is more vertical in *Symphalangus*. The ascending ramus

is short and broad, the angle is inflected to a greater or less extent; and the coronoid process exhibits a variable degree of recurving of the point even in the same species. The body of the bone is thickened round the incisor, canine and first premolar teeth, and its vertical height is greatest in these regions.

Keith (99) points out that the skull of the Siamang can be distinguished from those of all other Gibbons, but it is not possible to differentiate those of the various species of the genus *Hylobates* from one another. Perhaps the examination of a hundred or more skulls of each species might enable us to discover specific characters.

THE ORANG-OUTAN.*

The most characteristic feature in the vast majority of Orang skulls is the hollowing out of the middle of the face, a condition to which the term "**simognathism**" is applied. The degree of simognathism varies with age, sex and the locality from which the animal was obtained; so a large series of skulls exhibits marked differences in profile. Thus the facial outline may be nearly, but not quite, straight; or the skull appears constricted in the middle, thus showing up prominently the size of the cranium and jaws (fig. 22).

The skull resembles that of any Gibbon in a number of points, but differs from it in many respects, first and foremost of which is **size**. The absolute bulk is greater, the jaws are more massive, and the cranial capacity is

* The skull is described in whole or in part in papers 15, 20, 92, 109, 122, 235, 245, 246, 254, 261, 265, 267, 276, 280, 343, 365, 380, 451.

more. Not only is the capacity greater, but the sexual differences are more pronounced.

In the Gibbon the **capacity** is 76 to 90 c.c., and the female skull lodges a brain which is 98 per cent. of that of the male. In the Orang, on the other hand, according

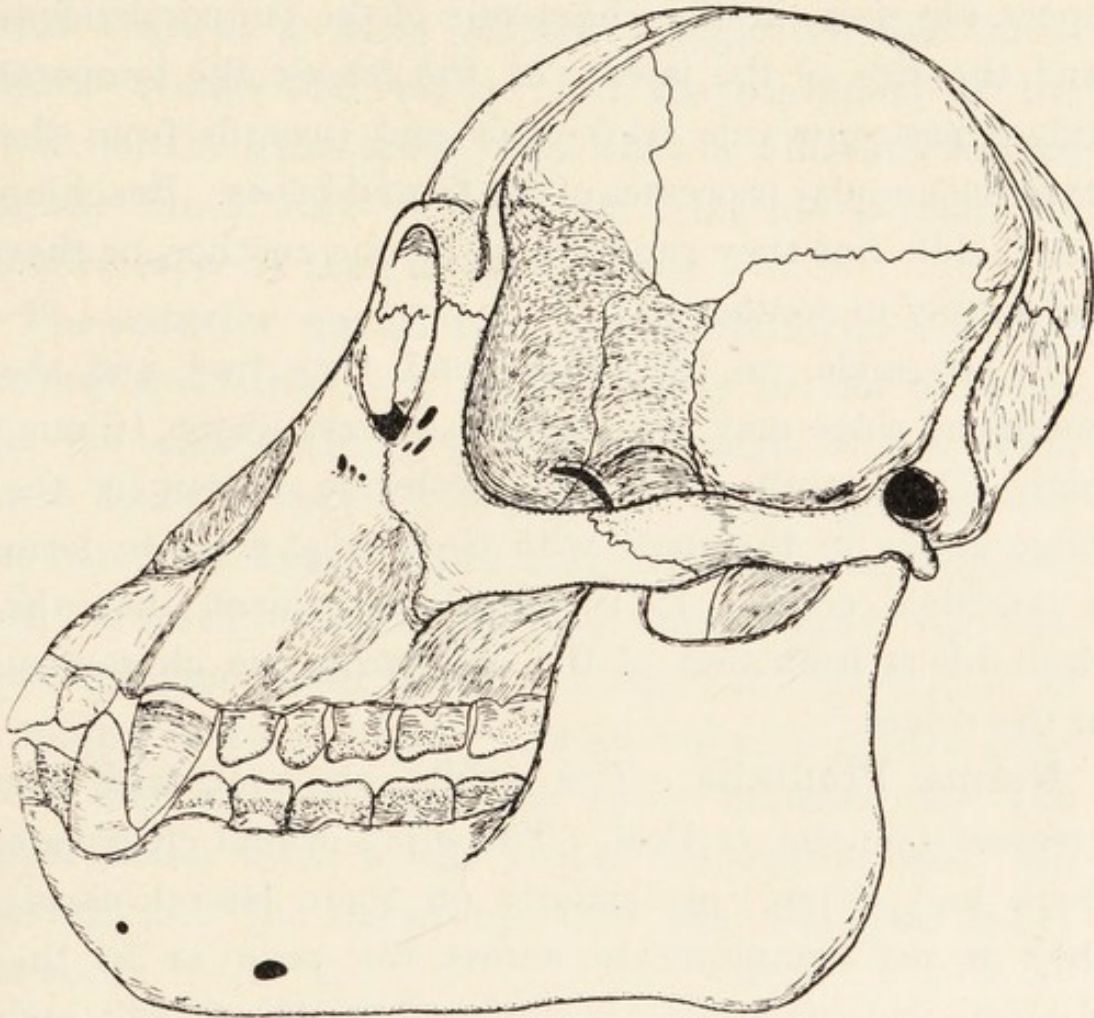


FIG. 22.—Skull of the Orang-Outan.

to Hrdlicka, the capacity is 350 to 540 c.c. in the adult male, and 300 to 490 c.c. in the adult female (i.e., the capacity in the female is 90 per cent. of that in the male). The cranial part is relatively shorter and wider than in the Gibbon, so the skull is more nearly brachycephalic.

The exterior of the skull shows **sexual differences**; and it is usually easy to distinguish the skull of an adult male from that of an adult female. In some cases, however, it is difficult or even impossible to determine the sex of the skull, for the female may assume male characters or *vice versa*. Sexual differences are seen in the characters of the temporal ridges and the size of the jaws. In the female the temporal ridges pass upwards, backwards and inwards from the external angular processes of the frontal bones. Reaching the middle line they run parallel to one another, or they are simply in contact.

In the male, on the other hand, they fuse, and the combined ridge may rise up into a crest about 10 mm. high (Duckworth). At the posterior extremity the ridge unites in the male with the nuchal crest to form a lambdoid crest. It is, therefore, evident that the skull differs from that of the Gibbon in the characters of the ridges.

Norma Frontalis.—The **orbits** are oval, with the greatest diameter vertical. The supra-orbital crests are thick and strong, particularly on their lateral parts; they do not communicate across the nose as in the Gibbons, but the crests are confluent in the Gorilla and Chimpanzee.

The articulation of the lachrymal and ethmoid bones has been studied by Regnault (380) and others; and it appears that the os planum of the ethmoid is frequently high anteriorly, so that the **lachrymo-ethmoidal suture** is long. The **lachrymal hamulus** is vestigial.

The bony walls of the orbit are more complete than in the Gibbons, for the speno-maxillary fissure is a

narrow cleft. Several important foramina are seen on the posterior wall. The **optic foramen** is separated from the wide anterior lacerate foramen by a thin septum; and the foramen rotundum is very obtrusive below these. The **foramen rotundum** is not always seen in the orbit in the Gibbons. On the floor of the orbit there is a wide, shallow trough for the infra-orbital vessels and nerve; and the beginning of the canal for the **naso-lachrymal duct** is a marked feature on the inner wall. The entire orbit has a relatively smaller capacity than in the Gibbons.

The **anterior narial aperture** is pyriform, with the narrow end above. It is bounded as in the Gibbons, but the area occupied by the free edge of the fused nasal bones is very much smaller. The Orang, in fact, has narrower **nasal bones** than all other Anthropoids, and the fused mass forms a long, narrow splint (fig. 21). The **anterior nasal spine** is absent, or represented by a slight median ridge. Occasionally a groove runs along the mid-line from the space between the two upper incisor teeth to the root of the septum nasi. On looking into the narial aperture the turbinate bones are seen.

The **infra-orbital foramina** vary. Thus in one skull there were three small foramina in a horizontal line on one side, and two large openings on the other. No supra-orbital foramen is present.

Norma Lateralis.—The zygomata are bent outwards and the alisphenoid is channelled, so the infra-temporal fossa is deep. The **pterion** is composed, as in the Gibbons and Man, by the articulation of the parietal and alisphenoid. In this respect the Asiatic Simiidæ

differ from the African forms, in which the frontal articulates with the squamosal, thus separating the parietal and alisphenoid. The infra-temporal crest is small.

The **zygoma** conceals the slightly recurved coronoid process of the mandible, and it sometimes shows the suture where the malar and temporal bones articulate. It is continued upwards and backwards above the long, bony, external auditory meatus.

Norma Basalis.—The **bony palate** has the usual hypsiloid, or U-shaped, form; but the relative proportions of length and width vary, as pointed out by Delisle (244). The differences are probably age changes, and are similar to the age changes which occur in the Chimpanzee and Gorilla. The sutures between the premaxillæ and maxillæ disappear early, and the anterior palatine foramina may be obliterated. The suture between the palatal processes of the maxillæ may persist, and the maxillary-palatine sutures are irregular. The palate bones are perforated by the posterior palatine foramina in all specimens; but there are variations in the characters of the posterior nasal spine. That process may be small, absent, or replaced by two small spicules of bone.

The **pterygoid plates** of the sphenoid diverge so as to include a wide fossa, as in the Gibbon, and the hamular processes are likewise small. The **alisphenoid** is tunnelled by the foramen ovale, but there is no alisphenoid canal for the internal maxillary artery. The suture between the basi-sphenoid and basi-occipital is irregular.

The **glenoid fossa** is shallow, but is bounded behind

by a strong, thick, post-glenoid process. An endoglenoid tubercle is present, and there is sometimes a small **styloid process**; so we have here two points in which the skull differs from that of the Gibbon. As in the Gibbon, there are neither vaginal nor mastoid processes.

The **carotid canal** tunnels the petrous temporal in a direction which is first upwards and then forwards; so the foramen is obtrusive on the basis cranii. In the Gibbon, on the other hand, the canal runs straight forwards, so the foramen is not so plain.

The **anterior condyloid** foramen is sometimes replaced by two apertures, but it is always single in the Gibbons. The **foramen magnum** is placed far back as in the Gibbons, and it lies partly on the basis cranii and partly on the occipital plane.

The **occipital condyles** are small. Their mesial borders do not diverge so much as in the Gibbons.

It is not usual to meet with anomalies round the foramen magnum, but the upper part of the suspensory ligament may be ossified, when a spicule of bone will be seen on the anterior border of the foramen magnum.

The **Cranial Cavity**.—The anterior compartment of the cranial cavity is reduced by the globular roofs of the orbits. The cribriform plate of the ethmoid articulates with the pre-sphenoid as in Man, but the crista galli is rudimentary or absent.

The anterior and posterior **clinoid processes** are frequently connected, and the tentorium, which is attached to them anteriorly, is said by Owen (276) to stop posteriorly at the petrosals. The Gasserian ganglion may be concealed by a shelf of bone continuous with the

bony lamina which sometimes roofs in the superior petrosal sinus.

The cerebral convolutions do not impress the cranial bones deeply, as in some of the Gibbons.

The cranial bones are excavated by **sinuses**, which help to lighten the skull. The sphenoidal sinus is almost entirely contained within the pre-sphenoid, and is subdivided by a longitudinal septum. There is no mastoid antrum, but tympanic air cells are contained in the squamosal. There is no proper frontal air sinus on either side, but the bone is cancellous. The maxillæ are excavated by the antra of Highmore. So it is evident that the air spaces in the Orang are much fewer than those in Man; and it will be seen later that they are less extensive than in the African Simiidæ. The latter have well-marked frontal sinuses, and the sphenoidal sinuses are more extensive.

The **septum nasi** is composed of the same elements as in Man, but the turbinate bones are less complex than in him and in the African Simiidæ.

The **mandible** is an exceedingly large and strong bone; but it shows many variations, which are of an individual character apart from the differences due to sex and age. The broad ascending ramus has a shallow sigmoid notch, and the point of the coronoid process is slightly recurved; its height varies, but it always rises more above the body of the bone than in the Gibbons. The lower border of the body is straight, curved or sinuous; and the strong, dense symphysis slopes downwards and backwards. On the back of the symphysis there is a pit for the genial muscles, and the halves of the mandible are united below it by a bony ledge called the "simian shelf."

The points in which the skull of the Orang differs from those of the African Simiidæ are enumerated on p. 132.

THE CHIMPANZEE.

(Fig. 23.)*

Of the three great Apes the Chimpanzee resembles Man most closely in the general appearance of the skull. Thus the cranium is relatively larger, and the facial skeleton relatively smaller than in the Gorilla and Orang; and there is no prominent sagittal crest in the adult male. The cranial capacity in the female, being ninety-five per cent. of that in the male, is not so disproportionate as in the Gorilla and Orang in which the percentages are respectively eighty-five and ninety. In the very young animal the preponderance of the cranium over the facial skeleton is still more marked.

The skull of the Chimpanzee is frequently used as a standard wherewith those of Man, both living and extinct, are compared, so its characters are of particular interest to the Anthropologist. Moreover, it has been shown that the skull of the young animal, with its ovoid cranium, slightly prognathous jaws and diminutive supra-orbital crests resembles the restored Piltdown skull; whereas the adult skull, with its prominent supra-orbital crests and jaws, resembles that of the Neanderthal Man. A full discussion of these points is beyond the scope of the present volume, but the reader will find them described and figured in the "Guide to the Fossil

* The skull has been described in whole or in part in papers 4, 14, 15, 20, 53, 59, 92, 109, 122, 306-309, 313, 327, 343, 365, 374, 380, 402, 405, 426, 452.

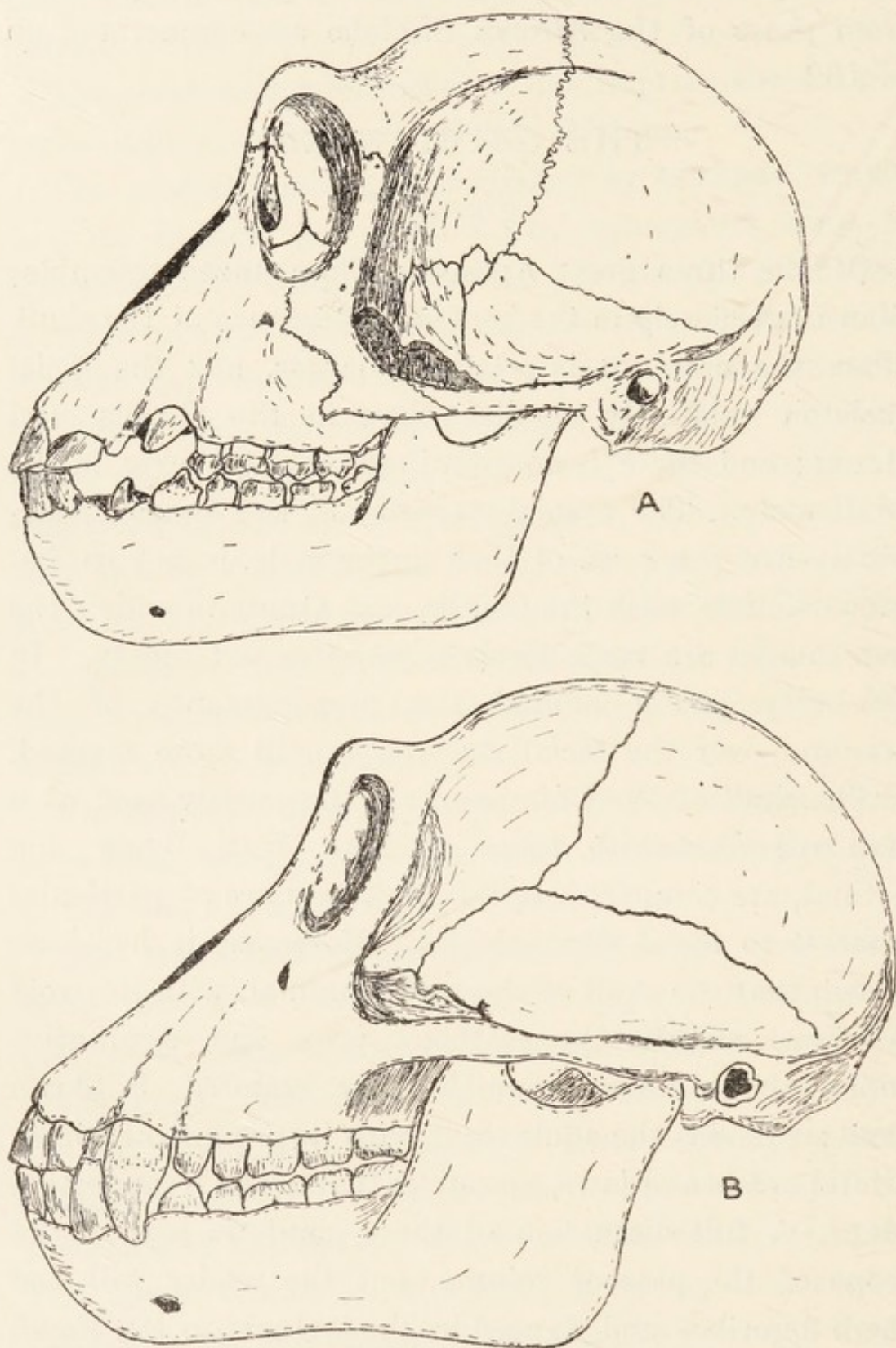


FIG. 23.—Skull of young (A) and adult (B) Chimpanzees. Note the Wormian bone in the pterion in the young animal.

Remains of Man in the British Museum" (Natural History).

When viewed from above the skull presents an oval **outline**. The profile is characterized by a flattened vertex rising to a variable, but never great, height above the well-marked supra-orbital crests. The face is sometimes simognathic, but never to such a degree as in the Orang.

In a young skull the **temporal ridges** run horizontally backwards from the external angular processes of the frontal bone. In adult animals they converge and run together along the vertex, diverging later to pass round to the caudal end of the zygoma. Owen (374) figures a skull where they meet in the mid-line of the head. The coronal, sagittal and lambdoid sutures may be very tortuous, and Wormian bones may lie along the latter. In the small animal whose skull is shown in fig. A, there is a large triangular bone in the lambda, and several small ones in the lambdoid suture.

Norma Frontalis.—The **supra - orbital crests**, which are well marked, are thrown into prominence by the flattening of the vertex. They meet across the nose as in the Gorilla, whereas they are discontinuous in the Asiatic Simiidæ. Laterally they meet the prominent external angular processes of the frontal bones. As age advances they increase in size, and the orifice or notch, through which the supra-orbital vessels and nerve pass, becomes better marked.

The **orbital apertures** are quadrangular, with rounded angles as in the Gorilla; and the transverse diameter exceeds the vertical. The walls are complete, and the foramen rotundum may be seen in some skulls at the

hinder end of the inferior orbital fissure. The **optic foramen** is separated from the foramen lacerum anticum, and the **spheno-maxillary fissure** is long and narrow. The **lachrymo-ethmoidal suture** is small, the **lachrymal hamulus** is vestigial, and in some skulls small ossicles lie in the sutures round the ethmoid bone. The naso-lachrymal duct is wide.

The **inter-orbital distance** is wide as in the Gorilla and Gibbons, whereas it is narrow in the Orang.

The **anterior narial aperture** is pyriform or ovate, with the narrow end uppermost. It is bounded above by the lower border of the fused nasal bones, and below and laterally by the pre-maxillæ, which rise up to meet the nasals and exclude the frontal processes of the maxillæ. Owen (374) records the pre-maxillæ as not reaching the nasal bones in an immature skull. The anterior nasal spine is rarely present, Keith (100) stating that it was seen by him in five out of forty-three skulls; but the suture between the pre-maxillæ is often seen.

The **infra-orbital foramina** vary considerably; and a large orifice shows some trace of a division in most skulls; the septum within the main foramen may be complete. Keith (100) states that the partition is vertical in the Gorilla and horizontal in the Chimpanzee, but that is not strictly true. The very first Chimpanzee skull examined by myself had a vertical septum in the infra-orbital foramen. Additional foramina may be present alongside the main orifice; and foramina for the zygomatico-facial vessels and nerve are always present on the flat malar bones.

The **nasal bones** fuse at or soon after birth to form a quadrilateral bone, and the lower borders of the conjoined

bones are not lower than the inferior margins of the orbits. Sometimes there is a well-marked ridge on the outer surface of the fused nasals. Keith (100) has pointed out that the nasal bones are never longer than 25 mm. in the Chimpanzee, whereas they are much longer in the Gorilla. The suture between the frontal and nasal bones is extremely irregular, and in some skulls there is almost an appearance of numerous Wormian bones.

Norma Lateralis.—The temporal fossa is deepened, as in the Orang, by the tunnelling of the outer surface of the alisphenoid; but the arrangement of the bones at the **pterion** differs from that in both Orang and Gibbon. The frontal and squamosal meet at the pterion and separate the alisphenoid from the parietal. The zygoma usually passes directly backwards, but it is sometimes bowed outwards to a slight degree. It frequently exhibits, even in fully adult skulls, a remnant of the suture between the malar and temporal bones. The infra-temporal crest is often represented by a single spinous process.

Norma Basalis. — The bony **palate** undergoes marked changes as age advances; and Keith (100), from the examination of a large amount of material, has come to the following conclusions: At birth the width of the palate between the outer margins of the alveoli is greater than the length as in Man; but the reverse is the case in the Gorilla, the length exceeding the width. In the adult male the width is sixty-three per cent. of the length, whereas it is seventy-seven per cent. in the Gorilla. The form of the palate seems also to vary with age; in the young animal (fig. 23, A) the sides are more

parallel than in the adult (fig. 23, B). The **maxillary premaxillary** suture is straight, and passes through several foramina; and the anterior palatine foramina are separate or confluent. The suture may vanish in adult skulls; but the suture between the maxillæ may remain. The **posterior palatine foramina** are on the horizontal parts of the palate bones. The posterior palatine spine is variable, being large, small or absent; and there are two small tubercles, one on each side of the middle line, between the posterior foramina. Owen (374) regards these eminences as characteristic of the Chimpanzee; so they help to distinguish it from the Gorilla.

The **pterygoid fossæ** are long, narrow and deep, and the hamuli are long and slender.

There is no tympanic bulla. The **glenoid fossa** is shallow, but slightly concave from side to side. The endo-glenoid tubercle is of moderate size, but the post-glenoid process is small. The mastoid process is a rough ridge, but styloid and vaginal processes are usually absent. The Eustachian process is common as in the Gorilla.

The orifice of the **carotid canal** is more oblique than in the Orang, and the anterior condyloid foramina vary from one to three in number. In several skulls the number is different on the two sides. The jugular foramen is well marked.

The **foramen magnum** is situated far back on the basis cranii. It varies in outline in different skulls, but the shape cannot be regarded as an age or sex peculiarity. Probably it is an individual peculiarity.

The **occipital condyles** are small, and their long axes diverge at different angles in different skulls.

The suture between the basi-occiput and basi-sphenoid is sinuous. Its width decreases as age advances, till there is no trace present in old animals. In all skulls examined by me there is a small foramen in the basisphenoid.

The median vertical occipital crest varies in prominence with age and sex. Thus it is small in the immature male, large in the adult male and small or absent in the adult female.

On making a vertical section through the skull the **air-sinuses** which excavate some of the bones make their appearance (fig. 47). The frontal sinuses (F.S.) are narrow and communicate with the inferior meatuses of the nose by the naso-lachrymal ducts. The sphenoidal sinus (S.S.) is large, undivided and excavates deeply into the alisphenoids; it communicates with the postero-superior part of the nasal fossa. When the turbinate bones are removed the antrum of Highmore makes its appearance. It is an irregular cavity with buttresses projecting into it; and its floor has elevations produced by the sockets of the incisor, molar and canine teeth. No mastoid antrum is present.

When the calvarium is removed the **cranial cavity** appears ovoid in outline, with the narrow end anterior. The anterior fossa is considerably reduced by the convex roofs of the orbits. Between the orbits there is a deep fossa, at the bottom of which the cribriform ethmoid plate is very obvious. There is a slight median antero-posterior crest on the cribriform plate, but no marked crista galli is present.

The lateral parts of the **middle cranial fossa** are deep towards their medial parts. The anterior clinoid processes are well marked, but are situated some distance

anterior to the posterior clinoid processes. The sella turcica is shallow or absent, but the surface for the pituitary body appears like a platform raised above the deep lateral parts of the middle fossa.

The **tentorial ridge** extends back to the internal occipital protuberance; it does not stop at the back of the petrosals as in the Orang. The posterior cranial fossa is deepest laterally, where its floor is grooved for the lateral sinuses; and either sinus may be the larger. The fossa is bounded behind by the occipital plane of the skull, and as the foramen magnum is slightly extended on to this plane the posterior part of the fossa is small and flat. This feature, which is common to all the Apes, distinguishes them from Man.

A line drawn back along the cribriform plate, if raised up to the level of the mouth of the pit between the orbits, will be continuous with one drawn along the basi-sphenoid and basi-occipital.

Keith (100) points out that the average cranial capacity of ten females is 364 c.c., and of sixteen males 405 c.c. But the cranial capacity does not help us to distinguish between the different varieties of Chimpanzee.

Mandible.—The ramus is broad, but not so large as in Simia. On its upper border a shallow sigmoid notch separates the sharp, recurved coronoid process from the condyle. The inclination of the ramus and body vary, being more vertical in the young animal. The outline of the lower border of the body varies considerably with age and sex. The symphysis slopes backwards; towards the lower part of its posterior surface there is a genial fossa in which the genio-hyoid and genio-glossus

muscles take origin; and several foramina are seen on this surface of the mandible, the largest being in the floor of the genial fossa. There is only one mental foramen on the exterior of the body of the mandible. Below the genial fossa the halves of the mandible are united by a ledge of bone known as the simian shelf. The mylo-hyoid ridge is small.

THE GORILLA. (Fig. 24).*

The skull of the Gorilla resembles that of the Chimpanzee in many points in which both differ from the skulls of the Asiatic Simiidæ. And there are some features in which it resembles the skull of Man and differs from those of all other Apes.

The skull is absolutely larger than that of the Chimpanzee, and the facial part is relatively larger than the cranium. The sexual differences too are greater, the female cranial cavity being 85 per cent. of that of the male, whereas it is 95 per cent. in the Chimpanzee.

Norma Frontalis.—When the skull of an adult male is viewed from the front two features become obvious at once. The temporal ridges converge on the frontal bone behind the massive supra-orbital crests and unite to form a high sagittal crest.

The only other Ape which exhibits a **sagittal crest** is the adult male Orang, but it is never as large as in the Gorilla. The crests and ridges increase as age advances

* The skull has been described in whole or in part in papers 14, 15, 17, 20, 44, 50, 53, 59, 87, 92, 109, 122, 343, 405, 421, 426, 431, 440, 447, 451, 452, 456, 460, 461, 480, 481, 485, 499, 500, 502, 503, 505, 506.

to give an extended origin to the powerful temporal muscles. The supra-orbital crests meet across the nose as in the Chimpanzee, but they are more massive, and the conjoined upper borders give a straight outline to

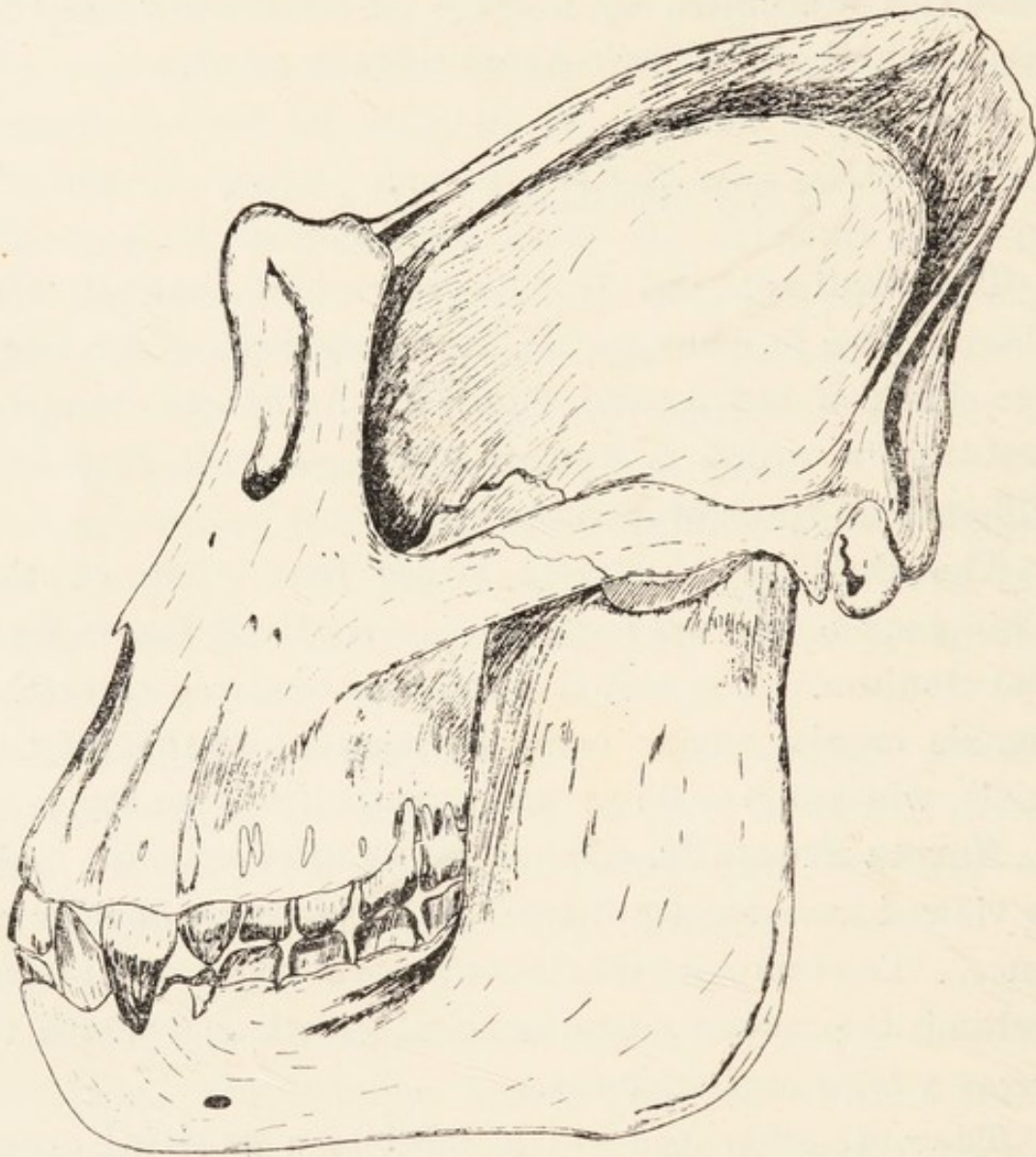


FIG. 24.—Skull of the adult male Gorilla

the upper part of the face. Moreover the characters of this crest and the shape of the malar bones and jaws make the face look square-cut.

The **orbital contour** approaches that in Man, in

whom it tends to be square, with rounded angles. It differs from the oval form in the Orang, and the more circular outline in the Gibbons and Chimpanzee. Owen (374) regarded this feature as of considerable value for taxonomic purposes, as it does not appear to be an adaptive character. The inferior margin of the orbit is bevelled off, whereas it is sharper and more defined in the Chimpanzee. Within the orbit the **lachrymo-ethmoidal suture** is present in about a third of a large number of skulls, whereas a fronto-maxillary suture is present in two-thirds. The **lachrymal hamulus** is vestigial or absent. The **infra-orbital canal** is open from the commencement to the point where it passes through the maxilla on to the face; in the Chimpanzee it is bridged over to a variable extent. The infra-orbital foramen is relatively lower down than in the Chimpanzee, and is divided into two or more foramina by vertical bars of bone.

The **inter-orbital width** is great, as in the Chimpanzee, being about the same size in both; and it is larger in the male than in the female.

The **nasal bones** are never less than 40 mm. long (Keith), and extend well below the inferior orbital margin, whereas they never exceed 25 mm. in the Chimpanzee. Their upper extremities pass into the interfrontal suture, whereas they do not in the Chimpanzee.

Some skulls have a **median nasal crest**. The form of the conjoined nasal bones is shown in fig. 21, B; and it will be seen on comparing it with those in figs. 21, C and 21, D that an approach to it is met with in some Chimpanzees, but in no Orang.

The **nasal aperture** varies in shape, being ovoid or

pyriform. It is bounded above by the lower border of the conjoined nasal bones, and below and laterally by the premaxillæ, which extend upwards to meet the nasal. The **anterior nasal spine** is very frequently, but not always, absent. And small tubercles may be found in this region; these, however, must not be regarded as nasal spines. At the sides of the lower part of the narial aperture the sockets for the upper canine teeth form pronounced swellings. In young skulls the **maxillo-premaxillary sutures** are evident running parallel to the nasal margin. The premaxillæ are about the same size as those in the Chimpanzee, but their anterior surfaces are not so undulated by the sockets of the incisor teeth in the Gorilla.

The **malar bones** are convex outwardly. Their vertical extent is greater than the transverse, whereas the reverse is the case in the Chimpanzee.

Norma Lateralis.—When the skull is viewed from the side the great size of the jaws compared with the cranium is at once evident, and the size of the cranium appears dwarfed by the temporal, sagittal and lambdoid cristæ. The size of these cristæ depends on age and sex, and Rothschild (485) shows that the characters are of value for distinguishing between sub-species (see page 101). In the very young skull the **temporal ridges** run backwards without meeting. As age advances, co-existent with the enlargement of the jaws and temporal muscles, the ridges approach and meet on the sagittal line. In the female they unite to form a small sagittal crest or a series of ridges and furrows. They form a marked crest in the male which varies from 20-45 mm. in height (Duckworth); but a height of 40-45 mm. is not very common.

Although the crests increase as age advances it is not an absolute rule that the older animal has always the larger crest.

The lambdoid crest varies in size, but the infra-temporal crest is small.

The **zygoma** is strong and massive, and its malar and temporal parts are of equal depth; but in the Chimpanzee it is slender, and its temporal part is narrower than its malar component. The **temporal fossa** is wide, its depth being further augmented by the channelling of the alisphenoid. The latter does not unite with the parietal bone at the pterion, but is excluded from it by the articulation of the frontal with the squamosal. In this the skull agrees with that of the Chimpanzee, but differs from those of Man and the Asiatic Simiidæ.

The **spheno-maxillary fissure** is narrow, as in the Chimpanzee, but is not so curved. The **external auditory meatus** is the same size as in the Chimpanzee, so it is smaller relatively to the size of the skull in the Gorilla.

Norma Basalis.—The bony palate differs in its general proportions from that in the Chimpanzee; its length predominates over its width, whereas the reverse is the case in the latter.

The premaxillary part of the palate is relatively longer, and the anterior palatine foramina are relatively smaller in the Chimpanzee. The absolute palatal area in the Gorilla greatly exceeds that in the Chimpanzee; thus Keith (**100**) found that the average area in seven adult male Gorillas was 7,200 mm., in fifteen adult male Chimpanzees it was 4,580 mm., in seven adult female Gorillas it was 5,600 mm., and in eleven adult female

Chimpanzees it was 4,200 mm. Hence the sexual differences in the palatal areas, like the cranial capacities, are more marked in the Gorilla. The posterior part of the palate shows variations.

The palatal processes of the palate bones may not unite, thus giving rise to a cleft palate; or the vomer or maxilla may separate the plates. The tuber maxillare may be large, and the posterior nasal spine occurs in about thirty-three per cent of skulls.

The **pterygoid region** varies considerably. The external pterygoid plate is small, and frequently exhibits a ridge, fossa, or pterygo-spinous foramen on its outer side. The hamular process on the internal pterygoid plate is slender and tapering, or replaced by a quadrate mass of bone. The scaphoid fossa may be very long.

The **glenoid fossa** is shallow, and there is a small endoglenoid process. The **mastoid processes**, which are definite and not represented by a rough ridge as in the Chimpanzee, are cellular with a thin wall. Owen (374) considered that the contemplation of this feature alone would lead the observer to conclude that the Gorilla may adopt the erect posture frequently, and comes nearer to Man than the other Anthropoids. The tympanic process has a vaginal ridge, and in some cases there is a distinct vaginal process as in Man. The styloid process is small.

The **occipital condyles** are frequently entire, but in some cases they are divided by longitudinal or transverse fissures. And a third occipital condyle appears occasionally. There may be as many as three anterior condyloid foramina.

Interior of the Skull.—The **olfactory fossa** is

relatively deeper in the Gorilla than in the Chimpanzee, and the crista galli is rudimentary or absent. At the sides of the fossa the roots of the orbits bulge up into the anterior cerebral fossa, but the roofs are more convex in the Chimpanzee. No ridge runs up from the fossa on the deep surface of the frontal bone as in the Chimpanzee. The **presphenoid** is grooved by the optic chiasma to a greater depth than in the Chimpanzee, and the sella turcica is overhung by the posterior clinoid processes. The cranial bones are considerably lightened by an extensive system of sinuses.

The **frontal sinuses** are separated by a septum. The **sphenoidal sinus** may be entire or subdivided and extends into the alisphenoids and pterygoid plates as in the Chimpanzee. The **antrum of Highmore** is large, and Owen (374) described it as follows: "The vast antrum extends to the floor and inner wall of the orbit and into the malar bone; it communicates with the nostrils by a wide aperture, overarched by the inferior turbinal, and sometimes also by a smaller opening overarched by the turbinal process above. Its walls being broken away on the left side in the skull of an old male Tr. Gorilla, shows what appears to be the convex back part of a second wall of the antrum, about half an inch from the outer one, and which is cribriform or reticulate; a portion of this convexity, removed vertically on the right side in the same skull, revealed light and delicate osseous texture . . . delicate bony plates and threads interlaced . . . and formed a reticulated inner wall."

The **mandible** is very massive, and its rami only diverge slightly. The ascending ramus is high and a

shallow sigmoid notch separates the recurved coronoid process from the condyle.

The coronoid process is loftier than the condyle, unlike that in Man. The symphysis menti is receding and bears a genial ridge on its posterior surface. The digastric and mylo-hyoid impressions are slight, but the latter is better marked than in the Chimpanzee.

The skull of the Gorilla differs from that of the Orang, and approaches the human skull in the following characters :—

1. The cranial part is larger in proportion to the facial part.
2. The foramen magnum is more advanced in position.
3. The supra-occipital forms a smaller angle with the basi-occipital.
4. The mastoids are processes instead of rough ridges.
5. There is a vaginal process.
6. The glenoid cavities are deeper.
7. The posterior nares are wider.
8. The zygomata are shorter and straighter.
9. The foramen ovale more completely perforates the alisphenoid.
10. Spheno-maxillary fissure is wider.
11. The orbits are squarer.
12. The upper parts of the nasal bones are more prominent.
13. The muzzle is narrower and less produced.
14. The inter-orbital width is greater.
15. The sella turcica is wider.
16. There are true frontal sinuses.
17. The orbital roofs are not so convex.

The Orang differs from the Gorilla and approaches Man more closely in the following characters :—

1. The calvarium is more convex.
2. The supra-orbital crests are smaller and separate.
3. The formation of the pterion.

4. The lachrymal bone is squarer.
5. The pterygoid fossæ are deeper.
6. The sphenoidal air sinuses are more restricted.

The skull of the Gorilla differs from that of Man in the following respects :—

1. The cranial part is relatively smaller and the facial part relatively larger.
2. There are sagittal and lambdoid cristæ.
3. The supra-orbital crests are large and confluent.
4. The lachrymo-ethmoidal junction is small.
5. The nasal bones are longer and anchylosed.
6. The premaxillæ are larger, and part of the maxillo-premaxillary suture persists.
7. The zygoma is stronger and relatively shorter.
8. The infra-temporal crest is reduced.
9. The alisphenoid does not meet the parietal in the pterion.
10. The external auditory meatus is smaller.
11. The supra-occipital is broader and lower.
12. The foramen magnum is larger, more oblique and farther back.
13. The occipital condyles are relatively smaller.
14. The basi-occipital is longer, and the suture between it and the basi-sphenoid persists.
15. The glenoid fossa is shallower and the post-glenoid processes are larger.
16. The mastoid and vaginal processes are smaller, and the styloid process is also smaller when present.
17. The ramus of the mandible is longer and the symphysis slopes backwards.
18. The vitreous table of the skull is better defined in some places.
19. The sphenoidal air-sinuses and antrum of Highmore are larger.
20. The olfactory fossa of the skull is larger, but the crista galli is rudimentary or absent.
21. The middle and posterior fossæ of the skull are smaller.
22. The sella turcica and posterior clinoid processes are small or absent.

23. The cribriform plate of the ethmoid bone is not so high above the foramen magnum.
24. The greatest longitudinal diameter of the cranial cavity runs between the glabella and the internal occipital eminence; in man it runs to a point above the eminence.
25. The cribriform plate of the ethmoid is level with the lower part of the orbit; in Man it is level with the middle of the orbit.
26. The nasal cavities are relatively longer.
27. The plane of the floor of the nose is parallel to the lower border of the basi-sphenoid and basi-occipital; in Man it forms an angle of forty-five degrees with them.
28. A line drawn back along the cribriform plate to the posterior clinoid processes in Man makes an angle of ninety-five degrees with one drawn on the cranial surfaces of the basi-occiput and basi-sphenoid. In the Gorilla the angle is described as 180° .
29. There is a simian shelf on the mandible.*

VERTEBRAL COLUMN, PELVIS, STERNUM AND RIBS.†

The **vertebral column** in the Apes differs from that in Man in its curvatures, in the characters of some of the bones, and in the number of rib-bearing elements. Its axis is never absolutely vertical as in Man, but it is oblique even when the Ape is erect.

In all Apes there are **seven cervical vertebræ** with capacious vertebral foramina. The spinous processes are long, and their free extremities are sometimes expanded. In Man some of the spinous processes are bifid, but the only approach to this in the Apes is the presence of two

* The Piltdown skull (*Eoanthropus*) has a marked simian shelf.

† The axial skeleton is described in papers 20, 25, 39, 40, 44, 55, 59, 122, 162, 188, 253, 269, 276, 461, 473, 494.

backwardly-directed processes from the apex of the spine of the axis. In the Siamang, as in Man, some of the spinous processes are directed downwards and backwards, but they are horizontal in the larger Simiidae.

As there is no **ligamentum nuchæ** the muscles attached to the spinous processes are more numerous than in Man.

In some specimens of the Chimpanzee the transverse process of the **atlas** is grooved, but not perforated; and in some Orangs the axis is grooved. But if many skeletons are examined it will be found that every species of Ape may have complete perforations of all the cervical transverse processes.

The number of **thoraco-lumbar vertebræ** is sixteen to eighteen. Of these, thirteen bear ribs in the Gorilla, Chimpanzees and Gibbon, but twelve have ribs attached to them in the Orang. In all cases seven ribs are attached to the sternum. These numbers, of course, are not absolute, for the addition or subtraction of a rib to the number which is most common is occasionally met with.

Treadgold has given the averages arrived at from the study of many Apes.

The number of lumbar, caudal and sacral vertebræ are as follows:—

| | | |
|------------|-----|--------------------------------|
| Gibbon ... | ... | L5, S3, C4 |
| Siamang | ... | L4, S3 |
| Orang ... | ... | L4 or 5, S5 or 6, C2 or 3 |
| Chimpanzee | ... | L3 or 4, S5 or 6, C2 or 3 |
| Gorilla... | ... | L4 or 3, S6—Coccyx rudimentary |

The **sacrum*** is relatively wider in the Siamang than

* The sacrum is described in papers 320, 377.

in other Gibbons, and it is relatively wider in the Orang than in the Chimpanzee and Gorilla. In the Gorilla the neural foramina are relatively smaller than in Man. In the African Simiidæ the first sacral vertebra corresponds to the fifth lumbar vertebra in Man. Cunningham (39) has shown that a forward curvature of the lumbar region of the vertebral column is not a human character, for it is present in all the Apes. It is, however, feeble in the Orang. In the Chimpanzee it includes one or two sacral vertebræ; it is developed at an early age, and it becomes as strong as in Man. No promontory of the sacrum separates it from the very slightly concave sacrum. In the Gibbon it includes the five lumbar vertebræ, and a slight promontory limits it below. The Gorilla also has a lumbar curve, but at present it is not possible to give accurate details of its characters. The size of the lumbar curve is inversely proportional to the degree of extensibility of the hip-joint.

The **vertebral ligaments** are very elastic, particularly the ligamenta subflava in the Gibbon; and this is of assistance in springing.

Pelvis (fig. 25).—The iliac bones in the Apes differ considerably from those in Man, but those in the Gorilla differ least. In the Gibbon they are prismatic and elongated, and the coarse ischial tuberosities support the ischial callosities; the tuberosities are not so flat as in the Drill and Mandrill.

In the Chimpanzee (fig. 26) the ilia are wider and flat, but they are wider and slightly concave in the Gorilla. The long axis of the pelvic cavity is antero-posterior in the Apes, and transverse in Man. The ischial spine is

small or absent in the Apes. The large ilia, wide pelvis and well-marked ischial spines are parts of Man's equip-

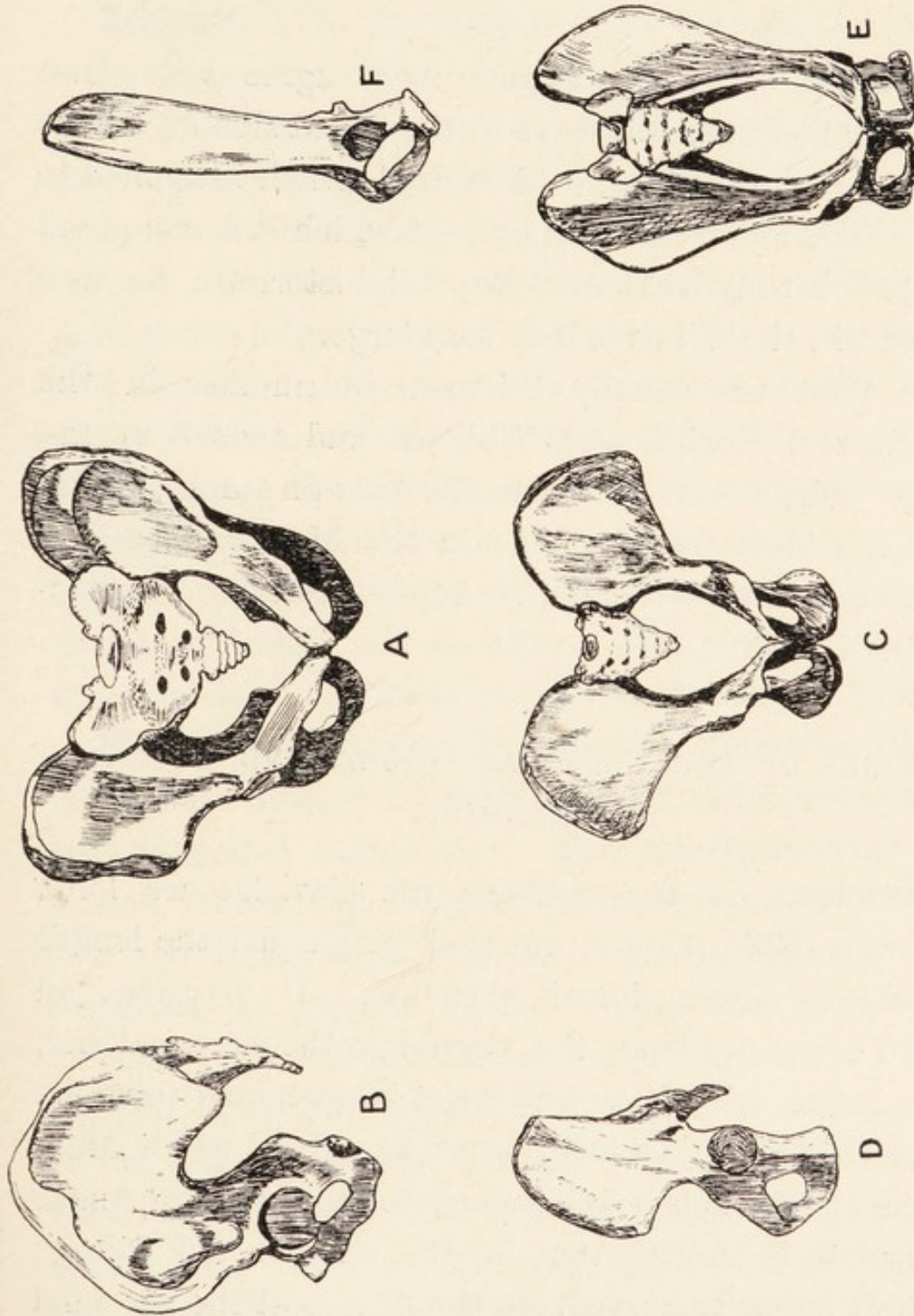


FIG. 25.—The pelvis in Man and the Apes.—A B, Man; C D, the Gorilla; E F, the Gibbon.
The pelvis of the Chimpanzee is shown in fig. 26. (After Huxley.)

ment whereby he maintains an erect attitude. And the characters of the pelvis make most approach to his in the Gorilla, which frequently assumes an erect attitude.

A line drawn between the anterior extremities of the ischial tuberosities passes in front of the vulva in the Chimpanzee, but it runs between the vulva and anus in Man.

Sternum.—The Anthropoid Apes agree with Man and differ from the Monkeys in the possession of a wide sternum, hence the name *latisternal* which is applied to them. The individual *sternebræ* of which it is composed may be distinguishable. The *xiphisternum* is well marked; in the Gibbons it is very large.

The **ribs** are usually thirteen in number in the Chimpanzee, Gorilla and Gibbons, and twelve in the Orang. Their curvatures give the Apes an ample thorax, which is widest transversely; in the Monkeys the long diameter of the thorax is antero-posterior (*ventro-dorsal*).

BONES OF THE PECTORAL GIRDLE AND UPPER EXTREMITY.

Clavicles.—In the Gibbons the clavicles are long, and Owen (122) pointed out that they equal the length of the first eleven dorsal *vertebræ*. It describes an upward convexity from the sternal to the acromial end, which is flat, triangular and has a large conoid tubercle. In the Orang the clavicle is not so curved as in Man, and the distal end is not so expanded. In the Chimpanzee the clavicle is shorter than in the Gibbon and Orang; the shaft is not so curved, but the flexure at the acromial end is more pronounced; the acromial end is less expanded, and the conoid tubercle is large. In the Gorilla the clavicle is thick, and the shaft is nearly

triangular on cross section; the flexure at the acromial end is less marked than in Man, but the acromial end is broader and flatter.

Scapula.—In the Gibbons the scapula is narrow, with large coracoid and acromion processes; and the spine divides the dorsum into nearly equal supraspinous and infraspinous fossæ. In the Orang it is nearly as wide as in Man, but the acromion is narrower and longer, and the spine is more vertical. The Chimpanzee has a long, narrow scapula, with strong coracoid and acromion processes; it is, therefore, similar to that of the Gibbon, but the suprascapular notch is narrower and deeper. The Gorilla has a broader scapula than the Chimpanzee, but it has no marked suprascapular notch; its spine is more oblique than in Man, and the coracoid process is longer and stronger. The glenoid fossa looks more obliquely upwards in the Gorilla than in Man.

Humerus.—In the Gibbons the humerus, like the radius and ulna, is a long bone with a delicate shaft and two expanded extremities. The intertubercular sulcus is well defined, but the pectoral crest is poor. No supracondylar foramen is present in young animals. Such foramina are present in the Orang, and in full-grown Gorillas, but are absent in the Chimpanzee. In the African Apes the humerus is strong, with well-developed crests, but the deltoid eminence is poor, whereas it is very well marked on the bone in Man. The lower end of the bone is wider than the upper end, it being one and a half times as broad as the upper end in the Chimpanzee. The back of the shaft is grooved for the musculo-spiral nerve in the Chimpanzee and Gorilla.

Radius and Ulna.—In the Gibbons these bones are

long and very slender, and the interosseous space is long and narrow; they are also long, and bound an extensive space in the Orang. And the African Apes have a wide space between the curved radius and ulna.

In the Chimpanzee the head of the radius is circular, and the lower end is massive, prismatic and deeply grooved by the extensor tendons. The roughness for the insertion of the tendon of the biceps is poor, but the interosseous ridge is sharp.

The ulna, on the contrary, has no interosseous ridge; its styloid process is very well marked. In the Gorilla the head of the radius is more elliptical, the bicipital tuberosity is better marked, and the cross section of the shaft is pyriform, the narrow part being produced by the interosseous crest. The lower end of the dorsal aspect is grooved by the extensor tendons. The ulna has a convex or reniform surface for articulation with the lower end of the radius.

The relative proportions between the length of the forearm and that of the arm have already been described in Chapter IV.

Carpus.*—The Gorilla and Chimpanzee have eight carpal bones arranged in two rows as in Man, but the Orang and Gibbons have nine bones, the extra element being termed the “os centrale” or “os intermedium” (fig. 21,B). In the Orang the scaphoid and semilunar bones articulate with the lower end of the radius, the cuneiform is connected to the styloid process of the ulna by a cord-like ligament, and the pisiform bone is large.

* The carpus has been described in papers 10, 42, 95, 122, 162, 217.

The os intermedium is situated between the scaphoid and semilunar bones proximally and the trapezoid and os magnum distally. The trapezium is small. A small sesamoid bone is present in the tendon of the abductor pollicis longus. In the Chimpanzee and Gorilla there is a deep carpal tunnel between the long pisiform bone and the equally long hook of the unciform on the medial side and the scaphoid and hook-like process on the trapezium on the lateral side. The long axis of the tunnel is directed towards the index and middle digits in the Chimpanzee. The trapezium is small.

Metacarpal Bones.—The metacarpal bone of the thumb is short, but those of the other digits are long and cylindrical.

The **phalanges** are flat, with concave palmar surfaces. In the Orang and Chimpanzee they are broader than the metacarpal bones.

BONES OF THE LOWER EXTREMITY.

Femur.—In the Gibbon the femur is long and the shaft is nearly straight. The head is globular, with an impression for the ligamentum teres about its centre. The neck is very short and oblique, and the trochanters are well marked.

The great trochanter reaches up to the level of the impression for the ligamentum teres. The linea aspera is a rough line on the upper three-quarters of the shaft. No adductor tubercle exists. The condyles reach down to about the same level, the inner one being slightly the longer ; and the outer one is convex and more prominent externally. In the Chimpanzee the small head with its

ligamentum teres is connected to the strong shaft by a comparatively slender neck; but the angle between them is not so wide as in the Orang. The trochanters are well marked, and the great trochanter reaches up to the level of the junction of the upper and middle thirds of the head. The shaft is slightly bent, but the linea aspera is variable. The internal condyle is wide, with an adductor tubercle; and the external condyle, whose articular surface is directed downwards and inwards, forms a semi-circle, which is not suitable for acting as a supporting agent like the more flattened condyle in Man. In the Gorilla the femur is shorter than in Man, and the neck is less oblique. The angle between the neck and shaft is 124° , whereas it is 128° to 141° in Man (Duckworth). The great trochanter rises up to the level to the top of the head. The small trochanter is farther from the great trochanter than in Man. The linea aspera is absent or poor, and confined to the upper half of the shaft, and the lower part of the shaft expands more gradually to the condyles than in Man. In the Orang there is no pit for the ligamentum teres.

The characters of the lower end of the femur are of great importance. The external condyle is larger than the inner one in man, but the reverse is the case in the Gorilla, Chimpanzee and Gibbon. The internal condyle reaches lower down than the outer one in Man, the Chimpanzee and Gibbon, but the outer one is lower in the Gorilla.

The Tibia and Fibula.—In the Gibbons the tibia is slightly curved, and the extremities of the fibula are almost equal. In the Chimpanzee the head of the tibia is relatively larger than in Man, and is inclined slightly

backwards; and the lower end of the fibula is relatively stronger than in Man.

Between the two bones there is a wider space than in Man. In the Gorilla the upper end of the tibia is very similar to that in Man, but the spine and anterior tuberosity are slightly larger. The internal tuberosity is also better marked, but the interosseous and subcutaneous borders are weaker. The articular surface of the lower end is shallower than in Man, and the surface for articulation with the well-developed lower end of the fibula is not concave. The latter bone has a flatter distal surface than in Man, and its two articular facets are well marked.

Bones of the Ankle and Foot.—The bones of the foot in the Gorilla are more for supporting purposes than in the Orang and Chimpanzee, in which they are more adapted for grasping and climbing; so they differ to a greater or less extent from those in Man. In the Gibbons the foot approaches that of Man more closely than does that of the Chimpanzee or Orang. The os calcis is very strong, and the hallux is relatively longer than in the other Apes. In the Chimpanzee the os calcis is relatively weak compared with that in Man, and it is transversely compressed. It projects farther back than in the Orang. The scaphoid projects farther down into the sole than in Man, and the internal cuneiform is rotated in the same way; the result is that the hallux is attached to the tarsus in a manner which allows it to be easily opposed towards the other digits. The whole foot is narrower than in Man, and it is also longer. And Vrolik (217) points out that these deviations from the human conditions are present, but to a still greater degree, in the Orang; and he

compares the physiological actions as similar to those in a club-foot of the varus variety. In the Gorilla the bones resemble those in Man more than do those of the other Apes, but still they deviate from the human state. And Owen (122) has compared them as follows :—

1. The calcaneum is longer and more slender than in Man.
2. The lower surface of the calcaneum is smooth, narrow, and longitudinally more concave.
3. The groove for the flexor tendons is wider.
4. The cuboidal surface is farther from the outer surface of the bone.
5. The navicular is wider transversely.
6. The entocuneiform is not so long, and it has a convex articulation for the hallux; the corresponding surface is flat in Man.
7. The metatarsal of the hallux is as long as in Man, but the proximal articular surface is more concave, and the distal one is more convex.
8. The proximal phalanx of the hallux is as long as, and the distal phalanx is smaller than in Man.
9. The remaining metatarsals are longer and stronger than in Man, the first and second phalanges are larger and more bent, and the ungual phalanges are longer and narrower than in Man.

THE TEETH.

In all Simiidæ the milk dentition consists of twenty teeth, but the permanent dentition consists of thirty-two teeth. The respective dental formulæ are :—

| | | | | | | |
|---------------------|-----|-----|---------|---------|----------|---------|
| Milk dentition | ... | ... | I_2^2 | C_1^1 | PM_0^0 | M_2^2 |
| Permanent dentition | ... | ... | I_2^2 | C_1^1 | PM_2^2 | M_3^3 |

DENTITION IN THE GIBBONS.

The **incisor teeth** are small and procumbent, with chisel-like cutting edges. The upper central incisors are

slightly larger than the upper lateral incisors, but the four lower incisors are more nearly equal. All the incisors have small crowns. The **canine teeth** are long and sabre-like. When the jaws are closed the lower canines pass up into diastemata between the upper canine and upper lateral incisor teeth. Owing to the locking of the canine teeth there is no great degree of lateral mobility in the temporo-maxillary joints.

The **upper premolar teeth** have three roots, of which two are external and one is internal. The first tooth has a large external and a small internal cusp; it is smaller than the second tooth whose cusps are nearly equal in size. The internal cusp is derived from the cingulum, which is a band surrounding the base of the crown. The first **lower premolar** tooth is larger than the second, but both have two roots lying anterior and posterior in position. The first has a large internal and a small external cusp, but the cusps of the second tooth are nearly equal.

The **upper molar teeth** have three roots placed like the roots of the upper premolar teeth. They decrease in size in the order 1, 2, 3; and their crowns are narrow mesially. There are four cusps on each tooth, and an oblique ridge connects the metacone and protocone. The protocone and paracone may be connected. The third upper molar tooth exhibits signs of degeneration. The **lower molar teeth** have anterior and posterior roots, and the middle of the crowns form basins for the reception of the inner cusps of the upper molar teeth. The second tooth is larger than the first and third. The crowns have five cusps.

The **enamel** of the post-canine teeth is not crenated or folded.

DENTITION IN THE ORANG-OUTAN.

The upper central **incisors** are much wider than the upper lateral incisors, but the crowns are all small as in the Gibbons. There is frequently a marked overbite. The **canines** form strong tusks capable of piercing the shells of fruits.

The **enamel** of the post-canine teeth is wrinkled and crenated, particularly on the lower molars. The wrinkling appears during development, and Gregory (509) regards it as an advanced specialization.

The **upper premolar teeth** are relatively stouter than in the Gibbons, and their antero-posterior diameter is less than the transverse. The first has a large outer and a small inner cusp, but the second tooth has nearly equal cusps. The first **lower premolar** is shorter than in the Gibbons, but longer than in the Chimpanzee; and its outer surface is abraded by the upper canine tooth. The first tooth has a large outer and a small inner cusp; whereas the second tooth, which approaches a molar tooth in character, has two nearly equal cusps.

The **upper molar teeth** have quadrilateral crowns and four cusps. The protocones and metacones are connected by oblique ridges; but the hypocones may be reduced, or replaced by small tubercles (Duckworth). The first and second teeth are equal in size and smaller than the third, which exhibits degeneration. The **lower molar teeth** are long and narrow, and have five cusps.

Supernumerary molar teeth are by no means uncommon in the Orang, as can be seen from a study of

the writings of Brühl (235), Bateson (12), Duckworth (50), Lucas (262), Maggi (266), Schmidt and Selenka (287).

The entire dental series varies considerably with age and sex, and there are probably many purely individual variations, so the foregoing account must be regarded as the average condition. The roots of the teeth are very long.

DENTITION IN THE CHIMPANZEE.

The upper central **incisors** are larger than the lateral incisors as in the Orang, but their crowns are large as in the Gorilla; and the central incisors may be absolutely larger than those in the Gorilla. The **canine teeth** are tusk-like as in the Orang and Gorilla, and the diastemata are similarly placed.

The **enamel** of the post-canine teeth is wrinkled and crenated, but it has not got the sharp crystalline form of the enamel in the Gorilla. This character, as Keith (100) points out, lends support to those who separate these Apes into two distinct genera.

The upper **premolar teeth** resemble those in Man more than the lower premolars. Both are bicuspid and small. The first has three roots, whereas the second has only two. And there is no sharp difference in size between the second premolar and first molar teeth in the lower jaw.

The **upper molar teeth** have four cusps, of which the hypocone is large. And the metacone may be connected to the protocone and hypocone by ridges. The inner root may be divided to a variable extent. The **lower molar teeth** have five cusps. The third molar tooth in

each jaw is reduced in size, the crowns are much wrinkled, and the cusps are small. The fifth cusp on the last molar tooth in the lower jaw is variable. The last molar tooth is really degenerating, so it cannot be used for taxonomic purposes.

Taking the dentition as a whole the Chimpanzee approaches Man more closely than does any other Ape.

Accessory teeth are less frequent in the Chimpanzee than in the Gorilla and Orang, and Duckworth (50) points out that this applies to both precanine and post-canine teeth. But no case of double-rooted canine teeth has been recorded in any of the Apes.

The actual order in which the permanent teeth erupt has not yet been established, but Keith (100) points out that the canine teeth usually erupt before the last molar teeth. The first permanent molar tooth is the first permanent tooth to appear. The permanent dentition is completed between the eleventh and thirteenth years, giving it as the eleventh or twelfth year, and Keith (100) as the twelfth or thirteenth year.

DENTITION IN THE GORILLA.

The upper central **incisors** are larger than the upper lateral incisors, but the disproportion is not so great as in the Orang and Chimpanzee. The crowns are large. The **canines** form large tusks which serve as formidable weapons. The diastemata are as in the other Apes.

The upper **premolar teeth** differ from those in the Chimpanzee in being equal in size; in the Chimpanzee the first is larger than the second. Each has three roots and two cusps, of which the outer is the larger; sometimes two minute cusps are present behind the

main ones. Both premolars are broad and oval in outline. The first lower premolar tooth is large and pyramidal; it has one large cusp, and its outer surface is worn and polished by friction against the upper canine tooth. The second lower premolar has two almost equal cusps lying in the labial and lingual positions.

The **upper molar teeth** have large, almost prismatic cusps, which are less crenated than those of the Chimpanzee and Orang; and the enamel is characterized by its crystalline appearance. The outline of the crowns is like the figure 8, with variations in the relative sizes of the anterior and posterior parts. The crowns have the usual four cusps, and the metacones and protocones are connected, except perhaps on the third tooth, which is degenerating. The teeth decrease in the order 2, 1, 3. There are three roots in each case. Keith (100) points out that any upper molar tooth over 12 mm. in length belongs to a Gorilla, and any upper molar under 12 mm. in length belongs to a Chimpanzee. The **lower molar teeth** are more elongated than in the Chimpanzee and Orang, and they increase in size in the order 1, 2, 3. Most have five cusps, but an additional sixth cusp may be present on the posterior part. The protoconid and metaconid may be connected by a crest.

The third molar and canine teeth usually cut together.

Dental anomalies, particularly supernumerary teeth, are more frequent than in the Chimpanzee.

Much assistance has recently been obtained in anthropological work from the examination of the teeth by X-rays, for that method has enabled us to settle whether

particular fossil teeth are human or simian. In the Anthropoid Apes, particularly the Chimpanzee, the roots of the molar teeth diverge widely and reach the dental canal ; and the small-pulp cavities are situated on the level of the necks of the teeth. In modern Man the roots of the teeth do not diverge much, nor do they reach the dental canal. The cavities are small and all lie above the alveolar border of the mandible, whereas they gradually sink lower down in the Apes in the order M1, M2, M3. In some fossil Men the pulp-cavities are very large, but the roots of the teeth do not diverge as much as they do in the Apes ; and the pulp-cavities all lie at the same level.

CHAPTER VI.

THE JOINTS.

Temporo-Mandibular Joint.—This joint has the same general structure as in Man, but the mandible moves in a shallower glenoid cavity. The capsule is thick and strong except on its anterior and inner aspects. Its cavity is divided into upper and lower parts by the meniscus, which is concavo-convex above and concave below. The disc, which is thicker in front, is attached in some Apes to the glenoid and post-glenoid processes. It is not perforated in the Orang and Chimpanzee. The external lateral ligament is strong in all Apes. The posterior temporo-mandibular, internal temporo-mandibular and stylo-mandibular ligaments are well defined, but the spheno-mandibular band is poor. The external pterygoid muscle is partly inserted into the capsule.

Vertebral Ligaments.—The anterior and posterior common ligaments run from the axis to the upper segment of the sacrum. The former is attached to the centra, but not to the intervertebral discs; and the latter is narrow on the centra and expanded on the discs. The supraspinous and interspinous ligaments are as in Man but the ligamentum nuchæ is absent or represented merely by a little fibrous tissue between the muscles. The ligamenta subflava are very elastic, as are the posterior costo-transverse ligaments. The inter-

transverse ligaments (fig. 26, I-T.L.) are fan-shaped, and run from the tip of the transverse process above to the upper border of the transverse process below.

Atlanto-axoid Ligaments.—In the Chimpanzee (fig. 26) a posterior atlanto-axoid ligament corresponds to the ligamenta subflava elsewhere; it is strengthened

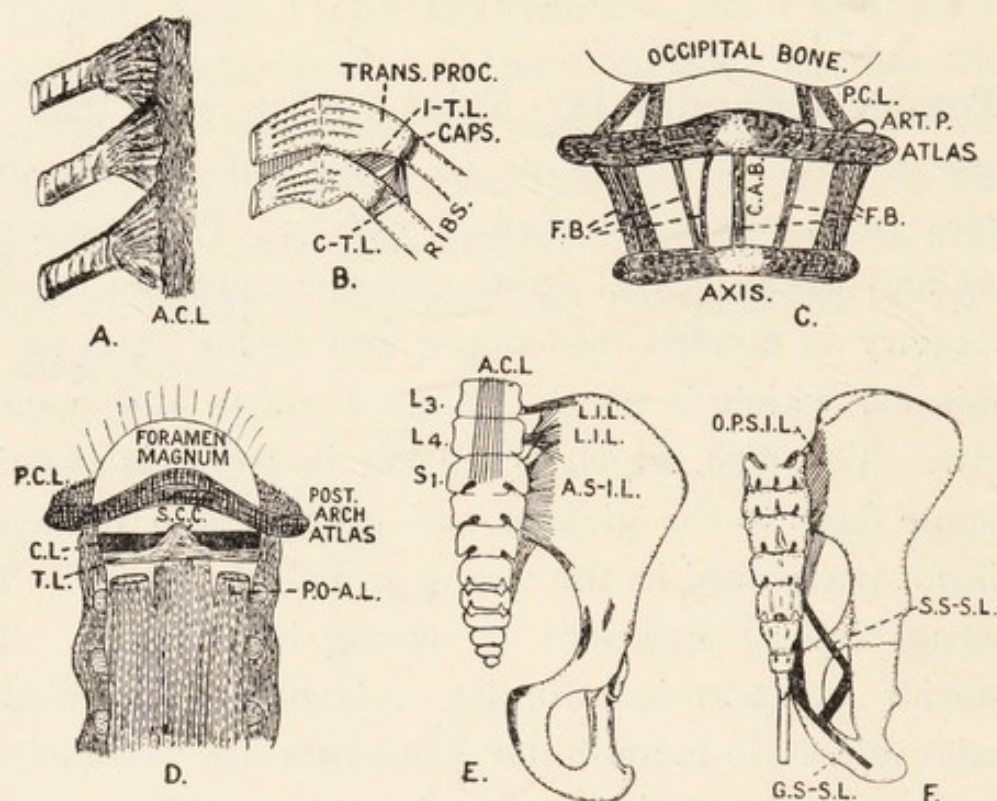


FIG. 26.—The spinal and pelvic ligaments of the Chimpanzee. A and B, costo-spinal joints; C and D, joints of the skull and vertebral column; E and F, pelvic joints; ART.P., articular process; CAPS., capsules; P.C.L., posterior capsular ligament; F.B., strengthening bands. Other letters as in text.

by a central (C.A.B.) and several small lateral strengthening bands. The anterior atlanto-axoid ligament corresponds to the anterior common ligament elsewhere.

Joints of the Occipital, Atlas and Axis.—The anterior occipito-atlantoid ligament is a strong membrane corresponding to the anterior atlanto-axoid ligament.

It runs between the arch of the atlas and the anterior margin of the foramen magnum. The membrana tectoria continues the posterior common ligament to the cranial surface of the basi-occipital bone. And the posterior occipito-atlantoid ligament runs from the posterior arch of the atlas to the posterior border of the foramen magnum; it is strengthened by accessory bands. The posterior occipito-axoid ligament (fig. 26, P.O-A.L.) is a strong band on each side on the deep aspect of the membrana tectoria. It passes lateral to the odontoid process and conceals the spinal aspect of the transverse ligament (T.L.). The latter runs between the inferior atlantic articular processes, and passes behind the odontoid process. The cruciate ligament has no inferior crus in the Chimpanzee, but the superior crus (S.C.C.) is shorter and broader than in Man. The middle odontoid and check (C.L.) ligaments are more horizontal than in Man.

Costo-vertebral Ligaments (fig. 26).—The head of each rib is connected to the anterior common ligament of the spine by a fan-shaped ligament (A.C.L.). Superior, middle and posterior costo-transverse ligaments are present, but the first and third are weaker than in Man.

Ligaments of the Pelvis (fig. 26, F).—In the Chimpanzee the lumbar vertebræ are included more closely between the ilia than in Man. The lumbo-inguinal ligaments (L.I.L.) consist of an upper horizontal and a lower fan-shaped band connecting the transverse processes of the third and fourth lumbar vertebræ to the inner lip of the iliac crest and the anterior surface of the dorsum ilii. The surfaces of the sacrum are connected

to the surfaces of the ilium by the sacro-iliac ligaments, of which there are three—an anterior ligament (A.S-I.L.), a short posterior, and an oblique posterior (O.P.S-I.L.) ligament. The great sacro-sciatic ligament (G.S-S.L.) is a strong cord with expanded ends running from the sides of the lower sacral and coccygeal vertebræ to the ischial tuberosity; it sends a process forwards to the sub-pubic ligament, and a band connects it to the rudimentary ischial spine. The small sacro-sciatic ligament (S.S-S.L.) runs from the lower end of the sacrum to the ischial spine. The symphysis pubis has the same ligaments as in Man. Keith (96) does not draw attention to any points in which the other Apes differ from the Chimpanzee in the characters of the pelvic ligaments; he mentions the suggestion that the great sacro-sciatic ligament represents an ancient part of the tendon of origin of the biceps flexor cruris, but he regards it as part of the great lateral intermuscular septum. The curvatures of the vertebral column are described on page 136.

The **Shoulder-joint.**—The ligamentous structures are more complex in the Chimpanzee than in the other Apes. In that animal there is a well-marked superior gleno-humeral ligament; it divides into two parts, which are attached separately to the humerus, and the sub-scapular bursa communicates with the shoulder-joint between them. Macalister (466) observed an inferior gleno-humeral ligament in the Gorilla. The posterior part of the capsule is weak and loose, but the anterior part has a broad anterior gleno-humeral ligament. Coraco-humeral and acromio-humeral ligaments are differentiated and the coraco-acromial ligament is well

marked. The insertions of the supra-spinatus, infra-spinatus and pectoralis minor are blended with the capsule. The cotyloid ligament and tendon of the biceps are as in Man. The range of movement of the shoulder joint is considerable.

The **sterno-clavicular joint** is much as in Man, and its meniscus may be ossified. The acromio-clavicular joint has a partial meniscus. The costo-coracoid membrane is strong, but it is not always possible to separate the coraco-clavicular ligament into conoid and trapezoid parts.

Elbow-joint.—Keith (96) does not draw attention to any essential difference between this joint in the Apes and that in Man; and Fick (247) points out that the ligaments are similar in the Orang and in Man. In the Chimpanzee the posterior part of the capsule has a strong band running from the tip of the olecranon to the outer part of the olecranon fossa; the anterior part of the capsule is strong by reason of the interlacing fibres which compose it. The internal lateral ligament is very powerful, and is stronger than the external lateral ligament.

Superior Radio-ulnar Joint.—The only point of difference between this joint in the Chimpanzee and that in Man is the absence of the oblique cord. Keith (96) points out that it is strong in the *Quadrumana* examined by him.

Wrist-joint.—In the Chimpanzee both aspects of the carpus are covered by ligaments, but there is no centre of radiation. The following bands deserve mention:—

- (1) A strong band from the base of the radial styloid process to the trapezium and os magnum.
- (2) A weak external lateral ligament.

- (3) A small internal lateral ligament.
- (4) A band from the back of the distal radio-carpal joint to the os magnum.
- (5) A band from the back of the radius to the cuneiform and uncinatæ bones.
- (6) Three interosseous ligaments.

The cavity of the joint (fig. 35, B) is complicated. The distal end of the radius has two facets for articulation with the scaphoid and semilunar bones; and a strong ligament runs from the distal end of the ulna to the os pisiforme, which is large. The synovial cavity between the radius and the scaphoid and semilunar bones is prolonged into the inferior radio-ulnar joint and the joint between the cuneiform and pisiform bones. A large synovial cavity separates the head of the os magnum from the scaphoid, semilunar, cuneiform and unciform bones, and is continuous with the cavity between the scaphoid and trapezoid bones. This transverse carpal cavity is prolonged distally on both sides of the os magnum; it is continuous with the carpo-metacarpal cavity. The intermetacarpal joints have prolongations of the carpo-metacarpal cavity, and interosseous ligaments connect the metacarpals to one another.

The metacarpo-phalangeal, interphalangeal and pollical joints are much as in Man.

Hip-joint.—Keith (96) points out that the ilio-femoral, ischio-femoral and pubo-femoral ligaments are more prominent than in Man, but in one Chimpanzee the only differentiated band was the anterior part of the ilio-femoral ligament. The ligamentum teres is usually present in all Apes except the Orang, which has none.

Knee-joint (fig. 36, F).—The following account of

the joint in the Chimpanzee is applicable to that of the other Anthropoids. The external lateral ligament is as in Man, but the internal lateral ligament is fixed to the upper part of the internal surface of the shaft of the tibia. The oblique popliteal ligament is absent, but is replaced by a strong femoral intercondylar cord connecting the sesamoid bones which give origin to the heads of the gastrocnemius. Keith (96) points out that the oblique ligament terminates above in this cord. The anterior cruciate ligament is attached to the tibia as in Man, and its femoral attachment is to the upper half of the mesial aspect of the external condyle. The posterior cruciate ligament is attached to the tibia farther back than in Man, and it receives a slip from the external semilunar cartilage. The ligamentum mucosum is as in Man. The internal semilunar cartilage is large and crescentic; it is attached in front of the anterior cruciate ligament, and its posterior attachment is as in Man. The external semilunar cartilage forms a small, complete circle. Internally it is attached to the outer side of the tubercles and spine of the tibia. Postero-mesially it is attached to the outer surface of the internal condyle of the femur, and it is connected to the posterior cruciate ligament. Humphry (340) pointed out that the femur in Man is broad and comparatively flat on the distal end of the external condyle, and the lateral ligaments are attached nearer the posterior parts of the bone; so the joint is firm and locked when it is fully extended. Moreover, when the joint is fully extended the lateral, cruciate and posterior ligaments are tight. In the Chimpanzee the distal end of the external condyle of the femur is rounded, the external ligament is not attached far back,

and the ligaments do not all become simultaneously tight when the joint is fully extended.

Ankle-joint.—This joint has received considerable attention from Aeby (2), Humphry (340), Keith (96) and Sonntag (399). In the Chimpanzee the capsule is attached as in Man. The deltoid ligament is small and runs from the medio-distal aspect of the tibia to the sustentaculum tali and talus. The fibular calcanean ligament and tibial calcanean ligament are both well defined. The anterior and posterior talo-fibular ligaments are present, but the former is poor. An additional ligament runs from the anterior border of the distal end of the tibia under the talus to the distal tubercle on the calcaneus. There are four talo-calcanean ligaments—dorsal, posterior and two lateral—but the median ligament is weak; and the posterior one helps to form the interosseous ligament. A small ligament connects the plantar naviculo-calcanean ligament to the talus.

Calcanean Ligaments.—In the Chimpanzee these are two in number—(1) a plantar calcaneo-navicular ligament running from the sustentaculum tali to the navicular bone; (2) a calcaneo-cuboid ligament.

Cuboid Ligaments.—In the Chimpanzee the cuboid is attached by ligaments to the calcaneus, internal cuneiform and metatarsal bones. The long plantar ligament connects the cuboid to the bases of the second, third and fourth metatarsals, and a separate ligament connects it to the fifth metatarsal. Besides the ligament uniting it to the internal cuneiform bone there is an interosseous ligament between the cuboid and the cuneiforms.

Navicular Ligaments.—A dorsal ligament connects

the navicular to the second metatarsal bone, and an internal ligament binds it to the internal cuneiform.

Plantar Metatarsal Ligaments.—The long plantar ligament ends in fibres which also connect the sheath of the tendon of the peroneus longus to the bases of the third and fourth metatarsal bones. A band of fibres derived from the long plantar ligament runs to join the external plantar metatarsal ligament, which is an aponeurotic band on the fourth metatarsal bone. Another band from the long plantar ligament lies along the third metatarsal bone and forms the internal plantar metatarsal ligament.

Humphry (340) draws attention to the following points regarding the mechanics of the foot in the Chimpanzee :—

(1) The shape of the talus throws the weight on the outer border of the foot.

(2) The talus and calcaneus are more for support than progression.

(3) The calcaneus rolls outward on its lower surface.

(4) The calcaneus is reduced, like its homotype the pisiform, to a lever for muscles.

(5) The talus, navicular and calcaneo-navicular ligament transmit weight.

(6) The posterior surface of the talus slopes downwards and inwards.

(7) The action of the calf muscles on the foot is unfavourable for lifting weight or propelling the body.

(8) There is no plantar arch.

(9) The bones, joints and muscles of the hallux act like those of the pollex.

(10) The digits can be more strongly flexed than in Man.

It may be stated by way of a summary that the construction of the bones and joints of the vertebral column, pelvis and limbs are such that they permit Man to assume a permanently erect attitude, whereas they only allow the Chimpanzee and Gorilla to be erect for short periods only.

CHAPTER VII.

THE MUSCULAR SYSTEM.*

MUSCLES OF THE HEAD AND NECK.

THE **platysma myoides** (fig. 27A) is the sole representative of the cutaneous muscle which envelops the greater part of the body in lower Mammals. It arises from the superficial fascia over the pectoralis major and deltoid in the Chimpanzee and Gorilla. In the Orang and Gibbon its origin extends to the mid-dorsal line. The muscles of both sides are continuous in the middle line of the neck, and the fibres may decussate below the chin. Some fibres are inserted into the mandible, but most sweep into the face and blend with the labial muscles. When it contracts the lips are retracted and the teeth are exposed.

The **occipito-frontalis** varies individually, for the occipitales, frontales and epicranial aponeurosis differ in their relative sizes.

The **orbicularis oculi** (fig. 27A) consists as in Man of an orbital part surrounding the orbit and a palpebral part within the lids. These parts vary in size, and the former frequently sends a slip to the zygomatic mass. The orbital part arises from the nasal process of the maxilla and loops round the orbit; and the palpebral

* Variations in human muscles are described in papers 7, 8, 11, 76, 77, 79, 133, 156, 163, 164.

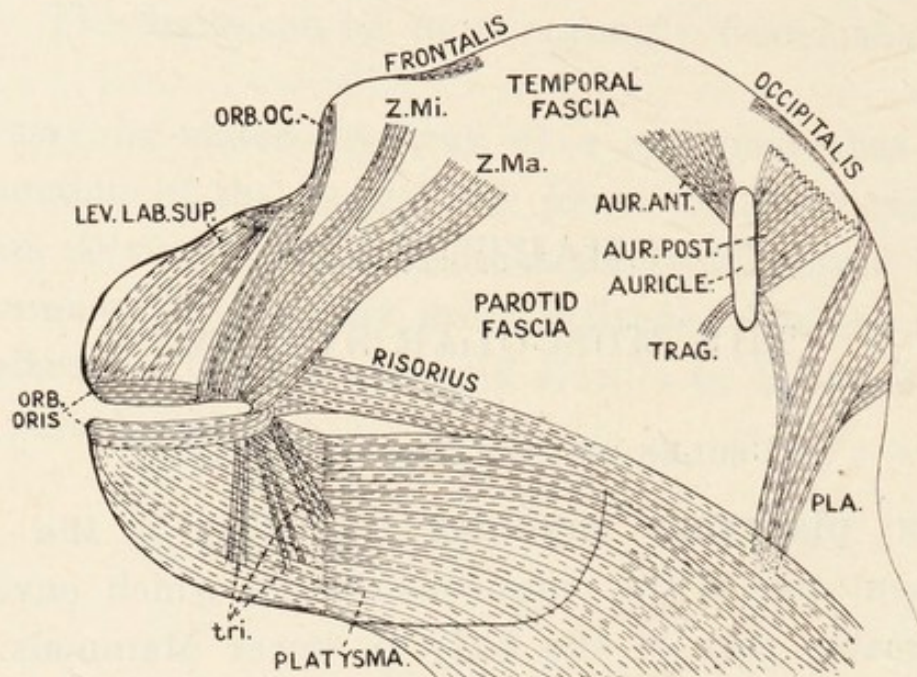


FIG. 27A.

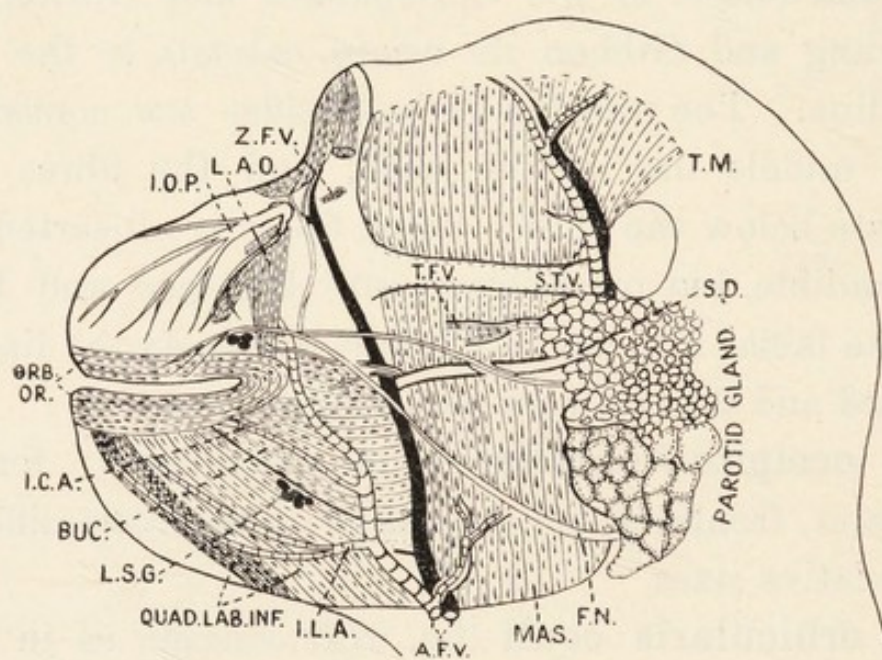


FIG. 27B.

Figs. 27A and 27B.—The facial muscles in the Chimpanzee. A.F.V., T.F.V. and Z.F.V., anterior facial, transverse facial and zygomatic facial vessels; AUR. ANT. and AUR. POST., anterior and posterior auricular muscles; BUC., buccinator; F.N., facial nerve; I.C.A. and I.L.A., inferior coronary and inferior labial arteries; I.O.P., infra-orbital nerve plexus; L.A.O., levator anguli oris; LEV. LAB. SUP., levator labii superioris; L.S.G., labial salivary glands; MAS. masseter; ORB. OC., orbicularis oculi; ORB. ORIS, orbicularis oris; PLA., platysma; QUAD. LAB. INF., quadratus labii inferioris; S.D., Stenson's duct; S.T.V., superficial temporal vessels; TRAG., tragus; tri., triangularis; Z.Ma. and Z.Mi, zygomaticus major and minor.

part runs from the internal tarsal ligament to the lateral tarsal raphé. Both parts are continuous, and the ciliary bundles are well marked.

The **facial muscles** have received considerable attention from Ruge (**141, 141a**) and Sonntag (**399**); and it appears that there are individual variations in the degree of subdivision.

The **zygomatic mass** (fig. 27A) consists of slips from the zygoma (zygomaticus major), malar bone and temporal fascia (zygomaticus minor) and musculus orbicularis oculi. These slips vary in the degree of fusion at their origins, but they all unite to form a thick bundle blending with the orbicularis oris at the angle of the mouth. Man has the best differentiated zygomaticus major.

The **depressor labii inferioris** (fig. 27B) arises from a variable extent of the lower border of the outer surface of the mandible. The fibres run forwards and blend with the orbicularis oris. The opposite muscles blend across the chin. Branches of the facial artery traverse it.

The **triangularis** varies in size. It emerges from the platysma and blends with the orbicularis oris.

The **levator anguli oris** (fig. 27B) arises from the maxilla below the infra-orbital foramen and blends with the orbicularis oris.

The **levator labii superioris** arises from the whole infra-orbital border of the maxilla, and is blended in the orbicularis oris with the other muscles. The most mesial fibres form the levator labii superioris alæque nasi.

The **buccinator** (fig. 27B) arises from the maxilla and mandible close to the last molar teeth, and from the

pterygo-maxillary ligament. It emerges from under the ascending ramus of the mandible and enters into the orbicularis oris. Its relations to the suctorial pad of fat,

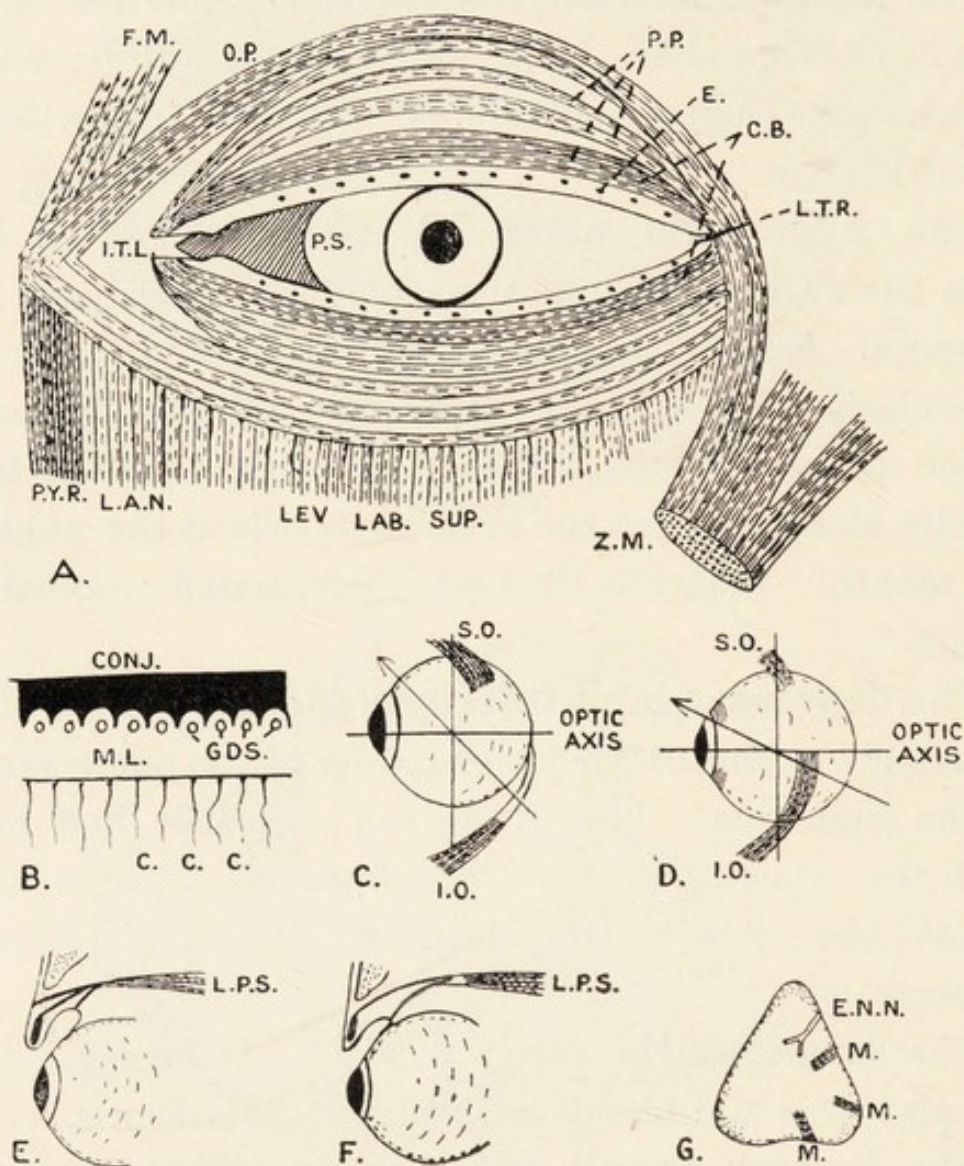


FIG. 28.—The ocular, orbital and nasal muscles in the Chimpanzee. C and E, eyelashes; CONJ., conjunctiva; E.N.N., external nasal nerve; F.M., frontalis; I.O. and S.O., inferior and superior oblique muscles; I.T.L., internal tarsal ligament; L.A.N., levator alae nasi; L.P.S., levator palpebrae superioris; L.T.R., lateral tarsal raphe; M., muscle slips; O.P., and P.P., orbital and palpebral parts of the orbicularis oculi; C.B., ciliary bundle; M.L. GDS., Meibomian glands; P.S., plica semilunaris.

labial salivary glands, vessels and nerves are as in Man. The fibres do not decussate in the Gibbon, Chimpanzee and Orang as they do in Man.

The **orbicularis oris** (fig. 27B) has the usual sphincteric arrangement. It is formed as in Man, and it likewise gives off from its deep surface the *musculi incisivi, canini* and *mentales*.

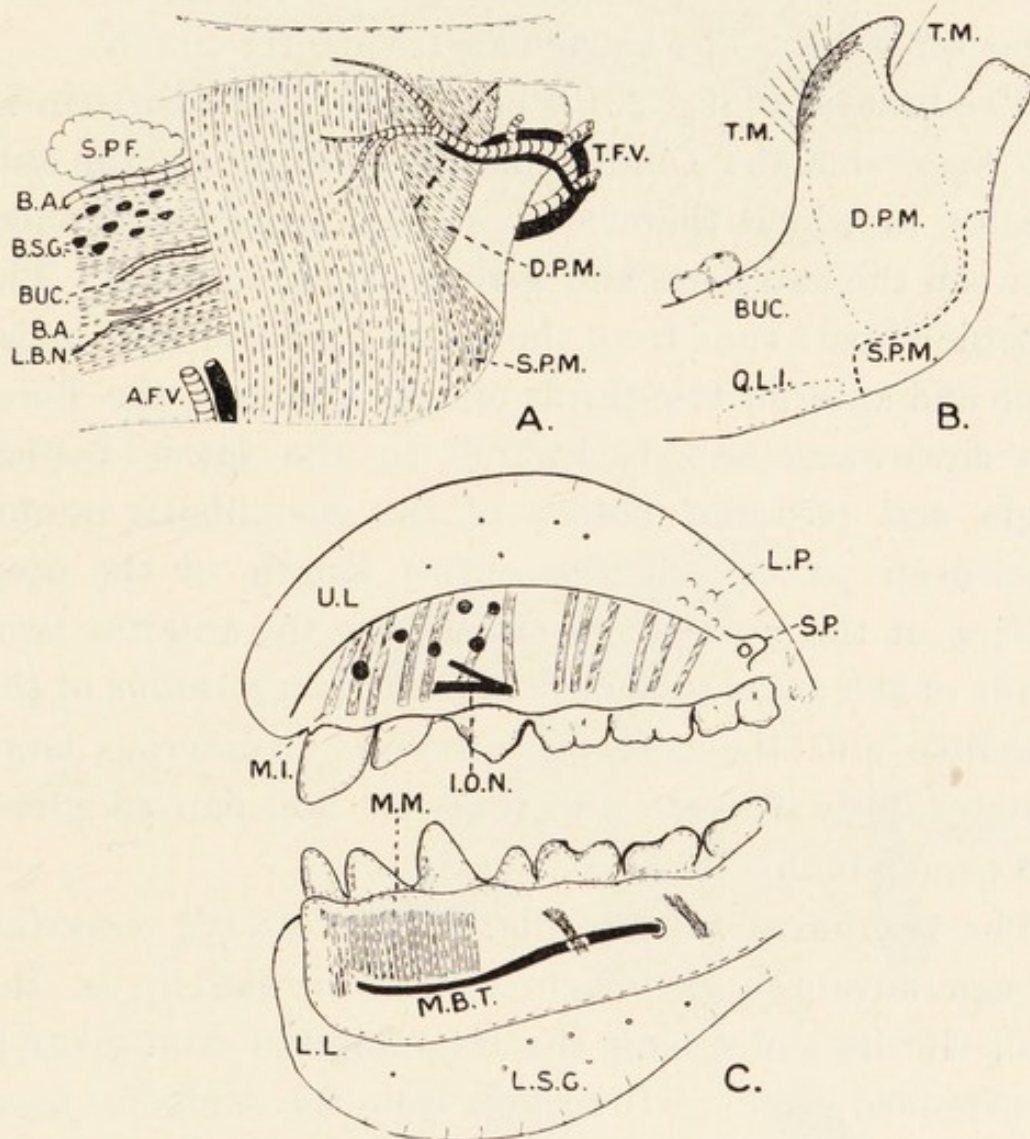


FIG. 29.—The lips, cheeks and masticatory muscles in the Chimpanzee. B.A. and B.S.G., buccal artery and salivary glands; BUC., buccinator; A.F.V. and T.F.V., anterior and transverse facial vessels; L.L. and U.L., lips; I.O.N., L.B.N. and M.B.T., infra-orbital, long buccal and mental nerves; L.P. and S.P., labial and salivary papillæ; M.I., *musculi incisivi*; M.M., *mentalis* muscle; D.P.M. and S.P.M., deep and superficial parts of masseter muscle; S.P.F., suctorial pad of fat; T.M., temporal muscle.

Auricular Muscles.—There are individual variations in each Ape, and the following arrangements have been seen :—

(1) Attolens, attrahens, retrahens and tragicus, all separate.

(2) Attolens and attrahens fused, retrahens and tragicus separate.

(3) Attrahens and retrahens fused, attolens and tragicus separate. The tragicus is frequently absent.

The **masseter** (fig. 29) is composed of two parts in all the Apes; but the Chimpanzee appears to be the only species in which there is a strong aponeurotic sheet between the two parts and giving origin to both. The superficial part runs from the lower border of the malar bone and anterior two-thirds of the zygoma; the fibres run downwards and backwards to the lower border, angle and posterior border of the mandibular ramus. The deep part, from the entire length of the deep surface of the zygoma, is attached to the anterior two-thirds of the outer surface of the ascending ramus of the mandible and the coronoid process. Numerous large vessels ramify between the masseter and parotid gland and supply both.

The **temporal muscle** (fig. 27B) is always powerful. As age advances its origin spreads upwards. In the adult Gorilla and Orang the large sagittal crest gives it an extended origin. It springs from the temporal fossa and the temporal fascia; and it is inserted into the anterior border, point and posterior border of the coronoid process. The muscular mass contains tendinous fibres, and its posterior part is very powerful. The deep temporal arteries ramify within it.

The **pterygoid muscles** (fig. 30, A) are disposed as in Man, and their relations to the vessels and nerves in the pterygoid space are similar.

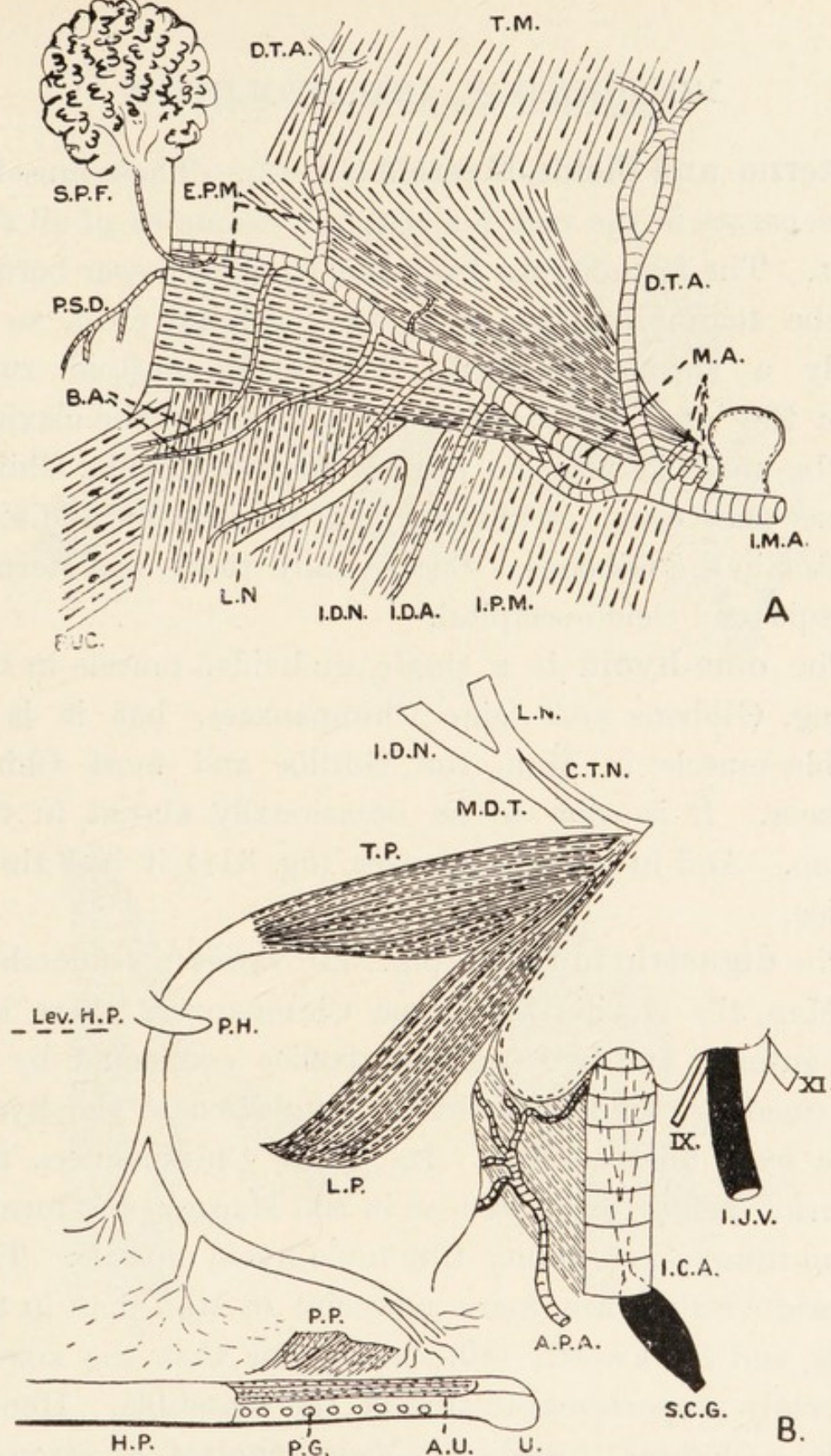


FIG. 30.—The pterygoid (A) and palatine (B) regions. A.P.A., ascending pharyngeal artery; A.U., azygos uvulae; I.C.A., internal carotid artery; I.J.V., internal jugular vein; I.M.A., internal maxillary artery and its deep temporal (D.T.A.), mid-meningeal (M.A.), inferior dental (I.D.A.), buccal (B.A.), and posterior superior dental (P.S.D.) branches; E.P.M. and I.P.M., external and internal pterygoid muscles; H.P., hard palate dropped below its true position (Lev. H.P.); L.P. and T.P., levator and tensor palati; M.D.T., mandibular nerve receiving chorda tympani (C.T.), and giving off lingual (L.N.) and inferior dental (I.D.N.) nerves; P.G., palatal glands; P.H., pterygoid hamulus; P.P., palato-pharyngeus; S.C.G., superior cervical sympathetic ganglion; U., uvula; IX and XI, cranial nerves.

Sterno- and Cleido-Mastoid (fig. 32).—These muscles are separate in the vast majority of examples of all the Apes. The former runs from the front or lower border of the manubrium sterni to the occipital crest, so is really a sterno-occipitalis. The cleido-mastoid runs from the inner third of the upper border of the clavicle to the mastoid area or process in the Gorilla, Chimpanzee and Orang, or to the wall of the external auditory meatus in the Gibbons. Occasionally there is a sterno-mastoid and cleido-occipital.

The **omo-hyoid** is a single undivided muscle in the Orang, Gibbons and some Chimpanzees, but it is a double muscle in Man, the Gorilla and most Chimpanzees. It is said to be occasionally absent in the Orang. And in one Chimpanzee (fig. 31B) it had three bellies.

The **digastric muscle*** (fig. 32) varies considerably. In Man, the Gorilla and some Chimpanzees there are two anterior and two posterior bellies connected by an intermediate tendon, which is connected to the hyoid bone by a fibrous arch. In other Chimpanzees the anterior bellies are fused as in the Macaques to form a broad muscle concealing the mylo-hyoid muscle. The anterior bellies are more powerful in Man than in the Apes, and Duckworth (50) points out that the size is inversely proportional to that of the mandible. Hence, with a lighter mandible, Man requires a stronger depressor. The anterior belly plays a more important part than the mylo-hyoid as a support for the tongue in

* See papers by Bovero (22), Châine (317), Dobson (165A), Futamura (64), Parsons (127A), and Toldt (290).

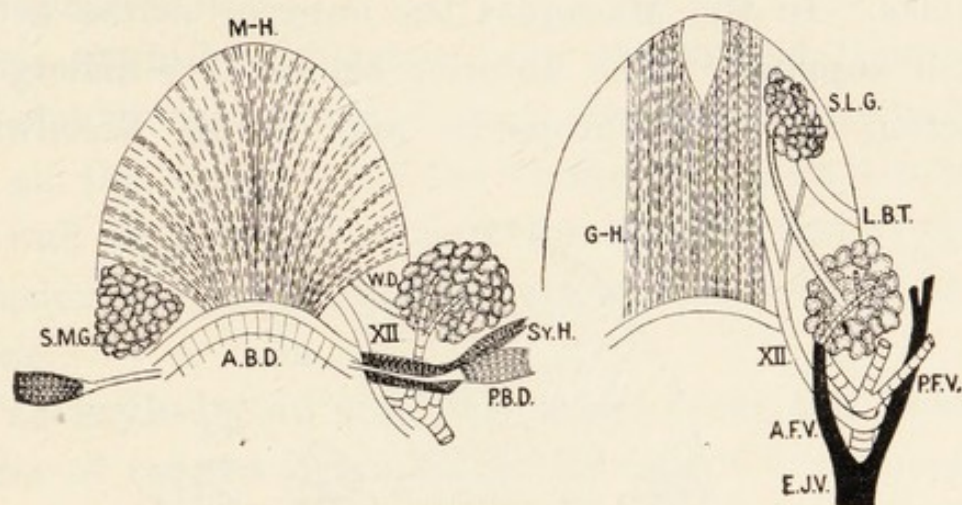


FIG. 31A.

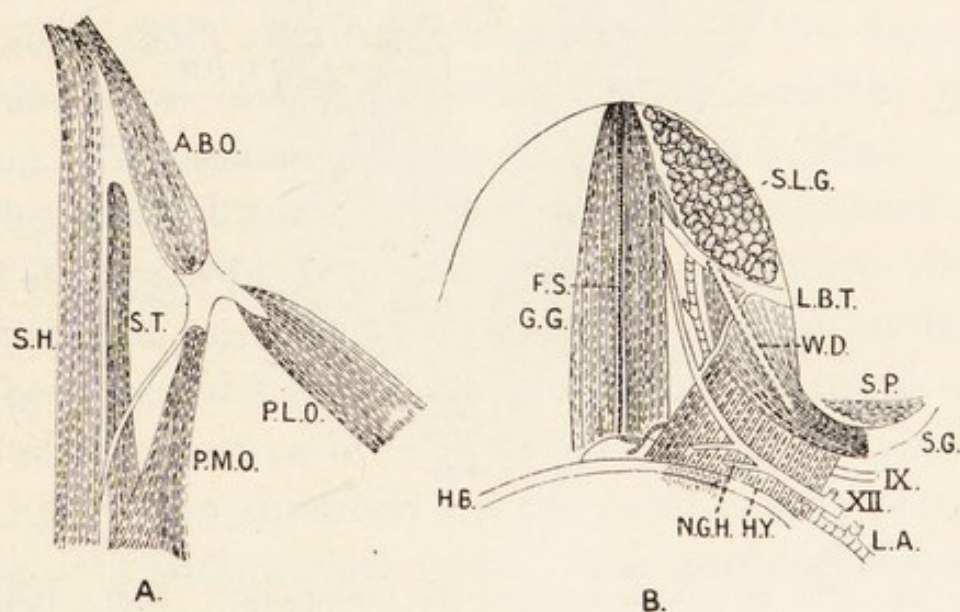


FIG. 31B.

Figs. 31A and 31B.—The submaxillary region and omo-hyoid muscle in the Chimpanzee. A.B.D. and P.B.D., anterior and posterior digastric bellies; A.F.V. and P.F.V., anterior and posterior facial veins; A.B.O., P.M.O. and P.L.O., anterior, postero-mesial and postero-lateral bellies of omo-hyoid; F.S., fatty septum; G.G., genio-glossus; G-H., genio-hyoid; H.Y. and N.G.H., hyoglossus and its nerve; M-H., mylo-hyoid; L.A., lingual artery; L.B.T., lingual nerve; S.H., sterno-hyoid; S.L.G., sublingual gland; S.M.G., submaxillary gland; S.G., stylo-glossus; S.T., sterno-thyroid; S.P., stylo-pharyngeus; W.D., Wharton's duct; IX, XII, cranial nerves.

Man, but the reverse is the case in the Apes of the family Simiidae. In the Macaques the anterior bellies act as lingual supports. The anterior bellies have undergone reduction in the Anthropoids, and Smith Woodward

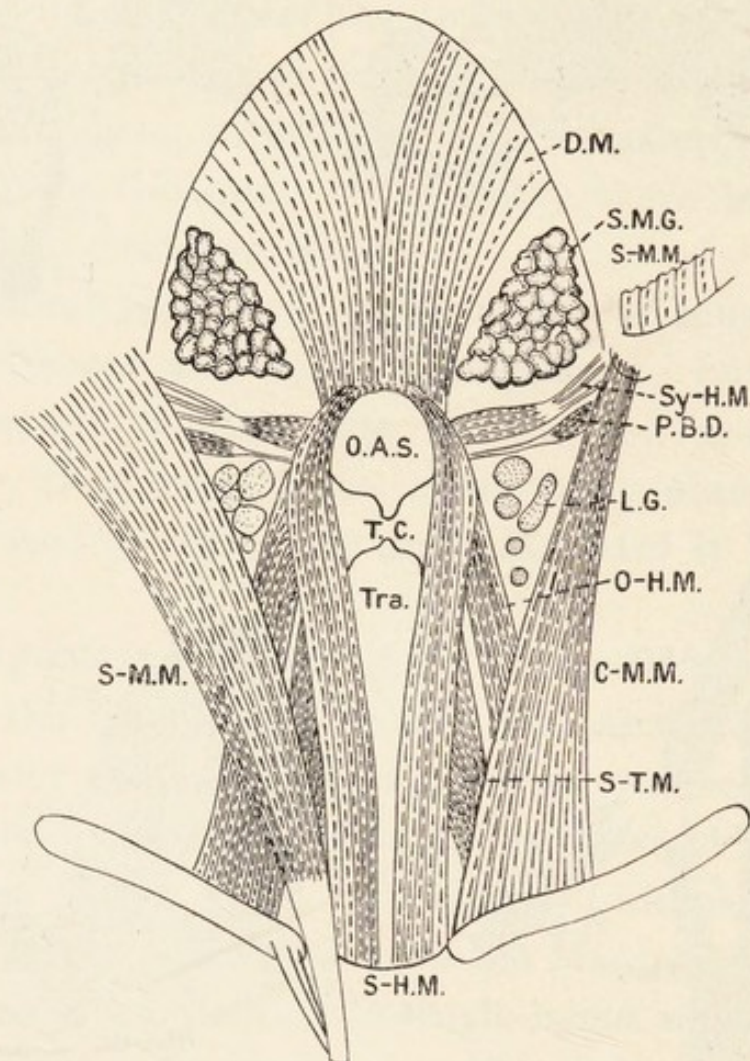


FIG. 32.—The cervical muscles in the Chimpanzee. D.M., digastric muscle; S-M.M. and C-M.M., sterno-mastoid and cleido-mastoid; S-H.M. and Sy-H.M., sterno-hyoid and stylo-hyoid muscles; O-H.M., omo-hyoid; S-T.M., sterno-thyroid; O.A.S., opening of air sac; L.G., lymphatic glands; T.C., thyroid cartilage; Tra., trapezius. Other letters as in fig. 31.

shows that the process has just begun in *Dryopithecus*. The extent of the attachments of the anterior bellies to the mandible is a point of importance in the study of the skulls of extinct Apes and Man. In the Orang

the posterior belly alone is present, and runs to the angle of the mandible.

The **stylo-hyoid** arises from the styloid process or the styloid region and runs to the hyoid bone in Man and all the Apes except the Orang, in which it runs to the wall of the air-sac, thus forming a stylo-laryngeus. Occasionally, however, there is a true stylo-hyoid in the Orang.

The **mylo-hyoid** (fig. 31A) arises from the anterior border of the hyoid bone over an extent corresponding to the insertions of the sterno-hyoid and omo-hyoid on the posterior border. The fibres radiate to be attached to the inner surface of the mandible; but there is no median raphé. The relations are as in Man. Gratiolet (**330**) described decussation of the fibres in a Chimpanzee, and I observed a similar condition in an Orang. The mylo-hyoid ridge is strongest in Man.

The **genio-hyoid muscles** in the Chimpanzee (fig. 31A) run from the lower part of the genial fossa on the back of the symphysis menti to the upper border of the body and part of the great cornu of the hyoid bone. The relations are as in Man. Between the genio-hyoidei and hyoid bone anteriorly and the genio-glossi posteriorly there is a well-marked bursa. The **genio-glossi** arise in the bottom of the genial fossa, and the fibres pass upwards into the tongue—some reach the hyoid bone under the hyo-glossus muscles. Between them and the mandible lie the hyo-glossus and stylo-glossus muscles, the sublingual glands, the lingual artery, and the lingual and hypoglossal nerves. Wharton's duct also courses in that area. The mutual relations of these structures are as in Man and the other Apes.

The **hyo-glossus** (fig. 31B) arises from the body and great cornu of the hyoid bone; and the fibres pass upwards to the side of the posterior half of the tongue under the stylo-glossus. It is not fused with its neighbour, but fibres from the thyro-hyoid pass into it in the Chimpanzee. The relations are as in Man.

The **stylo-glossus** (fig. 31B) arises from the base of the styloid process, or from the styloid area of the skull when no process is present. It is inserted into the side of the tongue from the base to near the apex. Its anterior part is concealed by the sublingual gland, with the lingual nerve encircling its posterior border. Wharton's duct crosses it obliquely from behind forwards, and the communication between the lingual and hypoglossal nerves runs downwards and backwards over it anteriorly.

The **superior constrictor of the pharynx** in the Chimpanzee is continuous above with the buccinator. It is attached to the mylo-hyoid line on the mandible, the internal pterygoid plate, the base of the tongue, the mucous membrane of the floor of the mouth, and the bucco-pharyngeal aponeurosis. Its lower border is overlapped by the middle constrictor of the pharynx, and the stylo-pharyngeus passes between them after sending some fibres into the superior constrictor. The sinus of Morgagni is large, but the tensor and levator palati which are contained within it are more horizontal than in Man. The constrictor is attached above and behind to the basis cranii. A bundle of fibres passes towards the angle of the mouth. The **middle constrictor** also receives fibres from the stylo-pharyngeus. It arises from the deep surface of the hyoid bone between the

greater and lesser cornua. It fuses with its neighbour in the mid-dorsal line, and it is overlapped by the inferior constrictor pharyngis. The latter arises from the oblique line on the thyroid cartilage and from the side of the cricoid, but it does not arise from the first tracheal ring, as stated by Gratiolet (330). It is inserted along with its neighbour into the mid-dorsal line of the pharynx.

The **stylo-pharyngeus** (fig. 31B) arises from the styloid process or from the tendon of the stylo-glossus. It enters the pharyngeal wall with or without sending bundles into the superior and middle constrictor muscles. The glosso-pharyngeal nerve hooks round it as in Man.

The **levator palati** and **tensor palati** (fig. 30, B) are disposed as in Man, but their origins may be separate or fused. They are more horizontal than in Man owing to the prognathism of the jaws. The levator (L.P.) passes in between the layers of the palato-pharyngeus and the tensor (T.P.) hooks round the pterygoid hamulus. The **azygos uvulæ** (A.U.) runs from the hard palate or posterior nasal spine to the uvula.

Scaleni.—The scalenus anticus, lying in front of the brachial plexus, arises from the anterior tubercles of the transverse processes of cervical vertebræ 3 to 5 or 4 to 6; and it is inserted into the scalene tubercle on the first rib. The scalenus medius and posticus are combined in one sheet, which extends to the second or third rib; but I observed it going to the fifth rib in a Chimpanzee. It may be strongly fused with the iliocostalis cervicis.

The **omo-trachelian**, which is absent in Man, runs from the transverse process of the atlas to the upper and outer aspect of the acromion process.

MUSCLES OF THE BACK.

The **trapezius** is built on the same general plan in the larger Simiidæ and Man, for its origin extends from the occiput to the lower dorsal region; the cervical part is, however, relatively shorter in the Apes. In the Gibbon there is no occipital origin, the muscle arising from the lower cervical and upper seven dorsal spinous processes. In the Gorilla and Orang the occipital origin is most extensive, for it extends out to the insertion of the sterno-mastoid; but the dorsal spinal origin is variable.

In the Chimpanzee it arises from the inner third of the occipital crest, the inion and the tips of the spines of the cervical and dorsal vertebræ and supraspinous ligament. No *ligamentum nuchæ* exists. Some authors give it as arising from the first ten to twelve spines. The lower border may be fused with the *latissimus dorsi*. The entire origin is muscular. It is inserted into the outer third of the posterior border of the clavicle, some fibres passing into the deltoid, the outer border of the acromion and the whole length of the spine of the scapula.

The **latissimus dorsi** arises from a variable number of dorsal spinous processes and ribs, from the posterior lamella of the lumbar fascia and from the anterior part of the outer lip of the iliac crest. It never arises from the scapula in the Apes. The observations regarding the origin which have been recorded are shown in the table on next page.

The fibres converge to a ribbon-like tendon, which is inserted into the floor of the bicipital groove on the

humerus. It is fused to a variable extent with the teres major and dorso-epitrochlearis.

| | Spinal origin | Costal origin | Iliac origin |
|-----------------------|-----------------------|-----------------|--|
| Gorilla (Sommer) .. | Lower 5 dorsal spines | Ribs 8—13 | } To 3½ in. behind the anterior superior spine |
| „ (Duvernoy) .. | | 2 ribs | |
| „ (Bischoff) .. | | 4 „ | |
| Chimpanzee (Sonntag) | Dorsal spines 9—13 | Ribs 9—11 | } Highest point to iliac spine |
| „ (Champneys) | | „ 10—13 | |
| „ (Hepburn) | | 3 costal slips | |
| „ (Gratiolet) | | 5 „ „ | |
| Orang-Outan (Fick) .. | Lower 3 spines .. | No costal slips | To within half an inch of the iliac spine |
| Bornean Gibbon .. | Lower 5 spines .. | Lower 5 ribs | Middle third of crest |

The **rhomboideus** is usually undivided, but Champneys (318) described a divided sheet. Its origin extends in the Chimpanzee from the sixth cervical to the fourth dorsal spine; in the Gibbon the origin is much as in the Chimpanzee; in the Gorilla it extends from the spine of the axis to a point which varies from the third to the sixth dorsal spine; in the Orang its origin reaches up to the occiput. Gratiolet (330) described an occipital origin in a Chimpanzee. The muscle is inserted into the lower two-thirds to three-fourths of the vertebral border of the scapula, there being individual differences in the extent in each Ape.

The **levator anguli scapulæ** exhibits great individual variation both in the extent of its origin and the degree to which the slips of origin fuse. It may be a single mass, as in most specimens, but Chimpanzees and Orangs have been seen in which the slips of origin remain separate to near the insertion into the upper part of

the vertebral border of the scapula. The following list gives the recorded observations regarding its origin:—

Gibbon (*Hylobates muelleri*) : cervical vertebræ 1 to 4 (Sonntag **399**).

Orang : five slips of origin (Fick **247**).

Chimpanzee : atlas and axis (Champneys **318**) ; cervical vertebræ 2 and 3 (Gratiolet **330**) ; cervical vertebræ 1 to 3 (Hepburn **83**) ; cervical vertebræ 1 to 4 (Wilder **414** ; Sonntag **399**) ; first five cervical vertebræ (Bland-Sutton **402**).

Gorilla : four slips of origin (Hepburn **83**) ; five slips of origin (Sommer **493**).

The **serratus posticus superior** (fig. 33) runs from the lower cervical and upper dorsal spines to ribs 1 to 4 or 2 to 5. The **serratus posticus inferior** in the Gibbon, Orang and Chimpanzee runs from the posterior lamella of the lumbar fascia to a variable number of lower ribs. It is absent in most Gorillas, but Duvernoy (**53**) saw it in his specimen. Seydel (**146**) made a thorough study of the posterior serrate muscles.

The **splenius** (fig. 33) is a powerful muscle, particularly the splenius capitis. In the Chimpanzee its origin varies, sometimes extending from the spine of the axis to the seventh dorsal spine. The *splenius capitis* (Spl. Cap.) is inserted into the mastoid process and outer half or third of the occipital crest. The *splenius cervicis* (Sple. Cer.) forms one to four slips inserted into the first one to four cervical transverse processes. There is a variable degree of fusion with the neighbouring cervical muscles. In the Gorilla there are one to three slips, and in the Gibbon. The splenius cervicis is absent in the Orang.

The **sacro-spinalis** (fig. 33) varies in the degree of fusion or separateness of its three component columns, which are as in Man. In one Chimpanzee I found the

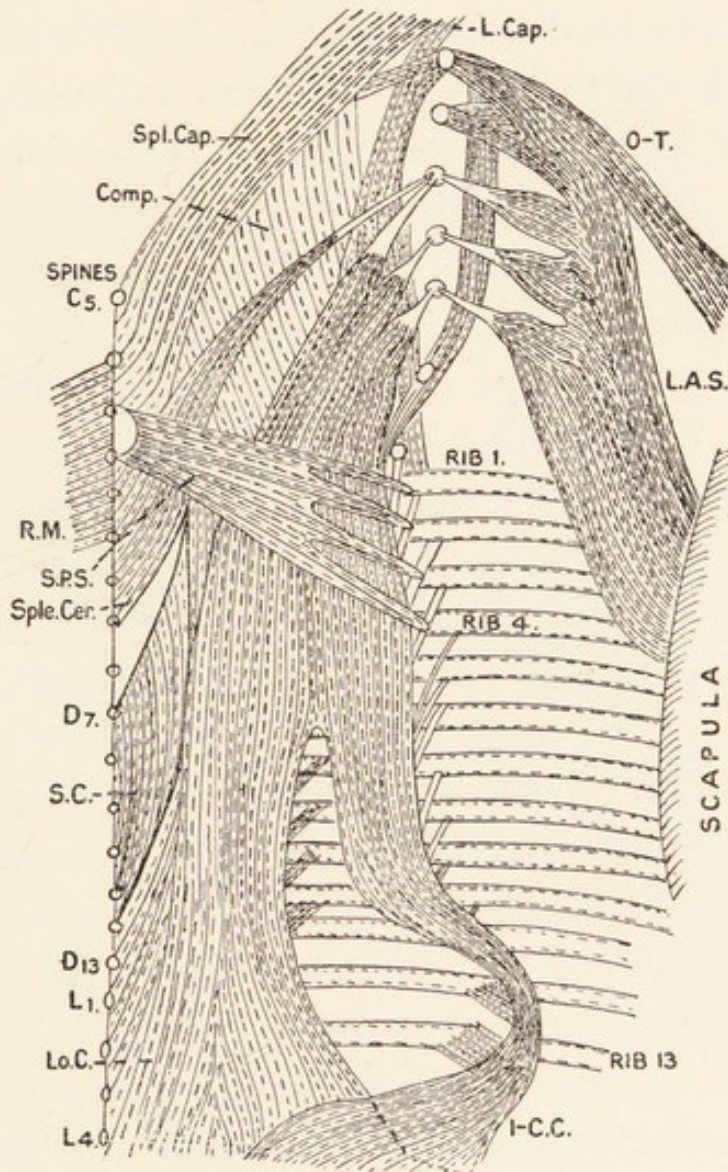


FIG. 33.—The sacro-spinalis muscle in the Chimpanzee. Comp., complexus; L.A.S., levator anguli scapulæ; O-T, omo-trachelian; R.M., rhomboideus; S.P.S., serratus posticus superior. Other letters described in the text.

columns entirely separate, but in two others the outer and middle columns fused in the greater part of the back; but the combined mass broke up into slips in the neck. The inner column separated off in the upper thoracic

region. The outer column or *ilio-costalis* (I-C.C.) arose along with the subjacent longissimus from the iliac crest between the highest point and the posterior superior spine, and it derives fibres from the covering posterior lamella of the lumbo-dorsal fascia. It gives two slips to the lower borders of the twelfth and thirteenth ribs, of which the former is the larger. It receives a large number of muscular slips from the outer surfaces of all the ribs, the size of the latter diminishing from below upwards. Many of the small muscular slips are continuous with the slips given off from the longissimus. From the outer border of the muscle, long, slender tendons run to the lower borders of the angles of the first nine ribs. The *longissimus* (Lo.C) arises from the crest of the ilium from the highest point to the posterior superior spine, the posterior sacro-iliac ligament, the back of the sacrum, all sacral and lumbar vertebral spines and the spines of the twelfth and thirteenth dorsal vertebræ. It gives slips to the lower borders of ribs 4 to 13 between their angles and the transverse processes. The attachments to the first three ribs come from the combined longissimus and ilio-costalis. The combined outer and middle columns divide into slips which are attached to the posterior tubercles of the transverse processes of the third, fourth and fifth cervical vertebræ along with the levator angulæ scapulæ. The third cervical vertebra thus receives splenius cervicis, levator anguli scapulæ and longissimus. The part of longissimus attached to these processes corresponds to longissimus cervicis in Man, but is not so extensive. The *spinalis dorsi* (S.C.) is a narrow muscle arising from the longissimus dorsi and the eleventh and twelfth dorsal spines. It is inserted

by muscular and tendinous fibres into the first eight dorsal spines. Between it and the longissimus is a triangular space into which the complexus passes and fuses with both. The *longissimus capitis* (L. Cap.) is

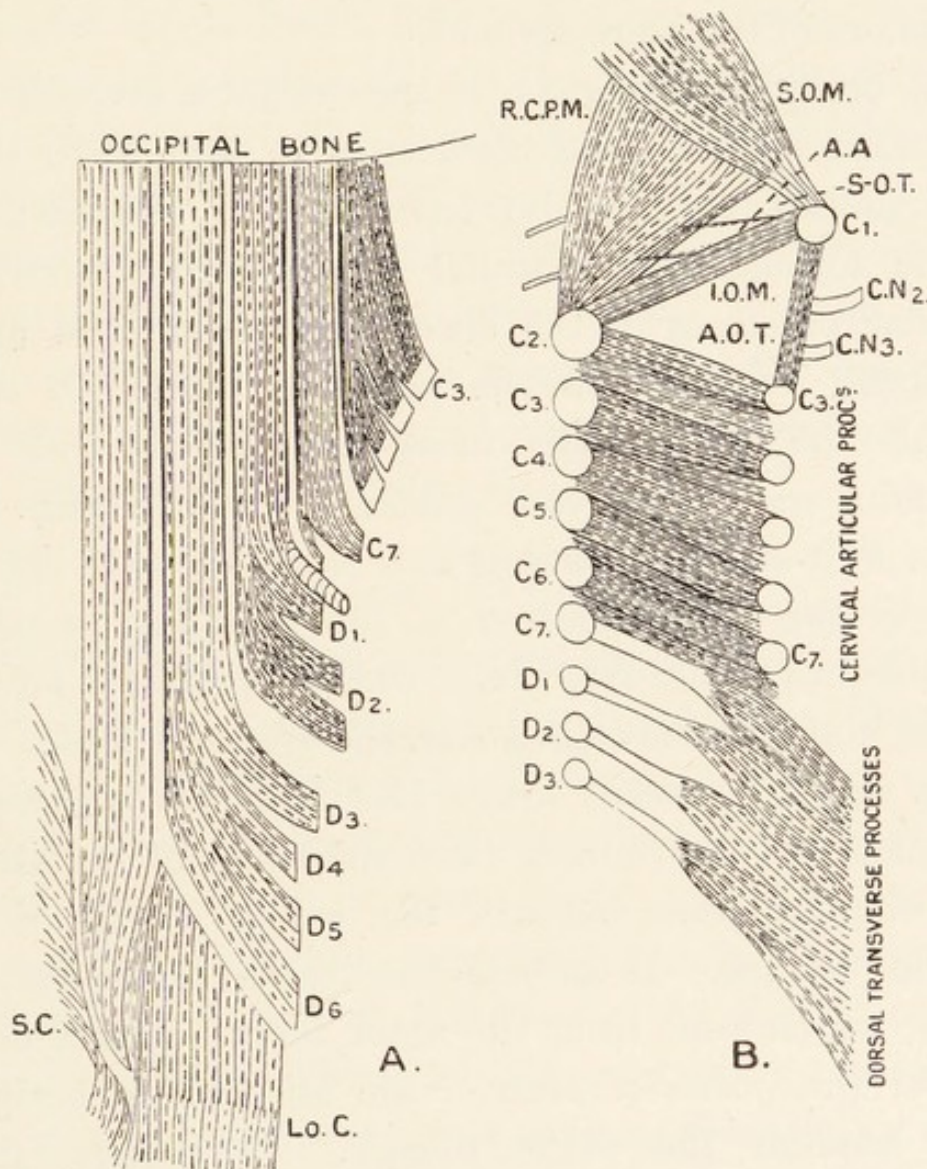


FIG. 34.—The deep muscles of the back in the Chimpanzee. A, complexus; B, semi-spinalis and sub-occipital muscles; A.A., posterior arch of atlas; A.O.T., accessory occipital triangle in one Chimpanzee; C.N., cervical nerves; Lo.C., longissimus; S.C., spinalis dorsi; S-O.T., sub-occipital triangle.

relatively stronger than in Man. It arises from the first six dorsal transverse processes by tendinous and muscular slips. It is fused with the longissimus dorsi, complexus

and scalenus posticus. It breaks up into slips which are inserted into the posterior tubercle of the atlas and the occipital bone below the crest. On the atlas its insertion is fused with the levator scapulæ and omo-trachelian. In other Apes there are also individual variations in the characters of the sacro-spinalis.

The **complexus** (fig. 34) in the Gorilla is divisible into complexus and biventer cervicis as in Man. In three Chimpanzees I found no trace of this division; the muscle formed close parallel slips running from the articular processes of the lower five cervical and upper six dorsal vertebræ to the occipital crest. In these animals the semispinalis dorsi, semispinalis colli and multifidus spinæ were very similar to those in Man.

The **sub-occipital triangle** is small or quite obliterated by the approximation of the bounding muscles. The obliquus superior (fig. 34, B) (S.O.M.), obliquus inferior (I.O.M.), and rectus capitis lateralis are as in Man. The rectus capitis posticus major (R.C.P.M.) is a powerful pyramidal muscle running from the spine of the axis to the occipital bone beneath the entire length of the superior oblique. It conceals the rectus capitis posticus minor, which runs from the inner three-quarters of an inch of the posterior arch of the atlas to the occipital bone beneath the major muscle. The interspinales, intertransverse, rotatores and levatores costarum are well marked.

Prevertebral Muscles.—In the Chimpanzee the longus colli consists of vertical, superior and inferior parts as in Man. The vertical part runs from the bodies of the lower two cervical and upper four dorsal vertebræ to the bodies of the second, third and fourth cervical

vertebræ. The superior oblique part runs from the third, fourth and fifth cervical vertebræ to the anterior arch of the atlas; and the inferior oblique part connects the first four thoracic vertebræ to the fifth and sixth cervical vertebræ. The rectus capitis anticus major runs from the third, fourth, fifth and sixth cervical vertebræ to the basi-occiput. It may receive a slip from the scalenus anticus. The rectus capitis anticus minor is as in Man. In the Gorilla, according to Sommer (491), these muscles are as in Man. Kohlbrügge (199) describes an arrangement of the prevertebral muscles in the Gibbon which corresponds in general to the description of the Chimpanzee given above, but he does not divide the longus colli into three parts.

MUSCLES OF THE ARM.

The **pectoralis major** in the Chimpanzee consists of clavicular, costo-sternal and abdominal parts. The clavicular part arises from the inner half of the front of the clavicle; and it may derive fibres from the tendon of the sterno-mastoid. It is quite continuous with the costo-sternal part, no groove intervening as in the other Apes and Man. It may be fused with the deltoid, or there may be a delto-pectoral triangle containing the thoracic axis vessels and the external anterior thoracic nerve, but no cephalic vein nor lymph glands. The costo-sternal part arises from the sternum and first six costal cartilages, and it is fused with the external oblique muscle. It receives the abdominal part of the muscle. The insertion into the pectoral crest, capsule of the shoulder-joint and deep fascia of the arm is musculo-aponeurotic. The abdominal part is not specialized to form a separate

pectoralis quartus as it is in the Gorilla, and occasionally in the Siamang (**181**). In the Orang the clavicular part is replaced by a slip from the manubrium sterni and first costal cartilage; and the muscle is split into three parts.

The **pectoralis minor** varies considerably, as can be seen by a study of the writings of Bland-Sutton (**402**), Champneys (**318**), Humphry (**340**), Hepburn (**83**), Gratiolet (**330**), Wilder (**414**), Sonntag (**399**), Fick (**247**), Sommer (**491**) and Kohlbrügge (**199**). In the Chimpanzee it arises from the first four, first five, second, third, and fourth, or third, fourth and fifth ribs; and it is inserted into the capsule of the shoulder-joint, the coracoid process, or both together, but the capsular insertion is most frequent. Sometimes it is double in the Chimpanzee as in the Gorilla. It arises in the Gorilla from ribs 3 to 7, in the Orang from the third and fourth ribs, and in the Gibbon from the third, fourth and fifth ribs. In the Gorilla and Orang it is inserted into the coracoid process; but it runs to the clavicle, coracoid process and conjoined tendons of the coraco-brachialis and biceps in the Gibbons.

The **subclavius** in the Chimpanzee and Gorilla is as in Man. In the Orang it rises from the first costal cartilage and second rib; but it springs from the second and third ribs in the Gibbon. It is enclosed between the layers of the costo-coracoid membrane.

The **deltoid** is coarsely fasciculate. In the Chimpanzee it arises from the front of the outer half of the clavicle, the outer border of the acromion, the whole length of the lower border of the spine of the scapula and the fascia over the infraspinatus. It covers a bursa

which lies between the acromion and the upper end of the humerus. Branches of the circumflex arteries and nerve enter the deep surface. It fuses to a greater or less extent with the brachialis anticus (Humphry **340**; Macalister **350**; Sonntag **399**). The fibres converge to the common deltoid insertion into the upper part of the shaft of the humerus.

Scapular Muscles.—The infraspinatus is larger than the supraspinatus. The supraspinatus, infraspinatus and subscapularis arise from the whole of the fossæ wherein they lie; and they are all inserted into the tuberosities of the humerus as in Man. The teres major springs from the inner half of the axillary border of the scapula, and it is inserted into the humerus at the root of the pectoral crest. The teres minor arises as follows:—

Gibbon: lower border of lip of glenoid cavity and outer inch of scapular border.

Chimpanzee: lower border of lip of glenoid cavity and outer two-thirds of scapular border.

Orang: lower border of lip of glenoid cavity and outer half of scapular border.

Gorilla: lower border of lip of glenoid cavity and outer third of scapular border.

Man: as in Chimpanzee.

The insertion is practically identical in the Apes and in Man.

All the muscles of the shoulder-girdle are innervated as in Man, but they can produce a wider range of movement in the Apes.

The **serratus magnus** arises by digitations, or by a continuous linear origin from the outer surfaces of a

variable number of ribs (Orang, 1 to 10; Gibbon and Chimpanzee, 1 to 11; Gorilla, 1 to 13). It has a thick insertion into the whole length of the vertebral border of the scapula. Its nerve supply is great in the Chimpanzee.

The **coraco-brachialis** arises from the tip of the coracoid process along with the short head of the biceps. Wood (164) showed that it is really a triple muscle, consisting of long, middle and short parts. The short part, running to the shaft of the humerus above the teres major, is absent in the Apes. The middle part, running to the middle of the shaft of the humerus, is present in all Apes. And the long part, which runs to the internal intermuscular septum and dorso-epitrochlearis is only present in the Orang and Chimpanzee; the musculo-cutaneous nerve passes between the parts. In Man the long and middle parts are fused, and the nerve perforates the muscle.

The **biceps flexor cubiti*** is similar in Man and the large Apes, but the two heads unite higher up in Man. In the Gibbon the long head is as in Man, the short head arises from the bicipital groove; and fibres spring from the entire length of the internal intermuscular septum, thus concealing the brachial vessels and nerves. The *lacertus fibrosus* is reduced in the Apes. In some cases the biceps in Man is as in the Gibbon.

The **brachialis anticus** is built on the same plan in the Apes and Man. Hepburn (83) states that it does not embrace the insertion of the deltoid, but I found it doing so in a Chimpanzee. The coraco-brachialis, biceps and brachialis anticus are supplied by the musculo-cutaneous nerve.

The **dorso-epitrochlearis*** is a climbing muscle, present in all Apes, but represented by fascia in Man. It arises from the latissimus dorsi at the junction of the muscle and tendon, and it is inserted into the internal intermuscular septum. Fibres may pass into it from the coraco-brachialis. It is innervated by the musculo-spiral nerve, so it is not a part of the latissimus dorsi, which is supplied by the middle subscapular nerve. Although it is a climbing muscle I have seen it larger in the Drill than in purely arboreal Monkeys (174).

The **triceps** is a powerful muscle in all the Apes. The outer and inner heads are as in Man; but the long head is more extensive, arising over an area extending from the border of the glenoid cavity to as far as the middle of the axillary border of the scapula. That extent includes the various individual conditions. It is inserted into the tip and dorsum of the olecranon process; and a bursa may lie between it and the bone. The anconeus is present in all, but the subanconeus is inconstant.

The **palmaris longus** is present or absent in one or both arms. It runs from the common flexor origin from the internal condyle of the humerus to the palmar fascia or the upper border of the synovial sheath of the flexor sublimis and flexor profundus digitorum.

The **pronator radii teres** has no coronoid head in the Gorilla and Gibbon, but it is present in the Orang and Chimpanzee. In the latter the condylar head is fused with the flexor carpi radialis, and the coronoid head with the flexor sublimis digitorum. Some fibres spring from the internal intermuscular septum. The median nerve passes

* Groenroos (75) has dealt with these muscles.

between the two heads. It is inserted into the middle third of the outer border of the shaft of the radius. In the Gibbon it is also inserted into the front of the radius.

The **flexor carpi radialis** in the Chimpanzee arises from the internal condyle of the humerus and the greater part of the shaft of the radius. Fibres also pass into it from the pronator radii teres and flexor sublimis digitorum. It passes through a tube in the anterior annular ligament, and is inserted into the palmar aspect of the bases of the second and third metacarpals. Hepburn (83) states that it is attached by a fibrous septum to the radius on the inner aspect of the pronator teres in all Apes except the Chimpanzee.

The **flexor carpi ulnaris** is similar in the Apes and Man. The ulnar nerve enters the forearm between its heads of origin. It is a large muscle.

The **flexor sublimis digitorum** in the Chimpanzee arises from the humerus, radius, ulna and other flexor muscles. The condylar head fuses with the flexores carpi radialis and ulnaris; it sends tendons to the ring and little fingers. The coronoid head quickly ends in a tendon to the index finger. The middle finger receives its tendon from a muscle arising from the lower two-thirds of the shaft of the radius. The tendons split and are inserted as in Man. Hepburn (83) points out that the arrangements are similar to those in the Gorilla and Orang. The variations in the Chimpanzee have been described by Bland-Sutton (402), Dwight (325), Champneys (318), Moore (363) and Macalister (350).

Flexor Longus Pollicis.—This muscle is absent in some Gorillas; but when it is present, as in the Chimpanzee, Orang and some Gorillas, it is merely a fine

tendinous thread given off from the tendon of the flexor profundus indicis. In the Gibbons it is a small, but distinct muscle.

In the Apes the conditions of the flexor longus pollicis and flexor profundus digitorum represent stages in the evolution of the arrangements present in Man. In lower animals the flexor mass is divisible into radial, ulnar and condylar parts. In the Apes and Man the condylar part forms the flexor sublimis digitorum, and the radial and ulnar parts form the deep flexors. The deep flexor mass undergoes vertical cleavage, the line of splitting moving medio-laterally in zoological order. In the Gibbons the division is such that the tendons for the annularis and minimus lie to the ulnar side, and those for the pollex, index and medius to the radial side of the cleavage line. In the higher Simiidæ the tendon for the medius also lies to the ulnar side, and the tendons for the pollex and index are placed on the radial side of the cleavage line. In Man the tendon for the pollex is split off and those for the other digits combine to form a true flexor profundus digitorum.

Lumbricales.—In the Chimpanzee the first and second muscles arise from the radial sides of separate tendons of the flexor profundus; and in one animal they were connected by a muscular slip. The third rose from two flexor tendons, and the fourth sprang from the ulnar side of the deep flexor tendon of the ring finger. In the Gorilla the first and fourth lumbricals arise from single tendons, but the second and third each arise from two flexor tendons. In the Gibbons and Orang the principle is similar to that in the Chimpanzee. The insertions in all Apes are as in Man.

The intrinsic muscles have received considerable attention from Bischoff (18, 19), Brooks (27, 28), Fick (247), Hepburn (83), Keith (99), Kohlbrügge (199), Sommer (491), Sonntag (399), and Windle (159, 160).

Hypothenar Muscles.—The *palmaris brevis* may be present or absent in one or both hands. The *abductor minimi digiti* (fig. 35, A.M.D.) arises from the pisiform

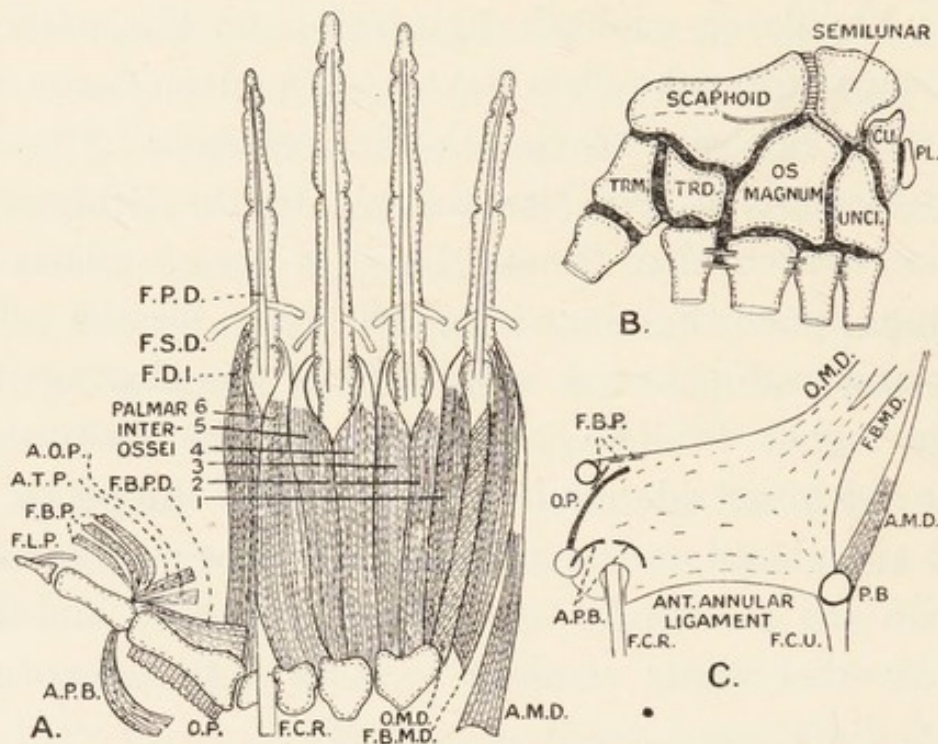


FIG. 35.—Muscles and joints of the hand in the Chimpanzee. A.O.P. and A.T.P., adductores obliquus and transversus pollicis; F.B.P.D., deep head of flexor brevis pollicis; F.C.R., flexor carpi radialis; F.C.U., flexor carpi ulnaris; F.D.I., first dorsal interosseous muscle; F.L.P., flexor longus pollicis; F.P.D., flexor profundus digitorum; F.S.D., flexor sublimis digitorum; CU., cuneiform bone; P.B., pisiform bone. Other letters in text.

bone, runs along the ulnar border of the hand, and is inserted into the ulnar aspect of the base of the first phalanx of the minimus. The *flexor brevis minimi digiti* (F.B.M.D.) has a single origin from the anterior annular ligament and hook of the unciform. It is inserted with the abductor, but it gets an additional insertion

into the distal part of the phalanx in the Gibbon. The *opponens minimi digiti* (O.M.D.) has a double origin from the anterior annular ligament and hook of the unciform; it is inserted into the ulnar aspect of the shaft of the fifth metacarpal bone.

Thenar Muscles (fig. 35).—The *abductor pollicis brevis* (A.P.B.) arises in the Orang and Gorilla from the anterior annular ligament, but it has an additional origin in the Chimpanzee from the scaphoid and sesamoid bone of the thumb. It may be divided into slips. It is inserted into the radial aspect of the base of the first phalanx of the thumb. The *opponens pollicis* (O.P.) arises from the anterior annular ligament and ridge on the trapezium; and it is inserted into the distal half of the shaft of the first metacarpal in all Apes except the Gibbon, in which it sends prolongations to the pollical phalanges. The *flexor brevis pollicis* (F.B.P.) has superficial and deep heads in all Apes except the Gorilla. The former arises from the anterior annular ligament and trapezium; and the latter springs from the anterior annular ligament and ulnar side of the first metacarpal bone. It is inserted into the ulnar side of the base of the proximal phalanx of the thumb. The Gorilla differs from all other Apes and Man in possessing the deep head only.

The **adductor transversus pollicis** is easily separated from the oblique adductor in Man and all the Apes except the Gibbons. It arises from a septum lying along the palmar aspect of the third metacarpal, but it gets an additional slip from the second and third metacarpals in the Gorilla. It is inserted into the ulnar aspect of the first phalanx] of the thumb in the larger Apes; but it gets an additional insertion to the ulnar

aspect of the first metacarpal in the Gibbon. The **adductor obliquus pollicis** arises from carpal bones in Man and all the Apes except the Orang. It is inserted along with the transverse muscle. Halford (83) applied the name "contrahentes" to a small group of muscles which adduct the thumb and fingers. In the Gorilla the adductores transversus and obliquus are the only contrahentes; in the Orang additional fibres run from the septum on the third metacarpal to the palmar interossei; in the Chimpanzee there are two adductores pollicis, and adductors of the annularis and minimus all having a common origin: in the Gibbon the contrahentes adduct all digits except the medius.

The extensor carpi radiales longior and brevior, extensor carpi ulnaris and supinator brevis are as in Man.

The **supinator longus** arises from the external humeral condyle, and from the external intermuscular septum; it may reach the deltoid insertion in the Chimpanzee. It is inserted into the lower part of the shaft of the radius.

The **extensor communis digitorum** arises from the external condyle of the humerus, the fascia over it, and the septa on each side. It sends tendons to the bases of the ungual phalanges of the fingers as in Man, and there are expansions over the interphalangeal joints.

The **extensor minimi digiti** arises in the Chimpanzee and Orang from the external condyle and the fascia over the anconeus; in the Gibbon and Gorilla it also rises from the septum between the extensor communis and extensor carpi ulnaris. It is inserted into the base of the ungual phalanx of the minimus in all the Apes except the Orang, in which it is inserted with the

tendons of the extensor communis to the fourth and fifth digits.

The **extensor indicis** is inserted similarly in Man and the Gorilla; in the Chimpanzee it may also supply the middle finger; in the Orang it supplies the medius and annularis, and it supplies the medius, index and annularis in the Gibbons.

Extensors of the Pollex.—In the Chimpanzee the *extensor ossis metacarpi pollicis* arises from the upper two-thirds of the mesial border of the radius; and its broad tendon is inserted into the trapezium and thumb sesamoid. The *extensor primi internodii pollicis* rises from the upper third of the lateral border of the ulna; its slender tendon goes to the base of the first metacarpal bone. In the Gorilla the extensor ossis metacarpi pollicis goes to the first metacarpal bone, but it goes to the pollical sesamoid bone in the Gibbon and Orang. In the Gorilla the extensor primi internodii is attached by a slip to the first phalanx of the pollex.

The **extensor secundi internodii pollicis** in the Chimpanzee arises from the third quarter of the shaft of the ulna below the extensor primi internodii pollicis and above the extensor indicis. It is inserted, according to Hepburn (83), into the base of the first phalanx, but Humphry (340), Macalister (350), Vrolik (411), Wilder (414), Wyman (417), and Sonntag (399) give its insertion as the ungual phalanx. In many Apes it sends a slip to the first phalanx, thus replacing the extensor primi internodii pollicis.

Interossei.—In the Apes and Man there are four dorsal interossei abducting the fingers from a line drawn through the medius, and in all except the Chimpanzee

(fig. 35, A), there are three palmar interossei adducting the fingers towards the medius. In the latter there are six palmar interossei: three—those to the ulnar side of the index and the radial sides of the annularis and minimus—are similar to the palmar interossei of the other Primates; the other three—to the sides of the medius and ulnar side of the annularis—are really dorsal interossei which act as abductors.

MUSCLES OF THE LEG.

The **psoas parvus** arises from the last dorsal and upper one or two lumbar vertebræ in the large Simiidæ; but it rises from the first three in the Gibbon. It is inserted into the ilio-pectineal line; the insertion is farthest forwards in the Chimpanzee in which it is attached close to the femoral vessels.

The **iliacus** arises as in Man. It is fused with the quadratus lumborum in the Chimpanzee.

The **psoas magnus** varies considerably as regards its origin. In the Chimpanzee it blends more with the iliacus than in Man. It arises from the last dorsal vertebra, the inner inch of the last rib and the transverse processes and centra of the four lumbar vertebræ. It is inserted as the ilio-psoas into the lesser trochanter and the femoral shaft a little below it. In the Gorilla it arises from the bodies of the first three lumbar vertebræ and intervertebral discs, the third lumbar transverse process and the crista ilii. In the Orang it springs from the last dorsal and all lumbar vertebræ, and in the Gibbon it also arises from the tendon of the rectus femoris.

Gluteus Maximus.—The origin extends from the posterior part of the iliac crest along the sacrum, coccyx, great sacro-sciatic ligament and ischial tuberosity; but the attachment to the crest is by fascia in the Chimpanzee. In the Gorilla and Chimpanzee the insertion reaches the external femoral condyle, and it may fuse with the short head of the biceps; in the Orang it reaches the middle of the femur; in the Gibbon the insertion is restricted to the upper part of the femur. The muscle is segmented in the Orang, but in other Apes the various parts are fused. Hepburn (83) pointed out that the part arising from the tuber ischii is the displaced agitator caudæ.

The **gluteus medius** is very similar in all the Apes, and it is more powerful than the last muscle. It arises from the whole dorsum ilii down to a line from the sciatic notch to the anterior inferior spine. It also arises by an aponeurosis from the anterior border of the ilium. It is inserted into the outer aspect of the great trochanter, and it may be connected to the pyriformis. The tendon is split by the vastus externus in the Chimpanzee. It is separated from the scansorius and pyriformis by bursæ (fig. 36, D).

The **gluteus minimus** is larger in the Gorilla and Chimpanzee than in the Orang and Gibbon; and it may be divisible into two parts, as in the Gorilla, or into three as in some Chimpanzees. It is inserted into the upper border of the great trochanter. In the Chimpanzee and Orang it gives off a muscular sheet—the **musculus scansorius**—which is inserted into the upper border of the great trochanter of the femur in close relation to the gluteus medius, pyriformis and vastus

externus. Some authors have stated that this muscle corresponds to the tensor fasciæ femoris, but both muscles are present in many examples of these Apes.

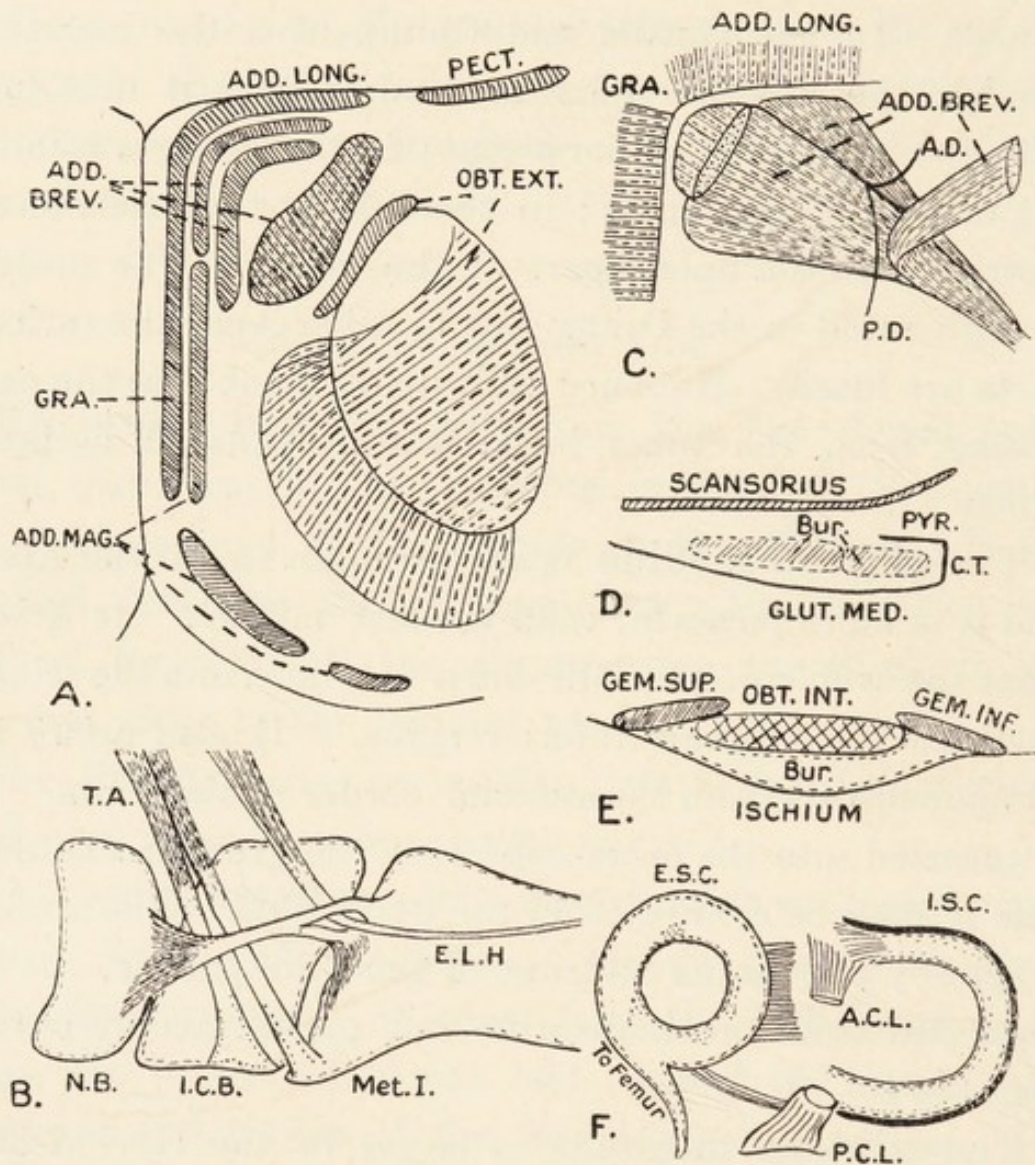


FIG. 36.—The muscles of the leg and the knee-joint in the Chimpanzee. A, origin of the muscles from the pelvis; B, muscles of the hallux; C, the adductor brevis and obturator nerve; D and E, situation of bursæ; F, the knee-joint. A.D. and P.D., anterior and posterior divisions of the obturator nerve; A.C.L. and P.C.L., anterior and posterior cruciate ligaments; ADD. BREV., ADD. LONG., and ADD. MAG., adductores brevis, longus and magnus; c.T., connecting fibrous strip; E.L.H., extensor longus hallucis; E.S.C. and I.S.C., external and internal semilunar cartilages; GEM., gemelli; GLUT. MED., gluteus medius; GRA., gracilis; I.C.B., entocuneiform; MET.I, first metatarsal; N.B., scaphoid; OBT. EXT. and OBT. INT., obturatores externus and internus; PECT., pectineus; PYR., pyriformis; T.A., tibialis anticus; Bur., bursæ. Note the ligamentous pulley for the tendon of the extensor longus hallucis in fig. B.

In the Gorilla and Gibbon it is blended with the *gluteus minimus*.

The **pyriformis** emerges from the pelvis through the great sciatic notch, and is inserted into the upper border of the great trochanter of the femur.

The **obturator internus and gemelli** are a closely-associated group of muscles. In the Chimpanzee the *gemellus superior* (fig. 36, E), which is larger than the *gemellus inferior*, arises from the rudimentary ischial spine and its associated ligament. The *gemellus inferior* (fig. 36, E) arises from the deep surface of the ischium and the outer surface of the *tuber ischii*. The tendon of the *obturator internus* is separated from the ischium by a bursa. It receives the *gemelli*, and the combined mass is inserted into the femur above the trochanteric pit. In the Orang the *gemellus inferior* is larger than the *gemellus superior*: and the latter is represented, according to Hepburn (83) by a small slip from the *obturator internus* in the Gibbon. The **obturator externus** is similar in the Apes and Man.

The **quadratus femoris** arises from the ramus and outer surface of the *tuber ischii*, and it may be fused with the *gemellus inferior*. In the Gorilla it has a vertical attachment into the back of the great trochanter, but its insertion is rectangular in the other Apes. In the Orang it is considerably fused with the *adductor magnus*.

The **sartorius** arises from a variable extent of the anterior border of the ilium. In the Chimpanzee it reaches down to the anterior inferior spine and up to near the anterior superior spine. The long ribbon-like belly is inserted into the upper third of the anterior border or inner surface of the shaft of the tibia. It is

connected to the deep fascia of the leg. Between it and the subjacent gracilis lie the saphenous nerve and vessels.

The **quadriceps extensor** is composed of the same elements as in Man, but they are more fused. The rectus femoris has a single head of origin in the Gibbon, but in the other Apes there are two heads forming an arch over the upper border of the acetabulum. In the Chimpanzee the vastus externus arises from the antero-lateral aspect of the great trochanter and the back of the shaft of the femur to a point an inch above the external condyle, and a small slip arises from the upper end of the intertrochanteric line; the vastus internus arises from the intertrochanteric line, except from its extreme upper end, and from the same extent of the shaft of the femur as the vastus externus; the crureus arises from the upper two-thirds of the shaft of the femur between the vasti; and the tendon of the quadriceps is inserted into the upper border of the patella, the capsule of the joint on either side of it, the external condyle of the femur and the two condyles of the tibia; and the ligamentum patellæ is inserted into the front of the upper end of the tibia. No subcrureus is present in the Chimpanzee.

The **adductor muscles** exhibit many specific and individual variations, as can be seen from the writings of Hepburn (83), Humphry (340), Gratiolet (330), Champneys (318), and Sonntag (399). In the Chimpanzee (fig. 36, A) the gracilis and adductor longus arise, together from the inner end of Poupart's ligament, the entire length of the symphysis and the upper third of the descending ramus of the pubis. The *adductor longus*

is inserted into the third quarter of the back of the femur, and is fused with the adductor magnus. The *gracilis* is inserted into the inner aspect of the tibia behind the internal lateral ligament; it is fused with the semimembranosus and the fascia over the gastrocnemius. Hepburn (83) points out that the attachment to the fascia is greater in the arboreal Orang and Gibbon than in the Gorilla and Chimpanzee. The *adductor brevis* arises from the pubis external to the above muscles and internal to the obturator externus. In the Chimpanzee (fig. 36, c) three interlocking, prismatic bellies unite to a flat tendon, which is inserted into a line from the lesser trochanter to the back of the femur. In the Orang the insertion is very similar. In the Gibbon the single muscle is inserted into the femur between the pectineus and adductor magnus. In the Gorilla it has an extensive insertion into the linea aspera. One of the bellies in the Chimpanzee may represent a muscle in the Gorilla known as the *adductor minimus*, which arises from the pubis between the adductores longus and brevis mesially and the obturator externus deeply, and is inserted into the back of the femur behind the pectineus. The *adductor magnus* is the most powerful of the group. In the Chimpanzee (fig. 36, A) there are three heads; the first from the body of the pubis unites with the second head from the pubic arch and upper part of the tuber ischii to form a large muscle, which is inserted into the greater part of the back of the shaft of the femur; the third head runs from the tuber ischii to the adductor tubercle on the internal condyle of the femur. The femoral vessels pass between these two muscles. The first muscle is supplied by the obturator

nerve ; and the second by the sciatic nerve, so it is to be regarded as a piece of the hamstring group. In the Gibbon the part arising from the tuberosity is fused with the rest of the muscle, but its tendon is inserted separately into the middle of the supracondylar crest of the femur. In the Gorilla the three parts are separate at their origin (Sommer) ; in the Orang the arrangements are very human. Sometimes the adductor magnus is inserted as far down as the back of the knee-joint. Deniker divides the adductor mass into adductor primus (adductor longus), adductor secundus (adductor brevis), adductor tertius (upper part of adductor magnus) and ischio-condyleus, or part to the adductor tubercle. The *pectineus* is much as in Man. When it contains part of the adductor longus it is innervated partly by the obturator nerve, in addition to the anterior crural nerve, which is constant.

Hamstring Muscles.—The *biceps* consists of a long head arising from the tuber ischii and fused with the gluteus maximus, and of a short head arising from the lower part of the shaft of the femur. The two heads may remain separate or be fused in each species (see papers by Sommer (491), Hepburn (83), Champneys (318), and Sonntag (399). It is inserted into the outer aspect of the head of the tibia, the head of the fibula and the fascia over the outer head of the gastrocnemius. The *semitendinosus* arises from the tuber ischii and is inserted into the anterior tubercle of the tibia and the deep fascia of the leg. The fascial insertion is very extensive, and helps to prevent the animal from assuming an erect attitude. Rolleston pointed out that the muscle has a strong insertion into the fascia in the new-born child,

and the insertions of the semimembranosus and semitendinosus move upwards as the child learns to walk and stand. The fascial attachment is feeble in the Gorilla. The *semimembranosus* runs to the tibia over an area situated more proximal than those of the other hamstrings. Its insertion was studied in detail by Gratiolet (330).

The **tibialis anticus** is built on the same plan in all the Apes. In the Chimpanzee it arises from the external condyle and upper half of the outer surface of the shaft of the tibia, the interosseous membrane and the fascia over it and between it and the extensor longus digitorum. It splits into two bellies which end in long tendons (fig. 36, B). The tendons are inserted into the internal cuneiform bone and the base of the first metatarsal. This double insertion is associated with the use of the hallux as a thumb; and Hepburn (83) believes the two divisions correspond to the extensor ossis metacarpi and extensor primi internodii pollicis.

The **extensor longus digitorum** arises from the external condyle of the tibia, the anterior border of the head of the fibula, the antero-mesial aspect of the shaft of the fibula, the fascia over it and the septa dividing it from the neighbouring muscles. It passes under the annular ligament and ends in tendons for the four outer toes. The tendons show many individual peculiarities in the manner in which they communicate with one another on the dorsum of the foot. The tendons form expansions over the metacarpo-phalangeal and interphalangeal joints. They are joined by the lumbricales, interossei and extensor brevis digitorum.

The **extensor longus hallucis**, which may corre-

spond to the extensor longus pollicis, arises from the middle third of the antero-medial aspect of the shaft of the fibula and the interosseus membrane. The tendon passes under the annular ligament and through the fibrous naviculo-metatarsal trochlea to the base of the ungual phalanx of the hallux. Its dorsal expansion is joined by the innermost tendon of the extensor brevis digitorum.

The **peroneus tertius** is absent. This is a human muscle. It combines with the tibialis posticus to steady the foot in walking.

The **extensor brevis digitorum** is a derivative of the peroneal muscles. In the Chimpanzee it rises from the upper surface of the os calcis, the dorsal calcaneo-cuboid ligament and the external annular ligament. It ends in four slender tendons to the four inner toes, that for the hallux being almost a separate muscle. The innermost tendon goes to the base of the first phalanx, but the others join the long extensor tendons. It is similar to the human muscle in the other Apes.

The **peroneus longus** is as in Man in the Chimpanzee. Sommer (491) and Deniker point out that it is as in Man in the Gorilla and Gibbon. And Fick (247) observed the same in the Orang. Hepburn (83) states that it is limited in its insertion to the base of the first metatarsal in the Apes.

The **peroneus brevis** in the Chimpanzee arises from the outer surface of the shaft of the fibula down to the lateral malleolus, the anterior peroneal septum and the fascia over it. It is inserted into the base of the fifth metatarsal bone, and it gives a slip to the dorsal expansion over the proximal phalanx of the fifth toe. Deniker

(44) describes a similar insertion in the Gibbon; Hepburn (83) points out that the tendon divides into three in the Orang; and Sommer (491) describes a double insertion into the fifth metatarsal in the Gorilla. Both peroneal muscles have synovial sheaths.

The **gastrocnemius** is less voluminous than in Man, so there is no marked calf. In the Chimpanzee it arises by two heads from the capsule of the knee-joint over the articular surfaces. The bellies are inserted into a median tendinous raphé, the inner belly slightly overlapping the external one. The flat tendon is implanted into the tendon of the soleus half an inch above the os calcis to form the tendo Achillis. The muscle is connected at its edges to the soleus. Fibres arise in addition from the posterior ligament of the knee-joint in the Orang. The Gibbon has a sesamoid bone in each head of origin. In the Gorilla the muscle is as in Man.

The **soleus** has no direct tibial origin, and is smaller than in Man. It arises from the posterior aspect of the head of the fibula and from the peroneal intermuscular septum in the Chimpanzee. The flat belly unites a short distance above the os calcis with the gastrocnemius to form the tendo Achillis. Between the tendo and upper part of the os calcis are a bursa and a pad of fat. In the Orang and Gibbon the attachment is much more oblique than in the Gorilla and Chimpanzee, which place the sole flat on the ground.

The **plantaris** is absent in the majority of Apes. In a Chimpanzee I observed it rising from the posterolateral side of the external femoral condyle. Its long, very slender tendon is inserted into the tendo Achillis.

The **popliteus** is single and similar to that in Man in

the Gorilla and Gibbon. In the Chimpanzee and Orang it is double. In the former the heads rose from the back of the knee-joint; the proximal one is inserted into a vertical line on the back of the internal condyle of the tibia, and the distal one is inserted into the oblique popliteal line, the posterior border of the subcutaneous area, the internal condyle and a line curving round it. In the Orang one head arises within the capsule of the knee-joint.

The **tibialis posticus** arises from the lower part of the head and upper part of the shaft of the fibula, the upper half of the interosseous membrane and the upper half of the tibia. It is inserted in the Chimpanzee as in Man. In the other Apes it has additional insertions. Thus it goes to the sheath of the peroneus longus in the Orang, to the peroneal sheath and plantar ligaments in the Gibbon, to the ectocuneiform in the Gorilla. Hepburn (83) describes it as going to the meso- and ectocuneiform bones in the Chimpanzee.

The **flexor longus digitorum** in the Chimpanzee arises from the popliteal line and its continuation downwards to about an inch from the internal malleolus, and from the septum between it and the tibialis posticus. The tendon passes behind the internal malleolus and under the annular ligament to the sole, where it is connected to the flexor longus hallucis, flexor brevis digitorum and accessorius. It divides into tendons for the four outer toes. These tendons vary considerably in different individuals, there being differences in the degree to which they are connected to the flexor longus hallucis and flexor brevis digitorum. The tendons are inserted as in Man. In the same animal the **flexor longus**

hallucis arises from the head and greater part of the back of the shaft of the fibula, the septa between it and the tibialis posticus and peroneal muscles and the interosseous membrane. The tendon runs through a trochlea attached to the base of the first metatarsal and is inserted into the base of the ungual phalanx of the pollex and capsule of the interphalangeal joint. In the Gorilla, according to Sommer (491) and Hepburn (83) both muscles are as in Man. In the Gibbon the flexor hallucis sends a tendon to each toe, and the flexor longus digitorum gives slips to it and to the flexor brevis digitorum. In the Orang the flexor hallucis supplies the third and fourth toes and the flexor longus digitorum supplies the second and fifth.

The **abductor hallucis** in the Chimpanzee arises mainly as in Man, but it also receives slips from the internal annular ligament, entocuneiform and capsule of the metatarso-phalangeal joint. It is inserted into the inner aspect of the base and shaft of the first phalanx of the hallux and the capsule of the metatarso-phalangeal joint. Within the insertion there is a sesamoid bone. In the Gibbon it is inserted as in the above; in the Orang it sends a slip to the first metatarsal bone; and it is inserted into the first phalanx in the Gorilla.

The **abductor minimi digiti** arises as in Man, but its insertion varies. In the Chimpanzee it is inserted into the outer and inner sides of the base of the fifth metatarsal bone, the plantar aspect of the capsule of the metatarso-phalangeal joint, and the proximal part of the shaft and base of the first phalanx of the minimus. In the other Apes the muscle is inserted into the base of the first phalanx of the minimus but additional slips are

present. Thus the Gorilla has the slip to the base of the fifth metatarsal, and the Orang and Gibbon have the slip to the shaft of the first phalanx.

The **flexor brevis digitorum** varies. It arises in all from the os calcis, but it may have an additional origin from the tendon of the flexor longus digitorum in any Ape. It has superficial and deep parts inserted as follows:—

| — | Superficial part | Deep part |
|--------------------------|-------------------------------|--------------|
| Chimpanzee (Hepburn) .. | Toes 2 and 3 .. | Toes 4 and 5 |
| „ (Sonntag) .. | Toe 2 .. | Toe 3 |
| Gibbon | Toe 2 .. | Toes 3, 4, 5 |
| Orang (Hepburn and Fick) | Three tendons to toes 2, 3, 4 | |
| Gorilla (Hepburn) .. | „ .. | „ 2, 3, 4 |
| „ (Sommer) .. | Toes 4 and 5 .. | Toes 2 and 3 |

The **accessorius** is a variable muscle, the literature on each Ape recording its presence or absence. In a Chimpanzee I found only the outer head running from the os calcis and long plantar ligament to the tendon of the flexor longus digitorum.

The **lumbricales** in all Apes arise from the adjacent sides of two deep tendons. They are inserted as in Man.

The **flexor brevis hallucis** varies. In the Chimpanzee the inner belly arises from the entocuneiform bone, the sheath of the tendon of the peroneus longus, the capsule of the first metatarso-phalangeal joint and the lower half of the first metatarsal. The outer belly arises from the sheath of the tendon of the peroneus longus and the external long plantar metatarsal ligament. No fibres arise from the cuboid bone. The two bellies are inserted along with the adductores hallucis into the base of the first phalanx of the hallux and the capsule of the

metatarso-phalangeal joint, a sesamoid bone intervening. Bischoff (18), Duvernoy (53) and Sommer (491) state there is no outer belly in the Gorilla, but Hepburn (83) recorded its presence. Fick (247) described only one head in the Orang.

The **flexor brevis minimi digiti** runs from the plantar aspect of the fifth metatarsal bone and sheath of the tendon of the peroneus longus to the capsule of the fifth metatarso-phalangeal joint and outer side of the base of the proximal phalanx. The **opponens minimi digiti** is a separate muscle in the Chimpanzee and Gorilla. In the former it rises from the plantar aspect of the fifth metatarsal bone and sheath of the tendon of the peroneus longus to the inner aspect of the capsule of the fifth metatarso-phalangeal joint.

The **adductores** are separate in all Apes except the Gibbons. In the Chimpanzee the adductor obliquus hallucis arises from the base of the third metatarsal bone and proximal half of the external long plantar metatarsal ligament. The adductor transversus hallucis arises from the two long plantar metatarsal ligaments and the capsules of the second and third metatarso-phalangeal joints. They are inserted with the flexor brevis hallucis. The Gibbon has two, the Chimpanzee has one and the Gorilla and Orang have no other contrahentes.

Interossei.—In all the Apes there are four dorsal and three plantar interossei. In the Gorilla they respectively abduct and adduct the toes from or to a line drawn through the second toe. In the Chimpanzee, Orang and Gibbon, the basal line as regards the action of the interossei is through the middle digit as in the

hand. So it is evident that the Gorilla approaches Man most closely in the action of the interossei of the foot.

MUSCLES OF THE ABDOMEN.

Diaphragm.*—In the Chimpanzee, the comparatively small central tendon receives two slips from the back of the sternum, and fibres on each side from ribs 7-13. These slips interdigitate with the transversalis abdominis. The right crus arises from the second lumbar vertebra and the left crus from the first. Additional slips also arise from the second lumbar transverse process and the first lumbar centrum. The lumbo-costal arches (arcuate ligaments) are as in Man. Sometimes the arches are not well defined. In the Gorilla the slips of origin of the muscular part do not interdigitate with the slips of the transversalis abdominis; and the tendinous part of the muscle is large. The pericardium adheres to the upper surface; and the same structures pass through it as in Man. In the Orang the slips are strongly fused at their origin with the quadratus and psoas.

Quadratus Lumborum.—In the Chimpanzee it arises from the posterior two-thirds of the inner lip of the iliac crest, where it is continuous with the iliacus, and from all the lumbar transverse processes; and it is inserted into the inner four-fifths of the last rib and the bodies of the last two dorsal vertebræ. In the Orang and Gorilla it is not fused with the iliacus.

External Oblique.—In the Chimpanzee it arises by digitations from the outer surfaces and lower borders of

* Bertelli (13) has studied the morphology of the diaphragm.

ribs 5-11. The mesial ones fuse with the pectoralis major, the lateral ones are covered by the latissimus dorsi, and all interdigitate with the serratus magnus. The lateral fibres are inserted into the anterior superior iliac spine and outer third of Poupart's ligament. The aponeurosis is inserted into the xiphisternum, last chondro-sternal junction, pubis and inner two-thirds of Poupart's ligament. It fuses with the aponeurosis of the internal oblique mesial to the splitting of the latter. Gimbernat's ligament is small, and the aponeurosis is attached to the fascia lata of the thigh. In the Gorilla it arises from ribs 5-13, interdigitating with the serratus magnus and latissimus dorsi. In the Orang, with its twelve ribs, the conditions are much as in Man, and Poupart's and Gimbernat's ligaments are well marked.

The **internal oblique** in the Chimpanzee arises from the outer half of the anterior border of the iliac crest, the anterior superior iliac spine, the outer third of Poupart's ligament, and the lower borders of the tenth to thirteenth costal cartilages. Its aponeurosis has a curved line of splitting, and runs from the tenth costal cartilage to the inner end of Poupart's ligament. In the Gorilla it arises from the inner third of the crista ilii and the outer two-thirds of Poupart's ligament, and from the fascia between the sartorius and scansorius; and it has an origin from fascia between the sartorius and iliacus in the Orang. Its aponeurosis may not split.

The **transversalis abdominis** in the Chimpanzee arises from the deep surfaces of ribs 10-13, the lumbar fascia, the anterior quarter of the inner lip of the iliac crest, the inner surface of the anterior superior iliac spine and the outer third of Poupart's ligament; the

aponeurosis is attached to the xiphoid and pubis. In the Gorilla, according to Sommer [491] the conditions are as in Man, but Bischoff observed no linea Douglasii. In the Orang, on the contrary, that line is well marked.

The **rectus abdominis** in the Chimpanzee has two origins as in Man, and four inscriptions run through it; its sheath is as in Man. In the Gibbon there are four inscriptions, and there are five in the Orang and Gorilla. These inscriptions really separate metameres, but they are not remnants of ribs.

The **pyramidalis** is frequently absent in the Chimpanzee, as in other Apes.

CHAPTER VIII.

THE ORGANS OF DIGESTION AND
ABSORPTION.

THE loose, thick, fleshy *lips* are projected forwards over the maxillæ, and in the living animal only a small part of the red margin of the lower lip is visible when the mouth is closed. Their inner surfaces are studded with the openings of numerous labial salivary glands. The labial frenula are long and narrow. The gape of the mouth is wide. The *cheeks* are loose and mobile, but no pouches exist. The *vestibule* is semilunar, and receives the secretions of Stensen's ducts, which open on papillæ placed as in Man. And a row of papillæ lies beside the salivary papilla on each side in the Chimpanzee (fig. 29, C). Rex (**132**) described the histology of the lips, and Ehlers (**441a**) described folds of mucous membrane connecting the gums and cheeks in the Gorilla. Deniker (**44**) believes, however, that these folds are individual variations.

The **palate** alters its relative dimensions as age advances (p. 121), and Keith (**100**) has tabulated figures showing how the length, width and area differ at birth and in the adult state in both sexes. Its mucous membrane is thrown into several rugæ, in contradistinction to those in Man. The incisive papilla is frequently

absent. The rugæ* radiate from the mid-line to the sides of the palate. These folds and the papilla vary considerably in Man; and I observed them to be large in a native of Siam. The soft palate has a well-marked uvula in all Apes except the Orang.

The palatal glands are numerous, and their patulous orifices stud both the hard and soft palates. The palatal muscles are very similar to those in Man with the exception of the palato-glossus and palato-pharyngeus.

The **tongue** is long and narrow in the Gibbons and Chimpanzee, but it is relatively wider in the Gorilla and Orang. Its form depends on the shape of the space within the dental arcade, so it must alter as the skull becomes increasingly prognathous. The apex is rounded or truncated, and, as a rule, is devoid of a notch. The lateral borders are full and rounded, and their posterior parts are cut up into laminæ by moderately deep sulci; the laminæ and sulci together compose the foliate papillæ or lateral organs of Mayer.

The *circumvallate papillæ* are in most cases fewer than in Man. They are arranged in the form of a V, Y, T or triangle; in the Gorilla and Orang the V form is most common, whereas the Y type is most frequent in the Chimpanzee and Gibbons; in Man the V type is almost universal. The observations recorded by many

* The palatal rugæ have been described or figured by Beddard (304), Bischoff (425), Ehlers (441a), Gratiolet (330), Sonntag (399), Symington (403), and Waldeyer (412). Gegenbaur (249) has studied them fully.

The tongue has been described by a large number of authors, whose works have been analysed by Sonntag (150).

The numerous works on the alimentary canal have been collected by Sperino (401) and Keith (99).

authors have been collected by Sonntag (150) and Oppel (120a). The *fungiform papillæ* do not differ in any Ape from those in Man. The *conical papillæ* take numerous forms, some of which are shown in fig. 37. Those on the base of the tongue are large in the Gorilla, Chimpanzee and all Gibbons except the Siamang; and there are no large conical papillæ on the base in Man and the Orang.

The *lateral organs* take two forms. In the Gorilla and Orang (figs. 37, 39) they appear as rows of laminae and sulci of equal length on the dorsum and lateral borders of the tongue; but they form curved organs, with the convexities inwards, on the lateral borders in the Chimpanzee and Gibbons (figs. 38, 40).

The under surface of the tongue is connected to the floor of the mouth by a well-developed *frenum linguæ*. In all Anthropoids* except the Orang there is placed astride the frenum a triangular plate or fold of mucous membrane, which Pocock called the "*frenal lamella*"; it is usually bifid at the apex, and Wharton's ducts open on the points. In the Orang there are two salivary papillæ, instead of a lamella, as in Man.

At the sides of the frenum there is a more or less prominent form of mucous membrane, termed the *plica fimbriata*, which is a vestige of the large plate or inferior tongue (sublingua) of Lemurs. It is present in the adult Gorilla, Chimpanzee and Orang, but it is only found in the fœtus in the Gibbons. In Man it is larger at birth, but it diminishes afterwards.

* In the tongue of a Siamang Gibbon in the Museum of the Royal College of Surgeons there is no lamella; but this may be due to defective removal of the tongue from the mouth.

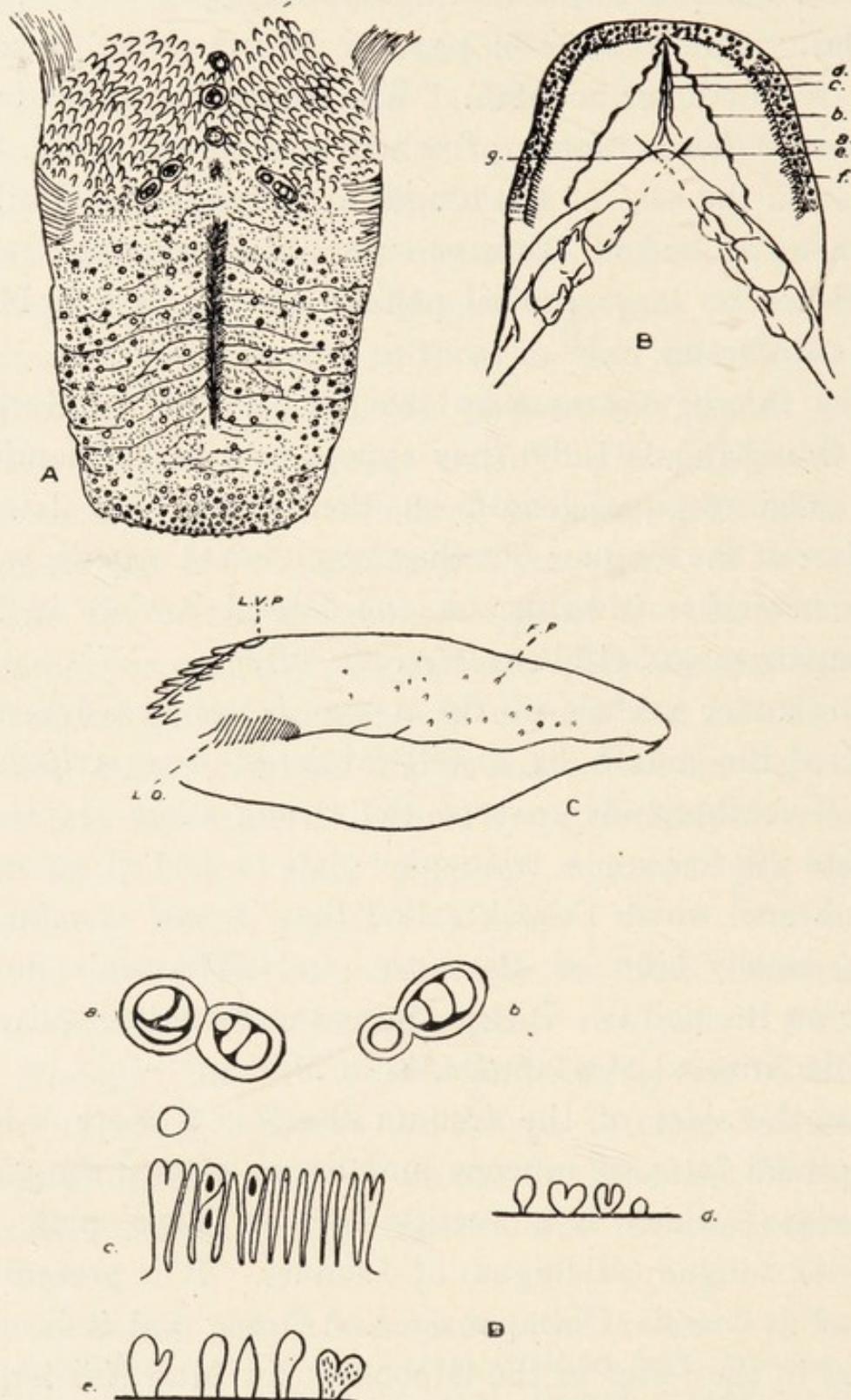


FIG. 37.—The tongue of the Gorilla. A, dorsum; B, under surface (*a.* *f.*, papillary border; *c.d.*, median raphe; *b.*, fimbriate plica; *e.*, frenal lamella; *g.*, Wharton's ducts); C, side view (*L.V.P.*, lateral vallate papilla; *L.O.*, lateral organ; *F.P.*, fungiform papillae); D, papillae highly magnified (*a.b.*, vallate papillae; *c.*, lateral organ; *d.*, fungiform papillae; *e.*, conical papillae).

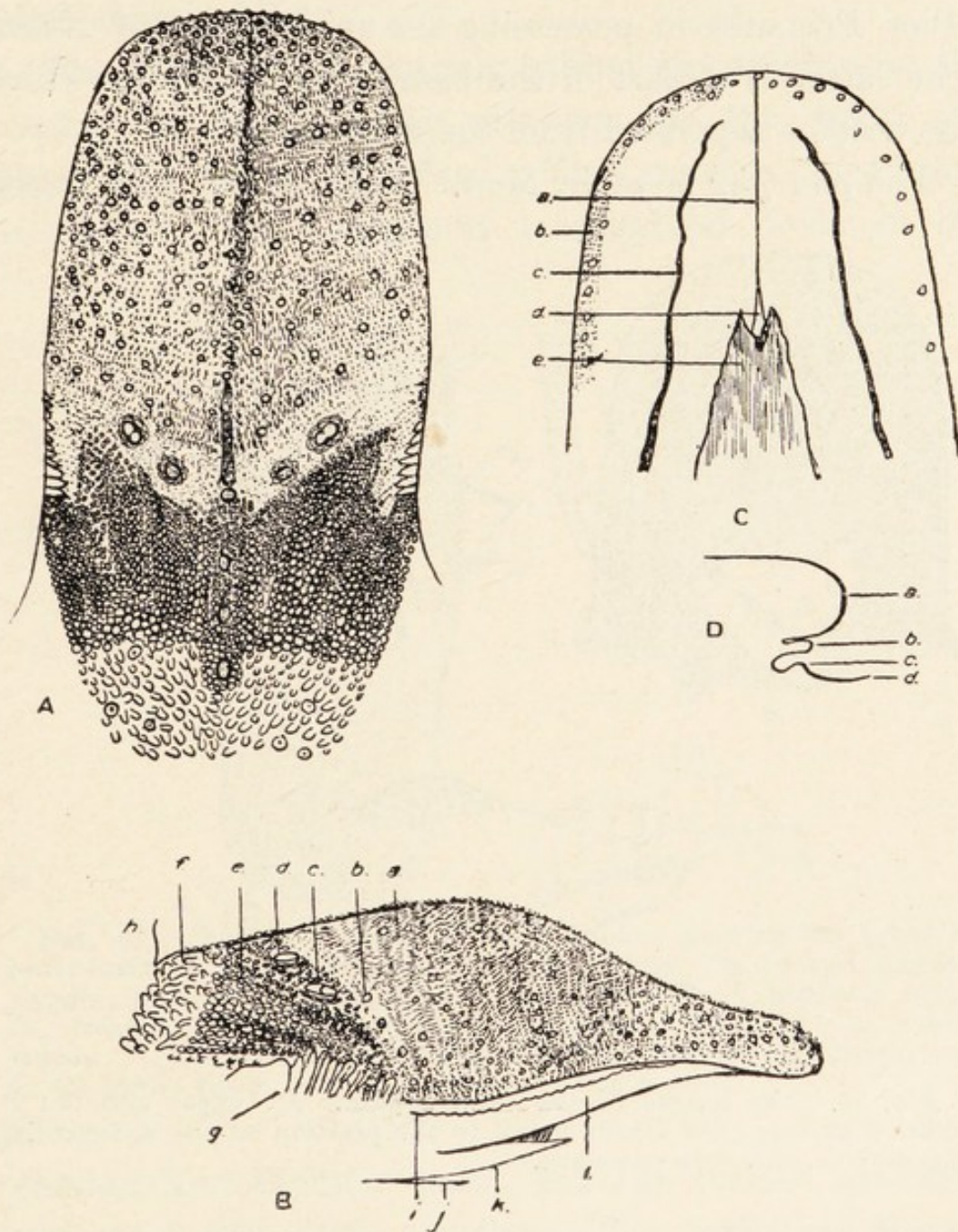


FIG. 38.—The tongue of the Chimpanzee. A, dorsum; B, side view (*a.d.e.f.*, conical papillæ; *b.*, fungiform papilla; *c.*, vallate papilla; *g.*, lateral organ; *h.*, epiglottis; *i.*, plica fimbriata; *j.*, floor of mouth; *k.*, frenal lamella; *l.*, inferior surface); C, under surface (*a.*, median sulcus; *b.*, papillary border; *c.*, plicæ fimbriatæ; *d.*, frenum; *e.*, frenal lamella).

The glands of the tongue belong to the serous and mucous types; but Man and the Orang differ from all other Primates in possessing the apical gland of Nuhn. The latter is a part of the basal mucous glands which has become separated from the main mass.

The *pharynx* is as in Man. Faucial and pharyngeal

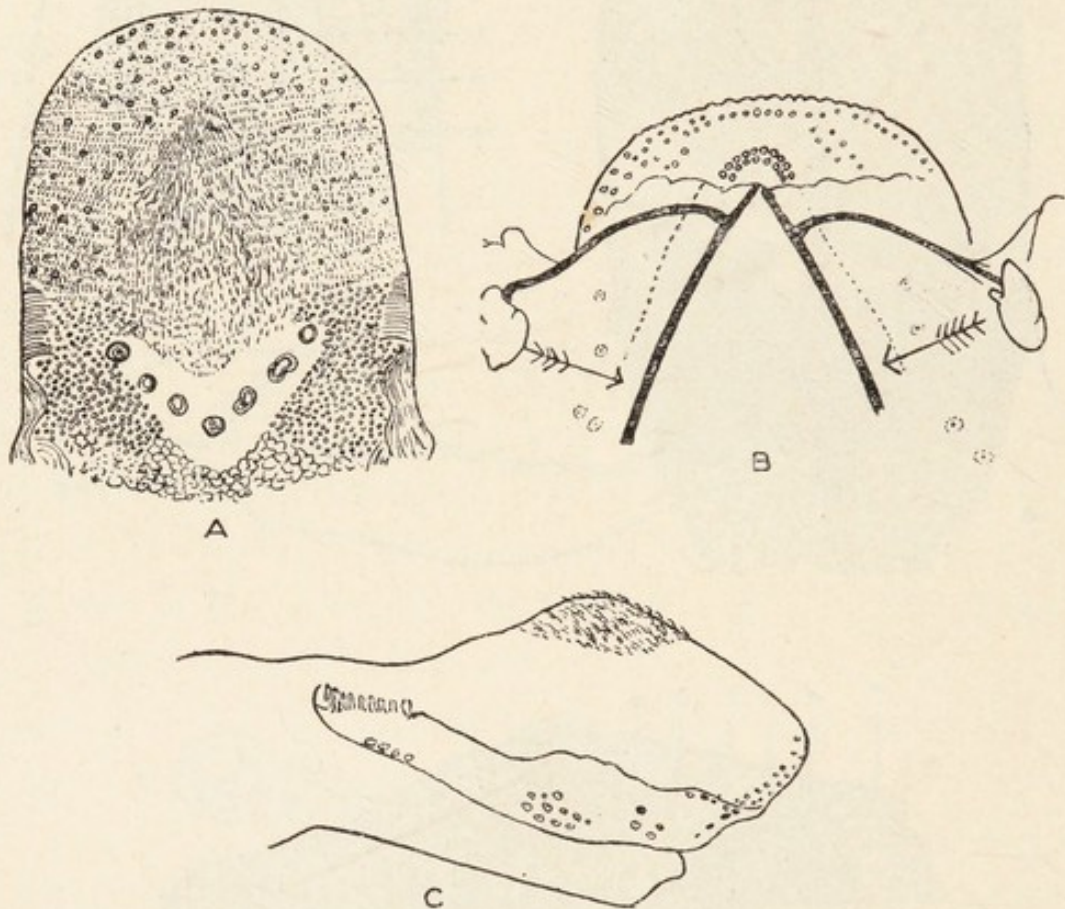


FIG. 39.—The tongue of the Orang-Outan. A., upper surface; B., inferior surface (the arrows point to the position of the submaxillary glands); C., side view of tongue.

tonsils are both present, and are nourished from the vascular circle formed by the branches of the ascending pharyngeal artery. The former is covered by fenestrated mucous membrane. Although lingual, faucial and pharyngeal tonsils are present I was unable to detect Waldeyer's lymphatic ring. Seesel's pocket is absent. The constrictor muscles are as in Man. The sinus of

Morgagni is large, and the levatores and tensores palati are more horizontal owing to the prognathism of the skull than in Man.

The *œsophagus* is entirely behind the trachea in the neck. It has similar relations in the neck and thorax to those in Man. The mucous membrane is thrown into prominent longitudinal folds in the

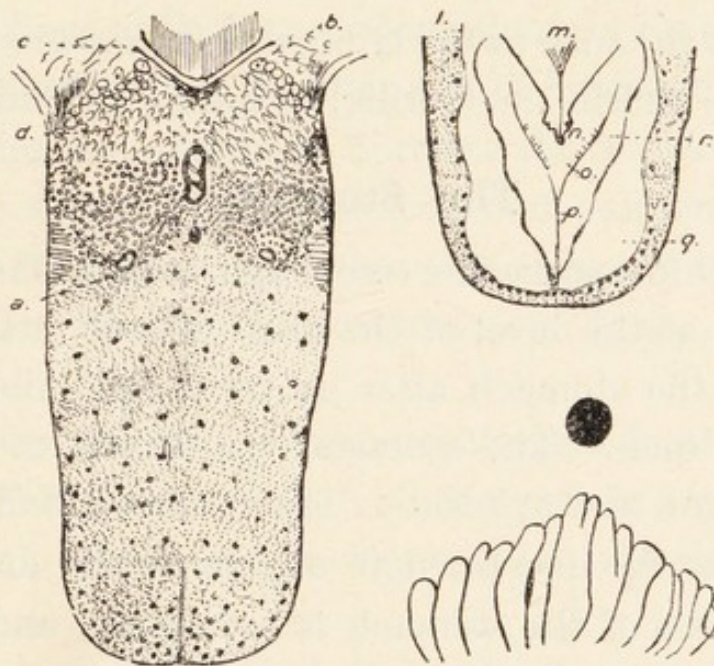


FIG. 40.—The tongue of the Bornean Gibbon showing the upper and lower surfaces and a highly magnified lateral organ. *a.*, central fungiform papilla; *b.*, tonsil; *c.*, epiglottis; *d.*, conical papillæ; *l.*, papillary border; *m.*, frenum; *n.*, frenal lamella; *o.*, non-pigmented area; *p.*, median sulcus; *r.*, pigmented area. The thick, black dot above the lateral organ in the lowest figure is the most lateral vallate papilla.

cervical and thoracic parts, but the former are more numerous and closer together. The walls are thinner and more dilated in the lower part of the *œsophagus*. In the upper part the inferior constrictor joins the outer longitudinal muscular coat of the *œsophagus*, which increases in thickness from above downwards, and becomes continuous with the outer coat of the gastric musculature. The circular muscle coat thickens from

above downwards and also becomes continuous with the circular fibres of the stomach. At the lower end of the œsophagus it forms the sphincter of the cardia, which is two inches long. The inner longitudinal fibres in the upper part consist of a few strands, and the submucosa bulges between them; they are entirely absent in the lower part of the œsophagus. Man has only two muscular coats. The folds of the mucous membrane extend throughout the tube in the Gibbon, but they are restricted to its lower end in the Gorilla, according to Deniker (44).

The Stomach.

In the Chimpanzee the œsophagus passes through the diaphragm at the level of the ninth dorsal vertebra, and opens into the stomach after an intra-abdominal course of half an inch. The stomach is divided into fundus, body, antrum, and pylorus. The fundus is well marked and projects up into the left cupola of the diaphragm. The long axis of the stomach is crescentic, and is more horizontal than in Man. The great curvature reaches a point half an inch below the fourth lumbar vertebra, and the lowest point of the lesser curvature is level with the first lumbar vertebra. Consequently the stomach is U-shaped, and the pylorus is not far from the œsophagus. The pyloric antrum is one and a half inches long, and the pylorus, whose walls are thick, is of the same length. Between the antrum and pylorus there is a slight incisura, and there is a sudden transition from the pylorus to the duodenum. The pylorus does not project like a knob into the duodenum as it does in Man.

The *serous coat* is a uniform covering, united in the usual manner to the omenta. The *muscles* are thin, but

three kinds are present. The external longitudinal layer is a complete covering, but it is thicker along the curvatures than on the intermediate parts of the body. The circular fibres are thickest; they are found in the body and pylorus, but only a few run from the œsophagus into the fundus. The oblique fibres are restricted to the fundus and part of the body to the left side of a downward prolongation of the long axis of the œsophagus, and they form rings as in Man. Consequently there are only two muscular layers—an outer one of longitudinal fibres, and an inner one of oblique fibres to the left and circular ones to the right. The subserous and submucous coats are thin. The *mucous membrane* is thin and soft, and it exhibits pits and glandular orifices as in Man. It is not greatly folded.

The arteries of the stomach are derived from the three branches of the cœliac axis, and the vessels are arranged as in Man. The gastric veins enter the portal vein (fig. 46).

The nerves are derived from the two vagi and the cœliac plexus. The left vagus runs along the lesser curvature as far as the pylorus.

Deniker, who made a thorough study of the Gorilla, pointed out that the stomach in the human and Gorilline foetuses lies behind the transverse colon, whereas it lies above it in the adult (44). In the adult animal the stomach is more globular than in Man, and the pyloric antrum is better defined. The mucous membrane has many rugæ in the pyloric region, but none in the cardiac part. Pits and glandular orifices are present as in Man.

In the Orang the stomach resembles that of the Chimpanzee rather than that of the Gorilla. It is

elongated, and a vertical partition marks off the pyloric antrum from the rest of the stomach; but the antrum communicates with the body of the stomach below it. Sandifort and Fick have described this arrangement. The vascular and nerve supply are as in the Chimpanzee.

Many observers have pointed out that the stomach in the Gibbons is more globular than in Man; and it is more elongated than in the Gorilla. The interior shows nothing peculiar.

The general relations of the stomach in the Anthropoid Apes are much as in Man.

A large body of literature dealing with the structure of the intestinal tract exists, but little has been written about the chemistry of digestion in the Apes. The only details which I have been able to trace are Wells's (413) articles on the purine enzymes. From the character of the diet there must be differences between the enzymes in Man and those in the Anthropoid Apes.

The Intestinal Tract.

In the Chimpanzee the *duodenum* begins opposite the first lumbar vertebra, and it is throughout entirely behind the peritoneum. It is divided as in Man into horizontal, descending and ascending parts which measure $1\frac{1}{2}$, 2, and $2\frac{1}{2}$ in. long respectively. There is a well-marked duodeno-jejunal flexure at the level of the first lumbar vertebra. The common bile-duct and pancreatic ducts have a common opening in the descending part, but there is no papilla. No *valvulae conniventes* are present, and the villi are small.

The *ileum and jejunum* are 11 ft. 5 in. long. Their villi are small. At intervals there are groups of small longitudinal folds of the mucosa. Four Peyer's patches are present at wide intervals in the lower half of the ileum; the lowest, which is also the largest, is 2 in. long and $\frac{3}{4}$ in. broad.

The *vermiform appendix* is $4\frac{1}{2}$ in. long, and the *cæcum* is 3 in. No appendix valve is present, but the ileo-cæcal orifice is guarded by a shelf valve.

The *colon* is 4 ft. long. It is sacculated as usual by two longitudinal muscle bands, and there are many appendices epiploicæ. No Peyer's patches are present. The most capacious part is the sigmoid colon.

The *rectum* and anal canal are $5\frac{1}{2}$ in. long. In the rectum there are eight circular folds, of which the fifth is very prominent, and below it there is a deep pocket on the left side. The anal canal shows numerous strongly-developed vertical folds of mucosa, representing the columns of Morgagni, but there are no traces of the valves of Ball. The entire rectum and anal canal form a straight tube without any trace of the flexures present in Man. Herrmann (84) has described the anal mucosa in detail, and Sperino (401) showed that the sebaceous follicles in the skin round the anus are large. In the Gorilla the **duodenum** is divided into three parts as in Man, but the first part is short. Valvulæ conniventes are present in the adult, but are absent in the early foetus; and Deniker (44) pointed out that they appear later in development in the Gorilla than in Man. The **ileum and jejunum** show nothing peculiar. Five or six Peyer's patches were observed by Deniker in the foetus. The *cæcum* is provided with a well-marked

vermiform appendix. Its base is expanded so that it appears to be a continuation of the cæcum in the foetus, but it has the usual uniform calibre throughout in the adult. It is provided with a mesentery, and it is disposed in a coil or spiral according to Bischoff and Bolau. The **large intestine**, particularly the ascending colon, is short. Deniker has drawn attention to the rate of growth of the whole intestinal tract as well as of its components. He showed that the whole canal grows more rapidly than the body until the end of the milk dentition, but it diminishes afterwards. In the foetus it is 4·4 times the length of the body, but it is 4·2 times as long as the body in the adult. The small intestine grows more rapidly than the colon till the milk dentition is complete, whereas the reverse is the case after that period. The vermiform appendix increases during life, whereas it decreases as age advances in Man.

In the Orang-Outan the intestinal tract is very long, the ratio of the bodily length to that of the canal from the pylorus to the anus being 1 to 6·13. Fick (247) gives the ratio as 1 to 4·3, which is similar to that in the Gorilla. In contradistinction to the Chimpanzee and Gorilla the **valvulæ conniventes** are very numerous; Bischoff denied their presence, but Barkow, Fick, Hartmann, Mayer, Owen and Sandifort describe or figure them. The **vermiform appendix** is very long, and arranged in a spiral as in the Gorilla. In the Gibbon the small intestine is 2·6 times the length of the body in the foetus (Deniker), but it is 3·7 to 5·9 times the length of the body after birth, according to the age of the animal. The **duodenum** is wide, and the common

bile and pancreatic ducts open into it together or separately. Valvulæ conniventes are absent, and there are five Peyer's patches. The **vermiform appendix** is long, and opens, according to Kohlbrügge (199), into the terminal part of the cæcum. This arrangement is present in several Gibbons seen by myself. The **colon** is about twice the length of the body, and its ascending part has many longitudinal and transverse folds which give it a reticulated appearance.

The Peritoneum.

In the Chimpanzee the great omentum is heavily laden with fat and reaches the symphysis pubis. All four layers are fused and can only be separated at the stomach and transverse colon. The anterior layers are attached to the greater gastric curvature, the first part of the duodenum and spleen, and bands connect it to the lateral abdominal parietes. Between the layers are the usual vessels and lymphatic glands.

The *lesser omentum* is attached as in Man, and the foramen of Winslow is large. It is bulged forwards above the stomach. Between its layers are numerous vessels, sympathetic nerves and lymphatic glands.

No gastro-pancreatic folds are present. The gastro-phrenic, gastro-splenic and lieno-renal ligaments are well marked. A peritoneal ligament connects the lower pole of the spleen to the transverse colon, and a small accessory spleen is connected to the colon at the same point. A well-marked ligament connects the pylorus to the right ribs, but no suspensory duodenal muscle exists.

The root of the mesentery of the small intestine runs

from the left side of the body of the first lumbar vertebra to the right iliac fossa. In the large intestine there is no mesentery to the cæcum, ascending, descending and pelvic colons. The appendix has a mesentery, but no other part has such a long mesentery as the iliac colon. In the rectum the peritoneum is disposed as in Man, being first surrounded by it, and then the peritoneum gradually leaves it till the lower part and the anal canal are quite devoid of a serous investment.

The other Apes have similar conditions. In lower Primates, which are pronograde, the colon is suspended on a complete mesentery; and the binding down of parts of it in the higher Apes is part of the changes which accompany the erect attitude.

The Salivary Glands.

THE CHIMPANZEE.

Many *labial salivary glands* are present.

The **parotid gland** (fig. 27) is pyramidal in shape, with the base upwards, immediately below the concha auris. The apex curves round the angle of the mandible and touches the submaxillary gland. The upper part is composed of small lobules, but the lower part is coarse. The capsule is well marked, but no lymphatic glands are included within it. Stensen's duct emerges from the upper part of the gland and its course and relations are as in Man. The relations of the gland to the large vessels and nerves are also as in Man.

The **submaxillary gland** (fig. 31) is flat and triangular and measures $1\frac{1}{2}$ in. in diameter. It is partly under the horizontal ramus of the mandible and partly on the inter-

ramal muscles. No strong capsule exists. It is composed of superficial and deep parts, each of which is coarsely lobulated. The duct emerges from the deep surface, runs as in Man, and opens on a frenal lamella beneath the tongue.

The **sublingual gland** (fig. 31) is pyramidal with the apex anterior. Its relations and the course of its duct are as in Man.

THE GORILLA.

Deniker (44) points out that the glands are well marked in the foetus, but his description does not differ in any essential point from the above account of the glands in the Chimpanzee. In the adult animal the **parotid gland** is relatively larger than in Man, and the part in contact with the concha auris is thicker than the part lying on the sterno-mastoid. Stensen's duct courses as in Man. The **submaxillary gland** is smaller than the parotid. The degree of development of these glands is associated with the herbivorous diet.

THE ORANG-OUTAN.

In the Orang, as in the Chimpanzee and Gorilla, the salivary glands are large, especially the parotid gland, whose outline is triangular.

THE GIBBON.

The position, relations and appearances of the salivary glands are similar to those in the Chimpanzee, and the ducts have the same course and relations.

In the Orang and Siamang Gibbon the **ducts of the submaxillary** glands open on small papillæ at the sides of the frenum linguæ as in Man. But in all other

Anthropoids they open at the apex of a triangular fold of mucous membrane, to which Pocock applied the name of frenal lamellæ.

The arterial and nervous supply, and the venous drainage of the salivary glands are similar in the Apes and Man, but Man has more lymphatic glands in the neighbourhood of the salivary glands.

The Liver.

In the Chimpanzee the liver resembles that in Man. The umbilical fissure is much bridged over, and the fissure of the vena cava is also enclosed. Indications of lateral fissures exist. Near the umbilical region of the right lobe there is a small lobule directed ventrally. The gall-bladder is superficial and extends beyond the ventral margin of the lobe and it is flexed on itself. In occasional specimens the gall-bladder is deeply embedded in the liver substance. The Spigelian lobe is subquadrate, and the caudate lobe is a triangular cone directed to the right. In some specimens the apex of the caudate lobe reaches the right margin of the liver, but in others it does not do so. The relative sizes of the hepatic lobes may be expressed by Garrod's method thus:—

$$R2 > L > Sp = C.$$

In the Orang the umbilical vein divides the liver into two halves, and there is no trace of lateral fissures. The umbilical fissure is bridged over, but the vena cava is not enclosed. The left lobe is flat, expanded and nearly semicircular; but the right lobe is thick and oblong. The Spigelian lobe has a tongue-shaped process which overhangs the portal fissure, and the caudate lobe is well

marked. The gall-bladder is long, narrow and straight, and its fundus projects well beyond the edge of the liver.

The liver in the Gibbon is much as in Man. The umbilical fissure is not bridged over on the inferior surface, and there are no lateral fissures. The Spigelian lobe is prominent, but the caudate lobe is insignificant. The gall-bladder is not convoluted and projects beyond the hepatic margin.

The Gorilla has a more primitive type of liver than any described above, and Flower (328) described it as follows: The upper surface has a very large triangular space devoid of peritoneum, having been attached to the diaphragm. The suspensory ligament passes from this surface to the umbilical fissure, which is a well-marked notch on the free border, nearly an inch in depth, placed only 1 in. to the right of the middle line, so that the right and left segments are more nearly equal to one another than in Man or the other Anthropoid Apes. The borders of the liver generally are very thin, especially the upper edge of the left lateral lobe.

The left segment is divided into two distinct lobes by a cleft extending from the anterior more than half way to the posterior border. Of these the lateral is much the largest, and is triangular in shape. On the upper surface it is overlapped by the left central.

Similarly, the right segment is divided into two lobes by a deep fissure; but of these the central is very much the largest, and of quadrate form, the lateral, being small and triangular, and overlapped above by the central.

On the under surface the portal fissure is placed very near the posterior border, and is 3 in. in width. The

duct, artery, and vein have their usual arrangement on entering it. The right and left fissures almost reach to its two extremities. The umbilical fissure extends for nearly 2 in. from the anterior border; thence to the portal fissure the round ligament is buried beneath the hepatic substance joining the right and left central lobes.

The Spigelian lobe is small but conspicuous, narrow from before backwards, forming a prominent transverse ridge, continued into a trihedral free process, projecting to the left. Of nearly the same size is the caudate lobe, continuous with the Spigelian on the left, and passing as a ridge on to the under surface of the right lateral lobe, close to its posterior border, marked off from it anteriorly by a deep groove, and terminating in a pointed apex, free for the distance of one inch. This is separated from the right lateral lobe posteriorly by the great fossa for the vena cava, which fills the fossa, and is not bridged over by any hepatic substance.

The posterior part of the right lateral lobe is very little developed, so that the caudate lobe is unusually posterior in position. The distance from the left apex of the Spigelian lobe to the right apex of the caudate lobe is 6 in.; from the latter point to the margin of the right lateral lobe is $1\frac{1}{2}$ in. The gall-bladder had been removed from the specimen before it came under examination.

The Pancreas.

The pancreas is arranged on the same plan as in Man, and in some specimens a process passes up alongside the portal vein. The duct joins the common bile duct, and the common opening may lie on the summit of a bile papilla.

CHAPTER IX.

ORGANS OF CIRCULATION, BLOOD AND
DUCTLESS GLANDS.

SECTION A.—HEART AND ARTERIES.

Pericardium.—The pericardium consists of fibrous and serous parts. The former is adherent to the central tendon of the diaphragm below, and is lost on the great vessels above. The serous part is disposed as in Man.

Heart.—In all the Apes the heart is small, but it is slightly longer relatively to the length of the body in the Gorilla than in Man. It has the same form in the adult as in Man, but Deniker (44) points out that it is more globular in the foetal Gibbon. Its long axis is directed downwards and to the left. The apex, which is formed by the left ventricle, lies in the fifth interspace as in Man and in the Chimpanzee. The structure of the interior of the heart does not differ in any important respect from that in Man. The long axis is more horizontal than in the lower Primates.

Aorta.—The aorta is divisible into the same parts as in Man, and the relations of each are similar. The branches, however, differ in many respects.

The branches of the aortic arch are arranged in one of two ways. In the first type, which is seen in all Gorillas and some Chimpanzees, the arrangement is as in Man. In the second type (fig. 41), which occurs in

some Chimpanzees, the Orang and the Gibbons, the arch gives off the *innominate* (I.A.) and *left subclavian* (L.S.A.) arteries; and the former, after giving off the *left common carotid artery* (L.C.C.A.), divides into the *right common carotid* (R.C.C.A.) and *right subclavian* (R.S.A.) arteries. In one Chimpanzee I observed the

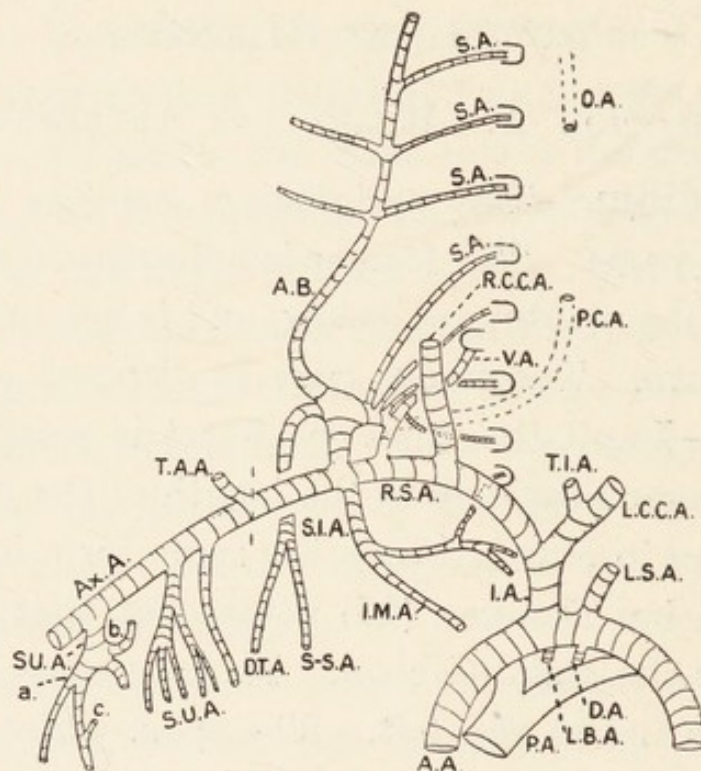


FIG. 41.—The aorta and subclavian vessels in the Chimpanzee. A.A., aorta; A.B., ascending branch; Ax.A., axillary artery; D.A., ductus arteriosus; D.T.A., descending branch of transverse cervical artery; I.A., innominate artery; I.M.A., internal mammary artery; L.C.C.A. and R.C.C.A., left and right common carotid arteries; L.S.A. and R.S.A., left and right subclavian arteries; L.B.A., left bronchial artery; O.A., occipital artery; P.A., pulmonary artery; P.C.A., deep cervical artery; S.A., spinal arteries; S.I.A., superior intercostal artery; S.S.A., suprascapular artery; S.U.A., subscapular vessels; T.A.A., thoracic axis; T.I.A., thyroidea ima; V.A., vertebral artery; a., subscapularis artery; b., humeral circumflex trunk; c., artery to teres-major.

main *left bronchial artery* (L.B.A.) arising from the concavity of the arch. In many very young animals the *ductus arteriosus* (D.A.) is seen running from the arch to the left pulmonary artery. It is said that this vessel

remains open till the milk dentition is complete in some of the Apes, but more investigation is necessary to settle this point. The ligamentum arteriosum is thick in the adult Gorilla (Eisler).

The pulmonary artery is as in Man, but is relatively wider in the Chimpanzee. It divides as in Man. Eisler (442) describes its relations to the bronchi in the Gorilla as being similar to those in Man.

Arteries of the Head and Neck.

The **common carotid arteries** divide into small internal and large external carotid arteries at the upper border of the thyroid cartilage. In many Apes it gives off branches to the thyroid gland when there is no thyroid branch of the subclavian artery. The following table shows some of the arrangements:—

| Man | Gorillas | Chimpan ee | Orang |
|----------------|---|--|-------------|
| No branches .. | (1) Inferior thyroid branch (442) Superior and inferior thyroid branches | (1) As in man (442).. (2) Inferior thyroid branch (399) (3) Middle and inferior thyroid arteries (399) | No branches |

The **external carotid artery** (fig. 42) has the same course and relations as in Man, but the branches are fewer in the Apes. There is a linguo-facial artery which breaks up into lingual and facial arteries; and the occipital and posterior auricular arteries arise from an occipito-auricular trunk in the Gorilla and Chimpanzee, but these vessels arise separately in the Orang. In the Gorilla alone there is an ascending palatine artery in addition to the ascending pharyngeal vessel. The

following account of the arteries in the Chimpanzee is generally applicable to the other Apes.

The *superior thyroid artery* (fig. 42 S.T.A.) describes the usual downward curve. It anastomoses with the other thyroid arteries, and supplies the gland and the pretracheal muscles.

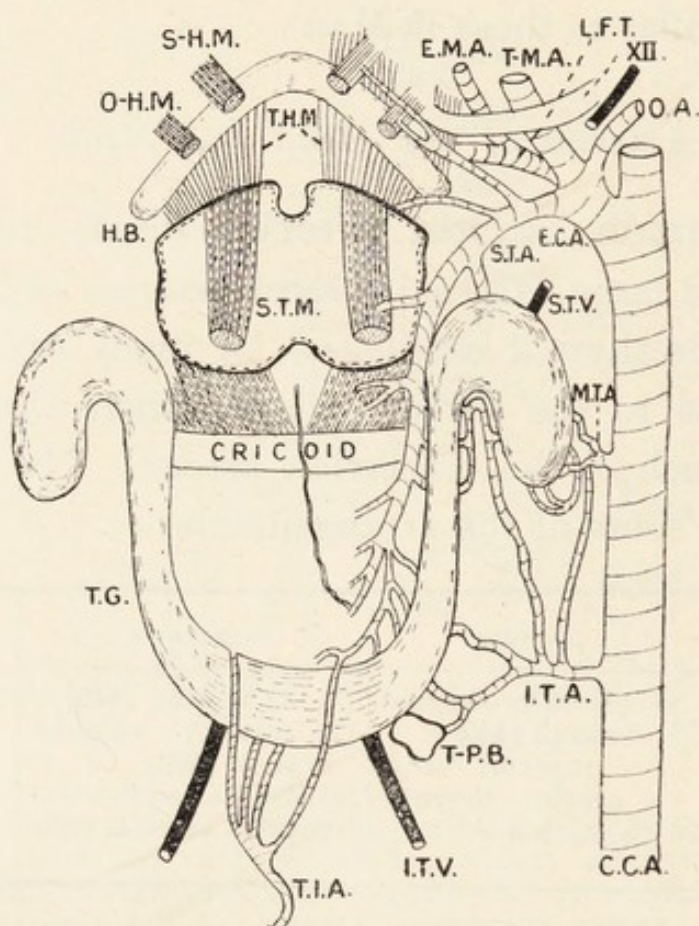


FIG. 42.—Arteries of the head and neck in the Chimpanzee. C.C.A. and E.C.A., common and external carotid arteries; E.M.A., facial artery; H.B., hyoid bone; I.T.A., M.T.A. and S.T.A., inferior, middle and superior thyroid arteries; I.T.V. and S.T.V., inferior and superior thyroid veins; L.F.T., linguo-facial trunk; O.A., occipito auricular trunk; O.H.M., omo-hyoid muscle; S.H.M. and S.T.M., sterno-hyoid and sterno-thyroid muscles; T.H.M., thyro-hyoid muscle; T.G., thyroid gland; T.I.A., thyroidea ima artery; T.M.A., temporo-maxillary artery; T.P.B., thymic-parathyroid mass; XII, hypoglossal nerve.

The *lingual artery* runs forwards between the hyoglossus and the middle constrictor of the pharynx. It then sinks into the genio-glossus muscle and passes

within the tongue to the apex, where it anastomoses with its neighbour. It supplies the submaxillary gland and the muscles of the tongue and suprahyoid region.

The *facial artery* (fig. 27 E.M.A.) runs forward between the submaxillary gland and mandible. At the anterior border of the masseter it gets into the face where its course and relations are as in Man. Before it reaches the face it gives off a large artery to the submaxillary gland (S.M.G.). In the face (fig. 27B) it gives off masseteric, inferior labial (I.L.A.), inferior coronary (I.C.A.) and superior labial (S.L.A.) arteries to the lips. The submaxillary branch supplies the mylohyoid muscle.

The *superficial temporal artery* (fig. 27, S.T.V.) is the apparent continuation of the external carotid artery. It runs upwards along with the corresponding vein and auriculo-temporal nerve. It divides into two vessels, which supply the scalp from the supra-orbital to the occipital crest.

The *internal maxillary artery* (fig. 30, I.M.A.) arises within the parotid gland. It runs as in Man, and its relations are similar. It gives off the following branches:—

A.—In the Parotid Gland:—

- (1) *Parotid arteries*.
- (2) *Transverse facial artery*, which supplies the parotid and masseter.

B.—In the Pterygoid Region:—

- (1) Branches to the pterygoid muscles.
- (2) *Inferior dental artery* (I.D.A.) which accompanies the inferior dental nerve.
- (3) *Meningeal artery* (M.A.), which divides into middle and accessory arteries. These run into the skull as in Man.

- (4) *Articular arteries* to the temporo-maxillary joint.
- (5) *Buccal artery* (B.A.), which accompanies the long buccal nerve into the face.
- (6) *Posterior superior dental artery* (P.S.D.) to the gums round the molar teeth.
- (7) Small vessels to the suctorial pad of fat (S.P.F.).
- (8) Two *deep temporal arteries* (D.T.A.), which divide and anastomose within the temporal muscle.

C.—In the Pterygo-maxillary region :—

- (1) *Infra-orbital artery*, which passes to the face. It supplies the incisor and canine teeth and the skin and muscles of the upper lip.
- (2) *Descending palatine artery* to the soft palate, gums and mucous membrane of the mouth.
- (3) *Pterygo-palatine* and *spheno-palatine arteries* to the pharynx, nose, Eustachian tube, sphenoidal sinus and ethmoidal air cells.

The *occipital artery* arises from the beginning of the external carotid artery and runs upwards and backwards under the cleido-mastoid and splenius capitis to end among the muscles of the neck. It gives off the *posterior auricular artery* to the auricle and parotid gland, the *descending cervical artery* to the muscles of the neck, and *muscular branches* to the muscles of the sub-occipital triangle.

The *ascending pharyngeal artery* (fig. 30, A.P.A.) runs upwards. Close to the basis cranii it curves laterally and passes into the jugular foramen. It supplies the pharynx and the soft palate with its muscles. Its branches form an arterial circle, whence twigs run to the pharyngeal tonsil.

The **internal carotid artery** has no cervical branches. It runs through the carotid canal in the temporal bone along with branches of the superior cervical ganglion of the sympathetic (fig. 30). It ends as in Man, and the *ophthalmic artery* is distributed as in the human orbit.

Arteries of the Arm.

Subclavian Artery.—The comparison between the branches in Man and those in the Apes is shown in the following table ; but the list does not show the order in which the branches arise :—

| Man | Gorilla | Chimpanzee (fig. 41) |
|------------------------|----------------------|-------------------------------|
| Vertebral | Vertebral | Vertebral (V.A.) |
| Thyroid axis .. | — | — |
| Inferior thyroid .. | — | —* |
| Ascending cervical.. | Ascending cervical.. | — |
| Superficial cervical.. | Superficial cervical | — |
| Transverse scapular | Transverse scapular | — |
| Internal mammary | Internal mammary | Internal mammary (I.M.A.) |
| Transverse cervical | — | — |
| Costo-cervical trunk | Costo-cervical trunk | Costo-cervical trunk |
| Deep cervical .. | Deep cervical .. | Deep cervical (P.C.A.) |
| Superior intercostal | Superior intercostal | Spinal arterial (S.A.) |
| — | Transverse cervical | Transverse cervical |
| — | — | Transverse scapular (S.S.A.) |
| — | — | Long thoracic (L.T.A.) |
| — | — | Ascending cervical (A.B.) |
| — | — | Superior intercostal (S.I.A.) |
| — | — | Prevertebral muscular |

In one Chimpanzee there was a separate inferior thyroid artery.

Although the vessels arise differently from those in Man, their distribution is generally similar in all. The *vertebral artery*, accompanied by twigs from the inferior cervical ganglion of the sympathetic, enters the foramen transversarium in the sixth cervical vertebra. The *deep cervical artery* supplies the muscles of the back of the neck, and anastomoses with a branch of the occipital artery. The *ascending cervical artery* supplies the muscles of the posterior triangle ; in the Chimpanzee it sends vessels into the first four intervertebral foramina, the lower four receiving spinal branches from the costo-cervical trunk. The *long thoracic artery* may arise from the subclavian in the Chimpanzee, but does not do so in

all specimens, nor in the other Apes. The *suprascapular and transverse cervical arteries* run much as in Man, but they do not form a marked anastomosis round the scapula in the Chimpanzee and Gibbon as in Man. The *superior intercostal artery* supplies the structures in the first or first two intercostal spaces ; in one Chimpanzee it passed into the first thoracic intervertebral foramen. The *internal mammary artery* may arise alone or together with the superior intercostal artery. Its course and relations are as in Man, but it divides at different levels into the musculo-phrenic and superior epigastric arteries, which are distributed as in Man. In the Chimpanzee it divides in the fifth intercostal space. It supplies the pericardium, thymus gland and mediastinal tissues.

The **Axillary Artery** has very similar relations to those in Man, but the branches differ, as the following table shows :—

| Man | Chimpanzee (fig. 41) | Gorilla |
|----------------------|----------------------|---------------------|
| Superior thoracic .. | — | — |
| Acromio-thoracic .. | Acromio-thoracic .. | Acromio-thoracic |
| Long thoracic .. | — | Long thoracic |
| Alar thoracic .. | — | — |
| Subscapular.. .. | Subscapular (major) | Subscapular (major) |
| Anterior circumflex | Muscular | Muscular |
| Posterior „ .. | Thoraco-dorsal .. | Thoraco-dorsal |
| — | Humeral trunk .. | Humeral trunk |
| — | Anterior circumflex | Anterior circumflex |
| — | Posterior „ .. | Posterior „ |
| — | Circumflex scapular | Circumflex scapular |
| — | Subscapular (minor) | Subscapular (minor) |

Although the branches arise differently in some cases the ultimate distribution is much as in Man. The most notable feature is the retention of a humeral circumflex trunk in the Apes, which divides later. This is a feature of the Cercopithecidae. In the Orang the artery gives off

the thyroid axis, subscapular trunk and circumflex trunk.

The **Brachial Artery** (fig. 43) lies superficial to the median nerve. It ends by separating into the radial and

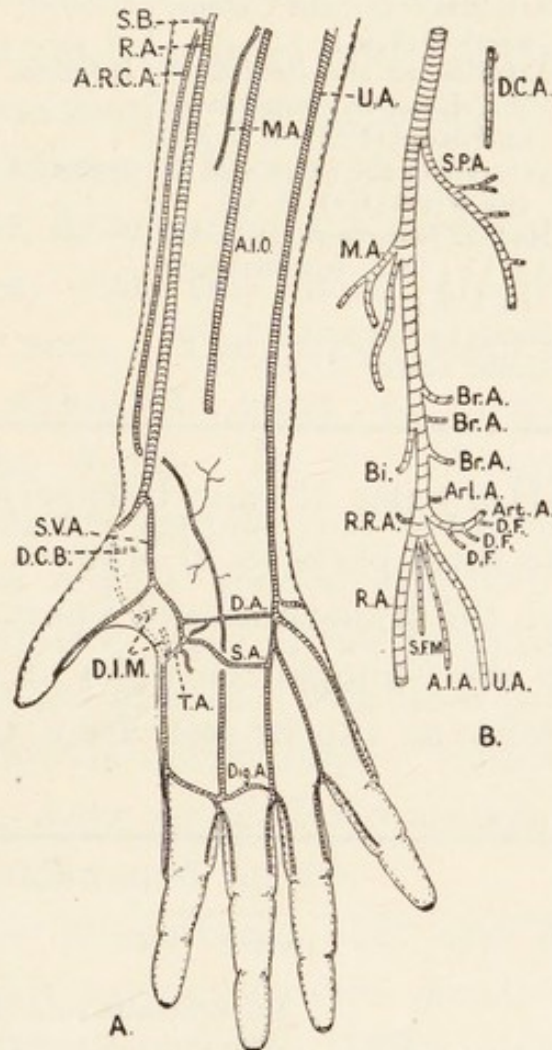


FIG. 43.—The arteries of the upper extremity in the Chimpanzee. A, arteries of the forearm and hand; B, brachial artery; D.A., deep palmar arch; Dig. A., digital arterial arch; S.A., superficial palmar arch. Other letters explained in text.

ulnar arteries, but in some animals it is apparently continued by the ulnar artery after giving off the radial artery. The branches differ as follows from those in Man:—

| Man | Chimpanzee (fig. 43) | Gorilla |
|-------------------|--|---------------------------|
| Superior profunda | Superior profunda (S.P.A.) | Profunda brachii |
| Inferior ,, | Muscular to the flexor muscles (M.A.) | Posterior collateral |
| Nutrient | Arteries to brachialis anticus (Br.A.) | Radial collateral |
| Anastomotic | Arteries to biceps (Bi.) .. | Superior ulnar collateral |
| Radial | Articular to the elbow joint (Art.A.) | Middle ,, ,, |
| Ulnar | Arteries to the flexors of the forearm (superficial and deep) (D.F.: S.F.M.) | Inferior ,, ,, |
| — | Arteries to the extensors of the wrist (Ext. M. A.) | Superior ulnar recurrent |
| — | Radial recurrent (R.R.A.) | — |
| — | Anterior interosseous (A.I.A.) | — |
| — | Radial artery (R.A.) .. | — |
| — | Ulnar artery (U.A.) .. | — |

The **Radial Artery** (fig. 43) may be superficial or deep. It is divisible into three parts as in Man—a part in the forearm, a part on the trapezium, and a part in the hand. The branches in the Chimpanzee differ in several ways from those in Man, as can be seen from the following table :—

| Man | Chimpanzee (fig. 43) |
|---|--|
| Part I. Radial recurrent Superficialis volæ Anterior radial carpal Muscular | Part I. — Superficialis volæ (S.V.A.) Anterior radial carpal (A.R.C.A.) Muscular to the superficial flexors Muscular to the supinator brevis (S.B.) |
| Part II. | Part II. Dorsal carpal arteries (D.C.B.) Muscular to the first dorsal interosseous (D.I.M.) |
| Part III. Radialis indicis Princeps pollicis | Part III. To thenar muscles (T.A.) To first dorsal interosseous muscle To adductor muscles To lumbricales To contiguous sides of pollex and index |

The *anterior radial carpal artery* supplies the inferior radio-ulnar, radio-carpal, carpo-metacarpal and inter-carpal joints. The *superficialis volæ* supplies the thenar muscles, the inner side of the pollex, and gives a twig to complete the superficial palmar arch. It is stated that the Gorilla has no superficial palmar arch because its hand has not yet been freed from the duty of supporting the body in locomotion. In the Orang the palmar arches are similar to those in Man.

The **Ulnar Artery** (fig. 43) gives off a deep branch which unites with the radial artery to form the deep palmar arch. The parent stem runs down into the hand, where it plays an important part in supplying the digits. In the Chimpanzee it bifurcates; one branch supplies the inner side of the minimus, and the second divides into two vessels which supply the adjacent sides of the minimus and annularis, and annularis and medius. The other parts of the fingers are supplied by the radial artery. Hence the radial and ulnar arteries have equal distributions as regards the skin of the pollex and fingers.

It must be remembered that the arteries of the limbs are liable to considerable variation as shown by Eisler (442), Manners Smith (149a), and others. Variations were observed by me in three consecutive Chimpanzees. The most notable differences were observed in the size of the superficial palmar arch, but it was present in all three animals. This seems to distinguish the Chimpanzee from the Gorilla, which has no superficial arch. The Orang has a large superficial arch.

Arteries of the Thorax, Abdomen and Pelvis.

The **thoracic aorta** in the Chimpanzee gives off intercostal arteries to the lower ten intercostal spaces, the first two being supplied by the superior intercostal branches of the subclavian artery. Branches are given to the œsophagus, right and left lungs. In the Gorilla, according to Eisler (442), there is an *arteria intercostalis prima* to the first intercostal space, twelve pairs of intercostal arteries including the subcostal arteries, and an *azygos tracheæ*; the latter, which supplies the lymph glands, trachea and œsophagus, arises near the concavity of the aortic arch. The bronchial arteries arise from the second intercostal arteries. Man has no *azygos tracheæ*; and the Gorilla is the only Ape possessing it.

The **abdominal aorta** divides at the lower border of the last lumbar vertebra into the two common iliac arteries. Its branches differ from those in Man, as can be seen from the following table:—

| Man | Gorilla | Chimpanzee | Gibbon |
|---------------------|---------------------|----------------------------------|---------------------|
| Phrenics .. | Phrenics .. | Phrenic | Phrenics |
| Coeliac axis .. | Coeliac axis .. | Coeliac axis .. | Coeliac axis |
| Suprarenals .. | Suprarenals .. | — | Suprarenals |
| Sup. mesenteric | Sup. mesenteric | Sup. mesenteric | Sup. mesenteric |
| Renals | Renals | Renals | Renals |
| Spermatics .. | Spermatics .. | Right ovarian or both spermatics | Spermatics |
| Inferior mesenteric | Inferior mesenteric | Inferior mesenteric | Inferior mesenteric |
| Lumbars (pairs) | Lumbars (5 single) | Lumbars (4 single) | Lumbars (pairs) |
| Mid sacral .. | Mid sacral .. | — | — |

It is, therefore, evident that the Chimpanzee differs more than the Gorilla and Gibbon from Man in the origin of the branches of the abdominal aorta. The *phrenic artery* is single and gives off arteries to the

suprarenal capsules. It divides into two diverging vessels which supply all parts of the diaphragm. The *suprarenal arteries* are derived from the phrenic and renal arteries, but no twigs come from the aorta. These peculiarities, likewise the absence of the middle sacral

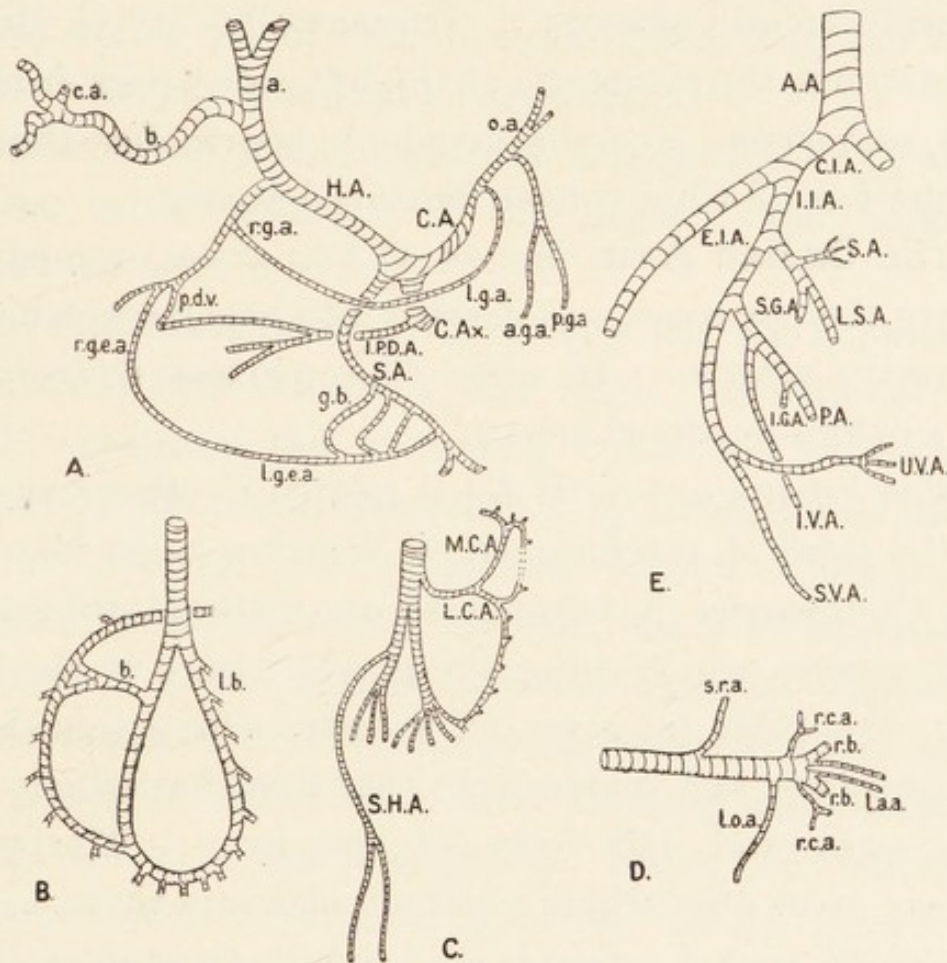


FIG. 44.—The abdominal and pelvic arteries in the Chimpanzee. A, coeliac axis; B, superior mesenteric artery; C, inferior mesenteric artery; D, left renal artery; E, hypogastric artery. A.A., aortic arch; C.I.A., E.I.A., I.I.A., common, external and internal iliac arteries; r.b., renal branches; r.c.a., renal capsule arteries; s.r.a., suprarenal arteries; l.a.a., anastomosis between renal and lumbar arteries; l.o.a., left ovarian artery. Other letters explained in text.

artery, were observed in three Chimpanzees. In a female Chimpanzee the *left ovarian artery* arose from the left renal artery (fig. 44, D.), but in two males both spermatic arteries came from the abdominal aorta.

When the *lumbar arteries* arose as median unpaired vessels, as they did in the three Chimpanzees, they bifurcated later; in one animal, as in the Gorilla described by Eisler (442), the fourth artery is an ilio-lumbar artery. In the Gorilla, the *middle sacral artery* gives off the first sacral artery, and divides into two lateral sacral arteries. Occasionally it is double. Sometimes the *spermatic* of the left side arises from the left suprarenal, a condition which approaches the state in the female Chimpanzee described above.

The **Cœliac Axis** (fig. 44, C.Ax.) arises immediately above the pancreas, and divides into hepatic, splenic and coronary arteries. In some Chimpanzees it also gives off a pyloro-duodenal artery.

The *hepatic artery* (H.A.) is related to other structures in the front of the foramen of Winslow as in Man. In the Chimpanzee it bifurcates; one half (a) divides into two vessels, which enter the portal fissure of the liver; the other half (b) gives off a *cystic artery* (c.a.) to the gall-bladder, and divides into two branches which enter the right and left lobes of the liver. The parent artery gives off a trunk which divides into three vessels: the *right gastric artery* (r.g.a.), which anastomoses with the left gastric artery; *pyloro-duodenal vessels* (p.d.v.), which anastomose with the pyloro-duodenal branch of the cœliac axis; and the *right gastro-epiploic artery* (r.g.e.a.), which anastomoses with branches of the splenic artery in the great omentum.

The *splenic artery* (S.A.) gives branches to the stomach, spleen and pancreas. Its branches form the *left gastro-epiploic artery* (l.g.e.a.) which anastomoses with a branch of the hepatic artery.

The *coronary artery* (C.A.) is continued through the œsophageal opening in the diaphragm by the *œsophageal artery* (o.a.). It gives off *anterior gastric arteries* (a.g.a.) to the anterior wall of the fundus and body of the stomach, *posterior gastric arteries* (p.g.a.) to the posterior wall of the fundus and body of the stomach, and the *left gastric artery* (l.g.a.), which anastomoses with the right gastric artery on the lesser curvature.

The *inferior pyloro-duodenal artery* (I.P.D.A.) anastomoses with branches of the hepatic and superior mesenteric arteries.

The **superior mesenteric artery** (fig. 44, B.) sweeps downwards into the right iliac fossa. It supplies the small intestines, the ascending colon and a variable amount of the transverse colon. It anastomoses above with the inferior pyloro-duodenal branch of the coeliac axis, and its lowest branch anastomoses with the middle colic branch of the inferior mesenteric artery. Between its two extremes of distribution, its branches anastomose with those on either side, thus forming an extensive arterial chain in the mesentery. There are, however, no large tiers of arterial arcades. Many lymphatic glands and sympathetic nerves lie among the branches.

The **inferior mesenteric artery** (fig. 44, E.) arises from the front of the abdominal aorta a short distance above its bifurcation. It gives off a *middle colic artery* (M.C.A.) which supplies the left part of the transverse colon and anastomoses with the right colic branch of the superior mesenteric artery and a branch of the left colic artery. The *left colic artery* (L.C.A.), the second branch of the inferior mesenteric artery, anastomoses by its branches with the middle colic artery above, and the

hæmorrhoidal vessels below ; it supplies the descending and iliac colons. In the Chimpanzee the *superior hæmorrhoidal artery* (S.H.A.) goes down into the pelvis to supply the rectum and anus ; it is relatively larger than in Man, and replaces part of the hæmorrhoidal distribution of the internal iliac artery.

The branches of the mesenteric arteries in the Gibbon differ from the above. Kohlbrügge (199) points out that the ileo-colic branch of the superior mesenteric artery supplies the ascending colon, and there is no right colic artery. The middle colic artery also arises from the superior mesenteric artery, and supplies the ascending and transverse colons. The inferior mesenteric artery supplies the descending colon and rectum. In the Orang the middle colic artery comes from the superior mesenteric trunk.

The **common iliac arteries** are similar in the Apes and Man.

The **external iliac arteries** course as in Man. In the Chimpanzee they may give off no branches at all, but sometimes the deep epigastric arteries arise from them. Eisler (442) points out that they give off the deep epigastric, spermatic, and deep circumflex iliac arteries in the Gorilla.

The **internal iliac artery** (fig. 44, E) in the Chimpanzee divides into anterior and posterior divisions, whose branches are as follows :—

A.—Anterior Division.

- | | | |
|--------------------------------|---|--|
| (1) A trunk which divides into | { | Uteri-vaginal vessels (U.V.A.). Superior vesical artery (S.V.A.). |
|--------------------------------|---|--|

(2) Pudendal Artery (P.A.) which courses as in Man.

It gives off :—

- (a) Inferior vesical artery (I.V.A.).
- (b) Inferior gluteal artery (I.G.A.).
- (c) Branches to the rectum, vagina, anus and perineum.

B.—Posterior Division.

- (1) Anterior sacral arteries (S.A.).
- (2) Lateral sacral artery (L.S.A.).
- (3) Superior gluteal artery (S.G.A.).

The ultimate distribution of these arteries is much as in Man.

Arteries of the Leg.

Femoral Artery.—In the Chimpanzee it begins about the level of the middle of Poupart's ligament and runs distally for $1\frac{1}{2}$ in. It gives off the arteria profunda femoris at that point and is continued as the superficial femoral artery. It passes between the two parts of the adductor magnus and becomes the popliteal artery. There is no Hunter's canal. The following are the branches in Man and the Chimpanzee :—

| Man | Chimpanzee |
|---|---------------------------------------|
| A.—From the Common Femoral Artery— | |
| (1) Superficial epigastric .. | — |
| (2) Superficial circumflex iliac | — |
| (3) Superficial external pudic | (3) Superficial external pudic |
| — | (4) A trunk dividing into : |
| | (a) Mesial femoral circumflex |
| | (b) Abdominal artery |
| | (i) Nutrient artery to ilium |
| | (ii) Deep epigastric artery |
| | (iii) Obturator artery |
| | (5) Deep circumflex iliac artery |
| B.—From the Deep Femoral Artery— | |
| — | (1) Lateral femoral circumflex artery |
| — | (2) Muscular to gluteus medius |
| — | (3) Muscular to the adductor muscles |
| | (not perforating arteries) |
| — | (4) Muscular to the biceps |
| C.—From the Superficial Femoral Artery— | |
| — | (1) Saphenous artery |

The *deep epigastric artery* in the Chimpanzee arises from the external iliac or femoral artery. It runs up in the sheath of the rectus muscle, but it does not anastomose with the superficial epigastric branch of the internal mammary artery. In rare cases it arises from the femoral artery in Man. The *obturator artery* is similar in the Apes and in Man.

The *circumflex arteries* in the Chimpanzee differ from those in Man. The mesial femoral circumflex artery runs down over the head of the femur under the adductor muscles and supplies the psoas, obturator internus, adductor magnus and capsule of the hip-joint. It then passes to the back of the thigh and sends branches to the adductor magnus, gluteus maximus, quadratus femoris and biceps. It also gives off an *arteria comes nervi ischiadici*. The lateral femoral circumflex artery divides into ascending, transverse and descending branches, each of which supplies muscles and the hip-joint. The ascending branch supplies the glutei and rectus femoris, the transverse branch supplies the gluteus maximus and vastus externus, and the descending branch supplies the rectus femoris, vastus externus and crureus. Eisler (442) points out that the vessels differ on both sides in the Gorilla; the circumflex arteries may arise from the profunda femoris; the mesial artery may give off the obturator artery, and the lateral artery may give off the superficial epigastric and external pudendal arteries.

The *profunda femoris* gives off two perforating arteries in the Gorilla, but there are no true perforating arteries in the Chimpanzee.

The **popliteal artery** in the Chimpanzee gives off branches to the gastrocnemius, an articular artery to the

knee-joint and a genicular trunk, and the latter divides into lateral, mesial and descending arteries. The lateral genicular artery gives a nutrient artery to the femur, a branch to the back of the knee-joint and one which passes round to the front of the capsule. The mesial genicular artery supplies the capsule in the popliteal space. The descending (sural) artery supplies the popliteus and passes between the tibia and fibula to the anterior tibial muscles. This plan is adopted in the Gorilla, but the genicular and sural branches are more numerous, and there is a recurrent artery in addition.

The **posterior tibial artery** is generally similar in the Gorilla and Chimpanzee. In the latter it continues the popliteal artery. It gives off a recurrent branch, which anastomoses with the geniculate arteries, but this vessel arises from the popliteal artery in the Gorilla. It gives off a vessel corresponding to the anterior tibial artery in Man; this branch runs down in the posterior tibial region and then curves into the anterior tibial region; and it gives off the following branches:—

(1) An artery which anastomoses with the saphenous artery to form the arterial arcade on the dorsum of the foot.

(2) Muscular arteries.

(3) Malleolar arteries.

(4) Nutrient artery to the fibula.

(5) Articular arteries to the ankle-joint.

The posterior tibial artery divides under the lacinate ligament into medial and lateral plantar arteries. The *medial plantar artery* gives off medial calcanean branches to the skin of the inner side of the sole, digital arteries to the three inner toes and muscular arteries to the

abductor hallucis and flexor brevis hallucis. The *lateral plantar artery*, after giving off the lateral calcanean artery to the skin of the heel and muscular branches to the flexor brevis digitorum, accessorius and abductor minimi digiti, divides into superficial and deep divisions. The former supplies the skin of the two outer digits; the latter supplies the interossei and tarso-metatarsal joints, and completes the plantar arch with the arteria dorsalis pedis.

The Apes are characterized by the possession of a well-marked branch of the femoral artery known as the **arteria saphena**. It runs down into the foot where it participates in the formation of an arterial arcade on the dorsum. Eventually it becomes the dorsalis pedis, which combines with the lateral plantar artery to form the plantar arterial arch. In the Chimpanzee the dorsal arterial arcade supplies the skin of all the toes except the hallux. In the Gorilla the arteria saphena gives off a deep plantar artery, and in all the Apes it supplies the tarsal joints.

Section B.—THE VEINS.

The venous system, unlike the arterial, does not exhibit many characters which are very different from those in Man.

Veins of the Head and Neck.

In the Chimpanzee (fig. 45, A.), the **anterior facial vein** (A.F.V.) begins by the confluence of palpebral veins from the eyelids and lateral nasal veins. It runs downwards and backwards and crosses the mandible at the anterior border of the masseter muscle. It runs between the mandible and submaxillary gland.

Finally it passes under the posterior belly of the digastric and the stylo-hyoid muscles, and unites with the temporo-maxillary vein to form the external jugular vein. It receives the following tributaries:—

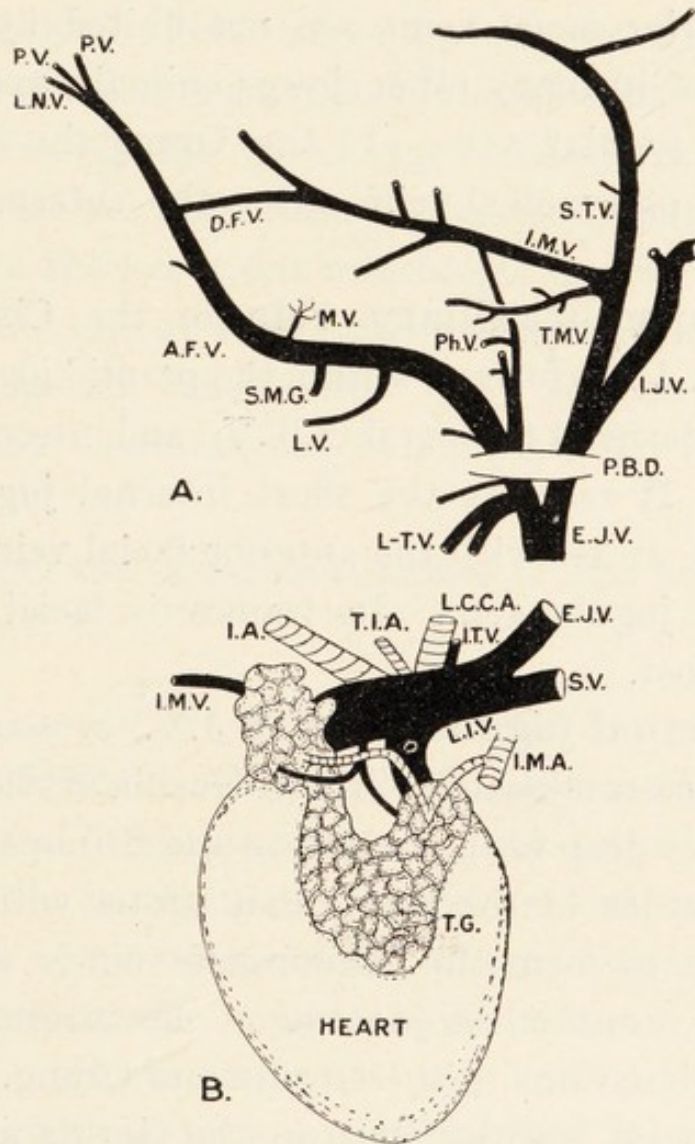


FIG. 45.—Veins of the head, neck and thorax in the Chimpanzee. I.M.A., internal mammary artery; I.A., innominate artery; L.I.V., left innominate vein; P.B.D., posterior belly of the digastric muscle; S.V., subclavian vein; T.G., thymus gland; T.I.A., thyroidea ima artery. Other letters explained in text.

- (1) *Palpebral veins* from the eyelids (P.V.).
- (2) *Lateral nasal veins* (L.N.V.).
- (3) *Masseteric veins* (M.V.).

- (4) *Deep facial vein* (D.F.V.).
- (5) *Submaxillary vein* (S.M.G.).
- (6) *Lingual veins* (L.V.).
- (7) *Laryngeal-thyroid trunk* (L.T.V.).
- (8) *Pharyngeal veins* (Ph. V.).

The anterior facial veins are not united by a transverse vein as in many other lower animals, and there is no anterior jugular vein. In the Orang the laryngeal, thyroid and pharyngeal veins enter the internal jugular vein.

The **temporo-maxillary vein** in the Chimpanzee (fig. 45, T.M.V.) is formed within the parotid gland by the union of superficial temporal (S.T.V.) and internal maxillary veins. It receives the short internal jugular vein (I.J.V.) and unites with the anterior facial vein to form the external jugular vein. Its transverse facial tributary is well marked.

The **external jugular vein** (E.J.V.) crosses the surface of the sterno-mastoid in the Gorilla (Eisler), but it always passes deep to the muscle in the Chimpanzee. At the outer border of the first rib it unites with the subclavian vein to form the innominate vein in the Chimpanzee, but it enters the junction of the internal jugular and subclavian veins in the Gorilla and Orang.

The **internal jugular vein** in the Gorilla and Orang is much as in Man. In the Chimpanzee it passes into the temporo-maxillary vein high up in the neck.

Veins of the Thorax.

In the Chimpanzee (fig. 45, B.), the **left innominate vein** runs obliquely; it receives inferior thyroid (I.T.V.), thymic, internal mammary (I.M.V.), and superior

intercostal (S.I.V.) veins. The short, vertical **right innominate vein** only receives the formative external jugular and subclavian veins. The **superior vena cava** (S.V.C.) runs as in Man, and receives the vena azygos major. The **azygos veins** drain the lower nine spaces, the first three being drained by the superior intercostal veins. No ascending lumbar veins are present.

In the Gorilla the vena azygos major drains all the interspaces on the right side. It receives the vena hemi-azygos from the lower left intercostal spaces. The blood from the first six or seven left intercostal spaces drains into the superior vena cava. The azygos and hemi-azygos veins communicate below with the renal veins (Eisler).

In all Apes the intrathoracic part of the inferior vena cava is short.

Veins of the Abdomen.

Portal System.—In the Chimpanzee (fig. 46) the system is almost bilaterally symmetrical. A vein formed by the confluence of gastric, splenic and inferior mesenteric veins unites with a vein formed by the superior mesenteric, pyloro-duodenal and transverse colic veins to form the portal vein. The venous arch in the transverse meso-colon connects these systems. The portal vein has the same origin, course and relations as in Man. The *splenic vein* (S.V.) passes through the lieno-renal ligament. It receives *vasa brevia* (V.B.) from the great gastric curvature, pancreatic veins and the *left gastro-epiploic vein* (L.G.E.V.) from the great curvature of the stomach. The *inferior mesenteric vein* (I.M.V.) drains the large bowel from the splenic flexure

to the rectum. The *superior mesenteric vein* (S.M.V.) drains the ileum, jejunum and large intestine from the appendix to the hepatic flexure. It receives *gastric* (g.v.) and *duodenal* (d.v.) veins.*

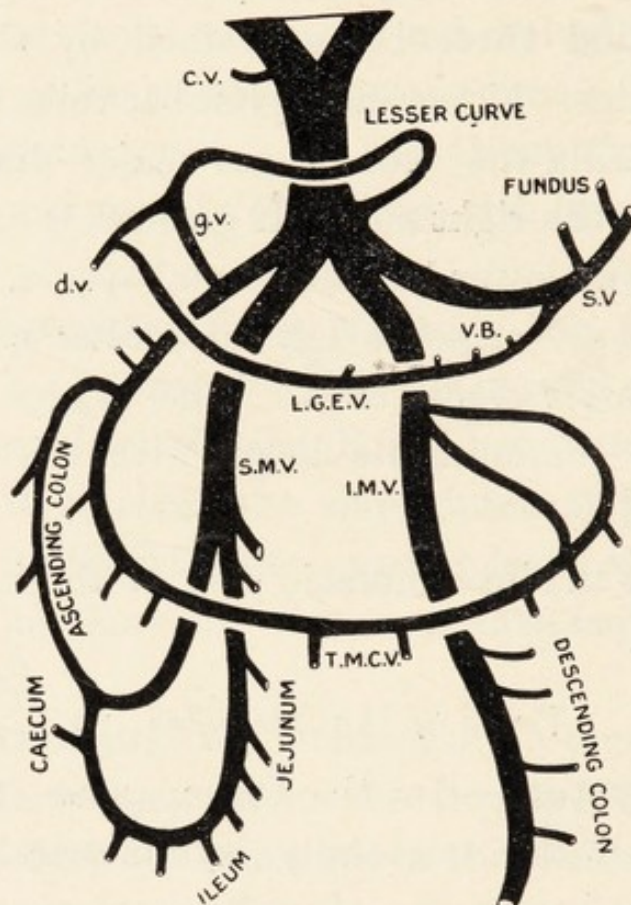


FIG. 46.—The portal vein in the Chimpanzee. c.v., cystic vein; d.v., duodenal vein; g.v., gastric vein. Other letters explained in text.

The transverse colon is drained by the vein (T.M.C.V.) which connects the mesenteric systems.

Inferior Caval System.*—The vena cava inferior has the same formation, course and relations in the higher Apes as in Man, but it may be divided for a considerable part of its course in the Gibbons. The tributaries are much as in Man.

* Wittmann (299) has dealt with the portal vein, Keith (196) with the inferior vena cava, and Giacomini (67) with the veins of the leg.

Veins of the Arm.

In the Chimpanzee there is no basilic vein. The cephalic vein reaches as far as the antecubital fossa, where it dips in and joins the venæ comites accompanying the branches of the brachial artery. There is a well-marked brachial vein instead of two venæ comites of the brachial artery as in Man. It passes upwards and is followed successively by the axillary and subclavian veins. These receive tributaries corresponding to the branches of the arteries.

In the Gorilla there is likewise neither basilic nor humeral cephalic veins, and there is a brachial vein (Eisler). But Chapman describes basilic, cephalic, radial, ulnar and median veins (435). In the Orang, Barkow figures a humeral cephalic vein dipping into the delto-pectoral triangle, and I observed the same in a young animal.

*Veins of the Leg.**

In the Chimpanzee two venæ comites accompany the branches of the posterior tibial artery. These all unite to form the popliteal vein which is followed by the femoral vein. On the dorsum of the foot there is a venous arch as in Man. From its inner side one or two internal saphenous veins run upwards, pass under the sartorius and enter the femoral vein. One large external saphena vein runs up the back of the leg and joins the popliteal vein. No saphenous opening exists. In the other Apes the conditions are essentially the same as in

* Wittmann (299) has dealt with the portal vein, Keith (196) with the inferior vena cava, and Giacomini (67) with the veins of the leg.

the Chimpanzee, there being no saphenous opening. In the Orang a saphena vein enters the femoral vein high up.

Section C.—THE LYMPHATIC SYSTEM.

In the Chimpanzee the **receptaculum chyli** is of considerable size. Two vessels emerge from it and run upwards to the level of the sixth dorsal vertebra where they unite to form a single duct, which opens into the junction of the left subclavian and jugular veins. The glands are fewer than in Man, as can be seen from the following table, which is based on the examination of three animals :—

A.—*Glands in the Head and Neck.*

- (1) A group of glands in the sub-occipital region.
- (2) A group of glands on the surface of the submaxillary gland.
- (3) Numerous glands between the cleidomastoid and trachea.

B.—*Glands in the Thorax.*

- (1) Bronchial glands.
- (2) Glands between the trachea and heart.

C.—*Glands in the Abdomen and Pelvis.*

- (1) Glands along the lesser curvature of the stomach.
- (2) Glands along the greater curvature of the stomach.
- (3) Mesenteric glands.
- (4) Iliac glands.

D.—*Glands in the Arm.*

- (1) Glands on the teres major.
- (2) Glands along the long thoracic artery.
 - (a) Upper group.
 - (b) Lower group.

E.—*Glands in the Leg.*

- (1) A group of glands close to the middle of Poupart's ligament.

In the Gorilla, according to Eisler (442), the thoracic duct is single, but the glands are fewer than in Man. He describes several glands in the neck, pulmonary roots, anterior mediastinum, axilla and posterior part of the pelvis. In the Orang I observed a single duct and many glands lie at the root of the neck.

Section D.—THE DUCTLESS GLANDS.

The **thyroid gland** varies in each Ape. In the Chimpanzee there may be two disconnected lobes, two lateral lobes united by an isthmus, or a long, narrow, U-shaped body (fig. 42). There is no strong capsule, and no pyramidal lobe. In the Gorilla the lateral lobes may be separate, or connected by an isthmus, and Deniker (44) observed it contained in a common sheath with the thymus in the foetus. In all specimens of *Hylobates* the isthmus is small and the lateral lobes are massive.

The **thymus** atrophies as age advances, but a trace is sometimes found even in old animals. In the Chimpanzee it consists of two parts reaching over the pericardium from the thoracic inlet to the third or fifth costal cartilage. It is coarsely lobulated, but is not hollowed out at any part. In the Gorilla it is divided into right, middle and left lobes in the foetus (Deniker), and it appears that it atrophies quicker than in Man. It is large in the Gibbons, and Kohlbrügge observed it covering the heart in an adult Siamang.

The **spleen** varies considerably in size and shape, not only in different examples of each Ape, but at different periods in digestion in each. Accessory spleens may be present (399).

The **suprarenal capsules** are very similar in all the

Apes, but they are not distinctly helmet-shaped as in Man. They are composed of the usual cortex and medulla.

There is no extensive literature on the other ductless glands in the Apes—pituitary body, pineal gland, islets of Langerhans and interstitial cells of the ovary and testicle.

Section E.—THE BLOOD.

It has been shown by Gulliver (**81**) that there is a slow, but progressive, increase in the diameter of the red blood corpuscles in the Primates from the Lemurs up to Man; and the following list, taken from his writings, shows the measurements in the Anthropoid Apes and Man:—

| | | | | |
|------------|--------|------|----|-----------|
| Man | 1/3200 | inch | in | diameter. |
| Orang | 1/3383 | „ | „ | „ |
| Chimpanzee | 1/3412 | „ | „ | „ |
| Gibbons | 1/3549 | „ | „ | „ |

Bio-chemical Reactions.—During the process of evolution the descendants of a common ancestor undergo modifications in structure as the result of changes in diet, the assumption of new habits or the effects of different climatic conditions. These changes may proceed so far that it is difficult to distinguish between the descendants, or to discover the common ancestor from which they have arisen. It is, therefore, obvious that any tests which will enable us to detect these descendants, in spite of the modifications in structure, will be of immense value. Such a test is present in the biochemical reactions of the blood. Professor Nuttall, who has devoted much attention to this subject, writes (**369**): “This method of

investigation permits of our drawing certain definite conclusions. It is a remarkable fact, as I stated on a former occasion with regard to my results with the *Anthropoidea*—and this applies as well to other groups of animals—that a common property has persisted in the bloods of certain groups of animals throughout the ages which have elapsed during their evolution from a common ancestor, and this in spite of differences of food and habits of life.”

The precipitin test is carried out as follows: A rabbit receives at intervals five or six intravenous injections of 5 c.c. of human blood serum. Seven to twelve days after the last injection it is killed and bled. The blood is allowed to coagulate, and the serum is collected and stored in small tubes with sealed ends. A few drops of chloroform are added to each for preserving purposes. As human blood serum is used for injections the rabbit serum is known as an anti-human serum, but anti-chimpanzee, anti-orang, anti-fowl and other sera are also prepared in a similar way. If fresh human serum is added to one of the tubes a thick precipitate is thrown down; and if the sera of the animals closely related to Man are added to successive tubes a precipitate is formed, but it is not so thick. Similarly an anti-chimpanzee serum yields a precipitate if the blood of Man and the other *Anthropoids* is added to it. After carrying out some hundreds of tests, Nuttall came to the following conclusions: (1) There is a close relationship between the *Hominidæ* and *Simiidæ*, and a more distant relationship with the *Cercopithecidæ*; (2) the bloods of the *Cebidæ* and *Hapalidæ* give poor reactions with those of the preceding families; (3) the anti-sera for all the

Anthropoidea give no reactions with the blood of the Lemuroidea, when used in the ordinary strengths; and Nuttall regards this as a reason for placing the Lemurs in a separate order. His last conclusion agrees with Weber's mode of classification (162), which is based on anatomical and palæontological evidence.*

Experimental Syphilis.—It has been shown by Metschnikoff, Roux, Lassar, Neisser and others that the Apes and Monkeys can be infected with syphilis. And the virulence of the resulting changes increases with the nearness of the relationship of the animals to Man. Thus it is weak in the Monkeys, stronger in the Orang-Outan, and strongest in the Chimpanzee; the experiments on the Gorilla have not yet led to definite conclusions; in the Chimpanzee the primary symptoms appear about thirty days after inoculation; secondary manifestations occur after a further period of longer duration in more than half of the animals treated; but tertiary signs have not occurred. When Macaques and Baboons are infected there only results the primary stage.

It is, therefore, evident that there is a similarity in the blood conditions, and the following conclusions can be drawn: (1) The red blood corpuscles gradually increase in size from the Lemurs up to Man; (2) the precipitin reactions increase in strength in zoological order; (3) the virulence of induced syphilis increases with the nearness of the relationship of the animal treated to Man.

* Mr. Le Gros Clark informs me that the blood of *Tarsius* does not give positive reactions with that of Man.

CHAPTER X.

ORGANS OF RESPIRATION AND VOICE.

Nasal Fossæ.—In the Chimpanzee (fig. 47) the nasal mucosa is pitted by the orifices of the ducts of glands, and the upper fourth of the septum shows well-marked striations caused by the terminal branches of the olfactory nerves. The vestibule is well marked, its orifice being guarded by vibrissæ. The inferior turbinate bone (I.T.B.) is long, and the naso-lachrymal duct (N.L.D.) opens below it into the inferior meatus. The middle turbinate bone (M.T.B.) is bifid, and conceals a bony crest; and the frontal sinus (F.S.) opens below it into the middle meatus. Above the middle turbinate bone there are three bony crests, of which one is the superior turbinate bone (S.T.B.). In the Gorilla the inferior turbinate bone is more inflated, the middle bone is not bifid and there is one superior turbinate crest. In the Gibbons (fig. 21B) the inferior turbinate bone is very inflated, the middle bone is club-shaped, and the superior crest is narrow. The sphenoidal sinus (S.S.) is relatively lower than in the Chimpanzee.

Laryngeal Cartilages.—In the Chimpanzee (fig. 42) the thyroid cartilage has well-marked upper and lower notches, and the alæ join at an angle of 90 degrees. Its superior and inferior cornua articulate with the hyoid bone and cricoid cartilage. It is connected to the hyoid

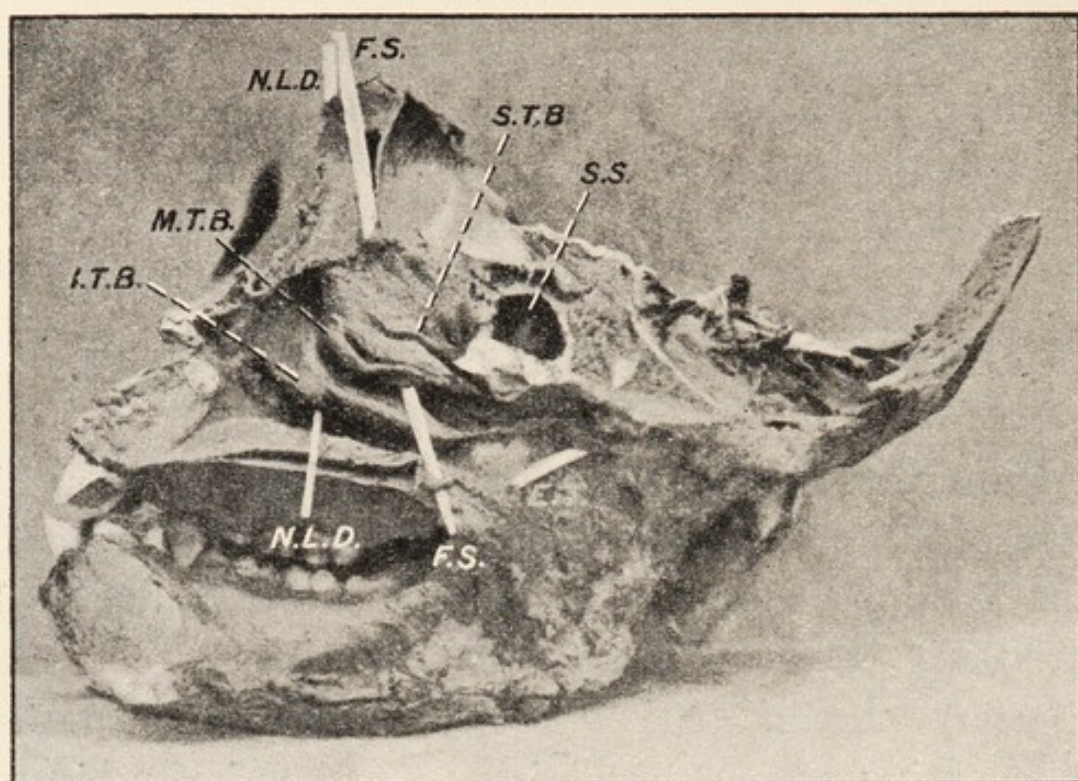


FIG. 47A.

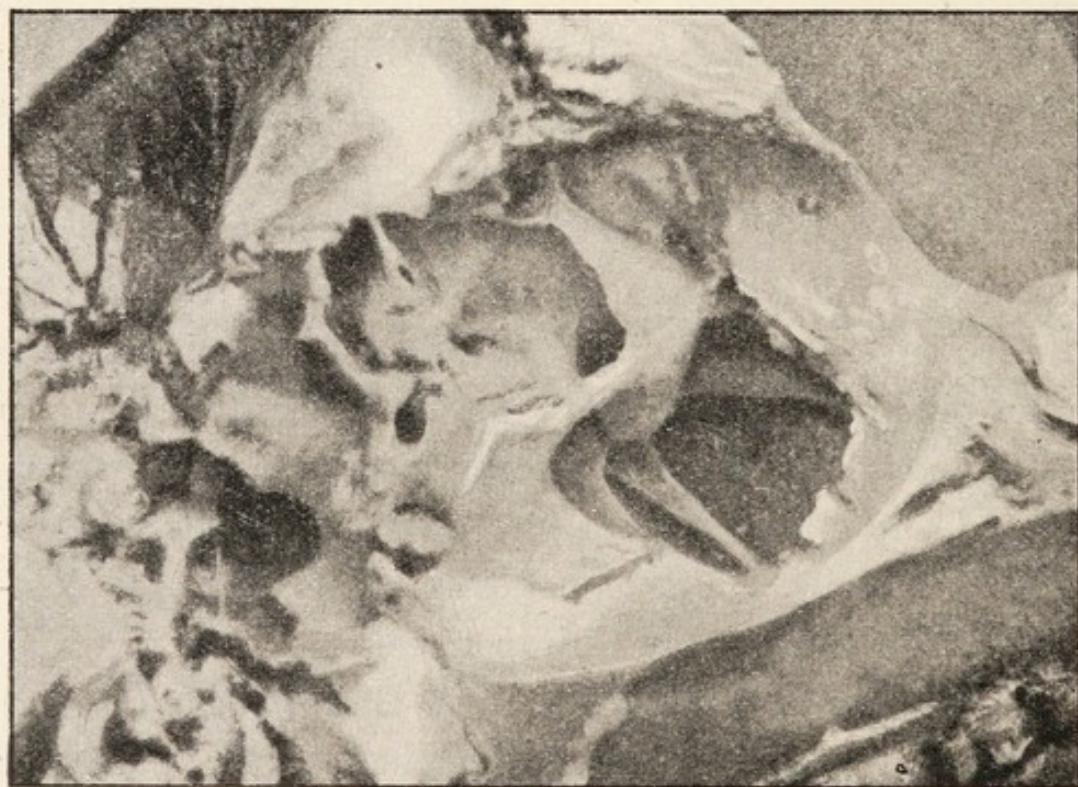


FIG. 47B.

FIGS. 47A and 47B.—The nasal meatuses (A) and antrum of Highmore (B) in the Chimpanzee. E.T., pharyngeal opening of the Eustachian tube. Other letters explained in text.

bone by the thyro-hyoid membrane, which is perforated by the communications between the air sac and laryngeal ventricles. The cricoid cartilage and crico-thyroid membrane are as in Man. The epiglottis is shaped as in Man, but it does not rise very fully above the small aryteno-epiglottic folds. The arytenoid cartilages are in many ways similar to those in Man; their processes are not greatly elongated, and they form parts of arcs. The cuneiform and corniculate cartilages are minute, but definite. The joints between the cartilages are as in Man. In the Gorilla the thyroid cartilage is smaller than in Man, and its lower border is not incised deeply as in the Chimpanzee. The cricoid cartilage is larger than in Man, and its anterior part is more slender than in the Chimpanzee. The arytenoid cartilages have long processes, but the cuneiform and corniculate cartilages are either absent or represented by fibrous rather than cartilaginous tissue. In the Orang the thyroid cartilage is larger and the cricoid cartilage is smaller than in Man, the arytenoid cartilages have three branches, but there are no cuneiform cartilages. The Gibbons have certain peculiarities, which are associated with their great vocal powers. The thyroid cartilage is large relatively to the cricoid, and differs from that of all other Apes in the possession of two inferior cornua. The anterior part of the cricoid cartilage is narrow and the posterior part is massive. The posterior part of the laryngeal cavity is deeper than the anterior part, and the arytenoid cartilages are lower than the vocal cords.

Laryngeal Muscles.*—In the Chimpanzee the

* Accounts of the larynx and its muscles have been given in papers 50, 53, 69, 122, 162, 199, 201, 259, 330, 357, 399, 401, 411.

thyro-hyoid muscle is as in Man. The crico-thyroid muscle is not fan-shaped as in Man; it runs from the lower and outer part of the cricoid cartilage to the lower border of the thyroid cartilage. The posterior crico-arytenoid muscle runs from the posterior cricoid lamina to the arytenoidal processus muscularis; whence the lateral muscle runs to the lateral part of the cricoid arch. The thyro-arytenoid muscle runs from the lower half of the inner surface of the thyroid ala, near the middle plane, to the outer border of the arytenoid cartilage above the crico-arytenoideus; it does not divide as in Man. The transverse arytenoid muscle is stronger than the oblique one. In the Gorilla the thyro-arytenoid muscle is as in Man, and the oblique arytenoid is stronger than the transverse arytenoid muscle. The Orang has no oblique band.

Interior of the Larynx.*—In the Chimpanzee the aryteno-epiglottic folds are small. The true vocal cords are soft, being composed mainly of mucous membrane and elastic tissue. The false cords are soft, and the ventricles are well marked; they communicate with the air-sac through the thyro-hyoid membrane. Posteriorly the cuneiform tubercles are close together. The pyriform sinus is better marked than in Man. The upper division of the larynx is shallow, the middle division is larger than, and the lower division is similar to, that in Man. In the Gorilla, according to Duckworth (50), the plica vocalis is less like that of Man than is that of the Chimpanzee. Its free margin has an attenuated membranous flange and no isolated muscle fibres are present.

* Accounts of the larynx and its muscles have been given in papers 50, 53, 69, 122, 162, 199, 201, 259, 330, 357, 399, 401, 411.

Air-Sacs.—In all Anthropoids, except the Gibbons of the genus *Hylobates*, there are air-sacs communicating with the ventricles of the larynx. They vary in size in different examples of each Ape, and Vrolik (411) points out that they vary with age and sex. In the Chimpanzee it lies immediately under the platysma, and its smooth, shining walls are formed by the deep cervical fascia. It consists of a central and two lateral parts. The former extends upwards to the excavated hyoid bone, and downwards to the lower border of the manubrium sterni between the origins of the sterno-mastoid muscles. The orifices of the latter lie under the cleido-mastoid muscles, and a finger passed into them can explore the entire axillæ. Many muscles, vessels and nerves form ridges in the walls of the sac. The central part communicates with the laryngeal ventricles through the thyro-hyoid membrane. The Gorilla has a complicated group of air-sacs branching off from a central cavity composed of conjoined saccules. There is a median, unpaired, infra-hyoid saccule passing upwards; two saccules pass upwards and outwards to the submaxillary region; and two large ones run downwards and outwards as axillary saccules. From the latter two small diverticula form pectoral saccules. Occasionally the central conjoined saccules have lateral diverticula. The conditions of the air-sacs are very complex in the Orang, and many descriptions have been published by Fick (247), Milne-Edwards (268), Camper (237), Duvernoy (53) and others. Deniker and Boulart show, from an examination of several animals, that there are two air-sacs in the Orang, which increase in size with age; and they are more frequently unequal in size in the male than

in the female. These main sacs give off many diverticula which run in the same directions as those in the Gorilla. When the sacs are inflated they are seen to form a large balloon between the mandible above and the sternum below, with lateral offshoots passing round the mandible towards the ears. Very large diverticula pass into the axillæ. In the Siamang the air-sac communicates with both laryngeal ventricles, and appears to be intermediate in character between those of Apes and those of the Monkeys.

The functions of the air-sacs in the Apes are not known, but it is almost certain that they are not entirely resonating chambers as in the Monkeys. They may however modify the voice and render it deep and sonorous. Some authors have ascribed to them the purely mechanical function of supporting the heavy jaws, and Vrolik (411) believes they are of great importance for this purpose in old age.

Trachea and Bronchi.*—The characters of these structures are similar in the Apes and Man.*

Lungs.—Many variations in the number of lobes into which the lungs are divided have been recorded. In the Gibbon, according to the observations of Kohlbrügge (199), Deniker (44) and myself, the left lung is divided into two lobes and the right one into four, of which one corresponds to the azygos lobe of the lower Mammalia. In the Gorilla the azygos lobe has only been observed in one animal described by Bischoff (425). In all other Gorillas, as in most Chimpanzees, the left lung is divided into two lobes and the right one into three. Sonntag (399) has

* Aeby (3) described the bronchi.

collected the observations which have been recorded regarding the variations in the degree of subdivision of the lungs in the latter. The Orang stands apart from the other Apes in the characters of its lungs, for they are undivided in most examples; and in this feature the lungs resemble those of the Sloth and some Marsupials.

Goodsir was the first, as far as I can ascertain, who pointed out that "the erect attitude in Man, by which the lungs are brought beneath, and the air sinuses of the head above the larynx, and, in addition, the vertical position of the organ itself, all conduce to the perfection of the mechanism of the human larynx."

CHAPTER XI.

THE UROGENITAL ORGANS.

Kidneys.—The kidneys have the same form and relative positions as in Man, but the right one may be very mobile. There is a variable quantity of perirenal fat, but I did not observe any supporting fascial shelf in the Chimpanzee and Gibbon. The capsule strips easily and is well vascularized. The cortex is thick, and the papillæ tend to fuse in the Apes. The numbers of papillæ vary, being one to four in the Gibbon, one in the Orang, one to four in the Gorilla, and one to six in the Chimpanzee, according to various authors. The calyces are small, and the pelvis may contain fat. The structures in the hilum of the kidney are arranged as in Man. The **ureter** runs as in Man, but I was unable to detect lymphatics accompanying it in the Chimpanzee.

Bladder.—In the Chimpanzee it is thick and muscular, but no urachus nor anterior ligaments are present. Lateral ligaments are well marked; and the thick round ligaments of the uterus are connected to them by peritoneal folds, so the utero-vesical pouch is crescentic. The mucosa is thick and corrugated, and the ureteric papillæ lie at the ends of prominent ridges. The patulous urethral orifice is close to the ridge, so the trigone is small. The vesical musculature consists of two layers. There is an external longitudinal layer, half an inch wide,

in the middle line. Lateral to this band the fibres run obliquely, both upwards and downwards, and interlace with one another. The submucous coat is thick, and composed of more elastic areolar tissue than in Man. The mucous membrane is loosely attached to it. The serous coat exhibits nothing peculiar.

Little attention has been paid to the bladder in the other large Apes. Deniker (44) has given measurements of the bladder in the foetal Gorilla; and Huxley (88), Fick (24), Sandifort (280), and Barkow have made a few remarks on the bladder of the Orang. None of these observers have drawn attention to essential differences between the bladder in their animals and in the Chimpanzee described above.

Section B.—THE FEMALE GENERATIVE ORGANS.

Ovaries.—In the Chimpanzee the ovaries vary in shape, not only in different animals, but on both sides in each. They lie vertically behind the broad ligaments, and at a higher level than the uterus (fig. 48). They have the same ligamentous connections as in Man, and the ovarian fimbriæ are well marked. On section one sees the cubical germinal epithelium covering the ovary. In the interior one observes many primordial ova and Graafian follicles in different stages of formation. The histology has been described by Giacomini, Duval (52), and Sperino (401). In the foetal Gorilla, according to Deniker (44), the ovarian ligaments are attached to the uterus lower down than in Man; and both ovaries are long and narrow. The same author observed them to be flattened in the foetal Gibbon.

Fallopian Tubes (fig. 48, F.T.).—In the Chimpanzee

the tubes form a gentle curve, and their diameter remains almost constant from end to end. Their orifices are patent, but it is difficult or impossible to pass a fine

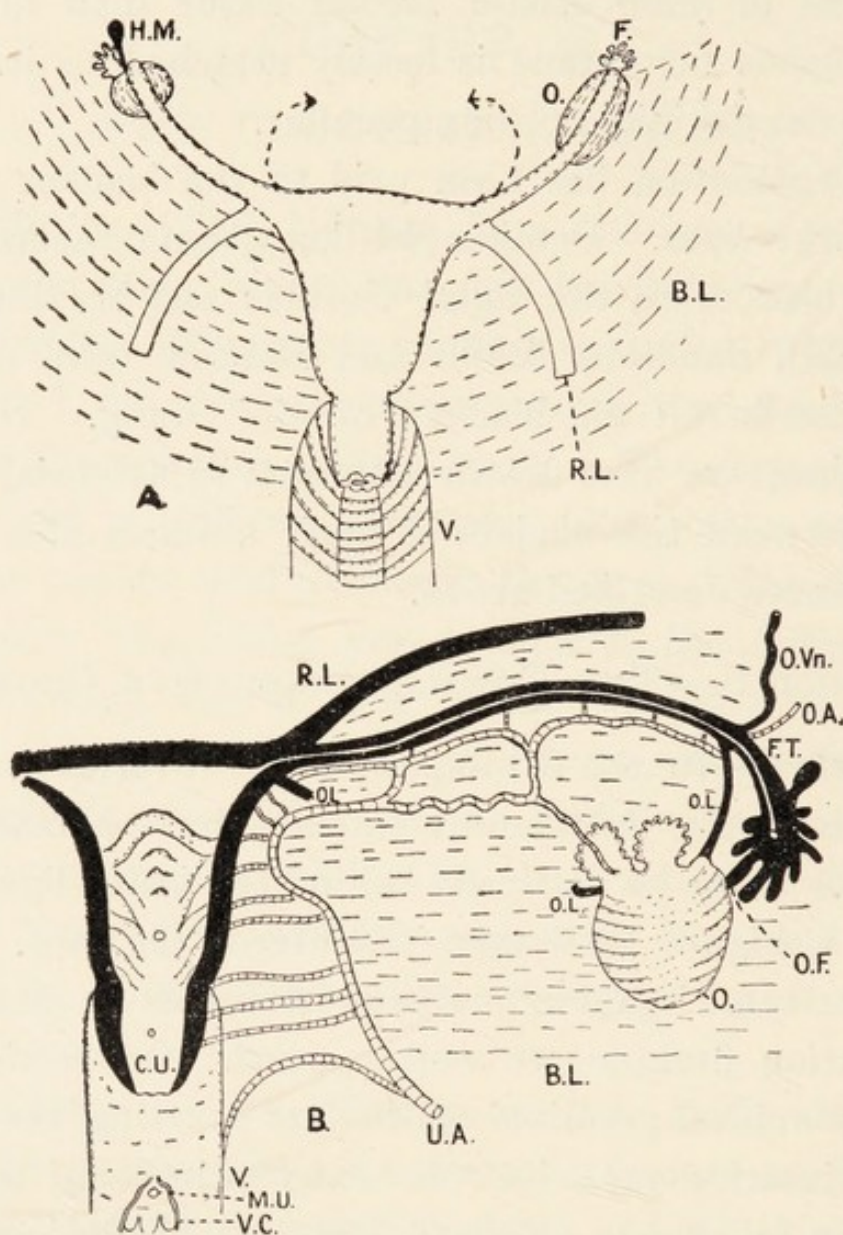


FIG. 48.—The internal organs of generation in the Chimpanzee from the front (A) and from behind (B). B.L., broad ligament; C.U., cervix uteri; F., fimbriæ; H.M., hydatid of Morgagni; M.U., meatus urinarius; O., O.A., O.F., O.L., O.Vn., ovary with its artery, fimbria, ligaments and vein; R.L., round ligament; V., vagina; V.C., vaginal columns. The arrows in A represent the true positions of the Fallopian tubes.

bristle through them. The fimbriæ form a dense cluster and the ovarian fimbria is well marked on each side. The relations of the tubes to the ovaries are as in Man.

The epoöphoron and paroöphoron have been described as present by several authors. In the Gorilla the tube is sinuous in the adult according to Bischoff (425), or it makes a double bend in the foetus according to Deniker (44). No parovarium is present, but Deniker described a cord, which may be a remnant of the Wolffian body, running upwards to behind the kidneys. In the Gibbon the tube may be sinuous or curved.

Uterus (fig. 48).—The uterus in the Apes, as in Man, is placed higher in the foetus than in the adult. As age advances it descends to the lower part of the pelvis, where it is separated by well-marked peritoneal fossæ from the bladder and rectum. It is always small, even in adult animals, being about the size of the uterus of the female child. The cervix is large relatively to the body. In a Chimpanzee forty-three inches long from the crown to the heels the body of the uterus was 1.5 cm. long, whereas the length of the cervix was 1.2 cm. The round ligaments, which are of considerable size and strength, run forwards and upwards from the utero-tubal junction. The fundus is rudimentary or absent. The interior of the body of the uterus is smooth between the tubes, but lower down the mucosa is thrown into vertical and transverse ridges. The muscular coat is thin in the upper part of the body, but it is thicker in the lower part of the body and in the cervix. The external os uteri is oval or slit-like, and its lips may be equal or unequal. Probably the form depends on whether the animal is nulliparous, or has borne young. Gratiolet (330) described a bicornuate uterus in a Chimpanzee.

Vagina (fig. 48).—The vagina expands from above downwards, and its upper part forms fornices round the

cervix uteri as in Man. Its mucosa is thrown into vertical and transverse or oblique rugæ. In the Chimpanzee the mucosa of the lower part shows several small pockets, and the meatus urinarius opens on to the middle of its anterior wall. In the foetal Gorilla, according to Deniker (44), the meatus urinarius lies in the vestibule. The same arrangement also exists in the Orang and Gibbon as in the Chimpanzee.

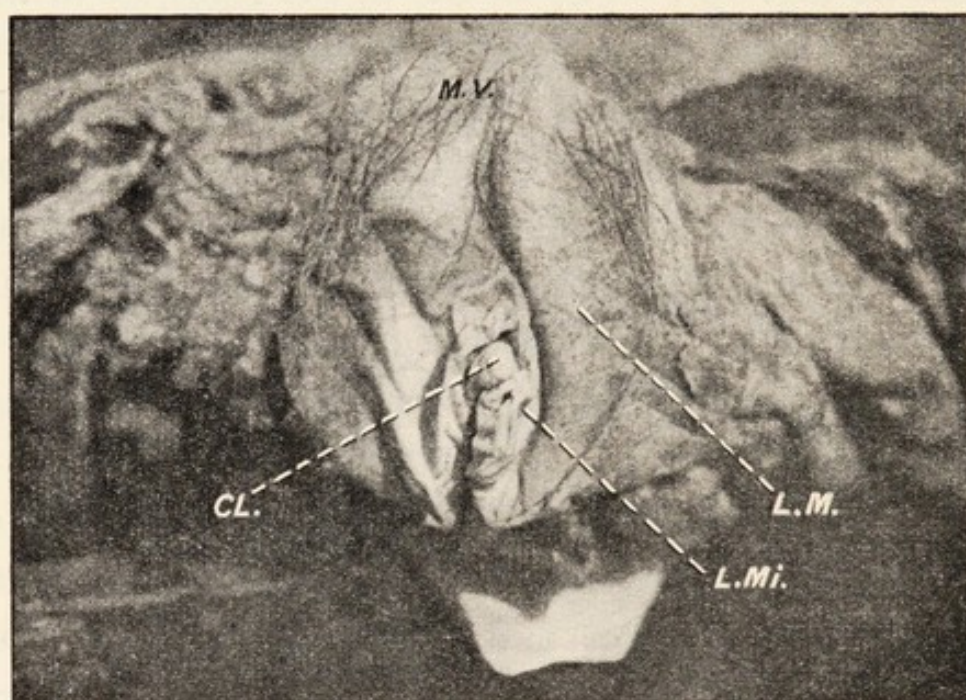


FIG. 94.—The external organs of generation in the Chimpanzee. Letters explained in text.

External Generative Organs.—It has been shown conclusively by Deniker (44), Bolk (311), and others, that the external generative organs of the Apes undergo a process of atrophy as development proceeds, whereas those of Man increase in size. In all Primates there are at an early period of development two external genital folds which give rise to the labia majora and mons veneris. In the Monkeys these structures disappear, leaving the labia minora and clitoris exposed. In Man

they persist. In the Chimpanzee (fig. 49) the conditions are intermediate between these extremes. The mons veneris (M.V.) is slight and has a few sparse hairs, and the labia majora (L.M.) are represented by slight elevations of the skin over thickenings of the subcutaneous tissue. The labia minora (L.Mi.) are large and folded, and divide as in Man into a frenulum and preputium, which surround the large clitoris (CL). A fourchette exists, but there is no hymen. In the absence of the latter the Chimpanzee resembles all Apes and differs from Man. Gratiolet (330) points out that the glands of Bartholin are deep down between the rectum and vagina. In the Gorilla the labia majora never quite vanish, according to Deniker (44), but there is no mons veneris.

The perineum is short, and a line connecting the anterior parts of the ischial tuberosities passes in front of the vulva, whereas it lies between the vulva and anus in Man. Copulation occurs in the position adopted by quadrupeds.

Menstruation.—Our knowledge of menstruation in the Apes is contained almost entirely in the works of Pocock (223), Bolau (232), Ehlers (441A), Sperino (401) and Keith (100). Winwoode Reade (283), Garner (329) and Mohrike (363) merely mention that there is a sexual season in the Gorilla and Chimpanzee.

As regards the discharge in the Hainan Gibbon, Pocock says it is sanguineous, stains the floor of the cage, and is about the same in quantity relatively to the size of the animals as in the historic Chimpanzee "Sally." The pudendal organs are always conspicuous by reason of their turgescence, and no very conspicuous change in

their condition precedes the menstrual discharge. After making a careful series of records, and noting how menstruation ceased during an attack of influenza, Pocock concludes "it may be laid down as an established fact that in Gibbons the interval between the menstrual discharges is a little over the calendar month, and that the discharge continues for from two to three days." In the Chimpanzee menstruation begins at the tenth year. It begins every twenty-eight days, and the discharge, which flows for three days, amounts to four or six ounces. Six days before each period the animal is in heat, the labia become swollen and turgid, and the nipples become erect and full. After the discharge appears the swelling of the external genital organs subsides. Keith points out that seasonal changes have no modifying influence on the periodicity of the menstrual flow. Nothing is known of the duration, periodicity or quantity of the menstrual discharge in the Gorilla and Orang. The genitalia become turgid and highly coloured before menstruation in the Cercopithecidae, so the Chimpanzee resembles them, whereas the Gibbon does not.

The **ovum** in the Apes has been described by Hubrecht and its characters are generally similar to those in Man.

The **placenta** consists of a single disc.

Section C.—THE MALE GENERATIVE ORGANS.

It has been stated by several writers that the **external generative organs** are small, but that is not the case in the male Chimpanzee. The penis in that Ape is long and tapering. No pronounced glans is present, but the lips of the vertical meatus urinarius are thickened.

No frenum præputii is present. Within the lower part of the penis near the point there is a fusiform bone about three-quarters of an inch long. The corpora cavernosa and corpus spongiosum are in general as in Man on cross section, but the former gradually fuse and the septum between them disappears; they arise from the pubis and triangular ligament as in Man. In the Gorilla, according to the descriptions and illustrations of Duvernoy (53), the glans penis is well developed and appears almost cleft into two portions. Behind the glans the penis is narrow and tapering. It contains a small os penis. In the Orang the penis is of the same type as that of the Chimpanzee, for it has no glans; the lips of the vertical meatus may be slightly pouting. A fine illustration of the penis and its bone is contained in the monograph by Milne-Edwardes (268). Fick (247) and Duvernoy (53) also describe the penis. In the Gibbons the conditions are different from those in the higher Simiidæ. There is no prepuce, the glans is naked and the urethra opens on its under surface, thus forming a variety of hypospadias.

The **scrotum** is absent in the Gibbons, but the testicles are covered by folds of the skin of the anterior abdominal wall. So this is a marked difference from the conditions in the higher Simiidæ which possess definite scrotal pouches. The tunics are much as in Man, and the vaginal sacs are identical. It has been pointed out by Pousargues (268) that the tunica vaginalis is shut off from the abdominal cavity in Man and the Chimpanzee, but always communicates with it in the other Apes.

The **testis** has the same general structure in the Apes and Man, but the corpus Highmorianum is large in the

Apes and reduced in Man. The epididymis is long and ends in the vas deferens, which has the usual cord-like consistence. The vas runs through the spermatic cord and inguinal canal. It then dips down, and passing on the back of the bladder it unites with the duct of the corresponding seminal vesicle. After receiving the latter it may become dilated.

The **vesiculæ seminales** in the Orang and Chimpanzee are large pyriform structures touching mesially and extending beyond the bladder laterally; so they differ from the vesicles in Man, in whom they never project beyond the bladder. Each consists of a tube which is greatly convoluted and coiled, and no glandular diverticula project from it. It is impossible to extend the tube completely, for many of the coils cannot be unravelled. Pousargues found that the tube could be extended to 40 cm., but that was not the entire length. Leuckart (107) pointed out that the length of the tube is inversely proportional to the number of diverticula projecting from it. Thus the Orang has a long tube with no diverticula, but Man has a tube 10 cm. long with many glandular pockets; he has, therefore, a seminal vesicle with a short tube and a large secreting area.

The **prostate** has the usual pyramidal form and is related to the triangular ligament, levator ani muscle and fasciæ as in Man. In the Chimpanzee and Orang the prostate is entirely retro-urethral.

Retzius (135) has shown how the spermatozoa of the Gorilla resemble those of Man most closely.

CHAPTER XII.

THE NERVOUS SYSTEM.

BEFORE we proceed to the consideration of the nervous system, which co-ordinates the activities of the organs, and brings the animal into relation with its environment, it will be useful to tabulate conclusions drawn from the preceding chapters:—

(1) The general anatomical structure and the biochemical reactions of the blood show that Man and the Apes are related. And pathological observations demonstrate that their constitutions have much in common.

(2) The ductless glands have helped to mould their external characters.

(3) A host of structural differences in all parts of the body are associated with the type of locomotion in each animal.

(4) Man is the most bimanous and the most bipedal of the Primates, and he stands alone in the power of speech.

It now remains for us to see how the brain, which makes all the organs work together in harmony, differs in the Apes and Man.

Section A.—THE BRAIN.

General Characters.—The brain of the Gorilla, whose volume exceeds that of any other Anthropoid, is

absolutely, and relatively to the size of the body, smaller than the human brain. It is also much smaller than the endocranial casts of the skulls of fossil men. These facts are shown in the following table, which is partly based on figures in the "Guide to the Fossil Remains of Man" in the British Museum.

| | Capacity | Relation to body weight |
|---|------------|-------------------------|
| Brain of Gorilla | 585 c.c. | 1/150—1/200 |
| " " Australian native | 1,250 c.c. | — |
| Endocranial cast of the Rhodesian Man .. | 1,280 c.c. | — |
| " " " Piltown Skull .. | 1,300 c.c. | — |
| Brain of European | 1,480 c.c. | 1/50 |
| Endocranial cast of the Neanderthal Man.. | 1,626 c.c. | — |

Keith (97) calculated the weights and ratios in Apes, and he has shown that the cranial capacity in cubic centimetres is not an index of the weight in grammes. Still the cranial capacity is a useful comparative standard. Keith's observations have shown that the human brain grows relatively more than that of the Apes, for the brain of the human infant is 36 per cent. of the adult brain, and the simian infantile brain is 70 per cent. of that of the adult.

Every Mammal is brought into relation with its environment through the organs of special sense and the nerve-endings in the skin. The impressions made on these structures induce stimuli which pass centripetally to different parts of the cerebrum. The olfactory stimuli pass via the piriform area and fascia dentata to the hippocampus, where they possibly meet gustatory stimuli. The visual and auditory stimuli, as well as those of general sensibility (temperature, touch and

pain), end in the neopallium, which also lodges the motor centres. The olfactory centres and neopallium vary considerably in their dimensions in different Mammals; and brains are divided into two classes—macrosmatic and microsmatic—according to the size of the olfactory areas. The Anthropoids have small olfactory areas and a large neopallium; and the latter reaches enormous proportions in Man. It is due to the enormous growth of the neopallium that the human brain is nearly three times as large as that of the Gorilla, whereas the Gorilla is equal to, or somewhat larger than him in bodily stature.

Professor Elliot Smith has pointed out that: "The neopallium assumes important functions and becomes a condition of survival for the first time in the Mammalia, and in each successive epoch it has become incumbent upon every mammal either, on the one hand, to adopt some eminently safe mode of life or some special protective apparatus to avoid extinction, or, on the other hand, to 'cultivate' a larger neopallium, which, as the organ of associative memory, would enable it to acquire the cunning and skill to avoid danger and yet adequately attend to its needs."

The Anthropoids and Man exhibit different methods of action when danger threatens. The Orang leads a retired life in the trees, so he escapes many dangers; and he is very tenacious of life. The Gibbons and Chimpanzees, whose sense of hearing is very acute, take refuge in flight when danger threatens. The Gorilla and Man have no one sense highly developed; but they act differently. The Gorilla shows fight, and his brutality and immense muscular power make him a

formidable antagonist. Man, on the other hand, is built on more elegant lines, but he copes with all emergencies as the result of a nimble mind. Speaking of his neopallium, Professor Elliot Smith says: "The neopallium has attained its maximum development, and its possessor has not had to seek refuge either in a retired mode of life or by any protective specializations of structure either for offence or defence, but has attained the dominant position in the animal kingdom, whilst retaining much of the generalized structural features of a primitive mammal." He has, moreover, by his inventive genius designed weapons which add to the powers with which he has been equipped by Nature. The superior development of the human neopallium is also associated with speech, the better and finer movements of the hands and all those attributes of mind which we term intelligence and "Soul." It is in high function rather than bodily structure that Man stands pre-eminent among the Primates. The cortical areas are of three kinds—sensory, motor and association. The latter do not belong to any one sense, but are rather to be regarded as the meeting places where the various impressions come together; they increase progressively throughout the Primates till they reach their maximum development in Man.

Of the Anthropoids the Gorilla is nearest to Man in the characters of the association areas. Brodmann (26) discovered that each cortical area is characterized by its own peculiar cyto-architecture, and the boundaries of each are sharply demarcated. Acting on this discovery he mapped out the surface of the brain, furnishing us with a series of geographical charts of the Primate cortex.

In Man there are fifty-two areas. Some correspond to parts whose functions are definitely known, but the greater number lie over parts of whose use we are ignorant. The various areas are linked together by association fibres.

Form of the Brain.—The brains of the Gibbons still retain much of the form of the brains of the Cercopithecidæ, and their surface does not exhibit a wealth of sulci and convolutions. In the large Apes the brain is more voluminous and convoluted. That of the Orang has an exaggerated ovoid form when viewed from above, and it resembles that of a Cercopitheque monkey rather than those of the Chimpanzee and Gorilla. Of the latter the brain of the Gorilla is the more human in appearance. The frontal lobes are more rounded in the larger Apes than in the Gibbons.

The posterior parts of the hemispheres are relatively larger in Man than in the Apes, possibly because of his more complex psychology. Schäfer and Horsley showed that idiocy is more readily produced in the Ape by removing parts of the cortex of both temporal lobes than by cutting off the prefrontal region.

Rüdinger observed that the parietal sulci and gyri are larger, and give a different shape to this part in cultured people than in ordinary individuals and in the lower human races. He examined the brains of Bischoff and Liebig. Luciani* quotes the results of observations on the brains of men famous in art and science, and his remarks are of considerable interest. “The study of the

* This paragraph is reproduced through the courtesy of Messrs. Macmillan and Co., the publishers of the English translation of Luciani's textbook of Physiology.

skulls of Kant, Gauss and Dirichlet showed marked development of the parietal region. In the skulls of Bach and of Beethoven, which have been studied by His and by Flechsig, there was a marked development of the posterior regions of the brain (parieto-occipito-temporal) and of the Rolandic region, while the prefrontal lobes were of only comparatively insignificant proportions. The brain of the astronomer Gylden, examined by Retzius, showed considerable development of the parietal lobe, especially of the angular gyrus. In Helmholtz's brain, according to Hansemann, the precuneus and parietal region included between the angular gyrus and the upper temporal gyrus were remarkable in size. Raffaello's cranium, studied by Mingazzini in an authentic chalk drawing at Urbino, shows a striking contrast between the modest height of the forehead and the great expansion of the occipital and parietal lobes. The skulls of Gauss and Richard Wagner, according to His and Flechsig, on the contrary exhibit a striking development not only of the posterior association area, but also of the anterior or prefrontal association area of Flechsig."

In all the Apes each cerebral hemisphere is divided into the same lobes as in Man—frontal, parietal, occipital, temporal and central (island of Reil). The cerebrum does not conceal the cerebellum so completely.

The **frontal and parietal lobes** are separated by the **central sulcus**, which is the boundary between the precentral and postcentral gyri. In the former are situated most of the motor centres. Our knowledge of the localization of the motor centres is due to the observations of Beever and Horsley (229) on the Orang, and

the later work of Sherrington and Grünbaum (80) on the Orang, Chimpanzee and Gorilla. The latter observers showed that the motor centres are localized in the pre-central gyrus and are continued into the cortex which dips into the central sulcus, and the secondary sulci by which this is limited. As the cortex loses its irritability the anterior boundary of the motor area retreats backwards, but the posterior limit always remains fixed. No motor centres exist in the postcentral gyrus, and the island of Reil is inexcitable. In the **frontal cortex** anterior to the Rolandic area there is an area which, when stimulated, produces conjugate deviation of the eyes, an action which is also elicited when the cortex round the calcarine fissure is stimulated. This latter region, however, is not part of the motor area, which lies only in the frontal lobe.

The parietal and occipital lobes are separated by the **parieto-occipital sulcus** which, however, is very variable in character in each species of Ape as in Man. It may be entire and deep, or it may be replaced by small sulci, thus showing that it is a complex when it is entire. A deep groove may have two sulci at the bottom.

The parietal and temporal lobes are separated by the **fissure of Sylvius**, whose characters differ considerably. It may be stated at the outset that Man alone of the Primates has a complete Sylvian fissure. It consists in him of three fissures—an anterior horizontal, an anterior ascending, and a posterior horizontal limb. These fissures run between undercut pieces of cerebral tissue, which constitute the opercula covering and concealing entirely the island of Reil. In the Apes the conditions are somewhat different. The posterior horizontal limb

of the fissure is present, and is frequently bifid at its posterior extremity. Its inclination varies, and in some cases it should really be called a posterior ascending limb. The anterior limbs are not properly constituted as in Man, and a part of the insula is exposed to view. The parallel sulcus may hook round the upper end of the Sylvian fissure.

The **calcarine fissure** is well marked in the Apes and in Man. It is really a complex of true calcarine and retro-calcarine sulci in the Apes, but these component sulci remain separate in Man. It produces the elevation in the lateral ventricle which is known as the calcar avis. The calcarine sulcus is not connected to the **calloso-marginal sulcus** (intercalary sulcus of Elliot Smith) as it is in many lower animals. It is embraced by the diverging limbs of the Y-shaped lateral occipital sulcus.

The **hippocampal fissure** is constant in the Apes.

The Apes have a large "**simian sulcus**," or "**Affenspalte**," which sweeps across the hemisphere. It may cross the margin of the great longitudinal fissure. It may be concurrent with the transverse occipital sulcus. It lies behind the parieto-occipital sulcus, and may pass into it. The transverse occipital sulcus receives the caudal extremity of the intraparietal sulcus. In Man the small sulcus lunatus corresponds to the Affenspalte.

The intraparietal sulcus is really a complex of sulci, and the system includes one or both postcentral sulci.

On the infero-lateral aspect of the occipital lobe there are to be found **inferior occipital and occipito-temporal sulci**; and the latter may increase in size at

the expense of the collateral sulcus. The **cerebellum** gradually increases in size from the Gibbons upwards, with a diminution in the parafloccular folia. The trapezium becomes more and more concealed and the pons enlarges.

From what has been said above, it is evident that the human brain differs from those of the Apes* in the following ways:—

(1) It is larger, both absolutely and relatively to the size of the body.

(2) The neopallium is larger and the association areas are more complex.

(3) The parietal and frontal lobes are more voluminous, and the latter are not rostrated.

(4) The Sylvian fissure is complete, and the insula is concealed.

(5) There are calcarine and retro-calcarine sulci.

* The following papers listed in the Bibliography (pp. 334-356) dealt with the brain in the Apes:—

Volume and weight—97.

Relation of cerebrum to cerebellum—158.

Development—44.

Convulsions and fissures—24, 36, 37, 73, 85, 87, 124, 125, 134, 139, 143, 147, 148, 149, 165, 167; on Gibbons 175, 187, 199, 217, 218, 219, 222; on Orang 230, 233, 247, 279, 280; on Chimpanzees 305, 309, 310, 325, 334, 345, 347, 354, 360, 361, 375, 376, 377, 400, 401, 407, 411; on Gorillas 422, 423, 425, 427, 428, 430, 433, 436, 450, 459, 482, 497.

Island of Reil—38, 110, 148 (accounts of the insula are also contained in several of the works noted under the heading Convulsions and Fissures).

Evolution—148, 149.

Histology—351, 360, 474.

Localization of centres—26, 80, 229, 202, 255.

Psychology—116, 255, 322, 359, 389.

(6) The small sulcus lunatus corresponds to the large Affenspalte.

(7) Secondary sulci are more numerous.

(8) The cerebrum conceals the cerebellum more completely, and the latter shows a higher phase of evolution.

(9) Many greater complexities are the result of a larger neopallium.

(10) Some of the cranial nerves are smaller.

(11) The corpus callosum is larger.

THE BRAIN IN THE GIBBONS (fig. 50).

The brain in the Gibbons is intermediate in its characters between those of the Cercopithecidae, on the one hand, and those of the larger Simiidae on the other. Moreover it indicates in some ways the path pursued by the latter in evolution.

The **central sulcus** (C.S.) runs downwards and forwards in a gently curved or sinuous manner. If it passes at all on to the mesial surface of the brain, it only does so for a very short distance. Its lower end, which may be bifid, usually stops short of the Sylvian fissure; but a narrow groove continues it into the latter occasionally. On the frontal lobe in front of the central sulcus there is a short **superior frontal sulcus** (S.F.S.), and the sulcus arcuatus (S.A.) and **sulcus rectus** (S.R.) are conjoined to form a long horizontal sulcus or a triradiate sulcus.

The surface of the parietal lobe is occupied by a more or less complex system of **intraparietal sulci** (I.P.S.). And it appears that there are individual peculiarities in their distribution and arrangement. The system may include the **sulcus postcentralis superior** of Cunning-

ham (S.P.S.). The posterior extremity of the intra-parietal sulcus may bifurcate, and the diverging halves constitute the **transverse occipital sulcus**. The sulcus postcentralis may be quite separate.

The **parieto-occipital sulcus** (P-O.S.) consists of parts on the external and mesial surfaces of the hemisphere, and these parts may be equal or unequal. The external part may be curved or angular. Beddard (175) describes it receiving the simian sulcus in a Siamang, but that is exceptional. The mesial portion may be very deep, and meet the **calcarine fissure** (Ca. S.), but this junction is not invariably present.

The **simian sulcus** (S.S.) sweeps far out over the hemisphere. It is concurrent with the transverse occipital sulcus, and it may enter the parieto-occipital sulcus.

The calcarine fissure may be entire as in some lower Monkeys, or bifid as in most Apes, and accessory sulci may be well developed around it. Its posterior extremity may be embraced by the diverging limbs of the Y-shaped **lateral occipital sulcus** (L.O.S.). In the strong development of the latter the brain resembles that of Monkeys rather than of Apes.

The **Sylvian fissure** (S.L.) ascends in a slightly sinuous manner, and the **parallel sulcus** (P.A.S.) hooks round its bifurcated caudal end. The anterior part of the **insula** (L.O.R.) is exposed at its anterior extremity. Two sulci run forwards from it along the margins of the exposed part of the insula. These sulci do not usually meet, but they did so in a specimen of *Hylobates hoolock* (fig. 50A). The **superior limiting sulcus** (S.L.S.), also known as Marchand's opercular sulcus, runs down-

wards and forwards on the dorsal aspect of the insula; its dorsal lip may be operculated, thereby depressing the insula. The other sulcus, namely, the **fronto-orbital** (F.O.S.), which may be very deep, bounds the insula below and anteriorly. These arrangements round the anterior part of the insula distinguish the Gibbons from the Monkeys, and ally them to the Orang, the Chimpanzee, and the Gorilla.

On the excavated inferior surface of the frontal lobe lies the linear **orbital sulcus** (O.S.), or the triradiate system of orbital sulci. And the infero-lateral parts of the occipital lobe exhibit the inferior **occipital sulcus**, which may be connected to the posterior extremity of the middle **temporal sulcus**; it may also be united to the **occipito-temporal sulcus**.

The latter, which is formed to relieve the tension of the expanding cerebral cortex, may be large, its increase in size taking place at the expense of the collateral sulcus.

The mesial aspect of the hemisphere exhibits in all specimens a very well marked **calloso-marginal or intercalary sulcus** whose upturned posterior extremity appears on the outer surface of the brain. It is a deep sulcus. The **collateral sulcus** is frequently seen to consist of two sulci.

In many brains the sulci are deep and the gyri are so pronounced that they are accommodated in deep depressions on the inner aspect of the skull.

In the **hind brain** the condition of the floccular parts of the cerebellum is of interest, for it is intermediate between that present in the brain of a Monkey and that in the higher Simiidae.

The flocculus is small, consisting of a number of small folia surrounding the auditory nerve. The paraflocculus is large and composed of three parts—dorsal, median and ventral, which are known respectively as the dorsal paraflocculus, petrosal lobule and ventral paraflocculus. In the higher Apes this region diminishes in size, and the petrosal lobule vanishes. Another important difference between the brain in the Gibbon and those in the higher Apes is seen in the pontine region. The trapezium which is exposed in the Cercopithecidae and buried in the higher Apes is hardly covered in the Gibbons.

THE BRAIN IN THE ORANG (fig. 50).

The brain is more voluminous than that in the Gibbons, and its surface is more convoluted and fissured. When viewed from above it presents an oval outline, and when seen from below the excavations and keel on the frontal lobes are marked features.

The keel is slightly larger than in other Apes.

The **central sulcus** (C.S.) has a genu. Superiorly it rarely passes on to the mesial surface of the brain, but it may be continued below by a shallow groove into the Sylvian fissure.

The **superior frontal** (S.F.S.) and **superior precentral** sulci (S.P.S.) are united to form a triradius; and there is a variable number of small middle **frontal sulci** (M.F.S.) between the superior frontal and **inferior frontal** (S.R.) sulci. The latter, or sulcus rectus, varies in development in different brains, and it unites behind with the triradiate inferior precentral sulcus, or **sulcus arcuatus** (I.P.S.). The sulcus arcuatus is sometimes connected to the Sylvian fissure by an inferior transverse

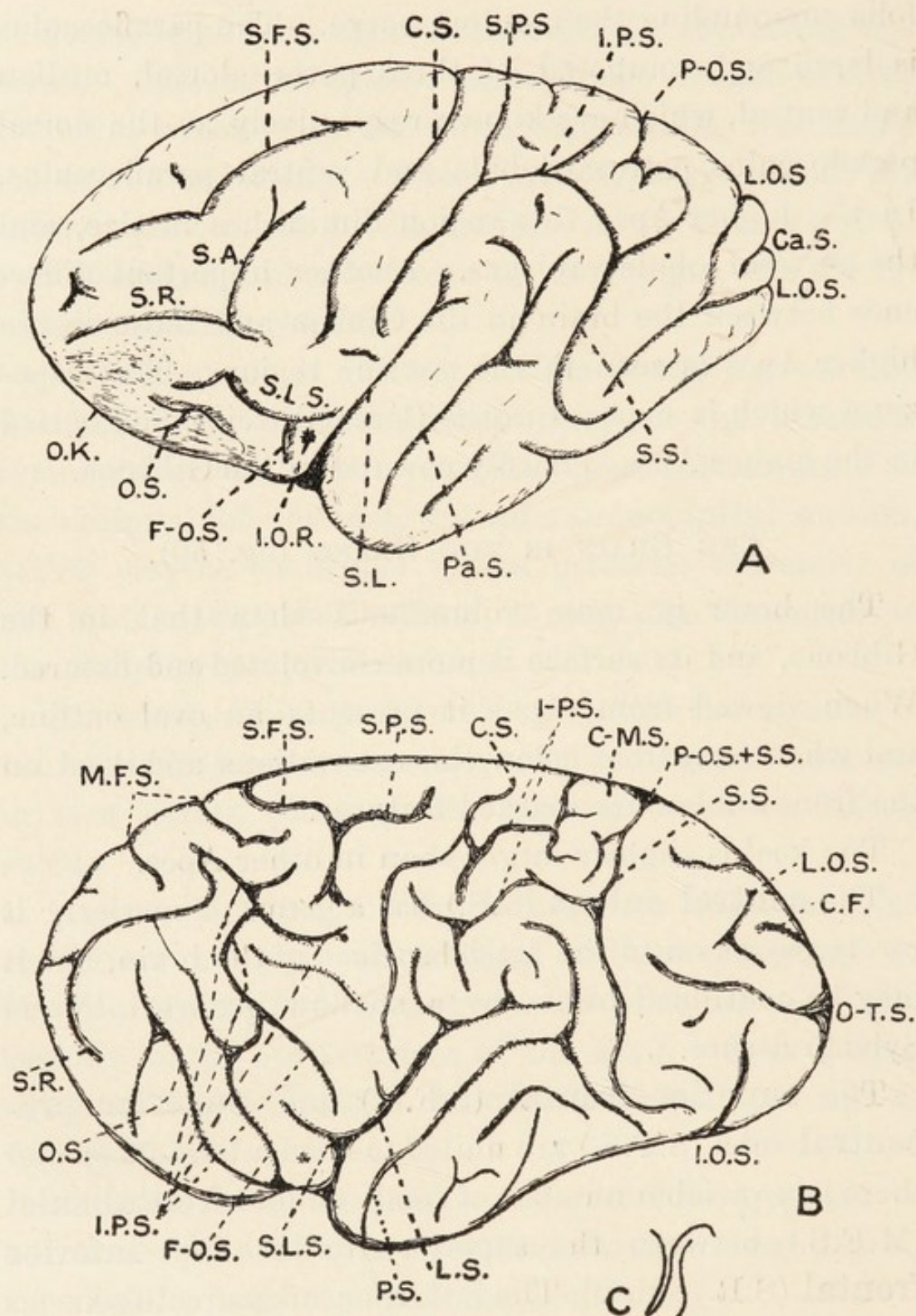


FIG. 50.—The brain in the Hoolock Gibbon (A) and Orang-Outan (B). The true relations of the parieto-occipital (wide) and simian sulci (narrow) are shown in C. o.k., orbital keel. Other letters explained in text.

sulcus, or sulcus diagonalis ; this connection is not present in fig. 50.

The anterior part of the insula (*) is exposed, and its bounding fissures, the **superior limiting sulcus** (S.L.S.) and **fronto-orbital sulcus** (F.O.S.), are deep and well marked. The latter ascends, and is frequently continuous with the arcuate sulcus.

The **orbital sulcus** (O.S.) ascends perpendicularly in front of the fronto-orbital sulcus on the keel of the frontal lobe.

The **Sylvian fissure** (L.S.) has a bifid posterior extremity round which the **parallel sulcus** (P.S.) winds, and the latter may also be bifid. The **intraparietal sulcus** (I-P.S.) is connected anteriorly to one or both of the postcentral sulci, and it runs posteriorly into the **simian sulcus** (S.S.); above its horizontal part there run several small compensatory sulci. The intraparietal and simian sulci form a long, curved sulcus surrounding the upper ends of the Sylvian and parallel sulci. The **parieto-occipital sulcus** (P-O.S.) is not confluent with the simian sulcus, but the occipital operculum conceals the little gyrus separating the termination of the former and the beginning of the latter (fig. 50, c).

The **calcarine sulcus** (C.F.) is as usual embraced by the diverging limbs of the **lateral occipital sulcus** (L.O.S.). The **occipito-temporal sulcus** (O-T.S.) runs horizontally below the lateral occipital sulcus, and the **inferior occipital sulcus** (I.O.S.) is almost perpendicular to it.

Several small sulci are present on the occipital and temporal lobes besides the above-mentioned fissures.

The **calcarine sulcus** is not branched, but there may

be a few small retrocalcarine grooves. And a gyrus separates it from the internal parieto-occipital sulcus. The **collateral sulcus** is well marked, and the calloso-marginal sulcus (C-M.S.) appears for a short distance on the outer surface of the hemisphere.

The **cerebellum** differs from that in *Hylobates*. The bulk is relatively greater, the paraflocculus is much reduced, and there is no petrosal lobule. The relative developments of the flocculus and paraflocculus vary, however, in different brains. The lateral parts of the trapezium are exposed.

THE BRAIN IN THE CHIMPANZEE (fig. 51).

The brain is larger than that in the Orang, and smaller than that in the Gorilla. The characters are very variable, and it is only by examining many specimens that one can come to the conclusion that the Gorilla's brain most approaches that of Man. The brain is ovoid in shape, and the inferior surfaces of the frontal lobes are rostrated. The cerebrum overlaps the cerebellum to a variable extent.

The **central sulcus** (C.S.) has genua of varying degrees of acuteness. It may not reach the great longitudinal fissure.

In front of the central sulcus there lie superior (S.P.S.) and inferior **precentral** (I.P.S.) sulci, which may come very close together. The former unites with one of the **superior frontal** sulci (S.F.S.) to make a triradius, and the latter does the same with the long **inferior frontal sulcus** (I.F.S.). **Middle frontal sulci** (M.F.S.) may be well marked. Sometimes the inferior precentral sulcus joins the central sulcus; and the anterior extremity

of the inferior frontal sulcus may be separated off as the fronto-marginal sulcus of Wernicke (F-M.S.).

The anterior part of the **insula** (*) is exposed. It is bounded by the **superior limiting** (S.L.S.) and **fronto-orbital** sulci (F-O.S.). The latter is long, and in fig. 51 it is seen to join the inferior frontal sulcus. In some brains these bounding sulci actually meet and map out the insula.

The excavated inferior surfaces of the frontal lobes have **orbital sulci** (O.S.), which vary in arrangement.

The **Sylvian fissure** (L.S.) is sometimes bifid posteriorly, and the posterior end of the **parallel sulcus** (P.S.) may not curve round it.

The **intraparietal system** (I-P.S.) consists of an inferior postcentral (I.Po.S.), horizontal and transverse occipital sulci, the latter being concurrent with the **simian sulcus** (S.S.), which reaches very large proportions in the Chimpanzee. Above the true intraparietal complex there is a long sulcus, which is **compensatory** in nature (Co.S.); and the **parieto-occipital sulcus** (P-O.S.) cuts on to the outer surface of the cerebrum behind it.

The region behind the simian sulcus has few sulci. It has the U-shaped **lateral occipital sulcus** (L.O.S.), which embraces the posterior part of the calcarine fissure (Ca.S.).

On the mesial aspect of the hemisphere there is a considerable internal part of the simian sulcus lying parallel to the parieto-occipital sulcus, and the latter joins the long calcarine sulcus, whose posterior extremity is bifid (fig. 51,c). The whole or part of the terminal

bifurcation appears on the outer aspect of the hemisphere.

The **collateral sulcus** is long. It has several branches, and it bifurcates posteriorly. Several little sulci are arranged alongside it.

The **calloso-marginal sulcus** is well marked.

A mesial section through the corpus callosum and lower parts of the brain reveals how the general appearances are much as in Man, and a series of horizontal sections reveals how the basal ganglia have also an identical disposition. The hind brain shows a reduced paraflocculus in some cases, and equal flocculi and paraflocculi in others.

THE BRAIN IN THE GORILLA (fig. 51).

Of all the Apes the Gorilla has the largest brain, and the cerebral characters resemble those of Man most closely. The frontal lobes are rostrated.

The **central sulcus** (C.S.) has a genu. It may not pass on to the mesial aspect of the hemisphere, and it may be connected to the Sylvian fissure by a groove. The **superior frontal** (S.F.S.) and **superior precentral** sulci form a triradius, and a **middle frontal sulcus** (M.F.S.) lies anteriorly between the superior frontal sulcus and **sulcus rectus** (S.R.). The latter varies in different brains, but it forms a triradius with the arcuate or **inferior precentral sulcus** (I.P.S.). The arcuate sulcus sometimes passes into the central sulcus. In fig. 51 it is seen to pass into the Sylvian fissure; so it may represent the arcuate and inferior transverse sulci of the Orang. There may be a fronto-marginal sulcus of Wernicke.

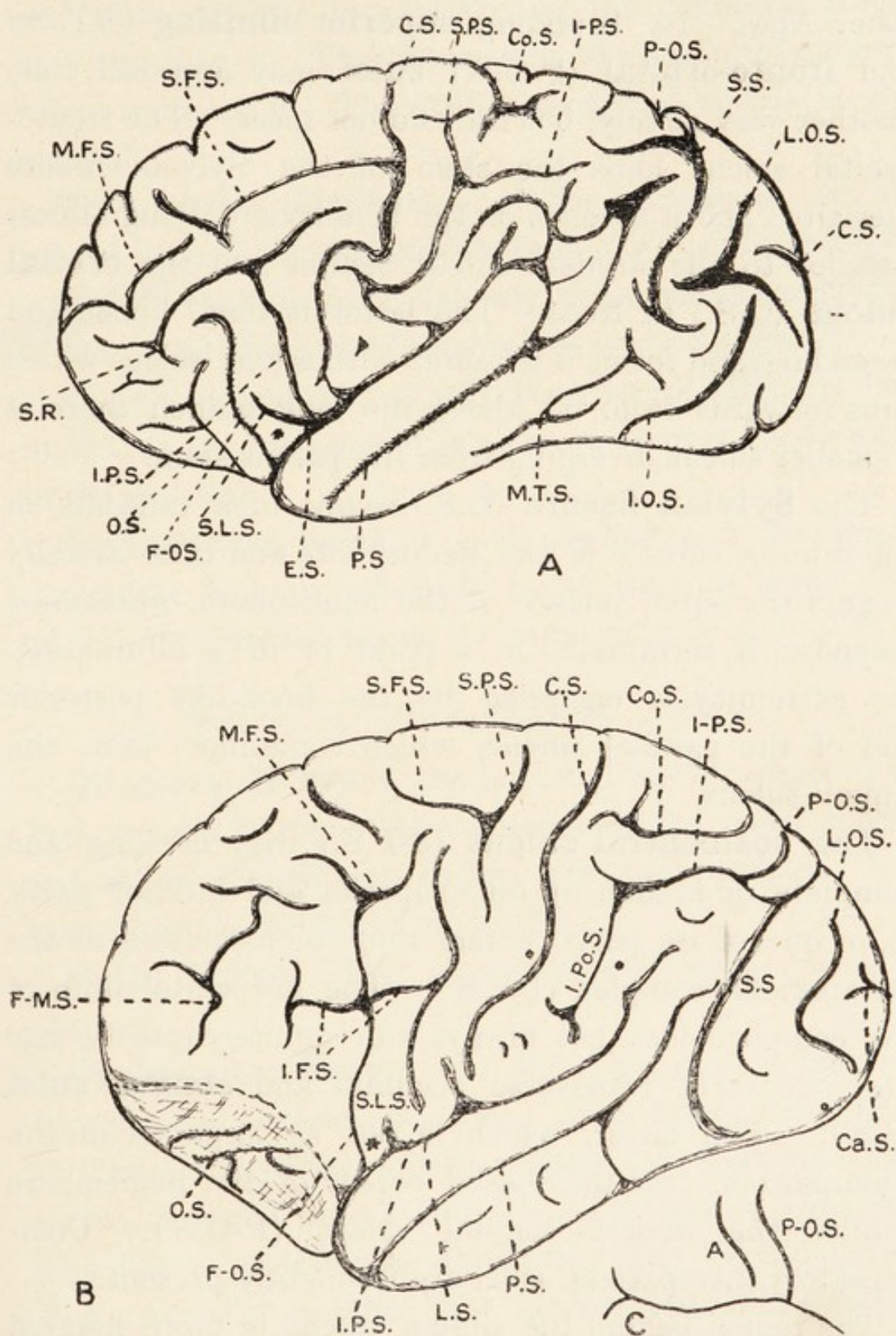


FIG. 51.—The brain in the Gorilla (A) and Chimpanzee (B). In C the internal parts of the simian (A) and parieto-occipital (P-O.S.) sulci are seen above the long calcarine sulcus. Other letters explained in text.

The anterior part of the insula is exposed as in the other Apes. Its bounding **superior limiting** (S.L.S.) and **fronto-orbital** (F-O.S.) **sulci** may approach one another very closely, but they do not meet. The fronto-orbital sulcus joins the stem of the Sylvian fissure mesially; and it ascends on the hemisphere, lying almost parallel to the arcuate sulcus behind and the **orbital sulcus** (O.S.) in front. The latter is long, linear and ascending, and forms a triradius with a long sulcus which runs forwards from it; above the long branch there is a smaller sulcus diverging from the parent stem.

The **Sylvian fissure** (L.S.) begins in a vallecule on the inferior surface of the hemisphere and runs laterally to gain the outer surface of the hemisphere, whereon it ascends: it terminates in a point or in a bifurcation. Its extremity is encircled by the hook-like posterior end of the parallel sulcus, which sometimes joins the simian sulcus.

The **postcentral sulcus** (S-P.S.) may be long and complete, or broken up into superior and inferior parts. It, or one of its parts, enters into the formation of the intraparietal complex (I-P.S.). The horizontal limb of the complex does not always run uninterruptedly into the concurrent transverse occipital and **simian sulci** (S.S.). The latter, which is not as large as in the Chimpanzee, cuts the mesial border of the hemisphere behind the parieto-occipital sulcus (P-O.S.). Compensatory intraparietal sulci are frequently present.

The region behind the simian sulcus is more fissured than in the Chimpanzee and exhibits inferior occipital (I-O.S.) and lateral occipital (L.O.S.) sulci. The latter is Y-shaped and embraces the calcarine sulcus (Ca.S.).

The unbranched calcarine sulcus is a blend of calcarine and retrocalcarine elements; and the collateral sulcus may run into it. The latter joins the occipito-temporal sulcus anteriorly. The calloso-marginal sulcus is well marked.

The general distribution of the structures on the mesial surface of the hemisphere is like that in Man.

The cerebellum has relatively larger paraflocculi than in Man, and the corpus trapezoides is concealed.

The neopallium has already been described, and Tilney finds that the histology of the brain-stem is very similar to that in Man.

The auditory nerve is well marked and the mesial geniculate body is relatively larger than in Man. The auricle is, however, about the same as in him.

Section B.—THE CRANIAL NERVES.

Olfactory Nerve.—The terminal ramifications of the first cranial nerve in the mucosa of the nasal septum and superior turbinate region are well marked. The nerve itself is large in the Gorilla.

Optic Nerve.—The second cranial nerve is as in Man.

Oculo-motor Nerve.—In the Chimpanzee there are superior and inferior divisions. The former, running on the inner side of the superior rectus, supplies the superior rectus, inferior rectus and levator palpebræ superioris. The latter, running on the outer side of the inferior rectus muscle, supplies the inferior rectus and inferior oblique muscles, and sends a motor branch to the ciliary ganglion.

Trigeminal Nerve.—Three divisions radiate from the

Gasserian ganglion. In the Chimpanzee the ophthalmic division courses as in Man, and breaks up into lachrymal, frontal and nasal nerves. The lachrymal nerve, lying between the wall of the orbit and the external rectus muscle, supplies the lachrymal gland, conjunctiva and skin of the eyelids. The frontal nerve breaks up into supra-orbital and supra-trochlear nerves which are as in Man.

The nasal nerve is distributed as in Man; its lateral terminal branch is large. The superior maxillary and inferior maxillary divisions of the trigeminal nerve are as in Man, but I was unable to detect as many branches radiating from Meckel's ganglion. The chorda tympani joins the inferior maxillary division or its lingual branch.

Ganglia connected to the Trigeminal Nerve.—The ciliary ganglion is larger than in Man in the Chimpanzee. It receives branches from both divisions of the third nerve, the naso-ciliary nerve and the sympathetic plexus on the internal carotid artery.

It gives off short ciliary nerves to the eyeball; one of these divides into upper and lower divisions which enter the globe.

The submaxillary ganglion is fused with the hypoglossal nerve.

Meckel's ganglion is placed as in Man. The otic ganglion was not definitely isolated.

Abducens Nerve.—The sixth cranial nerve is as in Man.

Facial Nerve.—The facial nerve courses as in Man. It is most complex in Man and the Orang, simplest in the Chimpanzee, and intermediate in complexity in the Gorilla. In the Chimpanzee it gives off a posterior

auricular nerve, which courses as in Man; and it divides into temporal, zygomatic, maxillary, buccal, mandibular and cervical branches. The temporal branches run upwards and are distributed as in Man. The zygomatic and maxillary nerves unite to form a trunk, which breaks up later into twigs to the facial muscles. The mandibular and cervical divisions are generally as in Man. In the

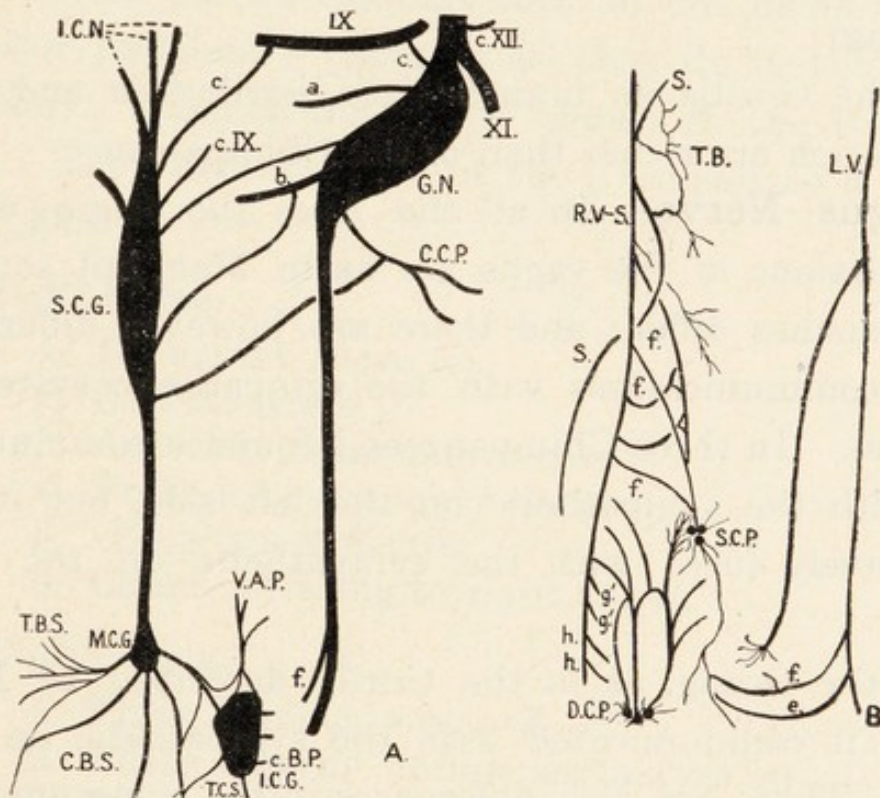


FIG. 52.—The cervical (A) and thoracic parts of the vagus and sympathetic nerves in the Chimpanzee; G.N., ganglion nodosum. Other letters explained in text.

Gorilla the posterior auricular nerve gives off a branch to the external auditory meatus, and Eisler (442) believes this takes the place of the auricular branch of the vagus. The styloid branch communicates with the glosso-pharyngeal ganglion, and a filament runs from the parent trunk to the cervical plexus. The trunk then separates into cervical and temporal divisions, whose

branches radiate widely over the face, communicating with one another and with branches of the trigeminal nerve. There is, however, no fusion of main trunks as in the Chimpanzee. In the Orang there is a most complicated buccinator plexus.

The **auditory nerve** is as in Man.

Glosso-pharyngeal Nerve.—In the Chimpanzee the ninth cranial nerve is similar to that in Man (Vrolik and Sonntag).

In the Gorilla its branches of distribution and communication are richer than in the Chimpanzee.

Vagus Nerve.—In all the Apes the origin, course and relations of the vagus are as in Man, but some of the branches differ; and there are, however, differences in its communications with the sympathetic system in the neck. In three Chimpanzees I found it communicating with the sympathetic on the left side, but it was extensively fused with the sympathetic on the right side.

In the Orang, as in the Gorilla described by Eisler (442), it communicated with the sympathetic on both sides. There are also differences in the communication with the spinal accessory nerve. In the Chimpanzee the two nerves are strongly fused in the foramen lacerum posticum, but a strong communication runs between them in the Gorilla. The following table gives the cervical branches in the Chimpanzee (fig. 52), Gorilla, Orang and Man :—

1. Communicating to the ninth (c. IX), and twelfth (c. XII) cranial nerves, superior cervical sympathetic ganglion (S.C.G.) and cervical plexus (C.C.P.).

2. Pharyngeal nerve (a).
3. Superior laryngeal nerve (b).
 - (i) External laryngeal nerve.
 - (ii) Internal laryngeal nerve.
4. Right recurrent nerve.
5. Cardiac branch of left vagus (f.)
6. To cardiac and tracheal plexus of right vagus.

The thoracic parts of the vagi have the same course as in Man. In the Chimpanzee they do not break up into posterior pulmonary plexuses as they do in the Orang and Man. Their branches are shown in the following table. Their arrangement in the Chimpanzee is shown in fig. 53.

Left Vagus.

1. Recurrent nerve (e).
2. Cardiac nerve (f).
3. Anterior pulmonary nerves.
4. Posterior pulmonary nerves.
5. Œsophageal nerves.
6. Communicating to right vagus.

Right Vagus.

1. Three cardiac nerves (f).
2. Three anterior pulmonary nerves (g).
3. Tracheal branches (T. B.).
4. Two posterior pulmonary nerves (h).
5. Œsophageal nerves.

In the Orang the vagi fuse below the pulmonary roots. The abdominal parts of the vagus nerves are extensive. In the Chimpanzee the left vagus passes through the anterior part of the Œsophageal opening in the stomach and runs along the lesser curvature of the stomach, supplying it and the Œsophagus and communicating with the right vagus. The latter ends in the left semilunar ganglion: it gives off Œsophageal (O.N.) and gastric

(L.C.N.) nerves, and twigs to the hepatic (H.P.), coronary (G.P.), splenic (S.P.), aortic (A.G.C.), superior mesenteric (S.M.P.) and inferior mesenteric (I.M.P.) plexuses. These filaments, however, could not be traced to the cæcum or descending colon.

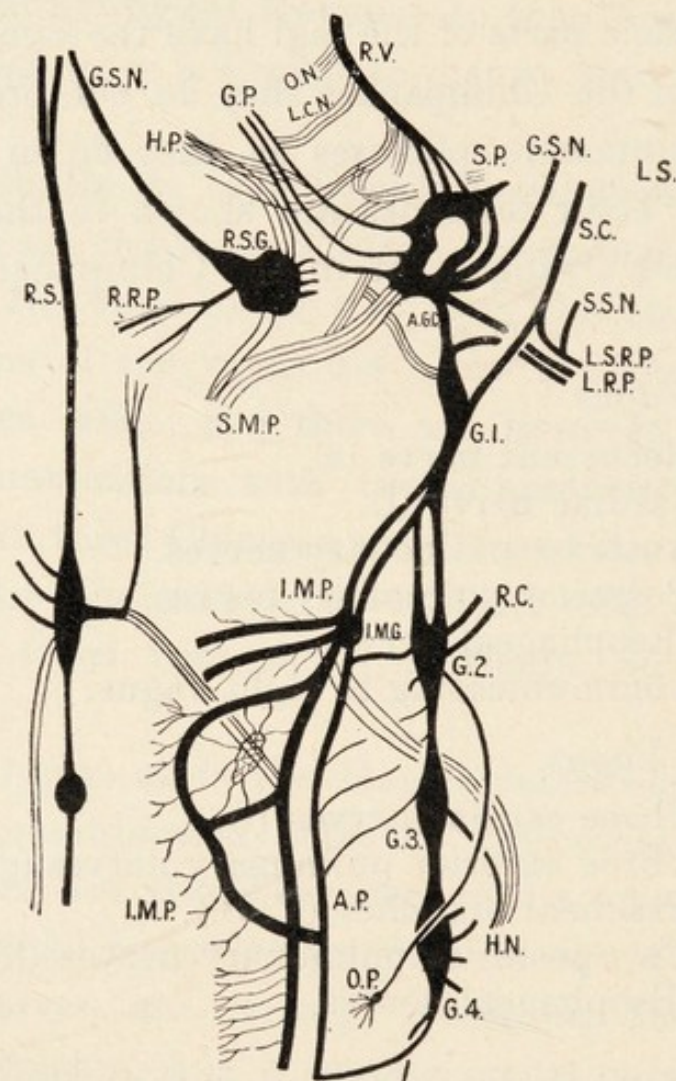


FIG. 53.—The abdominal parts of the vagus and sympathetic nerves in the Chimpanzee. Letters explained in text.

In the Orang the right vagus communicates with the solar plexus and is distributed to the gut.

Spinal Accessory Nerve.—In the Chimpanzee it perforates the cleido-mastoid muscle and runs deep to it and to the trapezius.

It can be traced down to the lower part of the latter muscle into which it sinks. It also supplies the sterno- and cleido-mastoid muscles. At the top of the neck it communicates with the vagus and cervical plexus, but not with the sympathetic cord.

It is essentially similar in all the Apes.

Hypoglossal Nerve.—The origin, course and relations are as in Man; and it likewise communicates with the vagus, sympathetic and lingual nerves. It sends the descendens hypoglossi to unite with the cervical nerves to form the ansa hypoglossi. It also supplies the thyro-hyoid, genio-hyoid, genio-glossus and stylo-glossus muscles. It is essentially similar in all the Apes and Man.

Section C.—THE SPINAL NERVES.

THE CERVICAL PLEXUS.

In all the Apes the first four cervical nerves unite in a looped manner to form the cervical plexus, whose position and relations are as in Man. There are slight differences in the branches; and the latter form cutaneous, muscular and communicating groups. The fourth cervical nerve communicates with the fifth.

The following table shows the branches in the Chimpanzee (fig. 54):—

A. Communicating Nerves (deep).

- (1) To vagus (G.N.), accessory (XI), hypoglossal (XII), from C1 and C2 and sympathetic.

B. Muscular Branches (deep).

Sterno-mastoid (S-M.) from C2.

Trapezius (Tra.) from C3 and C4.

Levator anguli scapulæ (L.A.S.) from C3.

Scalenus medius (Scal. Med.) from C4.

Omo-hyoid (O-H.M.) and sterno-thyroid (S-T.M.) from C2; sterno-hyoid (S-H.M.) from C2 and C3.

Diaphragm by phrenic nerve (P.N.) from C2-C5.

C. Cutaneous Branches (superficial).

Small occipital (O.N.), transverse cervical (T.C.N.) from C2-C3.

Acromial, clavicular and sternal from C3 and C4.

Great auricular from C2.

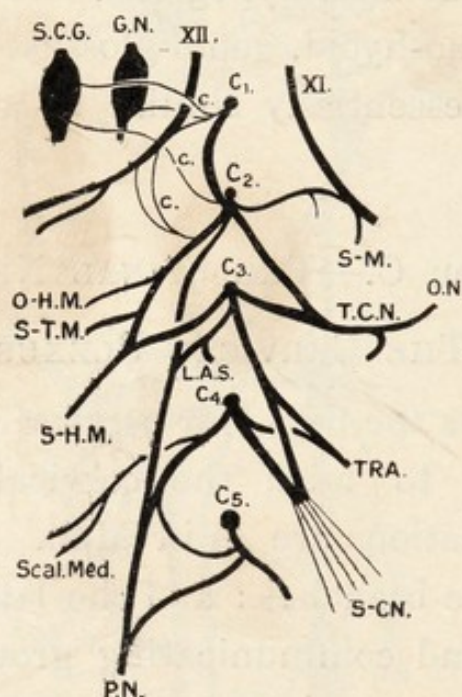


FIG. 54.—The cervical plexus in the Chimpanzee. Letters explained in text.

In the Gorilla the chief points in which the plexus differs from the above are: (1) The loop between C1 and C2 is double instead of single. (2) The supraclavicular cutaneous nerves are more numerous and form a plexus above the clavicle. (3) The sterno-mastoid muscle is innervated by C2 and C3. (4) The levator anguli scapulæ is innervated by C3 and C4. (5) The

phrenic nerve gets sympathetic filaments. (6) The ansa hypoglossi supplies the sterno-mastoid.

The **phrenic nerve** (P.N.) arises in the Chimpanzee from C3 and C4, from C3, C4 and C5, or from C2-C5. In the Orang and Gibbon it springs from C4 and C5; and in the Gorilla it arises from C3 and C4, or from C3, C4 and C5. In the Gorilla it receives sympathetic filaments. The course and relations are as in Man.

No filaments run through the caval opening in the diaphragm in the Gorilla (Eisler). It communicates with the phrenic plexus of the sympathetic.

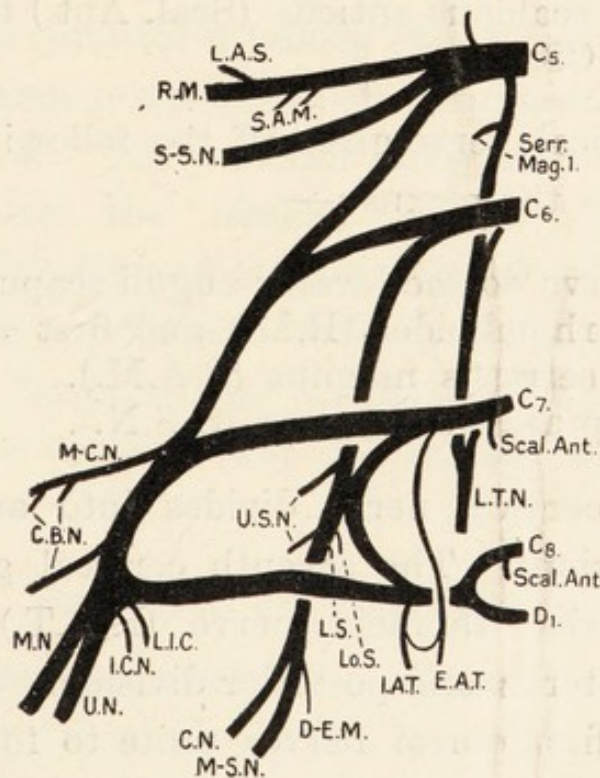


FIG. 55.—The brachial plexus in the Chimpanzee. Letters explained in text.

THE BRACHIAL PLEXUS.

In all the Apes the plexus is formed by the anterior divisions of the fifth, sixth, seventh and eighth cervical and first dorsal nerves. The nerves may unite to form

three trunks as in Man, but that is not always the case. The nerves divide and unite among themselves to form groups of nerves or distinct cords. The arrangement most closely approximates to the human condition in the Orang.

In the Chimpanzee (fig. 55), before the nerves form the plexus the following branches are given off:—

- (1) Communicating to the phrenic nerve from C5.
- (2) Long thoracic nerve (L.T.N.) from C5, C6, C7.
- (3) To first digitation of serratus magnus.
- (4) To scalenus anticus (Scal. Ant.) from C7 and C8.

The fifth cervical nerve gives off the following branches before it enters the plexus :—

- (1) Nerve to the levator anguli scapulæ (L.A.S.), rhomboidei (R.M.) and first digitation of serratus magnus (S.A.M.).
- (2) Suprascapular nerve (S-S.N.).

The sixth cervical nerve divides into anterior and posterior divisions. The seventh cervical gives off the external anterior thoracic nerve (E.A.T.) and then divides into anterior and posterior divisions. The eighth cervical and first dorsal nerves unite to form a lower trunk, which gives off the internal anterior thoracic nerve (I.A.T.) and then divides into anterior and posterior divisions. Thus there is no upper trunk as in Man.

The fifth cervical nerve unites with the anterior divisions of C6 and C7 to form a cord which, after giving off the musculo-cutaneous nerve (M-C.N.) unites with

the anterior division of the combined C8 and D1, from the union the median (M.N.) and ulnar (U.N.) nerves result. There is thus no distinct separation of outer and inner cords as in Man. The posterior divisions from the sixth cervical to first dorsal nerves unite to form a posterior cord from which four subscapular (U.S.N., L.S. and Lo.S.), the circumflex (C.N.) and musculo-spiral (M-S.N.) nerves arise. The internal cutaneous (I.C.N.), lesser internal cutaneous (L.I.C.) and coracobrachial nerves (C.B.N.) arise from representatives of the outer and inner cords.

In the Gorilla, according to Eisler (442) and Hepburn (83) the anterior divisions of C5 and C6 form the musculo-cutaneous nerve, which communicates with the median nerve. The anterior divisions of C6, C7, C8 and D1 form the median nerve. The anterior divisions of C7, C8 and D1 form the ulnar nerve.

The posterior divisions of C5 to D1 form a posterior cord, whose branches are as in the Chimpanzee. In the Orang the arrangement approaches most closely to that in Man.

BRANCHES OF THE PLEXUS.

The **suprascapular nerve** (n. dorsalis scapulæ) arises from C4 and C5 in the Gorilla, from C5 in the Gibbons and some Chimpanzees, and from C5 and C6 in other Chimpanzees and the Orang. Its course and branches are as in Man.

Anterior Thoracic Nerves.—These arise separately or from a single trunk. They are distributed to the pectoral muscles, and a loop connects them as in Man.

The **long thoracic nerve** is similar to that in Man.

Sometimes it is represented by separate filaments running down from the brachial plexus.

The **subscapular nerves** are from three to five in number. They supply the subscapularis, latissimus dorsi and teres major, but Hepburn (83) states that the circumflex nerve supplies the teres major in the Gorilla.

The **median nerve** in the Chimpanzee supplies the coraco-brachialis in the upper part of the arm. Just below the end of the elbow it supplies the flexor carpi radialis, flexor sublimis digitorum and both heads of the pronator radii teres. In the forearm lower down it communicates with the ulnar nerve and supplies the flexor sublimis and flexor profundus digitorum. It divides in the palm into outer and inner branches. The former supplies the thenar muscles, first lumbrical and the skin of the adjacent sides of the thumb and index finger. The latter supplies the third and fourth lumbricals and the skin of the adjacent sides of the second, third and fourth digits. The nerve to the second and third digits supplies the second lumbrical muscle.

In the Gorilla and Orang the muscular and cutaneous distribution are as in Man.

The **ulnar nerve** courses as in Man. In the Chimpanzee it supplies the flexor carpi ulnaris and flexor profundus digitorum.

Two inches proximal to the wrist it divides into anterior and posterior divisions. The former supplies the hypothenar muscles, and its cutaneous distribution is as in Man; the latter goes deeply to supply the palmar interosseous muscles. A dorsal branch of the main trunk runs to the interosseous muscles, adductores

pollicis and contrahentes. Hepburn points out that the ulnar nerve supplies the fourth lumbrical in the Chimpanzee, the third and fourth lumbricales in the Orang and Gibbon, and the second, third and fourth muscles in the Gorilla.

The **internal cutaneous nerves** of the arm and forearm and the intercosto-brachial nerves are much as in Man.

The **musculo-spiral nerve** courses as in Man. In the arm it supplies the skin, triceps and dorso-epitrochlearis. In the lower part of the arm it supplies the brachialis anticus in the Gorilla alone. At the bend of the elbow it supplies the muscles rising from the external condyle of the humerus, and divides into the radial and posterior interosseous nerves. These have the same course and distribution as in Man, and the latter may supply the pronator quadratus and wrist-joint.

The **musculo-cutaneous nerve** has the same course and distribution as in Man. The **circumflex nerve** is also similar.

THE LUMBAR AND SACRAL PLEXUSES.

These plexuses, which are formed by the anterior divisions of the lumbar and sacral nerves, are united by the lumbo-sacral cord. The formation of the nerves springing from them is liable to considerable individual variation. The mode of formation in the Chimpanzee is shown in fig. 56. And the origins of the nerves as recorded by various observers are shown in the following list:—

Ilio-hypogastric nerve (I-H.N.).*

Chimpanzee: Dxiii (Bolk, Champneys, Sonntag);
L1 (Sperino).

Gorilla: Dxiii and L1 (Eisler).

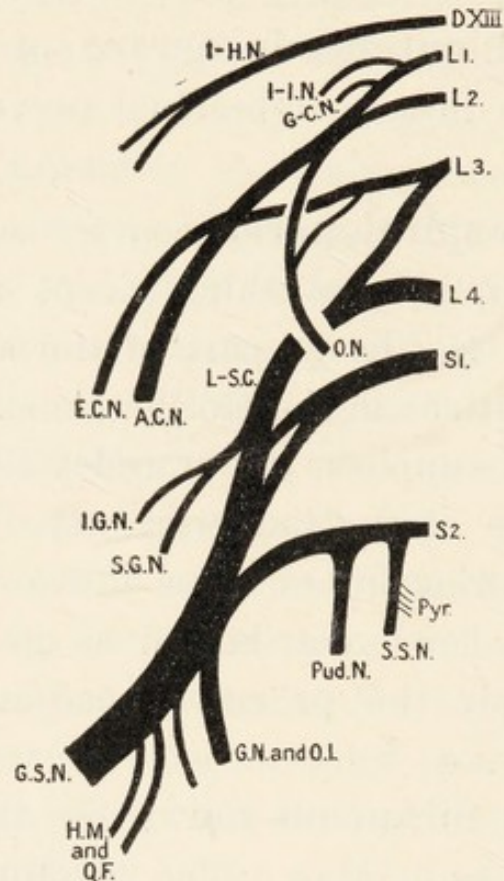


FIG. 56.—The lumbar plexus in the Chimpanzee. Letters explained in text.

Ilio-inguinal Nerve (I-I.N.).

Chimpanzee: Dxiii (Bolk, Champneys); L1 (Hepburn, Sonntag).

Gorilla, Orang, Gibbon: L1.

Genito-crural Nerve (G-C.N.).

Chimpanzee: Dxiii (Champneys); L1 (Hepburn, Sonntag).

Gorilla: L1 (Hepburn); Orang: L1; Gibbon: L2.

* The papers in which these observations are recorded are: Bolk (312), Champneys (318), Eisler (442), Hepburn (83), Kohlbrügge (199), Ruge (401), Sonntag (399), Sperino (401), Westling (298).

Anterior Crural Nerve (A.C.N.).

Chimpanzee and Orang : L1, L2, L3.

Gorilla : L1-L4 (Eisler) ; L1-L3 (Ruge) ; L2-L4 (Hepburn).

Gibbon : L2-4.

Lateral Cutaneous Nerve (E.C.N.).

In all Apes the origins recorded are L1 and L2 or L2 and L3.

Obturator Nerve (O.N.).

Chimpanzee and Gorilla : L1-L3 or L2-L4.

Orang : L1 and L2 ; Gibbon : L3 and L4.

Superior Gluteal Nerve (S.G.N.).

Arises from the lumbo-sacral cord or from the cord and S1.

Inferior Gluteal Nerve (I.G.N.).

Chimpanzee : L4, S1, S2 ; Gorilla : Lumbo-sacral cord and S1.

Great Sciatic Nerve (G.S.N.).

Chimpanzee and Gorilla : Lumbo-sacral cord, S1, S2.

Orang : L3, L4, S1, S2 (Hepburn) ; L2, S1 (Westling).

Small Sciatic Nerve (S.S.N.).

Chimpanzee : L3, L4, S1 (Champneys) ; S2 (Sonntag).

Gorilla : S1, S2 (Eisler).

Pudendal Nerve (Pud.N.).

Chimpanzee : S2 (Bolk, Sonntag).

Gorilla : S1, S2 (Eisler).

Gibbon : Thoraco-lumbar nerves XIX and XX (Kohlbrügge).

Nerve to Obturator Internus (O.I.).

Chimpanzee : Tibial nerve (Bolk) ; S1, S2 (Hepburn) ; S2 (Sonntag).

Gorilla : S1, S2.

Orang : S1, S2.

Gibbon : S1, S2.

Nerve to Pyriformis (Pyr.).

Chimpanzee: S2 (Hepburn, Champneys, Sonntag).

Gorilla: L-S.C.*, S1 (Hepburn).

Orang: L-S.C., S1 (Hepburn).

Gibbon: ———

Nerve to Quadratus Femoris (Q.F.).

Chimpanzee: Tibial (Bolk); Great Sciatic (Sonntag).

Gorilla: As in Man.

Orang: As in Man.

Gibbon: As in Man.

Nerve to Gemelli (G.N.).

Chimpanzee: S1, S2 (Hepburn); S2 (Sonntag).

Gorilla: S1, S2.

Orang: S1, S2.

Gibbon: S1, S2.

The **ilio-inguinal, ilio-hypogastric and genito-crural nerves** are distributed as in Man. The lateral cutaneous nerve supplies the skin of the outer surface of the thigh by several branches.

The **anterior crural (femoral) nerve** supplies the iliacus within the pelvis. In the thigh in the Chimpanzee it divides into anterior and posterior branches. The former supplies the sartorius, pectineus and gracilis and gives off the patellar and saphenous cutaneous nerves. The latter supplies the quadriceps extensor muscle.

The **obturator nerve** in the Chimpanzee divides into inner and outer parts, which emerge at the sides of the superficial head of the adductor brevis (fig. 36). The former supplies the pectineus, gracilis, adductor longus and adductor brevis. The latter supplies the obturator externus, adductor brevis and the whole of the adductor

* L-S.C. = lumbo-sacral cord.

magnus except the strip going to the internal condyle of the femur. The chief variation among the Apes is the presence or absence of the twig to the pectineus; when it is present the pectineus includes part of the adductor longus.

The **superior gluteal nerve** arises in the Gibbons alone from the lumbo-sacral cord. In other Apes it springs from sacral nerves. Its course and distribution are as in Man, with the addition of a twig to the scansorius. The **inferior gluteal nerve** is as in Man; and the **small sciatic nerve** ends in the skin of the calf.

The **great sciatic nerve** in the Chimpanzee emerges from the pelvis, winds round the ischial tuberosity and enters the back of the thigh. It divides at any point between the tuber ischii and popliteal space into the external and internal popliteal nerves. The former breaks up into anterior tibial and musculo-cutaneous nerves, and the latter becomes the posterior tibial nerve. In the Chimpanzee it first supplies the obturator internus, gemelli, quadratus femoris, biceps and gluteus maximus; and it supplies the hamstring muscles in the thigh. The external popliteal nerve supplies the biceps, extensor longus digitorum and knee-joint. Its continuation, the anterior tibial nerve, supplies the anterior tibial muscles, flexor brevis digitorum, ankle and tarso-metatarsal joints and the skin of the adjacent sides of the hallux and index. The musculo-cutaneous nerve supplies only the skin of the adjacent sides of the index, medius, annularis and minimus. No sural nerve exists. The posterior tibial nerve supplies both heads of the gastrocnemius, anterior tibial, posterior tibial and peroneal

muscles. It also supplies the ankle-joint and flexor brevis digitorum, and divides into three terminal branches:—

- (1) Muscular to the abductor minimi digiti.
- (2) Internal plantar nerve to the abductor hallucis, flexor brevis hallucis, adductor hallucis, lumbricales, the joints of the foot and the skin of the four inner toes.
- (3) Lateral plantar nerve to the adductor hallucis, abductor minimi digiti, flexor brevis minimi digiti, interossei, joints of the foot and skin on the inner side of the fifth toe.

In the other Apes the chief points to note are that the anterior tibial nerve does not reach the skin of the foot in the Orang, and the musculo-cutaneous nerve supplies the peroneal muscles.

The **pudendal nerve** in the Chimpanzee emerges through the sciatic notch and forms a prominent neighbour for the pudendal vessels. It lies in the outer wall of the ischio-rectal fossa and supplies the rectum, sphincter ani, levator ani, sphincter vaginæ, ischio-cavernosus, and skin of the perineum.

Section D.—THE SYMPATHETIC NERVOUS SYSTEM.

In the Chimpanzee (figs. 52 and 53) the long, oval superior cervical ganglion (S.C.G.) extends from the level of the hard palate to the level of the hyoid bone. It gives off the following branches:—

Communicating Branches:—

- (1) To the glosso-pharyngeal (IX), hypoglossal (XII), and ganglion nodosum of the vagus (G.N.).
- (2) To the superior laryngeal branch of the vagus (b).
- (3) To the first and second cervical nerves.

Branches of Distribution :—

- (1) Pharyngeal nerves.
- (2) External carotid plexus.
- (3) Internal carotid nerves (I.C.N.), which accompany the internal carotid artery.

The superior cervical ganglion is connected to the middle cervical ganglion (M.C.G.) which gives off the following branches :—

Communicating Branches :—

- (1) Communicating to the vertebral plexus (V.A.P.).
- (2) Communicating to the brachial plexus (c.B.P.).
- (3) Communicating to the right recurrent laryngeal nerve.

Branches of Distribution :—

- (1) Thyroid and tracheal plexuses (T.B.S.).
- (2) Cardiac and aortic nerves (C.B.S.).

The middle cervical ganglion is connected to the inferior cervical ganglion (I.C.G.), whose branches are :—

- (1) Communicating to the brachial plexus (c.B.P.).
- (2) Plexus accompanying the vertebral artery (V.A.P.).
- (3) Cardiac nerve.

The thoracic sympathetic cord leaves the lower pole of the fused inferior cervical and first thoracic ganglia.

In the Gorilla, according to Eisler's account (442) the cervical sympathetic is in general similar to the above; but the branches are more numerous and there is a communication between it and the phrenic nerve.

Thoracic Sympathetic.—In the Chimpanzee, Orang and many Gibbons the number of ganglia is less than the number of ribs. In the former the great splanchnic

nerve is given off at the level of the fifth and sixth thoracic nerves, and the small splanchnic nerve separates off at the level of the diaphragm. The usual rami communicantes and aortic nerves are given off. In the Gorilla there are eleven thoracic ganglia, and the great splanchnic nerve comes from the sixth to twelfth ganglia; the whole arrangement, in fact, is more complex than in the Chimpanzee and somewhat simpler than in Man.

Abdominal Sympathetic.—In the Chimpanzee the number of ganglia does not correspond always to that of the lumbar nerves; in one animal there were four left and two right ganglia. They give off the following branches in order from above downwards (fig. 53):—

1. Communicating to the inferior mesenteric plexus (I.M.P.) and renal plexus (R.P.).
2. Rami communicantes to the lumbar nerves (R.C.).
3. Ovarian plexus (O.P.).
4. Communicating to the aortic plexus (A.P.).
5. Inferior mesenteric plexus.
6. Hypogastric nerves (H.N.).
7. External iliac nerves.

The sacral ganglia give rami communicantes to the sacral nerves and hæmorrhoidal and vesical plexuses. Filaments also get into the genital plexuses.

VAGUS AND SYMPATHETIC PLEXUSES.

In all Apes and Man the pharyngeal plexus is formed by branches of the glosso-pharyngeal, vagus and sympathetic nerves.

Cardiac Plexus (fig. 52).—This plexus consists of superficial and deep parts communicating with one another. Their component nerves are:—

| Chimpanzee | Gorilla | Man |
|---|--|--|
| <i>Superficial Plexus (S.C.P.)</i> 1. Cardiac branch of left vagus | <i>Superficial Plexus</i> 1. Cardiac branch of left vagus | <i>Superficial Plexus</i> 1. Upper left cardiac sympathetic nerve 2. Lower cervical cardiac branch of left vagus |
| <i>Deep Plexus (D.C.P.)</i> 1. Filaments from left sympathetic 2. Thoracic branch of left vagus 3. Cervical branch of right vagus 4. Thoracic branches of right vagus 5. Branches from right cervical sympathetic 6. Branch from left recurrent laryngeal nerve | <i>Deep Plexus</i> 1. Filaments from right sympathetic 2. Branches of right vagus 3. Branch from the left recurrent nerve | <i>Deep Plexus</i> 1. All cervical cardiac branches of sympathetic except the upper left branch 2. All cardiac branches of the vagi except the lower left cervical one 3. Branches of both recurrent nerves |

The superficial plexus is placed as in Man, but the deep plexus is higher up about the innominate artery. In Man the conditions, particularly the sympathetic contributions to the plexuses, are more complex. In the Apes, as in many lower mammals, the vagus probably conveys many sympathetic filaments.

The **anterior pulmonary plexuses** are formed by branches of the vagus nerves, and the **posterior pulmonary plexuses** are formed by twigs from the vagus nerves and upper thoracic sympathetic ganglia.

Solar Plexus.—In the Chimpanzee (fig. 53) the annular left coeliac ganglion receives the greater part of the right vagus nerve, and each coeliac ganglion receives a great splanchnic nerve. The two ganglia are united by communicating filaments; and the plexus gives off the following plexuses:—

1. Communicating to the gangliated sympathetic cords (A.G.C.).

2. Gastric plexus (G.P.).
3. Splenic plexus (S.P.).
4. Hepatic plexus (H.P.).
5. Renal plexuses (L.R.P. and R.R.P.).
6. Left suprarenal plexus (L.S.R.P.).
7. Superior mesenteric plexus (S.M.P.).
8. Communication to inferior mesenteric plexus.
9. Phrenic plexus.

In the Gorilla the plexus is annular. Its offshoots, which are similar to those in the Chimpanzee, have more ganglia. In both the small splanchnic nerves run to the renal plexuses.

In the Orang the right vagus only communicates with the plexus and ends in branches which accompany the branches of the superior mesenteric artery to the small and large intestines. From this arrangement one may conclude that the fibres which run from the coeliac plexus to the large intestine via the superior mesenteric plexus are vagus fibres.

Section E.—THE SENSE ORGANS.

A.—THE ORGANS OF TOUCH.

Tactile corpuscles are present under the papillary ridges in the skin of the Apes and Man, but the functions are most highly developed in Man. The human hand has lost its power of supporting the body and it has become highly specialized as a tactile organ. The foot is also an important sense organ, for its nerve endings give information of his position on the ground; and Man's two feet have to do the work of the four feet of the Apes in this connection. When these stimuli are

cut off Man suffers from vertigo, particularly in the dark, or when he closes his eyes.

B.—THE EYE AND ITS APPENDAGES.

In the Chimpanzee the **eyebrows** are poorly developed, for they are merely represented by a few short hairs. The **eyelids** have well-marked meibomian follicles, which, however, may be concealed by pigmented conjunctiva. The **lacus lachrymalis** is wide, but has no caruncle; and the plica semilunaris is well marked. The lower lachrymal papilla is larger than the upper one. The **lachrymal gland** is small, flat and divided into two parts. And the lachrymal sac and ducts are much as in Man. The orbital fat is in good amount.

The **globe of the eye** is similar to that in Man, and the ophthalmoscopic appearances are similar also (93).

The **ocular muscles** in the Chimpanzee arise as in Man, and they are innervated in the same way. The four muscoli recti are inserted as in Man, but their relations to the structures in the orbits differ somewhat from those in him. The levator palpebræ superioris has no attachment to the skin, but is fixed to the superior tarsal cartilage and conjunctiva. The superior oblique muscle is more spread out after it passes through the trochlea than in Man. But the inferior oblique, which is inserted into the back of the eyeball, has a narrower insertion than in him. In the Orang, according to Ottley (272), the inferior oblique muscle is inserted farther forwards on the globe.

C.—THE ORGAN OF HEARING.

The **External Ear**.—During the process of evolution structures become increasingly complex and specialized,

or they undergo progressive degeneration as the result of loss of function. The external ear of the Apes and Man is a good example of an organ which has undergone changes of the latter type; and Wallis (412a) has aptly likened it to an outpost, once important, but no longer essential, from which the garrison is withdrawing. Keith (100) points out that these retrogressive changes have proceeded farthest in the Orang; they are not so marked in Man and the Gorilla; and they are least evident in the Chimpanzee. On the other hand, Wallis states that the human ear is most ancestral in type.

The *size of the ear* is related to habits. The Gibbons and Chimpanzees have the largest ears, for they require quick hearing to enable them to escape from enemies when they are on the ground. The Orang has the most degenerate ear for it leads a safe life among the branches of high trees. The Gorilla is less arboreal in its habits than the other Anthropoids, but its ears are small. It is, however, a most formidable animal and can defend itself when attacked, so acuteness of hearing is of no great consequence. Pocock (223) states that "it is important to note that of the two Apes inhabiting W. Africa, namely the Chimpanzee and Gorilla, and of the two inhabiting the East Indies, namely, the Orang and the Gibbon, the larger and stronger has in each case small, insignificant ears, and the smaller and weaker large ears."

The external ears are most prominent in Man and the Chimpanzee, for they are concealed by the hairs in the Gibbons, Orang and Gorilla. Their small size in the Gorilla and Orang permits them to be easily hidden.

Doran (**323**) has shown that the **ossicles** in the middle ear present features which resemble those of Man; but, taken as a whole, those of the Chimpanzee resemble the human condition most closely. And van Kampen pointed out that the whole structure of the **tympanum** is similar in the Apes and Man. Man, however, has advanced beyond the Apes in the specialization of the tympanic bone into a tympanic plate.

CHAPTER XIII.

THE EVOLUTION OF THE PRIMATES.

BEFORE we proceed to study the past history of the Primates it is necessary to consider briefly the cardinal principles of phylogeny, for the neglect of some of them has been productive of no small amount of error in theories of evolution.

It is now generally believed that all animals are the collateral descendants of a common ancestor of simple structure, which lived at a very remote period in the history of the earth. In course of time its descendants changed their habits and diet, and came under the influence of different environments, with the result that their tissues became more or less modified to enable them to survive under the altered conditions. Some primitive features were retained, but some organs became greatly modified or "specialized." And it is important to discover the nature of anatomical characters before one can assess their true value for taxonomic purposes, or for setting the blood-relationships of animals.

There appear to be two reasons for the retention of primitive characters. In the first place they are useful to their possessors, or they would have been masked by adaptive modifications. In the second place the overdevelopment of one or more special senses, the adoption of sheltered modes of life, or the possession of a large

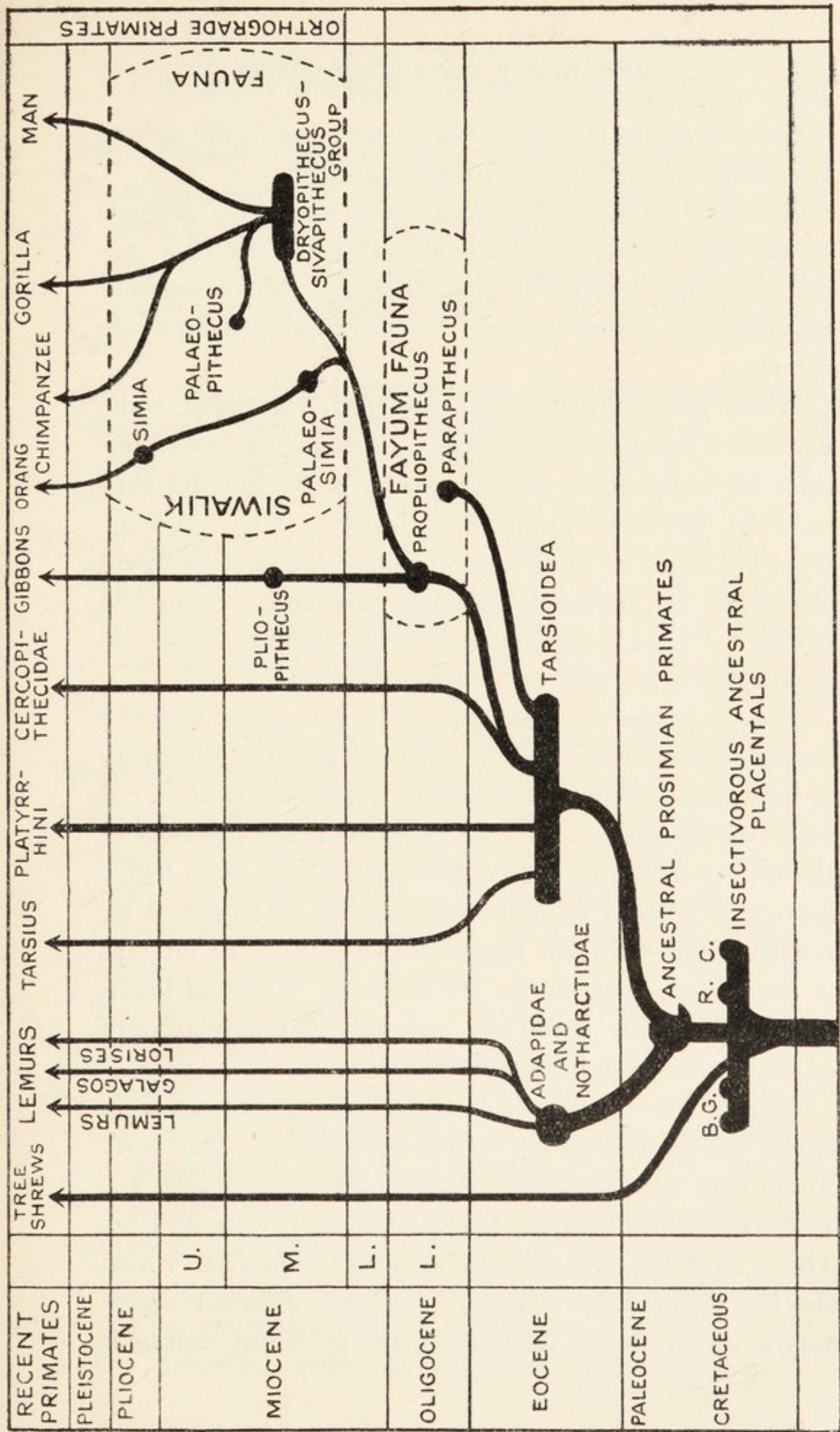


FIG. 57.—The evolution of the Primates. B, line leading to the Bats; C, line of the Creodonts leading to some Mammalian Orders; G, line leading to *Galeopithecus*; R, line leading to the Rodents. The Tree Shrews are placed close to the Lemurs although they are not yet included in the Primates.

neopallium, as in the case of Man, will enable the animal to survive and retain primitive features.

It must be strongly emphasized that two animals which retain several identical primitive features are not necessarily related in consequence. And systems of classification which ignore this cardinal principle are valueless.

When two animals, which are quite unrelated, come under the influence of the same physiological conditions some of their organs exhibit similar characters, for they have to function almost identically. They undergo what is known as convergent evolution, and convergent characters are frequently seen in the teeth, tongue and stomach. It is, however, easy to attribute too much to convergence, likewise to parallel evolution.

It is essential for the student to remember that the geological record is very incomplete, and the discovery of new fossils sometimes leads to a readjustment of our views of phylogeny. It has revealed many branches of the tree of life, and several ancestral forms from which groups of modern animals have arisen. At present we must postulate several hypothetical animals to fill gaps in the record, and wait for the discovery of actual fossils which take their places and give us a complete account of the evolution of living animals.

It is now established that Mammals have arisen from one of the families of the Cynodont Reptiles. The early Mammals, according to Huxley (89), constituted the Prototheria, from which the Monotremes were derived. These Prototheria gave way to Metatheria from which the Marsupials were evolved. And the Metatheria gave way to the Eutheria, from which the placental Mammals

were derived. The remains of the actual ancestral placentalia have not been discovered, so it is necessary to make a hypothetical type; and deductions from comparative anatomy and palæontology have led observers to place the hypothetical animals in the Cretaceous Period.

It is believed that the **ancestral, placental Mammals** were small creatures with comparatively simple teeth, arranged according to the formula $I \frac{3}{3} C \frac{1}{1} P M \frac{4}{4} M \frac{3}{3}$. Their food habits were insectivorous, and they may have been arboreal. They may be regarded as forming a central reservoir from which streams of life flowed in different directions; and each stream or radiation ended in one or more of the modern Mammalian Orders (fig. 57).

One branch or radiation is represented to-day by the **Tree Shrews** (Tupauidæ), which are in many ways very primitive. A second branch has as its sole living representative the **Flying Lemur** (*Galeopithecus volans*), which is allied to the Insectivora and Chiroptera.

Of the remaining branches of the ancestral stock the Primates alone concern us here.

The earliest remains of undoubted Primates have been found in the Eocene rocks of North America. And as these are remains of both Lemuroidea and Tarsioidea, which represent different lines of evolution, we must assume that they arose from a common ancestor, which lived at an earlier period. It is now believed that the separation of the Lemuroidea and Tarsioidea from common ancestral Primates took place in the Paleocene, or even as far back as the Cretaceous Period.

The ancestral Primates separated from the other

Mammals as the result of cerebral changes, which Professor Elliot Smith described as follows: "In the Primates it was the precocious expansion of the brain and the simultaneous cultivation of the visual, auditory, tactile and motor areas of the cerebral cortex that first differentiated the earliest Primates from all other Mammals, and provided them with the germs of the capabilities and the means of attaining the supreme position expressed in the name of the Order."

The fossil Prosimiæ of the American Eocene belong to two Families, the Notharctidæ, which were Lemur-oidea, and the Anaptomorphidæ, which were Tarsioidea.

The Family **Notharctidæ** includes the genus *Notharctus*, with several species, and the genus *Pelycodus*, with one species. And the remains, which include a nearly complete skull, a skeleton, fragments of jaws and teeth, and some limb bones, show that the animals varied considerably in size. The oldest forms were quite small, whereas *Notharctus crassus* was as large as a Howling Monkey (Gregory). Many examples might be taken from the different Mammalian Orders to show that there is a progressive increase in the size of the body in the course of evolution. The general characters of the skeleton resemble those of the modern Lemurs (see p. 17), but the cranial cavity was smaller, and the teeth were more primitive. The variations in the dental formula are.—

| | | | | |
|--------------------------------|----------------|----------------|-----------------|----------------|
| I. Ancestral placental Mammals | $I\frac{3}{3}$ | $C\frac{1}{1}$ | $PM\frac{4}{4}$ | $M\frac{3}{3}$ |
| II. Notharctidæ | $I\frac{2}{2}$ | $C\frac{1}{1}$ | $PM\frac{4}{4}$ | $M\frac{3}{3}$ |
| III. Modern Lemurs | $I\frac{2}{2}$ | $C\frac{1}{1}$ | $PM\frac{3}{3}$ | $M\frac{3}{3}$ |

Besides these quantitative changes there have been specializations of more or less profound character in most

of the teeth, so the dental characters of the modern Lemurs differ greatly from those of the Notharctidæ.

The Notharctidæ were closely related to the Lemuroidea of the Family Adapidæ, which migrated to Europe in Eocene times. The actual place from which they started is not known, but it was near America, possibly in the northern circumpolar land.

The Family **Anaptomorphidæ** contains several Tarsioids, which can be arranged in the genera *Anaptomorphus*, *Hemiacodon*, *Omomys*, *Tetonius*, *Uintanius* and *Washakius*. The remains are scanty, but they show that the animals were small and variously specialized. They differed from the Notharctidæ in the immense orbits, the expanded cranial cavity and the reduced muzzle. So we can assume that these changes were accompanied by the same alterations in the visual apparatus which distinguish *Tarsius* from a Lemur (see page 34). They resemble *Tarsius* in many ways, but no species hitherto discovered is ancestral to it.

Special interest is attached to *Anaptomorphus homunculus*, which is really a *Tetonius*. Cope (507) and others regarded it as ancestral to the Apes and Man. The dental formula, according to Matthew, is $I_0^2C_1^1PM_2^2M_3^3$. The canine teeth were well marked according to reconstructions, and the molar teeth are transversely expanded. The auditory bullæ are inflated and closely applied to the basis cranii; and the cranial cavity is about the same size as that of *Tarsius*. The importance of Cope's observation that *homunculus* was the most Ape-like Lemuroid discovered up to that time (1885) has been enhanced by subsequent investigations, which have proved that the Anaptomorphidæ gave rise to the

Apes. But the actual Tarsioids which gave rise to both Platyrrhini and Catarrhini have not yet been discovered. This is one of the most serious gaps in the geological record.

The remains of the **Adapidæ** have been found in the Eocene formations of France and Switzerland. They belong to three species: *Adapis magnus*, *A. priscus* and *A. parisiensis*. The skull agrees with that of the Notharctidæ in its general form, and in the communication between the orbit and temporal fossa under a post-orbital bar. The orbit is small, with a prominent lip-like ring, and the upper orifice of the naso-lachrymal duct is within the cavity. The sagittal crest is well marked and the zygoma is strong. The ramus of the mandible is large, the coronoid process is high up and recurved; and the glenoid cavity is such that it only permits the mandible to move in a hinge-like manner as in the Carnivora. The tympanic region is as in the Lemurs, and the cranial cavity is large. The teeth are not as specialized as in the modern Lemurs. It can be shown, from a study of all osseous fragments hitherto discovered, that the Adapidæ are intermediate between the Notharctidæ and the modern Lemurs to which they gave rise.

In Madagascar extinct Lemurs belonging to other Families have been discovered. Some, such as *Nesopithecus*, have a monkey-like appearance, and the discoverer, Forsyth Major, wondered whether that fossil was the highest Lemuroid or the lowest Ape. There is, however, no doubt that it is a Lemur, for the skull and skeleton provide very definite proof.

Of the extinct Lemuroidea, *Megaladapis insignis*,

whose remains were found in a cave in Madagascar, was truly gigantic, it was about as large as a donkey, and its mode of life was possibly aquatic. The orbits are surrounded by bony rims, which are prolonged outwards, the zygomata are strong and the sagittal crest is low. The mandibular rami are large, and Forsyth Major thought that the animal might have had an air-sac like the Howler Monkeys. The lower incisor teeth are procumbent, and the canine teeth are not large when compared with the size of the skull.

The **European Eocene Tarsioids**, whose remains have been found in France and Switzerland, can be arranged in several genera, the most notable of which are *Necrolemur*, *Microchærus*, *Nannopithec* and *Pseudoloris*. Of these *Pseudoloris* is very primitive, *Necrolemur* and *Microchærus* are highly specialized, and *Nannopithec* is an intermediate form. In *Necrolemur* the cranial cavity is large, and the large orbits, which are only separated by a narrow partition as in the modern *Tarsius*, communicate with the temporal fossæ behind post-orbital bars and incomplete orbital walls. The lachrymal ducts open on the face, and the tympanic bullæ have external auditory tubes. Forsyth Major and Gregory consider that *Microchærus* and *Necrolemur* are related to the Galagidæ.

It is generally believed that all Monkeys were evolved from a common Tarsioid stock; and the most primitive forms first appeared somewhere near America in Eocene times. The actual Tarsioid ancestor has not yet been discovered, however. Some of these early Monkeys migrated to South America where they developed in different ways into the various kinds of Platyrrhini.

Others made their way to the Old World and became Catarrhini. Very soon afterwards the Catarrhini separated into tailed Monkeys and tailless Apes.

Thus it can be seen that many stages in the evolution of the Primates took place in Eocene times. The Notharctidæ and Anaptomorphidæ were well established, and the former gave rise to the Adapidæ whence the Lemurs arose. The Anaptomorphidæ gave rise to *Tarsius*; and the Monkeys arose from a Tarsioid ancestor. The Monkeys separated into Platyrrhini and forms which became Catarrhini; and the Catarrhini separated into lines which led up to the Simiidæ and Cercopithecidæ.

During recent years the exploration of the Lower Oligocene formations of Egypt by British, American and German palæontologists has brought to light the remains of many Mammals belonging to various Orders. And the collection of fossils has become known as the **Fayûm Fauna**.* It contains the remains of two Primates of extraordinary interest—*Parapithecus* and *Propliopithecus*.

The remains of *Parapithecus* consist of a nearly complete mandible with a full set of teeth, arranged according to the Catarrhine formula $\frac{2}{2} I \ C \ \frac{1}{1} PM \ \frac{2}{2} M \ \frac{3}{3}$. The incisor teeth are slightly procumbent, and the canine teeth are small. The molar teeth have five conical cusps. The two halves of the mandible unite at a very acute angle, and the symphysis slopes downwards and backwards. The coronoid process is high and pointed and stands well above the condyle on each side. Although neither the skull nor the skeleton has been found one can infer from the characters of the mandible and teeth

* See the works of Schlosser (513) and Andrews (516).

that *Parapithecus* is a Catarrhine with traces of its Tarsioid ancestry. As it lived at the very beginning of the Oligocene Period it is a proof that Monkeys existed in the Eocene Period. And no fossil has yet been discovered of which it was the ancestor. Some believe, however, that it is on the line leading to *Propliopithecus*.

Propliopithecus is also known from an incomplete mandible which was discovered by Schlosser in 1911. It is the earliest Ape, so we must conclude that Egypt was the home of the Apes. The body of the mandible is deep, and the coronoid process is relatively lower when compared with the condyle than in *Parapithecus*. The halves of the angle unite in an acute angle, and the symphysis slopes downwards and backwards. The canine teeth are intermediate in size between those of *Parapithecus* and those of the higher Apes. The molar teeth have smooth enamel and have five cusps.

A considerable interval of time separated *Propliopithecus* from the more advanced Anthropoids, whose remains begin to appear in the Middle Miocene rocks of Northern India and Europe. During that interval the descendants of *Propliopithecus* migrated from Africa, and underwent more or less considerable structural changes, one of which was an increase in the size of the body. To reach their destinations they must have traversed stretches of land which are now submerged beneath the ocean. And there is evidence that such connections united Africa and Asia on more than one occasion.

In the year 1837 Monsieur Lartet announced to the Academy of Sciences at Paris that he had discovered the fossil remains of an Ape at Sansans near Auch in

Gascony; and he asserted that they were the remains of a Gibbon. He sent the fossil to Paris where it was examined by de Blainville, who described it as follows (20): "The principal figure consists in the lower jaw, almost complete, having all the teeth present, and wanting only the terminating portion of the ascending branches. This jaw measures in length an inch and a half from the incisive teeth to the anterior root of the ascending branches, and the same in width between these two points; the angle of union of the body and branches is 25 degrees, and the length of the symphysis is 9 lines: the profile view of the symphysis is rather oblique, since it forms with the base of the jaw an angle of 50 degrees. Of the two surfaces of the body of the mandible the external has a single foramen menti, small and opening immediately below the first anterior molar; the internal shows merely a cavity for the insertion of the genio-hyoideus muscle, without any distinct genioïd process. The base is thick, rounded and perfectly smooth; the alveolar margin occupied by a series of contiguous teeth, that is without any interval between them, pretty nearly of the same height, and forming a parabola or horseshoe figure." Many subsequent observers, from the examination of the original specimen or of the many others discovered in the Miocene and Pliocene rocks of France, Germany and Switzerland, came to the conclusion that the animal is closely allied to, or should be included in the genus *Hylobates*. Gervais named it *Pliopithecus antiquus*.

Schlosser and others regard *Pliopithecus* both as a descendant of *Propliopithecus* and an ancestor of the modern Gibbons. The incisor teeth are more vertical

than those of *Propliopithecus*; and the canine teeth are larger. The canines are smaller than those in the Gibbons, and the premolars are shorter antero-posteriorly. The mandible itself differs from that in the Gibbons in its longer and narrower symphysis, and in its stronger and relatively deeper body. The angle between the mandibular rami is wider than in *Parapithecus*. The gradual transformation in the characters of the jaw and teeth can be traced in succession through *Parapithecus*, *Propliopithecus* and *Pliopithecus* to *Hylobates*. Thus we have here one line of ascent from the Eocene Tarsioids to the modern Gibbons; and it is quite separate from that which leads from *Propliopithecus* to the Orang, Chimpanzee, Gorilla and Man.

Of the fossil Anthropoids *Dryopithecus* had the widest distribution, for its remains have been found in many parts of Europe, in Northern Africa and in Northern India. And these have been arranged in several species—*D. fontani*, *D. darwini*, *D. chinjiensis*, *D. punjabicus*, *D. giganteus*, *D. rhenanus* and *D. mogharensis*—which are distinguished by differences in the cusps and crenation of the enamel of the teeth. The genus also includes fossils which were formerly known as *Pliohylobates eppelsheimensis* Dubois, and *Paidopithecus rhenanus* Pohlig. The fossils have received considerable attention from Lartet, Gaudry, Abel, Schlosser, Smith Woodward (514) and others.

The mandible of *D. fontani* is very heavy. Anteriorly it is deep, and the symphysis descends steeply downwards and backwards. The posterior surface of the symphysis has the usual pit for the genio-hyoid muscles. The pit is bisected by a vertical ridge, which runs into

the well-developed crest for the attachment of the anterior bellies of the digastric muscles; these muscles must have been fused as in the modern Macaque Monkeys. The symphysis ends immediately in front of the digastric ridge, and is not separated from it by a flat area of bone as in the Apes. Smith Woodward points out that the adult Ape differs from *Dryopithecus* and from the new-born Ape in this antero-posterior elongation of the bony chin. No mylo-hyoid line exists. There is a single mental foramen a considerable distance below the first premolar tooth. The large symphysis and the deep body show that the masseter muscles must have been very powerful. Smith Woodward concludes that the mandible is of a generalized type, which "resembles the large modern Anthropoids no more closely than it agrees with the earliest known true Man. By slight changes in two different directions it may have passed into the one as readily as into the other." The lower molar teeth increase in the order 1, 2, 3. They have the usual five cusps, of which three lie on the external and two on the internal side, the hypoconulid being lateral instead of mesial in position. The outer cusps are more worn than the inner cusps, and the protoconid is surrounded by an external girdle or cingulum. The enamel is devoid of wrinkling. Other species show differences in the cusps, cingulum and crenation of the enamel; and the teeth of some species are relatively larger than those of others.

The femur of *Dryopithecus* was discovered in the sands of Eppelsheim. Dubois pointed out that it resembles the femur of the Gibbons, and gave the specimen the name *Pliohylobates eppelsheimensis*. Schlosser showed that it really belongs to *Dryopithecus*.

The Northern Indian species of *Dryopithecus* form part of the collection of fossils known as the **Siwalik Fauna**, because they were discovered in the region of the Siwalik Hills. The geological formations range from the Middle Miocene up to and including the Pliocene. Besides *Dryopithecus* it contains the remains of four fossil Apes—*Palæosimia*, *Palæopithecus*, *Sivapithecus* and *Simia*. The tooth of *Palæosimia* foreshadows those of the Orang, and those of *Sivapithecus* contain a mixture of human and simian characters. Pilgrim believes that *Sivapithecus* is an ancestor of Man.

The remains of *Palæopithecus sivalensis*, which consist of an incomplete palate and the canine and post-canine teeth of one side, were discovered by Theobald in 1878 at Jabi in the Punjab. Lydekker (510) pointed out its resemblances to the Chimpanzee, and Trouessart included it in the genus *Anthropopithecus*. Dubois (515) thought it belonged to an ancient group of Apes, which included *Pliopithecus* and *Dryopithecus*. And Gregory (509) placed it close to the ancestor of the Gorilla. The palate is long and narrow, the canine tooth is large, and the large, quadrilateral molar teeth have high cusps, a character which is possessed by the Gorilla (see p. 149). In a genealogical tree the arrangement which is most in accordance with our present knowledge is a Gorilline common stem which gives off *Palæopithecus* low down and *Anthropopithecus* high up (fig. 57).

The Apes in the Siwalik Fauna were large terrestrial creatures, which had advanced far beyond their humble ancestor *Propliopithecus* in the Lower Oligocene rocks of the Egyptian Fayûm. The group contained the ancestors of the Orang, Chimpanzee, Gorilla and

Man. One line led away to the Orang, and another led up to the African Simiidæ and Man. It is possible that the forms which gave rise to the African Simiidæ included *Dryopithecus* and *Sivapithecus*. The observations of Keith (102) and others lead to the view that the human stock separated from the Anthropoid stock in the Miocene Period; and Elliot Smith has pointed out that Man separated from the Apes as the result of cerebral changes, which enabled him to use his hands and voice and to profit by experience. The early members of the human stem were unlike modern Man, for they probably retained simian characters right through the Miocene and part of the Pliocene Period. And it is not till we arrive at the early part of the Pleistocene Period that true human remains appear. Should the fragments of the so-called Java Man (*Pithec-anthropus erectus*) turn out to be human remains of a low type we can assign the later part of the Pliocene Period as the date of the appearance of Man. Keith and others believe that Man assumed his characteristic human features in the Pliocene Period.

After their differentiation from common ancestral forms in the Siwalik Region the Apes and the ancestors of Man became dispersed. The Orang passed to Borneo and Sumatra, and the Chimpanzee and Gorilla settled down in Africa. They all retained certain constitutional resemblances, for the blood of Man and the Apes exhibits similar reactions. Changes were induced in their somatic features as the result of variations in the functions of their ductless glands; and it is probable that climatic and dietetic factors played important parts in inciting differences in function. They also exhibit differences in

many of their organs because they adopted different modes of life.

From a study of palæontology we must confess that the actual common ancestor of Man and the large Apes is still as unknown as it was in Darwin's day ; and it will be long before we can definitely point to it. We are unable to say with certainty that any of the Siwalik fossils is the common ancestor. But we know that none of the existing Apes is in the direct line of Man's descent.

Man is supreme in the Animal Kingdom. He surpasses the Apes in being bimanous and bipedal, in his power of articulate speech and in his complex psychology. He has attained this position, while retaining many primitive features, in virtue of his large neopallium.

BIBLIOGRAPHY.

GENERAL AND COMPREHENSIVE WORKS.

- (1) **Adachi, B.** "Hauptpigment beim Menschen und bei den Affen," *Zeitschr. Morphol.*, vi, pp. 1-131.
- (2) **Æby, C.** "Das Talo-tarsalgelenk des Menschen und der Primaten," *Arch. f. Anat. u. Physiol.*, 1883, pp. 312-327.
- (3) *Idem.* "Der Bronchialbaum der Säugetiere und des Menschen," Leipzig, 1880.
- (4) **Albrecht, P.** "Sur la fossette vermienne du crâne des mammifères," Bruxelles, 1884.
- (5) **Anderson, J.** "Anatomical and Zoological Researches," London, 1878.
- (6) *Idem.* "Catalogue of Mammalia in the Indian Museum," part i, 1881.
- (7) **Bahnsen, G.** "Abweichungen in der Muskulatur der unteren Extremität," *Zeitschr. f. ration. Mediz.*, 3. Reihe, Bd. xxii, pp. 49-57, 1868.
- (8) **Bankart, J.** "Notes of Abnormalities observed in the Dissecting Room," *Guy's Hosp. Rep.*, 1869, pp. 436-453.
- (9) **Bardeleben, K.** "Ueber die Hand und Fussmuskeln der Säugethiere, besonders die Praepollex und Postminimus," *Anat. Anz.*, 1890, p. 435.
- (10) *Idem.* "Ueber die Innervierung, Entstehung und Homologie der distalen Gliedmassmuskeln," *Verhand. d. Anat. Ges. auf der fünften Versammlung*, 1891, pp. 243, 246.
- (11) *Idem.* "Einige seltenere Muskelvarietäten," *S.B. der Jen. Ges. f. Med. u. Naturwiss.*, 1877.
- (12) **Bateson, W.** "On Numerical Variation in Teeth, with a discussion of the Conception of Homology," *Proc. Zool. Soc. London*, 1892, pp. 102-115.
- (13) **Bertelli, D.** "Sulla morfologia del muscolo diaframma," *Arch. per le Sci. mediche*, 1895.
- (14) **Bianchi, S.** "Sulla division dell' os planum dell' ethmoide nel crani dell' uomo et degli antropoidi," *Arch. Ital. Biol.*, 1895, p. 310, t. xxiv.
- (15) **Bischoff, T. L. W.** "Ueber die Verschiedenheit in der Schaedelbildung des Gorilla, Chimpanse und Ourang," München, 1867.
- (16) *Idem.* "Ueber die äussere weiblichen Geschlechts und Begattungs Organe des Menschen und der Affen," *Abh. Math. Phys. Cl. Ak. Wiss. Münch.*, 1880, pp. 209-274, Bd. xiii, Abth. ii.

- (17) *Idem.* "Ueber Brachycephalie und Brachyencephalie des Gorilla und der anderen Affen," *tom. cit.*, 1881, pp. 379-390, Bd. xi.
- (18) *Idem.* "Ueber die kurzen Muskeln des Daumens und der grossen Zehe," *S.B. Math-Phys. Cl. Ak. Wiss. Münch.*, 1870, pp. 303-315, Bd. i.
- (19) *Idem.* "Ueber die Bedeutung des musculus extensor indicis und den flexor longus pollicis," *op. cit.*, 1880, pp. 485-596, Bd. x.
- (20) **Blainville, H. de.** "Osteographie des mammifères," Paris, 1839-64.
- (21) **Blum, F.** "Die Schwanzmuskulatur des Menschen," *Anat. Heft*, 1894, p. 471.
- (22) **Bovero, A.** "Intorno ai muscoli diaphragmatici del' osso joide," *Monit. Zool. Ital.*, 1895.
- (23) **Braune, W.** "Etwas von der Form der menschlichen Hand und des menschlichen Fusses in Natur und Kunst," *Festschr. f. Carl Ludwig*, 1874.
- (24) **Broca, P.** "Anatomie comparée des circonvolutions cérébrales, le grand lobe limbique et la scissure limbique dans la série des mammifères," *Rev. d'Anthrop.*, 1872, pp. 385-498, sér. ii, t. i.
- (25) *Idem.* "Etudes sur la constitution des vertèbres caudales chez les primates," *ibid.*, 1872, pp. 577-605.
- (26) **Brodmann, K.** "Vergleichende Localisationslehre der Grosshirnrinde," Leipzig, 1909.
- (27) **Brooks, St. J.** "On the Short Muscles of the Pollex and Hallux of the Anthropoid Apes," *Journ. Anat. and Physiol.*, 1888, pp. 78-95, N.S. vol. ii.
- (28) *Idem.* "On the Morphology of the Intrinsic Muscles of the Little Finger," *ibid.*, 1886, pp. 641 and 645, vol. xx.
- (29) **Burdach, E.** "Beiträge zur vergl. Anatomie der Affen," *Bericht von der K. Akad. zu Königsberg*, 1838.
- (30) **Calori.** "Sull' alta divisione del nervo grando ischiatico, etc." *Mem. dell' Acad. d. Bologna*, 1881, p. 623.
- (31) **Carus.** "Lehrbuch der Zootomie." 1818.
- (32) **Chudzinski, T.** "Sur les muscles peaussiers du crâne, etc.," *Bull. Soc. Anthropol.*, Paris, 1884, pp. 608-616.
- (33) *Idem.* "Les anomalies des os propres du nez chez les Anthropoïdes." *op. cit.*, 1893, ser. 4, t. iv, pp. 788-790.
- (34) **Crisp, Dr.** "The Os Penis in Anthropoids," *Proc. Zool. Soc.*, 1865, p. 48.
- (35) **Cruveilhier, J.** "Traité d'anatomie descriptive."
- (36) **Cunningham, D. J.** "Contributions to the Surface Anatomy of the Cerebral Hemispheres," *Cunningham Memoirs, Royal Irish Academy*, 1892.
- (37) *Idem.* "The Sylvian Fissure in the Primate Brain," *Journ. of Anat. and Phys.*, 1891, pp. 286-291, N.S. vol. v.
- (38) *Idem.* "The Limiting Sulci of the Island of Reil," *Proc. Anat. Soc.*, July, 1896.
- (39) *Idem.* "The Lumbar Curve in Man and Apes, with an Account of the Topographical Anatomy of the Chimpanzee, Orang and Gibbon," *Cunningham Memoirs*, 1896.

- (40) *Idem.* "The Proportion of Bone and Cartilage in the Lumbar Section of the Vertebral Columns of Apes and Several Races of Men," *Journ. of Anat. and Phys.*, 1890, vol. iv, pp. 117-126.
- (41) *Idem.* "The Peroneus Quinti Digiti," *Proc. Roy. Irish Acad.*, ser. 3, vol. i, pp. 78-81.
- (42) **Cuvier.** "Leçons d'anatomie comparée," vols. i and iv.
- (43) *Idem.* "Planches de myologie."
- (44) **Deniker, J.** "Recherches anatomiques et embryologiques sur les singes anthropoïdes," *Arch. Zool. Exper.*, 1885, ser. ii, t. iii.
- (45) *Idem.* "Note sur les sacs laryngiens des singes anthropoïdes," *Journ. Anat. et Physiol.*, 1886, pp. 51-62.
- (46) *Idem.* "Sur les singes anthropoïdes de la ménagerie Bidel," *Bull. Soc. Zool. France*, 1882, p. 301.
- (47) **Drobnik.** "Für den Halssympathicus des Menschen," *Arch. f. Anat. u. Entwicklungsgeschichte*, 1887.
- (48) **Du Chaillu, P. B.** "Explorations and Adventures in Equatorial Africa," London, 1861.
- (49) **Duckworth, W. L. H.** "Further Notes on Specific Differences in the Anthropoid Apes," *Proc. Zool. Soc. Lond.*, 1898, pp. 312-314.
- (50) *Idem.* "Morphology and Anthropology," Cambridge, 1915.
- (51) **Dursy.** "Lehrbuch der Anatomie."
- (52) **Duval, M.** "Précis d'histologie," Paris, 1897, p. 696.
- (53) **Duvernoy, G. L.** "Des caractères anatomiques des grands singes," *Arch. Mus. Hist. Nat. Paris*, 1855-56, 3 memoirs.
- (54) **Féré, C.** Deuxième note sur la topographie cranio-cérébrale chez les singes," *Journ. Anat. et Physiol.*, 1885, pp. 298-303, t. xxi.
- (55) **Fick, A.** "Statische Betrachtung der Oberschenkenmuskulatur," *Zeitschr. f. ration. Medicin*, 1849.
- (56) **Fick, L.** "Beitrag zur Mechanik des Gehens," *Müller's Archiv*, 1853.
- (57) *Idem.* "Hand und Fuss," *ibid.*, 1857.
- (58) **Fischer, E.** "Zur Entwicklung des Affenschädels," *Zeitschr. Morphol.*, vi, pp. 388-414.
- (59) **Flower, W. H.** "Introduction to the Osteology of the Mammalia," London, 1885.
- (60) **Flower, W. H., and Lydekker.** "An Introduction to the Study of the Mammalia, Living and Extinct," London, 1891.
- (61) **Forster, A.** "Die Insertion des M. semimembranosus," *Arch. f. Anat. u. Physiol.*, 1893, pp. 257-320.
- (62) **Froger.** "Relation d'un voyage fait en 1695-97 aux côtes d'Afrique," Paris, 1699.
- (63) **Froriep, R.** "Die Characteristic des Kopfes nach der Entwicklungsgeschichte desselben," Berlin, 1845.
- (63a) **Friedenthal.** *Zeitschr. . Ethnol.*, 1912, vol. 43, p. 974.
- (64) **Futamura.** *Anat. Hefte*, 1906, xxx, pp. 433-514; 1907, xxxii, pp. 479-575.
- (65) **Gaudry, A.** "Sur la similitude des dents de l'homme et de quelques animaux," *Anthropologie*, 1901, pp. 93-102.

- (66) **Gerhardt, U.** *Anat. Anz.*, Jena, 1909, pp. 353-358 (on os penis and os clitoridis).
- (67) **Giacomini, C.** "Osservazioni anatomiche per servire allo studio della circolazione venosa della estremità inferiori," *Giorn. d. R. Ac. di Med. di Torino*, 1873.
- (68) *Idem.* "Topographia del Cuore," Torino, 1886.
- (69) *Idem.* "La plica semilunaris e la laringe, etc.," *Giorn. d. R. Ac. di Med. di Torino*, 1897.
- (70) **Gies, Th.** "Der Flex. digit. ped. comm long und seine Varietäten." *Arch. f. Anat. u. Physiol.*, 1868, pp. 231-239.
- (71) **Gläser, J.** "Anomaler Muskelbauch, die Art. tibialis, post ver deckend," *Berl. klin. Woch.*, 1867, p. 306.
- (72) **Görke, O.** "Beitrag zur functionellen Gestaltung des Schädels," *Arch. Anthropol.* (2), i, pp. 91-108.
- (73) **Gratiolet, P.** "Mémoire sur les plis cérébraux de l'homme et des primates," Paris, 1854.
- (74) **Gregory, W. K.** *Rep. Brit. Assoc.*, 1913, p. 529.
- (75) **Groonroos, H.** "Die Musculi biceps brachii, und latissimo condyloideus," *Jen. Zeitschr. f. Naturw.*, 1903.
- (76) **Gruber, W.** *Archiv für Anatomie und Physiologie*, 1874.
- (77) *Idem.* Several Papers on Variations, collected by Sommer (see No. 491).
- (78) *Idem.* "Ueber die Verbindung des N. medianus mit dem N. ulnaris," *Arch. f. Anat.*, 1870, p. 501.
- (79) **Guibé, M.** "Anomalie du jambier antérieur," *Bull. de la Soc. anat. de Paris*, 1871, pp. 231-232.
- (80) **Grünbaum and Sherrington.** *Proc. Roy. Soc.*, 1901 and 1903.
- (81) **Gulliver, G.** *Proc. Zool. Soc. London*, 1845, pp. 93-102.
- (82) **Hepburn, D.** "The Integumentary Grooves on the Palm of the Hand and the Sole of the Foot of Man and the Anthropoid Apes." *Journ. of Anat. and Physiol.*, 1893, pp. 112-130.
- (83) *Idem.* "The Comparative Anatomy of the Muscles and Nerves of the Superior and Inferior Extremities of the Anthropoid Apes," *ibid.*, 1892, pp. 324-356.
- (84) **Herrmann, G.** "Sur la structure et le développement de la muqueuse anale," *Journ. de l'Anat. et de la Physiol.*, 1880, pp. 434, 451, 472.
- (85) **Hervé, G.** "Le Circonvolution de Broca chez les Primates," *Bull. Soc. Anthropol. Paris*, 1888, pp. 275-314.
- (86) *Idem.* "Les prétendus quadrumanes," *ibid.*, 1889, p. 60.
- (87) **Huxley, T. H.** "Evidence as to Man's Place in Nature," London, 1863.
- (88) *Idem.* "The Structure and Classification of the Mammalia," *Med. Times and Gazette*, 1864.
- (89) *Idem.* "Laws of Evolution Applied to the Mammalia," *Proc. Zool. Soc. London*, 1880.
- (90) **Hrdlicka.** *Proc. U.S. Nat. Mus.*, xxxi, p. 560.
- (91) *Idem.* "Human Dentition and Teeth from the Evolutionary and Racial Standpoint," *Dominion Dental Journal*, 1911

- (92) **Jacoby, W.** "Unterschiede am Schädel des Schimpansen, Gorilla und Orang-Utan," *Zeitschr. Morphol.*, vi, pp. 251-284.
- (93) **Johnson, G. L.** "Observations on the Ophthalmoscopic Appearances of the Eyes of the Order Primates," *Proc. Zool. Soc. London*, 1897, pp. 183-188.
- (94) **Joseph, H.** "Histol. Beobacht. am Anthropoidenovarium," *Wien. Arb. Zool. Inst. Univ.*, 1909, pp. 83-112.
- (95) **Kehrer, G.** "Beiträge zur Kenntniss des Carpus," *Bericht. Naturf. Ges. zu Freiburg*, 1886, vol. i.
- (96) **Keith, A.** "The Ligamentous Structures of Man and Monkeys," *Journ. Anat. and Physiol.*, 1894, viii, pp. 149-168.
- (97) *Idem.* "The Growth of Brain in Men and Monkeys, etc.," *ibid.*, 1895, ix, pp. 282-303.
- (98) *Idem.* "The Modes of Origin of the Carotid and Subclavian Arteries from the Arch of the Aorta in some of the Higher Primates," *tom. cit.*, pp. 453-458.
- (99) *Idem.* "An Introduction to the Study of the Anthropoid Apes," *Natural Science*, 1896.
- (100) *Idem.* "On the Chimpanzees and their Relation to the Gorilla," *Proc. Zool. Soc. Lond.*, 1899, pp. 296-314.
- (101) *Idem.* "Human Embryology and Morphology," London, 1913.
- (102) *Idem.* "The Antiquity of Man," London, 1920.
- (103) **Kunze, G.** "Die Zungen papillen der Primaten," *Morphol. Jahrb.*, 1915, pp. 569-681.
- (104) **Lartschneider, J.** "Die Steissbeinmuskeln des Menschen und ihre Beziehungen zum M. levator ani und zur Beckinfascie," *Denkschr. K. Ak. Wiss. Wien.*, vol. lxii, 1895, pp. 95-136.
- (105) **Leboucq.** "Les muscles adducteurs du pouce et du gros orteil," *Bull. de l'Acad. de Méd. du Belgique*, 1893.
- (106) **Ledouble.** "Des conformations anormales des muscles de la face," *Bibliog. anatomique*, 1844, p. 141.
- (107) **Leuckart.** Arts. : "Vesicul prostat." and "Vesiculæ Seminales," in *Todd's Cyclopaedia of Anat. and Physiol.*, vol. iv.
- (108) **Lucae.** "Hand und Fuss," Frankfort, 1866, vol. v.
- (109) **Macnamara, N. C.** "The Craniology of Man and the Anthropoid Apes," *Rep. Smithson. Inst.*, 1904, pp. 431-449.
- (110) **Marchand.** "Die Morphologie des Stirnlappen und der Insel der Anthropomorphen," Jena, 1893.
- (111) **Maurer, F.** "Untersuchungen zur vergleichenden Muskellehre" (Phylogeny of the muscoli serrati postici), Jena, 1905.
- (112) **Mayer, J. C.** "Zur anatomie des Orang-Utang und des Chimpanse," *Arch. f. Naturg.*, von Troschel, 1856, pp. 281-304.
- (113) **McMurrich, J. P.** "The Phylogeny of the Forearm Flexors," *Amer. Journ. Anat.*, 1902, pp. 177-209.
- (114) **Meyer, A. B.** "Notizen über die anthropomorphen Affen des Dresdener Museums," *Mitth. Zool. Mus. Dresden*, 1877, pp. 228, 248.

- (115) **Michaelis, P.** "Beiträge zur vergl. Myologie der *Cynocephalus babuin*, *Simia satyrus* und *Troglodytes niger*," *Arch. Anat.*, 1903, pp. 205-256.
- (116) **Mingazzini, G.** "Il cervello in relazione coi fenomeni psichici," *Biblio. Antropologico-giuridica*, 1895.
- (117) **Mosso, A.** "Expériences faites sur les singes avec la dépression barométrique," *Arch. Ital. Biol.*, 1904, pp. 384-401.
- (118) **Müller, J.** "Beiträge zur Kenntniss des Anthropoiden-Gehirns," *Abhand. d. K. Zool. und Anthropol. Mus. zur Dresden*, 1890, pp. 1-16.
- (119) **Nepheu, M. G.** "Observations sur les corpuscles de Pacini chez le singe," *Ann. Sc. Nat.*, 1869, t. xii, pp. 326-337.
- (120) **Noehring.** "Die Anthropomorphen Affen des Lübecker Museums," Lübeck, 1876.
- (120a) **Oppel, A.** "*Lehrbuch der vergl. Mikr. Anat.*, vol. iii.
- (121) **Oudemans.** "Die Accessor. Geschlechtsdrüsen d. Säugethiere," 1892.
- (122) **Owen, R.** "The Comparative Anatomy and Physiology of Vertebrates," London, 1868.
- (123) **Pagenstecker, H.** "Mensch und Affe," *Der Zool. Garten*, 1867, pp. 161-172.
- (124) **Pansch, A.** "Ueber die typische Anordnung der Furchen und Windungen auf den Grosshirnhemisphären," *Arch. f. Anthropol.*, 1868, iii, pp. 227, 257.
- (125) **Parker, A. J.** "Morphology of the Cerebral Convolutions," *Journ. Acad. Nat. Sci. Phila.*, 1896, i, pp. 247, 365.
- (126) **Paterson, A. M.** "The Pectineus Muscle and its Nerve Supply," *Journ. Anat. and Physiol.*, 1892, p. 43.
- (127) **Perrin, J. B.** "Notes on some Variations of the Pectoralis Major, etc.," *Journ. Anat. and Physiol.*, 1871, pp. 233-240.
- (127a) **Parsons, F. G.** *Journ. Anat. and Physiol.*, xxxii, pp. 428-450 ; 721-752.
- (128) **Platner, J. Z.** "De musculo digastrico maxillae inferioris," Lipsiae, 1737.
- (129) **Popowsky, J.** "Das Arteriensystem der unteren extremitäten bei Primaten," *Anat. Anz.*, 1894, x, pp. 55, 99.
- (130) *Idem.* "Verschiebung in den Endgebieten der Nerven des Plexus lumbalis," Leipzig, 1893.
- (131) *Idem.* "Die Grenzlinien der Pleurasäcke und die Lagerung des Herzens," *Morph. Jahrb.*, 1894, pp. 149-249.
- (132) **Rex, H.** "Ein Beitrag zur Kenntniss der Muskulatur der Mundspalte der Affen," *Morph. Jahrb.*, 1887, xii, pp. 275-286.
- (133) **Richet, M.** "Anomalies musculaires," *Bull. de la Soc. Anat. de Paris*, 1873, p. 137.
- (134) **Rohon, J. V.** "Zur Anatomie der Hirnwindung bei den Primaten," München, 1884.
- (135) **Retzius, G.** *Biologische Untersuchungen*, vol. xiv, 1909 ; vol. xvii, 1912.
- (136) **Rothschild, W.** "Notes on the Anthropoid Apes," *Proc. Zool. Soc. London*, 1904, pp. 413-440.

- (137) *Idem.* "Further Notes on the Anthropoid Apes," *ibid.*, 1906, pp. 465-468.
- (138) **Rothschuh, E.** "Ueber die Fussmuskeln der Primaten," Diss., München, 1888.
- (139) **Rüdinger, N.** "Ein Beitrag zur Anatomie der Affenspalte, etc.," *Festchr. für J. Henle*, 1882, pp. 186, 198.
- (140) **Ruge, G.** "Untersuchung über die Extensorengruppe am Unterschenkel und Fusse der Säugethiere," *Morph. Jahrb.*, 1876, pp. 592-659.
- (141) *Idem.* "Untersuchungen über die Gesichtsmuskeln der Primaten," Leipzig, 1887, and *Morph. Jahrb.*, 1887, pp. 459-529.
- (142) **Schlaginhaufen.** "Das Hautleisten System," *Morph. Jahrb.*, 1905; "Zur Morphologie der Planta," *Zeitschr. Ethnol.*, 1906.
- (143) **Schwalbe, G.** "Ueber des Gehirnrelief des Schädels bei Säugethieren," *Ztschr. Morphol.*, vii, pp. 203-224, 1904.
- (144) *Idem.* "Ueber die Stirnnaht bei den Affen," *Verh. Ges. deutsch. Naturf.*, lxxv, pp. 214, 215 1904.
- (145) **Seydel, O.** "Ueber die Zwischensehnen und den metameren Aufbau des M. obliquus thoraco-abdominalis, etc." *Morph. Jahrb.*, 1892, xviii, pp. 544-604.
- (146) *Idem.* "Ueber die serratus posticus, etc.," *Morph. Jahrb.*, 1892, pp. 35-75.
- (147) **Smith, G. Elliot.** "On the Morphology of the Brain in the Mammalia, with special reference to that of Lemurs," *Trans. Linn. Soc. London*, viii, pp. 312-432.
- (148) *Idem.* Catalogue of the Museum of the Royal College of Surgeons of England, Physiological Series, vol. iii.
- (149) *Idem.* "Contribution to Discussion on Tarsius," *Proc. Zool. Soc. London*, 1919, pp. 465-475.
- (149a) **Smith, G. M.** *Journal of Anatomy*, 1910-1912.
- (150) **Sonntag, C. F.** "The Tongues of the Simiidae," *Proc. Zool. Soc. London*, 1921, pp. 1-29.
- (151) **Testut, L.** "Le long fléchisseur propre du pouce," *Bull. de la Soc. Zool. de France*, viii, 1883.
- (152) **Tanja, L.** "Ueber die Grenzen der Pleurahöhlen, etc.," *Morph. Jahrb.*, vol. xvii, 1891.
- (153) **Treves, F.** "The Anatomy of the Intestinal Canal and Peritoneum in Man," 1885.
- (154) **Tricot, Ch.** "Parallèle anatomique des extenseurs du pied chez l'homme et chez les singes," *Thèse de Bordeaux*, 1884.
- (155) **Trouessart, E. L.** [Works quoted by Sperino (401)].
- (156) **Turner, Wm.** "On Variability in Human Structure, with illustrations from the Flexor Muscles of the Fingers and Toes," *Trans. Roy. Soc. Edin.*, 1865, pp. 175-189.
- (157) **Wagstaffe, W.** "Observations in Human Myology," *Journ. Anat. and Physiol.*, 1871, pp. 274-281.
- (158) **Wilder, B. G.** "Relation Position of the Cerebrum and Cerebellum in Anthropoid Apes," *Proc. Amer. Assoc.*, 1884, xxxii, p. 527.

- (159) **Windle, B.** "A Note on the Extensor Tendons of the Manus of the Apes," *Proc. Phys. Soc. Birmingham*, 1888, pp. 22-25.
- (160) *Idem.* "The Flexors of the Digits of the Hand," *Journ. Anat. and Physiol.*, 1890, pp. 72-84.
- (161) **Windle, B., and Parsons, F. G.** "On the Morphology of the Femoral Head of the Biceps Flexor Cruris," *Journ. Anat. and Physiol.*, 1900, pp. 5-9.
- (162) **Weber, M.** "Die Säugethiere," 1904.
- (163) **Wood, J.** "Variations in Human Myology," *Proc. Roy. Soc.*, 1864, 1865, 1867, 1868.
- (164) *Idem.* "On Human Muscular Variations," *Journ. Anat. and Physiol.*, 1867, vol. i, pp. 44-59.
- (165) **Zuckerlandl, E.** "Zur Morphologie des Affengehirns," *Zeitschr. Morphol.*, 1903, pp. 284-321.
- (165a) **Dobson, G. E.** *Trans. Linn. Soc.*, (2) ii, pp. 259-264.

WORKS ON LEMURS, TARSIIUS AND MONKEYS.

- (166) **Burmeister, H.** "Beiträge zur Kenntniss der Gattung, *Tarsius*," 1846.
- (167) **Dubois, E.** *Proceedings of the Fourth International Congress of Zoology*, Cambridge, 1898, p. 91.
- (168) **Filhol, H.** "Nouvelles observations sur les mammifères de gisements de phosphates de chaux," *Ann. des Sciences Géologiques*, 1874.
- (169) **Hill, J. P.** "Contribution to the Discussion on *Tarsius*," *Proc. Zool. Soc. London*, 1919, pp. 473-490.
- (170) **Jones, F. Wood.** *Proc. Zool. Soc. London*, pp. 491-494.
- (171) **Pocock, R. I.** *Proc. Zool. Soc. London*, pp. 494-495.
- (172) *Idem.* "On the External Characters of the Lemurs and of *Tarsius*," *Proc. Zool. Soc. London*, 1918, pp. 19-53.
- (173) *Idem.* "On the External Characters of the South American Monkeys," *Proc. Zool. Soc. London*, 1920, pp. 91-113.
- (174) **Sonntag, C. F.** "On the Anatomy of the Drill (*Mandrillus leucophaeus*)," *Proc. Zool. Soc. London*, 1922, pp. 429-453.

WORKS ON THE GIBBONS.

- (175) **Beddard, F. E.** "On the Brain of a Siamang," *Proc. Zool. Soc. London*, 1900, pp. 187-190.
- (176) **Bennett, G.** "Wanderings in New South Wales, etc.," London, 1834, vol. ii, p. 142.
- (177) **Bischoff, T. L. W.** "Beiträge zur Anatomie des *Hylobates leuciscus*," *Abh. Math. Phys. Cl. Ak. Wiss. München*, vol. x, 1870, pp. 199-297.
- (178) **Blanford, W. T.** "The Fauna of British India, Ceylon and Burma," London and Calcutta, 1888, Mammalia, part i, pp. 5-10.

- (179) **Blythe, E.** "Notes on the Gibbons *hoolock* and *lar*," *Journ. Asiatic Soc. Bengal*, 1847, vol. xvi, pp. 729-730.
- (180) **Boutan, L.** Bordeaux: *Actes Soc. Linn.*, 1913 (on pseudo-language in the Gibbon).
- (181) **Broek, A.** *Anat. Anz. Jena*, 1910, pp. 591-596 (on a pectoralis quartus in a Siamang).
- (182) **Cander, G.** "Notes on the Habits of the Hoolock," *Proc. Zool. Soc. London*, 1903, pp. 187-190.
- (183) **Cantor, T.** "Catalogue of the Mammalia inhabiting the Malayan Peninsula and Islands," 1846.
- (184) **Dahlborn, A. G.** "Studia Zoologica," Lund, 1856.
- (185) **Duckworth, W. L. H.** (Anomalies of the Post-Orbital Wall), *Journ. Anat.*, vol. xxxvi, pp. 260-262.
- (186) **Eschricht, D. F.** "Beschreibung einiger neuen Muskeln am Kehlkopfe eines langarmigen Affen," *Müller's Archiv. f. Anat.*, 1834, pp. 218-221.
- (187) **Flower, W. H.** "On the Brain of the Siamang," *Nat. Hist. Review*, 1863, pp. 279-287.
- (188) **Fry, E.** "Osteology of *Hylobates agilis*," *Proc. Zool. Soc.*, 1846, pp. 11-18.
- (189) **Gerhardt, U.** *Anat. Anz. Jena*, 1909, pp. 353-358 (penis bone and clitoris bone of Gibbons).
- (190) **Giebel, C. G.** "*Hylobates syndactylus* und *leuciscus*," *Zeitschr. Ges. Naturwiss.*, 1866, pp. 186, 193-196.
- (191) **Gray, J. E.** "List of Mammalia collected in Camboja," *Proc. Zool. Soc. London*, 1861, p. 135.
- (192) **Groonroos, H.** "Ueber zwei Oberarmmuskeln bei der Gattung *Hylobates*," *S.B. Ges. naturf. Berlin*, 1902, pp. 254-256.
- (193) *Idem.* *Abh. Ak. Berlin*, 1903, p. 1 (Biceps Muscle).
- (194) **Harlan, R.** *Trans. Amer. Phil. Soc.*, 1834, pp. 52-59 (*H. hoolock*).
- (195) **Horsfield, T.** "Zoological Researches in Java and the neighbouring Islands," London, 1834.
- (196) **Keith, A.** "The Frequent Occurrence of a Divided Inferior Vena Cava in the Genus *Hylobates*," *Proc. Anat. Soc. Gt. Brit. and Ir.*, November, 1895.
- (197) *Idem.* "Anatomical Notes on Malay Apes," *Journ. Straits Br. Roy. Asiatic Soc.*, 1891, pp. 77-89.
- (198) **Klein, A.** "Die drei Gibbons im zoologischen Garten bei Kopenhagen," *Zool. Gart.*, 1894, p. 116.
- (199) **Kohlbrügge, J. H. F.** "Versuch einer Anatomie des Genus *Hylobates*," *Max Weber's Zool. Ergebnisse einer Reise in Niederland, Ost-Indien*, 1890, vol. i, pp. 211-355; vol. ii, pp. 139-206.
- (200) **Ogilby, W.** "On a New Species of Gibbon (*H. leucogenys*)" *Proc. Zool. Soc. London*, 1840, p. 20.
- (201) **Nischüyama, N.** "Die Kehlkopfmuskeln des *Hylobates lar* vergleichen mit denen anderen Affen und des Menschen," Rostock, 1904.

- (202) **Mott, F. W.** "Motor Localization in the Brain of the Gibbon, correlated with a Histological Examination," *Proc. Roy. Soc. London*, 1911, pp. 67-74.
- (203) **Pohl, L.** "Ein höhen varietät von Siamanga syndactylus," *Zool. Anz. Leipzig*, 1911, vol. xxxviii, pp. 51-53.
- (204) **Pousargues.** (On the Hainan Gibbon), *Bull. Mus. Paris*, 1900, p. 272.
- (205) **Ruge, G.** "Anatomische ueber den Rumpf der Hylobatiden," Weber's *Eryebnisse einer Reise in Nederland*, 1890, vol. i, pp. 366-460.
- (206) **Sanyal, R. B.** "Colour Change in *Hylobates hoolock*," *Rec. Ind. Mus. Calcutta*, 1907, vol. i, pp. 276-278.
- (207) **Schmidt, M.** "Der Grau Gibbon, *Hylobates leuciscus*," *Zool. Garten*, 1866, vol. xxvii, pp. 7-14.
- (208) **Schulze, F. E.** "Die Sehnenverbindung in der Planta des Menschen und der Säugethiere," *Zeitschr. Wiss. Zool.*, 1867, vol. xvii, pp. 1-22.
- (209) **Sclater, P. L.** *Proc. Zool. Soc. London*, 1870, p. 86 (Illustrations of *H. hoolock* and *H. lar*).
- (210) *Idem.* "On a White-Cheeked Gibbon (*H. leucogenys*)" *Proc. Zool. Soc. London*, 1877, p. 69.
- (211) **Sergi, S.** (Cerebral Sulci), *Monit. Zool. Ital.*, vol. xv, pp. 273-283, and *Roma. Ric. Lab. Anat. Norm.*, 1904, pp. 189-255.
- (212) **Swinhoe, R.** "On the Mammals of Hainan," *Proc. Zool. Soc. London*, 1870, p. 224.
- (213) **Thomas, O.** "Note on the Gibbon of the Island of Hainan," *Ann. Mag. Nat. Hist.*, 1892, p. 145.
- (214) *Idem.* "On Some Mammals from Mt. Dulit, North Borneo," *Proc. Zool. Soc. London*, 1892, p. 227.
- (215) **Tickell, S. R.** "On *Hylobates lar*," *Journ. Asiatic Soc. Bengal*, 1864, pp. 196-199.
- (216) **Trouessart, E. L.** "Note sur les espèces de Gibbons, etc.," *Bull. Soc. Philom. Paris*, 1879, pp. 122-128.
- (217) **Yrolik, W.** Art. "Quadrumania" in *Todd's Cyclopædia of Anatomy and Physiology*, London, 1847.
- (218) **Waldeyer, W.** "Das Gibbon-Hirn," *Virchow's Festschrift*, Berlin, 1891, pp. 1-401.
- (219) *Idem.* *S.B. Math.-Phys. Cl. Ak. Wiss. Wien.*, 1891, pp. 265-277. (Sylvian Fissure and Island of Reil.)
- (220) **Wunderlich, L.** "*Hylobates entelloides*," *Berichte Senckenb. Ges.*, 1886, p. 60.
- (221) **Yarrel, W.** "Notes on the Internal Appearance after Death of Several Animals in the Collection of the Zoological Society," *Zool. Journ.*, 1835, p. 14.
- (222) **Ziehen, Th.** "Die Grosshirnfurchen des *Hylobates*- und *Semnopithecus*-Gehirns," *Anat. Anz.*, 1896, pp. 470-481.
- (223) **Pocock, R. I.** "Observations upon a Female Specimen of the Hainan Gibbon," *Proc. Zool. Soc. London*, 1905, pp. 169-180.

WORKS ON THE ORANG-OUTAN.

- (224) **Abel, Clarke.** "Some Account of an Orang-Outang of Remarkable Height found on the Island of Sumatra," *Asiatic Researches*, 1825, pp. 489-498.
- (225) **Aggazotti.** *Atti Acc. Lincei.*, vol. xiv, p. 706. (Effects of Barometric Pressure.)
- (226) *Idem.* *Arch. Ital. Biol.*, vol. xlv, p. 39. (Effects of Barometric Pressure.)
- (227) **Anthony, R.** (Visceral Anatomy), *Bull. Soc. Anthropol. Paris*, (4) ix, pp. 246-270.
- (228) **Barnard, W. S.** "Observations on the Membra Musculature of *Simia satyrus* and the Comparative Myology of Man and the Apes," *Proc. Amer. Assoc.*, 1875, pp. 112-144.
- (229) **Beevor, C., and Horsley, V.** "A Record of the Results obtained by Electric Stimulation of the so-called Motor-Cortex and Internal Capsule in an Orang-Outang," *Proc. Roy. Soc.*, 1890, p. 159.
- (230) **Bischoff, T. L. W.** "Ueber das Gehirn eines Orang-Outan," *S.B. Math.-Phys. Cl. Ak. Wiss. München.*, 1876, pp. 193-205.
- (231) **Blyth, E.** "Remarks on the Different Species of Orang-Utan," *Journ. Asiatic Soc. Bengal*, 1853. vol. xxii, pp. 369-382; vol. xxiv, pp. 518-528.
- (232) **Bolau, H.** "Der erste erwachsene Orang-Utan in Deutschland," *Zool. Gart.*, 1894, pp. 97-102.
- (233) **Bolk, L.** *Morphol. Jahrb.*, xxvi, pp. 274-281.
- (234) **Brooke, J.** *Proc. Zool. Soc. London*, 1841, pp. 55-61. (Letter on the Species and Distribution of Orangs.)
- (235) **Brühl, C. B.** "Zur Kenntniss des Orang-Kopfes und Orang-Arten," Vienna, 1856. Reprinted at Berlin in 1877.
- (236) **Camerano, L.** *Boll. Mus. Torino*, xii, No. 291, pp. 1-3.
- (237) **Camper, Petrus.** "Natuurkundige Verhandeligen van Petrus Camper over den Orang-Outang," Amsterdam, 1782.
- (238) **Chapman, H. C.** "On the Structure of the Orang-Utang," *Proc. Acad. Nat. Sci. Philadelphia*, 1880, pp. 160-174.
- (239) **Chudzinsky, M.** "Note sur les poumons des Orangs-Outangs," *Bull. Soc. d'Anthrop.*, 1882, pp. 554-556.
- (240) **Chiò, M.** ("Affinities of the Blood"), *Torino Atti. Ac. sc.*, 41, 1905-6, pp. 1093-1097.
- (241) **Church, W. S.** "On the Myology of the Orang-Utang," *Nat. Hist. Review*, 1861, vol. i, pp. 510-514; 1862, pp. 82-94.
- (242) **Coenen, H.** "Das Trigeminusganglion des Orangs," *Arch. Mikr. Anat.*, lx, pp. 514-516.
- (243) **Cornfort.** *Asiatic Research*, xv, Serampore.
- (244) **Delisle, F.** "Les Orangs-Outangs du Jardin Zoologique, etc.," *L'Anthropologie*, 1893, pp. 648-651.
- (245) **Dumortier, B. C.** "Observations sur les changemens de forme que subit la tête chez les Orangs-Outangs," *Ann. Sci. Nat.*, 1839, pp. 56-58.

- (246) *Idem.* "Note sur les métamorphoses du Crâne de l'Orang-Outang," *Bull. Acad. Roy. des Sci. Bruxelles*, 1838, pp. 756-762.
- (247) **Fick, R.** "Vergleichend-anatomische Studien an einem erwachsenen Orang Utang," *Archiv f. Anat.*, 1895, pp. 1-100.
- (248) **Fitzinger, L. J.** "Untersuchung ueber die Existenz verschiedener Arten unter den asiatischen Orang-Affen," *S.B. Math.-Naturwiss. Cl. Ak. Wiss. Wien.*, 1853, pp. 400-449.
- (249) **Gegenbaur, C.** "Die Gaumenfalten des Menschen," *Morph. Jahrb.*, 1878, pp. 573-582.
- (250) **Grant, J.** "An Account of the Structure, Manners and Habits of an Orang-Outang from Borneo," *Edinburgh Journ. Sci.*, 1828, pp. 1-24.
- (251) **Harwood, J.** "An Account of a Pair of Hands of an Orang-Outang," *Trans. Linn. Soc. London*, 1827, p. 471.
- (252) **Hermes, O.** "Anthropomorphen Affen des Berliner Aquarium," *Verhandl. Berl. Ges. Anthrop.*, 1876, pp. 88-94.
- (253) **Hervé, G.** "Observations sur deux squelettes de jeunes Orangs," *Bull. Soc. d'Anthrop.*, 1889, pp. 378-391.
- (254) **Heusinger, C. F.** "Vier Abbildungen des Schaedels des Simia satyrus von verschiedenem Alter," Marburg, 1838.
- (255) **Hitzig.** "Ueber Localisation psychischer Centren in der Hirnrinde," *Verhand. Berl. Ges. Anthrop.*, 1874, pp. 42-50.
- (256) **Hornaday, W. T.** "Two Years in the Jungle," London, 1885.
- (257) *Idem.* "On the Species of Bornean Orangs, with Notes on their Habits," *Proc. Amer. Assoc. Adv. Sci.*, 1879, pp. 438-456.
- (258) **Kehrer, G.** "Beiträge zur Kenntniss des Carpus," *Berichte Naturf. Ges. zu Freiburg*, 1886.
- (259) **Koerner, O.** "Beiträge zur vergleichenden Anatomie und Physiologie des Kehlkopfes, etc.," *Abhand. Senckenterg Naturf. Ges. Frankfort*, 1884, pp. 147-261.
- (260) **Langer, C.** "Die Muskeln der Extremitäten des Orang, etc." *S.B. Math.-Naturwiss. Cl. Ak. Wiss. zu Wien.*, 1879, pp. 177-222.
- (261) **Lucae, J. C.** "Der Pongo- und der Orang-Schaedel in Bezug auf Species und Alter," *Abh. Senckenberg. Naturf. Ges. Frankfort*, 1854-55, pp. 154-167.
- (262) **Lucas, F.** "The Species of Orangs," *Proc. Soc. Nat. Hist. Boston*, 1881, pp. 228-233.
- (263) **Luna, E.** "Il cervello dell' Orang-Utan," *Monit. zool. ital. Firenze*, 1911, 22, pp. 106-112.
- (264) **Maggi, L.** "I mesognati asinchiti nei giovani antropoidi," *Rend. Inst. Lombardo, Milan*, 1891, pp. 993-998.
- (265) *Idem.* "Intorno alla forma primitiva della ossa nasali nell'orango," *ibid.*, pp. 808-820.
- (266) *Idem.* "Sopra una diminuzioni numerica dei denti nell' orango," *ibid.*, pp. 586-593.
- (267) **Mayer, C.** "Bemerkungen ueber den Bau des Orang-Outang Schaedels," *Archiv f. Naturgesch.*, 1849, pp. 352-357.

- (268) **Milne-Edwards, A.** "Observations sur deux Orang-Outans morts à Paris," *Nouv. Arch. Mus. Hist. Nat.*, 1895, pp. 31-114.
- (269) **Mivart, St. G.** "The Appendicular Skeleton of Simia," *Trans. Zool. Soc. London*, vol. vi, pp. 175-227.
- (270) **Möbius, K.** "A Note on the Differential Characters of the Bornean and Sumatran Orang," *Zeitschr. f. Ethnologie*, 1894, p. 382.
- (271) **Mohrke, O.** "Ueber die Affen auf den indischen Inseln," *S.B. niederrhein. Ges. f. Naturf. Heilkunde, Bonn*, 1871, pp. 35-39.
- (272) **Ottley, W.** "On the Attachment of the Eye Muscles," *Proc. Zool. Soc. London*, 1879, pp. 121-128.
- (273) **Owen, R.** "On the Anatomy of the Orang-Utang," *Proc. Zool. Soc. London*, 1831, pp. 4, 9, 28, 67.
- (274) *Idem.* "On a new Orang," *Proc. Zool. Soc. London*, 1837, pp. 91-96.
- (275) *Idem.* "Notes on the Dissection of a Female Orang-Utang," *Proc. Zool. Soc. London*, 1843 (1844), pp. 123-134.
- (276) *Idem.* "Osteological Contributions to the Natural History of the Orang-Utang," *Trans. Zool. Soc. London*, vol. ii, pp. 165-172.
- (277) **Patten, C. J.** (Cranium of Orang with divided parietals), *Journ. Anat. and Physiol.*, 1911, 46, pp. 33-40.
- (278) **Retterer, E.** (Blood Corpuscles), *Paris: C. R. Soc. biol.*, 1911, lxxi, pp. 150-153.
- (279) **Rolleston, G.** "On the Affinities of the Brain of the Orang-Utang," *Nat. Hist. Review*, 1861, pp. 201-217.
- (279a) **Rosenberg, Hoon.** *Zool. Garten*, 1882, xxiii, pp. 111-125.
- (280) **Sandifort, G.** "Ontleedkundige Beschouwing van een' volwassen Orang-Oetan," *Verhand. Natuur. Geschied. Nederland. overzseeche Bezittingen*, Leiden, 1840, pp. 28-56.
- (281) **Sanyal, K. B.** "Observations on the Orang-Utan in Captivity," *Journ. Asiatic Soc. Bengal*, lxxi, pp. 92 and 93.
- (282) **Schlegel, H., and Müller, S.** "Bijdragen tot de Natuurlijke Historie van der Orang-Oetan," *Froriep's Notizen*, 1840, pp. 1-28.
- (283) *Idem.* "Beiträge zur Naturgeschichte des Orangs-Outangs," *ibid.*, pp. 336-343.
- (284) **Schwalbe, G.** "Beiträge zur Anthropologie des Ohres," *Virchow's Festschrift*, 1891, pp. 95-144.
- (285) **Sclater, P. L.** "An Adult Male Example of what appears to be the Lesser Orang (*Simia morio*)," *Proc. Zool. Soc. London*, 1891, pp. 301.
- (286) **Seabra, A. F. de.** "Notes Mammalogiques (I. *Simia*)," *Lisbon Bull. Soc. Post. Sci. Nat.*, i, 1907, pp. 10-11.
- (287) **Selenka, E.** "Die Rassen und der Zahnwechsel des Orang-Utan," *S.B. Math. Phys. Cl. Ak. Wiss. Berlin*, 1896, pp. 381-392.
- (288) **Seydel, O.** "Ueber die Nasenhöhle der höheren Säugethiere," *Morph. Jahrb.*, 1891, pp. 44-96.
- (289) **Temminck, C. J.** "Monographies de Mammalogie," Leiden, 1835-1841, vol. ii.

- (290) **Toldt, K.** (Digastric Muscle and Muscles of Floor of Mouth), *Wien. S.B. Ak. Wiss.*, 1907, 116, Abth. iii, pp. 443-456.
- (291) **Topinard, P.** "Squelette rachitique d'Orang," *L'Anthropologie*, 1893, p. 767.
- (292) **Trinchese, S.** "Descrizione di un feto di Orang-Utan," *Ann. Mus. Stov. Nat. Geneva*, 1870, pp. 9-54.
- (292a) **Yeth.** "Natural History of Sumatra," Leiden, 1887, vol. iv, part 1.
- (293) **Wallace, A. R.** "On the Orang-Utan or Mias of Borneo," *Ann. Mag. Nat. Hist.*, 1856, pp. 471-476.
- (294) *Idem.* "The Malay Archipelago," 1872, pp. 35-64.
- (295) **Wagner, J. A.** Schreber's "Die Saugethiere."
- (296) **Wells, H. G.** "The Purine Enzymes of the Orang-Utan and Chimpanzee," *Journ. Biol. Chem. Baltimore*, 1904, xviii, pp. 157-165.
- (297) **Wenckstern, A. von.** "Orang-Utans von der Ostküste von Sumatra," *Cor. Bl. deut. Ges. f. Anthropol. München*, 1891, pp. 30-32.
- (298) **Westling, C.** "Beiträge zur Kenntniss des peripherischen Nervensystems," *Bihang. svenska. Ak. Handlingar, Stockholm*, 1886, pp. 1-48.
- (299) **Wittman, R.** "Die Schlagadern der Verdauungsorgane mit Berücksichtigung der Pfortader," *Arch. f. Anthropol.*, 1891, pp. 83-104.
- (300) **Wurmb, F. B. van.** "Beschrijving van de groote Borneoosche Orang-Outang," *Verhand. Bataviaasch. Genootschap der Kunsten*, 1780, pp. 245-261.

WORKS ON THE CHIMPANZEE.

- (301) **Alix, E.** "Recherches sur la Disposition des Lignes papillaires de la main et du pied," *Ann. des Sci. Nat.*, vols. viii and ix.
- (302) **Barkow, H. C. L.** "Comparative Morphologie des Menschen und der Menschenähnlichen Tiere," Breslau, 1863-1875, parts i and ii.
- (303) **Bartlett, A. D.** "On a Female Chimpanzee now living in the Society's Gardens," *Proc. Zool. Soc. London*, 1885, pp. 673-675.
- (304) **Beddard, F. E.** "Contributions to the Anatomy of the Anthropoid Apes," *Trans. Zool. Soc. London*, vol. xiii, pp. 177-218.
- (305) **Benham, W. B.** "A Description of the Cerebral Convolution of the Chimpanzee known as 'Sally,'" *Quart. Journ. Micros. Sci.*, 1895, pp. 47-85.
- (306) **Bianchi, S.** "Sulla divisione dell' os planum dell' ethmoide, etc.," *Arch. Ital. Biol.*, 1895, p. 310.
- (307) **Bischoff, T. L. W.** (On two male Chimpanzee skulls), *S.B. Math.-Phys. Cl. Ak. Wiss. München*, 1867, pp. 283-293.
- (308) *Idem.* (On a female Chimpanzee skull), *ibid.*, pp. 444-449.
- (309) *Idem.* (On the Chimpanzee brain), *ibid.*, 1871, pp. 98-105.
- (310) *Idem.* (On the genitalia and brain of the Chimpanzee), *Mitth. K. Zool. Mus. Dresden*, 1877, pp. 251-260.

- (311) **Bolk, L.** "The Relations between the Ductless Glands and Evolution of the Primates," *Lancet*, 1921, pp. 588-592.
- (312) *Idem.* "Beitrag zur Neurologie der unteren Extremität der Primaten," *Morph. Jahrb.*, xxv, 1897.
- (313) **Bouvier, T. B.** "Contribution à l'étude de l'ostéologie comparée du Chimpanzé," Paris, 1879, pp. 27.
- (314) **Broderip, W. T.** "On the Habits and External Characters of a Chimpanzee," *Proc. Zool. Soc. London*, 1835, pp. 160-168.
- (315) **Brühl, C. B.** "Myologisches über die Extremitäten des Schimpanse," *Wien. Med. Woch.*, 1871, pp. 4-8; 52-55; 78-83.
- (316) **Cavanna, G.** "Sulla splacnologia di un Troglodites niger," *Arch. per l'Antropologia*, 1876, pp. 211-215.
- (317) **Chaîne, J.** *C.R. Soc. Biol.*, lix, pp. 623-630. (Digastric Muscle.)
- (318) **Champneys, F.** "On the Muscles and Nerves of a Chimpanzee," *Journ. Anat. and Physiol.*, 1872, pp. 176-211.
- (319) **Chapman, H. C.** "On the Structure of the Chimpanzee," *Proc. Ac. Nat. Sci. Philadelphia*, 1879, pp. 52-63.
- (320) **Chudzinski, T.** "Sur le sacrum d'un Chimpanzé," *Bull. Soc. d'Anthrop.*, 1888, p. 483.
- (321) **Cushing, H.** "The Pituitary Body and its Disorders."
- (322) **Darwin, Ch.** "The Expression of the Emotions in Man and Animals," London, 1890.
- (323) **Doran, A.** "The Auditory Ossicles," *Trans. Linn. Soc. London*, 1887, pp. 371-497.
- (324) **Du Chaillu, P. B.** (Characters of Chimpanzees), *Proc. Boston Soc. Nat. Hist.*, 1861, pp. 296-299, 358-360.
- (324a) **Duckworth, W. L. H.** *P.Z.S.*, 1899.
- (325) **Dwight, T.** "Notes on the Dissection of the Brain of the Chimpanzee Gumbo," *Mem. Boston Soc. Nat. His.*, 1895, pp. 35-52.
- (326) **Embleton, D.** "Notes on Certain Parts of the Anatomy of a Young Chimpanzee," *Nat. Hist. Rev.*, 1864, pp. 250-258.
- (327) **Flower, W. H.** "Acrocephalic Skull of a Chimpanzee," *Proc. Zool. Soc. London*, 1882, p. 634.
- (328) *Idem.* "Lectures on the Organs of Digestion in the Mammalia," *Med. Times and Gazette*, 1872, pp. 335, 392.
- (329) **Garner, R. L.** "Gorillas and Chimpanzees," 1896.
- (330) **Gratiolet, P.** "Recherches sur l'anatomie du Troglodytes aubryi," *Nouv. Arch. du Mus. Nat. Hist.*, 1866, pp. 1-263.
- (331) **Gruber, W.** *Arch. f. Anat.*, 1870, p. 501.
- (332) **Gulliver, G.** "On the Size of the Red Blood Corpuscles," *Proc. Zool. Soc. London*, 1845, pp. 93-102.
- (333) **Halford, G. B.** "Not like Man, Bimanous and Biped, nor yet Quadrumanous, but Cheiropodous," Melbourne, 1863.
- (334) **Hamy, E. T.** "Contributions à l'étude du développement des lobes cérébraux des Primates," *Rev. d'Anthrop.*, 1872, pp. 425-431.
- (335) **Hartmann, R.** (Distribution of Wild Mammalia in North-east Africa), *Zeitschr. d. Ges. f. Erdkunde zu Berlin*, 1868, p. 28.

- (336) *Idem.* "Beiträge zur zoologische und zootomische Kenntniss der sog. anthropomorphen Affen," *Arch. f. Anat. u. Physiol.*, 1872, 1875, 1876.
- (337) *Idem.* (Appearances of two Chimpanzees), *Zeitschr. f. Ethnol.*, 1872, vol. iv, p. 198.
- (338) *Idem.* (A species of Chimpanzee from the Upper Nile), *Zeitschr. d. Ges. f. Erdkunde zu Berlin*, 1868, pp. 30-33.
- (339) **Hoefer, W.** "Vergleichend Anatomische Studien ueber di Nerven des Armes und der Hand," *Arbeit aus den Anat. Inst. München*, 1892.
- (340) **Humphry, G.** "On some points in the Anatomy of the Chimpanzee," *Journ. Anat. and Physiol.*, 1867, pp. 254-268.
- (341) **Jhering, H. von.** "Das peripherische Nervensystem der Wirbelthiere," Leipzig, 1878.
- (342) **Issel, A.** (Central African Apes), *Ann. Mus. Civ. di Storia Nat.*, Genova, 1870, pp. 55-61.
- (343) **Jacoby, G. L.** "Unterschiede am Schaedel des Schimpansen, Gorilla und Orangutan," *Zeitschr. Morphol.*, vi, pp. 251-284.
- (344) **Jennison, G.** "A Nest-making Chimpanzee," *Proc. Zool. Soc.*, 1915, pp. 535-536.
- (345) **Kallius, E.** "Ueber die Medulla spinalis und die Medulla oblongat. von *Troglodytes niger*," Inaug. Diss., Berlin, 1892.
- (346) **Kollmann, A.** "Das Tastapparat des Fusses von Affen und Mensch," *Arch. f. Anat. u. Physiol.*, 1885, pp. 56-101.
- (347) **Kükenthal and Ziehen.** "Untersuchungen ueber die Grosshirnfurchen der Primaten." *Jenaische Zeitschr. f. Naturwiss.*, 1895, pp. 1-122.
- (348) **Laborde, J. Y.** "La microcephalie vraie et la descendance de l'Homme," *Rev. Scien.*, 1895, pp. 577-585.
- (349) **Lazarus, P.** "Zur Morphologie des Fuss-skelettes," *Morph. Jahrb.*, 1896, pp. 1-165.
- (350) **Macalister, A.** "On some points in the Myology of the Chimpanzee and others of the Primates," *Ann. Mag. Nat. Hist.*, 1871, pp. 341-351.
- (351) **Macartney, J.** "On the Minute Structure of the Brain in the Chimpanzee and of the Human Idiot, compared to the Perfect Brain of Man," *Trans. Roy. Ir. Acad.*, 1843, pp. 322-327.
- (352) **Maggi, L.** "Il canale cranio-faringeo negli antropoidi," *Rend. Inst. Lombardo*, 1891, pp. 138-149.
- (353) **Manouvrier, L.** (Variations in human nasal bones), *Bull. Soc. d'Anthrop.*, 1893, pp. 712-714.
- (354) **Marshall, J.** "On the Brain of a Young Chimpanzee," *Nat. Hist. Rev.*, 1861, pp. 296-315.
- (355) **Martin, W. C. L.** "A general introduction to the Natural History of Man and Monkeys," London, 1841.
- (356) **Mayer, C.** "Zur Anatomie des Orang-utang und des Chimpanse," *Arch. f. Naturg.*, 1856, pp. 281-304.

- (357) *Idem.* "Ueber den Bau des Organes der Stimme, etc.," *Verhand. d. K. Leop. Carol. Ak. d. Wiss.*, 1851, pp. 661-766.
- (358) **Meijere, J. C. H. de.** "Ueber die Haare der Säugethiere, besonders ueber ihre Anordnung," *Morph. Jahrb.*, 1894, pp. 312-414.
- (359) **Mitchell, C. P.** "Notes, with Commentations, on the Psychology of a Chimpanzee," *Journ. Compar. Med. N.Y.*, 1885, pp. 38-53.
- (360) **Moeller, J.** "Zur Anatomie des Chimpanse-Gehirns," *Arch. f. Anthropol.*, 1888, pp. 175-185.
- (361) *Idem.* "Beiträge zur Kenntniss des Anthropoiden-Gehirns," *Abh. d. K. Zoolog. u. Anthropol. Mus. zu Dresden*, 1890-91, pp. 1-16.
- (362) *Idem.* (On optic chiasma of the Chimpanzee), *Anat. Anz.*, 1889, pp. 539-544.
- (363) **Mohrike, O.** "Das Ausland," 1872.
- (364) **Moore, E. G.** Contributions to Wilder's paper (see No. 414).
- (365) **Morselli, E.** "Sulla fossetta vermiana nei Primati," *Atti di Soc. Ligustica Sc. Nat.*, 1890, pp. 142-143.
- (366) **Nepheu, M. G.** "Observations sur le corpuscle de Pacini chez le singe," *Ann. Sc. Nat.*, 1869, pp. 326-337.
- (367) **Nissle, C.** "Die Dresdener Mafuka," *Zeitschr. f. Ethnologie*, 1876, pp. 46-59.
- (368) **Noack, T.** (Fauna of East and Central Africa), *Zool. Jahrb.*, 1886, pp. 291-301.
- (369) **Nuttall, G.** "Blood Immunity and Blood Relationship," Cambridge, 1904.
- (370) **Olivier, O.** "Le Chimpanse des Folies-Bergères," *Rev. Sci. Bourbonnais*, xvii, pp. 46 and 47.
- (371) **Owen, R.** "Post-mortem Examination of a Chimpanzee," *Proc. Zool. Soc. London*, 1836, pp. 41-42.
- (372) *Idem.* "Dissection of a Chimpanzee," *ibid.*, 1846, pp. 2-3.
- (373) *Idem.* "Odontography," London, 1840-45.
- (374) *Idem.* (Osteology of the Chimpanzee and Orang), *Trans. Zool. Soc. London*, vol. i, iii, iv, v.
- (375) **Parker, A. J.** "Morphology of the Cerebral Convolutions, with special reference to the Primates," *Journ. Acad. Nat. Sci. Philad.*, 1896, pp. 242-365.
- (376) *Idem.* "On the Brain of a Chimpanzee," *Medical Record*, 1880, pp. 28-31.
- (377) **Paterson, A. M.** "The Human Sacrum," *Sci. Trans. Roy. Soc. Dublin*, 1893, vol. v.
- (378) **Patten, C. J.** (Cranium with metopic suture), *Journ. Anat. and Phys.*, 1911, xlv, pp. 33-40.
- (379) *Idem.* (Cranium with partition of bones), *Zeitschr. Morph. Stuttgart*, 1912, xiv, pp. 527-608.
- (380) **Regnault, F.** "La suture lacrimo-ethmoïdale," *Bull. Soc. d'Anthropol.*, Paris, 1894, pp. 413-419.
- (381) **Reichart, P.** "Schimpanse am Tanganyika," *Arch. f. Naturgeschichte*, 1884, pp. 120-124.

- (382) **Retterer.** (Penis), *C.R. Soc. Biol.*, lxxviii, p. 362.
- (383) **Reuvens, C. L.** "Die Affen in Zoologischen Garten zu Rotterdam," *Zool. Garten*, 1889, pp. 182-187.
- (384) **Ribbing, L.** "Die distale Extremitätenmuskulatur eines Schimpansen," *Lund. Univ. Arsskr.*, N.F. 8, Afd. 2, No. 3, 1912.
- (385) **Roegholt, M. N.** (Topography of thorax and abdomen), Leiden, 1917.
- (386) **Rohon, J. V.** "Zur Anatomie der Hirnwindung bei den Primaten," München, 1884.
- (387) **Rollet, E.** "Maladies osseuses des grand singes," *C. R. Ac. Paris*, 1891, vol. cxii, pp. 1476-1478.
- (388) *Idem.* "Les os longs des grands singes," *tom. cit.*, vol. cix, pp. 75-78.
- (389) **Romanes, G. J.** "On the Mental Faculties of the Bald Chimpanzee (*Anthropopithecus calvus*)," *Proc. Zool. Soc. London*, 1889, pp. 316-321.
- (390) **Rüdinger, N.** "Ein Beitrag zur Anatomie des Sprach-Centrums," *Festschr. f. T. H. L. Bischoff*, 1882, pp. 135-191.
- (391) **Sayers, H. K.** "Description of the Habits of a Chimpanzee," *Proc. Zool. Soc. London*, 1839, p. 28.
- (392) **Schlaginhaufen, O.** (Bodily mass and external characters), *Dresden Abh. Zool. Mus.*, 1907, ii, 4, pp. 1-18.
- (393) **Schlegel, H.** "Monographie des Singes," Leiden, 1876.
- (394) **Schmidt, E.** "Ein Anthropoiden Fötus," *Festschr. f. R. Leuckart*, Leipzig, 1892, p. 26.
- (395) **Schmitt, R.** "Das Nervensystem von *Troglodytes niger*," *Anat. Anz. Jena*, 1909, xxxiv, 286-287.
- (396) **Schmidt, M.** "Die Krankheiten der Affen," *Zool. Klinik*, 1870, vol. i, p. 166.
- (397) **Schroeder van der Kolk en Vrolik, W.** "Hersenen van den Chimpanse," *Verh. Eerste-Kl. K. Nederl. Inst. Amst.*, 1849, vol. i, pp. 262-278.
- (398) **Schweinfurth, G.** "The Heart of Africa," London, 1873 (trans. by E. E. Frewer).
- (399) **Sonntag, C. F.** "The Anatomy, Physiology, and Pathology of the Chimpanzee," *Proc. Zool. Soc. London*, 1923, pp. 323-439.
- (400) **Spitzka.** "On the Chimpanzee Brain," *Journ. Mental and Nervous Diseases*, 1879.
- (401) **Sperino, G.** "Anatomie del Cimpanzè," Torino, 1897, 487 pp.
- (402) **Sutton, J. B.** "On some Points in the Anatomy of the Chimpanzee," *Journ. Anat. and Physiol.*, 1884, pp. 66-85.
- (403) **Symington, J.** "On the Viscera of a Female Chimpanzee," *Proc. Phys. Soc. Edin.*, 1890, pp. 297-312.
- (404) **Thomson, A.** (The influence of posture on the articular surfaces of the tibia and astragalus), *Journ. Anat. and Physiol.*, N.S. vol. iii.
- (405) *Idem.* "The Orbito-maxillary Frontal Suture in Man and the Apes," *tom. cit.*, N.S. vol. iv.

- (406) **Traill, Dr.** "The Anatomy of a Chimpanzee," *Mem. Wernerian Nat. Hist. Soc. Edin.*, 1817, pp. 1-49, vol. iii.
- (407) **Turner, W.** "Notes more especially on the Bridging Convolutions in the Brain of the Chimpanzee," *Proc. Roy. Soc. Edin.*, vol. v, pp. 578-587.
- (408) **Tyson, E.** "Orang-outang, sive Homo sylvestris, or the Anatomy of a Pygmie compared with that of a Monkey, an Ape and a Man," London, 1699.
- (409) **Utschneider, A.** "Die Lendennerven der Affen und des Menschen," *Münch. Med. Abhand.*, S. vii, Heft 1, 1882.
- (410) **Virchow, R.** (Muscles of back), *Arch. Anat. Physiol. Leipzig*, Anat. Abt., 1909, pp. 137-174.
- (411) **Yrolik, W.** "Recherches d'anatomie comparée sur le Chimpanse." Amsterdam, 1841, 47, pp. .
- (412) **Waldeyer, W.** "Ueber die Anatomie des Harten-Gaumens bei den Anthropoiden," *Monit. Zool. Ital.*, No. 4, pp. 73-74.
- (412a) **Wallis, H. M.** *Proc. Zool. Soc. London*, 1897, pp. 298-310.
- (413) **Wells, H. G.** "The Purine Enzymes of the Orang-utan and Chimpanzee," *J. Biol. Chem. Baltimore*, 1914, xviii, pp. 157-165.
- (414) **Wilder, B. G.** "Contributions to the Myology of the Chimpanzee," *Boston Journ. Nat. Hist.*, 1862, pp. 352-382.
- (415) *Idem.* "Relative Position of the Cerebrum and Cerebellum in Anthropoid Apes," *Proc. Amer. Assoc.*, 1884, p. 527.
- (416) **Windle, B.** (Muscles of the hand), *Proc. Phil. Soc. Birmingham*, 1886, pp. 377-397 ; 1888, pp. 22-25.
- (417) **Wyman, J.** "Notes on the Myology of a Chimpanzee," *Proc. Boston Soc. Nat. Hist.*, 1856, pp. 274-275.
- (418) **Zuckerkandl, E.** "Das periphere Geruchsorgane der Säugethiere," Stuttgart, 1887, 116 pp.

WORKS ON THE GORILLA.

- (419) **Aeby, Ch.** "Beiträge zur Osteologie des Gorilla," *Morph. Jahrb.*, 1878, Bd. iv, pp. 288-313.
- (420) **Alix, E., et Bouvier, A.** "Sur un nouveau Anthrope (Gorilla mayema) provenant de la région du Congo," *Bull. Soc. Zool. France*, 1877, pp. 488-90.
- (421) **Bischoff, T. L. W.** (Age and sex changes in the skulls of the Gorilla, Chimpanzee and Orang), München, 1867.
- (422) *Idem.* "Ueber das Gehirn eines Gorilla und die untere oder dritte Stirnwindung des Affen," *S.B. Math.-Phys. Cl. Ak. Wiss. München.*, 1877, pp. 96-139.
- (423) *Idem.* "Das Gorilla-Gehirn und die untere oder dritte Stirnwindung," *Morph. Jahrb.*, 1878, pp. 59-73.
- (424) *Idem.* "Ueber die äusseren weiblichen Geschlechts, und Begattungsorgane des Menschen und der Affen," *Abh. Math.-Phys. Cl. Ak. Wiss. München.*, 1880, pp. 209-274, part ii.
- (425) *Idem.* "Beiträge zur Anatomie des Gorilla," *tom. cit.*, 1880, part iii, pp. 1-48.

- (426) *Idem.* "Ueber Brachycephalie und Brachyencephalie des Gorilla und der anderen Affen," *S.B. Math.-Phys. Cl. Ak. Wiss. München.*, 1881, pp. 379-390.
- (427) *Idem.* "Die dritte oder untere Stirnwindung und die innere obere Scheitebogenwindung des Gorilla," *Morph. Jahrb.*, 1882, pp. 312-322.
- (428) **Beddard, F. E.** "The Brain of the Gorilla," *Proc. Zool. Soc. London*, 1899, pp. 65-76.
- (429) **Bolau, H.** "Die Menschenähnlichen Affen des Hamburger Museums," *Abh. aus dem Gebiete der Naturwiss., Hamburg-Altona*, 1876, Bd. 6, pp. 61-90.
- (430) **Bolk, L.** (Brain of Gorilla), *Zeitschr. Morphol.*, 1909, pp. 141-242.
- (431) *Idem.* (Bulla maxillaris of Gorilla), *Amst. Werk. Nat. Genes. Heilk.*, 1918, pp. 132-133.
- (432) **Bovero, A.** *Giorn. d. R. Accad. di Med. di Torino*, 1896.
- (433) **Broca, P.** "Étude sur le cerveau du Gorille," *Rev. d'Anthrop.*, 1878, pp. 1-46.
- (434) **Brossike.** "Ueber die Krankheiten und Todesursache des Gorilla Mpungu," *S.B. Ges. Naturf. Freunde Berlin*, 1877, pp. 262-267.
- (435) **Chapman, H. C.** "On the Structure of the Gorilla," *Proc. Ac. Nat. Sci. Philadelphia*, 1878, pp. 385-394.
- (436) *Idem.* "Observations upon the Brain of the Gorilla," *op. cit.*, 1892, pp. 203-212.
- (437) **Chudzinsky, T.** "Note sur le foie d'un jeune Gorille," *Bull. Soc. Anthropol. Paris*, 1884, pp. 608-616.
- (438) **Deniker, J.** "Sur un fœtus de Gorille," *Compt. rend. Ac. Paris*, 1884, pp. 753-756.
- (439) **Deniker, J., et Boulart.** "Note sur les sacs laryngiens des singes anthropoïdes," *Journ. Anat. et Physiol.*, 1886, pp. 51-62.
- (440) **Duckworth, W. L. H.** "Variations in the Crania of *Gorilla savagei*," *Journ. Anat. and Physiol.*, 1895, pp. 335-345.
- (441) *Idem.* *Journ. Anat. and Physiol.*, 1912.
- (441a) **Ehlers, E.** *Abh. Phys. Cl. Ges. Wiss, Göttingen*. 1881, Bd. xxviii.
- (442) **Eisler, P.** "Das Gefäß- und Periphere-Nervensystem des Gorilla," Halle, 1890.
- (443) **Falkenstein, J.** "Die Loango-Küste," Berlin, 1876.
- (444) *Idem.* "Ein lebender Gorilla," *Zeitschr. Ethnol.*, 1876, pp. 60-61.
- (445) **Famelart, L.** "Observations sur un jeune Gorille," *Bull. Soc. Zool. France*, 1883, pp. 149-152.
- (446) **Ford, H. A.** "On the Characteristics of the Troglodytes Gorilla," *Proc. Ac. Nat. Sci. Philadelphia*, 1852, pp. 30-33.
- (447) **Giglioli, E. H.** "Studii craniologici sui Cimpanze," *Ann. Mus. Civ. di Storia Nat. Genova*, 1872, pp. 56-179.
- (448) **Grabowsky, T.** "Ueber den Gorilla des Breslauer Zoologischen Gartens," *Verh. Ges. Breslau*, lxxvi, pp. 253-261.
- (449) *Idem.* "Beitrag zur Biologie des Gorilla," *Jen. Zeitschr. Naturw.*, 41, pp. 608-611.
- (450) **Gratiolet, P.** "Note sur l'encéphale du Gorille (*Gorilla gina*)," *Compt. rend. Ac. Paris*, 1860, pp. 801-805.

- (451) **Hamy, E. T.** "De l'épine nasale antérieure dans l'ordre des Primates," *Bull. Soc. Anthropol. Paris*, 1869, pp. 13-28.
- (452) **Hartmann, R.** (External characters and osteology of the Anthropoid Apes), *Arch. Anat. u. Physiol.*, 1872, 1875, 1876.
- (453) *Idem.* "Ueber neues die anthropomorphen Affen betreffendes Material," *S.B. Ges. Nat. Freunde Berlin*, 1876, pp. 22-26.
- (454) *Idem.* "Beiträge zur Kenntniss der sogenannten anthropomorphen Affen," *Zeitschr. Ethnol.*, 1876, pp. 130-133; 1877, pp. 85-89.
- (455) *Idem.* "Der Gorilla," Leipzig, 1880.
- (456) *Idem.* "Ueber den Torus occipitalis transversis," *S.B. Ges. Nat. Freunde Berlin*, 1880, pp. 159-162.
- (457) *Idem.* "Ueber die weiblichen Geschlechtstheile der anthropoiden Affen und die Brunst der Affen im Allgemeinen," *Verh. Berl. Ges. Anthropol.*, in *Zeitschr. Ethnol.*, 1886, pp. 431-433.
- (458) **Hermes, O.** "Aus dem] Gefangenleben des Gorilla," *Zeitschr. Ethnol.*, Berlin, 1892, pp. 576-582.
- (459) **Hervé, G.** "La circonvolution de Broca chez les Primates," *Bull. Soc. Anthropol. Paris*, 1838, pp. 275-314.
- (460) *Idem.* "Crâne du jeune Gorille," *op. cit.*, 1893, pp. 387-389.
- (461) **Kneeland, S.** "On the Skeleton of the Great Chimpanzee (*Troglodytes gorilla*)," *Boston Journ. Nat. Hist.*, 1853, pp. 336-347.
- (462) **Laboullay, G.** Art. in "Description des Mammifères nouveaux," by Geoffroy St. Hilaire, *Arch. Mus. Nat. Hist.*, 1858-61, pp. 1-102.
- (463) **Langle, F. de.** "Mœurs d'un jeune Gorille," *C.R. Ac. Paris*, 1866, p. 739.
- (464) **Lenz, H.** "Anthropomorphen Affen des Lübecker Museums," Lubeck, 1876.
- (465) **Lönnerberg, E.** "En ny Gorilla från Central-Africa," *Fauna och Flora Uppsala*, 1917, xii, pp. 145-155.
- (466) **Macalister, A.** "Muscular Anatomy of the Gorilla," *Proc. Roy. Ir. Acad. Sci.*, 1873, pp. 501-506.
- (467) **Magitot, E.** "L'Homme et les singes anthropomorphes," *Bull. Soc. Anthropol. Paris*, 1869, pp. 113-145.
- (468) *Idem.* "Traité des anomalies du système dentaire," Paris, 1870.
- (469) **Meyer, A. B.** "Notizen über die anthropomorphen Affen des Dresdener Museums," *Mitth. Zool. Mus. Dresden*, 1877, pp. 223-247.
- (470) *Idem.* "Ein angeblicher Bastard zwischen Gorilla und Chimpanse," *Zool. Garten*, 1881, pp. 231-236.
- (471) **Milne-Edwards, A.** "Sur l'existence d'un Gorille à la Ménagerie du Muséum d'Histoire Naturelle," *C.R. Ac. Paris*, 1884, pp. 959-960.
- (472) **Mivart, St. G.** "On the Appendicular Skeleton of the Primates," *Phil. Trans.*, 1867, pp. 299-429.
- (473) *Idem.* (On the axial skeleton of the Primates), *Proc. Zool. Soc. London*, 1865, pp. 545-592.
- (474) **Moeller, J.** "Beiträge zur Kenntnis des Anthropoid-Gehirns," Berlin, 1891.

- (475) **Neuville, H.** "A propos d'un crâne de Gorille, etc.," *Anthropologie*, Paris, 1912, xxiii, pp. 563-586.
- (476) *Idem.* "Remarques sur la variabilité de la crête sagittale du crâne des Gorilles," *Bull. Mus. Paris*, 1916, pp. 2-7.
- (477) **Nissle, C.** "Beiträge zur Kenntniss der sogenannten anthropomorphen Affen," iii, *Zeitschr. Ethnol.*, 1876, pp. 44-60.
- (478) **Owen, R.** "On a New Species of Chimpanzee," *Proc. Zool. Soc. London*, 1848, pp. 27-35.
- (479) *Idem.* "On the Gorilla (*Troglodytes gorilla* Sav.)," *ibid.*, 1859, pp. 1-23.
- (480) *Idem.* Osteological contributions . . on the Chimpanzees, *Trans. Zool. Soc. London*, 1849, 1853, 1857, 1862, 1865 (vols. iii, iv, v).
- (481) *Idem.* "Mémor on the Gorilla," London, 1865.
- (482) **Pansch, A.** "Ueber die Furchen und Windungen am Gehirn eines Gorilla," in *Abh. aus dem Gebiete der Naturwiss. Hamburg-Altona*, 1876, pp. 61-90 (article by Bolau).
- (483) **Reade, W. W.** "The Habits of the Gorilla," *Amer. Nat.*, 1867, pp. 177-180.
- (484) **Reading, J. H.** "Habits of the Gorilla," *Amer. Nat.*, 1884, pp. 1277-1278.
- (485) **Rothschild.** Exhibition of a Mountain Gorilla with remarks thereon, *Proc. Zool. Soc. London*, 1923, pp. 176 and 177.
- (486) **Ruge, G.** (Facial muscles of Gorilla), *Morph. Jahrb.*, 1887, pp. 459-529.
- (487) **Savage, T. S.** "Notice of the External Characters and Habits of Troglodytes, Gorilla, &c.," *Boston Journ. Nat. Hist.*, 1847, vol. v, pp. 417-443.
- (488) **St. Hilaire, J. G.** "Description des Mammifères nouveaux," *Arch. Mus. Hist. Nat.*, 1858-1861, pp. 1-102.
- (489) **Siffre.** "Présence sur une mandibule de Gorille d'une quatrième molaire," *Paris Bull. Mém. Soc. Anthropol.*, sér. 5, 1909, x, pp. 81-82.
- (490) **Slack, J. H.** "Mammalogical Notices," *Proc. Ac. Nat. Sci. Philadelphia*, 1867, pp. 34-38.
- (491) **Sommer, A.** "Das Muskelsystem des Gorilla," *Jenaische Zeitschr.*, 1906, Bd. xlii.
- (492) **Stahr, H.** "Ueber die Zungenpapillen des Breslauer Gorilla, weibchens," *Jenaische Zo. Naturw.*, 41, 1906, pp. 618-631.
- (493) **Struthers, J.** "On the Articular Processes of the Vertebrae in the Gorilla," *Journ. Anat. and Physiol.*, 1893, pp. 131-138.
- (494) **Swayne, S. H.** "Comparative Measurements of the Skeleton of Man and the Gorilla," *Proc. Bristol Nat. Soc.*, 1868, pp. 39-41.
- (495) **Symington, J.** "Observations on the Myology of the Gorilla and Chimpanzee," *Rep. Brit. Assoc.*, 1889, London, 1890, pp. 629 and 630.
- (496) *Idem.* "The Vertebral Column of a Young Gorilla," *Journ. Anat. and Physiol.*, 1889, pp. 42-51.
- (497) **Thane, G. D.** "The Brain of the Gorilla," *Nature*, 1876, vol. xv, pp. 142-144.

- (498) **Thomson, W.** "The Transversalis Pedis in the Foot of the Gorilla," *Austral. Med. Journ.*, Melbourne, 1864, pp. 15-24.
- (499) **Török, A. von.** "Sur le crâne du jeune Gorille du Musée Broca," *Bull. Soc. Anthropol. Paris*, 1881, pp. 46-57.
- (500) *Idem.* (Studies on the craniology of the Gorilla), *Month. Internat. Journ. Anat. and Physiol.*, 1887, 1893, 1894, 1895.
- (501) **Topinard, P.** "De l'évolution des molaires et des prémolaires chez les Primates," *L'Anthropologie*, 1892, pp. 641-670.
- (502) **Turner, W., and Burt.** "Exhibition of Three Skulls of the Gorilla," *Proc. Roy. Soc. Edin.*, 1865, pp. 341-350.
- (503) **Virchow, R.** (Skulls of young Gorillas), *Monatsber. Akad. Wiss. Berlin*, 1880, pp. 516-543.
- (504) **Waldeyer, W.** "Das Gorilla-Rückenmark," *Abh. Akad. Wiss. Berlin*, 1888, pub. 1889, art. 3.
- (505) **Wyman, J.** "Report on the Cranium of the Engéena (*Troglodytes gorilla*)," *Proc. Boston Soc. Nat. Hist.*, 1850, p. 179.
- (506) *Idem.* "Observations on the Cranium of a Young Gorilla," *ibid.*, 1863, p. 203, vol. ix.


WORKS ON PALÆONTOLOGY.

- (507) **Cope, E. D.** "The Lemuroidea and the Insectivora of the Eocene Period of North America," *Amer. Naturalist*, 1885, p. 467.
- (508) **Forsyth Major, C. J.** "On some Characters of the Skull in Lemurs and Monkeys," *Proc. Zool. Soc. London*, 1901, pp. 129-153.
- (509) **Gregory, W. K.** "The Origin and Evolution of the Human Dentition," New York, 1922.
- (510) **Lydekker, R.** "Siwalik Mammalia," *Mem. Geol. Surv. Palæontologica Indica*, 1886 (X), iv, pt. i, pp. 1-18.
- (511) **Matthews, W. D., and Granger, W.** *Bull. Amer. Mus. Nat. Hist.*, 1915, xxxiv, pp. 429-483.
- (512) **Pilgrim, G. E.** "New Siwalik Primates and their Bearing on the Question of the Evolution of Man and the Anthropoidea," *Rec. Geol. Surv. India*, 1915, xlv, pp. 1-74.
- (513) **Schlosser, M. von.** *Palæont. u. Geol. Österreich Ungarns u. des Orients*, 1911, xxiv, pp. 51-167.
- (514) **Smith Woodward, A.** "On the lower jaw of an Anthropoid Ape (*Dryopithecus*) from the Upper Miocene of Lérida (Spain)," *Quart. Journ. Geol. Soc.*, 1914, lxx, pp. 316-320.
- (515) **Dubois, E.** "Ueber drei aufgestorbene Menschenaffen," *Neuen Jahrb. für Mineralogie, Geologie u. Palæontologie*, 1897, i.
- (516) **Andrews, C. W.** "A Descriptive Catalogue of the Tertiary Vertebrata of the Fayûm, Egypt," British Museum (Nat. Hist.), London, 1906.
- (517) **Smith, G. Elliot.** *Encyclopædia Britannica*, supplementary vol. A, art. "Anthropology."

SPECIAL NOTE.

The following paper, which is of great importance, has recently been published:—

- (518) **Corner, G. W.** "Ovulation and Menstruation in *Macacus Rhesus*,"
Contributions to Embryology, No. 75 (*Extracted from Publication*
No. 332 of the Carnegie Institute, Washington, pp. 75-101).



INDEX.

A

Adapidæ, 324
 Air-sacs, 44, 261
 Air-sinuses, 116, 123, 131, 257
Alouatta, 35, 36, 38, 42, 43, 44
 Anaptomorphidæ, 323
 Anthropoid Apes, 2 (*see also* Gibbon,
 Orang, Chimpanzee and Gorilla)
 Anthropology, 1
Anthropopithecus (*see* Chimpanzee)
 Anticlinal vertebra, 19, 42, 53
 Anus, 75
 Aorta, 23, 32, 44, 57, 227, 238
Aotus 35, 36, 39, 42
 Artery—
 ascending cervical, 233
 ascending palatine, 229
 ascending pharyngeal, 214, 232
 auricular, 232
 axillary, 23, 234
 brachial, 23, 32, 57, 235
 bronchial, 228
 buccal, 232
 carotid—
 common, 228, 229
 external, 229
 internal, 18, 29, 40, 232, 311
 carpal, 236, 237
 circumflex femoral, 244
 circumflex humeral, 57, 234
 circumflex iliac, 243
 coeliac axis, 240
 coronary, 241
 costo-cervical, 233
 dental, 231, 232
 digital, 237
 epigastric, 234, 243, 244
 facial, 57, 231
 femoral, 23, 243
 gastric, 217, 240, 241
 gluteal, 243
 hæmorrhoidal, 242
 hepatic, 240
 iliac, 242, 243

Artery—*continued.*

 infra-orbital, 232
 innominate, 228
 intercostal, 233, 234, 238
 internal maxillary, 231
 labial, 231
 lingual, 57, 230
 linguo-facial, 229
 lumbar, 240
 mammary, 233, 234
 meningeal, 231
 mesenteric, 241, 242
 musculo-phrenic, 234
 obturator, 243, 244
 occipital, 232
 occipito-auricular, 229
 ovarian, 239
 palatine, 232
 palmar, 237
 phrenic, 238
 plantar, 246
 popliteal, 244
 pudendal, 243
 pulmonary, 229
 radial, 236
 renal, 239
 sacral, 240, 243
 saphenous, 52, 57, 246
 scapular, 233
 splenic, 240
 subclavian, 228, 233
 submaxillary, 231
 subscapular, 234
 suprarenal, 239
 temporal, 231, 232
 thoracica longa, 233
 thoracic axis, 234
 thyroid, 229, 230, 233
 thyroid axis, 233
 tibial, 245
 tonsillar, 232
 ulnar, 237
 uterine, 242
 vertebral, 233
 vesical, 242, 243

Arytenoid cartilages, 259
 Association centres, 43, 276
Ateles, 8, 35, 38, 39, 42, 43, 44
 Auditory meatus, 18, 52, 129, 295
 Auditory ossicles, 317
 Auricular muscles, 165
 Aye-Aye (*see Chiromys*)

B

Binocular vision, 34
 Bladder (gall), 23, 43, 56, 224
 Bladder (urinary), 264
 Blood, 24, 254
 Brachial plexus, 301-303
Brachyteles, 35, 36, 38, 43
 Brain (*see also* Sulci), 24, 33, 45, 58, 273-293, 322, 332

C

Cacajao, 35
 Cæcum, 32, 56, 219, 220, 221
Callicebus, 35, 39, 42
 Callosities, 8, 50, 65
 Carpus, 20, 43, 53, 140
 Catarrhini, 47-317
 Cebidæ, 35, 38, 41
Cebus, 35, 37, 38, 39, 42, 43, 44
Cercocebus, 9, 47
 Cercopithecidae, 47-61
Cercopithecus, 47
 Cerebellum, 26, 33, 43, 281, 284, 288, 293
 Cerebrum, 24, 33, 45, 58, 273-293
 Cervical plexus, 299-301
 Cheek-pads, 76
 Cheek pouches, 56, 209
 Chimpanzee, 9, 19, 85-92, 103, 117, 147, 161-317, 331, 332
 Chin, 76, 103
Chirogaleus, 17
Chiromys, 8, 10, 15, 17, 22, 24, 25
Chrysotrux, 43
 Classification, 5, 35, 47, 73, 84, 90, 101
 Clavicle, 19, 30, 53, 74, 138
 Claws, 8, 38
 Clinoid processes, 115
 Clitoris, 44, 58, 269
Colobus, 48
 Colon, 22, 32, 43, 56, 219, 220, 221
 Configuration of body, 65, 75, 85, 92
 Corpus callosum, 33, 282
 Cranial capacity, 109, 111, 124, 274
 Cranial cavity, 109, 111, 124, 274
 Cretaceous period, 321

Cricoid cartilage, 259
Cynocephalus, 47
 Cynodontia, 320
Cynopithecus, 47
 Curvature of spine (*see* Vertebral column)

D

Dentition (*see* Teeth)
 Diastema, 52, 145, 147, 148
 Diet, 5, 13, 47
 Digits, 8
 Distribution, 4, 26, 47, 73, 83, 90, 101
Dryopithecus, 4, 170, 329-331
 Ductless glands, 4, 253-254
 Duodenum, 22, 32, 219, 220

E

Ears, 13, 37, 76, 85, 92, 93, 315-317
 Endocranial casts, 274
 Endocrine organs, 4, 253-254
 Entoconid, 42
 Entocuneiform (*see* Tarsus)
Eoanthropus, 134, 274
 Eocene period, 321-326
 Epicondylar foramen, 19, 30, 43, 53
 Epiglottis, 24, 32, 57, 259
 Ethnography, 1
 Ethnology, 1
 Evolution (principles), 318-320
 Eyes, 9, 13, 33, 50, 75, 315

F

Fallopian tubes, 265
 Fayûm Fauna, 326, 327
 Feet, 13, 26, 38, 51, 68, 78, 88, 98
 Femur, 20, 54, 141
 Fibula, 142
 Flexure lines, 67, 77, 87, 96
 Flocculus, 24, 46, 285, 288, 290
 Foramen magnum, 109, 115, 122
 Foramen opticum, 30, 106, 113, 120
 Foramen rotundum, 113, 119
 Frenal lamella, 211
 Frontal bone in Lemurs, 19

G

Galago, 6, 13, 17, 25, 26
Galeopithecus, 321
 Gibbons, 9, 19, 65-74, 80, 105, 144, 161-317, 328, 329

Glenoid cavity, 18, 29, 108, 114, 122, 130
 Gorilla, 3, 92-103, 125, 148, 161-317, 332

H.

Habits, 13, 26, 35, 47, 69, 80, 88, 100
 Hair, 7, 13, 17, 29, 38, 48, 50, 69, 78, 92, 99
 Hallux (*see* Feet)
 Hands, 13, 26, 38, 51, 65, 77, 87, 95
Hapalemur, 8
Hapalidæ, 35, 38, 39, 40, 42
 Heart, 23, 44, 56, 227
Homunculus, 323
 Humerus, 19, 30, 43, 53, 139
Hylobates (*see* Gibbons)
 Hypocone, 41
 Hypoconid, 42
 Hypoconulid, 42

I, J, K

Indrisidæ, 18, 25
 Inferior orbital fissure, 106
 Infra-orbital foramen, 106, 113, 120, 127
 Insectivores, 321
 Insula, 59, 278, 279, 281, 283, 287, 289, 292
 Ischial callosities, 8, 50, 65
 Joints, 151-160
 ankle, 158
 elbow, 155
 hip, 156
 knee, 156
 pelvic, 153
 shoulder, 154
 spinal, 151
 temporo-maxillary, 151
 wrist, 155
 Kidney, 24, 32, 44, 58, 264

L

Labia majora, 32, 58, 268
 Lachrymal hamulus, 106, 112, 120, 127
 Lachrymo-ethmoidal suture, 106, 112, 120, 127
Lagothrix, 35, 38, 39, 44
 Larynx, 24, 57, 257-262
 Lemuroidea, 9, 10, 13-26, 36, 39, 40, 41, 45, 55, 60, 61, 321-323
 Ligaments (*see* Joints)
 Ligamentum nuchæ, 135

Lips, 32, 86, 209
 Liver, 23, 43, 56, 224, 225, 226
 Lorises, 8, 10, 13, 17, 23, 25, 26, 45
 Lumbar plexus, 305-308
 Lungs, 32, 57, 262
 Lymphatic system, 252, 253

M

Macacus, 47
 Mammary glands, 8, 29, 50, 69, 78, 100
 Man, 1, 2, 4, 6, 7, 9, 19, 21, 23, 33, 61, 66, 76, 78, 88, 89, 90, 92, 93, 96, 98, 103, 116, 117, 121, 124-126, 129, 130, 132-136, 138-140, 142-144, 147, 150, 151, 153-158, 160, 161, 163-173, 177-187, 190-192, 200-203, 208-224, 227, 229, 231-240, 243-256, 259, 260, 264-282, 293-299, 302-305, 312-317, 330-333
 Mandible, 40, 109, 116, 124, 131, 324-330
 Marmosets, 8, 35
Megaladapis, 324
 Menstruation, 269, 270
 Mesentery, 9, 221, 222
 Metacone, 41
 Metaconid, 42
Microchærus, 325
Midas, 43
 Miocene period, 327-332
 Mouth, 209
 Muscle
 abductor hallucis, 203
 abductor minimi digiti, 188, 203,
 abductor pollicis, 189
 accessorius, 204
 adductor brevis, 197
 adductor hallucis, 205
 adductor longus, 196
 adductor magnus, 197
 adductor pollicis, 189
 anconeus, 185
 arytenoideus, 260
 auricular, 165
 biceps brachii, 21, 184
 biceps femoris, 21, 31, 55, 198
 biventer cervicis, 180
 brachialis anticus, 184
 buccinator, 163
 complexus, 180
 constrictors of pharynx, 172
 contrahentes, 190
 coraco-brachialis, 21, 184
 crico-arytenoid, 260

Muscle—*continued*.

crico-thyroid, 260
 deltoid, 21, 31, 55, 182
 diaphragm, 206
 digastric, 21, 31, 54, 168
 dorso-epitrochlearis, 21, 31, 55, 185
 erector spinæ (see *Sacro-spinalis*)
 extensor brevis digitorum, 200
 extensor carpi radialis, 190
 extensor communis digitorum, 190
 extensor hallucis, 199
 extensor indicis, 191
 extensor longus digitorum, 199
 extensor minimi digiti, 190
 extensores pollicis, 191
 flexor carpi radialis, 185, 186
 flexor carpi ulnaris, 186
 flexor digitorum brevis, 22, 204
 flexor digitorum longus, 22, 55, 202
 flexor digitorum profundus, 187
 flexor digitorum sublimis, 186
 flexor minimi digiti brevis, 188, 205
 flexores hallucis, 22, 55, 202, 204
 flexores pollicis, 186, 189
 frontalis, 161
 gastrocnemius, 201
 gemelli, 195
 genioidei, 171
 glutei, 21, 31, 55, 193
 gracilis, 197
 hyoglossus, 172
 iliacus, 192
 ilio-costalis, 178
 ilio-psoas, 192
 incisivi, 165
 infraspinatus, 183
 interossei, 191, 205
 labial, 163
 latissimus dorsi, 21, 31, 55, 174
 levator anguli scapulæ, 175
 levator palpebræ, 315
 longissimus, 178, 179
 longus colli, 180
 lumbricales, 187, 204
 masseter, 166
 multifidus, 180
 mylo-hyoid, 171
 obliqui abdominis, 206
 obliqui capitis, 180
 obliqui oculi, 315
 obturatores, 195
 occipitalis, 161
 omo-hyoid, 168

Muscle—*continued*.

omo-trachelian, 55,
 opponens minimi digiti, 189, 205
 opponens pollicis, 189
 orbicularis oculi, 161
 orbicularis oris, 165
 palatine, 173
 palmaris brevis, 188
 palmaris longus, 185
 pectineus, 198
 pectoral, 31, 54, 181
 peronei, 55, 200
 plantaris, 22, 31, 55, 201
 platysma, 20, 30, 54, 161
 popliteus, 201
 prevertebral, 180
 pronators, 185
 psoas, 192
 pterygoid, 166
 pyramidalis, 208
 quadratus femoris, 195
 quadratus labii, 163
 quadratus lumborum, 206
 quadratus plantæ (see *Accessorius*)
 quadriceps femoris, 196
 rectus abdominis, 208
 rectus capitis, 180, 181
 rectus femoris, 196
 rectus oculi, 315
 rhomboideus, 20, 175
 risorius, 162
 sacro-spinalis, 177
 sartorius, 195
 scaleni, 173
 scansorius, 55, 193
 semimembranosus, 199
 semispinalis, 180
 semitendinosus, 198
 serrati, 176, 183
 soleus, 22, 31, 55, 201
 sphincter colli, 20, 30, 54
 spinalis, 178
 splenius, 176
 sterno-hyoid, 170
 sterno-mastoid, 20, 31, 54, 168
 sterno-thyroid, 170
 stylo-glossus, 172
 stylo-hyoid, 171
 stylo-pharyngeus, 173
 subclavius, 182
 subscapularis, 183
 supinators, 190
 supraspinatus, 183
 temporal, 166
 tensor fasciæ femoris, 194
 tensor palati, 173
 teres, 183

Muscle—*continued*.

- thyro-arytenoid, 260
- thyro-hyoid, 260
- tibialis, 22, 31, 199, 202
- tragicus, 166
- transversalis abdominis, 207
- trapezius, 20, 31, 174
- triangularis, 163
- triceps, 55, 185
- vasti, 196
- zygomatici, 163

N

- Nails, 8, 15, 38, 66, 77
- Nannopithecus*, 325
- Nares, 39, 106, 113, 120, 127
- Nasal bones, 120, 127
- Nasal duct, 18, 29, 39, 52, 106, 113, 257, 324, 325
- Nasal meatuses, 257
- Nasal septum, 36, 116, 257
- Nasal spines, 106, 108, 113, 114, 120, 122, 128
- Nasalis*, 48
- Neck, 78
- Necrolemur*, 325
- Neopallium*, 60, 275-277, 333
- Nerves—
 - abducens, 294
 - accessory, 298
 - anterior thoracic, 303
 - buccal, 295, 296
 - cardiac, 297, 311, 312
 - chorda tympani, 294
 - ciliary, 294
 - circumflex, 305
 - cutaneous, 305
 - descendens hypoglossi, 299
 - facial, 294
 - femoral (anterior crural), 308
 - gastric, 217
 - genito-crural, 308
 - glosso-pharyngeal, 296
 - gluteal, 309
 - hypoglossal, 299
 - ilio-hypogastric, 308
 - ilio-inguinal, 308
 - infra-orbital, 162
 - intercosto-humeral, 305
 - lacrimal, 294
 - laryngeal, 297
 - lateral cutaneous, 308
 - lingual, 167
 - long thoracic, 303
 - lumbo-sacral cord, 307, 308
 - maxillary, 293, 294

Nerves—*continued*.

- median, 304
- musculo-cutaneous, 305
- musculo-spiral, 305
- nasal, 294
- obturator, 308
- oculo-motor, 293
- olfactory, 257, 293
- optic, 293
- peroneal, 309
- phrenic, 301
- plantar, 310
- pudendal, 310
- pulmonary, 297, 313
- radial, 305
- sciatic, 309
- splanchnic, 312
- subscapular, 304
- supraclavicular, 300
- suprascapular, 303
- sympathetic, 310-314
- tibial, 309
- trigeminal, 293, 294
- ulnar, 304
- vagus, 296-298
- Nose, 76, 85, 93
- Nostrils, 35, 50
- Notharctidae, 322

O

- Occipital condyles (*see* Skull)
- Oligocene period, 326, 327
- Omomyids*, 323
- Orang-Outan, 9, 75-84, 110, 146, 161-317
- Orbits, 18, 29, 39, 105, 112, 119, 126
- Os calcis, 20, 30, 143, 144
- Os centrale, 20, 30, 43, 141
- Os penis, 32, 44, 58
- Ovary, 265

P

- Pads, 7, 16, 27, 51, 67
- Palaeopithecus*, 103, 331
- Palaeosimia*, 331
- Palate, 18, 29, 40, 55, 108, 114, 121, 129, 209, 210
- Paleocene period, 321
- Pancreas, 25, 226
- Papillary ridges, 7, 16, 27, 51, 67, 77, 87, 97
- Paracone, 41
- Paraflocculus, 33, 46, 285, 288, 290, 293
- Parapithecus*, 326, 327

Parotid gland, 222, 223
 Pelvis, 19, 30, 43, 53, 136
Pelycodus, 322
 Penis, 24, 44, 270, 271
 Pericardium, 227
 Peritoneum, 221, 222
Perodicticus, 8, 15
 Petrosal fossa, 40, 109
 Pharynx, 214, 215
Pithecia, 35, 39, 43, 45
 Placenta, 60, 270
 Platyrrhini, 35-46
 Plexus—
 brachial, 301
 cardiac, 312, 313
 cervical, 299
 gulæ, 297
 lumbar and sacral, 305
 pulmonary, 313
 solar, 314
 Pliocene period, 332
Pliopithecus, 327-329
 Post-orbital bar, 18
 Potto, 8, 15, 26
 Primates, 6
 Process—
 Eustachian, 109
 mastoid, 108, 115, 122, 130
 styloid, 109, 115, 122, 130
 vaginal, 115, 122, 130
Propliopithecus, 327
 Prostate, 58, 272
 Protocone, 41
 Protoconid, 42
 Psychology, 290
 Pterion, 18, 29, 108, 113, 121
 Pterygoid plates, 109, 114

R, S

Radius and ulna, 139
 Rectum, 219
Rhinopithecus, 48
 Ribs, 138
 Sacrum (*see* Pelvis).
Saimiris, 35
 Salivary glands, 56, 222, 223, 224
 Scapula, 139
 Scrotum, 44, 271
Semnopithecus, 48
Simia (*see* Orang)
 Simian shelf, 116, 125
 Simognathism, 110
Sivapithecus, 331
 Siwalik Fauna, 331, 333
 Skull, 17, 29, 39, 52, 75, 104-134,
 323-331

Spermatozoa, 272
 Spheno-maxillary fissure, 18, 108,
 120
 Spleen, 253
 Sternum, 19, 30, 43, 53, 138
 Stomach, 9, 22, 32, 43, 56, 216, 217,
 218
 Sublingua, 9 (*see also* Tongue)
 Sublingual gland, 223
 Submaxillary gland, 222, 223
 Sulci—
 calcarine, 25, 45, 60, 280, 283, 287,
 293
 calloso-marginal, 26, 45, 60, 280,
 284, 290
 central, 25, 45, 58, 282, 285, 288,
 290
 collateral, 45, 60, 284, 288, 290, 293
 fronto-orbital, 284, 287, 289, 292
 intraparietal, 25, 46, 59, 282, 287,
 289
 lunate (*see* Simian sulcus).
 occipital, 59, 280, 283, 287, 289
 orbital, 58, 284, 289, 292
 parallel, 25, 45, 59, 283, 289
 parieto-occipital, 279, 283, 287,
 289
 post-central, 282, 292
 post-lateral, 25
 precentral, 45, 58, 285, 288, 290
 rectus, 25, 45, 282, 290
 simian, 280, 283, 287, 289, 292
 superior limiting, 283, 287, 289,
 292
 Sylvian, 25, 45, 59, 279, 283, 292
 Supra-orbital crests, 112, 119
 Suprarenal capsules, 253
Symphalangus, 73

T

Tail, 8, 13, 35, 38, 65
 Tarsioidea, 8, 9, 26-34, 40, 60, 61,
 321-323, 325, 326-328, 330
 Tarsus, 143
 Teeth, 18, 30, 40, 52, 144-150, 321,
 322
 Temporal ridges, 128
 Testis, 9, 24, 32, 271
Tetorius, 323
Theropithecus, 48
 Thorax, 138
 Thymus gland, 253
 Thyroid cartilage, 257
 Thyroid gland, 253
 Tibia, 142
 Tongue, 22, 32, 43, 55, 210-214

Trachea, 24, 57, 262
 Tupaiidæ, 321
 Turbinate bones, 257
 Tympanic bullæ and annulus, 18,
 29, 40, 52, 109

U—Z

Uintanius, 323
 Umbilicus, 78, 100
 Urethra, 24
 Uterus, 9, 24, 32, 58, 267
 Uvula, 210
 Vagina, 58, 267
 Variations, 3
 Vas deferens, 272
 Veins—
 axillary, 251
 azygos, 249
 basilic, 251

Veins—*continued*.
 brachial, 251
 caval, 249, 250
 cephalic, 251
 facial, 246
 innominate, 248
 jugular, 248
 portal, 249
 saphenous, 251
 subclavian, 251
 Vermiform appendix, 32, 53, 219,
 220, 221
 Vertebral column, 19, 30, 42, 53,
 134
 Vesiculæ seminales, 24, 58, 292
 Vibrissæ, 17, 28, 50
 Vocal cords, 260
 Voice, 69
Washakius, 323
 Zygoma, 108, 114, 121, 129



