

The liver, spleen, pancreas, peritoneal relations, and biliary system in monotremes and marsupials / by William Colin MacKenzie.

Contributors

Mackenzie, Colin, 1877-1938.

Publication/Creation

Australia : Critchley Parker, 1918.

Persistent URL

<https://wellcomecollection.org/works/cb8djky>

License and attribution

Conditions of use: it is possible this item is protected by copyright and/or related rights. You are free to use this item in any way that is permitted by the copyright and related rights legislation that applies to your use. For other uses you need to obtain permission from the rights-holder(s).



Wellcome Collection
183 Euston Road
London NW1 2BE UK
T +44 (0)20 7611 8722
E library@wellcomecollection.org
<https://wellcomecollection.org>

12
an

The Comparative Anatomy of
Australian Mammals

PART II.

THE
LIVER, SPLEEN, PANCREAS,
PERITONEUM, AND BILIARY SYSTEM
IN
MONOTREMES AND MARSUPIALS.


MACKENZIE


118 G



22102058492

Med
K6585





Digitized by the Internet Archive
in 2017 with funding from
Wellcome Library

<https://archive.org/details/b29821125>



THE LIVER, SPLEEN, PANCREAS, PERITONEAL RELATIONS, AND BILIARY SYSTEM IN MONO- TREMES AND MARSUPIALS.

BY

WILLIAM COLIN MACKENZIE,
M.D., F.R.C.S., F.R.S. (Edin.).

Member of the Council of the Anatomical Society
of Great Britain and Ireland.

Illustrated with over 70 Original Figures.

*From the Australian Institute of Anatomical Research,
Melbourne.*

All proceeds from the sale of this work will be
devoted to the advancement of Medical Research in
the Commonwealth of Australia.

CRITCHLEY PARKER PTY.
AUSTRALIA, LTD.
1918.

20493590

WELLCOME INSTITUTE LIBRARY	
Coll.	welMOmec
Call No.	
	PL



INTRODUCTION.

Like the previous work, dealing with the gastrointestinal tract in Monotremes and Marsupials, the present volume, though structural in character, has been written from the point of view of physiology, *i.e.*, function. This also applies to the illustrations of the dissections. By a study of the two above-mentioned orders light is thrown on the nature of the primitive liver from which the human liver has been evolved; in the Platypus we have a multilobed liver, whilst some varieties of the Victorian Wombat may have a liver practically resembling the human in type. In this manner, *i.e.*, viewed from the comparative standpoint, anomalies of the human liver, which are not infrequent, become intelligible. As the function of the hepatic cells are multiple, and as these functions must bear an evolutionary sequence one to another, it is possible that in the near future the classification of diseases of the liver will be based on that sequence. Thus it is conceivable that there may be a loss of one, or some, but not necessarily all, of the functions of the hepatic cell. Again, the question might well arise—Does one portion of the human liver or spleen perform functions differing from those of some other? The possible differentiation in their action on cells of vital stains, for the interpretation of which we are so much indebted to Professor Herbert Evans of the University of California, holds out some promise of results in this direction.

If we compare the “highest” form of Australian reptile with the “lowest” mammal, the Platypus, three distinctive features stand out in the latter as compared with the former. These are—(a) the presence of a diaphragm

forming a complete septum between the thorax and abdomen, (b) great development of spleen, (c) development of great omentum. Great omental development is primarily correlated to great splenic development. With the assumption of the erect position in man, the great omentum is a factor in supporting the transverse colon. A human omentum that was free of transverse colon would be one liable to torsion, and this would be more likely on the left than on the right side.

In these studies variability is shown as regards the position of entrance of bile ducts relative to the pyloric sphincter and duodeno-intestinal junction, and also in the relation of the pancreatic to the bile duct; so that problems referring to digestive function are raised. In a typical section of the human pancreas the areas of Langerhans may be difficult to define; but in histological sections of the pancreas of, *e.g.*, the Wombat or Tasmanian Devil, numerous areas are to be met with.

Many other functional problems might be mentioned, but these few examples are cited to show what a rich field is open to the medical research scholar.

In conclusion, the writer wishes to thank the President and Council of the Royal College of Surgeons of England, and also Professor Arthur Keith, for facilities accorded him while working in the laboratories of the Hunterian Museum; Professor Sir Baldwin Spencer and Mr. Kershaw for the privilege of conducting researches at the National Museum in Melbourne; the Editor of the "Journal of Anatomy" for permission to reprint his article on the Spleen in Vol. LI. of that journal; his cousin, Major Charles Mackay, for valuable help in the preparation of the dissections; and also Mr. Finerty, of London, and Miss Esther Paterson and Mr. Victor Cobb, of Melbourne, for the excellent illustrations.

CONTENTS.

MONOTREMATA.

	Page
The Liver, Pancreas, Gall Bladder, Ducts and Peritoneal relations in Platypus (<i>Ornithorhynchus Anatinus</i>), and Echidna (<i>Echidna</i> <i>Aeuleata</i>)	1

MARSUPIALIA.

The Liver, Pancreas, Gall Bladder, Ducts and Peritoneal relations in Macropus (Kangaroos and Wallabies)	28
The Liver, Pancreas, Gall Bladder, Ducts and Peritoneal relations in Wombat (<i>Phascolumys</i>)	40
The Liver, Pancreas, Gall Bladder, Ducts and Peritoneal relations in Koala (<i>Phascolaretus Cinereus</i>)	67
The Liver, Pancreas, Gall Bladder, Ducts and Peritoneal relations in Tasmanian Devil (<i>Sarcophilus Ursinus</i>)	80
The Liver of Native Australian Cat (<i>Dasyurus Viverrinus</i>)	97
The Liver of Bandicoot (<i>Peramelidae</i>)	101
The Liver, Pancreas, Gall Bladder, Ducts and Peritoneal relations of Australian Phalangiers (<i>Trichosurus</i> and <i>Pseudochirus</i>)	104
The Liver of American Opossum (<i>Didelphis Marsupialis</i>)	120
Observations	122

MONOTREMATA.

The Spleen and Peritoneal relations in Platypus	135
The Spleen and Peritoneal relations in Echidna	137

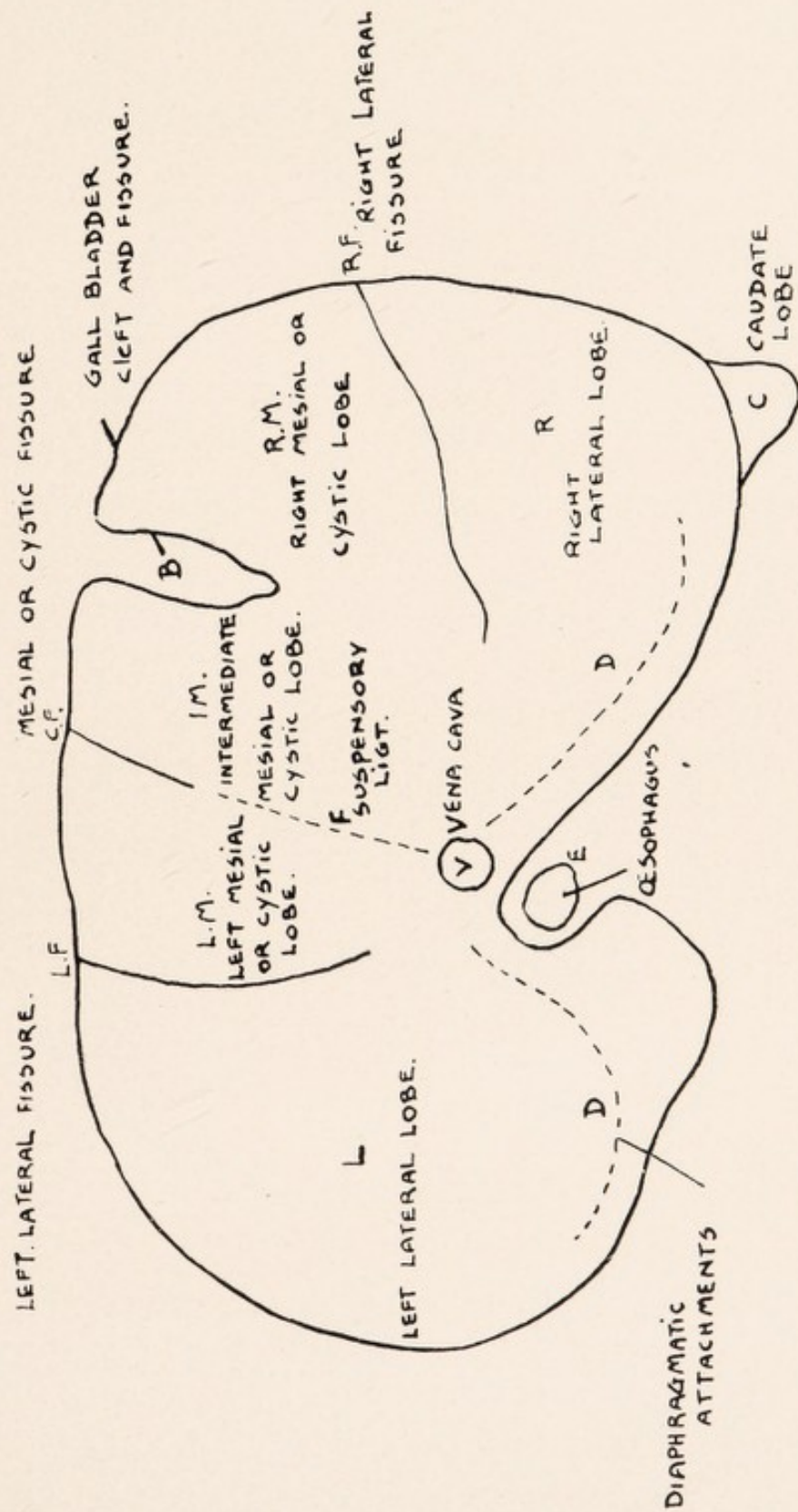
MARSUPIALIA.

The Spleen and Peritoneal relations in Tasmanian Devil	139
The Spleen and Peritoneal relations in Koala	140
The Spleen and Peritoneal relations in Macropus (Kangaroos and Walla- bies)	141
The Spleen and Peritoneal relations in True Phalangiers	143
The Spleen and Peritoneal relations in Wombat	146
Interpretation of Structural Anatomy	150

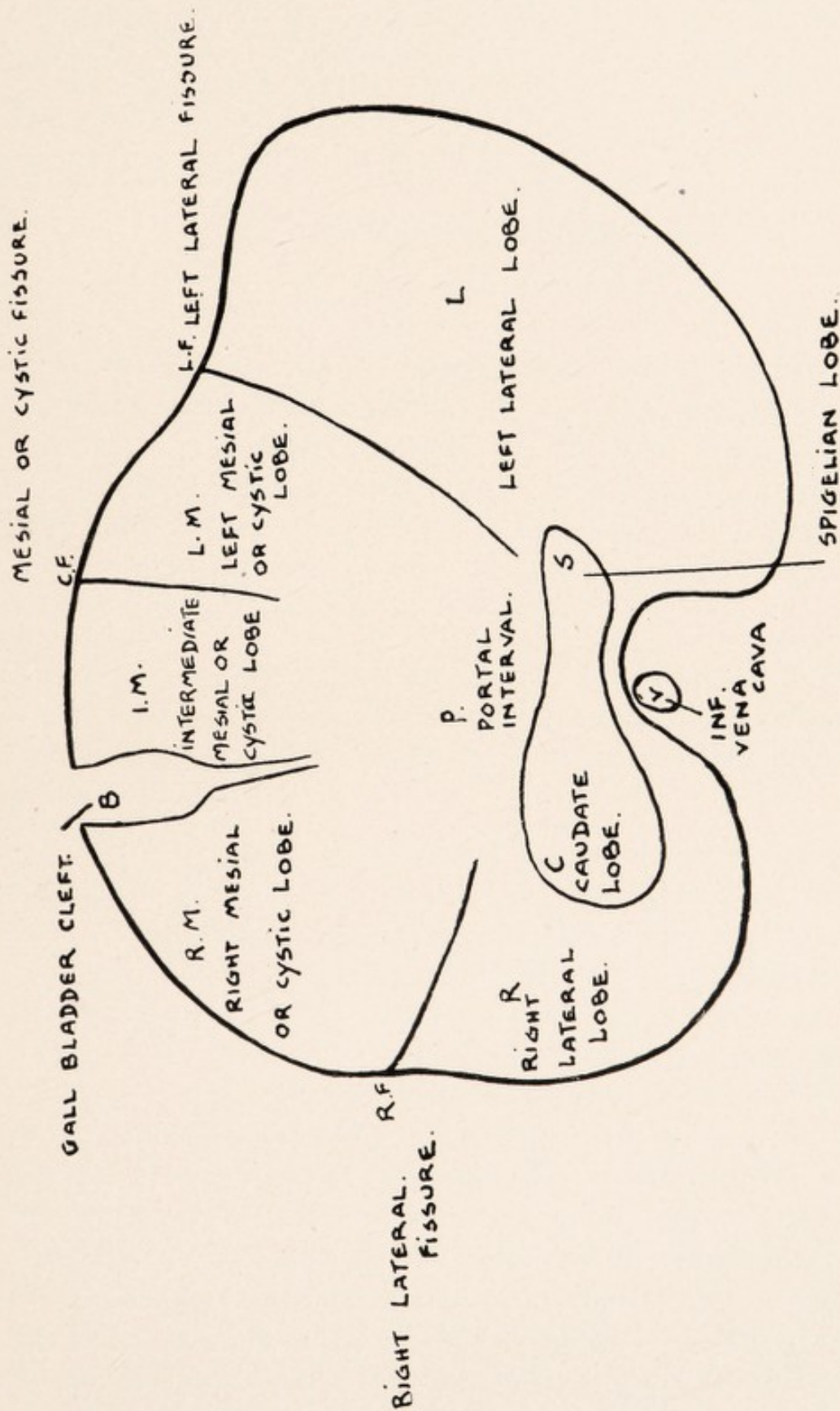
LIST OF ILLUSTRATIONS.

	Page
Mammalian Liver, General Plan Diaphragmatic Surface	xiii.
Mammalian Liver, General Plan Visceral Surface	xv.
Diaphragmatic Surface of Liver, Platypus	4
Diaphragmatic Surface of Liver, Echidna	4
The Multilobed Liver of Platypus, Visceral Surface	6
Visceral Surface of Liver, Echidna	9
The Gastro-Intestinal Tract and Peritoneal Relations, Platypus	11
Biliary and Portal Systems of Liver, Platypus	13
Stomach Duodenum and Ducts, Platypus	16
Pancreas and Pancreatic Ducts, Platypus	18
Biliary and Portal Systems of Liver, Echidna	20
The Pancreas in Echidna	24
Stomach and Liver in Echidna	26
Diaphragmatic Surface of Liver, Kangaroo	29
Visceral Surface of Liver, Kangaroo	32
Biliary and Portal Systems Liver, Kangaroo	36
The Gastro-Intestinal Tract in Kangaroo	38
Diaphragmatic Surface of Liver, Wombat (Specimen A)	41
Diaphragmatic Surface of Liver, Wombat (Specimens B.C.D.)	43
Visceral Surface of Liver, Wombat (Specimen A)	45
Visceral Surface of Liver, Wombat (Specimen B)	48
Visceral Surface of Liver, Wombat (Specimen C)	50
Liver, Stomach and Spleen, Wombat (Specimen D)	52
Visceral Surface of Liver, Wombat (Specimen D, E)	54
Biliary and Portal Systems, Liver, Wombat	56
Diaphragmatic Surface of Liver, Wombat (Specimen E, F)	60
Visceral Surface of Liver, Wombat (Specimen F)	63
The Gastro-Intestinal Tract of Wombat	65
Diaphragmatic Surface of Liver, Koala	68
Visceral Surface of Liver, Koala	70
Biliary and Portal Systems, Liver, Koala	74
The Gastro-Intestinal Tract in Koala	77
Diaphragmatic Surface of Liver, Tasmanian Devil (Specimen 1)	81
Diaphragmatic Surface of Liver, Tasmanian Devil (Specimen 2)	83
Visceral Surface of Liver, Tasmanian Devil (Specimen 1)	86
Visceral Surface of Liver, Tasmanian Devil (Specimen 2)	88
Biliary and Portal Systems, Liver, Tasmanian Devil	90
The Gastro-Intestinal Tract, Tasmanian Devil	94
Diaphragmatic and Visceral Surface of Liver, Native Cat	98
Diaphragmatic Surface of Liver, American Opossum	100
Diaphragmatic Surface of Liver, Bandicoot	100
The Gastro-Intestinal Tract of Bandicoot	102
The Gastro-Intestinal Tract of American Opossum	102
Diaphragmatic Surface of Liver, Trichosurus	105
Diaphragmatic Surface of Liver, Pseudochirus	105
Visceral Surface of Liver, Trichosurus	108
Visceral Surface of Liver, Pseudochirus	110
Biliary and Portal Systems, Liver, Phalanger	113
Gastro-Intestinal Tract, Spleen, Pancreas, Trichosurus	116
The Gastro-Intestinal Tract, Pseudochirus	118
Liver of Gorilla	128
The Peritoneal Relation of Spleen in Platypus	136
The Peritoneal Relations of Spleen in Echidna	136
Spleen in Koala	142
Spleens of Macropodidae	142
Visceral Surface of Spleen, Wombat	148
Surface of Spleen, Phalangers	154
Spleen, Young Orang	154
Spleen, Young Baboon	154
Spleens, Human Foetus	154
Spleens of Agama and Lygosoma	154

LIVER, PANCREAS, PERITONEAL RELATIONS
AND BILIARY SYSTEM IN MONOTREMES
AND MARSUPIALS.



MAMMALIAN LIVER. GENERAL PLAN DIAPHRAGMATIC SURFACE.



THE LIVER IN MONOTREMATA.

PLATYPUS AND ECHIDNA.

The liver, as in the human foetus, stretches across the upper abdomen, being placed in the epigastric and right and left hypochondriac regions. In the human adult it lies in the epigastric and right hypochondriac regions only. By means of the right lobe and the lobus caudatus the liver is prolonged along the right dorsal abdominal wall reaching as low as the 11th rib.

Diaphragmatic Surface. — (a) *Platypus.* — On this aspect of the liver an immediate division into three parts is evident, viz. mesial or cystic (ventral), right and left lateral (dorsal).

Dextrally and distinct from the right lobe we may see a portion of the lobus caudatus. The mesial or cystic lobe is separated from these two latter by means of a coronal or transverse fissure and the lateral lobes are separated by an oblique fissure running downwards and to the left. The oblique fissure is not prolonged as far ventrally as the coronal fissure. There is usually 1 cm. of hepatic tissue between the two. If it were so prolonged it would reach the exit of the inf. v. cava. At the dorsal extremity of the fissure is a gap; here the oesophagus passes to the stomach and in relation also to the gap is the small lesser curve of the latter. Towards the left aspect dorsally of the right lateral lobe a small fissure is seen about 1 cm. long—though more marked in some than in others—and serving to define a portion of

PLATYPUS AND ECHIDNA.

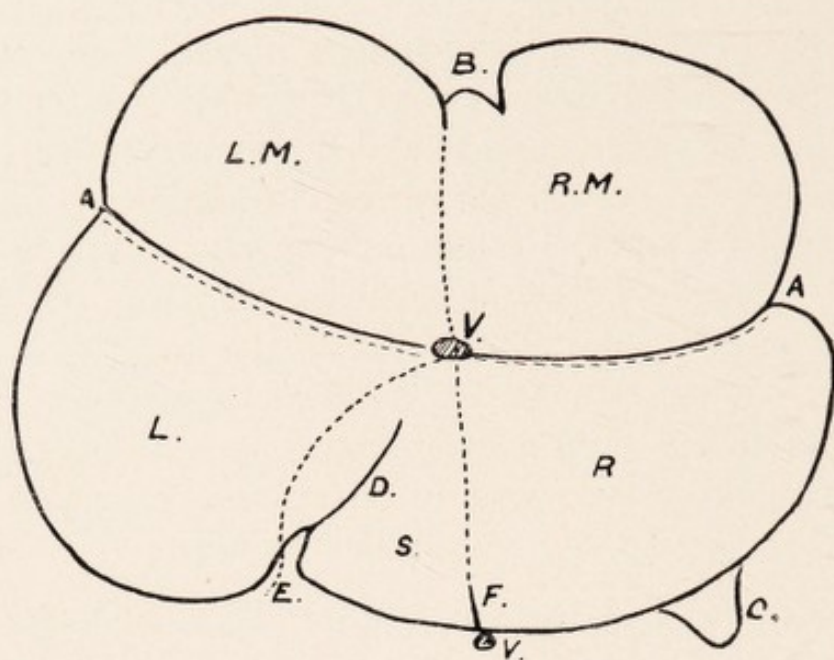
liver between it and the oblique fissure which is the spigelian lobe. Passing from the ventral extremity of the small fissure to the vena cava, so that it runs between the right lateral and spigelian lobes, is a membrane 2 cm. long attached above to the diaphragm. The fissure and membrane correspond to the hepatic relationship of the inf. vena cava, and the spigelian lobe is seen to be part of the right lateral lobe. The inf. v. cava. is not seen on this aspect. It lies behind the junction of the right lateral and spigelian lobes and the length from entrance to exit is 3.5 cm. Its exit corresponds to practically the middle of the coronal fissure. Passing backwards from about the middle of the ventral margin of the cystic lobe we may see a fissure 2 cm. long through which and especially if distended the gall bladder projects. More often a gap is seen on the ventral edge enabling the gall bladder to be seen on this aspect. It is 1 cm. long and .75 cm. wide, and from the gap we find passing dorsally two fissures—one mesial corresponding to the suspensory ligament and the other oblique and dextral in which the gall bladder projects. Between these two fissures we see on this aspect an early indication of the lobus quadratus so well defined in the human liver. It is about .75 cm. laterally.

In the middle of the mesial lobe we see the longitudinal or suspensory ligament—a triangular fold attached above to the muscular and tendinous portion of the diaphragm. It passes forward from the coronal fissure to the gall bladder cleft or fissure and measures 3 cm. on its ventral aspect. It represents part of the original ventral mesogaster. By its means and the cleft the mesial lobe is divided into right and left portions. In addition to the fold between the right lateral and spigelian lobes two fine peritoneal folds are noted from the dorsal margins of the right and left cystic lobes to the diaphragm. At the

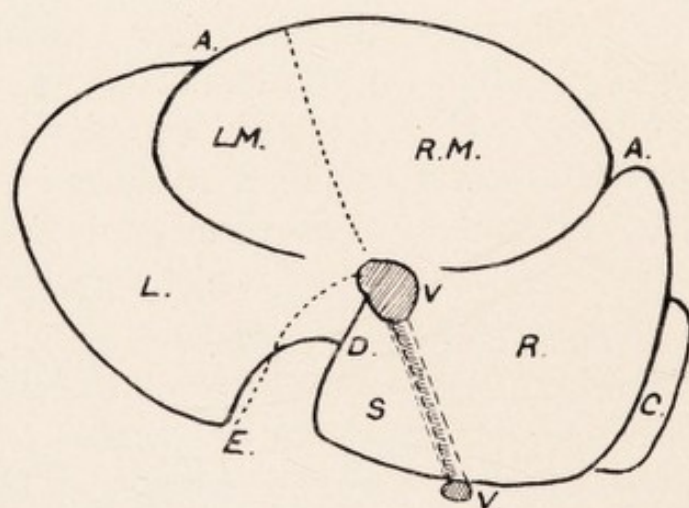
PLATYPUS AND ECHIDNA.

exit of the vena cava. meet the peritoneal folds connecting liver to diaphragm. From this point also where it is continuous with the suspensory ligament we see a membrane attached above to the diaphragm and curving down on the inner side of the left lateral lobe. At the dorsal curved portion of the oblique fissure it is continuous with the gastro-hepatic omentum. In a large male *Platypus* the lateral (*dextro-sinistral*) measurement of the liver was 13 cm. and dorso-ventral measurement was 9 cm. Laterally, cystic was 10 cm., left lateral was 7 cm., right lateral including spigelian was 8 cm.

(*b*) *Echidna*.—Here we distinguish the same divisions as in the *Platypus*, viz. mesial or cystic in front separated into a large right and smaller left portions by the suspensory ligament, and dorsally the right and left lateral lobes separated from the former by the coronal fissure. The cystic lobes form less of the anterior margin of the liver than in *Platypus*. The suspensory ligament runs obliquely backwards and to the right (not mesially) from the ventral border to the coronal fissure (inf. v. cava.). Its length is 4.5 cm. and it is attached above to the muscular and tendinous part of the diaphragm. There is no gall bladder fissure as in the *Platypus*, *i.e.* the gall bladder does not project on the diaphragmatic surface. In only one of a series of eight specimens was there a thinning of the liver substance over the gall bladder with a slight indentation on the ventral margin. This was to the right of the suspensory ligament. Though the coronal fissure may completely separate the cystic from the lateral lobes yet we frequently see evidence of fusion dorsally between the right lateral and right cystic and left lateral with the left cystic lobes, and especially the latter. Thus we have a right and left coronal fissure and the left coronal may be 1.25 cm. from the inf. v. cava. There is a more complete differentiation of the spigelian from



DIAPHRAGMATIC SURFACE OF LIVER. PLATYPUS.



DIAPHRAGMATIC SURFACE OF LIVER. ECHIDNA.

B Gall Bladder Cleft, LM Left Mesial or Cystic Lobe, RM Right Mesial or Cystic Lobe, V Inf. Vena Cava, C Caudate Lobe, S Spigelian Lobe, L Left Lateral Lobe, R Right Lateral Lobe, A Coronal Fissure (right and left lateral), D Oblique Fissure, E Gap for Oesophagus, F Fissure on right lateral lobe.

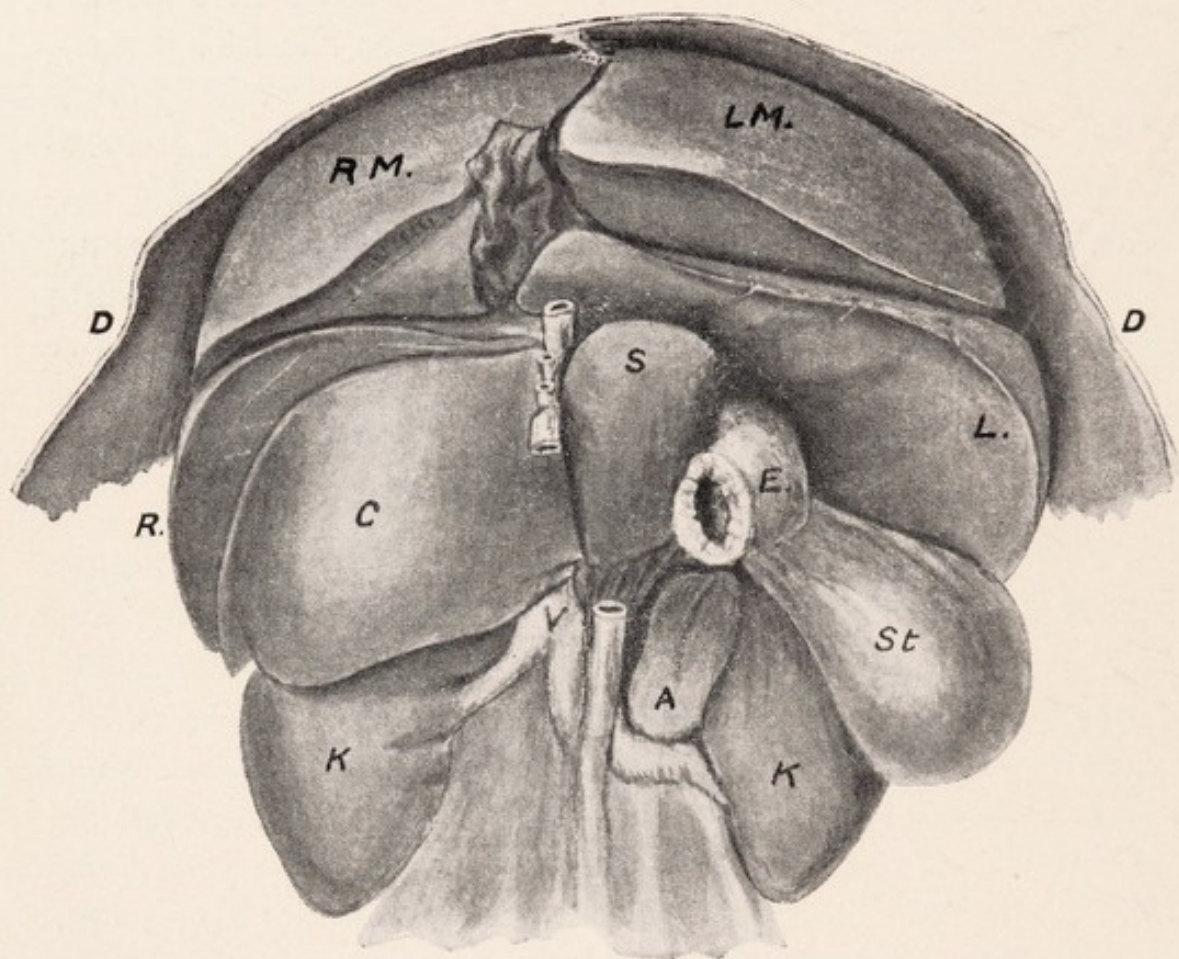
Dotted Lines represent Attachments to Diaphragm.

PLATYPUS AND ECHIDNA.

right lateral—a depression running between the two containing the inf. v. cava which is exposed in its hepatic relation on this aspect and not hidden as in the Platypus; occasionally one sees a thin bridge of hepatic tissue over the inf. v. cava anteriorly. Posteriorly at a pocket between the spigelian and caudate lobes the inf. v. cava comes into relation with the liver. Its exit corresponds to the junction of coronal and oblique fissure and suspensory ligament. The oblique fissure separating the spigelian and left lateral lobes is complete to the coronal fissure, and we see that the spigelian belongs to the right and not to the left lateral lobe. The lateral lobes are almost equal in size and measure approximately 7 cm. dorso-ventrally and 8 cm. laterally, while in the cystic the left laterally is 3 cm. and the right 7 cm.

Diaphragmatic Relations.—In addition to the suspensory fold a small fold may be occasionally seen passing from the inner and back of the right cystic lobe to the diaphragm. Compared with the Platypus the dorsal margins of the cystic lobes are free, being unattached to the diaphragm. As in the Platypus a fold is noted between the right lateral and spigelian lobes attached above to the muscular and tendinous portions of the diaphragm and traced to the wall of the inf. v. cava. The inner and back part of the left lateral lobe is concave and a gap is present between it and the spigelian lobes. Here the œsophagus passes on to the stomach.

A peritoneal fold is noted—attached above to the diaphragm—at the inner and back part of the left lateral lobe, leaving internally a small triangular area between the fold and the oblique fissure. It passes to the ventral surface with the œsophagus and becomes continuous with the gastro-hepatic omentum. About the exit of the vena cava between the two coronal fissures it is continuous with the suspensory ligament.



THE MULTILOBED LIVER OF PLATYPUS. VISCERAL SURFACE.

ST Stomach, V Inf. Vena Cava, K Kidney, A Adrenal, E Pylorus,
 L Left Lateral Lobe, R Right Lateral Lobe, C Caudate Lobe,
 S Spigelian Lobe, RM Right Mesial or Cystic Lobe, LM Left
 Mesial or Cystic Lobe, D Diaphragm.

PLATYPUS AND ECHIDNA.

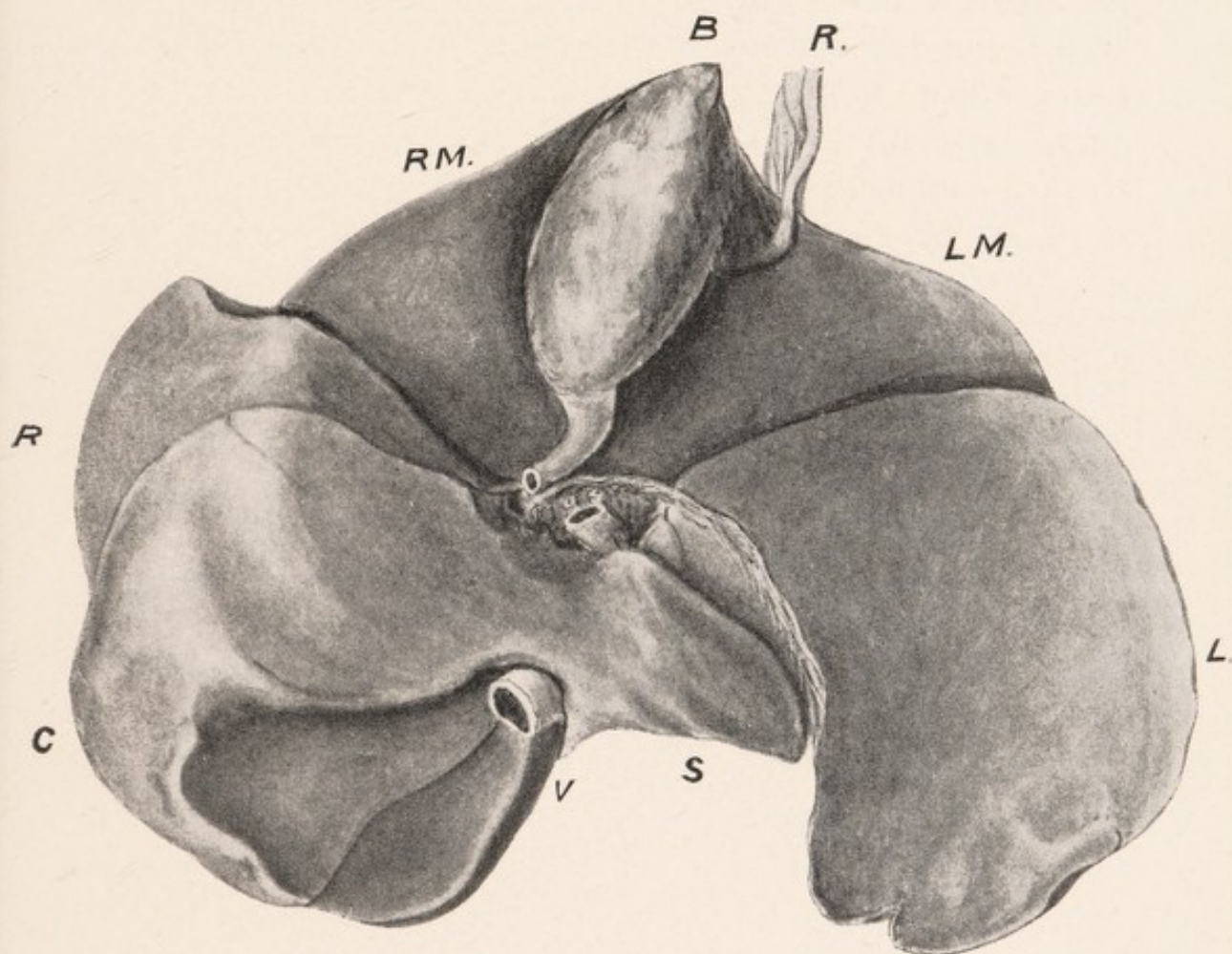
Visceral Surface.—(a) *Platypus.*—The three main divisions are seen to be present, viz., mesial or cystic separated by the gall bladder into a right and left portion, and the right and left lateral lobes. The under surface of the left lateral is free from projection, but from the right lateral we have projecting the lobus spigelii and dextrally the larger free caudate lobe. The caudate lobe is hollowed below, forming with the right lobe a concavity for the reception of the convex upper part of the kidney. Its ventral surface is related to the mesoduodenum, pancreas, and colon. It measures 4.5 cm. laterally and 3 cm. dorso-ventrally. The spigelian lobe is seen to lie below the under surface of the left lobe, from which it is free however and projects into the lesser peritoneal sac. It measures 2.3 cm. laterally and 2 cm. in greatest width. On its inner or sinistral surface is a groove corresponding to the pyloric knob and commencement of the duodenum, and ventrally it is related to the duodenum as far out as the duct. The right lateral lobe like the caudate has three surfaces—diaphragmatic—lower or caudal to receive with the caudate the upper pole of the right kidney—and the visceral. This latter is related to the duodenum which is lodged in a depression with a ridge internally. It curves along the outer part of the right cystic — right lateral — and occasionally the caudate. The gall bladder is placed on the under surface of the mesial or cystic lobe. Where a fissure exists on the diaphragmatic surface we have on this aspect also a fissure lodging the gall bladder, and the cystic lobes on each side are of equal size. Usually however the gall bladder is lodged in a fossa which encroaches more on the visceral surface of the right cystic than the left cystic lobe. The cystic duct may not be related to the cystic lobe—the gall bladder extending to the coronal fissure which separates the right and left

PLATYPUS AND ECHIDNA.

lateral from the cystic lobes. Or we may have the dorsal part of the fossa leading into a fissure lodging the duct which is partly between the right and left cystic lobes and partly in the portal interval. The portal interval lies between the narrow inner extremities of the right and left lateral lobes where the coronal and cystic fissures meet. Here the hepatic ducts join the cystic, and it may almost be regarded as the central point of the liver; between the lobus spigellii and the caudate lobe is a depression 1.75 cm. long, often fissured dorsally.

Here we have passing caudally the portal vein, common duct, and hepatic artery—the vein lying dorsally as in the human liver. The vena cava passes obliquely up and to the left in the liver substance behind the junction of the right lateral and spigelian lobes to the diaphragmatic surface. The membrane which we described curving round with the œsophagus from the diaphragmatic surface is continued as the gastro-hepatic omentum which is traced on the inner or right part of the visceral surface of the left lateral lobe to the portal interval. This represents the hepatic attachment of the lesser omentum. It is worthy of note that on the left lobe towards the outer boundary an oblique depression may be seen probably indicating the remains of a fissure between two divisions of the left lateral lobe, and a fissure or depression is sometimes noted towards the inner side of this lobe also.

(b) *Echidna*.—The mesial, right and left lateral, spigelian, and caudate lobes, are defined—as in the *Platypus*. The suspensory ligament is traced over the ventral edge from the diaphragmatic surface. There may or may not be a fissure where it crosses the ventral edge. It runs on the ventral surface for about .75 cm. and usually terminates in a fissure. Between the fundus of the gall bladder and the ligament there is usually a small area of hepatic

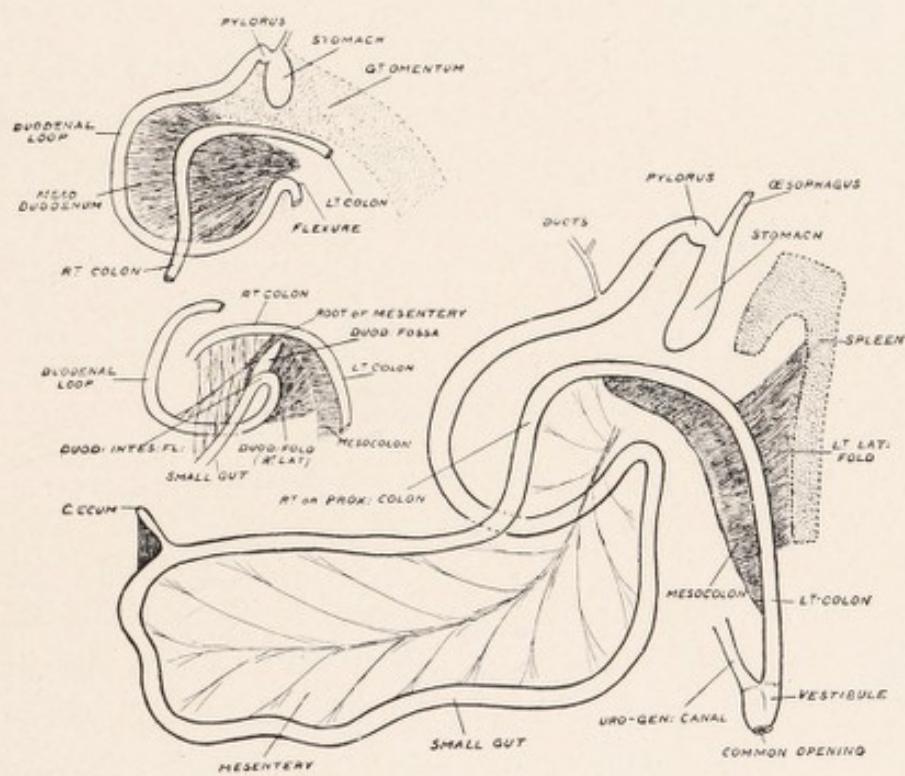


VISCERAL SURFACE OF LIVER. ECHIDNA.

B Gall Bladder, R Suspensory Ligament, LM Left Mesial or Cystic Lobe, RM Right Mesial or Cystic Lobe, R Right Lateral Lobe, L Left Lateral Lobe, V Inf. Vena Cava, C Caudate Lobe, S Spigelian Lobe.

PLATYPUS AND ECHIDNA.

tissue .25 to .5 cm. wide representing the lobus quadratus of the human liver. We have not as in the Platypus the projection of the spigelian lobe ventral to the left lateral lobe. The inner extremity of the left lateral lobe (*i.e.* at portal interval) is almost pointed. There is a well defined lobus caudatus ventral to the right lateral lobe and more prominent than in the Platypus, so that the greater part of the latter is hidden on this surface, only the upper and outer angle being usually seen. As in the Platypus the caudate lobe has three surfaces—dorsal—ventral for duodenum—and lower or caudal hollowed for the upper pole of the right kidney. In the Echidna more of the concavity for the kidney is formed by the caudate lobe than in the Platypus, in which, half is usually formed by the right lateral and half by the caudate lobe. The right lateral is the larger of the two however, measuring laterally 8 cm. and dorso-ventrally 6 cm., while the caudate measured 5 cm. in each direction. On this surface the right and left portions of the coronal fissure are continued to the portal interval. Here the spigelian lobe is relatively a much smaller structure than in the Platypus and a partial depression or groove between the spigelian and caudate lobes over which passes the portal vein—artery—and common duct constitutes the only distinction between them. The spigelian lobe appears as a somewhat pointed prolongation to the left of the caudate and passes behind the lesser omentum, being contained in the lesser sac and related to the lesser curve of the stomach. In a large male specimen its length was 3 cm. and greatest width 1.75 cm. Passing down in the groove on the dextral extremity of the lateral lobe between it and the spigelian lobe is the œsophagus. On the diaphragmatic surface we described a fold continuous at the inf. v. cava with the suspensory ligament passing vertically at the groove for the œsophagus on the inner margin of the left lateral



THE GASTRO-INTESTINAL TRACT AND PERITONEAL RELATIONS
IN PLATYPUS.

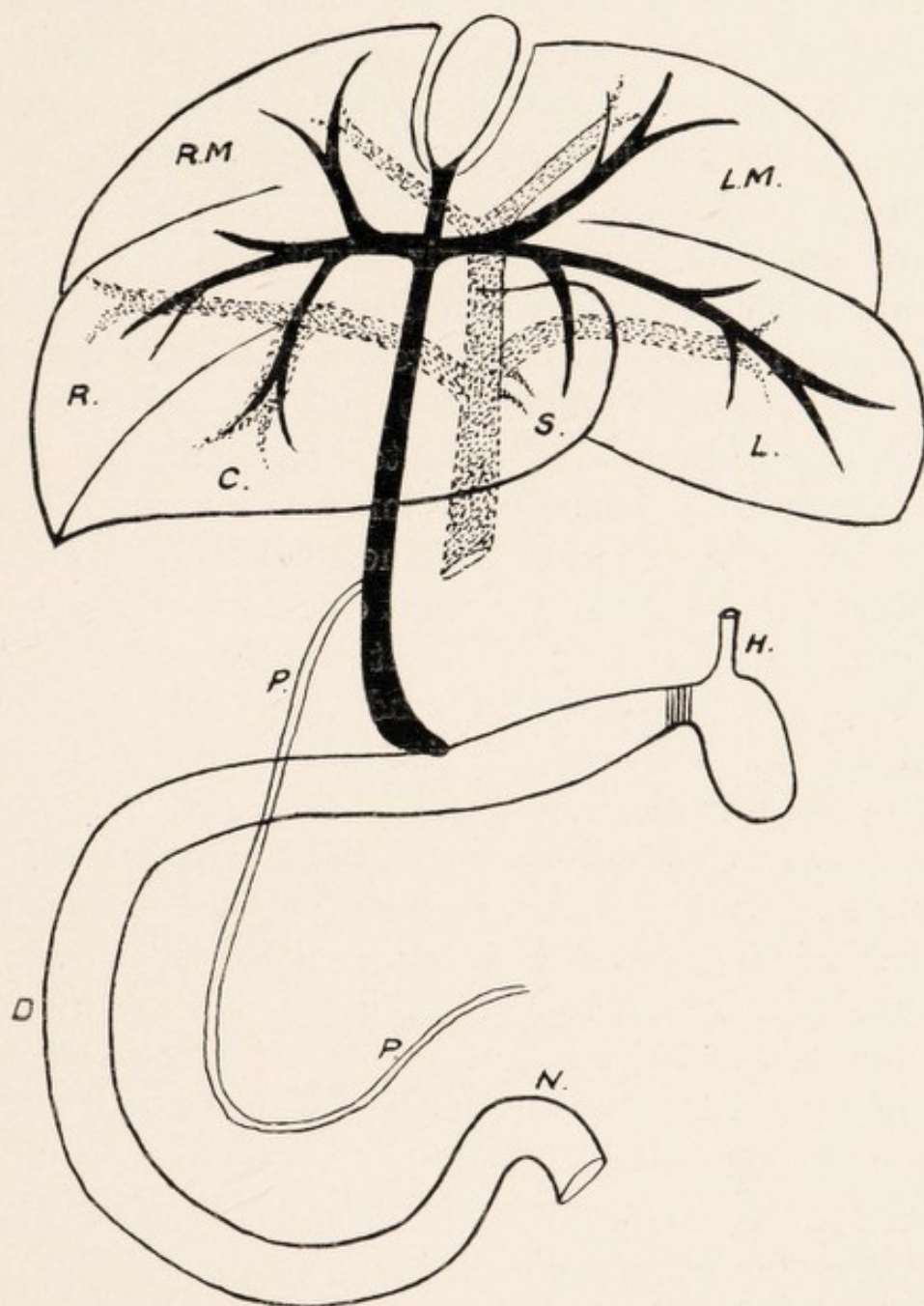
PLATYPUS AND ECHIDNA.

lobe. This becomes continuous with the hepatic attachment of the gastro-hepatic omentum which runs along the ventral surfaces of the narrow inner part of the left lateral lobe to the portal interval. On the inner side of the left lateral lobe a small lobe may be separated off by a fissure. On the caudal or renal aspect the inf. v. cava can be seen passing between the spigelian and caudate lobes but is not visible in its hepatic relation from this aspect. The left lateral measures 5-6 cm. laterally and the complete cystic 6 cm. The ventral surface of the left cystic and left lateral lobes are related to the body of the stomach. The duodenum is related to the right cystic, right lateral, and caudate lobes. The liver is larger in the Echidna than in the Platypus, its greatest lateral measurement being 16 cm. and dorso-ventral 10-12 cm., whilst in the Platypus the length laterally may reach 13 cm. and dorso-ventrally 8-9 cm.

Gall Bladder and Ducts.

(a) *Platypus*.—The Gall Bladder is smaller than in the Echidna and projects at the ventral margin of the mesial or cystic lobe. It is usually empty and collapsed, unlike that of Echidna, and measures 2 cm. long and 1-1.5 cm. wide ventrally. It is a somewhat pear-shaped structure presenting a fundus or ventral extremity and body. Though the fundus is mobile the gall bladder is really a fixed organ, being invested by peritoneum on the sides and under or ventral surface only. At the exit of the cystic duct it usually narrows somewhat, so that a neck may be described. On the other hand the duct may pass abruptly from the body.

Cystic Duct.—This measures 1 cm. long. It may lie partly between the right and left portions of the cystic or mesial lobe and partly in the portal interval, or it may



BILIARY AND PORTAL SYSTEMS OF LIVER. PLATYPUS.

The Biliary System is dark and Portal System dotted.

RM Right Mesial or Cystic Lobe, LM Left Mesial or Cystic Lobe,
 R Right Lateral Lobe, L Left Lateral Lobe, C Caudate Lobe,
 S Spigelian Lobe, H Stomach, P Pancreatic Duct, D Duodenum,
 N Duod.-Intest. Flexure.

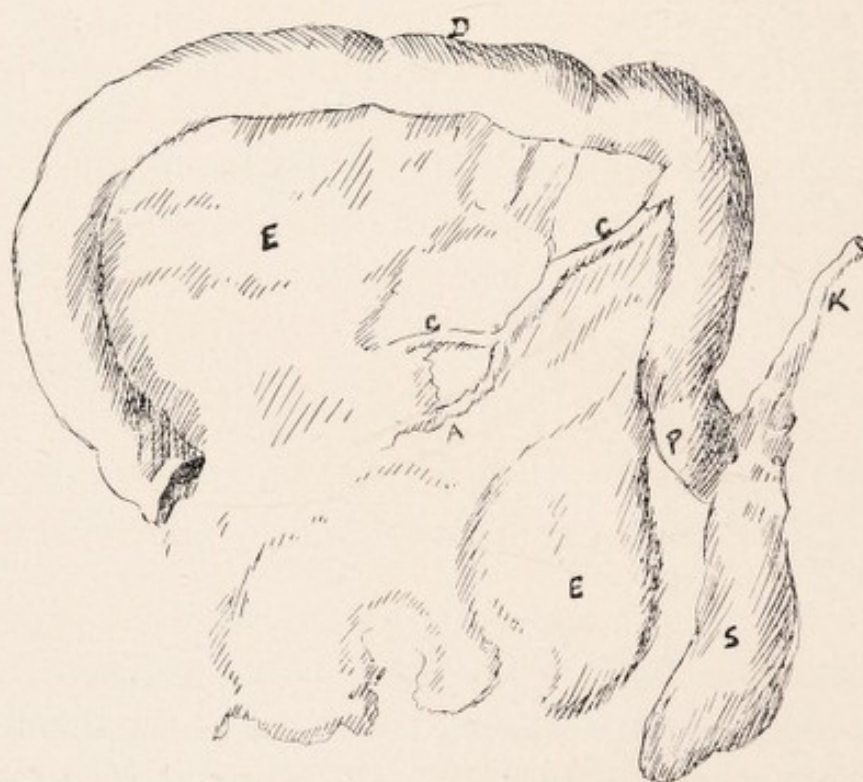
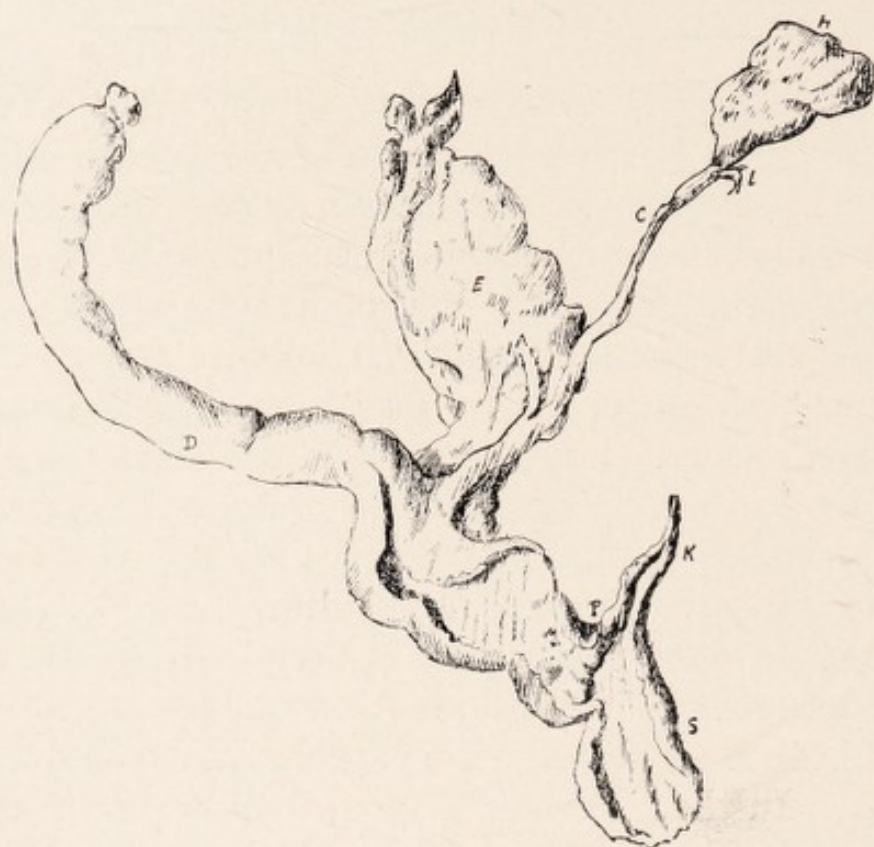PLATYPUS AND ECHIDNA.

be wholly in the portal interval, which lies between the inner extremities of the right and left lateral lobes. A fine peritoneal fold is noted passing from the ventral surface of the gall bladder and cystic duct to the lesser omentum. At the portal interval it is joined by two main hepatic ducts on each side, viz. right and left hepatic. Into the left hepatic duct three main branches pass from left mesial, left lateral, and spigelian lobes; into the right hepatic three main branches also pass, viz. from the right mesial, right lateral, and caudate lobes. At the portal interval the portal vein is posterior and the artery slightly to the left between the two. The combined or common bile duct then passes in the right extremity of the lesser omentum for about 5 cm., lying at first between the lobus caudatus and spigelian lobe and enters the duodenum about 2.5 cm. from the pyloric knob. The pancreatic duct opens into the common bile duct obliquely about 2-2.5 cm. from its termination in the duodenum and following somewhat the curve of the duodenum is traced on the left in the pancreatic tissue to the spleen receiving tributaries in its course. At the junction the common bile duct is seen to be almost double in its circumference that of the pancreatic duct. Thereafter, the circumference of the combined hepatico-pancreatic duct is almost double that of the common bile duct. At its termination the duct loops slightly to the left. The opening into the duodenum is minute and may be indistinguishable from the inner surface of the duodenum till the duct is opened and a hair seeker passed through. Furthermore, near the termination of the duct a valvular projection is to be seen, by which apparently the flow of bile is regulated. This valve lies .5 cm. from the termination. Between the valve and the duodenal wall the duct forms a dilatation, but on passing through the bowel wall it narrows again.

PLATYPUS AND ECHIDNA.

Lesser Omentum.—Foramen of Winslow.—In the Platypus there is no right margin of the lesser omentum (gastro-hepatic) as in the human type. The gastro-hepatic omentum is directly continuous with the mesoduodenum; and this, with the duodenum which it supports and the portion of proximal colon related to it, can be with the lesser omentum lifted in one piece, from the dorsal wall—right kidney—and liver as far as the portal interval. In the Echidna the duodenum is less mobile—the mesoduodenum has shortened and the pancreas is frequently fixed by the peritoneal adhesions to the caudate lobe; but the lesser omentum is free, and so the right margin becomes defined. This right margin is especially defined in the human subject where the duodenum is fixed dorsally. In the Platypus a big spleen and great omentum have developed projecting to the left with the gap (Foramen Winslow) in the mesogaster and upper mesoduodenum on the right. The foramen is large and readily admits the little finger. It is easily defined by throwing the mesoduodenum—duodenum—and lesser omentum to the left. In the human subject this cannot be done, so to define it we pass our finger behind the right edge of the lesser omentum. The foramen is limited above at the portal interval—ventrally we have the mesoduodenum with pancreas and lesser omentum—dorsally the fissure between the lobus caudatus and spigelian lobe—and caudally a fold from the mesoduodenum to the ventral part of the inf. v. cava.

Pancreatic Duct in Platypus.—This is traced within the mesoduodenum following the curve of the duodenum, and though close to the latter structure at its proximal portion gradually inclines out below, and may lie 3 cm. from the duodenal wall. Opposite the junction of the descending and transverse portions of the duodenum it



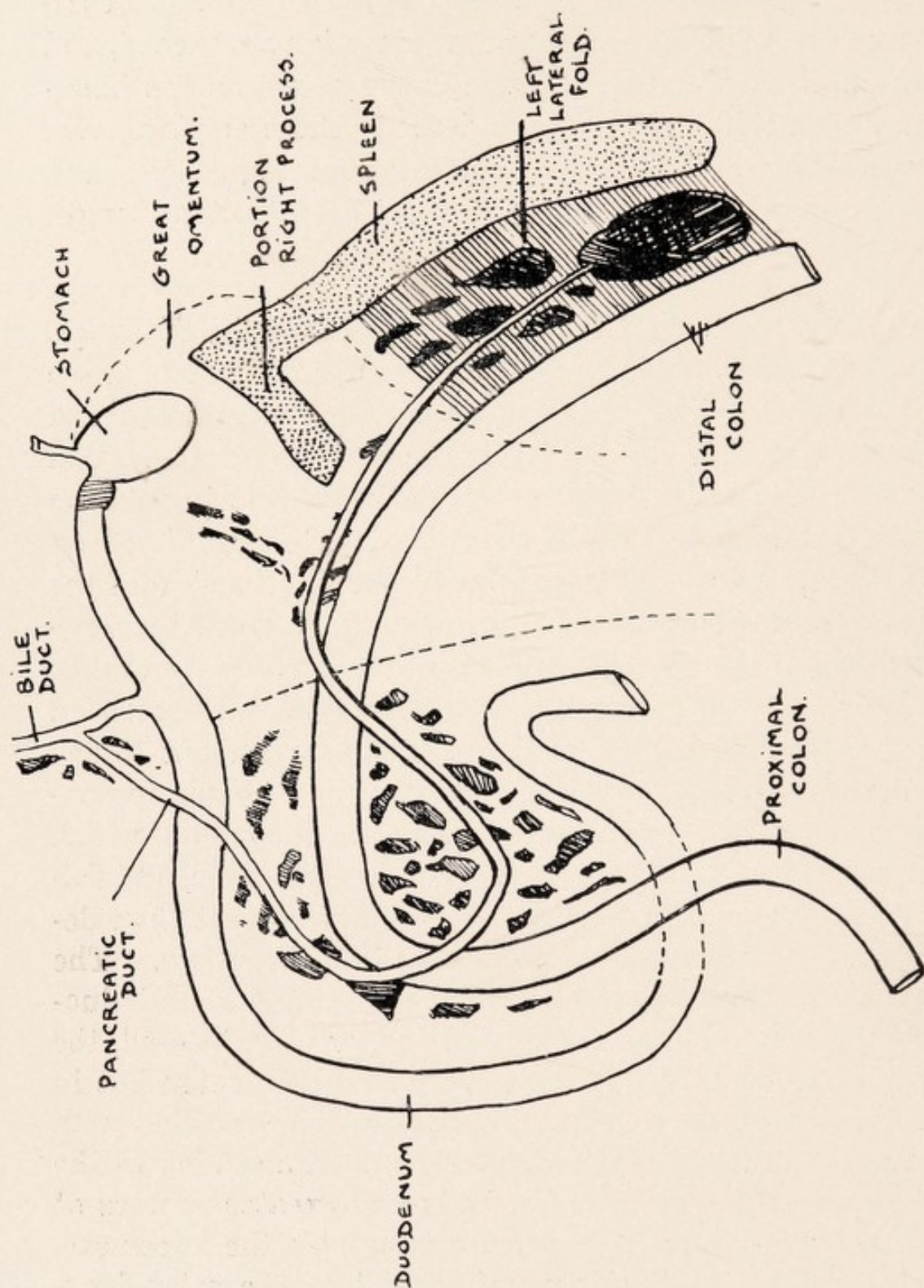
STOMACH, DUODENUM, AND DUCTS. PLATYPUS.

S Stomach, K Oesophagus, P. Pylorus, D Duodenum, E. Pancreas,
H Gall Bladder, L Hepatic Ducts, A Pancreatic Duct,
C Common Bile Duct.

PLATYPUS AND ECHIDNA.

forms an angle and is traced upwards and to the left above the duod-intest. junction. It lies in the wall of the lesser sac, which it leaves as the spleen is approached, and then curves downwards towards the pelvis on the lienomesocolic fold. Thus we can describe three portions, viz., descending, oblique and ascending, and descending, and as the length of each portion is about 7 cm. the total length is 21 cm.

Pancreas in Platypus.—The pancreas in Platypus, though abundant, is more diffuse and mobile than in the Echidna, in which we have a relative compactness and immobility. In the Platypus the most compact portion is as a rule to be found on the extreme left in relation with the lesser process of the spleen and descending part of the left colon. A knowledge of the relationship of the pancreas necessitates a brief knowledge also of the relationship of the spleen, stomach, and duodenum, as well as left colon. The stomach is a small tubular sac succeeded by a somewhat horseshoe-shaped duodenum about 18 cm. long. The colon, which is swung on the common mesentery, comes into relationship with mesoduodenum which suspends the duodenum making it freely mobile, and follows the curve of the latter as in diagram. It then descends swung on its own mesocolon into the pelvis. The great omentum is attached above to stomach and duodenum, extending as far to right as, or even beyond, the bile duct entrance. It does not include the colon but in the region of the duodeno-jej. flexure is in relation with its superior margin for about 2-4cm. Suspended in the great omentum we have the body and greater process of the spleen—the smaller process is outside the lesser sac, being related to the descending part of the colon by a fold, the left lateral or lienomesocolic fold. The pancreas diffuses itself in the duodenal loop between the

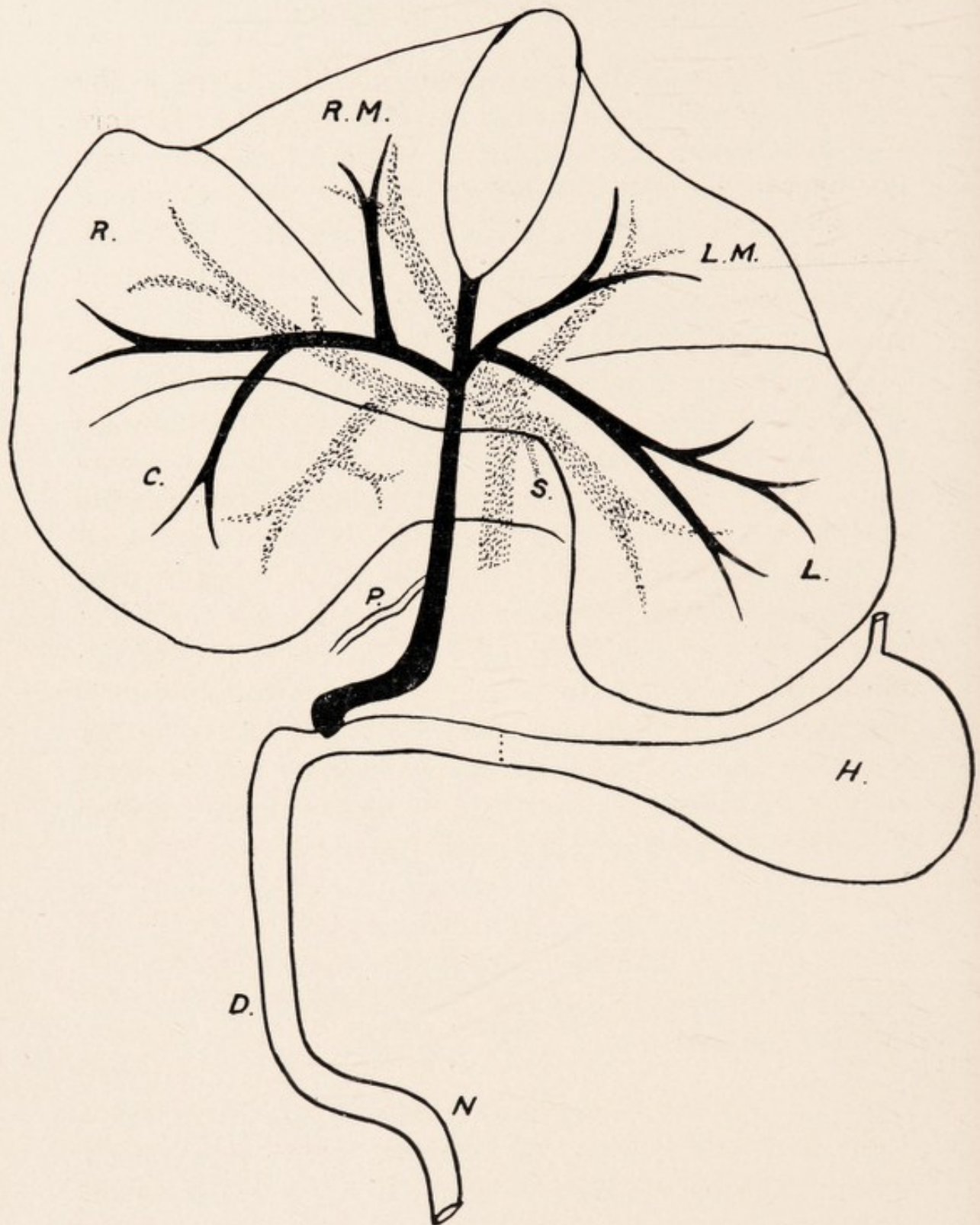


THE PANCREAS AND PANCREATIC DUCT IN PLATYPUS.

PLATYPUS AND ECHIDNA.

layers of the mesoduodenum, and as this is free so the pancreas is quite movable on the right side. It is more abundant below the relation of the colon to the mesoduodenum than above it and strands are found to extend along the common bile duct as far as the portal interval, but it does not extend in the gastro-hepatic omentum to the left of the duct, as in the Echidna. Except about the entrance of the ducts there is frequently a distinct interval in the mesoduodenum between the pancreas and the duodenum. From the duodenal portion of the pancreas a process is noted passing up and to the left in the lesser sac, *i.e.*, in relation with the great omentum, towards the pylorus. Apart from the process the pancreas is traced to the left in relationship with the colon lying at first in the wall of the lesser sac for about 2-4 cm. and then outside the sac it diffuses itself on the left aspect of the mesocolon, coming into relationship with the fold connecting the left posterior smaller process of the spleen with the mesocolon of the descending part of the left colon. As stated, the pancreas at its termination forms a somewhat compact mass, and approaches close to the left pelvic brim. It is important to note that there is no pancreas in relationship either with the body of the spleen nor with the greater right anterior process, both of which are in relationship with the great omentum, being contained in the lesser sac.

Portal Vein.—Two main branches are given off—right and left lateral—the former, which first arises, sending a branch to the caudate. On the left side, in addition, two small branches are noted to the spigelian lobe, one from the main trunk and the other from the commencement of the left lateral trunk. Finally, the main portal trunk divides into two terminal branches, one to the right mesial and the other to the left mesial lobe.



BILIARY AND PORTAL SYSTEMS OF LIVER. ECHIDNA.

RM Right Mesial or Cystic Lobe, LM Left Mesial or Cystic Lobe, R Right Lateral Lobe, L Left Lateral Lobe, C Caudate Lobe, S Spigelian Lobe, P Pancreatic Duct joining Common Bile Duct, H Stomach, D Duodenum, N Duod.-Intest. Flexure.

PLATYPUS AND ECHIDNA.

(b) *Echidna*.—*Gall Bladder*.—In the *Echidna* this is also somewhat pear-shaped, usually distended with bile, and presents for examination a fundus and body. Only rarely can a narrowed portion or neck be defined. It lies in a fossa on the under surface of the cystic or mesial lobe, and it is not usual for the fossa to reach the ventral edge of the liver. In one specimen there was an interval of .75 cm. of hepatic tissue between the fundus and the ventral edge. It measures 3-3.5 cm. in length and laterally 2.5 cm. The fundus usually projects beyond the ventral border, and is mobile, being completely invested with peritoneum, the body and cystic duct being invested on the ventral surface and sides only. Dorsally the cystic fossa narrows, forming a notch lodging the proximal half of the cystic duct, which thus lies between the right and left portions of the cystic lobe. The remaining half of the cystic duct lies in the portal fissure or interval between the inner portion of the caudate and right lateral on the right side and the left lateral on the left. On the other hand the fossa may extend to the coronal fissure, so that the cystic duct lies wholly related to the portal interval.

The Cystic Duct measures 1 cm. long, and at the portal interval it is joined by the hepatic ducts, and becomes the common bile duct. This is traced with the hepatic artery on the left and the portal vein dorsally in the groove at the junction of the caudate and spigelian lobes. It runs in the right extremity of the lesser omentum (gastro-hepatic), which is more defined from the mesoduodenum than in the *Platypus*, since the pancreas is becoming more fixed and even adherent to the caudate lobe. The common duct measures about 4 cm., and it is joined by the pancreatic duct 2 cm. from its termination in the duodenum, though in a female the distance was only .75 cm. Contrary to Owen's opinion, I have never

PLATYPUS AND ECHIDNA.

found a pancreatic duct opening into the duodenum independently of the common duct. The combined duct surrounded by pancreatic tissue is traced in the right margin of the lesser omentum, and after running parallel and to the right with the duodenum for 1 cm. enters it at a right angle about 3 cm. from the thickened pylorus in a well developed male, though in a female the distance was only 1.75 cm. Thus it forms a loop at its termination. As in the Platypus, this portion is about double in circumference that of the common duct, but opens into the duodenum by a distinct papilla, thus differing from that Monotreme. A slight bulbous swelling .75 cm. long is noted on the duct just before it enters the duodenal wall. A valve is noted at the junction of the duct and the bulbous swelling.

Hepatic Ducts in Echidna.—At the portal interval on the right side a well defined trunk (right hepatic) is noted, with branches passing into it from the right mesial—right lateral—and caudate and spigelian lobes. On the left side there may be a single trunk (left hepatic), with branches passing into it from the left mesial and left lateral lobes, or we may have a single branch from the left lateral joining the cystic duct opposite the right hepatic, and nearer the gall bladder a separate branch from the left mesial lobe. A compromise between the two on the left side is depicted in the diagram (page 20).

Pancreatic Duct in Echidna.—Although a single pancreatic duct entering the common duct on the right side is in my experience most frequent, nevertheless the following conditions should be noted:—

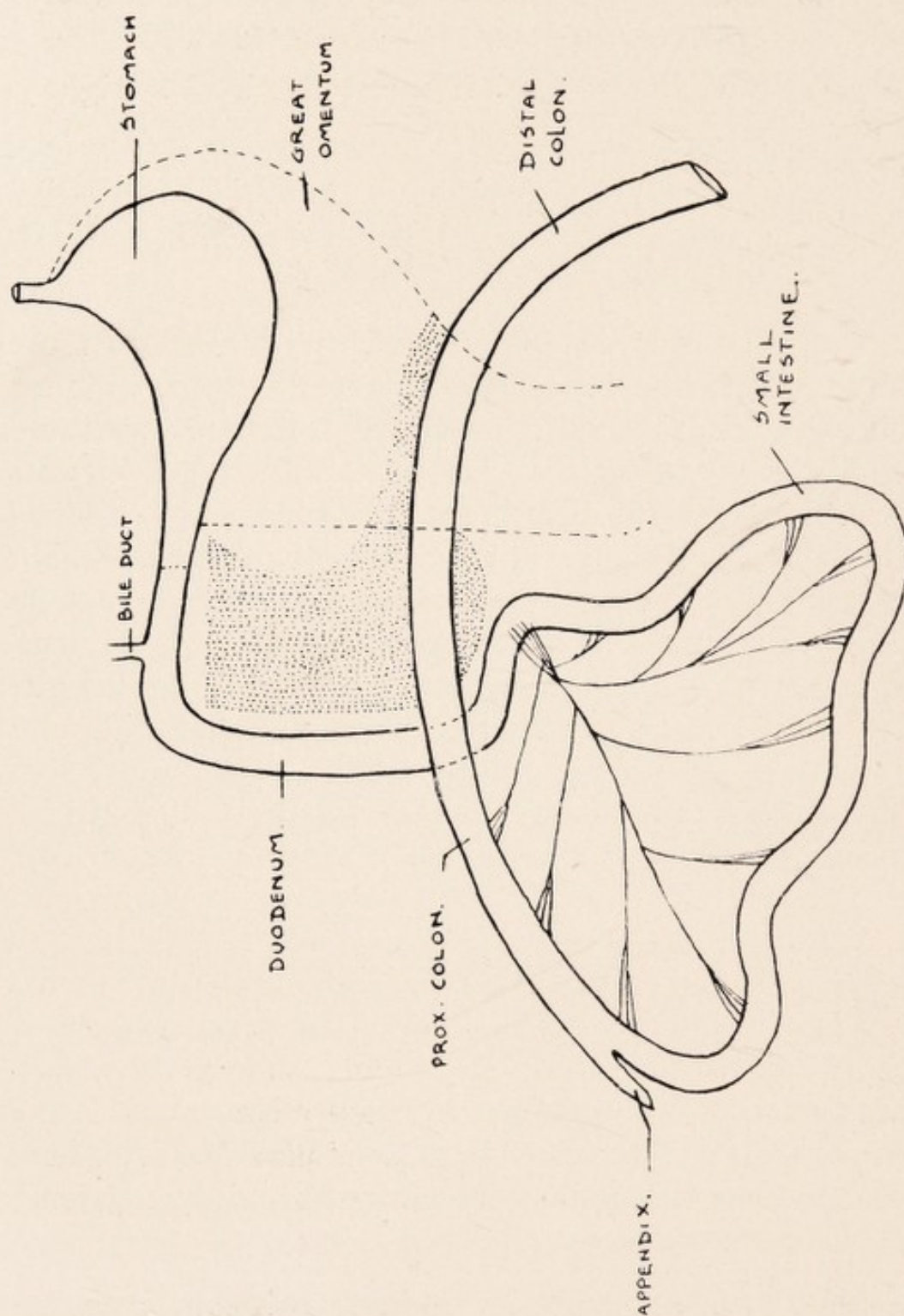
- (a) Single duct entering the common duct on the right. It passes parallel with the latter in the gastro-hepatic omentum for about .75 cm.

PLATYPUS AND ECHIDNA.

- (b) Two ducts opening opposite one another—one from pancreas in the gastro-hepatic omentum—one from rest of pancreas.
- (c) Two ducts, but left opens proximal to right.
- (d) Single duct on left—traced in the gastro-hep. omentum towards the pylorus, then down and to the right in mesoduodenum, and then to left. Total length, 12 cm.

Pancreas in Echidna.—(1) The pancreas is a more compact and less mobile organ than in *Platypus*, and may be in close relation with the dorsal abdominal wall and the lobus caudatus of the liver, so as to be regarded as a “fixed” organ. (2) The great omentum is well defined and traced along the great curvature of the stomach, but does not extend as far to the right along the duodenum as in the *Platypus*. It never extends beyond the pylorus, and may even end at the beginning of that elongated gizzard-like structure. It has the spleen on its left side, and its length is 16 cm., and width below 12 cm. (3) There is, as in *Platypus*, a well defined duodenal loop which contains the main portion of the pancreas. Pancreatic tissue may be traced to the left of the duct in the gastro-hepatic omentum above the pylorus, and even reaching to the stomach wall. It is also traced along the duct as far as the portal interval of the liver. The pancreas related to the duodenal loop is mobile usually, though the mobility is limited. This portion is usually connected to the lobus caudatus of the liver by a peritoneal band. There is a slight interval between the pancreas and the duodenal wall, as in *Platypus*.

(4) The colon comes into relation with the pancreas about the root of the mesentery and duod-intest flexure. Here the pancreas is fixed dorsally in all specimens examined. As in *Platypus* the body and right process of



THE PANCREAS IN ECHIDNA.

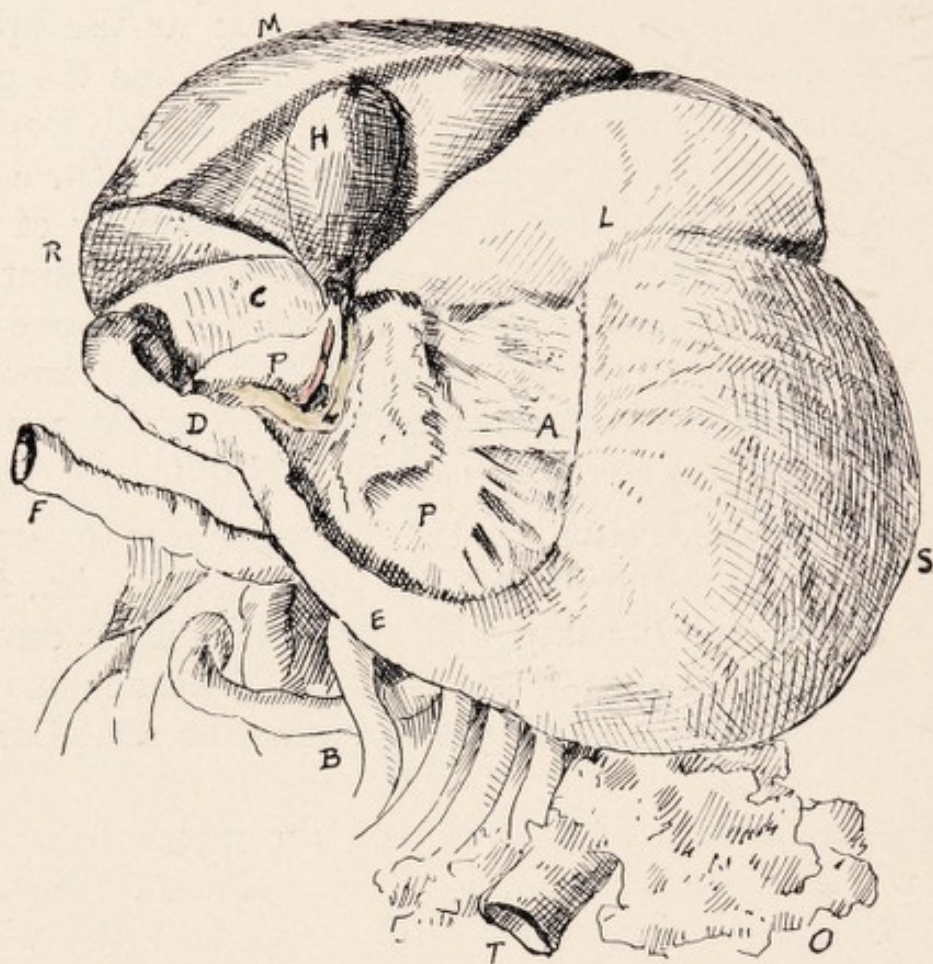
PLATYPUS AND ECHIDNA.

spleen are related to the lesser sac (great omentum), while the left process is outside the lesser sac and connected to the mesocolon of the descending part of the left or distal colon by the left lateral or lieno-mesocolic fold. The great omentum comes down as far as the upper border of the colon, but does not include it; and the pancreas—after more or less filling the duodenal loop as stated—is prolonged along the upper border of the colon as a process forming the lower dorsal boundary of the lesser sac, extending in an average specimen for about 2-3 cm. (It is to be noted that the main mass is above the colic relation to mesoduodenum, only a small amount being found dorsal to the commencement of the mesentery, while the reverse is the case in *Platypus*.)

In contradistinction to the *Platypus* the pancreas does not extend to the left beyond the lesser sac, *i.e.*, does not come into relationship with the posterior process of the spleen and the lieno-mesocolic fold. There is usually a well defined groove in the pancreas for the reception of the colon.

(5) In a male adult specimen the pancreas on the right was closely related to the lobus caudatus of the liver (thus lessening duodenal mobility), so that the whole organ could be regarded as fixed. In this mammal the distal colon was fixed, and not only the body and right process, but also the stem of left process of spleen, were in the lesser sac, only the nummular process being outside and related to colon. The lesser sac dipped down sinistral to the distal colon, and the pancreas also extended down on the left of the colon. The lesser omentum and the foramen Winslowii were poorly defined.

(6) In the *Platypus* the separation between mesoduodenum and gastro-hep. omentum is ill defined, and a gap is noted dorsal to the bile duct, *i.e.*, foramen of Winslow. A band is noted (of which a



STOMACH AND LIVER IN ECHIDNA.

H Gall Bladder with Common and Pancreatic Ducts, L Left Lobe Liver, M Mesial (Cystic) Lobe of Liver, R Right Lobe Liver, C Caudate Lobe Liver, S Stomach, P Pancreas, A Lesser Omentum, E Rigid Pylorus (Sphincter), D Duodenum, O Great Omentum, B Portions of Small Intestine, F Right Proximal Colon, T Distal Colon.

PLATYPUS AND ECHIDNA.

trace is seen in Tas. Devil) from the dorsum of duodenal pancreas to the inf. v. cava. But in the Echidna the definition of gastro-hep. omentum (lesser omentum) is distinct. The pancreas becomes attached by a peritoneal fold to the lobus caudatus, and this fold is really continuous with one to the inf. v. cava (which is present), so that the latter fold from pancreas to v. cava seen in Platypus is the starting point in the fixation of duodenum and pancreas. As a result, what may be regarded as a twist is put on the "junction" of the lesser omentum and mesoduodenum, and the former becomes defined, forming the anterior boundary of the foramen of Winslowii. In the Platypus this, as stated, was a gap on the right of gastro-hep. omentum and mesoduodenum, which were practically continuous. In only one Echidna did the condition resemble that of the Platypus, and here there was no attachment of pancreas to caudate. This throws light on formation of foramen Winslowii, and shows why we go behind lesser omentum to enter the lesser sac. Light is also thrown on the mobility of the caudate lobe—after fixation of pancreas, then immobility; but mobile first to give a yield to the band, and the pancreas itself, when evolving, is diffuse and mobile. Why fixed duodenum and pancreas? For erect posture, *i.e.*, no mobility of ducts allowed, thus obviating torsion.

Portal Vein.—On the right side a single branch passes, sending branches, one to right lateral, and another to the caudate and spigelian lobes. On the left side two branches are given off close together—one to left lateral lobe, and the smaller to the left mesial lobe. The branch to the right mesial would appear to be a continuation of the portal trunk.

LIVER IN MACROPUS.

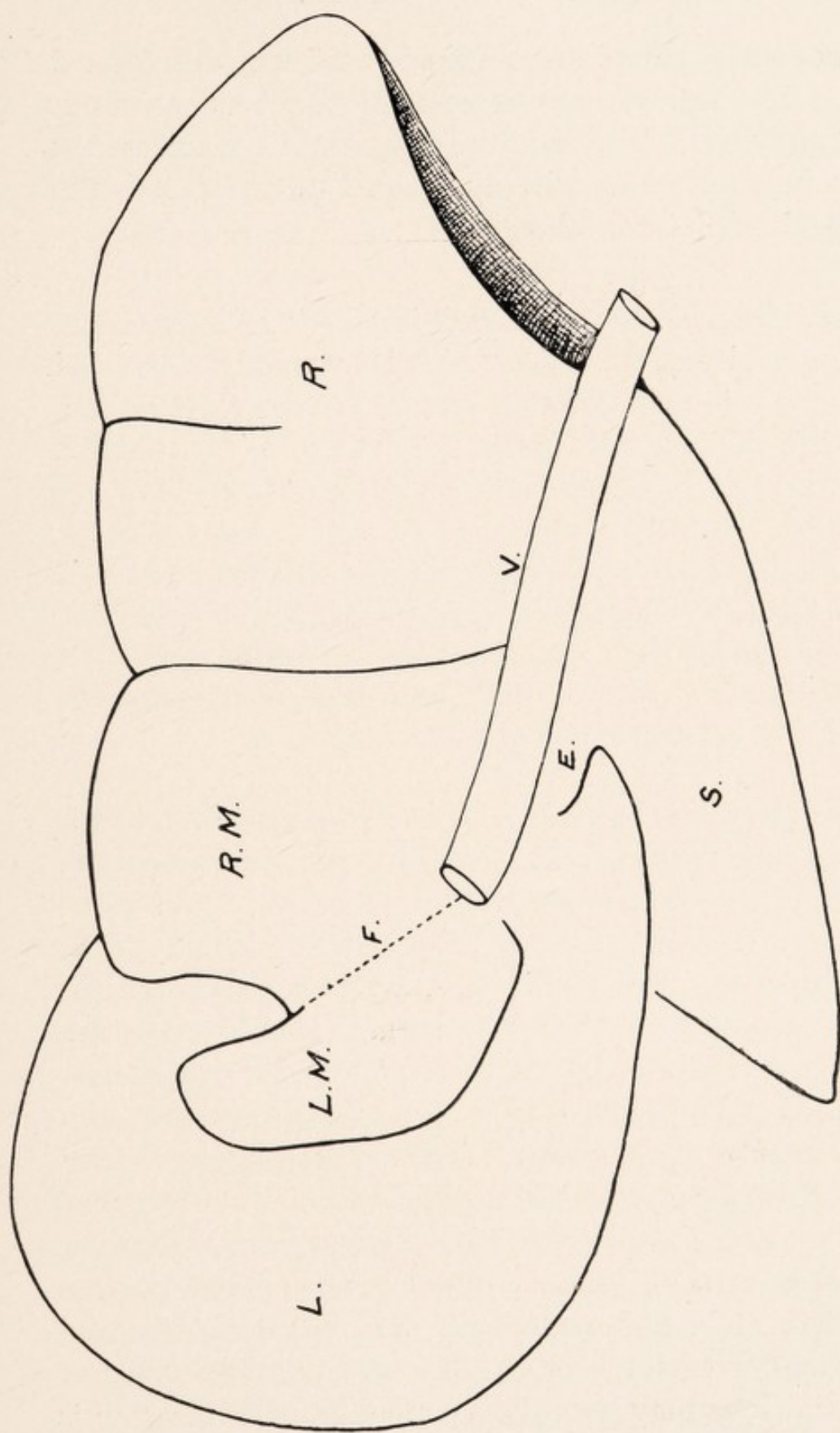
(KANGAROOS AND WALLABIES.)

Though certain minor differences may be noted the following can be regarded as the type, as evidenced by examination of *Macropus Giganteus* — *Ualabatus* — *Parryi*, and smaller varieties, such as the Tasmanian Wallaby.

The liver is somewhat obliquely placed—passing down to the right—and lies in the epigastrium and right hypochondrium.

Diaphragmatic Aspect.—The liver—both lateral and cystic lobes—is closely attached dorsally by bands to the tendinous portion of the diaphragm. The suspensory or longitudinal ligament passes between the cystic lobe and the diaphragm, and helps to separate the small left portion from the main right portion of the cystic or mesial lobe. It can be traced between the dorsal part of the cleft for the gall bladder and the inf. v. cava, being short where the cleft is prolonged dorsally as a fissure. In a *Macropus Parryi* the longitudinal ligt. ran from the middle of the left cystic and out from the gall bladder fissure.

Three distinct divisions of the liver are seen on this aspect, viz., large left lateral lobe—small mesial, or cystic—and right lateral, intermediate in size, between the two. In addition dorsally the left lateral aspect of the Spiegelian lobe is seen, somewhat triangular in shape—with a



DIAPHRAGMATIC SURFACE OF LIVER. KANGAROO.

F Suspensory Ligament, L Left Lateral Lobe, L.M Left Mesial or Cystic Lobe, R.M Right Mesial or Cystic Lobe, R Right Lateral Lobe, V Inf. Vena Cava, S Spigelian Lobe, E For Oesophagus.

KANGAROOS AND WALLABIES.

greatest dorso-ventral measurement of 5 cm., and lateral 10 cm. The inf. v. cava is seen to run between right lateral and mesial lobes and the spigelian lobe, and this is seen to be continuous with the dorsal parts of both the cystic and left lateral lobes.

Left Lateral Lobe.—A striking feature is the relatively large size of this lobe, which is seen to be separated from the mesial lobe by an irregular fissure (left lat. fissure), which does not reach the inf. v. cava dorsally, where the left lateral—mesial—and spigelian lobes are connected. This lobe measures 11 cm. dorso-ventrally, and 9 cm. laterally. Behind the dorso-internal prominence of the left lateral lobe, between it and the spigelian, and then on the left aspect of the spigelian, which is grooved for it, we have the œsophagus passing to the stomach.

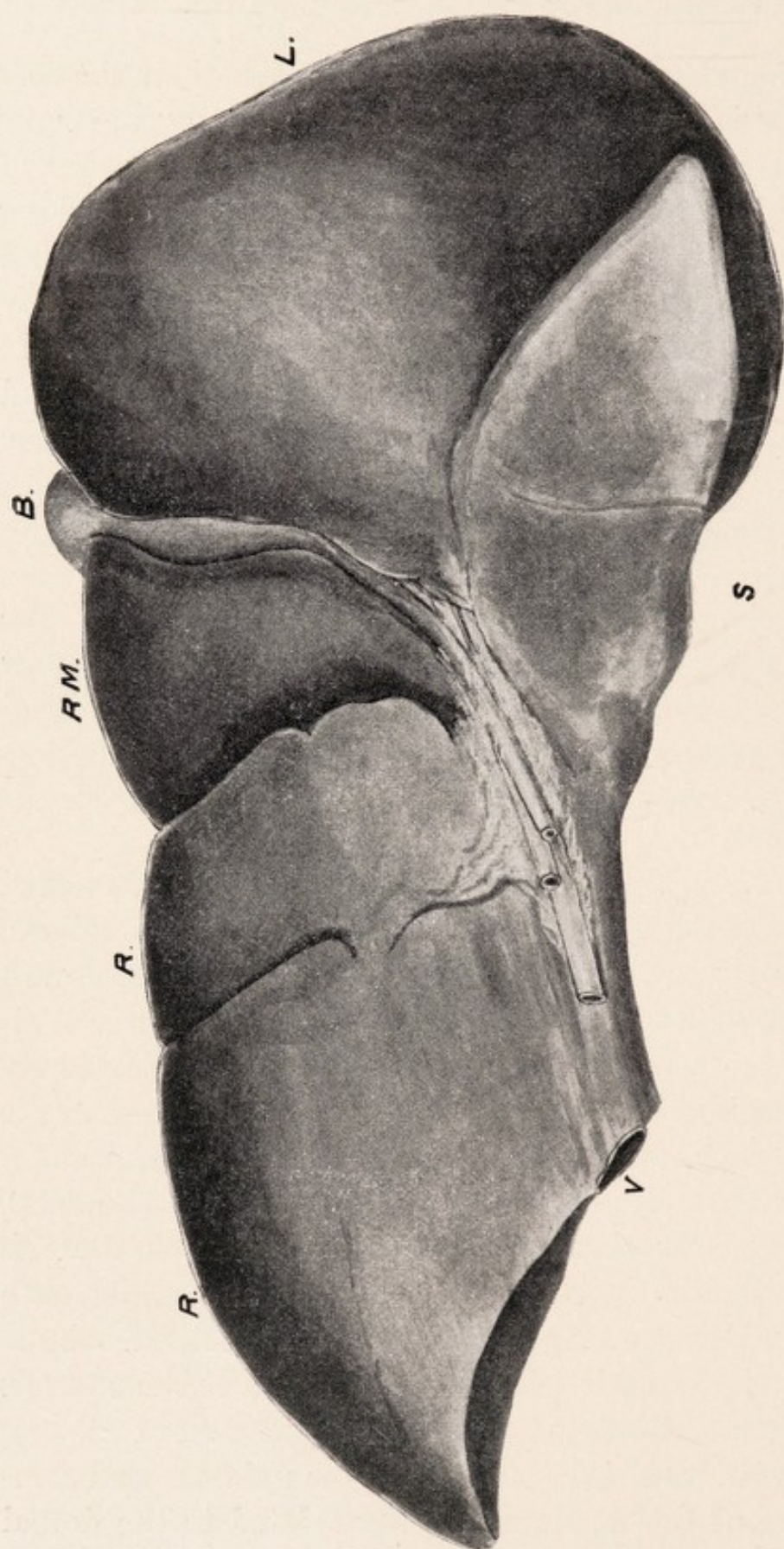
Mesial or Cystic Lobe.—This is separated from the right lat. lobe by the right lateral fissure, which does not frequently pass so far dorsally as the inf. v. cava, and measures 9 cm. laterally and 7.5 cm. dorso-ventrally. It is separated into two portions—the left smaller, and the right larger—by the cleft for the gall bladder in front, and the longitudinal lig. dorsally. The cleft, which may be fissured dorsally, measures 3 cm. dorso-ventrally, and 3 cm. laterally, and the gall bladder is seen freely on this aspect. Usually the ventral margin of the liver is formed by the left and right lateral lobes, and so the gall bladder is not seen at that edge. Sometimes the right portion of the cystic lobe may partake in the ventral margin, and in the smaller varieties of the Macropodidæ the whole of the mesial lobe may partake, so that the gall bladder is seen on the ventral edge.

KANGAROOS AND WALLABIES.

Right Lateral Lobe.—This is smaller than the left lateral, and is separated from the cystic lobe by the right lateral fissure. It is concave below for the reception of the right kidney, and presents a partial fissure 3 cm. long on the thin ventral edge. It measures 12 cm. laterally, and 10 cm. dorso-ventrally. The inf. v. cava is visible dorsally in its hepatic relationship, which is about 9 cm. long. It is placed on the dorsal aspect of the right lateral and right part of the cystic lobes, between these and the lobus spigelii—its exit being at the back of the right cystic lobe, almost on the level of the gall bladder cleft.

Visceral Surface.—Here the striking features are the relatively large size of the left lat. lobe, presenting neither fissures nor lobes, and the projection below it, and dorsal to the lesser omentum, of the spigelian lobe, which is broad at the base and pointed at the extremity.

Left Lateral Lobe.—This lobe, which is separated from the mesial or cystic lobe by the left lat. fissure, usually hides part of the gall bladder and its cleft, as well as the smaller left portion of the cystic lobe. In a Wallaby the left lat. lobe was so large as to occlude completely the two portions of the cystic lobe—gall bladder—and the inner portion of the right lateral lobe. The stomach in *Macropus* assumes a somewhat V-shape in the abdomen, with a large left portion including the fundus and its single or double pocket and also the abdominal œsophagus, and smaller right portion. The left lat. lobe is related to the summit of left portion, whilst the summit of the right portion is related to the right part of the left lateral, cystic, and right lat. lobes—the pylorus, and commencement of the duodenum being related to the dorsal or lower part of the right lateral lobe.



VISCERAL SURFACE OF LIVER. KANGAROO.
 B Gall Bladder, RM Right Mesial or Cystic Lobe, R Right Lateral
 Lobe, L Left Lateral Lobe, S Spigelian Lobe, V Inf. Vena Cava.

KANGAROOS AND WALLABIES.

Spigelian Lobe.—A well developed spigelian lobe is a characteristic feature of the liver of *Macropus*. It presents three surfaces—an upper corresponding to the under surface of the left lat. lobe, and a right and left lateral for the stomach. At the dorsal part of the left surface is a groove for the abdominal oesophagus, which is of considerable length in the *Macropodidæ*, and which passes between the spigelian lobe and the dorso-mesial projection of the left lat. lobe. It may project as far forward as the level of the ventral border of the left lat. lobe, and in Parry's Kangaroo I have seen it divided into two lobes by a fissure. It dips down behind the lesser omentum, between the two portions of the stomach, forming, as it were, a separation between the two.

Cystic or Mesial Lobe.—This is divided into two parts by the cleft of the gall bladder—a larger right and smaller left. The smaller left portion is always hidden by the left lat. lobe, which extends dextrally as far as the gall bladder cleft, so that only part of the bladder is seen—the main projection of the bladder being on the diaphragmatic, or upper surface. The Cystic Duct passes between the left lat. and the right cystic lobes, and the Common Bile Duct, with the artery and portal vein, are seen passing also in a groove between the right lateral and spigelian lobes.

Right Lateral Lobe.—Two portions, as on the diaphragmatic surface, may be recognized separated by a partial fissure, viz., an upper small and a lower larger portion hollowed below for the reception of the kidney. In a *Macropus Parryi*, and in a young Wallaby, I have found the upper portion to be more defined and mobile, projecting ventrally to the lower part and to the right cystic lobe—the “partial” fissure extending to the vena cava. There

KANGAROOS AND WALLABIES.

is no definite caudate lobe in *Macropus*. We may see a projection on the inner part of the right lat. lobe corresponding to it, but the important point is that the vena cava has come to the ventral surface. Why the fissure? Is this acquired for more elasticity in relation to the pyloric portion of the stomach—remembering the relatively enormous size of the *Macropod*'s stomach—or are we dealing with a primitive right lobe, *i.e.*, the upper part to be regarded as right lobe, since it is separated from the cystic by a fissure, and the lower to be regarded as caudate, hollowed below for the kidney. If we do regard the lower portion as caudate the inner portion has disappeared, and the two portions are now practically one. The liver of the *Macropod* then is important in reference to the evolution of the caudate lobe, suggesting atrophy internally and fusion—unification—externally.

Inf. V. Cava.—This is seen to lie obliquely on the inner or left margin of the right lateral lobe, and passing ventral to it between the spigelian on the left, and the two parts of the right lateral on the right, are the portal vein, artery, and common bile duct—the portal vein and inf. v. cava being in close relationship. The vena cava completely separates the spigelian and right lateral lobes—no caudate lobe is present—and the spigelian lobe is seen to be really connected with the left lat. lobe, and not with the right lateral.

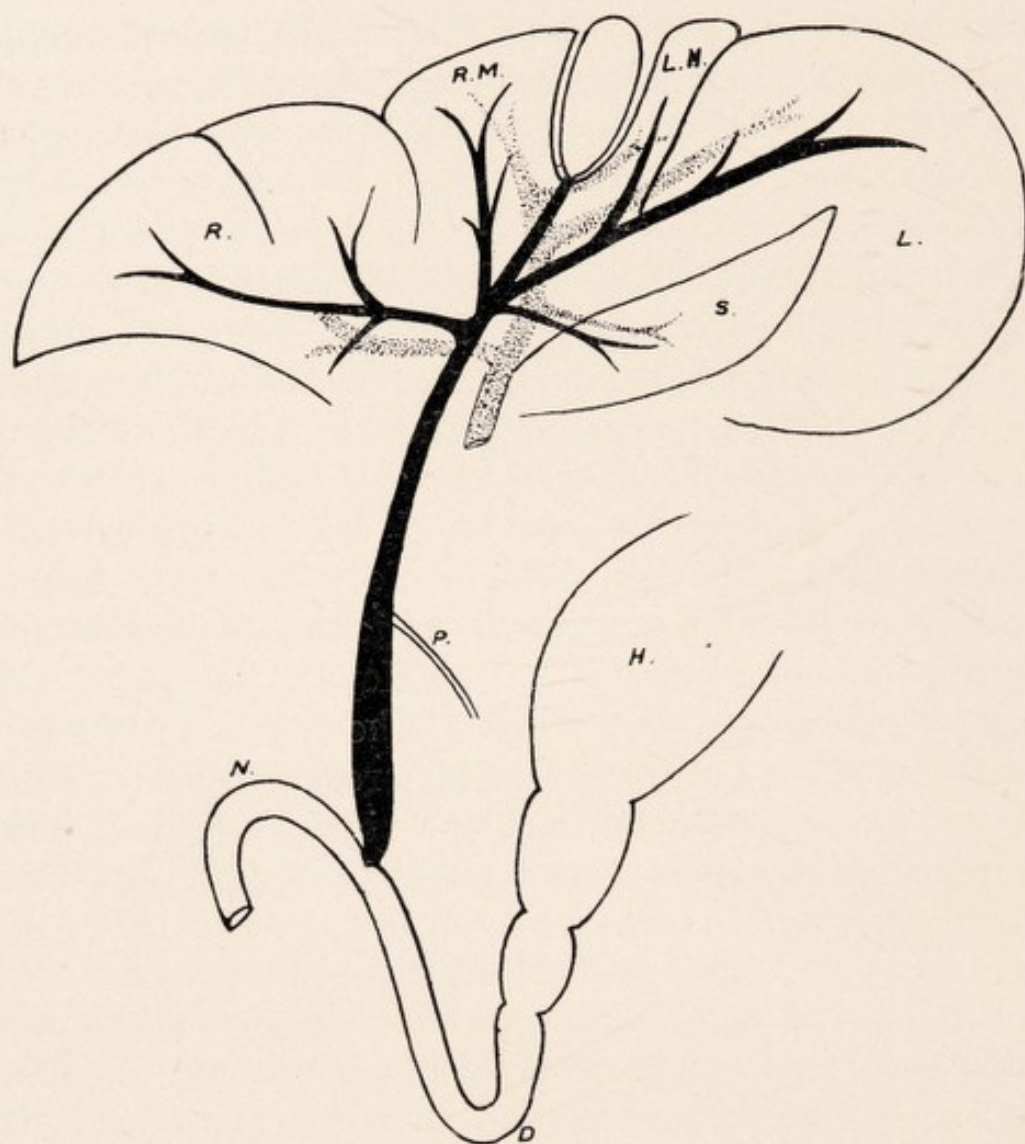Lesser Omentum.—A continuity is established with the suspensory membrane at the inf. v. cava on the diaphragmatic aspect. The membrane, which is really the old ventral mesentery, passes behind the projection on the dorso-internal aspect of the left lat. lobe to the visceral surface. The lesser omentum is traced along the internal or right margin of the left lat. lobe to the portal interval, being seen immediately above the lobus spigeli.

KANGAROOS AND WALLABIES.

Gall Bladder and Ducts.—The gall bladder is placed in the cleft in the cystic or mesial lobe, and owing to the projection to the right of the large left lat. lobe it is usually only seen partly from the visceral aspect, though projecting freely on the diaphragmatic face. As a rule it is best examined on the visceral aspect by removing the right portion of the left lat. lobe. It may be described as a somewhat rounded sac, 4-5 cm. long, with a greater mobility than the human bladder. Its ventral, two-thirds, are completely invested by peritoneum, while the dorsal, third, is less mobile, being invested on the under surface and sides only, and attached to hepatic substance above. From the dorsal extremity of the gall bladder the Cystic Duct, 2-2.5 cm. in length, passes, lying in a groove—the continuation of the gall bladder cleft—between the two portions of the mesial lobe. It is joined at its termination in the portal interval by the Hepatic Ducts, and becomes the Common Bile Duct. The portal interval, or fissure, which corresponds to the region where all the lobes meet, is placed between the right cystic and right lateral lobes dextrally, and the left lateral and spigelian on the left.

Hepatic Ducts.—On the left side the left hepatic trunk is formed by the union of two branches—one from the left cystic or mesial, and the other from the left lateral lobe; near its junction with the cystic duct it receives a branch from the spigelian lobe. On the right lobe main trunks are noted—the smaller ventral one from right mesial or cystic lobe, and the larger more dorsal branch from the right lateral lobe.

Common Bile Duct.—This is formed by the junction of the cystic and hepatic ducts, and passes down with the hepatic artery and portal vein—the vein lying dorsally as in the human liver—between the lobus spigellii, on the

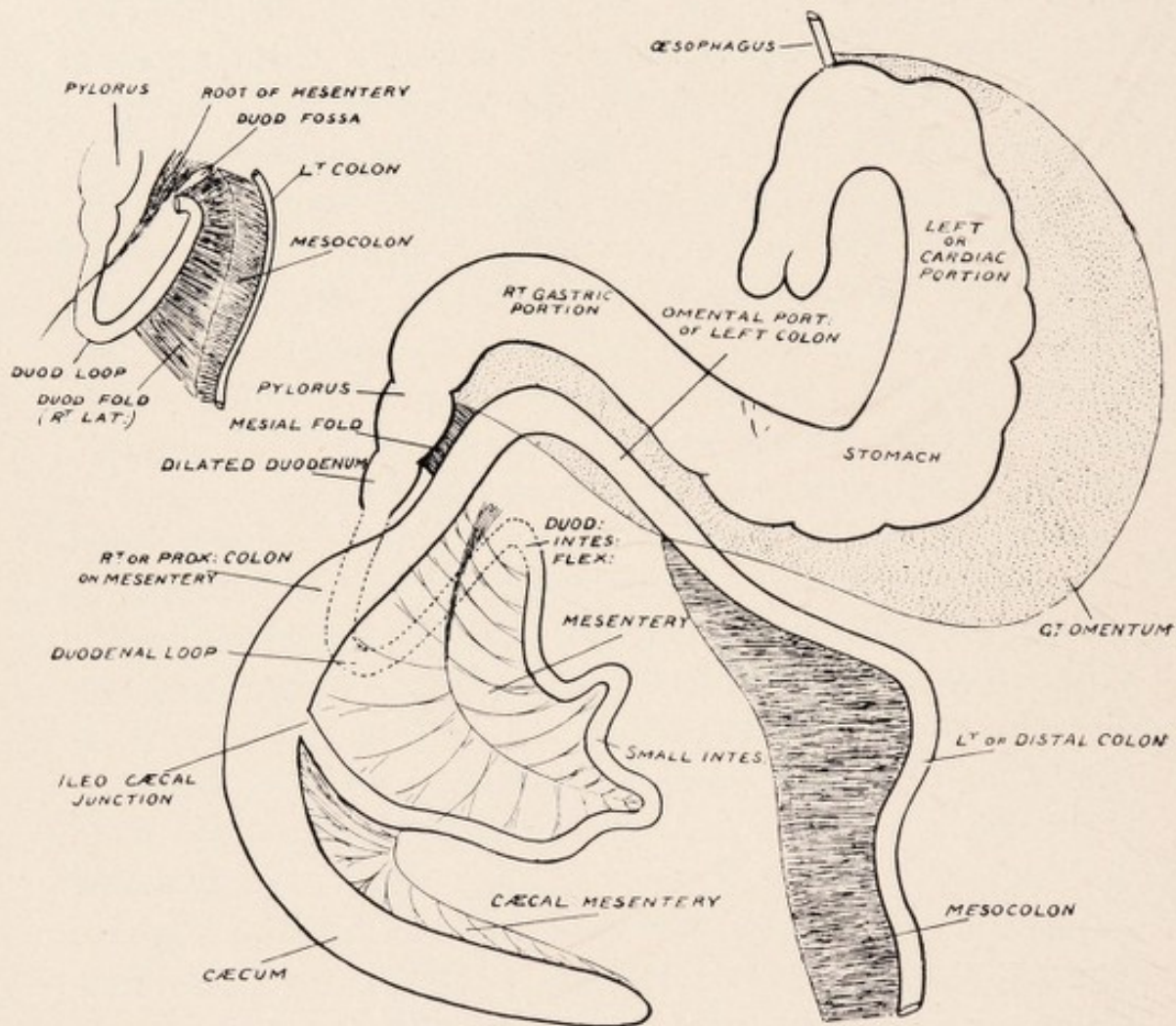


BILIARY AND PORTAL SYSTEMS. LIVER. KANGAROO.

R Right Lateral Lobe, L Left Lateral Lobe, S Spigelian Lobe, LM Left Mesial or Cystic Lobe, RM Right Mesial or Cystic Lobe, P Pancreatic Duct joining Common Bile Duct, H Portion of Stomach, D Duodenum, N Duod.-Intestinal Flexure.

KANGAROOS AND WALLABIES.

left, and the right lat. lobe on the right. It is traced on the right side of the lesser omentum, then behind the pylorus of the stomach, and coming into relation with pancreatic tissue it enters the mesoduodenum, which is not so defined as in *Trichosurus*, and finally terminates about the middle of the ascending stem of the duodenal loop, though in two Wallabies I found it entering close to the duod-intest. flexure. The opening into the duodenum, which is characterized by a slight papillary elevation, and is guarded by a sphincter, lies about 12-14 cm. from the pylorus in *Macropus Gig.* and about 7-10 cm. in *Macropus Ualab.* The pancreatic duct, which is usually relatively fine, and can be traced to the spleen on the left above the root of the mesentery, joins the common bile duct 3-5 cm. before its termination in the duodenum. From the entrance of the pancreatic duct to the portal fissure, *i.e.*, common bile duct, is 7-8 cm. The combined hepatico-pancreatic duct is much greater in circumference than the common duct, and has a thickened somewhat pipe stem feel. In a great Kangaroo I have found the circumference of this portion 2.5 cm., and in two Wallabies the terminal .5 cm. was bulbous, forming almost a right angle with the main duct before entering the duodenum. The lumen of the thickened hepatico-pancreatic portion of the duct is narrowed, and the interior rugous. The thickening of the wall suggests greater intra-duodenal tension than in the other Marsupials. In some specimens a valvular arrangement at the commencement of this portion is suggested. It is interesting to note the presence of a band, 2.5 cm. broad, which passes across the pylorus of the stomach from the right of the lesser omentum to the right of the great omentum. The thickened part of the duct usually begins just caudal to this band. This, though adherent slightly to the pylorus, forms a continuity between the colon at the pylorus and the lesser



THE GASTRO-INTESTINAL TRACT IN KANGAROO.

KANGAROOS AND WALLABIES.

(gastro-hepatic) omentum, and should be compared with the fold (ventral) found in Chameleon, and in the Cheiroptera.

Portal Vein.—The first branch given off is a well defined one on the right to the right lateral lobe. More ventrally on the left is a small branch to the spigelian lobe; and ventral to that a large branch to the left lateral lobe. It finally terminates in two divisions, one to the right mesial, and a smaller one to the left mesial lobe.

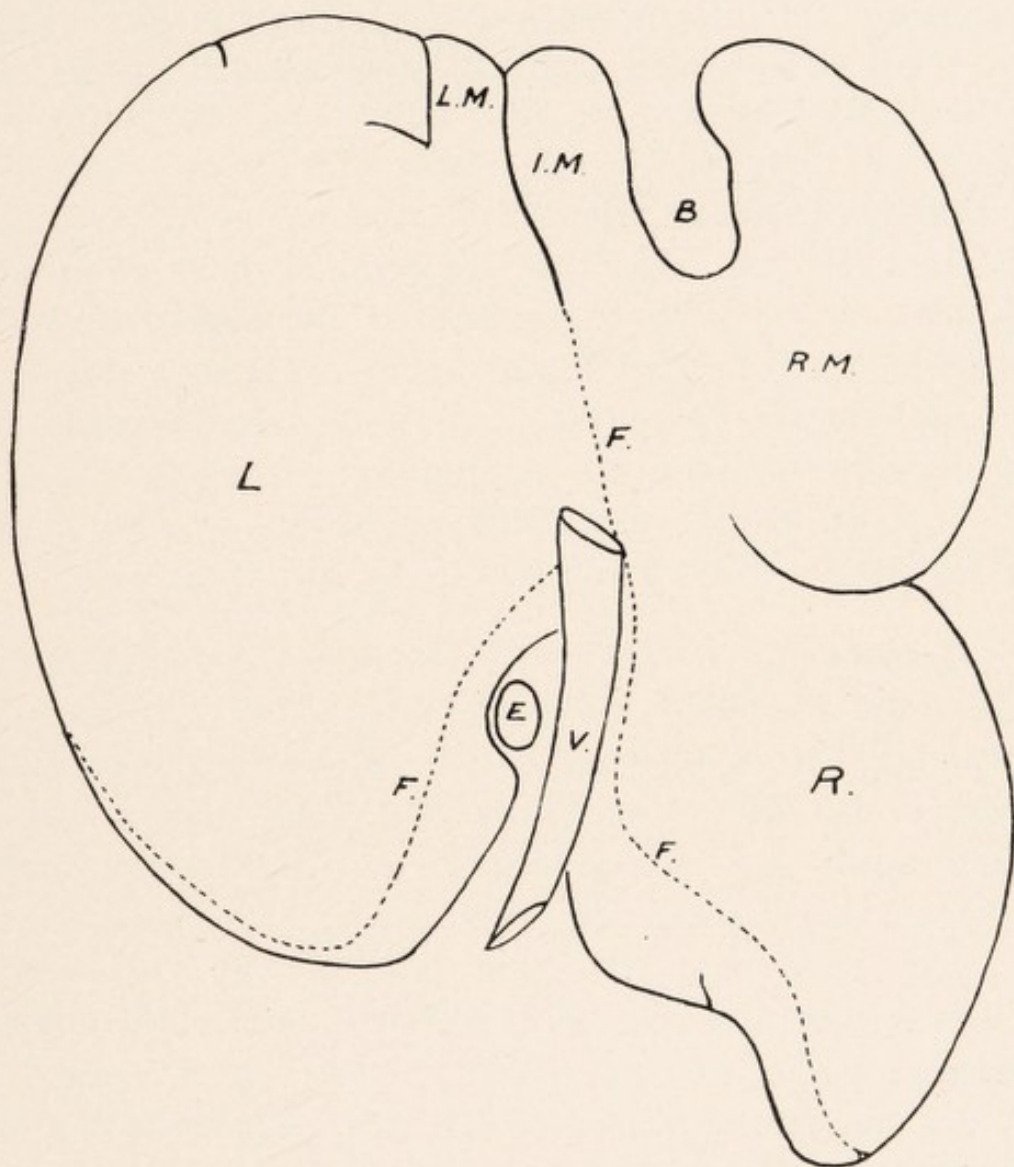
Pancreas.—If the stomach and duodenum be retracted towards the left a well defined portion of pancreas is seen in relation to the mesoduodenum, with its maximum development in the region of the thickened hepaticopancreatic duct. It is traced upwards towards the liver along the common duct, though not reaching as far as the portal fissure, and may be traced in the lesser omentum towards the spigelian lobe. This right portion lies ventral to the inf. v. cava, off which it can be raised, and does not usually descend to the lower part of the duodenal loop. It is traced to the left behind the stomach as a well defined compact gland, 3 cm. in width, passing above the root of the mesentery in relation to the dorsal abdominal wall. On the left of the root it defines the lower boundary of the lesser sac, and lies ventral to the left adrenal gland and upper pole of the left kidney, from which it is free; and although a fine strand, is continued on to the right or omental process of the spleen, *i.e.*, passes into the lesser sac, the main portion of the pancreas, passes downwards in relation to the left, posterior, or dorsal process of the spleen—on the lieno-mesocolic fold—and is continued to the extremity as a tapering process. This part, though forming an angle with the body of the pancreas, is to be regarded as the true continuation of the gland on the left.

LIVER IN WOMBAT.

(PHASCOLOMYS.)

The liver extends to the left beyond the mid line, and is found in the epigastric and right and left hypochondriac region.

Diaphragmatic Surface.—Left Lateral Lobe.—Specimen A.—Viewed from this aspect we are struck by the large relative size of the left lateral lobe, *i.e.*, the portion to the left of the mesial or “suspensory” ligament. The right margin of the liver is seen to be larger than the left, and the dorsal than the ventral. Though the liver of the Wombat is approaching the human, and unification of the hepatic lobes is becoming the type, yet we can—though much less distinctly than in other Marsupials—define a left lateral—right lateral—and mesial or cystic lobes. In this adult the left lateral lobe measured 17 cm. dorso-ventrally, and 13 cm. laterally. On the inner side dorsally a concavity is noted for the passage of the œsophagus. Between this lobe and the mesial or cystic is a fissure about 3.5 cm. long, and between its dorsal extremity and the inf. v. cava is 2 cm. of hepatic tissue, so that these lobes are becoming linked up, only the suspensory ligament passing between the fissure and the inf. vena cava. To the left of this fissure, *i.e.*, on the left lat. lobe, another complete, though small, fissure is seen only 1.5 cm. long, and between these two fissures is a portion of hepatic substance, measuring 1.5 cm. laterally. It represents the left cystic of other Marsupials, and the fissure is



DIAPHRAGMATIC SURFACE OF LIVER. WOMBAT. (Specimen A.)

B Gall Bladder Cleft, RM Right Mesial or Cystic Lobe, IM Intermediate Cystic Lobe, LM Left Cystic Lobe, L Left Lateral Lobe, R Right Lateral Lobe, F Relationships to Diaphragm, E Oesophagus, V Inf. Vena Cava.

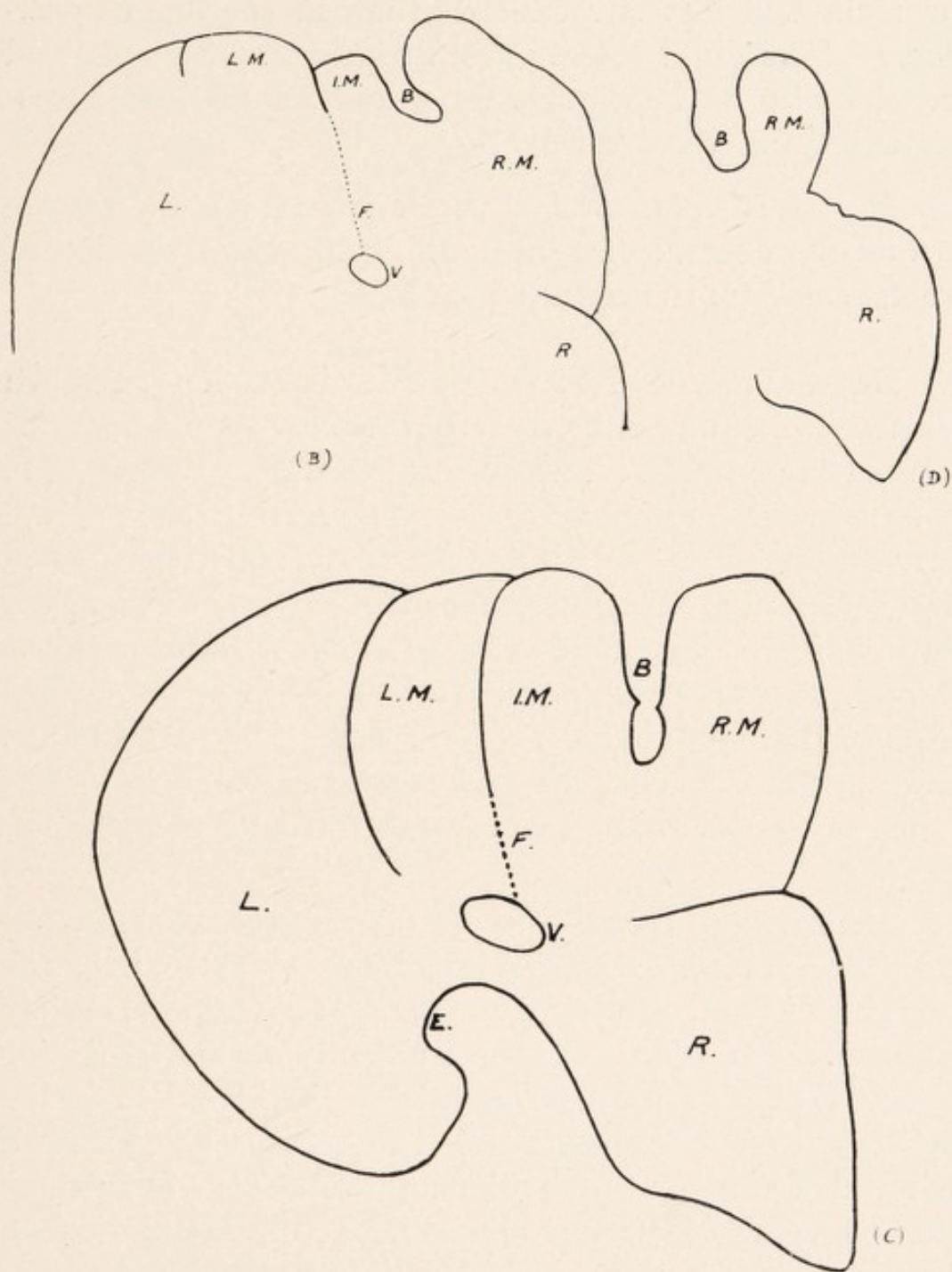
WOMBAT.

the remains of the left lateral fissure. The larger fissure, which here separates the mesial or cystic lobe from the left lateral lobe, represents the mesial or cystic fissure separating the intermediate cystic from the left cystic lobe. In B, however, unification is a more prominent feature; the fissure on the left (*i.e.*, old left lat. fissure) measures 1.5 cm., and the fissure dextral to that—connected with the suspensory lig.—only measures 1.75 cm. In C we see a much more primitive type of liver. The three portions of the mesial or cystic lobe are defined. The left lateral fissure between the left lat. and left cystic lobes is 6.5 cm. long, and the mesial or cystic fissure between the intermediate and left cystic is 4.5 cm. long, so that only 2 cm. exists between the dorsal extremities of these fissures and the inf. v. cava.

Mesial or Cystic Lobe.—A.—This is separated on the right from the right lateral lobe by a curved fissure—completely through hepatic tissue—measuring 5 cm. long. Between its left extremity and the vena cava 2 cm. of hepatic tissue is found, so that the cystic and right lateral lobes are also linking up. The mesial lobe measures 11 cm. dorso-ventrally, and 7 cm. laterally, and is characterized by the presence ventrally of a somewhat quadrilateral cleft for the gall bladder, 4 cm. dorso-ventrally, and 1.5 cm. laterally, and so the gall bladder is seen on this aspect. The ventral margin of the liver is formed partly by the mesial and partly by the left lateral lobes.

B.—Here the right lateral fissure is only 2 cm. long, and the gall bladder cleft measures 2 cm. dorso-ventrally, and .75 cm. across.

C.—As stated above, the three portions of the mesial or cystic lobe, viz., left, intermediate, and right are well defined. There is a greater definition of the cystic from



DIAPHRAGMATIC SURFACE OF LIVER. WOMBAT. (Specimens B, C, D.)

B Gall Bladder Cleft, RM Right Mesial or Cystic Lobe, IM Intermediate Mesial Lobe, LM Left Mesial or Cystic Lobe, R Right Lateral Lobe, L Left Lateral Lobe, V Inf. Vena Cava, F Relation to Diaphragm, E Cleft for Oesophagus.

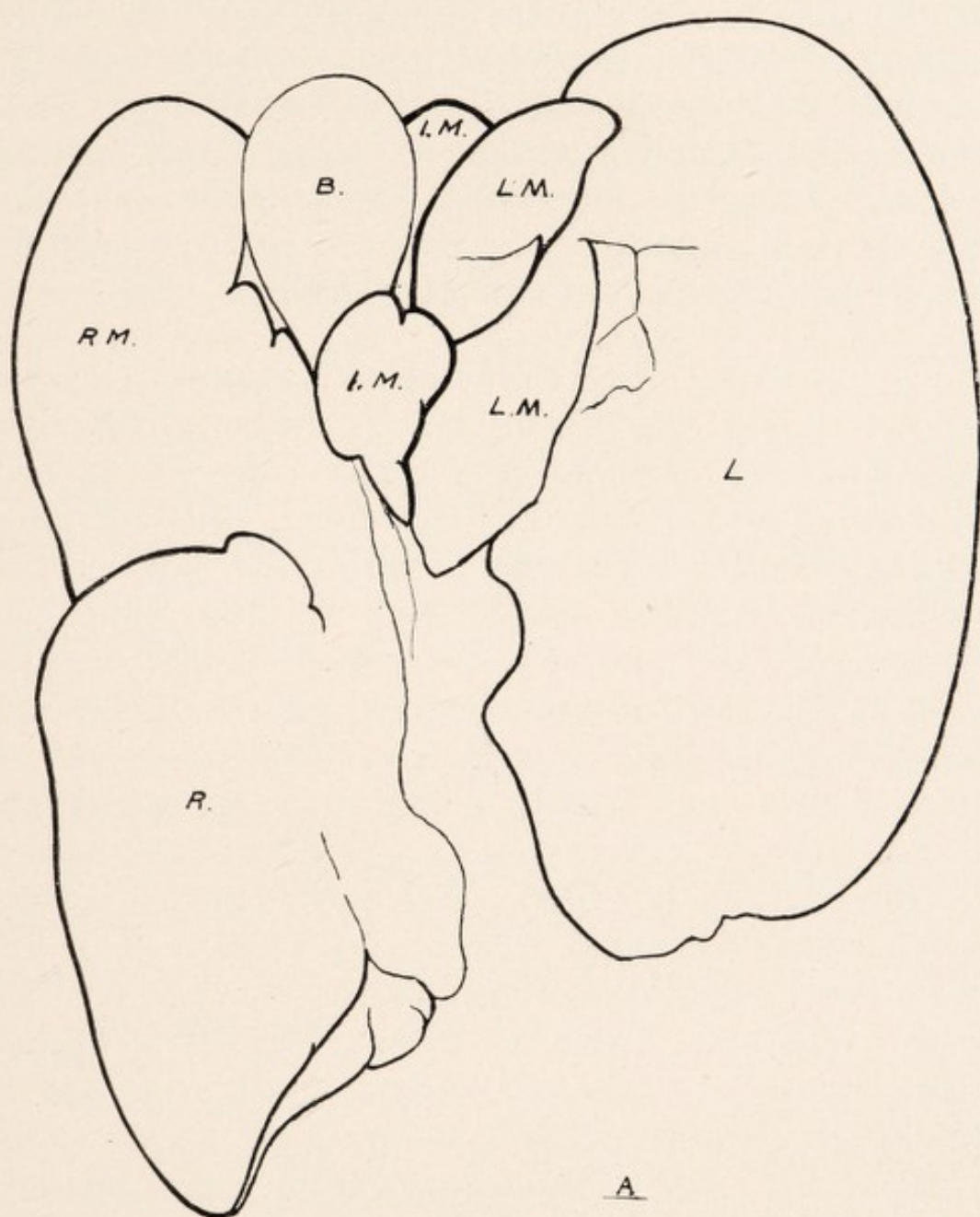
WOMBAT.

the right and left lateral lobes than in the other specimens. The right lateral fissure measures 3.5 cm., and the cleft for the gall bladder measures 4.5 cm. dorso-ventrally, and 1.25 laterally

D.—Here there was no right lateral fissure, only a gap on the dextral margin defining the right portion of the mesial from the right lateral lobe.

Right Lateral Lobe.—*A.*—This is prolonged down ventral and external to the right kidney as a somewhat pointed extremity, and is concave below for the reception of that organ. It measures dorso-ventrally 11 cm., and laterally 10.5 cm., being larger in size than the mesial lobe. Running along its inner or left part is the inf. v. cava, which is seen leaving the liver on its passage to the diaphragm above the upper part of the interval or gap between the right and left lateral lobes. The wall of the inf. v. cava in its hepatic relationship, which measures 7 cm., is seen dorsally, *i.e.*, is not covered by hepatic tissue.

Relations to Diaphragm.—In the region corresponding to the entrance of the œsophagus and the exit of the inf. v. cava the tendinous part of the diaphragm is closely applied to the liver. On the sinistral side the posterior or dorsal edge of the left lateral lobe is connected to the muscular and tendinous portion of the diaphragm by a thin but strong band, the width of which on the extreme left = 4.5 cm., and so a good deal of mobility is allowed to this part. Internally, *i.e.*, approaching the inf. v. cava, as shown in the diagram, the membrane encroaches on the diaphragmatic surface. On the dextral side the attachment of the membrane is rather to the dorsal portion of the diaphragmatic surface than to the dorsal edge, and the membrane is narrower, with the greatest measurement only 3 cm., and so dextrally the liver is less mobile.



VISCERAL SURFACE OF LIVER. WOMBAT. (Specimen A.)

B Gall Bladder, R Right Lateral Lobe, L Left Lateral Lobe,
 RM Right Mesial or Cystic Lobe, LM Left Mesial or Cystic
 Lobe, IM Intermediate Mesial or Cystic Lobe.

WOMBAT.

Suspensory Ligament.—This is well defined, and is traced from the back of the proximal fissure on the left of the gall bladder—into which it may project—to the inf. v. cava. It is attached above to the tendinous portion of the diaphragm, and at its ventral margin it may measure 5.5 cm. In one specimen I saw some tough bands attaching the ventral part of the liver, in the region of the mesial or cystic fissure to the diaphragm.

Visceral Surface. Right Lateral Lobe.—This is defined from the rest of the liver by means of the right lateral fissure. Its lower or caudal surface—which may be fissured and lobulated or smooth—is hollowed below for the reception of the right kidney. The inner portion of this surface is in relation with the descending duodenum, and the outer part is related to the proximal colon. This lobe is usually smooth, and the caudate and spigelian lobes are rudimentary. On the inner side of this lobe is a small raised portion, at the inner and back of which the inf. v. cava passes. This may be regarded as the caudate portion, and it is prolonged to the left in some specimens as a small narrow process scarcely deserving the name of the spigelian lobe, ventral to which pass the portal vein, artery, and bile duct. Strands of hepatic tissue are usually noted on the inner and ventral sides of the inf. v. cava, as it lies on the sinistral margin of the right lateral lobe. The large portal vein may measure 2.5 cm. laterally. Ventral to it are the common bile duct and the hepatic artery, and dorsally is the inf. v. cava, with which it is in direct relationship.

Left Lateral Lobe.—(A) This is the largest portion of the liver. It is smooth, and presents the concavity dorso-internally for the œsophagus. The lobe is concave on this aspect for the left large or cardiac portion of the stomach,

WOMBAT.

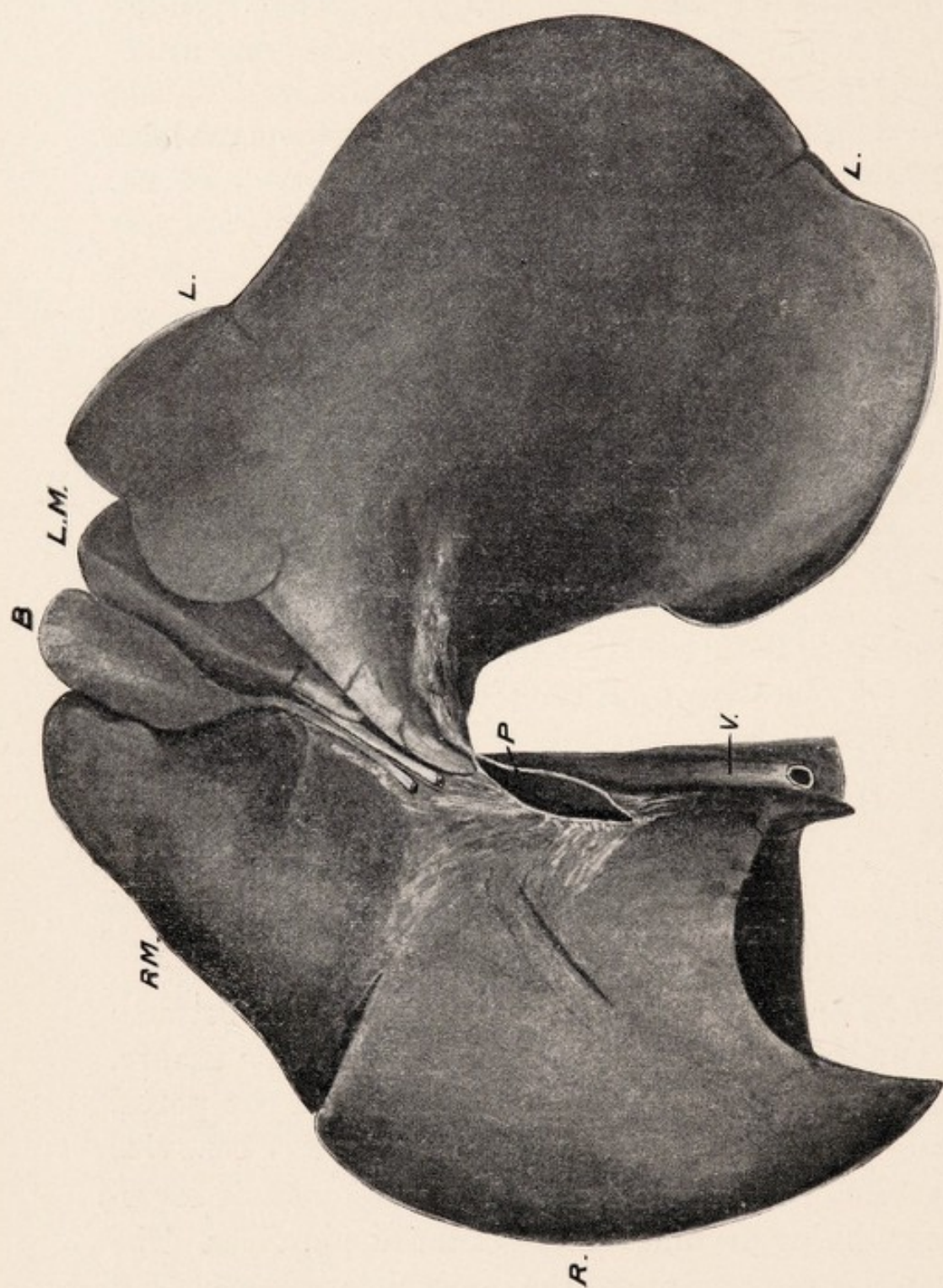
and more ventrally the colon is related to this surface. On its inner aspect some fissuring may be noted. On its ventral edge is a fissure (complete), 1.5 cm. long, which is prolonged dorsally as a depression or groove for 3 cm., passing obliquely inwards to the right margin of the lobe. This groove and fissure define a projecting lobule (4 cm. dorso-ventrally), which is now connected to the left lateral lobe, and represents the remains of the left cystic lobe—the groove and fissure representing the original left lateral fissure.

(B) Here the fissure was only .75 cm. long, and the oblique groove, apart from its termination, was nothing more than a faint depression, so that the fusion of the cystic (left) and left lateral lobes was more pronounced than in the preceding.

(C) Here the separation of the left cystic lobe and left lateral lobes was by a complete fissure (left lateral fissure) 4 cm. long.

(D) Here there was no fissure, even anteriorly, but a well defined groove or depression, so that the old left cystic was defined, and presented some secondary fissuring and lobulation.

Mesial or Cystic Lobe.—(A) The separation between the left lateral and cystic lobes is by means of a fissure, ventrally, and a groove dorsally reaching to the portal interval—the total length of which may reach 7 cm., viz., fissure 3 cm., and groove 4 cm. The whole of this corresponds to the longitudinal fissure of the human liver. The fissure and groove represent the interval (cystic or mesial fissure) seen in more primitive forms between the intermediate cystic and left cystic lobes. With this fissure the longitudinal or suspensory ligament is connected—



VISCERAL SURFACE OF LIVER. WOMBAT.

Resembling Human Type. (Specimen B.)

V Vena Cava, L Left Lat. Lobe, P Portal Vein, R Right Lat. Lobe, RM Right Mesial or Cystic Lobe, LM Left Mesial Lobe, B Gall Bladder.

LM is the original Intermediate Cystic Lobe—the original Left Mesial or Cystic Lobe becoming part of the Left Lateral Lobe with almost complete disappearance of the Left Lateral Fissure.

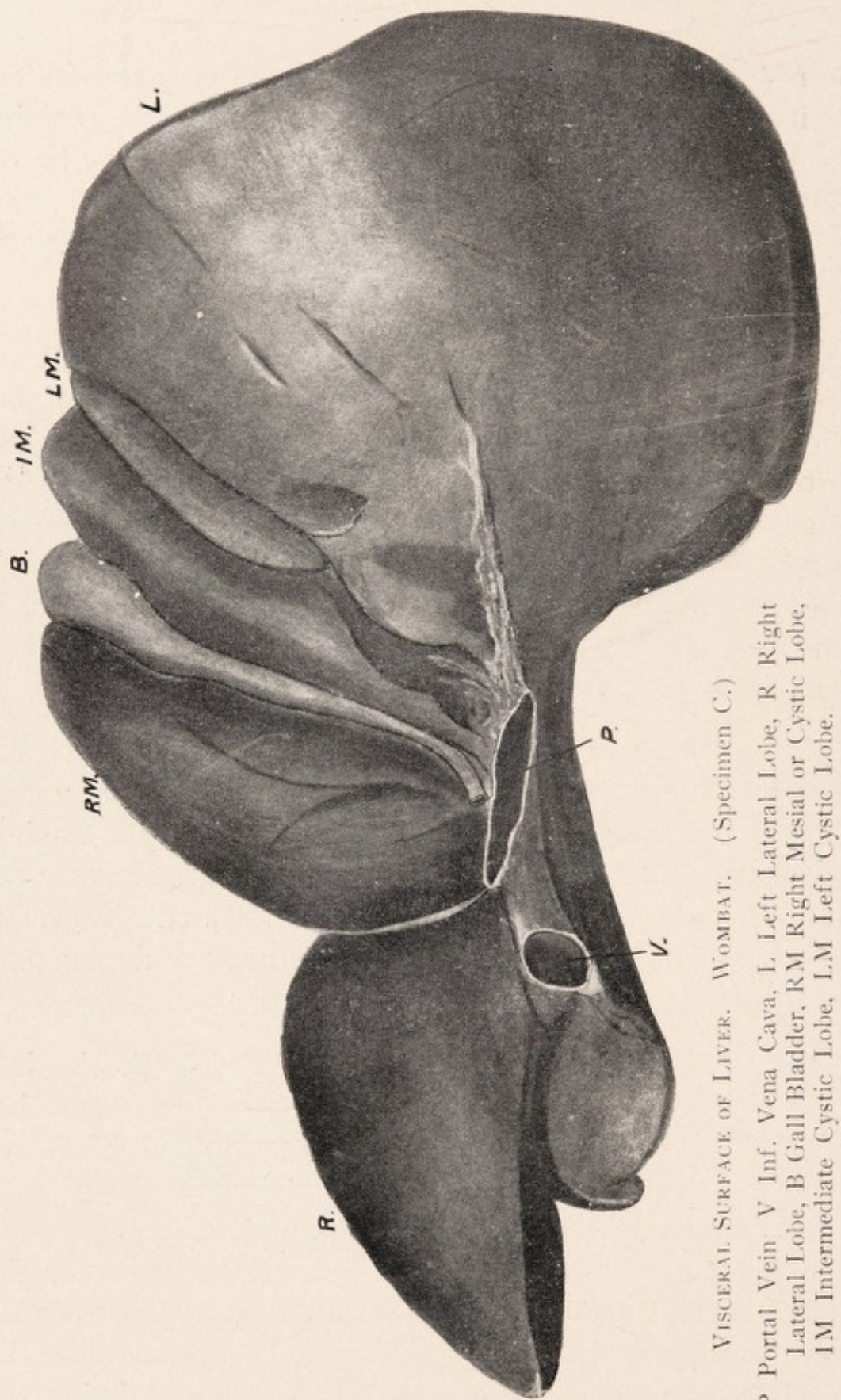
WOMBAT.

hence the selection value for the passage of the umbilical vein. In some specimens, whilst the fissure is the remains of the old cystic or mesial fissure, the groove may be regarded as the remains of the dorsal part of the left lateral fissure. This would be the case where the mesial or cystic fissure had failed to reach the portal interval.

(*B*) Here the left cystic has fused with the left lateral lobe, and although only a faint impression remains between the two, yet dorsally the remains of the old left lateral fissure is more clearly defined, curving on to the right edge of the left lateral lobe. The longitudinal fissure separating the cystic from the left lateral lobe is well defined ventrally, but by a groove dorsally, and is the remains of the cystic fissure between the left and intermediate cystic lobes.

(*C*) Here, although the left lateral fissure is well defined, and measures 4 cm., yet it does not reach the portal interval, as there is commencing fusion dorsally of the left cystic and left lat. lobes, but the cystic fissure between the intermediate and left cystic lobes is continued as a groove between the left lateral lobe and the narrow dorsal part of the intermediate cystic lobe.

(*D*) Here the left cystic has fused with the left lateral lobe, leaving a well defined groove, representing the old left lat. fissure. Between the cystic and left lat. lobes is a fissure ventrally 1.5 cm. long, continued dorsally as a well defined groove—longitudinal fissure—and is the remains of the mesial or cystic fissure between the original intermediate and left cystic lobes. Into this the groove representing the old left lateral fissure ends, so that there was no question of its dorsal part being the dorsal portion of the longitudinal fissure.



VISCERAL SURFACE OF LIVER. WOMBAT. (Specimen C.)

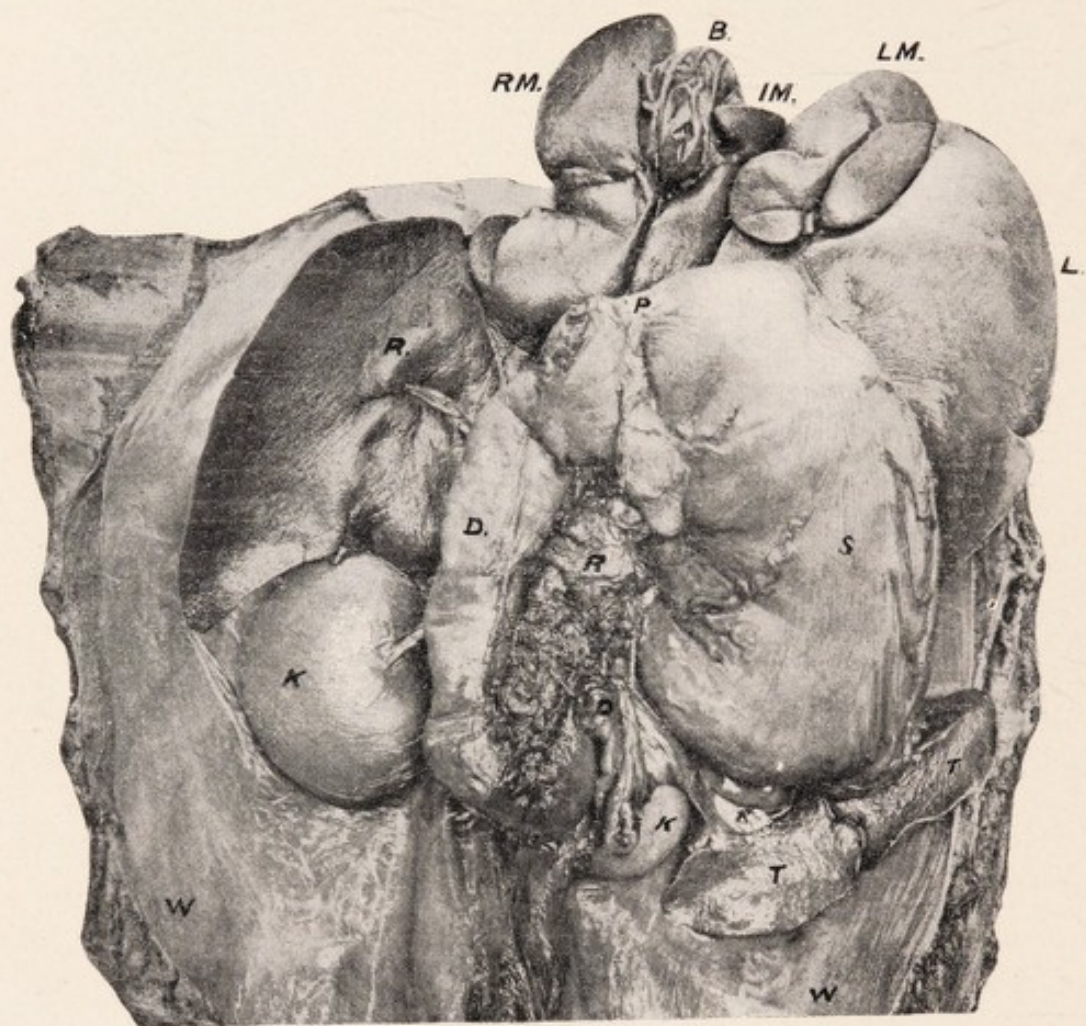
P Portal Vein V Inf. Vena Cava, L Left Lateral Lobe, R Right Lateral Lobe, B Gall Bladder, RM Right Mesial or Cystic Lobe, IM Intermediate Cystic Lobe, LM Left Cystic Lobe.

WOMBAT.

(A) The mesial or cystic lobe is divided into two portions, viz., left and right cystic, by the gall bladder cleft and groove for the cystic duct. The left portion corresponds to the intermediate cystic in the triparite cystic lobes, and to the lobus quadratus in man—the right portion being the old right cystic lobe, and is the larger of the two. The cystic lobe is separated from the left lateral by the longitudinal fissure explained above, and from the right lateral lobe by the right lateral fissure. The sides of the cleft are hollowed for the reception of the gall bladder, and the cleft is prolonged dorsally as a groove for the cystic duct between the right and left portions—the latter of which is greatly narrowed dorsally. The right cystic portion is usually smooth, though it may present some fissuring at the cleft. The smaller left lobe is narrow dorsally, and one can understand how this latter part might disappear and leave a condition similar to the human liver. A projection may be seen on the right margin of the left part, due to an accommodation effect for the gall bladder.

(B) Here the cystic lobe as a distinct entity is least marked of all the specimens. We have a distinct lobus quadratus as the dorsal narrow part of the left portion, *i.e.*, old intermediate has become detached, and only measures 1.25 cm. in length, and .5 cm. laterally. Apart from this small portion the fissure for the cystic duct and the longitudinal fissure would be merged very much as in the human liver.

(C) Here, as on the dorsal aspect, we distinguish the three divisions of the cystic lobe, viz., right, intermediate, and left. For the ventral, two-thirds the right and intermediate portions are of almost equal size, but dorsally the intermediate portion is greatly narrowed, so that while laterally at the ventral margin it equals 4 cm., at the



LIVER, STOMACH, AND SPLEEN. WOMBAT. (Specimen D.)

W Dorsal Abdominal Wall, K Kidneys, R Pancreas, T Spleen,
S Stomach, P Pylorus, D Duodenum, B Gall Bladder, R Right
Lateral Lobe, L Left Lateral Lobe, RM Right Mesial Lobe,
IM Intermediate Mesial or Cystic Lobe, LM Left Mesial Lobe.

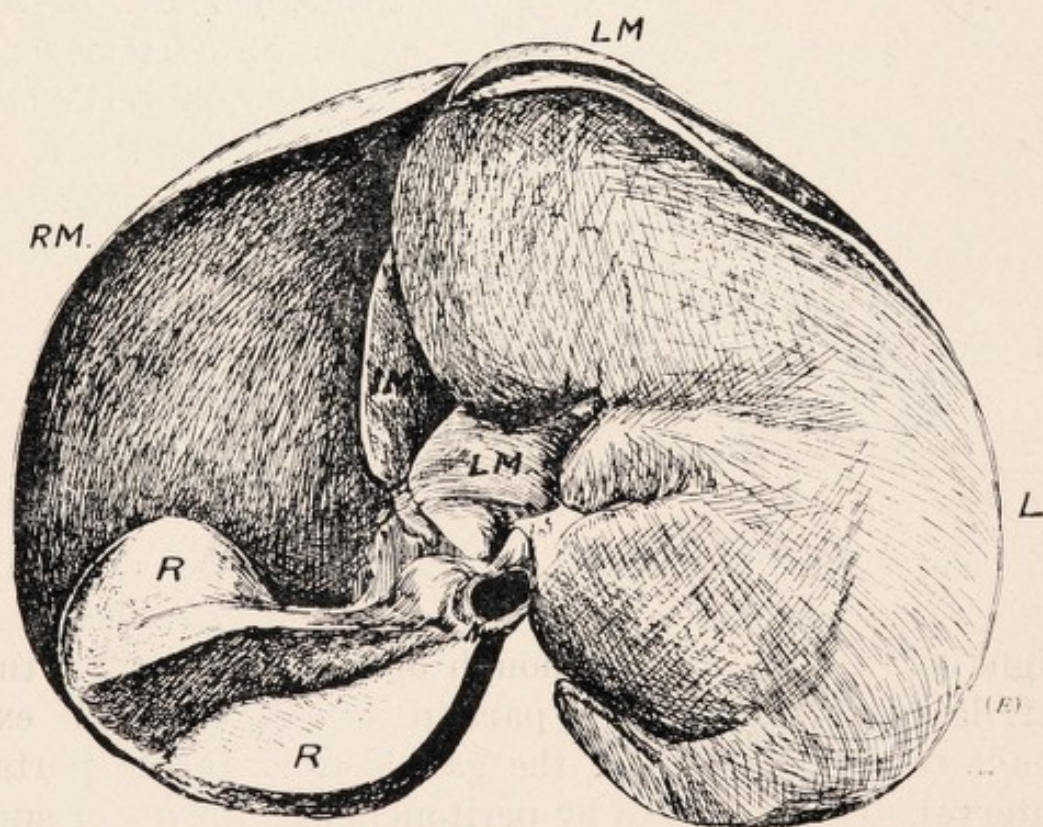
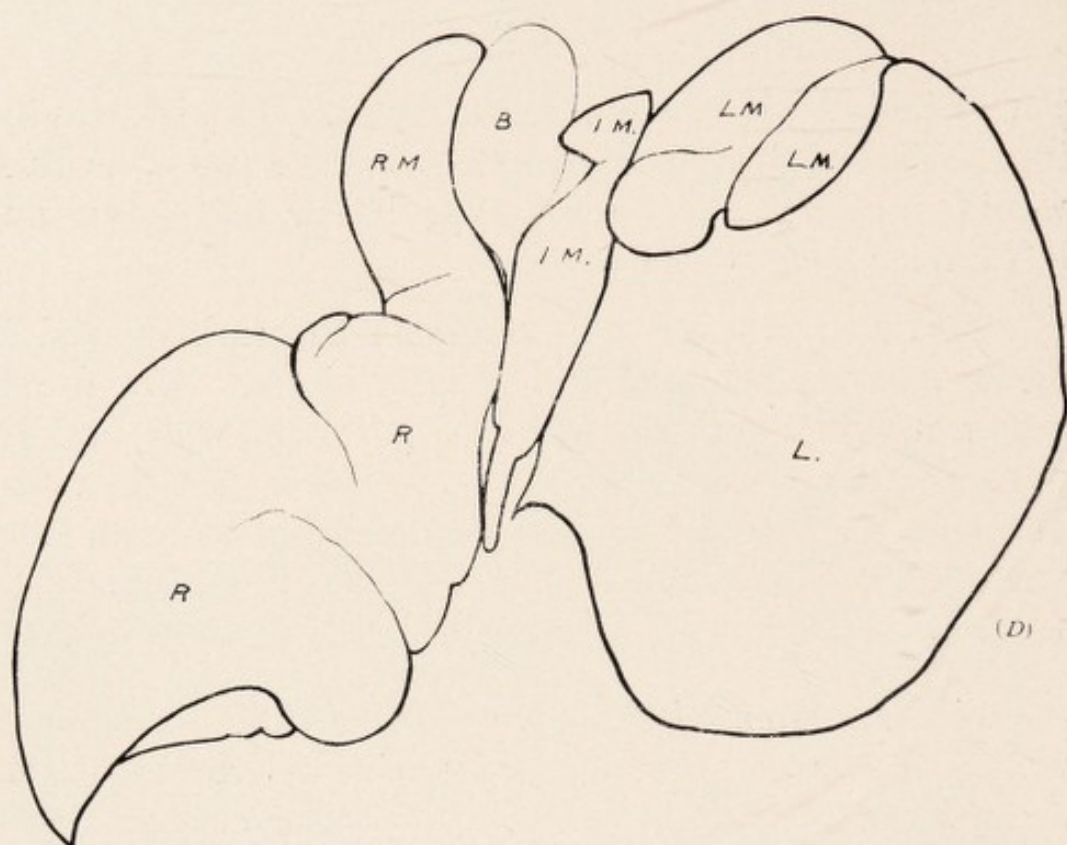
WOMBAT.

portal interval it is a pointed extremity, *i.e.*, is atrophying. Although apparently so primitive, yet this liver would approach the human type if the left cystic and left lateral lobes were linked up.

(*D*) Here the greatest width of the right mesial or cystic lobe was 3.5 cm., and of left 1.5 cm. The dorsal extremity of the left part was only 1-3rd cm. wide, and did not reach the portal interval, *i.e.*, the fissure for the cystic duct and the longitudinal fissure are being merged, since the dorsal portion of the left cystic is disappearing. Thus we see how the lobus quadratus becomes defined dorsally.

Gall Bladder.—This is a somewhat broad sac, measuring, in a large specimen, 4-5 cm. dorso-ventrally, and about 3 cm. laterally. In one male specimen the gall bladder was unusually small, only measuring 2 cm. dorso-ventrally, and 1 cm. laterally. It usually projects beyond the ventral border of the liver, and is lodged in the broad cleft or interval between the right and left portions of the mesial or cystic lobe (corresponding to the right and intermediate of the tripartite mesial lobe), and is seen both on the dorsal and ventral surfaces. It is mobile, being invested by peritoneum completely for the ventral 4-5ths, the dorsal 1-5th being invested on the upper and under surfaces, but bound laterally to the margins of the cleft.

Cystic Duct.—This passes back in the groove on the under surface of the cystic or median lobe, between its right and left divisions, though dorsally portion of the left lateral lobe may take part in its boundary. It extends from the cleft for the gall bladder to the portal interval, and is invested by peritoneum on the under surface and sides being attached above. It measures 4.5 cm. to 6.5 cm. long, and is joined by the hepatic ducts, and becomes the common bile duct.



1119 VISCERAL SURFACE OF LIVER. WOMBAT. (Specimens D, E.)
 B Gall Bladder, L Left Lateral Lobe, R Right Lateral Lobe,
 IM Intermediate Mesial or Cystic Lobe, RM Right Mesial or
 Cystic Lobe, LM Left Mesial or Cystic Lobe.

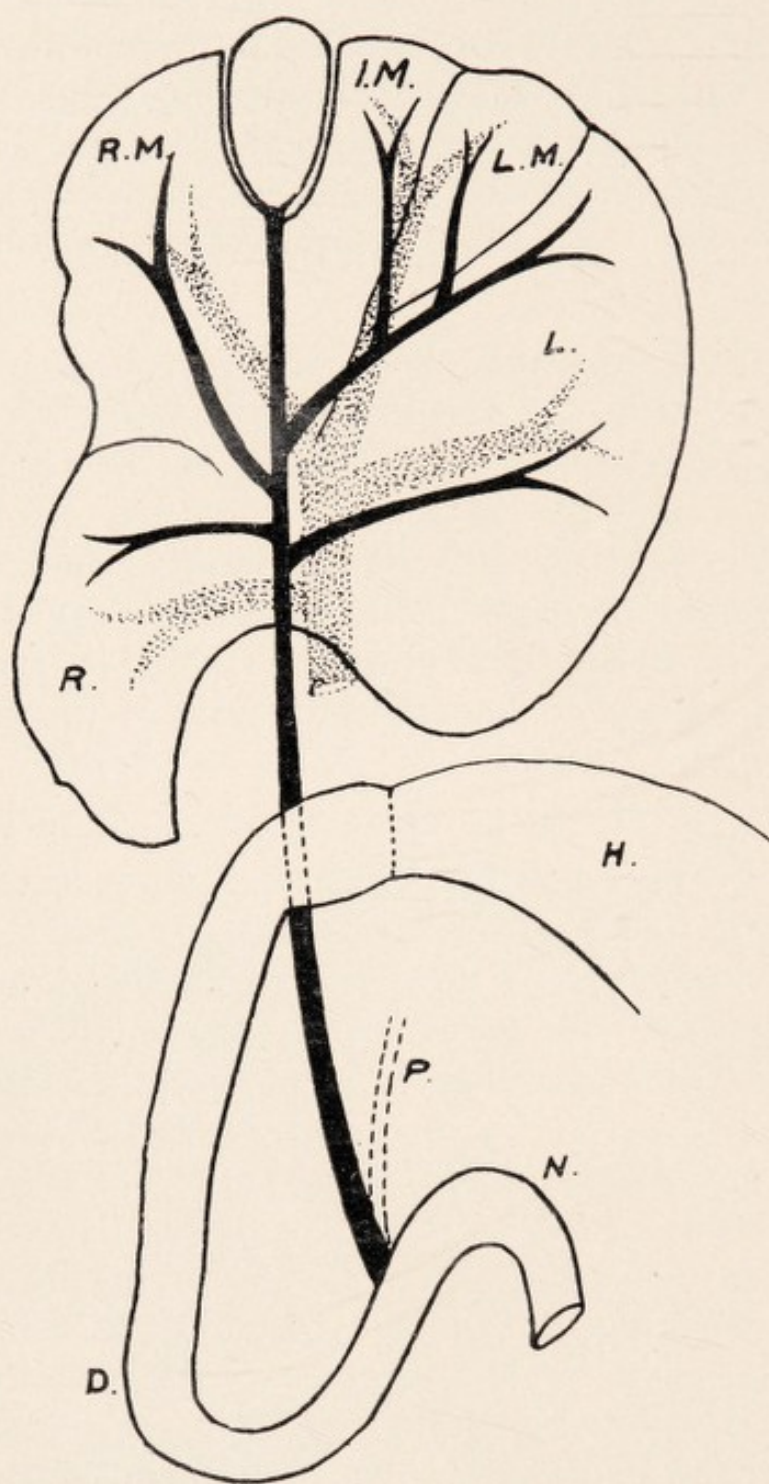
WOMBAT.

Hepatic Ducts.—On the left side two main trunks are seen, the interval between them varying from 1-1.5 cm., viz., a ventral one receiving branches from the left mesial and ventral part of the left lateral lobes—which latter may be absent—and a dorsal branch from the left lateral lobe.

Dextrally, two main branches are also seen, viz., a ventral one from the right mesial or cystic lobe, which may be absent, and a dorsal one from the right lateral lobe, which may receive branches from the right mesial also. The right and left ventral hepatic ducts join the cystic between the right mesial and thin part of the left mesial, *i.e.*, before reaching the portal fissure. The right and left dorsal hepatic ducts join at the portal interval.

Common Bile Duct.—This duct, formed by the junction of the cystic and hepatic ducts, passes with the hepatic artery and portal vein (which is placed dorsally), on the inner side of the right lat. lobe, and in front of the spigelian projection from the right lobe, when that is present. It is traced on the right of the gastro-hepatic omentum behind the pylorus and commencement of the duodenum, and descends in the substance of the pancreas, from which it has to be dissected—within the duodenal loop—to finally terminate in the ascending limb of the duodenum lying nearer to the duodeno-intest. flexure than to the duodenal bend. It may even terminate just proximal to the flexure. The width of the common duct is .75 cm., and its length measures 9-10 cm., so that from gall bladder to duodenum equals 14-16 cm.

Pancreatic Duct.—A dissection of this structure on the right side, where it is related to the common duct, is at first associated with some little difficulty. Passing from left to right it forms a bend, and is traced running



BILIARY AND PORTAL SYSTEMS. LIVER. WOMBAT.

H Stomach, D Duodenum, N Duod.-Intest. Flexure, P Pancreatic Duct, L Left Lateral Lobe, R Right Lateral Lobe, IM Intermediate Mesial or Cystic Lobe, RM Right Cystic Lobe, LM Left Cystic Lobe.

WOMBAT.

down within what may be regarded as the head of the pancreas parallel, and to the left of the common duct. About 3-4.5 cm. from the termination of the latter the pancreatic duct comes into close relation with it, becoming adherent to its wall, although it can be separated by careful dissection right down to the intestine.

As the wall of the pancreatic duct is thinner than that of the common duct it can be easily torn. It finally terminates with the common duct at the summit of a well defined papilla in the interior of the duodenum, which lies about 14-16 cm. from the pyloric sphincter. From this papilla a probe can be passed directly into either the common or the pancreatic duct. The common duct is usually about twice the size of the pancreatic duct.

Lesser (Gastro-Hepatic) Omentum.—The right margin is defined on account of the comparative dorsal fixation of the right pancreas, whilst the left margin is more defined than in the other Marsupials. It is for the most part attached above to the portal fissure, and is traced on the left to the œsophagus, lying dorsal to the mesial projection on the inner margin of the left lateral lobe.

Portal Vein.—The first branch is a well defined branch on the right to the right lateral lobe. More ventral is a large branch, on the left, to the left lateral lobe. Finally, two smaller branches are noted, one on right to the right mesial, and one on the left, to left mesial and ventral part of the left lateral lobes.

Pancreas.—Of all the Marsupials and Monotremes the pancreas of the Wombat is the one that most resembles the human type. A head, body, and, in many cases, a tapering left portion, or tail, may be distinguished. It is compact, and extends from the duodenal loop on the right to the spleen on the left side. The

WOMBAT.

main mass of pancreas (the head) is found applied to the left of the upper half of the descending limb of the duodenum, though pancreatic tissue is found filling the duodenal loop as well. It is not found extending along the common duct to the portal fissure. The head is characterized by a forward projection on the ventral surface. Though there is a limited amount of mobility allowed the duodenum, nevertheless the head and commencement of the body of the pancreas (which latter lies above the root of the mesentery) may be regarded as fixed dorsally—the cephalic mass lying opposite the gap between the right and left lobes of the liver. The body of the pancreas might be best described as a process passing from about the middle of the left margin of the head across the epigastric region above the root of the mesentery and the duod-intest. flexure to the left hypochondrium, and slightly narrowing as the inner or right surface of the spleen is reached. I have seen the reverse, *i.e.*, a narrow right body and a broad left. In an adult the body was 6 cm. long, and the head measured 10 cm. long, and 3 cm. across, while the left extremity, which was much thinner, was 2-3 cm. broad. Pancreatic tissue is found extending in the right of the gastro-hep. omentum towards the liver in relation to the common bile duct. As it passes to the left of the root of the mesentery to the mesocolon it is seen to form the lower boundary of the lesser sac—not being, however, itself included. On the left side it may send a small process to be included in the lesser sac. The important point is that outwards from the root of the mesentery to the spleen the pancreas (*i.e.*, really the body and tail) is movable, since it can be lifted with the spleen from the dorsal wall and the front of the upper part of the left kidney, to which it lies ventral. It lies in relation to the left lateral or lieno-mesocolic fold, which is seen to be somewhat tri-

WOMBAT.

angular in shape. Above, the fold is attached to what may be regarded as the left post. process of the spleen. Its left margin is free, and below it is attached to the caudal pole of the left kidney. Occasionally the left portion of the pancreas may be more compact and more fixed dorsally. The greatest length of the pancreas from side to side is 11 cm.

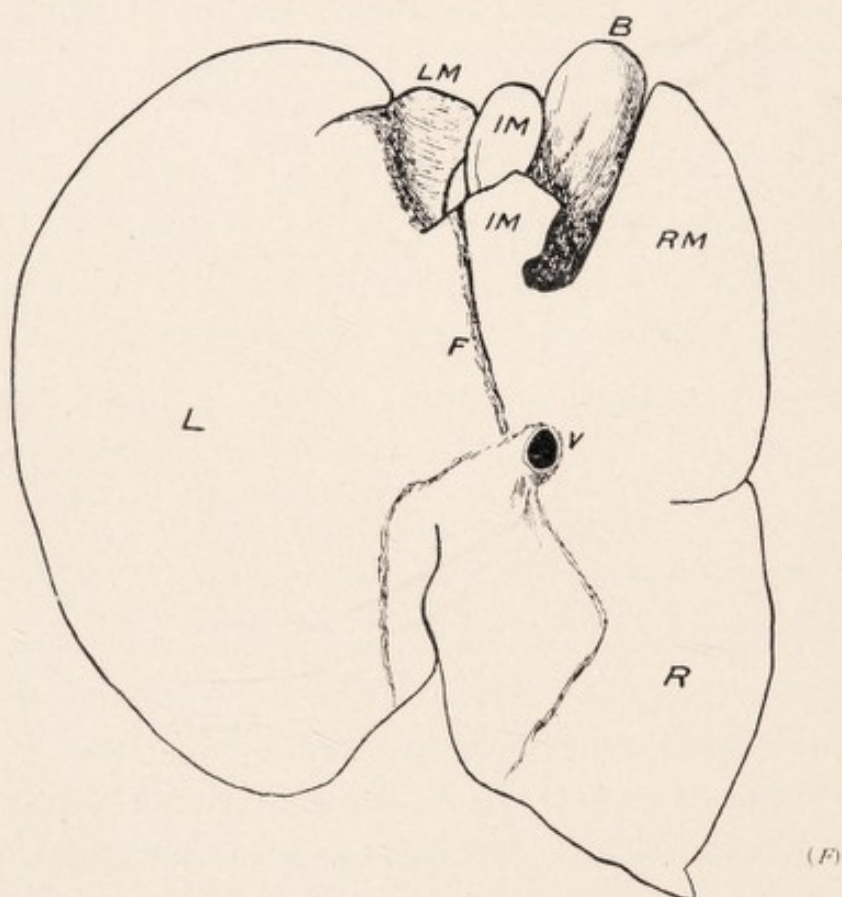
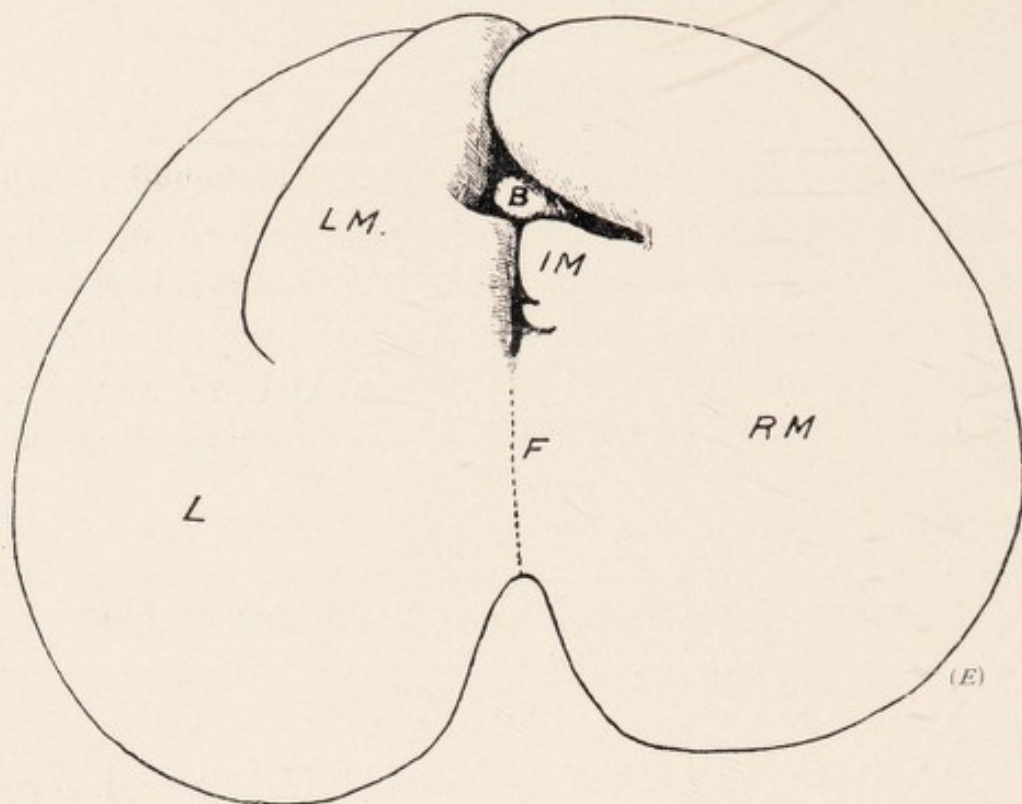
Notes on Diagrams of Visceral Surface of Liver.

Wombats (A. and D.).

Specimen (A).—The portions L.M., though representing the left mesial or cystic of the tripartite cystic lobe, are now part of the left (lateral) lobe, as is definitely shown on the diaphragmatic aspect. The anterior portion is still separated at ventral margin by a fissure, but on the visceral surface there is only a groove between the two, which is not seen diaphragmatically. The longitudinal fissure is between the portions I.M. and L.M.

I.M. represents the intermediate cystic or mesial of the tripartite, but is now L.M. The longitudinal fissure corresponds to the cystic or mesial fissure of the tripartite cystic lobe and on diaphragmatic surface, as is shown in diagram, it is related to the suspensory ligament.

Specimen (D).—The portion L.M. is now part of the left (lat.) lobe, and should be labelled L. The groove between these two portions, L.M., and the large portion, L., represents the old left lateral fissure. I.M. represents the intermediate lobe of the tripartite cystic lobe, and is now L.M. Its left boundary—the longitudinal fissure—represents the old mesial or cystic fissure, and is connected on diaphragmatic surface with the suspensory ligament.



DIAPHRAGMATIC SURFACE OF LIVER. WOMBAT.
(Specimens E, F.)

B Gall Bladder, IM Intermediate Mesial or Cystic Lobe, RM Right Mesial or Cystic Lobe, LM Left Cystic Lobe, L Left Lateral Lobe, R Right Lateral Lobe, V Inf. Vena Cava, F Relation to Diaphragm.

WOMBAT.

Notes on Liver of Wombat.

Specimen E.

In this specimen I was struck by the large relative size of the left and mesial lobes compared with the right lobe.

The measurements were:—

	Laterally.		Dorso-ventrally.
Right Lobe	7 cm.	..	5 cm.
Mesial	16 cm.	..	13 cm.
Left Lobe . .	13 cm.	..	15 cm.

In this large specimen interesting light is thrown on the evolution of the mesial lobe in *Phascolomyidæ*.

Visceral Surface.—The small right (lat.) lobe, large left (lat.) lobe, and the mesial or cystic, consisting of two main divisions, were all distinguishable—the left lobe of the mesial being mainly occluded, however, by the left lat. lobe, which projected as far dextrally as the visceral surface of the right mesial. The lower part of the original left mesial has fused to the left (lat.) lobe, an irregular depression being between the two. The left mesial now consists of the upper original part of the left mesial and the lower part of the intermediate mesial, only a partial fissuring being between the two. This left mesial is separated from the left (lat.) lobe by the original left lat. fissure above, and the remains of the mesial or cystic fissure below, and as will be seen on the diaphragmatic surface, the upper part of the intermediate mesial or cystic lobe (*lobus quadratus*) has almost disappeared.

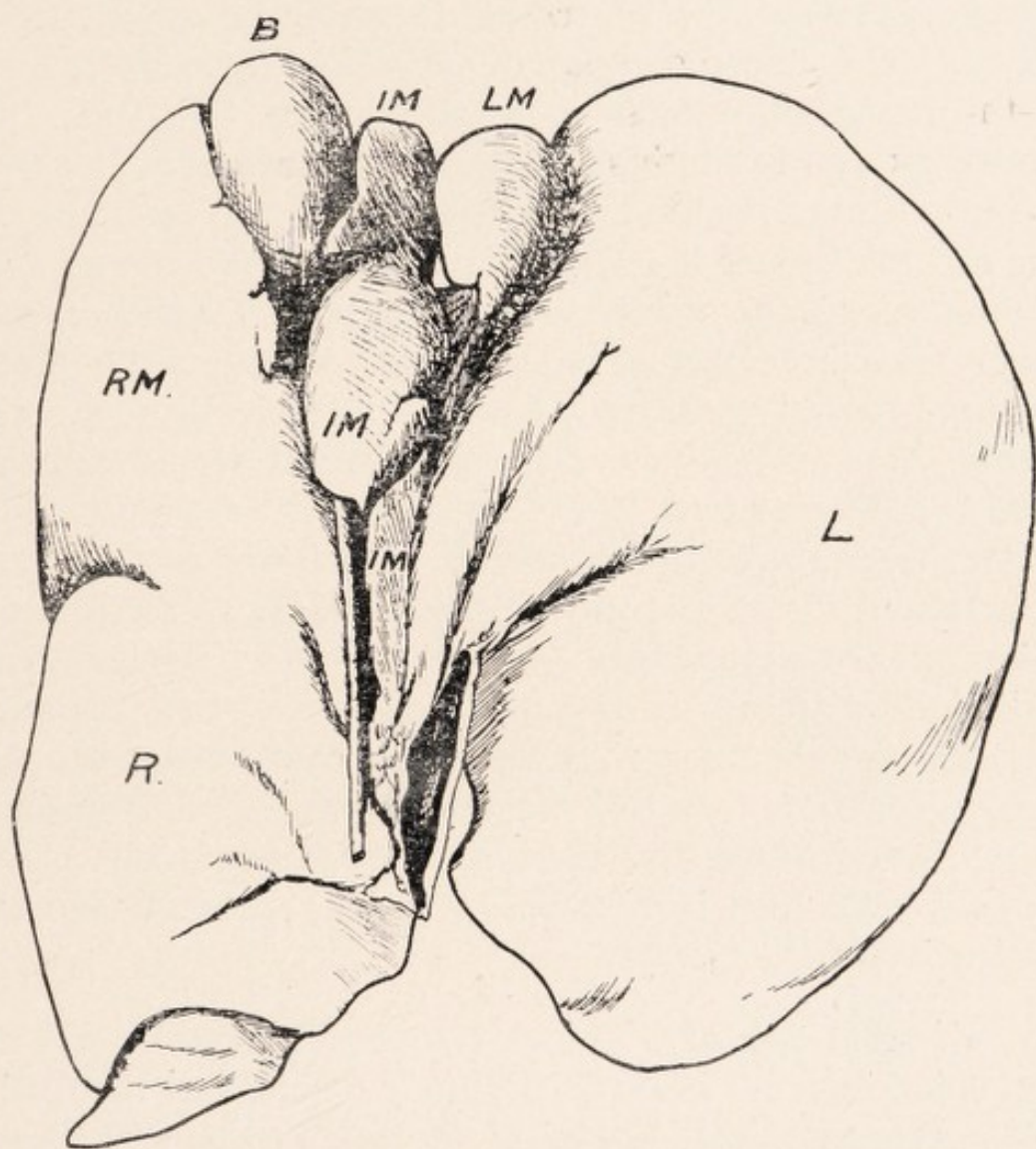
Diaphragmatic Surface.—Between the mesial and right lobes is the complete right lateral fissure. (Not shown in the diagram.) It measures 6.5 cm., and between its dorsal extremity and the inf. v. cava are 5 cm. of

WOMBAT.

hepatic tissue. The left lateral fissure, complete, between the left (lat.) and left mesial lobes (shown in diagram) measures 8 cm., and between its extremity and the dorsal margin are 5 cm. of hepatic tissue. On this aspect we are struck by the large relative size of the mesial or cystic lobe to the right of the suspensory ligament, which laterally measures 12 cm., while on the left it only equals 5.5 cm. Three portions of the cystic or mesial lobe are described, viz., large right mesial, small left mesial, and the insignificant intermediate mesial (lobus quadratus). Only a remnant of the cystic or mesial fissure (*i.e.*, between the intermediate and left mesial lobes) is seen, and measures 2 cm. To it the suspensory lig. runs from the inf. v. cava. Anteriorly it becomes part of the gall bladder cleft, which is 2.5 cm. long, and .5 cm. laterally. The gall bladder is seen projecting on the two surfaces of the liver. Between the cystic fissure and the gall bladder cleft is a triangular projection, the remains on this aspect of the intermediate mesial lobe (*i.e.*, lobus quadratus). It measures 3 cm. long, and 2.5 cm. laterally, *i.e.*, it has almost disappeared. The left mesial will fuse, as has partially happened on the visceral surface, to the left (lat.) lobe; and the suspensory lig. will pass to the gall bladder fissure with the final disappearance of the intermediate mesial lobe.

(Specimen F.)

Diaphragmatic Surface.—The liver measures laterally 14 cm., and the right and left lateral fissures, *i.e.*, between the mesial or cystic lobe and the right and left (lateral) lobes have practically disappeared, being only represented by fissures about 1.25 cm. long. Interest chiefly centres round the ventral portion of the mesial or cystic lobes. We distinguish firstly on the right the cleft for the gall bladder, 4 cm. dorso-ventrally, and 2 cm.



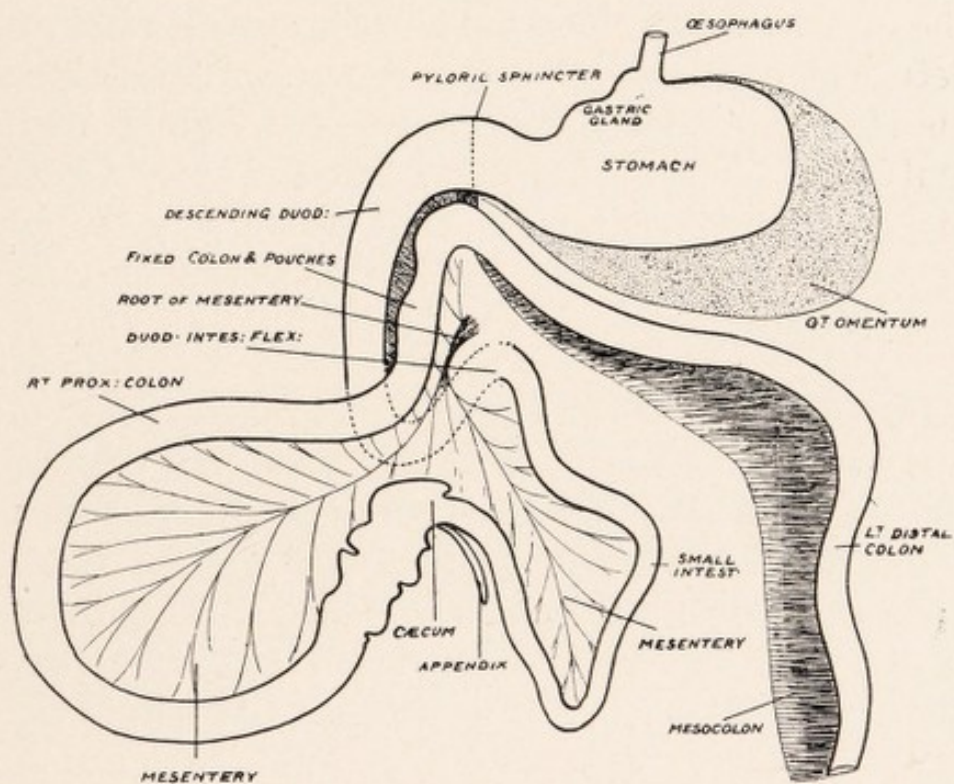
VISCERAL SURFACE OF LIVER. WOMBAT. (Specimen F.)

B Gall Bladder, L Left Lateral Lobe, R Right Lateral Lobe,
IM Intermediate Mesial or Cystic Lobe, LM Left Cystic Lobe,
RM Right Cystic Lobe.

WOMBAT.

laterally. To the left of this two portions are seen, which are continuous on the visceral surface, but are separated on this aspect by a partly fibrous depression or groove. These represent the intermediate cystic or mesial lobe. To the left of these two parts another short fissure is seen—the intermediate mesial or cystic fissure. Between the dorsal extremity of this and the inf. v. cava runs the suspensory lig. Between this fissure and the remnant of the left lat. fissure is a small flat portion—the remains of the left mesial or cystic portion of the tripartite cystic lobe. It is here part of the left (lat.) lobe, and the intermediate mesial portions are really left mesial. As regards these two intermediate portions it would appear that the anterior part (2 cm. long, and 1.25 cm. laterally) is atrophying and separating off—the lower part (2 cm. long, and 1.75 cm. laterally) corresponding to the human lobus quadratus, *i.e.*, between the suspensory lig. and the gall bladder cleft. With subsequent atrophy of this portion the gall bladder cleft would be connected with the suspensory lig. In this direction evolution is trending, and without doubt the atrophied lobus quadratus occasionally described in connection with the human liver is indicative of the trend.

Visceral Surface.—As on the diaphragmatic surface the chief interest is centred round the mesial or cystic lobe. Here the lower parts of the left mesial and intermediate have become incorporated in the left (lat.) lobe. Ventrally, the remains of the left mesial, 2.5 cm. long, and 1.5 cm. laterally, is seen, and in spite of a depression on this aspect and the slight fissuring on the ventral edge it has become incorporated into the left (lat.) lobe. So that as a distinctive portion the left mesial or cystic lobe has disappeared, having become incorporated in the left lat. lobe. The intermediate lobe (now the left mesial or cystic) is separated on the left side by a narrow cleft or



THE GASTRO-INTESTINAL TRACT OF WOMBAT.

WOMBAT.

fissure ventrally, and a depression dorsally. To the cleft, as stated, runs on the diaphragmatic surface the suspensory light. The cleft, or fissure, and the depression represent the mesial or cystic fissure of the tripartite lobe. The depression, or groove, does not run, however, to the portal fissure, *i.e.*, to portal vein, since the dorsal part of the intermediate has, with the left mesial, joined the left (lat.) lobe. The elongated remaining intermediate lobe shows constrictions indicative of atrophy. With atrophy of the narrow ventral portion a "lobus quadratus" would be left, which also shows a fissure, so that great instability is characteristic of the intermediate mesial and left mesial lobes. The intermediate cystic (now left cystic or mesial) is separated from the right mesial or cystic by the cleft for the gall bladder, and a well defined fissure for the cystic duct.

Portal Vein.—At the portal interval the width of the portal vein was 4 cm. Dorsal to it lay the cystic duct. This corresponded to the division of the vein—seen from the interior—into two main parts. From the left, branches passed to the right (lat.) lobe and intermediate lobe, and from the right to the right mesial or cystic, and to the right (lat.) lobe. The two circulations were distinctive.

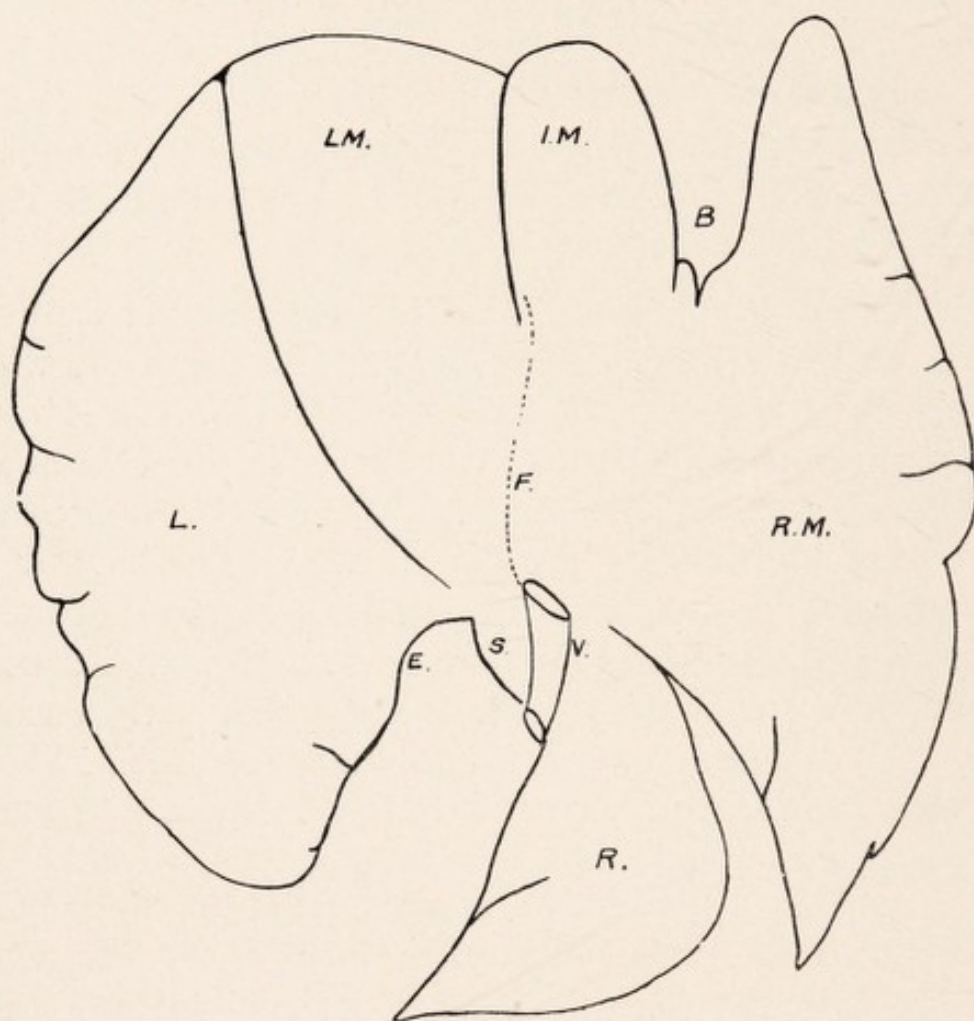
LIVER OF KOALA.

(PHASCOLARCTOS CINEREUS.)

Diaphragmatic Surface.—Three lobes are recognised on this aspect, viz., large mesial or cystic, and the right and left lateral lobes.

Right Lateral Lobe.—This is much smaller than the left lateral—having a greatest length of 9.5 cm., and width (laterally) 6 cm.—and is prolonged downwards into the lumbar region as a pointed extremity. It presents one or several fissures on this aspect. At the basal or attached portion of its inner or left margin we see the hepatic relationship of the inf. v. cava, 2 cm. long, the wall of which is usually distinguishable throughout, though in some specimens strands of hepatic tissue may partly occlude this. A portion of the spigelian lobe is seen to the left of the vein. This lobe is separated from the mesial or cystic by a fissure—right lateral—which may extend to the left almost as far as the inf. v. cava. On the other hand, the fissure may extend internally only for 3.5 cm., while between this and the vena cava is liver tissue for 3 cm. In other words, the right lobe and the mesial may be one, apart from an interval of 3.5 cm. The exit of the vena cava practically corresponds to the point of convergence of all three hepatic lobes.

Mesial or Cystic Lobe is the largest of the three lobes, and in one specimen, where the right lateral lobe was well separated from the cystic, it measures 18 cm. dorso-ventrally, and 14 cm. laterally. It presents three divisions, viz., a large right portion—small intermediate—and a left portion, usually mesial in size, between the two, al-



DIAPHRAGMATIC SURFACE OF LIVER. KOALA.

B Gall Bladder Cleft, RM Right Mesial or Cystic Lobe, IM Intermediate Cystic Lobe, LM Left Cystic Lobe, F Suspensory Ligament, L Left Lateral Lobe, R Right Lateral Lobe, E Cleft for Oesophagus, S Spigelian Lobe, V Inf. Vena Cava.

KOALA.

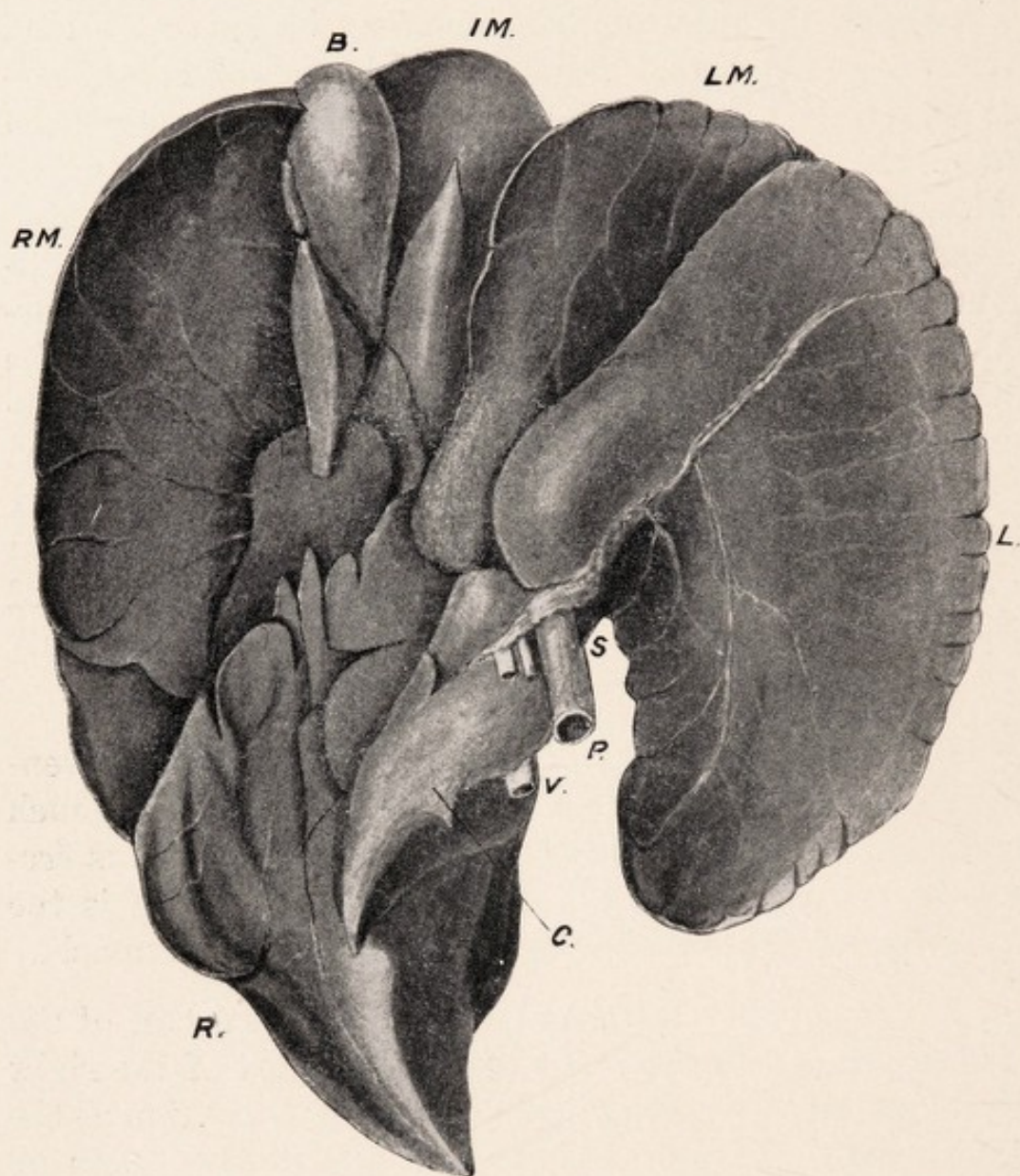
though occasionally the left lobe is the smallest of all. Along its right edge numerous small fissures may be observed, and the intermediate lobe may be partly divided into two by a fissure. Between the large and intermediate lobes a cleft is seen, where the gall bladder is described dorsally. Anteriorly this cleft measures 2.5 cm. in width, while posteriorly it narrows—its length ventro-dorsally is 5 cm. A well defined fissure separates the intermediate portion of the mesial lobe from the left portion. Traced from the back of the left portion at the inf. v. cava towards the posterior extremity of this fissure, along the right of which it may be traced for 1 cm., is the mesial or suspensory ligament. It is attached above to the diaphragm, and the length of its hepatic attachment is 3.5 cm. The cystic or mesial lobe is well separated from the left lateral lobe by a fissure extending dorsally to within a short distance of the post hepatic surface.

Left Lateral Lobe.—This may measure dorso-ventrally 14 cm., width laterally 8 cm., so that it is much larger than the right lateral lobe. Its left margin is frequently fissured. On the inner or right margin is the concavity for the œsophagus, on its way to the stomach.

Diaphragmatic Attachments.—The dorsal half of the left lateral, and of the inner and dorsal part of the right lateral are closely attached to the tendinous portion of the diaphragm. In addition, certain suspensory folds or bands may be recognized.

- (1) Mesial described above.
- (2) Right lateral, from the diaphragmatic aspect of the right cystic and adjacent right lateral lobe.
- (3) Left lateral (one or two), from the diaphragmatic aspect of the left lateral lobe.

All these go to the tendinous part of the diaphragm.



VISCERAL SURFACE OF LIVER. KOALA.

B Gall Bladder, IM Intermediate Mesial Lobe, LM Left Mesial Lobe, RM Right Mesial Lobe, L Left Lateral Lobe, R Right Lateral Lobe, C Caudate Lobe, S Spigelian Lobe, V Inf. Vena Cava, P Portal Vein with Duct and Artery.

KOALA.

Visceral Surface.—As on the diaphragmatic surface, we can recognize three divisions, viz., right, mesial, and left, but are struck with the large amount of fissuring, giving rise to divisions scarcely, however, in many cases, deserving the names of lobules. This feature, which at first sight makes a description of this aspect appear difficult, is much more common in some varieties than in others.

Left Lateral Lobe.—This is separated from the mesial lobe by the left lateral fissure, which dorsally may reach the inf. v. cava. It is usually smooth, although, as stated, the ventral edge may be fissured. This is associated possibly with rib pressure, as this lobe reaches to the left hypochondrium, and the dorsum is usually indented by the ribs. It is characterized by the presence on its dorso-inner side of a somewhat quadrilateral projection, which stands out for 1.5 cm., and the length of which is 4 cm.—at the dorsal aspect of this the portal vein is seen. This projection, which lies parallel with a somewhat similar projection of the left cystic lobe, forms with it the ventral boundary of the portal interval, while the dorsal boundary is formed by the right lateral and spigelian lobes. These two projections come into relation with the lesser curve of the stomach, dipping into the depression or interval between the left or cardiac, and the right or pyloric, portions of that organ. They lie ventral to the lesser omentum, behind which is the lobus spigelii, and may be regarded as accommodation effects. Owing to its relationship to the fundus of the stomach the visceral surface of the left lateral lobe is concave.

The œsophagus passes down in the concavity on the inner margin, and from the œsophagus along the portal interval passes the lesser omentum (gastro-hepatic), which becomes continuous on the right with the mesoduodenum. It is worthy of note that ventral and lateral

KOALA.

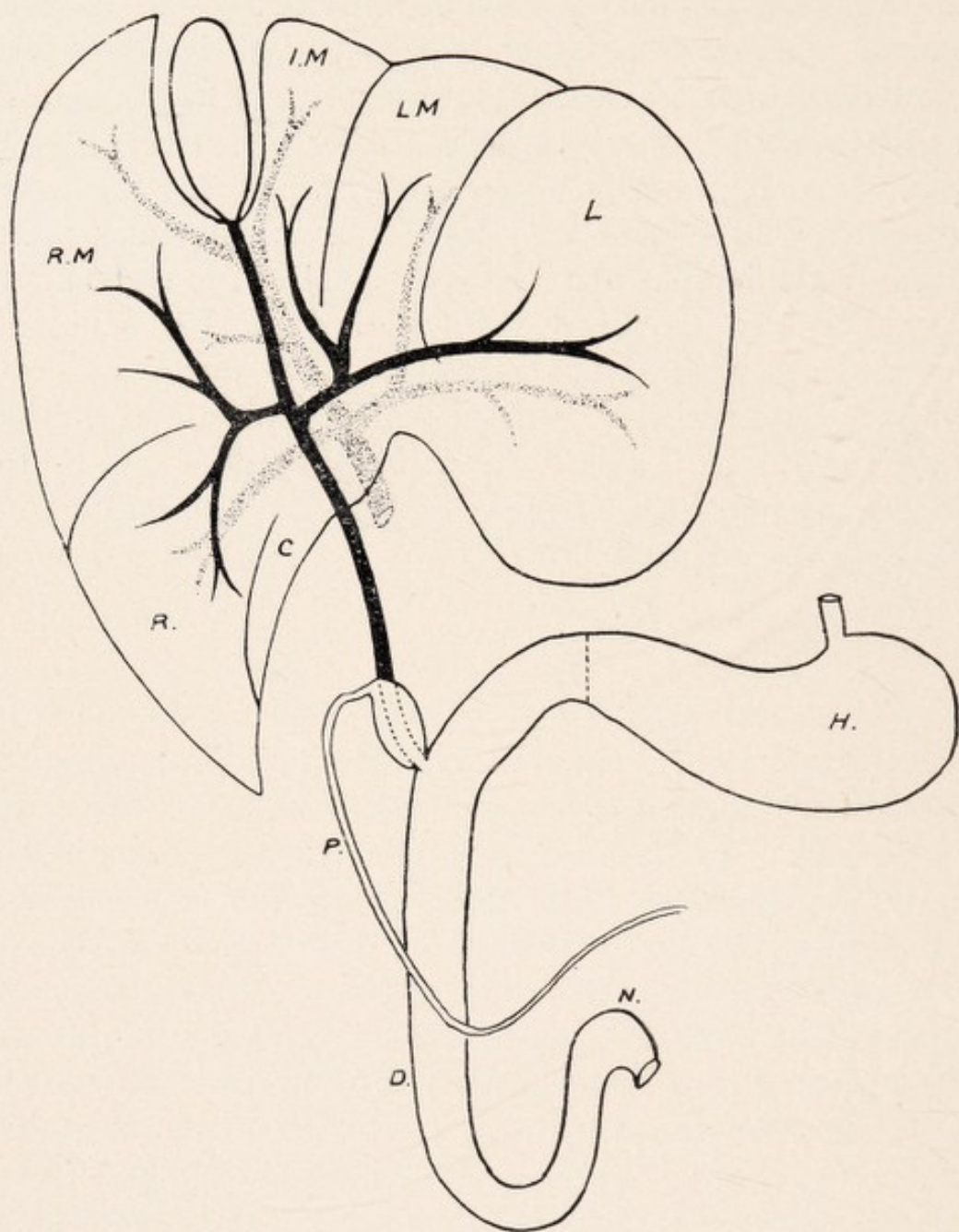
peritoneal bands are noted passing from the region of the lesser curvature of the stomach to the under surface of the left lateral lobe. These are ventral to the lesser omentum, are more developed in some specimens than in others—and may even approach the ventral border.

Mesial or Cystic Lobe.—As on the diaphragmatic aspect, three divisions of the mesial lobe are noted—the right being the largest, and the intermediate portion the smallest. Occasionally, however, the left may be smaller than the intermediate portion. The fissuring and lobulations on this surface of the liver are seen to be characteristic of the mesial and right lateral lobes. The left division of the mesial lobe is usually demonstrable from this aspect, but it may be almost completely hidden by the extension to the right of the left lateral lobe. This portion is frequently fissured ventrally, and posteriorly it narrows, presenting a projection lying parallel with the somewhat similar projections of the left lateral lobe. The left lateral fissure separates the mesial from the left lateral lobe, and it may extend to the inf. vena cava dorsally. Between the left cystic projection and the dorso-int. part of the right cystic is the dorsal part of groove for the cystic duct. The small intermediate portion of the cystic lobe is frequently divided into two lobules by a fissure. On its left is the fissure corresponding dorsally to the suspensory lig., and separating from it the left part of the cystic lobe, and on its right it is hollowed, forming part of the cleft lodging the gall bladder. Dorsally on this lobe we notice a sharp pointed projection, and between this and a projection on the right cystic is the commencement of the groove in which the cystic duct is lodged. The right or large portion of the mesial or cystic lobe presents abundant fissuring and lobulation. It is separated from the right lateral lobe by the right lat. fissure, which is well defined on this face. The fissuring

KOALA.

is simplified by a description of the right and left edges. The right margin may be devoid of fissuring—we may see one well defined fissure practically separating this part into two divisions, or we may see a series of small parallel fissures in the lower half separating off small lobules. Along the left, or gall bladder edge, fissuring is always present. The fissures vary from four to six, and usually three to five lobules are present, forming the right boundary of the gall bladder and the cystic duct. Dorso-internal it also forms part of the boundary of the portal interval. Thus on its inner side, ventrally, it is separated from the middle cystic by the cleft for the gall bladder and by the proximal part of the depressed groove for the cystic duct, and from the left cystic by the dorsal part of the depressed groove for the cystic duct. Towards its outer or right margin is a groove for the proximal colon.

Right Lateral Lobe.—This is characterized in all cases by its fissuring and lobulation. It is prolonged to a somewhat pointed extremity, and is hollowed below for the reception of the kidney. Like the right cystic, the main fissuring and lobulation are on the inner or left margin, and the right outer margin may present fissures, or be devoid. I have counted no fewer than eight lobules on the inner side, and of the lobules two are well defined. The upper of these two forms part of the boundary of the portal fissure, and the lower forms a somewhat mobile projection on the mesial part of the surface, and is the caudate lobe. The caudate lobe takes part below in the formation of the concavity for the reception of the kidney and is prolonged obliquely inward as the somewhat flattened small Spigelian lobe. Between the two ventrally is a groove for the passage of portal vein, artery, and duct, and dorsally is the inf. v. cava, the hepatic relationship of which is not seen on this aspect of the liver. The Spigelian lobe, which measures 2.5 cm. laterally and 1.5 cm. greatest



BILIARY AND PORTAL SYSTEMS. LIVER. KOALA.

H Stomach, P Pancreatic Duct, D Duodenum, N Duod.-Intest. Flexure, C Caudate Lobe, R Right Lateral Lobe, L Left Lateral Lobe, RM Right Mesial or Cystic Lobe, IM Intermediate Mesial Lobe, LM Left Mesial Lobe.

KOALA.

width, lies behind the lesser omentum, and on the inner or left side is the œsophagus as it lies in the concavity on the inner margin of the left lobe. The right lateral lobe may project beneath the ventral aspect of the right cystic or be wholly distinct from it. Important relations of the inner part of the ventral surface of the right lateral lobe are the right portion of the stomach and the descending pole of the duodenum, while in a groove near the right margin is the proximal colon. Unlike *Macropus*, the liver of the Koala extends across the upper abdomen from side to side, being found in the epigastric and right and left hypochondriac regions.

The Gall Bladder and Ducts.—The gall bladder is an elongated sac placed in the cleft of the cystic or mesial lobe, between the large right and the intermediate portions, both of which are hollowed for its reception, and it is seen both on the dorsal and ventral surfaces. It may project beyond the ventral margin of the liver. It is more mobile than the human gall bladder, since its ventral two-thirds are completely invested by peritoneum, but usually the dorsal third is more fixed, being only partly invested with that structure and held in relationship with the adjacent liver. It measures about 5.7 cm. dorso-ventrally and 2.5 cm. across when moderately distended. In some cases a cervix may be noted, but in others the cystic duct would appear to arise directly from the sac.

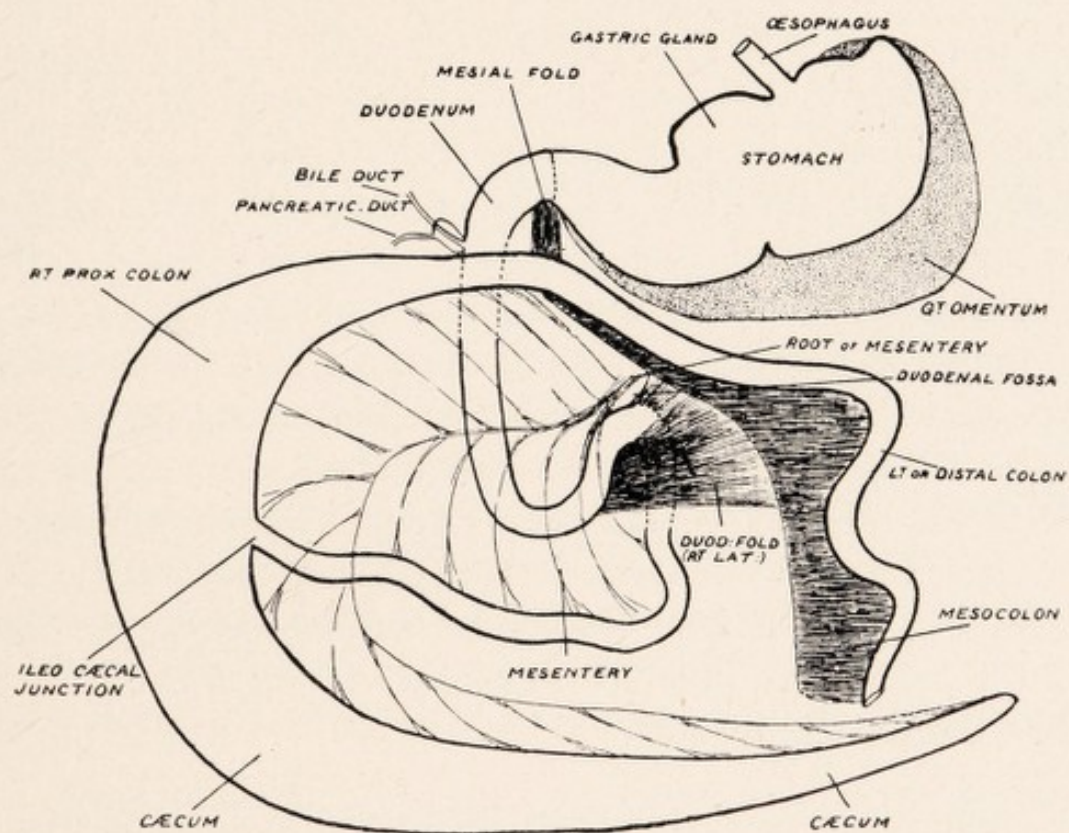
Cystic Duct.—This is lodged in a depressed groove between the inner side of the large right portion of the cystic lobe, and the dorso-internal portions of the intermediate and left portions of the cystic lobe on the left, and it may be necessary to remove parts of these to expose the duct and the dorsal portion of the gall bladder. The duct is closely related to the liver, being invested by peritoneum on the ventral and lateral surfaces only, and in a well

KOALA.

developed specimen may reach 5 cm. in length. At the portal interval, which really corresponds to a space between the three main divisions of the liver the cystic duct is joined by two hepatic ducts and becomes the common bile duct.

Hepatic Ducts.—On the left side the left hepatic trunk is formed by the junction of 2 main branches, one from the intermediate and left cystic, and the other from the left lateral lobe. The right hepatic trunk, which is the more proximal, receives branches from the right cystic and right lateral lobe.

The Common Bile Duct passes down to the duodenum, lying in a groove with the artery and portal vein at the junction of the caudate and spigelian lobes, the portal vein being dorsal to the duct as in the human liver. It runs at first in the right extremity of the lesser omentum, being related to pancreatic tissue, and finally enters the meso-duodenum. In this Marsupial the lesser omentum is definable though continuous with the meso-duodenum. The descending duodenum can be lifted from the right kidney and right lateral lobe of the liver, but the meso-duodenum is short and the right part of the pancreas is relatively fixed, and so a definition is made at the common duct, artery, and vein, between the meso-duodenum and lesser omentum. The length of the common duct is about 5 cm., and it terminates in the descending pole of the duodenum 4-5 cm. from the pyloric sphincter. There may or may not be a slight dilatation before it terminates. Unlike the monotremes and certain of the Marsupials, the pancreatic duct opens into the duodenum independently of the common bile duct.



THE GASTRO-INTESTINAL TRACT IN KOALA.

KOALA.

Pancreatic Duct.—This usually forms a loop on the right side, passing first down with the duodenum and then up to the left towards the spleen. For its terminal 2 cm. the pancreatic duct dilates into a sac measuring 1 cm. across. Dorsal to this lies the common bile duct in close relation with the wall, so that the most careful dissection is necessary to separate them. A probe passed through the common bile duct, however, shows its distinction from the pancreatic sac. On reaching the wall of the duodenum the pancreatic dilatation narrows and runs like the bile duct obliquely through the wall of gut. They open separately into the interior. These openings are noted at the summit of a papillary projection. This may occasionally be absent and the openings only detected after the passage of fine probes. The common duct is nearly three times the size of the pancreatic duct before the dilatation of the latter takes place. The pancreatic duct measures about 13-14 cm. long, and instead of forming a loop on the right it may describe an almost straight course to the left, receiving a well-defined branch from the duodenal portion of the pancreas. This joins the main trunk .5 cm. before the dilatation is reached.

Pancreas.—On the right side a well-defined vertical process is seen, which may be regarded as the head of the pancreas. Its width in a big specimen was 2.5 cm. It does not fill the duodenal loop, though reaching below almost to its extremity. It is placed in the dorsal part of the meso-duodenum in relation with the ascending pole of the duodenum, and is less mobile than the duodenal loop. The important feature is that the pancreas on the right side is becoming dorsally fixed and the meso-duodenum is shortening, although the duodenum can be raised off the right lateral lobe of liver and right kidney,

KOALA.

It is traced upwards as an elongated process in relation with the pancreatic and common ducts towards the liver, so that it comes in relation with the lesser omentum. Traced to the left it narrows to about 1.5 cm., lying in close relation to the dorsal abdominal wall above the duod-intest. junction, and is traced to the left of the distal colon and its mesocolon lying just above the left adrenal gland. It then enters the dorsal wall of the lesser sac. On reaching the spleen, which is suspended on the great omentum, it widens out, forming a piece which measures 5 cm. long and 3 cm. wide, in a well-developed specimen. The upper part of this is related to the body and beginning of anterior thin elongated process, while the lower part is in relation with the short broad left posterior process, beyond which it usually extends. As the lieno-mesocolic fold is absent, this latter process of spleen and pancreatic tissue related to it might be regarded as related to the lesser sac being swung on the great omentum. The pancreas may form a tongue-shaped process extending 3 cm. beyond the confines of the spleen. To sum up, the chief relation of the pancreas is to the short left process and the lower part of the body, of spleen, the upper half of the body and the right elongated omental process being practically devoid.

Portal Vein.—Five main branches are usually to be distinguished. Proximally we notice two, one on each side—the left sending branches to the left cystic or mesial and left lateral lobes, and the right branches to the right lateral lobes. More distally a branch is sent on the right to the right mesial or cystic. The vein finally terminates in two branches, one passing to the right cystic or mesial, and the other to the intermediate cystic lobe.

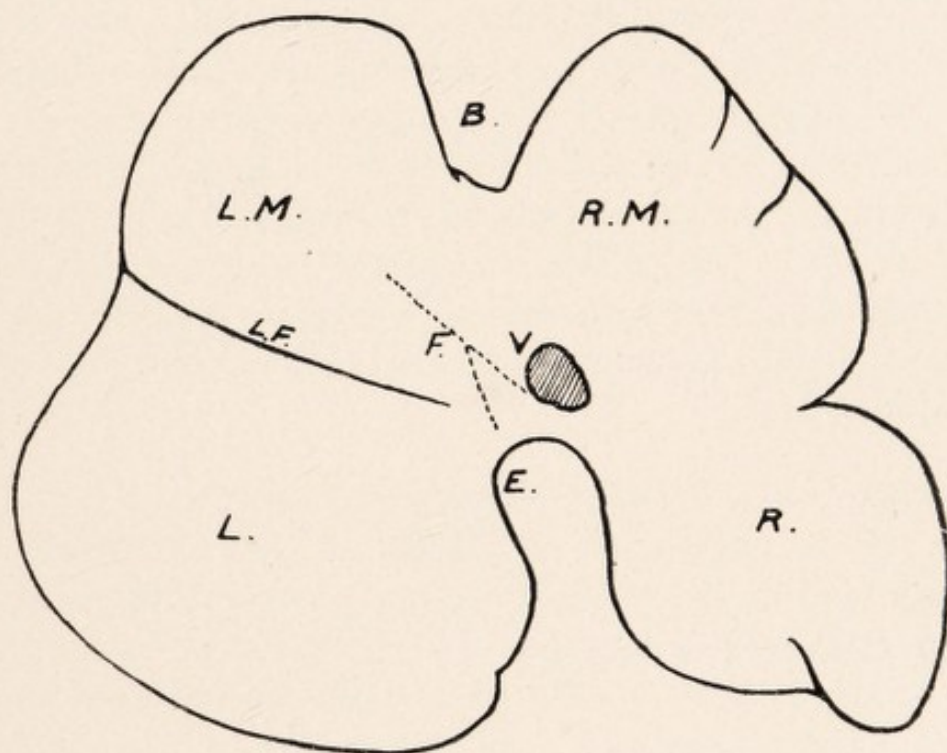
LIVER OF TASMANIAN DEVIL.

(SARCOPHILUS URSINUS.)

Diaphragmatic Surface.—Viewed from this aspect, the liver may present three main lobes or divisions, viz., mesial or cystic, right lateral, and left lateral. In some specimens, however, the right and cystic lobes form a single lobe, so that the liver consists of two main divisions only.

Left Lateral Lobe is larger than the right lateral, and usually projects well forward, forming part of the ventral border of the liver. Occasionally it does not project so far forwards, and practically the whole of the ventral border is formed by the anterior edge of the mesial lobe. This is specially noted in the two-lobed liver. In a well defined case the left lobe measured 14 cm. from before backwards, and 12 cm. laterally. In all cases this lobe is well defined by a left lateral fissure—usually traced internally to the inf. v. cava—from the mesial or cystic lobe. On the inner or right margin dorsally is the concavity for the passage of the œsophagus.

Mesial or Cystic Lobe.—This presents a well marked cleft for the gall bladder, and by this means two portions may be distinguished, viz., right and left mesial, and either of these may be the larger. Occasionally specimens may show subdivisions of either right or left portions. Thus in an adult male specimen I found the right and left portions separated by the cleft and fissure for the gall bladder, and, in addition, two well defined lateral lobes were noted (*i.e.*, four cystic lobes in all), and these were separated by well defined fissures. On the right portion one



DIAPHRAGMATIC SURFACE OF LIVER. TASMANIAN DEVIL.
(Specimen 1.)

B Gall Bladder Cleft, LF Left Lateral Fissure, F Attachments to Diaphragm, V Inf. Vena Cava, E Cleft for Oesophagus, LM Left Mesial Lobe, RM Right Mesial Lobe, L Left Lateral Lobe, R Right Lateral Lobe.

TASMANIAN DEVIL.

or several fissures may be met with, giving rise to several small lobules. Apart from the division formed by the gall bladder cleft the cystic or mesial lobe may be a single mass. As a rule, however, the cleft for the bladder is prolonged as a fissure dorsally. In one specimen the cystic lobe laterally measured 14 cm. and dorso-ventrally 11 cm., and the cleft measured 3 cm. dorso-ventrally and 2 cm. laterally, and was prolonged dorsally as a fissure for 3.75 cm. In another the cleft was 3 cm. dorso-ventrally as well as laterally and without fissure. The gall bladder is well seen in the cleft on this aspect, and at the back of the right portion of the cystic lobe corresponding to the inner extremities of the right and left laterals we see the inf. v. cava emerging from the liver before passing through the diaphragm.

Right Lateral Lobe.—This is the smallest of the three lobes. It is prolonged as a pointed extremity into the lumbar region above and external to the right kidney, and is hollowed below for the reception of the caudal pole of the latter. Usually the right lateral lobe is separated from the mesial by a fissure prolonged obliquely inwards towards the inf. v. cava. In others, beyond a slight lateral fissure, there may be no separation,—the mesial and right laterals forming practically one lobe. In others, with the slight fissuring we may find an irregular depression denoting the site of the old fissure. Thus in the Tasmanian Devil we may have—seen from this aspect—a liver consisting of only two lobes, viz., left lateral and right lobe, the latter being formed by the union of or a failure to separate of the mesial or cystic lobe and the right lateral. The greatest length of a free right lobe laterally is 8 cm., and dorso-ventrally 11 cm. Occasionally the right lobe may be subdivided by a well marked fissure. In some, small fissurings are met with on the right edge.

TASMANIAN DEVIL.

Diaphragmatic Attachments.—The liver is not, as a rule, closely bound dorsally to the diaphragm. Mesially we notice what we may regard as a suspensory ligament—a fine peritoneal fold attached above to the muscular and tendinous portion of the diaphragm, and below to the left portion of the cystic lobe, passing obliquely from the left of the gall bladder fissure to the inf. vena cava and the dorsal margin, and may reach the lesser omentum at the œsophageal concavity. A small fissure may be noted on the left cystic lobe directed to the left, in which the ventral part of the suspensory ligament is lodged. In another there was a small fissure on the middle of the left edge of the gall bladder cleft, and the gall bladder fissure curved out to the left for about 1.5 cm., and to this expansion the suspensory ligament was attached. In the 4-lobed cystic specimen the suspensory ligament runs from the back of the lobe on the immediate left of the cystic cleft, *i.e.*, left mesial cystic. In addition, we notice a series of fine lateral suspensory folds, *i.e.*, from the right lateral and right cystic dorsally to the tendinous part of the diaphragm, and also 3 or 4 fine suspensory folds from the left cystic and left lateral dorsally to the tendinous diaphragm, but none of these pass as far forwards as the mesial suspensory fold.

Visceral Surface.—As variations are met with in the liver of this Marsupial it will be necessary to present two descriptions of this.

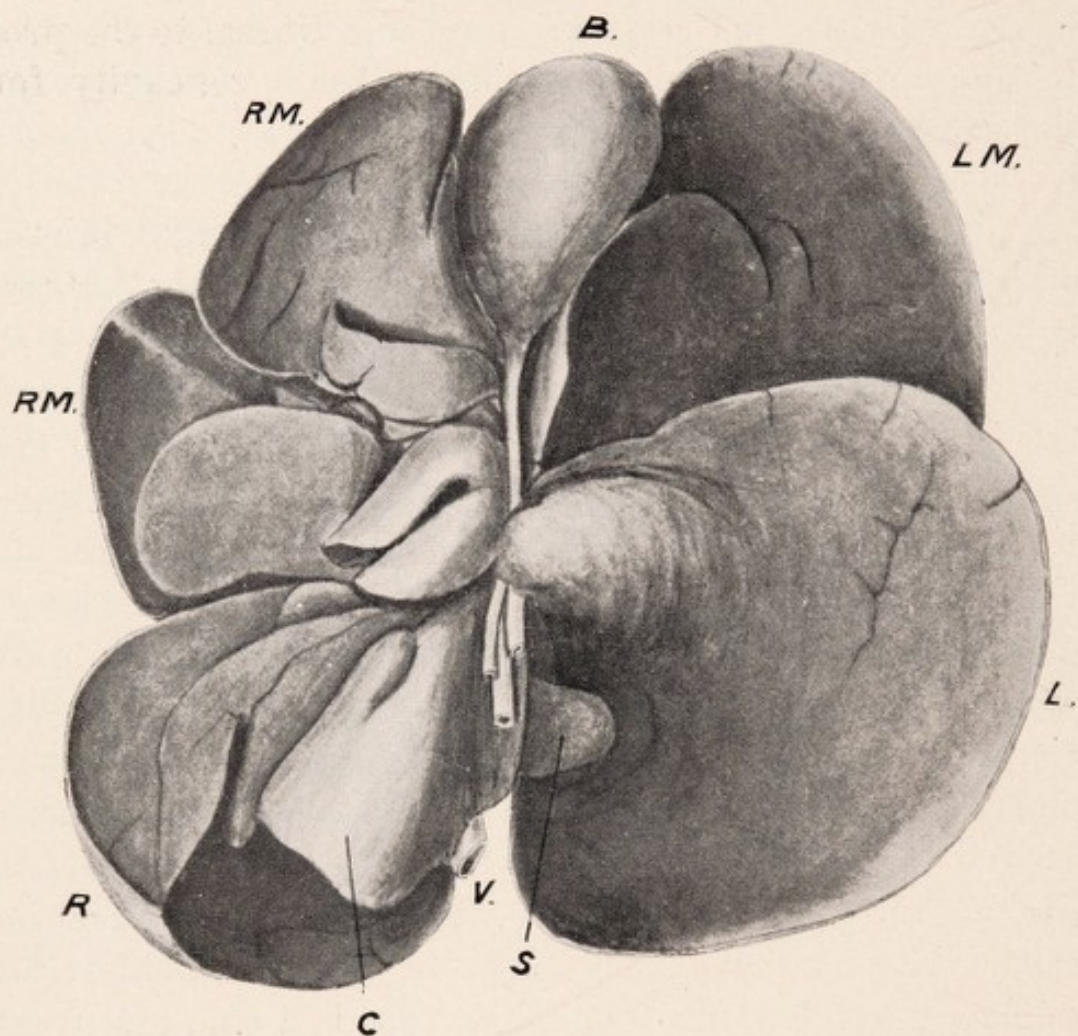
No. 1.—Here on the diaphragmatic aspect right lateral and cystic lobes are practically one. Small variety. Two-lobed liver.

Left Lateral Lobe.—This is separated from the rest of the liver by the left lateral fissure. It is smooth, and does not project forwards to form part of the anterior

TASMANIAN DEVIL.

border. On its inner or right side are one, sometimes two projections—the lower of which when two are present is the larger. The projection is grooved, overlapping the abdominal œsophagus before it reaches the stomach, and on its inner side is the portal interval. Dorsal to the projection along the inner margin, we see a concavity for the passage of the œsophagus.

Mesial or Cystic Lobe.—Although the right lateral and mesial lobes are practically one, yet a distinction can be made between the two by the curved prolongation of the right to the lumbar region, and a depression between the two. It forms the anterior or ventral margin of the liver. On this aspect the cystic lobe presents three portions, viz., a large comparatively smooth left portion, on the inner or right margin of which one or two fissures and an upper and lower projection are noted, while on the right we have two parts usually of almost equal size separated by a fissure which may be distinct or not, and so the cystic lobe may be said to consist of a left, intermediate, and right portions. In one the left lobe was subdivided also into two portions. Between the left and intermediate portions is the gap for the gall bladder, the width of which at the ventral margin is 2 cm., and these portions are hollowed for its reception. The intermediate and right portions are characterised by their fissuring and lobulation, and I have counted here no fewer than 11 lobules. Between the two parts of the right portion on one side and the left portion on the other we see the cystic duct, which is joined by the hepatic ducts at the portal interval. This interval is placed between the lower projection of the left cystic and the inner part of the left lateral lobes on the left side and the internal part of right cystic and right lateral on the right side.



VISCERAL SURFACE OF LIVER. TASMANIAN DEVIL.
(Specimen 1.)

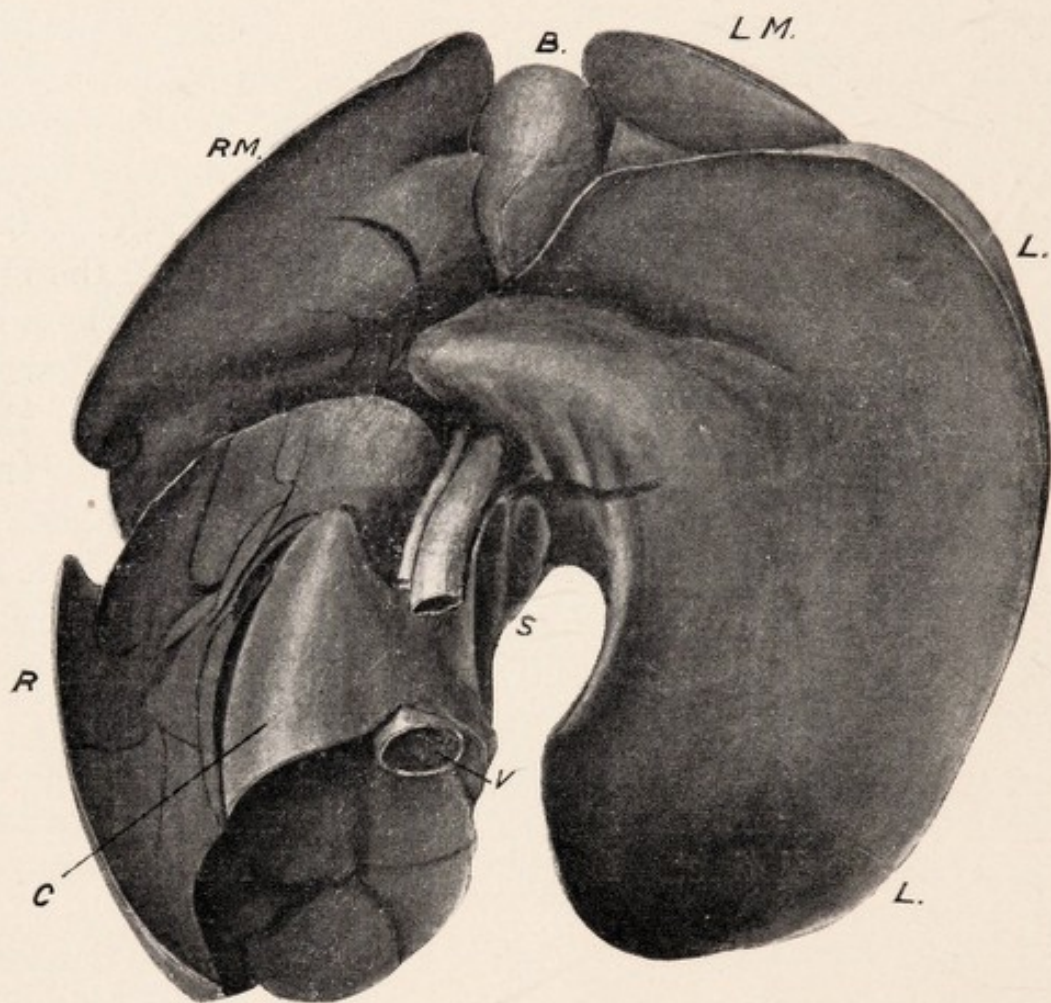
B Gall Bladder, LM Left Mesial or Cystic Lobe, RM Right Mesial Lobe, L Left Lateral Lobe, R Right Lateral Lobe, C Caudate Lobe, S Spigelian Lobe, V Inf. Vena Cava.

TASMANIAN DEVIL.

Right Lateral Lobe.—Though this is described as a separate lobe it really, as stated, is joined with the cystic lobe—the whole forming a large right lobe. It is characterized by its fissuring and lobulation, which is even met with on the renal surface. It is concave below for the reception of the right kidney, and is prolonged external to the kidney as a pointed extremity. Projecting on this right lobe, and forming the ventral part of the concavity for the upper pole of the kidney is the well defined lobus caudatus, 3 cm. laterally, and 2 cm. dorso-ventrally. This is prolonged to the left as a somewhat flattened, though pointed, lobus spigelii, which is traced ventral to the left lobe. Between the caudate and spigelian lobes is a well defined depression, and here, passing down between the two, we have the vein, artery, and duct. Dorsal to the inner extremity of the lobus caudatus is the entrance of the inf. v. cava. As regards its hepatic relationship it is hidden—only the entrance and exit, as described, being visible. The hepatic relationship of the vein measures 4 cm.

No. 2.—Here on the diaphragmatic aspect the three lobes of the liver, viz., right and left lateral, and mesial or cystic, are distinct. Large variety. Three-lobed liver.

Left Lateral Lobe.—This not only forms in the left hypochondrium the left margin, but also takes place in the formation of the ventral margin, and may extend in the epigastric region to the right of the ensiform cartilage. It is smooth, not being characterized by fissuring and lobulation, and presents a projection on the inner side, which forms part of the left boundary of the portal interval, or fissure. It tends to occlude the greater portion of the left part of the cystic lobe, and dorsal to the projection presents on the inner side a concavity for the œsophagus. It is separated from the left part of the cystic lobe by the well defined left lateral fissure, and is concave ventrally for the fundus of the stomach.



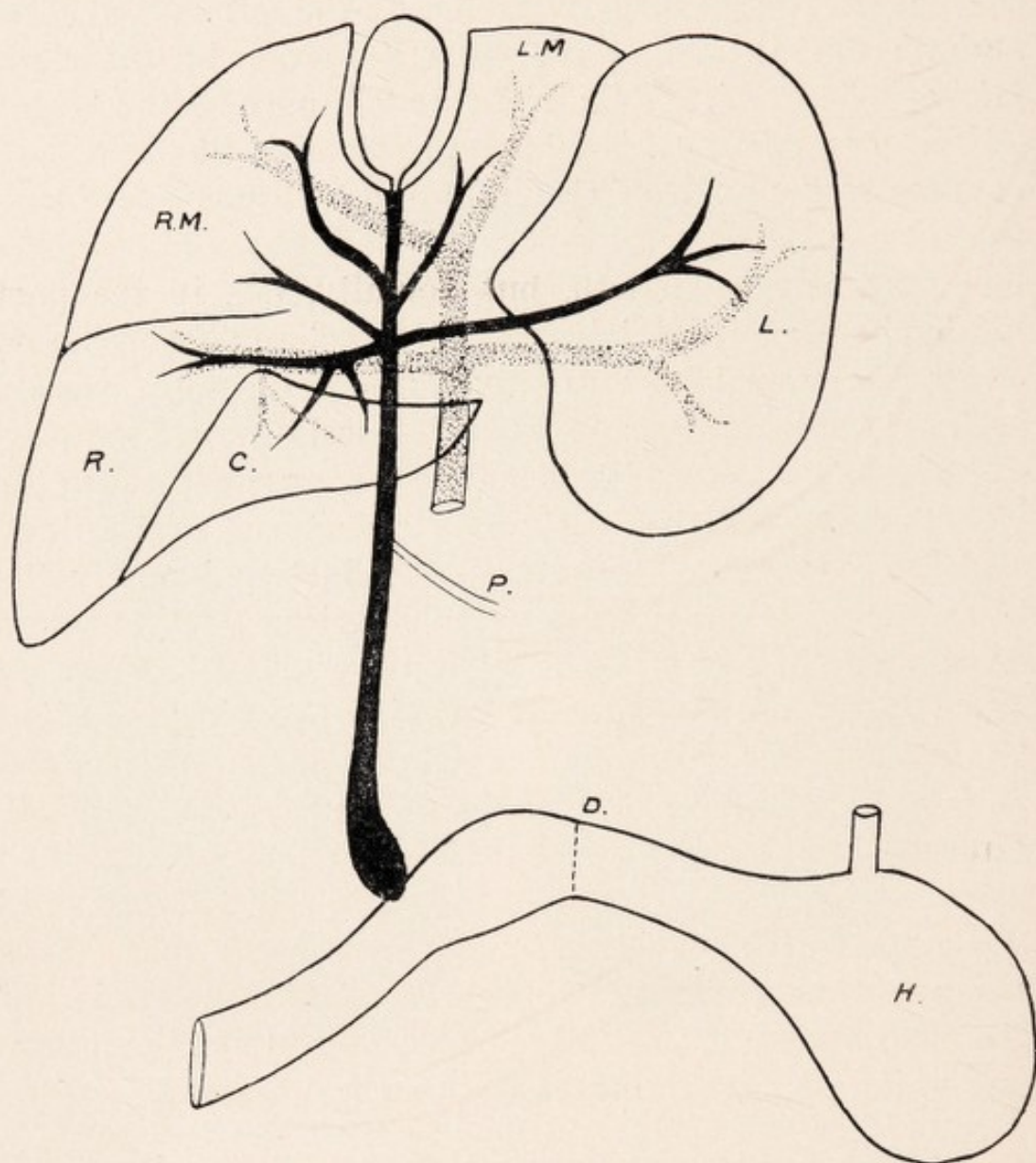
VISCERAL SURFACE OF LIVER. TASMANIAN DEVIL.
(Specimen 2.)

B Gall Bladder, LM Left Mesial or Cystic Lobe, RM Right Mesial Lobe, L Left Lateral Lobe, R Right Lateral Lobe, C Caudate Lobe, S Spiegelian Lobe, V Inf. Vena Cava.

TASMANIAN DEVIL.

Mesial or Cystic Lobe is divided into two parts by the cleft and fissure for the Gall Bladder. The left of these is, as stated, largely hidden by the left lateral lobe, and the dorsal part of the right is hidden by the right lateral lobe. Either the right or left may be the larger of the two portions. The Gall Bladder fits into concavities in the walls of the right and left portions, forming the margins of the cleft. The left part of the cystic lobe ventrally is smooth, but dorsally, *i.e.*, in the part hidden by the left lat. lobe it is lobulated and fissured, and on its inner, or right, extremity three fissures are usually seen, so that an upper or ventral—mesial—and lower, or dorsal portions, are described; the two upper forming the left boundary of the gall bladder cleft and cystic duct, and the lower partly of the cystic duct and partly the boundary of the portal fissure. The right portion shows as a rule no fissuring on the right margin, but is lobulated and fissured on the inner or left side, forming the right boundary of the gall bladder cleft and cystic duct fissure. It is separated by a well defined fissure from the right lateral lobe. It is worthy of note that this right-sided fissuring is not so marked in the three lobed livers as in those where the cystic and right lateral are one. This suggests that a big fissure or interval and separation of the lobes allows of elasticity. With closure of the fissure and union we have numerous lobules and fissures.

Right Lateral Lobe.—By means of a pointed extremity this lobe prolongs the liver down and to the right into the lumbar region, external to the right kidney. Fissuring and lobulation are characteristic of this part. It is noticeable that these, however, are practically confined to the upper and intermediate divisions—the caudate lobe being devoid of fissuring. Three main divisions may be recognized—an upper small division—an intermediate prolonged down and to the right—and a more mobile in-



BILIARY AND PORTAL SYSTEMS. LIVER. TASMANIAN DEVIL.

H Stomach, D Pyloric Sphincter, P Pancreatic Duct, C Caudate Lobe, R Right Lateral Lobe, L Left Lateral Lobe, LM Left Mesial Lobe, RM Right Mesial Lobe.

TASMANIAN DEVIL.

ternal portion—the lobus caudatus—prolonged to the left, as the small somewhat flattened lobus spigelii. Between the caudate and spigelian lobes is a well marked depression, ventral to which pass the portal vein—artery—and common duct. Both the intermediate division and the lobus caudatus form the concavity below for the reception of the kidney. Passing up at the inner and back part of the lobus caudatus is the inf. v. cava. Its hepatic relationship, which is similar to the preceding, measures 6 cm. The œsophagus, on its way to the stomach, passes between the left surface of the spigelian lobe and the concavity of the left lat. lobe. The portal interval corresponds to the interval between the ventro-internal portions of the right and left lateral lobes. Whilst the fundus of the stomach is, as stated, related to the left lat. lobe, the pyloric part of the stomach, and commencement of the intestine, slightly below the duct entrance, are related to the right cystic and right lateral lobes. In the Tasmanian Devil the liver is found in the epigastric and right and left hypochondriac regions, even extending to the right lumbar region.

Gall Bladder and Ducts.—The Gall Bladder may be described as a conical or ovoid sac, placed in the gall bladder cleft in the mesial or cystic lobe. Where the cystic lobe is divided into two parts it lies between the two, but when into three it lies between the left and intermediate lobes. It may or may not project at the anterior edge. The cleft involves the whole thickness of the lobe, and the surfaces forming the cleft are concave. This is more marked in some than in others, and it may be necessary sometimes to divaricate the divisions to see the bladder. Although for the most part completely invested by peritoneum, it is held by peritoneal bands to the lateral boundaries of the cleft. These adhesions rarely extend further

TASMANIAN DEVIL.

forward than the middle of the bladder. The posterior $\frac{1}{5}$ th is closely bound to the liver substance, so that it can only be regarded as invested by peritoneum on the under surface and sides. The Gall Bladder measures 3.5 cm. dorso-ventrally, and laterally, when collapsed, 2 cm.

Cystic Duct.—This measures about 2 cm. in length, and runs in a depression or channel between the left part of the cystic on one side, and the fissured and lobulated inner part of the right division on the other. It is joined by four main hepatic ducts from the liver, and becomes the common bile duct. The portal interval, where this union takes place, is situated between the ventro-inner projection of the left lat. lobe, the ventro-inner part of the right lat. lobe, and the dorso-inner parts of the right and left cystic lobes. To see the junction of the ducts it may be necessary to detach portions of the right or left lobes.

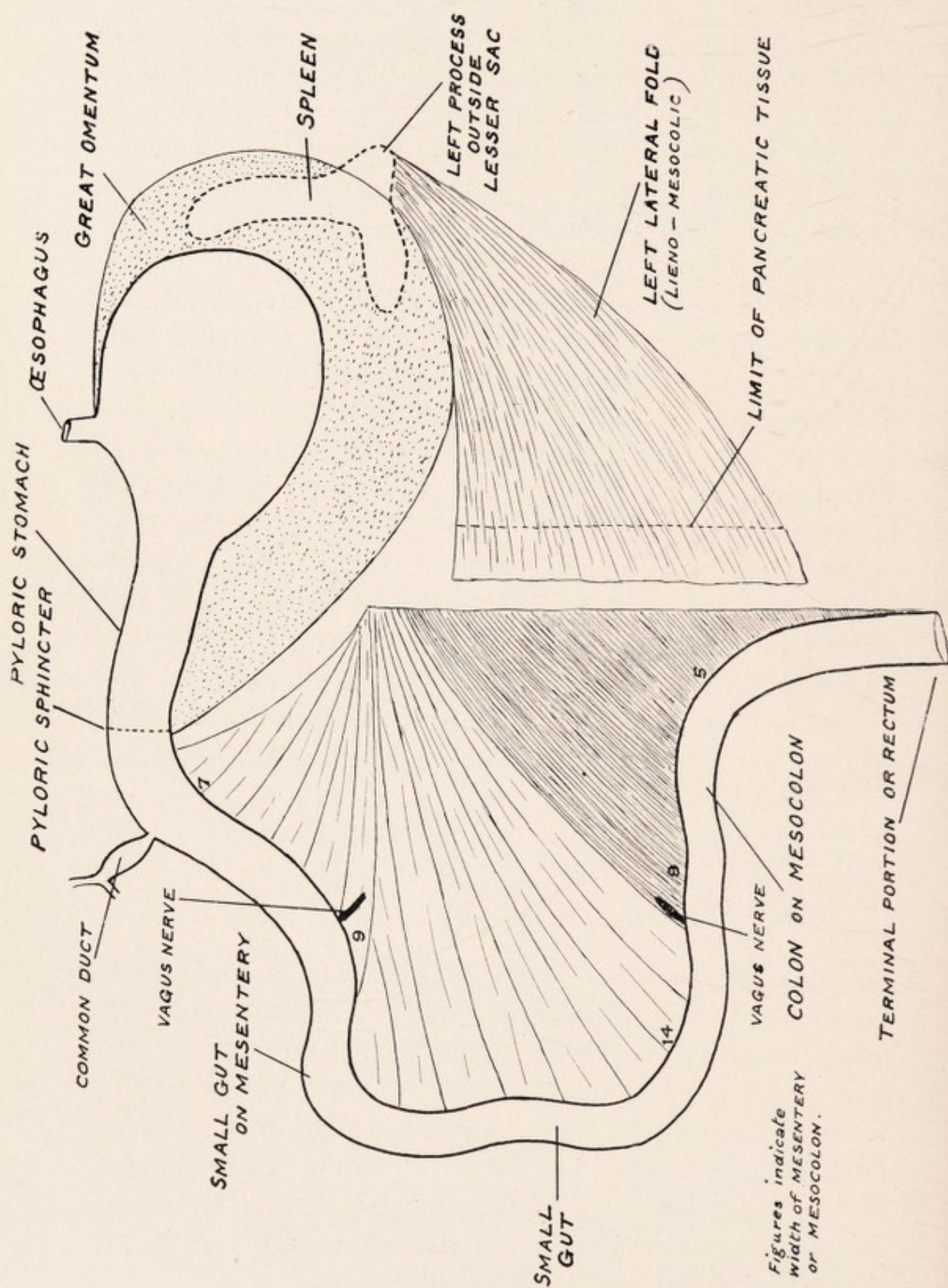
Hepatic Ducts.—On the left side we notice a smaller ventral branch from the left mesial lobe, and a larger dorsal branch from the left lat. lobe. On the right side we note a small branch ventrally from the right mesial, or from the intermediate mesial or cystic and ventral part of the right mesial, and a dorsal branch from the right lateral and caudate lobes, which receives, near its termination, a branch from the lower part of the right cystic, or right part of the mesial.

The Common Bile Duct, with the portal vein dorsally, and the artery dextral, passes down on the right of the lesser omentum, lying at first in the interval between the spigelian and caudate lobes (the inf. v. cava lying dorsally behind the inner part of the caudate), and, sur-

TASMANIAN DEVIL.

rounded by pancreatic tissue which is traceable up to the portal interval, it finally opens into the intestine about 3 cm. beyond the pyloric sphincter. The portion of gut between the pyloric sphincter and the duct entrance is dilated, and although there is no duodenal loop here, as in the other Marsupials, might be regarded as duodenal, since I have found Brunner's glands. The wall of this dilated part of intestine has a firm feel compared with the intestine beyond the duct entrance, and it is interesting to note the great vascularity of the intestine after the bile duct has entered. The duct terminates by an easily defined pin-hole opening. I have not found it associated with any papillary projection. The total length of the common duct, *i.e.*, from the portal interval to intestine, equals 9 cm. The pancreatic duct joins the common duct 5 cm. from its termination, *i.e.*, comparatively near the liver, and the tube is easily defined. After the entrance of the pancreatic duct the common duct dilates, and the circumference of the last 2 cm. is more than double that of the common bile duct. The pancreatic duct is traced out as a single duct towards the spleen. It is easily traced in the pancreatic tissue, and receives branches in its course. On the left it receives a well defined branch from the pancreas, on the left lateral (lieno-mesocolic) fold.

Lesser Omentum.—In this Marsupial a distinction between the dorsal mesentery, *i.e.*, "meso-duodenum" and lesser omentum, is made possible by the development of a large Foramen Winslowii, which usually will admit the thumb, and of which the portal vein, artery, and common duct form the ventral boundary. The upper attachment of the lesser omentum is short, and is traced from the œsophageal concavity on the dorso-internal margin of the left lobe to the portal interval.



THE GASTRO-INTESTINAL TRACT. TASMANIAN DEVIL.

TASMANIAN DEVIL.

Portal Vein.—Dorsally two main branches are given off on each side—one to the left lateral lobe, and the other to the right lateral, sending branch to the caudate and spigelian lobes. Ventrally, it terminates in two branches, one to the left mesial, and one to the right mesial lobes.

Pancreas.—Pancreatic tissue may be traced along the common duct on the right extremity of the gastro-hepatic omentum, up to the portal fissure. Only a relatively small amount is found in the back part of the dorsal mesentery, corresponding to the meso-duodenum. I have never been able to trace it in relation to the duodenal wall and about the common duct after being joined by the pancreatic duct, so that the amount in this animal in the region of the intestine corresponding to the duodenal loop of other Marsupials may be regarded as insignificant. The Tasmanian Devil has a well developed great omentum, which runs from the pyloric region along the great curve of the stomach. It is independent of the dorsal mesentery, by which we mean meso-duodenum—mesentery—and mesocolon, so that no portion of intestine is included in the lesser sac. If we throw the great omentum and stomach up on to the chest wall we see dorsally about the root of the mesentery a well defined piece of pancreas, from which strands are traced on to the great omentum. Traced to the left of the mesenteric root, the pancreas passes out to the spleen, but beyond sending several processes on to the great omentum it is really outside the lesser sac, forming its lower boundary. In some specimens no pancreas can be traced in relation to the body or the right ant. process of the spleen; in others, however, a piece may be found in the lesser sac related to the body of the spleen, *i.e.*, extending towards the fundus. The main pancreatic tissue diffuses itself over the mem-

TASMANIAN DEVIL.

brane (the lieno-mesocolic, or left lat. fold), extending between the short left process of the spleen and the dorsal wall close to the attachment of the meso-colon. This membrane is nearly 10 cm. long, but pancreatic tissue does not extend nearer than about 2 cm. to the posterior, or dorsal attachment. The membrane is somewhat triangular in shape, extending above from the root of the mesentery out along the lower part of the lesser sac to the left posterior or dorsal short process of the spleen, to which it is attached. This basal portion measures about 5-6 cm. Its right margin is, as stated, attached at dorsal wall to the left of the attachment of the mesocolon, while the left margin is free.

LIVER OF NATIVE AUSTRALIAN CAT.

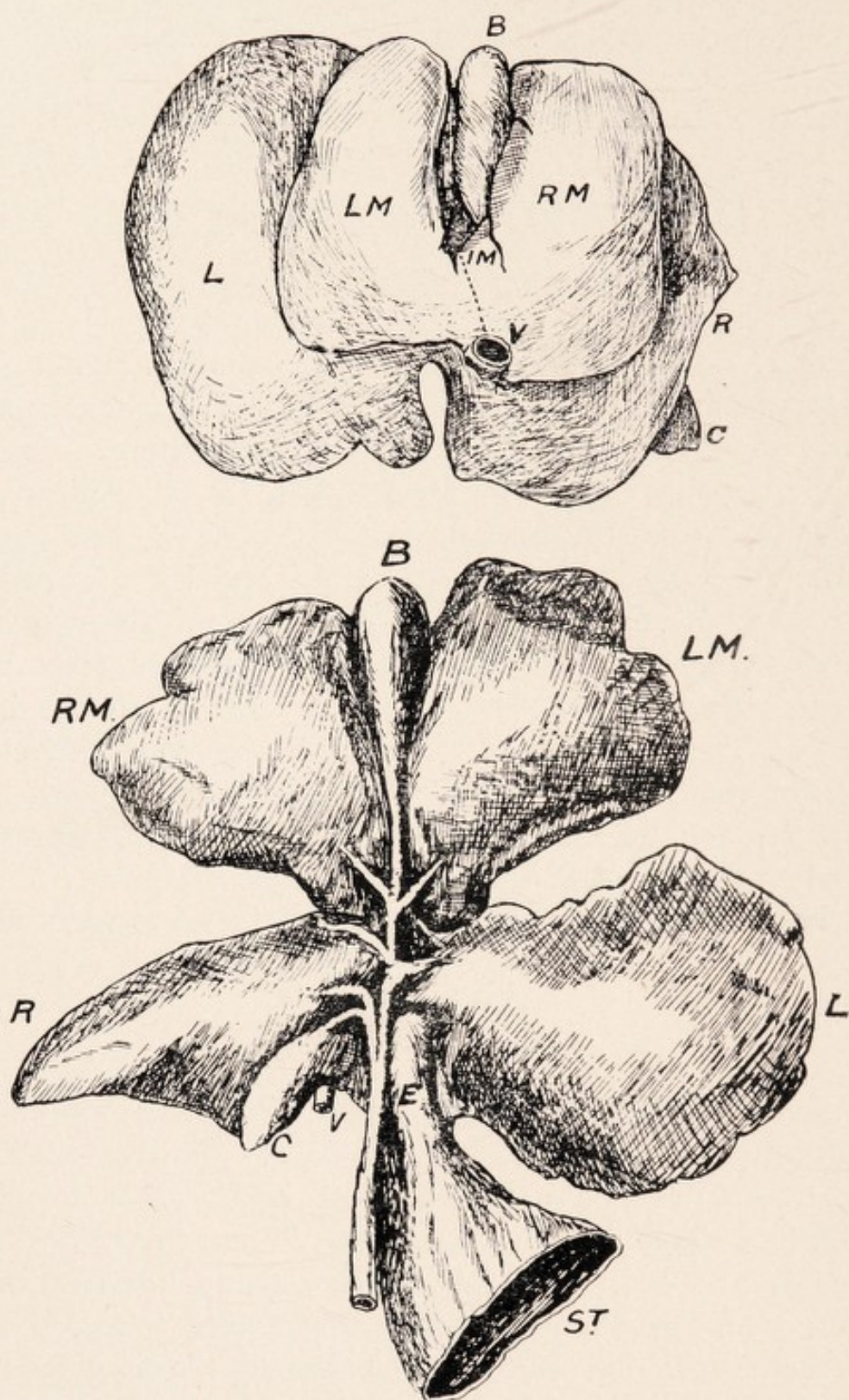
(DASYURUS VIVERRINUS.)

Here one is struck by the small amount of fusion that has taken place between the lobes, so that altogether the liver has a very primitive character. In a specimen (adult) given me by Professor J. P. Hill, when examined from the diaphragmatic surface, the three primary lobes, viz., mesial and right and left (laterals) were defined, and also the dorsal portion of the caudate lobes. The mesial division was quite distinct from the laterals, being but slightly attached dorsally at the inf. v. cava. The right and left (laterals) lobes were only connected dorsally by a narrow isthmus of hepatic tissue between the exit of the v. cava and the concavity for the passage of the œsophagus on the dorsal margin.

Maximum Measurements. Laterally. Dorso-ventrally.

Right	2.25 cm.	..	3 cm.
Left	4	..	4
Cystic or mesial	5	..	4

Chief interest, however, apart from the mobility, centres round the cystic or mesial lobe. On this surface there was a well defined cleft, anteriorally, for the gall bladder, measuring 1.5 cm. long, and .75 cm. laterally. At the base or dorsal part of the cleft a small lobule is differentiated, representing the intermediate mesial lobe. It measures .75 cm., and .5 cm. across, and is bounded by the gall bladder fissure on the right, and a depression on the left, really representing the cystic or mesial fissure of other Marsupials. Between it and the inf. v. cava passes the suspensory ligament. Thus a right, left, and intermediate mesial or cystic lobes could be distinguished.



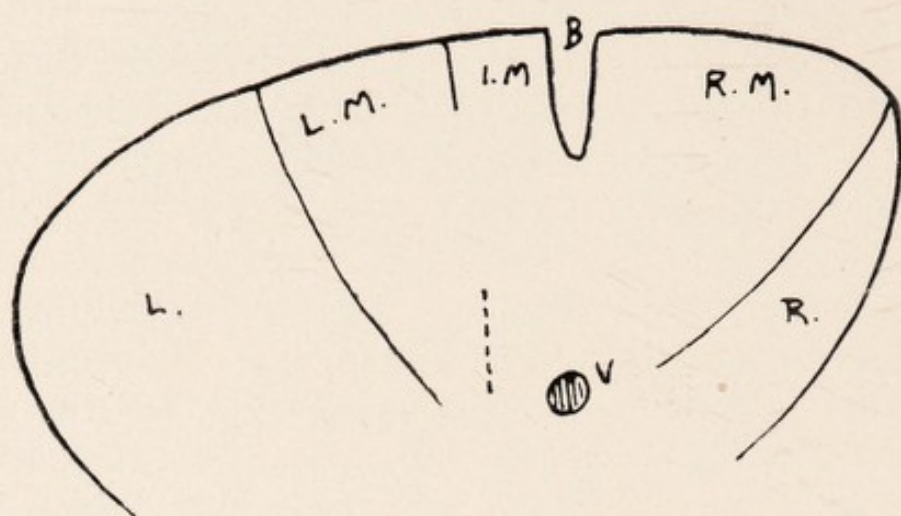
DIAPHRAGMATIC AND VISCERAL SURFACES OF LIVER.
NATIVE AUSTRALIAN CAT.

B Gall Bladder, LM Left Mesial Lobe, RM Right Mesial Lobe,
L Left Lateral Lobe, R Right Lateral Lobe, IM Intermediate
Mesial Lobe, C Caudate Lobe, V Inf. Vena Cava, E Oesophagus,
ST Stomach.

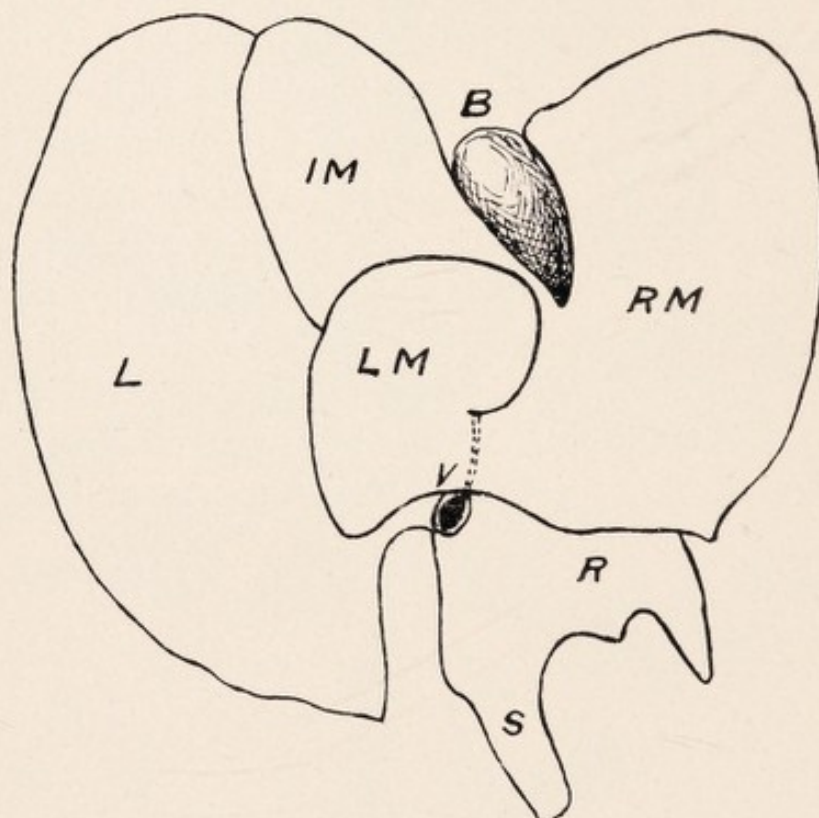
AUSTRALIAN CAT.

On *Visceral Surface* there was a division of the cystic lobe into two practically equal lobes, viz., right and left cystic, or mesial, by the gall bladder cleft, and a well defined fissure for the cystic duct. The left (lateral) lobe is concave for the reception of the stomach, and on this aspect of the right (lat.) lobe, the mobile caudate lobe—usually fissured above—is noted. It forms below, with the right lobe, part of the concavity for the upper pole of the kidney. At its dorso-inner part the entrance of the inf. v. cava is noted, and the vein is hidden in its hepatic relationship. There is a small lobus spigelii, and between the two pass in a groove the portal vein, artery, and bile duct.

In a specimen (see diagram) in the Hunterian Museum, London, that had been in spirit for many years, the primitive type of the lobulation was very marked, and the separation of the liver into right and left portions by the gall bladder and cystic and hepatic ducts was evident macroscopically. The hepatic ducts were right or left. Thus the left liver includes left mesial, left intermediate, and left lateral lobes, and the right liver includes right mesial, right lateral, and caudate and spigelian lobes.



(A)



(B)

DIAPHRAGMATIC SURFACE OF LIVER.

(A) AMERICAN OPOSSUM. (B) BANDICOOT.

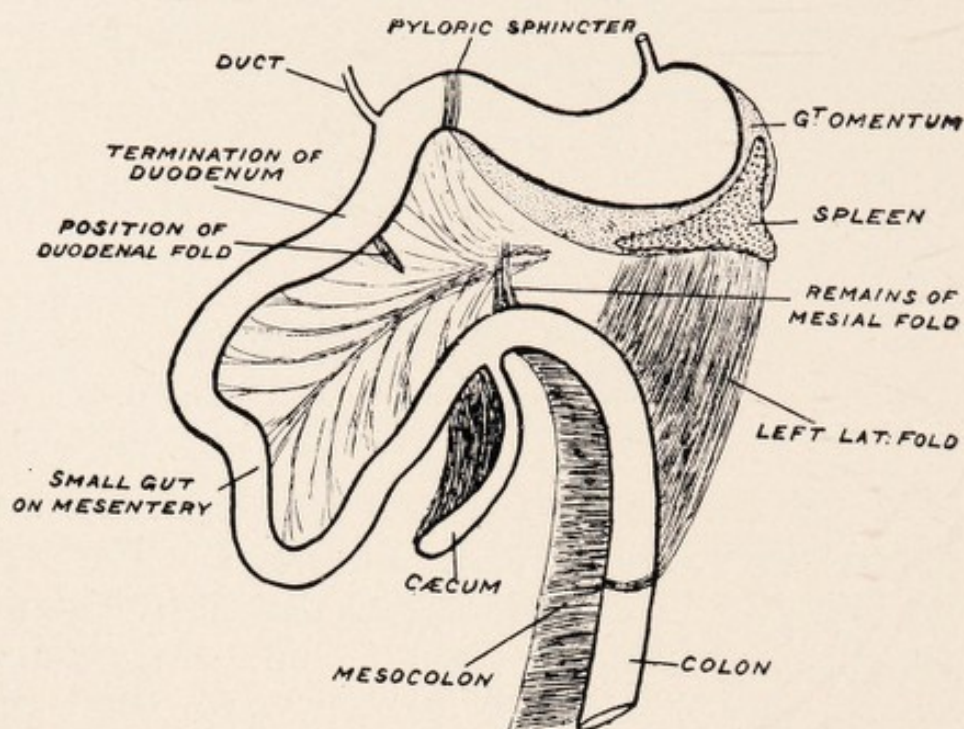
B Gall Bladder and Cleft, V Inf. Vena Cava, LM Left Mesial Lobe, RM Right Mesial Lobe, IM Intermediate Mesial Lobe, L Left Lateral Lobe, R Right Lateral Lobe, S Spigelian Lobe.

THE LIVER OF BANDICOOT.

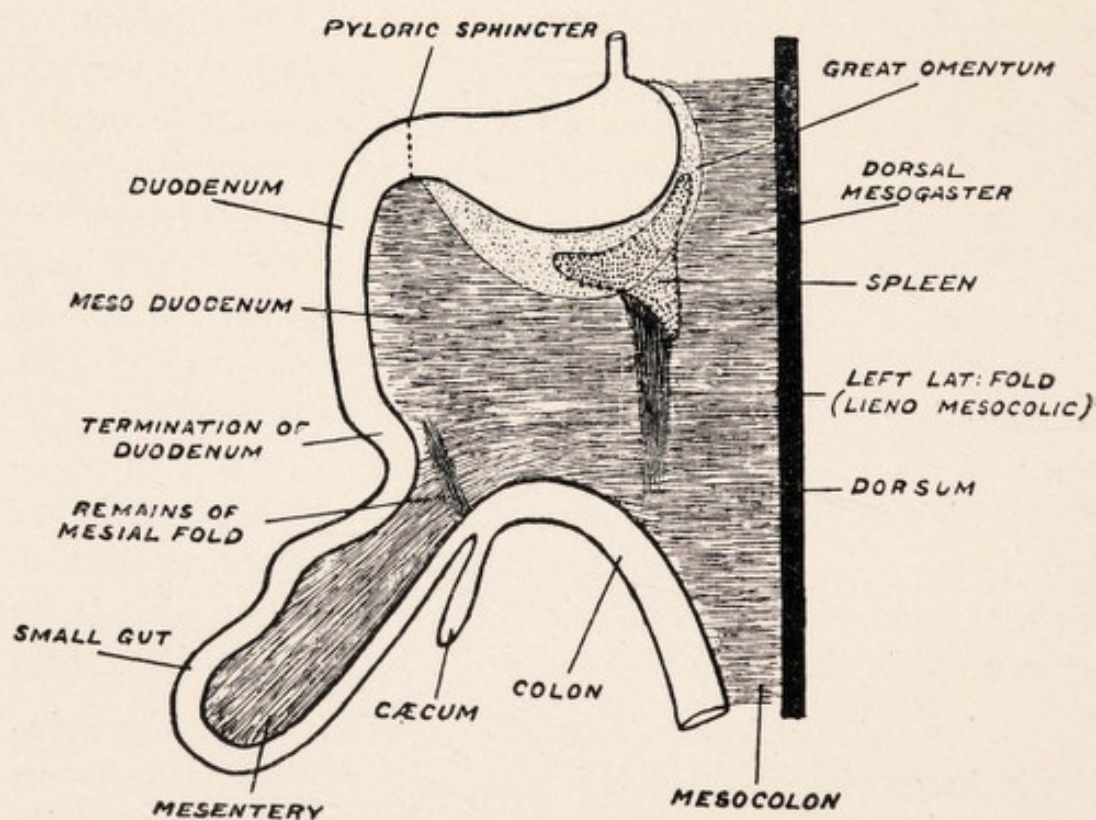
(PERAMELIDAE.)

Through the kindness of Professor J. P. Hill I was presented with a female N.S.W. Bandicoot. The liver is characterized by its resemblance to that of *Trichosurus*. When examined from the diaphragmatic surface a well defined separation into three primary divisions is seen, viz., right lateral, left lateral, and mesial or cystic. These are separated by well defined and complete right and left lateral fissures. Apart from the exit at the junction of the three divisions dorsally, the inf. v. cava is not seen in its hepatic relationship. Three portions of the mesial or cystic division, whose lateral measurement is 6 cm., are defined, viz., right and left mesial, and intermediate. The (smallest) left, and intermediate are separated by a complete fissure—mesial, or cystic fissure—not, however, extending as far dorsally, as the inf. v. cava—1.25 cm., intervening. Between the right and intermediate portions of the cystic is a well defined gap for the gall bladder, which is seen on this aspect, 2.5 cm. long, and 1 cm. laterally. The gap is not prolonged dorsally as a fissure. Between the mesial or cystic fissure and the exit of the vena cava is the attachment of the suspensory ligament.

Visceral Surface.—The striking feature is the relatively large size of the left lateral lobe, which occludes on this aspect the intermediate and left cystic lobes, and its edge may be traced on the right to the gall bladder. It measures 3 cm. laterally, and 5 cm. dorso-ventrally, is



THE GASTRO-INTESTINAL TRACT OF BANDICOOT.



THE GASTRO-INTESTINAL TRACT OF AMERICAN OPOSSUM.

BANDICOOT.

(hollow) concave below for the body of the stomach—and dorsally is the narrow concavity for the passage of the œsophagus. The three primary divisions are defined as on the diaphragmatic surface, and also the three portions of the mesial or cystic lobe—the right and intermediate portions being separated by the gall bladder gap and the curved well defined fissure for the cystic duct. The right mesial or cystic portion is the largest of the three. On this surface also we see in relation to the right lobe the caudate and spigelian lobes, and the former is well defined, and though distinct from the right lobe is attached dorsally to it, and mainly forms the concavity for the right kidney. The spigelian lobe is small. Between the spigelian and caudate portions is a sharp depression, along which pass the portal vein, artery, and duct, and at the dorso-inner part of the caudate lobe is the hepatic entrance of the inf. v. cava. The right lobe is the smallest of the three divisions of the liver, and the caudate lobe, which cannot be lifted free from it as in other Marsupials, is characterized by an elongated projection caudally towards the right kidney. The liver in the adult Bandicoot measures laterally 10 cm., and the inf. v. cava is not seen in its hepatic relationship.

LIVER OF AUSTRALIAN PHALANGERS.

(TRICHOSURUS AND PSEUDOCHIRUS).

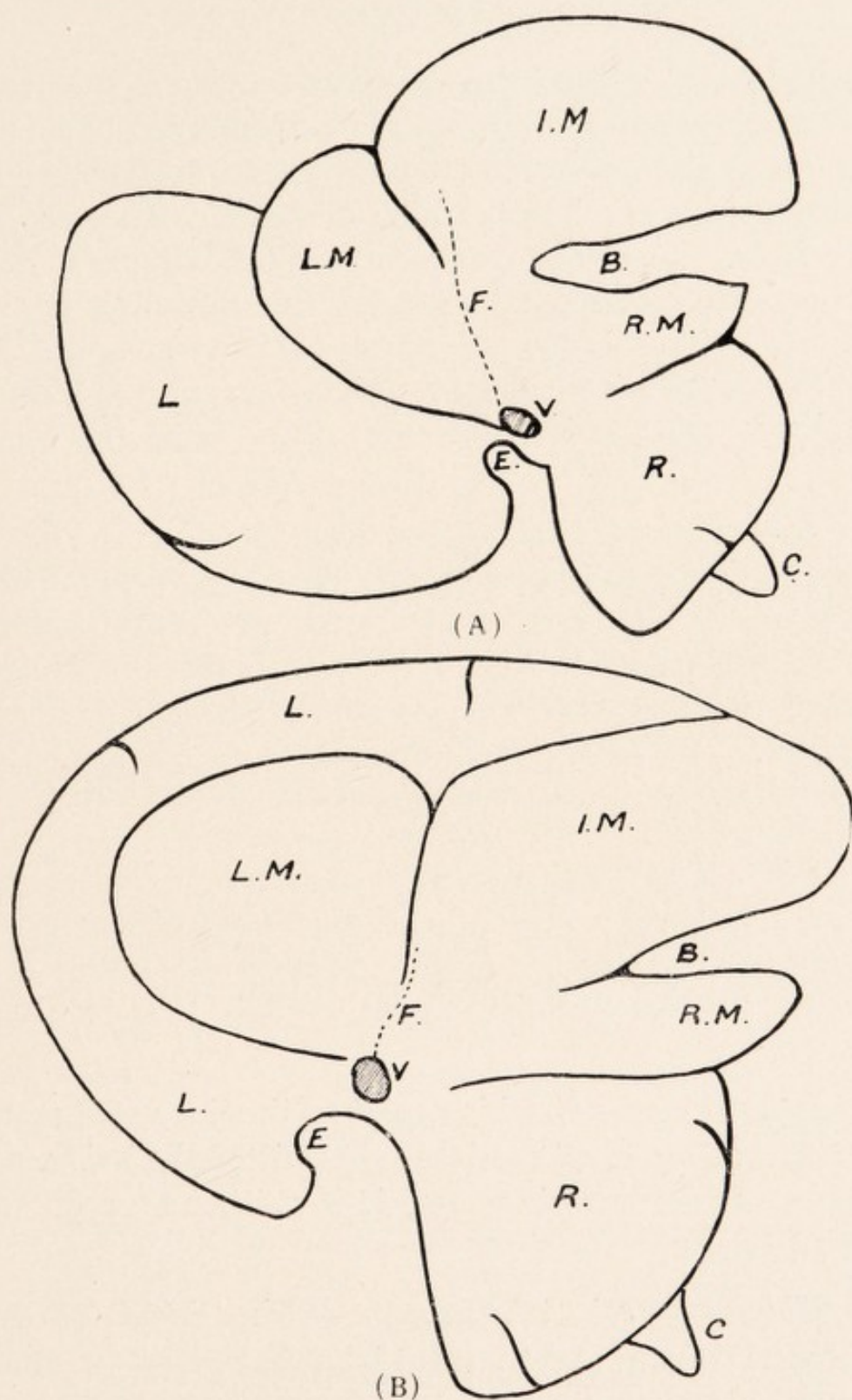
(1.) *Trichosurus*.—*Diaphragmatic Surface*.—The liver in this Phalanger lies in the epigastric and right and left hypochondriac region, and, as in the Platypus, there is a well marked separation of the right lateral, left lateral, and mesial lobes. The dextral margin is seen to be longer than the sinistral, and the ventral than the dorsal.

Three features are to be noted, viz.:—

- (a) The relatively small size of the right lat. lobe compared with the left lat., and the cystic, or mesial lobe.
- (b) The gall bladder is somewhat dextrally placed on the cystic lobe.
- (c) As in the Monotremes, a small portion of the lobus caudatus is seen on the dextro-dorsal aspect of the right lat. lobe.

The liver measures dorso-ventrally 7 cm., and laterally 10 cm.

Mesial or Cystic Lobe.—This presents three divisions, viz., right, intermediate, and left. Of these the right is the smallest, and the intermediate the largest. Between the intermediate and right portions is the cleft, 2 cm. long, and the width, .75 cm.—sometimes fissured below—for the gall bladder, extending from the dorsal to the ventral surfaces, so that the gall bladder is seen on each aspect. This lobe is separated from the right lateral by the right



DIAPHRAGMATIC SURFACE OF LIVER. AUSTRALIAN PHALANGER.

(A) *TRICHOSURUS*. (B) *PSEUDOCHIRUS*.

B Gall Bladder Cleft, L Left Lateral Lobe, R Right Lateral Lobe,
F Attachment to Diaphragm, V Inf. Vena Cava, E Gap for
Oesophagus, C Caudate Lobe, IM Intermediate Mesial Lobe,
LM Left Mesial Lobe, RM Right Mesial Lobe.

AUSTRALIAN PHALANGERS.

lateral fissure, which, though directed towards the exit of the inf. v. cava, does not reach it. It measures about 2.5 cm. It is also separated from the lateral lobe by the left lat. fissure (3 cm. long), which dorsally reaches the inf. vena cava. In addition a mesial or cystic fissure is noted between the intermediate and left mesial portions (1.75 cm. long), directed dorsally towards the vena cava. The mesial lobe measures 6.5 cm. laterally, and 5 cm. dorso-ventrally, and is definitely separated from the lateral lobes.

Left Lateral Lobe.—This measures 5 cm. laterally and 4.5 cm. dorso-ventrally, and usually presents a small fissure on its left margin. It forms, with the cystic lobe, the ventral margin of the liver, and is broader dorsally than ventrally. On its dorso-internal margin is a small concavity for the transmission of the œsophagus, which passes between it and the spigelian lobe.

Right Lateral Lobe.—This measures 3 cm. laterally and 3 cm. dorso-ventrally, and may present one or two fissures on its dorsal margin. At its dorso-dextral margin the dorsal extremity of the caudate lobe is usually seen.

Inf. v. Cava.—On this aspect of the liver at the point of convergence of all the lobes the exit of the inf. v. cava is seen. In its hepatic course it is neither seen dorsally nor ventrally.

Diaphragmatic Attachments.—Dorsally the left lateral—mesial—and right lateral lobes have all a fine membranous attachment to the tendinous diaphragm, and on the left margin of the left cystic an extension forward is seen, simulating a suspensory lig., and passing out to the muscular diaphragm above. The suspensory ligament is attached above to the tendinous and muscular dia-

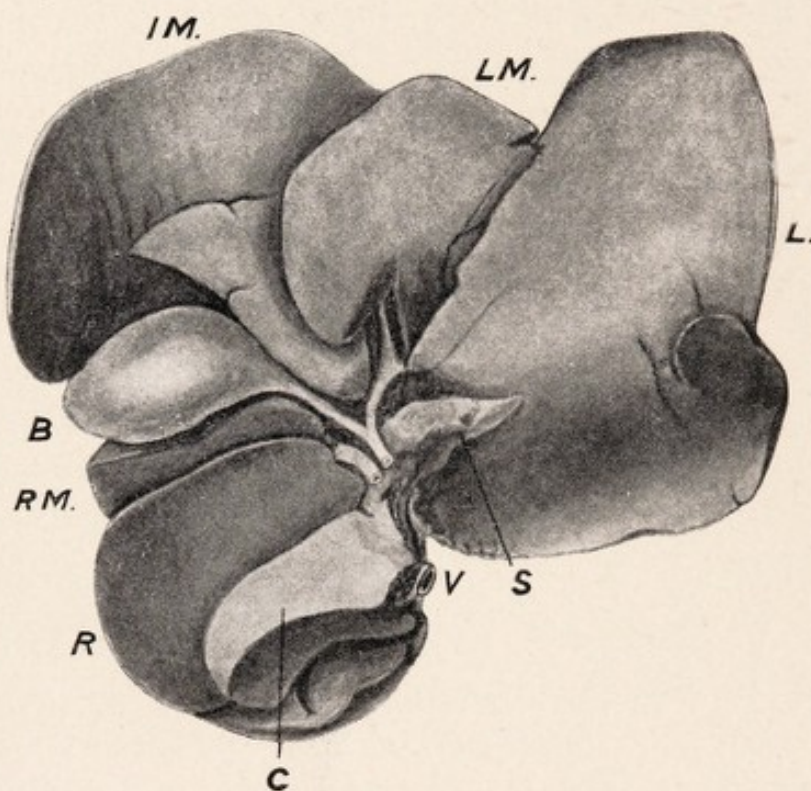
AUSTRALIAN PHALANGERS.

phragm, and below is attached to the intermediate cystic lobe, just to the right of the cystic or mesial fissure; and passing dorsally from the fissure to the inf. v. cava it serves with the fissure to define the left cystic from the rest of the mesial lobe.

(2.) *Pseudochirus*.—*Diaphragmatic Surface*.—Here the chief point is the encroachment ventrally of the left lateral lobe, so that it forms the chief portion of the ventral or anterior margin. The gall bladder is seen dextrally, and we distinguish a large right margin and smaller left. The three lobes are defined, viz., small right lateral, large left lateral, and the mesial or cystic lobe, with its three divisions. The dorsal part of the caudate is also seen projecting. The hepatic course of the inf. v. cava, as in *Trichosurus*, is not visible, only the exit being noted. Owing to its projection ventrally only a small portion of the left lateral lobe is visible on this aspect. The liver measures dorso-ventrally 9.5 cm., and laterally 9 cm.

(1.) *Trichosurus*.—*Visceral Surface*.—Here we notice, as on the diaphragmatic surface, the relatively small size of the right lateral lobe compared with the mesial or left lat. lobe, and in one specimen the left lateral lobe equalled 7 cm. in greatest length, which was double that of the right lateral (including the caudate lobe).

Left Lateral Lobe.—Is frequently fissured about the middle of its left margin, and may be prolonged as a saddle-flap lobe over the ventral aspect of the stomach. The left lateral fissure separating it from the mesial or cystic lobe is traceable to the portal interval. Dorso-internally is the concavity for the œsophagus, and projecting below the inner extremity is the spigelian lobe. This lobe is related to the left or cardiac portion of the stomach.



VISCERAL SURFACE OF LIVER. TRICHOSURUS.

L Left Lateral Lobe, R Right Lateral Lobe, IM Intermediate Mesial Lobe, B Gall Bladder, RM Right Mesial Lobe, LM Left Mesial Lobe, C Caudate Lobe, S Spigelian Lobe, V Inf. Vena Cava.

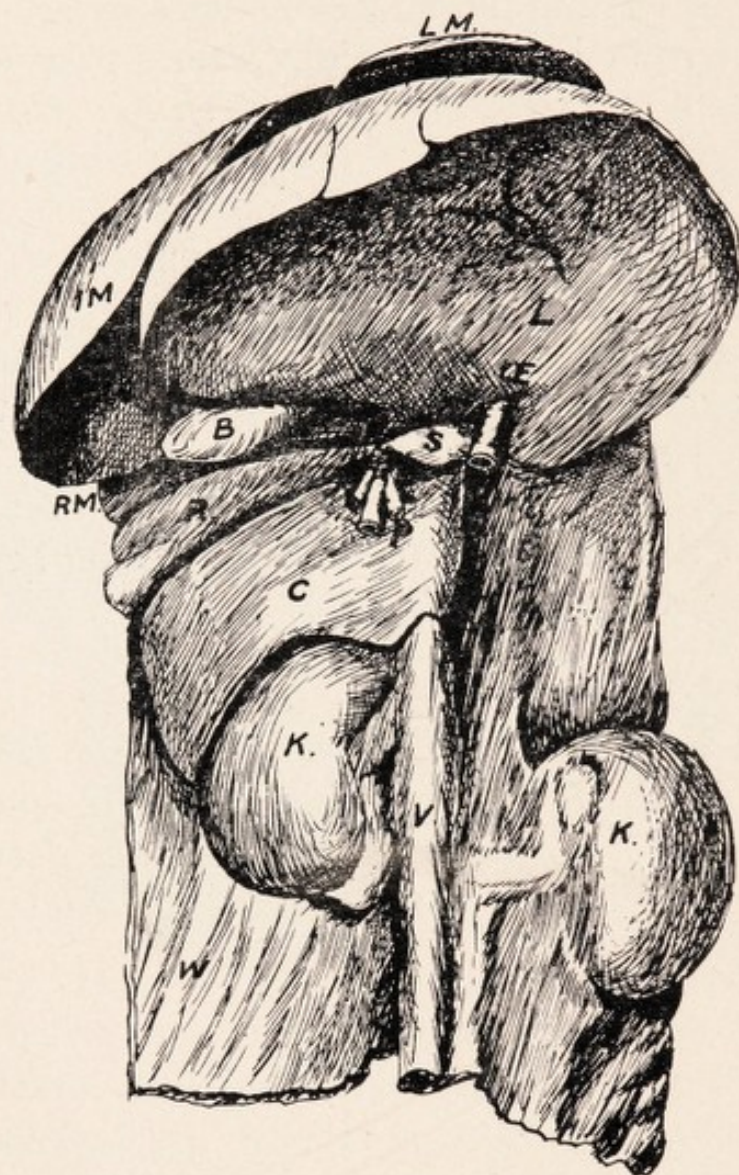
AUSTRALIAN PHALANGERS.

Mesial or Cystic Lobe.—The three divisions are all visible on this aspect, and the lobe is freely separable from the right and left lateral lobes. The intermediate portion, like the left lateral, may sometimes be prolonged as a saddle-flap portion. The right lateral fissure, as well as the mesial or cystic fissure between the intermediate and left cystic portions, are traceable to the portal interval. The right and left lat. fissures are complete from the dorsum to ventrum, but the cystic fissure is only partially through the substance. The gall bladder cleft between the middle and right portions is well defined, and the margins are hollowed out for the reception of the gall bladder, and to further accommodate the latter a projection is thrown forwards on the inner side of the intermediate portion, and between this and the right cystic is a depression for the cystic duct.

Right Lateral Lobe.—Two main portions are seen—the dorsal being the right lateral, and the ventral the caudate. In the former fissuring is usually noted about the middle and lower part. The caudal part forms, with the lobus caudatus, the concavity for the upper part of the right kidney.

The Caudate Lobe can be freely raised from the right lateral. It presents three surfaces, viz., dorsal for the right lateral—caudal for the kidney—and ventral for the pyloric sphincter and beginning of the duodenum. It measures 1.5 cm. dorso-ventrally, and 2.6 cm. lat.

Spigelian Lobe.—This is seen projecting from the inner side of the right lat. lobe and the caudate, below the left lat. lobe. It has a pointed extremity, is somewhat triangular in shape, and measures 1.25 cm. long. It lies dorsal to the lesser omentum. Passing in a depression between the spigelian and caudate lobes are the common



VISCERAL SURFACE OF LIVER. PSEUDOCHIRUS.

W Dorsal Abdominal Wall, K Kidneys, C Caudate Lobe, S Spigelian Lobe, L Left Lateral Lobe, R Right Lateral Lobe, B Gall Bladder, RM Right Mesial Lobe, IM Intermediate Mesial Lobe, LM Left Mesial Lobe.

AUSTRALIAN PHALANGERS.

bile duct, artery, and portal vein, the former being ventral, and the latter dorsal. The right part of the middle cystic—right cystic—and the right lateral lobes correspond to the left or pyloric part of the stomach. The portal interval or hilum, where we see portal vein, common bile duct, and hepatic artery corresponds to an interval between the dorsal part of the mesial lobes and the inner extremity of the right and left lateral lobes.

Inf. V. Cava.—This is not seen in its hepatic relationship dorsally or ventrally, *i.e.*, is hidden in hepatic tissue. Its entrance is placed at the dorsal part of the inner extremity of the lobus caudatus.

Lesser Omentum (gastro-hepatic).—From the exit of the inf. v. cava on the diaphragmatic aspect, where it is continuous with the suspensory ligament, it passes ventrally at the concavity for the œsophagus on the dorso-int. part of the left lateral lobe, and lies along the dorso-int. part of this lobe, between it and the spigelian lobe, being traced to the portal interval. A band is noted ventral to the lesser omentum from the ventral surface of the left lobe to the lesser curvature of the stomach corresponding to the angle or bend between the pyloric or right and cardiac or left portions.

(2.) *Pseudochirus.*—*Visceral Surface.*—*Left Lateral Lobe.*—The important feature is the ventral projection of this lobe, and in a specimen, where the lateral measurement of the liver was 7.5 cm., the left lateral lobe was 5 cm. Dorsally the concavity is noted for the œsophagus; also one or two fissures on its ventral margin, and some fissuring on its ventral surface. At the inner margin, dorsally we see the spigelian lobe—a pointed prolongation to the left of the caudate lobe—

AUSTRALIAN PHALANGERS.

slightly larger than in *Trichosurus*. The portal vein, artery, and common duct pass between the spigelian and caudate lobes. The hepatic course of the inf. v. cava is not seen.

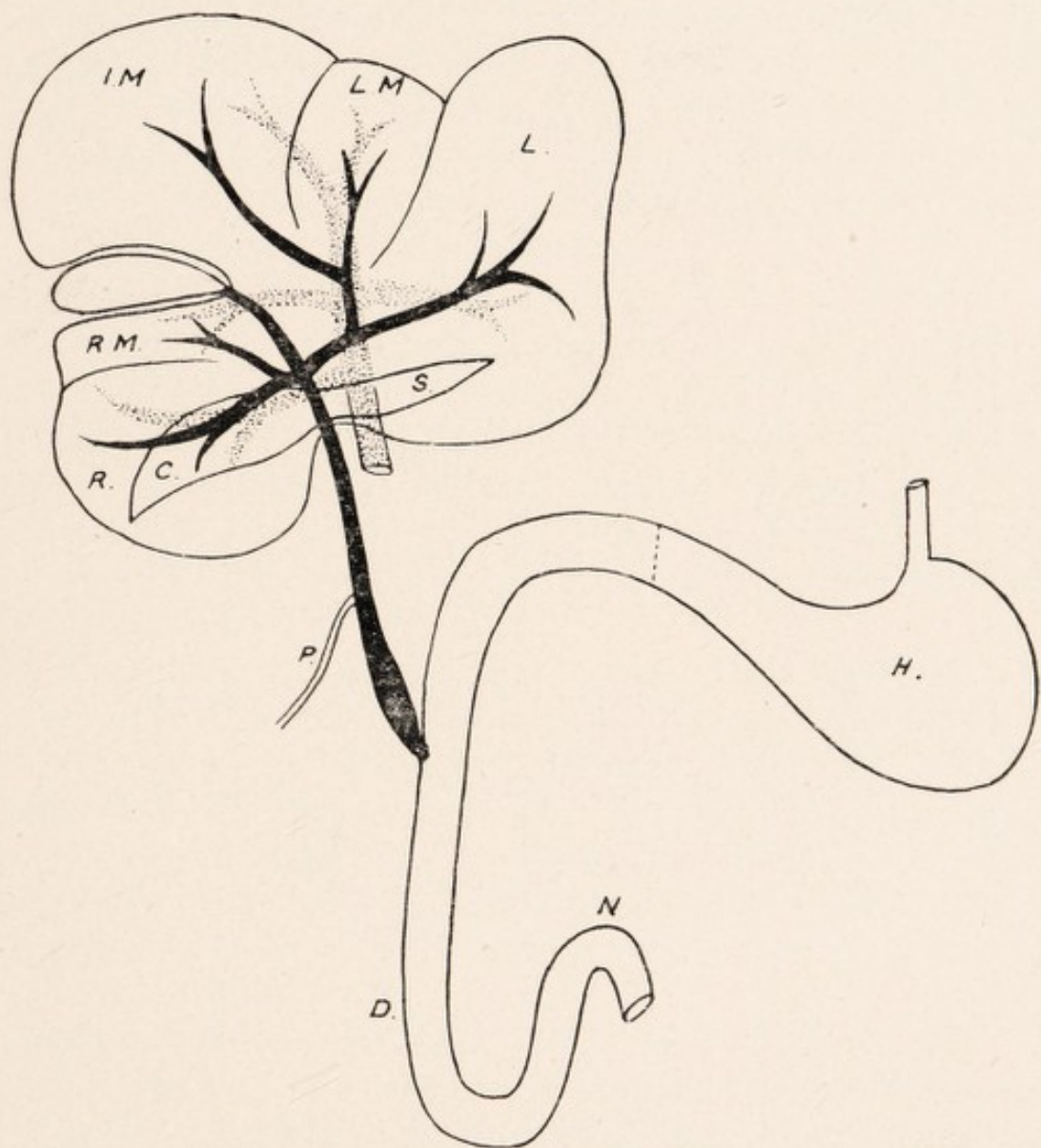
Mesial or Cystic Lobe.—The left cystic is completely hidden by the left lateral, also the greater part of the intermediate cystic, and partly the gall bladder cleft—otherwise it is similar to *Trichosurus*.

Right Lateral Lobe.—On its dextral margin a small fissure is noted. The lobus caudatus is proportionately larger than in *Trichosurus*, and forms a greater part of the concavity for the right kidney. In connection with the lobus caudatus in both *Trichosurus* and *Pseudochirus* the following points must be noted:—

- (1.) Good development.
- (2.) Comparative mobility.
- (3.) Relation to the upper pole of the right kidney.
- (4.) The inf. v. cava is not visible in its hepatic relationship.

Gall Bladder and Ducts in Phalangers.

The Gall Bladder is dextrally placed, and is seen both on the ventral and dorsal surfaces, since there is a gap in the mesial lobe between the small right and large intermediate portions where it is lodged—the gap being nearly 1 cm. wide. It is a somewhat elongated body, and rarely is found projecting beyond the ventral edge of the liver, though in *Pseudochirus* I have seen it projecting 1.5 cm. beyond. It measures about 2.5 cm in length, though in an adult male specimen I found the bladder was only 1 cm. long, and lay in the dorsal part of the cleft.



BILIARY AND PORTAL SYSTEMS. LIVER. AUSTRALIAN PHALANGER.

H Stomach, P Pancreatic Duct, D Duodenum, N Duod.-Intest. Flexure, S Spigelian Lobe, C Caudate Lobe, R Right Lateral Lobe, L Left Lateral Lobe, RM Right Mesial Lobe, IM Intermediate Mesial Lobe, LM Left Mesial Lobe.

AUSTRALIAN PHALANGERS.

It is for the most part a mobile organ, being freely invested with peritoneum, in contrast with the limited investment of the human liver, in which the peritoneum, apart from the fundus, invests the under surface and sides only. Its dorsal extremity is invested on the sides and ventral surfaces only, being attached above to the hepatic substance. In *Pseudochirus* lateral bands are noted connecting this dorsal portion with the liver.

Cystic Duct.—This lies in a groove between the small right portion of the cystic lobe and the projection on the right side of the intermediate portion—the result of an accommodation effect for the gall bladder. It measures 1.25 cm. long, but in *Pseudochirus* is rarely longer than 1 cm. At the portal interval or fissure it is joined by the hepatic ducts and becomes the common duct.

Hepatic Ducts.—On the left side a single trunk is noted, formed by the junction of two main divisions, the smaller for the left and intermediate cystic or mesial lobes, and the larger from the left lateral lobe. On the right side a small branch from the right cystic joins the larger branch from the right lateral, close to the junction of the latter with the cystic duct.

The Common Bile Duct.—This passes down between the spigelian and caudate lobes, with the hepatic artery and portal vein (the vein being placed dorsally) lying at first in the right extremity of the lesser omentum, and forming part of the ventral boundary of the Foramen of Winslow. This foramen serves to define the right extremity of the lesser omentum from the meso-duodenum, since the duodenum itself is not fixed. The duct terminates in the duodenum about 5 cm. from the pyloric opening, and measures 4.5 to 6 cm. in length. The pancreatic duct, which is traced in the pancreatic tissue as far

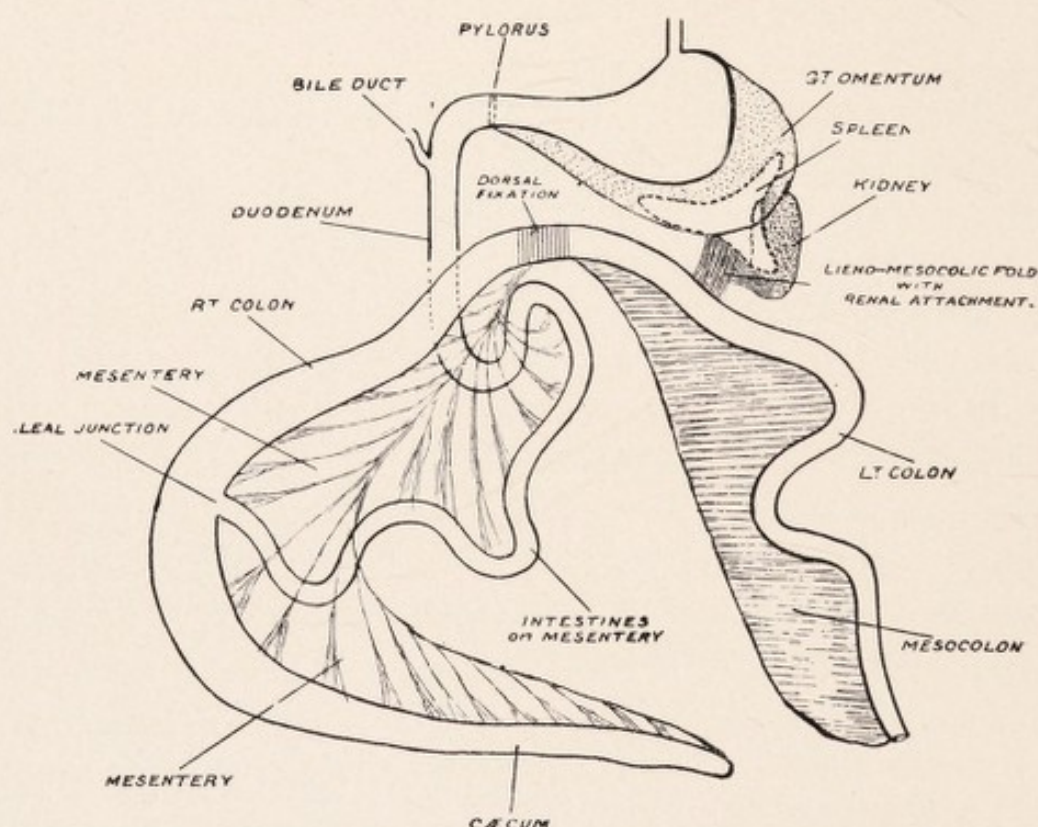
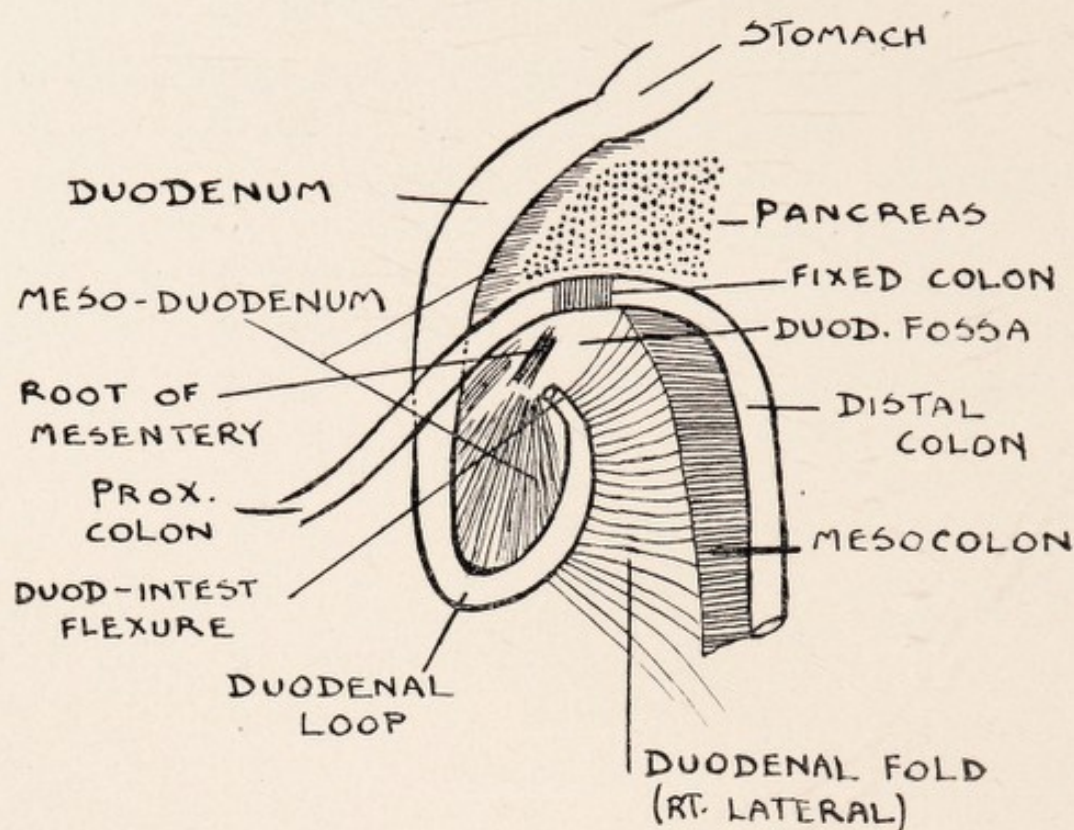
AUSTRALIAN PHALANGERS.

to the left as the spleen, opens into the common bile duct 1.5 to 2 cm. before it terminates in the duodenum. On opening the duodenum the termination of the duct is defined by a slight papillary projection. After the entrance of the pancreatic duct the combined hepatic-pancreatic duct gradually widens, and for the last 1 cm. the circumference is double that of the common bile duct. In *Pseudochirus* the combined duct lies ventral to the upper pole of the right kidney, to which the meso-duodenum has become attached.

Portal Vein.—On the right side a branch is seen passing to the right lateral and caudate lobes. Passing ventrally a well defined branch is seen passing on the left to the left lateral lobes, and on right to right mesial. It finally terminates in two branches, which are traced to the left mesial and intermediate mesial lobes.

Lesser Omentum.—The upper or hepatic attachment is short, and is traced from the inf. vena cava exit, dorsally, where it is continuous with the suspensory ligament. It is traced to the ventral surface at the concavity for the œsophagus on the dorso-internal part of the left lateral lobe, and lies along the dorso-int. part of the left lateral lobe, between it and the lobus spigelii, up to the portal fissure. A peritoneal band ventral to the lesser omentum is traced from the under surface of the left hepatic lobe to the lesser curvature, corresponding to a bend in the stomach between right small pyloric and left large cardiac portions.

Pancreas in Trichosurus.—As in the *Platypus*, the pancreas may be characterised by its diffuse character. It does not fill the duodenal loop but occupies the portion of the meso-duodenum above the attachment of the colon, being chiefly found in the

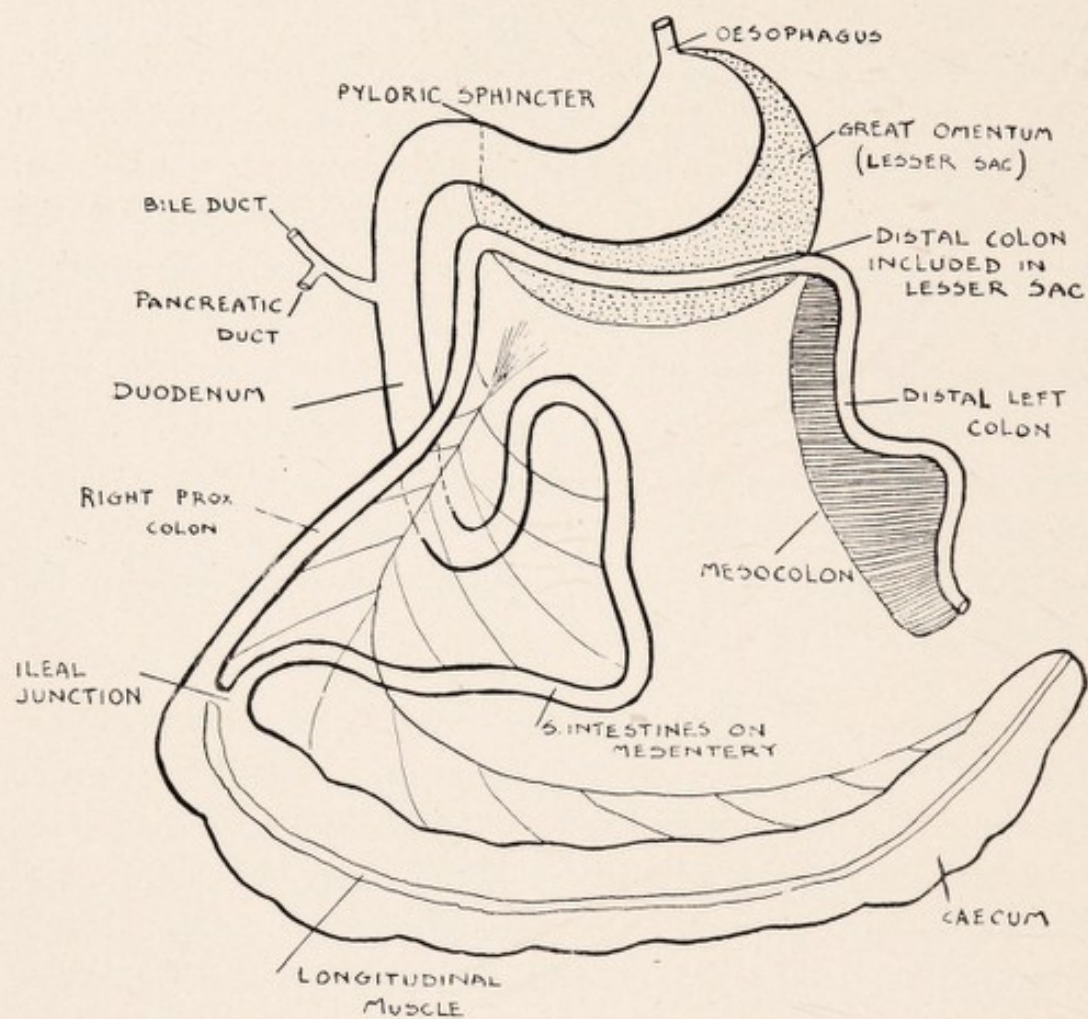


THE GASTRO-INTESTINAL TRACT, SPLEEN, AND PORTION OF PANCREAS.
TRICHOSURUS.

AUSTRALIAN PHALANGERS.

limited interval about 1.5 cm. between the colon and the first part of duodenum, extending as far to the left as the right limitation of great omentum. On one occasion I traced some strands of pancreatic tissue in lesser omentum up to the portal interval. Just above the duod-intest. junction, where it is fixed dorsally, the pancreas is seen passing to the left towards the spleen as a compact piece coming into relation with the lesser sac (great omentum), the lower dorsal boundary of which it forms, and strands of pancreatic tissue may even be sent on to the lesser sac. The pancreas is finally found to be outside the lesser sac in relation with the small left process of the spleen and the lieno-mesocolic fold connecting left process of spleen, kidney, and mesocolon; not being found in relation with the body or right anterior process. At its termination on the left at the spleen, in those cases where its character was diffuse on the right, it becomes more compact. The greatest length of the pancreas in the phalanger is about 6 cm.

Pancreas in Pseudochirus.—In *Pseudochirus* the pancreatic tissue is relatively greater in amount than in *Trichosurus*. A well defined piece is found about the duct entrance (to the left of which a small process is seen), and this is continued down to the duodenal loop closely attached to the duodenum, strands even extending to the extremity of the loop. These are all in the meso-duodenum. The pancreas passes thence from the meso-duodenum to the left by processes running in two directions, which are best seen by throwing up the colon on to the liver. One of these—the larger—is anterior or ventral, and lies between the colon and stomach, being within the lesser sac, and is traced outwards on the left in relation with the anterior right process and body of the spleen, and comes in relation with the “gastro-splenic” omentum.



THE GASTRO-INTESTINAL TRACT. PSEUDOCHIRUS.

AUSTRALIAN PHALANGERS.

The other lower, or dorsal, portion is a much finer strand, and is traced above the root of the mesentery, being in relation with the dorsal wall. The pancreas is greatly increased in amount on the left, and is prolonged outside the lesser sac in relation to the inner surface of the lesser process of the spleen, being traceable across the kidney to its outer side. This portion is on the lieno-mesocolic ligament, which has receded compared with *Trichosurus*, and brings into relationship the mesocolon, omental sac, spleen, pancreas and kidney. The point is that the greater part of the pancreas in *Pseudochirus* is within the lesser sac.

LIVER OF AMERICAN OPOSSUM

(DIDELPHIS MARSUPIALIS.)

Here important differences as regards the mesial lobe are noted when compared with *Trichosurus*.

On the Diaphragmatic aspect we notice three primary divisions of the liver, viz., mesial, small right, and large left lobes. These are separated by well defined complete fissures, viz., right and left lateral fissures. (page 100.) The mesial or cystic lobe is usually the largest of the three, and the ventral cleft or fissure, about 1.5 cm. long, for the gall bladder, forms on this aspect its separation into right and left mesial or cystic lobes. On the dorsal aspect of the mesial lobe, to the left of the gall bladder fissure or cleft, is the suspensory ligament, which does not come forward to the ventral edge. On this edge, however, to the left of the gall bladder cleft, a small fissure, about .5 cm. long, may be met with. Prolonged dorsally this would reach the suspensory ligament, but there is no depression between the two. I have, however, seen a distinct line, almost a depression (faint), from the ligament to the ventral edge, which latter, however, was not fissured. Here we see an early indication of the formation of the cystic or mesial fissure leading to the tripartite cystic lobe. It is not an instance where fusion of the intermediate and left cystic lobes has taken place, for in those instances the suspensory lig. has corresponded to the gall bladder fissure, while here it is distinctly to the left.

AMERICAN OPOSSUM.

Visceral Surface.—The left lateral lobe extends ventral to the left cystic lobe, occluding it, and may extend to the right of the gall bladder. It is concave for the body of the stomach. The cleft for the gall bladder and the well defined fissure passing dorsally for the cystic duct divide the mesial or cystic lobe into right and left portions. The right cystic is related to the pyloric portion of the stomach. (Page 102.) The right lateral lobe is the smallest of the three, and on its ventral aspect is a well defined and separate caudate lobe, hollowed below for the kidney. This is prolonged to the left as a small spigelian lobe. Between the two passes the portal vein, artery, and duct, and at the dorso-internal portion of the caudate is the hepatic entrance of the inf. v. cava.

OBSERVATIONS.

Diffuse or Compact Liver.

If we take the Platypus at one end of the Mammalian scale, and Man at the other, a striking feature of the liver is the multiplicity of lobes (diffusibility of hepatic tissue) in the former, and the compactness or tendency to unification in that of the latter. This we find true, not only as regards the liver, but also the spleen and pancreas. For the erect attitude consolidation would be advantageous for fixation, and so, amongst other things, the tendency to torsion lessened.

Development of the Mammalian Liver.

The hypoblastic diverticulum, or liver bud, springs from that portion of the fore gut which will afterwards become the second portion of the duodenum. Portion of this gives rise to the liver tissue, which at first consists of right and left masses of cells, and portion gives rise to the gall bladder and main ducts. It is interesting to note that all the specimens examined conform generally to a simple plan, namely, right and left lateral portions or masses, with the portal vein, and gall bladder, cystic, and common ducts, as a common stem. On the right side hepatic and portal branches are traced to the right portion (right cystic and right lateral), and on the left side branches pass to the left portion (left cystic and left

OBSERVATIONS.

lateral). This supports the contention of James Cantlie, who, in his important paper, held that a line drawn through the human gall bladder to the vena cava, at the dorsal border, divided the liver into right and left parts. This is well shown by a reference to the diagram of the liver of *Dasyurus Viverrinus*, which represents the most primitive Mammalian liver I have met.

Fixation of the Liver.

In Man the liver is separated dorsally with great difficulty. It is firmly held—apart from the suspensory ligament—by close adhesions to the diaphragm. In the Monotremes and Marsupials, however, the liver, as shown in the diagrams of the diaphragmatic surface, is less closely held dorsally. It can be easily separated. Firm dorsal fixation of the human liver is an adaptation to the erect position. This is associated, as in the case of the spleen and pancreas, with compactness, and so displacement and tendency to torsion is avoided. There is a greater fixation of the liver of the Koala than in the other Marsupials. This I regard as associated with the great weight of the proximal colon and cæcum (length of the latter sometimes reaching 240 cm.), which are swung on the common mesentery. The colon is suspended to the pyloric region by a strong mesial fold, and so torsion is prevented. As traction is transmitted to the liver through the lesser omentum the advantages of a firm hepatic attachment is obvious. Furthermore, when feeding, this animal sits erect.

Bile and Pancreatic Ducts.

In both orders no separate entrance of the pancreatic duct into the duodenum—apart from that associated with the bile duct—is noted, *i.e.*, the duct of Wirsung is the

OBSERVATIONS.

vehicle for the conveyance of pancreatic secretion. In the carnivorous Marsupial, as well as the Opossum and the herbivorous Kangaroo, the pancreatic duct opens into the common bile duct, as in the more primitive Monotremes, whilst in the Koala and Wombat the condition—with an independent control—resembles Man more closely. In the Koala a diverticulum is noted at the termination of the pancreatic duct. This animal is exclusively an Eucalyptus-leaf eater. By means of the reservoir, or diverticulum, a more perfect control of the pancreatic secretion necessary for digestion is instituted. In the Wombat and Kangaroo the entrance of the bile duct is nearer to the duod-intest. flexure than to the pyloric sphincter, whilst the reverse is noted in the Monotremes and other Marsupials. The reason is not easy of explanation. The duod-intest. flexure is to be regarded as a constant. In all the animals described it corresponds to the entrance of a direct branch of the right vagus. If we regard the liver as an outgrowth of the duodenum, *i.e.*, of that portion of the gut whose dorsal mesentery (mesoduodenum) represents comparatively a failure to develop, then the site of the entrance of the duct will depend on function. In the Wombat, *e.g.*, the lining membrane of the duodenum, down to the entrance of the duct, is rugous and scarcely distinguishable from that of the stomach. In this animal pancreatic and hepatic secretions are not necessary till the food has almost traversed the duodenum, *i.e.*, almost immediately before the release at the duod-intest. flexure of the food into the small gut, in marked contrast to Koala and the Monotremes. As the entrance of the vagus nerve at the duod-intest. flexure is to be regarded as a constant, and the entrance of the duct as a variable, it points to the importance in control of the former.

OBSERVATIONS.

Multiple Right-Sided Lobulation in Sarcophilus and Koala.

In these two highly specialized feeders—the one carnivorous, and the other phyllophagous—extensive right-sided fissuring and lobulation is noted. The effect of this must be to improve the elasticity of the organ. In the Koala we have, as stated, a large proximal colon and cæcum dependent from the pyloric region by the mesial band, and this would be advantageous. Possibly also this is a factor in preventing rupture of the organ from injuries during climbing. On the other hand these causes are not operative in the Tasmanian Devil, and furthermore, its intestinal tract is primitive. It is noteworthy, however, that the lobulation and fissuring are most marked in the varieties of liver where the right cystic and right lateral lobes tend to become fused.

The Spigelian and Caudate Lobes.

In the Monotremes and the Tasmanian Devil the caudate lobe is well developed, while in the Kangaroo and Wombat it may be regarded as non-existent. In the Monotremes and those Marsupials with a defined caudate lobe (to which may be added the Gorilla amongst primates) the inf. vena cava is not seen on the visceral surface. It lies dorsally behind the junction of the caudate and spigelian lobes. In the Kangaroo, Wombat, and Man the vena cava is seen on the visceral surface in its hepatic relationship. In an Orang, three months old, in the Hunterian Museum, there is a well defined caudate lobe. The inf. vena cava, which measures 2.5 cm. in its hepatic relationship behind the caudate and spigelian lobes, is not visible viscerally, and only on diaphragmatic surface for its terminal, .5 cm. In connection with the inf. vena

OBSERVATIONS.

cava and the caudate lobe of the early human fœtus the additional placental circulation must be borne in mind. Furthermore, in the more primitive livers, the caudate lobe is to a large extent an accommodation effect for the upper pole of the right kidney, as is seen in the Echidna. With, however, the comparative fixation of the duodenum and pancreas, and unification of the organ, a more limited relation of the kidney to the liver is seen.

The spigelian lobe is well defined in the Monotremes, but reaches its maximum in the Macropodidæ. It is poorly developed in the remaining Marsupials, and in the Wombat it may be regarded as non-existent. In the Platypus its definition is associated with four factors:—

- (a) Ventral to it lies the lesser omentum.
- (b) On the left side, looping round it, are the œsophagus—pyloric knob—and commencement of duodenum.
- (c) Behind lies the inf. vena cava, in its hepatic relationship, which is dorsal.
- (d) On its right we see the portal vein, artery, and duct, in a well defined depression between it and the caudate lobe.

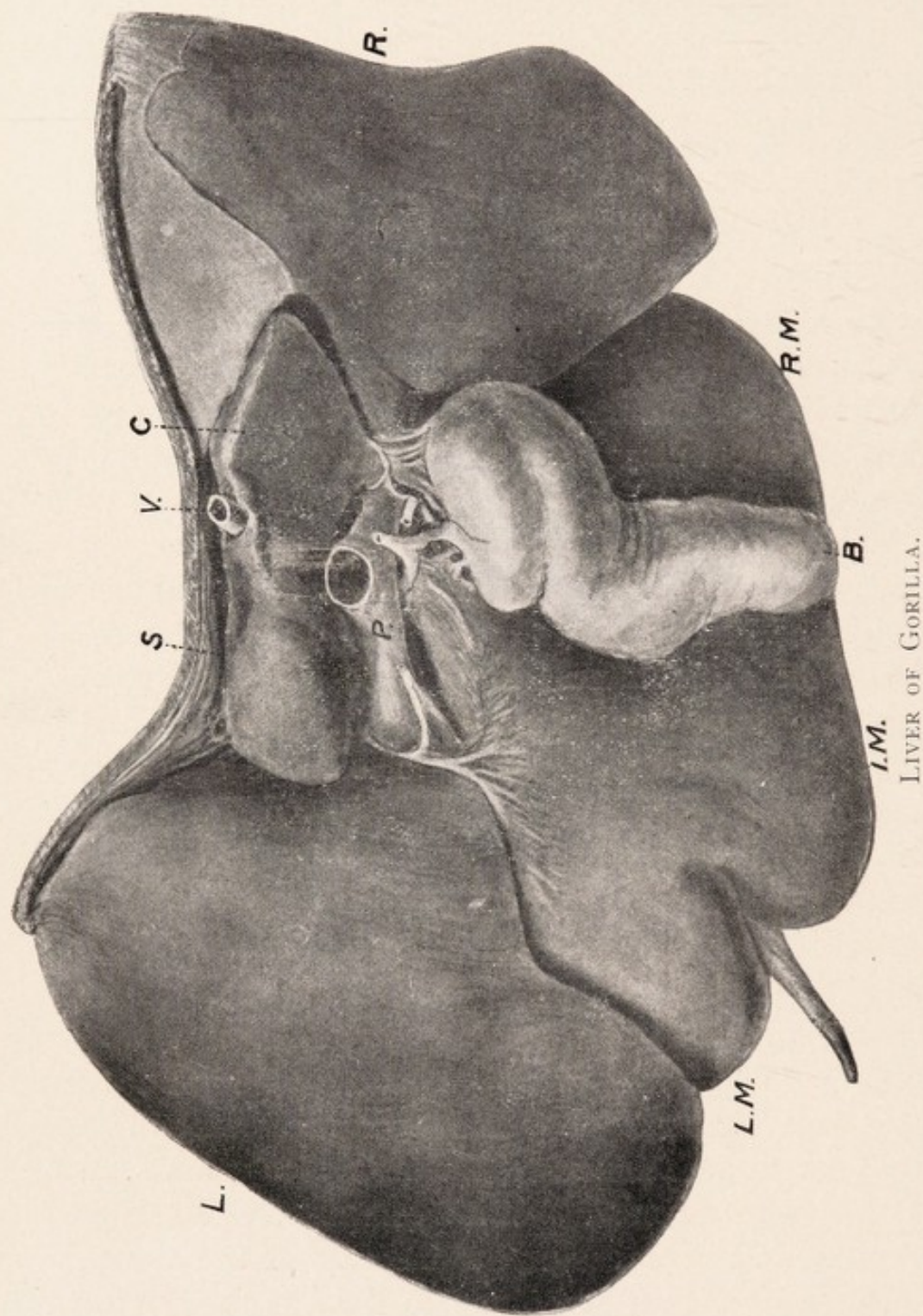
In Macropus we have the large spigelian lobe dipping down within the lesser sac in the interval between the right and left portions of its great stomach. In relation with this is a large abdominal œsophagus, frequently reaching 10 to 12 cm. in length. Defining it on the right we see the inf. v. cava, ventral to which lies the portal vein, artery, and bile duct. In neither Koala nor Wombat is there an abdominal œsophagus. According to the late Professor Cunningham, an abdominal œsophagus of varying length can usually be described in the human sub-

OBSERVATIONS.

ject. The association of a well defined abdominal œsophagus with any increase in size of the spigelian lobe is worthy of note. In the human liver, in addition, the ventral position of the inf. v. cava and the ductus venosus are factors helping to retain a spigelian projection.

Human Liver and Its Abnormalities.

Occasionally, human livers are met with presenting curious fissurings and lobulations, which are classified as abnormalities, but the significance of which is explained by a study of Australian mammals. In what may be regarded as a typical mammalian liver a primary division into five lobes may be recognized, namely, the mesial or cystic, lodging the gall bladder, which is separated on either side from the right lateral lobe and left lateral lobe by the right and left lateral fissures, and on the visceral surface of the right lateral lobe, as is well shown in Platypus, we have projecting the lobus spigelii and dextrally the larger free caudate lobe. The spigelian lobe reaches its maximum development in the Kangaroo, where it dips down within the lesser sac in the interval between the right and left portions of the great stomach, being grooved for the passage of a large abdominal œsophagus, 10 to 12 cm. in length. The caudate lobe, on the other hand, though well defined in Platypus, and especially in Echidna, may be regarded as non-existent in Kangaroo and Wombat. In the Echidna it is seen to be largely an accommodation effect for the upper pole of the right kidney and adrenal. With comparative fixation of duodenum and pancreas and unification of the organ, a more limited relation of kidney to liver is seen, with disappearance of the right lateral fissure. Amongst the members of the Australian fauna, the gall bladder forms a separation of the mesial or cystic lobe into two primary



LIVER OF GORILLA.

(From Specimen in Hunterian Museum, London.)

- L. Left Lateral Lobe, R Right Lateral Lobe, B Gall Bladder,
 RM Right Mesial or Cystic Lobe, IM Intermediate Cystic
 Lobe, LM Left Cystic Lobe, P Portal Vein, V Vena Cava,
 C Caudate Lobe, S Spigelian Lobe.

OBSERVATIONS.

divisions, the right and left cystic lobes; and in the Wombat, Koala, Phalanger, and Bandicoot, a definite separation of the left division into two portions by means of a fissure, the mesial or cystic fissure has taken place, so that three portions of the mesial lobe are recognized, viz., right mesial, intermediate mesial, and left mesial. The suspensory ligament is noted in relation with the mesial fissure, between the intermediate and the left mesial lobes, and not with the left lateral fissure, between the left mesial and the left lateral lobes. The conveyance of maternal blood to the liver, along the suspensory ligament, would be a factor favouring the retention of the mesial fissure, as compared with the left lateral fissure. The human longitudinal fissure corresponds to the mesial or cystic fissure, as is well shown in a study of Gorilla and Wombat, and the intermediate mesial lobe, *i.e.*, between the gall bladder and the mesial fissure, is represented in the human liver by the lobus quadratus. In the Wombat, in which animal great diversity of liver shape is met with, from the primitive multilobed type to one scarcely distinguishable from the human, irregularities can be studied in connection with this lobe, giving us an indication of its instability. It would further appear that cases of atrophy of the human lobus quadratus often met with represent the trend of Nature's evolution towards further unification and simplification of the organ, a fact to be remembered in cases of so-called "displacements of the gall bladder." This is the experimental region of the liver, and there is no reason why the gall bladder fissure in the human liver should not serve for the conveyance of the maternal blood to the portal fissure and vena cava, especially when we consider the proximity of portal vein and bile duct to the inferior vena cava in Kangaroo. In William Flower's classification of the lobes of the liver, followed generally by bio-

OBSERVATIONS.

logists, the longitudinal fissure is taken as the line of separation of the right from the left side. The left human lobe, however, really consists of the original left lateral lobe, together with the left mesial lobe, the original left lateral fissure having disappeared. The ideal division would be one applicable to all the mammalia, and Flower's arrangement is not even applicable to all members of such closely-allied orders as Monotremes and Marsupials. It could not apply to the Monotremes, Kangaroo, Tasmanian Devil, and some varieties of Wombat, nor would it hold for the liver of the Gorilla, in which the mesial or cystic fissure (human, longitudinal) is diminutive compared with the left lateral fissure. The division is best dominated by the arrangement of the vascular and biliary systems. In a minute examination of livers belonging to Monotremes and Marsupials, I found that they conformed to a single plan, viz., right and left portions, with the portal vein, gall bladder, cystic and common ducts, as the common stem. On the right side of the stem, cystic and venous branches were traceable to the right lateral and right mesial lobes, and on the left side to the left lateral and intermediate mesial and left mesial lobes. The true line for the division of the liver into right and left portions would be from the fundus of the gall bladder through the portal fissure to the dorsal border, as originally defined by James Cantlie. Apart from comparative anatomy, this division is supported by pathological findings. We can inject separately into one or other side of the human liver. Newlands, the distinguished Adelaide surgeon, has told me that he has seen hydatid involvement of the right side of the liver, with compensating enlargement of the left, and Cantlie observed this in connection with atrophy of the right side following chronic abscess, in which the liver was almost of normal weight. This conception of the

OBSERVATIONS.

liver offers up a new and interesting field in connection with the distribution and treatment of cancer, hydatid, and sepsis.

From a study of comparative anatomy, we see how the human liver and spleen acquire their shape. The question naturally arises: if the liver cells perform multiple functions, are the functional activities different in different portions of the organ? This would be best studied in the more primitive multilobed livers, like those of the Marsupials and Monotremes. And, similarly, in connection with the spleen, for it must be remembered that human spleens are often met with in which the body and right and left processes are all separately defined. To know the sequence of acquisition of function of liver cells is essential to a proper classification of diseases of the organ, for loss of one or more, not necessarily all, the functions of a cell must be surely as characteristic of hepatic disease as it is in connection with loss of function of a muscle.

Determining shape we must remember the following factors:—

- (1) Adaptation to surrounding structures.
- (2) Influence of respiration.
- (3) The orthograde posture.
- (4) Relation of the heart to the diaphragm.

The left hepatic lobe is well developed in the Monotremes and Marsupials, but the heart is not related to the diaphragm as in the case of Man and the Anthropoids, since, with the exception of the Koala, the azygos lobe from the right lung intervenes. Attention has frequently been directed to the primitive type of the liver of the Gorilla—the most orthograde of the Anthropoids. More interesting, however, is the fact that members of the

OBSERVATIONS.

Phascolomyidæ (Marsupials and Pronogrades) should exhibit a liver in some instances primitive in character—in some almost indistinguishable from the human—and in some intermediate, in type, between the two. As I have already pointed out, the internal arrangement of the Wombat's abdomen approximates closely to the human, and this is especially noteworthy as regards the spleen, pancreas, and the vermiform appendage, as well as the liver.



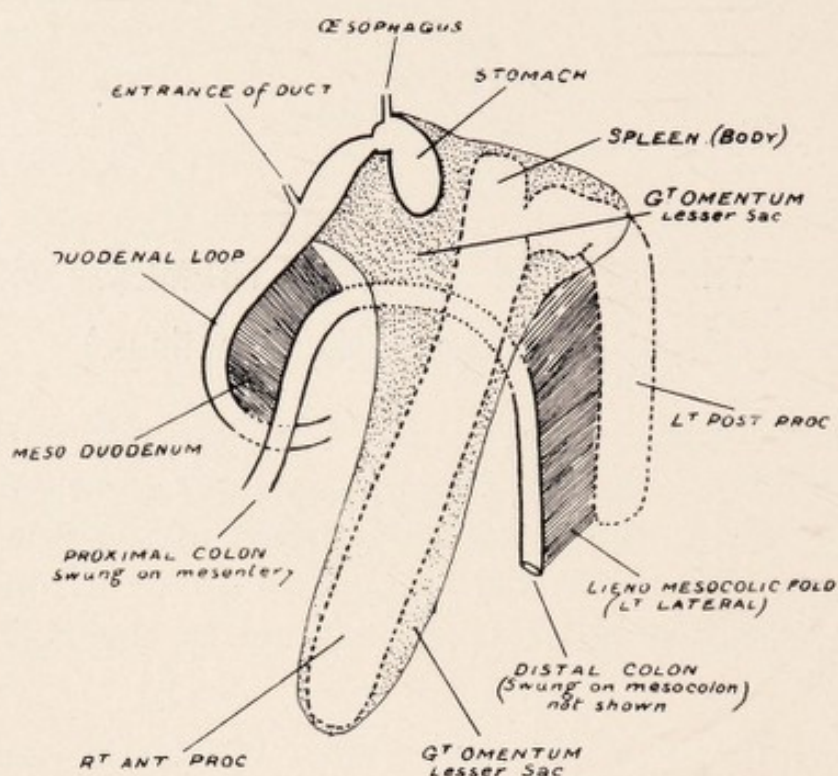
THE SPLEEN AND PERITONEAL
RELATIONS IN MONOTREMES
AND MARSUPIALS.

THE SPLEEN IN MONOTREMES.

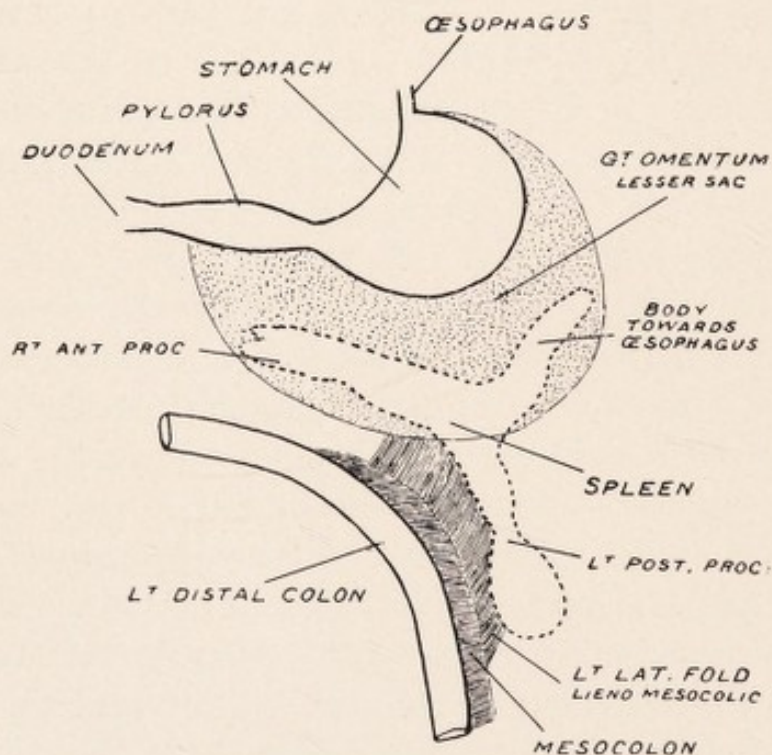
Platypus (*Ornithorhynchus anatinus*.)

On opening the abdomen of the *Platypus*, concomitant with the presence of a diaphragm and great omentum one is struck by the large development of the spleen and pancreatic tissue, and the right stem of the former may extend from the left hypochondrium to the right iliac region.

The spleen (p. 136) is somewhat V-shaped, and three portions are recognised, viz., a small body 2.5 to 3 cm. long directed towards the œsophagus and in the great omentum (lesser sac); a large right ventral (anterior) process lying freely in the abdominal cavity and suspended also in the great omentum, 12 to 15.5 cm. long, with the width varying from 2 to 2.5 cm. and thickness 1.5 cm.; and a shorter left dorsal (posterior) process 7 to 9 cm. long, with a width of 1.75 to 2 cm. and thickness of nearly 1 cm. This left process is outside the lesser sac in relation with a fold—the left lateral or lieno-mesocolic—connecting it to the mesocolon of the left or distal colon. The distal colon is never fixed dorsally, and the average maximum width of the mesocolon equals 5 cm. The pancreas is found diffusing itself on the left aspect of the mesocolon in relation with the left lateral fold. The fold with the left splenic process and pancreas can be lifted free from the ventrum of the left kidney and the dorsal wall. Whilst the right process and body of the spleen are continuous, the left process is arched and forms practically a right angle with the body. A deep notch is present



THE PERITONEAL RELATIONS OF THE SPLEEN IN PLATYPUS.



THE PERITONEAL RELATIONS OF THE SPLEEN IN ECHIDNA.

THE SPLEEN IN MONOTREMES.

at the cephalic margin between the two, and the actual width of attachment may be less than 2 cm. One or two small notches may be noted at the caudal border near the termination of the lesser process, and a notch directed towards the body between the right and left process. It is interesting to note that in an Agama (Reptilia) measuring 30 cm. snout to vent and abdominal width of 7 cm. the spleen was 1.5 cm. long and .4 cm. wide, while the snout to vent measurement of the Platypus is 37 cm. and width 13 cm.

Echidna (*Echidna aculeata*).

As in the Platypus, three main portions of the spleen may be recognised (p. 136), viz., body and two processes; but while uniformity is characteristic of the spleen of the Platypus, although conforming to the general character it is rare in the Echidna to find two spleens alike.

(1) *Body*.—This is better defined than in Platypus and is in relation to the stomach fundus, being directed towards the œsophagus. It is suspended in the great omentum, the width of which, even in a male adult, only equals 1 cm.; and so at this early stage we obtain the definition of a gastro-splenic omentum. Its length varies from 3 to 5 cm. and the width .5 to 1 cm.

(2) The right ventral process is the longer of the two and is also suspended in the great omentum (lesser sac), the width of which at its anterior extremity is 7 cm.; so that it is more mobile than the body. Its average length is 5 to 7 cm. and width .5 to 1.5 cm.

(3) *Left Dorsal Process*.—This is shorter than the anterior, and two portions may be recognised, viz., a stem terminating in a pear-shaped body, which may be smooth or (especially in smaller specimens) corrugated. The

THE SPLEEN IN MONOTREMES.

stem rarely runs directly into this portion. Usually there is narrowing at the point of attachment, and the connection between the two may be merely a slender fibrous thread. The stem varies from 1.5 to 3 cm. in length and average width .5 cm., while the body varies from 2 to 3.5 cm. in length and circumference may reach 5 to 6 cm. This process, as in *Platypus*, lies outside the lesser sac in relation to the lieno-mesocolic fold, extending caudally towards the pelvis on the left of the distal colon. In one specimen out of a large number examined, I found the left stem included in the lesser sac. The distance between the pear-shaped body and colon may only equal .75 cm. The pancreas is a less mobile organ than that of the *Platypus*, and in not one of the numerous specimens examined by me did it extend sinistral to the lesser sac, so as to come into relation with the lieno-mesocolic fold. The distal left colon is mobile, having a mesocolon. In one specimen this was greatly narrowed and the length of the distal colon in the abdomen only equalled 7 cm. In another—a male specimen—the pancreas was a “fixed” organ and on the right side was adherent to the lobus caudatus. The left or distal colon was fixed dorsally, describing an almost vertical course to the pelvis. In close relation in this specimen, and all fixed dorsally in the left lumbar region, were the left testis, kidney, pear-shaped process of spleen, and distal colon. The pancreas extended but a short distance on the left of the colon and apparently had little influence in the fixation of this structure, since it never extended to the left in relation with the lieno-mesocolic fold. Yet fixation has occurred. In this specimen, as well as the one with a shortened mesocolon, the distal left colon was relatively short; there was a failure to develop, with atrophy of the mesocolon. Instead of the distal colon from the duodeno-intestinal flexure to vestibule being 28 cm. long—the average adult male length—it only measured 13 cm.

THE SPLEEN IN MARSUPIALS.

In this order we meet not only with types of spleen presenting the early mammalian character seen in the Monotremes, but with types becoming dorsally fixed and resembling closely the human spleen.

Tasmanian Devil (*Dasyurus sarcophilus*).

In this Marsupial there is a well-defined great omentum extending from the pyloric region to the left along the great curve of the stomach. No duodenal loop is present, and no well marked distinction between colon and small intestine as in other Marsupials. The intestinal tract is reptilian in character, consisting of a canal 157 cm. from pylorus to pelvis, swung apparently on a single mesentery 7 cm. long at its dorsal attachment. This latter consists of two portions—an upper 1.5 cm. long (superior mesenteric) and corresponding to the duodenum and small gut (135 cm.), and a lower (5 cm.) representing the original mesocolon and corresponding to the remaining 22 cm. of intestine, which is large gut. (Page 94.)

As in *Macropus*, the spleen presents three distinct portions:—

(1) A large portion or body directed along the great curvature of the stomach towards the œsophagus. It is swung on the great omentum, which is 2 cm. wide at the left extremity and 10 cm. at the right. At the left extremity, in addition to the shortened omentum (gastro-

THE SPLEEN IN MARSUPIALS.

splenic), a peritoneal band stretches across the omentum between the stomach and spleen. The body varies from 7 to 8 cm. in length, and greatest width is 1.75 cm.

(2) The right ventral process is also in relation with the lesser sac, being swung freely on the great omentum. It varies from 4 to 5 cm. long and is about 1.75 cm. wide. This portion forms almost a right angle with the body.

(3) The left dorsal process, 2.5 cm. long and 2 cm. wide, is outside the lesser sac and gives attachment to the left lateral fold. This membrane is somewhat triangular in shape and measures 9 to 10 cm. long, and over it the main pancreatic tissue diffuses itself, but it never extends nearer than 2 cm. to the dorsal attachment. The basal portion of the membrane (5 to 6 cm. long) extends from the root of the mesentery out along the lower part of the lesser sac to the left dorsal process of the spleen. Its left margin is free. The right margin is not continuous dorsally with the mesocolon of the large intestine, but with the peritoneum slightly to its left. The left lateral fold, as in the Platypus and Kangaroo, is free from dorsal wall and ventrum of the left kidney.

Koala (*Phascolarctus cinereus*).

The spleen is suspended in the great omentum, being contained in the lesser sac, and is characterised by the relative shortness of the left dorsal process and the absence (this being the only instance among Marsupials and Monotremes) of the left lateral or lieno-mesocolic fold. The shape of the spleen varies slightly in different animals. In all there is an elongated right ventral process varying from 7 cm. to 12.5 cm. long. It is usually constricted and fissured where it joins the main splenic mass. The remainder of the spleen or body may approach

THE SPLEEN IN MARSUPIALS.

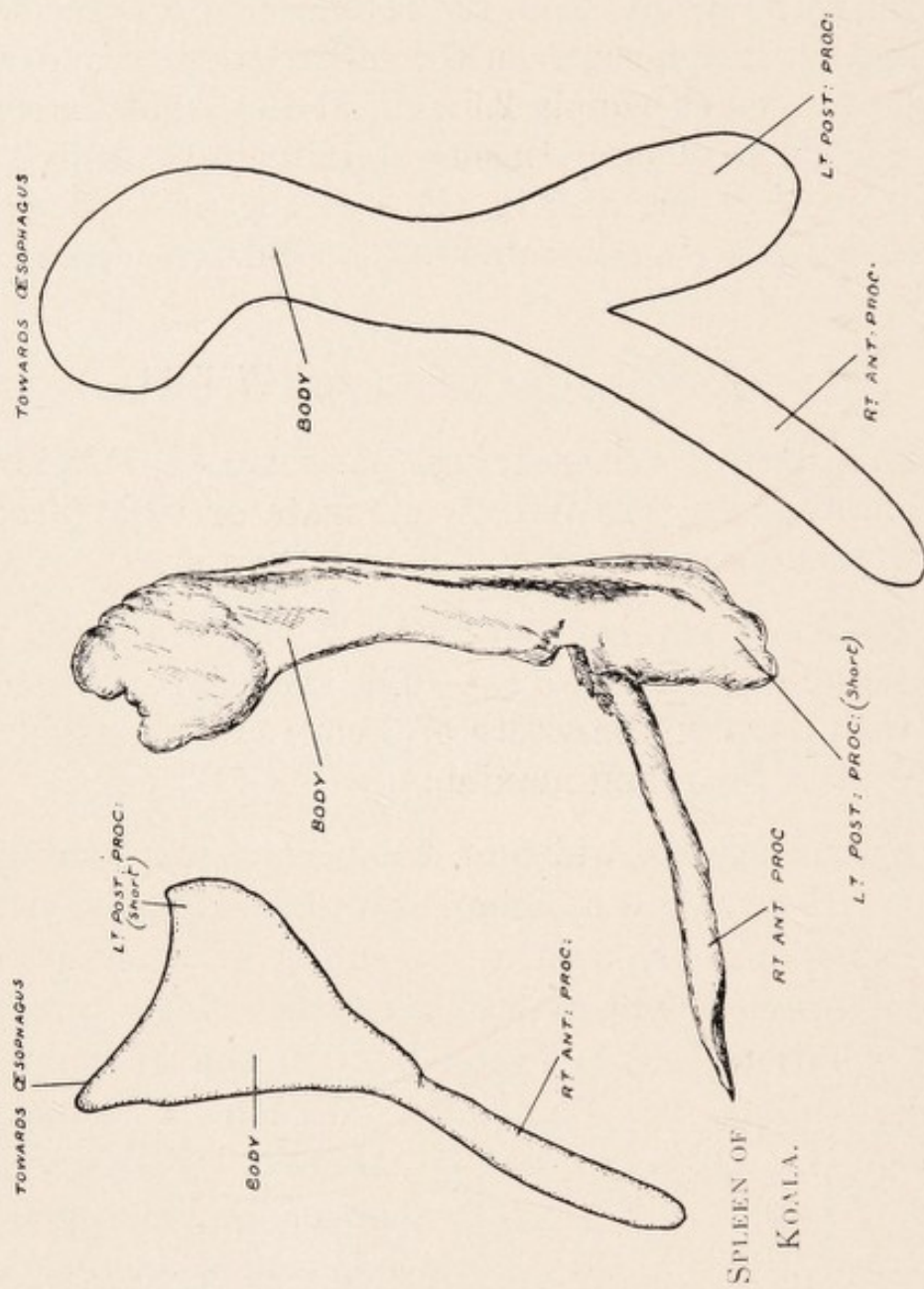
somewhat in shape the human type, forming a triangular body 7 cm. long and 4 cm. across, with two small projections, one directed towards the œsophagus and the other representing the left dorsal process. The right process is much more mobile than the body, and while the width of great omentum between the left extremity and great curve of stomach equals 2.5 cm., at the right extremity this equals 9 to 10 cm. In some specimens the body is not relatively so large, and in place of the projections two processes are seen, separated by a well-defined interval or gap.

Macropodidae (Kangaroos and Wallabies.)

The spleen consists of three portions: (1) left, largest portion or body; (2) narrow elongate or right process; (3) wider, though shorter, dorsal left process.

The body varies from 11 to 15 cm. in length, with a maximum width of 4.5 cm. The short left process is 6 cm., with a maximum width of 3 cm.; and the right process 9.5 cm. long, and maximum width 1.75 cm.

Frequently the width of this process may only equal 1 cm., with a narrow attachment to the body—the connection being fibrous, with a sprinkling of splenic tissue. Such a process is one apparently undergoing a retrogressive evolution, and is found both in the Wallaby and Kangaroo. In the Tasmanian Wallaby I found the anterior process to be not only narrower but shorter than the left process. The great stomach in *Macropus* is a V-shaped organ with a large left and a smaller right limb, and the well-defined Spigelian lobe of the liver depending between the two. The body and elongated right process are suspended on the great omentum (lesser sac), being related to the greater curvature of the left limb as far to the right as the bend in the stomach. The pro-



SPLEENS OF MACROPODIDAE.

THE SPLEEN IN MARSUPIALS.

cess is less closely attached than the body. The short, wide left dorsal process is outside the lesser sac, being connected to the mesocolon of the distal colon by the triangular fold, the left lateral or lieno-mesocolic, which is more developed in some specimens than in others. It is free from the dorsal wall and ventrum of the left kidney. Both as regards its shape and the disposition of the left lateral fold, the spleen of the Macropod presents the primitive Mammalian type, and resembles closely that of the Monotreme.

True Phalangers (Trichosurus—Pseudochirus).

In *Trichosurus* a marked advance towards the human type of spleen is to be noted, and light is thrown on the formation of the lieno-renal ligament and the mode of fixation of the distal colon and spleen. Although three portions of the spleen are noted, viz., body, right, and short left processes, the organ is more compact and the processes less defined than in the preceding mammals (page 116). The body is directed towards the œsophagus and is suspended—like the right ventral process, which is directed along the great curvature of the stomach—on the great omentum, *i.e.*, lesser sac.

The width of the great omentum (gastro-splenic) at the extremity of the body is 1.5 cm., and at the extremity of the right process the width is 5.5 cm., so that the narrowing gastro-splenic omentum is here well defined. The short left dorsal process is outside the lesser sac in relation with the left lateral fold. Its average length is only 1.5 to 2 cm. The total average length of the spleen is 7 cm. and the width 1.5 to 2 cm. In addition to the outer or left and inner visceral or right surfaces, three margins can be defined, viz., renal or dorsal margin formed by the body and left process; right ventral margin formed by the body and right process; and left colic margin

THE SPLEEN IN MARSUPIALS.

formed by the left dorsal and right anterior processes. On examining the inner or visceral surface (page 154) of the spleen we are struck with the resemblance borne to that of Man and the Wombat. We note a well-defined renal surface, concave, formed by the body and left process; a gastric surface formed by the body and right process, with the gastro-splenic omentum (great omentum) attached along a groove extending from the extremity of the body to the extremity of the anterior process. This surface is separated dorsally by a distinct raised edge from the renal surface, but unless there is a defined concavity this is not marked. From the gastro-splenic omentum, running down the left dorsal process, we see the attachment of the left lateral fold (lieno-mesocolic). This, with the anterior part of the gastro-splenic omentum, separates off the lower left or colic surface. Below the attachment of these two membranes we have a ridge simply the result of the impressions of the colon and stomach, just as the posterior ridge separating the renal from the gastric surface is the result of the renal impression. The lieno-mesocolic (left lateral fold), instead of being free as in the preceding specimens from the short left splenic process to the mesocolon of the distal colon, has, in addition, become attached to the ventrum and outer surface of the lower half of the left kidney. The result is that the spleen and left portion of the pancreas which is supported on the fold are brought into relation with the kidney, and so we have defined the concave renal surface of the spleen related to the upper and outer convex portion of the kidney—the pancreas lying ventral to that organ. Thus we see that we have a definitely formed lieno-renal fold which is really the upper part of the lieno-mesocolic fold, and the lower part of the fold is really now reno-mesocolic. A peritoneal band is noted in both *Trichosurus* and *Pseudochirus* from

THE SPLEEN IN MARSUPIALS.

the middle of the convex border of the kidney to the lateral abdominal wall, and continuous over the kidney with the lieno-mesocolic fold. The attachment of the lieno-mesocolic fold to the left kidney (zygosis) is thus a factor in bringing the spleen into close relation with that organ, and this is more marked in some specimens than in others. In two specimens the pancreas lay ventral to the left kidney, and the renal surface of the spleen was related to the outer part; but all could be raised off the kidney, as they were suspended on the lieno-mesocolic fold, and this was not attached to the ventrum of the kidney as above described. The fold, however, was really lieno-renal, as its lower attachment was to the dorsal wall at the lower pole of the kidney, *i.e.*, it did not extend to the mesocolon, the lower portion being atrophied. In a smaller variety of Australian Phalanger (*Pseudochirus*), though the spleen is practically similar to that of *Trichosurus*, the fixation of structures in the left hypochondrium and lumbar regions is more pronounced. The renal surface of the spleen is in relation with the upper and outer convex surface of the kidney, and the left process of the spleen can be raised slightly off that organ. The pancreas, however, is seen to be in close relationship with the ventral and outer surface of the kidney. In *Trichosurus* the left distal colon and meso-colon are free of lesser sac, but in *Pseudochirus* they are included for about 8 cm. This inclusion must be an important factor in approximating colon to spleen, although in *Pseudochirus* it is associated with a large process of pancreatic tissue in the lesser sac and free from the dorsum. Whilst in *Trichosurus* the colon and mesocolon are not brought close to the kidney, in *Pseudochirus* the lieno-mesocolic fold is relatively shortened up and the mesocolon is brought in direct relation with the caudal pole of the kidney, so that we find in close connec-

THE SPLEEN IN MARSUPIALS.

tion pancreas, left process of spleen, kidney, and mesocolon, only the shortened remains of the lieno-mesocolic fold intervening. In these two varieties of Phalanger important light is thrown on the combination of correlated factors necessary to produce the close relationship of spleen, pancreas, and colon in the left human hypochondrium.

Wombat (*Phascolomys*).

The spleen is placed in the left hypochondrium in relation with the left part of the stomach and upper portion of the left kidney. It may be described as triangular in shape, presenting three margins: (1) dorsal or renal; (2) right, gastric, or ventral; (3) left, lower, or colic.

We also note three extremities or angles, viz., an œsophageal or upper, a right ventral, and a left extremity. In addition, two main surfaces, viz., outer, lateral or left, and inner, mesial, visceral, or right. Its greatest length is 12 cm. and breadth 11 cm.

Extremities.—(a) The œsophageal or superior extremity is most dorsal and frequently the most pointed, and lies 3 to 4 cm. from the œsophagus. It is in relation with the great curvature of the stomach, to which it is connected by gastro-splenic omentum, *i.e.* upper part of the great omentum, and which is thickened in this region, with a width of only 1 cm. Frequently, as in the human, it bends towards the inner surface so as to give a rounded shape to the upper end of the spleen. This is probably an accommodation effect for a well-developed left hepatic lobe, with the lower and inner part of which it is related.

(b) The ventral or right extremity is usually rounded and corresponds to the right ventral process seen in the Monotremes and other Marsupials. It is connected to the great curve of the stomach by the gastro-splenic (great) omentum, the width of which is 4 cm., so that it is more

THE SPLEEN IN MARSUPIALS.

mobile than the superior angle. It is to be noted that the gastro-splenic omentum does not extend to the tip of either extremity.

(c) The left extremity corresponds to the left process seen in other Marsupials and in the Monotremes, and is related to the outer margin of the left kidney about the middle.

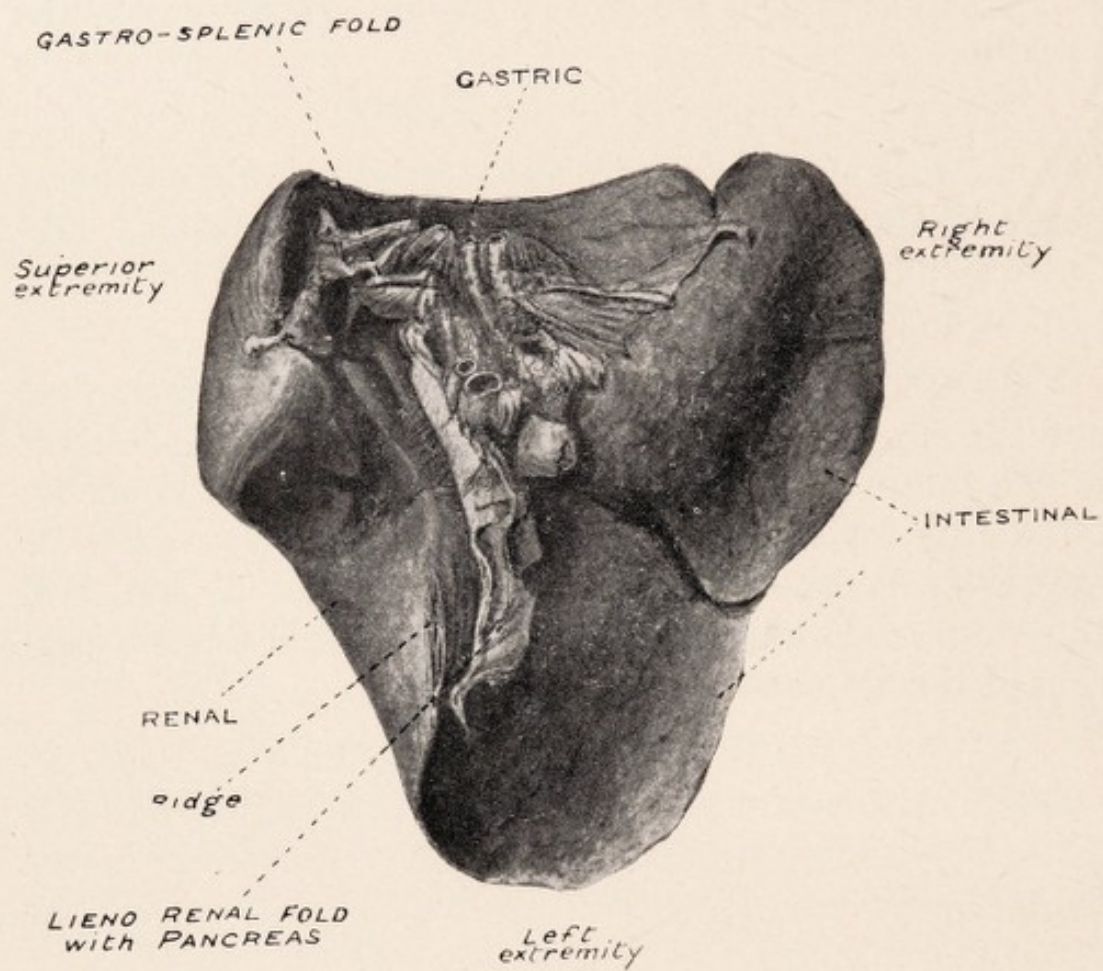
Margins.—(a) Right (anterior of human) lies between the superior and right extremities along the great curve of the stomach. It is thin, usually concave, frequently notched below, and formed by the body and right ventral process.

(b) The left margin extends between the right ventral and the left extremities. It is usually thin, is the longest of the three, and presents a well-defined notch about its middle or towards the left, so that the left process or extremity becomes differentiated off. It is free and comes into relation with the distal colon and the left portion of the stomach.

(c) The renal or dorsal margin extends between the superior and left extremities, being formed by the body and left posterior process. It is thicker and more dorsal than the others and is curved—being in relation with the outer convex margin of the left kidney.

Surfaces.—(a) The outer or left surface is usually smooth, slightly convex, corresponding to 8, 9, 10, 11, and 12 ribs. It is related to the diaphragm and the mesial or visceral surface of the left lobe of the liver.

(b) Inner, right or visceral surface is more complex and presents, as in the human spleen, certain very definite areas, viz. right, gastric, or upper; left, lower, or colic; dorsal or renal. The attachment of the gastro-splenic omentum extends on the gastric surface close to the pos-



SPLEEN. WOMBAT.
(*Phascolomys*)

INNER OR VISCERAL SURFACE OF THE SPLEEN OF WOMBAT.

THE SPLEEN IN MARSUPIALS.

terior boundary obliquely down and forward from within 1 cm. of the superior extremity to within 1 cm. of the tip of the right ventral extremity below. The lieno-mesocolic fold—which supports the left pancreas and the chief vessels—is attached on this aspect of the left process, and may or may not extend to the left angle or tip. Below it is attached to the ventrum of the caudal pole of the left kidney, so that it is lieno-renal. The left pancreas—unlike the human—can be raised from the front of the kidney. By means of this fold and the anterior part of the gastro-splenic omentum the lower or colic surface is defined. In addition, certain ridges are noticed on this aspect of the spleen. Along the attachments of the lieno-mesocolic and anterior parts of the gastro-splenic membranes is a blunt ridge, and following the curve of the upper part of the gastro-splenic membrane a slight ridge may be noticed. Dorsal to the upper part of the gastro-splenic membrane is a sharper ridge—renal ridge—the result of renal pressure, and separating off the renal and gastric surfaces. The renal ridge is traced along the left extremity, forming a prominence below.

(1) Gastric surface (right or upper) is somewhat triangular and concave for the fundus of the stomach. It corresponds to the body and right anterior process. Dorsally is the attachment of the gastro-splenic omentum with some small vessels, and below it is separated from the colic surface by the gastro-splenic membrane in front and the lieno-mesocolic behind. The pancreas, supported on the lieno-mesocolic fold, tends to encroach on the gastric surface between this fold, the renal ridge, and the gastro-splenic omentum. The dorsal limitation of this surface is the ridge behind the gastro-splenic omentum; or where the depression for the kidney is well marked a defined margin separates it from the renal surface.

THE SPLEEN IN MARSUPIALS.

(2) Left, lower, or colic surface.—This is separated from the gastric surface by the gastro-splenic omentum, and from the renal and gastric by the lieno-mesocolic fold with pancreas, and more posteriorly the renal ridge, since the renal concavity extends to the left extremity. A well-defined fissure is seen a little below its middle, which, extending inwards, serves to define the left process. This surface corresponds to the right ventral and left dorsal processes of the Platypus, the notch on the edge leading to the fissure representing the original interval between the two. It is related to the distal colon, and when distended the stomach is seen to be related to the upper or ventral half (*i.e.* above the fissure), which portion is included in the gastric surface of the human.

(3) Dorsal or renal surface is the narrowest of all the surfaces and corresponds to the body and left posterior process. It is really a concavity for the upper part of the left kidney, and can be regarded as an accommodation effect. The concavity may extend almost along the whole length or be only limited to the lower four-fifths, since in cases with a well-developed left hepatic lobe the upper end of the spleen may be curved over towards the inner surface. The result of renal accommodation or pressure is to define on the inner and dorsal aspect of the spleen a ridge or margin—renal ridge—best defined below, where it forms a distinct projection or angle. This ridge separates the renal and gastric surfaces and, with the lieno-mesocolic fold, the renal from the colic below.

INTERPRETATION OF THE FOREGOING FACTS.

A study of the spleen in these two orders throws light on the significance of shape of the human spleen and on the correlations associated with its fixation in the left hypochondrium. The spleen of the Wombat (*Phasco-*

THE SPLEEN IN MARSUPIALS.

lomys) (page 148), though conforming more to the primitive Mammalian type, yet resembles the human so closely as to be at times almost indistinguishable, and so the so-called anterior, posterior, and superior angles of the human spleen become significant. These all have their prototypes in the Platypus. Two spleens are illustrated, taken at random from full-time fœtuses (page 154). As one might expect, the anterior process (*i.e.* ventral, right process of the Platypus) is well defined, while the posterior (*i.e.* dorsal, left process of the Platypus) is poorly defined. In both, fissures are seen defining the body from the processes. From the point of view of biology, *i.e.* function, the human spleen of the text-books cannot be accused of affording much information. Post-mortem examinations made for a period of six years with Dr. S. Strachan at a benevolent home for the aged showed me the great relative frequency of perigastric adhesions, perisplenitis, and old left pleuritis, all of which would profoundly modify shape. To throw light on the significance of shape it would be better if young subjects were chosen. One naturally wonders whether different portions of the Mammalian spleen have different functions. There is no biological evidence of this, nor can it be said to be borne out by histological examination, although important differences were noted in the spleen in the different members of the orders described. As regards the fixation of the human spleen, this, it must be borne in mind, is associated with fixation of the distal colon and left pancreas. The attempts made by nature can be studied in the Monotremes and Marsupials. In a study of the peritoneum of the members of these two orders, three primary folds are noted, which are traced in varying degree throughout the Mammalia, and play an important part in the fixation of the gut, which is coadjusted to the erect posture:—

THE SPLEEN IN MARSUPIALS.

(1) Mesial fold, approximating the colon to the pyloric region, and continuous in the Chameleon with the gastro-hepatic omentum or ventral mesogaster.

(2) Duodenal or right lateral, passing from the ascending duodenum to the right aspect of the mesocolon of the distal colon, which I regard as an acquired or physiological fold (zygosis).

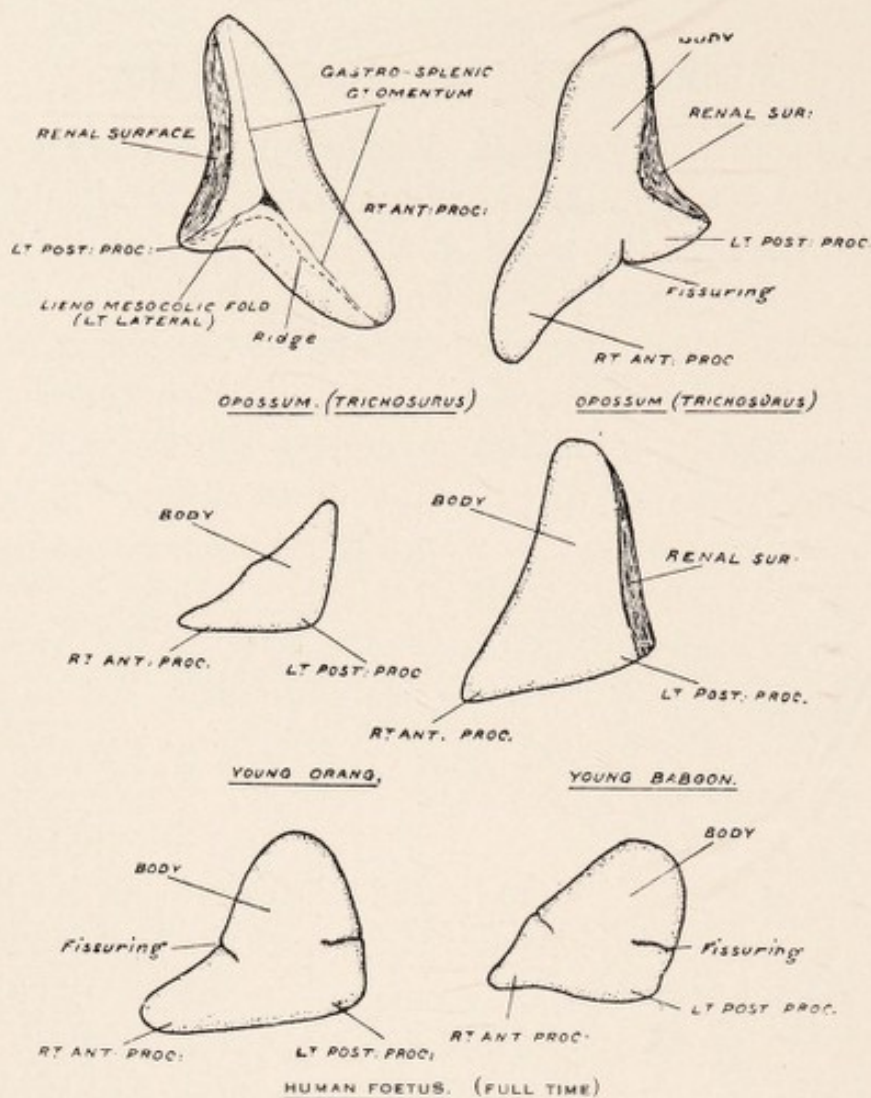
(3) Left lateral or lieno-mesocolic, from the left, dorsal, or posterior process of the spleen to the left aspect of the mesocolon of the distal colon. The mesial fold is best defined in the Koala, the duodenal in *Trichosurus*, and the lieno-mesocolic fold in the *Platypus* and *Dasyures*. The origin of the left lateral or lieno-mesocolic fold was certainly very puzzling, and at first I was inclined to regard it as an acquired or physiological adhesion (zygosis) from a spleen which had wholly developed in relation to the lesser sac. A study of certain lizards supplied me, however, with a different explanation (page 154).

In *Agama* we notice the narrow splenic body in the mesogaster running parallel with the stomach. In *Lygosoma* (*Scincidae*) the spleen was noticed passing almost vertically close to the dorsal wall and in relation not only with the mesogaster but with the mesentery and mesocolon as well. Correlated with the development of the Mammalian spleen we have the development of great omentum, and, in the case of the *Agama*, the enlargement would be wholly related to the lesser sac, as actually happens in *Koala*, in which the left process is insignificant; while in the case of *Lygosoma* an enlargement of the spleen would involve not only the mesogaster (great omentum, lesser sac) but the mesocolon as well. In *Lygosoma* the pancreas is noted as a single strand extending from the commencement of the duodenum to the

THE SPLEEN IN MARSUPIALS.

lower portion of the spleen. Diffusibility is characteristic of its early Mammalian development. In the *Platypus* it diffuses itself on the right in the meso-duodenum and on the left on the lieno-mesocolic fold. Mesially it is fixed, forming the lower dorsal boundary of the lesser sac.

With development of the spleen is a correlated great omentum, but no inclusion primarily by the great omentum (lesser sac) of distal colon or pancreas. The pancreas as we ascend in the Mammalian scale becomes more compact. From the point of view of selection it would not be advantageous for it to be included in the lesser sac. It could not then conform to the abdominal law of dorsal fixation of solid bodies by which torsion especially of ducts is prevented in the erect posture. In addition, the dorsal fixation of duodenum, spleen, and left distal colon, of which its own further dorsal fixation is an important factor, would be interfered with; and the significance of the relationship of the pancreas on the left to a fold (left lateral) connecting spleen and distal colon in the production of that arrangement becomes understood. This fold is completely absent in *Koala*, and in that Marsupial there is no fixation of distal colon, spleen, or left pancreas. Primary inclusion by the great omentum of the proximal 8 cm. of distal colon actually happens in *Pseudochirus* (Australian *Phalanger*), and in this Marsupial, though distal colon, spleen, and kidney are proximal, there is a considerable amount of pancreatic tissue free in the lesser sac. Furthermore, a study of the *Mammalia* shows that for adaptability to a mixed diet selection requires not atrophy but development of the distal colon, which becomes ultimately fixed as in erect *Man* in the left hypochondrium. In the *Echidna*, whose diet is chiefly ants, a failure to develop or atrophy of the distal colon and mesocolon is correlated with the dorsal fixation of that gut and of the pancreas, but not of the spleen. I regard that as the evolutionary tendency in the *Echidna* (since I have



SPLEENS OF PHALANGER (OPOSSUM), ORANG, BABOON, AND HUMAN FOETUSES.

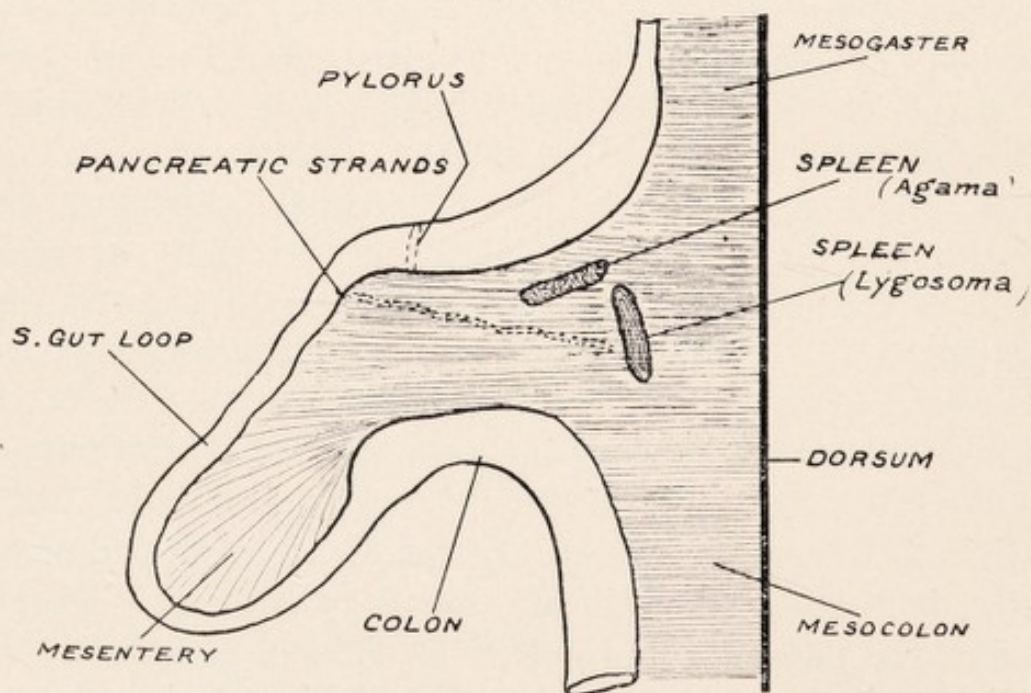


DIAGRAM TO SHOW CONTRASTED POSITIONS OF SPLEEN IN AGAMA AND LYGOSOMA.

THE SPLEEN IN MARSUPIALS.

seen the various grades of shortening of the mesocolon), and nature does not retrace her steps. From the point of view of "selection" for the evolution of the human type, the arrangement in the *Platypus* is superior to that of the *Echidna*.

The "selection" factors would be:—

- (a) Lieno-mesocolic fold lying ventral to left kidney, connecting spleen and mesocolon, and supporting pancreas.
- (b) Pancreas outside the lesser sac.
- (c) Shortening of the great omentum (gastro-splenic omentum) between the left extremity of the spleen and stomach fundus, with secondary peritoneal bands between the two.
- (d) Development—not atrophy—of the distal colon.

As evolution proceeds, the pancreas, which even in the *Platypus* is fixed dorsally about the root of the mesentery, approaches the dorsum on the right and left sides (in the *Echidna* direct adhesions may be noted between pancreas and lobus caudatus), which means some approximation of spleen and mesocolon. Adhesions form between the lienomesocolic fold and ventrum of the left kidney as in *Trichosurus*—the fold ending in the *Wombat* at the lower pole of the kidney. Thus is developed the lienorenal band. The development of the so-called human "intermediate" angle (which really represents the lower limitation of the renal ridge) is now easy to understand. Further evolution results in further atrophy or shortening of the lienorenal (mesocolic) fold. The pancreas and colon become more closely related to the spleen, with an encroachment on the lower portion of the renal concavity and atrophy of the lower part of the renal ridge.


THE SPLEEN IN MARSUPIALS.

A new feature becomes added which can be effectively studied throughout the Primates, viz. the inclusion by great omentum first of the mesocolon and later of the distal colon—the pancreas now being a dorsal organ. This inclusion or fusion begins from right to left, and the importance of the mesial fold previously mentioned, between the colon and pyloric region, is seen. Early phases of this can be studied in *Macropus*. In a young Baboon (*Catarrhina*) (page 154), the “lienomesocolic” is simply a fold between the spleen and the upper part of the kidney, *i.e.* it is atrophying, and the ridge on the inner surface of the posterior angle or process has almost gone. The lower part of the renal and the colic surfaces are becoming continuous with the “intermediate” angle becoming evident. Here, however, the colon is not fixed, but the mesocolon at its commencement is partially applied to the great omentum. The colic surface is not, as in the human spleen, encroached on by the stomach, *i.e.* the relationship of colon to spleen is not limited as in the human, and the gastro-splenic omentum goes almost to the tip of the anterior process. In a young Orang Utang, however (p.154), the colon is fixed dorsally. It is included (secondarily) in the lesser sac by the great omentum, and has only a limited relation to the spleen. The anterior portion of the colic surface is encroached on by the stomach as in the human spleen. Thus, with its fixation the colon comes into relation with a limited area of spleen only, though previously related to the whole colic surface. As to whether the stomach will encroach on the colic surface depends on the atrophy of the right or anterior part of the gastro-splenic omentum. With dorsal fixation of the spleen the membrane further atrophies and the stomach encroaches as in the human spleen. But where there is mobility, *i.e.* not good dorsal fixation, the anterior part of the lower surface is colic not gastric. Thus we

THE SPLEEN IN MARSUPIALS.

may see the human foetal spleen with the remaining lieno-mesocolic (renal) fold and the anterior part of the gastro-splenic omentum extending to the extremities of the anterior and posterior processes, and practically shutting off the lower surface which is related to colon only. This is associated with a greater amount of mobility than is present in the human adult spleen.

It is worthy of note that broadening of the base of the mesentery, *i.e.* fixation of the proximal colon, begins from the mesial fold also, spreading from above downwards. Similarly, further fixation of the distal (descending) colon spreads downwards from the splenic fixation or flexure. The supporting phrenico-colic fold and the suspending lieno-phrenic, also lateral processes from the spleen to the abdominal wall, are adaptive physiological membranes freely modified to meet local conditions.



NOTES

NOTES

NOTES

