

**Introduction to the histology and histopathology of the nervous system /
by Paul Schröder ; authorized translation from the second revised German
edition, by Baldwin Lucke and Morton McCutcheon.**

Contributors

Schröder, Paul, 1873-1941.

Publication/Creation

London : J. B. Lippincott Company, [1923], ©1923.

Persistent URL

<https://wellcomecollection.org/works/jh43g92j>


License and attribution

This work has been identified as being free of known restrictions under copyright law, including all related and neighbouring rights and is being made available under the Creative Commons, Public Domain Mark.

You can copy, modify, distribute and perform the work, even for commercial purposes, without asking permission.

**wellcome
collection**

Wellcome Collection
183 Euston Road
London NW1 2BE UK
T +44 (0)20 7611 8722
E library@wellcomecollection.org
<https://wellcomecollection.org>

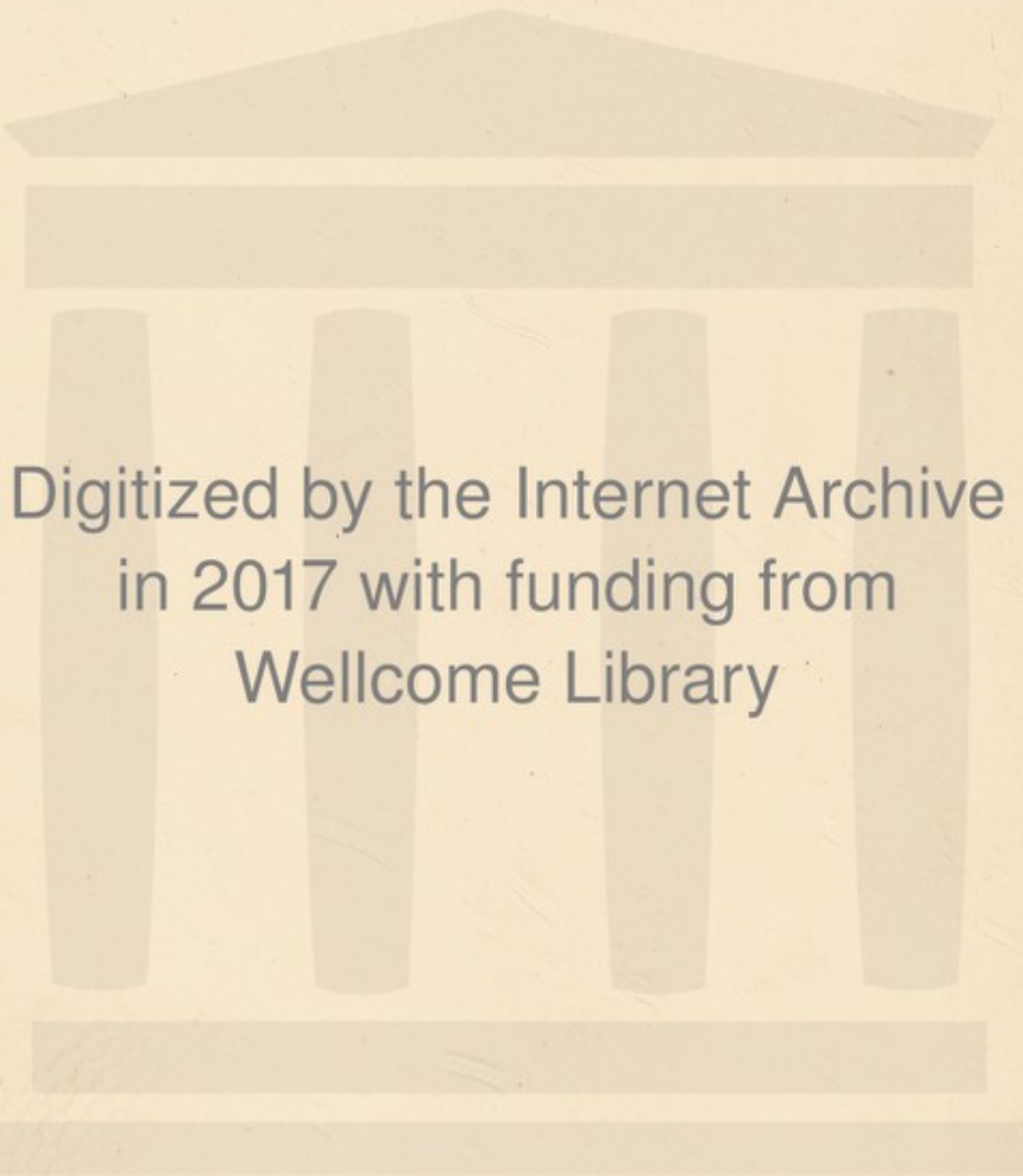

147 1



22102128924





Digitized by the Internet Archive
in 2017 with funding from
Wellcome Library

<https://archive.org/details/b29820601>

25.1.24

137-unt

185

INTRODUCTION TO THE HISTOLOGY AND HISTOPATHOLOGY OF THE NERVOUS SYSTEM

BY

DR. PAUL SCHRÖDER

PROFESSOR OF PSYCHIATRY AND NEUROLOGY IN GREIFSWALD



AUTHORIZED TRANSLATION FROM THE SECOND
REVISED GERMAN EDITION

BY

BALDWIN LUCKE, M.D.

ASSISTANT PROFESSOR OF PATHOLOGY, SCHOOL OF MEDICINE,
UNIVERSITY OF PENNSYLVANIA

AND

MORTON McCUTCHEON, M.D.

INSTRUCTOR IN PATHOLOGY, SCHOOL OF MEDICINE,
UNIVERSITY OF PENNSYLVANIA

WITH 53 ILLUSTRATIONS




LONDON :

J. B. LIPPINCOTT COMPANY,
16 JOHN STREET, ADELPHI.

COPYRIGHT, 1923, BY J. B. LIPPINCOTT COMPANY

PRINTED BY J. B. LIPPINCOTT COMPANY
AT THE WASHINGTON SQUARE PRESS
PHILADELPHIA, U. S. A

WELLCOME INSTITUTE LIBRARY	
Call	we!MOmec
Call	
No.	WL
	K54335



AUTHOR'S PREFACE TO THE FIRST EDITION

The following lectures do not claim to be a complete presentation of all that is known in the field of the histology and histopathology of the nervous system. They have been given for a number of semesters as lectures introductory to the demonstration of microscopic preparations on the projection apparatus. They treat, for the most part, of general fundamental questions. Histological and histopathological minutiae have been presented only where it seemed unavoidable. No illustrations have been included, for these are of value only when they are numerous and good, and such are costly. References have been given particularly to such papers as contain good illustrations. Histological methods have been brought into the discussion in many places, since clear comprehension and interpretation of our observations are largely dependent on the understanding and evaluation of the methods used.

The lectures were originally intended to be confined to the histopathology of the nervous system, but it was soon found that such discussions were not practicable without previous agreement concerning the normal histological structure. To assume any previous familiarity with the subject was not possible, because of the gaps in our present knowledge, and because of differences in interpretation of apparently contradictory histological observations. Therefore the pathological part has been preceded by a histological part, which is more or less independent of the

former, so that it may be used even by those who are less interested in pathological questions.

In the present state of our knowledge of the histology and histopathology of the nervous system, any presentation of the subject which is not to be merely a compilation of the literature, must necessarily have a strong subjective coloring. This is exemplified in the choice of observations and conclusions of others, regarded as important and correct. No extended discussion of conflicting opinions has been given, for the reason that a brief coherent presentation of the more important questions was aimed at, rather than a complete presentation of the entire field.

Any one familiar with the subject will easily recognize the influence of the investigations of Nissl upon the treatment of the material and the selection of the themes. Nissl's researches form the foundation of a large part of the entire presentation. To his teaching and influence the author owes the pleasure which he has found in the subjects treated here.

PAUL SCHRÖDER.



AUTHOR'S PREFACE TO THE SECOND EDITION

The first edition has been criticised because of the absence of illustrations; this has been remedied in the second edition. By agreement with the publisher, instead of expensive lithographs from drawings, half-tones, mostly from microphotographs, have been used. A part of the illustrations has been borrowed from the works of the great masters in the field of histology and histopathology of the nerve cell and neuroglia—Nissl, Alzheimer, Bethe, Bielschowsky, Held. Others are reproductions from former publications of the author. Illustrations have been limited to those having particular instructive value since their purpose in a book such as the present one is to help in the understanding of the more difficult portions of the text.

The general character of the work has not been altered. It is an introduction for those who wish to become familiar with the subject, and is designed as a stimulus to further independent investigation. It is no more a text- or reference-book than was the first edition.

The text has been thoroughly revised, additional matter has been added and whole sections have been rewritten; this applies particularly to the Second Chapter, on the neurofibrils; the Fourth, on the lymph paths; the Sixth, on the vessels; and the Eighth, on inflammation.

PAUL SCHRÖDER.

TRANSLATORS' NOTE

This book is what its name implies: an introduction to the histology and histopathology of the nervous system. It treats of general and fundamental questions, of like importance to the pathologist, the physiologist, the histologist and the neurologist. The separation of the text into histological and histopathological parts renders it of more ready value to those interested only in one or the other phase of the subject.

Dr. Schröder himself kindly reviewed the translation within the past few months and added many new references as well as some new material.

The translators have attempted to render the book into readable English; yet where it seemed best they have sacrificed smooth diction to close adherence to the text. In controversial subjects they have not made any comments, believing that the reader had best form his own opinion from the references cited. The translators have added an index.

Our thanks are due to Professors A. J. Smith and W. H. F. Addison for kindly advice.

University of Pennsylvania,
June, 1923.

BALDWIN LUCKE,
MORTON McCUTCHEON.

CONTENTS

PART I: HISTOLOGY OF THE NERVOUS SYSTEM.

	PAGE
CHAPTER I.	
INTRODUCTION.....	1
GANGLION CELLS.....	3
Methods of demonstration. Nissl's method of ganglion-cell staining, its use in pathology. Some types of ganglion cells in Nissl's preparations. Significance of the stainable portions. The doctrine of the ganglion cell—equivalent picture. The non-stainable substances of the Nissl picture. The pigment. The nucleus. The shape of the ganglion cells.	
CHAPTER II.	
THE NEUROFIBRILS.....	22
Apathy's observations on fibrils. Bethe's observations. The neurofibrils in lower and higher animals. The pericellular apparatus of vertebrates. The Golgi method. The neurone doctrine.	
CHAPTER III.	
THE NERVE FIBRES.....	37
Their histological structure. Differences between peripheral and central fibres. Regeneration of nerve fibres. The investigations of Reich and others on peripheral nerves.	
The neuroglia. Its ectodermal origin. Weigert's doctrine of the glia. The investigations of Held; the glia a syncytium. The glia in the Nissl preparation.	
CHAPTER IV.	
THE MESODERMAL TISSUE IN THE NERVOUS SYSTEM.....	55
Its amount, its behavior. The blood supply of the central nervous system. The structure of the vessel walls, their several layers.	
The lymph paths of the central organs. Subdural, subarachnoidal, epicerebral spaces. Lymph paths in the interior of brain and spinal cord; the adventitial and perivascular lymph spaces; confusion of these with artificial shrinkage spaces.	
THE HISTOLOGICAL STRUCTURE OF THE NERVOUS TISSUE.....	68
White and gray substance.	

PART II: HISTOPATHOLOGY OF THE NERVOUS SYSTEM.

CHAPTER V.		PAGE
GENERAL PRELIMINARY REMARKS.....		76
Localization and trend of investigation in histopathology. Choice of staining methods. The elective staining methods.		
THE PATHOLOGY OF GANGLION CELLS.....		79
Early over-optimistic hopes, and the reasons for these. Nissl's fundamental investigation. General significance of ganglion cell changes. Use of Golgi method in pathology. Fibril stains. The most important types of cellular disease, according to Nissl.		
CHAPTER VI.		
THE PATHOLOGICAL CHANGES OF THE GLIA.....		91
General laws. Glia fibrils and glia plasma. The space-filling function of the glia, its phagocytic function, the gliogenic granule cell. Pathological glia forms in the Nissl picture. Their significance for histopathology. Pathological changes in the vessel walls and the connective tissue. Arteriosclerosis and endarteritis.		
CHAPTER VII.		
PATHOLOGY OF THE NERVE FIBRES.....		110
Different behavior of the peripheral and the central nerve fibres. Disintegration of the myelin sheath. The secondary degenerations. The Wallerian law. The histopathological changes in secondary degeneration of peripheral nerves, of central nerve fibres. The discontinuous disintegration of the myelin sheath. So-called anemic foci.		
CHAPTER VIII.		
SOME HISTOPATHOLOGICAL COMPLEXES.....		127
The ectodermal type, the mesodermal type. Reparatory processes in hemorrhage, softening.		
GRANULE CELLS.....		131
Origin of the granule cells in the glia, proliferating vessel wall elements, neurolemma cells.		
SOME GENERAL PATHOLOGICAL CONCEPTS. INFLAMMATION.....		137
The development of this concept. Small round-cell infiltration, so-called perivascular round-cell infiltration; hemorrhagic inflammation.		

PART I.

HISTOLOGY OF NERVOUS SYSTEM

CHAPTER I.

INTRODUCTION—THE GANGLION CELLS.

THE anatomy of the central nervous system is a well-tilled field of research, but in spite of this fact our knowledge of structure is still inadequate as a basis for physiology and pathology.

That part of our knowledge which relates to external form, to general structure, and to division into white and gray matter may in a sense be looked upon as complete. As regards the fibre tracts, little has been learned in the last few decades; indeed a whole series of fundamental questions cannot be answered for lack of adequate methods, and, in particular, our knowledge of the fibre tracts of the cerebral hemispheres is even now rather scanty.

Recently, chief interest has been directed to another branch of neuroanatomy, the finer histology. A mass of observations has been collected, for the most part quite new, although there are many contradictions as to details, and not all of the data can be regarded as permanent contributions to our knowledge.

Hand in hand with this a similar change appeared in the field of *pathological* anatomy of the central nervous system. This subject was dominated in the last third of the nineteenth century by problems relating to localization and to fibre tracts, that is, by attempts to determine

exactly the seat of morbid processes and to follow the secondary degenerations resulting therefrom. Meanwhile, the study of the finer structural changes was neglected. This trend of research was undoubtedly due to the advances made by the physiologists and anatomists in the study of localization. It followed that neurology and brain pathology made rapid gains, while psychiatry profited but little. The return to histology, so neglected during this time, was initiated by Karl Weigert and Franz Nissl. Both these men advanced our knowledge of the normal histology of the central nervous system to an unprecedented extent, Weigert concerning himself chiefly with the neuroglia, Nissl with the ganglion cells; while both showed us how to apply these new facts to histopathology. In particular the researches of Nissl on morbid changes in the nerve cells led to great hopes for the histopathology of the central nervous system, and stimulated others to produce an immense amount of work. Nissl himself warned us that instead of centring our attention on the ganglion cells we should take into consideration all the elements making up the nervous system, without regard to prevailing opinions on their relative functional importance. To this study we must bring the principles of general pathological anatomy, correlating tissue alterations with clinical pictures. In this way we might possibly find that alterations in the supporting tissues (the glia and the connective tissue—vascular apparatus) prove more important than the changes in the specific nervous elements (nerve cells and nerve fibres).¹

Moreover, the researches of men like Held, Alzheimer, Bethe, Reich, Brodmann, Bielschowsky, and others, have

¹ Nissl, *Zentralbl. f. Nervenheilkunde u. Psychiatrie*, 1903, p. 519.

enriched our knowledge in the field of histology and histopathology in numerous details, partly in entirely new and unexpected directions. If we wish to understand this progress, it must first of all be made clear what we may look upon as definitely established in our knowledge of normal structure; later on, when we come to study the histology of pathological changes, we will find many indications that our knowledge does in fact rest upon a firm foundation of truth.

GANGLION CELLS.—Among the structural elements of the nervous system which we wish to discuss, at first separately, and then in their relation to the whole of the nervous tissues, the most important are, according to orthodox views, the *ganglion cells*. Whether they really have the supreme importance for the function of the organ that has long been attributed to them, has become somewhat questionable.

For their staining, we possess a whole series of methods. The older diffusely staining substances (carmin, nigrosin, hæmatoxylin, van Gieson's, etc.) give for the most part indefinite pictures, which are especially difficult to interpret under pathological conditions; while fixation by chromic salts (Müller's fluid), formerly so generally used, causes numerous artefacts. Our definite knowledge of the characteristics of ganglion cells we owe to three so-called specific methods—the Nissl, the Golgi, and the methods of fibril-staining. These three are entirely different in principle, and of all of them there are numerous modifications, which however lead only to unimportant differences in the microscopic pictures.²

² There are several such methods for the elective demonstration of the neurofibrils.

These three different methods give very dissimilar pictures of the nerve cells; thus the silver impregnation of Golgi gives black silhouettes of the entire cell body (Fig. 1); the methods for the demonstration of fibrils (Fig. 13 and 14) show only the nucleus and fibrils, but no other cell substances; while Nissl's method stains certain constituents of the nucleus (but in a different way), and

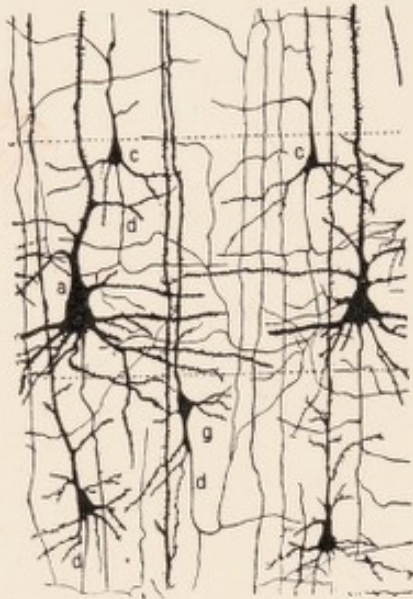


FIG. 1.—From the deep layers of the visual cortex of a young cat. Golgi preparation. After Cajal. (a) large pyramidal cell. (c) smaller pyramidal cells with branching axis-cylinder processes. (g) small pyramidal cell. (d) axis-cylinder processes.

certain portions of the protoplasm lying between the fibrils, but it does not stain the fibrils themselves. (Figs. 2 and 4.)

The most important method for pathology, and the one that hitherto has been most frequently and successfully used for the staining of ganglion cells, is that of Nissl.

Nissl called it a specific method for the staining of nerve cells, but this is not to be taken literally. The method, to be sure, does not stain the ground substance nor the nerve fibres; hence the distinctness with which the cell bodies are brought out. It does stain certain parts of all cell nuclei, not only of the ganglion cells, but also of the glia, the connective tissue, and the vascular elements. In the cell body, only certain substances of the cytoplasm are intensely colored. And such stainable substances are normally present, in the nervous system, only within ganglion cells.³ The bodies,

³ There are also ganglion cells which possess only extremely small quantities of these stainable substances.

particularly those of the large nerve cells, stain very deeply. But in morbidly changed parts of the nervous system, conditions are considerably different; all sorts of tissue cells, particularly those which are youthful or proliferating, may form protoplasmic substances which are stained more or less distinctly with Nissl's method. Among these are included plasma cells, mast cells, fibroblasts, and most of the progressively altered glial elements. This property eliminates Nissl's method as a specific staining method for nerve cells, but is the basis for its great usefulness in pathological anatomy even where the recognition of structural changes in ganglion cells is not concerned. In particular, the method lends itself to the demonstration of proliferating glia, as well as of alterations and pathological elements in the connective tissue-vascular apparatus. What may be seen in the ganglion cells in Nissl preparations has been described most thoroughly and extensively by Nissl himself. Later authors have added little of real importance.⁴ Nissl distinguishes, in the cell body, those parts which retain the basic aniline dye after differentiation, and those which do not retain it; he speaks, in a purely descriptive sense, of stainable and of non-stainable substances (Figs. 2 and 4).

The stainable parts are tinged in part deeply, in part less deeply. With high magnification they are seen as smaller or larger granules, as groups, rows, or chains of granules, or as larger bodies of regular or irregular shape (spindles, nuclear caps and branch-cones). Between the

⁴ The following description of the normal morphology of the ganglion cells is based chiefly upon publications by Nissl, which are scattered through various journals; cf. especially, *Neurol. Zentralblatt*, Vol. XIII and XIV; *Allgem. Zeitschr. für Psychiatrie*, Vol. LIV; *Beiträge zur Frage nach der Beziehung zwischen klinischem Verlauf und anatomischem Befund*, Vol. I, Nos. 1-3, Berlin 1913-15, Julius Springer.

stainable portions there run small or broad unstained tracts, which, as Nissl supposed, and as was later demonstrated to be the case, represent the paths of the neurofibril bundles through the cell body. The stainable parts are continued, chiefly in the form of thin, long spindles, for a distance into the dendritic processes of the cell. The axis-cylinder process is always free from stainable substances. The various forms, sizes, numbers, and grouping of the stainable parts produce a great variety of pictures, but it is not difficult to recognize a certain number of frequently recurring types, and to learn that, as an important rule, such typical structural forms are characteristic of certain localities in the central nervous organs. The position and form of stainable portions in the protoplasmic body are just as constant for a certain type of cell as are the size of the cell, its external form, its nucleus, and so on.

Of such types, only a few of the more generally known ones are here given, according to Nissl's description.

The Large Motor Cells.—They are called motor cells because we know that they are somehow closely related to motor function. They are found in the spinal cord as the large cells of the anterior horns, and in their analogues, the motor nuclei of the medulla oblongata; also as the so-called Betz giant pyramidal cells in the motor region of the cerebral cortex. In the spinal cord and the medulla oblongata they are more spherical in form, and they send out dendrites of equal size in all directions. In the cerebral cortex they take on the well-known pyramidal form. In external form and structure the separate elements of the same region show striking similarity, but there is also considerable individual variation. They constitute the largest nerve cells occurring

in the human central organs. In general, they exhibit rather large stainable portions which are clearly differentiated from the unstained paths. Their striped pattern is typical for these cells and is most plainly seen at the base of the processes. The tracts which stream in from

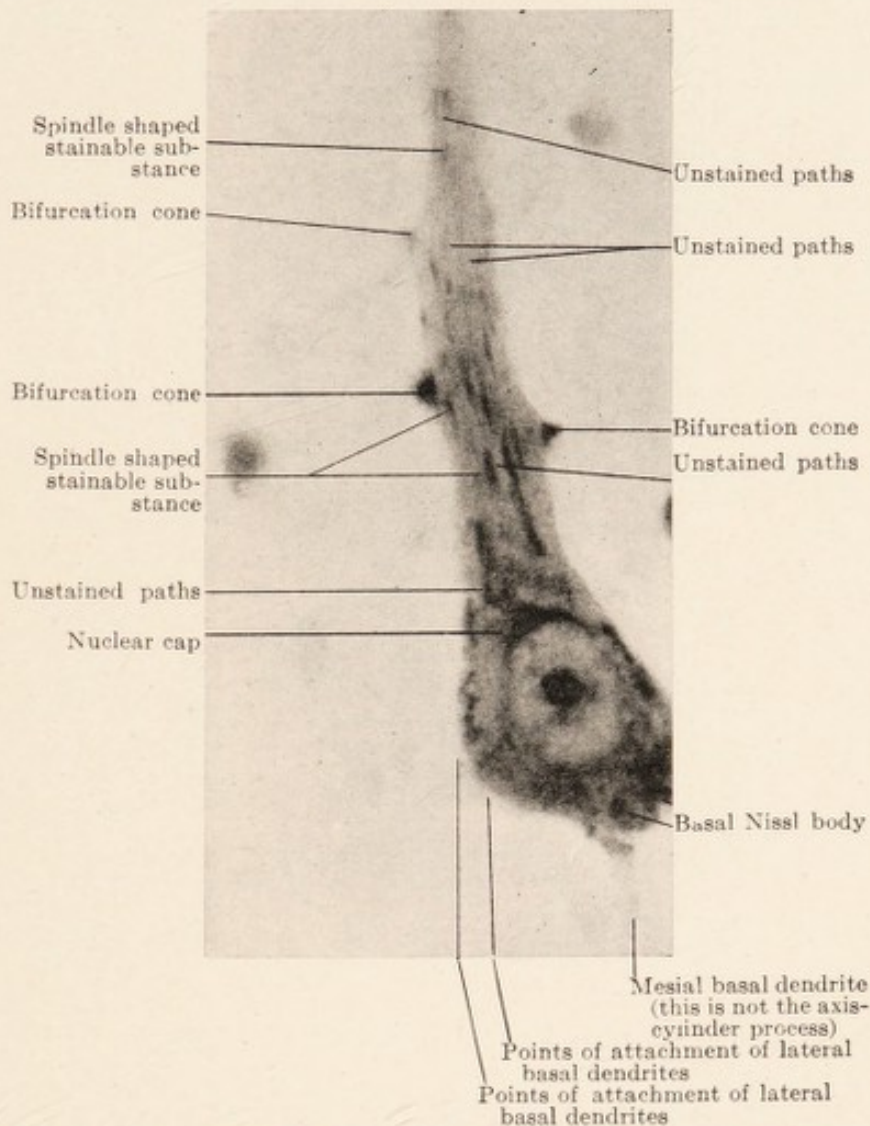


FIG. 2.—Normal large pyramidal cell from the third layer of the human frontal cortex. Nissl stain. After Nissl and Ranke. Magnification x 930.

the dendrites are spirally twisted. These cells possess a relatively large horse-shoe shaped axone hillock, which does not contain stainable substances, and which passes

into the short, broadly lance-shaped axis-cylinder process; in the Betz cells of the cortex it is always situated at the base of the cell, or at the point of exit of one of the large basal dendrites. The motor cells are further characterized by a large pale nucleus, which contains a large nucleolus, the nuclear membrane being usually invisible because it

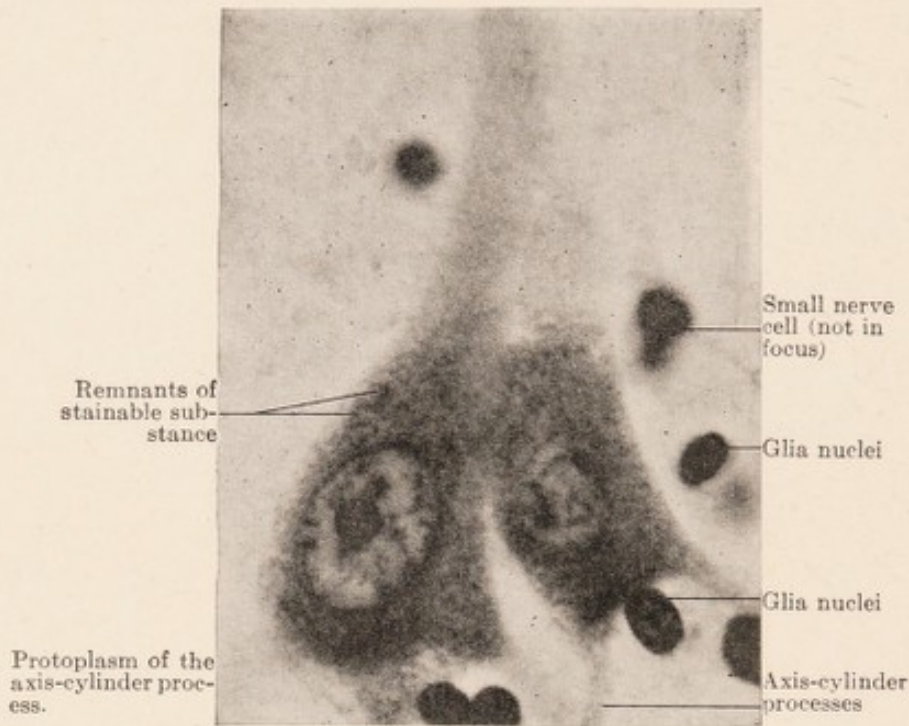


FIG. 3.—Two large pyramidal cells of frontal cortex in state of "acute degeneration." Nissl stain. After Nissl and Ranke. Magnification x 930. Compare with Fig. 2.

is covered up by the adjacent stainable substances of the cell body.

The large *pyramidal cells of the third layer* of the human cerebral cortex (Fig. 2) rarely reach the size of the giant pyramidal cells of Betz. They likewise have large pale nuclei, which, however, can be always recognized from the fact that the nuclear membrane is definitely visible. Adjacent to it are saucer- and shield-shaped stainable substances. At the base of the cell body there are similar

but larger masses without definite arrangement. The apical dendrite may exactly resemble that of a motor cell; but usually it contains only pale fine threads and rows of granules, and no axone hillock is present. The

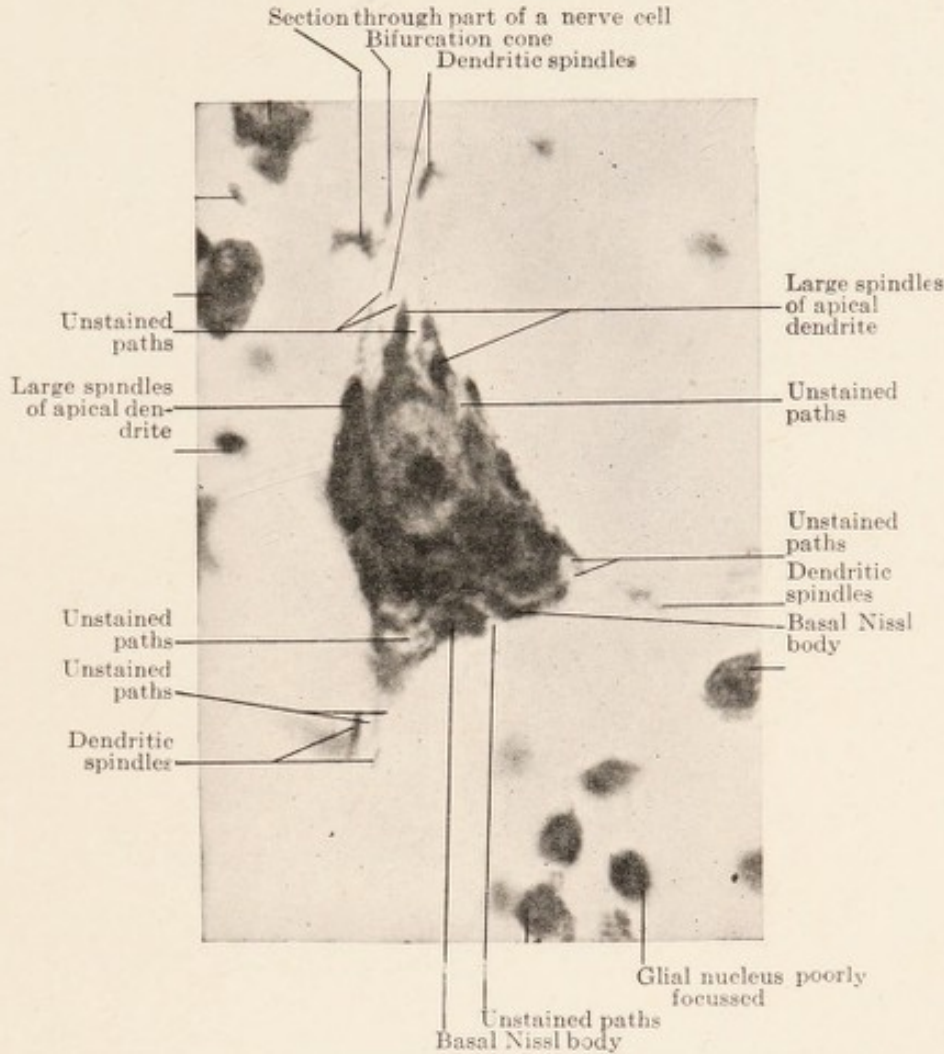


FIG. 4.—Large cell from normal calcarine cortex. Nissl stain. After Nissl and Ranke. Magnification x 860.

axone breaks through at the base between two thick portions of the stained substance.

The *spinal ganglion cells* are spherical structures of very unequal size, and with only one process. Their stainable substance consists of larger and smaller parts,

which are arranged in chains, and which concentrically surround the nucleus.

In the *Purkinje cells* of the cerebellum the stainable portions are united in a net-like fashion within the cell

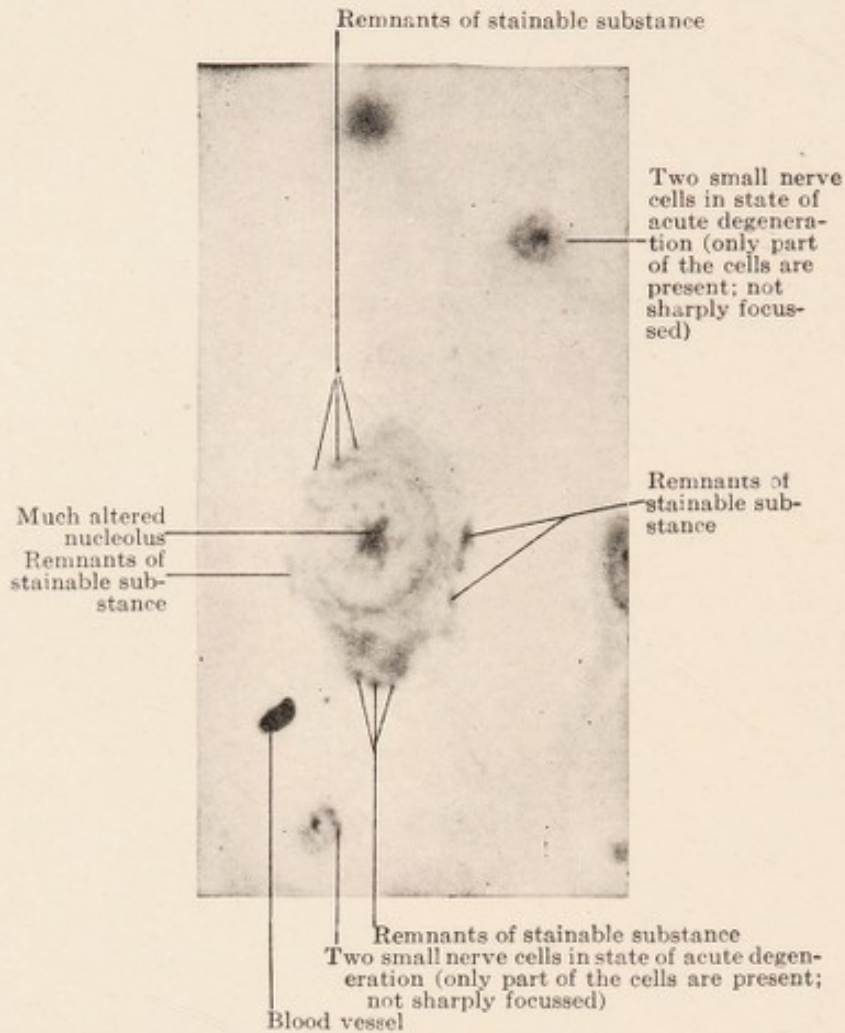


FIG. 5.—Large cell from the calcarine cortex in advanced stage of acute degeneration. Nissl stain. After Nissl and Ranke. Magnification $\times 860$. Compare with Fig. 4.

body. In addition there is a striped arrangement, the knots of the net-work being arranged in rows; the processes consist chiefly of unstainable substance.

Of such types there are many more. Nissl further described the cells of the large sympathetic ganglia, certain cells in the lenticular nucleus, the mitre cells in the olfac-

tory bulb, the large cells in the tuberculum acusticum, and the large pyramidal cells of the cornu ammonis.

Interest has always centred around the characteristic *large* nerve cells; but besides these there are in the central nervous organs a great number of smaller, and of very tiny ganglion cells. The latter often possess so insignificant a cell body, or there are within their protoplasm only such scanty amounts of stainable substance, that it may be very difficult to recognize them at all as ganglion cells.

Nissl attempted to incorporate this wealth of form of the nerve cells into a system; particularly he classified the elements with distinct or large cell bodies according to the form of their stainable portions (net-like, chain-like, striped, granular). This purely descriptive division is not generally practicable and has not found much support.

The question as to the exact *nature of Nissl's stainable substances* is of more importance. It was soon realized that they probably have little to do with nervous function. Nissl early recognized that the unstained pathways are the really important structure of the nerve cells, and that the intervening stainable portions act in a sense only as fillers. It has been suggested that the latter serve chiefly nutritive purposes, or that, analogous to the medullary sheath around the axis cylinder of the nerve

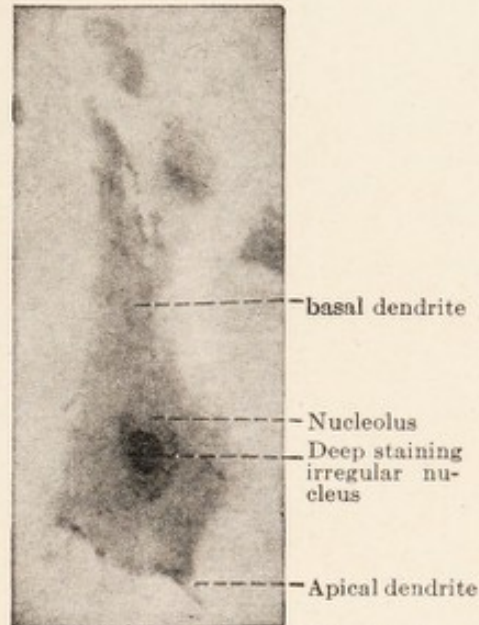


FIG. 6.—Special type of cellular disintegration. Nissl stain. Micro-photograph, oil immersion.

fibre, they isolate the individual neurofibrils and fibrillar bundles coursing in the unstained pathways of the cells. It early became manifest, that these stainable structures are extremely *labile*, and that their form and staining qualities are quickly altered by various factors. The demonstration by Nissl that such changes after certain injuries always occur in the same manner became the basis for the pathology of the nerve cell. Even in the domain of physiology different conditions of the stainable substances have been observed; thus G. Mann and others have shown that their quantity decreases during function; and this led to the belief that the stainable substances are used up during activity and stored during rest.⁵

It has further been a matter of controversy whether the stainable material represents preformed substances existing in the living cell, or whether it is merely a precipitate formed after death or through the action of fixing agents. That the stainable portions differ chemically from the neurofibrils, as well as from the other parts of the cell protoplasm which do not stain by Nissl's method, cannot be doubted. However, it has been questioned whether they have the same arrangement and structure in the living cell as in the Nissl picture. For normal histology this question is of great importance, but in pathological anatomy it may be disregarded. This was clearly expressed by Nissl in his doctrine of "the *equivalent* (comparable) *picture* of nerve cells." "Whether what we

⁵ Kronthal (*Nerven und Seele*, Jena 1908; *Neurol. Zentralblatt* 1919) has formulated a theory to the effect that what we term nerve cells are really more or less large accumulations of wandering cells from the blood, which surround the fibrils at their nodal points and which are constantly replaced by new ones. It is said that the generally uniform shape of the nerve cells in different localities is produced by the constancy of the position of the fibrils. All pathological experiences with nerve cells contradict these claims of Kronthal.

see is preformed or not is really of no moment so far as the application of the method to the pathology of the nerve cells is concerned, so long as it is accepted that a standard technic will invariably give us the definite and recognizable nerve cell picture, which we have described." The reason for any variation in this picture must lie, then, only in an antemortem condition of the cell itself. Just what effect our reagents and technical procedures have upon the preformed cell structures is a question for

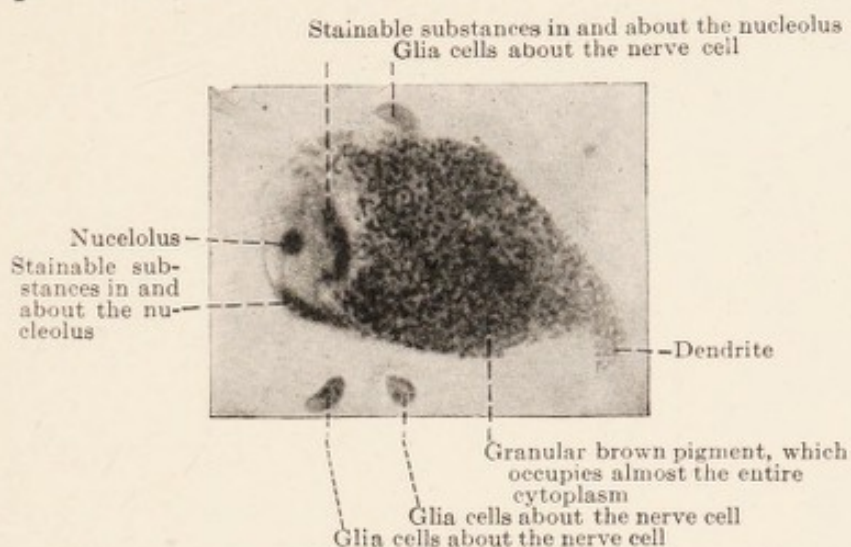


FIG. 7.—Large nerve cell with brown pigment, from the substantia nigra of the brain. Nissl stain. Microphotograph, oil immersion.

anatomy to answer.⁶ Experience teaches us the constancy of the "equivalent picture;" so that, whenever we do not find this picture, we are justified in believing that pathological changes have occurred in the cell during life. This doctrine of Nissl of the "equivalent picture" contains, if rightly considered, nothing really new. In fact, we make similar deductions every day in pathological anatomy; for neither at the autopsy table, nor in our collections, nor under the microscope, do we see tissues and organs in

⁶ *Neurol. Zentralblatt*, XVI, pp. 105-106.

exactly the same condition as they were during life. Death, as well as our methods of preserving, fixing, and hardening, leads to alterations, but we have long been used to disregarding them; in determining the presence of pathological changes in our material, we always compare it with mental pictures previously gained from material which has been prepared according to the same technic.

Only one assumption must be made, and that is the constancy of the technic; and this is of special importance when the evaluation of the finest histological structures is

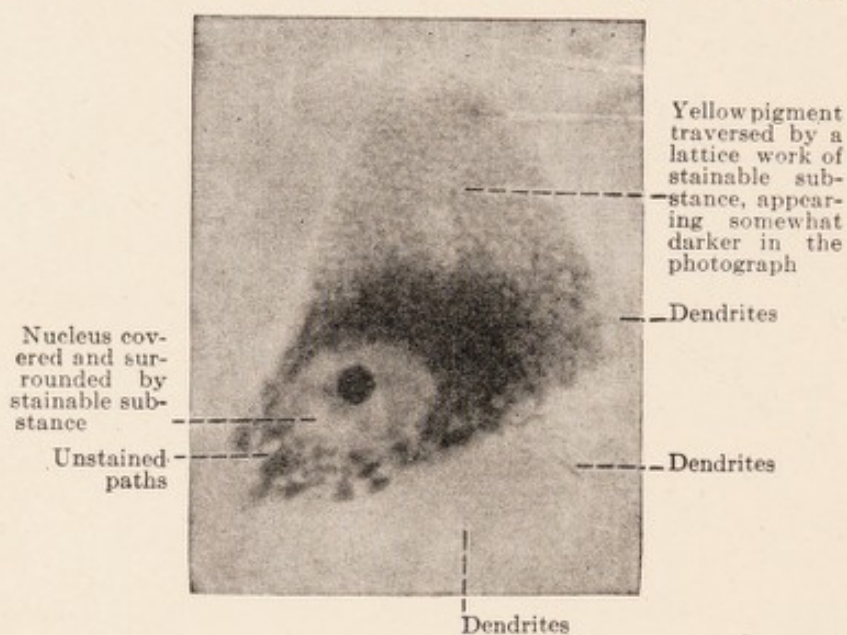


FIG. 8.—Giant pyramidal cell of Betz, (anterior central convolution), not quite in longitudinal section. Nissl stain. Oil immersion.

in question. Any variation in the treatment of the specimens always produces more or less deviation from the "equivalent picture." If we want to compare our preparations with one another or with those of others, we must be certain that the microscopic technic is the same unless it be that we are familiar with several different "equivalent pictures."

This is the reason why Nissl emphasizes that in study-

ing nerve cells a certain technic of staining, as for instance the one advocated by him, should be followed in every detail. The fixation of the nerve tissue, *e. g.*, in formalin, gives different pictures from those obtained after fixation in 96 per cent. alcohol as used in Nissl's technic; and this apart from the inconstancy of formalin fixation. Even with identical fixation, etc., different aniline dyes give different "equivalent pictures."

Nissl recommends the cutting of the pieces without embedding them, if at all possible, since the embedding in celloidin or paraffin, and the use of absolute alcohol, alcohol and ether, etc., necessary to such methods, may produce various artefacts. For bringing out only the grosser alterations in the stainable substances of the large nerve cells it is less necessary to observe so strictly all technical details. For routine preparations, and in cases where examination of the vascular and connective tissue apparatus is necessary, embedding is to be always recommended.⁷

The portions of the cell bodies which do not stain by Nissl methods have been mentioned several times. We know now that they are composed of at least two constituent elements, *viz.*, the neurofibrils and a plasma, in which the fibrils are embedded. In the Nissl picture the former

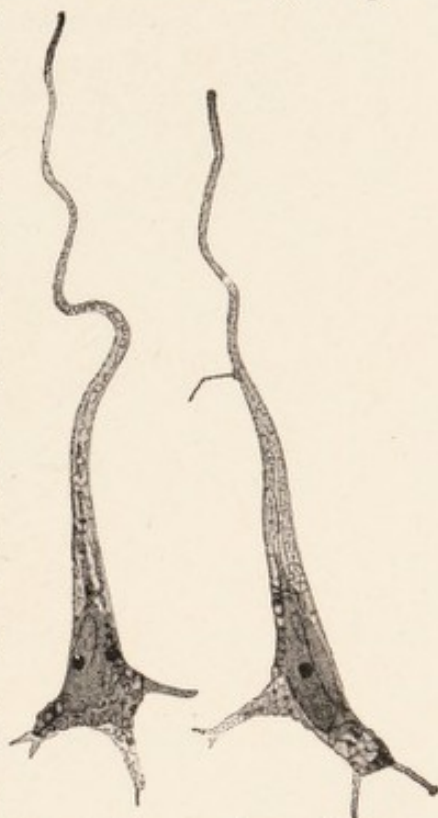


FIG. 9.—Two ganglion cells in state of "chronic degeneration" from the third layer of the frontal cortex. Nissl stain (after drawing by Alzheimer).

⁷ Nissl: *Enzyklopädie der mikroskopischen Technik*, 1910 (second edition), Article "Nervensystem."

appear as unstained "paths;" but, unless very thin sections are examined, only the coarser tracts, the pathways for the thicker fibril bundles, are recognizable. It may be demonstrated that fine threads of non-stainable substance permeate even the stainable portions in all directions, so that the latter are not to be regarded as compact masses, but as a spongy, porous material.

As final constituent elements of the cytoplasm, we

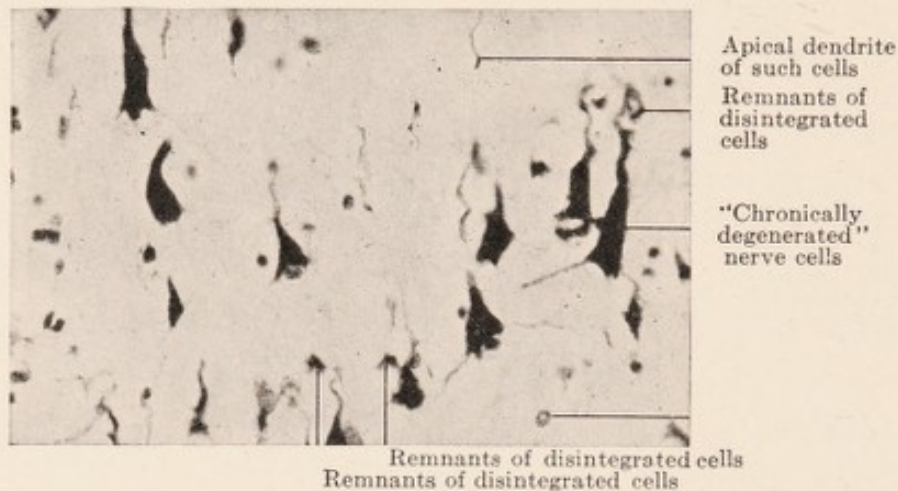

FIG. 10.—Nerve cells from the third layer in the region of the central fissure in a state of "chronic degeneration." Nissl stain. Magnification x 300. After Nissl-Rosenthal.

have substances generally known as *pigments*. Of these, two deserve to be particularly mentioned.

A light golden-yellow pigment may, in the adult, be found widely spread throughout the entire central nervous system. It is absent in the young child, appears in small quantities at about the age of six to eight years, gradually increases with age, and is most plentiful in advanced senility. Under pathological conditions it is frequently found in considerable quantity earlier in life (Fig. 8). This pigment is not of hematogenous origin; it is rather to be looked upon as a metabolic product of the stainable, and possibly, in part, of the non-stainable cell substances. As one can see in the Nissl picture, it is scattered through,

and replaces the stainable portions, and it is more or less diffusely distributed in the protoplasmic body of the cell. It is blackened with osmic acid, but has probably nothing to do with fat (Nissl).

A brown pigment is, even in very large quantities, a normal constituent of certain cells in different regions (locus ceruleus, substantia nigra, nucleus of the vagus). In the cerebral cortex it does not appear. It is developed very early, and then remains constant in quantity. It has different chemical properties from the yellow pigment;

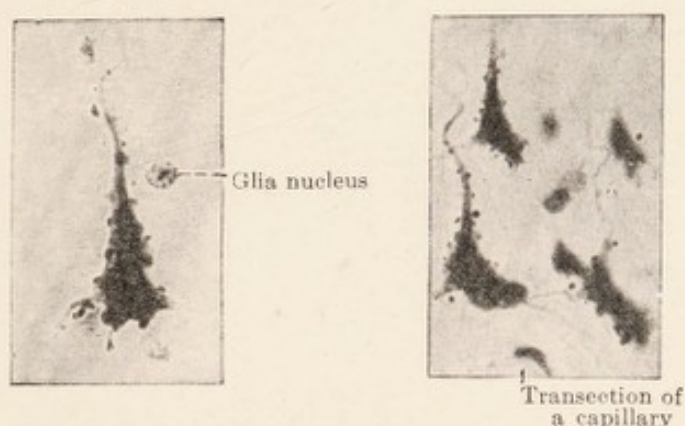


FIG. 11.—Nerve cells from the cortex with adjacent dark, rounded or irregular granules, the so-called incrustations of the pericellular Golgi nets. The cell change is similar to that of the chronic degeneration. Nissl stain.

for instance, it is not blackened with osmic acid. It is composed of regular, sharply defined granules (Fig. 7).

An important constituent of the cell is the *nucleus*. The determination of its condition is, for pathology, of great importance. Of its morbid alterations, not much is known. What we do know, we likewise owe largely to Nissl. In deciding how severely diseased a nerve cell is, and in particular whether it is still capable of returning to normal, the changes in the nucleus frequently give us more valuable information than the changes observed in the cytoplasm. Cells with much damaged stainable sub-

stance, may, under certain circumstances, entirely recover, if only the nucleus is not badly damaged.

The nerve cells of man have but one nucleus. Two nuclei are not of unusual occurrence in animals. In man two have been observed under pathological conditions, probably as expression of a developmental fault, and then particularly in the Purkinje cells of the cerebellum.

Fixation in 96 per cent. alcohol, as required for Nissl's

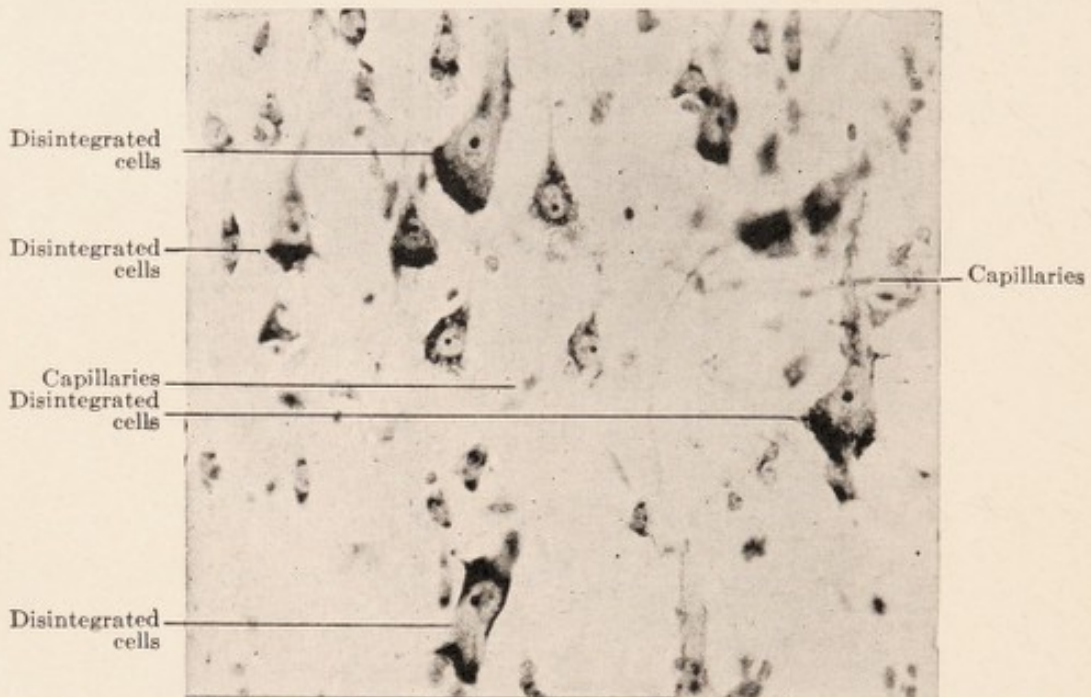


FIG. 12.—From the third layer of the frontal cortex. Nissl stain. "Disintegration" of nerve cells. After Nissl and Rosenthal. Magnification x 300. In the nerve cells the nucleus is apparently enlarged on account of loss of perinuclear stainable substance and of stainability of the nuclear membrane; the nucleolus appears prominent.

technic, is not very suitable for the demonstration of nuclear structures. For nuclear study the methods of fixation customary in embryology are recommended. Fairly good results are obtained after alcohol with Heidenhain's iron hematoxylin.

The nuclear membrane is sharply defined in the Nissl picture.⁸ The nuclear contents are unstained in the

⁸ It often shows irregular folds.

majority of the cells; in others, a faint, washed-out suggestion of the internal structure may be recognized. In man, with rare exceptions, only one nucleolus is present.

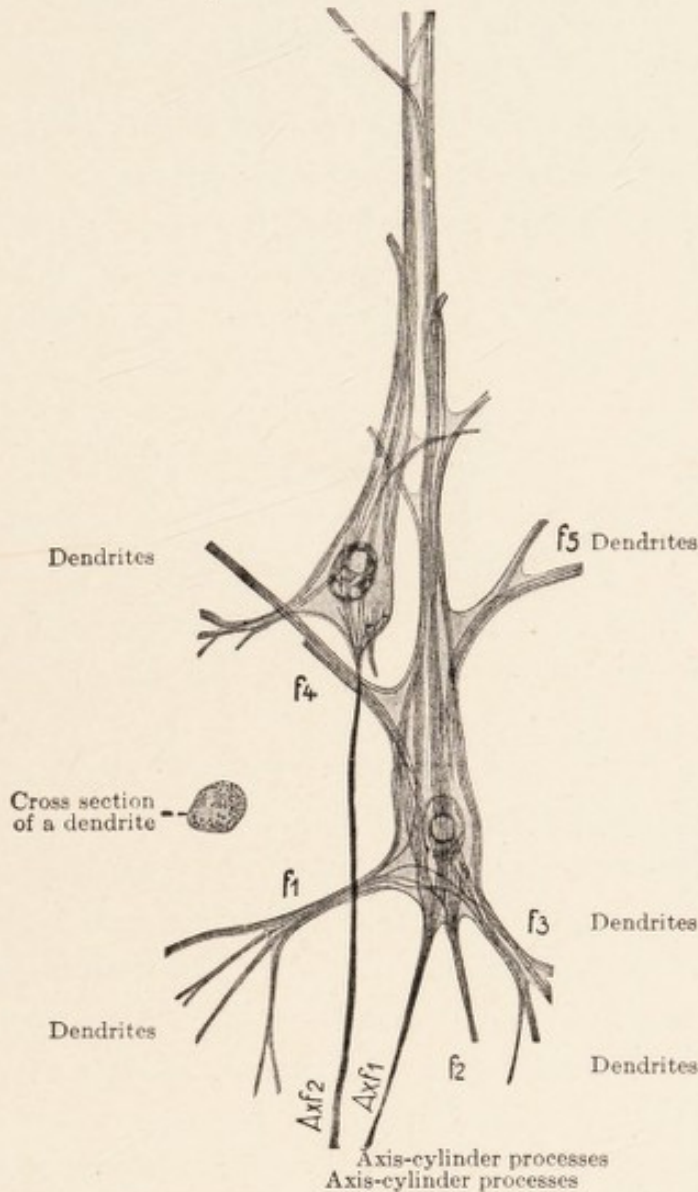


FIG. 13.—Two medium-sized pyramidal cells from the anterior central convolution. Bethe's fibril stain (after Bethe).

This is relatively large and stains deeply. In its interior there is a small, round, pale dot (the so-called crystalloid), which rarely is visible in normal cells, but which becomes quite distinct if the nucleolus, because of disease changes,

is less deeply stained. In the immediate vicinity of the nucleolus, there is regularly found a variable number, (2, 3 and more) of small, round, dark bodies, the so-called polar bodies.⁹

We must finally consider the *general shape* of the ganglion cells. With Nissl methods, their cytoplasm is everywhere sharply defined. The dendrites, as well as the axone, end not far from the cell body. Only the apical

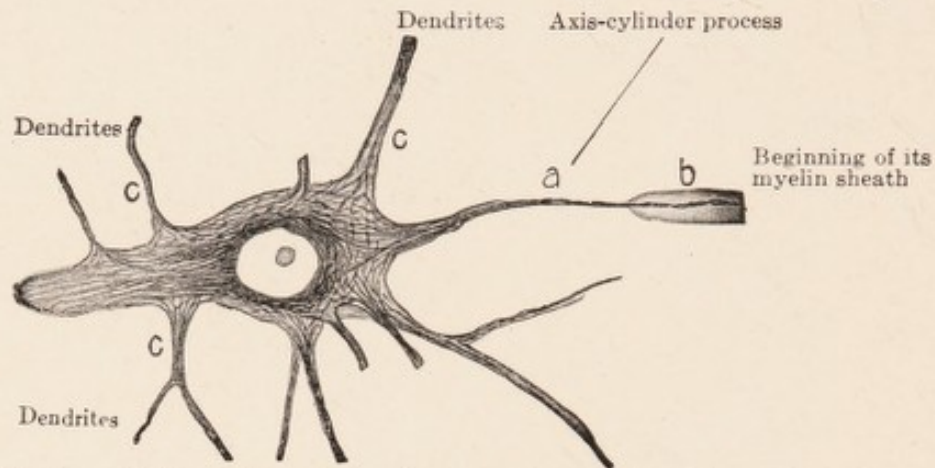


FIG. 14.—Giant pyramidal cell from the anterior central convolution of man. Bielschowsky's fibril stain. After Bielschowsky.

dendrite of the pyramidal cells is, as a rule, considerably longer. However, the Nissl picture of a normal cell shows the dendrites much shorter than they are in reality; because only the stainable portions are visible, and these extend for only a short distance into the protoplasmic processes. But even with the use of Nissl's method, one has frequently an opportunity to see the cell in its entire extent, namely when the normally non-stainable substance, under pathological conditions, becomes stainable (*e. g.*, in acute, as well as in chronic degenerations of the cell) (Figs. 3 and 9). According to Nissl,¹⁰ the lance-

⁹ These are more easily recognized by the use of toluidin blue and thionin than with a methylene blue stain.

¹⁰ *Die Neuronenlehre and ihre Anhänger*, Jena, 1903.

shaped axone also terminates sharply after a short distance; neurofibrils may pass from its apex over into the axis cylinder, but the cytoplasm of the cell body terminates suddenly at the lower end of the lance.

Neurofibril preparations (see the following chapter) give the same picture of cell outline and of the dendrites as does the Nissl technic (Figs. 13 and 14). But in Golgi preparations the shape of the ganglion cells appears considerably different; instead of short, sharply defined processes, we see widespread and extraordinarily richly branching dendrites, as well as very long axis-cylinder processes (Fig. 1).

This is partly due to the fact that silver impregnation blackens not only the cytoplasm of the cell body, but the fibrils as well; therefore the lanceolate protoplasmic axis-cylinder process and the fibrils emerging from it are stained alike. Besides, this method makes the cell processes look as if they were continuous with terminal arborizations of other nerve elements, and in this way gives an exaggerated impression of the rich branching of the ganglion cells.

CHAPTER II.

NEUROFIBRILS AND THE NEURONE THEORY.

THE theory that nerve cells and nerve fibres possess *fibrillar structure* has long been held. Bethe calls Max Schultze the father of the fibrillar doctrine, even though Schultze had probably rather suspected the existence of the fibrils than had actually seen them. Communications on this subject date back to 1868 and 1871. Fifteen years later (1883) Apathy and Kupfer published simultaneously and independently their researches on the fibrils. The impulse to the thorough investigation of the neurofibrils in the closing years of the past, and the early years of the present century, was given by the extensive monograph of Apathy, in 1897;¹ to the importance of this for neuropathology Bethe first drew attention, and, soon after him, Nissl.

Apathy's work was done mostly with *lower animals* (leech and earth worm). He demonstrated by specific staining methods the existence of certain units, the conducting primitive fibrils, which, from the anatomical viewpoint, are optically and mechanically separate elements, and which run uninterruptedly in the nerve fibres to their peripheral end. These fibrils, according to his description, remain of equal thickness throughout their entire extent; they never branch, and they nowhere anastomose with one another. Wherever there is a branching of a nerve, a number of fibrils detach themselves from the original stem; but the sum of all fibrils contained in the

¹ *Mitteilungen aus der zoologischen Station zu Neapel*, Vol. XII.

branches is always the same as that in the original stem. A greater or lesser number of fibrils, eventually only a single thick one, is surrounded by a sheath, so constituting a nerve fibre; and a number of such sheathed nerve fibres together form a peripheral nerve. In the earthworm and the leech, the fibrils vary in thickness. They are very thick in the motor, but, to a greater or less degree, thin in the sensory nerves. In the higher vertebrates, such differences are not known. Here all axis cylinders contain approximately the same number of fibrils of equal size. Otherwise the details are the same. The axis cylinder is not an anatomical unit, but a complex of units (primitive fibrils), embedded in a common protoplasm. In the neuropil, that is, in the fibrillar mass which forms the center of each ganglion, at the periphery of which the ganglion cells are situated, the primitive fibrils in worms are split into still finer elements, the elementary fibrils;² and these latter form a reticulum, through free anastomosis, "the diffuse elementary reticulum." But later they are collected again and run on, united once more as primitive fibrils. Each separate thread of the fine reticulum corresponds to a single elementary fibril. At the nodal points, usually three threads come together and fusion takes place, not merely an interweaving nor a division of one thicker branch into two more delicate ones.

Another such reticulum is found, in the lower animals, in the body of the ganglion cells. Apathy describes this as follows: "Conducting primitive fibrils enter the somatoplasm of the ganglion cells and here break up into elementary fibrils; these spread out in the cell body to form a conducting feltwork or reticulum, in which a regroup-

² Their thickness according to Apathy is $1/20$ to $1/5$ of a micron.

- see foll
page -

ing of the elementary fibrils takes place. The same number of elementary fibrils now leaves the cell body as was contained in the primitive fibrils when they entered it. The neurofibrils neither begin nor end in, nor do they fuse with, the somatoplasm of the ganglion cells; nor is there any connection of the neurofibrils with the cell nucleus."

The arrangement and form of the fibrillar reticulum differs greatly in different ganglion cells; but there is a series of easily recognizable types. Apathy recognizes at least two types in the leech; in the one, all fibrils are

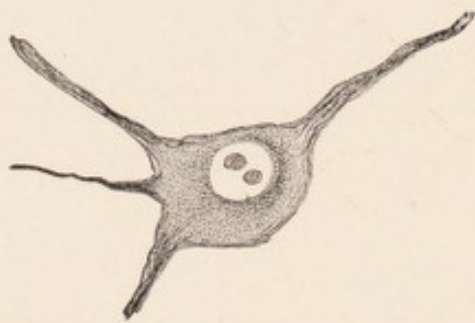

FIG. 15.—Cell from the facial nucleus of the rabbit after section of nerve. After Bielschowsky.

about equally thick and lie in one zone; in the other, they are divided into two zones, forming an external reticular sphere of very delicate, and an inner one of coarser primitive fibrils. The two reticula shade into one another through radiating connecting links. The interior one is collected into a single thick primitive fibril, which leaves the cell, and can always be traced directly into a motor nerve fibre. In the earth worm, however, the structure of the reticula is in many ways different; while concerning the condition of the fibrils in the ganglion cells of vertebrates, Apathy makes only short and indecisive statements.

In the periphery of the body of the leech, according to Apathy, each sensory cell receives a single primitive fibril from the nerve. In the body of the sensory cell this fibril forms a delicate reticulum about the nucleus; but the greater part of it reunites and runs further, leaving the cell, and probably forming, with the fibrils emerging from

other cells, another intercellular neurofibrillar reticulum. According to this, the fibrils would not terminate at the periphery. Nor, in all probability, is there any termination of the fibrils in the muscle cells.

If we now collect these findings of Apathy, we obtain the following conception of the structure of the neurofibrils in the nervous system of the worm.

Through the peripheral nerves and the central masses there run everywhere distinct fibrils mostly united into bundles. The sensory fibres, originating from the peripheral sensory cells, split up in the central ganglia, into a reticulum of elementary fibrils, and reassemble into delicate fibres. Of these fibres one part enters the motor cells of the ganglia, and, after forming a second reticulum in the cell, becomes united into a thick fibril, which passes into a motor nerve fibre belonging to a muscle cell. There is, according to this, a continuous path from the sensory cells of the body surface to the muscle cells of the body; it is probable that there are no free terminations of the fibrils even at the periphery, but that even there the chain is closed. The path in the central nervous organs runs always through one or more ganglion cells, not necessarily motor in character.

These researches of Apathy have been supplemented by the physiologist Bethe, from extensive investigation of the fibrils *in the higher animals and in man*. His preparations give extraordinarily clear and distinct pictures.³ In the dendritic processes of the ganglion cells fibrils run side by side, often in spiral curves, and these usually

³ See particularly: *Morphol. Arbeiten*, edited by Schwalbe, Vol. VIII, 1897; *Archiv. f. mikroskop. Anatomie*, Vol. LV, 1900; further: *Allgem. Anatomie u. Physiologie des Nervensystems*, Leipzig, 1903.

group themselves at the base of the processes into several bundles, and then enter the cell body; they pass through it isolated and without dividing, regroup themselves into bundles and leave it again (Fig. 13). The fibrillar picture becomes the more complicated the more processes the cell has, since as a rule, all processes exchange fibrils. The axis-cylinder process is different from the dendrites only in that its fibrils, at the end of the protoplasmic lance, known to us from the Nissl picture, become very closely bunched into an apparently solid strand, and then, after a short course, again separate. Many fibrils do not come in contact with the perinuclear portion of the cell body; they take an outside course, from a side branch of one dendrite to that of another. There remain portions of the cytoplasm not occupied by fibrils, and in these spaces there lie the substances stainable by Nissl methods. The Nissl picture and the fibrillar picture, are therefore, roughly speaking, one the negative of the other. The course of the fibrils explains, as Nissl had previously supposed, the position of the stainable substance.

This, according to Bethe's preparations, is the condition in the majority of the nerve cells of the higher animals. A definite and important difference from the lower animals consists in the absence of the intracellular fibrillar network.

In certain other cells, the course of the fibrils and of the fibril bundles is clear only in the external portions of the cell body; while in the region about the nucleus, the individual fibrils are too closely interlaced to allow of their being followed. True fibrillar networks, as seen in the ganglion cells of the invertebrates, have been found by Bethe only in certain definite elements.

In one other point the fibrils of the vertebrates differ from those of the invertebrates. In the leech, the fibrils enter through the axone into the ganglion cells, and after formation of a reticulum within the cytoplasm, they make their exit again through the axone. The end of a fibril is nowhere to be found. In the vertebrates, however, the fibrils terminate sharply within or at the apex of the protoplasmic processes. Only in the axis-cylinder process they may under favorable circumstances be traced for long distances.

A number of other observers, however, state definitely that the overwhelming majority of the fibrils in man do not, as Bethe describes, traverse the protoplasm evenly and without any anastomosis, but that the fibrils everywhere, within the cell body, in the dendrites, in the axone, and the axis cylinder form meshes and reticula; that they constantly separate and again fuse; and that at most only in certain localities definite paths in the network exist. On the question whether there are intracellular reticula or traversing fibrils in the ganglion cells of the vertebrates, a lively discussion has arisen. Those observers who believe in the reticular arrangement of the fibrils in the ganglion cells, base their opinion on preparations made after the silver-impregnation method of Cajal or some similar technique, or on those made after the method of Donaggio. Both methods, Jäderholm claims, but especially the latter, produce artefacts through the shrinkage of the tissue and fusion of fibrils. If one treats consecutive sections of the same material according to the method of Bethe and that of Donaggio, there are obtained in the one case the characteristic pictures of smooth isolated fibrils, in the other, all kinds of reticular structures. It is therefore probable

that the contradictions may be partly traced to differences in technic, and to faults inherent in the various methods; besides this, there appear to be some authors who mean by a fibrillar reticulum or by a fibrillo-reticular framework totally different things from the fibrils of Apathy and Bethe.

The chief significance of this question lies in its *physiological application*. If the fibrils in man are not separate and distinct structures, then there is less ground for looking upon them as a real specific constituent of the nervous system, as the "essential nerve substance," as Apathy expressed it. Indeed the impression is gradually gaining ground that the neurofibrils, even in the invertebrates, do not form the conducting element of the nervous system, but merely a framework for the nerve cells. R. Goldschmidt, according to Alzheimer, answers the question thus: "The neurofibrils represent a cellular skeleton arranged according to Koltzoff's principle; their presence and arrangement is merely a physical necessity, which has nothing whatever to do with nervous function, except that, without it, the cell would not be supported and would disintegrate. The neurofibrils are not a specific functional structure of the nerve cell, but the expression of a law applying to all animal cells." According to Goldschmidt, the morphological analogy of the neurofibrils with the skeletal fibrils of other cells is so marked that Apathy erroneously regarded the skeletal fibrils of the muscle cell in the leech and the fibrils of the basal bodies of ciliated epithelium as neurofibrils. But the evidence on this point is conflicting.

Disregarding these controversial points, the fact remains that what we really know about these fibrils in man

is decidedly incomplete, compared with what Apathy has reported in the case of the invertebrates. In the earth worm and the leech, distinct fibrils may be traced from the sensory cells of the body surface into the extra and intracellular networks of the ganglia, and back again to the muscle cells of the body. In the vertebrates, however, we have knowledge only of fibrils in the ganglion cells, and these fibrils mostly terminate where the cell body ends, at its periphery, and at the termination of the dendrites. Only a small portion passes beyond the limits of cell body at the axone hillock, and may be traced as a bundle of fibrils into a nerve fibre, and through this, nearly to the motor and sensory end-apparatus, or to the neighborhood of other ganglion cells, or to distantly situated gray masses. The controversy over the neurone doctrine was brought about largely by the results of investigations on the fibrillæ. It would have been of decisive importance in this question to know what becomes of the intracellular fibrils and of the fibrils of the axis cylinders; whether, and in what manner, the fibrils of different cells and of axis cylinders are connected; and whether a continuity of fibrils throughout the entire nervous system can be demonstrated in the higher vertebrates, as Apathy has described it in the invertebrates. According to the basic principles of the neurone theory, the axis cylinders split up into fine branches at their ends after casting off the myelin sheath in case they are myelinated;⁴ these branches (the terminal arborization) reach the surface of other nerve cells, and thus render possible the transmission of stimuli. In what manner, or whether at all, an exchange

⁴ See Nissl's critique on the general justification of this concept in: *Die Neuronlehre*, etc. Jena, 1903, p. 378 ff.

of neurofibrils takes place between such nerve terminations and nerve cells in the gray substance of man, is answered differently by different observers. Some hold that such a communication does not take place; others have seen it frequently or else only occasionally in their preparations. Some describe these histological relations as very simple, others as very complicated.

Bethe teaches that the ganglion cells and their dendrites are surrounded by a terminal arborization of approaching nerve fibres (axis-cylinder "stockings" around the cells) and that these "stockings" represent a wide-spread arrangement in the nervous system. From them delicate short fibrils go to the cell and form a network, which closely hugs the cell's surface; a network in which Bethe supposes there is a true fibrillar reticulum in the sense of Apathy. The fibrils now pass through the superficial regions of the nerve cell, and unite with the intracellular fibrils. These fibrillar connections between the endings of nerve fibres and the fibrils of cells are, according to Bethe, difficult to demonstrate by staining, and, for that reason, have been seen only occasionally by him.

Much easier to demonstrate is an apparatus widely distributed in the body in which the delicate connecting fibrils and the reticula referred to above are embedded, the so-called pericellular *Golgi nets*. They constitute a relatively coarse anastomosing trabecular framework, which surrounds the nerve cells and their dendrites on all sides, in one or several layers.⁵

⁵ This is regarded by Cajal as a layer still belonging to the cell body, lying beneath the cell membrane; Held regards it as a glial apparatus; likewise Adamkiewicz (*Ztschr. f. d. ges. Neurol. u. Psych.*, Vol. LI, 1919).

Nissl shares Bethe's view concerning the relation of the neurofibrils within the nerve cells to the pericellular and peridendritic Golgi network, but he believes that these relations are so simple only in certain cell types. According to his conception, the axis cylinders mostly terminate quite a distance from the cells which they are approaching; they form, with many other terminals of nerve fibres, a "nervous gray," that is a "specific nervous, non-cellular constituent of the gray substance," which extends far beyond the region of the Golgi network, and which would correspond to the extracellular reticulum in the neuropil of the invertebrates. About the structure of this network we have no definite knowledge, since it has not been possible as yet to stain it. The existence of such a "nervous gray" is sponsored by Nissl, because of a series of comparative anatomical and embryological data.

The investigations on the fibrils of the nervous system created a lively interest, due to the fact that the demonstration of these fibrils was from the beginning offered as evidence of the incorrectness of certain ideas which were generally held regarding the finer structure of the nervous system. These conceptions had crystallized during the preceding few decades into the so-called neurone theory;⁶ and it was this theory that was questioned on the basis of the views arrived at from these studies upon the fibrils.

Even if it should be shown that the neurofibrils do not have the importance which was attached to them by Apathy, Bethe, and their followers, the investigation of the question has made us revise our ideas about the structure of the functioning nervous elements; and so our knowledge of them has become more clearly defined.

⁶ This term originated with Waldeyer, 1891.

The neurone theory is, in its nature, an anatomical hypothesis. Its principles may be formulated, according to Nissl, as follows:⁷ all nerve fibres are processes of nerve cells; the whole nervous system of the adult is (except the meninges and supporting structures) a vast conglomeration of neurones, that is, of structures having the dignity of cells, each consisting of ganglion cell, axis cylinder, and terminal arborization; the entire nervous system, as far as its specific function is concerned, is nothing but the sum of such neurones. A discussion of the truth of this doctrine must be restricted to these principles; anything beyond them does not directly concern the doctrine.

What may be urged against the neurone doctrine as a result of studies on the fibrils is plain. Apathy's descriptions give a well-connected account of the nervous system in certain low forms of invertebrates, assuming his assertion, that the fibrils are the conducting mechanism, to be correct. Fibrils run from the periphery of the body to the central organs and return to the periphery without any interruption at the ganglion-cell terminus. There can therefore be no acceptance, so far as these animals are concerned, of a nervous system made up of conglomerations of neurones. But in the case of the vertebrates our knowledge is too full of gaps, even with the use of present-day staining methods, to afford absolute proof that the neurone doctrine does not apply.

But as doubts began to arise about the truth of the neurone doctrine, its anatomical basis was called to mind. It was recalled that in reality no attempt had ever been made to demonstrate that, as was demanded by the neu-

⁷ Concerning this and for much of the following see Nissl's discussion in his book, *Die Neuronenlehre und ihre Anhänger*, Jena, G. Fischer, 1903.

rone theory, the relation of cell plus nerve fibre plus terminal arborization exists everywhere; that each nerve fibre arises from a cell; that cell plus fibre plus terminal arborization form the only constituents of the nervous system, and that each nerve cell has an axis-cylinder process (Nissl). Generalizations had been made merely on the basis of a few isolated observations. The motor tracts were pointed to repeatedly as an example, but as a matter of fact, Apathy's descriptions of worms show that in the motor part of the fibrillar tracts, and only in it, there exist conditions which closely approximate the scheme of the neurone doctrine. Furthermore, it has been pointed out that the embryological data of His, which have always been looked upon as a very important support for the neurone doctrine, have been much overrated in this connection. His has made probable the outgrowth of axis cylinders from ganglion cells only for one certain type of cell (anterior horn cells of spinal cord,) and even for this type, only in certain elements found at a very early developmental stage. The assertion that all axis cylinders in the entire nervous system have similar origin is a generalization not supported by sufficient data; this fact has been forgotten under the reign of the neurone theory.

A series of investigators who admit these objections cite, as a last support for the neurone theory, certain facts of clinical experience, as well as of normal and pathological fibre anatomy, which cannot be explained without this doctrine. This shows, however, a misapprehension of



FIG. 16.—Motor anterior horn cell of man, from a case of acute spinal cord disease. Bielschowsky's fibril stain. Loss of fibrils in cytoplasm. After Bielschowsky.

the essential points at issue, since our knowledge of neuropathology and fibre anatomy has nothing to do with the basic principles of the neurone doctrine; such facts can be cited as evidence either way. The claims that are usually made are, that more or less circumscribed masses of myelinated fibrils (fasciculi) emerge from certain regions of the gray cortex, the sub-cortical ganglia, and the spinal cord, and after a shorter or longer course enter other gray masses, where they lose their myelin sheath. Further, that after destruction of the gray matter or of the fasciculi at any point, secondary degenerations occur, always in the same direction; and that the clinical phenomena are always the same, no matter at what point of such a complex of gray matter and fibre systems destruction has taken place. No opponent of the neurone theory doubts the existence of separate fasciculi, nor the influence, functional, nutritive, and trophic, of certain gray masses upon certain fibre systems. But all this has nothing to do with the neurone theory. The latter claims that all elements of all such complexes are neurones, meaning that each one of their fibres originates from a certain nerve cell of the gray matter and ends with a terminal arborization at another nerve cell of another gray nucleus. This, however, can never be proved by the aid of myelin fibre preparations or by tracing secondary degenerations. Of course, if we were able to destroy individual cells of a gray mass, or individual isolated fibres, it might perhaps be possible, on the ground of secondary degenerations, to assert something more definite concerning the relations of individual cells and individual fibres. But we can only destroy considerable portions of the gray matter, that is, a complex of cells plus the debated intercellular fibrillar

networks; and even if we see that degenerated nerve fibres leave such a focus, or that, after section of a fasciculus, certain groups of nerve cells exhibit certain morbid alterations, such findings can never be used as proof that every one of the degenerated fibres is a direct continuation of the diseased nerve cells or that every one of these fibres ends in a nerve cell of another gray mass.

The same objection applies to the position taken by those who would reconcile the views of the supporters and opponents of the neurone doctrine. These admit that the histological unity of the neurone in the adult can no longer be maintained, but insist that the nerve cell has a trophic or nutritive influence upon its fibre even in post-foetal life. Here again the methods of pathology are able to prove or disprove the influence of a gray mass upon a fibre bundle, but never that of the individual cell upon the individual fibre, and yet the latter would have to be established, should we wish to cite the results of experiments as either favoring or opposing the neurone theory.

For these reasons it is evident that in discussion of the principles of the neurone doctrine all our present-day knowledge of fibre anatomy of secondary degenerations of white fasciculi must be left out of consideration. It throws no light on the relative merits of the neurone doctrine and the theory of continuous fibrils. The neurone doctrine is merely an anatomical hypothesis, the proof of which must depend on histology; for clinical medicine and for the interpretation of experimental work it is unessential. From the viewpoint of the clinic and experimentation it is certain only that the nervous system consists of an aggregation of well-defined units composed of gray masses and fibre systems or fasciculi, the latter being

connected with other gray masses. More than that we do not know. If we wish for a term to designate such a complex, we might call it a "neural." But it must be clearly understood that a "neural" is not a collection or conglomeration of neurones in the sense of the neurone doctrine, for we do not know the real histological relation within the "neural" of all the cells to all the fibrils. This gives us a conception corresponding to the facts in every respect; whereas the neurone doctrine is an hypothesis which cannot be supported by satisfactory anatomical facts. It is not, then, necessary to condemn the neurone theory as false, rather we should retain it as a valuable scheme for teaching.

CHAPTER III.

NERVE FIBRES, NEUROGLIA.

ANOTHER important constituent of the nervous system is represented by the *nerve fibres*. United by connective tissue into bundles, they form the peripheral nerves of the body. In the central nervous system they make up the white masses and the white tracts, and are found, too, everywhere penetrating into the gray matter, separately or in fasciculi.

In the nerve fibres we distinguish a central continuous filament, the axis cylinder, and its coverings, the latter consisting of the myelin sheath and the so-called sheath of Schwann or neurilemma. The most important constituent for the function of the nerve fibre is the axis cylinder. The myelin sheath may be absent, as for instance in the non-medullated fibres of the sympathetic system; the sheath of Schwann may be absent, as in all medullated fibres of the central nervous system; and, in all probability both may be absent (in the so-called naked axis cylinders found in the end arborizations in the gray matter). The peripheral nerve fibres are provided with a medullary sheath as well as a neurilemma.

The *axis cylinder* consists, as we have learned in the previous chapter, of a bundle of probably uninterrupted and distinct neurofibrils embedded in a plasma.¹ According to the neurone theory every axis cylinder is a direct continuation of a nerve cell. This may often if not regu-

¹ For the demonstration of axis-cylinder fibrils, preliminary treatment with osmic acid is important. With the use of other fixing methods, the fibrils shrink into an apparently solid strand (Bethe).

larly be demonstrated in the case of the motor-nerve fibres; even in the lower animals examined by Apathy, the thick motor fibrillæ make their exit at the axonal hillock of a motor ganglion cell and run without interruption and without further reticular formation to the motor end apparatus at the periphery of the body. But whether all other axis cylinders, especially those of sensory nerves are, in higher animals, always direct processes from certain ganglion cells, is not proved. The sheaths of the myelinated nerve fibres within the central nervous organs exhibit some important differences from those of peripheral nerves. The former do not possess the so-called sheath of Schwann, and their medullary sheath is an uninterrupted tube; while in the peripheral nerves, the medullary sheath is interrupted at regular intervals (Ranvier's nodal points), and has a delicate covering known as Schwann's sheath, which possesses a nucleus between every two nodes.

Of the grosser physiological differences, we know further that the peripheral nerves exhibit excellent regenerative ability, while this is lacking or poorly developed in the central fibres.

If we section a peripheral nerve, the distal segment degenerates according to the law of Waller; this is called "secondary degeneration." Axis cylinder and medullary sheath disintegrate, but the nuclei of the neurilemma remain intact and proliferate. A portion of the proliferating elements eventually becomes granule cells, and these serve to remove products of disintegration. Another part becomes arranged into cellular ribbons, and in such ribbons there eventually appears the new, regenerated axis cylinder with a medullary sheath. As to the way in which

this new axis cylinder forms, there are two opposing opinions.² Some authors claim that the proximal part of the old axis cylinder, which remains intact and which supposedly is always connected with a ganglion cell, grows out and pushes forward along the path pointed out by the nuclei of the neurilemma; at the same time or later, it acquires a new sheath. Other authors believe that the axis cylinder arises in a "discontinuous" manner; they look upon the so-called neurilemma nuclei as the matrix of the new axis cylinder, and hold that, within cells arranged in ribbon-like fashion, there are formed fibrils. These fibrils eventually meet and finally form a continuous filament.³ For the fibres of the central nervous system this method of investigation cannot be used, since regeneration of central fibres does not take place, after preliminary destruction and secondary degeneration.⁴

Interesting and important communications concerning the structure of the peripheral nerve fibres have been made by Reich.⁵ According to his observation of normal nerves of adults, it may be accepted that the entire covering of each length of nerve fibre between two nodes of Ranvier is a highly complicated structure, but really a single cell. The nucleus of this structure is the neurilemma nucleus

² Cf., e.g., Edinger (*Deutsche Zeitschr. f. Nervenheilkunde*, Vol. LVIII, 1918), who takes an intermediate standpoint.

³ Concerning the embryological development, these two views on the development of the axis cylinder are opposed to one another.

⁴ Cf. here Koichi Miyake, (*Arbeiten aus dem Obersteinerschen Institut*, Vol. XIV, 1908). Bielschowsky (*Journ. f. Psychol. u. Neurol.*, Vol. XIV, 1909) and others energetically espouse the regenerative ability of the central nerve fibres. However, they hold that these regenerations are not orderly, but without plan and irregular; so that reconstruction of the old path, and therefore re-establishment of function, does not take place.

⁵ Reich, *Journ. f. Psychol. u. Neurol.*, Vol. VIII, 1907. Similar statements are made by Nemiloff, *Arch. f. Mikroskop Anatomie*, 1908.

of the fibre segment concerned. This nucleus lies in a little mass of protoplasm which is continuous with the neurilemma; the latter envelopes the entire cellular structure like a cell membrane. From this membrane, funnel-shaped septa go to the interior; they become reunited axially where the axis cylinder lies, to form a homogeneous substance. It is probable that the plasma, in which the individual axis-cylinder fibrils are embedded, is formed by this substance. The spaces between the septa, which

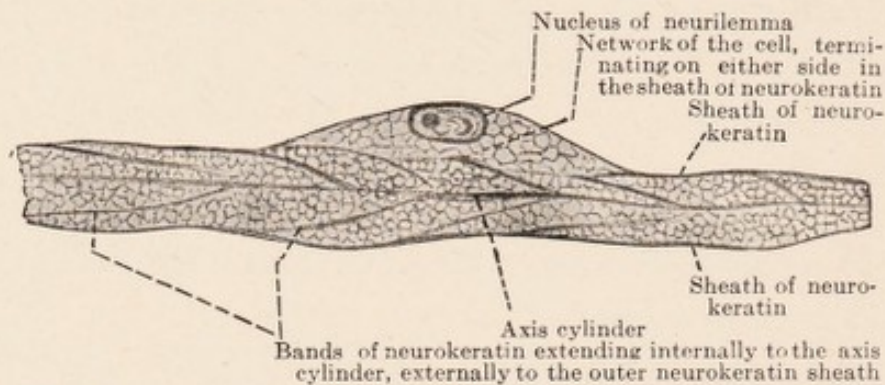


FIG. 17.—Peripheral nerve fibre. Longitudinal section. Van Gieson stain. After Reich.

pass externally into the neurilemma, internally into the axis-cylinder plasma, are filled with myelin, a substance which hitherto was regarded as a second independent covering of the nerves, the medullary sheath (Fig. 17). According to these observations, the peripheral nerve consists, even in the adult, of a chain of cellular structures (neurilemma cells), which are apposed at their narrow sides; and only the fibrils of the axis cylinder are continuous, running through this chain of cells.

Similar assertions had previously been made by Ranvier, by Apathy (for invertebrates), and by other observers. Stransky⁶ regarded the nucleus of the neurilemma as a point of proliferation of the tubular cell which extends as

⁶ Stransky, *Journ. f. Psychol. u. Neurol.*, Vol. I, 1903.

neurilemma from one node to the other. At the node the cell fuses with a contiguous cell, and in so doing forms a sieve-like plate, through which passes the axis cylinder with its fibrils. According to Doinikow⁷ the structure of the myelin sheath is as follows: the cytoplasm of the neurilemma cell consists of a dense perinuclear "court" provided with a loose reticulum, which penetrates the medullary sheath of an internodal segment in its entire extent, and contains the myelin substance in its meshes. The extremely delicate meshes of this framework are strengthened by coarser trabeculae; the latter forming for instance, the funnel-like structures which run obliquely to the surface of the axis cylinders.

Within the nerves there are regularly found small quantities of so-called Elzholz bodies, which stand out in Marchi preparations because of their very deep color. They have a round shape, and are of the size of small lymphocytes. They are formed as globules at the expense of the medullary sheath, and are an expression of the normal metabolism of the latter. Their increase is an indication of pathological change. In the cytoplasm of the neurilemma cells occur similar but smaller bodies, and also the protagon-like granules of Reich.

Similarly the nerve fibres of the central organs are often asserted to be derived embryologically from cells arranged in rows. Italian authors particularly have dealt with this question. Among others, Fragnito has seen in chick embryos of 12 to 18 days, in place of the later nerve fibres, chains of long stretched-out cells, each with a nu-

⁷ Detailed description of the structure of peripheral nerve fibre (with literature) given by Doinikow (*Histol. u. Histo-pathol. Arb. von Nissl u. Alzheimer*, Vol. IV, 1911); of the central, by Jakob, *ibid.*, Vol. V, 1912.

cleus. He was able to trace these nucleated spindles into the axis-cylinder processes of ganglion cells and even into the cell body. But probably the central nerve fibres differ from the peripheral in that, in the former, the cells which form the nerve fibre fuse later into a filament, and their nuclei then disintegrate; also in that an external cover (which in the peripheral nerves is called a neurilemma) does not remain.

Reich supposes that a part of the glia cells may stand in particularly close relation to the nerve fibres in the central organs, and that the nuclei of these glial elements are in a sense analogues of the neurilemma nuclei of the peripheral nerves. According to Paladino and Held (see Jakob⁷) the medullary sheaths of the central nervous system are not only everywhere surrounded by protoplasmic processes of glial cells, but probably fine filaments of the glia penetrate into the meshes of the medullary sheath and through them, extending to the axis cylinder. Around it they form nodes at intervals. Be this as it may, the writers agree in supposing that the formation of myelin in the central fibres is a function of the neuroglia, just as in the peripheral fibres it is a function of the neurilemma cells; and that the protoplasm of the nerve fibre is embedded immediately in the protoplasmic structures of the glia.

Finally, in this series of new observations, the contribution of Held must be mentioned. He asserts that the neurilemma cells, hitherto regarded as of connective tissue nature, are derived from cells which grow out from the medullary tube; that they are emigrated glial cells, that is, elements of ectodermal origin. He compares the neurilemma with the *membrana limitans gliæ* of the central

nervous system. Externally is the closely applied endoneurium, of connective tissue nature. This conception, taken with those already mentioned, would mean that in the peripheral nerves not only the axis cylinders but also all their coverings are derivatives of the outer germinal layer, just as is the entire central nervous system.

Ganglion cells, nerve fibres, and the fibrillar apparatus which connects them constitute the specific functional parts of the nervous system. These parts are embedded in a supporting framework. Of the other organs of the body it is known that their supporting framework is of mesodermal origin. In the nervous system it is different; this possesses a characteristic ectodermal framework—the *neuroglia* or nerve cement. Specific nervous tissue and neuroglia originate from a common anlage, the ectoderm; and they become distinct only late in their development. A result of this late separation is a lasting, very close relation between the two. The nervous system contains also true mesodermal connective tissue; but, excepting the external coverings (dura mater, pia mater; perineurium, etc., of peripheral nerves) this is present only in scanty quantities and only accompanying the blood vascular system.

Concerning the nature and the behavior of the neuroglia, we have only very gradually obtained any definite knowledge. Thus it was with great difficulty that its ectodermal origin was established. The most important opponent of this conception, His, only shortly before his death in 1904, admitted the purely ectodermal origin of the glia. Until the end of the last century, "a confusion mocking description" (Nissl) prevailed concerning the

neuroglia.⁸ It was not possible to differentiate between the nuclei of many glia cells and those of certain ganglion cells; many of the apparently "free" glial nuclei were regarded as lymphocytes, and so on. Remnants of this confusion are even now met with everywhere in the literature.

More precise knowledge was first gained with the help

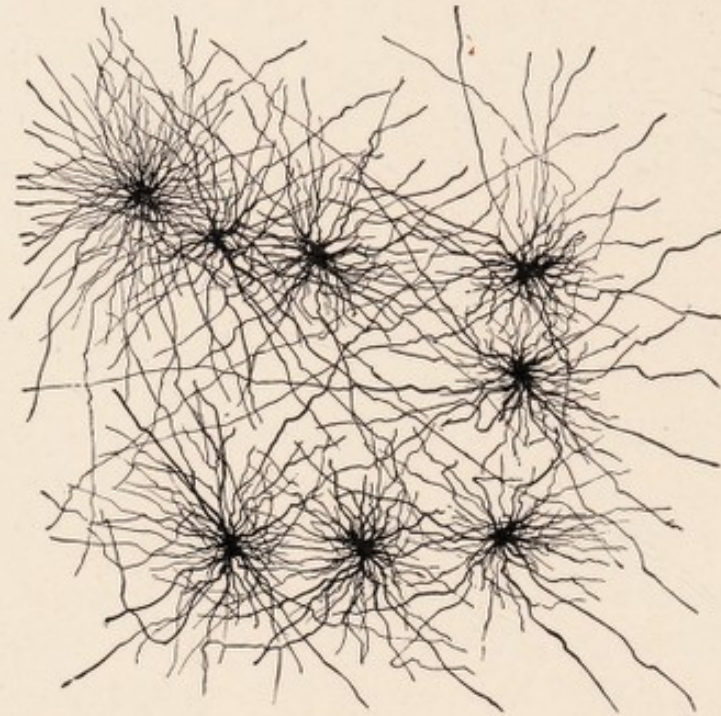


FIG. 18.—Normal glia cell (long-rayed astrocyte) from the white matter of the cerebrum. Golgi method (after Golgi, from Koelliker's Handbuch).

of Golgi pictures. Silver impregnation preparations show a large part of the glia as isolated cell units, each of which appears as a spider-like cell structure with longer or shorter processes radiating from the cell body. These processes are often quite long, and in such cases form a network (Fig. 18). Such preparations give the impression that the glia consists entirely of well-defined cells and their numer-

⁸ For a historical review of the glia, see Nissl, *Histol. u. histopathol. Arbeiten*, Vol. I; Held, *Abhandl. der math.—phys. Klasse der Königl. Sächs. Ges. der Wissensch.* Vol. XXVIII, 1903; Eisath, *Monatsschr. f. Psychol. u. Neurol.*, Vol. XX, 1906.

ous crossing and interlacing processes, and of nothing else.

Something entirely new is presented in the teaching of Weigert on the glia.⁹ He demonstrated, by means of a specific staining method (now known as Weigert's glia stain), that there are independent glia fibres (glia fibrils) which, though formed by the glia cells, are different from them chemically, and therefore may be electively stained

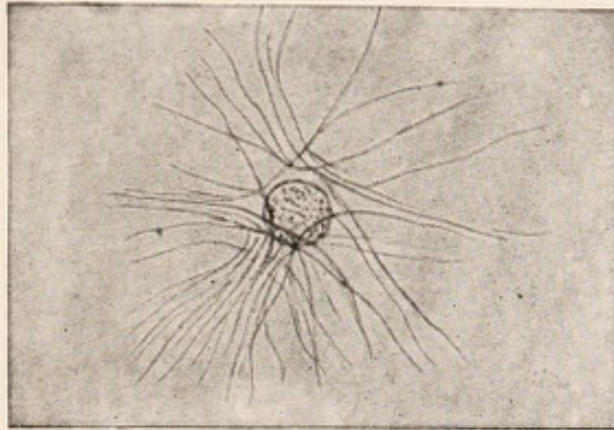


FIG. 19.—Normal glia cell from the posterior horn of the spinal cord. Weigert's glia stain (after Weigert). The glia fibrils run in a curve past the nucleus. Cell body unstained.

(Fig. 19). He further emphasized his belief that these chemically different fibrils in their mature condition are separated from the cells, that they lie outside of the cell bodies, and therefore represent a true intercellular substance. These fibrils are in part much separated from their parent cells, in part lie close to them; and in the latter case they tend to sweep past the cell in curves that have their convexity toward the nucleus.

Weigert taught that the older staining methods produced the well-known astrocyte picture (short-rayed astrocytes, long-rayed astrocytes) simply because they stained or impregnated the cell body and the glia fibres in

⁹ Weigert, *Beiträge zur Kenntnis der normalen menschlichen Neuroglia*, 1895, Frankfurt a. M.

the same manner. The specific glia fibrils are, according to Weigert's opinion, not processes of the cell bodies, but lie entirely outside them and are chemically distinct. They are smooth, peculiarly stiff structures, which never divide or anastomose.

This new theory separates the mature glial tissue into two constituents, well-defined glial cells and intercellular fibres set free from them. A comparison of the different parts of the central nervous system proved to Weigert that the cells are everywhere fairly evenly, but the fibres very irregularly, distributed. Beneath the ependyma of the ventricle there is always a thick layer of very closely interwoven neuroglia fibres; likewise the external layers of the central nervous system and all portions of the tissue adjoining blood vessels show a greater density of the neuroglia. In the interior of the gray and white substances the number and the mass of the glia fibrils vary in different regions; thus for instance in the cerebral cortex there is always a thin but dense feltwork on the surface beneath the pia; from this, glia fibrils radiate into the depth, but they become more and more scanty, so that in the deeper layers glial fibrils are not to be found for considerable stretches, and only in the white matter a rich feltwork again appears.¹⁰

Weigert's work on the neuroglia is of fundamental importance. It has definitely enriched our knowledge of the central nervous organs. Unfortunately, his method for the demonstration of the glia fibrils has a number of imperfections, which Weigert, in spite of all his efforts, was unable to overcome. The method is capricious even in the hands of the expert, and that without any apparent cause.

¹⁰ Weigert, *l. c.*, p. 136 ff., p. 172.

It is particularly disappointing in studies on the cerebral cortex, especially when no pathological increase of the fibres is present; furthermore it cannot be applied in animal work.¹¹

After Weigert's publication, objections to his conception of the structure of neuroglia were not wanting. It was asserted that his method does not stain all the constituents of the glia; that besides the nuclei only some elements, in certain developmental stages, with certain definite chemical properties, (the specific glia fibrils) can be electively demonstrated; that it scarcely shows the cell body at all. Therefore it is claimed that Weigert reached his conclusion on the separation of the glia fibrils from the glia cells only through a one-sided emphasis on the nuclei and fibrils, neglecting the cytoplasmic portion of the glia.

These objections show the trend of development in the nuclei and neuroglia theory since Weigert.

The most important of these later researches in the normal histology of the glia are those of Held.¹² Held entirely accepts Weigert's description of the form and the tinctorial reaction of the glia fibrils; but he is unwilling to regard these fibrils as a true intercellular substance. In other words, he accepts their chemical differentiation from the glial cell body, but he denies their physical separation.

Held, in contrast with Weigert, tried to stain not only the nuclei and the fibrils, but especially to demonstrate the cytoplasm of the glia as completely as possible. Such preparations have led to a distinctly different conception

¹¹ Erik Müller, *Archiv. f. mikroskop. Anatomie u. Entw.-Gesch.*, Vol. LV, 1899.

¹² Hans Held, *Über den Bau der Neuroglia*, etc. *Abhandl. der math., phys. Klasse der Königl. Sächs. Ges. der Wissensch.*, Vol. XXVIII, 1903. *Die Neuroglia marginalis* etc. *Monatsschr. f. Psychiatrie u. Neurol.*, Vol. XXVI, 1909.

of the structure of the entire glial apparatus. This view emphasizes that the glia is a richly branching but continuous syncytial network, consisting of a protoplasmic substance which envelopes the functional elements of the central nervous system and fills all spaces between them. At the nodal points of this network are embedded nuclei, and, strengthening the whole, there are the specific fibrils demonstrated by Weigert, lying, however, in the cytoplasm and not outside of it.

This conception of Held, of the syncytial character of the glia, conforms in many respects to certain embryonal facts, the knowledge of which we owe particularly to His.¹³ The first anlage of the central nervous system is an uninterrupted plate of closely placed cells. This assumes tubular form and soon loses its compactness. In the second week its place has already been taken by the so-called myelospongium, which is a continuous protoplasmic network. The latter is condensed externally and internally into a membrana limitans (externa and interna), in this there are embedded somewhat radially arranged nuclei. This myelospongium remains as a lasting constituent of the future neuroglia. To it there are added, by division of pre-existing nuclei, widely distributed cell elements, which are connected with those of the myelospongium and with each other as a syncytium. The inner layer of the myelospongium becomes the ependyma. In a still later stage the separation of these elements into spongioblasts and neuroblasts takes place; the former become glia cells, the latter, nerve cells.

¹³ See his last work on the nervous system: *Die Entwicklung des menschlichen Gehirns während der ersten Monate*, Leipzig, 1904.

This syncytial character, traced embryologically by His, is retained permanently by the glia according to Held's observation. The ramifications of the cell bodies form a network; the anastomoses are in many places very rich and dense, elsewhere they are scarce and less compact, or they may be recognizable only as a very delicate coating of the neuroglia fibrils. The fibrils of Weigert serve the purpose of lending greater rigidity to the reticulum; they are embedded within the glial protoplasm, and are not

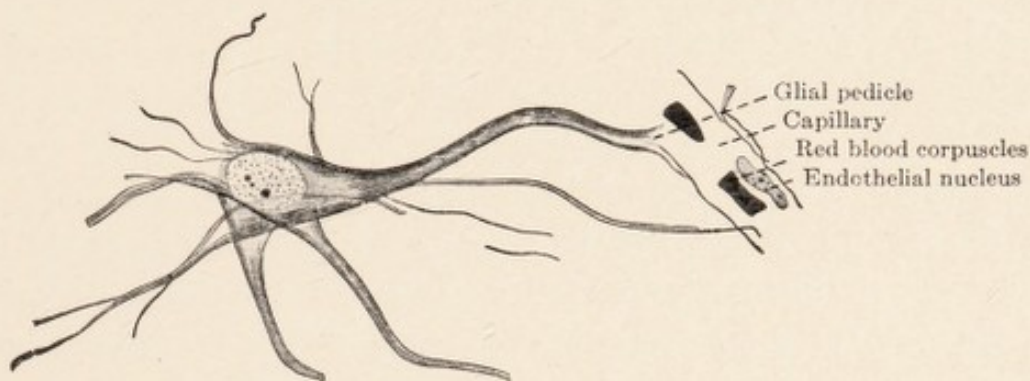


FIG. 20.—Large fibre-forming glia cell. Weigert's glia stain. After a drawing by Alzheimer. Numerous newly formed glia fibrils along the borders of cell body and processes.

separated from it even in the mature condition (Fig. 21). Occasionally Held has not been able to discover in his preparations a protoplasmic coating of the glia fibrils, but he has likewise never been able to convince himself that such fibrils are free in their entire extent; he has rather always seen them dip somewhere into the protoplasmic glial reticulum. The majority of the specific fibrils lies in the cytoplasm near the nuclei, but another portion lies at a distance in the irregular protoplasmic network. Not uncommonly the fibrils traverse several cells; they do not always belong to a single cell.

Held distinguishes between glia cells that have no fibrils, those that have few, and those that have many.

A very frequent type of the fibre-containing cell is the one in which the fibrils are radially arranged. This type according to Held, is produced, when numerous fibrils sweep from the long processes of the glia cells through the cytoplasm in the neighborhood of the nucleus, and then pass out again into another process. Such elements appear as the well-known astrocytes shown by silver impregnation methods (Golgi). In Weigert preparations, as a result of the decolorization of the greater part of the protoplasm, we get a picture in which large numbers of fibrils sweep in curves past the nucleus. Other tinctorial methods for the demonstration of neuroglia (Eisath, Alzheimer, Cajal *et al*) also show the frequency of such astrocytes. Held recognizes, besides cells in which the fibrils are arranged longitudinally or transversely, those in which the majority of the fibrils pass near the periphery of the cell far from the nuclear portion of the protoplasm. Many glia cells do not show any specific fibrils at all in their cytoplasm.

It was known before Weigert's time, but it was particularly emphasized by him, that the glia is more densely concentrated on the surface of the central organs than in most other places. Weigert recognized that the same condition prevails at the surface of contact between the nervous tissue and the blood vessels, which everywhere stream in from the pia; this surface of contact he called the "internal" surface. With this "marginal" glia Held has concerned himself; and, here again, contrary to Weigert, he has paid particular attention to the protoplasmic portion of the glia. He was able to demonstrate in his preparations that the syncytial protoplasmic network of the glia is everywhere condensed on such surfaces (the external

as well as the internal) into a continuous membrane (membrana limitans superficialis and perivascularis). In this manner the ectodermal nervous tissue is everywhere sharply separated from the mesodermal tissue (pia, vessels). The membrana limitans is sometimes delicate, sometimes coarse; it is composed of broadened protoplasmic processes, the so-called pedicles; these belong to several more or less distant glia cells. If we section the membrana on the flat, we can then verify the fact that it consists of individual pedicles, which are seen to form an irregular mosaic. The membrane itself and the pedicles are in many places reinforced by glia fibrils, which are demonstrated by Weigert's method.

To our knowledge of the nature and structure of the neuroglia these observations of Held form an important supplement. We learn from them that the glia represents a continuous reticulum which is only imperfectly and in some places differentiated into cells, a reticulum that in fact envelopes and holds together as a nerve cement the ganglion cells, fibrils, and nerve fibres; the rigid fibrils described by Weigert are merely embedded in it.

Held regards as a component of the glia the fine granular or lumpy masses, so-called "nets of Bethe," which envelope the nerve fibres of the white substance like a sheath, and the periganglionic or pericellular Golgi nets, already discussed in a previous chapter. We learned there that delicate protoplasmic filaments of the glia probably penetrate through the meshes of the medullary sheath to the axis cylinder of the nerve fibre. Held emphasizes, in connection with all this, that the "reticulum" of the glia is largely not an ordinary but a differentiated type of protoplasm.

These structural relations of the neuroglia in the central organs, together with observations made on pathological material, indicate that the neuroglia is not merely the supporting framework of the central nervous system, but that its protoplasm forms the pathways for the tissue juices as well. In these the nutrient exchange

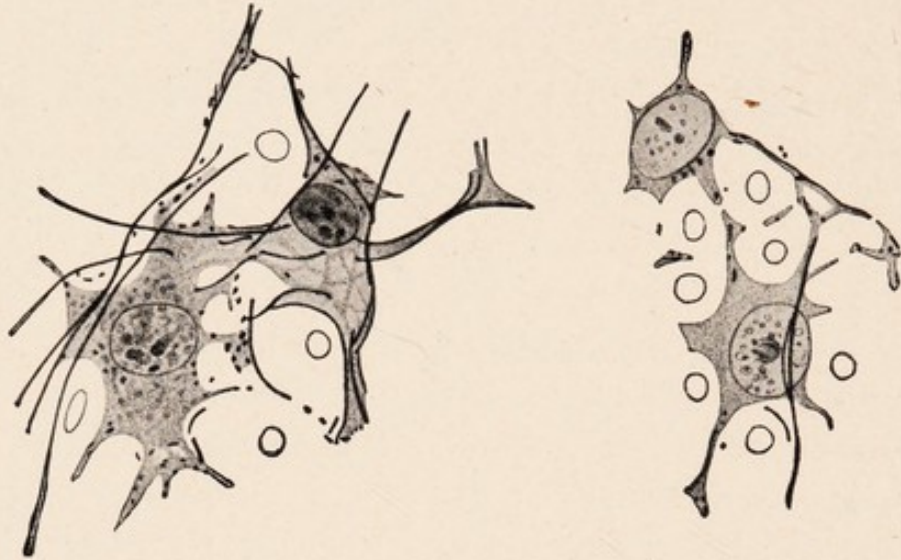


FIG. 21.—Four glia cells from the white substance of the spinal cord. After Held. The dark and dots are longitudinally and transversely sectioned glia fibrils.

takes place between the capillaries or lymphatics and the functional nervous elements.

A large portion of what we know to-day of the morbid changes in the glia has been gained from Nissl preparations. To be sure, Nissl's method stains only a portion of the glial structure, that is, the nuclei and the cytoplasm in close proximity to them; it does not stain the fibrils, the protoplasmic network of His and Held, or the limiting membranes. But the pictures obtained by Nissl methods are extraordinarily clear and useful; they are remarkable for a constancy not possessed by any other method, and they allow the certain recognition of even slight pathological changes. We now possess many methods (Held,

Eisath, Alzheimer, Walter, Cajal) which present the glia much more completely, and which are invaluable for special studies; but none of them is so easy to use or has the constancy necessary in the study of pathological material, as Nissl's stain.

How the normal glia appears in Nissl preparations has been described most thoroughly by Nissl himself.¹⁴ He, like Weigert, distinguishes among the nuclei, those that are small, round, deeply staining, that is, richly chromatic,

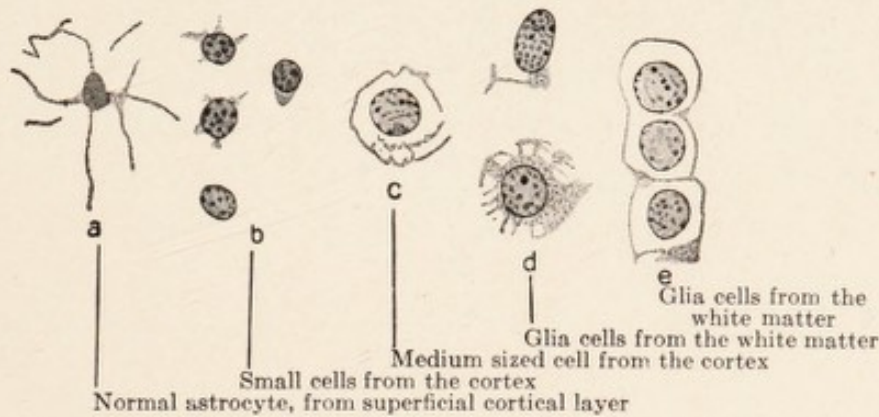


FIG. 22.—Normal glia cell, after drawings by Alzheimer. Nissl stain.

those that are large, poorly staining, usually egg-shaped, and transitional forms with moderately intense or light staining (Fig. 22). The nuclear membrane is always distinct, and frequently shows a composition of closely placed granules. Frequently, there is only a suggestion of the cell body, made out rather by its optical than by its staining properties. The cells of the white matter of the brain as a rule show a somewhat larger body, which lies like a little pale crescent about the nucleus, or surrounds it as a loose network. In the white columns of the cord, there is frequently a suggestion of spider-like forms of the

¹⁴ Nissl, *Histol. u. histopathol. Arbeiten*, Vol. I, 1904, and: *Über einige Beziehungen*, etc. *Archiv. f. Psych.*, Vol. XXXII, 1899.

cell body. The cytoplasm, so far as it can be demonstrated by the methylene blue method, is a definitely web-like structure; its external delineation, in the vast majority of cases, is not possible, and a cell membrane is never present.¹⁵

The cell body may contain pigment. Finally it is well to remember as an established fact that the glia cells which have produced fibrils tend to undergo slow and gradual retrogression. The nucleus becomes smaller and stains more deeply, the cell body likewise takes on a deeper stain, and finally the entire element shrinks into an irregular, spider-like, dark-staining body. This applies not only to pathological conditions, but one frequently finds such forms normally, for instance in the external glial layer of the cerebral cortex (Fig. 22 a).

¹⁵ This is readily understood if we recall the diffuse mesh-like structure of the entire glia protoplasm; by Nissl's method only the protoplasm in the immediate neighborhood of the nuclei is brought out, and this gradually disappears in the surrounding meshwork.

CHAPTER IV.

THE MESODERMAL TISSUE. BLOOD-VASCULAR AND LYMPH VASCULAR APPARATUS. GENERAL HISTOLOGICAL STRUCTURE OF THE NERVOUS TISSUE.

ACCORDING to what has been said in the previous chapter, the neuroglia holds together the various constituents of the central nervous system in a very complete manner, and wherever surfaces exist forms limiting membranes. Virchow's term "nerve cement" is a most suitable one for it.

In the central nervous organs, mesenchymal connective tissue is not a component of the nervous tissue proper. But the peripheral nerves, as nerve trunks and as fibres, are enveloped and held together by connective tissue; of ectodermal origin here we have only the actual sheaths of the axis cylinder, the medullary sheath and the neurilemma. The glial envelope terminates sharply at the nerve roots as they leave the brain, medulla, and spinal cord; even the spinal ganglia are embedded in connective tissue, and each of their ganglion cells is surrounded by a layer of connective tissue cells.

The central nervous system likewise contains a certain amount of mesodermal tissue, but this is limited, aside from the pia and dura, exclusively to the walls of the blood vessels and the scanty, loose, fibrous tissue accompanying them. Both the larger vessels and the rich capillary network (Fig. 35) penetrate the substance of the central organs in all directions, but everywhere the ectodermal nervous tissue is separated from them by a glial limiting membrane. "The vessels are no more an integral part

of the central nervous system than is the pia itself" (Weigert). An interlacing of connective tissue and glia fibrils, a penetration of the connective tissue between the ectodermal constituents of the nervous tissue nowhere takes place; wherever there are vessels with their accompanying connective tissue, they are surrounded on all sides by the smooth glial membrana limitans perivascularis.

The *arteries* of the central organs all come from the pia. Short branches radiate into the cerebral cortex perpendicularly to the surface. They split soon after their entrance into delicate arterioles and capillaries. A portion of them penetrates more deeply and supplies parts of the subjacent white matter. The brain stem and the greater part of the white matter are nourished by arteries which branch off perpendicularly from the circle of Willis. In the spinal cord the white substance obtains its blood supply from vessels which penetrate radially from the surrounding pia. Short arterial branches pass horizontally into the depth from the pial septum lying in the ventral median fissure of the spinal cord, enter the gray substance on both sides of the central canal, and split here rapidly into a number of branches which supply the anterior and posterior horns of the spinal cord. The *venous* vessels of the brain are partly collected in the pia, partly they are united in the deeper parts below the splenium of the corpus callosum into the vena magna Galeni. The pial veins as well as the vena Galeni empty into the sinus duræ matris. It is important to remember the presence of solid, protoplasmic, connecting bridges between neighboring capillaries. In these, new formation of capillary tubes takes place under pathological conditions.

The scanty connective tissue which accompanies the

ingoing and outgoing vessels as adventitia is the only connective tissue in the central organs, and may be regarded as the direct prolongation of the pia.¹

We distinguish in the vascular walls of the central nervous organs, as well as elsewhere in the body, three layers—intima, media, and adventitia.² This is only a gross external division; in reality the vascular tube is developed as a homogeneous protoplasmic network of the mesenchyme, in which muscle cells, collagen and elastic fibres are formed. Only the origin of the endothelial cells is still in dispute.³ In the present state of our knowledge the elastic fibres and membranes play an important rôle in histopathology; for their selective demonstration we possess in Weigert's resorcin fuchsin stain an excellent method. The vessels show beneath the endothelium a special layer, the membrana elastica. In the arteries this is present as a compact layer of laminated structure, with the well-known fenestrations, whence the term membrana fenestrata, and exhibits a regular waviness, with projections into the lumen of the vessel at regular intervals (Fig. 37). (The translators regard this appearance as an artefact produced by postmortem conditions and by the fixation and contraction of the tissue). It is less marked, less compact, and less wavy in the veins. (A very delicate elastic membrane is also present in the capillaries; though it stains with much greater difficulty.) Elastic fibres and very fine lamellæ pervade the muscularis in the form of a relatively open network. They envelope here

¹ Held differentiates between an inner layer of the adventitia, belonging to the vessel, and an outer (intima piae perivascularis), which represents the continuation of the pia mater.

² Cf. Evensen, *Beiträge zur normalen Anatomie der Hirngefäße. Histol. u. histopathol. Arbeiten von Nissl*, Vol. II, 1908.

³ O. Ranke, *Zeitschr. f. d. ges. Neurol. u. Psych., Orig-Bd.*, XXVII, 1914.

every individual muscle fibre. Where a definite adventitia is present, abundant elastic fibres also may be found in this layer.

The *endothelium* of the vessels of the brain and cord is everywhere single-layered.⁴ It consists of large, flat, diamond-shaped cells, the cytoplasm of which stains normally with difficulty, but the borders of which may be made visible by gold impregnation methods. They form an uninterrupted inner coating of the vessels. The nuclei of these cells are elongated and their long axis always lies in that of the vessel. Their size is everywhere approximately the same, even in vessels of the most different calibre. In the capillaries one finds the nuclei at regular intervals, alternately left and right, or above and below. They possess a distinct nuclear membrane, which frequently permits recognition of its composition of fine granules; and in their interior there are mostly two to four small deep-staining bodies like nucleoli. In form, the nuclei are much flattened; they therefore appear pale when viewed on the flat, and dark, when viewed on edge (Figs. 46 and 50; Fig. 48). The endothelial nuclei frequently contain peculiar small vacuoles, to which Nissl first called attention (Fig. 37). The latter appear as circular holes with sharp margins, as if punched out, and possess strongly refractile contents which do not stain with any of the common dyes. They are frequently found lying partly in the nucleus and partly in the cytoplasm. Apparently they are regularly extruded into the cell body, the endothelial nucleus then closing itself behind them and assuming its previous form. Their significance

⁴This is important in histopathology; the presence of more than one layer is pathological.

is still uncertain. They occur not only in man but in animals as well. Their recognition may be of importance; nuclei which contain them may be at once regarded as endothelial nuclei.

The capillary tube consists only of a very delicate protoplasmic membrane (Fig. 53) which on the inside is lined by a delicate elastic membrane, upon which is placed the endothelial cell layer. Externally it passes into the scanty adventitia.

The muscularis, in the majority of the arteries of the central organs, consists simply of one layer of circularly arranged muscle fibres, since, with few exceptions, only small vessels are concerned here. The long axis of their nuclei, therefore, is perpendicular to that of the endothelial nuclei.

The adventitia consists of a loose, syncytial, protoplasmic network of varying width and density. The trabeculæ of the network exhibit a varying number of nuclei, as well as collagenous and elastic fibres (Held). The entire adventitia may be well demonstrated by the silver method of Achuccaro. In the Nissl preparation one recognizes only the individual spindle-shaped or more rounded nuclei, without distinct cell bodies.

LYMPHATICS.—In the brain and cord, there are no closed lymph channels with walls of their own. Larger lymphatics are only formed outside of the substance of the brain and cord. They emerge from the skull through the jugular foramen and the carotid canal and leave the spinal canal with the vertebral vessels. The cerebral lymphatics communicate with the deep cervical lymph nodes. There are also probably connections with the ear, nose, and pharynx (A. Hauptmann). Concerning the

direction of the lymph current, contradictory statements have been made. Within the brain and cord the lymph circulation takes place merely in spaces around the blood vessels; and these spaces communicate with the great lymph sacs lying in the clefts of the connective tissue coverings of the central nervous system (dura and pia).⁵ They stand also in communication with the ventricles. They all belong to the general lymph system of the body, although constituting only an accessory part of it (Bartels).

The dura mater surrounds the brain and cord as a smooth walled sac. Two sickle-shaped processes (the falx and tentorium) penetrate into the great clefts between the cerebral hemispheres and between the cerebrum and cerebellum respectively. The pia mater, however, which carries the nutrient vessels, is everywhere closely applied to the surface of the central nervous organs. It follows all depressions and fissures, fills them, and bridges them with an externally smooth investment. It has been customary from early times to divide the pia mater into a loosely meshed external layer of connective tissue trabeculæ, the arachnoid, and an inner sheet of connective tissue (the pia in the narrower sense⁶) which closely hugs the surface of the nervous organs; the latter contains the pial vessels. (For the following see Fig. 44). The space lying between the smooth inner surface of the dura and the

⁵ Cf. Schröder, *Paralyse und Entzündung, Zeitschr. f. d. ges. Neurol. u. Psych.*, Vol. LIII, 1920.

⁶ Others restrict the term arachnoid to that delicate layer which is everywhere adjacent to the dura; and the connecting meshwork between this arachnoid and the inner layer of the pia (pia in the more restricted sense) is called subarachnoidal tissue. A sharp separation is nowhere possible. The free surface of the arachnoid, like the opposite inner surface of the dura, is covered with a continuous layer of flat endothelium; in it there are found, at regular short intervals, small round nodules consisting of accumulations of endothelial cells; these may enlarge in all irritative conditions.

equally smooth outer surface of the arachnoid is spoken of as the subdural space; it is lined by a continuous layer of endothelium and contains small quantities of lymph.

The loose trabeculæ of the arachnoid, likewise everywhere covered with endothelium, serves as a framework for another lymph space. In its entirety it forms a sac filled with fluid, and is particularly spacious around the spinal cord, protecting the cord like a water cushion from mechanical injuries. This is known by the term subarachnoidal space.

Between the innermost layer of the pia and the external surface of the brain and cord, represented by the glial membrana limitans superficialis, lies only an imaginary space (His), the epicerebral or epispinal space.

There are therefore found within the meninges the subdural space, between the dura and the arachnoid, and the subarachnoidal space, within the loose tissue of the pia-arachnoid. The pia and the surface of the brain and cord are closely apposed, and there is no space between them.

If we now wish to obtain an idea of the situation of the lymph paths within the brain and spinal cord, we must recall the blood supply of these organs. The central nervous organs do not possess blood vessels in their interior during the first developmental stages. Only when a later stage has been reached, vascular buds from the pia push in against the hitherto exclusively ectodermal tissue of the brain and cord. These buds everywhere thrust themselves against the glial membrana limitans superficialis, invaginating without ever penetrating it. Thus the specific ectodermal nervous tissue remains everywhere closed and sharply separated from the vessels as they push forward, by the glial membrana limitans peri-

vascularis; this latter is nothing more than a continuation of the membrana limitans superficialis and therefore of ectodermal nature. These relations hold for the larger vessels as well as for the capillaries.

Along with these vessels, a scanty amount of connective tissue pushes in from the pia. It plays the rôle of adventitia, and its external layer lies in close apposition to the perivascular glia membrane.

As the result of this arrangement the subarachnoidal lymph spaces are continued into the interior of the brain and cord, as spaces which accompany all vessels, large and small, within their adventitial connective tissue; and the latter is merely a continuation of the pia. These spaces internally are contiguous to the vessel wall (muscularis or intima); externally they are bordered by a delicate layer of the adventitia closely applied to the glial membrana limitans perivascularis. In this manner a system of clefts, serving for the circulation of the lymph, encircles all vessels of the central organs down to the capillaries; it empties on the surface of the brain and cord into the great lymph sac of the pia mater.⁷ (For what follows, compare Fig. 45.)

These lymph paths around the vessels are the adventitial or Virchow-Robin spaces. They are of greatly varying width, larger in the gray substance than in the white. Under pathological conditions, they may be distended with fluid or cellular elements, and then assume considerable dimensions. The adventitial connective tissue which

⁷ See Nissl *et al* in *Zentralbl. f. Nervenheilk. u. Psych.*, 1903, p. 90; Held, *Monatschr. f. Psych. u. Neurol.*, Vol. XXVI, 1909, and *Abhandl. d. math., phys. Klasse der Königl. Sächs. Ges. der Wissenschaften*, Vol. XXVIII, 1903. Concerning the respective relations in retina and optic nerves, see Krückmann, *Zeitschr. f. Augenheilkunde*, Vol. XXXVII, 1917.

forms them is always very scanty in the smallest vessels; as a rule, a fine connective tissue layer rests on the vessel wall, but a second layer regularly is applied to the *membrana limitans gliæ*, and the space between these two layers is traversed by a very few *trabeculæ*; in some places these are entirely absent (Held; see Fig. 45).

Mention is frequently made in the literature of a second, so-called perivascular system of lymph spaces, which surrounds the inner or adventitial system. These have been termed the spaces of His by analogy with the *epicerebral* and *epispinal* spaces. It has been supposed that they represent a dilatation of the supposititious cleft between the usually firmly adherent *adventitia* and the *limitans gliæ*. But Held has shown that this is not true. *Membrana limitans* and external adventitial layer are always closely welded together; it is believed that they are united in such a manner as to form together the limiting membrane between the vascular system and the connective tissue; there is therefore no second lymph space between them. What is usually described as such a "perivascular" space lies, as a matter of fact, external to the *limitans gliæ*, therefore actually within the *ectodermal* tissue. If artefacts are avoided by careful fixation of the material there is seen everywhere external to the glial limiting membrane another layer, consisting of *protoplasmic* and *membranous* portions of the glial *syncytium* which are arranged *radially* and stand *perpendicularly* to the limiting membrane; these form a *meshwork* (Held). With ordinary methods of fixing and preparing tissues, especially *alcohol* fixation, these filaments and membranes are torn apart by shrinkage, and larger spaces are created; these are pure artefacts, not

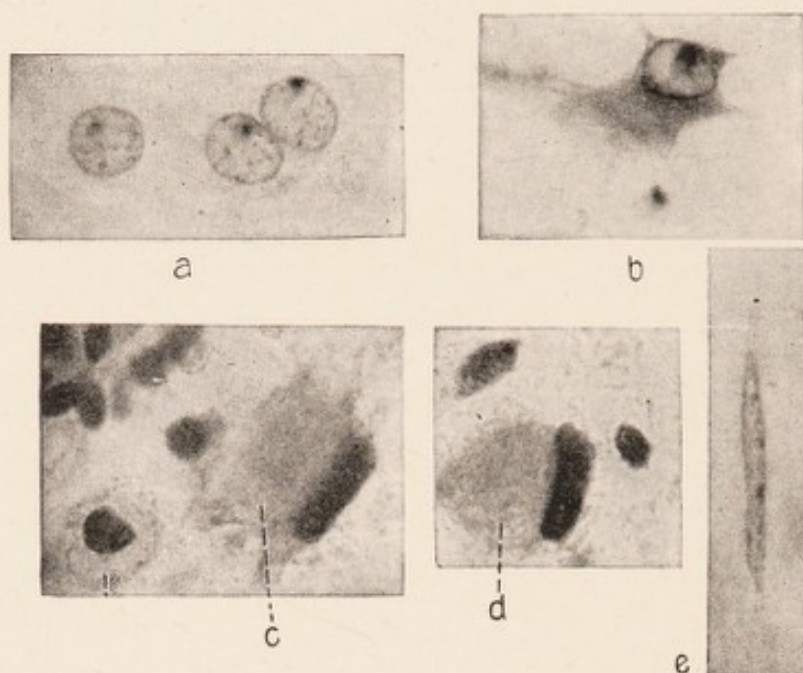
preformed structures. In such sections one finds the vessel occupying a markedly eccentric position within a widely dilated space; closer observation shows that the vessel wall is encircled first by a more or less wide adventitial space, lined on both sides by scanty adventitial connective tissue, and traversed by a few filaments; external to this space lies the smooth, untorn *membrana gliæ*. Outside of this in turn is the large shrinkage space (Fig. 45), traversed in places by ragged, torn, glial threads adherent to the glial membrane. The tear always takes place in an irregularly circular manner just external to the *membrana limitans*. This membrane being tough, and moreover being made more rigid by its glial fibrils, does not shrink but remains closely adherent entirely or in part to the blood vessel, while the soft, juicy surrounding nervous tissue retracts. It is these shrinkage spaces that are often regarded as preformed lymph spaces, are confused with the spaces of His, with which, however, they have nothing to do; for the spaces of His lie internal to the *membrana limitans perivascularis*, while the artificial shrinkage spaces are found external to this membrane.

In the literature, the statement is often encountered that lymph spaces exist around the ganglion cells of the brain and cord, the so-called pericellular spaces. Obersteiner⁸ asserts that in specially well-made injection preparations one may satisfy himself that these pericellular spaces may be injected by way of the perivascular spaces. These pericellular spaces likewise are artefacts, due to distortion or tearing of the tissues through shrinkage. In fact Golgi expressed himself as opposed to regarding

⁸ Obersteiner, *Anleitung beim Studium des Baues der nervösen Zentralorgane*, 1901, p. 220; see also Sittig, *Zeitschr. f. d. ges. Neurol. u. Psych.*, Vol. VIII, 1911.

them as pre-existing spaces; afterward Nissl, and, following him, Held, furnished experimental proof that they are only present after the use of certain fixing and hardening agents, particularly alcohol. It is furthermore possible to produce extremely large spaces, if one places fresh blocks of postmortem tissues for a while in water before further preparation; and a similar condition is seen in cases of antemortem cerebral or spinal edema.

Nissl has further shown that even the term "pericellular" is inaccurate for these spaces, since they do not lie outside the cell surface but inside the cytoplasm. In the process of shrinking, the surface of the ganglion cell, with its fibrillar and Golgi net apparatus (see Chapter II) is remarkably resistant. Because of this, the surface of the ganglion cell is firmly united to the surrounding tissue. On the other hand the soft and obviously more watery protoplasmic body is considerably retracted during the process of dehydration. Hence it is within the cell that the tear occurs, though usually near its surface. Within the shrinkage space thus formed, lies the nucleus with the larger part of the more or less shrunken cytoplasm, the external border of which is jagged or frayed. And the external wall of the space is covered on the inside by a delicate, likewise irregular fringe of cytoplasm, which remains attached to the Golgi nets. At the base of many small pyramidal cells of the cortex there is usually torn off with the axis cylinder a shield-shaped mass of cytoplasm; often it may still be recognized that the projections and indentations of the outer fringe fit those of the retracted cell body, or that still untorn filaments traverse the space between. In close proximity to the ganglion cells lie as a rule one or two glia cells (the so-called satellites). The



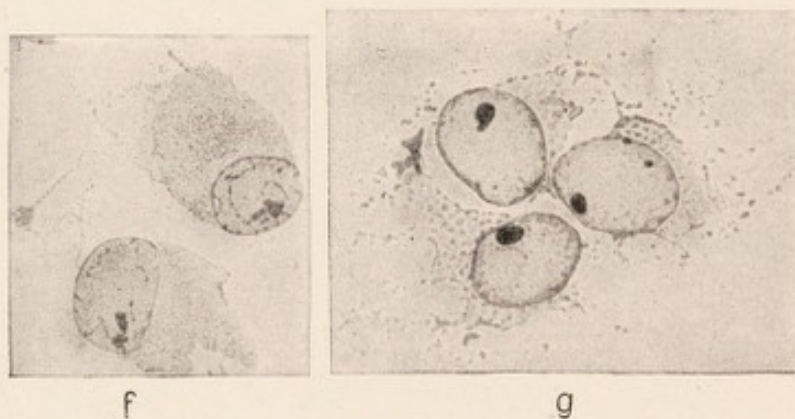
(a) Three pale ballooned glia nuclei with a nucleolus-like body, and a pale, naked, irregular cytoplasm. From the neighborhood of an abscess. Nissl stain.

(b) Large stellate glia cell, with large clear nucleus and dark cytoplasm, which has everywhere concave borders. From a case of amyotrophic lateral sclerosis. From the pyramidal tract. Nissl stain.

(c) So-called monster glia cell; dull opaque cytoplasm with irregular contour, very dark, rod-shaped nucleus. From a case of diffuse sclerosis. To the left is a gliogenic granule cell. Nissl stain.

(d) As in c, stained with hematoxylin, van Gieson.

(e) Rod cell, Nissl stain.



(f) Greatly proliferated glia cells from the cortex of a case of dementia paralytica, with a large nucleus and large cytoplasm.

(g) Glial syncytium composed of huge glia cells.

FIG. 23.—Different forms of pathological glia cells. (a) to (e) photographs, oil immersion; (f) and (g) after drawings by Alzheimer.

nuclei of these satellites during the process of shrinking not infrequently get into the external portion of the shrinkage space, and appear as if they were lying free in the space. Such elements have been looked upon by some authors as endothelial cells or as freely circulating lymphocytes, and their presence has been wrongly regarded as additional evidence for considering these clefts as true lymph spaces.

We are apt to overlook the fact that in most preparations we find entirely analogous spaces around the glia cells; these are likewise to be regarded as shrinkage, and not as lymph spaces.

We see from the above that in the brain and cord only the adventitial spaces of the vessels are lymph spaces; these are direct continuations of the great lymph sac which surrounds the entire central nervous system. The clefts around the vessels and cells, which are frequently so striking in our preparations, are artefacts, and not pre-existing spaces. Following the finest capillaries the adventitial lymph paths everywhere penetrate deeply into the tissues; but the ectodermal tissue is everywhere sharply separated from them by glial membranæ limitantes. The fluid exchange beyond these membranes takes place either through the delicate clefts between the individual ectodermal constituents or along the protoplasmic paths within the polymorphic glial reticulum. A series of observations on pathological material emphasizes the importance of the latter route.

Whatever else has been asserted about the lymph paths, and even about closed lymph vessels, has not hitherto stood the test of critical examination.

An exact knowledge of the lymph paths in the brain and cord, and of the significance of the adventitial spaces as lymph channels, is of great value in understanding a series of important pathological processes. Within these channels are collected, under pathological conditions, elements such as lymphocytes, leucocytes, plasma cells, granule cells, etc. Further, they are the places in which products of disintegration and of metabolism, and in which cells from the tissues accumulate, to be transported by the lymph stream. The interpretation of such findings without exact knowledge of the lymph paths has frequently led to erroneous conceptions.

From the tissue elements described in the preceding chapters, the various parts of the nervous system are constructed.

The histological structure of the *peripheral nerves* is simple. Parallel myelinated nerve fibres possessing a neurilemma are joined into round bundles by scanty laminated connective tissue (endoneurium) and enveloped by a tougher connective tissue layer which is interwoven with elastic fibres (the perineurium); a smaller or larger number of such bundles has again a common connective tissue covering (epineurium), and constitutes a peripheral nerve.

In the *spinal cord*, as well as elsewhere in the central nervous system, we recognize two different types of tissue, the white and the gray matter. The gray matter of the spinal cord surrounds the central canal, and, in cross sections, has the well-known shape reminding one of a butterfly. The white matter in turn, surrounds the gray, and gives to the spinal cord the shape of a long

round rod, which shows, throughout its entire length, on its ventral surface, a deep cleft, the anterior median fissure. The white matter contains, of the specific functional nervous elements, only nerve fibres. These fibres are medullated but do not possess a neurilemma or nodes of Ranvier, as do the peripheral nerves. Their calibre shows considerable variation. They are of varying length; and, for the most part, they run in the longitudinal axis of the spinal cord. Only the roots which enter and leave, and the arcuate fibres, run transversely. Grouping into

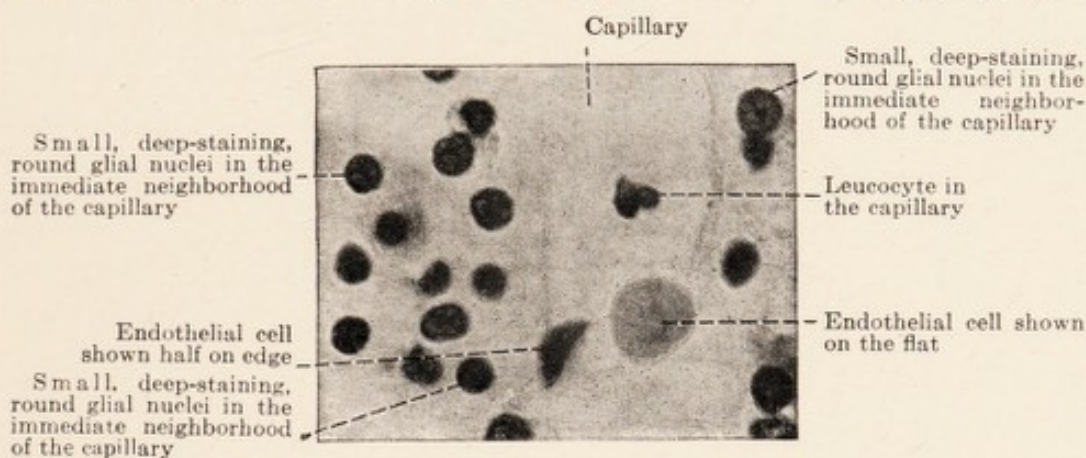


FIG. 24.—From the white matter of a case of symptomatic psychosis. Nissl preparation. Oil immersion.

separate bundles does not take place; the rough, incomplete separation of the white matter into the so-called anterior, lateral, and posterior columns is due to the anterior and posterior horns of the gray matter, which project wing-like antero-laterally and postero-laterally, as well as through the root bundles.

The medullated fibres of the *white substance* are embedded in the general protoplasmic glial network, which is stiffened by considerable numbers of Weigert's fibrils running for the most part longitudinally. The glia fills the spaces between the parallel round nerve fibres. Where

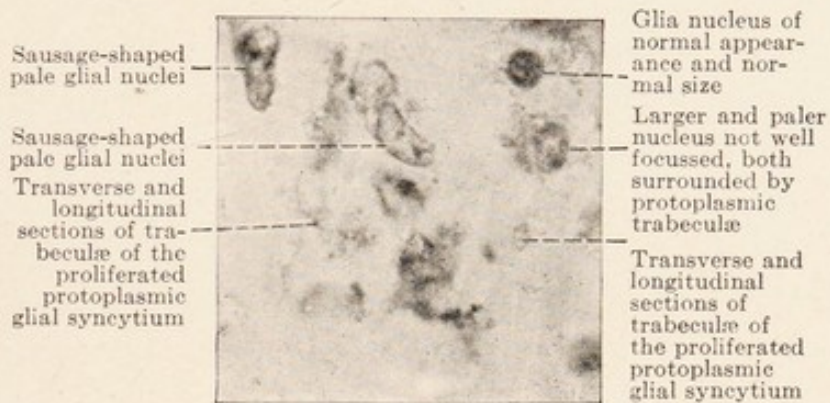
the fibres are predominantly thin, as for instance in the tract of Goll, we find a closely meshed lattice work of delicate filaments, while in places where the nerve fibres are thick, as in the lateral pyramidal tracts and the tract of Burdach, the meshes are wider. On the surface of the spinal cord the glia is denser and more rich in fibrils; from this glial border delicate and coarser glial septa make their way into the interior, the majority tapering into finer filaments as they go. Owing to its constancy there stands out among them a mesial septum between the two posterior columns, and one on each side of these. The lateral septa in the upper part of the spinal cord separate the tract of Goll from that of Burdach.⁹ In the radiating septa the larger vessels enter from the pia. The adventitia accompanying the vessels nowhere fuses with the glia; the vessels are here, as elsewhere in the central nervous system, separated from the ectodermal tissue by a glial limiting membrane. The glial nuclei are regularly scattered throughout the white substance; they lie in the angles formed by several neighboring nerve fibres.

The gray matter of the cord has a more complicated structure, being made up of a greater variety of elements. It contains the ganglion cells of the cord; these are not distributed evenly through the tissue but are arranged in groups, each of which contains one or several types of cells (motor anterior horn cells, posterior horn cells, cells of Clarke's column, etc.) The gray matter contains, besides, the medullated nerve fibres which enter from the roots and white columns, and form a dense network. All of these fibres have the characteristics of the nerve fibres

⁹ There is no such septum between the two anterior columns; here is the ventral median fissure, into which extends a continuation of the pia with vessels.

elsewhere in the central organs, that is, they have no neurilemma or nodes of Ranvier. The third constituent is the glia. Weigert's glia fibrils are arranged in a specially close lattice work around the central canal. They are present in abundance in the anterior horns, much more plentifully than in the white matter. The posterior horns show a very close network of delicate fibrils in the tract of Lissauer, while the substantia gelatinosa is poor in specific fibrils. The gray matter is considerably richer in capillaries than is the white.

In the brain and medulla oblongata the white matter



(Figs. 25 to 29 represent syncytial proliferation of glial elements. In Figs. 28 and 29, beginning granule cell formation is shown. All are photographs; oil immersion).

FIG. 25.—Proliferated glia. Nissl preparation. (From a case of lyssa).

shows the same general histological structure as in the cord; only the grouping of white and gray matter is more complicated. In the cerebral hemispheres, the gray matter constituting the cortex lies as a thick external covering on the white fibre masses. The basal ganglia and the nuclei of the interbrain, midbrain, and hind-brain constitute separate gray masses.

The gray matter, just as in the spinal cord, contains the ganglion cells; it includes also medullated nerve fibres of varying number. Cells and fibres are embedded in a matrix which in sections shows a finely granular or some-

what spongy structure. Concerning the highly complicated composition of this, only the modern selective staining methods have brought any clear information; it is made up of dendrites and axis-cylinder processes of the embedded ganglion cells, the Golgi nets of these cells, the arborizations of axis cylinders from other portions of the gray matter, with the fine intercellular fibrillar reticulum which probably arises from them, and finally the diffuse

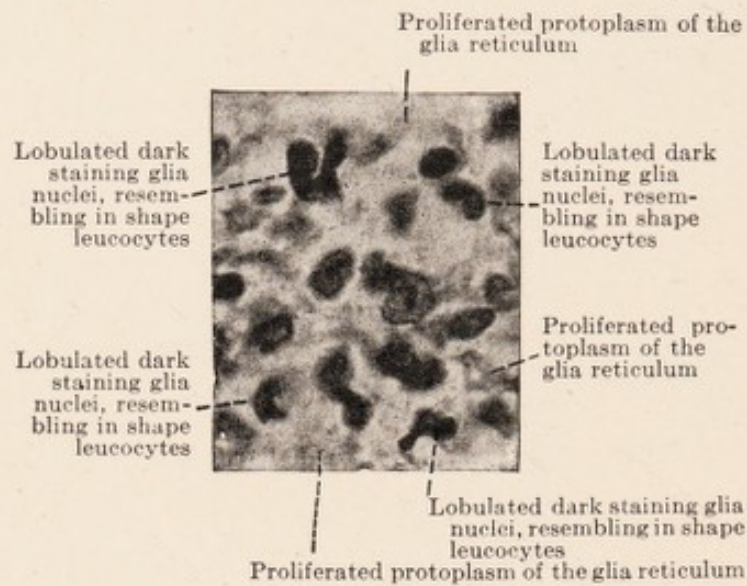


FIG. 26.—Proliferated glia in the neighborhood of a vessel, from the same case as is Fig. 25. Nissl stain.

protoplasmic glial reticulum, with its specific Weigert's fibrils. In the lattice work of the glia, nuclei are fairly uniformly distributed. One regularly finds such nuclei in close proximity to the ganglion cells, particularly at their bases (so-called satellites); and more numerous than elsewhere about the larger vessels. This tissue, composed of the ectodermal constituents enumerated, is traversed by arteries, veins and a rich capillary network, but there nowhere takes place an interlacing of the mesodermal tissues with the ectodermal.

In the cerebral cortex the various ectodermal tissue elements are not represented in equal quantities at the various levels. This leads to the formation of layers. The medullated nerve fibres penetrate in radiating bundles from the subjacent white matter, and lose, after a shorter or longer course, their medullary sheaths. Therefore such radiating fibres are to be found in greatest quantities in the deeper layers of the cortex, while toward the surfaces they become more and more scanty. About in the middle of the cortex there run, at right angles to these, several loose networks of medullated nerve fibres, parallel with the surface. A similar layer of fine medullated fibres is found just below the external surface (tangential fibres). The region of the radiating bundles is traversed also by isolated fibres running obliquely. Marked variations in these details are found in the different regions of the cortex.

The variation in the number of Weigert's glial fibrils in the different layers of the cerebral cortex has already been mentioned. They are very numerous only in the most superficial layer of the cortex, where the tangential fibres are found. Toward the depth the fibrils diminish rapidly in numbers. On the other hand the protoplasmic glial network is apparently equally well developed at all levels. Radiating glial septa, such as are found in the spinal cord, are not present in the cerebral cortex.

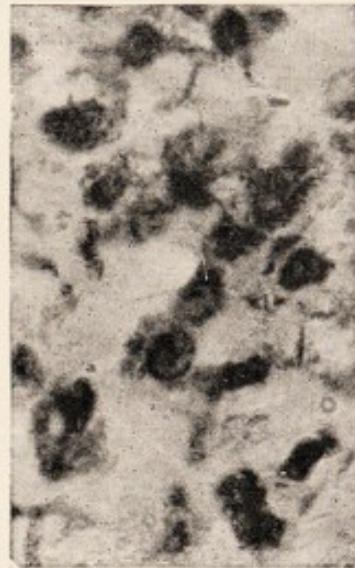


FIG. 27.—Proliferated glia. Nissl stain. Alcoholic polio-encephalitis. Enlarged dark staining nuclei within dense deep staining protoplasmic trabeculae.

The ganglion cells of the cortex also are divided into layers, which run parallel with the surface; these layers, however, are not sharply defined. Further, if we make perpendicular sections through the cortex, the ganglion cells are found to be in radially disposed rows. This arrangement is largely due to the course of the radiating medullated bundles. In general the size of the ganglion cells increases toward the depth; although the lower-most layer consists again of smaller elements. The narrow, most superficial layer of the cortex is free from ganglion cells. Except for the elements in the vessel walls, the nuclei here belong exclusively to the glia cells; it is this layer in which the tangential fibres are found.

The number of nerve cells present in a given area of the cortical tissue varies greatly in different portions of the cortex. The ones farthest apart from one another are those of the motor region; they lie most closely together in the occipital lobes. Nissl has further shown that in general, in animals, the lower the animal is in the developmental scale, the more cells there are in a unit of space in the cortex; he attributes this variation in the numbers of cells to the greater or less development of that reticulum of very fine nerve fibrils which is termed by him the specific "nervous gray." This analogue to the neuropil of the invertebrates is supposed to lie between the ganglion cells; but it has not as yet been demonstrated with certainty by staining methods.

The finer structure of the cortex in different portions of the cerebral surface presents further variations. For the experienced worker it is not difficult to determine the cortical area from which a given microscopic section comes. He makes use of such guides as the number of the

cell layers, the particular structure of certain layers (for instance the layer of granule cells), the existence of definite cell types (for instance the Betz giant pyramidal cells), the width of the entire cortex, the quantity of the tangential and radiating fibres, the width of the strip of Gennari, etc. These local differences have been utilized to divide the surface of the cerebrum into anatomical territories; this is the object of a newly developed field of investigation, cortical architecture.¹⁰ Flechsig used for this purpose the study of the successive myelination of the projection and association fibres of the foetus and of the young child.¹¹ Kaes¹² undertook a careful count of the medullated fibres of the cortex of the adult, in different places. The investigations of Brodmann,¹³ who undertook a cytoarchitectonic inventory of man and of the entire series of mammals, and mapped out the brain cortex, are classical and of particular value. Others have used the Golgi methods for similar studies.¹⁴

¹⁰ Delimitation according to fissures and convolutions of hemispheres rarely corresponds even approximately with definite anatomical and physiological zones.

¹¹ Flechsig, *Gehirn and Seele, Rektoratsrede*, Leipzig, 1894 and later editions. O. Vogt, *Journal f. Psychol. u. Neurol.*, 1919, *Ergänzungsheft*.

¹² Kaes, *Die Grosshirnrinde des Menschen*, etc. Atlas and Text, Jena, 1907.

¹³ Brodmann, *Journal f. Psychol. u. Neurol*, Vols. II-X, 1903-1908; *Vergleichende Lokalisationslehre der Grosshirnrinde*, Leipzig, 1909; *Handbuch der Neurologie*, edited by Lewandowsky, Vol. I.

¹⁴ Ramon y Cajal, *Studien über die Hirnrinde des Menschen*. German translation by Bresler. Leipzig, 1900-1906.

PART II
HISTOPATHOLOGY OF NERVOUS SYSTEM
CHAPTER V.

PRELIMINARY REMARKS ON GENERAL PATHOLOGY. PATHOLOGICAL CHANGES IN THE GANGLION CELLS.

THE nervous system as a whole may be looked upon as a single complex organ. Damage or destruction in one part of this organ results in a great variety of morbid disturbances, depending on the nature and number of nerve connections which the seat of the initial injury has with other parts of the nervous system or with the periphery of the body. The most important question, therefore, for clinical and pathological studies is often the localization of the lesion; the great progress which has been made in these branches in the past few decades has been largely in the field of localization. Even in the pathological anatomy of the nervous system localization of the morbid changes has been largely the object of investigation. To the histopathology and histopathogenesis of the processes little attention has been given for a long time. This neglect of histopathology was seemingly justified by the experience that mere localization of a lesion often permits conclusions to be drawn concerning its nature, inasmuch as certain pathological processes are exclusively, or at least largely, limited to definite localities within the nervous system.

STAINING METHODS.—The principal anatomical method for investigation of localization is Weigert's medullary sheath stain in serial sections. For the demonstration of products of disintegration in early stages, Marchi's method

(blackening of fatty substances by osmic acid) has won a place for itself. Both methods allow histopathological conclusions to be drawn, but only to a limited degree.

Weigert's medullary sheath stain was the first of a series of so-called selective staining methods. Such methods, designed to bring out only certain definite components of the tissue, are both in number and in excellence available for the nervous system as for no other organ of the body. Following the medullary sheath stain came Nissl's cell stain, Weigert's glial fibril stain, and the series of new neurofibril and axis-cylinder methods.¹ Employment of such methods permitted a better insight into the complicated structure of the nervous system.

For the study of normal histology the number of such selective staining methods can hardly be large enough; but their use in histopathology is rather limited. The conditions under which the histopathologist must work are in many respects different from those of the histologist. The former must above all demand from his methods reliability; which means, that under all conditions, in every specimen which he examines, he must get dependable results if he is not to waste his material. In this regard the pure histologist is usually much better off. The pathologist must demand, and this applies not only to the selective methods, that the preparation give constant equivalent pictures (Nissl), that is, that all the normal constituents of the tissue are represented always in the same manner, precise knowledge of which is already possessed by the observer. With this knowledge at hand he is at any time justified in interpreting deviations from an equivalent picture as expressions of pathological changes

¹ The Golgi method also, with certain restrictions, belongs among the selective methods.

in vivo. There must be no room for doubt as to how far the caprices or imperfections of technic have to be taken into account. Finally, it is desirable that any method employed should allow the recognition of as many different details as possible.

There is no single method which meets all these requirements. Certain structural relations and certain pathological products can only be demonstrated by specific staining methods. Therefore the pathologist must always make a choice from the great number of fixing and staining methods at his disposal. Even his choice of a fixing method is of decisive importance. For the demonstration of the ganglion cells by Nissl's method, fixation of the fresh material in strong alcohol is necessary. Formalin is required for Bielschowsky's neurofibril stain. For Weigert's medullary sheath stain, chromating of the blocks is imperative (with or without previous fixation in formalin); preliminary treatment with alcohol is not permissible, since alcohol extracts the myelin. For Weigert's glial stain and for other technics special fixing methods are required.

By selective staining methods it is possible to demonstrate some individual constituents of the tissues (medullary sheath, glia fibres, ganglion cells, neurofibrils), but the histological picture so obtained is necessarily an incomplete one. On the other hand, the diffuse stains (carmin, hematoxylin—van Gieson, hematoxylin-eosin, etc.) differentiate poorly the various elements from one another, particularly in the gray matter. It is therefore always recommended in histopathological studies that, besides diffusely staining dyes, selective methods be employed.

The best method for preliminary orientation, as well

as for the study of many details, is Nissl's; and this is true, as already stated, even when changes in the ganglion cells are not the chief object of investigation. Nissl's method is remarkable for its absolute reliability and constancy. It gives very clear general pictures; and while the nerve fibres, glial fibrils, and fine punctiform or spongy intercellular tissues remain unstained, yet it brings out better than does any other method the slightest changes in the glial nuclei and the surrounding cytoplasm, as well as in the vessels. And in the present state of our knowledge these are the particular elements, changes in which must be studied most carefully for proper comprehension of morbid processes. Then, too, Nissl's is almost the only method for the study of the cellular "architecture" (the arrangement of the cells, layer by layer) of the cortex and deeper parts of the brain.

In the articles on the histopathology of the central nervous system descriptions of the morbid alterations of *ganglion cells* have for a long time occupied much space. There was a time when many investigators believed, with Nissl, that chief emphasis should be placed on the demonstration of such changes. These men cherished the hope, that it might be possible to found a system of pathological anatomy of the brain and cord merely on specific changes in the ganglion cells. The result was that many investigators occupied themselves exclusively with these cells, more or less neglecting the other tissue elements. Experience has taught that these hopes were ill founded, and that such diagnostic importance for pathological anatomy cannot be attributed to morbid alterations in the ganglion cells.²

² S. P. Schröder, "Franz Nissl." *Monatsschr. f. Psych.* Vol. XLVI, 1919.

We understand now, in retrospect, why such exceptional importance was attributed to alterations in these cells. The time of these views and hopes corresponded to the golden age of the neurone doctrine, a theory which, as we have seen, regarded the ganglion cells alone as the place of all active nervous and psychic processes. It looked upon the nervous system, considered from a functional standpoint, merely as a conglomeration of ganglion cells with axis-cylinder processes which connected them with each other and with the periphery. Another important factor was the publication about this time of Nissl's staining method, which brought out the slightest changes in certain parts of the ganglion cells with unprecedented certainty and clarity. These two facts in conjunction had the effect of giving to the ganglion cell an almost dominating position in the field of pathological neuroanatomy.

Nissl himself, in 1890, described a change in the large motor cells of the anterior horns of the cord and in the motor nuclei of the medulla oblongata, which follows transection of, or tearing out of the motor nerves belonging to them. This well-characterized change of cell body and nucleus (Nissl's so-called acute cell degeneration) appears constantly after injury of the axis cylinders of motor nerve fibres. Therefore it has been used to demonstrate experimentally that certain nerve fibres are connected with certain gray nuclei. However, these changes in the ganglion cells result not only from injury to the axis cylinder, but often follow certain generalized processes in the nervous system.

A few years later Nissl³ reported the results of extensive and careful studies on changes in nerve cells of ani-

³ Nissl, *Die Hypothese der spezifischen Nervenzellenfunktion*, etc. *Allg. Zeitschr. f. Psychiatrie*, Vol. LIV, 1898.

mals following "subacute maximal" intoxications. He investigated a variety of poisons (organic, inorganic, toxins), and reached the conclusion that all of these substances produce definite cellular alterations, and that each of them affects the cell in a characteristic manner. His descriptions are masterly, and are done with a thoroughness unrivaled by any other writer on the subject.

Following this work of Nissl, contributions began to pour in from all sides. Changes in nerve cells were described in the most varied intoxications, in starvation, insomnia, experimental uremia, experimental anemia, experimental fever, freezing, from strong electric currents, in cerebral abscess, in injuries, asphyxia, autointoxications, as well as in the most diverse diseases of the peripheral and central nervous organs.⁴ In a large proportion of such reports we meet the open or hidden tendency to claim the described nerve cell changes as "specific" for the injurious factor. Many merely concern themselves with the large motor cells, which are the easiest to find and to identify. Even in the field of psychiatry search was made for changes in the nerve cells specific for the various psychoses; and here again the inclination existed to explain the entire pathological anatomy of the cerebral cortex solely in terms of changes in the nerve cells.

Only gradually have these Utopian hopes been discarded. Nissl himself was one of the first to warn against exclusive attention to the nerve cells, and against exaggerating the importance of their changes to histopathology. He contended that there are no specific nerve cell changes in any disease, and that it is not to be assumed offhand that certain nerve cell changes correspond to

⁴ An English review of the literature (*Brain*) in 1899 already cites 523 references.

definite disturbances in nervous function. A certain disappointment was the immediate result; but subsequently, as often happens in such cases, the pendulum swung too far in the other direction. Long and diligent study of the morbid alterations of the ganglion cells has given us a mass of observations, a part of which at least will undoubtedly have permanent value. But it is now recognized that the changes in the nerve cells with which we are familiar, with the possible exception of a few special types, are of significance only in connection with the changes of all the other tissue constituents, that is, as part and parcel of the whole histological picture. To seek for specific nerve cell changes in a particular clinical disease picture must be looked upon today as useless. Whether one or another disease of the nervous system will prove in the final analysis to be characterized by definite alterations in the nerve cell equivalent picture, must be reserved for further investigation to determine.⁵ Experience thus far gained has taught that in human pathology the majority of the known cellular changes may be traced to the general somatic disturbances which accompany the nervous malady (fever, anemia, malnutrition, exhaustion, edema, etc., including the special changes occurring in a long agonal period), and that they therefore cannot be regarded as "specific" to any disease process.

The pathological changes in the nerve cells have been studied chiefly with the help of Nissl's method. The older diffuse tissue stains gave only indefinite pictures of the ganglion cell body. Moreover, fixation of the material

⁵Such characteristic changes appear to be the cellular alterations found by Schäffer in familial amaurotic idiocy. In obviously closely related conditions, Spielmeier (*Histol. u. histopathol. Arbeiten von Nissl*, Vol. II, 1908) has described widely distributed cytoplasmic inclusions of a peculiar granular mass.

in chrome salts, formerly generally used, caused various artefacts; Nissl's introduction of strong alcohol in the technic meant a great advance in this respect. The agents used for fixation of nervous tissues, such as formalin, bichloride and others, give, in part, equally good pictures of the cell body; but it must not be forgotten that the equivalent pictures which they produce are different from, and therefore cannot be compared offhand with that obtained after alcohol fixation. By Nissl's method there are stained, besides the nucleus, only certain cytoplasmic substances lying between the neurofibrils. These substances are apparently of extremely labile structure, rapidly and markedly changed by injuries of all kinds, probably even during normal function. This may be the reason that perfectly normal cell pictures may be said to be almost never obtained from human material.⁶ The injuries during the agonal period often suffice to produce changes; and even in decapitated human subjects the great majority of the cortical cells do not give the normal equivalent picture as we know it in healthy animals which have been decapitated. These experiences alone show that one must be cautious in evaluating nerve cell changes for the histopathology of certain disease processes. The changes described may be interpreted in different ways; for this reason the much used terms sclerosis, chromatolysis of nerve cells, etc. have little definite meaning. Only a detailed analysis of the changes can be of value, going hand in hand with definite knowledge as to how the deviations from the equivalent pictures are to be evaluated in the individual case, and especially whether they

⁶ Nissl in 1914 stated that in his collection of about 1000 human cases he possessed but a single brain which in a measure corresponded to all the requirements of a normal one.

allow a conclusion as to the severity of the condition and possibility of recovery from it. Of such observations Nissl has reported a whole series.

Of the other selective cell stains, Golgi's is of little use for pathological purposes. It does not give histological details of cellular structure, but merely shows the cell in its entirety as a silhouette. It is furthermore not dependable or constant. Care is therefore indicated in attempting to interpret results gained by this method in the field of pathological anatomy. There has been no lack of such attempts; thus the occurrence in Golgi preparations of certain irregular, rosary-like thickenings of the dendrites has been interpreted as the anatomical expression of the ability to retract on the part of the cell processes (so-called theory of the plasticity of the neurones); and certain writers have attempted to explain physiological processes (sleep) as well as pathological (stupor) on this ground. More critical observers have demonstrated that such thickenings may at any time be artificially produced by modification in the fixation of the material.

In diseased ganglion cells stained by Nissl's method the most striking changes are in the appearance of the stainable substances. The normal arrangement of this material into lumps, or rows of granules, or heaps of granules, etc., to which is so largely due the characteristic appearance of the Nissl equivalent picture, undergoes a variety of changes under pathological conditions. But, besides this, the Nissl picture permits recognition of changes in the normally unstainable substances (unstained paths, axis-cylinder processes), chiefly in that the normally unstained portions become more or less distinctly colored. Furthermore, the method shows changes

in the external form of the cells and their processes, changes in the size, form, staining qualities and position of the nucleus, changes in the structure of the nuclear contents, particularly of the nucleolus, as well as in other details. By far the best descriptions dealing with this subject come from Nissl himself; he has not only defined a considerable number of characteristic types of cell changes, but he has also traced as far as possible the various stages through which they pass.⁷

One of these types has been termed by Nissl *chronic cell degeneration*. This may be recognized by the fact that the entire cell becomes smaller, that the unstainable parts become stainable, and that the stainable substance shrinks somewhat. At the same time the nucleus becomes smaller; it assumes a somewhat elongated form; its contents stain somewhat more intensely. In further stages the cell shrinks more and more, the dendrites assume a corkscrew form. The stain of the entire cell becomes denser and more uniform, and finally no structural details may be recognized in the interior (Figs. 9 and 10).

Another equally well-known and recognizable type is termed by Nissl *acute degeneration of nerve cells* (Fig. 3 which compare with normal cell, Fig. 2; Fig. 5, compare with Fig. 4). But this certainly does not represent the only way in which nerve cells can become acutely diseased. In contrast to the chronic type, the cell here undergoes a swelling and rounding of its external form. The stainable portion appears pale, and becomes peculiarly and uni-

⁷See for the following: Nissl, *Über einige Beziehungen zwischen Nervenzellerkrankungen*, etc., *Archiv. f. Psych.* Vol. XXXII, 1899, and *Beiträge zur Frage nach der Beziehung zwischen klinischen Verlauf und anatomischen Befund*, etc., Vol. I, No. 3, Berlin, 1915. (Nissl himself pointed out, later on, how ill chosen his terms "chronic," "acute" etc., were, and proposed the use of a simple letter for each type of cell change.)

formly granular, so that the entire cell appears as if it were finely dusted over. As the result of this, the clear definition of the equivalent picture is lost. The nucleus becomes ballooned, globular, and shows on a clear background indications of a framework which under normal conditions does not stain by Nissl's method. The nucleolus usually retains its size, but in it there often appear one or several clear spaces ("vacuoles") which in extreme cases give the nucleus the likeness to a delicately reticulated sphere. The entire nucleus shows a tendency to move to the periphery of the cell body. The unstainable portions take on a light tone; for which reason dendrites and axones become visible for long distances. Finally there is characteristically a peculiar metachromasia with a violet tinge. The changes in this stage are reparable or else they may lead to *disintegration of the cell*. In this latter condition the pale cellular substance crumbles to pieces and the nucleus breaks up, pale cell shadows often remaining for a long time in the tissues as remnants of the previous cells. This acute cell degeneration regularly follows any interruption of the connection between nerve cell and muscle cell. Nissl first demonstrated this in 1890, describing its occurrence in the nucleus of the facial nerve of the rabbit after tearing out the nerve. According to him, the first alterations in the motor cells of the facial nucleus can be recognized after twenty-four hours; they reach their height after 18 to 30 days, then remain stationary for a while. Only a small part of the cells disintegrate; much the larger part recover, so that after 50 to 60 days the cells of the diseased facial nucleus can hardly be differentiated from those of the normal side. The same acute cell degeneration is very frequently spread over the entire central nervous system after death from acute

severe systemic diseases (toxic and infectious processes, violent excitement, etc.).

More rare, but likewise important, is Nissl's *severe cell degeneration*. According to Nissl, the changes in the nucleus are characteristic for this. It becomes small, globular, and assumes a peculiar uniform metachromatic stain. The nuclear membrane becomes very prominent, and the nucleolus lies eccentrically. In typical cases the nuclear wall becomes thin in one or several places, and pouches out like a diverticulum. In addition there are frequently, but not invariably, characteristic changes in the cytoplasm; the protoplasm becomes transformed into small granular, isolated products of disintegration, each of which appears as a deeply staining ringlet with pale centre.⁸ Cells which present the characteristics of true "severe" degeneration cannot recover; they disintegrate.

As further well-characterized types of cellular degeneration Nissl describes *cell wasting* (Zellschwund; Fig. 12), *granular disintegration of cells*, *cell atrophy*, *foamy degeneration*, two types of *pigmentary degeneration*, and various types of *necrobiosis*. There is a form of necrobiosis frequently found in small circumscribed foci, which is characterized by diminution in size of the cell, almost entire disappearance of the Nissl bodies, metachromasia of the cytoplasm, and swelling of the irregularly shaped, deeply staining nucleus. Sometimes, however, the cell changes are like those usually seen in "chronic degeneration"; particularly characteristic is the occurrence of

⁸Nissl points out that the presence of ringlets, without characteristic nuclear changes, may also occasionally be observed in the uppermost cortical layers, and may then probably be regarded as an artefact. He has not infrequently seen very similar pictures in small children. According to my experience, not only the nerve cells of small children but also those of animals (monkeys, dogs) show a great tendency to disintegration of the cytoplasm of ganglion cells into small ring-like bodies.

very dark staining granules and irregularly shaped bodies on the surface of the cell and its dendrites (Nissl's "incrustation" of the Golgi nets) (Figs. 6 and 11).⁹ Spielmeyer has lately termed this "chronic cellular degeneration."

These various forms of diseased nerve cells described by Nissl are types; they are, according to Nissl's own statement, but rarely met with in man as pure forms. Indeed, the variety of the pictures is very great and difficult to arrange in groups. Combinations of several types may often be found, as for instance when chronically changed, shrunken cells possess one or other feature of the acute cellular degeneration, or when mixed forms between the chronic and severe forms of Nissl are met with.

For deciding whether an altered cell would have been capable of restitution under favorable conditions, the nuclear changes furnish the chief criterion. Changes of the cytoplasm alone, even if at first glance they appear ever so severe, do not as a rule exclude the possibility of recovery. In necrobiotic processes, the nucleus is always severely damaged.

The number of artefacts which may be mistaken for pathological changes is not very great, if Nissl's directions are strictly followed. One frequently finds, as has already been mentioned, that because of shrinkage the external portions of the cytoplasm become deformed and contracted, so that spaces are formed about the cell, which have been wrongly looked upon as pericellular lymph spaces. Another change in the ganglion cells described by Nissl is an artificial swelling, characterized by the nucleus and cytoplasm forming a uniform, lumpy, washed-

⁹ Schröder, *Lues cerebrospinalis*, *Deutsche Zeitschrift f. Nervenheilk.*, LIV, 1915, p. 131.

out mass. It affects the ganglion cells in small groups, and as a rule causes similar changes in the intervening glia cells. Among the more frequent artefacts are to be mentioned also the fragmentation of the dendrites near their base, as well as the extrusion of nucleolus from nucleus and cell body, brought about by the microtome knife in sectioning.

The methods for the staining of fibrils are likewise very useful for pathological purposes. Best suited is Bielschowsky's method; however, "at present, no fibril method furnishes such a constant and clear equivalent picture as is produced by the stainable cell substance with Nissl's technic" (Bielschowsky).¹⁰ Nor has any work with the fibril stain described the condition of the nerve cells as thoroughly and systematically under all the various conditions as has Nissl by the use of his cell method. There are isolated papers by different authors based upon various methods. These investigations have not always remained free from the fundamentally false assumption and hope of connecting definite cell changes with definite functional disturbances, manifestations of disease with disease processes.

The most thoroughly investigated *fibrillar changes* are those *occurring in Nissl's acute cellular degeneration*, especially following axis-cylinder section. According to Bielschowsky the fibrillar framework becomes first hazy and indistinct; later the fibrils in the cell body form stretched-out bundles traceable for a long distance. With unfavorable termination of the cellular disease, signs of severe degeneration appear early in the fibrils. It is interesting to note that dendrites and axones always retain their

¹⁰ Bielschowsky in the *Handbuch der Neurologie*, edited by Lewandowsky, Vol. I, 1910, p. 43 ff.

normal fibrillar structure much longer than does the cell body (Figs. 15 and 16).

As further abnormal types, Bielschowsky mentions a *spongy degeneration of fibrils, fragmentation or granular disintegration, and hyalinization*. The fibril changes occurring in senile dementia, in Alzheimer's disease, and in amaurotic idiocy have been regarded as especially significant.

An exact knowledge of the nerve cell changes, following Nissl especially, is indispensable for the study of pathological preparations of the nervous system. They often give us useful hints as to the nature of the disease, and as to the conditions under which death has taken place. We may infer from them whether the changes which preceded death were chronic or acute, and whether the degeneration would have been reparable or whether permanent cellular disintegration had already set in or was about to do so.

If we limit ourselves to such deductions as these we will recognize and evaluate the changes in the ganglion cells as well as is possible in the present state of our knowledge; they will moreover give us valuable guidance for the critical examination of pathological material; and we will be cherishing no hopes that are doomed to disappointment.

CHAPTER VI.

PATHOLOGICAL CHANGES IN THE NEUROGLIA, THE CONNECTIVE TISSUE, AND THE VESSELS.

THE nerve cells are highly differentiated elements; this fact may account for their inability to proliferate. Multiplication of the mature ganglion cells through division has probably never been definitely observed in man.¹ They do not seem to possess even the ability to grow through intracellular increase of protoplasm.² Accordingly, their reparative ability after previous injury is slight; replacement of disintegrated cells is probably not at all possible. The same thing holds true for the nerve fibres of the central organs; restitutio ad integrum is only observed when injury has been slight; and only in a very meagre way do they possess the ability to proliferate and regenerate. On the other hand, the *neuroglia* is able to proliferate actively and to multiply throughout life. It is always in a state of unstable equilibrium, and it is therefore possible to observe in it not only regressive changes, as in ganglion cells and central nerve fibres, but a variety of progressive alterations as well. It is this tendency to metamorphosis that makes the glia so important in histopathology.

Regressive changes in the glia are found either in the form of acute necrosis, in the immediate neighborhood of

¹ v. Orzechowski (*Arbeiten a. d. Obersteinerschen Institut., Vol. XIII, 1906*) has described nuclear changes in the motor anterior horn cells after amputation of an arm, and is inclined to regard them as attempts at nuclear division of the severely diseased ganglion cells; see here literature on the subject.

² The swelling of the cell body in the acute cellular degeneration of Nissl is probably not due to a cytoplasmic increase but to a fluid intake.

foci of disintegration; or else they may develop slowly and gradually as the result of chronic injuries, as, for instance, through malnutrition in arteriosclerosis. We regularly see such regressive changes in the glial tissue when, after previous proliferation, the process has become stationary. In general it is true that the glia is more resistant to injuries of all types than are nerve cells and nerve fibres. Under various conditions (Alzheimer's incomplete softening in arteriosclerosis, anemic foci, diffuse sclerosis of the brain, etc.) it may be observed that in circumscribed foci or diffusely the specific functional nervous tissue disintegrates, while the glia in the same foci is not vitally damaged, but is rather stimulated to proliferate. If in the centre of such foci the glial tissue is also destroyed, then the glia in the immediate neighborhood will proliferate. When its ability to proliferate is not sufficient for the replacement of the destroyed substance, or when such replacement is hindered for other reasons, the glia forms at least a more or less thick limiting membrane (capsule).

An important principle in histopathology is the tendency of the glia to proliferate wherever constituents of the specific nervous tissue disintegrate, even if other stimuli which produce proliferation are lacking. The classical example for this is the secondary degeneration of white tracts far distant from the primary focus of disintegration. This is a law which Weigert has particularly emphasized, and which, with a few exceptions, is generally applicable.⁵ The condition of the glia is therefore a good index of disintegration of specific nervous substance.

⁵ As such exceptions, Nissl cites the absence of glial scar formation following focal destructions in foetuses and very young children; a further exception may be demonstrated not uncommonly in the regions of certain focal cortical changes following vascular disease, particularly arteriosclerosis and luetic endarteritis.

Not rarely progressive changes in the glia may be easily recognized before it is possible with the methods at our disposal to demonstrate disease of the specific nervous constituents. Proliferation of the glia is often our only available guide to the presence of degenerative processes in the nervous apparatus. In this proliferation, Weigert's fibrils play a minor part, an increase of these appearing only late in the process and not being a constant feature. It is rather the protoplasmic glia that is chiefly concerned; a marked increase of this, along with swelling and multiplication of the nuclei, is the earliest and most regular change that is seen. If now, material showing these progressive alterations be studied with Nissl's stain (which only imperfectly brings out the glia), it is possible to demonstrate disorganization of even a single large nerve cell, or indeed of some of its processes.⁴

The disintegration of nerve cells and nerve fibres is but one of the most frequent causes for the appearance of progressive changes in the glia (secondary glial proliferation). Besides this it doubtless often happens, as has already been mentioned, that one and the same noxious factor destroys or severely damages the specific nervous tissue and at the same time stimulates the glia to primary proliferation. It is obvious that it may often be impossible in an individual case to tell which of these two processes is operative. A primary proliferation of the glia which of itself may secondarily bring about disintegration of nerve cells and nerve fibres is apparently rare; here belong gliomas. Many other disease processes in the brain and cord have been interpreted as resulting from conditions primarily affecting the glia, but definite proof of this is lacking.

⁴ Spielmeier, *Münch. med. Wochenschr.*, 1919, p. 709.

All the constituent elements of the glial tissue take part in its progressive alterations, the nuclei as well as the cytoplasm and the specific Weigert's fibrils.

An extensive literature, dealing with changes in the *glia fibrils* under pathological conditions, has accumulated since Weigert showed how these fibrils could be specifically stained. It has been shown that in the vast majority of morbid processes in the central nervous system Weigert's fibrils are increased, and that, generally, their increase and proliferation of the protoplasmic glia very frequently go hand in hand. Under the influence of Weigert's investigations the protoplasmic portion of the glia has been neglected, and principal attention in pathologic-anatomical research has been more or less exclusively focussed upon the fibrils, particularly upon their numbers. Such an attitude is unjustified. Storch⁵ has called attention to an important point in relation to the multiplication of fibrils, in pointing out the fact that in chronic disease-processes in which the structural plan of the nervous system remains unchanged (*e. g.* in secondary degeneration, multiple sclerosis, etc.) the newly formed glial fibrils, however numerous, show the same arrangement as those normally present in smaller quantities, while in stormy processes, as in rapid destruction, such regularity does not obtain. Storch therefore distinguished between "an isomorphic" and "a reparative" sclerosis.

The new formation of fibrils in acute processes occurs chiefly, but by no means exclusively, in the region of the protoplasmic accumulations about the nuclei of the glial reticulum (glia cell bodies). In such cases the fibres tend

⁵ Storch: *Über die pathologisch-anatomischen Vorgänge am Stützgerüst des Zentralnervensystems.* Virchow's *Archiv. f. pathol. Anat.*, Vol. CLVII, 1899.

to sweep close by the nuclei in arcs with the concavity directed outwards. In this way are formed the often described *astrocyte pictures*. Such "*spider cells*" are most frequent in the neighborhood of fresh foci of disintegration. Especially in those processes which Storch termed reparative, one often finds multitudes of the so-called *monster cells*, with large nucleus and abundant cytoplasm, along the concave borders of which sweep layers or bundles of glial fibrils (Fig. 20). In later stages, the glial cell bodies undergo retrogression, and the relation of the newly formed specific fibres to individual nuclei is then less easily recognizable. In slow proliferation such characteristic relations are from the beginning less marked.

The fibrils, however, are only one of the components of the neuroglia, differing in chemical composition from the cell protoplasm. The study of their changes is important, but alone does not suffice for the evaluation of progressive changes in pathological material. The protoplasm and the nuclei of the glia may have proliferated, without the glia fibres being definitely or at all increased. This applies particularly to very fresh acute processes.⁶ The formation of these chemically differentiated fibrils as a rule occurs only late, and the proliferative processes are at first largely limited to an increase in the protoplasmic substance and to nuclear changes (Figs. 23, and 25 to 29). The normally scanty protoplasm about the nuclei often increases in such cases to considerable size, staining more definitely with Nissl's method, and showing in its interior fine, more deeply staining granules. The external shape of the cells sometimes becomes more distinctly star-like or

⁶ There are also gliomata which nowhere and at no stage of development form typical fibrillar intercellular substance (Storch, *l. c.* p. 213).

spider-like, sometimes more ballooned and rounded. At the same time the delicate protoplasmic glial reticulum, which envelopes all nervous elements and connects the glia cells one with the other, swells up; its filaments and trabeculae become thicker, more prominent, and easily stainable, its meshes closer (Figs. 27 and 28). In addition, the nuclei regularly change their appearance; they become larger, often attain the diameter of the nuclei of large ganglion cells; their membrane becomes more prominent,

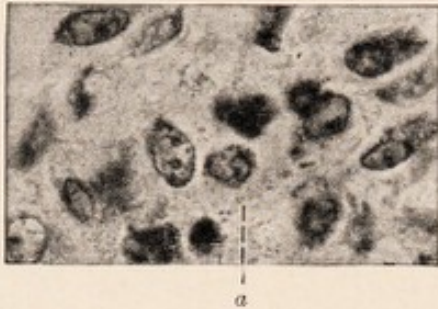


FIG. 28.—Proliferated glia in the neighborhood of a capillary. (From a case of typhus fever.) Closely placed nuclei in a broad irregular cytoplasm which is becoming partly foamy-reticular for instance at (a) (beginning granule cell formation).

their contents clearer, the chromatin clumps together into a few or often into a single body, which, however, differs from the nucleolus of the ganglion cells by its irregular shape (Fig. 23). Besides this growth of the protoplasm and the changes in shape of the nuclei, there is sometimes a multiplication of the nuclei by karyokinesis, and in acute disease

processes one may observe all stages of indirect nuclear division of the glia. But more often in spite of marked and obvious increase in the number of the glial nuclei karyokinetic figures are seldom found, nor are there indications of direct cell division. The mode of such an increase is still obscure.⁷ One must of course be able to exclude the possibility that all this is merely a condensation of glia elements resulting from disintegration of the functional nervous tissue.

⁷ P. Grawitz assumes, for other organs, in such cases a development of new cells from old nuclei which had remained dormant in the tissues, and a reversion of already differentiated cell products (elastic fibres) to chromatin and cells (see *Archiv. f. klin. Chir.*, Vol. CXI., 1919).

The proliferated glia arising in all these ways fills the spaces resulting from the disintegration of the specific nervous elements, these latter having no ability to regenerate. The protoplasmic masses which, in acute processes, at first, abundantly proliferate, gradually regress after they have produced fibrils. In the arrangement of these fibrils static influences play an important rôle. Where, as the result of the morbid processes, new surfaces (cysts) have been formed, there arise, as under normal conditions, limiting membranes, which are frequently strengthened by great quantities of fibrils. The glial scar tissue which definitely replaces disintegrated or destroyed parts usually takes up a space smaller than that corresponding to the original degenerated focus; shrinkage therefore takes place regularly, more pronounced after acute, less marked after chronic processes.

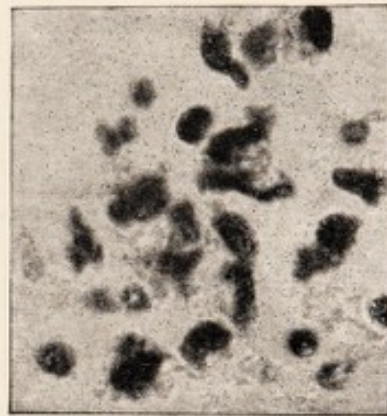


FIG. 29.—Proliferated glia, from a case of acute anterior poliomyelitis. Nissl stain. Irregular deep-staining nuclei with pale reticular cytoplasm.

This does not exhaust the list of the functions of the glia in the course of more wide-spread pathological processes. The glia takes part, under conditions which we will learn later, in the removal of products of disintegration arising in the course of morbid processes. Wherever nervous elements disintegrate, as for instance in a region of secondary degeneration,⁸ the proliferating glia envelops the various broken-down particles and phagocytizes them; the larger masses are often rapidly removed piecemeal;

⁸ When in destructive processes, the vascular tissues are involved (as in hemorrhages, "softening" etc.) the removal of the detritus is chiefly undertaken by other elements.

the glial protoplasm in this manner becomes loaded with granular detritus and takes on a foamy reticular structure (Figs. 28 and 29). Gradually these enclosed granules disappear; and it may be assumed that one portion, so far as its chemical composition permits, is assimilated and resorbed on the spot by the glia. Another portion is carried away in the protoplasmic paths of the glial

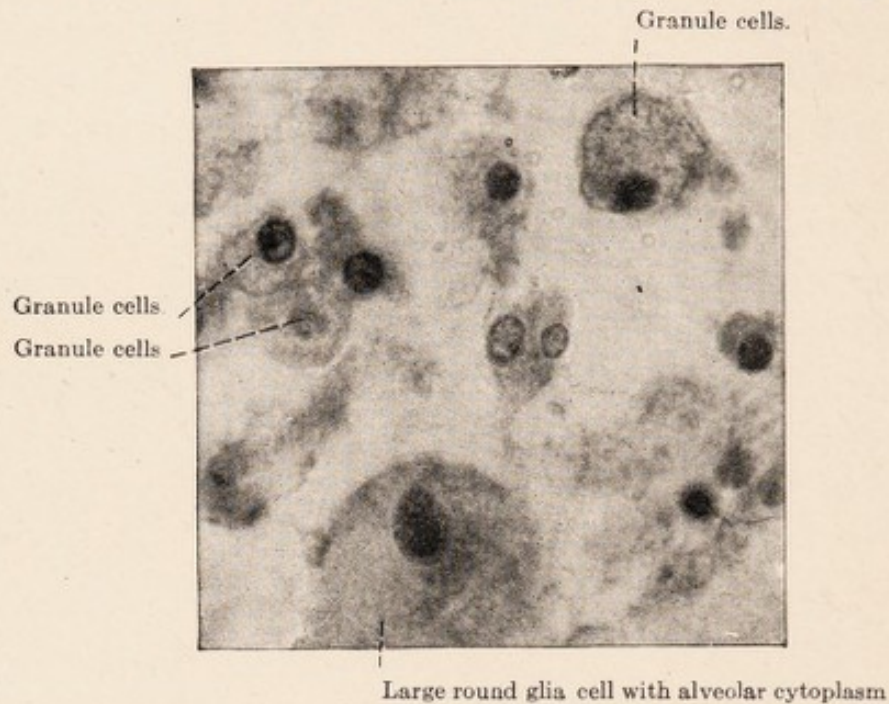


FIG. 30.—Gliogenic granule cells. From a case of diffuse cerebral sclerosis. Nissl stain. Micro-photograph, oil immersion.

reticulum, and in this manner reaches the perivascular limiting membranes and is pushed through these into the perivascular lymph spaces. From the latter it is carried into the general lymph stream of the body. Under certain conditions, however, the assimilating ability of the glia and the transportation of disintegrated products through the glia reticulum does not suffice. Then one sees that the protoplasmic substance around the nuclei becomes gradually loaded with enormous masses of lumps and granules which cause it to swell to a globular form possessing one or

several nuclei. The original connections with neighboring cells are torn in this process, and the protoplasmic masses become free from the general glial reticulum as rounded cellular elements (Figs. 30 and 31). Such cells show a reticular cytoplasm, in the meshes of which there are numerous fine and frequently also a few coarser granules. These *glial granule cells* or *reticular cells* then penetrate the limiting membranes (Fig. 32); or, if tissue continuity is already destroyed, they are carried away by the lymph stream. They are later to be found in the perivascular sheath, in which they partly rapidly disintegrate and give up their contents, or else are transported further.⁹

The course of these processes is not the same under all conditions. In many instances one sees that coarse disintegrated

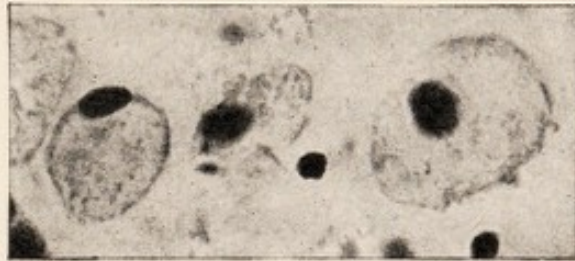

FIG. 31.—Large gliogenic granule cells. Nissl stain. Microphotograph, oil immersion.

products ingested by the glia remain for many months at one place, and only gradually diminish in size and finally disappear. In other cases, the proliferated protoplasmic masses of the glia are filled up after a short time with fine granules, and numerous reticular cells may be found in the tissues and about the vessels. The latter condition seems to occur especially when the glia is stimulated, either through the disease process itself or through associated factors, to marked proliferation, as occurs for instance in the course of the simple secondary degenerations.

It is only in pathological processes associated with marked destruction of nervous tissue that disintegration

⁹ For corresponding conditions in the retina see the work of Krückmann, *Ztschr. für Augenheilk.* Vol. XXXVII, 1917.

is brought about by means of granule cells. In other processes, which are diffuse rather than focal, this does not occur; in the latter group belong for instance many subacute and acute, as well as a part of the chronic psychoses. To the disintegrative products, their chemical nature and their tinctorial peculiarities in histological preparations Alzheimer has devoted extensive study.¹⁰

For the study of the glial protoplasm, diffuse stains, such as van Gieson's, are of service only in the presence of

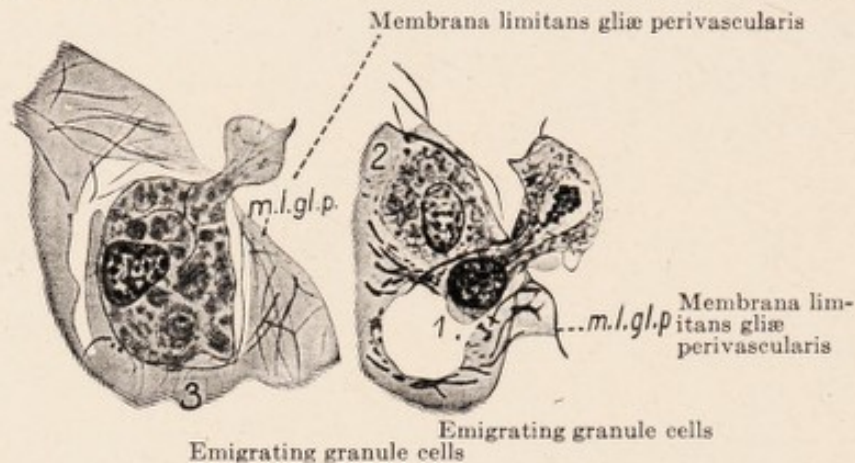


FIG. 32.—Gliogenic granule cells in the process of penetration through the perivascular glial membrane. After Held. Drawing.

marked changes resulting from severe acute processes. In all cases Nissl's method here again gives good results. To be sure, it only gives an incomplete picture of the extent of the glial reticulum; it only permits the recognition of the cytoplasm where it is rather dense, or where it contains granular inclusions which stain deeply; but it has the advantage of absolute constancy and dependability, qualities which must not be underestimated for pathological histology. Of methods which demonstrate the glia more completely, those of Held, Alzheimer, Cajal, *et al.* have already been mentioned.

¹⁰ Alzheimer, *Histol. u. histopathol. Arbeiten, herausg. von Nissl. u. Alzheimer*, Vol. III, 1910.

The *variety of types* of the altered glial elements in the Nissl preparation is very great, as regards their size, shape, and appearance.¹¹ Attempts to classify these diverse pictures and to evaluate their significance in pathological processes originate largely with Nissl (Figs. 23 to 29).

Nissl¹² recognized a division into two great groups of

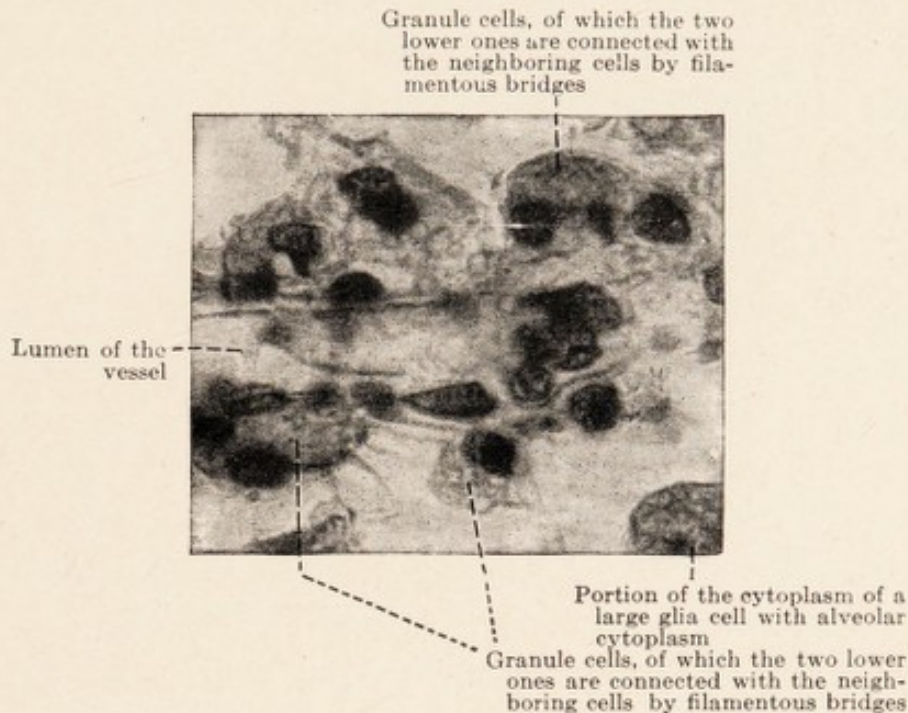


FIG. 33.—Granule cells about a vessel, from a monkey (*Macacus*) with focal lesions in the brain. Hematoxylin—Van Gieson.

changes, *the progressive* and *the regressive*. The chief characteristics of the first are enlargement of the nuclei, pale staining of their contents, and appearance of a few dark-staining bodies resembling nucleoli; in addition,

¹¹ A good illustration of these manifold varieties is afforded in Table IX of Alzheimer's work on general paralysis of the insane in *Histol. u. histopathol. Arbeiten von Nissl.*, Vol. I, 1904; also in Tables XXVIII-XXXIV, *ibid.*, Vol. III, 1910.

¹² Cf. Nissl, "Über einige Beziehungen usw.," *Archiv. f. Psych.*, Vol. XXXII, Heft 2, and *Histol. u. histopathol. Arb.*, Vol. I, S. 455 ff.

swelling and pale staining of the cell body. In regressive alterations, on the other hand, the nuclei become smaller, stain more deeply, assume irregular outline, and the cell bodies shrink. Complicated pictures arise when previously proliferated cells undergo subsequent regression.

The cell bodies in the Nissl picture may in places be sharply defined and rounded off, or be supplied with processes. Very frequently they become gradually paler

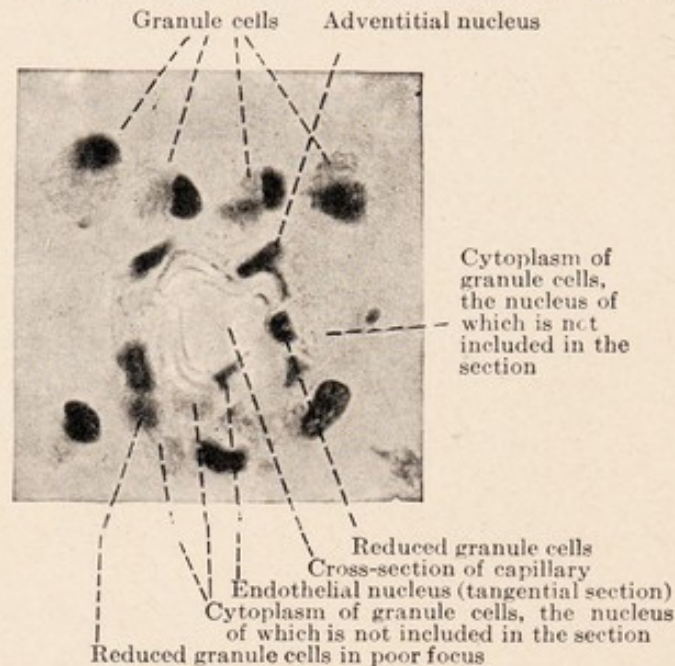


FIG. 34.—Granule cells about a capillary. Nissl stain.

toward the periphery and gradually fade out in the surrounding tissue. The sharp concave borders of the bodies are sometimes formed by bright refractile lines; these are the fibrils, which cannot be stained with basic aniline dyes, but which may be brought out by other suitable methods. The increase in cytoplasm may be slight compared with the normal, but often is quite considerable. Not infrequently several or many nuclei lie in great irregular masses of protoplasm (Nissl's glial syncytium) (Fig.

23 g). A frequent type is represented by elements with small or medium-sized, very clear nucleus, having a distinct membrane and a single eccentrically placed nucleolus-like body; the small foamy cell body may lie entirely to one side of the nucleus (Fig. 23 a and g).

Among the very large types, Nissl describes particularly one which he designates as "fattened" (*gemästet*). This has a large dull-staining cell body, of round or sausage-shape, with cell outline fairly well defined. The nuclei are pleomorphic, and always lie quite eccentrically in the cell body (Fig. 23 c and d). These elements are identical with the large monster cells of the Weigert pictures, which form great masses of fibrils at their borders. They have a marked tendency to undergo regressive change, and later usually appear as round plaque-like bodies, the nuclei of which are much altered or have disappeared entirely.

In the regressively altered neuroglia of the uppermost cortical layer and of the peripheral portions of the spinal cord, the spider-like branching protoplasm tends to take the same deep stain as the dark shrunken nuclei; whence arise characteristic spider-like bodies which are small, deeply stained, and ragged (Fig. 22 a).

To another group belong elements showing remarkably elongated, regular or more angulated nuclei, and long, filamentous, frequently branched cell bodies (Fig. 23 e). There has been much discussion about the significance of such "rod cells," which are regularly found, for instance, in progressive paralysis. Nissl, who first described them, at first regarded them as glial, later as mesodermal elements belonging to the vessels. There is good reason to

believe that they may be of ectodermal as well as of mesodermal origin.¹³

Forms with a very irregular, lobed or split nucleus and scanty cytoplasm are met with in acute anterior poliomyelitis and other acute processes. In sections stained with hematoxylin and similar dyes it is often not easy to distinguish between these and leucocytes (Figs. 26 and 29).

The delicate reticular formation within the syncytial protoplasm of this glia, as well as within the free round granule cells of glial origin, is also well demonstrated by Nissl's method; one recognizes in them the delicate little filaments of the protoplasmic network including round spaces which are or have previously been filled with fatty waste products. The nuclei of these elements are small, and always bear stigmata of regressive alterations, such as irregular contour, indentations and shrivelling (Figs. 30 to 34).

The extraordinarily diverse forms of glia cells have various significance, and often enable us to draw inferences as to the general character of the morbid process, whether it is an acute or a chronic one, whether it is progressive or has been arrested. Large forms, like the mast cells of Nissl and the giant spider cells are always indications of an active, acute morbid process. Smaller cells, not showing such evident progressive alterations, indicate chronic irritation or gradual disintegration of the nervous tissue. Many small, deeply staining nuclei suggest an older pathological process, in the course of which glial fibril formation takes place. Regressive alterations in proliferated glial elements allow the conclusion that an

¹³ U. Gerletti, "Zur Stäbchenzellenfrage," *Folia neurobiologica*, Vol. III, 1910 and *Histol. u. histopathol. Arbeiten von Nissl u. Alzheimer*, Vol. III, 1910, S. 329; Spielmeyer, *Zeitschrift f. d. ges. Neur. u. Psych.*, Vol. XLVII, 1919, S. 39.

acute process has existed for some time. Reticular cell formation always points to severe acute injuries. The various inclusions (products of disintegration) have special significance.

The importance of this subject in the present state of our knowledge is apparent. Observation of the ganglion cells themselves often gives us little information as to pathological conditions in the nervous tissue. The latter are often better indicated by the changes in the glial structure. These, too, better permit us to draw conclusions about the functional structures of the central organs, and are often more significant than the changes to be observed in the nerve cells and nerve fibres themselves.

An important rôle in the histopathology of the central nervous organs is taken by the *connective tissue and the blood vessels*. That compact connective tissue layer completely enveloping the brain and cord, the pia mater, is the starting point of many disease processes which spread to the neighboring nervous tissue; or both tissues may simultaneously become diseased (acute and chronic forms of meningitis, tuberculosis, cerebro-spinal lues).

The adventitia, with its lymphatics, is the seat of marked changes following necrosis and atrophies of the nervous tissue. In it, various cells (leucocytes, lymphocytes, plasma cells, granule cells, etc.) (*cf.* Figs. 48 and 50) which appear in the course of such processes, accumulate in large quantities and are then transported further. Often the elements of the adventitia actively participate in these events; increase of its fibres and nuclei is therefore of frequent occurrence.¹⁴

¹⁴ Besides diffusely staining methods (hematoxylin-van Gieson's, eosin etc.) and "special" methods (Held, etc.), the silver method of Achucarro is particularly suited for the demonstration of the general group of connective tissues.

In all the more extensive destructive processes of the nervous tissue the capillaries, including their adventitia, begin the work of removing detritus and of forming the first scar tissue. Large numbers of mesodermal granule cells and of young connective tissue cells arise by active proliferation (see 8th chapter). The increase in capillaries met with in many processes takes place partly through budding from already functioning capillaries, and partly through tubulation of the mesenchymal vascular bridges everywhere present between neighboring capillaries.

Independent changes may occur in the vessel walls, and these frequently produce important lesions in the nervous system. Changes in the capillaries, the small arteries and veins, and particularly in the endothelial cells, which are well shown in the Nissl picture, and changes in the delicate elastica are frequent findings in various acute and chronic morbid processes in the brain and cord; systematic data concerning these are not yet at hand; individual observations are numerous. Well-known coarser changes in the vascular tubes are usually grouped together as arteriosclerosis and as endarteritis.

ARTERIOSCLEROSIS.—Atheromatosis of the vessels is very probably a collective term for various processes. In the cerebral vessels the best-known histological changes are those in the membrana elastica and in the endothelium.¹⁵ In the larger vessels the elastica loses its usual uniform wavy appearance, becomes stretched, irregular, split, and new lamellæ become superimposed upon the old (Figs. 36, 38 and 39). In the later stages necrotic changes,

¹⁵ Cf. Schröder, D., *Zeitschr. f. Nervenheilk.*, Vol. LIV, 1915, S. 136 ff.; Cerletti, *Rivista spirit. di frenetria*, Vol. XXXVII, 1911; *Histol. u. histopathol. Arbeiten von Nissl u. Alzheimer*, Vol. IV, 1910.

hyaline degeneration, hemorrhages, with masses of granule cells and with new connective tissue formation, take place here. Proliferating muscle tissue from the media may also be met with. Calcareous infiltration is not frequent in cerebral vessels.

The endothelial cells show exclusively regressive alterations; even with very marked splitting and increase of the elastic membrane, the number of nuclei remains scanty in most cases. There are, however, particular disease conditions of the vessel walls, usually grouped with arteriosclerosis (and predominately found in more youthful individuals and having a hereditary basis) in which from the beginning the number of cells is considerable and remains so.

In the muscularis, regressive changes predominate in arteriosclerosis. In the capillaries, sclerotic changes are recognized by the irregular shape of the normally regular vessels, by altered optical and tinctorial properties of the walls, by thickening of the normally very delicate elastica, and finally by regressive changes of the endothelial nuclei and cell bodies.

In *endarteritis obliterans* (Heubner) of the larger vessels, proliferation of the endothelial cells is the predominant feature, in contrast to arteriosclerosis. Such pro-

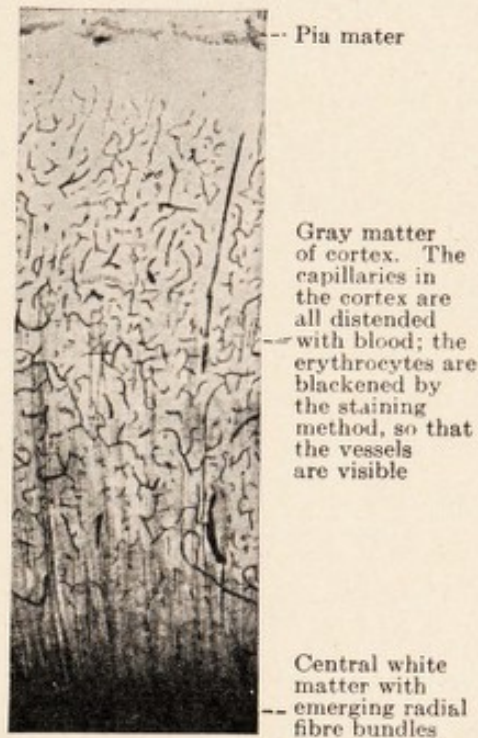


FIG. 35.—The capillary network of the brain cortex in a section 20 micra thick. Weigert's myelin sheath stain. Low magnification.

liferation is easily recognized, because in the brain and cord the intima is always lined by a single layer of endothelial cells, even in the largest arteries such as the basilar and the internal carotid. Any increase is just as certainly pathological as an increase in the membrana elastica, which likewise normally consists of but one layer. In well-developed instances of endarteritis obliterans one sees the vascular lumen encircled by a uniformly thick, richly cellular layer, beneath which is the original membrana elastica bordering on the media (Fig. 42). Not infrequently, cellular bridges occur between the opposing

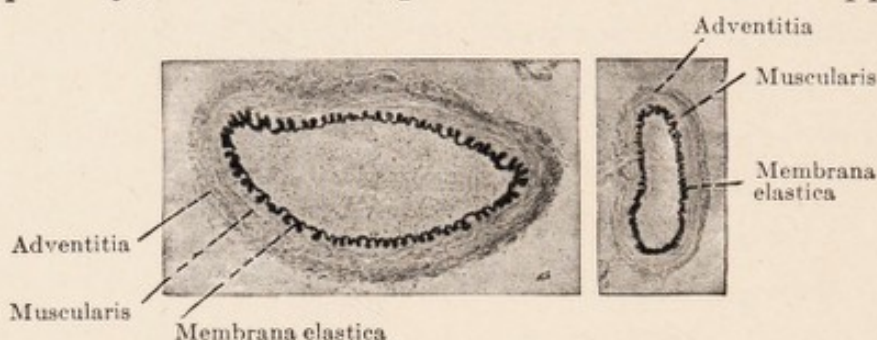


FIG. 36.—Cross-section through two basal arteries of a 3-month old child. Elastica stain. (Weigert's resorcin-fuchsin). Low magnification.

walls. The elastica, outside this cellular zone, is split into several rather irregularly arranged layers (Alzheimer) (Figs. 40 and 41); or one finds, scattered over the entire layer, the delicate elastic fibres, which are usually cut longitudinally in cross section of the vessel, and which are bordered externally by the old membrana elastica; the latter remains unsplit or nearly so. The inner border of this layer is formed by a new elastic membrane toward the vascular lumen (Fig. 41).

The arteriosclerotic changes differ from those of endarteritis in the greater irregularity of the picture, in the many regressive phenomena of the proliferated intima, and in the scarcity of nuclei.

Nissl contrasted with Heubner's endarteritis of the large and medium-sized vessels an analogous disease of *capillaries*. Again the most important change is here the proliferation of the endothelial cells (Fig. 43). However, the adventitial cells also take part in this, so that it is frequently impossible to differentiate between endothelial and adventitial elements. The vascular tube is lined with closely placed, large, richly chromatic nuclei, their cell bodies being quite prominent. The lumen is often difficult to recognize, and frequently it has the appearance of a series of lumina lying side by side.¹⁶

Heubner's, as well as Nissl's, type of vascular disease occurs most frequently in lues, but not exclusively so. There is beside this a true gummatous disease of the vessel walls (Baumgarten's syphilitic cerebral arteritis).¹⁷

The diffuse endarteritis of the small vessels of the brain is closely simulated by the vascular proliferations which regularly occur in reparatory processes in the immediate neighborhood of degenerative foci (areas of softening, hemorrhage, etc.). Not infrequently regressive changes may at the same time be recognized in the markedly proliferated vessel elements.

The infiltration of the adventitia or the surrounding pial tissues with lymphocytes and plasma cells is, in the literature, often termed periarteritis.

¹⁶ Nissl, *Beiträge zur Frage nach den Beziehungen usw.*, Vol. I, S. 39, Berlin, 1913; Sioli, *Archiv. für Psychiatrie*, Vol. LXVI, 1922, p. 318.

¹⁷ Schröder, *l. c.*, P. 145.

CHAPTER VII.

HISTOPATHOLOGY OF THE NERVE FIBRES.

FOR decades pathological anatomy of the nervous system meant little more than the study of the nerve fibres. However, this sort of investigation was not histological in our sense of the word; the absence of medullated fibres was used merely as a guide to the localization of morbid processes and of secondary degenerations resulting from them. Weigert's medullary sheath stain was employed for this purpose as a chemical staining reaction, to determine the presence or absence of medullary sheaths in certain places in the central or peripheral nervous system. The interest of those times lay not so much in histopathological questions as in localization and in the pathological physiology of certain parts of the nervous system based upon this.

Under pathological conditions peripheral myelinated nerve fibres behave, in many respects, differently from the central ones. These differences in behavior are closely connected with differences in the histological structure, which we have already described. The sheaths of the peripheral fibres consist of a continuous regular band of cells of Schwann, the outer border of which is known as the sheath of Schwann (neurilemma), whereas their inner parts are filled with myelin, constituting what we know as the medullary sheath. In the central organs the nerve fibres do not have such a definite architecture; in particular, they do not have a continuous neurilemma. We shall see that on the possession of this sheath depends the ability of the nerve fibres to undergo progressive changes,

to proliferate, and, after destruction, to regenerate. Axis cylinder and medullary sheath always react to irritation by undergoing regressive changes; on the contrary the same injurious agencies which severely damage these structures or even bring about their disintegration actually stimulate the neurilemma nuclei and their protoplasm to proliferation. With this proliferation there is directly connected, circumstances permitting, the beginning of the new formation of fibres. Regenerative processes of the fibres are absent in diseases of the central white matter. The glia in the brain and cord it is true, acts to a certain extent as a substitute for the neurilemma of the peripheral nerves, but this substitution is obviously an incomplete one. The end result of the processes initiated by the glia after destruction of central nervous tissue is the formation of a scar, but never the regeneration of conducting nerve fibres.

Of regressive changes in the *medullary sheath* the best known and most common is a disintegration into large rounded or elongated lumps. This breaking up is associated with chemical alterations. In contrast to normal myelin these coarse lumps are stained black, in the course of but a few days, with osmic acid (upon this depends Marchi's method for the demonstration of recent secondary degeneration). They do not, however, give the fat reaction with sudan and scarlet R; their further fate is, as we have already seen, not always the same. This change is from the beginning irreparable; it always leads to the disintegration of the medullary sheath.

Besides this, there are other, often less severe pathological conditions about which we possess as yet but little definite knowledge. In slight injuries small round globules

become extruded from the myelin, and these, after osmic acid treatment, take on a brown to black color (so-called Elzholz' bodies). These same bodies are normally present in small quantities.

In the *axis cylinder* morbid changes are histologically recognizable through swelling or shrinkage, crumbling apart, granular degeneration of the fibrils, decrease or increase in the stainability of the substance of the axone.

When the axis cylinder is severely damaged the medullary sheath regularly disintegrates conjointly with it. On the other hand there are disease conditions of the medullary sheath in which the axis cylinder remains intact, or shows only slight alterations. Severe changes involving the entire thickness of the nerve fibre at any point always result in disintegration of the entire distal portion of axis cylinder and medullary sheath; slight changes, which do not interrupt the continuity of the conducting fibres, may remain limited locally (so-called discontinuous disintegration).

From what has been said, it is already evident that various morbid changes may take place in the nerve fibres. There are still many gaps in our knowledge as to details, but a mass of observations is even now at hand.

Description of the accepted facts will be brought out best in a discussion of the histological processes found in *secondary degeneration* of the nerve fibres.¹ This has been most thoroughly studied, because it may be produced at any time experimentally with ease and absolute certainty; and it also plays an important rôle in pathology because of its frequency. We designate as *secondary degeneration* those anatomical changes in peripheral nerves and white

¹ Called "secondary" in contradistinction to the "primary" changes at the focus of disease or injury.

matter of the brain and spinal cord which regularly take place when the continuity of axis cylinders is interrupted at some point. Upon the investigations of Waller is based the well-known general law that divided nerve fibres undergo complete degeneration in their entire distal (centrifugal) segment, while the proximal stump still connected with the central organs remains intact.² No exceptions are yet known to the first part of Waller's law; but there is a series of observations indicating that changes may be recognized also in the proximal segment. That in peripheral nerves the disintegration progresses centripetally to the nearest node of Ranvier is generally admitted; but frequently disintegration of further segments has been reported. After subsequent septic infection of the operative wound degeneration of the entire central segment has been observed. When motor nerves or roots are not cleanly sectioned but are forcibly torn, such a retrograde degeneration of the intraspinal or intramedullary segments regularly takes place (Bregmann, Raimann and particularly Lugaro and von Gehuchten);³ the same usually occurs if complicating systemic diseases are present (Raimann). A part of these changes in the central stump is probably to be explained as due to damage to the centres of origin of the injured nerves. A slight slow atrophy in the proximal portion of the resected nerve (thinning of part of the medullary sheath, increase of Elzholz' bodies) probably always occurs. It is further known that in the absence of other injuries certain motor

² The question as to whether all axis cylinders arise each from a ganglion cell may here be disregarded.

³ Lugaro in: *Handbuch der pathol. Anatomie des Nervensystems von Flatau, Jacobsohn, Minor*, 1904, S. 180; Von Gehuchten, *Le Névrite*, Tome V, 1903. See first: Spatz, *Zeitschrift für die ges. Neurol u. Psych.*, Vol. LVIII, 1920, p. 327.

fibres of the vagus, after section, regularly undergo centripetal disintegration, and von Gehuchten has shown that probably certain fibre bundles of the spinal cord and the medulla oblongata always degenerate in both directions, even after carefully performed interruption of continuity. In these, however, the disintegration of the central portion takes place somewhat more slowly than that of the peripheral. Among these bundles do not belong any of the usually investigated long fibre tracts.

The histological processes regularly occurring in the course of secondary degeneration are independent of the nature of the injury which leads to interruption of the axis cylinder, unless it be that the injury at the same time change the degenerating fibres, and that in such manner, the process of secondary degeneration become complicated with a morbid process of different kind. The changes in simple secondary degeneration are essentially composed of two series: *viz.*, processes of *regressive*, necrobiotic nature in the axis cylinder and medullary sheath, and *progressive* changes of the neurilemma or of the surrounding glia.

In peripheral nerves⁴ the beginning of disintegration may be histologically demonstrated after as short a time as 24 hours in the medullary sheath of the distal segment. There appear, as may be seen with simple staining methods,⁵ irregular fissures. The myelin tube disintegrates into rounded, ovoid, or elliptical clumps, most of which include a piece of the axis cylinder; then a further

⁴ Cf. the papers by von Büngner, Schütte, Mönckeberg-Bethe, and especially: Stroebe (*Ziegler's Beiträge*, Vol. XIII, *Zentralbl. f. Allg. Pathol.*, 1895); also Doinikow, *Histol. u. histopathol. Arbeiten von Nissl u. Alzheimer*, Vol. IV, 1911.

⁵ More complicated technic permits the recognition of many other details (see: Doinikow, *l. c.*).

disintegration of the clump into ever smaller globules and droplets takes place. The fibrils of the axis cylinder are transformed into fine granules, which soon disappear entirely from the picture given by the ordinary technical methods.

But along with this purely degenerative process *progressive changes* set in relatively early. The nuclei of the neurilemma begin to proliferate on the second day. According to Stroebe, the height of their multiplication through mitosis is reached about the eighth day. Conjointly with the proliferation of the nuclei there is a growth of the protoplasm; it pushes into all the gaps and clefts between the myelin clumps, surrounds them, at first as irregular, then as roundish or oval, well-defined, uni- or multi-nuclear cellular structures, in the interior of which the clumps of myelin become rapidly reduced to fine granules (von Büngner, Stroebe). In this manner there arise multitudes of granule cells, with round cell body and a delicate reticular protoplasm, in the meshes of which the granules are enclosed. Such elements are to be found from about the fourth week onwards in the lymph spaces of the neighboring vessels.⁶ Stroebe and Schütte mention that the genesis of these granule cells has formerly been often misunderstood. They have been looked upon as leucocytes or so-called wandering cells, and have been assumed to originate from the ruptured vessels at the primary focus of destruction of the nerve. It was thought that they move along the nerve sheaths and everywhere phagocytize the disintegrated

⁶ These processes in the region of *secondary* degenerations must be differentiated from the conditions which occur at the point of injury, that is in the region of *so-called primary* degeneration. Here the blood vessels and the connective tissue play an active part; the majority of the granule cells here are therefore derivatives of these structures.

myelin along the nerve fibres. Other authors have entirely overlooked the fact that the rounded masses of disintegrated myelin are enclosed in cellular bodies and that they represent granular cells and not merely granular aggregates.

The complete understanding of the formation of these granule cells from neurilemma elements was first attained in the studies of Reich, Nemiloff, *et. al*, upon the normal histology of the nerve sheath. According to these writers we must suppose that the entire process is in a sense nothing more than a disintegration of each interannular segment into a number of cellular bodies. These bodies each contain in their interior a portion of the medullated tube, which, normally present in every uninjured segment, is here disintegrated into fragments and granules. Their nuclei are all derivatives of the one proliferated neurilemma nucleus.

Of the cellular elements arising by growth and proliferation from the neurilemma, only a part is used as granule cells for the purpose of removal of the detritus. Another part is transformed into long spindle-shaped cells, which arrange themselves end to end into bands; they serve in the process of regeneration. We have already learned that there are two opposing views as to the way in which this regeneration takes place; according to one, the end of the central stump of the sectioned axis cylinder grows out and into the chain of young spindle-like cells; according to the other, these adjacent cells themselves produce new axis-cylinder fibrils, while the rest of their protoplasmic body with the nuclei becomes the elements of the new neurilemma, in the meshes of which myelin is then deposited.

The histology of secondary degeneration of *central*

nerve fibres has been most frequently studied in the compact long tracts of the spinal cord, the posterior tracts and the lateral pyramidal tracts. The literature contains numerous reports of systematic investigations in animals as well as on human pathological material (Schieferdecker, Homén, Tooth, and others, especially Stroebe⁷ and Jakob.⁸) The investigators agree that the end result is always the complete disintegration of the entire distal part of the interrupted fibres, that the glial framework in the degenerated field increases, and that a regeneration of central nerve fibres, disregarding abortive attempts, does not occur in higher animals or in man. Concerning the course of the histological processes in detail, and particularly whether and in what quantities granule cells take part in the removal of the detritus, the origin of these granule cells, the behavior of the glia, the rôle which the mesodermal connective tissue and the vessels play, on all these questions the various views differ considerably.⁹

The first disintegrative phenomena in the axis-cylinder and medullary sheath (swelling, fragmentation, chemical transformation) are the same in central and peripheral nerve fibres. The earliest degeneration products may be demonstrated about the second day; the height of the disintegration is reached from about the eleventh to the fifteenth day, if one takes Marchi's method as a guide. However, according to Stroebe and others, the further breaking up and transportation of the coarser fragments or lumps from the tissues takes place much more slowly

⁷ Stroebe, *Ziegler's Beiträge*, Vol. XV, 1894.

⁸ Jakob, *Histol. u. histopathol. Arb. von. Nissl u. Alzheimer*, Vol. V, 1912.

⁹ In the central organs it is also necessary sharply to separate the "primary degenerations," produced through experimental injury or through disease, from the "secondary degenerations."

in the central than in the peripheral nerves. Abundant quantities of myelin droplets remain in place for months, and may here be demonstrated by Marchi's method. According to Stroebe, the granule cells take a very small part in the transportation of the fragments, and the progressive changes in the glia as well as in the mesodermal connective tissue are only slight. Other authors, however, report great proliferation of the framework and abundant granule cell formation.

These contradictions are explained if one takes into consideration the different materials used.

Stroebe's statements apply to secondary degenerations which have been produced by careful and aseptic transection of the spinal cord in animals. In such material one can observe¹⁰ that the medullary sheath and axis-cylinder rapidly disintegrate into rounded fragments, which blacken relatively quickly with osmic acid, but which do not stain red with sudan. From about the sixth day onward the glial nuclei become clearer and larger in the degenerated region; the cell processes become more prominent; there is a swelling of the protoplasm about the nuclei and in the processes, and here and there a delicate reticular structure may be recognized in it. The fragments and clumps, which at the beginning lie in irregular rows, become enveloped on all sides by the proliferating glial protoplasm. Then they very gradually crumble into fine granules, beginning at the periphery. As soon as these granules can be recognized as such, they are seen to lie in the glial protoplasm which has forced its way among them. During this time multiplication of the nuclei through division is fairly marked. Where such absorp-

¹⁰ Knick, *Inaug.-Diss.*, Breslau, 1908, and *Journ. f. Psychol. u. Neurol.*, Vol. XII, 1908. The subject is still more thoroughly discussed by Jakob (*l. c.*).

tion takes place the reticular structure of the glial protoplasm becomes increasingly prominent and distinct. Particularly, close about the nuclei there is a considerable swelling of the cell bodies, and some commence to assume round forms; but everywhere their connection with the rest of the glial reticulum is definitely visible. Only rarely under these conditions do these bodies with nucleus and reticular protoplasm become entirely globular, their connections with the surrounding glia become severed, and in this manner free granule cells (reticular cells) arise.

All these processes take place very slowly, requiring weeks and months. The larger fragments gradually become fewer, the reticular elements, connected nearly everywhere with one another and with the rest of the reticulum, become more prominent. Even after the lapse of a year, coarse clumps as well as fine droplets may be found. In the lymph spaces about the vessels, independent granule cells are just as rare during this time as in the tissue; but fine free fat droplets may be demonstrated within them in abundant quantities with osmic acid as well as with sudan. Hand in hand with these processes which serve for the removal of products of disintegration, there is a slow, and never very marked increase in the fibrillar glial framework.

The distinguishing features of such secondary degeneration in *central* nerve fibres are: slow absorption of the originally coarse detritus by the proliferating glial reticulum, formation of "reticular structures" in the glial protoplasm, occasional liberation of such glial elements with reticular body which then appear as rounded granule cells; finally complete disappearance of the disintegrated

remnants and slight increase of the glial framework. Connective tissue and vessels do not take part.

This histological picture however is altered if, in order to produce secondary degeneration, instead of making a clean section of the cord, pressure necrosis is produced, as for instance, through introduction of a glass pearl into the vertebral canal. In such cases we find in the region of the secondarily degenerating white tracts the same changes as after transection, but the disintegration of the fragments into fine fat droplets takes place more rapidly, the reaction of the glia is more energetic, the formation of reticular cells in the protoplasm more abundant; above all, free granule cells are met with in larger numbers. The same stormy phenomena may be found if after simple section an infection from the operative wound takes place.

These observations enable us to understand the varying and partly contradictory findings in secondary degenerations in the spinal cord of man. The human material on which investigations are based comes largely from cases of spinal cord tumors, of caries of the vertebræ, of fractures of the vertebræ, and similar conditions. In all these cases, pressure upon the spinal cord has continued for some time, and infectious febrile diseases have usually been superadded (cystitis, bed sores, etc.). Under such conditions one always finds in the region of the degenerations considerably more glial proliferation than after clean transection in animals, and a much more rapid disintegration of the myelin fragments into aggregates of fatty granules; large, often very large, numbers of free granule cells (reticular cells) are always to be found in the tissues as well as in the lymphatics about the vessels. Where the complicating factors (pressure, infection) are

absent, as for instance in isolated descending secondary degeneration of the pyramidal tracts resulting from focal destruction of the cerebrum (Homén), the histologic picture in man corresponds to that obtained after simple transection in animals. In both cases identical histological processes are concerned; the difference lies especially in the rapidity and extent of the reaction on the part of the glia, that is, it is purely one of degree.

Secondary degeneration is not the only way in which nerve fibres may become altered. Stransky¹¹ has recently recalled attention to a histologically well-defined morbid process of *peripheral* nerves, which was previously described by Gombault in 1880. This process, in contrast to secondary degeneration, leads merely to a local (discontinuous) and partial disappearance of the medullary sheath, to merely a slight injury of the axis cylinder, and only under certain conditions to definite disintegration of the involved fibres. It has been most frequently observed in peripheral neuritides of toxic origin (lead, alcohol, diphtheria, etc.). Gombault and Stransky have experimentally produced these conditions in animals by sub-acute and chronic lead poisoning.

According to Stransky the first anatomical changes consist in the appearance within a part of an interannular segment, or in one entire or several adjacent segments, of numerous small round bodies (Elzholz bodies), which lie within the medullary substance and stain deeply with Marchi's method. In normal fibres these bodies appear only in scanty numbers. At the same time the neurilemma protoplasm begins to swell, and the neurilemma

¹¹ E. Stransky, "Über diskontinuierliche Zerfallsprozesse an den peripheren Nervenfasern," *Journ. f. Psychol. u. Neurol.*, Vol. I, 1903.

nuclei to multiply. Then the myelin tube disintegrates, always beginning at the periphery, in scattered places, forming groups and aggregates of smaller and larger bodies, which stain brown to black with osmic acid. They are usually embedded in large numbers in the spindle-shaped cytoplasm of one of the proliferated neurilemma nuclei. The remaining medullary sheath appears, because of this, smaller and irregularly eroded. In the further progress of the process the fibres in the affected region appear sprinkled with smaller or larger products of disintegration; the protoplasm is greatly proliferated; the nuclei much increased (eight to ten and more to one internodal segment of Ranvier). Later, spindle-shaped groups of disintegration products separate themselves more and more distinctly. They usually lie in the cytoplasm about a nucleus, and are enveloped by a protoplasmic mantle. Finally, they become independent elements, the contents of which are transported, at least in part, by the lymph stream.

At first the axis cylinder remains intact or shows at the most a broadening out and but slight tinctorial alterations. Later on it may entirely lose its stainability in the diseased portion of the fibre, but at either end of this region appears again as a normal structure. If the process continue it may finally lead to definite destruction of the axis cylinder. Then, and only then, the well-known changes of secondary degeneration appear in the entire distal portion of the fibre. If the original injurious agent is removed early enough restitution of the medullary sheath soon begins.

That which distinguishes this pathological process from secondary degeneration is its limitation to one or

several fibre segments, its late extension to the axis cylinder, and finally the disintegration of the medullary sheath into fine granules and globules, always beginning at the outer margin, and not *in toto* or into coarse fragments or clumps. Formation of granule cells from proliferated neurilemma elements takes place in both. The mesodermal connective tissue does not participate in either process.

Probably belonging to the same group of morbid changes is a series of slight alterations in the medullary sheath of peripheral nerves, which may occur in all sorts of systemic diseases. Among such diseases belong, besides toxic and infectious processes, disturbances of metabolism, arteriosclerosis, progressive paralysis, particularly when these lead to marasmus and cachexia. In such cases one finds in the nerve fibres an increase of the Elzholz bodies, and now and again the earliest characteristic appearance of discontinuous disintegration of the medullary sheath.¹² Related to this are perhaps also the slight alterations appearing in the proximal stumps of injured nerves; *viz.*, moderate increase of Elzholz bodies, later a permanent thinning of the myelin mantle of the fibres.¹³ The majority of investigators, however, look upon this as a special "atrophic" process.

In the *central* fibre tracts and in the white matter in general there are likewise changes which differ from those of secondary degeneration. Whether they are morbid processes which must be looked upon as true

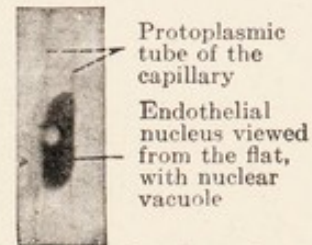


FIG. 37.—Capillary, longitudinal section. Nissl stain. Oil immersion.

¹² Stransky, *Arbeiten a. d. Neurol. Institut. von Obersteiner*, 1907.

¹³ Elzholz, Pilez, Raimann, Stransky, Homén, u. a.

analogues of Stransky's medullary sheath disintegration in peripheral nerves is still an open question. We find them chiefly in those not infrequent cases of toxic multiple neuritis in which the central organs are affected.¹⁴ At present there are no available histological observations

FIG. 38.

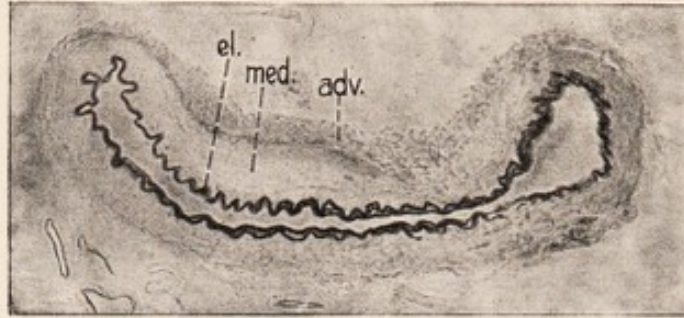


FIG. 39.

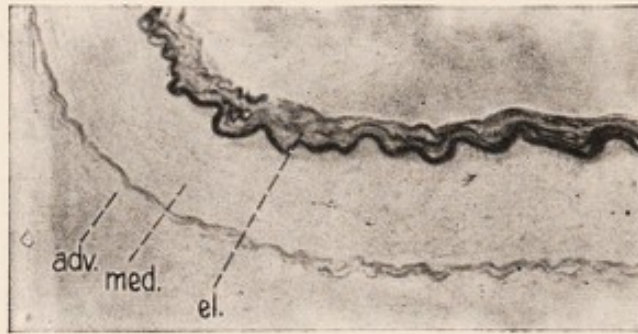


FIG. 38 and 39.—A small portion of a large brain artery of a 72-year-old man, suffering from cerebral arteriosclerosis. Legends as in Fig. 36.

on this matter. However, it has already been noted by several authors that the cord changes in multiple neuritis are not always strictly limited to definite fibre tracts as one necessarily expects in secondary degenerations, and that the process is often local ("discontinuous").

There is not infrequently a better-known histological change met in the spinal cord in *severe anemias*.¹⁵ It is

¹⁴ Heilbronner, *Monatsschr. f. Psych. u. Neurol.*, 1898.

¹⁵ Nonne, *Deutsche Zeitschr. f. Nervenheilk.*, Vol. XIV; Boedeker und Juliusburger, *Archiv. f. Psychiatrie*, Vol. XXX; Schröder, "Die funikuläre Sklerose," *Deutsche Med. Wochenschrift*, 1923.

characterized by the acute or subacute development of small confluent foci, which usually first appear, like many other pathological processes, in the posterior columns, but which, when more widely disseminated, may be found in other cord tracts. The gray matter is never involved. Histologically the foci may be recognized by regressive changes in the medullary sheath and by proliferation of the glia, of the same nature as is seen in places of secondary degenerations of central fibre tracts in man. There is a considerable swelling of the protoplasm of the glia network, assuming in the affected foci its well-known reticular structure. From the diffuse reticular protoplasm, granule (reticular) cells gradually become differentiated and reach the perivascular lymphatics. The medullary sheaths do not first disintegrate into coarse globules and fragments, but apparently always directly into fine granules. The axis cylinders are, just as in Stransky's discontinuous disintegration of the peripheral nerves, attacked only late.¹⁶ Therefore by suitable staining methods many intact axis cylinders may always be demonstrated in the foci. These axis cylinders are frequently still surrounded by a thin myelin covering which may be demonstrated in medullary sheath preparations. However, in all fairly advanced cases complete disintegration of at least a portion of the fibres takes place, this continuing into secondary degeneration, with superimposition of its well-known changes upon the original histological picture. The end result in each case is thickening of the glial tissue. The connective tissue and the vessels do not actively participate in the histopathological process.

¹⁶ Contrary results are reported by Thumazuri: *Archiv. f. Psychiatrie*, Vol. LIII, and Wohlwill, *Deutsche Zeitschrift für Nervenheilkunde*, Vols. 68 and 69, 1921.

In the same class belongs a group of not very frequent extensive diseases of the white matter of the brain and cord, the so-called diffuse sclerosis of the brain (encephalitis periaxialis diffusa of Schilder), and the cases of so-called acute or malignant multiple sclerosis. The histopathological processes in these are obviously identical with those described in anemia, different as the original injurious factors may be; and one may collectively speak of them as a myelinoclastic process.¹⁷ There are probably quite a number of morbid conditions in which the medullary sheaths are involved first, while the axis cylinder for a time remains intact, and there is a reactive proliferation of the glia. In progressive paralysis as well, formation of flecks and streaks occurs, in which only the medullary sheaths disintegrate while the axis cylinders are not at first affected, and gliogenic granule cells make their appearance.¹⁸

Concerning the histopathology of other focal diseases like multiple sclerosis and of tract diseases such as tabes, amyotrophic lateral sclerosis, etc., we know next to nothing.

¹⁷ Schröder, "Encephalitis und Myelitis," *Monatsschr. f. Psych. u. Neurol.*, Vol. XLIII, 1918.

¹⁸ O. Fischer, *Allg. Zeitschr. f. Psych.*, Vol. LXVI, 1909, and Spielmeyer, *Zeitschr. f. d. ges. Neurol. u. Psych.*, Vol. I, 1910.

CHAPTER VIII.

CONCERNING SOME HISTOPATHOLOGICAL COMPLEXES. THE GRANULE CELLS. THE CONCEPT OF INFLAMMATION.

IN the last chapter we extended our discussion of morbid changes in the various individual tissue elements of the nervous system to a consideration of certain *histopathological complexes*. The changes in the tissue elements are numerous and various; each new technical method brings out new details. On the other hand the number of complexes is limited, and probably each tissue has but a few such histological complexes by which it may react to injuries. The course of each complex is as regular as the course of the changes in its constituent elements. But the picture may vary considerably at different times, as when in the beginning the mesodermal, later the ectodermal, tissue elements are chiefly involved.

We have come to recognize from the above a series of pathological processes in the peripheral nerves, and in the white matter of the spinal cord and brain, which are quite similar in their nature and course. This similarity lies in the fact that the changes are limited to the ectodermal tissues,¹ the mesodermal parts (vessels and connective tissue) not participating; that axis cylinders and medullary sheaths undergo retrogressive alterations (complete or partial disintegration) while the neurilemma elements or the glia show proliferation of their protoplasm and multiplication of their nuclei. We have seen that these processes occur in the same manner in secondary degen-

¹ The neurilemma cells, as has been pointed out in Chapter III belong to the ectodermal group.

eration of the peripheral nerves as in the brain and cord. They occur in discontinuous disintegration of peripheral nerves as well as in the white matter of the cord in cases of severe anemia, and they are found likewise in extensive or diffuse lesions of the central organs. Differences can be observed only in the rapidity of the myelinic degeneration and the extent of the glial or neurilemma proliferation. In some cases the process has more of a subacute, in others more of an acute character.

Changes of this type occur under the most varying conditions. They may appear either isolated and constitute by themselves the whole picture of certain histopathological processes; or they may form merely a part of more complicated morbid processes. We shall not go astray if we regard this complex of histological processes as the morphological expression of a regular and definite mode of reaction of the nervous system to definite injuries (*ectodermal type*). The nature of the injurious agents may be very diverse.

In contrast there is another type in which the vascular-connective tissue system plays the chief rôle (*mesodermal type*). This we meet wherever nervous tissue has disintegrated *in toto*, no matter what the size of the lesion, whether produced by trauma, by crushing, hemorrhages, thrombotic or embolic softening, cauterization, freezing, etc.; provided that, besides the ectodermal tissue, at least a part of the vascular network has been injured or destroyed. Its prototype is the tissue change which develops in connection with hemorrhages in the central organs, in the gray as well as in the white matter.²

² See the publications of Nissl and of some of his pupils (Farrar, *Histol. u. histopathol. Arbeiten von Nissl*, Vol. II, 1908).

In such cases we always find the histological picture in the beginning dominated by proliferative changes in the vascular and connective tissue system. The endothelium of the vessels in the surrounding zone becomes swollen and multiplies, and the affected capillaries proliferate. They form young vascular buds, which press in from the periphery toward the destroyed or necrotic area and grow into it. Another portion of the proliferating mesenchymal cells become fibrous elements (fibroblasts) which temporarily replace the destroyed tissue. Finally, there arise from these proliferated vascular elements great numbers of granule cells, which become packed with detritus (Nissl).

The glia within the focal lesion has disintegrated with the nerve cells and the nerve fibres and cannot actively participate in the process. However, the glial tissue outside the zone of capillary growth swells and proliferates. This proliferation at first lags behind that of the connective tissue and vessels, but soon attains considerable prominence. One finds diffuse, poorly defined, protoplasmic masses and the various type of progressively altered glia cells. Among them there are regularly met the gigantic "mast cells" of Nissl (Fig. 23 c and d), which appear after but a few days in a narrow zone near the lesion. We know of these cells that they form large quantities of glia fibrils. Within this zone the glia also participates, as described above, in the ingestion and transportation of particles of ectodermal tissue which here disintegrate secondarily to the actual lesion (through nutritional disturbances, secondary degeneration, etc.). Later the proliferated glia forms greater and greater masses of fibrils about the focus, and these gradually encapsulate the disorganized region. Later this mass of

glia gradually extends inward, and finally displaces the originally mesodermic scar. If the lesion is a small one, the connective tissue will finally be entirely replaced by glia fibrils; otherwise a loose connective tissue remains in the centre of the focus, or a cystic cavity is formed which is lined by a layer of mesodermic tissue, and which is externally bordered by a dense glial capsule.

These processes are somewhat modified if the destruction of the tissue is less complete, and if the damage is a gradually progressing one, as, for instance, not infrequently happens in thrombotic softening or pressure necroses (compression). One may then observe that only a part of the glia within the lesion disintegrates, and that glia as well as connective tissue participates in the reparative process. Thus there arise mixed forms between the mesodermal and the ectodermal types. That the glia also participates in the proliferative processes in the border regions of completely destroyed areas has already been stated; this is an example of a mixture of the ectodermal type of reaction at the periphery of the lesion with the pure mesodermal type at the centre.

The brain of the foetus and of the new-born behaves differently, as we know from Nissl. Both in secondary degeneration and in focal destruction, if the lesions are not too large the remaining tissue closes in, so that later no mesenchymal nor glial scar tissue will be present to indicate the site of the lesion. According to Spatz³ the more extensive lesions lead, in the *fetal* brain and cord, to softening, and are not organized as they are in adults. There is no formation of fibroblasts; the granule cells

³ Spatz, *Zeitschr. für die gesamte Neurol. u. Psychiatrie*, Vol. LIII, 1920 and *Histolog. u. histopatholog. Arbeiten von Nissl u. Alzheimer, Ergänzungsband*, 1921.

disappear with extraordinary rapidity. The end result is a cyst.

The characteristic changes of acute inflammation (in the sense of Cohnheim) in the central and peripheral nervous system are, as in all other organs, of vascular nature. The nervous tissue itself, however, is always involved. The sequels of nutritional changes are necrobioses of different types, and they in turn are followed, as are other degenerative and destructive lesions by the two types of tissue reactions discussed (but more especially by the mesodermal type). These are no more characteristic of inflammation than of hemorrhage, a puncture wound, a crushing injury, or a burn. This fact has been largely disregarded, whence have arisen many of the difficulties and misunderstandings concerning the histological correlation of inflammation in the nervous system.

A discussion of the histological phenomena of some more chronic types of retrogressive changes than those considered above may be found in the papers of Alzheimer.⁴

The important rôle which the *granule cells* take in acute and subacute morbid processes has been indicated. The histopathology of the nervous system has been much concerned with these.⁵ Gluge described (1837) "inflammatory globules" in areas of cerebral softening; their cellular nature was only later demonstrated. Since

⁴ Alzheimer, *Histol. u. histopathol. Arbeiten, herausg. von Nissl und Alzheimer*, Vol. III, 1910, S. 522 ff. Concerning a special type of disintegration of cortical tissue, see also: Schröder, *Hirnrindenveränderungen bei arteriosklerot. Demenz. Naturforscherversamml.*, Dresden, 1907.

⁵ For the older literature consult: Batimier, *Inaug., Diss.*, Halle, 1881, for the more recent literature, Nissl, *Histol. u. histopathol. Arbeiten*, Vol. I. S. 328 ff., 1904; also: Merzbacher, *ibid.*, Vol. III, 1910, and Held, *Monatsschr. f. Psych. u. Neurol.*, Vol. XXVI, 1909

then there has been much dispute about their significance, and the most diverse assertions have been made in regard to their origin in the brain, cord, and peripheral nerves. There is no histological element in the nervous system which has not been regarded by one investigator or other as the source of the granule cells; ganglion cells, glia cells, cells of the vessels' walls, fixed connective tissue cells, various white blood corpuscles, so-called wandering cells, and pus cells have been implicated (Nissl).

Nissl has properly emphasized that all cellular elements, even the highly differentiated ganglion cells, may under certain conditions ingest in their protoplasmic bodies certain foreign substances (granules). But he goes on to say that we do not always speak of these as granule cells, that we have rather been accustomed to reserve this term for histological elements of a very definite character. It is customary to designate as granule cells free, relatively large, rounded elements, with small, often eccentrically placed nucleus, and a cytoplasm which shows a foamy or definitely alveolar reticular structure, containing in its meshes phagocytized "granules" of heterogeneous source (Fig. 32). The granule cells are therefore always phagocytes; their business is the ingestion and transportation of tissue detritus and of small foreign bodies.⁶ The ingested detritus is gradually broken up and as far as possible assimilated and liquefied. We find granule cells wherever a large amount of tissue undergoes disintegration or necrosis and where the remaining tissue retains sufficient vitality to remove the necrotic substances. The inclusions of the granule cells may be of greatly varying nature, and accordingly their appearance varies to

⁶ Therefore also called "Abräumzellen" (Merzbacher).

a certain degree, according to the size and physical and chemical properties of these inclusions. In hemorrhagic areas they appear at first choked with erythrocytes, later with pigments. Where nerve fibres have undergone disintegration these cells contain fragments of myelin and axis cylinders, and so on. Their characteristic cell structure is well demonstrated by Nissl's method and by diffuse stains (hematoxylin-van Gieson).

This long-disputed question concerning the origin of the granule cells may be settled by regarding these structures as arising in the peripheral and central nervous system from at least three different sources: the glia, the elements of the vessel walls (involving adventitia) and the neurilemma. The oldest conception of granule cells attributed their origin to white blood corpuscles which had phagocytized tissue detritus. Closely associated with this explanation is the widely spread idea that the presence of granule cells is as indicative of the inflammatory nature of a morbid process as the presence of extravasated leucocytes. We have not discussed the possibility that granule cells may be derived from white blood corpuscles, for it must be regarded as very improbable that any considerable numbers of leucocytes are ever so transformed in the nervous system. This statement applies even to reparatory processes after hemorrhage, in which, in the first few days, large numbers of leucocytes are regularly met with; and it also applies, as we shall see, to suppuration.

Nissl showed from extensive research that one source of granule cells lies in the connective tissue elements of the proliferating vascular system (mesodermal granule cells).⁷

⁷ Compare the illustrations in the article of Farrar in Nissl's *Histol. u. histopathol. Arbeiten*, Vol. II, Taf. I u. II.

This is true, however, of only a certain group of morbid processes, namely those which we have briefly designated as reparatory processes of the mesodermal type. Under other conditions the development of granule cells may be traced step by step from the glia, with the vessels and connective tissue taking no part whatever (gliogenic granule cells). Putting the two sets of observations together, we learn that the typical free granule cells in either case represent the end stage of a process of development that begins in fixed tissue elements, and that all transitional stages between these fixed elements and the granule cells may be found. The histological end product is the same in either case, whether they arise from vessel walls or from glia. No morphological distinction is yet known; and in fact Nissl recommended as the most suitable and appropriate name for these mesodermal bodies the term "*reticular cells*" (*Gitterzelle*), which Boedeker and Juliusburger proposed for elements that according to their description doubtless arise from the glia.

As the third source of granule cells, we mentioned, in the seventh chapter, the neurilemma.

We see, therefore, that granule cells in the nervous system may develop from different cellular elements, and particularly from those that possess marked proliferative ability. It has already been mentioned that we must regard both the circulation of tissue juices as well as the transportation of metabolic products from the tissues, as taking place within the protoplasmic paths of the glial syncytium. Under normal conditions local blockage and accumulations of such products in the shape of granules and droplets are not infrequent within the bodies of the glia cells; and even well-formed granule cells may be found.

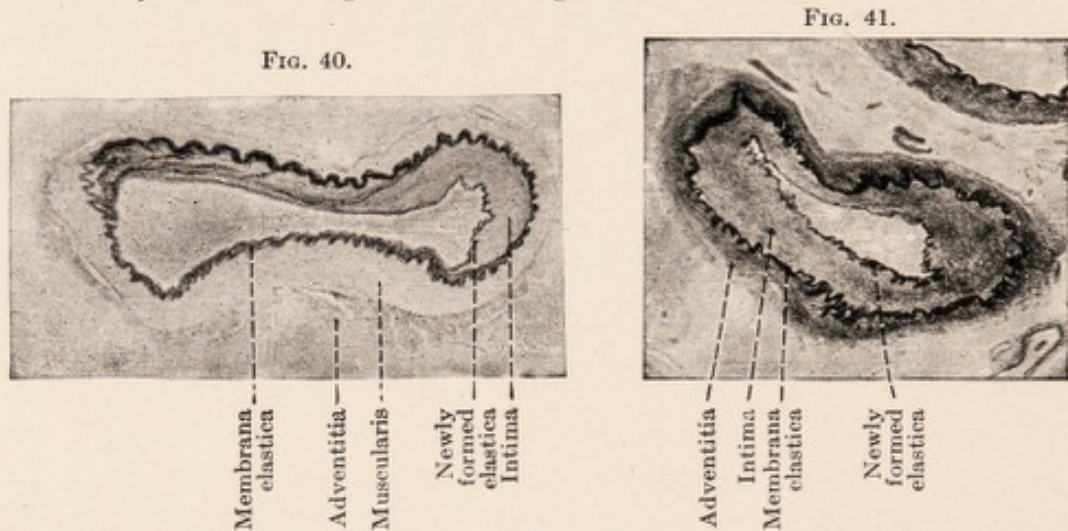
In morbid processes granule cells arise when through acute changes such considerable masses of disintegrated products are formed that the normal ways and means for absorption and transportation no longer suffice.⁸ They are altered tissue cells which have separated from their original histological connections, and are therefore always doomed to be destroyed. Wherever we find them fully developed, regressive changes in them are recognizable (dark, pyknotic, indented nuclei). When, after swelling and rounding of their cell body and separation of their processes, they have become free and mobile, they wander, laden with granules, into the lymph spaces. Held has directly observed the penetration of granule cells close to the capillaries through the glial perivascular limiting membrane into the adventitial spaces (Fig. 32). Their amoeboid or more passive locomotion in the tissue juices is in many instances facilitated by the broken continuity of tissue caused by destructive processes at their point of origin. The further fate of the granule cells is probably that, either at first in the tissue or later in the lymph stream, they burst; or that their liquefied contents are lost through diffusion. Their remnants may often be mistaken for blood lymphocytes (Held, "reduced" granule cells). Such nuclei are not infrequently found in considerable quantities forming mantels about the capillaries (Fig. 34).

Other less frequent elements must not be mistaken for the granule cells, in spite of their similarity. These are certain degeneration forms of plasma cells (known as Russel cells or Y-cells of Perusini) and therefore deriva-

⁸ On the other hand in the embryonal brain and spinal cord fatty granule cells play a considerable role in the myelinization of nerve fibres ("Aufbauzellen," Merzbacher, *l. c.*).

tives of lymphocytes. We deal here not with phagocytic cells, which have taken up and elaborated tissue detritus, but with degeneration forms of plasma cells, showing a mullberry-shaped, or more uniformly rounded body, in which are included certain bodies formed intracellularly.⁹ They are illustrated in Figs. 49 and 50.

In the pathological anatomy of the nervous system formerly much emphasis was placed on the determination



FIGS. 40 and 41.—Arteries of the base of brain from a case of brain syphilis. Endarteritis obliterans. Elastica stain (Weigert's resorcin-fuchsin). Proliferation and splitting of the elastic membrane.

of *hyperemia* and *anemia* in the tissue. The histological estimation of the amount of blood in the vessels is difficult on account of the alterations in the blood distribution occasioned by death and by physical factors after death.

The histological study of *edema* is even more difficult. The fluid contents of the tissues are so changed through our fixing and embedding methods that all conclusions based upon the examination of microscopic preparations

⁹ Spielmeyer, *Die Trypanosomenkrankheiten*, Jena, Fischer, 1908; Perusini, *Rivista speriment. di Frenetria*, Vol. XXXVI, 1910. Schröder, *Zeitschrift für die gesamte Psychiatrie u. Neurol.*, Vol. LXIII, 1920, p. 143. E. von Müller, *Frankfurter Zeitschr. f. Pathologie*, Vol. XXIII.

must be accepted with reservation. Reichardt¹⁰ has repeatedly emphasized the point that under pathological conditions the brain is especially subject to great fluctuation in fluid content, and that the various resulting conditions should not be neglected in the examination of diseased brains. However, these conditions of swelling or shrinking of the tissue can only be identified by histological examination when it is possible to recognize associated histopathological phenomena which are constantly associated with them.

Under the macroscopical concept of *atrophy* a number of diverse conditions are included. All severe morbid processes lead, at least in the central nervous system, to a loss of specific nervous substance. Atrophy of some parts or regions is therefore the end result of all severe morbid processes, no matter what their nature may be. In contradistinction to such secondary atrophies, it is customary to look upon as primary those processes which are assumed to have been insidious from the beginning, and which lead to a loss of nervous substance without stormy phenomena. But concerning their histopathology we still know very little that is certain.

The concept of *inflammation* in the nervous system, finally, necessitates a somewhat more detailed discussion.¹¹ A glance through the literature and through the clinical text-books shows that in neurology and brain pathology the terms neuritis, myelitis and encephalitis are used very glibly and extensively, and that there are

¹⁰ *Über die Untersuchung des gesunden und kranken Gehirns mittels der Wage*, Jena, 1906; *Hirnschwellung*, *Zeitschr. f. Psych.*, Vol. LXXV, 1918.

¹¹ Nissl, *Archiv. f. Psych.*, Vol. XXXIII, 1900, S. 685; Schröder, *Enzephalitis und Myelitis*, *Monatsschr. f. Psych. u. Neurol.*, Vol. XLIII, 1918; "Paralyse und Entzündung," *Zeitschr. f. d. ges. Neurol. u. Psych.*, Vol. LII, 1920. "Über Entzündung, insbesondere im Nervensystem," *Ziegler's Beiträge*, Vol. LXXI, 1922, p. 1.

few of the diseases of the nervous system that are not generally, or at least by some of the authors, called by one or the other of these names. In the course of time terminology has become very loose in this respect. Anatomical descriptions accord more or less closely with these clinical concepts. Only in recent times have many dissenting voices been raised against such usage. We find that a large number of investigators are content to make

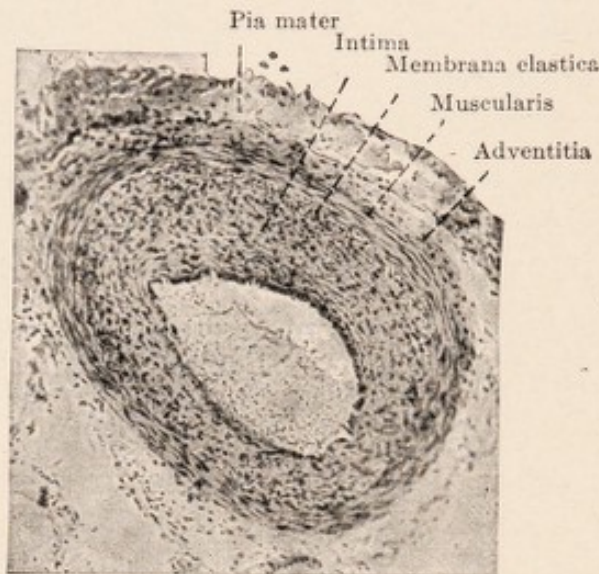


FIG. 42.—An anterior spinal artery from a case of spinal syphilis. Hematoxylin-van Gieson. Uniform proliferation of the intimal cells.

an anatomical diagnosis of *neuritis* on the strength of demonstrating medullary sheath disintegration with Marchi's or Weigert's method. Since this disintegration is also a regular finding in simple secondary degeneration, these observers assume that it is impossible sharply to differentiate between the two morbid processes, and such terms as traumatic "neuritis" and degenerative "neuritis" have been introduced. The word *myelitis* is used to designate any, but especially an acutely developed focal disease of the spinal cord; and the term *encephalitis* is used equally loosely. This custom is only partly founded on

surviving though discredited pathologic-anatomical conceptions. To the old authors softening in the brain and cord implied inflammation; hardening (sclerosis) was regarded as the end result of inflammatory processes. And even to-day we do not invariably find an attempt to differentiate acute inflammatory processes from simple hemorrhages, softening, pressure necrosis, trauma, etc. After we became acquainted with "inflammation without softening," the question was raised whether the greater part of all known morbid processes really belongs under inflammation. An attempt was even made to differentiate histologically between parenchymatous and interstitial inflammation of the nervous system. It has already been mentioned that the alleged derivation of granule cells from leucocytes seemed to furnish an additional argument for regarding as inflammatory all processes in which granule cells occur. Serious attempts were not lacking to establish scientifically this conception of inflammation. In order to group all these histological pictures together, all tissue changes which result from "inadequate" stimulation were designated inflammatory.¹² A long series was then constructed beginning with the slightest changes and ending with suppurative disintegration of the tissue. It was taught that all these changes are stages of one and the same process, namely inflammation, which may terminate sometimes at one stage, sometimes at another.

The difficulty arises that, if we follow this conception, almost all morbid processes attended by progressive alterations of any of the tissue elements may be included under inflammation. Trauma would stand as the type of

¹² Friedmann: "Inflammation is the general reaction to any inadequate stimulus"; Virchow: "Inflammation is only different quantitatively from simple irritation."

non-suppurative inflammation, a case of crushing of the cord would be regarded as "by its very nature" inflammatory and the phenomena of secondary degeneration would be considered as characteristic of neuritis. But it is apparent from this that it would be obviously impossible to make a sharp distinction histologically between inflammatory processes and diffuse glial proliferations or cerebral softening. Nor would it be possible in many cases to make the anatomical diagnosis of inflammation solely from the

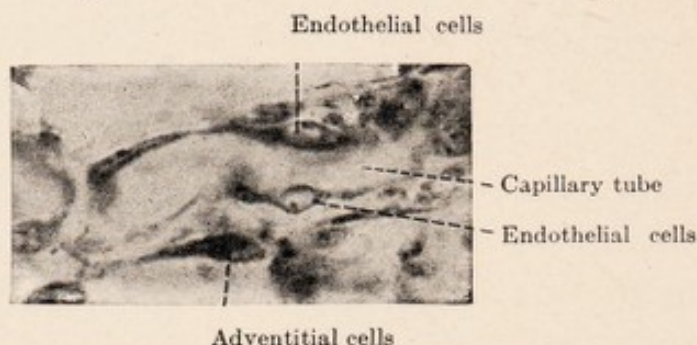


FIG. 43.—Proliferating capillary. Nissl stain. Microphotograph, oil immersion.

histological picture, without at the same time considering the etiology and the clinical course. Such conclusions are inevitable if one holds to the above definition; and they demonstrate that this conception of inflammation has no value for histopathology.

The same principles apply to the elements of the central organs as to all other organs; we are acquainted with many different regressive and progressive changes in them, but none of them can claim to be characteristic or decisive for the inflammatory nature of the disease, unless one sweepingly regards all progressive changes as inflammatory.

We may therefore regard it as an advance, that from different sides a tendency has developed to drop this conception of inflammation, and to recognize a series of

simple histological processes. The present tendency is to reserve this term for a more restricted field, and to leave it to the future to determine whether it be necessary or desirable to regroup these processes, in whole or in part, to form a new complex.¹³

Nissl made the first step in this direction for the central nervous system, by sharply defining a group of tissue changes particularly studied by him, which we designated above as the mesodermal type. He showed "that wherever brain substance is destroyed, no matter in what way, or wherever necrotic brain substance or a foreign substance is surrounded by living tissue, the latter reacts in a very definite manner;" that this reaction is essentially the same in polioencephalitic hemorrhages, in the neighborhood of a sarcoma, after penetrating wounds made by a hot needle, after the introduction of a bit of cotton saturated with a streptococcic culture, or after corrosion of the brain substance with chromic acid. Definite and characteristic processes, already described, are always set in motion in the surrounding intact tissues.

These changes of mesodermal type are, however, merely secondary accompanying phenomena; they are the anatomical expression of reactive processes which have nothing to do with the injurious agent or the disease which led to the disintegration or the destruction of the nervous tissue. If we keep this in mind, the presence of this type of reaction will not tempt us to regard the histological changes in a simple hemorrhage from rupture of a vessel or from trauma as essentially the same as and only differing quantitatively from those of an abscess.

¹³ Nissl: "In my opinion pathological anatomy would not be fundamentally disturbed, if one off-handedly abolished the present-day concept of inflammation." *Hist. and Histopath. Arbeiten*, Vol. I, p. 466.

In the same manner there should be grouped those histological processes which are collectively known as the ectodermal type. We saw that they developed sometimes apparently without known cause,—primary; at times obviously as a reaction to various injuries of the tissues. They are often considerably intermingled with the changes of the mesodermal type. They have been described as the type of “non-suppurative” encephalitis.

The above-mentioned grouping together of processes supposed to be inflammatory was possible only by focussing attention on these two types of *secondary* degenerations, by regarding them as characteristic of inflammation, and neglecting the other findings as immaterial or as merely indicative of its stage or severity.

This arrangement is further quite artificial in that it does not correspond to the experience of pathologists, that the several changes may merge into one another. Suppuration is always suppuration from the beginning, and is characterized as such histologically; the reactive processes in connection with a hemorrhage, with a non-infectious embolic softening, a crushing injury, never develop into an abscess, unless it be that a secondary infection is superadded; the so-called parenchymatous neuritis never develops into an exudative interstitial form; and the latter is never a preliminary stage of a “parenchymatous” neuritis.

Inflammation is in origin purely a clinical concept, applied to a symptom complex of the external parts, with the symptoms of rubor, dolor, and tumor. For a long time its gross anatomical and histological basis has been sought. Since Cohnheim’s classical investigation the exudation of white and red blood corpuscles and of fluid

constituents of the blood through unruptured vessel walls has been regarded as the chief anatomical characteristic of the inflammatory process. For the nervous system Nissl shared Cohnheim's viewpoint, and taught that only those histological processes should be termed inflammatory, in which, beside progressive and regressive changes in the parenchyma, exudative vascular phenomena may be demonstrated.

Chief emphasis is usually placed on the demonstration of extravasated white blood-corpuses, since

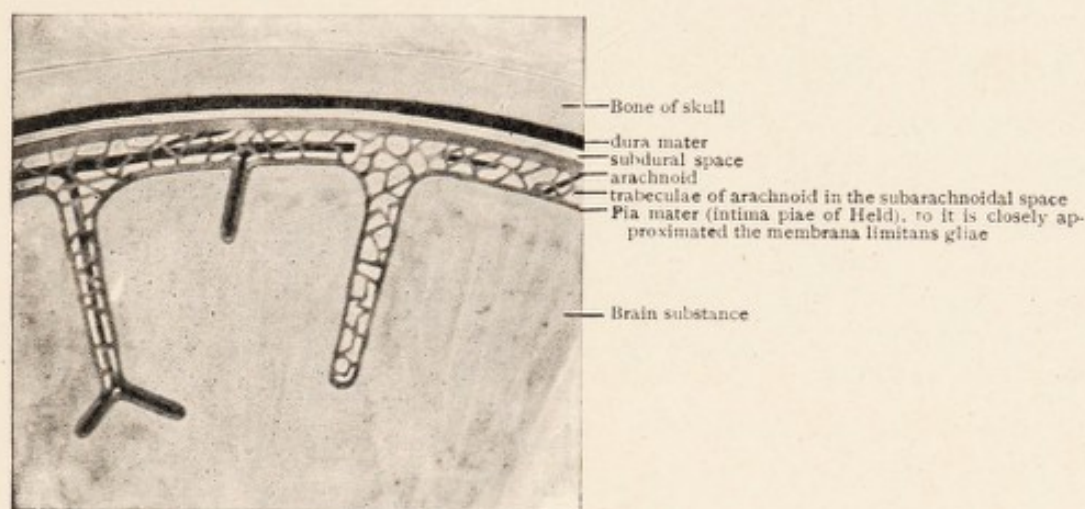


FIG. 44.—Schema of membranes and lymph paths of the brain.

the demonstration of increased fluid exudate is difficult with the available histological methods. The presence or absence of erythrocytes is as a rule regarded as of slight significance.

When white blood cells in the central organs emigrate from unruptured vessels they reach first the perivascular lymph spaces, and only afterwards the specific nervous tissues (see Chapter IV). Accordingly we find extravasated blood elements as *perivascular accumulations* or as a *diffuse infiltration* of the tissue. This brings us to two

important concepts for the doctrine of inflammation, which have been often misinterpreted, and the clear definition of which was established by Nissl. Accumulation of cellular elements in the lymph spaces and increase of nuclei in the tissues may have very different significance, according to the nature and source of these elements. They are indicative of the "inflammatory"

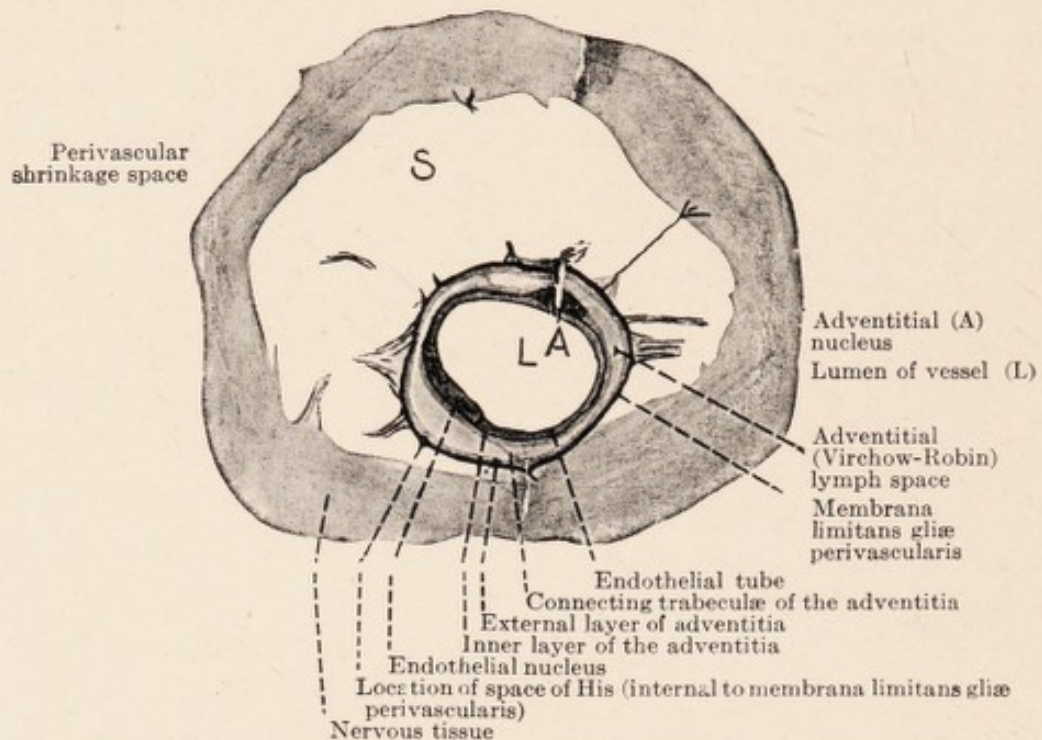


FIG. 45.—Vessel wall and lymph spaces. Semi-schematic, after drawings by Held.

nature of pathological processes only when they can be shown to have arisen from the blood stream. That which is in literature designated as "round-cell infiltration" is of very heterogeneous nature.

Of primary importance is the different significance of the two chief types of white blood corpuscles, the *mononuclear lymphocytes*, and the *polymorphonuclear leucocytes*. The latter are the specific extravasated elements of all suppurations (Fig. 51). They show a pronounced tendency to penetrate rapidly through the lymphatics

into the tissue, to form accumulations and lead to liquefaction necrosis (abscess formation).¹⁴

Diapedesis of leucocytes through the injured vessel wall and necrobiosis (even to liquefaction) of the infiltrated tissue and of the infiltrating leucocytes constitute the findings in every abscess. Associated with these are the well-known reactions of the surrounding tissue, and, competing with them, the further progress of the liquefaction necrosis.

But not only in the formation of an abscess may we observe the extravasation of leucocytes through the vessel walls. Nissl wrote: "If I destroy the cortical tissue with a hot needle or make a simple incision into it, or introduce a drop of blood, or freeze the tissue, we find in all these cases at first a more or less pronounced accumulation of multinuclear leucocytes and progressive changes in the parenchyma; but the leucocytes very soon disintegrate." One of his pupils, Devaux, states more exactly that the leucocytes appear after about 12 hours, begin to degenerate after 24 hours, and have disappeared after 3 days. This means that after any single, acute, temporary injury leucocytes at first emigrate from the vessels into the tissues just as Cohnheim found in his studies on inflammation; but they disappear in a few days. They are transient guests and rapidly disintegrate. In suppuration on the contrary, the extravasation continues, fresh leucocytes keep pouring in as the old ones break up, and an abscess is formed with liquefaction of the tissue. However, these phenomena are not due to the original injury, but to the added, persistent insult due to multiplying

¹⁴ It is questionable whether this is due to the activities of the leucocytes *per se*, or to those of the contemporaneous etiologic factors or metabolic products.

microorganisms.¹⁵ From this it follows that the much discussed classical observation of Cohnheim on the extravasation of leucocytes is a phenomenon which lasts merely for a few days after the injury and rapidly disappears, except when the conditions leading to inflammation persist; and, above all, it is without influence on the nature of the consequent reactive and reparatory processes.

In contrast to the leucocytes, which rapidly scatter through the tissue, we find that the lymphocytes accu-

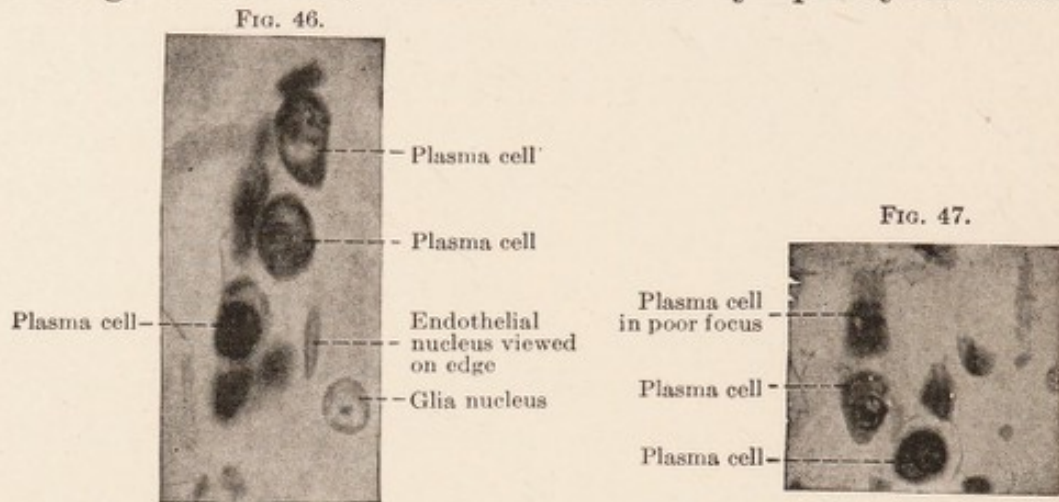


FIG. 46 and 47.—Capillaries with plasma cells. Nissl stain. Oil immersion.

multate, particularly in the perivascular lymph spaces, and that they do not simultaneously appear in the surrounding tissue; they form the true "perivascular infiltrations." Nissl has expressed this by stating that the lymphocytes respect the biological border lines between the vessels with their connective tissue and the ectodermal tissue, while the leucocytes do not.

In many cases, especially in the more chronic morbid processes, we find, mixed with the lymphocytes or outnumbering them the *plasma cells* of Unna and Marschalko. These are mononuclear elements characterized by the

¹⁵ For a detailed discussion see: Schröder, "Über Entzündung," Ziegler's *Beiträge*, Vol. LXXI, 1922, p. 1.

arrangement of the nuclear chromatin to resemble the spokes of a wheel; they possess a more or less large cell body containing irregularly shaped lumps of a material that stains deeply with basic aniline dyes, and with a pale perinuclear "court" (Figs. 46 to 48). Concerning the origin of the plasma cells there has been much debate,¹⁶

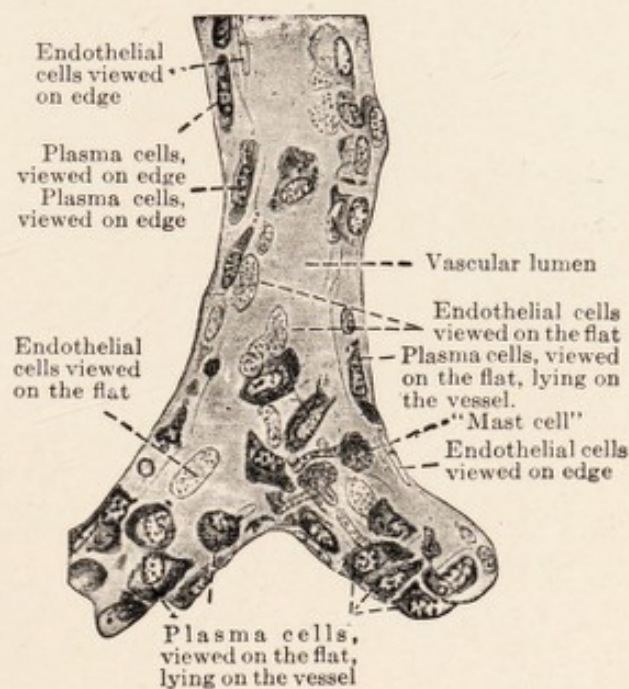


FIG. 48.—Longitudinal section of a vessel, infiltration of the adventitial sheath with large plasma cells. Nissl stain. After a drawing by Alzheimer. High magnification (oil immersion).

but it is now generally accepted that they are derivatives, transitional forms, of mononuclear lymphocytes; between plasma cells and lymphocytes all intermediate forms occur.

Alzheimer, Nissl, and after them many others believed that the lymphocytes which become transformed into plasma cells are of hematogenous nature, that is, they emigrate per diapedesin through the vessel walls. According to the belief of Nissl and others, their presence

¹⁶ For a historical discussion on plasma cells see: Nissl, *Histol. u. histopathol. Arbeiten*, Vol. I. S. 247 ff.; Marchand, "Referat auf der Tagung Deutschen Pathol. Gesellschaft zu Marburg," 1913.

is always to be regarded as proof of the inflammatory nature of the disease process, in the sense of Cohnheim. However, the histological demonstration of diapedesis of lymphocytes and plasma cells is difficult. In spite of their great numbers in many cases, hardly ever has one of them been observed in the act of passing through the vessel wall, in contrast to what is seen in the case of leucocytes. For that reason the possibility of a different origin of the perivascular lymphocytic and plasma cell infiltration cannot be dismissed, namely the lymphatics.¹⁷

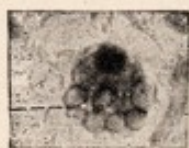


FIG. 49.—Russell cell (degenerated form of a plasma cell having a mulberry shape). Photograph, oil immersion. Nissl stain.

According to this view the lymphocytes do not come from the blood but from the lymph, occurring as collections and accumulations (occasioned by chemotaxis or similar factors) within the adventitial lymph spaces of the vessels, which freely communicate with the subarachnoidal space and the general lymph system of the body. If this be true these perivascular infiltrations have not arisen by extravasation; and therefore do not constitute proof of the inflammatory nature of the lesions in which they are found. They would be accumulations of cells from the lymph, swimming in the lymph stream of the adventitial lymph spaces; their origin might be looked for outside of the brain and in the hemopoietic organs.¹⁸

Of another cellular element which may produce the picture of diffuse tissue infiltration, as well as of perivascular accumulation, much has already been said; this is the *granule cell*. We have seen that granule cells develop

¹⁷ Schröder, *Zeitschr. f. d. ges. Psych. u. Neurol.*, Vol. LII, 1920.

¹⁸ Tumors also may grow into the lymph paths of the brain, and fill the adventitial spaces with their cells, so that the resulting picture is like that of a perivascular infiltration.

from various fixed tissue elements, that they become free only when fully developed, that they then reach the perivascular lymph stream, and that they are in part locally formed from the adventitial elements of the vessels. After loss of their contents and disintegration of their cell body, the nuclei of such granule cells may very closely resemble lymphocytes (Held's reduced granule cells, Fig. 34). The development and composition of "infiltrates" thus originating is accordingly very different from that of true cellular extravasations: in the one case the

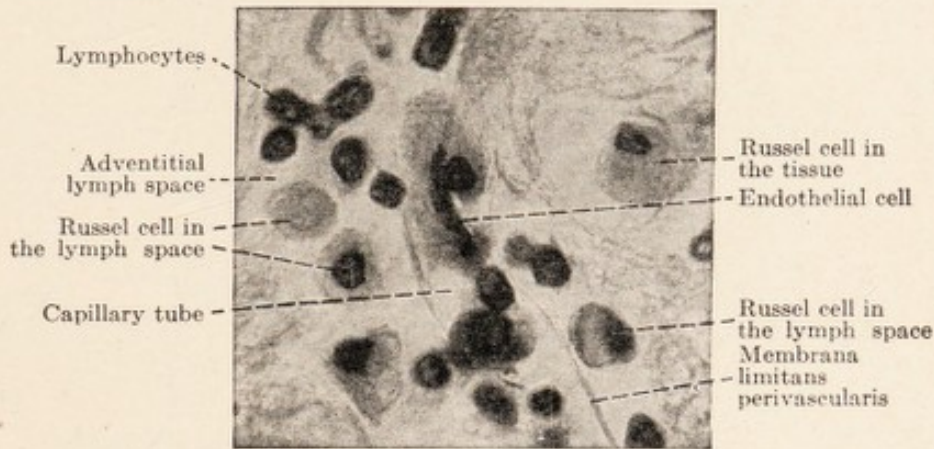


FIG. 50.—Capillary, infiltration of the adventitial sheath with Russel cells. Hematoxylin-van Gieson. Oil immersion.

elements immigrate from the blood stream through the vascular wall into the lymph spaces and into the tissue; in the other case, from the tissue into the lymph spaces (Fig. 52 and Figs. 26 to 29). It is therefore obvious that these two types of infiltration do not have the same significance in our study of the underlying morbid processes.

It was formerly assumed that white blood corpuscles are everywhere present, free in the nervous tissue. It was therefore not difficult to suppose that tissue infiltrations could be produced through multiplication of these elements. Weigert and Nissl, however, demonstrated

that structures formerly regarded as free nuclei (Henle) and thought to be identical with lymphocytes, are nuclei of neuroglia, the nature of which it was not possible to recognize with the older methods; and that normally lymphocytes occur not at all or very rarely free in the nervous tissue.¹⁹

An increase of the nuclei in the tissue frequently occurs under pathological conditions, through various proliferative changes in the glia. Not infrequently this

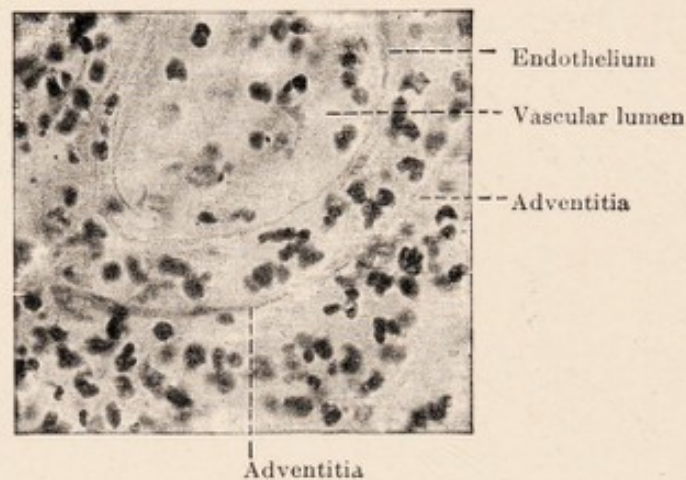


FIG. 51.—From a small recent brain abscess in the white matter of the cerebral hemispheres. Nissl stain. Infiltration of the vessel wall and the surrounding tissue with leucocytes.

glial nuclear proliferation in the cortex, as well as in the deeper portions of the central organs, is particularly pronounced in the immediate neighborhood of the vessel walls. If, as is frequently true in such cases, the nuclei lie in rows quite close to the glial membrana limitans perivascularis, the picture of a true perivascular exudation may readily be simulated, since these nuclei possess a certain superficial resemblance to lymphocytes (Figs. 24, 53, 26, and 28).

¹⁹ Cf. Nissl, *Histol. u. histopathol. Arbeiten*, Vol. I. p. 440 ff.; Ranke, *ibid.*, Vol. II, S. 276.

It may also be mentioned that, with superficial examination, even an increase of the elements of vessel walls (*e. g.* in endarteritis obliterans) may impress one as an extravasation (Fig. 43).

In Cohnheim's experiments on inflammation, besides the white corpuscles, *red blood cells* were found to escape

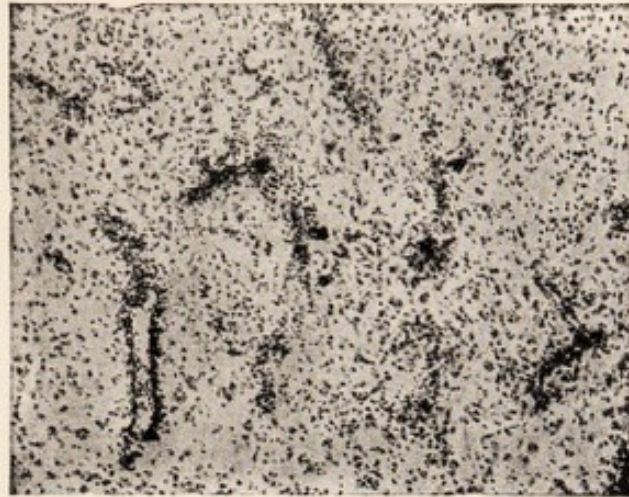


FIG. 52.—"Small round cell infiltration" of the cerebral cortex. Nissl preparation. Low magnification. The infiltration, perivascular as well as diffuse, consists solely of granule cells and large glia cells. Of the latter the opaque bodies are recognizable.

from the vessels. This observation is partly responsible for the conception of the so-called *hemorrhagic encephalitis* or *myelitis*. In human pathology hemorrhages in true inflammatory (exudative, diapedetic) processes are not at all as frequent as is usually assumed. Miliary or even somewhat larger hemorrhages are found for the most only in very acute inflammatory injuries; and even in such cases it is not certain whether they should be regarded as part and parcel of the inflammation or whether they do not rather represent merely secondary changes resulting from miliary thrombi and ruptures.

Another group of processes, commonly designated as hemorrhagic encephalitis, has in all probability nothing whatever to do with inflammation. These are processes,

the recognizable morbid changes in which consist merely in punctiform hemorrhages, and the well-known reactions that regularly follow upon the hemorrhages in the surrounding tissue.

If we now sum up the conceptions discussed in the preceding and in this chapter we have a series of arguments in favor of dividing up that great group of histopathological processes which even today is too often inclusively called *inflammation*. It seems better to avoid entirely the term parenchymatous inflammation and to separate from inflammation both those simple reactions of the supporting tissue which regularly follow degener-

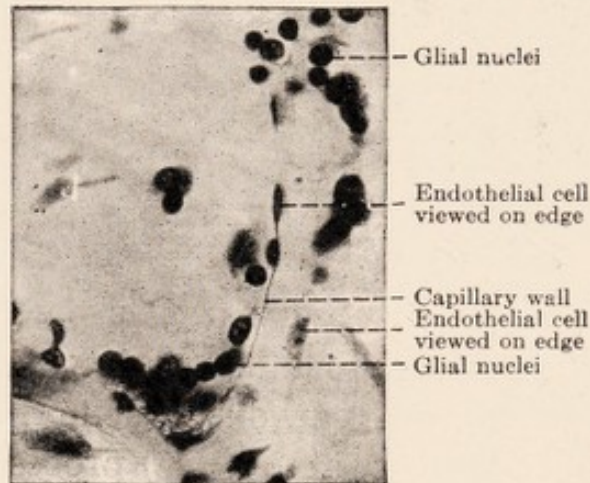


FIG. 53.—Capillary surrounded by numerous glial nuclei. Nissl stain.

ative processes in the parenchyma, and the reactions consequent to destruction of tissue. If we wish to retain the term inflammation at all we should restrict it to those morbid changes in which cellular extravasations occur unquestionably; this occurrence at present is certain only in the case of suppuration. Where this is lacking it is well at present to be cautious about making the histological diagnosis of inflammation. It is quite likely that various other histopathological changes may be met with

in inflammatory areas, such as degenerative processes in the "parenchyma," and regressive and progressive alterations in the ectodermal and mesodermal supporting tissues. However, these changes most not be looked upon as characteristic of the inflammatory process, but merely as the anatomical expression of injuries, with the resulting reactive tissue proliferation which is produced in the living organs by any injury under all conditions (proliferation of vessels, formation of fibroblasts and granule cells, proliferation of glia).

INDEX

A

- Abraumzellen, 132
Abscess, 145
Achuccaro, adventitia demonstration,
59
staining method, 105
Adamkiewicz on Golgi nets, 30 (ref.)
Alzheimer on chronic retrogressive
changes, 131 (ref.)
on disintegration products, 100 (ref.)
on glial changes, 101 (ref.)
Anemia, 136
cord changes in, 124
Apathy on neurofibril studies, 22
(ref.), 32
Arachnoid, 60
Artefacts in ganglion cells, 88
see lymphatics
Arteries, 56
endarteritis obliterans, 107
sclerosis, 106
syphilis, 109
Arteriosclerosis, 106
Astrocyte, 45, 50, 95
Atheroma, 106
Atrophy, 137
Aufbauzellen, 135
Axis cylinder, 37
in anemias, 125
changes regressive, 112, 114
regeneration, 116
degeneration discontinuous, 122

B

- Bartels on lymphatics, 60
Baumgarten, syphilitic arteritis, 109
Bäumler on granule cells, 131 (ref.)

- Bethe on axis-cylinder fibrils, 37
nets of, 51
on neurofibril studies (ref.), 30
Betz, cells of, 6
Bielschowsky on neurofibril changes,
89
on regeneration of central fibres
(ref.), 39
stain, 78, 89 (ref.)
Bodies of Elzholz, 41, 112, 113, 121,
123
Boedeker on cord changes in anemia,
124 (ref.)
Brain architecture, 75
fetal, reaction to injuries, 130
histological structure, 73
Brodmann on cerebral architecture,
75 (ref.)

C

- Cajal on architecture of cerebrum, 75
(ref.)
views on Golgi nets, 30
Capillaries, 59
changes in, 109
Cells, of Betz, 6
endothelial, in arteriosclerosis, 107
glial, 46
Nissl picture, 53
proliferation, 95
progressive changes, 101
regressive changes, 101
stainable substances, 4
staining methods, 100
granule, 131
definition, 132
in degeneration of nerve fibres,
119

- Cells, granule, demonstration of, 133
 fate of, 135
 functions, 132, 135
 gliogenic, 99, 134
 in inflammation, 148
 mesodermal type, 133
 of neurilemma, 115, 134
 origin, 133
 reduced, 135, 149
 mast, 104, 129
 monster, 95, 103
 nerve, 3
 artefacts, 88
 degeneration, acute, 80, 85, 89
 chronic, 85
 severe, 87
 disintegration, 86
 fibrillar reticulum, 23
 Golgi picture, 84
 in cerebral cortex, 74
 cord, 70
 necrobiosis, 87
 neurofibril changes, 89
 Nissl picture, 83
 nucleus, 17
 pathology of, 79
 pigments, 16
 proliferation, 91
 see lymphatics pericellular
 shape, 20
 spinal, 9
 stainable substance, 4, 11, 26, 84
 staining methods, 3, 4
 fibril, 4, 22
 Golgi's, 4, 21
 Nissl's, 4, 15
 unstained paths, 84
 of Russel, 135
 plasma, 136, 146
 Purkinje, 10
 pyramidal, 8
 reticular, 99, 105, 125, 134
 rod, 103
 satellite, 65, 72
- Cells, spider, 95, 103, 104
 Cerletti, on arteriosclerosis, 106
 Compression, 130
 Cord, spinal in anemia, 124
 neuroglia of, 70
 structure of, 68
 vessels of, 70
 Cysts, 97, 130, 131
- D**
- Degeneration of nerve cells, acute, 85,
 89
 chronic, 85
 severe, 87
 of nerve fibres
 discontinuous, 21
 of nerves, peripheral, 114
 primary, 115
 secondary (Wallerian), 38, 112
 of central fibres, 116
 Disintegration, discontinuous, 112
 Doinikow, on degeneration of per-
 ipheral nerves, 114 (ref.)
 on fibre structure (ref.), 41
- E**
- Edema, 136
 Edinger, on fibre regeneration (ref.),
 39
 Elzholz, bodies of, 41, 112, 113, 121,
 123
 Encephalitis, 137
 hemorrhagic, 151
 non-suppurative, 142
 periaxialis, 126
 Endarteritis obliterans, 107
 Endoneurium, 68
 Endothelium, 58
 Ependyma, embryology, 48
 Epineurium, 68
 Evensen, on artery structure, 57
 (ref.)

F

- Fibres, nerve, 37
 in anemia, 124
 axis-cylinder changes, 112
 degeneration, 38
 discontinuous, 121
 primary, 115
 secondary, 112, 116
 embryology of, 41
 histopathology, 110
 in neuritis, 124
 regeneration, 39, 91, 111, 117
 sheaths, 38
 changes in, 111
 of spinal cord, 69
- Fibrils, glial, 45, 49
 of brain, 73
 of cord, 69, 71
 proliferation, 93, 94
 reaction to injuries, 129
 see Neurofibrils
- Fischer, O., on progressive paralysis, 126 (ref.)
- Flechsig, on architecture of cerebrum, 75 (ref.)
- Fragnito, on embryology of nerve fibres, 41

G

- Ganglion cell, see cell, nerve
- von Gehuchten, on fibre degeneration, 113 (ref.)
- Gerletti, U., on rod cells, 104 (ref.)
- Gitterzellen, 134
- Glia, see cell, glial
 ependyma
 fibre, glial
 membrana limitans
 neuroglia
 spongioblast
- Glioma, 93
- Gluge, on "inflammatory globules," 131

- Goldschmidt, on neurofibrils, 28
- Golgi, nets, 30, 51, 65
 in necrobiosis, 88
 stain, 4, 21
 for glia demonstration, 44
 for nerve cells, 84
- Granules of Reich, 41
- Grawitz, P., on glial proliferation, 96 (ref.)
- "Gray, nervous," 31

H

- Hauptmann, A., on lymphatics, 59
- Heilbronner, on fibre degeneration, 124 (ref.)
- Held, on adventitia, 57
 on glia derivation, 43
 on glia histology, 47 (ref.)
 on Golgi nets, 30
 on granule cells, 131, (ref.)
 on lymphatics, 63
 on neurilemma, 42
 on sheath medullary, structure of, 42
- Hemorrhage, 141, 151
- His, on glia embryology, 48 (ref.)
 spaces of 61, 63
- Hyperemia, 136

I

- Infiltration, calcareous, 107
 round cell, 144
- Inflammation, 137, 152
 erythrocytes in, 143, 151
 granule cells in, 148
 hemorrhage in, 151
 leucocytes in, 143
 lymphocytes in, 144, 146
 non-suppurative, 142
 plasma cells in, 146
 suppurative, 142, 145

J

- Jäderholm, on fibril staining, 27
 Jakob, on degeneration of central fibres, 117 (ref.)
 on structure of central nerve fibres, (ref.) 211

K

- Kaes, on architecture of cerebrum, 75 (ref.)
 Kronthal, theory of nerve cells, 12 (ref.)
 Krückmann, on glial granule cells, 99 (ref.)
 on lymphatics, 62

L

- Leucocytes, duration, 145
 in inflammation, 144
 Lugaro, on fibre degeneration, 113 (ref.)
 Lymphatics, 59
 adventitial, 62
 embryology, 61
 fluid exchange, 67
 functions, 68
 intracerebral, 61
 pericellular, 64
 perivascular, 63
 subarachnoidal space, 61
 subdural space, 61
 Lymphocytes, in inflammation, 144, 146
 in tissues, 150
 origin, 148

M

- Mann, G., on stainable substance, 12 (ref.)
 Marchand, on plasma cells, 147 (ref.)
 Marchi, stain, 76, 111

- Mater, dura, 60
 pia, 60
 Matter, gray, of brain, 71
 of cord, 70
 white, of brain, 71
 of cord, 69
 Membrana fenestrata, 57
 limitans gliae, 48, 51, 61, 64
 in cyst formation, 97
 Merzbacher, on granule cells, 131 (ref.)
 Metachromasia, in cell degeneration, 86
 in necrobiosis, 87
 Miyake, on regeneration of central fibres, (ref.), 39
 von Müller, E., on plasma cells, 136 (ref.)
 Myelitis, 137
 hemorrhagic, 151
 Myelospongium, 48

N

- Necrobiosis of ganglion cells, 87
 Nemiloff, on sheaths of nerve fibres, (ref.), 39
 Nerves, peripheral, 68
 degeneration of, 114
 Nets of Bethe, 51
 of Golgi, 30, 51, 65
 in necrobiosis, 88
 Neural, 36
 Neurilemma, 38, 39, 110
 derivation of, 42
 granule cells, 115
 progressive changes, 114
 regeneration, 111, 115
 Neuritis, 124, 137
 Neuroblast, 48
 Neurofibrils, 6, 15, 22
 Apathy's conception, 22, 32
 Bethe's conception, 25
 in degeneration, acute cellular, 89

- Neurofibrils, in earthworm and leech,
22
elementary, 23, 25
function, 28
Goldschmidt's views, 28
in man, 25
primitive, 23
reticula, 23, 26
staining method, 4, 89
- Neuroglia, 43
in anemia, 125
cell—see cell, glial
of cord, 69
derivation of, 43
embryology, 48
fibril—see fibril, glial
functions, 52
Golgi picture, 44, 50
granule cells, 99
in nerve degeneration, 118
Nissl picture, 52
phagocytic power, 97
progressive changes, 92
in cells, 95
in fibrils, 93
proliferative power, 91
reaction to injuries, 129
regressive changes, 91
relation to vessels, 55
staining methods, 100
Weigert method, 45, 50
syncytial character, 47
- Neurone theory, 29, 31, 32
- Neuropil, 23, 74
- Nissl, on axone, 20 (ref.)
on capillary changes, 109 (ref.)
on degeneration, acute cellular, 80
(ref.), 85, 89
chronic cellular, 85
severe cellular, 87
on disintegration of cells, 86
on equivalent picture, 12, 13 (ref.)
on glial cell changes, 101 (ref.)
- Nissl, on granule cells, 131 (ref.)
on inflammation, 137 (ref.), 141
(ref.)
on lymphatics, 62 (ref.)
on lymphocytes, 150 (ref.)
on mesodermal tissue reaction, 128
(ref.)
on necrobiosis, 87
on nerve cells, altered, 85 (ref.)
morphology of, 5 (ref.)
on "nervous gray," 31
on neurofibrils, 29 (ref.)
on neurone theory, 32 (ref.)
on pathology, general, 2 (ref.)
on plasma cells, 147 (ref.)
on section preparation, 15 (ref.)
on spaces, pericellular, 65
stainable substance, 4, 11, 26
in ganglion cells, diseased, 84
staining method, 4, 15, 78, 79, 83
glia picture, 52, 53 (ref.)
glial alterations, 101
- Nodes of Ranvier, 38
- Nonne, on cord changes in anemia,
124 (ref.)
- O
- Obersteiner, on pericellular spaces, 64
(ref.)
- v. Orzechowski, on regeneration of
nerve cells, 91 (ref.)
- P
- Paladino, on structure of medullary
sheath, 42
- Paralysis, progressive, 126
- Paths, unstained, 16
in diseased cells, 84
- Perineurium, 68
- Perusini, on plasma cells, 136 (ref.)
- Picture, equivalent, 12, 77
- Pigments, 16
- Purkinje, cells of, 10

R

- Ranke, O., on vessel structure, 57 (ref.)
 Ranvier, nodes of, 38
 Reich, granules of, 41
 on sheaths of nerve fibres, (ref.), 39
 Reichardt, on edema, 137 (ref.)
 Reticulum, diffuse elementary, 23
 intracellular, 23, 26

S

- Satellites, 65, 72
 Schröder, on anemic changes of cord, 124 (ref.)
 on arteriosclerosis, 106 (ref.)
 on arteritis syphilitica, 109 (ref.)
 on cerebral changes in dementia, 137 (ref.)
 on encephalitis and myelitis, 126 (ref.)
 on ganglion cell changes, 79 (ref.)
 on incrustation of Golgi nets, 88 (ref.)
 on inflammation, 137 (ref.), 146 (ref.)
 on lymphatics, 60 (ref.)
 on plasma cells, 136 (ref.), 148 (ref.)
 Schultze, fibrillar doctrine, 22
 Schwann, sheath of, see Neurilemma
 Sclerosis, diffuse, 126
 malignant multiple, 126
 multiple, 126
 Sheath, medullary, 38, 110
 in anemia, 125
 in systemic disease, 123
 degeneration, discontinuous, 121
 regeneration, 111
 regressive changes, 111, 114
 of Schwann, see Neurilemma
 Softening, 130

- Space, epicerebral, 61
 epispinal, 61
 of His, 61, 63
 pericellular, 64
 subarachnoidal, 61
 subdural, 61
 Spatz, on degeneration of nerve fibres, 113 (ref.)
 on fetal brain reaction to injury, 130 (ref.)
 Spielmeyer, on ganglion cell changes, 82 (ref.)
 on glial proliferation, 93 (ref.)
 on plasma cells, 136 (ref.)
 on progressive paralysis, 126 (ref.)
 on rod cells, 104 (ref.)
 Spongioblast, 48
 Stains, Achuccaro's, 105
 Bielschowsky's, 78
 fibril, 4
 Golgi's, 4, 21
 for ganglion cells, 84
 for glia, 44
 Marchi's, 76, 111
 for morbid changes, 76
 for neuroglia, altered, 100
 Nissl's, 4, 15, 78, 79, 100
 ganglion cell picture, 83
 glia picture, 52
 Weigert's medullary sheath, 76, 78
 resorcin fuchsin, 57
 Storch, on glia fibril proliferation, 94 (ref.), 95 (ref.)
 Stransky, on degeneration of nerve fibres, 121 (ref.), 123 (ref.)
 on neurilemma structure, (ref.), 40
 Stroebe, on degeneration of central fibres, 117 (ref.), 118 (ref.)
 on degeneration of peripheral nerves, 114 (ref.)
 Substance, "essential nervous," 28
 stainable of Nissl, 4, 11, 26
 in diseased ganglion cells, 84
 Syphilis of blood vessels, 109

T

- Theory, neurone, 29, 31, 32
Thrombosis, 130
Thumazuri, cord changes in anemia,
125 (ref.)
Tissue, connective, changes, 105, 129,
141
distribution, 55

V

- Veins, 56
Vessels, blood, Achuccaro's method,
59
adventitial changes, 105
arteriosclerosis, 106
capillary changes, 109
of cord, 70
endarteritis obliterans, 107
reactive changes, 129

- Vessels, blood, relation to nervous
tissue, 55
syphilis, 109
Weigert's stain, 57
lymphatic, see lymphatics
Virchow-Robin, spaces of, 62

W

- Waldeyer, neurone theory, 31
Waller, law of, 113
secondary degeneration, 38
Weigert, glial fibres, 45 (ref.), 49
proliferation, 93, 94
stain for medullary sheath, 76, 78
resorcin fuchsin, 57
Wohlvill, cord changes in anemia,
125 (ref.)

Y

- Y-cells, 135



