

Veterinary obstetrics / by W. L. Williams.

Contributors

Williams, W. L. 1856-1945.

Publication/Creation

Ithaca : W. L. Williams, 1943.

Persistent URL


<https://wellcomecollection.org/works/v9r9884j>

License and attribution

Conditions of use: it is possible this item is protected by copyright and/or related rights. You are free to use this item in any way that is permitted by the copyright and related rights legislation that applies to your use. For other uses you need to obtain permission from the rights-holder(s).



Wellcome Collection
183 Euston Road
London NW1 2BE UK
T +44 (0)20 7611 8722
E library@wellcomecollection.org
<https://wellcomecollection.org>





376
subh

Digitized by the Internet Archive
in 2017 with funding from
Wellcome Library

<https://archive.org/details/b29820510>

VETERINARY OBSTETRICS

Veterinary Obstetrics

BY

W. L. WILLIAMS

PROFESSOR EMERITUS, CORNELL UNIVERSITY

FOURTH EDITION

PUBLISHED BY W. L. WILLIAMS
209 WHITE PARK ROAD, ITHACA, N.Y.

1943

COPYRIGHT BY
W. L. WILLIAMS
1943

Ministry of Agriculture,
Fibres and Food,
Veterinary Laboratory
Library X

Class No. 4W.X
Auth. Mk. WIL
Access No. L66/b30
Demand No.

WELLCOME INSTITUTE LIBRARY	
Coll.	WelMOMec
Coll.	
No.	V

2762922

PREFACE

A SERIES of years devoted chiefly to the practice of veterinary obstetrics and to the handling of other interferences with reproduction, deeply impressed me with the scarcity of literature in this field. The discussion of the pathology of reproduction was virtually limited, in the English language, to the excellent *Veterinary Obstetrics* of Fleming, which appeared in 1877. Various minor works had preceded, and followed the treatise of Fleming, without materially adding to the knowledge of the subject. Veterinary obstetrics was taught in most veterinary colleges by lectures by men without clinical experience in the field.

Following an extensive experience as a private practitioner, fifteen years of teaching obstetrics in the veterinary college led me to believe that the knowledge of the subject might be advanced by the publication of my personal observations along with those of other clinicians, in so far as available, not for the purpose of superseding existing literature, but to add new views and observations which might add to our means for controlling the interferences with reproduction. Accordingly I prepared and published in 1909 *Veterinary Obstetrics; Including the Diseases of Breeding Animals and of the New-Born*. At that time the pathology of reproduction was the most highly controversial problem in veterinary medicine, and during the thirty-four years which have since elapsed, no spectacular advancement toward unanimity has occurred.

The treatise of 1909 was divided. In 1917 there was published *Veterinary Obstetrics*, and in 1921 appeared *The Diseases of the Genital Organs of Domestic Animals*. A second edition of *Veterinary Obstetrics* followed in 1931, a second edition of *The Diseases of the Genital Organs of Domestic Animals* in 1939, a third edition of *Veterinary Obstetrics* in 1940, and a third edition of the *Diseases of the Genital Organs of Domestic Animals* in 1943.

The 1931 edition of *Veterinary Obstetrics* departed from the ancient tradition that dystocia, about which veterinary obstetrics largely revolves, is due to the whims of chance, and the ground was taken that difficult labor is the consequence of errors in animal husbandry, that many of these errors are definitely recognizable and consequently preventable. As a repercussion to this view, Dott. Attilio Grignani translated the treatise into Italian and it was published in 1936 by Urico Hoepli of Milan with an introduction by Prof.

Giuseppe Gerosa of the Milan veterinary school, who especially emphasized the new view that dystocia and allied phenomena are predictable and preventable.

Similar considerations led to the publication in 1942 of both treatises in the Spanish language by Salvat Editores, Barcelona-Buenos Aires, thus rendering them available in Spain and throughout Latin America. Quite naturally the effort is continued in the present edition to strengthen the view that dystocia and allied phenomena are the logical consequences of errors in animal husbandry.

The clinical observations which have led me to such wide divergence from the established traditions have been numerous and impressive. In 1924, Professors Udall and Frost, with their clinical staffs, including Fincher, Cushing, Gibbons, Mabey, Errington and others, collected a great volume of highly significant material from their clinics, and I joined with them in extended studies of the clinical pathology of the uterus, fetal membranes and fetus. Professor Udall generously provided facilities and equipment for the work, and, as editor of *The Cornell Veterinarian*, extended invaluable assistance in the arrangement of the results of the studies, and in their publication. It was necessary that financial aid should be obtained in order that an accurate record of the lesions observed might be properly recorded and illustrated. An appeal was made to the Heckscher Research Council at Cornell University, which extended a generous grant of funds.

The researches made it apparent that many of the pathological phenomena of reproduction are clearly and authentically registered in macroscopic lesions of the fetal membranes, fetus and uterus. Later Professors Milks and Stephenson joined in the studies and supplied valuable clinical material pertaining to the pathology of reproduction in carnivora.

There followed closely an opportunity to act as resident veterinarian in a stud of thoroughbred mares in which reproduction was highly pathological. Later I enjoyed a unique opportunity for mass observations in a large dairy herd, the foundation stock for which I had largely selected ten years previously. I was intimately or fairly cognizant of the breeding conditions in the herds from which nearly all the foundation animals had come. The herd records, which were unusually complete, included the fourth generation of progeny. No females had been added and none sold or discarded except for cessation of reproduction. No males had been added. An unusual opportunity presented itself for intimate study of dystocia and other pathological phenomena of reproduction as affected by the known

character of food and method of feeding and breeding. The value of the observations was greatly increased by the presence upon the same estate of a herd of 25,000 beef cattle, freely available for comparison.

Important suggestions or communications have come from Professor Danks, at Cornell, Professor Krill of Ohio State University, Professors Frank and Frick of the Kansas State College, as well as from other colleagues, at home and abroad. It has been aimed to mention these in the text and bibliography.

The conclusions reached will naturally not be universally endorsed. That is not vital. The advancement of veterinary obstetrics is best assured when the reader examines critically each statement. It may be well to respect the author's views, but the veterinary obstetrict should compare the observations of an author with his personal experience, and finally draw his own conclusions. The highest value of a treatise upon veterinary obstetrics is that it may encourage the reader to observe and think.

W. L. WILLIAMS

Ithaca, N.Y., October, 1943.

CONTENTS

SECTION I OBSTETRICAL ANATOMY

	PAGE
CHAPTER I. THE PELVIS	3
CHAPTER II. THE GENERATIVE ORGANS	8
The Ovaries	8
The Genital Tract	10
The Muellerian Ducts	10
The Oviducts	12
The Uterus	14
The Cervix	19
The Vagina	19
The Vulva	20

SECTION II OBSTETRICAL PHYSIOLOGY

CHAPTER III. REPRODUCTION	23
Maturation of the Ovisac	25
Estrum	25
Copulation	29
Ovulation	30
Fertilization	31
Menstruation	31
CHAPTER IV. ANOMALIES IN FERTILIZATION	33
The Migration of Genital Cells	33
Superfecundation	34
Superfetation	34
Extrauterine Pregnancy	35
CHAPTER V. PREGNANCY. GESTATION	40
CHAPTER VI. EMBRYOLOGY. TERATOLOGY	42
Segmentation of the Egg	43
The Primitive Streak	47
Formation of the Embryo	47
The Celom or Body Cavity	48
The Nervous System	49
The Brain	54
The Spinal Cord	56
Development of the Organs of Special Sense	56
The Nose	56
The Eyes	58
The Ears	59
Formation of the Digestive and Respiratory Apparatus	63
The Lungs	65
The Teeth	66

	PAGE
The Circulatory System	72
The Heart	72
The Arteries	75
The Veins	78
The Fetal Circulation	79
The Urino-Genital System	82
The Wolffian Bodies and Ducts	82
The Kidneys, Ureter and Bladder	83
The Gonads or Sex Glands	84
The Male Reproductive Organs	85
The Testicles	85
The Limbs	89
The Fetal Membranes and the Placenta	94
The Vitelline Sac	94
The Amnion	95
The Allantois	98
The Chorion	99
The Placentae	105
The Umbilical Cord	112
CHAPTER VII. THE CLINICAL DIAGNOSIS OF PREGNANCY	114
CHAPTER VIII. THE PREGNANT UTERUS	116
The Form and Position of the Pregnant Uterus	116
The Position and Movements of the Fetus during Gestation	117
The Number of Fetuses in the Uterus	123
Twins	124
The Duration of Pregnancy	127
The Duration of Reproductive Power and the Rate of Reproduc- tion	132
Sex Parity	135
CHAPTER IX. THE BACTERIAL FLORA OF THE PREGNANT UTERUS	140
CHAPTER X. THE HYGIENE OF BREEDING ANIMALS	143
CHAPTER XI. THE DISEASES OF THE PREGNANT ANIMAL	149
SECTION III	
CHAPTER XII. PHYSIOLOGICAL BIRTH	155
CHAPTER XIII. ARTIFICIAL INTERFERENCES IN PHYSIOLOGICAL PARTURI- TION	166
SECTION IV	
CHAPTER XIV. DYSTOCIA	173
CHAPTER XV. THE BASIC CAUSES OF DYSTOCIA	176
Dystocia due to Teratological Causes	176
Teratological Hypoplasia of the Female Genitalia	176
Genital Hypoplasia in Young Animals	177
Arrested Development of the Female Reproductive System during First Pregnancy	178
Dystocia from too Early Post-Partum Breeding	179

	PAGE
The Dystocia of Hybridization	179
Dystocia due to Bulldog Calves	179
Dystocia due to Muscle Contracture Monsters	180
Dystocia Attributed to Short Nose. Hereditary Hydrocephalus ...	185
Pathological Ovulation. Twin Dystocia	186
Dystocia due to Pathological Anchorage of Fetus	188
Dystocia from Bicornual Pregnancy in Solipeds	189
Sterno-Abdominal Position	190
Rotated Bicornual Pregnancy	192
Dystocia due to Bicornual Pregnancy in Ruminants	193
Dystocia due to Bicornual Pregnancy in Multipara	194
Dystocia due to Displacement of the Pregnant Uterus. Uterine Torsion	196
Dystocia referable to Traumatic Hernia	199
Dystocia referable to Pelvic Abnormalities	199
Dystocia attributed to Size of Sire	200
Dystocia due to Pre-Conceptional Uterine Lesions	200
Dystocia referable to the Pathology of the Sex Cells	201
CHAPTER XVI. THE EXCITING OR IMMEDIATE CAUSES OF DYSTOCIA	206
Presentation, Position and Posture	206
Excessive Volume of the Fetus	208
CHAPTER XVII. THE HANDLING OF DYSTOCIA	210
Equipment	210
Appliances for Exerting Traction	210
Repellers	216
Instruments for Section	217
The Dress of the Operator	220
Position and Control of the Patient	221
Epidural Anaesthesia	223
The Examination of the Patient	225
The Prevention of Infection during Obstetrical Operations	228
CHAPTER XVIII. OBSTETRICAL OPERATIONS	230
Mutation	230
Repulsion	230
Rotation	232
Version	235
Extension and Adjustment of the Extremities	235
Forced Extraction	238
Embryotomy	242
Embryotomy in the Anterior Presentation	243
Decapitation	243
Cephalotomy	244
Amputation of Head and Neck	245
Subcutaneous Amputation of Anterior Limbs	246
Amputation at Humero-Radial Articulation	249
Detruncation	250
Destruction of the Pelvic Girdle	252
Embryotomy in the Posterior Presentation	253

	PAGE
Amputation of Posterior Limbs at Tarsus	254
Intra-Pelvic Amputation of Posterior Limbs	255
Evisceration	258
Miscellaneous Embryotomy Operations	259
Cesarean Section. Gastrohysterotomy	260
Hysterectomy	266
CHAPTER XIX. THE HANDLING OF THE VARIOUS FORMS OF DYSTOCIA . . .	268
Hypoplasia of the Reproductive System and of the Pelvis	268
Juvenile Pelvis	270
Persistent Median Wall of the Muellerian Ducts	271
CHAPTER XX. DISEASES AND INJURIES OF THE PELVIS AND PELVIC ORGANS WHICH MAY CAUSE DYSTOCIA	272
Rachitic Deformities of Pelvis	272
Pelvic Fractures and Exostoses	272
Compression and Atresia of Vagina	274
Dystocia due to Cervical Disease	275
CHAPTER XXI. DYSTOCIA DUE TO DISLOCATION OF THE REPRODUCTIVE ORGANS	278
Vagino-Cervical Prolapse	278
CHAPTER XXII. UTERINE HERNIAE. HYSTEROCELE	284
Dystocia due to Inguinal and Umbilical Herniae	284
Ventral Herniae	284
Rupture of the Prepubian Tendon	284
CHAPTER XXIII. TORSION OF THE UTERUS. UTERINE VOLVULUS	292
CHAPTER XXIV. DYSTOCIA FROM ABNORMAL FETAL VOLUME	304
Fetal Giantism	304
Dystocia due to Excessive Volume of Parts of the Fetus or of the Fetal Fluids	307
Dystocia due to Fetal Ascites	307
Fetal Anasarca	308
Edema of the Allantochorion	310
Amnio-Allantoic Dropsy	314
Dystocia due to Monsters	320
Double Monsters	323
Hydrocephalus	323
Schistosomus Reflexus	327
Deformity and Rigidity of Extremities	329
CHAPTER XXV. TWIN DYSTOCIA	332
CHAPTER XXVI. DYSTOCIA DUE TO BICORNUAL PREGNANCY. DYSTOCIA FROM TRANSVERSE PRESENTATION	334
Dystocia due to Bicornual Pregnancy in the Mare	335
Transverse Abdominal Presentation of Bicornual Pregnancy	335
The Compound or Rotated Bicornual Pregnancy	340
Dystocia from Bicornual Pregnancy in Ruminants	348
Dystocia from Bicornual Pregnancy in Multipara	351
CHAPTER XXVII. DYSTOCIA DUE TO POSTMORTEM CHANGES IN THE FETUS	353
The Static Fetal Cadaver	357
Papyraceous Mummification	358
Mummification of the Bovine Fetus	359

CONTENTS

xiii

	PAGE
Emphysema and Purulent Decomposition of the Fetus	360
CHAPTER XXVIII. THE DYSTOCIA OF UTERINE INERTIA	363
CHAPTER XXIX. DYSTOCIA DUE TO PATHOLOGICAL PRESENTATION, POSI- TION OR POSTURE	365
Dystocia due to Pathological Disposition of the Umbilical Cord ..	365
CHAPTER XXX. DYSTOCIA IN THE ANTERIOR PRESENTATION	367
The Dorso-Iliac and Dorso-Pubic Positions	367
Deviations of the Head and Neck	368
Lateral Deviation of the Head	368
Wry-Neck	371
Downward Deviation of the Head between the Anterior Limbs .	373
Upward Deviation of the Head	374
Deviations of the Anterior Limbs	374
Flexion of the Anterior Feet	375
The Fore Limbs Crossed over the Neck	377
Flexion of the Anterior Limbs at the Elbow	378
Complete Retention of the Anterior Limbs	380
Interlocking of the Maternal and Fetal Pelves	382
Forward Extension of the Posterior Limbs beneath the Fetal Body	384
CHAPTER XXXI. DYSTOCIA DUE TO PATHOLOGICAL POSITIONS AND POS- TURES IN THE POSTERIOR PRESENTATION	388
Dorso-Iliac and Dorso-Pubic Positions in Posterior Presentation ...	389
Flexion of the Posterior Limbs at the Tarsus	390
Complete Retention of the Posterior Limbs, Breech Presentation ..	391
Lateral Deviation of the Head in Posterior Presentation	393

SECTION V

CHAPTER XXXII. WOUNDS AND INJURIES OF THE GENITAL AND NEIGH- BORING ORGANS	397
Postpartum Hemorrhage	397
Rupture of the Uterus and Vagina	398
Prolapse of the Intestine through the Ruptured Walls of the Uterus or Vagina	400
Prolapse of the Bladder through a Rupture in the Floor of the Vagina	400
Uterine Invagination and Prolapse	401
Prolapse of the Rectum	417
Prolapse and Eversion of the Bladder	417
Rupture of the Perineum	419
Hematoma of the Vulva	422
Contusion of the Lumbo-Sacral Nerves	422
Contusion of the Gluteal Nerves. Gluteal Paralysis	423
Contusion of the Obturator Nerves	424
Coxo-Femoral Dislocation	426
Necrotic Vaginitis	428
Miscellaneous Parturient Injuries	430
Puerperal Infections	430

	PAGE
SECTION VI	
CHAPTER XXXIII. PUERPERAL ECLAMPTIC DISEASES. PARTURIENT PARESIS.	
THE TOXAEMIAS OF PREGNANCY AND PUERPERIUM	433
Parturient Eclampsia	435
Puerperal Eclampsia in the Sow, Goat, Ewe and Bitch	441
CHAPTER XXXIV. PARTURIENT PARESIS	443
Parturient Paresis in the Cow. Milk Fever. Parturient Apoplexy ...	443
Parturient Paresis in Goat, Ewe and Sow	455
CHAPTER XXXV. THE PUERPERAL FEMALE AND THE NEW-BORN YOUNG	457
BIBLIOGRAPHY	465
INDEX	469

ILLUSTRATIONS

COLORED PLATES

- I. Gravid uterus of cow at full term Frontispiece
- II. Fetal sac of cow at about one hundred days Opposite p. 98
- III. Gravid uterus of cow, estimated at four months. Non-gravid horn of
fetal sac, necrotic, and surrounded by exudate Opposite p. 104
- IV. Torsion of uterus. Cow Opposite p. 292

ILLUSTRATIONS IN THE TEXT

	PAGE
1. Pelvis of cow with pelvic ligaments	4
2. Uterus of mare viewed from above	13
3. The uterine caruncles in veal heifers	15
4. Uterus from heifer estimated at 90 to 100 days pregnant	16
5. Ovaries, oviducts, uterus, and cervix of cow	18
6. Cervixes of virgin heifers showing the annular folds of mucosa	19
7. Section of ovary of cow showing a follicle 0.6 mm., with ovum	24
8. Section of ovary of cow showing a follicle of 2 mm., with ovum	26
9. Section of ovary of cow with a nearly ripe ovum in an ovisac 5 x 7 mm. showing vacuoles in the cumulus preparatory to ovulation ..	26
10. Secondary extrauterine fetuses. Swine	36
11. A fully formed ovum of the rabbit shortly before its discharge from the ovary. (Marshall after Bischoff.)	43
12. Ovum of rabbit from the upper end of the oviduct after extrusion of the two polar bodies. (Marshall after Bischoff.)	43
13. A rabbit's ovum from the middle of the length of the oviduct about 22 hours after copulation, showing division of the ovum into two cells. $\times 200$. (Marshall after Bischoff.)	45
14. A rabbit's ovum from the lower end of the oviduct, about the middle of the third day; showing the morula stage, shortly before the com- pletion of segmentation. $\times 200$. (Marshall after Bischoff.)	45
15. A rabbit's ovum seventy hours after copulation, taken from the lower end of the oviduct just before entering the uterus and showing the condition at the close of segmentation. $\times 200$. (Marshall after Van Beneden.)	45
16. A transverse section across the hinder part of the embryonal area of a rabbit embryo at the end of the seventh day, the section passing through the primitive streak. $\times 80$. (Marshall after Kölliker.) ..	48
17. <i>Schistocephalus bifidus</i> . (Gurlt.) Calf. Frontal view of head	50
18. Sagittal section of Fig. 17	51
19. <i>Schistocormus fissidorsualis</i> . Complete splitting of the spinal column. Calf	51
20. A median longitudinal, or sagittal, section through a rabbit embryo, at the end of the twelfth day. (Marshall.)	52

	PAGE
21. Sagittal section of acardiac monster. Cow	53
22. Head of cyclops. Foal	55
23. Hernia cerebri. Pig	55
24. The under surface of the head of a human embryo, lettered by Professor His, Hn, and estimated as about twenty-nine days old. $\times 7\frac{1}{2}$. (From Marshall after His.)	56
25. Cleft palate. Foal	57
26. The left ear of a human embryo, lettered by Professor His, Br. 2, and estimated as thirty-five days old. $\times 20$. (From Marshall after His.)	60
27. Ears and face of foal following the removal of "ear teeth"	61
28. Diagrammatic view of ear and skull from Fig. 27	62
29. Three successive stages in the development of a tooth germ of a pig embryo. (Heisler.)	66
30. Sagittal section through an inferior grinder of an equine embryo, 4 inches long	67
31. Sagittal section of superior molars of adult horse showing on the left normal development and on the right arrested development of the cement area	69
32, 33. Crown, and longitudinal cross section of a superior grinder of adult horse showing absence of cement in central infundibulum and erosion of the enamel and dentinal plates	69
34. Cross section of molar of adult horse	70
35. Table surface and section of inferior molar of adult horse, showing non-fusion of dentinal lamellae, followed by infection and purulent pulpitis	70
36. Reconstruction of human embryo of about 17 days. (Heisler.)	74
37. Diagram illustrating the fate of the aortic arches. (Modified from Heisler.)	75
38. Fissicollis. Cervical ectopia cordis. (Gurlt.)	77
39. Genito-urinary system of a foal, 24 hours old, to illustrate descent of testicles and behavior of ruptured umbilical arteries	86
40. Right inguinal region of foal, 24 hours old	87
41. Rabbit embryo of the ninth day, seen from the dorsal side. $\times 21$. (Heisler.)	89
42. Human embryo of about 28 days, showing limb buds. (Heisler.)	90
43. Perosomus elumbis. Calf. (<i>Cornell Veterinarian</i> .)	91
44. Limited hydrocephalus. Club foot. Calf. (<i>Cornell Veterinarian</i>)	92
45. Transverse section of the embryonic area of a fourteen-and-a-half-day ovum of sheep. (Heisler after Bonnet.)	93
46. Transverse section of a sixteen-and-a-half-day sheep embryo. (Heisler after Bonnet.)	93
47. Transverse section of a sixteen-and-a-half-day sheep embryo with six somites. (Heisler after Bonnet.)	94
48. Schematic longitudinal sections of fetal annexes of mammalia. (Bonnet.)	96
49. Schematic illustration of fetal annexes of the embryo of the horse, 28 days after fecundation. Perpendicular section through the embryo and its envelopes. (Bonnet.)	98

	PAGE
50. Schematic longitudinal section of a horse embryo in its annexes, at about five months' gestation. Reduced to about 1/6. (Bonnet.)	100
51. Schematic sagittal section through the fetal annexes of ruminants. The parts between the two end portions and the central piece are represented as having been excised. (Bonnet.)	101
52. Twelve-day and 2½-hour-old blastodermic vesicle of sheep. Natural size. (Bonnet.)	101
53. Swine embryo and its membranes. 48 cm. long. Reduced to about ½ size. (Bonnet.)	101
54. Section through the chorion and uterine mucosa of the horse at 9½ months. Enlarged about 45-1. (Bonnet.)	103
55. Allantochorion from a sexually healthy cow	104
56. Allantochorion from a sexually unsound cow.	105
57. Fetal cotyledons from healthy and diseased cows. (<i>Cornell Veterinarian.</i>)	106
58. Allantochorion from very badly diseased uterus	107
59. Vascular allantois of mare. (<i>Cornell Veterinarian.</i>)	108
60. Vascular allantois of mare. (<i>Cornell Veterinarian.</i>)	109
61. Badly diseased allantois from mare, seen from the placental side. (<i>Cornell Veterinarian.</i>)	110
62. Allantochorion of bicornual pregnancy in mare, viewed from endodermal side. (<i>Cornell Veterinarian.</i>)	118
63. Normal allantochorion of mare. (<i>Cornell Veterinarian.</i>)	120
63a. Hypothetical descendants of an ideal breeding cow during ten breeding years	133
64. Method of securing the lower jaw by means of a looped cord	211
65. Group of common obstetrical instruments	213
66. Obstetrical forceps	216
67. Schematic illustration of the extension of a fore limb flexed at the carpus. (Franck)	236
68. Guiding ring of Lindhorst	245
69. Loop carrier of Schriever	245
69a. Destruction of the pelvic girdle	251
70. Constricted pelvis of mare, inducing irremediable dystocia	273
71. Pelvis of mare	274
72. Rupture of prepubian tendon in mare in advanced pregnancy	287
73. Rupture of prepubian tendon in pregnant mare	288
74. Torsion of uterus in ewe	296
75. Torsion of uterine cornu. Cat	297
76. Fetal anasarca in twin lambs	309
77. Edema of the chorion. Rupture of the uterus. Cow	312
78. Abdominal viscera of cow showing extreme hydrops of amnion and allantois. (<i>Cornell Veterinarian.</i>)	313
79. Uterus from Fig. 78 seen from the endometrial side. (<i>Cornell Veterinarian.</i>)	315
80. Placental side of allantochorion from case of dropsy of amnion and allantois. (<i>Cornell Veterinarian.</i>)	316
81. <i>Gastrodidymus octipes</i>	321

	PAGE
82. Pygodidymus aversus. (Gurlt.)	322
83. Hydrocephalus. Foal	324
84. Hydrocephalus. Foal. Skull from Fig. 83	325
85. Hydrocephalus. Calf. With club feet	325
86. Schistosomus reflexus. (<i>Cornell Veterinarian.</i>)	326
87. Schistosomus reflexus. (<i>Cornell Veterinarian.</i>)	326
88. Schistosomus reflexus. (<i>Cornell Veterinarian.</i>)	327
89. Perosomus elumbis. Calf. (<i>Cornell Veterinarian.</i>)	329
90. Bicornual pregnancy with fetus in ventral presentation prior to rotation. (Schematic.)	336
91. Oblique presentation in bicornual pregnancy	337
92. Compound or rotated bicornual pregnancy	341
93. Bovine uterus illustrating bicornual pregnancy	349
94. Gravid uterus of bitch in situ	350
95. Twin abortions. Mare. (<i>Cornell Veterinarian.</i>)	358
96. Lateral deviation of the head. (Saint-Cyr.)	368
97. Flexure of the anterior limbs at the carpus. (Saint-Cyr.)	375
98. Incomplete extension of anterior limbs	379
99. Complete retention of the anterior limbs. (Saint-Cyr.)	381
100. Forward deviation of posterior limbs in anterior presentation. (Saint-Cyr.)	384
101. Retention of the posterior limbs at the tarsus. (Franck.)	389
102. Breech presentation. (Saint-Cyr.)	392
103. Rope truss of Rainard. (de Bruin.)	414
104. Sagittal section of the pelvis of the mare, showing lumbo-sacral nerves	423
105. Contusion of obturator nerve	425

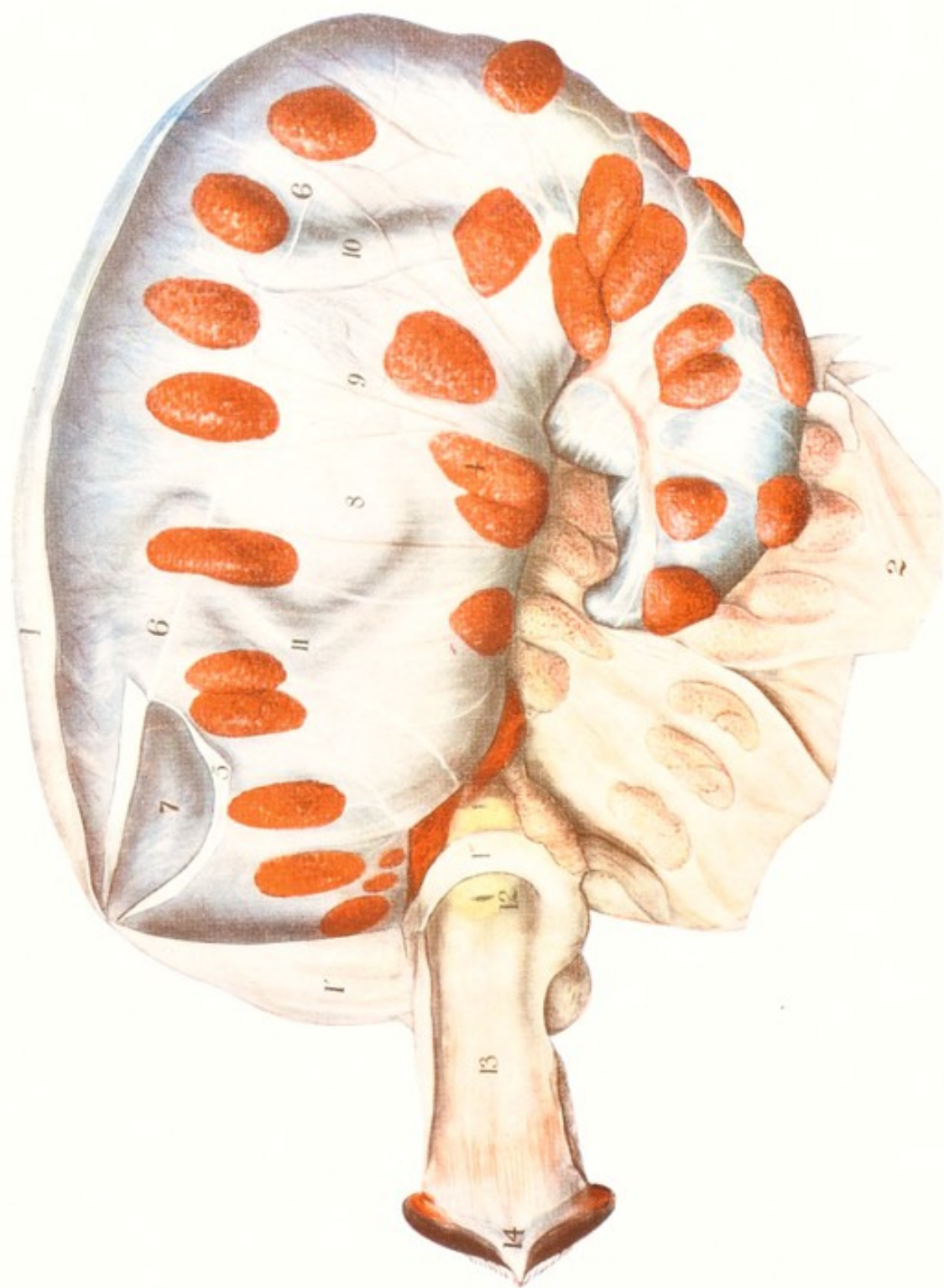


PLATE I

GRAVID UTERUS OF COW AT FULL TERM LAID OPEN TO SHOW FETAL SAC
WITH FAINT OUTLINE OF FETUS

1, dorsal or greater curvature of uterus; 1', supra-vaginal pouch of uterus; 1'', section through uterus at cervix; 2, right wall of uterine horn detached from chorion and turned down; 4, ventral row of chorionic (fetal) cotyledons. The first two are partly hidden beneath the fetal sac against the cervix. The apex of the fetal sac is rolled outwards showing the median raphe to the left of the last four cotyledons; 5, dorsal margin of the allantoic sac incised and turned down, exposing 7, the amniotic sac; 6, 6, dorsal line of allantoic sac, above which only the vascular layer of the allantois extends over the amnion, closely adhering to it; 9, umbilical cord; 10, left fetal tibia; 11, left fetal carpus; 12, os uteri externum and cervix, showing the cervical canal directed along the uterine floor; 13, vagina; 14, vulva.

SECTION I

OBSTETRICAL ANATOMY

SECTION I

OBSTETRICAL ANATOMY

CHAPTER I

THE PELVIS

THE pelvis plays a passive role in veterinary obstetrics. The attachment of the vulva to the pelvis constitutes the fixed base of support for the vagina, cervix and uterus. This attachment enables the uterus, at the time of parturition, to contract longitudinally in a manner to aid in dilating the canal and to force the fetus toward the vulva. Since the fetus must traverse the pelvic canal during parturition, it is essential that its amplitude be sufficient when compared with the transverse diameters of the normal fetus.

Pathologically, the pelvis is of limited interest in veterinary, as compared with human obstetrics. The quadrupedal position of domestic animals largely relieves the pelvis of weight-bearing, prevents deformities from pressure upon diseased pelvic bones in the young and renders pelvic deformities comparatively rare. The pelvis is composed of the sacrum and coxae with their ligaments.

The sacrum consists of a series of fused vertebrae: in the horse and ruminants five, in the pig four, and in carnivora three. In sagittal section it presents the form of a truncated cone with its base articulating anteriorly with the last lumbar vertebra and its apex posteriorly with the first coccygeal bone. In cross section it is triangular, with its base inferior. The lateral surfaces offer roughened facets for articulation with the coxae. The inferior surface contributes to the formation of the pelvic roof, is concave from before to behind, essentially plane from side to side, and shows transverse lines of demarcation between the individual vertebrae, in the form of ridges varying in prominence with species, age, breed, and individual.

The spinal canal, extending through the sacrum, is occupied by the terminal nerves of the spinal cord. The inferior surface of the bone shows a series of paired openings, through which the sacral nerves emerge to take a prominent part in the formation of the lumbo-sacral plexus. The lumbar nerves contributing to the lumbo-sacral plexus, especially those from the last lumbar pair, which contribute to the anterior gluteal and obturator nerves, have to pass over the

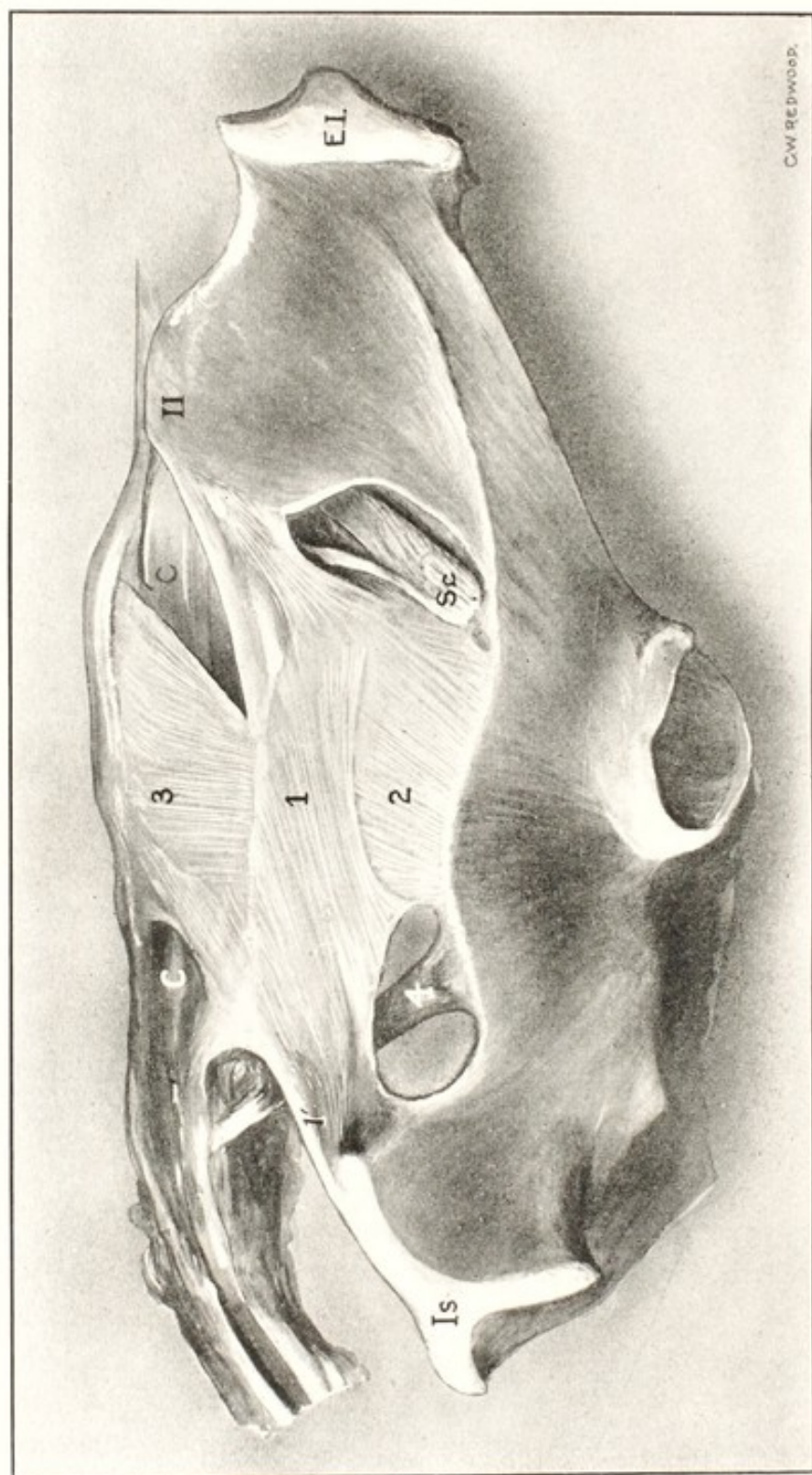


FIG. 1. Pelvis of Cow with Pelvic Ligaments.

1, central portion of sacro-sciatic ligament; 1', perineal border of ligament; 2, ischial portion; 3, sacral portion; 4, depressor coccygeus muscle; II, internal ilial tuberosity; C, C, coccygeal muscles;

EI, external ilial tuberosity; Is, ischial tuberosity; Sc, sciatic nerve.

promontory marking the lumbo-sacral articulation, *A*, Fig. 104, in such a manner that they may be, and not rarely are, crushed between the bony ridge and some unyielding part of the fetus during its passage through the pelvic canal. The obturator nerve may also be injured in a similar manner, at *O* in Fig. 104, as it enters the obturator foramen (see Contusions of Lumbo-Sacral Nerves).

The two coxae, each consisting of an ilium, ischium, and pubis, are elongated, flattened bones, widely expanded at each extremity, where they are composed chiefly of cancellated tissue, and constricted in the center, where they partake more of the structure of long bones. The relations between the pelvis and the dorso-lumbar area of the spinal column are maintained by ligaments, tendons and muscles. The sacro-iliac articulation is very rigid. The two ilia are closely applied to the sacrum by means of roughened articular surfaces and connected by short and very strong inter-osseous ligaments.

The integrity of the sacro-iliac articulation is further preserved behind and above by the sacro-sciatic ligament and in front and ventrally by the prepubian tendon and the muscles contributing thereto.

The sacro-sciatic ligament arises from the transverse spinous ridge of the sacrum, commencing immediately behind the sacro-iliac articulation and extending to the posterior extremity of that bone. Passing downwards, it is attached along the supero-external border of the ilium and ischium from the sacro-iliac articulation, backwards to the ischial tuberosity. The two ligaments thus consist of wide and thick aponeurotic sheets, which form the greater portions of the lateral pelvic walls. They furnish attachment for the vulva and for numerous powerful muscles, serve to prevent the posterior portion of the pelvis, or ischia, from receding from the sacrum, and form a strong and somewhat flexible and yielding wall to the pelvic cavity. Under the pressure of parturition, they yield enough to permit the constricted outlet to equal in dimensions the larger bony inlet of the pelvis.

The powerful prepubian tendon arises from the pubic brim and finds attachment in front, through the linea alba and the contributory muscles, to the ensiform cartilage of the sternum. It prevents the pubis and ischium from passing upwards and backwards toward the sacrum when the body weight is thrown upon the coxo-femoral articulation, which lies behind the ilio-sacral joint. It plays a very important part in the large herbivora, especially in the mare, where it sometimes becomes ruptured during advanced pregnancy, result-

ing in a hernia of the gravid uterus and a destruction of the normal relation of the pelvis to the spinal column (see Rupture of Pre-pubic Tendon). The pelvic cavity is somewhat conical. Since the wider base, or inlet, consisting of the bony pelvic girdle, constitutes the only non-extensible part, if a fetus can traverse the bony inlet, it can pass through the outlet because of the yielding of the sacro-sciatic ligaments. In woman, the relations between the sacro-pubic and bisiliac diameters of the pelvis are inconstant, resulting in a spiral passage which necessitates a rotation of the fetus upon its long axis, in order that the diameters of the fetal head and the maternal pelvis may correspond.

In cross section, the pelvic cavity, in each genus, is commonly slightly oval. Its sacro-pubic diameter is usually slightly greater than its bisiliac. The sacro-sciatic ligaments become markedly relaxed as parturition approaches. In the cow the sinking of the broad ligaments constitutes one of the standard signs of the near approach of calving, and is of special importance because the ischial notch is narrow, the tuberosity high, and the fetus in its exit needs pass over, rather than between, the ischial tuberosities.

The measurements of the pelvic cavity vary widely in different species, breeds, and individuals, rendering it impracticable to make any but the most general statements regarding the dimensions of the pelvis of domestic animals. The variations in size of the animals of a given species are extreme, owing to artificial selection in breeding, growing here a giant, there a pigmy. Horses vary between 2500 and 250 pounds in weight, with corresponding variations in the pelvic dimensions. The differences in size of individuals and of their pelvises are even greater in dogs. In the mare and the cow, the superficial area of a cross section of the fetal chest or hips is greater than that of the pelvic inlet of the mother. Birth is rendered practicable by the ready displacement of some fetal parts. In solipeds and ruminants, the volume of the chest and hips—not the head—is the determining factor in parturition. In woman, where the fetal head is so large that it constitutes the chief factor of resistance, and in the carnivora, in which the conditions are somewhat analogous, the fetal cranium, less completely ossified than in solipeds and ruminants, admits of some change in form. In herbivora, the cranial and facial bones of the mature fetus are too completely ossified to admit of any change of form under the compression of labor pains. The unyielding head must pass the equally unyielding pelvic girdle.

It has been asserted that significant sexual differences exist in the pelvises of domesticated animals, especially in the horse, and that the

sacrum varies in form according to sex. It has been stated that the pelvis of the mare is more ample than that of the stallion or gelding, that its foramen ovale is larger, that the ischiatic notch is broader and shallower, that the sacrum has less prominent articular ridges—in other words, that the pelvis of the mare is especially constructed as an organ of reproduction in a manner to facilitate the passage of the fetus at the time of parturition. This I have been unable to verify. Examining critically a number of equine pelves, I have found among them those of stallions or geldings fulfilling the description given by some anatomists as typical of the mare in every regard, and, vice versa, the pelves of mares meeting fully all the alleged characteristics of that of the male. So far as I have been able to determine, it is impossible to authentically identify, by the form or size of the pelvis, the sex of any species of domestic animal.

CHAPTER II

THE GENERATIVE ORGANS

THE genital system of the mammalian female consists of the ovaries, oviducts, uterus, cervix, vagina, and vulva. The mammary glands constitute essential organs for the nutrition of the newborn.

The Ovaries

The ovaries are the essential reproductive glands of the female. They elaborate the ovum or egg, which, after having been discharged from the ovisac and fertilized by the spermatozoon or male cell, becomes a distinct, but in mammalia not immediately an independent individual. The fertilized ovum is still dependent upon the oviducts for its migration to the uterus and upon the uterus for its nutrition and protection during pregnancy and its expulsion at fetal maturity. The young animal is dependent upon the milk from the udder of the mother for a time after birth.

The size, form, and location of the ovaries of domestic animals differ greatly according to species, breed, age, and individual: even the two glands in the same animal are not ordinarily alike and may vary greatly in size and form. The right gland is usually larger than the left. The ovary of the mare is generally much the largest seen in the domestic animals, reniform, very dense owing to its thick tunica albuginea, with a smooth surface which is elevated here and there in many cases by the presence near the surface of cysts varying from less than 0.25 inch to 2 or more inches in diameter. The gland attains its maximum size when the animal has reached the age of three or four years, and begins to diminish in volume at eight to fifteen years of age, largely owing to the disappearance of the cysts. The ovary of the young mare, if free of cysts, may be one inch in diameter or less, but with the usual presence of cysts, not demonstrably pathological, it is often $3\frac{1}{2}$ to 4 inches in its greatest diameter and weighs about 4 ounces. The ovary of the cow is much smaller than that of the mare, varying in its greatest diameter between 0.25 and 2 inches and weighing about 0.25 to 0.5 ounce; it is oblong and generally regular in outline.

The ovary is formed in the embryo beneath and on either side of the notochord in contact with the Wolffian body. It arises from the deeper layers of the peritoneum and descends later into the abdomi-

nal cavity, carrying with it the parietal peritoneum. The peritoneal layers approach each other behind the ovary, to form a double layer, which serves to preserve its attachment to the sub-lumbar region. Between the two folds, the vessels and nerves pass to the gland.

The location of the ovary in the adult varies much with species. Apparently the size of the gland, when normal, has little or no influence upon its position. It rests upon the superior surface of the anterior border of the broad ligament of the uterus, naked in most animals but closely invested in the bitch by the pavilion of the oviduct. The pavilion of the oviduct in other animals than the bitch is attached by one of its fimbriae to the ovary near its hilus.

The position of the ovary is further influenced by the round, or inguinal ligament, and its distal end, the utero-ovarian ligament. Arising from the skin and dartos at the point where the fundus of the scrotum of the male normally appears in the given species, it extends up through the inguinal ring behind the peritoneum, to become attached to the uterine cornu, or oviduct, not far from the ovary. These attachments tend to cause the ovary to follow a line of descent comparable to that of the testicle, but normally it becomes arrested in its migration at some point between its place of origin and the internal inguinal ring. In the bitch, it remains closely applied to the sub-lumbar region, immediately behind the kidney, virtually at its point of origin. In the mare, its movement is arrested early and it remains rather firmly suspended not far behind the kidney and above the middle of the posterior part of the abdominal cavity. The ovary of the ruminant lies loosely in the pelvis, alongside the cervix uteri or the base of the cornu, behind the internal inguinal ring. The ovary of the sow floats quite freely in the peritoneal cavity. Teratologically it sometimes passes out through the inguinal ring and comes to rest in that part of the perineal region corresponding to the scrotum of the boar. The same displacement of the ovary occurs rarely in bitches. It is possible in any species. In general it may be said that in the elongated uteri of multiparous animals the ovaries are situated further forward than in the uniparous or biparous genera. The location of the ovary is further modified by the pregnant state. The gravid uterus, in its descent, drags the gland downwards and forwards.

The functional activity of the ovary modifies its size and form. During the breeding life of the animal the cortex, or peripheral area, of the ovary is largely composed of egg columns, or masses, consisting of germinal cells arranged in the form of a hollow sphere. Resting upon an intruding mass of genital cells is a specially de-

veloped cell, the ovum. The spheroidal hollow mass of cells contains a fluid, the follicular liquid. When estrum, or "heat," is approaching, an ovum, or ova, matures, the ovisac becomes distended with follicular fluid, presses aside the superposed ovarian tissues, and attenuates or destroys the tunica albuginea at the involved point. In most animals the active ovisac pushes its way above the general ovarian surface as a hemispherical cyst with very thin walls. In the mare it regularly protrudes just at the hilus of the gland, where it is not readily apparent. The ripe ovisac—or ovisacs—ruptures at the close of estrum, producing a lesion, which usually behaves differently according to whether the discharged ovum becomes fertilized and undergoes development into a fetus or, failing of fecundation, perishes. The crater resulting from the rupture of the sac becomes filled with lymph, blood, or other products of the disturbances of the tissues.

After the ovisac has ruptured, there is soon present the corpus luteum, or corpora lutea, of estrum or of pregnancy. Should the ovum perish, the lesion tends to heal rapidly, the blood and lymph in the crater are resorbed, and from its walls there forms a characteristic tissue, known as the corpus luteum of estrum. In the cow and in most other animals it is identical in form, consistence, and volume with the corpus luteum of pregnancy, but its color usually differs. In the non-pregnant cow it is generally chocolate-colored. Prior to the next estrum, it atrophies.

Should the ovum become fecundated and undergo normal development, the corpus luteum forming in the crater is almost always markedly yellow or orange. It projects beyond the ovarian surface. Physiologically it persists, except in the mare, up to the time of parturition or abortion and for a varying length of time thereafter. It is known as a *true corpus luteum*. The size and form of the ovary are accordingly modified by the presence of a ripe ovisac or ovisacs or of a corpus luteum. In the cow the corpus luteum is frequently larger than the remainder of the ovary—approximately $\frac{5}{8}$ to $\frac{3}{4}$ inch.

The Genital Tract

THE MUELLERIAN DUCTS

THE OVIDUCTS, UTERUS, CERVIX, AND VAGINA

The beginning of the female genital tract in the small embryo consists of two parallel rods, which later become excavated to form tubes—the ducts of Mueller—extending from near the posterior body opening upwards and forwards to the region of the ovary. Eventu-

ally the two ducts fuse at their posterior ends, producing a single tube. The ducts become differentiated, through specialization in their development, into four essentially separate segments, each having its distinctive function. The anterior segment constitutes the oviduct, or Fallopian tube, dilated at its anterior end to form the ampulla, or pavilion. The oviduct constitutes a conduit through which the spermatozoon of the male may pass from the vagina and uterus to the ampulla, there to meet and fertilize the freshly discharged ovum. Later the oviduct serves as a conduit for the passage of the ovum, fertilized or unfertilized, to the uterus. The second, or middle portion of the genital tube constitutes the uterine cavity, in which the fetus may find lodgment, nutrition, and protection during its development. The third segment consists of the cervix, which acts as a barrier between the uterus and vagina. The fourth, or posterior segment—the vagina—extending from the cervix to the vulva, serves first as an essential copulative organ and later as a passage for the fetus at the time of birth.

The distance to which the fusion of the Muellerian ducts extends and the extent of the specialization of the different areas modify greatly the form and relations of the various segments. The entire genital tube, having a common embryonic origin, has a similar structure, characterized primarily by three coats—peritoneal, muscular, and mucous. The peritoneal layer, which invests the genital tract almost completely, is derived from the peritoneum of the body wall, behind which the ducts of Mueller originate. At the anterior extremity the genital tract opens, through the pavilion of the oviduct, into the peritoneal cavity. The peritoneum stops at the margin of the pavilion, to be succeeded by the mucous membrane of the oviducts.

The genital tract is supported by the broad ligaments, or mesometrium, which consists of two peritoneal layers resulting from the departure of the genital tube from its seat of origin behind the peritoneum. Along the line of their attachment to the genital tube, the peritoneal investment is interrupted to the extent of the area between the two peritoneal folds occupied by the vessels, nerves, pale muscle, and connective tissue fibres constituting the body of the ligament. At the posterior extremity of the genital tract, where it opens into the cloaca of the embryo, the peritoneum is reflected upon neighboring organs and the genital tube is surrounded by the intra-pelvic connective tissue, so that eventually the peritoneum covers, in addition to the oviducts and uterus, only the more anterior portions of the vagina. The fusion of the two Muellerian ducts, to form the vagina and uterus, destroys the contiguous median walls of the tubes as far

as they coalesce, and the two adjacent tubes become a single canal. The broad ligament varies greatly in its form and amplitude according to species and the functional activity of the genital tract. In the bitch, cat, and sow, in which the anterior extremities of the uterine cornua remain throughout the life of the animal about as far forward as the posterior border of the kidney, the broad ligament maintains its anterior attachment to the abdominal wall at or near the point of origin of the ovary; in the ruminant, where the ovary and the anterior ends of the uterine cornua are turned backwards to the immediate vicinity of the internal inguinal ring, the parietal attachment of the anterior border of the ligament likewise moves backwards for a considerable distance so that the middle of the recurved cornu tends to project forwards beyond the anterior margin of the ligamentous attachment. When the uterus of a quadrupedal mammal becomes gravid, the weight of the fetus drags the occupied portion downwards and forwards until the organ comes to rest upon the abdominal floor in front of the anterior point of fixation of the ligament to the abdominal wall and, especially in unipara, the gravid uterus ultimately comes to rest against the diaphragm. The genital tube is further maintained in its position by its attachment posteriorly to the vulva and also by the round ligament of the uterus.

The muscular walls of the genital tubes are composed of circular and longitudinal layers of pale fibres, varying greatly in the different sections of the tract and also according to whether the animal be pregnant or not.

The mucous coat of the genital tract offers the greatest possible variations and in the different areas assumes widely differing and highly important functions.

The Oviducts

The oviducts, formed from the anterior, or ovarian extremities of the Muellerian ducts, are two long, tortuous tubes, varying in length and other characters according to species. Their length is much greater than the distance from the anterior extremity of the uterine cornu to the ovary. This distance is fixed by the utero-ovarian ligament. In some animals the oviducts are naked and clearly visible. In the bitch they are hidden in the abundant fat of the broad ligament. The utero-ovarian ligament in the dog and cat is very short, so that the anterior end of the uterine cornu is virtually in contact with the ovary, while the oviduct, 3 to 4 inches in length, is thrown into numerous folds, to terminate in the immediate region of its origin: casual

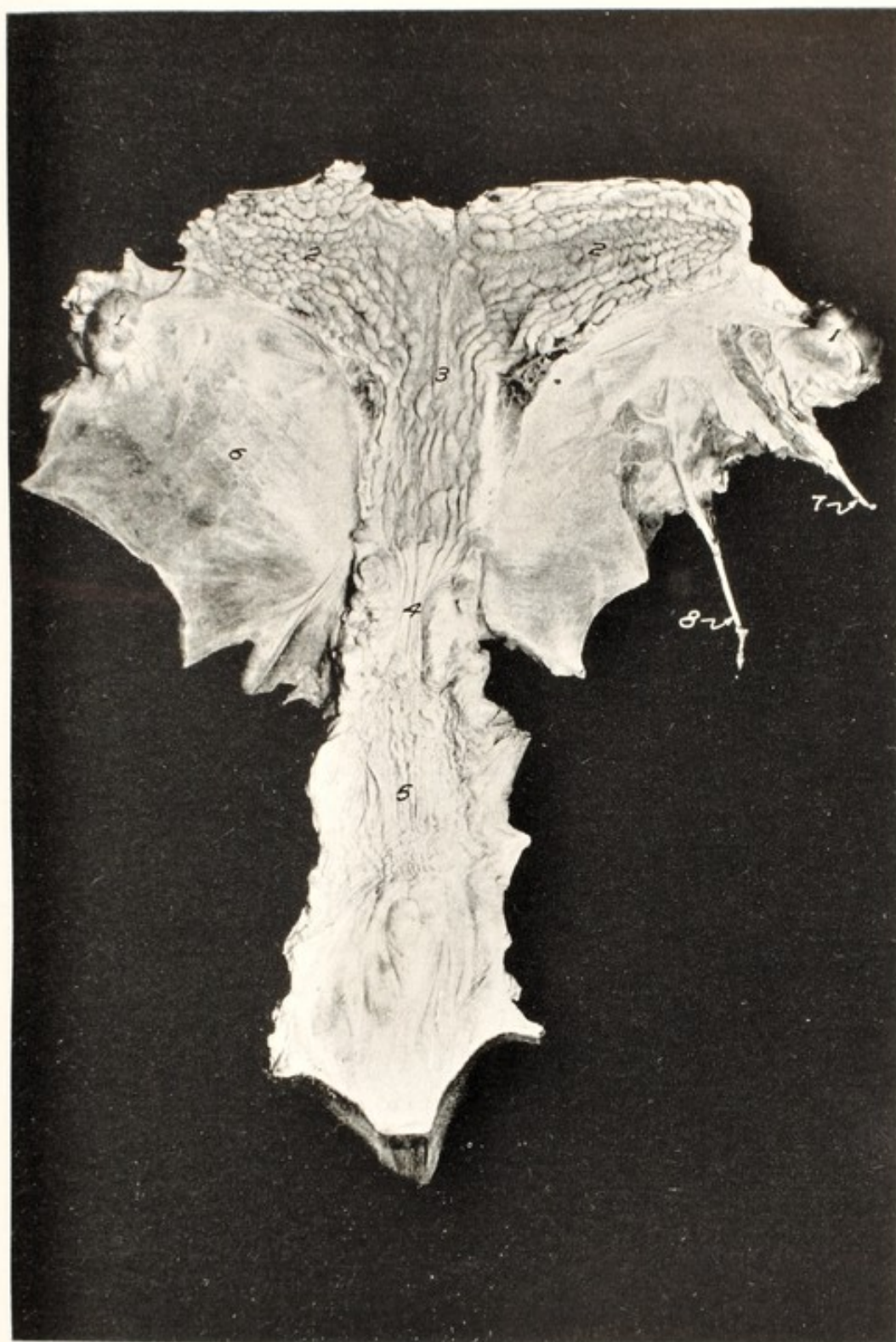


FIG. 2. Uterus of Mare viewed from above.

The upper wall of the uterine body has been removed. The uterine cornua have been incised along the dorsal side of the attachment of the mesometrium and the dorsal wall spread out forward.

1, 1, ovaries; 2, 2, uterine cornua; 3, uterine body; 4, cervix; 5, vagina; 6, mesometrium or broad ligament; 7, ovarian artery; 8, uterine artery.

observation, without dissection, might lead to the assumption that the oviduct was well-nigh absent, whereas it is very similar in actual length to that of other species. When divested of any concealing coverings of peritoneum, fat, or other tissues, the oviduct appears as a very convoluted white cord about 0.1 inch in diameter, of variable length in different species of animals. It is very firm to the touch and gives a sensation much like its analogue in the male, the vas deferens. After it is dissected out from the surrounding tissues and its numerous abrupt curves are carefully eliminated, a very fine sound, as one of the tail hairs of a horse, may be inserted at one opening and passed through its entire length. While technically the oviducts complete a communication between the peritoneal cavity and the exterior, the tubes are virtually impassable, except to ova and spermatozoa. They do not ordinarily permit the passage of liquids through them into the peritoneal cavity when douching the uterus under a column of water 3 or 4 feet high. When diseased, the oviducts provide a favorable domicile for bacteria. These may emerge from the tubes during pregnancy and invade the endometrium and fetal membranes; or the bacteria may advance toward the ovary, whether the female be pregnant or non-pregnant, and lead to adhesion of the pavilion to the ovary, or to ovarian abscess.

The muscular coat of the oviducts is characterized chiefly by its density, which gives to it a cartilaginous consistency, and its paleness, which amounts almost to translucency. The superficial layer of the mucosa of the oviducts consists of ciliated columnar epithelium with the cilia vibrating toward the uterus.

The Uterus

The uterus—a musculo-membranous sac, designed for the reception, nutrition, and protection of the ovum—finally takes the initial part in the expulsion of the fetus at the time of birth.

The uterus varies greatly in form and dimensions, according to the species and breed, primarily depending upon the degree of fusion attained by the two Muellerian ducts. Technically, the uterus is commonly described as being divided into a body and two horns. In uniparous domestic mammals the tendency is toward extensive fusion of the ducts of Mueller, with disappearance of their median walls, in some cases forming an extensive uterine body with correspondingly less important horns. The uterine body is greatest, among domestic mammals, in the mare, in which twin gestation is most infrequent and pathological. In woman, in sharp contrast with domestic mammals, the uterus consists essentially of a body, and



FIG. 3. The Uterine Caruncles in Veal Heifers.

The heifer calves are estimated at 5 to 10 weeks old. The inter-cornual muscles and ligaments have been severed and the cornua spread out at right angles to the cervix. The cornua have been opened along the greater curvature. The dorsal rows of caruncles are at the margins and the two ventral rows of caruncles are central.

1, vagina; 2, cervix; 3, right cornu; 4, ovary.

the horns, although technically present, play no essential part in the maintenance of pregnancy.

The uterus of the mare, with its cornua, constitutes a somewhat cruciform organ: the horns leave the body laterally at right angles or slightly curved. The peculiarity in form, as indicated in Fig. 2, invites bicornual or transverse pregnancy, an anomaly which occurs rarely in ruminants. Bicornual pregnancy provides one of the most trying obstacles to birth known to the veterinarian.

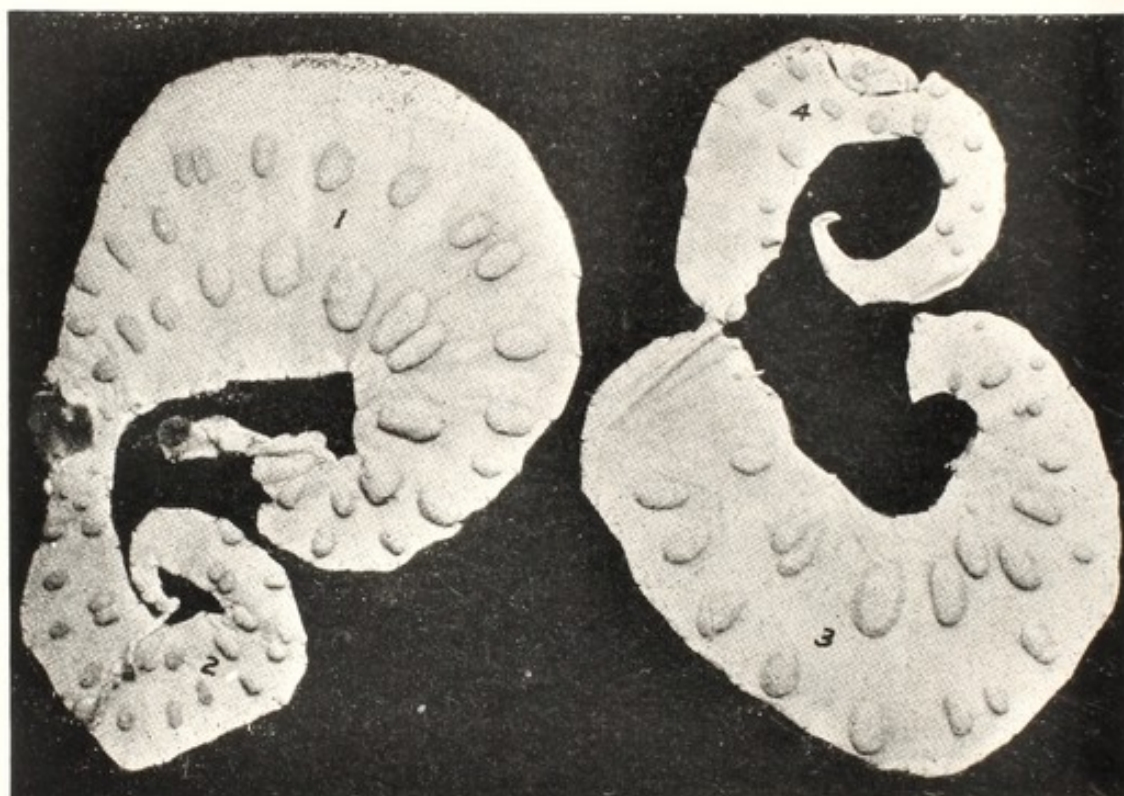

FIG. 4. Uterus from Heifer estimated at 90 to 100 Days Pregnant.

Uterus prepared as in Fig. 3.

1, lateral side of gravid horn; 2, do. of non-gravid horn; 3, median side of gravid horn; 4, do. non-gravid horn. The uterine seal is seen midway between 1 and 2.

Veterinary obstetrists and anatomists generally state that the uterus of the ruminant has a definite "body," but this appears to be due to the method of dissection. When the two horns are separated from each other to the point of fusion and then laid out at right angles to the cervix, all trace of a uterine body vanishes and there exists a tubular organ extending from one ovarian pole to the other, with the cervical canal entering it from the posterior or vulvar wall. This is well shown in Figs. 3 and 4. In fusing, the median walls of the two Muellerian ducts have been absorbed for a distance equal to the transverse diameter of the cavity of one of the cornua. It is difficult,

therefore, to define accurately the uterine body of the ruminant. The small ruminants, ewe and goat, serve somewhat as a bridge between uniparous and multiparous genera. The ewe frequently, and the goat generally, bears twins in a quasi-physiological manner. On the other hand, when the definitely uniparous mare or cow conceives twins, the phenomenon is generally associated with clearly recognizable evidences of genital disease.

An important difference between uniparous and multiparous animals in the scheme of reproduction lies in the fact that, in the former, the allantochorion abuts directly against the os uteri internum throughout gestation, while in multipara no fetal sac approaches the cervix until parturition commences. The mare is the most definitely uniparous among the domestic mammals and has, comparatively, by far the largest uterine body. In the bitch, cat, and sow the uterine body is limited in extent and is physiologically unimportant, containing no portion of a fetal body except while in transit at time of birth. The two cornua are extensive, and in them develop the fetuses, so that physiologically the horns represent the two separate uteri of the rabbit, in which there exists no uterine body, but two distinct tubular uteri, opening separately into the vagina.

The mucous coat, or endometrium, of the uterus and of its cornua constitutes the essential avenue through which the fetus receives its nutriment and discharges its waste materials. The mucous epithelium is very elaborate, consisting superficially of columnar cells, embedded deeply within which are numerous tubular structures of a glandular character, the utricular glands, believed to secrete the so-called *uterine milk*, which is presumed to play an important role in the nutrition of the ovum pending the formation of the embryo. Yet more important, it is through a special elaboration of the uterine mucosa that the highly intricate and essential maternal placenta is formed, to constitute a physical and physiological bond between the mother and fetus during the span of pregnancy.

So far as has been determined, the endometrium alone, in domestic mammals, possesses the power of elaborating placental structures and establishing nutritive relations with the ovum, embryo or fetus. In sharp contrast, it has been clearly and definitely shown that in woman the mucosa of the oviduct may elaborate placental structures competent to nourish an embryo imperfectly for a time, to constitute tubal pregnancy. While this possibly occurs in domestic mammals, it has not been indisputably proven. Fetal cadavers are now and then discovered in domestic animals in the peritoneal cavity, the cervix,

and the vagina, and the phenomenon is described as abdominal, cervical, or vaginal pregnancy respectively, but it has not been shown that in such locations placental structures were elaborated. So far as has been determined, the embryo or fetus of no species of

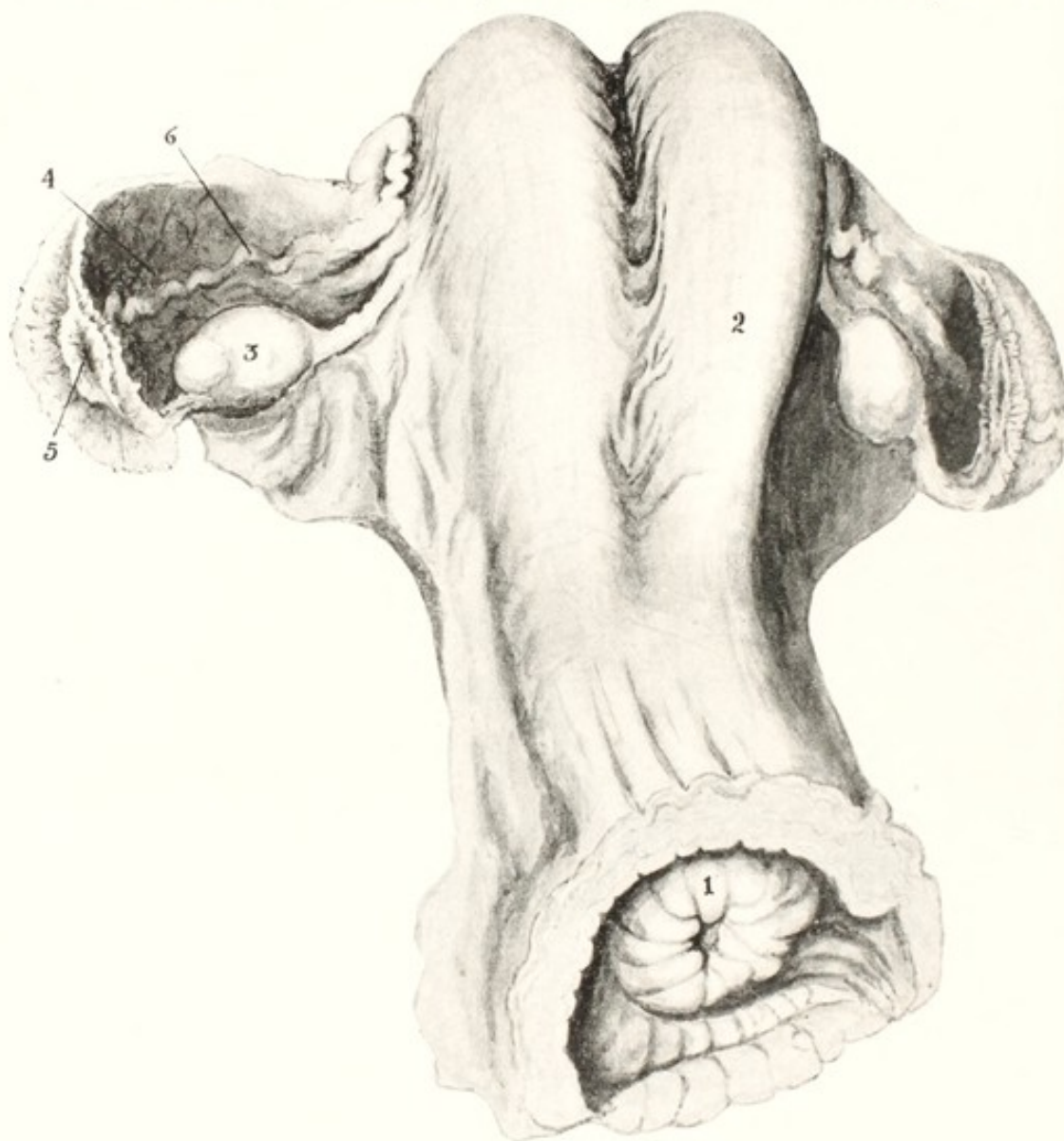


FIG. 5. Ovaries, Oviducts, Uterus, and Cervix of Cow.

1, os uteri externum; 2, right cornu; 3, ovary; 4, ovarian ventricle; 5, ostium abdominale of the oviduct; 6, oviduct.

domestic mammal may develop or grow except by contact through its membranes with the endometrium.

The endometrium of the uterine body of multiparous domestic animals—sow, bitch, cat—possesses no known powers to elaborate placental tissues. The body contributes to the length of the birth canal.

The Cervix

The cervix, or neck of the uterus, consists of a powerful, sphincter-like segment of the genital tract, serving to separate anatomically and physiologically the uterus from the vagina. It is continuous anteriorly with the uterine body and posteriorly with the vagina. Its walls are thicker and more rigid than those of the uterus and vagina, although the organ varies greatly in form and density according to species. It

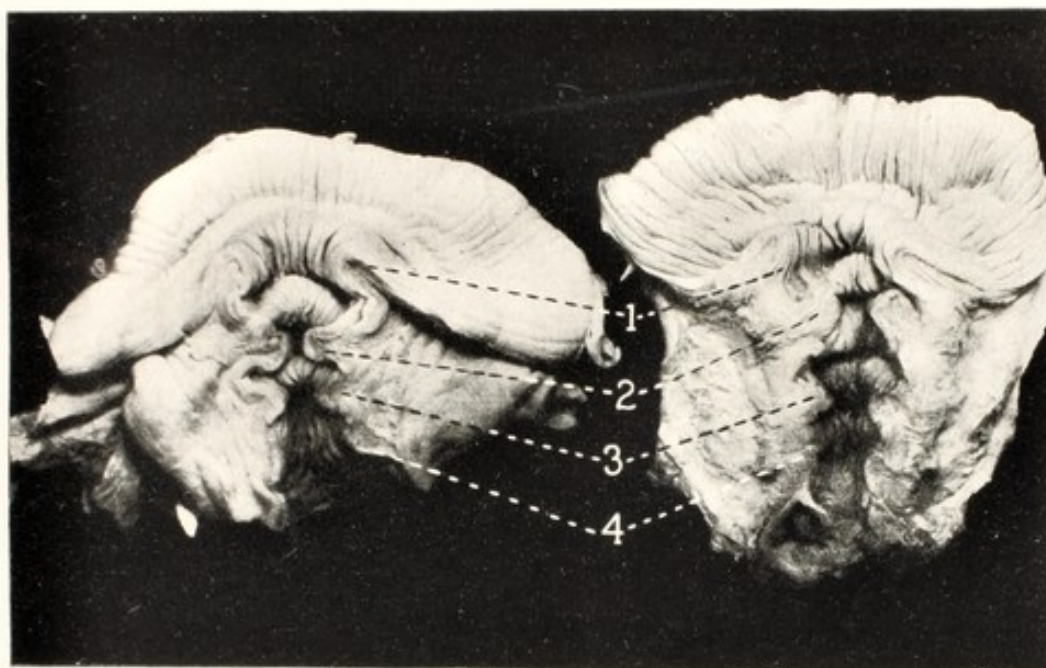


FIG. 6. Cervixes of Virgin Heifers showing the Annular Folds of Mucosa.

Opened along the median line on the dorsal surface.

1, first or vaginal ring (labiae of the os uteri externum); 2, second, 3, third, and 4, fourth annular ring.

is most complex, and most frequently pathological, in the cow, in which animal its walls are so rigid that mechanical dilation is extremely difficult, while physiologically it dilates freely during estrum and parturition.

The Vagina

The vagina, representing the fused caudal ends of the Muellerian ducts, extends from the cervix to the vulva. The hymen of the embryo, which sometimes persists teratologically to adult life, represents the line of demarcation between vagina and vulva. The vagina is freely dilatable.


The Vulva

The vulva, located immediately beneath the anus, constitutes the posterior termination of the genital canal. Instead of being derived from the mesodermic Muellerian ducts, like the preceding organs, the vulvar epithelium originates from the ectoderm of the embryo. The muscles of the vulva, chiefly circular, and very powerful, act as sphincters, serving to close the posterior terminus of the genital canal.

Through the medium of the surrounding aponeuroses, the vulvar muscles acquire continuity with the ischium, sacrum, and postero-superior border of the sacro-sciatic ligament, thus affording the vulva a secure attachment to the posterior opening of the pelvis and furnishing a fixed base upon which the entire genital canal may act in parturition. This fixation enables the contracting uterus to efface the cervix and to dilate the vagina and vulva adequately for the passage of the fetus.

SECTION II

OBSTETRICAL PHYSIOLOGY



SECTION II
OBSTETRICAL PHYSIOLOGY
CHAPTER III
REPRODUCTION

REPRODUCTION is a *luxus* function not physiologically performed by mammals until the animal is practically of adult size. At the time of birth, especially of solipeds, ruminants and swine, all reproductive organs have acquired their ultimate form and location, but are not yet ready to function. In well bred, well fed colts, ova mature in the filly and spermatozoa in the colt at 10 to 12 months of age. Dairy heifers commonly ovulate, and bulls commence to form spermatozoa, at 6 to 8 months. Conception then becomes possible, but such pregnancies mostly end disastrously because the general strength of the reproductive organs and of the body as a whole has not yet reached that point where a surplus of nutrition and of physiological power enables the young animal safely and successfully to bear the load inherent in reproduction. The power of reproduction, once healthy genital organs have matured sufficiently to function, is dependent fundamentally upon the strength of the animal and, other factors being equal, is greatest in adult life, beginning with the completion of dentition. It commences to wane, except disease intervenes, when the teeth commence to wear out and physical strength declines. In domestic mammals there is no cessation of breeding directly due to age, comparable to the menopause of woman.

The ultimate rate of reproduction is dependent fundamentally upon three factors: the duration of reproductive life; the number of progeny produced at a birth; and the frequency of parturition. The duration of reproductive life is greatest in horses and cattle, which are uniparous. Among common domestic mammals their periods of gestation are longest, about 336 days for the mare, and 285 for the cow. In contrast, the domestic rabbit and hare have a gestation period of about 30 days. Their new-born young are the most immature and helpless among domestic animals, while the calf and foal are the most mature at birth, and when healthy are on their feet and walking or running an hour after birth.

The principal domestic mammals belong to the temperate zone, with wide fluctuations of food supplies according to the season of the year. The effect is that most herbivorous animals naturally produce their young in spring or early summer, when forage is most abundant. This has been interpreted by some as a natural adjustment of birth time, but it also transpires that conception occurs when the forage is good. The technically possible ratio of increase of all domestic animals is much greater than the economic needs. The num-

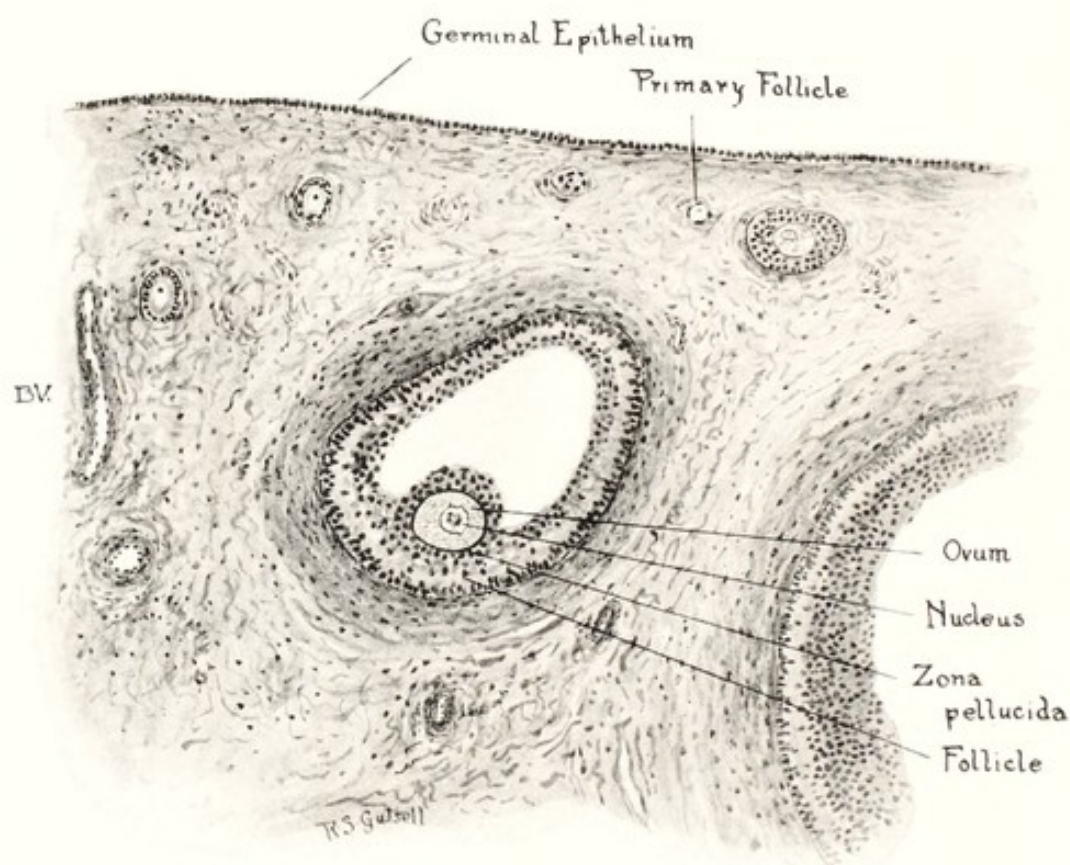


FIG. 7. Section of Ovary of Cow showing a Follicle 0.6 mm., with Ovum.

bers are controlled in the healthiest, and least valuable groups, by castration and by slaughter, while in the more highly valued breeding animals, where attempts are made to increase reproduction to the utmost, disease intervenes and restricts or destroys the breeding powers. The object of veterinary obstetrics and of studies of the diseases of the genital organs is especially to obviate or ameliorate the losses among the more valuable animals.

Reproduction is a complex physiological process, accompanied by or associated with phenomena which bear important relations to each other. In approximately the following order, there are observed the maturation of the ovisac, or Graafian follicle, estrum, copulation,

rupture of the ovisac, fecundation, and sometimes menstruation. The chain of phenomena is finally completed by pregnancy, parturition, and the nutrition of the new-born.

Maturation of the Ovisac

ESTRUM

The ovaries consist at first of a mere thickening of the peritoneum, due to an elaboration of its epithelial cells. The external cell layer becomes columnar. The cells of the deeper strata assume a more or less cuboidal form, to constitute the germinal cells, and certain of their number become distinctly larger than the others, to form the *primitive ova*. The deeper epithelial layers are broken into irregular columnar masses, or *egg columns*, through the growth among them from below of blood vessels and connective tissue. Prior to birth, in those young which are born in a well developed state, and shortly after birth in the immature young like that of the rabbit, some of the *primitive ova* become materially changed, to constitute *permanent ova*. In the cell masses the *permanent ova* become much larger than the others, while the nucleus, or germinal vesicle, enlarges and its enveloping membrane becomes distinct. The contents of the nucleus become massed at one point to form a distinct reticulum, in which one or more nodal points enlarge to constitute the nucleolus, or *germinal spot*. The neighboring germinal cells become arranged about the ovum in such a manner as to enclose it completely in a follicle, which has at first a single layer of cells. Later a second layer forms within the first, closely investing the ovum and continuous at one point with the cellular layer of the wall. This mass of cells, bearing within it the permanent ovum, constitutes the *discus proligerus*.

The cells of the follicular walls multiply rapidly. The external enveloping layer extends more rapidly than the inner *discus proligerus*, causing a separation between the two, except at the point of attachment of the latter. A section through the *discus proligerus* and follicle reveals a crescent-shaped cavity filled with fluid. Fully developed, this constitutes the ovisac, which consists of the outer layer of follicular cells, or *tunica granulosa*, and the inner granular cells, the *discus proligerus*, embedded within which lies the ovum. The cavity of the follicle between the two masses of cells is occupied by the follicular fluid. The immature egg sac usually lies deep within the ovary. As it matures and the volume of follicular fluid increases, it approaches the surface of the ovary. In the cow, about one-half of the ripe ovisac protrudes beyond the general ovarian

surface as a hemisphere, while the other half remains below the general level of the gland. The ripe ovisac of the cow is about one-half to five-eighths of an inch in diameter. In the sow the ovisac grows completely beyond the ovarian surface and appears as a pedunculated cyst one-fourth inch in diameter. In pushing toward and beyond the ovarian surface, the tunica albuginea, or ovarian



FIG. 8. Section of Ovary of Cow showing a Follicle of 2 mm., with Ovum.

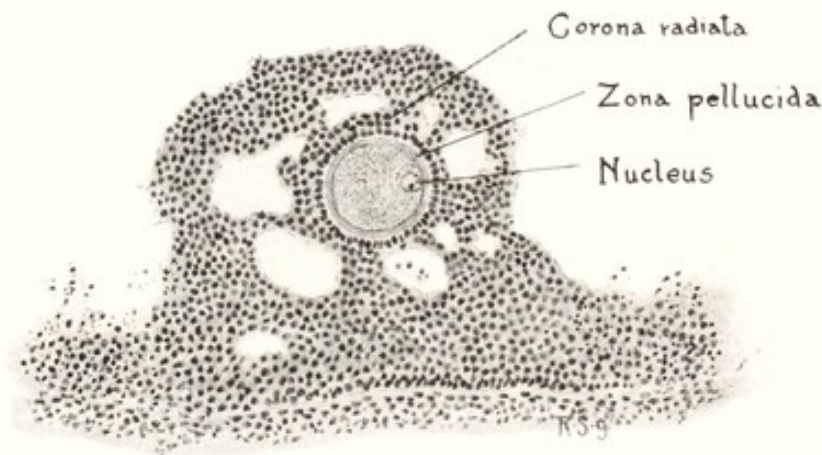


FIG. 9. Section of Ovary of Cow with a nearly Ripe Ovum in an Ovisac 5 x 7 mm. showing Vacuoles in the Cumulus preparatory to Ovulation.

capsule, atrophies and disappears at the summit of the distended sac, and the peritoneum is pushed outward. The follicular wall becomes very thin. During rectal palpation in the cow in estrum, the ovisac often ruptures under very slight pressure. During the maturation of the ovisac, the ovum undergoes important changes. Before the ovisac ruptures, the nucleus of the ovum passes from the center of the egg toward its periphery; a definite *vitelline* membrane is formed within the *zona radiata* immediately about the nucleus of the ovum; the nucleus becomes indistinct; and, while the yolk retracts slightly from the vitelline membrane at one point, the

first polar body, a small mass apparently derived from an unequal division of the nucleus, is assumed to be extruded.

When the egg has fully ripened and the ovisac has completed its growth and is distended with fluid, estrum, or "heat," occurs.

Estrum or sexual desire in the female is physiologically dependent upon the ripening of the ovisac. In the male, sexual desire is considered due chiefly to a hormone elaborated by the interstitial testicular tissue. Hence there may be present intense sexual desire in males without the presence of spermatozoa or the ability to produce them. This is occasionally observed in young dairy bulls in which the spermatogenic tissues fail to develop. In equine and other cryptorchids, where spermatozoa fail to mature, psychopathic sexual desire is often severe and erratic.

Psychopathic sexual desire often appears in the female in the absence of a mature ovum. In such cases the ovisac undergoes cystic degeneration, without ovulation, and produces a profound sexual derangement known as nymphomania. Hence sexual desire is not always attributable in either sex to the presence of mature genital cells, although under physiological conditions such cells are uniformly present. Neither is sexual desire wholly dependent upon the sex glands themselves. Mature stallions and other males, after castration, retain readily recognizable though decreased sexual desire.

Estrum occurs prior to ovulation. The phenomenon varies in different genera. In general, the female is nervous and excitable. The nervousness is especially notable in mares and cows. Mares, otherwise gentle and tractable, at times becomes unmanageable or even dangerously vicious. Cows, normally gentle and readily led or driven, become less tractable and can be handled in some cases only with difficulty. In working with cattle not broken to stanchion or halter but living entirely in the open in a semi-wild state, I have found that animals not in estrum are usually readily driven into a chute for examination while those in heat frequently need to be roped and virtually dragged into the chute for confinement.

Sexual derangements constitute the most important psychoses observed in domestic animals. Nymphomania causes extensive economic losses, especially in highly valuable dairy cows. Some mares are a decided menace to men who must handle them during estrum. Bulls frequently develop a sudden homicidal mania and annually destroy numerous human lives. However severe the psychosis, the affected animal does not attack a member of the opposite sex of its own species.

In some genera, for example the cow, and especially the bitch, the vulva becomes swollen during estrum. In most species there is a notable increase in the secretion of mucus, commonly stated to come from the vagina, but certainly in the cow formed chiefly by the cervix. In the cow the secretion is so abundant that it escapes from the vulva in long, stringy masses. The mucus facilitates coitus and renders it safer. It is probably of equal or even far greater importance in acting as a detergent carrying free resident bacteria from the cervix, vagina and vulva, covering over those which may be more securely attached to the genital mucosa, and acting as a viaduct, enabling the spermatozoa to pass over dangerously infected territory.

The uterus of the cow, and presumably of other animals, is in an erectile state during estrum. The organ is enlarged, tense and rigid. When palpating the organ per rectum, it sometimes becomes alternately erected and relaxed. This erectile state is presumably related intimately with the assumed approximation of the pavilion of the oviduct to the surface of the ovary at the time of ovulation.

Female ruminants and swine commonly imitate the copulatory act of the male by mounting other individuals of their own kind. The cow bellows inordinately and the voice is modified in tone. Pathologically, in nymphomania of cows the voice is greatly modified in its pitch, resembling that of the bull; hence the common designation of the nymphomaniac as a "buller."

In all animals there is a tendency during estrum for the female to wander from home. This is most noticeable in the bitch and the cat, which, if not securely confined, disappear, tending to wander long distances and to remain away during a large part or all of the estrual period. The sexual wanderings of domestic animals constitute an interesting chapter in the dissemination of infectious diseases.

For each species there is commonly a fairly definite estrual cycle, modified by food supply, extreme temperatures and disease. In the mare, estrum ordinarily occurs 8 or 9 days after foaling. In studs where genital disease prevails, there is generally a profuse uterine discharge at this time and, in the foal, diarrhea. In spite of this genital discharge, mares largely conceive if bred at this first estrum, but they abort, according to limited observations, in 3 to 4 times the ratio observed in equally healthy mares bred at the next estrum. Estrum occurs in the mare most commonly at intervals of about three weeks. In temperate climates, the estrual cycle weakens during the extreme heat of mid-summer associated with defective

pasturage because of the drought, and with the prevalence of flies, which serve to depress vigor; it then commonly reappears in autumn, with cooler weather and greater abundance of food, only to become markedly depressed again during the extreme cold of winter. In spring and early summer, with fresh and abundant pasturage, estrum is most regular. The conception rate, following copulation, runs approximately parallel to the regularity of the estrual cycle. The ratio of conception following winter breeding in the north temperate zone is comparatively low. The duration of estrum varies according to species and is modified by the state of health of the individual. The physiological duration of estrum in the mare has not been authentically determined and there is much conflict of observation. It is difficult to distinguish between physiological and pathological estrum. Schmaltz⁴⁶ cites Lehndorf as stating that the duration may be as brief as 1 to 3 days but may continue for 9 days or more. Pathological estrum may continue indefinitely. When bred early in estrum, if conception follows, it appears to end more promptly. In the mare, as in other domestic animals, those in which the duration of estrum is brief are the healthier individuals and conceive most readily.

The cow is ordinarily in estrum within 40 to 60 days after calving, and in the healthy individual heat regularly occurs every three weeks. The duration of heat is very brief in the healthiest of cows, continuing not over 24 hours. Temperature, food, etc., act upon estrum as they do in the mare, but the dairy cow is commonly so highly fed and warmly housed that the influence of winter upon her estrual cycle is largely or wholly nullified.

COPULATION. COITUS

Physiologically, female domestic animals copulate only during estrum, at which time an unruptured ripe ovisac or Graafian follicle is present. Pathologically, they may be in false estrum as in nymphomania, in which ovarian cysts without ova are present. Pathological estrum may also occur in the pregnant animal, sometimes apparently owing to cystic destruction of the corpus luteum, and sometimes to uterine or fetal disease. If the male regularly consorts with the female, he does not seek to copulate with her except when she is in estrum. The breeding male kept in confinement, especially the stallion and bull, will rape the female not in estrum if she is confined by man. Pathological estrum is logically most abundant in dairy cows, in which genital disease is most severe.

During the act of copulation, the semen from the male is injected into the vagina of the female, possibly in part into the cervical canal. Some think that the urethral opening of the male comes in direct contact with or enters the os uteri and that most or all of the semen is ejaculated directly through the cervical canal into the body of the uterus. In a sterile mare with atonic cervix and dependent uterus, the semen may largely drop through the dilated canal into the uterus. The otherwise healthy male copulates successfully after a considerable portion of the penis has been amputated. Clinically, a large part of the semen is ejected from the vulva of the female immediately after copulation, and quantities of it are readily obtained from the vagina at this time. The condition essential to fecundation, so far as the male is concerned, is that physiologically perfect spermatozoa shall gain the cervical canal, traverse the uterus and oviducts, and meet the ovum in the pavilion of the tube. Of the countless myriads of sperm cells in one discharge of semen, but one can take part in the fertilization of an ovum.

OVULATION

The phenomena of ovulation are most readily and authentically studied in the cow, in which the growth and rupture of the Graafian follicle are easily followed by rectal palpation. Histological study shows that, prior to the rupture of the ovisac, preparation for the detachment of the ovum from the enveloping and supporting cells of the *discus proligerus* has been made by the formation of numerous vacuoles in the mound, as shown in Fig. 8. The attachment of the ovum is rendered exceedingly frail, and is readily terminated upon the slightest disturbance. The ovum is apparently maintained in situ chiefly, if not wholly, by the sustaining pressure of the follicular liquid. At the close of estrum, the ovum, the follicular fluid, and some of the granular cells of the *discus proligerus*, in which the ovum was embedded, are then discharged into the pavilion of the oviduct, which is at this epoch erected and closely applied to the ovary at that point where the ovisac is about to rupture. Here, if successful copulation has occurred, spermatozoa meet the ovum and a single spermatozoon fuses with each ovum to constitute fertilization.

The precise period at which ovulation occurs is not known for most domestic animals. In the rabbit which has given birth to young, copulation occurs immediately following parturition. Ovulation follows about twelve hours later—an interval sufficiently great for the

migration of spermatozoa from the vagina to the ovary. The rabbit and cat do not ovulate unless coitus occurs: without coitus the ripe ovisacs atrophy and disappear. In the cow, estrum persists ordinarily from twelve to twenty-four hours, and ovulation occurs at about the close of this period. If copulation occurs early in estrum, it possibly hastens ovulation and a better opportunity is afforded for the arrival of spermatozoa at the pavilion of the oviduct prior to the rupture of the ovisac and discharge of the ovum.

The number of ovisacs rupturing at a given estrual period equals, as a rule, the maximum number of embryos. Rarely, it appears, two ova may be discharged from one ovisac. In twin conceptions in the cow, so far as records show, two corpora lutea, marking two ovisacs, are present, though they may be in one or both ovaries. In woman it has been determined that a single ovum divides to form two individuals, identical twins. This possibly occurs in domestic animals. In multipara, it is assumed that at least as many ova have been discharged as there are embryos in the uterus.

FERTILIZATION

Physiological copulation between a healthy male and female is followed by fertilization of the ovum. Immediately following coitus, spermatozoa travel along the genital tube and arrive at the pavilion of the oviduct at about the time the ovum escapes from the ovary. The head of a spermatozoon penetrates the egg and fuses with its nucleus. Conception has occurred and the development of a new individual has begun.

MENSTRUATION

Some believe that if a cow fails to conceive after ovulation she commonly menstruates within 24 to 36 hours after cessation of estrum. Sometimes menstruation occurs in animals which have conceived. The phenomenon is due to capillary hemorrhage from the caruncles of the endometrium. Upon the killing floor of the abattoir, heifers or cows having in their ovaries ripe ovisacs have engorged uteri with special engorgement of the placental areas. If the ovisac has ruptured, and presumably fertilization has failed, the placental areas are covered over with thin coagula of bright red blood. Later this is expelled, to constitute the menstrual fluid. The sanious discharge, which is bright red, soils the ventral surface of the tail and exterior of the vulva. It is most pronounced in sterile heifers and is sometimes quite profuse.

The menstruation of the cow has been thought by some to be analogous to, or identical with menstruation in woman. By others this is denied. Corner¹⁴ in researches upon monkeys concludes that menstruation occurs at about 14 days after ovulation, or midway between two ovulations, and reasons therefrom that in woman the relation between ovulation and menstruation is similar.

Aside from a very slight sanious discharge from the vulva of the bitch during estrum, and the above mentioned sanious discharge from the cow, no phenomena are known in domestic animals which can well be regarded as menstruation.

CHAPTER IV

ANOMALIES IN FERTILIZATION

The Migration of Genital Cells

CLINICAL and experimental evidence have been recorded indicating that spermatozoa or fertilized ova may move along unnatural paths. It has been claimed for example that spermatozoa may pass through one oviduct into the peritoneal cavity, across to the other oviduct, and there serve to fertilize an ovum. The evidence is not perfect. Theoretically the possibility needs be admitted. It has no known clinical importance. When in a uniparous animal a fetus is present in one uterine horn and a corpus luteum in the other ovary, Schmaltz⁴⁶ accepts the phenomenon as proof that the fertilized ovum has passed down the corresponding oviduct and cornu to the cervix and thence up the other cornu and there become located. I have clinically observed the atrophy of the original corpus luteum in the pregnant cow, followed by the ripening and rupture of a second ovisac in the other ovary accompanied by estrum. This naturally produces a corpus luteum, resulting in the phenomenon of a fetus in one horn and a corpus luteum in the other ovary. If the corpus luteum of pregnancy be dislodged by manual compression, the cow aborts, but when it becomes gradually destroyed, as by cystic degeneration, abortion does not usually follow.

In the sow the number of fetuses in one horn may exceed the number of corpora lutea in the corresponding ovary, while the reverse may be true of the other side. Schmaltz⁴⁶ states that in the dog and swine two or more ova in one ovisac are not rare, and, should all be fertilized, there are more embryos than corpora lutea.

There is convincing evidence that in multipara there is a physiological tendency, when unequal ovulation occurs in the two ovaries, to equalize the embryonic load in the two cornua through the migration of some of the ova from the relatively overloaded cornu across into the opposite horn. This has been especially brought out by Corner¹⁵ in his studies of the pregnant uteruses and ovaries of sows. Such migration of the ovum, in the cervical direction on the side of origin, and thence toward the ovary in the other cornu, is facilitated in multipara because the ovum need not enter the *body* of the uterus, but may pass directly across into the opposite horn.

The multiparous bitch sometimes seems to pathologically dis-

charge but one ovum during a given estrum. In such case there appears to be an effort to balance the load between the two cornua and the fetus sometimes becomes lodged with one end in each cornu to constitute *bi-cornual* pregnancy. The subject will be further discussed under dystocia.

Superfecundation

When a female discharges from her ovaries two or more potent ova during one estrual period, and copulates more than once during the period, one or more ova may be fertilized at one coitus, and the other, or others, at a subsequent service. If all services are by one male, superfecundation is not recognizable, but when the fertilizations occur by males of different breeds (Holstein and Hereford cattle) or by different species (horse and ass) the superfecundation becomes apparent. Lanzillotti-Buosanti records an interval of eight days between the services of a horse and an ass—a duration of estrum not uncommon in the mare, especially in the presence of genital derangement. Since twin pregnancy in mares and cows commonly has a pathological background, there should be no surprise because of prolonged estrum or of unusual intervals between the discharge of two ova. The brevity of estrum in healthy ruminants renders superfecundation highly improbable.

Superfetation

It is asserted by some, and seriously doubted or denied by others, that a female which is definitely pregnant may again come in estrum and copulate, and a second conception occur while the uterus already contains a living fetus. So Harms³² states that instances have been observed in horses, ruminants, swine and dogs. He further states that the occurrence of the phenomenon in man is well authenticated. In the latter case, J. Whitridge Williams⁵⁷ states "The occurrence of superfetation has never yet been clearly demonstrated." I have not observed superfetation and doubt its occurrence in domestic animals. The records of alleged cases appear unauthentic. It is claimed by some that if a female pregnant from a given service is again in estrum and copulates, and two fetuses are born or expelled at one time showing differences in size in harmony with the interval between estrual periods, or one fetus is expelled after a proper interval from the first coitus and a second at a corresponding interval after the second service, superfetation is established.

I have seen a mare give birth to twins after a single coitus, the

one of normal size and form and non-viable, and the other a dwarf with the general characters of dwarfism, but vigorous and viable. Equine twin abortions, widely separated in size as shown in Fig. 95, are not rare in the mare, but the smaller fetus is generally papyraceous, indicating much earlier death than in the mate.

Hadley (University of Wisconsin) has supplied me with interesting data upon a suspected case of superfetation. A cow was bred Dec. 9, 1928 and rebred Jan. 19, 1929, an interval of 41 days. She dropped a viable bull calf on Sept. 3, 1929, after an interval of 268 days from first service and 227 days after the second breeding. She gave birth to a second bull calf on Nov. 4, 1929, 62 days subsequent to the first calving, 330 days after the first breeding and 289 days after the second service. A photograph taken after the second birth showed the two calves to be practically equal in size. One logical conclusion seems to be that both calves were of the same breeding, the first being born at 227 days and of small size while the second was born at 289 days and of large size, each individual having grown at the same rate subsequent to the birth of the first calf, the one extrauterine, the other intrauterine. Had the cow conceived at the first service and continued pregnant during the interval of 41 days, the cervical canal would have been sealed, the allantochorion of the fetus would have occupied the entire uterine cavity, a fetal cotyledon would, physiologically, have been in contact with each and every uterine caruncle, and placental contact would have been denied to the new embryo. Since the calves were purebred, application for registration caused confusion, because the registration officers questioned the authenticity of the record. In general the question has no economical importance and in the case of these calves it was of scant significance. The use of either of them as a sire involved unjustifiable risks.

Extrauterine Pregnancy

Exterauterine pregnancy in domestic animals provides a highly confusing medley of truth and error. It is the mass of error rather than the smaller volume of truth which renders a brief discussion desirable. What is pregnancy? If by pregnancy it is meant that a female has within her uterus physiologically, or elsewhere within her body cavity, pathologically, a living ovum, then extrauterine pregnancy is an extremely rare occurrence in domestic animals. If pregnancy may also be held to signify the presence of a fetal cadaver, which is misleading, extrauterine pregnancy is not remarkably rare.

I believe the question may be made clearer by dividing the phenomena commonly designated as extrauterine pregnancy into two classes: (1) true extrauterine pregnancy in which the fertilized ovum is said to acquire nutritive relations with other organs or tissues than the endometrium and undergoes in such extrauterine location recognizable embryological development; (2) secondary extrauterine fetus, in which the ovum acquires physiological relations with the endometrium, and attains a recognizable development and growth,

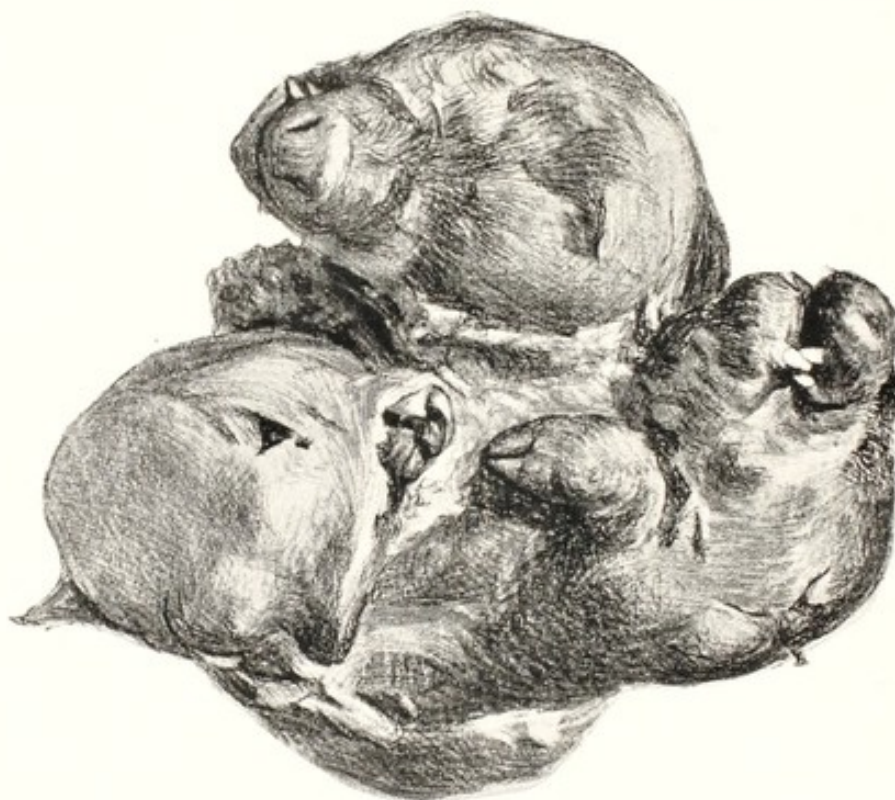

FIG. 10. Secondary Extrauterine Fetuses. Swine.

The two fetuses are closely adherent to each other and encapsulated in fibrous tissue.

after which it escapes from the uterine cavity and perishes without further development. Almost all alleged cases of extrauterine pregnancy recorded in veterinary literature belong to the latter class. Two such specimens are in the museum of the New York State Veterinary College, one of which is shown in Fig. 10. In each case the fetuses had developed elsewhere than in the location in which they were discovered, certainly within the uterine cavity. Their ruptured membranes, brought with them, are closely compressed in masses against the bodies; and surrounding the entire ovum exists an adventitious fibrous capsule, isolating the "foreign bodies" and rendering them non-irritant.

It is not extremely rare, when called to attend a cow at or near term, to discover a vast rent in the uterine body, cervix or vagina, through which the fetus has recently escaped into the peritoneal cavity. Generally this seems to be fundamentally a case of torsion of the uterus, with transverse rupture: the fetus has fallen through the opening and the uterus, relieved of its contents, has resumed its normal disposition. The fetus is dead; the mother dies.

During recent decades, with great activity in the handling of sterility in cattle, the operator sometimes errs and attempts to douche a pregnant uterus. The fluid fails to return, the uterus contracts violently, its walls rupture, the fetus falls out and dies, and the cow quite surely succumbs. One practitioner reported such a case as extrauterine pregnancy, with a history indicating clearly that the fetus had become extrauterine through his error.

Not only are errors made in assuming that fetuses discovered outside the uterus had developed in the abnormal location, but now and then extrauterine pregnancy has been reported when the fetus lay within the uterus. In the rotated bicornual pregnancy of the mare the fetus comes to lie transversely beneath the vagina and the equally slender, elongated corpus uteri, the ovarian end of which answers as a false cervix. The inexperienced obstetrice feels the fetus lying underneath the vagino-uterine body tube, and extrauterine pregnancy immediately presents itself as the logical explanation. Thus Forster²⁶ reports a case of dystocia in a mare which he failed to relieve. Upon autopsy he found the fetus, with its membranes normally developed, located within a cavity, the walls of which appeared to him like those of a uterus. He failed to report having seen the real uterus. Apparently he mistook the greatly elongated, inevitably vacant uterine body for the uterus as a whole and failed to identify the two cornua of approximately like development, in which the fetus lay as in a single tube. Later Goodfellow²⁹ observed a similar case which he diagnosed as *abdominal pregnancy*, and removed the living foal by laparotomy; the mare died immediately and no autopsy was made.

While discussing uterine torsion there is noted an instance in which torsion occurred in one cornu in a cat (Fig. 75), involving a mature fetus. The torsion resulted in detachment of the involved segment of the cornu. Dry maceration of the fetus occurred and adhesions of the isolated portion of the cornu with surrounding parts obscured its nature. The fact that the fetal cadaver was in the cornu could only be determined with difficulty by recognizing one

short cornual stump at the bifurcation and another at the ovarian pole, from each of which there passed to the fetal capsule a small, twisted tissue thread. In ruminants, especially in the sheep and goat, torsion of the uterus often leads to complete detachment, in which case the fetus sometimes sloughs out through the abdominal wall or into the rumen or other viscus. This is sometimes described as extrauterine pregnancy.

In the first class, true extrauterine pregnancy, several varieties are theoretically possible—ovarian, pavilion, tubal, vaginal and abdominal. In human obstetrics, tubal pregnancy occurs relatively frequently, is important, and is clinically diagnosable. Most cases terminate in abortion or in tubal rupture. Severe pain in the tubal region is generally present at the crisis. If the tube ruptures, hemorrhage is severe; frequently the patient collapses and may die within a few hours unless surgical relief is applied. In tubal abortion the embryo and blood may escape through the pavilion into the peritoneal cavity or externally, through the genital canal. Or the dead embryo may be retained within the tube and become enveloped in an extensive hematoma, which finally becomes permanent as a blood mole. This reminds the veterinarian of the blood mummy of the cow.

The oviduct provides the most favorable environment for extrauterine pregnancy in woman; its epithelium is analogous to the endometrium and offers possibilities for nutrition not elsewhere met outside the uterus. However, J. Whitridge Williams⁵⁷ cites Mall, who after extensive studies, found but sixteen normal embryos in 117 cases of tubal pregnancy.

A careful search of veterinary literature fails to reveal apparently authentic cases of tubal pregnancy in domestic animals. With millions of cattle, sheep and swine slaughtered annually, tubal pregnancy should be discovered upon the killing floor of abattoirs, if it exists at all frequently. Why tubal pregnancy should be so common in woman and virtually or wholly unknown in domestic animals, is not clear.

A search of veterinary literature for authentic instances of ovarian, primary (true) abdominal or interstitial pregnancy, proves fruitless. Alleged cases of vaginal pregnancy appear, but seem wholly unauthentic. It is not extremely rare to find a fetal cadaver caught in the cervix or vagina. I have observed a tiny fetus in the vagina of a cow, invested by its membranes, portions of which were still retained within the uterus. It is theoretically possible that such a fetus might

pass into the vagina yet alive, but if classed according to its source of nutrition, it is clearly uterine pregnancy.

Fully admitting the technical possibilities of extrauterine pregnancy in domestic animals, the subject should, in behalf of science, be divested of its burden of error and myth. When a fetus is discovered outside the uterus, its nature should be studied with great care. Before reaching a conclusion as to its character, every available test should be applied. It has been thought that if a fetus develops in the uterus and passes into the peritoneal cavity through a rupture, this may be recognized, but Keller³⁷ draws attention to the fact that such ruptures of the uterus may heal virtually without a scar. Since the pregnant uterus is greatly distended, a rupture large enough to permit the escape of a fetus becomes a very small trauma as soon as the emptied uterus contracts. Physiological development of the fetus, so far as known, demands ample fetal membranes, with abundant fluids in which it may move freely. That is not known to be provided, in the later stages of development, outside the uterus. The swine fetuses in Fig. 10 are fully matured and free from anatomical or teratological defect. The gnarled state is clearly due to constriction of the fibrous envelope after development had ceased. They could not have developed in the oviduct nor in the peritoneal cavity, but only within the uterus.

CHAPTER V

PREGNANCY. GESTATION

PREGNANCY, or gestation, is, physiologically, that period between the fertilization of the ovum and the birth of the young—the antenatal period of life. Pathologically, pregnancy terminates with the death of the ovum. During physiological gestation the ovum develops from a single, nucleated cell into a highly organized individual. Antenatal life is the least understood and one of the most important periods in the history of the animal. During evolution certain processes in development have become established with remarkable precision. In each species, each organ and tissue is developed at a regular period and in a uniform manner. Physiologically, the duration of pregnancy is fixed with great precision. The animal husbandman knows accurately when to expect parturition in a healthy animal, and confidently expects that the fetus will present in the birth canal in a given manner, with each portion of the fetus in its ideal relation with every other part. It is known that the fertilized ovum promptly enters the oviduct and after a few days arrives in the uterus. It is there detained until the close of pregnancy. The force which governs the transit of the ovum through the oviduct is not definitely known. It is commonly believed, with apparently good reason, that the ovum is carried along by the cilia of the epithelial cells lining the oviduct, and that the process is aided by the muscular contractions of the walls of the tube. The fact that, in the tubal pregnancy of woman, the majority of embryos are teratological suggests that the defectiveness of the ovum contributes to the arrest in its migration. The participation of the ovum in its migration is further supported by the evident migration from cornu to cornu in swine.

The ovum, having arrived within the uterus, remains comparatively fixed throughout gestation. The uterine walls continue throughout pregnancy in a state of tonic contraction which serves to maintain its position. This is best studied in the cow, in which the uterus is freely palpable per rectum. The bovine uterus is arciform with its concave border directed ventrally, so that the position is mechanically unstable. This instability must be overcome by uterine tonicity, which maintains the form shown in colored Plate I. In uterine disease the organ often becomes flaccid and atonic and rotation upon

its long axis ensues, in varying degrees. It is quite practicable in some cases to foretell abortion, or other pathological outcome of pregnancy, by the flaccidity of the organ when palpated.

While the forces which govern the processes of gestation and birth are none too well understood, it is a matter of common observation that various recognizable agencies tend to interrupt their physiological course. The rate of mortality of fertilized ova during the span of pregnancy is much higher than that for any equal unit of time after birth. Physiological reproduction is attainable only when two healthy animals are mated and the female continues in health throughout pregnancy. If either the ovum, or the spermatozoon which fertilizes it, is defective, the health and life of the resulting individual is menaced. Even more, when the uterus is diseased or weak, the life of the ovum is exposed to danger throughout pregnancy.

When the fertilized ovum dies prior to the formation of the embryo, or the embryo itself perishes, or a very young fetus succumbs to disease, the product of conception is disintegrated or expelled unseen. This death, which, as a rule, can only be determined indirectly, is called sterility or barrenness. Some embryos which are attacked by disease or disturbing forces may recover in part and survive to be later aborted or born. If the injury has occurred prior to the establishment of the fetal organs, these fail to develop regularly and the individual becomes a monster or there are deviations from the physiological type of less importance. Once the fetus has attained sufficient development that the pregnancy is recognized, and it then dies and is expelled, the phenomenon is known as abortion. Finally, when disease or abnormality of the uterus or other organs of reproduction, or of the contained fetus and its membranes, is of such character as to render the birth, or the expulsion of the dead fetus, difficult or impossible, the phenomena are known collectively as dystocia or difficult birth. The three groups of phenomena pass by imperceptible gradation one into another. Veterinary obstetrics has to do chiefly with those diseases or abnormalities which render birth difficult or impossible or which endanger the life or health of mother or young, or both, at the close of pregnancy. Quite commonly, veterinary obstetrics is made to include sterility and abortion. These related phenomena have been considered in the companion volume, *The Diseases of the Genital Organs of Domestic Animals*. In this treatise the discussion is limited as closely as practicable to the field comprised within the above definition of obstetrics.

CHAPTER VI

EMBRYOLOGY. TERATOLOGY

IT is attempted to present a brief sketch of embryology and teratology, not as an authentic or complete treatise, but rather to lead the clinician to more careful observations concerning the diseases and defects during prenatal life. Before the veterinary obstetrict may attain ideal efficiency, it is requisite that he shall have acquired an adequate conception of the physiology and pathology of the intrauterine young. Embryology has to do with the physiological development and growth of the fertilized ovum, while teratology is the study of defects in the structure or organs or systems. When fertilization is due to the union of two cells, one or both of which are structurally or functionally defective, or when destructive forces attack the newly fertilized ovum without killing it, and the embryo partly recovers, it probably becomes a monster, to be later aborted or born. Monsters provide some of the most difficult types of abortion and birth with which the obstetrict meets. Later, after the embryo has completed its organization and becomes technically a fetus, disease continues to jeopardize its life and constantly invites a difficult or pathological termination of pregnancy. Non-mortal diseases of the embryo, after having caused important or even gross deviations in the formation of one or more organs, leave the fetus less capable of resisting disease. Accordingly monsters, which have their origin usually within about twenty days after conception, frequently succumb to fetal disease and are aborted. So, in the cow, the cadaver of the monster is frequently expelled at 150 to 280 days, bearing marks of diarrhea or other fetal disease. Probably the disease forces have been continuous, but have for a time been inactive.

While it is impossible to consider here either embryology or teratology as such, it seems desirable to sketch very briefly the relationship between antenatal physiology and pathology, limiting the consideration of the pathology practically to that of the embryo (teratology), and leaving the general discussion to subsequent chapters. For the present, accordingly, teratology is emphasized simply as one phase of antenatal pathology. Teratology is important because it constitutes the one available record of injury to the ovum, and therefore comprises virtually all knowledge available during this

critical epoch of prenatal life. Those embryos and fetuses suffering pathological injury, but having sufficient resistance to be born, offer many problems of importance in obstetrics, surgery and other fields of veterinary practice. Naturally, embryonic disease, with the resultant development of monsters, is most frequent and serious in dairy cattle, where genital disease is most common and virulent. Those arrests in development which occur early in the life history of an embryo show a marked tendency to recur in the offspring of the defective individual, should it live to breeding age. This is limited chiefly to the milder types of aberration. The more extreme ones, known as monsters, rarely live to adult life and are then usually incapable of reproduction. Such arrests in development as the failure

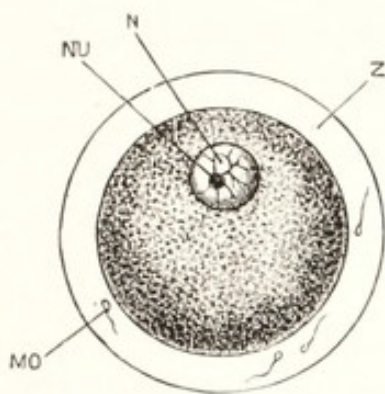


FIG. 11.

FIG. 11. A fully formed Ovum of the Rabbit shortly before its Discharge from the Ovary. (Marshall after Bischoff.)

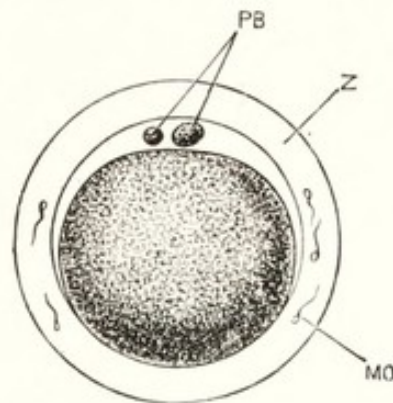


FIG. 12.

FIG. 12. Ovum of Rabbit from the Upper End of the Oviduct after Extrusion of the two Polar Bodies. (Marshall after Bischoff.)

MO, spermatozoon; N, nucleus, or germinal vesicle; NU, nucleolus, or germinal spot; PB, polar bodies; Z, zona pellucida.

of one testicle to descend—monorchidy—or the failure of the umbilical, or inguinal ring to close—hernia—tend to become fixed traits and to be reproduced in the progeny.

Segmentation of the Egg

Immediately after the ovum has become fertilized through its fusion with a spermatozoon, the resulting cell undergoes a progressive division by the process of mitosis, which is termed segmentation. The observations upon the fertilization of the mammalian egg have been carried out largely upon the rabbit. Generally copulation ensues in the rabbit immediately after the doe has given birth to young. Eight or twelve hours later the ovisacs rupture. The sperma-

tozoa have already passed through the uterus and the oviduct and have reached the ampulla of the tube, so they may at once meet the egg when it is discharged. Fertilization follows immediately. The spermatozoa may even have reached the ovum while yet in the ruptured ovisac, before it has been discharged into the oviduct, as shown in Fig. 12.

In the typical fertilization of the rabbit ovum, where the spermatozoa have already reached the anterior end of the oviduct when the ovisac ruptures, and fertilization occurs at once, the fertilized ovum undergoes segmentation during its passage toward the uterus. According to Van Beneden, the segmentation of the ovum begins ten or twelve hours after fertilization, or eighteen to twenty-four hours after copulation, and continues for the next two days, or until about the end of the third day after copulation, when the ovum reaches the uterus and its segmentation has been completed. It has usually been assumed that the newly fertilized ovum has no inherent power of migration, and that it is transported through the oviducts by the cilia of the tubal epithelium. Evidences are being revealed—the incarceration of teratological ova in the oviducts of woman to constitute tubal pregnancy and the abundant migration of swine ova from one cornu to the other—suggesting that the ovum actively participates in its movements, location and attitude throughout antenatal life. The muscular walls of the oviducts and uterus quite certainly participate importantly in the movements of the ovum. There is a well marked attraction between the ovum and uterine epithelium. This is strikingly evident when the ovum enters the uterine cavity and becomes physiologically fixed for the duration of gestation, after which, at birth, the attraction changes to repulsion, and the uterus pushes the fetus out.

The force which determines the fixation of the fertilized ovum within or upon the endometrium is unknown. It has apparently been believed by some that it is the inherent function of the ovum alone, but there is important evidence that the attraction is mutual between the ovum and endometrium. When the fertilized ovum reaches the uterine cavity it is about the same size as the original ovum, or possibly somewhat smaller.

About ten to twelve hours after the fertilization of the egg of the rabbit, the ovum undergoes cleavage, by which there arise two spherical cells, essentially alike in all respects, except that some observers believe that one is slightly smaller than the other. See Fig. 13. Each of these, after a brief pause of a few hours, divides

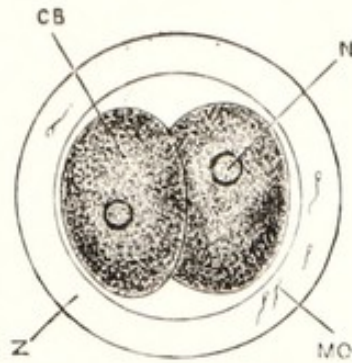


FIG. 13. A Rabbit's Ovum from the Middle of the Length of the Oviduct about 22 hours after Copulation, showing Division of the Ovum into Two Cells. $\times 200$. (Marshall after Bischoff.)

CB, blastomere, or segmentation cell; MO, spermatozoon embedded in the zona pellucida; N, nucleus; Z, zona pellucida.

again into two, forming a mass of four ovoid cells, which again subdivide to constitute a group of eight. Those derived from the supposedly larger of the two first cells are now clearly larger than the others. The larger ones are grouped together centrally, and the smaller rest upon them as a cap. Later the segmentation of the small cells proceeds somewhat more rapidly than that of the larger, and the former tend to grow around and enclose the latter. According to Marshall, when the ovum of the rabbit has reached the 70th hour after fertilization, its segmentation has been completed and it passes from the oviduct into the uterus. At this time it is a spherical mass consisting of an exterior layer of small, nearly spherical, transparent

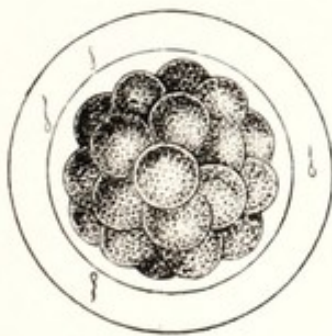


FIG. 14.

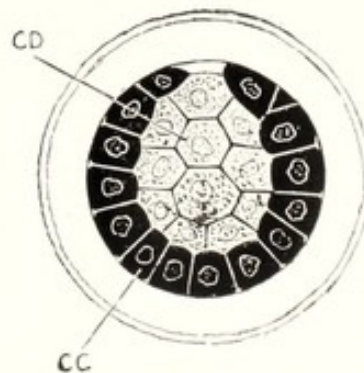


FIG. 15.

FIG. 14. A Rabbit's Ovum from the Lower End of the Oviduct, about the Middle of the Third Day; showing the Morula Stage, shortly before the Completion of Segmentation. $\times 200$. (Marshall after Bischoff.)

FIG. 15. A Rabbit's Ovum Seventy Hours after Copulation, taken from the Lower End of the Oviduct just before entering the Uterus and showing the Condition at the Close of Segmentation. $\times 200$. (Marshall after VanBeneden.)

CD, internal mass of large cells; CC, external layer of small cells.

cells, enclosing almost completely the group of larger, more granular cells: it has reached what is known as the *morula*, or mulberry, stage, Figs. 14, 15. At this stage the external layer of smaller, and the internal mass of larger cells are firmly attached to each other at one point only. The segmented ovum is still surrounded by the zona pellucida.

Within a few hours after entering the uterus, the ovum becomes greatly enlarged, owing to the accumulation of a considerable volume of fluid between the external layer of small, and the mass of larger inner cells, except at the point of attachment between the two. The inner mass now occupies a comparatively small area at the superior pole of the ovum. At this stage of development the ovum is known as the *blastodermic vesicle*. The mass of inner cells is flattened out in the form of a disc, consisting at the center of several layers of somewhat spherical cells, known as the embryonal or germinal area. At the periphery of this area there are but one or two layers of cells. As the vesicle increases rapidly in size, the zona pellucida disappears.

During this stage of development, which continues in the rabbit to about the seventh day, the ovum lies free within the uterine cavity. In multiparous animals the ova, which enter the uterus almost simultaneously, tend to become distributed at more or less uniform intervals throughout that horn of the uterus leading from the ovary from which the fertilized ova have come, and assume the positions which they are to retain throughout their period of intrauterine development. It has been observed that sometimes in the sow, and possibly in other multipara, there is gross inequality in the numbers of ova produced by the two glands, in which case some of the ova from the excessive side migrate to the other cornu and tend to balance the load. The location of each embryo is indicated early by a bulging of the uterine walls.

Toward the close of the development of the blastoderm, important changes take place, by which there are established three distinct germinal layers, each of which is destined to take a special part in the formation of certain tissues of the embryo. These changes affect chiefly the embryonal area at that point in the blastoderm at which the various layers are united and the large internal polygonal cells are massed.

In the embryonal area, which is a circular or discoid patch, three layers of cells may be recognized: an upper or external layer of epithelial cells, the *ectoderm*; a middle layer of larger, cuboidal cells, the *mesoderm*; an inner layer of epithelial cells, the *entoderm*. At the margin of the embryonal area, the walls of the blastodermic

vesicle consist of two layers of cells representing the external and internal germinal layers; passing slightly beyond this, the remainder of the blastodermic vesicle, constituting about three-quarters of its total surface, consists of a single layer of cells, the ectoderm. According to Rauber and Kölliker, the uppermost layer of the blastodermic vesicle—the primitive ectoderm—disappears from the embryonal area, to be succeeded by a new ectoderm arising from the inner mass of large cells, so that the entire embryonal area is ultimately derived from the inner mass, which, in the morula, consisted of the larger, granular, slowly multiplying cells. Late in the blastodermic stage, the embryonal area becomes pyriform, its greater diameter corresponding to the long axis of the blastodermic vesicle in the rabbit, which has now assumed the elliptical form. In other domestic animals the long axis of the embryonal area is transverse to that of the blastodermic vesicle. The broader end of the embryonal area is designated the anterior, or head end, and the narrower the posterior, or tail end.

The Primitive Streak and the Primitive Groove

As the blastodermic vesicle approaches the completion of its development, there appears the *primitive streak*, consisting of an axial thickening of the ectoderm at the posterior, or tail end of the embryonal area. This thickening, which extends longitudinally until it attains a length equal to about two-thirds of that of the embryonal area, has in its center a faint longitudinal depression, the *primitive groove*. A cross section of the primitive streak shows it to consist of a multiplication on the median line of the deeper cells of the permanent ectoderm. From the deeper layers of the thickened, dense, primitive streak, the cells grow out in lateral plates between the ectoderm and the entoderm, to constitute the permanent mesoderm, Fig. 16. In the median line a rod-shaped mass of mesodermic cells becomes closely packed together and somewhat clearly separated from the adjacent mesoderm, to constitute the notochord, about which the final axial skeleton is to form.

Formation of the Embryo

The embryo is formed in the embryonal, or germinal, area. A longitudinal depression, the *neural groove*, is formed immediately in front of the primitive streak. The neural groove is bordered on the sides by the neural folds. These grow upward from the ectoderm, approach each other, and become united above to form a tube, in

the walls of which eventually forms the central nervous system. In the anterior, or head end of the neural groove, the brain vesicles soon appear.

By an infolding of the walls of the blastodermic vesicle about the margins of the embryonic area, the latter becomes constricted off from the rest of the vesicle, which eventually becomes the *vitelline*, or *yolk sac*. The yolk sac of the mammalian embryo is usually small and of little consequence, as it contains no appreciable amount of nutriment for the embryo, but simply a small quantity of a presumably inert fluid. Unlike in most animals, the vitelline sac of ruminants and swine grows rapidly as a greatly elongated tube distended with liquid. In the companion volume evidence has been submitted tending to show that in disease the vitelline tube is largely responsible for the peculiar monster, *Schistosomus reflexus* (Gurlt). After this constriction takes place, dividing the embryo from the yolk sac, the dorsal surface of the embryo grows much more rapidly

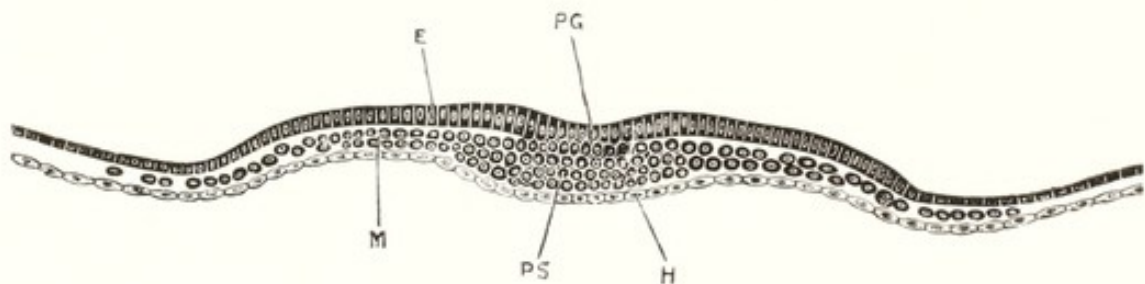


FIG. 16. A Transverse Section across the Hinder Part of the Embryonal Area of a Rabbit Embryo at the End of the Seventh Day, the Section passing through the Primitive Streak. $\times 80$. (Marshall after Kölliker.)

E, ectoderm; H, entoderm; M, mesoderm; PG, primitive groove; PS, primitive streak.

than the ventral, causing it to bend ventralwards very rapidly, so that the head end is soon at right angles to the remainder of the embryo. The different parts of the brain soon become recognizable, and later the beginnings of the nose, eyes, and ears. Upon the sides of the head and neck the visceral arches and imperfect gill clefts appear.

The Celom, or Body Cavity

On the eighth or ninth day after fertilization in small animals—perhaps somewhat later in the larger ones—there is a rearrangement of the cells of the mesoderm, by which the *celom*, or body cavity, is formed, radiating outwards from the region of the notochord, to pass beyond the embryo itself and extend outward in the walls of the

blastoderm to near the margin of the mesodermic area. This change serves to divide the mesoderm into two layers, the external and internal. The external, with the closely adherent ectoderm, constitutes the *somatopleure*. The inner layer, with the intimately adherent entoderm, forms the *splanchnopleure*.

From the ectoderm arise finally the epidermis, hair, nails, hoofs, horns, etc., and the cerebro-spinal nervous system. From the mesoderm of the somatopleure arise the striped, or voluntary muscles, bones, connective, and other skeletal tissues, and the deeper layers of the skin.

The mesoderm of the splanchnopleure gives origin to the heart and circulatory system and to the muscular portions of the digestive, respiratory, and urino-genital organs, and, in a general way, to the pale, or unstriped muscle fibers. The entoderm of the splanchnopleure forms the epithelium of the digestive and respiratory tracts. The origin of the various tissues from the three embryonic layers is of great interest in the study of disease and repair. A wound of the epithelium can be perfectly repaired by epithelial tissues only. Cells originating from the mesoderm have not the power to repair an ectodermic injury.

Ere the blastoderm can proceed far in its development, new provision must be made for its nutrition, which, in mammalia, must be derived from the mother through an intimate relation between the endometrium of her uterus and the fetal placenta. At a very early period, the nutritive relation between the mother and the fertilized ovum is established by two embryonic outgrowths: one from the extraembryonal somatopleure, to constitute the amnion and amniotic chorion (false amnion or prochorion); the other from the splanchnopleure, to constitute the allantois and allanto chorion.

The Nervous System

The *neural groove* of the blastoderm marks the beginning, location, and form of the future cerebro-spinal nervous system. The neural folds, consisting of thickened ectoderm, increase in prominence, while the groove between them deepens and the summits of the folds approach each other, as segments of an arch, to meet finally and fuse above the groove, converting it into a closed tube which, lined with ciliated ectodermic cells and filled with fluid, is to persist throughout the life of the animal as the central canal of the spinal cord and as the ventricles of the brain. From the deeper ectodermic cells in the walls of the tube are to develop the nerve cells and

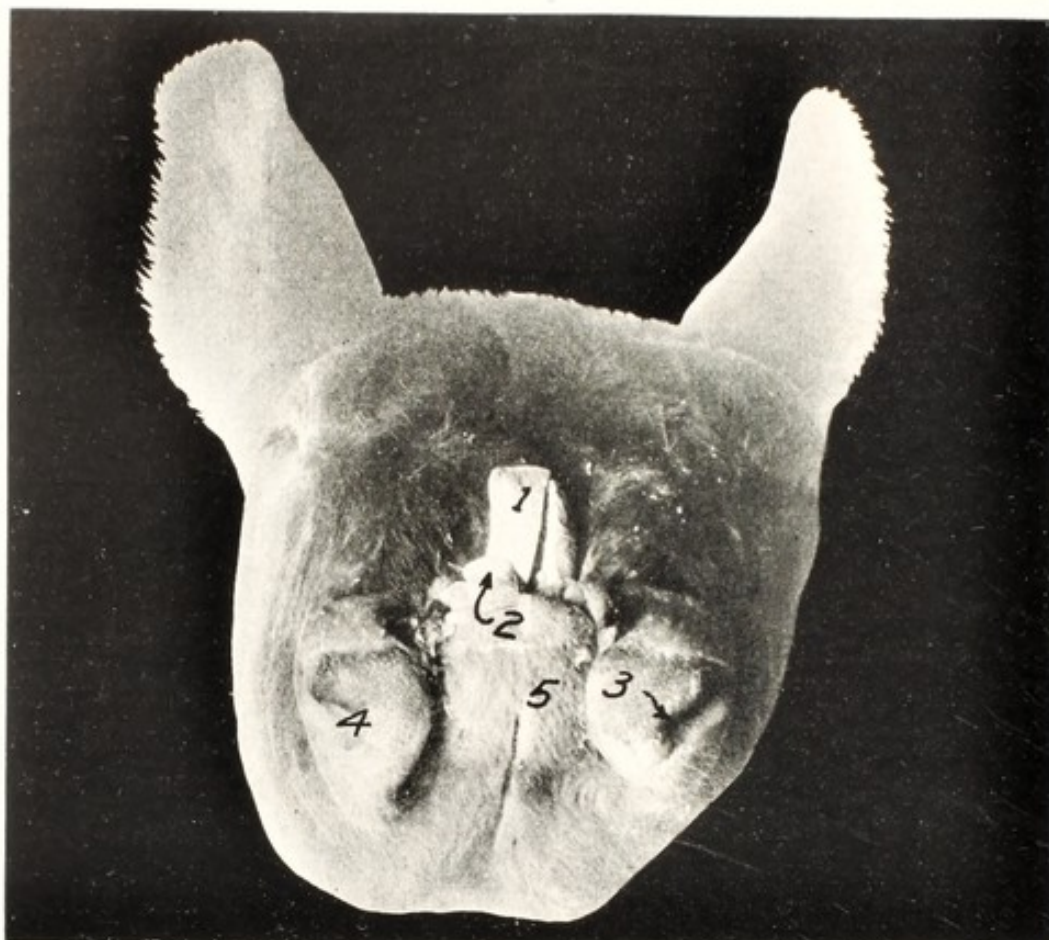


FIG. 17. Schistocephalus Bifidus. (Gurlt.) Calf. Frontal View of Head.
1, tongue; 2, incisor; 3, left nostril; 4, right nostril; 5, mandible.

fibers of the cerebrospinal axis. Normally the neural groove grows rapidly in length and depth. In the rabbit the lips of the neural folds have met and fused to constitute a complete tube by the end of the ninth day. At this time one can distinguish the spinal cord, the fore-brain, the mid-brain, and the hind-brain.

The cerebro-spinal nervous system of mammalia constitutes the central organ, about which, physiologically, the other portions of the embryo develop symmetrically. The cerebro-spinal canal closes first in the middle portion while it remains open at the anterior end to constitute the *anterior*, and posteriorly to form the *posterior neuropore*. Development may be interrupted at the anterior end of the neural groove, which, failing to kill the embryo, may prevent the closure of the neuropore or cause it to re-open as a result of disease, especially in the cow, as shown in Figs. 17, 18.

The posterior, or caudal neuropore may be disturbed in its evolution and the vertebral arches fail to close completely, but remain open dorsally, exposing the spinal cord to constitute *spina bifida*.

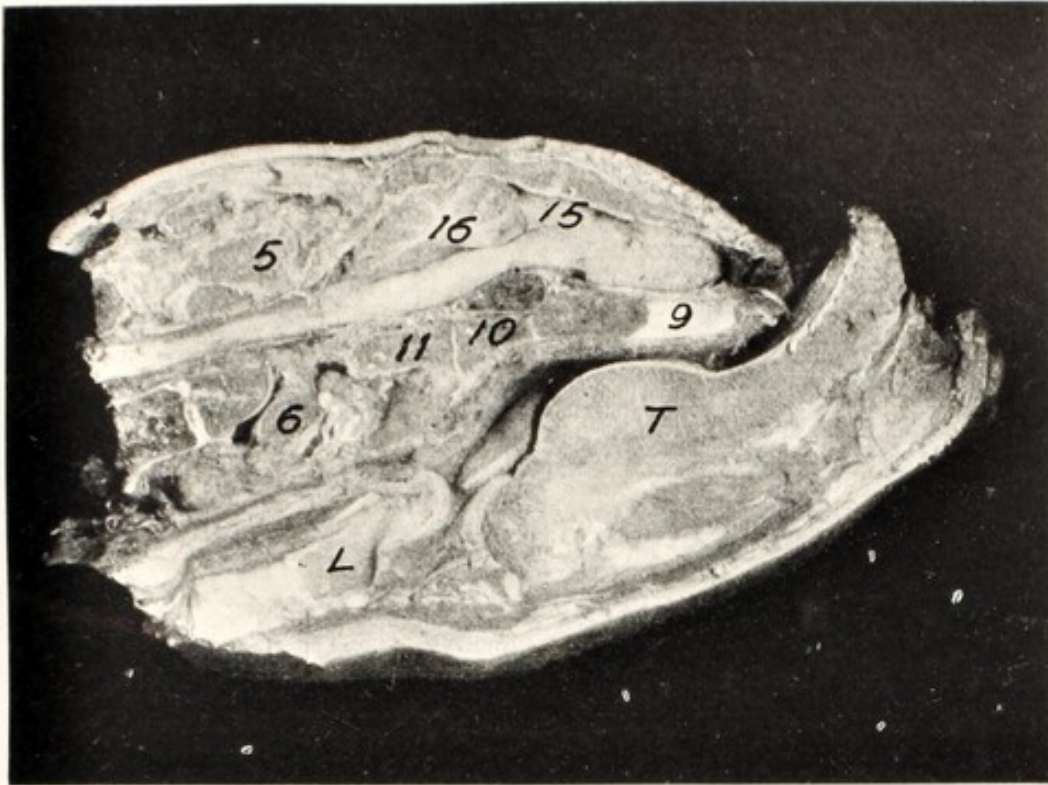


FIG. 18. Sagittal section of Fig. 17.

1, anterior opening of cranial cavity; 5, occipital bone; 6, atlas; 9, ethmoid; 10, sphenoid; 11, basioccipital; 15, cerebrum; 16, cerebellum 17, medulla; T, tongue; L, larynx.

In some low forms of embryonic life the posterior neuropore, or opening of the neural canal, is in continuity with the primitive gut to constitute the neurenteric canal. For a time, this exists to a degree in higher animals, and in event of disturbance may persist as a

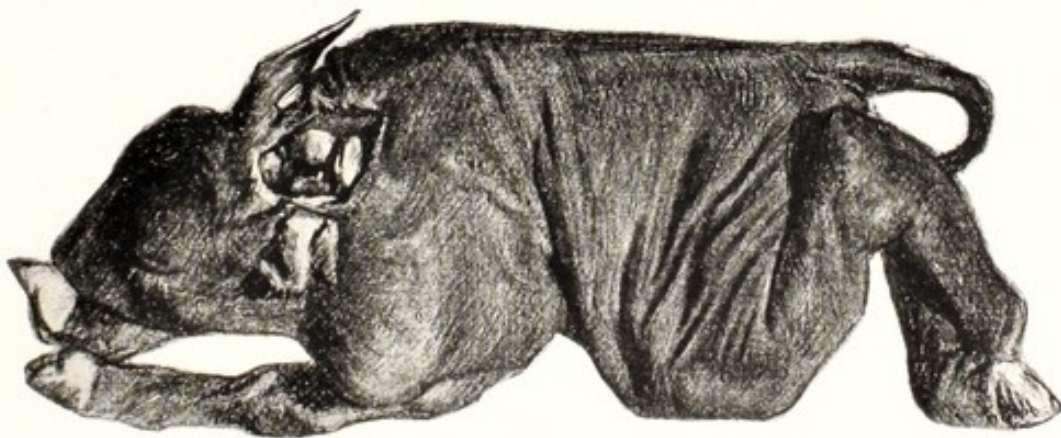


FIG. 19. *Schistocormus Fissidorsualis*. Complete Splitting of the Spinal Column. Calf.

The crater-like opening through the head and cervical spine involves the dorsal wall of the pharynx. The everted rumen and reticulum protrude through the crater.

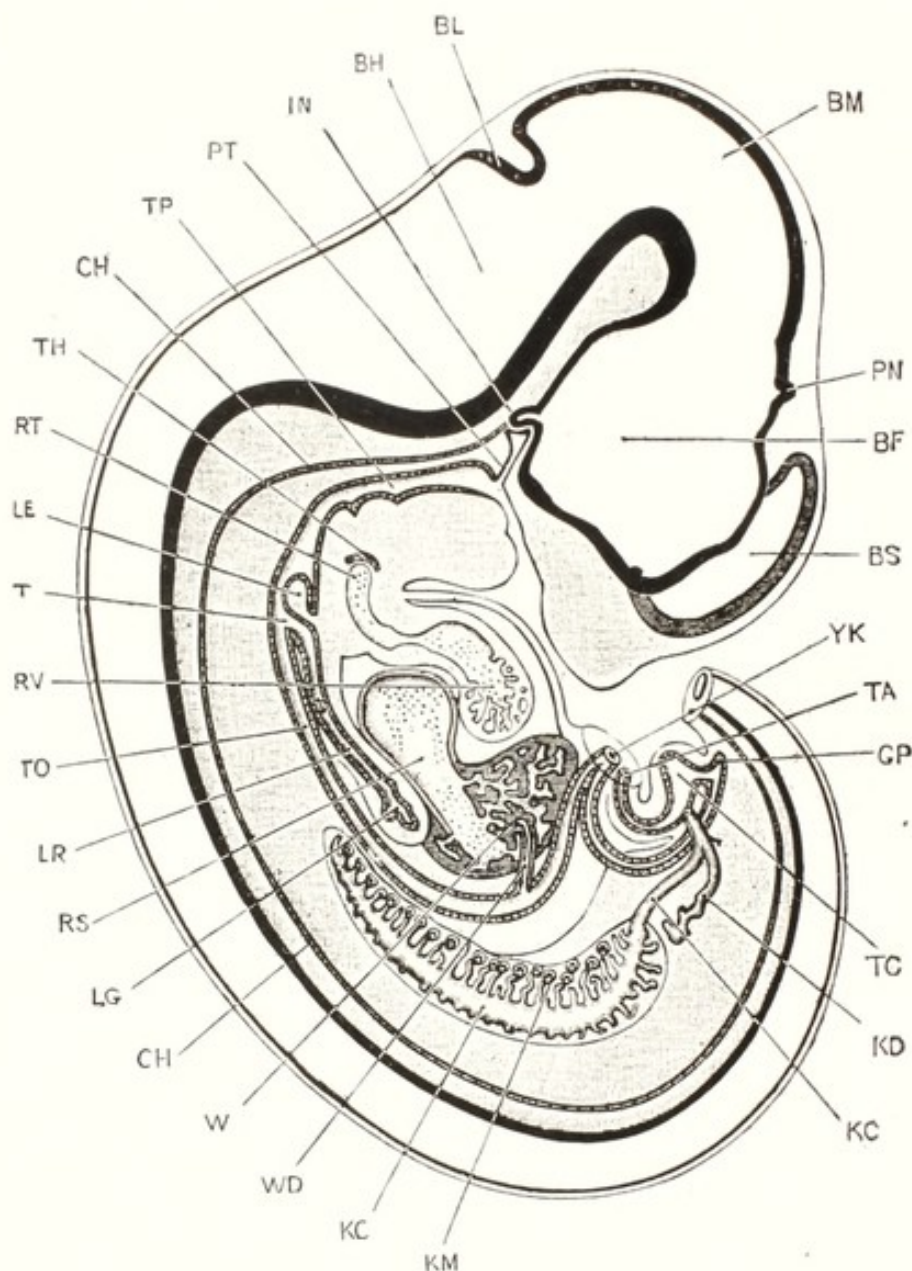


FIG. 20. A Median Longitudinal, or Sagittal, Section through a Rabbit Embryo, at the End of the Twelfth Day.

The section is a strictly median one except in two respects: the cerebral hemisphere of the left side has been introduced in order to render the figure more complete; and the Wolffian body and ureter of the right side added. The terminal portion of the tail has been removed.

BF, cavity of fore-brain, or thalamencephalon; BH, cavity of hind-brain, or fourth ventricle; BL, cerebellum; BM, cavity of mid-brain; BS, cavity of cerebral hemisphere, or lateral ventricle; CH, notochord; GP, post-anal gut; IN, finger-like process of infundibulum; KC, Wolffian duct; KD, ureter; KM, Wolffian body; LE, epiglottis; LG, lung; LR, trachea; PN, pineal body; PT, pituitary body; RS, sinus venosus; RT, truncus arteriosus; RV, ventricle of heart; T, glottis; TA, stalk of allantois, cut short; TC, cloaca; TH, thyroid body; TO, oesophagus; TP, pharynx; W, liver; WD, bile duct; YK, yolk stalk, cut short. (Marshall.)

complete fissure of the spinal column and permanent communication of the alimentary canal through the spinal axis, as indicated in Fig. 19, described by Gurlt as *Schistocormus fissidorsualis subecostatus*. The posterior portion of the cranium, the entire cervical spine and the first segments of the dorsal spine are completely split upon the median line, through the dorsal wall of the pharynx. The pharyngeal mucosa, at the margin of the slit, is in continuity outwardly, first with the meninges of the spinal cord and through it with the

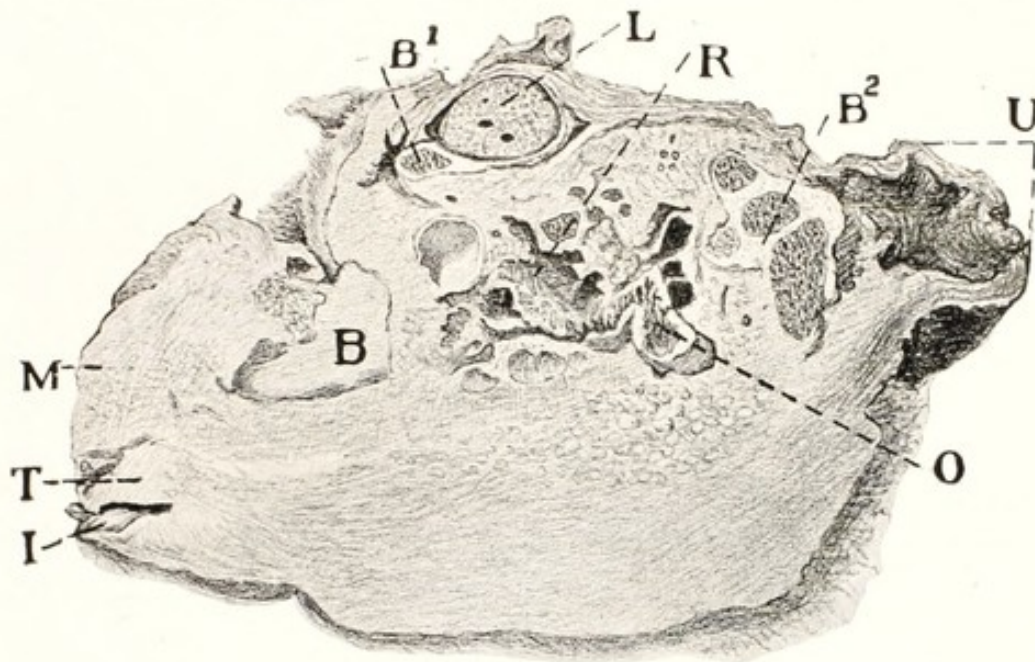


FIG. 21. Sagittal Section of Acardiac Monster. Cow.

I, incisors; T, tongue; M, muzzle; B, bone (skull); B1, sternum; B2, bone (pelvis?); L, lung; R, rumen and reticulum; U, umbilicus; O, omasum.

skin. Through this crater the rumen and reticulum, everted, had prolapsed and had been mutilated by swine. It appears that in this case, the fission occurred anterior to the cephalic end of the notochord. A study of Fig. 20 at IN and PT indicates the existence of an area of low resistance through two infundibuli. It appears that the fission had occurred through the normal location of the pituitary pouch or in its immediate vicinity.

Should the neural groove become disturbed in its development and become more or less branched or doubled, various double monsters may form. It is believed that when a fertilized ovum or an embryo separates equally into two complete parts, or two germinal areas develop upon one blastodermic vesicle, uniovular or identical twins result. While such twins are not rare in man, they are seldom recognized in domestic animals. Occasionally the veterinarian encounters

an amorphous or acardiac monster, regarded by some as due to the unequal fission of a fertilized ovum. Instead this monster has been attributed, in the companion volume, to the fertilization of an imperfect ovum which has developed as a parasite upon a normal twin. It is attached to the navel cord of the approximately normal fetus, the heart of which sustains the circulation of the monster, as shown in Fig. 21.

Such an acardiac monster, which usually becomes detached during parturition, sometimes consists of an almost complete sphere, covered with hair; sometimes the exterior is calcareous.

The Brain

The brain commences to form and is recognizable before the neural canal has been completed. It consists at first chiefly of a series of vesicles which are known as the fore-brain, mid-brain, and hind-brain. The cerebral hemispheres are developed first as a median prolongation at the anterior end of the fore-brain, which later becomes divided into the two hemispheres by its anterior wall growing back into it from the front. The two hemispheres appear first as large vesicles with very thin walls. These cavities persist throughout life as the two lateral ventricles of the brain, which communicate, through the foramina of Munro, with the third ventricle, BM, Fig. 20.

The fore-brain gives rise early to the optic vesicles, as lateral outgrowths, which are ultimately converted into the essential parts of the eye. Normally, there are two of these outgrowths, one from each half of the forebrain. The anterior portion of the forebrain is sometimes arrested in development, the two optic vesicles fail to form, and instead a single vesicle grows out on the median line, to constitute the one-eyed monster, or cyclops. In such case the cerebral hemispheres fail, the maxilla is greatly shortened and the mandible turns upward in front, as shown in Fig. 22.

In some cases the fluid in the lateral ventricles of the cerebral hemispheres becomes enormously increased, to constitute the fetal disease of hydrocephalus, as indicated in Figs. 83, 84, 85. In other instances the cerebral hemispheres grow rapidly and the walls of the skull fail to close over them, so that they protrude, to constitute hernia cerebri, as shown in Fig. 23.

The olfactory vesicles grow out from the anterior ends of the vertebral hemispheres, to form later the olfactory lobes, from which the olfactory nerves pass to the nose. In the cyclops, Fig. 22, these fail to develop and the young is born without nose or olfactory power.

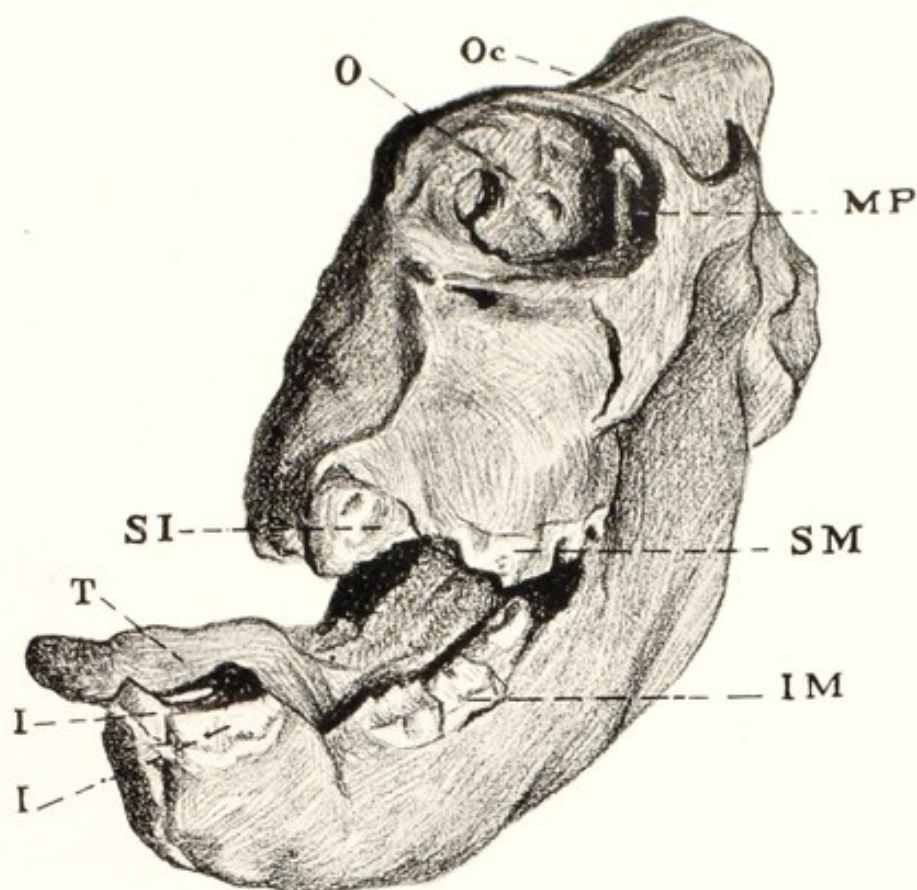


FIG. 22. Head of Cyclops. Foal.

OC, occiput; O, single orbital cavity; MP, coronoid process of inferior maxilla; SM, superior grinders; SI, superior incisors fused into a single organ; IM, inferior grinders; T, tongue; I, I, inferior incisors.

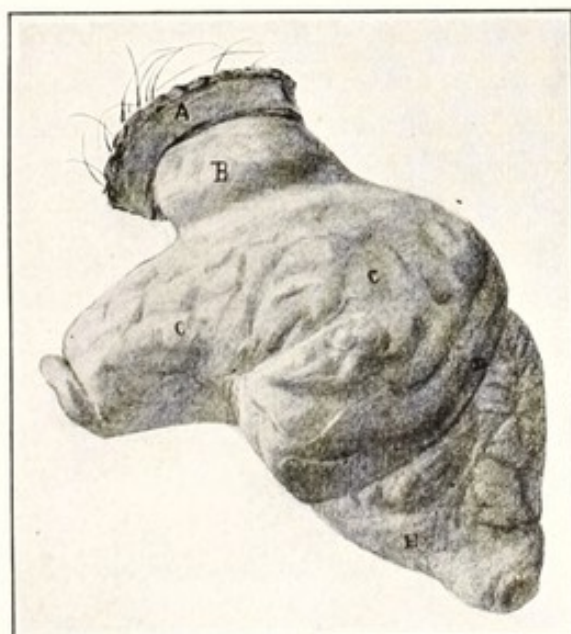


FIG. 23. Hernia Cerebri. Pig.

Lateral view of brain, seen from the left.

A, segment of skin covering the herniated portion of the brain, B; C, C, cerebrum; D, cerebellum; E, medulla oblongata.

The Spinal Cord

The essential parts of the spinal cord—the nerve cells and their axis cylinders—arise from the deeper layers of the columnar epithelial cells surrounding the central canal. The nerve cells, or neuroblasts, are at first spheroidal in form and show upon their surface one to several prolongations, which are later to constitute the polar elongations, or axis cylinders.

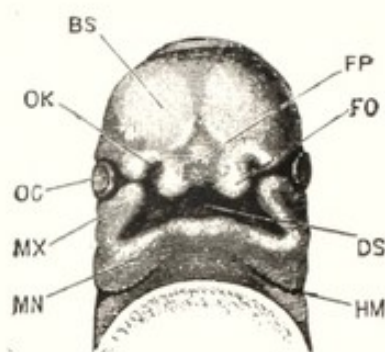


FIG. 24. The under surface of the head of a human embryo, lettered by Professor His, Hn, and estimated as about twenty-nine days old. $\times 7\frac{1}{2}$. (From Marshall after His.)

BS, cerebral hemisphere; DS, stomatodæum; FO, processus globularis, or lateral portion of fronto-nasal process; HM, hyomandibular cleft; MN, mandibular arch; MX, maxillary arch; OC, eye; OK, olfactory pit; FP, median portion of fronto-nasal process.

The sensory spinal nerves develop from the spinal ganglia, which appear in the neural folds. From the median sides of these there grow centralwards nerve fibers into the spinal cord, to constitute the superior, or dorsal roots. They become the centripetal, or sensory roots of the nerves. The ventral, or motor nerves arise as small outgrowths from the lower part of the sides of the spinal cord, in the position they occupy during adult life. The ventral roots grow outward to meet the dorsal roots just beyond the ganglia and fuse with them. Up to this point of fusion, the spinal nerves are pure—the superior one sensory, the inferior motor. Later they divide again into dorsal and ventral twigs, each of which is composed of mixed nerves containing both sensory and motor filaments.

Development of the Organs of Special Sense

THE OLFATORY ORGANS. THE NOSE

The olfactory organs appear early as thickened patches of ectoderm upon the antero-inferior parts of the head. These soon sink inwards to constitute the olfactory pits, into the bottom of which

the nerves of smell grow out from the olfactory bulbs of the brain.

The olfactory pits are at first incomplete. Their lower borders, which are deeply notched, communicate with the stomatodaeum, somewhat as an extension of that cavity. The olfactory pits and the stomatodaeum are connected by a narrow isthmus, bordered inwardly by the *processus globulares* of the fronto-nasal process and externally by the maxillary processes of the maxillary arch. Soon the maxillary processes approach and fuse with the *processus globulares*, to complete the circumference of the olfactory pits and, by separating them from the mouth, to constitute the nostrils. As far as the incisive foramen of the adult, the *processus globulares* sends projections inwards to constitute the anterior portion of the palate, while, behind

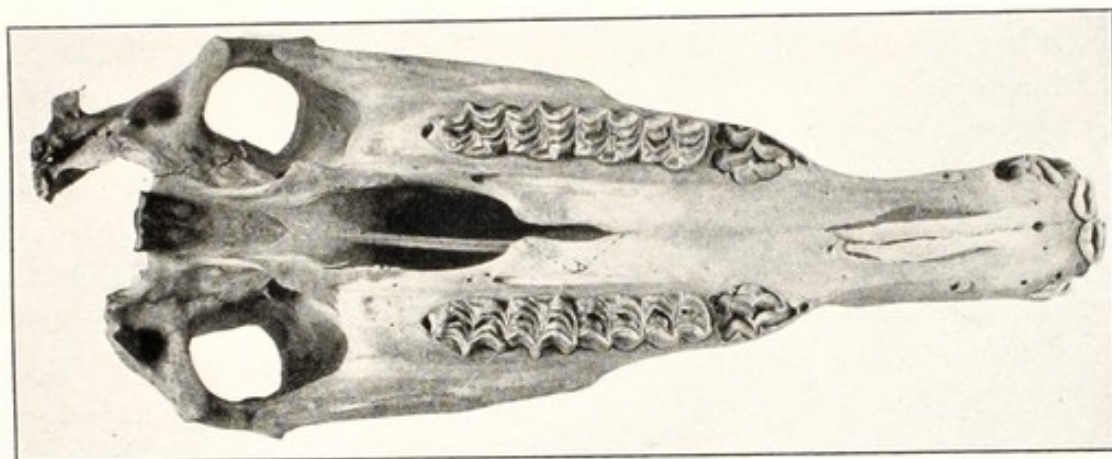


FIG. 25. Cleft Palate. Foal.

the foramen, the maxillary processes send out shelf-like projections, which meet on the median line to constitute the posterior portion of the palate and, from their fusing borders, send projections upward which reach and fuse with the lower surface of the fronto-nasal process, to constitute the nasal septum, dividing the nasal chamber into two distinct cavities. The nasal passages are at first very short, but, as the nose elongates, the palatine processes from the maxillary arch grow backward and, fusing on the median line, separate completely the oral and nasal cavities, so that the latter finally open posteriorly, through the posterior nares, into the pharynx.

The upper lip is formed by a fusion of the fronto-nasal processes with the maxillary arch. Aberrations in the development of the anterior nares and upper lip are not rare, especially in bovidae, where in some instances the *processus globulares* fails to fuse with the maxillary processes, constituting harelip. When the anterior opening of the neural groove, or anterior neuropore, remains open, the entire

group of facial bones may fail to fuse on the median line, the two halves of the vomer and septum nasi developing independently, to form a deep crater in the median line of the face, into which the mandible sinks, to constitute the monster, almost always bovine, of *Schistocephalus bifidus*, as shown in Figs. 17 and 18.

In dealing with diseases of the septum nasi, its origin should always be recalled and it should be remembered that, in some forms of disease, fluids may collect or new tissues may develop between the two laminae, from which the septum takes its origin.

In some cases the palatine processes fail to fuse, resulting in a cleft palate, as shown in Fig. 25. In other instances the membrane stretching across the stomatodeal pits fails to disappear and constitutes a permanent wall across the pharynx, completely separating the nasal chamber from the mouth and pharynx, constituting atresia of the posterior nares, by which arrest in development the animal, unable to breathe through the nostrils, must respire entirely through the mouth. The horse, having a greatly elongated soft palate, which renders oral breathing extremely difficult, can not live if both posterior nares are closed; if the atresia affects but one nostril, the animal can breathe readily when not severely exerted, but if put to hard work shows extreme dyspnoea as a result of the restricted breathing room.

THE EYES

The eyes originate partly from the optic vesicles of the brain and partly from the optic pits in the ectoderm upon the sides of the head.

The optic nerves develop from the optic vesicles, which appear ten to twenty days after fertilization, varying apparently according to species, as lateral outgrowths of the fore-brain. The optic vesicles appear first as tubular outgrowths from the fore-brain, but the distal end of each soon becomes enlarged, while the connecting stalk remains a narrow tube. The anterior wall of the enlarged distal end becomes invaginated, to constitute the optic cup, the walls of which are later to form the retina, within the depression of which the vitreous body develops. The lens develops somewhat later, appearing first as a pit in the ectoderm upon the side of the head. The pit gradually sinks deeper and its mouth narrows, until it finally closes, to constitute the vesicle of the lens.

The vesicle sinks into the optic cup and the margins of the latter come in close contact with it except at one point on the ventral sur-

face, where there is a distinct groove, the *choroidal fissure*. The vesicle becomes the *lens*.

The *vitreous body* is believed to arise from the retina as a secretion or outgrowth from its anterior surface.

As the lens becomes invaginated and separated from the external ectoderm, a layer of mesoderm extends across between the vesicle and the external ectoderm, constituting the *cornea*, the tissues of which become transparent. The choroid and sclerotic coats develop from the mesodermic tissues surrounding the optic cup; the iris is formed by a forward growth of the margins of the optic cup; and the anterior chamber appears somewhat later as an excavation between the cornea and lens. The eyelids, consisting of folds of the skin from above and below, are the last structures to form in connection with the eye. These extend over the eyeball, to meet finally and become completely fused without adhering to the surface of the cornea, so that they create between their internal surfaces and the cornea, a closed cavity—the lacrymal sac. In the rabbit and carnivora, the eyelids remain closed for a short time after birth; in ruminants and solipeds the eyelids open prior to birth. The *membrana nictitans*, or third eyelid, which exists in all domestic mammals, is formed from a fold of skin in a manner similar to the two ordinary eyelids. The lacrymal duct is formed in the groove existing between the external nasal process and the maxillary arch.

In domestic animals there are occasional aberrations in the development of the eye. Sometimes the eyelids have become so intimately fused that they fail to open at the proper time, a condition which is not usually subject to remedy; or the cornea fails to undergo the normal transformation into a transparent body, remaining opaque; or long hairs, which may be subject to surgical removal, grow from the neighborhood of the lacrymal duct in the third eyelid, irritating the eye. Sometimes there is a contraction of the inner, or mucous layer of the eyelid or a comparative overgrowth of the external skin, which causes the eyelids to become inverted, causing entropium, or everted, producing ectropium.

THE EARS

The first traces of the ears consist of open pits opposite the hind-brain, usually when the embryo is about ten to fifteen days old. The pits sink in deeply, until they come into close contact with the hind-brain, and early acquire a communication with the auditory nerves. The mouths of the pits soon close, and the invaginated portion be-

comes separated from the external ectoderm, to constitute the auditory vesicles, in which the essential parts of the ear—the semi-circular canals, vestibule, cochlea, etc.—are developed.

The Eustachian tube is formed from the hyomandibular pouch, which extends out from the pharynx as a diverticulum. At one time it pushes out against the ectoderm and is separated from the exterior by a very thin membrane consisting of ectoderm externally, in immediate contact with the inner layer of entoderm, with no mesoderm between. Later, a layer of mesoderm grows in between the ectoderm and entoderm; the three constitute the tympanic membrane. This pouch does not normally reach the surface at any time during fetal

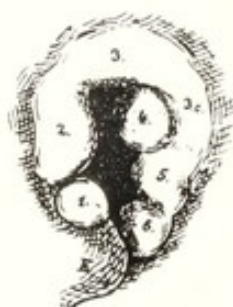

FIG. 26. The Left Ear of a Human Embryo, lettered by Professor His, Br. 2, and estimated as Thirty-Five Days Old.

(From Marshall after His.) $\times 20$.

1, tuberculum tragicum; 2, tuberculum anterius helices; 3, tuberculum intermedium helices; 3 and 3c, cauda helices; 4, tuberculum anthelicis; 5, tuberculum antitragicum; 6, tuberculum lobulare.

life. Abnormally, though but rarely, the gill slits open upon the surface, as in fishes, and, persisting, constitute at birth gill-slit fistula. In the soliped, there is a large infundibulum formed in connection with the Eustachian tube, which is known as the guttural pouch, or air sac. It communicates with the Eustachian tube by an elongated slit which is sometimes abnormal in the new-born foal and causes air to become impacted in the sac (tympany of the guttural pouch), which may so press upon the larynx as to strangle the young animal.

The formation of the external ear, or pinna, has not been so well studied in domestic animals as in man. The conchal cartilage arises from the mandibular and hyoid arches, which bound on either side the hyomandibular cleft. As shown in Fig. 26, in the human ear the concha consists of a series of tubercles with deep fissures extending between them. There are no data to show that the early stages of development of the concha in domestic animals are precisely parallel, but they are presumably essentially so. By observing Fig. 26, it will



FIG. 27. Ears and Face of Foal following the Removal of "Ear Teeth."

A, level of tooth in left ear; F, mucous fistula leading down to T, the cavity from which the tooth has been removed.

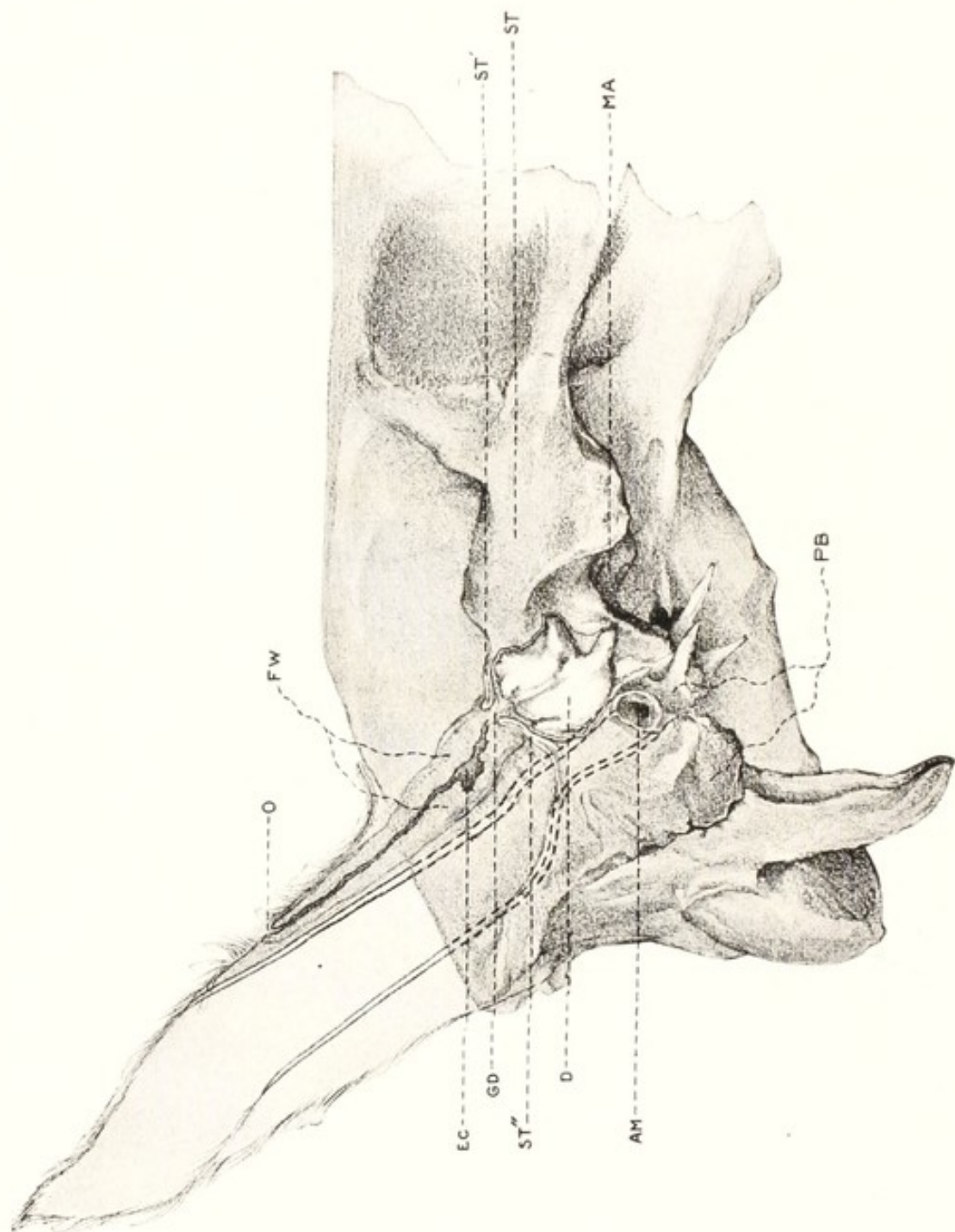


FIG. 28. Diagrammatic View of Ear and Skull from Fig. 27.

Showing the method of formation, from invagination of the ectoderm.

O, orifice of invaginated area; FW, fibrous wall of invaginated canal; EC, ectodermic cavity; D, tooth; ST, squamous temporal bone; ST', ST'', incarcerating outgrowths of squamous bone tending to isolate EC from D; GD, persistent fibrous cord connecting EC with the capsule of D (the ectodermic canal in this cord has been obliterated); PB, petrous temporal, or ear bone, which constitutes a separate bone in the horse; AM, auditory meatus; MA, maxillo-mandibular articulation.

be seen that between 1 and 2 there is an especially deep fissure which, in the ear of the horse, is apparently marked by an important ridge inside the concha. It is interesting, in connection with this fissure, to observe that foals are sometimes born with a deep invagination of the ectoderm at this point, causing a long, narrow fistula which extends downwards between the exterior of the cartilage and the skin, from about the middle of the internal border of the concha to near its base. From this fistula there usually exudes a viscid mucus. In some cases the invagination extends more deeply and penetrates the squamous temporal bone. In the development of the osseous tissues, the distal end of the invaginated epithelium becomes cut off by the bone and a closed sac is formed, in which ordinarily one or more teeth (ear teeth) develop, which resemble closely the molars of the horse and may grow to almost any size, projecting above the external surface, or growing inward, causing an inward bulging of the skull into the cranial cavity, Figs. 27 and 28. Some authors ascribe these formations to outgrowths from the buccal mucous membrane. A glance at the figures, prepared from a clinical case, indicates, to the contrary, that they arise from the ectoderm of the conchal margin, in a manner parallel to the formation of the teeth within the mouth from the stomatodeal ectoderm.

It is to be remembered also that the concha is formed by an evagination of the skeletal mesoderm. In such evagination there occurs a folding of the cartilage matrix so that the two laminae, continuous at the summit, come into immediate contact, blend intimately, and come to be regarded as a single layer of cartilage. Pathologic conditions arise however to remind one of the mode of origin when lymph accumulates between the two laminae to constitute otohematoma, or "blood ear," in dogs and horses. Forgetting this embryological origin, the practitioner sometimes errs in regarding the collection of lymph as being located between the skin and the cartilage instead of between the two cartilaginous laminae.

Formation of the Digestive and Respiratory Apparatus

The alimentary canal of the embryo consists at first of that portion of the splanchnopleure of the blastoderm which is included within the embryo in the process of ventral infolding and finally becomes constricted off from the yolk sac. For a time the alimentary tract continues to communicate with the extra-embryonal portion of the blastoderm, or yolk sac, by means of the yolk-stalk, or vitelline duct. In some species of animals, traces of the tube may be found in

the umbilical cord at the time of birth. It does not normally retain its relation with the intestine, and all traces of continuity between the gut and the vitelline duct are effaced.

The intestinal tract, during the early life of the embryo, is divided into three sections, known respectively as the fore-, mid-, and hind-gut. The first comprises that portion anterior to the communication with the yolk-sac; the second, the middle portion, including the yolk-stalk; and the third, or hind-gut, that portion which projects from the yolk-stalk posteriorly. In the fore-gut there appear early two dilations—the pharynx and the stomach. The gut is at first closed at both its anterior and its posterior end; the communications with the exterior become established later. The anterior gut opens first. There appears, in that region of the embryo which is later to constitute the mouth, a depression known as the stomatodeal pit, by which the ectoderm sinks inward towards the pharynx, until finally the two cavities are separated merely by a thin layer each of ectoderm and entoderm. The intervening mesodermic tissues have been absorbed. Eventually, the thin membrane gives way and the mouth communicates with the anterior end of the fore-gut or pharynx.

The pharynx shows a marked dilation in comparison with the other parts of the digestive tube. In sagittal section, the internal surface shows the prominent visceral arches, between which extend the visceral pouches. Among these visceral pouches, the hyomandibular and first branchial are the most prominent. They have on the outer surface, corresponding visceral grooves, which do not normally open upon the exterior, but the hyomandibular groove becomes very thin and ultimately forms the tympanum.

The embryonic line of demarcation between the stomatodaeum and fore-gut is not perfectly known in the adult, but is in the immediate vicinity of the soft palate. The buccal mucosa and the teeth are derived from the stomatodeal ectoderm, and the tongue grows forward from the entoderm of the floor of the fore-gut.

Later in the life of the embryo, varying according to species, there appears, opposite the posterior end of the hind-gut, a distinct depression in the ectoderm—the proctodeal pit. The invagination of this pit, of a character similar to that of the stomatodaeum, extends toward the hind-gut sufficiently that only a thin membrane remains between them, consisting externally of a layer of ectoderm and internally of entoderm. Normally, this pit soon opens into the hind-gut. The alimentary canal then communicates with the exterior, both anteriorly and posteriorly.

Various aberrations occur in the development of these parts. The most common is an arrest in the development of the hind-gut. Sometimes a portion of it is wanting, it does not become connected with the proctodeal pit to open exteriorly, and the young animal is born without a rectum. Sometimes the membrane between the proctodeal pit and the hind-gut fails to disappear, and the young animal is born without an anus.

The alimentary canal forms immediately beneath the notochord, and is at first of the same length as the body cavity, but later it increases in length far more rapidly than the body and drops away from the dorsal portion of the body cavity, to float freely, confined in position only by the mesentery, which it has derived from the peritoneum of the superior wall of the abdomen and carried with it in its descent.

At first the final portion of the posterior gut of the embryo, representing jointly the intestine and genito-urinary passages, consists of a single dilated chamber, or cloaca, but later there grows back, from the angle between the stalk of the allantois and the hind-gut, a partition which serves to separate the digestive tube from the genito-urinary tract. This partition is sometimes incomplete. If the proctodeal pit fails to open in the dorsal, or anal area of the female, the cloacal partition may become arrested, and the meconium, and later the feces escape through the vulva. When the anal portion of the proctodeal pit fails to open in the male, the retention of meconium and feces is absolute. Since the fetus normally does not defecate, this occasions no disturbance until some hours after birth, when the obstruction to defecation becomes notable and important. In the female the ventral portion of the proctodeal pit finally constitutes the hymen, which may persist, especially in ruminants, as an impervious membrane and cause retention of the utero-vaginal secretions, causing, ultimately, enormous distention of the uterus and vagina.

THE LUNGS

The lungs, formed as an outgrowth from the floor of the pharynx in the region behind the branchial arches, begin as a longitudinal groove, which soon develops into a blind pouch. This evagination extends backward beneath the pharynx. At its distal end the pouch soon divides into right and left halves, to constitute the two lobes of the lungs. The growth continues backward beneath the esophagus and above the heart. The distal ends become enlarged and divide into small lobes. These elongate greatly, giving rise to buds ending

in ampullae, which subdivide to constitute the air cells. The smaller tubes leading from the air cells are the bronchioles, the larger ones the bronchii, the original tube leading from the floor of the pharynx the trachea, and the slit which first appeared in the bottom of the pharynx, the glottis.

THE TEETH

The teeth, which appear very early, originate from the ectoderm of the stomatodaeum in the form of a longitudinal invagination of

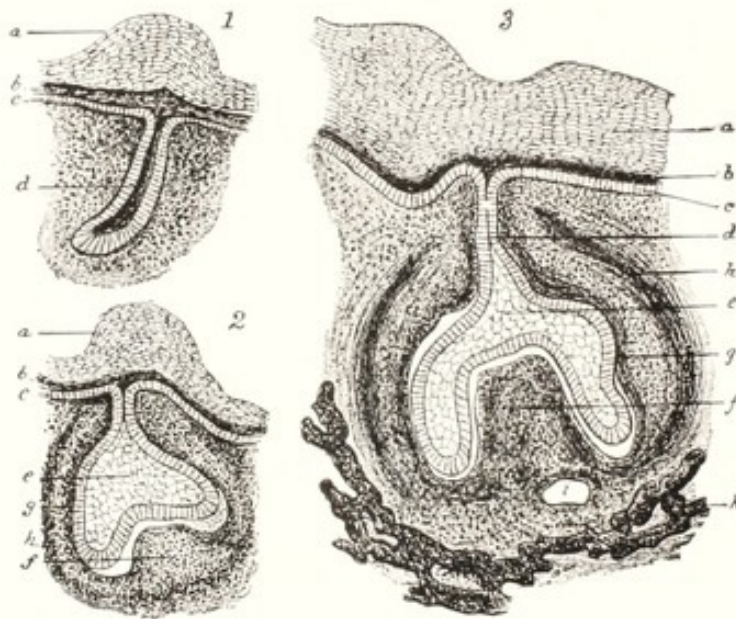


FIG. 29. Three Successive Stages in the Development of a Tooth Germ of a Pig Embryo (after Frey and Thiersch).

a, b, c, layers of thickened oral epithelium, showing dental groove on surface in 3; e, enamel organ; f, dental papilla; g, h, internal and external layers of follicle wall; i, blood-vessel; k, maxilla; d, epithelial ingrowth, the end of which expands into the enamel sac. (Heisler.)

thickened epithelium along the border of the jaw, which eventually sinks down into the substance of the jaw as a continuous ridge, known as the common enamel germ. Later, the ridges become enlarged at intervals, to constitute the individual enamel organs, while the portions between these enlargements tend to atrophy and finally disappear.

Each enamel organ soon consists of a flask-like vesicle of ectoderm with a narrow neck, which is still continuous with the epithelium of the mouth, by a cord-like constriction, the gubernaculum dentis. The distal end, or fundus, of the flask is enlarged and spherical. Beneath the enamel organ, there soon forms from the mesodermic connective tissue the dental papilla, which pushes up into the sac, causing an

invagination of its base. The enamel sac soon invests the top of the papilla as a cap and takes on the form of the future tooth. The enamel organ acquires the form of a flattened sac, the distal end of which is invaginated so that the two walls are brought into close proximity, Fig. 29.

Upon the external surface of the dental papilla, odontoblasts arise, from which the dentine of the tooth is formed. The enamel prisms




FIG. 30. Sagittal Section through an Inferior Grinder of an Equine Embryo, 4 Inches Long.

The enamel cap is at most points detached from the dentine papillae. The section through the tooth follicle is so made that the plicae of the enamel cap have split each of the dentine papillae so that there are four instead of two.

ect, ectoderm of mouth cavity; mes, mesoderm; eo, enamel organ; ec, enamel cells; d, dentine; eb, embryonic bone.

are formed from the epithelium of that part of the walls of the enamel sac lying in immediate contact with the dental papilla. The superficial wall of the enamel sac—that portion continuous with the neck-like mass of epithelial cells still maintaining connection with the mouth cavity—disappears without taking any recognized part in the formation of the enamel tissue. The dentine, forming from the odontoblasts upon the apex and sides of the papilla, soon invests these portions in the hard ivory substance. The base and center of the dental papilla continue as the tooth pulp. The base of the papilla is at first wide open, but gradually contracts as the tooth develops,

and finally there grow out in some teeth projections, or septa, of dentine, to constitute the roots, or fangs, which divide this cavity, according to the individual tooth, into two or more distinct openings, through which the blood vessels and nerves pass to the pulp of the tooth, Fig. 30.

As the enamel organ sinks into the jaw, a condensation of the surrounding mesodermic connective tissue occurs, to constitute a capsule—the tooth follicle—which closely invests the enamel organ and papilla. When the bony tissue of the jaw forms, the follicle serves as periosteum for the tooth and alveolus, while from its inner layers the external tooth tissue—the cement—is developed. The origin of the dental tissues is, then: 1, the enamel from the invaginated ectodermic cells; 2, the papilla, vessels, nerves and dentinal tubules from the mesodermic connective tissue; and 3, the cementum and the dental and alveolar periosteum from the mesodermic dental follicle.

When the bony jaws form, the teeth are at first in continuous grooves, but transverse osseous partitions later extend between the tooth germs, to constitute finally a separate compartment, or alveolus, for each. The permanent teeth are developed as outgrowths from dental ridges adjacent to the enamel organs of the temporary set, in those cases where they are preceded by such; otherwise they are formed the same as the temporary teeth from a backward growth of the common enamel germ (dental ridge).

In all species of mammals there are many varieties of aberration in the development of the teeth. These acquire distinct economic and surgical importance in horses, which provide more such aberrations than any other mammal, if not more than all other mammals together. The mesodermic connective tissue follicle, under disturbances, may undergo serious aberration during its developmental stages. A large amount of fluid may be formed within the follicle, to constitute follicular cysts, which may cause the destruction of the tooth germ and may become enormously increased, to the extent of one, two, or more pints of fluid, and, in the upper jaw, may cause serious distress to the animal by projecting into the sinuses and interfering with respiration. In other cases, there is formed in the walls of the follicle an abnormal amount of cement, to constitute a cement tumor, or cementoma. Sometimes there is a distension of the follicle with fluid, accompanied by a growth of cement upon its inner surface, giving rise to compound follicular cysts. Sometimes the walls of the tooth follicle become greatly thickened by an abnormal growth of connective tissue, to constitute a fibrous odontome.

In the horse, and to a less extent in other animals, where there are deep invaginations from the sides or upon the crown of the enamel organ into the dental papilla, there is normally formed in the grinders enough cement to close completely the spaces between the infolded layers of enamel. In some instances this formation of cement is in-

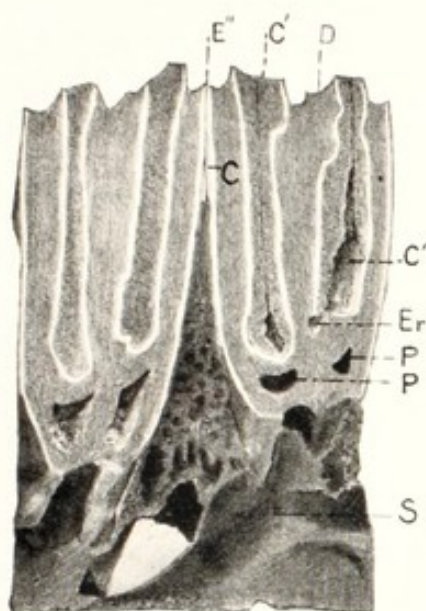


FIG. 31.

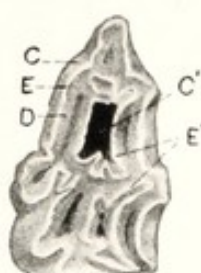


FIG. 32.

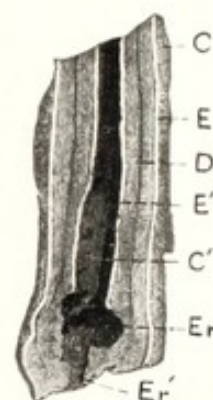


FIG. 33.

FIG. 31. Sagittal Section of Superior Molars of Adult Horse showing on the Left Normal Development and on the Right Arrested Development of the Cement Area.

FIG. 32, 33. Crown, and Longitudinal Cross Section of a Superior Grinder of Adult Horse showing Absence of Cement in Central Infundibulum and Erosion of the Enamel and Dentinal Plates.

C, external cement; C', central cement area; E, external enamel layer; E', central enamel; E'', external enamel at point of contact between adjacent molars; *the adjacent enamel laminae project above the surrounding tissues, have no cement between them, and are so arranged as to prevent the impaction of food particles between;* D, dentine; Er, erosion area; Er' erosion canal penetrating the tooth fang; P, pulp cavity; S, superior maxillary bone.

complete and an opening is left through the central portion of this substance, from the grinding surface of the tooth down to the bottom of the infundibulum, in close contact with the enamel. Through this cleft, food particles pass and, becoming lodged in the deepest part, undergo bacterial decomposition, which may cause a solution of the enamel and dentine and, finally, a perforation of the pulp cavity, leading to a purulent inflammation of the tooth pulp and a destruction of the life of the organ, with many complications of a highly important character. (See C', Figs. 31, 32 and 33.)

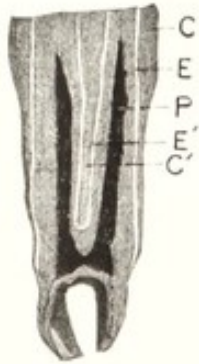


FIG. 34. Cross Section of Molar of Adult Horse.

C, external cement; C', central cement; E, external enamel; E', central enamel; P, pulp cavity surrounded by dentine.

The enamel organ is subject to aberrations in its development, by which a tumor is formed constituting a multilocular cyst which may prevent eruption of the tooth.

The dental papilla undergoes two important forms of fetal aberration, or arrest in development. First, there may be an excessive development of the dentinal substance to constitute an ivory tumor, or radicular odontome. Occasionally such tumors in the horse attain a weight of five or more pounds.

There is frequently an arrest in the development of dentine at the

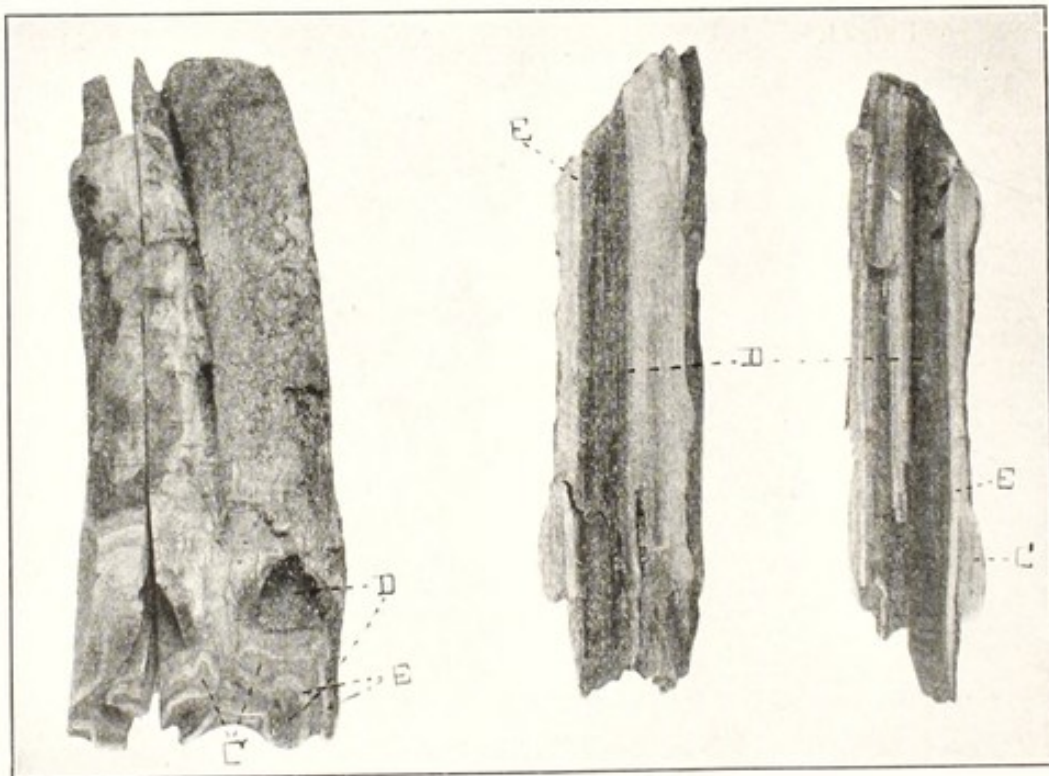


FIG. 35. Table Surface and Section of Inferior Molar of Adult Horse, showing Non-fusion of Dentinal Lamellae, followed by Infection and Purulent Pulpitis.

C, cement; E, enamel; D, open pulp cavity surrounded by dentine.

wearing surface of the tooth. In the grinder of the horse, where the enamel dips down into the body of the tooth from its grinding surface, two lamellae of dentinal substance are brought into close contact. The papilla, or radicle of the tooth, *d*, Fig. 30, splits up into several sharp elevations, which push their way up into the enamel organ. The dentine forms from the odontoblasts upon the exterior of these projections. The soft tissues, or tooth pulp, occupy the interior of these elevations, so that at their apexes, before the tooth erupts and the crown is worn away, the inner, or pulp surfaces of the dentinal plates should come into immediate contact. Normally the opposing faces of these two plates should fuse at the grinding surface and hermetically seal the pulp cavity, as shown between C and C' in Fig. 34 and at D in Figs. 31 and 32. In some cases, as shown in Fig. 35, this fusion fails to occur, causing, when the dentinal summit is worn away, an opening into the pulp cavity, with food particles passing through between the unfused laminae into the pulp, leading to a purulent inflammation.

Thus, in the early stages of embryonic life, aberrations in the formation of the tooth germs serve in a variety of ways to induce defects in the teeth which lead to their early disease and destruction, accompanied by an endless variety of complications of more or less serious importance for the well-being of the animal.

The enamel of the mammalian tooth, the hardest tissue in the body, is normally a product of ectodermal growth from the stomatodaeum, which has become invaginated into the bones of the maxilla and mandible, but teratologically tooth tissues are not confined to these parts. It has been previously related that tooth tissue, histologically and anatomically, is also formed in the squamous portion of the temporal bone of the equine embryo, but here the conditions simulate closely those obtaining in the oral cavity itself. That is, ectodermal cells are invaginated into the deeper layers of mesoderm. From the mesodermal cells, the squamous temporal bone is formed, and from the incarcerated ectoderm, as in the jaws, the enamel tissue. Occasionally in horses, and more rarely in other animals, there are observed dental tissues in the ovaries and testicles. Apparently they arise from the primitive genital cells of these glands.

Teeth, hair, or other ectodermic derivatives are liable to develop when limited sacs of ectoderm, invaginated into mesoderm, become incarcerated and separated from the general ectodermic layer, and the surrounding mesoderm is converted into bone or firm layers of unyielding connective, or other dense tissues.

THE LIVER

The liver of the embryo appears about the end of the second week, as an outgrowth from the ventral wall of the intestine, just beyond the dilation which marks the future stomach. The formation of the liver resembles in many respects that of the lungs. The outgrowth becomes enlarged at its distal end, and the proximal portion becomes narrowed to constitute the bile duct. The liver, the most conspicuous of all the glands in the embryo, constitutes at the time of birth the largest and heaviest portion of the viscera. In volume and weight, it is equal to the entire intestinal tract, with the lungs and heart added. The liver of the monster, *Schistosomus reflexus*, is remarkably arrested in its development, while other internal organs pursue their regular course. The liver frequently, if not generally, becomes cystic with apparently very little hepatic tissue. This peculiar arrest is apparently the result of the very early reflexion of the embryo before the physiological relations with the umbilical vein have become established: the spectacular reflexion shifts the course of the vein and it enters the anterior vena cava, leaving the liver without placental blood.

This monster is more extensively discussed in the companion treatise. Although the hepatic functions are commonly thought essential in both ante- and postnatal life, many of these monsters, virtually destitute of a liver, survive to the close of the normal duration of pregnancy, and most organs and systems attain almost, or entire structural and functional development.

THE PANCREAS

The pancreas forms at about the same time as the liver, as two infundibuli, one from the ventral and one from the dorsal wall of the duodenum, in the tissue of the mesentery between the intestine and dorsal wall. The gland quickly divides up into lobules, from which the acini and duct are formed.

The Circulatory System

THE HEART

During the second week of embryonic life the heart is recognizable as two distinct, symmetrical, straight tubes, lying along the head-end of the embryo between the yolk-sac and the neural folds and connected at their posterior ends with the vitelline vessels. The two soon unite to form a single tube, which becomes twisted upon

itself and forms a prominent swelling on the ventral surface of the embryo in the region of the pharynx. It is twisted in an S-shaped loop, free in its middle portion, with the ends attached anteriorly and posteriorly to the ventral surface of the fore-gut. The posterior, or dorsal, portion of the heart, representing the future auricles, is separated by a somewhat marked constriction from the ventral portion, which is to become the ventricles. The anterior end of the loop is somewhat enlarged, to constitute the *truncus arteriosus*, which is attached to the fore-gut in the vicinity of the mandibular arches.

The heart increases rapidly in size. Within a week from the first traces of its formation, the constriction between the auricular and ventricular portions has become very narrow, the auricles have assumed their ear-like form, and the ventricular portion lies transversely across the body, shaped somewhat like the simple adult stomach.

THE SINUS VENOSUS. THE AURICLES AND VENTRICLES

The blood is returned to the heart by three symmetrical pairs of veins—the Cuvierian vein from the body of the embryo, the vitelline vein from the yolk-sac, and the allantoic vein from the placenta. These three pairs unite to constitute the sinus venosus, lying transversely across the body and opening into the auricular portion of the heart. The *sinus venosus* ultimately becomes a part of the auricle.

The auricular chamber early becomes imperfectly divided into the two auricles by outgrowths from the walls, which finally separate completely the two chambers. The septum between the two auricles does not become complete during fetal life, but closes normally at the time of birth; abnormally, it may persist after birth, constituting the defect known to human obstetrists as persistent foramen ovale and inducing cyanosis of the new-born. The arterial and venous blood remain mixed, giving a bluish color to the skin and mucous membranes, ending usually in the early death of the young. Persistence of the foramen after birth is not authentically recorded in domestic animals. The constriction between the auricular and ventricular portions gradually develops to form the septum between these cavities and the auriculo-ventricular valves. Toward the close of the first month, the ventricular cavity becomes divided into two somewhat unequal halves. There forms also, in the *truncus arteriosus*, *ta*, Fig. 36, a median partition, which, growing backwards, divides the vessel into two parts, which are to represent in the future the common aorta and the pulmonary artery.

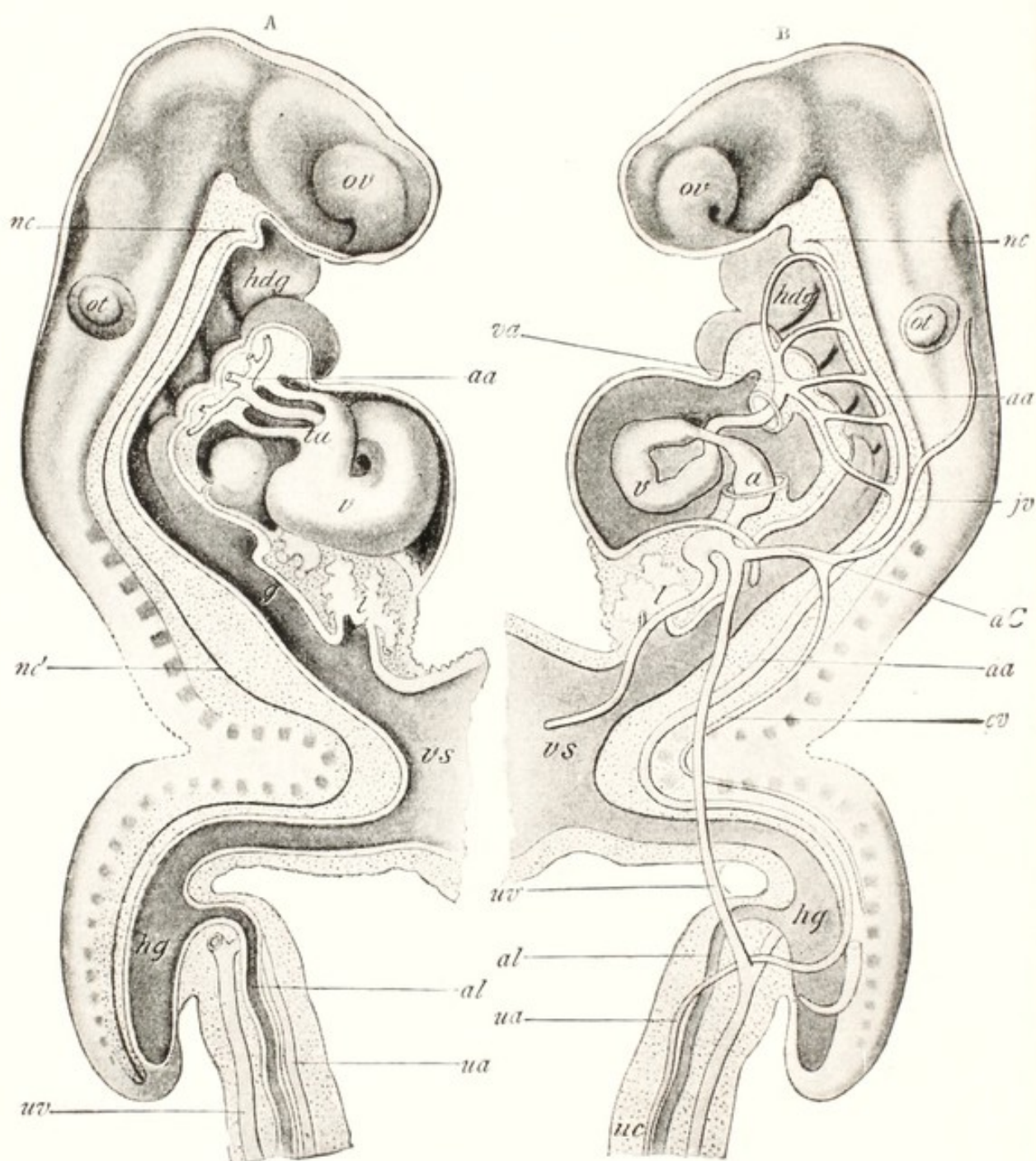


FIG. 36. Reconstruction of Human Embryo of about 17 Days. (His.)

ov, optic vesicle; ot, otic vesicle; nc, nc', notochord; hdg, head gut; vs, vitelline sac; l, liver; v, ta, primitive ventricle and truncus arteriosus; va and da, ventral and dorsal aortae; a, sinus venosus; aa, aortic arches; jv, primitive jugular vein; cv, cardinal vein; dC, duct of Cuvier; uv, ua, umbilical vein and artery; al, allantois; uc, umbilical cord. (Heisler.)

THE ARTERIES

Early in the third week of embryonic life a series of aortic arches—one for each of the visceral arches, the more anterior appearing first (see between *va* and *da*, Fig. 36)—arise from the anterior extremity of the truncus arteriosus. At first there are two wholly separate dorsal aortae, which run parallel to each other throughout the length of the body just beneath the notochord, but they soon

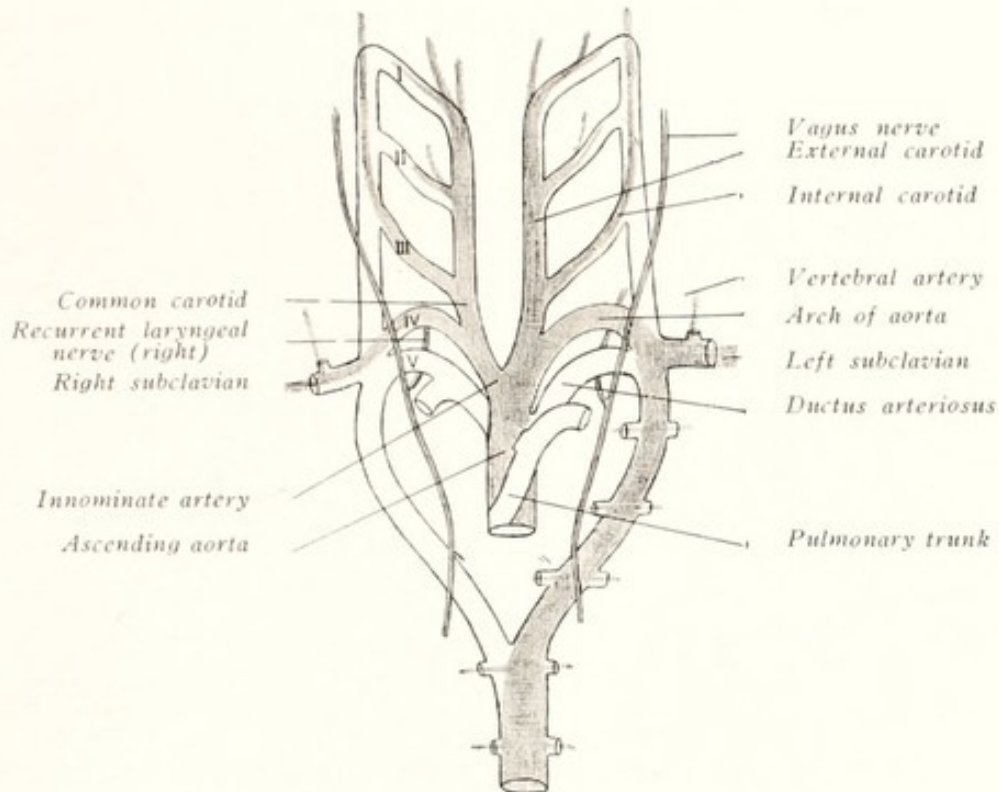


FIG. 37. Diagram illustrating the fate of the Aortic Arches.
(Modified from Heisler.)

I, II, III, IV, V, the first to fifth aortic arches.

become fused posteriorly to constitute the single dorsal aorta, from which are given off the vitelline arteries to the vitelline sac. Further back the aorta divides into the two allantoic arteries, which carry the blood to the allantois. The aortic arches pass from the ventral aortae on the floor of the pharynx up through the visceral arches on either side and open into the dorsal aorta. They are soon complete: five—or, according to some authors, six—pairs are present, one for each branchial arch, all connected above with the dorsal aorta.

The attachment of the truncus arteriosus begins to shift backward along the floor of the mouth. The vessel divides into two branches, the anterior of which maintains connection with the man-

dibular and hyoidean aortic arches, while the posterior is connected with the three—or four—remaining vessels.

The aortae continue forward beyond the aortic arches and run alongside the brain, to constitute the internal carotid arteries.

Changes now begin to appear, progressing toward the foundation of the adult plan of circulation. The middle portions of the aortic arches in the mandibular and hyoidean arches disappear, and the connection between the truncus arteriosus and the aortae, through these arches, ceases to exist. The proximal ends of these vessels remain as the external carotid arteries.

The third aortic arch retains its connection with the anterior portion of the aorta, and its proximal end, or stem, constitutes the common carotid artery. The connection between the portion of the aorta posterior to the junction with the third aortic arch and anterior to the fourth disappears, thus separating the carotid system from the aortic vessels.

The left fourth aortic arch persists, to become eventually the aorta, while the sixth arch ultimately becomes the pulmonary artery. (See Figs. 36 and 37.)

At approximately the fifth or sixth week of embryonic life, the heart leaves the region of the pharynx and passes backward; the neck becomes elongated and the head extended forward, causing a great lengthening of the common carotid artery.

During the formation of the cranial nerves, the inferior laryngeal divisions of the pneumogastrics cross behind the sixth aortic arches, between the aorta and truncus arteriosus, to reach their destination in the muscles of the larynx. As the heart recedes toward the chest and the head grows forward, the laryngeal nerves are necessarily dragged along with the aortae into the chest cavity, thus bringing about their recurrent course.

While the heart is moving backward, the right aortic, or systemic arch becomes smaller and finally disappears. As a result, the right laryngeal nerve is released from the dragging of the aorta, but still passes around the right subclavian artery. The persistence of the left arch, which becomes the common aorta, continues the dragging upon the left recurrent nerve, which, throughout the life of the animal, must pass into the chest, around the aorta, and retrace its way back to the larynx. It has been assumed by some that the greater degree of degeneration of the left nerve in the disease known as *roaring* in horses is due to its excessive length. Possibly the great length lowers its resistance to pathogenic forces. There is no ex-

planation why the recurrent character of the nerve should cause disease in the horse, and not in other animals. There is, it should be remembered, a general tendency toward an inferior development of some organs upon the left side of mammals. This is especially marked in the ovaries and testicles.

Sometimes the heart, becoming arrested in its movement backward, remains in the pharyngeal or cervical region. Thus, especially in ruminants, the viable young may be born with the heart just beneath the pharynx or at any point between this and the first rib, as

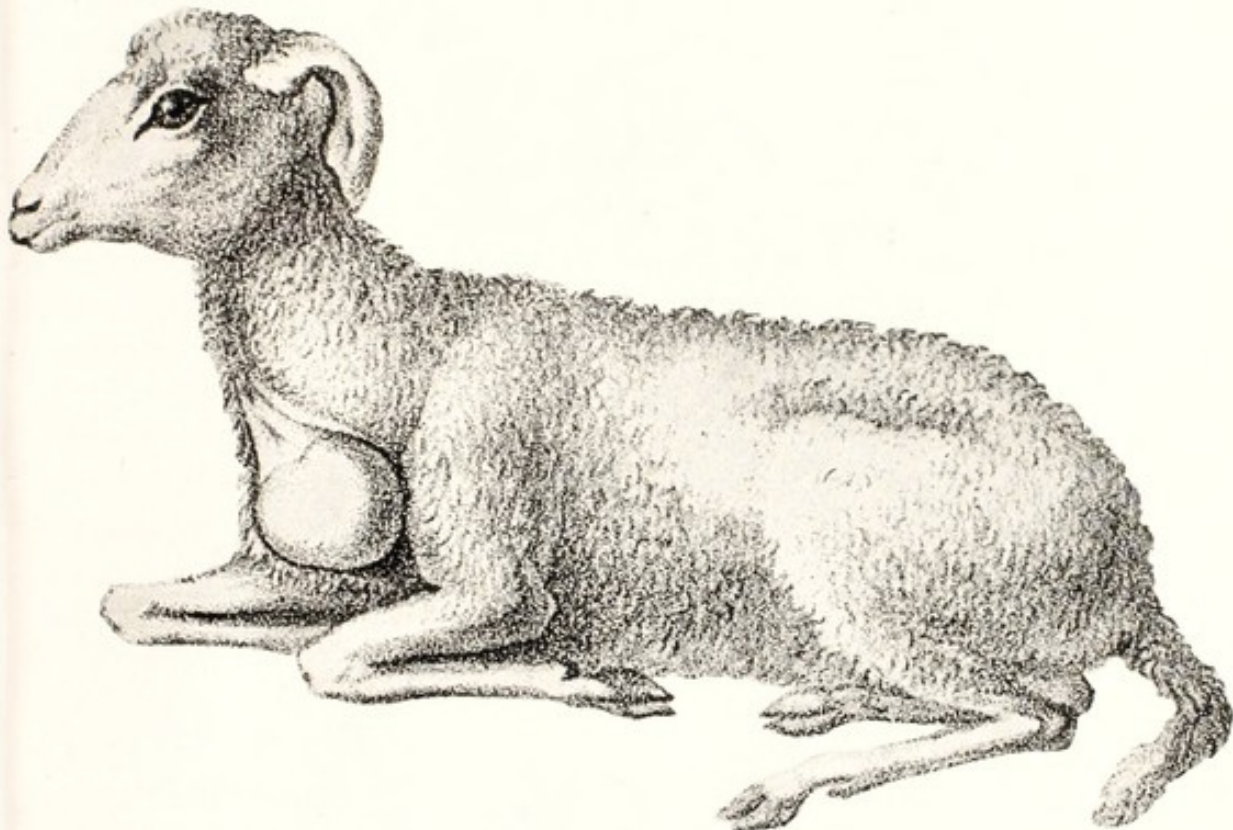


FIG. 38. Fissicollis. Cervical Ectopia Cordis. (Gurlt.)

shown in Fig. 38, graphically reminding one of the normal shifting of the location of the heart in the embryo, from its first position along the floor of the pharynx, toward the posterior portion of the body, to become lodged within the chest cavity. The sheep or ox with this defect in the migration of the heart sometimes survives to adult life without recognizable discomfort.

The sixth aortic arch gives off a branch, before joining the aorta, to go to the lungs and constitute the pulmonary artery. In the right vessel, the arch disappears between the pulmonary artery and the aortic arch; in the left, it continues, as the ductus arteriosus, which,

up to the time of birth, maintains an indirect communication between the right ventricle and the posterior aorta, and persists throughout life as a fibrous cord, the *ligamentum arteriosum*.

THE VEINS

When the mammalian embryo is about three weeks old there are three pairs of veins—the Cuvierian, the vitelline, and the allantoic. The first of these, formed by the union of the cardinal veins, returns the blood from the embryo itself. The vitelline veins, formed in the walls of the yolk-sac, carry blood from it along the vitelline stalk to the heart. The third pair returns blood from the placenta along the stalk of the allantois. The vitelline veins of mammals are naturally small, since the vitellus, or yolk, containing essentially no nutriment, affords small opportunity for any important functions in these vessels. They are situated in the mesoderm of the splanchnopleure, enter the embryo at the umbilicus and, passing forward along the sides of the alimentary canal, empty into the sinus venosus.

In growing out from the intestine, the liver surrounds the vitelline veins before they empty into the sinus venosus. Here the veins break up into a series of capillaries, converging later to form the efferent hepatic vessels. In this way, the venous capillary system of the liver is formed. A vein divides up into capillaries in the same way as arteries regularly do and these converge again to form a second venous trunk. At about the same period that the vitelline veins are breaking up to constitute the functional circulation of the liver, they become connected with each other just before their entrance into that gland, by three communicating branches, two of which pass beneath the duodenum and one over it, thus forming venous rings surrounding the intestine. From the anterior ring, there arise veins which carry the blood into the liver. The right and left vitelline veins soon unite to form a single trunk, which, a little later, is joined by veins returning blood from the intestine. After this, it is known as the hepatic portal vein. The veins which previously established the communication between the right and left vitelline veins disappear later in part, in such a way that the remaining portions, which constitute later the direct trunk, are twisted about the duodenum much the same as in adult life.

The allantoic veins are first paired, and outside the fetus remain permanently separate. They arise in the placenta, pass along the sides of the allantoic stalk on either side of the urachus, enter the fetal body through the umbilicus, and eventually reach and empty

into the sinus venosus. Later they lose their connection with the sinus venosus. The right vein becomes smaller and finally disappears; the left increases much in volume and, as it nears the liver, gives off some vessels which enter it directly, while the main portion of the vessel joins the hepatic portal vein prior to its entrance into that gland.

At a slightly later date, when both vitelline and allantoic vessels have ceased to empty into the *sinus venosus*, all the blood from these two vessels must pass through the capillaries of the liver before it can reach the heart. At this period, a communication, the ductus venosus, is established between the right hepatic and portal veins, by which the blood may pass from the vitelline and allantoic vessels across to the hepatic vein, without passing through the capillaries of the liver. In the equine fetus the ductus venosus becomes obliterated some time prior to birth, so that all blood from the allantois must pass through the liver. The posterior vena cava does not acquire much size until the hind limbs begin to form and the iliac veins unite to constitute its principal branches. It enters the *ductus venosus* near its termination in the hepatic vein. The anterior and posterior cardinal veins unite to form the Cuvierian veins. The anterior cardinal vein persists in some adult domestic animals, such as cattle, as the internal jugular vein. The middle portion of the posterior cardinal vein disappears; the posterior end becomes the internal iliac vein; and the anterior portion of the right posterior cardinal vein persists as the vena azygos. The anterior vena cava represents the right anterior Cuvierian vein, and the left vein disappears completely, with the possible exception of the coronary sinus of the heart.

THE FETAL CIRCULATION

In the earlier stages of the fetal circulation, all the blood returned to the heart—whether from the embryo, the placenta, or the vitelline sac—is emptied into the sinus venosus, from which it passes into the cavity of the common auricle. In this way a complete mixture of the blood from all sources necessarily occurs. The mixed blood is then forced to the ventricle, through the truncus arteriosus, toward the head of the fetus.

The sinus venosus later becomes a part of the auricle, into which empty the Cuvierian veins and the posterior vena cava. Gradually the septum between the two auricles is formed, but there remains the foramen ovale, through which the blood can pass with more or less freedom. The posterior vena cava opens very near to the

foramen ovale, where a small valve tends to cause the blood to flow from the posterior vena cava to the left auricle, by way of the foramen. In this way, considerable admixture of blood from the three different vessels still ensues. Later, as the left Cuvierian vein disappears, the blood from the head and anterior limbs is all returned through the right vein, or anterior vena cava, so that there are now only two vessels, both of which empty into the right auricle. At this period, the blood which enters the auricle from the anterior vena cava, coming from the head and both fore-limbs, is entirely venous in character, while that from the posterior vena cava is chiefly arterial, or red blood coming from the placenta, with a small portion of venous blood added from the posterior limbs and other parts of the body.

By an elaboration of the valve in the foramen ovale and a valvular fold at the opening of the posterior vena cava, the blood from this vein appears to be largely carried directly across the right auricle into the left auricular chamber. The right auricle now receives blood from the anterior and posterior venae cavae and a small amount from the coronary sinus.

The blood which is carried to the heart by the posterior vena cava is largely arterial in character—that is, it has given up its carbon dioxide and other waste material in the placenta and has derived from the blood of the mother oxygen and nutritive materials. Into the posterior vena cava enters also the blood which has been to some degree favorably modified by passing through the kidneys and the liver, in which glands certain deleterious substances have been removed. The waste materials extracted by the kidneys and thrown into the bladder may be discharged either into the amniotic sac through the urethra or the allantoic sac through the urachus. The liver excretions pass to the intestines, where they become desiccated and are stored up in the large intestine, to constitute an important part of the meconium.

The blood passes into the right auricle and thence into the right ventricle, from which it is driven along the pulmonary artery. Since the lungs are not yet functioning, the blood is diverted through the ductus arteriosus into the dorsal, or posterior aorta. Entering the latter at an acute angle, the blood is directed backward toward the posterior part of the body, whence it passes largely to the placenta, through the umbilical arteries, where it is relieved of its waste matters and, in exchange, receives oxygen and nutrient material. The arterial blood returning through the umbilical veins, from the placen-

tal capillaries, with a small addition of wholly venous blood from the posterior limbs and some blood which has been modified by passing through the kidneys and liver, re-enters the right auricle, to pass at once into the left auricle and thence into the left ventricle. From this latter cavity, it is driven along the common aorta until it reaches the carotid and subclavian arteries, through which it is largely carried to the head and anterior limbs.

Although the aorta is freely open from the heart along the posterior aorta toward the posterior portions of the body, it appears that very little of the blood from the left ventricle passes backward. This is largely because the blood from the right ventricle, which at this period is as strong as the left, has already filled that portion of the posterior aorta posterior to the juncture of the ductus arteriosus with that vessel. Consequently, the blood pressure in the two portions of the vessel is approximately equal, so that there is as great a tendency for the blood from the right ventricle to pass forward from the ductus arteriosus as for that from the left to pass backward from the opening of the ductus arteriosus when propelled through the common aorta.

In some cases, it has been found that the aorta has become obliterated during embryonic life at a point just anterior to its juncture with the ductus arteriosus and posterior to the fourth aortic arch, so that all the blood to the posterior end of the fetus must pass through this vessel. The wholly independent anterior and posterior circulations do not interfere with the development of the fetus, but at the time of birth the circulation is at once blocked to all the posterior portions of the body, so that the new-born young must promptly perish. Sometimes the right, instead of the left primitive aorta persists in the dog. This causes the ductus arteriosus to pass over the esophagus, incarcerating the latter and preventing the pup from swallowing solid food, leading to early death.

The plan of the fetal circulation is in a measure the reverse of that after birth: the purified or red blood comes from the placenta along the posterior systemic veins to the right auricle, whence it passes largely to the head, neck and anterior limbs through the right ventricle, ductus arteriosus, carotid and subclavian arteries. Throughout the fetal life, the blood of the entire body is of a mixed character. The red blood of the umbilical veins becomes somewhat mixed with venous blood before reaching the heart.

Prior to birth, the vitelline vessels have disappeared except in so far as they have persisted as portions of other vessels within the

body. The blood supply to the lungs has been limited to their nutritive requirements. When birth occurs the functional circulation must be promptly established. In order that the blood from the right ventricle shall pass through the pulmonary arteries to the lungs, instead of through the ductus arteriosus into the aorta, it is essential that the latter become promptly obliterated.

The rupture of the umbilical cord finally interrupts the placental circulation and renders useless all those vessels within the fetal body whose sole office was the maintenance of the placental circulation.

The Urino-Genital System

The Wolffian Bodies and Ducts

The urinary and genital systems are closely allied in their origin. Both arise, directly or indirectly, from or in intimate association with the Wolffian bodies and their excretory ducts.

The Wolffian ducts are claimed by some embryologists to originate as a pair of longitudinal grooves in the ectoderm, on the lateral surface of the body, at about the level of the notochord or somewhat below. The invaginations of ectoderm continue to sink inward into the mesoderm of the somatopleure until they come in contact with the peritoneum. Other investigators hold that the Wolffian ducts are of mesodermic origin, though at first lying immediately against the ectoderm, as solid rods, which later become excavated in their center to constitute hollow tubes. The ectodermic origin of the Wolffian system is suggested by the frequency, especially in solipeds, of dermoid cysts in the testicles and ovaries, containing teeth and hair. For a time the Wolffian ducts end blindly behind, but later they open into the cloaca.

The Wolffian bodies—one on either side of the mesentery—are first recognizable during the third week of the embryo, as longitudinal thickenings in the dorsal surface of the body cavity. They develop rapidly and become greatly elongated so that they soon reach from the posterior portion of the cervical, to the end of the lumbar region.

The essential tissues of the Wolffian bodies appear to develop, independently of the Wolffian ducts, from the mesoderm, in the form of cords of cells. The cords coil somewhat upon themselves, and become excavated to constitute tubes. One end of each tube grows toward the Wolffian duct, and empties into it; the other end becomes dilated, and then invaginated, to constitute the Malpighian bodies,

or glomeruli. Into these glomeruli, branches of the aorta penetrate to furnish the functional blood supply. The veins from these glands empty into the posterior cardinal veins.

Later the Wolffian bodies commence to degenerate and atrophy; finally the essential tissues of the organs almost wholly disappear. Those portions of the Wolffian bodies which persist become concerned in the origin of accessory portions of the reproductive apparatus. The Wolffian bodies play no important part in the formation of the ovaries, but they send some outgrowths into these glands, which persist for a time. Some remnants of the Wolffian bodies persist as the parovarium, or organ of Rosenmueller, and from these vestigial portions arise some of the cystic tumors seen occasionally in the mare and the cow. In rare cases pedunculated parovarian tumors become looped about the rectum, inducing fatal incarceration.

In the female, some traces may remain of the anterior end of the Wolffian duct as a part of the parovarium. It is not rare to see in cows a cystic condition of the parovarium. The cystic tubular swelling attached to the anterior surface of the ovary feels, upon rectal palpation, much like a cystic oviduct. No remains of the posterior portion of this duct are observed in most animals. In the cow, however, they usually persist as Gartner's canals. These sometimes become blocked at their mouths, causing retention cysts, which appear as elongated sacs, arising close to the meatus urinarius on either side and extending upward and forward along the walls of the vagina. In other cases the Gartner canals become elongated, tubular abscesses and very rarely in presence of disease, they become distended with calcareous masses.

In the male the Wolffian bodies largely disappear, but portions of them take a somewhat prominent part in the formation of the testicles and thus persist throughout life. Tubules grow out from the anterior part of the Wolffian bodies and finally enter the substance of the testicle, to constitute the vasa efferentia, which eventually become connected with the seminal tubules. The epididymis and vas deferens are formed from the Wolffian duct.

The Kidneys, Ureter and Bladder

Before the disappearance of the Wolffian body, there appears toward the posterior end of the Wolffian duct an outgrowth, or diverticulum, which is later to constitute the ureter and which, shifting backward toward the cloaca, finally acquires an independent opening into the urinary bladder.

At the anterior end, the infundibulum grows forward beneath the Wolffian body and dilates to form a sac which is to constitute the pelvis of the kidney. From the walls of the pelvis of the kidney a number of branched converging tubules, the secreting tubules, arise as rods of cells from the contiguous mesoderm; the rods become hollowed out and at their ends enlarge to constitute the glomeruli of the kidney.

The urinary tract of the cloaca, posterior to the entrance of the ureter, becomes narrowed to form the urethra; anterior to the point of entrance of the ureter, the urinary segment of the cloaca dilates to form the urinary bladder. From the anterior end, or fundus, of the bladder, the allantois continues, the first segment being constricted to form the urachus, which extends through the umbilicus and umbilical cord to the allantoic cavity. During the life of the fetus, the urine may pass either through the urachus into the allantoic sac or through the urethra into the amniotic cavity.

The Gonads or Sex Glands

The sex glands develop from thickened areas of peritoneal epithelium, contiguous to the Wolffian bodies, known as genital ridges. For a time the glands of the two sexes can not be differentiated. Later, if the embryo is healthy, the gonads acquire definitely male or female anatomical and histological characters. Among bovine twins and multiples, the gonads of one or more of the embryos may fail to develop sex characters, but remain asexual or neuter and be designated freemartins. Similar arrests in development occur in goats, sheep and swine, in all of which the fetal membranes are liable to fuse and the fetal vascular systems may anastomose. As has been stated in *The Diseases of the Genital Organs*, the asexual embryos apparently come from imperfect ova and do not develop except they acquire vascular connection with a quasi-normal mate and live as parasites. So far as known, asexual singles do not survive, but various aberrations occur in the gonads which later interfere with physiological reproduction. It is of interest to note that, so far as known, asexual individuals are restricted to ruminants and swine, in which there is present a long, and rapid-growing vitelline tube.

Instead of the one pair of excretory ducts of the Wolffian bodies there develop an additional two pairs, so that at one stage of embryonic life there are present the Wolffian ducts, which persist as the vasa deferentia of the male; the ureters which arise as outgrowths from the Wolffian ducts; and the Muellerian ducts which

arise independently to constitute the oviducts, uterus and vagina of the female. When the sex glands become differentiated, the Wolffian ducts atrophy in the female and are ultimately represented by vestigial structures without important physiological office; similarly the Muellerian ducts atrophy and become vestigial structures in the male.

The derivatives of the Muellerian ducts, the oviducts, uterus, cervix and vagina, as described on page 10, develop variously according to genera, and are subject to many defects which lead ultimately in some cases to serious interferences with reproduction. These defects are most prevalent in dairy cows. They have been described at some length in the companion volume.

There is an interesting tendency toward parallelism in congenital or teratological deviations in the genital and urinary systems, suggestive of their closely allied origin. Thus if but one kidney be present, there is a probability of a single ovary or testicle, and, in the female, of a one-horned uterus.

The Male Reproductive Organs

THE TESTICLES

The testes, like the ovaries, form in the genital ridges of the peritoneum. In the earliest stages the male and female glands can not be differentiated. In the indifferent gland the reproductive cells become grouped in cords containing small cells along with the larger and more important primitive sexual cells. The sexual cords are formed from the roundish masses of cells, separated from each other by connective tissue sheaths. Eventually they become elongated and hollowed out to constitute the seminiferous tubules.

The developing testicle shifts its location early from its primary lumbar position toward its final resting place in the scrotum. Formed in the peritoneum of the body wall in the sub-lumbar region, the gland is outside or behind the parietal peritoneum. As it shifts its position and descends into the cavity of the abdomen toward the internal abdominal ring, it necessarily carries with it a peritoneal covering and remains attached to its point of origin by a double peritoneal fold, the mesorchium, between which its vessels and nerves pass.

At about the same time as the Wolffian system is forming, a fibrous cord develops, arising from the fundal area of the male scrotum or of the female vulva, which extends through the inguinal canal,

crosses the Wolffian and Muellerian ducts, to which it is attached, and extends to the vas deferens of the male, to constitute the gubernaculum testis; or to the ovary of the female, to be known as the

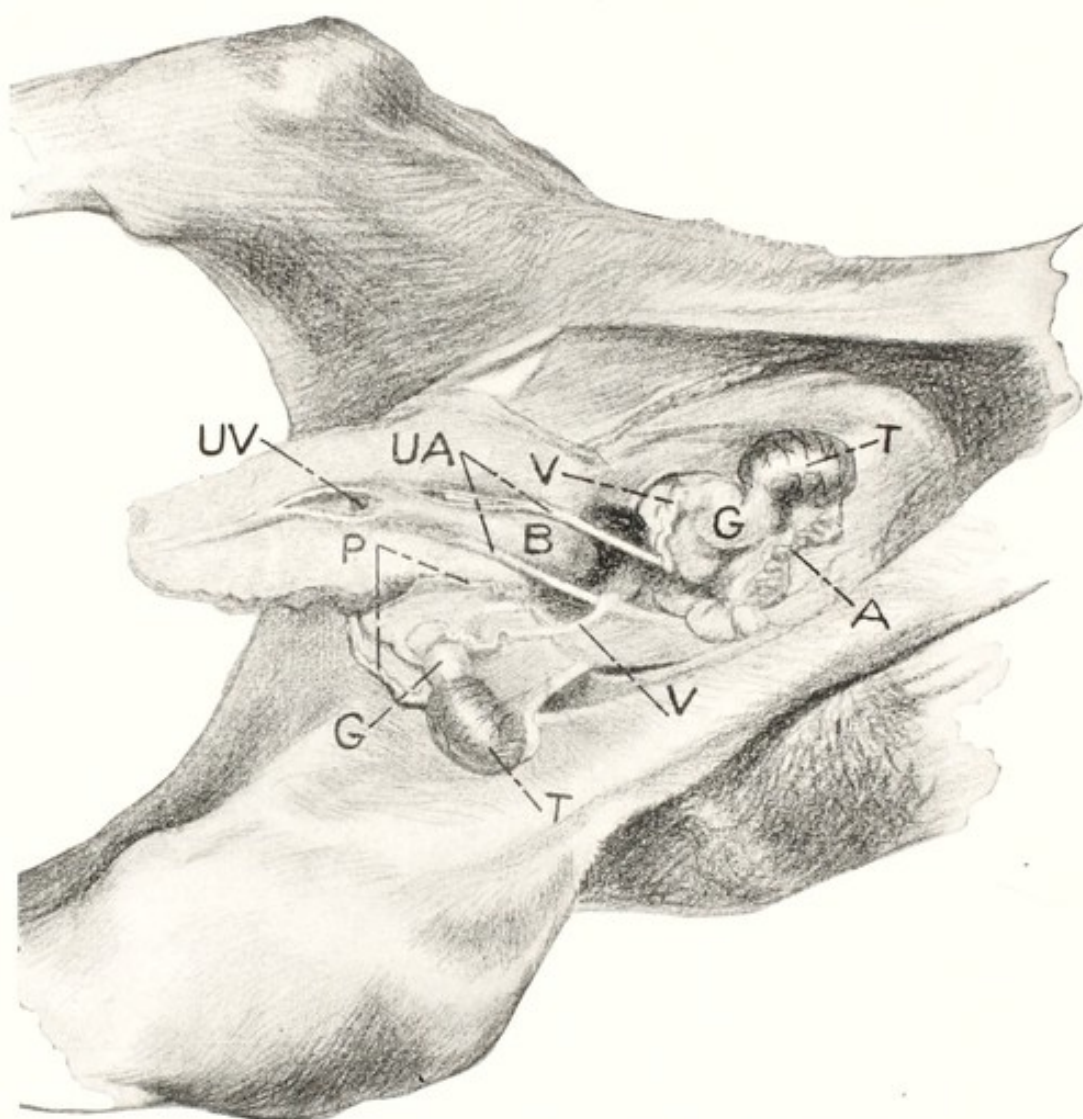


FIG. 39. Genito-urinary System of a Foal, 24 Hours Old, to illustrate Descent of Testicles and Behavior of Ruptured Umbilical Arteries.

The central portion of the abdominal floor has been partly excised and laid back. Seen from below.

T, testicle; A, artery of testicle; G, gubernaculum testis; V, vas deferens; B, bladder; UA, ruptured ends of umbilical arteries retracted within abdomen; P, processus vaginalis; UV, umbilical vein.

ovarian, or round ligament. The gubernaculum testis consists of connective tissue and unstriped muscle fibres, surrounded by peritoneum. Since the testicle, the gubernaculum testis, and the vas deferens form outside of or behind the peritoneum, each of the three structures, as the organ descends, must drag with it a double peri-

toneal fold, so that finally there appear three peritoneal folds, as shown in Figs. 39 and 40—one for the testicle and its artery, *A*; one for the vas deferens, *V*; and a third for the gubernaculum testis, *G*, *G'*, and *G''*—all of which are continuous. As the gland continues to descend toward the inguinal ring, the peritoneum of the abdominal floor, which stretches across it, evaginates through the ring as the processus vaginalis at *P*, into which pouch the epididymis, *E*, de-

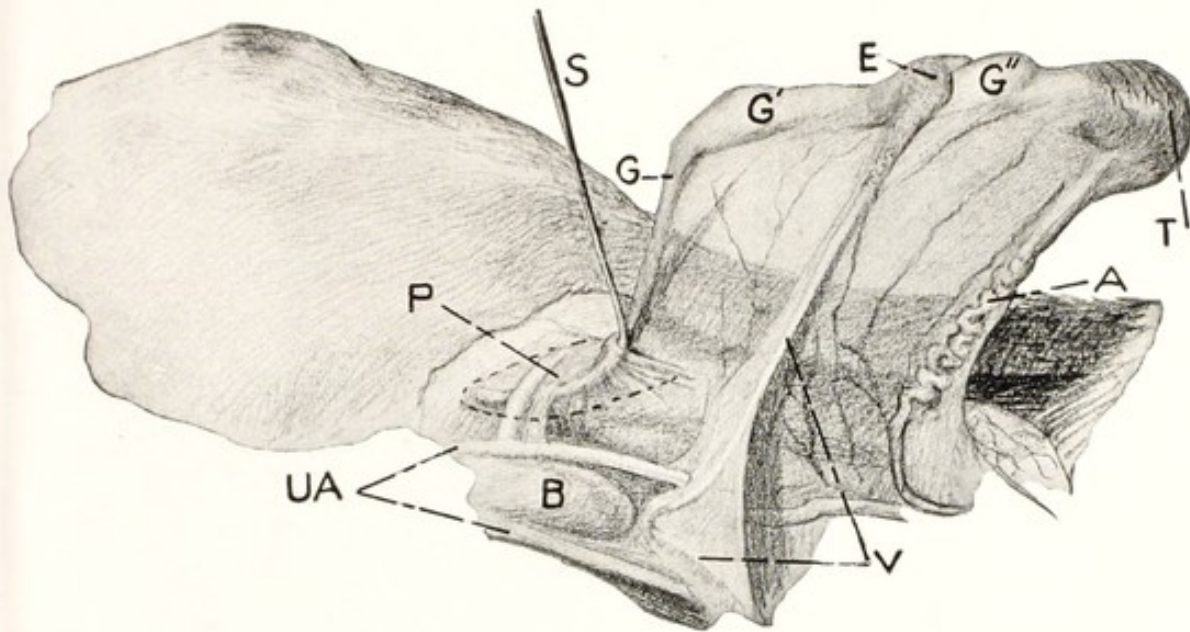


FIG. 40. Right Inguinal Region of Foal, 24 Hours Old.

Illustrating the descent of the testicle, viewed from below; the testicle is lifted upwards to reveal attachments.

P, processus vaginalis, surrounded by a dotted line and containing a curved sound, *S*; *G*, gubernaculum testis emerging from the internal inguinal ring and reaching to the larger portion, *G'*, which extends to the epididymis, *E*, and is succeeded by the final or third section of the gubernaculum, *G''*, reaching from *E* to the testicle, *T*; *A*, artery of testicle; *V*, vas deferens; *B*, bladder; *UA*, umbilical arteries.

scends, followed later by the gland, *T*. Since the testis has been formed on the median side of the Wolffian duct, which later forms the epididymis, the two structures maintain their original relation throughout and, when the testicle comes to rest in the scrotum, the epididymis lies upon the supero-external face of the gland. In the descent of the testicle and epididymis, their relations with each other become reversed. In the abdomen, processus vaginalis, and inguinal canal, the epididymis is beneath the testicle and precedes it in the descent. In the horse, however, when the testicle finally reaches the bottom of the scrotum it performs a partial revolution forwards on its short axis, reversing the relation and bringing the epididymis

above the testicle. In ruminants this reversal of relation does not occur, as the long diameter remains perpendicular. The processus vaginalis remains normally open throughout life in domestic animals, but in the adult it is physiologically so narrow that abdominal viscera may not escape through it.

The testicle, when it has descended into the scrotum, is attached below and posteriorly to the fundus of the sac by the gubernaculum testis and upwards along the posterior wall of the scrotum and inguinal canal by the frenum, or mesorchium, consisting of the peritoneal duplicature between *V* and *G* in Fig. 40; above, it is attached by means of the testicular, or spermatic cord, consisting of the vas deferens, arteries, veins and lymphatics covered by peritoneum. In the foal, pig, and more rarely in other species, at the time of birth, there is frequently present a hernia (congenital scrotal hernia) of intestines or omentum through an abnormally large processus vaginalis, alongside the spermatic cord.

In some instances, the epididymis, *E*, Fig. 40, descends into the scrotal sac, while the gland remains in the abdomen or incarcerated in the internal ring. Far more frequently, both gland and epididymis are retained within the peritoneal cavity, to constitute cryptorchidy. The successful castration of cryptorchid animals depends fundamentally upon the possession by the veterinarian of a practical knowledge of the path and mode of descent of the testicle, and of its attachments, through the medium of the gubernaculum testis, vas deferens, and testicular artery.

The penis of the male and clitoris of the female arise as outgrowths from the ischial arch; in the female it stops short in its growth as a non-essential erectile organ, while in the male it becomes greatly elongated and, curving downwards and then forwards, passes between the thighs to end in a special sheath and prepuce. The urethra extends throughout the entire length of the penis, to open at its extremity.

Arrests or aberrations in the development of the penis occur, consisting usually of an abbreviation in its length, suggesting a gradation in development between a normal penis and a clitoris. Sometimes the defective penis is directed more or less backwards, leading to a backward direction of the urinary stream. In other instances, the formation of the urethra is aberrant and it opens at the ischial arch or lower down along the penis, to constitute hypospadias or epispadias.

Defects in the development of the penis and the clitoris are largely

associated with aberrations in the essential genital organs themselves, of a more or less hermaphroditic or bisexual character. The tendency towards aberrations varies greatly in character and extent and tends largely to follow certain types for each species of animals. In the horse it is not rare to meet with an animal having a well developed vulva, vagina, and uterus, the vulva and vagina functioning as in a normal mare. No ovaries are present, but instead typical cryptorchid testicles producing the ordinary cryptorchid sexual reflexes—a male voice, form, and behavior. An animal may have one male and one female genital gland.

THE LIMBS

In a rabbit embryo of about the tenth day, the mesoblastic cells on either side of the notochord become grouped into cuboidal masses,

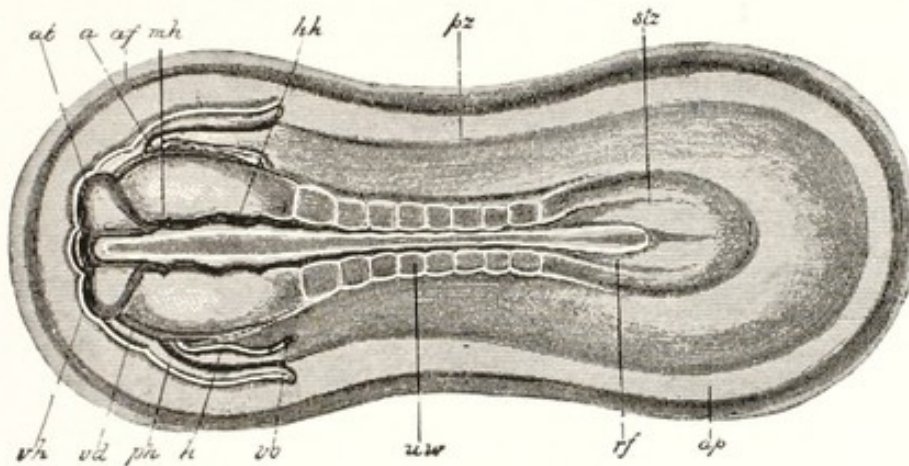


FIG. 41. Rabbit Embryo of the Ninth Day, seen from the Dorsal Side. (After Kölliker.) $\times 21$.

stz, stem zone; pz, parietal zone; in the stem zone 8 pairs of somites appear on either side of the chorda dorsalis and neural tube; ap, area pellucida; rf, medullary groove; vh, fore-brain, ab, eye vesicle; mh, mid-brain; hh, hind-brain; uw, primitive segment; h, heart; ph, perichardial portion of body cavity; vd, margin of entrance to foregut; af, amniotic fold; vo, vena omphalomesenterica. (Heisler.)

divided by transverse lines into somites or primitive segments. The first pair appears in the cervical region prior to the closure of the neural tube. Additional somites appear, extending forward toward the head end and backward toward the tail. From these somites arise the vertebral column; the skeletal muscles, tendons, and ligaments; and the corium, or deeper layer of the skin.

The limbs begin as small buds, or outgrowths, arising from the mesoderm opposite the ventral margins of the mesodermic somites soon after the third week in the human embryo, earlier in the rabbit,

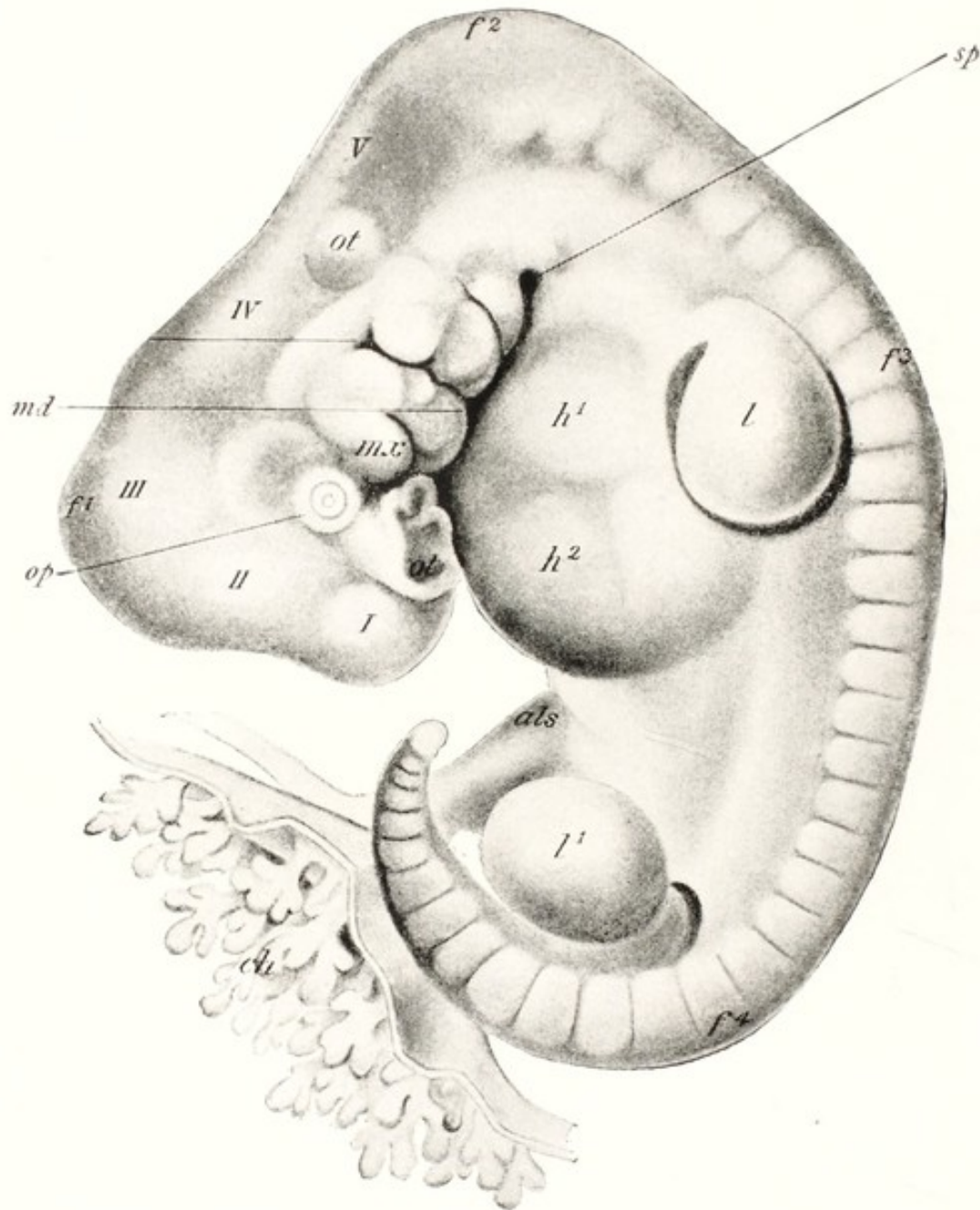


FIG. 42. Human Embryo of about 28 Days, showing Limb Buds. (His.)

I, to V, brain vesicles; f^1 , f^2 , f^3 , f^4 , cephalic, cervical, dorsal and lumbar flexures; op, eye; ot, otic vesicle; ol, olfactory pit; mx, md, maxillary and mandibular processes of first visceral arch; sp, sinus precervicalis; h^1 , h^2 , heart; 1, 1', limbs; als, allantoic stalk; ch, villous chorion. (Heisler.)

and probably in most domestic mammals. Each vertebra represents a somite. Each limb bud occupies an area corresponding to that of several mesodermic somites, as indicated by the fact that the nerves passing to each limb are formed by the union of branches from several intervertebral nerves. The buds lengthen to constitute the limbs, the bones arise from the connective tissue, and the muscles develop

from the muscle plates of the mesoderm. The segments of the limbs are brought about by transverse grooves where the joints are later to form, and the digitations begin as longitudinal grooves, which deepen into clefts.

Various aberrations occur in the development of the limbs. The buds may appear and, within them, rudimentary bones representing

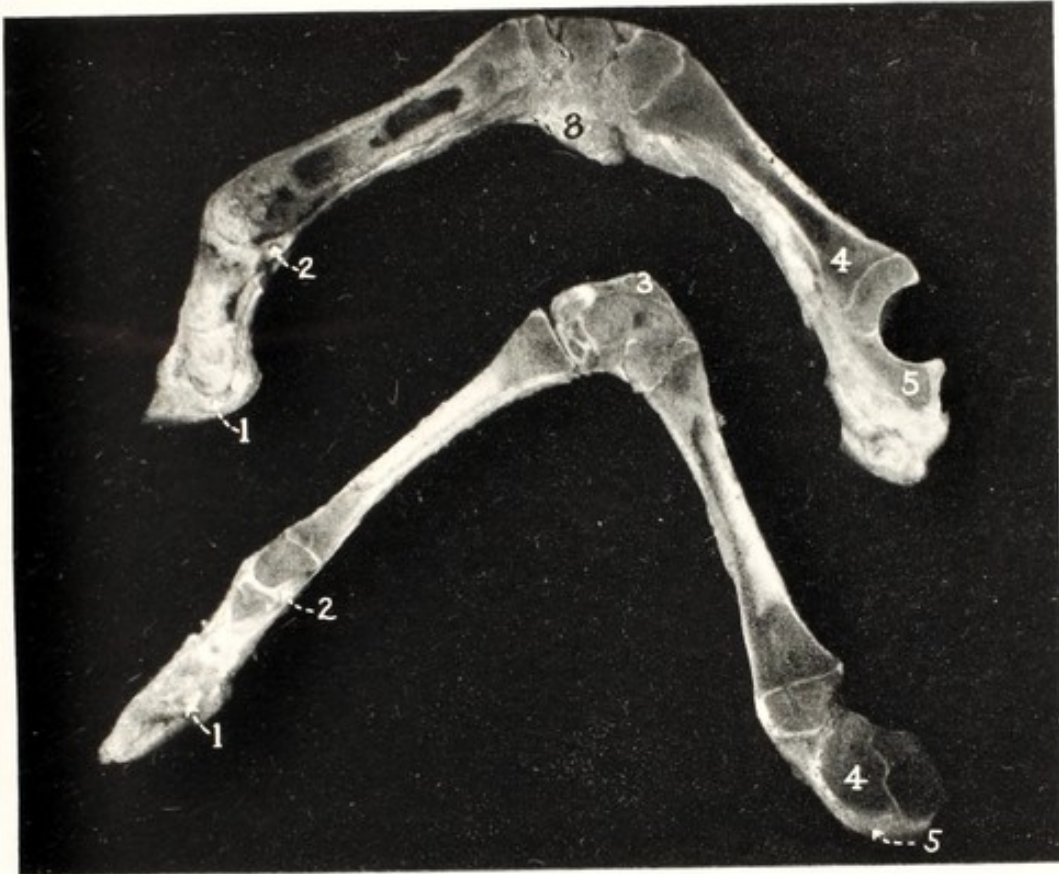

FIG. 43. Perosomus Elumbis. Calf.

Median longitudinal section of one anterior (upper) and one posterior (lower) limb, showing the subnormal development of the posterior member in circumference, articular development and texture.

Anterior leg: 1, navicular bone; 2, sesamoid; 3, pisiform; 4, radius; 5, ulna. Posterior limb: 1, dwarfed navicular bone; 2, sesamoid; 3, os calcis; 4, femur; 5, patellar center. (Cornell Veterinarian.)

the scapula, pelvis, humerus, or femur, while the other parts may fail of development. Any one, or all of the limbs may be wanting. Commonly such absence of a limb or limbs is attributable, in the present state of knowledge, to intrinsic causes, acting wholly upon the limb buds, while other parts of the embryo develop normally and the young animal is born in a viable state except for locomotive ability. In the human embryo it has been claimed that in rare instances a limb may become incarcerated within a loop of the navel cord and

become amputated. This has been disputed by eminent authorities and the loss of the parts attributed to necrosis of unknown character. Such a possibility exists in the equine fetus, where the navel cord is comparatively long. Harms³² (Richter), citing Geyzi, illustrates the amputation of the leg of an equine fetus through the metatarsus. In other genera than equidae, the navel cord is so short as to almost exclude the possibility.

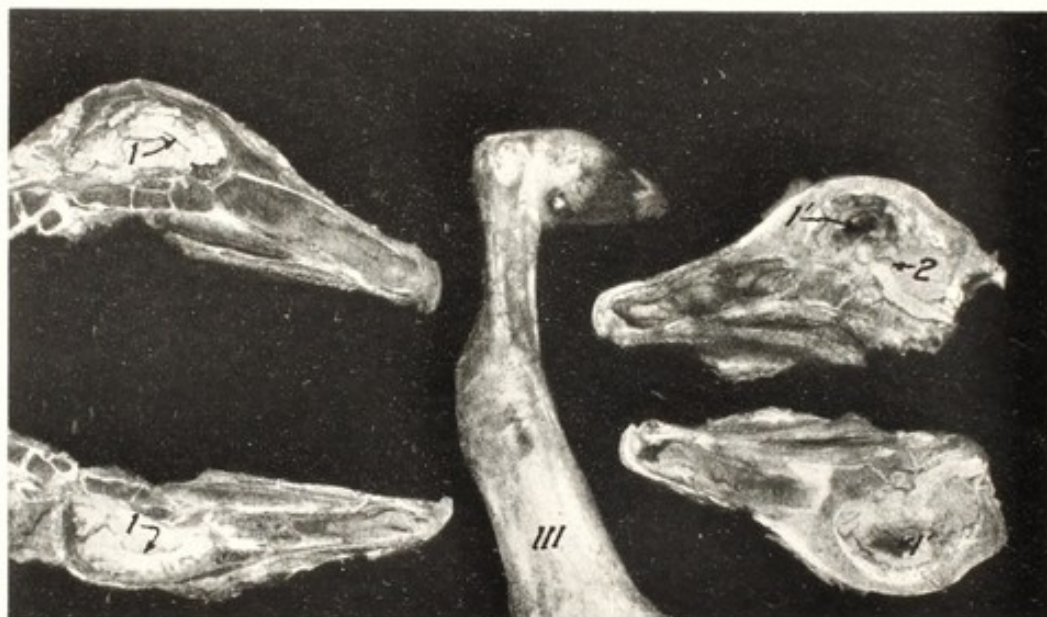

FIG. 44. Limited Hydrocephalus. Club Foot. Calf.

1, 1, sagittal section of head showing normal lateral ventricles; 1', 1' distended lateral ventricles from calf with slight hydrocephalus, with bulging cranium; 2, dilated aqueduct of Sylvius; III, club foot of right anterior limb from the calf with slight hydrocephalus. (Cornell Veterinarian.)

In contrast with such deviations from the normal development of the limbs, various aberrations occurring in the brain and spinal cord, as in *Perosomus elumbis*, Fig. 43, or in hydrocephalus, Fig. 44, lead to deformities of the limbs rather than to their absence.⁷² These defects, instead of inhibiting the development of the limbs, distort them in various ways, largely in the form of rigidity and of club foot, although all parts of the limbs are present. In *Perosomus elumbis*, the patella fails to become separated from the femoral condyle, which suggests that the patella of the bovine fetus is the last bone of the limbs to become differentiated.

A common aberration in the feet is abnormal fission, by which their digitations become multiplied. In equidae the occurrence of two toes on one foot appears reminiscent of the prehistoric horse. How-

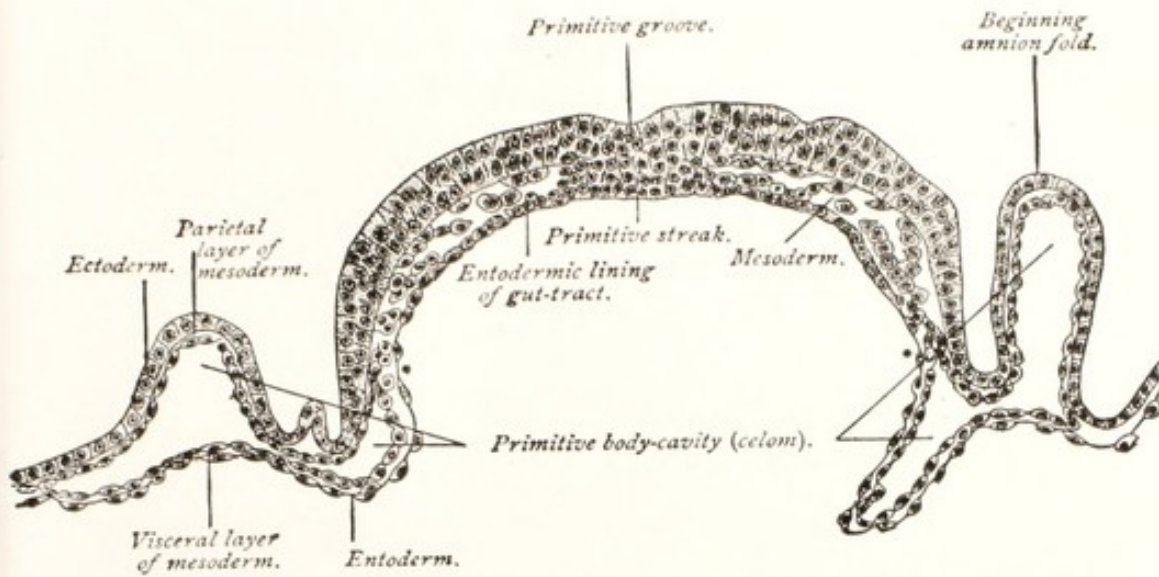


FIG. 45. Transverse Section of the Embryonic Area of a Fourteen-and-a-half-day Ovum of Sheep. (Heisler, after Bonnet.)

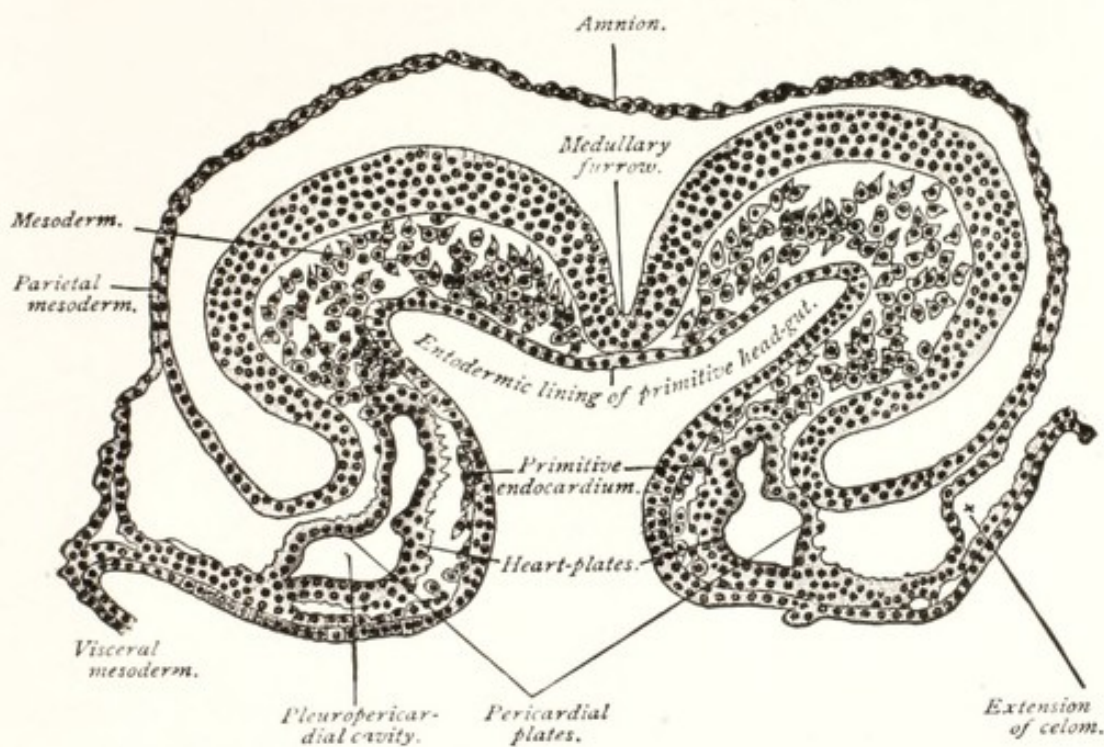


FIG. 46. Transverse Section of a Sixteen-and-a-half-day Sheep Embryo. (Heisler, after Bonnet.)

ever, four-toed animals occasionally produce five digits and among five-toed genera, six or more toes occur. Again, the normally four-toed swine may become one-toed (mule-footed) and the deviation fixed by selection. Swine, normally without a clavicle, may develop that bone.

The Fetal Membranes and the Placenta

The maintenance of the intrauterine life of the ovum, and the development of the young to that degree which will enable it to maintain a more or less independent existence after birth require that effective means be established for the exchange of nutritive and waste materials between it and its mother. The embryo must be fixed at a given point in the uterus, where its position can be maintained throughout the duration of pregnancy, in such a manner as best to protect and insure its life and normal growth. To this end there are

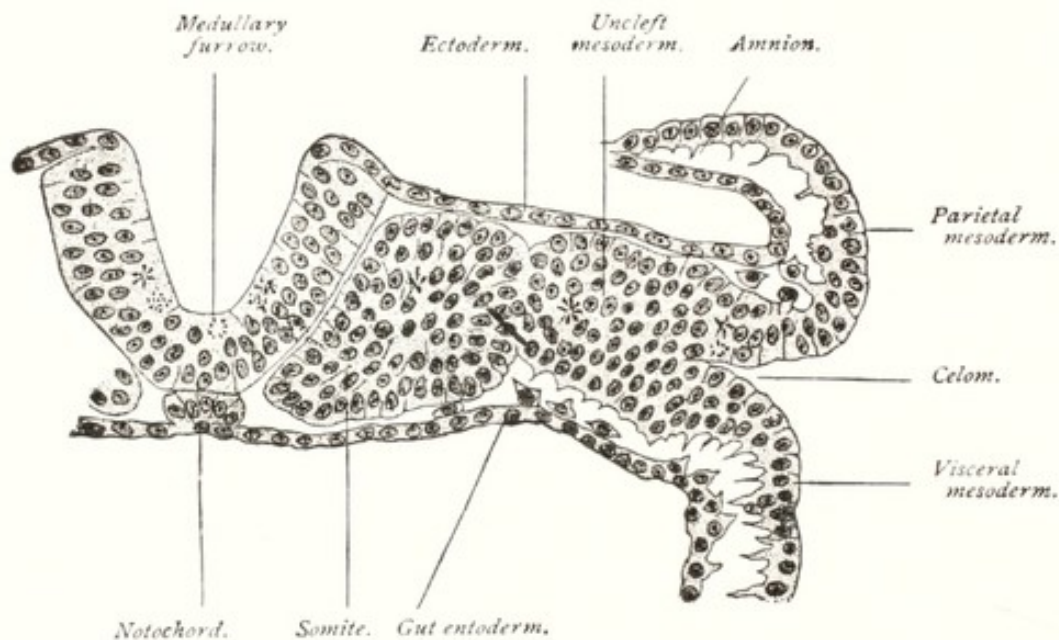


FIG. 47. Transverse Section of a Sixteen-and-a-half-day Sheep Embryo with Six Somites. (Heisler, after Bonnet.)

formed three structures from the blastodermic vesicle, which undergo changes to constitute finally the fetal membranes and placenta.

THE VITELLINE, OR YOLK SAC

When the embryo commences to develop, the embryonic area folds downward and inward at its borders, leading to a constriction between this area and that part of the blastodermic vesicle which lies beyond and constitutes the vitelline sac. The embryonic area and the vitelline sac finally become separated by a narrow neck, the vitelline duct. The yolk plays but a minor part in the development of the embryo. The yolk sac disappears completely in most species, though in some it persists as an embryonal vestige to the time of birth. In the mare the yolk sac is very inconspicuous early in fetal life and disappears almost completely at a very early stage. Fig. 49 outlines

the general plan of the sac at the twenty-eighth day of pregnancy. Fig. 50 indicates that at five months the vitelline sac has well-nigh disappeared.

In ruminants and swine, as indicated in Fig. 52, the blastodermic vesicle assumes a wholly different form and undergoes great elongation. In other domestic animals there are variations in the form of the sac, but in each alike the vitelline sac is of little importance except during the very earliest stages of embryonic life. Prior to the formation of the amnion, the surface of the blastoderm, and later the vitelline sac, must perform in a primitive way the placental functions, affording means for the limited exchange of nutriment and excrement, necessary for the development of the ovum.

THE AMNION

The amnion commences to form soon after segmentation has been completed and the ovum, after passing through the oviduct, has reached the uterus. In the embryo of the sheep, the amnion forms at about the thirteenth or fourteenth day of gestation, and is soon complete. The date of the formation of the amnion in other domestic animals is approximately the same.

The amnion arises from the extra-fetal portion of the somatopleure, which folds upward around the margin of the embryonic area. It forms a double membrane which, by continuing to grow upward and converge, finally meets above the dorsal surface of the embryo and fuses. By the fusion there is formed a double sac which envelops the fetus completely except at its point of origin at the ventral surface, where it takes part in the formation of the umbilicus. The inner of these two membranes constitutes the true amnion; the external one forms the external (false) amnion, or primitive chorion. Later, the allantois grows out and blends with it to contribute to the formation of the permanent, or allanto chorion.

The outer, or false amnion is merely a portion of the external wall of the blastodermic vesicle, without its relations having been changed exteriorly. Between the inner, or true amnion and the fetus is the amniotic cavity, filled with the amniotic fluid.

When the amniotic cavity becomes distended with fluid, the amnion closely invests the vitelline stalk and the allantoic vessels. The amount of liquor amnii varies greatly in different animals and at different periods of pregnancy, but it is generally most abundant at about the middle of gestation. In the cow and the mare, the amount of amniotic liquid varies from 5 to 8 liters; in the sheep, according

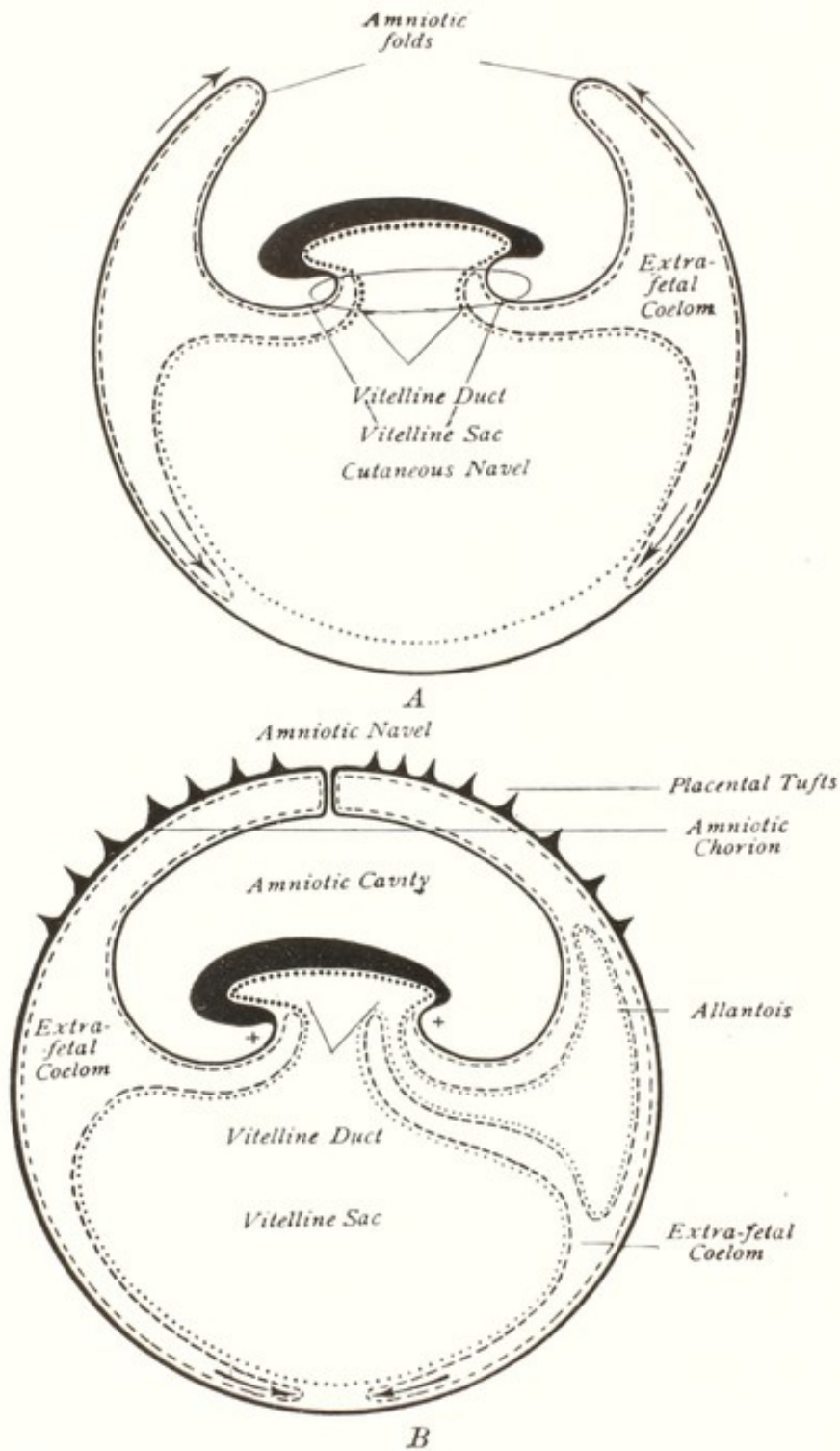


FIG. 48. Schematic Longitudinal Sections of Fetal Annexes of Mammalia.
At the points indicated by X, the skin is continuous with the amnion. (Bonnet.)

to St.-Cyr and Violet, it varies between 100 and 500 grammes; in woman, the amount is variously stated as being from 0.6 to 2 liters.

A pathologic increase of this fluid constitutes dropsy of the amnion. In woman there exists only the amniotic sac, while in domestic

animals there is present also the larger allantoic cavity. While dropsy of the fetal sacs is common, hydrops amnii is not readily distinguished from dropsy of the allantois. Together the amniotic and allantoic fluids sometimes reach the amount of fifty or more gallons in the cow. This will be further discussed in connection with dystocia.

The liquor amnii is physiologically clear and colorless, and slightly heavier than water. It contains albumin, sugar and urea. In both disease and apparent health it frequently contains bacteria. In the presence of fetal disease the constituents of the fluid vary widely. It may then become more or less opaque and show reddish, or other color. In bovidae, which normally have soft feces, and show in post-natal life a marked tendency to diarrhea, fetal diarrhea is a common phenomenon, especially in dairy cattle. It almost always precedes abortion, and is not rare in calves at birth. In the presence of fetal diarrhea the volume of amniotic contents often becomes greatly augmented, and when the fetus is expelled, there are at times four or five gallons of thick fluid in which the meconium is thoroughly mixed. Apparently the production of meconium has been enormously increased: there seems to be far more present than the amount normally stored in the fetal intestine. Fetal diarrhea is also observed in sheep, in the presence of genital disease. In contrast, the equine fetus in the presence of utero-fetal disease tends rather toward impaction of the large intestine with meconium.

The source of the normal amniotic fluid has not been fully determined. Some believe that it is due to a secretion by the amnion itself and some that it is at least partly composed of urine. The case of *Schistocormus reflexus* cited on page 327, in which about ten gallons of fluid were imprisoned within the reflexed cutaneous sac, apparently justifies the conclusion that the amniotic fluid may be largely derived from the fetal skin. In that case the imprisoned liquid could not come from the amnion nor from the urinary bladder. The case suggests that the cutaneous secretions of the fetus may be very extensive. We know, by washing the meconium, that the shedding of hair is abundant, and we do not know that the associated sweat glands are less active. In one instance of aproctus⁷² in the absence of a normal urethra, the urinary bladder had forced urine into the rectum and pushed the meconium toward the fetal head. In a case of hydrops amnii-allantois, the kidneys were enormously enlarged. Physiologically the urethra and urachus offer ample outlet for any fluid contents within the urinary bladder.

At first the membrane commonly designated the amnion consists,

upon the fetal side, of a layer of ectoderm and outwardly of a layer of somatopleuric mesoderm. Since the amnion is a double membrane, or sac, the arrangement of the tissues of the outer wall is the reverse of those of the inner, so that, as indicated in Fig. 50, in the outer wall the ectoderm, facing outward and in contact with the endometrium, constitutes, with its mesodermic layer, the primitive, or

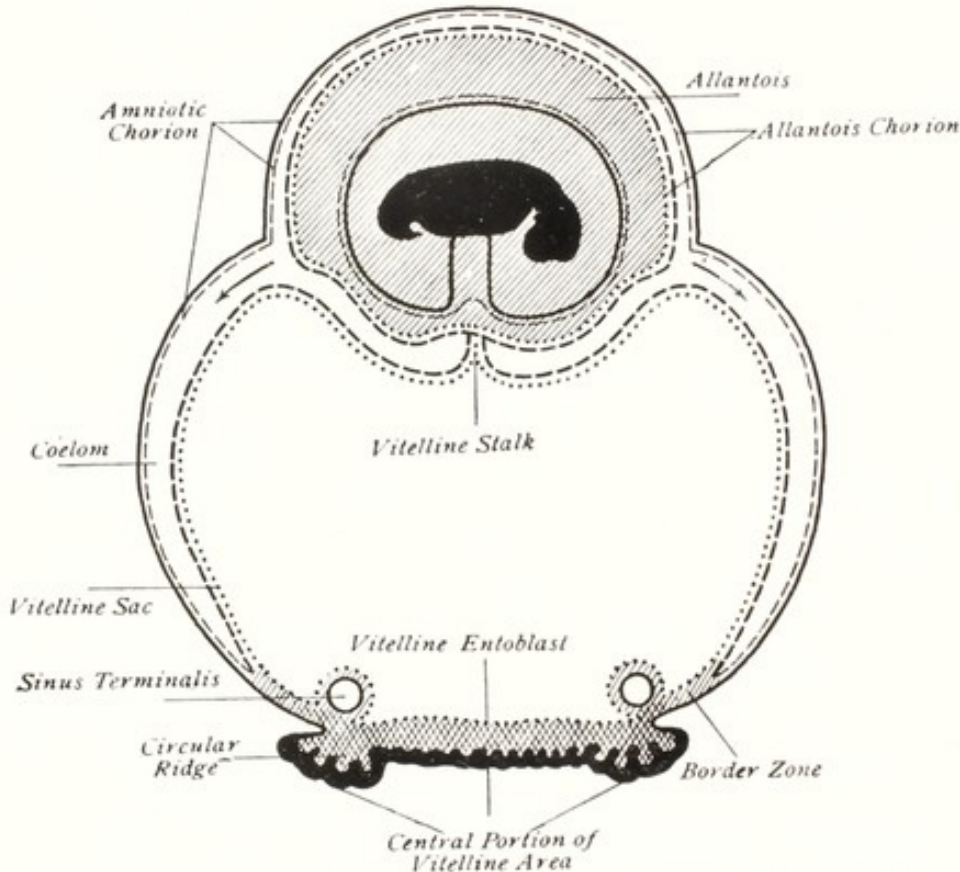


FIG. 49. Schematic Illustration of Fetal Annexes of the Embryo of the Horse, 28 Days after Fecundation. Perpendicular Section through the Embryo and its Envelopes.

The embryo is black. — Ectoderm. . . . Vitelline layer. - - - Parietal mesoderm. - - - Visceral mesoderm. (Bonnet.)

amniotic chorion. It thus serves, temporarily, as the contact organ between the embryo and endometrium, and performs placental functions. The space primarily existing between the outer and inner amniotic walls is soon occupied by the outgrowing allantois. The outer, or vascular allantois promptly becomes fused with the outer amniotic wall, which ceases to exist as a readily distinguishable organ, and the fused layers together constitute the allantochoion, or permanent contact organ between the fetus and the endometrium.

THE ALLANTOIS

The allantois arises as an evagination from the hind gut, just pos-

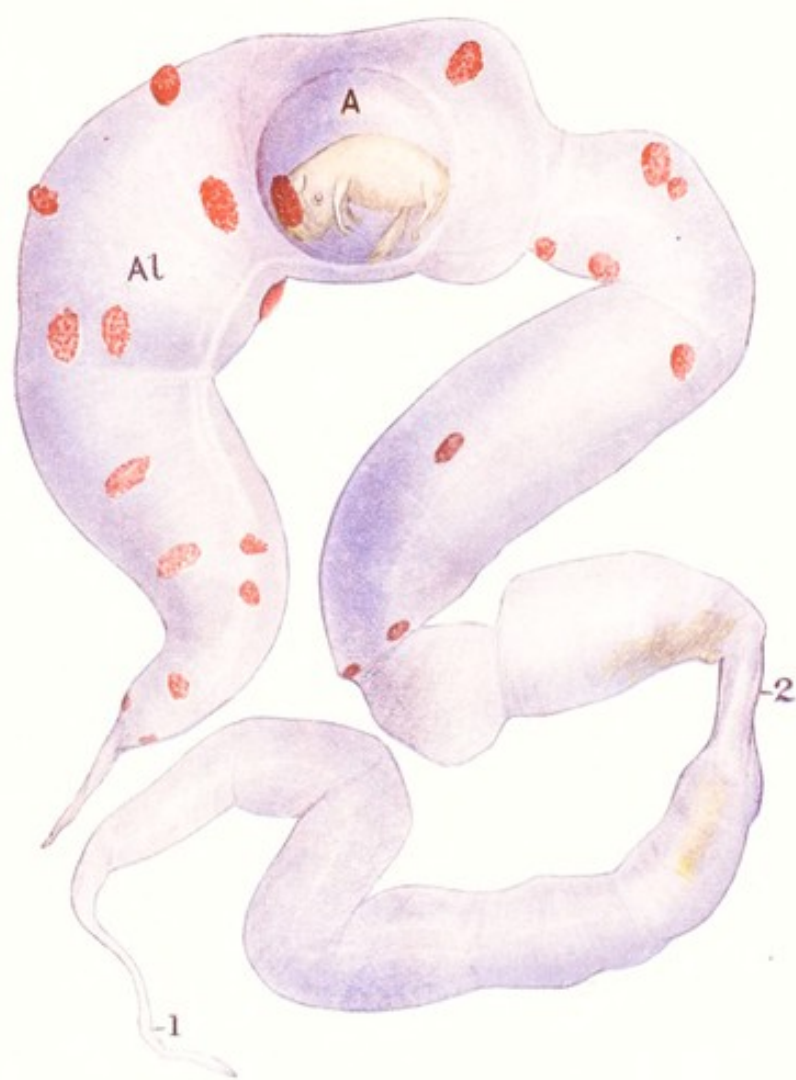

PLATE II

FETAL SAC OF COW AT ABOUT 100 DAYS.

A, amnion; Al, allantois; 1, necrotic tip of non-gravid horn; 2, cervical isthmus between gravid and non-gravid horn.

terior to the vitelline duct, and grows outward between the amnion and the primitive chorion (false amnion). In solipeds, swine and carnivora, the allantoic sac completely surrounds the amnion, thus forming two membranous sacs, the amniotic and allantoic cavities, as indicated in Figs. 49 and 50, each of which is filled with fluid. The inner layer of the allantoic tube is derived from the entoderm of the hind gut, and the outer from the splanchnopleuric mesoderm. The mesodermic layer of the allantois, directed toward the embryo, is in contact with the mesodermic layer of the true amnion, and becomes intimately adherent to it. Outwardly the mesodermic layer of the allantois fuses with the mesoderm of the false amnion, or primitive chorion. From the mesodermic, or outer wall of the allantois arise the allantoic or navel vessels, which eventually divide to constitute the extremely elaborate vascular allantois or allanto chorion, the vascular system of the fetal placenta.

Tracing the tube of the allantois from its origin in the hind gut, we find it modified within the body cavity to form the urinary bladder, important parts of the urethra and the first portion of the urachus. Outside of the abdominal cavity, after a varying length of the urachus, the tube expands to constitute the very large allantoic sac, which in unipara extends from one ovarian pole of the uterus to the other and is in contact with the cervix. It is much larger than the amniotic sac, as indicated in Colored Plate II. The volume of allantoic fluid varies widely in health. Passing imperceptibly from physiological to pathological proportions, it may be almost none at all or may exceed fifty gallons in the cow.

In health, the allantoic fluid is clear. It appears to be derived chiefly from the fetal kidneys and contains albumen, sugar and urea. The contents of the fetal urinary bladder may be expelled either through the urethra into the amniotic cavity, or through the urachus into the allantoic sac. Through the urethra, urinary bladder and urachus, there exists an open communication between the amniotic and allantoic cavities. The human embryo is virtually without an allantoic cavity. The amnion, the allantois, and the remains of the vitelline sac, constitute the fetal membranes, or afterbirth.

THE CHORION

In the brief interval elapsing between the formation of the amnion and the allantois, the external, or false amnion performs temporarily the functions of embryonic nutrition and excretion and is known as the primitive or amniotic chorion. In all domestic animals the vascular, or outer layer of the allantois quickly spreads over the inner

surface of the false amnion, or primitive chorion, and the two structures soon blend. The resulting structure is designated the fetal placenta or allantochorion. It constitutes the most extensive and vital organ of the fetus.

During intrauterine life the fetus depends for its growth and development upon the chorion. Through it, all nutrition must pass from the mother to the fetus, and all excretory matters which cannot be harmlessly stored in the fetal organs (meconium) must escape. Since the placental tissues constitute the medium for the exchange of nutritive and excretory substances between the mother and her intra-

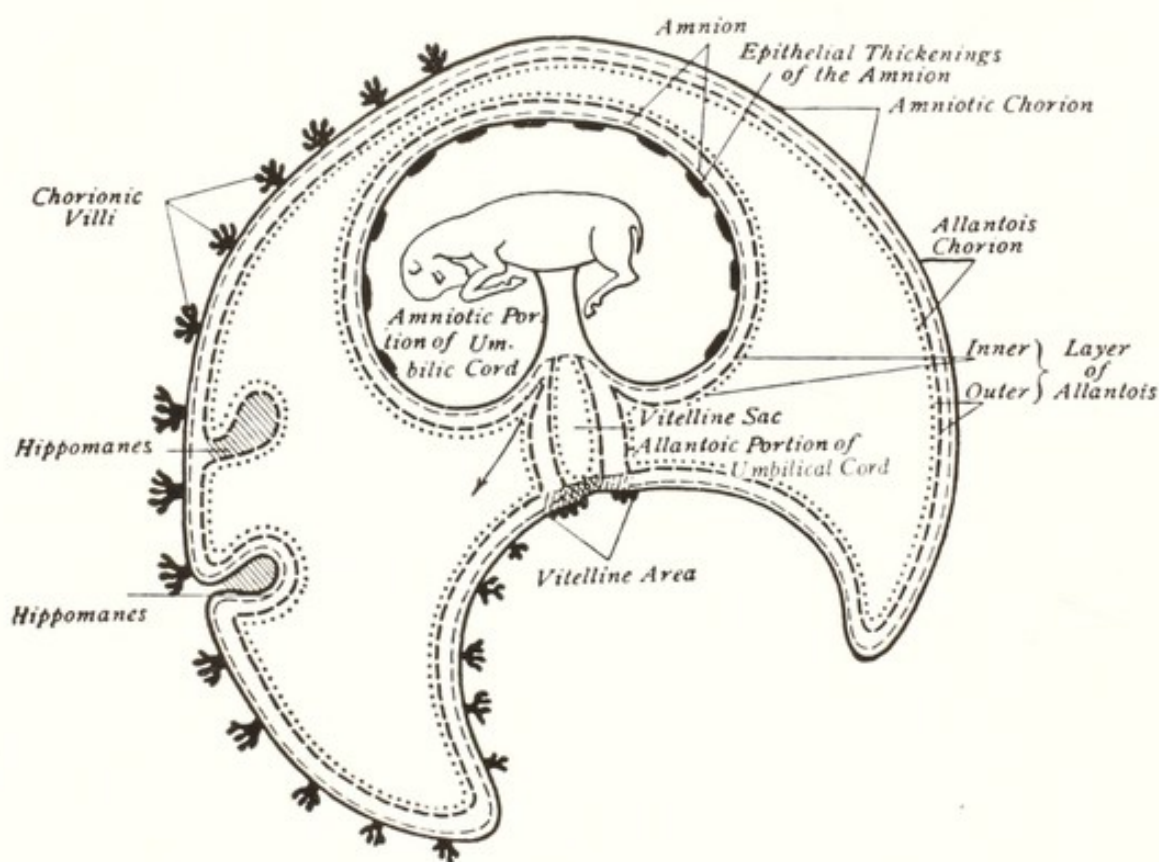


FIG. 50. Schematic Longitudinal Section of a Horse Embryo in Its Annexes, at about Five Months' Gestation. Reduced to about 1/6. (Bonnet.)

uterine young, it follows that the allantochorion must be healthy and of adequate size, if the fetus is to develop physiologically. This is in turn dependent upon the health of the uterus. Placental contact is so intimate that, while gases and liquids pass through the intervening walls of the contiguous maternal and fetal blood vessels, solids cannot be exchanged. Any disease either of the endometrium or of the endometrial surface of the allantochorion inevitably involves the contiguous surface of the other organ.

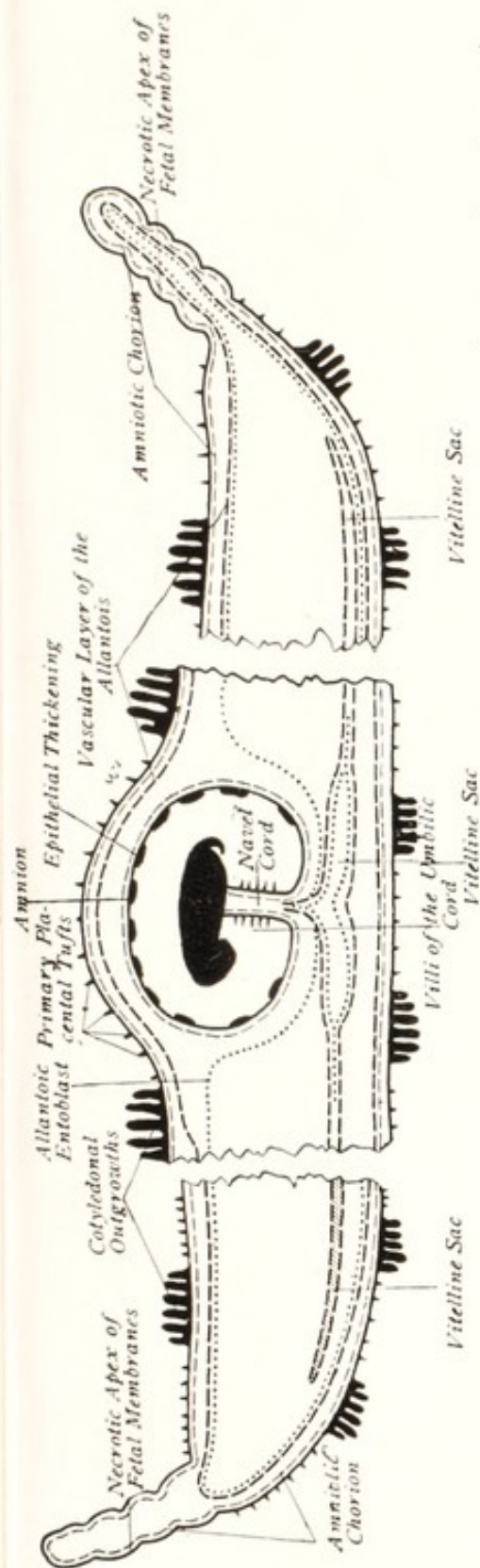


FIG. 51. Schematic Sagittal Section through the Fetal Annexes of Ruminants. The parts between the two end portions and the central piece are represented as having been excised. (Bonnet.)

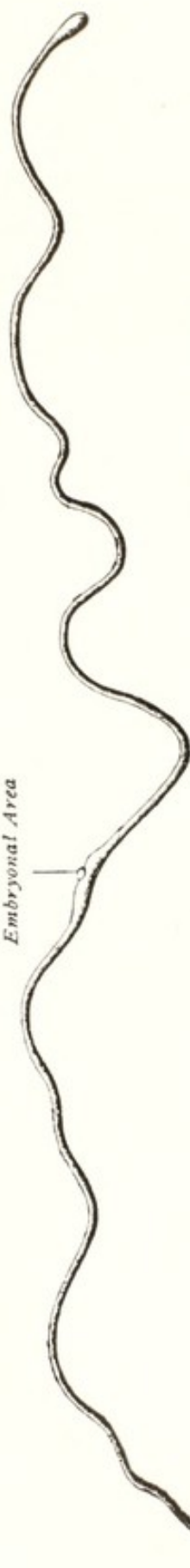


FIG. 52. 12 day and 2 1/2-hour-old Blastodermic Vesicle of Sheep. Natural size. (Bonnet.)

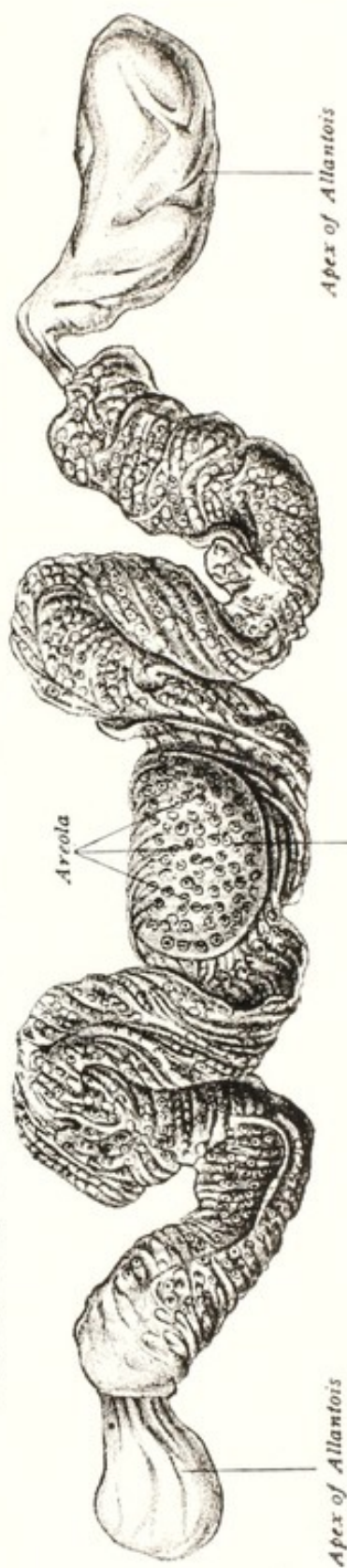


FIG. 53. Swine Embryo and Its Membranes, 48 cm. long. Reduced to about 1/2 size. (Bonnet.)

The form, extent, and relations of the allantochorion differ greatly according to species. In the mare, as indicated in Figs. 49 and 50, the allantoic sac completely surrounds the amnion, forming a second complete double envelope, except for the area occupied by the vestigial yolk sac. Thus, it separates completely the true from the false amnion, or amniotic chorion. A study of Fig. 50 shows that the somatopleuric mesoderm, or outer layer of the true amnion, is in contact with the splanchnopleuric mesoderm of the allantois. The two membranes are separable by exercising great care, but are so intimately blended that ordinarily the two, taken together, are regarded as the amnion, though actually distinct. Similarly, the external wall of the allantois presses against the mesoblastic layer of the amniotic chorion, or false amnion, fuses with it, and constitutes the allantochorion.

The vitelline sac, the amniotic chorion and the allantois of solipeds, as indicated in Fig. 49, remain globular or ovate for a considerable period. The vitelline sac of ruminants and swine, as may be seen from Figs. 51, 52 and 53, early becomes enormously elongated. This elongated vitelline tube does not physiologically persist, but atrophies and almost wholly disappears before birth.

The amniotic chorion and the allantochorion of ruminants and swine, like the vitelline sac, become greatly elongated, and their very fine apices become necrotic. As indicated in Fig. 51, the necrosis in some instances involves the amniotic chorion only, as shown at the left of the figure, or may include the allantois also, as seen on the right. According to some embryologists this necrosis is due to the compression of the fetal sac owing to its great length, which prevents vascularization. It is extremely difficult to understand how a sac with such delicate walls and filled with fluid could so extend its length as physiologically to cause self-necrosis. There is no known law controlling the extent of the necrosis. According to my observations, the more healthy the uterus and fetus, the smaller the area of necrosis: in a badly diseased bovine fetus the necrotic tip may be one or two feet long, while in the healthiest individuals the necrosis may be limited to a globular mass 2 or 3 mm. in diameter, hidden in the walls of the allantochorion.

Sometimes an extended necrotic tip becomes invaginated into the allantoic sac, toward the umbilicus, for a distance of two or three feet, as described elsewhere.⁶¹ The apex of the necrotic tip may then cause a contact necrosis in the allantoic tube, completely perforating it and establishing a path of communication between the allantoic cavity and the utero-chorionic space.

The fundamental cause of the necrotic tip of the fetal sac of ruminants and swine is unknown. In numerous cases the extent and macroscopical appearance definitely indicate that it is pathological and that it is due to some pathogenic virus, bacillus or protozoan. As has been stated in the companion volume, the apical necrosis of the fetal membranes is not always limited to the allantochorion, but

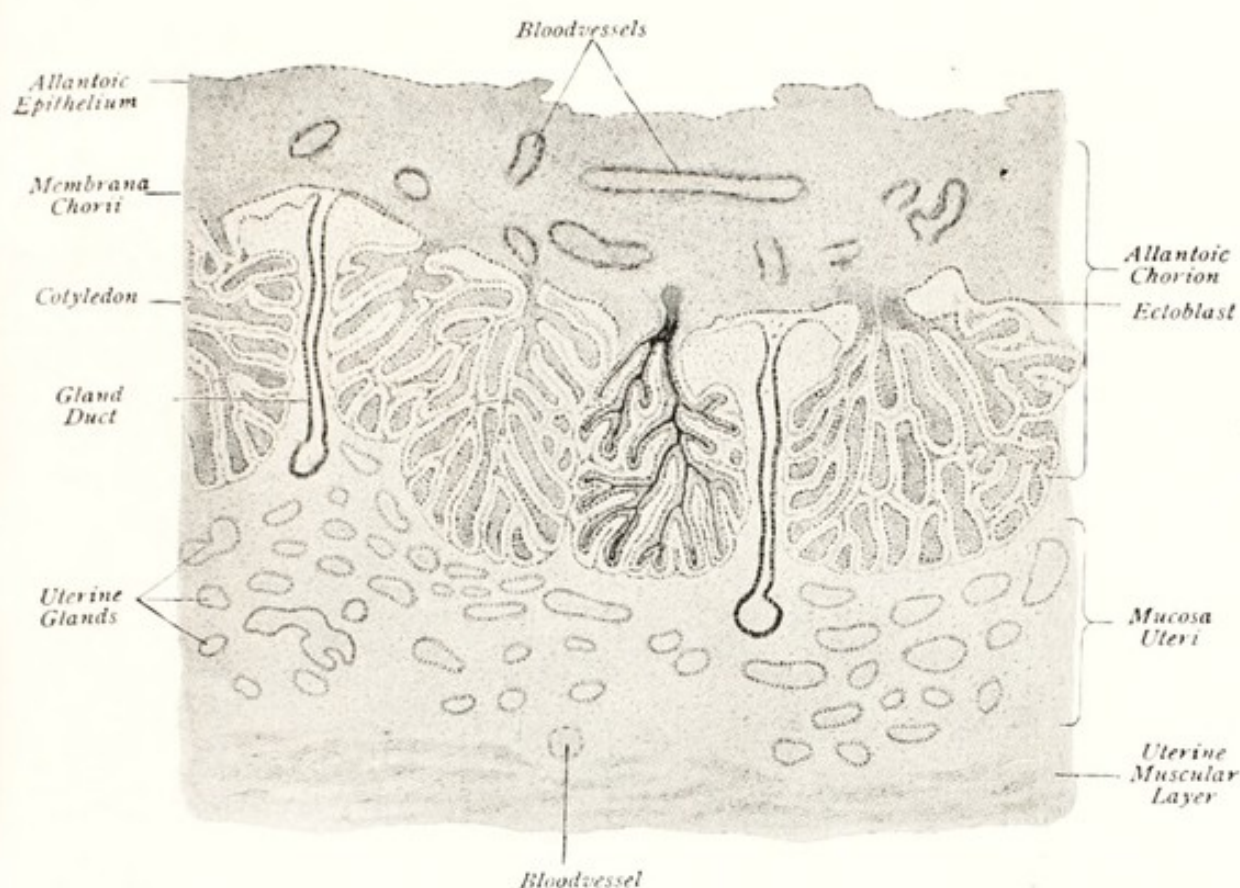


FIG. 54. Section through the Chorion and Uterine Mucosa of the Horse at 9½ Months. Enlarged about 45-1. (Bonnet.)

in *Schistosomus reflexus* includes in the necrosis the adherent tip of the vitelline tube. Sometimes the entire non-pregnant horn becomes necrotic, as shown in Colored Plate III. The condition is then undeniably pathological, and the life of the fetus is in great peril. In healthy pregnancy of solipeds and ruminants, the allantochorion completely fills the uterine body and cornua. At first the allantoic cavity of ruminants, filled with fluid, almost surrounds the amnion, as indicated in Colored Plate II, but later the inner entodermic layer of the allantochorion becomes closely applied to the surface of the amniotic sac over most of its extent. This is in marked contrast to the arrangement in solipeds, as indicated in Figs. 49 and 50.

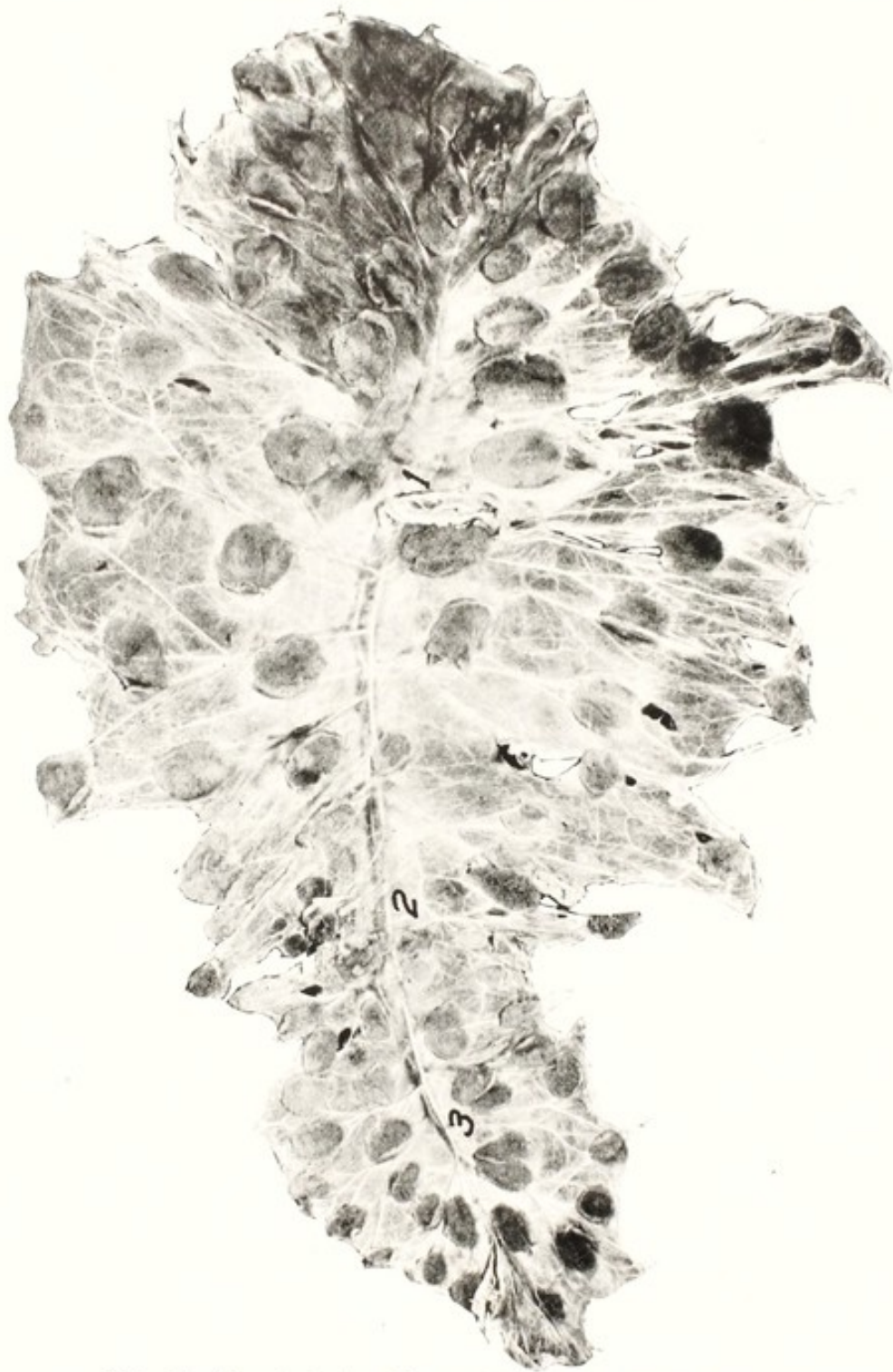

FIG. 55. Allantochorion from a Sexually Healthy Cow.
1, the chorionic navel; 2, the cervix; 3, the non-gravid cornu.

The differences in the relations of the amniotic and allantoic sacs in solipeds and ruminants cause the phenomena of parturition to be unlike. In the mare the amniotic sac, with its contained fluid and fetus, lies free within the allantoic sac, except for the long allantoic navel cord. Hence the foal may be born more or less invested by its

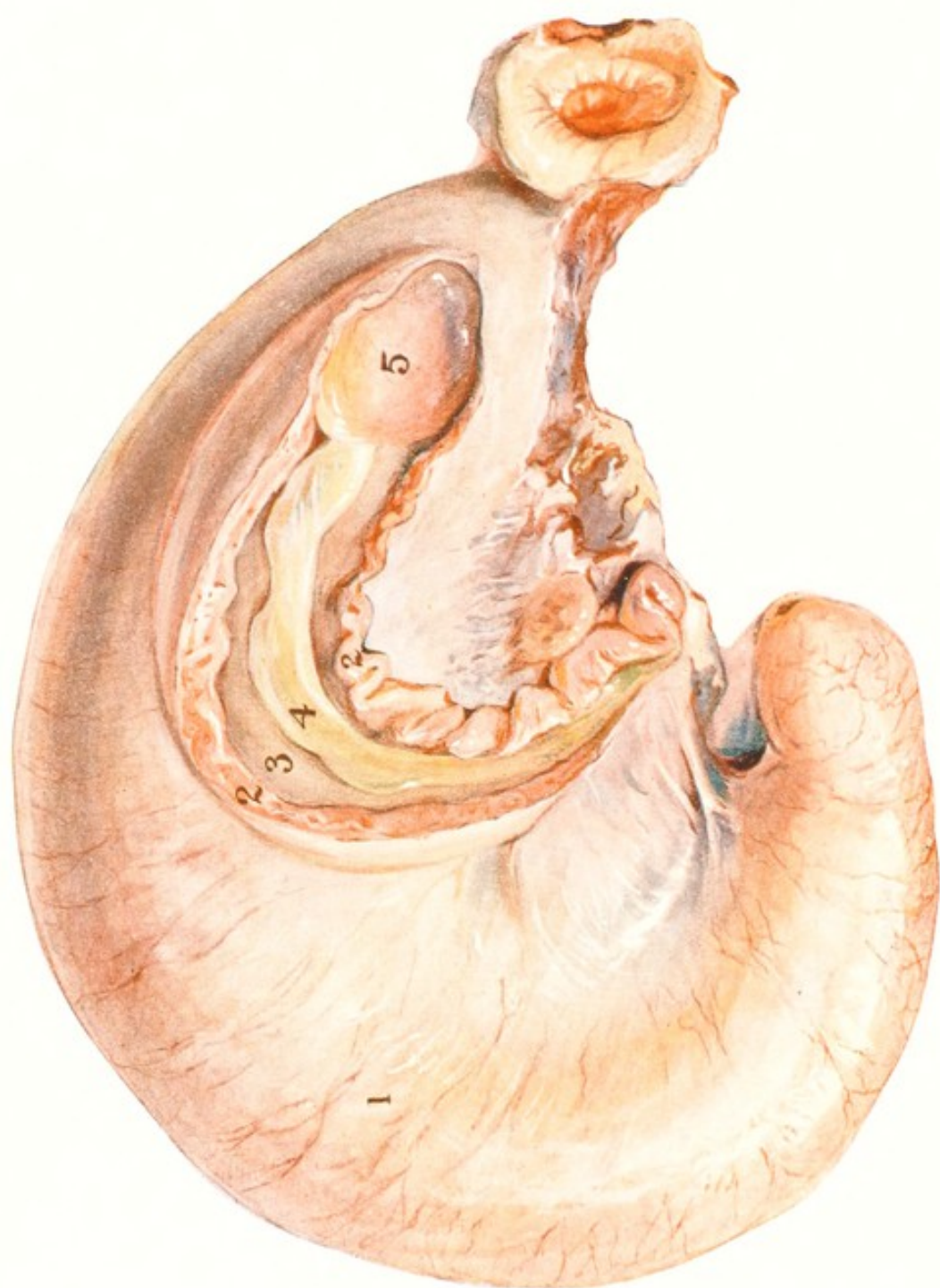

PLATE III

GRAVID UTERUS OF COW AT ABOUT FOUR MONTHS, SHOWING ABORTION EXUDATE IN THE NON-GRAVID HORN

1. Right (gravid) horn. 2, 2. Cut margins of non-gravid horn. 3. Cavity of non-gravid horn, the mucosa covered with the "exudate of contagious abortion." 4. Necrotic chorion of non-gravid horn covered over with brownish-yellow "exudate of contagious abortion." 5. Healthy base of the fetal sac of the non-gravid horn, continuous with the healthy fetal sac of gravid horn.

amnion. The entire amnion regularly escapes from the allantoic sac and from the birth canal, with the foal. It has been stated that the foal is sometimes born so completely enveloped within its amnion that it dies from asphyxia unless the attendant promptly removes it, but no such occurrence is authentically recorded. In healthy parturition, the amniotic, or second "waterbag" regularly ruptures at its caudal end, permitting the escape of that portion of the amniotic fluid which is located in advance of the fetus. This exposes the nose in



FIG. 56. Allantochorion from a Sexually Unsound Cow.

The cow has required repeated breedings for conception. Some of her gestation periods have been prolonged, others abbreviated.

1, very small, naked non-gravid horn; 2, the cervix; 3, the chorionic navel; 4, the ovarian pole of the pregnant horn, with adventitious placental growths.

physiological presentation. The membrane is so very delicate that any struggles by the foal would rend it completely.

THE PLACENTAE

The placentae, as understood in veterinary obstetrics, comprise two newly formed structures—the one uterine or maternal and the other fetal. The uterine placentae are structures developed from the endometrium after conception has occurred. The simplest type in domestic animals is that of solipeds, in which the entire endometrium undergoes placental development, to constitute a diffuse placenta, as illustrated in Fig. 54. In ruminants, the summits of the caruncles are especially prepared for placental activity, and in healthy animals it is restricted to these. The inter-caruncular areas also have the power to elaborate placental tissues, when the caruncles have become destroyed or injured, but such adventitious placental formations are

frail and cannot alone afford proper nutrition for the fetus. This is well illustrated in Figs. 55-58.

Since there is virtually no nutrient reserve in the vitellus, the development of the mammalian embryo can proceed independently for but a brief period, and its further growth must depend upon nutritive substances obtained from the uterus of the mother.

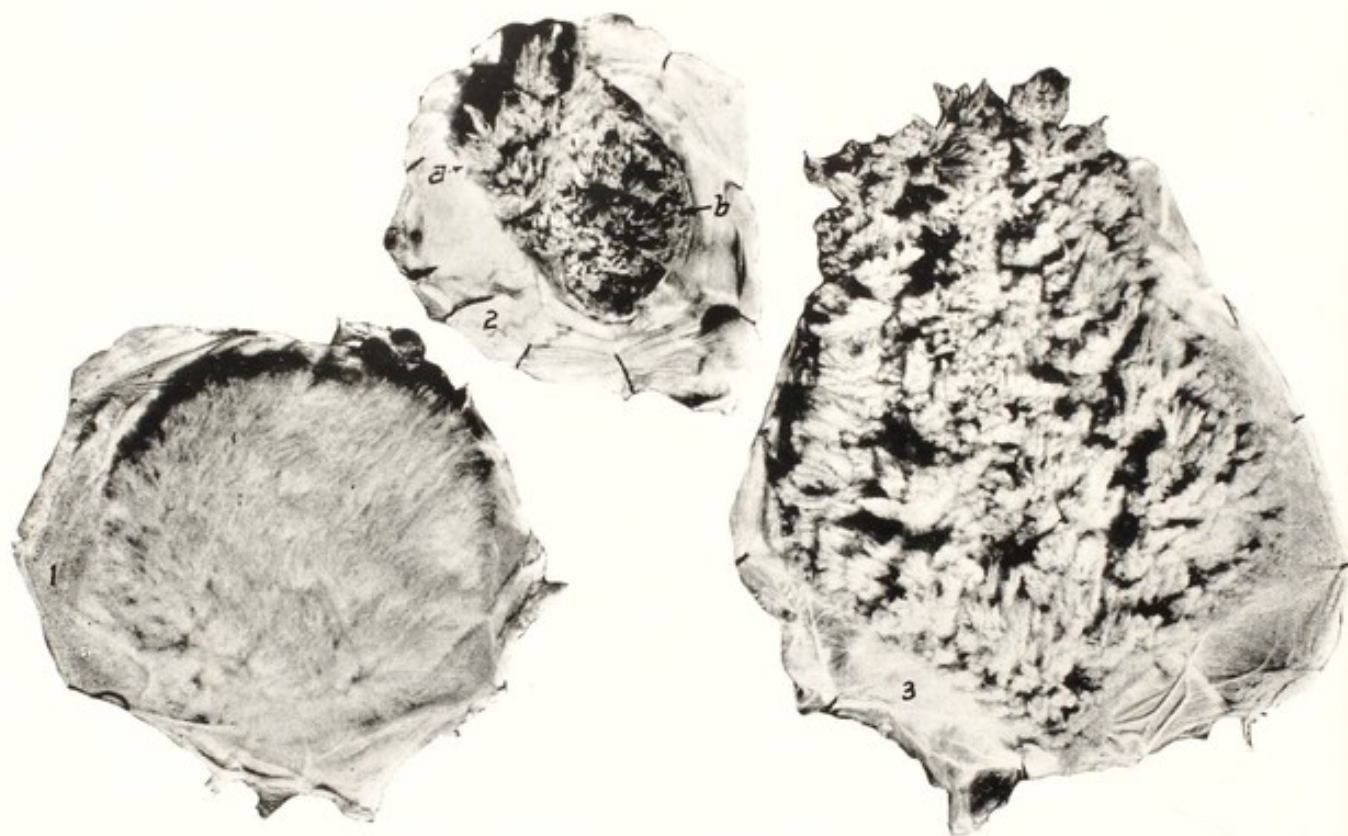


FIG. 57. Fetal Cotyledons from Healthy and Diseased Cows.

1, a typically healthy cotyledon with closely packed, very fine chorionic tufts or villi; 2, a cotyledon from a sexually diseased cow. The villi have been almost all destroyed by necrosis. A few coarse tufts remain at *a*, while at *b* the necrosis is complete; 3, a gigantic cotyledon from same cow as 2, showing very coarse, clumpy tufts with extensive naked areas. (*Cornell Veterinarian*.)

When the morula reaches the uterine cavity at the eighth to tenth day, the primitive chorion throws out tufts, the primordial chorion, which enter into somewhat intimate relations with the uterine mucosa. This zone soon becomes attenuated, and disappears, as the blastoderm rapidly enlarges within it. The primitive chorion, or prochorion, must be replaced by a more permanent and efficient structure for the nutrition of the fetus.

The external, or false amnion is but a continuation of the somatopleuric wall of the yolk sac, which completely invests the embryo. Over the entire surface of this embryonic sac, villi grow out to establish relations between the embryo and uterus constituting the am-

niotic chorion. It also is temporary in character and soon becomes lost as an independent structure, to become blended with the allantois.

When the vascular layer of the allantois develops, it grows out and fuses with the amniotic chorion, and largely becomes lost as a separate membrane, while the blood vessels from the allantois grow out through it to constitute new tufts, which soon attain an intimate relation with the blood vessels of the uterus. The capillaries of the allantois become greatly branched and grow out as villi, which, sink-



FIG. 58. Allantochorion from very Badly Diseased Uterus.

All caruncles had been destroyed following a prior pregnancy. Conception occurred after much delay and the embryo had to be nourished through adventitious placental growths (placenta previa of woman?).

1, dome-like non-gravid horn; 2, the amnion at the middle of the pregnant horn; 3, naked prolongation of the gravid horn.

ing into the mucous membrane of the uterus, come into immediate contact with corresponding capillary loops from the uterine vessels and become closely applied to each other, with extremely thin walls, through which there is a free interchange of liquid and gaseous nutritive and waste products, but not of cellular elements.

The health, vigor and rate of growth of the fetus are determined primarily by the degree of perfection of the placentae. The principles involved for all herbivorous domestic animals are well illustrated in Figs. 55-61. In the ideally healthy allantochorion of the cow, as shown in Fig. 55, all uterine caruncles have functioned physiologically, the cotyledons are regularly arranged, and their vascular supply is regular and ample. A cow with such a uterus breeds well and calves physiologically.

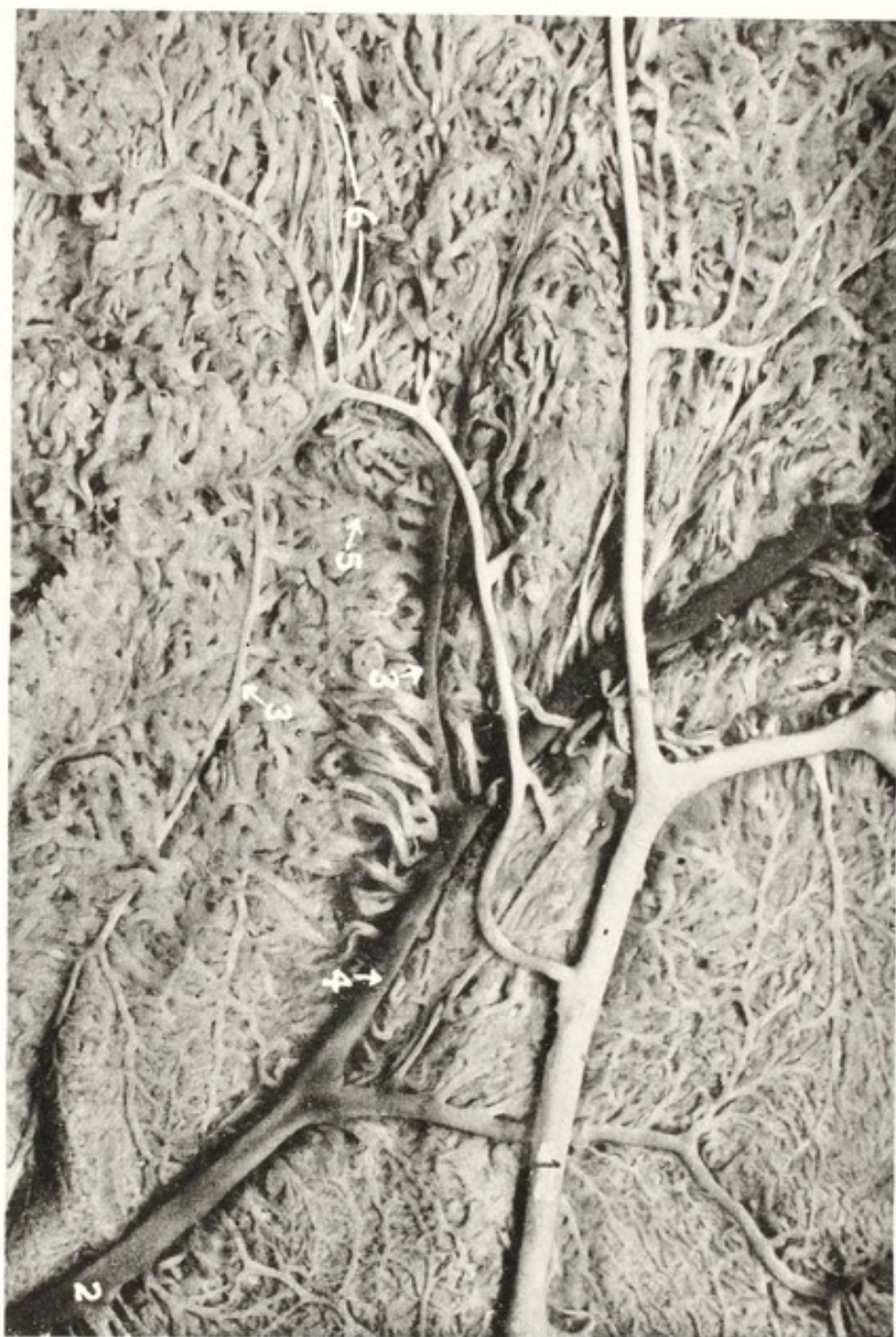

FIG. 59. Vascular Allantois of Mare.

The non-vascular, endodermic layer has been stripped off to show the vascular network.

1, arterial trunk; 2, venous trunk; 3, 3, ultimate arterial and venous trunks, giving off sinusoidal, or cavernous vessels, without themselves visibly decreasing in size; 4, secondary venous trunk; 5, a sinusoidal vessel, apparently passing from artery to vein; 6, a very slender, non-branching artery. (*Cornell Veterinarian.*)

The contrast between healthy and diseased placentae is brought out in Fig. 57. The cow from which cotyledon 1 was obtained was an excellent breeder, while 2 and 3 are from a uterus which had been badly damaged during a prior gestation or puerperium, rendering

conception difficult, gestation insecure, duration of pregnancy uncertain, and pathological birth probable. The problem is further illustrated by Fig. 58, in which the cow had suffered from severe endo-

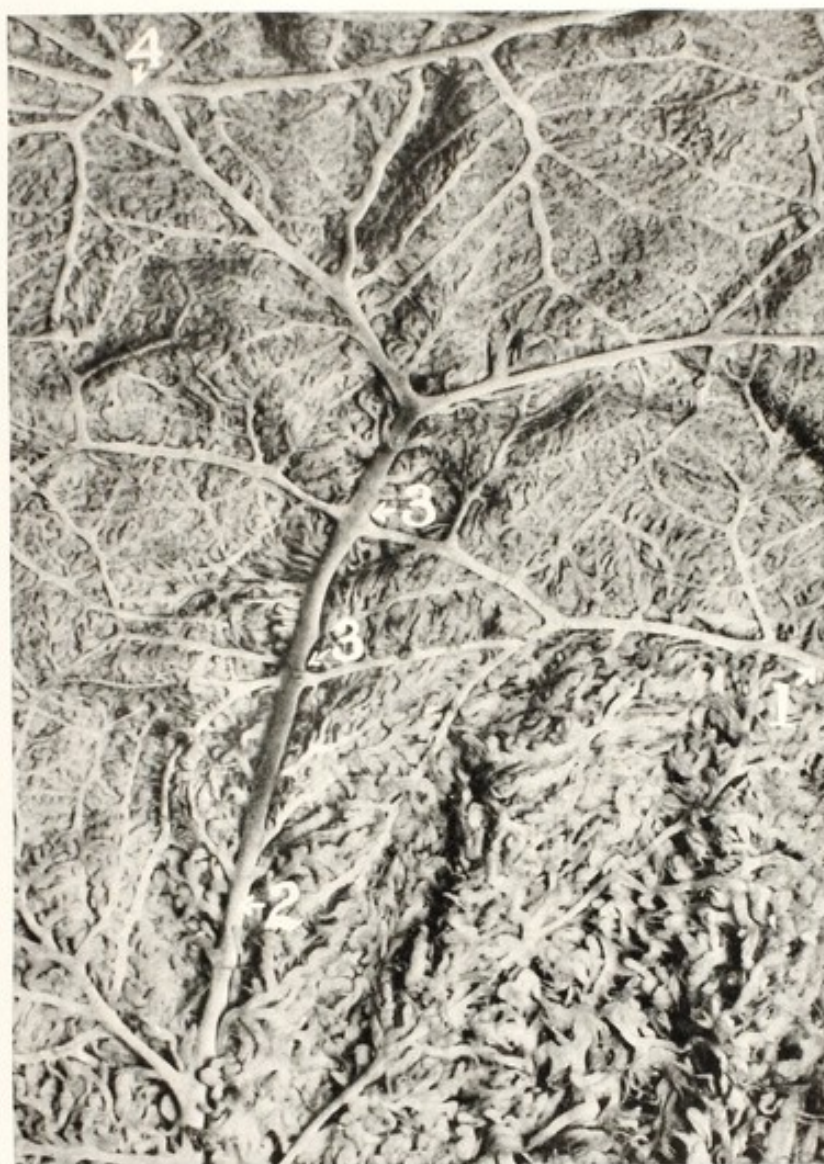

FIG. 60. Vascular Allantois of Mare.

Prepared same as Fig. 59 to illustrate arterial anastomoses near the median line opposite to the mesometrial attachment.

1, 2, arterial trunks; 3, 3, ordinary anastomoses; 4, multiple anastomosis. (*Cornell Veterinarian.*)

metritis in the preceding puerperium, with destruction of all caruncles except two or three badly damaged ones. The intercaruncular endometrium of the non-pregnant horn had been wholly destroyed, except for an inch or two at its base, as shown at 1. The ovarian end of the pregnant horn had also lost its endometrium, so that the chorion in that part was naked. Had the cow not been destroyed when ninety days pregnant, she would quite certainly have aborted.

The adventitious placental formations were frail, placental hemorrhages diffuse and severe, and the proper nutrition of the fetus impossible. Had the pregnancy continued to near term, the wrecked

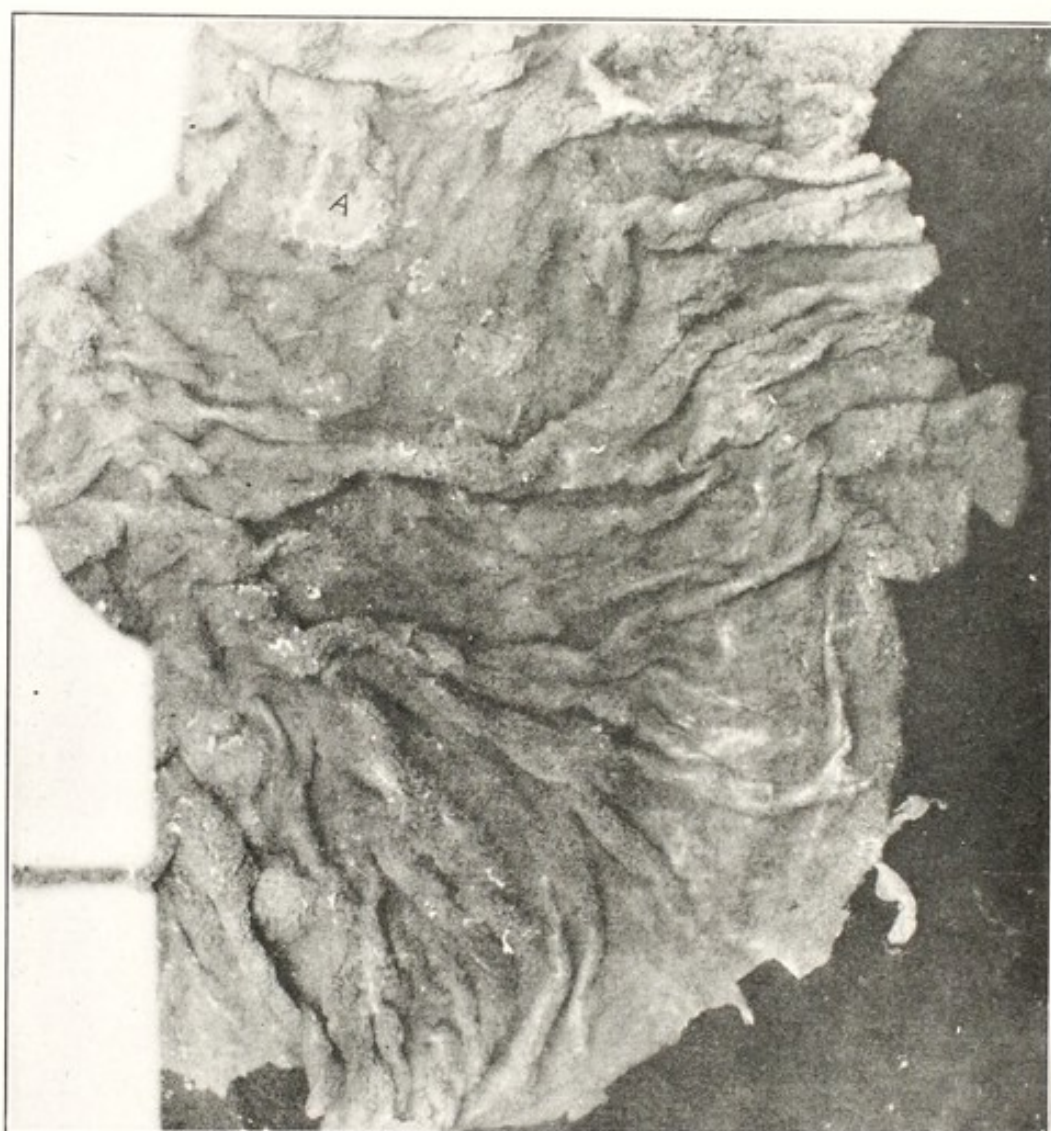


FIG. 61. Badly Diseased Allantois from Mare, seen from the Placental Side.

The mare was sterile and carried her few foals 387 days. The entire placental surface, of the grossly thick and heavy chorion was studded over with pale necrotic masses. The necrotic mass, at A, was one inch in diameter. (*Cornell Veterinarian.*)

uterus could not have contracted properly and dystocia would have been highly probable.

The facts are equally striking in the mare. The vascular supply of the healthy allantochorion, as shown in Figs. 59, 60, is exquisite and luxuriant, assuring abundant nutrition, with well regulated duration of pregnancy and physiological birth. In contrast, Fig. 61 shows the placental surface of a badly diseased allantois, with interrupted nutrition, prolonged pregnancy (387 days), dystocia, and an extremely emaciated and weak foal.

The separation of the fetal from the maternal circulation is so complete that most micro-organisms of disease do not pass through, and consequently where the mother is affected with a contagious disease the fetus does not ordinarily contract it through the blood stream. For example, in tuberculosis the fetus is rarely infected, but is born free from the malady, however badly the mother has been affected during the period of pregnancy. In those cases of fetal tuberculosis which are recorded, the infection is usually attributed, not to the passage of the tubercle bacillus through the undamaged placental filter, but to placental tuberculosis, in which the tuberculous lesions, having become established in the maternal placentae, extend by contact into the fetal tissues.

There are important variations in the placentae of domestic animals, according to genera and species. In carnivora the relations formed between the maternal and fetal placental structures are so intimate that when the afterbirth comes away at birth, portions of the new-formed placental tissues elaborated by the endometrium come away with the allantochorion. In solipeds, ruminants and swine the contact is more simple: the villi or tufts of the chorion fall away from the crypts in the uterine or maternal cotyledons, leaving the latter intact. Upon this basis, the former is classed as deciduate placentation and the latter as indeciduate. The form and extent of the placenta in the different species vary greatly. In equidae the chorionic villi are diffused over the entire surface of the chorion, as small elongated tufts. In swine the placental tufts are distributed over the chorion much as in the mare, but the ends of the fetal sacs, abutting against each other, naturally prevent the placental formations at these points of contact. In ruminants, the placental formation in the uterus is physiologically restricted to some 110 to 140 elevations in the endometrium (Fig. 3) known as caruncles.*

When conception occurs, the caruncles become highly vascular and their mucous membrane undergoes marked development, while from the chorion there grow out, at points corresponding to these eminences, numerous branched tufts, which ultimately sink deeply into the mucosa of the cotyledons. The placenta of carnivora is zonular, encircling the uterine cavity and the embryonic sac. The poles of the embryonic sac have no placental tissues.

* Confusion of nomenclature has arisen in veterinary literature: *cotyledon* (a cavity) is applied to the elevated areas instead of *caruncle* (an elevation). *Cotyledon* is appropriately used to designate the mass of tissue, consisting of the crypts with their septa, which develop during pregnancy upon the summits of the caruncles of the ruminant uterus. The cotyledons are temporary structures, resorbed after parturition; the caruncles are permanent elevations, formed early in the fetal uterus and persisting throughout life unless destroyed by disease.

THE UMBILICAL CORD

The umbilical cord serves as a bond of communication between the embryo and its placenta. It is formed by the allantoic stalk, surrounded by the amnion, and includes the vestiges of the vitelline duct. In the mare and carnivora, it is divided into the amniotic and allantoic portions. The amniotic portion, or the umbilical cord proper, extends from the umbilicus of the embryo, through the amniotic cavity, to the allantois. The allantoic section extends across the allantoic sac, from the amnion to the allantochorion. A cross section of the umbilical cord in the amniotic portion exposes the investing amniotic sheath; the two umbilical arteries; the pair of umbilical veins, sometimes fused to constitute a single vessel; the urachus; and the vestiges of the vitelline duct. Around these vessels, filling out the amniotic sheath and investing the urachus and vessels within, to constitute a more or less even cord, is the Whartonian jelly embedded in a network of delicate connective tissue.

The allantoic portion of the umbilical cord consists essentially of the mass of umbilical vessels, which have become more or less branched. Partially surrounded by, and adherent to these vessels, may exist more or less evident remnants of the vitelline duct and sac, prominent in the very early stages of fetal life, rapidly disappearing later. The urachus expands into a funnel-shaped dilation just beyond the amniotic sac, to constitute the allantoic sac.

During the earlier stages of gestation in the cat, and occasionally in other animals, there projects into the umbilical cord, in front of the allantoic stalk, one or more loops of intestine, and in some cases portions of the liver or of other viscera. The protruding intestinal loop escapes through the umbilical ring of the somatopleure, beside the allantoic stalk, inside the skin and amniotic sheath. Apparently the primary protrusion of viscera through the umbilicus occurs because the abdominal cavity has not developed with sufficient rapidity to accommodate the rapidly growing visceral mass. Consequently, portions of viscera are crowded out through the umbilical opening alongside the vessels and remain outside the abdominal cavity until the contraction of the umbilicus gradually forces them back into the now more capacious abdomen, where they remain permanently. Sometimes the umbilical ring does not contract normally: it remains open, the intestinal loop fails to return within the abdominal cavity, and the fetus is born with umbilical hernia.

The vessels of the umbilical cord vary in their arrangement and length. Zietzschmann⁷⁶ gives the navel cord of the mare as about 1 m. (39 inches). In thirty thoroughbred mares I found the average length

of the navel cord, omitting the navel stump remaining with the fetus, nineteen inches, approximately equally divided between the amniotic and allantoic portions. The longest cord was 30 inches.

According to Zietzschmann the navel cord of the swine fetus is about 10 inches long, comparatively the longest navel cord in domestic animals. The navel cord of the bovine fetus is only 12 to 15 inches long. It is almost inevitably ruptured as the fetus emerges from the vulva, since it is too short to remain intact thereafter. The cord, frail when compared with that of the foal, ruptures more readily. The cord of carnivora varies with the breed, being generally about one-half the length of the fetal body.

Early in pregnancy it appears possible for the fetus to revolve upon its transverse axis and thereby directly twist its navel cord. Later the length of the fetal body renders its revolution about its transverse axis extremely improbable, if not impossible. It may, however, revolve about its longitudinal diameter, and the umbilical cord slip over the caudal or the cephalic end, indirectly becoming twisted. Very limited observations suggest that the twist in the equine navel cord is generally, if not constantly clockwise, looking toward the placenta. Naturally torsion of the navel cord is most observed in the mare, where the twist occurs within both the amniotic and the allantoic sac. The amount of twisting appears greater in those fetuses having the longest cords, and seems to be more severe in some types of fetal disease. The brevity of the cord in ruminants almost prohibits twisting. In solipeds the cord is sufficiently long that, when the foal is born normally and the dam is in the recumbent position, it remains intact and may even persist after the mare has risen to her feet, but ruptures when she turns her head to the foal, to lick it, or starts to move away from it. Sometimes the foal, by its struggles, ruptures the cord. It is stated that in some cases the navel cord remains intact until the allantochorion has been expelled. Then the foal must break the cord by its struggles. As a rule there is a lapse of 15 to 30 minutes between the expulsion of the fetus and of its placenta. During that interval the mare usually gets up or the foal struggles, and the cord yields. In prolonged parturition, when the fetus is dead, the cord may remain intact.

The normal point of rupture of the navel cord of the foal is about $1\frac{1}{2}$ to 2 inches from the umbilicus, at a well marked constriction. This delimits the cord proper from what may be called the *umbilical base*, or cutaneous navel—a hairless, cylindrical, firm segment 1 to $1\frac{1}{2}$ inches long. At the termination of this portion, a softer and more fragile cord begins, with a somewhat constricted neck.

CHAPTER VII

THE CLINICAL DIAGNOSIS OF PREGNANCY

THE clinical diagnosis of pregnancy has already been quite fully discussed in the volume upon genital diseases, and a lengthy repetition is unjustified. The early diagnosis of pregnancy in the mare and cow is of definite scientific and economic importance, although its value has been exaggerated. It is essential in the handling of female genital diseases, in order to avoid abortion by instrumental interference in pregnant animals, supposed to be non-pregnant; in animals which mistakenly may appear pregnant, a proper diagnosis may hasten measures for overcoming sterility.

The human obstetrice endeavors to diagnose pregnancy in order that he may study the pregnant woman and forestall, where practicable, dystocia or other disaster. Veterinarians have not extensively sought this end. I have been able to foretell abortion by the flaccidity of the uterine walls, but that was of no material advantage, as I had no means at hand for preventing the disaster. In the bi-cornual pregnancy of the mare and cow, its early recognition might indicate the desirability of inducing abortion, or would forewarn owner and veterinarian of impending dystocia at the termination of pregnancy.

Pregnancy may be presumed to exist if, after breeding a female, she fails to be again in estrum at the next logical period: estrum frequently fails owing to a low state of nutrition, to genital disease or to other causes.

Menstruation does not notably occur in domestic animals except in the cow. The phenomenon apparently differs fundamentally from the menstruation of woman and has no important significance regarding conception.

The palpation of the genital organs of the mare and cow offers means for authentic diagnosis early in pregnancy. Within 30 to 40 days after conception the vaginal mucus loses the lubricant character of non-pregnancy and becomes definitely adhesive. The cervical mucosa becomes highly active, especially in the cow, and the cervical canal becomes firmly closed by a highly resistant, dense, adhesive secretion termed the *uterine*, or *cervical seal*. This is readily recognized by digital palpation per vaginam.

Rectal palpation in the mare and cow affords a convenient and

highly authentic means for the early diagnosis of pregnancy. When but a single ovum is present, and it is physiologically located, the pregnant cornu is definitely enlarged and distended at 30 to 40 days, while the non-pregnant horn has not materially increased in volume. Should bicornual twins be present, the two horns are similarly distended. The corpus luteum of pregnancy is readily palpated in the bovine ovary. As pregnancy advances, the fetus may be clearly palpated. The uterine arteries are also readily palpable. The main uterine artery, especially upon the pregnant side, enlarges rapidly and enormously and the pulsation becomes highly characteristic.

Various laboratory tests for pregnancy have been advocated, but none have attained, for the mare and cow, the convenience and authenticity of the vaginal and rectal palpations. Numerous other signs of pregnancy occur, but are of minor value compared with those already mentioned.

CHAPTER VIII

THE PREGNANT UTERUS

The Form and Position of the Pregnant Uterus

THE vast increase in the volume of the uterus during pregnancy necessitates important changes in position. The ducts of Mueller, having originated outside the peritoneum in the dorsal region, descend into the peritoneal cavity during development, and in most species come to rest upon the pelvic or the abdominal floor. In their descent they carry with them a double fold of peritoneum, to constitute, in the uterine area, the mesometrium or broad ligament, between the two layers of which the blood vessels and nerves pass to the uterus. Although the ovaries and the ovarian end of the Muellerian ducts originate near the kidney, as the organs descend the ovary and ovarian pole become displaced caudalwards for a varying distance, according to species. In ruminants the descended uterus, much longer than the antero-posterior extent of its mesometrium, is thrown into a spiral loop. This principle applies in all genera, and the vagina-uterus-oviduct tube attains a length exceeding the basic attachment of the mesometrium and projects cephalically beyond its anterior border.

The uterus of all domestic animals is tubular, in solipeds and multipara of nearly the same transverse diameter from the cervix to the oviduct; in ruminants it is conical with the cervix as its base.

Pregnancy does not fundamentally change the form or direction of the uterus. Its vast expansion compels great modifications in location. Anatomico-physiological factors restrict the change in location to a cephalic elongation of the uterus or cornu, deflected in some species from a direct line by the interference of such viscera as the stomachs of ruminants and the large colon of solipeds. At the same time it is deflected perpendicularly according to the plane of the abdominal floor.

The specific gravity of the pregnant uterus exceeds that of the alimentary tract, especially that of the intestines. Consequently the pregnant uterus comes to rest upon the abdominal floor, which is lower than the pelvic floor. The degree of depression varies according to species and individual. The high specific gravity of the uterus and its contents, with its great weight in the mare, may rarely cause

it to become pathologically displaced, as I observed in one instance⁶⁶ in which it rested upon the large intestine, strangulated it and caused the death of the patient.

The cerebro-spinal axis of the equine and bovine fetus attains a length approximately equal to, or exceeding the distance from the maternal pubis to the diaphragm. This results, in some cows, in the cephalic end of the fetus pushing into the pelvis, with the nose and fore feet lying upon the cervix or further caudalwards, as indicated in the colored frontispiece. In the non-gravid ruminant uterus, the cornu is curved like a ram's horn, so that the ovary is located near the cornual base, and the ovarian pole of the uterus just in front of it, as indicated in Fig. 5. The ovary and ovarian pole of the uterus are dragged forward and downward in pregnancy but the uterus largely retains its form, as indicated in Fig. 77, with the gravid horn disposed as a great loop and the ovarian end resting not far anterior to the pelvis. The mesometrium is attached to the lesser, or concave curvature. In the embryo the mesometrium is naturally attached to the median dorsal line of the cornu, but in its descent the cornu revolves on its long axis through 180 degrees, and the original ventral surface of the cornu turns medianwards-upwards-lateralwards. This position of the uterus, with the enlargement of pregnancy, facilitates uterine torsion. When unicornual twins are present in the cow or other ruminant, and gestation nears its close, there is insufficient room for both fetuses in a direct line. Accordingly the looped form of the uterus becomes accentuated, and the two unicornual fetuses lie parallel to each other. The fetus in the ovarian end of the cornu lies on the lateral side of that in the cervical pole. Consequently when birth occurs, after the cervical fetus has been expelled, the ovarian pole of the cornu, with its contained fetus, must revolve through 180 degrees upon its long axis, before the fetus may be expelled. This causes a markedly greater delay than occurs in the expulsion of bicornual twins, and leads at times to overlooking of the second fetus for a period of one to several hours.

The gravid cornua of multipara must be massed by sinuous folding, similar to that of the small intestines, as indicated in Fig. 94. The pregnant cornua of the sow, freed from their mesometrium, and laid out straight, attain a length of ten to twelve feet, or more.

The Position and Movements of the Fetus During Gestation

In studying the position of the fetus in the uterus it is essential that anatomical, physiological and pathological forces be considered.



FIG. 62. Allantochorion of Bicornual Pregnancy in Mare, viewed from Endodermal Side.

The chorionic sac has been laid open from one ovarian pole to the other, the incision having been made opposite to the attachment of the mesometrium, A, and B. The vessel, 3, at the upper border, reappears below at 3'. The chorion of the "body" of the uterus was so divided that it is mostly at the lower margin, 6, 6, while the point of division at the upper margin is also indicated at 6, 6.

A, right cornu; B, left cornu; 1, bifurcation of navel vein; 2, 2 navel arteries; 3, main arterial trunk to right horn; 4, chief vessel of left cornu; 5, allantoic navel; 6, 6, 6, 6, portions of chorion of "body." (Cornell Veterinarian.)

The position of the fetus in a dead pregnant female may be quite unlike that of the living animal, and the position of a dead fetus in the diseased uterus of a living female frequently differs radically from that of a healthy fetus in a sound uterus.

The uteri of all domestic animals are definitely tubular and the occipito-sacral diameter of the fetus is two or more times as great as its transverse measurement. This necessitates that the occipito-sacral diameter of the fetus shall parallel the cervico-ovarian diameter of the uterus. This rule does not prevent a segment of the multiparous uterus, with a contained fetus, from lying transversely in the abdomen. In uniparous animals in advanced pregnancy, the physiological rule is that the cephalic end of the fetus be directed toward the cervix.

Schmaltz⁴⁶ cites Kehrer as having observed, in the Berbeck stud, among 408 births, 404 (99%) in the anterior, and 4 in the posterior presentation. The veterinary obstetrice sees almost exclusively the difficult births. Thus Tapken, cited by Harms,³² saw, among 57 cases of difficult birth in the mare, 8 (14%) in posterior presentation: the dystocia ratio as observed by Tapken was 14 times as great in the posterior, as in the anterior presentation. That is, dystocia is 14 times more probable in posterior, than in anterior presentation in the mare. Von Oettingen⁴³ saw in the Trakehnen stud, among 3388 births, 38 dystocias, of which 12 (32%) were in posterior presentation. If Kehrer's ratio of 1% of posterior presentations be accepted, dystocia in the posterior presentation was 32 times more frequent than in the anterior.

Similar conditions prevail in the slightly less emphatically uniparous cow. With a ratio of about 95% anterior presentations, Tapken⁵³ records 130 dystocias in posterior presentation in a total of 253 (51%). This apparently indicates that dystocia in the cow is ten-fold more probable in posterior, than in anterior presentation. Nevertheless most writers upon veterinary obstetrics designate alike the anterior and posterior presentations as normal, regardless of the species. The relatively smaller fetuses of multipara, with shorter and more pliable limbs, rest in the uterus, and present at birth by the cephalic or caudal end indifferently.

In my personal experience, posterior presentation has been common in dystocia in both mares and cows, but usually the fetus has been dead or clearly and definitely diseased. The more the problem is studied, the more evident it seems that the great majority of caudal presentations are pathological.

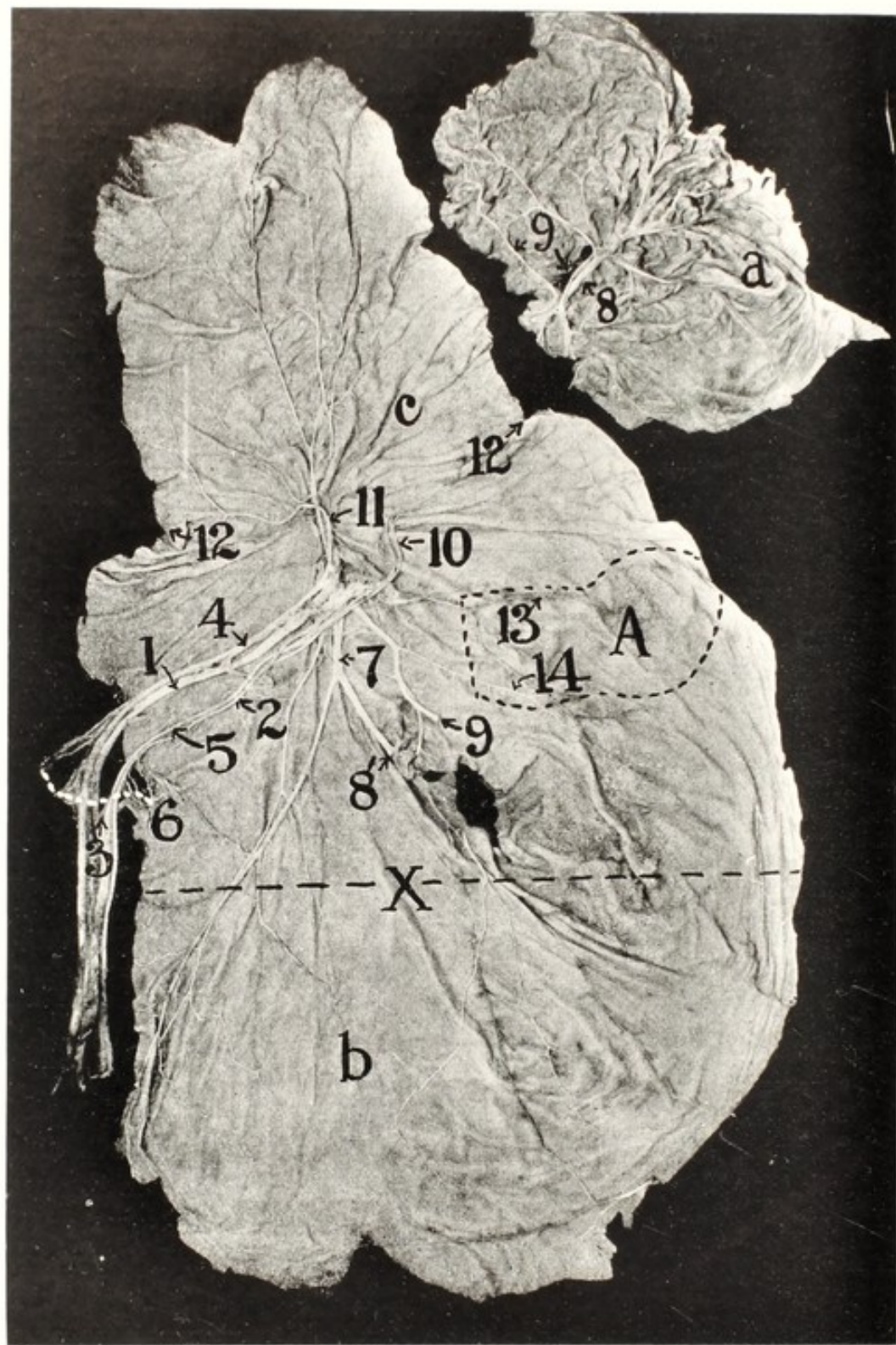


FIG. 63. Normal Allantochorion of Mare. (For comparison with Fig. 62.)

a, excised non-pregnant horn, its location indicated by the aperture just beneath, 9; b, the body of the uterus; c, the pregnant horn; X, approximate line of demarcation between the body and the cornua; 1, chief umbilical vein; 2, minor umbilical artery. Slight variations in size of the arteries are common, but the variation is rarely so marked; 4, major umbilical artery; 5, minor umbilical vein; 6, vestiges of amnion; 7, chief venous trunk to the base of the pregnant horn, the body and non-gravid horn; 8, 8', chief branches of 7; 9, 9, chief arterial trunk to the base of the gravid horn, the body and the non-gravid horn; 10, minor allantoic trunks; 11, chief vascular trunks to ovarian pole of gravid horn; 12, 12, location of ovarian pole of amnion. (*Cornell Veterinarian.*)

An important deviation from this law sometimes occurs in the form of bicornual pregnancy, most frequently observed in the mare. When the equine ovum becomes elongated sufficiently that its cervical pole emerges from the base of the gravid horn, it physiologically becomes deflected toward the cervix, into the uterine body, with a minor extension of the allantochorion into the non-gravid cornu. Pathologically the head end of the fetus with its membranes may pass across into the opposite horn and only a minor extension of the allantochorion, 6, Fig. 62, extend into the uterine body. The spinal axis of the fetus is then perpendicular to the longitudinal axis of the uterine body, but no part of the fetus is in the latter portion of the organ. Such abnormality is rare in ruminants owing to the parallel disposition of the cornua, and virtual absence of a uterine body, so that the fetus in order to lie partly in each cornu must be doubled sharply in the middle of its spinal column. In multipara, the endometrium of the body of the uterus is devoid of placental function, so far as observed, and becomes physiologically a segment of the vagina. The cornua of the bitch leave the body at nearly right angles, so that their cavities are almost in a direct line. Sometimes the distal end of an ovum pushes across the uterine bifurcation and enters the opposite horn, so that the fetus comes to rest lying approximately across the long axis of the uterine body.

In those animals which have a distinct uterine body, whether with placental functions as in the mare, or without such office, as in multipara, the organ is supported by one broad ligament upon either side and is held in an approximately median, and fairly stable position. The horns, upon the other hand, except as retained by inter-cornual muscles, etc., as in ruminants, swing freely within the pelvic or abdominal cavity, held by the single broad ligament or mesometrium.

Accordingly the uterine blood supply, reaching it through the broad ligaments, enters the body from either side; and the cornu from the lesser curvature. The main vascular trunks traverse the uterus and cornu along the mesometrial line, and correspondingly the chief trunks of the allantochorion parallel these and converge near the base of the gravid horn (mare) or near its middle (ruminants) to form the navel cord. Since the fetus of unipara constitutes an arc of a circle and the uterus or cornu is curved, it naturally follows that the two curvatures should be parallel, the umbilicus face the lesser curvature of the uterus, and the navel cord pass in a direct line to the umbilicus.

The literature concerning the physiological position of the fetus

in the uterus is extremely vague. It has been stated for more than a century, by eminent veterinarians, that the equine fetus lies upon its back throughout intrauterine life and is then magically born with its dorsum facing the sacrum of the mare. The basis for the statement has not been revealed. No known effort has been made to describe the force which at the moment of parturition turns the fetus through 180 degrees upon its long axis. When the obstetrice encounters the fetus in dorso-pubic position, he not infrequently finds it difficult to reduce the position to the normal. Apparently the hypothesis rests upon tradition and has gathered force by repetition.

At my instance, several colleagues have recently made numerous rectal palpations upon pregnant mares, and like myself have found all fetuses in the dorso-sacral position, none lying on their backs with their feet toward the spine of the mother. If the alleged position occurs physiologically, it would be highly interesting to learn the details of the rotation at birth. Does the fetus rotate through 180 degrees within the amniotic cavity, the amnion remaining static; do the amnion, and its contained fetus revolve together; or does the fetus, with its amniotic sac, and the allantois-chorion and uterus, revolve as a unit (uterine torsion)? In rotated bicornual pregnancy, page 192, the two uterine cornua, constituting a direct line, unquestionably rotate upon the combined long axis, and, with the cornua, the amnion and fetus also turn. Until further evidence is presented, the generally accepted hypothesis that the equine fetus during intrauterine life physiologically lies in the dorso-pubic position, should be considered extremely doubtful. At the same time it is to be granted that pathologically, through rotation of the uterus or otherwise, the fetus of the mare, sick or dead, is not infrequently encountered in the dorso-pubic position, and almost certainly the diseased uterus has revolved in harmony.

The bovine fetus and uterus are both so distinctly arciform that physiologically it is very doubtful that the harmony of the two arcs should become seriously disturbed during the later stages of gestation. The relations of the amnion to the allantochorion exclude the possibility, which exists in the mare, of the amniotic sac, together with the fetus, rotating within the allantoic sac. The brevity of the navel cord does not readily permit rotation of the fetus within its amniotic sac. Clinically, rectal palpation reveals the fetus with its convex dorsal surface directed toward the convex dorsal line of the uterus, and this in turn physiologically facing the spinal column of the cow. None the less some writers state that the fetus lies almost upon its back and that the navel cord is located at the roof of the

uterus instead of upon the floor, where it physiologically belongs. Not all writers concur. The United States Department of Agriculture⁵⁵ illustrates the fetus as in virtually a standing position with its back toward that of its mother and its tail end directed toward the birth canal. This is copied, with implied endorsement by a dairy husbandman, in a recent bulletin upon artificial insemination.

The uterus, with the fetus, when diseased or atonic, frequently rotates, to constitute uterine torsion. Slight rotation, occupying the hazy boundary line between physiology and pathology, is common in dairy cows. Palpated per rectum, the gravid cornu is found rotated through 10 to 20 or more degrees, and the fetus maintaining its uterine relationship, with its dorsum in the greater curvature. Such a uterus is sometimes palpably atonic and flaccid, suggesting insecurity of pregnancy. The rotation may right itself within a few hours. The fetus then lies with its dorsum directed toward the spinal column of the mother, the fore feet moderately extended and the muzzle resting upon the digits or metacarpi. The position and posture of the fetus are in general favorable for physiological birth, without modification.

When the fetus has been formed, physiological movements begin and apparently become continuous. As soon as the pharynx has opened into the fore gut, deglutition begins, and the stomach contains any recognizable particles obtainable from the amniotic fluid. As soon as the fetal hairs commence to form, some are shed and swallowed, and may be recognized in the stomach or in the large intestine as a constituent of the meconium. As soon as the limbs grow out, their movements begin. Should disease accomplish their incarceration and thereby prevent motion, the limbs are rigid, deformed, and in some instances dwarfed. In the bicornual pregnancy of the mare, since the transverse position does not afford adequate room for movements of the head, it is sometimes forcibly doubled back along the side of the fetus, and wry-neck results.

The Number of Fetuses in the Uterus

Domestic animals are divided into groups, reproductively: those regularly producing one fertilizable ovum at each ovulation period are known as unipara, while those physiologically producing a number of ova at each period are designated as multipara. Between these two groups, some breeds of goats and sheep produce two or more young at a given birth, so often that the term *biparous* is suggested. In the uniparous mare, twins occur, and in cows twins are frequent. There rarely occur triplets and quadruplets. On the other hand, a single fetus is not unknown in multipara. A highly important differ-

ence between unipara and multipara is found in the anatomical and physiological characters of the uterine cornua, body and cervix. In unipara there is either a prominent uterine body which alone performs the placental functions (primates) or which contributes largely to the placentation (solipeds), or there is no distinct body, the bases of the cornua coalesce at the cervix, and their median walls disappear for a distance not greater than the transverse diameter of the cornu (ruminants). In multipara there is an elongated, narrow uterine body, devoid, so far as known, of placental function. All fetuses develop within the cornua. In unipara, the law is that the entire endometrium, including the body of the uterus (when present) and both cornua, participate in the placental functions; in multipara the placentation is restricted to that horn in which the fetus concerned is located, except that one pole of the chorion of one fetus may project into the base of the opposite cornu. If one horn contains no fetus or fetuses it performs no placental function.

In unipara a well defined cervix establishes an important barrier between the uterus and vagina, while in multipara the cervix is wanting or functionally negligible, and the vagina and uterine body constitute a common canal, serving as a copulatory organ and birth passage. In multipara the cornua leave the nonplacental uterine body at almost right angles. Hence when birth sets in, should a fetus be pushed toward the birth canal, from each cornu, they would tend to meet end to end and block the birth until one of the two fetuses acquires precedence. On the other hand, when bicornual twins are present in the ruminant uterus, parts of each tend to enter the cervix simultaneously and become wedged in the passages. The comparatively longer limbs and neck of uniparous fetuses contribute to the danger of wedging. Under these conditions, the wedging of twins in ruminants becomes common, while in multipara the phenomenon is virtually unknown. Dairy cows, with their great preponderance of reproductive disease, naturally lead all other species in the wedging of fetuses in the birth canal.

Twins

When a zoologically uniparous animal gives birth to two or more young or expels two or more fetuses at the close of a given period of pregnancy, the fetuses or young are designated twins, triplets, etc. Comparatively little study has been given to the subject. Most consideration has been given the problem from the standpoint of genetics, and the phenomenon of the bovine freemartin, or asexual, twin has probably elicited more study than any other feature of twin-

ning. The freemartin is not however, in itself, an important breeding or veterinary problem. The chief clinical problem is to determine, so far as may be possible, the basic cause of twinning. Superficially the immediate cause of twinning may be generally determined satisfactorily without difficulty. Two fertilizable eggs are produced at one ovulation, or it is barely possible that twins in domestic animals may develop from a single ovum (uniovular, identical or monozygotic twins).

To the veterinary obstetrice the prime interest in twins lies deeper than this. The breeder of horses and cattle knows well, if fairly observant, that twinning is, upon the whole, an economic waste, but generally neither he nor the veterinary obstetrice accumulates sufficient observations to enable him to authentically compute the loss. It is probably not far amiss to say that it is the general consensus of opinion that twinning in the mare and cow is an expression of exalted fecundity in the individual. I have recently taken occasion⁷⁴ to disagree unqualifiedly with this general view, although freely admitting the occurrence of exceptions.

The ratio of twins in mares is low. Von Oettingen⁴³ states that, amongst 1297 mares, in the Trakehnen stud, number of pregnancies not given, 136 either aborted or gave birth to twins. Nine mares had two twin pregnancies each, and 2 mares 3 each. In the Beberbecker stud there were 13 twin pregnancies amongst 342 mares. Von Oettingen places the average twin conceptions for Trakehnen at 1.5%, while for cross-breds in Germany he estimates twin conceptions at 0.18 to 0.23%, and triplets at 1 in 300,000.

In a small stud of thoroughbreds where I served for a time as stud veterinarian, the owner had largely assembled famous mares, which were purchasable because they had been sterile. These mares were bred to famous stallions, most of which were of low fertility because of heavy breeding and advanced age. The ratio of reproduction was low. I made an effort to improve the sexual health of the mares, and they were mated with younger and more highly fertile stallions. Among 26 recognized pregnancies the following year, there were 6 pairs of twins with one viable dwarf foal. There was dystocia in one of the mares. Five of the mares had been sterile the previous year, some of them for several years, and five were sterile the following year. Two had aborted a previous pregnancy. Von Oettingen also observed that the ratio of twins was higher in years when a high rate of conception occurred, but he fails to state the ratio of abortion and sterility in the twinning mares the previous or following years. Fleming²⁵ reports a series of cases of equine twin pregnancies. Some of

the mares had required several services for conception. One mare died from hydrops (amnio-allantoic) and most fetuses were aborted or were non-viable. In some instances one, dead, was expelled early and the other, either dead or alive, some weeks or months later. Some excellent brood mares have produced twins and some twins have proven splendid breeding or racing animals, but these constitute exceptions.

The data regarding bovine twins are more voluminous and the basic facts more accessible. In a dairy herd where the calves were raised under very unhealthful conditions, the heifers regularly aborted in first pregnancy at a rate of 50%. A group of 18 of these, of approximately the same age, aborted heavily in first pregnancy and many died or were discarded. In five years there ensued 46 recognized pregnancies, of which there were 3 (6.5%) twin conceptions. In each case the female was sterile or had aborted the previous year. One died of metritis, one was slaughtered on account of sterility, and one was sterile when observations were interrupted.

In 1920-21, 55 unbred or pregnant heifers were assembled to constitute a dairy herd. They were purchased from nine herds, varying in sexual health. The largest lot, 17 (Group A) was from an unusually healthy herd, and all were in excellent health. The other 38, (Group B) had been indifferently to poorly raised.

The herd records show:

Group	No.	Total viable calves	Calves per cow	Aborts and non-viable calves	Per cent	Twins	Per cent
A	17	137	8.04	7	5	1	0.73
B	38	220	5.08	33	15	9	3.90

The 55 animals were in a common herd, were not stabled, had identical food and handling, and were bred to the same bulls.

Like abortion, twinning is common in first pregnancy in dairy heifers. In Group A, the 17 heifers produced in their first year 17 viable calves and no twins. The 38 heifers in Group B produced 26 single viable calves in the first year, with 9 abortions or non-viable single calves and two pairs of twins. The twinning animals mentioned have shown, with remarkable constancy, definite evidences of genital disease previous to twin conception, the twin gestations were generally pathological in duration and termination, and following gestation the animals have been largely unsound sexually.

When heifers conceive twins in their first breeding year, they have usually been in poor health as calves, and frequently show delay in conception. In cows there is usually a history of previous abortion, of tardy conception, or of the cow having been rebred early after calving while the genital organs were yet in a state of fatigue. McIntosh⁴¹ reports that an eight-year-old Holstein cow had produced four single calves. In her fifth pregnancy she aborted triplets at third month, and again in her sixth pregnancy. She aborted twins in her seventh pregnancy, and again in her eighth gestation—a total of ten dead fetuses in twenty months. Haubold³³ states that one bull was used for breeding 100 cows, and in one year there were 23 twin conceptions and 5 monsters. Details are not available. The simultaneous occurrence of twins and monsters is logical, and the habitual use of one bull to serve 100 cows normally leads to genital pathology.

The important consideration for the veterinarian is that twinning is usually pathological and that at the termination of pregnancy dystocia or other pathological phenomena may be anticipated.

The Duration of Pregnancy

Studies regarding the physiological duration of pregnancy in domestic animals have led to considerable variation of opinion. No minimum, maximum or average physiological duration of pregnancy has been established. Published data apparently indicate that the authors consider a possibly viable calf as proof of a *normal* duration of pregnancy. The following statistics will serve to illustrate:

		No.	Average Duration	Min- imum	Max- imum	Difference in days	Per cent increase over minimum
St. Cyr	Mare	284	346	307	394	87	28
St. Cyr	Cow	1062	283	241	301	60	21
Keller	Sheep		150	137	162	25	18
Schmaltz	Goat		151	142	164	22	15
Schmaltz	Swine		115	106	124	18	17
Schmaltz	Bitch		63	60	64	4	7

The general plan in recording data seems to have been to accept as normal any birth in which the fetus is expelled alive. This limitation is not constant and the statement is not rare that a cow "calved normally" and that the calf was dead. In recording "normal" births, pathological phenomena like retained afterbirth, uterine prolapse, dystocia, etc., are not considered in the computation. In fact, no clear definition of physiological birth has been agreed upon or seriously

discussed. In 1901 Sohnle⁴⁹ significantly stated, "Dams of very weak foals largely go over their time." Viewing the problem from a different angle, von Oettingen⁴³ states, without definitely saying that fetal disease tends regularly to cause either abortion or prolonged gestation, that numerous foals born at 315 to 320 days become outstanding brood mares or sires; in Trakehnen, foals carried over 11 months (335 days) seldom, and those over 346 days, or $11\frac{1}{3}$ calendar months, almost never become conspicuously valuable for breeding. He adds that as a rule prolonged gestation is most frequent in those mares in which the estrual period was abnormally long (pathological?) and several services occurred. Thus Sohnle emphasizes the fact that the mare having prolonged gestation commonly produces a diseased foal, while von Oettingen finds that the foal of prolonged gestation is of low economic value. The ultimate result is identical. I have discussed this problem elsewhere at greater length than admissible here.⁶⁷ My observations agree in principle with those of Sohnle and von Oettingen. I have observed that the lower the rate of conception in a stud, the greater the duration of pregnancy of viable foals, and the higher the ratio of disease in the foals. Most foals born later than 365 days are evidently diseased, and many are non-viable, becoming comatose soon after birth and dying within 24 to 48 hours. If viable, they are frequently dwarfs. If of normal size, they are largely emaciated. DeLee¹⁸ has made similar observations in women, and states that dystocia is common after prolonged gestation, apparently because of uterine atony. He mentions an instance of a 3.5 lb. child born 3 weeks beyond usual term.

In the Trakehnen stud, von Oettingen found the average duration of gestation 334 days, with the conception rate falling between 72 and 82%. In a moderately fertile stud in Kentucky, with 120 pregnancies and a conception rate of 64.17%, the duration of gestation was 342.78 days, or about 8 days longer than in the Trakehnen stud. In a smaller Kentucky stud, the rate of conception was 62.16% and the duration of pregnancy 343.54 days. Of the 37 foals born in the latter stud, 8 were carried 350 to 380 days, of which 3 had goitre, 2 were critically ill, one had abnormally long shaggy hair and one was hopelessly diseased, although it lived. In the latter case birth occurred at 380 days, with dystocia due to uterine atony and fetal disease. The foal had prenatal rupture of both extensor pedis longus muscles of the anterior limbs; the tendons pulled away from the muscles above the carpus. This caused ventral flexion of the toes, which resulted in dystocia by becoming caught against the pubis. The foal also had goitre. Apparently the two flexor pedis muscles of the posterior limbs

had pulled out of the third phalanx, so that the toe turned up as in rupture of the tendons following neurotomy.

According to my limited observations, most foals carried over 365 days are males. Of 19 foals born in 1925 in the small stud mentioned, 11 (57.9%) were males, with average gestation periods of 350.5 days, and 8 (42.1%) were females with an average of 344.1 days, or 6.4 days longer in males than in females. The usual average duration of pregnancy for males exceeds that of females 1.5 to 3 days.

Mares show a definite tendency toward prolonged gestation with few premature births. When pregnancy terminates early it usually ends in abortion. On the other hand cows exhibit a marked tendency toward abbreviated pregnancy with but few prolonged periods. The prolonged gestations are so few that it is difficult to assemble a sufficient number of observations to warrant important conclusions. So far as it has been practicable to study it, prolonged gestation in the cow is analogous in principle and result to that in the mare. Cows occasionally produce viable calves at about 225 days, and many at 270 days or less. The average is usually given as 282 or 283 days. The tendency toward abbreviated gestation in the cow results in an average below the ideal, while in the mare the average is above the ideal. That is, in mares, the higher the reproductive health, the shorter the average gestation period of viable foals; in cows the higher the sexual health, the longer the average period of pregnancy. The following tables illustrate the point. In Table I it is indicated

TABLE I

No.	Num-ber live calves born	Average duration pregnancy in days	Services per calf	Duration of gestation in days										Per cent of abortions
				270 days or less		271 to 275 days		276 to 280 days		281 to 285 days		286 to 290 days		
				No.	%	No.	%	No.	%	No.	%	No.	%	
7	30	276.	4.1	6	20.	7	23.3	9	30.0	7	23.3	1	3.3	34.8
3	19	284.5	2.9	0	0	0	0	3	15.8	7	36.8	9	47.4	13.6

that calves of the unsound bull No. 7 showed an average duration of pregnancy for viable calves of 276 days, while the average for the healthier bull No. 3 was 284.5 days, an advance of 8.5 days. No. 7 shows 73.3% of calves born at 280 days or less, as compared with 15.8% for No. 3. The abortion rate for the two bulls is in harmony with the duration of gestation. In Table II the same principle is illustrated.

TABLE II

	Calendar years	Number breeding years	Number copulations	Sterile		Aborted		Calves		Per cent metritis		Average duration of gestation in days	Average copulations per pregnancy
				No.	%	No.	%	No.	%	Fatal	Non fatal		
Healthy bull	1918-1920	62	82	5	8.1	1	1.6	56	90.3	0	0	285.0	1.5
Diseased bull	1919-1920	34	49	5	14.7	8	23.5	21	61.8	8.8	17.7	277.5	2.3

Available data indicate with great emphasis that the physiological duration of pregnancy is narrowly limited. Any material deviation in either direction from the ideal is indicative of pathological influences. The greater the deviation from the ideal, the more probable is serious disease of both mother and young. Calves born at less than 260 days and foals born at over 365 days are very largely seriously or mortally ill. There is parallel peril to the dam.

The principles of antenatal and postnatal nutrition are the same: the nutritive supply needs be ample in quantity and quality. In antenatal life the nutritive supply is dependent upon the placenta, and the general health and vigor of the female.

If the placenta is not healthy, the general health of the female cannot overcome the defect, and if the general health is not good the placenta cannot be perfect. For example, in Fig. 57 the cotyledons 2 and 3 were from a cow apparently in as good general health as 1. The placenta-forming tissues in 2 and 3 had been seriously damaged by disease, and no known power could restore them to health. The general health of the pregnant female is of great value in sustaining fetal nutrition, but is not an effective substitute for damaged placenta. In 2 and 3, the growth of the fetus is inevitably slower and less secure than in 1, and the duration of pregnancy is inevitably affected. In cows, placental disease tends to cause abbreviation of pregnancy, but exceptionally causes prolonged gestation. An extreme example of placental disease is shown in Fig. 58. The animal, born in 1919, was represented as having calved normally in 1922. Severe metritis was recognized six days after calving. This developed into pyometra, for which she was handled intermittently in 1923 and up to July 14, 1924, when several ounces of pus were removed. Repeatedly bred unsuccessfully in 1923-24, she was turned to pasture with a bull, and sent to slaughter October 16, 1924, 92 days after the last examina-

tion. She was found pregnant, and had apparently conceived soon after the examination. The non-gravid horn was represented by a rounded dome, 1; a portion of the amnion is shown protruding from the allantochorion at 2; and an extensive naked ovarian pole at 3. The figure shows that all endometrium had been destroyed at the poles of both horns. At the cornual bases the caruncles, with a few exceptions badly damaged, had been destroyed and an attempt had been made to provide for nutrition by the formation of adventitious placental growths in the least damaged areas. The attempt had virtually failed and in less than 90 days profuse hemorrhage occurred, as shown by the blackness of the allantochorion and the numerous coagula. There was a large volume of blood filling the uterus and surrounding the fetal sac. Whether abortion or mummification would have occurred is not wholly clear, but the gestation was undoubtedly near its end, owing to the inability of the endometrium to supply healthy placental formation. In a lesser degree such destruction of caruncles, with adventitious placental formations, is common in cows, and living calves are often born after most caruncles have been destroyed and nutrition is largely supplied by adventitious placental growths, but such pregnancies are usually abbreviated, and the calves are small or only medium in size and are prone to be diseased. The birth is pathological and the uterine contractions atonic.

Fig. 61 illustrates prolonged gestation in the mare, referable to chronic uterine disease. Her record by breeding years was:

1. Sterile.
2. Foal, mortally ill.
3. Sterile.
4. Viable foal.
5. Non-viable foal.
6. Sterile.
7. Sterile.
8. Sterile.
9. Foal mortally ill. Pregnancy 387 days.
10. Sterile.
11. Seriously ill, viable foal at 387 days.

The illustration is from a portion of the allantochorion, seen from the placental side, from the foal of the eleventh breeding year. The foal, extremely emaciated, lay in a partial torpor unable to rise for over 24 hours. The membranes were grossly overweight and the placental surface of the chorion was thickly dotted over with grayish

or yellowish-gray necrotic areas, one at A being one inch across. Recent researches,^{61, 63, 65, 67, 68, 69} have made it clear that a study of the allantochorion and other available tissues shows that the health of the fetus and mother is as the health of the placenta. If the placenta is healthy, the fetus will be healthy and will complete its intrauterine life in a physiological manner within narrowly prescribed limits: in the cow between 280 and 290 days, with an average of about 285 days; in the mare at about 334 days. Poor nutrition of the pregnant female lowers the nutritive supply to the placenta, weakens the organ, and invites pathogenic activity of bacteria present, which might otherwise remain dormant. So von Oettingen⁴³ states that in some German studs, owing to scarcity of food, the duration of pregnancy advanced about 5 days during the World War. The survival of the mother and viability of the fetus is not proof of physiological reproduction.

The Duration of Reproductive Power and the Rate of Reproduction

The two most outstanding factors which determine the reproductive life in female domestic animals are the wearing out of the teeth and the pathological destruction of the uterine mucous membrane. Aside from numerous diseases and accidents which imperil life, the inescapable limitation in reproduction depends upon the power of the animal to eat. When that fails, senility ensues, and the sexual powers diminish and disappear. The advent of senility through wearing out of the teeth is determined partly by the state of nutrition as it affects the hardness of the teeth, and largely by the methods of feeding, whether grazing or artificially fed. In desert regions or areas where sand or gritty earth is blown upon forage, and especially where animals live entirely by grazing, the attrition upon the teeth is severe, but in most climates without sand upon the forage, the dental wear is slight. In some localities with sand-strewn, tough forage, the incisors of cows wear away at ten to fifteen years, the teeth pull out in efforts to nip forage, the animal becomes emaciated and the breeding and physical life comes to an end. This ultimate factor has an opportunity to act only rarely. Many females die from diseases of the reproductive organs and very many more suffer from genital diseases which destroy their breeding power. Von Oettingen⁴³ lists 213 mares, from the General Stud Book, which produced 17 to 22 foals each, and adds 30 in the same class in the Trakehnen stud. Since thoroughbred mares are not usually bred until three years old,

the mares need in these cases to continue to breed until 20 to 25 years of age. The thoroughbred mare, "Look at me Lads," born in 1731 and foaling first at 20 years, produced her 12th foal at 33 years.

FIGURE 63a

Chart of hypothetical descendants of a healthy breeding cow and healthy progeny during 10 consecutive breeding years. It is assumed that each heifer shall first calve at the beginning of her third year and that the calves shall alternate in sex. B = bull. H1, H2, H3, H4 = heifer of 1st. 2nd. 3rd. and 4th. generations resp.										
	I	II	III	IV	V	VI	VII	VIII	IX	X
I	H1	-	B	H2	B	H2	B	H2	B	H2
										H3
								B	H3	B
						H3	B	H3	B	H3
										H4
II		B						B	H4	B
III			H1	-	H2	B	H2	B	H2	B
										H3
							B	H3	B	H3
IV				B						H4
V					H1	-	B	H2	B	H2
VI						B				H3
VII							H1	-	H2	B
VIII								B		
IX									H1	-
X										B
*	1	0	1	1	2	2	2	4	6	9
**	1	1	2	3	5	7	9	13	19	27

* Annual increase of heifers.

** Total female progeny in successive years.

Many thoroughbred mares have continued to breed up to 25 to 30 years.

Corresponding data for cattle are wanting. Occasional records are found of cows which have produced an unusual number of calves. Schmaltz,⁴⁶ citing Werner, mentions a Polled Angus cow which lived

to 36½ years and produced 25 calves, the last at 29 years. I knew one Shorthorn cow which ceased breeding at 24 after having produced 22 vigorous calves. An occasional cow produces 12 to 18 calves. Upon the most vital point, the reasonable expectancy of reproduction in a group of animals, there is little of value recorded. Groups of cattle are rarely kept intact, but are bought, sold and bartered for variable reasons, rendering intelligible statistics virtually impossible. In the herd mentioned on page 137, the group of 17 heifers purchased from a highly fertile and healthy herd produced 8.4 viable calves each, while 38 heifers, selected from 8 other herds of indifferent breeding health, produced 5.8 calves each. For the former group the average was about 0.78 calves per annum; for the latter, 0.55 calves per annum. One encounters now and then the statement that a given herd regularly produces one viable calf per cow each calendar year and in at least one instance²¹ a claim is made of one calf each 11½ months. I have not been able to verify such bizarre claims. By jugglery in adding and discarding females from a herd almost any rate of reproduction desired may be claimed. The accompanying chart shows that a cow calving annually, and with sex parity of calves, should according to the idealistic fertility mentioned, have 27 female descendants at her tenth breeding year. If such fantastic reproduction were attainable there would be no sterility-abortion-dystocia problem in dairy cattle: the great problem would be to keep reproduction within bounds. The greatest departure from the ideal rate of reproduction occurs in dairy cows, race horses and pet dogs. The chief economic loss occurs in dairy cattle. They are mostly so located that the cost of maintenance is high. The losses from genital diseases are enormous: in many herds the necessary replacements reach an annual rate of 30%, many of which must be purchased from areas where the rate of reproduction is higher. At the same time, the dairy cow is expected to furnish one of the most important foods for mankind. The economics of milk production and the healthfulness of the milk as human food are vitally involved.

The pathology of reproduction, which expresses itself in infinite variety as the result of many causes, is crudely divisible into three chief groups of phenomena—sterility, abortion and dystocia. The three groups pass imperceptibly one into the other and overlap upon the imperfect boundaries. Writers upon sterility announce, without defining their meaning, that they cure 75 or 80% of their cases. Writers upon abortion in cattle would lead readers to infer that this

or that cure or prophylactic would virtually eliminate that phenomenon. Between the claims and the accomplished facts, there is a wide abyss.

The problem confronting the veterinary practitioner is to gain sufficient knowledge of the underlying causes of the pathology of breeding, in order that the great chasm between the theoretical ideal and the existing ratio of reproduction may be lessened. Unfortunately the problem has thus far defied veterinary effort, and the chasm grows ever deeper and wider. It is interesting, though not a source of comfort, to learn from medical literature, that the older and more highly developed medical profession is not especially proud of its achievements in the control of the pathology of reproduction in mankind. Before great advances are made in the control of the diseases of reproduction of animals, the misleading claims of 80% of *cures* in sterility, the 90 to 95% efficiency in *controlling* abortion, and the fabulous *recoveries* from dystocia need be quietly laid aside, and the *facts* learned and faithfully and modestly recorded. It is especially desirable that the methods of computation of breeding efficiency be radically revised and rendered informative instead of misleading.

Sex Parity

There are many conflicting theories regarding the forces which determine the sex of a fetus. Various unsuccessful efforts have been made to control sex. On the whole, sex parity is fairly well maintained in domestic animals, and if breeding animals are healthy abundant progeny of each sex is produced, as has been indicated in the chart on page 133. Perhaps the dairyman desires, more than any other livestock husbandman, to control the sex of the progeny of his herd, because of his wish to have an ample number of females, but in a healthy herd there is a great surplus of heifer calves, over and above his needs. The ratio existing between the two sexes is of interest because in studying the pathology of reproduction it is found that amongst abortions and stillbirths there is a marked excess of males over females and that in dystocia the male again predominates. Schmaltz⁴⁶ states that among 59 million human births the ratio of male to female was 106.3:100. In domestic animals he states that the male births predominate in dogs, cattle and goats; sheep maintain accurate parity; and females outnumber males in horses. Citing various authorities, the ratio of males to females is:

Wilkins	Dogs	110	:100
	Cattle	107.3	:100
	Swine	111.8	:100
	Sheep	97.4	:100
Machan	Swine	102.7	:100
	Goats	155	:100
	Sheep	99	:100
Darwin	Horses	99	:100
von Oettingen	Horses	100.3	:100

In a small stud, genitally unsound, with 19 foals in one year, there were 12 colts: 7 fillies, or a ratio of 158.3:100. The average duration of pregnancy was 348.1 days; for colts 350.3 and for fillies 344.3. The excess duration for colts was 6 days.

In a healthier stud, the ratio of colts to fillies was 110.7:100 with an average duration of pregnancy of 344.22 days, with 344.68 for colts and 343.66 for fillies, a difference of 1.02 days in duration. In another thoroughbred stud, among 98 live foals were 45 colts and 53 fillies, a ratio of 84.9:100. The average gestation period was 340.1, with colts 342.6 and fillies 337.7, a difference of 4.9 days.

In general, it appears that, as the fertility of a stud or group of mares decreases, the average duration of pregnancy increases, the ratio of males advances, and the excess of duration of pregnancy for colts over fillies rises.

The findings of different observers vary widely. Inevitably they make their observations in different localities and upon animals variously handled. Thus my observations in a beef herd of high fertility show that at branding time (4 to 6 months), among 94,436 calves the ratio of male to female was 102.3:100. In a group of grade Holstein cows upon the same ranch, among 873 calves the ratio was 119:100. Upon the same premises a purebred Holstein herd with 615 calvings shows a ratio of 104.9:100 when stillbirths and non-viable calves are included, but when the computation is based solely upon the viable young the ratio becomes 98:100. It is well known that the male sex greatly predominates in human abortion, ranging as high as 130 or 140:100. Yet the living births show a marked excess of boys, but the mortality amongst children during the first postnatal year is much greater for boys, and hence the parity of the sexes tends to become established at one year of age. Domestic animals, especially horses and ruminants, are far more developed at birth than are children. Aside from those non-viable young which perish within a few hours to a few days after birth, it is not known that males die in a higher ratio than females during their first year. At first glance the above herd of purebred Holsteins appears to fur-

nish data upon sex parity which are in conflict with those from other herds. A closer study of details discovers some highly interesting facts. Dairy heifers lead all domestic animals in the pathology of reproduction in the first breeding year. If, possibly, genital disease unbalances sex parity toward a predominance of the male, a study of the breeding records of primipara in the herd should show disturbances in sex parity in harmony with the degree of health or disease in separable groups of heifers.

In this herd the heifers may be divided into three fairly distinct groups. In the foundation herd 17 heifers (Group A) came from a very healthy herd of high fertility, were unusually healthy as calves, and were not bred until well matured. The other 38 heifers (Group B) of the foundation herd came in small groups from a number of herds where the genital health was poor and the young calves were unhealthy. The progeny of these two groups (Group C) were badly handled as young calves and the heifers came to breeding age with juvenile genital organs. The sex of the calf or abort is recorded for a total of 209 first pregnancies, with 110 bulls and 99 heifers or a ratio of bulls to heifers of 111.1:100. If the abortions and non-viable calves are omitted from the computation, the ratio shifts to 86:100.

The 17 heifers of Group A produced in their first year 7 bulls and 10 heifers, all viable—a ratio of 70:100. The 38 heifers of Group B produced as primipara 23 bulls and 11 heifers—a ratio of 209:100. Seven of the bulls were dead while all the heifers were viable. In Group C the ratio of bulls to heifers is 102.6:100, but if abortions and non-viable calves are deducted the ratio becomes 77.6:100. In Group C there has been much delay in recognized conception, with convincing evidence that many conceptions were interrupted in embryonic or early fetal life. In human obstetrics recognized authorities state that there is a marked predominance of males in abortion and that the earlier in gestation the abortions occur the higher the ratio of males. If the analogy holds for cattle there is an interesting possibility that in group C a great number of male embryos or unrecognized fetuses perished and disappeared. This is supported by the fact that 43.7% of the bulls were dead as compared with 23.1% of heifer calves. The wide variation in sex ratio between Groups A and B might well be regarded as a mere coincidence, were it not that A continues after a period of ten years to show a great superiority over B in the production of both calves and milk. In pedigree, as commonly interpreted, Group B is superior to A and should, technically, have excelled in both calves and milk. Among the 209 terminations

of first pregnancy in which the sex of the fetus is recorded, there were 62 abortions, still births and non-viable calves, in which the ratio of bulls to heifers was 210:100.

In a group of 18 badly diseased purebred heifers, observed through 5 breeding years, the sex of abortions was not recorded, but of the living calves the sex ratio was 200:100. Du Toit²⁹ in researches upon cattle with a low birth rate, grazing upon a portion of the South African veld said to be deficient in phosphates, found that a liberal feeding of bone meal controlled the pica (bone chewing) and advanced reproduction. The calves from cows fed bone meal showed a sex ratio of 102.3:100, while in the controls the ratio was 145.5:100. The cattle in the experiment consisted of four groups—native Africanders, crosses between these and Holsteins, Sussex, and Red Polled cattle. The Africander cattle have been inured through centuries to the defective veld, and mature slowly, calving first at not earlier than three years. The calves of the native Africanders, fed on bone meal, showed a sex ratio of 78.3:100. Hence the high ratio of bull calves for the entire group apparently comes from the less resistant cross-breds, and preeminently from the controls not fed bone meal.

Seymour and Koerner⁴⁸ record 5840 births following artificial insemination, with semen obtained from the husbands, among which there was a ratio of 157.1 boys to 100 girls. Among 3649 infants following artificial insemination from donors the ratio was 136.6 boys to 100 girls. The inference is apparently warranted that the semen from selected donors was of superior quality to that from husbands in childless families. The latter, even when fertile, participated somewhat in causing the sterility which it was sought to remedy by artificial insemination.

According to J. Whitridge Williams⁵⁷ primipara first giving birth at 40 to 50 years show a ratio of 130-140 boys to 100 girls, whereas the usual ratio is about 106:100. The influence of old age of the husband is not stated. Lehndorf³⁹ relates that an emaciated, decrepit stallion of 26 years, Sir Hercules, was fed and carefully handled for a period, after which he was caused to serve 23 mares when 27 years of age, resulting in 23 pregnancies, including 1 twin pregnancy. All the 24 foals were males! This suggests that senility of either sex tends to increase abnormally the ratio of male progeny.

No matter what known theory of sex determination be accepted, the fact remains that in my observations and available data, in those herds where the pathology of reproduction is most prevalent, the

parity of the sexes has been unbalanced and the male sex has been excessive. Further study indicates, however, that it is only the ratio which is advanced and that the total number of males per 100 cows bred is greater in healthy herds. In other words, the available data indicate that, with sexual health, the number of young advances, the parity of sexes is well balanced, and abortion and dystocia decline.

CHAPTER IX

THE BACTERIAL FLORA OF THE PREGNANT UTERUS

THERE is much conflict of opinion regarding the bacterial or microbiological status of the gravid uterus of domestic animals. One group contends that the gravid uterus and the communicating Fallopian tubes and cervix commonly contain bacteria or other microorganisms, not pathogenic in all or most individuals, but competent to develop pathogenicity in the presence of lowered resistance of the tissues. Another group contends that the *healthy* gravid uterus is wholly free from bacteria or other pathogenic factors. They fail to state clearly what they consider a "healthy pregnant uterus." The clinician, especially the surgeon, views the problem from another angle. He has been taught by the bacteriologist, and has partly or wholly verified the teaching by his personal experience, that generally he cannot absolutely prevent the entrance of bacteria into the wound which he makes, nor wholly eliminate bacteria from an invaded wound. But he may, and largely does, so minimize the number of bacteria and preserve the resistance of the injured tissues that he secures what he defines as aseptic healing.

The claim that the healthy pregnant uterus is bacteria-free is based upon negative evidence. Day,¹⁷ at my request, in 1910, took cultures from the uteri of 18 non-pregnant and 25 pregnant cows. The cultures proved positive in 55% of the non-pregnant, and in 32% of the pregnant. The growths were not identified as to species. In general there were recognized, in the non-pregnant animals, streptococci 3 times, staphylococci 7 times, short bacilli 6 times; in the pregnant animals, streptococci 3 times, staphylococci 5 times, short bacilli 5 times. Hagan,³¹ in examining the meconium of calves at birth, found it negative in all six samples from one herd and positive in five out of six calves in another. The findings could be explained only upon the hypothesis that the bacteria had come from the uterine cavity, reached the amniotic fluid, and were swallowed by the fetus. The organisms included streptococci, staphylococci and colon bacilli. H. also studied the uteri of 15 pregnant and 5 non-pregnant abattoir cows. The pregnancies were estimated at 2 to 8.5 months. Cultures from the utero-chorionic space proved positive in 12 and negative in 3. The cultures from the non-pregnant

uteri proved positive in 4 and negative in 1. The bacteria were identified as streptococci, colon bacilli, *M. albus*, *M. citreus* and paracolon. Cultures from the fetal fluids proved positive in 5 and negative in 10. The fetal blood was cultured in 7 cases, with one positive. The cultures from non-pregnant uteri were positive in all cases. Carpenter¹² in 11 pregnant cows, one of which showed evidences of disease, found cultures from the uterus or its contents positive in 6, with a growth of Bang's bacillus in one, among ten kinds of bacteria recorded. In 18 non-pregnant uteri, classed as normal, 13 were positive, with essentially the same bacteria as in the pregnant uteri, but Bang's bacillus was not found. In 51 diseased non-pregnant uteri, 50 were positive, and Bang's bacillus was recognized twice. The varieties of bacteria were essentially the same as in healthy pregnant uteri. Among 10 virgin heifers, 4 gave positive cultures.

Beller,⁶ in researches upon 28 cows and 15 ewes at the Hohenheim agricultural school, obtained bacterial growths from each of the 43 animals, either from the navel sheath, placenta, placental vessels, amniotic, or allantoic fluid, or generally from several of these. The bacteria are classed as cocci and rods, without further identification, although there was an extended variety. The types of bacteria in cows and ewes were unlike. The bacteria were alike in type, whether the birth was physiological, the fetus was born ill, or abortion occurred. Several cows were under observation at the close of two successive pregnancies. The same types of bacteria were obtained at each period, even though abortion occurred in one and physiological birth in the other.

Wagner⁵⁶ continued the researches of Beller at Hohenheim, and included mares and swine. The percentage of positive findings in his cultures were for mares, 75; cows, 61; swine, 71; and sheep, 41. The principal types were diplococci, streptococci and colon bacilli. Both Beller and Wagner append extensive bibliographies.

The studies of the pathology of reproduction by means of the placentae, first advocated by Sohnle⁴⁹ of the Hohenheim school, without attracting much attention, were finally brought into prominence by clinical studies at the N. Y. State Veterinary College.⁶¹ These have done much to establish the fact that in domestic animals there commonly exists in the pregnant uterus and the placentae an extensive variety of tissue changes. The character of these is such that clinicians inevitably suspect or believe that they are due to the action of bacteria, virus, or other force, which may be either patho-

genic or non-pathogenic, according to the volume and virulence of the agent as compared with the power of resistance of the tissues concerned. The line of demarcation between health and disease is not readily determinable. The changes exist in nearly all placentae of all species of domestic animals. They differ in intensity and in extent, in cases of physiological birth, in premature birth, in dystocia, and in abortion. The presence of various types of bacteria is perfectly consistent with ideal reproductive health. The bacteria probably vary according to geographic and climatic location. They vary according to species of animal. The type possibly varies according to the stage of gestation. *Bacillus abortus* appears to be most prevalent of all bacteria in cows aborting in late pregnancy, but it is rarely recognized in early abortions. Interesting researches in this field are recorded by Conklin¹³ who submits evidence that intrauterine conditions change with the progress of gestation and render the environment increasingly favorable for the activity of Bang's bacillus.

The clinical study of the placentae, with cooperative bacteriological researches, has opened a new opportunity to the veterinary obstetrists. Heretofore, veterinary obstetrics has been considered as a conglomerate of accidental phenomena which interfere with physiological birth. Careful study of the placentae, with other modern sources of clinical information, promises to place veterinary obstetrics upon a far more scientific basis than it has heretofore enjoyed.

CHAPTER X

THE HYGIENE OF BREEDING ANIMALS

MUCH has been written regarding the hygiene of pregnant animals, but so far as may be determined by the records, the measures advocated have produced no outstanding benefits. In the companion volume upon the diseases of the genital organs, I have taken the definite stand that physiological reproduction is fundamentally dependent upon the mating of two sexually healthy individuals. If this is wanting, the pregnancy will probably be pathological, regardless of any and all hygienic measures applied to the pregnant female. Keller³⁷ draws attention to the fact that limited hydrocephalus becomes a fixed racial characteristic in some breeds of dogs with large cranial cavities and short muzzles. It is a fairly well established law in teratology that, with embryological aberrations of the brain, there is a marked tendency toward club foot, cork-screw tail and arrest in the development of the reproductive system. No hygienic measures applied to the pregnant female can circumvent the inherited weakness of her uterus or obviate the characteristic abnormal head. The breeder has established the necessity for delivery by Cesarean section. Fincher and Williams²³ record observations upon a group of incestuously bred heifers, in which the economic loss was almost total because of sterility, abortion and dystocia. The hygienic measures advocated for pregnant cattle could not undo the genetic error of having bred the dams of the heifers to their sire. Many mares have very definite endometritis, with copious uterine discharge at about 9 days after foaling. The 9th day is generally believed the most favorable date for breeding, but available data indicate that abortion is three or four times as probable from 9th day, than from later conceptions. In the presence of uterine disease, the pregnant mare which fails to abort has a marked tendency toward prolonged gestation, ending frequently in dystocia with a non-viable or weak foal, or, as stated by von Oettingen,⁴³ a foal which when mature will not be an excellent individual. Hygienic measures applied during pregnancy cannot overcome these handicaps.

In a large dairy herd, already mentioned, the proper growing of calves broke down. The mortality was low, but the calves were uniformly unthrifty and their growth was far subnormal until they

reached the age of six months. The reproductive system is the last to be completely established. At the close of the unhealthy six months, ovulation began, with a definitely arrested sexual development. The vulvae, vaginae and uteri were abnormally small. When bred the heifers conceived with difficulty, their gestation was insecure and dystocia highly prevalent. In the terminations of 53 consecutive first pregnancies the records show 17 (32%) of serious dystocia, amongst which were 6 (11%) of recognized dropsy of the amnion and allantois. The vulvae were in all cases too small to permit of physiological birth. Hygienic measures during pregnancy could not have overcome the hypoplasia of the vulva nor the juvenile character of the uterus with low resistance to disease. There were three twin pregnancies (6%). One pair (bulls) was aborted; one pair (bull and neuter) was destroyed because worthless and the dam killed owing to septic metritis. No rules of hygiene applied to the pregnant heifers could have averted the disaster, referable to the pathological discharge of two ova. In the dairy cows the vast majority of abortions, dystocias and retained afterbirths occur in first pregnancy. One of the fundamental reasons for this is that the zoological plan of reproduction, by which the female first produces young when she has reached adult size, is violated, and the burden of reproduction is placed upon the immature heifer. Once the animal is pregnant, no known hygienic measures can overcome the injury.

Reference is made on page 109 to a Guernsey cow, whose after-birth is shown in Fig. 58. No sterility expert could render her fertile, no abortion nostrum could insure her pregnancy, and no hygienic measures during gestation could be of material value. In Figs. 77-79 are illustrated the lesions in two cases of hydrops of the amnion and allantois. In each instance the evidence is clear that the placenta-forming tissues of the uterus had been wrecked in a prior pregnancy. The conclusion is well-nigh inevitable that the disease of the fetus was dependent upon the uterine lesions present before conception and not attributable to any error in handling during pregnancy. Similarly in Fig. 79, the edema of the allantochorion, which was present to an estimated extent of 400 lbs. or over, caused fatal rupture of the uterus. The figure shows beyond challenge that at the close of her first, and only prior pregnancy, destructive changes occurred in her uterus by which all caruncles in one horn were irrevocably destroyed and those remaining in the other horn were damaged. These injuries rendered physiological pregnancy highly improbable.

Modern clinical observations show clearly and indisputably that

the vast majority of disasters of pregnancy are due to pathological conditions which existed at the date of conception. These cannot be eliminated by means of any known form of handling the pregnant female.

The belief that only perfectly healthy animals conceive, and that errors or omissions in the proper care of pregnant animals are responsible for abortion, stillbirth, dystocia, premature birth and such disasters, diverts attention from the fundamental nature of genital diseases and represses logical efforts for advancement towards physiological reproduction.

Even with such limitation, the subject of the hygiene of pregnancy possesses sufficient intrinsic merit to command careful study. Little can be said regarding the hygiene of the pregnant female, which would not be true of the hygiene of the non-pregnant animal. The possible rate of reproduction far excels the demands of the individual and the state. It is therefore important that the best individuals be selected for breeding. Such animals are of special value, and merit greater care in handling, whether non-pregnant or pregnant. The pregnant animal assumes a very definite and important burden beyond that of the non-pregnant individual. This calls for greater care in order to assure equal safety. The rapid growth of the uterus in volume and function, and the need for its even more sudden return after parturition to its former size and activity, imposes a great load upon both the reproductive organs and the female organism as a whole. To meet this demand, the same food, light and air suffice. The fetus requires for its proper growth and development the same nutritive elements that it will need in postnatal life. It is hence essential that the pregnant female be supplied with these in proper quantity and quality. This is amply provided for in the ordinary foods. When these become damaged during growth, preservation or storage, they may become dangerous for pregnant and non-pregnant alike. A few decades ago, great emphasis was placed upon the dangers from egotized forage and grain. Certainly these fungi damage the food, lower its nutritive value and may provide injurious substances. They lower the vitality of the pregnant female, and provide a less favorable nutritive supply to the fetus. In lowering the vitality of the female, the power of resistance to the resident bacteria within the uterus (page 140) is depressed and the micro-organisms may thereby change from harmless, dormant, to dangerous pathogenic organisms.

The added weight and volume of the pregnant uterus and its contents render the animal less agile, and hence more subject to

physical injury. This danger, which is real, has been magnified beyond justification. It has been, and continues to be taught by veterinary obstetrists and other influential writers that mechanical insult (kicks, blows, falls, etc.) frequently lead directly to abortion.

Modern observations deny the power of accidental physical injury to directly cause abortion. I have examined some thousands of pregnant uteri of cows, ewes and swine upon the killing floors of abattoirs, and have failed to discover in a single instance any signs of injury which might conceivably have led to abortion had the animal been permitted to live. These pregnant females had been driven or transported by truck or wagon from the point of origin to the shipping point, loaded none too gently into railway cars, shipped as far as one or two thousand miles, unloaded in stock yards and driven into the abattoir under great excitement and physical stress. Few, if any, pregnant domestic animals escape some type of physical violence. If the violence chances to be observed, and the animal later aborts, the physical accident is held responsible. Mortal injuries to pregnant animals are not rare. Rupture of the gravid uterus, with the fetus and its membranes falling into the peritoneal cavity, is observed by every veterinary obstetrist of experience, but such animals do not abort. Instead, the pregnant animal dies from hemorrhage or from purulent decomposition of the fetus, or the fetus or fetuses become encapsulated to constitute secondary extra-uterine fetuses as illustrated in Fig. 10. Numerous other serious or fatal injuries occur in pregnant females, without abortion being probable or possible. Many pregnant animals are known to have undergone severe physical violence, followed by physiological parturition. The value of such observations is minimized by their comparative isolation. They occur one by one, and in a given instance may constitute an exception. Mass observations are difficult to obtain. On page 137 I have mentioned a group of 17 pure-bred dairy heifers with an unusual record for reproductive efficiency. When they were purchased, 15 were in various stages of pregnancy. They were shipped 3000 miles upon an ordinary freight train, then 2000 miles by boat, and in order to reach their ultimate destination were shipped by a small boat for a normal sail of 14 hours. Caught in a terrific sea, the small boat floundered about for 32 hours, the deck upon which the heifers were located was awash constantly from the tremendous seas. The heifers were thrown about so violently that some of their halters broke. They had neither food nor

water during the 32 hours, and when they finally came ashore they were the most completely exhausted group of cattle I have seen. All calved physiologically.

It has been asserted by eminent writers that physical violence may cause detachment of the fetal from the maternal placenta, but in solipeds, ruminants and swine the placentae, instead of being anatomically attached, are retained in functional contact by means of attractive forces which cease soon after the rupture of the navel cord, when the two placentae fall apart. The allantochorion completely fills the uterine cavity in solipeds and ruminants and completely encircles the swine fetus. The uterus hangs comparatively freely within the abdomen and any force affecting it compels the fetus and its sac to move with the uterus, unless the latter ruptures, after which the animal cannot abort.

By far the most convincing evidence against fundamentally accidental abortion is furnished by the recently inaugurated studies of the pathology of reproduction by means of the examination of the afterbirth following abortion or birth.⁶¹ These researches show beyond cavil that abortion is immediately and directly dependent upon lesions. These lesions are of a character which compels the conclusion that they are dependent upon bacterial or virus injury and not due to trauma. Accidental abortion is an invaluable scapegoat in those abortions where other explanation is inconvenient or out of harmony with highly prized theory. The disadvantage lies in the circumstance that the belief, diverting attention from the fundamental cause, obstructs progress toward physiological reproduction.

It is to be freely admitted that physical violence depresses the constitutional vigor of the pregnant female and correspondingly renders the uterus and ovum vulnerable to bacterial attack. Hence there is ample reason for guarding the pregnant female against physical injury.

The medication of, or surgical operation upon pregnant females is now and then followed closely by abortion. This is in accord with the general principle that such interference lowers the resistance of the patient and aggravates established disease, and may hasten, or render more probable the disaster. The prudent practitioner should safeguard his reputation by advising his client that, in case of intra-uterine disease, the administration of depressing drugs or the performance of severe operations may add to any existing peril to gestation. At the same time the owner should clearly understand that the disease for which medication or surgery is being considered

is in itself a menace to gestation. Hence it becomes a question of choice between two dangers.

Healthy domestic females do not copulate during pregnancy. When the male regularly consorts with healthy females he pays no sexual attention to those which are pregnant. When the male, especially the stallion, is kept apart from the females except when service is desired, he will attempt copulation although the mare is not in estrum or is pregnant. The stallion is then in serious danger, but there is little peril for the mare. She is quite capable of defending herself.

Sometimes mares, more frequently cows, come in estrum during pregnancy and copulate. In the cow, where observation is more accurate because the corpus luteum and mature ovisac is each readily palpable per rectum, I have been able to determine that the corpus luteum of pregnancy had atrophied, and an ovisac had matured in the opposite ovary, with estrum and coitus. This is apparently due to cystic degeneration of the corpus luteum, which thereby loses its restraining power. Generally coitus in such cases is apparently without danger. The real peril lies in the pathological destruction of the corpus luteum, which may induce expulsive contractions of the uterus. The veterinarian regularly resorts, in the cow, to the expression of the corpus luteum to induce abortion, to cause the expulsion of a mummy, and to stimulate uterine contractions in pyometra. The results of such abrupt dislodgement are quite uniform and reliable, but, when the atrophy is gradual, the expulsion of the uterine contents does not regularly occur. In some instances a cow will be discovered in the act of abortion a few hours subsequent to coitus. So far as I can determine, an erroneous conclusion is generally reached and the abortion attributed to the coitus. A careful study of these cases would probably show that utero-fetal disease was present, causing the abortion, the disappearance of the corpus luteum and the ripening of a Graafian follicle. In other words, genital disease caused both abortion and estrum and the coitus was a mere incident in the series of pathological phenomena. On the whole, coitus during pregnancy is pathological, is not common, and so far as many be determined is of little or no significance as a cause of abortion and dystocia.

CHAPTER XI

THE DISEASES OF THE PREGNANT ANIMAL

THE chief pathological phenomena of pregnancy have already been described in the volume upon genital diseases. The burden of reproduction is such that the pregnant female is far less capable of resisting general diseases. Logically, nutritional diseases more readily attack and more seriously affect pregnant, than non-pregnant animals. There is an important coordination between systemic and genital diseases. Systemic diseases tend constantly to intensify existing reproductive pathology, and diseases of the reproductive organs tend to cause or aggravate the diseases of other organs or systems. Thus in a purebred Hereford herd in the northern range country of the United States, the heifers are bred at about 27 months, to calve at 3 years. The ensuing calf crop is eminently satisfactory. Since the forage during portions of the year is deficient, the load carried in first pregnancy is relatively heavy for the nutritive supply. While suckling the first calf, and depressed by the burden borne, the animals are again bred in order to have them calve at four years. Then evidences of trouble appear, running the whole gamut of the pathology of reproduction, with the addition of bone-chewing and emaciation. Whatever the technical cause may be, the phenomena are ameliorated by feeding bone meal or cottonseed meal. In other areas, with yet more defective forage, the bone-chewing or other variety of *pica* occurs in the absence of pregnancy. Hence the conclusion that the defective forage and the pregnancy cooperate in inducing the *pica*. In areas where osteo-malacia is indigenous, pregnancy apparently intensifies it.

There exists an extensive list of diseases observed during pregnancy which are indirectly or directly related to gestation. The increased weight and dimensions of the abdomen, due to pregnancy, lower the agility of the animal and increase the danger of physical injuries. Pregnancy may also lower the tone of the tissues and organs, thereby adding to the peril of traumatic injuries. Fractures and dislocations of the posterior limbs are especially invited. These are observed most frequently in dairy cows, preeminently of course in stanchioned animals. The injuries cannot be wholly and directly attributed to physical violence: the close confinement tends to cause important degeneration of the bones and other tissues inviting

fractures, ruptures and dislocations. The commonest injuries are dislocation of the coxo-femoral articulation and fracture of the femur. The symptoms are essentially the same as in non-pregnant animals, exaggerated by the increased weight, which more certainly causes decubitis. The prognosis is poor to hopeless. The handling, if undertaken, is along the general lines of surgery.

The gravid uterus has no fixed location in the abdominal cavity beyond that dictated by gravity under some control of the uterine ligaments. An instance is mentioned on page 117 in which the equine gravid uterus was displaced in such a manner that it strangulated the large colon and caused death of the mare. The commonest uterine displacement is that of torsion of the uterus, observed in all domestic animals, especially in dairy cows. Torsion has already been discussed in the companion volume and is further considered under dystocia, page 292. Hemorrhages within or about the pregnant uterus are not unknown. Escape of blood from the vulva of the pregnant female is now and then observed, but as a rule the source of the blood is not determined. Perhaps in some cases it is due to pyelonephritis, especially in the cow, where this disease is becoming more readily recognized and is apparently increasing in frequency. The hematic bovine mummy has already been described in *The Diseases of the Genital Organs*. A mare in advanced pregnancy attempted to run across a trestle railroad bridge, fell, and was rescued with difficulty. She was apparently in dystocia a few hours later. I found her pelvic cavity impassably obstructed by blood coagula in the pelvic connective tissue. The mare died from the hemorrhage. I failed to identify accurately the source of the hemorrhage, presumably from rupture of one of the uterine arteries.

Rupture of the gravid uterus is not rare in the dairy cow as a result of uterine torsion, elsewhere discussed. With Dr. Cushing I saw, and have described on page 311, rupture of the uterus caused by extreme edema of the allanto-chorion. Rupture of the uterus sometimes occurs because of an error in diagnosis of pregnancy, followed by attempts at douching of the uterus. Rupture of the gravid uterus is generally, but not always, followed by the death of both mother and young. Sometimes rupture of the uterus in multipara is followed by encystment of an escaped fetus; sometimes the fetus decomposes and sloughs out through the abdominal walls or into the rumen or other hollow organ; sometimes the decomposed fetus becomes encysted.

There is an extensive group of phenomena in domestic animals, characterized by paraplegia, including milk fever, the pregnancy disease of sheep, etc., which are observed late in pregnancy, during labor or early during the puerperal period, which are described later, and may be attributed, with some degree of confidence, to toxaemias of pregnancy. Paralysis or paraplegia is also associated with extensive amnio-allantoic dropsy, edema of the chorion and other pathological conditions of advanced pregnancy. Inability to rise may also occur from starvation of the female in advanced pregnancy.

SECTION III

SECTION III

CHAPTER XII

PHYSIOLOGICAL BIRTH

MANY theories have been advanced, and much speculation indulged in, to explain the physiological forces which cause birth to occur in healthy females after a comparatively uniform duration of pregnancy, but the cause has not yet been discovered. The phenomenon appears to be upon the same plane as the force which causes the fertilized ovum to migrate through the oviduct and become anchored in the uterus. It is known that pathological forces frequently abbreviate or prolong gestation.

The signs of approaching birth consist chiefly of changes in the birth canal preparatory to sufficient extensibility to permit the safe passage of the fetus; increased activity in the mammary glands, preparatory to the adequate nutrition of the new-born; and instinctive provisions by the female for her safety and that of her young during, and immediately after parturition.

The advent of milk secretion, the preparation of a maternity bed and other signs of approaching birth may arise in the absence of pregnancy. The bitch, especially, shows at times what is termed *false pregnancy*. Lactation appears, and the bitch, although non-pregnant, makes a crude bed preparatory to whelping. Sometimes she carries the delusion farther by adopting and suckling young animals of other species. Possibly that is more rarely true of all animals. In one instance, my father detected a half-grown pig sucking a heifer, which was near calving. He caught the pig while it was sucking the heifer in order to confine it, but she charged him, compelling him to release the pig and retreat. I have observed a sterile heifer yield twenty pounds of milk daily, and a mare mule lactate so profusely that her thighs were kept wet. Such deviations from the normal are sometimes definitely associated with recognizable genital disease.

As birth approaches, the sacro-sciatic ligaments relax so that the pelvic canal may dilate to the full size of the bony pelvis. This relaxation is quite marked in the cow and some other species, and is known as *sinking of the broad ligaments*. Physiologically it is a reliable indication of the near approach of birth; pathologically it indicates, in the pregnant cow, threatened abortion, and in the non-

pregnant, cystic disease of the ovaries. The walls of the cervix relax and soften. The mucous glands of the cervix become stimulated to greater function and secrete an abundance of thin, lubricant mucus. The uterine seal of pregnancy becomes dissolved and, with the vaginal secretions, escapes in stringy masses from the vulva. The vulva becomes edematous, the labiae enlarged, soft and yielding. The milk glands regularly become engorged and the milk cisterns distended with colostrum milk. Sometimes in the mare and cow there is an incontinence of milk, large quantities escaping from the teats.

The instinctive preparations for birth by the pregnant female vary with species and degree of domestication. Multiparous animals, in the wild state, tend to prepare a parturition bed where the young may be protected from weather and enemies and the mother may lie down in safety while the young suck. The semi-wild sow builds a mound of coarse grass, weeds or brush. This instinct has been repressed by domestication, and she accepts any available substitute about as she finds it. Uniparous animals prepare no birth bed but seek a locality where they and their young may be more or less hidden from sight and left undisturbed. They produce highly mature young which are capable of standing up within a few minutes after birth and within a day or two can run rapidly.

Physiological birth is divided into three stages: first, the preparatory stage consisting of contractions of the uterine walls and dilation of the cervical canal; second, active expulsive efforts by the uterine walls and abdominal muscles, driving the fetus through the birth canal; and third, the dropping away or expulsion of the fetal membranes. The expulsive contractions of the uterus are exerted both longitudinally and circumferentially. The longitudinal contraction is the more obvious because of the length of the organ and the contained fetus or fetuses. The longitudinal contraction is especially notable in the very long uteri of pluripara. The combined length of the uterine cornua of the sow at term, with ten to sixteen fetuses, exceeds one foot for each fetus contained. When the fetus at the ovarian end of the cornu is to be expelled, its life is largely dependent upon the obliteration of the vacated vaginal area, so that the fetus being born need not traverse too great a distance after its placenta has become detached or navel cord ruptured. This is equally essential in bovine unicornual twins. The firm anchorage of the placenta, the fixation of the amnion within the chorion, and the short navel cord, require that the area vacated by the cervical fetus be largely eliminated in order that the ovarian fetus may be born.

Otherwise the short navel cord ruptures so early that the fetus may not survive the interval pending expulsion.

During the first, or premonitory stages, the uterus contracts sufficiently to push the fetal sac against the cervix, and accelerate the dilation of the canal already initiated by its spontaneous relaxation. During this period there may be some evidences of pain or discomfort expressed by alternately lying down and getting up, by moving about uneasily, pawing (mare), or kicking at the belly. Generally there are no marked expulsive efforts due to contraction of the abdominal walls: the activity is limited almost wholly to the contraction of the uterus. During this stage the length of the uterus is being decreased and the fetus, preceded by portions of the allantochorion and the amnion, is pushed against the cervix or into the cervical canal. Physiologically the allantochorion cannot penetrate far into the cervical canal, because its placental relations immediately about the os uteri internum prevent. Pathologically, the placental relations in the cervical area are frequently abnormal, and the membrane may readily push out through the cervix or even the vulva, as the allantoic waterbag. Usually the allantochorion ruptures during the first stage, and a small volume of allantoic fluid escapes from the vulva. After the rupture of the allantois has occurred, the cervical pole of the amnion, distended with amniotic fluid, enters the cervical canal and aids in its dilation. Since it is less confined in its relations than the allantois, it passes beyond the vulva to constitute the second, or true waterbag.

The physiological arrangement of the fetus in relation to the birth canal is confined within narrow limits; pathologically the fetus approaches or enters the canal in many ways. The tubular form of the uterus, or rather of the cornua, and the elongated fetal body dictates that the long, or cerebro-spinal axis of the fetus shall be parallel with the longitudinal or cervico-ovarian axis of the uterus or cornu. In uniparous domestic animals, the highest safety further limits the arrangement of the fetus so that it shall approach the birth canal by its head end, with the dorsum of the fetus facing the spinal column of the dam, its anterior limbs fully extended and the head resting upon the dorsal side of the feet. It is commonly held that the uniparous fetus may be physiologically born in posterior presentation. Most writers believe, however, that posterior presentation imperils the life of the fetus by asphyxia owing to rupture of the umbilical cord, or the interruption of its blood supply by compression before respiration is possible. Consequently some advise the

application of traction in posterior presentation, which automatically constitutes dystocia.

As already noted on page 119, Schmaltz⁴⁶ states that in unipara at least 95% of fetuses present by the anterior end. It might be assumed that posterior presentations should furnish 5% of dystocias. But Tapken⁵³ records six posterior presentations in 57 dystocias in mares (10%), while in 383 dystocias in the cow, 130 (34%) presented posteriorly. The ratio of dead or non-viable fetuses expelled in posterior presentation is very high. According to my observations this high mortality is not chiefly due to asphyxiation of an otherwise physiological fetus. After the buttocks have passed the vulva the fetus comes away rapidly. On the other hand the posterior presentation bespeaks generally, in unipara, a defective or diseased fetus. As in human obstetrics, so in uniparous domestic animals, a large ratio of fetuses presenting posteriorly are emphysematous prior to the advent of labor. Bovine twins frequently present, one anteriorly, the other posteriorly. Since twin ovulation is itself generally pathological, physiological gestation and birth should not be anticipated. During pregnancy the equine or bovine fetus largely rests with its hind feet extended or folded beneath its abdomen. When presenting anteriorly the hind feet logically become more or less fixed along the uterine floor and are extended backward as the fetal body advances over them. In posterior presentation this is often reversed and retention of the feet (tarsal presentation) or of the entire limbs (breech presentation) ensues to cause serious dystocia.

Multiparous fetuses frequently present posteriorly and are born physiologically, apparently as well as if presenting anteriorly. The limbs, comparatively far shorter and more flexible, become favorably adjusted. Similar considerations apply to the arrangement of the anterior limbs. The equine and bovine fetuses, without clavicles, admit of extensive physiological displacement of the shoulders forward along the sides of the neck, or, pathologically, backwards over the chest, to increase greatly the volume of the thoracic area. The limbs are long and rigid. In multipara the limbs are short and flexible, and in carnivora the shoulders are somewhat fixed upon the anterior thoracical area by clavicles.

After the cervix has become dilated, and the allantochorion or amnion, with the contained fluids has entered it, the uterus is wanting in sufficient power to force the fetus through the birth canal promptly. The abdominal walls are brought into active support. Their muscular contractions press the viscera against the uterus,

supporting the uterine walls and adding essential expulsive power. This constitutes the second stage of labor. The uterus is the directive force and drives the fetus toward and into the cervical canal and vagina. The abdominal pressure, devoid of directive force, raises the intra-abdominal pressure alike in all directions. So in the cow the exalted intra-abdominal pressure frequently forces a foreign body, located within the rumen or reticulum, through a protective fibrous capsule to cause the death of the cow soon after calving, from foreign body peritonitis or pericarditis.

As the fetus is forced along the birth canal, the abdominal contractions grow in energy and reach their greatest force when the fetus reaches the vulva. A healthy fetus, healthy uterus and intact abdominal walls are essential to physiological birth. The uterus is the governing force which, with the proper coordination of a healthy fetus, assures a physiological presentation, position and arrangement of fetal extremities.

The physiological path of the fetus through the birth canal is in an almost straight line from side to side, instead of the spiral course of the fetal head through the human pelvis. Since the gross size of the rumen deflects the pregnant ruminant uterus somewhat to the right, the fetus needs bend slightly to the left as it enters the pelvis. The great colon of solipeds deflects the gravid uterus very slightly to the left, and this needs be overcome in the pelvis. In all unipara, since the ovarian end of the uterus occupies a lower level than the vaginal extremity, the fetus needs be lifted to a higher level if the pregnant animal assumes the standing position; if she lies down, as is largely the case, the obstacle disappears. The ischial tuberosities of the cow are so prominent and near together that the fetus must be lifted over them.

As expulsion progresses, those portions of the fetus which have passed the vulva curve downwards, and the curvature increases as the propulsion continues. This curvature, with arching of the fetal back, stretches the dorso-pelvic muscles and correspondingly relaxes the linea alba and the muscles passing from the pubis to the ensiform cartilage of the sternum. This relaxation of the ventral line of the fetal body causes its pelvis to become extended backward upon the fetal sacrum and thus decrease greatly the sacro-pubic diameter. When persons erroneously apply traction to a fetus in a straight line, or upward, they not infrequently force the fetal pubis into the maternal pelvis ere the tuberosity of the fetal ilium has passed the sacral prominence of the dam, causing dystocia of a formidable type

through the interlocking of the fetal and maternal pelvises. Such interlocking rarely occurs in the mare or cow when the course of parturition is not interrupted by attendants, but is not at all rare when imprudent traction is applied along the wrong line.

The duration of time required for the expulsion of the fetus varies with species and individuals. The actual duration of time has not been accurately determined and the estimates submitted by authors vary widely. The difficulty lies in the failure to determine the line of demarcation between physiological and pathological birth. The second stage, during which the fetus is forced through the birth canal, commonly requires fifteen to thirty minutes in the healthy mare.

The observations upon the duration of the birth act in cattle have been largely or wholly confined to dairy cows. Not only is the birth act more frequently pathological in dairy, than in beef cattle, but pathological reproduction upon the whole is far more common and serious in dairy cows than in any other group of domestic animals. In a badly diseased herd of purebred cows comprising representatives of four breeds, I studied in detail the duration of labor in 20 females. The preparatory, or first stage of labor, combined with the expulsion of the fetus, or second stage, averaged for the 20 animals, 3.2 hours with a minimum of 20 minutes and a maximum of 35 hours. The animals were under close observation and no interference made unless urgent. The third stage of birth, the expulsion of the placenta, required an average of 14 hours, with a minimum of 1.2 and a maximum of 43.4 hours. There were 30 females in the group under observation, which included 14 primipara. Of the primipara, 7 (50%) aborted, while among the pluripara, 1 (6.2%), a heifer in second pregnancy, aborted. This was the prevailing abortion rate for primipara for a number of years. One of the remaining seven calved unseen at pasture. The average duration of the first and second stages of the six remaining primiparous births was 1.4 hours, with a minimum of 0.5, and a maximum of 3.0 hours. The third stage of birth, the expulsion of the fetal membranes, required an average of 9.4 hours with a minimum of 1.2, and a maximum of 23.5 hours. The average duration of gestation, with viable calves, was 277.6 days, with an average of 276 days for the primipara. The greatest duration of pregnancy in the primipara was 288 days, a heifer calf. The three stages of birth occupied in her case 3.0 hours, the second shortest time in the entire group. The briefest gestation in the primipara was 270 days, a bull calf, and the total birth act occupied 26.5

hours, the longest among the primipara. Schmaltz,⁴⁶ citing Rinehart, makes the duration of first and second stages of labor as much as 6 hours, with an average of 3.5 hours. Stoss⁵¹ gives a similar duration.

The duration of the birth act evidently depends upon the sexual health of the individual and is subject to wide modification when traction is applied to the fetus in atonic (pathological) labor. The duration of the third stage, the expulsion of the afterbirth, may be greatly modified artificially by medication and surgery.

Hence physiological birth in the cow may be of almost any duration, according to the viewpoint of the observer. I have defined physiological birth in the cow⁷⁰ as follows:

1. Pregnancy shall follow a single service.
2. The duration of pregnancy is 285 days with a variant of five days above or below that figure.
3. The fetus is expelled, without human aid, within one hour after the commencement of labor.
4. The afterbirth drops away within one hour after the birth of the calf.
5. No recognizable discharge occurs from the genital organs, beyond a small amount of blood and lymph, for 2 or 3 hours following the dropping away of the afterbirth.
6. The calf, when expelled, shall be clean and free from stains or indication of diarrhea before birth. It shall be lively, active and on its feet without aid within an hour. It shall not break down within 48 hours from diarrhea or other disease referable to infection within the uterus.
7. The afterbirth shall be free from important evidences of disease.

If such standard be applied to dairy cattle, physiological parturition becomes exceptional. Stoss⁵¹ states that the first, or preliminary stage in the goat may be as much as a day while the second or expulsive stage occupies 0.5 to 2.0 hours. The birth act in sheep is more rapid.

Stoss assigns for the first stage in the sow 2-6 hours, and for the second stage, for the entire number of fetuses, an equal period, or a total for first and second stages of 4-12 hours. Similar estimates are given for the bitch and cat. On the whole the birth act apparently requires a greater duration of time in multipara than in unipara. The very long uterine cornua and birth canal tend to prolong the first stage, during which the first fetus is driven through a relatively great distance before it enters the vagina and pelvis. The birth act is further prolonged by the number of fetuses. After the first fetus has been born, the others follow, physiologically, at intervals of 10 to 30 minutes.

The soliped fetus may be expelled partly covered by the amnion, but the membrane is so thin and frail that complete enclosure of the fetus within it is highly improbable. The ruminant fetus is expelled

free of its amnion, because of its firm attachment to the allanto-chorion. The swine fetus is said to be sometimes expelled surrounded by its amnion.

The long navel cord of solipeds permits the young generally to be born with the cord intact. It is usually broken when the mare gets up and turns to care for the foal. Otherwise it is not long until the foal, if vigorous, gets upon its feet and in its struggles, often with falls, breaks the cord. The navel cord of ruminants is so short that it usually breaks as the fetus is expelled from the vulva. Swine and carnivora sever the cords of their young with their teeth. Whatever the details of the method of division of the cord, the highly elastic and resistant umbilical arteries are severed by laceration, overstretching or linear tension. Freed from their distal fixation in the allantochorion, they immediately retract. The urachus, lying between the two arteries and quite adherent to them, is retracted with them and the three vessels come to rest inside the abdomen, posterior to the umbilical ring. The vestiges of the fibrous sheath of the umbilical arteries and the urachus persist, to constitute the anterior ligament of the bladder.

The exact point at which the arteries and urachus naturally become severed is unknown, because the great elasticity of the arteries causes the broken ends immediately to leave the locality where broken. While the sheath of the navel cord, and the umbilical vein may be broken at some distance from the umbilicus, the fact that the severed ends of the urachus and arteries come to rest at an approximately uniform location, within the abdomen, suggests that the point of division is quite uniform. Hemorrhage from the fetal ends of the ruptured umbilical arteries is doubly controlled. The facts are best observed in the foal, with the long navel cord which does not ordinarily rupture immediately. As soon as the foal breathes the pulsation in the navel arteries at once diminishes and soon ceases: intrinsic forces have made provision against possible hemorrhage before the impending rupture has occurred. After rupture has occurred, further security against hemorrhage is provided by the retraction of the broken ends into the abdomen. The act of retraction thickens the walls of the vessels and decreases their lumen. The laceration of the arterial coats at the point of rupture, with the retraction of the surrounding fibrous tissues, further limits hemorrhage. Hence physiologically only mere traces of escaped arterial blood are present about the intra-abdominal broken ends of the navel arteries. When the arteries become divided before the young

animal has breathed, there may be a few jets of blood forced out. The navel vein is not retractile, is firmly fixed in the umbilicus, and has only rudimentary, if any valves. The blood within the vein, at the moment of rupture, drops away immediately, and the vessel collapses. Except for cardiac defects, no important hemorrhage follows the division of the navel cord.

The rupture of the navel cord constitutes a physiological lesion with highly efficient, though not perfect, provisions against infection. The retraction of the arteries and urachus guards them against direct bacterial invasion. The residual blood in the vein escapes immediately and the venous walls fall together. The liquids of the Whartonian gelatin and other tissues of the cord escape through the broken end. The removal of the liquid from the navel stump is further assured by the mother's licking or compressing the stump between her lips. Under favorable conditions, the amniotic sheath of the cord, with the enclosed venous stump and other tissues, promptly desiccates, and thereby imprisons and renders harmless any bacteria which may have invaded the tissues. The navel heals under the desiccated scab.

The placenta or afterbirth ordinarily drops away in the various species of domestic animals, within 30 minutes after the expulsion of the fetus. A notable exception is claimed for the cow. The claim is based, so far as may be determined from observations upon the dairy cow, not upon the domestic cow as a genus. If the discharge of the placenta in animals other than the dairy cow be accepted as a basis for determining the physiological duration of the third period of labor, then the expulsion of the fetal membranes of the dairy cow is generally pathological. Accordingly there is a wide variation of opinion amongst veterinary obstetrists regarding the line of demarcation between physiological and pathological placental expulsion in dairy cows. No definite records are available to show that beef cows do not physiologically conform to the general rule for all species and expel the membranes within 30 minutes. My personal observations upon range beef cattle have been extensive in volume but very casual in character. My impression is that physiologically the afterbirth is expelled within about 30 minutes. Occasionally a very healthy dairy cow expels the placenta within 30 minutes, most of them go 1 to 3 hours, and some 15 or 16 days. Between the minimum lapse of time, which is not always physiological, and the maximum duration of retention, which is indisputably pathological, there is every gradation.

The forces which cause the expulsion of the placenta, and accelerate or delay the process, are not definitely known. It is observed clinically that, the healthier the female, as a rule, the more prompt the discharge of the membranes. There are two distinct elements in placental expulsion which are not kept separate in discussions. The first and most important is placental dehiscence or separation of the placenta from the uterus, and the second, or minor phase, is its expulsion from the genital tract. It is commonly stated that the dehiscence is caused by the contractions of the uterine walls. Physiologically the uterine walls contract and the placenta becomes separated from the uterus, but the simultaneous occurrence of the two phenomena does not prove that the one is the result of the other, instead of both phenomena being due to a common cause. The healthy pregnant uterus is constantly in a state of contraction, and in the cow the fetal and maternal placentae are held in intimate contact. If the cow is killed in early gestation, there is immediate and simultaneous relaxation of the uterus and detachment of the placentae, but it would not be safe to say that the uterine relaxation caused the placental separation. That would be directly antagonistic to the other view that contraction causes dehiscence. No muscular tissues have been recorded in the caruncles of ruminants or in the cotyledonal or placental tissues elaborated upon their summits during pregnancy; consequently, uterine contractions cannot act to express the chorionic tufts or villi of ruminants from the cotyledonal crypts set upon the pedunculated caruncles. Clinically, in very bad retained placentae, the uterus is often in a state of excessive contraction. And in the mare I have observed the prompt expulsion of the fresh placenta, amnion and all the membranes while the naked, full-term fetus remained in the uterus. Under these conditions the dehiscence of the fetal placenta could not be attributed to a marked diminution in the size of the uterus. Herbivorous domestic animals and swine have non-deciduate placentae which acquire no anatomical anchorage within the endometrium, but the fetal and maternal placental structures are held in intimate contact through the agency of a highly efficient attractive force. The phenomenon, especially as observed in the adeciduate solipeds and ruminants, might well be designated animal magnetism. While the mother and fetus live, the contact is secure, but when the fetus is expelled and the navel cord ruptures, the work of the placenta has been completed, the attraction ceases and placental dehiscence follows. Or if the fetus dies in the uterus, as in the mare mentioned, the attraction ceases,

the dehiscence of the placenta follows and it may become expelled in advance of the fetal cadaver.

Domestic animals commonly devour their placentae if physiologically expelled. The mare constitutes the only important exception to this rule. Stoss⁵¹ states that she only rarely consumes her afterbirth. I have observed no attempt upon her part to do so. If the cow retains her membranes for several days until badly decomposed, she does not eat them, according to my observation. Multipara not only eat the membranes but commonly also consume any fetal cadavers expelled. Occasionally a sow kills her live pigs and eats them. Very rarely the goat and ewe have been observed to eat their young. Various theories have been evolved to account for the eating of the afterbirth. The act is not known to be beneficial in any way. It is rarely harmful, though in some instances it apparently causes indigestion. Whether the indigestion followed the eating of a healthy or a diseased afterbirth is not recorded. It would appear more logical for the diseased membrane to do harm. The late Professor Law related to me his unusual observation of having been called to attend a cow which began swallowing the protruding portion of her afterbirth, got it impacted in her oesophagus, and failed either to break off the protruding portion or to withdraw the retained portion from the uterus. It is commonly assumed that the cow eats the afterbirth only after it has wholly come away, but that is not at all true. She frequently grasps the protruding portion and causes it to break, either at the cervix or at the allantoic navel, between the two allantoic arteries. She then swallows the detached mass, leaving the ovarian half of the gravid allanto chorion hidden in the uterus. This may mislead the attendant by causing him to believe that the entire membrane has come away.

CHAPTER XIII

ARTIFICIAL INTERFERENCES IN PHYSIOLOGICAL PARTURITION

THE logical conclusion to be drawn from the preceding description of physiological birth is that interferences by attendants are unnecessary and ill advised. Under ideal natural environment, such conclusion is emphatically correct. The female at the beginning of labor seeks seclusion for the express purpose of avoiding annoyance from individuals of her own or other species. The healthy female, given natural environment, is quite competent to give birth to her young and to look after its welfare immediately after the birth. Often she violently resents the approach of man during labor or immediately afterwards. A neighbor, of unusual physical strength, approached a sow which had recently farrowed. She angrily charged him. With difficulty he managed to place a bag, which he fortunately carried, over the sow's head and then hurriedly retreated over a fence. Another neighbor, wishing to move a mare and her new-born foal, picked up the latter and started to carry it. The mare, kicking at him violently with both hind feet, hit the foal on the head and killed it in his arms. In other cases the disturbed mother treads upon her young and injures or kills it.

Under domestication the environment is such that it may interfere in various degrees with normal labor and care of the young. Dairy cattle are so managed that in temperate climates a large proportion of calves are born in the stable, which is inevitably inimical to physiological birth. At other times the female is confined in a barnyard, sty or other polluted enclosure. When the mare or cow is placed in a box stall, the enclosure is usually inadequate, the female lies down too near the wall and the fetus is jammed against the side during its expulsion. When birth occurs in the stable, barnyard or sty, the freshly ruptured navel cord is dangerously exposed to perilous infection which may lead to omphalophlebitis and the death of the young. These, and innumerable other factors serve to endanger successful birth, and suggest or demand watchfulness by the animal husbandman. Breeding females of exceptional value justify close observation at the time of expected labor, to the end that pathological conditions may be discovered early and available interference employed. This is especially important in highly valuable mares, in which parturition is stormy and obstacles to birth need be overcome promptly.

There is often a tendency upon the part of the attendant to apply traction to the fetus as soon as it appears at the vulva in a supposedly physiological birth. This is unjustifiable. An examination may be in order to determine whether the position and posture of the fetus are physiological; if pathological, corrective measures should be employed, but this is dystocia, not physiological birth.

Asdell and Willman³ advocate the administration of pituitary extracts to farrowing sows in order to prevent asphyxiation of the fetuses during expulsion from the birth canal. They report that in the Cornell University herd there was a ratio of 6.6% of fetuses born dead, which was reduced to 3.5% after the administration of pituitrin following the expulsion of the first fetus. If the size of the litter be placed at 10 pigs, the loss in each litter when undisturbed was 0.66 and after the use of the pituitrin 0.35, an apparent gain of 0.31 or a trifle less than one pig gained for each three litters. The cost of watching the sows and being prepared to give the pituitrin when the first pig is expelled, the cost of the remedy and its administration, etc., is not stated. The sows are not identified: presumably the sows to which no pituitrin was given were not the same as those treated. It is not stated that the same or equivalent boars were used or that the sows were bred, fed and handled the same in both groups except for the pituitrin.

The tremendous force exerted by the foaling mare dilates her birth canal with the maximum rapidity consistent with safety. It is urged by some writers that without application of traction the placenta may become detached and the fetus die. I have seen the entire afterbirth come away and the naked foal retained in the uterus, but the posture of the fetus was pathological and the case had nothing to do with physiological parturition. Traction not only hastens unduly the dilation of the cervix, vagina and vulva, but also constantly tends to pull these structures backwards (caudally) and to cause transverse folding of the cervical and vaginal walls. This process lessens the lumen of the birth canal and invites laceration. But the most immediate danger from traction is laceration of the superior vulvar commissure. This commonly follows traction in what would otherwise be physiological birth in the mare. On the other hand, in an experience exceeding 60 years, I do not recall vulvar or perineal laceration in physiological birth in a domestic animal, when not tampered with by attendants.

There is a deeply entrenched tradition that when the waterbag, either allantoic or amniotic, protrudes beyond the vulva it should

be ruptured. But range mares and cows, where no interference is practicable, get on very well without the artificial rupture of waterbags. I have not observed any harm from either leaving the waterbags alone or rupturing them. In amnio-allantoic dropsy I have been compelled to rupture the allantochorion in the cow before it had entered the cervix. It was so tough and so immense that the atonic uterus could not rupture the membrane. That again is dystocia.

When the birth act has been completed, if the animal is confined in a stall, due care should be taken for the safety of mother and young. Nervous mares, especially primiparous thoroughbreds, may become frightened from the dangling afterbirth and kick and buck violently, with peril to attendants and the foal. A halter should be applied to the mare before she gets up, and care taken to control her for a few minutes. The mother should be left free to care for her young and the stall or other enclosure should be well cleaned.

In proper environment the mother gives ample and efficient attention to the young, and the physiological young in turn is capable of finding the teat, with such aid as the mother gives, and proceeds promptly to suck. The young of unipara take the milk alike from all teats. The pig adopts a certain teat and gets its nourishment permanently from the one mammary gland. Any mammae in excess of the number of fetuses promptly atrophy, so that in the sow one may authentically determine the number of pigs by counting the functioning glands. If there is but one living pig, only one mammary gland is functional. The stronger pigs select the larger, most active glands and if the litter is large, dwarfed pigs are compelled to accept the smaller posterior glands.

Under natural environment the ruptured umbilical cord of domestic animals requires no attention from the husbandman: the healthy female is amply able to look after all the details. When the dam or fetus is diseased, or the birth occurs in polluted surroundings, care of the navel may become desirable or imperative. In one instance where tuberculosis was being fought by segregation, a cow calved unseen, and licked the navel stump of the calf. Umbilical tuberculosis followed, probably from the licking by the tuberculous mother, although the infection may have been prenatal. When young are born in the stable, barnyard or sty, important protection to them may be exerted by proper care of the navel. The tying of the navel cord should be avoided. If tied prior to the rupture of the cord, before the umbilical artery stumps have retracted, they may possibly be incarcerated and detained outside the abdomen and some blood may

be confined within them. Ligation of the navel imprisons any blood remaining in the umbilical vein and invites its decomposition.

When possible, the division of the navel cord should be permitted to occur normally, by linear tension in herbivora and by laceration by biting in carnivora. When artificial division becomes desirable or necessary it should be accomplished by ecrasement, tension or scraping under aseptic precautions. Whenever infection is threatened, disinfection should be applied. This may be done in a variety of ways. A sufficient quantity of 1:1000 alcoholic solution of corrosive sublimate may be placed in a small glass or cup and pressed against the abdominal floor in a manner to submerge the navel stump. The application may be continued for 5 to 10 minutes. After the alcohol has been allowed to evaporate, the desiccation should be hastened by the application of a drying powder, such as powdered alum, tannic acid, zinc oxide or other drugs, to which iodoform may be added. It is to be remembered that navel ill is sometimes congenital, as already stated in the companion volume, in which case the post-natal disinfection can not act successfully, although it may be of some benefit.



SECTION IV



SECTION IV

CHAPTER XIV

DYSTOCIA

DYSTOCIA, or difficult labor, constitutes one of the most important pathological phenomena among the diseases interfering with reproduction. As the incidence of sterility and abortion increases, the frequency and severity of dystocia advances among pregnant females which are not in perfect health and carry their young near, or quite to term. Dystocia is even more probable when gestation is prolonged beyond the physiological duration; it is sometimes referable to giantism, along with which is commonly associated uterine and fetal disease.

No clear line of demarcation can be drawn between physiological birth and dystocia because they pass into each other by imperceptible gradations. Largely dystocia is deemed present when the personnel in attendance concludes that interference is necessary or advisable in behalf of the pregnant female or her young.

When describing physiological birth on page 155 it was noted that the act was divisible into three stages: the premonitory, during which the cervical canal is dilated by contraction of the uterine walls, the second stage during which the fetus is propelled through the birth canal by the combined power of uterine and abdominal walls, and the third, the dropping away or expulsion of the fetal membranes. Dystocia may occur in either of the two first stages. The incidence of dystocia in domestic animals has not been extensively determined for the various groups. Von Oettingen⁴³ records that in the mares at the Trakehnen stud amongst 3388 births there were 38 (1.1%) of dystocias. This included only those cases in which von Oettingen considered it necessary or desirable to call a veterinarian. Apparently the computation was based upon the difficulties of the second stage of labor and did not include retained afterbirth. Schmaltz⁴⁶ cites Stüeven as having found, amongst 450,000 births in cows, 15,000 cases of dystocia (3.3%). The basis of computation is not revealed. Tapken, cited by Harms³² states that, among domestic animals, the ewe suffers least from dystocia.

The value of recorded observations concerning the incidence of dystocia is seriously disturbed by the failure of most writers to

state fully the character of the group of animals studied. Thus while I was engaged in the study of a herd of dairy cattle, in which I encountered well marked dystocia in more than 40% of the primipara, my attention was called to one instance of dystocia among 5000 calvings in a commercial herd of Herefords on the same estate. Presumably more dystocias occurred in the beef herd, but I did not see or hear of them. In some breeds of dogs, with short faces and limited hydrocephalus, and kept in relatively close confinement, dystocia prevails, but the ordinary street mongrel whelps readily. Writers upon the incidence of pathology in the reproduction of domestic animals usually concern themselves with the phenomena of sterility and abortion and remain silent regarding dystocia. The chief volume of available data upon the pathology of reproduction consists of the published reports of investigators who are engaged in studying Bang's bacillus. These investigators have published observations upon many thousands of cattle. The results are generally classified as aborted, died, sold or calved normally. Dystocia is apparently not thought worthy of record.

The causes of dystocia may be profitably divided into two groups—the basic or fundamental, and the exciting or immediate. The basic causes have their origin at an early date, not infrequently determined by defects in the spermatozoon or ovum, which unite to form the embryo, or by defects in the oviducts, uterus, vagina, vulva or pelvis which foreordain dystocia in the event of pregnancy. So far as these basic causes are known and recognized, dystocia may be circumvented by proper measures, or the breeder and veterinarian are enabled to know in advance that dystocia is highly probable or unavoidable and preparations may be made in advance for meeting the impending peril with the greatest possible safety for the mother or fetus or both. Thus the genital hypoplasia of young animals, described on page 177, inevitably leads to many cases of highly destructive dystocia which cannot be readily overcome: the hypoplasia may be avoided by prudent care of the young, and the dystocia avoided. Or turning to the dystocia of bicornual pregnancy in the mare, described on page 189, such dystocia as that illustrated in Figs. 90, 91 may be authentically foretold by rectal palpation in advanced pregnancy, and cesarean section performed prior to the onset of birth, with possible rescue of the mare, the foal or both. When labor comes on, the lives of both mare and foal are commonly doomed.

Intelligent prevention or control of this group of dystocias offers

the greatest field for advancement in veterinary obstetrics—a field which as yet has attracted no material interest.

The immediate or exciting causes of dystocia largely consist of barriers to the expulsion of the fetus which have grown out of, or developed from the basic causes. Thus in dystocia attributable to genital hypoplasia (page 177) the narrow birth canal does not constitute the sole barrier to birth. Owing to the intrinsic weakness of both mother and young, the latter is liable to present to the pelvic inlet by its tail end, with undue peril to birth because of the great probability that the posterior limbs will be misplaced and bar expulsion of the fetus. If it offers at the pelvic inlet by its head end, the anterior feet, legs and head are prone to be displaced variously and cause serious dystocia aside from the narrowness of the birth canal. Accordingly the one problem remaining before the obstetrict is the salvaging, in so far as practicable, of the values of the pregnant female and her young.

CHAPTER XV

THE BASIC CAUSES OF DYSTOCIA

VETERINARY obstetrists of the past have generally regarded dystocia as the result of some whim of chance and have largely restricted their efforts to attempts to salvage the mother or her intrauterine young after the dystocia had become established and recognized. It is becoming increasingly clear that difficult birth is largely due to errors in animal husbandry and that the problem demands thoughtful and extensive study by the breeder and his veterinarian. Without neglecting the measures for overcoming established dystocia, its anticipation and prevention need be accorded the chief attention. This is to be reached through careful study of the fundamental causes. The knowledge of the etiology of dystocia is at present extremely primitive and fragmentary. Some of the more obvious causes merit discussion.

Dystocia Due to Teratological Causes

TERATOLOGICAL DISPLACEMENT OF THE GENITALIA

The inguinal canal of the sow, bitch, ewe, and possibly of other species, sometimes remains open and the ovary passes out through it in a manner parallel to the physiological descent of the testicle, accompanied by the oviduct and the apex of the uterine cornu. If the animal becomes pregnant, one or more fetuses may be located in the inguinal canal and demand cesarean section for relief. Apparently the same defect occurs very rarely in woman.

TERATOLOGICAL HYPOPLASIA OF THE FEMALE GENITALIA

Embryonic arrest in the development of the reproductive system not infrequently occurs to such an extent that pregnancy may ensue but physiological birth be impossible, or, if fetal death occur during the latter half of gestation, the fetal cadaver can not be expelled without surgical aid.

Fincher and Williams²³ record in detail the results of incestuous breeding in a dairy herd. The herd sire and all the foundation females were, so far as known, genitally healthy, and all progeny from mating them were reproductively healthy so far as known. The heifers were all bred to their sire. Among 23 heifers produced by this in-

cestuous breeding, 14 (56.5%) were virtually or technically sterile owing to arrested development of the Muellerian ducts, and two additional females showed important anatomical defects though technically fertile. Thus 16 (69%) of the incestuously bred heifers were genitally defective. As a group, sterility, abortion and dystocia prevailed.

Aberrant genital organs occur in all animals but are most commonly observed in dairy cows. Numerous cows, with one-horned uteri, with double uteri or with remnants in the vagina of the median walls of the Muellerian ducts, breed, but they tend strongly to transmit their defects, and to invite sterility, abortion and dystocia. Individuals are not usually traceable to incestuous breeding; largely their histories are unknown.

Geneticists and breeders claim that incestuous breeding is often valuable and that, if closely related individuals are sexually normal, the process is safe. So far as determinable, the bull and the cows of the above herd were sexually healthy. Just when incestuous breeding is safe and advisable, is not easy to state.

Isolated cases are frequently observed in dairy cows in which the median walls of the Muellerian ducts persist at the vaginal end of the cervix as a perpendicular median muscular column.

The immediate cause of the dystocia in such cases is referable to the female, but as shown by Fincher and Williams,²³ the male is equally responsible; in other words, the teratologically defective male may cause dystocia to occur in his female progeny.

Lagerlöf records that in certain families of Swedish cattle the calves of both sexes are largely born with genital hypoplasia, inevitably associated with low fertility. When a male is of low fertility, the ratio of dystocia in his pregnancies is regularly high.

Genital Hypoplasia in Young Animals

The reproductive system is the last group of organs to be laid down in the embryo and the most primitive system at the date of birth. If the fetus suffers from disease or malnutrition, as indicated by abbreviated or prolonged gestation or by other pathological phenomena, the physiological development of the reproductive organs of the new-born is repressed and the defective development may lead to dystocia when the female young reaches breeding age.

A far more obvious arrest in the development of the reproductive system occurs because of malnutrition of the young during the interval between birth and the advent of ovulation and spermatogene-

sis. The duration of this period has been greatly abbreviated by breeding, feeding and handling. This is especially marked in the dairy cow, in which the date of the advent of ovulation has been advanced from about two years to approximately six months. Concurrently, by shifting from natural nursing to artificial feeding, and largely to artificial foods, the nutrition and the health of the calf is importantly depressed. Under such conditions the maintenance of physical life and growth takes precedence over the development of the reproductive system and genital hypoplasia naturally follows, with defective ovulation and spermatogenesis. The outstanding phenomenon following this arrest in development in the female, as expressed by dystocia, is the defective growth of the birth canal, the vagina and vulva remaining juvenile, and too narrow to permit the physiological expulsion of the fetus through it, as already discussed in the companion volume upon the diseases of the genital organs.

This type of dystocia is highly prevalent in some herds of dairy cattle and is common in individuals in many herds. The dystocia is commonly attributed by veterinary obstetrists to a *relatively too large fetus*, thus obscuring the fundamental cause, the erroneous method of growing the calf.

Due primarily to malnutrition as a young calf, every organ of the reproductive system is inevitably involved. The hypoplastic ovaries ovulate erratically, the ova are defective in vigor and largely perish, abortion in first pregnancy is prevalent and dystocia is common. The dystocia is not wholly due to the narrow birth canal, but is the sum total of a weak ovum from which an atonic embryo develops, and the uterus is feeble, participating with the birth canal in causing the dystocia.

Arrested Development of the Female Reproductive System During First Pregnancy

A third highly important developmental period of the female reproductive system extends from the beginning to the close of the first pregnancy. The health of the mother during these three periods, not only fixes the character of the first birth, but, as I have tried to show in the diseases of the genital organs, fixes for life the maximum reproductive efficiency of the individual. As soon as the first pregnancy becomes established, the reproductive system begins the most rapid and important developments known in animal life. The uterus needs undergo phenomenally rapid growth, with its vascular supply increased manifold for the nutrition of the rapidly growing fetus.

The uterus must acquire greatly increased contractile power in order that it may be able promptly to expel the fetus when the moment for birth arrives. The dilatibility of the cervix, vagina and vulva needs also be vastly increased to permit the ready passage of the fetus. When the female is bred at too early an age, the concurrent demands for her physical life and growth repress the required development of the reproductive system. Dystocia, abortion and retained afterbirth are most common in dairy heifers, which are usually bred when comparatively less mature than are beef heifers or other primipara.

Dystocia from too Early Postpartum Breeding

Dystocia is invited by the breeder when he rebreeds a female too early after the termination of a pregnancy. Evidence has been submitted in the companion volume indicating that ovulation in dairy cows is highly erratic during sixty or more days postpartum and that conception at such early period is unsafe and threatens dystocia. Early rebreeding also favors twin pregnancy, in which the ratio of dystocia is notably high.

The Dystocia of Hybridization

When an American bison bull is mated with a domestic cow, dystocia commonly follows. Boyd¹⁰ attributes this to the very large withers of the hybrid fetus. It is admitted, however, that extreme amnio-allantoic dropsy is regularly present, and equally admitted that such excess of fetal fluids uniformly causes serious dystocia. I have observed a few cases of this kind, where the dystocia was clearly due to the excess of fetal fluids.

Dystocia Due to Bulldog Calves

According to Crewe, when Dexter cows are mated with Dexter bulls the type of monster designated as bulldog calf follows in so great a ratio that the breeding of Dexter cattle becomes an economic failure, whereas if Dexter be mated with Kerry, typical Dexters are produced, not accompanied by dystocia. The dystocia associated with bulldog calves is due primarily to an excess of fetal fluids. The monster is regularly non-viable and the inertia of the fetus contributes largely to the dystocia because of the abnormal positions of the extremities.

The Dexter cattle are very, if not abnormally, compact. They are believed to have been developed largely from the Kerry breed, prob-

ably with some infusion of Devon. As in the establishment of new breeds, generally, there may have been inbreeding with a view to establishing the type. Carmichael reports analogous prevalence of bulldog calves and dystocia in Nganda cattle, a breed due to crossing the short-horned Zebu with the long-horned Eastern Province cattle.

Adametz and Schultze record the general prevalence of dystocia in Tux-Zillertaler cattle in the Austrian Tyrol, associated with an excessive quantity of fetal fluids. The breed was abnormally compact and had originated, it was said, by the crossing of shorthorn and longhorn breeds. The breed was changed, and the dystocia ceased.

Dystocia Due to Muscle Contracture Monsters

A disastrous prevalence of dystocia in cows and ewes has been frequently recorded due to a monstrosity usually designated as *muscle contracture*, and sometimes known as *anchylosis*. Individual cases now and then occur which are not authentically referable to a definite cause. The occurrence of the monster in important numbers, so far as records show, is associated with incestuous breeding. The cranial motor nerves and the muscles supplied by them develop normally; the spinal motor nerves apparently do not develop and the muscles supplied by them are functionally arrested, pale and inelastic. They do not *contract*, as the designation would imply, are of normal length, but extremely subnormal in volume, pale in color and rigid. The designation *anchylosis* is equally inept. The bones are approximately normal in length, but the articulations are not formed; the spinal column consists of a single bone and the articulations of the limbs are largely absent, without evidence that they had ever been formed. The severe dystocia is due to the rigidity of the fetal skeleton owing to the absence of articulations, and to the presence of an excessive volume of fetal fluids.

Dystocia Commonly Associated with an Excessive Volume of Fetal Fluids

In the several foregoing paragraphs the dystocia is largely attributed to the presence of an abnormal volume of the amniotic and allantoic fluids. The excess of fluids is largely associated with other fetal defects sufficient in themselves to cause dystocia.

All domestic mammals have both amniotic and allantoic sacs, and the fluids within either or both of them may be excessive or subnormal in quantity and pathological in quality. The allantoic sac, especially of ruminants, is vastly more extensive than the amnion,

particularly in the earlier stages of pregnancy, as indicated in Colored Plate II. Later in pregnancy the amniotic fluid becomes comparatively increased. Excessive volume of the fetal fluid in domestic animals appears to be far most frequent and gross in the allantoic sac. This may be due in part to the fact that when the fetal body is anatomically and physiologically approximately normal, the fetus regularly swallows its amniotic fluid, the water is resorbed when it reaches the large intestine, returned to the fetal blood stream and thence to the placenta. This evident tendency to obviate abnormal accumulations of fluid within the amnion may be variously thwarted. Thus I have elsewhere described⁷⁵ a case of bovine *Schistocormus reflexus* in which the reflexion was so extreme that the virtually closed cutaneous sac was distended with an estimated ten gallons of fluid, requiring incision of the sac to permit the contents to escape in order to overcome the dystocia. In a second case of *Schistocormus reflexus*, the fetus had swallowed its amniotic fluid, which had accumulated in its stomachs, distending them to approximately ten gallons and necessitating incision in order to overcome the dystocia. The intestines were not available for study. Perhaps there was atresia of the small intestine, preventing the fluid from reaching the colon, where it would probably be absorbed. This thought is supported by the contribution of Jöhnke cited by Harms³² who observed in three cases of bovine dystocia symptoms of ascites of the fetus necessitating abdominal incision for the overcoming of the dystocia. Autopsies of the three fetuses revealed in each complete atresia of the small intestine near the junction of the duodenum and jejunum, thus preventing the fluid from passing into the large intestine.

Accordingly the amniotic fluid may accumulate in sufficient volume in at least three areas to cause dystocia: 1, in the amniotic cavity proper; 2, within the cutaneous sac of *Schistocormus reflexus*; 3, in the ruminant stomachs, owing to atresia of the small intestine.

In contrast, as elsewhere discussed,⁶⁰ the hereditary atresia of the colon of the equine fetus, as recorded by Yamane, does not cause a notable accumulation of amniotic fluid. Apparently the fluid entered the large intestine to a sufficient degree that it was resorbed.

The origin of the amniotic and allantoic fluids has long provided a rich field for imagination. Until their sources shall have been authentically determined, the basic causes of their variations in quantity and quality can not be clearly learned.

The allantoic fluid apparently has but two readily identifiable sources: the kidneys, via the urinary bladder and the urachus, and the walls of the allantoic sac themselves. The only apparent exit for the fluid is through the walls of the sac.

In sharp contrast, the amniotic cavity is in communication with all the cavities of the fetal body having external openings. Added to these, the entire cutaneous surface of the fetus is surrounded completely by the amniotic sac. Both the oral and anal orifices of the alimentary tract open within the sac. The respiratory system communicates via the nostrils; the kidneys via the urinary bladder and urethra; the genital tract of the male via the urethra, and of the female via the vulva.

The amnion itself is an extremely thin membrane, with scant vascular supply. It seems highly improbable that the membrane itself acts significantly as a secretory, or excretory organ: apparently it may be regarded as a neutral reservoir for the amniotic fluid which emanates from other organs. Ordinarily it seems that the amniotic fluid is generally regarded merely as a convenient medium in which the fetus may float, with important freedom of movement and protection of the fetus against external violence. Carefully studied, the fluid appears to possess other highly significant functions in the life of the fetus.

The cutaneous surface of the fetus should be accorded a highly important role in the formation and character of the amniotic fluid. Early in fetal life, especially in herbivora, fetal hair is abundantly formed and much of it is shed and drops into the amniotic fluid. Along with the hair there naturally occur excretions from the sebaceous glands, mixed with epithelial debris. These waste tissues can not be allowed to accumulate without injury to the health of the fetus. The filtration of the fluid is accomplished by being constantly swallowed by the fetus. The liquid traverses the alimentary canal to the large intestines, where the water is resorbed and the hair and other solid debris stored aseptically within the colon and rectum, pending birth, as meconium. So far as known, no intestinal contents physiologically escape per anum during fetal life.

Pathologically the fetus often suffers from diarrhea and discharges from its rectum, into the amniotic sac, vast quantities of liquid, or semi-liquid meconium, filled with hair and other debris, presumably contaminated with bacteria, protozoa or other invaders. Profuse fetal diarrhea is common in bovine abortion and is not rare in those fetuses carried to term, and "born dead" or non-viable. In one

outbreak of ovine abortion observed by me, presumably not unique, almost all the young, whether aborted or born, were thickly smeared over with dark, repulsive meconium. The live lambs were generally repelled by their dams, were not licked nor permitted to suck.

Fetal diarrhea is also prevalent in prolonged bovine gestation, as related by Andres² and others. Since the hair is especially abundant and long, and freely shed by these fetal giants, great quantities of hair are found in the amniotic cavity and throughout the alimentary canal. Physiologically, bovine meconial pellets, when carefully studied, consist of masses of hair, pasted together and largely hidden by deposits of biliary, cutaneous, epithelial, and other debris. When the gestation is pathologically prolonged, and vast quantities of hair are shed and swallowed, it apparently forms abnormally large meconial pellets. When diarrhea sets in, the liquid discharges from the intestines dissolve some of the deposited epithelium from the exterior of the large pellets, exposing the hairs to view, causing observers to designate them "hair balls." Some of these are expelled and discovered in the amniotic cavity; others may have been again swallowed and found at any point within the alimentary canal.

In sharp contrast, fetal diarrhea is not prominently mentioned in either equine abortion or the very common prolonged gestation, although in the latter case the fetus is often dead or non-viable when expelled or extracted. On the contrary, there is commonly present serious meconial impaction in the rectum and colon, which requires medical interference. The fetus is greatly emaciated. The phenomenon has not been adequately studied. From the little known, the hypothesis seems justified that, in prolonged equine gestation, there exists severe water starvation of the fetus. Physiologically, the fetal tissues consist very largely of water. This the fetus chiefly obtains by the constant swallowing of its amniotic fluid. It is then promptly absorbed from the large intestines, reaches the fetal blood stream, and every tissue of the fetal body. It thus supplies the necessary water enabling the skin, urino-genital system and other vital organs to perform their functions and to return at least a very large proportion of the water to the amniotic cavity. Should this aqueous circulation fail, and the volume of water become pathologically scant, excessive absorption from the large intestines may fail, with extreme desiccation of the meconium, causing meconial impaction, and the subnormal volume of water in the tissues of the fetal body produces extreme emaciation.

Very rarely a somewhat similar desiccation of the meconium oc-

curs in the calf, the meconial pellets hanging together in long chains.

In other instances, especially in ruminants, it appears that ample water, absorbed from the large intestine, or otherwise obtained, enters the body tissues, but for some unknown cause, fails to reach, and become excreted by the skin or other excretory surface. It then accumulates in the subcutaneous, or other connective tissues, to constitute fetal anasarca, as illustrated in Fig. 76. Accordingly the amniotic fluid appears to play a highly vital role in the life of the intrauterine young. Any pathological disturbances in its quantity, quality or circulation endangers the health and life of mother and young, thereby inviting dystocia.

Although veterinary obstetrists generally mention dystocia as a result of the excess of fetal fluids, it should not at all be forgotten that difficult parturition is equally prevalent and serious when the volume of the liquids is subnormal. Fundamentally, each betokens fetal or uterine disease, or both, and the want of vigor of either mother or young dictates difficult labor.

In the dystocia occurring in what I have designated *static fetal cadaver*, there appears to be an absence of fetal fluids. This robs the uterus and fetus of all physiological power. It seems also to invite extreme torsion of the uterus. Two of the three cases I have observed or found recorded, have been associated with extreme uterine torsion, at least two complete revolutions. This could not well occur, in the presence of the normal volume of fetal fluids, without causing transverse rupture of the uterus.

There appear to be ample reasons for believing that a subnormal volume of fetal fluids plays an important part in the ordinary uterine torsion, which plays a conspicuous role in dystocia in dairy cows and is not rare in other animals.

Among the outstanding primary causes of the accumulations of fetal fluids in such excessive amounts as to cause dystocia is the genetic incompatibility of parents, such as the hybridization between the American bison and the domestic cow, and inbreeding in the production of bulldog calves and other types already mentioned. These notable instances tend to justify the suspicion that generally the occurrence of excessive volumes of fetal fluids is primarily due to errors in the mating of parents, and that, when dystocia arises, study should be instituted in an effort to trace the origin and apply prophylactic measures where indicated.

Apparently opposed to this view is the prevalence of excessive

volumes of amnio-allantoic fluids in twin gestation. My studies have led me to the definite conclusion that twin ovulation, especially in the mare and cow, is preponderantly pathological, and that the fertilization of a defective ovum, by a perfect spermatozoon, inevitably tends toward the production of a defective embryo. The causes of twin ovulation, as elsewhere discussed, are fairly well known, and correspondingly avoidable by intelligent breeding.

Dystocia Attributed to Short Nose. Hereditary Hydrocephalus

Keller³⁷ states that in dwarf bulldogs, dwarf spaniels and other races of dogs with enlarged cranium and short muzzle, congenital hydrocephalus of a limited degree is common: it has become a breed characteristic. I have pointed out⁷² that arrests and aberrations in the development of the reproductive system, such as abdominal testes, hydrometra, corkscrew tail, club foot, etc., are common phenomena in the presence of hydrocephalus, or other diseases of the cerebrospinal axis. Thus Professor Milks operated upon a Boston bulldog for hypospadias. The dog died and autopsy revealed definite hydrocephalus; the cerebral and genital aberrations were associated.

In so far as the laws of teratology are understood, three factors contribute to the production of dystocia in those breeds of dogs which have large crania and short muzzles. The hydrocephalous parents transmit the large crania and short muzzle, rendering the presenting part spherical instead of conical; the pelvis is relatively small; and the reproductive organs are weak. The aberration of the central nervous system so depresses the reproductive organs that fecundity is lowered and physiological birth imperiled. Some canine specialists deliver such bitches largely by cesarean section, thus shortening the birth act and, they believe, adding to the safety of both mother and young. In other words, fashion creates a breed through artificial selection which tends toward the necessity for cesarean section as a substitute for natural birth.

A colleague who regularly resorts to cesarean section in Boston bulldogs, relates that a highly bred female became pregnant through accident, by a male of a larger breed, and cesarean section was planned, but labor set in unexpectedly and a numerous litter of extra large pups was born without difficulty, thus suggesting that the common dystocia in the breed was not due to the large or blunt head, but to the lowered vitality and energy of the female and the fetuses, which in the one case had been largely ameliorated by the outcross.

Pathological Ovulation. Twin Dystocia

Evidence was submitted on page 124 tending to show that twin ovulation and gestation, especially in the mare and cow, is generally pathological; that it is frequently preceded or followed by sterility; and that the pregnancy is insecure and abortion notably invited. If the twin pregnancy is not interrupted by abortion before the fetuses have attained near-normal volume, dystocia is highly probable. The forces which ordinarily lead to dystocia in single pregnancy are much aggravated; teratological aberrations are more frequent; amnio-allantoic dropsy is notably more common; the fatigued uterus, primarily of low tone at date of conception, is further depressed by the excessive load. The expulsive energy of the uterus is defective, inviting thereby pathological presentation, position and placement of extremities. The fetus is weak and fails to react physiologically to the uterine contractions. Retained afterbirth abounds.

Bearing in mind that in unipara the occurrence of twin or multiple ovulation and the posterior presentation are alike usually pathological, it is well to note that these two factors are conspicuously associated in the production of a high ratio of dystocias in twin and multiple pregnancies, especially among ruminants. Although authentic records are not available, clinical observations indicate that one of ruminant twins usually lies in the uterine cavity with the caudal end directed toward the cervix, which inevitably signifies caudal presentation at birth. Stoss⁵¹ and other writers upon veterinary obstetrics state that as a rule bovine twins present alternately—one cephalically, the other caudally. The ratio of posterior presentations then becomes 50% instead of the usual 5% as observed in singles. This inevitably increases the ratio of dystocia in twin births. The fact that twin individuals are commonly somewhat smaller than singles of like parentage, ameliorates somewhat the tendency to, and seriousness of twin dystocia.

In addition to the increased frequency of those causes which lead to dystocia in single young, there are two types of dystocia of twins and multiples of unipara, which are unknown in multipara or in unipara with a single fetus.

1. *The wedging or jamming of portions of two fetuses in the birth canal.* As indicated in Fig. 2, the mare has a capacious uterine body, in which portions of both twins may develop. Nearly all equine twins are aborted too early to invite dystocia. Rarely, when pregnancy continues near to term, dystocia may arise from the simultaneous entrance of portions of both fetuses into the pelvis.

Fleming²⁵ cites Liautard as having observed one case of equine twin dystocia; and Harms³² cites Levens as having observed one instance of twin dystocia in the mare as compared with 26 in the cow. The nature of the dystocia is not stated in the citations.

Twin dystocia in ruminants, especially in the dairy cow, due to the impaction or wedging of portions of both twins in the birth canal is a relatively common phenomenon. Here all the causes of dystocia cited above come into play as a background for the wedging. As may be readily understood by a study of Fig. 5, the ruminant uterus is essentially didelphic, the two cornua, firmly bound together, lying parallel. Just anterior to the *os uteri internum*, as shown in Fig. 3, the two cornua communicate by an opening due to the resorption of the median walls of the ducts of Mueller for a distance approximately equal to the transverse diameter of the cornual canal, which is designated the "body" of the uterus. When bicornual twins are present, complete fusion of the two chorions occurs, and portions of each fetus, separated only by their amnions, present in contact, with equal right-of-way when parturition begins. So far as known the two cornua contract simultaneously and equally and tend to propel portions of each fetus into the cervix, vagina and pelvis where they become wedged. This frequently results in dystocia.

In sharp contrast, the cornua of multipara open almost directly opposite each other, as is partly shown in Fig. 94, at the extreme anterior end of the non-placental so-called uterine "body," which obstetrically constitutes the anterior extremity of the elongated birth canal. The chorion of one fetus ordinarily projects across the anterior end of the "body" and enters slightly the base of the opposite cornu. This gives precedence to the contained fetus when labor sets in. As labor progresses, one fetus after another, probably alternating between the two horns, is propelled into the birth canal directly against the proximal or cervical end of any fetus located within the base of the opposite cornu. Thus but one fetus may enter the birth canal at a given time and the wedging of two fetuses is essentially unknown.

In sharp contrast, when a multiparous female pathologically has only one fetus in her uterus, it may become anchored jointly in the bases of the two cornua to constitute bicornual pregnancy (page 195) leading to very serious dystocia. So it may be said that when a uniparous female attempts multiparity, or a multiparous female attempts uniparity, dystocia is invited.

2. *Dystocia due to unicornual twins.* Unicornual twins are not rare in the cow, ewe and goat. When higher multiples of young are present, two fetuses in one horn becomes inevitable. Since each mature fetus is as long as the distance between the maternal pubis and diaphragm, the two can not lie in a direct line. The gravid cornu must then double upon itself at the point of contact between the two fetuses. If they originally lay tail-to-tail, when they finally come to rest the fetus in the ovarian end of the cornu lies with its head directed toward the pelvis of the mother. Since the intercornual ligament binds the cornual bases firmly together, the doubling needs occur in the free, ovarian end, and the bend must occur lateralwards, as shown in Fig. 94. When labor sets in, and the proximal or caudal fetus is being, or has been expelled, the distal or cephalic fetus with the enveloping ovarian pole of the cornu, must be revolved about the transverse axis, through 180° , before the expulsion of the fetus may occur. This pathological position of the cornu and fetus delays the expulsion of the first fetus, owing to the interference with the efficient contraction of the longitudinal uterine muscular walls, and may cause sufficient dystocia to lead to calling the veterinarian.

After the proximal fetus has been expelled or extracted, the ovarian twin may escape recognition. Ordinary intra-uterine palpation may fail to discover the fetus. Hence one finds reports of cases in which the second fetus has been overlooked for hours or days, the atonic uterus unable to produce the required revolution of the cornu upon its transverse axis and expel the fetus. In the meantime the fetus probably dies and putrefies. The failure to discover the presence of such fetus constitutes a highly embarrassing, however natural, oversight by the veterinarian, which it is very difficult to explain to the client.

Dystocia Due to Pathological Anchorage of the Fetus

It has previously been stated on page 35 that extrauterine pregnancy, if it occurs, is extremely rare and of scant obstetrical interest. Owing to the extensive development of the uterine cornua in solipeds and the essentially didelphic uterus of ruminants and multipara, there is the ever-present possibility that a fetus may become anchored with its cranial end in the base of one horn and its caudal extremity in the base of the other cornu, to constitute bicornual pregnancy. The phenomenon is by far most frequent, and most disastrous economically, in unipara.

Physiologically the fertilized uniparous ovum migrates to a point near the base of the cornu, upon the side of the acting ovary, and becomes anchored along the mesometrial line. When the fetus develops physiologically its cephalic end grows toward the cervix, entering the uterine body of solipeds, while in ruminants the head invades the area of communication between the two cornua, designated as uterine body.

Dystocia from Bicornual Pregnancy in Solipeds

Writers upon veterinary obstetrics commonly describe, without tangible explanation, the *transverse presentation* of the fetus, generally without comment regarding the genus or species of animal. Neither do they state clearly whether the fetus, in case of the soliped, is lying transversely within the longitudinally disposed uterus or whether the uterus, with the contained fetus, is pathologically displaced so that the two lie horizontally across the abdominal cavity. A study of Fig. 2 indicates that the equine fetus cannot well lie transversely in either the gravid horn or the uterine body. It may lie transversely in the two horns and all four limbs may be located within the uterine body and, with the middle area of the fetus, cause a disproportionate development of the uterine body cavity, with a relatively limited volume of the head end in the base of one cornu and of the tail end in the other. So far as recorded, such disposition is extremely rare, while the abnormality in which the entire fetus lies within the cornua until labor sets in is abundant.

The equine ovum is regularly located near the base of the cornu upon the ovulating side. As it grows, its cephalic end physiologically extends into the uterine body and comes to rest against or near to the cervix, surrounded by its membranes and fluids. Pathologically it frequently extends into the base of the opposite horn instead and the body of the uterus is occupied, if at all, by a narrow, tubular extension of the chorion. This produces a highly complex group of difficulties in birth, which tax to the utmost the skill of the obstetrice. The fetus almost invariably perishes, the death ratio of mares is appalling, and the obstetrice not rarely fails to extract the fetus.

New light of profound interest has come from the recent studies of the fetal membranes^{61, 62} which afford convenient and authentic information in the pathology of reproduction. The application of this is well illustrated by Williams and Fincher.⁷¹ Fincher attended a fourteen-year-old mare for dystocia. The labor was atonic, the birth canal abnormally long and narrow, the fetal cadaver was in posterior pres-

entation, right dorso-ilial position, not engaged in the pelvis but lying far forward. I examined the membranes and was astonished to find that the pregnancy had been bicornual and that the presentation had shifted to posterior during labor. The case establishes two highly important points: (1) that bicornual pregnancy may continue to term, one pole of the fetus become dislodged from the cornu during labor, and the fetus thus assume longitudinal presentation, and (2) that an examination of the afterbirth shows clearly and authentically the pathological fixation and development of the ovum. The authenticity of the diagnosis is well illustrated by Figs. 62, 63.

Among the more common types of dystocia due to bicornual pregnancy in the mare are:

THE STERNO-ABDOMINAL POSITION

The ovum, as in all species, is physiologically anchored with its umbilicus or ventral body line toward the mesometrium, so that the chief vessels of the uterus and allantois are in juxtaposition. Accordingly all bicornual ova are primarily anchored with the ventral surface facing the vulva of the pregnant mare. It might well be termed *umbilical position*, since the umbilicus of the fetus is directed toward the os uteri internum of the mother. The four limbs are variously arranged: they may be folded closely against the ventral surface of the fetus—the hind feet against the fetal sternum, the anterior beneath the abdomen and the body of the uterus essentially vacant except for a portion of allantois—or the limbs may rest more or less within the uterine body.

As the fetus develops, its cephalo-sacral diameter soon exceeds the transverse diameter of the maternal abdominal cavity, and readjustment must occur.

One of the most frequent adjustments is in the lateral curvature of the neck to constitute wry-neck. With the very long head and neck, the abrupt bending of the neck at its base abbreviates the length of the fetal mass more than one third. The fetal head rests in the fetal flank, molded by the compression of the uterus to the fetal loins, so that the side of the fetal head in contact with the loins is concave and that facing the uterine wall becomes convex. The wry-neck and laterally curved head are not known to occur in other species of animal. The great length of the head and neck and the rigid confinement of the fetus within the two cornua, as may be understood by a study of Fig. 90, logically leads to such deformity.

Wry-neck also occurs in the foal in the longitudinal presentation.

So far as I have observed, the fetus has uniformly been in the *anterior* presentation. No one has yet tried to explain, and it is inconceivable in the present state of knowledge, how such deformity could occur in the physiological position of the fetus, with its cephalic end in the uterine body and its caudal extremity in the gravid horn. Any hypothesis which might be offered as to the cause of such deformation while the fetus was physiologically located in the uterus would upset all our ideas regarding the physiological movements of the fetus. The only logical conclusion is that the pregnancy had been bicornual, the wry-neck produced by compression of the maternal abdominal walls, and that when labor set in, or possibly at some earlier date, the head end had been forced out of the base of the cornu into the uterine body.

The birth canal in bicornual pregnancy is pathologically elongated and narrowed. As soon as the longitudinal axis of the fetus exceeds the transverse diameter of the maternal pelvis, pathological tension is exerted upon the vagina, cervix and uterine body, since the fetus must lie anterior to the pelvic inlet. Unfortunately the relations have not been studied until after labor has set in. It is then found that the vagina, cervix and uterine body are greatly elongated and narrow. The physiological constriction of the cervix has become obliterated. In the rotated bicornual pregnancy to be described later, the obliteration of the cervical constriction quite certainly occurs, at the latest, immediately following the rotation, so that there is a birth canal of uniformly narrow lumen, comprising the vagina, cervix and uterine body. Presumably this occurs in a lesser degree in most cases of bicornual pregnancy, where the tension mechanically eliminates the cervical constriction.

With the fetus in the sterno-abdominal (umbilical) position, the posterior limbs frequently extend completely across the maternal pelvis, firmly, often immovably, incarcerated in front of the maternal ilium, calling for amputation. The anterior feet may be variously retained, but are more flexible and adjustable, and may project into the birth canal between the lower hind leg and the pubis, between the upper hind leg and the sacrum, between the two posterior limbs, etc.

It is not improbable that bicornual pregnancy is responsible for those cases of dystocia observed in the mare where the head and all four limbs are in the birth canal. Personally I recall but two cases, in both of which, as they occurred in that era when dystocia was regarded as a whim of chance, no study was made of the uterus after the embryotomy. The most logical hypothesis is that the pregnancy

was bicornual and that with the advent of labor the head was forced into the birth canal, all four limbs presenting in advance. It is difficult to explain otherwise how the posterior limbs could become extended along the ventral surface of the chest and neck. Normally, if the posterior limbs are not extended backward, they are folded beneath the abdomen as in sternal recumbency. In such case, they would naturally unfold backwards as the fetus is propelled through the birth canal.

When the fetus of bicornual pregnancy reaches a stage of development at which its occipito-sacral diameter exceeds that of the transverse diameter of the abdominal cavity of the mare, whether in the primary sterno-abdominal position, or in the more complicated rotated bicornual pregnancy, to be mentioned below, the relation of the fetus to the available intra-abdominal room needs to be modified. A degree of accommodation may be attained by one cornu of the uterus, with its contained fetal parts, moving forward toward the maternal diaphragm while the other cornu rests against the anterior border of the maternal ilium, to constitute an oblique position. The combined long axis of the two pregnant cornua then ceases to be at right angles to the uterine body and vagina but crosses the longitudinal axis of the birth canal obliquely, as indicated in Fig. 91.

ROTATED BICORNUAL PREGNANCY

The primary sterno-abdominal (umbilical) position of the fetus in bicornual pregnancy is unstable and is largely maintained by the firmly impacted fetus within the cruciform uterus, supported by the broad ligaments. The instability is aggravated by the fact that the ventral, concave line of the fetus faces the concave transverse line of the posterior body walls. The compression exerted by the abdominal walls upon the spinal axis of the fetus tends to bend the fetal body dorsalwards, not ventralwards. The dorsum of the fetus, with the cornua, drops downward upon the abdominal floor, while the ventral portion, with the feet and legs, is directed toward the dorsal wall of the maternal abdomen. The fetus then temporarily lies upon its back, transversely in front of the maternal pelvis. The original floor of the cornua has become the posterior wall.

The instability has only been exaggerated and the revolution of the fetus, along with the cornual walls, continues until it has reached 180° and the fetus comes to rest with its concave, ventral surface directed toward the maternal diaphragm, while its convex, dorsal line rests against the pelvic inlet.

The dorsum of the fetus does not directly face the birth canal, but lies beneath it. The primary floor of the cornua has become its roof and lies against the floor of the birth canal. The birth canal loses, in a way, its primary relation to the fetal umbilicus, and the obstetrice, after palpating the fetus underneath the floor of the birth canal, must follow the vagina and elongated vacant uterine body to its juncture with the cornua and then downwards, and perhaps somewhat backwards, to contact directly the ventral surface of the fetus, usually the feet. He must reach over the fetal body to make direct contact with its ventral wall.

Dystocia Due to Bicornual Pregnancy in Ruminants

As in solipeds, so in ruminants, the fertilized ovum physiologically migrates to near the base of the cornu corresponding to the acting ovary, and there becomes anchored, with its umbilicus facing the line of attachment of the broad ligament. The ruminant uterus is essentially didelphic, with a single cervix, as is indicated in Figs 3, 4, 93. The fetus and its amnion physiologically remain within the pregnant horn, while the allantochorion extends into the non-gravid cornu to the ovarian pole. The two cornua are firmly bound together, from their bases almost to their ovarian poles, by the intercornual ligament. As shown in Fig. 93, the fetus can only become anchored with its cephalic end in one cornu, and its caudal in the other through an acute bending of the fetal body, like the letter U.

Physiologically the umbilicus of the fetus faces the mesometrial, or concave uterine wall so that the chief uterine vessels of the allantochorion are parallel to the main uterine vessels lying within the broad ligaments. Both the fetus and cornu are arciform, the ventral line of the fetus being concave. This renders it difficult for the fetus to become bent U-shaped, within the almost parallel cornua. The anatomical relations had caused me to doubt the occurrence of bicornual pregnancy (transverse presentation) in ruminants. Recently Krill authentically described two cases in the cow, and later Fincher (personal relation) observed a third. I have not personally observed a case. The fetuses in all three instances mentioned had revolved upon their spinal axes through 180° . A concurrent revolution of the uterine cornua, as in the rotated bicornual pregnancy of the mare, was impossible because of the intercornual ligament. Consequently the fetus revolved within the cornual cavity, while the cornua remained static. This permitted the fetus to bend ventrally, which is the direction of greatest flexibility, and caused it to

present dorsally to the cervical canal and the pelvic inlet. Krill destroyed one of his cases as hopeless and resorted to embryotomy in the other; Fincher, whose case was less obstinate, succeeded in adjusting the position and extracting the fetus entire.

This abnormality probably accounts for the majority of the cases of bovine dystocia designated as dorsal transverse presentation, a condition well-nigh anatomically impossible in the ruminant uterus, if it is meant thereby that the entire fetal body, or most of it lies transversely within the uterine body or one horn. Fortunately Krill, making a postmortem study of one of his cases, found the cephalic end of the fetus in one cornu and the caudal in the other, in which location it had evidently been since an early date in pregnancy. If practitioners follow up these observations and, after overcoming the dystocia in apparent dorsal transverse presentation, carefully examine the uterine cavity and the afterbirth, the question of the nature of the phenomenon may be greatly clarified.

The fetus is inevitably bent double. The varying flexibility of the fetal body renders the ventral (sterno-pubic) doubling by far the easiest: the dorsal bending of the fetus (occipito-sacral), except in the monster *Schistosoma reflexus*, is virtually impossible. I encountered one case of lateral doubling which may possibly have been due to bicornual pregnancy. The fetus offered at the pelvic inlet in head-and-tail presentation, which I diagnosed as twins. When I attempted to advance the head end, the tail advanced equally; when I tried to repel the caudal end, the head also retreated. Extracting the torso after partial embryotomy, I found that the spinal column was permanently folded laterally. If it was due to bicornual pregnancy, the deformed fetus had become reversed during labor and presented by its two ends instead of by the middle. It was full term and alive at the beginning of embryotomy.

The doubling of the fetus in ruminant bicornual pregnancy is analogous in one respect to the wry-neck of equine bicornual gestation: it is the natural consequence of compression. The doubling of the fetus in ruminant bicornual pregnancy is apparently inescapable and universal; in solipeds the wry-neck occurs in only a minority of cases, other adjustments rendering it unnecessary in the majority.

Dystocia Due to Bicornual Pregnancy in Multipara

The two ovaries of domestic mammals are usually similar in volume and consequently somewhat alike in activity. The most noted exception is that of the cow, in which as a rule the right ovary is

distinctly larger than the left, and pregnancy is definitely more common (55:45) in the right horn. It is not known if this prevalence of pregnancy in the right cornu is due to the greater frequency of ovulation by the right gland or to greater viability of its ova.

The relative ovulation activity of the two glands in multipara has not been extensively studied. Ovulation is commonly well balanced, but in an important minority of individuals there is marked inequality in the number of ova discharged by the two glands. When gross inequality occurs in the sow there is often a marked migration of fertilized ova from the excessive to the defective side, tending to balance the load. The inequality of ovulation is possibly pathologic. The observations have been made in highly domesticated swine.

The two cornua (uterus didelphys) open into the narrow birth canal immediately opposite each other, enabling the migrating ova to pass directly across from one, into the other. The migration is almost always complete, with the fetus exclusively in one horn, although a portion of the chorion, without placental tissues, may project across into the base of the other horn. I find no authentic record of bicornual pregnancy in the sow.

The bitch, when of low fertility, may discharge very few or only a single ovum. Sometimes an ovum becomes anchored bicornually, especially when only one viable ovum exists. Then follows dystocia, virtually demanding cesarean section for relief. The placentation in these cases has not been recorded: probably there are two placental girdles, one in each horn.

It is reliably shown that bicornual pregnancy occurs in solipeds, ruminants and carnivores and is apparently quite possible in all domestic mammals. The underlying cause seems to be pathological conditions in the uterus or ovaries or both. Bicornual pregnancy in the mare, and possibly also in the cow and bitch occurs chiefly in pluripara. The body of the equine uterus is more prone to disease than the cornua. If the uterine body has been injured by disease, then it would seem probable that the ovum would pass into the non-gravid horn instead of the diseased body.

Bicornual pregnancy provides a path for transverse presentation not otherwise available. Transverse presentation is described as occurring in all species of domestic animals, and veterinary obstetrists generally (Stoss⁵¹ is an outstanding exception) leave the reader to believe that the fetus lies transversely within the birth canal. In the transverse presentation of bicornual pregnancy in the mare,

where it is by far most frequent and destructive, the fetus is not in the birth canal. Stoss⁵² states that among 100 pregnant mares examined in the 2nd month of gestation, 16% of the ova were in the body of the uterus. Unfortunately the outcome of the pregnancies is not recorded. It seems highly probable that the 16% recorded as pregnant in the uterine body were actually bicornual pregnancies and largely ended in disaster.

Some writers state that the transverse presentations they describe are not actually transverse, since the tubular uterus and birth canal do not permit this, but instead are oblique. It is not entirely clear whether the writers have in mind the fetus lying transversely or obliquely within the uterus or vagina, with the genital tract remaining direct, or whether it is meant that the fetus and uterus or vagina lie transversely or obliquely.

Dystocia due to Displacement of the Pregnant Uterus. Uterine Torsion

Writers upon human obstetrics describe ante- and retroversion, and ante- and retroflexion of the pregnant uterus as causes of dystocia. Some veterinary obstetrists, possibly in imitation, describe similar displacements as causes of dystocia in domestic animals. It is difficult to comprehend such displacements in quadrupeds, although quite plausible in bipedal woman. When a pregnant woman walks, stands or sits, the gravid uterus is physiologically upright or perpendicular and may pathologically topple in various directions. The pregnant uterus rests upon the cervix and vagina and by mechanical pressure may tend to weaken them. On the contrary the gravid uterus of domestic animals, especially of the unipara, hangs partly suspended from its vulvar attachment, in a manner to invigorate rather than depress. Accordingly, so far as can be readily seen, these displacements observed in woman do not occur in quadrupeds, because of anatomical considerations.

In sharp contrast, the anatomical relations lead to frequent torsion of the uterus in domestic animals, a displacement apparently unknown in woman. Torsion of the uniparous uterus inevitably involves the body and both cornua in solipeds and both cornua of the didelphic uterus of ruminants. Torsion of the multiparous uterus commonly involves but one cornu, and largely only a segment of the horn, including one or more fetuses. In the latter the torsion is plainly analogous in principle to intestinal volvulus. In unipara as well, that principle is present, although less obvious.

Torsion is far more frequent in unipara than in multipara and is of greatest scientific and economic importance in dairy cows. The phenomenon which has already been discussed in the companion volume upon genital diseases, needs be considered here primarily in its relation to dystocia. Stoss⁵¹ attributes the torsion in the cow to atonic condition associated with stabling and cites Tapken as having observed it more than thrice as often in stabled cows as in those at pasture. But Tapken was apparently speaking of cows which were at pasture only a portion of the year. I have not observed torsion of the uterus in range cows entirely free from stabling. Probably it does occur rarely, but they are free from it as compared to the dairy cow, the most degenerate of our larger domestic animals through breeding, feeding and handling. A colleague, practicing for more than 30 years in a concentrated dairying region, relates that during a recent winter the incidence of uterine torsion more than quadrupled over previous experience. There had been serious drouth in the area for several years, which reached its climax in the summer of 1939. The pastures provided very limited grass, the better varieties of grasses were dormant, the available herbage deficient in water and nutritive elements, the hay of extremely low quality, and the drinking water so scanty that many dairymen hauled water for miles in order to avoid water starvation. Under these conditions, uterine torsion multiplied amazingly.

Did the inadequate supply of water directly increase the incidence of torsion? I have recorded a case⁶⁵ in which there was uterine torsion, of 23 months' duration, with two complete revolutions of the uterus; and Boyd has recorded a similar instance of 20 months. In each case the fetus was plump but the fetal fluids were absent. The torsion may have been due to the absence of the fetal fluids; certainly the absence of rupture of the uterus or of mortal necrosis could well be ascribed to the want of the normal fluids which permitted extensive revolution without uterine rupture. The question then arises: does a relatively moderate want to fetal fluids importantly contribute to the causation of uterine torsion? In the two extreme cases of torsion cited above, coupled with what I have termed *static fetal cadaver*, no fetal fluids were present. I saw one other case of the static fetal cadaver, in which torsion did not occur. Hence, according to available data, of three cases, two underwent torsion. In contrast, I have not observed or learned of uterine torsion in amnio-allantoic dropsy or in edema of the chorion in any species of animal. The hematic mummy of the cow is not known to

be associated with uterine torsion: at first the volume of amniotic and allantoic fluids is not known to be abnormal and the copious inter-placental hemorrhage distends the uterus comparable to amnio-allantoic dropsy. The monster designated *muscle contracture* with subnormal liquid in the body tissues is associated with an excess of amniotic and allantoic fluids. At present there is not sufficient evidence to conclude definitely that a subnormal amount of fetal fluids generally accompanies uterine torsion: clinical observation fully justifies the conclusion that uterine torsion is linked with malnutrition and uterine atony. Professor Fincher personally relates having observed two heifers which suffered from uterine prolapse at first calving and torsion of the uterus at the second, and last calving.

Veterinary obstetrists regularly recognize as causes of dystocia the revolution of the fetus through 90° to 180° upon its long axis in longitudinal presentations. Careful study in this field is wanting. There is important evidence that many, if not most dorso-ilial and dorso-pubic positions are fundamentally limited uterine torsion. The prevalent belief is that in these pathological positions, the fetus has revolved about its spinal axis while the uterus retains its normal relations with the surrounding organs. This view is open to question. The gravid uterus of the cow, in which most uterine torsions occur, constitutes the segment of a circle, within which lies the arciform fetus, with its convex curvature parallel to the convex curvature of the uterus. This renders the revolution of the fetus upon its long axis, after mid-term, difficult and improbable as a fixed attitude. The twisted navel cord of solipeds suggests that the fetus revolves either upon its transverse or its longitudinal axis, or both, and continuously in one direction, since any counter-revolution would reduce the torsion. There is no proof that such revolutions occur late in pregnancy, and there is nothing to indicate that, if they occur, the revolution is arrested at any abnormal position. Both human and veterinary obstetrists suggest that, when the twisting of the cord is extreme, serious fetal disease (abortion, etc.) is invited: my observations have led to the reverse conclusion, that disease of the ovum invites torsion of the navel cord, so that chronologically the disease of the ovum antedates the torsion of the umbilicus. While discussing bicornual pregnancy in the cow it was held that the embryo, owing to compression, almost inevitably revolved through 180° because of the firmly fixed uterine cornua. In the rotated bicornual pregnancy of the mare, with a markedly different anatomical form of the uterus, the two cornua revolved with the fetus.

When a fetus is in the dorso-ilial position, if the uterus has revolved with the fetus through 90° , the torsion is largely anterior to the pelvis and may not be readily detected. The obstetrice naturally revolves the fetus in the proper direction and unconsciously turns the uterus with it. If the torsion is through 180° , the evidences of uterine torsion may again be trivial until the obstetrice attempts to correct the position. He then finds that, when he attempts to revolve the fetus upon its spinal axis in one direction, he fails; when he reverses his force, the revolution is readily accomplished. In the first case he has attempted to increase the torsion; in the other, to reduce it. In all probability many of the dystocias in dorso-ilial and dorso-pubic positions are due to unrecognized uterine torsion.

Dystocia referable to Traumatic Hernia

Dystocia due to the gravid uterus dropping into a traumatic hernia is comparatively rare. The rupture of the prepubian tendon in the pregnant mare, which is not at all rare, has been ascribed in the companion volume to degeneration of that structure, although a majority of writers apparently regard it as wholly accidental. Since it occurs late in gestation, the wound margins cannot heal prior to foaling, the uterus hangs far below its normal position when the mare is standing, and the abdominal walls are deprived of contractile power. The disadvantage of gravity is negative when the mare lies down: the uterus must expel the fetus almost alone.

Dystocia referable to Pelvic Abnormalities

In sharp contrast to human obstetrics, defects of the pelvis play a minor role in the dystocia of quadrupeds. I have met with one case (Fig. 70) in which the animal had suffered, when a young filly, from fracture of one ilium and dislocation of the opposite sacro-iliac articulation, and recovery had failed to occur from either injury. Exostoses occur following pelvic fractures and other osseous diseases.

The pelves of solipeds and ruminants are well ossified at birth. The quadrupedal position shifts the greater portion of the body weight to the anterior limbs and the pelvis carries only an unimportant ratio. In multipara, and especially in carnivora, numerous authors describe pelvic narrowing from rachitis, but fail to render the question wholly clear. The carnivorous young are usually healthfully and naturally reared upon their mothers' milk until the most vital period for rachitis has passed. Rickets doubtless occurs in

young carnivora, but its frequency and its damage to the form and size of the pelvis is not clear. It is easy to say that a Boston bulldog suffers from dystocia owing to a constricted pelvis, but it is difficult to determine whether this is a fact or whether the dystocia is due to the feebleness of degeneracy brought about by the plan of breeding and want of contractile energy of the uterine walls.

When very young females are bred, such as dairy heifers at 15 months or less, the pelvis is unavoidably subnormal in capacity when parturition arrives. This probably plays an important role in dystocia in dairy heifers, but it is so interlocked with subnormal development of the entire reproductive system that its importance is not accurately measurable.

Dystocia attributed to the Size of the Sire

It has been claimed that excess of size of the sire over that of the females causes dystocia. This has not been clear in my observations. I have seen mares of 700 to 800 pounds crossed with stallions weighing 1600 to 2000 pounds, without having been able to observe that the two extremes caused, or tended to cause, dystocia. I have been unable to determine that dystocia is caused in any species of animal by such gross preponderance of weight of the male over the female. The literature upon the subject is not fully authentic. The statements found are usually purely categorical and any facts submitted are quite open to other interpretation. Immature females, or badly raised heifers, are liable to be bred to large males. Such females will largely suffer from dystocia, but the cause is intrinsic in the females. If the male is sexually unsound, that fact will add to the ratio of dystocia. Whenever a diseased male is used, those females which become pregnant by him, and do not abort early, are quite certain to show a high ratio of dystocia.

Dystocia due to Pre-conceptional Uterine Lesions

In Figs. 77, 78, 79, 80 it is shown that in the cases of hydrops of the amnion and allantois, and of edema of the chorion, gross uterine lesions had existed at the beginning of the pregnancy, which ended in dystocia. It cannot be told precisely when these injuries occurred, but it was certainly before conception. The cow with edema of the chorion, was in her second pregnancy. No disease was observed by the owner at the close of her first pregnancy. Extensive and highly destructive disease with gangrene of the caruncles (including the cotyledons) may readily, and does, occur without recognizable exterior manifestation. The caruncles undergo maceration and resorp-

tion, or dry gangrene occurs with unobserved expulsion of the caruncles. The origin of the lesions is not confined to the recognized puerperal state. A supposedly pregnant heifer or cow frequently shows estrum unexpectedly at 60 to 120 days after the last breeding. In many of these cases it may be justifiably assumed that conception had occurred, and the embryo died and macerated, resulting in the necrosis of all caruncles in the gravid cornu. The principle is identical whether the process was observed or passed unseen. A heifer may conceive, the embryo perish and macerate, the caruncles of the gravid horn decompose, and all be absorbed without external evidences of disease. Then, at the close of the first known gestation, the afterbirth reveals that the endometrium of an entire horn has been destroyed. So far as yet determined, if the caruncles were destroyed prior to the conception under consideration, the chorion of the involved area may be free from recent lesions, as indicated in Figs. 77 and 79, and devoid of cotyledons; if the injury occurred during the gestation in question, the chorion and its cotyledons are necrotic, as indicated in Colored Plate III.

Dystocia referable to the Pathology of the Sex Cells

It has been aimed in the foregoing discussion to show that dystocia in domestic animals is the logical result of errors in breeding, feeding and handling. Specific instances have been enumerated in an effort to stimulate keener observation, with the hope that valuable improvements may be made so that the prevention of dystocia may take precedence over its relief, or at least that prophylaxis shall be accorded an important place in veterinary obstetrics. In a broader, more significant outlook, the responsibility of the methods of animal husbandry in the control of dystocia deserves thoughtful consideration. It was attempted to show in the companion volume that the foundation for genital disease is largely established prior to the union of the sex cells: it was insisted that dystocia is merely one of the many phenomena of reproductive disease.

Speaking more generally than in the specific examples cited, it needs be recognized that a faulty or weak spermatozoon or ovum contributing to the formation of a new individual has the potential power of leading to dystocia. For example, J. Whitridge Williams⁵⁷ quotes Seitz as having noted that breech presentations in woman were much more frequent in macerated than in normal fetuses. Breech presentation in unipara usually means dystocia. Many human, and some veterinary obstetrists have presented numerous hypotheses in an effort to show why the overwhelming majority of

uniparous fetuses present by the head end, but have reached no definite conclusion, and the fact remains that it is an old and well established custom of healthy fetuses to present by the head end. The fetus presenting by the breech does not macerate (except in neglected dystocia) because of the breech presentation, but offers by the breech because it was diseased, and the disease dates back to very early pregnancy if not to a diseased spermatozoon or ovum from which the fetus developed. When a sire is producing a large ratio of defective spermatozoa, and is therefore of low fertility, his pregnancies will largely end in dystocia. If a heifer calf is so badly fed that she suffers from diarrhea or pneumonia and is unthrifty until 6 months or older, she will probably be in dystocia at the close of her first pregnancy. When in any way the energy of the individual is lowered, the ultimate effect is a general disturbance of reproduction, and one of the phenomenon in the female is dystocia.

Any and all elements which unfavorably affect the general health and vigor of the pregnant female, invite dystocia. Insufficient or damaged food lowers the resistance to bacteria existing in a non-pathogenic state in the uterine cavity, or in the oviducts or cervix, and also invites the invasion of the uterus by bacteria or viruses from the blood stream. Inevitably any bacterial activity within the endometrium threatens invasion of the ovum. Uterine and fetal pathology alike imperil physiological birth.

Dystocia is accordingly one of the natural results of the pathology of the reproductive organs and of the fetus. In so far as the causes may be identified and removed, dystocia is preventable. If the cause is not recognizable, or, being recognizable, is not eliminated, dystocia ensues, and the veterinary obstetrict must then apply his best skill to its amelioration or cure.

The prognosis of the handling of existing dystocia in animals is very favorable in the recorded literature but is discouragingly unfavorable if closely studied. Most dystocia occurs in those animals which have been set aside for breeding purposes, or for the subsidiary sexual function of lactation, which is dependent upon breeding, because they possess special value for these purposes. The basic consideration in the prognosis of dystocia is the prospective value of the female for future breeding. The second element in prognosis is the prospective value of the fetus or fetuses involved in the dystocia. A third potential gain from handling dystocia is the prospective value of the female for milk during the ensuing period of lactation, her value as a beast of burden, or her flesh as human food. In pet animals a fourth object, sentiment, arises for consideration. Re-

corded data are essentially worthless in most of these respects. There is great need for a more accurate system of computing the value of obstetrical operations. In most computations a balance sheet or its equivalent is made up. For dystocia it might be thus arranged:

DEBIT	CREDIT
1. Veterinary fees.	1. Value of surviving mother.
2. Mortality risk.	a. Breeding value.
3. Cost of labor and food pending restoration of value.	b. Food value. Milk for ensuing lactation. Meat value. Work value.
	2. Value of the offspring.
	3. Sentimental value.

In veterinary literature, as a rule, but one of the three debit items (2) is recorded, and that only imperfectly, while all the credit items are omitted, and it is apparently taken for granted that if the mother, or young, or both survive, the handling of the dystocia has been profitable. As an illustration, the observations of von Oettingen⁴³ in the Trakehnen stud may be used. Of the 38 dystocias amongst 3388 births, 4 (10%) of the mares died, and 25 (66%) of the foals succumbed. Von Oettingen is silent concerning the subsequent breeding value of the surviving mares, and of the 34% of living foals. If the mares were sterile, which was probably the case with a majority, they, as thoroughbreds, were unfitted for ordinary work, but may have had value as mounts in the military organization or in sports. The dams of 2 out of 13 live foals succumbed, leaving them to be raised by hand or by a nurse mare. In the former case, the foal would generally be unthrifty and not develop into a highly valuable individual. Even in the 11 cases where both mare and foal survived, the incidence of metritis would be high. The foal would logically suffer from diarrhea and poor nutrition, and when mature its value would be subnormal.

In the group of heifers mentioned above as having been unthrifty as young calves and reaching breeding age with juvenile reproductive organs, the dystocia was followed by endometritis, cervicitis, vaginitis and vulvitis. Further time needs elapse before the economic results may be ascertained. Some of the cows will prove hopelessly sterile; some, in which most or all the caruncles sloughed away, will breed with difficulty, the fetus will get insufficient nutrition through adventitious placental tissues, the duration of pregnancy will be subnormal, the calves will be under size and subnormal in vigor. Upon the credit side, most of those which again breed will milk acceptably and their heifer calves, under proper care, may outgrow their inherited handicap and develop into healthy, profitable dairy

cows. The sterile cows will possess considerable value for beef. The handling of the heifers for dystocia will preserve the continuity of the herd and maintain or increase the number of cows and volume of milk until the healthfully grown calves now in the herd shall have come into breeding and dairying.

Richter⁴⁵ cites extensive records upon the mortality of both the dam and progeny following cesarean section in domestic animals. These records are fairly favorable for the life of mother and young, being least promising in the mare, and most so in the sow and bitch. His citations are all European. In the United States the recorded observations would probably be more favorable because of the strong tendency to report those cases in which the female recovers. In neither case is there any substantial ground upon which one may compute the economic value of the operation. If cesarean section is necessary to overcome dystocia in a given pregnancy, there is a strong probability that physiological birth may not occur at the close of the next gestation. But by no means all animals delivered by cesarean section again become pregnant. I have recently observed with interest the outcome of cesarean section in a two-year-old Holstein heifer. As she is subnormal in size and her genitalia are juvenile, the fetus could not be removed by traction, nor could embryotomy be performed through the narrow birth canal. She recovered promptly from the operation. The fetus was dead. She has failed to come into profitable lactation. Future conception is only a remote possibility. It will require months to put her in beef condition. Admittedly the heifer has recovered—but recovered what? A liability! Some say that such a recovery is a good professional advertisement, but the art of advertising is not being discussed.

The outlook for profitable cesarean section may be favorably advanced by the prudent selection of cases, such as heifers suffering from genital hypoplasia, in which the operation may be classed as a means for prevention, rather than cure. In such, as a rule, the goal would be the ultimate value of the cow for beef and the worth of her calf. When a mare is concerned, the most desirable goal is her value as a work animal and any worth of the foal immediately concerned. Economically it is not prudent to look forward to the rebreeding of a rescued female.

So along parallel lines the entire gamut might be run and at the end little authentic proof will have been uncovered of the economic value of the handling of dystocia. The fundamental difficulty is that, in the handling of dystocia, the veterinary obstetrict is dealing with "a ship upon rocks." The ship may be pulled off the rocks and re-

main, or be made seaworthy, but upon the whole it will never again be as valuable as before. The cargo may be partly or wholly salvaged, possibly undamaged, but generally more or less seriously damaged, often ruined. The handling of dystocia should be regarded simply as a salvaging process and its economic value computed upon that basis. If reasonable prudence is employed in selecting the cases to be handled and determining promptly which animals are to be destroyed, the handling of dystocia becomes a highly meritorious professional activity, of distinct economic value to the breeder and the state. In this respect the prognosis in dystocia is neither better nor worse than that of sterility and abortion. In each of these, great results have been claimed. If a sterile cow, after long handling, conceives, after her treatment and keep have outrun her potential value, the handling is classed as successful even if the pregnancy ends in abortion or the calf is born with hydrocephalus. Or if an aborting heifer is handled, conceives again, calves prematurely and dies from metritis, it is classed as a success. Thus, throughout the field of the pathology of reproduction, the prognosis is not commonly based upon a secure foundation.

Dystocia, along with sterility and abortion, is increasing in destructiveness, especially in dairy cattle. Commendable progress has been, and continues to be made in the appliances and technic for combating dystocia, but dystocia in dairy cows is quite certainly more abundant and virulent. Any gain in equipment and skill is exceeded by the increased incidence and seriousness. Great efforts are made to ameliorate or annul the results of dystocia, but its fundamental causes are being ignored. The general prognosis will be vastly improved when the basic causes of dystocia are studied and, in so far as possible, removed. Thus in the group of heifers discussed above, most of which have juvenile genital organs, dystocia needs be accepted as the logical termination of the first gestation, but the heifer calves grown under a radically improved plan will develop normal genital organs, quite capable of supplying ample nutrition to the fetus, and with a vagina and vulva sufficiently capacious to permit the physiological passage of the fetus at birth.

The attempt is therefore made in the succeeding pages to discard the tradition that dystocia consists of a conglomerate assemblage of unrelated accidents. In so far as possible, the fundamental causes are assigned. When the causes are recognizable and removable, dystocia is as readily preventable as other pathological phenomena.

In the meantime, the prevention of dystocia having failed, its proper handling is to be considered with the utmost care.

CHAPTER XVI

THE EXCITING OR IMMEDIATE CAUSES OF DYSTOCIA

WHEN there has been a failure to control the basic causes of dystocia, which have been partially enumerated above, there logically follow many forms of interference with the physiological expulsion of the fetus. About these types of obstruction revolve the chief obstetrical procedures. The obstetrists' efforts are largely directed toward the overcoming or amelioration of such interferences as pathological presentations and positions of the fetus; the pathologically defective expulsive power of the uterus; inequalities between the volume of the fetus to be expelled and the size of the birth canal, through which it must pass.

Presentation, Position and Posture or Attitude

Presentation signifies the relationship between the long, or cerebro-spinal axis of the fetus and the longitudinal axis of the maternal birth canal, at the onset of labor. When the obstetrists examines the patient by vaginal palpation, the portion of the fetus contacted at the anterior end of the birth canal—cephalic or caudal end or the middle of the body—serves to identify the presentation. If the head or tail of the fetus is first contacted, it is designated *longitudinal* presentation, since the long axes of the fetus and mother are approximately parallel. If instead the middle area of the body, dorso-lumbar or abdominal floor, is contacted, the long axis of the fetus is approximately perpendicular to that of the dam and a *transverse* presentation follows. The definitions are general and not always clear. Stoss⁵¹ defines presentation as the relation existing between the long axes of the fetus and mother's uterus, while Harms⁵² defines it as the relation between the long axes of the fetus and mother. When bicornual pregnancy occurs in the mare, though the long axes of the fetus and of the functioning uterine cornua are parallel, it does not constitute longitudinal presentation: it is the most definitely transverse presentation known. The U-shaped fetus of bovine bicornual pregnancy rests with its mid-dorsum facing the birth canal while the long axes of the head, and tail ends are parallel to the long axis of the mother's spinal column. Accordingly any definition

of presentation is general in character, and exceptions arise which are without great significance.

When the fetus is in longitudinal presentation, in solipeds and ruminants, the long axes of the fetus and dam are not strictly parallel. The pregnant uterus of the cow is logically deflected somewhat to the right by the large rumen; that of the mare, slightly to the left by the great colon. This deviation is too slight to be recognizably significant. When bicornual pregnancy is present in the mare, the deviation from the transverse presentation, illustrated in Fig. 91, becomes of vital concern and may be best described as *oblique* presentation.

The fetus, in all species, must present longitudinally in order to be born or expelled. Writers upon veterinary obstetrics regard as physiological both anterior and posterior presentations. The fetuses of healthy unipara present in an overwhelming majority by the head end. Extensive data are wanting. Schmaltz,⁴⁶ citing Renner, reports that among 408 equine births, 404 (99%) presented by the head end, and adds that in ruminants 95% present anteriorly. Turning to Harms³² citing Tapken, among 383 cases of bovine dystocia, 130 (34%) were in posterior presentation, thus indicating that dystocia occurs about seven times as frequently, among those fetuses presenting posteriorly, as in the anterior presentation. According to my observations, fetal diseases such as diarrhea and emphysematous decomposition, are far more frequent in the posterior, than in the anterior presentation, not because the posterior presentation causes disease, but rather because disease of the fetus invites posterior presentation.

Multiparous fetuses are born apparently indifferently whether presenting anteriorly or posteriorly, and so far as known the anterior and posterior presentations are approximately equal in ratio.

Position signifies the relationship between a stated portion of the fetus—the dorsum—and a given point in the pelvic girdle. Physiologically, in the anterior presentation, the fetal occiput or dorsum is directed toward the maternal sacrum—the dorso-sacral position. If the fetus revolves upon its long axis through 90° , the dorsum faces the right or left ilium and the position is designated right or left dorso-ilial; when the fetus revolves through 180° , its dorsum is directed toward the maternal pubis and the position is known as dorso-pubic.

Benesch⁵ departs technically from the above definition, defining position as the relationship of the dorsum of the fetus to the uterine

walls, and recognizing, instead of the above, right and left lateral, and superior and inferior positions. Strictly speaking, under this nomenclature, a fetus may revolve through 90° , without the uterus revolving with it, and be in the lateral position, whereas if the uterus revolves with the fetus (uterine torsion) the fetus remains in the dorsal or upper position. Apparently Benesch assumes that when the fetus revolves through 90° about its long axis the uterus remains fixed in its position, a conclusion of doubtful character.

The transverse presentation logically offers but two positions—the right and left cephalo-iliac. The distinction between the two is of no material importance. Veterinary obstetrists also describe vertical transverse presentations—dog-sitting position—which may be either ventral or dorsal in presentation. In each of these presentations the fetal head is described as directed toward the maternal sacrum. It appears more logical to regard these as longitudinal presentations: the ventral as an anterior presentation with the posterior extremities extended beneath the fetal body; and the dorsal as the breech presentation. The two positions become exaggerated owing to the extreme extension of the posterior limbs beneath the body and marked ventro-flexion of the fetal pelvis upon the lumbar spine, thus creating an attitude of the fetus suggestive of vertical position. The position is confined, apparently, to solipeds and ruminants.

The *posture* or *attitude* of the fetus signifies the relationship between the fetal body and its limbs and head and neck. As already stated on page 157, the young of unipara physiologically present anteriorly with the chin resting upon the dorsal surface of the anterior feet. One, two or all three of these parts may deviate from the physiological posture, the head variously directed to the right or left, up or down, etc. The limbs may be flexed pathologically at any articulation. Similar conditions may exist in the posterior presentation, and the feet and legs be abnormally fixed or extended at various points. The transverse presentations provide opportunity for an indefinite variety of abnormal postures of the head, neck, feet and limbs.

Such deviations of the extremities are less frequent in multipara, and when they occur are usually of less significance, because of the greater flexibility of the fetus, the comparatively short limbs and neck, and less complete ossification of the skeletal system.

Excessive Volume of the Fetus

Excessive volume of the fetus has been authentically recorded in rare instances in the cow, as a consequence of prolonged gestation.

On the contrary, prolonged gestation in the mare does not, so far as clearly recorded, result in excessive size. Cases coming under my observation have resulted in small foals—in one instance, a definite dwarf.

Excessive fetal volume is not rare from fetal anasarca, as shown in Fig. 76. When the fetus succumbs to disease, at near term, its volume is frequently enormously increased by emphysematous decomposition, which is logically associated with perilous uterine disease. The two combine to cause critical dystocia.

Dystocia not infrequently arises from the excessive volume of fetal parts, dependent upon disease, largely from an excessive volume of various fluids. One of the most common of these is hydrocephalus or distension of the lateral ventricles of the brain. Ascites or distension of the peritoneal cavity is not rare. Amnio-allantoic distension has already been mentioned in the preceding chapter. In the monster designated *Schistosomus reflexus* (Gurlt) the reflexed cutaneous sac sometimes has a small aperture which becomes occluded by parts serving as a valve. This may lead to extreme distension of the sac with amniotic fluid to the extent of ten gallons, barring the expulsion of the fetus until the imprisoned liquid has been permitted to escape. Also in the same monster I have recorded a case in which the fetal rumen was distended with an estimated ten gallons of fluid, presumably amniotic fluid which had been swallowed and failed to become absorbed.

Fetal rigidity, arising from various causes, frequently bars the expulsion of the fetus. Thus the deformity designated *muscular contraction* generally causes severe dystocia immediately referable to the rigidity of the fetal body, usually complicated by abnormally projecting parts. The condition designated *static fetal cadaver*, or permanent rigor mortis, so far as known, uniformly causes serious dystocia.

CHAPTER XVII

THE HANDLING OF DYSTOCIA

Equipment

THE equipment for obstetrical work should be ample for all contingencies, and yet limited to the necessary articles. Each part of the equipment should be simple in design, well constructed of good material, and well adapted for some particular service. They should be carefully assembled in convenient form, ready for immediate use. Throughout the history of veterinary obstetrics, the design of instruments and equipment has undergone constant change. New instruments have been devised, have been widely adopted and highly praised, only to disappear later, more or less completely, and be forgotten. Some of the oldest and simplest instruments retain their place as highly useful and essential appliances. The chief obstetrical appliances may be classified as instruments for traction, repulsion and incision or excision.

APPLIANCES FOR EXERTING TRACTION

Cords. The most useful appliance for the exertion of traction in dystocia in the larger animals is a twisted cotton cord. It is simple and economical, and affords the greatest available degree of safety for mother, young and operator. It is readily applied, when compared with other devices designed for the same purpose, retains its hold well, and offers ample power, the direction of which is under good control. The twisted cord is more pliable than the braided, holds better and injures the soft parts of the genital passages less. The size of the cord should vary from $3/16$ to $1/4$ inch. The smaller the size, the easier applied and the more secure its hold. Sometimes the small cord has a measure of safety in avoiding excessive traction. When there are bystanders, there is a strong tendency for more persons to take part in the traction, behind the operator's back, than he has directed. The breaking of the cord may then avoid injury. The cord should be about four feet long. It should be fitted with a spliced loop at one end, to be applied to the fetus, and the other end should be secured against ravelling. The cords should be prepared in advance, in ample numbers according to the prospective requirements. They should be disinfected or sterilized and separately wrapped in cellophane or other impervious or sterile fabric.

It is important that, before attempting to apply a cord for traction, the fetal part should be freed as well as practicable from the membranes; otherwise the application is difficult and the hold insecure. When it is attempted to pass the cord around a limb, it is commonly carried as far as practicable around one side, the hold released, and




FIG. 64. Method of securing the lower jaw by means of a looped cord.

then grasped from the other side of the leg. There is a tendency, especially when membranes intervene, for the cord to follow the operator's hand and thereby defeat the operation. This may be largely overcome by coiling part of the cord in the hollow of the hand, so that when the cord is released it tends to retain its location because of bulk. Even better, a heavy metallic ring about 2 inches in diameter may be attached to the end of the cord, which will tend

to retain its position by both weight and volume. Numerous types of these guide rings are available, amongst which those of Schriever and Lindhorst appear of special value.

If the cord is to be applied to the head or the foot presenting toward the vulva, the noose is prepared, and pushed over the part, until the desired point for fixation is reached. Fears have been expressed that the application of traction upon a cord looped about the neck would kill the young animal by choking, but it does not breathe until the chest has passed through the vulva, when the noose should be detached and the traction limited to the legs. With the noose about the neck, traction tends to deflect the head laterally. The deflection may be overcome by placing the loop beneath the pharynx and then throwing a second loop of the cord over the nose, thus giving the effect of a halter.

An ordinary noose upon the inferior maxilla is not very secure, as the jaw is markedly conical. Neither is a hook safe, because the two rami of the jaw are but frailly joined, and separate under very moderate traction upon a hook inserted between them. In the various deviations of the head, there are few methods more advantageous than traction upon the lower jaw. A cord, properly applied, affords a very secure attachment, permitting almost unlimited traction in a very advantageous direction. The cord may be very securely attached to this part by the method shown in Fig. 64.

With the ring-knife or other cutting instrument, make an incision two to four inches long, between the rami of the lower jaw, through the skin and superposed tissues, into the oral cavity. Next, pass the prepared noose of the cord over the jaw and push it back beyond the incision with the loop resting in the mouth of the fetus. Then pass the free end through the incision from the oral cavity outward, and draw firmly to tighten it, after which any amount of traction desired may be employed without any danger of slipping or of tearing out. By this method the two rami of the jaw are held together, instead of being split apart as when a hook is used. The objection may be raised that, in case of a living fetus, mutilation is caused, but the wound is so insignificant in character that there is no reason why it should not heal very promptly and without blemish. In some countries, bands are preferred to cords. They are more impressive perhaps, they are more costly, and it is not clear that they possess advantages. The cords are so inexpensive that if badly soiled they may be discarded. In recent years, obstetrical chains have been introduced, and are preferred to cords by many practitioners. They are cheap, readily

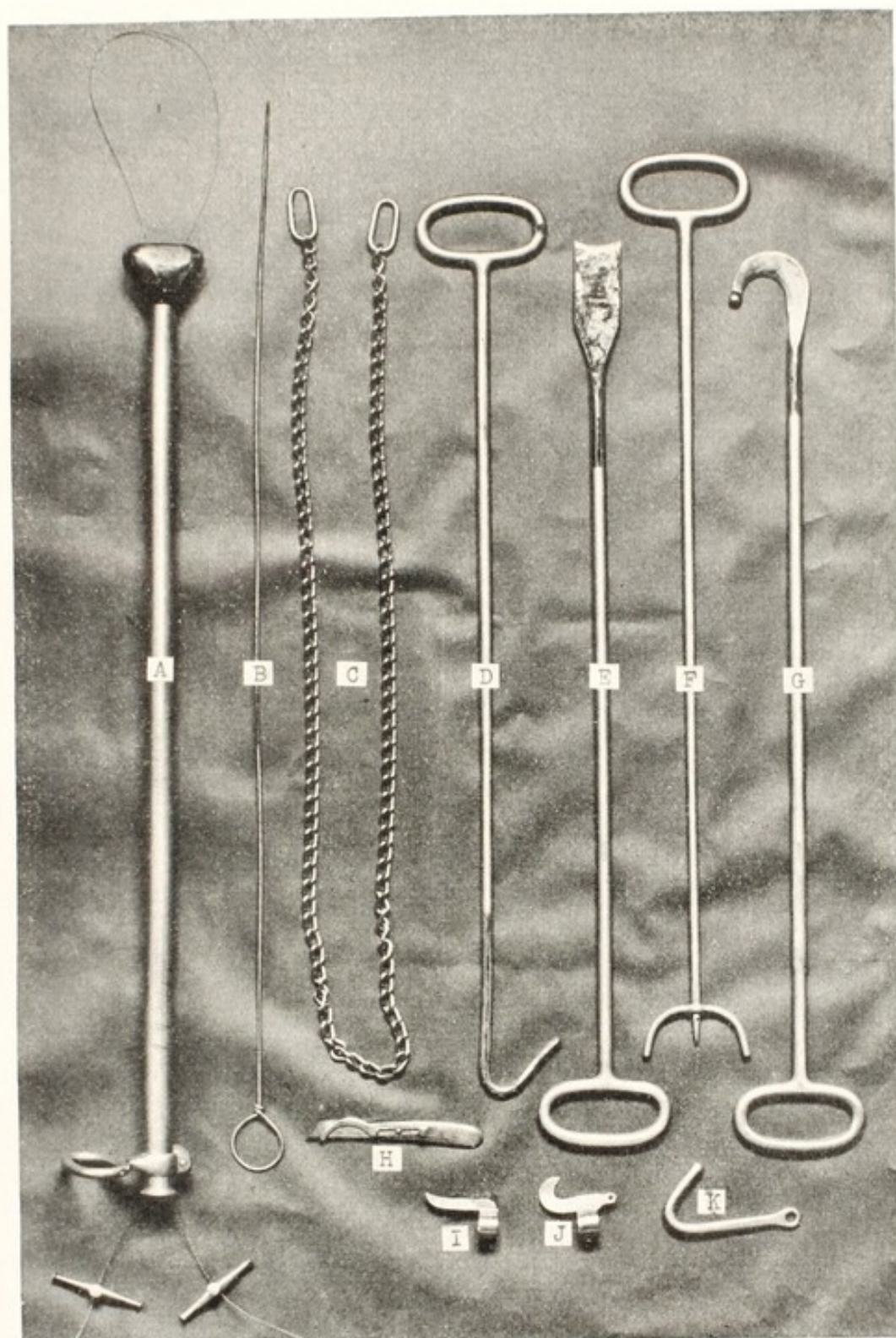


FIG. 65. Group of Common Obstetrical Instruments.

A, Fetotome of Benesch; B, carrier for introducing wire in A; C, obstetrical chain; D, long blunt hook; E, chisel; F, repeller with removable spike; G, sharp cutting hook; H, Colin's scalpel; I, concave finger knife; J, hooked finger knife; K, short blunt hook.

cleansed and very durable. They are easily applied to most parts, but in some instances are less convenient than cords, if at all practicable. The chains, which are smooth, have little tendency to abrade the soft parts.

In addition to cords and bands, there are used for applying traction, for small animals, such devices as a small tube of metal or other suitable material, through which is passed a wire loop.

Hooks. Few obstetrical instruments have been so much used, and made of so many patterns, as hooks. They may be either long or short, sharp or blunt. With short hooks or finger hooks, the traction must be applied by means of a cord passed through an eye in the hook or the hook is held in the operator's hand. Long hooks are applied to the desired point, accompanied by the hand of the operator, and traction is exerted from the outside with the aid of an assistant.

The advantages and disadvantages of long and short hooks are largely matters of personal experience. One practitioner becomes accustomed to the short hook, another to the long, and each believes that his kind is better. There are few, if any, places that a short hook can be applied where a long hook could not be inserted with equal facility, or vice versa.

There is one difference which is of importance. With the long hook the operator may, by pushing upon the instrument from the outside, aid the hand in reaching a trifle further and implanting the hook in a part which cannot be reached with the short instrument. Also, the point of the long hook may be turned in any direction, through the agency of the outside hand, when such control might not be possible with the short hook wholly dependent for guidance upon the inserted hand.

In comparing the sharp and blunt hooks, most practitioners favor the latter for excellent reasons. It is exceedingly difficult to apply a sharp hook with safety for either the mother or the operator. It is an ugly instrument to handle unless the patient is first placed under anaesthesia. Otherwise when an operator is carrying a sharp hook in his hand for insertion at a given point, the operation is almost certainly interrupted by violent expulsive efforts. It is only by the very greatest caution and dexterity that one can avoid at such times serious wounds of his hands or of the genital organs of the dam. After repeated trials with the sharp hooks, without finding them valuable in a single case, I finally abandoned all attempts to use them. Even should it be desired to fix a hook in a part where the blunt point would not penetrate, the skin may be incised and an opening provided for the blunt instrument.

The form of the hook is highly important. It is made in every conceivable form. Many makers, apparently ignoring all mechanical principles, construct an instrument which does not serve the purpose with that security and safety desired. Aside from the question of strength and finish, it is essential that a hook be so constructed that, when once inserted into the tissues and traction is exerted upon it, its form shall cause it to sink deeper and deeper into the parts and acquire a hold with constantly increasing security. The hook should leave the shaft at an angle of about 45° and continue in a straight line, or nearly so, to the end, as illustrated by D, Fig. 65.

When a hook is used for the development of traction the instrument must be constantly guarded by the operator's hand, lest it slip or tear out and lacerate the uterus.

In the application of hooks, the operator should always aim to select a point where the instrument will be secure against tearing out. In order to do this he needs have well in mind the anatomical structure of the fetus and the resistance of various parts.

Anteriorly, the hooks may be inserted with comparative safety in the orbit. If the fetus is dead, the point of the hook should be sunk deeply and force its way through the bony walls of that cavity into the sinuses of the face. For this purpose the hook should be about three inches in length. In correcting a slight deviation of the head, it may be allowable at times to insert the hook into the lower jaw between its two branches, but this constitutes a very insecure hold, which will give way under very moderate traction, and consequently does not permit of great force. When it is wished to apply severe traction to the lower jaw, the cord should be used, as already described.

In the anterior presentation with deviation of the head so that it is directed away from the vulva, the nostril or the commissure of the lips may form an adequate point of insertion for the blunt hook for moderate traction, but as soon as the head is drawn to a position where it lies transverse to the pelvic canal the hold becomes insecure. However, the most urgent part of the correction has been accomplished.

Obstetrical forceps of great variety have been constructed, largely in imitation of those used by the human obstetrice. They have uniformly failed in the obstetrics of large animals.

In small animals, obstetrical forceps have proven highly useful and practical. They constitute one of the safest and most efficient methods for applying traction to the fetus of the cat, bitch, and sow. Some of these are illustrated in Fig. 66.

Repellers. In obstetrical operations it frequently becomes essential that the fetus be pushed away from the pelvis, vagina or cervix into the uterine cavity or the abdomen, in order that room may be obtained in which to make certain changes in the posture of parts or to carry out other operations which may be essential to the extraction of the fetus. This procedure is designated repulsion, or retropulsion. The most primitive and safest method is that of pushing the fetus backward by means of the operator's hand. This is the most effective means for bringing about changes in the location and direction of the fetus, because the force may be constantly applied at the proper angle and may be at once modified according to any changes in the position of the fetus during the progress of the operation.

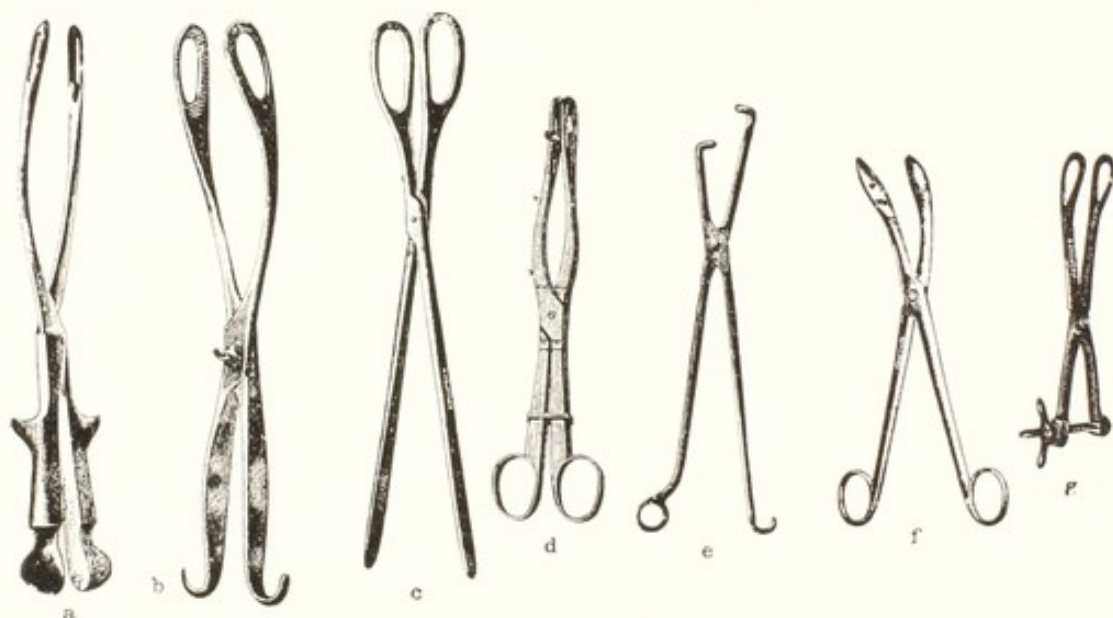


FIG. 66. Obstetrical Forceps.

a, Roeder's obstetrical forceps for swine; b, Walch's pig forceps; c, Witt's obstetrical forceps for swine and goats; d, Moeller's bitch forceps; e, Ellinger's pig forceps; f, de Bruin's forceps for sheep; g, de Bruin's bitch forceps. (Hauptner.)

Manual repulsion has the disadvantage that it places upon the operator the full burden of a more or less difficult task and makes a demand upon his physical resources, which may later be needed for the accomplishment of other important operations. In harmony with the rule that the operator should delegate to other persons whatever they may safely and properly do, leaving him to direct the application of force, the repeller has been introduced to relieve the obstetrice from the physical strain involved in this operation.

It should be about 30 to 36 inches long, and made of steel which will not corrode, or which is heavily plated. The width of the crutch

should not exceed 3 inches, in order that it may be fully guarded by the operator when inserting the instrument. The security of the position of the repeller may be increased by means of a detachable spike, as shown at F in Fig. 65. The operator needs to guard the repeller constantly while the fetus is being repulsed, but once the fetus has been satisfactorily located, it may be retained in its position by an assistant, while the obstetrict undertakes other manipulations. Repellers of great variety are made, such as the Kühn crutch, which differs from F in Fig. 65 in that the two branches of the crutch are fitted with an eye at the distal end, through which a loop of cord may be passed. This may be passed around the extremity and a secure hold obtained.

Instruments for Section. The obstetrict sometimes desires to diminish the size of the fetus by excising one or more of the parts in order to permit of its easy passage through the birth canal. A great variety of instruments has been devised for this purpose. Each operator has his preference, and for each those instruments to which he is accustomed may be the best, because there is no place in the realm of surgery where familiarity with an instrument constitutes a greater part of its value to the operator than in embryotomy.

Knives. These are made in infinite variety. They may be classified as finger (ringed) knives and short-handled scalpels. The finger-knife is highly useful. Representative varieties are shown in Fig. 65. For all those operations where it is desired to make a long, drawing cut, by inserting the hand to the point where the incision is to be begun and then making the cut as the hand is drawn outward, the blade may advantageously be hooked. In such case the hooked knife sinks into the tissues automatically and the operator simply keeps his hand against the surface which he wishes to cut and draws the knife, guarded by his hand, backward.

Finger-knives, as made by most instrument dealers, are too long for some practitioners and cannot be easily handled. The operator with a small hand cannot guard the ordinary finger-knife in such a way that he can readily introduce it to the point where he desires to work. Because of this difficulty obstetricts with short fingers need have finger-knives constructed to order. The blade of the finger-knife should be of such a length that, when it is placed upon the finger, the hand can close about it in such a way as to protect the point completely, with safety alike to the operator and to the patient. These instruments, which admit chiefly of incisions in a line parallel to the long axis of the operator's hand and arm, cannot very well be used

for a transverse section. If the ring is larger than the finger, so that it fits loosely, it may be turned more or less obliquely across the hand and, by bending the finger somewhat, the operator may be enabled to make a transverse incision.

Scalpels. There is also a very extensive list of scalpels or bistouries with straight handles, the blades of which may be either naked or concealed. In some the blade is concealed within the handle; in others by a movable guard. A good representative of this type is the Colin scalpel, H, Fig. 65.

The advantage of the scalpel over the finger-knife is that it may be turned in any direction, so that an incision may be made longitudinally or transversely, as the operator may desire. With it the operator may also make either a pushing (stab) or drawing cut, as may be desired. It has been suggested that an objection to this kind of knife is the possibility of losing it in the uterus, but in my experience this objection is not well grounded. To guard against such a possibility, some of these instruments are made with an eye at the extremity of the handle, through which a safety cord may be passed and secured about the operator's wrist. It is important that these scalpels be made very short and the handle be of such a character as to afford a firm hold. The knife should not exceed four inches in length, so that it may readily be concealed in the hand and carried to any part of the uterus.

The long cutting hook has been made in great variety. Those which are sharp-pointed are highly dangerous for operator and patient. The sphere-pointed instrument, G, in Fig. 65, is safe in the hands of a capable operator, and in some cases is highly useful. The obstetrict may readily sever the fetal ribs with it after evisceration, may divide the pelvic symphysis or the pelvic girdle at other points, and accomplish other operations.

The severance of the fetal ribs is especially useful in excessive emphysema, because the lacerations, affording an exit for the gases, decrease the size of the mass.

Embryotomes. Embryotomes, such as that of Pflanz, are of great variety and design. They are intended to cut, crush, or tear through any portion of a fetus to which they may be applied, whether the tissues be soft or hard. Although in use for a great many years, they have not acquired a very wide application. They are so large and heavy that they are exceedingly difficult to introduce into the genital passages. When they have been introduced, the part which is to be amputated must present in a position essentially perpendicu-

lar to the long axis of the pelvic canal, since otherwise the instrument cannot be applied to it.

Chain and wire saws of various designs have been introduced. At first these were used unguarded, and the important objection was raised that they caused abrasions of the birth canal. In more recent years notable advances have been made, and they have been rendered far more efficient and safe. The fetotomes or embryotomes of Thygessen, Neubarth and Benesch have acquired deservedly great popularity. That of Benesch, A, Fig. 65, is best known in America. The instrument is readily applied, it severs rapidly skin, muscle, bone or other tissues, leaving a smooth surface. Injuries to the soft parts of the birth canal are amply guarded against. Amputations of the head and limbs are quickly accomplished. The extremity to be amputated need not present transverse to the birth canal, as with many instruments, but may be oblique or even longitudinal. The instrument is unquestionably of great value. Some have unqualifiedly endorsed it as displacing all other instruments for embryotomy. This, as in the case of many new instruments of value, is too enthusiastic. There remain important uses for other appliances. In anterior presentation of the equine fetus, with wry-neck, the fetotome will remove the foreleg, but will not properly denude the chest wall for the highly important evisceration. In both anterior and posterior presentations it is often highly essential that the pelvic girdle be destroyed. While it is claimed that this may be accomplished with the fetotome, it is certainly easier and quicker to use the obstetrical chisel. So with other operations. The fetotome should be accorded a high place in embryotomy, but it is erroneous to depend upon it alone.

Obstetrical chisels of various types have long been in use and have been constructed in great variety. They continue to have distinct advantages in a few embryotomies, and in those few cases deserve a high place. The plain chisel, E, Fig. 65, has proven highly useful in my hands in comminuting the head. It may be driven here and there into the face and cranium, and forcibly turned upon its long axis, breaking up, and loosening the bones until they may be removed manually, or if the skin is attached, a cord may be looped about it and the piece torn away by traction. Similarly, this type of chisel is readily driven through the pelvic girdle at any point, whether the fetus be in anterior or posterior presentation. In some double monsters and in hydrocephalus with excessive cranial bones, the instrument is very convenient.

Another useful type of chisel is the V-shaped instrument, with the branches of the V guarded by spherical or probe tips. It is highly prized by some operators for separating the skin from the limb, in the subcutaneous amputation of the anterior extremity.

The chisel can make a *pushing* cut only. Sometimes it is advantageous to make a *drawing* cut through the skeletal tissues, in which case the guarded sharp hook, shown in Fig. 65, becomes distinctly useful. Such is the case in extreme emphysema of the fetus, in which, after evisceration, it is often well to cut the ribs, thus mutilating the chest walls so that the imprisoned gases may escape from the tissues.

Careful study should be given by each obstetrict to his equipment. Obstetrical instruments are being constantly improved, and as in other fields, many alleged improvements prove fictitious. The practitioner needs be ready always to discard a given appliance for a better one, yet sufficiently conservative to refuse to accept an instrument simply because of its newness.

The veterinary obstetrict should further include, in his equipment, general operating instruments, disinfectants, local and general anaesthetics and equipment for their use, hypodermic syringes with uterine and general excitants, lubricants, and douching apparatus.

THE DRESS OF THE OPERATOR

When dressing for an obstetrical operation upon large animals, the veterinarian should have due regard for his health and comfort, for the safety of himself and the animal from infection, and for convenience and economy. Obstetrical work must in many cases be carried out in a cold stable amidst much dirt. The abundant fetal fluids, the waters used in washing, and liquids from other sources, add to the problem of keeping dry. The operator is best guarded against cold, wet and noxious or repulsive discharges by wearing impervious clothing. Trousers or overalls of rubber cloth afford the best protection for the lower portions of the body and legs. They are readily washed, are clean, durable and of reasonable cost. Similarly the short leggin boots now available, which will slip over the shoes, protect the feet splendidly.

The upper parts of the body may be conveniently protected by a sleeveless cotton blouse or jacket, or in cold weather by a rubber coat with the sleeves cut out and the armholes adjusted to fit snugly upon the arms. Rubber gloves afford desirable protection against dangerous infections and repulsive odors.

Position and Control of the Patient

One of the most disagreeable features to the veterinary obstetrict is the surroundings in which he finds his patient and is compelled to do his work. In many cases this is inimical to the comfort and health of the obstetrict and it is sometimes a question how far it is proper for him to ignore these factors in the course of his professional duties.

Sometimes a stable is exceedingly cold, but this, as a rule, does not seriously discomfort the veterinary obstetrict, since once he is engaged in his work he can usually keep warm. Sometimes the place for his work is disagreeably hot. In one instance, working in the hot sun upon a recumbent mare in an open field, my arms were so badly sunburnt that I was incapacitated for some days. Rubber gloves with long sleeves would have avoided this.

In the interest of the veterinarian and owner alike, the patient should be provided with as clean and comfortable a room as is practicable, with ample space for carrying out the required operations with the highest degree of safety. Where adequate hospital and trucking facilities are available, their use is highly desirable in severe dystocia in mares and cows, adding greatly to the safety of the patient and convenience of the operator.

The position of the pregnant animal during obstetrical operations is of fundamental importance. In the larger animals most operations can be best carried out with the patient in the standing position. In this position the abdominal floor slopes downward and forward below the pubis, and the gravid uterus drops forward toward the diaphragm. This admits of readier repulsion of the fetus, facilitates the correction of any deviations in its extremities, and favors the carrying out of most obstetrical operations.

Sometimes the animal, especially the cow, is exceedingly obstinate and refuses to stand, even under the greatest punishment. It is usually of little use to lift the cow by force, because she absolutely refuses to stand. If able, the cow will usually rise promptly when a dog is brought in and either takes hold of her or threatens to do so. She is also very sensitive to skin pricks and will generally get up if the skin is mildly pricked, but not penetrated, with a pointed object.

Some animals suffering from dystocia are vicious, and the operator must take precautions against injury from them. In carnivora it is wise to muzzle the patient before attempting any work which may induce any vicious resistance. In ruminants there is almost no danger to the operator because of any viciousness upon the part of the pa-

tient. Very rarely the cow may kick, but this is usually more annoying than dangerous. It is very rare that the mare offers any violent resistance to the work of the operator.

In an extensive experience in the obstetrics of mares, I have met with but one case which required mechanical restraint because of extreme viciousness. In that one I found it necessary to cast the animal and tie all feet securely. This compressed the abdomen and rendered the embryotomy, already very difficult, extremely trying. General anaesthesia would have been far better but was not available. Epidural anaesthesia was then unknown; its use might have overcome the viciousness.

Although the standing position is usually the most favorable one for operating, in some instances recumbency is preferable. Whether the recumbency is unavoidable or is brought about by the operator for special reasons, the position of the recumbent animal is highly important. If, for instance, an animal is recumbent and there is a deviation of the fetal head toward the left side of the mother, it would be highly unfavorable for the operator, should the mother lie upon her left side, because the weight of the fetal body would thus be thrown upon its head. If the patient lay upon her right side instead, the fetal head would rest upon its body and it would be more readily extended. Hence in many instances it is desirable to change the attitude of the recumbent animal or even to cast the patient in order to effect certain manipulations or changes of position. Usually, when an animal is recumbent, she should be placed with her hind parts elevated, in order that the fetus may drop away forward toward the diaphragm, affording increased room for repulsion, changes in position, or other desired operations. It is important generally that the recumbent animal should lie prone upon her side with all her limbs free and extended.

It is very disadvantageous to the operator for the patient to lie upon her sternum, since this position causes undue pressure upon the abdomen and crowds the gravid uterus against or into the pelvis so tightly as to render repulsion well-nigh impossible, and any other changes in the position of the fetus or the correction of any deviation of an extremity very difficult.

In order to elevate the hind quarters of a recumbent animal, extra bedding is sometimes placed beneath the posterior parts to any degree desired, but this is not always efficient. Sometimes advantage may be taken of sloping ground, such as a terrace. I have sometimes placed an animal in a doorway where the floor within was higher than the

ground without. The doorsill is well padded with straw, and the cow is placed with her head outward and her buttocks in the stable, at the higher elevation. The elevation of the posterior parts is best and most efficiently obtained by placing the recumbent animal upon a heavy door or on a platform of heavy boards, and raising that portion of the door or platform upon which the posterior portion of her body rests, supporting it by means of blocks placed underneath. Usually, the greater the elevation of the posterior parts of the recumbent animal, the better for the operator. In order to prevent the patient from sliding down the incline, ropes may be attached to the hind feet, and held by assistants or attached to a post or beam.

Even greater advantages may be afforded sometimes by placing stout ropes upon the hind legs, carrying them over pulleys attached to a beam above, and turning the patient upon her back, more or less completely suspending her with the head downwards. This causes the fetus, along with the rumen and other viscera, to drop forward by gravity, and affords room for version or other manipulations. The position cannot be maintained for a very long period. The question of the exact position of the patient during obstetrical operations is to be determined in each case by the character of the obstacle to parturition.

The expulsive efforts of the mother frequently constitute an important impediment to obstetrical operations, and sometimes render an otherwise very trivial procedure exceedingly difficult, or impossible. Sometimes the slight deviation of a fore limb could be corrected in a few minutes if the patient would not strain, but under constant and violent expulsive efforts it may become a very laborious operation of long duration. So with many other manipulations. It is consequently important that one should understand and apply as fully as possible all means for controlling the expulsive efforts of the mother.

Expulsive efforts of the mare may be diminished in some instances by the application of a twitch to the upper lip, and similar results may be attained in the cow with the leading ring applied to the nose.

Epidural Anaesthesia

The application of epidural anaesthesia by means of cocaine, or preferably novocaine, has largely and advantageously replaced other methods for the control of resistance to obstetrical operations, especially in the mare and cow. The plan was brought to the attention of the profession by Benesch⁷ in 1926, Richter⁴⁵ and yet more fully by Benesch⁸ in 1936. The technic has been well developed for the

mare and cow and the principles involved apply to all species. Benesch advises the administration of 10 to 22 cc of a 1% solution of novocaine for the standing mare or cow of 700 to 1200 pounds. If the animal is recumbent the dose may be increased to 30 to 60 cc.

Some advise a 2% solution, while others have found that the more concentrated solution sometimes induces posterior paralysis, causing the patient to go down and rendering the operation less convenient. If a large dose is used it is well to have the patient in surroundings where recumbency would offer a minimum of inconvenience.

Epidural anaesthesia is far more effective in essentially all cases than the older methods. The mechanical restraint of the patient does not control the violent expulsive efforts, and the application of the twitch or other pain-producing appliances can at best operate only very imperfectly. The epidural anaesthesia virtually eliminates labor pains; the animal, free from the excruciating pain, usually stands quietly, without kicking, lying down or other disturbing movements. The anaesthesia enables the operator to repel the fetus far more easily, in order to correct abnormal deviations of extremities or make other adjustments favoring the removal of the fetus; vastly increases the facility and safety in embryotomy; adds to the safety of the patient by shortening the duration of the operation; protects her against accidental instrumental, or other injuries; adds to the safety of the obstetrice; and reduces the fatigue of the operator to the minimum.

The injection is made between the first and second caudal vertebrae. The articulation is identifiable by palpating the dorsal area with the finger tips of one hand, while the tail is elevated and depressed with the other hand. The area is clipped or shaved and disinfected. A strong hypodermic needle, $2\frac{1}{2}$ to $3\frac{1}{2}$ inches long, is used, which is inserted upon the median dorsal line, perpendicularly, or slanted slightly toward the sacrum, to a depth of $\frac{4}{5}$ to $1\frac{3}{5}$ inches for the cow. The mare requires a needle $3\frac{1}{2}$ to 4 inches long, inserted for a distance of $1\frac{1}{2}$ to 3 inches, until the needle point enters the neural canal. The position of the needle may best be tested by a trial injection: if the needle point is in the epidural canal, the fluid passes into it under relatively light pressure; if it has passed too far, and entered the walls of the distal side of the canal, the fluid does not readily pass. In the latter case the needle should be withdrawn and a second effort made. If a small vessel is wounded and blood escapes through the needle, the latter may be withdrawn and the blood clot removed.

The fluid should be injected slowly with occasional brief pauses. Anaesthesia follows after five to ten minutes and endures for 1 to 1½ hours. Since the anaesthesia may render the animal unable to stand, it is best to anticipate this by providing adequate safeguards against falling, such as slings or bands underneath the body.

Epidural anaesthesia is somewhat more difficult in the mare than in the cow, owing to the greater diameter of the tail. The same principles apply in each. Chloroform anaesthesia may be used instead, if the novocaine is unavailable.

The Examination of the Patient

Before proceeding with obstetrical operations, it is essential that the practitioner should make a careful examination of his patient. First he should determine as well as practicable her condition, whether she is strong and vigorous or weak and debilitated. He should note if there is anything in her general condition which would suggest some serious or fatal internal lesion, such as hemorrhage from a uterine rupture. This knowledge can be gained partly by the general appearance of the patient and partly by the examination of the pulse and visible mucous membranes.

It is highly important, both from the forensic and the professional standpoint, that the veterinarian determine very early whether empirics or others have meddled with the case prior to his arrival and have caused thereby more or less serious injury, which, if it passes unnoticed, may lead later to serious embarrassment. It is exceedingly unfortunate, for example, for a veterinarian to be called to attend a case which has previously been meddled with by an empiric, to the extent of rupturing the uterus or causing some other fatal lesion, and to proceed with the operation of delivering the animal without having first discovered that the fatal injury exists. Should this error be committed, the veterinarian is almost inevitably blamed for having caused the injury himself, and may even be unjustly held legally responsible for the consequences. I was called to attend a valuable mare suffering from dystocia, in which the head of the fetus was deviated to the side. An empiric had attempted to catch the head with a butcher's hook in order to correct the deviation, but failed to do this and ruptured the uterus. I was not advised that anyone had attempted delivery, and, in fact, meddling with the case was denied. Embryotomy was proceeded with, without examining the uterus very carefully except in the posterior part. When nearly through, the rupture was discovered owing to the prolapse of the intestines of the mare through the rent

in the uterus. It was only under hard pressure that the owner was finally compelled to admit that other parties had attempted the delivery before I had been called. Similar experiences are common in veterinary practice, and should always be guarded against as carefully as possible, because such oversight is liable at any time to affect very unfavorably the professional standing of the veterinarian.

In such an examination the practitioner should also determine the condition of the genital organs in every way—whether the passages are fully dilated or are dilatable, whether they are normal or obstructed, and whether they are inflamed, swollen or necrotic. It is highly important also to learn at once whether there is any displacement of the uterus, such as torsion. The condition of the fetus is also highly important in reference to the course to be pursued and the prognosis. It should be determined as early as possible whether the fetus be dead or alive; in case it is dead, much depends upon whether it has undergone decomposition.

Since cows sometimes exhibit a high degree of resistance to infection, an emphysematous or putrid fetus may sometimes be removed and the life of the animal conserved.

It is difficult to save the life of a mare if her fetus has become putrid. It is also exceedingly difficult to save the life of a mare if she has been in labor more than twenty-four hours, although much will depend upon the position in which the fetus lies, whether it has become impacted in the pelvic canal, and the amount of interference which the mare has suffered at the hands of incompetent persons.

The veterinarian needs determine precisely the nature of the obstacle which is to be overcome, to which end it is essential that he shall be able to identify the various portions of the fetus by the sense of touch, and to determine thereby the presentation, position, and deviation with which he has to deal. While apparently it should be easy for the operator to determine which portion of the fetus he touches, it is not, after all, a light task.

The differentiation between the anterior and posterior limbs is sometimes difficult. With the fetus inside the uterus, and that organ closely investing it, the differences, to the touch, between the anterior and posterior limbs are sometimes not so marked as the obstetrician would wish. He cannot tell the fore and hind feet apart until he reaches the carpus and tarsus. Even then the tarsus may be so extended that it may present a very strong resemblance to the carpus, though the two articulations may generally be differentiated because the os calcis, with the tendo-Achilles attached to its summit, is more

prominent and clear-cut than the pisiform bone of the carpus with its attached tendons. If the elbow can be reached and compared with the stifle, they are generally quite easily distinguished, and as soon as one can reach above these two parts the difficulty of differentiation usually ceases to exist.

In examining the limbs for purposes of identification, the inexperienced veterinarian must not be too hasty in his conclusions, but deliberately study the extremities with which he is dealing until they are clearly identified upon anatomical grounds. In the event of three or four limbs being presented simultaneously, it is sometimes more difficult because of their intricate entanglement to trace and identify each member. The passages are so filled, because of the extra number of limbs, that one can insert the arm only with difficulty, and under such severe pressure that the sense of touch is somewhat dulled. When the feet of twins present simultaneously, they are liable to cause very great confusion in diagnosis.

One or more extremities of each twin may have entered the birth canal, with every complication possible for two heads and eight feet. If the obstetrice is at all careless he may, and occasionally does, apply traction simultaneously upon the extremities of both twins. A single fetus may be so deformed, by the spinal column being sharply bent, that the head and all four feet present simultaneously, offering the suggestion of twins. This is true of *Schistocormus reflexus* and *Campylorrhachis contortus*.

In some cases, where there are important teratologic conditions, it is difficult to determine the part of the body with which one is dealing. It is necessary to study carefully the anatomical relations of each part. In hydrocephalus, with a large amount of fluid in the greatly distended cranial cavity, the part sometimes reminds one very much of the fluctuating abdomen of the fetus, and can be differentiated only by finding and recognizing the ears, eyes, mouth, or some other definite part.

Double monsters sometimes offer great difficulties in diagnosis. Fortunately they are ordinarily symmetrical, so that two cephalic, or two caudal ends may be recognized, either by palpating their point of union or by finding that the repulsion or advancement of one affects identically the other. When double monsters are connected end to end, either by the cranium or by the ischium, the condition is not readily determinable until the expulsion becomes stalled when the second half enters the pelvis. If the hand can be introduced alongside the first member, the second may be palpated recognizably. If

that fails, the diagnosis may be reached in the cow or mare by rectal palpation. Should these means fail, embryotomy of the first segment brings the second within reach.

The Prevention of Infection During Obstetrical Operations

The rules laid down by obstetrists for the conduct of labor in women are impossible of application in veterinary obstetrics. The patient is thickly covered with hair which is saturated with every available variety of dirt. In valuable cows, where climatic or thermal conditions render it safe, a thorough bath just before labor sets in is of distinct value and falls well within economic limitations. It has not been widely adopted because its intrinsic value has not been sufficiently recognized.

Obstetrical operations upon dairy cows, in which dystocia is most common and serious, must generally be undertaken in the stable, commonly filled with cows. The bedding is dusty and contaminated with excreta. The air is laden with dust from movements of the patient, of other cattle and of attendants. The occasional voiding of soft feces and of urine by the patient does not lessen the difficulties. When operating upon large animals, the veterinary obstetrist may wear rubber gloves.

The veterinarian ordinarily attends in labor only those animals suffering from dystocia, which as a rule are already abundantly infected. The problem then arises of avoiding so far as possible the introduction of additional infection and of controlling and ameliorating the present infection the best one may. The patient needs be placed in the very cleanest surroundings available, and the tail and rump washed and disinfected as thoroughly as possible. If the patient is recumbent, and unable or unwilling to stand, a clean, disinfected sheet of ample strength and proportions should be spread over the bedding and beneath the buttocks of the animal.

The veterinarian should include such a cloth in his obstetrical outfit, and ample pails or other large vessels for containing a supply of disinfecting solutions.

Lubricants, such as oil, fats, powdered elm bark, or other agents, should be constantly and abundantly used, and care should be taken to avoid, so far as possible, abrasions of the soft parts by the hands, by cords or other appliances and, in embryotomy, by projecting bones.

When the dystocia has been relieved it is important, in large animals, to palpate carefully every part of the uterus, making a general survey of its condition and keeping a special outlook, in unipara, for

an unanticipated twin; for penetrant wounds of vagina or uterus; for intussusception of the ovarian pole of one of the horns; or other important injury. If the afterbirth remains, it should be removed if practicable. The uterus is inevitably exhausted, in varying degree, and more or less incompetent to expel the membranes and secretions. If the fluids remain behind, after the placenta has come away, a long soft rubber catheter or douching tube should be introduced to the lowest and most distant parts of the uterus, the tube filled with physiological salt solution, the outer end lowered, and the contents siphoned out. In anticipation of probable increase of the intrauterine infection, there should be introduced, into the deepest part of the uterus, one or two pints of white mineral oil in which has been suspended one-half to one ounce each of iodoform and subnitrate of bismuth or other feebly soluble, non-irritant antiseptics.

The obstetrice should make ample provision against infection of his hands and arms. The skin of some veterinarians is so highly sensitive to infection that they are in constant trouble, especially when working with putrid fetuses or afterbirths. The best that can be done, so far as determined, is that the operator pause frequently in his work, to wash and disinfect his hands and arms and apply lubricants to them. After finishing the operation he should lose no time in cleansing and disinfecting his hands and arms. There is probably no more efficient method of disinfecting than by first washing with hot water and soap, then immersing the parts in a hot, concentrated solution of permanganate of potash, and later decolorizing with oxalic acid solution. This leaves the epithelium somewhat denuded, but the ill effects may be largely overcome, and the disinfection advanced, by applying a mixture of ten parts of glycerine with one part of tincture of iodine. A thorough bath, with complete change of soiled clothing, should follow as quickly as practicable.

CHAPTER XVIII

OBSTETRICAL OPERATIONS

IN overcoming dystocia, a number of operations may be demanded, which vary greatly in character and may admit of many variations in technic. The obstetrict should be as conservative as possible in the selection and carrying out of a plan for the overcoming of obstacles to delivery. He should have in mind the entire list of available obstetrical operations, and determine which of these he should elect to carry out in a given case. In determining upon a plan for operating, he should consider first that plan which is the most conservative, since if it succeeds it is best from the standpoint of the well-being of the mother, the fetus, and the operator, and the economic interests of the owner.

The chief obstetrical operations are: mutation, forced extraction, embryotomy, hysterotomy and hysterectomy.

Mutation

It has been indicated on page 157 that physiological birth in uni-para demands that the fetus present by the head, in dorso-sacral position, with the anterior limbs extended. In multipara the presentation may be either anterior or posterior. The carnivorous fetus, when it presents anteriorly, usually presents by the head alone, with the anterior limbs folded back beneath the chest. Any deviations from such physiological arrangements call for interference by the veterinary obstetrict in order that birth may proceed. It is the function of the obstetrict to bring each part into the normal relation and position, or otherwise to overcome the obstacles to birth. The chief operations or manipulations, collectively designated mutations, by which it is hoped to correct the position or attitude of a fetus, are repulsion, rotation, version, and extension.

Repulsion or Retropulsion

Repulsion or retropulsion of the fetus consists of pushing it out of the maternal pelvis, toward the diaphragm, into the abdominal cavity, and contemporaneously into the uterine cavity, where space is available for changing the position of the various extremities or of the entire body. Repulsion is necessitated by the fact that the birth canal is so narrow, and so completely filled by the fetus when it has

once entered, that there is little or no room for carrying out any extensive changes in the arrangement of the fetus, which must consequently be repelled or pushed out of this narrow channel into a more commodious cavity, where ample room may be obtained.

It is to be recognized that repulsion is not wholly the actual pushing of the fetus forward toward the head of the mother in a direct line. It consists largely of the partial version of the fetus. The body of the fetus as a whole is driven away from the vulva but little, though a given part of the fetus is driven through a considerable distance. Ordinarily when repulsion is desired, the fetus is lying inclined, if in the longitudinal presentation, and that end of the fetus presenting toward the vulva of the mother is higher than the opposite extremity. When it is repelled, the proximal end is ordinarily pushed obliquely upward toward the maternal spine and forward toward the head of the mother. At the same time the distal end of the fetus possibly approaches nearer to the pelvis than it was at the beginning of the repulsion. Repulsion therefore commonly means that a certain part of the fetus is pushed away from the pelvic inlet, not that the entire fetus is pushed toward the mother's head.

Frequently when repulsion is desired the fetus is dead. It is then best to use a repeller having a sharp spike in its center, F, Fig 65, which sinks into the tissues of the fetus and gives the instrument a secure hold. Even if the fetus is alive, the small spike, passing into the soft tissues, usually produces an aseptic wound, which, healing without inflammation and without requiring material attention, is not highly objectionable. In order to overcome any such objection, however, the spike should be detachable. In case the fetus is alive and the spike not absolutely necessary to secure fixation of the instrument, it may be unscrewed and removed and the instrument used without it. The Kühn crutch mentioned on page 217 is preferred by many obstetrists.

When using any type of repeller, the hand of the operator should constantly accompany the end which is in contact with the fetus during the entire operation of repulsion, thereby guiding and directing the force of the repeller and guarding constantly against its slipping or otherwise injuring adjacent parts. When the repulsion has been accomplished and it is desired to hold the fetus in its position while the operator carries out some change in the position of an extremity or brings about some other modification, it is allowable to take the hand away from the instrument and instruct the assistant to press steadily upon it. The person handling the repeller must be prepared to withdraw his force immediately, and even the instrument, in case

there is any suspicious change in position of the fetal body, especially if it seems to yield in such a way as to suggest that the instrument may be displaced.

Some obstetrists condemn the repeller as dangerous, but this is not true if it is used prudently. The repeller should be used in most cases where repulsion is desired. The operator should, as a rule, abstain from using his own strength for bringing about repulsion. Others may do this quite as well, or better, if the operator will place the instrument securely against the desired portion of the fetus and, accompanying it constantly with his hand, direct the force of the assistant.

When force is applied to repel the fetus, the movements almost inevitably arouse more or less vigorous expulsive efforts, which tend to prevent the attainment of the desired end. In such case the expulsive efforts should be overcome by the use of epidural, or of general anaesthesia. If this is not done, little, if any progress can be made during the labor pains: the operator must wait until the expulsive efforts cease and then, by a prompt thrust, push the fetus away toward the anterior end of the uterus. During the expulsive efforts, however, the operator should attempt to prevent the fetus from being driven far toward the pelvis or into it, by maintaining a steady pressure in the opposite direction and then being ready, as soon as the expulsive efforts relax, to accomplish quickly the results which are desired.

Rotation

In order that a fetus may pass readily through the birth canal, it must offer in the longitudinal presentation and the dorso-sacral position. When presenting otherwise, it is desirable, if not necessary, that the fetus be rotated upon its long axis until it is brought into the dorso-sacral position, and its expulsion or extraction rendered possible.

The rotation of the fetus upon its long axis is naturally most practicable when its body is lying within the abdominal cavity. Once the fetus has become impacted within the pelvic canal, rotation is extremely difficult or impossible. The body of the fetus should be pushed into the abdominal cavity, while its limbs are retained in the pelvic canal, as levers through which the rotation may be largely accomplished. Preparatory to rotation, it is highly advantageous to lubricate thoroughly the uterine cavity and fetal body.

Before attempting the rotation of the fetus, the obstetrist should determine whether the pathological position is purely fetal or is due

to uterine torsion, the uterus and fetus having revolved together. As indicated on page 292, uterine torsion through 90° to 180° is very common in dairy cows. Since both uterus and fetus are crescent-shaped, the fetus cannot readily turn upon its long axis without involving the uterus. Then the rotation of the fetus corrects or aggravates the uterine torsion according to the direction of the rotation. Hence it is highly essential to make this determination. In the mare, with the complete double sac, the fetus may revolve with its amnion without involving the uterus.

Unfortunately our knowledge of the subject is extremely defective. We have recognized what we termed dorso-ilial and dorso-pubic positions and proceeded to revolve the fetus upon its long axis, without determining the basic causes underlying the dystocia. Writers describe various degrees of uterine torsion in unipara, without making clear the fact that uterine torsion to the extent of 180° may exist with the presenting end of the fetal body extending into the vagina and pelvis. The torsion needs be regarded as having occurred prior to the advent of labor. If the torsion exceeds approximately 180° , the cervico-vaginal canal is closed, and the end of the fetal body cannot be forced through the occlusion into the caudal area of the vagina and the pelvis. If the torsion be extreme, the uterus becomes paralyzed and labor does not set in. If the torsion is limited to 90° or 180° , the enfeebled uterus may have the power to force the weak or dead fetus into the caudal area of the vagina and the pelvis, where it becomes stalled. The posterior end of the vagina is then distended by the contained portion of the fetal body, and the spiral foldings of the vaginal walls, by which uterine torsion is most frequently identified, are obliterated or reduced to a minimum and are not usually recognized by the obstetrice.

While there is abundant room for conflict of opinion, the conclusion seems warranted that the vast majority of dorso-ilial and dorso-pubic positions in unipara are the result of uterine torsion and that the fetus and uterus have revolved through 180° or less, prior to the onset of labor. In any event it is quite certain that when the fetus is rotated upon its long axis in order to overcome the dystocia, the uterus also revolves about its long axis. Harms³² suspects that uterine torsion may be largely responsible for the abnormal position and significantly remarks that when attempting unsuccessfully to reduce the dorso-pubic position by rotation in one direction, the operator should try the opposite: that is, if he attempts to rotate the fetus in the direction of the torsion, and fails, he should try to rotate the fetus in the opposite direction and reduce the uterine torsion.

Before one attempts to rotate the fetus in dorso-pubic position, an attempt should be made to determine the direction of the torsion. When the uterus has revolved through 180° the broad ligaments have been pulled across the uterus. If the dorsum or upper side of the uterus has turned to the right, the left broad ligament is pulled over the uterus and the uterine artery, instead of passing obliquely downward to enter the uterus from beneath, passes over the uterus from left to right. It is therefore essential to the highest success, that the direction of the torsion be determined in the dorso-pubic malposition. If the position is dorso-iliac, the direction of the torsion is obvious; if the torsion has extended through 270° , no portion of the fetal body, so far as can be determined, can enter the birth canal, and the case becomes one of recognized torsion with the birth canal occluded by spiral folds, and is to be handled as uterine torsion without reference to dystocia.

Many of the cases demanding rotation offer in the posterior presentation, and usually in the dorso-pubic position. After the repulsion of the fetus and lubrication of the parts, the two posterior feet should be secured by means of cords, to be held by assistants. The operator inserts one hand with the palm upwards and passes it over the brim of the pubis beneath the buttocks of the fetus in such a way that the buttocks rest in the palm of his hand. The pubic brim serves as a fulcrum, upon which the operator uses his hand and arm as a lever of the first class. Lifting upwards against the buttocks of the fetus renders its position less stable and tends to cause it to revolve to the right or left and approach the dorso-sacral position. The instability which has thus been produced may be accentuated by the operator exerting his force somewhat obliquely upwards to the right or left, instead of pushing directly upward. This tends to rotate the body of the fetus in that direction which may seem most favorable.

The assistants in charge of the corded hind feet actively second the efforts of the operator by such means as he may direct. Slight rotary force may be applied by having an assistant flex the foot at the metatarso-phalangeal articulation and use the flexed portion as a lever. It has been advised by leading veterinary obstetrists that the two feet be tied together, a short rod passed between them, and rotary power developed by using this rod as a lever. According to my experience, the most effective method is the application of cross traction upon the hind limbs. A cord is placed upon each limb, and each cord given into the hands of an assistant. The operator places his hand beneath the croup of the fetus, over the brim of the pubis of the mother. If it be desired to rotate the dorsum of the fetus

toward the right ilium of the mother, the operator lifts the buttocks upward and to the right. The assistant in charge of the left (upper) foot of the fetus stands upon the left side of the patient and draws obliquely upwards and to the left, then horizontally, and finally downwards. The assistant having charge of the right foot crosses it behind and beneath the left and draws downwards and obliquely to the right. The cross traction exerted upon the two coxo-femoral joints causes the fetus to revolve upon its long axis. The simultaneous and equal traction upon the two sides of the fetal pelvis prevents it from becoming impacted against the pelvic girdle of the mother. The rotation of the fetus reduces the torsion of the uterus.

In the anterior presentation, the general plan of the operation is similar, though it may be rendered more difficult by the presence of the head and neck. It may even be necessary that the head be amputated before the rotation can be effected. Aside from this the plan should be carried out essentially the same, the operator's hand acting upon the withers of the fetus, instead of upon the buttocks, as in the preceding case.

Version

Version commonly signifies that the fetus is revolved upon its short, or transverse axis. The degree of possible version is limited. The turning of the fetal body upon its transverse axis through 180° , so that a cephalic may be changed to a caudal presentation, or vice versa, is essentially impossible in the tubular uteri of domestic animals, nor is there any well known reason for the operation, were it practicable. In transverse presentation it becomes desirable to rotate the fetus upon its transverse axis through 90° , to the longitudinal presentation. In any species, the presentation may be somewhat oblique and require version through a few degrees. The version is to be accomplished by repelling one extremity while exerting traction upon the other. Partial embryotomy is often necessary in the bicornual pregnancy of the mare before version may be safely attempted. This will be considered later.

Extension and Adjustment of the Extremities

When discussing physiological birth, page 157, the proper posture of the limbs was described. When their arrangement deviates from this plan, birth becomes difficult or impossible. As a rule the deviations cannot be corrected within the pelvis, but generally necessitate repulsion into the abdominal cavity. The process of repulsion has an inherent tendency automatically to correct the deviation. Thus

if the head is deviated laterally, repulsion toward the opposite side, by pressure against the sternum or shoulder, tends to cause the head to move toward its proper posture.

The veterinarian must intelligently apply his knowledge of mechanics and anatomy to his task. If the fetal head is deflected to its left side along the right side of the mother, it is very evident that, if the patient is lying upon her right side, the weight of the fetus upon its bent neck will offer a serious mechanical obstacle to the correction of the deviation. In such a case the recumbent patient should be turned to her left side. Similar directions apply also to deviations of the limbs, and should constantly be borne in mind.

Another mechanical principle which should be constantly applied is that, if it is wished to extend a flexed extremity, one may at least double the efficiency of his efforts by the simultaneous application of traction upon the distal end of the flexed extremity and repulsion upon its proximal end or upon the fetal body. For example, in the deviation of the head to the left, if traction can be applied to the

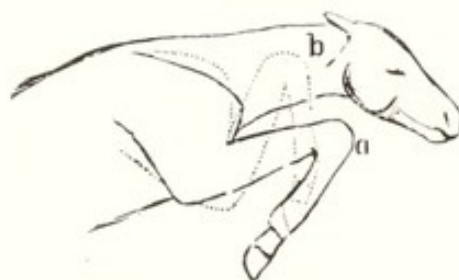

FIG. 67. Schematic Illustration of the Extension of a Fore Limb Flexed at the Carpus. (Franck.)

head by means of a hook in the orbit, mouth, or nose, or by a cord attached to the inferior maxilla, as shown in Fig. 64, and described on page 211, while the body of the fetus is being repelled by force applied to the sternum or to the base of the neck, the efficiency of the effort is very greatly increased. The simultaneous application of these two forces should be the constant aim of the veterinarian. The traction may be applied with hooks or cords; the repulsion by the operator's hand, or by a repeller in the hands of an assistant, guarded by the operator.

In extending a flexed limb, the same general mechanical rules are to be applied. For example when a fetus, presenting anteriorly in the dorso-sacral position, an anterior limb flexed at the carpus, as in Fig. 67, has been repelled, with or without decapitation, and sufficient room for operating obtained, the retained foot is corded at the pastern, or as near to that point as is possible, by one of the two methods

described on page 211. The cord is entrusted to an assistant. While traction is applied upon this cord by an assistant, the operator may pass a second cord beyond the first, and, as the foot is being brought nearer by traction upon the first cord, the noose of the second may be pushed over the fetlock and engaged upon the pastern. It is to be emphasized that in correcting a deviation of a limb, whether anterior or posterior, the ultimate aim is to get the noose upon the pastern. Until that can be accomplished, the correction of the deviation is uncertain.

While the fetus is being repelled, the assistant draws upon the cord and advances the foot. The carpus, by this process, and with the aid of the operator, passes into the lumbar region, directed obliquely outwards and upwards into the upper portion of the flank in order to afford the greatest possible amount of room. The carpus (or tarsus) must not, for this purpose, abut against the unyielding lumbar vertebrae or their lateral processes, but must be pushed outward against the yielding flank, and room thereby afforded for the necessary extension of the foot. At the proper time the operator inserts his hand, palm upwards, between the pubic brim and the foot of the fetus. Grasping the toe in the palm of his hand, the assistant, directed by the operator, applies traction upon the cord. The foot glides over the pubic brim, to become extended in the pelvic canal.

Should the anterior limb be completely retained, instead of merely flexed at the carpus, the procedure is similar. The foot is now wholly out of reach, and the forearm can be reached only with difficulty, or not at all until repulsion has occurred. When sufficiently repelled, the forearm advances by its own elasticity towards the vulva, and may then be grasped with the hand and corded while the repulsion is continued. The carpus is gradually drawn up until it comes against the pubic brim, when its further correction is carried out in the manner above suggested.

Similar rules apply to the corrections of the deviations of the posterior limbs: that is, the fetus must be repelled from the pelvic inlet, and that part of the limb which can be reached must be corded and brought up. This in itself acts as a repellant to the fetal body. Finally the tarsus is pushed obliquely outwards and upwards into the upper flank region, the pastern is corded, and the toe, resting in the hollow of the operator's hand, is guided over the pubic brim and extended in the pelvic canal.

The changes in the position of deviated members constantly require a careful application of mechanical principles, combined with caution.

Forced Extraction

By forced extraction is understood the withdrawal of the fetus from the mother, through the genital canal, by the application of traction. It is indicated when the uterus, owing to disease, is incapable of expelling its contents with the greatest promptness and safety. It is applied when the fetus, owing to any cause, is comparatively too large to be forced through the birth canal unaided, when with the addition of traction it may be more safely removed than by embryotomy or other means. Forced extraction should be rigidly limited to cases in which the presentation, position and posture of the fetus are normal, and in which the extraction by force will, in the judgment of the obstetrict, be best for the interests of the owner as affecting the life and value of mother or fetus or both. Forced extraction is highly useful when the uterus is atonic because of disease. It then serves as a substitute for the absent expulsive powers. Prudently applied, it is of much merit in primipara with juvenile genital organs, where the expulsive powers do not suffice alone to dilate the abnormally narrow birth canal. It may also become advisable when the birth canal is compressed by tumors or other pathological conditions.

The direction in which traction is to be applied will depend very largely upon the posture of the fetus and the point which it has reached in the birth channel. The uniparous fetus is physiologically somewhat curved dorso-ventrally, with the ventral side concave and the dorsal convex. The obstetrict may sometimes increase this curvature in a manner to facilitate birth; but any attempt to decrease the curvature or to reverse it, and render the dorsal line concave, impedes or blocks birth.

As the fetus approaches the pelvic inlet, in the larger domestic animals, and especially in those cases where the animal is standing, much of its volume and weight is located below the pubic brim and must mount that obstacle in order to gain the pelvic canal. If traction is desired, it should be applied to the fetus obliquely upward and backward, to lift it over the pubic brim.

During the progress of the fetal head through the pelvis, the traction should be directly backward or slightly upward and backward, but, when the fetal head arrives at the vulva, if the traction is continued upward it tends to force the poll of the head too powerfully against the superior vulvar commissure, and not only tends thereby to cause an obstruction to delivery by jamming the fetal head against this part, but also endangers the integrity of the superior commissure of the vulva itself and tends to cause more or less laceration of it.

The inferior vulvar commissure is fixed in the ischial notch. The fetus cannot be impacted or caught against the inferior commissure, because of the presence of the ischium. The superior commissure, attached to the anus, is open to injury. The fetal head or other part may push the vagino-vulvar roof upwards and become caught in front of and above the superior commissure, threatening the integrity of the perineum. Consequently the direction at this point should be somewhat downward in order to avoid as far as possible any injury to the soft parts.

At this point the operator may add much to the safety by pushing against the vulva, and especially by inserting the hand in the vulva with the palm resting upon the poll of the fetus and serving as a shield to protect the perineum.

After the head has passed through the vulva, the traction should be continued more and more downward as the body of the fetus advances, until finally, when the withers have passed the vulva, the line of traction should be almost perpendicular to the long axis of the spinal column of the mother or parallel to the long axis of her posterior limbs. In this manner the tension upon the fetal body is concentrated upon the spinal column and dorsal muscles, while the linea alba, or abdominal floor, is relaxed. This permits the fetal pubis to move caudalward, depressing the supero-external angles of the ilia and elevating the tuberosities of the ischia, thus decreasing its sacro-pubic diameters. The tension upon the dorsal muscles also tends to extend the femora upon the pelvis. The direction of the traction during the final stages of passage exerts an equal, or greater effect upon the sacro-pubic diameter of the maternal pelvis.

The *ossa innominata* leave the sacro-iliac articulation at an acute angle, downward and backward. If the traction is exerted directly backward, the tension upon the fetal linea alba, drawing its pubis forward, increases the sacro-pubic diameter of the fetal pelvis and causes its impaction against the maternal pubis. This drags the maternal pelvis backward. Hence such traction possesses the double vice of increasing the sacro-pubic diameter of the fetal, while decreasing that of the maternal pelvis. The pelvis of the cow possesses the greatest mobility among domestic animals. The sacro-iliac ligaments become greatly relaxed as parturition approaches, and when the animal stands, the iliac tuberosities tend to drop downwards and the ischial tuberosities to move upwards.

When the abdominal muscles of the mother come into play, the tension upon the linea alba draws the pubis forward and increases the pelvic diameters. If the pelvic ligaments are relaxed, and traction

is exerted upon the fetus, the maternal pubis is drawn backwards, and the pelvic diameters lessened. When severe traction is applied to the fetus, the cow voluntarily or involuntarily assumes lateral recumbency. In this position, the traction aggravates the strain upon the pubis and decreases the pelvic room. A rope or band looped about the buttocks of the cow in lateral recumbency, and securely tied in front to the manger, or other fixed object, tends to draw the maternal pubis forward when traction is applied to the fetus. This also removes the danger of breaking the horns, if the cow is tied by these. With such precautions and the downward traction upon the fetus, stalling of the latter at the pelvis does not occur. At least I have never had a fetus stall at the pelvis, but I have been called to overcome it where others had, after having tied the cow securely by the head and hitched one or two horses to the fetus. In one instance, after the fetal body had advanced until the fetal pelvis became impacted in the maternal pelvis, it stalled, and two horses were unable to extract it. The more severe and brutal the traction, in a straight line, the more severe the impaction.

The amount of traction. In passing through the birth canal, the fetus and the maternal parts in contact with the fetus undergo an enormous pressure, which is to a great extent inevitable. Only when it becomes excessively high has it danger for the fetus or mother.

In veterinary practice danger to the fetus from the pressure during its passage through the birth canal is scarcely recognizable, nor as a rule is there observed any injury to the fetus because of traction applied to any of its extremities. The amount of traction by the head or the limbs which a live fetus will bear during its passage through the canal is astonishing.

The mother, however, not infrequently suffers seriously from severe, or rather injudicious traction. How much pressure the pelves of domestic animals will withstand, when applied through the medium of a fetus impacted within its canal, is not known. The chief danger to the organs of the domestic animal is not to the bony, but to the soft parts, which are the first to be injured by an excessive pressure.

The amount of traction which may safely be applied to the fetus is modified by its position. Since, when the fetus presents normally and the traction is exerted in the direction advised above, there is no point where the soft tissues of the fetus may not to some extent move upon each other, thus relieving the pressure upon a given point. Normally the pressure of the fetus against the walls of the birth canal is well-nigh equal over the entire surface.

When the fetus presents improperly, with an extremity retained in such a way that a greatly increased pressure is brought to bear upon a small area of the genital passages of the mother, the question of the amount of admissible traction changes abruptly. If a fetus is presenting with its head deviated to the side, one man by drawing upon it may cause far more injury than five men might if the fetus were presenting normally. I wholly disapprove of delivery by forced extraction when the position or posture of the fetus is pathological.

Different practitioners, working under varying conditions, have obtained apparently contradictory results in reference to the amount of traction which it is desirable to employ. Some claim that only moderate traction should be employed, and define their term "moderate" as the force of from two to four men pulling simultaneously. Others have unhesitatingly employed the combined strength of from six to ten men, and have claimed that their success has fully warranted the amount of force employed. When hard pressed, I have applied a force equal to that of three to six men, in those cases in the cow and mare where the fetus lay in a wholly natural position, so that the force of the traction fell alike over the entire birth canal. I have applied the maximum force in cases of emphysematous fetuses. Here ordinarily the breeding life of the animal is at an end and the only possible salvage is the value of the animal for work or meat. In these the gases move with considerable freedom, so that the pressure is alike at all points. In the absence of adequate man power, mechanical power may be substituted, but since its force cannot so well be measured, its application is not subject to equal control.

When traction is being applied the operator should take his place immediately behind the patient, constantly watch and examine the progress of the fetus, command the direction and amount of force to be applied at this or that time, and determine when the traction should cease. When there seems to be any great impediment which apparently bars the progress of the fetus at a given point, the traction should cease and the operator should determine the nature of the obstacle and devise the necessary means for overcoming it. The operator should not join in the traction unless circumstances should arise making it necessary, but should devote his attention to the direction of the force to be applied by others.

So long as the patient is competent to exert important expulsive force, traction should be applied only during expulsive efforts. These may be stimulated by the use of pituitary extract. When expulsive efforts have ceased, traction is accompanied by much danger, because

the vagina and uterus tend to be dragged along with the fetal body, and their walls to become seriously injured. In spite of such danger, traction may offer the only possible or practical hope for relief.

Haste in traction upon a fetus is justifiable only very rarely. The maternal parts should be allowed to dilate gradually as the fetus slowly advances in the form of a wedge. In the posterior presentation, when a supposedly live fetus is well advanced in the pelvis and the umbilical cord presumably impinged between the fetal body and pelvic floor, hasty completion of the delivery is commonly urged. How many young animals of value have been saved in this way, is not a matter of record. Probably very few. Perhaps more dams have been irretrievably ruined than valuable fetuses rescued. Equine and bovine fetuses presenting posteriorly constitute an unpromising group. As stated on page 157 and following, they are largely dead when labor sets in, or they are perilously pathological. Though extraction may be hastened, they largely die during, or soon after delivery. According to my observations, as many valuable fetuses will be saved, and fewer dams injured, if haste is abandoned.

Embryotomy

Embryotomy is the diminution of the size of the fetus by means of the removal of some of its parts, in a manner to overcome the obstacles to its birth. Necessarily embryotomy involves the sacrifice of the life of the fetus, if living, and the object of the operation becomes limited to the preservation of the life of the mother. It is comparatively a common operation in the larger animals, but is virtually inapplicable in the smaller ones.

Embryotomy possesses certain dangers, such as injuries to the maternal organs, from a slip or misdirection of an instrument or from the projection of a severed fetal bone which may wound or penetrate the uterus or other parts. Not infrequently it involves a long and tedious operation, which may greatly exhaust the strength of the patient.

For the operator, embryotomy frequently means a protracted and disagreeable operation, with danger of wounds from instruments, injuries from the mother, or infection in case the fetus is putrid. Nevertheless embryotomy is one of the most valuable obstetrical operations. It requires, for its proper application, thorough study, supplemented by extensive practical experience.

The performance of embryotomy may involve any portion of the fetal body, and presents the greatest possible variations, according to the presentation and position. The veterinarian must have a thoroughly practical knowledge of the anatomy of the fetus and the re-

sistance of tissues and parts. Embryotomy may be necessary or advisable in any presentation or position which the fetus may assume, whether normal or abnormal. The technic of the removal or destruction of certain portions of the fetal body will be discussed here in the order of the fundamental presentations. The application of these operations will be considered under the various forms of dystocia.

Embryotomy may be imperfectly divided into two groups—intra-fetal and extra-fetal. In the first group, except for an invading incision, the dismemberment of the fetus, with the removal of parts, is conducted subcutaneously or within the body cavity. It possesses a higher degree of safety for the patient in so far as instrumental wounds are concerned; largely limits the irritation and abrasions of the birth canal by the operator's hands and equipment; and reduces to a minimum the danger of injury from exposed, projecting bones.

The extra-fetal method, made more valuable during recent years, through the introduction of improved equipment, offers in many cases more rapid methods, which are of value through the shortening of the task. Long, tedious embryotomy, however carefully conducted, depresses the outlook for the patient and exhausts the veterinarian. Each plan has its advantages and disadvantages, and both should be considered according to the problem presenting.

Embryotomy in the Anterior Presentation

Amputation of the Protruding Head. Decapitation. When dystocia arises in unipara, owing to the retention of one or both fore limbs, and the fetal head has been advanced to, or beyond the vulva, repulsion of the fetus is generally necessary in order to correct the deviation of the limb. In many cases the repulsion of the head is inexpedient or impossible, and its amputation is made advisable or necessary in order that the fetal body may be repelled and the deviated extremity brought into position.

Technic. Attach a cord to the inferior maxilla, as shown in Fig. 64, or fix a blunt hook in the orbit, and have an assistant draw the head out as far as practicable. Make an incision through the integument, encircling the head at a convenient point, and separate the skin backward, by forcing the hand between it and the bones, by using the chisel or spatula, or by dissecting it away with a scalpel, continuing the separation over the occiput to the atloid region. Make a transverse incision below, across the trachea and esophagus and surrounding muscles, and above through the ligamentum nucha and cervical muscles. Grasp the head firmly with both hands, flex it

upon the neck, twist it forcibly on its long axis, rupturing the articular ligaments and the remaining soft tissues, and detach the head at the occipito-atloid articulation. The skin flap should be caught and secured over the exposed atlas by means of a small cord in the form of a running noose. The remnant is then to be repelled, the deviated parts brought into the desired position, or other operations performed.

The operation may be more rapidly and easily performed with Persson's chain saw or the fetotome or wire saw embryotome of Thygessen, or one its various modifications such as that of Benesch, Fig. 65.

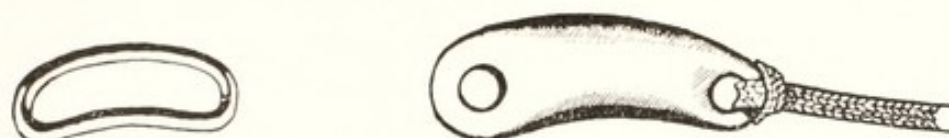Cephalotomy. When the fetal head becomes firmly impacted within the maternal pelvis, and it is impracticable either to repel or to extract it, or when the head, because of hydrocephalus or other cranial deformity, is too large to enter or pass through the pelvis, cephalotomy or comminution of the cranium becomes advisable. Perhaps the most frequent call for cephalotomy occurs in dairy heifers owing to genital hypoplasia.

Sometimes the head is so firmly engaged in the canal that no further fixation is necessary. In hydrocephalus it may be necessary to engage the head with a hook or cord and hold it in position by traction. After thoroughly cleansing and disinfecting the parts, inject a copious amount of warm normal salt solution into the vagina. Carry the obstetrical chisel into the passage, carefully guarded in the hand, and place it accurately upon that part of the fetal head where it is desired to begin the operation, generally on the median line of the nose, with the blade of the chisel parallel to the septum nasi of the fetus. Holding the blade of the chisel firmly against the part, with the hand in such a position as to guard the instrument from slipping aside and wounding the maternal organs, steady and direct the handle with the other hand and have an assistant drive the chisel, by means of blows of proper vigor with a mallet, into the bones of the face and head.

Do not drive the chisel deeper than the length of the blade without first stopping and forcibly revolving the instrument upon its long axis, breaking the fetal bones apart. The partially detached pieces of bone may be grasped by the operator and torn away. While the partially detached fragment is held with one hand, the operator, introducing the chisel with the other hand, may complete the detachment. The removal of the partially detached pieces of bone may in many cases be greatly facilitated by looping a small cord over them and having an assistant apply sufficient traction to pull them away,

while the operator guards the maternal organs by holding the piece of bone, during its detachment and extraction, in the palm of his hand. The use of the chisel should be repeated here and there upon the head, as often as may be necessary in order to bring about the required diminution, taking care at all times not to wound the maternal parts and to conserve as far as practicable the fetal skin of the face and head, in order that it may protect the maternal parts from the jagged fetal bones during the remainder of the operation.

In hydrocephalus the diminution of the head alone usually removes the sole obstacle to delivery. The same is true occasionally of beginning emphysema, where only the head is greatly involved. In other cases, the destruction of the head and face does not wholly relieve the dystocia. It may be necessary to continue the diminution by decreasing the volume of the neck and body. The cervical vertebrae may be divided with the chisel on their median line, the muscu-



FIGS. 68, 69. Guiding Ring (left) of Lindhorst, and Loop Carrier of Schriever (right).

lar and ligamentous attachments broken down or cut with the chisel, and the bone fragments secured in a rope noose and drawn away, covered by the hand. Or the wire embryotome of Benesch may be looped over the neck stump and the part amputated. Later the fetal body may be further diminished by subcutaneous amputation of the fore limbs at the shoulder, evisceration, destruction of the pelvic girdle, or other means to be described later.

Amputation of the Head and Neck. When the head is completely deviated in a manner to render adjustment impossible or impracticable, amputation is sometimes advisable, removing the head, with as much of the neck as is practicable.

Technic. The amputation may be accomplished in the cow with Persson's chain saw. The instrument needs to be lengthened by fixing in each end a 24" cord. The application of the saw may best be carried out with the aid of a rope leader, such as that of Lindhorst, or Schriever, Figs. 68 and 69. Apparently the most convenient instrument known at present is the wire saw or fetotome of Thygessen, Neubarth or Benesch, Fig. 65. The wire saw is passed around the neck with the aid of the rope leader of Lindhorst or other convenient appliance. In default of one of these, a cord may be passed around the neck by folding a considerable portion of the distal end and

carrying the mass in the hand as far as possible from above or below, releasing the mass and reaching for it upon the opposite side. If the single end of the cord is deposited at the farthest point which can be reached, when the hand is withdrawn, the cord follows, but if folded liberally, the end remains where released. Similarly the cord may be prevented from following the hand by winding the end into a ball large enough to be caught by compression between the fetal neck and chest.

The head of the equine fetus is retained by lateral deviation of two distinct types: the lateral deviation due to compression in utero, generally, if not always because of bicornual pregnancy (page 189); and a second type, identical with that in the bovine fetus, and developing during, or immediately prior to labor. The compression deviation (wry-neck) of bicornual pregnancy cannot safely be overcome either by adjustment or by amputation of the head and neck, but as a rule the operator should immediately proceed with the subcutaneous amputation of the exposed anterior limb, described below, followed by evisceration.

The second type of lateral deviation of the head may sometimes be remedied by mutation, or by amputation of the head and neck as in the bovine fetus. These failing, the obstetrict should resort to the technic advised in the preceding paragraph.

Amputation of the Anterior Limbs. Subcutaneous Amputation. Amputation of the anterior limbs is very frequently advisable, especially with the foal in the ventral transverse presentation, with all four feet offering and the head retained; in wry-neck of the foal in the anterior presentation, dorso-sacral position, when it is impracticable to correct the deviation of the head or to amputate the head and neck with the wire saw, as described in the preceding paragraph; or in any case in the mare or the cow where deviation of the head cannot be otherwise so readily overcome.

Technic. The larger herbivorous animals are devoid of a clavicle, and the anterior limb, attached to the thorax by means of the skin and muscles only, is comparatively easily amputated. A cord is to be attached to the pastern of the limb, traction exerted upon it by one or two assistants, and the limb drawn out as far as possible with safety to the mother. The technic varies greatly in the hands of different operators. In general, one of two plans is followed, each of which varies in detail. One plan is initiated by dividing the skin from the withers to the foot upon the lateral or dorsal surface, and then separating the skin from the underlying tissues. The other plan is to partly girdle the skin at the pastern, and detach the skin with the fingers,

a knife or otherwise, sufficiently to permit the introduction of a chisel or spatula.

In the first instance the operator introduces one hand, armed with the hooked ring embryotomy knife, well guarded in the palm of the hand and resting against the limb of the fetus, up to the top of the scapula, or as near thereto as can be reached. The knife is then pressed into the skin and subcutaneous tissues, and, as the hand is drawn downward along the leg, the skin and subcutaneous tissues are slit freely and deeply from the top of the scapula down to the pastern. The knife is then laid aside and, while an assistant keeps the limb stretched by moderate traction, the operator forces this thumb, fingers, or hand between the skin and subcutaneous tissues and, pushing the hand towards the fetal body, detaches the skin from the limb until the upper region of the scapula is reached.

The separation of the skin may require at certain points, such as the region of the olecranon or carpus, the aid of the chisel, spatula, or knife to divide the firm bands of connective tissue. The separation of the skin from the subjacent parts removes the chief resistance to tearing of the limb away from the body. Until the separation of the skin from the leg and shoulder has been completed, the skin should be kept intact at the pastern, so that when traction is applied the integument, as well as the leg, is rendered tense and the operation is greatly favored. When the skinning of the leg and shoulder is completed, the skin is to be divided at the foot by girdling the pastern. The detached skin will be of no further importance, and may be ignored. If required, it may be grasped and corded.

After the detachment of the skin, the chief remaining resistance to the removal of the limb is the pectoral muscles. These may be torn asunder by first being separated into small bundles and then torn through with the fingers, between the sternum and the limb. The process may be aided by incision with the knife or the chisel.

In the second method of detaching the skin more quickly the cutaneous incision should extend about three-fourths around the foot and a subcutaneous pocket created by separating the skin from the underlying tissues over an area which will permit the convenient introduction of chisel or spatula. The limb is kept well extended and the chisel or spatula forced upward beneath the skin, to the shoulder. The instrument beneath the skin is to be constantly followed by the operator's hand outside the skin, so as to avoid any danger of puncturing the skin and injuring the mother. The chisel illustrated in Fig. 65 may be used for this purpose, but the corners are inconveniently sharp. Professor Guard, Ohio State University, uses with

great satisfaction a V-shaped chisel, the branches of which end in spheres (probe-pointed). The muscles between the shoulder and chest are divided with the chisel. The skin may then be divided over the entire length of the leg, the separation of the skin inspected by palpation and any defects corrected, after which the original incision is completed around the foot.

When the pectoral muscles have been divided, the remaining impediments to tearing away the shoulder consist essentially of the trapezius and rhomboideus muscles at the top, the latissimus dorsi behind, and the serratus beneath the scapula, all of which come into action only when the shoulder is nearly severed, and then offer no serious resistance. Consequently it is only necessary to separate the skin from the limb and divide the pectoral muscles in order to draw the limb away by traction.

When the skin has been detached and the pectoral muscles divided, two or three assistants exert traction upon the limb, while the operator places his hand against the sternum and pushes in the opposite direction. The impact upon the maternal organs from the traction may be reduced to any desired degree, by applying a repelling force to the sternum of the fetus. The impact upon the maternal organs equals the difference between the traction applied upon the cord and the repulsion applied to the fetal sternum. Should the hand of the operator not suffice, the repeller should be applied, carefully guarded by the hand of the operator, and any additional force required supplied by one or more assistants. Should the traction fail to bring the limb away promptly, the operator should attempt to extend the division of the muscles attaching the limb to the thorax, while moderate traction upon the limb is continued.

The foregoing technic has its greatest value in the foal with wry-neck. The amputation of the anterior limb of the bovine fetus, and of the equine fetus when presenting transversely with all four limbs in the birth canal, is perfectly feasible by the same technic. Many prefer, however, to use the wire saw or fetotome. The wire is carried over the limb as a loop, with the head of the fetotome on the lateral or uterine surface of the limb, and the flat side of the fetotome facing the uterus. The head of the instrument is pushed along the scapula as far as possible toward its superior extremity. After the muscles and skin of the pectoral region have been severed, the saw may then be so readjusted that most, or all of the scapula may be included in the excision. Usually the scapula is severed, sometimes at the neck, sometimes near the cartilaginous prolongation. When the equine fetus presents transversely owing to bicornual pregnancy, and all

four limbs are in the birth canal, it may be necessary to amputate the two posterior feet at the tarsus (page 254) before the anterior limbs may be removed. When amputating the fore limb with the fetotome, if any considerable portion of the scapula remains, it may seriously interfere with evisceration, should that be necessary or advisable.

Benesch⁸ advises that the amputation of the anterior limb be accomplished with the fetotome by making a deep incision through the skin, trapezius and rhomoides muscles, freeing the distal end of the scapula from the subjacent tissues. The wire saw is then lodged in the incision between the chest and the end of the scapula, bringing the ends of the wire together in the pectoral area. The head of the instrument is located upon the median side of the leg, and the entire shoulder thus enclosed within the loop. This brings the entire limb away and leaves the side of the chest freely exposed as in the subcutaneous method above described. This plan appears applicable usually in bovine fetuses, but some colleagues find it impracticable in equine fetuses. Since my personal experience in the field has been chiefly with heavy draft horses, with the size of the fetus and the shortness of my arm, I fail to understand clearly the practicability of the technic in equine dystocia.

When the fetus presents transversely, with all four feet in the passage, both fore legs should be amputated. It may be difficult or impossible to amputate the lower shoulder entire by either of the above methods and the operator may be compelled to amputate the one leg at the humero-radial articulation as described below. After the one leg has been removed, including the entire shoulder, evisceration (page 258) may be employed to reduce the volume of the torso and, of yet greater advantage, render it flaccid and highly flexible.

When the equine fetus presents anteriorly with wry-neck, the subcutaneous removal of the exposed limb, followed by evisceration, affords ample room generally for the extraction of the torso without overcoming the deviation of the head, or room is gained which facilitates the amputation of the head, or the easy reduction of the deviation.

Amputation of the Anterior Limb at the Humero-Radial Articulation. Amputation of the anterior limb at the humero-radial articulation may become advisable or necessary, especially for the under limb of the equine fetus in transverse, abdominal presentation, since the subcutaneous amputation above described is sometimes difficult or impossible. The most convenient technic is with the fetotome, the wire saw being applied as high up as possible—preferably above the

olecranon. In default of the fetotome or some equivalent equipment, attach a cord to the pastern and have an assistant render the leg tense by exerting moderate traction. Introduce the hand, armed with the embryotomy knife, carefully concealed in the palm, and girdle the skin around the articulation. Passing above the head of the olecranon on the posterior side, divide the attachment of the anconeal group of muscles by a cut directed forward. Then divide transversely, as far as possible, the muscles and ligaments passing over the articulation. Rotate the limb forcibly on its long axis, while strong traction is maintained, and rupture the remaining ligaments until the limb is completely detached and comes away.

In cases of limited room, it may sometimes be easier to detach the skin of the limb from the pastern up to the articulation, as in the operation for the subcutaneous amputation of the limb at the shoulder, described above. By this plan the skin is separated up to the olecranon, the muscles divided transversely, and the operation otherwise carried out as in the preceding paragraph.

Detruncation in the Anterior Presentation. In the mare, when a fetus in the anterior presentation has one or both posterior limbs deviated forward beneath its body, and the feet engaged against or in the pelvis, the dystocia may be overcome by detruncation.

Technic. If practicable, secure the two hind feet by means of cords. Apply cords to the two anterior limbs and head, and have one or two assistants draw the anterior part of the fetus as far out as is safe. Then girdle the fetal body immediately against the maternal vulva, by making an incision through the skin and skin muscle. It is frequently best to remove first one or both shoulders subcutaneously, as described on page 246, and follow with evisceration, as described on page 258, in order to give operative room and increased pliability of the fetus.

Insinuate the hand between the skin and the deeper structures, and forcibly separate the skin from the fetal body backward until the last rib is passed. Force the finger tips through the abdominal wall behind the last rib and, passing along the entire posterior border of each last rib, separate the abdominal walls from the ribs and sternum. Forcibly rotate the thorax upon its long axis. This causes a division of the vertebral column near the dorso-lumbar articulation, and the anterior portion of the fetus falls away.

Secure the two posterior feet with cords, unless this has already been done. Spread the detached skin, which has been pushed back from the thorax, carefully over the stump of the lumbar vertebrae. Push the remnant of the fetal trunk into the uterus, while an attend-

ant draws upon the cords attached to the hind feet, and convert the torso into a posterior presentation. This may result in a dorso-pubic position, which should be converted by rotation into the dorso-sacral position, which should be converted by rotation into the dorso-sacral,

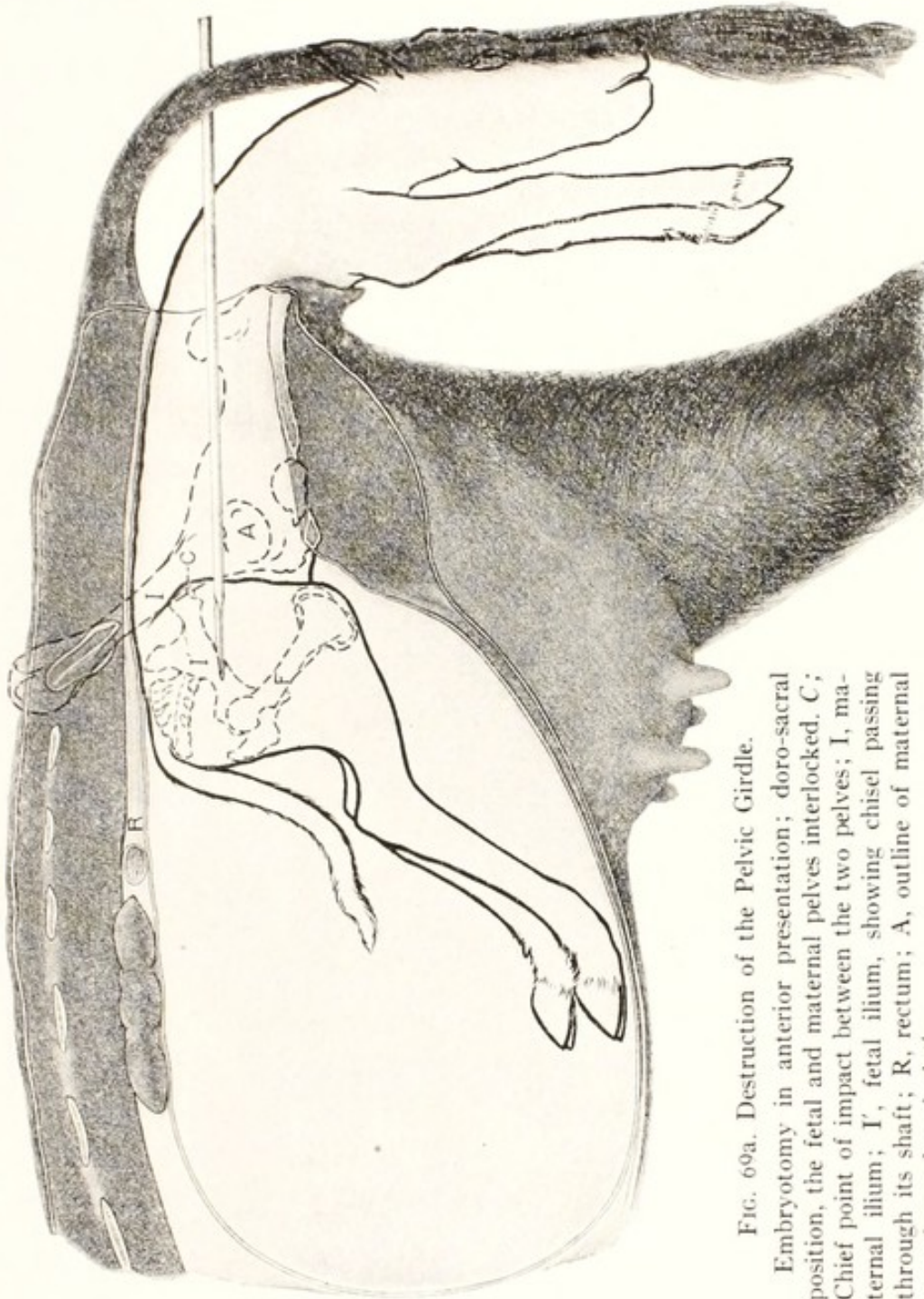


FIG. 69a. Destruction of the Pelvic Girdle.

Embryotomy in anterior presentation; dorso-sacral position, the fetal and maternal pelvis interlocked. C; Chief point of impact between the two pelvis; I, maternal ilium; I', fetal ilium, showing chisel passing through its shaft; R, rectum; A, outline of maternal coxo-femoral articulation.

when the extraction of the torso can be readily brought about. It may be possible, in some of these cases, to detruncate the fetus more quickly with the fetotome, slipping the wire saw over the head and body back to the lumbar region. Fortunately the position is rare, too rare for different methods to have been fully tested. A better and

safer method for overcoming this type of dystocia, so far as yet known, consists of the following operation:

Destruction of the Pelvic Girdle in the Anterior Presentation. When an equine fetus presents anteriorly in the dorso-sacral position with the two hind limbs thrust forward against or into the maternal pelvis beneath the fetal body, as mentioned above, the difficulty may be more readily overcome by breaking down the fetal pelvis than by detruncation. The bovine fetus, in anterior presentation, dorso-sacral position, occasionally becomes stalled at the hips owing to improper traction, as stated on page 239. The correction of this condition is best accomplished by the destruction of the bony girdle of the pelvis. The operation is also useful when an emphysematous fetus in anterior presentation is stalled at the hips.

Technic. Remove one or both anterior limbs subcutaneously, as directed on page 246, and eviscerate, as described on page 258, through an opening made by the removal of two or three of the ribs exposed in removing the shoulder. Introduce the chisel through the eviscerated body cavity, carry it back, carefully guarded by the hand, and place it against the shaft of the fetal ilium. Have an assistant drive the chisel deeply into the iliac shaft and, when the chisel blade is well buried in the ilium, revolve the instrument forcibly upon its long axis, and thoroughly divide the pelvic girdle by separating the cut ends of the bone. Then withdraw the chisel, replace it against the pubic brim, either at the symphysis pubis or opposite the foramen ovale, and drive it through the pubis and ischium. Again revolve the chisel forcibly upon its long axis, and thoroughly break the bones apart. In the instance of the bovine fetus stalled by improper traction, the isolation of the one coxo-femoral articulation suffices so to reduce the volume that the torso comes away easily. In other cases the destruction of the pelvic girdle is to be completed by severing the remaining ilium through its shaft. This destroys all rigidity of the pelvic girdle. In cases where the two posterior limbs are engaged in the pelvis, the legs become pliable and may be rotated upon their long axes, or otherwise adjusted. By exerting moderate traction upon the corded hind feet, while the operator, with his hand inside the eviscerated abdomen, applies repulsion at the pelvic region until the hind legs are fully extended in the birth canal, the torso is readily removed under light traction.

In the emphysematous fetus the breaking down of the pelvic girdle decreases the diameter through collapse of the fetal pelvis, and the mutilation serves as a portal of exit for the accumulated gases of decomposition.

Embryotomy in the Posterior Presentation

Embryotomy in Posterior Presentation, Dorso-Lumbar Position, with the Posterior Limbs extended. Serious dystocia occurs at times when the fetus presents posteriorly in the dorso-sacral position with the posterior limbs fully extended and the feet projecting through the vulva. It occurs especially in dairy heifers which are immature or have suffered from genital hypoplasia. The fetus, which may be quite normal in volume, but too large to pass through the birth canal, becomes stalled when the thighs or buttocks enter the pelvis. In any female such dystocia may arise from fetal anasarca or emphysema, or from various fetal defects or diseases of the pelvis. The amputation of the posterior limbs of the fetus, under epidural anaesthesia, usually offers the best remedy.

Technic. Benesch⁸ advises alternate plans for amputation with the wire saw embryotome (fetotome) of Thygessen: (1) By acute-angle sawing. The head of the embryotome is placed against the side of the buttocks upon the external tuberosity of the ilium, and the wire is lodged in a perineal incision extending between the ischial tuberosities. The saw thus acts first upon the median line of the pelvic outlet, and the excision progresses from the caudal, toward the cephalic end of the fetus. In order to hold the fetotome in position Benesch advises that after the wire loop is in position, the involved limb be forcibly stretched, while the instrument is firmly pushed against the buttocks, and the distal end of the instrument firmly bound to the foot. By this plan a quite considerable portion of the pelvic girdle is excised; (2) Amputation by an obtuse angle. A deep incision is made in the skin and muscular tissues between the sacrum and external angle of the ilium and the wire loop lodged in the cut so that it cannot slip down over the leg. The head of the instrument is lodged upon the median side of the thigh, with the base of the tail included in the wire loop. Again an important portion of the pelvic girdle is included in the excised part.

One limb having been thus removed, the pelvis is sufficiently open for evisceration and other procedures. The other limb is readily removable, if advisable, but this necessitates the cording of the sacrum or of the lumbar spine for traction.

Another quite satisfactory technic is to apply traction to the member it is desired to remove, and make a deep longitudinal incision with the embryotomy knife from above the coxo-femoral articulation along the latero-posterior side of the leg down to the lower portion of the metatarsus. Separate the skin from the underlying tissues, completely around the leg, as described above for the subcutaneous

amputation of the anterior limb (page 246) and divide the skin at the lower end of the metatarsus. While traction is applied to the foot, cut through the semimembranosis, semitendinosis and gluteal muscles as completely as possible. Apply vigorous rotation to the limb, which results in the dislocation of the coxo-femoral articulation, with the rupture of its ligaments, and the leg drops away. The rotation is greatly facilitated by flexing the limb at the tarsus, using the metatarsus as a lever.

This plan of amputation does not break the pelvic girdle or afford convenient opportunity for evisceration, but the girdle is readily severed with the obstetric chisel.

Amputation of the Posterior Limbs at the Tarsus. When a fetus, especially a foal, presents posteriorly, with one or both posterior limbs retained at the tarsus, the conditions may be such that it may be difficult or impossible to repel the fetus and extend the feet. I recall one case in the mare where I could not effect repulsion preparatory to correcting the deviation, and was forced to amputate. In a second case, in the transverse ventral presentation, the two posterior limbs were crossed over the two anterior limbs, crossing the pelvic inlet and barring all progress until I had amputated each at the tarsus. The need for the operation is rare. The difficulty of the correction of such a deviation is intensified by recumbency, the comparatively large size of the fetus, and fetal emphysema. It is occasionally desirable or necessary in the rigid, deformed limbs of muscle contracture, and other monsters when the limb projects at a dangerous angle.

The operation is comparatively simple and may be performed variously. Professor Fincher prefers Persson's chain saw. The division may be made with the fetotome.

The chisel, Fig. 65, is also highly efficient in this amputation, is readily applied, and acts rapidly. A cord should be passed around the leg above the summit of the os calcis, and an assistant should hold the leg steady by gentle traction. The chisel should be introduced, carefully guarded in the palm of the hand, and placed against the lower part of the tarsus, as nearly perpendicular to the long axis of the metatarsus as possible. The proper direction of the chisel may at times be greatly favored by placing the cord upon the metatarsus instead of the tibia, thus forcing the tarsus toward the sacrum of the mother and tending to throw the metatarsus straight across the pelvic inlet.

The chisel should at all times be held in the palm of the hand, with the dorsal surface of the hand against the vaginal or uterine wall,

and the instrument carefully guarded and guided during the entire operation. The amputation should preferably be through the lower section of the tarsus, but may be made through the head of the metatarsus. The chisel should not be driven entirely through without removal, as it may become caught and clamped between the divided bones. Instead, drive it first for only a few inches along the lateral side of the tarsus, being sure that the skin at that point is included in the cut along with the bone. Then loosen the chisel, and force the divided bones apart by rotating the instrument upon its long axis, after which it may be driven somewhat deeper into the tarsus, until the foot is completely severed.

Withdraw the severed metatarsus, remove any dangerous fragments of bone remaining on the stump, and see that the latter is safely secured by a cord passing around the leg above the os calcis. Repeat the operation on the other hock. Apply traction to the two stumps, and effect a posterior delivery.

Intra-Pelvic Amputation of the Posterior Limbs when Completely Retained. Embryotomy in the Breech Presentation. This operation is designed for the overcoming of dystocia due to the so-called breech presentation, when the deviation cannot be readily corrected.

Introduce the hand, armed with the embryotomy knife, scalpel, or chisel, through the maternal passages, until the perineum of the fetus is reached, and make a free incision through that part, including the anus in the male fetus and the anus and vulva in the female, enlarging the incision to the full size of the outlet of the fetal pelvis.

Locate the sacro-sciatic ligament of the fetal pelvis and divide it from its posterior border to the shaft of the ilium, thus enlarging the pelvic cavity and giving ample room for the insertion of the operator's hand. The severing of the sciatic ligament may be accomplished by cautiously cutting from behind forward, either with Colin's scalpel or with the chisel.

The operator should then carefully free the skin from its attachments to the ischiatic tuberosity and from the posterior border of that bone. The powerful gluteal muscles passing to the femoral trochanter should next be divided by a deep longitudinal incision through the skin and muscles above the summit of the trochanter major, between it and the sacrum. When this has been done, place the chisel against the shaft of the ilium as nearly perpendicular to the long axis of the iliac shaft as possible. Keeping the hand in touch with the chisel blade, have an assistant drive it through the bone until it and its periosteum are completely severed. Forcibly rotate the chisel upon its long axis, in order to complete the division

of the bone and attached soft parts. Disengage the chisel, place it against the symphysis pubis or against the ischium opposite the foramen ovale, and drive it through the ischium and pubis at either of these points. Again revolve the chisel upon its long axis and, using it as a lever, separate the isolated portion of the pelvis as completely as practicable from the surrounding tissues. The value of revolving the chisel upon its long axis, in order to separate completely the ends of the bones, should always be recognized. If this is not done, the periosteum, tendons, or aponeurosis may hold the severed ends together and prevent the operator from passing the cord noose over the isolated segment of the pelvic girdle. The rotation of the chisel should therefore be continued as long as there is material resistance, and the segment of the pelvis detached as completely as possible.

With the fingers, aided by the chisel if necessary, detach the muscles from the isolated segment of the pelvic girdle for a short distance from each severed end. It is especially important to separate the skin, aponeurosis, and muscles from the ischial tuberosity so that the noose will readily engage the pelvic fragment and the skin and muscle attachments will offer no resistance. Attach a strong looped cord about the detached pelvic segment, and have traction applied by one or more assistants. If the skin, aponeurosis and muscles attached to the posterior end of the ischium, and the powerful gluteal muscles, have been properly severed, only moderate traction is required to remove the limb. During the extraction of the limb, the operator should guard with his hand any sharp ends of the severed pelvic bones. Sometimes the round ligament of the hip joint breaks, and the isolated piece of the pelvis comes away alone. The cord is then to be applied over the head and trochanter of the femur, and traction again exerted, drawing the limb away in a reversed position. As it advances, the skin is turned backward or everted until the region of the hock is reached, where the integument does not so readily separate and only requires division to allow the limb to drop away.

During the removal of the limb, the operator is to note constantly the progress by manual exploration, and sever by tearing or cutting any tendons or muscles which offer special obstruction to the operation. During the tearing away of the limb, the operator largely or wholly counteracts the impact of the traction upon the maternal organs, by applying repulsion to other portions of the fetal pelvis, either with his hand or with the aid of a repeller in the hands of an assistant.

Repeat the operation upon the opposite limb. This requires but

one incision through the bone, that is, through the shaft of the ilium. The entire operation is carried out intra-fetally. If properly performed, the operation does not endanger the maternal parts.

The size of the fetal trunk may be further reduced, if desired, by evisceration, as described on page 258. The remnant of the fetus may then be extracted, by traction upon a cord looped about the lumbar vertebrae.

After evisceration has been accomplished, should the fetal remnant still seem too large, because of emphysema or for other reasons, to be safely drawn through the pelvic canal, further diminution in volume should be accomplished. The chisel may be carried into the fetal cavity and placed against the last rib, close alongside the spinal column. Light blows upon the chisel by an assistant, while the cutting end is constantly accompanied and guarded by the operator's hand, readily severs each rib successively. The operation can be applied on on both sides of the spinal column, dividing all the ribs.

The ribs may also be severed by means of the long-handled sphere-pointed cutting hook, G, Fig. 65. The instrument is introduced into the fetal body-cavity and hooked over the first anterior rib, or the most anterior rib within reach, and the ribs are cut one after another as the instrument is drawn backward. The sphere upon the point obviates the danger of the instrument's penetrating the fetal skin and wounding the maternal organs.

If neither of these instruments is at hand, the obstetrict may destroy the ribs by manual force. The tips of one or more fingers may be forced through the intercostal muscles between the last two ribs, the intercostals then torn asunder from the base or spinal end down to the sternal cartilages, and the rib grasped and broken. Rib after rib may be treated thus, until all are broken. This is a tedious operation, and there is constant danger to the operator of wounds from the sharp broken rib ends.

The division of the ribs is of very great importance. It allows complete collapse and obliteration of the fetal body cavity, and renders the fetal remnant very flaccid and pliable. More important, it permits the escape of the imprisoned gases of emphysema under the pressure of the labor pains. It should always be borne in mind in emphysema that, the greater the mutilation, especially the more thoroughly the skin, the pleura, and the peritoneum are incised or lacerated, the more readily the gases are pressed out, and hence the cadaver decreased in volume.

Benesch⁸ advises that in the breech presentation the fetotome or wire saw be used for the amputation, the wire being passed around

the thigh in the same position as that already described for the amputation of the extended hind limbs. The wire is carried around the limb with the aid of the Lindhorst cord carrier (Fig. 68). Different plans are advocated by various obstetrists: those mentioned indicate the general principles involved. That with the obstetrical chisel as described offers the maximum of safety for the patient, is easily carried out and provides free access to the body cavity for evisceration and other operations.

Evisceration. The removal of the fetal viscera frequently becomes advisable or necessary to the overcoming of dystocia. It greatly decreases the volume of the fetal trunk, renders it flaccid, permitting the torso to be freely bent or more readily moved for the correction of any deviations, and permitting freedom of intra-fetal operations directed against other parts as for detruncation or for destruction of the pelvic girdle. When a putrefying fetus becomes enormously enlarged as a result of emphysema, evisceration removes the gases collected in the viscera and body cavity, and permits the escape, under pressure in the birth canal, of much of the gas imprisoned within the other fetal tissues.

Evisceration may be employed in the anterior, posterior, or transverse presentations.

In the anterior presentation, unless the fetus is far advanced through the vulva, evisceration is best performed by the removal of one of the anterior ribs. The ribs are best reached by the subcutaneous amputation of the anterior limbs, as described above.

When the ribs have been laid bare in the manner described, the operator can thrust the finger tips through the muscles in the first intercostal space, and enlarge the opening thus made by tearing through the muscles, upwards to the spinal column and downwards to the sternum. Then, grasping the rib near its middle, he can fracture it by means of a sudden and vigorous pull. The fractured ends may then be grasped, and pulled, broken, or twisted off.

The chisel may be brought into use, if necessary, in order to divide the rib, the hand of the operator constantly guiding and guarding the chisel blade. The operation is then to be repeated upon other ribs until an opening into the chest is secured, ample in size for the introduction of the operator's hand.

Force the hand through the opening, and tear the mediastinum from the thoracic walls, above and below. Then grasp either the trachea at its bifurcation, or the heart, and tear away the lungs and heart, as nearly as possible in one mass. The heart, which constitutes the great-

est bulk of the thoracic viscera, is best grasped by engaging the fingers in the aorta and pulmonary arteries.

When the thoracic viscera have been withdrawn, thrust the fingers through the diaphragm, locate the liver, isolate the area of the diaphragm to which it is attached, and, engaging both with the fingers, remove the two together.

The liver, in a normal fetus, constitutes the chief intra-abdominal mass, and occupies more space than all the other organs combined. After the liver has been removed, the intestinal tube, with its contents, may be withdrawn without difficulty, as its attachments are feeble. The kidneys may also be removed.

In the posterior presentation, evisceration is preferably performed through the pelvis, generally in connection with intra-pelvic amputation of the posterior limbs, as described above.

When free entrance has been gained into the abdominal cavity, introduce the hand and withdraw the alimentary tube. Then rupture the diaphragm about the liver and tear away the latter organ in the same manner as in the anterior presentation. The liver is so friable that it cannot well be removed by grasping the organ itself, but comes away entire, with the central part of the diaphragm. Remove the heart and lungs as directed in the anterior presentation.

The decrease in the volume and rigidity of the fetal body may be pursued further by the division of the fetal ribs as noted on page 258. If desired, a fore leg may be amputated with the wire saw.

Miscellaneous Embryotomy Operations. There remain innumerable atypical cases to which the general principles must be applied. In the various forms of monstrosities, some plan must be evolved by which the monster may be sufficiently reduced in size to permit of its removal. Double monsters may be divided equally, if possible, or a portion of each body may be removed, so that the remnants of the more or less double body may be safely extracted.

Sometimes other persons have performed partial embryotomy, in such a way as to embarrass the veterinarian. A limb has been amputated at such a place that the stump becomes a positive menace to the patient and interferes with delivery. For example, the amputation of an anterior limb at the carpus, when the foal is presenting anteriorly or in the transverse presentation, is an obstacle and a menace. In such cases the stump of the limb must not be pushed back into the uterine cavity and permitted to puncture the uterus, but must be amputated higher up, until at least the fore-arm has been removed. Similar mutilations are met when the fetus presents posteriorly and

some portion which has protruded beyond the vulva has been cut away. I met with an anterior presentation, with the two hind feet projecting forward and engaged in the pelvis, in which detruncation had been performed through the thorax, without preserving a skin-flap, and jagged bones left, which seriously abraded the soft tissues of the mother. It is absolutely necessary in such a case that the spinal column be shortened by the removal of all the dorsal vertebrae and ribs, in order that version may be accomplished and the remnant converted into the posterior presentation. It is equally necessary that the spinal column be shortened in order that a flap of the skin and soft tissues may be acquired, which will cover the stump and protect the uterus and vagina from injury.

Complications of the greatest variety may arise, and are to be met by judicious planning and having the necessary instruments and appliances at hand for carrying out the work.

Cesarean Section. Gastrohysterotomy. Hysterotomy

Sometimes the veterinarian encounters a mare, cow or other female near the close of pregnancy in which death is unavoidable and imminent, and the living intrauterine young has a potential value if it can be hurriedly removed in a viable state. The death of the pregnant animal being inevitable, her welfare may well be ignored. The environment largely excludes all usual preparations for an orderly surgical operation. For example, my most interesting cases in this field were two aged, purebred beef cows about eight months pregnant. Caught in a severe drought, they had pulled out all their incisor teeth in their efforts to nip tough, dry grass. They were down, unable to rise, and were dying of inanition. The two anterior feet of the cows were caught in a rope and the other end secured to the saddle pommel of a trained cow horse, the two hind feet tied with a second rope likewise attached to the saddle of a cow horse and the cow stretched and held securely by the two horses. The animal was stunned by a blow on the head, the abdomen and uterus quickly and freely incised, and the calf removed. Artificial respiration soon had the calf in viable condition. For this task the animal needs be secured with the hind legs stretched backwards and the anterior legs forward so tightly and safely that the operator may not be disturbed in his work by the death spasm of the mother. The more quickly the fetus can be extracted, the more favorable the prospect for its life. In this way a calf, and presumably a foal, may be successfully removed a month or more prior to the normal end of gestation.

Cesarean section for the removal of the intrauterine young is one of the oldest of surgical operations. Its usefulness has been greatly advanced by the introduction of anaesthesia and asepsis. It has been performed upon all species of domestic animals, and its application may be considered in those cases in which the female is incapable of physiologically giving birth, or the veterinarian can not satisfactorily remove the fetus by forced extraction or by embryotomy.

Forced extraction or embryotomy is usually more readily available and satisfactory than cesarean section in unipara. The great weight of the abdominal viscera of solipeds and ruminants creates a formidable problem in the safe closing of the laparotomy wound.

The actual economic value of cesarean section in domestic animals has not been comprehensively studied and determined. I have related above that I removed in viable condition two purebred calves from dying cows. Both were heifers and supposed to be potentially valuable, but I failed to follow them to and through adult life and do not know if they constituted assets or liabilities. They were removed somewhat prematurely, the dams were dying of inanition and their intrauterine young could not logically be regarded as of maximum vigor. The cows having been destroyed, the calves were necessarily fed artificially, which placed their normal development in peril. Dairy calves are ordinarily fed artificially, and consequently suffer no additional disadvantage following the death of the cow. Generally, however, the physical health of the dam which requires cesarean section for delivery is poor or indifferent, so that if the young is alive, it is not highly vigorous.

Similarly there is not clearly available proof of the general value of any surviving females. Harms³² citing Franck and others, reports that of five mares under the operation, one survived. One needs bear in mind, in the assembling of data in such a field, that allegedly successful results are more frequently reported than are those which clearly fail. The reports upon the operation in cows is better in so far as the mortality is concerned, showing a survival of 35 to 50% or more. Götze³⁰ reported that, among five heifers operated upon chiefly because of genital hypoplasia, three survived. Their commercial value after recovery is not stated. There is no suggestion that any of them again bred or yielded a valuable quantity of milk. Presumably they were later slaughtered for beef. In the United States, where good beef is relatively abundant, only well selected cases can be made to repay the owner for the cost of veterinary service and of fattening for the market. Yet that is the chief outlook for

possible economic success in the operation. Some years ago, after listening to a highly optimistic paper upon cesarean section in the cow, I asked the essayist regarding the profits to the owners and was rather curtly reminded that the operation caused abundant publicity and that the economic profits might well be ignored. The outlook for the sow is much better and cesarean section in reasonably well selected cases appears economically favorable.

Cesarean section in the bitch is far more successful because it is largely performed in anticipation of dystocia, as in hereditary hydrocephalus, such as described on page 185. Here the outlook for survival of both dam and young is excellent. Since the value of dogs is primarily sentimental, the economic question needs not arise. Thus a colleague and former student, engaged in small animal practice, reports having performed more than 700 cesarean sections during 15 years, confined practically to *cesarean section breeds*. The breeds with short nose and limited hydrocephalus demand cesarean section in such a high ratio that the operation is adopted as a rule of practice. One bitch in the Vienna clinic underwent four successful cesarean sections, and several others have been operated upon two or three times. The prognosis is highly favorable. No material effort is made at delivery by other means. Cesarean section is anticipated and is performed before the bitch has been exhausted by fruitless labor. Largely for this reason the prognosis of laparotomy in such bitches is highly favorable, as compared with the outlook in other species. When labor has been long and exhausting, when unsuccessful efforts at delivery by traction have extensively abraded the birth canal, or when one or more fetuses have died and become emphysematous, or if the bitch shows fever or subnormal temperature with coma, etc., the prognosis for the bitch sinks to the common level of that for other species in analogous condition.

The outlook for the mother and young is far better in human obstetrics than among solipeds and ruminants. The difference largely rests upon the fact that in modern obstetrics the pregnant woman is carefully examined for the purpose of determining existing obstacles to birth through the regular channels, and, in the presence of serious impediments, cesarean section is planned in advance. Unfortunately this has not yet been attained in the large domestic animals, but is confined to those breeds of dogs which have been bred in a way to assure dystocia in a large ratio of females. Cesarean section in mares and cows is generally first considered after dystocia has developed, and one or several laymen or veterinarians have vainly attempted delivery by forced extraction or embryotomy. Thus, in the mare suffer-

ing from oblique bicornual pregnancy shown in Fig. 92, had a careful examination been made at six to nine months, and a correct diagnosis reached, it would have been quite possible to rescue both mare and foal by cesarean section ten to twenty days prior to anticipated labor. So in all my cases of rotated bicornual pregnancy, had I been able to make a correct diagnosis at the proper time and carefully conducted cesarean section, there would have been a fair prospect for saving mares and foals: instead all foals and mares perished, I was physically exhausted from my efforts at delivery and my professional reputation unfavorably affected.

Under present environment the veterinarian having to consider the propriety or advisability of cesarean section in solipeds and ruminants, should be on his guard, select his cases carefully and frankly explain the outlook to his client.

The technic of cesarean section in domestic animals has not been well established, and opinions regarding the best methods vary greatly. Primarily the operation resolves itself into the two steps of laparotomy, or the opening of the abdominal cavity, and the incision into the uterine cavity. The laparotomy is performed in the flank; along the median line through the linea alba; or through the abdominal floor either lateral, or median to, and parallel with the left subcutaneous abdominal vein (milk vein). The plan of the laparotomy logically affects the method of confinement and of anaesthesia. The method of anaesthesia is also profoundly modified by the species of animals involved, since the various narcotic and anaesthetic drugs act quite differently upon the several species.

Chloroform narcosis is well-nigh unavoidable in the mare. Morphine induces no reliable narcosis and often renders the animal unmanageable through excitation. Ruminants under chloroform narcosis tend to regurgitate ingesta into the larynx, whence it is inhaled. Local anaesthesia with novocain, tutocaine, etc., meets all requirements for the cow. Keller³⁷ advises chloral hydrate narcosis for the goat. For swine he would avoid chloroform narcosis, because of its danger, especially since it must commonly be administered by inexperienced persons. For the bitch some favor morphine, followed later by chloroform mixture (chloroform and petroleum ether, each 1 part, and sulphuric ether 2 parts). In the Vienna clinic, however, local anaesthesia is much preferred. Inhalation anaesthesia cannot be dissociated from danger; the patient may die from collapse during the operation or from pneumonia or hepatic degeneration later.

Whatever the type of laparotomy to be performed, the animal in general, and especially the area for the laparotomy, should be well

cleansed. The immediate operative area should be clipped or shaved, thoroughly washed and disinfected. A sterilized sheet of gauze, for small animals, or of muslin for large animals, should be provided, of ample size to cover the operative field in such a manner that any portion of the uterus or other viscera protruding from the incision will not come in contact with the skin or hair.

The cesarean section by flank laparotomy may be performed advantageously upon the cow in the standing position. Local anaesthesia should be applied to the skin along the line of the intended incision. The cow should be secured in stocks, or with her left side against a wall, and ample precautions taken against lying, or falling down.

The incision is made in the right flank, beginning above at a point about equidistant from the last rib, the margins of the lateral processes of the lumbar vertebrae, and the supero-external tuberosity of the ilium. It should extend obliquely downward and forward for a distance of twelve to sixteen inches, dividing the skin, the fleshy panniculus and the abdominal tunic, down to the great oblique muscle. The sterilized protective cover, described above, should be applied to the part before the primary incision is made, and included in the cut. It is then to be secured to the margins of the wound by a few strong silk sutures. The margins of the wound are then to be held apart by means of dilators and the muscular layers separately divided parallel to the direction of their fibers. This conserves the strength of the various muscles, so that by the divisions crossing each other at oblique angles, the abdominal incision tends to close automatically, preventing hernia. The peritoneum may be punctured with a convex bistoury, or with a finger tip, or it may be picked up with forceps and opened with blunt scissors. The opening may then be extended to the desired size with the blunt scissors or probe-pointed bistoury, guarded by the fingers.

If the cow is unable or unwilling to stand, or if an operating table is convenient, she is to be confined upon her left side with the posterior legs secured backwards (or downwards on the operating table) and the fore legs stretched forwards. The laparotomy incision is to be made the same as in the standing position.

Götze³⁰ strongly advises that the laparotomy incision in the cow be made about three inches lateral to, and parallel with the left subcutaneous, or milk vein. The cow is confined in oblique dorsal position, so inclined as to expose the lower left abdominal area. The incision is begun immediately in front of the mammary gland and extended forward twelve to fifteen inches, through the skin and aponeurosis, to the rectus muscle. The bundles of the muscle are

separated with a blunt instrument, the margins held apart with retractors and the peritoneum incised.

Drs. E. R. Frank and E. J. Frick, of the Kansas State College, have recently reported (personal communication) a highly interesting and significant series of cesarean sections upon heifers. Instead of the technic advised by Götze in 1928, they made the incision midway between the median line and the right subcutaneous abdominal vein. Muscular tissue being almost absent in the area, the incision is made directly through skin, linea alba and peritoneum.

The cesarean sections were chiefly upon range beef heifers (Herefords) which had imprudently been allowed to become pregnant at six to seven months of age, at which period the pelvis is regularly juvenile and dystocia invited. In addition, the rainfall had been erratic and the heifers were probably somewhat defective in genital development for their age.

The results in these cases were highly satisfactory both surgically and economically.

The laparotomy in the mare is made in the right flank, as in the cow. The operation is performed under chloroform anaesthesia, and the mare is preferably confined upon the operating table. In default of table, the mare is cast in lateral decubitis and confined with the limbs fully extended, exposing the abdomen completely.

The flank laparotomy in multipara may be made upon either side, the animal being confined in lateral decubitis with legs extended preferably upon the operating table, and the operation performed under local or general anaesthesia according to species and the habits of the surgeon. The incision may be directly through the abdominal wall, without consideration for the direction of the muscle fibers: the small volume of the abdominal viscera renders hernia improbable after careful suturing of the abdominal wound.

Laparotomy along the linea alba is largely dictated by sentiment and fashion in carnivora. The flank operation may leave a visible scar which is objectionable. Because of the intimate contact of the mammae near the pubis, the median incision is best made somewhat near the ensiform cartilage. The incision needs be of sufficient extent to permit the removal through it of the pregnant uterine horn, according to the size of the patient.

A sufficient portion of the uterus, preferably the ovarian pole in unipara, or (unless otherwise indicated) the base of a cornu in multipara, should be drawn out through the incision and the organ opened by means of a median, longitudinal incision along its convex non-vascular border. This is especially important in ruminants, since this

area is physiologically free from caruncles and without important blood vessels. Except because of unusual impediments, all fetuses of multipara and twins or multiples in unipara, should be removed through the one incision. The anatomy of the multiparous uterus, Fig. 94, is such that generally the fetuses of one horn may be forced into the other by gentle digital compression.

As a rule the afterbirth should be detached and removed and the uterine cavity cleansed.

The uterine incision should be closed by Lembert sutures of catgut. If the cervix or other portion of the birth canal is closed, as in irreducible uterine torsion, or important placentitis exists, drainage needs be provided. The peritoneal incision should be closed with interrupted catgut sutures. The musculo-cutaneous incision should be closed by strong interrupted silk sutures. The wound may then be covered by some variety of adhesive plaster, or a pad of antiseptic gauze of ample size placed over it and secured in position by bandages. The sutures may be removed after eight to ten days.

It is generally impolitic to attempt to re-breed uniparous females after apparent recovery following cesarean section: the bitch frequently breeds successfully and again commands cesarean section.

Hysterectomy

Sometimes when cesarean section has been evoked for the overcoming of dystocia, the condition of the uterus after the performance of laparotomy are found to be such that the life of the female is in serious peril and her recovery extremely improbable or utterly hopeless if the uterus is permitted to remain. Sometimes the inadvisability or hopelessness of cesarean section is recognizable without laparotomy: in cases where there has been much delay; where there has been serious injury to the genital tract from unsuccessful attempts at delivery followed by serious infection and exhaustion with abnormal or subnormal temperature; or where one or more fetuses are in advanced putrid decomposition, and the removal of the uterus, with its contents, offers the remaining possibility for saving the life of the patient. The ovaries should be removed along with the uterus and the patient wholly relieved of sexual functions.

In solipeds and ruminants, where the decision must be based upon purely economic grounds, hysterectomy is of scant value. In swine, where again the computation must be strictly economic, it has scant value, according to Keller,³⁷ apparently because of the vast volume of the pregnant uterus. The pregnant uterus of the sow may exceed 10 or 12 feet in length, which involves a very large bulk of tissue

with much blood. Apparently the removal of the vast amount of blood, or of some other unrecognized element, is more than the sow can endure. To begin with, the sow is quite probably in poor physical health; otherwise she would not have dystocia. Hysterectomy acquires its chief value in carnivora, where sentiment rather than economics constitutes the basis for measuring results, and where the gravid uterus, compared with that of the sow, is small.

The laparotomy is the same as for cesarean section. When the uterus has been exposed, and conditions demand hysterectomy instead of hysterotomy, it is usually preferable to leave the organ unopened. In exceptional instances, the cornu may contain living young, which should be removed. That done, the ovarian and uterine arteries are ligated, and the mesometrium divided upon the uterine side of the ligature, with scissors or by tearing with the fingers. The other horn is then similarly exposed and handled. The amputation of the uterus may then be carried out by one of three distinct plans, under variable details of technic: (1) The amputation may be through the birth canal and the stump left in the peritoneal cavity; (2) the stump may be drawn into the laparotomy wound and fixed there: in this case the laparotomy incision needs be on the median line and the stump fixed in its posterior or pubic end; (3) the amputated stump may be everted, drawn through the vulva, re-amputated, and returned into the vagina. Keller prefers this plan, under the following technic. Upon the body of the uterus, not far from the bifurcation, place a secure ligature of heavy silk—fine silk will cut through. Divide the uterus 1 to 2 cm. beyond the ligature, having first clamped the uterus on the cornual side in order to prevent escape of infected contents. Immediately dry and iodize the amputation stump. Introduce a pair of double tenaculum forceps through the vulva and vagina up to the point of amputation, open the jaws and push the ligated end down between them. Close the forceps and carefully draw the stump out through the vagina, thereby bringing about a vaginal prolapse. The vaginal stump is then temporarily abandoned until the laparotomy incision has been closed. Returning to the amputation stump, it is drawn out as far as may be safe, and an elastic ligature securely placed as far from the end of the stump as is practicable, leaving the original silk ligature and its enclosed tissues free. The end of the stump involved in the silk ligature is then excised, and the shortened stump returned into the vagina. By this plan no infective discharges may escape from the stump into the peritoneal cavity.

CHAPTER XIX

THE DIAGNOSIS AND HANDLING OF THE VARIOUS FORMS OF DYSTOCIA

Hypoplasia of the Reproductive System and of the Pelvis

THE problem of hypoplasia of the reproductive system has been discussed at length in the companion volume upon the diseases of the genital organs, and has been mentioned on page 176 of this treatise as a highly important basic cause of dystocia. It is by far most frequent and destructive in dairy cattle, commonly in bad health during the artificial feeding period during calfhood; it may occur in the beef breeds of cattle and in other species of domestic animals subjected to unfavorable environment during early postnatal life. In some instances there is apparent evidence that the hypoplasia antedates birth. This seems quite probable in abbreviated pregnancy, so common in dairy cows. The calf born after a subnormal duration of gestation is inevitably arrested in development, not wholly because of the brevity of gestation, but more because of the defective nutrition available to the fetus in the atonic or diseased uterus. Genital hypoplasia must also be recognized when the female is bred at too early a period in life, before she has attained sufficient physical maturity in size and strength.

When females suffering from genital hypoplasia, such as in the dairy herd described on page 143, reach breeding age, they conceive with difficulty, pregnancy is unsafe, and if gestation goes to or near term, dystocia is well-nigh inevitable. The defectively developed genital system is atonic and extremely vulnerable to bacterial invasion which lowers the expulsive powers of the uterus. At the same time the vagina and vulva are too small to permit physiological birth. In the herd mentioned, about 200 heifer calves born during a period of five or six years were poorly handled, and physiological reproduction when they came to breeding age was the exception. Illustrative of this condition is heifer A, a first calf born at 274 days, May 24, 1926. Her dam was a poor breeder and her grandmother somewhat worse. I attended her for abortion dystocia on Aug. 21, 1929, when she was 3.25 years old, and pregnant about 120 days. The heifer, a Holstein, was undersized and would weigh about 700 pounds. Her general condition was good. Portions of the fetal membranes protruded from the vulva. The vulva would readily admit but two fingers. After about

one hour of patient and fatiguing labor I succeeded in forcing my hand, which is small, through the vulva to the cervical end of the vagina. There I could grasp the head of the fetus, but the vulva would not permit the simultaneous passage of my hand and of the head. I passed a pair of Albrechtsen uterine forceps along my hand and grasped the fetal head, but when I wished to withdraw my hand the forceps had so decreased the available room in the vulva that I had great difficulty. The little fetus was easily brought out. The after-birth came away promptly, and after I had introduced my hand several times the vulva became moderately dilated. There was no lactation. On March 5, 1931, she was again in dystocia at 280 days, the fetus dead and removed by forced extraction. As lactation was very poor, she was discarded.

As a second illustration from the same group, heifer B, born Sept. 10, 1927, had a bad start with a gestation duration of 268 days. Her dam and granddam were both good breeders. She had been bred four times at irregular intervals, suggesting unobserved disasters. On Jan. 31, 1930, when she was 2.3 years old, I could readily pass but two fingers into her vulva. She was in vigorous general health and would weigh 800 to 900 pounds. After long effort her vulva was dilated sufficiently for me to pass my hand and douche her uterus. On March 12, 1931, when she was 3.5 years old and 287 days pregnant, she was in dystocia, and the calf was dead. After prolonged effort and patience the cadaver was extracted. Since lactation was almost nil, she was discarded.

In the group of heifers under study, between these extreme cases and some that calved in a manner which would ordinarily be termed physiological, there occurred every gradation of small vulvae, interfering in varying degree. Prior to my being consulted, the calves had been forcibly drawn through the narrow vulvae, several cows had died immediately from hemorrhage, and two had survived and again bred after complete rupture of the perineum.

The method of handling adopted was moderate traction, not exceeding the power of two small men, slowly and patiently dilating the canal. Neither embryotomy nor cesarean section was considered. Neither would dilate the vulva fully and possibly prepare the heifer for normal or quasi-normal parturition in the future. There was no material economic object in saving the heifers except for the hope that a considerable proportion of them would breed and milk acceptably, thus maintaining the numbers in the milking herd until a new series of heifer calves could be efficiently raised and placed upon a satisfactory basis.

In those individual cases of small vulva, so frequently encountered in dairy herds, the best method for handling the dystocia is slow, patient, forced extraction, in the hope that the vulva may thereby be dilated sufficiently that the patient may calve acceptably in later pregnancies. There will be failures. The defect is too fundamental to justify the hope that such a heifer may thereafter prove an excellent breeder. In a recent case of this kind a breeder tried to extract the fetus and failed. A veterinarian attempted embryotomy and failed. Another veterinarian performed cesarian section: the heifer lived and milked 20 pounds per day. She will fatten and furnish a small amount of poor beef. She will probably not readily breed again, and if she does there is nothing to suggest that she will escape dystocia. I recall one instance of constriction of the vulva of a mare, following gangrene of the vulvar lips after dystocia. She was not rebred, after I had advised the owner it would be highly dangerous.

Juvenile Pelvis

The pelvis of the healthy young female logically develops parallel with physical growth, and does not attain its maximum until the animal has reached its adult occipito-sacral length. Keller³⁷ and others state that the pelvis of the goat remains juvenile—that is, smaller than in the adult—until 1 to 1¼ years and that of the sow until 10 to 12 months. As a consequence, dystocia sometimes occurs when these animals are bred to give birth to young at so early an age. The subject is none too clear. Although the first 30 years of my life were spent in an area of extensive swine breeding, I can recall no instance of dystocia in a primiparous sow. The swine were free to range widely. While their basic diet was corn (maize), they had access to a wide variety of grasses and other herbaceous foods. The pigs were naturally grown and weaned at the option of the sow. It is perfectly evident from recent veterinary literature that, along with intensive swine breeding and gross changes in methods of feeding and handling, dystocia has become an important problem. The young of primipara, when the mother gives birth at an early age, are regularly smaller than those of pluripara. This automatically adapts the size of the young to the pelvic diameters. Upon the other hand, if the new-born female is badly nourished, she suffers from hypoplasia of the reproductive system, as discussed on page 143 and dystocia follows. When dystocia occurs in such undeveloped primipara, it may be variously ascribed to an abnormally small bony pelvis, to a narrow vagina and vulva, or to a weak, non-resistant uterus. All three defects co-exist and are referable to a common cause.

Persistent Median Wall of the Muellerian Ducts in the Vagina

I have met, in dealing with sterile cows, several cases of persistence of the median walls of the ducts of Mueller. In the cases which I have seen, the persistent embryonic structure consisted of a perpendicular column, stretching from the floor to the roof of the vagina, and located immediately against the vaginal opening of the cervical canal. The column is roundish, sometimes more than one inch in diameter. Instances of dystocia have been recorded in which one extremity of the fetus has passed upon one side of the fleshy column, while another part has passed upon the other side.

The structure is identifiable by passing a finger into the cervical canal upon one side and bending the finger around its anterior border, into the canal upon the other side. The structure is non-vascular and may be severed with impunity. The defect is embryological and heritable. The cow should be discarded as a producer of breeding stock.

CHAPTER XX

DISEASES AND INJURIES OF THE PELVIS AND PELVIC ORGANS WHICH MAY CAUSE DYSTOCIA

Rachitic Deformities of the Pelvis

VETERINARY writers generally describe rachitic deformations of the pelvis without submitting details or showing that the patient had at any time suffered from rickets. Possibly the idea has been largely borrowed from the human obstetrice, without critical scrutiny. The bony pelvis of uniparous animals is already far advanced in ossification when the animal is born. The fibro-cartilage of the symphysis pubis disappears early as a macroscopically recognizable structure, and the pelvic girdle becomes a rigid, osseous ring except for the sacro-iliac articulation. In quadrupeds the weight upon the pelvis is insignificant when compared with man. If the hind legs were removed at the coxo-femoral articulation, the trunk would almost balance upon the anterior limbs. Hence there is very little stress upon the pelvis and in case of rachitis, at least as I have observed it, the effect is lordosis, kyphosis, scoliosis or vertebral fracture—not pelvic deformity.

While admitting the possibility of its occurrence in all species of domestic animals, it does not constitute a frequent cause of dystocia, largely because animals which clearly show injury from rachitis are not generally bred. When present, the dystocia needs be relieved by forced extraction or by cesarean section.

Pelvic Fractures and Exostoses

Pelvic fractures are rare in domestic animals. They are most common in swine and carnivora. The incidence of pelvic fracture in dogs has naturally increased with the advent of automobiles. I have observed but one instance of dystocia from a fractured pelvis. An escaped stallion mounted a sucking foal and crushed her pelvis. She lived. The fracture failed to heal, as indicated in Fig. 70. Worthless for work, she was bred. At foaling time I was called, because of severe dystocia, and found the fetus presenting normally at the pelvic inlet, but the pelvic canal very constricted, so that whenever traction was applied to the fetus it seemed to recede instead of advance. The foal could not possibly be extracted by traction because, on account

of the non-united fracture on the one side of the pelvis and the movable sacro-iliac articulation on the other side, whenever traction was applied, the pubis moved toward the coccyx and closed the pelvic channel. Since the fetus was dead and the mare worthless, the animal was at once destroyed. Healed pelvic fractures may also bar the expulsion of the fetus through the presence of a large callus or other deformity. Fortunately, most females which have suffered from fracture of the pelvic girdle are not bred. Coxo-femoral dislocation with the head of the femur impacted in the foramen ovale causes, if the

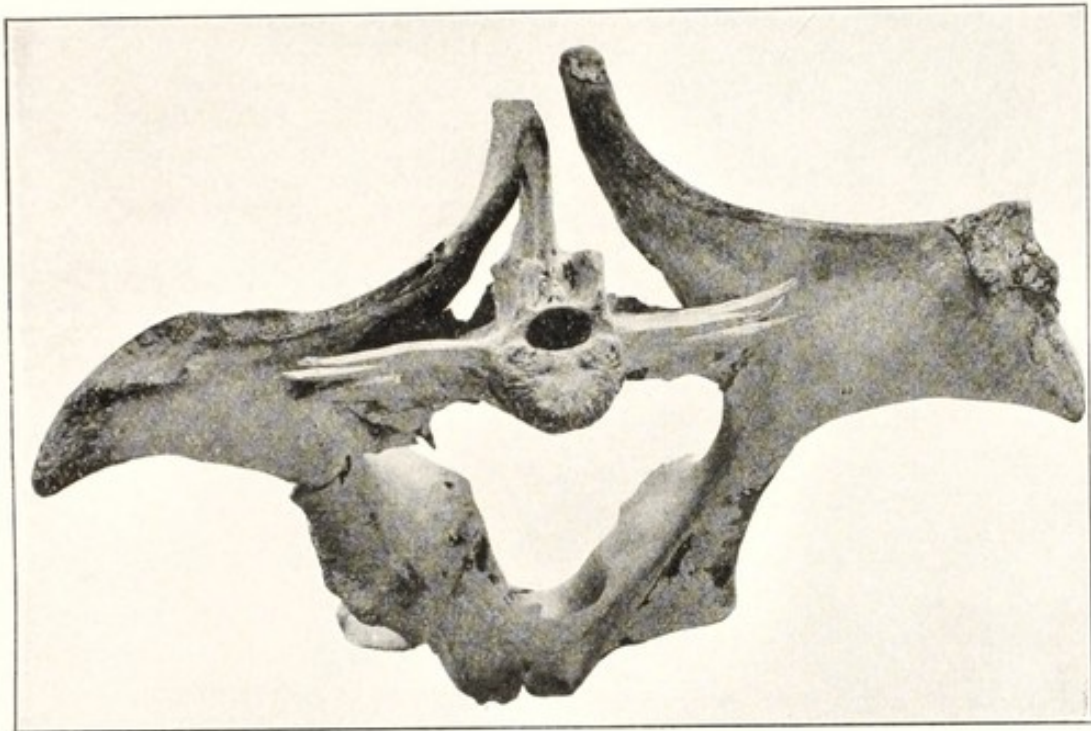


FIG. 70. Constricted Pelvis of Mare, inducing irremediable Dystocia.

Dislocation of right sacro-iliac articulation. Green-stick fracture through right acetabulum. Non-union of fracture of left iliac shaft.

animal is unfortunately permitted to live, an exostosis upon the floor of the pelvis competent to cause dystocia. Occasionally, especially in the mare and cow, there are conical elevations at the pubic margin, as indicated in Fig. 71. These do not materially interfere with the expulsion or extraction of the fetus, but tend to impinge and perforate, or destroy the integrity of the vaginal floor. When observed, care should be taken to avoid the danger.

When the state of the pelvic girdle inhibits physiological birth, forced extraction, embryotomy and cesarean section are to be considered in turn. Forced extraction in unhealed fractures of the type

shown in Fig. 70 is hopeless, because the traction forces the pelvis backward and upward, and grips the fetus with increasing force as the traction increases. Embryotomy is applicable in some cases. Cesarean section, page 260, is available in swine and carnivora. Cesarean section should not be considered in unipara except for

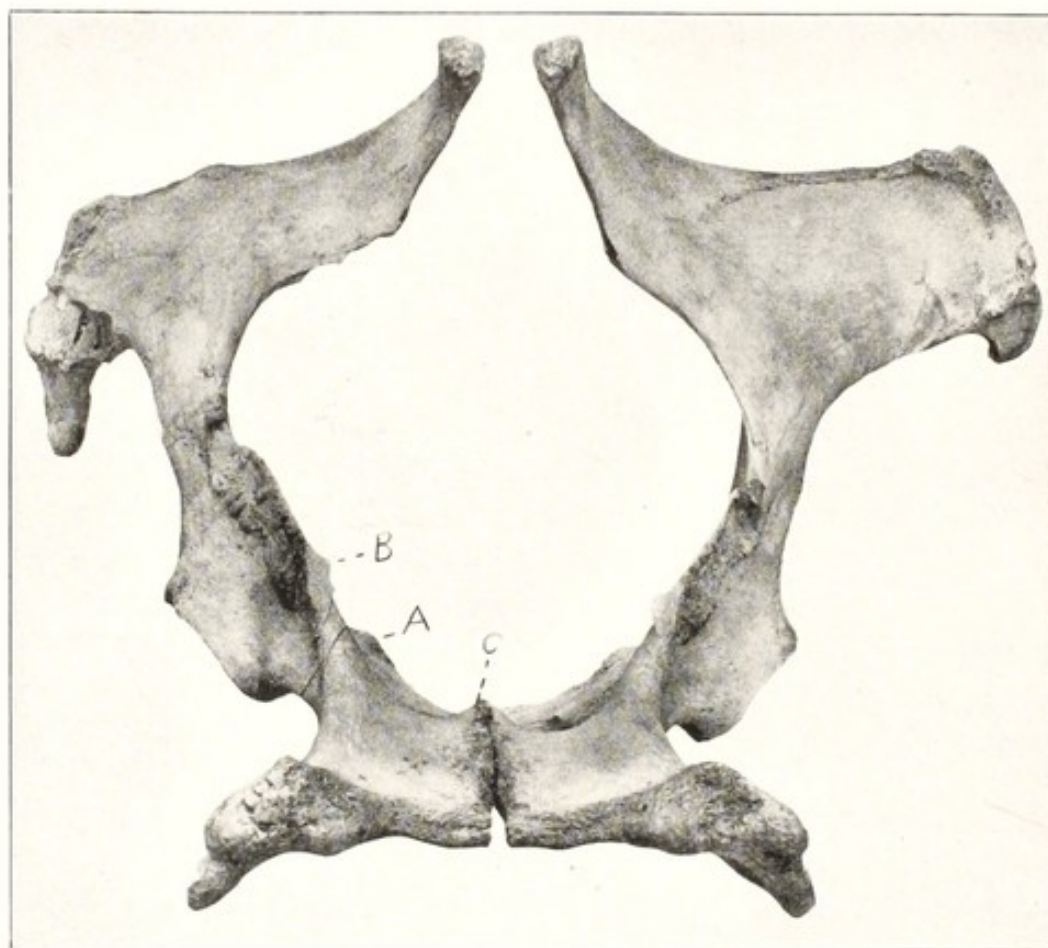


FIG. 71. Pelvis of Mare.

Showing prominent elevations. A, B and C, on the anterior margin of the pelvic inlet.

salvaging the young or the meat or milk value of the mother. Such animals should not be rebred.

Compression and Atresia of the Vagina

Compression and atresia of the vagina occur from an endless variety of causes and may lead to more or less serious dystocia. An instance has been related on page 150 in which intra-pelvic hemorrhage so compressed the vagina as to cause serious dystocia. Malignant new growths within the pelvic cavity are rare and are commonly identifiable. Benign new growths appear occasionally. As a rule such

growths prevent conception, or the tumors having been recognized, the female is not bred.

I have seen a considerable number of cows, both dairy and beef, with serious constriction, in some cases complete atresia of the vagina, due as far as I could determine, to necrotic vaginitis, following parturition. I recall but one individual, a moderate case, which later became pregnant. She calved without aid. I have not observed dystocia from this cause, though apparently it may occur, but is generally excluded by sterility.

The cause of the dystocia is usually readily determined and is generally to be remedied by forced extraction, rarely by cesarean section. If the female survives, she should not again be bred.

Dystocia Due to Cervical Disease

The pathology of the cervix is largely confined to uniparous animals and among these it is by far most common in dairy cows, where it plays a major role in sterility and abortion. The very complexity of the bovine cervix, as compared with that of other domestic animals, invites disease. The evil effects of cervical disease are chiefly expressed in sterility and abortion, and it is only rarely that it is a recognizable cause of dystocia.

The frequency of dystocia in cows, due to cervical lesions or disease, has quite certainly been overestimated. Physiologically the cervix of the cow is a very rigid, semi-tendinous organ, with a very tortuous narrow canal. Between estrual periods the passage through it of a metal catheter the size of an ordinary lead pencil requires some skill, and frequently much patience, while the cervix of the mare may be quickly dilated to permit the passage of a man's hand. The cervix relaxes somewhat during estrum and will sometimes, in pluripara, admit the passage of a finger. Under normal physiological conditions it becomes so relaxed at the close of gestation that it readily dilates to a diameter equal to that of the pelvis, permitting the passage of the fetus without recognizable laceration or abrasion. The forces which regulate the rigid closure of the canal at one period and its free dilation at another are not accurately known. If an attempt is made to dilate the canal mechanically, a high regard is attained for the forces which close it. It can be ruptured more easily than dilated. Physiological birth contractions of the uterus dilate the cervix, push the "water bag" through it and the fetus into it. But there is something more than mere mechanical pressure. Amnio-allantoic dropsy of 40 to 50 gallons certainly affords intrinsic

mechanical pressure, but it does not dilate the cervix nor prevent the mechanical dilation of the canal from being a difficult and discouraging task.

These considerations serve to complicate the diagnosis and to justify the suspicion that error is not rare, especially when an individual reports a considerable number of cases in rapid succession. Two types of induration or constriction are recognized: induration in which the cervix remains in situ and is not recognized until the advent of dystocia, and cervical induration associated with vaginocervical prolapse prior to the close of gestation. The latter is, in my experience, the more common. It will be considered under prolapse. The remarks in this section apply to the first only. It has been taught that induration of the cervix is the result of mechanical injuries, and hence is necessarily a disease of animals which have given birth to young or aborted, and suffered from laceration of the cervix during the expulsion of the fetus. During more than fifty years of obstetrical experience and observation, I have observed two recognizable cases of dystocia due to cervical induration, both in primipara. I have seen plenty of cases of non-dilation of the cervical canal in the presence of amnio-allantoic dropsy, uterine atony and other diseases in which no pathological lesions of the cervix could be recognized. My impression is that many of the cases of cervical induration or constriction reported as the basic cause of dystocia, rest upon erroneous diagnosis.

The diagnosis of induration of the bovine cervix is not easy, because it has, physiologically, a consistency not unlike that of sclerosis. When the forces which serve to relax the cervical walls and dilate the canal cease to operate, the canal is not readily dilatable by ordinary mechanical means. An authentic diagnosis must accordingly rest upon the recognition of definitely pathological changes in the organ.

In one of the two heifers falling under my observation I was unavoidably cognizant of a decidedly constricted cervical canal, but the induration became perfectly clear to me after I had removed the fetus by forced extraction and the cervix had ruptured from end to end—fortunately on the dorsal side. In the other, the heifer had expelled the afterbirth some weeks previously and the fetus was recorded as "lost." A fetid genital discharge developed, but the heifer remained in fair general condition and milked reasonably well. The cervix, extremely hard at the vaginal end, would admit but one or two fingers. The tail skin of the fetus lay in the canal. The canal was enlarged by incision, and the fetal bones and other tissues manually removed. With the fetal debris there were removed many grains

of corn and oats, indicating a communication between the uterus and rumen. The heifer had suffered several times with a very fetid diarrhea.

Both heifers recovered their general health, and were sent to slaughter. In the handling of dystocia due to cervical induration, all prospect of salvaging the breeding life of the animal should be abandoned, and attention concentrated upon salvaging the fetus and the milk or meat value of the dam. Embryotomy is naturally ruled out, and the choice lies between forced extraction, with or without vaginal hysterotomy, and cesarean section. It is believed that the vaginal hysterotomy adds materially to the safety of forced extraction. It should preferably consist of several incisions on the dorsal and lateral walls of the cervix, in the hope that the cervical walls will yield at the several points of incision, and that the occurrence of one extensive rupture may be avoided. But there can be no authentic assurance of this. If the fetus is alive and the salvage of both fetus and mother is economically desirable, the condition offers a reasonable opportunity for cesarean section. But the afterbirth will probably be irremovable, and if the induration is extreme its presence may prove a serious problem later.

CHAPTER XXI

DYSTOCIA DUE TO DISLOCATION OF THE REPRODUCTIVE ORGANS

Vagino-Cervical Prolapse

PROLAPSE of the vagina occurs in all species of domestic animals, most frequently in the dairy cow. When the walls of the posterior end of the vagina become prolapsed through the vulva, the cervix and uterus follow to an equal distance, and the cervix frequently protrudes from the vulva, fully exposed. Generally it is readily diagnosable. Prolapse of the urinary bladder (mare) may cause some confusion. Vaginal tumors, especially those emanating from the hymeneal ring, may at first be mistaken for prolapse of the vagina. Usually the differentiation between these lesions is not difficult.

The causes have not been as extensively investigated as the subject deserves. It is reasonably clear that the causes are not usually in the vagina itself, but are the signs of disease or disturbance in other parts. Keller³⁷ logically attributes it to an atony of the reproductive tract or to general weakness of the patient. The two factors are not readily separable. General atony destroys the power of resistance of the uterus toward resident bacteria or viruses, and this in turn increases the general atony. Fetal life becomes imperilled, preëminently in the ewe. Fetal decomposition aggravates the disease and annuls the contractile power of the uterus. The exposure of the inverted vagina and prolapsed cervix to the air and dirt invites inflammation and necrosis; these increase the irritation, with increase of abdominal expulsive efforts and decrease of the power of the uterus to dilate the cervix and expel its contents. The prognosis is one of the unsolved puzzles of veterinary obstetrics. The disease may be trivial, offer no interference with birth and disappear without leaving a mark as soon as parturition is over, only to recur faithfully in the next pregnancy. Or the phenomenon may be associated with very grave disease and lead to total loss of mother and young despite any and all measures which may be applied. Since between these extremes occurs every possible gradation, the proper evaluation of a given case is difficult and none too dependable.

The greatest obstacle in the determination of the best course of preventing or handling lies in the defective knowledge of the basic causes. By tradition vaginal prolapse has been largely attributed to

close confinement and over-distension of the abdomen. It is true that the phenomenon is chiefly observed in closely confined animals. At first, as a rule, the prolapse is not observed except when the patient is lying down. This lends color to the popular belief that excessive intra-abdominal pressure is the most important cause. That view is opposed by the fact that, when the intra-abdominal tension is increased by amnio-allantoic dropsy, by twins, etc., vaginal prolapse does not follow. Because of the prevalence of vaginal prolapse in stanchioned dairy cows, it has been concluded by some that the chief cause is to be sought in the backward-sloping floor upon which the cow is forced to lie, which causes the abdominal viscera to push backwards into the pelvis and mechanically cause the prolapse. This view is not supported by clinical observations. I have observed vagino-cervical prolapse more frequently in the ewe than in the cow. In the ewe it cannot well depend upon lying on a floor sloping backward. Sheep are not confined in stanchions and ordinarily lie upon a level floor. So far as I have observed, the affection is seen almost entirely in closely housed pregnant animals. I have especially noted the affection in ewes which were kept for growing winter, or "hothouse" lambs. In these cases the ewes are bred about August or September, so that they may give birth to lambs during mid-winter. The ewes are closely confined in very warm stables, and highly fed. Under these conditions I have seen as high as five to ten per cent of a herd of ewes affected. So far as I have observed, the conditions under which the disease arises in the cow are similar. I do not recall having seen a case of prolapse of the vagina in a pregnant animal of any species, except it was closely housed.

While the prolapse is generally visible at first only when the animal is recumbent, and only the vagina is visibly displaced, as the disease advances the cervix protrudes beyond the vulva when the cow is lying down, and finally may protrude constantly, whether the animal is lying or standing, though the protrusion is far greater when she is lying. The vaginal portion of the cervix then becomes soiled. Feces, urine, soiled bedding, and other filth come in contact with, and adhere to it. Inevitably, severe irritation follows, and the cervix becomes inflamed, thickened, hard, and greatly enlarged. When the protrusion is severe and the displacement persists much of the time, the surface of the cervix and the vagina suppurate. The more exposed parts, the mucosa, and even deeper structures may undergo necrosis. Sometimes the uterine seal is plainly visible, resting securely in the cervical canal. Sometimes the uterine seal is broken down and the mucosa of the cervical canal is suppurating. Sometimes the fetus is expelled.

Often the cervicitis, acting as a formidable barrier, prevents the discharge of the uterine contents and putrid decomposition of the fetus follows, with its sequelae. The death and decomposition of the fetus, followed by the death of the mother, have been common in my experience in ewes suffering from prolapse of the cervix. The same is apparently true of goats.

In the cow, especially, vaginal prolapse often causes but slight inconvenience, and may remain comparatively mild to the close of gestation. Spontaneous birth may then occur, and the prolapse disappear until the next pregnancy. The prolapse, with the attendant infection and swelling, lowers the tone of the birth canal and renders it increasingly vulnerable to disease.

Vagino-cervical prolapse is essentially incurable, so far as has yet been determined. The symptoms—and only the symptoms have yet been handled—may be materially ameliorated, but the underlying disease, once established, tends to progress, to disappear with the close of pregnancy, and to reappear in the next gestation. The exposure of the vagina to the air, bedding, tail, feces and other dirt irritates the patient and provokes abdominal straining. The uterus, in many cases, is apparently as atonic as the vagina and vulva: it does not contract recognizably. Hence abdominal pressure and straining do not tend to force the fetus through the birth canal, but push the birth canal out through the vulva. On page 40 it has been stated that the walls of the physiological pregnant uterus are in a constant state of muscular activity, and that such activity is essential to healthy gestation. It is reasonably certain that such physiological activity of the uterine muscles, like that of the vagina, is in abeyance or is disordered during vaginal prolapse. As in birth, so in gestation, physiological activity of the muscular walls is essential.

The handling of vaginal prolapse is unavoidably directed chiefly to the amelioration of symptoms. Prevention and cure cannot be widely applied until more is learned of the causes. So far it is impossible to separate the causes of vaginal prolapse from those of dystocia and genital diseases as a whole, already discussed on page 200. Since vaginal prolapse is almost unknown except in animals confined in the stable for considerable periods, the amelioration of the evils of close confinement should lessen the occurrence.

The tradition that the prolapse is due to keeping the animal upon a backward-sloping floor is deeply entrenched, but observations upon sheep and goats, which though they are not so confined, suffer worse, cast doubt upon its importance. When such doubt is raised, the logic of the almost uniform recommendation that the affected animal be

confined upon a forward-sloping floor is at once challenged. It is necessarily intended to apply to the cow. I have tried it and failed to see any value. It is doubtful whether such position can be maintained in any domestic animal without prejudice to its well-being. It is a position not naturally assumed when the animal is free.

When considering the handling of vaginal prolapse the veterinarian needs determine, if possible, the condition of the uterus and the contained fetus. If the fetus is alive and viable, as is often the case in the cow, palliative measures pending the completion of gestation are logically indicated. Usually in the ewe, as it has fallen under my observation, the fetus is dead and undergoing decomposition: it apparently causes the prolapse. A diagnosis between living and dead fetus is authentically available by rectal palpation in the cow.

If it can be determined that the fetus is alive, and that it is prudent to await the completion of gestation, the exposed vaginal mucosa should be protected against the irritation of air, feces, friction from the tail and injuries from bedding and other objects. This is best accomplished by replacing the exposed organs and mechanically closing the vulva. The inflamed, abraded tissues cannot be chemically disinfected. They may be softened and mechanically cleansed to an important degree by the free use of warm physiological salt solution. If the vaginal floor is extensively prolapsed, the urinary bladder is involved and is inverted. Its fundus is directed upward and backward, covered by the vaginal wall, and the urethral opening is directed downward and forward against or near the inferior vulvar commissure. The urethra is sometimes so doubled upon itself as to cause retention of urine. This needs be relieved prior to attempts at replacement. It may be done by gentle manual compression, or with a catheter, a trocar or a hypodermic needle. The catheter involves some danger of the introduction of infection. The hypodermic needle is probably safer than the catheter or the larger trocar.

Reposition is most readily accomplished, generally, with the animal standing, preferably with the posterior parts elevated. At times, especially in small animals, replacement is difficult or impossible in the standing animal, but in such cases the reposition is usually readily accomplished if the animal be suspended by its hind legs. Pressure is to be carefully applied with the palms of the hands in the form of a shallow cup. The pressure should be gradual, and ample time allowed for gravity and compression to eliminate much of the engorgement of the parts. If the animal strains, apply epidural anaesthesia, as described on page 223. This not only facilitates reposition, but eliminates pain and straining afterward.

Since ordinary antiseptics irritate and invite straining they should be avoided after replacement, as well as before. Non-irritant antiseptics may be useful. The liberal use of warm physiological salt solution relieves pain and irritation and favors auto-disinfection. Bland oils, fats and demulcents relieve irritation and may have suspended in them feebly soluble drugs, such as iodoform or bismuth.

The replaced organs will not remain in position unless mechanical support is given. Trusses, pessaries and sutures have been advocated. The first has been useless in my hands, and I believe this is the general observation. The pessary is dangerous mechanically and bacterially and should not be considered. I greatly prefer sutures, and avoid having them pass through the vulvar lips. A heavy needle, armed with silver wire or with tape, is inserted through the skin and aponeurosis at a point about two inches to one side of the vulva, and just below the superior commissure. The needle is carried downwards parallel to the vulvar opening and brought out at a point two inches above the lower commissure. The suture is then carried across the vulva to the opposite side, inserted as before, and brought out at a point opposite the place of beginning. This provides a double suture of secure bearings, which does not penetrate the vulvar mucosa. A suitable aseptic or antiseptic pad may be laid over the vulvar opening and retained in position by the suture. The suture should be so secured that it may be untied and the birth canal washed with salt solution and inspected and handled.

When the prolapse is quite certainly due to utero-fetal disease, as seems to be the rule in the ewe, and perhaps in the goat, it would evidently be bad surgery to apply mechanical devices to overcome a prolapse dependent upon causes still existing, which the means applied would intensify rather than overcome. When it can be reliably determined that a dead or diseased fetus, with a diseased uterus, is causing the prolapse, the handling had best be directed toward the emptying of the uterus. For this purpose no standard technic has been established. Mechanical dilation of the cervical canal, with the hypodermic administration of pituitrin in moderate doses, probably offers the best promise.

A heifer in ambulatory clinic had suffered seriously from vesicovaginocele for 24 hours. The animal had reached the end of the ninth month of gestation. She was lying prone in the stanchion, unable to rise, even with assistance. She was somewhat emaciated, apparently very feeble. The floor of the vagina, within which was the bladder filled with urine, was extruded through the vulva and returnable only with great difficulty. It was impossible, from the beginning,

to retain the organ in position after its return. The animal was moved to a suitable place for operating, where the posterior parts could be elevated. After much tedious and patient labor, the os uteri was dilated and the fetus removed. The afterbirth was left in the uterus, the cavity of which was filled with a warm disinfecting solution. The prolapsed organ remained in position without any mechanical appliance. Relieved of the weight of the fetus, the patient was soon able to regain her feet, and made an uneventful recovery.

If vagino-cervical prolapse be attributed in most cases to general atony of the reproductive system, in which presumably bacteria play a part, such view suggests the possible value of more definite efforts than have yet been made toward restoring the tone of the uterus and birth canal. If the prolapse is causing definite inconvenience and a living fetus be present, not yet sufficiently viable if expelled, it would appear that pituitrin in small doses might prove of distinct value by stimulating normal muscular contractions. With the advent of labor, whether natural or artificial, the expulsive efforts should be prudently seconded by traction. In those cases where traction is not practicable, cesarean section may be considered with a view to saving the intra-uterine young and the meat or milk value of the dam.

CHAPTER XXII

UTERINE HERNIAE. HYSTEROCELE

Dystocia due to Inguinal and Umbilical Herniae

THE inguinal ring of multiparous domestic animals sometimes remains teratologically open and the ovary passes out into the normal position of the testicle of the male. The ovary is so closely attached to the ovarian pole of the uterine cornu that a portion follows into the sac, especially in the bitch, and at times an embryo develops in the extra-abdominal segment to constitute inguinal pregnancy. The dislocated ovary is readily recognized. The exclusion of the defective female from breeding avoids danger. When the defect is ignored, a fetus may develop in the displaced cornu, readily recognizable and calling for cesarean section (page 260). Ovariectomy should be performed upon the female and any viable young should be excluded from breeding.

Umbilical hernia, common in all species of domestic animals, constitutes a hereditary defect. As a rule, females with extensive umbilical herniae are not bred, and those with small herniae should be excluded from breeding in order to prevent the transmission of the defect to progeny. Should the defect be ignored and a fetus pass into the sac and become incarcerated, hysterotomy is indicated.

Ventral Herniae

Ventral herniae, referable to trauma, occur in all species of animals. If the hernial ring is of sufficient size and in favorable position, the pregnant uterus may pass into the sac, the fetus develop there and create dystocia, demanding cesarean section. When ventral hernia occurs during gestation, efforts should be made to prevent uterine hernia by means of abdominal bandages.

Rupture of the Prepubian Tendon

EDEMA OF THE ABDOMINAL FLOOR

Writers on veterinary obstetrics generally include rupture of the prepubian tendon among the ventral herniae, without directing special attention to this characteristic and very serious lesion with its premonitory symptoms. The eventual lesion consists of a transverse rupture of the prepubian tendon immediately in front of the pubis

between the two abdominal, or inguinal rings. The rupture is usually complete and obliterates all tissues between the two openings. Its occurrence is limited, so far as known, to unipara; it is seen by far most frequently in the mare, and rarely in ruminants. The rupture occurs only, or practically only in advanced pregnancy, rarely prior to the tenth month in the mare.

The causes, so far as determined, are:

1. The increased strain upon the abdominal floor caused by the presence of the gravid uterus, which represents at the close of pregnancy probably 30 to 40% of the total weight of the abdominal contents.

2. Degenerative changes in the tissues of the abdominal floor, including the prepubian tendon, closely associated with profuse edema of this region.

3. Very rarely there is a definite history of violence. In one instance a mare, becoming mired in deep mud with her hind feet, overexerted herself in gaining the bank of the stream, thus pulling the hind limbs forcibly backwards, and with them the pubis, causing its chief anterior stay, the prepubian tendon, to give way. No edema or other evidence of disease preceded the accident.

Almost always there can be no reasonable presumption of accident. The rupture may generally be designated as spontaneous. Usually it takes place gradually, frequently preceded for days or weeks by premonitory warnings.

The disease is apparently more common in draft mares than in those of lighter breed, but as my experience has been largely with the former class the grounds for comparison are not ample. The lesion is observed most frequently in idle mares which are well fed.

The first symptom noticed is an extensive edema of the abdominal floor, beginning just in front of the mammary gland and extending thence forward and backward until it reaches from the anterior pectoral region to the perineum, covering the entire floor of the body for a depth of 2 to 4 inches. The edema presents the usual clinical characters, except that it is possibly somewhat firmer than generally seen and somewhat more inclined to be painful to the touch. The exact relationship of the edema to the rupture of the tendon is undetermined. Apparently the edema is an expression of serious degenerative changes which are taking place in the deeper parts. The edema from the first seems to involve the tendon itself.

The movements of the patient soon become restricted to such locomotion as is essential, marked by care and deliberation. The restriction of movement may be due partly to the mechanical im-

pediment of the edema, but it appears rather to result from pain. This restriction of motion generally precedes the rupture of the tendon, and is increased as the rupture extends.

Should the tendon remain intact until relieved of its excessive load through parturition, the edema quickly disappears and the parts become normal, but in many cases the tendon gives way before the foal is born. The mare then succumbs or, surviving, is ruined. The foal generally perishes.

When the tendon begins to part between the two abdominal rings, characteristic symptoms arise which serve to distinguish it from other lesions. The spinal column of the horse forms an arch from the first dorsal vertebra to the sacrum. This arch is chiefly maintained by the linea alba, originating from the sternum in front and ending behind on the pubis, as the prepubian tendon, thus acting as a powerful tie. If the prepubian tendon parts at the abdominal rings, the arch of the spine can no longer be completely maintained: the back drops downward, as is shown in Fig. 72, producing lordosis, or "sway back," and the pubis becomes displaced backward. This causes the external ilial tuberosity to descend and the ischial tuberosity to become displaced upwards, decreasing the slant of the hip.

The rupture of the tissues between the abdominal rings obliterates these and relaxes the fixation of the mammae. The abdominal tunic also becomes ruptured on the same level, the skin becomes greatly stretched, the milk glands are displaced downwards and forwards, as indicated by the position of the teat in Fig. 72, and the glands become less conspicuous because of the compression from the stretching of their capsule, derived from the ruptured abdominal tunic. In Fig. 72, the displacement is comparatively mild. In some cases it is much greater.

The umbilicus is necessarily displaced forward and downward. When the rupture has involved the entire prepubian tendon, and the abdominal tunic has given way, the rent may extend on either side outwardly from the external side of the inguinal ring until it includes the entire abdominal floor. Through this great rent, the gravid uterus and other viscera drop down upon the skin and skin muscles and, pushing the abdominal tunic and musculo-tendinous portions of the abdominal floor forward, bear the skin and skin muscle downward until the hernial sac may reach the level of the tarsus, or even drop lower. Early in the progress of the lesion, firm upward pressure with the hand, in the pre-mammary region, discloses a tense hernial touch without a distinct boundary. As the rupture progresses, the hernial touch becomes more pronounced.

The downward displacement of the abdominal viscera, with the backward displacement of the pubis, causes the flanks to sink in and greatly reduces the transverse diameter of the body.

The skin and skin muscle tend, by their elasticity, to check or stop the progress of the rupture. In some cases the skin and its muscle do not suffice to stay the progress of the rupture, but give way, causing eventration, necessitating immediate destruction of the patient.

In those very rare instances where violence has played an essential



FIG. 72. Rupture of Prepubian Tendon in Mare in Advanced Pregnancy.

The udder and one teat are shown displaced forwards. There is slight lordosis and marked depression of the supero-external angle of the ilium and elevation of the tuberosity of the ischium and of the caudal end of the sacrum.

part in causing the rupture, there need be no premonitory edema. The symptoms appear very suddenly; the tumor is large, the pain intense, the expression anxious, the body bedewed with cold sweat, respiration hurried, the pulse rapid and weak. The patient tends to collapse quickly from shock or hemorrhage.

The character and extent of the lesions, with the reparative efforts in a surviving case, are well shown in Fig. 73, in which it is seen that the peritoneum, prepubian tendon, and abdominal tunic have all parted just anterior to the pubis and passed forward about halfway

to the sternum, dragging with them, for a part of the way, the teats. Posterior to the teats, occupying the area previously filled by them, is an expansion of dense connective tissues, *C*, which has assumed the functions of the ruptured parts.

In Fig. 73 it is shown that the sub-peritoneal fat, *A*, does not in-

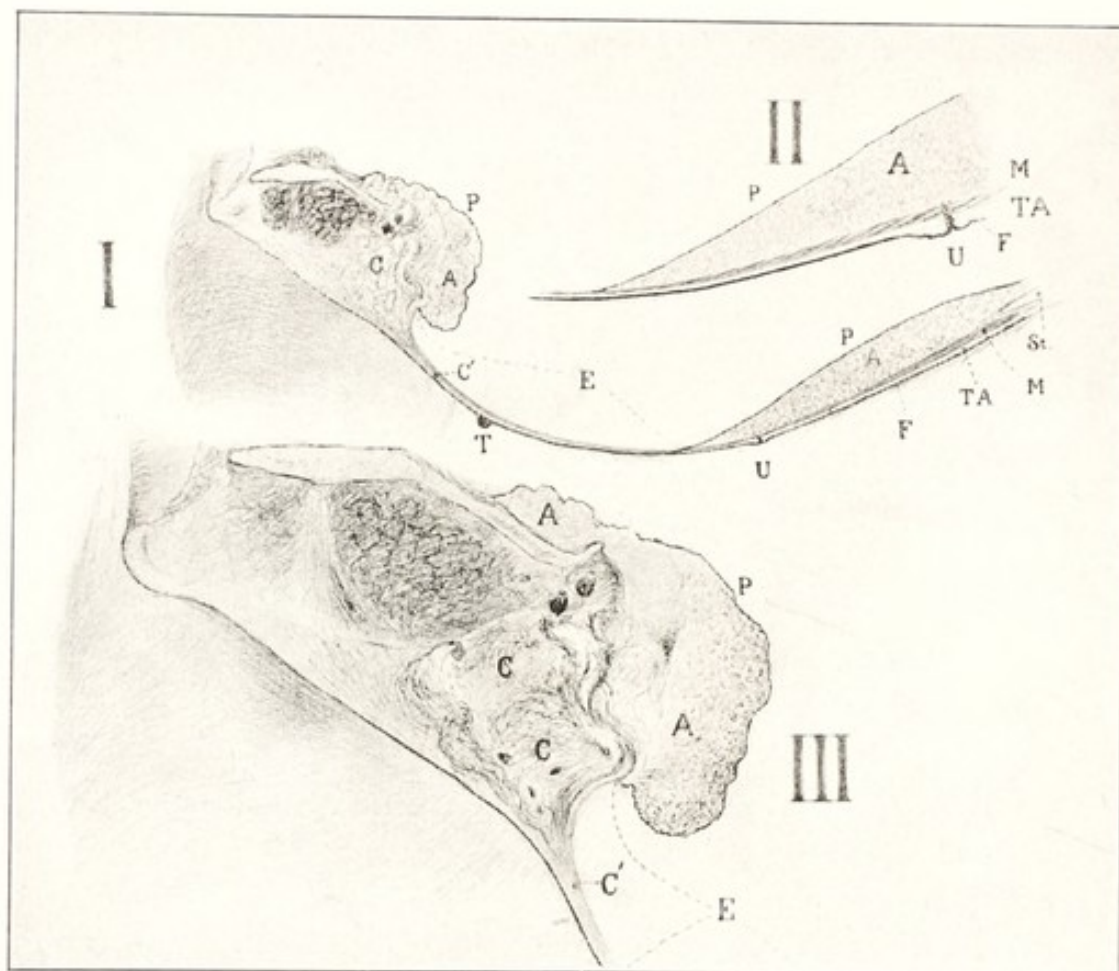


FIG. 73. Rupture of the Prepubian Tendon in the Pregnant Mare.

Sagittal or median section of abdominal floor.

I, section extending through pelvis and sternum; II, detail of anterior portion; III, detail of posterior portion; P, P, peritoneum; E, extent of rupture in the abdominal floor; A, A, subperitoneal fat, occupying entire area except that comprised in E, where peritoneum is absent as a result of the rupture; C, curled connective tissue, the pelvic remnants of the prepubian tendon, posterior to the point of rupture; C', cicatricial tissue occupying the space between the ruptured ends of the prepubian tendon, devoid of peritoneum and adipose tissue; T, displaced teat; U, umbilicus, displaced forwards; F, skin and skin muscle; TA, abdominal tunic; M, transversalis muscle; St, sternum.

vade the ruptured area, *E*: that is, the formation of the fat depends upon the presence of the peritoneum.

The prognosis of complete rupture of the prepubian tendon is very grave, since most mares, along with their foals, perish before the conclusion of the pregnancy during which the rupture occurs.

If the pregnancy existing at the time of the accident is safely terminated, the animal may thereafter breed without danger or difficulty, but is so unsightly that her value for this purpose is seriously diminished. She may do ordinary slow work, but here the unsightliness becomes even more serious and few persons are willing to use such an animal.

When a threatened or beginning rupture is promptly recognized, and appropriate measures for prevention or relief applied, the prognosis is highly favorable.

The opinion of some obstetrists, that extensive edema of the abdominal floor in pregnant mares is unimportant and may be safely ignored, and that the disease will quickly disappear after parturition with little or no attention, leads to serious disaster. *Edema of the abdominal floor in advanced pregnancy in the mare is a serious condition, which calls for prompt and energetic handling.* It should always be regarded as a precursor of rupture of the prepubian tendon. If left without attention, many of the mares will succumb from rupture; if proper attention is rendered, the danger will be almost wholly averted.

Treatment. In the handling of threatened rupture of the prepubian tendon, mechanical support of the greatly overloaded and weakened abdominal floor should receive prompt consideration. Whenever extensive edema occurs along the floor of the abdomen in a mare far advanced in pregnancy, unless the condition is clearly referable to unimportant causes, the immediate application of an abdominal bandage of canvas or other strong material is urgently advised. The bandage should be constructed with eight to ten strong buckles and billets and fitted to the oval form of the abdomen by means of a gore placed in the center of the canvas. One does not at all times have the time required for properly constructing the bandage. In order to avert immediately threatening disaster, a many-tailed emergency bandage should be quickly applied. In order to adapt this to the oval form of the abdomen, the tails should be crossed so that the most posterior of one group of tails shall be tied to one of the most anterior of the other end, and the remaining tails united upon a similar plan. The spine and the point where the ends of the bandages are tied should be amply padded to avoid pressure necrosis of the skin. The bandage should be carefully readjusted daily, or as often as conditions may dictate.

In applying the emergency bandage to cases where the tendon has already parted or its rupture seems imminent, it must be quite tight. In order to facilitate this, it is best to tie a solid loop in each upper

tail—that is, in each tail of the bandage which passes over the back of the patient—through which each lower tail may run as through a pulley. The bandage cannot be properly tightened at the first effort. One after another of the tails is to be tightened as well as convenient at the first tying. As soon as all are fastened, the obstetrice should go back to the first ones and tie them over again. This process should be continued until the desired support is secured and the great weight of the viscera lifted from the abdominal floor and largely transferred to the spine through the bandage.

A decrease in the weight of the abdominal viscera is also of very great importance. The practitioner should lessen the weight of the digestive viscera by replacing all bulky food with limited quantities of concentrated aliment. The unloading of the intestinal tract may be hastened by the aid of small doses of eserine sulphate or arecoline, such as one-half grain every half hour, until the desired effect has been attained.

If the tendon has parted, the induction of premature labor should receive careful consideration. As a rule, the foal perishes unless aid is given. Even under close watching, the uterine contractions go on unobserved and cause the death of the foal through separation of the placenta. The displaced uterus has largely lost its expulsive power and the rupture of the abdominal floor destroys its power. Therefore it seems desirable to anticipate this danger to the fetus by bringing about artificial delivery early, in a way best to safeguard the life of the fetus. Premature delivery is best effected by carefully dilating the cervical canal with the hand, grasping, and if necessary cording, the fetal parts presenting, and applying moderate traction to compensate for the lost expulsive power of the abdominal muscles. It is best to have the patient in lateral recumbency during delivery, since this raises the fetus approximately to a level with the pelvic inlet. When the mare is in the standing position, the fetus drops down below the pelvis, through the immense rupture, and rests upon inert parts. If premature delivery is not decided upon, the mare should be closely watched and prompt aid given at the first signs of parturition.

If the tendon has not ruptured, the bandage may be removed immediately after delivery and the case dismissed; if it has ruptured, the bandage should be readjusted and retained until such time as the ruptured tissues have healed and the weakened abdominal floor has been reinforced by the formation of connective tissue.

The mare may be retained until the foal is ready to wean, and then destroyed; she may be kept permanently as a brood mare, with

reasonable assurance that thereafter she will foal unaided; or she may be used at moderate work without discomfort.

In the very severe cases, where the skin and skin muscles are giving way so that eventration is imminent, or where accompanied by shock and serious internal hemorrhage, the mare should be promptly destroyed, after performing gastrohysterotomy if it is desired to save the foal.

CHAPTER XXIII


TORSION OF THE UTERUS UTERINE VOLVULUS

AN important displacement of the gravid uterus, occurring in all species of domestic animals, has been inaccurately defined as a rotation of the organ upon its long axis. It is most common in ruminants, in which, as indicated in Colored Plate III, the gravid organ is disposed in an almost complete circle. When the organ revolves, the twist inevitably occurs about the long axis of the vagina or cervix and about the transverse axis of the fundus, at 1. Accordingly the displacement is essentially the same as *volvulus* of the intestine and wholly unlike *torsion* of the navel cord. The identity in principle between uterine torsion and intestinal volvulus is yet more clearly seen in multipara, in which the torsion involves a segment of one cornu, containing one fetus, in a greatly elongated, intestine-like organ. It might be contended that the rotated bicornual pregnancy of the mare is a true rotation of the uterus upon its long axis, but in that case the uterine body is not involved and the rotation is confined to the cornua.

The nature of the displacement has already been discussed as one of the basic causes of dystocia on pages 188 to 193. The consideration here may be limited to the problems of diagnosis and handling.

The displacement may be profitably separated into three fairly well defined categories: (1) torsion or volvulus in unipara through 180° or less, without wholly occluding the cervico-vaginal tube and permitting fetal extremities to enter the birth canal; (2) a rotation of the uterus in unipara of more than 180° with complete occlusion of the birth canal; (3) volvulus of a segment of one cornu in multipara, strangulating the tube and leaving the birth canal—cervix and vagina—uninvolved.

The diagnosis of the case belonging to the first group is not clear. Writers upon veterinary obstetrics largely so describe dorso-ilial and dorso-pubic positions as to lead the reader to understand that the fetus has revolved through 90° to 180° upon its long axis while the uterus remains static. Some few writers record surprisingly great numbers of uterine torsion, apparently including numerous cases which others designate simply as dorso-ilial and dorso-pubic positions. Harms³² (Richter) significantly advises that, in rotating



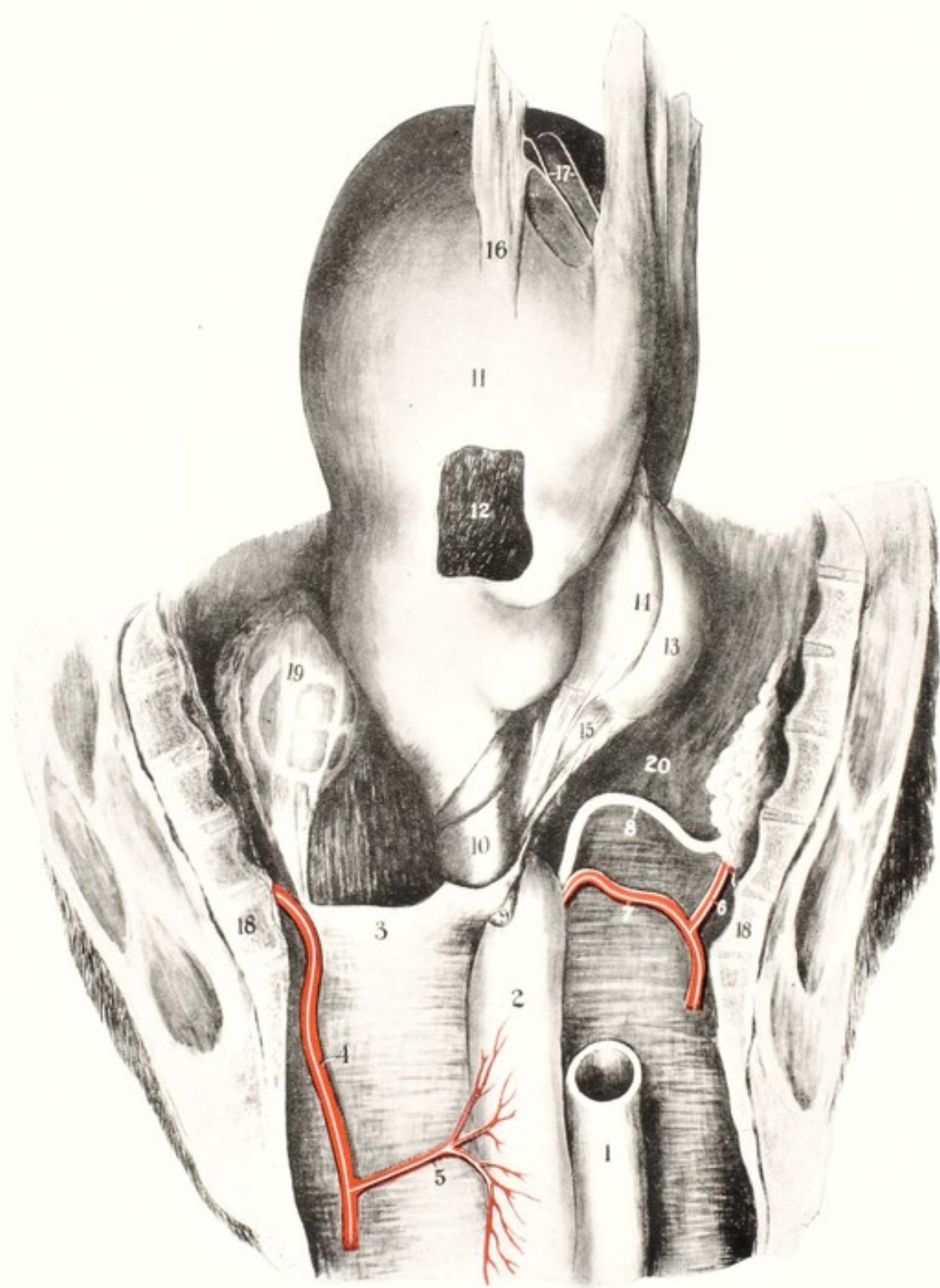


PLATE IV

OLD-STANDING TORSION OF THE UTERUS. COW. VIEWED FROM ABOVE.

1, rectum; 2, vagina; 3, left mesometrium; 4, left internal pudic artery; 5, left vaginal artery; 6, right pudic artery; 7, right uterine artery, passing *beneath* the cervix; 8, right ureter; 9, left ovary; 10, cervix; 11, uterus; 12, fenestrum exposing the fetus; 13, apex of gravid horn; 14, cordiform adhesive band; 15, broad adhesive band between gravid horn and peritoneum about urinary bladder; 16, omental adhesions; 17, adhesive threads uniting chief bands of omentum; 18, sacro-coccygeal articulation; 19, left kidney; 20, abdominal floor. (*Cornell Veterinarian.*)

the fetus from dorso-pubic to dorso-sacral position, if the operator fails to rotate in one direction, he should reverse the effort. If torsion is present he would naturally fail when trying to increase the rotation, and just as logically succeed if attempting to rotate opposite to the direction of the torsion. Much of the confusion seems to have arisen from the early belief, before rectal palpation had been developed, that the fetus primarily lay with its back in contact with the abdominal floor up to the onset of labor, when it promptly turned through 180° , in response to some mysterious force, and entered the pelvis in dorso-sacral position, while the uterus retained its position.

At present it seems safe to say that in the vast majority of cases of dorso-ilial and dorso-pubic positions in unipara the obstetrice has to do with uterine torsion of not to exceed 180° . If the degree of volvulus exceeds 180° , the birth canal is occluded and no portion of the fetus can be propelled into it by uterine contraction. When it is essayed to rotate the fetus in order to correct the position, the uterus is also rotated with the fetal body. The confusion should be clarified by rectal palpation in the positions named. If torsion is present, as seems quite certain, and the uterus has rotated to the right, along with the fetus, to the dorso-ilial position, the right broad ligament should have moved ventralward and the left should have passed approximately to the mid-dorsal line. If the fetus is in dorso-pubic position, the left broad ligament should have passed over the top of the uterus to the right, and within the ligament the pulsating uterine artery should be readily identified.

The handling of such uterine torsion is inevitably based upon rotation as described on page 232. The critical point arising for decision is the correct direction for conducting the rotation when the fetus is in dorso-pubic position. This needs be determined by rectal palpation. This failing, the direction is to be learned by trial and error. If the force is applied in the proper direction, the rotation succeeds; if in the wrong direction, it fails.

There are no clinical manifestations associated with the foregoing group of cases until labor sets in and dystocia becomes apparent. The torsion may have existed days or weeks before labor set in, without evident discomfort to the animal. The picture generally changes in the second group. Rarely the torsion may occur at about the conclusion of the sixth month of gestation. It is usually restricted to late pregnancy and presumably does not occur generally until near full term. Exceptionally torsion of the uterus occurs in non-pregnant females when an atonic uterus is distended with pus or other pathological material. Keller³⁷ observed uterine torsion in a

bitch affected with pyometra. I observed a case of severe torsion in a cow at six months and had to roll her over nine or ten times in order to effect detorsion. She went to term and gave unaided birth to a live calf.

Symptoms. The degree of torsion varies so widely, the effects of the torsion differ so greatly in individual cases, and so many elements enter into the picture, that no description of symptoms can answer for all cases. There may be extensive torsion without any visible symptoms whatever. Such was the case mentioned above of uterine torsion in a cow at six months. She appeared perfectly well in all respects, so far as the herdsman or others could see. The condition was wholly unsuspected until, in the course of rectal palpation of the genital organs of all cows in the herd, I recognized the displacement. After detorsion had been effected by rolling, the cow remained to all appearances healthy, so that the disease ran its entire course without visible symptoms. The symptoms of uterine torsion as commonly described are apparently based upon those cases occurring at or near term, which include the vast majority of the total. Visible symptoms develop only when the torsion interferes definitely with the uterine circulation and the physiological functions dependent upon it. The first symptoms observed may with some justification be defined as those of visceral incarceration or strangulation. There is subdued abdominal pain, variously expressed according to species and genera. The symptoms may have some of the characters of subdued colic. The general movements of the animal may suggest abdominal pain of a character not to be relieved by violent movements. Apparently the pain restrains movement. The animal may lie down and get up frequently, but does so with caution. She may, if at term, show faint expulsive efforts. If the torsion is so great that the birth canal is firmly closed and the vascular supply to the uterus is obstructed, that organ cannot contract upon its contents. Powerful abdominal contractions, as are common in dystocia and physiological birth, are effectively excluded. They can only increase the pain already existing. Severe cases show loss of appetite, fever, or subnormal temperature indicative of sepsis. When gangrene becomes established, or transverse rupture of the uterus occurs, there are usually symptoms of collapse. When an animal in advanced pregnancy exhibits obscure signs of disease, the clinician should first of all determine, as accurately as possible, the state of the uterus and its contents. Uterine torsion is usually easy of authentic diagnosis in the mare and cow by rectal and vaginal palpation. Since a vast majority of severe

uterine torsions occur in dairy cows, it is highly important that the veterinarian impress the dairyman with the importance of early diagnosis in all cases exhibiting unusual phenomena: if a cow in advanced pregnancy appears to be suffering from slight colic or indigestion, it may be uterine torsion; if unusual size of the abdomen suggests twin pregnancy, it may very well be amnio-allantoic dropsy.

The diagnosis of uterine torsion rests primarily upon two palpable facts: the spiral twist in the vagina, cervix or uterus and the displacement of the mesometrium. The rotation of the uterus inevitably causes the walls of the vagina, cervix or uterus to be thrown into spiral folds. If the torsion is extensive in the vagina, its walls are thrown into marked spiral folds which close the canal and prevent the examiner from introducing his hand to the cervix. In right torsion, the spiral folds, when traced from the median dorsal line, coil to the right, downwards and forwards, and thence to the left beneath the organ. Since the rigidity of the cervix of the cow largely prevents the torsion at that point, it tends to occur in the vaginal or uterine area, although the three areas may be simultaneously involved. In right torsion, as indicated in Colored Plate IV, the left mesometrium passes *over* the cervix and cervical pole of the uterus and the right uterine ligament passes *beneath* the cervix. The examiner is able, usually at least, to pick up and recognize the anterior border of the stretched ligament. In the early stages, the compression of the ovarian and uterine arteries causes their distension and increases the pulse impact. Thus in right torsion, the left uterine artery, enlarged and with abnormal pulsation, becomes clearly palpable. When the fetus dies, or the uterus ruptures or other gross changes occur, the symptoms of these are added to those of torsion.

The pathology of uterine torsion varies. The torsion may be so mild that it causes no pronounced lesions. The first effect of the torsion is the disturbance of the innervation and circulation. The venous circulation, with less force than the arterial, suffers first. This results in venous engorgement and transudation into the uterine cavity and fetal membranes. As the degree of torsion extends, the arterial compression increases, the arterial circulation becomes impeded or halted, and the fetus dies.

The destiny of the fetal cadaver varies. Some confusion arises regarding certain phenomena encountered. The commonest destiny of the fetal cadaver is emphysematous decomposition with early death of the mother from sepsis. In other instances purulent decomposition of the fetus occurs, the uterine walls undergo necrosis and, as in Fig. 74, they adhere to the abdominal floor and the abscess evacuates

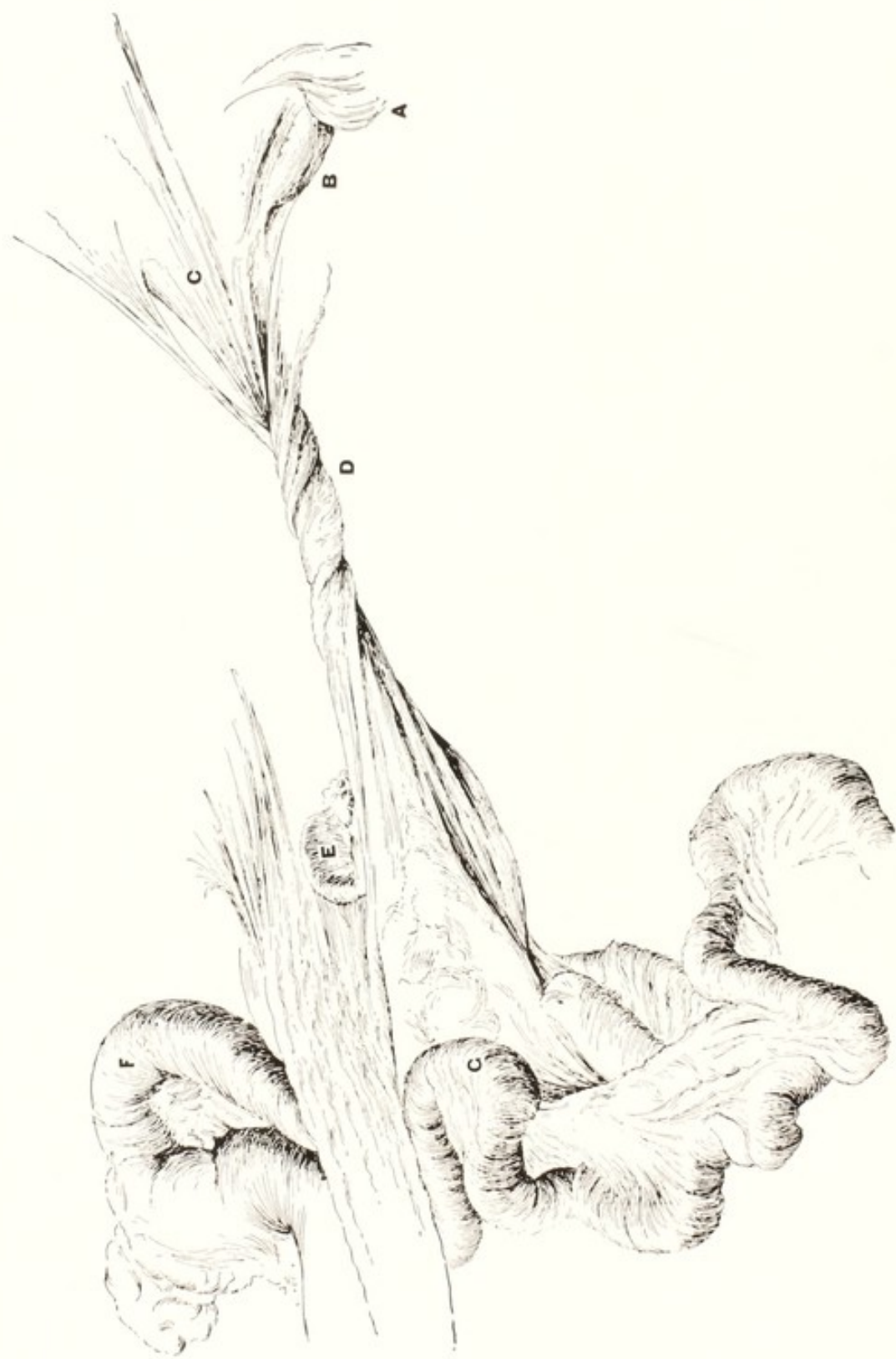

FIG. 74. Torsion of the Uterus in the Ewe.

Followed by transverse rupture of the vagina and sloughing of the putrid fetus through the abdominal floor.
 A, vulva; B, vaginal stump; C, broad ligament; D, cord-like cervix entwined with broad ligament; E, ovary; F, uterine cornu; G, intestine.

itself externally. In two cases to be later discussed, page 357, the fetus was found many months after its death in the state I have designated *static fetal cadaver*. The static condition also occurs without torsion. With rupture of the uterus, as in Fig. 75, there occurs at times what may be termed a dry maceration, with resorption, through the capsule, of the fluids resulting from the liquefaction of the soft

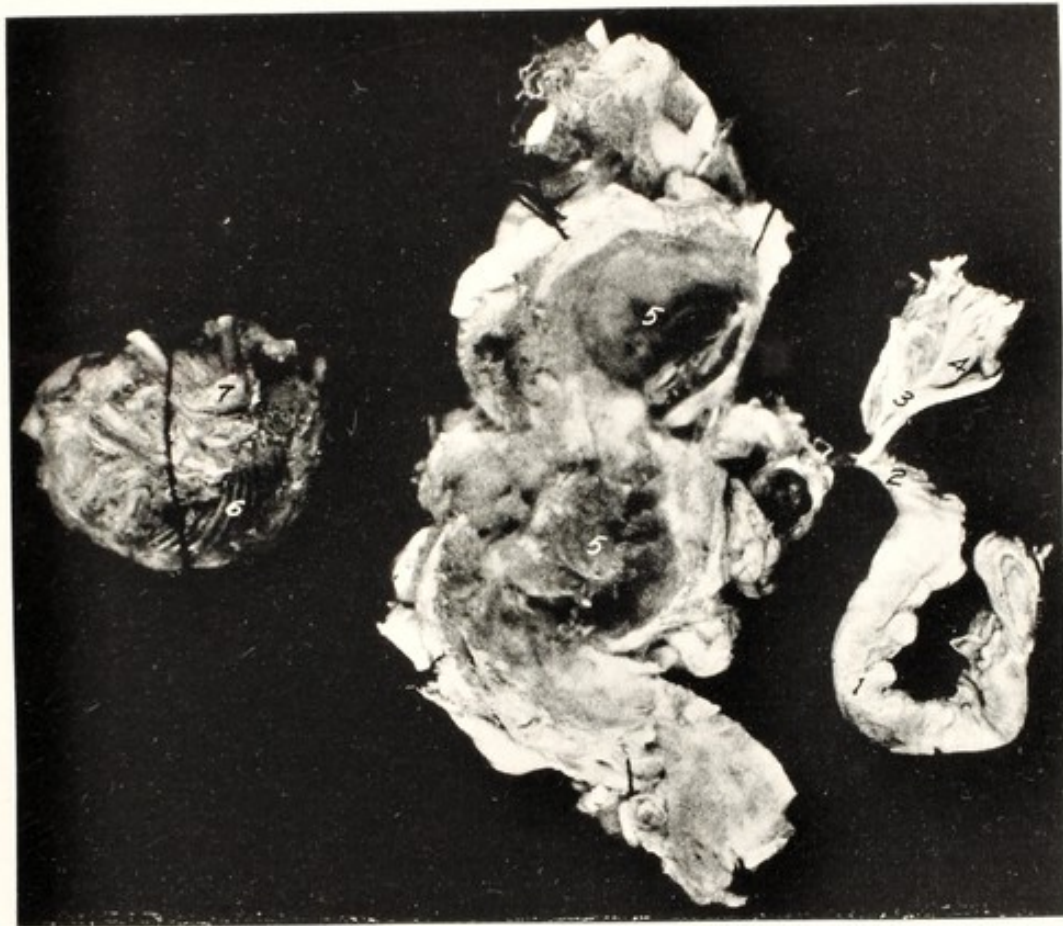


FIG. 75. Torsion of Uterine Cornu. Cat.

1, right uterine cornu; 2, base of left horn; 3, ovarian pole of left horn; 4, left ovary; 5, 5, capsule, consisting of walls of detached ampulla after the fetal cadaver had been removed; 6, fetal ribs; 7, femoro-tibial articulation.

tissues. The details of the process are not fully known and the pathological activities can only be reconstructed from the observations when discovered. So far as determinable, such secondary abdominal fetuses as illustrated in Fig. 10 are probably generally due to uterine rupture from torsion, the fetal cadavers remaining unchanged in the capsule formed about them.

Rupture of the uterus is a common result of torsion. There are several types of the phenomenon. In unipara, transverse rupture in the cervical region, as shown in Fig. 74, is not rare. It is attributable

to the great force of the twist. It naturally occurs chiefly at or near term, when the great weight of the organ with its contents, added to the tension of the twist itself, overtakes the resistance of the birth canal. When it parts, the mesometrium frequently, or generally, retains its continuity. The rupture reveals its presence variously. In my first case of torsion in the cow, after having brought about detorsion by rolling, I was disappointed to find an extensive transverse rupture. The patient was destroyed. Possibly the rupture was due to my error in having had the cow rolled at first in the wrong direction. This type of rupture leaves a wide opening which invites prolapse of abdominal viscera. It is one of the causes, perhaps the chief cause, of vaginal rupture with fatal intestinal prolapse in pregnant mares at term. A second type of rupture, through the greater curvature of a cornu in multipara, probably provides most of the secondary extra-uterine fetuses, recorded in veterinary literature. A rupture through the peritoneum and involving the muscular coat is faintly shown below 17 in Plate IV. A third type is shown in Fig. 75, in which the cornu has become divided at each margin of the detached ampulla.

Except for the *static fetal cadaver* already mentioned, the fetal cadaver uniformly undergoes emphysematous decomposition, maceration, or purulent decomposition, with rupture of intrauterine abscess.

In 1876 Franck apparently fell into the error of concluding that uterine torsion frequently led to mummification of the fetus. The error was continued by Goering in 1887.²⁷ In that day the error was natural. The phenomenon was rare and its discovery limited to the abattoir. In more recent years, the concentration of dairying and vast increase of genital diseases of cattle have multiplied the incidence of fetal desiccation. The development of rectal palpation of the genital organs has enabled the practitioner readily to diagnose the phenomenon. No authentic case is recorded of mummification of the fetus following uterine torsion, and there is abundant evidence that it does not and cannot occur.

The extent of torsion varies, and its ultimate limits are unknown. I was long of the belief that reports of $1\frac{1}{2}$ to 2 complete revolutions were based upon error of the observers because the uterus would give way in a transverse rupture. In the case illustrated in Plate IV, having observed that the rotation was severe, I measured the twist with unusual care and found it necessary to cause the uterus to make two complete revolutions in order to produce detorsion. As suggested on page 196, the extreme torsion was presumably made

possible without rupture, owing to the absence of the normal volume of fetal fluids, which rendered the uterus abnormally flaccid.

The prognosis is grave. Some of the recorded observations, with highly favorable results from handling, are of uncertain completeness. There are two methods of assembling data, each of which has its virtues. In my first case of uterine torsion, after reducing it by rolling, I destroyed the cow because of a transverse rupture. My second case, in a mare, had existed a week or more: the fetus was emphysematous and the mare dying from sepsis. My third case was the ewe illustrated in Fig. 74. In my fourth case, which had been neglected a week or two, adhesive peritonitis had so firmly bound the organ to parietal peritoneum and to viscera that, after having destroyed the cow and opened the abdomen, the adhesions had to be dissected before the uterus could be moved. In my fifth case the fetus was so tremendously swollen from emphysema that the uterus tightly filled the entire abdomen. It could not be untwisted by rolling. I performed laparotomy, introduced my hand and tried in vain to overcome the torsion by manual force. The uterus was too profoundly diseased for the cow to have survived, could I have effected detorsion or had I resorted to cesarean section. Later experiences proved less discouraging. It is not quite clear to what extent such cases as I have related enter into recorded data. Harms³² (Schmidt) submits extensive bibliography and interesting statistics. Bach reports 183 cases, of which but 15 had to be slaughtered; 67% of calves were viable. Wyssman had 38 cases of torsion amongst 100 dystocias. Levens had 103 torsions amongst 910 dystocias. The destruction of the patient was necessary in 13.6%. Tapken succeeded in saving the lives of 2 out of 7 mares. I find no American statistics. The incidence of uterine torsion in continental Europe apparently exceeds that observed in America, but I am not certain. There are reasons for suspecting that a goodly proportion of the apparent difference lies in a different standard of diagnosis. It has been my habit, which is possibly representative, when I encountered dystocia with the fetus in dorso-ilial or dorso-pubic position, to bring it into dorso-sacral position and proceed with delivery without critical study of the displacement. A careful study of the original contributions of some of the observers cited leads me to suspect that I have repeatedly overlooked the actual nature of the dystocia. Recognition of the milder cases of torsion, as discussed on page 367, and their inclusion in the statistics, increases the incidence and advances the ratio of successful handling.

The handling of torsion of the uterus in this group must be based

upon the period of pregnancy at which it occurs, the extent and duration of the torsion, and the character of the pathological changes present.

The common indications in the cow are to reduce the torsion and promptly evacuate the uterus. There are exceptions, as illustrated in my case above mentioned where the torsion, having been recognized at six months, was reduced by rolling, the cow continued to term and calved successfully. In irreducible torsion, cesarean section may be indicated in ruminants.

In torsion occurring at term in the cow, the cervix is usually flaccid when detorsion has been completed and delivery is easily effected if the fetus is not emphysematous.

The reduction of torsion is effected in a great many ways. The reduction of the torsion in the milder group of cases is described on page 367.

Whether the patient is standing or recumbent, it is highly advantageous that the posterior portion of her body be elevated so that the gravid uterus will tend to drop away from the pelvis and become pendant: some advise that the patient be partly suspended by the posterior limbs. When the uterus becomes pendant, detorsion is invited by the weight of the organ, as when one suspends a weight upon a twisted thread.

Various considerations appear to indicate that the rolling of the cow is the safest and most effective method for accomplishing detorsion in severe cases. The process of rolling the patient varies in detail. I have practiced chiefly the rolling of the patient over and over in the same direction. The operation is best performed in the open field, if weather and other conditions permit. Otherwise, a commodious room is selected. If the torsion is to the right, the patient should be cast upon the right side. The two fore feet should be firmly bound to each other and the two hind feet to each other. The two fore feet may with advantage be lashed against the chest floor. This is accomplished by attaching securely to each pastern a cord or strap five or more feet in length. The limbs are flexed against the sternum. The free ends of the cords or straps are tied tightly over the withers. With the fore feet thus secured, the patient cannot resist the rolling process by bracing with the feet. The fore feet should not be attached to the hind feet, because this exerts compression upon the abdomen and interferes with the rotation of the uterus.

The operator should kneel or lie behind the patient and insert his hand as far as possible, to hold the vagina or uterus as firmly as may be and also to determine the result of the operation. The operation

proceeds upon the assumption that, when the body of the animal is rolled, the gravid uterus may remain static, and consequently the normal relationship may be restored by the patient's body revolving around the gravid uterus in the same direction in which the latter had previously turned. Assistants turn the animal upon her right side, thence upon her back, and over upon her left side. The patient's feet are folded beneath her body, and she is again rolled upon her chest and over upon her right side. The posterior limbs are then extended and the rolling continued as before. When the rolling process is begun, it should be done rather quickly, in order, if possible, to bring about the revolution of the body of the mother, without having the gravid uterus follow its motion.

Some favor a modified rolling process by causing a partial revolution of the body of the mother with an attempt to turn the gravid uterus in the opposite direction or to hold it from turning with the maternal body by means of external force applied to the fetus through the abdominal walls. The patient is turned slowly and gently upon her back, while the operator or an assistant identifies the fetus by palpating the abdominal floor. If the torsion is to the right, the operator pushes against the fetus from the right to the left and attempts to cause the gravid organ to revolve toward the left, or at least to aid materially in holding it and preventing it from rotating to the right as the body of the patient is suddenly brought down on her right side.

As soon as it is believed that the operation has been successful, the cow is allowed to stand. When the torsion has been reduced and the cervical canal is open, there is usually a gush of dark bloody exudate from the uterus. If the operation has been successful, the spiral folds of the vagina have disappeared, the hand can be advanced without difficulty to the os uteri, and, if the cervical canal is dilated, may be passed on into the uterine cavity and the fetus grasped.

It is highly important, in this operation, that the veterinarian should keep his hand in the vagina, or frequently insert it, in order to determine what progress is being made. Sometimes the operator becomes confused in reference to the direction of the twist, and consequently in reference to the direction in which the animal should be rolled. If his hand is introduced into the birth canal, and the rolling process is begun in the wrong direction, he recognizes the fact at once by the increased pressure upon his hand as the twist becomes aggravated. If the turning is in the right direction, and the torsion is reducible, the vagina becomes more open and commodious, and the hand can be advanced further into it.

In some instances the torsion is not promptly reduced, although

it may eventually be accomplished by perseverance. If turning the animal once does not completely accomplish the object, one should not despair, but should resort to several or many turns and watch closely the result.

When the rolling process alone, or with external manipulation, fails to bring about a reduction of the torsion, some cases of torsion in the cow may be successfully overcome by means of laparotomy as described on page 260. It is a much less conservative procedure than rolling and should not be applied until the latter has definitely failed. Some advise laparotomy as a primary operation, without having first attempted rolling. Among such patients laparotomy may succeed in those instances where adhesions have not occurred or where, owing to fetal emphysema or other causes, the pregnant uterus does not fill the abdominal cavity so tightly that the organ cannot be rotated. If the torsion is to the right, the operator reaches down between the right abdominal wall and the gravid uterus; inserting the hand as far as possible alongside and beneath the organ, lifts upward; and, drawing somewhat to the right, attempts to cause it to revolve to the left. If the twist is to the left, the operator passes his hand over the top of the organ to the left side, and downward as far as possible, and, grasping some projecting portion, draws the organ upward and to the right. How often this process succeeds, where rolling or external palpation fails, is unknown. Probably not often. The gravid uterus is so voluminous and heavy, its exterior so even and smooth, and it is so closely imprisoned in the abdomen that grasping the organ with the hand and exerting efficient force is not easy. The force must be largely exerted by placing the palm of the hand at a favorable point and pressing against the uterine walls in an advantageous direction to induce rotation. If the operator can grasp one of the feet through the uterus, it affords a secure hold for the safe exertion of force. I have attempted the operation twice after rolling had failed, each time without results.

When the torsion has been reduced the question of delivery arises. In the case to which I have referred previously, in which torsion was corrected at six months gestation, there was no occasion to attempt delivery. This is exceptional. When mild uterine torsion has occurred at term, has been reduced, and has not caused pathologic changes which have destroyed the functions of the uterus, labor generally begins very shortly afterward, and the fetus is expelled. If the torsion has been extensive, the uterus is inevitably atonic. It is then advisable to apply moderate traction, to replace the uterine power lost through the torsion. The traction needs be applied cautiously.

Before applying traction for the removal of the fetus or carrying out other manipulations, after the organ has been replaced, the practitioner should search for transverse rupture of the vagina or other important injuries.

Cesarean Section. The chief hope, in cases of irreducible torsion, is cesarean section, the value of which should always be judiciously considered. Usually there can be no hope for the life of the fetus, and the fertility of the mother is at an end. There remains for consideration the question of the economic value of the animal for meat, wool, or labor, or of the sentimental value of the saving of the life of the animal. Whether one operates or not, should be determined after considering all these factors. The operation is described on page 260. It is only exceptionally of value in cows and mares.

Uterine Torsion in Multipara. The third category of uterine torsion, that in multipara, is not usually authentically diagnosable by clinical search. Mechanically equivalent to intestinal volvulus, and involving one or more ampullae of one horn, it causes no torsion of the vagina, and rectal palpation is not available. Palpation through the abdominal walls does not usually lead to a safe diagnosis. When a pregnant, multiparous female exhibits signs of distress at or near the expected date of labor, especially when there are evidences of abdominal or labor pains, torsion of the uterus should be regarded as one of the most probable causes of the phenomena, justifying an exploratory laparotomy (page 260). If uterine torsion is revealed, the operator is in position to choose between hysterotomy and hysterectomy. If the uterus is free from gangrene or severe metritis and the young are not putrid or emphysematous, hysterotomy is generally preferable, with a favorable outlook for mother and young; if serious fetal or uterine disease is present, hysterectomy, with the removal of the ovaries, is advisable.

CHAPTER XXIV

DYSTOCIA FROM ABNORMAL FETAL VOLUME

Fetal Giantism

FETAL giantism in domestic animals is infrequent and is difficult to define. In a given case one obstetrict may regard the phenomenon as constricted or juvenile pelvis or vulva, and another as too large a fetus. The two terms are largely relative and the line of demarcation is often impossible. At the extremes, both phenomena unquestionably occur.

So far as definitely known, fetal giantism does not occur during a normal period of gestation. There is suggestive evidence of the phenomenon from surplus nutrition in a solitary fetus in multipara. In unipara it is sometimes suspected in normal duration of gestation.

Prolonged gestation is very common in sexually unhealthy mares, but the fetus is generally either dwarfed or greatly emaciated. Never, as far as I have observed, does prolonged gestation in the mare cause giantism. In the cow, where prolonged gestation is comparatively rare, giantism unquestionably occurs. As a rule the records of fetal giantism are vague, and unfortunately defective in many details. Where the details suffice there generally appears a background of sexual disease or derangement, either in the form of aberrant conception or of teratological or pathological phenomena in the fetus indicative of uterine disease. Confusion apparently arises in some instances regarding the duration of gestation. The pregnancy may in some cases have been due to accidental, unknown breeding subsequent to the assumed date. In other instances the fetus has died, and strictly the pregnancy has ended, long before the attempted delivery. In numerous records the size of the fetus is categorically stated as large, or very large, without stating even the approximate size of either dam or fetus. There are, however, a goodly number of apparently thoroughly authentic cases of fetal giantism in the cow. I find no clear records of marked fetal giantism in other domestic animals. One of the most complete and authentic available records of fetal giantism is that of Andres.² The patient was a Brown Swiss cow, 9 years old, bred by the owner. The environment excluded accidental breeding. The records of the owner of the cow and the keeper of the bull agreed. The gestation period was 369 days. Dystocia irremediable, cow slaughtered. The male fetus weighed 99 kg. (218.25 lbs.).

Citing Cornevin, the average weight of male Brown Swiss calves is 49.1 kg., 48.6 per cent of weight of the giant fetus. The length from the muzzle to the sacrum was 148 cm., as compared with 80 to 90 cm. for the race. The proportions of the body were normal. The hair was thick. Much of it had been shed and had become felted into hair balls. In general, the skeleton and skeletal muscles and all organs were proportionally large. The history of the cow furnishes an interesting background. She was twin to a bull, was probably born after an abbreviated gestation, and was perhaps below average vigor. She had been pregnant five times; the first and fifth pregnancies were single, and the second, third and fourth, twins. In considering twins on page 124, data are submitted indicating that twin gestation in mares and cows is generally pathological. Assuming that the patient was bred to calve first at 3 years and should ideally have calved annually, at 9 years she should have calved 7 instead of 5 times. When considering sex parity on page 135, evidence was submitted suggesting that when in low sexual health there is apparently a tendency for the sex ratio to be disturbed in the direction of a predominance of males. In the 5 pregnancies with 8 calves, there were 5 males and 3 neuters (freemartins). In discussing the duration of gestation on page 127, it was held that either abbreviation or prolongation indicates pathological interferences. The uterus of the cow showed an area of adventitious placental growth, indicative of prior endometritis. The liver of the fetus was diminutive, weighing 860 gr. The author computed that according to the weight of the fetus the liver should have weighed 1500 gr. The suprarenal glands were very small. The thyroid weighed 40 gr., as compared with the usual 7-8 gr. The thymus weighed 410 gr., as compared with a normal average of 220.33 with maximum of 250.

Andres submits an extensive bibliography of credible reports of prolonged gestation and giant fetuses in cows, with a total of 32 citations involving 53 pregnancies. The sex is recorded in 8, of which 6 were males. The presentation of the fetus is stated as normal in 2 cases, without indicating whether anterior or posterior. Three posterior and one anterior presentation are definitely recorded. It is not definitely shown that more than one of the fetuses were in anterior presentation, dorso-sacral position. The imperfect data, so far as they go, support the hypothesis that, under pathological conditions, the ratio of males becomes abnormally great, the duration of gestation prolonged, fetal giantism tends to occur, and the fetuses present posteriorly in a markedly excessive ratio.

Turning from the regrettably defective statistics regarding fetal giantism in domestic animals, to the more voluminous records in human obstetrics, Starcke⁵⁰ discusses the problem at length with extensive citations and bibliography. The average weight of children is placed at approximately 3500 grammes (7.7 lbs.), and when a child reaches 4.5 kg. (10 lbs.) or 5 kg. (11 lbs.) it is regarded as abnormal. Numerous authors believe that the size of the child increases as the age of the woman; others that the weight increases as the number of pregnancies. There is no adequate ground for comparison in this respect. Primiparous women are largely fully matured. In domestic animals, especially in dairy animals, if a female fails to breed before mature she is discarded. There is no menopause in domestic animals. Many women are in prime health and vigor at the time of menopause. The young of aged mares and cows are commonly undersized. Among 1166 giant children in Starcke's clinic, there were 824 boys and 342 girls, or a ratio of 240:100.

The sex ratio of births is commonly about 105:100. Records indicate that in woman the presentations are cephalic in 95 to 96%, and caudal in less than 4%. Starcke found in 133 giant fetuses, 4.6% of caudal presentation. Amongst the 10 largest fetuses found recorded by Starcke, the duration of gestation was unavailable in 5, recorded as normal in 1, and as 315, 326, 311 and 305 days for the remaining 4. The normal duration is given as 270 to 290 days. The sex was not recorded in 4; the other 6 were boys. The fate of the fetuses was unrecorded in 3; the remaining 7 were dead. In giant children, atonic uterine hemorrhage after delivery is common. The limited observations upon fetal giantism in domestic animals are in substantial accord with the more extensive records in woman.

The cause of giantism is not clear but the phenomenon is closely associated with genital disease. The mortality of both fetus and mother is high. The data of Andres show:

Cows		CALVES	
Unrecorded	36	Unrecorded	32
Died	11	Died	17
Lived	5	Lived	3
<hr/>		<hr/>	
52		52	

The diagnosis presents many difficulties in numerous cases. Atony of the uterus and (in primipara) juvenile vulva, constantly tend to confuse. In either instance a fetus of relatively normal size is too large to be driven through the birth canal, in one instance due to deficient expulsive power, in the other to an abnormal barrier to expulsion.

The handling is to be decided according to conditions. Forced extraction should be applied in those cases where a successful result appears probable. As a rule embryotomy, as already described, offers the most favorable course. If forced extraction and embryotomy have failed or are inapplicable, the most economical course to pursue, if the cow is in good flesh, without fever, and the fetus not decomposed, is slaughter for beef, provided the laws and sentiment of the community permit. This is generally not permissible in America. There remains for consideration the resort to cesarean section, which may, in some instances, yield an acceptable degree of salvage in milk or meat.

Dystocia due to Excessive Volume of Parts of the Fetus or of the Fetal Fluids

Hypertrophy may occur in any gland of the body of such degree as to cause dystocia. Harms³² cites instances of dystocia due to hypertrophy of the thyroid and thymus glands and of the kidneys, and illustrates a bovine fetus with an enormous enlargement of the right thymus gland. These are extremely rare and need be diagnosed by their anatomical relations. As a rule the dystocia may be overcome by incisions into the abnormal glands, allowing any liquids, and the usually friable glandular parenchyma to escape.

Any hollow organ of the fetus may become cystic to such an extent as to cause dystocia, but this is extremely rare. Distension of the urinary bladder is stated to occur rarely. No record of such abnormality in animals has been found: it would logically be less probable in domestic animals because, unlike the human fetus, all species have two alternative outlets, the urethra and the urachus. The lateral ventricles of the brain become distended in all species, to constitute hydrocephalus (page 323) and I have described one case of distension of the rumen in a bovine fetus owing to *Schistosomus reflexus* (page 327).

Dystocia due to Fetal Ascites

Fetal ascites is occasionally encountered as a cause of dystocia in the bovine fetus, and may occur in any species. It is not clinically differentiated from cystic distension of hollow abdominal organs, nor is their differentiation of great practical importance. All alike cause enlargement of the abdomen with fluctuating contents. Birth may proceed more or less normally, whether in anterior or posterior presentation, until the fetal abdomen arrives at the pelvic inlet, where the fetus becomes stalled. When the progress of the fetus is blocked

with the abdomen at the pelvic inlet, ascites is to be suspected. Inserting the hand alongside the fetal body, the distended abdomen may be felt and recognized.

The handling of the dystocia consists fundamentally of releasing the fluid from the abdominal cavity. This may be done in a variety of ways.

From the standpoint of safety to the mother, and convenience to the operator, it is best to liberate the fluid, when the fetus is in anterior presentation, through the chest cavity, externally. The head and neck have already passed the vulva. It is the work of but a few minutes to remove one anterior limb subcutaneously, as described on page 246, after which one or two of the exposed fetal ribs may be severed. The operator can then eviscerate, as described on page 258, pass his hand through the chest cavity, and rupture the diaphragm. The ascitic fluid, or any collection of fluid within a fetal organ, then promptly escapes externally. Delivery readily follows.

In the posterior presentation, the fluid may be caused to escape through the fetal pelvis by an incision through the perineum, followed by severing of the sacro-sciatic ligaments, which affords room for the hand of the operator to pass into the abdomen, releasing the fluid, whether in the peritoneal cavity or in a cystic fetal organ. The distending liquid may also be released by incising the abdomen and permitting the fluid to escape into the uterine cavity. The escape is not so free as by the technic advised above.

Fetal ascites is intimately associated with other fetal dropsies, especially with fetal anasarca and with edema of the chorion, to be discussed below. It is said to be associated also with fetal hydrothorax and perhaps in some degree with amnio-allantoic dropsy.

Fetal Anasarca

Anasarca of the fetus apparently occurs in all species of domestic animals. It is by far the commonest in dairy cows, with apparently the dwarf type of bulldogs ranking second. It is rare in the mare, ewe and goat. I find no record of it in beef cattle. Seemingly, anasarca follows the observation already noted on page 201, that the ratio of dystocia is in harmony with the prevalence of genital disease. The frequency of anasarca in the small races of dogs with short muzzles and abnormally large crania, associated with limited hydrocephalus as a breed characteristic, supports the view of an inherited pathological condition, brought about by artificial selection.

In cows, Harms³² (Richter) cites Levens as having observed in a single year, in one stable, 5 anasarcous fetuses, all by one bull. The

bull was discarded and no more "water calves" appeared. In twin gestation, records show that one may perish from anasarca and the other remain healthy, or, as indicated in Fig. 76, both twins may suffer alike. In multipara, according to Keller,³⁷ speaking especially of the bitch, the rule is that but one or two fetuses suffer, and the others remain healthy. In my observation, anasarca is interrelated with other dropsies, as in the fetuses shown in Fig. 76.




FIG. 76. Fetal Anasarca in Twin Lambs.

Weight $26 + 32 = 58$ lbs. Seen from the dorsal surface.

While the anasarca fetus sometimes acquires three to four times its normal size, most cases do not cause dystocia because in the cow they are aborted commonly in the 6th or 7th month, when the volume of the fetus is not a serious impediment to its expulsion. Sometimes they are carried to term and cause serious, or fatal dystocia. Such was the case in a ewe which came under my observation. The lambs, when removed postmortem, weighed 26 and 32

pounds respectively—a total weight of 58 pounds, which was more than half the weight of the non-pregnant ewe. The weight of the lambs was so great that the ewe finally could not stand, and apparently succumbed to decubitis. Beyond the abnormal distension of the maternal abdomen, apparently no symptoms appeared to attract the attention of the owner until the time of the death of the ewe. Even then they were vague, consisting of the greatly enlarged abdomen and inability to stand. Fetal anasarca might possibly be diagnosed in the cow by rectal palpation, prior to the advent of labor; commonly it is neither recognized nor suspected until abortion has occurred or dystocia has become established. In the latter case the edematous character may be established by palpation.

Each of the two fetuses in Fig. 76 shows an identical, deep groove encircling the body at the umbilicus. There is a tendency in veterinary obstetrics to attribute spiral or annular grooves of the fetal body or extremity to incarceration by the navel cord. It would be hazardous to attempt thus to explain the phenomena.

In the older German veterinary obstetrics references occur to fetuses which are hypertrophic in the regions of the shoulders and croup, to which the term *doppelender* was applied. Possibly this is the condition they had in mind. I have no opinion to offer regarding its cause.

In the handling of dystocia resulting from anasarca, the life of the fetus is to be ignored. Probably already dead, if living it is almost certainly non-viable. If the fetus is not too large, it may be delivered by forced extraction. The tissues cut easily under cords, and hooks will not hold under material strain. Usually embryotomy is indicated. The tissues are so non-resistant that embryotomy operations are relatively easy. Mutilation, by which the edematous liquid may escape, is important, as is also the opening of the body cavities, which are probably distended. In small animals, where embryotomy is difficult or impracticable, cesarean section may be considered. If the patient survives, she should not again be bred.

Edema of the Allantochorion

Edema of the amnion and chorion in a mild degree are common accompaniments of abortion and other phenomena of genital disease. Now and then, almost wholly in the cow, the allantochorion becomes the seat of extensive edematous deposits. The membrane may reach a diameter of 3 to 6 inches. The edematous deposit may be colorless and transparent or of a reddish hue.

The general characters of the phenomenon are well illustrated by

a case in the ambulatory clinic of the New York State Veterinary College. The patient was a purebred Holstein cow, three years old, which had calved apparently physiologically one year previously. The owner observed no puerperal disease. She was rebred, and pregnancy appeared uneventful for 225 days, when she refused her grain and walked stiffly. The owner's observations were probably defective. She was in good pasture and may have eaten far less than the owner assumed, since later developments showed an empty rumen like that in Fig. 78. The increase in the edema counterbalanced the decrease in eating and left the abdomen not strikingly pathological in dimensions.

The owner suspected indigestion, gave a pound of magnesium sulphate, which he repeated a few hours later, gave a warm enema, and forced her to walk for about two hours. The following day the cow was down, and making continued expulsive efforts. Temperature 100.2 F., pulse 90, respiration 30, with expiratory grunt. No appetite nor peristalsis. Compelled to get up, the expulsive efforts increased. The abdomen was enlarged. Rectal palpation revealed an immense uterus which was extremely hard and tense. Fetus not palpable.

The cow died about 40 hours after the owner had first observed that she was ill and an autopsy, in which I participated, followed a few hours later. The abdominal cavity contained an enormous quantity of thin, reddish fluid, estimated at 50 gallons. The uterus had ruptured near the base of the gravid cornu, and the fetus lay outside it within the abdominal cavity. The fetus was highly edematous.

The uterus was of enormous size and very firm. It occupied almost the entire cavity and had pressed the empty rumen and other alimentary viscera forward against the liver and diaphragm much as in Fig. 78. The caruncles and surmounting cotyledons were completely buried within the chorion, so that the non-placental, inter-caruncular portions were in immediate contact with the non-placental areas of the uterus. The edematous chorion was fully five inches thick. As the fetus, with its amniotic and allantoic fluids, had escaped from the uterus, the inner surfaces of the chorion were in contact and with the uterine walls constituted a firm cylindrical body over 10 inches in diameter.

The uterus was opened. In detaching the edematous chorion, much edematous fluid escaped, 13.75 lbs. of which was collected. After this and prior losses, the chorion still weighed 75.5 lbs., or a total at the beginning of the detachment of 88.75 lbs. The source of the estimated 400 lbs. of fluid within the peritoneal cavity could not be determined. Perhaps some maternal ascites existed. Certainly much

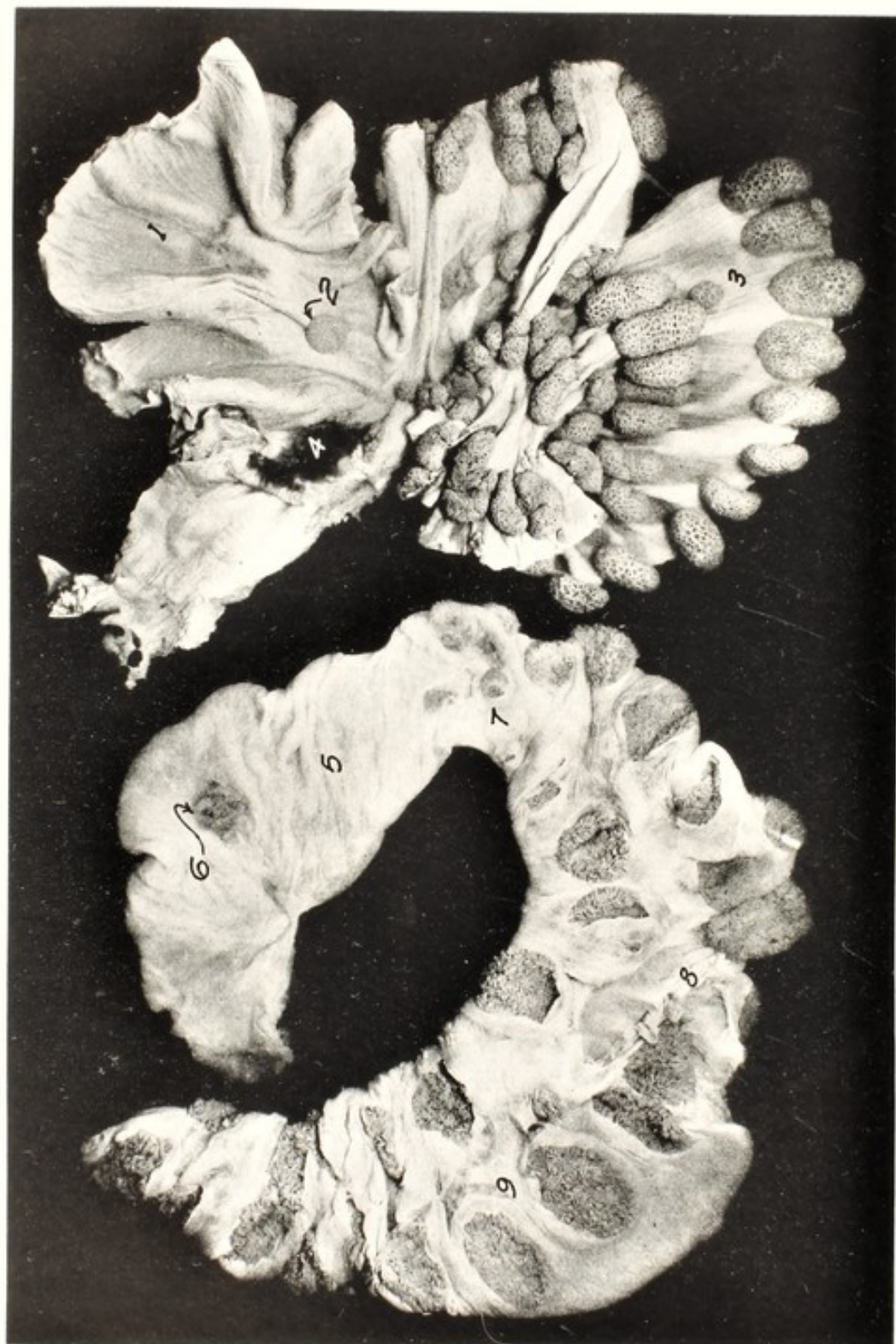


FIG. 77. EDEMA OF CHORION. RUPTURE OF UTERUS. COW.

The uterus laid open to show the endometrial surface. The allantochorion is shown closed, revealing but two rows, one ventral, one dorsal, of cotyledons.

1, the non-gravid uterine cornu, without cotyledons; 2, inset, a normal cotyledon introduced for comparison with the coarse cotyledons of the gravid horn, 3, with abnormally large crypts; 4, the cervical canal, sealed; 5, the non-gravid chorion destitute of fetal cotyledons; 6, inset, a normal fetal cotyledon for comparison; 7, the cervix of the chorion; 8, the allantoic vessels; 9, the gravid chorion bearing mammoth cotyledons, which compensates for the absence of placental structures in the non-gravid horn.

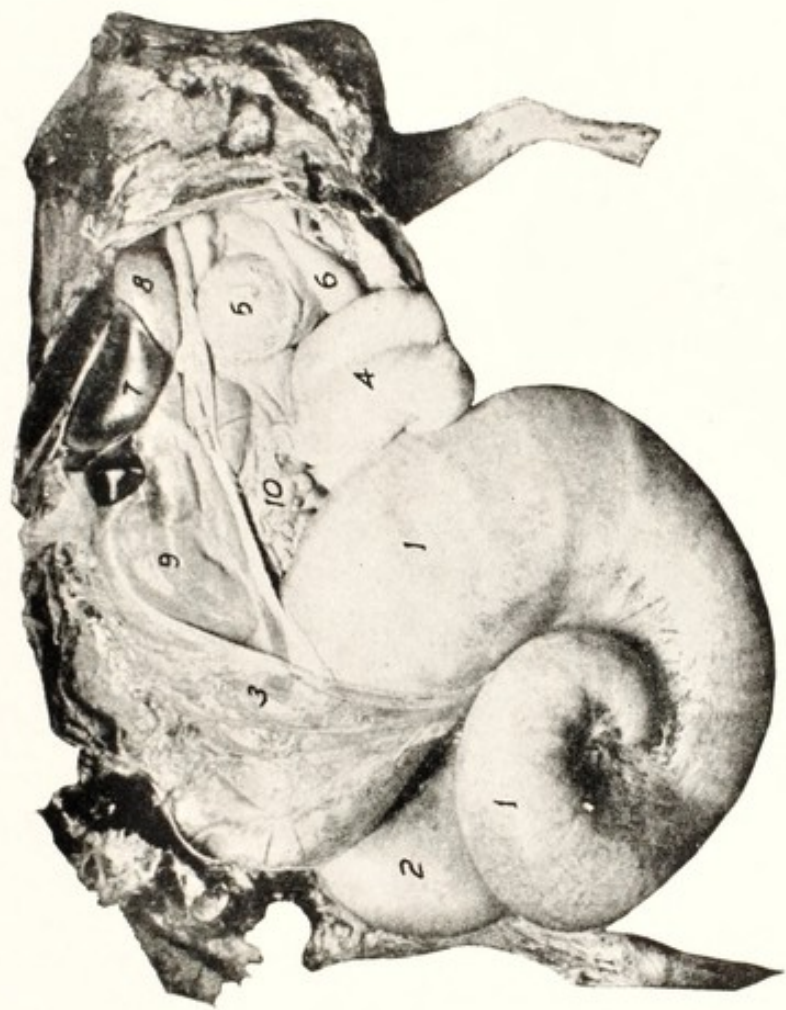


FIG. 78. ABDOMINAL VISCERA OF COW SHOWING EXTREME HYDROPS OF AMNION AND ALLANTOIS.

1, 1, right (gravid) cornu, 12.5 feet long upon its upper curvature; 2, ovarian pole of the non-gravid cornu lying upon the left hind leg; 3, mesometrium; 4, rumen, empty and displaced far forwards; 5, omasum; 6, abomasum; 7, liver; 8, gall bladder; 9, large intestine; 10, small intestine; 11, left tarsus; 12, sixth right rib. (*Cornell Veterinarian*.)

of the edematous fluid within the chorion had escaped, and it is highly probable that there was a large volume of amniotic and allantoic fluids. If essentially all the fluid within the abdominal cavity, estimated at 400 lbs., came from the uterus, the weight of the original uterine contents may be thus computed:

Escaped fluid in peritoneal cavity, est.	400	lbs.
Edematous fetus	70	lbs.
Edematous allantochorion	88.75	lbs.
	<hr/>	
	558.75	lbs.

The navel cord was edematous, 3 inches in diameter. The fetal abdomen contained 1 gallon of ascitic fluid.

The chorion, freed from the uterus, was 12 feet long. The non-gravid cornu of the uterus was devoid of caruncles, 1, 5, Fig. 77. The cotyledons of the gravid horn, 3, were mammoth, measuring 5 to 6 inches across. Their crypts were gross. A normal cotyledon, 2, is set in for comparison. The chorionic tufts or villi of the giant cotyledons were extremely coarse and irregular. They may be profitably compared with Figs. 55, 57.

The uterus of Fig. 77 is essentially a replica of Fig. 79. The absence of caruncles in the non-pregnant horn in Fig. 77, authentically disproves the correctness of the clinical history of physiological birth in the one prior pregnancy, unless there was a third, unrecognized pregnancy, with early fetal death and complete destruction of the endometrium with the caruncles in the horn involved. In any case, the photograph shows, beyond any ground for challenge, that the endometrium of one horn had been totally destroyed prior to the advent of the pregnancy under discussion.

The case illustrates well the interrelation of the various phenomena associated with edema. The fetus was edematous and had ascites. Hydrops of the amniotic and allantoic cavities was in all probability present. The chorion was extremely edematous. Possibly the cow had ascites. Behind these there clearly existed extensive, highly dangerous, and ineradicable endometrial lesions.

Chorionic edema needs be differentiated from hydrops of the amnion and allantois by the extra firmness upon palpation. The prevention, prognosis and method of handling are analogous.

Amnio-Allantoic Dropsy. Hydrops Amnii. Hydrallantois

The fetal envelops of all domestic animals contain two capacious cavities, the amniotic and allantoic, each of which contains fluids in varying quantities. Physiologically the amniotic sac of the mare

and cow is stated to contain 3 to 6 quarts of fluid, and the allantoic cavity 6 to 15 quarts. The volume of these fluids may be distinctly subnormal (static fetal cadaver, uterine torsion) or may be grossly abnormal. Excess of the fetal fluids is most frequent and important in dairy cows, but occurs in the beef breeds and in all species of domestic animals. Keller³⁷ has observed the disease in the bitch

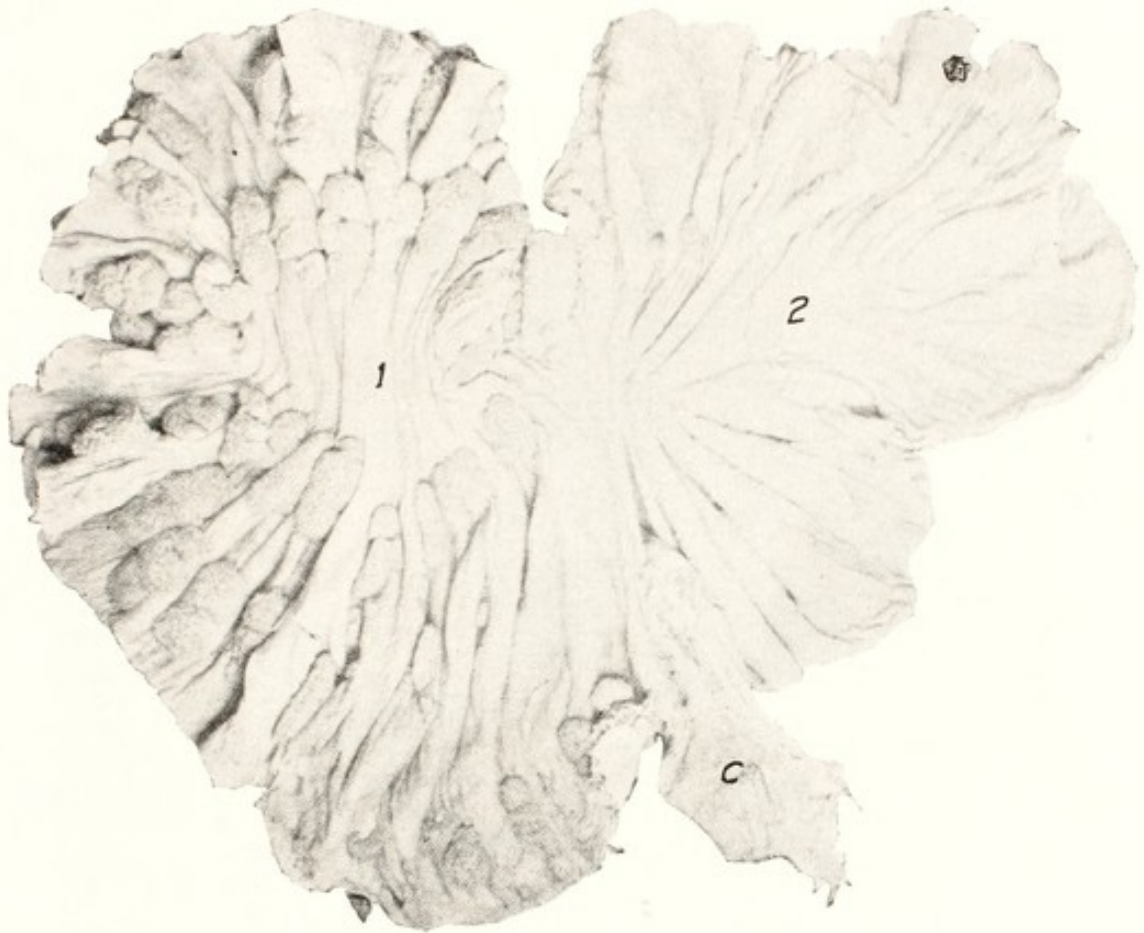


FIG. 79. Uterus from Fig. 78 seen from the Endometrial Side.

1, the gravid cornu with numerous cotyledons; 2, the non-pregnant horn almost devoid of cotyledons; c, cervix. (*Cornell Veterinarian.*)

associated with fetal anasarca. Since the allantoic sac of the human embryo ceases to exist early in embryonic life, only dropsy of the amnion occurs.

The malady has been extensively described in the companion volume upon genital diseases, and it remains chiefly to discuss here the diagnosis and handling. The disease is prevalent or universal in the hybridization of the American bison with the domestic cow and has been observed in the hybridization of the bison with the zebu. It is a prominent accompaniment with bulldog calves and *muscle con-*

tracture monsters, which are associated with inbreeding. It prevailed in a commune, as described by Adametz and Schultze* in Tux-Zillertaler cattle. In some cases it is clearly associated with general, and sexual disease. Kammermann³⁶ observed a high prevalence of the disease following a wet summer with consequently damaged forage. My observations agree with those of Kammermann. I have noted in certain districts that a large percentage of cows became affected with this malady in a year when the food had been much

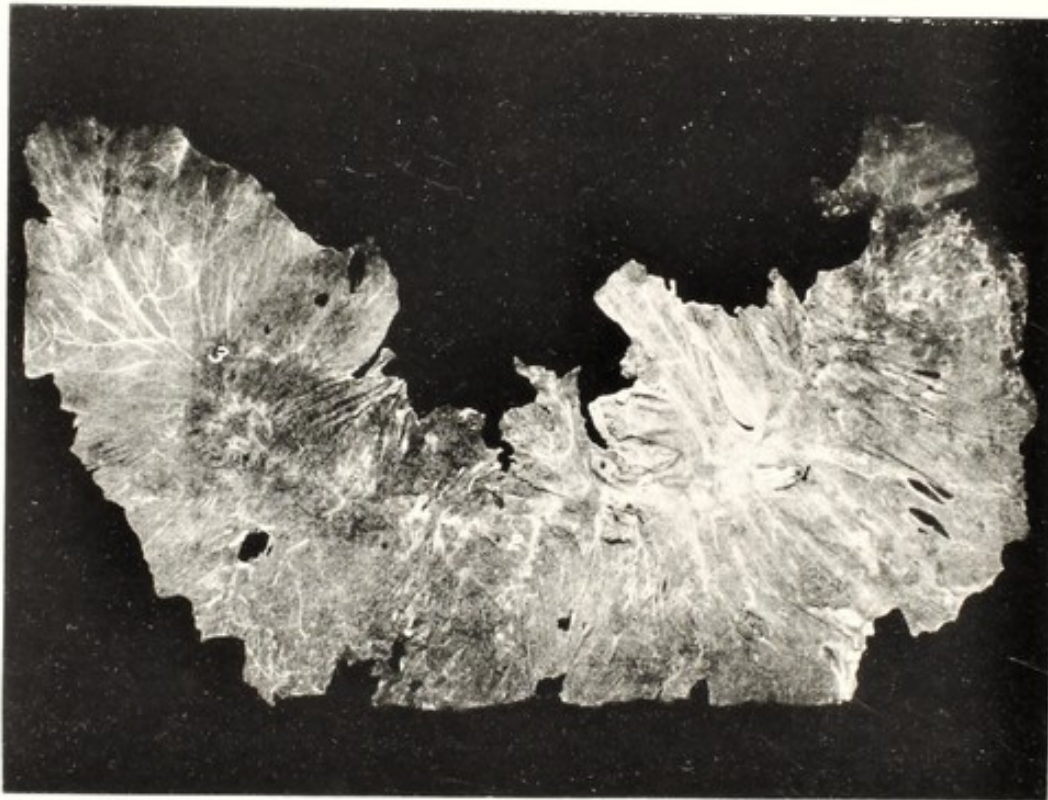

FIG. 80. Placental Side of Allantochorion from Case of Dropsy of Amnion and Allantois.

1, the four chorionic vessels at center of gravid horn; 2, the cervix with adventitious placental tissue; 3, the non-gravid horn, essentially devoid of placental structures at the ovarian pole and thickly covered with adventitious placental growths, very dark from hemorrhage, at cervical pole. (*Cornell Veterinarian.*)

damaged, and consequently afforded insufficient nourishment, with consequent low resistance to utero-fetal disease. That is, like other genital diseases, it is favored by deficient nutrition. The cases re-

* Adametz, L. and Schultze, R. Untersuchungen ueber die wichtigsten Rassenmerkmalen, der Habitus und Constitutionstypus der Tux-Zillertaler Rinder mit besondere Berücksichtigung ihrer Wirtschaftlichen Leistung dieser Rasse. *Zeitschrift für Züchtung*. Series B. (1932) Vol. XXIII, p. 123.

ported by Fincher, Frost and myself²⁸ and illustrated by Figs. 77-79, seem quite clearly to have been due to necrotic destruction of the uterine caruncles over a large portion of the uterus because of disease antedating the pregnancy during which the dropsy developed. The disease is frequently associated with fetal anasarca and ascites, and perhaps at times with maternal ascites. It is not infrequently associated with twin pregnancy, which in turn is regarded in itself as largely pathological.

The symptoms are not always pathognomonic. The mild or moderate cases usually first become evident when labor sets in, associated with dystocia, depending partly upon the want of tone in the uterus, and partly upon pathological resistance in the membranes. Thus in my experience in a large group of heifers suffering from severe genital hypoplasia as a consequence of ill health as young calves, there were no indications of the hydrops until the normal duration of pregnancy had been reached and labor set in. The hydrops was usually not extreme, estimated at 10 to 20 gallons. The expulsive efforts were atonic. The cervical canal was moderately dilated and through it protruded the chorion as a hemispherical mass, in some as large as a man's head. It required considerable force to thrust a finger through it. In one case, second pregnancy, the chorion was hard, thickened and calcified. The allantoic fluid was generally dark red to reddish brown, sometimes opaque. The amniotic fluid was commonly yellowish, sometimes very opaque, yellowish brown from suspension of particles of meconium (fetal diarrhea). Of 6 cases, 4 were primipara, 1 II-para, and 1 IV-para. Each of the two latter had aborted the previous pregnancy. The 4 primipara had each been repeatedly bred at irregular intervals, and may have suffered from fetal maceration, unrecognized, with uterine injury. Five of the calves were dead when extracted. The sixth was extracted, at 227 days, after the subcutaneous amputation of one fore leg. It died within a few minutes after extraction. The IV-para cow died after 5 days. There was extensive necrosis of omentum, which was 3 inches thick, and of kidney fat, estimated at 16 quarts. There were 4 male and 2 female fetuses, thus lending support to the inference, mentioned while considering sex parity, page 136, that sexual disease apparently disturbs the parity of the sexes and increases the preponderance of males.

In a second group of cases, including those of the hybridization of the American bison with the domestic cow, there is simply a growing distension of the maternal abdomen, suggesting twin pregnancy, until the gross weight begins to interfere markedly with the move-

ments of the cow. It may then be noted that the appetite is poor, but the enlarged abdomen tends to conceal the inadequate partaking of food. The impediment of the abnormal weight gradually becomes more apparent and it is increasingly difficult for the animal to rise when down. No signs of labor become apparent in the severest cases. Occasionally the remark is made that in twin pregnancy the very great tendency to abort is due to the distension of the uterus, but in severe amnio-allantoic dropsy (where the distension of the uterus surpasses that of quadruplets) instead of inviting expulsive efforts, it quite definitely bars labor or abortion. Finally when the volume of fluid reaches 300 or 400 pounds or more, the cow is unable to rise and perishes soon thereafter. Few diseases advance so insidiously and so nearly unrecognizable to the uninitiated. The cow may drink an inordinate volume of water, but that is not observed: she may consume very little food, but that is masked by the ever enlarging abdomen. After the cow has become prostrate, or the massive size of the abdomen arouses anxiety, diagnosis may usually be made by rectal palpation: the uterus is enormously distended with fluid. The fetus falls by gravity to the floor of the abdomen and uterus and is probably not palpable per rectum. If the cow can stand, the fetus may sometimes be recognized by ballottement. The cervix is closed and sealed. There is great prostration, the pulse is weak, appetite and rumination absent and the general symptoms of exhausting disease are present but fail to indicate the character of the malady.

The prognosis is unfavorable. The calf is usually dead or non-viable: at best, it is probably an inferior male. The dystocia may generally be overcome by forced extraction without great difficulty. Delivery will probably be followed by severe retention of the fetal membranes. The mortality of the cows is high and the value of the animal for breeding is probably ruined. There remains the salvage for beef.

The prognosis in the very severe cases, when the animal is prostrate, is virtually hopeless by any method of handling now known. I have not observed, nor seen recorded, an instance in which a cow prostrate from the malady has survived. A valuable method for handling this extreme type is yet to be discovered.

Mild or moderate cases, in which labor becomes established, can usually be relieved by moderate traction, after the cervix has become fairly dilated. If the cervix does not dilate when labor sets in, a difficult task faces the obstetrice. The cervix of the cow is phenomenally obstinate toward any and all efforts at dilation by force acting from

the vaginal end; however it readily dilates from the uterine end under physiological contraction of the uterine walls. I have found cervical dilation almost impossible.

Unfortunately uterine contraction with cervical dilation is absent in a large ratio of cases, and thus far no convenient and reliable method for causing it has been devised. The causes, as discussed in the companion volume upon genital diseases, and to which allusion has been made on page 179 of this treatise, are sufficiently known that generally the losses from amnio-allantoic dropsy may be avoided. The errors in mating, such as those leading to bulldog calves and muscle contracture monsters, are primarily a problem in animal husbandry. The exclusion from breeding of cows which have suffered from uterine disease, as illustrated in Figs. 77-79, is a difficult undertaking and calls for a new spirit, especially in dairy husbandry in cooperation with clinical veterinary medicine. The dairyman needs learn that retained afterbirth with post-partum purulent discharge is more than a passing mist. When the dairyman observes a few ounces of pus in the gutter behind a cow which has recently calved or aborted, he needs appreciate that it has a very serious meaning. The veterinarian needs learn and frankly admit that the "cure" of such a cow, so that she may again become pregnant, is more likely to be a liability than an asset. The sterility expert who claims to cure 75 to 80% of sterile cows should carefully check up the ultimate behavior of his "cured" patients.

The means for prevention having been ignored or overlooked, and the presence of the disease recognized, the evacuation of the uterus should be considered. Reliable means for the artificial induction of labor in amnio-allantoic dropsy have not been established. When it is desired to induce abortion artificially in early pregnancy in the cow, or to cause the expulsion of a hematic mummy from her uterus, it is usually easy to accomplish the desired end by expressing the corpus luteum of pregnancy by rectal manipulation. In amnio-allantoic dropsy the ovary cannot usually be reached per rectum. It is not known that the dislodgment of the yellow body by means of laparotomy would be effective. Perhaps it would be worth while to try. Or it might prove of value in some cases to administer pituitrin.

Harms³² cites various writers who have succeeded in arousing uterine contractions and the expulsion of the fetus by partly emptying the fluid through a trocar introduced in the right flank. It is not clear that the cases were so extreme that the cow was prostrate. I used the trocar in my first prostrate cow, and after the escape of

perhaps 30 gallons of fluid she got up and seemed greatly relieved. She ate little or nothing but drank great volumes of water, was as badly distended as before within two or three days, again went down and soon died. The fetus was emphysematous. It is possible that, had I performed laparotomy and removed the corpus luteum, after having drawn off the fluid, the uterus might have contracted effectively. Or had pituitrin been administered after the trocarization, the result might have proven advantageous.

Some advise cesarean section, but I have not known of a success upon a prostrate cow. A recent report of cesarean section upon a prostrate cow, associated with greatly prolonged gestation, states that the weak fetus promptly died. The cow, after drinking enormous volumes of water which quickly distended the uterus as greatly as before, promptly succumbed. It is of great interest that the uterus re-filled in the absence of the fetus, thus suggesting that the dropsy is not a fetal, but a uterine disease, and emphasizing the role played by uterine disease in the cases illustrated in Figs. 78-80.

Dystocia due to Monsters

Monsters which are carried to, or near term largely lead to dystocia. The primary causes of monsters are not definitely known. They occur most frequently in animal groups where genital diseases are most prevalent. A few of them are apparently limited to a species or genus because of structural type of the early embryo: thus the monster *Schistocormus reflexus* appears to be restricted to those species in which the ovum develops a prominent, elongated vitelline tube, as in ruminants and swine. Logically then it should be most frequently observed in dairy cows, in which genital diseases are most abundant and severe. Monsters may generally be attributed to disease or deviation from the normal course of the development of the ovum in its early life. This causes aberrations in, or the absence of organs, with abnormal variations in volume, form or texture, which may lead to dystocia.

The injury to the embryo is not necessarily fatal. Presumably, most diseased embryos die and vanish without a trace. Those which survive encounter all the perils of any fetus. The original pathology of the uterus which occasioned the monster may persist throughout gestation and cause hydrops of the amnion and allantois, anasarca, fetal diarrhea, or any other of the endless phenomena of fetal pathology. The gestation may be abbreviated, to end in abortion or

premature birth, or prolonged gestation may result. When gestation approaches, or continues to, or beyond the normal, monsters supply an endless variety of obstetrical difficulties, from mild to insurmountable. Not alone may the monster cause dystocia because of its volume, form or texture, but there is commonly present a degree of uterine disease which disturbs its function. The fetus also is incapable of proper adjustment of its position and posture.

Monsters produce no symptoms as such, and their presence is ordinarily neither recognized nor suspected until they have been expelled or have resulted in dystocia. When causing dystocia they

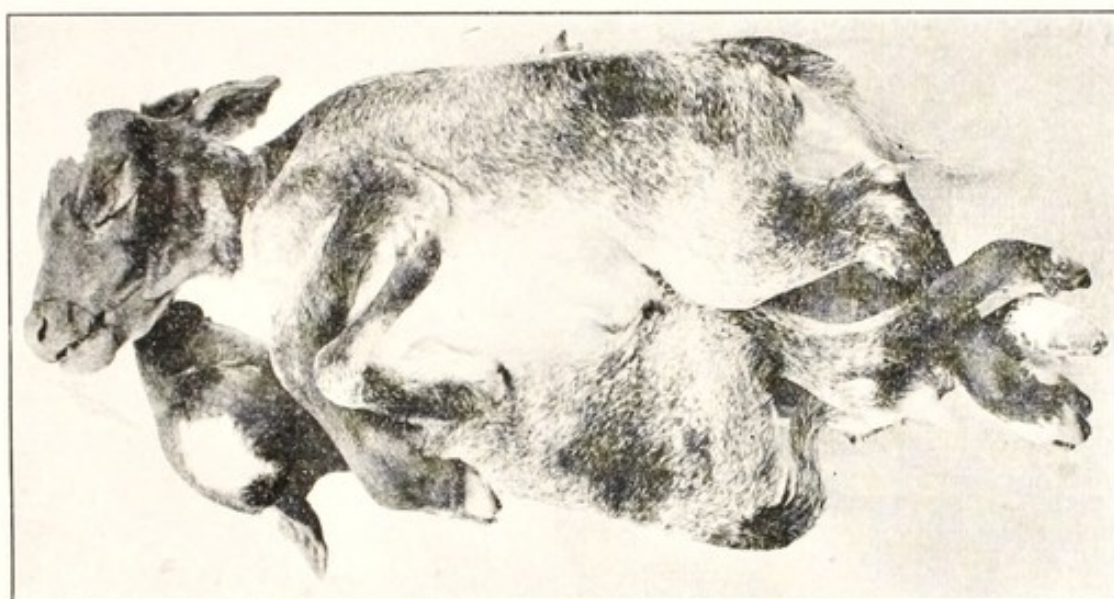


FIG. 81. *Gastrodidymus Octipes*.

may usually be diagnosed without material difficulty, if the aberrant part or parts are within reach. They are to be recognized upon anatomical grounds, either by their own form or by their relation to other definite parts. In extreme hydrocephalus, the cystic cranium may not be in itself recognizable, but the identification of the ears, eyes, nose or mouth, and the continuity therewith of the hydrocephalic mass, fixes its character. In those double monsters in which two embryos lie side-by-side, they are virtually always symmetrical in size and form, as shown in Fig. 81. They are alike in presentation, while in twins there is often one in anterior and the other in posterior presentation. One twin may be repelled and the other advanced, but in double monsters the two move together. My most confusing experience was a case of campylorrhachis in which there was a complete

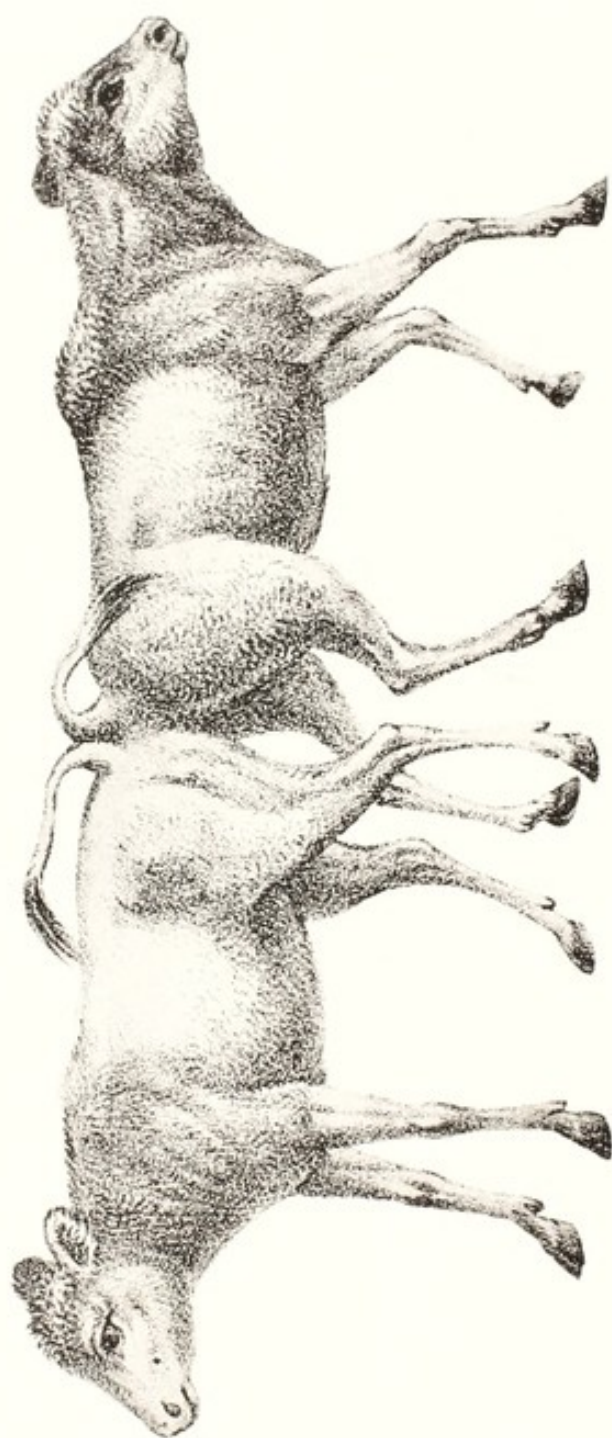


FIG. 82. *Pygodidymus Aversus*. (Gurlt.)

lateral bending of the spinal column, and the monster was in anterior-posterior, or nose-and-tail presentation, with both ends in dorso-sacral position. The repulsion of either end compelled the retreat of the other. As a rule, the point of union is within reach and can be palpated.

Those double monsters like *Pygodidymus aversus* (Gurlt.) Fig. 82, and its converse, *craniodidymus*, offer a far greater problem in diagnosis, as well as in handling. The union of the ischia cannot, at first, be reached. The presenting half needs be well advanced in the birth canal, and usually partial embryotomy performed before the nature of the obstacle may be more than suspected. The diagnosis is made additionally difficult because the enormous length of the monster exceeds the pelvo-diaphragmatic dimension of the patient, and the distal half must be turned about and with the ovarian pole of the gravid horn be directed somewhat toward the pelvis. The same holds true of unicornual twins. So far as I have observed, the two lie either ischium-to-ischium or face-to-face. There too, if the fetus in the cervical pole presents anteriorly, that in the ovarian pole must turn about and its head be directed toward the pelvis until the first fetus is expelled and the second, with the ovarian pole of the uterus, undergoes version through 180° to present posteriorly.

In handling, each monster virtually presents its own individual problems. Some of the most common types are briefly considered.

DOUBLE MONSTERS

Double monsters occur chiefly in the cow, not infrequently in the small ruminants, sow and carnivora, and are extremely rare in the mare. If carried to, or near to term, they regularly cause severe dystocia. It is sometimes possible, especially in abbreviated gestation, to extract the calf, sometimes alive and viable, by traction. Generally embryotomy is indicated in the cow, the details of which should follow the general plan described on pages 242 to 259. In the main, it is well to amputate one or more legs, either subcutaneously at the shoulder, or intrapelvically in posterior presentation. Follow by evisceration, which affords room for further diminution by the amputation or excision of parts. The chisel is probably the most useful embryotomy instrument in these cases, although other instruments are valuable.

HYDROCEPHALUS

An abnormal volume of fluid in the lateral ventricles of the brain invites dystocia in various ways. I have elsewhere suggested⁷² that

hydrocephalus may be divided into three categories. One group, seen so far as I know, in the cow only, apparently consists of an early reopening of the anterior neuropore with rupture of the lateral ventricles and the permanent prevention of the fusion of the facial bones, as shown in Figs. 17, 18. It causes no dystocia because of the volume, but the limbs may be distorted and rigid. Reference has already been made on page 185 to dystocia due to limited or mild hydrocephalus as an inherited attribute in dogs of the dwarf bulldog type, which



FIG. 83. Hydrocephalus. Foal.

largely calls for cesarean section, page 262. The third type, and chief one for consideration here, is the gross hydrocephalus ordinarily discussed in obstetrics. In these cases, in the equine and bovine fetus, the volume of fluid may reach or exceed five gallons, as indicated in Figs. 83, 84. It may induce dystocia either because of the volume of liquid present or of the gross development of the cranial bones. The fetus is devoid of intrinsic power to adjust its position or posture, and its limbs are liable to deformation as shown in the posterior extremities in Fig. 85.

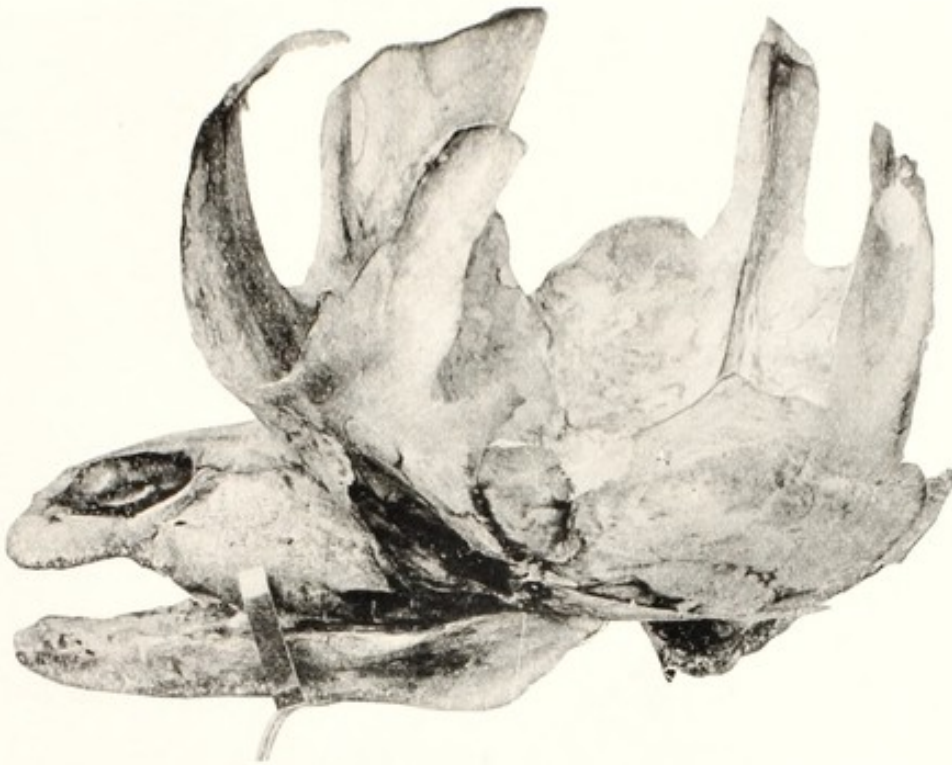

FIG. 84. Hydrocephalus. Foal. Skull from Fig. 83.

The voluminous hydrocephalic sac sometimes ruptures through the cribriform plates of the ethmoids, the fluid escapes through the nostrils, the sac collapses, and delivery proceeds. In absence of such rupture, the sac is to be incised and the fluid permitted to escape.



FIG. 85. Hydrocephalus. Calf. With Club Feet.

Measuring transversely 12, and antero-posteriorly 13.5 inches.

That alone often suffices. But when the cranial bones are grossly enlarged, as in Fig. 84, it is necessary that they should be comminuted, for which by far the best instrument is the chisel, E, Fig. 65.

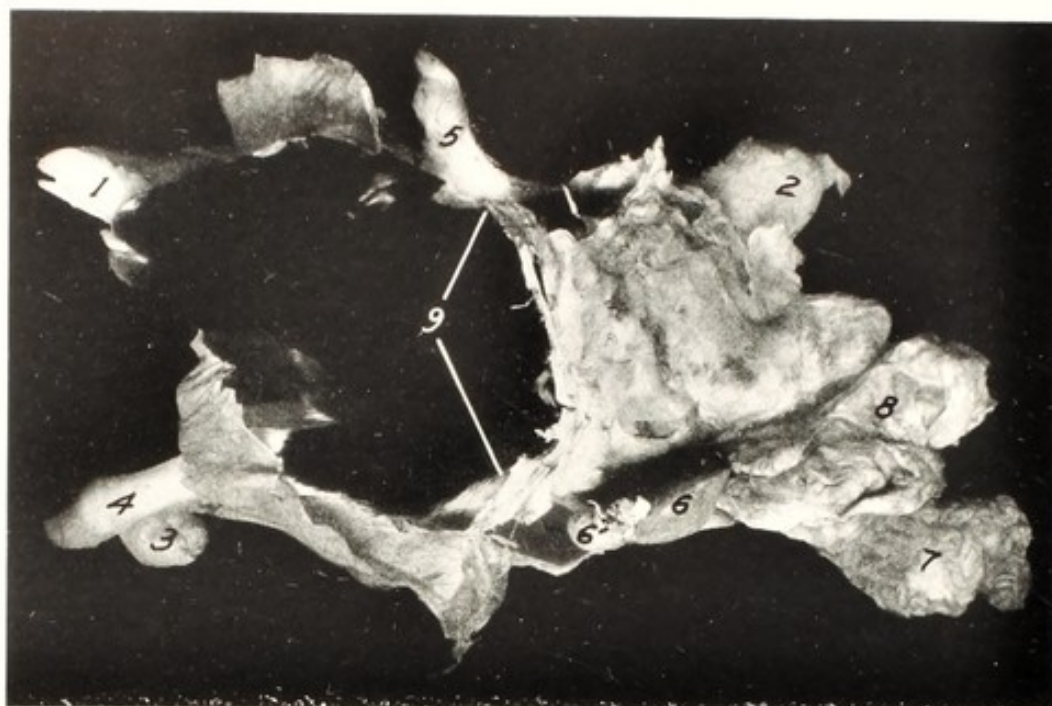

FIG. 86. Schistosomus Reflexus.

Viewed from left side.

1, right hind foot; 2, incarcerated left tarsus covered by the body wall; 3, right anterior foot; 4, left fore foot; 5, tail; 6, liver; 6', liver cyst; 7, small intestine; 8, large intestine; 9, margin of umbilical ring; 10, umbilical cord. Projecting upward from beneath the head is a portion of the amnion, and a second part lies across the left fore foot, 4. (*Cornell Veterinarian.*)

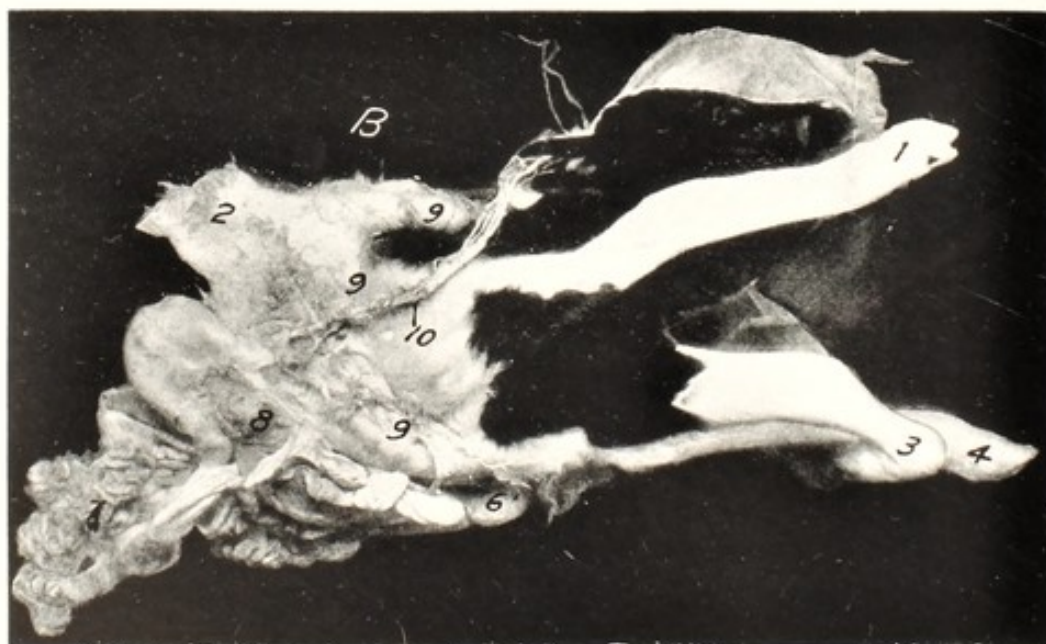


FIG. 87. Schistosomus Reflexus.

Same as Fig. 86 seen from the right side. Markings same. The head and feet lie upon the outspread amnion. (*Cornell Veterinarian.*)

Recently Frost and I* have described a case of subdural hydrocephalus in a calf in which the dura mater protruded through the anterior neuropore and was distended to constitute a bag six inches in diameter. Had it been larger it would have invited dystocia because of abnormal volume.

SCHISTOSOMUS REFLEXUS

One of the most frequent types of monster leading to dystocia in the dairy cow, and less frequently in beef cattle, and in sheep, goats

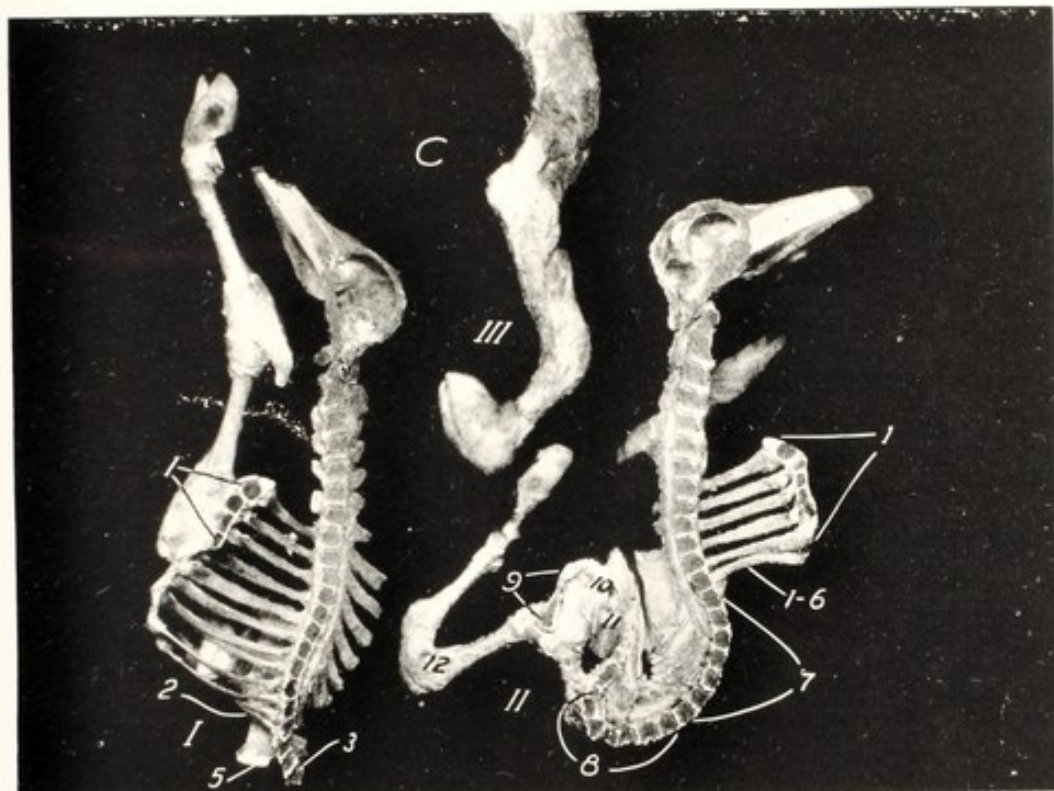


FIG. 88. Schistosomus Reflexus.

Sagittal section of portions of the skeleton from Figs. 86, 87 viewed from the median side.

I, right half; II, left half; III, right anterior limb; 1, 1, sternum; 2, ribs xi and xii fused together; 3, lumbar spinal column; 5, ischium; 6, 1-6, ribs, i-vi; 7, dorsal vertebræ vi-xii; 8, lumbar vertebræ; 9, pubic symphysis; 10, vagina; 11, rectum; 12, dwarfed left tarsus. (*Cornell Veterinarian*.)

and swine, is that designated as *Schistosomus reflexus*. Its nature has already been described in the companion volume upon genital diseases and is incidentally mentioned on page 103 of this treatise. Although it is usually attributed to amniotic adhesions, recent observations have led me to the conclusion that the basic cause is necrosis

* Williams, W. L. and Frost, J. N. Subdural hydrocephalus in a calf. (*Cornell Veterinarian*) (1938) xxviii, 340.

of the tip of the vitelline duct and its adhesion within the necrotic tip of the chorion. Before the somatopleure folds ventralwards to form the body cavity, its movement becomes reflected dorsalwards and the peritoneum and pleura, instead of the skin, form the exterior covering. Since the amnion arises from the margin of that portion of the somatopleure destined physiologically to form the umbilical ring, the reflection moves the body of the embryo outward through this area so that it comes to rest chiefly or wholly outside the true amnion, within the allantois. The head, tail and limbs are more or less completely enclosed within a cutaneous sac, with the spinal column sharply doubled dorsalwards upon itself, with the occiput and sacrum close together. The head and limbs undergo compression deformities of an indescribable variety.

The monster regularly causes dystocia, chiefly owing to its excessive transverse diameter, partly to the absence of response by the fetus and to existing uterine disease which lies behind the aberration. It may present by head-and-tail, with all four feet, or by its visceral end. The general character of the monster is illustrated in Figs. 86-88. The fetus is generally alive at the outset of labor and in some cases the fetal heart may be grasped and palpated while yet beating. The details of presentation and deformation are too variable to permit of more than general advice for overcoming the dystocia. According to the deformation and presentation, the mass should be sufficiently decreased in volume that it may readily and safely pass the birth canal.

Taking Figs. 86-88 as illustrative, with the monster presenting by the visceral end, once the viscera, 6, 7, 8, Figs. 86, 87, have been cleared away, the lumbar spine, 8, Fig. 88, is fully exposed to palpation, and may readily be severed with the chisel. This destroys the rigidity of the bent spine, and further incision may cut the mass in halves. Similarly, the pelvis may be comminuted and one or both hind limbs withdrawn. Or a skin incision from the umbilical line, 9, Fig. 86, over the line of the left shoulder will expose the scapula and enable the operator to withdraw the left fore leg.

I have recently had opportunity⁷⁵ to study two unusual cases of this monster which caused severe dystocia. The one case was so completely reflected that some parts of the fetus acted as a valve in the small communication between the cutaneous sac and the miniature amnion, and caused the sac to become distended with an estimated ten gallons of viscid amniotic fluid. The sac was punctured, the accumulated fluid permitted to escape, and sufficient portions of

the torso removed to permit extraction. In the second case, presenting by the visceral portion, delivery was barred by the rumen distended with an estimated ten gallons of slimy fluid. Incision of the sac overcame the difficulty. With such possibilities in mind, the veterinarian should be able to diagnose the condition without great difficulty. In the first case it appeared that the fetus had failed to swallow the liquid excretions from its skin; in the second, the fluid was swallowed but failed to pass into the intestines and become digested and absorbed. The liver, so important in digestion in post-

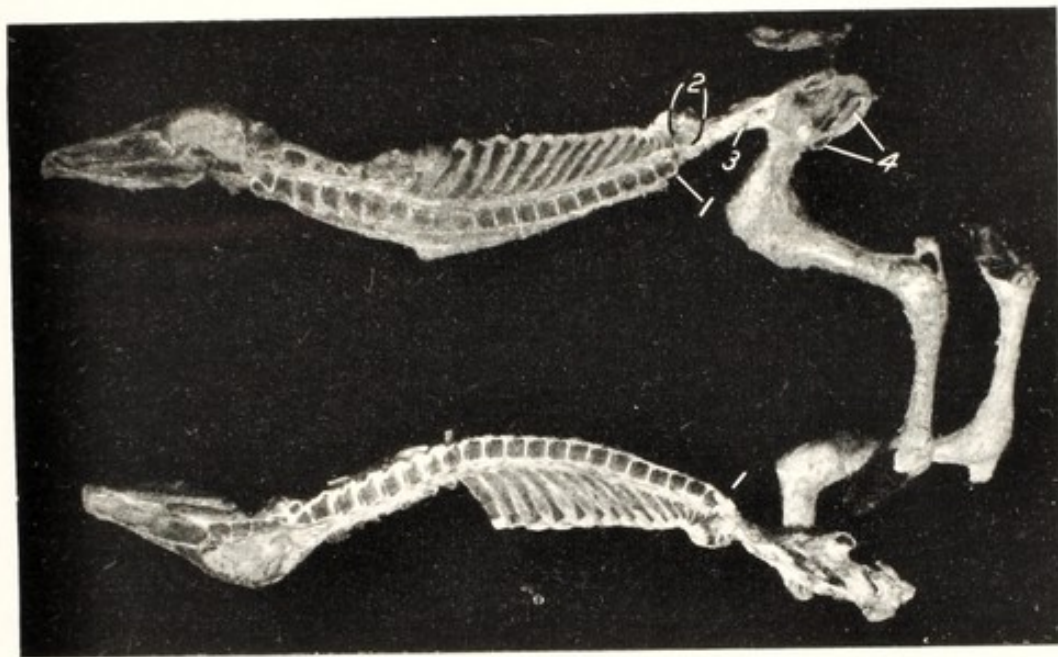


FIG. 89. *Perosomus Elumbis*. Calf.

Median sagittal section through cerebro-spinal axis.

1, thirteenth dorsal vertebra, where spinal cord ends; 2, confused mass of vestigial lumbar vertebrae; 3, ilium; 4, ischio-pubic symphysis. (*Cornell Veterinarian*.)

natal life, probably plays a highly important role in fetal life as well. Sometimes, if not generally in *Schistocormus reflexus*, the liver, failing of development, consists chiefly of cysts with very little, if any functional hepatic tissue. Apparently this is due to the failure of the physiological blood supply from the umbilical vein, which does not enter the liver, but joins the anterior vena cava, probably through the primary channel of the vitelline vein.

DEFORMITY AND RIGIDITY OF EXTREMITIES

Much has been written regarding *ankylosis* and *contraction* of joints and muscles as a cause of dystocia. The basic causes of these

abnormalities have been discussed in the treatise upon genital diseases at far greater length than justified here. Such rigidity of extremities is brought about in various ways. In the monstrosity designated *Perosomus clumbis*, Figs. 43, 89, deformation and rigidity of the posterior limbs is regular. The patella, 5, Fig. 43, fails to form and separate from the femur. This automatically locks the entire limb beyond. Here the lumbar portion of the spinal cord is wanting, the general nutrition of the hind limbs is repressed, and the formation of the patella inhibited. In the total absence of motor nerves to the posterior limbs, the joints are not used and consequently acquire no mobility. The cause of the rigidity lies, not in the legs, but in the spinal cord. In hydrocephalus also, deformation of the extremities, with rigidity, is common: the limbs are frequently bent rigidly at the joints. In hydrocephalus the deformation is common in the fore feet, but also involves the hind legs as in Fig. 85. Again the joints are free from basic disease: the cause resides within the cerebro-spinal nervous system, through which the joints fail to be moved by the fetus.

Another common group of deformations occurs in *Schistosomus reflexus*, Figs. 86, 87, 88. In these the cause is usually extrinsic and referable to the incarceration of a limb within the cutaneous sac. While all parts and tissues are adequately formed, compression inhibits motion, and hence mobility fails to become established.

Deformation and rigidity of extremities are commonly attributed to some trivial matter of chance, but such is not the case. They have a definite background of disease of a character which logically inhibits the formation of a joint, such as the femoro-tibial articulation in *Perosomus clumbis*, in the absence of motor nerves or in firm incarceration.

So far as known, deformation and immobility do not occur in a fundamentally normal embryo or fetus, normally located within the uterus. The one apparent exception to this rule is the wry-neck of the foal. Recent observations indicate with much force that this deformation is one of the phenomena of bicornual pregnancy in the mare. This tends to confine the fetus transversely within the posterior abdominal cavity, where the transverse diameter of the mare's abdomen is less than the longitudinal diameter of the fetus. As a result, the elongated fetus, incarcerated between the right and left abdominal walls of the mare, sometimes becomes significantly decreased in length by the neck becoming sharply bent lateralward. The principles involved in wry-neck are analogous to those in *Schistosomus reflexus*:

the compression is exerted in the one case by the body walls of the mother, in the other by its own reflected body walls.

Wry-neck is considered with the dystocias of the anterior presentation, page 371. In *Perosomus clumbis*, the interfering deformed limbs may be severed with fetotome or chisel, or, owing to their being very frail, they may usually be readily broken. The cut or broken ends need be guarded to prevent injury to the birth canal. The rigidity may in some cases be overcome by dividing short tendons.

CHAPTER XXV

TWIN DYSTOCIA

WHEN considering twin conception, page 124, and twin pregnancy, page 186, as a basic cause of dystocia, it was noted that twin ovulation commonly occurs in sexually unhealthy mares and cows. Dystocia is predestined, because of the inefficiency of the diseased, and hence atonic uterus, and of probable disease of the fetuses, which limits their power to assume physiological presentation, position and posture. Furthermore, as unipara, the probability is that the cornua contract in unison, instead of alternately as in multipara, which tends to propel both fetuses simultaneously into the birth canal. Most twin dystocias occur in the cow. The uterine cornu meet at an acute angle, which favors the simultaneous entry of parts of each fetus into the birth canal, with consequent wedging. This is in sharp contrast with multipara, in which the "uterine body" is non-placental, extremely narrow, and functionally a part of the birth canal. The cornu approach the "body" at almost right angles, so that a fetus, emerging from one, inhibits the exit of another fetus from the opposite horn. Since the two horns apparently contract alternately and the anatomical relations are adapted to multiparity, the impaction of two fetuses in the birth canal is well-nigh unknown in them. Twin dystocia is seen chiefly in dairy cows. I have not observed it in beef cows. In small ruminants, sometimes quasi biparous, genital disease is not so severe, and twin dystocia from simultaneous entrance of both fetuses in the birth canal is less prevalent. Another specific source of twin dystocia in the cow is supplied by unicornual twins. Their combined length far exceeds the pubio-diaphragmatic distance in the abdomen of the cow; the uterus is sharply doubled upon itself, so that the fetus in the ovarian pole, if in posterior presentation, lies with its head directed toward the pelvis. In this bent form the uterus must contract to expel the fetus in the cervical pole; and the ovarian pole, with its contained fetus, needs undergo version to the extent of 180° before the uterus may expel it. This places an excessive load upon the gravid horn.

The simultaneous entrance of portions of both twins into the birth canal is commonly easy of diagnosis. In applying traction to a head and two feet, the obstetrice should in all cases first determine that all three belong to one individual. That done, it must next be decided

which of the twins should be first delivered. The one selected should be advanced by traction, while the other is repelled and held in the abdomen until the former has reached a point in the birth canal where it excludes the entrance of the other. Generally it is an easy type of dystocia to overcome. Retained placenta and metritis, commonly following twin pregnancy, militate against recovery of breeding health. In the dystocia of unicornual twins, patience is required, and any assistance should be extended which may be advisable. It is probably in this type of twin dystocia that now and then the obstetrict delivers one twin and overlooks the other, which may be expelled later.

CHAPTER XXVI

DYSTOCIA DUE TO BICORNUAL PREGNANCY DYSTOCIA FROM TRANSVERSE PRESENTATION

THE literature concerning dystocia from transverse presentation is extremely vague and confusing. All domestic animals have definitely tubular uteri. The enormously distended bovine uterus shown in Fig. 78 had a diameter of 17 inches. According to Schmaltz⁴⁶ an ordinary calf measures 31 to 40 or more inches from muzzle to ischium. Just how a fetus 35 inches long may lie transversely in a tube 12 to 15 inches in its transverse diameter, no writer explains. But most obstetrists describe and illustrate fetuses lying transversely. They do not usually state exactly where the fetus lies or its exact posture. Stoss⁵¹ states that the fetus may develop in one uterine horn with its long axis perpendicular to the long axis of the cornu: or it may develop in the two horns, parallel to their long axes and perpendicular to the long axis of the uterine body. Franck²⁷ says that transverse presentation does not occur in the larger domestic animals and is impossible. Harms³² recognizes transverse presentation, both dorsal and ventral and cites Jöhnk as having observed it in 4% of dystocias in the mare and 1.2% in the cow. Apparently Harms includes among abdominal transverse presentations those in which the head and anterior limbs are well advanced in the birth canal and the hind legs extended along the ventral line of the fetus to constitute the vertical, or dog-sitting presentation mentioned by some writers. This is here regarded as anterior presentation with the hind legs extended beneath the body. Among dorsal transverse presentations Harms apparently includes the breech presentation more or less exaggerated in type.

Amidst the confusion in nomenclature, and with due respect for the tubular type of the uteri of domestic animals, and the elongated form of the fetuses, it appears justifiable to restrict the designation of *transverse presentation* to those cases of dystocia having their origin in bicornual pregnancy. I also place within this group some cases which present anteriorly or posteriorly but apparently are primarily due to bicornual pregnancy. With the advent of labor, or shortly prior to its onset, one extremity has become dislodged from the horn in which it had developed and entered the uterine body. Those cases described by some authors as *vertical* or dog-sitting

presentations will be considered as complications of the anterior and posterior presentations. The subject of bicornual pregnancy has been discussed at length in the companion volume upon genital diseases and has been briefly considered on page 189 of this volume, as one of the important basic causes of dystocia.

Dystocia Due to Bicornual Pregnancy in the Mare

PRIMARY BICORNUAL PREGNANCY. TRANSVERSE ABDOMINAL PRESENTATION

Primarily, the equine, like other embryos of domestic animals, becomes anchored with its ventral, or umbilical area facing the mesometrium or broad ligament of the uterus. Accordingly when the equine embryo becomes anchored in the two horns, it lies upon its side, parallel with the combined axes of the two cornua, perpendicular to the long axis of the uterine body and vagina and with its ventral surface facing the birth canal, with the head end lodged in one cornu and the tail end in the other. Unless rotation (rotated bicornual pregnancy) occurs, or one end of the fetus becomes dislodged and enters the uterine body, when labor sets in, the fetus presents transversely with its navel directed toward the vulva. The head is retained, all the feet are somewhere near the pelvic inlet, and the fetus lies upon its side, more or less transverse to the spinal axis of the mother, with the fetal head resting in the region of one of the maternal ilia—right or left cephalo-ilial position. In typical cases, all the feet appear at or near the vulva, but no essential progress is made, although the animal may make violent expulsive efforts while laymen and empirics attempt to aid by force. Frequently wry-neck is present. If the wry-neck is to the right, the fetus usually lies upon its right side; if to the left, upon its left side, so that the head is generally entirely out of reach. In many respects, this is fortunate. Upon inserting the hand, the obstetrice usually meets with, and can identify, all four limbs. In some cases it may be exceedingly difficult to differentiate between the different members, so badly are they entangled with each other, and so tightly impacted in the pelvic canal.

The dystocia is in some ways favorable for the mare, because the owner or his neighbor is usually balked at once in any effort to meddle with the case, and must consequently await the arrival of the veterinarian. Even more or less violent traction upon the fetus, as a general rule, produces little harm, because its position is such that any moderate force applied to the feet cannot wedge the fetal body

in the pelvic inlet or force any hard, projecting portion of the fetus against the soft parts of the mother.

Version without embryotomy has been advised by some writers, but of this I cannot approve. If it is decided to perform version, the two posterior limbs are to be corded at the pastern, and the two anterior limbs pushed forward as far as the operator can reach, while

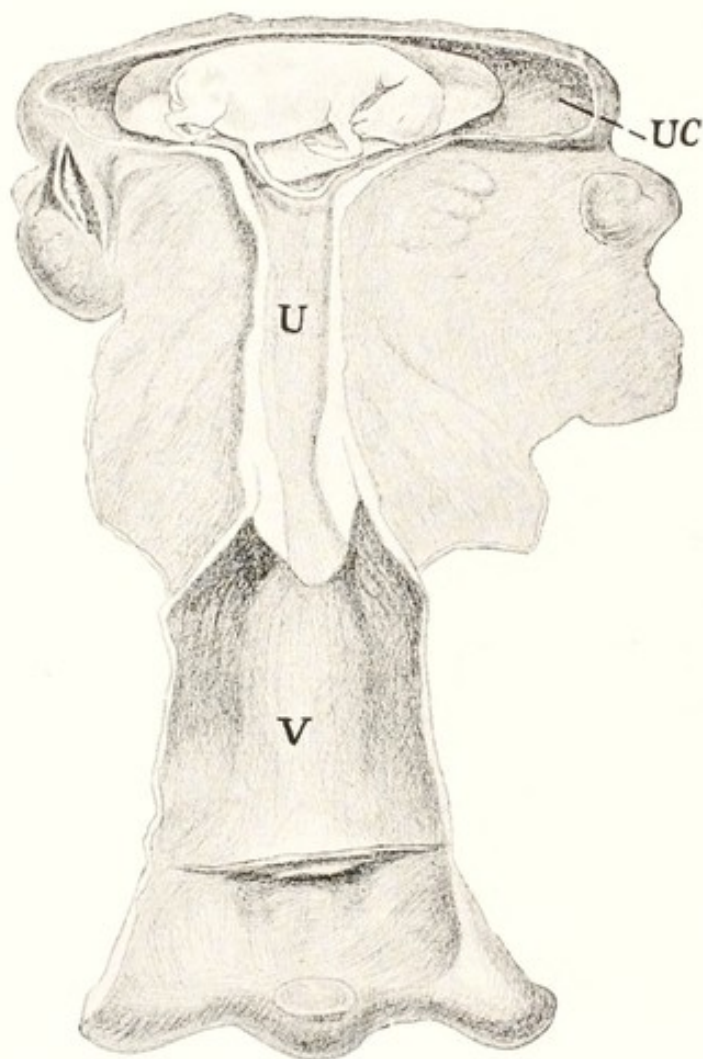


FIG. 90. Bicornual Pregnancy with Fetus in Ventral Presentation prior to Rotation. (Schematic.)

V, vagina; U, uterine cavity, which is later to blend with the vagina to constitute an elongated tube; UC, uterine cornu.

an assistant advances the posterior limbs by exerting traction upon the cords. The operator thus converts a transverse into a posterior presentation, after which the delivery is completed as such.

I regard embryotomy, followed by version, as immeasurably simpler and safer than primary version, without generally involving any great amount of labor upon the part of the obstetrict. Embryotomy in these cases consists of the subcutaneous removal of the two anterior limbs, as described on page 246, followed by version of the fetal remnant, which is to be brought about by repelling the chest and applying traction to the two posterior limbs, in order to convert

the transverse into a posterior presentation. It is not always possible to remove both anterior limbs subcutaneously. Usually the upper foreleg is quite available, but it may be difficult or impossible to

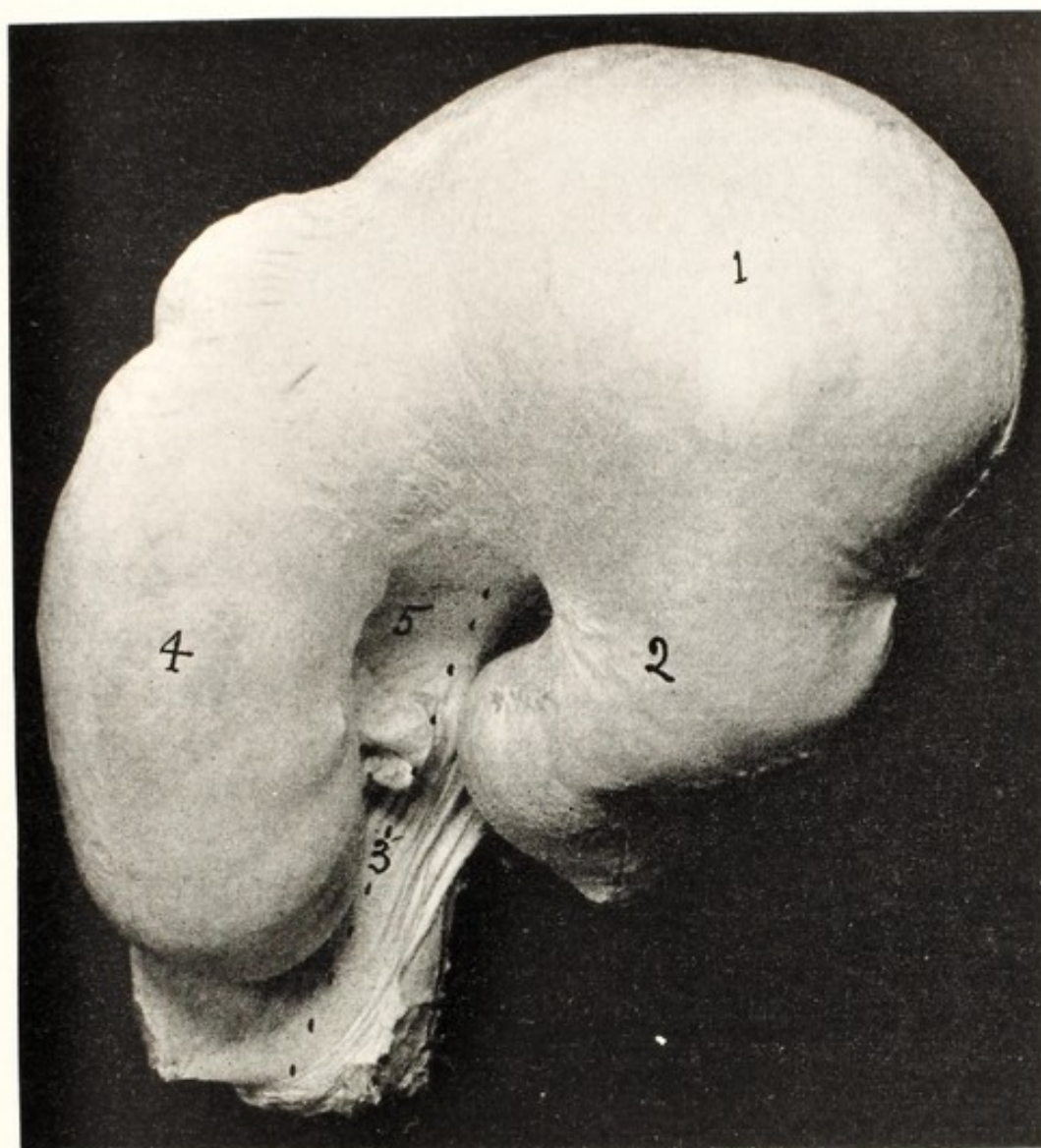


FIG. 91. Uterus from Undeliverable Bicornual Pregnancy in Mare, Oblique Presentation. Dorsal View.

1, right cornu with buttocks and posterior limbs of fetus; 2, apex of right cornu, containing ovarian pole of allantois; 3, the uterine body, cervix and anterior portion of vagina, constituting the birth canal; 4, left horn of uterus containing head and one anterior limb; 5, location of one anterior limb.

reach the scapula of the under leg. It may then be necessary to amputate it in the vicinity of the humero-radial articulation. Some inexperienced operators have imprudently amputated at the carpus. This is a very grave error. The metacarpus and phalanges fold freely against the radius, so that amputation at the carpus does not shorten

the obstetric length of the member, and leaves, instead of the large rounded surface of the fixed carpus, well padded with skin and tendons; the small, naked, sharp end of the radius, ready to penetrate the uterine walls at any moment. This amputation is always to be condemned as useless and highly dangerous.

Generally the lower fore leg may be removed successfully by the subcutaneous plan under a modified technic in which the longitudinal cutaneous incision is made upon the median, instead of the lateral side of the leg, the skin incision extending partly or entirely across the sternum. The skin is then separated from the underlying structures as directed on page 246, up to the scapulo-humeral articulation or well along the scapula. If evisceration has been applied following the amputation of the upper fore limb, the removal of the lower one is greatly facilitated. Before attempting to pull the lower leg away by this technic, the pectoral muscles, and any others in reach should be severed. Recently the wire saw or fetotome of Thygessen, Benesch and others (A, Fig. 65) has come into high favor for the amputation of the limbs. The operation with the fetotome is easier and quicker, but it cannot always be so applied as to remove the entire limb, including the scapula, and injury may come from the exposed ends of the severed bones. If the fetotome is preferred, adequate precautions should be taken against these injuries.

The presentation is subject to a variety of complications, which may tax the skill and endurance of the operator. In the typical case, it requires only one to one and one-half hours to perform embryotomy and deliver the fetus as outlined. An expert operator may even accomplish the task in less time. When certain complications are present, it may require very much longer.

In one of my cases, all four feet had already passed through the vulva, and the four large, bony limbs were tightly impacted in the pelvic canal, completely filling it, so that it was only with difficulty that the arm could be inserted alongside or between them. I could reach neither of the shoulders to amputate subcutaneously, but was forced to amputate one at the elbow joint, and the other with difficulty at the scapulo-humeral articulation. However, these amputations served my purpose, and permitted delivery after some five or six hours of fatiguing labor. The case was further complicated by the viciousness of the mare, which persistently fought by kicking, striking, or biting at anyone within her reach, so that it became necessary to cast her and securely tie all four feet. The recumbency, with the cramped position of all four feet, induced abnormal pressure upon the ab-

domen and greatly restricted the operative room. Nevertheless she made a good recovery. The case occurred prior to the introduction of epidural anaesthesia, which might have overcome the vicious resistance of the mare. Chloroform anaesthesia would have been very helpful, but no chloroform was available.

In another instance the two anterior limbs were well advanced in the pelvis, with the feet protruding beyond the vulva, and the two hind feet were jammed across the pelvic inlet. The upper hind foot crossed above the upper fore foot in front of the pelvic inlet, the toe was firmly caught in front of the shaft of the maternal ilium, and the hock lay immovably fixed against the iliac shaft on the other side. The lower hind foot passed between the two anterior limbs, and was otherwise engaged in the same way as the upper hind foot. It was impossible to repel the fetus, and equally impossible to reach the uppermost shoulder to amputate the anterior limb, because of its being crossed by the metatarsus. With the chisel I amputated the upper hind foot through the lower part of the tarsus in the manner described on page 254, removed the foot, and secured the stump above the os calcis with a cord. The amputation would have been far simpler with the fetotome. The upper fore leg was then removed subcutaneously. Next the lower hind foot was amputated at the tarsus, in the same manner as the first one, and the stump was secured with a cord. Finally the lower anterior limb was amputated subcutaneously, after which the chest was repelled, while traction was applied to the stumps of the amputated hind limbs, and the remnant of the fetus was converted into a posterior presentation.

In performing direct version, the torso is brought into the dorso-iliac position. In practice however, the version is spiral or combined with rotation, so that when the version is completed the torso usually assumes almost typical dorso-sacral position and is ready at once for extraction. The limbs may be folded in every possible manner and in some cases may be deformed by compression. Especially the posterior limbs by their extreme extension may be so straight at the tarsus that it is almost impossible to distinguish that articulation from the carpus. The fetus and its extremities may rest in varying proportions in the cornua and the body. A study of Fig. 2 may explain how an equine fetus may predominantly occupy the body of the uterus in transverse presentation, the limbs wholly within the uterine body and only small portions of the head end resting in the base of one cornu and an equally small volume of the buttocks in the other, the bases of the limbs acting as props to force the lateral

walls of the uterine body apart. This may be designated as uterine body pregnancy.

Radical shifts in the posture and presentation of the fetus may occur with the advent of labor. Thus in a case in the ambulatory clinic, Williams and Fincher⁷¹ were surprised to learn, by a study of the fetal membranes following dystocia diagnosed as due to posterior presentation, that the pregnancy had been bicornual. This is clearly indicated in Fig. 62. The buttocks had glided out of the base of the cornu in which they had rested and imperfect posterior presentation had followed.

Other cases of similar significance arise when the head end of the fetus is dislodged from the cornu and an anterior presentation follows. This seems especially true in those cases of anterior presentation accompanied by wry-neck from compression. This compression deformity is not otherwise explainable at present. The dystocia is severe and calls for embryotomy as directed on page 246.

Recently Professor Fincher was called in consultation by a colleague upon a severe case of dystocia in a heavy draft mare. All efforts at the removal of the fetus proved unavailing and the mare was destroyed. Figure 91 indicates that the fetus was completely bicornual, with no portion extending into the uterine body, and no portion of the fetus could be so secured through the long, extremely narrow birth canal for the performance of embryotomy. The photograph reveals that the fetus had found accommodation by an oblique position, the longitudinal axis of the two cornua crossing the axis of the birth canal (uterine body, cervix and vagina) at an angle of about 90°.

The Compound or Rotated Bicornual Pregnancy

The earliest mention found of a case which was evidently one of rotated bicornual pregnancy in a mare, but the significance of which was not clearly grasped at the time, was that of Pauli¹⁴ who attended a twelve-year-old mare because of dystocia in 1837, and recorded his experience 5 years later. The mare had been a regular breeder for 8 years. The labor pains were feeble, the cervix open, the water-bag in the vagina. Pauli could palpate the withers and mane in front of the cervix. Failing to deliver the mare, he called two colleagues, and all together failed. The mare died. Autopsy showed that the head, neck and anterior limbs lay in the right cornu, and the rump and hind legs in the left horn.

In 1883, Boulet-Josse failed to deliver a mare. Upon autopsy he

found the head and anterior limbs in the right, the rump and posterior limbs in the left horn. The limbs were upon the anterior side of the fetus. From his experience he concluded that transverse presentation in the mare with the feet forward is rare and incurable, while the ventral presentation is common and curable.

In 1889⁵⁸ I described three cases of rotated bicornual pregnancy occurring in my practice. All occurred in pluriparous draft mares without history of prior breeding difficulty. In the first one there were

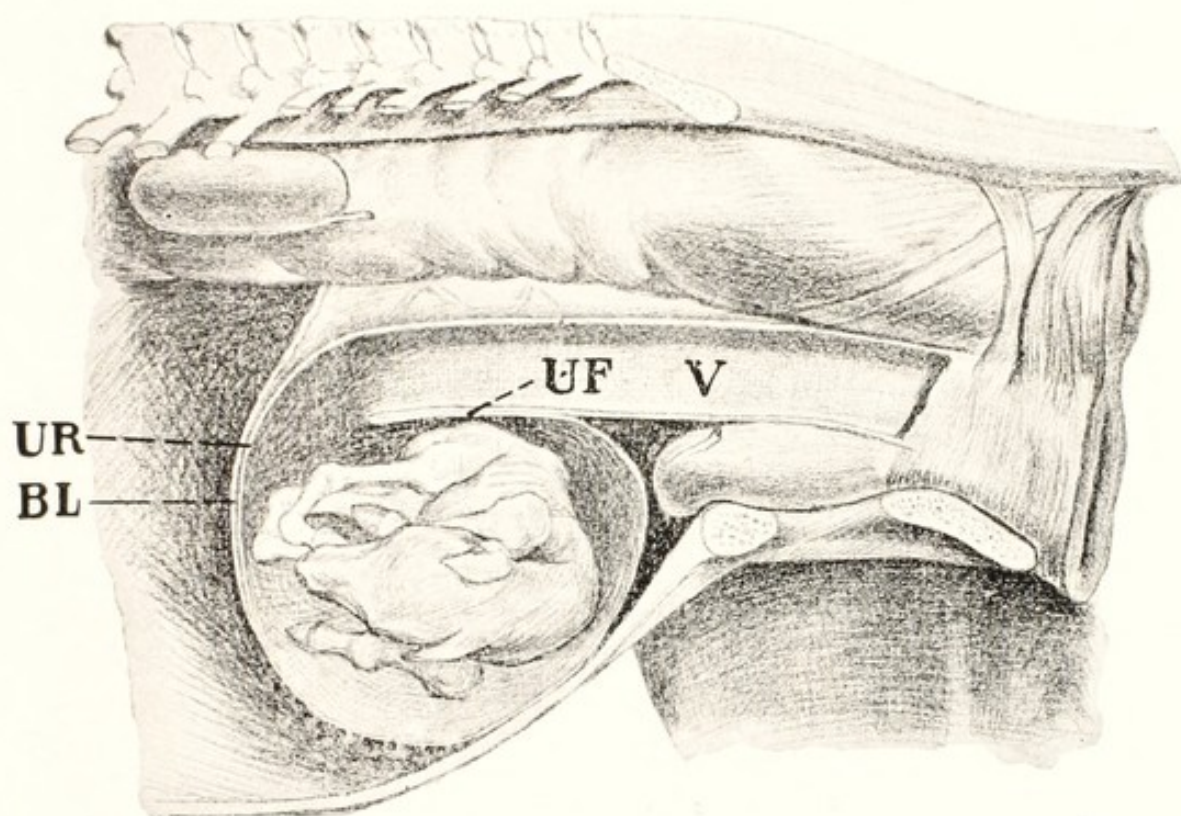


FIG. 92. Compound or Rotated Bicornual Pregnancy.

Second stage, the fetus, with the cornua and fetal membranes having made one-half revolution on its long axis. (Schematic.)

V, elongated vagina and uterine body; UF, floor of uterine cornua, now become the roof; UR, roof of uterine cornua, now become the anterior wall; BL, broad ligament.

no definite labor pains. The birth canal was extremely long and narrow. Beneath the birth canal, lying transversely with its dorsum against the pubis of the mare, the foal could be clearly palpated. No membranes were in the birth canal. Since the difficulty was new to me, and the mare in apparently fair condition, delivery was not attempted. Forty-eight hours later, portions of the membranes were in the vagina. By following the membranes along the very narrow birth canal I found it opening abruptly downward and apparently backward, far anteriorly, barely within my reach. At that time I mis-

takenly believed that the abnormally long and narrow canal consisted entirely of the greatly stretched vagina, but further study showed that it comprised the three structures of vagina, cervix, and uterine body. The tension eliminated all trace of the cervix and the uterine body was devoid of material placental function. Reaching to my utmost, over the plainly palpable fetal body, I was unable to grasp any part of the fetus. When the mare was placed on her back I could reach and attach cords to the hind feet, but was unable to bring them into the birth canal until I had amputated each below the tarsus. Traction was applied and the foal extracted. Since the foal lay beneath the vagina and posterior to the opening of the birth canal, it was necessary that the fetal body, in order that it might be extracted, should pass forward from beneath the vagina and thence upward and backward in order to enter the birth canal. In doing this, the floor of the non-placental uterine body, along with the floor of the cornu UF, Fig. 92, necessarily served as a fulcrum. This ruptured when traction was applied. The mare was promptly destroyed.

In my second case, the birth canal, again consisting of vagina, cervix and non-gravid uterine body, was extremely long and narrow. When the roof of the birth canal was followed, I found that at the limit of my reach it curved abruptly downwards. Through the floor of the birth canal the fetus was clearly palpable, lying transversely. Cephalic to the fetus, the birth canal ended by turning abruptly downward and backward so that I could grasp the sharp transverse border, consisting of the floor of the birth canal (non-gravid uterine body) with the contiguous wall of the cornu, UF, Fig. 92. Portions of the fetus could be touched, but not grasped until the mare had been turned upon her back. One anterior limb was amputated, cords applied to the two posterior limbs, and the fetus extracted. As the owner was regularly the client of another veterinarian, I did not again see the patient. She died two days later. In my third case I was called in consultation by a colleague who was unable to effect a delivery. Although my colleague was a large, powerful man, with long arms, neither of us could directly grasp any portion of the fetus while the mare was standing, although it was plainly palpable through the floor of the birth canal. With the mare cast and turned upon her back, we finally reached, and applied a cord to one fore foot, and brought it into the birth canal. But the leg was pulled backwards over the fetal body so that, while the former projected into the birth canal, we dared not exert traction upon it because that would certainly have torn the uterus asunder.

The patient was destroyed. The autopsy revealed a very large foal, well matured in all respects, lying upon its right side with its dorsum against the maternal pubis. The head was in the right uterine cornu, the buttocks and hind legs in the left. The long axis of the fetus was perpendicular to the spinal axis of the mare and to the long axis of the birth canal. The two cornua were equally developed. Each contained an equal volume of the fetus. The fetal body lay behind the opening of the birth canal, beneath the floor of the vagina and non-placental uterine body. The superior wall of the birth canal curved abruptly downward so that what had been the roof of the cornu had become its anterior wall. The floor of the birth canal ended abruptly. What had been the posterior wall of the cornu had moved backward and upward to constitute the roof. Through this double wall, consisting above of the floor of the vagina and of the cervix and uterine body, and below of what was originally the posterior cornual wall, but now the roof, the fetus was readily palpable.

Knowledge of bicornual pregnancy in the mare has developed slowly and uncertainly. Some writers upon veterinary obstetrics clearly recognize its occurrence; others admit it vaguely. The above evidence appears clear and authentic. However, in these outstanding cases, it needs be clearly understood that the relations described are not primary, but secondary, being the result of a pathological displacement of the cornua caused by a pathological location of the fetus. Hence such cases represent but a minority of the bicornual pregnancies. The majority do not undergo the peculiar secondary displacement. Rotated bicornual pregnancy, because of the virtually insurmountable dystocia accompanying it, and the consequent post-mortem examinations, has provided the authentic proof of its nature. Fig. 2, shows that the arrangement of the equine uterus clearly invites bicornual pregnancy. Physiological forces regularly cause the distal pole of the growing ovum to become deflected toward the cervix into the uterine body, instead of pushing across the cornual end of the uterine body into the opposite horn. This causes a change in relationship. The enlarged horn ceases to leave the body at a right angle as in Fig. 2, and moves toward the ultimate parallel relation indicated in Fig. 63. In unipara the membranes of the ovum physiologically project from the cornu of conception into the uterine "body" and into the non-gravid cornu, making contact with the entire endometrium. The fetus later follows the membranes into either (physiologically) the uterine body or (pathologically) the opposite cornu. The allantochorion of that compartment, or third,

of the uterus, into which the fetus does not project, is hypoplastic, and merely serves to occupy the otherwise vacant compartment. That is well illustrated in Figs. 62 and 63. In Fig. 62 the chorion of the uterine body, 6, 6, constitutes a trivial projection, while in Fig. 63 the chorion of the uterine body is the most extensive of the three compartments. The forces which deflect the ovum from its physiological path into the opposite cornu are unknown. A faint suggestion may be obtained from the placental behavior in the cow. If the endometrium of one uterine cornu of a cow is utterly destroyed, the chorion does not enter it. When considering the formation of the placentae on page 105, the view was expressed that the movements of the allanto-chorion are dictated by a mutual attraction between it and the endometrium. Destroy the endometrium, and the attraction ceases; injure the endometrium, and the attraction is disturbed. In my observations, and so far as found in the recorded experiences of others, bicornual pregnancy in the mare most frequently occurs in pluripara. This suggests the possibility that the endometrium of the uterine body had been damaged, and that of the non-gravid cornu had thereby acquired a superior attractive force.

Physiologically, the navel vessels of the chorion are centered over the course of the principal vascular trunks of the uterine vessels which lie between the uterine attachments of the two peritoneal layers of mesometrium. The umbilicus of the embryo faces this. So far as determined, the ventral surface of the fetus in bicornual pregnancy regularly faces the cervix. It is therefore highly improbable, if not impossible, for bicornual pregnancy to become established except in ventral presentation. Later, the fetus, lying in the arc of a circle and having longitudinal diameter greater than the distance between the lateral abdominal walls of the mother, may rotate upon its long axis and carry the two cornua with it. In such revolution the dorsum drops downward, and the feet move upward, forward, and finally downward. The mesometrium of the cornua checks the rotation, causing the free or convex borders to move upward and backward, and the fetus comes to rest lying transversely beneath the vagina, as indicated schematically in Fig. 92.

Authentic knowledge of bicornual pregnancy in the mare has advanced slowly, largely because the methods of identification have remained undeveloped. Autopsies during pregnancy have been few. Veterinary obstetrists have not availed themselves of the opportunity to palpate the recently emptied uterus, influenced possibly by the teaching of human obstetrists, who for good reasons frown upon such

examination. The study of the telltale afterbirth is of recent origin. Williams *et al.*⁶¹ first emphasized this study in 1924. In that contribution the principal stress was placed upon placental lesions, their location, character and extent. In 1928 Fincher²² attended in the ambulatory clinic of the college an aged Shire mare in dystocia. The birth canal was very long, the fetus in posterior presentation, right dorso-ilial position, the hind feet extended. The customary study of the afterbirth followed. We were interested and surprised to find that bicornual pregnancy had been followed by dystocia, not in *transverse* but in *posterior* presentation. The incident revealed a new value in placental examination and broadened the scientific interest and economic importance of bicornual pregnancy. A comparative study of Figs. 62, 63, renders clear the diagnostic value of placental examination in this field. It is indisputably shown that the fetal development had been bicornual and that when labor began the caudal end of the fetus slipped out of the cornu, into the body of the uterus, to present posteriorly.

Symptoms. The condition naturally passes unobserved until an examination is made in order to determine the cause of the dystocia. The symptoms are then unique. The labor pains are weak. The contraction of the walls of one horn pushes the fetus, not towards the cervix, but towards the opposite horn. If the two horns contract simultaneously, they merely counterbalance each other. The fact that no portion of the fetus, or at least no considerable portion of it, can usually be forced into the vagina tends to inhibit any well marked expulsive efforts. Such would necessarily prove futile, and dangerous to the integrity of the uterus.

When the obstetrict inserts his hand, he is first struck by the extremely elongated and narrowed passage, which is nearly twice its ordinary length, although very much decreased in its transverse diameter. No cervix is distinguishable. If the obstetrict follows the roof of the vagina, the hand glides along it almost as far as the arm can reach; perhaps he cannot reach the anterior end of the roof, where it finally turns down in a gradual curve, without any recognizable line of demarcation between the vagina, cervix, and uterus. If he follows the floor of the vagina, and palpates carefully, he will discover the fetus lying directly against the vaginal floor, impressing him very strongly at first with the idea of extrauterine pregnancy. If he follows the floor of the birth canal further, to the extent of nearly the entire length of his arm, his hand suddenly passes downward into the cornual cavity, and he finds that the floor which he has been

following bends backward to constitute the roof of the cornu, immediately beneath which the fetus lies transversely with its dorsal surface presenting toward the pelvic inlet.

In some cases the obstetrice may find one or more feet projecting from the uterus into the vagina, which may readily be reached and grasped. In such case the limb has undergone extreme displacement dorsalwards. So far as I have observed, it has been the upper posterior limb, so displaced that the leg has been extended dorsalward across the body of the fetus. In a large proportion of cases, however, no portion of the fetus projects into the vagina, and before the operator can bring his hand into immediate contact with any portion of the fetus he must reach far forward and, bending the hand downward and backward, touch the ventral portion of the fetus or some of the extremities which are folded along it. In order to accomplish this, he reaches clear over the body of the fetus, passes beyond its ventral line, and then, after passing the point of version where the floor of the vagina ends, turns the hand downward, and more or less backward, into the cornual cavity. These peculiarities serve to differentiate this condition from any other known in veterinary obstetrics.

The prognosis is exceedingly unfavorable. The fetus inevitably dies and the mare almost always succumbs. I have had no success with either mare or foal. Rarely a mare is saved. In one of my cases the mare survived delivery for some days, but finally succumbed to metritis. In that one it would seem possible that, had I understood the conditions better and given closer attention afterward, she might have been saved.

Before undertaking delivery, it would be well to advise the owner of the highly unfavorable prognosis, so that he may be forewarned of the probable outcome. Forensically, professionally, and in the economic interests of the owner, the attending veterinarian may request consultation with a colleague.

Method of Handling. In general, it is well to secure any of the extremities which may lie within reach, and cord them, so that force may be exerted upon them at any time that it may become desirable. If all four feet can be reached, it is usually advisable to amputate the two anterior limbs, either subcutaneously or at the humero-radial articulation, and then attempt to convert the presentation into a posterior one by drawing carefully upon the hind legs.

The position of the animal is important. Fig. 92 suggests that, if the mare is turned upon her back, the rotation of the uterus will tend to disappear and the fetus will be brought nearer to the operator, so

that parts which previously had not been in reach may be grasped. Placing the mare upon her back also relaxes the projecting floor of the vagina, and, by tending to overcome the uterine rotation, renders traction upon the fetus less dangerous.

Various positions of the mare may be tried in an effort to overcome the difficulty. It must be remembered that it is exceedingly exhausting to the mare to remain for a long time upon her back, and this position should not be continued beyond the absolute necessities of the case. If the work can be done nearly as well with her standing, this position should be preferred until the critical time arrives for extracting the fetus by force, when it would generally be best to turn the mare upon her back for this brief period, thereby relieving the vaginal floor and cornual roof.

The position of the fetus and its relation to the uterus render most forms of embryotomy exceedingly difficult or impossible. I have been able to amputate only the anterior limbs. If evisceration could be accomplished, it would be a very great help, by decreasing the size of the fetal body, and still more by rendering it flaccid so that it could be more readily adjusted and extracted.

After the extraction of the fetus, if the obstetrict has been so fortunate as to accomplish this without fatally injuring the uterus, unusual care should be taken to guard against sepsis. Fig. 92 shows that the form of the uterine cavity is extremely unfavorable for adequate drainage, and suggests that this be overcome as far as possible by careful and repeated irrigation of the uterus and siphoning out of the contents.

Should the time ever arrive when mares are examined when six to eight months pregnant in order to determine whether serious obstacles to birth exist, the prognosis for the outcome of bicornual pregnancy may be enormously improved, for both the mare and her young, by pre-arranged cesarean section. The case of Fincher and Stevens, illustrated in Fig. 62, had a pregnancy examination and diagnosis been made, could have been carried to the college in a truck at about 330 days, placed upon the operating table and, under chloroform anaesthesia, cesarean section performed with a high degree of assurance that both mare and foal would have survived. So with essentially all cases of bicornual pregnancies in the mare, if the diagnosis could be made at an opportune date and cesarean section definitely planned, the prognosis could be enormously improved. Although, as stated above, the primary abdominal transverse presentation can generally be relieved by embryotomy, the cesarean

section would have the distinct advantage of saving the life of the foal. At the same time it would greatly lower the mortality ratio of the mares.

Dystocia from Bicornual Pregnancy in Ruminants

As already stated on page 193 and in the volume upon genital diseases, it has recently been shown by Krill and Fincher that bicornual pregnancy occurs in the cow and presumably in the ewe and goat. It differs inevitably from the picture in the mare owing to fundamental differences in the anatomy of the uterus. As indicated in Figs. 5 and 93, the bovine uterus is didelphic with the two uteri firmly bound together almost parallel. In order for a fetus to be bicornual it must bend sharply upon its transverse axis and the two halves of the body lie almost parallel, connected by a brief transverse section, so that the fetus lies U-shaped. Unlike the uterus of the mare, the cornua of the cow are so intimately bound together that the fetus with the enveloping uterine walls may not revolve on its long axis as in the rotated bicornual pregnancy of the mare. As in the mare, the primary anchorage of the embryo is with its ventral side facing the endometrium. Bicornual pregnancy demands that the fetus be doubled, and if it retained its primary presentation it would need double dorsalwards, which is almost impossible. Hence the fetus revolves through 180° upon its spinal axis while the cornual walls remain fixed. Consequently bicornual pregnancy in the cow generally, if not always, results in a dorsal presentation. When dystocia becomes apparent, vaginal palpation reveals the dorsum of the fetus crossing the long axis of the vagina and cervix at right angles with the fetus lying upon its side. The dorsal spinous processes of the vertebrae should be clearly palpable, and not far to the right or left, if not in the center, the fetal ribs should be identified, and a diagnosis reached.

Perhaps rarely, as in Fincher's case, the head end of the fetus may be repelled (or propelled) toward the ovarian pole of the cornu in which it rests, the posterior limbs secured and a longitudinal presentation attained. In other cases possibly the position may be shifted to the anterior presentation. Usually it would seem that embryotomy is demanded and should consist of the transverse division of the fetus upon or near the median line of the birth canal. If practicable, the division should be at the dorso-lumbar articulation, so that the caudal half would have no ribs. If then the caudal half were first extracted, more room would be provided for the extraction

of the rib-bearing anterior half. If the wire saw or the Persson's chain saw can be passed around the fetal body, the division may be quickly and easily made with either appliance. If these cannot be passed around the fetal trunk, the division is readily, though more

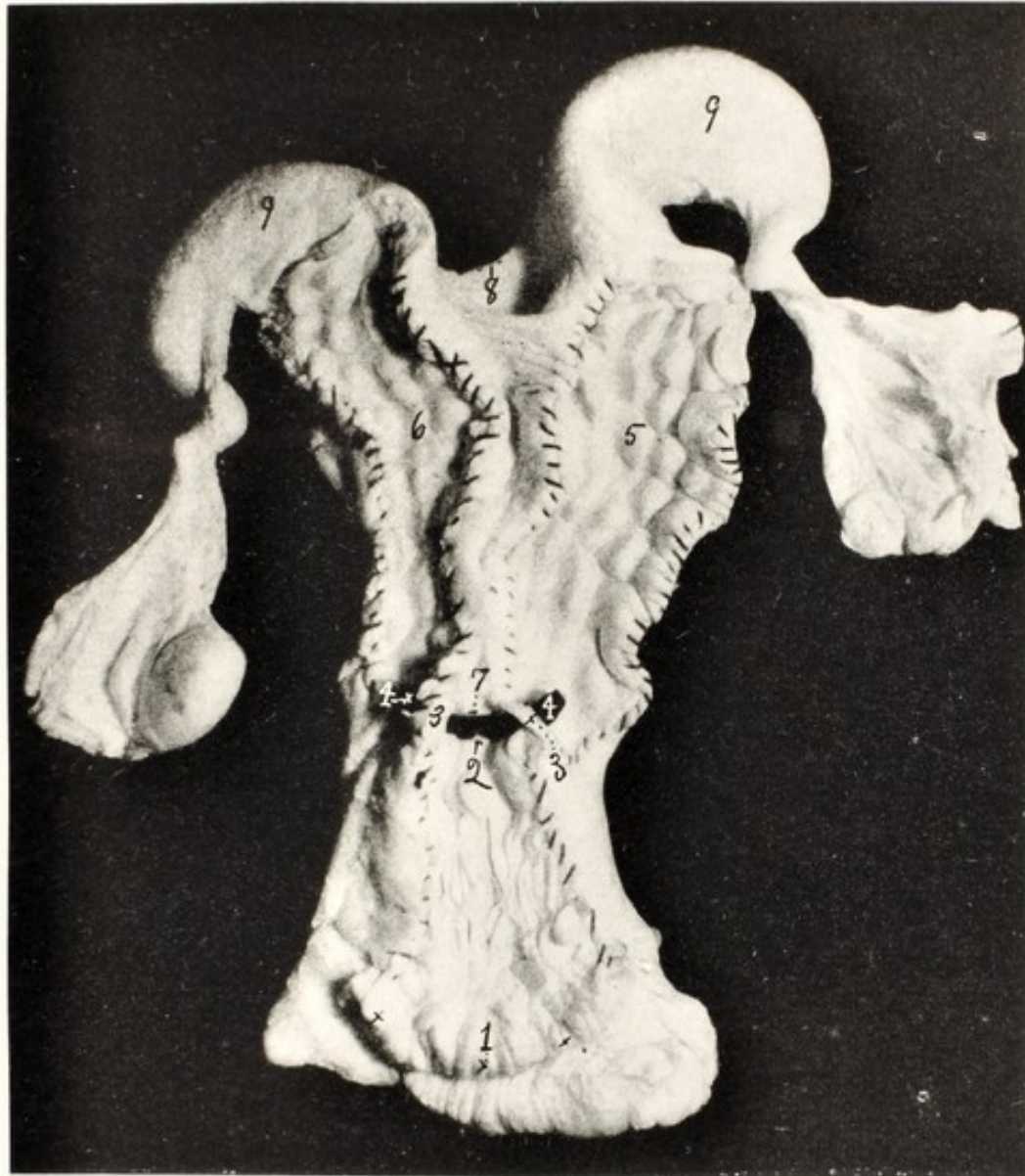


FIG. 93. Horizontal Section through the Genital Tube of the Cow to illustrate the Didelphic Type of the Uterus.

1, the lips of the cervix; 2, the os uteri externum; 3, 3, narrow bands of the dorsal walls of the uterine cornua left uncut to indicate the breadth of the communication between the two cornua; 4, 4, a strip of black fabric inserted into the bases of the two cornua, between 2 and 7, to illustrate the area commonly designated 'the body of the uterus'; 5, the cavity of the right uterine cornu laid open along the mid-dorsal line and exposing the uterine caruncles in four rows; 6, the cavity of the left cornu; 7, the vaginal end of the intercornual ligament. In order to preserve the relations and to define the borders, the peritoneal and endometrial layers have been sutured together by overcasting with black thread; 8, the anterior border of the intercornual ligament; 9, 9, the free ovarian poles of the cornua, beyond the intercornual ligament.




FIG. 94. Gravid Uterus of Bitch in Situ.
U, U, direct cornua; U', U', retrograde portion of cornua.

slowly, made with the embryotomy chisel for severing the spinal column, and completed by incising the skin and muscles with the finger knife. One of the halves, preferably the posterior first, should be secured by looping a cord about it and extracting by traction. If need be the halves should be reduced in size according to indications in a given case.

Dystocia from Bicornual Pregnancy in Multipara

The literature upon bicornual pregnancy in multipara and transverse presentation arising during labor, is somewhat confusing. Citation is found of transverse presentation in the sow in such a manner as to permit the inference that bicornual pregnancy occurred; a careful reading of the original article shows that the observer found two fetuses in the abdominal cavity, associated with uterine rupture, and assumed they had been in transverse presentation. My studies, which are limited, show that in the pregnant sow, the chorion, but not the amnion, of a fetus in the base of one horn often extends across the cornual mouth of the uterus into the base of the other horn. I have not found a fetus extending from one horn into the other. The angle at which the horns leave the uterine body tends to bar bicornual development of the fetus. The fetus itself is relatively thick and rigid, so that it may not readily bend and accommodate itself to the acute angle of the cornual tube.

The bitch presents a different picture. The uterine cornua leave the cephalic end of the body at virtually right angles, continue for a short distance, and then curve sharply forward, after which the two cornua lie parallel. This gives to the cornua a U-shape, Fig. 94, so that an embryo may become located at the bottom of the U, with each end abutting against the forward curvature and thus becoming stabilized.

A peculiarity of the multiparous bitch is the occurrence of solitary conception, the reverse of twin gestation in unipara. There seems to be a tendency in multipara toward the equalization or stabilization of the fetal load between the two horns. Thus Corner¹⁵ shows that in the sow there appears a strong tendency toward the equalization of the load in the two uterine horns, when there is unequal ovulation; some of the embryos in the cornu, having a preponderant number, pass to the base and cross over to take their place on the opposite side. But Corner reports no instances of a fetus stalling between the two cornua, nor have I found any record of such occurrence. The phenomenon is apparently by far most frequent in the bitch. Thus Cuillé¹⁶ records in the Toulouse clinic two cases of bicornual preg-

nancy in the bitch, each with a solitary fetus. One of the bitches died shortly after entrance and the autopsy revealed that the fetus was located transversely. The two horns were equally developed and contained equal proportions of the fetus. The head, neck and anterior limbs were in the right; the rump and hind legs in the left cornu. The fetus was extraordinarily elongated. The placental attachment was central. It occupied that part of the free or cephalic side of the cornu which faces the anterior opening of the non-placental body and from this central area extended equally into the bases of both horns. The placental attachments proved beyond question that it was a true case of bicornual pregnancy, not a displacement during labor. My former assistant, Fehr, also reports to me a similar case, a solitary fetus, unquestionably the result of bicornual pregnancy. The fetus was extra large.

Keller³⁷ reports the occurrence of a type of transverse presentation of the canine fetus which acquires the bicornual position during labor. Here one or more pups are born, then birth is blocked, and a fetus is found bicornually located. The cause appears to be that one fetus is stalled for a time in the birth canal, another fetus is forced against it, and the advancing pole is deflected and pushed across into the base of the opposite cornu. While fundamentally differing in origin, the two offer the same problem in handling.

Bicornual pregnancy in the mare and bitch provide highly interesting facts in the physiology and pathology of birth. Bicornual pregnancy in the definitely uniparous mare resembles multiparous pregnancy because the fetus lies entirely within the cornua, with only trivial extension of the allantochorion into the uterine body. Perhaps in some cases the placental structures do not enter the uterine body at all. The multiparous bitch, through some pathological disturbance, becomes uniovular, and the fetus is located as nearly as possible like that of a uniparous animal. As a rule, bicornual pregnancy in the bitch is not authentically diagnosable by clinical examination, but requires an exploratory laparotomy. Cuillé delivered one of his cases successfully by traction upon a presenting fore leg. The fetus was extracted with the head folded back upon its croup. This was favored by the elongated body.

When the normal duration of pregnancy has been reached, and clinical evidences of the obstruction to birth are present, exploratory laparotomy (page 260) should be made, and cesarean section performed if conditions so warrant. If the uterus is in fair condition, the prognosis is good. If the uterus contains a putrid fetus or other perilous lesions are present, hysterectomy is to be preferred to cesarean section.

CHAPTER XXVII

DYSTOCIA DUE TO POSTMORTEM CHANGES IN THE FETUS

WHEN considering the basic causes of dystocia, on page 200 and thereafter, it was held that uterine, or endometrial, and fetal diseases are inseparable. Neither the placental surface of the allantochorion nor the endometrium can be the seat of active pathological processes without the extension of the disease from the one to the other by contiguity.

Any notable disease of the uterus lowers its power to expel its contents and disturbs the precision with which the remaining power may act. The ovary also participates and greatly influences the uterine functions. Thus, so long as the corpus luteum of pregnancy persists, it may inhibit the contraction of the uterus when a mummified or macerated fetus should, in the interest of the patient, be expelled. Concurrently, any disease of the fetus disturbs or inhibits its physiological power and function to assume the required presentation, position or posture consistent with easy birth. When the fetus dies, its power to assume the correct posture ceases and its position and posture are determined by gravity and the pressure of surrounding organs. As a rule when a fetus dies, the uterus is more seriously diseased than when the fetus is alive and its power to act upon the cadaver is disturbed or lost.

Generally fetal death in unipara is a signal for abortion, but in numerous instances no immediate effort is made by the uterus to expel its contents, although such effort may be made later. When the uterus makes a delayed effort to expel the fetus, or it is deemed desirable to empty the uterus by artificial means, dystocia may arise. During the interval between fetal death and a natural or artificial effort at delivery, various postmortem changes may occur, some of which are well known to veterinary obstetrics. Such changes, not under the continuous scrutiny of the obstetrice, but hidden away in the uterus, develop unseen. Theories or hypotheses arise regarding the course of events, and after much repetition, become a tradition or established faith. If an attempt is made to substitute fact for tradition, the problem becomes bewildering. Traditionally, the most outstanding consequences of the retention of a fetal cadaver are putrefactive decomposition, mummification and calcification. The

postmortem changes have been regularly explained by veterinary obstetrists upon the theory that if atmospheric air reaches the dead fetus it macerates, and if atmospheric air is excluded, it mummifies or calcifies. Numerous important observations challenge the authenticity of the conclusion.

The assumption is, that purulent decomposition is the consequence of bacterial activity, while mummification and calcification are not. On the other hand bacterial activity is invoked in the preparation of ensilage and in other ways for the preservation of food stuffs. The contention of veterinary obstetrists seems to be that the bacteria causing fetal decomposition require atmospheric air in order to be effective, but the general teaching of bacteriology is that putrefactive, and emphysema-producing organisms are not always aerobic. Clinically, a badly lacerated wound, extensively contaminated with dirt and filth, heals far better if handled as an open wound. When sutured and the bacteria are imprisoned amongst the maimed tissues, the danger from the included bacteria deprived of atmospheric air is greater than if the wound be left open and the bacteria exposed to the air. Purulent destruction of tissues occurs in abscesses of the ovaries, seminal vesicles, testicles and other organs far distant from atmospheric air. Clinically it is difficult to imagine a fetus more thoroughly shielded from atmospheric air than in torsion of the bovine uterus. The bovine cervix is the most complex among domestic animals: it is relatively very long and narrow, possesses numerous longitudinal and annular folds of mucosa, and its walls are firmly contracted, pressing the mucous folds tightly together and rendering it difficult to penetrate the canal with a small metal catheter. Early in pregnancy the physiological barrier of dense, highly resistant mucus, the uterine seal, fills the entire canal, from end to end, and in detail all spaces between the numerous folds. When torsion occurs, the occlusion of atmospheric air is further assured by the twisting. Emphysematous decomposition is the regular destiny of the dead fetus of unrelieved torsion. At the same time the conflicting view is maintained by some that torsion of the uterus is an important, or the regular, cause of mummification, although no authentic record of such a case can be found. The most virulent and rapidly fatal case of emphysematous decomposition of a fetus which I have seen was in a heifer, apparently healthy at night, in dying condition next morning. The fetus was emphysematous, the uterus gangrenous, a severe fetid diarrhea and profuse nasal discharge present, the uterine seal present, the cervix not dilated and fetal membranes unruptured. Similar cases are not rare. In Fig 75, a feline fetus has under-

gone purulent maceration following cornual torsion. The involved central segment of the cornu was separated from each pole. It was not only cut off from atmospheric air, but from the genital tract, except for the wholly isolated segment in which it lay.

Neither is mummification inhibited by an open cervical canal and the presumptive evidence of the presence of abundant bacteria or other biological entities. When considering the basic causes of dystocia on page 200 and elsewhere, reference has been made to a large dairy herd where errors in the handling of young calves have produced, during a series of years, an extensive group of heifers with prevalent juvenile organs, which are breeding badly. I had opportunity to observe a succession of these heifers which had profuse uterine hemorrhages shortly after the termination of pregnancy. The blood was at first scarlet, coagulated freely and became dark. The milk from all four quarters was pale red—not bloody—until I had succeeded in breaking up the coagula and removing them by siphoning. I have observed such hemorrhages repeatedly, in isolated cases. The blood coagula have a definite tendency to mummification, and a very distinct resistance to putrefaction. In the abattoir these mummified or desiccated blood coagula are not rare, and they remain indefinitely as inert bodies. This is more extensively discussed and illustrated in the companion volume.⁶⁰ These coagula are to all appearances identical with those of the interplacental hemorrhage of pregnancy leading to mummification. Moutiejūnas⁴² records that a lactating cow showed red milk from all four quarters. Four months later, complete fetal mummification was diagnosed. The breeding record, with the size of the mummy, showed that the interplacental hemorrhage, prerequisite to the mummification, and the red milk, were contemporaneous. Until further investigations reveal additional facts, it is justifiable to conclude that, when this specific type of placental hemorrhage occurs in the cow, whether pregnant or in the early puerperal state, if the animal is lactating, the milk will be of a pale red—not blood color—and that when the milk of a pregnant lactating cow is pale red, it is a reliable signal that interplacental hemorrhage has occurred and fetal mummification is inevitable. Fetal mummification, and mummification of puerperal blood coagula appear identical in fundamental cause and show that mummification may proceed alike in the sealed, or in the open uterus.

It is commonly stated that, soon after pregnancy becomes established, a special mass of mucus, the uterine seal, forms in the cervical canal and closes it hermetically for the duration of pregnancy. The declaration is true of all uniparous domestic animals. The structure

is most elaborate in the cow. My searches for the structure in the swine uterus have been futile, and it probably does not exist in multipara. Its presence in multipara appears illogical. There is no very elaborate cervix: that area constitutes simply a segment of the birth canal. The cavity of the corpus uteri is non-placental, and from its anterior end the cornua leave at varying angles, according to species.

The birth canal of multipara (vulva-vagina-cervix-corpus uteri) is a very narrow sinuous channel, 12 to 15 inches long in the sow, with the walls in firm contact. The passage of atmospheric air through the birth canal of the sow is a mere myth. The amount of air reaching the uterine cavity through the birth canal in any healthy domestic animal probably exerts little or no influence upon the postmortem changes occurring in the fetus.

Another current belief, which has long been accepted by veterinary obstetrists as a scientific fact, but which has not been clearly proven, is the calcification of the fetal cadaver or the formation of a lithopedion. The origin of the tradition is obscure, but apparently arose from the extreme hardness of the bovine mummified fetus: in common parlance it was "as hard as a stone." When a careful search of veterinary literature is made, it is found that the meaning of lithopedion is very vague. It is essentially impossible to learn just what constitutes a calcified fetus or lithopedion. The most natural inference would be that the tissues of the fetal cadaver had become saturated with calcium or other inorganic salts, but the only known way in which that may occur is for the dead body to be submerged in a liquid holding such salts in solution. Such conditions do not occur, and, so far as I can find, there is no authentic record of the tissues of a fetus of a domestic animal having become calcified. The bovine endometrium, the contiguous chorion and portions of the amnion are often calcified, but that is not incompatible with a viable fetus. When a fetus passes from the uterus into the peritoneal cavity and becomes encapsulated, the capsule may in some cases be the seat of calcareous deposits, and the fetus said to be encrusted, but even this is not clearly recorded. The chief misfortune to which the tradition has led is that writers upon human obstetrics have sometimes accepted in good faith the vague statements of veterinary obstetrists, and stated that calcified fetuses are common in lower animals when in fact no authentic case is known, either intrauterine or extrauterine.

Early fetal death in unipara is generally followed promptly by abortion. In multipara, the death of one or more fetuses, while other approximately healthy individuals remain, is not ordinarily followed

by expulsion: this would sacrifice the viable fetuses. In numerous cases of fetal death in unipara, there is no immediate effort at expulsion. In such instances the destiny of the fetal cadaver and of the mother varies greatly. Some cases lead quickly to maternal death. In others, efforts are eventually made by the uterus to expel its contents, or for economic reasons, artificial emptying of the uterus is desired. Dystocia often results. Some of these are of obstetrical interest.

The Static Fetal Cadaver

I have observed, and find recorded, several instances of intrauterine fetal cadavers which exhibit no notable tendency to undergo change, if left undisturbed. The fetus dies, its tissues are hard and firm, there are no changes in the color of the skin and hair. If there is any change in weight it is not apparent. In two of these cases, there was torsion of the uterus. In one recorded by Boyd¹⁰ the torsion of the uterus and death of the fetus had apparently taken place about 20 months prior to the autopsy, without the occurrence of recognizable decomposition or of change in weight by desiccation. In the other observation⁶⁵ so far as could be determined, the fetal death and the torsion had occurred 23 months previously. Again there had been no notable changes in the fetal tissues: neither putrefaction nor desiccation was recognizable. The conclusion might be reached either that the condition of the fetus was referable to the torsion, or that the torsion was dependent upon the state of the fetus. Neither hypothesis can at present be proven or disproven. But I have seen two other cases of a fetus of the same character, in which torsion of the uterus was not present. Hence uterine torsion is not prerequisite to the condition of the fetus.

So far as known, the condition is peculiar to the cow. Fetal death in the cases known to me occurred at or near term. It is to be diagnosed by the history and rectal palpation. It needs be differentiated from fetal emphysema, maceration and mummification, in each of which there are changes in size, form, texture or other definite characteristics, while the static fetal cadaver simply remains essentially the same as at the hour of its death, except for the disappearance of the amniotic and allantoic fluids.

The prognosis, according to my experience, is hopeless. In the two cases associated with uterine torsion, detorsion, if ever possible, was impossible at date of diagnosis. Had detorsion been effected, it would have been followed immediately by the perplexing problem of what to do next. In my two cases without uterine torsion, the cervical canal

was dilated and time given for labor to set in and the uterus to contract. The fetus promptly underwent emphysematous decomposition, and the cow died. Perhaps embryotomy would have been possible, but with a hard, firm fetus, no fetal fluids present, and the uterine walls in close contact with the fetus, the outlook to me was highly discouraging. Had that been accomplished, the next consideration would have been the prospective value of the cow. As a breeder




FIG. 95. Twin Aborts. Mare.

The smaller fetus died at 5 to 6 months, the larger at about 10 months. The first was retained and underwent papyraceous mummification, until the latter had also died. (*Cornell Veterinarian.*)

there would be no ground for any confidence. As a beef animal she would be less valuable than before the operation. The most economic course to pursue, if the cow is in good flesh and the laws and sentiments of the community permit, would be slaughter. Otherwise embryotomy or cesarean section should be considered.

Papyraceous Mummification

When one or more fetuses die in the uterus of a multiparous animal and there remain one or more approximately healthy fetuses, a conservative type of disintegration of the ovum occurs, which is compatible with the continuation of gestation to term, when the living fetuses are born and any existing papyraceous cadavers expelled. The membranes become desiccated and the soft tissues disintegrated, without fetor or emphysema. Those embryos which perish early may

wholly disappear, while those which die later decrease in volume, becoming leathery in texture, and of yellowish or pale brownish color. The same phenomenon occurs in twin pregnancy in the mare, as shown in Fig. 95, but is unknown in single pregnancy in unipara. It is a conservative process which may prevent the sacrifice of the remaining living fetuses. This type of cadaver rarely causes dystocia.

Mummification of the Bovine Fetus

In the cow there frequently occurs a specific type of mummification or desiccation, not authentically recorded in other species of animals. At variable periods of gestation, largely from the fourth to the sixth month, a profuse inter-placental hemorrhage occurs which entirely separates the allantochorion from the endometrium and completely envelops the ovum in a vast coagulum. Like abortion, it is observed most frequently in primipara and, naturally, in the dairy heifer. The blood coagulates, and then undergoes gradual disintegration, the nature of which has not been studied. It is resorbed, leaving behind a layer of very dark brown, almost black, debris. The fluids of the fetal cavities and tissues are also resorbed, and in the course of two to four months the cadaver has become a dry, hard, gnarled mass, of a dark color throughout.

The cause of the inter-placental hemorrhage is unknown. Early in the history of veterinary obstetrics, when genital diseases of cattle were far less common and virulent, and before sexual pathology in cattle was commonly studied by rectal palpation, Franck²⁷ mistakenly concluded that the mummification was due to uterine torsion. While torsion may cause some transudation of blood into the uterus and its contents, there is no evidence that it could possibly precipitate the enormous hemorrhage observed. While every veterinarian with experience in bovine obstetrics observes cases of both fetal mummification and uterine torsion, the concurrence of the two is not seen. By dislodging the corpus luteum of pregnancy the mummy is regularly and promptly expelled. This could not take place, were torsion present.

As stated above, there is current the hypothesis that the exclusion of atmospheric air is a prerequisite to mummification. Harms (Richter)³² adds the further limitation that bacteria shall not enter the uterus through the blood stream. All ignore the importance of the bacterial flora of the uterus, which is discussed on page 140.

Moutiejūnas⁴², in a series of 12 cases of mummification, observed red milk in one cow from all four quarters at the date of inter-placental hemorrhage. The desiccation was complete four months

later. In the 12 cases of Moutiejūnas, the sex of the fetus is recorded in but 4, including one pair of twins: all five were bulls. In the 12 cases there was one pair of unicornual twins and one pair of bicornual, a twin ratio of 1:6. There were also two monsters—brachygnathus—recognized among the 12 cases. In two cases, calcification of chorion and cotyledons was present, indicative of utero-fetal disease prior to the hemorrhage. There were 4 primipara and 8 pluripara. Of the 4 primipara, 1 had juvenile genital organs, with a vulva so narrow it would admit but 3 fingers. The fetus was caught in the vagina. The vulva was incised to permit delivery. In general there is a well defined background of genital disease, prior to the inter-placental hemorrhage; a preponderance of male fetuses; an excessive ratio of monsters and of twins; calcification of cotyledons and chorion; and narrow vulva suggesting arrest in genital development in early calfhood.

The diagnosis is made by rectal palpation. The prognosis is bad. Some cows have bred at least once after the expulsion or extraction of a mummy, but this is apparently exceptional. The expulsion of the mummy usually occurs within three to five days after the dislodgment of the corpus luteum. It may be so deeply embedded that it cannot be removed by digital compression until the capsule of the ovary has been punctured with the ovarian scalpel as described in the volume on genital diseases. Before attempting to cause the expulsion of the mummy by dislodgment of the corpus luteum, the economic outlook for the cow should be carefully considered. While some of them breed later, the ratio of fertility is probably low and the delay is considerable. There are dangers from lacerations and other injuries during expulsion or extraction. Since there is no known reason why the flesh of the cow is not wholly free from objection for beef, regardless of the existence of the mummy, if she is in acceptable flesh, she may at once be slaughtered.

If it is desired to retain the animal for breeding or dairying despite the cost and risk, the corpus luteum should be dislodged, and provision made for prompt veterinary attendance when labor sets in. The genital passages should be protected as well as possible during the passage of the fetus, and any extremities which may project dangerously should be removed. Lubricant fluids should be introduced into the uterus generously.

Emphysema and Purulent Decomposition of the Fetus

Purulent decomposition of the fetus, with or without known emphysema, occurs in all species of domestic animals. Death and decom-

position may occur at any period after the middle of gestation, or even earlier. In unipara the rule is that the pathological changes which lead to fetal death also arouse expulsive efforts before notable decomposition ensues. There are numerous exceptions to this rule: the patient may die from acute sepsis without any effort to expel the cadaver; maceration may proceed until only the bony skeleton of the fetus remains; the skeletal debris may remain, especially in the cow, in the thickened, sclerotic uterus for years; or some of the bones may slough into the alimentary tract and be expelled.

When labor begins soon after the fetus has died, or it dies during labor, and a barrier to expulsion is present which is not overcome, the fetus, as a rule, decomposes promptly. If artificial delivery is undertaken at a favorable moment, the fetus will sometimes be found emphysematous at the presenting pole but not visibly changed at the ovarian end. If an attempt is made to arouse expulsive efforts in cases of hydrops of the amnion and allantois, or in the above described static fetal cadaver, by dilating the cervical canal and then postponing the operation pending expulsive efforts, rapid decomposition of the fetus is highly probable. This violent reaction has been largely attributed to the admission of air. It seems more probable that the chief cause lies in the disturbance of the equilibrium of the reproductive system by the mechanical insult to the tissues, with inhibition of the power of the tissues to resist invasion by bacteria present. The operator may add important infection also.

The diagnosis is to be made by the existence of fetid genital discharges, by palpating the decomposing fetus in the vagina or per rectum, by palpating the crepitant skeletal mass per rectum in far advanced maceration, and by other means. In multipara the diagnosis, not always authentic, is based upon the fetid genital discharge, digital palpation per vaginam, and symptoms of sepsis. In numerous cases it is authentically diagnosable only by exploratory laparotomy.

The prognosis is bad for the physical life of the patient, and well-nigh hopeless, except in the milder cases occurring in unrelieved dystocia, for the reproductive life of the animal.

In some cases, the emphysematous fetus may be extracted by force. Generally embryotomy, page 243, is indicated in unipara, the details of which must be adjusted according to the presentation, position and posture. The removal of one or more limbs, followed by evisceration, is valuable. It is highly important that mutilation be extensive, because the greater the laceration of tissues, the more readily the imprisoned gases may escape. The volume of gases in the subcutaneous tissues is especially great, and ample provision should be made

for its escape, either externally or through the body cavity. The presence of the emphysema renders the division of muscles and other tissues relatively easy, and greatly facilitates the detachment of the skin. When the cadaver has been adequately or availably decreased in volume, the birth canal should be abundantly lubricated before traction is applied. The imprisoned gases equalize the degree of pressure upon all parts of the birth canal, thereby permitting the application of greater traction than in other forms of dystocia. When maceration is far advanced and emphysema has ceased as a factor, the fetal debris may sometimes be removable through the cervix. In other cases, with a mass of skeletal debris in a cornu, laparotomy and hysterotomy may be applied.

In multipara, emphysematous fetuses are sometimes removable by traction, but largely call for hysterotomy, page 260, or hysterectomy, page 266.

CHAPTER XXVIII

THE DYSTOCIA OF UTERINE INERTIA

THE necessity of uterine health and vigor in physiological birth has already been emphasized, principally in association with such fetal diseases as anasarca, emphysema, or hydrops of the amnion and allantois. Later, consideration will be given to dystocia due to vicious presentation, position and posture, in which uterine inertia plays the vital role. Dystocia is frequently observed which, so far as may be seen, is due wholly to uterine inertia. The genital organs of the patient are apparently normal anatomically and the cervix dilated or dilatable. The fetus is at or near term, alive or only recently dead, and has undergone no important postmortem changes. Birth is not obstructed by any vicious presentation, position or posture. Perhaps one or both membranes have ruptured. No material progress is made. The only recognizable explanation is an absence of vigorous expulsive efforts. The uterus has evidently contracted somewhat and dilated the cervix, but not sufficiently to engage the fetus in the birth canal.

Among domestic animals, the phenomenon is seen chiefly in dairy cows, and occurs most frequently in herds where genital disease is intense. When milk fever sets in at the beginning of labor, all efforts to expel the fetus cease. If the milk fever is successfully overcome, the expulsive efforts reappear. In most, if not all other cases, the first, or premonitory signs of labor are present, but definite expulsive efforts fail to develop. The cow shows neither distress nor anxiety: she eats, drinks and behaves in an essentially natural manner except for the evidences of the first stage of labor. The phenomenon drags along, for six to thirty-six or more hours. Ultimately, in most cases, the second stage of labor sets in, there are definite expulsive efforts, and the fetus is expelled, probably without assistance. Retained placenta and metritis commonly follow, or rather, the uterine disease underlying the inertia continues and becomes aggravated.

The causes of uterine inertia have not been fully determined. In those rare cases associated with milk fever, it is easy to say that it is due to that disease. That is only a makeshift, because the nature of milk fever is not accurately known. Uterine inertia is so inseparably associated with sexual pathology that the veterinary obstetrict must tentatively assign intrauterine infection as the basic cause. Beyond the infection, account needs be taken of improper feeding, breeding,

housing and other factors which may depress the general vigor and invite bacterial activity.

The prognosis is generally fair for cow and calf. The handling should consist of stimulation of labor and the application of artificial aid by prudent traction. Labor pains are to be stimulated by the use of pituitrin, by manual excitation, or by both. In the cow, sufficient expulsive efforts may usually be aroused by inserting the hand into the uterus, grasping a foot or other portion of the fetus, and causing it to move in the uterus by alternate traction and relaxation or repulsion. In multipara this method is not available. In these, the most reliable means is the administration of pituitrin in proper dosage. Pituitrin is also of value in the cow, in addition to the manual excitation. Given guardedly, it hastens the expulsion and favors the early completion of the third stage of labor, the expulsion of the placenta.

The atonic uterus should be aided by prudent traction. The degree of traction employed should be approximately sufficient to replace the power lost through disease; it should, with the natural forces remaining, suffice to deliver the fetus in approximately the physiological duration of time.

CHAPTER XXIX

DYSTOCIA DUE TO PATHOLOGICAL PRESENTATION, POSITION, OR POSTURE

UTERINE and fetal diseases are inseparable: the relation through the placenta is such that neither the uterus nor the fetus may become extensively affected without involving the other to some degree. Disease inevitably disturbs the power of the uterus to function physiologically. It cannot contract with physiological power, or precision. If one portion of the uterus is notably more diseased than another area, the organ logically fails to contract uniformly, and the fetus is ineffectively driven in a direction oblique to the physiological path of expulsion, becomes jammed against the pelvic inlet or elsewhere, and is then further deflected from its course. If the fetus is not in good health, as for example, a bovine fetus with diarrhea, it suffers in its general vigor, as it does in postnatal life: it is atonic and fails to establish and maintain the position and posture required for physiological birth. Accordingly the ratio of dystocia because of pathological presentation, position and posture increases as sexual disease advances. As in other obstetrical phenomena, there are infinite variations in detail; one class frequently passes into another by imperceptible gradations.

Dystocia Due to Pathological Disposition of the Umbilical Cord

Obstetrists state that in the human fetus the navel cord is found looped about the neck or otherwise pathologically disposed, in about one birth in four. This is in sharp contrast with observations in veterinary obstetrics. The difference is explained by the relatively much longer navel cord of the human fetus and vastly longer and more rigid extremities of the herbivorous domestic animals. The looping of the navel cord about the head or other part is rare in domestic animals. Harms³² records numerous cases in domestic animals in which the navel cord has been looped about an extremity, but only very rarely has the loop been about the neck. Most frequently the loop is around one hind leg and the fetus is in posterior presentation. In one instance, amputation had occurred through the metatarsus of an equine fetus, which was attributed to incarceration within a coil of the umbilical cord, but as discussed more fully in the companion volume, this view is probably erroneous. Usually the displacement seems to occur in late pregnancy, causes no pressure necrosis, but may cause dystocia. In the citations by Harms,

the greatest number of cases recorded by any one observer was three. During fifty years of obstetrical experience, I failed to observe a case of dystocia due to looping of the navel cord. In my fifty-first year of obstetrical work, while handling dystocia in a heifer with juvenile genital organs and the fetus in posterior presentation, I found delivery obstructed by a cord passing over the left thigh. This I pulled in two; a few jets of blood, and vigorous death struggles of the fetus made clear the nature of the obstruction. From the navel, the cord passed backwards, thence to the left over the thigh, and downwards. Apparently it was so tightly stretched over the leg that the pulsation was not notable beyond. It would have been impossible to have disengaged the cord without dividing it. The vulva of the heifer was so small and the fetus so diseased that the delivery of a living calf was essentially impossible, had the navel cord been in its place.

The prognosis for the fetus is essentially hopeless. Harms³² cites one instance in which a living calf was delivered after dividing the cord. The presentation was posterior. The subject is of very scant economic importance in veterinary obstetrics.

CHAPTER XXX

DYSTOCIA IN THE ANTERIOR PRESENTATION

The Dorso-Iliac and Dorso-Pubic Positions

THE dorso-iliac and dorso-pubic positions of the fetus are practically limited to unipara, chiefly to the mare and the cow. In these species the fetus physiologically lies *en arc*, with the ventral line concave and the dorsal convex. It is essential to physiological birth that the fetus be in the dorso-sacral position. The body does not readily bend dorsally. The very long and rigid limbs contribute to the crescent disposition. The anterior limbs project beyond and below the head; the hind limbs project downward and backward from the pelvis. When freed from all restraint, the limbs project ventrally at approximately right angles to the spinal column. During birth they need assume a posture which deviates slightly from the spinal axis in the ventral direction. The crescent line is thus continued from the toes of the fore feet, through the spinal column and limbs, to the toes of the hind feet.

So long as the uniparous fetus remains within the uterus and abdomen, its arciform posture renders it mechanically unstable. Its posture is stabilized by the physiological actions of a healthy uterus and a healthy fetus.

In multipara the fetus is virtually cylindrical and the limbs are relatively short and pliable. Dorso-iliac or dorso-pubic displacement, which apparently occurs rarely, has not been recorded as a cause of dystocia.

When considering uterine torsion, page 292, the question was raised of the probable confusion of the dorso-iliac and dorso-pubic positions with uterine torsion. The actual position of the fetus is the same in each, but in the dorso-pubic position, should uterine torsion be present, the obstetrice may err in the direction of the rotation. It is therefore prudent, in dorso-iliac and dorso-pubic positions, for the obstetrice to differentiate between uterine torsion and simple rotation of the fetus within its amniotic cavity, when the uterus is normally disposed. If mild torsion exists, the rotation of the fetus should be in that direction which will concurrently correct both uterine torsion and fetal posture.

The prognosis is only fair. A large proportion of such fetuses are either dead or non-viable, or frail and highly vulnerable to the

diseases of the new-born. The uterus is commonly involved to a recognizable degree. Retained placenta and metritis are common.

The indications are to rotate the fetus upon its long axis to convert the dorso-ilial, or dorso-pubic, into the dorso-sacral position as described on page 232.

Deviations of the Head and Neck

The tendency of the head to become more or less deviated at the time of birth varies greatly in the different species. The neck of the pig is so short and thick that the head rarely becomes deviated; the

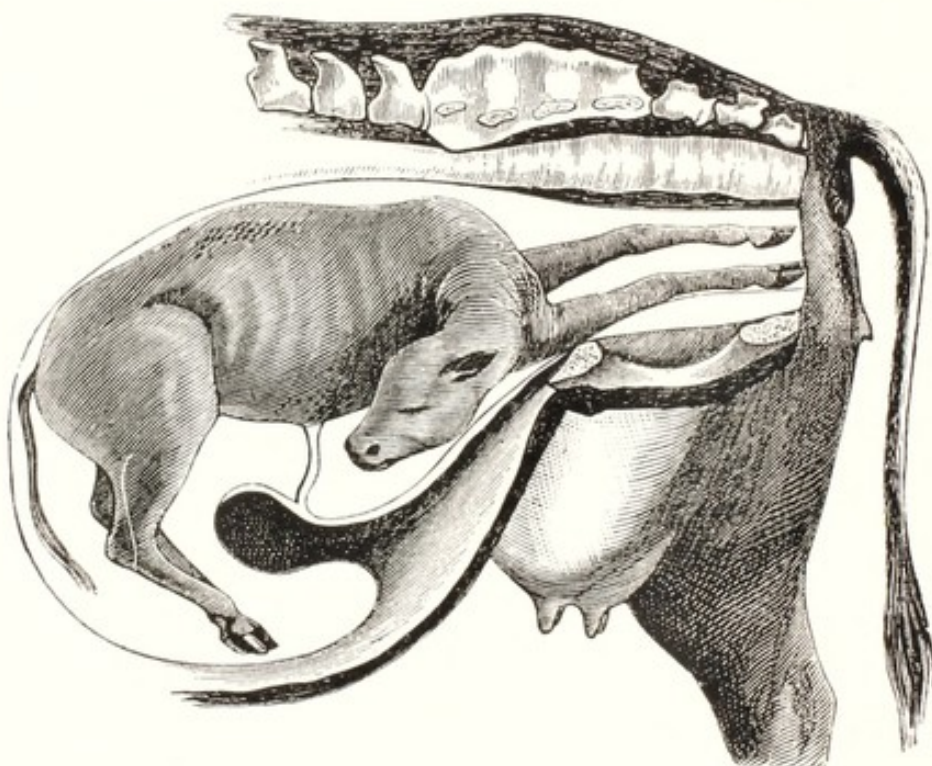


FIG. 96. Lateral Deviation of the Head. (Saint-Cyr.)

neck of the foal is so long and flexible that deviations of the head are of outstanding importance in the obstetrics of the mare.

LATERAL DEVIATION OF THE HEAD

The lateral deviation of the head is the commonest type observed in unipara. It occurs in two wholly distinct and unrelated forms.

Simple lateral deviation, possible in any domestic animal, occurs most frequently in the cow and mare. The displacement apparently occurs during labor. It is referable mainly to a want of vigor of the fetus, which renders it impotent to maintain the physiological posture. As the fetus is being forced along the genital canal the nose

or other portion of the head becomes somewhat deflected to the right or the left, and, becoming impacted against some projecting portion of the pelvis or genital canal or entangled in some way in the fetal membranes, is drawn to one side, and becomes caught between the side of the fetal body and the wall of the uterus or vagina. When this occurs it is highly improbable that delivery can proceed spontaneously. Instead, the head tends to become farther and farther deviated as the body of the fetus advances. Finally the neck is doubled directly backward as far as possible, and the head lies against the side of the chest, or in the mare, in the flank.

The diagnosis usually offers little difficulty. The operator must identify the two anterior limbs, one or both of which are ordinarily in the birth canal, and it needs be determined whether the head is deviated to the right or the left. The determination of the direction is not always easy. If the head can be reached, that decides the question. When the head cannot be reached with the hand, the diagnosis becomes more difficult. As a general rule it is only in the foal that the head cannot be reached and examined with the hand, and here one is aided by the presence of the somewhat prominent mane. If the head is bent laterally and the operator passes his hand as far as possible along the presenting portion of the fetus, he will usually be able to identify the withers. From this point, turning either to the left or to the right and then backwards, he may trace the top of the neck by the mane. At the lower margin of the neck, the operator will usually be able to identify the trachea. In one direction he can trace this to its point of disappearance within the fetal chest between the two anterior limbs, and in the other may follow it across the right or left anterior limb, where it later turns backward toward the mother's head.

The indications in this form of lateral deviations of the head will vary greatly according to species and individual cases.

Mutation. In those cases where the fetus is not emphysematous, or there are no other insurmountable obstacles to the correction of the deviation, mutation is the conservative and proper course. The cow or mare should be operated upon in the standing position, or, if recumbent, should be placed in lateral recumbency on the side opposite to that toward which the fetal head is bent—that is, with the fetal head *above*, not underneath the fetal body.

The operation consists first of repulsion, page 230, which is to be applied to the chest of the fetus, directed obliquely backward and away from the misdirected head. If the head is deviated to the right side of the mother, the repulsion should be obliquely toward her left

side, thereby tending to release the head and cause it to advance toward the pelvic inlet. During the operation of repulsion, the operator must keep constantly in mind the great fundamental value of keeping the posterior part of the body of the mother decidedly elevated, whether she be standing or recumbent. The means for bringing this about have been discussed on page 221. While attempting repulsion, severe expulsive efforts need be controlled by the means advised on page 223.

After repulsion has been accomplished, the operator should secure and extend the head of the fetus by those means most available in the particular case, under the rules laid down on page 235. In many instances it is merely necessary to grasp some portion of the head with the hand or fingers, and give it a sharp pull, by which it is brought into its normal position. When the nose is pointing backward—that is, toward the anterior part of the mother—the nostrils and commissure of the lips offer a secure hold for the fingers of the operator or for the insertion of a blunt hook. This may prove of value until the head has turned somewhat.

In the correction of this deviation, it will often prove highly advantageous to place a repeller securely against the chest of the fetus and have an assistant maintain constant repulsion, thus keeping the body pushed away from the pelvic inlet in a manner to insure to the operator the greatest amount of room for manipulating the head.

The bitch, cat, or ewe may be more or less suspended by the hind legs, the vagina filled with a warm, unctuous fluid, and the fetus repelled, partly by gravity, partly by the pressure of the fluids, aided by shaking the animal, by pushing upon the fetal limbs, or by means of a finger tip placed against the fetal chest. When repulsion has been accomplished, the operator may locate the fetal head through the abdominal wall, and by external manipulations push it toward the vulva, while a finger or fingers inserted in the vulva aid in adjusting the head in proper position. Traction may then be applied.

Forced extraction has been advised in the mare by some veterinary obstetrists, with the idea that by this means it is possible to save a foal. I have been unable to find a record of so fortunate an occurrence. Only rarely has the mare survived.

A mare was entered in our clinic from which a fetus in this position had been extracted by force. Her perineum was completely ruptured, the afterbirth was retained, she was very weak and exhausted, and presented a repulsive and pitiable sight. The afterbirth was removed, and the ruptured perineum was disinfected. In a few days she succumbed. Upon postmortem examination there was found a small

perforation upon the floor of the cervix, which had caused a septic peritonitis. Forced extraction of the equine or bovine fetus with deviation of the head is generally if not always unnecessary, unsurgical, and brutal.

Embryotomy. When mutation fails, in unipara, or when it promises to require an amount of time and manipulation inimical to the recovery of the patient, embryotomy should be employed without delay. The obstetrice should constantly keep in mind the fact that, when the deviation is severe, the fetus is probably dead or so diseased that, if extracted alive, it will be of limited value. Under such conditions, it is imprudent to prolong efforts at mutation.

Two methods of embryotomy are available, at the option of the operator. If the Persson's saw or Thygessen fetotome can readily be passed around the neck, decapitation may be quickly performed and the withdrawal of the excised head overcomes the obstacle. The alternate plan consists of the subcutaneous amputation of the anterior limb, page 246, upon the side opposite to the deviated head. After the removal of the anterior limb, the chest should be opened at the exposed point and evisceration carried out, as described on page 258. When this has been accomplished, the fetal torso has been so reduced in volume, and the evisceration has rendered it so flaccid, that the thorax may readily be repulsed and the deviation of the head corrected.

Hysterotomy or hysterectomy is not called for in the larger domestic animals, nor usually in the sheep and goat. In the smaller animals, where the correction of the deviation fails and embryotomy is not available, because of the small size of the birth canal, one of these operations, pages 260, 266, is the only recourse, and offers a fair prognosis if undertaken at the proper time and under proper conditions. Lateral deviation of the head is not always direct. It may be obliquely upwards or downwards, thus constituting intermediate stages between the typical lateral, and the dorsal or ventral deviations. Sometimes the neck has undergone torsion through 50 to 90°. In handling, the general principles for lateral deviation apply.

Wry-neck

A second type of lateral deviation of the head, known to veterinarians as wry-neck, is limited to the soliped fetus. As already suggested, page 189, it is quite certainly due in all cases to bicornual pregnancy. When labor sets in, either the cephalic or the caudal end of the fetus may be expelled from the base of the cornu in which it lies and the presentation become secondarily anterior or posterior

respectively. The sharply folded head and neck facilitate the displacement of the cephalic pole of the fetus. It thus becomes converted into anterior (shoulder) presentation. The displacement of the head and neck occurs early in gestation; the head and neck become incarcerated between the wall of the cornu and the fetal body, and are firmly held in the bent position, because the shoulders, with the base of the bent neck, abut directly against one, while the buttocks press against the other abdominal wall of the mare. All movements of the head and neck are inhibited. The articulations are developed, but the cervical vertebrae acquire a curved form. The head, which lies with the side against the fetal loins, becomes molded to the cylindrical body. That side of the fetal head in contact with the body becomes concave; the side in contact with the wall of the cornu, convex.

Wry-neck is to be diagnosed by the extreme deviation, the abrupt curve of the neck, and the marked tendency of the head and neck to move in unison with the fetal body. In the ordinary lateral deviation of the head, the cervical spine describes a comparatively wide curvature, while in wry-neck the compression bends the neck abruptly. This increases the distance of the head from the shoulder. If the operator can reach the head, he may recognize the distinct curvature. If the fetal body is repelled, the head and neck accompany it: in ordinary lateral deviation of the head, repulsion of the body tends to overcome the deviation. After the fetus has been removed and the placenta becomes available, its examination authentically reveals the cause as shown in Figs. 62, 63.

The outlook for the foal is essentially hopeless. If extracted alive it is valueless. The dystocia is readily relieved by embryotomy and the prognosis for the life of the mare is good. It is not known that she may not later breed physiologically. Mutation should not be attempted. Embryotomy should be immediately performed. The exposed anterior limb, upon the side away from the head, should be amputated subcutaneously (page 246) followed by evisceration through the chest wall (page 258) and the severing of the ribs. Much room is thereby gained and the torso is rendered highly flexible. The deviation may then be readily corrected. Usually the torso may be safely extracted without the correction of the deviation, the accurately molded head and neck occupying the room gained by evisceration. In some cases it may prove convenient to pass Persson's saw or the Thygessen fetotome about the neck and amputate it instead of the anterior limb. When practicable, this is far quicker, and preferable.

DOWNWARD DEVIATION OF THE HEAD BETWEEN
THE ANTERIOR LIMBS

Veterinary obstetrists occasionally encounter a downward deviation of the head in which the nose or the entire head passes downward between the two anterior limbs. The deviations may be arranged in two groups. The first group includes those of a minor character, in which, when the fetus advances along the birth canal, its nose catches against the pubic brim. As the fetus is pushed along, there is a constant tendency for the nose to turn more and more downward and backward, while the head becomes sharply flexed upon the neck and the poll passes into the pelvis, to constitute what is sometimes known as the poll presentation. In such cases the head ordinarily remains above the anterior limbs.

In the second group the displacement apparently occurs earlier, and, before the metacarpo-phalangeal articulations have entered the pelvis, the head has dropped down between and beneath the anterior limbs. Apparently it is only during the early stages of labor that the fetal muzzle or the head may drop down between the feet. As the two anterior limbs advance they become pressed together. In the first group the muzzle must drop between the metacarpi only far enough to become caught upon the pubic brim, and the close approach of the two limbs to each other prevents the entire head from passing downward beneath the feet. In the second group the entire head has already dropped down between the anterior limbs before the feet have entered the pelvic cavity. As soon as the metacarpi are engaged within the pelvic cavity the two limbs are pressed together over the head.

The diagnosis by manual exploration is comparatively easy. In the first instance the head is found lying upon the anterior limbs, with the poll directed more or less upward and toward the vulva, while the nose projects downward between or alongside the limbs and is caught against the public brim. In the second instance the head at first cannot be felt, but the limbs seem to be pushed somewhat apart as they near the chest. Careful palpation will generally enable the obstetrists to determine that the top of the neck, surmounted by the mane in the foal, disappears almost straight downward from the top of the withers, finally recurving backward. By reaching around underneath the anterior limbs and fetal chest, some portion of the head will probably be reached and identified. The deviation may usually be corrected in unipara if the entire head has not passed completely down between the anterior limbs. The muzzle may usually be grasped with the hand and carried upward over the pubic brim, and

the head extended in the pelvic canal. The birth canal of multipara does not ordinarily permit the introduction of the hand, but the deviation may be corrected by a finger or by grasping the head with forceps, supplemented by abdominal palpation.

When the head is completely deviated downward and the anterior limbs are pressed together above the poll, mutation is usually inadvisable. The head of the bovine fetus has a great transverse diameter, the transverse diameter of the neck is small, and the margin between the head and neck is abrupt. In a limited experience with this deviation in the cow I have definitely failed to correct it by mutation. Embryotomy should be resorted to without delay. It is best to amputate one limb subcutaneously (page 246) after which the deviated head is readily brought into normal posture. Cesarean section may be indicated in multipara.

UPWARD DEVIATION OF THE HEAD

Upward deviation of the head is rare in unipara. The head is so long, compared with its width, that it tends to turn upon the cervical axis and assume lateral deviation. The fetuses of carnivora have broader heads and the necks are comparatively flexible in the dorsal direction. The upward displacement of the head is accordingly most common in the bitch and cat.

In unipara the diagnosis is made by manual exploration. The head can generally be palpated and the trachea, passing upward and then backward, is recognizable. In multipara the diagnosis is to be made by digital exploration.

The handling is the same in principle as that for lateral deviation.

Deviations of the Anterior Limbs

The relatively long and rigid anterior limbs of the larger unipara cause frequent and serious dystocia. Any variation from the physiological complete extension beneath the fetal head, regularly interferes with birth. Solipeds and ruminants are destitute of a clavicle. Physiologically during birth the shoulder and the massive scapulohumeral articulation are displaced from the chest and lie alongside the neck. Pathologically when a portion of the anterior limb deviates and becomes caught, the shoulder is pushed backwards upon the chest and stalls the progress of the fetus until the deviation has been corrected. The anterior limbs of multipara are short and very flexible, so that their deviation is not usually a serious obstacle to birth. Carnivora have a rather rudimentary clavicle which materially prevents the pushing of the shoulder back upon the chest.

FLEXION OF THE ANTERIOR FEET

Flexion of the anterior feet occasionally causes dystocia in unipara. Dystocia rarely occurs from this cause in multipara, because their legs are so short and flexible that birth may occur almost regardless of the posture of the feet. The frequency and severity of dystocia due to displacement of the feet, increases as the relative length and rigidity of the limbs increase. It has already been stated,

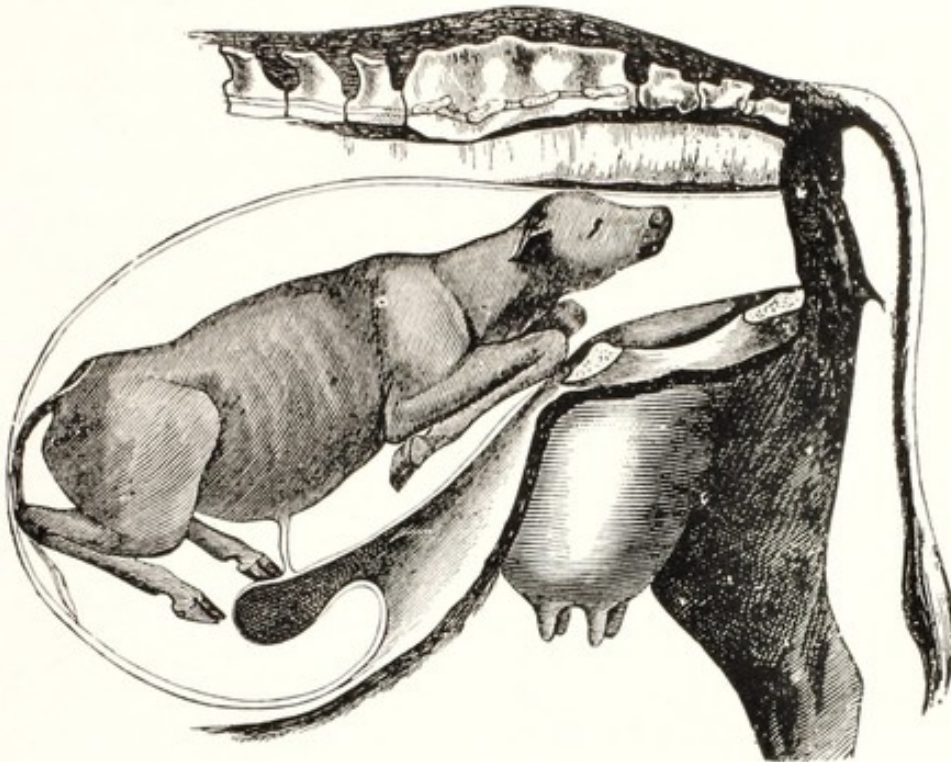


FIG. 97. Flexure of the Anterior Limbs at the Carpus. (Saint-Cyr.)

page 323, that hydrocephalus and other embryonic diseases tend constantly to cause deformities of the feet. These aberrations in development constantly invite dystocia because the foot becomes caught upon the pubic brim or elsewhere in the birth canal. In addition to the deformation of the feet, the fetus which has been diseased as an embryo is very liable to continue to suffer actively from disease at term, and this adds to the probability that the feet will be misdirected when labor begins.

The degree of dystocia varies. The toe or fetlock may be caught against the pubis and bar the advancement of the fetus before the head has passed the vulva. In such case palpation reveals the head in the birth canal, unaccompanied by one or both feet. This constitutes a minor form of dystocia, usually readily overcome by repulsion, page 230, and the extension of the fore foot, page 235, in the birth canal.

A far more serious dystocia due to misplacement of the feet occurs when one or both limbs become completely flexed at the carpus.

In this deviation, the metacarpus is flexed upon the radius, the radius upon the humerus, and the humerus upon the scapula, so that the entire limb is folded and the shoulders are pushed back upon the chest, thus greatly increasing the perpendicular and transverse diameters of the region.

The seriousness of the dystocia is further increased because the head may be advanced beyond the vulva. Once this has occurred it constitutes a formidable or impassable barrier to repulsion. In such cases the fetus presumably approaches the pelvic inlet with the carpus already completely flexed instead of presenting in the physiological extension.

The indications are to secure the deviated foot or feet and bring them into their physiological position.

Mutation. In order to bring about the extension of the limb or limbs, repulsion of the fetus is necessary. If the head of the fetus, with or without one anterior limb, has advanced only a short distance along the pelvic canal, it may be quite practicable to push it into the uterus and acquire room for the correction of the deviation in the abdominal cavity. If the fetus is very small, or the pelvis of the mother quite roomy, it may be possible to repel the fetus after its head has passed completely beyond the vulva, but this generally proves very difficult, and sometimes impossible. If the fetus is dead, which is generally the case with the foal, and the head has passed beyond the vulva or can readily be brought beyond it, the most desirable method of procedure is to resort at once to decapitation, page 243, and then repel. Decapitation, a very simple procedure under these conditions, decreases very greatly the amount of labor required for repulsion and the time necessary for the correction of the deviation. It increases greatly the favorable outlook for the mother.

When the head of the calf has passed beyond the vulva, its prominent, blunt poll makes its repulsion more difficult than that of the foal. Hence, if the head has protruded beyond the vulva and the calf is dead or is of little or no value to the owner, or if the conditions are such that the life of the mother will be greatly jeopardized by tedious repulsion, the obstetrice, as in the foal, should proceed at once with decapitation.

Pronounced elevation of the posterior parts of the mother's body greatly facilitates repulsion. In the ewe and other small animals, the patient may be almost or quite suspended by the hind legs in order

to favor repulsion. Tepid unctuous fluids may then be introduced by gravity through the vulva into the vagina. The fluid lubricates the walls, rendering fetal movements easier, and the weight of the liquid contributes toward repulsion. The repulsion may be aided by manual force.

Having accomplished repulsion, with or without decapitation, the obstetrice should secure the anterior limb, or limbs, with the hand or by means of cords. The bent carpus should be lifted from beneath the pubis, a cord placed upon the pastern, page 235, and the limb extended.

As soon as the foot has been brought into the birth canal, the limb is extended by traction. The other fore foot, if retained, is handled in the same manner. After proper adjustment of the relations between the two anterior limbs and the head, delivery is proceeded with.

Forced extraction with the feet deviated should not be attempted.

Embryotomy. When the head has passed the vulva, embryotomy is usually desirable or necessary. The embryotomy should usually be limited to decapitation, page 243. Rarely it may be desirable to amputate the leg at the carpus. This may be most readily accomplished with the fetotome, page 218.

THE FORE LIMBS CROSSED OVER THE NECK

Except in the mare, it is very rare that a fetus enters the birth canal with one or both feet crossed over its neck. The displacement is akin to the downward deviation of the head and neck between the fore legs. In the downward displacement of the head, the anterior limbs present and the head is depressed; in the crossing of the feet over the neck, the nose presents and the feet are misplaced upward. The length of the neck and limbs in the foal favors this displacement. The resulting dystocia is important. The misplaced foot lying on the neck increases the volume in itself. Even more it increases the chest diameters by causing the olecranon to become impacted against the pubis, and the shoulder to be forced backward upon the chest at its largest area.

There is the further very important danger that, when a foot is so misdirected, it is liable to become engaged in the roof of the vagina and, perforating it, cause a rupture of the rectum or of the perineum. The false position of the deviated foot or feet is readily recognized upon examination.

It is not difficult ordinarily to seize the misdirected foot with the hand and, while exerting some traction upon it, push it toward the side where it belongs, first somewhat upward to cause it to glide

over the poll, thence in a lateral direction and downward, and finally toward the central line to bring it beneath the head and neck. If both feet are crossed over the head, that one which is uppermost—the one which is crossed over the other foot as well as over the head—should first be brought into position, after which the other is to be similarly handled. It is not essential to repel the fetus, unless the fore foot has become engaged in the roof of the vagina and has pushed its way into it so far that the repulsion is necessary for its disengagement.

Should the replacement of the limb prove difficult, it is advisable to apply a cord to the foot and have an assistant exert traction upon it in such direction as the operator may indicate, while he guides and aids the reposition directly with his hand. After the foot has been replaced the operator should see that the elbow is disengaged from the pubic brim and fully extended in the birth canal, before applying traction to other parts. Unless this is done, extraction of the fetus is difficult if not impossible.

FLEXION OF THE ANTERIOR LIMBS AT THE ELBOW

The chest of the uniparous fetus is relatively large. Since the newborn is regularly upon its feet a few minutes after birth, and able to travel swiftly within a few hours, the muscles of locomotion are in a highly advanced state of development at birth. The scapulo-humeral muscles are highly developed. Since these animals are without a clavicle, the shoulders, in physiological birth, move forward; the scapulo-humeral articulations, with their great muscular mass, rest upon the sides of the neck, relieving the chest almost completely of their great volume.

It is not very rare to meet with instances in the calf and foal in which the two anterior feet present in their normal position and appear at the vulva, accompanied generally by the nose, which is advanced to nearly the same degree as the feet themselves. At first glance the position seems to be essentially normal, but when the fetus has reached the point where the feet and nose are visible its advance becomes checked and the expulsive efforts of the mother are quite unavailing to cause any further progress.

During the passage of the fetus through the birth canal, complete extension of the humero-radial articulation fails to occur and the ulna projects downward. The ulnar projection lodges against the maternal pubis. The expulsive forces drive the fetal head, neck and body onward while the olecranon is detained at the pubis. This forces the scapula and humerus backward upon the largest part of the chest.

The transverse diameter of the chest of the fetus is greatly increased by the retention upon its sides of the entire volume of the fetal shoulders, including the scapula and scapular muscles, the humerus, and the bulky anconeal group of muscles. The perpendicular diameter of the chest is also increased because the distal end of the hu-

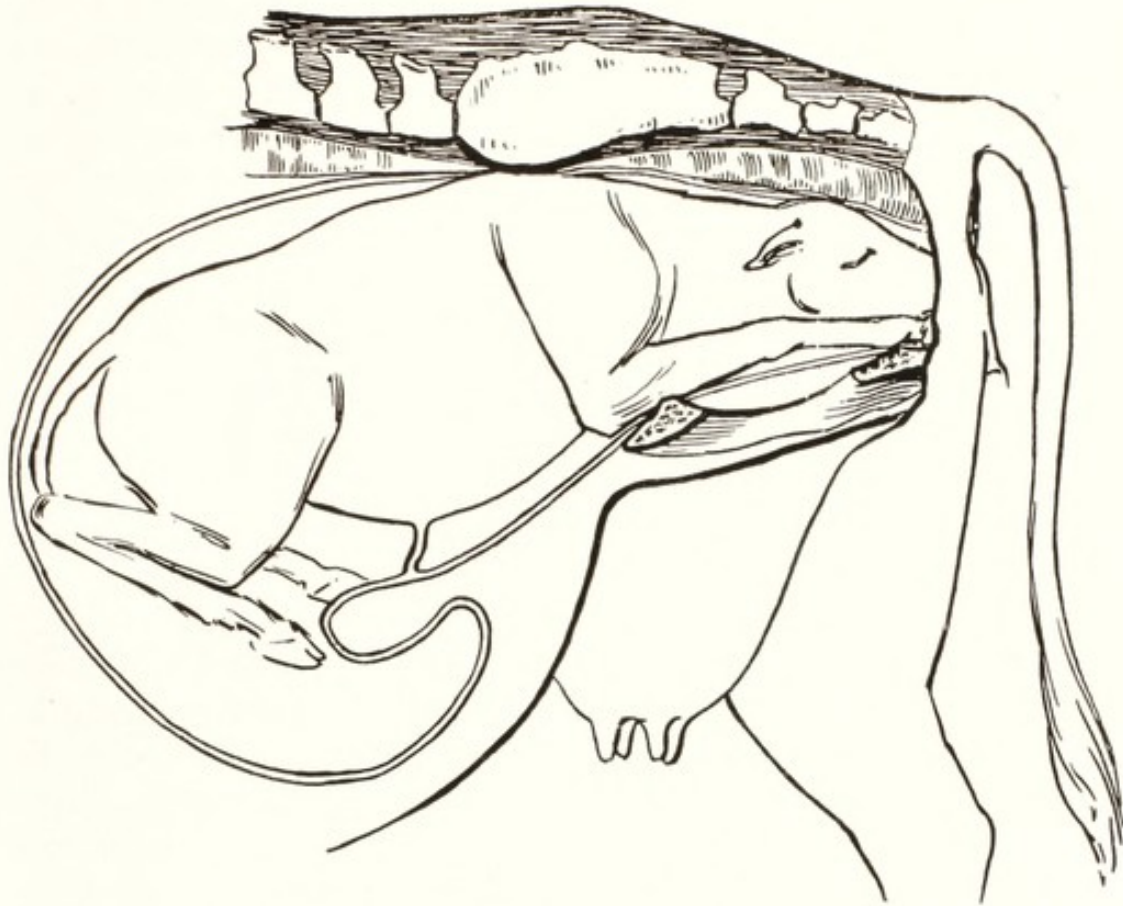


FIG. 98. Incomplete Extension of Anterior Limbs.

merus and the head of the radius and ulna extend below the level of the sternum. The olecranon projects obliquely downward, constituting an unyielding obstacle which becomes lodged against the pubic brim.

The diagnosis depends fundamentally upon two facts. While the two fore feet present normally and the nose is resting on top of them in a normal position, so far as it is independently concerned, there is an abnormal relation between the degree of advancement of the feet and the nose. While physiologically the fetal nose rests upon the metacarpus at about its middle, in these cases the nose is advanced to the metacarpo-phalangeal joint or beyond. If the operator will introduce his hand along the ventral surface of the fore leg until the pubic brim is reached, it will be found that the olecranon is impacted firmly against the pubis.

The indications are simple and obvious. They consist of releasing the olecranon from its incarceration in front of the pubis and extending the limb in the birth canal. Little, if any repulsion is required. When both limbs are retained, each should be handled separately. The operator should insert his hand along the inferior surface of the limb, with the palm turned upward, until it has been forced between the pubis and the olecranon, so that the latter rests in the hollow of the hand. Then an assistant should exert traction sharply upward and backward, while the operator causes the olecranon to glide over the pubic brim. The shoulder glides forward from the chest and rests alongside the neck, and the anterior limb becomes extended in the pelvic canal. The same operation is carried out upon the other limb, after which the fetus is delivered under ordinary precautions in the dorso-sacral position.

COMPLETE RETENTION OF THE ANTERIOR LIMBS

In the larger unipara, the mare and the cow, the complete retention of the anterior limbs, Fig. 99, constitutes an impassable barrier to birth. In the small ruminants, birth is possible with the limbs so located. In swine, the extension or retention of the anterior limbs is immaterial. The anterior limbs of the carnivorous fetus are regularly retained and the head presents alone. When the anterior limbs are completely retained in the mare or cow, the upper end of the radius is lodged against the anterior border of the maternal pubis, with the radius fully extended upon the humerus. The olecranon becomes lodged in the condyloid fossa of the humerus, and the arm and forearm constitute a long, rigid column. There can be no flexion at the elbow in a posterior direction. As a consequence of this deviation, the shoulders of the fetus are pushed far back upon the sides of the chest so as to increase greatly its transverse diameter, while the perpendicular diameter is still more profoundly increased by the rigidity of the limb, and now equals the distance from the fetal withers, or back, to the carpus.

It is highly probable that in most instances of complete retention of the anterior limbs, the deviation is primary and the dead or atonic fetus approaches the pelvic inlet with the displacement already present. Perhaps in some cases the limb is flexed at the carpus; the carpus abuts against the pubis and becomes deflected downwards and finally backwards as the head and neck advance.

The diagnosis is comparatively easy. The condition permits the head and neck to advance further than when the limbs are flexed at the carpus. As a rule, when the veterinarian is called, the head has

passed beyond the vulva and manual exploration promptly reveals the nature of the deviation.

The indications are to correct the deviation of the anterior limb or limbs. The fetus must be repelled, page 230. Before this may be accomplished it is generally desirable, or necessary to decapitate the fetus, page 243. With or without decapitation, the repulsion should be made obliquely backward and upward, assuming that the fetus

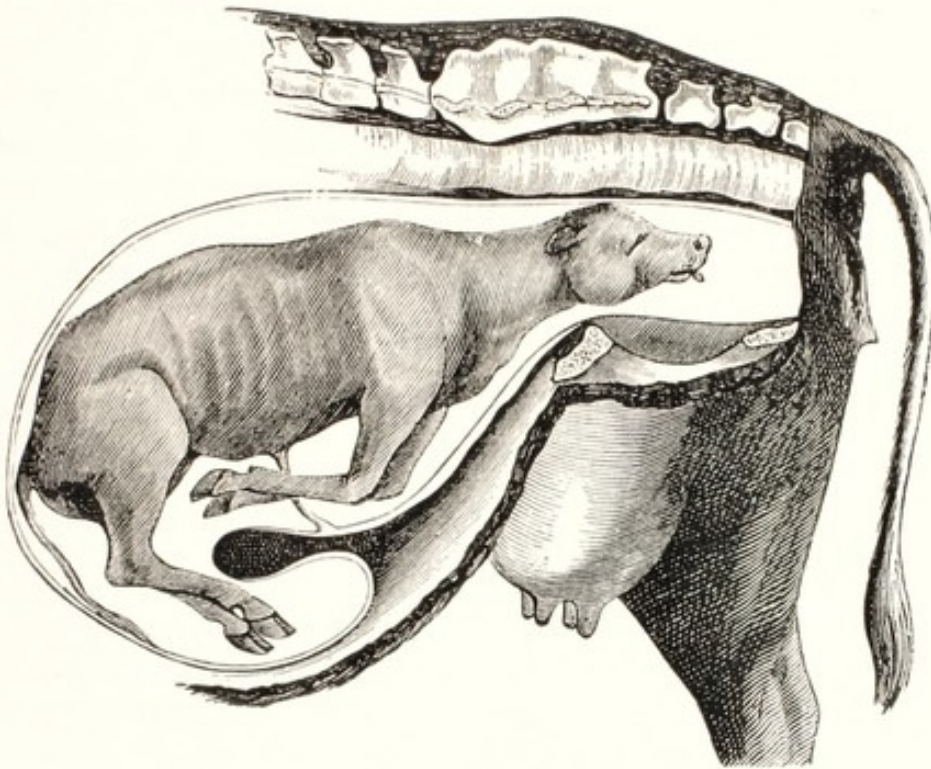


FIG. 99. Complete Retention of the Anterior Limbs. (Saint-Cyr.)

has presented in the dorso-sacral position. As the fetus is repelled, the forearm tends to advance towards the pelvis and come within reach, so that it may be grasped. The operator should bear in mind especially that, the further upward and backward the fetus is repelled, the nearer the radius approaches to the pubis, and consequently the more readily it is reached. Without repulsion, it is frequently quite impossible to reach the radius at all. As repulsion progresses and the radius comes within reach, a cord should be passed around it and a running noose applied as low down toward the carpus as is possible. Drawing from time to time upon the cord, the operator should continue the repulsion and, with the aid of the cord and his hand, bring the limb into the position of carpal flexion, already described. He should then proceed with delivery in the manner advised.

Forced extraction has been advocated. It is sometimes practicable

in the sheep and goat. In the mare and cow it is wholly unwarranted. If a fetus can be safely drawn away by forced extraction when an anterior limb is completely retained, it must be because it is very small, in which instance there is no necessity for forced extraction, because the deviation is easily corrected.

Except the amputation of the head, which is generally advisable, embryotomy is rarely demanded in this deviation.

When the head has been removed and the torso repelled, and it is still impracticable or impossible to correct the deviation, the embryotomy may be carried further. Such need may arise in fetal emphysema and otherwise. If one limb be extended, it may be amputated subcutaneously, page 246. If both limbs are retained and the fetotome, page 218, can be applied to one, it may be thus amputated. Should this prove impracticable, the operator may divide and detach the skin over the region of the shoulder, and follow with a division of the muscles which attach the scapula to the chest. The first muscles to be encountered and divided are the trapezius and rhomboideus, which would free the superior end of the scapula and permit it to be secured by means of a cord with a running noose. Then should follow the division of the latissimus dorsi, serratus, and pectoral muscles, after which the limb may be drawn out by the scapula, the skin becoming inverted. After one limb has been removed, the chest of the fetus may be opened, and evisceration, page 258, employed. Further diminution in the size of the fetus may be prosecuted to any desired extent, and the remnant finally drawn away.

INTERLOCKING OF THE MATERNAL AND FETAL PELVES

Sometimes when a fetus, especially in the cow, presents in physiological position and posture, the birth act progresses satisfactorily until the fetal hips have reached the pelvic inlet, when the progress is interrupted and the fetus refuses to move, even under vigorous traction. The interpretation of this condition varies with different obstetrists.

Some hold that the dystocia occurs because the two stifles are in a state of abduction and thus, standing apart, catch upon the pelvic margin and stop the progress of the fetus. It is difficult to conceive of the possibility of such a condition, because there is nothing to maintain such abduction; instead, all the expulsive forces tend to overcome it promptly and effectively.

It has been pointed out on page 238 that, according to my experi-

ence, most cases of this type of dystocia result from the application of traction in a faulty direction. A study of the pelvis of the cow (Fig. 1) shows that, if traction be applied through the spinal column at II, any obstacle to the advancement of the fetal pubis, about opposite to the acetabulum, would tend to cause the ischium, Is, to move backwards and upwards toward the tail. This decreases the diameter of the fetal pelvis perpendicular to the spinal column. On the contrary, if the traction be applied to the pubis through the linea alba, the fetal pubis is pulled forwards and the pelvis becomes definitely flexed anteriorly upon its sacral articulation and its diameter upon a line perpendicular to the spinal axis greatly increased. Since the sacro-iliac articulation is wedge-shaped, the forward flexion forces the superior ends of the ilia apart and increases the bisiliac diameter at EI. Accordingly should the cow be lying down in a position to cause the projecting part of the fetus to move toward the sacrum of the cow, or if traction is so applied to the fetus that the strain comes upon the linea alba, the fetal and maternal pelves may become interlocked and serious dystocia result.

When the fetal pelvis is large and the external iliac tuberosities prominent, the hips may offer serious resistance in passing the pelvic inlet, even without the complication of misdirected traction. I have not encountered the interlocking of the pelves in animals which I have attended prior to the application of injudicious traction.

The symptoms and diagnosis of this form of dystocia require but little consideration. The fetus, possibly rather large, generally offers in the normal anterior presentation, and advances somewhat slowly until the hips have reached the pelvic inlet, when the progress is stopped and the fetus cannot be advanced by traction parallel to the long axis of the body of the mother or somewhat upward. If the operator can succeed in inserting his hand along the fetus into the uterus, he will find that everything is apparently normal, except that the pelvis of the fetus is firmly wedged against that of the mother and seems immovable. There is but one condition from which it needs be differentiated—the double monstrosity known as *Pygodidymus aversus*. Fig. 82.

When a fetus has advanced without serious difficulty until it has reached the hips, and is in every way normal, there is no good reason why its extraction should not be readily completed, if care is taken to apply the traction directly downward toward the feet of the mother, according to the technic given on page 238.

Failing to bring about extraction under moderate force, the ob-

stetrict should at once resort to embryotomy, consisting of the destruction of the pelvic girdle, page 252.

FORWARD EXTENSION OF THE POSTERIOR LIMBS BENEATH THE FETAL BODY

In the mare, and according to some writers, also in the cow a fetus sometimes presents anteriorly, with the anterior limbs and head in an approximately normal position, and the two posterior limbs thrust forward in extreme extension beneath the body of the fetus, so that the two hind feet are lodged just in front of the maternal pubic brim, or have passed some distance along the pelvic canal, as indicated in Fig. 100. Some obstetrists designate the position as 'vertical,' as 'transverse' presentation, or as the 'sitting-dog' position.

When the fetus has advanced sufficiently that the anterior feet and head have entered or passed the vulva, further progress becomes arrested. If the operator inserts his hand beneath the anterior limbs and the thorax, the posterior feet are recognized along the floor of the pelvic canal or immediately in front of the pubis. The soles of

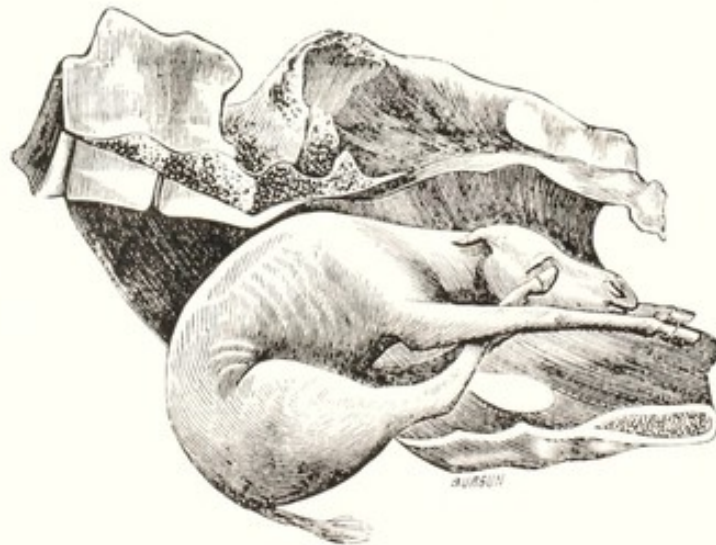


FIG. 100. Forward Deviation of Posterior Limbs in Anterior Presentation. (Saint-Cyr.)

the feet are directed downward. The spinal column of the fetus is jammed hard against that of the mother. This form of dystocia is by far most frequent and dangerous in the mare. The cause of the prevalence in the mare has not been fully explained.

Recent observations point to an acceptable solution. The case reported by Fincher and Williams²² shows beyond doubt that in

bicornual pregnancy, pages 189 and 334, when labor begins, the uterus sometimes dislodges one end of the fetus from the cornu and converts the bicornual, transverse presentation into a longitudinal one. A study of Fig. 90 will show that in bicornual pregnancy the posterior limbs are naturally thrust forward along the ventral surface of the fetus. If the cephalic end of the fetus is dislodged and an anterior presentation established, the posterior limbs are already in their pathological posture.

The above reasoning cannot explain the few recorded cases of this form of dystocia in the cow and goat, and suggests that sometimes the fetus of any species may, by pathological struggles at the commencement of labor, thrust its posterior limbs forward ventral to its body. With the knowledge now available, the authenticity of this view may be readily determined by an examination of the after-birth in such cases. If correct, the placenta will be like that shown in Fig. 63.

The prognosis is extremely unfavorable. This is one of the most dangerous positions of the fetus encountered in the mare. The fetus is doubled up in such a manner as to cause very severe pain and violent straining, constantly threatening serious or fatal injury to the mother. The deviation especially invites severe and highly dangerous traction by laymen. When the two posterior feet are lodged against the brim of the pubis, the danger is perhaps greater than when the hind feet are well advanced in the pelvis, because the expulsive efforts of the mare, or traction applied by attendants, tend to force the two posterior feet through the floor of the uterus. The deviation may also tempt laymen to undertake embryotomy, under the general misconception that in dystocia the removal of any portion of the fetus which has passed the vulva proportionally lessens the dystocia. In one case I attended, detruncation had been performed through the dorsal region, but the genital organs had not been protected from the sharp bones which had been left exposed. As a consequence, the vagina was very badly lacerated and a chronic vagino-cystitis followed, from which the mare never recovered, although she survived.

In my practice, one mare died from uterine hemorrhage while I was preparing to attempt delivery, although the case was a very recent one and had not been greatly tampered with.

I was called to attend a vigorous young mare suffering from this form of dystocia. The case was recent and had not been meddled with. Delivery by detruncation was prompt and easy. The mare died two days later from gangrene of the vulva and vagina.

In a fourth case a foal was found one morning incarcerated in this position. Apparently the dystocia had existed much of the night. The delivery was easy. Gangrene of the vulva with sloughing occurred, followed by vulvar constriction of such a degree that copulation was not possible.

I have not had a satisfactory recovery in this form of dystocia in the mare.

The method of handling varies greatly in the hands of different obstetrists.

Some advise the adjustment of the misplaced members, but I find no data to show in what proportion of cases, if at all, such a plan may succeed. The directions given are to repel the two hind feet as far as possible into the uterine cavity and abdomen, and then by traction to bring the fetus away. It must be evident that it is only in very favorable cases that such an operation can succeed. With the anterior portion of the fetus impacted firmly in the pelvic canal, the operator cannot reach very far into the abdominal cavity, and cannot expect to repel the two posterior feet to any very great degree.

The character of the position excludes all possibility of repelling the head and body of the fetus, and if the hind limbs are very far advanced in the pelvic canal it would seem impossible to repel them. Even when repulsion has succeeded to a degree, it is impossible for the operator to know whether the two hind feet rest in a safe position where they may turn backward as the fetus moves forward.

I consider all attempts at mutation in this form of dystocia in the mare wholly unjustifiable and dangerous. It may be practical in the extremely rare cases in ruminants.

Forced extraction is not to be countenanced.

Embryotomy is by far the most desirable and rational plan. The older operation and the one which I have followed is that of detruncation, page 250, after which the torso is converted into a posterior presentation. Professor Guard (Ohio State University) advises me that he has operated by a quite different plan with gratifying results. He amputates one anterior limb subcutaneously, page 246, eviscerates, page 258, and severs the pelvic girdle with the obstetrical chisel upon both sides of each hip joint, page 252. This greatly reduces the volume, and renders the entire torso very flexible. One of the outstanding merits of the plan is that it destroys the skeletal continuity of the posterior limbs with the spinal column. The hips may then be drawn forward to occupy the space evacuated by evisceration and each limb may be rotated at will upon its long axis. The operator may repel or

hold the sacrum in place while the hind legs are advanced, after which traction may be exerted simultaneously upon the spinal axis and both posterior limbs. Extraction is accomplished by very moderate traction.

CHAPTER XXXI

DYSTOCIA DUE TO PATHOLOGICAL POSITIONS AND POSTURES IN THE POSTERIOR PRESENTATION

WHILE considering physiological birth, page 155, doubts were expressed regarding the frequency of posterior presentation in healthy uniparous domestic animals. With the long, rigid limbs of this group of animals, birth in the posterior presentation is perilous. The human fetus is so constructed that it may be born in posterior presentation in a variety of positions or postures. The legs are so pliable and straight that birth may proceed with them extended or completely flexed. In unipara, especially in the mare and cow, both legs must be fully extended or birth cannot occur.

The available data for mares and cows upon the presentations of fetuses at birth are neither extensive nor clearly reliable. Most births in domestic animals occur unseen. Veterinary obstetrists see few physiological births; they see chiefly pathological births. Even so, the primary presentation is not always known. Thus in bicornual pregnancy in the mare, the basic presentation is transverse, but secondarily one end of the fetus may slip out of the base of the cornu in which it had developed and become anterior or posterior in presentation. The available data indicate four or five per cent of posterior presentations for the mare and cow. It is certain that more than four or five per cent of dystocias occur in posterior presentations. However, a large proportion of dystocias have no known relationship to presentation, as for example, torsion of the uterus. My impression is that physiological birth in posterior presentation, in either mare or cow, is exceptional. I have not observed a single instance among the relatively few physiological births I have seen. There is great need for authentic data upon the subject.

The question of the frequency of physiological birth in the posterior presentation is of fundamental importance in the handling of dystocia due to posterior presentation. Most veterinary writers advise the hasty extraction of a uniparous fetus in posterior presentation, as soon as the umbilicus of the fetus has passed over the brim of the pubis of the mother. The haste is advised because of the danger of asphyxiation owing to compression of the navel cord. Hasty extraction of a fetus in any presentation inevitably means

peril to the mother in almost every case. I cannot recall a case of dystocia in which hasty extraction of the fetus was not inseparably associated, in varying degree, with peril to the mother. I have delivered very, very few living fetuses in the posterior presentation. My observation has been that bovine fetuses in posterior presentation suffer in far greater ratio from fetal diarrhea than those in anterior presentation. This is one of the best indices regarding the health of the bovine fetus. In antenatal, as in postnatal life, the calf registers ill health most frequently by diarrhea.

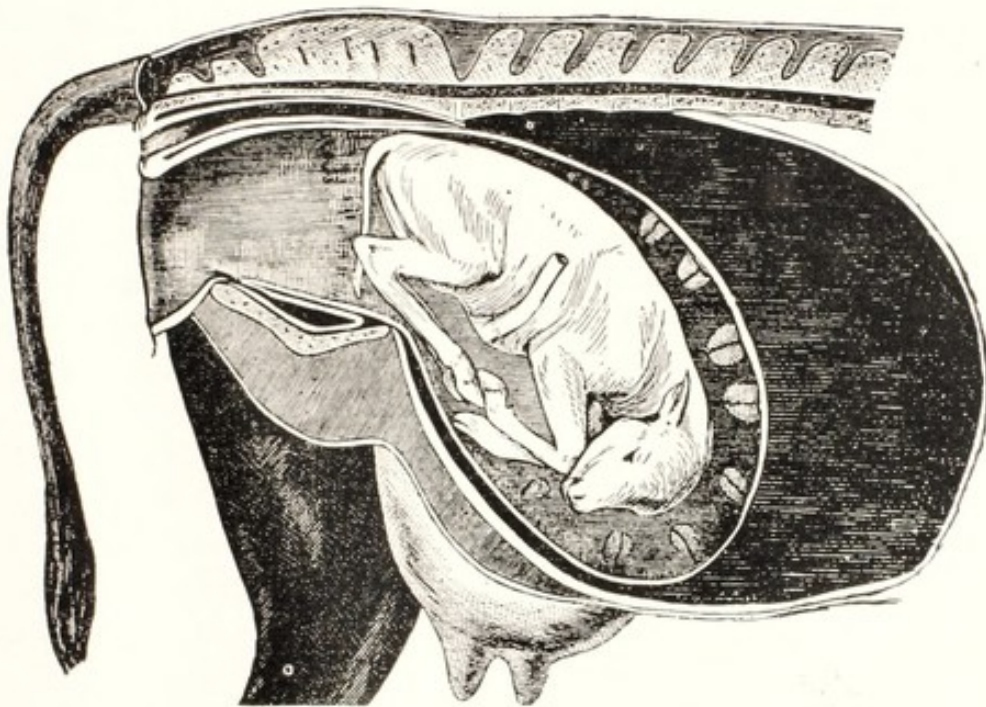


FIG. 101. Retention of the Posterior Limbs at the Tarsus. (Franck.)

Hence in considering dystocia occurring in the mare or cow with the fetus presenting caudally, the basic significance of the posterior presentation is to be kept in mind and a high rate of mortality of the young anticipated. The high mortality should not be wholly, or largely attributed to asphyxia from compression of the navel cord: the mortality is already high before the navel cord is compressed.

Dystocia Due to Dorso-Iliac and Dorso-Pubic Positions in Posterior Presentation

The dorso-iliac (sacro-iliac) and dorso-pubic (sacro-pubic) positions in posterior presentation are analogous in principle to the corresponding positions in the anterior presentation. They are simpler

because the obstetrice needs deal only with the two posterior limbs instead of with the two limbs and head as in the anterior presentation. When presenting posteriorly in the dorso-pubic position, especially in the mare, there is special peril owing to the marked upward projection of the posterior feet where they may become caught in the vaginal roof and penetrate it and the rectum.

The method of handling is like that of the dorso-iliac and dorso-pubic positions of the anterior presentation. The operator is prudent to assume that the position is due to uterine torsion in most, if not all cases. When the position is dorso-pubic, care needs be taken that the rotation be made in the proper direction, so that the torsion may be reduced instead of advanced. The rotation of the fetus (page 232) is regularly indicated and is generally effective without further manipulation beyond moderate traction. The rotation is more readily accomplished in the posterior presentation, since the rump is evenly rounded instead of sharply conical like the withers. The two feet are to be separately corded and traction exerted in opposite directions while the operator inserts his hand between the maternal pubis and fetal buttocks and lifts upwards and to the right or left, according to the direction of the torsion.

Flexion of the Posterior Limbs at the Tarsus

Dystocia in the mare and cow, due to the tarsal articulations becoming flexed and either entering the pelvic canal or becoming caught just in front of the pubis, is comparatively common. This displacement constitutes a formidable obstacle to the expulsion of the fetus, because it necessarily involves the flexion of all the articulations of the limb, and consequently increases greatly the diameter as measured from the fetal sacrum down through the folded limb, as indicated in Fig. 101. The femur is flexed upon the pelvis, the tibia upon the femur, the metatarsus upon the tibia, and the phalanges upon the metatarsus. One of these articulations cannot be completely extended until the others are ready to be simultaneously extended. The folding of the limbs in this manner quite effectively prevents the passage of a fetus of normal dimensions through the pelvic canal.

The diagnosis is easy. Upon inserting the hand, the operator may first touch the tail, or the ischiatic tuberosities. Further search reveals the summits of the hocks within the pelvic cavity or lodged against the pubic brim. The fetus is thus lying in the position of ordinary sternal recumbency with the hind feet closely doubled immediately beneath the body.

Mutation is generally practicable and readily accomplished. The

overcoming of the deviation consists first of the repulsion of the fetus obliquely forward and upward, page 230. The mother should preferably be in the standing position, with the hind parts elevated. If unable to rise, she should be placed in lateral recumbency, or—sometimes still better—in the dorsal position, still applying the rule of keeping the posterior portions of the mother elevated. When the repulsion has been accomplished, the extension of the limbs is to be carried out as described on page 235.

Embryotomy occasionally becomes necessary or desirable. In case of a very large foal, or when the foal or calf is dead and emphysematous, and especially in those cases where the patient is unable or unwilling to stand, it may be impossible, or at least impracticable, to adjust the position. Consequently embryotomy must be performed.

Embryotomy in these cases is very simple, consisting merely of the amputation of the foot with the chisel, or the wire saw, through the lower portion of the tarsus, page 254.

Hysterotomy or hysterectomy, pages 260 and 266, may become necessary in the smaller domestic animals, where the adjustment of the deviated limbs or embryotomy is not available.

Complete Retention of the Posterior Limbs

The breech presentation may occur in any species of domestic animal. It acquires its greatest significance in the mare, where it constitutes a very formidable cause of dystocia. It differs from the preceding deviation in that, instead of the limbs being flexed at the tarsus, they are extended forward upon the pelvis, beneath the abdomen and chest of the fetus, each joint in rigid extension. The causes are essentially identical with those of the preceding deviation. Probably in many cases complete retention originates from flexion at the tarsus. The flexed tarsus becomes caught against the brim of the pubis. The expulsive efforts of the mother, pushing the fetal body toward the vulva, cause the ossa calces to glide downward and then forward, and the tarsus to become extended, until finally the entire limb is pushed forward beneath the body. Probably a large ratio of this type of vicious presentation in the mare is due to bicornual pregnancy. The operator, upon examining the case, usually meets first with the tail or buttocks of the fetus, and in many cases can touch the tibia or other portion of the limb only with very great difficulty. Sometimes no part of the hind limb can be grasped or recognized until after repulsion has taken place.

The adjustment of the deviated limbs is generally the preferable method of handling. The fetus should be repelled, page 230, after

which the tibia or metatarsus, as may be available, should be secured by means of cords, as described on page 210. By continuing repulsion, the position is to be converted into a hock presentation, after which the further handling of the case is identical with that described above for retention of the posterior limbs at the tarsus.

Forced extraction has been advised by some operators. How successful they have been, veterinary literature does not make clear. While forced extraction may be somewhat easier, it is not warranted by modern surgical principles and is quite unnecessary.

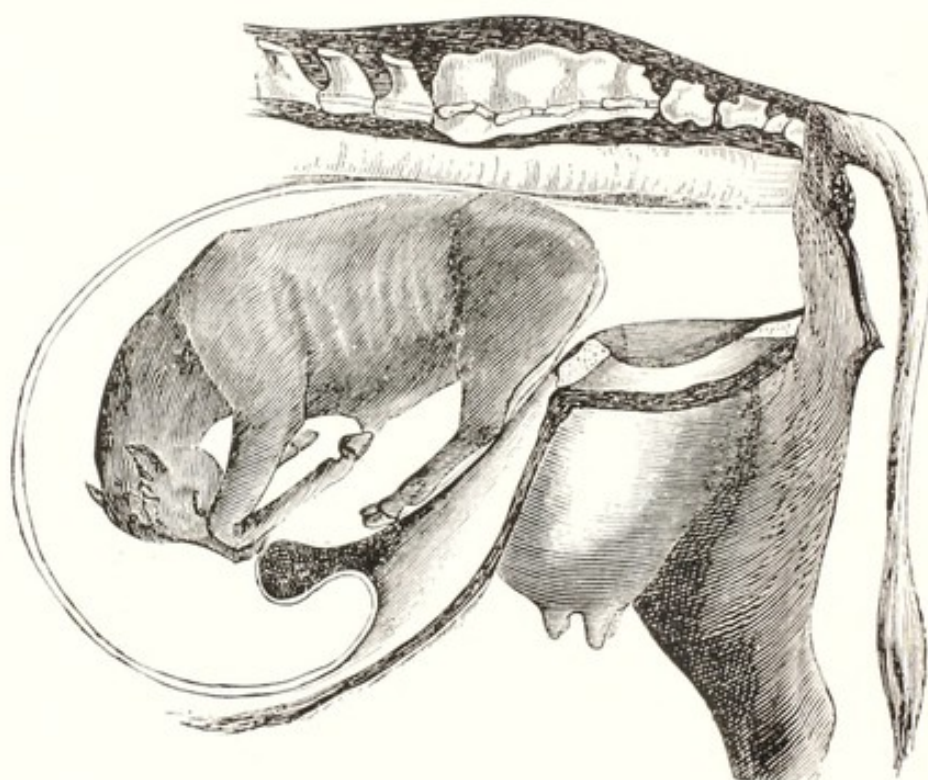


FIG. 102. Breech Presentation. (Saint-Cyr.)

Embryotomy offers the most valuable method for overcoming this form of dystocia, especially in the mare. Whenever the fetus is comparatively large or is emphysematous, or for any other reason it is exceedingly difficult, or impracticable to bring about a prompt adjustment of the position, embryotomy is highly efficient. It should be undertaken promptly, before the operator and patient have become exhausted in fruitless endeavors at mutation. Various forms of embryotomy have been recommended by different writers. I prefer the intra-fetal amputation of the two posterior limbs, page 255. Others prefer to amputate the limbs extra-fetally, with the knife, Persson's saw, or the Pflanz embryotom, or—better than either of these—with

the wire saw. The intra-pelvic amputation of the limbs is however the most efficient plan. It destroys the pelvis and buttocks, one of the chief obstacles to delivery, and permits ready evisceration and other operations for decreasing the size of the torso.

Gastrohysterotomy or hysterectomy, pages 260 and 266, may become necessary or advisable in swine and carnivora, but is uncalled for in the cow and the mare, because embryotomy is always readily available.

Lateral Deviation of the Head in Posterior Presentation

Harms,³² citing Jöhnke, records observations upon two cases of severe dystocia in mares, with the fetus in posterior presentation and the head in lateral deviation. Wry-neck was present in both cases. The fetal head was concave on the side in contact with the body, and convex upon the other side. It would be impossible to imagine dystocia, in the posterior presentation, due to lateral deviation of the head, except in wry-neck. Consequently it can only occur in the mare. So far as known, wry-neck never occurs in the mare except in bicornual pregnancy, page 189.

Jöhnke failed to diagnose the displacement until after the fetus had been removed by forced extraction—16 men in one case, ropes and pulleys in the other. The observations of Jöhnke suggest that when dystocia occurs in the posterior presentation and delivery progresses favorably until the buttocks have passed the vulva, and there stalls, there is some unusual fetal abnormality of the anterior portion of the body and diligent search should be made for the cause ere forced extraction is attempted. Sometimes the obstetrice should be able to pass his hand alongside the fetal body and recognize by palpation the obstruction to delivery. The ultimate resource for diagnosis is embryotomy. The fetus is surely already dead in the mare and almost certainly dead in the cow, or must unavoidably die before delivery may be completed. Hence such gross force as that applied by Jöhnke cannot save the life of the fetus or avoid unjustified peril to the life of the mare. The two commonest abnormalities which may stall the passage of a fetus in posterior presentation and with the rump in the vulva are hydrocephalus and wry-neck, the latter being much more frequent than the former.

The embryotomy serves the dual purpose of enabling the veterinarian to make an accurate diagnosis and to accomplish delivery in comparative safety. One posterior limb should be amputated, the pelvic girdle destroyed (page 255) and the fetus eviscerated. Ample

room is thereby obtained, rendering accurate diagnosis available, and facilitating the correction of deviations and the application of further reductions in the volume of parts.

Following the extraction of the torso, if wry-neck is present, an examination of the afterbirth (Figs. 62 and 63) or of the uterus serves to determine the existence of bicornual pregnancy.

SECTION V

WOUNDS AND INJURIES OF THE GENITAL
AND NEIGHBORING ORGANS

SECTION V

CHAPTER XXXII

WOUNDS AND INJURIES OF THE GENITAL AND NEIGHBORING ORGANS

Postpartum Hemorrhage

POSTPARTUM hemorrhage may be placental—that is, capillary—or it may be traumatic. The dehiscence of the placenta unavoidably wounds some maternal capillaries, followed by limited inconsequential hemorrhage.

In domestic animals, severe placental hemorrhage is virtually confined to the cow; it occurs both antepartum and postpartum. The former type of hemorrhage has already been considered in connection with fetal mummification, page 358. In the cow there sometimes occurs a very profuse and alarming intrauterine hemorrhage, within a few hours to several days after the expulsion of the fetus. I have seen from two to five gallons of bright scarlet coagulated blood in the uterus. In one instance the hemorrhage occurred during the night and the next morning the cow's stall looked like shambles: bright scarlet blood was scattered everywhere, and the uterus was filled with it.

Prompt and free subcutaneous administration of adrenalin chloride appears to be highly beneficial and to constitute the best known method of handling. As soon as the hemorrhage has been brought under control, the obstetrice may begin the removal of the blood from the uterus. Douching is not particularly effective. It is best, in my experience, to break up the coagula and dilute the blood through the introduction of warm, physiological salt solution. This is best accomplished with an irrigator and a long, soft rubber catheter. A quart or two of the salt solution should be introduced deeply into the uterus, the end of the tube lowered and as much of the blood siphoned away as is possible. The process is to be repeated so long as a material amount of blood is being withdrawn. The blood should not be completely removed at a single operation, but the effort is to be continued day after day until the uterus is empty. There need be no great hurry in its removal; the blood usually shows resistance to decomposition. My patients have all lived; I have no record of their later breeding history.

Traumatic hemorrhage during and immediately after parturition is of great variety in cause and severity. It may follow rupture of the uterus, and the blood escape partly or wholly into the peritoneal cavity. It then presents the common signs of internal hemorrhage: anxiety of the patient, rapid, weak pulse, pallidity of the mucous membranes, etc. I have observed rapidly fatal hemorrhage in a cow when a layman tore off the uterine caruncles in an effort to remove the afterbirth immediately after calving.

In handling traumatic genital hemorrhage, the most that may be done is to apply the general principles of surgery. These consist of the hormonal control of the hemorrhage by the use of adrenalin; the surgical closure of the wounded vessels if possible; the timely removal of coagula; and general precautions against infection.

Rupture of the Uterus and Vagina

Rupture of the uterus or vagina is liable to occur at any time during labor, and especially toward the close of the act, as the fetus is being forced along the genital passages. The accident occurs in a great variety of ways. It sometimes occurs through the projection of an extremity of the fetus in an improper direction, so that it is forced through the wall of the organ because of a concentration of pressure upon a small area. Ruptures from this cause naturally occur most frequently in the mare and cow, where the fetus has long and rigid extremities, capable of inducing great injury when they become misdirected.

In the anterior presentation, with the two posterior limbs extended beneath the body of the fetus (Fig. 100) and lodged just in front of the pubic brim, the extended limbs are forced, under enormous pressure, downward and forward against the floor of the uterus. Such pressure is constantly liable to cause the toes of the fetus to force their way through the uterine floor.

When the fetus presents anteriorly in the dorso-sacral position, with a foot crossed over the head, or a foot misdirected upward from other cause, the misplaced toe tends constantly to push upward and force its way through the roof of the vagina.

In rotated bicornual pregnancy (page 340) extensive and fatal rupture of the uterus is very liable to occur when traction is applied in order to bring about delivery.

In torsion of the uterus, page 292, transverse rupture, a common result of the displacement, follows regularly when the torsion has become extreme.

A further, and not uncommon, cause of uterine rupture is the

attempt of the veterinarian to force a normal fetus through a constricted passage, or a fetus which presents improperly through a normal passage. In discussing induration of the cervix on page 275, a case was related in which, in a heifer, an attempt to force the fetus, normal in size and position, through a very badly diseased cervical canal, ruptured the cervix for its entire length.

Another, and highly important way by which rupture of the uterus may be caused during traction consists of contusing and perforating the walls by forcing the uterus against some projecting portion of the pelvis, Fig. 71.

In other cases, when forced extraction is attempted with a fetus in an improper position, such as a deviation of the head, the uterine wall may be caught by some projecting portion of the fetus and dragged along in such a way that it doubles upon itself and tends to bring about its rupture.

Of all the ruptures of the uterus, the most embarrassing and unfortunate are those which are brought about by improper manipulation by the obstetrice himself or by the meddling of laymen or empirics. In discussing the general subject of obstetrical work upon page 225, the suggestion has been made that it is to the professional and legal interest of the veterinary obstetrice to examine very carefully each case of dystocia to which he is called, determine whether the animal has been subjected to injurious meddling before his arrival, and discover, if possible, any important injuries which may have taken place, before he attempts to handle the case.

When the obstetrice exhausts himself in unsuccessful and injudicious efforts at mutation, although embryotomy or other course is clearly indicated, he is liable to rupture the uterus through error dependent upon his exhaustion. Early in my career I exhausted myself in an imprudent effort to relieve dystocia due to wry-neck. The outcome was that, no longer able to adequately control my operations, I ruptured the uterus with a blunt hook and was obliged to destroy the mare.

The symptoms of rupture of the uterus vary according to the position and extent of the rupture, the degree of hemorrhage, and the character and volume of matter which may escape from the uterine, into the peritoneal cavity. If the rupture is very extensive, and a large amount of liquids, especially if infected, escape into the peritoneal cavity, there is at once a profound collapse, under which the animal is liable to die very suddenly.

The handling of rupture of the uterus must be adapted to each individual case. It should always be remembered that the involution

of the uterus brings about a great decrease in the size of a rupture in its walls. If the rupture is in the roof of the uterus there is always a possibility of spontaneous recovery, and every opportunity should be allowed for its occurrence. It is possible to close a rupture by means of sutures. In the large uterus of the mare or the cow, a rupture may be closed by sutures without disturbing the position of the uterus.

In all cases of uterine rupture it is clearly inadvisable to inject liquid antiseptics or other fluids into the uterus, and take the risk of their escaping into the peritoneal cavity.

Prolapse of the Intestine through the Ruptured Walls of the Uterus or Vagina

When uterine or vaginal rupture occurs during difficult parturition and the intra-abdominal pressure is increased by the straining, a portion of the intestine is liable to prolapse into the uterus or the vagina, and finally beyond the vulva. In one instance an effort had been made by a layman to catch some portion of the fetus by means of a hooked stick, and in so doing a large rent had been caused in the wall of the vagina. The fetus was retained within the uterine cavity because of bad position. The expulsive efforts of the mare forced the floating colon through the rent in the vagina. At the time of my arrival the intestine dragged upon the ground.

The indications usually are to destroy the patient at once, since the prognosis must necessarily be extremely bad. The protrusion generally occurs before the expulsion of the fetus, and it then becomes almost impossible to extract the fetus without incidental injury to the intestine and infection of the peritoneal cavity. If it be possible to return the intestines with hope of saving the life of the patient, this should be done, and sutures applied or other measures taken to keep the intestines out of the way until the fetus has passed beyond the point of injury. After the fetus has been removed, if the utero-vaginal wound has not been previously sutured, or the sutures have torn out during birth, it may in some cases be practicable to suture the wound in a manner to guard against further prolapse, and decrease the danger of infection.

Prolapse of the Bladder through a Rupture in the Floor of the Vagina

When the floor of the vagina becomes ruptured during parturition, there is a remote possibility that the urinary bladder may be forced through the rupture into the vagina. Necessarily, such a prolapse

involves the bending of the organ upon itself to an extent which tends to cause an obstruction to the passage of urine through the urethra, and thereby favors distension of the bladder. The accident has occurred only with sufficient frequency to establish the possibility.

The symptoms consist of the presence of the prolapsed organ in the vagina or vulva, with its fundus turned toward the vulvar opening, or protruding through it, according to the degree of distension. The bladder is not everted, and shows the peritoneum upon its surface. A careful examination of the floor of the vagina will reveal the presence of the rupture, through which the organ protrudes. In the mare or cow, a further test of the character of the injury may be made by inserting a finger into the urethra and passing it along that canal until the finger turns upward, to reappear again in the vagina inside the prolapsed organ.

The indications in such cases are to return the bladder to its proper position, under aseptic precautions, and suture the wound, bringing the peritoneal surfaces in contact. If the bladder should be so greatly distended that it is exceedingly difficult or impossible to return it through the rupture, the urine may be drawn off by passing a small trocar or hypodermic needle into the distended organ.

Uterine Invagination and Prolapse

Intussusception, or inversion, and prolapse of the uterus is a common and formidable obstetrical phenomenon, especially liable to occur in cows, chiefly in large dairies where genital disease is severe.

Usually the lesion consists at first of an invagination of the ovarian pole of one cornu. It has been shown by Williams *et al.*⁶¹ that, in the cow, such intussusception may become established during pregnancy at the ovarian pole of the gravid horn. So far as known, the invagination usually begins during, or soon after, the expulsion of the fetus.

Invagination behaves variously. In a cow the invaginated ovarian pole became incarcerated and necrotic, and the cow died under the clinical signs of septic metritis. The basic cause was revealed upon autopsy.

At the other extreme, I attended a mare in dystocia, the fetus in breech presentation. When the large fetus was extracted, the uterus immediately and completely prolapsed and the mare died within a few minutes. In the profound coma of milk fever in cows, the uterus sometimes apparently falls out *en masse*, or is pushed out as an inert body by tympany of the rumen.

In most cases, in the cow, the invagination begins at the ovarian pole of the gravid horn and gradually extends until the entire gravid horn becomes everted and with the cervix and vagina, also everted, prolapses through the vulva and reaches to or beyond the tarsus. The inter-cornual attachments of the ruminant uterus, Fig. 5, render complete invagination, or evagination, of both cornua impossible. The free ovarian poles of the ruminant cornua may, technically, both become invaginated as far as the attachment of the one to the other. Beyond that point, the continuation of the invagination of one horn drags the other horn along with it, inside the peritoneal cavity of the invaginating cornu. In spite of this anatomical impossibility, some writers state that both horns sometimes become invaginated. The anatomy of the soliped uterus, Fig. 2, without inter-cornual attachments, renders it technically possible for both cornua to invaginate into the cavity of the uterine body. When the ruminant uterus prolapses through the vulva, both horns are involved in the prolapse: one horn is evaginated; the other horn lies within the evaginated one. The cervical end of the non-evaginated horn opens as a narrow slit, directed toward the vulva. The anatomical character of the multiparous uterus regularly limits the evagination and prolapse to one horn; the presence of the evaginated cornu within the non-placental uterine "body" bars the egress of the other horn. Uterine prolapse is preëminently a phenomenon of unipara. It is most frequent in dairy cows.

When complete prolapse has become established, the inverted peritoneal covering of the cornu, uterine body, cervix and anterior segment of the vagina constitutes a diverticulum of the peritoneal cavity. Naturally the urinary bladder may be involved in the displacement and become prolapsed, but not everted, within the peritoneal sac. Not infrequently, also, the small intestines pass out through the vulva within the sac. Careless and uninformed operators occasionally excise portions of the intestine when amputating the prolapsed uterus.

The symptoms of uterine prolapse are too obvious to require comment. The invagination of the ovarian pole of the cornu which may, or may not eventually end in prolapse, is more or less difficult of diagnosis. Sometimes the condition is not suspected until an autopsy is made. So far as known, the invagination of the ovarian pole of the gravid cornu in the cow causes no clinical manifestations during pregnancy. Williams *et al.*⁶¹ have shown satisfactorily that ample utero-fetal disease is present, and evidence was submitted tending to show that such invagination is etiologically associated with *Schistosomus reflexus*, page 327. Just what the destiny of this invagina-

tion of pregnancy may be after the termination of gestation, is yet to be learned. Three distinct courses appear possible or probable and the associated symptoms, if any, would vary accordingly. Spontaneous reduction of the invagination may occur and no symptoms develop. This probably occurs rarely. The cornual wall at the base of the invaginated pole tends to become constricted like a hernial ring thus constituting an obstacle to reduction. The invaginated cornua may become strangulated at the "hernial ring," causing fatal metritis and gangrene. This appears to be the most logical explanation for those cases of invagination discovered at autopsy without having been recognized clinically. The symptoms are essentially those of metritis. Possibly such cases could be diagnosed by rectal palpation if their presence were suspected. A third eventuality and perhaps the most common result, is that such invaginations of pregnancy advance soon after the fetus has been expelled and lead to uterine prolapse. The symptoms will then be the same as in those cases due to other causes.

In other cases the invagination of the ovarian, or of the cervical pole of the cornu is etiologically associated with retained fetal membranes. A cow had retained her placenta for twenty-four hours. Almost all the afterbirth was hanging from the vulva, but was retained by a few cotyledons at the base of the gravid horn. The base of the cornu, lying within the vulva was readily recognized by sight and by palpation. In the college clinic Fincher readily recognized an invagination of the ovarian pole of the non-gravid horn in a mare. The invagination was discovered when the removal of the retained afterbirth was begun. In another mare in the college clinic, Errington recognized invagination of the ovarian end of the non-gravid horn as a tumor six inches in diameter protruding into the cavity of the base of the horn. Ordinarily the invagination of the ovarian pole should be clearly recognized, in the mare and cow, by palpation. Probably in most cases there are clinical signs—expulsive efforts, uneasiness, and in some cases, retained afterbirth. The tumor fills the lumen of the base of the horn or of the body of the uterus (mare). The examiner can pass a finger between the undisplaced cornual wall and the tumor, upon all sides. The presenting end of the tumor should have a recognizable depression, the *os uteri abdominale*. The invagination of the cornual apex in multipara causes general symptoms of ill health. Since it is associated with parturition, invagination may be suspected. It is said that in some cases one horn of the multiparous uterus may evacuate its contents and become evaginated, blocking the exit of fetuses remaining in the other horn.

When the eversion is extensive and complete, it forms a characteristic tumor, varying in its appearance somewhat according to species. In the mare and cow it constitutes an immense pear-shaped tumor, which, when the animal is standing, hangs down in the neighborhood of the tarsus. The mucous surface has become external, and capillary hemorrhage occurs upon its surface. Litter and other foreign substances may be adherent to its exterior.

If the eversion has existed for some time, the organ becomes dark, and occasionally covered with an exudate, or, if it is of very long standing, with pus. It may be badly torn, abraded, or gangrenous. The position of the uterus causes an intense mechanical congestion and an enormous increase in size.

The general symptoms are by no means uniform. Occasionally a cow is observed, with her uterus completely prolapsed, grazing or ruminating. In some instances the condition produces such debility that the animal is unable to rise. Sometimes uterine prolapse occurs in a cow which is already down and unable to rise. Such is true in milk fever, and in other cases of obligatory recumbency. In such cases the recumbency itself plays an important role.

The causes of uterine invagination and prolapse have been only superficially studied. Obstetrical writers attribute it to non-contraction of the cervix, to atony of the uterus, to retained afterbirth, to relaxation of the mesometrium and of the broad ligaments of the pelvis, to after pains, etc., etc. The phenomena mentioned are admittedly present, but when their existence is invoked as the primary cause of the prolapse or eversion, the conclusion may be evasive rather than elucidative. The authentic determination of the primary cause of the retained placenta is of far greater scientific and economic value than the conclusion that the retention of the membranes caused the prolapse. Similar remarks apply to the other phenomena brought forward as explanations of the occurrence of uterine prolapse. I believe it has been authentically shown by Williams *et al.*⁶¹ that the invagination of the ovarian pole of the gravid horn in the pregnant cow is due to inflammatory adhesions between the ovarian poles of the cornua and of the amnion and allantois. Such inflammatory adhesions can be attributed only to the presence within the uterus of bacteria or of virus capable of pathogenic action. If such conclusion be accepted it appears justifiable to regard uterine prolapse as the result of intrauterine infection. It is reasonably certain that the amnio-allantoic adhesions date back to early pregnancy, perhaps to fifteen or twenty days after conception. It naturally follows that the principle involved, with varying details, applies to uterine invagina-

tion generally. Such reasoning makes uterine invagination and prolapse the result of basic uterine disease, referable to the presence of intrauterine infection, largely present at the date of conception. This conclusion would lead to the expectancy that uterine prolapse would be most common in dairy cows, which lead all domestic animals in the volume and virulence of genital infections.

Uterine prolapse has been so largely regarded as accidental, and the result of very recent happenings, that veterinary literature is virtually a blank regarding the clinical history of the patients. Harms (Schmidt)³² states that prolapse is most frequent in the cow, and says, "Young, vigorous animals suffer less than those which are aged and debilitated." The opinion of Harms coincides in general with the views of writers upon veterinary obstetrics. My observations lead to an opposite conclusion. I have observed uterine prolapse most frequently in primipara. The conflict of view is perhaps quite understandable. It seems unfortunate that authors generally associate debility with old age, and vigor with youth. If vigor and debility were dissociated from age, my views would be in harmony with those of Harms. It has fallen to my lot to observe many badly raised heifers which have been bred while yet immature, and calved or aborted while in a state of low vitality. Upon the other hand, I have seen comparatively few aged cows which were senile. Most dairy cows I have been permitted to observe have died or gone to slaughter before they had reached adult age. Those which remained have been largely vigorous animals. In pluripara, I have observed prolapse in milk fever and in severe dystocia relieved by traction, but in these the patients were usually rather vigorous.

In the college clinic Fincher attended a mare because of retained placenta of ten hours standing. The mare had produced several foals, generally defective or deformed. The foal, the afterbirth of which was retained, was weak, and suffered severely from diarrhea. Hence there was a record of pathological breeding in prior years. The case thus takes its place in the general picture of pathological reproduction; the prolapse was merely one note in the scale. It seems reasonably clear that if the sexual history of cases of uterine prolapse were available, it would be shown that the phenomenon is simply one of the manifestations of genital disease.

The details of the development of invagination and prolapse vary. Most cases apparently begin at the apex of the cornu. In the cow, so far as I have observed, it usually occurs in the gravid horn; in the mare it frequently occurs in the non-gravid horn. That harmonizes with the incidence of retained placenta, which is most fre-

quent in the gravid horn of the cow and in the non-gravid horn of the mare. In the cow mentioned above, where the membranes remained attached by a few cotyledons at the base of the pregnant horn, the prolapse began at the point of placental retention, at the cornual base. In the mare in the college clinic attended by Fincher, the placenta was retained at the ovarian pole of the non-gravid horn and the invagination began there. In milk fever and in some cases of severe dystocia relieved by forcible traction, the uterus apparently falls out in a mass and the prolapse is complete at once.

The prognosis of uterine prolapse in domestic animals varies widely in different cases. In available data the prognosis has not been placed upon a satisfactory basis. The prognosis is generally predicated upon whether the patient lives or dies, not upon her subsequent economic value in case she lives. In some cases it is recorded that a cow has recovered and again bred but it is not usually stated whether she later calved physiologically or pathologically, or how many, if any, physiological births ensued.

I have observed two cases of uterine prolapse in the mare. One followed immediately the removal of the fetus by severe traction. The fetus was in posterior presentation. The mare died within a few minutes. No autopsy was made. The second mare was unable to stand after the reduction of the prolapse, and was placed in slings. Before she had become strong enough to warrant their removal, tetanus set in, and the slings were retained until she recovered from that disease. I failed to follow her subsequent history.

In my experience, all cows suffering contemporaneously from uterine prolapse and obligatory recumbency (milk fever, coxo-femoral dislocation, fracture, weakness from disease) have perished. The majority of my cases requiring amputation have succumbed. Cows able to stand, if the handling was instituted early and the uterus was not critically injured, have generally lived. Their later breeding histories are unknown to me. No adequate ground exists for determining the ability of the animal subsequently to produce young in a satisfactory manner. My impression is that it is generally best to discard the animal as a breeder. There are, perhaps, some exceptions. In favorable cases the dairy cow may lactate satisfactorily during the ensuing period and be in good beef condition at the close of the milking period. In small ruminants the outlook is analogous to that in the cow. The prognosis for multipara is necessarily unfavorable; the prolapsed cornu cannot well be replaced.

In all cases of dystocia, the obstetrict should examine the uterus

after the extraction of the fetus, in order to determine whether the organ has assumed its proper position and relations, and especially whether any inversion of the organ has begun. If such inversion is present, it should be reduced by applying pressure upon the advancing portion of the organ, either with the clenched fist or with the ventral surface of the fingers, taking care at all times not to wound or otherwise injure the organ. After replacement of the organ, unless there are reasons to the contrary, such as a rupture of the uterus, the obstetrice should introduce into the uterus a large volume of warm physiologic salt solution. The solution is best introduced by gravity by means of an irrigator and a long, soft rubber catheter. Later, the catheter should be passed as deeply into the uterus as possible and the fluid carefully siphoned out. In this way the uterus tends to become accurately replaced by the weight of the water and is cleansed from any irritants which may be present. The solution also stimulates energetic contractions of the uterus, and favors involution. The uterine contractions may be further stimulated by the administration of pituitrin.

When the uterus has become prolapsed it should, as a rule, be replaced. The replacement may usually be accomplished in the mare and cow with the patient standing. This is uncertain, however. There is the constant danger that at the critical moment, when the uterus is in the final stage of reduction, the pain is so great that the animal throws herself violently to the ground. This usually undoes all which has been accomplished. On one occasion, before the introduction of epidural anaesthesia, I worked long and hard to replace the prolapsed uterus in a standing cow. Several times the operation had progressed far enough that almost the entire organ had been returned through the vulva, when expulsive efforts would come on and the cow would throw herself upon the ground and undo all. Finally she threw herself violently, fell into an excavation, and lay with her head down hill upon as steep a bank as would permit her to retain her position without sliding downward. She was held down. When I attempted again to return the uterus, it fairly fell back into place after one or two minutes of work. The operation at which I had worked in vain for an hour or two was completed in a few minutes.

The value of the elevation of the posterior part of the body, when it is desired to replace a prolapsed uterus, cannot well be overstated, especially in the cow and mare with abdominal viscera weighing several hundred pounds. In handling uterine prolapse in the cow, unless it is reasonably clear that the operation can be readily performed

with the patient in the standing position under epidural anaesthesia, the patient should be secured in lateral, or in very severe cases, in dorsal recumbency, with partial suspension by the hind legs if necessary. In lateral recumbency, pressure upon the abdomen by the posterior limbs should be prevented by binding them in extension. The posterior portion of the body should be elevated until the slant of the body reaches 45 to 90 degrees. This may be attained by placing the cow upon a heavy door or other available apparatus or by means of a platform constructed of heavy boards. Out of doors, the cow may be secured in a slanting position on a steep terrace or hillside. In other cases it is advisable to secure the cow in dorsal recumbency and to partly suspend her by the hind legs with the aid of ropes and pulleys. Small ruminants and multipara should be almost or wholly suspended by the posterior legs. The prolapsed uterus should be protected against danger of mechanical injury while the patient is being secured. This is best accomplished by placing the uterus in the center of a strong sheet and having two assistants, one on either side of the cow, draw firmly upon the gathered ends of the sheet. The uterus should be kept at or near the level of the vulva and firmly compressed. The compression favors the return into the pelvic or abdominal cavity of any viscera protruding into the uterine sac (intestines, urinary bladder) and relieves the engorgement.

After the animal has been secured for the operation, the uterus should be properly prepared for the reduction of the prolapse.

If the placenta remains attached, this should be removed if at all practicable. In the everted state, removal of the placenta is undertaken under the very best possible conditions, so that it is nearly, if not always, perfectly practicable and easy. It is needless to say that this should be done with very great caution, since any abrasions or lacerations of the uterus tend to produce very profuse hemorrhage.

In almost all cases of prolapse of the uterus, the organ has become more or less befouled with dirt of various kinds, and especially with manure and bedding, bearing abundant and serious infection, which it is the province of the veterinarian to overcome as far as possible. In order to properly cleanse the uterus, the organ must first be protected from further contamination by being placed upon a clean sheet, tray, or other suitable apparatus. Having provided ample protection, the operator should proceed to cleanse the organ, chiefly by irrigating it with a tepid physiological saline solution, removing most of the dirt by mechanical washing. The washing should be abundant

and should be accompanied by gentle massage, which will tend to overcome the congestion of the organ, thereby decreasing its volume.

It should constantly be borne in mind by the obstetrice that the position of the organ, as related to the body of the patient, affects its size, and that, if the organ can be held somewhat above the level of the vulva, or at least as high as that organ, the blood tends to gravitate into the body, thus relieving the engorgement to an appreciable degree, and rendering the replacement more practicable.

If the uterus has been torn or abraded, the wounds should be given proper attention. If any perforations have occurred, they should be closed by means of sutures, in such a manner that the two peritoneal surfaces of the organ are brought in contact. Should any blood vessels be wounded, the hemorrhage should be controlled before it is attempted to return the organ to its position.

The chief obstacle to be overcome in the replacement of the organ are the intra-abdominal pressure; the engorgement of the uterus; the prolapse of the bladder through the vulva within the uterus and its distension with urine; and the prolapse of intestines through the vulva, within the uterus.

The intra-abdominal pressure is best overcome and a negative pressure established by placing the patient in the inclined position with the posterior parts elevated, as already advised. Straining is to be controlled by epidural anaesthesia.

The engorgement of the uterus is best overcome by compression, massage, and elevation. The compression is best exerted, in the mare and the cow, by means of a broad sheet of strong, smooth cloth, such as heavy muslin—a bed sheet in case of emergency. As a stock bandage, it is advised to use a piece of heavy muslin or light duck 3 feet wide by 6 feet long. At the center of the sheet or bandage the operator may make a round opening of sufficient size to permit the passage of the hand.

When the prolapsed organ is lodged in the center of the sheet and the ends are gathered together by an assistant, the center assumes the form of a basin in which the uterus rests securely while the assistants pull upon the ends. With the continued compression and massage the engorgement is largely overcome.

After the engorgement has been satisfactorily reduced, it is important to overcome any obstacle offered by a prolapsed, distended bladder or by prolapsed intestine enclosed within the uterine sac. Ordinarily the urinary bladder and the intestines are replaced inci-

dentally while the uterus is being pushed back into its normal position. If the prolapse has existed for some time the bladder may be distended with urine. Since the urethra has been sharply bent by the displacement, the urine cannot be expelled. The distended bladder should be pressed upon very carefully. As soon as the bladder resumes its normal position, the urine escapes. If the distension is too great to permit the bladder to be pressed through the vulva without danger of rupture, the obstetrice should draw off the urine with a small trocar or a large hypodermic needle passed into the bladder through the uterine or vaginal wall. The intestines, which may be prolapsed into the uterus, rarely, if ever, offer serious difficulty, but are readily pushed forward into the abdomen.

In most cases of uterine prolapse, the invagination begins at the ovarian pole of the involved cornu. There remains a very small area, in ruminants, at the tip of the cornu where it connects with the oviduct, which does not become wholly everted and causes at that point a small, funnel-shaped depression. At this point the operator should exert pressure in the efforts at replacement. For this purpose he passes one hand through the opening in the center of the bandage. The hand should be well oiled or lubricated. Steady pressure is to be maintained and the ovarian pole of the everted cornu gradually pressed forward, into and through the pelvis. At the same time the operator applies pressure with his other hand, at that point which appears most important. When the operator has advanced his hand, pushing before it the ovarian pole, as far as he can readily reach, he needs to withdraw his arm and transfer his manual pressure to the margin between the displaced and replaced portions. When withdrawing the engaged arm, the margin of the cornual opening should be grasped with the free hand. The thumb of the free hand should be inserted alongside the engaged arm, while the palm of the free hand rests against the everted portion of the cornu. The margin of the cornual mouth is to be pushed forward with the previously free hand while the engaged hand and arm are being withdrawn. The reduction is then to be continued by exerting pressure against the free margin, and the process continued until the displacement has been fully reduced.

During replacement, compression of the prolapsed mass is to be continued by the assistants by means of traction upon the bandage. With the prolapsed uterus enclosed in the bandage as advised, pressure and massage may be freely applied with safety. Throughout the operation, the prolapsed organ should be kept soft and pliable by frequent irrigation with warm physiological salt solution. As the

uterus returns through the pelvis into the abdominal cavity, the operator's hand should accompany it. Every part of the uterine cavity should be carefully palpated and complete replacement assured.

When complete replacement has been accomplished, it is well to keep the hand in the cavity of the organ for a few minutes, until straining and uneasiness cease, and the organ has undergone some contraction and begins to recover its tone. Sometimes severe straining continues, with the probability of a recurrence of the prolapse. The most efficient means for overcoming the expulsive efforts is the introduction into the uterine cavity of warm physiological salt solution which not only completes the replacement but also soothes the organ, washes away any blood clots or extraneous matter, and favors a normal involution of the organ. As soon as the uterine cavity is well filled, the fluid excites expulsive efforts, by which the solution is thrown out. The contractions aroused in the uterine walls cause each part to become properly replaced in detail. If the uterus is atonic and fails to completely evacuate the saline solution, the fluid should be siphoned out with a soft rubber catheter.

Should the straining persist, additional epidural anaesthesia should be applied. The introduction of iodoform and oil aids materially in overcoming straining, as well as having antiseptic value. The cow is virtually immune to any toxic action from iodoform. One-half ounce or more of iodoform may be suspended in one to two pints of white mineral oil and introduced as deeply as possible by gravity. Chloral, per mouth or rectum, may be used in case of need. Opium and morphine are not trustworthy in solipeds and ruminants. They may give satisfactory service in the bitch.

The replacement of the prolapsed uterus in small ruminants is best undertaken with the body almost suspended by the hind legs. Once the uterus has been pushed through the vulva, the completion of the replacement may be aided by introducing salt solution by gravity, while the patient remains partly suspended. Multipara may be similarly handled, but with limited success. The prolapse in these largely calls for amputation of the uterus. The cornu is too long and tortuous for reduction to be readily or safely accomplished. When the mesometrium is cut away so that the organ may be laid out straight, the pregnant cornua of the sow may attain a combined length of ten to twelve feet or more. The shorter cornua of carnivora offer greater possibilities for reduction of prolapse, but even there success is doubtful.

As a general rule there is little call for the use of either narcotics or

anaesthetics after the uterus has been replaced. If the uterus has been properly cleansed, without the use of irritants, and has been accurately replaced in every detail, expulsive efforts are rare. If the patient is very weak and unable to stand, recurrence of the displacement is probable and an anaesthetic, by relaxing the entire body and rendering tympany highly probable, may favor the displacement instead of preventing it.

In most cases, when the prolapsed uterus has been promptly reduced and properly replaced the animal becomes calm, ceases to strain, and a recurrence of the prolapse is not probable. This holds true especially in all cases where the animal can stand. Many obstetrists deem it essential, nevertheless, that some mechanical appliance be used to prevent a recurrence. However advisable this may be, it should not tend in any way to decrease the attention of the obstetrist to the measures which have been advised for bringing about a thorough replacement of the organ in every detail, its proper cleansing and soothing by irrigation, and the stimulation of the uterus to normal involution. When these are done, and thoroughly done, it is only in a minority of cases that any mechanical appliances for the retention of the organ are essential or desirable. Admittedly, however, it is very unfortunate to leave an animal without adequate protection, and permit the prolapse to recur after the obstetrist has left the premises. The application of mechanical apparatus to prevent a recurrence of the prolapse is possibly of greater psychological, than scientific value. Mechanical appliances have so long been used that some dairymen regard them as essential. Various appliances known as pessaries have long been used. The idea was apparently borrowed from human obstetrics. The pessary for woman is an appliance introduced into the vagina and placed against the cervix. The appliances called pessaries in veterinary obstetrics pass through the widely dilated cervical canal into some unstated and undeterminable portion of the uterus or cornu. It has definite possibilities for causing serious injury, but no known virtue in preventing a recurrence of uterine prolapse.

Sutures, in great variety, have been recommended. They are usually passed directly through the lips of the vulva. It is better to insert them through the skin and aponeurosis upon either side of the vulva, thus avoiding the wounding of the vulvar mucosa. Necessarily, they must be strong and deeply inserted, in order to afford that amount of security which the obstetrist desires. Usually two sutures will suffice. A very good plan, with the cow or the mare, is to in-

sert a long, heavy needle, armed with silver wire or silk tape, at a point one or two inches below the superior vulvar commissure, and an equal distance laterally from the median line. Insert the suture deeply through the skin and aponeurosis, and bring it out one or two inches above the inferior vulvar commissure and an equal distance laterally from the median line. Tie the two ends of tape together. Insert a second suture of similar character in the tissues upon the opposite side of the vulva. Then take two pieces of tape and tie them across the vulva from one suture to the other, one at the upper ends and the other at the lower ends of the sutures described. These should be so tied that they may be readily untied and readjusted.

Sutures are efficient in preventing a recurrence of prolapse, but not perfect. If straining of the animal is very violent, the sutures may be torn out by the great force. When there is little or no straining, they remain in position, and are effective. At least the prolapse does not recur. This may be because the sutures do not readily permit it, or because the animal does not strain and the prolapse would not occur anyway. The ordinary labial sutures have the further disadvantage that they produce wounds in the birth canal at a time when it is highly susceptible to infection. Sutures applied as above advised are free from this objection.

Sutures necessarily cause pain, and suture infection inevitably ensues. Consequently it must be confessed that sutures, like the pessary, have objections, but not the same in each case.

The bandage, or truss, is usually constructed of ropes, Fig. 103, and is so arranged that it may compress the vulvar opening, offering thereby a more or less effective obstacle to the protrusion of the uterus. The truss is conveniently made from two pieces of cord about one-half inch in diameter and twelve to fifteen feet long. Each is doubled in the center, and the two are united by a loop in their middle, so as to leave an oval space somewhat in the form of a ring, which will surround the vulvar opening. The two ends of one of these cords are then passed downwards between the hind legs, on either side of the udder, and thence diagonally, forwards and upwards, to meet and be tied together at the top of the neck in front of the withers, from which point they extend downwards upon either side of the neck and are tied together to form a collar. The two ends of the other cord are to be carried upwards on either side of the tail and tied together over the loins, thence diagonally downward and forward to pass between the forelegs and beneath the sternum. There they are tied together and the two ends passed upward to meet those of the

other cord and tied to them as a part of the collar. When so applied, the ropes tend to continue their compression when the patient arches her back to strain. If the cords are carried straight forwards, from the vulva along the back and belly, they are immediately loosened whenever she arches her back. Some obstetrists prefer a metallic loop, through which compression is to be exerted upon the vulva. It is maintained in position by cords arranged the same as the rope truss. It is exceedingly difficult so to apply a truss that the patient cannot force the uterus out if she strains persistently and vigorously. Trusses

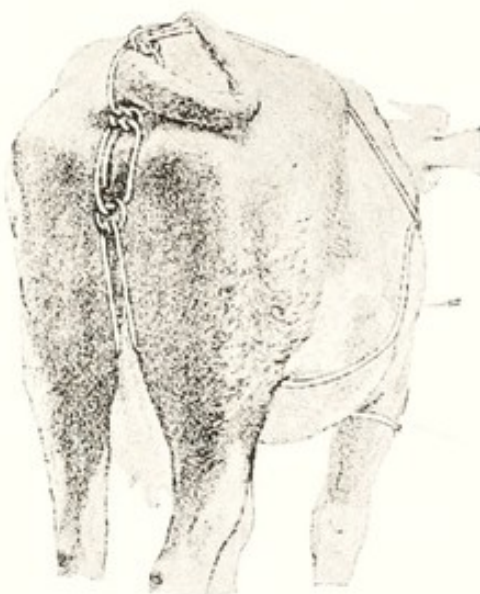

FIG. 103. Rope Truss of Rainard. (de Bruin.)

generally become relaxed and loosened when the patient arches her back to strain. The truss cannot prevent the inversion of the organ and its passage into the vagina and vulva, but can only tend to prevent its prolapse through the vulvar opening. This is equally true of sutures. The scientific value of the truss is not so great as many suppose. Its chief value is psychological. It is essentially free from the objections which may be urged against pessaries and sutures.

Before the uterus becomes prolapsed, it is in a pathological state. Otherwise it would not evert. While prolapsed, it becomes variously contaminated. Under certain conditions, especially in the mare, the administration of tetanus antitoxin has value. The uterus may be seriously abraded or lacerated while prolapsed. Its exposure to the desiccant, irritant action of the air causes engorgement and other injuries. The patient should be well nursed and fed. The uterus, in the cow and mare, should be examined daily, and some normal salt solution may be introduced deeply into the uterine cavity and then

siphoned out. Any pathological exudate will thus be recognizable. After the uterine cavity has been cleaned, it is well to introduce a pint of white mineral oil with one-half ounce of iodoform in suspension.

Amputation of the uterus is generally advisable when the prolapse cannot be reduced. This is commonly so in multipara. Amputation is also advisable when the uterus is so badly injured or diseased that its replacement is dangerous.

The prognosis following uterine amputation is bad. The breeding life terminates. A dairy cow may in some cases milk well during the lactation period involved. The mortality is high. The prognosis is said to be better in multipara than in unipara.

The animal is to be properly secured, according to species. The prolapsed organ is to be well cleansed, especially in the area of the proposed amputation. The portion to be amputated should be securely covered with antiseptic gauze or other fabric. Aseptic covering should be applied to the rump of the patient. In the cow, epidural anaesthesia should be applied.

The amputation may be made by ligature or suture. Before resorting to either, the operator should assure himself that neither the bladder nor the intestine is within the prolapsed cavity. Both the bladder and the intestine have been irremediably injured through lack of precaution. In order to determine authentically whether any viscera extend into the cavity of the prolapsed organ, the veterinarian should always open the peritoneal cavity of the reversed uterus, and make a careful manual exploration of its interior. The amputation is to be carried out by ligating or suturing the vagina or cervix. In unipara, the operation includes both horns. In multipara the amputation may be limited to one cornu.

Ligation is the most primitive method. It is effective in the slender compressible cornu of multipara. In these, the ligature securely closes the lumen of the cornu, brings all parts of the peritoneal layer in contact and effectively controls hemorrhage. Ligation is less effective in the mare and cow. The ligature is applied to the cervix or to the anterior portion of the vagina. Both vagina and cervix are quite large, and when amputation is called for their walls are commonly much engorged. The ligature inevitably throws the walls into innumerable folds, the compression is unequal, and the peritoneal layer of the prolapsed uterine sac is not brought into accurate contact except under great pressure. After the ligature has been applied, its pressure largely dissipates the engorgement and thickening from extravasation upon

its distal side, permitting the ligature to slip off, or hemorrhage to occur. These possibilities should be constantly borne in mind. The ligature should be very strong, but whether it be silk, linen, cotton or hemp is not vital. The cord should possess ample strength to withstand the power of two men; it should be not less than three feet long; and should have affixed to each end a short rod which will serve as a handle. While the ligature needs have ample strength, when that has been attained, its diameter should be as small as practicable, so that it may cut deeply into the tissues, rendering its position secure. The prolapsed organ having been cleansed, and the operator having assured himself that neither urinary bladder nor the intestine is protruding into it, the ligature is laid about the cervix or anterior end of the vagina and half tied. An assistant grasps each end and draws the cord tight. If the ligature tends to slip and become loosened during the completion of the knot, lay a second small cord beneath the knot and, when the two men have drawn the ligature tight, tie the smaller cord over the half knot so it cannot slip. After the ligature has been securely tied, the uterus is to be excised. Some recommend that the division be made very near to the ligature. This is quite unnecessary. If the ligature is properly applied, the stump promptly becomes necrotic and it is immaterial whether the necrotic mass is large or small. It is best to leave three or four inches of stump. The stump is to be well cleansed, preferably with physiological salt solution, and returned into the vagina. After its return, an application of iodoform and oil relieves irritation and tends to limit infection. The vagina should be douched once or twice daily with saline solution and the application of the iodoform and oil repeated.

Some practitioners prefer the elastic ligature to that mentioned above. The technic differs little. The ligature should be as strong as an ordinary rubber horse catheter; the catheter will meet the need if other elastic ligature is not at hand. Before applying the ligature, a strong cord should be laid along the dorsal surface of the cervix and vagina, and the elastic ligature laid over this. The ligature is then applied tightly, surrounding the cervix or vagina several times. The ends of the elastic ligature are then to be secured by bringing up the ends of the underlying cord and tying them tightly around it. In multipara, the ligature should ordinarily be placed about the base of the prolapsed horn. The caliber of the ligature is to correspond with the size of the ligated organ.

In the cow, I prefer amputation by means of sutures. I use heavy linen or silk thread. The uterus is grasped on the distal side of the

amputation area by an assistant and firmly stretched. Interrupted sutures are applied in such manner that each suture overlaps slightly the contiguous one, so that when completed, the blood supply is accurately cut off and prompt necrosis of the stump assured. Otherwise the operation is the same as with the ligature.

Prolapse of the Rectum

Prolapse of the rectum occurs rarely as a result of expulsive efforts during or immediately after the act of parturition. In the horse the anus becomes somewhat everted normally with each defecation, but returns at once to its position when the act has been completed. This peculiarity is regarded as a predisposing cause of rectal prolapse.

Slight eversion of the rectum is not uncommon in the mare, on account of the violent expulsive efforts. In some cases of difficult parturition, where the animal is not attended constantly, the prolapse of the rectum may become extensive and imperil the animal's life.

In one case occurring in my practice, a valuable mare, suffering from dystocia, was found with the rectum prolapsed to the extent of three feet, involving about six feet of the organ. With some difficulty it was replaced, and the extraction of the foal accomplished without material delay or visible injury to the rectum or genital organs, but the patient perished a few hours later. Extreme prolapse of the rectum is sometimes observed during parturition in the sow.

During labor the obstetrice should make note of any threatened eversion of the rectum, especially in the mare, and should take all necessary precautions against its occurrence. This may be best accomplished by having an assistant press upon the anus with a towel or other cloth. When the organ has already become prolapsed, it should be replaced as promptly as possible, and retained in position. It should be carefully cleansed by bathing with physiological salt solution. As the organ returns it should be followed by the hand to make sure that all parts of the walls are straightened out.

The prognosis of prolapse of the rectum in the mare during parturition is highly unfavorable. In other animals the prognosis is more favorable.

Prolapse and Eversion of the Bladder

Eversion of the bladder may occur in any animal. It has been noted chiefly in the mare, though it has been recorded in the cow and sow. The very wide urethral opening of the mare tends to make the eversion more probable.

Eversion of the bladder may occur at any time immediately prior to, during, or following labor. The accident, when occurring before or during parturition, does not constitute any great impediment to the expulsion of the fetus, but the integrity of the organ and the life of the patient may be endangered during the passage of the fetus through the vulva. When eversion occurs after the passage of the fetus, the danger to the patient is less.

The causes of eversion of the bladder are chiefly the exalted intrapelvic pressure due to expulsive efforts, and, in the mare, the very large urethral opening.

The symptoms of eversion of the bladder are such as to render diagnosis easy and clear in the majority of cases. A tumor appears, which is somewhat pear-shaped and has its attachment on the median line of the floor of the vulva, at the point where the urethra normally exists. The urethral opening has disappeared, and its place has been taken by the everted organ. The tumor varies in size, according to its degree of congestion, which is largely dependent upon the duration of the eversion. If the eversion is recent, or if the bladder has not protruded beyond the vulva to any great extent, or has not been seriously abraded or injured, it presents a fresh mucous surface. Upon either side, near the neck of the tumor, may be observed the two urethral openings, from which urine escapes drop by drop, or sometimes in small jets during an expulsive effort. If not much swollen, the bladder may remain almost or completely hidden, especially when the animal is standing, or become exposed when she is lying down or straining.

Eversion of the bladder is to be differentiated chiefly from hernia of the bladder, through a rent in the vaginal floor, and from hematoma or tumors in the vagina or vulva. In rupture of the vaginal floor with hernia of the bladder, the peritoneal surface of the bladder remains external, and the ureters, still emptying inside the organ, may cause it to become distended with urine. The rupture in the vaginal floor is recognizable. The urethra is present in its normal position on the vulvar floor. Through it the finger or a catheter may be passed into the herniated organ. The mucous surface of the everted bladder is external, and the ureters open upon the external surface. The viscus does not become dilated with urine. The meatus urinarius is not palpable.

In the handling of eversion of the bladder, the organ should first be thoroughly cleansed by washing with a non-irritant fluid, such as a physiological saline solution. The organ should be examined and proper attention given to any injuries. If any perforations of the

walls exist, these should be carefully closed by means of sutures, so applied that the peritoneal surfaces of the lips of the wound are brought into contact. If a portion of the wall of the organ has been severely lacerated or contused or has become so badly infected or otherwise damaged that its recovery cannot well be expected, the damaged portion should be removed and the edges of the wound brought together, thus amputating as much of the organ as may be necessary. In such an operation it is essential to preserve the outlet of each ureter.

After due preparation, the organ is to be returned to its normal position, through the urethral opening. Usually the operation is not difficult, especially if the organ has not been long everted. Grasping the organ in the hollow of one or both hands, the operator should press firmly and evenly over the entire mass until it gradually returns into its position. Generally the operation cannot be carried out hastily. Firm and evenly applied pressure with the hands gradually forces the blood out of the organ, and reduces its volume, until finally, when the engorgement has largely disappeared, the organ returns through the urethral opening. General anaesthetics or narcotics, such as chloral and morphine, or epidural anaesthesia may be used in order to overcome the expulsive efforts, by which the replacement or retention of the organ is made difficult.

After replacement, any irritation present may be ameliorated to some extent by irrigating the cavity with a warm saline solution. If this does not suffice, local anaesthetics may be applied, such as cocaine or novocaine with adrenalin chloride.

The prognosis in prolapse of the bladder is usually favorable, if it is handled early and properly.

Rupture of the Perineum

Parturient injuries to the perineum are observed chiefly in the mare but may occur in any species of domestic animal. Various factors render the mare more vulnerable to perineal injuries. Her anus is relatively large and the vaginal roof easily becomes sacculated and elevated to the level of the anus. It may then be occupied by a portion of the fetus. Cases are recorded in which the two anterior feet and the nose have penetrated the vaginal roof and the rectal floor, and the foal has been expelled through the anus. The expulsive efforts are far more violent and stormy in the mare than in any other domestic animal. Even with the fetus in proper presentation, position and posture, the force is so violent that the healthy vulva may become somewhat lacerated, because it cannot dilate with sufficient celerity

to meet the rapidity of the expulsion of the fetus. The equine fetus more than any other, tends to present with one or both feet crossed over its neck: the feet become deflected upward, penetrate the vagino-rectal partition, emerge from the anus, and the perineum is torn asunder. The violence of parturition puts terror into attendants and they fly to the conclusion that it is a matter of life and death, and that the only hope is prompt and severe traction. If the head is in lateral deviation, the attendant thinks the fetus must be so extracted.

The extent of the lacerations varies widely: they may be roughly divided into three classes. There may be slight laceration of the vulva, usually at the superior commissure; there may occur a vagino-rectal perforation; or the entire perineum may be torn asunder to form a vast cloaca. The milder lacerations are quite common when physiological birth has begun in the mare and panicky attendants have applied traction. Dairy heifers which have been unhealthy as young calves, and arrive at calving time with juvenile genital organs, inevitably suffer from perineal lacerations when severe traction is applied. In such cases I have known complete perineal rupture, with fatal hemorrhage.

The lacerations which involve the superior vulvar commissure or the entire perineum are readily recognized. When the entire perineum is torn asunder, feces drop into the vagina, irritate the vaginal mucosa and cause a continuous, repulsive discharge. The patient so injured, when moved rapidly, alternately draws in and forces out air, accompanied by a characteristic sound. The dairy cow passes feces involuntarily and keeps the posterior parts of the body repulsively soiled.

The symptoms of a rupture extending from the vulva or vagina into the anus or rectum, without involving the sphincter muscles, are not well marked externally at first, but may be followed soon by swelling. At the time of the accident the obstetrice or attendant may observe that some portion of the fetus has passed from the vulva or vagina upward into the anus or rectum. Later, feces drop occasionally from the vulva. The relative amount of feces which may escape from the vulva and anus respectively will depend upon the size of the opening. Sometimes but small quantities of feces escape from the vulva; sometimes most of the feces escape thus. There is frequently an involuntary passage of flatus, especially when the animal is driven at a trot.

The prognosis for the life of the animal, in all degrees of lacerated perineum, except for the immediate peril from hemorrhage, is good.

In the group of heifers repeatedly mentioned, which came to calving time with juvenile genital organs, imprudent traction was applied by means of rope and pulleys, and at least three animals in the one herd perished from hemorrhage. Aside from the danger from hemorrhage, the mortality is not high.

The breeding life of the animals has not been extensively recorded. In the herd just mentioned, two heifers which suffered complete rupture, which remained unhealed, conceived again without material delay. One expelled a dead fetus; the other bore a viable calf.

In the milder cases, without penetration of the rectum or the anal sphincter, the wound will usually heal spontaneously but with a gaping scar which is unsightly and prevents proper apposition of the vulvar lips. In the more severe lacerations, unless wounds are successfully handled, the animals, while technically efficient, are essentially worthless because of their repulsive appearance.

The technic for the handling of the lacerations has not been well established. Apparently the most rational and successful technic is that of Harms³² (Schmidt), which is based upon the relief of the tension upon the lacerated parts by means of incisions dividing the skin, connective tissues and muscles, which fix the vulva and anus laterally to the ischial tuberosity and to the free border of the sacro-ischiatic ligaments. The sphincters of the anus and the vulva, while intact, have ample power to close the openings which they surround. When the sphincters are divided, the tissues connecting the anus and vulva with the pelvis pull the lacerated surfaces apart, so that when an attempt is made to close these with sutures, the latter are torn out by the force of the pelvic attachments.

The technic of Schmidt seeks to overcome this. Two parallel incisions are made beginning above, at about the dorsal level of the anal sphincter, and carried down to a point below the superior vulvar commissure. The incision is made at about the line of demarcation between the naked and the hairy skin. At the upper end of each incision, a second, horizontal incision is made towards, but not to, the median line. This largely isolates the ano-vulvar area from its pelvic fixation, leaving it attached, above, to the sacrum and, below, to the ischiatic notch. By this means, the tension upon the lacerations is virtually eliminated.

Under local, or epidural anaesthesia, the lacerated wound may be conveniently sutured. The operation may be undertaken immediately after the laceration; it may be deferred until granulation has become established; or it may be delayed until the injury has healed. In the first instance, the badly lacerated tissues need be removed; in the

second, mere cleansing is demanded; in the third, the cicatrized area needs to be denuded.

After the incisions have been made, two heavy, deep sutures, one-half to three-fourths inch from the margins of the laceration are inserted, to hold the wound margins together, after which the edges of the wound are accurately brought together with ordinary interrupted sutures.

Hematoma of the Vulva

Reference has already been made, page 150, to hemorrhages in or about the vulva and vagina of the pregnant mare. Hemorrhages of a more superficial type are common at parturition. Sometimes, especially in the vulva of the mare, such hemorrhage appears without any history of mechanical injury. The hemorrhage is usually readily diagnosed. In one instance, a pedunculated hematoma had formed near the median line of the vulva, in a manner to suggest eversion of the bladder. Search revealed the urethra in its normal relation and unconnected with tumor. In all animals the vulvar lips are quite vulnerable to capillary hemorrhage from contusion. The obstetrice needs be on his guard in dealing with tumors in the vulva and vagina. Before undertaking to excise them or take other radical steps, their nature should be accurately determined. There may be intestinal hernia, prolapse of the bladder through the vaginal floor, eversion of the bladder through the urethra, suffusion of blood from ruptured capillaries, or a blood sac may exist owing to the rupture of an artery. In the latter case, incision may mean very serious hemorrhage. Usually there is little occasion for haste. If the enlargement is due to blood, time should be given for the artery to become occluded by a firm clot.

Contusion of the Lumbo-Sacral Nerves

The lumbo-sacral plexus of nerves, Fig. 104, is so disposed in domestic animals, especially in the mare, that certain trunks are somewhat subject to impingement between the bony walls of the pelvis and prominent, unyielding portions of the fetus, by which they may become more or less seriously contused and their functions interrupted. The probability of these nerves becoming injured during parturition is not alike for all the trunks: the gluteal and obturator nerves are especially exposed, where they pass over the articular eminence between the last lumbar and the first sacral vertebrae; the obturator nerve again becomes exposed to injury as it rounds the margin of the obturator foramen.

Contusion of the Gluteal Nerves. Gluteal Paralysis

In two draft mares, I observed paralysis of the gluteal muscles, followed by atrophy. The difficulty was not referable to dystocia, in the ordinary acceptation of the term, since birth occurred without aid and, so far as known, without difficulty. The mares were in prime condition: no infection was recognizable and there was no fever, loss of appetite, or loss of flesh. When the mares were down it was difficult for them to get up; when up, they walked with an unsteady gait. In one case, where the paralysis was unilateral, the difficulty in rising was not great. When moved, the animal had a

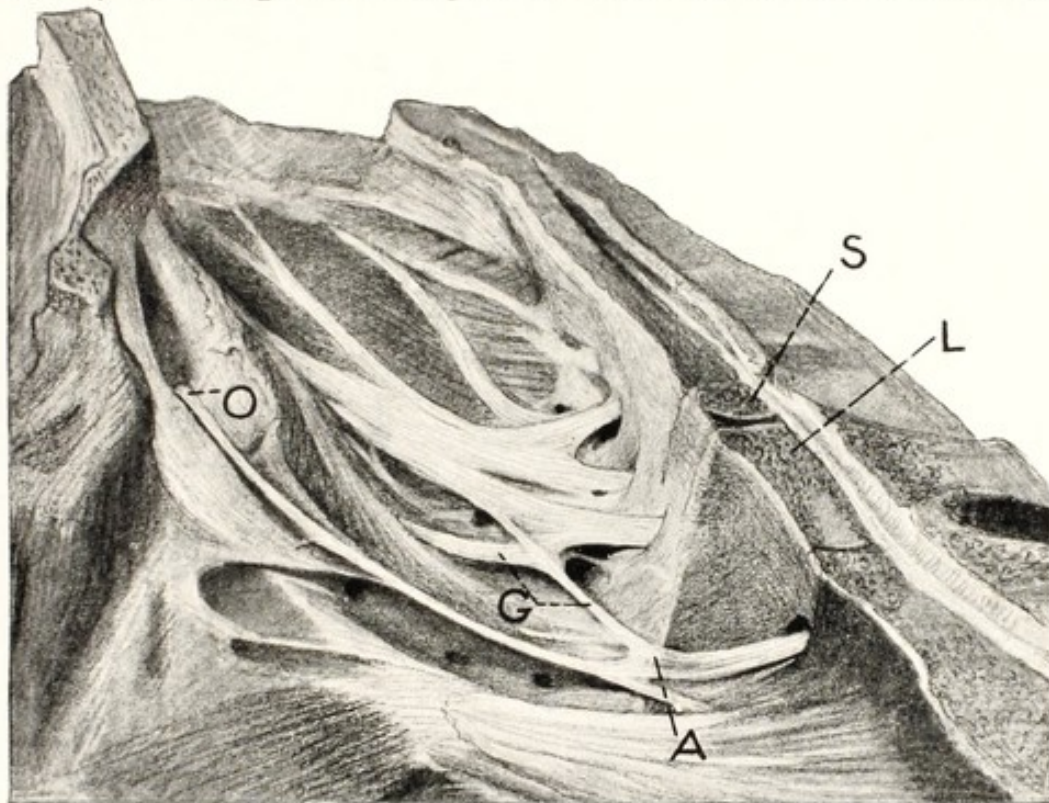


FIG. 104. Sagittal Section of the Pelvis of the Mare, showing Lumbo-Sacral Nerves.

S, first sacral vertebra; L, last lumbar vertebra; A, last lumbar nerve, passing over the lumbo-sacral eminence; G, gluteal nerves; O, obturator nerve entering foramen.

very distinct paralytic limp in the affected limb. After a few days the muscles of the gluteal region commenced to atrophy rapidly to an extreme degree, but most of the paralysis soon subsided, although there was a certain deficiency in the strength of the part. After several weeks, the muscles began to recover their volume, but the recovery was very slow, and nearly a year elapsed before the parts resumed their normal appearance.

In a second patient the paralysis was very profound because both

hind limbs were involved and it was necessary for a time to aid the mare somewhat when she attempted to get up. Once she had gained her feet, she could walk with some difficulty. The paralytic symptoms subsided in the course of two or three weeks, but the atrophy was extreme and the restoration of the muscles was very slow, though eventually complete.

The handling of contusion of the gluteal nerves must depend fundamentally upon the general care of the animal, since there is nothing very direct to be accomplished. It is not necessary as a rule that anything definite should be done. The animal should be not be permitted to struggle in getting up, or otherwise exert herself violently in a manner to increase the injury to the nerves and muscles, but should be watched closely and guarded against further injury. To this end she should have comfortable quarters, and her stall should be so managed that she will have the best footing possible in order to avoid any slipping in attempting to rise. Furthermore, it is desirable, as far as practicable, to aid the animal by lifting upon the tail whenever she wishes to get up, unless she can rise unaided with comparative ease and safety. Slings may be applied, should conditions require, but it is preferable to avoid them. Should indications warrant, the veterinarian may apply electricity, in the later stages, by placing one of the poles of the battery over the lumbar region and moving the other over the surface of the atrophied gluteal muscles.

According to my observations, the prognosis is highly favorable. The paralysis disappears in a few days to two or three weeks. At the same time atrophy is increasing, but from this the animal tends to recover completely in from six to eighteen months, and in the meantime may do light work if desired.

Contusion of the Obturator Nerves Obturator Paralysis

The obturator nerve is subject to injury from the fetus, at its point of passage over the eminence of the lumbo-sacral articulation, and again at the point where it rounds the lip of the obturator foramen.

The symptoms are acute and unique. They consist essentially of a loss of power in the obturator group of muscles, which include all of the adductors of the limb—the obturator externus, the adductors of the thigh, the pectineus, and the short adductor of the leg.

It matters not, so far as symptoms are concerned, if the nerve is injured at its point of passage over the lumbo-sacral eminence or of its disappearance through the obturator foramen. If one nerve only

is contused, the animal is able to progress with some difficulty, but the affected limb is carried in extreme abduction, though the power of bearing weight or of advancement is not interrupted. In advancing the limb, it is brought forward in extreme abduction, and is placed upon the ground some inches laterally from the normal point.

If both obturator nerves are injured simultaneously, the symptoms assume an entirely different type. Both limbs now become sharply abducted, the hind feet are drawn apart, the animal is unable to support her weight and drops upon her pubis. If assisted to her feet and the hind limbs are held in adduction, the animal can stand

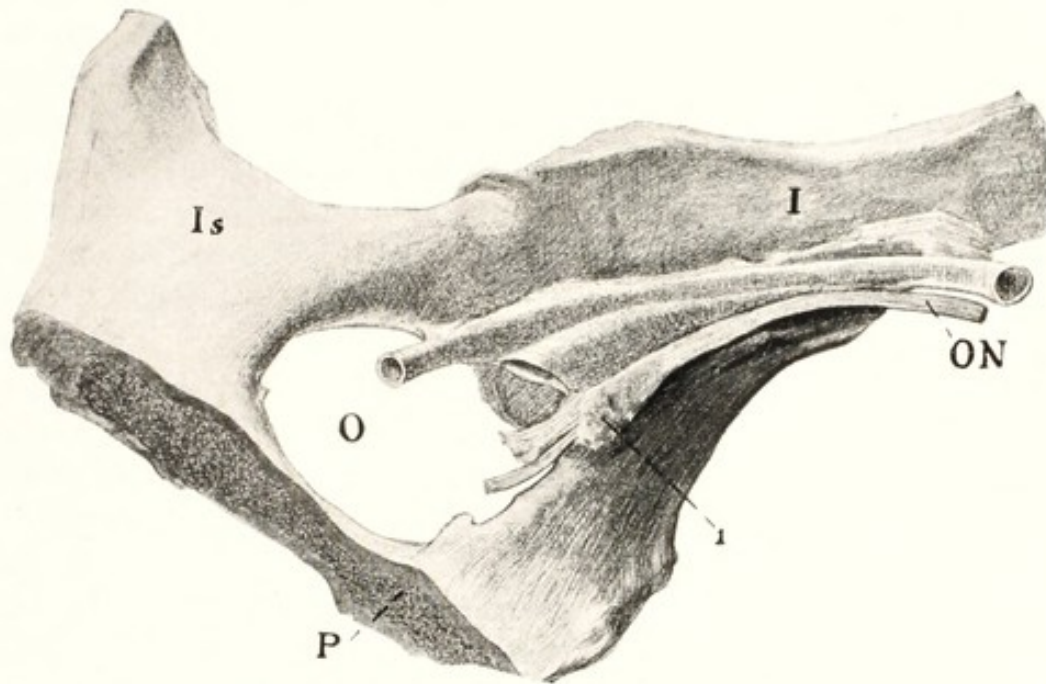


FIG. 105. Contusion of Obturator Nerve.

I, ilium; Is, ischium; P, pubis; ON, obturator nerve; O, obturator foramen; 1, inflammatory induration of obturator nerve.

without difficulty, but the moment she raises one foot the two move apart again and she falls.

In one case a mare had foaled apparently naturally, but immediately afterward it was seen that in walking she carried the leg in extreme abduction, so that it was exceedingly difficult for her to walk. The condition had existed for about a year before she was presented at our clinic. Injury to the obturator nerve upon the affected side was promptly diagnosed. She still walked with the affected limb in extreme abduction. The muscles of the inside of the thigh were greatly atrophied. Believing her incurable, we destroyed her. Postmortem examination showed all the muscles supplied by

the injured obturator nerve to be very pale and greatly atrophied, so that their volume was only about one-third of that of the corresponding muscles of the opposite side. The other muscles of the limb were normal. The obturator nerve was apparently normal except at its point of disappearance in the obturator foramen, where there existed a very distinct enlargement, consisting chiefly of connective tissue, as shown at 1 in Fig. 105.

In a second case, observed in private practice, an imported four-year-old French draft mare had given birth to her first foal without difficulty, but was unable to get up. I placed slings under the patient and helped her to her feet, but she could not stand on the hind limbs because they parted immediately and she tended to drop upon her pubis. If a man would hold the feet in adduction, she could stand without difficulty. After the slings were properly adjusted and the two hind feet tied together, she stood comfortably and without difficulty. After three days, upon the removal of slings, it was found that she could walk with but little difficulty. She made a rapid and complete recovery.

The handling of contusions of the obturator nerve should consist of the application of slings. The feet should be tied together to prevent abduction. Later, electricity may prove useful, one electrode being applied over the loins and the other to the inside of the thigh.

Coxo-Femoral Dislocation

Parturient coxo-femoral dislocation is not rare in cows. I have seen it most frequently in stanchioned animals, but also in cows at pasture. It seems to occur during parturition, though possibly sometimes just prior to calving. I have observed it most frequently in heifers in first pregnancy and in poor or indifferent physical condition, but have seen it also in adult cows in good condition. In most cases the dislocation has been associated with dystocia. It could not be determined that indirectly the dystocia caused the dislocation, but this appeared probable. It has appeared that, in the agony and exhaustion of difficult birth, the animal has slipped in lying down or rising, which has caused the dislocation. The weight of the uterine contents, at this time at its maximum, adds materially to the danger of falling. Another element possibly enters into the causation of the dislocation. In cows, far beyond other animals, when parturition approaches, the pelvic ligaments relax, and as a corollary the rigidity of the pelvic skeleton becomes materially reduced. There follows an uncertainty of step, which, added to the above causes, may abet the accident.

The symptoms are obscure. The veterinarian is called because the patient is unable to rise. No clinical history is available except that she went down in calving and has not been able to stand. Sometimes—and this appears to be most common—the veterinarian is called because of the dystocia. When he arrives, the dystocia is present and the patient is down, unable to rise, and, with the extra weight of the gravid uterus, unable to stand if helped up. The dystocia must be overcome with the patient in decubitis. After the fetus has been removed, the patient is still unable to rise. The chief body functions—pulse, temperature, and respiration—are not materially abnormal. There are no marked evidences of pain or suffering. After the uterus has been unloaded, the patient can possibly stand when lifted up. Usually she will not do so. Apparently she does not try to stand, possibly because of the pain, to which she gives no other expression.

At best, the diagnosis is not easy, and in many cases is made difficult or impossible by the unfavorable environment. When the patient is in a dark stanchion or stall where there is little room for handling, a safe diagnosis is extremely difficult. When the patient is moved into the open, with abundant light and room, the diagnosis can be made without serious difficulty. For examination, the cow should be placed in lateral recumbency. An assistant should grasp the upper hind foot, and, while the veterinarian manipulates the hip joint and examines carefully the location and movements of the trochanter major, the assistant should move the limb in harmony with the orders of the operator. The limb should be flexed and extended, abducted and adducted, extended backward and forward, and moved in any other way which may reveal important data. After the one hip has been thoroughly examined, the patient should be rolled over and the other hip examined comparatively. It is essential to measure or otherwise note the position of the trochanter major of the femur as related to the external tuberosities of the ilium and ischium. Whenever dislocation occurs, the distances between the trochanter major and neighboring bony prominences are inevitably changed. Sometimes the ligamentum teres is ruptured without dislocation following, or at least the dislocation does not persist. There is then no disturbance of location of the trochanter, but, as in dislocation, there is a marked change in the mobility of the limb, especially in abduction. There may be some evidences of pain, but the cow is too stoical to give definite expression thereto. Careful comparisons between the normal and the dislocated hip constitute the chief ground for a safe diagnosis. In one case, in which the dislocation was bilateral, this basis of

diagnosis failed. There remained however the great mobility of the hip joints and a definite change in the position of the trochanter when compared with that of healthy cows.

The prognosis is hopeless. It is difficult or impossible to reduce the dislocation, because the annular cartilage on the brim of the acetabulum dislocates and pushes into the cavity in front of the head of the femur. Even if the replacement could be accomplished, there is no way to retain the femur in position. The animal need not die. A false joint may form and the animal survive indefinitely, as a worthless cripple. In the one case of bilateral dislocation which I observed, the cow lived. After she had lost nearly all her flesh she was able to get up and walk about slowly with a rolling, uncertain gait. Apparently she could survive year after year, but she was absolutely worthless.

The best course to pursue, when the accident is diagnosed, is to slaughter the cow at once, and, if in at all proper condition, use her meat for food.

Necrotic Vaginitis

Necrotic vaginitis sometimes prevails amongst cattle in certain areas. The nature of the disease has not been sufficiently determined to permit it to be ascribed to any definite, specific infection. I have observed it almost wholly in dairy heifers, arriving at calving time with juvenile genital organs. The subnormal capacity of the vagina and vulva renders dystocia inevitable. The fetus is expelled or extracted tediously with excessive pressure upon the vulvo-vaginal walls. The genital system of such a heifer is highly vulnerable to bacterial invasion. Intrauterine infection is usually abundant during gestation. The abrasion and compression of the walls of the birth canal during the expulsion or extraction of the fetus further depresses the low powers of resistance of the vulvo-vaginal walls. The situation is often further aggravated, according to my observation, by metritis, with or without retained placenta, which causes a constant contamination of the birth canal from the uterus.

This disease is not wholly confined to dairy heifers. I have observed a few cases in cows, which had calved without aid and apparently without material difficulty. I have also observed stricture or complete atresia of the vagina in beef cows, which apparently had resulted from necrotic vaginitis, but no definite clinical history was available.

The principal symptoms consist of constant vulvar discharge, with swollen vulva, elevated tail and arched back. The appetite is depressed and emaciation is rapid. Manual exploration of the birth canal causes intense pain to the patient; the vulvo-vaginal walls

are greatly swollen, rendering the introduction of the operator's hand very difficult; the mucosa bleeds freely upon touch; the vulvo-vaginal mucosa sloughs extensively, the sloughed tissues having a more or less diphtheritic aspect.

When neglected or badly handled, possibly sometimes in spite of good handling, constriction or atresia of the vagina may follow. When the constriction is severe, it is usually located near the vulvar end of the vagina. This tends to establish a reservoir for purulent detritus between the stricture and the cervix. Sometimes there is complete atresia of the vagina. This cannot readily be permanent if there is active suppuration anterior to the occlusion. Instead there may be an accumulation of non-purulent utero-cervical excretions, principally, to all appearances, consisting of estrual mucus. When the vagina anterior to the occlusion becomes distended, the pressure gradually dilates or effaces the cervix. Then there becomes established a mucous cyst filling the anterior end of the vagina, the cervix and both cornua. The volume of fluid may reach or exceed two or three gallons. By rectal, but without vaginal examination, the condition may be mistaken for twin gestation (bicornual).

The disease demands prompt, continuous and careful handling. Ordinary antiseptics are not endurable. If the afterbirth is retained, it should be removed at the earliest practicable period. Until the membranes come away or can be removed, no material volume of liquid should be introduced into the uterus. I have had best results by limiting the invasion of the uterus to the introduction of one or two pints of white mineral oil in which one-half to one ounce of iodoform has been suspended. This may be repeated daily until the afterbirth has come away. Once the placenta is out, if there is recognizable uterine discharge, before using the iodoform and oil it is advantageous to introduce a pint or two of physiological salt solution into the uterus, and siphon it out immediately. If the uterus be flaccid and air is drawn in through the catheter, or the salt solution is all permitted to run through the catheter, additional salt solution should not be introduced into the uterus. Instead, the catheter should be refilled, the end compressed and lowered, establishing a siphon. The salt solution is then all drawn out. The process is repeated until the uterus is emptied of its contents. The iodoform and oil are then to be introduced.

The vagina itself should be freely and abundantly douched with warm physiological salt solution at least daily, preferably twice daily, followed by the introduction of oil into its anterior end. An intelligent

layman may readily carry out this portion of the treatment. The vagina should be repeatedly dilated in order to prevent stricture or atresia. This may be done by elevating the irrigator containing the salt solution three or four feet above the vulva, and compressing the vulvar opening while the solution is flowing in, until the vagina is well dilated. Care should be taken also to occasionally insert the hand in the vagina in order to make sure that constriction does not become established. Moderate constriction may not interfere with conception, and may disappear with the next birth.

Miscellaneous Parturient Injuries

There is a well-nigh endless variety of injuries which may so rarely occur at birth that while the cases are individually important, they scarcely justify detailed description. They may usually be diagnosed and handled according to the general principles of surgery. They include such cases as rupture of the bladder, intestines, and diaphragm, and various pelvic fractures and other injuries.

Puerperal Infections

Puerperal infections in general are described in the companion volume upon genital diseases, including puerperal laminitis, largely associated with retained placenta, and puerperal tetanus occurring in the mare and cow largely following uterine prolapse.

SECTION VI

SECTION VI

CHAPTER XXXIII

PUERPERAL ECLAMPTIC DISEASES PARTURIENT PARESIS

THE TOXAEMIAS OF PREGNANCY AND PUERPERIUM

IN domestic animals there occurs with considerable frequency a group of diseases characterized chiefly by a profound disturbance of the central nervous system, which usually express themselves either by tonic and clonic spasms or by coma. These diseases generally appear soon after parturition, but may occur during or shortly prior to that event. They all run a very rapid and stormy course. Some of them are highly mortal, as for example, milk fever of the cow, unless promptly and skillfully handled; others often run a favorable course without material interference.

The pathology of the diseases or phenomena falling within this group is unknown. Many theories and hypotheses have been advanced but none universally or permanently accepted. Postmortem study has revealed various lesions but has failed to show whether such lesions are the cause or the result of the disease. In some cases, like pneumonia in milk fever, the pneumonia is clearly the result, not the cause.

The phenomena included in the group are largely considered separately, and conclusions reached in a given member of the group are thereby wholly inapplicable to others. This is unfortunate if they are all due to identical, or closely related causes. It appears possible that this group of diseases is not limited to the pathology of reproduction in domestic animals, but includes also important phases of the pathology of reproduction in woman. It appears highly desirable, therefore, to study the entire list as a correlated group. That done, any discovery regarding the basic nature of one member logically adds to the knowledge of the entire group.

One of the most serious manifestations of disease associated with reproduction in woman is parturient eclampsia. There is much room for conflict of opinion regarding the possible relationship between the eclampsia of woman and the eclamptic, and coma-producing diseases associated with parturition in domestic animals.

Numerous facts serve to create confusion regarding the nature and cause of each member of the group or of the group as a whole. In veterinary medicine, the *milk fever* of the dairy cow holds by far the most important position because of its great economic importance. In some respects, milk fever apparently isolates itself from the group and is studied largely as a distinctive disease without analogy in other mammals. There is a far greater ratio of milk fever in dairy cows than of eclamptic diseases in other domestic animals, in accordance with the general rule that they are most diseased, sexually. Milk fever is characterized by profound coma: cattle generally exhibit a marked predilection for coma as opposed to convulsions. Milk fever is largely limited to pluripara. In most species, primipara are almost or quite mature when first caused to produce young, while dairy heifers are bred when immature. The innumerable contrasts create a highly confusing maze. At the same time there occur many striking analogies. While milk fever is preëminently characterized by coma, many cases begin with very definite eclampsia. In other genera, eclampsia is the rule, but exceptions occur, and coma is not at all unknown. Eclampsia in woman is largely a phenomenon of pregnancy; milk fever is not at all rare in pregnant cows, at or near term, and is probably more frequent than is recognized. Identical or analogous causes acting upon different species or genera of animals, or even upon individuals of the same species, produce phenomena which may be very dissimilar. The eclamptic group of diseases is quite generally closely associated with parturition and occurs either shortly before, during, or shortly after labor. It is commonly stated that milk fever in the cow *follows an easy birth with prompt expulsion of the fetal membranes*. This is largely true. But milk fever occurs prior to the onset of labor and inhibits parturition; it begins during parturition and arrests the expulsion of the fetus so long as the milk fever continues; and it occurs sometimes so quickly after the expulsion of the fetus that the afterbirth has not been expelled and it is retained until the milk fever ceases. The observation that milk fever appears chiefly in cows which up to the moment of the violent onset of the clinical symptoms have apparently been in perfect health, applies generally throughout the group. However, the general principles of pathology compel the conclusion that a foundation for the phenomena had been constructed before, perhaps long before, the sudden manifestations of critical disease. Thus far the recognition of the basic cause or causes has defied the efforts of investigators. Many interesting facts have been determined, and upon these numerous hypothe-

ses have been based. In recent years, the researches have been largely concentrated upon the chemistry of the blood in the milk fever of cows. This is apparently due to the two facts that the material available for study is greatest in milk fever and that milk fever is most important economically.

In domestic animals eclampsia and coma appear interchangeable. In some species convulsions dominate the picture; in others, coma is the more prominent. In general, convulsions, which may later pass into coma, seem to be the usual order. In the parturient paresis or milk fever of the cow, the convulsive stage is very brief or even unrecognizable and the disease comes to be regarded as a deep coma from the outset. In some cases the premonitory convulsions are very marked and may not pass into coma. Generally, close observation will reveal a brief convulsive stage.

In the mare the disease is profoundly convulsive and is succeeded by coma only when near death.

Superficially, the phenomena are divisible into two groups, based upon the preponderance of convulsions or of coma.

Recently much study has been devoted to biochemical tests of the blood and urine of animals for the laboratory diagnosis of pregnancy. It would appear possible that the presence in the blood or urine of abnormal volume or character of these products of pregnancy might cause pathological phenomena, but thus far no adequate study has been made in this direction. It seems quite possible that adequate study of the blood content of pregnancy might yield highly interesting knowledge.

Parturient Eclampsia

PARTURIENT ECLAMPSIA IN THE MARE

Parturient eclampsia in the mare, according to my observations, occurs most commonly a few days after foaling. It is characterized by violent symptoms of eclampsia, including trismus. It pursues a very rapid course and soon terminates in recovery or death. No definite lesions have been recorded.

The earliest definite description available is mine.⁵⁹ My first case occurred in an adult grade draft mare, which had at her side a healthy, vigorous foal, some ten days old. The mare had foaled naturally and easily at the ordinary time. The very apparent vigor of the foal showed clearly that she had been furnishing an abundant supply of milk. The owner reported that a few hours prior to my arrival the mare suddenly became strangely nervous, assuming a

wild look, with staring eyes, restlessness, stiffness of gait, twitching of the muscles, occasionally lying down and getting up. The disease progressed very rapidly, until upon my arrival she lay prostrate on her side, unable to rise. In this position I found her, with the whole muscular system exceedingly rigid, breathing labored, convulsions constant, pupils greatly dilated, mucous membranes livid, firm trismus, and the muscles of her limbs so rigid that they could not be flexed sufficiently to raise her upon her chest.

The second case was a high-grade draft mare aged six years, used exclusively for breeding purposes. The mare was quite large, very robust, and had foaled ten days previously without difficulty. The foal at her side was very vigorous and well nourished. I found the mare lying quietly on her sternum, showing no evidences of suffering, and looking quite bright and healthy. Upon approaching her, however, she showed marked nervousness, and tried at once to get up, but appeared to have lost the power of coördination. Her efforts brought on clonic spasms of a severe character. Her hind legs knuckled at the pasterns, much as in azoturia. During my stay she became more nervous and uneasy. She made repeated unsuccessful attempts to rise. Respiration was rapid and laborious, and there were constant and severe cramps of the entire body, trembling, and profuse perspiration, all of which appeared to decrease in intensity when we withdrew and permitted her to become more tranquil. The passage of the catheter increased the convulsions quite markedly. There was apparently hyperaesthesia of the vulva, and of the body generally. I diagnosed azoturia, and prognosticated a favorable termination. Later observations have shown me that mares with young foals do not contract azoturia. Moreover, the fact that the mare had been running constantly at grass precluded the possibility of that disease. She died a few hours later.

During the summer of 1889 an unusual number of cases occurred in rapid succession, showing every degree of intensity. At this date, since the rapidly developing horse-breeding interests in my locality had about reached their maximum, large numbers of mares were kept solely for breeding purposes. Favorable weather during the season furnished exceedingly luxuriant pasturage. During that year I observed seven well-marked cases, several of which offered favorable opportunities for observation throughout a greater part of the course of the disease.

A well-bred road mare, in high condition, with a vigorous, well-nourished foal, eight to ten days old, at her side, was brought from the pasture preparatory to being bred. Soon after her arrival at the

owner's stable, it was noticed that the mare was restless and nervous, her eyes somewhat staring, and there were occasional muscular twitchings. Most noticeable of all was a peculiar, well-marked throbbing of the chest, which shook the entire body. It seemed like an exaggerated heartbeat, and was quite regular in rhythm and force, but was not rhythmical with the heartbeat. The disturbance seemed greatest along the line of attachment of the diaphragm to the ribs. The phenomenon could be attributed to no other cause than clonic spasm of the diaphragm. There was some trismus, but not enough to prevent the patient from eating with relish and comparative ease. With quiet and moderate doses of belladonna and cannabis Indica, she made a good recovery in a few hours.

I was called to attend a half-blood draft mare, aged seven years, in prime condition and perfect health prior to the date of my visit. She had foaled ten days before without trouble. The foal was vigorous and well nourished. She was then brought from the pasture for the first time, and placed in the stable. Within a few hours, symptoms of disease were manifested. I found the animal in great pain, very nervous, and easily disturbed by any movements or noise. She lay down quite frequently. While lying, she became more tranquil, and all the symptoms abated. She lay on her sternum, and did not attempt to roll. She rose with apparent ease. While standing there were constant clonic twitchings of the muscles of the entire body, spasmodic movements of the limbs, frequent changes in posture, trembling, profuse sweating, distension of the nostrils, and stiff movements as in tetanus. There was no protrusion of the membrana nictatans over the eyeballs, but the eyes were staring, the pupils dilated, and the conjunctivae dark livid in color. There was severe trismus: the jaws were wholly immovable. As in the preceding case, there was violent spasm of the diaphragm. She was bled freely from the jugular, and given large and repeated doses of belladonna and cannabis Indica. For nearly thirty-six hours the symptoms remained about the same, when they began to abate rapidly, and in forty-eight hours after the beginning of the attack the mare was in her usual health.

On the same day, on a neighboring farm, I attended another grade draft mare with a similar history of recent easy parturition, healthy foal at her side, etc. Prior to my arrival, she had shown a train of symptoms similar to those noted above, but, as the owner delayed calling me, upon my arrival I found the animal prostrate on her side, the whole muscular system thoroughly tetanized, the eyes set and insensible to light, firm trismus, well-marked opisthotonos, and repeated severe convulsions of the entire body, readily increased by

any sudden noise. Barring the want of protrusion of the membrana nictatans and the greater nervousness, the case closely simulated recumbent tetanus. The animal succumbed after about twenty-four hours.

I was called to attend a full-blood draft foal, five or six days old, which was suffering from lameness. In order that the foal might be well attended, the mare was brought from the pasture and placed in the stable. The next morning I was called hurriedly to attend the mare, which I had seen the previous day in apparently perfect health and unusually robust and vigorous. Upon my arrival at the farm I found her greatly agitated, the whole body tetanized, with constant clonic twitchings, spasmodic movements of the limbs, hurried, labored respiration, nostrils widely dilated, visible mucous membranes of a dark livid hue, firm trismus, and profuse sweating. When on her feet she could not stand still, but continually moved about involuntarily, and so very uncertainly that she could scarcely be approached with safety. The perspiration was so profuse that it streamed from the dependent parts of her body, the nose was poked out, the head elevated, the back arched, the tail erected, giving the entire body the posture assumed in severe tetanus, but the well-marked protrusion of the membrana nictatans seen in the latter disease was wanting. The animal lay down frequently, usually on the sternum, in which position she became more tranquil and apparently obtained some relief. Sometimes she lay prostrate on her side, in severe convulsions, the legs all rigid, so that the upper feet did not touch the ground, but projected in a straight line from the body. The spasm of the diaphragm was so violent that even when the mare was lying on her sternum her whole body shook violently at each contraction. When she was standing fifteen or twenty feet away, a loud thumping noise could be heard, emanating from the chest, like violent palpitation of the heart, but upon close examination it was found that the disturbance was not synchronous with the heartbeat. With great difficulty, owing to the uncertain convulsive movements of the animal, I drew about three gallons of blood from the jugular. This was followed by heavy and repeated doses of fluid extract of belladonna and cannabis Indica every hour. My prognosis was very unfavorable, as death seemed imminent. After twelve to fifteen hours the symptoms rapidly abated, and within twenty-four hours after my visit she was apparently in her usual health.

A high-grade draft mare of vigorous constitution, with a well-nourished healthy foal about fifteen days old at her side, was taken from the pasture for the first time since foaling and put to light farm

work. In a few hours she had developed all the symptoms enumerated in the preceding cases, and when I arrived she was unable to regain her feet. She grew worse rapidly and died the same day, within twelve hours from the time she was brought from the pasture in prime condition, and only five to eight hours after the beginning of the attack.

An imported pony mare in high condition, with a well-nourished foal at her side, six or eight weeks old, was brought from the pasture for the first time since foaling, saddled, and placed in the hands of children, who used her for a few hours in the morning. At noon the stableman found some difficulty in removing the bit from her mouth. This attracted no particular attention, but when the owner attempted to bridle her again after dinner, and failed on account of firm trismus, it was evident that something serious was wrong. A veterinarian was at hand in a few hours. The pony rapidly developed all the symptoms enumerated in the preceding cases. She was bled from one jugular on the first, and the other on the second day. In about forty hours after the beginning of the attack, the symptoms suddenly abated, and within forty-eight hours the pony was apparently as well as ever.

I have recorded briefly here a series of cases presenting symptoms no more varied than would be expected in different individuals in various stages of the disease. The separate clinical pictures pass from one into the other by imperceptible gradations, and are all apparently due to the same cause.

In the earlier stages, and in the very mild cases throughout, all showed the restlessness, the staring eyes, and the clonic spasms, especially marked in the diaphragm. In proportion to the nervousness, the pulse and temperature are little altered. If unchecked, the clonic spasms are largely succeeded by those of a more tonic nature, trismus becomes a marked symptom early in the malady, the restlessness and convulsions increase in intensity, the respiration becomes more labored, the mucous membranes are livid from partial asphyxia, and the whole muscular system is extremely tetanized. Finally the animal becomes unable to stand, or to find relief in lying on the sternum, but lies prostrate on the side in constant convulsions, until she succumbs.

The history is quite uniform. The disease occurs exclusively in vigorous mares, in high condition, of mature age, but not old. They have recently foaled naturally and easily, and have healthy, well-nourished foals at their sides. The mammary glands are well developed and active in all cases. In nearly, if not all the cases I have related, the mares had been enjoying unrestricted freedom at pasture constantly since foaling, until taken up a few hours prior to the

attack, which was suddenly ushered in without warning. It seems that a sudden change of surroundings, change from freedom to the stable or harness, possibly by causing maternal anxiety for the foal, has an essential influence in the immediate causation of the disease. The symptoms indicate a grave disturbance of the central nervous system, expressed for the most part in convulsions and spasms of the striated muscles. The symptoms enumerated in the mare bear a close resemblance to those of eclampsia of other lower animals and of woman, as well as to the early stages of parturient apoplexy of the cow.

The disease in the mare is ushered in suddenly, runs a rapid course of twenty-four to forty-eight hours, and terminates as abruptly as it began, in complete recovery or in death.

Harms³² cites Tapken as having observed eclampsia in a mare, one and one-half hours postpartum, which quickly disappeared, to reappear the next day following the removal of the placenta. Harms also cites Gutbrod as having observed the phenomenon three days postpartum, and Hub as having observed convulsion with maniacal symptoms in a mare, eight days prior to expected foaling. She became so violent that she demolished her stall. She later foaled and recovered.

The cause of the disease, as in the group as a whole, is unknown. In my cases the onset of the disease was usually at seven to ten days after foaling. Later observations show⁶⁴ that at this date, at which time the mare is usually in estrum, there is often a definite fulmination of endometritis with a profuse genital discharge of a thin, odorless, watery exudate. But in the cases cited above, no signs of genital infection of any known kind were observed. There is nothing to indicate infection. At this time also, the foal shows a marked tendency to diarrhea. The citation of Tapken by Harms, in which retained afterbirth was present, is in harmony, in those cases, with the idea of the association of eclampsia with uterine disease.

The diagnosis should apparently be quite easy in all cases. The history of the case, so far as observed, seems of special value. The clonic and tonic spasms, the extreme trismus, and the peculiar spasms of the diaphragm are quite characteristic. The disease may be confounded with:

(a) Tetanus, from which it is distinguished by the sudden onset, the earlier and more complete trismus, the peculiar spasm of the diaphragm, the greater nervous irritability and greater tendency to clonic spasms, the greater tendency to lie down, the dilation of the pupil, the absence of the protrusion of the membrana nictatans, the

absence of any antecedent wound, the far more rapid course, and the usually more favorable termination.

(b) Cerebro-spinal meningitis, from which it is distinguished by its history, its more sudden onset, its cramp unaccompanied by paralysis, its well-marked trismus, rapid course and more favorable termination.

(c) Azoturia, from which it differs essentially in attacking animals not subject to that affection—that is, mares enjoying unrestrained liberty and having young foals. Aside from the fact that azoturia cannot be induced in such animals, the spasms are more general over the entire body, the trismus is characteristic, and the urine neither abundant nor highly colored.

Evidently, the treatment should consist first of quiet and comfort. The foal should be allowed with the mare. In my cases, free blood-letting apparently alleviated the symptoms, if resorted to early. Fluid extract of belladonna and of cannabis Indica, in large and repeated doses, apparently allayed the excitability, and exerted a favorable influence upon the course of the disease. Various narcotics would probably be quite as effective.

PUERPERAL ECLAMPSIA IN THE SOW

In some countries the sow apparently suffers frequently from eclampsia. Thus Kjeldbjerg³⁸ reports observations upon over one hundred cases. It occurred chiefly before or during parturition, rarely afterward. There is loss of appetite, and unsteadiness of the posterior parts. The recumbent patient squeals frequently. When standing, the animal trembles. If the disease sets in during labor, parturition is halted and convulsions develop. The convulsions are very violent; there is champing of the jaws with dribbling of saliva. The convulsions may pass into coma at any time. In some cases the coma sets in early, and convulsions are not notable. Kjeldbjerg estimates the mortality at thirty per cent. DeBruin recommends handling by means of electuaries. The sow cannot be safely drenched. Intrajugular injections are not available. The electuaries should have as their basis, narcotics. Mixed with a heavy syrup, they may be spread upon the tongue with a wooden spatula.

ECLAMPSIA IN THE GOAT AND EWE

Eclamptic symptoms are apparently more frequent in small ruminants, in the first stages of parturient paresis, than they are in milk fever of the cow. The subject is more fully discussed under the latter title.

PUERPERAL ECLAMPSIA IN THE BITCH

Keller³⁷ states that the bitch suffers from puerperal eclampsia more frequently than any other domestic animal. It occurs before, during and after labor, most frequently one to three weeks after parturition. The psychic disturbance produced by taking away the puppies sometimes apparently ushers in the disease. This is in harmony with the clinical observations in other domestic animals; the anxiety produced by taking away the young apparently precipitates the disease. Keller has observed the disease exclusively in the smaller breeds, under twenty-two pounds weight.

The symptoms are analogous to those of the eclampsia already described in the mare. The first symptoms are anxiety, restlessness, and uncertain gait. The patient falls in convulsions. The voluntary muscles are affected with severe tonic and clonic spasms. As in other eclamptic diseases, the body excretions are largely in abeyance, the bowels are torpid, the urinary secretions are suspended, and the mammae are flaccid and devoid of milk. During the convulsions, the patient at first remains conscious. Later the convulsions may be followed by coma and unconsciousness. While in the convulsions, the visible mucosa are cyanotic. The affection greatly resembles strychnine poisoning, but de Bruin points out the important difference that in strychnine poisoning the patient is easily excited, while in eclampsia no hypersensitiveness is apparent.

The course of the disease, as in other members of the eclamptic group, is usually stormy. Unless it is energetically handled, it ends fatally in 24 to 48 hours. The prognosis is good when the disease is promptly handled.

DeBruin strongly recommends 20-40 mg. (0.3-0.6 grains) of morphia hydrochlorate, hypodermically, repeated in a few hours if necessary. Some advise chloroform inhalations or chloral hydrate enemas. Some have recommended the administration of ether or chloroform syrup by the mouth, but, as in all diseases of this group, the powers of deglutition are uncertain, and there is constant danger that, when it is attempted to administer medicines by the mouth, they may pass into the lungs with unfortunate consequences.

CHAPTER XXXIV

PARTURIENT PARESIS

Parturient Paresis in the Cow. Milk Fever. Parturient Apoplexy

PARTURIENT paresis has long been known as an exceedingly common, and until recently highly fatal malady of dairy cows. Apparently it has been known as long as dairying has been followed as a scientific pursuit and cows have been bred especially for dairying purposes. Somewhat rarely it may attack cows belonging to the distinctively beef breeds, but even then it is usually in those which are heavy milkers. The disease occurs usually in adult cows, rarely in the young or aged. Harms,³² citing Bavarian statistics by Göring, gives the following table of the ages at which 127 cows were attacked by milk fever.

At the age of 3 years	1
" " " 4 "	4
" " " 5 "	20
" " " 6 "	14
" " " 7 "	22
" " " 8 "	18
" " " 9 "	22
" " " 10 "	12
" " " 11 "	3
" " " 12 "	6
" " " 13 "	2
" " " 14 "	1
" " " 15 "	2

The above data indicate the relative frequency of milk fever according to the age of the cow. The table does not show the percentage of milk fever in cows of a given age. In America, most dairy heifers are bred to first calve at two years. In the above statistics, no cases are recorded as having occurred at two years, and it is not related that any of them calved at so immature an age. In numerous dairy herds in America, so far as may be learned, the average number of viable calves does not exceed four per cow. In such case, one-fourth of the calving females would be under three years of age. It would consequently appear possible that among the 127 cases of milk fever above listed, if all ages were alike susceptible, there may have occurred about fifty cases in primipara instead of the one reported.

At the other end of the table, cows of fourteen and fifteen years are rare and the actual ratio in fifteen-year-old cows, in which two cases are recorded, is probably higher than in the five-year-olds with twenty cases. That is, there were probably twenty times as many five-year-olds as fifteen-year-olds. Accordingly, while most cases of milk fever occur in cows from five to ten years of age, it is not shown that cows falling within those ages are more subject to milk fever than are those of greater age. Statistics are extremely weak regarding the ages of dairy cows. An overwhelming majority are under seven years of age.

Harms, quoting Haycock, gives the following duration of time after parturition at which parturient paresis made its appearance.

5	times	immediately	after	calving.
8	"	20	hours	" "
5	"	23	"	" "
5	"	24	"	" "
3	"	30	"	" "
2	"	36	"	" "
1	"	72	"	" "

Here again data are defective. There is much confusion regarding the correct definition of milk fever. Since the actual pathology of milk fever is unknown and the symptoms are not clearly definable, it is difficult to state accurately at what period the disease may set in.

Parturient paresis also occurs before and during parturition. In these cases, all the cardinal symptoms of the malady present themselves, and the course and termination are the same as observed in cows attacked after parturition. I was called to attend a cow because of dystocia, and found her standing with portions of the membranes hanging from the vulva. Upon examination it was found that the fetus was in its normal position and alive, and that the cervix was fully dilated. All that appeared to be wanting was a moderate expulsive effort on the part of the cow, but this did not occur. She seemed well in a general way, except that she was unsteady upon her feet. The fetus was extracted under very moderate traction, without any aid from the mother. Some two hours later she fell, exhibiting all the symptoms of parturient paresis, and perished therefrom a few hours later. In another instance I saw a typical case of paresis, where the animal was down and comatose and the placenta was still retained in the uterus.

The disease is one of well-nourished animals. It does not occur in those cows which have been starved or have been kept upon food of very bad quality. On the other hand, the excessively fat cow does not show so great a tendency to the disease as the one which is in

good flesh. It is a disease belonging to the highly-nourished animal, not to the obese or the emaciated.

In those cases of parturient paresis occurring subsequent to parturition, the disease follows an easy birth. In almost every case, there is prompt expulsion of the fetal membranes. But the prompt expulsion of the fetal membranes does not constitute proof of a healthy uterus. On the contrary, the uterus may be very badly diseased and yet the placenta come away promptly.

Symptoms. When the animal is under close observation, preceding the full development of the symptoms of parturient paresis there is usually noted first a staring expression of the eyes, with dilation of the pupil and a wild look. There may be occasional muscular twitchings or contractions, and unrest. In rare cases there are very distinct clonic spasms, especially of the neck, with grinding of the teeth and slabbering. The animal acts as if affected with mania, and executes various movements with the head. In one case I observed that the cow would bite at her shoulder. If the cow is caused to move, she does so with a more or less unsteady gait. She seems especially weak and uncertain in her hind limbs, and sways somewhat from side to side or knuckles over. She may show considerable uneasiness and nervousness, and lie down, only to get up again after a few minutes, perhaps with some difficulty.

As the disease progresses the animal goes down and is unable to rise. At first she lies upon her sternum, usually upon the left side, in a somewhat natural attitude, with the head up. Later she shows a tendency to extend the head and rest the muzzle on the ground or to drop the head in the right flank with the nose lying upon the ground. Still later, she tends to lie prone upon the side.

Early in the disease coma sets in and the animal becomes more or less insensible. Convulsive struggles occur for a time, in which the patient throws herself about violently. She may make unsuccessful and unconscious efforts to arise, and may succeed in getting upon her knees and floundering about violently. She may throw the head from side to side with great violence, may shift from sternal to lateral recumbency, and from time to time may resume sternal decubitis. As the disease advances, there is a constantly increasing tendency to lie flat upon the side.

At first the pupils are dilated and the eyes have a wild and glaring look. The normal movements of the eyelids soon cease, the eye remains open, and the surface of the cornea becomes dry and listless, because the eyelids are not closed frequently to distribute the tears over the cornea and keep it moist. Early in the disease, there may

be an abundance of tears, which may flow down over the cheeks and keep them wet. There is an involuntary flow of saliva, due rather to the failure of the animal to swallow it than to any increase in the amount secreted.

The temperature is subnormal. Rarely in the earlier stages of the disease, when accompanied by more or less violent muscular twitchings, there may be elevation of temperature. Later, when the disease has existed for some hours and there has been partial improvement, if a relapse occurs, not of paresis, but of inhalation pneumonia or other inflammatory complication, the temperature may become elevated. The respiration is deep and slow as a general rule, though in some cases it may be rapid and shallow. There is sometimes a moan during expiration.

The disturbances in the alimentary tract consist essentially of a profound paralysis. There is difficulty and uncertainty in deglutition. In former times many cows were killed in attempting to drench them. Instead of being swallowed, the liquids passed into the lungs, causing fatal strangling or bringing about an equally fatal foreign-body pneumonia. The rumen is paralyzed, and as a consequence tends to become filled with gas owing to the decomposition of contained food. This is especially marked if the animal lies upon her side. This symptom is one of great danger for the animal, because the tympany tends to press the food up through the esophagus into the pharynx, whence it drops into the larynx and is inhaled, to cause either fatal strangling or, later, a fatal foreign-body pneumonia. The intestines are likewise paralyzed, and little or no defecation occurs. If the hand is introduced into the rectum, a small amount of dry feces is found.

The kidneys cease to function, and little or no urine is emptied into the bladder. Some veterinarians formerly urged that it was essential in the treatment of the disease for the catheter to be passed frequently in order to prevent rupture of the bladder. As a matter of fact, unless the bladder is distended when the disease comes on, it does not become so until after the malady has ceased.

The secretion of milk is wholly in abeyance. There may be a small amount of milk in the udder at the time that the cow goes down, and this may remain for a time, but there appears to be some tendency for it to be resorbed and the udder to become very flaccid.

The pulse at first may be slow and weak, becoming later more frequent and irregular.

The general sensation is much depressed. Early in the disease the eye seems somewhat sensitive to light or touch, but later the cornea

may be touched without causing any reaction, and the skin may be pricked at any point with a pin or other sharp object, without producing any evidence of feeling.

As the disease progresses, the coma and paralysis become more and more profound, and death may occur at any time without warning, or the coma may gradually deepen and the animal appear almost lifeless for hours before death occurs. As the fatal termination approaches, the breathing becomes shallower, the pulse becomes weaker and more irregular, and the temperature continues to sink.

The course of the disease is rapid. Generally, the earlier the advent of the malady after parturition, the more rapid its course. The animal may die within six or eight hours from the beginning of the attack, or the disease may be prolonged to two or three days.

Complications of great variety may occur. In some especially stormy cases, there is complete prolapse of the uterus as one of the earliest symptoms, and death usually ensues very quickly. In two cases in my experience, the animals perished within two or three hours after the advent of the first symptoms of the disease.

One of the commonest and most serious complications observed in the course of the disease is strangling owing to the inhalation of solids or liquids. This may cause immediate death, or later may lead to foreign-body pneumonia. A few years ago it was common, in handling milk fever, to attempt drenching a cow with large volumes of oil or of solutions of saline cathartics or other medicines, which in many cases flowed directly into the lungs because of the unconsciousness of the animal and the paralysis of the pharynx. In other cases in the comatose animal, there is an involuntary passage of food from the rumen through the esophagus into the pharynx, from which it is inhaled into the lungs. In either case the animal may be quickly strangled by the blocking of the bronchial tubes with the food or medicines. Formerly it was a common experience for the veterinarian to give a large dose of medicine and have the animal perish before he could get off the premises.

When immediate death from the inhalation of food or drugs does not ensue, the paralysis and coma may continue, and the symptoms of parturient paresis pass imperceptibly into those of pneumonia. Sometimes the animal partially recovers, seems brighter, and may even recover so far as to regain her feet and possibly take some food. After some hours, or even a day or more, she may show signs of pneumonia with elevation of temperature, and go down again, to perish finally from the complication.

Diagnosis. It has already been intimated that milk fever cannot, at

present, be clearly and authentically defined. Some would limit the time of the onset of the disease to the first two or three days of the puerperal period. Personally, I have certainly observed as clear cases of milk fever before and during labor as I have seen after calving. Difficulty arises from the fact that the cow has a marked predilection for coma. With the coma goes subnormal temperature. When the Schmidt treatment was introduced, it was thought that its efficacy might serve to authentically differentiate milk fever from other comas. This has proven disappointing. The Schmidt treatment does not rescue all cases of milk fever, and not all diseases responding to Schmidt's treatment are milk fever. The fact that a cow has calved recently does not prevent the occurrence of other diseases which may simulate parturient paresis. Schmidt⁴⁷ draws attention to the fact that indigestion in the cow may simulate parturient paresis very closely.

In one case which I observed, a cow went down in the pasture with what strongly resembled parturient paresis in all essential respects, including paralysis, coma, and subnormal temperature, but she had calved six weeks previously. The disease was apparently due to a slight purulent mammitis. The injection of oxygen into the udder was followed by a complete recovery. This would lead many to believe that the malady was really parturient paresis. I cannot subscribe to this view. The coma and the associated subnormal temperature could occur as readily in other diseases. It is not known why udder inflation cures parturient paresis, nor why it may not cure other diseases, if coma is the chief symptom.

While the fundamental nature of milk fever remains unknown, some intimately associated facts are well determined. It is preëminently a disease of those dairy cows which are good milkers, but the reason for this is unknown. It cannot be authentically attributed to excessive lactation, because it sometimes occurs in the dry cow just prior to calving. At that time the mammae are engorged but active lactation is not present.

The state of nutrition has a very marked influence upon the occurrence of parturient paresis. It is a disease of the cow in excellent condition, not of the emaciated or excessively fat. It occurs in those animals which are apparently in perfect health up to the hour of attack.

Food and housing have been claimed to influence the tendency to parturient paresis. The disease is observed in both stable and pasture. It is most common in the stable. Dairying is largely an industry of

temperate climates where dairy cows are usually confined in stables. It occurs in mild climates where dairy cows are stabled little or not at all. In temperate climates where cows are regularly stabled during winter, milk fever is not rare in the late spring after the cows have been running on rich pasture for a time, without any allowance of grain. When following parturition, as is the usual case, the labor has generally been apparently physiological. It would be unsafe, however, to say that *physiological parturition* predisposes the patient to a *pathological puerperium*. There must be some unrecognized abnormality present.

The pathology of milk fever is unknown. No basic lesions are clinically recognizable and none are discovered by autopsy. The theories regarding the pathology of milk fever are almost endless. Some have believed that it is due to congestion or engorgement of the brain and spinal cord; others regard it as an anaemia of these organs. Neither is capable of demonstration.

Others believe that milk fever is a toxæmia, and that the toxic substance is derived from the uterus. The nature of the toxin is sometimes attributed to the intrauterine infection, sometimes to some placental product.

The Schmidt treatment for milk fever, which has proven profoundly efficient, had its origin in the belief of Schmidt⁴⁷ that the disease was due to a toxin derived from the uterus and mammary gland. My collaborators and I⁶¹ have recorded an instance of the high prevalence of milk fever in the cows bred to a genitally unsound bull. The herd is composed of purebred Holstein, Ayrshire, Guernsey and Jersey cattle. Milk fever was virtually limited to the Jersey cows; the ratio of milk fever in the Jerseys was extremely high over a series of years. The Jersey bull was known to be suffering from extensive, chronic inflammation of the seminal vesicles. The management was finally induced to discard the diseased bull, whereupon the milk fever ceased among the cows. The observation suggested etiological relationship between the genital disease of the bull and the milk fever in the cows, but such relationship was not proven.

During recent years, interesting studies have been made in the blood chemistry of milk fever. This has led to the hypothesis that milk fever is due to a quantitative deficiency of calcium or other inorganic salt in the blood; or to an excess of blood sugar (hyperglycaemia) or a deficient volume of blood sugar (hypoglycaemia). It seems well established that in milk fever calcium salts and glucose are abnormal in volume, but it has not yet been authentically shown

whether the abnormal chemical nature of the blood causes, or is caused by, milk fever.

Until the discovery of Schmidt, the treatment of milk fever was marked by extremely embarrassing inefficiency based upon erratic theories and hypotheses. Many plans were tried, recommended and then discontinued.

Schmidt⁴⁷, of Kolding, Denmark, conceived the hypothesis that milk fever was due to toxins derived from the mammae, the uterus or both organs and that, by the introduction of antiseptics into these organs, the disease could be cured. Whether the hypothesis rested upon fact or error, the method of handling based upon it has proven one of the most brilliant chapters in the history of veterinary therapeutics. The original plan of Schmidt has undergone many changes in concept and detail. At first Schmidt injected, into the four quarters of the udder, a liter of one per cent potassium iodide solution, air being carefully excluded. Later he had better results by the introduction into the udder of small volumes of air, alternating with the potassium iodide solution. There were soon many workers in the field, and modifications of the original plan were numerous. Sodium iodide was used in place of potassium salt. Physiological salt solution, bicarbonate of soda, weak solutions of lysol, carbolic acid and other antiseptics were tried, as substitutes for iodide of potash. Others discarded the antiseptic measures and fully inflated the entire mammary gland with atmospheric air. Some proposed to substitute oxygen, and the results were good. The air was so constantly and freely at hand and its use was so brilliantly successful that it was quite universally adopted as the final plan evolved from the basic recommendation of Schmidt.

The generally accepted outline for insufflation of the udder follows:

As soon as the patient has been reached and a diagnosis of milk fever has been made, a sufficient volume of air should be introduced into each quarter of the udder to distend quite thoroughly all parts of the gland. In order to avoid the escape of the air through the teat canal, it may sometimes be desirable to apply temporarily to the teat a soft ligature, which is to be removed after the expiration of three or four hours.

The ligature should consist preferably of a soft peice of tape, which should be tied around the teat tightly enough barely to prevent the injected air from escaping through the teat orifice. If tied too tightly, and allowed to remain for several hours, necrosis of the teat may follow. The teat is to be closely watched, and the ligature removed

promptly whenever serious injury is threatened. The broader the ligature and the more evenly applied, the less the danger to the teat. An elastic ligature or ordinary rubber band may be used, but its power needs be carefully adjusted to the resistance of the teat in order to obviate necrosis.

The ligation of the teat is not usually necessary. The necessity for ligation in order to retain the air in the udder is largely dependent upon the character of the teat sphincters. In those cows which leak their milk, there will naturally be greater necessity for ligatures than in hard milkers. The amount of gas injected is subject to no fixed rule. The udder should be firmly distended. Usually the sphincters of the teats will retain sufficient air and permit any excess to escape. Some believe that, the greater the distension of the udder, the more prompt and effective the treatment. This has not been clearly shown. Occasionally the distension is overdone, and extensive emphysema of the udder, thighs, and croup follows. No harm ensues. If the distension seems insufficient, if the response is tardy or feeble, more air may be introduced at any time.

Should the first inflation fail to produce the desired results after an interval of three to six hours, a second distension of the gland should be made. There is no evidence that any harm may occur from repeated inflations of the udder so long as no infection is carried into the gland.

The precautions to be taken are analogous to those for any surgical operation. They include the disinfection of the operator's hands; the disinfection of the cow's udder, especially the teats; the sterilization of the injection apparatus, especially the tube which is to be introduced into the teats; and the protection of the udder from infection during the operation. The patient needs be placed in such position that all four quarters of her udder are readily available. Usually it is best to place her, temporarily, in lateral or oblique recumbency.

The udder should be placed upon a clean cloth, or tray, after which the entire gland, especially the teats, is to be thoroughly washed and disinfected. The apparatus to be used for injecting the air, especially the tube to be inserted into the teat, should be sterilized by boiling.

Before inserting the tube into the teat, all antiseptics should be carefully washed away from the tube and from the end of the teat, with sterile water. The operation is to be *aseptic*, not *antiseptic*.

The mechanism by which the inflation is brought about is not essential, so long as the general rules of asepsis are maintained. Vari-

ous forms of apparatus have been introduced for the purpose of avoiding infection, but few, if any of them are free from objection. No difference what the particular type of apparatus, the general rules of aseptic surgery must be carefully applied by the veterinarian: the apparatus is not sufficient in itself. Many of these devices consist of a rubber bulb, attached to an elongated tube, into which is inserted a filter of asbestos, cotton, or other substance. Beyond this, the rubber tubing ends with an ordinary milk, or teat tube, which is inserted into the milk canal. If the filter is not properly sterilized, it acts as a constant menace to the udder of the patient. The simplest apparatus, the one which can be most readily sterilized by boiling, is the best. There is no great danger of the introduction of infection with the air, if moderate care is taken not to stir up dust in the stall while the operation is in progress. This danger may be eliminated in a variety of ways which are very simple. If a wash-bottle is constructed, and the air forced through the water, and thence into the udder, any floating particles of dirt will be retained in the water, leaving the air free from infection.

The safest and most convenient apparatus for the work is the compressed-air tank. The tank may be charged by the veterinarian. The air should be filtered through sterile gauze as it enters the tank. Thus charged, under suitable precautions, the apparatus is always ready, compact, light, easily applied, and workably free from the danger of causing infection. The milk tube or other tube inserted into the teat should be short, barely long enough to freely enter the milk cistern. A long tube may wound the parts during unexpected struggles. The tubes may be sterilized in advance, and enclosed in a hermetically sealed container, so that they are ready for use. It is apparently immaterial whether any milk which may be in the udder is withdrawn before the injection or not.

Some practitioners advise treatment supplementary to the inflation of the udder, but they have not yet clearly shown by clinical data that any good has come from such additions. Generally those who desire to add something to the udder inflation prescribe powerful heart stimulants, such as strychnine or caffeine.

Harms³² states that while the udder method was undergoing evolution, Baroni, Cozette, and Perussel attained encouraging results from the subcutaneous injection of two to five liters of physiological salt solution. Peter and Wessel also recorded successful handling by the intravenous injection of two liters of .5% iodide of potash solution. These gained no popularity.

More recently, when Dryerre and Grieg,¹⁹ Auger⁴ and numerous other investigators began their studies of the chemistry of the blood in milk fever and found a deficiency of blood sugar (hypoglycaemia) or of calcium or phosphorous, intravenous medication was revived. Glucose, calcium and other elements, the deficiency of which was believed to have caused the disease, were injected intravenously in the belief that the deficiency was thus restored. The method, which was followed by a gratifying measure of success, largely replaced the inflation of the udder. This plan directly introduces into the blood calcium and glucose, elements found wanting in the blood of the diseased animal; the inflation of the udder with air also restores to the blood the normal content of these two substances. The calcium gluconate treatment is advocated in preference to the inflation of the udder because it is held by some that the inflation is dangerous because of mastitis. Milk fever is most abundant and destructive in those breeds and individuals most intensely bred and handled for the production of milk: likewise mastitis is most common and destructive in the milk breeds. Both milk fever and mastitis are well-nigh unknown in the beef breeds. It is consequently easy to cause mastitis by inflating the udder in milk fever: the infection may already exist in the udder and the inflation may aggravate it. Data are wanting regarding the incidence of mastitis following recovery from milk fever without udder inflation: it is probably high. I have observed no marked increase in the incidence of mastitis following udder inflation. The risk must be admitted. It would be safer if separate milk tubes were used for each quarter and the transfer of infection from one to another quarter avoided. Any carelessness in asepsis invites mastitis. Yet many practitioners continue its use, frequently as an alternate. If the calcium-glucose treatment fails, they resort to inflation; if inflation fails, they turn to calcium gluconate.

Calcium gluconate in a 20% solution may be injected intravenously in a dosage of 250 to 500 cc., and may be repeated after a few hours; if improvement fails to appear, the udder inflation may be substituted. The calcium gluconate may be used hypodermically. Dextrose may be substituted for glucose.

The attitude of the patient is of very great importance. Except when it is necessary for a few minutes while inflating the udder, the cow should from the first be carefully and zealously guarded against assuming lateral recumbency, or this position promptly corrected if already attained. The cow, like other ruminants, promptly suffers

from tympany of the rumen whenever lateral recumbency is maintained for a prolonged period. The distension of the rumen, by its pressure upon the diaphragm, interferes seriously with respiration and with the action of the heart and other organs. The most serious danger from this position is that, in the paretic state of the animal, there is imminent risk of the involuntary passage of food from the rumen into the pharynx, and its inhalation into the lungs, to cause fatal strangling or foreign-body pneumonia. Consequently it is essential to keep the animal in sternal recumbency. This may be facilitated by packing bundles of straw about the animal. When the patient is very violent it may be desirable to secure the two anterior feet in such a way that the limbs cannot be extended. This is best accomplished by attaching a short strap or cord to each anterior foot, carrying them upward over the withers, and tying them together in such a manner as to keep the anterior feet completely flexed upon the carpus against the chest.

When parturient paresis occurs before or during parturition, the fetus should not be disturbed, but the udder inflated or calcium gluconate administered. The dystocia, or rather atocia, due to uterine paresis from the disease, vanishes after recovery. I have seen cases where parturition was due, the cervical canal dilated, the calf alive and presenting normally, but the uterus inert. Such cows respond promptly to the inflation of the udder, get up quickly, and parturition comes on and is completed with alacrity.

In those cases of parturient paresis complicated by prolapse of the uterus, the inflation of the udder is the urgent primary duty of the veterinarian. When that has been done, immediate attention should be given the prolapsed organ and it should be reduced as already advised, page 401, before the udder inflation has taken effect and resistance to replacement has been aroused.

It is quite unnecessary to suggest that the animal be well bedded and otherwise made comfortable.

The practitioner should be on his guard against the dangers of moving the recumbent animal from place to place. If the patient has fallen in a bad situation, out of doors or elsewhere, it may appear desirable that she should be conveyed to a stable or other suitable place for handling. In bringing about this transfer it is well-nigh unavoidable that she be placed in lateral recumbency and undergo a form of handling which will tend strongly to cause the regurgitation and inhalation of some of the contents of the rumen. Therefore it is best in all cases to make the patient comfortable, if possible, where

she falls. Abundant bedding, with blankets if the weather is cold or rainy, usually suffices as well as a stable and avoids the danger of transfer. Should the moving of a patient to another location become imperative, she should be kept on her chest until all is in readiness, the transfer then made promptly and carefully, and the patient quickly replaced upon her sternum.

When the practitioner is called to attend a case of parturient paresis, he should rigidly abstain from drenching the patient, and inquire, before he takes charge, whether any drugs or medicines have been given by the mouth. If cows suffering from parturient paresis are drenched, the mortality is exceedingly high, because portions of the drench usually pass down the trachea into the lungs. It does not matter at what stage of the disease the attempt to drench the animal occurs. While she is still upon her feet, and merely beginning to stagger, she is nevertheless very liable to become strangled. There appears to be from the first an anaesthesia or paresis of the larynx, pharynx, and other parts, which prevents coughing or any other signs of strangling. If the animal has received a drench, especially one which would be highly irritant to the lungs or could not be absorbed from the respiratory mucous membrane, an unfavorable prognosis should be given at once, and the handling begun with a definite understanding that the animal will probably die from inhalation pneumonia.

From the standpoint of prophylaxis, the attitude of the profession has been quite generally modified by the advent of the present method of handling. Formerly it was advised in many cases to withdraw a portion of the milk from the udder before the cow calved, and to keep her well milked immediately after calving, but this rule has been reversed, and it is now advised to leave the udder fully distended with colostrum or milk.

It is now advised, in case there appears to be any danger of an attack of parturient paresis, that the udder be inflated at once with air, as a prophylactic measure. Others advise the administration of calcium gluconate as a prophylactic. It may be given intravenously or hypodermically.

Milk Fever in the Goat and Ewe

The goat and the ewe suffer from milk fever less frequently than the dairy cow. Harms³² and Keller³⁷ describe the disease in these animals and add extensive bibliography. The disease appears most frequently in profuse milkers. The literature is not quite clear, but

apparently the incidence of the disease in the goat and the ewe corresponds to that of the cow and occurs chiefly, if not wholly, in animals used for dairying. In America, ewes are rarely, if ever, milked, and milk goats are restricted to limited areas, chiefly mountainous sections. Little or nothing is recorded regarding milk fever in either animal in this country.

The disease usually appears shortly after parturition, sometimes before. The symptoms and treatment are the same as for the cow. The prognosis is more favorable than in the cow.

Milk Fever in the Sow

Harms,³² Keller³⁷ and other continental European writers describe a disease in the sow which develops just before, during, or soon after parturition, which presents the general symptoms of milk fever in the cow. It is benign, and the animals largely recover. The character of the mammary glands renders their inflation very difficult and tedious. A fine hypodermic needle, with the point cut off and rounded, may be used as a milk catheter.

Swine are so handled in America that parturient paresis is not well known. It probably occurs in some districts where brood sows are closely confined and highly fed. Little or nothing is found in American veterinary literature upon the subject.

CHAPTER XXXV

THE PUERPERAL FEMALE AND THE NEW-BORN YOUNG

IN the companion volume⁶⁰ the diseases of the parturient female and her new-born young have been extensively considered. Subsequent to the publication of that treatise, clinical observations have been made which justify or require important modifications at certain points. It was then maintained, and yet more emphatically declared now, that the puerperal period is one of the most important eras in the reproductive history of the female. This is preëminently true of the dairy cow and of other females used for dairying. It is of fundamental importance, from both the standpoint of dairy economics and that of public health, that the sexual health of the puerperal dairy animal be accurately determined and that the most efficient means be applied for the cure of existing, and prevention of threatened disease.

It is essential, first of all, to learn whether a puerperal dairy cow is physiological or pathological. No easily defensible standard for differentiating between a physiological and pathological parturient cow has been established. The field is greatly obscured by custom and tradition.

One of the most confusing traditions in veterinary obstetrics is bound up in the general conception of *lochia*. The term was apparently borrowed from human obstetrics. Even in human obstetrics, the veterinary reader may find ground for uncertainty. J. Whitridge Williams⁵⁷ states that "in normal cases its (the lochia's) total quantity varies between five hundred and one thousand grams, being less profuse in women who suckle their children." Upon the whole, the suspicion may be justified that the healthiest women suckle their children more frequently than those diseased; that may be the reason for the larger volume of lochia in non-nursing mothers. Woman presents the most complex, deciduate placenta, and the assumption logically follows that there would be a relatively high degree of disintegration of placental tissues which would be discharged in the form of lochia. Upon the other hand, in solipeds, ruminants and swine, which are adeciduates, the dehiscence between the maternal and fetal placentae ideally leaves both placental areas intact (Figs. 55 and

57). Two structures have been held in functional contact throughout gestation without having acquired any anatomical continuity or mechanical interlocking. When the placental surfaces separate, there is left behind a cellular layer unprovided with protective epithelium. In the cow, there forms during pregnancy, over the summits of the caruncles, a new tissue, the cotyledons. During the puerperium, as has been well shown by Hilty,³⁴ the cotyledons—not the caruncles—disappear. The tissues are greatly engorged with blood and lymph, which is promptly resorbed; the superfluous cells largely undergo physiological destruction and resorption. Some of the cells are inevitably broken; some chorionic tufts or villi become broken off and remain in the cotyledonal crypts. These are largely discharged with a few blood cells and some lymph. After the lapse of a few hours following calving, the ideally healthy cow has no notable genital discharge, and no significant intrauterine accumulations of liquid secretions or tissue debris. Veterinary writers largely accept as *normal* or *physiological* a variable genital discharge. Some accept as *normal* the discharge of disintegrated caruncles, which is to me very decidedly and critically pathological. The principle applies to domestic animals generally.

Genital secretions are not always discharged. In domestic animals, the uterus is dependent (Figs. 5 and 78); it lies far below the level of the vulva. The absence of visible genital discharges is not proof of a healthy uterus. I have siphoned four or five gallons of pus from a cow in a *certified* dairy. Although the pus had undoubtedly been in the uterus for a year or more, the cow had passed repeated official veterinary inspections and her milk had been accepted by the board of health of America's metropolis. In a lesser degree, that incident has always been and continues to be repeated constantly.

In woman, the obstetrice apparently depends upon the presence or absence of discharge, the pulse, the temperature and the general appearance, for information regarding the state of the interior of the uterus. That affords no assurance in cows. The caruncles of a cow may be undergoing putrid decomposition or dry necrosis, while the patient shows no external discharge. Her appetite may be good, pulse and temperature normal, and lactation good. The problem then arises whether the veterinarian should or should not know what is going on in the uterine cavity of a puerperal dairy cow. If decided in the affirmative, it remains to be determined how he shall go about it. In many cases, external evidences are manifest and the recognition of puerperal disease authentic. In what ratio of cases this is true, is unknown. I have had opportunity, as herd veterinarian, to observe

constantly hundreds of cows during the puerperium. I enjoyed absolute freedom in the method of observation and examination. My conclusion is that reliance upon temperature, pulse, appetite, presence of genital discharge, lactation and general appearance will cause one-fourth to one-half the cases of importantly diseased puerperal cows to escape detection. Fig. 79 illustrates the point. The cow, which had calved the previous year as a primipara, in an apparently physiological manner, seemed perfectly healthy during her puerperium. After she had died in her second pregnancy and her uterus and allantochorion were examined, it became clear that during her first puerperium, the caruncles in one horn had undergone disintegration (lochia!) and left her uterus too badly injured to permit her to bear the burden of reproduction. Hers was not an isolated example. My colleagues and I⁶¹ have elsewhere shown that an examination of the fetal membranes reveals time and again authentic evidence of hidden uterine disease at the close of a previous pregnancy. Such examinations reveal highly important facts. The injury may be ameliorated by proper handling, but it cannot be undone. If the injury is to be averted, the danger must be recognized early and proper measures applied.

In human obstetrics there is a distinct tendency toward dependence upon temperature, genital discharge, and clinical symptoms as a guide in the recognition of puerperal disease. In the absence of definite symptoms of disease the human obstetrict hesitates to invade the puerperal uterus lest he introduce dangerous infection. While the principle must largely apply in veterinary obstetrics, for some reason there appears to be less danger of introducing serious infection in domestic animals than in woman. Possibly the human obstetrict is a more effective carrier of an infection active in his own species than is the veterinary obstetrict in carrying a species of bacterium not prevalent in human tissues. At least no evidence has been recorded in which a veterinary obstetrict has carried puerperal infection with such dire results as those recorded by Oliver Wendell Holmes in 1843 and by other able obstetricians. It has been only by a strict application of letting the case alone when all looks well and the most careful adherence to asepsis and antisepsis that maternity hospitals have been made endurable. Yet leading obstetricts regretfully confess that the incidence of puerperal disease in individual women still pursues its destructive way. Obstetricts have controlled the epidemics of puerperal infection.

In the face of the accumulated evidence in human obstetrics, any proposal to amend the rule and make routine examinations of the

uterine cavity of puerperal dairy cows the regular procedure needs be approached carefully. In my recent experiences, when acting as herd veterinarian, I have regularly examined the uterine cavity of parturient cows at one to two days after calving. I have been unable to detect any harm therefrom and am very positive that I have accomplished great good. In one herd, numerous cows had become hopelessly diseased through neglect during the puerperium. They failed in lactation and the breeding life closed. The intensity of genital disease was continuing. Routine examination of the uterine cavity of puerperal cows at twenty-four to forty-eight hours after parturition was adopted. The examinations were repeated and the cases handled as conditions suggested. In one hundred terminations of pregnancy, two were destroyed on account of puerperal infection associated with twins, and two were discarded for failure in lactation. Satisfactory lactation was maintained in the others and the prospects for breeding were favorable. None were left with important chronic sexual disease. My technic was briefly as follows:

The birth canal was freely douched with warm, physiological salt solution, and the vulva and adjacent parts were carefully disinfected, as were my hands and arms. A long, soft rubber catheter was connected with an irrigator, the end was carried to the cervical canal with the hand, and then gently pushed through until it was halted at the lowest possible point of the uterus. One or two pints of physiological salt solution were introduced, the catheter compressed while filled, the end lowered and the salt solution with any exudate siphoned out. This revealed the amount and character of exudate in the uterus. The examination was repeated according to indications. Puerperal disease was so common that the examination was regularly followed by the introduction of iodoform in oil. The milk, tainted by iodoform, was fed to calves. Difficulties were encountered. In some cases the uterus was so paretic that the catheter failed to become lodged in the exudate and the siphon failed. The catheter was inserted more or less deeply, and attempts made to start the siphon by attaching a piston syringe to it and establishing a vacuum. Care was taken to avoid introducing more fluid until that inserted had been recovered. Sometimes the catheter became blocked with fragments of fetal membranes or with sloughed caruncles. In such case the piston syringe was again used, as complete a vacuum as possible established, the external end of the catheter compressed to maintain the vacuum, and the catheter withdrawn. The necrotic tissue was held securely by the vacuum. In some instances, almost, if not all

caruncles were thus withdrawn one at a time through a well contracted cervix. The putrefactive processes were thus restricted to the available minimum, satisfactory lactation in quantity and quality regularly assured, and the utmost done to preserve the reproductive life of the patient. In some cases the cervix became so contracted that the catheter could not be pushed through, with the hand in the vagina. The cervix was then grasped with forceps and retracted. A small Albrechtsen catheter or other curved instrument was inserted in the fenestrum of the rubber catheter and the latter carefully guided through the cervix. Based upon clinical observations I have been able to make, the veterinary obstetrists, concerned with dairy cows, can render a far higher service from the standpoints of dairy economics and human health by routine examinations of the uterine cavity of puerperal cows, and the prompt application of curative or prophylactic measures, than is at all possible in the handling of established uterine diseases. A large part of the detailed work may be safely carried out by an intelligent layman under veterinary instruction.

Prompt and skillful handling of the new-born is of equal importance to the care of the puerperal female. The problem reaches its maximum importance in the dairy calf. The general principles involved are alike for all domestic animals. The dairy calf involves the problem of artificial, instead of natural feeding. Researches in this field have been largely confined to the superficial problem of the cost of feeding as related to the mortality and rate of growth. When considering the basic causes of dystocia, page 176, the influence of the health of the young calf upon its ultimate breeding value was discussed. In the companion volume the methods of feeding and handling were fully considered. It is justifiable to review that discussion in outline and modify the plan so far as may be warranted by recent observations.

The line of demarcation between health and disease in dairy calves is largely limited to the question of the absence or presence of diarrhea. Pneumonia is frequently associated with diarrhea. Generally, dairy calves suffer from sticky feces, rough coat, pot-belly and other evidences of poor health.

There are many conflicting opinions regarding the causes of diarrhea in calves. It is usually attributed to postnatal causes. In the abattoir, the examination of the fetuses in the second half of gestation in dairy cows, reveals an abundance of diarrhea. In some groups of cull dairy cows, fetal diarrhea is present in twenty-five to fifty per

cent. I have repeatedly seen fetal diarrhea at birth, with gallons of thin feces in the amniotic cavity. Fetuses with diarrhea often die in the uterus. Fetuses born with diarrhea largely die. Many calves born without diarrhea must be upon the brink of that phenomenon; a trivial error in diet may then precipitate the symptoms. On the other hand, the dairy calf is rare which is so healthy at birth that it will successfully withstand any and all dietetic errors heaped upon it by the calf feeder. There has always been, and continues to be great conflict of opinion upon the feeding and care of calves. The two most perplexing problems, in the feeding and care of calves, are to see that the calf takes the quantity and quality of food its health requires and to prevent it from swallowing substances which it does not require and which may constitute danger. The fetus is well nourished through the placentae until the navel cord is severed. There is no urgent need for milk or other food for some hours; no material harm is probable if the calf fasts for twenty-four hours. Hence there is no need for great haste. The average new-born animal will take an injurious amount of milk from its dam, if an excess is available in the udder. In most species of animals, such excess does not usually exist; it is generally present in dairy cows.

In order to prevent indigestion (white scours, calf scours) I advocated for a number of years the administration of calf scours serum. It appeared to be the best available remedy, but was far from satisfactory. The transfusion of blood from the dam to her young has been widely used, especially in foals, with excellent results. With competent aid and two large hypodermic syringes at hand, one person may draw a syringe-full of blood from the jugular of the mare, and an assistant inject it subcutaneously in the foal in volumes of 10 to 20 cc. in a location until a total of 50 to 100 cc. has been given. With dairy calves my observations as herd veterinarian have led me to adopt the following plan with the most gratifying results. The calf is allowed with its dam for twelve hours and is then fasted for twelve hours. Its first feed after separation from its dam consists, for a calf of sixty to eighty pounds, of one pound of whole milk, one pound of lime water, and four ounces of castor oil. The oil is thoroughly emulsified in the lime water and milk. If all goes well, only the one dose of castor oil is given. The calf drinks the mixture as willingly as it does milk alone. The calf is fed twice daily, the amount of milk and lime water remaining constantly at one pound each for several days, after which the milk is gradually increased. If the calf is free from all signs of diarrhea or indigestion, such as watery feces, blood

or mucus in the droppings, adherence of feces to the tail, etc., the lime water is discontinued at seven days. If the signs of diarrhea as stated above recur, the first ration, one pound each of milk and lime water and four ounces of castor oil, is repeated.

Calves suffering from digestive disturbances acquire *pica* and swallow any available rubbish: straw, weeds, leather, wood (shavings), feces, cotton or woolen fabrics, etc. These immediately aggravate the diarrhea. While ideally healthy calves are not liable to develop *pica*, ideal health prevails in so low a proportion of dairy calves that it is unwise to trust them. After so feeding calves that they will probably not develop *pica*, the precaution should be taken that they cannot indulge their morbid appetite in case it appears. There are various means for accomplishing this purpose. As herd veterinarian in the tropics, I had no stable for the calves. They were prevented from eating rubbish by placing each calf in a separate, portable pen in an open pasture. Weeds and long grass were carefully removed. The portable pens were ranged in a row at one end of the field. Each pen was moved daily toward the opposite end of the enclosure. The turf acted as the only bedding. The identity of the feces passed by a given calf, and lying in plain sight, was authentic. By the time the pens had been moved to the farther end of the field, air, sun and rain had cleaned the turf at the point of starting. When one month old the calves were massed and fed in outdoor stanchions with concrete floor. In stables bedding is essential. Any calf not ideally healthy will swallow part of its bedding if permitted. Inevitably, if the bedding is soiled with feces, these are also swallowed. The swallowing of bedding may be obviated by the constant use of a wire muzzle, as advocated by me in 1921⁶⁰ and later rendered more practicable by the studies of Udall.⁵⁴

A third means by which the calf may be prevented from swallowing rubbish in a bedded stall is by means of a cover of canvas or other heavy fabric laid over the bedding. Attached to a metal or wooden frame, it is readily removable for cleaning. It is somewhat more expensive than the muzzle, but possesses important advantages. With the muzzle plan, the feces are lost in the bedding. With the canvas cover over the bedding, the droppings from the calf are in plain view and afford the most authentic evidence possible of the state of health of the digestive tract. The labor is less than with the muzzle and open bedding, and the cost of bedding is far less, because it does not become so rapidly soiled.

The ration suggested for the new-born calf is far below that com-

monly advised. For example, Brainard and Davis¹¹ recommend, according to the size of the calf, eight to twelve pounds of milk daily, or, on the average, five times as much milk as advised above. The plan, in my hands, definitely eliminates diarrhea and the calf retains permanently its lustrous coat, does not become pot-bellied, makes rapid growth and is as vigorous as young animals naturally suckled by the mother. Some of the calves in the herd where I conducted my observations are now ten years old. They are of distinctly larger size and greater vigor, they breed far better, the average duration of pregnancy has increased several days, and abortion, dystocia and retained afterbirth have vastly decreased. The change in feeding is limited to the six months of milk feeding. Under the revised plan, the young animals are far larger at their age, they are larger framed and are free from the abnormal compactness or "blocky" form prevailing under the old plan. The vulvae are large and there is every reliable indication that they are sexually vigorous.

The milk, lime water and castor oil, and any one of the plans named for preventing the calf from eating rubbish, collectively cost less than the milk alone, as calves are ordinarily fed as illustrated by the plan advised by Brainard and Davis. The dairyman should be provided with a stock of especially prepared calcium oxide with which he can correctly and safely prepare lime water as needed.

BIBLIOGRAPHY

1. ABDERHALDEN. Die Serodiagnostik der Schwangerschaft. Deutsche med. Wochenschrift. 1912. No. 6.
2. ANDRES, J. 369 Tage Trächtigkeit bei der Kuh. Deutsche tier. Wochenschrift. B. 31. S. 67. Jan. 1931.
3. ASDELL, S. A., and WILLMAN, J. P. The causes and prevention of birth mortality in pigs. An. Rep. Cornell Station. 1938.
4. AUGER, L. Recherches sur la pathogonie de la fièvre vitulaire. Rev. Gen. de med. Vet. xxxv. 353. July 1926.
5. BARKER, J. R. Blood plasma changes and variations in the female bovine toxæmias. Veterinary Record, (1931) 51, 575.
6. BELLER, K. F. Anatomische, physiologische, und bakteriologische Untersuchungen der Trächtigkeit und Geburt bei Haustieren. Deutsche tier. Wochenschrift. B. 33. S. 211. 1925.
7. BENESCH, F. Tutocaine and epidural anaesthesia. Cornell Veterinarian, xvi. 227. July 1926.
8. BENESCH, F. Geburtshilfe bei Rind und Pferd. 1936.
9. BOULET-JOSSE. Une présentation transversale. Rec. d. Med. Vet. 1883. 9.
10. BOYD, W. L. Mummification of the fetus. Jour. A. V. M. A. lxxv. 737. Sept. 1924
11. BRAINARD, W. K. and H. P. DAVIS. Feeding and management of dairy calves. Farmers bul. 777. U. S. Dept. Agriculture. 1917.
12. CARPENTER, C. M. An. Rep. N. Y. State Vet. Col. 1920-1921. Page 67.
13. CONKLIN, R. R., J. B. MCCARTHY, R. R. THOMPSON, and L. I. PUGSLEY. Chemical, bacteriological and physio-chemical studies of the pregnant bovine uterus. Cornell Veterinarian. xxi. 177. Apr. 1931.
14. CORNER, G. W. Ovulation and menstruation in macacus rhesus. Pub. 332. Carnegie Inst. Page 75.
15. CORNER, G. W. Internal migration of the ovum. Johns Hopkins bul. xxxii. No. 361. Mar. 1921.
16. CUILLÉ. Rev. Vét. xxx. 554. Aug. 1905.
17. DAY, L. Enos. Pathologist U. S. Bureau Animal Industry at Chicago, Ill.
18. DE LEE, J. B. Principles and practice of obstetrics. 1916.
19. DRYERRE and GRIEG. Further studies in the etiology of milk fever. Edinburgh. 1928.
20. DU TOIT, J. P. An. Rep. Dir. Vet. Services. Union So. Africa. 1929. Page 1059.
21. ELDER, J. C. Control of Bang's Disease in Missouri. Missouri University Experiment Station Bulletin 388 (1936).
22. FINCHER, M. G. and W. L. WILLIAMS. Bicornual pregnancy in a mare. Cornell Veterinarian. xx. 289. July 1930.
23. FINCHER, M. G. and W. L. WILLIAMS. Arrested development of the Muellerian ducts associated with inbreeding. Cornell Veterinarian. xvi. 1. Jan. 1926.
24. FISH, P. A. The physiology of milk fever (with extensive bibliography). Cornell Veterinarian. xvii. 99. Apr. 1927.
25. FLEMING, G. Veterinary Obstetrics. 1877.
26. FORSTER, J. P. Extra-uterine pregnancy in mare. Cornell Veterinarian. viii. 127. 1918.
27. FRANCK (Göring). Tierärztlichen Geburtshilfe. 1887.
28. FROST, J. N., M. G. FINCHER and W. L. WILLIAMS. Two severe cases of hydrops of amnion and allantois with a background of severe endometritis in the prior gestation. Cornell Veterinarian. xxi. 212. Apr. 1931.
29. GOODFELLOW, WM. A. Abdominal gestation: foal survives. Jour. Am. Vet. Med. Assn. 1942. p. 150.
30. GÖTZE, R. Der Kaiserschnitt beim Rinde. Festschrift zur Jubiläumsfeier der Tierärztlichen Hochschule, Hannover. Special number Deutsche tierärztliche Wochenschrift. (1928) p. 86.

31. HAGAN, W. A. An. Rep. N. Y. State Vet. Col. 1916-1917. Page 155.
32. HARMS (J. RICHTER, J. SCHMIDT and R. REINHARDT). Lehrbuch der tierärztlichen Geburtshilfe. 6 Auflage. 1924.
33. HAUBOLD. Miscellany. Sachs. Bericht. 1880. S. 89.
34. HILTY, H. Untersuchungen über die Evolution und Involution der Uterusmucosa vom Rind. Schw. Archiv. f. Tierheilkunde. 1908. 1. 263.
35. HUTT, F. B. Bovine quadruplets, including twins apparently monozygotic. Jour. Heredity. xxi. 8 Aug. 1930.
36. KAMMERMANN. Die Eihautwassersucht des Rindes. Schw. Archiv. f. Tierheilkunde. 1890. S. 149.
37. KELLER, KARL. Geburtshilfe bei den kleineren Haustiere. 1928.
38. KJELDBJERG, JOH. Die puerperal Eklampsie beim Schwein. Eclampsia puerperalis suis. Berliner tier. Wochenschrift. B. 41. S. 821
39. LEHNDORF, Graf. Handbuch für Pferdezüchter. 1886.
40. McCAMPBELL, C. W. Beef cattle experiments. Fort Hays branch, Kan. Expt. Station. Apr. 1920.
41. McINTOSH, R. A. Prolific abortion. Rep. Ont. Vet. Col. 1924. Page 124.
42. MOUTIEJUNAS, JNOZAS. Beitr. zur Mumification und Verkalkung (Versteinerung) des Rindsfötus. Schw. Archiv. f. Tierheilkunde. lxx. S. 525. Nov. 1928.
43. VON OTTINGEN, BURCHARD. Die Pferdezücht. 1921.
44. PAULI. Miscellany. Gurlt u. Hertwig's Magazin. viii. 1842. S. 185.
45. RICHTER, J. Erfahrungen mit der Epiduralanesthesia vom geburtshilflichgynäkologischen Standpunkt. Ber. t. Wochenschrift. 1929. S. 1.
46. SCHMALZ, R. Das Geschlechtsleben der Haussäugetiere. 3. Auf. 1921.
47. SCHMIDT-KOLDING. Gebärpärese. Monatsch. f. prakt. Tierheilkunde. 1898. S. 241.
48. SEYMOUR, FRANCIS J. and KOERNER, ALFRED. Artificial insemination. Jour. Am. Med. Assn. 116. 1941. 2747.
49. SOHNLE, H. Untersuchungen ueber Fohlenlähme. Monatsch. f. prakt. Tierheilkunde. xii. S. 1337. 1901.
50. STARCKE, ERNST. Über Geburten, bzw. Spätgeburten bei Riesenwuchs der Kinder und über die Dauer der menschlichen Schwangerschaft. Archiv. f. Gynaekologie. 1905. S. 567.
51. STOSS, A. O. Tierärztliche Geburtkunde und Gynaekologie. 1928.
52. STOSS, A. O. Die Klinische Trächtigkeitsdiagnose bei der Stute. Archiv. f. wissenschaft. u. prakt. Tierheilkunde, Vol. 50, p. 211.
53. TAPKEN, ANTON. Über Geburtshilfe beim Pferde. Monatsch. f. prakt. Tierheilkunde B. 18. S. 148.
54. UDALL, D. H. Diseases of the newborn. Cornell Veterinarian. xviii. 246. July 1928.
55. United States Department of Agriculture. Bureau of Animal Industry. Special Report. Diseases of Cattle. 1916.
56. WAGNER, H. Untersuchungen über Gebärmutter-und Jungkrankheiten. Deutsche tierärztliche Wochenschrift. B. 35. S. 655. Oct. 1927.
57. WILLIAMS, J. W. Obstetrics. 1917.
58. WILLIAMS, W. L. Transverse development of the fetus of the mare. Am. Vet. Rev. xii. 298. 1889.
59. WILLIAMS, W. L. Parturient eclampsia in the mare. Am. Vet. Rev. xiv. 559. 1890-1891.
60. WILLIAMS, W. L. The diseases of the genital organs of domestic animals. 1943.
61. WILLIAMS, W. L., and D. H. UDALL, J. N. FROST, S. A. GOLDBERG, E. R. CUSHING, M. G. FINCHER and M. H. MABEE. Studies in genital disease. Cornell Veterinarian. xiv. 315. Oct. 1924.
62. WILLIAMS, W. L. A technic for the study of genital disease by means of the fetal membranes. Cornell Veterinarian. xv. 225. Apr. 1925.
63. WILLIAMS, W. L., and M. G. FINCHER. Arrested development of the Muellerian ducts associated with inbreeding. Cornell Veterinarian. xvi. 1. Jan. 1926.
64. WILLIAMS, W. L. Genital diseases of horses. Cornell Veterinarian. xvi. 107. Apr. 1926.

65. WILLIAMS, W. L. A case of torsion of the uterus with comments upon mummification and calcification of the fetus. *Cornell Veterinarian*. xvi. 280. Oct. 1926.
66. WILLIAMS, W. L. Strangulation of the great colon in a mare by its displacement beneath the pregnant uterus. *Cornell Veterinarian*. xvii. 81. Jan. 1927.
67. WILLIAMS, W. L. The significance of the duration of pregnancy. *Cornell Veterinarian*, xvii. 331. Oct. 1927.
68. WILLIAMS, W. L., and W. J. GIBBONS. The equine vascular allantois. *Cornell Veterinarian*. xix. 3. Jan. 1929.
69. WILLIAMS, W. L. The significance of utero-chorionic lesions. *Cornell Veterinarian*. xix. 254. July 1920.
70. WILLIAMS, W. L. The burden of reproduction. *Scientific Agriculture* (Ottawa). x. 161. Nov. 1929.
71. WILLIAMS, W. L. and M. G. FINCHER. Bicornual pregnancy in a mare. *Cornell Veterinarian*. xx. 289. July 1930.
72. WILLIAMS, W. L. Studies on teratology. *Cornell Veterinarian*. xxi. 25. Jan. 1931.
73. WILLIAMS, W. L., H. C. STEPHENSON, and J. D. SWEET. Torsion of uterus. *Cat. Cornell Veterinarian*. xxi. 302. July 1931.
74. WILLIAMS, W. L. Equine and bovine twins. *Cornell Veterinarian*. xxi. Oct. 1931.
75. WILLIAMS, W. L. Three cases of *Schistocormus reflexus*. *Cornell Veterinarian*. (1936) xxvi, p. 297.
76. ZIETZSCHMANN, OTTO. *Lehrbuch der Entwicklungsgeschichte der Haustiere*. 1924.

INDEX

- Abdominal floor, edema of the, 284.
transverse presentation, 335.
- Abnormal fetal volume, dystocia from, 304.
- Abnormalities of pelvis, dystocia referable to, 199.
- Acardiac monsters, 53.
- Adjustment of the extremities, 235.
- Afterbirth, the, 94, 163.
- Allantochoion, 99.
edema of the, 310.
- Allantoic veins, 79.
- Allantois, the 98.
dropsy of the, 314.
the necrotic tip of, 103.
- Amnion, the, 95.
dropsy of the, 314.
false, 99.
- Amniotic cavity, 95.
fluid, 95.
- Amount of traction, the, 240.
- Amputation at the humero-radial articulation, 249.
of the anterior limbs, subcutaneous, 246.
posterior limbs at the tarsus, 254.
posterior limbs when completely retained, intra-pelvic, 255.
head and neck, 243, 244.
uterus, 415.
- Anaesthesia, epidural, 223.
- Anasarca, fetal, 308.
- Anatomy, obstetrical, 3.
- Anchorage of fetus, dystocia due to pathological, 188.
- Anchylosis of joints as a cause of dystocia, 329.
- Animals, the hygiene of breeding, 143.
pregnant, 143.
- Anomalies in fertilization, 33.
- Anterior feet, flexion of the, 375.
deviations of the, 374.
downward deviation of the head between the, 373.
flexion of the, at the elbow, 378.
limbs, complete retention of the, 380.
subcutaneous amputation of the, 246.
- Anterior neuropore, 50.
presentation, destruction of the pelvic girdle in, 252.
detruncation in the, 250.
dystocia in the, 365.
embryotomy in the, 243.
- Apoplexy, parturient, 443.
- Appliances for exerting traction, 210.
- Arrested development of the female reproductive system during first pregnancy, 178.
of the Muellerian ducts, 176.
- Arteries, the, 75.
the uterine, 115.
- Ascites, fetal, 307.
- Atresia, cervical, 274.
vaginal, 274.
- Attitude of fetus, 206.
- Auricles, the, 73.
- Bacterial flora of the pregnant uterus, the, 140.
- Basic causes of dystocia, the, 176.
- Bicornual pregnancy in the bitch, 195, 351.
cow, 348.
dystocia due to, 189, 192, 194, 334, 348.
mare, 335.
multipara, 194, 351.
rotated, 192, 340.
ruminants, 348.
the ventral presentation of, 325.
- Birth canal, dystocia due to compression of the, 274.
dystocia due to defects or diseases of the, 275.
- Birth, physiological, 155.
- Bitch, bicornual pregnancy in the, 195, 351.
puerperal eclampsia in the, 442.
- Bladder, the, 83.
eversion of the, 417.
prolapse of the, 417.
through a rupture in the floor of the vagina, 400.
- Blastodermic vesicle, 46.
- Body cavity, the, 48.
- Bovine fetus, mummification of the, 359.
- Brain, the, 54.
hernia of the, 55.
- Breech presentation, 391.
embryotomy in the, 255.
- Breeding animals, the hygiene of, 143.
- Breeding, dystocia from too early postpartum, 178.

- Breeding immature healthy females, dystocia from, 177.
- Bulldog calves, dystocia from, 179.
- Canals of Gartner, 83.
- Care of the new-born, 457.
- puerperal female, 457.
- Caruncles, 111.
- Caudal presentation, 388.
- Causes of dystocia, the basic, 176.
- exciting or immediate, 206.
- Celom, the, 48.
- Cells, migration of the genital, 33.
- Cephalotomy, 244.
- Cervical atresia, 275.
- Cervical ectopia cordis, 77.
- Cervix, the, 19.
- induration of the, 275.
- uteri, prolapse of, 278.
- Cesarean section, 260.
- Chain saws, 219.
- Chisels, obstetrical, 219.
- Chorion, the, 99.
- primitive, 99.
- Choroidal fissure, 59.
- Circulation, the fetal, 79.
- Circulatory system, the, 72.
- Cleft palate, 57.
- Club foot, 325.
- Coitus, 29.
- Complete retention of the anterior limbs, 380.
- posterior limbs, 391.
- splitting of the spinal column, 51.
- Compound bicornual pregnancy, 340.
- Compression and atresia of the birth canal, 274.
- of the birth canal, dystocia due to, 274.
- Congenitally deformed pelvis, the, 270.
- Constriction, vaginal, 274.
- vulvar, 274.
- Contraction of limbs as a cause of dystocia, 329.
- Control of the patient, 221.
- Contusion of the gluteal nerves, 423.
- lumbo-sacral nerves, 422.
- obturator nerves, 424.
- Copulation, 29.
- Cord, the spinal, 56.
- the umbilical, 112.
- Cords, obstetrical, 210.
- Cornea, 59.
- Cornua, the uterine, 14.
- Corpus luteum, 10.
- Corpus luteum of pregnancy, the, 115.
- Cotyledons, 111.
- Cow, parturient paresis in the, 443.
- dystocia from bicornual pregnancy in, 348.
- Coxae, the, 5.
- Coxo-femoral dislocation, 426.
- Cutting hook, the long, 218.
- Cuvierian veins, 78.
- Cyclops, 55.
- Decapitation, 243.
- Decomposition of the fetus, emphysematous, 360.
- purulent, 360.
- Defects or diseases of the birth canal, dystocia due to, 272.
- Deformed pelvis, the congenitally, 268.
- Deformities of the pelvis, rachitic, 272.
- extremities, 329.
- Destruction of the pelvic girdle in anterior presentation, 252.
- Detruncation in the anterior presentation, 250.
- Development, arrested, of the reproductive system during first pregnancy, 178.
- of the organs of special sense, 56.
- urino-genital system, 82.
- Deviations of the anterior limbs, 374.
- head, wry-neck, 368.
- between the anterior limbs, downward, 373.
- lateral, 368.
- upward, 374.
- in posterior presentation, lateral, 393.
- and neck, 366.
- Diagnosis of pregnancy, the clinical, 114.
- Digestive apparatus, formation of the, 63.
- Discus proligerus, 25.
- Diseases and injuries of the pelvis, 272.
- of the birth canal, dystocia due to defects or, 272.
- fetus and its membranes, excessive volume due to general or localized disease, 308.
- pregnant animal, 149.
- puerperal eclamptic, 433.
- Dislocation, coxo-femoral, 426.
- of the hip joint, 426.
- of the reproductive organs, dystocia due to, 278.
- Displacements, dystocia due to uterine, 278.
- of the genitalia, teratological, 176.

- of the pregnant uterus, dystocia due to, 196.
- Distension of the fetal organs, 307.
- Dorso-iliac positions, the dystocia from, 367, 389.
- Dorso-pubic positions, the dystocia from, 367, 389.
- Double monsters, 323.
- Downward deviation of the head between the anterior limbs, 373.
- Dress of the operator, the, 220.
- Dropsy, amnio-allantoic, 314.
- Ducts, arrested development of the Muellerian, 174.
 - the Muellerian, 10.
 - the Wolffian, 82.
- Duration of pregnancy, 127.
 - reproductive power, 132.
- Dystocia, 173.
 - attributed to short nose, hereditary hydrocephalus, 185.
 - size of sire, 200.
 - basic causes of, 176.
 - due to abnormal fetal volume, 304.
 - anchylosis, 329.
 - anterior presentation, 367.
 - bicornual pregnancy, 188, 334, 348.
 - breeding immature, healthy females, 176, 178.
 - bulldog calves, 179.
 - cervical disease, 275.
 - compression of the birth canal, 274.
 - contraction of limbs, 329.
 - dislocation of the reproductive organs, 278.
 - dorso-iliac position, 389.
 - dorso-pubic position, 389.
 - excessive fetal fluids, 307.
 - fetal ascites, 307.
 - volume, 307.
 - hybridization, 179.
 - monsters, 320.
 - muscle contracture monsters, 180.
 - pathological anchorage of the fetus, 188.
 - disposition of the umbilical cord, 365.
 - position, 365.
 - and posture in the posterior presentation, 388.
 - posture, 365.
 - presentation, 365.
 - posterior presentation, 388.
 - postmortem changes in the fetus, 353.
 - pre-conceptional uterine lesions, 200.
 - teratological causes, 176.
 - too early postpartum breeding, 178.
 - transverse presentation, 334.
 - uterine displacement, 278.
 - inertia, 363.
 - exciting or immediate causes of, 206.
 - handling of the various forms, 268.
 - hereditary, 176, 180.
 - pelvic, 268.
 - referable to pathology of the sex cells, 201.
 - pelvic abnormalities, 199.
 - traumatic herniae, 199.
 - sire as a cause of, 201.
 - twin, 186, 332.
 - Ear, the, 59.
 - "Ear teeth," 60.
 - Early postpartum breeding, dystocia due to, 179.
 - Eclampsia in the bitch, puerperal, 442.
 - ewe, 441.
 - goat, 441.
 - mare, parturient, 435.
 - sow, puerperal, 441.
 - Eclampsia, parturient, 435.
 - Eclamptic diseases, puerperal, 433.
 - Ectoderm, 46.
 - Edema of the abdominal floor, 284.
 - allantochorion, 310.
 - Egg columns, 25.
 - segmentation of the, 43.
 - Elbow, flexion of the anterior limbs at the, 378.
 - Embryo, formation of the, 47.
 - Embryology, 42.
 - Embryotomes, 218.
 - Embryotomy, 242, 253.
 - in the anterior presentation, 243.
 - breech presentation, 255.
 - operations, miscellaneous, 259.
 - posterior presentation, 253.
 - Emphysematous decomposition of the fetus, 360.
 - Enamel, formation of the, 66.
 - Entoderm, 46.
 - Epidural anaesthesia, 223.
 - Epispadias, 88.
 - Equipment, obstetrical, 210.
 - Estrum, 25.
 - Eversion of the bladder, 417.
 - Evisceration, 258.
 - Ewe, eclampsia in the, 441.
 - milk fever in the, 455.
 - Examination of the patient, the, 225.

- Excessive volume due to general or localized diseases of the fetus and its membranes, 307.
 of the fetus, 208.
- Expulsion of the fetal membranes, 163.
- Extension of the extremities, 235.
 posterior limbs forward, beneath the fetal body, 384.
- Extent of uterine torsion, the, 298.
- Exostoses, pelvic fractures and, 272.
- Extraction, forced, 238.
- Extrauterine fetus, the secondary, 35.
 pregnancy, 35.
- Extremities, adjustment of the, 235.
 deformity of the, 329.
 extension of the, 235.
 rigidity of the, 329.
- Eyes, the, 58.
- False amnion, 99.
- Feet, flexion of the anterior, 375.
- Female, dystocia from breeding immature healthy, 178.
 genitalia, teratological hypoplasia of, 176.
 the puerperal, 457.
 reproductive system, arrested development of during first pregnancy, 178.
- Fertilization, 31.
 anomalies in, 33.
- Fetal anasarca, 308.
 ascites, 307.
 body, forward extension of the posterior limbs beneath the, 384.
 cadaver, the static, 357.
 circulation, the, 78.
 fluids, dystocia due to, 307.
 giantism, 304.
 and maternal pelves, interlocking of the, 382.
 membranes and the placenta, the, 94.
 membranes, the expulsion of, 163.
 organs, distension of the, 307.
 volume, dystocia from abnormal, 304.
- Fetotomes, 218.
- Fetus, dystocia due to pathological anchorage of, 188.
 emphysematous decomposition of, 360.
 excessive volume of, 208.
 and its membranes, excessive volume of due to local or general disease, 307.
 mummification of the bovine, 359.
 palpation of, per rectum and vaginam, 114.
 position of the, 206.
 position and movements of during gestation, 117.
 postmortem changes in, 353.
 presentations of, 206.
 purulent decomposition of, 360.
 secondary extrauterine, 35.
- Fetuses, number of in uterus, 123.
- Fever, milk, 443.
- First pregnancy, arrested development of the reproductive system during, 178.
- Fissicollis, 77.
- Flexion of the anterior feet, 375.
 limbs at the elbow, 378.
 posterior limbs at the tarsus, 390.
 uterus, 196.
- Forced extraction, 238, 370.
- Forceps, obstetrical, 215.
- Fore limbs, crossed over the neck, the, 377.
- Form and position of the pregnant uterus, 116.
- Formation of the brain, 54.
 digestive apparatus, 63.
 embryo, 47.
 respiratory apparatus, 63.
- Forward extension of the posterior limbs beneath the fetal body, 384.
- Fractures, pelvic, 272.
- Freemartins, 124.
- Gartner's canals, 83.
- Gastrodidymus octipes, dystocia from, 321.
- Gastrohysterotomy, 260.
- Generative organs, the, 8.
- Genital cells, migration of, 33.
- Genital and neighboring organs, wounds and injuries of the, 307.
 hypoplasia in young animals, 177.
 organs, juvenile, 176, 268.
 tract, the, 10.
- Genitalia, teratological displacement of the, 176.
 teratological hypoplasia of the female, 176.
- Germinal layers, 46.
- Gestation, 40.
 duration of, 127.
 the position and movements of the fetus during, 117.
- Giantism, fetal, 304.
- Glandular hypertrophy, 307.

- Glands, sex, 84.
Gluteal nerves, contusion of the, 423.
paralysis, 423.
Goat, eclampsia in the, 441.
milk fever in the, 455.
Gonads, the, 84.
Gravid uterus, rupture of the, 150.
Groove, neural, 47.
the primitive, 47.
Gubernaculum testis, 86.
- Handling of dystocia, 210, 268.
Head and neck, amputation of the, 243, 244.
and neck, deviations of the, 366.
between the anterior limbs, downward deviation of the, 373.
lateral deviation of the, in posterior presentation, 393.
lateral deviations of the, 366.
upward deviation of the, 374.
the amputation of the, 243.
Heart, the, 72.
Hematoma of the vulva, 422.
Hemorrhage, postpartum, 397.
of pregnancy, the, 150, 359.
Hereditary dystocia, 176, 180.
hydrocephalus, 180.
Hernia cerebri, 55.
dystocia referable to traumatic, 199.
Herniae, inguinal, 176, 284.
umbilical, 284.
uterine, 284.
ventral, 284.
Hip joint, dislocation of, 426.
Hooks, obstetrical, 214.
Hook, the long cutting, 218.
Humero-radial articulation, amputation at the, 249.
Hybridization, the dystocia of, 179.
Hydrallantois, 314.
Hydrocephalus, 323.
hereditary, 185.
limited, 185.
Hydrops amnii, 314.
Hygiene of breeding animals, the, 143.
of the pregnant animal, the, 143.
Hypertrophy, glandular, 307.
Hypoplasia in young animals, genital, 177.
of the female genitalia, teratological, 176.
pelvis, 268.
reproductive system, 268.
Hypospadias, 89.
Hysterectomy, 266.
Hysterotomy, 260.
- Hysterocele, 284.
- Immature healthy females, dystocia from breeding, 178.
Implantation of the ovum, pathological, 188.
Induration of the cervix, 275.
Inertia, the dystocia of uterine, 363.
Infections during obstetrical operations, the prevention of, 228.
puerperal, 430.
Inguinal herniae, 176, 284.
Injuries and wounds of the genital and neighboring organs, 397.
parturient, 430.
of the pelvis, 272.
Instruments for section, 217.
obstetrical, 210.
Interference in physiological parturition, 166.
Interlocking of the maternal and fetal pelves, 382.
Intestines beneath the pregnant uterus, strangulation of the large, 150.
prolapse of the, through the ruptured walls of the uterus or vagina, 400.
Intra-pelvic amputation of the posterior limbs when completely retained, 255.
Invagination, uterine, 401.
- Juvenile genital organs, 176, 270.
pelvis, the, 270.
reproductive system, narrow vulva associated with, 176, 270.
- Kidneys, the, 83.
Knives, obstetrical, 217, 218.
- Laminitis, puerperal in the cow, 430.
in the mare, 430.
Lateral deviation of the head, 368.
posterior presentation, 393.
wry-neck, 371.
Lesions, dystocia due to pre-conceptional uterine, 200.
Ligaments, the sacro-sciatic, 5.
Limbs, formation of the, 89.
subcutaneous amputation of the anterior, 246.
Limited hydrocephalus, 185.
Liquor amnii, 95.
Liver, the, 72.
Lumbo-sacral nerves, contusions of the, 422.
Lungs, the, 65.

- Male reproductive organs, the, 85.
 Mare, bicornual pregnancy in the, 334.
 parturient eclampsia in the, 435.
 Maternal and fetal pelves, interlocking of, 382.
 Maturation of the ovisac, 25.
 Median wall of the Muellerian ducts in the vagina, persistent, 271.
 Membranes, excessive volume due to general or localized diseases of the fetus and its, 307.
 Menstruation, 31.
 Mesoderm, 46.
 Migration of genital cells, 33.
 Milk fever, 443.
 in the cow, 443.
 ewe, 455.
 goat, 455.
 sow, 456.
 Monster, acardiac, 53.
 Monsters, double, 322.
 dystocia due to, 320.
 Movements and position of the fetus during gestation, 117.
 Muellerian ducts, the, 10.
 arrested development of the, 174.
 in the vagina, persistent median wall of the, 271.
 Multipara, 123.
 bicornual pregnancy in, 194, 351.
 Mummification of the bovine fetus, 359.
 papyraceous, 358.
 Muscle contracture monsters, dystocia due to, 180.
 Mutation, 230.

 Narrow vulva associated with juvenile reproductive system, 176, 268.
 Navel cord, dystocia due to, 365.
 Neck, the fore limbs crossed over the, 377.
 Necrotic tip of allantois, 102.
 Necrotic vaginitis, 428.
 Nerves, contusion of the gluteal, 423.
 contusion of the lumbo-sacral, 423.
 contusion of the obturator, 424.
 Nervous system, the, 49.
 Neural groove, 47.
 Neuropore, anterior, 50.
 posterior, 50.
 New-born young, 457.
 Nose, formation of the, 56.
 Number of fetuses in the uterus, 123.
 Obstetrical anatomy, 3.
 chisels, 219.
 cords, 210.
 forceps, 215.
 hooks, 214.
 knives, 217.
 operations, 230.
 physiology, 23.
 prevention of infection during, 228.
 scalpels, 218.
 Obturator nerves, contusion of the, 424.
 paralysis, 424.
 Olfactory organs, the, 56.
 Operations, miscellaneous embryotomy, 259.
 obstetrical, 230.
 preparations for obstetrical, 210.
 the prevention of infection during obstetrical, 228.
 Operator, the dress of, 220.
 Optic vesicles, 58.
 Organs, the generative, 8.
 juvenile genital, 176, 270.
 male reproductive, 85.
 of special sense, development of, 56.
 olfactory, 56.
 Ova, permanent, 25.
 primitive, 25.
 Ovaries, the, 8.
 Oviducts, the, 12.
 Ovisac, maturation of the, 25.
 Ovulation, 30.
 pathological, 186.
 Ovum, pathological implantation of the, 188.

 Palate, cleft, 57.
 Palpation of the uterus per rectum, 114.
 fetus per vaginam or per rectum, 114.
 Pancreas, the, 72.
 Papyraceous mummification, 358.
 Paralysis, gluteal, 423.
 obturator, 423.
 Paraplegia of pregnancy, 150.
 Paresis, parturient, 433.
 in the cow, parturient, 443.
 Parturient apoplexy, 443.
 eclampsia, 435.
 in the mare, 435.
 sow, 441.
 injuries, 430.
 paresis, 433, 443.
 paresis in the cow, 443.
 Parturition, interference in physiological, 166.
 Pathological anchorage of the fetus, dys-

- tocia due to, 188.
 disposition of the umbilical cord, dystocia due to, 365.
 implantation of the ovum, 188.
 ovulation, 186.
 position, dystocia due to, 365.
 positions and postures in the posterior presentation, dystocia due to, 388.
 posture, dystocia due to, 365.
 presentation, dystocia due to, 365.
 Pathology of the sex cells, dystocia, referable to, 201.
 Patient, control of the, 221.
 the examination of the, 224.
 position of the, 221.
 Pelves, interlocking of the maternal and fetal, 382.
 Pelvic abnormalities, dystocia referable to, 199.
 dystocia, 268.
 exostoses, 273.
 fractures, 273.
 girdle, destruction of the, in anterior presentation, 252.
 Pelvis, the, 3.
 the congenitally deformed, 268.
 diseases and injuries of, 272.
 hypoplasia of, 268.
 the juvenile, 272.
 rachitic deformities of the, 272.
 Perineum, rupture of the, 419.
 Permanent ova, 25.
 Persistent median wall of the Muellerian ducts in the vagina, 271.
 Perosomus elumbis, 91.
 Physiological birth, 155.
 parturition, interference in, 166.
 Physiology, obstetrical, 23.
 Pigodidymus aversus, 322.
 Placenta, the fetal membranes and the, 94.
 Placentae, formation of the, 105.
 Position, dystocia due to pathological, 365.
 and form of the pregnant uterus, 116.
 and movements of the fetus during gestation, the, 117.
 of the patient, 221.
 the dorso-iliac, dystocia from, 367, 388.
 the dorso-pubic, dystocia from, 367, 388.
 Positions of the fetus, 206.
 Posterior limbs beneath the fetal body, forward extension of the, 384.
 complete retention of the, 391.
 intra-pelvic amputation of the, when completely retained, 255.
 amputation of the, at the tarsus, 254.
 flexion of the, at the tarsus, 390.
 Posterior neuropore, 50.
 Posterior presentation, dorso-iliac and dorso-pubic positions in the, 389.
 dystocia due to pathological positions and postures in the, 388.
 embryotomy in the, 253.
 lateral deviation of the head in, 393.
 Postmortem changes in the fetus, dystocia due to, 353.
 Postpartum breeding, dystocia from too early, 178.
 hemorrhage, 397.
 Posture, dystocia due to pathological, 365.
 Posture of fetus, 206.
 Pre-conceptional uterine lesions, dystocia due to, 200.
 Pregnancy, 40.
 arrested development of the female reproductive system during first, 178.
 bicornual in multipara, 194, 351.
 in bitch, 195, 351.
 mare, 335.
 compound bicornual, 340.
 corpus luteum of, 115.
 diagnosis of, 115.
 duration of, 127.
 dystocia due to bicornual, 188, 192, 194, 334, 348.
 in cow, 348.
 in ruminants, 348.
 extrauterine, 35.
 hemorrhages of, 150, 359.
 paraplegia of, 150.
 and puerperium, toxæmias of, 433.
 rotated bicornual, 192, 340.
 toxæmias of, 433.
 ventral presentation of bicornual, 335.
 Pregnant animal, the diseases of, 149.
 the hygiene of the, 143.
 uterus, the, 116.
 the bacterial flora of the, 140.
 dystocia to displacement of, 196.
 the form and position of the, 116.
 rupture of the, 150.
 strangulation of the large intestine beneath the, 150.
 Prepubian tendon, rupture of the, 284.
 Presentation of bicornual pregnancy, the ventral, 325.
 breech, 391.
 destruction of the pelvic girdle in anterior, 252.
 detruncation in the anterior, 250.

- dorso-iliac and dorso-pubic positions in posterior, 389.
 of fetus, 206.
 dystocia in the anterior, 367.
 due to pathological, 367.
 due to pathological positions and postures in the posterior, 388.
 dystocia from transverse, 334.
 embryotomy in the anterior, 243.
 embryotomy in the breech, 255.
 embryotomy in the posterior, 253.
 lateral deviation of the head in posterior, 393.
 Presentations of fetus, 206.
 Prevention of infection during obstetrical operations, 228.
 Primitive chorion, 99.
 groove, the, 47.
 ova, 25.
 streak, the, 47.
 Processus globulares, 57.
 Prolapse of the bladder, 417.
 of the bladder through a rupture in the floor of the vagina, 400.
 of the intestine through the ruptured walls of the uterus or vagina, 400.
 of the rectum, 416.
 uterine, 401.
 vagino-cervical, 278.
 Puerperal eclampsia in the bitch, 442.
 in the goat and ewe, 441.
 in the sow, 441.
 eclamptic diseases, 433.
 female, the, 457.
 infections, 430.
 laminitis in the cow, 430.
 laminitis in the mare, 430.
 tetanus, 430.
 Puerperium, toxæmias of pregnancy and, 433.
 Purulent decomposition of the fetus, 360.

 Rachitic deformities of the pelvis, 272.
 Rectum, prolapse of the, 416.
 Rate of reproduction, the, 132.
 Repellers, 216.
 Reproduction, 23.
 the rate of, 132.
 Reproductive organs, dystocia due to dislocation of, 278.
 organs, the male, 85.
 power, the duration of, 132.
 system, hypoplasia of, 268.
 during first pregnancy, arrested development of the female, 176.
 system, narrow vulva associated with juvenile, 176, 270.
 Repulsion, 230.
 Respiratory apparatus, formation of, 63.
 Retention of the anterior limbs, complete, 380.
 posterior limbs, complete, 391.
 Retina, 58.
 Retroflexion of the uterus, 196.
 Retropulsion, 230.
 Retroversion of the uterus, 196.
 Rigidity of extremities, 329.
 Rotated bicornual pregnancy, 192, 340.
 Rotation, 232.
 Round ligament of ovary, 86.
 Ruminants, dystocia from bicornual pregnancy in, 348.
 Rupture in the floor of the vagina, prolapse of the bladder through a, 400.
 of the gravid uterus, 150.
 perineum, 419.
 prepubian tendon, 284.
 uterus, 150, 398.
 vagina, 398.
 Ruptured walls of the uterus or vagina, prolapse of the intestine through the, 400.

 Sacro-sciatic ligament, the, 5.
 Sacrum, the, 3.
 Saws, chain, 219.
 wire, 219.
 Scalpels, obstetrical, 219.
 Schistocephalus bifidus, 50.
 Schistocormus fissidorsualis, 51.
 Schistosomus reflexus, 326.
 Seal, the uterine, 114.
 Section, instruments for, 217.
 Secondary extrauterine fetus, 35.
 Segmentation of the egg, 43.
 Sense, development of the organs of special, 56.
 Sex cells, dystocia referable to pathology of, 201.
 glands, 84.
 Sex parity, 135.
 Short nose, dystocia attributed to, 185.
 Sinus, venosus, the, 73.
 Sire as a cause of dystocia, the, 194, 200.
 dystocia attributed to size of, 200.
 Somatopleure, 48.
 Sow, milk fever in the, 441, 456.
 puerperal eclampsia in the, 441, 456.
 Special sense, development of the organs of, 56.
 Spina bifida, 50.

- Spinal column, complete splitting of the, 50.
 cord, the, 56.
 Splanchnopleure, 49.
 Static fetal cadaver, the, 357.
 Sterno-abdominal position, 190.
 Strangulation of the large intestines beneath the pregnant uterus, 150.
 Subcutaneous amputation of the anterior limbs, 246.
 Superfecundation, 34.
 Superfetation, 34.
- Tarsus, amputation of the posterior limbs at the, 254.
 flexion of the posterior limbs at the, 390.
 "Teeth, ear," 60.
 the formation of the, 66.
 Tendon, rupture of the prepubian, 284.
 Teratological causes, dystocia due to, 176.
 displacement of genitalia, 176.
 hypoplasia of female genitalia, 176.
 Teratology, 42.
 Testicles, the, 84.
 Tetanus, puerperal, 430.
 Torsion of the uterus, 196, 292, 303.
 extent of uterine, 298.
 Toxaemias of pregnancy and puerperium, 433.
 Traction, appliances for exerting, 210.
 the amount of, 240.
 Transverse presentation, 334.
 Traumatic hernia, dystocia referable to, 199.
 Truss, 414.
 Tunica granulosa, 25.
 Twin dystocia, 186, 332.
 Twins, 124.
- Umbilical cord, the, 112.
 dystocia due to pathological disposition of the, 365.
 Umbilical herniae, 284.
 Unipara, 123.
 Upward deviation of the head, 374.
 Ureter, the, 83.
 Urino-genital system, development of the, 82.
 Uterine arteries, the, 115.
 displacements, dystocia due to, 278.
 herniae, 284.
 inertia, the dystocia of, 363.
 invagination, 401.
 lesions, dystocia due to preconceptional, 200.
 prolapse, 401.
 seal, the, 114.
 torsion, 196, 292, 303.
 volvulus, 292.
- Uterus, the, 14.
 amputation of the, 415.
 bacterial flora of the pregnant, 140.
 dystocia due to displacement of pregnant, 196.
 eversion of, 401.
 flexion of the, 196.
 number of fetuses in the, 123.
 palpation of the, per rectum, 114.
 position and form of the pregnant, 116.
 pregnant, 116.
 prolapse of, 401.
 prolapse of the intestine through the ruptured walls of the, 400.
 rupture of the, 460, 398.
 rupture of the gravid, 150.
 strangulation of the large intestines beneath the pregnant, 150.
 torsion of the, 196, 292, 303.
 version of the, 196.
- Vagina, the, 19.
 compression and atresia of, 274.
 persistent median wall of the Muellerian ducts in the, 271.
 prolapse of the intestine through the ruptured walls of the uterus or, 400.
 prolapse of the bladder through a rupture in the floor of the, 400.
 rupture of the, 398.
- Vaginal atresia, 274.
 constriction, 274.
 Vaginitis, necrotic, 428.
 Vagino-cervical prolapse, 278.
- Veins, 78.
 Veins, allantoic, 79.
 Cuvierian, 78.
 the formation of, 78.
 vitelline, 78.
- Ventral herniae, 284.
 presentation of bicornual pregnancy, the, 335.
- Ventricles, the, 73.
- Version, 235.
 of the uterus, 196.
- Vesicle, blastodermic, 46.
- Vesicles, optic, 58.
- Vitelline sac, 48, 94.
 veins, 78.
- Vitreous body, 59.

- Volume, excessive, due to general or localized diseases of the fetus and its membranes, 308.
of the fetus, excessive, 208.
- Volvulus, uterine, 292.
- Vulva, the, 20.
hematoma of the, 422.
narrow, associated with juvenile reproductive system, 176, 270.
- Wire saws, 219.
- Wolffian bodies, the, 82.
ducts, the, 82.
- Wounds and injuries of the genital and neighboring organs, 397.
- Wry-neck, dystocia from, 371.
- Yolk sac, 48, 94.
- Young animals, genital hypoplasia in, 177.
the new-born, 457.
- Zona radiata, 26.



