

**The topographical anatomy of the limbs of the horse / by O. Charnock
Bradley.**

Contributors

Bradley, O. Charnock 1871-1937.

Publication/Creation

Edinburgh : W. Green, 1920.

Persistent URL

<https://wellcomecollection.org/works/nh96vtpc>

License and attribution

Conditions of use: it is possible this item is protected by copyright and/or related rights. You are free to use this item in any way that is permitted by the copyright and related rights legislation that applies to your use. For other uses you need to obtain permission from the rights-holder(s).



Wellcome Collection
183 Euston Road
London NW1 2BE UK
T +44 (0)20 7611 8722
E library@wellcomecollection.org
<https://wellcomecollection.org>



X
BMK.G.XM
BRA

MINISTRY OF
AGRICULTURE, FISHERIES AND FOOD

CENTRAL VETERINARY LABORATORY
NEW HAW, WEYBRIDGE, SURREY

LIBRARY

X
Class No. BMK.G.XM/BRA

Accession No. L 66/634

652947



22500593881



Med
K51539


25/2
RETURN TO
VETERINARY LABORATORY
NEW HAW, WEYBRIDGE, SURREY.

The Edinburgh Veterinary Series

General Editor—

O. CHARNOCK BRADLEY, M.D., D.Sc., M.R.C.V.S.

THE LIMBS OF THE HORSE



Digitized by the Internet Archive
in 2017 with funding from
Wellcome Library

THE
TOPOGRAPHICAL ANATOMY
OF THE
LIMBS OF THE HORSE

BY

O. CHARNOCK BRADLEY

M.D., D.Sc., M.R.C.V.S.

PRINCIPAL, ROYAL (DICK) VETERINARY COLLEGE, EDINBURGH;
LECTURER ON COMPARATIVE ANATOMY, UNIVERSITY OF EDINBURGH.

EDINBURGH

W. GREEN & SON, LIMITED

1920

Ministry of Agriculture
Fisheries and Food
Veterinary Laboratory

Library X

Class No BMK.G.XM

Auth No BRA

Access No 466/634

Demand No.....

8923423

WELLCOME INSTITUTE LIBRARY	
Coll.	WelMOMec
Coll.	
No.	V

P R E F A C E.

WERE it not that the conventional preface affords a means by which an author may convey his grateful thanks to those from whom he has received advice and assistance, the present book would have been sent forth without the usual preamble. Seeing, however, that the illustrations form a highly important, helpful, and essential part of the book, it would be worse than ungrateful to neglect this opportunity to thank Mr. James T. Murray for the infinite care he has bestowed upon the drawing of the various dissections. The publishers were indeed fortunate in securing the services of one whose long experience in the illustration of works on anatomy has given him knowledge that, combined with an artistic skill it would be impertinence in me to praise, places him in the forefront of anatomical illustrators. It is greatly to be deplored that the labour difficulties of peace have not spared the workshop of the blockmakers, but have resulted in the frequent neglect of Mr. Murray's instructions respecting the reduction in size of his drawings. Some of the figures have been reduced beyond the carefully determined scale indicated on the originals, and some companion figures have not been reduced to scale. Unfortunately, these errors could have been rectified only at much expense and after long delay.

To Dr. E. B. Jamieson, of the University of Edinburgh, thanks are due for help in the revision of the footnotes in which the derivation of anatomical terms is indicated. It is hoped that these brief notes will lead the student—and possibly others—to realise that terms are more than mere collections of letters.

Finally, I cannot abstain from thanks to the publishers, who have been most generous in meeting all suggestions, and in permitting the free use of illustrations.

O. C. B.

November 1919.

CONTENTS.

	PAGE
THORACIC LIMB	1
THE HOOF AND ITS CONTENTS	78
ARTERIES OF THORACIC LIMB	93
NERVE AND BLOOD SUPPLY OF THE MUSCLES OF THE THORACIC LIMB	94
PELVIC LIMB	96
ARTERIES OF PELVIC LIMB	164
NERVE AND BLOOD SUPPLY OF THE MUSCLES OF THE PELVIC LIMB	165
INDEX	167

LIST OF ILLUSTRATIONS.

FIG.	PAGE
1. Cutaneous nerves of the thoracic limb	3
2. Lateral wall, floor, and contents of the axilla	5
3. Superficial dissection of the shoulder and arm	9
4. Dissection of the region of the shoulder	11
5. Lateral aspect of the scapula and scapular cartilage, with areas of muscular attachment	12
6. Medial aspect of the scapula and scapular cartilage, with areas of muscular attachment	13
7. Glenoid cavity of the scapula, with areas of muscular attachment in its neighbourhood	14
8. Deep dissection of the shoulder and arm	17
9. Dissection of the medial aspect of scapular region and arm	19
10. Deep dissection of the medial aspect of the arm	20
11. Diagram of the arteries of the thoracic limb	22
12. Diagram of the veins of the thoracic limb	23
13. Lateral aspect of the humerus, with areas of muscular attachment	26
14. Anterior aspect of the humerus, with areas of muscular attachment	27
15. Medial aspect of the humerus, with areas of muscular attachment	28
16. Posterior aspect of the humerus, with areas of muscular attachment	29
17. Proximal end of the humerus, with areas of muscular attachment	30
18. Distal end of the humerus, with areas of muscular attachment	30
19. Evolution from pentadactyl to monodactyl condition in the manus of the horse	32
20. Dissection of the lateral aspect of the forearm and carpal region	36
21. Dissection of the medial aspect of the forearm and carpal region	42
22. Lateral aspect of the radius and ulna, with areas of muscular attachment	43
23. Anterior aspect of the proximal part of the radius and ulna, with areas of muscular attachment	44
24. Medial aspect of the proximal part of the radius and ulna, with areas of muscular attachment	44
25. Posterior aspect of the radius and ulna, with areas of muscular attachment	45
26. Lateral aspect of the carpus, etc., with areas of muscular attachment	46
27. Dorsal (anterior) aspect of the carpus, etc., with areas of muscular attachment	46
28. Medial aspect of the carpus, etc., with areas of muscular attachment	47
29. Volar (posterior) aspect of the carpus, etc., with areas of muscular attachment	47
30. Key-outline of the thoracic limb to indicate the level of the transverse sections illustrated in subsequent figures	48
31. Section across the forearm at the level indicated by A in Fig. 30	49
32. Section across the forearm at the level indicated by B in Fig. 30	50
33. Section across the forearm at the level indicated by C in Fig. 30	51
34. Section across the forearm at the level indicated by D in Fig. 30	52
35. Section across the forearm at the level indicated by E in Fig. 30	53
36. Section across the most distal part of the forearm at the level indicated by F in Fig. 30	54

FIG.	PAGE
37. Medial aspect of the carpus, metacarpus, and digit	56
38. Lateral aspect of the skeleton of the digit with areas of muscular attachment	58
39. Volar (posterior) aspect of the skeleton of the digit with areas of muscular attachment	59
40. Section across the metacarpus at the level indicated by G in Fig. 30	61
41. Section across the metacarpus at the level indicated by H in Fig. 30	62
42. Section across the metacarpus at the level indicated by I in Fig. 30	62
43. Section across the distal end of the metacarpus as indicated by J in Fig. 30	63
44. Section across the first phalanx at the level indicated by K in Fig. 30	63
45. Section across the first phalanx at the level indicated by L in Fig. 30	64
46. Lateral aspect of the shoulder joint	67
47. Medial aspect of the shoulder joint	68
48. Anterior aspect of the elbow joint	69
49. Medial aspect of the elbow joint	70
50. Lateral aspect of the carpal articulations	72
51. Dorsal (anterior) aspect of the carpal articulations	73
52. Medial aspect of the carpal articulations	74
53. Lateral aspect of the matrix of the hoof	79
54. Volar aspect of the matrix of the hoof	79
55. Outline of the volar and plantar aspects of the hoof of the thoracic and pelvic limbs	81
56. Inner surface of the hoof	82
57. Volar aspect of the hoof	83
58. Longitudinal section of the digit	85
59. Key-outline to indicate the position of the sections illustrated in Figs. 60 and 61	86
60. Transverse section of the foot at the level indicated by line A in Fig. 59	86
61. Transverse section of the foot at the level indicated by line B in Fig. 59	87
62. Lateral aspect of the phalanges and the cartilage of the third phalanx, to show the position of the joint and cartilage relative to the surface of the limb and the border of the hoof	88
63. The tendons and ligaments of the lateral aspect of the digit	90
64. Ligaments of the volar (posterior) aspect of the digit	91
65. Superficial dissection of the medial aspect of the thigh (female)	97
66. Dissection of the medial aspect of the thigh after removal of the sartorius and gracilis muscles (male)	99
67. Deep dissection of the medial aspect of the thigh	100
68. Diagram of the arteries of the pelvic limb	102
69. Diagram of the veins of the pelvic limb	103
70. Ventral aspect of the hip bone, with areas of muscular attachment	105
71. Cutaneous nerves of the pelvic limb	108
72. Superficial dissection of the gluteal region and lateral aspect of the thigh	110
73. Deep dissection of the gluteal region and lateral aspect of the thigh	112
74. Lateral aspect of the hip bone, sacrum, and associated ligaments, with areas of muscular attachment	114
75. Lateral aspect of the femur, with areas of muscular and ligamentous attachment	116
76. Anterior aspect of the femur, with areas of muscular and ligamentous attachment	117
77. Medial aspect of the femur, with areas of muscular and ligamentous attachment	118
78. Posterior aspect of the femur, with areas of muscular and ligamentous attachment	119
79. Proximal end of the femur, with areas of muscular attachment	120

FIG.	PAGE
80. Distal end of the femur, with areas of muscular and ligamentous attachment	120
81. Key-outline of the pelvic limb to indicate the level of the transverse sections illustrated in subsequent figures	121
82. Section across the thigh at the level indicated by M in Fig. 81	122
83. Anterior aspect of the hip joint	123
84. Medial aspect of the hip joint	124
85. Superficial dissection of the medial aspect of the leg and tarsus	126
86. Superficial dissection of the lateral aspect of the leg and tarsus	130
87. Deep dissection of the popliteal region	131
88. Lateral aspect of the proximal part of the tibia and fibula, with areas of muscular and ligamentous attachment	133
89. Anterior aspect of the proximal part of the tibia and fibula, with areas of muscular and ligamentous attachment	133
90. Medial aspect of the tibia and fibula, with areas of muscular and ligamentous attachment	134
91. Posterior aspect of the tibia and fibula, with areas of muscular and ligamentous attachment	135
92. Dissection of the dorsal (anterior) aspect of the tarsal region	138
93. Section across the pelvic limb at the line indicated by N in Fig. 81	140
94. Section across the proximal part of the leg at the level indicated by O in Fig. 81	141
95. Section across the leg at the level indicated by P in Fig. 81	142
96. Section across the leg at the level indicated by Q in Fig. 81	143
97. Section across the leg at the level indicated by R in Fig. 81	144
98. Section across the most distal part of the leg at the level indicated by S in Fig. 81	145
99. Section across the tarsus at the level indicated by T in Fig. 81	146
100. Section across the tarsus at the level indicated by U in Fig. 81	147
101. Lateral aspect of the tarsus, with areas of muscular attachment	148
102. Dorsal (anterior) aspect of the tarsus, with areas of muscular attachment	149
103. Medial aspect of the tarsus, with areas of muscular attachment	150
104. Plantar (posterior) aspect of the tarsus, with areas of muscular attachment	151
105. Section across the proximal end of the metatarsus at the level indicated by V in Fig. 81	152
106. Section across the metatarsus at the level indicated by W in Fig. 81	152
107. Section across the metatarsus at the level indicated by X in Fig. 81	153
108. Lateral aspect of the femoro-patellar and femoro-tibial articulations	155
109. Anterior aspect of the femoro-patellar and femoro-tibial articulations	156
110. Posterior aspect of the femoro-tibial articulation	157
111. Proximal end of the tibia, with areas of ligamentous attachment	158
112. Proximal end of the tibia, with the ligaments and menisci attached thereto	158
113. Lateral aspect of the tarsal articulations	161
114. Dorsal (anterior) aspect of the tarsal articulations	161
115. Medial aspect of the tarsal articulations	162

THORACIC LIMB.

BECAUSE it affords the greatest convenience to the dissectors of other parts of the body, the dissection of the thoracic limb should begin with the animal on its back. In this position the pectoral region offers itself for examination.

The dissector should note the rounded prominence, formed by the superficial pectoral muscle, extending from the cranial end of the sternum to the limb. The prominence is bounded laterally by the *lateral pectoral groove*, which marks the line of contact of pectoral and brachiocephalic muscles. In the middle line, between the pectoral prominences, is the shallow *median pectoral groove*, which bifurcates at the manubrium of the sternum, the two limbs of the groove diverging, each to join the lateral pectoral groove in the shallow *supraclavicular fossa*.

The position of the caudal border of the superficial pectoral muscle is marked by a distinct fold of skin, but the limits of the deep pectoral muscle cannot be defined on the surface of the body.

Dissection.—Make an incision through the skin in the middle line of the body extending the full length of the sternum. A second incision, transverse in direction, should then be carried from the sternum to the level of the elbow joint. The two flaps of skin thus marked out must be raised from the underlying pectoral mass of muscles. As this is being done, note must be taken of small cutaneous nerves and vessels which pierce the pectoral muscles close to their sternal attachment. Larger cutaneous nerves, derived from the sixth cervical spinal nerve (*n. supraclavicularis*), will be seen crossing the surface of the superficial pectoral muscle.

Clean the surface of the superficial pectoral, taking care to preserve a vein of some size (*v. cephalica*) and a small artery (*a. transversa scapulæ*) which will be found at its cranial border.

The thin fascia (*fascia pectoralis*) which covers the surface of the pectoral muscles furnishes a layer that passes on to the lateral face of the triceps muscle, and thence becomes continuous with the scapular fascia.

M. PECTORALIS SUPERFICIALIS.—The superficial pectoral¹ muscle is generally described as divisible into two parts. The more cranial is

¹ *Pectus* [L.], breast, breast-bone.

known as the *clavicular portion* (pars clavicularis), on the assumption that it corresponds to that part of the pectoral which arises from the clavicle¹ in those animals in which this bone exists. In the horse, where the clavicle has disappeared, the muscle has shifted its origin to the nearest bone, namely, the sternum. The caudal or *sternocostal*² part (pars sternocostalis) of the muscle is more extensive and composed of bundles of fibres converging somewhat as they proceed towards the elbow joint.

It is not altogether easy to separate the clavicular and sternocostal parts of the pectoral muscle; nor is it of much profit to do so. If the dissector desires to make the separation he should look carefully for a very indistinct groove at no great distance from the cranial border of the muscle, and, in effecting the separation, he should bear in mind that the sternocostal portion of the muscle overlaps the clavicular.

The origin of the superficial pectoral muscle is from the sternum from its cranial end to a level with the sixth rib-cartilage. It will be noticed that some of the fibres spring from a fibrous partition between the muscles of the two sides of the body. Its insertion is into the crest of the greater tubercle of the humerus and to the fascia lining the inner aspect of the forearm.

Dissection.—The superficial pectoral muscle is to be reflected by making a longitudinal incision through it at a short distance from its sternal attachment. Care should be taken to avoid injury to the underlying deep muscle, as the two pectorals are generally intimately associated with each other close to the sternum. As the superficial muscle is being raised and turned outwards, its nerve of supply should be noted, as it pierces the narrow interval between the two parts of the deep muscle.

The surface of the deep pectoral muscle must be cleaned and its borders defined. In doing this, an examination should be made of a triangular space bounded by the pectoral and brachiocephalic muscles and a strong band of the cutaneous muscle attached to the extremity of the sternum. In examining the contents of the space the dissector of the limb should work along with those who are dissecting the head and neck. The triangle contains a group of lymph glands, the cephalic vein, and the transverse scapular artery. Deep down in the space is the jugular vein.

The definition of the caudal border of the deep pectoral must be conducted with care, for it is overlapped by the cutaneous muscle, and associated with it are the external thoracic vein and the caudal pectoral nerve.

¹ *Clavicula* [L.], dim. of *clavus*, a nail, or of *clavis*, key; probably from κλείς [Gr.], key or bolt, collar-bone. The clavicle of the horse has disappeared, and is now represented by a fibrous line in the brachiocephalic muscle. In the dog it is a rudimentary bone embedded in that muscle.

² *Sternum* [L.], στήρνον (sternon) [Gr.], breast or chest. *Costa* [L.], rib.

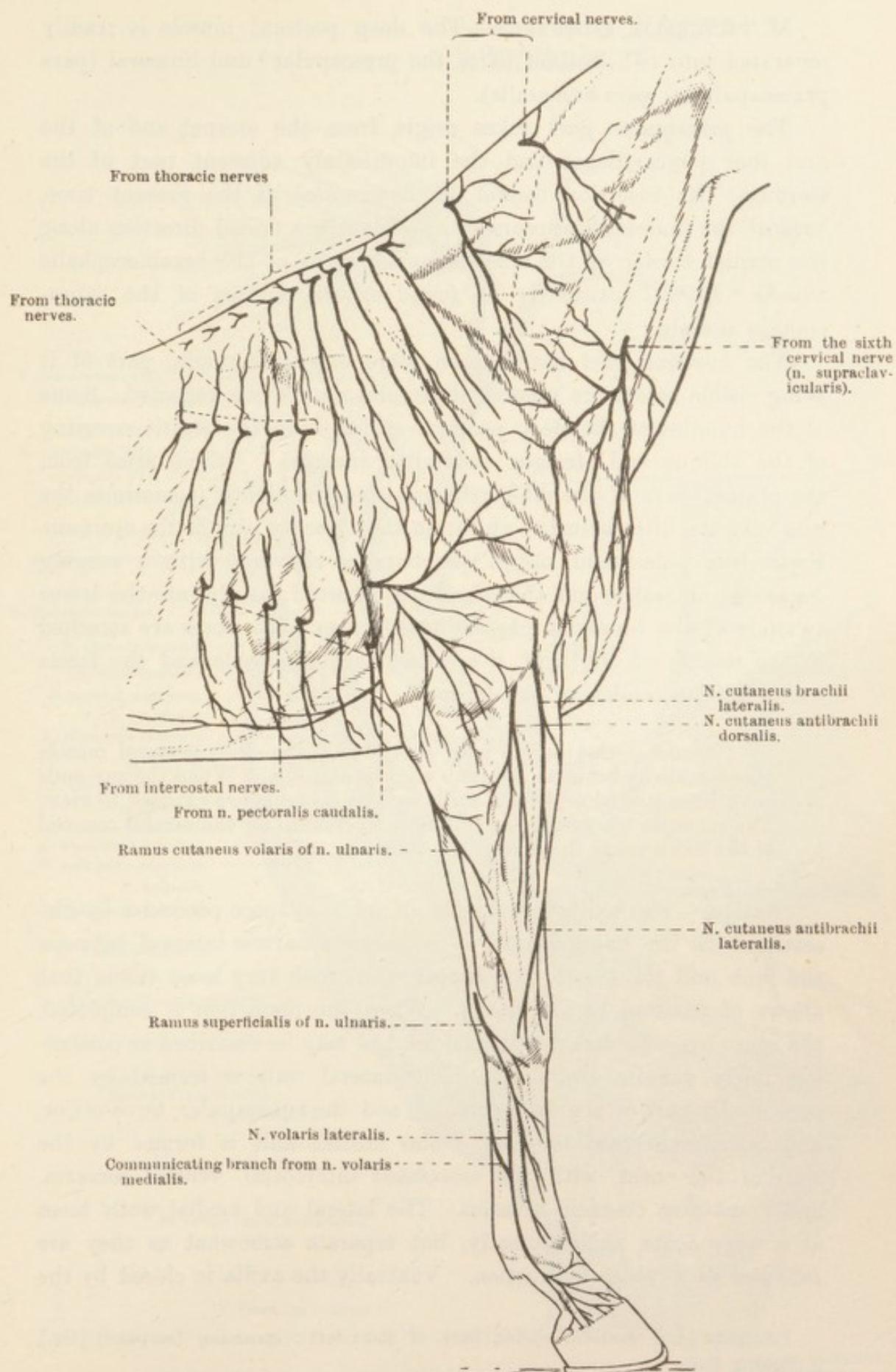


FIG. 1.—Cutaneous Nerves of the Thoracic Limb.

M. PECTORALIS PROFUNDUS.—The deep pectoral muscle is readily separated into two distinct parts, the prescapular¹ and humeral (*pars praescapularis: pars humeralis*).

The *prescapular part* takes origin from the sternal end of the first four rib-cartilages and the immediately adjacent part of the sternum. Its insertion cannot be determined at the present time, because the muscle disappears by sweeping in a dorsal direction along the cranial border of the scapula under cover of the brachiocephalic muscle. It will ultimately be found on the surface of the supraspinous muscle.

The *humeral part* has a much more extensive origin, part of it being visible before the superficial pectoral muscle was reflected. Some of the bundles of the deep pectoral spring from the elastic covering of the oblique and straight abdominal muscles. Others arise from the sternal ends of the rib-cartilages from the eighth (sometimes the ninth) to the fifth inclusive, and from the adjacent part of the sternum. From this widespread origin the bundles converge with a varying degree of obliquity, and the muscle is inserted mainly into the lesser tubercle of the humerus. In addition, some of the fibres are attached to the tendon of origin of the coracobrachial muscle and the fascia overlying the tendon of the biceps.

Dissection.—Cut across both portions of the deep pectoral muscle about midway between the limb and the sternum. When the cut ends have been turned aside, the axilla and its contents are exposed to view. The contents are numerous, and must be cleaned by the careful removal of the loose tissue that surrounds them.

AXILLA.—The axilla² is largely an artificial space produced by dissection. In the living animal it is merely a narrow interval between the limb and the side of the thorax filled with very loose tissue that allows of freedom of movement. When the dissection is completed, the space has considerable dimensions, and may be described as possessing fairly definite boundaries. The lateral wall is formed by the prescapular part of the deep pectoral, and the subscapular, teres major, and latissimus dorsi muscles. The medial wall is formed by the wall of the chest, with the associated intercostal, ventral serratus, and transverse thoracic muscles. The lateral and medial walls meet at a very acute angle dorsally, but separate somewhat as they are followed in a ventral direction. Ventrally the axilla is closed by the

¹ *Scapulæ* [L.], shoulder-blades, back of shoulders; *σκαπάνη* (*scapanē*) [Gr.], a digging tool.

² *Axilla* [L.] (dim. of *ala*, wing), arm-pit.

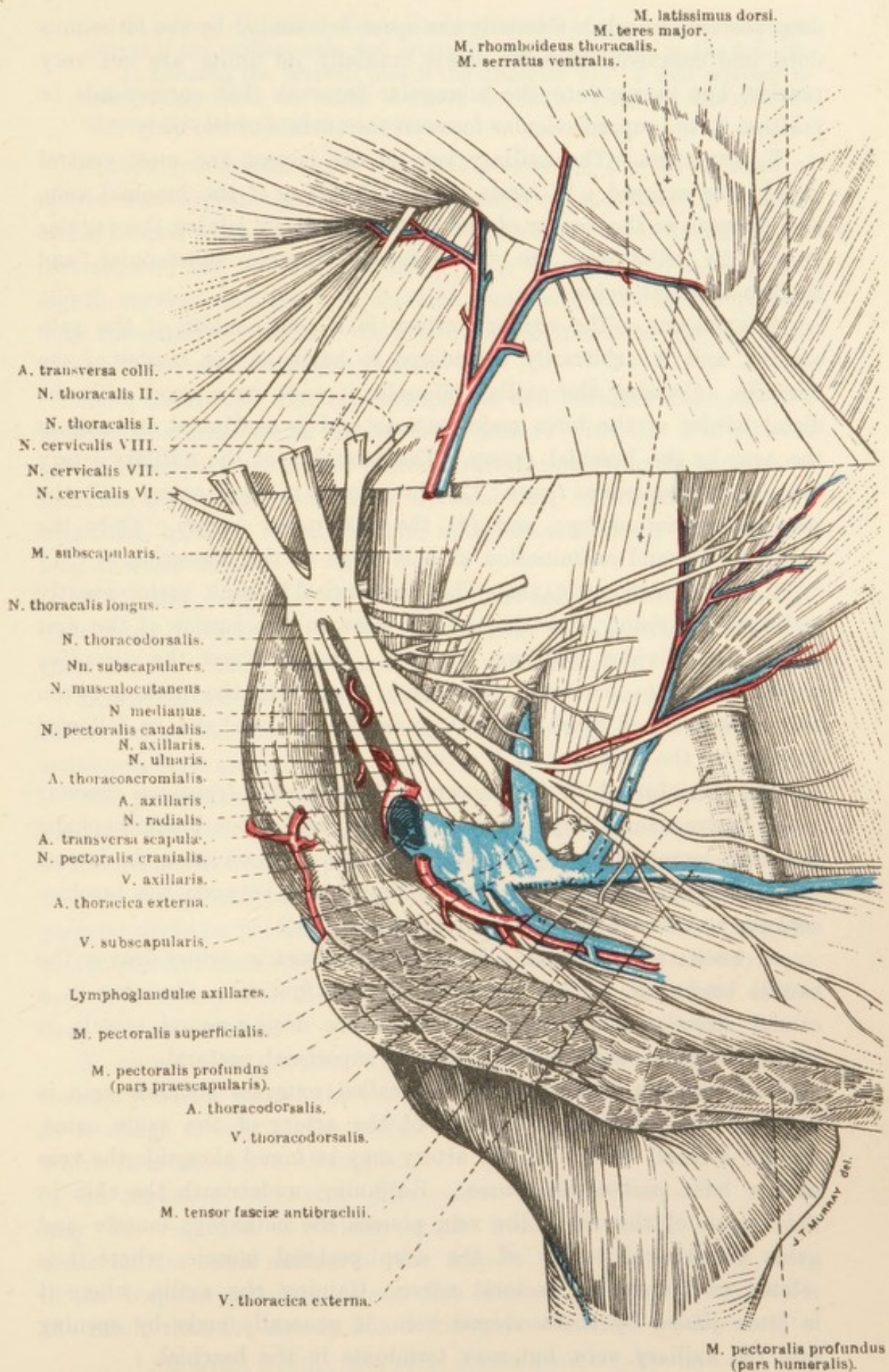


FIG. 2.—Lateral Wall, Floor, and Contents of the Axilla.

deep pectoral muscle. Caudally the space is bounded by the latissimus dorsi and cutaneous muscles, while cranially its limits are not very precise, but merge into the triangular interval that corresponds in position to the supraclavicular fossa on the surface of the body.

V. AXILLARIS.—The axillary vein is the largest and most ventral vessel now exposed. It forms the continuation of the brachial vein, and, running to the border of the first rib, ends by joining the jugular vein. Its tributaries are the external thoracic, subscapular, and thoraco-acromial veins.

A. AXILLARIS.—The axillary artery is a continuation of the subclavian, and is arbitrarily considered to begin at the border of the first rib. Crossing the axilla obliquely, it ends on a level with the distal border of the teres major muscle, and is continued onwards in the arm by the brachial artery. The branches of the axillary artery are (1) the *omocervical trunk*; (2) the *external thoracic artery*; (3) the *thoraco-acromial artery*; and (4) the *subscapular artery*. Only the first two demand examination at this stage of the dissection.

TRUNCUS OMOCERVICALIS.—The omocervical¹ trunk varies greatly in length. Arising from the axillary close to the border of the first rib, it soon divides into two branches. One of these, the *ascending cervical artery* (a. cervicalis ascendens), turns into the neck between the omohyoid and brachiocephalic muscles, and need not be followed further by the dissector of the limb.

The other branch of the omocervical trunk is the *transverse scapular artery* (a. transversa scapulæ), which lies at first under brachiocephalic and deep pectoral (prescapular part) muscles. It soon gains the lateral pectoral groove, where it has already been found between the brachiocephalic and superficial pectoral (clavicular part).

A. THORACICA EXTERNA.—The external thoracic artery leaves the caudal border of the axillary close to the first rib. Coursing in a caudal direction along the deep face of the deep pectoral muscle, it supplies this as well as the overlying superficial pectoral.

V. THORACICA EXTERNA.—The so-called external thoracic vein is not, strictly speaking, a satellite of the artery of the same name, though a small branch of the artery may be found alongside the vein in the later part of its course. Beginning underneath the skin in the region of the flank, the vein pierces the cutaneous muscle and gains the lateral border of the deep pectoral muscle, where it is related to the caudal pectoral nerve. Gaining the axilla, where it is often joined by thoracodorsal vein, it generally ends by opening into the axillary vein, but may terminate in the brachial.

¹ ὤμος (ōmos) [Gr.], shoulder. Cervix [L.], neck.

Dissection.—It will facilitate the examination of the brachial plexus of nerves if the axillary vein and artery are cut across close to the first rib.

In cleaning the brachial plexus the dissector will be well advised to work solely from the trunk towards the limb. This will diminish the chance of a false division of nerves.

PLEXUS BRACHIALIS.—The brachial plexus¹ is the broad band of nerves that appears between the two parts of the scalenus muscle, and is formed by the ventral divisions of the sixth, seventh, and eighth cervical, and the first and second thoracic nerves. The seventh and eighth cervical and the first thoracic contribute most to the plexus; only comparatively slender contributions are furnished by the sixth cervical and second thoracic nerves.

From the narrow interval between the two portions of the scalenus muscle, where its caudal border is in contact with the first rib, the plexus sweeps in a caudal and ventral direction into the axilla and divides into the following branches:—Suprascapular, subscapular, musculocutaneous, axillary, radial, median, ulnar, thoracodorsal, pectoral, and long thoracic nerves.

With the exception of the three last-named, these nerves are distributed to the limb. At the present time it will suffice to identify them and leave their fuller examination until later.

N. THORACODORSALIS.—The thoracodorsal nerve pursues an oblique course across the medial face of the scapular region, and ends in the latissimus dorsi muscle.

NN. PECTORALES.—The pectoral nerves may be divided into two groups:—(1) The cranial nerves (nn. pectorales craniales) are three or four in number, and supply the cranial part of the pectoral mass of muscles as well as a part of the brachiocephalic muscle. (2) A caudal pectoral nerve (n. pectoralis caudalis) furnishes twigs to the remainder of the pectoral mass and the cutaneous muscle. It has already been seen in company with the external thoracic vein at the border of the deep pectoral muscle.

N. THORACALIS LONGUS.—The long thoracic nerve is somewhat isolated from the rest of the branches of the brachial plexus, inasmuch as it clings closely to the surface of the ventral serratus muscle, of which it is the nerve of supply.

M. SERRATUS VENTRALIS.—The extensive ventral serratus² muscle may be regarded as taking origin from the rough triangular areas on the costal surface of the scapula and the adjoining part of the scapular cartilage. From this origin the fibres diverge, with the result that the muscle has a triangular or fanlike outline. The

¹ *Plexus* [L.], plaiting, from *plecto*, to plait, braid, or interweave.

² *Serratus* [L.], saw-edged, serrated, from *serra*, a saw.

insertion of the muscle is to the transverse processes of the last four or five cervical vertebræ, and the first eight or nine ribs in the neighbourhood of the junction of the rib-bone and the rib-cartilage. The serrated character of the border of the muscle is best marked at its insertion into the fifth to ninth ribs. In this region it will be observed that the precise outline of the muscle is somewhat obscured by an overlapping of the yellow, elastic tunic that clothes the abdominal muscles.

M. LATISSIMUS DORSI.—This extensive muscle cannot be completely examined at this stage of the dissection, but its identity should be established.

M. OMOHYOIDEUS.—Being a muscle of the neck, only the origin of the omohyoid¹—from the fascia over the subscapular muscle near the shoulder joint—need be examined by the dissector of the limb.

Dissection.—The brachial plexus should be severed close to the point at which it appears between the two parts of the scalenus muscle. Next cut through the serratus ventralis a short distance from its scapular attachment. The origin of the omohyoid muscle should also be freed.

The body must now be turned into such a position as will permit the dissection of the lateral scapular region. Though all the muscles (with the exception of the latissimus dorsi) now to be examined are attached to the scapula, their origins are very widespread. The trapezius and rhomboid extend far into the neck, while the latissimus dorsi has part of its origin as far distant as the loins. It is advisable, therefore, to make an extensive surface examination before beginning to turn aside the skin. The spine of the scapula can generally be identified and palpated. Cranial to it is a sloping, elongated prominence, produced by the supraspinous muscle and the prescapular portion of the deep pectoral, bounded by a shallow groove that marks the junction of the neck and shoulder. Caudal to the scapular spine is a broader area corresponding to the infraspinous and deltoid muscles. An oblique groove indicates the border of the latter muscle, and ventral and caudal to it is a distinct swelling, reaching to the region of the olecranon, caused by the triceps.

Dissection.—A longitudinal incision should be made along the mid-dorsal line from the level of the epistropheus to the lumbar region. A vertical incision is now carried from the interscapular region (withers) to well beyond the shoulder joint. The two flaps of skin thus demarcated are now to be turned aside. Immediately under the skin is the cutaneous muscle, which, over the scapula, is very thin, but becomes thicker as it is followed over the wall of the thorax. Its dissection from

¹ ὄμος (ōmos) [Gr.], shoulder. ὑοειδής [Gr.], U-shaped, from the resemblance of the human hyoid bone to the letter U.

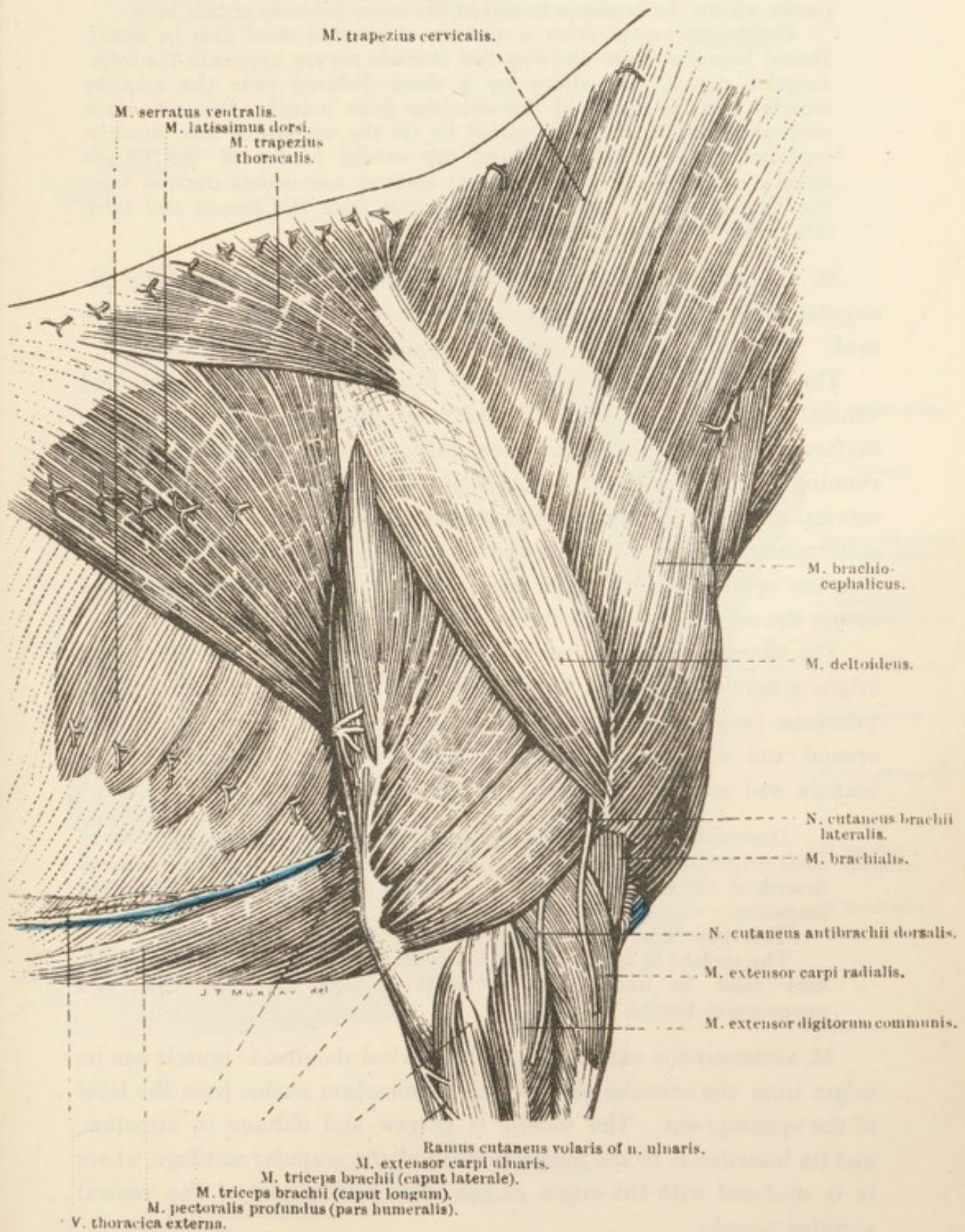


FIG. 3.—Superficial Dissection of the Shoulder and Arm.

the surface of the latissimus dorsi should be performed with some degree of care, and note must be taken of a thin tendinous band that passes within the humerus to end at the lesser tubercle of this bone.

Cutaneous nerves from a variety of sources must also be noted. Dorsal branches from the first few thoracic nerves appear in the interscapular region, and sweep for a short distance over the scapular muscles. In the region of the shoulder joint branches from the sixth cervical nerve (*n. supraclavicularis*) lie on the surface of the brachiocephalic muscle. Curving round the caudal border of the triceps muscle and spreading out over its surface, are nerves derived from the caudal pectoral with which branches from the second and third intercostal nerves are connected.

M. TRAPEZIUS.—The trapezius¹ muscle forms a thin, irregularly triangular sheet over the scapular region, and extending well into the neck. Two parts, a thoracic and a cervical, are to be distinguished.

The cervical trapezius consists of fibres running in a caudal and ventral direction, and some difficulty is experienced in clearing its surface of a thin, closely adherent fibrous investment with strands running at right angles to the fibres of the muscle. The origin of the cervical trapezius is from the ligamentum nuchæ from the level of the epistropheus to the third thoracic vertebra, and its insertion is partly into the spine of scapula and partly into the fascial aponeurosis that covers the scapular muscles and is continued into the arm.

The thoracic trapezius has a much more definite outline. From an origin extending from the fourth to about the ninth thoracic spinous processes (supraspinal ligament) the fibres of the muscle pass in a cranial and ventral direction, to be inserted into the spine of the scapula and more particularly into its tubercle.

Dissection.—Cut through both parts of the trapezius muscle close to their origin and turn them downwards. In doing so, seek for the dorsal branch of the accessory nerve that travels down the neck to end in the trapezius.

This dissection exposes the rhomboid muscles.

The surface of the latissimus dorsi should be cleaned. Considerable care must be exercised when working over its broad, thin, and aponeurotic tendon of origin.

M. RHOMBOIDEUS CERVICALIS.—The cervical rhomboid² muscle has its origin from the cordlike part of the ligamentum nuchæ from the level of the epistropheus. The muscle is narrow and oblique in direction, and its insertion is to the medial surface of the scapular cartilage, where it is confused with the origin of the most cranial part of the ventral serratus muscle.

M. RHOMBOIDEUS THORACALIS.—The thoracic rhomboid is not clearly

¹ *Trapezium* [L.], from *τραπέζιον* (trapezion) [Gr.], a small table. From the four-sided outline of the muscles of the two sides of the body taken together.

² *Rhombus* [L.], *ῥόμβος* (rhombos) [Gr.], a rhomb. *εἶδος* (eidos) [Gr.], form.

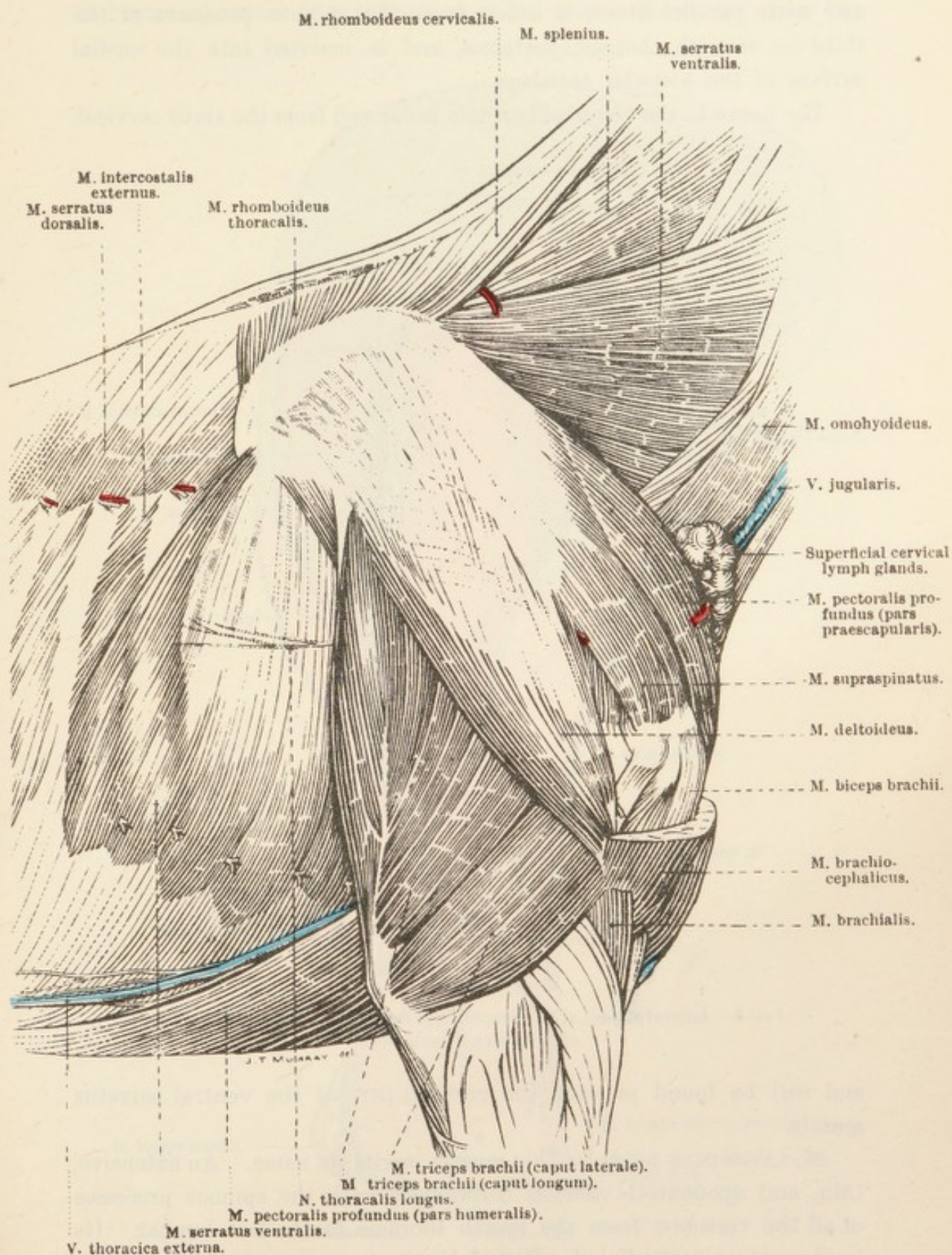


FIG. 4.—Dissection of the Region of the Shoulder.

defined where it meets the cervical muscle of the same name. Thin, and with parallel fibres, it arises from the spinous processes of the third to seventh thoracic vertebræ, and is inserted into the medial surface of the scapular cartilage.

The nerve to the rhomboid muscle is derived from the sixth cervical,

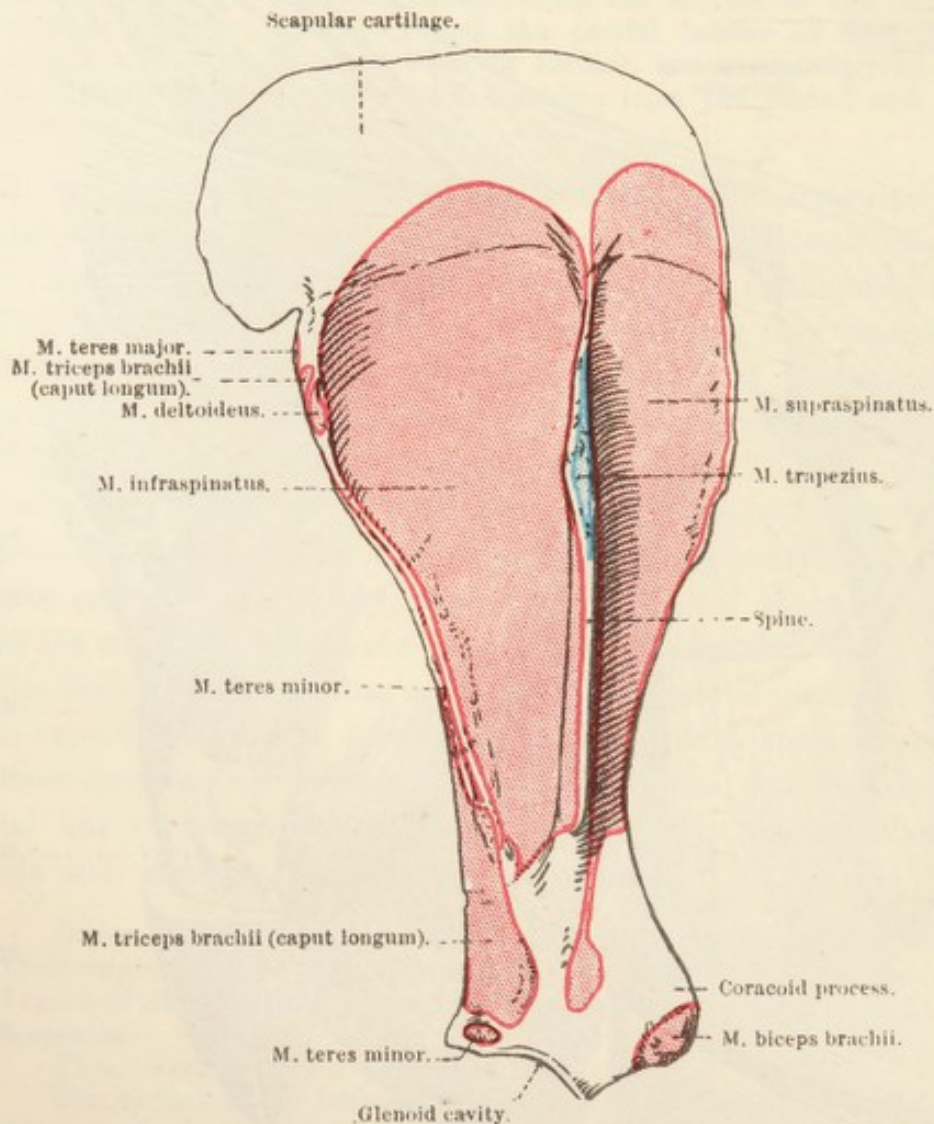


FIG. 5.—Lateral Aspect of the Scapula and Scapular Cartilage, with Areas of Muscular Attachment.

and will be found piercing the cervical part of the ventral serratus muscle.

M. LATISSIMUS DORSI.¹—This muscle merits its name. An extensive, thin, and aponeurotic tendon connects it with the spinous processes of all the vertebræ from the fourth thoracic to the last lumbar. Its lumbar spinal connection is effected by the mergence of its aponeurosis into the lumbodorsal fascia. The fleshy part of the muscle begins at a curved line approximately on a level with the twelfth rib. At the

¹ *Latissimus* [L.], superlative of *latus*, broad, wide. *Dorsum* [L.], the back.

present stage of the dissection the insertion (into the medial surface of the humerus) cannot be examined, since the muscle disappears under the

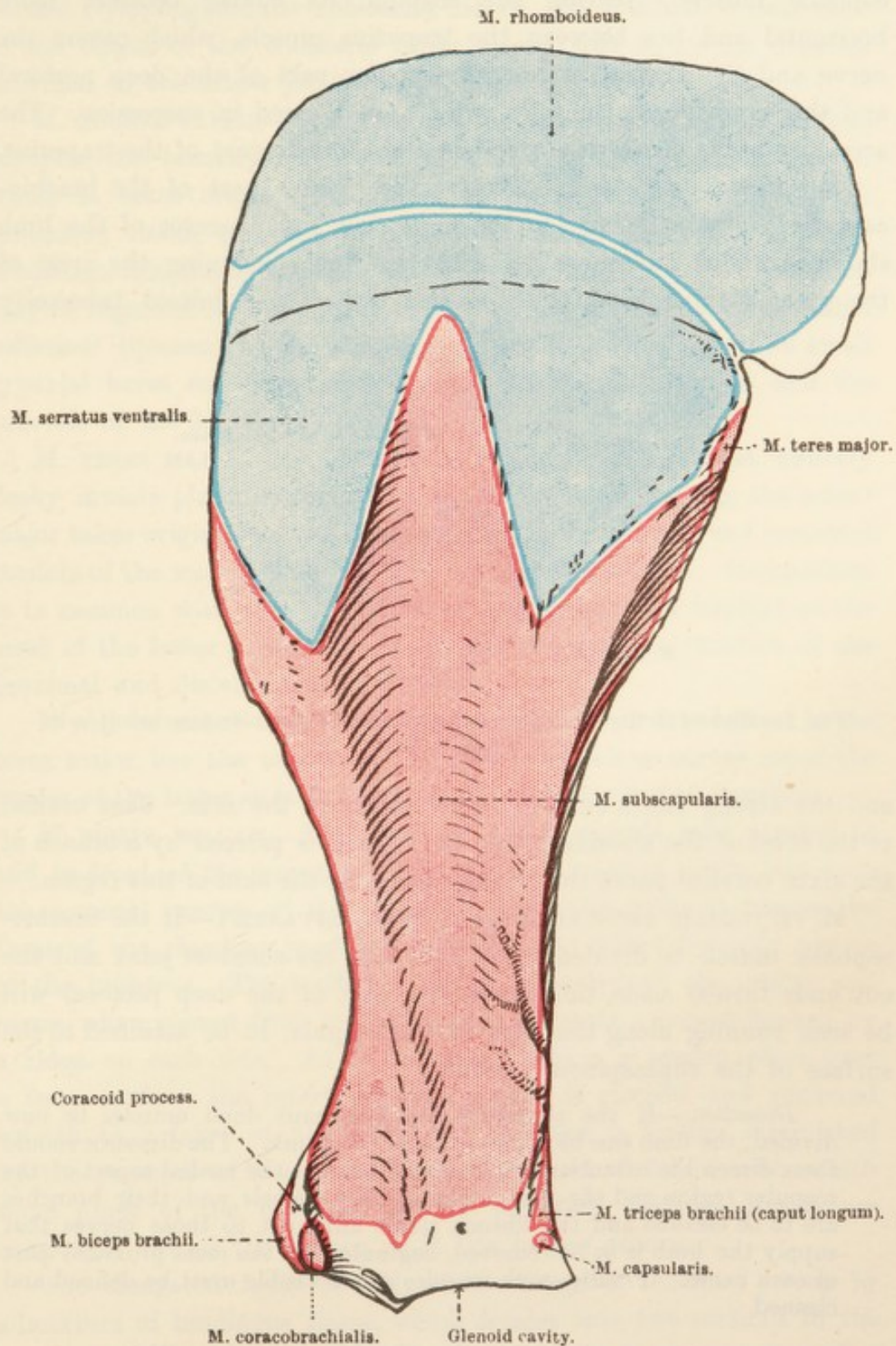


FIG. 6.—Medial Aspect of the Scapula and Scapular Cartilage, with Areas of Muscular Attachment.

border of the triceps. It should be noted that the most cranial fibres of the latissimus dorsi play over the caudal dorsal angle of the scapula.

N. ACCESSORIUS.—The dorsal branch of the accessory or eleventh cerebral nerve passes down the neck partly under cover of the brachiocephalic muscle. Nearing the scapula, its course becomes more horizontal and lies between the trapezius muscle, which covers the nerve, and the ventral serrate, prescapular part of the deep pectoral and the supraspinous muscles, which are crossed in succession. The accessory nerve comes to an end in the thoracic part of the trapezius.

M. BRACHIOCEPHALICUS.—By far the greater part of the brachiocephalic¹ muscle belongs to the neck; but the dissector of the limb should examine its connection with the line continuing the crest of the greater tubercle of the humerus beyond the deltoid tuberosity

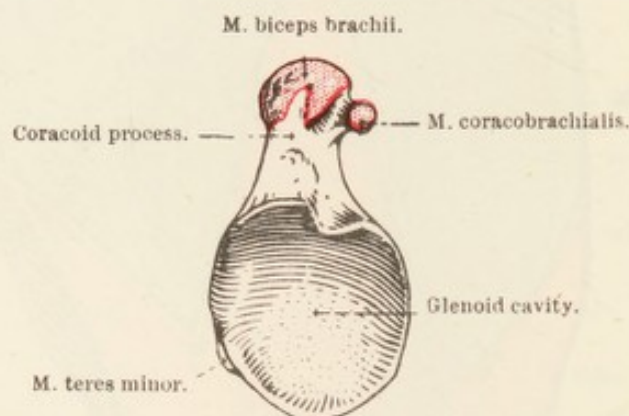


FIG. 7.—Glenoid Cavity of the Scapula, with Areas of Muscular Attachment in its Neighbourhood.

and the strong fascia on the lateral aspect of the arm. Just cranial to the level of the shoulder joint the muscle is pierced by a branch of the sixth cervical nerve that is distributed to the skin of this region.

M. PECTORALIS PROFUNDUS (PARS PRAESCAPULARIS).—If the brachiocephalic muscle be divided on a level with the shoulder joint and the cut ends turned aside, the prescapular part of the deep pectoral will be seen running along the edge of the scapula, to be attached to the surface of the supraspinous muscle.

Dissection.—If the rhomboid and latissimus dorsi muscles be now divided, the limb can be removed from the trunk. The dissector should then direct his attention to the structures on the medial aspect of the scapular region and the arm. The axillary vessels and their branches are to be cleaned and the fibrous tissue adherent to those nerves that supply the limb is to be removed, beginning at the most proximal part of each nerve. Finally, such muscles as are visible must be defined and cleaned.

LYMPH GLANDS OF THE ARM.—In clearing away the fibrous tissue from the vessels and nerves that cross the distal part of the teres

¹ *Brachium* [L.], *βραχίον* (brachiōn) [Gr.], the arm (above the elbow). *Cephalicus* [L.], *κεφαλικός* (cephalicos) [Gr.], pertaining to the head (*κεφαλή*).

major muscle, the small mass of axillary lymph glands (lymphoglandulæ axillares) will be discovered. A second group of lymph glands, the cubital (lymphoglandulæ cubitales), lie on the brachial vessels close to the origin of the collateral ulnar artery, that is, a short distance proximal to the elbow joint.

M. SUBSCAPULARIS.—The flat and triangular subscapular muscle occupies the homonymous fossa of the scapula, from the whole of which it takes origin. The fibres of the muscle, intermixed with tendinous tissue, converge to a stout insertion, partly fleshy, partly tendinous, into the tuberculum minus of the humerus. This insertion may be regarded as functionally equivalent to the presence of a medial collateral ligament of the shoulder joint. It is usual to find a small synovial bursa interposed between the tendon of insertion and the tubercle of the humerus.

M. TERES MAJOR.—An elongated, flattened, and almost entirely fleshy muscle placed immediately caudal to the foregoing, the teres¹ major takes origin from the angle separating the axillary and vertebral borders of the scapula, and from the subscapular muscle. Its insertion is in common with that of the latissimus dorsi to an imprint on the crest of the lesser tubercle of the humerus about the junction of the proximal and distal thirds of the bone.

It will be noted that the latissimus dorsi is at first lateral to the teres major, but the tendon of the former muscle so curves round the border of the latter as to be medial to it at their common insertion.

M. BICEPS BRACHII.—The powerful biceps² muscle runs parallel to and in front of the humerus. The strong tendon of origin begins on the coracoid process of the scapula. From this point it crosses the front of the shoulder joint and traverses the intertubercular groove of the humerus. The tendon is closely moulded on the groove and hence, when viewed from its deep aspect, presents a groove flanked by a ridge on each side. As is customary where a tendon plays over a bony surface, the intertubercular groove is clothed and rendered smooth by a layer of fibrocartilage. Friction is further diminished by the presence of a synovial bursa. A band of fascia, with which some fibres of the humeral part of the deep pectoral muscle are connected, crosses the tendon as it lies in the groove.

The elongated, fusiform belly of the biceps is rendered strong by admixture of tendinous tissue, which divides into two portions in the distal part of the muscle.

¹ *Teres* [L.], rounded (long and round).

² The name "biceps" has been translated from human anatomy, but in none of the domestic mammals is the muscle two-headed, *i.e.* provided with a double origin.

The insertion of the biceps, partly concealed by the medial collateral ligament of the elbow joint, with which some of its fibres are blended, is into the tuberosity of the radius. It will be observed that a stout, flattened tendinous band passes from the biceps to the surface of the radial extensor of the carpus and the fascia of the forearm.

M. CORACOBRACHIALIS.—The coracobrachial¹ muscle is comparatively small. Its long narrow tendon of origin begins on the projection on the medial surface of the coracoid process of the scapula, and appearing between the supraspinous and subscapular muscles crosses the insertion of the latter and gives place to a fusiform fleshy belly. A small synovial bursa is interposed between the tendon of origin of the coracobrachialis and the tendon of insertion of the subscapular muscle.

The insertion of the coracobrachialis is into the medial surface of the humerus both proximal and distal to the common insertion of the latissimus dorsi and teres major.

M. TENSOR FASCIAE ANTIBRACHII.—The flattened tensor of the antibrachial² fascia has an extensive and very thin membranous tendon of origin attached to the axillary border of the scapula and intimately connected with the origin of the long head of the triceps and the tendon of insertion of the latissimus dorsi. The fleshy portion of the tensor, placed medial to the triceps mass, is inserted into the posterior border of the olecranon and the fascia of the forearm. In raising the tensor from the triceps upon which it rests, the dissector should begin at the posterior border of the muscle where it is thickest. This will prevent accidental destruction of the thin tendon of origin.

Dissection.—Cut across the tensor of the antibrachial fascia about the middle of its length and turn the cut ends aside in order to expose the triceps muscles.

M. TRICEPS BRACHII.—The triangular gap between the scapula and the humerus is occupied by the powerful triceps³ muscle. As its name indicates, three parts of the muscle are to be distinguished; but only two of them—caput longum and caput mediale—can be dissected at this stage. The third head must be left until the lateral aspect of the arm is examined.

Caput longum.—The long head of the triceps is a thick, triangular

¹ *κόραξ* (corax) [Gr.], raven. The coracoid process is so called from its resemblance, in man, to the beak of a raven. *Brachium* [L.], *βραχίον* [Gr.], the arm.

² Objections have been raised to the use of the term *anti-brachium*. It is contended, with reason, that the prefix should be *ante*.

³ *Tres* [L.], three. *Caput* [L.], head.

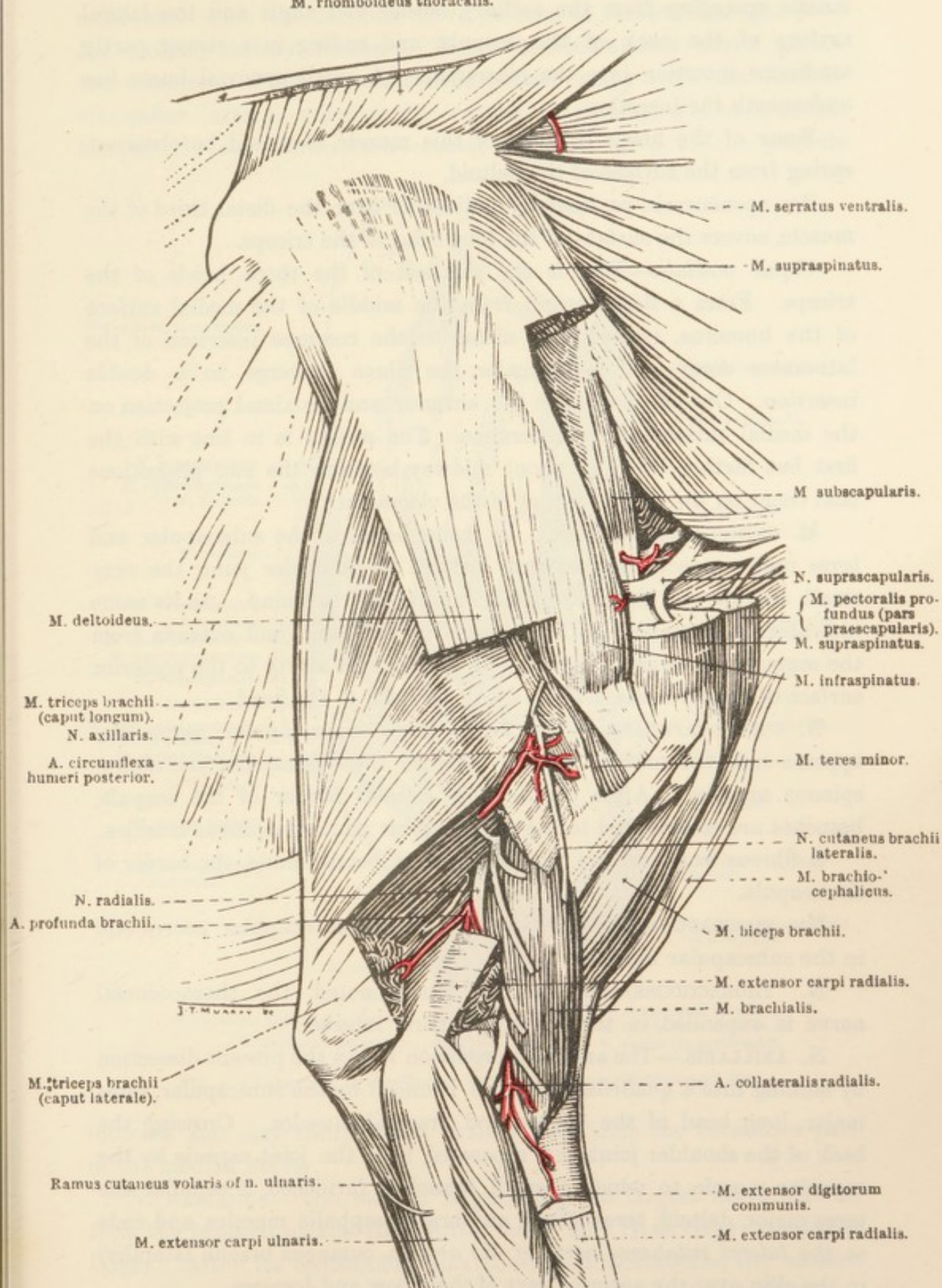
M. rhomboideus thoracalis.

FIG. 8.—Deep Dissection of the Shoulder and Arm.

muscle springing from the axillary border and angle and the lateral surface of the neck of the scapula, and ending in a strong, partly tendinous insertion into the olecranon. A small synovial bursa lies underneath the insertion.

Some of the fibres of origin of this muscle, it should be observed, spring from the surface of the deltoid.

An aponeurosis, particularly noticeable over the distal third of the muscle, covers the surface of the long head of the triceps.

Caput mediale.—This is the smallest of the three heads of the triceps. From a fleshy origin from the middle of the medial surface of the humerus, immediately distal to the common insertion of the latissimus dorsi and teres major, the fibres converge to a double insertion. One of these is to the anterior and proximal projection on the medial surface of the olecranon. The second is in line with the first but farther back, *i.e.* about midway between the two projections that occur on the medial aspect of the olecranon.

M. CAPSULARIS.—If search be made between the subscapular and teres major muscles immediately behind the shoulder joint, the very small, narrow, and slender capsular muscle will be found. As its name indicates, it is applied to the capsule of the joint, and extends from the scapula just beyond the edge of the glenoid cavity to the posterior surface of the humerus, a short distance distal to the head.

N. SUPRASCAPULARIS.—The fairly large suprascapular nerve disappears into the narrow interval between the subscapular and supraspinous muscles. After crossing the cranial border of the scapula, branches are contributed to the supraspinous and infraspinous muscles.

A fibrous band crosses the nerve as it bends round the border of the scapula.

NN. SUBSCAPULARES.—Two or three slender subscapular nerves end in the subscapular muscle.

N. THORACODORSALIS.—As previously noted, the thoracodorsal nerve is expended in the latissimus dorsi muscle.

N. AXILLARIS.—The axillary nerve soon leaves the present dissection by sinking into a quadrilateral space bounded by the subscapular, teres major, long head of the triceps, and brachial muscles. Crossing the back of the shoulder joint, but separated from the joint capsule by the capsular muscle to which a small branch is furnished, it supplies the teres major, deltoid, teres minor, and brachiocephalic muscles, and ends as the *lateral cutaneous nerve of the arm* (*n. cutaneus brachii lateralis*) in the skin over the anterior part of the elbow and forearm.

N. MUSCULOCUTANEUS.—The musculocutaneous nerve leaves the more cranial part of the brachial plexus. By a connection that it

establishes with the median nerve, a loop is formed through which the axillary artery passes. The musculocutaneous nerve pierces the insertion of the coracobrachial muscle along with the anterior circumflex artery, supplies the muscle in passing, and ends in the biceps. It also furnishes a cranial pectoral nerve to the pectoral

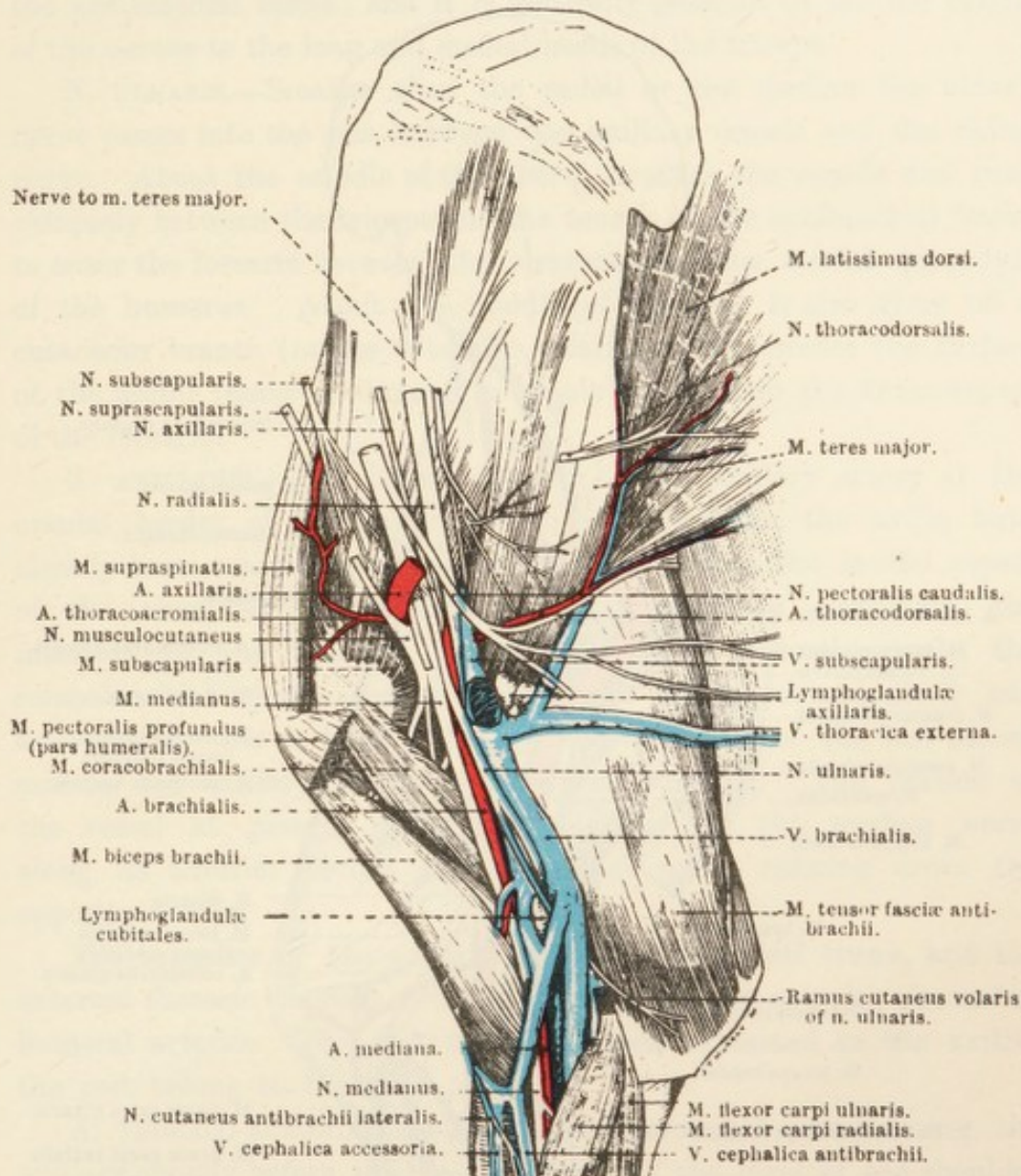


FIG. 9.—Dissection of the Medial Aspect of Scapular Region and Arm.

muscles, and may contribute a branch that joins the cutaneous part of the median nerve.

N. MEDIANUS.—The median is generally the largest nerve derived from the brachial plexus, though the radial may be as large or possibly larger. After its connection with the musculocutaneous, the median passes down the arm along the anterior border of the axillary and brachial arteries, and enters the forearm in company with the median artery.

Only one branch leaves the median nerve while it is in the arm. This arises about the middle of the arm and at once sinks between the coracobrachial and biceps muscles. It then continues obliquely between the brachialis and biceps, supplying branches to the former muscle, crosses the flexor aspect of the elbow joint, and thus gains the

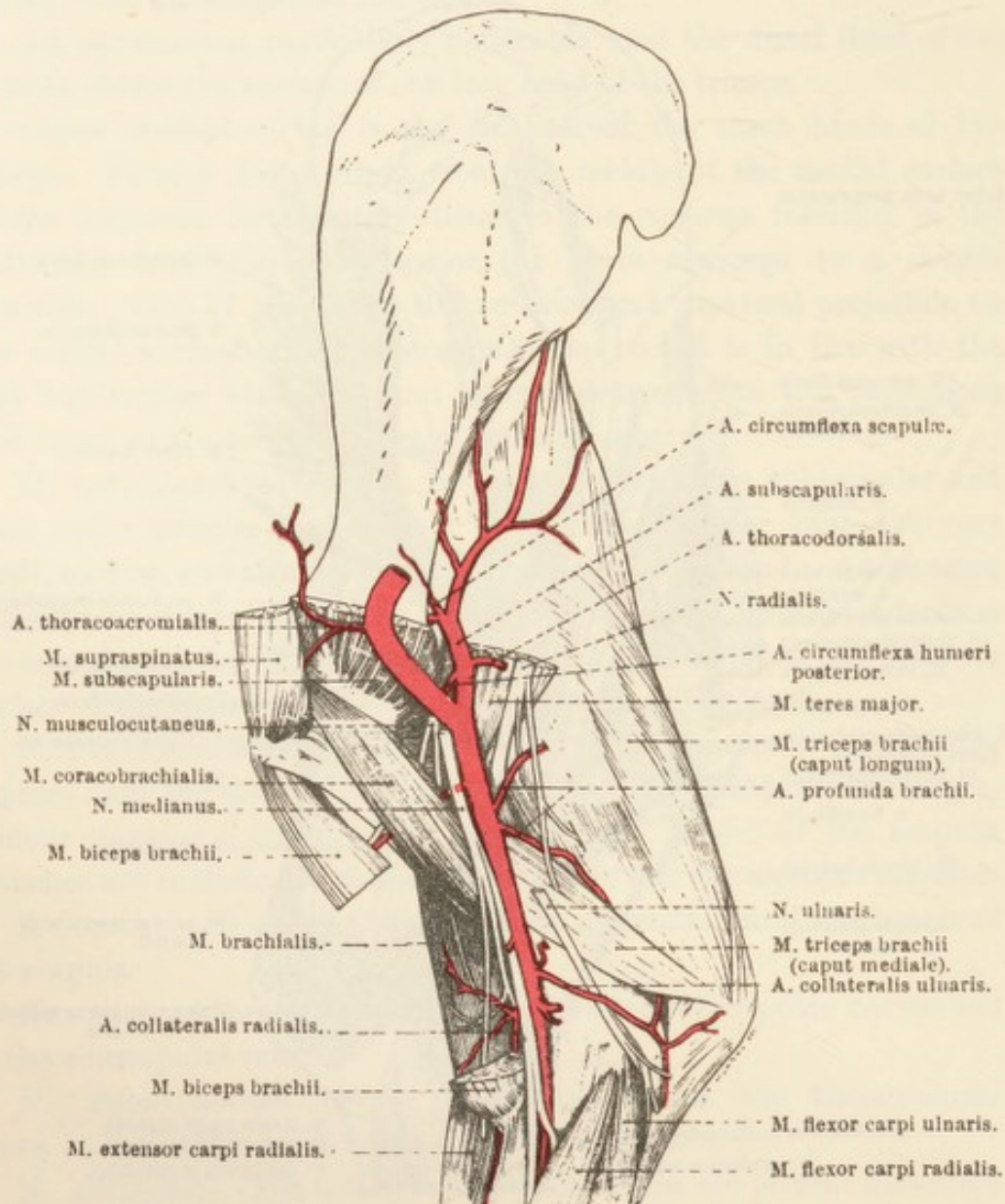


FIG. 10.—Deep Dissection of the Medial Aspect of the Arm.

forearm, where it will be seen later as one of the cutaneous nerves of the region (n. cutaneus antibrachii lateralis). Although, for the sake of convenience and because of its obvious origin, this nerve is here described as a branch of the median, there is reason for assuming that, morphologically, it is part of the musculocutaneous nerve. The fibres composing it apparently become separated from the other components of the musculocutaneous during the temporary fusion of this nerve with the median.

N. RADIALIS.—Nearly or quite as large as the median, the radial¹ nerve leaves the more caudal part of the brachial plexus, accompanies the ulnar nerve, and, about the middle of the arm, disappears between the long and medial heads of the triceps. Before disappearing from the present dissection, the nerve furnishes a branch to the tensor of the antibrachial fascia; and it is generally possible to see the origin of the nerves to the long and medial heads of the triceps.

N. ULNARIS.—Smaller than the radial or the median, the ulnar² nerve passes into the arm between the axillary vessels and the radial nerve. About the middle of the arm it forsakes the vessels and runs obliquely between the triceps and the tensor of the antibrachial fascia, to enter the forearm between the olecranon and the medial epicondyle of the humerus. About the middle of the arm it also gives off a cutaneous branch (*ramus cutaneus volaris*), which crosses the surface of the tensor fasciæ antibrachii to supply the skin on the flexor aspect of the forearm.

A. AXILLARIS.—The commencement of the axillary artery at the cranial border of the first rib and its course in the axilla have already been examined. It is now found crossing the medial aspect of the shoulder joint obliquely, passing over, in succession, the insertion of the humeral part of the deep pectoral muscle, the coracobrachial muscle, and the insertions of the subscapularis and teres major. On a level with the distal border of the last-named muscle, the axillary artery becomes the brachial. The portion of the vessel at present under examination has the median nerve along its anterior border, and the ulnar nerve running down the opposite border.

The branches of the axillary are the omocervical trunk, and the external thoracic, thoraco-acromial, subscapular, and anterior circumflex humeral arteries. The first two have been examined in the axilla; the rest belong to the limb proper.

A. THORACO-ACROMIALIS.—The thoraco-acromial³ artery leaves the axillary shortly before this vessel arrives at the level of the shoulder joint. Running in a dorsal direction, it supplies branches to the prescapular and humeral parts of the deep pectoral muscle. Another branch enters the cleft between the supraspinous and subscapular muscles to which it furnishes twigs.

A. SUBSCAPULARIS.—The subscapular artery is by far the largest

¹ *Radius* [L.], a staff or rod, a spoke of a wheel.

² *Ulna* [L.], ὠλένη (*ōlenē*) [Gr.], the elbow.

³ *Thorax* [L.]; θώραξ (*thorax*) [Gr.], the chest; ἄκρον (*acron*) [Gr.], summit or point; ὄμος (*ōmos*) [Gr.], the shoulder.

branch of the axillary. Arising opposite the cleft between the subscapularis and teres major, it immediately disappears between these muscles. In order that the course of the artery may be followed, it is necessary to detach the greater part of the teres major from its origin. When this has been done, the artery can be traced along nearly the whole of the axillary border of the scapula. It ends in the

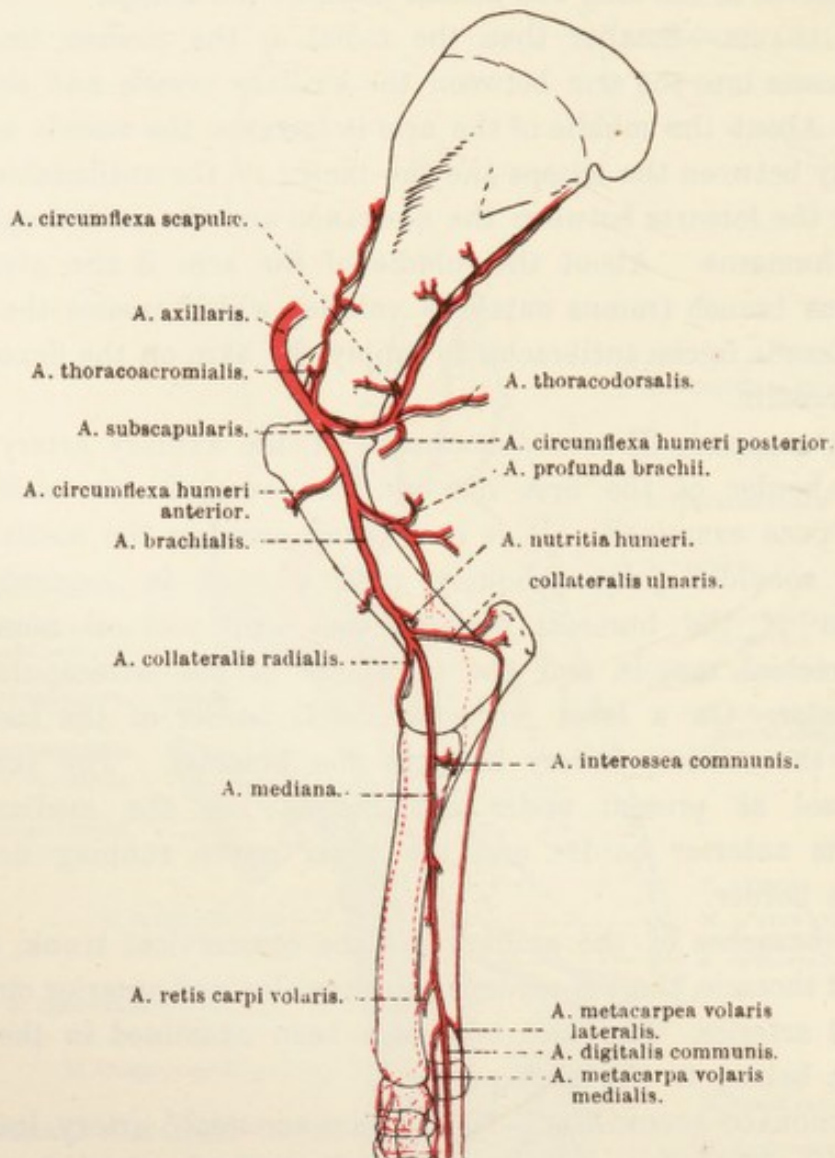


FIG. 11.—Diagram of the Arteries of the Thoracic Limb.

infraspinous muscle, which is reached by bending round the border of the scapula.

The branches of the subscapular are as follows:—

1. *A. thoracodorsalis*.—Arising close to the commencement of the subscapular, the long thoracodorsal artery crosses the medial surface of the teres major and ends in the latissimus dorsi and cutaneous muscles. Small twigs are furnished to the axillary lymph glands.

2. *A. circumflexa humeri posterior*.—The posterior circumflex

humeral artery. accompanies the axillary nerve round the back of the shoulder joint. In the dissection of the lateral aspect of the shoulder it will be found under the deltoid muscle.

3. *A. circumflexa scapulæ*.—The circumflex artery of the scapula leaves the subscapular a short distance beyond the point of origin of the posterior circumflex. A branch is given to the subscapular

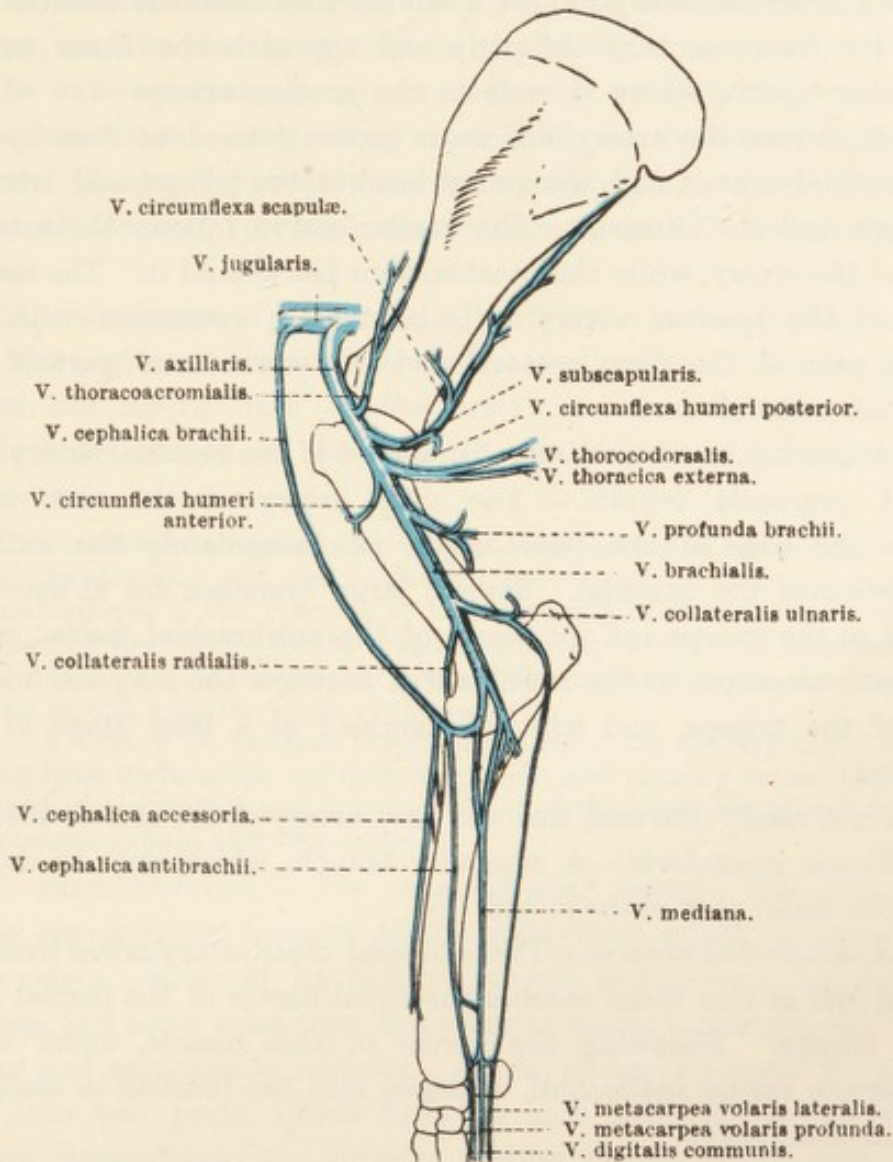


FIG. 12.—Diagram of the Veins of the Thoracic Limb.

muscle, after which the artery pierces the origin of the long head of the triceps and bends round the axillary border of the scapula to enter the infraspinous fossa. Rami supply the infraspinous, teres minor, and supraspinous muscles, and terminal twigs reach the skin in the acromial region. The nutrient artery of the scapula is furnished by the circumflex scapular.

4. A number of inconstant muscular branches (rami musculares) are supplied to the subscapular, teres major, and triceps muscles.

A. CIRCUMFLEXA HUMERI ANTERIOR.—The anterior humeral circumflex artery leaves the axillary as this vessel lies upon the teres major. Piercing the coracobrachial muscle, to which it supplies branches, the artery is chiefly expended in the biceps. A feeble anastomosis with twigs from the posterior circumflex may be demonstrated.

A. BRACHIALIS.—From its origin at the distal border of the teres major, the brachial artery follows a course that causes it to cross the line of the humerus very obliquely and approach the flexor aspect of the elbow joint, where it ends in the median artery.

In its course the artery lies in a groove formed at first by the coracobrachial muscle and the medial head of the triceps, and later by the biceps and the humerus. The median nerve follows the anterior border of the artery, while the brachial vein lies behind it. The medial surface of the brachial artery is in contact in succession with the humeral part of the deep pectoral and the sternocostal part of the superficial pectoral.

The following are the collateral branches of the brachial artery:—

1. *A. profunda brachii.*—The deep artery of the arm arises opposite the edge of the teres major, *i.e.* immediately the axillary artery becomes the brachial. Several large branches are at once distributed to the triceps and the tensor of the antibrachial fascia; while one branch accompanies the radial nerve between the long and medial heads of the triceps, and will be examined at a later stage of the dissection.

It is not rarely the case that the deep artery of the arm is double.

2. *Ramus muscularis.*—A muscular branch, which may be double, enters the distal part of the biceps.

3. *A. collateralis ulnaris.*—The collateral ulnar artery arises from the brachial just as this vessel reaches the distal border of the medial head of the triceps. Following the border of this muscle, under cover of the tensor fasciæ antibrachii, it passes into the forearm in company with the ulnar nerve.

4. *A. nutritia humeri.*—The nutrient artery of the humerus springs either from the brachial close to its termination or from the collateral ulnar near its commencement. It immediately enters the nutrient foramen of the humerus.

5. *A. collateralis radialis.*—The collateral radial artery leaves the brachial at an acute angle a short distance proximal to the elbow joint. It lies at first between the humerus and the biceps, and then between the bone and the brachialis muscle, where it comes into relation with the radial nerve. The two structures, with one or, possibly, two veins, enter the forearm by crossing the flexor aspect of the elbow joint.

VV. BRACHIALIS ET AXILLARIS.—Generally speaking, the veins of the region receive tributaries corresponding to the like-named arteries. Some differences, however, may be noted. The brachial vein is frequently double near the elbow, in which case the artery is flanked by a vein on each side. In the same region the brachial receives a strong communicating branch from the cephalic vein.

The external thoracic vein may join the brachial instead of the axillary, and frequently it receives the thoracodorsal vein.

The external thoracic vein is not really a satellite of the artery of the same name. Beginning superficially in the lateral wall of the abdomen (flank), it pierces the cutaneous muscle, to reach the lateral border of the deep pectoral muscle, along which it travels into the axilla.

The main veins of the arm lie behind the corresponding arteries until the region of the shoulder is reached. Here the axillary vein crosses the medial face of the artery, so that, by the time the vessels have arrived at the first rib, the vein is the more ventral of the two.

Dissection.—Proceed now to the examination of the lateral aspect of the shoulder and arm. Though not strictly necessary, it makes for convenience if the remains of the trapezius muscle be removed. In cleaning the surface of the scapular muscles, look for the terminal twigs of the circumflex scapular artery a little proximal to the shoulder joint and in line with the spine of the scapula.

A branch (*n. cutaneus brachii lateralis*) of the axillary nerve appearing from underneath the deltoid muscle, and running across the lateral head of the triceps and down the front of the brachialis muscle into the forearm, should also be secured.

M. SUPRASPINATUS.—The supraspinous¹ muscle fills the whole of the supraspinous fossa of the scapula from which it takes most of its origin. Some of its fibres, however, spring from the scapular cartilage, and some arise from the common septum between the supraspinous and subscapular muscles. At the coracoid process the muscle splits into two parts, which form an arch over the biceps tendon, and are inserted into the anterior portion of the greater and lesser tubercles of the humerus. On a superficial examination both insertions appear to be wholly fleshy. Deeper investigation, however, reveals a core of tendinous tissue. It should also be noted that both parts of the insertion are closely connected with the joint-capsule. Not infrequently a synovial bursa lies between the supraspinous muscle and the coracoid process of the scapula.

M. DELTOIDEUS.—The deltoid² muscle occupies the angle formed

¹ *Supra* [L.], above. *Spina*, see footnote, p. 27.

² *Deltoides* [L.], triangular; $\Delta\epsilon\lambda\tau\alpha$ [Gr.], the letter Δ , or delta; $\epsilon\acute{\iota}\delta\omicron\varsigma$ (*eidōs* [Gr.], shape.

by the scapula and the humerus. It has a partly fleshy, partly tendinous, origin from the axillary border of the scapula close to the caudal angle, and a broad, aponeurotic origin from the spine of the scapula. The tendinous aponeurosis can be raised from the underlying infraspinous muscle in the more distal part only. Elsewhere

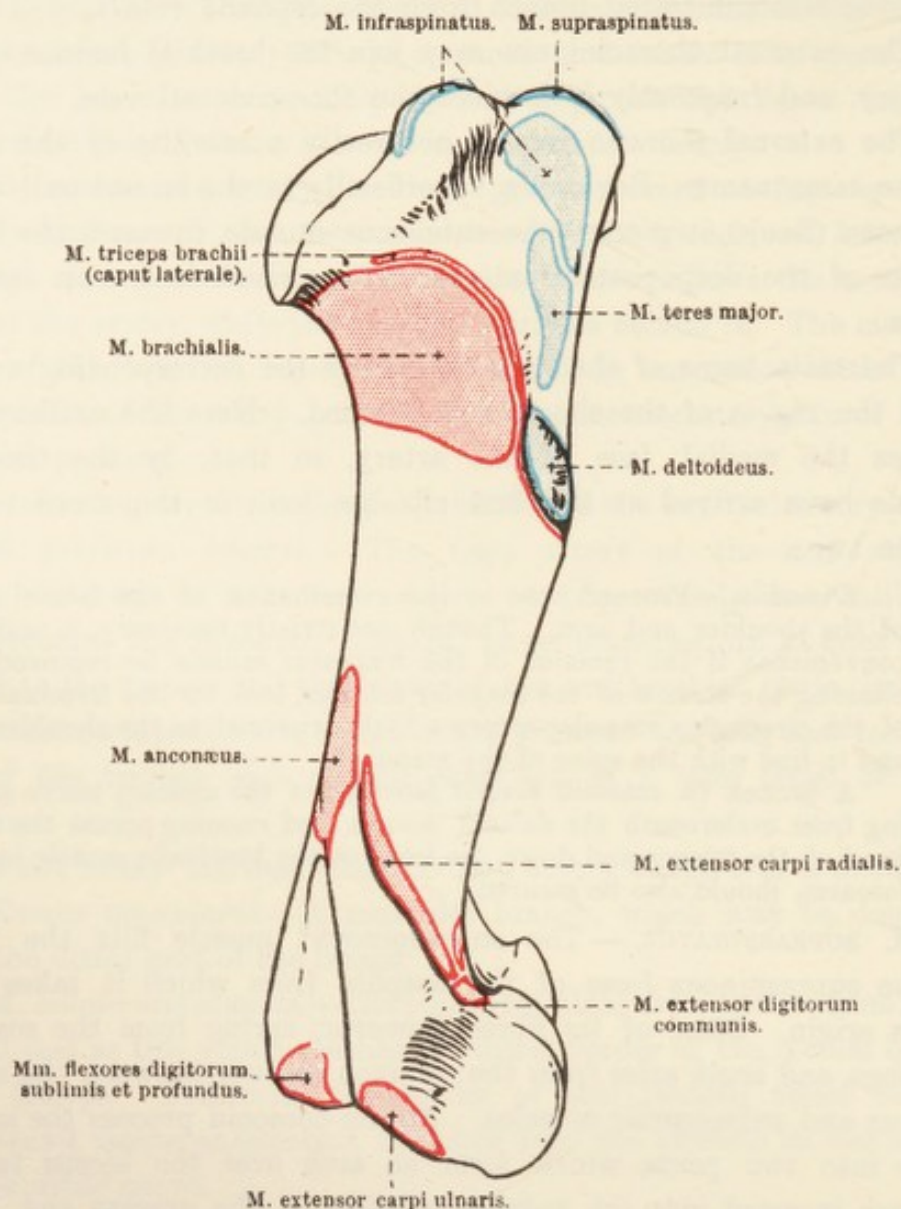


FIG. 13.—Lateral Aspect of the Humerus, with Areas of Muscular Attachment.

the origin of the deltoid and the aponeurotic covering of the infraspinous are so intimately blended as to be one structure.

The insertion of the deltoid is into the deltoid tuberosity of the humerus.

An imperfect division of the deltoid into two parallel portions might lead to the assumption that in the horse, as in the dog and the ruminants, the muscle consists of *scapular* and *acromial* parts. There is, however, little justification for this assumption. It is more

reasonable to regard both portions as representing the *pars scapularis* only.

Dissection.—Cut across the deltoid within a short distance of its insertion and turn it aside as far as possible without, however, endeavouring to remove its tendinous origin from that part of the infraspinous muscle to which it is closely adherent. This dissection exposes the teres minor muscle, the origin of the lateral head of the

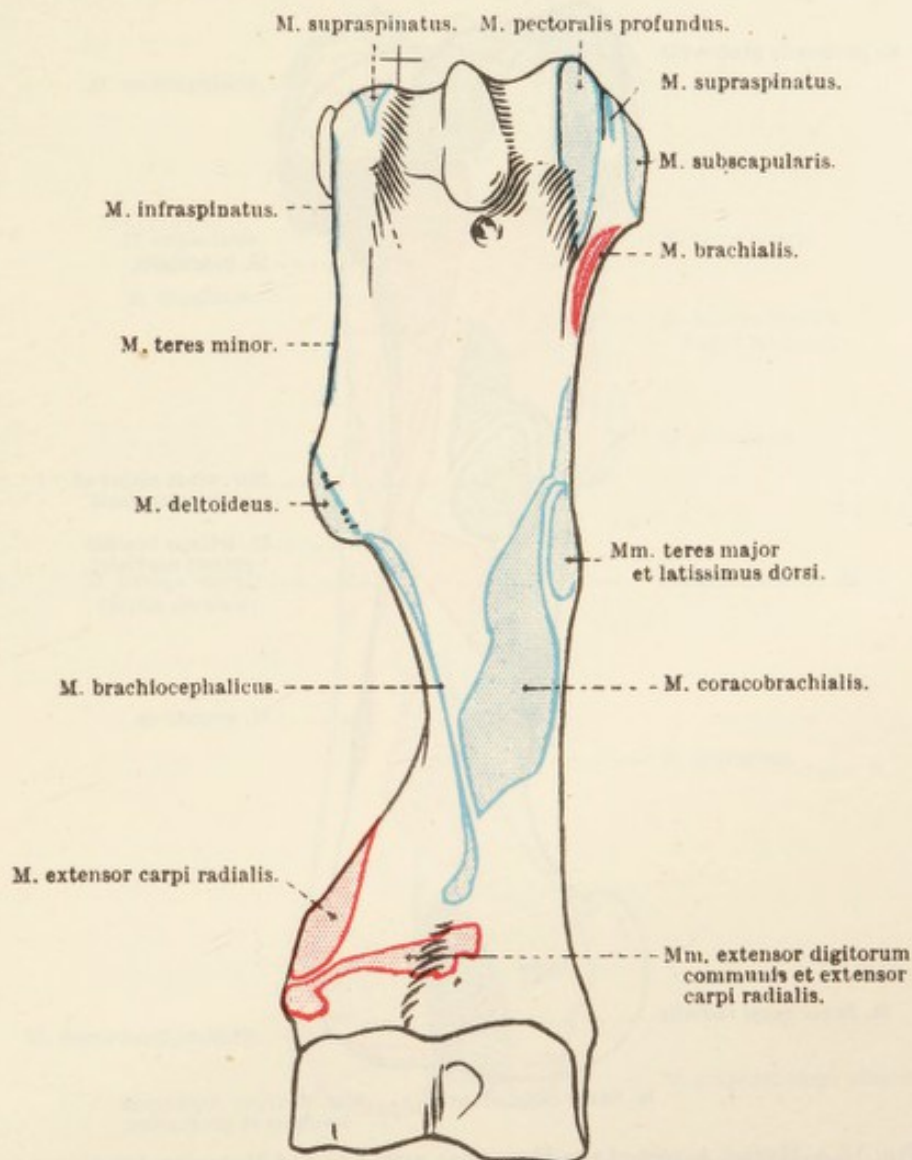


FIG. 14.—Anterior Aspect of the Humerus, with Areas of Muscular Attachment.

triceps, and the axillary nerve as it appears, along with the posterior circumflex vessels, from the narrow, triangular space bounded by the long and lateral heads of the triceps and the teres minor.

M. INFRASPINATUS.—The infraspinous¹ muscle occupies the fossa of the same name. Its origin is from the whole of the fossa, and also from the aponeurotic origin of the teres minor muscle. As

¹ *Infra* [L.], beneath. *Spina* [L.], a low wall dividing the circus lengthwise. In man the muscle lies beneath the spine of the scapula.

the scapular spine fades away distally, the infra- and supra-spinous muscles become intimately connected.

The muscle has a double insertion—(1) A strong, flattened tendon plays over the smooth, convex area of the greater tubercle of the humerus, to be attached to a distinct impression on the crista tuberculi

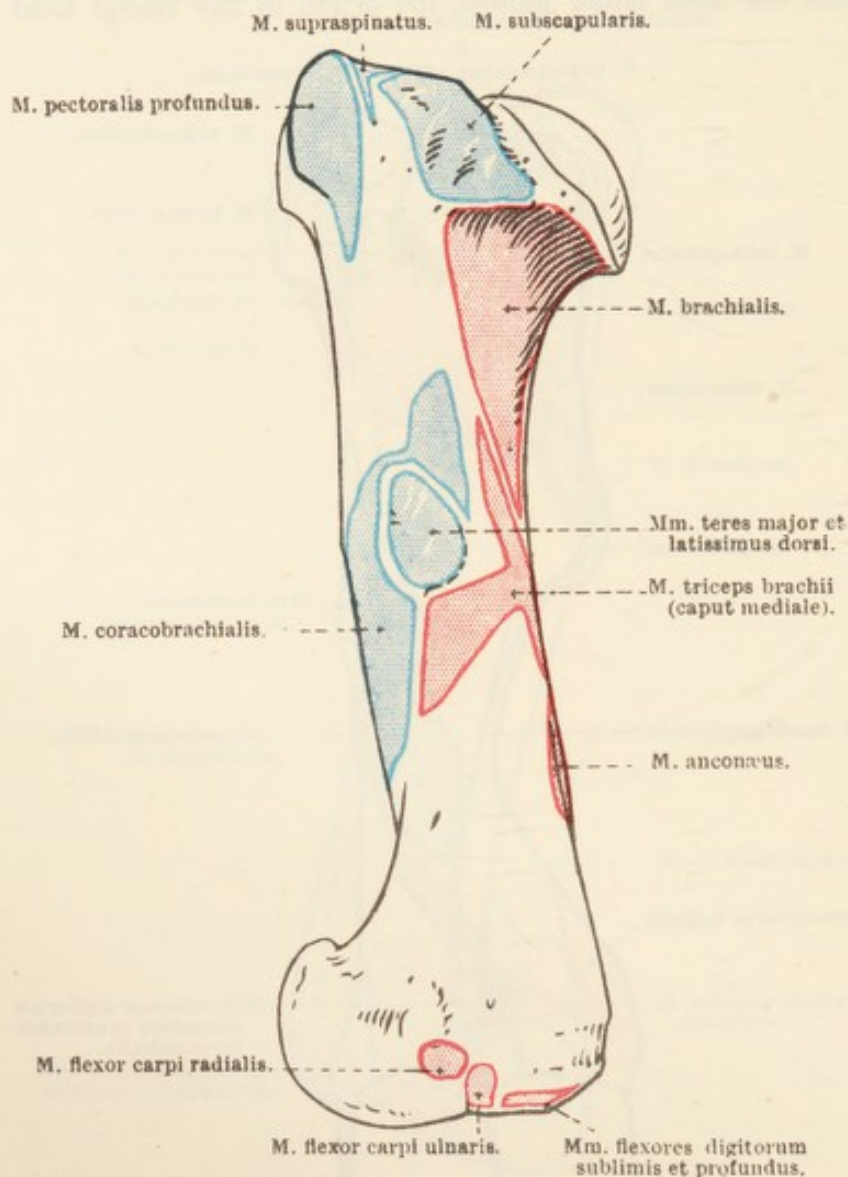


FIG. 15.—Medial Aspect of the Humerus, with Areas of Muscular Attachment.

majoris. It should be observed that the tendon, as it crosses the bony convexity, is retained in its place by a transverse band of fibres. If this tendon be now severed about its middle, the second insertion can be displayed. At the same time it must be observed that, as is commonly the case where a tendon plays over a bony surface, the convexity is made smooth by a veneer of fibro-cartilage, and friction is still further reduced by the presence of a synovial bursa. (2) The second insertion is mainly fleshy and is into the medial aspect of the convexity of the greater tubercle, in close relation to the joint-capsule.

Just as the insertion of the subscapular muscle may be regarded as functioning as a medial collateral ligament, so may the strong tendinous insertion of the infraspinous muscle be regarded as rendering the presence of a lateral collateral ligament unnecessary.

M. TERES MINOR.—The teres minor muscle lies on the flexor side of

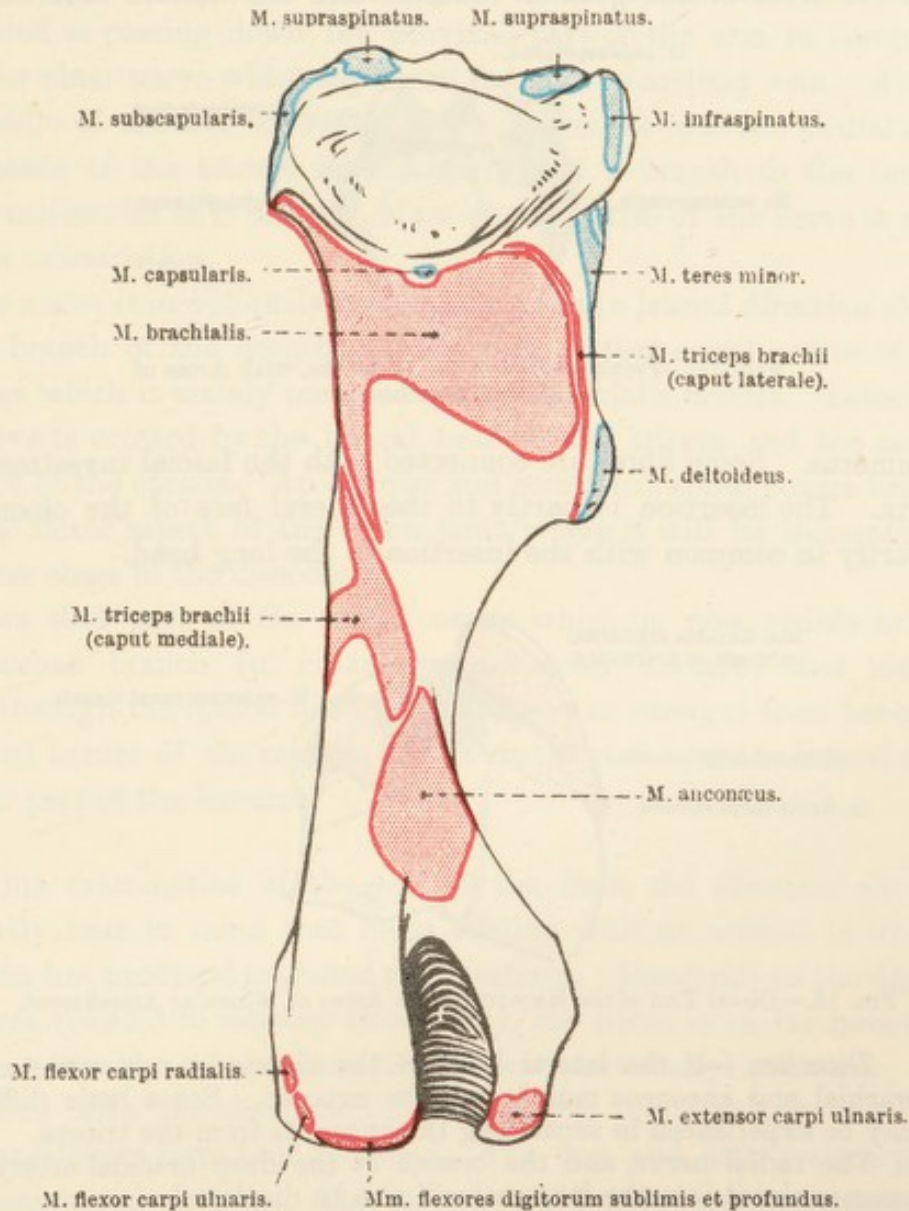


FIG. 16.—Posterior Aspect of the Humerus, with Areas of Muscular Attachment.

the shoulder joint, between the triceps and the deltoid and infraspinous muscles. To see the origin of the muscle it is necessary to remove a part of the infraspinous.

The teres minor has a tendinous origin from the greater part of the axillary border of the scapula and an oblique line in the distal part of the infraspinous fossa, and a fleshy origin from a tubercle close to the margin of the glenoid cavity. The insertion is to the proximal part of the crest of the greater tubercle of the humerus.

M. TRICEPS BRACHII.—Two heads—the long and the medial—of the triceps have already been examined. It will be noticed that the long head is included in both the medial and lateral aspects of the arm.

Caput laterale.—The four-sided lateral head arises from the posterior face of the crest of the greater tubercle and the deltoid tuberosity of

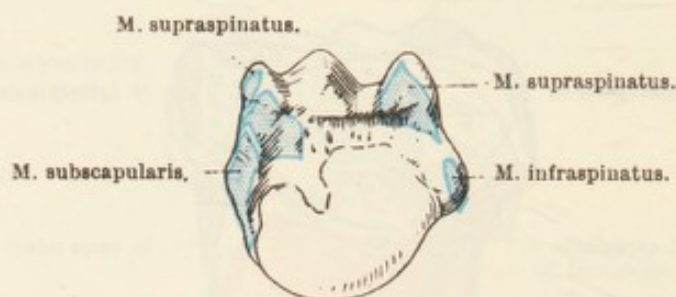


FIG. 17.—Proximal End of the Humerus, with Areas of Muscular Attachment.

the humerus. Some fibres are connected with the fascial investment of the arm. The insertion is partly to the lateral face of the olecranon and partly in common with the insertion of the long head.

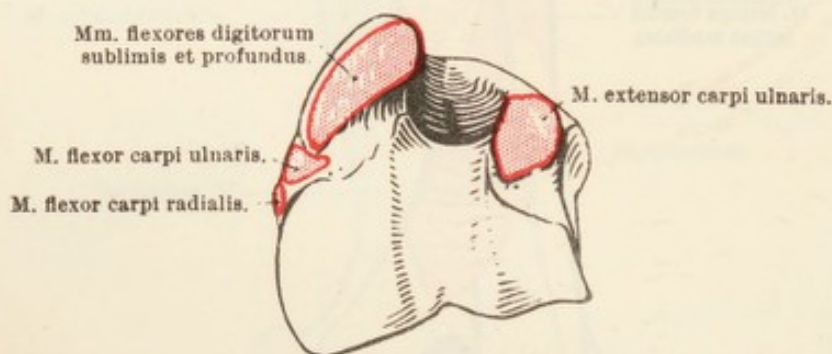


FIG. 18.—Distal End of the Humerus, with Areas of Muscular Attachment.

Dissection.—If the lateral head of the triceps be now reflected, the brachial and anconeus muscles will be exposed. Some little difficulty may be experienced in separating the anconeus from the triceps.

The radial nerve, and the branch of the deep brachial artery that accompanies it into the forearm, will also be displayed.

M. BRACHIALIS.—The brachial muscle is almost entirely fleshy, and occupies the spiral groove (sulcus nervi radialis) that traverses the lateral surface of the humerus. Its origin is from the posterior surface of the humerus close to the head of the bone. It will be seen that the muscle crosses the flexor aspect of the elbow joint and enters the forearm, but its ultimate insertion into the radius and ulna cannot yet be demonstrated.

M. ANCONÆUS.—The fleshy anconeus¹ muscle lies under cover of

¹ ἀγκών (ancōn) [Gr.], the elbow.

the triceps, with the lateral head of which it is very closely associated. Its fibres arise from the distal part of the posterior surface of the humerus, and its insertion is to the lateral surface of the olecranon. The deeper fibres of the muscle are adherent to the capsule of the elbow joint.

N. RADIALIS.—At a previous stage of the dissection, the radial nerve was noted as passing down the proximal part of the arm in company with the ulnar nerve which separated it from the axillary vein. About the middle of the arm the radial nerve dipped between the medial and long heads of the triceps muscle, giving off a branch to the tensor fasciæ antibrachii as it did so. More of the course of the nerve is now open to examination.

The nerve runs obliquely downwards and in a lateral direction along with a branch of the deep humeral artery, in that spiral groove of the humerus which is mainly occupied by the brachialis musculé. Laterally the nerve is crossed by the lateral head of the triceps and the radial extensor of the carpus. An oblique and somewhat spiral course brings it to the flexor aspect of the elbow joint, where it will be encountered at a later stage in the dissection.

From that part of the radial nerve which is now visible arises a cutaneous branch (n. cutaneus antibrachii dorsalis) that either passes through the lateral head of the triceps or emerges from beneath the distal border of the muscle, and is distributed over the lateral and anterior part of the forearm.

In his examination of the rest of the limb, the dissector should constantly bear in mind that he is dealing with an animal in which evolution has produced profound modifications. Inasmuch as the digits have been reduced in number to one only, the horse is as far removed as he conceivably can be from the typical pentadactyl mammal. In association with the disappearance of all the digits except one, the metacarpal bones have been modified. The first and fifth metacarpals have disappeared entirely. The second and fourth are represented by comparatively slender and tapering rods, which fail to stretch the full length of the metacarpal region. At the distal end of each rudimentary bone it seems probable that sometimes, at least, there may be imperfect representatives of phalanges; but these are very variable in size, and always firmly blended with the metacarpal bone to which they belong. The third metacarpal bone has been transformed in the opposite direction. It has increased in length and strength, and, like the phalanges it carries, has attained a considerable volume.

As these bony changes were taking place, and as the manus as

a whole was increasing in length, its relation to the ground became gradually altered and more and more restricted. Not only has the single remaining digit developed in such a way as to be now capable of sustaining the whole weight of the body; it does so by contact with the ground by its extreme end only. That is, the modern horse is no longer digitigrade: he is unguligrade.

The bones of the forearm have also undergone a striking change. While the radius has increased in size and strength, the ulna has been reduced to a proximal extremity and a tapering shaft that does not reach much beyond the middle of the radius. The disappearance of

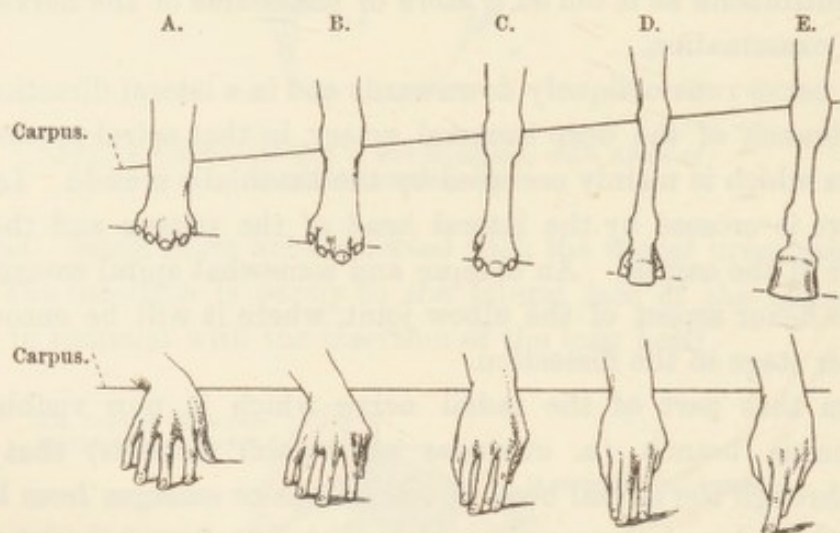


FIG. 19.—Evolution from Pentadactyl to Monodactyl Condition in the Manus of the Horse. The lower part of the figure shows the human hand for comparison.

A. = Pentadactyl, hypothetical ancestral stage. B. = Tetradactyl, *Protohippus* stage. C. = Tetradactyl-tridactyl, *Ephippus* stage (three digits touching the ground, one slightly raised). D. = Tridactyl, *Mesohippus* stage. E. = Monodactyl, *Equus* stage; modern horse. (After H. F. Osborn.)

part of the shaft has caused the detachment of the distal end of the ulna, which has fused with the distal end of the radius. These modifications in the bones of the forearm have been accompanied by their intimate bony union with each other, and the consequent loss of any possibility of movement between them. The limb, therefore, has been fixed permanently in the position of pronation.

The above alterations in the bony skeleton have, naturally, been accompanied by great modification in the muscular apparatus. Some muscles, for example the supinators, have lost their function and have disappeared. Some, of which the abductor of the pollex is an illustration, have been compelled to change their attachments. Other muscles have assumed a different structure and a different function, as is exemplified in a remarkable manner by the interosseous muscle of the metacarpus. Naturally, also, the blood-vessels and nerves of the manus have been simplified. In short, it must always be remembered

that in the dissection of the limbs of the horse one is dealing with an extreme departure from the typical mammalian architecture.

Before proceeding to remove the skin, the dissector should examine the surface of the forearm. In the anterior, lateral, and posterior regions the bones are buried under muscular masses, which present considerable resistance to palpation owing to the stoutness of their fascial investment. Of bony prominences, the most obvious are those produced by the olecranon of the ulna and the projection at the posterior and lateral part of the carpus, due to the accessory carpal (pisiform) bone. The medial border of the radius can be followed throughout the whole of its length. Of the lateral border, however, only the distal portion can be felt through the skin. The position of the rest of the border is indicated by a shallow groove, which becomes deeper towards the carpus, where it is complicated by a ridge formed by the edge of the extensor digiti quinti muscle.

The outstanding rounded mass in front of the forearm is formed by the fleshy portion of the radial extensor of the carpus and the common extensor of the digits.¹

The resisting muscular mass at the back of the forearm is formed by flexors and one extensor.

A flattened, oval, horny callosity, popularly known as the "chestnut," occurs on the skin in the distal third of the medial face of the forearm. The prominence and size of the callosity is subject to much variation, and is related to the "fineness" of the skin over the body generally. In the average animal its greatest (vertical) diameter is about 50 mm. The exact location of the callosity is also variable; and, while one can say that it lies over the radial flexor of the carpus, it is impossible to give any useful indication respecting its distance from the radiocarpal joint. A similar callosity occurs in the pelvic limb in connection with the skin of the medial surface of the tarsus.

Conflicting views are held respecting the homology of these callosities. Authorities have regarded them variously as representing the rudiment of a digit, modified skin glands such as are present in the carpal region of certain mammals, degenerate carpal sense-organs, and even as altered foot-pads. It is safest to conclude that the question is still open.

Dissection.—The skin must now be removed from the entire forearm and carpus, and from the proximal part of the metacarpus. In doing

¹ Though the horse possesses but one functional digit, the plural is used here and throughout in order that it may be clear that the muscle (in the main) corresponds to the common extensor of other mammals.

this the cutaneous nerves and the superficial veins must be preserved. The nerves are branches of the ulnar, radial, axillary, and median, and, with one exception, their origins from the parent nerves have already been observed.

(1) The *volar cutaneous branch* (*ramus cutaneus volaris*) of the ulnar nerve spreads out over the posterior border of the forearm. (2) The *dorsal cutaneous nerve* (*n. cutaneus antibrachii dorsalis*) is that branch of the radial which becomes superficial at the distal border of the lateral head of the triceps, and is distributed over the lateral aspect of the forearm. (3) The *lateral cutaneous nerve* (*n. cutaneus brachii lateralis*) is derived from the axillary, appears from beneath the deltoid, and divides into two branches for the skin of the lateral and anterior part of the forearm. (4) The *lateral cutaneous nerve of the forearm* (*n. cutaneus antibrachii lateralis*) left the median about the middle of the arm, and is now seen to be distributed over the anterior and medial aspects of the forearm, carpus, and metacarpus. It divides into two main branches, which follow the cephalic and accessory cephalic veins. (5) The only cutaneous nerve of the forearm that does not proceed from the arm is the *superficial branch* (*ramus superficialis*) of the ulnar. This becomes subcutaneous immediately proximal to the accessory carpal (pisiform) bone. Some of its filaments are distributed over the lateral aspect of the carpus, but the greater part of the nerve is continued into the metacarpal region.

The superficial veins of the forearm are the cephalic and accessory cephalic.

V. CEPHALICA ANTIBRACHII.—The cephalic vein of the forearm is the direct continuation of the median volar metacarpal vein. Lying at first in the groove between the radial flexor of the carpus and the radius, it crosses the medial aspect of the forearm very obliquely and becomes continuous with the cephalic vein of the arm. This latter, ascending the groove formed by the brachiocephalic and superficial pectoral muscles, enters the triangular space at the root of the neck and ends by uniting with the jugular. A considerable communicating branch connects the cephalic vein of the forearm with the brachial about the insertion of the biceps.

V. CEPHALICA ACCESSORIA.—The accessory cephalic vein begins in a network of vessels on the dorsal aspect of the carpus and the distal part of the radius and runs up the forearm, following the median border of the radial extensor of the carpus, to join the cephalic vein close to the elbow.

Dissection.—The loose and scanty superficial fascia into which the superficial pectoral muscle is inserted, must be removed, in order that a clear view of the dense and definite deep fascia may be obtained.

FASCIA OF THE FOREARM.—The glistening antibrachial fascia¹ (*fascia antibrachii*) forms a complete investment to the muscles of the forearm and is firmly connected with those parts of the radius and ulna that are not covered with muscles. In the neighbourhood of the carpus

¹ *Fascia* [L.], a band, a surgical bandage, swathe, girth.

there is no difficulty in showing that it blends with the ligaments and the periosteum of the bone.

The tensor fasciæ antibrachii is mainly inserted into the fascia, with which also certain fibres of the brachiocephalic and biceps muscles are connected.

A definite compartment for the extensor digiti quinti is formed by the fascia sinking in between this muscle and its immediate neighbours to form intermuscular septa. Similar septa will be found elsewhere, as, for example, between the radial extensor of the carpus and the common extensor of the digits, and between the radial and ulnar flexors of the carpus. Furthermore, the deep fascia is strengthened by transverse fibres to form the *dorsal carpal ligament* (ligamentum carpi dorsale) that retains the extensor tendons in the grooves at the distal end of the radius.

But the most conspicuous thickening of the fascia occurs over the volar aspect of the carpus where the strong *transverse carpal ligament* (ligamentum carpi transversum) forms a stout bridge from the accessory carpal (pisiform) bone to the medial collateral ligament and the proximal end of the second metacarpal bone. The transverse ligament constitutes the volar boundary of a short canal in which are contained the flexor tendons with their synovial sheaths, the common digital artery, and the medial volar nerve.

Dissection.—Remove the deep fascia over the extensor muscles and proceed with their examination.

The extensor muscles in front and on the lateral aspect of the forearm are arranged in two layers, superficial and deep. The superficial layer contains the extensor carpi radialis, extensor digitorum communis, extensor digiti quinti, and extensor carpi ulnaris—in this order from the radial to the ulnar border of the limb. The deep layer in the horse contains one muscle only, namely, the m. abductor pollicis longus.

M. EXTENSOR CARPI RADIALIS.—In man and in the dog the radial extensor of the carpus¹ is divisible into two portions—long and short; but in the horse no such division is possible. A powerful muscle with a prominent and distally tapering belly, the radial extensor takes its main origin from the lateral epicondyle of the humerus. In addition, part of its tendinous origin is from the coronoid fossa in common with the common extensor of the digits. It will be observed that the muscle at its origin has some of its fibres disposed in a curved manner as a consequence of their attachment to a strong fascia overlying the brachialis muscle. Note also the strong tendinous slip (lacertus²

¹ *Carpus* [L.], *καρπός* (carpos) [Gr.], the wrist.

² *Lacertus* [L.], the arm, from the shoulder to the elbow; a lizard.

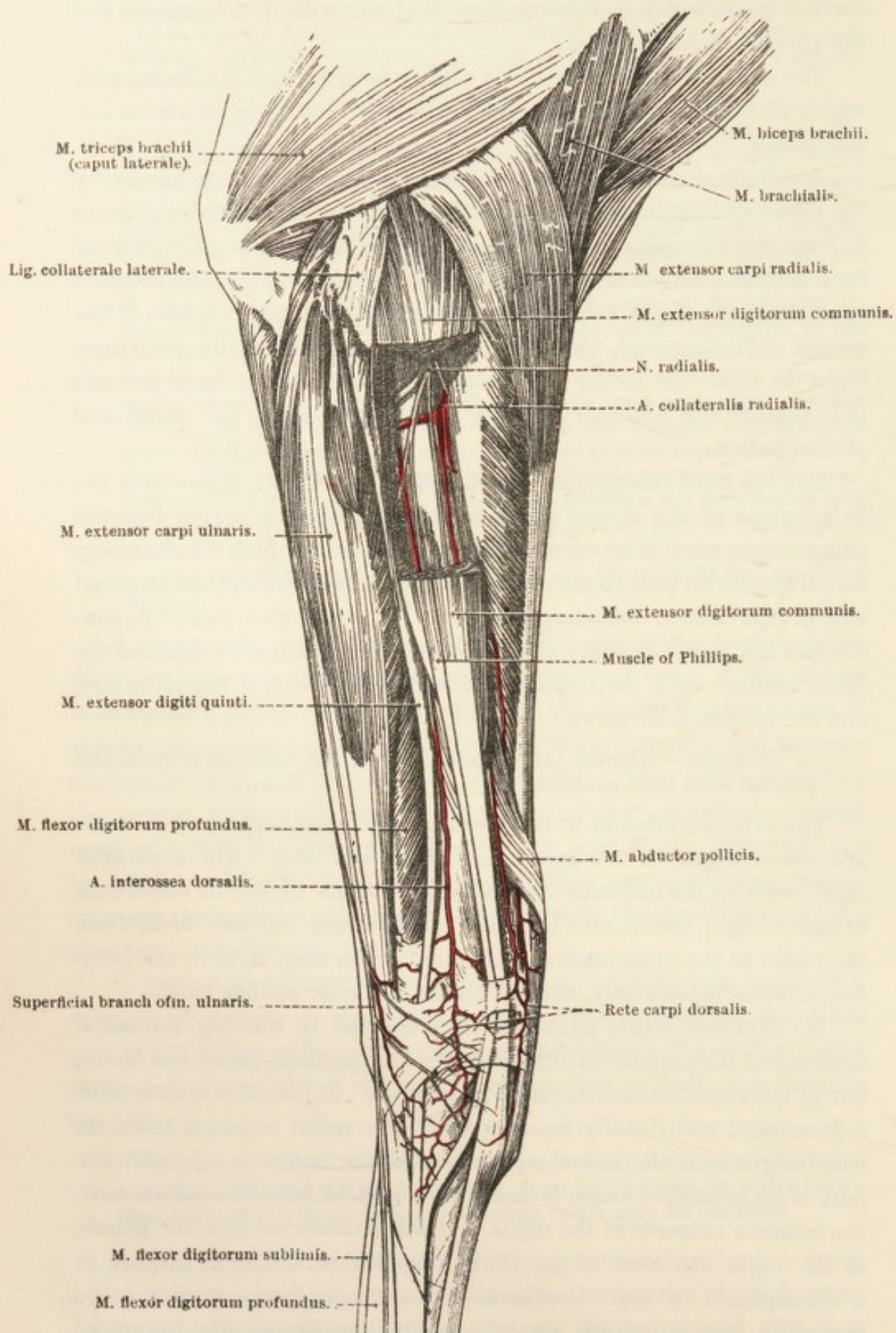


FIG. 20.—Dissection of the Lateral Aspect of the Forearm and Carpal Region.

fibrosus) that leaves the biceps near its insertion and merges into the surface investment of the radial extensor. In the distal third of the forearm the tapering fleshy part of the muscle gives place to a strong, flattened tendon that, traversing a groove at the distal end of the radius and crossing the dorsal aspect of the carpus, is inserted into the muscular imprint on the dorsal (anterior) medial part of the base of the third metacarpal bone. The tendon is bound down in the groove on the radius by the dorsal carpal ligament, and here, as well as over the carpus, is surrounded by a synovial sheath.

M. EXTENSOR DIGITORUM COMMUNIS.—Smaller than the preceding, and lateral to it in position, the common extensor of the digits arises from the anterior and most distal part of the lateral epicondyle of the humerus, the coronoid fossa (in common with *m. extensor carpi radialis*), the lateral collateral ligament of the elbow joint, the lateral aspect of the proximal part of the radius, and the adjacent part of the ulna. Some fibres also arise from the intermuscular septum between this muscle and the radial extensor of the carpus.

Commonly, the most lateral part of the muscle can be isolated as the *muscle of Phillips*, and occasionally another and smaller bundle of fibres, medial to the preceding, may be separated from the main muscle—the *muscle of Thiernesse*. If the last-named is separable, it is provided with a thin tendon which soon joins the main tendon of the muscle. The tendon of the *muscle of Phillips* accompanies the main tendon into the metacarpus and there joins that of the extensor digiti quinti.

The main tendon of the common extensor leaves the tapering distal part of the muscle, plays down a groove at the distal end of the radius, crosses the extensor aspect of the carpus and enters the metacarpus. At a later stage of the dissection it will be followed to the extensor process of the third phalanx.

Like the tendon of the radial extensor, that of the common digital extensor is secured in a groove on the radius by the dorsal carpal ligament, and is provided with a synovial sheath here and over the carpus. Since this arrangement is common to the extensor tendons of the region, the tendon sheath should be slit open and an examination made of the mode of disposition of its synovial lining. The sheath may be regarded as a closed bag closely applied to the surface of the tendon as well as to the wall of the fibro-osseous canal in which the tendon lies. The layer upon the tendon is connected with that lining the canal by a thin membrane known as the *mesotenon*.

To establish the strict homology of the three parts of the horse's common extensor is not without difficulty. There are those who see in the muscle of Phillips the equivalent of that part of the dog's common

extensor which provides tendons for the fourth and fifth digits. There can be little question that the main tendon in the horse is the homologue of that tendon of the dog's common extensor which ends in the third digit. The greatest difficulty arises with the muscle of Thiernesse—assuming that it is really something apart from the main mass of the muscle. Its suggested homology with the *m. extensor indicis proprius* of man gives ground for debate.

M. EXTENSOR DIGITI QUINTI.—Though here named the extensor of the fifth digit, it is conceivable that this muscle may represent a combination of the extensors of the third, fourth, and fifth digits of the dog, and, to avoid difficulties of homology, it is frequently called the lateral extensor of the digit. The muscle is narrow and semipenniform, and is enclosed in its own compartment of antibrachial fascia. Its position is along the lateral aspect of the forearm, insinuated between the common extensor of the digits and the ulnar extensor of the carpus.

The origin of the muscle is from the lateral collateral ligament, the back of the projection on the head of the radius, and a narrow area of both bones of the forearm bounding the lateral line of their union. In the distal part of the forearm the muscle gives place to a tendon that traverses a groove on the lateral part of the distal end of the radius, then travels down the corresponding aspect of the carpus partly embedded in ligament, and enters the metacarpus, where it will be examined subsequently. Like the preceding extensors, its tendon is surrounded by a synovial sheath.

M. EXTENSOR CARPI ULNARIS.—Though morphologically an extensor and in receipt of a nerve supply (radial) like that of the other extensors, this muscle in the horse is doubtless physiologically a flexor. Unlike its fellow-extensors, it is placed behind the lateral border of the radius.

The origin of the muscle is from the distal part of the lateral epicondyle of the humerus. Its insertion is double. A strong tendon connects it with the proximal edge of the accessory carpal (pisiform) bone; while a narrow, rounded tendon runs somewhat obliquely along a groove on the lateral face of the accessory bone and across the lateral border of the carpus (embedded in ligament) to reach the base of the fourth metacarpal bone. The second tendon is provided with a synovial sheath.

M. ABDUCTOR POLLICIS LONGUS.¹—This thin, triangular muscle arises from the lateral border and adjacent area of the dorsal (anterior) surface of the middle third of the radius. At first the muscle is beneath the common extensor of the digits, but its narrow tendon

¹ This muscle, in all probability, represents the short extensor as well as the long abductor of the pollex. *Pollex* [L.], the thumb.

crosses that of the radial extensor of the carpus to reach the base of the second metacarpal bone to which it is inserted. The insertion affords a good example of the shifting of a muscular attachment rendered necessary by modification of the skeleton. In the dog the insertion is into the first metacarpal bone. In consequence of the disappearance of this bone in the horse, the insertion has been transferred to the nearest available bony point.

Dissection.—In order to expose the nerves and blood-vessels of the front of the forearm it is necessary to reflect the radial and ulnar extensors of the carpus. Cut across each muscle about the middle of its fleshy belly, bearing in mind that the collateral radial artery is closely applied to the deep surface of the radial extensor.

It may be necessary to reflect the biceps also, but it is better to avoid doing this if possible.

N. RADIALIS.—In the dissection of the arm the radial nerve was observed to follow the brachial muscle round the humerus, accompanied by a branch of the deep artery of the arm. The continuation of the nerve will now be found in front of the elbow joint between the brachialis and the radial extensor of the carpus. Branches to the following muscles should be demonstrated: brachialis, extensor carpi radialis, extensor digitorum communis, extensor digiti quinti, and extensor carpi ulnaris. A thin branch continues down the forearm between the radius and the common extensor of the digits to end in the m. abductor pollicis longus.

A. PROFUNDA BRACHII.—The terminal division of the deep artery of the arm was disclosed by reflection of the lateral head of the triceps. All that now remains to be noted is that a twig from the artery enters the radial extensor of the carpus, while another passes underneath the ulnar extensor to join the recurrent interosseous artery. An anastomosis is also effected with the collateral radial artery.

A. COLLATERALIS RADIALIS (DISTALIS).—Immediately on its origin from the brachial the collateral radial artery disappears between the humerus and the biceps. The present dissection shows that the artery next lies between the brachialis muscle and the humerus, and then crosses the flexor aspect of the elbow joint, between the brachialis and radial extensor, where it comes into contact with the radial nerve. Branches from the artery supply the radial extensor, the common extensor, and the long abductor of the pollex; and an anastomosis is established with the dorsal interosseous artery. The small terminal branch of the vessel joins the dorsal rete of the carpus.

A. INTEROSSEA DORSALIS.—The dorsal interosseous artery arises from the common interosseous at the back of the forearm and enters the extensor region by traversing the opening between the radius and the

ulna. Thereupon it runs in a distal direction following the extensor digiti quinti closely, and ends near the carpus in the rete carpi dorsale. It furnishes branches to the adjacent muscles, and gives origin to two named arteries. (1) *A. nutritia radii* (the nutrient artery of the radius) arises as the interosseous artery passes between the two bones of the forearm and immediately disappears into the radius. (2) *A. interossea recurrens* (recurrent interosseous artery) is very small and sometimes difficult to demonstrate. It has its origin close to the gap between the radius and the ulna, runs upwards on the lateral surface of the ulna, and anastomoses with branches of the deep artery of the arm and the collateral ulnar artery.

RETE CARPI DORSALE.—The dorsal rete¹ of the carpus consists of a network of small arteries lying over the distal end of the radius and the dorsal surface of the carpus. It is formed by branches from the collateral radial and dorsal interosseous arteries, and from it arise the two dorsal metacarpal arteries (*a. metacarpea dorsalis medialis*: *a. metacarpea dorsalis lateralis*) that follow the grooves between the metacarpal bones and anastomose with the volar metacarpal arteries.

Before leaving this region the dissector should take the opportunity to examine the insertion of the biceps and brachialis muscles. The strong tendon of the biceps is attached to the tuberosity of the radius, but a slender continuation can be followed under the medial collateral ligament as far as the edge of the ulna.

The brachial muscle is inserted mainly to the border of the radius at a point just distal to the tuberosity. Some tendinous fibres pass underneath the medial collateral ligament and blend with the transverse ligament that joins the ulna to the radius.

Dissection.—The dissector must now turn his attention to the structures lying behind the radius, and, of these, the muscles should be examined first. So far as position is concerned, the extensor carpi ulnaris could legitimately be included in the group of muscles which now fall to be examined; but, for morphological reasons, and because it is supplied by the radial nerve, this muscle has already been dissected.

The muscles lying behind the radius may be considered as disposed in three strata: (1) The most superficial, enumerated from the radial to the ulnar border of the limb, are: *Mm. flexor carpi radialis*, *flexor carpi ulnaris*, *flexor digitorum profundus* (*caput ulnare*), *extensor carpi ulnaris*. (2) The second layer consists of *mm. flexor digitorum sublimis*, *flexor digitorum profundus* (*caput humerale*). (3) The third layer is of limited extent and formed solely by the radial head of the deep flexor of the digits.

¹ *Rete* [L.], a net.

M. FLEXOR CARPI RADIALIS.—The radial flexor of the carpus runs parallel with the medial border of the radius. Its origin is from the medial epicondyle of the humerus close to the articular margin and immediately behind the point of attachment of the medial collateral ligament. In the distal third of the forearm a rounded tendon replaces the elongated fusiform fleshy belly of the muscle. The tendon, enclosed in a synovial sheath, traverses a canal in the ligament at the medial border of the carpus and is inserted to the base of the second metacarpal bone.

M. FLEXOR CARPI ULNARIS.—The ulnar flexor of the carpus possesses two heads: (1) The humeral head (*caput humerale*) is strong and arises from the medial epicondyle of the humerus behind the origin of the radial flexor with which it is intimately connected. (2) The ulnar head (*caput ulnare*) is weak, flattened, and narrow, and springs from the medial surface of the olecranon of the ulna. The two heads unite in the proximal third of the forearm.

The strong tendinous insertion of the muscle is to the accessory carpal (pisiform) bone.

Dissection.—In order to obtain a satisfactory view of the flexors of the digits, it is necessary to reflect the ulnar flexor of the carpus.

M. FLEXOR DIGITORUM SUBLIMIS.—The superficial flexor is a strong, largely tendinous muscle of irregularly triangular outline in section. Its origin is from the medial epicondyle of the humerus in common with the deep flexor. Near the carpus a powerful tendon begins, and, passing down the groove-like volar (posterior) surface of the carpus under cover of the transverse ligament, is continued into the metacarpus. The further course of the tendon will be followed later.

From an impression on the volar (posterior) surface of the radius, at about the junction of the middle and distal thirds and close to the medial border of the bone, a strong tendinous band (*caput tendineum*) arises and joins the tendon of the superficial flexor about the level of the radiocarpal articulation.

M. FLEXOR DIGITORUM PROFUNDUS.—The deep flexor is by far the largest and most powerful muscle in the region now being examined. Three heads can readily be distinguished:

1. *Caput ulnare.*—The ulnar head belongs to the most superficial layer of muscles behind the radius, where it will be found along the posterior border of the ulnar extensor of the carpus. Arising from the medial surface and posterior border of the olecranon, the fleshy portion of the ulnar head about the middle of the radius gives place to a narrow, rounded tendon, which passes down the forearm under the edge

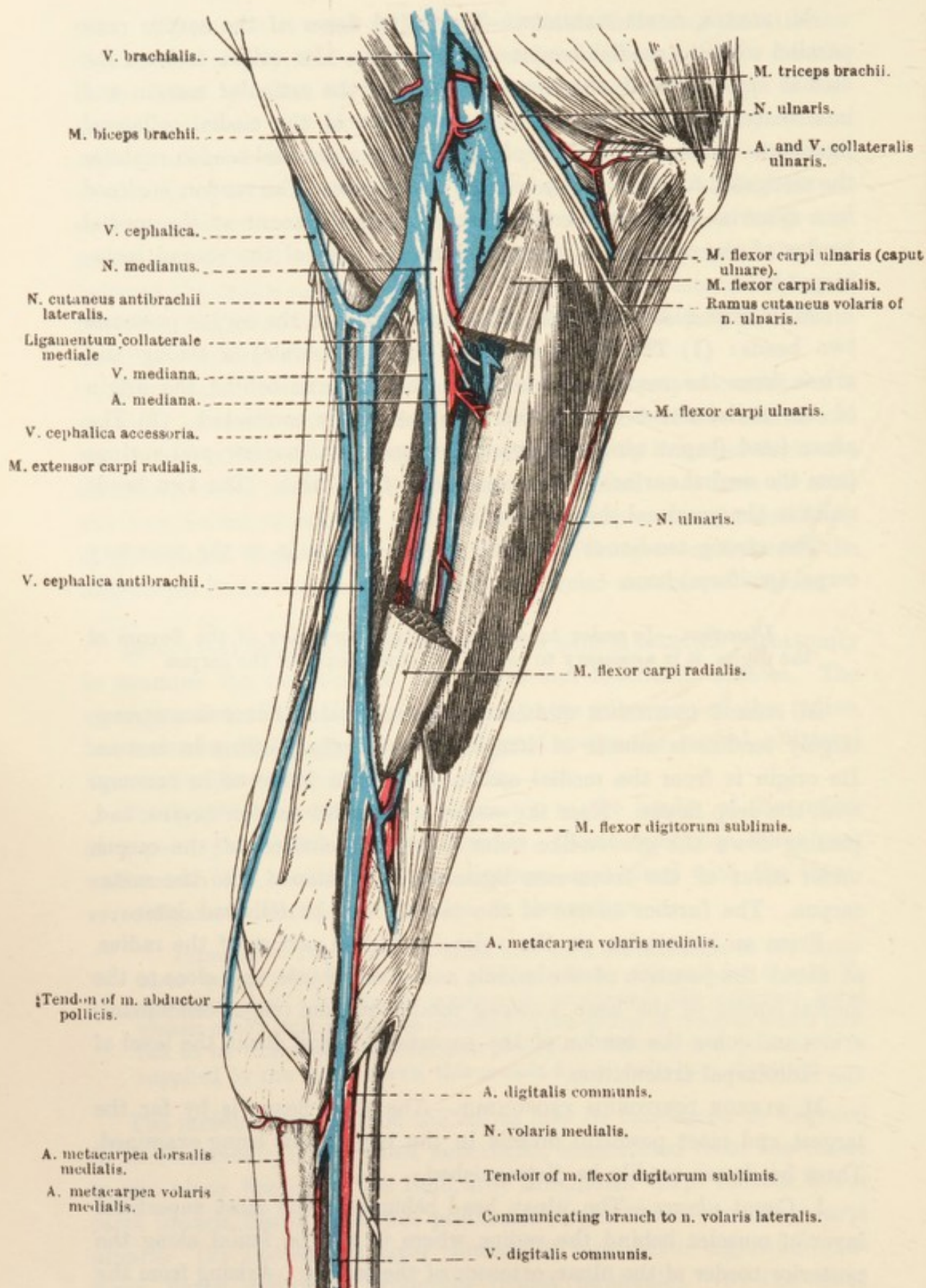


FIG. 21.—Dissection of the Medial Aspect of the Forearm and Carpal Region.

of the extensor carpi ulnaris to join the main tendon of the deep flexor close to the carpus.

2. *Caput humerale*.—The massive humeral head can be divided

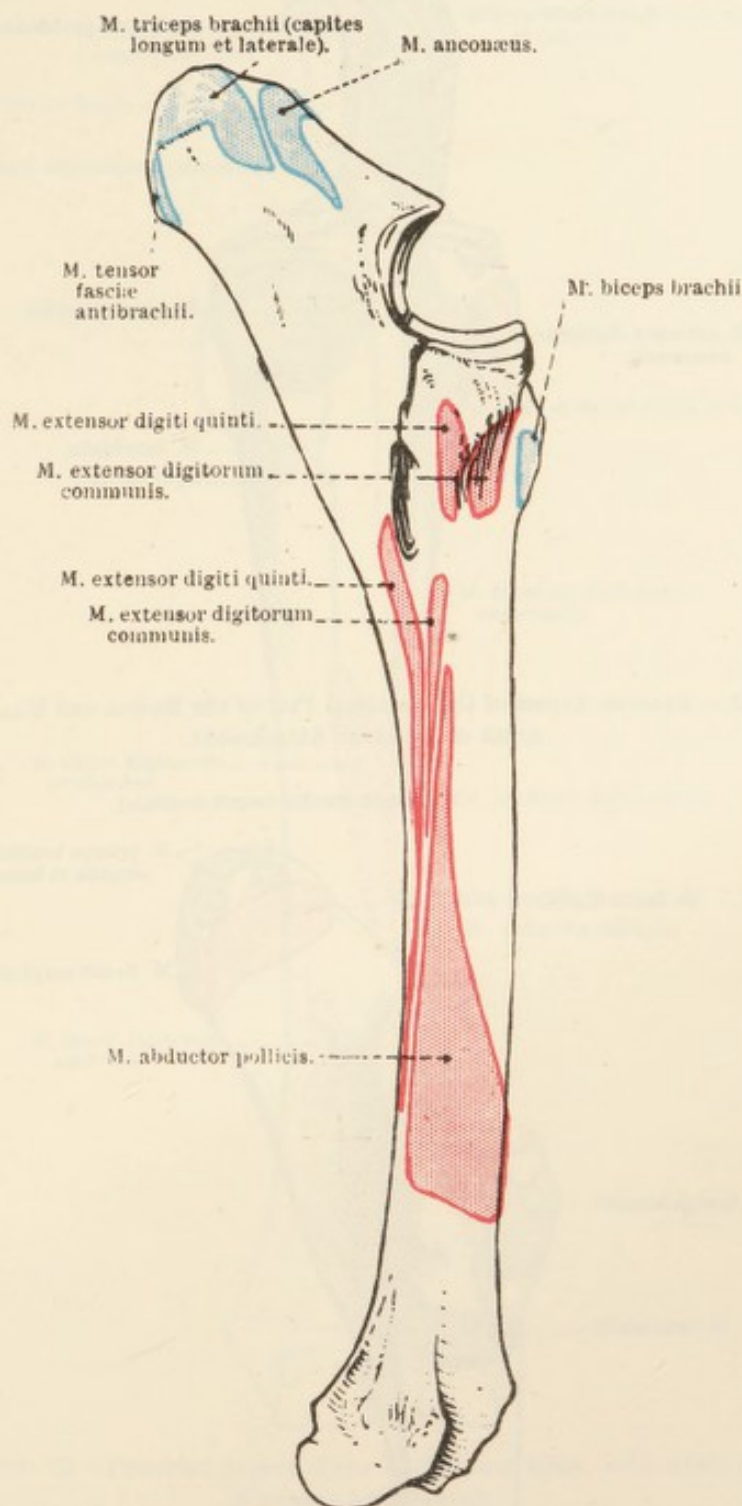


FIG. 22.—Lateral Aspect of the Radius and Ulna, with Areas of Muscular Attachment.

into three parts, one of which, in the proximal part of the forearm, comes to the surface between the ulnar head and the superficial flexor of the digits. This head has its origin from the medial epicondyle of the humerus in common with that of the superficial flexor. Near the

carpus the fleshy belly is continued distalwards by a very dense, flattened tendon.

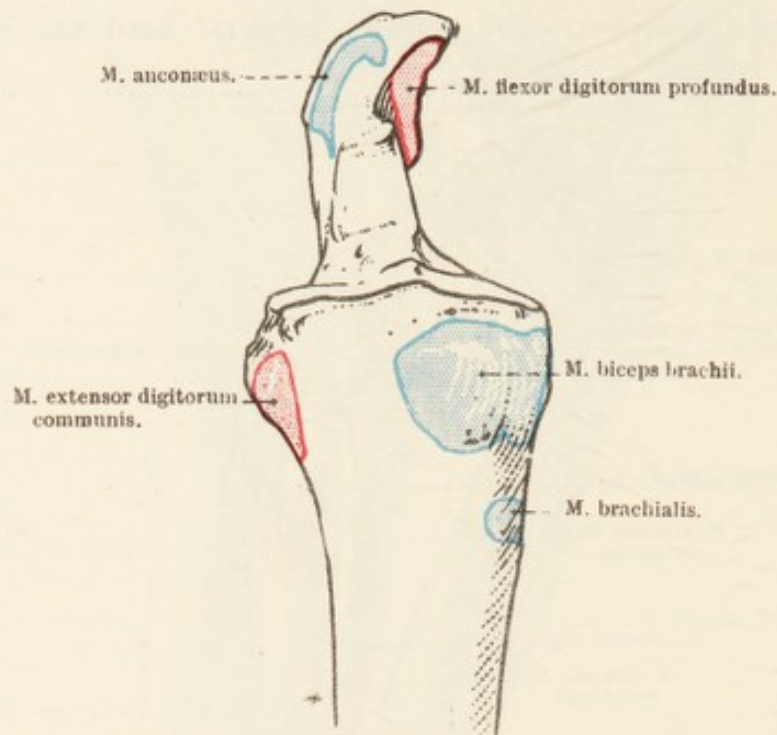


FIG. 23.—Anterior Aspect of the Proximal Part of the Radius and Ulna, with Areas of Muscular Attachment.

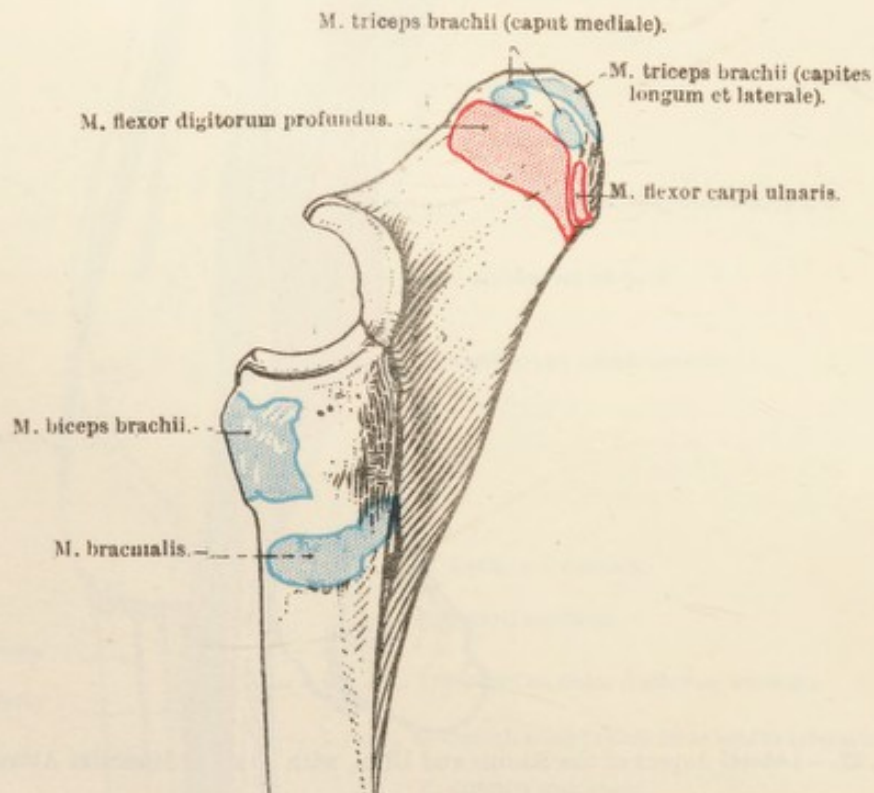


FIG. 24.—Medial Aspect of the Proximal Part of the Radius and Ulna, with Areas of Muscular Attachment.

3. *Caput radiale*.—The radial head of the deep flexor constitutes the only member of the deepest layer of the flexor group. It is feeble

and flattened, and sometimes can scarcely be said to exist. Its origin is from the volar (posterior) surface of the radius immediately distal

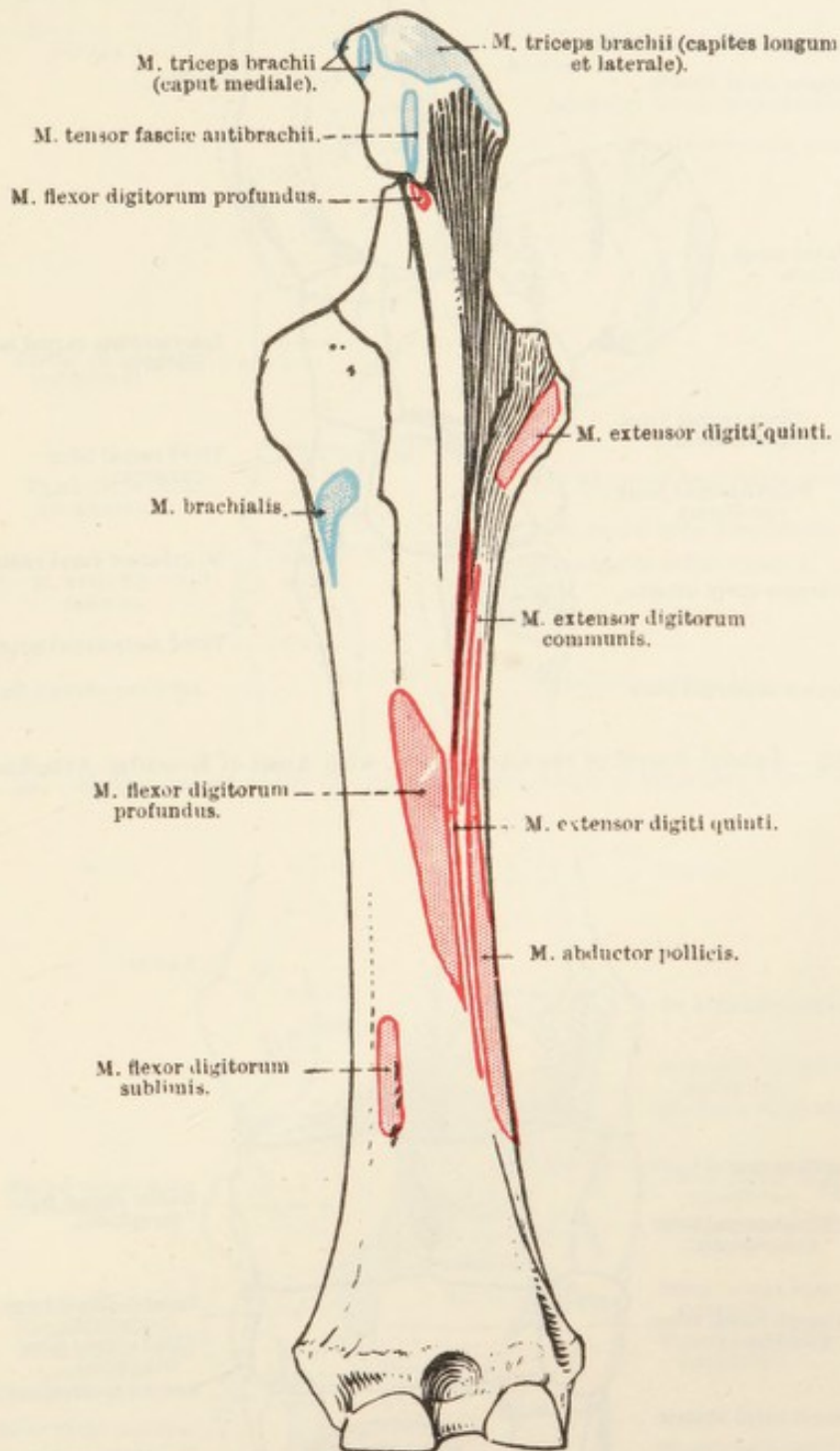


FIG. 25.—Posterior Aspect of the Radius and Ulna, with Areas of Muscular Attachment.

to the middle of the bone. The tendon of the radial head joins the main tendon in the neighbourhood of the carpus.

The very powerful and dense common tendon of the deep flexor traverses the canal at the volar aspect of the carpus and will be

followed later down the rest of the limb to its ultimate insertion into the flexor area of the third phalanx.

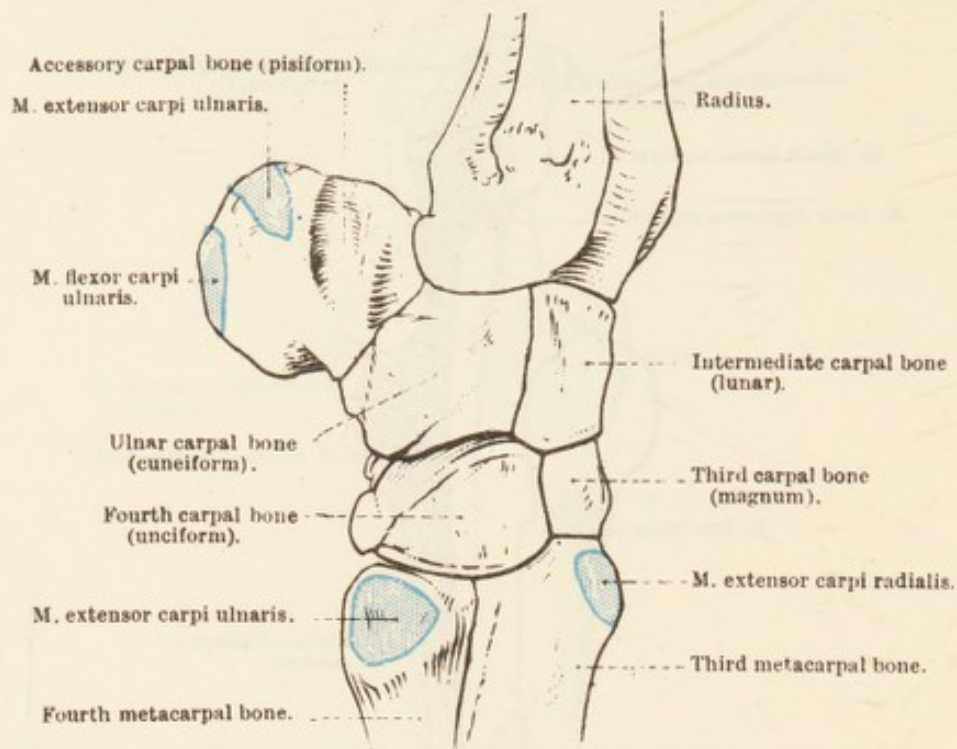


FIG. 26.—Lateral Aspect of the Carpus, etc., with Areas of Muscular Attachment.

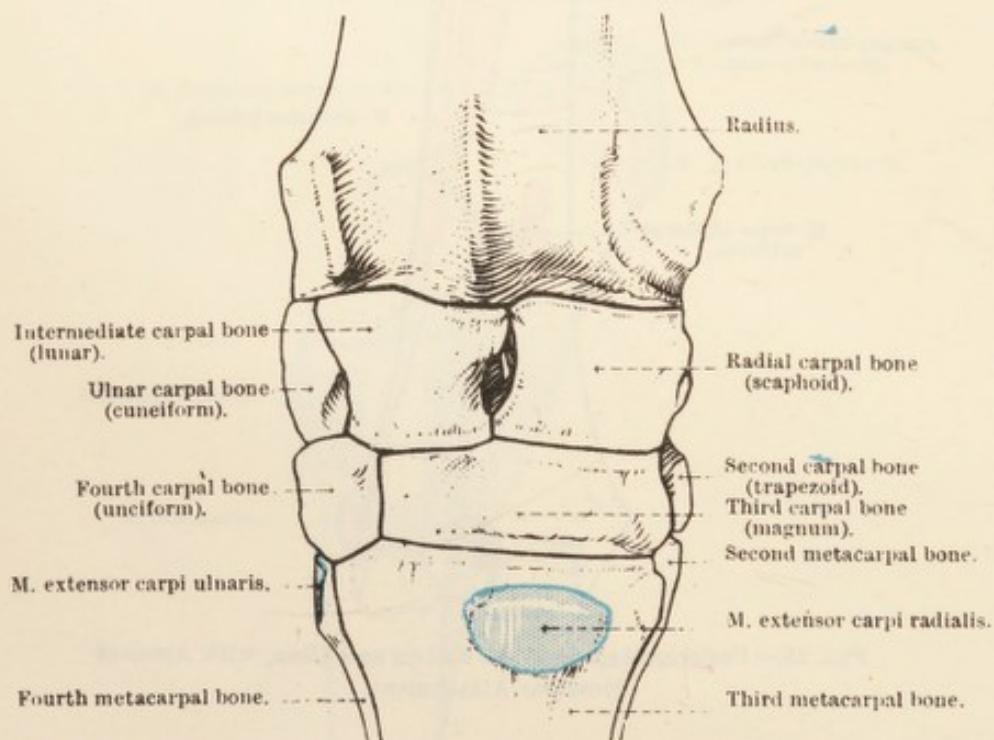


FIG. 27.—Dorsal (Anterior) Aspect of the Carpus, etc., with Areas of Muscular Attachment.

The tendons of the superficial and deep flexor muscles are enclosed in a common synovial sheath (*vagina carpeæ*) that extends upwards

for some distance proximal to the radiocarpal joint and downwards to near the middle of the metacarpus.

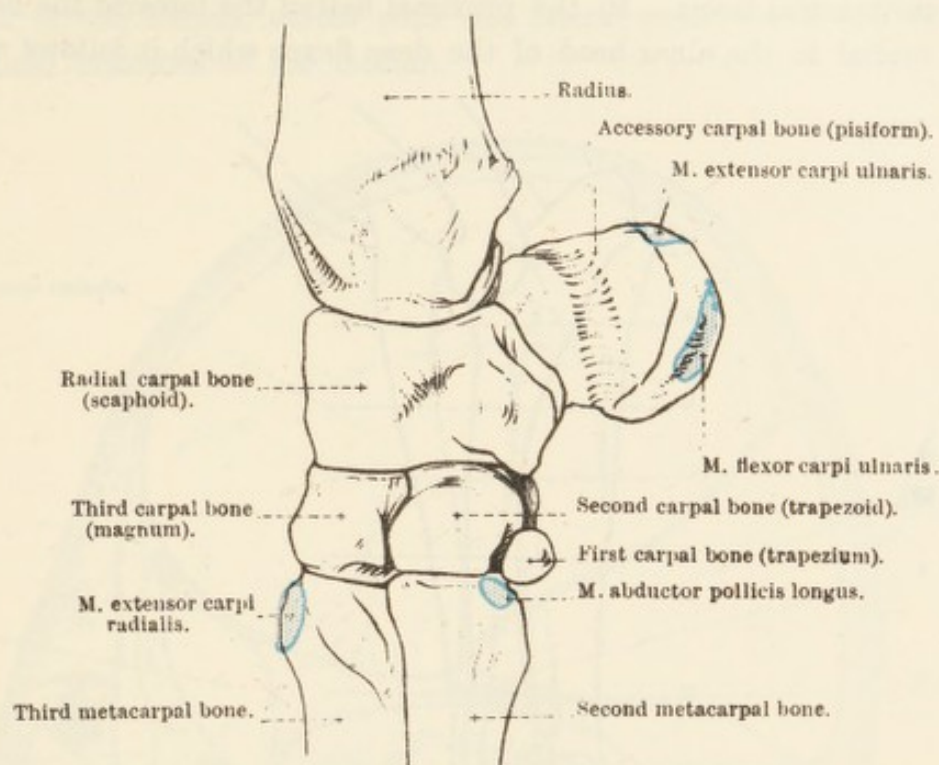


FIG. 28.—Medial Aspect of the Carpus, etc., with Areas of Muscular Attachment.

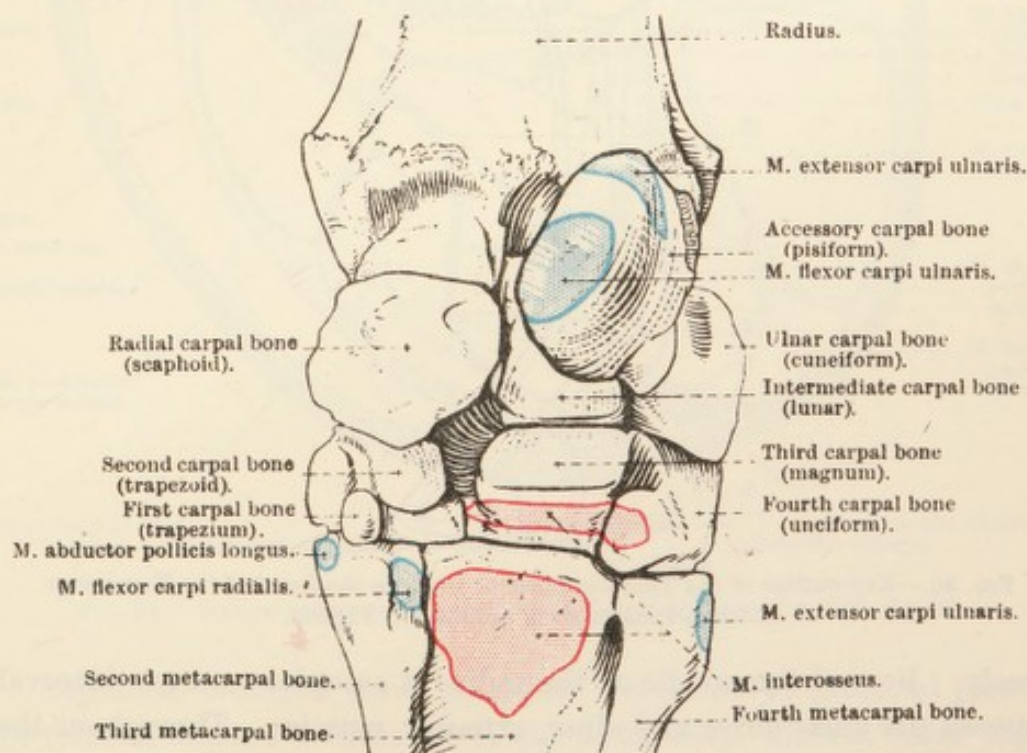


FIG. 29.—Volar (Posterior) Aspect of the Carpus, etc., with Areas of Muscular Attachment.

N. ULNARIS.—In the dissection of the arm the ulnar nerve was followed as far as the interval between the medial epicondyle of the

humerus and the olecranon of the ulna, where it lies on the origin of the superficial flexor of the digits and under cover of the tensor of the antibrachial fascia. In the proximal half of the forearm the nerve lies medial to the ulnar head of the deep flexor which it follows very

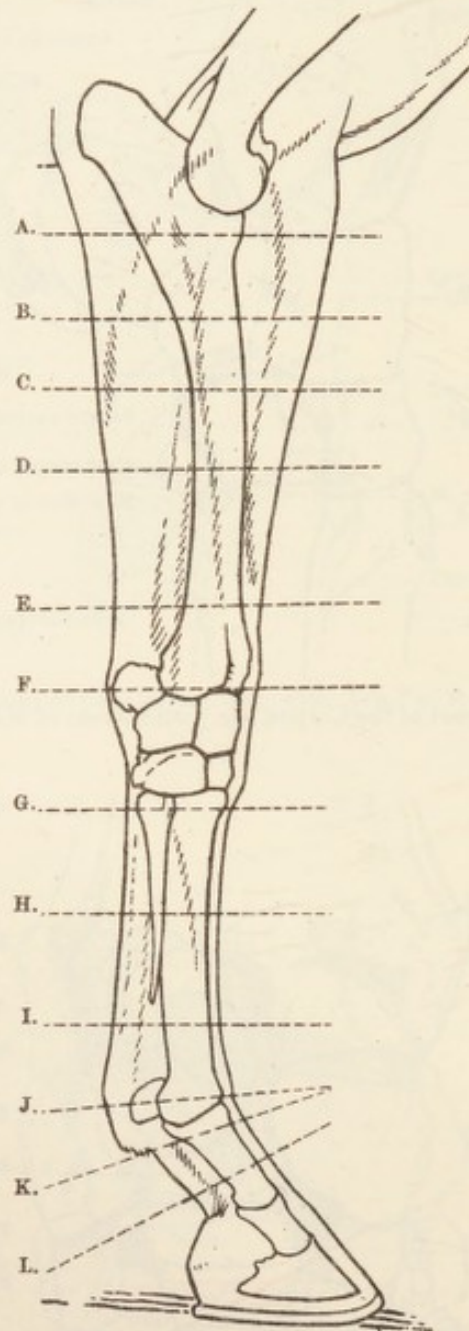


FIG. 30.—Key-outline of the Thoracic Limb to Indicate the Level of the Transverse Sections Illustrated in Subsequent Figures.

closely. Beyond the middle of the radius it occupies a narrow interval between the ulnar flexor and ulnar extensor muscles. Throughout the greater part of its course in the forearm the nerve is superficial. Close to the carpus it divides into a superficial and a deep branch. The *ramus superficialis* bends round the tendon of the ulnar extensor, pierces the deep fascia, and has already been noted as a cutaneous

nerve distributed over the lateral and dorsal surface of the carpus and metacarpus. The *ramus profundus*, under the tendon of the ulnar flexor of the carpus, unites with the lateral volar nerve, one of the terminal branches of the median.

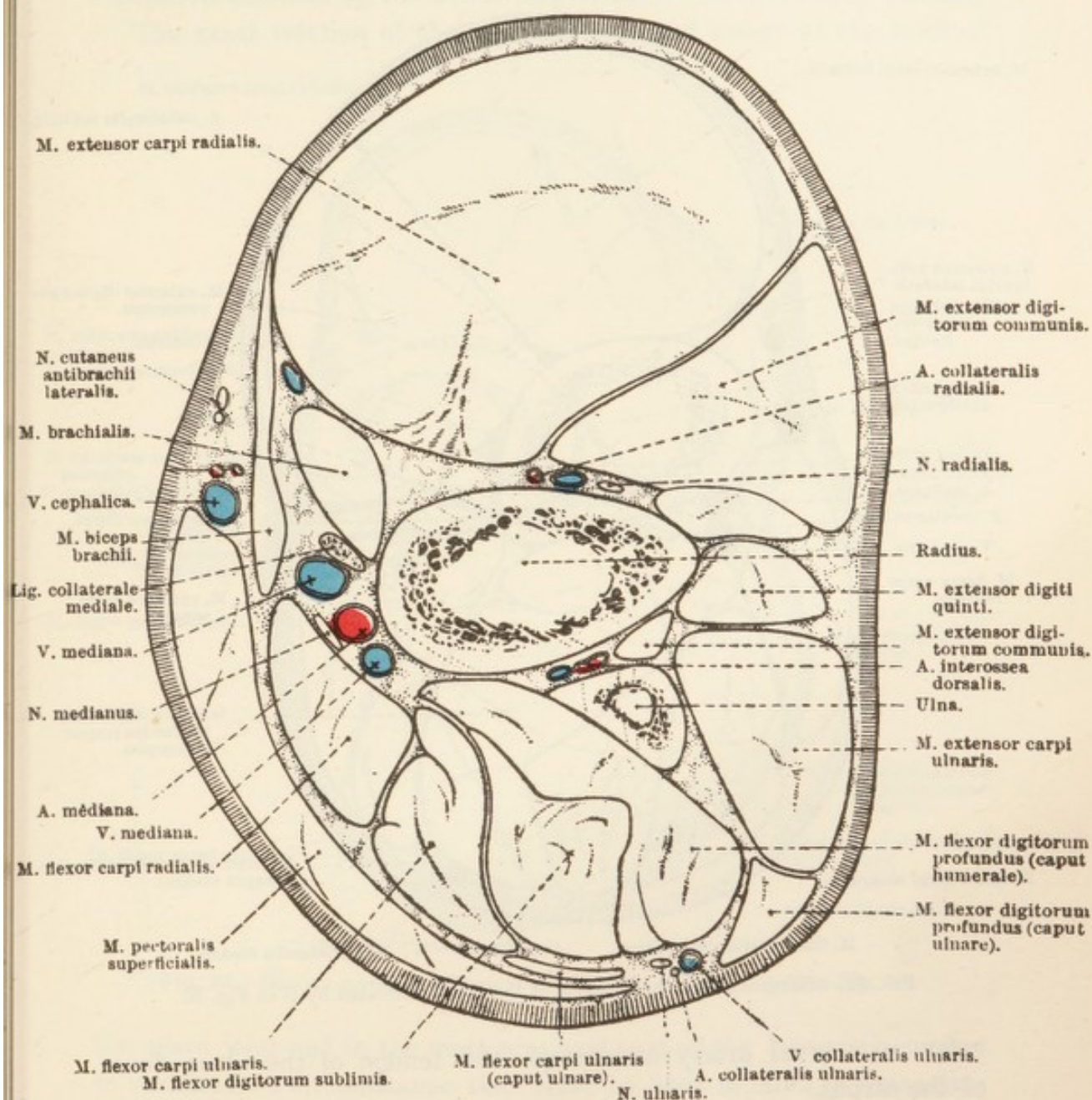


FIG. 31.—Section across the Forearm at the Level indicated by A in Fig. 30.

Collateral branches leave the ulnar nerve in the proximal part of the forearm and are distributed to the flexor carpi ulnaris, flexor digitorum sublimis, and the ulnar head of the flexor digitorum profundus.

A. COLLATERALIS ULNARIS (PROXIMALIS).—On its origin from the brachial the collateral ulnar artery follows the distal border of the medial head of the triceps towards the elbow joint. Under cover of

the tensor of the antibrachial fascia the artery meets the ulnar nerve and the two travel down the forearm in close company.

The collateral ulnar artery furnishes branches to the adjacent muscles, the elbow joint and the skin, and ends by joining the lateral

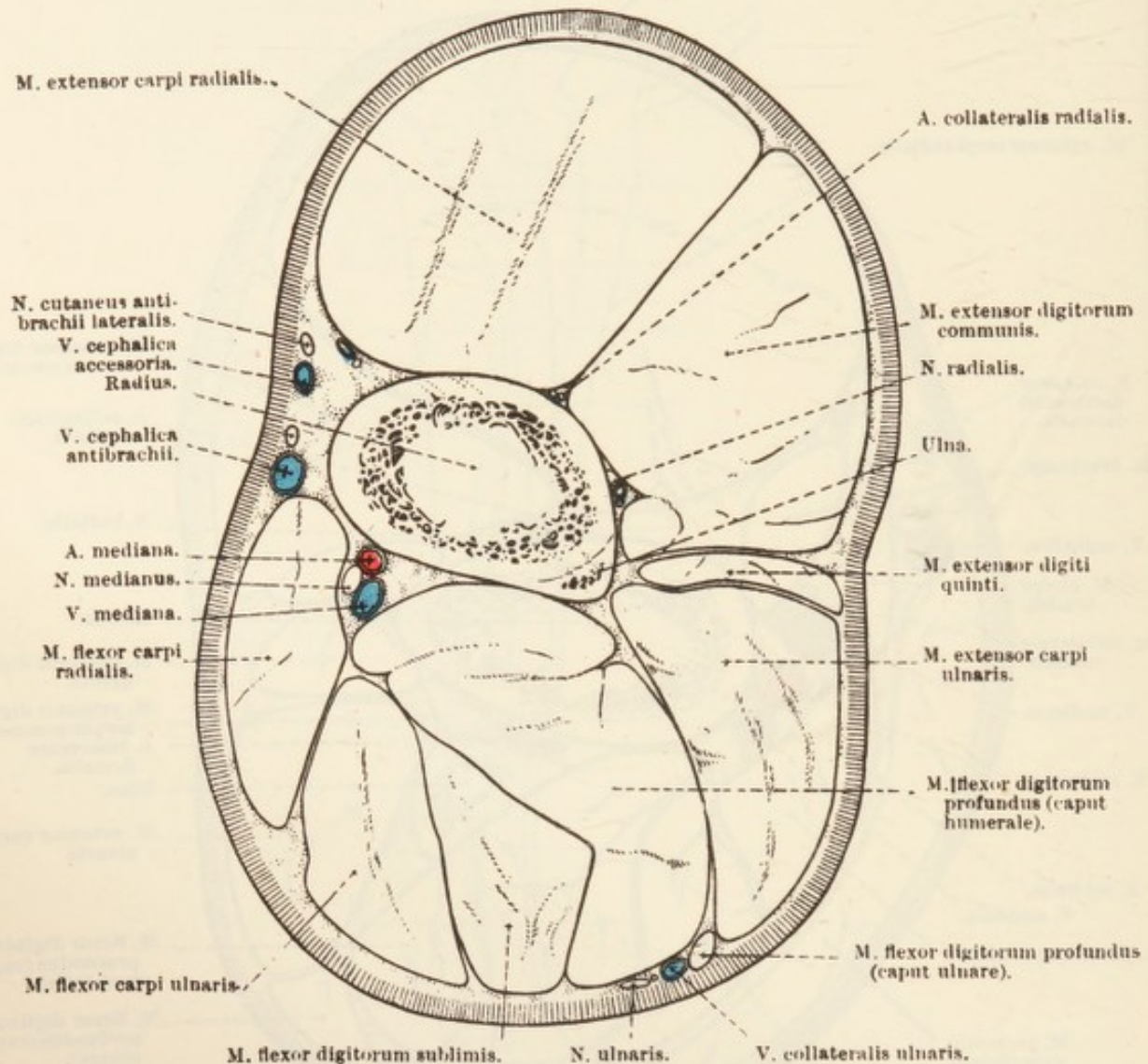


FIG. 32.—Section across the Forearm at the Level indicated by B in Fig. 30.

volar metacarpal artery underneath the tendon of the ulnar flexor of the carpus.

V. COLLATERALIS ULNARIS.—The collateral ulnar vein is a companion of the like-named artery and ends by pouring its blood into the brachial vein. At the carpus it is connected with the lateral volar metacarpal vein.

N. MEDIANUS.—The median nerve has been followed in the arm where it lies along the anterior border of the brachial artery. The nerve, running in the groove between the biceps and the medial collateral ligament, follows the median artery into the forearm where the first part of its course is superficial; soon, however, the nerve as well

as the artery buries itself between the radius and the flexor carpi radialis muscle, and, later, between this muscle and the deep flexor of the digits. In some instances the nerve becomes again superficial just as it is about to terminate in the distal third of the forearm in the depression bounded by the flexor carpi ulnaris and flexor carpi radialis.

The exact relation of the median nerve and artery at the level of

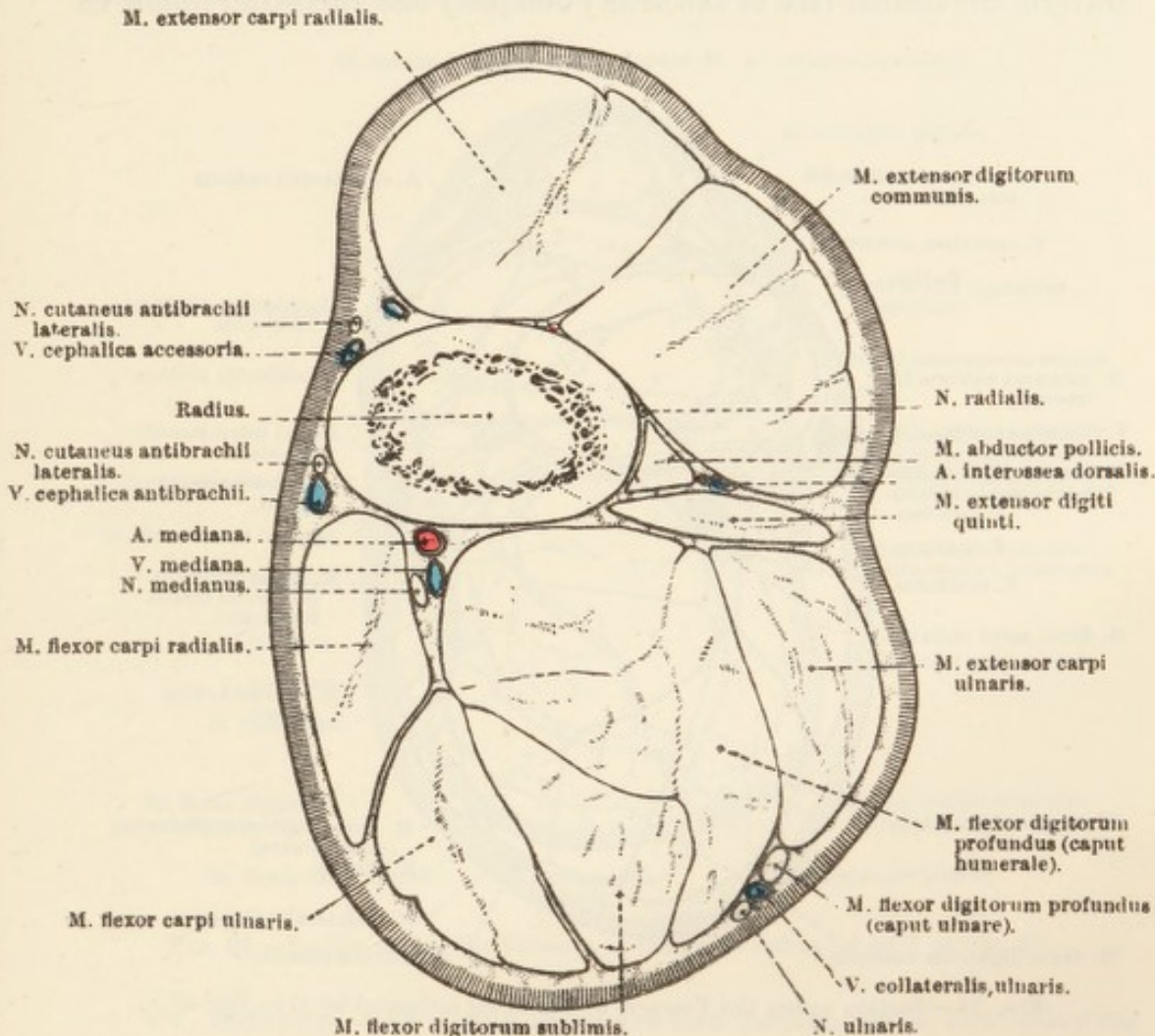


FIG. 33.—Section across the Forearm at the Level indicated by C in Fig. 30.

the elbow joint and in the most proximal part of the forearm is subject to variation—a circumstance that must be kept in mind in connection with operations in this region. Commonly, the nerve passes obliquely over the medial face of the artery, as the elbow joint is being crossed. It may, however, run for a distance upon (that is, superficial to) the artery. Or it may follow the anterior (dorsal) border of the artery throughout.

The median nerve ends by dividing into the medial and lateral volar nerves. The collateral branches are all given off a short distance beyond the elbow joint and supply the flexor carpi radialis and the

humeral and radial heads of the deep flexor. A very minute *interosseous nerve* (n. interosseus) passes through the gap between the radius and the ulna and ends in the periosteum.

A. MEDIANA.—The median artery, the direct continuation of the brachial, follows the median nerve very closely. As the two structures cross the line of the elbow joint, it is customary for the nerve to traverse the medial face of the artery obliquely and thereafter follow its

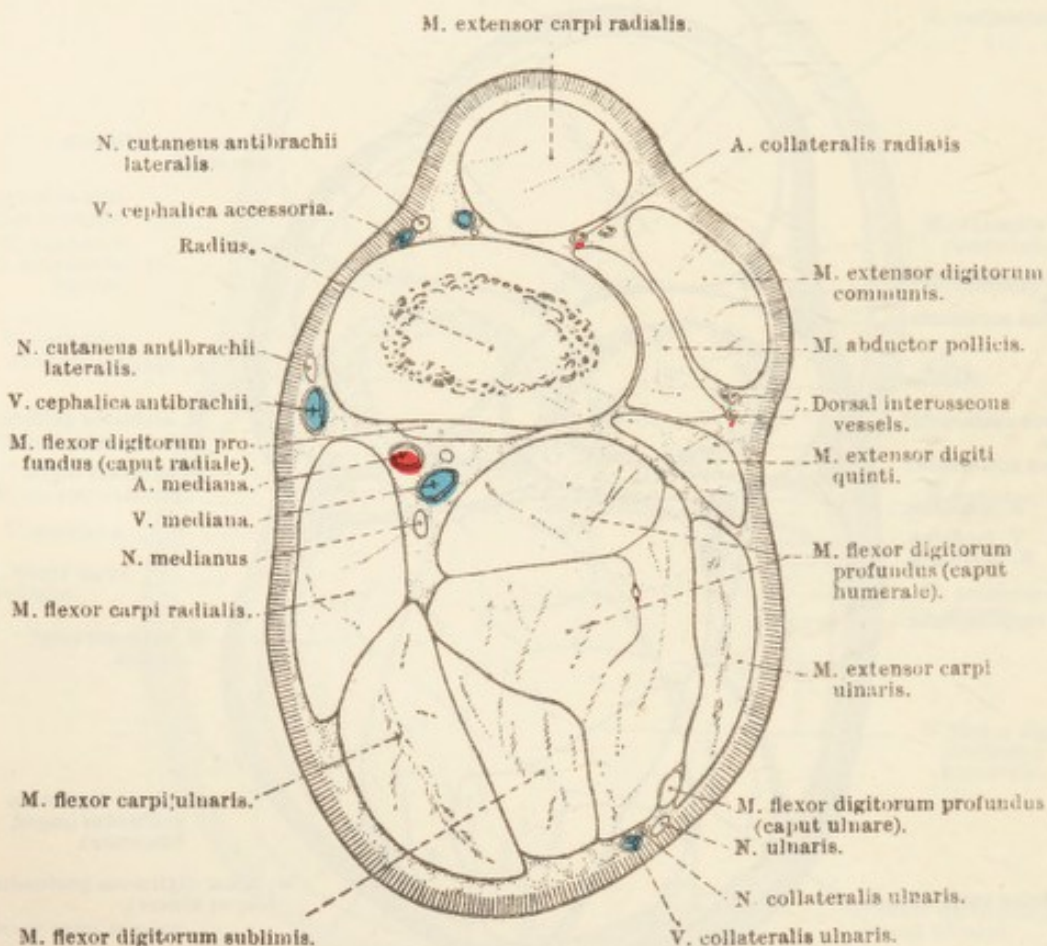


FIG. 34.—Section across the Forearm at the Level indicated by D in Fig. 30

posterior border for a variable distance, but other relations are possible, as mentioned above.

In the space between the radial and ulnar flexors the artery terminates, after giving off the medial and lateral volar metacarpal arteries, by becoming the common digital artery.

In addition to articular, muscular, and cutaneous branches, the median furnishes the common interosseous artery and the artery of the volar rete of the carpus.

A. INTEROSSEA COMMUNIS.—The common interosseous artery arises opposite the space between the radius and the ulna. In the dog and pig it divides into volar and dorsal interosseous branches, but in the horse the volar is very small or absent. In this animal, therefore, the

common interosseous may be regarded as being continued between the radius and ulna as the dorsal interosseous artery, the course of which has already been followed in the anterior radial region.

A. RETIS CARPI VOLARIS.—In the distal third of the forearm a small vessel leaves the median artery and passes down to the volar aspect of the carpus, where it assists the volar metacarpal arteries in the formation of a network of small vessels, the *rete carpi volaris*.

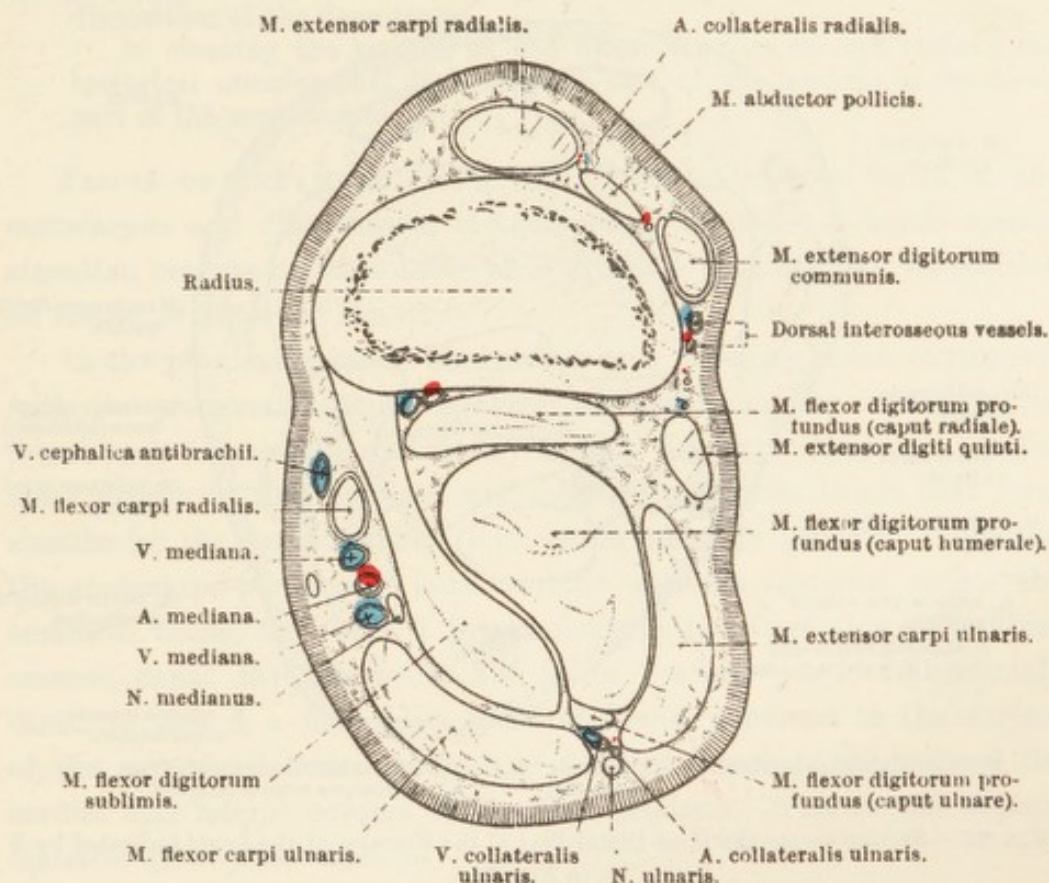


FIG. 35.—Section across the Forearm at the Level indicated by E in Fig. 30.

VV. MEDIANÆ.—As a rule there are two median veins, one following each border of the median artery, radicles of which are contributed by each of the three metacarpal veins. A *common interosseous vein* (v. interossea communis) joins the posterior median, as does also a large vessel that drains the deep flexor muscle of the digits.

The metacarpal region and the digits as far as the margin of the hoof must next be examined. The "foot" can be satisfactorily dissected only in a specimen that has been specially prepared so as to allow of the removal of the hoof without injury to the soft structures contained therein, and this is not possible in the preserved limb upon which the dissection, so far, has been performed.

Before the removal of the skin, determine by sight and touch the

position of the metacarpal bones and the first phalanx. A large amount of the anterior (dorsal) surface of the third metacarpal bone can be felt through the skin. The tendons of the digital extensors, however, overlie it in part, and their position should be determined by palpation. The small second and fourth metacarpal bones should be followed from the vicinity of the carpus to the distal third of the meta-

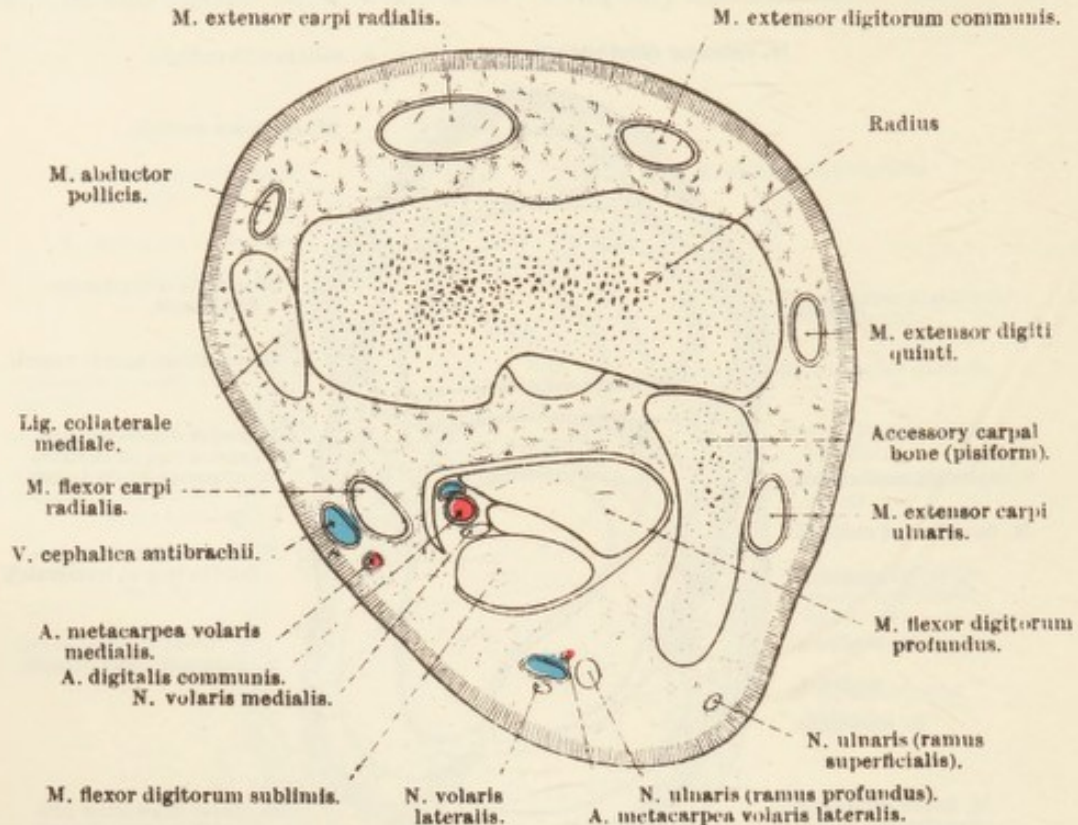


FIG. 36.—Section across the Most Distal Part of the Forearm at the Level indicated by F in Fig. 30.

carpal region, where commonly their expanded distal ends can be detected.

The prominent line of the flexor tendons can be followed with ease. Between them and the metacarpal bones is a groove on each side of the limb, and herein a gradually increasing ridge—formed by the middle interosseous muscle—can be determined.

Over the prominence corresponding to the sesamoid bones of the first phalanx is a tuft of long hairs (their length varies with the breed of horse) among which a horny callosity, the "ergot," will be found resting upon a fibrous cushion. It is generally accepted that the "ergot" is the homologue of the large central foot-pad of the dog; and it is assumed that, though now rudimentary and vestigial, it was of considerable functional importance in those ancestors of the horse that were digitigrade.

Roughly on a level with the middle of the first phalanx there is a depression bounded by the bone and the flexor tendons. Lastly, the region adjoining the hoof on each side of the digit should be manipulated to detect the presence of normally resilient cartilaginous extensions of the third phalanx.

Dissection.—Having made a careful examination of the surface, now remove the skin, and in doing so exercise caution lest the vessels and nerves of the region should be injured. Pay particular attention to the disposition of the deep fascia.

In cleaning the surface of the flexor tendons do not remove the lumbrical muscles that lie along the side of the tendons in the distal part of the metacarpus.

FASCIA OF THE METACARPUS AND DIGIT.—The deep fascia of the metacarpus and digit (*fascia metacarpea et digitalis*) demands special attention because of its notable strength and characteristic disposition on the volar aspect of the limb.

In the proximal part of the metacarpus a strong sheet, continuous with the transverse carpal ligament, crosses from the second to the fourth metacarpal bone and closely invests the flexor tendons. On the volar aspect of the digit are well-marked transverse bands that form sheaths for the flexor tendons and retain them in position. Opposite the metacarpo-phalangeal joint a *volar annular ligament* assists the sesamoid bones, to which it is attached, in the formation of a fibro-osseous canal through which the flexor tendons play. Immediately distal to this is a four-sided sheet of fascia, adherent to the surface of the superficial flexor tendon and fixed by bands to the ends of the medial and lateral borders of the first phalanx. This is the *vaginal ligament of the flexor tendons*.

A third annular band, only partially visible at the present stage of the dissection, is associated with the terminal part of the deep flexor tendon, between which and the digital torus the greater part of it is interposed. In general outline the band is crescentic, the horns of the crescent being represented by strong fascial strands attached about the middle of the borders of the first phalanx. Connected with each side of this part of the tendon sheath is the so-called *ligament of the ergot*, which, beginning as a comparatively narrow band in the fibrous basis of the "ergot," crosses the digital artery and nerve obliquely, widens at the side of the joint between the first and second phalanges, and merges into the third annular band of fascia.

M. EXTENSOR DIGITORUM COMMUNIS.—The tendon of the common extensor has been followed over the distal end of the radius and the dorsal face of the carpus. It continues along the front or dorsal surface of the metacarpus and digit and ends at the extensor process of the

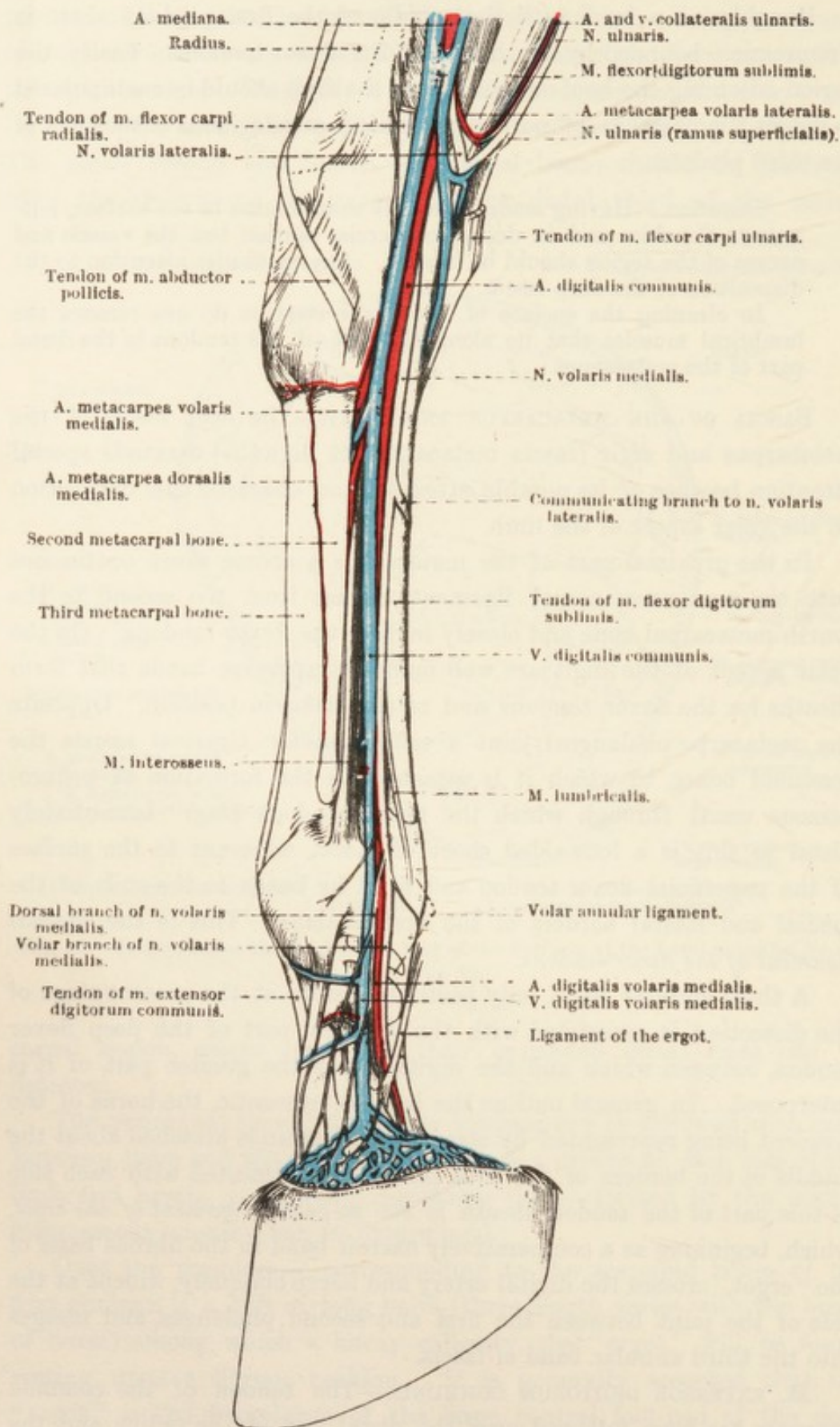


FIG. 37.—Medial Aspect of the Carpus, Metacarpus and Digit.

third phalanx. At the proximal end of the metacarpus the tendon is placed decidedly lateral to the middle line of the limb. This position, however, is gradually changed until, by the time the metacarpo-phalangeal joint is reached, the tendon is equidistant from the two borders of the limb. In the neighbourhood of this joint, also, as well as in the digit, the tendon is wider and thinner than elsewhere. It is intimately connected with the capsules of the several joints associated with the phalanges, but a synovial bursa of limited extent is placed between the tendon and the capsule of the metacarpo-phalangeal articulation.

In the proximal third of the metacarpus a strong fascial band from the lateral aspect of the carpus is connected with the extensor tendon, and about the middle of the first phalanx each border of the tendon is joined by a strong oblique offset from middle interosseous muscle.

M. EXTENSOR DIGITI QUINTI.—After passing through the ligamentous canal at the lateral border of the carpus, the tendon of this muscle pursues an oblique course along the dorsal-lateral part of the metacarpal bone and is inserted to the proximal part of the dorsal (anterior) surface of the first phalanx.

Soon after its entry into the metacarpal region the tendon is joined by the thin tendon of the muscle of Phillips and a strong fascial band from the lateral part of the carpus. Compact hitherto, the tendon now broadens, and not infrequently divides into more or less isolated bundles of fibres. A small synovial bursa lies beneath the tendon as it crosses the head of the third metacarpal bone and the joint between this bone and the first phalanx.

M. FLEXOR DIGITORUM SUBLIMIS.—The tendon of the superficial digital flexor demands careful examination. In the first place it will be noticed that it passes through fascial sheaths—lined by synovial tendon sheaths—at the carpus and in the region of the metacarpo-phalangeal joint.

The tendon leaves the forearm by running through the roughly triangular passage or canal bounded by the carpus in front, the accessory carpal (pisiform) bone laterally, and the transverse ligament of the carpus on the volar side. In its passage through the canal the flexor tendon is enclosed in a synovial investment (*vagina carpea*) the extent of which is to be determined by dissection.

In the digital region the tendon traverses the canal formed by the phalanges (and the superposed ligaments) and the specialised fascial bands (fibrous tendon sheaths) already noted, and is surrounded by a second synovial or mucous sheath.

Turning now to the tendon itself, it will be found that until it

arrives at the distal part of the metacarpus it is only slightly flattened. From this point onwards the flattening becomes more and more pronounced. In the distal fourth of the metacarpus the tendon of the superficial flexor has an annular appendage through which the tendon of the deep flexor passes. At about the middle of the first phalanx the superficial tendon splits into two limbs that are inserted to the proximal part of the volar aspect of the second phalanx and to the immediately adjacent parts of the first phalanx.

M. FLEXOR DIGITORUM PROFUNDUS.—The tendon of the deep flexor accompanies the superficial tendon down the back of the carpus—where the two structures are enclosed in a common synovial or mucous sheath—metacarpus and digit. In the distal fourth of the metacarpus the

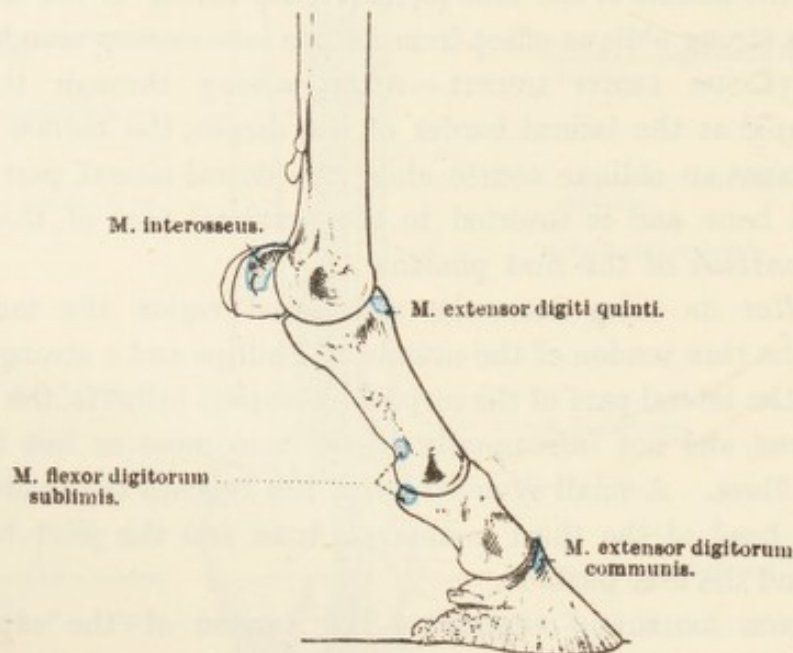


FIG. 38.—Lateral Aspect of the Skeleton of the Digit, with Areas of Muscular Attachment.

tendon traverses the ring provided by the superficial tendon and then plays over the groove-like surface formed by the two sesamoid bones and the cartilage that clothes their volar face. Then, passing between the two limbs into which the superficial tendon finally divides, it crosses the sesamoid bone of the third phalanx and is inserted to the flexor area of the third phalanx. The ultimate insertion cannot be examined as yet, inasmuch as it is buried within the hoof.

Careful note should be made of the extensive synovial or mucous sheath associated with the deep and superficial tendons beginning in the distal fourth of the metacarpus and continued to the middle of the second phalanx, where it comes into contact with a similar sheath clothing the deep tendon as it plays over the sesamoid bone of the third phalanx.

A strong reinforcing tendinous band (caput tendineum) of some physiological importance passes from the back of the carpus, where it is connected with the volar carpal ligament, and joins the deep flexor tendon about the middle of the metacarpus.

There can be little question that the tendinous heads of the superficial and deep flexors serve the purpose of mechanical stays to the limb and so relieve the fleshy part of these muscles from strain when the standing posture is long maintained.

THE SYNOVIAL SHEATHS (VAGINÆ¹ MUCOSÆ) OF TENDONS.—At this stage of the dissection it is advisable to make a general review of the

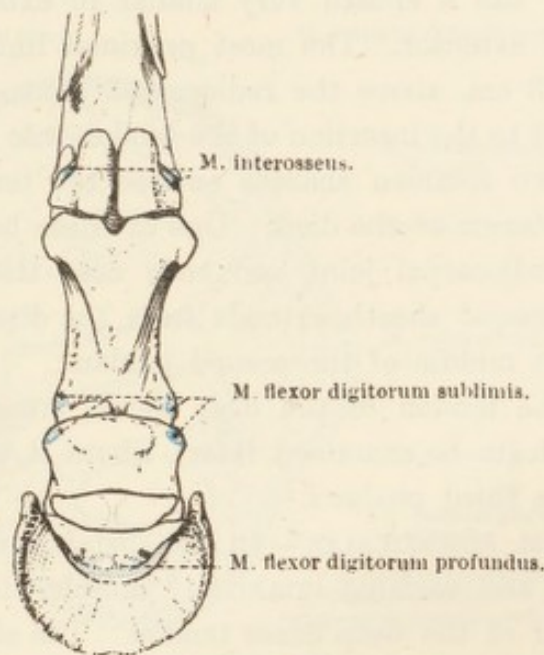


FIG. 39.—Volar (Posterior) Aspect of the Skeleton of the Digit, with Areas of Muscular Attachment.

synovial or mucous sheaths, connected with the extensor and flexor tendons, in the carpal, metacarpal, and digital regions.

Each extensor tendon is furnished with an independent sheath as it plays through the groove provided for it at the distal end of the radius. All the sheaths begin, roughly speaking, on a level with the upper edge of the accessory carpal (pisiform) bone. The sheath of the extensor carpi radialis ends close to the insertion of the muscle. The sheath of the extensor carpi ulnaris belongs to that tendon of the muscle which lies in the oblique groove on the lateral surface of the accessory carpal bone, and terminates near the insertion of this tendon into the fourth metacarpal bone.

The synovial sheaths of the extensor digitorum communis and extensor digiti quinti end in the proximal fourth of the metacarpus;

¹ *Vagina* [L.], a sheath.

a short diverticulum from the sheath of the common extensor follows the thin tendon of Phillips' muscle for a distance towards its union with the tendon of the extensor digiti quinti. There is, however, no union between the synovial sheaths of the two tendons.

The slanting abductor pollicis has a sheath that ends close to the insertion of the tendon into the base of the second metacarpal bone.

A small synovial bursa lies under the tendon of each of the extensors of the digits as it crosses the joint between the third metacarpal bone and the first phalanx.

The tendon of the flexor carpi ulnaris has no sheath. The radial flexor has a sheath very similar in extent to that provided for the radial extensor. The most proximal limit of this sheath is, roughly, 7 to 8 cm. above the radiocarpal joint, and the sheath is continued almost to the insertion of the tendon into the second metacarpal bone.

Two common sheaths enclose the tendons of the superficial and deep flexors of the digit. One of these begins about 8 to 10 cm. above the radiocarpal joint and ends near the middle of the metacarpus. The second sheath extends from the distal fourth of the metacarpus to the middle of the second phalanx.

The tendon of the deep flexor muscle has, in addition, a third sheath (to be examined later), where it plays over the sesamoid bone of the third phalanx.

MM. LUMBRICALES.—In the distal part of the metacarpus a pale, weak, and variable lumbrical¹ muscle will be found attached to each border of the deep flexor tendon. The slender tendon of each is lost in the fibrous basis of the "ergot." These muscles cannot be regarded as of functional value, but are of interest as being vestiges of structures that formerly served a definite purpose.

MM. INTEROSSEI.—Like the lumbricals, the interosseous muscles have been profoundly affected by the marked modifications that have taken place in the manus during the evolution of an animal with only one functional digit. Three interosseous muscles are represented in the modern horse, but, of these, two, which may be named medial and lateral, are rudimentary. They have a slender, pale fleshy belly arising from the base of the second or fourth metacarpal bone as the case may be. Very attenuated tendons end variously in the neighbourhood of the metacarpo-phalangeal joint.

The middle interosseous muscle (m. interosseous medius) has, during its evolution, increased considerably in size—in conformity with the great increase in the size of the digit with which it is associated—and has so changed in structure that it is now almost entirely tendinous.

¹ *Lumbricus* [L.], an earthworm. From the shape of the muscles in man.

Some few scattered bundles of muscular tissue, more obvious in the young than in the old, still remain as a record of its ancestral history. The strong, flattened tendinous band into which the muscle has been transformed lies between the flexor tendons and the groove-like space formed by the three metacarpal bones. Its origin, confused with the volar carpal ligament, is from the posterior surface of the distal row of carpal bones and the neighbouring part of the third metacarpal.

In the distal third of the metacarpus the band divides into two limbs, each of which is attached to a sesamoid bone. A continuation of each limb passes obliquely across the border—medial or lateral, as

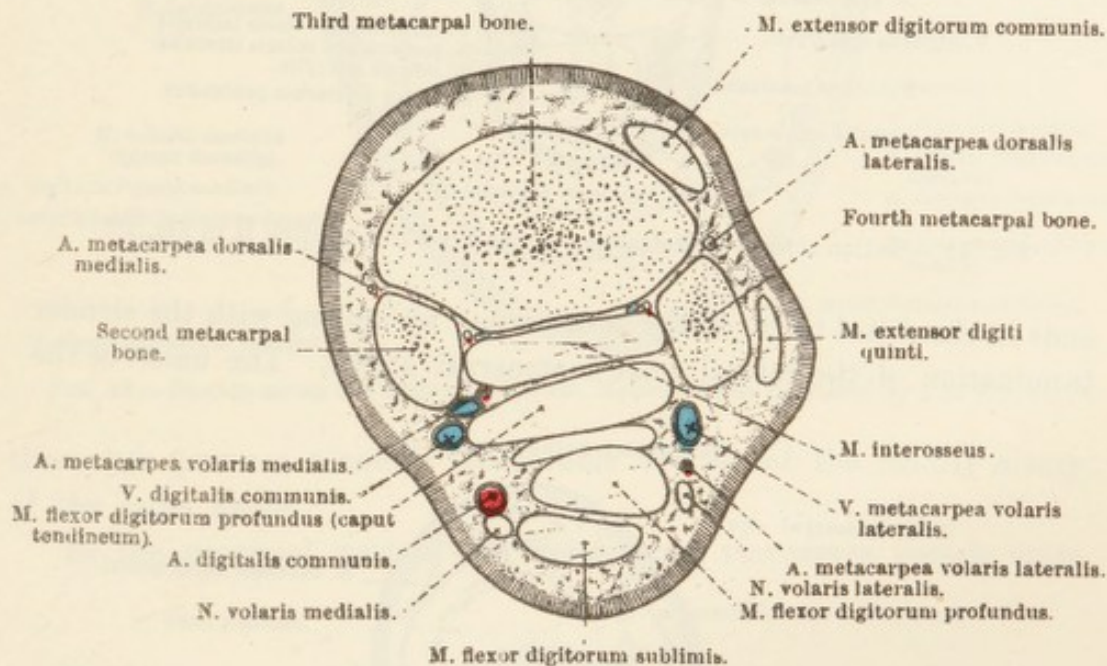


FIG. 40. — Section across the Metacarpus at the Level indicated by G in Fig. 30.

the case may be—of the first phalanx to reach the dorsal aspect of this bone and here join the tendon of the common extensor of the digit.

The strong tendinous structure representing the middle interosseous muscle obviously serves as a mechanical stay when the weight of the body is sustained by the limb, and thus prevents over-extension of the metacarpo-phalangeal joint, while, at the same time, removing strain from the flexor muscles.

ARTERIES OF THE METACARPUS AND DIGIT.—As has been seen, the median artery terminates as the common digital, and, at the same point, contributes the medial and lateral volar¹ metacarpal arteries.

The medial volar metacarpal artery (a. metacarpea volaris medialis) follows the tendon of the flexor carpi radialis very closely in its course down the medial posterior part of the carpal region. Having distributed twigs to the rete carpi dorsalis, the artery sinks into the cleft

¹ *Vola* [L.], the palm.

between the second metacarpal bone and the middle interosseous muscle. It follows the medial margin of the deep face of the modified muscle, supplies the nutrient artery of the third metacarpal bone, and

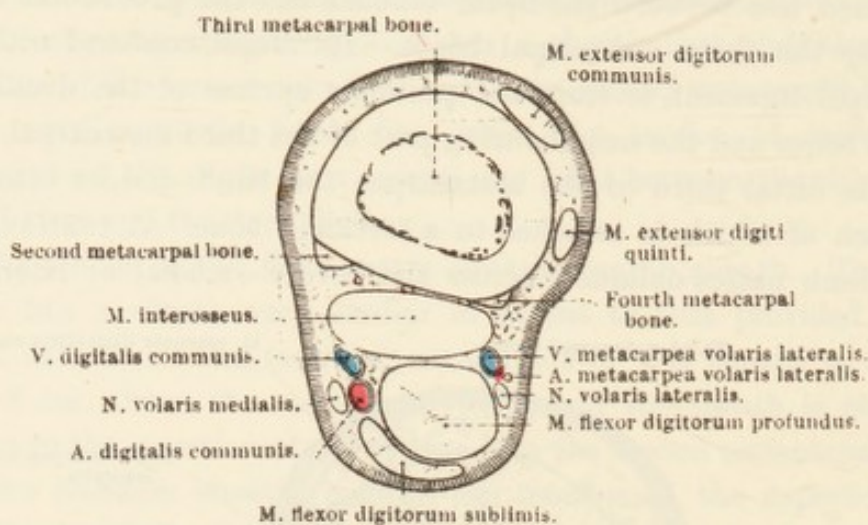


FIG. 41.—Section across the Metacarpus at the Level indicated by H in Fig. 30.

ends in the distal third of the metacarpus by uniting with the slender termination of the lateral volar metacarpal artery. The union of the

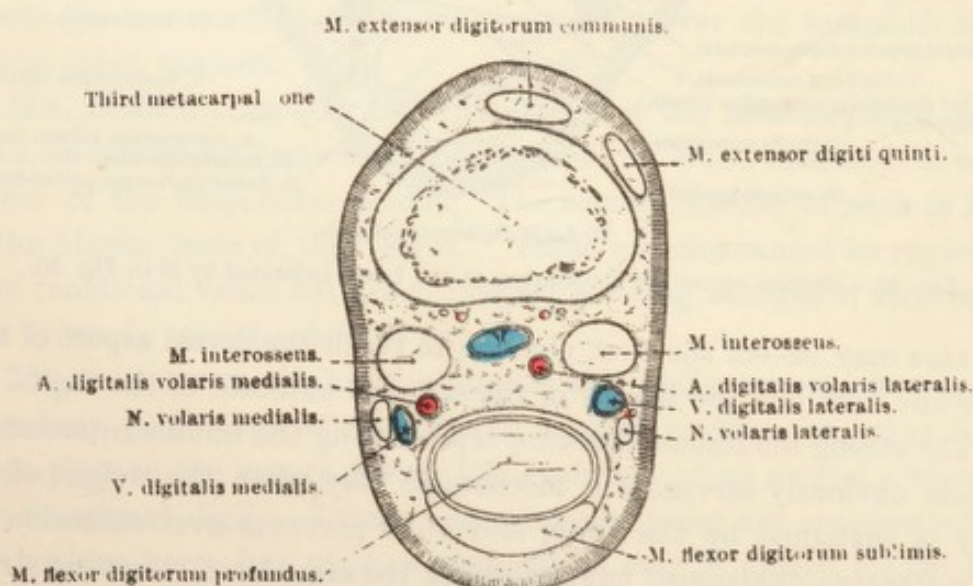


FIG. 42.—Section across the Metacarpus at the Level indicated by I in Fig. 30.

two vessels results in the formation of a small artery that, passing between the two limbs of the interosseous muscle, joins either the common digital or the lateral volar digital artery.

The *lateral volar metacarpal artery* (a. metacarpea volaris lateralis) is smaller than the medial vessel of the same name. Under cover of the tendon of the flexor carpi ulnaris it unites with the terminal part of the collateral ulnar artery. After passing the carpus along the

lateral edge of the flexor tendons, it enters the narrow interval between the fourth metacarpal bone and the middle interosseous muscle, and

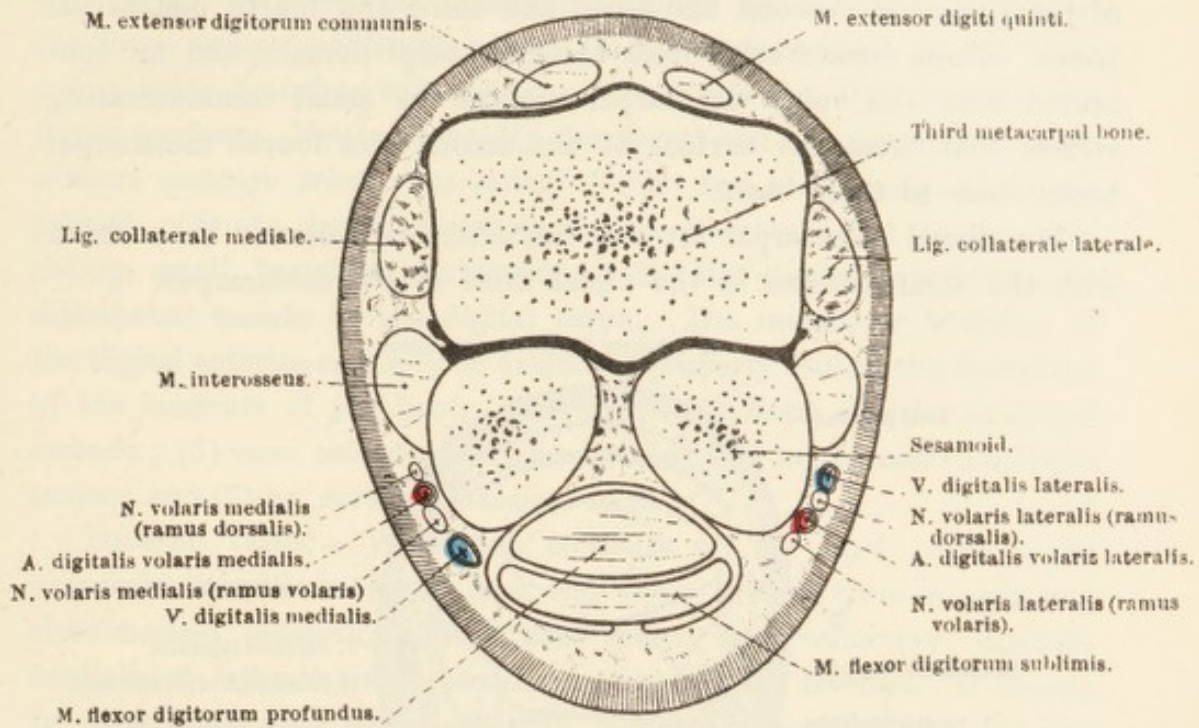


FIG. 43.—Section across the Distal End of the Metacarpus as indicated by J in Fig. 30.

thereafter pursues a course comparable to that of the medial artery of the same name.

In the proximal part of the metacarpus transverse vessels unite

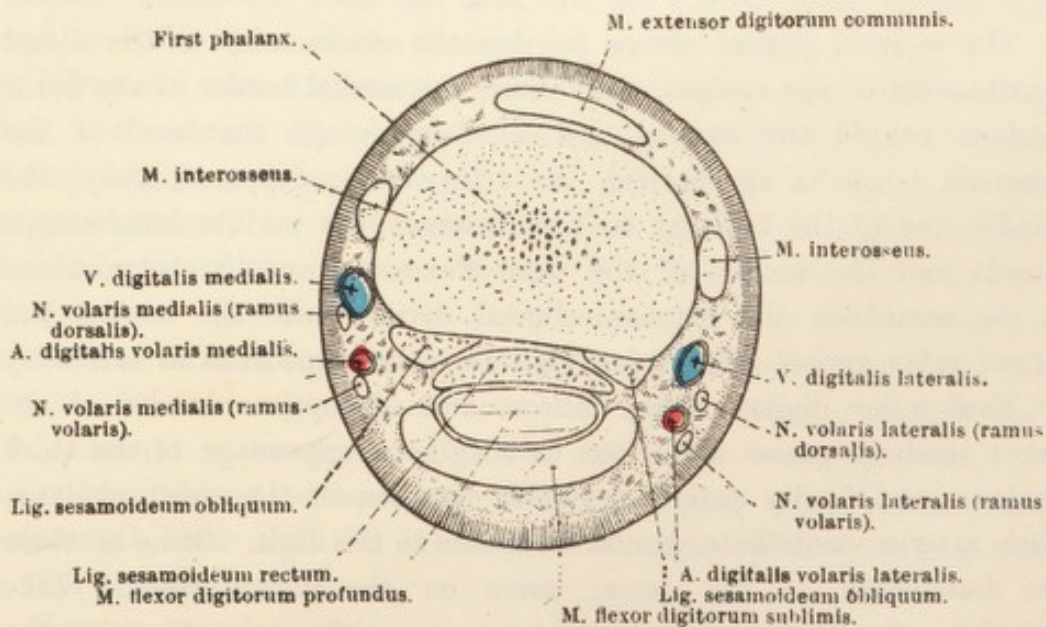


FIG. 44.—Section across the First Phalanx at the Level indicated by K in Fig. 30.

the two volar metacarpal arteries by crossing the limb deep and superficial to the middle interosseous muscle. These communicating vessels constitute the *deep volar arch* (arcus volaris profundus).

Very slender *dorsal metacarpal arteries* (aa. metacarpea dorsalis medialis et lateralis) will be found in the shallow grooves at the line of junction of the second and third and third and fourth metacarpal bones. These vessels arise from the rete carpi dorsalis, and are connected with the volar metacarpal arteries by small communicating vessels that cross the surface of the second and fourth metacarpal bones close to their bases.

The dorsal metacarpal arteries can often be followed to a union with the volar arteries in the distal third of the metacarpus.

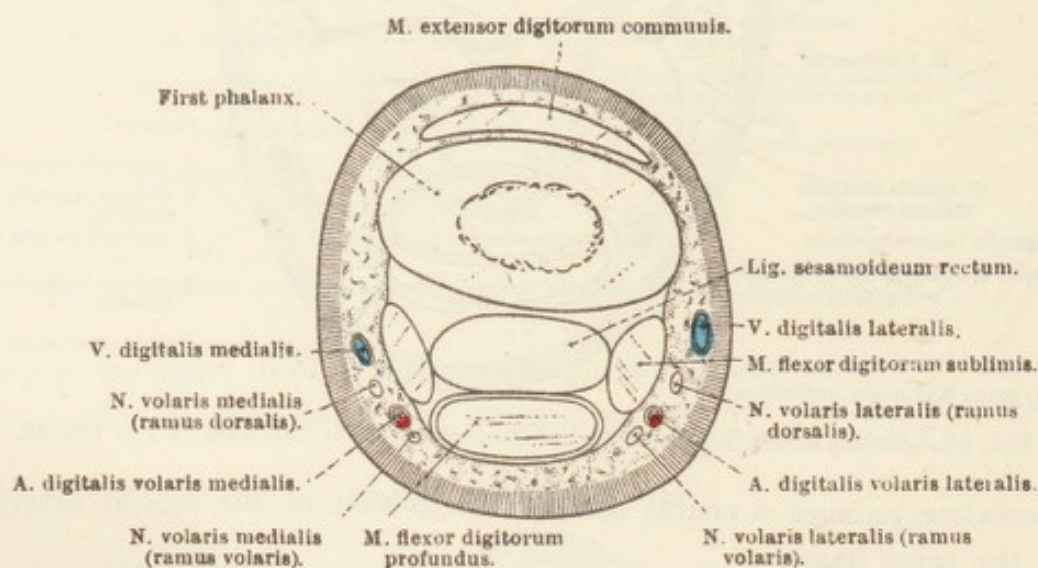


FIG. 45.—Section across the First Phalanx at the Level indicated by L in Fig. 30.

The *common digital artery* (a. digitalis communis) is the direct continuation of the median, and follows the medial border of the flexor tendons behind the carpus and metacarpus. As the level of the sesamoid bones is approached, the artery gains (approximately) the middle line of the limb by sinking between the middle interosseous muscle and the tendon of the deep flexor. Immediately proximal to the sesamoids the common digital divides into the *medial* and *lateral volar digital arteries* (aa. digitalis volaris medialis et lateralis).

Each volar digital artery follows the appropriate border of the flexor tendons, passes under the cartilaginous appendage of the third phalanx, and finally enters the volar foramen of the third phalanx. Both arteries contribute similar branches to the digit. Some of these are distributed on the dorsal, some on the volar aspect. Like branches of the two arteries anastomose with each other in the middle line of the limb, and thus produce a series of vessels that encircle the digit at different levels. Small twigs are also furnished for joints, tendons, "ergot," and skin.

The named branches of the digital arteries are as follows:—

(1) *Rami dorsales phalangis primæ*.—On a level with the middle of the first phalanx a dorsal branch arises from each digital artery and passes between the common extensor tendon and the bone. (2) *Rami volares phalangis primæ*.—At the same level as the foregoing, volar branches take origin and encircle the digit beneath the flexor tendons. Not infrequently the dorsal and volar rami arise from a short common trunk, the *artery of the first phalanx* (a. phalangis primæ). (3) *Aa. toricæ phalangis terciæ*.—Shortly distal to the preceding, small branches are given off by the digital arteries to be distributed mainly in the digital torus. The remaining branches of the digital arteries can only be examined properly during the dissection of the contents of the hoof. They are:—(4) *Rami dorsales phalangis secundæ*; (5) *rami volares phalangis secundæ*; (6) *aa. coroneales phalangis terciæ*; and (7) *aa. dorsales phalangis terciæ*.

DIGITAL VEINS.—When the contents of the hoof come to be examined, it will be found that the veins therein form a rich and close-meshed network. From this spring two veins (vv. digitalis medialis et lateralis) that accompany the digital arteries. It should be noted that each digital vein is dorsal to (*i.e.* in front of) the corresponding artery.

Between the flexor tendons and the middle interosseous muscle, and immediately proximal to the sesamoid bones, there is an anastomotic union of veins known as the *volar venous arch* (arcus venosus volaris). Connected with the arch are the digital veins on the one hand, and the veins of the metacarpus on the other.

VEINS OF THE METACARPUS.—(1) Beginning at the volar venous arch, the *common digital* (or medial metacarpal) *vein* (v. digitalis communis) is a companion of the like-named artery. At the carpus, however, its chief connection is with the origin of the cephalic vein of the forearm, though it is also connected with the median vein. (2) The *lateral volar metacarpal vein* (v. metacarpea volaris lateralis) accompanies the artery of the same name to the carpus. In this region it is connected with both the median and the collateral ulnar veins. (3) The *deep volar metacarpal vein* (v. metacarpea volaris profunda) is variable. Lying between the third metacarpal bone and the interosseous muscle, its main connection is with the median vein.

NERVES OF THE METACARPUS AND DIGIT.—At a variable point in the distal half of the forearm the median nerve divides into two terminal branches—the medial and lateral volar nerves. The *medial volar nerve* (n. volaris medialis) follows the common digital artery along the medial border of the flexor tendons down the back

of the carpus and through the metacarpal region. At the carpus the relative positions of the nerve and artery do not remain constant; but in the metacarpus the nerve lies behind the artery. In the metacarpus, therefore, the common digital vein, the common digital artery, and the medial volar nerve lie together in the order in which they are here enumerated, the vein being the most anterior of the three structures. About the middle of the metacarpus an oblique communicating branch from the medial volar nerve crosses the flexor tendons superficially to join the lateral volar nerve.

The *lateral volar nerve* (n. volaris lateralis) crosses the surface of the superficial flexor tendon obliquely in order to gain a more lateral position, and, under cover of the tendon of the flexor carpi ulnaris, is joined by the deep or terminal branch of the ulnar nerve. After this union, the volar nerve passes down the back of the carpus, partly embedded in the transverse ligament, and, on reaching the metacarpus, follows the lateral border of the flexor tendons, where it bears the same relations to the lateral volar metacarpal vein and a small branch of the lateral volar metacarpal artery as does the medial nerve to the common digital vessels. For surgical reasons it is necessary to remember that, while the medial volar nerve is accompanied by a large artery, the lateral nerve is related to a small one; and it is further to be noted that the medial nerve is forsaken by the common digital artery when this vessel sinks towards its termination just proximal to the sesamoid bones.

A deep branch of the lateral volar nerve arises behind the carpus, and terminates in numerous filaments that supply the three interosseous muscles. This nerve is of some moment inasmuch as it is responsible for the sensibility of the middle interosseous muscle (suspensory ligament); and apparently, like the volar nerve from which it arises, it contains fibres derived from both the ulnar and median nerves.

On a level with the metacarpo-phalangeal joint each volar nerve divides into two branches: (1) The *volar branch* (ramus volaris), the larger of the two, follows the posterior border of the digital artery, and will be found again during the examination of the contents of the hoof. (2) The smaller *dorsal branch* (ramus dorsalis) crosses the digital artery superficially, and runs along the side of the digit between the artery and its companion vein. This branch distributes filaments to the skin in front of the digit, and to the coronary matrix of the hoof.

It is worthy of observation that, at the middle of the first phalanx, there are commonly three nerves with an artery and vein in close

relation. Enumerated from behind forwards, these structures are as follows:—The volar ramus of the volar metacarpal nerve; the digital artery; the dorsal ramus of the nerve; the digital vein; a branch of the dorsal ramus of the nerve.

In the consideration of this region from the surgical point of view it is also necessary to remember that the volar and dorsal rami of each nerve are connected by anastomotic filaments, with the

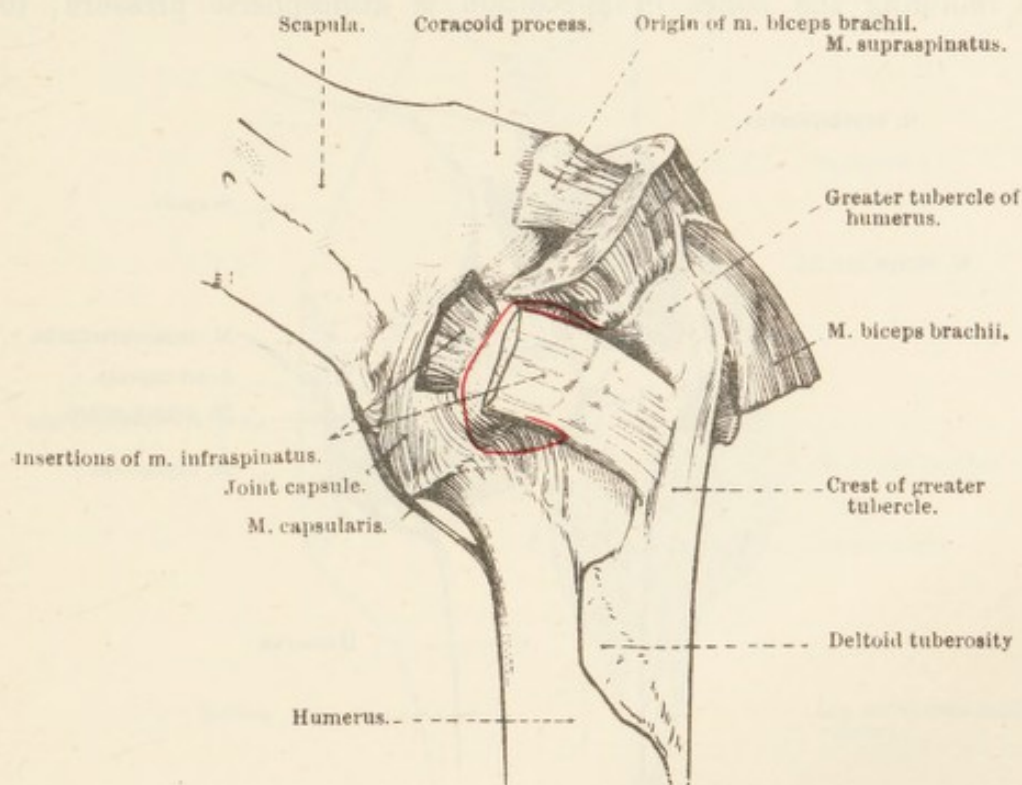


FIG. 46.—Lateral Aspect of the Shoulder Joint.

The red line indicates the extent of the synovial bursa between the lateral tendon of insertion of m. infraspinatus and the convex area of the greater tubercle of the humerus.

result that their areas of distribution are ill-defined and overlap each other. This confusion of territory is, however, more pronounced in front of the digit than behind; so that division of the volar ramus destroys sensation in the more volar structures contained within the hoof.

Dissection.—The dissector must now examine the articulations of the limb, with the exception of those between the three phalanges of the digit which will be dissected in connection with the contents of the hoof.

THE SHOULDER JOINT (articulatio humeri).—The bony surfaces entering into the formation of the shoulder joint are the glenoid cavity of the scapula and the head of the humerus. It is noteworthy that the glenoid cavity has scarcely more than half the area of the humeral head.

The necessity for many and powerful ligaments in connection with the joint is obviated by the presence of the numerous strong muscles that closely surround the articulation and hold the bones in their place. As has been previously noted, the thick insertions of the subscapular and infraspinous muscles act functionally as collateral ligaments; while the supraspinous, biceps, and triceps have bony attachments within a short distance from the joint. A further factor in retaining the bones in apposition is atmospheric pressure; for,

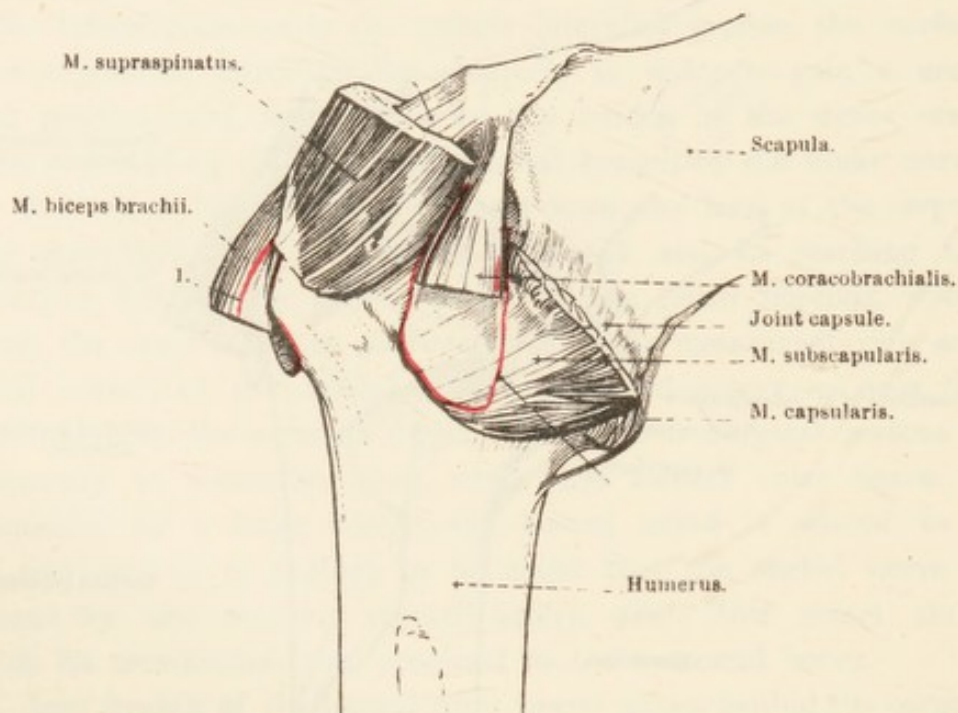


FIG. 47.—Medial Aspect of the Shoulder Joint.

1. = The line of attachment of synovial bursa of m. biceps brachii.
 2. = The line of attachment of synovial bursa of m. coracobrachialis.

though the bony surfaces are separated with difficulty so long as the joint capsule is intact, if an opening is made into the capsule the bones may be separated to the extent of 2 or 3 cm.

The only ligament connected with the joint is a *capsule* (capsula articularis) attached 1 or 2 cm. from the margins of the glenoid cavity of the scapula and the head of the humerus. The capsule is strengthened by elastic fibrous bands, notably so by one that springs from the base of the coracoid process of the scapula, and splits into two limbs that are attached to the greater and lesser tubercles of the humerus. On opening the capsule it will be observed that its synovial lining is not, in the horse, in any way connected with the synovial (mucous) sheath of the biceps tendon.

Although movement at the shoulder joint is possible in all directions, flexion and extension alone are of any marked degree of

freedom. Adduction and abduction are restricted by the subscapular and infraspinous insertions, and rotation and circumduction are limited by the other muscular attachments about the joint.

THE ELBOW JOINT (*articulatio cubiti*).—The term "elbow joint," strictly speaking, includes three joints, namely, the *humero-radial*

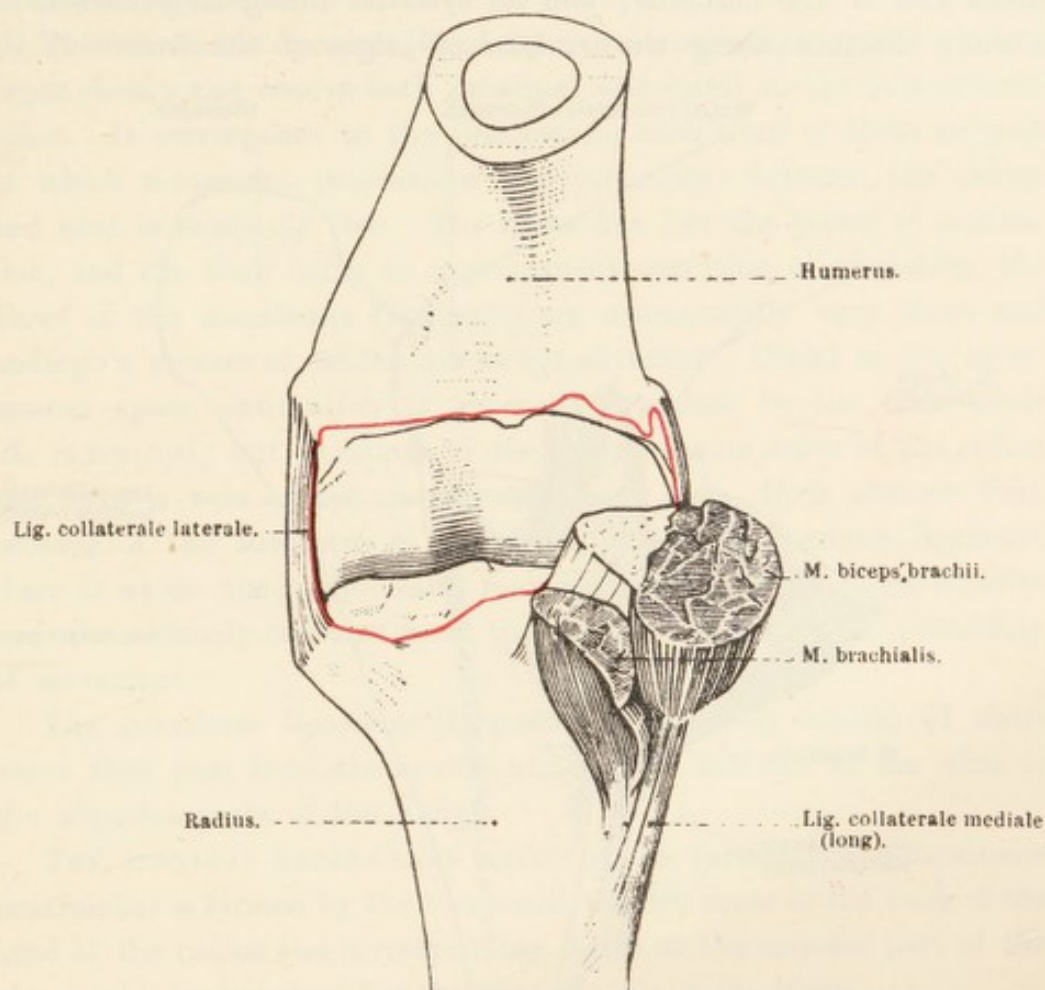


FIG. 48.—Anterior Aspect of the Elbow Joint.

The red line indicates the line of attachment of the synovial lining of the joint capsule.

articulation (*articulatio humeroradialis*), the *humero-ulnar articulation* (*articulatio humeroulnaris*), and the *proximal radio-ulnar articulation* (*articulatio radioulnaris proximalis*). In describing the joint of the horse it is convenient to include the union between the shafts of the radius and ulna as well.

The opposed bony surfaces of the humerus and the radius and ulna are so moulded and adapted to each other as to convince the dissector that movement in the joint can take place in one plane only. The presence of strong collateral ligaments contributes to the limitation of movement to flexion and extension.

The *joint capsule* (*capsula articularis*), attached to the articular margins of all three bones, is strongest on the extensor (anterior)

aspect of the joint, where it is reinforced by oblique fibres; but behind, where it is supported by the anconeus and triceps muscles, it is much weaker and more membranous. The capsule is very firmly adherent to the tendons of the various muscles that are inserted to the proximal end of the radius, and to those that take origin from the distal end of the humerus; and its synovial lining is continued for a short distance along the tendons of origin of the flexors of the

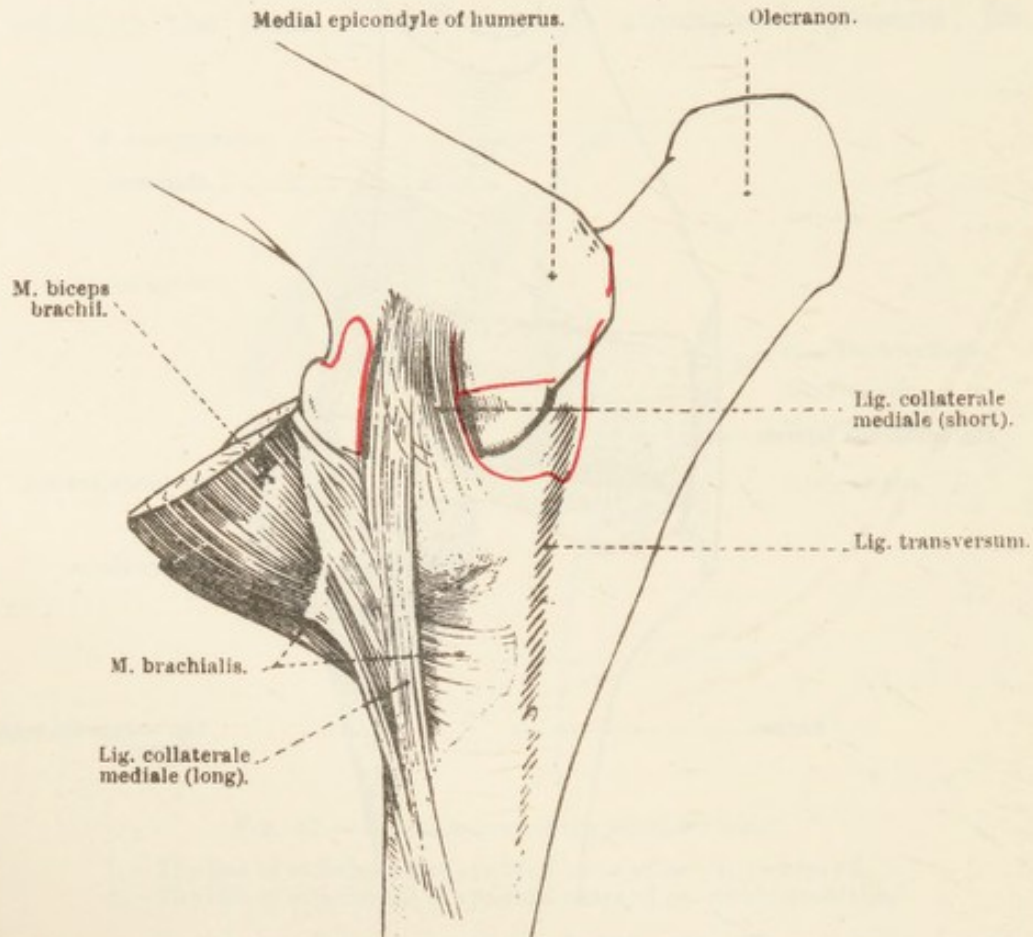


FIG. 49.—Medial Aspect of the Elbow Joint.

The red line indicates the line of attachment of the synovial lining of the joint capsule.

carpus and digit, as well as into the small articulations between the head of the radius and the ulna.

The *medial collateral ligament* (ligamentum collaterale mediale) springs from the depression and prominence close to the articular margin of the humerus, and is divisible into two parts. The longer and more superficial (and more anterior) portion is attached to the medial border of the shaft of the radius; while the shorter, stronger, deeper, and more posterior part of the ligament ends on the prominence at the medial part of the head of the radius. The most distal fibres of the tendon of insertion of the brachialis muscle pass between the two parts of the ligament.

The *lateral collateral ligament* (ligamentum collaterale laterale) is by far the stronger—as it is also the shorter—of the two ligaments. It arises from a depression on the humerus, and ends on the prominence at the lateral part of the head of the radius.

The firm union of the radius and ulna is effected by interosseous and transverse ligaments.

The *interosseous ligament* (ligamentum interosseum) connects the two bones closely and occurs both proximal and distal to the interosseous space. It corresponds to the interosseous membrane of those animals in which movement (supination and pronation) between the radius and ulna is relatively free. The horse has lost the power of supination, and the limb being in a permanent condition of pronation, the fibres of the membrane (ligament) are consequently very short and undergo a process of ossification as age advances. Distal to the interosseous space, ossification is generally complete by the time adult life is reached; but proximal to the space, osseous union of the radius and ulna is rare except in very advanced age. It is obvious that, because of the shortness of the fibres of the interosseous ligament, there is at no time appreciable movement between the horse's radius and ulna: clearly ossification of the ligament abolishes all possibility of movement.

The *transverse ligaments* (ligamenta transversa) consist of short fibres that pass from the medial and lateral surfaces of the ulna to the adjacent parts of the radius.

THE PROXIMAL RADIO-ULNAR ARTICULATION (articulatio radioulnaris proximalis) is formed by the two small, smooth areas at the back of the head of the radius and corresponding facets on the opposed part of the ulna, and is included within the joint capsule of the elbow.

In the adult horse there is little or no trace of a DISTAL RADIO-ULNAR ARTICULATION (articulatio radioulnaris distalis), because the distal end (head) of the ulna, having become detached from the rest of the bone, has fused with the distal end of the radius.

THE CARPAL ARTICULATIONS (articulatio carpi).—The carpal joint is a complex collection of articulations between the distal end of the radius, the individual carpal bones, and the bases of the three metacarpal bones. In consequence, the whole joint may be divided as follows: (1) The *radiocarpal articulation* (articulatio radiocarpea), (2) the *intercarpal articulation* (articulatio intercarpea) between the two rows of carpal bones, (3) *interosseous articulations* (articulationes interosseæ) between the members of the same row of carpal bones, and (4) the *carpometacarpal articulation* (articulatio carpometacarpea).

Before examining the ligaments that bind the bones together, the

dissector should satisfy himself as to the range and nature of the possible movements. Obviously the arrangement itself of the bones points to the hinge-like character of the combined articulations. The most free movement is clearly one of flexion and extension; but this, it must be remembered, is the result of the sum of the movements between the radius and the carpus, and between the two rows of carpal bones—the former contributing more than the latter. Between the distal row of bones and the bases of the metacarpals there is no

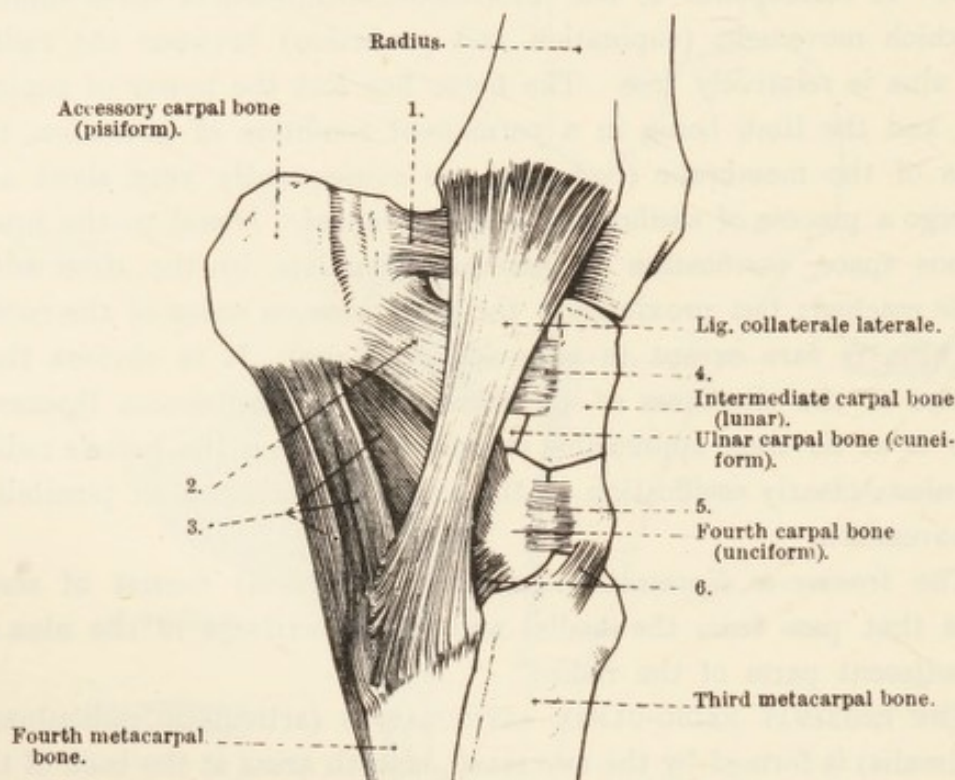


FIG. 50.—Lateral Aspect of the Carpal Articulations.

1. = Ligament from accessory carpal bone to radius.
2. = Dorsal ligament from accessory carpal to ulnar carpal bone.
3. = Ligament from accessory carpal to fourth carpal and fourth metacarpal bones.
4. = Dorsal ligament connecting ulnar and intermediate carpal bones.
5. = Dorsal ligaments connecting third and fourth carpal bones.
6. = Dorsal ligaments connecting third and fourth carpal bones to third and fourth metacarpals.

movement of a nature that would add to flexion and extension, ligaments being so disposed as to prevent more than a limited amount of gliding of one bone over another.

The movement of flexion is accompanied by the gliding of one carpal bone over its neighbour; especially is this the case between the different members of the proximal row.

Under normal conditions it is doubtful if there is any movement of abduction and adduction in the carpal articulations themselves; though, owing to the form of the bony surfaces, the distal part of the limb is slightly abducted during flexion.

The ligaments of the carpal joint may be classified as (1) those common to the whole series of articulations, (2) those joining two or three bones together, and (3) those particularly connected with the accessory (pisiform) bone.

The common ligaments consist of a joint capsule and two collaterals.

Joint capsule (capsula articularis).—The fibrous layer of the capsule is of considerable thickness, especially on the volar aspect of the carpus. It is attached to the radius close to its articular margin, the dorsal and

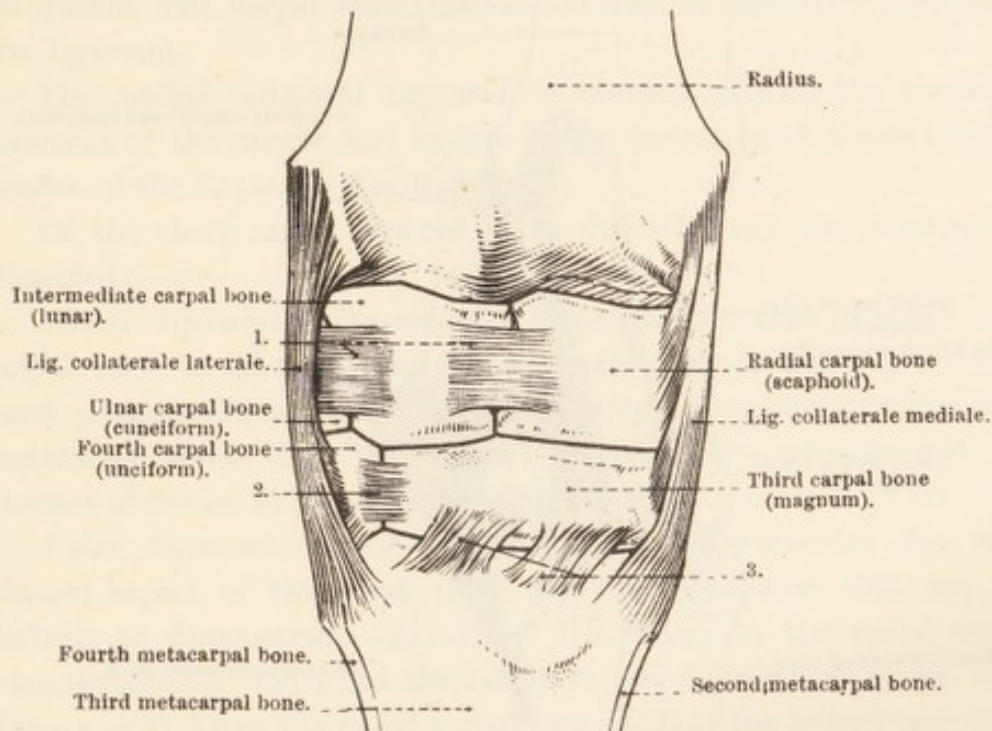


FIG. 51.—Dorsal (anterior) Aspect of the Carpal Articulations.

1. = Dorsal ligaments connecting the bones of the proximal row.
2. = Dorsal ligament connecting the third and fourth carpal bones.
3. = Dorsal ligaments connecting the third carpal and third metacarpal bones.

volar surfaces of the carpal bones and their associated short ligaments, and the bases of the metacarpal bones. On the extensor (dorsal) aspect of the carpus the capsule is connected with the fascia of the forearm, and helps to bind down those extensor tendons that cross the carpus. In accordance with the range of movement in the radiocarpal and intercarpal articulations, the capsule is roomy on this face of the carpus.

On the flexor (volar) aspect of the joint the capsule assists the transverse carpal ligament in the formation of a short canal in which the flexor tendons are contained, and is, consequently, covered by the synovial (mucous) sheath of the tendons. It should be noted that the great strength of this portion of the capsule is important as a check to over-extension of the joint. Its connection with the tendinous head of the deep flexor is also of some physiological moment.

The synovial lining of the joint capsule is divided into three parts in agreement with the three articulations over which the capsule extends. Its radiocarpal part is most extensive, lubricates the radiocarpal joint, and is continuous with the articulations of the accessory carpal (pisiform) bone. It also lubricates the articulations between the neighbouring bones of the proximal row above the interosseous ligaments. The intercarpal part of the synovial lining lubricates the

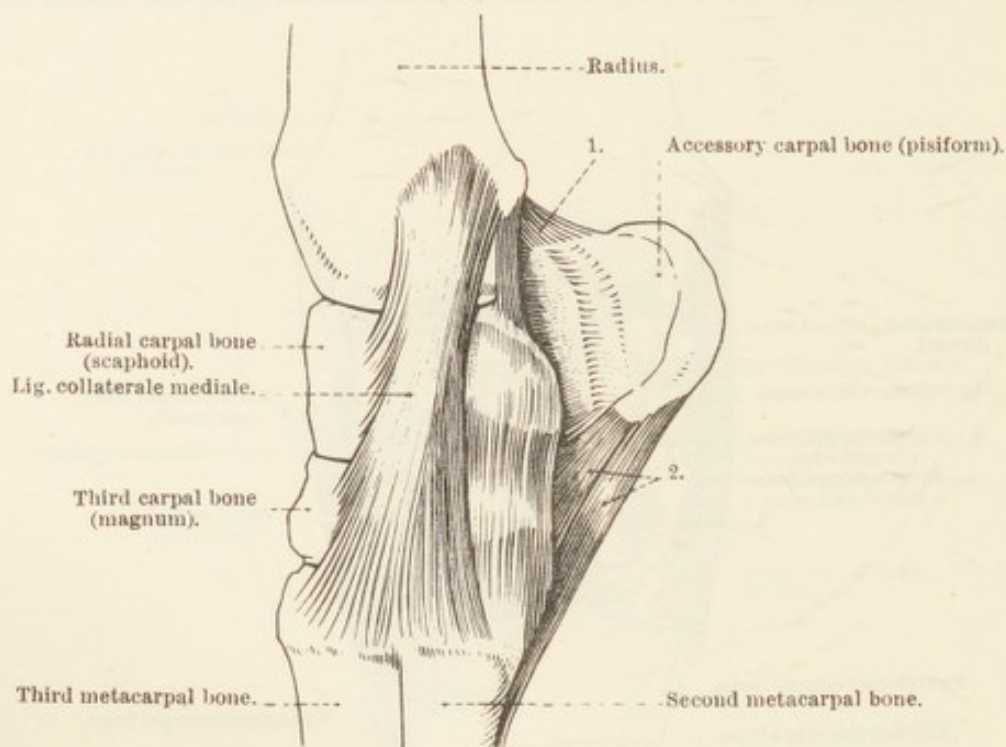


FIG. 52.—Medial Aspect of the Carpal Articulations.

1. = Ligament from accessory carpal bone to radius.
2. = Ligament from accessory bone to fourth carpal and fourth metacarpal bones.

articulations between the two rows of bones, and extends between the individual bones of a row as far as the interosseous ligaments. The least extensive part (carpometacarpal) of the synovial lining is that connected with the carpometacarpal articulation, the intermetacarpal articulations, and the small joints between the members of the lower row of carpal bones distal to the interosseous ligaments. The interior of the intercarpal and carpometacarpal sacs intercommunicate by a small passage between the third (magnum) and fourth (unciform) carpal bones.

Lateral collateral ligament (ligamentum collaterale laterale).—The fibres of the lateral collateral ligament spring from the projecting lateral part of the end of the radius, and are attached to the ulnar carpal bone (cuneiform), fourth carpal bone (unciform), and the base of the fourth metacarpal bone. A few of the more superficial fibres

end on the third metacarpal bone. The ligament is pierced by a short canal containing the tendon of the extensor digiti quinti.

Medial collateral ligament (ligamentum collaterale mediale).—The medial collateral ligament has a concentrated origin from the projection on the medial side of the end of the radius. By somewhat divergent fibres it is attached to the radial carpal bone (scaphoid), first, second and third carpal bones (trapezium, trapezoid, and magnum), and the bases of the second and third metacarpal bones. The variable and inconstant first carpal bone (trapezium) may be entirely embedded in the ligament.

The medial collateral ligament is continuous with the transverse ligament of the carpus, and assists in the formation of a canal for the tendon of the flexor carpi radialis.

Of the short carpal ligaments the following are the most readily dissected:—

Dorsal ligaments (ligamenta intercarpea dorsalia) connect each carpal bone to its neighbour in the same row. In addition, a double band passes obliquely from the third carpal (magnum) to the third metacarpal bone. This is of some importance in connection with the absence of flexion in the carpometacarpal joint.

Volar ligaments (ligamenta intercarpea volaria).—On the volar (flexor) aspect of the joint there are four ligaments that are not difficult to demonstrate. (1) From the radius to the radial carpal bone (scaphoid). (2) From the radius to the intermediate carpal bone (lunar). (3) From the radial carpal (scaphoid) to the second and third carpal bones (trapezoid and magnum). (4) From the ulnar carpal (cuneiform) to the third and fourth carpal (magnum and unciform) bones.

Interosseous ligaments (ligamenta intercarpea interossea) are attached to the depressed areas on the opposed surfaces of the bones in the same row; and two of them connect the bones of the distal row with the three metacarpals.

The accessory carpal (pisiform) bone is held in position by four ligaments. (1) A band from the radius. (2) A dorsal ligament attached to the ulnar carpal (cuneiform) bone. (3) A strong ligament divided into two limbs and connected with the fourth carpal (unciform) and fourth metacarpal bone. (4) A volar band attached to the ulnar carpal (cuneiform) and intermediate carpal (lunar) bones.

THE INTERMETACARPAL ARTICULATION (articulatio intermetacarpea).—The bases of the three metacarpal bones are provided with small, smooth areas lubricated by the secretion of the synovial layer of the carpal joint capsule. For the rest, the second and fourth bones are

closely united to the third metacarpal by *interosseous ligaments* (ligamenta interossea), the short fibres of which generally become ossified as age advances.

THE METACARPOPHALANGEAL ARTICULATION (articulatio metacarpophalangea).—The head of the third metacarpal bone possesses an articular surface composed of two convexities separated by an antero-posterior ridge. These three parts together form a continuous smooth area the width of which increases towards the back (volar part) of the joint. The proximal end of the first phalanx is closely moulded upon the head of the metacarpal bone. At the back of the joint the two sesamoid bones (of the first phalanx) together form a continuation of the articular surface of the first phalanx; but it should be remembered that, in the horse, there is no direct contact between the sesamoids and the phalanx.

The *joint capsule* (capsula articularis) in front of the joint is supported by and connected with the tendons of the digital extensors. On the flexor aspect of the joint it is attached to the articular margins of the third metacarpal and sesamoid bones, and has a pocket-like extension insinuated between the modified interosseous muscle and the third metacarpal bone. If the capsule becomes pathologically distended, the support afforded by tendons and ligaments is so disposed that a bulging can only take place through the interval between the two limbs of the interosseous muscle. From the circumstance that the flexor tendons lie superficial to this interval, it follows that more marked distension must of necessity make itself manifest on each side of the limb, between the flexor tendons and the interosseous muscle immediately proximal to the sesamoid bones.

The *lateral* and *medial collateral ligaments* (ligamentum collaterale laterale: mediale) are stout bands springing from the depressions at the side of the head of the third metacarpal bone. Each ligament is composed of superficial fibres attached close to the articular margin of the first phalanx, and a deep and stronger set of fibres inserted to the sesamoid bones and the angular projection at the base of the phalanx.

On cleaning the surface of the collateral ligaments, the dissector will observe that a sheet of oblique fascial fibres covers them and the joint capsule on the dorsal face of the joint.

An exceedingly dense *inter-sesamoid*¹ *ligament* (ligamentum inter-sesamoideum) binds the two sesamoid bones together, and extends

¹ *Sesamum* [L.], σήσαμον (sēsamon) [Gr.], sesame (the plants *Sesamum indicum* and *S. orientale* carry oil-yielding seeds). εἶδος (eidos) [Gr.], form. The sesamoid bones of the smaller mammals resemble sesame seeds.

beyond their proximal limit. The surface of the ligament and the adjoining surfaces of the sesamoids are covered by a veneer of fibro-cartilage, and thus form a smooth, oval, groove-like area over which the deep flexor tendon plays.

The *lateral and medial sesamoid ligaments* (ligamentum sesamoideum laterale: mediale) are partly covered by the lateral and medial collateral ligaments and the limbs of the interosseous muscle. When these have been reflected, the sesamoid ligaments are disclosed as short bands passing from the sesamoid bones to the third metacarpal bone and the first phalanx.

The *straight sesamoid ligament* (ligamentum sesamoideum rectum) is a strong band springing from the bases of the two sesamoid bones, and, narrowing somewhat, running down the volar aspect of the first phalanx to be attached to the complementary cartilage of the second phalanx between the two limbs of the tendon of the superficial flexor with which it is intimately connected. The straight ligament must be cut across, and raised from the oblique ligaments which it partly covers, and with which some of its fibres are blended.

The *oblique sesamoid ligaments* (ligamenta sesamoidea obliqua) are attached to the bases of the sesamoid bones and to the V-shaped line on the volar surface of the first phalanx.

If the oblique ligaments are reflected, the *cruciate sesamoid ligaments* (ligamenta sesamoidea cruciata) are brought into view. Each of these is flattened, and consists of short fibres running from the base of a sesamoid bone to the back of the proximal part of the first phalanx, crossing the fibres of the fellow ligament in the middle line of the digit.

Still deeper ligamentous fibres (ligamenta sesamoidea brevia) may be revealed on examination of the joint from within. These are few in number and oblique in direction, and are attached to the sesamoids and the first phalanx close to the articular margin.

From the character of the bony surfaces and the disposition of the ligaments, it is evident that the movements in the metacarpophalangeal joint are limited to flexion and extension. The dissector cannot fail to observe that, when the weight of the body is borne by the limb, the long axes of the metacarpus and the first phalanx are not in the same line, and that the condition of the joint might be described as one of over-extension. He will also notice that a greater degree of over-extension is prevented by the attachments of the structurally modified interosseous muscle to the sesamoid bones, and the morphological extension of the muscle to the first and second phalanges by the ligaments distal to the sesamoids. In brief, the interosseous muscle

has taken on both a ligamentous structure and a ligamentous function—a modification to be associated with the circumstance that the horse walks on the tip of the third digit.

THE HOOF AND ITS CONTENTS.

Seeing that, without considerable injury to soft structures, it is well-nigh impossible to remove the hoof from a limb that has been prepared for dissection as a whole, the dissector should obtain a special specimen in which the hoof has already been removed.

During the whole of his dissection the student should keep certain facts clearly in view. The “foot,” as the hoof and the structures contained therein are commonly comprehensively named, is the distal part of the digit, and all the component parts thereof have been modified for two purposes. In the first place, the extremity of the digit is protected from injury by a dense, horny covering—the hoof—which is merely a specially thickened portion of the epidermis. Secondly, the hoof and everything in it (except vessels and nerves) are capable of absorbing and diminishing shock.

The skeleton of the “foot” consists of part of the second phalanx, the whole of the third phalanx with its cartilaginous appendages (ungual cartilages), and the sesamoid bone of the third phalanx. These, with the elastic digital torus, form a basis to which modified skin is attached. The skin, here as elsewhere, consists of a highly vascular corium or dermis and epidermis. The greatly thickened epidermis forms the hoof or ungula, for which the corium provides a matrix.

Although the name *matrix* is applied to the corium in the foot, this should not lead the student into the error of supposing that it plays any part, except that of providing nourishment, in the formation and growth of the hoof. The hoof, being epidermis, grows from its own deepest layer, or stratum germinativum, in the same manner as the epidermis in any other region of the body.

The dissector will do well to begin his examination with the corium or matrix.

THE MATRIX (*matrix ungulæ*¹).—The highly vascular matrix of the hoof differs from the corresponding stratum of ordinary skin in several respects. It contains no sebaceous glands, and sweat glands are comparatively few and of limited distribution. Its papillæ are large, and, in one region, modified so as to form ridges. Subcutaneous

¹ *Matrix* [L.], the womb, the form or mould in which something is shaped, from *mater*, mother. *Unguis* [L.], nail.

tissue, such as is present beneath the skin in general, is absent, with the result that the matrix is firmly adherent to the skeleton

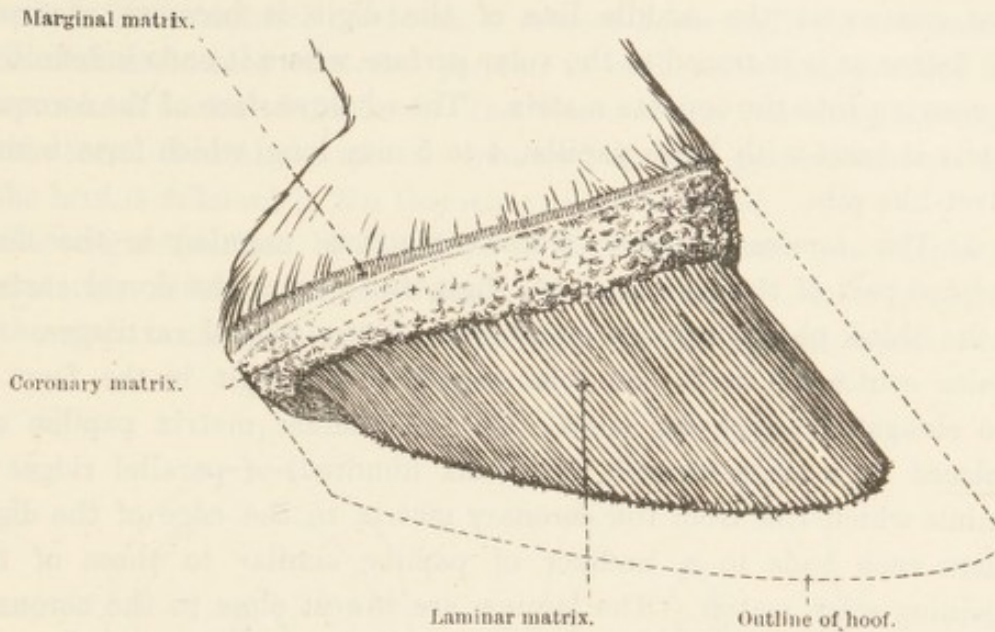


FIG. 53.—Lateral Aspect of the Matrix of the Hoof.

of the digit. From custom and convenience the matrix is divided into certain regions.

1. The *marginal matrix* (*margo*¹ *matricis ungulæ*) forms a narrow

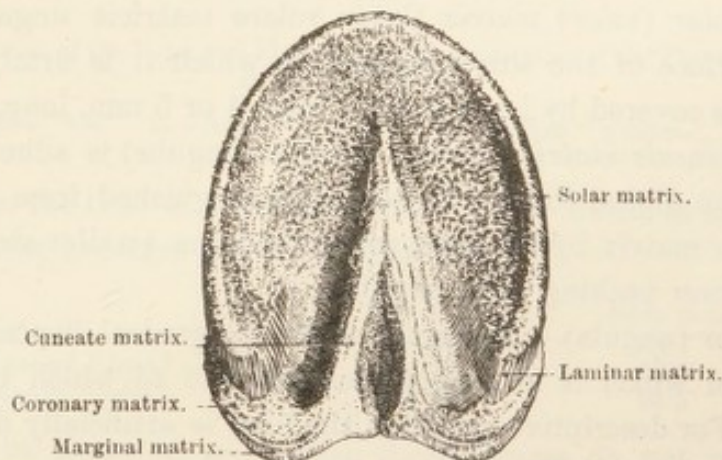


FIG. 54.—Volar Aspect of the Matrix of the Hoof.

band, about 5 mm. wide, at the junction of the matrix and the ordinary skin of the digit. Each end of the band is continuous with the matrix covering the digital torus, and its surface is studded with papillæ that are smaller than those of the adjacent part of the matrix.

2. The *coronary matrix* (*corona*² *matricis ungulæ*) is immediately adjacent to the foregoing, from which it is separated by a shallow

¹ *Margo* [L.], an edge or border.

² *Corona* [L.], a crown, something crown-like.

and narrow groove only. In the form of a bulging band, this part of the matrix encircles the digit almost completely. Broadest and most convex at the middle line of the digit, it becomes narrower and flatter as it is traced to the volar surface, where it ends indefinitely by merging into the cuneate matrix. The whole surface of the coronary matrix is beset with large papillæ, 4 to 5 mm. long, which form a soft, velvet-like pile.

3. The *laminar matrix* (*latus*¹ *matricis unguæ*) is the most modified part of the corium of the digit, and covers the dorsal surface of the third phalanx and a small part of the ungual cartilages. It is also continued on to the volar aspect of the digit in the form of two elongated triangular areas. On the laminar matrix papillæ are replaced by a large number (about six hundred) of parallel ridges or laminae which run from the coronary matrix to the edge of the digit, where each ends in a number of papillæ similar to those of the adjoining solar matrix. The laminae are lowest close to the coronary matrix, from which point they gradually increase in height until a maximum is reached about the middle of their length. If the laminae are examined microscopically, it will be seen that the surface of each carries a considerable number of smaller ridges or secondary laminae.

4. The *solar (volar) matrix* (*latus volare matricis unguæ*) covers the volar surface of the third phalanx, to which it is firmly attached. Its surface is covered by large papillæ some 4 or 5 mm. long.

5. The *cuneate matrix* (*cuneus matricis unguæ*) is adherent to the surface of the digital torus. It can be distinguished from the neighbouring solar matrix by its paler colour and the smaller size (1-2 mm. long) and closer packing of its papillæ.

THE HOOF (*ungula*).—The hoof follows the general disposition of the matrix, upon which it is closely moulded and to which it is firmly adherent. For descriptive purposes the hoof is artificially divided into three parts—the wall, the sole, and the “frog.”

1. The *wall* (*paries unguæ*) is that part of the hoof which is visible when the limb is in a state of rest, and has tapering continuations (“bars”) inflected on to the volar aspect of the digit. For topographical reasons it is convenient to divide the wall into “toe” (*paries unguæ dorsalis*), “quarters” (*paries unguæ medialis: lateralis*), and “heels” (*paries unguæ volaris s. plantaris*); but this division has no morphological foundation.

If the wall could be flattened out it would present a crescentic outline, the horns of the crescent being represented by the abruptly

¹ *Latus* [L.], the side (exposed part).

inflected parts or "bars." The wall, therefore, presents two surfaces and two borders for consideration. The outer surface is convex from side to side, and, in the natural condition, is crossed horizontally by a number of incremental lines that run parallel to each other and parallel to the proximal border of the hoof. The curve of the convexity is wider at the lateral than at the medial "quarter," and the general conformity of the hoof is different in the thoracic and pelvic limbs.

The angle described by the slope of the wall and the ground plane is obviously different at the "toe" and the "heels." It is greater, *i.e.* the slope is steeper, on the medial than on the lateral aspect, and

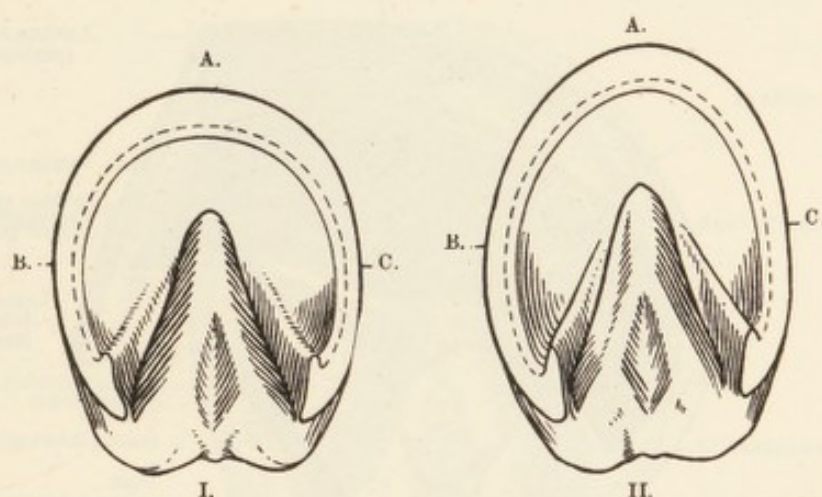


FIG. 55.—Outline of the Volar and Plantar Aspects of the Hoof of the Thoracic (I.) and Pelvic (II.) Limbs.

A. = "toe." B. = lateral "quarter." C. = medial "quarter."

also differs in the hoof of the thoracic and pelvic limbs, as is indicated in the following averages given by Lungwitz:—

	Thoracic limb.	Pelvic limb.
"Toe"	47·26°	54·1°
Lateral "heel"	101·37°	96·1°
Medial "heel"	101·57°	96·5°

It must be borne in mind that these figures do not necessarily apply to any particular specimen. There is a notable variation in the general form and angles of the hoof of apparently perfectly normal feet.

The length of the wall, *i.e.* the distance between the two borders, at the "toe," "quarter," and "heel," may be indicated by the ratios 3:2:1 for the hoof of the thoracic limb, and 2:1½:1 for the hoof of the pelvic limb.

In the neighbourhood of the coronet the outer surface of the hoof is covered by a thin layer of very elastic horn (*limbus ungulæ*)—connected with the marginal matrix—polished and glistening when dry, but whitish, swollen, and fibrous when moist.

The inner surface of the wall is laminated in conformity with the lamination of that part of the matrix to which it is applied. In the natural state the laminæ (*cristæ ungulæ*) of the hoof occupy the intervals between the laminæ of the matrix. Though to the naked eye the laminæ appear simple, under magnification each surface of every lamina is found to carry secondary laminæ which interdigitate with corresponding secondary ridges of the laminar matrix.

The coronary border (*margo occultus*) of the wall gradually thins away, because of the presence of a groove into which the coronary

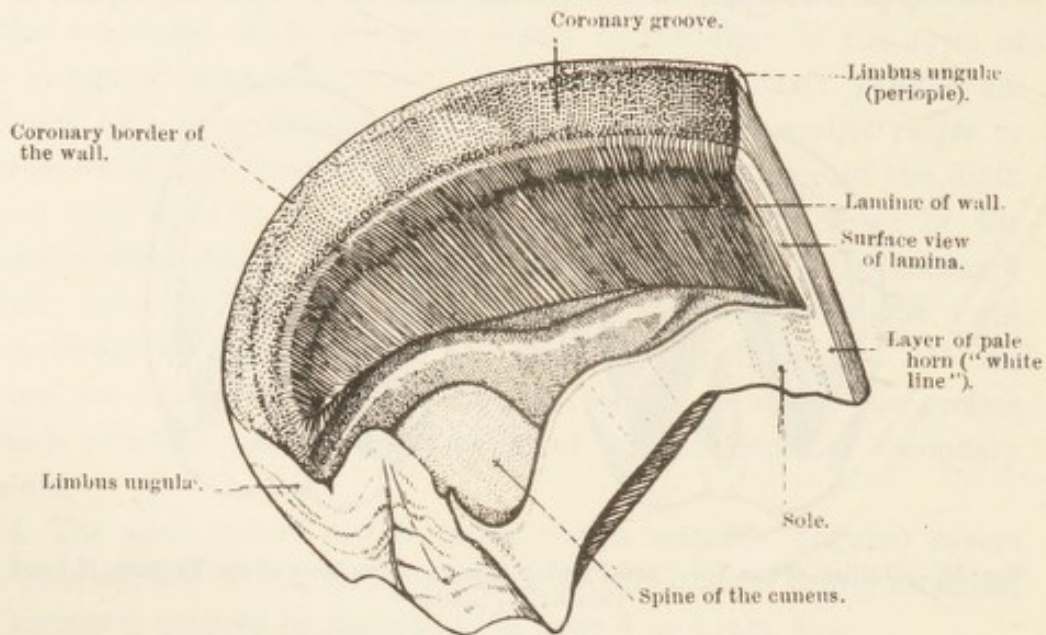


FIG. 56.—Inner Surface of the Hoof.

matrix is received. The groove is closely punctated with small holes into which the papillæ of the matrix are received.

The free border (*margo liber*) in the unshod animal comes into contact with the ground, and has a more or less ragged appearance due to destruction of the hoof by friction and attrition. The thickness of the border is greatest at the "toe" (about 10 mm.), and gradually becomes less towards the "heel," where it is barely half that of the "toe." The free border is connected with the margin of the sole of the hoof by a definite line of pale and relatively soft horn.

The inflected part (*pars inflecta*, "bar") of the wall forms a gradually tapering ridge on the volar aspect of the digit, between the sole and the cuneus ("frog").

2. The *sole* (*solea ungulæ*) is a strong plate of horny tissue applied to the solar (volar) matrix, and indented by a deep triangular notch into which are fitted the inflected parts of the wall and the "frog." Speaking generally, therefore, the sole may be said to have a crescentic

outline, and may be divided into a body and two rami or cornua. Its convex or greater border is connected with the wall by the comparatively soft and elastic layer of horn to which reference is made above.

The free surface of the sole is more or less concave, the degree of concavity depending in some measure on the breed of the animal; but the hollow always contains flakes of horn that are in process of being shed. The inner surface is pitted with small holes for the reception of the papillæ of the solar matrix, and is convex in form with the highest point of the dome close to the apex of the "frog." The curvature of the sole is greater in the pelvic than in the thoracic limb.

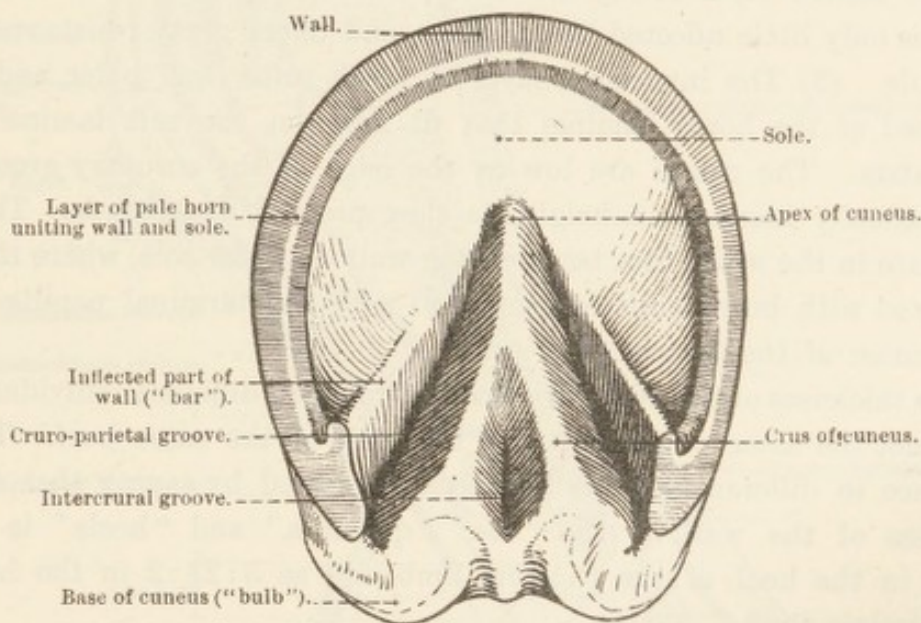


FIG. 57. — Volar Aspect of the Hoof.

3. The *cuneus*¹ or "frog" (*cuneus ungulæ*) may be best described as having four surfaces. The inner or upper surface presents two grooves, converging and meeting in front, with an abruptly sloping projection or spine (*spina cunei ungulæ*) between them. The whole of this surface is pitted with minute holes into which the papillæ of the cuneate matrix are received.

The free surface of the cuneus is triangular in form, and carries two ridges or crura (*crura cunei ungulæ*) that converge and meet in front at the apex (*apex cunei ungulæ*). Between the crura is the deep intercrural groove (*sulcus intercruralis*) corresponding in position to the spine on the upper surface, and, therefore, deepest posteriorly, with a rapidly shelving anterior part. The medial and lateral surfaces are partly connected with the sole and the inflected parts of the wall, and partly free where they help to bound the cruro-parietal grooves (*sulci*

¹ *Cuneus* [L.], a wedge.

cruro-parietales). The base of the cuneus is posterior and forms two eminences separated from each other by a continuation of the intercrural groove.

The dissector should make sections of the hoof by means of a saw in order that he may compare the thickness of the different parts. The same method will permit him to determine the strata of the wall.

Three layers can be distinguished in the wall. (1) The most superficial is the thin, incomplete, glistening layer already described as being present at the limbus unguis. Because of its density and glassy or varnish-like appearance it has been called the vitreous layer. (2) The second layer forms the dense and hard portion of the wall, which is only little affected by moisture and offers great resistance to the knife. (3) The innermost layer is much softer and paler, and is composed of the horny laminae that fit between the soft laminae of the matrix. The ridges are low at the edge of the coronary groove, but gradually increase in height as they proceed distalwards. They terminate in the white line between the wall and the sole, where they are mixed with horny tubules connected with the terminal papillae of the laminae of the matrix.

The thickness of the wall varies considerably in different individuals, and is not the same in all parts of the wall of the same hoof. The difference in different regions has been expressed by saying that the thickness of the wall at the "toe," "quarters," and "heels" is as 4:3:2 in the hoof of the thoracic limb, and as $3:2\frac{1}{2}:2$ in the hoof of the pelvic limb.

The thickness of the sole may range from 7 to 10 mm.; while that of the "frog" is from 10 to 15 mm.

The relative density and rigidity of the hoof in different regions are of moment from the physiological point of view. The oldest horn, *i.e.* that at the extreme end of the "toe," is most rigid and least yielding; whereas pliability, though nowhere very great, increases in all parts of the wall as the coronary border is approached. The horn of the sole is less rigid than that of the wall, and the "frog" is composed of the softest and most pliable horn of the whole digit. The presence of a layer of comparatively flexible horn at the junction of the sole and the wall permits a certain amount of movement at this place.

THE DIGITAL TORUS (*torus digitalis*).—The digital torus¹ is a pyramidal mass of fibrous and elastic tissue placed between the "frog" and the tendon of the deep flexor muscle. Each side of the base of the torus is intimately connected with one of the cartilages of the

¹ *Torus* [L.], a bulge, protuberance, or prominence.

third phalanx. Its deep (dorsal) surface slopes from above downwards and forwards in conformity with the obliquity of the deep flexor tendon close to its insertion. Between the torus and the tendon

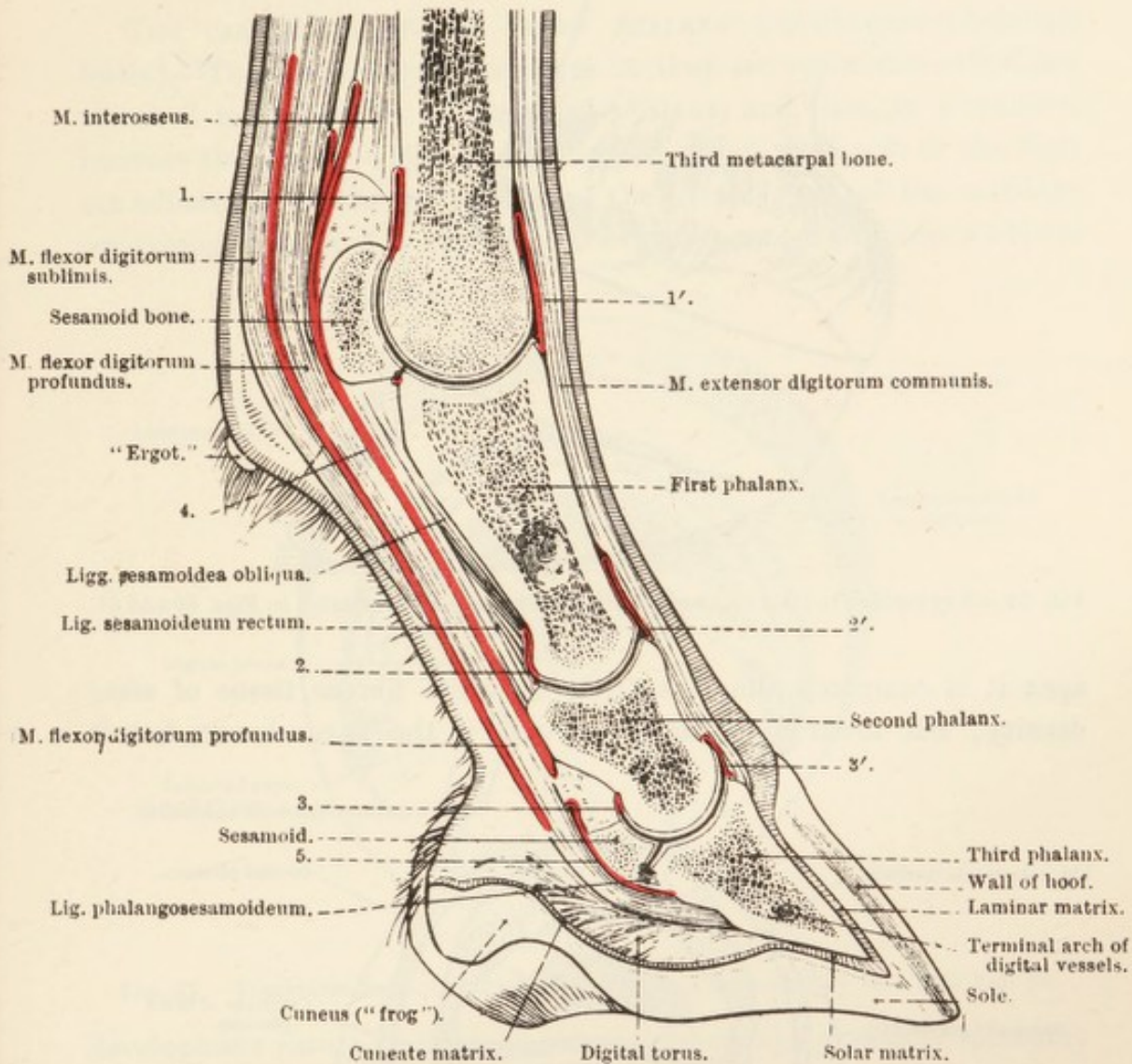


FIG. 58.—Longitudinal Section of the Digit.

1 and 1', 2 and 2', 3 and 3'.=Joint capsules of the metacarpo-phalangeal, proximal interphalangeal, and distal interphalangeal articulations respectively. 4.=Synovial sheath of the flexor tendons. 5.=Synovial sheath of the deep flexor tendon.

there is a fascial sheet that is proximally connected with the first phalanx.

The more superficial (volar) surface of the torus is almost horizontal when the weight of the body rests on the limb. It is covered by the cuneate part of the matrix, and upon this surface the cuneus ("frog") is moulded. Two diverging ridges bound a cleft into which the spine of the "frog" fits. The ridges blend in front, and behind they end in two rounded eminences that constitute the base or bulbs of the torus. The apex of the torus is firmly adherent to the insertion of the deep

flexor tendon and the periosteum of the third phalanx immediately in front of the semilunar crest.

The structure of the torus is not uniform throughout. Towards the

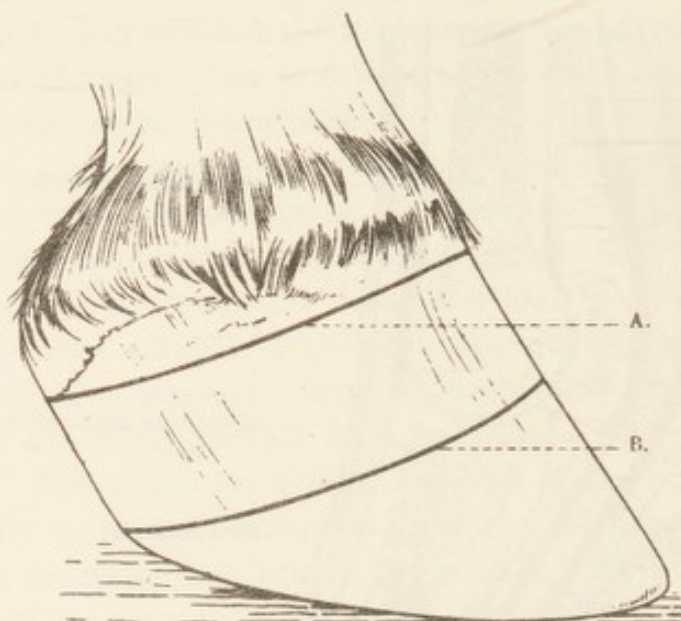


FIG. 59 — Key Outline to Indicate the Position of the Sections Illustrated in Figs. 60 and 61.

apex it is composed almost entirely of white fibrous tissue of some density; but towards the base, not only is the tissue looser, but it

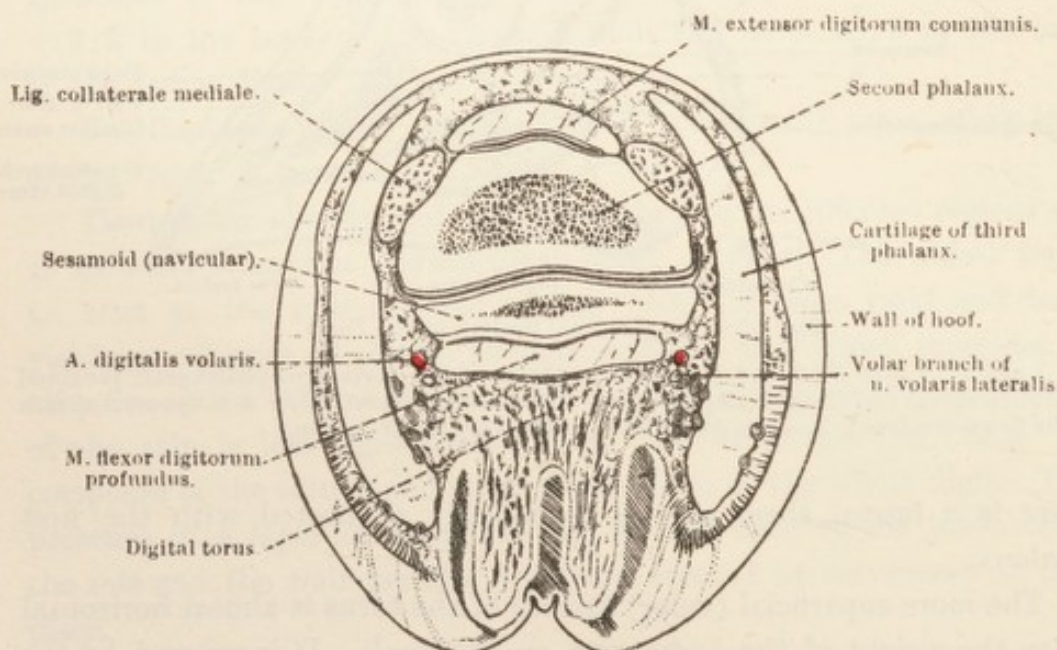


FIG. 60. — Transverse Section of the Foot at the Level Indicated by Line A in Fig. 59.

contains a considerable amount of fat. The presence in it of modified skin-glands seems to indicate that the torus is subcutaneous tissue specially thickened and structurally adapted to absorb shock.

Dissection.—The digital torus should be removed entirely, and the two surfaces of the ungual cartilages exposed and cleaned. In conducting this operation the dissector must preserve the arteries and nerves of the region, and, at the same time, observe the venous plexuses from which the digital veins take their origin.

THE CARTILAGES OF THE THIRD PHALANX (*cartilagine phalangis tertia*).—These, the ungual cartilages as they are sometimes called, are attached to the angles of the third phalanx, and thus, in a manner, increase the area to which the matrix and other soft parts of the digit are adherent. In the young animal the greater part of the cartilage composing them is of the hyaline variety; but, as age advances a fibrous

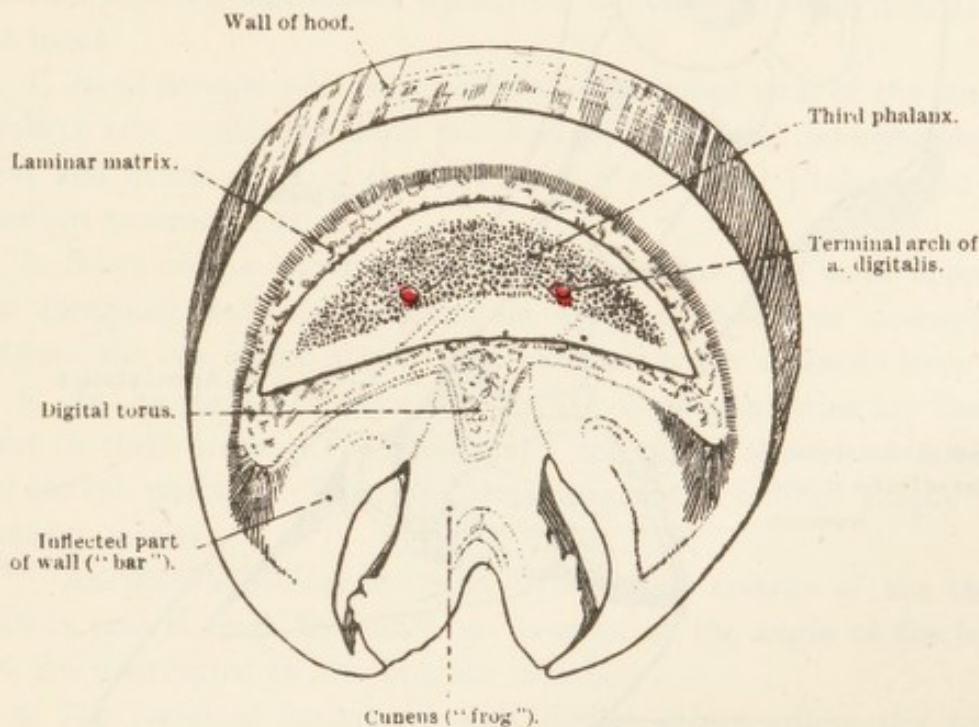


FIG. 61.—Transverse Section of the Foot at the Level Indicated by Line B in Fig. 59.

development ensues, beginning at the periphery and gradually spreading inwards, until almost the whole structure is converted into fibro-cartilage. Pathologically a considerable extent of the cartilage may be converted into bone; and some amount of bone formation in that part of the cartilage next to the third phalanx may be regarded as the natural accompaniment of age.

The superficial surface of each cartilage is convex and smooth and covered with a venous plexus from which vessels pierce the cartilage to gain its deeper face. It is important to note that, while the lower part of this surface gives attachment to matrix and is therefore enclosed within the hoof, the upper part is beyond the border of the hoof and can consequently be felt through the skin.

The deep surface of each cartilage is concave and intimately adherent to the digital torus posteriorly, while anteriorly it covers

part of the joint between the second and third phalanges. The upper (proximal) border is convex and thin. The lower (distal) border is thicker and connected with the third phalanx and the digital torus. Short ligamentous fibres pass between the contiguous edges of the cartilage and phalanx.

The anterior end of each cartilage reaches the edge of the tendon of

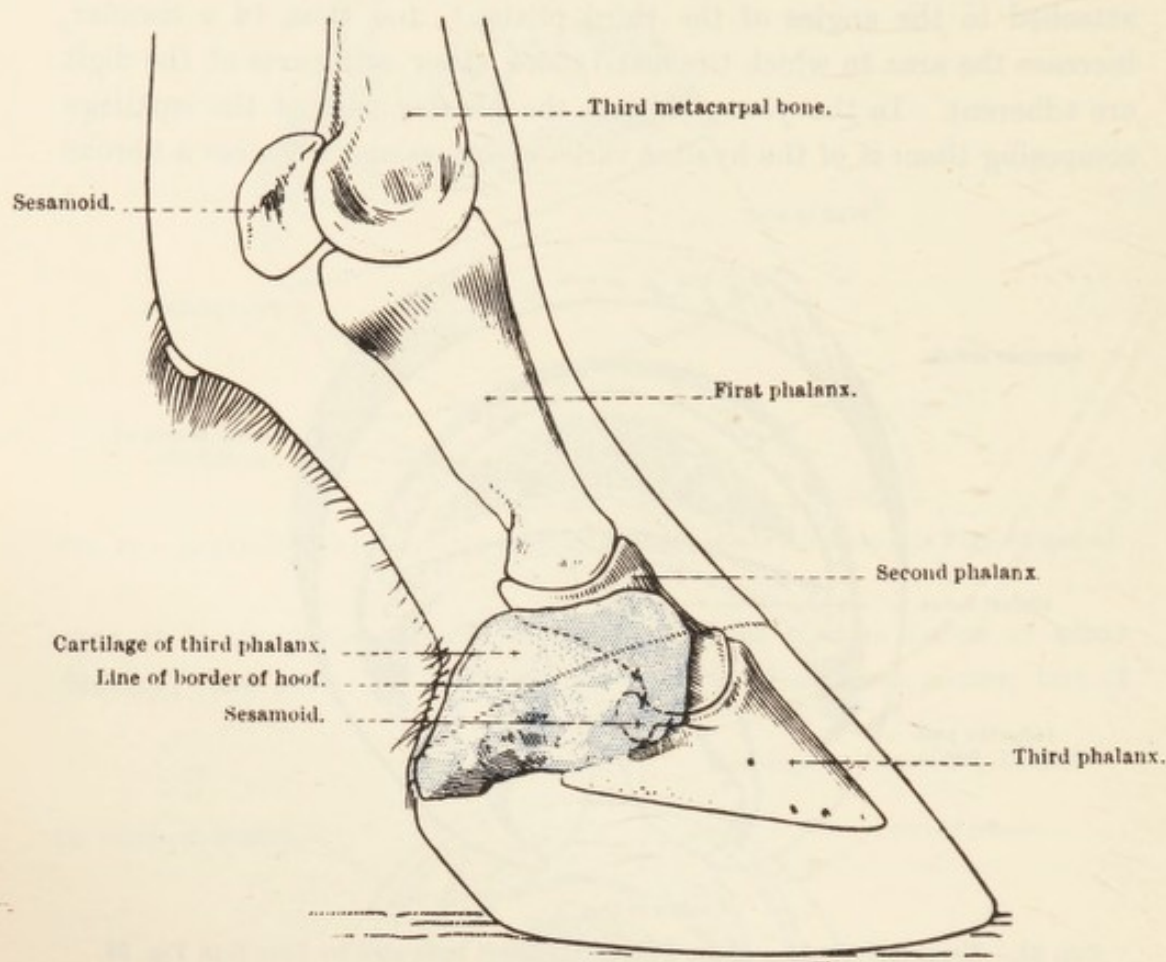


FIG. 62.—Lateral Aspect of the Phalanges and the Cartilage of the Third Phalanx, to show the Position of the Joint and Cartilage relative to the Surface of the Limb and the Border of the Hoof.

the common extensor muscle, and blends with the collateral ligament of the joint between the second and third phalanges. The posterior end forms a blunt in-curved angle reaching a considerable distance beyond the angle of the third phalanx.

Ligamentous bands should be defined and demonstrated as connecting the cartilages to the first and second phalanges.

A short ligament passes from the anterior end of each cartilage to the anterior (dorsal) surface of the second phalanx. An ill-defined elastic band stretches from the deep surface of each cartilage to the side of the distal end of the first phalanx. In addition, a short, strong ligament connects the extremity of the sesamoid bone with the nearest point on the neighbouring cartilage; and a band connects the anterior

part of each cartilage with the common extensor tendon near its insertion.

AA. DIGITALES VOLARES.—During the dissection of the limb in general some of the branches of the volar digital arteries were examined, but some could not be followed until the contents of the hoof had been dissected.

1. The *dorsal* and 2. *volar branches of the first phalanx* have been dissected. The following remain for examination:—

3. *Aa. toricæ phalangis terciæ*.—These leave the digital arteries about the level of the proximal border of the cartilages of the third phalanx, and are distributed mainly on the surface (in the matrix) of the torus.

4. *Rami dorsales phalangis secundæ*.—The dorsal rami of the second phalanx run round the digit proximal to the distal interphalangeal joint and under cover of the cartilages of the third phalanx and the common extensor tendon.

5. *Rami volares phalangis secundæ*.—The volar rami arise opposite the foregoing and, by anastomosis, form a transverse connection between the two digital arteries just proximal to the sesamoid bone.

6. *Aa. coroneales phalangis terciæ*.—The coronal arteries are inconstant in their origin. They frequently arise from the dorsal rami of the second phalanx. Whatever their origin, the arteries supply the coronary matrix.

7. *Aa. dorsales phalangis terciæ*.—The dorsal arteries of the third phalanx pass through the notch or foramen at the angle of the bone and are distributed in the laminar matrix.

8. The terminal branch of each digital artery enters the volar foramen of the third phalanx and, in the semilunar canal in the interior of the bone, anastomoses with its fellow vessel to form the *terminal arch* (arcus terminalis), from which numerous small arteries arise and pierce the foramina on the dorsal surface and at the distal border of the phalanx.

The insertion of the deep flexor tendon may now be examined. The tendon widens as it crosses the surface of the sesamoid bone—where it is provided with a synovial (mucous) sheath—and is inserted to the flexor area of the third phalanx.

THE PROXIMAL INTERPHALANGEAL ARTICULATION (*articulatio phalangis secundæ*).—The opposed surfaces of the first and second phalanges are accurately adapted to each other. This, and the presence of strong collateral ligaments, limits the movement to flexion and extension. The articular area of the second phalanx is extended posteriorly by a fibro-cartilaginous glenoidal lip.

The *joint capsule* (*capsula articularis*) has the customary attachment to the articular margins of the two bones that enter into the formation of the joint. The dorsal part of the capsule is the strongest, and is supported by the tendon of the common extensor muscle. On each side it is connected with a collateral ligament; and behind, where it is thin, the straight sesamoidean ligament, the volar ligaments, and the insertion of the superficial flexor tendon afford support.

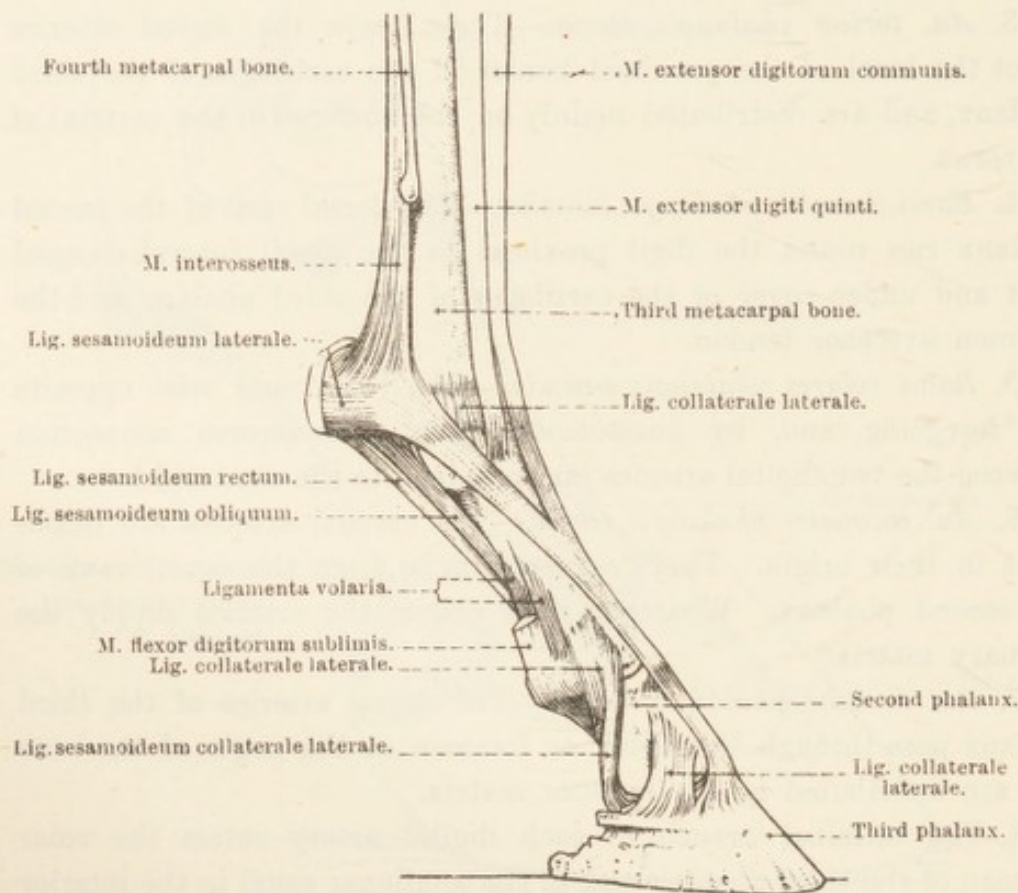


FIG. 63.—The Tendons and Ligaments of the Lateral Aspect of the Digit.

The short, but very strong, *collateral ligaments* (*ligamentum collaterale mediale: laterale*) are attached to the sides of the distal extremity of the first phalanx and to the adjoining parts of the second phalanx.

There are four *volar ligaments* (*ligamenta volaria*), all of which arise from the posterior (volar) surface of the first phalanx, about the middle of this bone and close to the attachment of the oblique sesamoidean ligament. The two central ligaments join the glenoidal fibro-cartilage of the second phalanx, where they blend with the straight sesamoidean ligament and the insertion of the superficial flexor tendon. The most medial and most lateral of the four ligaments are attached to the proximal end of the second phalanx.

THE DISTAL INTERPHALANGEAL ARTICULATION (*articulatio phalangis tertiae*).—The joint between the second and third phalanges is one in which movement is limited to flexion and extension. Movement, moreover, is not very free owing to the inclusion of the joint in the hoof. The dissector will observe that the articular surface of the third phalanx is not, in itself, sufficiently extensive to accommodate the

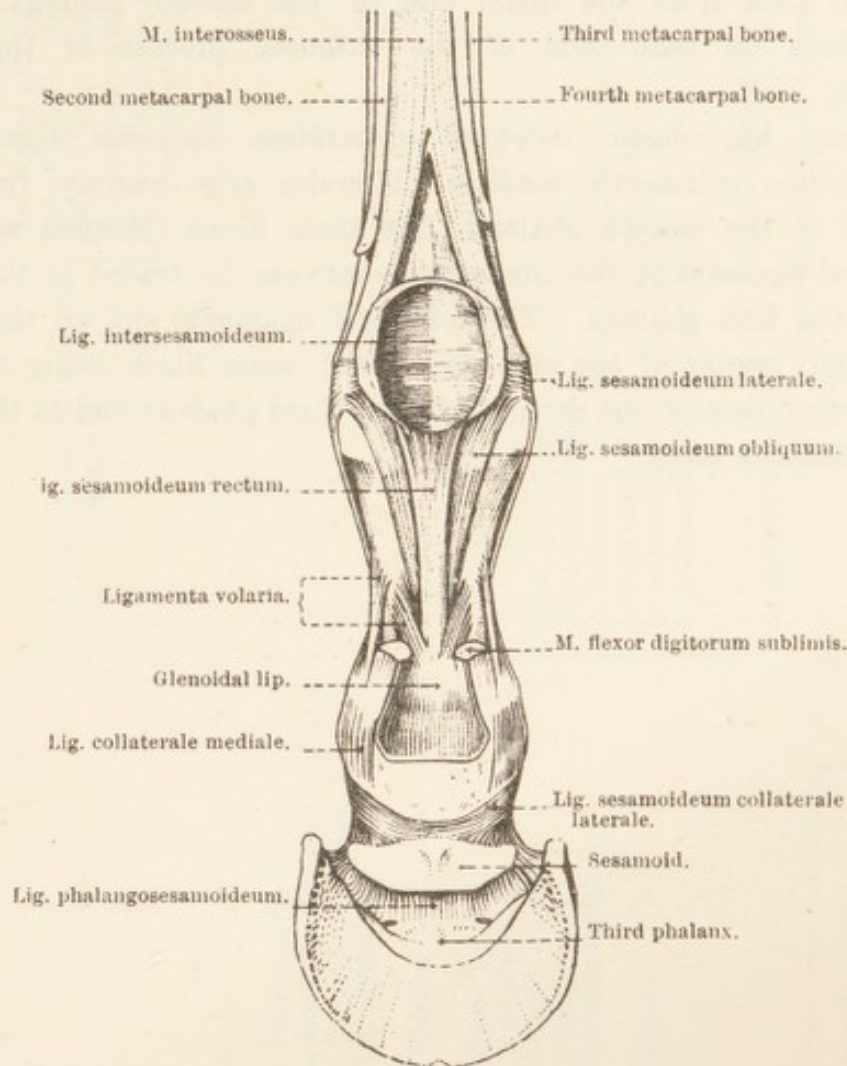


FIG. 64.—Ligaments of the Volar (Posterior) Aspect of the Digit.

whole of the distal end of the second phalanx. The sesamoid bone completes the articular cavity. Between the ligamentous border of the sesamoid and the immediately adjacent part of the third phalanx, short, but strong, fibres form a *phalango-sesamoidean ligament* (*ligamentum phalangos sesamoideum*) that, while permitting a certain measure of movement, retains the sesamoid firmly in position.

The *joint capsule* (*capsula articularis*) is attached to the articular margin of the three bones which enter into the formation of the joint. In front (dorsal) it is intimately connected with the common extensor tendon and the collateral ligaments. Behind the joint the capsule is

thinner and more roomy, and extends for some distance between the second phalanx and the deep flexor tendon. For surgical reasons it is important to note that there is a small diverticulum of the joint capsule, in contact with the deep surface of each cartilage of the third phalanx immediately behind a collateral ligament.

The stout *collateral ligaments* (ligamentum collaterale mediale: laterale) pass from the distal end of the second phalanx to the depressions on each side of the extensor process of the third phalanx.

Strong, but elastic, *collateral sesamoidean ligaments* (ligamentum sesamoideum collaterale mediale: laterale) arise mainly from the borders of the second phalanx, but some fibres (blended with the collateral ligament of the preceding joint) can be traced to the distal end of the first phalanx. The collateral ligaments end on the upper (proximal) border of the sesamoid bone; some fibres being attached to the deep face of the cartilage of the third phalanx and to the angle of the phalanx itself.

ARTERIES OF THORACIC LIMB.

A. digitalis volaris medialis
(*lateralis*). { Rami dorsales et volares phalangis primæ.
Aa. toricæ phalangis tertiæ.
Rami dorsales phalangis secundæ.
Rami volares phalangis secundæ.
Aa. coroneales phalangis tertiæ.
A. dorsalis phalangis tertiæ.
Arcus terminalis.

A. thoracico-acromialis.

A. subscapularis. { *A. thoracico-dorsalis*.
A. circumflexa humeri posterior.
A. circumflexa scapulæ.
Rami musculares.

A. axillaris.

A. circumflexa humeri anterior.

A. brachialis. { *A. profunda brachii*.
Rami musculares.
A. collateralis ulnaris.
A. nutritia humeri.
A. collateralis radialis.
A. *mediana*

Rami articulares.

Rami musculares.

A. interossea communis—A. interossea dorsalis. { Rete carpi dorsalis.

A. retis carpi volaris. — Rete carpi volare.

A. metacarpea volaris medialis.

A. metacarpea volaris lateralis.

A. digitalis communis. { *A. digitalis volaris medialis*.

A. digitalis volaris lateralis.

Rete carpi dorsalis. { *A. metacarpea dorsalis medialis*.
A. metacarpea dorsalis lateralis.

NERVE AND BLOOD SUPPLY OF THE MUSCLES OF THE THORACIC LIMB.

<i>Nerve Supply.</i>		<i>Blood Supply.</i>
Accessory	M. trapezius.	Deep cervical, and intercostals.
6th and 7th cervical .	Mm. rhomboidei.	Deep cervical, and transverse artery of the neck.
Thoraco-dorsal . . .	M. latissimus dorsi.	Subscapular, intercostals, and lumbar.
From brachial plexus	Mm. pectorales.	Internal and external thoracic, intercostals, transverse scapular, anterior circumflex, and thoraco-acromial.
Long thoracic . . .	M. serratus ventralis.	Deep cervical, transverse artery of the neck, vertebral, and intercostals.
Suprascapular . . .	M. supraspinatus.	Posterior circumflex, circumflex scapular, and thoraco-acromial.
	M. infraspinatus.	Subscapular, and circumflex scapular.
Axillary	M. deltoideus.	Subscapular, and posterior circumflex.
	M. teres minor.	Subscapular, and circumflex scapular.
	M. teres major.	Subscapular, and thoraco-dorsal.
	M. capsularis.	Posterior circumflex.
Subscapular	M. subscapularis.	Subscapular, circumflex scapular, and thoraco-acromial.
Musculo-cutaneous .	M. coraco-brachialis.	Anterior circumflex, and thoraco-acromial.
	M. biceps brachii.	Brachial, collateral radial, and anterior circumflex.
	M. brachialis.	Brachial, collateral radial, and deep brachial.
	M. tensor fasciæ anti-brachii.	Subscapular, collateral ulnar, and deep brachial.
	M. triceps brachii.	Subscapular, deep brachial, posterior circumflex, and collateral ulnar.
	M. anconæus.	Deep brachial.
Radial	M. extensor carpi radialis.	Collateral radial, and deep brachial.
	M. extensor digitorum communis.	Collateral radial, and dorsal interosseous.
	M. extensor digiti quinti.	Dorsal interosseous, and collateral radial.
	M. extensor carpi ulnaris.	Common interosseous, collateral ulnar, and median.
	M. abductor pollicis.	Dorsal interosseous, and collateral radial.

<i>Nerve Supply.</i>		<i>Blood Supply.</i>
Median	M. flexor carpi radialis.	Median.
	M. flexor carpi ulnaris.	Collateral ulnar and median.
	M. flexor digitorum sublimis.	Median.
Ulnar and median	M. flexor digitorum profundus.	Collateral ulnar, median, and common interosseous.
	Mm. lumbricales.	Volar metacarpals.
	Mm. interossei.	Volar metacarpals.

PELVIC LIMB.

It is convenient to begin the dissection of the pelvic limb with the examination of the structures on the medial aspect of the thigh; but if the subject is a male, the dissector of the limb cannot start his work until the external genital organs have been examined by the dissectors of the abdomen.

Comparatively little of the anatomy of the inner aspect of the thigh can be determined before reflexion of the skin. The position of the saphenous vein may be visible, but only if it happens to be filled with blood. If it is possible to follow the vein with the eye, it will be noted that it disappears before actually reaching the groin. Palpation at the point of disappearance discloses a groove formed by the adjacent margins of two muscles, the gracilis and sartorius; and deep palpation of the groove should permit the dissector to determine the presence of the deep inguinal lymph glands.

Dissection.—In the male an incision should be made from the proximal third of the leg to the incision already made by those who have dissected the external genital organs. In the female a second incision along the line of the pelvic symphysis will be necessary. It must be remembered that the skin of this region is thin, and that, therefore, the incisions must not be deep. Two triangular flaps of skin are now turned aside from the underlying structures.

The dissector must now isolate the saphenous vein, artery, and nerve and demonstrate the fascia of the region and its connection with the wall of the abdomen. The surface of the gracilis and sartorius must then be cleaned.

A. SAPHENA: V. SAPHENA: N. SAPHENUS.—The saphenous¹ artery, vein, and nerve appear from the narrow cleft between the gracilis and sartorius muscles, and run down the medial surface of the thigh into the leg, where their subsequent course will be followed in a later dissection.

The artery lies in front of the vein, and, at the point where they first become superficial, the nerve is in front of the artery. Before its

¹ *Saphena* [L.], σαφήνης (*saphēnēs*) [Gr.], manifest; from the prominence of the vein in the living animal.

appearance at the present stage of the dissection the nerve has already divided into several (3 or 4) branches, which separate as they proceed down the thigh.

Not infrequently the saphenous vein, instead of sinking into the

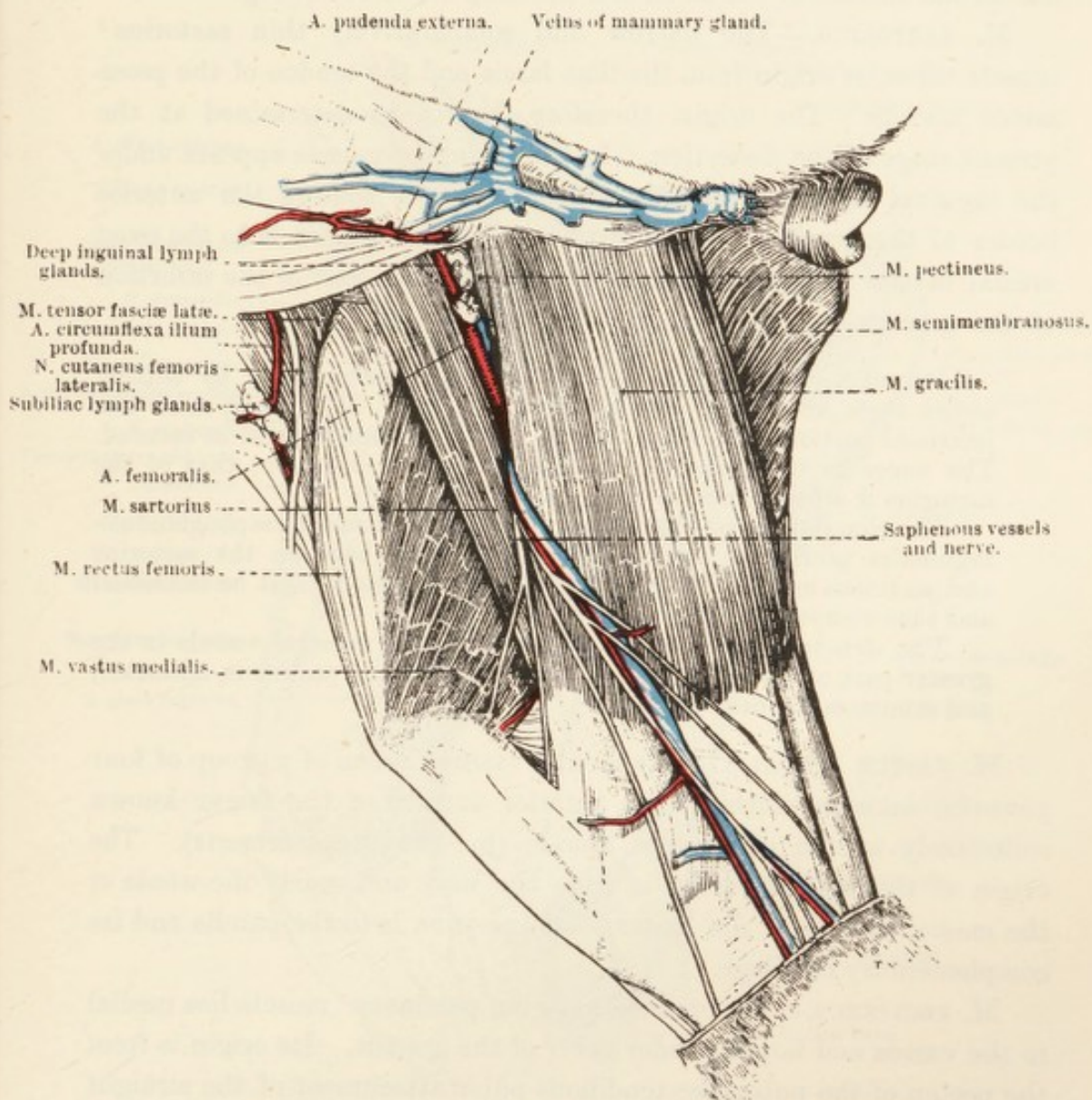


FIG. 65.—Superficial Dissection of the Medial Aspect of the Thigh. (Female.)

narrow cleft between the sartorius and the gracilis, continues its superficial course and ends by joining the external pudental vein.

M. GRACILIS.—The gracilis¹ is a broad, flat muscle covering the greater part of the medial aspect of the thigh. Its origin is from the pelvic symphysis, the tendon of insertion of the straight abdominal muscle where this is attached to the pecten of the pubis, and the accessory ligament of the hip joint. Some fibres arise from a tendinous septum

¹ *Gracilis* [L.], thin, slender, lean; from the thinness of the human muscle.

that separates the muscles of the two limbs. At the distal part of the thigh the fleshy portion of the muscle merges into an aponeurotic tendon, which is connected with a similar tendon of the sartorius. The insertion of the muscle is to the most medial of the three patellar ligaments, the medial surface of the tibia, and the deep fascia of the leg.

M. SARTORIUS.—The narrow and comparatively thin sartorius¹ muscle takes its origin from the iliac fascia and the tendon of the psoas minor muscle. The origin, therefore, cannot be determined at the present stage of the dissection. In the groin, the muscle appears under the inguinal ligament (of Poupart), and thence follows the anterior border of the gracilis. The insertion of its thin tendon is to the most medial of the patellar ligaments in common with part of the insertion of the gracilis.

Dissection.—Reflect the gracilis and sartorius muscles by cutting across them about the middle of their length. In turning aside the proximal portion of each muscle the nerve of supply should be secured. The nerve to the gracilis is derived from the obturator; that of the sartorius is a branch of the saphenous.

The elongated group of *deep inguinal lymph glands* (lymphoglandulae inguinales profundæ), which occupy the space between the sartorius and pectineus muscles and overlie the femoral vessels, must be examined and then removed.

The structures now to be dissected are the femoral vessels in the greater part of their course, and the medial vastus, pectineus, adductor, and semimembranosus muscles.

M. VASTUS MEDIALIS.—The medial vastus² is one of a group of four powerful muscles clothing the anterior surface of the femur known collectively as the quadriceps muscle (m. quadriceps femoris). The origin of the medial vastus is from the neck and nearly the whole of the medial surface of the femur. Its insertion is to the patella and its complementary cartilage.

M. PECTINEUS.—The rounded tapering pectineus³ muscle lies medial to the vastus and largely under cover of the gracilis. Its origin is from the pecten of the pubis, the tendinous pubic attachment of the straight abdominal muscle, and the accessory ligament of the hip joint. The narrow tendinous insertion is to a muscular impression close to the nutrient foramen of the femur.

M. ADDUCTOR.—The strong adductor is entirely covered by the gracilis. The origin of the muscle is from an elongated area on the ventral surface of the pubis and ischium, close to the pelvic symphysis,

¹ *Sartor* [L.], a tailor. The muscle is said to be well developed in tailors, owing to the special attitude assumed when sewing.

² *Vastus* [L.], great, vast, immense.

³ *Pecten* [L.], a comb; from the connection of the muscle with the pecten of the pubis.

some fibres in addition springing from the tendinous origin of the gracilis. Its insertion is to the posterior surface of the femur, from near the third trochanter to the medial epicondyle, and to the medial collateral ligament of the femoro-tibial joint. Sometimes fibres are

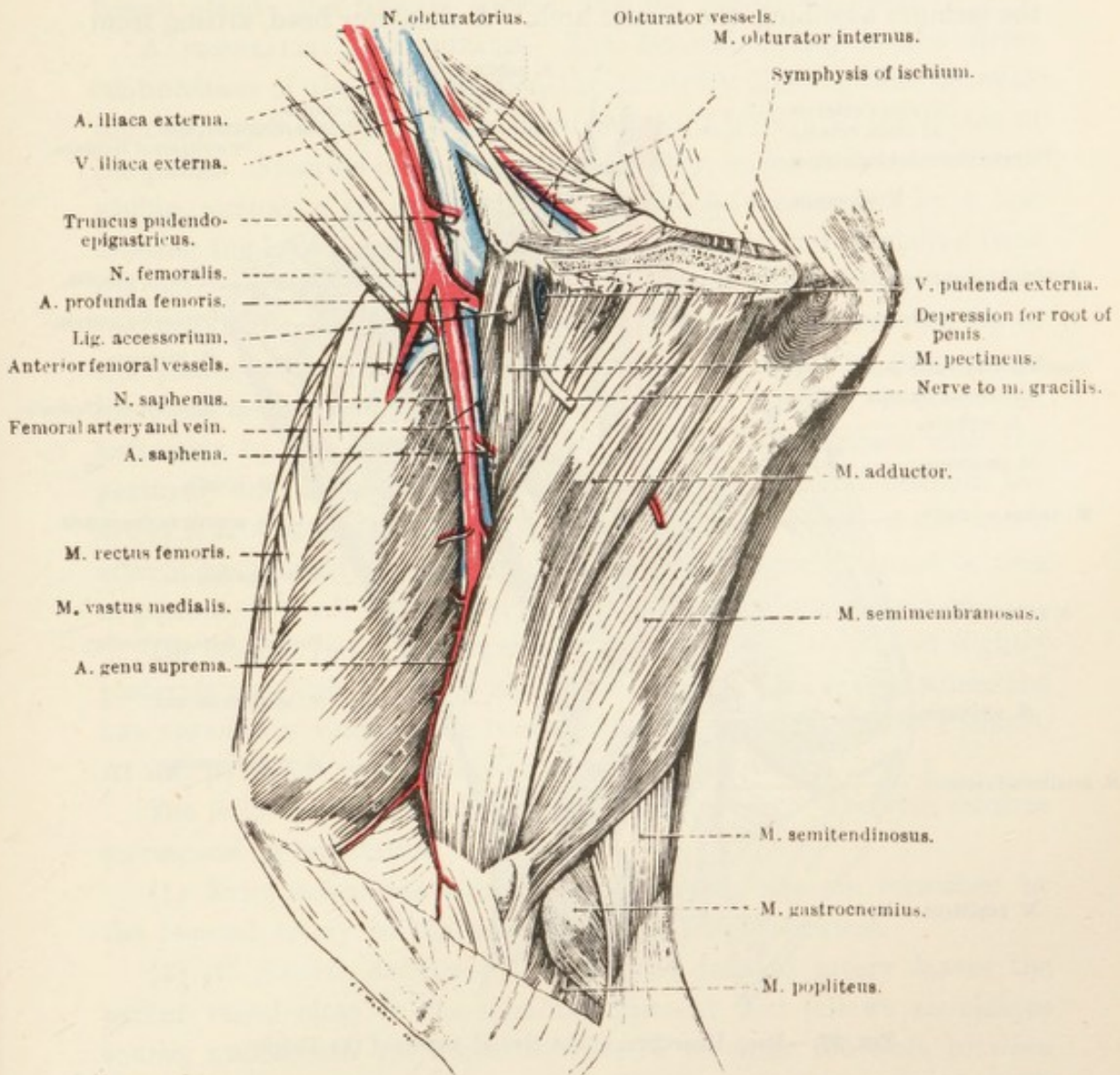


FIG. 66.—Dissection of the Medial Aspect of the Thigh after Removal of the Sartorius and Gracilis Muscles. (Male.)

continued to the tibia itself. Distal to the middle of the femur, *i.e.* immediately distal to the insertion of the pectineus, the insertion is pierced by the femoral vessels.

Occasionally the most proximal part of the muscle can be isolated from the rest. If this portion is regarded as equivalent to the *m. adductor longus* of the human body, the rest of the muscle must be considered as representing the *m. adductor brevis* and *m. adductor magnus*. So seldom

is a satisfactory separation possible in the horse that it appears unnecessary to describe the muscle as other than a single structure.

M. SEMIMEMBRANOSUS.—This is the largest and most posterior of the muscles at present being examined. Its main origin is from the ventral and medial part of the sciatic tuber and the ventral surface of the ischium adjoining the sciatic arch. A slenderer head, arising from

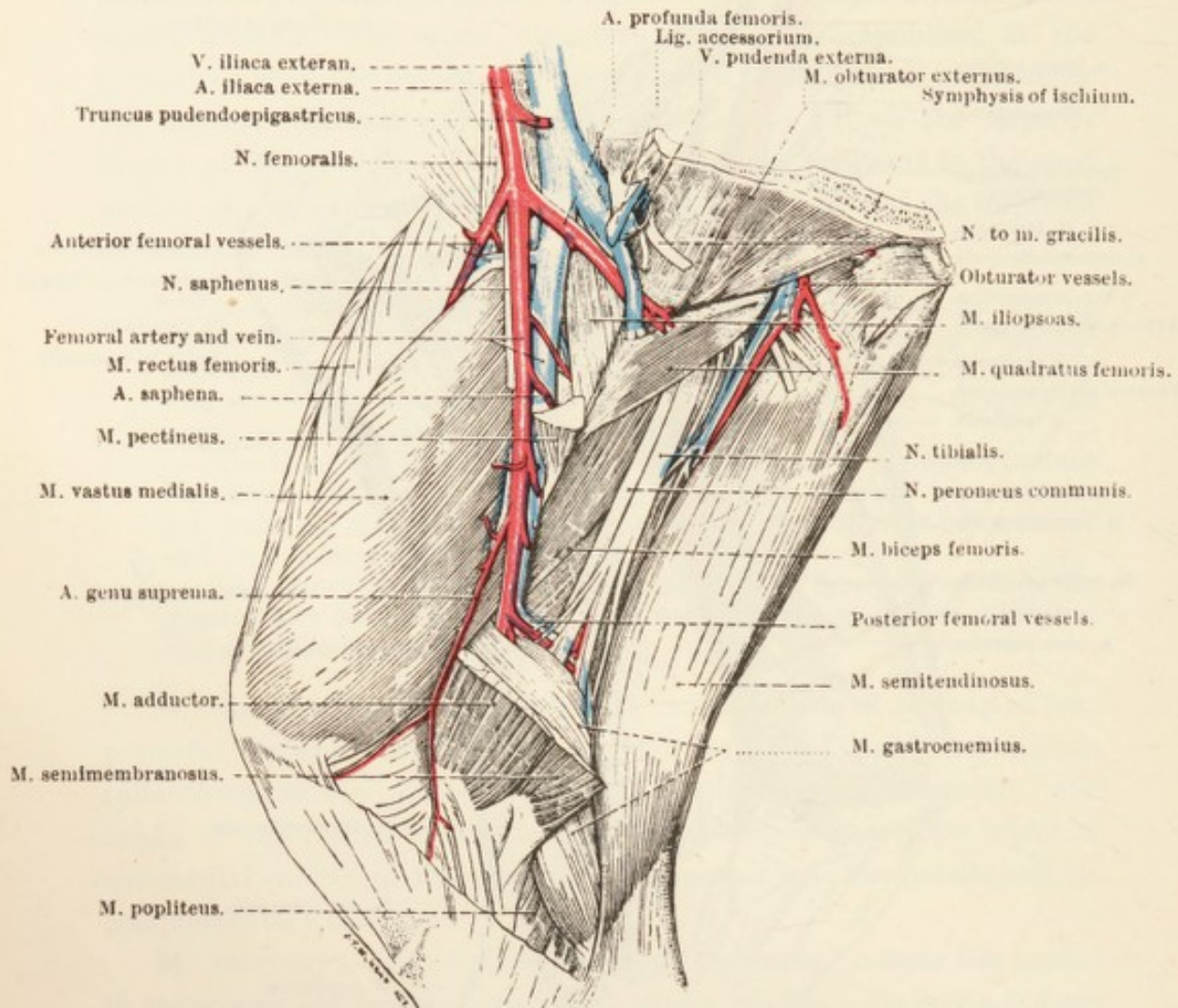


FIG. 67.—Deep Dissection of the Medial Aspect of the Thigh.

the transverse process of second (possibly also the first) coccygeal vertebra and the edge of the sacro-tuberous ligament, passes over the sciatic tuber, beyond which it joins the larger main head. A synovial bursa may intervene between the muscle and the tuber.

The short tendon of insertion of the semimembranosus is attached to the medial epicondyle of the femur and the medial collateral ligament of the femoro-tibial joint, along with part of the insertion of the adductor, while beyond this it becomes continuous with the fascia of the leg.

The term *femoral triangle* (*trigonum femorale*) is applied to a space

bounded by the inguinal ligament of Poupart,¹ which forms its base, and the sartorius and pectineus muscles. The narrow apex of the triangle is distal. Owing to the extensive development of the gracilis muscle in the horse the triangle is not completely exposed until this muscle has been reflected. The triangle contains the deep inguinal lymph glands, the femoral vessels, and the saphenous nerve.

A. FEMORALIS: V. FEMORALIS.—The femoral artery is the direct continuation of the external iliac, the arbitrary dividing line between the two vessels being taken as occurring on a level with the pecten of the pubis. From its origin the femoral artery, so far as it is at present visible, pursues a course in the thigh that is represented by a line crossing the long axis of the femur very obliquely and extending from the border of the ilium, where this bone enters into the formation of the acetabulum, to the vascular groove that indents the medial lip of the linea aspera. The artery lies at first on the terminal part of the ilio-psoas muscle, and later on the medial vastus muscle. It is covered anteriorly by the sartorius, and posteriorly it is in contact with the pectineus and adductor muscles. While in the femoral triangle the artery is related medially to the gracilis. The termination of the vessel, after it has pierced the insertion of the adductor muscle, cannot be seen at present, but will be revealed at the next stage of the dissection.

The femoral vein is a close satellite of the artery, lateral and slightly posterior to which it lies in the whole of its course except where the two vessels are disappearing beneath the inguinal ligament of Poupart. At this point the vein is wholly posterior to the artery.

The following are branches of the femoral artery. The vein receives corresponding tributaries.

(1) *Rami musculares*.—Branches of varying size are furnished by the femoral artery to the muscles in the neighbourhood.

(2) *A. femoris anterior*.—The anterior femoral artery leaves the parent vessel close to the inguinal ligament, and follows an oblique course, underneath the sartorius muscle, to enter the cleft between the medial vastus and rectus femoris muscles, with the supply of which it is mainly concerned.

(3) *A. saphena*.—The thin saphenous artery has already been examined as it lies under the skin of the thigh. Its origin within the femoral triangle is now disclosed.

(4) *A. genu suprema*.—The articular branch of the femoral is small, and follows the groove of contact between the medial vastus and adductor muscles, to terminate on the medial aspect of the femoro-tibial joint.

¹ François Poupart, French anatomist, 1661-1709.

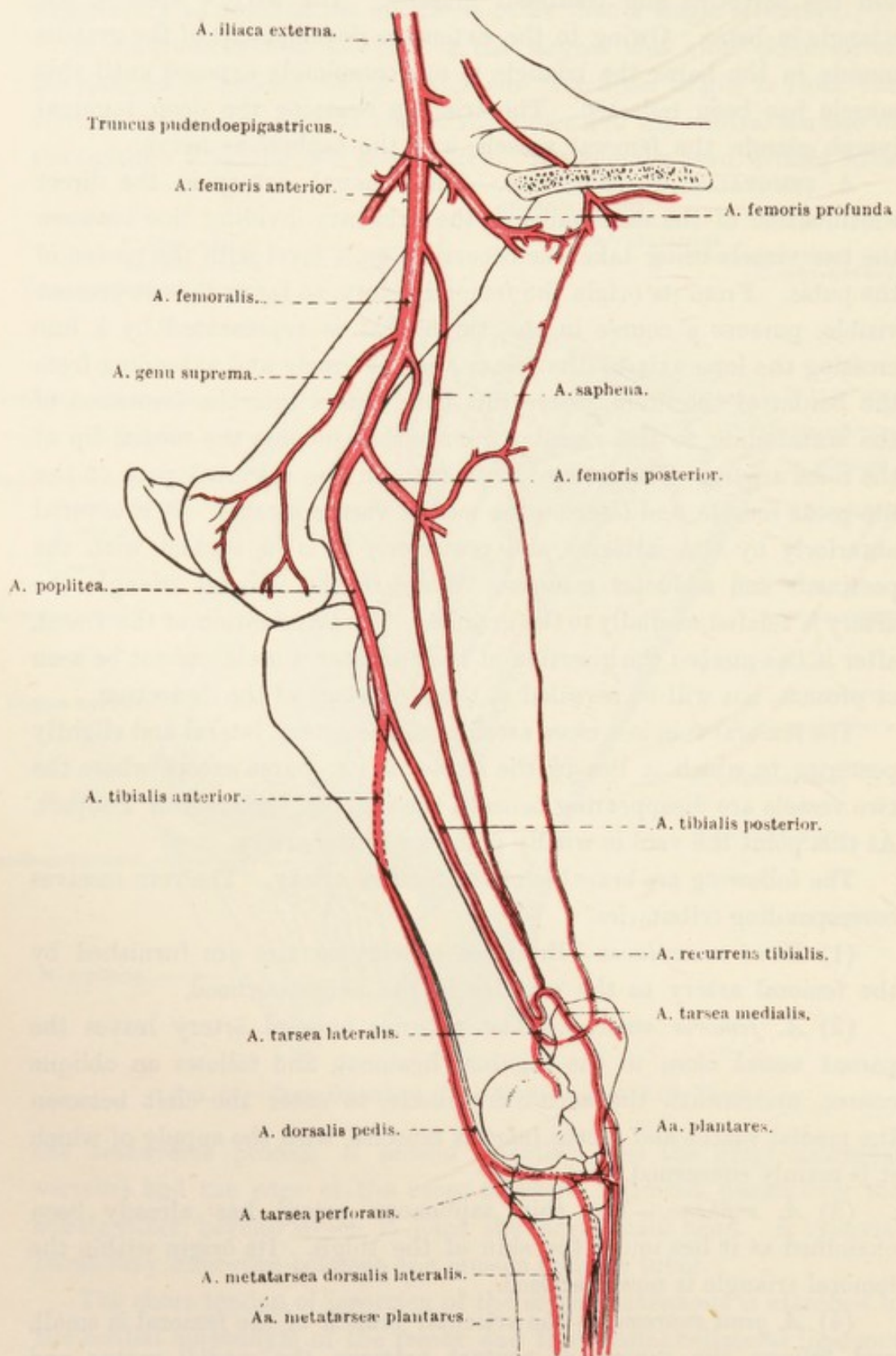


FIG. 68.—Diagram of the Arteries of the Pelvic Limb.

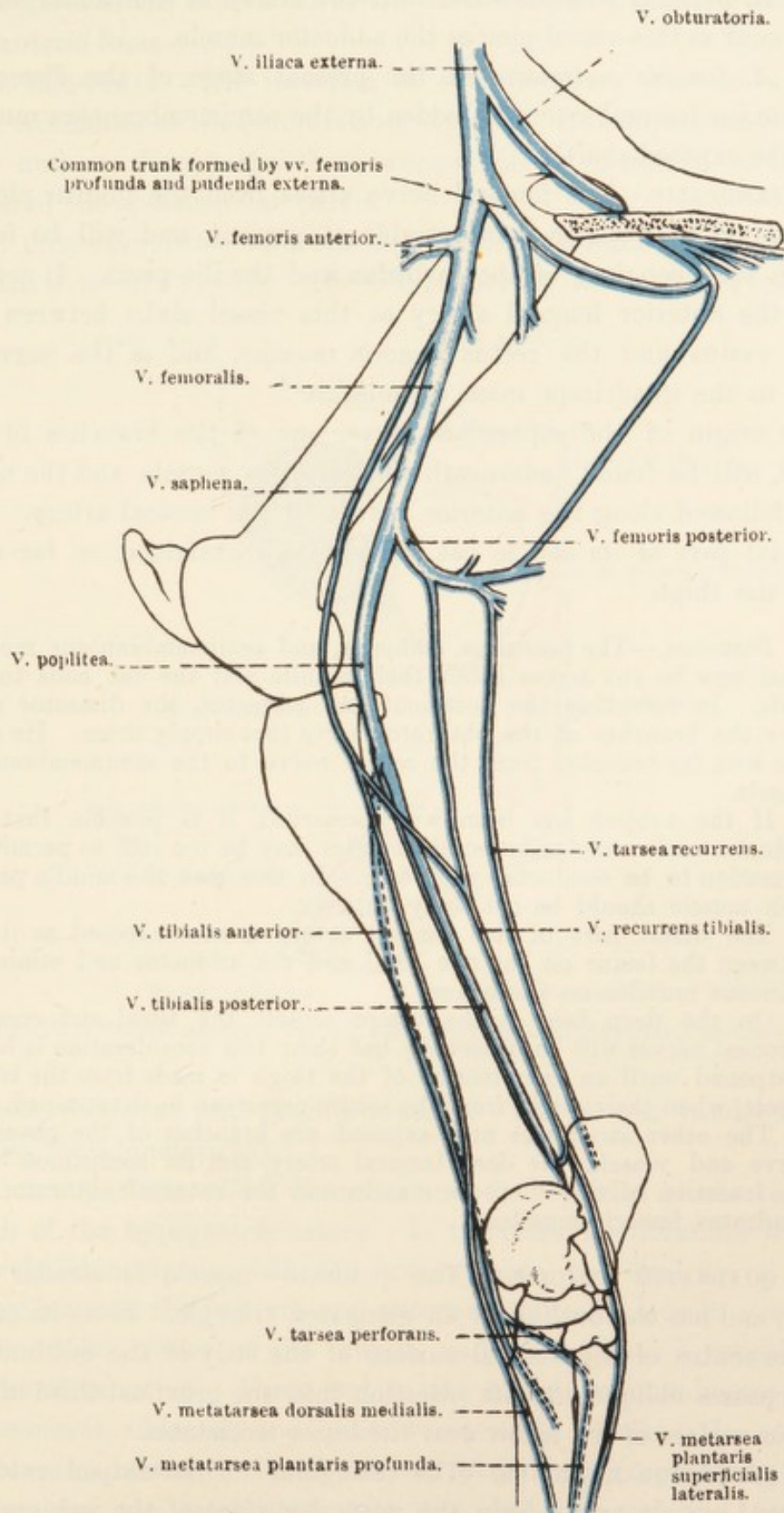


FIG. 69.—Diagram of the Veins of the Pelvic Limb.

(5) *A. nutritia femoris*.—The nutrient artery of the femur leaves the femoral as this vessel pierces the adductor muscle.

(6) *A. femoris posterior*.—At the present stage of the dissection the posterior femoral artery is hidden by the semimembranosus muscle. It will be exposed shortly.

N. FEMORALIS.—The femoral nerve arises from the lumbar plexus. Its termination alone is demonstrable at present, and will be found between the deep face of the sartorius and the ilio-psoas. It accompanies the anterior femoral artery as this vessel sinks between the medial vastus and the rectus femoris muscles, and is the nerve of supply to the quadriceps mass of muscles.

The origin of the saphenous nerve, one of the branches of the femoral, will be found underneath the sartorius muscle, and the nerve can be followed along the anterior border of the femoral artery. The superficial part of its course has already been examined, so far as it lies in the thigh.

Dissection.—The pectineus, adductor, and semimembranosus muscles must now be cut across about their middle and the cut ends turned aside. In reflecting the pectineus and adductor, the dissector must note the branches of the obturator nerve that supply them. He must also look for branches from the sciatic nerve to the semimembranosus muscle.

If the subject has been well preserved, it is possible that the adductor and semimembranosus muscles may be too stiff to permit the dissection to be conducted with ease. In this case the middle part of each muscle should be cut away entirely.

The distal part of the femoral artery is now exposed as it lies between the femur on the one hand and the adductor and semimembranosus muscles on the other.

On the deep face of the biceps muscle the tibial and common peroneal nerves will be observed; but their full consideration is better postponed until an examination of the thigh is made from the lateral aspect, when their origin from the sciatic nerve can be determined.

The other structures now exposed are branches of the obturator nerve and vessels, the deep femoral artery and its companion vein, the insertion of the ilio-psoas muscle, and the external obturator and quadratus femoris muscles.

M. QUADRATUS FEMORIS.—The quadrate¹ muscle is slender and narrow, and has the outline of an elongated triangle. From its origin near the centre of the ventral surface of the body of the ischium the muscle passes obliquely to its insertion into the proximal third of the posterior surface of the femur near the lesser trochanter.

M. OBTURATOR EXTERNUS.—The triangular or fan-shaped external obturator² muscle arises from the ventral surface of the ischium and pubis in the neighbourhood of the obturator foramen. The converging,

¹ *Quadratus* [L.], squared or square; from the outline of the human muscle.

² *Obturo* [L.], to stop up, to close.

coarse fibres of the muscle cover the foramen, and are inserted into the trochanteric fossa.

M. ILIO-PSOAS.—The insertion of the ilio-psoas¹ muscle into the lesser trochanter of the femur is now exposed. Its components (*m. psoas major* and *m. iliacus*), and their origins, will be examined in the dissection of the abdomen and pelvis.

N. OBTURATORIUS.—Two branches of the obturator nerve pierce the external obturator muscle. The cranial branch furnishes nerves to the

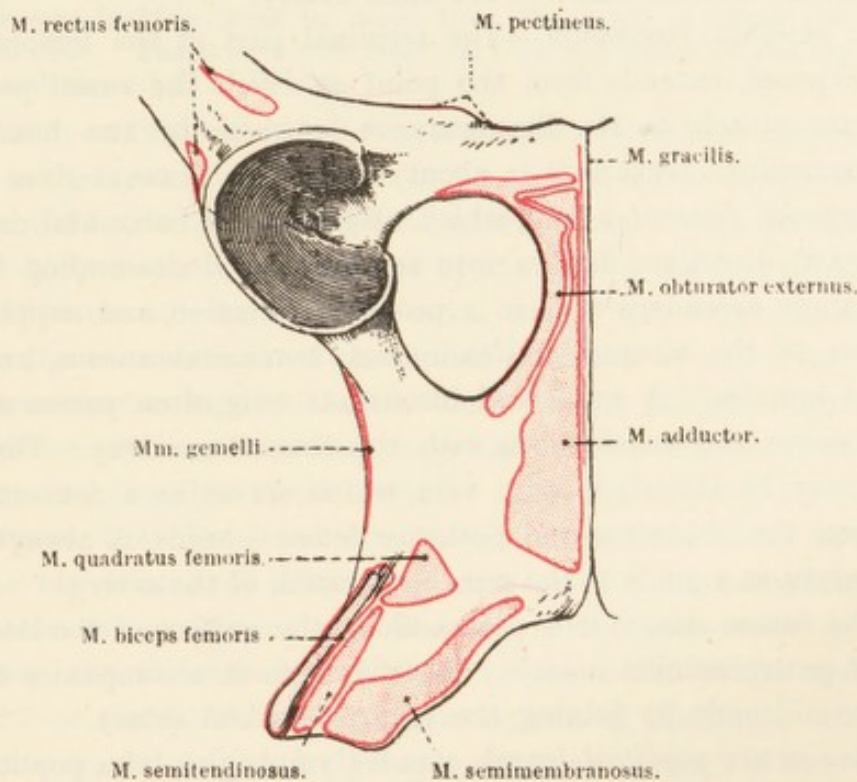


FIG. 70.—Ventral Aspect of the Hip Bone, with Areas of Muscular Attachment.

adductor, pectineus, and gracilis muscles. The shorter caudal branch supplies the adductor only.

A. OBTURATORIA.—The obturator may be regarded as the terminal branch of the hypogastric artery. It traverses the obturator foramen obliquely in company with the homonymous vein and nerve. Continuing between the ischium and external obturator muscle, it appears at the caudal border of the muscle, and divides into a considerable number of branches. These end in the biceps, semitendinosus, semimembranosus, adductor, and quadratus femoris muscles. In addition, the obturator furnishes the *deep artery of the penis* (*a. profunda penis*). Anastomoses are established with the deep femoral and posterior femoral arteries.

The *obturator vein* (*v. obturatoria*) is a satellite of the artery.

¹ *Ilio* [L.], the flank. *ψόα* (*psoa*) [Gr.], the loin.

A. PROFUNDA FEMORIS.—The deep femoral artery leaves the external iliac just before this vessel merges into the femoral. Generally the deep femoral arises in common with the pudendo-epigastric trunk, but often its origin is independent. It runs between the pectineus muscle and the hip joint, and, at the proximal border of the insertion of the quadratus femoris, furnishes a large branch, the *medial circumflex femoral artery* (a. circumflexa femoris medialis), which curves round the back of the femur to end in the biceps muscle. Branches of the deep femoral anastomose with the obturator artery.¹

A. FEMORIS POSTERIOR.—The terminal part of the femoral artery, now exposed, extends from the point at which the vessel pierces the adductor muscle to its disappearance between the two heads of the gastrocnemius. Just as it is about to end the femoral gives origin to the *posterior femoral artery*, which, after a short horizontal course in a backward direction, divides into ascending and descending branches. The ramus ascendens runs in a proximal direction, and supplies small arteries to the biceps, semitendinosus, semimembranosus, and lateral vastus muscles. A small and inconstant twig often passes along the tibial nerve and anastomoses with the obturator artery. Though this twig may be absent, a large vein, which serves as a connecting link between the obturator and posterior femoral veins, is always present, and serves as a guide to the possible position of the artery.

The ramus descendens passes along the surface of the lateral head of the gastrocnemius muscle. A twig from it accompanies the tibial nerve, and ends by joining the recurrent tibial artery.

Five or six *popliteal lymph glands* (lymphoglandulæ popliteæ) form a small group about the division of the posterior femoral artery.

N. ISCHIADICUS.—A more complete examination of this nerve will be possible during the dissection of the gluteal region. In the meantime its two terminal branches should be noted. Of these; the more medial—the *tibial nerve*—is the larger, and leaves the present dissection by disappearing between the two heads of the gastrocnemius muscle. Muscular branches (rami musculares proximales) pass from the tibial nerve to the semimembranosus, semitendinosus, and biceps.

The smaller branch of the sciatic—the *common peroneal nerve*—enters the leg between the biceps and the lateral head of the gastrocnemius.

Dissection.—The gluteal and hip region and the lateral aspect of the thigh must now be examined. Before the skin is removed, certain

¹ Because the point of origin of the deep femoral artery is subject to variation, and because the origin may occur distal to the border of the pubis, some writers describe the vessel as a branch of the femoral artery. The specimen from which Figs. 66 and 67 were drawn illustrates a distal origin independent of the pudendo-epigastric trunk.

bony points should be located. There will be no difficulty in determining the position of the projecting angle of the ilium (coxal tuber), but careful and deep palpation will be necessary if the true position of the sciatic tuber and great trochanter is to be ascertained. If the subject is thin, grooves marking the lines of apposition of the gluteal and biceps and the biceps and semitendinosus muscles may be recognised, and a projection caused by the sacral tuber of the ilium may be noticeable.

An incision is to be made through the skin round the root of the tail and along the line of the vertebral spinous processes as far as the level of the last rib. In all probability dissectors of other regions have already removed the skin from the loins. If this has not been done, a transverse incision must be made from the point at which the first incision ends. The skin is now removed from the whole of the hip and thigh and about half of the leg.

CUTANEOUS NERVES OF THE HIP AND THIGH.—Cutaneous nerves are numerous in this part of the limb. (1) Three, derived from the dorsal branches of the lumbar nerves, appear a short distance from the middle line of the body in the area bounded by the line of the last rib and a transverse line on a level with the coxal tuber. (2) Five cutaneous nerves are the terminations of the dorsal branches of sacral nerves. Four of them become superficial in a line with the lumbar cutaneous nerves, and one of them (the first) appears close to the coxal tuber. (3) The terminal branches of the *posterior cutaneous nerve of the thigh* appear between the biceps and semitendinosus muscles distal to the level of the hip joint. (4) About the same point a cutaneous branch of the sciatic nerve appears. (5) The *lateral cutaneous nerve of the thigh* pierces the abdominal wall close to the coxal tuber, and is distributed over the lateral and anterior aspects of the thigh. (6) A short distance cranial to the foregoing a cutaneous branch of the ilio-inguinal nerve pierces the wall of the abdomen and passes downwards to the patellar region. (7) Cutaneous branches of the tibial nerve emerge from the biceps muscle close to its insertion.

FASCIA OF THE HIP AND THIGH.—After removal of the comparatively loose and fat-laden superficial fascia the very strong deep fascia is exposed. In the gluteal region (fascia gluteæ) it is closely adherent to the underlying muscles, and affords origin to some of their fibres. The gluteal fascia is attached to the spinous processes of the sacrum, the short sacro-iliac ligament, and the coxal and sacral tubers of the ilium. Cranially it is continuous with the lumbo-dorsal fascia, and behind with the fascia of the tail.

Over the lateral aspect of the thigh is spread the stout *fascia lata*, into which a muscle—the tensor of the fascia lata—is inserted. Round the front of the thigh this fascia is continuous with that already examined on the medial aspect of the limb. A prolongation of it passes underneath the cranial border of the biceps, to become connected

with the tendon of insertion of the superficial gluteal muscle. Distally the fascia lata is continuous with the fascia of the leg, and is attached

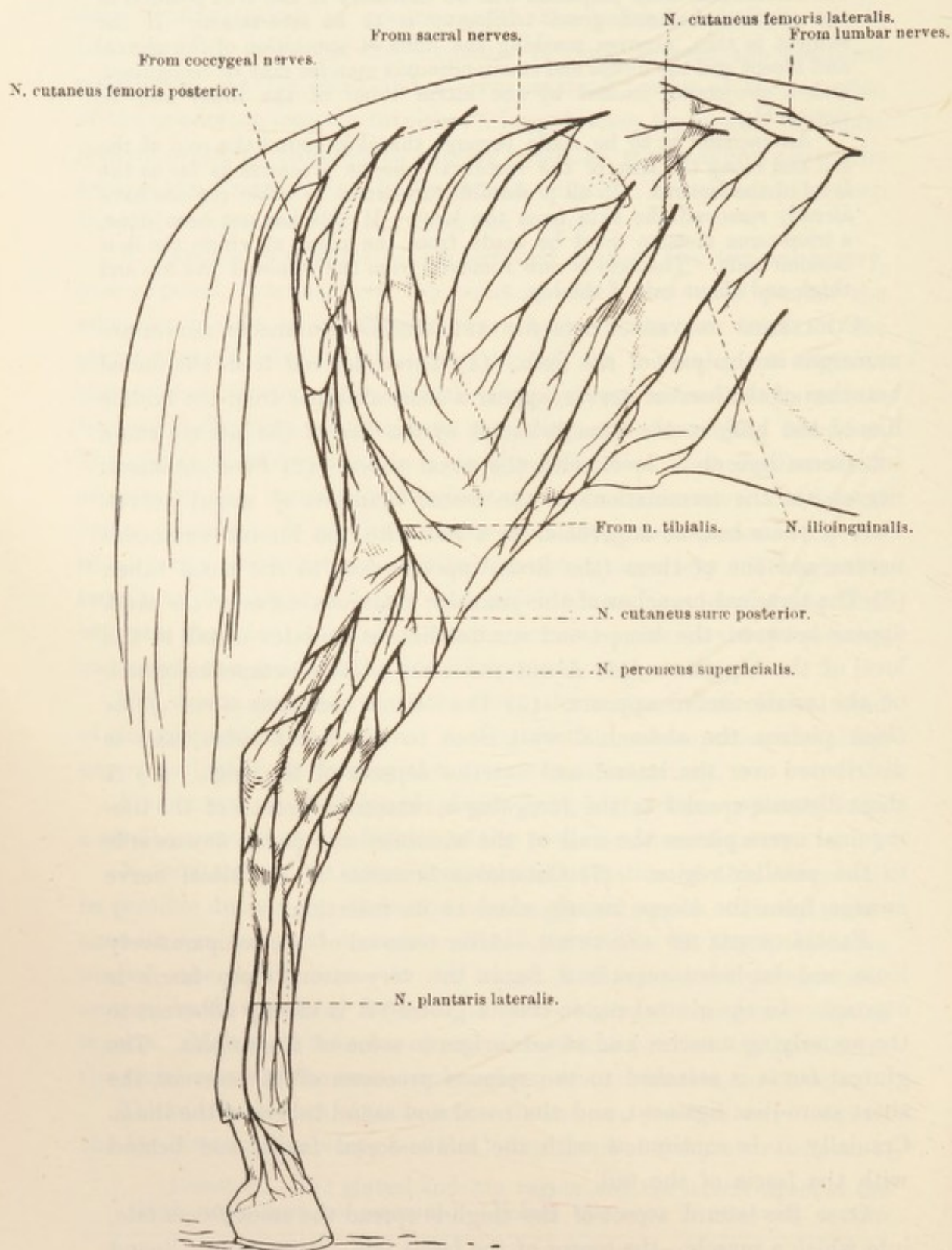


FIG. 71.—Cutaneous Nerves of the Pelvic Limb.

to the surface of the patella and blended in part with the patellar ligaments.

Dissection.—The removal of the deep fascia is tedious, and more particularly so over the gluteal muscles. The dissector will be well advised to begin its removal just distal to the level of the hip joint and work in a proximal direction. The fascia lata should not be interfered with until its tensor muscle has been examined.

M. TENSOR FASCIÆ LATÆ.—The tensor of the fascia lata has a comparatively restricted origin from the coxal tuber of the ilium; but, in addition, some fibres spring from an intermuscular septum that is adherent to the lateral border of the ilium, and from which some of the fibres of the superficial gluteal muscle arise. From this origin the fibres of the muscle spread out in fan-like manner, to merge into the fascia lata and the fascia of the leg. Through its fascial connections the muscle may be regarded as having indirect insertions to the patella, the most lateral of the three patellar ligaments, and the crest of the tibia.

Dissection.—The fascia lata should now be cut across about the middle of the thigh and transverse to the long axis of the limb. Its tensor should then be turned forwards as far as possible.

M. GLUTEUS SUPERFICIALIS.—The superficial gluteal¹ muscle consists of two fleshy parts that converge and blend towards the insertion of the muscle into the third trochanter of the femur. The lateral portion of the muscle arises from the coxal tuber of the ilium in common with the tensor fasciæ latæ, from the lateral border of the ilium in the neighbourhood of the coxal tuber, and from the intermuscular septum between the gluteal muscle and the tensor fasciæ latæ. The medial part takes origin from the gluteal fascia not far from the sacral tuber of the ilium.

M. BICEPS FEMORIS.—The very powerful and thick biceps muscle has a double origin. One head arises from the spinous processes of the third, fourth, and fifth sacral segments, the short dorsal sacro-iliac ligament, the coccygeal and gluteal fasciæ, and the sacro-tuberous ligament. The other head is tendinous, and has origin from the sciatic tuber. The two heads combine to form a single muscular mass that soon divides into three parts. (1) The most anterior portion is the strongest, and, by means of an aponeurotic tendon, is inserted into the patella and the most lateral of the three bands that represent the patellar ligament. It is also connected, by a flattened tendinous band, with the femur behind and immediately distal to the third trochanter, where a synovial bursa lies between the tendon and the bone. (2) The aponeurotic tendon of the middle portion of the muscle is attached to the crest of the tibia and the fascia of the leg. (3) The posterior part of the biceps also is connected with the fascia of the leg, and, by means of a stout band

¹ γλουτός (gloutos) [Gr.], the buttock.

(tendo accessorius), which accompanies the tendon of Achilles, with the tuber of the calcaneus.

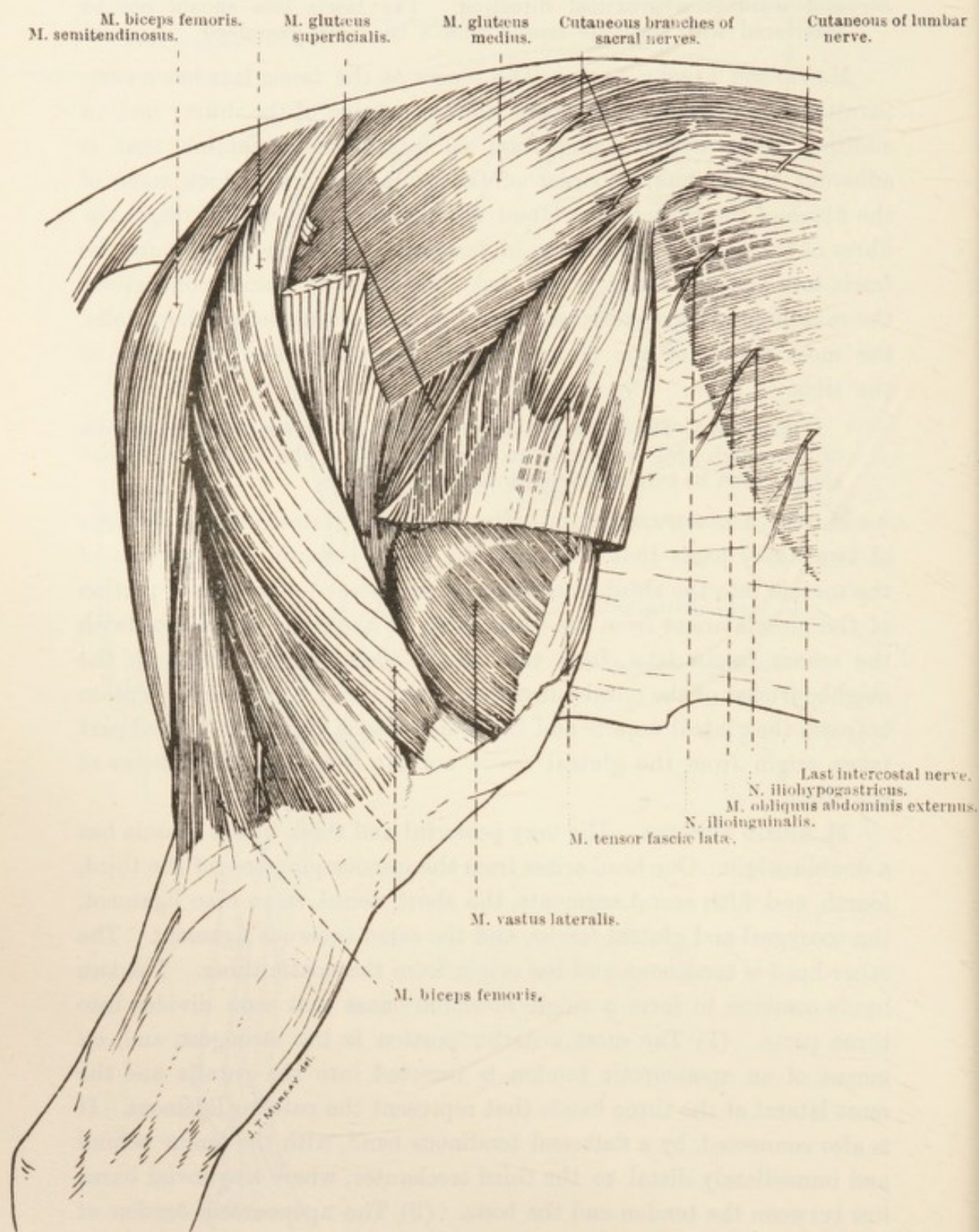


FIG. 72. —Superficial Dissection of the Gluteal Region and Lateral Aspect of the Thigh.

Though the biceps muscle is described above as having a two-headed origin, it must be remembered that the two heads do not correspond

to the double origin of the muscle in man and many other mammals (*e.g.* the dog). The name "biceps" was originally given to the muscle in man, because in him it arises by two heads, one from the ischium, and one from the femur; that is to say, in the horse the two heads of the human and canine muscle are represented by one head only. That head of the horse's muscle which is attached to the sacrum is apparently not a part of the biceps proper, but represents a gluteal muscle (part of the superficial gluteal?) that has become continuous with the biceps. Hence it has been suggested that the resultant combined muscle should be called *m. glutæo-biceps*.

M. SEMITENDINOSUS.—The semitendinous muscle forms the greater part of the posterior border of the thigh, where it lies between the biceps and the semimembranosus muscles. It has two heads of origin. One arises from the spinous process of the last sacral segment, the transverse processes of the first and second coccygeal vertebræ, the aponeurotic fascia of the tail, the edge of the sacro-tuberous ligament where it is blended with the origin of the biceps, and the intermuscular septum shared by the biceps. The other head springs from the ventral surface of the sciatic tuber and the ridge that runs forwards from this tuber. The aponeurotic tendon that succeeds the fleshy belly of the muscle is partly attached to the crest of the tibia and partly blended with the fascia of the leg. Its connection with the tendo-accessorius of the biceps, and its consequent indirect attachment to the tuber of the calcaneus, should also be noted.

As with the biceps, so also with the semitendinosus of the horse, it appears probable that the sacral origin represents portion of a gluteal muscle. In man, ruminants, and the domestic carnivora the muscle had only one origin, namely, from the sciatic tuber.

Dissection.—Cut through the sacral origin of the biceps and semitendinosus muscles a short distance from the sacrum. Do the same with their origin from the sciatic tuber. Then cut across the muscles about half-way down the thigh and remove the intervening portions. In doing this dissection, note the nerve supply (from the caudal gluteal and sciatic) of the two muscles.

A small lymph gland should be looked for under the biceps and on the course of the caudal gluteal artery.

The sheet of fascia that continues the fascia lata underneath the biceps and is connected with the sciatic tuber and the sacro-tuberous ligament must be examined and removed. Observe the continuity of this fascia with the tendon of the superficial gluteal muscle.

Next liberate both origins of the superficial gluteal muscle and thus expose the middle member of the group. Note that a branch of the caudal gluteal nerve bends round the edge of the piriformis muscle in order to reach the superficial gluteal.

M. GLUTEUS MEDIUS.—The middle gluteal muscle is the thickest and strongest muscle of the whole body. It entirely covers the surface

of the ilium and overlaps the longissimus dorsi muscle, gradually thinning away until it reaches the level of the last rib. The origin of

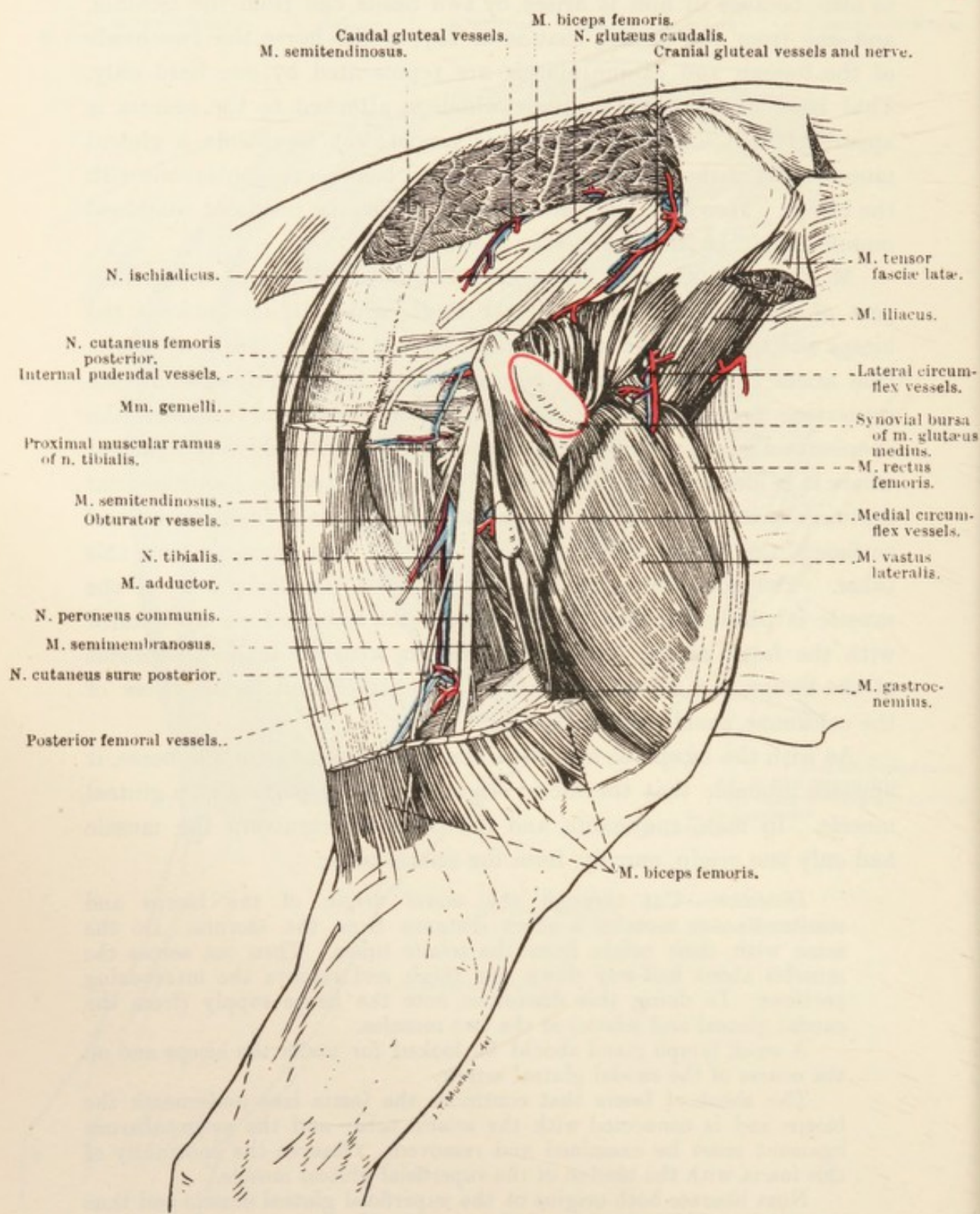


FIG. 73.—Deep Dissection of the Gluteal Region and Lateral Aspect of the Thigh.

the muscle is from the aponeurotic covering of the longissimus dorsi, the gluteal surface and both tubers (coxal and sacral) of the ilium, the

long and short dorsal sacro-iliac ligaments, and the gluteal fascia. Several tendinous strata occur in the substance of the muscle, the strongest of these being attached to the gluteal line of the ilium, thus dividing the muscle into superficial and deep portions.

The insertion of the middle gluteal is double: (1) The greater (superficial) part is inserted to the highest and most posterior part of the great trochanter of the femur. (2) The deeper part ends in a stout, flattened tendon that plays over the convex, anterior portion of the great trochanter, and is attached to a special ridge immediately distal to the convexity. The trochanteric bursa (*bursa trochanterica*) intervenes between the tendon and the bone. According to some authorities, the deeper part of the middle gluteal muscle should be regarded as a separate *m. glutæus accessorius*.

M. PIRIFORMIS.—The piriformis¹ muscle lies along the posterior border of the middle gluteal, with which it is so blended as to lead the dissector to regard the two muscles as one, unless warned to the contrary.

The origin of the piriformis (inseparably blended with the middle gluteal muscle) is from the edge of the sacrum, and its insertion is to the inter-trochanteric crest of the femur.

Dissection.—The whole of the middle gluteal muscle, except its insertion, must now be removed. This must be done with care, otherwise there is danger that the underlying deep gluteal muscle may be injured. The removal of the middle gluteal permits the dissector to determine that its deeper portion (*m. glutæus accessorius*) is attached to the gluteal line of the ilium and to that area of the bone that is lateral to the line. Examination of the trochanteric bursa also is now possible.

M. GLUTÆUS PROFUNDUS.—The short but strong deep gluteal muscle arises from the rough lateral surface of the sciatic spine, a portion of the adjacent surface of the ilium, and a narrow area of the sacro-spinous ligament where this is attached to the sciatic spine, and is inserted into the margin of the convex portion of the great trochanter. As will be seen later, some of its fibres are connected with the capsule of the hip joint.

MM. GEMELLI.—Though generally named in the plural, there is some justification for regarding the gemelli² of the horse as constituting a single muscle, divisible into two strata except along its cranial border. Both strata arise from the lateral border of the ischium opposite the lesser sciatic foramen. The superficial stratum is inserted into the trochanteric fossa close to the insertion of the internal obturator muscle. The more extensive deep stratum is inserted within the inter-

¹ *Pirum* [L.], a pear. *Forma* [L.], shape.

² *Geme'llus* [L.], twin.

trochanteric crest, immediately lateral to the insertion of the external obturator.

M. OBTURATOR INTERNUS.—In the present dissection only the flattened terminal part of the internal obturator muscle is visible. Leaving the interior of the pelvis by the lesser sciatic foramen, where there is a synovial bursa between the muscle and the bone, the flattened tendon lies on the surface of the gemelli muscles, and is inserted into the proximal part of the trochanteric fossa.

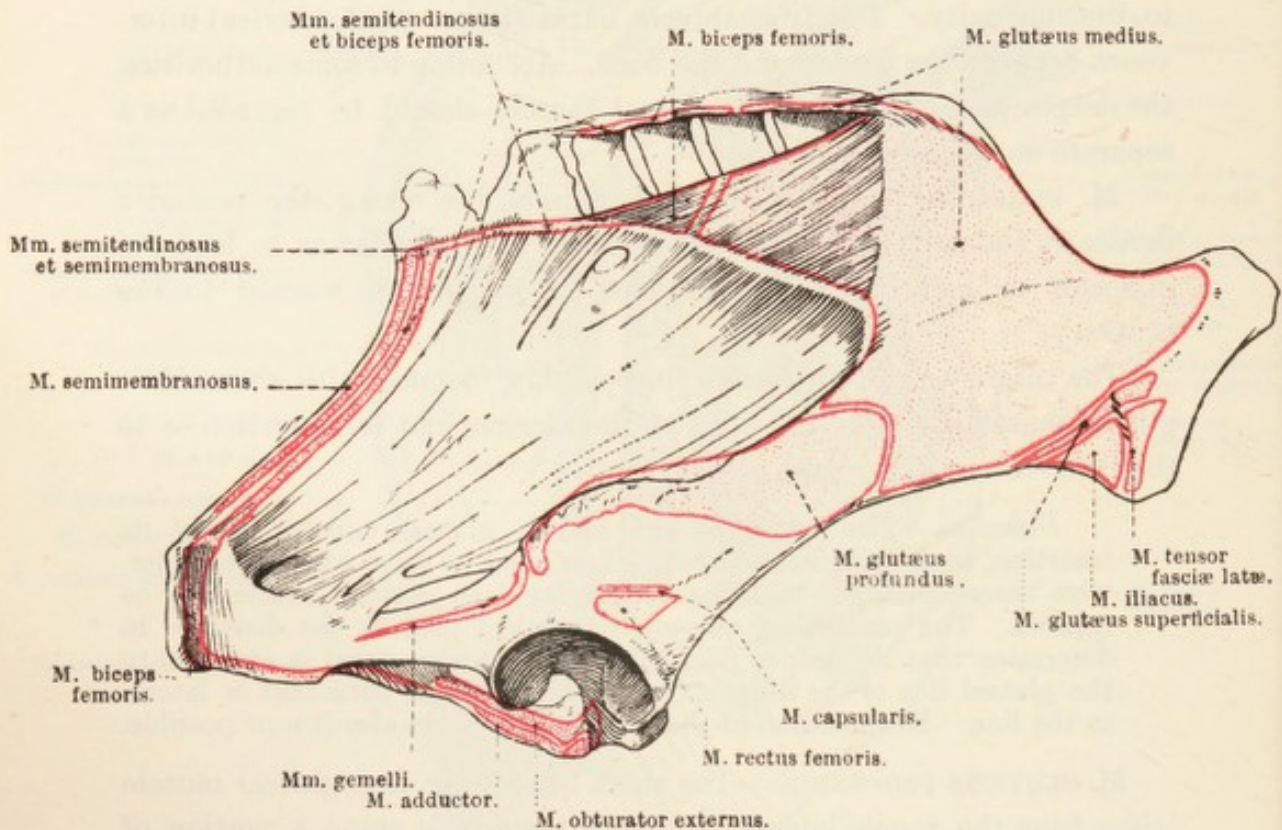


FIG. 74.—Lateral Aspect of the Hip Bone, Sacrum, and associated Ligaments, with Areas of Muscular Attachment.

M. VASTUS LATERALIS.—The lateral vastus muscle arises from the greater part of the lateral and anterior surfaces of the femur. Its insertion is to the patella in common with the rectus femoris.

A. GLUTÆA CRANIALIS.—The cranial gluteal artery is one of the branches of the hypogastric. Its origin will be disclosed during the dissection of the pelvis, and it will then be seen that the vessel quickly divides into a number of branches, which leave the pelvis by the greater sciatic foramen, and are exposed in the present dissection. They supply the gluteal muscles.

A. GLUTÆA CAUDALIS.—The caudal gluteal artery is a vessel of some size. A branch of the lateral sacral artery, it pierces the sacro-tuberous ligament close to the border of the sacrum, and terminates in branches

that supply the biceps, semitendinosus, semimembranosus, superficial gluteal, and coccygeus muscles. Branches also anastomose with the obturator and deep femoral arteries.

N. GLUTEUS CRANIALIS.—As will be seen in the dissection of the pelvis, the cranial gluteal nerve arises by roots derived from the sixth lumbar and first sacral nerves. As a single nerve-trunk it can scarcely be said to exist, for it almost immediately divides into three, four, or five branches, which the dissector of the gluteal region will find traversing the greater sciatic foramen along with the cranial gluteal vessels and the sciatic nerve. These branches supply the gluteal muscles, and one runs between the middle and deep gluteal to end in the tensor of the fascia lata.

N. GLUTEUS CAUDALIS.—Of the two nerves that run backwards (caudalwards) on the surface of the blended sacro-spinous and sacro-tuberous ligaments, the more dorsal is the caudal gluteal. Its origin from the sacral nerves will be revealed during the dissection of the pelvis. At the present time the dissector has to note the exit of the nerve from the greater sciatic foramen and its distribution in the middle gluteal, piriformis, and biceps muscles. One of its branches—to the superficial gluteal muscle—has been previously observed as it bends round the border of the piriformis muscle.

N. CUTANEUS FEMORIS POSTERIOR.—The posterior cutaneous nerve of the thigh leaves the pelvis by the greater sciatic foramen along with the sciatic nerve, with which it is connected for a longer or shorter distance. The nerve runs along the surface of the sacro-spinous and sacro-tuberous ligaments in the direction of the sciatic arch. After giving a communicating branch to the pudendal nerve it divides into two branches. The more dorsal of these ends in the semitendinosus muscle.¹ The ventral branch is mainly cutaneous in its distribution. After passing over the lateral aspect of the sciatic tuber it runs between the biceps and semitendinosus muscles to gain the surface of the limb, where it is distributed to the skin of the lateral and posterior part of the thigh.

N. ISCHIADICUS.—The sciatic nerve leaves the pelvis by the greater sciatic foramen in company with the gluteal nerves and vessels. As a broad band of nerve fibres it passes backwards (caudalwards) obliquely to the level of the hip joint, where it ends by dividing into two branches of unequal size—the tibial and common peroneal nerves. The exact point of division of the sciatic is variable, being occasionally so early as to be close to the greater sciatic foramen.

In its course the nerve lies in succession on the sacro-spinous

¹ Some writers regard this branch as a part of the caudal gluteal nerve.

ligament, the deep gluteal muscle, the extra-pelvic part of the internal obturator, the gemelli, and (possibly) the quadratus femoris muscles. It is covered by the middle gluteal, piriformis, and biceps muscles.

Only one small collateral branch leaves the sciatic nerve. This is

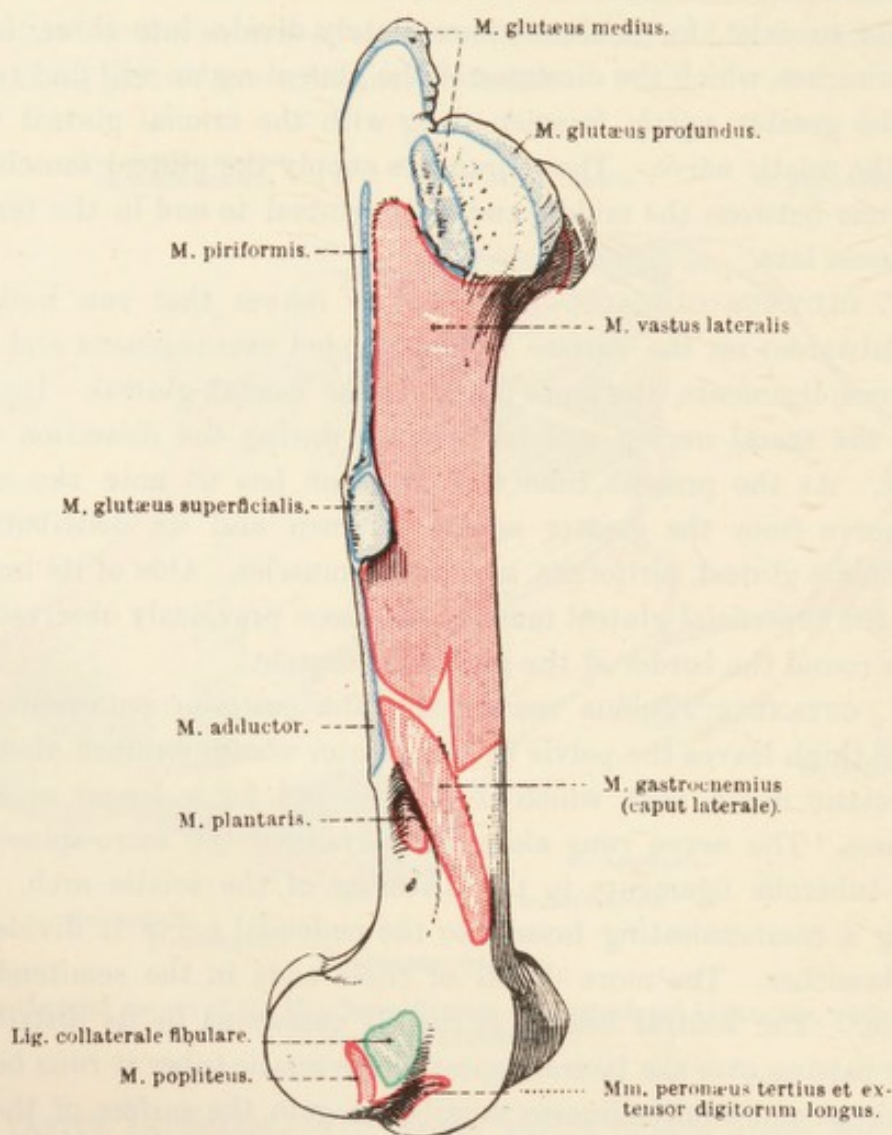


FIG. 75.—Lateral Aspect of the Femur, with Areas of Muscular and Ligamentous Attachment.

distributed to the internal obturator, gemelli, and quadratus femoris muscles. The twig to the internal obturator enters the pelvis by the anterior part of the lesser sciatic foramen.

N. TIBIALIS.—The tibial nerve is the larger and more posterior of the two nerves into which the sciatic divides. It runs down the back of the thigh between the biceps (lateral) and the adductor and semi-membranosus muscles (medial), to disappear from the present dissection by entering the gap between the two heads of the gastrocnemius

muscle. Its subsequent course will be followed in the dissection of the leg.

While in the thigh, the tibial nerve gives off two branches. (1) The *proximal muscular ramus* (ramus muscularis proximalis) is large, and leaves the tibial close to the level of the hip joint. It very soon divides into nerves that are distributed to the biceps, semimembranosus,

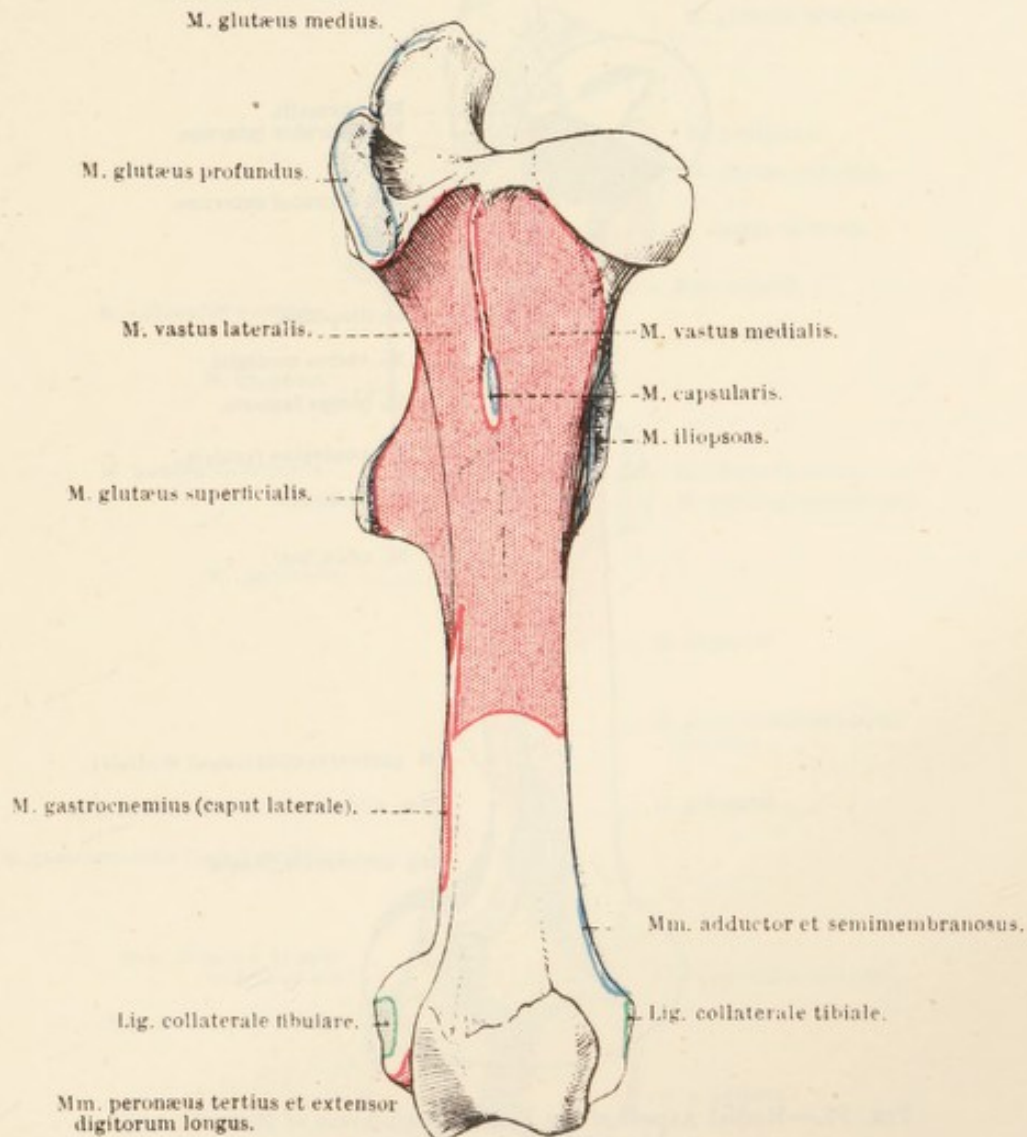


FIG. 76.—Anterior Aspect of the Femur, with Areas of Muscular and Ligamentous Attachment.

and semitendinosus muscles. (2) The *posterior cutaneous sural*¹ nerve (n. cutaneus suræ posterior (medialis)) is a small branch that leaves the tibial just before it passes between the two heads of the gastrocnemius muscle. Leaving the thigh by following the lateral face of the gastrocnemius, the sural nerve will be examined later in the dissection of the leg.

N. PERONÆUS COMMUNIS.—The common peroneal² nerve travels down

¹ *Sura* [L.], the calf of the leg.

² *περόνη* (perone), [Gr.] the pin of a brooch or buckle (fibula).

the back of the thigh in company with, and immediately anterior to, the tibial nerve. Arriving at the gastrocnemius muscle, the two nerves part company, the peroneal running over the lateral head of the gastrocnemius, under cover of the biceps, to reach the region of the

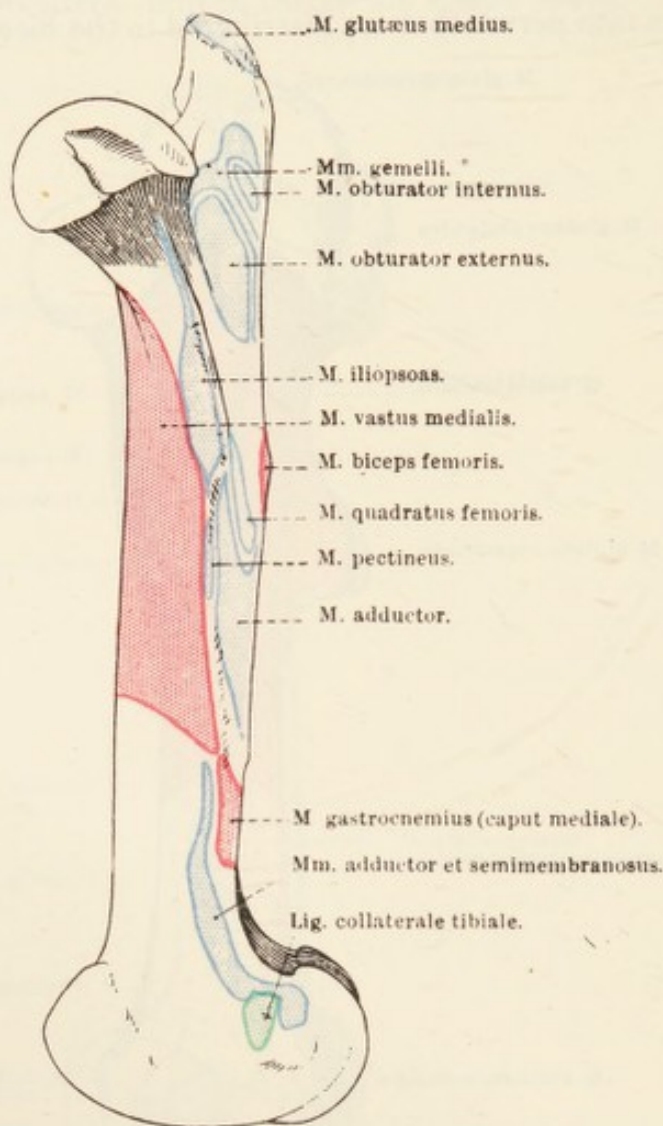


FIG. 77.—Medial Aspect of the Femur, with Areas of Muscular and Ligamentous Attachment.

head of the fibula, where it divides into the superficial and deep peroneal nerves.

The collateral branches of the common peroneal nerve are three in number. (1) A small nerve to the biceps muscle. (2) A small filament (occasionally absent) that arises about the middle of the thigh and joins the posterior cutaneous sural nerve. (3) The *anterior cutaneous sural nerve* (n. cutaneus suræ anterior (lateralis)), which, dividing into two or three branches, pierces the distal part of the biceps and is distributed to the skin of the lateral surface of the leg.

Dissection.—The deep gluteal muscle must be reflected in order that the origin of the rectus femoris and capsularis muscles may be thoroughly exposed. Care must be taken not to injure the capsule of the hip joint, with which the deep gluteal muscle is intimately associated.

A strong sheet of fascia connects the tensor of the fascia lata with the border of the ilium, and covers the lateral margin of the iliacus muscle. This must be cut away.

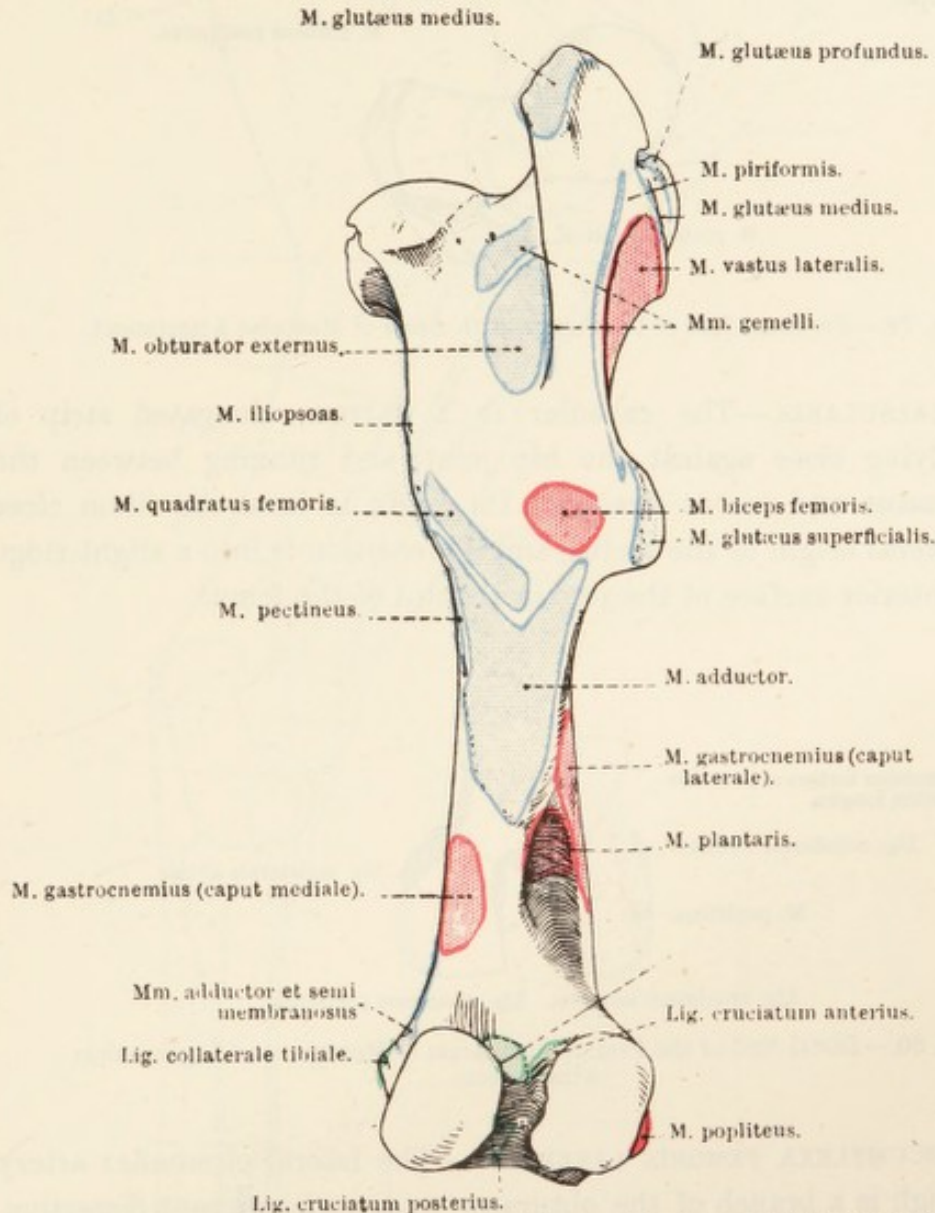


FIG. 78.—Posterior Aspect of the Femur, with Areas of Muscular and Ligamentous Attachment.

*—Area of attachment of one of the ligamentous bands of the lateral meniscus.

M. QUADRICEPS FEMORIS.—Although named the quadriceps, only three heads can be satisfactorily demonstrated. These are the two vasti muscles (*m. vastus medialis* and *m. vastus lateralis*), already dissected, and the straight muscle of the thigh (*m. rectus femoris*), now to be examined. The fourth head (*m. vastus intermedius*) is so much blended with the medial vastus as to be, to all intents and purposes, part of this muscle.

M. rectus femoris.—The rectus femoris muscle is the middle member of the quadriceps group, and arises by two short tendons from depressions on the ilium just in front of the acetabulum: there is a mucous (synovial) bursa between the lateral tendon and the ilium. Its insertion is into the patella along with the other parts of the quadriceps.

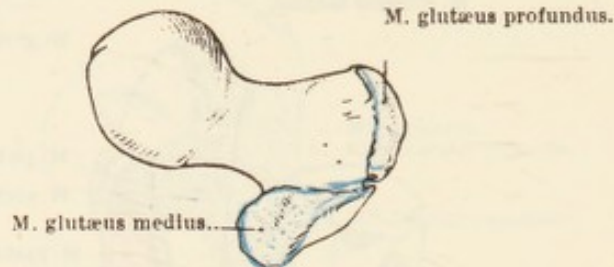


FIG. 79.—Proximal End of the Femur, with Areas of Muscular Attachment.

M. CAPSULARIS.—The capsular is a narrow, elongated strip of muscle lying close against the hip joint, and running between the lateral vastus and rectus femoris. Its origin is from the ilium close to the lateral origin of the rectus, and its insertion is into a slight ridge on the anterior surface of the proximal third of the femur.

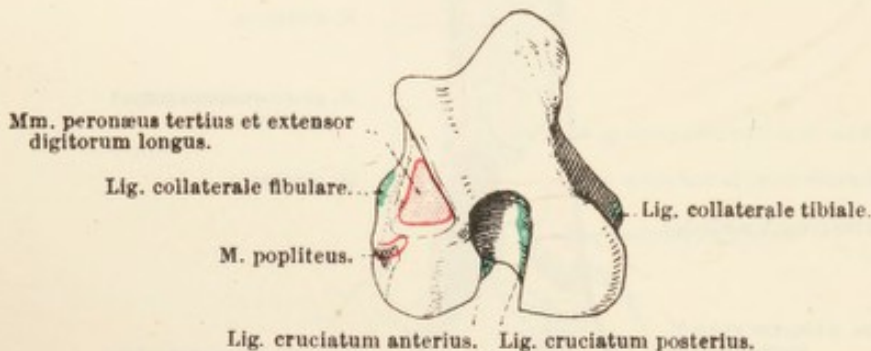


FIG. 80.—Distal End of the Femur, with Areas of Muscular and Ligamentous Attachment.

A. CIRCUMFLEXA FEMORIS LATERALIS.—The lateral circumflex artery of the thigh is a branch of the obturator, and, in the present dissection, appears between the ilium and the iliacus muscle. Branches are furnished to the superficial and middle gluteal muscles and the tensor of the fascia lata. The main continuation of the artery disappears between the rectus femoris and the lateral vastus muscles, in which it is expended.

Dissection.—Cut across the sciatic nerve a short distance from the greater sciatic foramen and the femoral vessels on a level with the hip joint. Remove the remains of those muscles that are attached in close proximity to the hip joint, and clean the outer surface of the joint capsule.

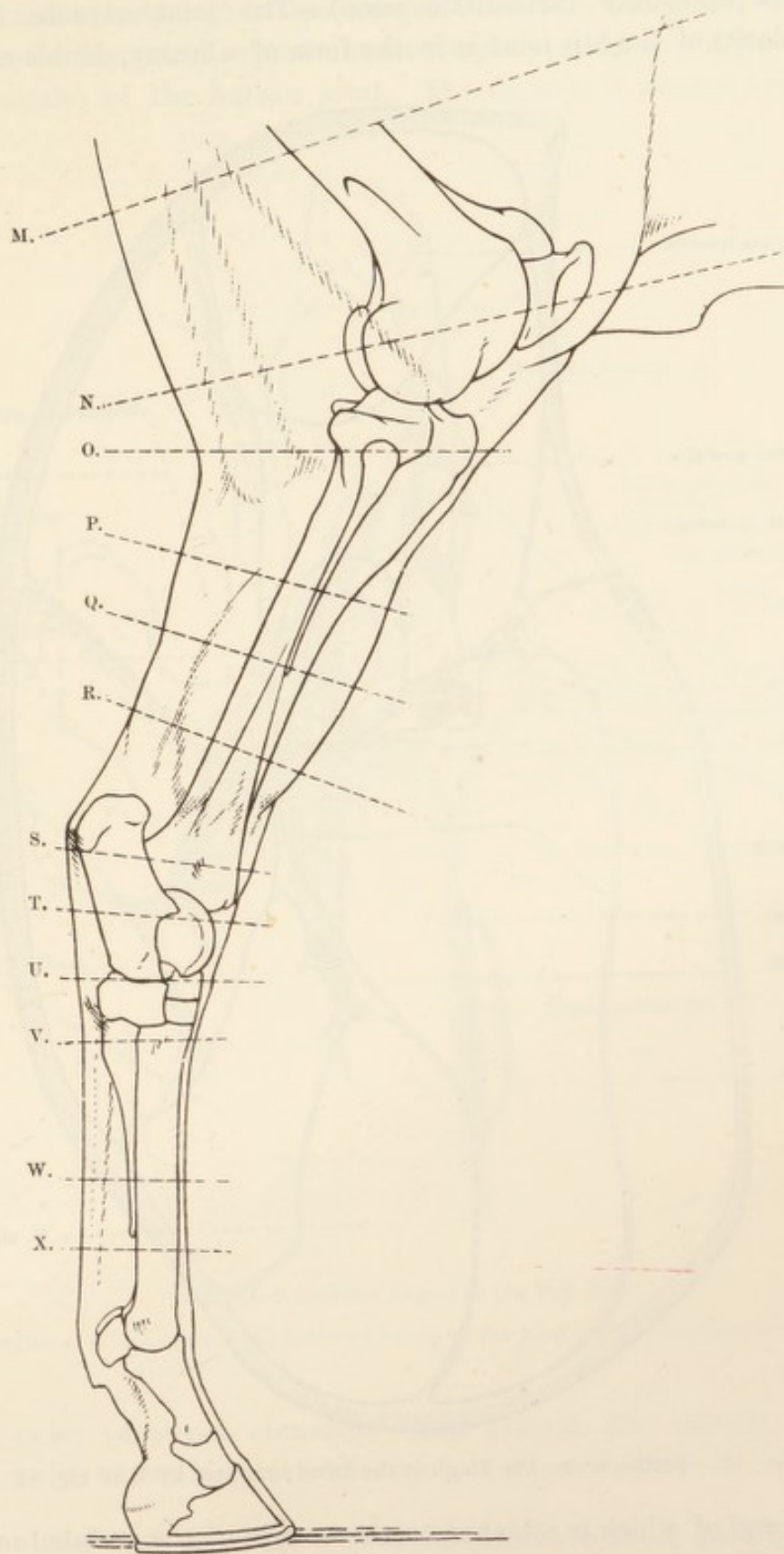


FIG. 81.—Key Outline of the Pelvic Limb to Indicate the Level of the Transverse Sections illustrated in Subsequent Figures.

THE HIP JOINT (*articulatio coxæ*).—The joint capsule (*capsula articularis*) of the hip joint is in the form of a roomy, double-mouthed

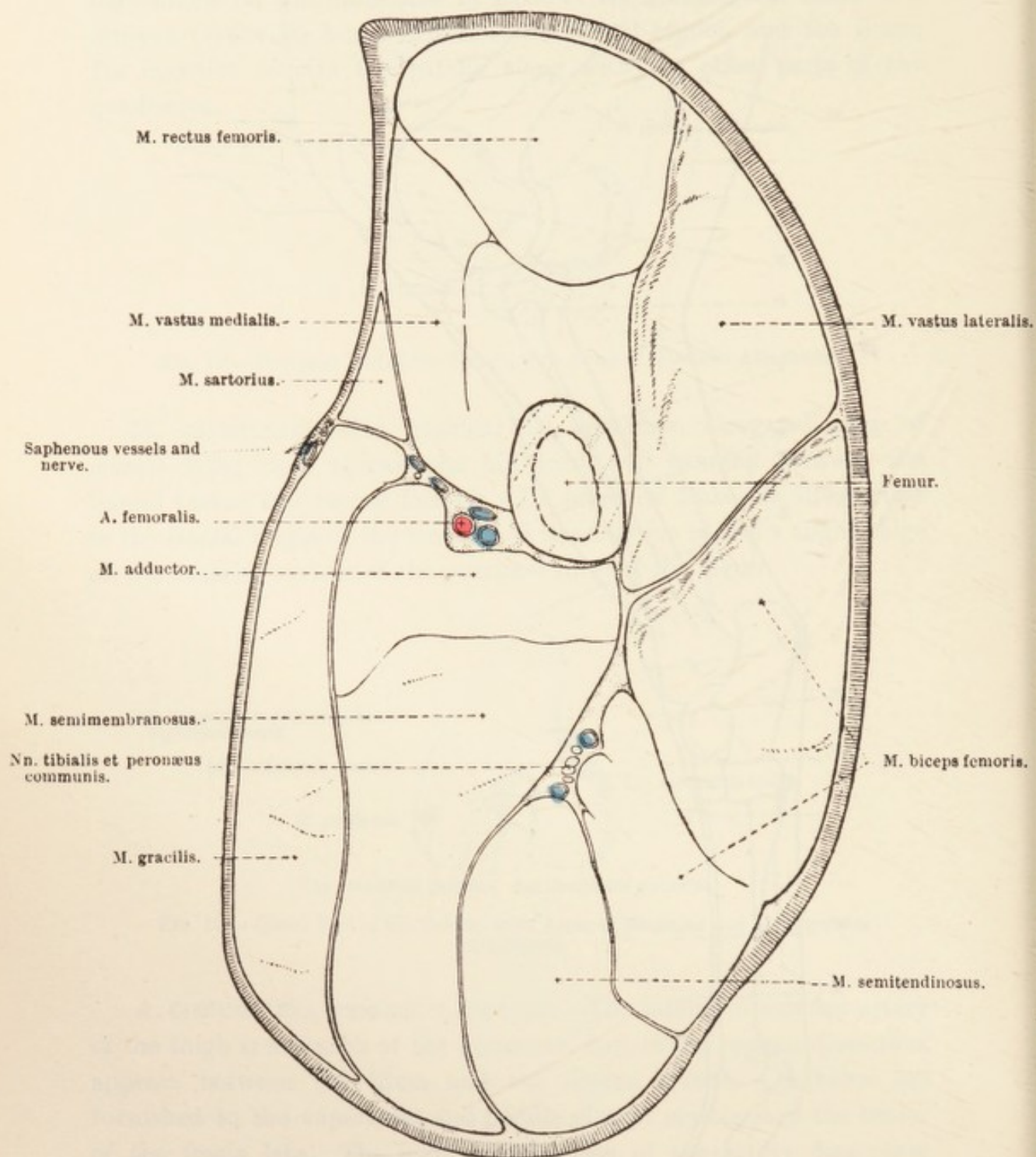


FIG. 82.—Section across the Thigh at the Level indicated by M in Fig. 81.

sac, one end of which is attached to the margin of the acetabulum and the transverse ligament thereof. The femoral attachment is to the neck of the bone, a very short distance from the articular margin, except at the lateral part of the joint, where 2 or 3 cm. of the neck is included within the capsule. The strongest part of the capsule is

lateral and anterior, where an oblique band of fibres passes from the ilium to the femur and represents the *ilio-femoral ligament* (ligamentum ilio-femorale) of the human joint. The capsule is closely supported

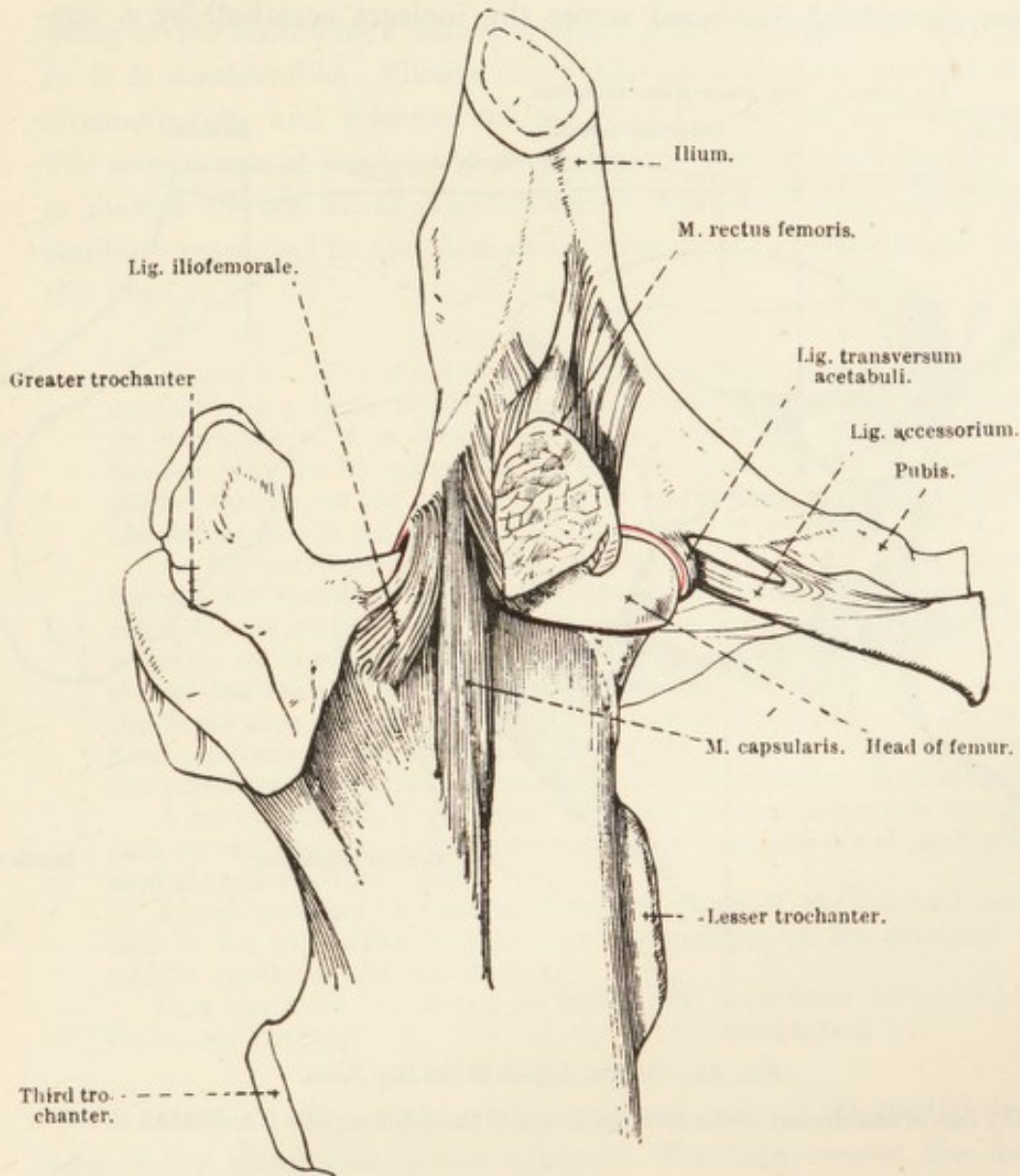


FIG. 83.—Anterior Aspect of the Hip Joint.

The line of attachment of the synovial lining of the joint capsule is indicated in red.

by muscles (external obturator, deep gluteal, and capsular) except posteriorly, where it is overlaid by a cushion of fat.

Dissection.—Open the joint capsule and examine its contents.

The hip joint is formed by the acetabulum and the head of the femur; but it must be remembered that the whole of the acetabulum is not articular, inasmuch as its medial half contains a depressed non-

articular *fossa acetabuli*.¹ Nor is the whole of the head of the femur articular, for it carries an extensive *fovea* to which ligaments are attached.

Surrounding the acetabular margin is a ring of fibro-cartilage, the *labrum glenoidale*,² continued across the incisura acetabuli by a liga-

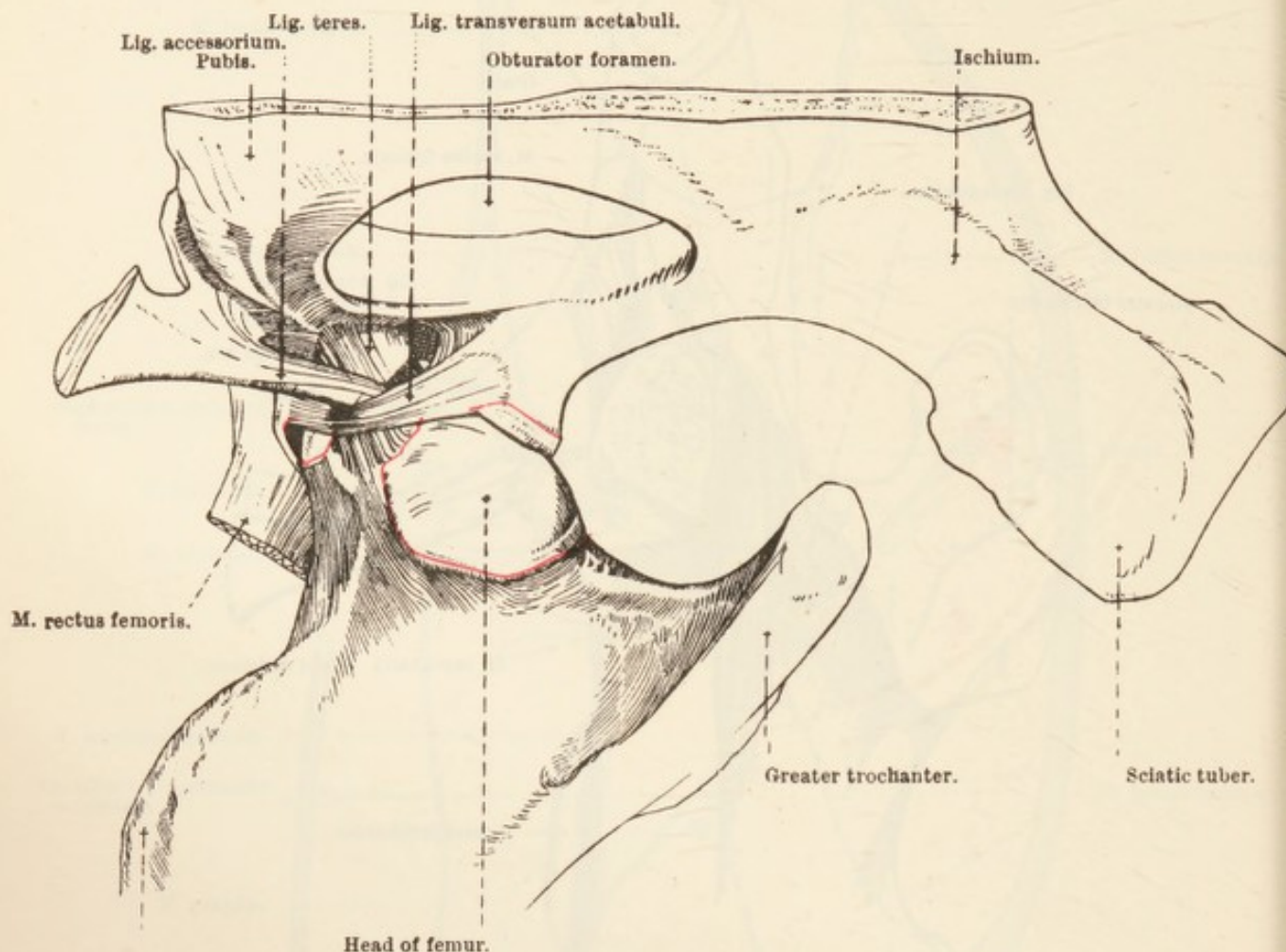


FIG. 84.—Medial Aspect of the Hip Joint.

The line of attachment of the synovial lining of the joint capsule is indicated in red.

mentous bridge, the *transverse ligament* (ligamentum transversum acetabuli).

Passing from the fossa acetabuli, close to the acetabular notch, to the fovea on the head of the femur is the short, strong *round ligament* (ligamentum teres). In the hip joint of the Equidæ a ligamentous band, the *accessory ligament* (ligamentum accessorium), springs partly from the pubic insertion of the straight abdominal muscle and partly

¹ *Fossa* [L.], a ditch or trench. *Acetabulum* [L.], a vessel for vinegar (from *acetum*, vinegar). C. Plinius Secundus applies the name to the socket of the hip bone.

² *Labrum* [L.], a lip or rim. γλήνη (glēnē) [Gr.], a cavity or pit. εἶδος (eidos) [Gr.], shape.

from an oblique groove on the ventral surface of the pubis, and enters the joint cavity through the acetabular notch dorsal to the transverse ligament, to blend with the femoral attachment of the round ligament.

The articulation between the acetabulum and the head of the femur being of the nature of a ball-and-socket joint, the range of movement in it is considerable. Flexion and extension, abduction and adduction, circumduction, and rotation are all possible, but not in like degree. The movements of flexion and extension are most free, while abduction is limited by the round and accessory ligaments, and adduction is similarly restricted by the close association of the gluteal muscles with the joint.

Dissection.—The anterior, lateral, and posterior aspects of the leg are occupied by a thick layer of muscles closely invested by stout fascia. In consequence, it is impossible to distinguish the boundaries of the various muscles by palpation in the proximal half of the leg. The medial surface, on the contrary, carries no muscles, with the result that the flat surface of the tibia can readily be felt through the skin.

As the tarsus is approached, the tendons of some of the muscles become sufficiently obvious to permit of ready recognition. For example, the tendon of Achilles (gastrocnemius and plantaris tendons) is visible in its relation to the tuber of the calcaneus, a hollow on each side of the limb giving it greater prominence. A sharp fold of skin on the flexor aspect of the tarsus is also a prominent feature of the superficial anatomy of the limb, and marks the position of the tendons of the peroneus tertius, long digital extensor, and anterior tibial muscles.

A horny callosity ("chestnut"), similar to that present in the distal part of the forearm, projects from the skin over the distal part of the medial surface of the tarsus.

The skin should be removed from the whole of the leg and tarsus, and as far in a distal direction as the junction of the proximal and middle thirds of the metatarsus.

Care must be taken not to injure the superficial veins and the cutaneous nerves.

V. SAPHENA.—The origin of the saphenous vein as the medial dorsal vein of the metatarsus is now exposed. The vein crosses the flexor aspect of the tarsus, and then runs up the medial aspect of the leg and thigh in order to reach the apex of the femoral triangle. Near the tarsus the saphenous vein is connected with the anterior tibial, and in the proximal third of the leg it is joined by the recurrent tibial vein.

V. RECURRENS TIBIALIS.—The recurrent tibial begins at the tarsus as the continuation of the lateral plantar metatarsal vein. Near its origin it is connected with the posterior tibial and recurrent tarsal veins. It follows the medial border of the tendon of Achilles and the medial head of the gastrocnemius muscle to join the saphenous vein in the proximal part of the leg. Union with either the posterior

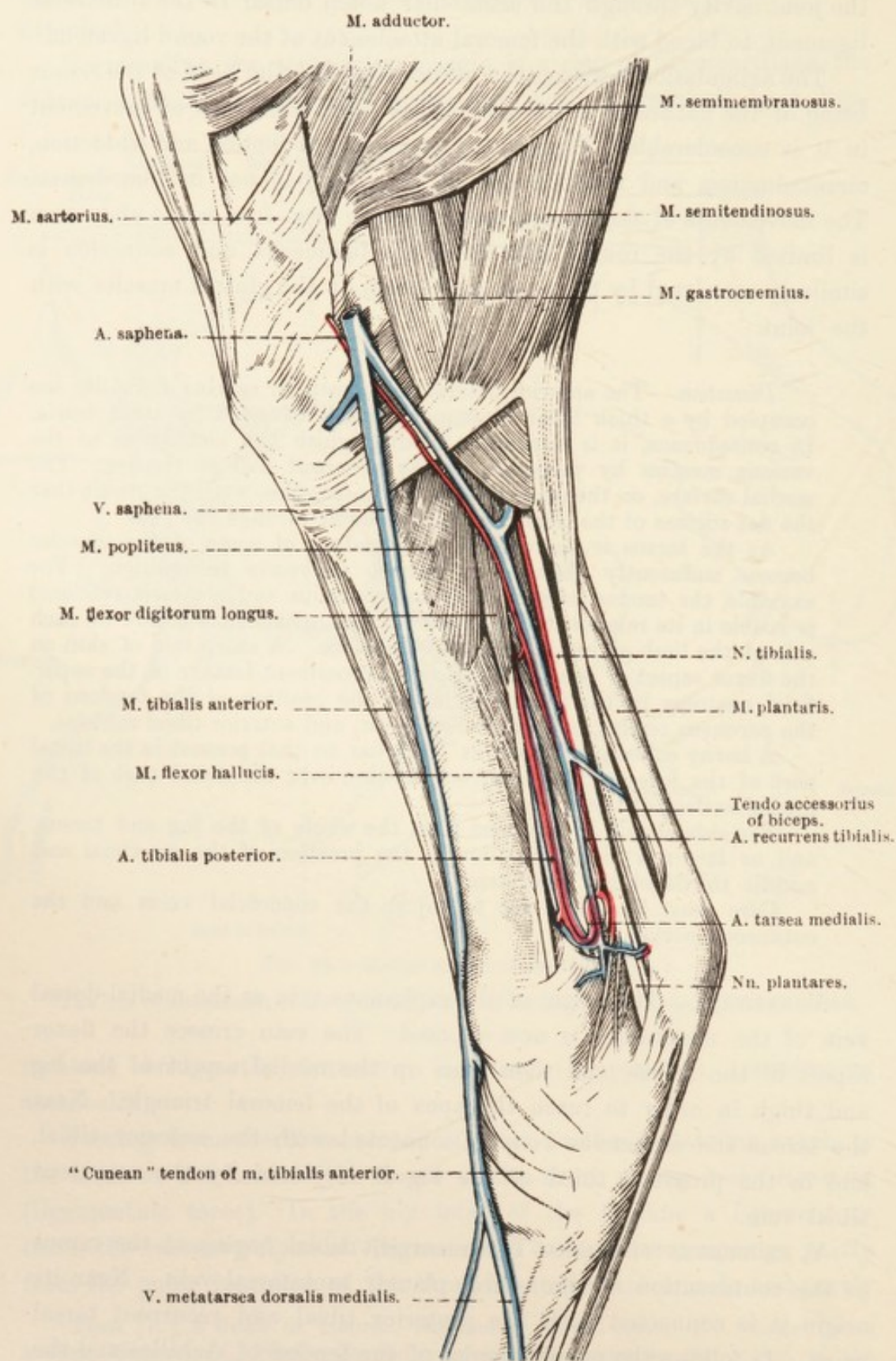


FIG. 85.—Superficial Dissection of the Medial Aspect of the Leg and Tarsus.

femoral or the popliteal vein is established through an anastomotic vessel of some size.

V. TARSEA RECURRENS.—The recurrent tarsal vein follows the lateral border of the tendon of the gastrocnemius, and ends by uniting with the posterior femoral vein, which it gains by passing between the biceps and the lateral head of the gastrocnemius. In the region of the tarsus it communicates with the lateral metatarsal and recurrent tibial veins.

N. SAPHENUS.—The skin over the medial aspect of the leg and tarsus is supplied by branches of the saphenous nerve.

N. CUTANEUS SURÆ POSTERIOR (MEDIALIS).—As has been seen already, the posterior cutaneous sural nerve is a branch of the tibial. It accompanies the recurrent tarsal vein along the lateral head of the gastrocnemius and the lateral border of the tendon of this muscle, and supplies the skin over the posterior and lateral face of the leg, tarsus, and metatarsus.

N. CUTANEUS SURÆ ANTERIOR (LATERALIS).—The anterior cutaneous sural nerve, a branch of the common peroneal, pierces the biceps close to the aponeurotic tendon of this muscle, and is distributed to the skin over the lateral surface of the leg.

N. PERONÆUS SUPERFICIALIS.—The superficial peroneal, the smaller of the two terminal branches of the common peroneal nerve, pierces the fascia about the middle of the tibial region, and supplies the skin over the anterior and lateral aspect of the leg, tarsus, and metatarsus. Its muscular branch—to the long peroneal muscle—will be disclosed at a later stage of the dissection.

FASCIA OF THE LEG AND TARSUS.—The strong fascia of the leg (fascia cruris) can be resolved into several layers, but whether to do this is worth the while of the dissector is open to question. It is probably sufficient to note that there is little difficulty in distinguishing three layers. The most superficial layer is a continuation of the fascia lata and the fascia of the medial surface of the thigh; while the middle layer is connected with the expanded tendons of the tensor fasciæ latæ, biceps femoris, gracilis, sartorius, and semitendinosus muscles. These two layers are closely associated with each other, and together form a common investment for the muscles of the leg. They are firmly attached to the tibia and blend with the ligaments of the patella, and, distally, they are continuous with the fascia of the tarsus and metatarsus. In addition, they are connected with the calcaneal attachment of the biceps and semitendinosus muscles.

The deepest layer of the fascia of the leg forms intimate sheaths for the muscles, and furnishes intermuscular septa from which, not

infrequently, fibres of the muscles have origin. As a consequence of the attachment of the septa to the tibia the muscles of the leg are grouped within three fascial compartments: (1) Tibialis anterior and extensor digitorum longus; (2) peronæus longus; (3) flexor digitorum longus, flexor hallucis longus, tibialis posterior, and popliteus. Strictly speaking, the popliteal muscle should be regarded as occupying a special compartment of its own.

The tarsal fascia (fascia tarsi) is attached to the various bony prominences in the region of the tarsus, and blended with the neighbouring ligaments. At the back of the tarsus it is particularly strong, forming a bridge from the medial collateral ligament on the one hand to the tuber calcanei and the plantar ligament on the other. The bridge converts the groove formed by the tarsus into a short canal, through which the deep flexor tendon and the plantar vessels and nerves pass to gain the metatarsus. As it passes through the canal, the tendon is provided with a mucous (synovial) sheath.

In front of the tarsus also the fascia is strong, and here it is connected with the tendon of the long extensor muscle. In this region there are three fascial bands (transverse ligaments), which will be examined in connection with the tendons of the anterior and lateral tibial muscles.

Dissection.—The fascial investment of the muscles must now be removed. It is well to begin this dissection at the back of the leg. In the hollow bounded posteriorly by the tendon of the gastrocnemius considerable care must be exercised to avoid injury to small vessels. On the medial aspect of the limb in this region the small recurrent tibial artery must be secured as it runs in a proximal direction close to the edge of the gastrocnemius tendon. Risk of destruction of the vessel will be minimised by first disclosing the medial tarsal artery from which it arises. Over the lateral surface of the tuber of the calcaneus the very small lateral tarsal artery is distributed.

As the dissection proceeds, it will be found necessary to remove the fascial insertions of the biceps and semitendinosus muscles.

M. GASTROCNEMIUS.—The strong, tendinous gastrocnemius¹ muscle takes origin from the femur by two heads, each definite and flattened. The lateral head (caput laterale) arises from the margin of the plantaris fossa, while the medial head (caput mediale) springs from a rough elevated area on the medial lip of the linea aspera at the same level as the fossa. Through the gap between the two heads the popliteal vessels and the tibial nerve gain the leg. The two heads soon join to form a common fleshy belly, which tapers to a strong rounded tendon about the junction of the proximal and middle thirds of the tibia.

The tendon of the gastrocnemius (tendo calcaneus Achillis) is very

¹ γαστήρ (gastēr) [Gr.], belly. κνήμη (cnēmē) [Gr.], the leg.

intimately related to that of the plantaris muscle. At first the plantaris tendon is the deeper of the two; but, twisting spirally round the medial edge of the tendon of the gastrocnemius, it becomes the more superficial before the summit of the tuber of the calcaneus is reached. An extensive synovial bursa intervenes between the two tendons from the point where the twist begins to about the middle of the tarsus. A strong but narrow fascial band springs from the femur close to the origin of the lateral head of the gastrocnemius, and, running down the surface of this muscle, is blended with its tendon, as well as that of the plantaris.

The insertion of the gastrocnemius is to a transversely disposed depression on the summit of the tuber of the calcaneus, a small synovial bursa intervening between the tendon and the anterior convex area of the tuber.

M. SOLEUS.—The narrow, thin soleus¹ muscle lies along the lateral border of the gastrocnemius. Its origin is from the head of the fibula, and its slender tendon joins that of the gastrocnemius.

Dissection.—Cut across the gastrocnemius muscle just where the two heads are about to join. The reflexion of the lateral head is made a little difficult by its close connection with the underlying plantaris muscle.

M. PLANTARIS.²—The rounded plantaris³ muscle possesses a strength out of all proportion to its volume, from the circumstance that it is mainly composed of tendinous tissue among which are scattered muscular fibres. The origin of the muscle is from the depths of the plantaris fossa, where it is closely connected with the lateral head of the gastrocnemius. As has been already noted, its powerful, rounded tendon curves spirally round that of the gastrocnemius, and flattens out over the summit of the tuber of the calcaneus, to which it is attached by a medial and a lateral slip. As previously stated, a large synovial bursa is interposed between the plantaris and gastrocnemius tendons and between the plantaris tendon and the bone.

From the tuber of the calcaneus, the plantaris tendon appears to be continued into the metatarsus; but there is reason for regarding this apparent continuation as a modified short flexor of the digit (*m. flexor digitorum brevis*).

¹ *Solea* [L.], a sole fish (in a borrowed sense, from the outline of the fish having a resemblance to the sole of the human foot). The name is given to the human muscle on account of its shape.

² This muscle is often termed the superficial flexor of the digit—*m. flexor digitorum (pedis) sublimis*.

³ *Plantaris* [L.] (from *planta*, the sole of the foot), of or belonging to the sole of the foot.

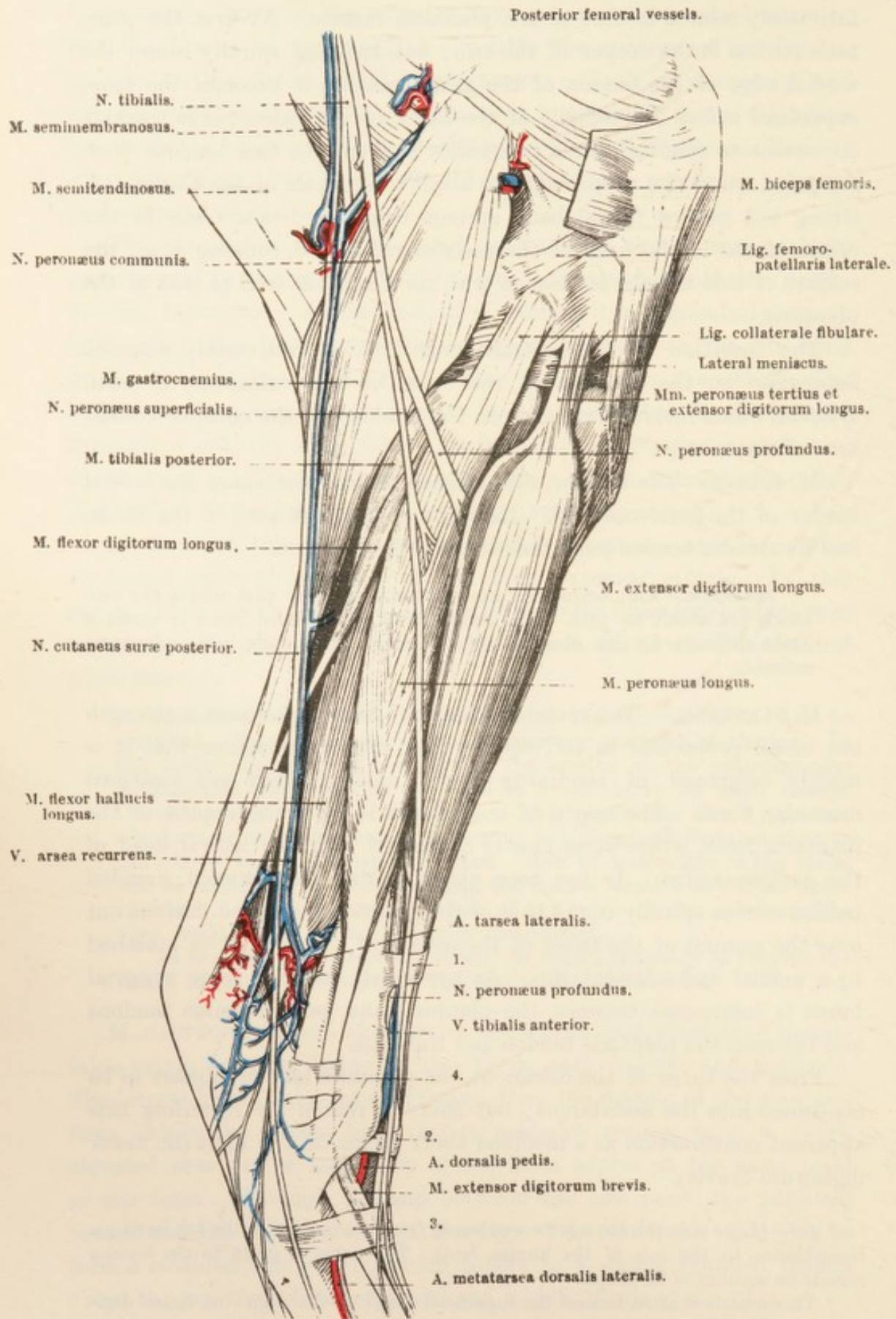


FIG. 86.—Superficial Dissection of the Lateral Aspect of the Leg and Tarsus.
1, 2, 3, 4—Transverse ligaments that retain the extensor tendons in position.

N. TIBIALIS.—The tibial¹ nerve, the larger of the two divisions of the sciatic, has already been followed down the back of the thigh to the point where it disappears between the two heads of the gastrocnemius muscle. The rest of its course is now revealed. Between the heads of the gastrocnemius the nerve comes into relation with the plantaris muscle, the medial border of which it follows closely until the level of the summit of the tuber calcanei is reached. At this point it divides into the medial and lateral plantar nerves, which, passing down the

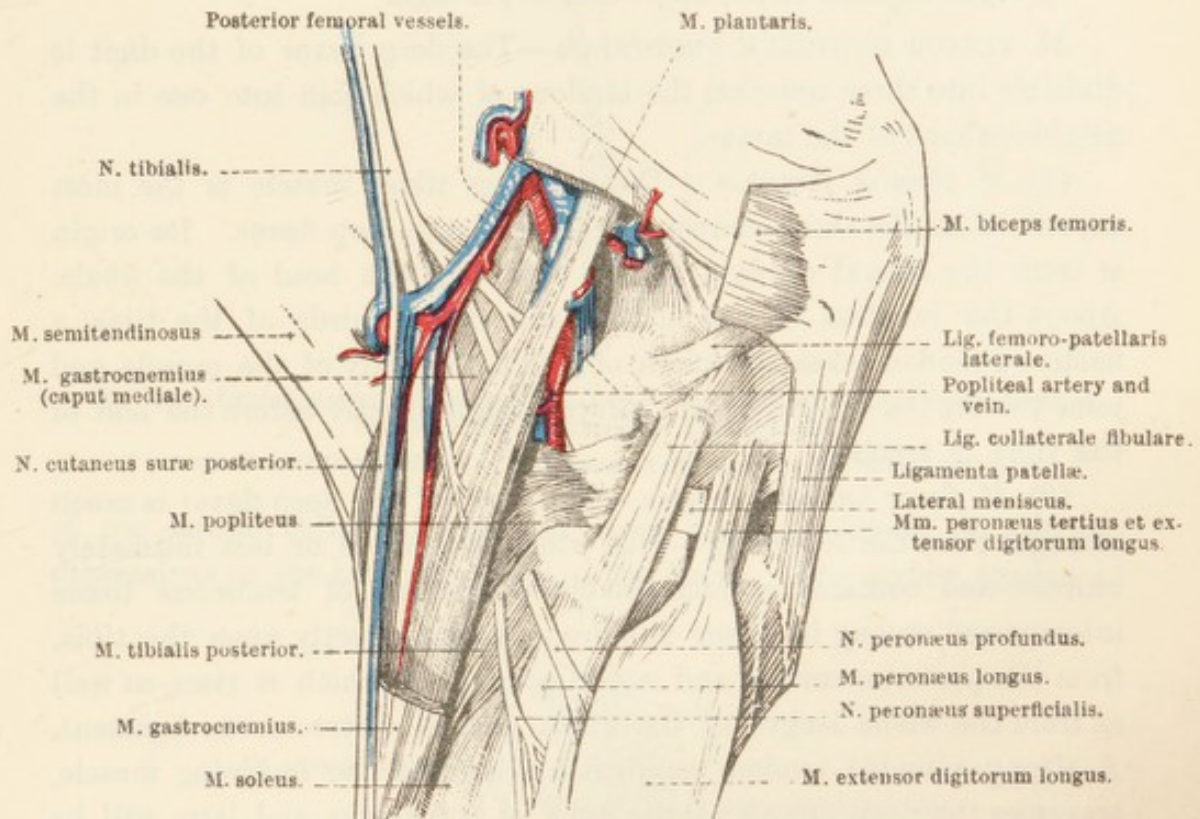


FIG. 87.—Deep Dissection of the Popliteal Region.

short canal at the back of the tarsus, will be traced in the metatarsus in a later dissection. In its course down the leg the tibial nerve is related to a small artery (and its companion vein) that forms an anastomotic link between the posterior femoral and recurrent tibial arteries.

The collateral branches of the tibial nerve are the proximal and distal muscular rami, and the posterior cutaneous sural nerve. The *proximal muscular branch* (ramus muscularis proximalis) was examined during the course of the dissection of the thigh. The origin of the *posterior cutaneous sural nerve* (n. cutaneus surae posterior (medialis)) was noted as occurring about the middle of the thigh. The nerve crosses the surface of the lateral head of the gastrocnemius muscle and

¹ *Tibia* [L.], the shin-bone; the name was used in a borrowed sense to signify a musical pipe, or flute, which was originally made of bone.

becomes superficial about the middle of the leg. Its superficial course has already been examined. The *distal muscular branch* (ramus muscularis distalis) arises from the tibial nerve as this lies between the heads of the gastrocnemius muscle. It furnishes filaments to the gastrocnemius, soleus, plantaris, the flexors of the digit, and the popliteus.

Dissection.—Reflect the plantaris muscle, and examine the deep muscles of the leg. These are four in number, three of which (flexor hallucis longus, flexor digitorum longus, and tibialis posterior) may be grouped together as the deep flexor of the digit.

M. FLEXOR DIGITORUM PROFUNDUS.—The deep flexor of the digit is divisible into three muscles, the tendons of which join into one in the neighbourhood of the tarsus.

(1) *M. tibialis posterior*.—The posterior tibial muscle is the most superficial of the three component parts of the deep flexor. Its origin is from the lateral condyle of the tibia and the head of the fibula. About the junction of the middle and distal thirds of the tibia a flattened tendon takes the place of the fleshy belly of the muscle and joins the tendon of the flexor hallucis longus shortly before the end of the tibia is reached.

(2) *M. flexor hallucis¹ longus*.—This head of the deep flexor is much stronger than the foregoing—with which it is more or less intimately united—and contains a considerable proportion of tendinous tissue interspersed among its fleshy bundles. It lies directly upon the tibia, from the posterior surface and lateral condyle of which it rises, as well as from the whole length of the fibula and the interosseous ligament. A strong, rounded tendon, common to this and the foregoing muscle, traverses the deep groove at the back of the tarsus, and later will be followed down the metatarsus. It should be noticed that the common tendon is exceedingly dense and partly cartilaginous where it plays over the groove formed by the tuber and sustentaculum tali of the calcaneus.

(3) *M. flexor digitorum longus*.—The slender medial head of the deep flexor is the most distinct, and lies in the groove between the foregoing muscles and the popliteus. Its origin is from behind the lateral condyle of the tibia. A slender, rounded tendon begins about the middle of the tibia, traverses a groove provided with a synovial sheath on the medial malleolus of the tibia, and joins the main tendon of the deep flexor in the proximal third of the metatarsus.

M. POPLITEUS.—The triangular popliteal² muscle covers part of the

¹ *Hallux* [L.], the great toe. ἅλλομαι (hallomai) [Gr.], to spring, leap, bound.

² *Poples* [L.], the ham or hough. (In the horse, the term *hough* or *hock* is used to indicate the tarsal region, instead of the back of the femoro-tibial joint.)

flexor aspect of the joint between the femur and the tibia. Its origin is within the capsule of the joint and beneath the femoral attachment

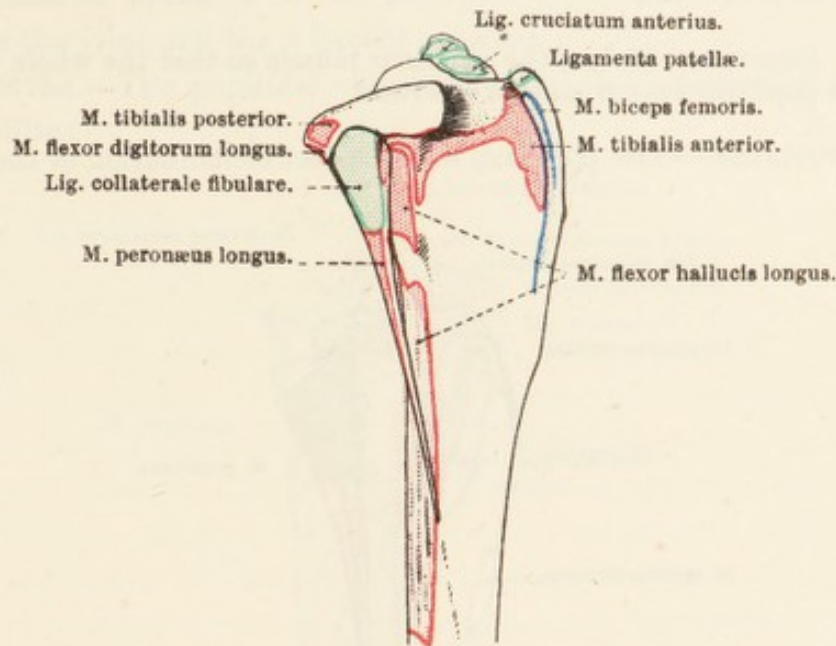


FIG. 88.—Lateral Aspect of the Proximal Part of the Tibia and Fibula, with Areas of Muscular and Ligamentous Attachment.

* = Area of attachment of one of the ligamentous bands of the lateral meniscus.

of the lateral collateral ligament, from the more distal of the two depressions on the lateral condyle of the femur. The strong tendon of

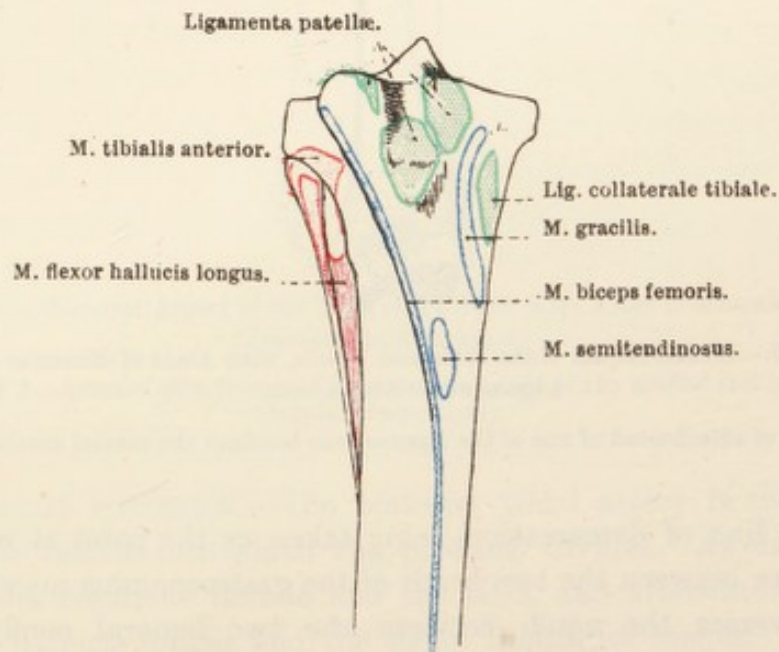


FIG. 89.—Anterior Aspect of the Proximal Part of the Tibia and Fibula, with Areas of Muscular and Ligamentous Attachment.

origin is clothed by part of the synovial lining of the joint, and is in contact with the border of the lateral meniscus of fibro-cartilage.

The fibres of the muscle spread out with different degrees of

obliquity, and are attached to the triangular area on the proximal posterior part of the tibia and the corresponding stretch of the medial border of this bone.

Dissection.—Reflect the popliteus muscle so that the whole course of the popliteal vessels may be followed.

A. POPLITEA.—The popliteal is the direct continuation of the femoral

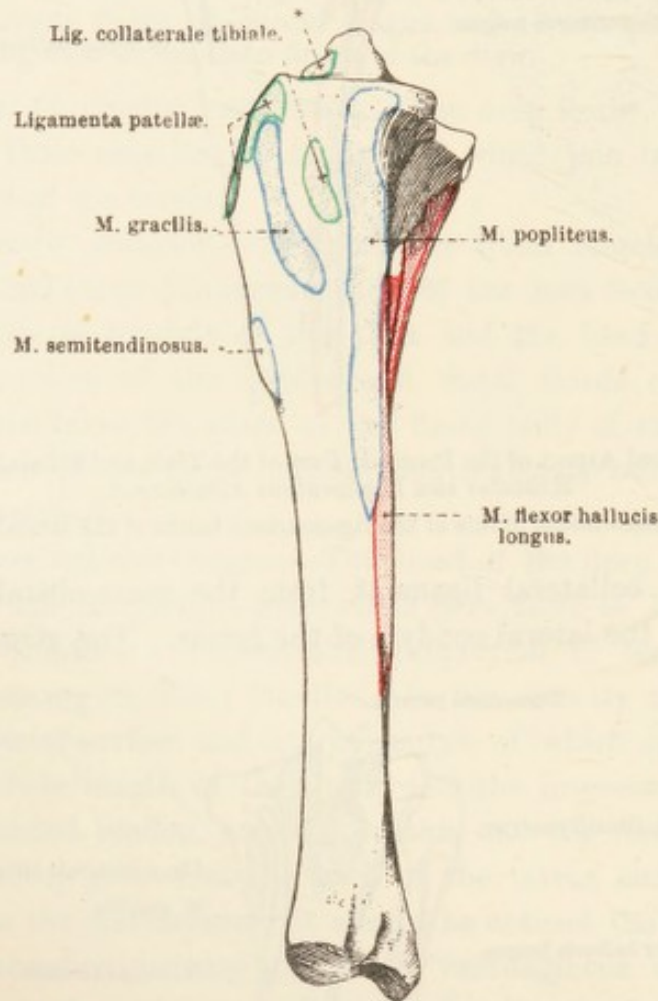


FIG. 90.—Medial Aspect of the Tibia and Fibula, with Areas of Muscular and Ligamentous Attachment.

* Area of attachment of one of the ligamentous bands of the medial meniscus.

artery, the line of demarcation being taken as the point at which the vessel passes between the two heads of the gastrocnemius muscle. The artery traverses the notch between the two femoral condyles and comes into close relation with the capsule of the femoro-tibial joint. During the first part of its course the artery runs parallel to and in front of the plantaris muscle. It next passes between the popliteus muscle and the joint capsule, and afterwards between this muscle and the proximal part of the tibia. It ends, under cover of the popliteus

muscle, by dividing into two vessels of unequal size, the anterior and posterior tibial arteries.

The collateral branches of the popliteal artery are small, and distributed to the joint and the adjacent muscles.

V. POPLITEA.—The popliteal vein lies medial to the artery of which it is a satellite.

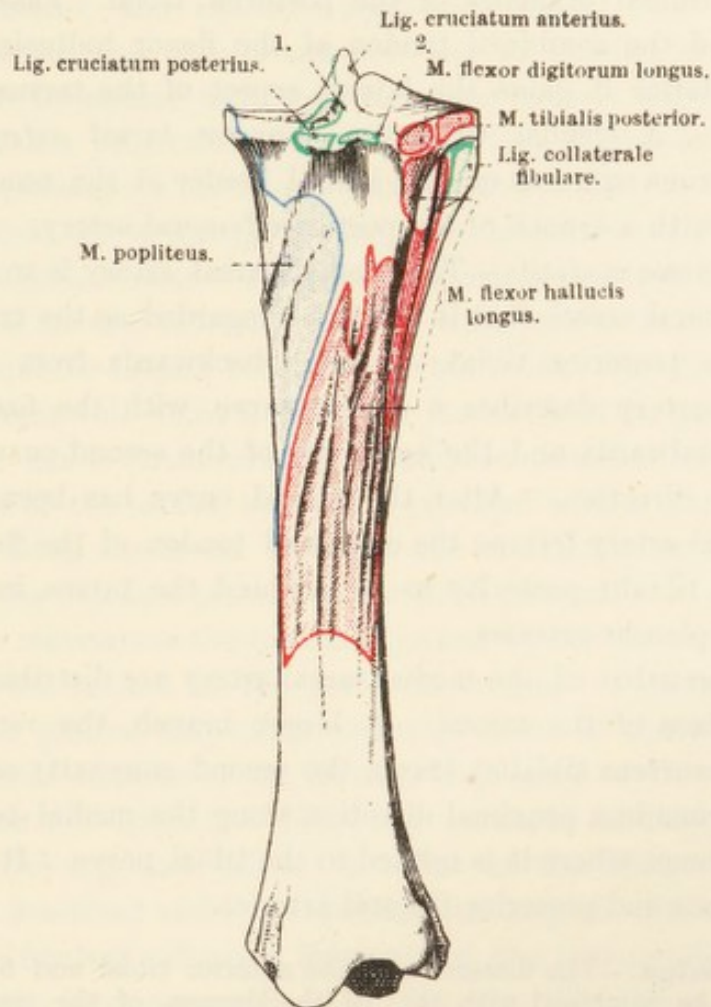


FIG. 91.—Posterior Aspect of the Tibia and Fibula, with Areas of Muscular and Ligamentous Attachment

1 and 2 — Areas of attachment of ligamentous bands of the medial and lateral menisci respectively.

A. TIBIALIS POSTERIOR.—The posterior tibial artery is the smaller of the two vessels into which the popliteal divides. At first it lies between the popliteus muscle and the tibia, and afterwards between the flexor hallucis longus and the flexor digitorum longus. As far as the middle of the tibia the artery is deep-seated, but, following the posterior border of the tendon of the long flexor of the digit, it becomes more superficial as the distal end of the tibia is approached. About the level of the summit of the tuber calcanei the vessel ends by dividing into the lateral and medial tarsal arteries.

The branches of the posterior tibial artery are:—

(1) *A. nutritia tibiæ*.—The nutrient artery of the tibia leaves the parent vessel as this emerges from beneath the popliteus muscle.

(2) *Rami musculares*.—Numerous muscular branches are distributed to the popliteus and the deep flexor muscles.

(3) *A. tarsea lateralis*.—The lateral tarsal¹ artery is the smaller of the two terminal branches of the posterior tibial. Passing between the tibia and the combined tendon of the flexor hallucis longus and tibialis posterior it gains the lateral aspect of the tarsus, over which it ramifies. A slender twig, the *recurrent tarsal artery* (*a. tarsea recurrens*), runs upwards on the lateral border of the tendo calcaneus, and unites with a branch of the posterior femoral artery.

(4) *A. tarsea medialis*.—The medial tarsal artery is so much larger than the lateral vessel that it might be regarded as the true continuation of the posterior tibial. Passing backwards from its point of origin, the artery describes a double curve, with the first convexity directed distalwards, and the convexity of the second curve looking in a proximal direction. After the second curve has been formed the medial tarsal artery follows the combined tendon of the flexor hallucis longus and tibialis posterior to end, behind the tarsus, in the medial and lateral plantar arteries.

Small branches of the medial tarsal artery are distributed over the medial surface of the tarsus. A larger branch, the *recurrent tibial artery* (*a. recurrens tibialis*), leaves the second convexity of the medial tarsal and runs in a proximal direction along the medial border of the tendo calcaneus, where it is related to the tibial nerve. It unites with the saphenous and posterior femoral arteries.

Dissection.—The dissection of the anterior tibial and fibular regions should be combined with that of the dorsum of the metatarsus and digit. The combined dissection, while not being too complicated, permits of a connected view of the muscle and tendons of this part of the limb.

During the removal of the tarsal fascia certain specialised bands (transverse ligaments) should be retained in position. One of these will be found a short distance proximal to the end of the tibia. By the attachments of its extremities to the bone it forms a ring through which the tendons of the extensor digitorum longus, tibialis anterior, and peronæus tertius play. Another band crosses the tendon of the long digital extensor just beyond the joint between the tibia and the talus. One extremity of this transverse ligament is attached to the calcaneus; the other blends with the lateral limb of the peronæus tertius tendon of insertion.

A third very definite transverse ligament has its ends attached to

¹ *Tarsus* [L.], *ταρσός* (tarsos) [Gr.], any broad, flat surface; for example, the flat of the human foot.

the third and fourth metatarsal bones, and crosses the tendons of the extensor digitorum longus and peronæus longus.

A fourth and less definite transverse ligament retains the tendon of the peronæus longus in the groove on the surface of the lateral malleolus.

The muscles in the region now being examined are five in number, namely, extensor digitorum longus, tibialis anterior, peronæus longus, peronæus tertius, and extensor digitorum brevis. Two of these—peronæus tertius and tibialis anterior—are so blended as to lead the uninstructed to assume that they form one muscle only.

M. EXTENSOR DIGITORUM LONGUS.—The long digital extensor arises from the depression on the femur between the patellar surface and the lateral condyle by a strong tendon that is common to this muscle and the peronæus tertius. The tendon of origin traverses the muscular notch lateral to the tuberosity of the tibia, and is succeeded by an elongated, spindle-shaped belly that extends into the distal third of the leg. From this point a flattened tendon, held in position by the three fascial bands (transverse ligaments) mentioned above, crosses the flexor aspect of the tarsus, where it is provided with a synovial sheath, and travels along the dorsal aspect of the metatarsus and digit to be inserted to the extensor process of the third phalanx. In the proximal third of the metatarsus the tendon is joined by the extensor digitorum brevis and the tendon of the peronæus longus. Otherwise its connections and general disposition resemble those of the tendon of the common digital extensor of the thoracic limb (*q.v.*).

M. PERONÆUS LONGUS.¹—The long peroneal is the most lateral muscle of the leg, and follows the line of the fibula between the muscle just described and the flexor hallucis longus. Its origin is from the lateral (fibular) collateral ligament of the femoro-tibial joint, the fibula, and the interosseous ligament between the tibia and the fibula. The tapering fleshy belly gives place to a rounded tendon, which passes along the groove on the lateral malleolus and through a sheath on the lateral aspect of the tarsus. About the junction of the proximal and middle thirds of the metatarsus the tendon joins that of the long digital extensor at an acute angle.

M. EXTENSOR DIGITORUM BREVIS.—The short extensor of the digit is a small, pale, flattened muscle occupying the angle formed by the converging tendons of the long extensor and long peroneal muscles. Its origin is from the lateral limb of the tendon of insertion of the peronæus tertius and the lateral (fibular) collateral ligament of the tarsus.

¹ This muscle is also known as the lateral digital extensor, a proceeding which is permissible on account of its doubtful homology.

Dissection.—Reflect the extensor digitorum longus by cutting across the middle of its fleshy belly. The three transverse ligaments which hold the extensor tendons in position should also be cut through, in order that the long extensor tendon may be turned aside from the flexor aspect of the tarsus. Care must be exercised not to injure the vessels and nerves related to the extensor longus tendon.

M. PERONÆUS TERTIUS.—Though this is called the third peroneal muscle, there is some reason to question whether it actually corre-

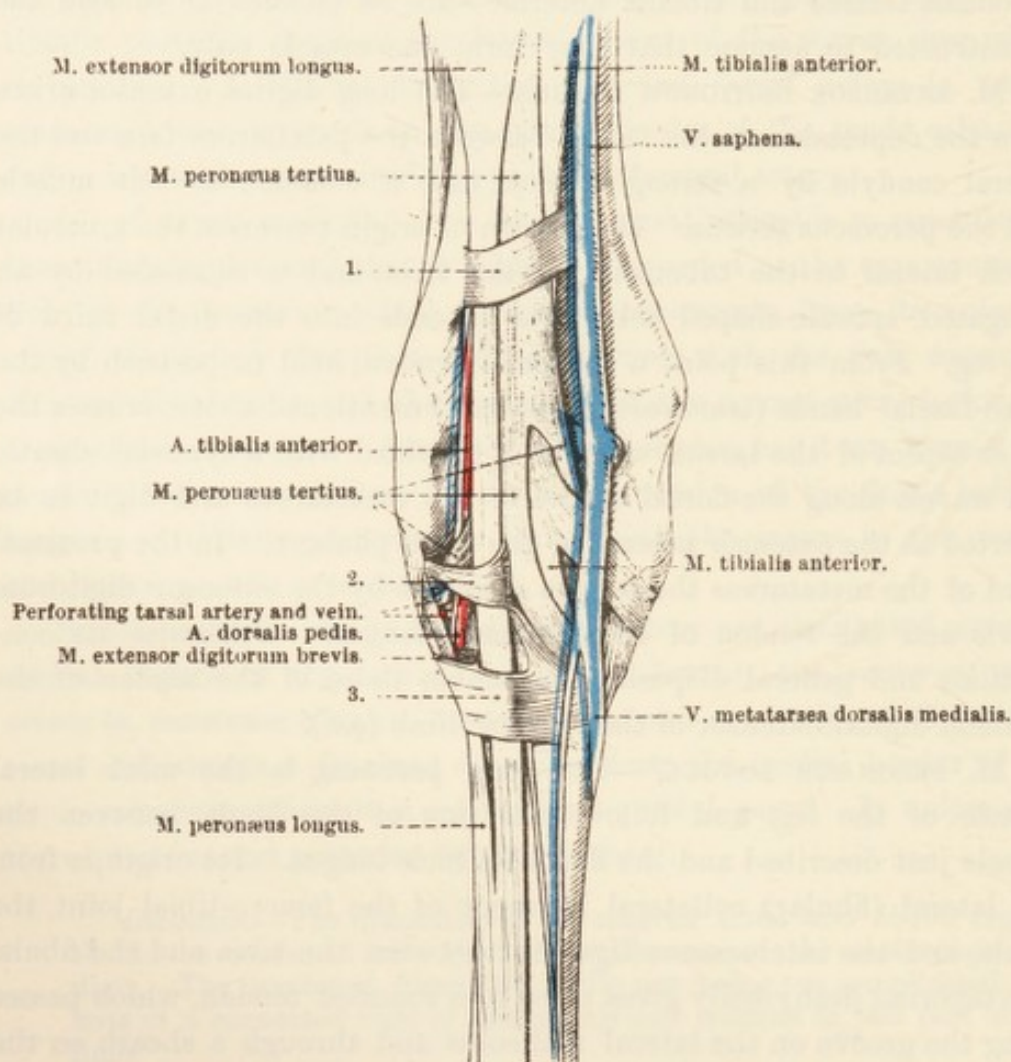


FIG. 92.—Dissection of the Dorsal (Anterior) Aspect of the Tarsal Region.

1, 2, 3 = Transverse ligaments that retain the extensor tendons in position.

sponds to the human muscle of this name. Its structure is noteworthy, inasmuch as it is almost entirely tendinous. Functionally, therefore, it is reasonable to assume that the muscle serves a purely mechanical purpose. Doubtless, in conjunction with the largely tendinous plantaris muscle at the back of the leg, it acts as a passive mechanical stay, which relieves the other muscle of the leg of a considerable amount of strain when the animal is in the standing posture. The peronæus tertius also causes mechanical flexion of the tarsal joint when the

femoro-tibial joint is flexed, just as the plantaris muscle effects mechanically simultaneous extension of these joints.

The origin of the peronæus tertius is common to that of the long digital extensor, namely, from the depression between the patellar surface and the lateral condyle of the femur. The common tendon of origin lies in the notch lateral to the tuberosity of the tibia, being here furnished with a diverticulum from the synovial lining of the femoro-tibial joint.

Opposite the extreme distal end of the tibia the tendon splits to allow the passage of that of the anterior tibial muscle, and then divides into three limbs that are attached as follows: The lateral limb is inserted to the calcaneus and the fourth tarsal bone (cuboid), and with it is associated one end of middle transverse ligament; the middle limb is connected with the third metatarsal bone; while the medial limb is attached to the third tarsal bone (lateral cuneiform) and the proximal end of the second and third metatarsal bones.

M. TIBIALIS ANTERIOR.—The anterior tibial muscle lies between the long digital extensor and the peronæus tertius on the one hand, and the tibia on the other. Its origin is from the proximal part of the lateral surface of the tibia and the adjoining part of the fibula. In the middle of the leg it is intimately connected with the peronæus tertius. A strong tendon begins before the tarsus is reached, pierces the cleft in the tendon of the peronæus tertius, and then divides into two limbs. The lateral of these ends on the proximal end of the third metatarsal bone along with the middle slip of the tendon of the peronæus tertius. The medial limb, commonly called the "cunean tendon" in books dealing with surgery, takes an oblique course to reach the combined first and second tarsal bones (medial cuneiform) and the base of the second metatarsal bone.

THE SYNOVIAL SHEATHS (VAGINÆ MUCOSÆ) OF TENDONS.—The present is a convenient time at which to review the various synovial bursæ and sheaths associated with the tendons in the region of the tarsus. The sheaths and bursæ in the more distal part of the limb are similar to those belonging to the tendons of the thoracic limb (*q.v.*).

An extensive bursa lies between the tendons of the gastrocnemius and plantaris from the point (about the junction of the third and distal fourths of the tibia) at which these tendons twist round each other to the level of the middle of the tarsus. A very much smaller bursa lies anterior to the point of insertion of the gastrocnemius tendon to the tuber of the calcaneus.

Where the combined tendon of the flexor hallucis longus and tibialis posterior lies in the canal behind the tarsus it is surrounded

by a long synovial sheath, which has its proximal limit slightly higher than the level of the summit of the tuber of the calcaneus (5 to 7 cm. proximal to the medial malleolus), and its distal limit about the junction of the first and second fourths of the metatarsus. A sheath

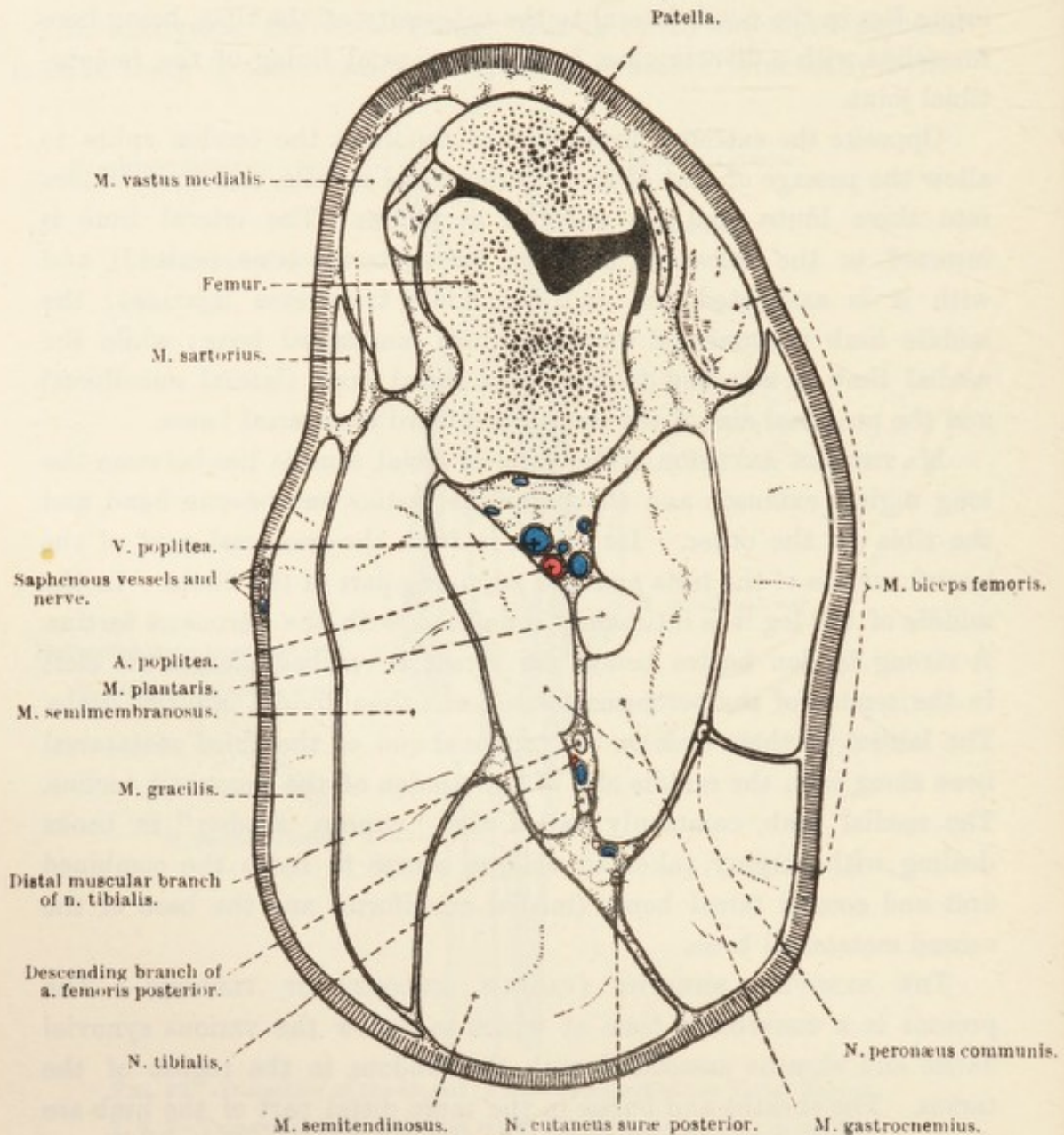


FIG. 93.—Section across the Pelvic Limb at the Level indicated by N in Fig. 81.

of very similar extent clothes the tendon of the flexor digitorum longus as it traverses the canal provided for it by the medial collateral ligament of the tarsus. Although the two sheaths connected with the tendons of the deep flexor terminate at the same level and close together, they are entirely independent of each other. It is noteworthy also that, close to the medial malleolus, they are separated from each other by a pouch of the joint capsule of the talo-crural articulation.

The synovial sheath of the extensor digitorum longus begins slightly above the lateral malleolus, and extends over the tarsus and into the proximal third of the metatarsus. A sheath of very similar extent, but beginning at a rather more proximal point, surrounds the tendon of the peronæus longus as it passes down the groove on the lateral malleolus and obliquely over the tarsus. Since the tendons of the extensor digitorum longus and peronæus longus converge and join, their syno-

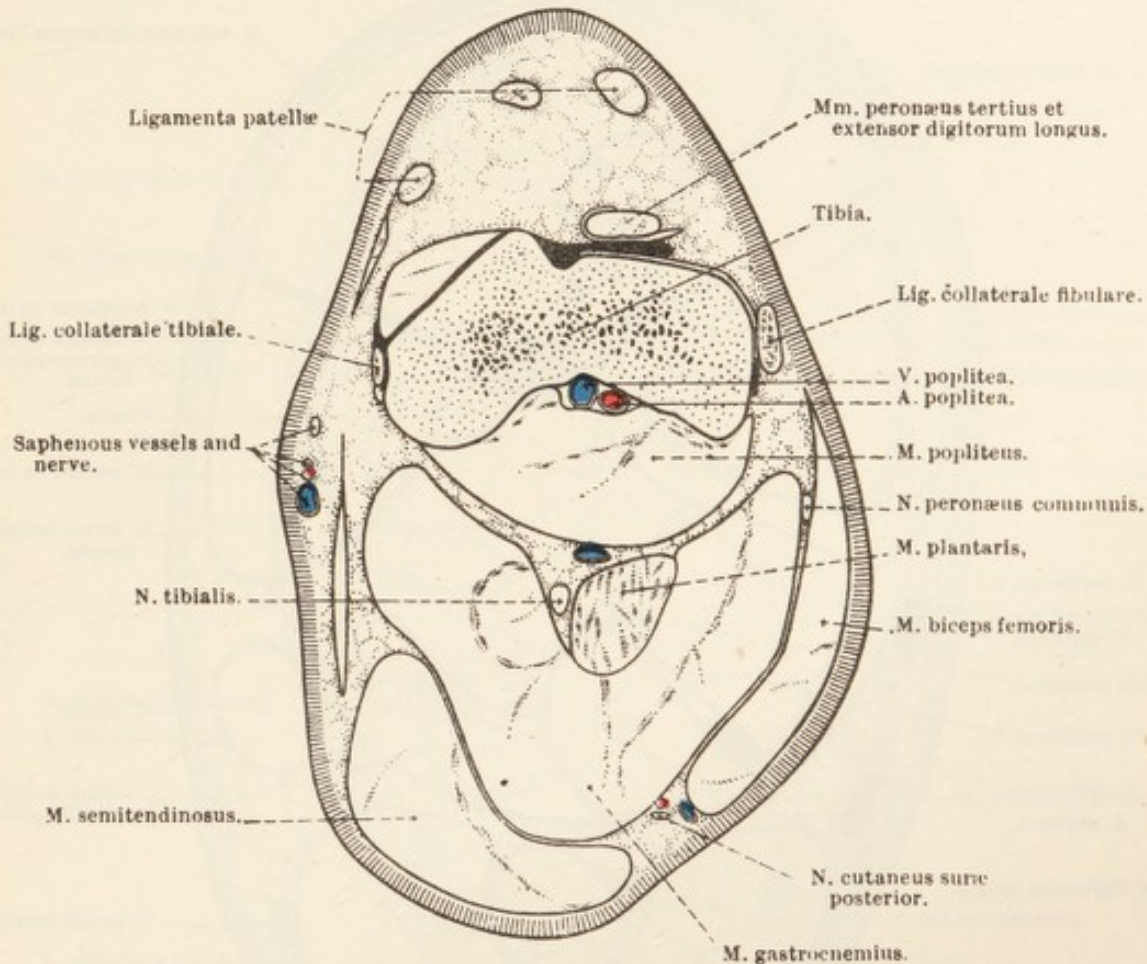


FIG. 94.—Section across the Proximal Part of the Leg at the Level indicated by O in Fig. 81.

vial sheaths necessarily also converge distally; but there is no union between them.

A synovial sheath of limited extent surrounds the tendon of the tibialis anterior as it passes between the two limbs of the peronæus tertius, and a small bursa lies under its medial tendon of insertion.

N. PERONÆUS COMMUNIS.—The origin of the common peroneal nerve from the sciatic, and its course down the thigh in company with the tibial nerve, have already been noted. Its passage between the biceps and the lateral head of the gastrocnemius brings it to a superficial position on a level with the head of the fibula, where it divides into the superficial and deep peroneal nerves. The collateral branches of

the common peroneal nerve are: (1) To the biceps muscle; (2) a filament which joins the posterior cutaneous sural nerve; and (3) the anterior cutaneous sural nerve. The last named has been examined already.

N. PERONÆUS SUPERFICIALIS.—The superficial peroneal nerve is the

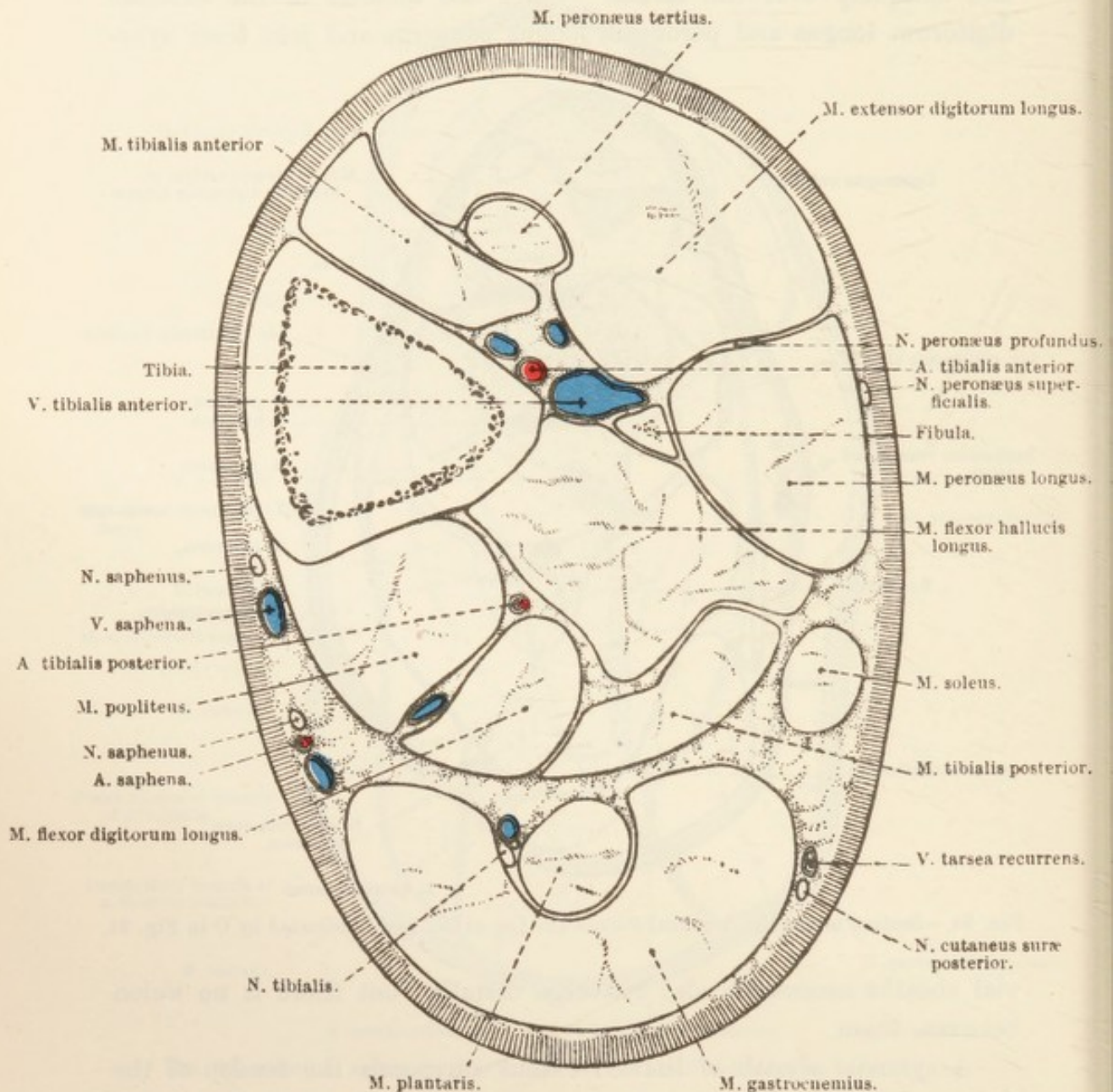


FIG. 95.—Section across the Leg at the Level indicated by P in Fig. 81.

smaller of the two terminal branches of the common peroneal. It crosses very obliquely the surface of the peronæus longus muscle, to which it furnishes a branch, runs down the groove between the peronæus longus and the extensor digitorum longus, and ends in the skin over the anterior and lateral surfaces of the leg, tarsus, and metatarsus.

N. PERONÆUS PROFUNDUS.—The deep peroneal nerve crosses the proximal part of the long peroneal muscle, sinks into the interval between this muscle and the extensor digitorum longus, and early expends a considerable amount of its fibres in the supply of branches to these muscles and the tibialis anterior. The much reduced continuation of the nerve runs down the groove formed by the lateral border

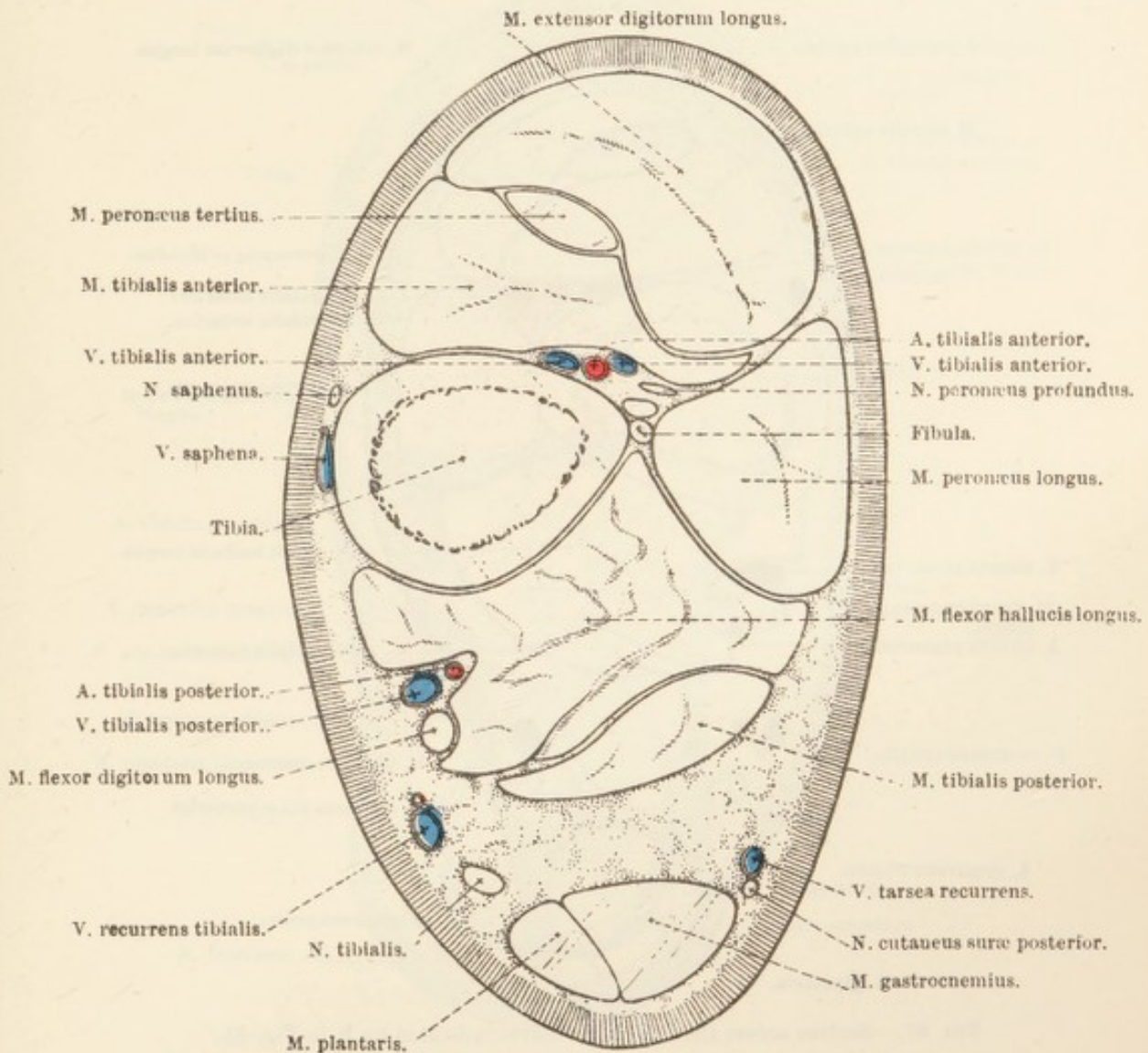


FIG. 96.—Section across the Leg at the Level indicated by Q in Fig. 81.

of the long extensor and the anterior tibial muscles, and then follows the lateral border of the long extensor to the flexor aspect of the tarsus, where it divides into medial and lateral branches.

The medial branch (*ramus medialis*) runs obliquely down the dorsal surface of the metatarsus, and ends in the skin over the dorsal and medial aspect of the metatarso-phalangeal joint. The lateral branch (*ramus lateralis*) supplies the extensor digitorum brevis, passes underneath the tendon of the peronæus longus in company with the lateral

dorsal metatarsal artery, and ends in the skin over the lateral surface of the first phalanx.

A. TIBIALIS ANTERIOR.—The anterior tibial artery is the larger of the two terminal branches of the popliteal. By piercing the interosseous membrane between the fibula and the tibia the artery gains the lateral surface of the latter bone, along which it runs towards the

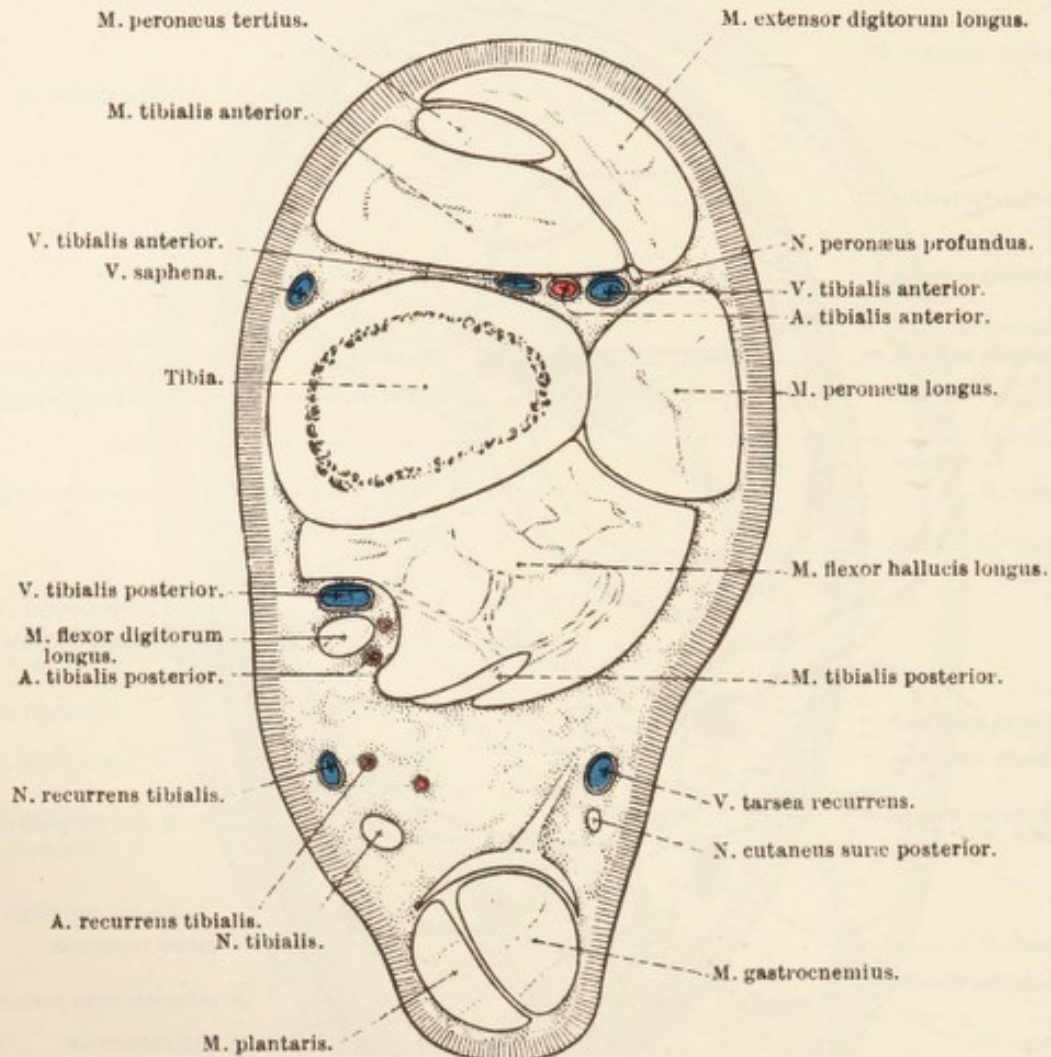


FIG. 97.—Section across the Leg at the Level indicated by R in Fig. 81.

tarsus under cover of the anterior tibial muscle. It should be noted that it is only when the tarsus has very nearly been reached that the anterior tibial artery and the deep peroneal nerve come into relation with each other.

The collateral branches of the anterior tibial artery are: (1) *A. peronea*, a small and not very constant branch that leaves the parent early, descends along the fibula, and supplies twigs to the flexor hallucis longus, peronæus longus, and tibialis anterior. (2) *Rami musculares* are furnished to the muscles on the lateral aspect of the

tibia. (3) *Rami articulares* are expended in the ligaments of the tarsus.

Opposite the joint, between the tibia and the talus, the anterior tibial artery changes its name to that of the *dorsal artery of the pes* (a.

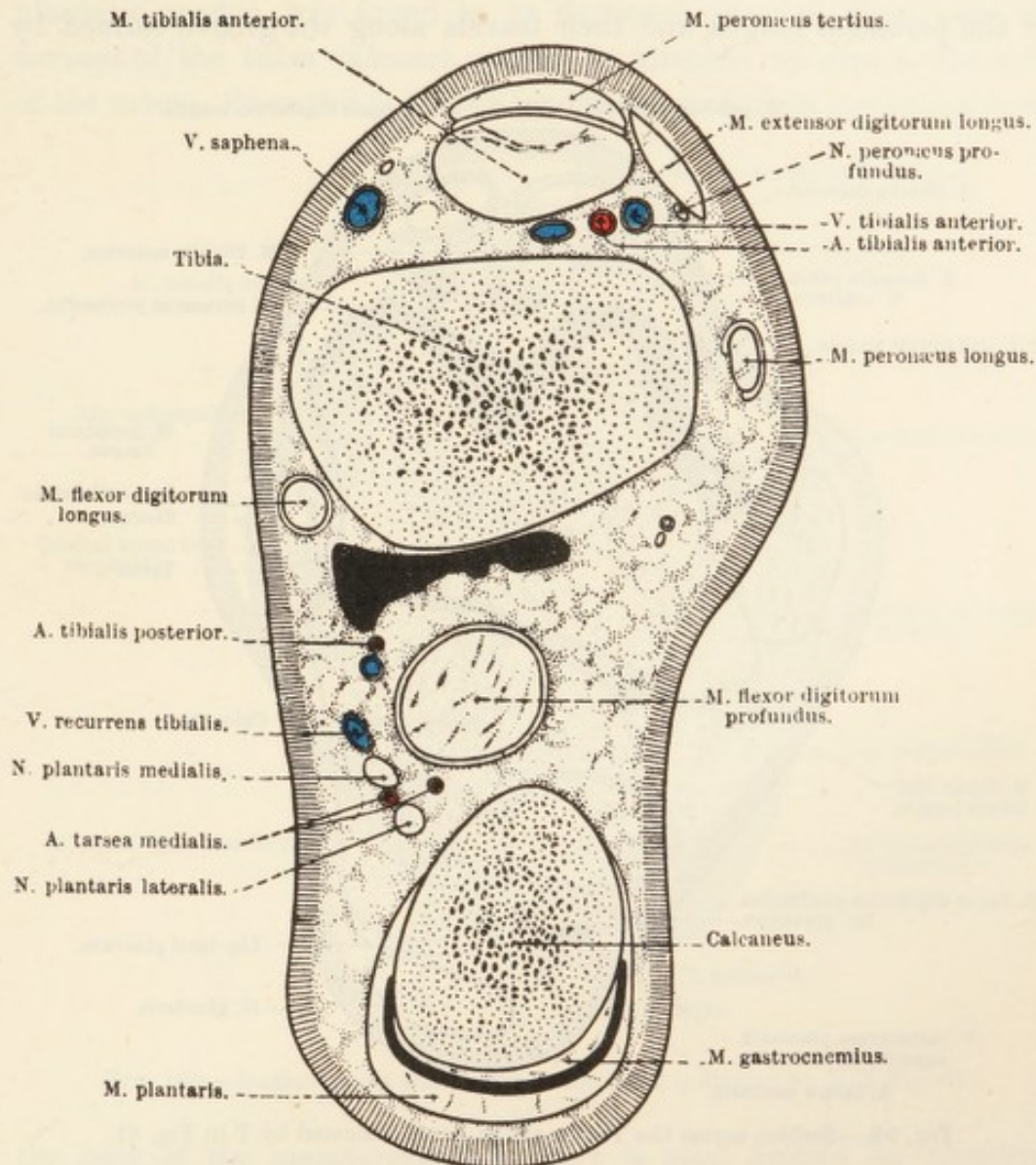


FIG. 98.—Section across the Most Distal Part of the Leg at the Level indicated by S in Fig. 81.

The irregular black area behind the tibia is the upward extension of the talo-crural (hock) joint-cavity.

dorsalis pedis). This vessel crosses the tarsus obliquely, mainly under cover of the tendon of the extensor digitorum longus, and, on reaching the base of the third metatarsal bone, becomes the lateral dorsal metatarsal artery. The dorsalis pedis gives off the large *perforating tarsal artery* (a. tarsea perforans) that, traversing the canal formed by the third (cuneiform) and fourth (cuboid) tarsal and the central (scaphoid)

bones, reaches the back of the tarsus, where it will be examined in connection with the vessels of the metatarsus.

The *lateral dorsal metatarsal artery* (a. metatarsæ dorsalis lateralis) passes obliquely over the lateral aspect of the base of the third metatarsal bone underneath the extensor digitorum brevis and the tendon of the peronæus longus, and then travels along the groove formed by

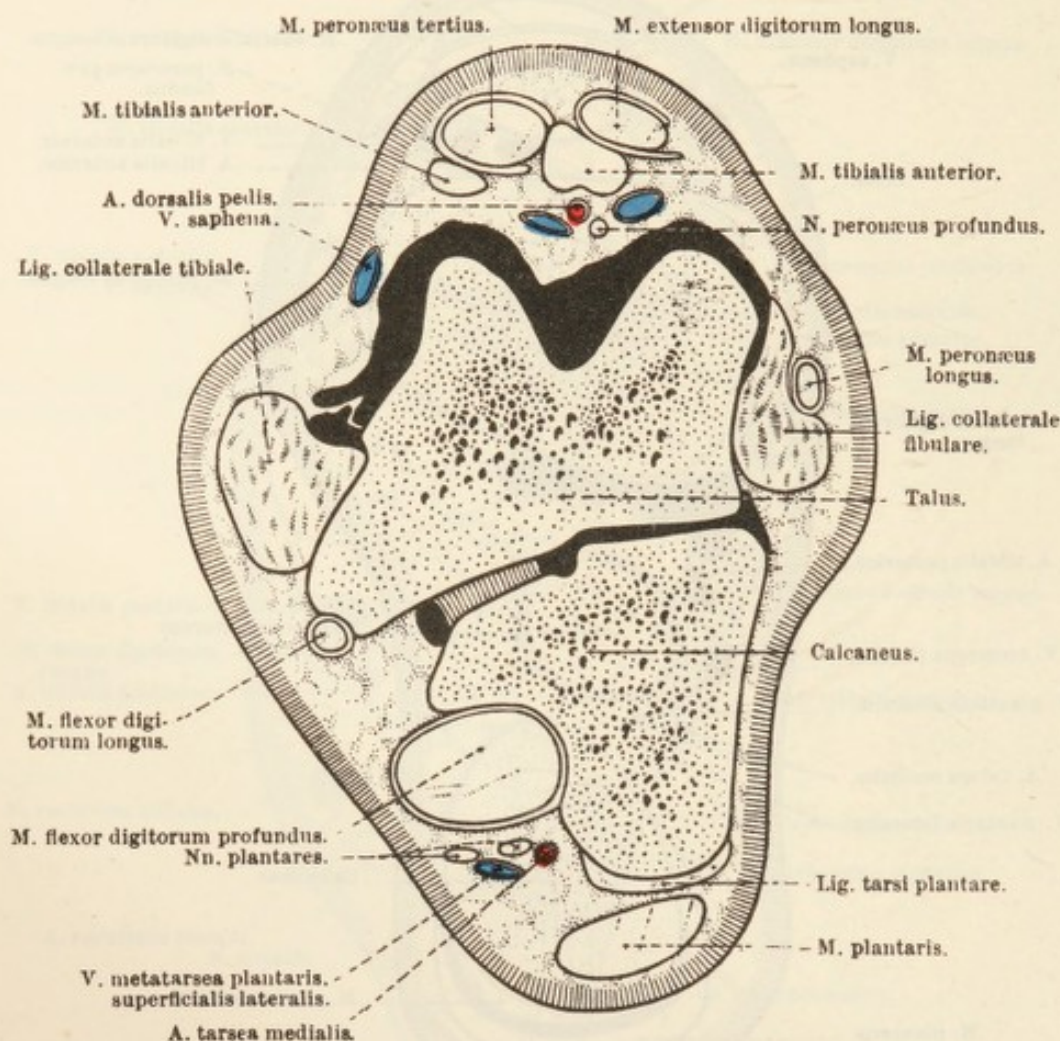


FIG. 99.—Section across the Tarsus at the Level indicated by T in Fig. 81.

the union of the third and fourth metatarsal bones. Near the distal end of the latter it passes between the two bones to reach the plantar aspect of the metatarsus, where it will be met with later under the name of the *common digital artery*.

V. TIBIALIS ANTERIOR.—The anterior tibial vein is frequently double, one vein lying on each side of the homonymous artery. Its main radicle of origin is the deep medial plantar metatarsal vein, which accompanies the perforating tarsal artery in its passage through the tarsus. The anterior tibial and saphenous veins are connected by a large communicating vessel.

Dissection.—The plantar aspect of the pes—tarsus, metatarsus, and digit—now remains to be examined. After the skin has been removed, it will be found that the arrangement of the fascia is similar to that of the thoracic limb (*q.v.*)

M. FLEXOR DIGITORUM BREVIS.—In the dissection of the leg the plantaris tendon was found to be flattened where it plays over the summit of the tuber calcanei, and to be attached by slips to the sides of the tuber. From this point the tendon appears to be continued down

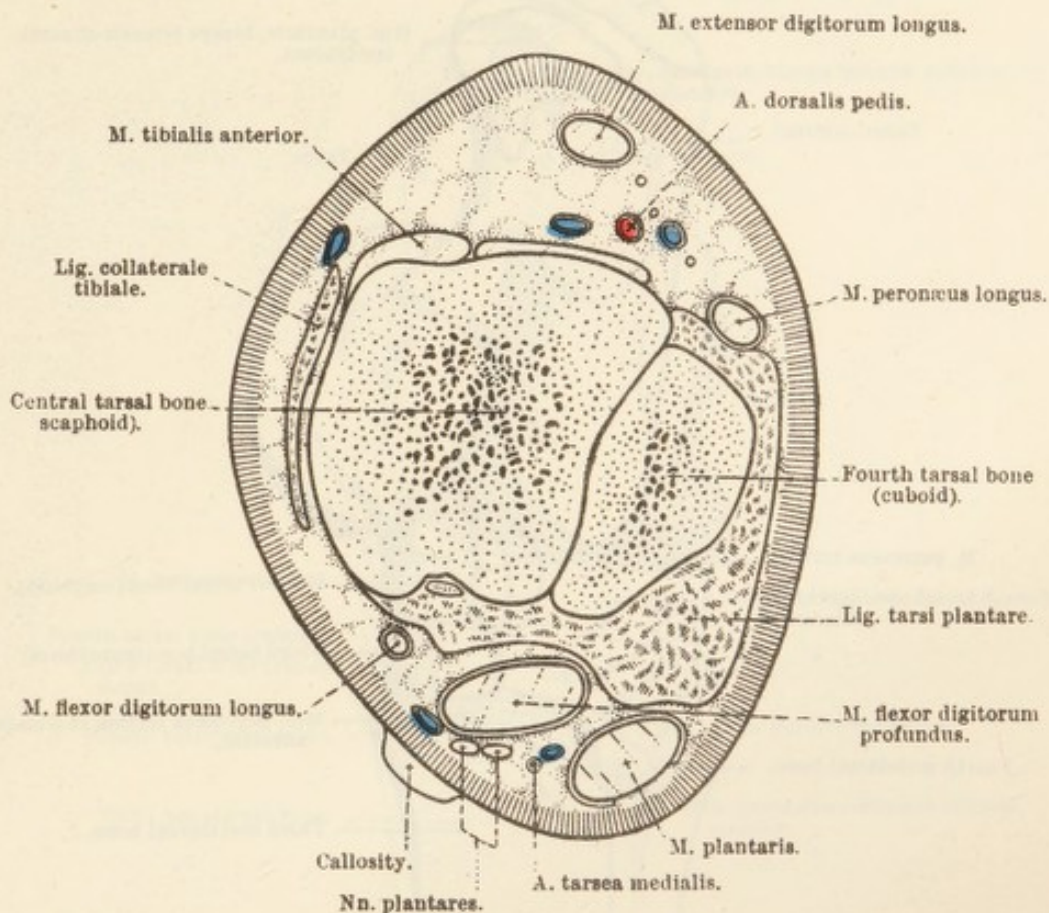


FIG. 100.—Section across the Tarsus at the Level indicated by U in Fig. 81.

the back of the metatarsus; but there is good ground for supposing that the short flexor of the digit has lost its muscular tissue and has become continuous with the extremity of the plantaris tendon. The long, flattened continuous tendon thus produced comports itself exactly as does the metacarpal portion of the superficial flexor tendon of the thoracic limb (*q.v.*).

M. FLEXOR DIGITORUM PROFUNDUS.—As has been seen, the strong, rounded tendon produced by the union of the flexor hallucis longus and tibialis posterior immediately proximal to the end of the tibia traverses the grooved posterior surface of the calcaneus, where it is bound down by a stout ligamentous band, and thence continues down the back of the metatarsus. In the proximal third of this region it is joined by the

rounded tendon of the flexor digitorum longus, and, about the same level, also by a relatively slender *caput tendineum* arising from the ligaments of the plantar aspect of the tarsus. From this point onwards the tendon is disposed and terminates in a manner comparable to that of the deep flexor tendon of the thoracic limb (*q.v.*).

MM. INTEROSSEI; MM. LUMBRICALES.—The interosseus and lumbrical

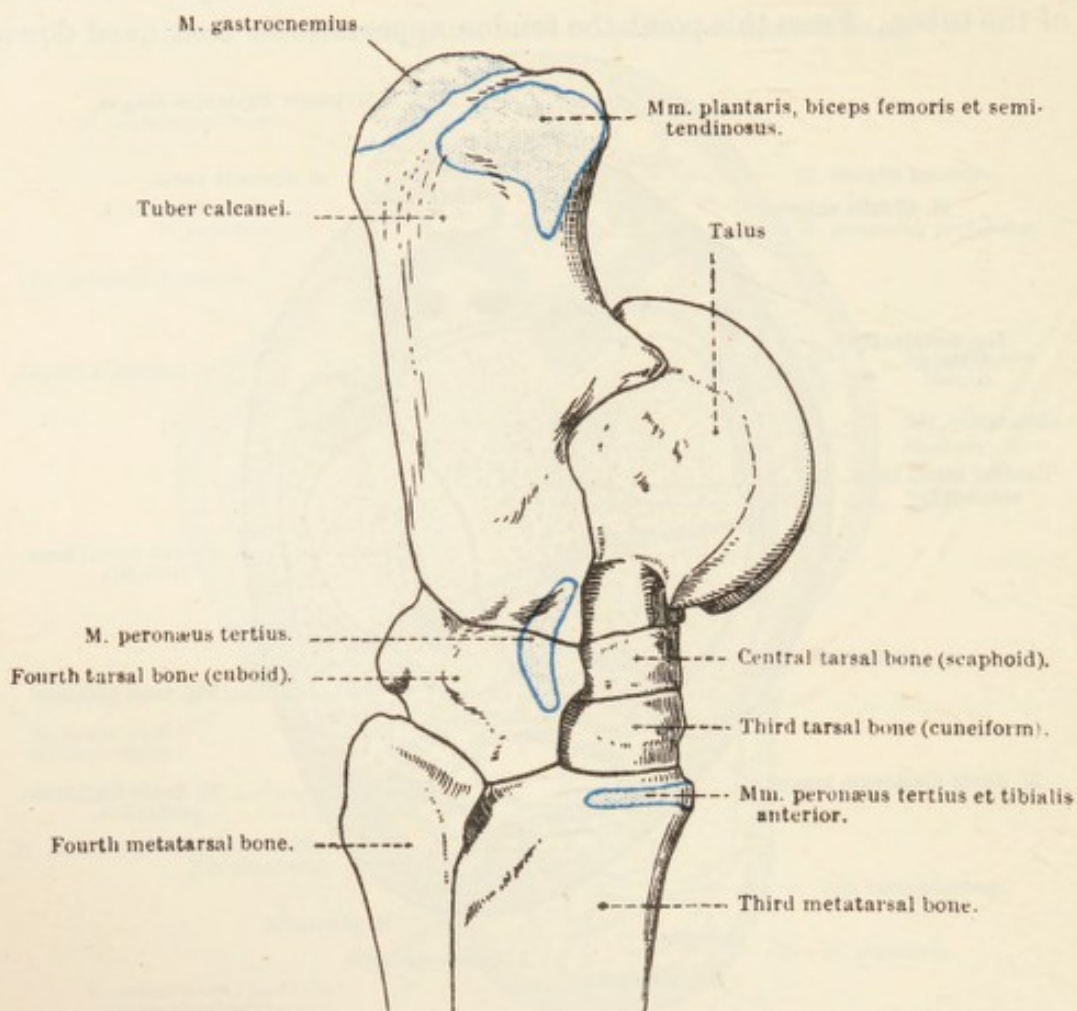


FIG. 101. — Lateral Aspect of the Tarsus, with Areas of Muscular Attachment.

muscles are the same in number and disposition as the like-named structures of the metacarpus.

NERVES OF THE METATARSUS AND DIGIT.—At the distal end of the leg the tibial nerve divides into the *medial* and *lateral plantar nerves* (*n. plantaris medialis*; *n. plantaris lateralis*). These, at first, lie close together on the surface of the combined tendon of the flexor hallucis longus and tibialis posterior; but, before the metatarsus is reached, the lateral nerve passes obliquely between the superficial and deep flexor tendons, and thus arrives at the lateral border of the deep tendon. The medial and lateral nerves follow the medial and lateral

borders respectively of the deep flexor tendon, and behave in the same manner as the volar nerves of the thoracic limb. The oblique anastomotic branch from the medial to the lateral nerve is always smaller than that in the metacarpus, and is frequently absent altogether.

ARTERIES OF THE METATARSUS AND DIGIT.—The *medial tarsal artery* (a. tarsea medialis), the larger of the two terminal branches of the

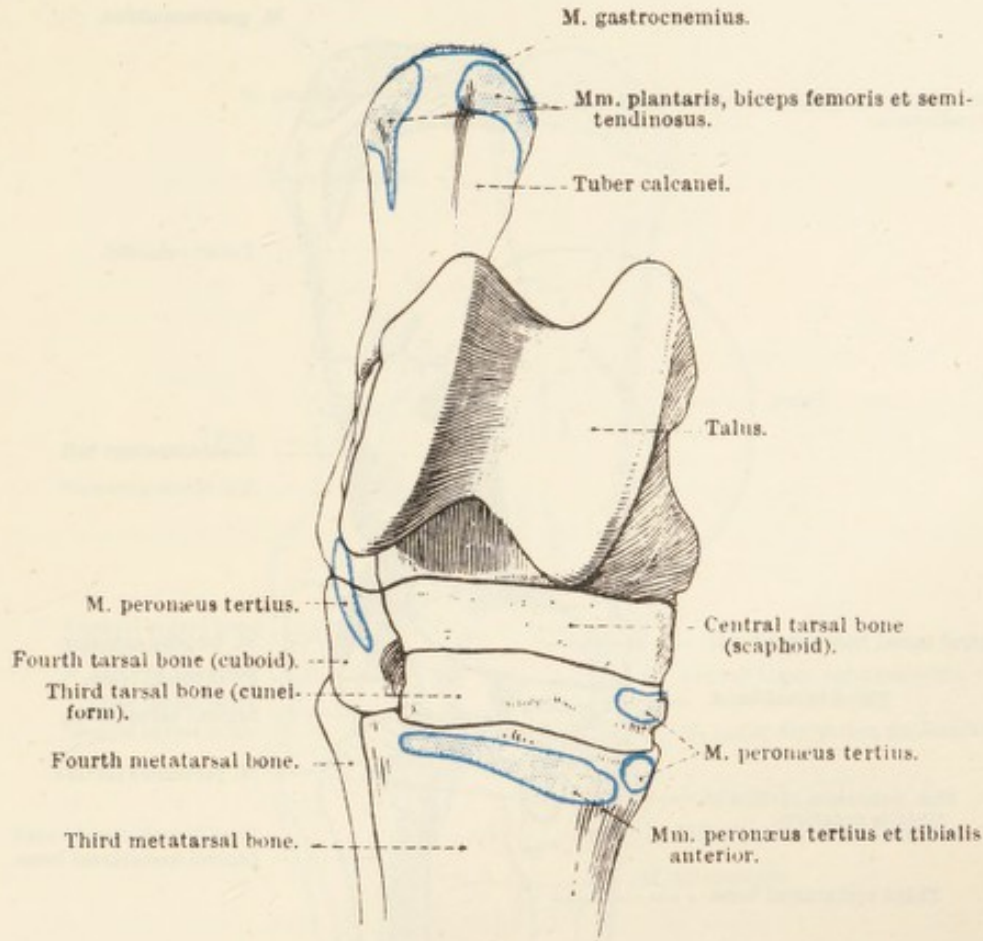


FIG. 102.—Dorsal (Anterior) Aspect of the Tarsus, with Areas of Muscular Attachment.

posterior tibial, has already been observed to produce a double curve on a level with the summit of the tuber calcanei, and the origin of the recurrent tibial artery from the convexity of the second curve has also been noted. After the formation of the second curve the medial tarsal artery proceeds in a distal direction upon the deep flexor tendon in company with the plantar nerves. Just before the base of the metatarsal bone is reached the vessel divides into the *medial* and *lateral plantar arteries* (a. plantaris medialis; a. plantaris lateralis).

Of the two plantar arteries the lateral is the larger, and follows the lateral plantar nerve (posterior to the nerve) along the border of the

deep flexor tendon. It ends by joining either the common digital or the lateral plantar digital artery.

The slender medial plantar artery follows the medial plantar nerve, and ends in the same manner as does the lateral artery. In the proximal part of the metatarsus it is generally united to the medial plantar metatarsal artery by a communicating branch.

Occasionally the two plantar arteries unite in the distal part of the

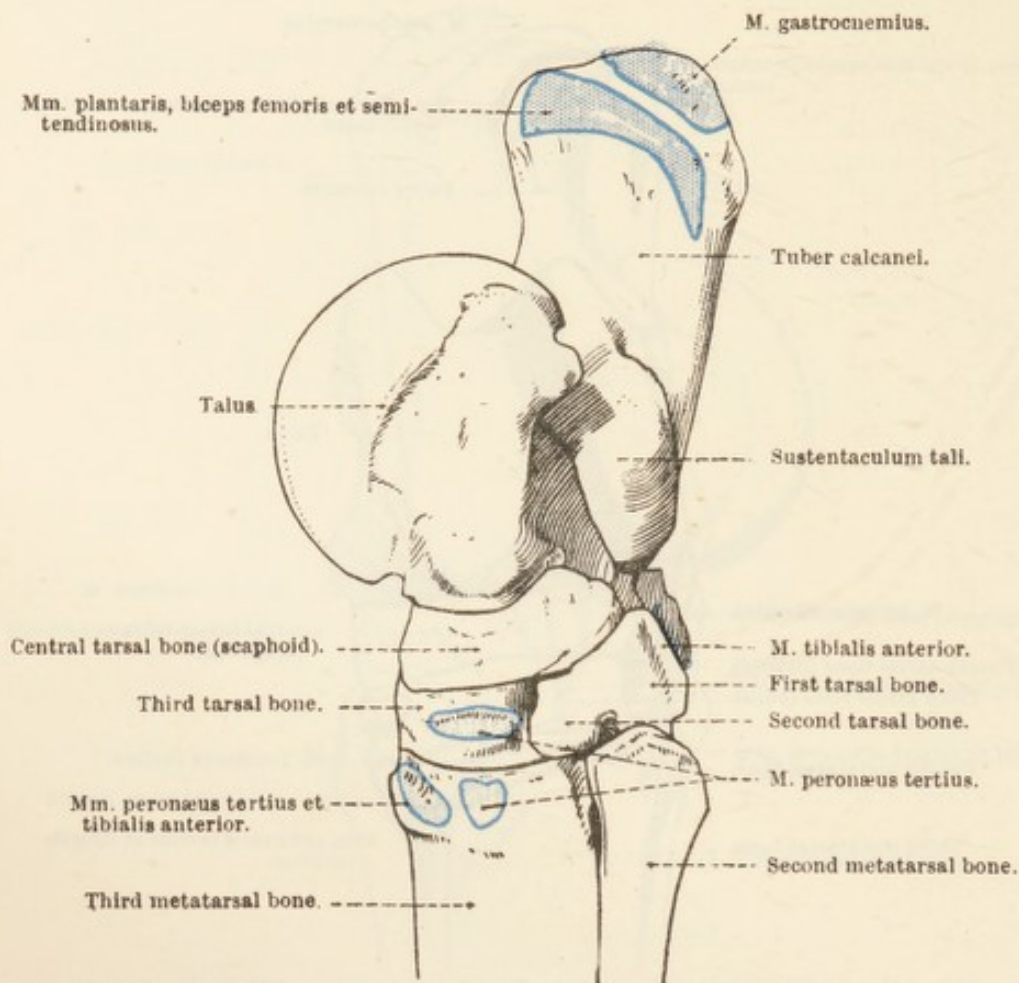


FIG. 103.—Medial Aspect of the Tarsus, with Areas of Muscular Attachment.

metatarsus and form a single vessel that joins one of the plantar digital arteries.

The *perforating tarsal artery* (a. tarsea perforans) has been seen to enter a canal formed by the tarsal bones. It reappears on the plantar aspect of the tarsus about the line of junction of the bases of the second and third metatarsal bones. Immediately on its reappearance it is joined to the lateral plantar artery (possibly to the medial plantar artery also) by a communicating branch. Thus is formed the *proximal plantar arch* (arcus plantaris proximalis) from which the *medial and lateral plantar metatarsal arteries* arise. The plantar

metatarsal arteries, of which the medial is the larger, run down the metatarsus in the depths of the grooves formed by the middle interosseous muscle and the small metatarsal bones, and end by uniting with the common digital artery, thus forming the *distal plantar arch* (*arcus plantaris distalis*). The medial artery furnishes the nutrient vessel for the third metatarsal bone.

On its passage between the third and fourth metatarsal bones the lateral dorsal metatarsal becomes the *common digital artery*

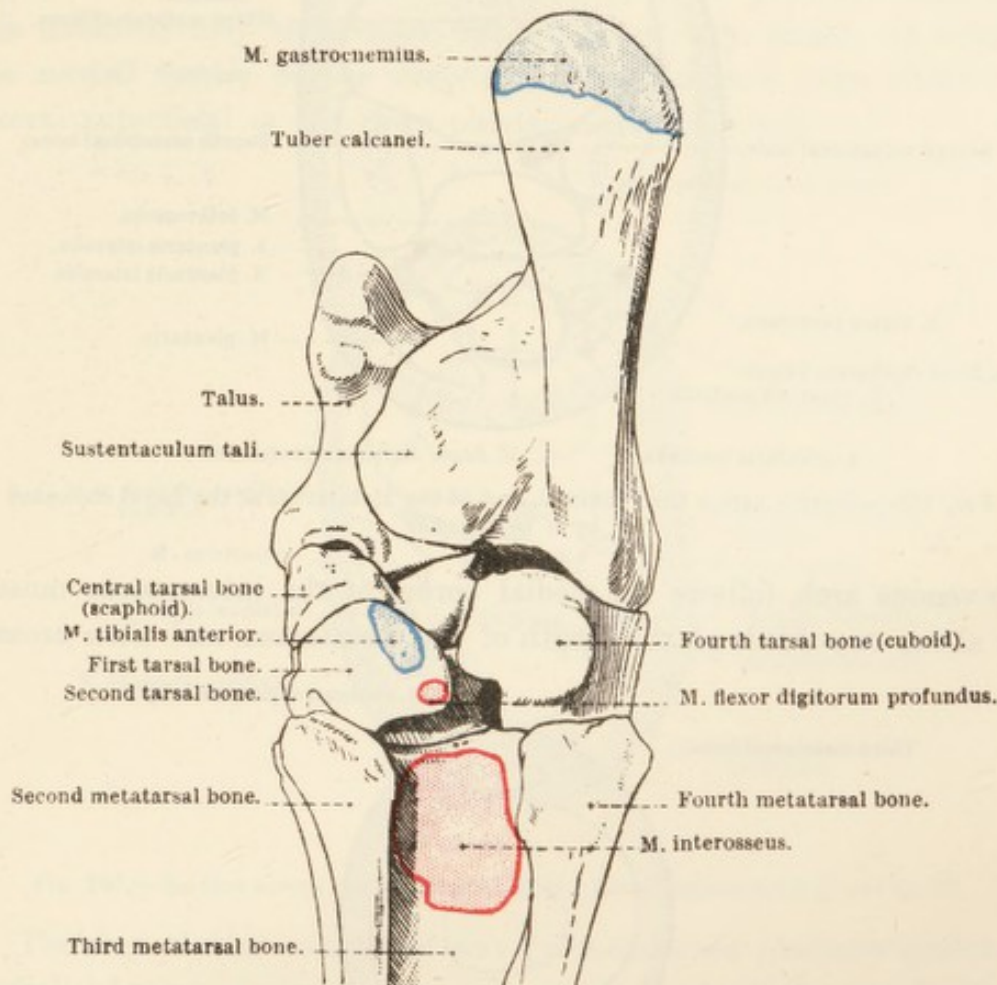


FIG. 104.—Plantar (Posterior) Aspect of the Tarsus, with Areas of Muscular Attachment.

(a. digitalis communis), which traverses the gap between the two limbs of the interosseous muscle and, between this and the deep flexor tendon, divides into the *medial* and *lateral plantar digital arteries*. The digital arteries have a distribution similar to that of the corresponding vessels of the thoracic limb.

VEINS OF THE METATARSUS AND DIGIT.—The plexuses and veins of the digit are similar to those of the thoracic limb, the two digital veins, medial and lateral, being joined in the formation of a *distal plantar venous arch* (*arcus venosus plantaris distalis*).

There may be six veins in the metatarsus, but of these three are

small and not always present. The largest of the six is the *medial dorsal metatarsal vein* (v. metatarsæ dorsalis medialis), which begins at

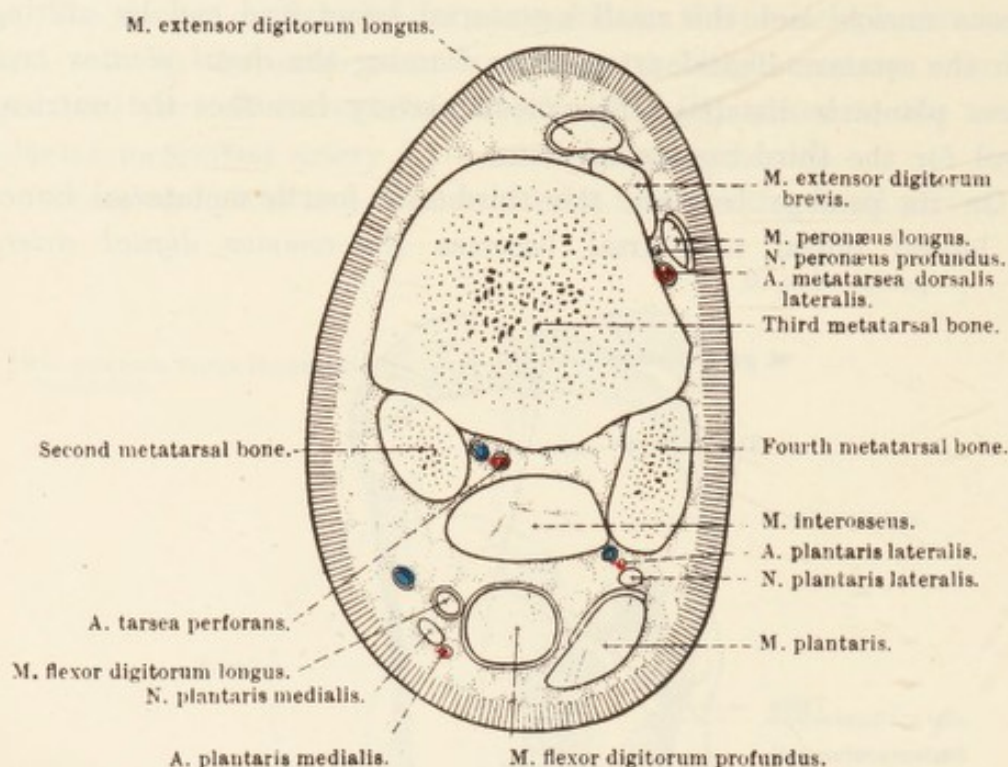


FIG. 105 —Section across the Proximal End of the Metatarsus at the Level indicated by V in Fig. 81.

the venous arch, follows the medial border of the interosseous muscle for about two-thirds of the length of the metatarsus, and then crosses

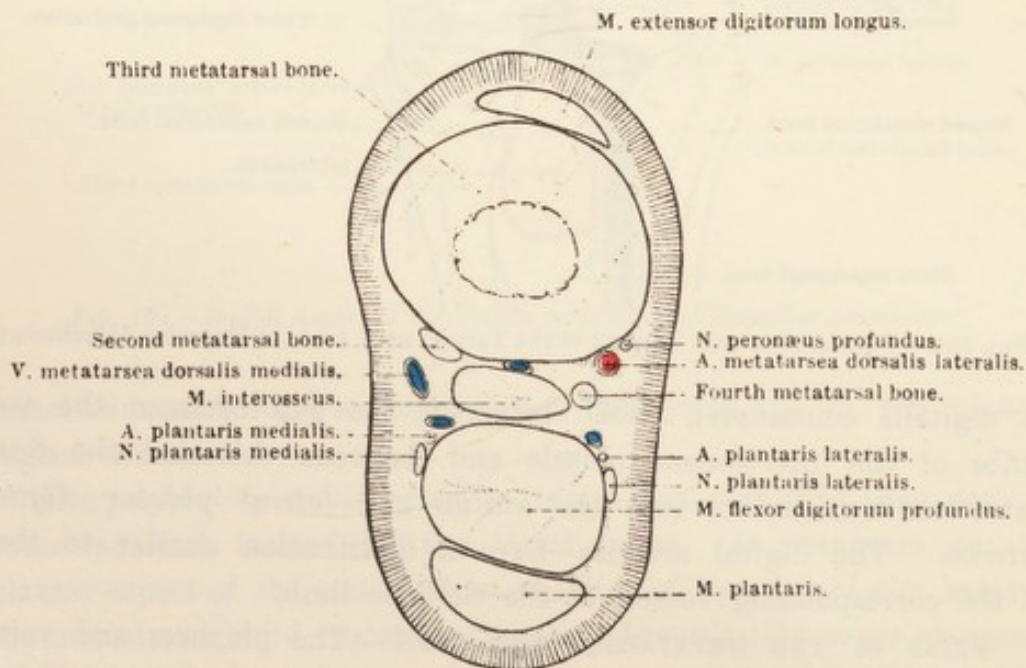


FIG. 106.—Section across the Metatarsus at the Level indicated by W in Fig. 81.

the medial aspect of the limb to form the main radicle of the saphenous vein. The *lateral dorsal metatarsal vein* (v. metatarsæ

dorsalis lateralis) is small, and may be absent. When present, it is a satellite of the like-named artery. There is often a small *middle dorsal metatarsal vein* (v. metatarsæ dorsalis media) that joins either the medial dorsal metatarsal or the saphenous vein.

The *lateral superficial plantar metatarsal vein* (v. metatarsæ plantaris superficialis lateralis) begins at the venous arch, ascends along the lateral border of the deep flexor tendon in front of the plantar nerve, and is continued as the recurrent tibial vein. A *medial superficial plantar metatarsal vein* (v. metatarsæ plantaris superficialis medialis) may be present, but, if so, is very small. It follows the medial border of the deep flexor tendon, and joins either the lateral superficial or the deep plantar metatarsal vein.

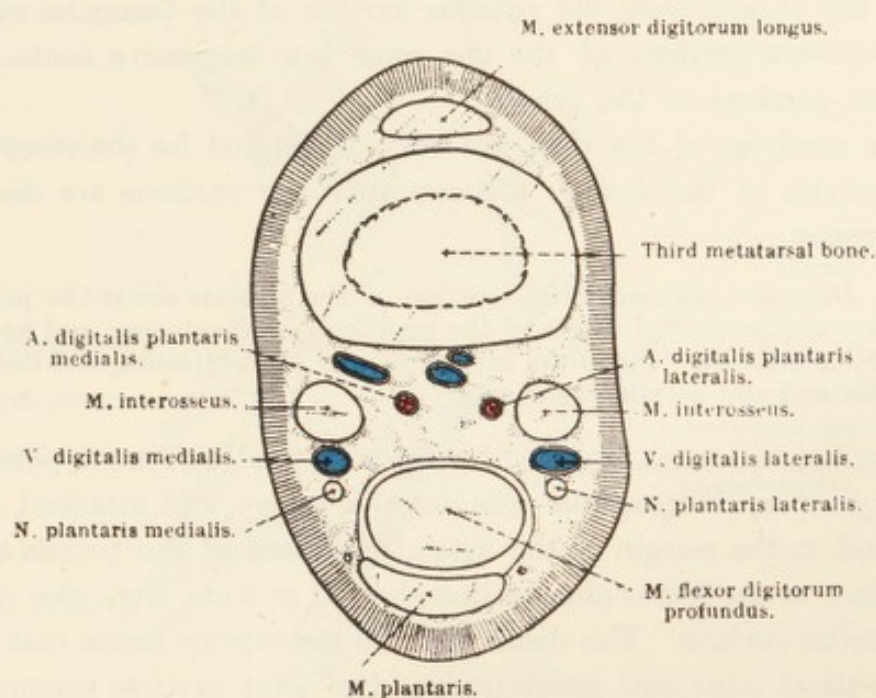


FIG. 107.—Section across the Metatarsus at the Level indicated by X in Fig. 81.

The *deep plantar metatarsal vein* (v. metatarsæ plantaris profunda medialis) begins at the venous arch, passes between the two limbs of the interosseous muscle, and ascends between this structure and the third metatarsal bone, to be continued as the *perforating tarsal vein* (v. tarsæ perforans), which pierces the tarsus along with the homonymous artery.

Near the proximal end of the metatarsus the deep and lateral superficial plantar veins are connected by a transverse branch, and thus the *deep plantar arch* (arcus plantaris profundus) is formed.

THE FEMORO-PATELLAR AND FEMORO-TIBIAL ARTICULATIONS (articulatio genu).—These two articulations, taken together, correspond to the knee-joint of man, and, in the horse, are generally referred to by the collective name of the "stifle-joint." Although the adaptation of the bony surfaces

is indifferent, the joint, in virtue of the character and number of its ligaments, is of considerable strength.

Before examining the joint itself the dissector should obtain specimens of the bones that form it and study the articular surfaces. If he does this, he will observe that, though the articular face of the patella is, in general, the reverse of the patellar surface of the femur, the opposed surfaces are not capable of accurate and complete application. Nor is the transverse diameter of the patella equal to that of the patellar surface of the femur. In the recent and unmacerated bone, however, a complementary piece of cartilage is attached to the medial angle of the base of the patella, and moulded upon the large medial lip of the pulley-shaped patellar surface of the femur. If the dissector glides the patella over the patellar surface of the femur he will find that different portions of the one come into successive contact with different portions of the other.

The condyles of the tibia are very ill-adapted for the reception of the condyles of the femur: the opposed bony surfaces are decidedly incongruent.

Dissection.—Remove the remains of the muscles about the joint, but leave the tendons of origin of the popliteus, long extensor, and peronæus tertius muscles. Clean the surface of the joint-capsules, and define the collateral and patellar ligaments.

THE FEMORO-PATELLAR¹ ARTICULATION (*articulatio femoro-patellaris*).—The *joint-capsule* (*capsula articularis*) is roomy, and attached, on the one hand, to the margin of the articular surface of the patella and, on the other, to the femur along a line about 2 or 3 cm. from the edge of the patellar surface. The distal part of the capsule meets that of the femoro-tibial joint, and, generally, the two joint cavities communicate with each other by one or, possibly, two narrow slit-like openings. In the region where the two capsules meet there is a considerable accumulation of fat. The proximal part of the femoro-patellar capsule is prolonged beyond the base of the patella, as a tri-locular diverticulum, between the extensor quadriceps muscle and the anterior surface of the femur, a pad of fat separating the muscle from the capsule.

The *femoro-patellar ligaments* (*ligamenta femoro-patellaris*), medial and lateral, may be regarded as thickenings of the joint-capsule, with which they are most intimately connected. The lateral band is the stronger, and passes from the femur to the lateral angle of the base of the patella. The weaker medial ligament also has one extremity attached to the femur, the other being connected with the cartilaginous extension of the patella.

¹ *Patella* [L.], dim. of *patina* or *patera*, a pan, dish, or plate.

The three, slightly converging, *patellar ligaments* (*ligamenta patellæ*) correspond to the single ligament of man and the dog. The lateral and middle ligaments spring from the lateral and distal angles respectively of the patella. The medial ligament is connected with the patellar supplementary cartilage. The distal attachment of each band is to the tuberosity of the tibia, the middle ligament being fixed to the distal part of the groove-like depression of the tuberosity.

The lateral ligament receives one of the insertions of the biceps

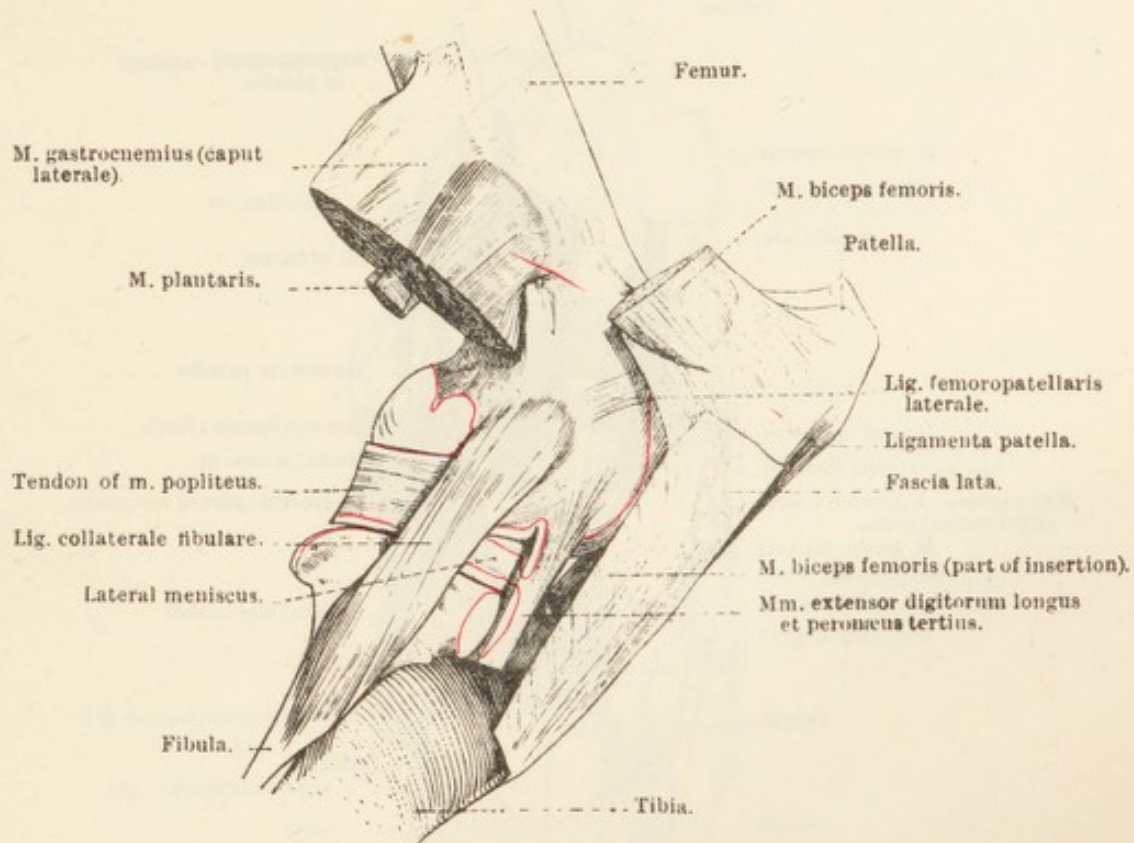


FIG. 108.—Lateral Aspect of the Femoro-Patellar and Femoro-Tibial Articulations.

The lines of attachment of the synovial linings of the joint-capsules are indicated in red.

muscle and part of the fascia lata, while the medial ligament receives the conjoint aponeurosis of the sartorius and gracilis.

The patellar ligaments, strictly speaking, represent the tendon of insertion of the quadriceps muscle of the thigh, the patella being a sesamoid bone developed therein.

THE FEMORO-TIBIAL ARTICULATION (*articulatio femoro-tibialis*).—A roomy *joint-capsule* (*capsula articularis*), weak in front but strong behind is attached to the articular margin of the tibial condyles and about 1 cm. from the margin of the condyles of the femur. Its fibrous layer is also attached to the convex border of the interarticular cartilages (medial and lateral menisci) and to the cruciate ligaments. The synovial

layer clothes the cruciate ligaments in such a manner as to be divided into two sacs. As previously stated, the joint-capsules of the femoro-patellar and femoro-tibial articulations are in contact with each other distal to the patella, but it must be noted that a considerable quantity of fat separates the femoro-tibial capsule from the patellar ligaments.

On opening the joint-capsule it will be found that, because of its fixation to the margin of the interarticular cartilages, each synovial sac

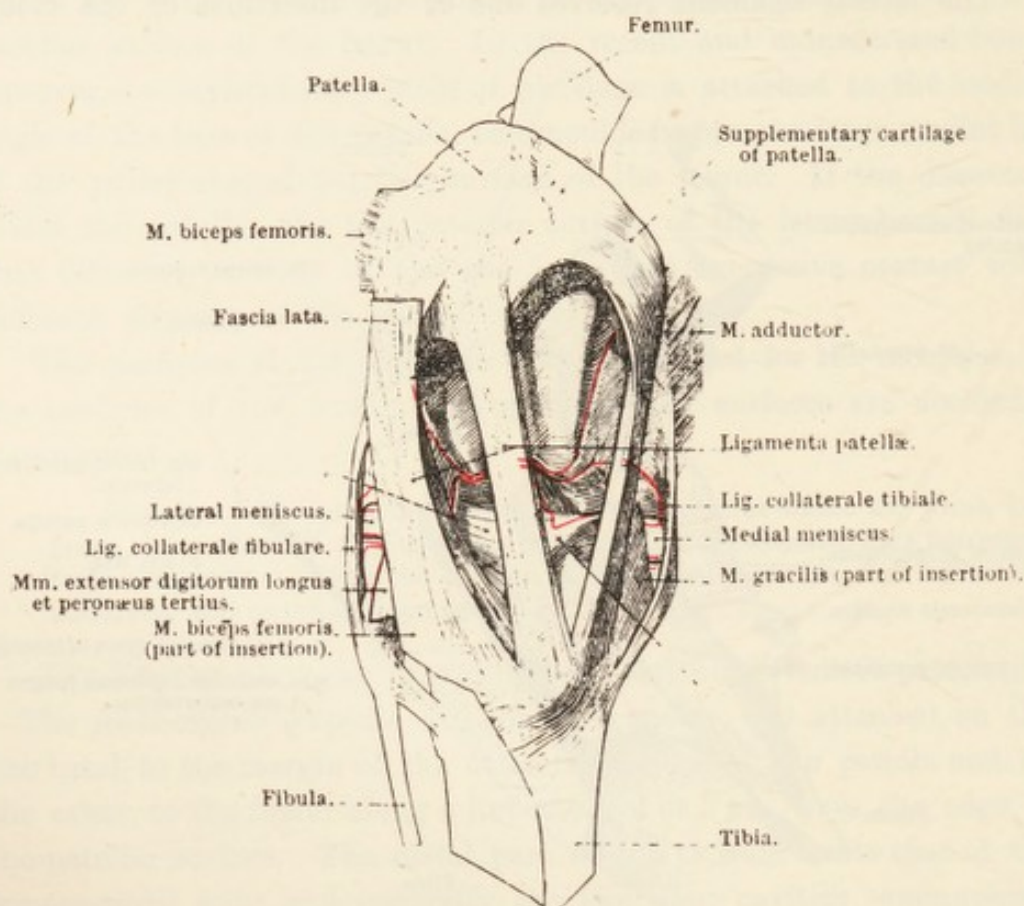


FIG. 109.—Anterior Aspect of the Femoro-Patellar and Femoro-Tibial Articulations.

* = Ligamentous bands attaching the menisci to the tibia.

The lines of attachment of the synovial linings of the joint-capsules are indicated in red.

is partially separated into two parts communicating with each other round the concave edge of the meniscus. The lateral sac covers the tendon of origin of the popliteus muscle, and is continued down the muscular notch of the tibia underneath the common tendon of origin of extensor digitorum longus and peronaeus tertius.

The *medial (tibial)* and *lateral (fibular) collateral ligaments* are attached by one extremity to the condyles of the femur. The medial ligament (ligamentum collaterale tibiale) is connected with the medial meniscus, and ends on the medial condyle of the tibia. The longer and stronger lateral collateral ligament (ligamentum collaterale fibulare) is separated from the lateral meniscus by the tendon of the popliteus

muscle, and ends on the head of the fibula. A small synovial bursa intervenes between the ligament and the lateral condyle of the tibia.

Dissection.—Make a transverse incision through the femoro-patellar capsule just proximal to the patella, and longitudinal incisions on each side of the patella—through the capsule and the femoro-patellar ligaments—so that the bone, with its three ligaments intact, may be turned downwards.

Now dissect away the femoro-tibial capsule and the accumulations of fat, so that a clear view of the cruciate ligaments and the menisci may be obtained.

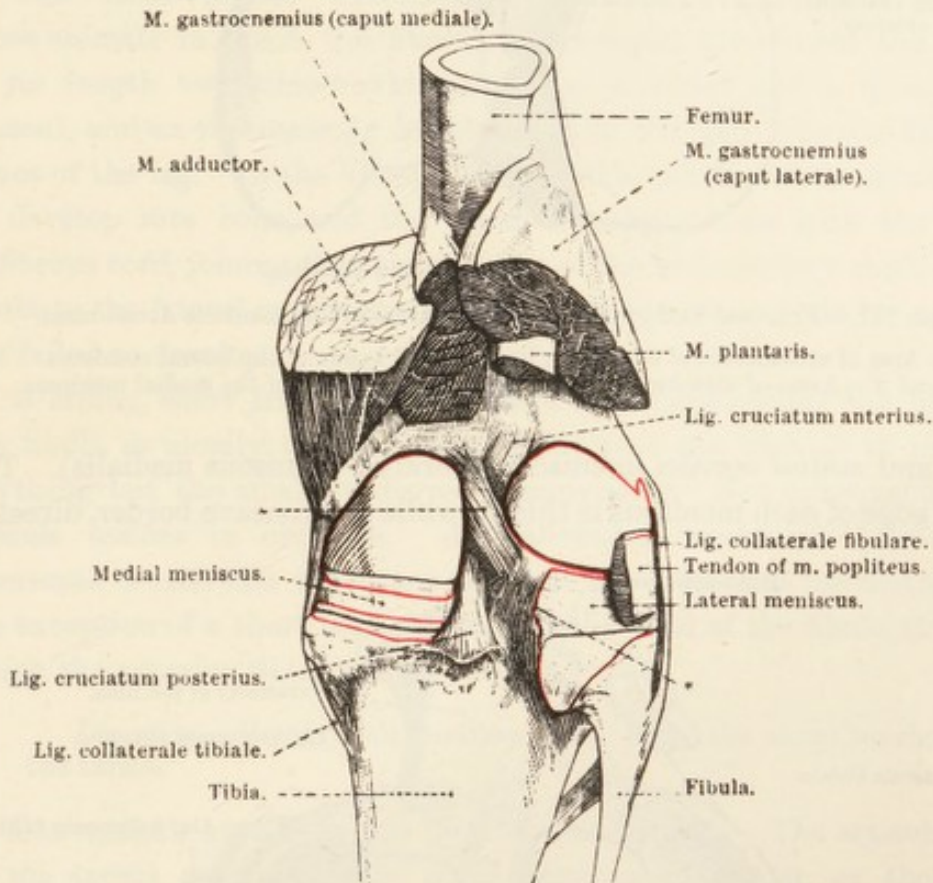


FIG. 110.—Posterior Aspect of the Femoro-Tibial Articulation.

* Two ligamentous bands attaching the lateral meniscus to the femur and tibia. The lines of attachment of the synovial linings of the joint-capsule are indicated in red.

The *anterior cruciate ligament* (ligamentum cruciatum anterius) passes obliquely from the depression on the intercondyloid eminence of the tibia to the medial face of the lateral condyle of the femur. The *posterior cruciate ligament* (ligamentum cruciatum posterius) crosses the medial surface of the anterior. It arises from the medial part of the popliteal notch of the tibia and the adjacent part of the posterior intercondyloid fossa. An oblique course forwards and upwards carries it to its point of fixation to the lateral face of the medial condyle of the femur.

The poor adaptation of the femoral and tibial condyles is partly compensated by the presence of two crescentic, cartilaginous pads, the

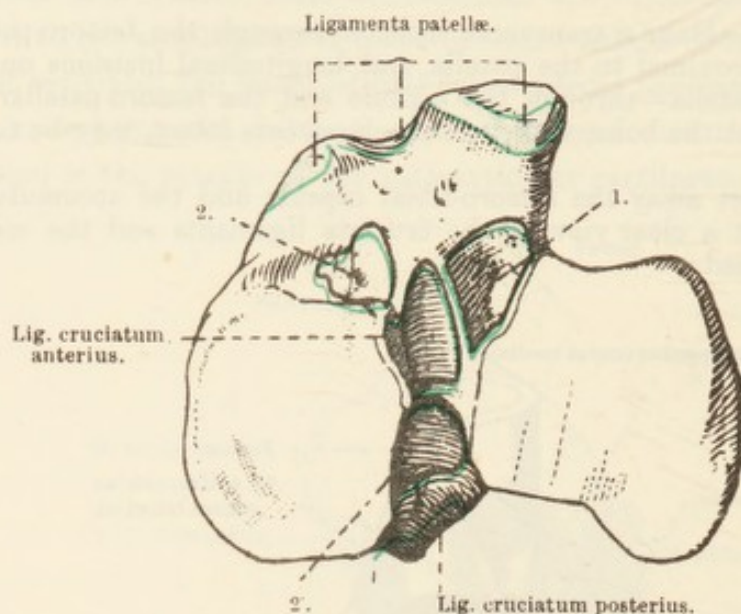


FIG. 111.—Proximal End of the Tibia, with Areas of Ligamentous Attachment.

1 = Area of attachment of one of the ligamentous bands of the lateral meniscus.
2 and 2' = Areas of attachments of the ligamentous bands of the medial meniscus.

lateral and medial menisci (meniscus lateralis; meniscus medialis). The convex edge of each meniscus is thick; while the concave border, directed

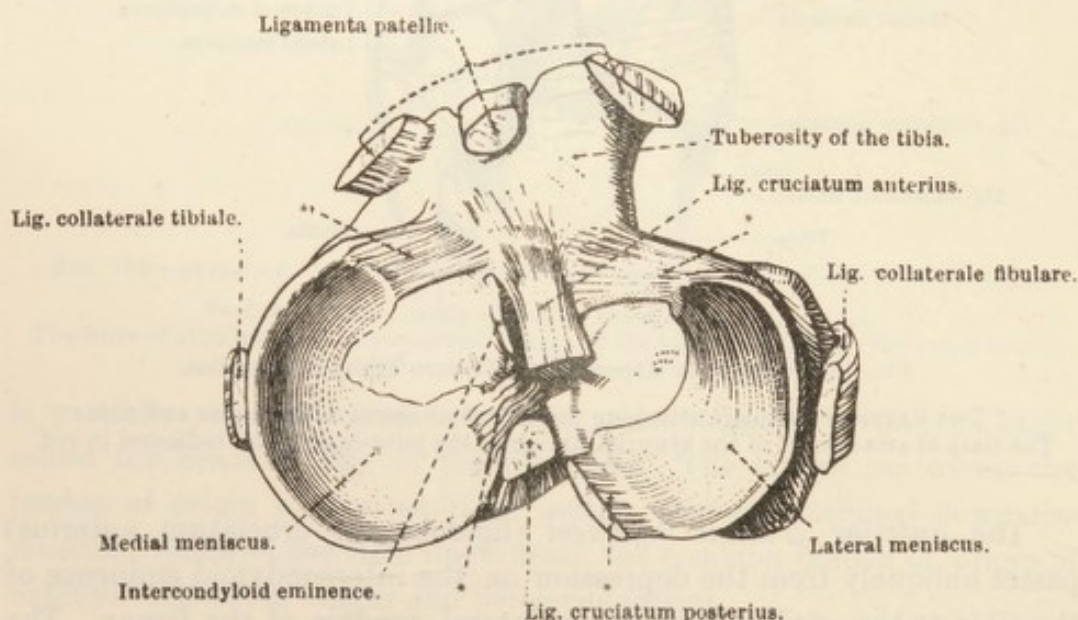


FIG. 112.—Proximal End of the Tibia, with the Ligaments and Menisci attached thereto.

* = Ligamentous bands holding the menisci in position.

towards the intercondyloid eminence of the tibia, is so thin as to be translucent. The proximal (femoral) surface of each meniscus is concave for the reception of one of the condyles of the femur. The distal or tibial surface is flattened. Each meniscus is attached in front by a

ligamentous band to an anterior intercondyloid fossa of the tibia. Behind, the medial meniscus is fixed to the tibia by a ligament attached to the posterior intercondyloid fossa. The lateral meniscus has two posterior ligamentous attachments; one band is attached in the popliteal notch, the other, crossing the posterior cruciate ligament obliquely, ends on the medial condyle of the femur.

Dissection.—The articulation between the tibia and the fibula must next be examined. The remains of all muscles attached to the fibula and the adjacent part of the tibia must be cleaned away.

THE TIBIO-FIBULAR ARTICULATION (*articulatio tibio-fibularis*).—In those animals in which the fibula¹ is developed throughout the whole of its length two tibio-fibular joints—a proximal and a distal—are present, and an interosseous membrane fills the gap between the two bones of the leg. In the horse, a considerable portion of the fibula fails to develop into bone, and the distal extremity fuses with the tibia. A fibrous cord, joining the tapering end of the rudimentary shaft of the fibula to the lateral malleolus, represents that portion of the bone which has failed to develop.

A strong, short *joint-capsule* (*capsula articularis*) binds the head of the fibula so closely to the lateral condyle of the tibia as to prevent anything but the smallest degree of movement. Not infrequently the capsule ossifies in old age. An *interosseous membrane* (*membrana interossea cruris*) fills the space between the tibia and the fibula with the exception of a short interval, close to the head of the fibula, through which the anterior tibial vessels pass.

Dissection.—Remove all tendons, etc., from the neighbourhood of the tarsus.

THE TARSAL ARTICULATIONS (*articulationes tarsi*).—The articulations of the tarsus resemble those of the carpus in so far as they are susceptible of a similar grouping. Unlike the carpal joints, however, those of the tarsus—with one exception—are capable of very restricted movement.

The joints included in the tarsal articulations are: (1) The *talo-crural*² *articulation* (*articulatio talo-cruralis*), between the distal end of the tibia and the trochlea of the talus (tibial tarsal bone); (2) the *inter-tarsal articulations* (*articulationes intertarsea*), between the rows of tarsal bones; (3) the *interosseous articulations* (*articulationes interossea*),

¹ *Fibula* [L.] [contraction of *figibula*, from *figo*, to fix or fasten], a clasp, pin, buckle, or brace.

² *Talus* [L.], the ankle-bone of animals; an oblong die used for gaming (originally made from the ankle-bone of certain animals), rounded on two sides and marked on the other four. *Crus* [L.], the leg or shin.

between the neighbouring bones of the same row; and (4) the *tarso-metatarsal articulation* (articulatio tarso-metatarsea), between the distal row of tarsal bones and the bases of the three metatarsals.

The ligaments of the tarsal articulations may be classified as (1) those that are common to the whole series of articulations, and (2) those that join two or more bones together. The common ligaments consist of a joint-capsule and two collaterals.

Though it is customary to describe the fibrous layer of the *joint-capsule* (capsula articularis) as extending from the distal end of the tibia to the proximal end of the metatarsus, that portion of it associated with the talo-crural joint is most definite and spacious. The rest of it is firmly adherent to the free surfaces of the tarsal bones, and blends most intimately with the collateral and other ligaments, as well as with tendons inserted in the immediate neighbourhood. That part of the capsule attached to the plantar (posterior) surfaces of the tarsal bones is of great strength, and reinforced by a cartilaginous plate, which assists in the formation of the smooth groove down which the deep flexor tendon plays.

The synovial layer of the joint-capsule is divided into four sacs. (1) The most capacious of these is between the tibia and the talus. On the flexor (dorsal or anterior) aspect of the joint the membrane forms a small diverticulum over the end of the tibia; and behind the joint, that is, on its plantar or extensor aspect, there is a larger diverticulum extending for a short distance (4 or 5 cm.) upwards between the tibia and the tendon of the flexor hallucis longus. (2) The second synovial sac is associated with the joint formed by the tibial tarsal (talus), fibular tarsal (calcaneus), central (scaphoid), and fourth tarsal (cuboid) bones. (3) The third synovial membrane belongs to the joint between the central (scaphoid) and the bones of the distal row; (4) while the fourth sac belongs to the tarso-metatarsal articulation.

The most powerful ligaments of the tarsus are those that extend from the tibia to the metatarsus (the two collateral ligaments) and those that pass from the proximal row of tarsal bones to the metatarsus (dorsal and plantar ligaments).

The *lateral collateral ligament* (ligamentum collaterale fibulare (laterale)) is composed of two strong bands, both of which arise from the lateral malleolus. The more superficial and longer band is connected with the talus, calcaneus, fourth tarsal (cuboid), and the third and fourth metatarsal bones. The deeper, short ligament crosses the foregoing obliquely to be attached to the talus and calcaneus.

The *medial collateral ligament* (ligamentum collaterale tibiale (mediale)) has its origin from the medial malleolus, and is also divisible

into two parts crucially disposed. The long ligament is attached to the talus, the first, second, and third tarsal (cuneiform), and the second and

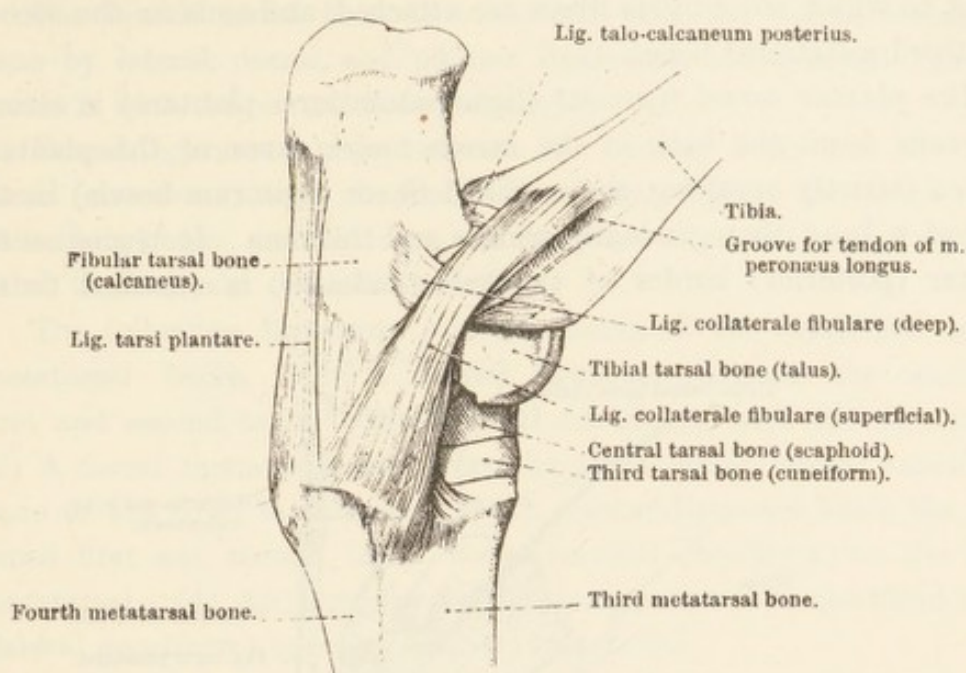


FIG. 113.—Lateral Aspect of the Tarsal Articulations.

third metatarsal bones. The short ligament divides into two portions; one of which ends on the talus, while the other, somewhat longer, is attached to the sustentaculum tali of the calcaneus.

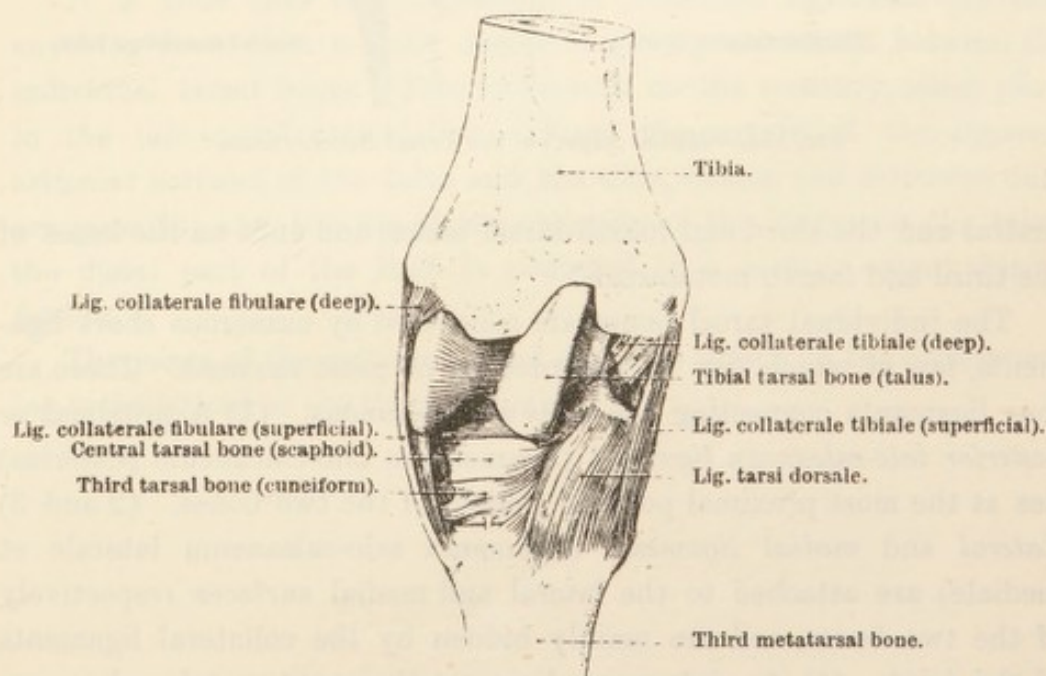


FIG. 114.—Dorsal (Anterior) Aspect of the Tarsal Articulations.

The *dorsal tarsal ligament* (ligamentum tarsi dorsale) is triangular in outline, and consists of fibres diverging from the projection on the

medial surface of the talus. The ligament spreads out over the dorsal surface of the central (scaphoid) and third tarsal (lateral cuneiform) bones, to which some of its fibres are attached, and ends on the second and third metatarsal bones.

The *plantar tarsal ligament* (ligamentum tarsi plantare) is strong, and runs down the back of the tarsus under cover of the plantaris tendon (strictly speaking, the modified flexor digitorum brevis) in the form of a band that gradually widens and thickens. It begins on the plantar (posterior) border of the tuber calcanei, is attached to the

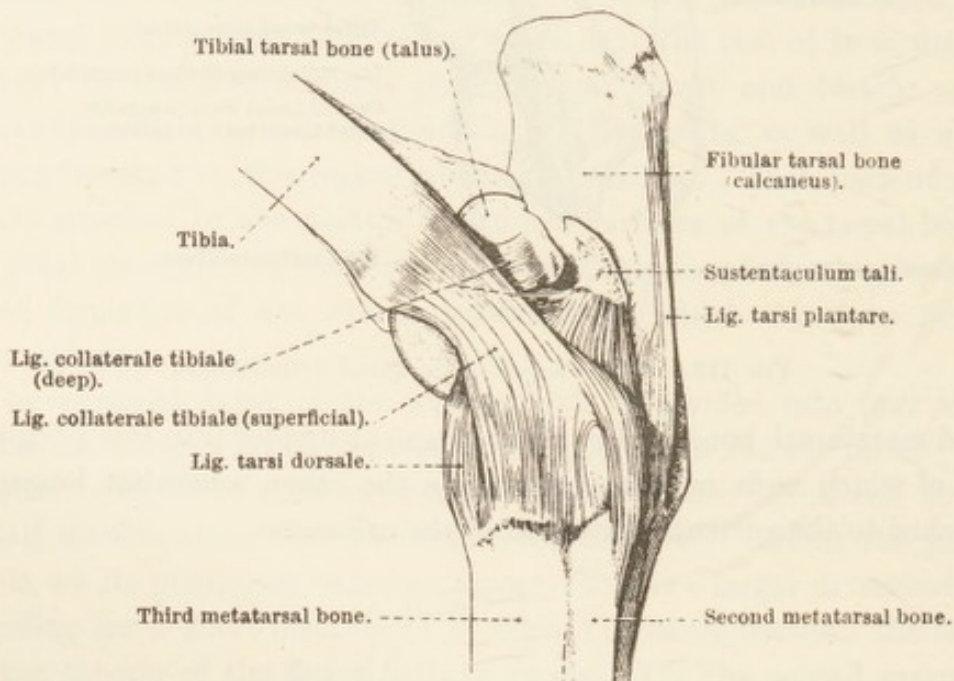


FIG. 115.—Medial Aspect of the Tarsal Articulations.

central and the third and fourth tarsal bones, and ends on the bases of the third and fourth metatarsals.

The individual tarsal bones are connected by numerous short ligaments, few of which can be regarded as of great moment. There are four ligaments connecting the talus and calcaneus. (1) A proximal or *posterior talo-calcanean ligament* (ligamentum talo-calcaneum posterius) lies at the most proximal point of contact of the two bones. (2 and 3) *Lateral and medial ligaments* (ligamenta talo-calcaneum laterale et mediale) are attached to the lateral and medial surfaces respectively of the two bones, and are mainly hidden by the collateral ligaments of the joint. (4) An *interosseus ligament* (ligamentum talo-calcaneum interosseum) passes between the two bones, and is attached to the depressions between their articular facets.

A lateral and a plantar ligament join the calcaneus to the fourth tarsal bone (cuboid). A dorsal ligament joins the calcaneus to the

central tarsal bone (scaphoid), and a plantar ligament connects the calcaneus and the combined first and second tarsal (cuneiform) bones.

The fourth tarsal bone is connected with the fourth metatarsal bone by lateral, dorsal, and plantar ligaments, and a dorsal ligament unites it with the central bone (scaphoid).

Dorsal ligaments pass between the central bone and the third tarsal (cuneiform) bone, the fourth tarsal (cuboid) and the third tarsal (cuneiform) bone, and between the combined first and second and the third tarsal bones (cuneiform bones).

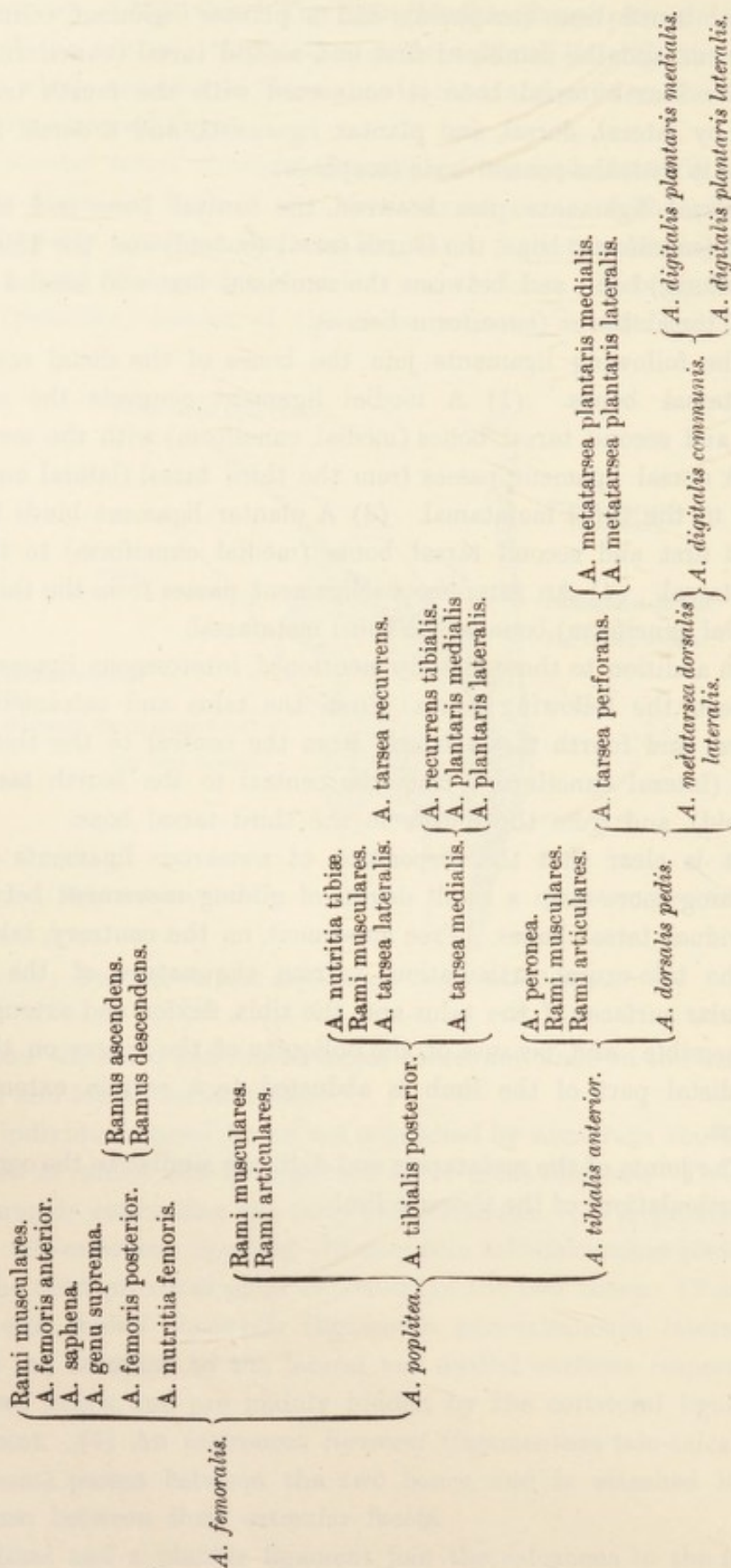
The following ligaments join the bones of the distal row to the metatarsal bones. (1) A medial ligament connects the combined first and second tarsal bones (medial cuneiform) with the metatarsus. (2) A dorsal ligament passes from the third tarsal (lateral cuneiform) bone to the third metatarsal. (3) A plantar ligament binds the combined first and second tarsal bones (medial cuneiform) to the third metatarsal. (4) An interosseous ligament passes from the third tarsal (lateral cuneiform) bone to the third metatarsal.

In addition to those already mentioned, interosseous ligaments pass between the following bones: From the talus and calcaneus to the central and fourth tarsal bones, from the central to the third tarsal bone (lateral cuneiform), from the central to the fourth tarsal bone (cuboid), and from the fourth to the third tarsal bone.

It is clear that the disposition of numerous ligaments prevents anything more than a small degree of gliding movement between the individual tarsal bones. Free movement, on the contrary, takes place in the talo-crural articulation. From the nature of the opposed articular surfaces of the talus and the tibia, flexion and extension only are possible; and, because of the obliquity of the ridges on the talus, the distal part of the limb is abducted to a certain extent during flexion.

The joints of the metatarsus and digit are similar to the corresponding articulations of the thoracic limb.

ARTERIES OF THE PELVIC LIMB.



NERVE AND BLOOD SUPPLY OF THE MUSCLES OF THE PELVIC LIMB.

<i>Nerve Supply.</i>		<i>Blood Supply.</i>
Cranial gluteal .	M. tensor fasciæ latae.	Circumflex iliac, ilio-lumbar, and lateral circumflex.
	M. glutæus superficialis.	Cranial gluteal, caudal gluteal, and lateral circumflex.
	M. glutæus medius.	Cranial gluteal, lateral circumflex, ilio-lumbar, and lumbar.
	M. piriformis.	Cranial gluteal.
	M. glutæus profundus.	Cranial gluteal.
Caudal gluteal and sciatic	M. biceps femoris.	Caudal gluteal, obturator, posterior femoral, and deep femoral.
	M. semitendinosus.	Caudal gluteal, obturator, posterior femoral, and deep femoral.
Obturator	M. gracilis.	Femoral, deep femoral, and saphenous.
	M. pectineus.	Femoral, and deep femoral.
	M. adductor.	Femoral, obturator, deep femoral, and posterior femoral.
	M. obturator externus.	Deep femoral, and obturator.
Saphenous. . . .	M. sartorius.	Femoral, and saphenous.
Femoral	M. rectus femoris.	Femoral, anterior femoral, and lateral circumflex.
	M. vastus lateralis.	Lateral circumflex, and posterior femoral.
	M. vastus medialis.	Anterior femoral, femoral, and articular branch of femoral.
	M. vastus intermedius.	Anterior femoral, and lateral circumflex.
	M. capsularis.	Lateral circumflex.
Sciatic	M. semimembranosus.	Femoral, obturator, caudal gluteal, and posterior femoral.
	M. quadratus femoris.	Deep femoral, and obturator.
	M. obturator externus.	Internal pudendal, and obturator.
Superficial peroneal	Mm. gemelli.	Obturator.
	M. peronæus longus.	Anterior tibial.

*Nerve Supply.**Blood Supply.*

Deep peroneal . . .	{	M. extensor digitorum longus.	Anterior tibial.
		M. peronæus tertius.	Anterior tibial.
		M. tibialis anterior.	Anterior tibial.
		M. extensor digitorum brevis.	Dorsalis pedis, and lateral dorsal metatarsal.
Tibial	{	M. gastrocnemius.	Popliteal, and posterior femoral.
		M. soleus.	Posterior tibial.
		M. plantaris.	Posterior femoral, and recurrent tibial.
		M. flexor digitorum longus.	Posterior tibial.
		M. tibialis posterior.	Posterior tibial.
		M. flexor hallucis longus.	Posterior tibial.
		M. popliteus.	Popliteal, and posterior tibial.
		Mm. lumbricales.	Plantar metatarsals.
		Mm. interossei.	Plantar metatarsals.

INDEX.

- ABDUCTOR** pollicis, 38.
 Accessory cephalic vein, 34.
 Accessory ligament of the hip joint, 124.
 Accessory nerve, 14.
 Adductor muscle of the thigh, 98.
 Anconeus muscle, 30.
 Anterior circumflex artery of the humerus, 24.
 Anterior cutaneous sural nerve, 118, 127.
 Anterior femoral artery, 101.
 Anterior tibial artery, 144.
 Anterior tibial vein, 146.
 Antibrachial cephalic vein, 34.
 Antibrachial fascia, 34.
Arch—
 deep plantar venous, 153.
 deep volar arterial, 63.
 distal plantar arterial, 151.
 distal plantar venous, 151.
 proximal plantar arterial, 150.
 terminal, of digital arteries, 89.
 volar venous, 65.
Arteria or Arteriæ—
 arcus plantaris distalis, 151.
 arcus plantaris proximalis, 150.
 arcus terminalis, 89.
 arcus volaris profundus, 63.
 axillaris, 6, 21.
 brachialis, 24.
 cervicalis ascendens, 6.
 circumflexa femoris lateralis, 120.
 circumflexa femoris medialis, 106.
 circumflexa humeri anterior, 24.
 circumflexa humeri posterior, 22.
 circumflexa scapulæ, 23.
 collateralis radialis, 24, 39.
 collateralis ulnaris, 24, 49.
 coronales phalangis tertię, 89.
 digitales plantares, 64, 151.
 digitales volares, 64, 89.
 digitalis communis, 64, 151.
 dorsales phalangis tertię, 89.
 dorsalis pedis, 145.
 femoralis, 101.
 femoris anterior, 101.
 femoris posterior, 104, 106.
 genu suprema, 101.
 glutæa caudalis, 114.
 glutæa cranialis, 114.
 interossea communis, 52.
 interossea dorsalis, 39.
 interossea recurrens, 40.
 mediana, 52.
Arteria or Arteriæ—continued.
 metacarpea dorsalis lateralis, 64.
 metacarpea dorsalis medialis, 64.
 metacarpea volaris lateralis, 62.
 metacarpea volaris medialis, 61.
 metatarsæ dorsalis lateralis, 146.
 metatarsæ plantares, 150.
 nutritia femoris, 104.
 nutritia humeri, 24.
 nutritia radii, 40.
 nutritia tibiæ, 136.
 obturatoria, 105.
 peronea, 144.
 phalangis primæ, 65.
 plantares, 149.
 poplitea, 134.
 profunda brachii, 24, 39.
 profunda femoris, 106.
 profunda penis, 105.
 recurrens tibialis, 136.
 rete carpi dorsale, 40.
 rete carpi volare, 53.
 saphena, 96, 101.
 subscapularis, 21.
 tarsæ lateralis, 136.
 tarsæ medialis, 136, 149.
 tarsæ perforans, 145, 150..
 tarsæ recurrens, 136.
 thoracica-externa, 6.
 thoraco-acromialis, 21.
 thoracodorsalis, 22.
 tibialis anterior, 144.
 tibialis posterior, 135.
 toricæ phalangis tertię, 65, 89.
 transversa scapulæ, 1, 6.
 truncus omocervicalis, 6.
Arteries of the metacarpus and digit, 61.
Arteries of the metatarsus and digit, 149.
Arteries of the pelvic limb, table, 164.
Arteries of the thoracic limb, table, 93.
Articular artery (of femoral), 101.
Articulation or Articulations—
 carpal, 71.
 carpo-metacarpal, 71.
 distal interphalangeal, 91.
 elbow, 69.
 femoro-patellar, 153, 154.
 femoro-tibial, 153, 155.
 hip, 122.
 humero-radial, 69.
 humero-ulnar, 69.
 intercarpal, 71.

Articulation or Articulations—*continued*.

- intermetacarpal, 75.
- intertarsal, 159.
- metacarpo-phalangeal, 76.
- proximal interphalangeal, 89.
- radio-carpal, 71.
- radio-ulnar, 71.
- shoulder, 67.
- talo-crural, 159.
- tarsal, 159.
- tarso-metatarsal, 159.
- tibio-fibular, 159.
- Ascending cervical artery, 6.
- Axilla, 4.
- Axillary artery, 6, 21.
- Axillary lymph glands, 15.
- Axillary nerve, 18, 34.
- Axillary vein, 6, 25.
- BICEPS brachii muscle, 15, 40.
- Biceps femoris muscle, 109.
- Blood supply of the muscles of the pelvic limb, table, 165.
- Blood supply of the muscles of the thoracic limb, table, 94.
- Brachial artery, 24.
- Brachial plexus, 7.
- Brachial vein, 25.
- Brachialis muscle, 30, 40.
- Brachiocephalic muscle, 14.
- CALLOSITY of the forearm, 33.
- Callosity of the tarsus, 125.
- Capsular muscle (of the arm), 18.
- Capsular muscle (of the thigh), 120.
- Carpal articulations and ligaments, 71.
- Carpometacarpal joint, 71.
- Cartilages of the third phalanx, 87.
- Caudal pectoral nerve, 7.
- Cephalic vein, 1, 34.
- Cervical artery, ascending, 6.
- "Chestnut," 33, 125.
- Circumflex femoral artery, lateral, 120.
- Circumflex femoral artery, medial, 106.
- Circumflex humeral artery, anterior, 24.
- Circumflex humeral artery, posterior, 22.
- Circumflex scapular artery, 23.
- Collateral radial artery, 24, 39.
- Collateral ulnar artery, 24, 49.
- Collateral ulnar vein, 50.
- Common digital artery, 64, 151.
- Common digital vein, 65.
- Common interosseous artery, 52.
- Common peroneal nerve, 106, 117, 141.
- Coracobrachial muscle, 16.
- Coronal arteries of third phalanx, 89.
- Coronary groove of the hoof, 82.
- Coronary matrix of the hoof, 79.
- Cranial pectoral nerves, 7.
- Cruciate ligaments of femoro-tibial joint, 157.
- Cruro-parietal groove of the hoof, 83.
- Cubital lymph glands, 15.
- Cuneate matrix of the hoof, 80.
- Cuneus of the hoof, 83.

Cutaneous nerves—

- dorsal antibrachial, 31, 34.
- forearm, 20, 25, 31, 34.
- gluteal and hip region, 107.
- lateral antibrachial, 20, 34.
- lateral brachial, 25, 34.
- leg, 117, 118, 127.
- pectoral region, 1.
- scapular region, 10.
- tarsus and metatarsus, 117, 127.
- thigh, 107, 115.
- DEEP artery of the penis, 105.
- Deep brachial artery, 24, 39.
- Deep femoral artery, 106.
- Deep inguinal lymph glands, 98.
- Deep peroneal nerve, 143.
- Deep plantar venous arch, 153.
- Deep volar arterial arch, 63.
- Deltoid muscle, 25.
- Digital arteries, common, 64, 151.
- Digital arteries, plantar, 151.
- Digital arteries, volar, 64, 89.
- Digital fascia, 55.
- Digital torus, 84.
- Digital veins, 65.
- Distal interphalangeal joint, 91.
- Distal plantar arterial arch, 151.
- Distal plantar venous arch, 151.
- Dorsal arteries of third phalanx, 89.
- Dorsal carpal ligament, 35.
- Dorsal cutaneous nerve of the forearm, 31, 34.
- Dorsal interosseous artery, 39.
- Dorsal ligament of the carpus, 35.
- Dorsal metacarpal arteries, 64.
- Dorsal metatarsal veins, 152.
- Dorsal rete of the carpus, 40.
- Dorsal tarsal ligament, 161.
- Dorsalis pedis artery, 145.
- ELBOW joint, 69.
- Eleventh cerebral nerve, 14.
- "Ergot," 54.
- Evolution of the horse's limb, 31.
- Extensor carpi radialis, 35.
- Extensor carpi ulnaris, 38.
- Extensor digiti quinti, 38, 57.
- Extensor digitorum brevis, 137.
- Extensor digitorum communis, 37, 55.
- Extensor digitorum longus, 137.
- External thoracic artery, 6.
- External thoracic vein, 6, 25.
- FASCIA—
 - antibrachial, 34.
 - digital, 55.
 - gluteal, 107.
 - lata, 107.
 - metacarpal, 55.
 - of leg, 127.
 - pectoral, 1.
 - tarsal, 128.
- Femoral artery, 101, 106.
- Femoral artery, anterior, 101.
- Femoral artery, deep, 106.
- Femoral artery, lateral circumflex, 120.

- Femoral artery, medial circumflex, 106.
 Femoral artery, posterior, 104, 106.
 Femoral nerve, 104.
 Femoral triangle, 100.
 Femoral vein, 101.
 Femoro-patellar joint, 153, 154.
 Femoro-patellar ligaments, 154.
 Femoro-tibial joint, 153, 155.
 Flexor carpi radialis, 41.
 Flexor carpi ulnaris, 41.
 Flexor digitorum brevis, 129, 147.
 Flexor digitorum longus, 132.
 Flexor digitorum profundus, 41, 58, 132, 147.
 Flexor digitorum sublimis, 41, 57.
 Flexor hallucis longus, 132.
 Foot, 78.
 Fossa, supraclavicular, 1.
 "Frog" of the hoof, 83.

GASTROCNEMIUS muscle, 128.
 Gemelli muscles, 113.
 Gluteal arteries, 114.
 Gluteal muscle, deep, 113.
 Gluteal muscle, middle, 111.
 Gluteal muscle, superficial, 109.
 Gluteal nerves, 115.
 Gracilis muscle, 97.
 Groove—
 coronary, of the hoof, 82.
 cruro-parietal, of the hoof, 83.
 intercrural, of the hoof, 83.
 pectoral, lateral, 1.
 pectoral, median, 1.

HIP JOINT, 122.
 Hoof, 80.
 Humeral artery, anterior circumflex, 24.
 Humeral artery, posterior circumflex, 22.
 Humero-radial joint, 69.
 Humero-ulnar joint, 69.

ILIO-FEMORAL ligament, 123.
 Ilio-psoas muscle, 105.
 Infraspinous muscle, 27.
 Inguinal lymph glands, deep, 98.
 Intercarpal joint, 71.
 Intercrural groove of the cuneus, 83.
 Intermetacarpal joint, 75.
 Internal obturator muscle, 114.
 Interosseous artery, common, 52.
 Interosseous artery, dorsal, 39.
 Interosseous artery, recurrent, 40.
 Interosseous ligament of the elbow joint, 71.
 Interosseous membrane of tibio-fibular joint, 159.
 Interosseous muscles, 60, 148.
 Interosseous nerve, 52.
 Interphalangeal joint, distal, 91.
 Interphalangeal joint, proximal, 89.
 Intertarsal joint, 159.

JOINTS. See Articulations.
 LABRUM glenoidale of acetabulum, 124.
 Lacertus fibrosus, 35.
 Laminæ of hoof, 82.
 Laminar matrix, 80.
 Lateral circumflex femoral artery, 120.
 Lateral cutaneous femoral nerve, 107.
 Lateral cutaneous nerve of the arm, 25, 34.
 Lateral cutaneous nerve of the forearm, 20, 34.
 Lateral dorsal metatarsal artery, 146.
 Lateral pectoral groove, 1.
 Lateral tarsal artery, 136.
 Latissimus dorsi muscle, 8, 12.
 Ligament or Ligaments—
 accessory, 124.
 cruciate, of femoro-tibial joint, 157.
 dorsal carpal, 35.
 dorsal tarsal, 161.
 femoro-patellar, 154.
 ilio-femoral, 123.
 interosseous, of elbow joint, 71.
 interosseous, of tibio-fibular joint, 159.
 of carpal articulations, 73.
 of cartilages of the third phalanx, 88.
 of distal interphalangeal joint, 90.
 of elbow joint, 69.
 of "ergot," 55.
 of femoro-patellar joint, 154.
 of femoro-tibial joint, 155.
 of hip joint, 122.
 of proximal interphalangeal joint, 90.
 of shoulder joint, 67.
 of tarsal articulations, 159.
 patellar, 155.
 phalango-sesamoidean, 91.
 plantar tarsal, 162.
 round, of the hip joint, 124.
 sesamoid, 76, 92.
 talo-calcanean, 162.
 transverse carpal, 35.
 transverse, of acetabulum, 124.
 transverse, of elbow joint, 71.
 transverse, of tarsal region, 128, 136.
 vaginal, of flexor tendons, 55.
 volar annular, 55.
 Limbus ungulæ, 81.
 Long thoracic nerve, 7.
 Lumbrical muscles, 60, 148.
 Lymph glands—
 axillary, 15.
 cubital, 15.
 deep inguinal, 98.
 of the arm, 114.
 popliteal, 106.

MARGINAL matrix, 79.
 Matrix of the hoof, 78.
 Medial circumflex femoral artery, 106.
 Medial tarsal artery, 136, 149.
 Median artery, 52.
 Median nerve, 19, 34, 50.
 Median pectoral groove, 1.
 Median vein, 53.
 Menisci of femoro-tibial joint, 158.
 Metacarpal arteries, 61.
 Metacarpal fascia, 55.
 Metacarpal nerves, 65.

Metacarpal veins, 65.
 Metacarpo-phalangeal joint, 76.
 Metatarsal arteries, plantar, 150.
 Metatarsal artery, lateral dorsal, 146.
 Metatarsal nerves, 148.
 Metatarsal veins, 152.
 Muscles of the pelvic limb, nerve and blood supply, table, 165.
 Muscles of the thoracic limb, nerve and blood supply, table, 94.
 Musculo-cutaneous nerve, 18.
 Musculus or Musculi—
 abductor pollicis longus, 38.
 adductor, 98.
 anconæus, 30.
 biceps brachii, 15, 40.
 biceps femoris, 109.
 brachialis, 30, 40.
 brachiocephalicus, 14.
 capsularis (brachii), 18.
 capsularis (femoris), 120.
 coracobrachialis, 16.
 deltoideus, 25.
 extensor carpi radialis, 35.
 extensor carpi ulnaris, 38.
 extensor digiti quinti, 38, 57.
 extensor digitorum brevis, 137.
 extensor digitorum communis, 37, 55.
 extensor digitorum longus, 137.
 flexor carpi radialis, 41.
 flexor carpi ulnaris, 41.
 flexor digitorum brevis, 129, 147.
 flexor digitorum longus, 132.
 flexor digitorum profundus, 41, 58, 132, 147.
 flexor digitorum sublimis, 41, 57.
 flexor hallucis longus, 132.
 gastrocnemius, 128.
 gemelli, 113.
 glutæo biceps, 111.
 glutæus accessorius, 113.
 glutæus medius, 111.
 glutæus profundus, 113.
 glutæus superficialis, 109.
 gracilis, 97.
 ilio-psoas, 105.
 infraspinatus, 27.
 interossei, 60, 148.
 latissimus dorsi, 8, 12.
 lumbricales, 60, 148.
 obturator externus, 104.
 obturator internus, 114.
 omohyoideus, 8.
 pectineus, 98.
 pectoralis profundus, 4, 14.
 pectoralis superficialis, 1.
 peronæus longus, 137.
 peronæus tertius, 138.
 piriformis, 113.
 plantaris, 129.
 popliteus, 132.
 quadratus femoris, 104.
 quadriceps femoris, 119.
 rectus femoris, 120.
 rhomboideus cervicalis, 10.
 rhomboideus thoracalis, 10.

Musculus or Musculi—continued.

sartorius, 98.
 semimembranosus, 100.
 semitendinosus, 111.
 serratus ventralis, 7.
 soleus, 129.
 subscapularis, 15.
 supraspinatus, 25.
 tensor fasciæ antibrachii, 16.
 tensor fasciæ latae, 109.
 teres major, 15.
 teres minor, 29.
 tibialis anterior, 139.
 tibialis posterior, 132.
 trapezius, 10.
 triceps brachii, 16, 30.
 vastus intermedius, 119.
 vastus lateralis, 114.
 vastus medialis, 98.

NERVE and blood supply of the muscles of the pelvic limb, table, 165.

Nerve and blood supply of the muscles of the thoracic limb, table, 94.

Nerves of the metacarpus and digit, 65.

Nerves of the metatarsus and digit, 148.

Nervus or Nervi—

accessorius, 14.
 axillaris, 18, 34.
 cutaneus antibrachii dorsalis, 31, 34.
 cutaneus antibrachii lateralis, 20, 34.
 cutaneus brachii lateralis, 25, 34.
 cutaneus femoris lateralis, 107.
 cutaneus femoris posterior, 107, 115.
 cutaneus suræ anterior, 118, 127.
 cutaneus suræ posterior, 117, 127, 131.
 femoralis, 104.
 glutæus caudalis, 115.
 glutæus cranialis, 115.
 interosseus, 52.
 ischiadicus, 106, 115.
 medianus, 19, 34, 50.
 musculocutaneus, 18.
 obturatorius, 105.
 pectorales craniales, 7.
 pectoralis caudalis, 7.
 peronæus communis, 106, 117, 141.
 peronæus profundus, 143.
 peronæus superficialis, 127, 142.
 plantares, 148.
 plexus brachialis, 7.
 radialis, 21, 31, 34, 39.
 saphenus, 96, 104, 127.
 subscapulares, 18.
 supraclavicularis, 1, 10.
 suprascapularis, 18.
 thoracalis longus, 7.
 thoracodorsalis, 7, 18.
 tibialis, 106, 116, 131.
 ulnaris, 21, 34, 47.
 volaris lateralis, 66.
 volaris medialis, 65.

Nutrient artery of the femur, 104.

Nutrient artery of the humerus, 24.

Nutrient artery of the radius, 40.

Nutrient artery of the tibia, 136.

- OBTURATOR artery, 105.
 Obturator externus muscle, 104.
 Obturator internus muscle, 114.
 Obturator nerve, 105.
 Obturator vein, 105.
 Omo-cervical arterial trunk, 6.
 Omohyoid muscle, 8.
- PATELLAR ligaments, 155.
 Pectineus muscle, 98.
 Pectoral fascia, 1.
 Pectoral grooves, 1.
 Pectoral muscle, deep, 4, 14.
 Pectoral muscle, superficial, 1.
 Pectoral nerves, 7.
 Penis, deep artery of, 105.
 Perforating tarsal artery, 145, 150.
 Perforating tarsal vein, 153.
 Peronæus longus muscle, 137.
 Peronæus tertius muscle, 138.
 Peroneal artery, 144.
 Peroneal nerve, common, 106, 117, 141.
 Peroneal nerve, deep, 143.
 Peroneal nerve, superficial, 127, 142.
 Phalanges, arteries of, 65, 89.
 Phalango-sesamoidean ligament, 91.
 Phillips' muscle, 37.
 Piriformis muscle, 113.
 Plantar arterial arch, distal, 151.
 Plantar arterial arch, proximal, 150.
 Plantar arteries, 149.
 Plantar digital arteries, 151.
 Plantar metatarsal arteries, 151.
 Plantar metatarsal veins, 153.
 Plantar nerves, 148.
 Plantar tarsal ligament, 162.
 Plantar venous arch, deep, 153.
 Plantar venous arch, distal, 151.
 Plantaris muscle, 129.
 Popliteal artery, 134.
 Popliteal lymph glands, 106.
 Popliteal vein, 135.
 Popliteus muscle, 132.
 Posterior circumflex artery of the humerus, 22.
 Posterior cutaneous femoral nerve, 107, 115.
 Posterior cutaneous sural nerve, 117, 127, 131.
 Posterior femoral artery, 104, 106.
 Posterior tibial artery, 135.
 Proximal interphalangeal joint, 89.
- QUADRATUS femoris muscle, 104.
 Quadriceps femoris muscle, 98, 114, 119.
- RADIAL artery, collateral, 24, 39.
 Radial nerve, 21, 31, 34, 39.
 Radio-carpal joint, 71.
 Radio-ulnar joint, 71.
 Rectus femoris muscle, 120.
 Recurrent interosseous artery, 40.
 Recurrent tarsal artery, 136.
 Recurrent tarsal vein, 127.
 Recurrent tibial artery, 136.
 Recurrent tibial vein, 125.
- Rete carpi dorsale, 40.
 Rete carpi volare, 53.
 Rhomboideus muscle, 10.
 Round ligament of the hip joint, 124.
- SAPHENOUS artery, 96, 101.
 Saphenous nerve, 96, 104, 127.
 Saphenous vein, 96, 125.
 Sartorius muscle, 98.
 Scapular artery, circumflex, 23.
 Scapular artery, transverse, 1, 6.
 Sciatic nerve, 106, 115.
 Semimembranosus muscle, 100.
 Semitendinosus muscle, 111.
 Sesamoid ligaments, 76, 92.
 Shoulder joint, 67.
 Solar matrix, 80.
 Sole of the hoof, 82.
 Soleus muscle, 129.
 Spine of cuneus, 83.
 "Stifle-joint," 153.
 Subscapular artery, 21.
 Subscapular muscle, 15.
 Subscapular nerve, 18.
 Superficial peroneal nerve, 127, 142.
 Supraclavicular fossa, 1.
 Supraclavicular nerve, 1, 10.
 Suprascapular nerve, 18.
 Supraspinous muscle, 25.
 Sural cutaneous nerves, 117, 118, 127, 131.
 Surface anatomy—
 pectoral region, 1.
 scapular region, 8.
 forearm, 33.
 metacarpus and digit, 53.
 thigh, medial aspect, 96.
 gluteal and hip region, 107.
 leg, 125.
- Synovial tendon sheaths, pelvic limb, 139.
 Synovial tendon sheaths, thoracic limb, 59.
- TALO-CALCANEAN ligaments, 162.
 Talo-crural joint, 159.
 Tarsal artery, lateral, 136.
 Tarsal artery, medial, 136, 149.
 Tarsal artery, perforating, 145, 150.
 Tarsal artery, recurrent, 136.
 Tarsal joints, 159.
 Tarsal ligament, dorsal, 161.
 Tarsal ligament, plantar, 162.
 Tarsal vein, perforating, 153.
 Tarsal vein, recurrent, 127.
 Tarso-metatarsal joint, 159.
 Tendo calcaneus Achillis, 128.
 Tendon sheaths of pelvic limb, 139.
 Tendon sheaths of thoracic limb, 59.
 Tensor fasciæ latæ, 109.
 Tensor of antibrachial fascia, 16.
 Teres major muscle, 15.
 Teres minor muscle, 29.
 Terminal arch of digital arteries, 89.
 Thiernes's muscle, 37.
 Thoracic artery, external, 6.

Thoracic nerve, long, 7.
 Thoraco-acromial artery, 21.
 Thoracodorsal artery, 22.
 Thoracodorsal nerve, 7, 18.
 Tibial artery, anterior, 144.
 Tibial artery, posterior, 135.
 Tibial artery, recurrent, 136.
 Tibial nerve, 106, 116, 131.
 Tibial vein, anterior, 146.
 Tibial vein, recurrent, 125.
 Tibialis anterior muscle, 139.
 Tibialis posterior muscle, 132.
 Tibio-fibular joint, 159.
 Torus, digital, 84.
 Torus, digital, arteries of, 65, 89.
 Transverse carpal ligament, 35.
 Transverse ligament of acetabulum, 124.
 Transverse ligaments of elbow joint, 71.
 Transverse ligaments of tarsal region, 136.
 Transverse scapular artery, 1, 16.
 Trapezius muscle, 10.
 Triceps brachii muscle, 16, 30.
 Trigonum femorale, 100.

ULNAR artery, collateral, 24, 49.
 Ulnar nerve, 21, 34, 47.
 Ulnar vein, collateral, 50.

VAGINA carpeæ, 46, 57.
 Vaginæ mucosæ, 59, 139.
 Vaginal ligament of the flexor tendons, 55.
 Vastus intermedius muscle, 119.
 Vastus lateralis muscle, 114.
 Vastus medialis muscle, 98.
 Ventral serratus muscle, 7.
 Veins of the metacarpus, 65.
 Veins of the metatarsus, 151.
 Vena or Venæ—
 arcus plantaris profundis, 153.
 arcus venosus plantaris distalis, 151.
 arcus venosus volaris, 65.

Vena or Venæ—*continued.*
 axillaris, 6, 25.
 brachialis, 25.
 cephalica, 1.
 cephalica accessoria, 34.
 cephalica antibrachii, 34.
 collateralis ulnaris, 50.
 digitalis communis, 65.
 digitalis lateralis, 65.
 digitalis medialis, 65.
 femoralis, 101.
 medianæ, 53.
 metacarpea volaris lateralis, 65.
 metacarpea volaris profunda, 65.
 metatarsea dorsalis lateralis, 152.
 metatarsea dorsalis media, 153.
 metatarsea dorsalis medialis, 152.
 metatarsea plantaris profunda medialis, 153.
 metatarsea plantaris superficialis lateralis, 153.
 metatarsea plantaris superficialis medialis, 153.
 obturatoria, 105.
 poplitea, 135.
 recurrens tibialis, 125.
 saphena, 96, 125.
 tarsea perforans, 153.
 tarsea recurrens, 127.
 thoracica externa, 6, 25.
 tibialis anterior, 146.
 Volar annular ligament, 55.
 Volar arterial arch, deep, 63.
 Volar digital arteries, 64, 89.
 Volar matrix, 80.
 Volar metacarpal arteries, 61.
 Volar metacarpal veins, 65.
 Volar nerves, 65.
 Volar rete of the carpus, 53.
 Volar venous arch, 65.
 WALL of the hoof, 80, 84.





